

Donna L. Gruol · Noriyuki Koibuchi  
Mario Manto · Marco Molinari  
Jeremy D. Schmahmann · Ying Shen *Editors*

# Essentials of Cerebellum and Cerebellar Disorders

A Primer For Graduate Students

 Springer

# Essentials of Cerebellum and Cerebellar Disorders

Donna L. Gruol • Noriyuki Koibuchi  
Mario Manto • Marco Molinari  
Jeremy D. Schmammann • Ying Shen  
Editors

# Essentials of Cerebellum and Cerebellar Disorders

A Primer For Graduate Students

 Springer

*Editors*

Donna L. Gruel  
Molecular and Cellular Neuroscience  
Department  
The Scripps Research Institute  
La Jolla, CA, USA

Noriyuki Koibuchi  
Department of Integrative Physiology  
Gunma University Graduate School  
of Medicine  
Maebashi, Gunma, Japan

Mario Manto  
FNRS, ULB-Erasme  
Bruxelles, Belgium  
  
Service des Neurosciences  
Université de Mons  
Mons, Belgium

Marco Molinari  
Clinical Translational Research  
Santa Lucia Foundation  
Rome, Italy

Jeremy D. Schmahmann  
Ataxia Unit, Cognitive Behavioral  
Neurology Unit, Laboratory for  
Neuroanatomy and Cerebellar  
Neurobiology, Department of Neurology  
Massachusetts General Hospital, Harvard  
Medical School  
Boston, MA, USA

Ying Shen  
Department of Neurobiology  
Zhejiang University School of Medicine  
Hangzhou, People's Republic of China

ISBN 978-3-319-24549-2

ISBN 978-3-319-24551-5 (eBook)

DOI 10.1007/978-3-319-24551-5

Library of Congress Control Number: 2016954967

© Springer International Publishing Switzerland 2016

This work is subject to copyright. All rights are reserved by the Publisher, whether the whole or part of the material is concerned, specifically the rights of translation, reprinting, reuse of illustrations, recitation, broadcasting, reproduction on microfilms or in any other physical way, and transmission or information storage and retrieval, electronic adaptation, computer software, or by similar or dissimilar methodology now known or hereafter developed.

The use of general descriptive names, registered names, trademarks, service marks, etc. in this publication does not imply, even in the absence of a specific statement, that such names are exempt from the relevant protective laws and regulations and therefore free for general use.

The publisher, the authors and the editors are safe to assume that the advice and information in this book are believed to be true and accurate at the date of publication. Neither the publisher nor the authors or the editors give a warranty, express or implied, with respect to the material contained herein or for any errors or omissions that may have been made.

Printed on acid-free paper

This Springer imprint is published by Springer Nature  
The registered company is Springer International Publishing AG Switzerland

# Contents

<b>1</b>	<b>Introduction</b> .....	<b>1</b>
	Donna L. Gruol, Noriyuki Koibuchi, Mario Manto, Marco Molinari, Jeremy D. Schmammann, and Ying Shen	
<b>Part I Brief Historical Note</b>		
<b>2</b>	<b>A Brief History of the Cerebellum</b> .....	<b>5</b>
	Jeremy D. Schmammann	
<b>3</b>	<b>Pivotal Insights: The Contributions of Gordon Holmes (1876–1965) and Olof Larsell (1886–1964) to Our Understanding of Cerebellar Function and Structure</b> .....	<b>21</b>
	Duane E. Haines	
<b>Part II Anatomy and Histology of the Cerebellum</b>		
<b>4</b>	<b>Gross Anatomy of the Cerebellum</b> .....	<b>33</b>
	Jan Voogd and Enrico Marani	
<b>5</b>	<b>Vascular Supply and Territories of the Cerebellum</b> .....	<b>39</b>
	Qiaoshu Wang and Louis R. Caplan	
<b>6</b>	<b>The Olivocerebellar Tract</b> .....	<b>55</b>
	Yuanjun Luo and Izumi Sugihara	
<b>7</b>	<b>Precerebellar Nuclei</b> .....	<b>63</b>
	Mayumi Yamada and Mikio Hoshino	
<b>8</b>	<b>Vestibular Nuclei and Their Cerebellar Connections</b> .....	<b>69</b>
	Neal H. Barmack	
<b>9</b>	<b>Spinocerebellar and Cerebellospinal Pathways</b> .....	<b>79</b>
	Tom J.H. Ruigrok	

<b>10 Visual Circuits</b> .....	89
Manuel Jan Roth, Axel Lindner, and Peter Thier	
<b>11 The Cerebrocerebellar System</b> .....	101
Jeremy D. Schmahmann	
<b>12 Cerebello-Cerebral Feedback Projections</b> .....	117
Kim van Dun, Mario Manto, and Peter Mariën	
<b>Part III Embryology and Development of the Cerebellum</b>	
<b>13 Cerebellar Neurogenesis</b> .....	127
Ketty Leto, Richard Hawkes, and G. Giacomo Consalez	
<b>14 Zones and Stripes</b> .....	137
Carol Armstrong and Richard Hawkes	
<b>15 Specification of Cerebellar Neurons</b> .....	143
Mikio Hoshino	
<b>16 Cerebellar Nucleus Development</b> .....	149
Hong-Ting Prekop and Richard J.T. Wingate	
<b>17 Development of Glutamatergic and GABAergic Synapses</b> .....	155
Marco Sassoè-Pognetto	
<b>18 Synaptogenesis and Synapse Elimination in Developing Cerebellum</b> .....	161
Kouichi Hashimoto, Masahiko Watanabe, and Masanobu Kano	
<b>19 Cerebellar Epigenetics: Transcription of MicroRNAs in Purkinje Cells</b> .....	167
Neal H. Barmack	
<b>Part IV Cerebellar Circuits: Biochemistry, Neurotransmitters and Neuromodulation</b>	
<b>20 Granule Cells and Parallel Fibers</b> .....	177
Egidio D'Angelo	
<b>21 The Purkinje Cell: As an Integrative Machine</b> .....	183
Anais Grangeray, Kevin Dorgans, Sebastien Roux, and Jean-Louis Bossu	
<b>22 Stellate Cells</b> .....	189
Siqiong June Liu and Christophe J. Dubois	
<b>23 Basket Cells</b> .....	195
Masahiko Watanabe	
<b>24 Golgi Neurons</b> .....	201
Stéphane Dieudonné	

<b>25</b>	<b>Lugaro Cells</b> .....	207
	Moritoshi Hirono	
<b>26</b>	<b>Unipolar Brush Cells</b> .....	213
	Marco Martina and Gabriella Sekerková	
<b>27</b>	<b>Glial Cells</b> .....	219
	Katharine L. Dobson and Tomas C. Bellamy	
<b>28</b>	<b>GABA Pathways and Receptors</b> .....	225
	Tomoo Hirano	
<b>29</b>	<b>Glutamatergic Pathways and Receptors</b> .....	231
	Susumu Tomita	
<b>30</b>	<b>Norepinephrine and Synaptic Transmission in the Cerebellum</b> .....	237
	Gerard Zitnik, Daniel J. Chandler, and Barry D. Waterhouse	
<b>31</b>	<b>Serotonin in the Cerebellum</b> .....	243
	Marlies Oostland and Johannes A. van Hooft	
<b>32</b>	<b>Nitric Oxide</b> .....	249
	Sho Kakizawa	
<b>33</b>	<b>Cerebellar Circuits: Biochemistry, Neurotransmitters and Neuromodulators</b> .....	255
	Gary J. Stephens	
<b>34</b>	<b>Purinergic Signalling in the Cerebellum</b> .....	261
	Mark J. Wall	
<b>35</b>	<b>Neuropeptides in the Cerebellum</b> .....	267
	Georgia A. Bishop and James S. King	
<b>36</b>	<b>Neurosteroids</b> .....	273
	C. Fernando Valenzuela	
<b>37</b>	<b>Cerebellar Modules and Networks Involved in Locomotion Control</b> .....	279
	Carla da Silva Matos, María Fernanda Vinueza Veloz, Tom J.H. Ruigrok, and Chris I. De Zeeuw	
<b>38</b>	<b>Distributed Plasticity in the Cerebellar Circuit</b> .....	285
	Egidio D'Angelo	
 <b>Part V Basic Physiology</b>		
<b>39</b>	<b>Oscillation in the Inferior Olive Neurons: Functional Implication</b> .....	293
	Rodolfo R. Llinas	
<b>40</b>	<b>Simple Spikes and Complex Spikes</b> .....	299
	Thomas S. Otis	

<b>41</b>	<b>Rebound Depolarization and Potentiation</b> .....	305
	Steven Dykstra and Ray W. Turner	
<b>42</b>	<b>Cerebellar Nuclei</b> .....	311
	Dieter Jaeger and Huo Lu	
<b>43</b>	<b>Plasticity of the Cerebellum</b> .....	317
	Ying Shen	
<b>44</b>	<b>Physiology of Olivo-Cerebellar Loops</b> .....	323
	Robin Broersen, Beerend H.J. Winkelman, Ozgecan Ozyildirim and Chris I. De Zeeuw	
<b>45</b>	<b>Long-Term Depression at Parallel Fiber-Purkinje Cell Synapses</b> .....	329
	Kazuhisa Kohda, Wataru Kakegawa, and Michisuke Yuzaki	
<b>46</b>	<b>Regulation of Calcium in the Cerebellum</b> .....	335
	Donna L. Gruol	
<b>Part VI Neuroimaging of the Cerebellum</b>		
<b>47</b>	<b>Cerebellar Closed-Loops</b> .....	343
	Christophe Habas	
<b>48</b>	<b>MRI Aspects: Conventional, SWI, DTL</b> .....	349
	Thomas M. Ernst, Marc Schlamann, and Dagmar Timmann	
<b>49</b>	<b>SPECT and PET</b> .....	359
	Martina Minnerop	
<b>50</b>	<b>MR Spectroscopy</b> .....	367
	Vladimír Mlynárik	
<b>51</b>	<b>Functional Topography of the Human Cerebellum</b> .....	373
	Catherine J. Stoodley and Jeremy D. Schmahmann	
<b>Part VII Functional Properties of the Cerebellum</b>		
<b>52</b>	<b>Cerebro-Cerebellar Networks</b> .....	385
	Iolanda Pisotta and Marco Molinari	
<b>53</b>	<b>Clinical Functional Topography in Cognition</b> .....	391
	Maria Leggio	
<b>54</b>	<b>Sequencing</b> .....	397
	Marco Molinari	
<b>55</b>	<b>Speech and Language</b> .....	403
	Peter Mariën and Kim van Dun	



**Part VIII Cellular and Animal Models of Cerebellar Disorders**

**56 The Zebrafish Cerebellum** ..... 411  
 Jan Kaslin and Michael Brand

**57 The Teleost Fish**..... 423  
 Takanori Ikenaga

**58 Lurcher Mouse** ..... 429  
 Jan Cendelin, Jan Tuma, and Zdenka Purkartova

**59 The Tottering Mouse**..... 437  
 Russell E. Carter and Timothy J. Ebner

**60 The Rolling Nagoya Mouse** ..... 443  
 Jaap J. Plomp, Arn M.J.M. van den Maagdenberg,  
 and Else A. Tolner

**61 Ataxic Syrian Hamster** ..... 449  
 Kenji Akita

**62 Lesions of the Cerebellum** ..... 455  
 Maria Teresa Viscomi and Marco Molinari

**63 Cellular and Animal Models of Cerebellar Disorders:  
 Staggerer Mouse**..... 463  
 N. Morellini, A.M. Lohof, R.M. Sherrard, and J. Mariani

**Part IX Human Cerebellar Symptoms: From Movement to Cognition**

**64 Cerebellum and Oculomotor Deficits**..... 471  
 Amir Kheradmand, Ji Soo Kim, and David Zee

**65 Speech Deficits**..... 477  
 Maria Caterina Silveri

**66 Deficits of Limbs Movements**..... 481  
 Giuliana Grimaldi

**67 Lesion-Symptom Mapping** ..... 489  
 Dagmar Timmann, Thomas M. Ernst, Winfried Ilg,  
 and Opher Donchin

**68 The Cerebellar Cognitive Affective Syndrome  
 and the Neuropsychiatry of the Cerebellum**..... 499  
 Jeremy D. Schmahmann

**69 Ataxia Scales for the Clinical Evaluation** ..... 513  
 Katrin Bürk

## **Part X Human Cerebellar Disorders: From Prenatal Period to Elderly**

<b>70 Differential Diagnosis of Cerebellar Ataxias on the Basis of the Age at Onset</b> .....	523
Francesc Palau and Javier Arpa	
<b>71 Overview of Ataxias in Children</b> .....	531
Andrea Poretti and Eugen Boltshauser	
<b>72 Cerebellar Pathology in Autism</b> .....	539
S. Hossein Fatemi	
<b>73 Autosomal Recessive Ataxias</b> .....	545
Marie Beaudin and Nicolas Dupré	
<b>74 X-Linked Ataxias</b> .....	553
Josef Finsterer	
<b>75 Imaging of Malformations of the Hindbrain and Craniocervical Junction</b> .....	561
Christian Herweh	
<b>76 Cerebellar Stroke</b> .....	569
Keun-Hwa Jung and Jae-Kyu Roh	
<b>77 Immune Diseases</b> .....	581
Marios Hadjivassiliou	
<b>78 Paraneoplastic Cerebellar Degeneration</b> .....	587
Raffaele Iorio and Peter Sillevs Smitt	
<b>79 Essential Tremor</b> .....	595
Elan D. Louis	
<b>80 Toxic Agents</b> .....	601
Mario Manto	
<b>81 Endocrine Disorders</b> .....	613
Mario Manto and Christiane S. Hampe	
 <b>Part XI Therapies of Cerebellar Ataxias</b>	
<b>82 Drugs in Selected Ataxias</b> .....	627
Dagmar Timmann and Winfried Ilg	
<b>83 Cerebellar Stimulation</b> .....	635
Giuliana Grimaldi	
<b>84 Motor Rehabilitation of Cerebellar Disorders</b> .....	641
Winfried Ilg and Dagmar Timmann	
<b>Index</b> .....	649

# Chapter 1

## Introduction

**Donna L. Gruol, Noriyuki Koibuchi, Mario Manto, Marco Molinari, Jeremy D. Schmahmann, and Ying Shen**

**Abstract** The depth and breadth of knowledge regarding cerebellar functions in health and disease continue to grow exponentially. Most of the currently available books dealing with the cerebellum and its disorders are highly specialized, usually written for neurologists with a particular interest in the cerebellar disorders. The four-volume *Handbook of the Cerebellum and Cerebellar Disorders* (Springer 2013) is the most comprehensive monograph on the cerebellum published to date covering both fundamental and clinical aspects. As valuable a resource as this has proven to be, however, the treatise is too extensive for students, and not practical as a brief, authoritative overview of the subject. The editors therefore concluded that there is a compelling need to distill the vast amount of basic science and clinical information in the four-volume text into a clear and concise précis of the work accessible to clinicians and students. Hence, this work, *Essentials of the Handbook of the Cerebellum and Cerebellar Disorders*.

**Keywords** Essentials • Cerebellum • Cerebellar disorders • Ataxia • Students

---

D.L. Gruol

Molecular and Cellular Neuroscience Department, The Scripps Research Institute,  
La Jolla, CA, USA

e-mail: [gruol@scripps.edu](mailto:gruol@scripps.edu)

N. Koibuchi, M.D., Ph.D.

Department of Integrative Physiology, Gunma University Graduate School of Medicine,  
Maebashi, Gunma, Japan

M. Manto (✉)

FNRS, ULB-Erasme, 808 Route de Lennik, 1070 Bruxelles, Belgium

Service des Neurosciences, Université de Mons, 7000 Mons, Belgium

e-mail: [mmanto@ulb.ac.be](mailto:mmanto@ulb.ac.be)

M. Molinari

Clinical Translational Research, Santa Lucia Foundation, Rome, Italy

J.D. Schmahmann

Ataxia Unit, Cognitive Behavioral Neurology Unit, Laboratory for Neuroanatomy and  
Cerebellar Neurobiology, Department of Neurology, Massachusetts General Hospital,  
Harvard Medical School, Boston, MA, USA

Y. Shen

Department of Neurobiology, Zhejiang University School of Medicine,  
Hangzhou 310058, People's Republic of China

The depth and breadth of knowledge regarding cerebellar functions in health and disease continue to grow exponentially. Most of the currently available books dealing with the cerebellum and its disorders are highly specialized, usually written for neurologists with a particular interest in the cerebellar disorders. The four-volume *Handbook of the Cerebellum and Cerebellar Disorders* (Springer 2013) is the most comprehensive monograph on the cerebellum published to date on fundamental and clinical aspects. As valuable a resource as this has proven to be, however, the treatise is too extensive for students, and not practical as a brief, authoritative overview of the subject. The editors therefore concluded that there is a compelling need to distill the vast amount of basic science and clinical information in the four-volume text into a clear and concise précis of the work accessible to clinicians and students. Hence, this work, *Essentials of the Handbook of the Cerebellum and Cerebellar Disorders*.

The editors of *Essentials* have selected what we believe to be major topics with direct scientific and clinical implications for understanding cerebellar anatomy, physiology, clinical neurology, and management of cerebellar disorders. With this monograph, we hope to foster a deeper understanding of the most important aspects of the complex phenomena that characterize cerebellar neurology. In so doing, we hope to encourage students to further explore its many facets, ranging from ataxiology (the study of cerebellar motor disorders) to the cognitive neuroscience of the cerebellum and its connections.

The pocket format of the book makes it readily available for consultation. The chapters are arranged in eleven sections covering fundamental, translational and clinical aspects of the cerebellum and cerebellar disorders. The length of each chapter is approximately four printed pages, enabling the reader to review the necessary information rapidly and efficiently. Critical references provided at the end of each chapter can be consulted for more in-depth information.

The editors are grateful for the outstanding contributions to this work by the renowned international panel of experts in some of the premier clinical centers, universities, and research centers in the USA, Europe, and Asia. We hope that this concise volume achieves its purpose of stimulating students, trainees, and practitioners to enhance their knowledge of the cerebellum and its disorders, and promote further clinical and scientific exploration in the field.

**Part I**  
**Brief Historical Note**

# Chapter 2

## A Brief History of the Cerebellum

Jeremy D. Schmahmann

**Abstract** Cerebellar structure and function have intrigued investigators and clinicians for millennia. Major anatomic features were recognized early, and the role of the cerebellum in coordinating movements was established two centuries ago. Cerebellar involvement in nonmotor functions was described in clinical and experimental observations starting around the same time, but attention to their importance rose to the fore only recently. Functional localization was first derived from comparative morphology. Ablation degeneration and physiological studies in animals and neurological observations in patients with focal injury led to the lobular theory of organization. This was refined by delineation of the mediolateral parasagittal zonal organization of cerebellar connections. Histological studies date back to Cajal, with descriptions of additional neuronal elements and circuitry evolving over the years. Recognition of the cerebellar cognitive affective syndrome and the neuropsychiatry of the cerebellum, observations from connectional neuroanatomy, and advances in anatomic, task-based, and functional connectivity magnetic resonance neuroimaging provide contemporary support for the earliest notions that cerebellum is engaged in a wide range of neurological functions. Together with new theories of cerebellar function, and elucidation of the genetic basis of inherited or sporadic ataxias and neurobehavioral disorders, the cerebellum has become increasingly relevant to contemporary clinical neurology and neuropsychiatry.

**Keywords** Historical background • Cerebellum • Ataxia • Dysmetria • Cognition • Vestibular

The cerebellum has been recognized since antiquity. Notions regarding its functions included the belief that it imparted strength to the motor nerves (Galen A.D. 129/130–200/201), was a center for memory (Nemesius, c.A.D. 390, and Albert von Bollstädt/Albertus Magnus, 1193–1280), controlled sensory functions including unconscious sensibility (Co(n)stanzo Varolio/Variolus, 1543–1575), was involved

---

J.D. Schmahmann (✉)

Ataxia Unit, Cognitive Behavioral Neurology Unit, Laboratory for Neuroanatomy and Cerebellar Neurobiology, Department of Neurology, Massachusetts General Hospital, Harvard Medical School, Boston, MA, USA  
e-mail: [jschmahmann@mgh.harvard.edu](mailto:jschmahmann@mgh.harvard.edu)

with involuntary activity including the functions of the heart and respiration (Thomas Willis, 1621–1675), and was the seat of amative love (Franz Joseph Gall, 1758–1828) (Citations in Neuburger, 1897/1981; Clarke and O'Malley 1996; Schmahmann and Pandya 2006). As is apparent from the historical account below, the conclusions of these pioneers, although based on flimsy or fanciful evidence, were actually rather prescient.

## 2.1 Early and Evolving Views of Cerebellar Organization and Function

Luigi Rolando (1809) first demonstrated that ablation of the cerebellum results in disturbances of posture and voluntary movement. Michele Foderà (1823) showed release of postural mechanisms, and extensor hypotonia following acute cerebellar injury in pigeons, guinea pigs and rabbits. Marie-Jean-Pierre Flourens (1824) showed in pigeons that the cerebellum is responsible for the coordination, rather than generation, of voluntary movement and gait, a concept that has remained the guiding principle of cerebellar function. François Magendie's lesion studies (1824) led to the understanding that the cerebellum is essential for equilibrium. Disturbances of motor control following focal cerebellar lesions in monkeys were demonstrated by Luigi Luciani (1891), David Ferrier and William Aldren Turner (1893) and Rissien Russell (1894).

Comparative anatomists such as Lodewijk 'Louis' Bolk (Bolk 1902; Glickstein and Voogd 1995) derived structure-function correlations by comparing the size of a cerebellar region with the characteristics of the species to which it belonged. They concluded that the vermis coordinates bilateral symmetrical movements, the cerebellar hemispheres coordinate unilateral movements of the limbs, and the development of manual dexterity corresponded with the expansion of the lateral cerebellar hemispheres. The lobular theory (Fulton and Dow 1937; Larsell 1970; Brodal 1967; see Angevine et al. 1961) held that the cerebellum is functionally organized into lobes. The flocculonodular lobe, archicerebellum, and vestibulocerebellum became synonymous. The anterior lobe, pyramis and uvula in the vermis of the posterior lobe, and the paraflocculus were termed the paleocerebellum or spinocerebellum. The lateral parts of the cerebellar hemispheres and the middle portion of the vermis were termed the neocerebellum, or pontocerebellum.

Ablation-degeneration studies in animals (Jansen and Brodal 1940; Chambers and Sprague 1955a, b) introduced the concept of the organization of cerebellum into three bilaterally symmetrical longitudinal corticonuclear zones. These studies (see Dow and Moruzzi 1958 for review) showed that the medial zone (vermis and fastigial nucleus) regulates vestibular function and the tone, posture, locomotion, and equilibrium of the body, with somatotopic localization in the vermal cortex – the head, neck and eyes at the posterior vermis, the tail and lower limbs at the rostral aspect of the anterior vermis, and the upper limbs situated in between. The intermediate zone (paravermal cortex and nucleus interpositus) regulates spatially organized and skilled movements and the tone and posture associated with these

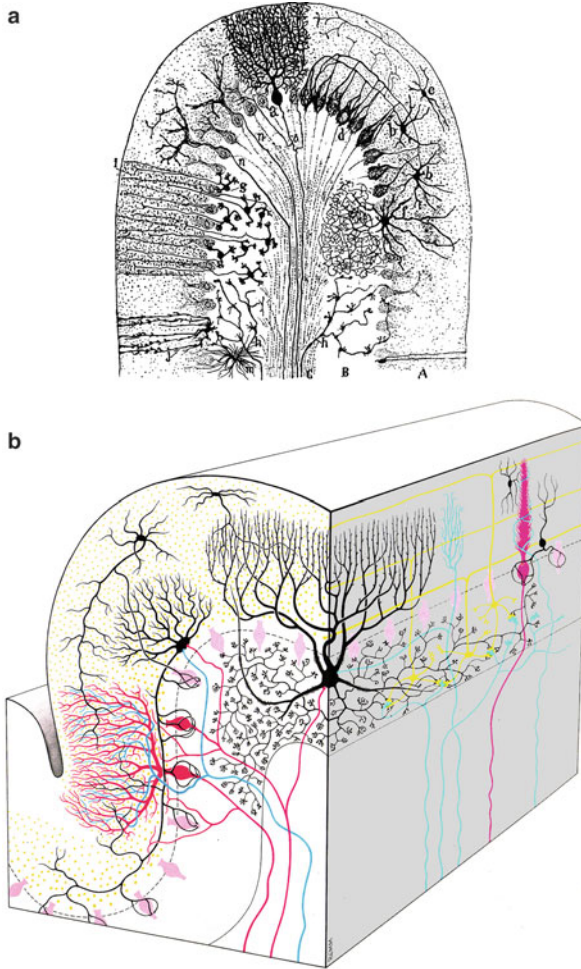
movements of the ipsilateral limb, and lesions in the intermediate zone produced motor deficits including tremor, ataxia, and postural instability. The lateral zone (hemispherical cortex and dentate nucleus) was thought to be involved in skilled and spatially organized movements of the ipsilateral limbs, although lateral hemispheres or dentate nucleus lesions produced only minor impairments of the distal extremities, without clear somatotopic organization. Dow (1942, 1974) identified the dentate nucleus in man and anthropoid apes as consisting of two parts, a dorsomedial microgyric, magnocellular older part homologous to the dentate nucleus of lower forms, and an expanded new part comprising the bulk of the dentate nucleus, the ventro-lateral macrogyric parvicellular part. He postulated that the newer “neodentate” expanded in concert with, and was connected to, the frontal, temporal and parietal association areas of higher primates and man, an idea he later expanded upon with Leiner et al. (1986).

The study of the cerebellar role in nonmotor functions has a rich history (see Schmahmann 1991, 1997a, b, 2010 for review and citations). Physiological and ablation studies demonstrated cerebellum to be engaged in autonomic functions such as pupil diameter, blood pressure, and sleep wake cycle. Cerebellar stimulation influenced size of stroke following middle cerebral artery ligation in rats, produced generalized arousal of the electroencephalogram, evoked hyperactivity in monkey and cat, and produced complex behaviors including grooming, predatory attack, aggression and sham rage. Studies also showed cerebellum to be essential for conditional associative learning including fear-conditioned bradycardia in the rat and the nictitating membrane response in rabbit, in addition to its role in spatial navigation and visual spatial learning.

## 2.2 Cerebellar Cortex

Jan Evangelista Purkyně (1787–1869) described the cell that would come to bear his name (Purkyně 1837), and Santiago Ramon y Cajal (1909) provided the first detailed description of the neuronal architecture of the cerebellar cortex, including mossy fibers, granule cell glomeruli, and parallel and climbing fibers (Eccles et al. 1967; Palay and Chan-Palay 1974; Brodal et al. 1975) (Fig. 2.1). Later investigators described Lugaro cells (Fox 1959; Palay and Chan-Palay 1974) and unipolar brush cells in the vestibulocerebellum (Mugnaini and Floris 1994). Using acetylcholinesterase, Voogd and colleagues (Voogd 1967, 1969; Marani and Voogd 1977) demonstrated parasagittal zonal organization in cerebellar white matter: zones A and B at the vermis, paravermal zones C1, 2, and 3, and zones D1 and 2 in the hemispheres. Hawkes and colleagues (Gravel and Hawkes 1990) demonstrated this zonal pattern in the cortex using monoclonal antibodies. Histochemical markers confirmed these parasagittal zones, each with topographically arranged connections with the deep cerebellar nuclei (Haines 1981) and inferior olive (Groenewegen and Voogd 1977; Hoddevik and Brodal 1977; Groenewegen et al. 1979). The demonstration of fractured somatotopy in sensory projections to cerebellum (Shambes et al. 1978;





**Fig. 2.1** General organization of the cerebellar cortex. **(a)** Santiago Ramon y Cajal's (1911/1995) diagram of the neurons in the cerebellar cortex oriented perpendicular to the long axis of the folium, as well as fibers and glial cells. Abbreviations: *A* molecular layer, *a* Purkinje cell, *B* granular layer, *b* basket cell, *C* white matter of the folium, *d* pericellular baskets around the PC soma formed by the basket cell axon, *e* superficial stellate cell, *f* Golgi cell, *g* granule cell, *h* mossy fiber, *i* ascending axon of granule cell, *j* Bergmann glial cell, *m* astroglial cell, *n* climbing fiber, *o* recurrent collateral branches of a PC. **(b)** Diagram redrawn from Eccles et al. (1967) in Gray's Anatomy (1995). A single cerebellar folium is shown sectioned in its longitudinal axis (*diagram right*) and transversely (*left*). Purkinje cells are *red*; superficial and deep stellate, basket and Golgi cells are *black*; granule cells and ascending axons and parallel fibers are *yellow*; mossy and climbing fibers are *blue*. Also shown are the glomeruli with mossy fiber rosettes, claw-like dendrites of granule cells, and Golgi axons. Lugaro and unipolar brush cells are not shown (Figures reproduced with permission)

Bower and Kassel 1990) is consistent with the observation that Purkinje cells (PCs) can be activated by the ascending axons of granule cells (Llinas 1984; Cohen and Yarom 1998) as well as by beams of parallel fibers.

### 2.3 Connectional Anatomy

Myelin and degeneration studies in the nineteenth and early twentieth centuries revealed that cerebellar connections with spinal cord, vestibular system, brainstem, and cerebral cortex are topographically arranged. Bechterew (1888) showed that the caudal pons is linked with the cerebellar anterior lobe, but rostral pons is linked with the cerebellar posterior lobe. Sherrington's (1906) physiological studies showed cerebellar afferents from the proprioceptive system (he viewed cerebellum as the "head ganglion of the proprioceptive system"), and others showed topographically arranged inputs to cerebellum following proprioceptive, cutaneous (Dow and Anderson 1942; Snider and Stowell 1942; Hampson et al. 1952) vagal, visual, and auditory stimulation (Snider and Stowell 1942; Dow and Moruzzi 1958).

Oscarsson (1965) demonstrated that spinocerebellar tracts terminate exclusively in the anterior lobe and lobule VIII (sensorimotor areas of cerebellum). Spinal-recipient olivary nuclei project to sensorimotor cerebellum (anterior lobe and lobule VIII), whereas most of the principal olive (devoid of spinal afferents) projects to the cerebellar posterior lobe (Oscarsson 1980; Ruigrok et al. 1992; Groenewegen et al. 1979).

Anatomical studies of the feedforward loop of the cerebrocerebellar system (Brodal 1978; Glickstein et al. 1985; see Schmähmann 2004), and electrophysiological experiments of the cerebrocerebellar system (Henneman et al. 1952; Sasaki et al. 1975; Allen and Tsukahara 1974) demonstrated predominantly motor connections of cerebellum in a topographically precise manner. Studies also linked cerebellum with limbic structures – hippocampus, septum and amygdala (Maiti and Snider 1975; Heath and Harper 1974). Anterograde isotope studies of corticopontine pathways demonstrated precisely arranged inputs from motor and supplementary motor areas (Schmähmann et al. 2004), and also from associative and paralimbic regions of the prefrontal, posterior parietal, superior temporal, and parastriate cortices concerned with higher order functions (Schmähmann and Pandya 1997a, b; see Schmähmann 2010). Transynaptic viral tracing studies revealed that cerebellar linkage with association areas is reciprocal – cerebral areas that project via pons to cerebellum in turn receive projections back via thalamus from the cerebellum (Middleton and Strick 1994). They also showed that cerebellar anterior lobe and dorsal dentate nucleus are linked with motor cortices, whereas cerebellar posterior lobe and ventral dentate nucleus are linked with prefrontal and posterior parietal regions (Clower et al. 2001; Dum and Strick 2003).

## 2.4 The Cerebellar Motor Syndrome

Early studies in patients with Friedreich's ataxia, cerebellar cortical atrophy and penetrating gunshot injuries of the cerebellum (Sanger Brown 1892; Pierre Marie 1893; Joseph Francois Felix Babinski 1899; Gordon Holmes 1907) established the critical role of cerebellum in coordination of extremity movement, gait, posture, equilibrium, and speech. Holmes (1939) later analyzed the motor and speech deficits resulting from focal cerebellar injury. Much of Holmes' terminology and neurologic examination remain in contemporary use. (See Chap. 3). These clinical studies confirmed in human that the vestibular cerebellum was important for posture and equilibrium, the spinocerebellum for locomotion and extremity movement, and they suggested that the neocerebellum was important for manual dexterity. The anterior superior cerebellar vermis was particularly important for gait. Hypotonicity was a frequent accompaniment of bilateral cerebellar lesions. Lesions involving both cerebellar hemispheres produced characteristic cerebellar dysarthria. More than a century of clinical neurology has further refined the understanding of the cerebellar motor syndrome, and now clinical rating scales are helpful in defining the nature and severity of the motor incapacity.

## 2.5 The Cerebellar Cognitive Affective Syndrome

From the earliest days of clinical case reporting, at least since 1831 (Combette 1831), instances of mental and intellectual dysfunction were described in the setting of cerebellar pathology (Schmahmann 1991). Sizable posterior lobe strokes may produce only nausea and vertigo at the onset, and gait impairment subsides once the vestibular syndrome improves (Duncan et al. 1975; Schmahmann et al. 2009). Surgically induced dentate nucleus lesions in humans do not produce motor disability (Zervas et al. 1967). Cerebellar abnormalities have been identified in autism (Bauman and Kemper 1985), schizophrenia (Moriguchi 1981; Snider 1982), and attention deficit disorder (Berquin et al. 1998). Cognitive impairments were noted in patients with cerebellar stroke (Botez-Marquard et al. 1994; Silveri et al. 1994), cerebellar cortical atrophy (Grafman et al. 1992), and in those with cerebellar developmental disorders (Joubert et al. 1969; see Schmahmann 1991, 1997a). The spinocerebellar ataxias have changes in cognition to varying degrees throughout the course of the illness (Manto 2014); and in children, mutism and subsequent dysarthria occur following excision of cerebellar tumors (Wisoff and Epstein 1984), often accompanied by regressive personality changes, emotional lability and poor initiation of voluntary movement (Pollack et al. 1995; Levisohn et al. 2000).

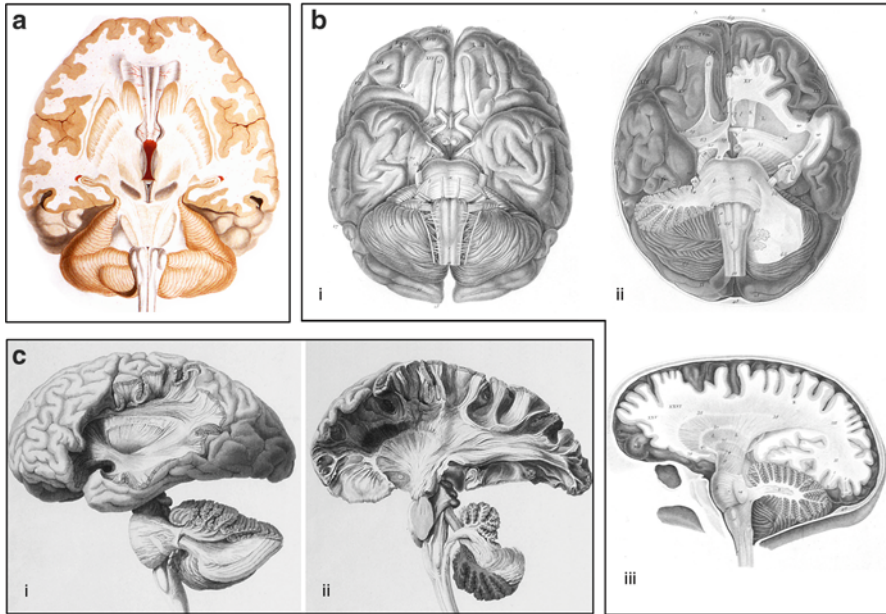
Schmahmann and Sherman (1998) described the cerebellar cognitive affective syndrome (CCAS) in patients with acquired cerebellar lesions characterized by impairment of executive functions such as planning, set-shifting, verbal fluency, abstract reasoning, and working memory; difficulties with spatial cognition

including visual-spatial organization and memory; personality change with blunting of affect or disinhibited and inappropriate behavior; and language deficits including agrammatism and dysprosodia. The CCAS occurred following lesions of the cerebellar posterior lobe, and the vermis was usually involved when there was a prominent affective component. The CCAS was then described in children (Levisohn et al. 2000) with a similar pattern of cognitive deficits, the affective changes reflecting damage to the vermis, and it has been replicated widely (e.g., Neau et al. 2000; Riva and Giorgi 2000; Tedesco et al. 2011). Metalinguistic deficits (Guëll et al. 2015) are related to impaired social cognition (Hoche et al. 2015), and neuropsychiatric symptoms occur in the domains of attention, mood, social cognition, autism and psychosis spectrum behaviors (Schmahmann et al. 2007). It is now apparent that there is a double dissociation in the motor vs cognitive dichotomy of cerebellar clinical neurology. Holmes' (1917) cerebellar motor syndrome of ataxia, dysmetria and dysarthria arises following lesions of the sensorimotor anterior lobe but not the posterior lobe; the CCAS/Schmahmann syndrome (Manto and Mariën 2015) arises from the cognitive – affective posterior lobe, but not the anterior lobe (Schmahmann and Sherman 1998; Levisohn et al. 2000; Schmahmann et al. 2009). The cognitive and limbic consequences of cerebellar injury and the underlying neurobiology and theory of the putative cerebellar role in cognition were crystallized in the 1997 monograph on this topic (Schmahmann 1997b).

## 2.6 Atlases and Functional Neuroimaging

Vincenzo Malacarne provided the first detailed description of the cerebellum (Malacarne 1776), naming the vermis, lingula and tonsil. The atlas of Felix Vicq-d'Azyr (1786) showed the structure of the cerebellum. Depictions of cerebellum and brainstem were included in drawings by Franz Joseph Gall (Gall and Spurzheim 1810) and Herbert Mayo (1827), and in numerous volumes on cerebellum (Bolk 1906; Edinger 1909; Ingvar 1918; Riley 1929; Ziehen 1934; Larsell and Jansen 1972) (Fig. 2.2). The most detailed human atlas available was that of Angevine et al. (1961), until the introduction of the three dimensional MRI Atlas of the Human Cerebellum (Schmahmann et al. 2000) for use with anatomic and functional neuroimaging. It depicted cerebellum in the 3 cardinal planes in Montreal Neurologic Institute stereotaxic space, included histological specimens with cerebellar nuclei, and revised Larsell's nomenclature. This atlas facilitated the development of the on-line SUIT atlas (Diedrichsen 2006) for functional neuroimaging.

Magnetic resonance imaging (MRI) revolutionized the ability to visualize posterior fossa structures and lesions. Task based functional MRI reliably shows cerebellar activation by motor (Fox et al. 1985) and nonmotor tasks (Petersen et al. 1989; Gao et al. 1996). The topography of functions in cerebellum is exemplified in an fMRI meta-analysis and prospective study showing areas of cerebellum dedicated to motor control, cognition and emotion (Stoodley and Schmahmann 2009; Stoodley



**Fig. 2.2** Depictions of the cerebellum by early anatomists. **(a)** Image from the atlas of Félix Vicq D’Azyr (1786). His Plate IV includes the cerebellum. The image is flipped vertically, as in the atlas the cerebellum is shown at the *top*. **(b)** Images from the atlas of Franz Joseph Gall and Johann Kaspar Spurzheim (Gall and Spurzheim 1810). *i* Gall and Spurzheim’s Plate IV, shows the base of the brain with cerebral hemispheres, cerebellum and brainstem. *ii* Plate XIII, shows dissections of the cerebral hemisphere and cerebellum. *iii* Plate X, shows cerebral and cerebellar hemispheres partially dissected in the sagittal plane. **(c)** Depictions of white matter dissections of the cerebral hemisphere, cerebellum and brainstem by Herbert Mayo (1827). *i* Plate III shows dissection of the middle cerebellar peduncle. In *ii* Plate IV, brainstem and cerebellar dissection with removal of the MCP reveals the inferior and superior cerebellar peduncles

et al. 2012). Resting state functional connectivity MRI has added physiological connectivity evidence to the connectional data from non-human primates, showing functionally and anatomically distinct cerebrocerebellar circuits (Buckner et al. 2011; Habas et al. 2009; O’Reilly et al. 2010).

## 2.7 Evolving Techniques

Walker (1938) showed that stimulation of the cerebellum alters electrical activity of the motor cortex. Cerebellar stimulation in patients produced amelioration of aggression (Heath 1977) and reduced the frequency of seizures (Riklan et al. 1974).

Transcranial magnetic stimulation (TMS) has been used to study cerebrocerebellar interactions in health (Hashimoto and Ohtsuka 1995) and disease (e.g., Wessel et al. 1996) and cerebellar TMS has been explored as a therapeutic option in ataxias

(Grimaldi et al. 2014) and neuropsychiatric illness (Demirtas-Tatlidede et al. 2010). Magnetoencephalography (MEG) can record activity in the human cerebellum (Tesche and Karhu 1997), and provides a temporal dimension to the study of cerebellar circuitry and function. Magnetic resonance spectroscopy (MRS) is sensitive to metabolic changes (Ross and Michaelis 1996), is abnormal in patients with cerebellar degeneration (Tedeschi et al. 1996), and may be useful as a biomarker of cerebellar dysfunction in ataxia (Öz et al. 2011).

## 2.8 Genetics

Since the discovery of the genetic basis of Friedreich's ataxia (Campuzano et al. 1996), the understanding of autosomal dominant spinocerebellar ataxias and recessive ataxias has produced a paradigm shift in the care of patients and families with heritable cerebellar disorders. Exome sequencing and the promise of genome sequencing has catapulted this further forward.

## 2.9 Theories

Snider (1952) proposed that cerebellum is the great modulator of neurologic function, Heath (1977) regarded it as an emotional pacemaker for the brain. Gilbert and Thach (1977) confirmed the hypothesis of Marr (1969) and Albus (1971) that cerebellar climbing fibers and mossy fibers work in collaboration to facilitate a cerebellar role in motor learning. Ito used the model of the vestibular ocular reflex (Lisberger and Fuchs 1978) to suggest that the cerebellum engages in error correction in the realms both of movement (Ito 1984) and of thought (Ito 1993). Leiner et al. (1986; Leiner and Leiner 1997) drew on evolutionary considerations of the dentate nucleus expanding in concert with cerebral association areas to propose that cerebellum serves as a multi-purpose computer designed to smooth out performance of mental operations. Thach (1996) suggested that the cerebellum uses the mechanism of context-response linkage for motor adaptation, motor learning, and higher function. Llinas and Welsh (1993) highlighted the role of the olivocerebellar system in entraining cerebellar neuronal firing, focusing on the cerebellar role in movement. Other ideas include the view that the cerebellum is critical for timing (Ivry and Keele 1989), sensory perception (Bower 1995), anticipation and prediction (Courchesne and Allen 1997), and sequence learning (Molinari et al. 1997). Schmahmann's dysmetria of thought theory (Schmahmann 1991, 2000, 2010) holds that there is a universal cerebellar transform that maintains function around a homeostatic baseline according to context; information being modulated is determined by topographically arranged anatomical circuits; the universal cerebellar impairment is dysmetria – resulting in the motor ataxia syndrome when the motor cerebellum is damaged, the CCAS when the cognitive-limbic cerebellum is damaged.

## 2.10 Therapies

Physical, occupational and speech rehabilitation strategies have long been the mainstay of therapy for ataxia. Many non-ataxic symptoms, including rest tremor are now amenable to intervention. Medications are being repurposed or newly developed for the treatment of kinetic ataxia that address the underlying molecular and physiological defects that produce cerebellar motor, cognitive and other syndromes.

**Acknowledgements** Supported in part by the MINDlink, Birmingham, and Sidney R. Baer Jr Foundations, the National Ataxia Foundation and the Ataxia Telangiectasia Children's Project. The images in Figs. 2.1 and 2.2 were acquired in the Harvard Medical School Countway Library of Medicine Rare Books and Special Collections Department, and reproduced in Schmahmann and Pandya 2006.

## References

- Albus JS (1971) A theory of cerebellar function. *Math Biosci* 10:25–61
- Allen GI, Tsukuhara N (1974) Cerebrocerebellar communication systems. *Physiol Rev* 54:957–1008
- Angevine JB, Mancall EL, Yakovlev PI (1961) The human cerebellum: an atlas of gross topography in serial sections. Little, Brown and Company, Boston
- Babinski JFF (1899) De l'asynergie cerebelleuse. *Rev Neurol* 7:806–816
- Bauman M, Kemper TL (1985) Histoanatomic observations of the brain in early infantile autism. *Neurology* 35:866–874
- Bechterew W (1888) Zur Frage über die secundären Degenerationen des Hirnschenkels. *Arch Psychiatr Nervenkr* 19:1–17
- Berquin PC, Giedd JN, Jacobsen LK, Hamburger SD, Krain AL, Rapoport JL, Castellanos FX (1998) Cerebellum in attention-deficit hyperactivity disorder: a morphometric MRI study. *Neurology* 50:1087–1093
- Bolk L (1902) Hauptzüge der vergleichenden Anatomie des Cerebellums der Säugetiere mit besonderer Berücksichtigung des menschlichen Kleinhirns. *Monatschr f Psychiat Neurol* 12:432–467
- Bolk L (1906) Das Cerebellum der Säugetiere. De Erven F. Bohn, Haarlem
- Botez-Marquard T, Léveillé J, Botez MI (1994) Neuropsychological functioning in unilateral cerebellar damage. *Can J Neurol Sci* 21:353–357
- Bower JM (1995) The cerebellum as sensory acquisition controller. *Hum Brain Mapp* 2:12–13
- Bower JM, Kassel J (1990) Variability in tactile projection patterns to cerebellar folia crus IIA of the Norway rat. *J Comp Neurol* 302:768–778
- Brodal A (1967) Anatomical studies of cerebellar fibre connections with special reference to problems of functional localization. In: Schade JP (ed) *The cerebellum, progress in brain research*. Elsevier, Amsterdam, pp 135–173, 25
- Brodal P (1978) The corticopontine projection in the rhesus monkey. Origin and principles of organization. *Brain* 101(2):251–283
- Brodal A, Walberg F, Hoddevik GH (1975) The olivocerebellar projection in the cat studied with the method of retrograde axonal transport of horseradish peroxidase. *J Comp Neurol* 164(4):449–469
- Brown S (1892) On hereditary ataxia, with a series of twenty-one cases. *Brain* 15:250–282

- Buckner RL, Krienen FM, Castellanos A, Diaz JC, Yeo BT (2011) The organization of the human cerebellum estimated by intrinsic functional connectivity. *J Neurophysiol* 106(5):2322–2345
- Cajal S Ramón y (1909–1910) *Histologie du système nerveux de l’homme et des vertébrés*. Translated into French by L. Azoulay. Paris: Maloine. Translated into English by Swanson N, Swanson LW. (1995) *Histology of the nervous system of man and vertebrates*. New York, Oxford University Press
- Campuzano V, Montermini L, Moltò MD et al (1996) Friedreich’s ataxia: autosomal recessive disease caused by an intronic GAA triplet repeat expansion. *Science* 271(5254):1423–1427
- Chambers WW, Sprague JM (1955a) Functional localization in the cerebellum. I. Organization in longitudinal corticonuclear zones and their contribution to the control of posture, both extrapyramidal and pyramidal. *J Comp Neurol* 103:105–130
- Chambers WW, Sprague JM (1955b) Functional localization in the cerebellum. II. Somatotopic organization in cortex and nuclei. *Arch Neurol Psychiatr* 74:653–780
- Clarke E, O’Malley CD (1996) *The human brain and spinal cord. A historical study illustrated by writings from antiquity to the twentieth century*, 2nd edn. Norman Publishing, San Francisco
- Clower DM, West RA, Lynch JC, Strick PL (2001) The inferior parietal lobule is the target of output from the superior colliculus, hippocampus, and cerebellum. *J Neurosci* 21(16):6283–6291
- Cohen D, Yarom Y (1998) Patches of synchronized activity in the cerebellar cortex evoked by mossy-fiber stimulation: questioning the role of parallel fibers. *Proc Natl Acad Sci U S A* 95:15032–15036
- Combette (1831) Absence complète du cervelet, des pedoncules posterieurs et de la protuberance cerebrale chez une jeune fille morte dans sa onzième annee. *Bull Soc Anat de Paris* 5:148–157
- Courchesne E, Allen G (1997) Prediction and preparation, fundamental functions of the cerebellum. *Learn Mem* 4(1):1–35
- Demirtas-Tatlidede A, Freitas C, Cromer JR, Safar L, Ongur D, Stone WS, Seidman LJ, Schmahmann JD, Pascual-Leone A (2010) Safety and proof of principle study of cerebellar vermal theta burst stimulation in refractory schizophrenia. *Schizophr Res* 124(1-3):91–100
- Diedrichsen J (2006) A spatially unbiased atlas template of the human cerebellum. *Neuroimage* 33(1):127–138
- Dow RS (1942) The evolution and anatomy of the cerebellum. *Biol Rev* 17:179–220
- Dow RS (1974) Some novel concepts of cerebellar physiology. *Mt Sinai J Med* 41:103–119
- Dow RS, Anderson R (1942) Cerebellar action potentials in response to stimulation of proprioceptors and exteroceptors in the rat. *J Neurophysiol* 5:363–372
- Dow RS, Moruzzi G (1958) *The physiology and pathology of the cerebellum*. University of Minnesota Press, Minneapolis
- Dum RP, Strick PL (2003) An unfolded map of the cerebellar dentate nucleus and its projections to the cerebral cortex. *J Neurophysiol* 89(1):634–639
- Duncan GW, Parker SW, Fisher CM (1975) Acute cerebellar infarction in the PICA territory. *Arch Neurol* 32(6):364–368
- Eccles JC, Ito M, Szentagothai J (1967) *The cerebellum as a neuronal machine*. Springer, New York
- Edinger L (1909) *Über die Einteilung des Cerebellums*. *Anat Anz* 35:319–323
- Ferrier D, Turner WA (1893) A record of experiments illustrative of the symptomatology and degenerations following lesions of the cerebellum and its peduncles and related structures in monkeys. *Philos Trans R Soc B* 185:719–778
- Flourens P (1824) *Recherches Experimentales sur les Proprietes et les Fonctions du Systeme Nerveux dans les Animaux Vertebres*, 1st edn. Crevot, Paris
- Fodéra M (1823) *Recherches expérimentales sur le système nerveux*. *J Physiol Exp Pathol* 3:191–217
- Fox CA (1959) The intermediate cells of Lugaro in the cerebellar cortex of the monkey. *J Comp Neurol* 112:39–53



- Fox PT, Raichle ME, Thach WT (1985) Functional mapping of the human cerebellum with positron emission tomography. *Proc Natl Acad Sci U S A* 82:7462–7466
- Fulton JF, Dow RS (1937) The cerebellum: a summary of functional localization. *Yale J Biol Med* 10:89–119
- Gall FJ, Spurzheim G (1810) *Anatomie et Physiologie du Système Nerveux en général, et du Cerveau en particulier*. Atlas. Paris, Chez F. Schoell
- Gao J-H, Parsons LM, Bower JM, Xiong J, Li J, Fox PT (1996) Cerebellum implicated in sensory acquisition and discrimination rather than motor control. *Science* 272:545–547
- Gilbert PFC, Thach WT (1977) Purkinje cell activity during motor learning. *Brain Res* 128:309–328
- Glickstein M, Voogd J (1995) Lodewijk Bolk and the comparative anatomy of the cerebellum. *Trends Neurosci* 18:206–210
- Glickstein M, May JG 3rd, Mercier BE (1985) Corticopontine projection in the macaque: the distribution of labelled cortical cells after large injections of horseradish peroxidase in the pontine nuclei. *J Comp Neurol* 235(3):343–359
- Grafman J, Litvan I, Massaquoi S, Stewart M, Sirigu A, Hallett M (1992) Cognitive planning deficit in patients with cerebellar atrophy. *Neurology* 42:1493–1496
- Gravel C, Hawkes R (1990) Parasagittal organization of the rat cerebellar cortex: direct comparison of Purkinje cell compartments and the organization of the spinocerebellar projection. *J Comp Neurol* 291:79–102
- Grimaldi G, Argyropoulos GP, Boehringer A et al (2014) Non-invasive cerebellar stimulation – a consensus paper. *Cerebellum* 13(1):121–138
- Groenewegen HJ, Voogd J (1977) The parasagittal zonation within the olivocerebellar projection. I. Climbing fiber distribution in the vermis of cat cerebellum. *J Comp Neurol* 174:417–488
- Groenewegen HJ, Voogd J, Freedman SL (1979) The parasagittal zonation within the olivocerebellar projection: 2. Climbing fiber distribution in the intermediate and hemispheric parts of cat cerebellum. *J Comp Neurol* 183:551–602
- Guëll X, Hoche F, Schmahmann JD (2015) Metalinguistic deficits in patients with cerebellar dysfunction: empirical support for the dysmetria of thought theory. *Cerebellum* 14(1):50–58
- Habas C, Kamdar N, Nguyen D, Prater K, Beckmann CF, Menon V et al (2009) Distinct cerebellar contributions to intrinsic connectivity networks. *J Neurosci* 29(26):8586–8594
- Haines DE (1981) Zones in the cerebellar cortex. Their organization and potential relevance to cerebellar stimulation. *J Neurosurg* 55:254–264
- Hampson JL, Harrison CR, Woolsey CN (1952) Cerebro-cerebellar projections and somatotopic localization of motor function in the cerebellum. *Res Publ Assoc Nerv Ment Dis* 30:299–316
- Hashimoto M, Ohtsuka K (1995) Transcranial magnetic stimulation over the posterior cerebellum during visually guided saccades in man. *Brain* 118:1185–1193
- Heath RG (1977) Modulation of emotion with a brain pacemaker. Treatment for intractable psychiatric illness. *J Nerv Ment Dis* 165:300–317
- Heath RG, Harper JW (1974) Ascending projections of the cerebellar fastigial nucleus to the hippocampus, amygdala, and other temporal lobe sites: evoked potential and histological studies in monkeys and cats. *Exp Neurol* 45:2682–2687
- Henneman E, Cooke PM, Snider RS (1952) Cerebellar projections to the cerebral cortex In: Bard P (ed) *Patterns of organization in the central nervous system*. *Res Publ Ass nerv ment Dis* 30:317–333
- Hoche F, Guëll X, Sherman JC, Vangel MG, Schmahmann JD (2015 Nov 19) Cerebellar contribution to social cognition. *Cerebellum* [Epub ahead of print]
- Hoddevik GH, Brodal A (1977) The olivocerebellar projection studied with the method of retrograde axonal transport of horseradish peroxidase. V. The projection to the flocculonodular lobe and the paraflocculus in the rabbit. *J Comp Neurol* 176:269–280
- Holmes G (1907) A form of familial degeneration of the cerebellum. *Brain* 30:466–488
- Holmes G (1917) The symptoms of acute cerebellar injuries due to gunshot wounds. *Brain* 40:461–535

- Holmes G (1939) The cerebellum of man (HughlingsJackson memorial lecture). *Brain* 62:1–30
- Ingvar S (1918) Zur Phylo- und Ontogenesae des Kleinhirns. *Folia Neuro-Biologica* 11:205–495
- Ito M (1984) *The cerebellum and neural control*. Raven Press, New York
- Ito M (1993) Movement and thought: identical control mechanisms by the cerebellum. *Trends Neurosci* 16:448–450
- Ivry RB, Keele SW (1989) Timing functions of the cerebellum. *J Cogn Neurosci* 1:136–152
- Jansen J, Brodal A (1940) Experimental studies on the intrinsic fibers of the cerebellum. II. The corticonuclear projection. *J Comp Neurol* 73:267–321
- Joubert M, Eisenring JJ, Robb JP, Andermann F (1969) Familial agenesis of the cerebellar vermis. A syndrome of episodic hyperpnea, abnormal eye movements, ataxia, and retardation. *Neurology* 19:813–825
- Larsell O (1970) In: Jansen J (ed) *The comparative anatomy and histology of the cerebellum from monotremes through apes*. The University of Minnesota Press, Minneapolis
- Larsell O, Jansen J (1972) *The comparative anatomy and histology of the cerebellum. The human cerebellum, cerebellar connections, and cerebellar cortex*. The University of Minnesota Press, Minneapolis
- Leiner HC, Leiner AL (1997) How fibers subserve computing capabilities: similarities between brains and machines. In: Schmähmann JD (ed). *Int Rev Neurobiol* 41:535–553. San Diego, Academic Press
- Leiner HC, Leiner AL, Dow RS (1986) Does the cerebellum contribute to mental skills? *Behav Neurosci* 100:443–454
- Levisohn L, Cronin-Golomb A, Schmähmann JD (2000) Neuropsychological consequences of cerebellar tumour resection in children: cerebellar cognitive affective syndrome in a paediatric population. *Brain* 123(Pt 5):1041–1050
- Lisberger SG, Fuchs AF (1978) Role of primate flocculus during rapid behavioral modification of vestibuloocular reflex. I. Purkinje cell activity during visually guided horizontal smooth-pursuit eye movements and passive head rotation. *J Neurophysiol* 41:733–763
- Llinas R (1984) Functional significance of the basic cerebellar circuit in motor coordination. In: Bloedel JR (ed) *Cerebellar functions*. Springer, New York, pp 171–185
- Llinas R, Welsh JP (1993) On the cerebellum and motor learning. *Curr Opin Neurobiol* 3:958–965
- Luciani L (1891) *Il cerbelletto: Nuovi studi di fisiologia normale e pathologica*. Firenze: Le Monnier. German translation, Leipzig: E. Besold, 1893
- Magendie F (1824) Mémoire sur les fonctions de quelques parties du système nerveux. *J Physiol Exp Pathol* 3:376–407
- Maiti A, Snider RS (1975) Cerebellar control of basal forebrain seizures: amygdala and hippocampus. *Epilepsia* 16:521–533
- Malacarne MVG (1776) *Nuova esposizione della vera struttura del cerveletto umano*. G M Briolo, Torino
- Manto M (2014). Cognitive deficits in autosomal dominant ataxias: what did we learn? In: Koziol et al. (ed) *Consensus paper: the cerebellum's role in movement and cognition*. *Cerebellum* 13(1):151–177
- Manto M, Mariën P (2015) Schmähmann's syndrome – identification of the third cornerstone of clinical ataxiology. *Cerebellum Ataxias* 2:2. doi:10.1186/s40673-015-0023-1, eCollection
- Marani E, Voogd J (1977) An acetylcholinesterase band-pattern in the molecular layer of the cat cerebellum. *J Anat* 124:335–345
- Marie P (1893) Sur l'hérédo-ataxie cérébelleuse. *Sem Méd* 13:444–447
- Marr D (1969) A theory of cerebellar cortex. *J Physiol* 202:437–470
- Mayo H (1827) *A series of engravings intended to illustrate the structure of the brain and spinal cord in man*. Burgess and Hill, London
- Middleton FA, Strick PL (1994) Anatomical evidence for cerebellar and basal ganglia involvement in higher cognitive function. *Science* 266:458–461

- Molinari M, Leggio MG, Solida A, Ciorra R, Misciagna S, Silveri MC et al (1997) Cerebellum and procedural learning: evidence from focal cerebellar lesions. *Brain* 120(Pt 10):1753–1762
- Moriguchi I (1981) A study of schizophrenic brains by computerized tomography scans. *Folia Psychiatr Neurol Jpn* 35:55–72
- Mugnaini E, Floris A (1994) The unipolar brush cell: a neglected neuron of the mammalian cerebellar cortex. *J Comp Neurol* 339(2):174–180
- Neau JP, Arroyo-Anllo E, Bonnaud V, Ingrand P, Gil R (2000) Neuropsychological disturbances in cerebellar infarcts. *Acta Neurol Scand* 102(6):363–370
- Neuburger M (1897) Die historische Entwicklung der experimentellen Gehirn- und Rückenmarksphysiologie vor Flourens. Ferdinand Enke Verlag, Stuttgart. Translated and edited, with additional material, by Edwin Clarke (1981) *The Historical Development of Experimental Brain and Spinal cord Physiology before Flourens*. Johns Hopkins University Press, Baltimore/London
- O'Reilly JX, Beckmann CF, Tomassini V, Ramnani N, Johansen-Berg H (2010) Distinct and overlapping functional zones in the cerebellum defined by resting state functional connectivity. *Cereb Cortex* 20(4):953–965
- Oscarsson O (1965) Functional organization of the spino- and cuneocerebellar tracts. *Physiol Rev* 45:495–522
- Oscarsson O (1980) Functional organization of olivary projection to the cerebellar anterior lobe. In: Courville J, de Montigny C, Lamarre Y (eds) *The inferior olivary nucleus: anatomy and physiology*. Raven Press, New York, pp 279–289
- Őz G, Iltis I, Hutter D, Thomas W, Bushara KO, Gomez CM (2011) Distinct neurochemical profiles of spinocerebellar ataxias 1, 2, 6, and cerebellar multiple system atrophy. *Cerebellum* 10(2):208–217
- Palay SL, Chan-Palay V (1974) *Cerebellar cortex*. Springer, New York
- Petersen SE, Fox PT, Posner MI, Mintum MA, Raichle ME (1989) Positron emission tomographic studies of the processing of single words. *J Cogn Neurosci* 1:153–170
- Pollack IF, Polinko P, Albright AL, Towbin R, Fitz C (1995) Mutism and pseudobulbar symptoms after resection of posterior fossa tumors in children: incidence and pathophysiology. *Neurosurgery* 37:885–893
- Purkyně JE (1837) Bericht die Versammlung deutscher Naturforscher und Ärzte in Prag im September. Prague. Pt. 3, sec. 5. Anatomisch-physiologische Verhandlungen. (Quoted in Clarke and O'Malley, 1996)
- Riklan M, Marisak I, Cooper IS (1974) Psychological studies of chronic cerebellar stimulation in man. In: Cooper IS, Riklan M, Snider RS (eds) *The cerebellum epilepsy and behavior*. Plenum Press, New York, pp 285–342
- Riley HA (1929) The mammalian cerebellum. A comparative study of the arbor vitae and folial pattern. *Res Publ Assoc Res Nerv Ment Dis* 6:37–192
- Riva D, Giorgi C (2000) The cerebellum contributes to higher functions during development: evidence from a series of children surgically treated for posterior fossa tumours. *Brain* 123(Pt 5):1051–1061
- Rolando L (1809) *Saggio sopra la vera struttura del cerbello dell'uomo e degli animali e sopra le funzoini del sistema nervosa*. Sassari: Stampeia da S.S.R.M. Privilegiata. (Quoted in Dow and Moruzzi, 1958)
- Ross B, Michaelis T (1996) MR spectroscopy of the brain: neurospectroscopy. In: Edelman RR, Hesselink JR, Zlatkin MB (eds) *Clinical magnetic resonance imaging*, 2nd edn. W.B. Saunders Co, Philadelphia, pp 928–981
- Ruigrok TJ, Osse RJ, Voogd J (1992) Organization of inferior olivary projections to the flocculus and ventral paraflocculus of the rat cerebellum. *J Comp Neurol* 316:129–150
- Russell JSR (1894) Experimental researches into the functions of the cerebellum. *Philos Trans R Soc Lond B* 185:819–861

- Sasaki K, Oka H, Matsuda Y, Shimono T, Mizuno N (1975) Electrophysiological studies of the projections from the parietal association area to the cerebellar cortex. *Exp Brain Res* 23:91–102
- Schmahmann J (1991) An emerging concept. The cerebellar contribution to higher function. *Arch Neurol* 48(11):1178–1187
- Schmahmann JD (1997a) Rediscovery of an early concept. In: Schmahmann JD (ed) *The cerebellum and cognition*. Academic, San Diego, pp 3–27, *Int Rev Neurobiol.* 41:1997
- Schmahmann JD (ed) (1997b) *The cerebellum and cognition*. Academic, San Diego, *Int Rev Neurobiol.* 41:1997
- Schmahmann JD (2000) The role of the cerebellum in affect and psychosis. *J Neurolinguist* 13:189–214
- Schmahmann JD (2004) Disorders of the cerebellum: ataxia, dysmetria of thought, and the cerebellar cognitive affective syndrome. *J Neuropsychiatry Clin Neurosci* 16(3):367–378
- Schmahmann JD (2010) The role of the cerebellum in cognition and emotion: personal reflections since 1982 on the dysmetria of thought hypothesis, and its historical evolution from theory to therapy. *Neuropsychol Rev* 20(3):236–260
- Schmahmann JD, Pandya DN (1997a) Anatomic organization of the basilar pontine projections from prefrontal cortices in rhesus monkey. *J Neurosci* 17:438–458
- Schmahmann JD, Pandya DN (1997b) The cerebrocerebellar system. In: Schmahmann JD (ed) *The cerebellum and cognition*. Academic, San Diego, *Int Rev Neurobiol* 41:31–60
- Schmahmann JD, Pandya DN (2006) *Fiber pathways of the brain*. Oxford University Press, New York
- Schmahmann JD, Sherman JC (1998) The cerebellar cognitive affective syndrome. *Brain*. In press
- Schmahmann JD, Doyon J, Toga A, Evans A, Petrides M (2000) *MRI atlas of the human cerebellum*. Academic, San Diego
- Schmahmann JD, Rosene DL, Pandya DN (2004) Motor projections to the basis pontis in rhesus monkey. *J Comp Neurol* 478(3):248–268
- Schmahmann JD, Weilburg JB, Sherman JC (2007) The neuropsychiatry of the cerebellum – insights from the clinic. *Cerebellum* 6(3):254–267
- Schmahmann JD, MacMore J, Vangel M (2009) Cerebellar stroke without motor deficit: clinical evidence for motor and non-motor domains within the human cerebellum. *Neuroscience* 162(3):852–861
- Shambes G, Gibson M, Welker W (1978) Fractured somatotopy in granule cell tactile areas of rat cerebellar hemispheres revealed by micromapping. *Brain Behav Evol* 15:94–140
- Sherrington C (1906) *The integrative action of the nervous system*. Yale University Press, New Haven
- Silveri MC, Leggio MG, Molinari M (1994) The cerebellum contributes to linguistic production: a case of agrammatic speech following a right cerebellar lesion. *Neurology* 44:2047–2050
- Snider RS (1952) Interrelations of cerebellum and brainstem In: Bard P (ed) *Patterns of Organization of the Central Nervous system*. Res Publ Assoc Nerv Ment Dis 30:267–281
- Snider RS (1982) Cerebellar pathology in schizophrenia – cause or consequence? *Neurosci Behav Rev* 6:47–53
- Snider RS, Stowell A (1942) Evidence of tactile sensibility in the cerebellum of the cat. *Fed Proc* 1:82
- Stoodley CJ, Schmahmann JD (2009) Functional topography in the human cerebellum: a meta-analysis of neuroimaging studies. *Neuroimage* 44(2):489–501
- Stoodley CJ, Valera EM, Schmahmann JD (2012) Functional topography of the cerebellum for motor and cognitive tasks: an fMRI study. *Neuroimage* 59(2):1560–1570
- Tedeschi G, Bertolino A, Massaquoi SG, Campbell G, Patronas NJ, Bonavita S et al (1996) Proton magnetic resonance spectroscopic imaging in patients with cerebellar degeneration. *Ann Neurol* 39:71–78

- Tedesco AM, Chiricozzi FR, Clausi S, Lupo M, Molinari M, Leggio MG (2011) The cerebellar cognitive profile. *Brain* 134(Pt 12):3672–3686
- Tesche CD, Karhu J (1997) Somatosensory evoked magnetic fields arising from sources in the human cerebellum. *Brain Res* 744:23–31
- Thach WT (1996) On the specific role of the cerebellum in motor learning and cognition: clues from PET activation and lesion studies in man. *Behav Brain Sci* 19:411–433
- Vicq-d'Azyr F (1786) *Traité d' anatomie et de physiologie, avec des planches coloriées: Tome premier*. Francois Ambrose Didot l' aîné, Paris
- Voogd J (1967) Comparative aspects of the structure and fibre connexions of the mammalian cerebellum. In: Fox CA, Snider RS (eds) *The cerebellum*, vol 25, *Progress in brain research*. Elsevier, Amsterdam, pp 94–135
- Voogd J (1969) The importance of fiber connections in the comparative anatomy of the mammalian cerebellum. In: Palay SL, Chan-Palay V (eds) *Neurobiology of cerebellar evolution and development*. Springer, Berlin, pp 134–161
- Walker AE (1938) An oscillographic study of the cerebello-cerebral relationships. *J Neurophysiol* 1:16–23
- Wessel K, Tegenthoff M, Vorgerd M, Otto V, Nitschke MF, Malin JP (1996) Enhancement of inhibitory mechanisms in the motor cortex of patients with cerebellar degeneration: a study with transcranial magnetic brain stimulation. *Electroencephalogr Clin Neurophysiol* 101:273–280
- Wisoff JH, Epstein FJ (1984) Pseudobulbar palsy after posterior fossa operation in children. *Neurosurgery* 15(5):707–709
- Zervas NT, Hoerner GG, Gordy PD (1967) Cerebellar dentatectomy in primates and humans. *Trans Am Neurol Assoc* 92:27–30
- Ziehen T (1934) *Centralnervensystem*. *Handbuch der Anatomie*. Verlag von Gustav Fischer, Jena

# Chapter 3

## Pivotal Insights: The Contributions of Gordon Holmes (1876–1965) and Olof Larsell (1886–1964) to Our Understanding of Cerebellar Function and Structure

Duane E. Haines

**Abstract** Among the notables who have contributed to our knowledge of cerebellar structure and function, two individuals stand out. The neurologist Gordon M. Holmes, consequent to his clinical observations on patients with cerebellar damage, especially those with injuries in WW I, provided a remarkable understanding of deficits, their laterality in relation to lesion location, and whether or not it involved cortex, nuclei, or both. He also defined, and refined, the clinical terminology describing cerebellar deficits to a level of accuracy, and especially relevance, that it is commonly used today. The anatomist Olof Larsell, in 1920, embarked on a line of investigation that would result, over 25+ years later, in a coherent and organized terminology for the lobes and lobules of the cerebellum that is widely used today and was the structural basis for numerous later experimental investigations. In this effort Larsell used a developmental approach, mapped the sequential approach of the cerebellar fissures and folia, and offered a terminology that clarified the existing, and confusing, approach that existed prior to 1920.

**Keywords** Gordon Holmes • Olof Larsell • Cerebellum • History of neuroscience

Discoveries in function commonly follow the clarification provided by dogged investigations of brain morphology. Based on chronology, one could argue that the reverse is seen in the contributions of the protagonists in this brief story: the British clinical neurologist, Gordon Morgan Holmes (Feb. 22, 1876–Dec. 29, 1965) and the American neuroanatomist Olof Larsell (Mar. 13, 1886–Ap. 8, 1964).

---

D.E. Haines (✉)

Department of Neurobiology and Anatomy, Wake Forest School of Medicine,  
1 Medical Center Blvd, Winston-Salem, NC 27157-1010, USA

e-mail: [dhaines@wakehealth.edu](mailto:dhaines@wakehealth.edu)

### 3.1 Gordon M. Holmes

Holmes (Fig. 3.1) received his medical training at Trinity College, Dublin (1899). Consequent to a successful stint at the Richmond Asylum, Dublin, he spent over 2 years studying with Karl Weigert and Ludwig Edinger where he gained appreciation for the intricacies of brain morphology. He went on to hold positions at the National, Charing Cross, and Moorfields Ophthalmic Hospitals.

With the beginning of World War (WW) I Holmes attempted to enlist but was rejected (he was myopic). He bypassed this obstacle by joining a Red Cross hospital immediately behind the front where he rose through the ranks. The combination of his work ethic, skill as a neurologist and the unfortunate availability of injured soldiers, provided the means for Holmes to make clinical observations that were remarkably insightful for their time.

This great World War provided literally hundreds of soldiers with injury to the occipital region and the cerebellum, due to poorly designed helmets. This provided Holmes the opportunity to observe, study, and refine clinical concepts of cerebellar function that stand to this day. Quotes are liberally used here to clearly illustrate the contemporary nature of Holmes' (and Larsell's) descriptions.



**Fig. 3.1** Holmes (*light suit, hands in pockets*) during a stay at the Senkenberg Institute. Back row, *L to R*: Juliusberg, Rosenberg, Jensen, Philipp, Franz. Front row, *L to R*: Von Jagic, Southard, Edinger, Holmes, Herxheimer, Tiegel, Kunicke, Friedmann. Sitting, Weigert (Courtesy of *The Cerebellum*, 2007; 6: 141–156)

Holmes published a large body of information regarding cerebellar influence on somatomotor activity from his clinical research (Holmes 1917), and presented in his Croonian Lectures of 1922 (Holmes 1922a, b, c, d). He acknowledged that his cases were:

...determined largely by the opportunities I have had of observing the effects of local lesions of the cerebellum in both warfare and civil life.

While he acknowledged the numerous prior studies that attempted to answer fundamental questions he noted:

...there is still a remarkable divergence between the symptoms attributed in various textbooks and monographs to lesions of the cerebellum in man.

Holmes made detailed studies of patients (acute and long term) with cerebellar lesions to clarify the unique traits of particular somatomotor deficits. Using this patient population, he made definitive observations that not only clarified previous misconceptions, but expanded the understanding of cerebellar function at that time. Many ideas and concepts were clarified, or discovered, by Holmes and described in terms/phrases that could come from any twenty-first century comprehensive textbook.

First, Holmes definitively clarified the fact that

The effects of cerebellar injuries fall almost exclusively upon the motor system, ... of the same side.

This is now a well established concept, along with the newer recognition of the wider role of the cerebellum.

Second, Holmes noted the difficulty of sorting out what difference may exist between lesions of only the cerebellar cortex versus cortex plus nuclei. He described deficits resultant from clearly superficial lesions (cortex) and those with deeper damage (cortex + nuclei) and concluded:

... we find that when the lesion is so superficial that the nuclei cannot have been directly injured the symptoms are less intense, less regular, and that they disappear much more rapidly. ... rapid improvement is never seen when the damage extends to the neighborhood of the central nuclei.

This is observed in the contemporary clinic: a distal PICA lesion (cortex) results in a cascade of vestibular and motor deficits that resolve quickly, within days to very few weeks, while a SCA lesion (cortex + nuclei) results in a similar cascade of motor deficits lasting weeks, months, or years.

Third, Holmes noted that a “...*most striking feature*...” is a decrease in muscle tone. He reported that;

When a lesion involves a large part of one-half of the cerebellum, ... the hypotonia is rigidly limited to ... the same side ... often most pronounced at the proximal than at the distal joints.

He clarified the variety of tests that could be used to arrive at an accurate diagnosis.



Fourth, Holmes accurately described the variety of movement disorders that characterize cerebellar lesions;

Dysmetria ... striking abnormality in the affected limbs ... their movements are not correctly adapted or proportioned ... they are ill-measured.

He noted that dysmetria may exist in two forms:

“... the range of movement is most commonly excessive ...” (hypermetria) or that “... the movement is arrested or slowed down before the point the patient wishes to attain is reached ...” (hypometria).

Fifth, three common cerebellar deficits are the rebound phenomenon, diadochokinesia, and the intention tremor. Concerning the first Holmes noted (see also Koehler et al. 2000):

... resistance that effectively prevents a movement of a normal limb in response to a strong voluntary effort be suddenly released, the limb, after moving a short distance ... is arrested abruptly by the action of the antagonist muscles... this sudden arrest fails frequently in cerebellar disease ... when the grasp is suddenly relaxed the hand on the affected side swings violently toward his face or shoulder, and ... may be flung above his head.

Diadochokinesia is the inability of a patient to rapidly;

... pronate and supinate his forearms ... a very striking difference is noticed between the movements on the two sides ....

Holmes noted that if the limb was hypotonic the abnormal movements may be slow, irregular in “... *rate and range* ...” and “... *become more pronounced the longer the effort is continued* ...”. Holmes described the intention tremor as complex movements, its individual components are disrupted, uncoordinated, and largely ineffective. He noted:

In the early part of the movement the limb sways about in a purposeless manner as soon as it is raised from its support ... in trying to touch his nose, his finger, for instance, often comes to his cheek or eye.

A remarkable element of the work by Holmes on the cerebellum is its accuracy, detail, insights, and relevance to modern day neurology. In fact, one can read Holmes and get information that is just as detailed, correct, and useful with respect to the motor phenomena following cerebellar injury as in any contemporary text.

### 3.2 Olof Larsell

Larsell (Fig. 3.2, Mar, 13, 1886–April 8, 1964) was born in Rättvik, Sweden and came to the United States with his mother at age 5; his father had established a home in Tacoma, Washington. He received the B.S degree (in Biology) from McMinnville (now Linfield) College in 1910. His academic travels were circuitous. He taught at Linfield (1910–1913), attended Northwestern University (1913–1914, M.S. degree in Zoology), taught at Linfield (1914–1915), re-entered Northwestern in 1915 and received his Ph.D. degree in 1918 (Haines 1999).

**Fig. 3.2** Olof Larsell in his office at the University of Oregon Medical School, ca. 1945. Author's collection (Courtesy of Mr. Robert Larsell)



During the summers of 1913 and 1914 Larsell took summer courses at the University of Chicago under the renowned American neuroanatomist, Charles Judson Herrick. These fortuitous summer experiences greatly influenced Larsell's thinking, research direction, and life-long fascination with brain anatomy.

### 3.3 The Problem

During the period spanning the 1880s and up to about the mid 1940s, the terminology utilized to designate the lobes/lobules, folia, and fissures of the cerebellum was highly variable. It consisted of different names being given to the same folia/lobes/lobules; in some cases lower and upper case letters intermixed with numbers/numerals (Arabic and Roman) and what constituted a lobe was inconsistently applied (Angevine et al. 1961). For example, the vermis part of the culminate lobule (IV and V of Larsell) was called the culmen, culmen monticule, pars culminus of the lobus anterior, lobe B, or lobules 3 and 4. This represented a significant confusion of terminology.

Stemming from his time with Herrick, Larsell began a series of studies that would span over 40 years and focus on the morphology of the cerebellum utilizing a developmental approach. Whether or not Larsell realized it, this approach would reveal homologies in lobes, lobules, and fissures across a wide range of biological forms that are not evident in a study of the adult form. This would clearly establish a broad-based biological pattern. Larsell's first paper, published in 1920, and identifies the source of his motivation:

It was at the suggestion of Professor Herrick that the present study was begun. It is a pleasure for the writer to acknowledge his sense of indebtedness to Professor Herrick....

### 3.4 Early Studies, 1920–1932

Larsell's first paper, "The cerebellum of *Amblystoma*" appeared in 1920. This early period focused on non-mammalian forms. Interestingly, Larsell listed his first affiliation as the "Anatomical Laboratories of the University of Chicago" and "the University of Wisconsin" where he was an Assistant Professor (1918–1920). While Herrick had influenced the study, and provided some material, Larsell was not in residence at Chicago.

In this time frame Larsell methodically detailed the cerebelli of the tiger salamander, frog, newt, and a variety of snakes and lizards. He used silver impregnation methods (Golgi, Cajal), myelin and hematoxylin stains, and the Marchi method. He described aspects of development and the external anatomy of adult forms, specified a larger corpus cerebelli and a smaller auricular lobe, the cortical histology of these primitive forms, and the primordial cerebellar nuclei. He did not use a lobule designation, but the dye was cast (Larsell 1920, 1923, 1925, 1926, 1931, 1932a, b).

### 3.5 The Middle Period, 1932–1947

In this period Larsell expanded on the concept of a large cerebellar mass, the corpus cerebelli. The first superficial feature to appear was a shallow fissure along the caudal and lateral edge of the cerebellar anlage. Larsell identified the lateral part of this groove as the "*parafloccular fissure*" and the medial part as the "*uvulonodular fissure*" (or floccular fissure), terms used by previous investigators. This combined fissure separated a large rostral part of the cerebellum, the "corpus cerebelli", from a smaller caudal part, the "vestibular floccular lobe" (Larsell 1931, 1932a, 1934, 1936a, b, 1937, 1947a, b).

In studies during this period on opossum, bat, and human specimens, Larsell carefully refined the basis for his new nomenclature. He noted that a "*posterolateral fissure*" (his term) replaced the combined terms of parafloccular and uvulonodular fissures, that this fissure was first to appear in the cerebellar anlage dividing it into a "*flocculonodular lobe*" and "*corpus cerebelli*", and that the "*primary fissure*" was the second to appear and divided the corpus cerebelli into anterior and posterior lobes. Larsell (1935, 1936a, b, 1945, 1947a, b) noted:

The flocculonodular lobe and the corpus cerebelli are the fundamental cerebellar divisions morphologically, and ... functionally.

At this point two old concepts were disproven; first, the primary fissure was not the first to appear in development, and second, the concept of a 'median lobe' was no longer viable,

### 3.6 Later Studies and the Solution, 1948–1954

After 10 years of study on the avian cerebellum, Larsell used, for the first time (1948), the unique terminology that he had been working toward since 1920. He noted that the posterolateral fissure was first to appear in the cerebellar plate dividing it into a *flocculonodular lobe* and the *corpus cerebelli*. Larsell (1948) indicated that an orderly appearance of subsequent fissures in the corpus cerebelli resulted in an adult structure of 10 main folia (Roman numerals I–X).

For convenience of description they will be numbered I to X beginning anteriorly.

In this introduction of his method Larsell used the term “...*folia*...” recognizing the simple structure of the avian cerebellum, which lacked a hemisphere, and the vermis consisted of leaf-like structures.

Between 1952 and 1954 Larsell reported his extensive observations on the cerebellum of the white rat, cat, monkey, pig, and human using developmental stages and adult specimens (Larsell 1952, 1953a, b, 1954; Larsell and Dow 1939; Larsell and Whitlock 1952). Using these mammals he clearly showed that the mature mammalian cerebellum was composed of subdivisions called “...*lobules*...”.

I have pointed out...the striking similarities between folia I–X of birds and the vermian segments of the rat which the present investigation has brought to light ... I shall call these segments lobules I–X, corresponding to the similarly named avian folia.

Each lobule of the vermis, beginning with the lingual and ending with the nodulus, was identified by Roman numerals (I, II, III ... X). The lateral extension of each vermis lobule, the hemisphere portion, was identified by the same Roman numeral but with the prefix H (HII, HIII ... HX) specifying “*hemisphere portion of*...”. Larsell recognized that the basic pattern of a cerebellar plate being transected by two fissures (joining to make one – the posterolateral) formed a larger corpus cerebelli and a smaller flocculonodular lobe. In concert he noted that the development of the primary fissure, the second to appear and first in the corpus cerebelli, resulted in an anterior lobe (lobules I–V) and a posterior lobe (lobules VI–IX); the further development of additional fissures in these lobes clearly established to a fundamental plan. He postulated that this ten lobule arrangement would prove to be applicable to a wide range of forms, a point well-taken.

In studying Larsell’s correspondence with Herrick, it is clear that he was a quiet, reserved man who was concerned about the wider impact of his life-long work. In a letter to Herrick (dated July 20, 1948) Larsell says;

I treaded on Brouwer’s and Ingvar’s toes somewhat – gently enough I hope..., but I do not think my work will need repeating.

Indeed, it did not merit repeating, and by the late 1950s and 1960s was adopted by giants of the day and, to the present, is the standard.

## References

- Angevine JB, Mancall EL, Yakolev PI (1961) The human cerebellum: an atlas of gross topography in serial sections. Little, Brown and Company, Boston, pp 1–138
- Haines DE (1999) In: Garraty JA, Carnes MC (eds) American national biography, vol 13. Oxford University Press, New York, pp 204–206
- Holmes G (1917) The symptoms of acute cerebellar injuries due to gunshot. *Brain* 40:461–535
- Holmes G (1922a) Clinical symptoms of cerebellar disease and their interpretation, lecture I. *Lancet* 202:1178–1182
- Holmes G (1922b) Clinical symptoms of cerebellar disease and their interpretation, lecture II. *Lancet* 202:1232–1237
- Holmes G (1922c) Clinical symptoms of cerebellar disease and their interpretation, lecture III. *Lancet* 203:59–65
- Holmes G (1922d) Clinical symptoms of cerebellar disease and their interpretation, lecture IV. *Lancet* 203:111–115
- Koehler PJ, Bruyn GW, Pearce JMS (2000) Neurological eponyms. Oxford University Press, Oxford, pp 172–178
- Larsell O (1920) The cerebellum of amblystoma. *J Comp Neurol* 31:259–282
- Larsell O (1923) The cerebellum of the frog. *J Comp Neurol* 36:89–112
- Larsell O (1925) The development of the cerebellum in the frog (*Hyla regilla*) in relation to the vestibular and lateral-line systems. *J Comp Neurol* 39:249–289
- Larsell O (1926) The cerebellum of reptiles: lizards and snake. *J Comp Neurol* 41:59–94
- Larsell O (1931) The cerebellum of *Triturus torosus*. *J Comp Neurol* 53:1–54
- Larsell O (1932a) The cerebellum of reptiles: chelonians and alligator. *J Comp Neurol* 56:299–345
- Larsell O (1932b) The development of the cerebellum in *Amblystoma*. *J Comp Neurol* 54:357–435
- Larsell O (1934) Morphogenesis and evolution of the cerebellum. *Arch Neurol Psychiat (Chicago)* 31:373–395
- Larsell O (1935) The development and morphology of the cerebellum in the opossum. Part I. Early development. *J Comp Neurol* 63:65–94
- Larsell O (1936a) The development and morphology of the cerebellum in the opossum. Part II. Later development and adult. *J Comp Neurol* 63:251–291
- Larsell O (1936b) Cerebellum and corpus pontobulbare of the bat (*Myotis*). *J Comp Neurol* 64:275–302
- Larsell O (1937) The cerebellum: a review and interpretation. *Arch Neurol Psychiat (Chicago)* 38:580–607
- Larsell O (1945) Comparative neurology and present knowledge of the cerebellum. *Bull Minn Med Found* 5:73–85
- Larsell O (1947a) The cerebellum of myxinoids and petromyzonts, including developmental stages in the lampreys. *J Comp Neurol* 86:395–445
- Larsell O (1947b) The development of the cerebellum in man in relation to its comparative anatomy. *J Comp Neurol* 87:85–129
- Larsell O (1948) The development and subdivisions of the cerebellum of birds. *J Comp Neurol* 89:123–189
- Larsell O (1952) The morphogenesis and adult pattern of the lobules and fissures of the cerebellum of the white rat. *J Comp Neurol* 97:281–356
- Larsell O (1953a) The cerebellum of the cat and the monkey. *J Comp Neurol* 99:135–199
- Larsell O (1953b) The anterior lobe of the mammalian and the human cerebellum. *Anat Rec* 115:341
- Larsell O (1954) The development of the cerebellum of the pig. *Anat Rec* 118:73–107
- Larsell O, Dow RS (1939) The cerebellum: a new interpretation. *West J Surg Obstet Gynaecol* 47:256–263

- \*Larsell O, Jansen J (1967) The comparative anatomy and histology of the cerebellum from myxinooid through birds. The University of Minnesota Press, Minneapolis, pp 1–291
  - \*Larsell O, Jansen J (1970) The comparative anatomy and histology of the cerebellum from monotremes through apes. The University of Minnesota Press, Minneapolis, pp 1–269
  - \*Larsell O, Jansen J (1973) The comparative anatomy and histology of the cerebellum: the human cerebellum, cerebellar connections, and cerebellar cortex. The University of Minnesota Press, Minneapolis, pp 1–268, 67 plates
- Larsell O, Whitlock DG (1952) Further observations on the cerebellum of birds. *J Comp Neurol* 97:545–566

Letter: Larsell to CJ Herrick, July 20, 1948, The Herrick Collection, Neurology Collection, C. J. Herrick papers, Kenneth Spencer Research Library, University of Kansas Libraries, Lawrence, Kansas.

---

\*Although Larsell began writing his monographs in the early 1940s, at his death in 1964 it fell to Jan Jansen, a friend of many years, to assume the significant task of seeing the partially finished manuscripts to completion (Larsell and Jansen, 1967, 1970, 1973).

**Part II**  
**Anatomy and Histology of the Cerebellum**

# Chapter 4

## Gross Anatomy of the Cerebellum

Jan Voogd and Enrico Marani

**Abstract** After the first description of the cerebellar foliation by Vincenzo Malacarne (1744–1816) in his “Vera struttura del cervelletto umano” (the genuine structure of the human cerebellum, Malacarne V, Nuova esposizione della vera struttura del cervelletto umano. G. Briolo, Torino, 1776) many different nomenclatures have been proposed for the gross anatomy of the cerebellum (Angevine Jr JNB, Mancall EL, Yakovlev PI, The human cerebellum. Little Brown, Boston, 1961). Here we will consider the classical nomenclature of the human cerebellum and the comparative anatomical nomenclatures of Bolk (Das Cerebellum der Säugtiere. Fischer, Haarlem, 1906), Larsell (J Comp Neurol 97:281–356. 1952), and Larsell and Jansen (The comparative anatomy and histology of the cerebellum. III. The human cerebellum, cerebellar connections, and cerebellar cortex. University of Minnesota Press, Minneapolis, 1972) and their application to the human cerebellum, and to the small cerebellum of the mouse.

**Keywords** Vermis • Hemisphere • Fissures • Lobules • Folial cains • Mouse cerebellum • Human cerebellum

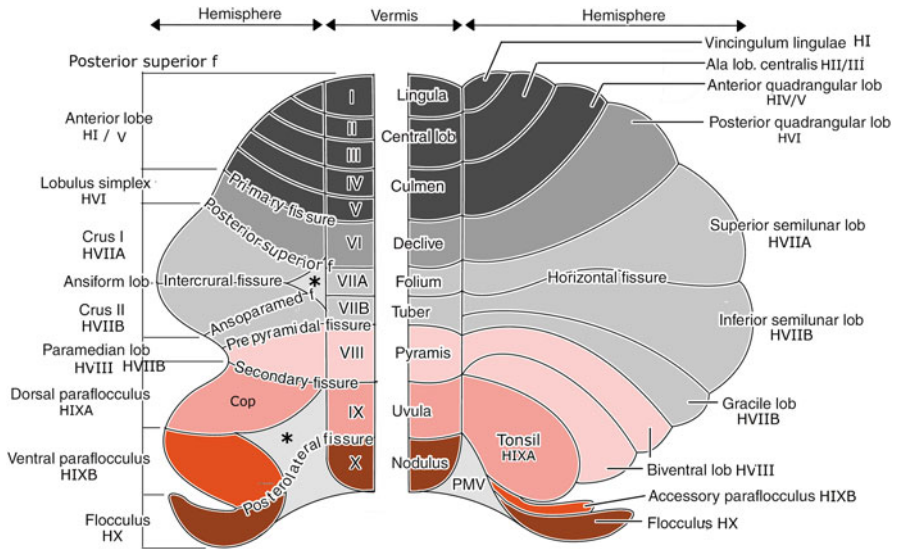
After the first description of the cerebellar foliation by Vincenzo Malacarne (1744–1816) in his “Vera struttura del cervelletto umano” (the genuine structure of the human cerebellum, 1776) many different nomenclatures have been proposed for the gross anatomy of the cerebellum (Angevine et al. 1961). Here we will consider the classical nomenclature of the human cerebellum and the comparative anatomical nomenclatures of Bolk (1906), Larsell (1952), and Larsell and Jansen (1972) and their application to the human cerebellum, and to the small cerebellum of the mouse.

---

J. Voogd (✉)  
Department of Neuroscience, Erasmus Medical Center Rotterdam,  
Rotterdam, The Netherlands  
e-mail: [janvoogd@bart.nl](mailto:janvoogd@bart.nl)

E. Marani  
MIRA Institute for Biomedical Engineering and Technical Medicine, Department of  
Electrical Engineering, Mathematics and Computer Science, Biomedical Signals and Systems  
group, University of Twente, Enschede, The Netherlands

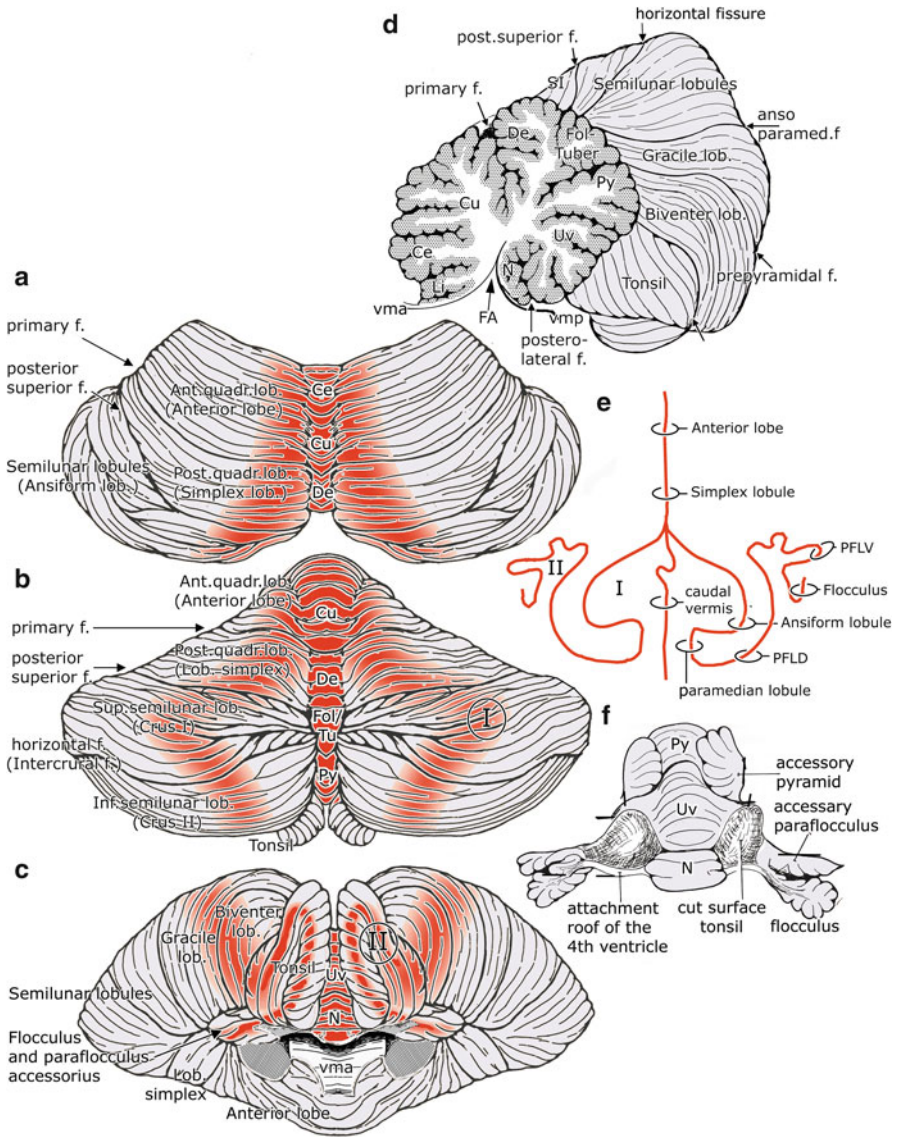




**Fig. 4.1** Nomenclature of the cerebellum. *Left* panel illustrates the comparative anatomical nomenclature for the hemisphere and Larsell's (1952) numbering system for the lobules of the vermis and hemispheres. *Right* panel shows the classical nomenclature of the human cerebellum. The homology of these lobules is indicated using the same color. *Asterisks* denote areas devoid of cortex in the center of folial rosettes of the ansiform lobule and the paraflocculus. Abbreviations: *Cop* copulapiramidis, *PMV* posterior medullary velum

In the classical nomenclature of the human cerebellum vermis and hemispheres, separated by the paramedian sulcus, are distinguished (Figs. 4.1, right panel and 4.2). The paramedian sulcus is shallow in the anterior cerebellum, but is a deep cleft posterior to the posterior superior sulcus. Here, the cortex can be interrupted, with white matter appearing at the surface. In the antero-posterior subdivision the cerebellum is divided into anterior and posterior lobes, separated by the primary fissure, the deepest fissure on a midsagittal section of the cerebellum. Names of the lobules are derived from their shape or their resemblance to particular structures (Malacarne 1776; Glickstein et al. 2009).

Bolk (1906) based his nomenclature on the comparison of numerous species of mammals. Bolk considered the vermis and the hemispheres as folial chains (Figs. 4.1, left panel and 4.2e). The cortex within a chain is always continuous, in the paramedian sulcus the cortex, or more precisely, the parallel fibers in the molecular layer may be interrupted. In the anterior lobe and in the simplex lobule, located immediately caudal to the primary fissure, the folial chains of vermis and hemisphere are aligned and the transverse fissures continue uninterruptedly from the vermis into the hemisphere. Caudal to the simplex lobule the folial chain of the hemisphere makes two loops, the ansiform lobule and the paraflocculus. The most caudal lobule of the folial chain of the hemisphere, the flocculus, is reflected upon the distal part of the paraflocculus. The cortex in the center of the ansiform lobule,



**Fig. 4.2** (a–c) Anterior, dorsal and posterior views of the human cerebellum. *Red lines* indicate the direction of the folial chains of vermis and hemispheres. (d) Midsagittally sectioned human cerebellum. (e) Bolk's (1906) diagram of the folial chains of vermis and hemispheres. (f) Dissection of the posterior cerebellum after removal of the tonsil. Abbreviations: *I*, *II* folial loops of the ansiform lobule and the para-flocculus, *Ce* central lobule, *Cu* culmen, *De* declive, *Fol/Tu* folium and tuber vermis, *N* nodulus, *PFLD* dorsal para-flocculus, *PFLV* ventral para-flocculus, *Py* pyramid, *Uv* uvula, *Vma* anterior medullary velum

lateral to the folium/tuber (Larsell's lobule VII) is interrupted. The rostral and caudal limbs of the folial loop of the ansiform lobule are known as the Crus I and II. The cortex is absent between the caudal vermal lobules, the uvula and the nodulus (IX and X), and the paraflocculus (HIX) and the flocculus (HX). The rostral and caudal limbs of the paraflocculus are known as the dorsal and ventral paraflocculus. At the level of the paramedian lobule, located between the ansiform lobule and the paraflocculus, the folial chains of vermis and hemispheres are aligned and the paramedian sulcus is indistinct. Interlobular fissures, if present, continue uninterruptedly from the pyramis (VIII) into the paramedian lobule.

Larsell (1952) emphasised the medio-lateral continuity of the lobules of vermis and hemispheres. He distinguished ten lobules in the vermis, indicated with the roman numerals I–X (Fig. 4.1, left panel). Their hemispherical counterparts are indicated with the prefix H. From Larsell's description it becomes clear that the paramedian lobule consists of rostral and caudal subdivisions. Its rostral portion (lobule HVIIIB, the gracile lobule) is continuous with vermal lobule VII, its caudal portion (HVIII: the copula pyramidis) is continuous with lobule VIII (the pyramis).

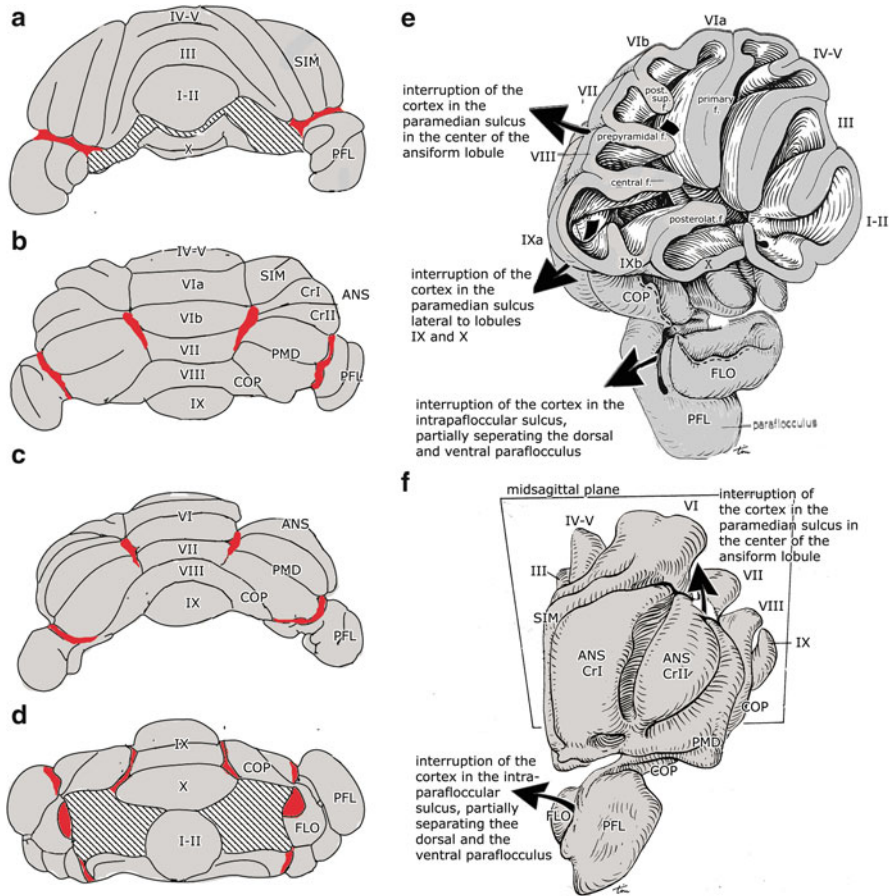
Several MRI atlases of the human cerebellum have been published (Schmahmann et al. 2000; Dietrichsen et al. 2009). They use a mixture of the classical and comparative anatomical nomenclatures, retaining the terms Crus I and II of the ansiform lobule. In applying Larsell's numeral system they discarded the prefix H for lobules of the hemisphere, thus introducing some confusion because it is not always clear whether lobules of vermis or hemispheres are meant.

For the homology of the paraflocculus and the flocculus with lobules in the human cerebellum it is important to note that the cortex of the flocculus can be subdivided into five longitudinal Purkinje cell zones (Voogd and Barmack 2006; Schonewille et al. 2006). Two zonal pairs connect through vestibulooculomotor neurons with the external eye muscles. In most mammals these floccular zones extend for some distance on the ventral paraflocculus. In monkeys they occupy the entire ventral paraflocculus. A narrow cortical bridge connects the ventral with the dorsal paraflocculus. In the human cerebellum this cortical bridge is broken. The dorsal paraflocculus is represented by the tonsil and the ventral paraflocculus by the accessory paraflocculus. In most mammals the folial loop of the paraflocculus is directed laterally. The folial loop of the tonsil, however, is directed medially (Fig. 4.2f).

The cerebellum of the mouse conforms to Bolk's general pattern (Marani and Voogd 1979). In the anterior lobe the lobules (H) I and II and (H) IV and V are fused (Fig. 4.3). A paramedian sulcus is absent in the anterior lobe and the simplex lobule.<sup>1</sup> An area without cortex is present lateral to lobule VII in the center of the ansiform lobule and lateral to the rostral paramedian lobule. White matter in the

---

<sup>1</sup>Because the vermis projects to the fastigial and vestibular nuclei, the lateral border of the vermis is located lateral to the Purkinje cell zone B that projects to the lateral vestibular nucleus. The location of the B zone in the anterior cerebellum and lobule VIII was established for the rat by Voogd and Ruigrok (2004) the corresponding white matter compartment was located for the mouse by Marani (1986).



**Fig. 4.3** The cerebellum of the mouse. (a–d) Anterior, dorsal, posterior and ventral views of the cerebellum of the Mouse. Interruptions of the cortex are indicated in red. (e) View of the midsagittally sectioned molecular layer of the cerebellum of the mouse. Dotted line indicates the attachment of the roof of the fourth ventricle. (f) Lateral view of a reconstruction of the molecular layer of the cerebellum of the Mouse. Note continuity between the copula pyramidis and the parafofoculus. Arrows point to regions where the cortex is interrupted (Modified from Marani and Voogd (1979)). Drawings by Jan Tinkelenberg. Abbreviations: ANS ansiform lobule, COP copula pyramidis, CrI, II, Crus I II of the ansiform lobule, FLO flocculus, PFL parafofoculus, PMD paramedian lobule, SIM simplex lobule

paramedian sulcus separates lobules IX and X from the parafofoculus and the flocculus. The cortexless areas extend from the paramedian sulcus into the superior part of the lobules IX and X. The copula pyramidis (HVIII) lateral continues into the dorsal parafofoculus. The folial loop of the parafofoculus remains separated from the paramedian lobule by the white matter in the parafofocular sulcus, an extension of the

white matter surrounding the cerebellum. The paraflocculus is incompletely divided into dorsal and ventral limbs by the intraparafloccular sulcus on the medial side of this lobule.

## References

- Angevine JNB Jr, Mancall EL, Yakovlev PI (1961) *The human cerebellum*. Little Brown, Boston
- Bolk L (1906) *Das Cerebellum der Säugetiere*. Fischer, Haarlem
- Dietrichsen J, Balsters JH, Flavell J, Cussans E, Ramnani M (2009) A probabilistic MR atlas of the human cerebellum. *Neuroimage* 46:39–46
- Glickstein M, Strata P, Voogd J (2009) Cerebellum: history. *Rev Neurosci* 162:549–559
- Larsell O (1952) The morphogenesis and adult pattern of the lobules and tissues of the cerebellum of the white rat. *J Comp Neurol* 97:281–356
- Larsell O, Jansen J (1972) *The comparative anatomy and histology of the cerebellum. III. The human cerebellum, cerebellar connections, and cerebellar cortex*. University of Minnesota Press, Minneapolis
- Malacarne V (1776) *Nuova esposizione della vera struttura del cervello umano*. G. Briolo, Torino
- Marani E (1986) Topographic histochemistry of the cerebellum. *Progr Histochem Cytochem* 16:1–169
- Marani E, Voogd J (1979) The morphology of the mouse cerebellum. *Acta Morphol Neerl Scand* 17:33–52
- Schmahmann JD, Doyon D, Toga AW, Petrides M, Evans AC (2000) *MRI atlas of the human cerebellum*. Academic, San Diego
- Schonewille M, Luo G, Ruigrok TJ, Voogd J, Schmolesky MT, Rutteman M, Hoebeek FE, de Jeu FE, de Zeeuw CI (2006) Zonal organization of the mouse flocculus: physiology, input and output. *J Comp Neurol* 497:670–682
- Voogd J, Ruigrok TJ (2004) The organization of the corticonuclear and olivocerebellar climbing fiber projections to the rat cerebellar vermis: the congruence of projection zones and the zebrin pattern. *J Neurocytol* 33:5–21
- Voogd J, Barmack NH (2006) Oculomotor cerebellum. *Prog Brain Res* 151:231–268

# Chapter 5

## Vascular Supply and Territories of the Cerebellum

Qiaoshu Wang and Louis R. Caplan

**Abstract** Within the posterior circulation, Caplan and colleagues characterized brain and vascular structures as involving the proximal, middle, and distal posterior circulation territories. The *proximal intracranial posterior circulation territory* includes regions supplied by the intracranial vertebral arteries (ICVAs)-the medulla oblongata and the posterior inferior cerebellar arteries (PICAs)-supplied region of the cerebellum. The ICVAs join at the medullo-pontine junction to form the basilar artery (BA). The *middle intracranial posterior circulation territory* includes the portion of the brain supplied by the BA up to its superior cerebellar artery (SCA) branches- the pons and the AICA-supplied portions of the cerebellum. The BA divides to form the 2 posterior cerebral arteries (PCAs) at the junction between the pons and the midbrain, just beyond the origins of the SCAs. The *distal intracranial posterior circulation territory* includes all of the territory supplied by the rostral BA and its SCA, PCA and their penetrating artery branches- midbrain, thalamus, SCA-supplied cerebellum, and PCA territories.

**Keywords** Cerebellum • Vertebral artery • Brainstem • Basilar artery • Cerebellar arteries

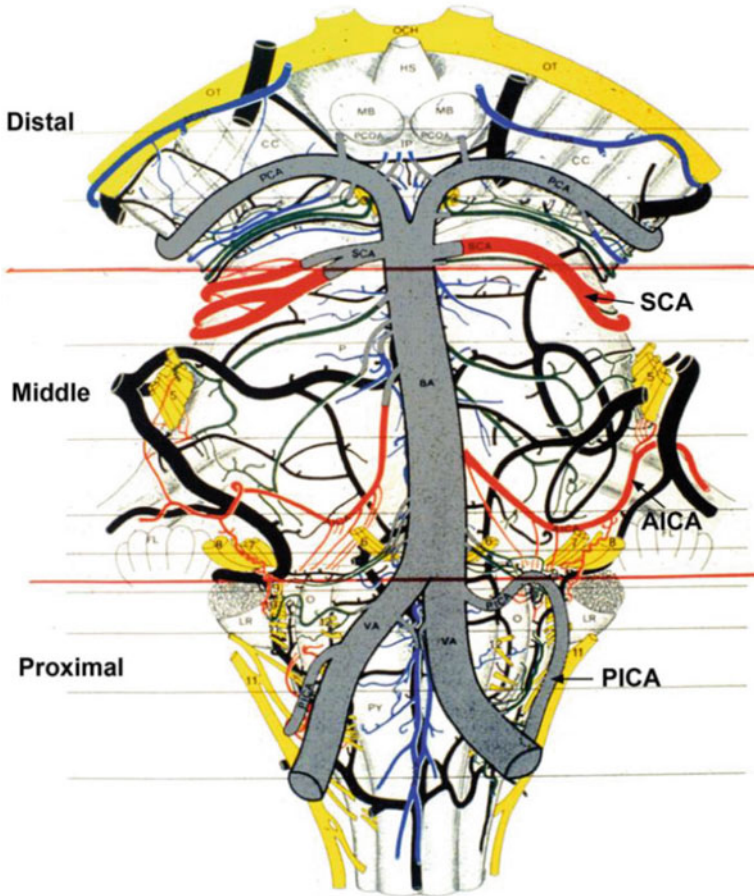
### 5.1 Overview

Within the posterior circulation, Caplan and colleagues characterized brain and vascular structures as involving the proximal, middle, and distal posterior circulation territories (Caplan 1996, 2000; Caplan et al. 2004, 2005; Chaves et al. 1994; Savitz and Caplan 2005). The *proximal intracranial posterior circulation territory* includes

---

Q. Wang (✉)  
Shanghai General Hospital, Shanghai, China  
e-mail: [qwang624@139.com](mailto:qwang624@139.com)

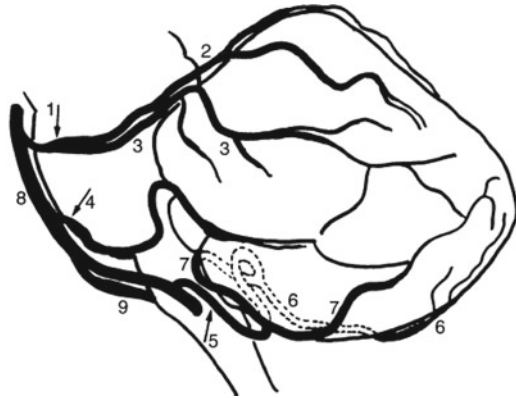
L.R. Caplan  
Beth Israel deaconess Medical Center, Boston, MA, USA  
e-mail: [lcaplan@bidmc.harvard.edu](mailto:lcaplan@bidmc.harvard.edu)



**Fig. 5.1** Schema of the proximal, middle, and distal intracranial territories of the vertebo-basilar arterial system (Drawn by Laurel Cook-Lowe, modeled after a figure in Duvernoy HM 1978)

regions supplied by the intracranial vertebral arteries (ICVAs)-the medulla oblongata and the posterior inferior cerebellar arteries (PICAs)-supplied region of the cerebellum. The ICVAs join at the medullo-pontine junction to form the basilar artery (BA). The *middle intracranial posterior circulation territory* includes the portion of the brain supplied by the BA up to its superior cerebellar artery (SCA) branches- the pons and the AICA-supplied portions of the cerebellum. The BA divides to form the two posterior cerebral arteries (PCAs) at the junction between the pons and the midbrain, just beyond the origins of the superior SCAs. The *distal intracranial posterior circulation territory* includes all of the territory supplied by the rostral BA and its SCA, PCA and their penetrating artery branches- midbrain, thalamus, SCA-supplied cerebellum, and PCA territories. This distribution is shown diagrammatically in Fig. 5.1.

**Fig. 5.2** Schematic diagram of the cerebellar arteries. 1 Superior cerebellar artery (SCA); 2 medial branch of the SCA; 3 lateral branch of the SCA; 4 anterior inferior cerebellar artery (AICA); 5 posterior inferior cerebellar artery (PICA); 6 medial branch of PICA; 7 lateral branch of PICA; 8 basilar artery; 9 vertebral artery (From Amarenco 1991)



The three surfaces of the cerebellum are: tentorial (or superior) facing the tentorium cerebelli, petrosal facing towards the petrous bone, and suboccipital facing the suboccipital bone located between the lateral and sigmoid dural sinuses (Lister et al. 1982). The PICAs encircle the medulla and supply the suboccipital cerebellar surface; the AICAs course around the pons and supply the petrosal surface of the cerebellum, and the SCAs encircle the midbrain and supply the tentorial, superior surface of the cerebellum (Lister et al. 1982).

The arteries to the cerebellum are distributed rostrocaudally so that the PICAs arise from the ICVAs, the anterior inferior cerebellar arteries (AICAs) arise from the BA, and the most rostral arteries, the SCAs, arise near the BA bifurcation (Fig. 5.2). The PICAs and the SCAs, the two largest arterial pairs have medial branches that supply mostly the vermian and paravermian portions of their respective regions of the cerebellum, and lateral branches which supply the cerebellar hemispheres. Infarcts in the cerebellum are often limited to the territory of one of these branches e.g. medial PICA (mPICA), lateral SCA (ISCA) etc. These cerebellar branch territory infarcts correspond to functional regions such as the inferior vermis or superior lateral neocerebellum. The AICAs, in contrast, supply only a small part of the anterior inferior cerebellum and the flocculus, but their major supply is to the lateral pontine tegmentum and the brachium pontis. The AICAs do not divide into medial and lateral major cerebellar branches but give off twigs to various structures.

## 5.2 Posterior Inferior Cerebellar Arteries (PICAs)

The PICAs usually originate from the ICVAs about 2 cm below the origin of the basilar artery, and, on average, about 8.6 mm above the foramen magnum (Marinkovic et al. 1995). The site of origin, however, varies from 14 mm below the foramen magnum to 26 mm above the foramen magnum (Marinkovic et al. 1995).

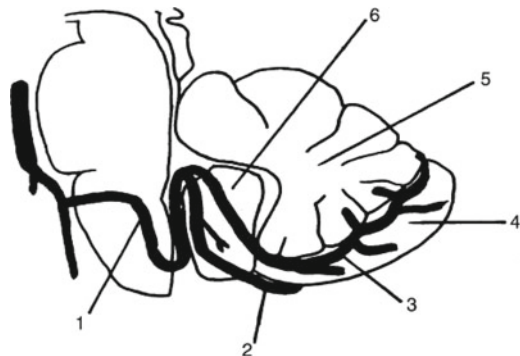


About 10% arise from the basilar artery (Amarenco and Hauw 1989). Size varies; The diameters varied between 0.58 and 2.10 mm in one analysis (Amarenco and Hauw 1989). Some ICVAs end in PICA, and PICA can be absent in which case there usually is a large artery that arises from the proximal basilar artery that supplies both the PICA and AICA territories. Occasionally PICA is duplicated.

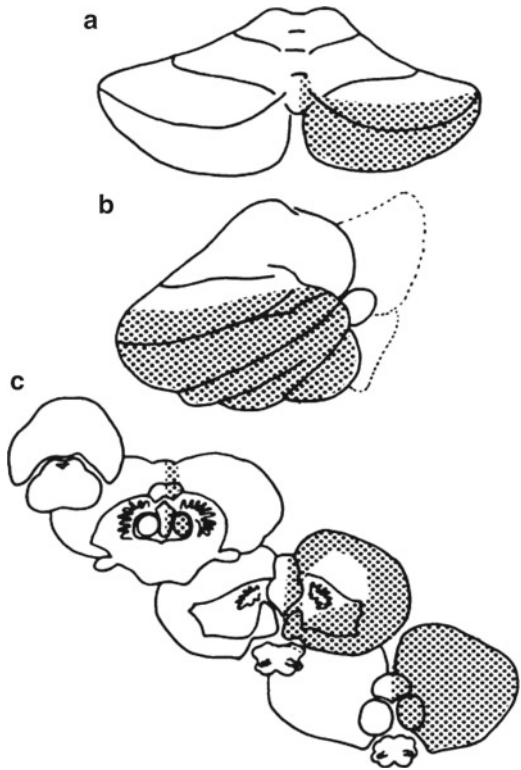
After coursing laterally and downward to go around the lateral medulla (the lateral medullary segment), the PICAs make a cranially directed loop and ascend between the dorsal portion of the medulla and the caudal part of the cerebellar tonsil on that side (the tonsillo-medullary segment) (Lister et al. 1982; Marinkovic et al. 1995). They then make a second loop above the cranial portion of the tonsil and descend along the inferior vermis coursing between the inferior medullary velum and the rostral portion of the tonsil (the telovelotonsillar segment). Finally the artery becomes superficial and supplies branches to the tonsil, medulla, choroid plexus and cerebellar cortex. Medial and lateral branches (mPICA, and lPICA) arise from the main trunks (Fig. 5.3) at variable locations between the two PICA loops. mPICA supplies the inferior vermis including the nodulus, pyramis, uvula, tuber, and sometimes the declive and the medial portions of the semilunar lobule, gracile lobule, and the tonsil (Chaves et al. 1994; Amarenco and Hauw 1989; Amarenco et al. 1989, 1993; Amarenco 1991; Gilman et al. 1981; Duvernoy 1978). mPICA often sends a supply to the dorsal medulla. lPICA supplies the inferior two thirds of the biventer, most of the inferior portion of the semilunar and the gracile lobules, and the antero-lateral portion of the tonsil (Chaves et al. 1994; Amarenco and Hauw 1989; Amarenco et al. 1989, 1993; Amarenco 1991; Gilman et al. 1981; Duvernoy 1978). Figures 5.4, 5.5, and 5.6 show diagrammatically the supply territories of PICA, mPICA, and lPICA. The PICAs sometimes supply the deep cerebellar structures including the fastigial nuclei but usually do not supply the dentate nuclei (Amarenco and Hauw 1989).

Although many equate the Wallenberg syndrome with an occlusion of PICA causing infarction in the lateral medulla, PICA does not supply the lateral medullary tegmentum. This region is supplied by a group of parallel small arteries that originate directly from the intracranial vertebral artery and pass through the lateral med-

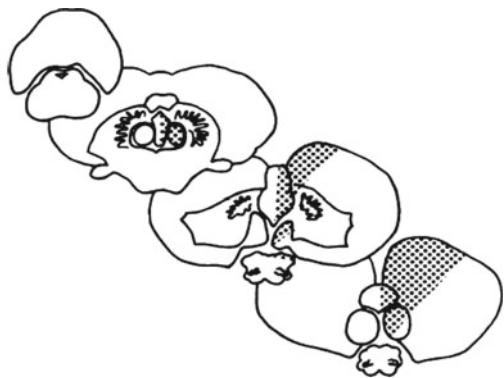
**Fig. 5.3** Sketch showing course and branching of the Posterior inferior cerebellar artery (PICA). 1 PICA; 2 lateral branch of PICA; 3 medial branch of PICA; 4 cerebellar hemisphere; 5 cerebellar vermis; 6 cerebellar tonsil (Reproduced with permission from Amarenco et al. 1993)



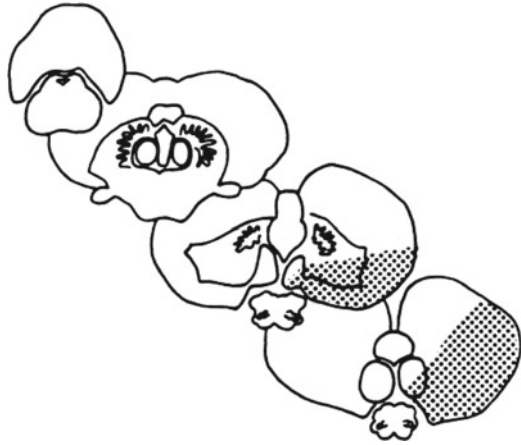
**Fig. 5.4** The supply zone of PICA (Reproduced with permission from Amarenco 1991)



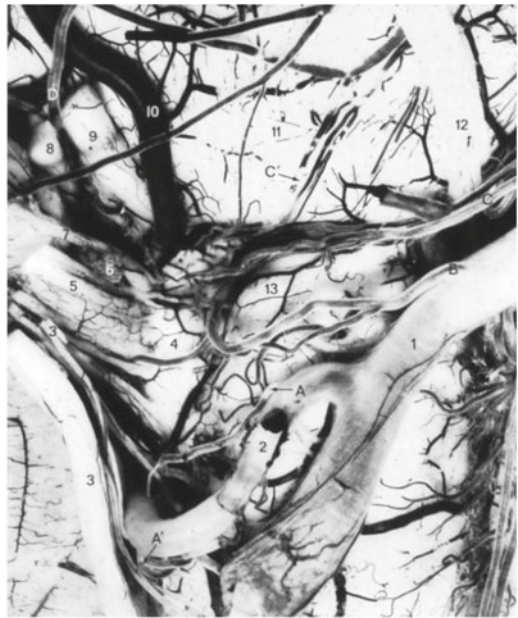**Fig. 5.5** The supply zone of the medial branch of PICA (Reproduced with permission from Amarenco 1991)



**Fig. 5.6** The supply zone of the lateral branch of PICA (Reproduced with permission from Amarenco (1991))

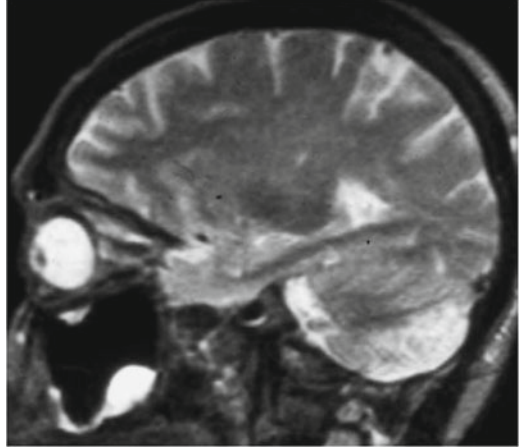


**Fig. 5.7** Right lateral medullary fossa. 1 Vertebral artery; 2 Posterior inferior cerebellar artery (*PICA*); 4 lateral medullary fossa; 5 vagus nerve; 6 IV ventricle choroids plexus; 7 glossopharyngeal nerve; 8 vestibulo-cochlear nerve; 9 Facial nerve; 10 lateral pontine vein; 11 pons; 12 abducens nerve; 13 Olive; (a) A'- rami arising from PICA; (b) rami arising from the vertebral artery to supply the lateral medulla; (c) rami arising from the basilar artery; (c, d) Rami arising from AICA (From Duvernoy 1978)



ullary fossa to supply the lateral medulla (Fig. 5.7) (Duvernoy 1978). Sometimes the medial branch of PICA supplies a small area in the dorsal medulla that includes vestibular nuclei and the dorsal motor nucleus of the vagus. The medial branch of PICA supplies a triangular area with a dorsal base and a ventral apex towards the fourth ventricle on an axial mid-medullary and cerebellar section (Amarenco and Hauw 1989). Figure 5.8 is a sagittal section MRI showing a PICA infarct. Figure 5.9 shows a brain specimen with a medial PICA territory infarct. Figure 5.10 is an axial section MRI of a mPICA infarct.

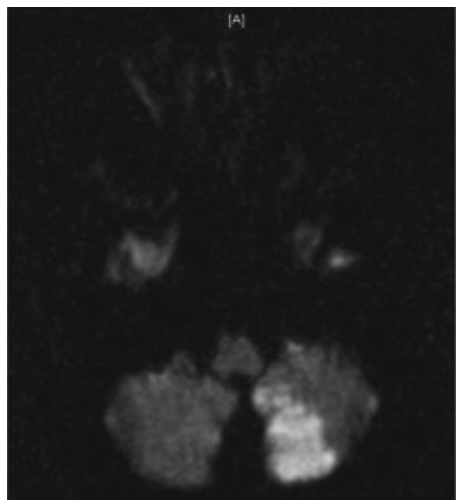
**Fig. 5.8** MRI sagittal T2-weighted scan showing a PICA territory infarct (From Caplan 1996)



**Fig. 5.9** Necropsy specimen showing an infarct in the territory of the medial branch of the posterior inferior cerebellar artery (From Amarenco et al. (1989) with permission)



**Fig. 5.10** MRI sagittal diffusion-weighted scan showing (a) mPICA territory infarct

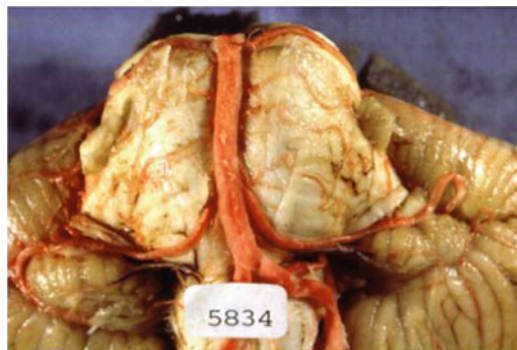

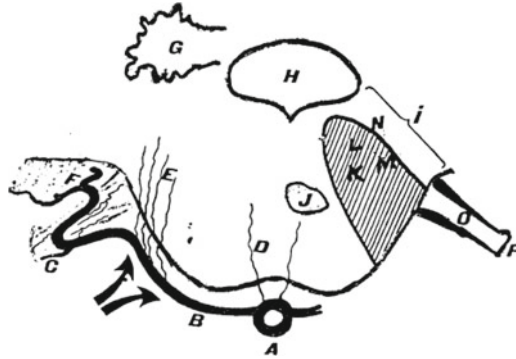
### 5.3 Anterior Inferior Cerebellar Arteries (AICAs)

The AICAs are nearly constant arteries but their origins, sizes, and supply zones vary greatly. In 4% of people, there is no AICA branch (Lazorthes 1961). The AICAs have the smallest territory of supply of any of the cerebellar arteries. The AICAs usually arise about 1 cm above the vertebrobasilar artery junction (Fig. 5.11), and sometimes from the middle third of the basilar artery. Occasionally, they can arise directly from the ICVA, or from a common trunk with PICA. The internal auditory arteries are usually branches of the AICAs but in some individuals they arise directly from the basilar artery. In one study the diameters of AICA ranged from 0.38 to 1.8 mm (mean 1.1 mm) (Marinkovic et al. 1995). After arising from the basilar artery the AICAs travel towards the cerebellopontine angle, passing below the Vth nerve, crossing the VIth nerve, and meeting the VIIth and VIIIth nerves at the cerebellopontine angle (Marinkovic et al. 1995; Amarenco and Hauw 1989, 1990a; Amarenco et al. 1993; Amarenco 1991; Gilman et al. 1981; Duvernoy 1978; Perneczky et al. 1981). After crossing the VIIIth nerve, the AICAs give rise to the internal auditory arteries and then divide into two branches. One branch courses laterally and inferiorly to supply the anterior inferior portion of the cerebellum on the petrosal surface. The other branch loops around the bundle made by the VIIth and VIIIth nerves, and supplies the flocculus, brachium pontis, middle part of the cerebellar hemisphere, and the lateral part of the pons (Marinkovic et al. 1995; Amarenco and Hauw 1989, 1990a; Amarenco et al. 1993; Amarenco 1991; Perneczky et al. 1981). The internal auditory arteries supply the facial and vestibulo-cochlear nerves as well as the structures of the inner ear.

Asymetry and reciprocal size relationship of AICA and PICA are common. Studies show a balance between AICA and PICA. In some individuals AICA can substitute for a hypoplastic PICA, taking over the supply of the inferior surface of the cerebellum (Stopford 1915–1916; Foix and Hillemand 1925; Atkinson 1949; Takahashi 1974). Usually the flocculus is always irrigated by AICAs, but for 3–5% of people the AICA is replaced by the PICA (Lazorthes 1961). According to Lazorthes, in 40% of individuals the AICA terminates on the flocculus; (Lazorthes

**Fig. 5.11** Base of the brain at necropsy showing the origin of the Anterior Inferior Cerebellar arteries



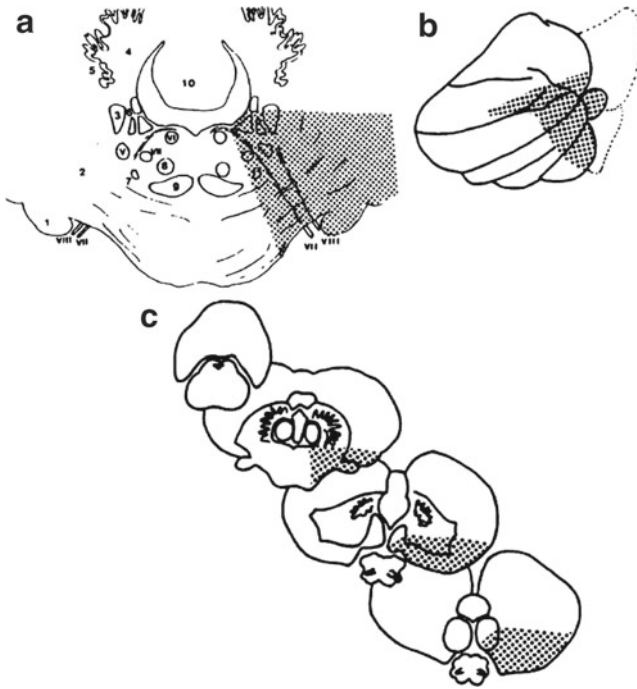


**Fig. 5.12** Blood supply of the caudolateral pons from the Anterior Inferior Cerebellar Artery (AICA). The shaded area to the *right* is the supply of a lateral branch of AICA. (a) Basilar artery; (b) medial pontine segment of AICA; (c) loop segment of AICA around flocculus; (d) paramedian basilar artery branches; (e) brainstem branches of AICA; (f) flocculus; (h) IV ventricle; (i) brachium pontis; (j) medial lemniscus; (k) lateral spinothalamic tract; (l) motor nucleus of V; (o) VII and VIII cranial nerves; (p) internal acoustic meatus (From Perneczky et al. (1981) with permission)

1961) in others it passes through the sulcus separating the anterior lobes and the semilunar lobules and the terminal branches supply the nearby lobules: anterior, simplex, superior semilunar, inferior semilunar, gracilis, and biventer in 18–50% of individuals (Lazorthes 1961; Takahashi et al. 1968). Figure 5.12 is a schematic drawing of the AICA and its supply (Perneczky et al. 1981). Figure 5.13 shows the brainstem and cerebellar distribution of the AICA supply territory. Figure 5.14 is a necropsy specimen showing an AICA territory infarct at the level of the pons. Figure 5.15 is a sagittal and axial section MRI of a AICA infarct.

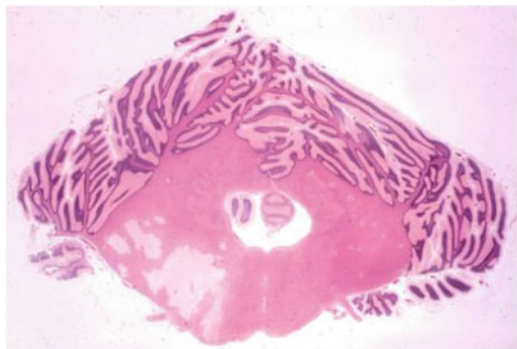
#### 5.4 Superior Cerebellar Arteries (SCAs)

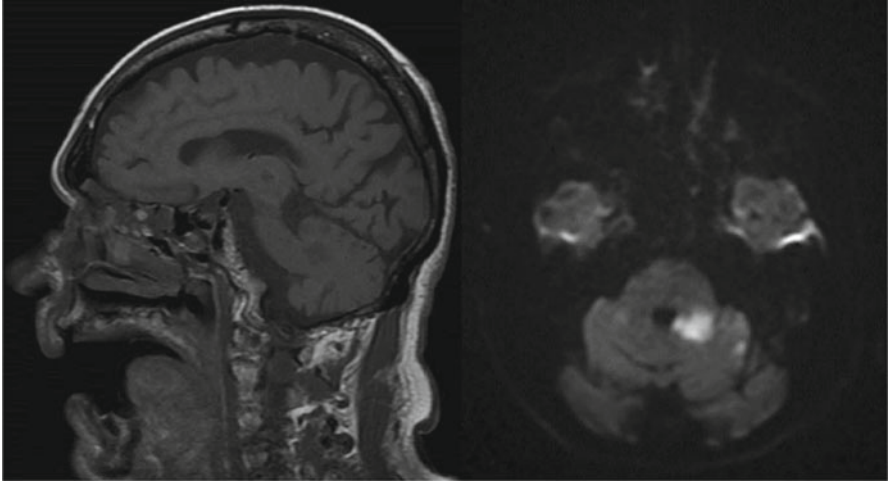
The SCAs arise as the last pair of branches from the basilar artery just before the basilar artery bifurcates into the paired PCAs (Fig. 5.16). The third cranial nerves run between the SCAs and the PCAs near the posterior communicating arteries. In about 15% of patients there are bifid SCAs. In one series the diameters ranged from 0.7 to 1.93 mm (mean 1.1 mm) (Marinkovic et al. 1995). The SCA encircles the brainstem close to or within the ponto-mesencephalic sulcus, just below the third nerve and just above the trigeminal nerve. While coursing around the midbrain, the SCAs give off branches that supply the brainstem including the superior portion of the lateral pontine tegmentum and the pontine and mesencephalic tectum. The SCAs have an early division within the cerebello-mesencephalic cistern where it divides into the mSCA and lSCA branches. Figure 5.17 shows the usual branching



**Fig. 5.13** Diagrammatic depiction of the supply zones of the anterior inferior cerebellar arteries. (a) Shows the pontine territory. 1 flocculus, 2 brachium pontis, 3 restiform body, 4 brachium conjunctivum, 5 dentate nucleus, 6 vestibular nuclei, 7 spinothalamic tract, 8 central tegmental tract, 9 medial lemniscus, 10 cerebellar nodulus. (b) Shows the cerebellar supply on a lateral view of the cerebellum and (c) shows the supply on cut sections of the cerebellum and brainstem. The supply zones are shaded (Reproduced with permission from Amarenco et al. 1993)

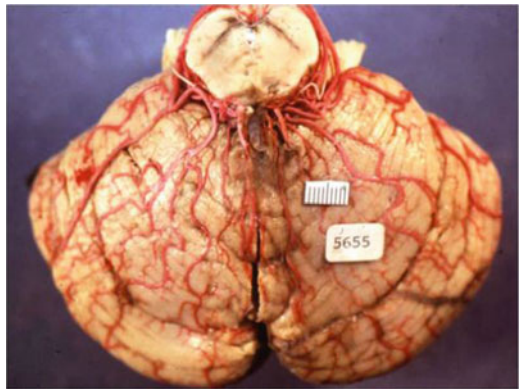
**Fig. 5.14** Necropsy specimen (H & E stained) showing an anterior inferior cerebellar artery territory infarct



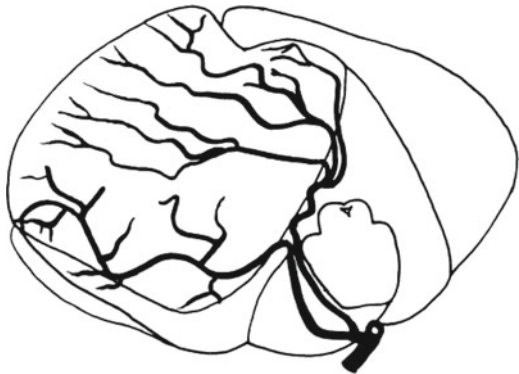


**Fig. 5.15** MRI sagittal T1 (*left*) and axial diffusion-weighted scan showing an AICA territory infarct

**Fig. 5.16** Brain at necropsy showing the superior cerebellar arteries circling the midbrain and giving off branches

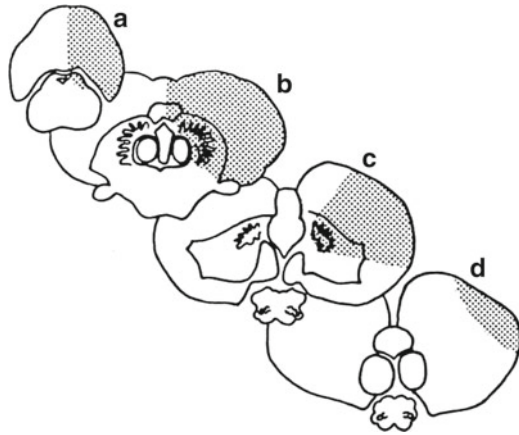


**Fig. 5.17** Schematic diagram of the superior cerebellar artery (*SCA*) and its medial (*mSCA*) and lateral (*lSCA*) branches. The *top* branch is the *mSCA* and the *lower* branch is the *lSCA* (From Amarenco et al. (1991) with permission)





**Fig. 5.18** The SCA supply territories are shaded (From Amarenco and Hauw 1989)

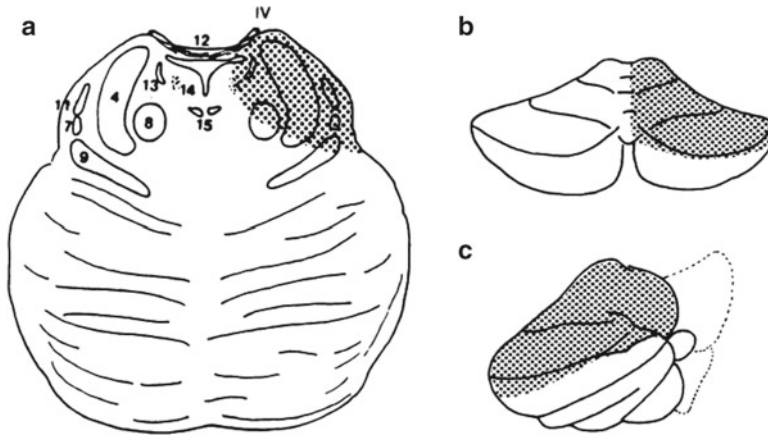


of the SCAs and the course of the lateral and medial branches. The mSCA branch extends more laterally than the mPICA. Occasionally these branches arise directly from the basilar artery and the SCAs.

Both the major branches of the SCAs course towards the pedunculo-cerebellar sulcus and reach the superior and anterior aspects of the cerebellum above the horizontal fissure. At the pedunculocerebellar sulcus, ISCA turns off at a right angle and follows the anterosuperior margin of the cerebellum anteriorly and laterally. A terminal deep branch of ISCA follows the superior cerebellar peduncle and reaches the dentate nucleus (Duvernoy 1978). The mSCAs mostly supply the superior portions of the vermis including the central, culmen, declive, and folium lobules; the ISCAs supply mostly the lateral portions of the cerebellar hemispheres including the anterior, simplex, and superior portion of the semilunar lobules. The SCAs also supply the cerebellar nuclei (dentate, fastigial, emboliform, and globose) as well as the bulk of the cerebellar white matter (Amarenco and Hauw 1989, 1990b; Amarenco et al. 1991, 1993; Amarenco 1991). Figures 5.18 and 5.19 show the cerebellar and brainstem supply territories of the SCA. Figure 5.20 is a necropsy specimen showing a large SCA territory infarct. Figure 5.21 shows three MRI scans that illustrate the imaging distribution of various SCA territory infarcts. The distribution of the supply territories of the cerebellar arteries as found on CT and MRI scanning has been illustrated and reviewed (Savoirdo et al. 1987; Courchesne et al. 1989; Press et al. 1989, 1990).

## 5.5 Cerebellar Veins

The venous drainage of the cerebellum is divided into superficial veins, deep veins and draining groups. Superficial veins are divided according to the cortical surfaces they drain: superior hemispheric and superior vermian veins (tentorial surface),

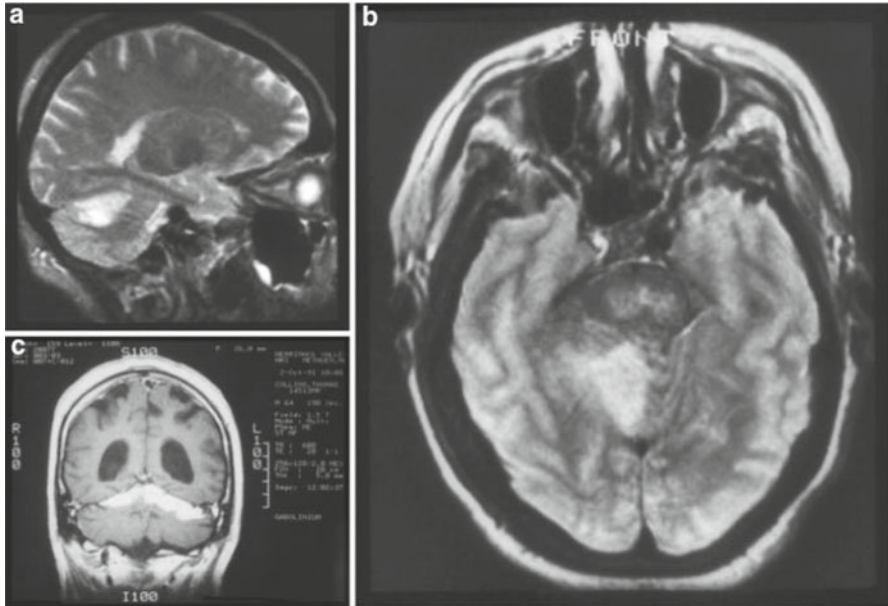


**Fig. 5.19** Supply zones of the superior cerebellar arteries. (a) Shows the superior pontine supply. 4 Brachium conjunctivum, 7 lateral lemniscus, 8 cortico-tegmental tract, 9 medial lemniscus, 11 spinothalamic tract, 12 decussation of IV, 13 mesencephalic tract of V, 14 locus coeruleus, 15 medial longitudinal fasciculus. (b) Shows an antero-posterior view and C a lateral view of the cerebellum (From Amarenco and Hauw 1989)

**Fig. 5.20** Necropsy specimens showing SCA territory infarct in the rostral pons. The pontine tectum and a small part of the dorsolateral pontine tegmentum are involved (From Amarenco and Hauw (1990), with permission)



inferior hemispheric and inferior vermian veins (suboccipital surface), and anterior hemispheric veins (petrosal surface) (Tschabitscher 1979; Kapp and Schmidek 1984; Matsushima et al. 1983). The major deep veins course in fissures between the cerebellum and brain stem. These are designated as the veins of the cerebellomesencephalic, cerebellopontine and cerebellomedullary fissures. The veins that drain the cerebellar peduncles are referred to as the veins of superior, middle and inferior cerebellar peduncles (Matsushima et al. 1983). There are diffuse anastomosis between veins before they are collected into draining groups. The groups are designated according to the dural sinuses into which they drain. The Galenic group drains



**Fig. 5.21** MRI T2-weighted scans (From Caplan 1996). (a) Sagittal view showing SCA territory infarct. (b) Axial section showing small vermian cerebellar infarct in the territory of the medial branch of the superior cerebellar artery (*mSCA*). (c) Coronal section showing a bilateral SCA territory infarct appearing like “icing on a cake”

via the vein of Galen and the straight sinus. The petrosal group drains via the petrosal sinuses. The tentorial group drains into the torcula and transverse sinuses.

The superior and inferior veins of the cerebellum usually collected and drain into the midline draining groups: vein of Galen, straight sinus, or torcular. Many small veins drain into superior or inferior vermian veins before their connection with the vein of Galen or straight sinus. Some of the superior and inferior veins run laterally to the transverse sigmoid sinuses, or to the superior or inferior petrosal sinuses. The superior petrosal sinus collects anterior cerebellar veins, including branches from the precentral fissure, the medial tonsillar veins, the veins of the lateral recess, and some tributaries related to the cerebellar hemispheres (Huang and Wolf 1974; Lasjaunias et al. 1990; Rhoton 2000).

## References

- Amarenco P (1991) The spectrum of cerebellar infarctions. *Neurology* 41:973–979
- Amarenco P, Hauw J-J (1989) Anatomie des arteres cerebelleuses. *Rev Neurol* 145:267–276
- Amarenco P, Hauw J-J (1990a) Cerebellar infarction in the territory of the anterior and inferior cerebellar artery. *Brain* 113:139–155
- Amarenco P, Hauw JJ (1990b) Cerebellar infarction in the territory of the superior cerebellar artery: a clinicopathologic study of 33 cases. *Neurology* 40:1383–1390

- Amarenco P, Hauw J-J, Henin D et al (1989) Les infarctus du territoire de l'artère cérébelleuse postéro-inférieure; étude clinico-pathologique de 28 cas. *Rev Neurol* 145:277–286
- Amareno P, Rouillet E, Goujon C et al (1991) Infarction in the anterior rostral cerebellum (the territory of the lateral branch of the superior cerebellar artery). *Neurology* 41:253–258
- Amarenco P, Hauw J-J, Caplan LR (1993) Cerebellar infarctions. In: Lechtenberg R (ed) *Handbook of cerebellar diseases*. Marcel Dekker, New York, pp 251–290
- Atkinson WJ (1949) The anterior inferior cerebellar artery: its variations, pontine distribution, and significance in the surgery of cerebello-pontine angle tumours. *J Neurol Neurosurg Psychiatry* 12:137–151
- Caplan LR (1996) *Posterior circulation disease: clinical findings, diagnosis, and management*. Blackwell Scientific, Boston
- Caplan LR (2000) Posterior circulation ischemia: then, now, and tomorrow The Thomas Willis Lecture – 2000. *Stroke* 31:2011–2013
- Caplan LR, Wityk RJ, Glass TA et al (2004) New England medical center posterior circulation registry. *Ann Neurol* 56:389–398
- Caplan LR, Wityk RJ, Pazdera L et al (2005) New England Medical Center posterior circulation stroke registry: II. Vascular lesions. *J Clin Neurol* 1:31–49
- Chaves CJ, Caplan LR, Chung C-S, Amarenco P (1994) Cerebellar infarcts. In: Appel S (ed) *Current neurology*, vol 14. Mosby-Year Book, St Louis, pp 143–177
- Cook-Lowe L (1978) Modeled after a figure. In: Duvernoy HM (ed) *Human brainstem vessels*. Springer, Berlin, p 41
- Courchesne E, Press GA, Murakami J et al (1989) The cerebellum in sagittal plane-anatomic-MR correlation: 1. The vermis. *AJNR* 10:659–665
- Duvernoy HM (1978) *Human brainstem vessels*. Springer, Berlin
- Foix C, Hillemand P (1925) Les artères de l'axe encephalique jusq'au diencephale inclusivement. *Rev Neurol* 2:705–739
- Gilman S, Bloedel J, Lechtenberg R (1981) *Disorders of the cerebellum*. FA Davis, Philadelphia
- Huang YP, Wolf BS (1974) Veins of posterior fossa. In: Newton TH, Potts DG (eds) *Radiology of the skull and brain: angiography*, vol 2, bk 3. CV Mosby, St Louis, pp 2155–2219
- Kapp JP, Schmidek HH (eds) (1984) *The cerebral venous system and its disorders*. Grune and Stratton, New York, pp 20–22
- Lasjaunias P, Berenstein A, Raybaud C (1990) Intracranial venous system. In: Lasjaunias P, Berenstein A (eds) *Surgical neuro-angiography: functional vascular anatomy of brain, spinal cord and spine*, vol 3. Springer, Berlin, pp 223–296
- Lazorthes G (1961) *Vascularisation et Circulation Cérébrales*. Masson, Paris
- Lister JR, Rhoton AL, Matsushima T, Peace DA (1982) Microsurgical anatomy of the posterior inferior cerebellar artery. *Neurosurgery* 10:170–199
- Marinkovic S, Kovacevic M, Gibo H, Milisavljevic M, Bumbasirevic L (1995) The anatomical basis for the cerebellar infarcts. *Surg Neurol* 44:450–461
- Matsushima T, Rhoton AL Jr, de Oliveira E et al (1983) Microsurgical anatomy of the veins of the posterior fossa. *J Neurosurg* 59:63–105
- Perneczky A, Perneczky G, Tschabitscher M, Samec P (1981) The relation between the caudolateral pontine syndrome and the anterior inferior cerebellar artery. *Acta Neurochir* 58:245–257
- Press GA, Murakami J, Courchesne E et al (1989) The cerebellum in sagittal plane-anatomic-MR correlation: 2. The cerebellar hemispheres. *AJNR* 10:667–676
- Press GA, Murakami JW, Courchesne E et al (1990) The cerebellum:3. Anatomic-MR correlation in the coronal plane. *AJNR* 11:41–50
- Rhoton AL (2000) The posterior fossa veins. *Neurosurgery* 47:S69–S92
- Savitz SI, Caplan LR (2005) Current concepts: vertebrobasilar disease. *N Engl J Med* 352:2618–2626
- Savoirdo M, Bracchi M, Passerini A, Visciani A (1987) The vascular territories in the cerebellum and brainstem: CT and MR study. *AJNR* 8:199–209
- Stopford JSB (1915–1916) The arteries of the pons and medulla oblongata. Part 2. *J Anat Physiol (London)* 50:255–280

- Takahashi M (1974) The anterior inferior cerebellar artery. In: Newton TH, Potts DG (eds) *Radiology of the skull and brain*, vol 2, Book 2. C. V. Mosby, St Louis, pp 1796–1808
- Takahashi M, Wilson G, Hanafee W (1968) The anterior inferior cerebellar artery: its radiographic anatomy and significance in the diagnosis of extra-axial tumors of the posterior fossa. *Radiology* 90:281–287
- Tschabitscher M (1979) Die venen des menschlichen kleinhirns. *Acta Anat (Basel)* 105:344–366

# Chapter 6

## The Olivocerebellar Tract

Yuanjun Luo and Izumi Sugihara

**Abstract** Neurons in the inferior olive nucleus, the sole origin of cerebellar climbing fibers, project their axons to the cerebellum through the olivocerebellar tract. A single olivocerebellar axon gives rise to multiple climbing fibers (about seven in rat) which typically terminate into longitudinal compartments in the cerebellar cortex. These compartments match with the longitudinal striped arrangement of aldolase C-positive and -negative Purkinje cell subsets. As a result of this topographic arrangement, the olivocerebellar projection relays the synchronous activity of the electrically coupled adjacent inferior olive neurons to complex spike firing of Purkinje cells in a narrow longitudinal stripe. Olivocerebellar axons show a dynamic morphogenetic process. An immature axon has abundant terminal branches that innervate multiple Purkinje cells. Several terminal branches (climbing fibers) grows to eventually establishing a powerful one-to-one synaptic connection between a single climbing fiber terminal and a single target Purkinje cell. Furthermore, these axons are capable of strong compensatory re-innervation after lesion even in adult.

**Keywords** Inferior olive • Climbing fibers • Branching • Collaterals • Purkinje cells • Reinnervation • Compartments

### 6.1 Introduction

The olivocerebellar tract is the axonal path of inferior olive neurons, which project to the cerebellum. This projection system is peculiar in morphological, physiological and developmental aspects, which contribute significantly to characterizing the cerebellar system. In this short article, we summarize these aspects based on relevant studies, including our own work.

---

Y. Luo • I. Sugihara (✉)  
Department of Systems Neurophysiology and Center for Brain Integration Research,  
Tokyo Medical and Dental University Graduate School  
of Medical and Dental Sciences, Tokyo, Japan  
e-mail: [Isugihara.phyl@tmd.ac.jp](mailto:Isugihara.phyl@tmd.ac.jp)

## 6.2 Gross Morphology of the Olivocerebellar Tract

The inferior olive nucleus, located in the caudoventral medulla, or between rhombomeres 8–10, is a complex of multi-lamella structure packed with small-sized neurons with round somata and curved dendrites. All neurons in the inferior olive nucleus, except for a very small number of scattered GABAergic neurons, project to the cerebellum terminating as climbing fibers. The inferior olive is the sole origin of climbing fibers. Therefore, functionally, the inferior olive can be regarded as a part of the cerebellum.

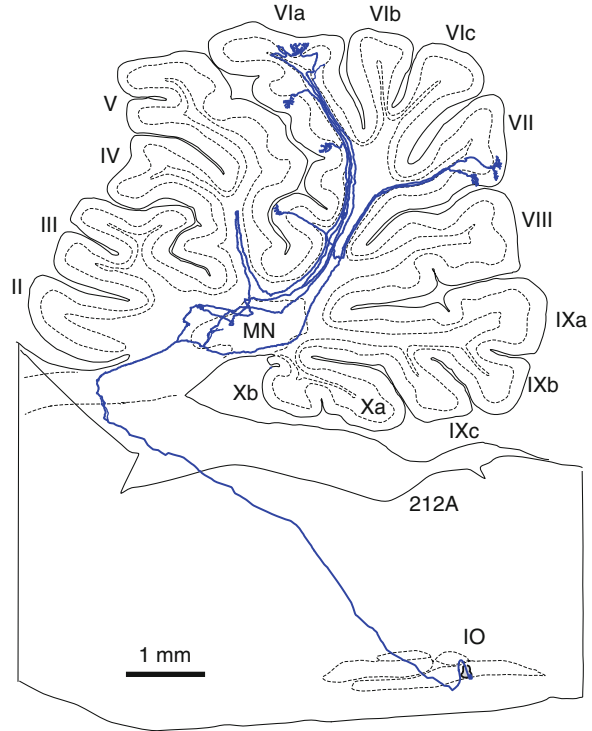
The olivocerebellar tract is the bundle of axons of the inferior olive neurons projecting to the cerebellar cortex. The axons run medially crossing the midsagittal plane, and continuing through or above the contralateral inferior olive, before entering the white matter under the lateral surface of the medulla that connects to the inferior cerebellar peduncle (Sugihara et al. 1999). Prior to entering the cerebellum through the inferior cerebellar peduncle, the axons that terminate in the vermis pass through the rostral most part of the cerebellar peduncle dorsal to the superior cerebellar peduncle intermingled with the uncinate fasciculus and the ventral spinocerebellar tract. Other olivocerebellar axons pass through the conventional inferior cerebellar peduncle.

Upon entering the cerebellum, each axon gives rise to collaterals to the cerebellar nuclei and branches into multiple (seven on average in rat) branches that terminate on a single adult Purkinje cell as climbing fibers (Fig. 6.1). Thus, “climbing fibers” which were discovered by Ramón y Cajal are terminations of the multiple branches of the olivocerebellar axons. Besides giving rise to branches that terminate as climbing fibers, olivocerebellar axons also give rise to several thin collaterals mainly terminating in the granular layer with a small number of swellings. Synaptic contact and functional significance of these collaterals are not well clarified (Sugihara et al. 1999). The multiple climbing fibers originating from a single axon are usually distributed in a narrow longitudinal band-shaped area (Sugihara et al. 2001). The olivocerebellar axon’s longitudinal projection pattern is in contrast with the transversely wide projection pattern of mossy fiber axons (Quy et al. 2011).

## 6.3 Topography in the Olivocerebellar Tract

The entire olivocerebellar pathway is topographically arranged. The topography has been resolved in detail. The inferior olive is subdivided into many subareas, usually a portion of a single lamella. Neurons in each subarea of the inferior olive project topographically to a particular subarea in the cerebellar nuclei and a particular striped area in the cerebellar cortex (Sugihara and Shinoda 2004, 2007). These specific subareas in the cortex and nuclei are also topographically connected by the corticonuclear Purkinje cell projection (Sugihara et al. 2009). Specific subareas in the cerebellar nuclei also topographically project to a precise subarea in the inferior

**Fig. 6.1** Lateral view of a trajectory of a reconstructed single olivocerebellar axon. This axon originated from the medial and caudal part of the medial accessory olive, a subnucleus of the inferior olive, and terminated in lobules VI and VII in the vermis. Abbreviations, *II–Xb* lobule II – lobule Xb, *IO* inferior olive, *MN* medial nucleus



olive (Ruigrok and Voogd 1990). As a whole, a triangular topographic loop of neuronal connection is formed among subareas in the inferior olive, cerebellar cortex and cerebellar nuclei. Each set of topographically connected subareas in the cerebellar cortex, cerebellar nuclei and inferior olive is designated as a cerebellar module (Ruigrok 2011). A standing question of how many modules the entire cerebellum is divided into remains. Conventionally, modules A, B, C1, C2, C3 and D have been recognized (Voogd and Bigare 1980). However, most of these modules have been further subdivided into smaller modules (Ruigrok 2011; Sugihara et al. 2009). In addition, there are other modules that are not involved in these sets of modules in the flocculus and nodulus (Sugihara et al. 2004). Most cerebellar modules are consistent with the cortical compartments defined by the molecular expression profile in Purkinje cells (Sugihara and Shinoda 2004, Sugihara et al. 2009). More specifically, modules linked with aldolase C-positive and -negative compartments are all located in the caudoventral and rostradorsal parts of the cerebellar nuclei, respectively (Sugihara and Shinoda 2007). Generally, modules are involved in different aspects of motor control and other cerebellar functions presumably due to different connections that each module has with other parts of the CNS (Horn et al. 2010).



## 6.4 Physiological Properties

The inferior olive neurons show oscillatory fluctuation of membrane potential at about 10 Hz (Llinas and Yarom 1986). This activity is synchronized among nearby neurons through dendro-dendritic gap junction (Llinas and Yarom 1986; Long et al. 2002). Excitatory input to the inferior olive, which originate from the somatosensory and vestibular systems in the medulla and spinal cord and from midbrain nuclei (see Sugihara and Shinoda 2004), may reset the oscillatory rhythm to evoke firing (Leznik and Llinás 2005). Olivary cells may fire at the peak of the oscillation of one action potential or a few action potentials in burst. The firing of an action potential (or a brief burst of action potentials) occurs solitary or in sequence with about 100 ms interval (Marthy et al. 2009). On the average, the firing frequency of the olivary neuron is one in a second (Eccles et al. 1966).

Firing of olivary neurons is conveyed all the way to the axon terminals, i.e., climbing fiber terminals, with a conduction time of approximately 4 ms (in rat, Sugihara et al. 1993). An action potential (or a brief burst of action potentials) in the climbing fiber produces a complex spike response in target Purkinje cells (Eccles et al. 1966). Olivocerebellar axon collaterals elicit an excitatory effect in the cerebellar nuclei (Llinás and Mühlethaler 1988; Blenkinsop and Lang 2011). However, its effect in the granular layer is yet unclear.

Since adjacent inferior olive neurons generally project to a narrow longitudinal striped area in the cerebellar cortex, it often matches with a single aldolase C stripe (Sugihara et al. 2007). Because of this property in the olivocerebellar projection, Purkinje cells arranged in the longitudinal band (width = ~0.25 mm) tend to fire complex spikes synchronously in awake and anaesthetized states (Sasaki et al. 1989; Lang et al. 1999). The band of complex spike synchrony generally matches with a single aldolase C stripe (Sugihara et al. 2007). This synchronous complex spike firing of Purkinje cells may be functionally important to form cerebellar output in the cerebellar nuclei (Blenkinsop and Lang 2011).

## 6.5 Morphological Development of the Olivocerebellar Tract

The immature olivocerebellar axonal projection is formed in the late embryonic stage when Purkinje cells are arranged in clusters before settling into striped compartments (Fujita et al. 2012). Basic topographic projection pattern is already established in the olivocerebellar bundle at this stage (Chédotal and Sotelo 1992). Axonal terminals form fine plexus with abundant branching known as the creeper terminal (Sugihara 2005). In accordance with the development of Purkinje cells in the second postnatal week, axonal branches are pruned to leave only those that begin to form a dense arbor around a single Purkinje cell soma (nest terminal). The nest terminals

grow to a full climbing fiber terminal in the following few weeks. Besides the above local refinement of climbing fiber-Purkinje cell contact, the compartmental topographic projection pattern of axons may also be refined during development.

The above process of climbing fiber development leads to the establishment of a one-to-one synaptic connection between a single climbing fiber terminal and a single target Purkinje cell. A loss of granule cells and some genetic mutations prevent normal development of climbing fibers (Sugihara et al. 2000). Together with abnormal immature morphology of climbing fibers, impairment of one-to-one innervation can occur in these situations. A Purkinje cell may be innervated by multiple climbing fibers that originate from one olivocerebellar axon (pseudo-multiple innervation) of different olivocerebellar axons (true multiple innervation, Sugihara et al. 2000).

## 6.6 Morphological Plasticity of the Olivocerebellar Tract

Since the normal olivocerebellar projection is nearly exclusively contralateral, increase of ipsilateral projection can be used to measure plastic change in the projection. Such plastic change is seen after unilateral cut of the cerebellar peduncle in neonatal stage (Sugihara et al. 2003). A similar transcommissural olivocerebellar projection to the ipsilateral cerebellum is seen even in adult after administration of substances that can facilitate axonal plasticity (Dixon and Sherrard 2006).

Semitotal lesion of the inferior olive by neurotoxin 3-aminopyridine (3-AP) induce axonal sprouting of remaining olivary neurons to compensate the loss of many olivocerebellar axonal terminals (Rossi et al. 1991). Axonal sprouting occurs only in their terminal portions, mainly in the terminal arbor of climbing fibers and possibly also at the terminal of thin collaterals in the granular layer and cerebellar nuclei. However, no axonal sprouting from the stem axon in the cerebellar white matter was evident at least in adult (Aoki and Sugihara 2012).

## 6.7 Conclusion

The above is a brief summary of our knowledge on the morphological, physiological and developmental aspect of the olivocerebellar tract. The projection is highly organized and comprises an important element of the cerebellar system. The activity of the olivocerebellar system produces significant modulatory changes in Purkinje cell properties at the cellular and molecular levels, which were not the focus of this article. The general morphological properties of the olivocerebellar system summarized here are important when considering the effect of olivocerebellar activity on cerebellar function as a whole.

## References

- Aoki H, Sugihara I (2012) Morphology of single olivocerebellar axons in the denervation-reinnervation model produced by subtotal lesion of the rat inferior olive. *Brain Res* 1449:24–37
- Blenkinsop TA, Lang EJ (2011) Synaptic action of the olivocerebellar system on cerebellar nuclear spike activity. *J Neurosci* 31:14708–14720
- Chédotal A, Sotelo C (1992) Early development of olivocerebellar projections in the fetal rat using CGRP immunocytochemistry. *Eur J Neurosci* 4:1159–1179
- Eccles JC, Llinás R, Sasaki K (1966) The excitatory synaptic action of climbing fibres on the Purkinje cells of the cerebellum. *J Physiol* 182:268–296
- Fujita H, Morita N, Furuichi T, Sugihara I (2012) Clustered fine compartmentalization of the mouse embryonic cerebellar cortex and its rearrangement into the postnatal striped configuration. *J Neurosci* 32:15688–15703
- Horn KM, Pong M, Gibson AR (2010) Functional relations of cerebellar modules of the cat. *J Neurosci* 30:9411–9423
- Dixon KJ, Sherrard RM (2006) Brain-derived neurotrophic factor induces post-lesion transcommissural growth of olivary axons that develop normal climbing fibers on mature Purkinje cells. *Exp Neurol* 202:44–56
- Lang EJ, Sugihara I, Welsh JP, Llinás R (1999) Patterns of spontaneous complex spike activity in the awake rat. *J Neurosci* 19:2728–2739
- Leznik E, Llinás R (2005) Role of gap junctions in synchronized neuronal oscillations in the inferior olive. *J Neurophysiol* 94:2447–2456
- Llinás R, Mühlethaler M (1988) Electrophysiology of guinea-pig cerebellar nuclear cells in the in vitro brain stem-cerebellar preparation. *J Physiol* 404:241–258
- Llinás R, Yarom Y (1986) Oscillatory properties of guinea-pig inferior olivary neurones and their pharmacological modulation: an in vitro study. *J Physiol* 376:163–182
- Long MA, Deans MR, Paul DL, Connors BW (2002) Rhythmicity without synchrony in the electrically uncoupled inferior olive. *J Neurosci* 22:10898–10905
- Marthy A, Ho SSN, Davie JT, Duguid IC, Clark BA, Häusser M (2009) Encoding of oscillations by axonal bursts in inferior olive neurons. *Neuron* 62:388–399
- Quy PN, Fujita H, Sakamoto Y, Na J, Sugihara I (2011) Projection patterns of single mossy fiber axons originating from the dorsal column nuclei mapped on the aldolase C compartments in the rat cerebellar cortex. *J Comp Neurol* 519:874–899
- Ramón y Cajal S (1911) *Histologie du système nerveux de l'homme et des verébrés, vol II*. Maloine, Paris
- Rossi F, Wiklund L, Van der Want JJJ, Strata P (1991) Reinnervation of cerebellar Purkinje cells by climbing fibers surviving a subtotal lesion of the inferior olive in the adult rat. I. Development of new collateral branches and terminal plexuses. *J Comp Neurol* 308:513–535
- Ruigrok TJ (2011) Ins and outs of cerebellar modules. *Cerebellum* 10:464–474
- Ruigrok TJ, Voogd J (1990) Cerebellar nucleo-olivary projections in the rat: an anterograde tracing study with Phaseolus vulgaris leucoagglutinin (PHA-L). *J Comp Neurol* 298:315–333
- Sasaki K, Bower JM, Llinás R (1989) Multiple Purkinje cell recording in rodent cerebellar cortex. *Eur J Neurosci* 1:572–586
- Sugihara I (2005) Microzonal projection and climbing fiber remodeling in single olivocerebellar axons of new born rats at postnatal days 4–7. *J Comp Neurol* 487:93–106
- Sugihara I, Shinoda Y (2004) Molecular, topographic and functional organization of the cerebellar cortex: a study with combined aldolase C and olivocerebellar labelling. *J Neurosci* 24:8771–8785
- Sugihara I, Shinoda Y (2007) Molecular, topographic and functional organization of the cerebellar nuclei: analysis by three-dimensional mapping of the olivonuclear projection and aldolase C labeling. *J Neurosci* 27:9696–9710

- Sugihara I, Lang EJ, Llinás R (1993) Uniform olivocerebellar conduction time underlies Purkinje cell complex spike synchronicity in the rat cerebellum. *J Physiol Lond* 470:243–271
- Sugihara I, Wu H-S, Shinoda Y (1999) Morphology of single olivocerebellar axons labeled with biotinylated dextran amine in the rat. *J Comp Neurol* 414:131–148
- Sugihara I, Bailly Y, Mariani J (2000) Olivocerebellar climbing fibers in the granulo-prival cerebellum: morphological study of individual axonal projections in the X-irradiated rat. *J Neurosci* 20(10):3745–3760
- Sugihara I, Wu H-S, Shinoda Y (2001) The entire trajectories of single olivocerebellar axons in the cerebellar cortex and their contribution to cerebellar compartmentalization. *J Neurosci* 21:7715–7723
- Sugihara I, Lohof AM, Letellier M, Mariani J, Sherrard RM (2003) Post-lesion transcommissural growth of olivary climbing fibres creates functional synaptic microzones. *Eur J Neurosci* 18:3027–3036
- Sugihara I, Ebata S, Shinoda Y (2004) Functional compartmentalization in the flocculus and the ventral dentate and dorsal group y nuclei: an analysis of single olivocerebellar axonal morphology. *J Comp Neurol* 470:113–133
- Sugihara I, Marshall SP, Lang EJ (2007) Relationship of complex spike synchrony bands and climbing fiber projection determined by reference to aldolase C compartments in crus IIa of the rat cerebellar cortex. *J Comp Neurol* 501:13–29
- Sugihara I, Fujita H, Na J, Quy PN, Li BY, Ikeda D (2009) Projection of reconstructed single Purkinje cell axons in relation to the cortical and nuclear aldolase C compartments of the rat cerebellum. *J Comp Neurol* 512:282–304
- Voogd J, Bigare F (1980) Topographical distribution of olivary and cortico nuclear fibers in the cerebellum: a review. In: Courville J, de Montigny C, Lamarre Y (eds) *The inferior olivary nucleus anatomy and physiology*. Raven Press, New York, pp 207–234

# Chapter 7

## Precerebellar Nuclei

Mayumi Yamada and Mikio Hoshino

**Abstract** The cerebellar cortex receives several inputs from the surrounding nuclei, the precerebellar systems. Two major types of precerebellar systems are known; mossy fiber (MF) and climbing fiber (CF) systems. MF neurons are found in several nuclei in the brain stem. Four major nuclei in the hindbrain contain MF neurons; the pontine gray nucleus (PGN), the reticulotegmental nucleus (RTN), the lateral reticular nucleus (LRN) and the external cuneate nucleus (ECN). In addition, MF neurons also reside in the spinal trigeminal nucleus (Sp5) in the hindbrain and Clarke's column (CC) in the spinal cord. MF neurons extend their glutamatergic projection to granule cells conveying peripheral and cortical information to the cerebellum. In contrast, CF neurons are located mainly in the inferior olive nucleus (ION), which receive inputs from the cerebral cortex, the red nucleus, spinal cord and other brain stem nuclei, and extend their glutamatergic projection to Purkinje cells. Both types of precerebellar neurons also project to neurons in the cerebellar nuclei. It is thought that these precerebellar systems transmit the external and internal information to the cerebellar cortex to modulate cerebellar function, including regulation of animal movement.

**Keywords** Precerebellar system • Mossy fiber neuron • Climbing fiber neuron • PGN • RTN • LRN • ECN • ION • Cerebellum • Transcription factor • Rhombomere • Neuroepithelial domain

---

M. Yamada  
Graduate School of Medicine, Kyoto University,  
Shogoin-Kawahara, Sakyo-ku, Kyoto 606-8507, Japan

Department of Biochemistry and Cellular Biology, National Institute of Neuroscience,  
National Center of Neurology and Psychiatry,  
4-1-1 Ogawa-Higashi, Kodaira, Tokyo 187-8502, Japan

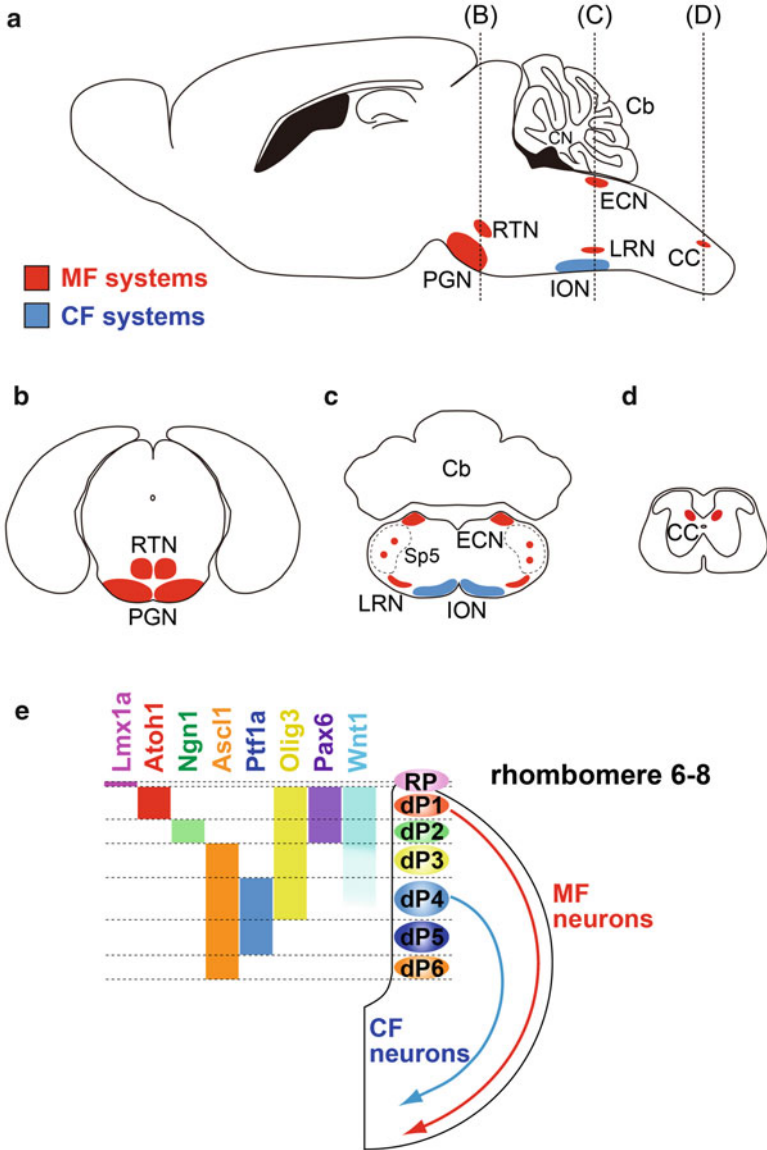
M. Hoshino (✉)  
Department of Biochemistry and Cellular Biology, National Institute of Neuroscience,  
National Center of Neurology and Psychiatry,  
4-1-1 Ogawa-Higashi, Kodaira, Tokyo 187-8502, Japan  
e-mail: [hoshino@ncnp.go.jp](mailto:hoshino@ncnp.go.jp)

## 7.1 Anatomy and Histology of the Precerebellar Nuclei

The cerebellar cortex receives several inputs from the surrounding nuclei, the precerebellar systems. Two major types of precerebellar systems are known; mossy fiber (MF) and climbing fiber (CF) systems. MF neurons are found in several nuclei in the brain stem. Four major nuclei in the hindbrain contain MF neurons; the pontine gray nucleus (PGN), the reticulotegmental nucleus (RTN), the lateral reticular nucleus (LRN) and the external cuneate nucleus (ECN) (Altman and Bayer 1987) (Fig. 7.1a–c). In addition, MF neurons also reside in the spinal trigeminal nucleus (Sp5) in the hindbrain and Clarke’s column (CC) in the spinal cord (Fig. 7.1a–d). MF neurons extend their glutamatergic projection to granule cells conveying peripheral and cortical information to the cerebellum. In contrast, CF neurons are located mainly in the inferior olive nucleus (ION) (Fig. 7.1a, c), which receive inputs from the cerebral cortex, the red nucleus, spinal cord and other brain stem nuclei, and extend their glutamatergic projection to Purkinje cells (Ruigrok et al. 1995). Both types of precerebellar neurons also project to neurons in the cerebellar nuclei. It is thought that these precerebellar systems transmit the external and internal information to the cerebellar cortex to modulate cerebellar function, including regulation of animal movement.

## 7.2 Specification of Precerebellar Nuclei Neurons

Birthdating studies using  $^3\text{H}$ -thymidine and BrdU in mice showed that CF neurons are produced at relatively early neurogenesis stages (embryonic day (E) 9.5–11.5) and MF neurons are generated at slightly later stages (E10.5–16.5) (Pierce 1973). Avian grafting studies as well as mammalian fate map analyses have revealed that in the hindbrain, both MF and CF neurons are generated from the caudal part, around rhombomeres 6–8 (Fig. 7.1e) (Ambrosiani et al. 1996; Cambronerio and Puelles 2000; Farago et al. 2006; Kawauchi et al. 2006). In contrast, MF neurons in the Clarke’s nucleus are produced in the spinal cord (Birmingham et al. 2001). Classic anatomical and immunohistochemical studies have suggested that these precerebellar nuclei neurons in the hindbrain are generated from the dorsal part of the rhombomere and migrate circumferentially to their final loci (Bloch-Gallego et al. 1999; Yee et al. 1999; Kyriakopoulou et al. 2002). However, they take slightly different pathways; MF and CF neurons migrate extramurally and intramurally, respectively (Fig. 7.1e). Introduction of a GFP-expressing vector into the embryonic dorsal hindbrain enabled the dramatic visualization of migrating precerebellar nuclei neurons during development (Kawauchi et al. 2006; Okada et al. 2007; Shinohara et al. 2013).



**Fig. 7.1** Precerebellar systems in the brain stem. (a–d) Two types of precerebellar afferent systems; MF (red) and CF (blue) systems. Cb cerebellum, CN cerebellar nucleus. (e) In the caudal hindbrain (r6-8), the dorsal neuroepithelium can be divided into six domains (dP1 ~ dP6) according to the expression pattern of transcription factors during embryonic development. While MF neurons (red) are derived from the dP1 domain, CF neurons (blue) are generated from the dP4 domain

Several transcription factors are reportedly expressed within the dorsal neuroepithelium of the caudal rhombomeres 6–8 during embryonic development, and have been used to try to define domains along the dorso-ventral axis. *Lmx1a* is expressed in the roof plate, the dorsal-most part of rhombomere, which gives rise to the choroid plexus (Chizhikov et al. 2006). Other transcription factors are expressed in the dorsal neuroepithelium, which can be divided into six domains (dP1 ~ dP6) according to the pattern of transcription factors, such as *Atoh1*, *Ngn1*, *Ascl1*, *Ptf1a*, *Pax6* and *Olig3* (Fig. 7.1e). Using genetic lineage tracing methods, a series of studies have tried to clarify the precise origins of MF and CF neurons.

Analyses of genetically engineered mice that express *lacZ* or *Cre recombinase* under the control of the endogenous or exogenous *Atoh1* promoter revealed that MF neurons of PGN, RTN, LRN and ECN were generated from the *Atoh1*-expressing neuroepithelial domain (dP1, Ben-Arie et al. 2000; Rodriguez and Dymecki 2000; Landsberg et al. 2005; Wang et al. 2005). Loss of the *Atoh1* gene resulted in a defect in production of these MF neurons, suggesting the involvement of *Atoh1* in MF neuron development.

Landsberg et al. also performed lineage tracing using two variants of FLP (Flippase recombinase) with different recombinase activities that were expressed under the control of the *Wnt-1* promoter whose strength is the highest at the dorsal-most part and decreases ventrally. They observed that CF neurons are generated from the neuroepithelial region where *Wnt-1* is very weakly expressed, whereas MF neurons are derived from the strong *Wnt-1*-expressing region (Landsberg et al. 2005). In addition, Nichols and Bruce showed that in mice carrying a *Wnt-1*-enhancer/*lacZ* transgene, MF neurons but not CF neurons were labeled by  $\beta$ -gal (Nichols and Bruce 2006). These findings suggested that CF neurons are derived from the neuroepithelial region ventral to the *Atoh1*-expressing domain.

Yamada et al. performed Cre-loxP-based lineage trace analysis and showed that all CF neurons in the ION are generated from the *Ptf1a*-expressing neuroepithelial domain (Yamada et al. 2007). Targeted disruption of the *Ptf1a* gene caused defects in the production of these CF neurons and in fate change of some CF neurons to MF neurons, suggesting that *Ptf1a* plays a critical role in fate determination of CF neurons. They also showed that *Ptf1a* is important for migration, differentiation and survival of CF neurons. Storm et al. used Cre-loxP-based lineage tracing to show that not only MF neurons but also CF neurons are generated from the *Olig3*-expressing neuroepithelial region that broadly expands within the dorsal hindbrain (Storm et al. 2009). Loss of the *Olig3* gene resulted in the disorganized development of MF neurons and complete loss of CF neurons (Liu et al. 2008; Storm et al. 2009). Moreover, ectopic co-expression of *Olig3* and *Ptf1a* induced the expression of a CF neuron marker in chick embryos (Storm et al. 2009). These findings suggest that CF neurons are derived from the *Ptf1a*/*Olig3*-expressing neuroepithelial domain (dP4) and that *Ptf1a* and *Olig3* cooperatively regulate the development of CF neurons. The domain structure of the dorsal neuroepithelium in the caudal hindbrain is shown in Fig. 7.1e.



## References

- Altman J, Bayer SA (1987) Development of the precerebellar nuclei in the rat. I–IV. *J Comp Neurol* 257:477–552
- Ambrosiani J, Armengol JA, Martinez S, Puelles L (1996) The avian inferior olive derives from the alar neuroepithelium of the rhombomeres 7 and 8: an analysis by using chick-quail chimeric embryos. *Neuroreport* 7:1285–1288
- Ben-Arie N, Hassan BA, Bermingham NA, Malicki DM, Armstrong D, Matzuk M, Bellen HJ, Zoghbi HY (2000) Functional conservation of atonal and Math1 in the CNS and PNS. *Development* 127:1039–1048
- Bermingham NA, Hassan BA, Wang VY, Fernandez M, Banfi S, Bellen HJ, Fritzsche B, Zoghbi HY (2001) Proprioceptor pathway development is dependent on Math1. *Neuron* 30:411–422
- Bloch-Gallego E, Ezan F, Tessier-Lavigne M, Sotelo C (1999) Floor plate and netrin-1 are involved in the migration and survival of inferior olivary neurons. *J Neurosci* 19:4407–4420
- Cambroner F, Puelles L (2000) Rostrocaudal nuclear relationships in the avian medulla oblongata: a fate map with quail chick chimeras. *J Comp Neurol* 427:522–545
- Chizhikov VV, Lindgren AG, Curre DS, Rose MF, Monuki ES, Millen KJ (2006) The roof plate regulates cerebellar cell-type specification and proliferation. *Development* 133:2793–2804
- Farago AF, Awatramani RB, Dymecki SM (2006) Assembly of the brainstem cochlear nuclear complex is revealed by intersectional and subtractive genetic fate maps. *Neuron* 50:205–218
- Kawauchi D, Taniguchi H, Watanabe H, Saito T, Murakami F (2006) Direct visualization of nucleogenesis by precerebellar neurons: involvement of ventricle-directed, radial fibre-associated migration. *Development* 133:1113–1123
- Kyriakopoulou K, de Diego I, Wassef M, Karagogeos D (2002) A combination of chain and neurophilic migration involving the adhesion molecule TAG-1 in the caudal medulla. *Development* 129:287–296
- Landsberg RL, Awatramani RB, Hunter NL, Farago AF, DiPietrantonio HJ, Rodriguez CI, Dymecki SM (2005) Hindbrain rhombic lip is comprised of discrete progenitor cell populations allocated by Pax6. *Neuron* 48:933–947
- Liu Z, Li H, Hu X, Yu L, Liu H, Han R, Colella R, Mower GD, Chen Y, Qiu M (2008) Control of precerebellar neuron development by Olig3 bHLH transcription factor. *J Neurosci* 28:10124–10133
- Nichols DH, Bruce LL (2006) Migratory routes and fates of cells transcribing the Wnt-1 gene in the murine hindbrain. *Dev Dyn* 235:285–300
- Okada T, Keino-Masu K, Masu M (2007) Migration and nucleogenesis of mouse precerebellar neurons visualized by in utero electroporation of a green fluorescent protein gene. *Neurosci Res* 57:40–49
- Pierce ET (1973) Time of origin of neurons in the brain stem of the mouse. *Prog Brain Res* 40:53–65
- Rodriguez CI, Dymecki SM (2000) Origin of the precerebellar system. *Neuron* 27:475–486
- Ruigrok TJ, Cella F, Voogd J (1995) Connections of the lateral reticular nucleus to the lateral vestibular nucleus in the rat. An anterograde tracing study with Phaseolus vulgaris leucoagglutinin. *Eur J Neurosci* 7:1410–1413
- Shinohara M, Zhu Y, Murakami F (2013) Four-dimensional analysis of nucleogenesis of the pontine nucleus in the hindbrain. *J Comp Neurol* 521:3340–3357
- Storm R, Cholewa-Waclaw J, Reuter K, Brohl D, Sieber M, Treier M, Muller T, Birchmeier C (2009) The bHLH transcription factor Olig3 marks the dorsal neuroepithelium of the hindbrain and is essential for the development of brainstem nuclei. *Development* 136:295–305
- Wang VY, Rose MF, Zoghbi HY (2005) Math1 expression redefines the rhombic lip derivatives and reveals novel lineages within the brainstem and cerebellum. *Neuron* 48:31–43
- Yamada M, Terao M, Terashima T, Fujiyama T, Kawaguchi Y, Nabeshima Y, Hoshino M (2007) Origin of climbing fiber neurons and their developmental dependence on Ptf1a. *J Neurosci* 27:10924–10934
- Yee KT, Simon HH, Tessier-Lavigne M, O'Leary DM (1999) Extension of long leading processes and neuronal migration in the mammalian brain directed by the chemoattractant netrin-1. *Neuron* 24:607–622

# Chapter 8

## Vestibular Nuclei and Their Cerebellar Connections

Neal H. Barmack

**Abstract** The vestibular complex exists at a sensory-motor crossroad that is composed of five separate nuclei defined primarily by a common vestibular primary afferent projection. These five nuclei are located just beneath the dorsal surface of the medullary brainstem. They include: Descending, lateral, medial and superior nuclei (DVN, LVN, MVN and SVN) as well as the Parasolitary nucleus (Psol). Each vestibular nucleus can be recognized by a combination of boundaries that include fiber bundles and histological characteristics such as cell size. With the exception of Psol, a nucleus that is composed of small GABAergic cells (5–7  $\mu\text{m}$  in diameter), the DVN, LVN, MVN and SVN contain a variety of cell types and cell sizes. Here we review the afferent and efferent connections of the vestibular nuclei and discuss how these characteristics might influence function.

**Keywords** Flocculus • Nodulus • Uvula • Vestibular complex • Purkinje cells

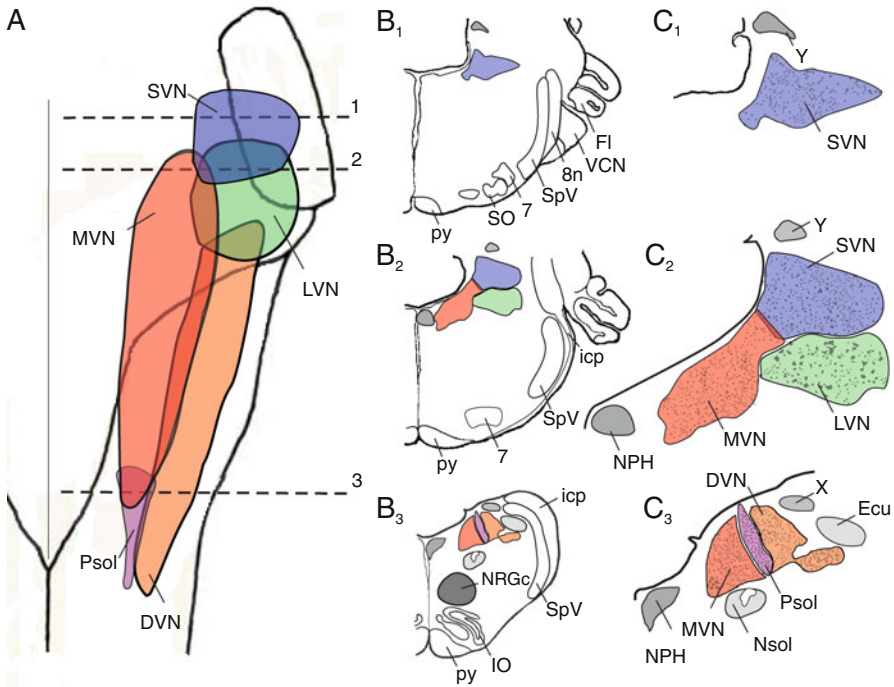
Five vestibular nuclei, defined by an ipsilateral projection of primary vestibular afferents, are located just below the dorsal surface of the medullary brainstem (Fig. 8.1). They include: Descending, lateral, medial and superior nuclei (DVN, LVN, MVN and SVN) as well as the Parasolitary nucleus (Psol). Each vestibular nucleus can be recognized by a combination of boundaries that include fiber bundles and histological characteristics such as cell size (Fig. 8.1c<sub>1-3</sub>). With the exception of Psol, a nucleus that is composed homogeneously small GABAergic cells (5–7  $\mu\text{m}$  in diameter), the DVN, LVN, MVN and SVN contain a variety of cell types. While the LVN includes the largest cells in the brain (>50  $\mu\text{m}$ ), it is also comprised of many smaller cell types (Brodal and Pompeiano 1957; Brodal 1974; Barmack et al. 1998). Here we review the afferent and efferent connections of the vestibular nuclei and discuss how these characteristics might influence function.

---

N.H. Barmack (✉)

Department of Physiology and Pharmacology, Oregon Health & Science University,  
3181 S.W. Sam Jackson Park Road, Portland, OR 97239, USA

e-mail: [barmackn@ohsu.edu](mailto:barmackn@ohsu.edu)



**Fig. 8.1** Vestibular nuclei. (a) Horizontal view of vestibular nuclei. The *horizontal dashed lines* indicate the anterior-posterior level of the three transverse sections illustrated in (b<sub>1-3</sub>) and at higher magnification in (c<sub>1-3</sub>). Abbreviations: *DVN*, *LVN*, *MVN* and *SVN* descending, lateral, medial and superior vestibular nucleus, *Ecu* external cuneate nucleus, *Fl* flocculus, *icp* inferior cerebellar peduncle, *IO* inferior olive, *NPH* nucleus prepositus hypoglossi, *NRGc* nucleus reticularis gigantocellularis, *Nsol* solitary nucleus, *Psol* parasolitary nucleus, *Py* pyramidal tract, *SO* superior olive; *sol*, *SpV* spinal trigeminal nucleus, *7* facial nucleus, *x* nucleus x, *YY*-group (Modified from Brodal and Pompeiano 1957)

## 8.1 Vestibular Primary Afferents

The peripheral vestibular apparatus consists of three semicircular canals and two otoliths. The semicircular canals are oriented orthogonally and sense angular acceleration about horizontal, vertical and oblique axes. Otoliths sense linear acceleration imposed by the gravitational vector during roll-tilt of the head about the longitudinal axis (utricle) and during pitch about the intra-aural axis (sacculle). Each of the vestibular endorgans contributes primary vestibular afferents to the vestibular nerve that branches into two fiber bundles of unequal thickness as they enter the brain stem. The thicker branch enters the medulla between the ventral aspect of the inferior cerebellar peduncle and the dorsal aspect of the spinal tract of the trigeminal nucleus. It turns caudally and passes into the vestibular complex to terminate on secondary vestibular neurons. The thinner branch ascends to the cerebellum where it terminates on granule cells in the uvula-nodulus (Cajal 1911).

The primary vestibular afferent projection to the vestibular nuclei has regional specificity, but does not conform to the boundaries of individual vestibular nuclei. For example, neurons in the SVN respond to stimulation of the ipsilateral anterior semicircular canal and are found more laterally than are SVN neurons responsive to stimulation of the ipsilateral horizontal semicircular canal. Horizontal semicircular canal primary afferents project to the DVN, MVN and SVN, but not the LVN and Psol. Psol neurons are driven exclusively by stimulation of ipsilateral *vertical* semicircular canals and utricule. Secondary neurons within the LVN receive a primary vestibular projection from the ipsilateral saccule, but not from the utricule (Sato and Sasaki 1993).

## 8.2 Visual Projections to Vestibular Nuclei

Vestibular primary afferents comprise only one of the sensory inputs to the vestibular complex. Most secondary vestibular neurons are also driven by visual (optokinetic) stimulation (Henn et al. 1974). Although visual signals to the vestibular nuclei originate from a variety of brainstem and cortical sources, optokinetic signals reach the vestibular complex from the accessory optic system (AOS) (Simpson et al. 1988). Direction selective retinal ganglion cells project to the AOS. AOS neurons, in turn, project to vestibular nuclei, the cerebellum and the inferior olive. The AOS also receives a descending projection from the visual cortex. In primates this projection originates from the pre-striate cortex (areas OAa and PGa) (Ilg and Hoffmann 1996). Selective stimulation or inactivation of this region modifies the directional selectivity of neurons in the AOS.

## 8.3 Neck-Proprioceptive Inputs to Vestibular Nuclei

Signals from proprioceptors embedded in the intertransverse muscles at the base of the cervical vertebrae also activate secondary vestibular neurons (Hikosaka and Maeda 1973; McCouch et al. 1951). Injection of HRP into the caudal MVN and DVN retrogradely labels neurons in ipsilateral C<sub>2</sub>-C<sub>3</sub> spinal ganglia, in the contralateral central cervical nucleus and bilaterally in C<sub>1</sub>-C<sub>6</sub> dorsal horn cells (Bankoul and Neuhuber 1990; Sato et al. 1997). Neurons in the vestibular complex also receive secondary cervical afferents relayed through the external cuneate nucleus (Ecu) (Fig. 8.1b<sub>3c3</sub>) (Prihoda et al. 1991). Movement of the head with respect to the body stimulates neck proprioceptors and evokes reflexive eye movements as well as postural adjustments of the limbs (McCouch et al. 1951; Barmack et al. 1981; Hikosaka and Maeda 1973).

## 8.4 Cerebellar Projections to the Vestibular Complex

Cerebellar projections to the vestibular complex include, but are not restricted to efferents from the uvula-nodulus (folia 9-10) (Walberg and Dietrichs 1988). Purkinje cells located within sagittal zones in these folia as well as the flocculus project to different regions within the vestibular complex (De Zeeuw et al. 1994).

While Purkinje cells project onto the same vestibular nuclei from which cholinergic mossy fiber projections to the uvula-nodulus originate, the overlap is far from perfect. The dorso-caudal MVN and DVN receive dense projections from uvula-nodular Purkinje cells. Cells in this region of the MVN, DVN and LVN give rise to the medial vestibulo-spinal tract. The uvula-nodulus also projects to the SVN (Tabuchi et al. 1989; Shojaku et al. 1987; Bernard 1987; Walberg and Dietrichs 1988; Wylie et al. 1994).

Within the vestibular complex, LVN neurons receive the most dense cerebellar projection. This projection arises mostly from the “b zone” of the vermis (Andersson and Oscarsson 1978a, b). The “b-zone” receives climbing fiber projections conveying cutaneous information from the forelimbs and hind limbs. The non-uniform immunolabeling of Purkinje cell axon terminals within the MVN, NPH, SVN, DVN and Psol suggests that each vestibular nucleus contains a subset of neurons whose activity is modulated by cerebellar projections.

## 8.5 Projections Within Vestibular Nuclei

The pattern of interconnections within the vestibular complex has been mapped with microinjections of HRP into the vestibular complex of the rabbit. Interconnections between the SVN-DVN and SVN-MVN are mostly reciprocal (Epema et al. 1988). However, clusters of larger neurons in the rostro-ventral MVN, SVN and LVN receive inputs from smaller cell regions of MVN, SVN and DVN, but do not reciprocate (Ito et al. 1985). The MVN has a non-reciprocal projection to the DVN.

## 8.6 Commissural Projections Between Vestibular Nuclei

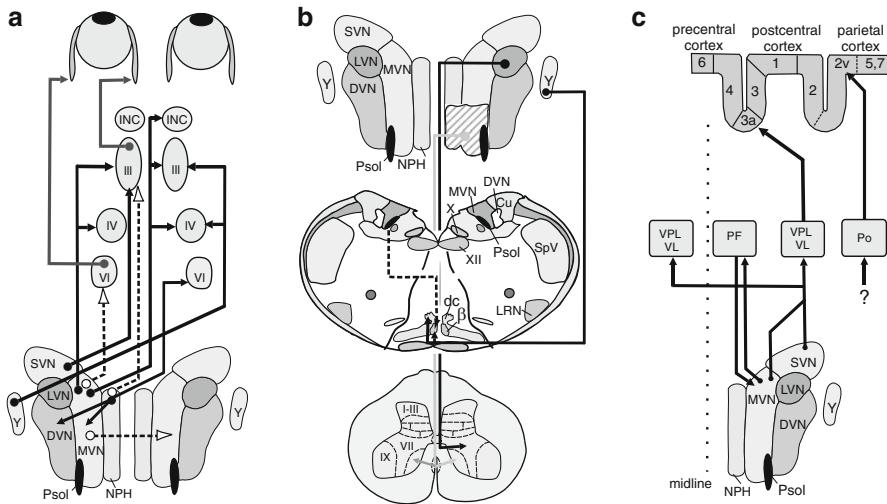
The vestibular nuclei, with the exceptions of the LVN and Psol, are interconnected through a commissural system. However, the connections are not restricted to homologous nuclei. Rather, cells within a nucleus on one side of the brainstem, say the left MVN, project to the contralateral SVN and DVN as well as the contralateral MVN (Epema et al. 1988; Newlands et al. 1989). Electrical stimulation of the utricular macula evokes excitation in ipsilateral secondary vestibular neurons and inhibition in more than 50% of the contralateral secondary vestibular neurons excited by

ipsilateral utricular stimulation. Only 10% of secondary neurons responsive to ipsilateral stimulation of the saccule are inhibited by contralateral saccular stimulation.

## 8.7 Ascending Projections of Vestibular Nuclei

Targets of secondary vestibular afferents are diverse. The rostral halves of DVN, MVN and SVN provide an ascending input to cranial motor nuclei III, IV and VI, controlling the reciprocal contractions of extraocular muscles (Fig. 8.2a) (Büttner and Lang 1979; Deecke et al. 1977; Büttner-Ennever 1992; Graf et al. 1983).

Other brainstem nuclei that receive ascending projections from secondary vestibular neurons include: nucleus Darkschewitch, sensory trigeminal nucleus, interstitial nucleus of Cajal and the subparafascicular complex (Barmack et al. 1979). The subparafascicular complex projects reciprocally back to the ipsilateral MVN (Fig. 8.2c).



**Fig. 8.2** Ascending and descending connections of the vestibular complex. **(a)** Projections of vestibular complex onto oculomotor apparatus. **(b)** Descending projections of vestibular complex to spinal cord and to inferior olive. **(c)** Ascending projections of vestibular complex to thalamus and cortex. *Dashed lines* indicate inhibitory projections. *Abbreviations:*  $\beta$   $\beta$ -nucleus, *Cu* cuneate nucleus, *dc* dorsal cap of Kooy, *DVN*, *MVN*, *LVN*, *SVN* descending, medial, lateral and superior vestibular nuclei, *INC* interstitial nucleus of Cajal, *LRN* lateral reticular nucleus, *NPH* nucleus prepositus hypoglossi, *PF* parafascicular nucleus, *Psol* parasolus, *SpV* spinal trigeminal nucleus, *PO* posterior thalamic nuclear group, *VL* ventrolateral nucleus, *VPL* ventral posterior lateral nucleus, *III*, *IV*, *VI* oculomotor cranial nuclei, *X* dorsal motor nucleus of vagus, *XII* hypoglossal nucleus, *Y* *Y*-group (Modified from Büttner and Lang (1979), Deecke et al. (1977), Büttner-Ennever (1992), and Graf et al. (1983))

Several ascending projections from the rostral part of the vestibular complex terminate on neurons in the ventro-basal thalamus (VPL, VPM, VPI and VPL) (Fig. 8.2c). Neurons in the ventro-basal complex are driven by stimulation of deep proprioceptors and joint receptors as well as vestibular inputs (Lang et al. 1979; Deecke et al. 1977; Bacskai et al. 2002; Shiroyama et al. 1999).

Thalamic neurons, in turn, terminate in Areas 3aV, T3 and parietal visual cortices (Fukushima 1997). These cortical areas receive optokinetic and somatosensory as well as vestibular inputs (Fig. 8.2c). The importance of this projection is illustrated by the observation that humans with damage to parietal cortex, and without visual cues, do not recognize true vertical (Leigh 1994). Vestibular cortices project reciprocally to vestibular nuclei, suggesting that these cortical regions may supersede reflexes evoked by primary vestibular afferents (Akbarian et al. 1993, 1994; Nishiike et al. 2000).

## 8.8 Cholinergic and GABAergic Vestibular Projections to the Cerebellum from the MVN, Nucleus Prepositus Hypoglossi and Y-Group

Although neurons in the nucleus prepositus hypoglossi (NPH) lack a vestibular primary afferent projection, they receive a secondary vestibular afferent projection as well as projections from cerebellum and cerebellar nuclei. NPH neurons project bilaterally to the vestibular nuclei as well as the inferior olive (McCrea and Baker 1985). The projection from NPH to the dorsal cap is both cholinergic and GABAergic (Barmack et al. 1993a; De Zeeuw et al. 1993).

Neurons in the caudal aspects of the NPH and MVN project to several folia within the cerebellum (uvula-nodulus, ventral paraflocculus, flocculus) (Epema et al. 1990; Barmack 2003). Immunohistochemical surveys show that most if not all of these ascending mossy fiber projections from the caudal MVN, NPH are cholinergic.

The NPH also projects to the reticular formation, medial rectus subdivision of the ipsilateral oculomotor nucleus (III), contralateral abducens nucleus (VI) and contralateral dorsal cap of the inferior olive (Fig. 8.2a).

The Y-group also receives bilateral projections from the SVN. The ventral division of the Y-group projects to the ipsilateral flocculus, nodulus and contralateral oculomotor complex. The dorsal division projects contralaterally to the dorsal cap and beta nucleus of the inferior olive (Fig. 8.2a, b). This projection is excitatory (Kumoi et al. 1987). Y-group and NPH neurons project directly to the cerebellum as mossy fibers. Y-group and NPH neurons also influence the activity of neurons in the inferior olive that make overlapping projections to the cerebellum as climbing fibers.

## 8.9 Descending Projections of Vestibular Nuclei

Descending lateral and medial vestibulospinal tracts originate from the LVN and MVN and DVN (Brodal 1981). The lateral vestibulospinal tract is organized within the LVN topographically. Fibers to the lumbosacral spinal cord originate from the dorso-caudal LVN. Fibers to the cervical cord originate from the rostro-ventral LVN (Fig. 8.2b). Axons in the lateral vestibulospinal tract terminate in the ipsilateral lumbosacral region where they make monosynaptic and polysynaptic connections with motoneurons (Rose et al. 1992). Axons in the medial vestibulospinal tract terminate bilaterally in the medial part of the cervical ventral horn. The bilateral representation of vestibulospinal axons is most dense in the cervical enlargements from which motoneurons supplying the suboccipital muscles originate. These motoneurons participate in vestibulocollic reflexes.

The output of Psol is GABAergic. It descends to the ipsilateral inferior olive where it modulates the activity of cells in the  $\beta$ -nucleus ( $\beta$ ) and dorsomedial cell column (dmcc) (Fig. 8.1b) (Barmack et al. 1993b, 1998). These olivary neurons terminate as climbing fibers in the contralateral uvula-nodulus (Fig. 8.2b). In route to the inferior olive, Psol neurons also distribute collateral axon terminals to nuclei in the reticular formation, particularly the nucleus reticularis gigantocellularis (Fig. 8.1a) (Fagerson and Barmack 1995).

## 8.10 Autonomic Influences of the Vestibular Nuclei

The vestibular nuclei not only participate in reflexes mediated by skeletal muscles, but also are part of the circuitry through which autonomic reflexes (blood flow, respiration rate and heart rate) are regulated (Kaufmann et al. 2002; Rossiter et al. 1996; Kerman et al. 2000). Specifically this circuitry includes projections from the caudal vestibular nuclei (DVN, MVN and Psol) to the solitary nucleus (Nsol). The Nsol receives autonomic afferents, from the heart, esophagus and stomach, carried chiefly by branches of the IX and X cranial nerves.

## 8.11 Functions of Vestibular Nuclei

The vestibular nuclei are at a sensory-motor crossroad. The discharge of secondary vestibular neurons is influenced by visual and neck proprioceptive signals as well as signals generated by cerebellar and cerebral cortices. Consequently the discharge of secondary vestibular neurons comprises an adaptive hierarchy of sensory-motor responses. This hierarchy renders the famed “three neuronal arc” under central control (Lorente de N6 1933).



## References

- Akbarian S, Grusser OJ, Guldin WO (1993) Corticofugal projections to the vestibular nuclei in squirrel-monkeys – further evidence of multiple cortical vestibular fields. *J Comp Neurol* 332:89–104
- Akbarian S, Grüsser O-J, Guldin WO (1994) Corticofugal connections between the cerebral cortex and brainstem vestibular nuclei in the macaque monkey. *J Comp Neurol* 339:421–437
- Andersson G, Oscarsson O (1978a) Climbing fiber microzones in cerebellar vermis and their projection to different groups of cells in the lateral vestibular nucleus. *Exp Brain Res* 32:565–579
- Andersson G, Oscarsson O (1978b) Projections to lateral vestibular nucleus from cerebellar climbing fiber zones. *Exp Brain Res* 32:549–564
- Bacsikai T, Szekely G, Matesz C (2002) Ascending and descending projections of the lateral vestibular nucleus in the rat. *Acta Biol Hung* 53:7–21
- Bankoul S, Neuhuber WL (1990) A cervical primary afferent input to vestibular nuclei as demonstrated by retrograde transport of wheat germ agglutinin-horseradish peroxidase in the rat. *Exp Brain Res* 79:405–411
- Barmack NH (2003) Central vestibular system: vestibular nuclei and posterior cerebellum. *Brain Res Bull* 60:511–541
- Barmack NH, Henkel CK, Pettorossi VE (1979) A subparafascicular projection to the medial vestibular nucleus of the rabbit. *Brain Res* 172:339–343
- Barmack NH, Nastos MA, Pettorossi VE (1981) The horizontal and vertical cervico-ocular reflexes of the rabbit. *Brain Res* 224:261–278
- Barmack NH, Fagerson M, Errico P (1993a) Cholinergic projection to the dorsal cap of the inferior olive of the rat, rabbit and monkey. *J Comp Neurol* 328:263–281
- Barmack NH, Fagerson M, Fredette BJ, Mugnaini E, Shojaku H (1993b) Activity of neurons in the beta nucleus of the inferior olive of the rabbit evoked by natural vestibular stimulation. *Exp Brain Res* 94:203–215
- Barmack NH, Fredette BJ, Mugnaini E (1998) Parasolitary nucleus: a source of GABAergic vestibular information to the inferior olive of rat and rabbit. *J Comp Neurol* 392:352–372
- Bernard J-F (1987) Topographical organization of olivocerebellar and corticonuclear connections in the rat – an WGA-HRP study: I. Lobules IX, X, and the flocculus. *J Comp Neurol* 263:241–258
- Brodal A (1974) Anatomy of the vestibular nuclei and their connections. In: Kornhuber HH (ed) *Handbook of sensory physiology, vestibular system, morphology*, vol 6. Springer, Berlin
- Brodal A (1981) *Neurological anatomy*, 3rd edn. Oxford University Press, New York
- Brodal A, Pompeiano O (1957) The vestibular nuclei in the cat. *J Anat* 91:438–454
- Büttner U, Lang W (1979) The vestibulocortical pathway: neurophysiological and anatomical studies in the monkey. In: Granit R, Pompeiano O (eds) *Reflex control of posture and movement*. Elsevier/North-Holland Biomedical Press, Amsterdam, pp 581–588
- Büttner-Ennever J (1992) Patterns of connectivity in the vestibular nuclei. In: Cohen B, Tomko DL, Guedry F (eds) *Sensing and controlling motion*. Annals of the New York Academy of Sciences, New York, pp 363–378
- Cajal SR (1911) *Histologie du système nerveux de l'homme et des vertébrés*. Maloine, Paris
- De Zeeuw CI, Wentzel P, Mugnaini E (1993) Fine structure of the dorsal cap of the inferior olive and its GABAergic and non-GABAergic input from the nucleus prepositus hypoglossi in rat and rabbit. *J Comp Neurol* 327:63–82
- De Zeeuw CI, Wylie DR, DiGiorgi PL, Simpson JI (1994) Projections of individual Purkinje cells of identified zones in the flocculus to the vestibular and cerebellar nuclei in the rabbit. *J Comp Neurol* 349:428–447
- Deecke L, Schwarz DWF, Fredrickson JM (1977) Vestibular responses in the rhesus monkey ventroposterior thalamus. II. Vestibulo-proprioceptive convergence at thalamic neurons. *Exp Brain Res* 30:219–232

- Epema AH, Gerrits NM, Voogd J (1988) Commissural and intrinsic connections of the vestibular nuclei in the rabbit: a retrograde labeling study. *Exp Brain Res* 71:129–146
- Epema AH, Gerrits NM, Voogd J (1990) Secondary vestibulocerebellar projections to the flocculus and uvulo-nodular lobule of the rabbit: a study using HRP and double fluorescent tracer techniques. *Exp Brain Res* 80:72–82
- Fagerson MH, Barmack NH (1995) Responses to vertical vestibular stimulation of neurons in the nucleus reticularis gigantocellularis in rabbits. *J Neurophysiol* 73:2378–2391
- Fukushima K (1997) Corticovestibular interactions: anatomy, electrophysiology, and functional considerations. *Exp Brain Res* 117:1–16
- Graf W, McCreary RA, Baker R (1983) Morphology of posterior canal related secondary vestibular neurons in rabbit and cat. *Exp Brain Res* 52:125–138
- Henn V, Young L, Finley C (1974) Vestibular nucleus units in alert monkeys are also influenced by moving visual fields. *Brain Res* 71:144–149
- Hikosaka O, Maeda K (1973) Cervical effects on abducens motoneurons and their interaction with vestibulo-ocular reflex. *Exp Brain Res* 18:512–530
- Ilg UJ, Hoffmann KP (1996) Responses of neurons of the nucleus of the optic tract and the dorsal terminal nucleus of the accessory optic tract in the awake monkey. *Eur J Neurosci* 8:92–105
- Ito JI, Matsuoka I, Sasa M, Takaori S (1985) Commissural and ipsilateral internuclear connection of vestibular nuclear complex of the cat. *Brain Res* 341:73–81
- Kaufmann H, Biaggioni I, Voustianiouk A, Diedrich A, Costa F, Clarke R, Gizzi M, Raphan T, Cohen B (2002) Vestibular control of sympathetic activity – an otolith-sympathetic reflex in humans. *Exp Brain Res* 143:463–469
- Kerman IA, McAllen RM, Yates BJ (2000) Patterning of sympathetic nerve activity in response to vestibular stimulation. *Brain Res Bull* 53:11–16
- Kumoi K, Saito N, Tanaka C (1987) Immunohistochemical localization of g-aminobutyric acid- and aspartate-containing neurons in the guinea pig vestibular nuclei. *Brain Res* 416:22–23
- Lang W, Büttner-Ennever JA, Büttner U (1979) Vestibular projections to the monkey thalamus: an autoradiographic study. *Brain Res* 177:3–17
- Leigh RJ (1994) Human vestibular cortex. *Anal Neurol* 35:383–384
- Lorente de Nó R (1933) Vestibulo-ocular reflex arc. *Arch Neurol Psychiatr (Chic)* 30:245–291
- McCouch GP, Deering ID, Ling TH (1951) Location of receptors for tonic neck reflexes. *J Neurophysiol* 14:191–196
- McCreary RA, Baker R (1985) Anatomical connections of the nucleus prepositus of the cat. *J Comp Neurol* 237:377–407
- Newlands SD, Kevetter GA, Perachio AA (1989) A quantitative study of the vestibular commissures in the gerbil. *Brain Res* 487:152–157
- Nishiike S, Guldin WO, Bäurle J (2000) Corticofugal connections between the cerebral cortex and the vestibular nuclei in the rat. *J Comp Neurol* 420:363–372
- Prihoda M, Hiller MS, Mayr R (1991) Central projections of cervical primary afferent-fibers in the guinea-pig – an Hrp and Wga/Hrp tracer study. *J Comp Neurol* 308:418–431
- Rose PK, Wainwright K, Neuber-Hess M (1992) Connections from the lateral vestibular nucleus to the upper cervical spinal cord of the cat: a study with the anterograde tracer PHA-L. *J Comp Neurol* 321:312–324
- Rossiter CD, Hayden NL, Stocker SD, Yates BJ (1996) Changes in outflow to respiratory pump muscles produced by natural vestibular stimulation. *J Neurophysiol* 76:3274–3284
- Sato F, Sasaki H (1993) Morphological correlations between spontaneously discharging primary vestibular afferents and vestibular nucleus neurons in the cat. *J Comp Neurol* 333:554–556
- Sato H, Ohkawa T, Uchino Y, Wilson VJ (1997) Excitatory connections between neurons of the central cervical nucleus and vestibular neurons in the cat. *Exp Brain Res* 115:381–386
- Shiroyama T, Kayahara T, Yasui Y, Nomura J, Nakano K (1999) Projections of the vestibular nuclei to the thalamus in the rat: a *Phaseolus vulgaris* leucoagglutinin study. *J Comp Neurol* 407:318–332

- Shojaku H, Sato Y, Ikarashi K, Kawasaki T (1987) Topographical distribution of Purkinje cells in the uvula and the nodulus projecting to the vestibular nuclei in cats. *Brain Res* 416:100–112
- Simpson JI, Leonard CS, Soodak RE (1988) The accessory optic-system – analyzer of self-motion. *Ann NY Acad Sci* 545:170–179
- Tabuchi T, Umetani T, Yamadori T (1989) Corticonuclear and corticovestibular projections from the uvula in the albino rat: differential projections from sublobuli of the uvula. *Brain Res* 492:176–186
- Walberg F, Dietrichs E (1988) The interconnection between the vestibular nuclei and the nodulus: a study of reciprocity. *Brain Res* 449:47–53
- Wylie DR, DeZeeuw CI, DiGiorgi PL, Simpson JI (1994) Projections of individual Purkinje-cells of identified zones in the ventral nodulus to the vestibular and cerebellar nuclei in the rabbit. *J Comp Neurol* 349:448–463

# Chapter 9

## Spinocerebellar and Cerebellospinal Pathways

Tom J.H. Ruigrok

**Abstract** Although the cerebellum participates in many different functions, its coordinating role in learning and execution of movements remains its most visible aspect to our behavior. Multiple pathways convey information from the body to the cerebellum. These spinal pathways can be divided in systems that, either directly or indirectly, enter the cerebellar cortex to terminate as mossy fibers and in pathways that reach the cerebellum by way of the inferior olive and as a consequence will terminate as climbing fibers. Cerebellar processing is also mediated to the spinal cord by a multitude of routes. Corticospinal, rubrospinal, tectospinal, vestibulospinal and reticulospinal tracts may all, at least to some extent, be controlled by cerebellar output.

**Keywords** Cerebellar nuclei • Corticospinal tract • Rubrospinal tract • Reticulospinal tract • Spinocerebellar tracts • Spino-olivocerebellar tracts • Vestibulospinal tracts

Although it has become clear that the cerebellum is involved in many functions, its role in the control and coordination of reflexive as well as voluntary movements has been its most visible contribution to our behavior. In order to execute these tasks the cerebellum requires considerable input from the body by way of multiple spinocerebellar routes. Similarly, output of the cerebellum participating in the control of movements reaches its destination by several pathways. This chapter reviews the tracts that reach the cerebellum with information from the body as well as provide an overview of descending corridors used by the cerebellum to influence movements.

---

T.J.H. Ruigrok (✉)  
Department of Neuroscience, Erasmus MC Rotterdam,  
2040, 3000 CA Rotterdam, The Netherlands  
e-mail: [t.ruigrok@erasmusmc.nl](mailto:t.ruigrok@erasmusmc.nl)

## 9.1 Information Routes from Spinal Cord to the Cerebellum

Information from the body to the cerebellum should be divided into pathways that reach the cerebellum by way of the mossy fiber system and routes that reach the cerebellum by way of the inferior olive and its climbing fibers to the cerebellar Purkinje cells. In both pathways a distinction can be made into direct routes from spinal cord to cerebellum and inferior olive (Fig. 9.1a, b), respectively, or by way of pathways that use an intermediary in the (lower) brainstem.

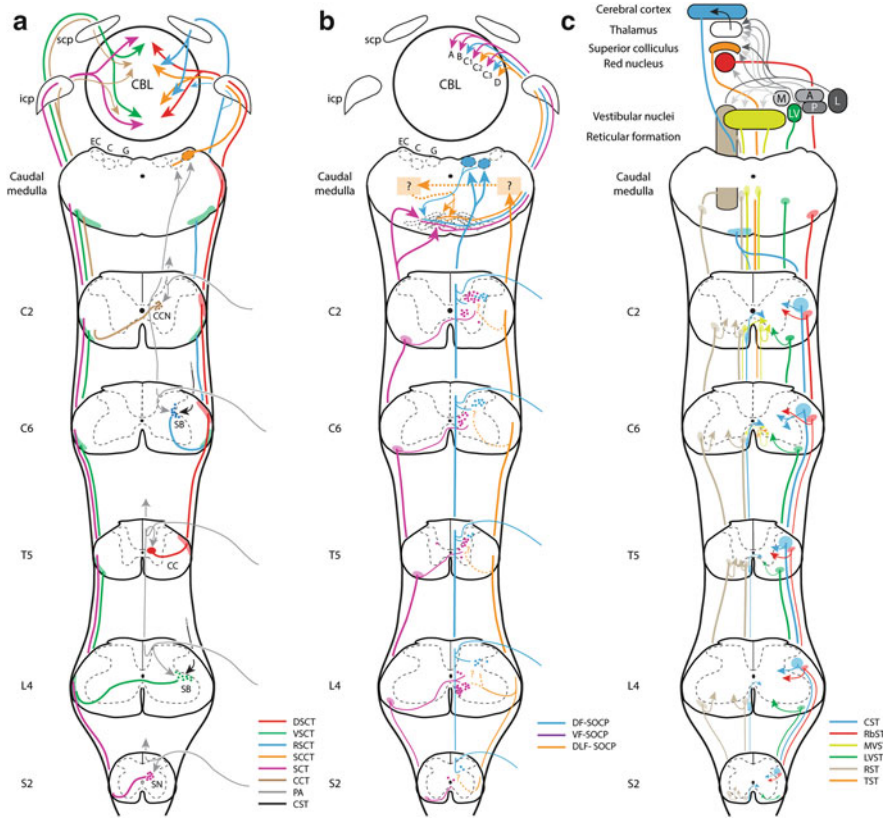
### 9.1.1 Direct Spinocerebellar Mossy Fiber Tracts

Four direct tracts from the spinal cord that terminate as mossy fibers in the cerebellar cortex can be recognized. The column of Clarke (located medially in lamina VII at thoracic and upper lumbar levels, also called ‘dorsal nucleus’ or ‘posterior thoracic nucleus’), is at the origin of the dorsal spinocerebellar tract. It ascends ipsilaterally in the superficial aspect of the dorsal half of the lateral funiculus and enters the cerebellum by way of the inferior cerebellar peduncle (Fig. 9.1a). It conveys mostly proprioceptive information from the ipsilateral lower body half. Stilling’s nucleus, located medially within lamina VII at sacral levels and the central cervical nucleus are thought to be the tail and neck equivalent of the column of Clarke. However, in contrast to the dorsal spinocerebellar tract, fibers from Stilling’s nucleus and the central cervical tract reach the cerebellum by way of a mostly contralateral route and by way of the superior cerebellar peduncle (Matsushita et al. 1995).

The ventral spinocerebellar tract originates predominantly from the so-called spinal border cells within the lateral part of the ventral horn of the lumbosacral cord, and from cells located within the intermediate gray of the cervical enlargement. In addition, there are many cells scattered throughout the dorsal, intermediate and ventral parts of the entire cord that will send projections to the cerebellum. Most of these spinocerebellar fibers ascend by way of the contralateral ventral (or anterior) spinocerebellar tract (Kitamura and Yamada 1989), and enter the cerebellum along the superior cerebellar peduncle (Fig. 9.1a). Spinocerebellar neurons travelling by way of the ventral spinocerebellar tract convey information from wide receptive fields and are also targeted by descending supraspinal systems.

---

**Fig. 9.1** (continued) its importance is doubted. The vestibulospinal tracts can be divided into the lateral vestibulospinal tract (*LVST*), originating from the lateral vestibular nucleus (*LV*) and whose cells are directly controlled by Purkinje cells of the lateral vermis, and the medial vestibulospinal tract (*MVST*) who is specifically controlled by M. The reticulospinal tracts (*RST*) can be divided into a medial tract, which originates from the pontine reticular formation and a more laterally positioned tract, which predominantly originates from the medullar reticular formation. For the sake of clarity the reticular tracts are only depicted on the contralateral side although they essentially are present bilaterally. Also note that the interstitiospinal tract is not depicted in this scheme. *Additional abbreviations:* *C* cuneate nucleus, *CC* column of Clarke, *CCN* central cervical nucleus, *G* gracile nucleus, *SB* spinal border cells, *SN* Stilling’s nucleus



**Fig. 9.1** Schematic diagrams showing the main ascending pathways from the spinal cord to the cerebellum (*CBL*) and the cerebellar influence on descending spinal tracts

(a) The direct spinocerebellar tracts. These tracts involve the dorsal spinocerebellar tract (*DSCT*), the ventral spinocerebellar tract (*VSCT*), the rostral spinocerebellar tract (*RSCT*), the sacral spinocerebellar tract (*SSCT*) and the cervicocerebellar tract (*CCT*). Due to the homology with the *DSCT* the external cuneocerebellar tract (*ECCT*) is also included in the direct spinocerebellar tracts. Note that some tracts take a contralateral course to the cerebellum but mainly terminate ipsilateral to their origin. Fibers mostly use the inferior cerebellar peduncle (*icp*), but some tracts enter the cerebellum by way of the superior cerebellar peduncle (*scp*)

(b) Essentially three spino-olivocerebellar paths (*SOCPs*) are recognized, although some paths can be further subdivided. A direct route from spinal cells to the inferior olive essentially takes a route by way of the contralateral ventral funiculus (*VF-SCOP*). A second route courses the ipsilateral dorsal funiculus (*DF-SCOP*), synapses at the dorsal column nuclei from where the contralateral inferior olive is targeted. This path, at least partly, originates from so called postsynaptic dorsal funiculus interneurons located in the dorsal horn. The third spinocerebellar path follows the ipsilateral dorsolateral funiculus (*DLF-SCOP*) and has one or two synaptic stations of unknown location before reaching the inferior olive. Single cerebellar cortical zones can receive input from multiple *SOCPs*

(c) Descending pathways influenced by cerebellar output. The corticospinal tract (*SCT*) is influenced by all cerebellar nuclei as these all reach the motor thalamus. The tectospinal tract (*TST*) can be influenced by the medial (*M*), posterior interposed (*P*) and lateral (*L*) cerebellar nuclei. It descends mostly contralateral to cervical levels. The rubrospinal tract (*RbST*) is activated by the anterior interposed (*A*) nucleus. It descends in the lateral funiculus throughout the cord. In human

Although the spino-cuneo-cerebellar pathway involves a brainstem nucleus it can be considered the forelimb homologue of the dorsal spinocerebellar tract. The main intermediary is formed by the external cuneate nucleus which receives mostly proprioceptive input from forelimb primary afferents travelling within the dorsal funiculus. It enters the cerebellum by way of the ipsilateral inferior cerebellar peduncle terminating mostly unilaterally in the cortex of the spinocerebellum.

The rostral spinocerebellar tract is considered to be the forelimb equivalent of the ventral spinocerebellar tract. It mostly arises from neurons at the intermediate laminae of the cord throughout the cervical levels but, contrasting its lower limb homolog, their axons reach the cerebellum by way of an ipsilateral route passing through the ventral part of the lateral funiculus and entering the cerebellum by either the inferior or superior peduncles (Fig. 9.1a).

### ***9.1.2 Indirect Spinocerebellar Mossy Fiber Tracts***

The lateral reticular nucleus, situated ventrolaterally in the caudal medulla, is an important intermediary supplying spinal information to the cerebellum. It can be divided into a magnocellular dorsomedial, a parvocellular ventrolateral, and a subtrigeminal part. In cat, physiological studies, often corroborated by tracing studies, have shown that the ventrolateral part mediates information from both lower limbs by way of the ventral flexor reflex tract, while the dorsomedial part receives proprioceptive information from the ipsilateral forelimb specifically (Pivetta et al. 2014; Azim et al. 2014).

The vestibular nuclei may also function as a brainstem intermediary transmitting spinocerebellar information as the central cervical nucleus also supplies afferents to predominantly the magnocellular part of the medial vestibular nucleus. This information may be involved in the control of the vestibulocollicular reflex (Matsushita et al. 1995). Similar to the vestibulo-ocular reflexes the vestibulocerebellum is likely to be involved in the adaptive control this reflex (Barmack 2003).

### ***9.1.3 Cerebellar Targets of Spinocerebellar Mossy Fiber Tracts***

Within the cerebellum, both the direct and indirect spinocerebellar mossy fiber projections are supplied bilaterally with an ipsilateral preponderance which indicates that the contralaterally ascending fibers recross in the cerebellum (Matsushita and Yaginuma 1989). Spinocerebellar mossy fibers mainly terminate in the so-called spinocerebellum, which mostly consists of the vermal and paravermal regions of the anterior lobe (and adjacent simple lobule) as well as in vermal and paravermal parts of lobule VIII and adjacent parts of VII and IX. A coarse somatotopy can be recognized in that the hindlimb is represented anterior to the forelimb in the rostral cerebellar lobules but posterior to it in its caudal representation. It is not known to what extent terminal clusters from axons travelling by way of the dorsal

spinocerebellar tract overlap with those from the ventral spinocerebellar tract. Spinocerebellar systems collateralize to the cerebellar nuclei but from the external cuneate nucleus these projections are sparse (Quy et al. 2011).

### ***9.1.4 Spino-Olivocerebellar Pathways***

Spino-olivocerebellar pathways (SOCs) have been extensively studied in cat using electrophysiological techniques employing selective lesions of the spinal white matter (Oscarsson and Sjolund 1977). As such it was established that spinal afferents can affect olivary processing by way of the ventral (or ventrolateral), (dorso-) lateral, and dorsal funiculi (Fig. 9.1b).

The ventral funiculus SOCP originates from several clusters of neurons located at the deeper layers of the contralateral cord and includes the lateral cervical nucleus. These neurons relay mostly proprioceptive, but also cutaneous, information which, after crossing at segmental level ascends just ventral to the ventral spinocerebellar tract to reach the caudal part of contralateral medial accessory and entire dorsal accessory olive. Olivocerebellar axons from the caudal parts of the accessory olives again cross the midline to reach the cerebellum by way of the inferior cerebellar peduncle to terminate unilaterally in A and B zones of the vermis (caudal parts of medial and dorsal accessory olives, respectively), whereas the rostral dorsal accessory olive targets the paravermal C1 and C3 zones.

A second pathway from the spinal cord to the inferior olive uses the dorsal funiculus and relays at the dorsal column nuclei (DFSOC). At least part of this pathway originates from neurons from the deeper layers of the dorsal horn and is also referred to as the postsynaptic dorsal column pathway to the inferior olive. Available evidence suggests that the postsynaptic dorsal column pathway originates from different spinal sources and mediates less sensitive and/or nociceptive signals to the inferior olive as compared to the direct spino-olivary route (Flavell et al. 2014).

Finally, the third spino-olivocerebellar route passes mostly through the ipsilateral lateral funiculus and relays through several, as yet not further specified, brainstem intermediaries before activating the contralateral inferior olive (i.e. rostral part of the medial accessory and the principal olives) that supply climbing fibers to the C2 and D zones.

SOCs can activate climbing fibers of all major cerebellar zones (excepting those of the vestibulocerebellum) but do so with different latencies.

## **9.2 Information Routes from the Cerebellum to the Spinal Cord**

Descending pathways to the spinal cord usually influence motor programming. However, obviously, several autonomic and visceral pathways are also directed to their respective spinal control sites. Here, we will concentrate on the first group of



descending routes in order to provide an overview of the involvement of the cerebellar control on these generally motor control pathways.

Classically, medial descending systems, which course through the ventral funiculus, and lateral descending systems, which pass the lateral funiculus, were distinguished by Lawrence and Kuypers (1968). Medial systems comprise the uncrossed medial corticospinal tract and the tectospinal, vestibulospinal, reticulospinal and interstitiospinal pathways. The lateral systems involve the crossed corticospinal tract and the rubrospinal tract (Ruigrok 2013).

### 9.2.1 *Lateral Systems*

The crossed corticospinal tracts originates mostly from the primary motor (area 4), premotor (area 6) and, to a lesser extent, from somatosensory (areas 1–3) cortices. As output from all cerebellar nuclei will reach the ventral lateral and ventral anterior parts of the thalamus (i.e. the classic ‘motor’ thalamus), but not the ventral posterior nucleus, cerebellar processing will be important for voluntary movement control (Fig. 9.1c). It should be noted that cerebellar control over the corticospinal tract originates from larger areas of the cerebellar cortex than the classic spinocerebellar regions. Presently, it is debated to what extent cerebellar output is involved in corticospinal information processing within somatosensory cortical regions (cf. Proville et al. 2014).

The rubrospinal tract originates from the magnocellular part of the red nucleus, which is under the exclusive cerebellar control of the anterior interposed nucleus (Fig. 9.1). Its fibers cross at the level of the nucleus and descend in the ventrolateral medulla to take up position in the lateral funiculus just ventral to, and partly intermingled with, the fibers from the crossed corticospinal tract. Although in most mammals the tract terminates throughout the spinal cord, its contribution to cervical processing seems to have increased in animals with reaching capacities of their forelimbs. In primates the importance of the rubrospinal tract seems to have degraded; in man only a few hundred rubrospinal fibers are described that may not even reach caudal cervical levels (Onodera and Hicks 2009).

### 9.2.2 *Medial Systems*

The origin of the uncrossed corticospinal tract seems to be similar to that of the crossed corticospinal tract. However, caudal to the pyramidal decussation it takes an ipsilateral route through the ventral funiculus to terminate predominantly contralaterally on interneurons in the medial part of the ventral horn.

The tectospinal tract originates from large cells in the deeper layers of the caudolateral part of the superior colliculus. As this structure is involved in directing gaze to objects of interest, this tract is involved in controlling head and neck position

relative to the body. Its fibers mostly decussate in the dorsal tegmental tract and descend in the ventral funiculus down to the upper cervical cord. Tectospinal projections are widespread and usually involve a segmental relay. Tecto-reticulo-spinal projections can also contribute to tectal control of spinal motor systems. Cerebellar output from the fastigial, posterior interposed and lateral cerebellar nucleus reaches the superior colliculus (Fig. 9.1c). As such these regions might influence tectospinal processing.

The vestibular nuclear complex, classically divided into a medial, spinal, lateral and a superior vestibular nucleus, is intimately connected with the cerebellum. Not only is a large part of its output directed to the cerebellar cortex and nuclei, but it also receives a main input from the cerebellum. Indeed, the vestibular complex is special because it is the only brainstem system that receives afferents from the cerebellar nuclei as well as directly from the cerebellar cortex. Descending output of the vestibular nuclei is directed the spinal cord by way of the medial and lateral vestibulospinal tracts (Fig. 9.1c). The medial tract descends by way of the medial longitudinal fascicle, entering and coursing the ventral funiculus at its dorsal aspects. Its fibers originate from the ipsilaterally located inhibitory neurons and from excitatory, but contralaterally located vestibular neurons. The medial tract terminates bilaterally in the ventromedial aspects of the spinal gray where they mostly influence motoneurons that innervate neck and axial musculature. It does not seem to descend beyond midthoracic levels. Vestibular neurons contributing to the medial vestibulospinal tract may receive information from either the medial cerebellar nucleus or from Purkinje cells of the vestibulocerebellum that project directly to the vestibular nuclei. The rostral part of the medial cerebellar nucleus provides a glycinergic projection to the ipsilateral medial vestibular nucleus and a glutamatergic projection to its contralateral counterpart (Bagnall et al. 2009).

The lateral vestibulospinal tract originates from the ipsilateral lateral vestibular nucleus (LV), is excitatory, and descends laterally in the ventral funiculus to terminate, throughout the length of the cord, in the ventromedial laminae of the spinal grey (Fig. 9.1c). Direct synaptic contacts with motoneurons that control extensor or anti-gravity muscles has been established (Arshavsky et al. 1986). Cerebellar control of the LV is provided by the axons of the Purkinje cells of the B-zone of the lateral vermis of the anterior lobe and lobule VIII. Indeed, as most LV neurons are active during the stance phase of locomotion, it was shown that cooling of the anterior cerebellar vermis results in prolonged stance phases (Arshavsky et al. 1986; Udo et al. 1976). Yet, using transneuronal labeling, it was demonstrated that B-zone Purkinje cells may influence both agonists and antagonists (Ruigrok et al. 2008).

The medioventral pontomedullary reticular formation forms the origin of several long descending systems that travel ipsilaterally in medial (mostly from pontine levels) and bilaterally in ventral or ventrolateral reticulospinal tracts (mostly from medullary levels: Fig. 9.1c). Many fibers provide collaterals to cervical as well as lumbar levels. Reticulospinal systems have been described as subserving many different functions as they are involved in maintaining and controlling ongoing motor activity of proximal but also distal muscles (e.g. Esposito et al. 2014), in the gating of somatosensory information to segmental as well as supraspinal levels, and in the

control of autonomic activity including pain modulatory systems (e.g. Fields 2004). Several regions of the cerebellar nuclei supply projections to the reticular formation and, as such, may influence processing in reticulospinal systems. The caudal part of the medial cerebellar nucleus projects contralaterally to the medial pontine reticular formation as well as to the dorsomedial medullary reticular formation. Other parts predominantly reach parvocellular reticular regions. The rostral part of the medial nucleus, although mostly supplying terminals to the vestibular nuclei, also projects to intermediate (mediolateral) levels of the reticular formation and to the lateral paragigantocellular nucleus. The medial cerebellar nucleus has also been implicated in the control of several autonomic functions (Nisimaru 2004). A second cerebellar nuclear area that is intercalated between the medial and the interposed nuclei has projections to selective regions of the contralateral pontomedullary reticular formation, such as the gigantocellular reticular nucleus. In rodents, a prominent ipsilateral projection emerges from the enlarged lateral part of the anterior interposed nucleus, termed the dorsolateral hump, and which supplies afferents to the parvocellular regions of the ipsilateral pontomedullary reticular formation but also invades the deeper layers of the spinal trigeminal nucleus. Stimulation evokes movements of lips, neck and forelimb (Cicirata et al. 1992). The dorsolateral hump receives its Purkinje fiber input from the D0 zone, which is intercalated between the D1 and D2 zones of lobules V–VII. It is not known if a primate equivalent exists. Finally, the connections of the lateral nucleus with the pontomedullary reticular formation are well documented for rat, cat and monkey and are particularly dense to the contralateral gigantocellular reticular nuclei (Fig. 9.1c). The projection originates mostly from the dorsal, magnocellular, aspects of the nucleus. Projections may also reach the ipsilateral reticular formation and have been shown to activate reticulospinal neurons monosynaptically (Tolbert et al. 1980). The role of this disynaptic dentate-reticulo-spinal connection is not yet clear.

The interstitiospinal tract originates from a region with scattered large neurons located within and surrounding the medial longitudinal fascicle at midbrain levels, and which is known as the interstitial nucleus of Cajal. This region is known to be involved in oculomotor control but at least some of its fibers descend ipsilaterally to the spinal cord where they terminate in laminae VII and VIII. The interstitiospinal tract has excitatory monosynaptic contacts with neck musculature but also provides di- and polysynaptic activations of other muscles (Fukushima et al. 1978; Holstege and Cowie 1989). Cerebellar projections to the interstitial nucleus of Cajal arise mostly from the medial cerebellar nucleus, but other areas also contribute.

### 9.3 Conclusion

The cerebellum is widely known as a structure with a uniform internal circuitry that processes information in a stereotypic way. Within the internal circuitry a number of sagittally organized modules are recognized which form functional entities (Apps and Hawkes 2009; Ruigrok 2011). The organization of the input to these modules

and the organization of their output channels, therefore, will determine the type of information processed within such a module and which structures will be informed of its result. The overview presented in this chapter demonstrates that detailed knowledge of the spino-cerebellar and cerebello-spinal connections with these modules is still not at a level that enables a deeper understanding of cerebellar functions. A detailed description of the interaction of the various spinocerebellar systems with the cerebellar modular circuitry is required together with an improved perception of how the output of modules is distributed to and processed within the centers from which descending tracts originate.

## References

- Apps R, Hawkes R (2009) Cerebellar cortical organization: a one-map hypothesis. *Nat Rev Neurosci* 10(9):670–681
- Arshavsky YI, Gelfand IM, Orlovsky GN (1986) Cerebellum and rhythmical movements, vol 13, *Studies of brain function*. Springer, Berlin
- Azim E, Jiang J, Alstermark B, Jessell TM (2014) Skilled reaching relies on a V2a propriospinal internal copy circuit. *Nature* 508(7496):357–363. doi:[10.1038/nature13021](https://doi.org/10.1038/nature13021)
- Bagnall MW, Zingg B, Sakatos A, Moghadam SH, Zeilhofer HU, du Lac S (2009) Glycinergic projection neurons of the cerebellum. *J Neurosci* 29(32):10104–10110
- Barmack NH (2003) Central vestibular system: vestibular nuclei and posterior cerebellum. *Brain Res Bull* 60(5-6):511–541
- Cicirata F, Angaut P, Serapide MF, Panto MR, Nicotra G (1992) Multiple representation in the nucleus lateralis of the cerebellum: an electrophysiologic study in the rat. *Exp Brain Res Exp Hirnforsch Exp Cereb* 89(2):352–362
- Esposito MS, Capelli P, Arber S (2014) Brainstem nucleus MdV mediates skilled forelimb motor tasks. *Nature* 508(7496):351–356. doi:[10.1038/nature13023](https://doi.org/10.1038/nature13023)
- Fields H (2004) State-dependent opioid control of pain. *Nat Rev* 5(7):565–575
- Flavell CR, Cerminara NL, Apps R, Lumb BM (2014) Spino-olivary projections in the rat are anatomically separate from postsynaptic dorsal column projections. *J Comp Neurol* 522(9):2179–2190. doi:[10.1002/cne.23527](https://doi.org/10.1002/cne.23527)
- Fukushima K, van der Hoeff-van Halen R, Peterson BW (1978) Direct excitation of neck motoneurons by interstitiospinal fibers. *Exp Brain Res* 33(3-4):565–581
- Holstege G, Cowie RJ (1989) Projections from the rostral mesencephalic reticular formation to the spinal cord. An HRP and autoradiographical tracing study in the cat. *Exp Brain Res* 75(2):265–279
- Kitamura T, Yamada J (1989) Spinocerebellar tract neurons with axons passing through the inferior or superior cerebellar peduncles. A retrograde horseradish peroxidase study in rats. *Brain Behav Evol* 34(3):133–142
- Lawrence DG, Kuypers HG (1968) The functional organization of the motor system in the monkey. II. The effects of lesions of the descending brain-stem pathways. *Brain* 91(1):15–36
- Matsushita M, Yaginuma H (1989) Spinocerebellar projections from spinal border cells in the cat as studied by anterograde transport of wheat germ agglutinin-horseradish peroxidase. *J Comp Neurol* 288(1):19–38. doi:[10.1002/cne.902880103](https://doi.org/10.1002/cne.902880103)
- Matsushita M, Gao X, Yaginuma H (1995) Spinovestibular projections in the rat, with particular reference to projections from the central cervical nucleus to the lateral vestibular nucleus. *J Comp Neurol* 361(2):334–334. doi:[10.1002/cne.903610210](https://doi.org/10.1002/cne.903610210)
- Nisimaru N (2004) Cardiovascular modules in the cerebellum. *Jpn J Physiol* 54(5):431–448

- Onodera S, Hicks TP (2009) A comparative neuroanatomical study of the red nucleus of the cat, macaque and human. *PLoS One* 4(8):e6623
- Oscarsson O, Sjolund B (1977) The ventral spino-olivocerebellar system in the cat. I. Identification of five paths and their termination in the cerebellar anterior lobe. *Exp Brain Res* 28(5):469–486
- Pivetta C, Esposito MS, Sigrist M, Arber S (2014) Motor-circuit communication matrix from spinal cord to brainstem neurons revealed by developmental origin. *Cell* 156(3):537–548. doi:[10.1016/j.cell.2013.12.014](https://doi.org/10.1016/j.cell.2013.12.014)
- Proville RD, Spolidoro M, Guyon N, Dugue GP, Selimi F, Isope P, Popa D, Lena C (2014) Cerebellum involvement in cortical sensorimotor circuits for the control of voluntary movements. *Nat Neurosci* 17(9):1233–1239. doi:[10.1038/nn.3773](https://doi.org/10.1038/nn.3773)
- Quy PN, Fujita H, Sakamoto Y, Na J, Sugihara I (2011) Projection patterns of single mossy fiber axons originating from the dorsal column nuclei mapped on the aldolase C compartments in the rat cerebellar cortex. *J Comp Neurol* 519(5):874–899
- Ruigrok TJ (2011) Ins and outs of cerebellar modules. *Cerebellum (Lond Engl)* 10(3):464–474
- Ruigrok TJH (2013) Cerebellar influences on descending spinal motor systems. In: Manto M, Gruol JD, Schmähmann N, Koibuchi N, Rossi F (eds) *Handbook of the cerebellum and cerebellum disorders*. Springer, Dordrecht, pp 497–528
- Ruigrok TJ, Pijpers A, Goedknecht-Sabel E, Coulon P (2008) Multiple cerebellar zones are involved in the control of individual muscles: a retrograde transneuronal tracing study with rabies virus in the rat. *Eur J Neurosci* 28(1):181–200
- Tolbert DL, Bantli H, Hames EG, Ebner TJ, McMullen TA, Bloedel JR (1980) A demonstration of the dentato-reticulospinal projection in the cat. *Neuroscience* 5(8):1479–1488
- Udo M, Oda Y, Tanaka K, Horikawa J (1976) Cerebellar control of locomotion investigated in cats: discharges from Deiters' neurones, EMG and limb movements during local cooling of the cerebellar cortex. *Prog Brain Res* 44:445–459. doi:[10.1016/S0079-6123\(08\)60751-7](https://doi.org/10.1016/S0079-6123(08)60751-7)

# Chapter 10

## Visual Circuits

Manuel Jan Roth, Axel Lindner, and Peter Thier

**Abstract** The cerebellum receives substantial input from visual and eye movement-related areas by way of the pons. These signals are used to guide and refine motor behavior and to establish spatial orientation. Accordingly, damage to the cerebellum can lead to imprecise eye movements and deficits in visual perception. Here we discuss cerebro-cerebellar circuits supporting vision.

**Keywords** Cerebellum • Cerebellar anatomy • Visual perception • Sensory predictions • Forward models

### 10.1 Anatomical Considerations

Visual information processing in the cerebrum engages various areas that make up a large amount of cerebral cortex. Interestingly, many of these areas also project to the cerebellum. There, visual information, in combination with other kinds of inputs such as vestibular signals, is integrated in order to provide spatial orientation and to (visually) guide and refine motor behavior, such as eye movements (Thier and Möck 2006).

To allow for such close interaction, both cerebral and cerebellar cortices must share information. Hence, it is not surprising that the extensive projection system connecting these two structures by way of the pons constitutes one of the largest circuits in the human brain. Information from sensory and motor areas of the cerebral cortex, which accounts for the largest portion of pontine afferents, and also from additional subcortical structures such as the superior colliculus (Glickstein 2013), is sent to the cerebellum mainly via the pontine nuclei (PN) and another precerebellar nucleus, the nucleus reticularis tegmenti pontis (NRTP), which will not be further discussed here.

The PN are located around the cerebral peduncles in the ventral portion of the pons and are commonly subdivided into several nuclei based on their cytoarchitec-

---

M.J. Roth • A. Lindner • P. Thier (✉)

Department of Cognitive Neurology, Hertie Institute for Clinical Brain Research,  
University of Tübingen, Hoppe-Seyler-Strasse 3, 72076 Tübingen, Germany  
e-mail: [manueljanroth@gmail.com](mailto:manueljanroth@gmail.com); [a.lindner@medizin.uni-tuebingen.de](mailto:a.lindner@medizin.uni-tuebingen.de);  
[thier@uni-tuebingen.de](mailto:thier@uni-tuebingen.de)

ture and their general location. They consist of roughly 20,000,000 neurons there-with accounting for almost 40 % of pontine brainstem volume (Matano et al. 1985; Tomasch 1969). The large majority of these neurons are believed to be projection neurons connecting cerebral and cerebellar cortex (Cooper and Fox 1976). Because of its intermediate position between the two cortices receiving cerebrocortical and collicular visual and eye movement-related signals, the PN are believed to be an important integrative relay of the visual and eye movement pathway on which we focus here.

### ***10.1.1 Cerebrocortical Areas Projecting to the Pons***

Using retrograde tracers injected into the PN to study the distribution and density of corticopontine projections, Glickstein and colleagues found labeled layer 5 pyramidal cells within a contiguous region covering parts of frontal, parietal, and temporal lobe (Glickstein et al. 1985) Fig. 10.1a. More precisely, the region containing substantial numbers of labeled cells ranged from the insular cortex within the sylvian fissure laterally to the ventral edge of the cingulate cortex medially and from the arcuate sulcus rostrally to the superior temporal sulcus caudally (Brodmann's areas 1–10, 13, 14, 19, 23–25; (Brodmann 1909)).

Importantly, this region found to project to PN comprises of all known cortical areas involved in providing visual and other signals necessary for eye movements such as saccades and smooth pursuit, but also for example the ocular following response. These visual and eye movement-related areas include the frontal eye fields (FEF; (Bruce et al. 1985; Gottlieb et al. 1994)), supplementary eye fields (SEF, (Heinen 1995; Schlag and Schlag-Rey 1985, 1987)), lateral intraparietal (LIP) and medial parietal areas (MP; (Andersen et al. 1990; Barash et al. 1991a, b; Thier and Andersen 1997, 1998)), medial superior temporal area (MST; (Newsome and Wurtz 1988; Thier and Erickson 1992; Kawano et al. 1994)), and middle temporal area (MT; (Dursteler and Wurtz 1988; Newsome et al. 1988)). Further analyses of the cerebro-pontine projections of these regions showed that most of them terminate in the dorsal part of the ipsilateral PN in several elongated lamellae often spanning several sub-nuclei. This suggests that the subdivision of the PN into several nuclei based on cytoarchitecture does not seem to correspond to the organization of afferent terminations (Thier and Möck 2006).

### ***10.1.2 Ponto-Cerebellar Projections and Cerebellar Output***

The pontine projection neurons' axons enter the cerebellum by way of the middle cerebellar peduncle and terminate as mossy fibers in the granular layer of the cerebellar cortex. From there they give rise to the parallel fibers, which connect to purkinje cells as the only output neurons of cerebellar cortex. While most of the ponto-cerebellar fibers terminate in the contralateral part of the cerebellum, there

seem to be also ipsilateral projections (Rosina et al. 1980). Major projection sites of these neurons that show an involvement in eye movements and will be discussed in the following chapter are the lobuli VII and VIc of the posterior vermis and the dorsal paraflocculus (Thier 2011) Fig. 10.1b.

Visual and eye movement-related signals leave the cerebellum through the projection of purkinje cells to the deep cerebellar nuclei (DCN). The caudal fastigial and the posterior interposed nucleus have been studied the most with respect to oculomotor functions and both have been shown to connect to the PN (Thier and Möck 2006).

## 10.2 Cerebellum and Eye Movements

The previous section provided a rough overview about circuits underlying cerebrocerebellar information transfer with a focus on visual and eye movement related signals. Here we will focus on behaviorally and/or perceptually relevant cerebellar contributions to eye movements and visual perception.

The cerebellum is of utter importance for visual perception because it optimizes goal-directed eye movements such as saccadic and smooth pursuit eye movements as well as ocular reflexes stabilizing visual perception such as the vestibulo-ocular reflex (VOR) or the ocular following response (OFR) (Thier 2011). The ability to precisely direct gaze towards objects of interest as well as to perceive a stable visual world despite one's own movements lies at the heart of our visual perceptual abilities. At this point it is important to note, however, that the cerebellum is of course not only involved in directing and optimizing eye movements. It is, on the contrary, also involved in visually guiding limb movements, such as reaching, among many other tasks. Yet, discussing these cerebellar features goes beyond the scope of this chapter. Therefore, in the following section we will explore effects of damage to the cerebellum or the PN on eye movements.

### 10.2.1 *Effects of Cerebellar Lesions on Saccades and Smooth Pursuit*

Saccades are fast and goal-directed eye movements that serve to bring an object of interest onto the fovea, i.e., onto the part of the retina with highest visual acuity. Hence, being able to perform precise saccades is important to ensure proper object analysis. Likewise, in cases in which an object of interest is moving and/or the observer is moving, smooth pursuit eye movements are additionally engaged to track the object by matching eye velocity to target velocity and thereby keeping it on the fovea (often supported by head and body tracking).

Immediate insights into the importance of the cerebellum for eye movements are provided by lesion studies. Barash and colleagues showed that after lesioning small parts of the oculomotor vermis in macaque monkeys, visually guided saccades



became dramatically unreliable and hypometric, i.e., saccades fell too short relative to the saccade target (Barash et al. 1999). Similar effects, namely imprecise saccades with a high variability in saccade end points, can also be observed in human subjects suffering from cerebellar damage (Golla et al. 2005) Fig. 10.1c. Comparable problems in precision arise during smooth pursuit eye movements. While healthy subjects are capable of smoothly tracking a constantly moving visual target, patients and animals with cerebellar lesions fail in doing so (May et al. 1988; Haarmeier and Thier 1999). This is because their eye velocity is typically too small to match target velocity. Therefore, the distance between the tracked object and the fovea continuously increases during the course of a tracking movement and this “foveation error” then needs to be repeatedly compensated with (so-called) catch-up saccades (Fig. 10.1d).

## 10.2.2 Cerebellar Adaptation of Eye Movements

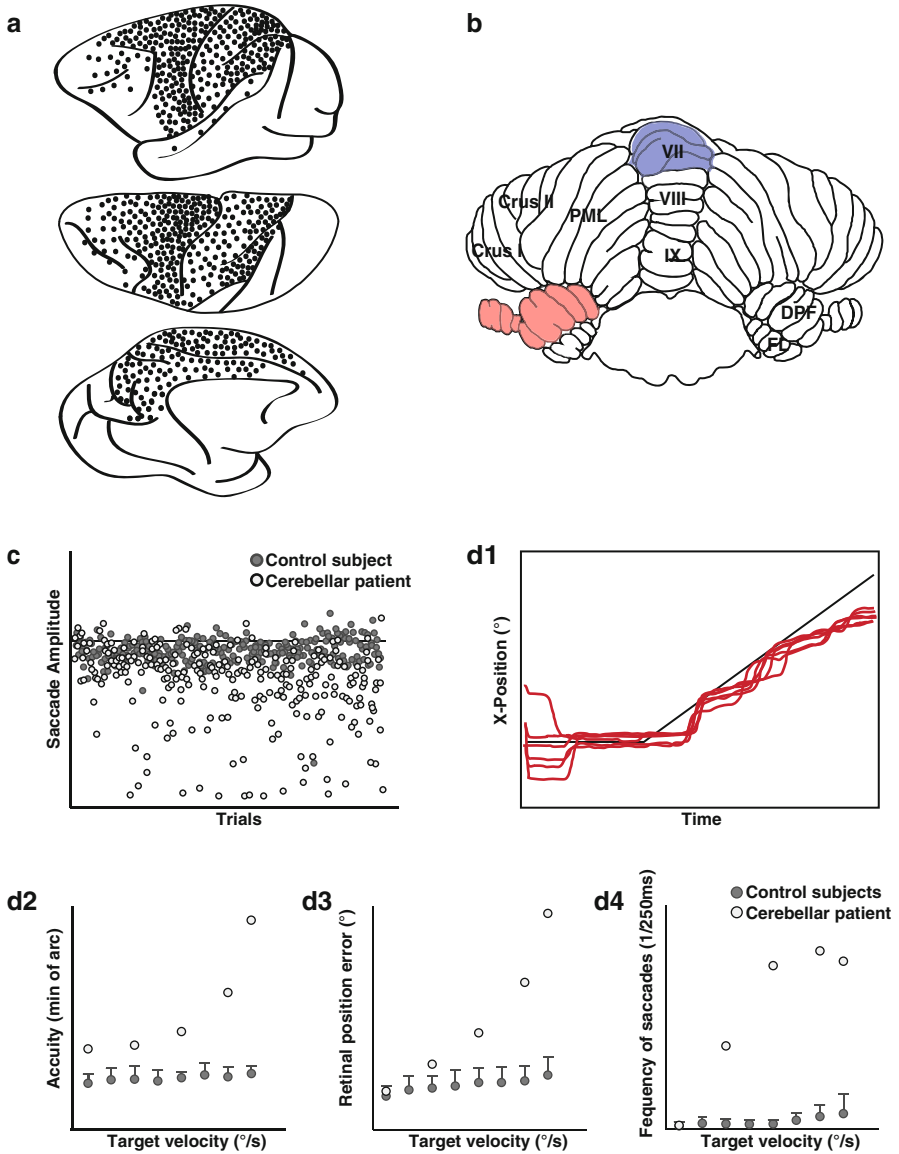
As we have seen in the previous paragraph, damage to certain parts of the cerebellum can lead to imprecise visually guided eye movements. The role of the cerebellum thus seems to be the optimization and coordination of movement. The lack of coordination and fine-grained motor abilities is indeed a typical symptom of (cerebellar) ataxias in a clinical context.

Such an involvement in refining motor output would be essential for learning new or for adapting already learned motor skills. Interestingly, in the study by Barash and colleagues referred to above, monkeys’ saccades on average returned to pre-lesion amplitudes after some time, although displaying bigger variation. What was completely abolished, however, was the capacity to adapt saccade amplitude in an adaptation paradigm (Barash et al. 1999). This finding is in agreement with a large body of literature describing adaptation deficits of saccades and smooth pursuit in cerebellar disease, e.g. (Takagi et al. 2000; Straube et al. 2001). Furthermore, these deficits are also reported for skeletomotor movements in tasks that call for an adaptation of motor (and possibly sensory) output in response to altered sensorimotor relationships (Martin et al. 1996). In fact, motor learning and adaptation deficits are usually one of the strongest symptoms of patients suffering from cerebellar damage (Bastian 2011).

Adapting and recalibrating movements is not only required in experimental settings but, on the contrary, is a continuous process ensuring precise motor output and

---

**Fig. 10.1** (continued) Note the wide spread of saccade endpoints of the patient (dysmetria) compared to the control (Modified from Golla et al. 2005). **(d)** Performance in smooth-pursuit of a patient suffering from cerebellar degeneration compared to a healthy control group. **(d1)** Eye movement traces (*red lines*) in a task where the subject was supposed to track a moving target at 8°/s (*black line*). The pursuit velocity is insufficient to stay on the target, which leads to compensatory corrective saccades. **(d2–d4)** Psychophysical evidence for impaired visual analysis of a moving object **(d2)** as a result of smooth pursuit deficits **(d3–d4)** in a cerebellar patient (*light grey*) compared to a healthy control group (Modified from Haarmeier and Thier 1999). *DPF* dorsal parafoveus, *FL* flocculus, *PML* paramedian lobule



**Fig. 10.1** (a) Location of cells (*black dots*) in the cortex that have been found to project to the PN using retrograde tracers in a monkey. Layer 5 pyramidal cells within a region involving parts of frontal, parietal, and temporal lobe, ranging from the insular cortex within the sylvian fissure laterally to the ventral edge of the cingulate cortex medially and from the arcuate sulcus rostrally to the superior temporal sulcus caudally project to the PN (Modified from Glickstein et al. 1985). (b) Schematic drawing of a caudal view of cerebellar cortex with the location of the two main oculomotor regions highlighted. The oculomotor vermis (OMV) is shown in *blue* and the dorsal paraflocculus in *red* (Adapted from Thier and M $\ddot{o}$ ck 2006). (c) Exemplary data on visually guided saccades of a cerebellar patient (*light grey*) and a control subject (*dark grey*).

self-motion perception despite the continuous changes of the motor plant due to aging, disease etc. (Haarmeier et al. 2001). It has been shown, for instance, that even the compensation of eye movement fatigue critically depends on the cerebellum (Golla et al. 2008).

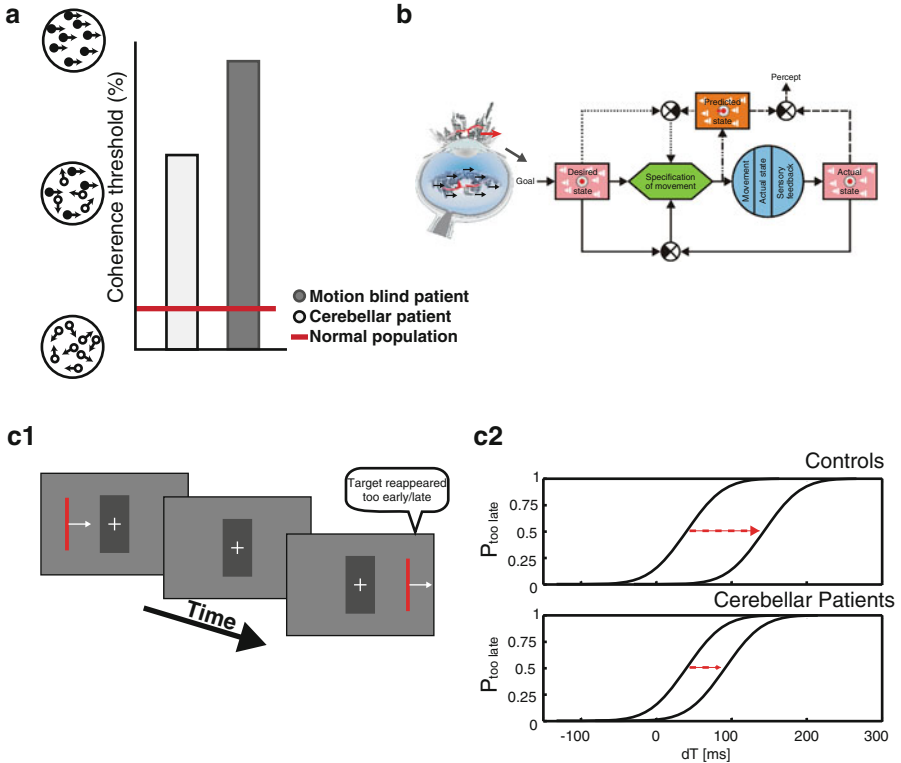
Motor updating is believed to depend on so called *forward models*, which predict the sensory consequences of movements on the basis of motor commands and (sensory) information about the current state of the system. Using these predictions, movements can be corrected on the fly and do not (only) depend on delayed sensory feedback, thereby guaranteeing fast and accurate movements (Wolpert and Ghahramani 2000; Wolpert and Flanagan 2001). Accordingly, it is currently believed that the cerebellum is responsible for predicting the sensory consequences of movement and/or, in particular, for keeping these forward model predictions precisely tuned (Wolpert et al. 1998; Bastian 2006; Tseng et al. 2007).

### 10.3 Deficits of Visual Perception in Cerebellar Patients

Up to this point, the reported influence of the cerebellum on perception/vision was an indirect one – one that is mediated by imprecise eye movements. In the following we will focus on seemingly isolated visual deficits and on visual functions that are informed by forward models. At least one purely visual deficit that is seemingly unrelated to motor action has been consistently reported over the last years. That is, deficits in detecting a global visual motion component embedded in randomly moving dots (Nawrot and Rizzo 1995; Thier et al. 1999; Jokisch et al. 2005; Händel et al. 2009). Compared to healthy controls, cerebellar patients need a much higher degree of coherently moving dots within a moving random dot pattern to establish a global visual motion percept (Fig. 10.2a).

#### 10.3.1 *Role of the Cerebellum in Global Visual Motion Perception*

But why and how should the cerebellum influence such motion perception? A key for a better understanding of such findings could be provided by the fact that the causes for visual motion can either be a “true” motion in the environment, or an ego-motion (in light), which in itself can induce visual motion signals. This is, for instance, the case when one is moving her eyes. In order to extract the part of the incoming visual afference that is chiefly important to the brain, i.e., the exafference (von Holst and Mittelstaedt 1950) that has not been self-caused, the cerebellum is believed to predict the visual sensory consequences of performed movements by also resorting to forward models. In case of smooth pursuit eye movements, this prediction is then used to cancel out the self-induced (reafferent) visual motion to ensure perceptual stability (Haarmeier et al. 2001) Fig. 10.2b.



**Fig. 10.2** (a) Deficits of a cerebellar patient suffering from spinocerebellar ataxia type 6 (SCA6) in global visual motion perception. When measuring the percentage of coherently moving dots necessary to evoke a percept of global motion in a display of otherwise randomly moving dots, this SCA6 patient (light grey bar) has not only a strongly elevated threshold compared to a healthy population (red line), but her perceptual threshold is in fact closer to the one of a motion blind patient due to cortical lesions (Zihl et al. 1983). (b) Depiction of a comparator model used to predict and possibly subtract self-induced motion, for example in the case of smooth pursuit eye movements. If one is tracking a moving object with the eyes in order to stabilize the retinal image, a motor command is generated to achieve this desired state. This desired state is then compared with the actual state and a possible motor error can be fed back into the system to improve its function (solid lines). Furthermore, the system forms a prediction about the sensory outcome of the behavior based on the motor command (predicted state). This prediction can then be used for feed-forward movement control, but also to remove or attenuate self-caused sensory afference, e.g. the self-caused retinal image slip during smooth pursuit (dotted lines; Adapted from Lindner et al. 2005). (c) Deficit of cerebellar patients in recalibrating a spatiotemporal prediction in response to altered stimulus statistics. (c1) Subjects had to predict the time of reappearance of a constantly moving visual target that disappeared behind an occluder for a part of its movement trajectory. The time the visual target spent behind the occluder was manipulated in such a way, that in half of the trials the target reappeared too late, denoted by a positive  $dT$ . (c2) While healthy controls recalibrated their prediction about when the target should reappear in response to the target reappearing too late ( $dT > 0$ ) in half of the trials, as indicated by a shift of the psychometric function towards more positive  $dT$ , cerebellar patients did not show this recalibration. Hence, cerebellar patients show a deficit in adapting perceptual predictions that is similar to the reported deficits in motor tasks (Adapted from Roth et al. 2013)

As already discussed in the section on (motor) adaptation, also such *sensory predictions* need to undergo constant recalibration in order to match not only the changing properties of the motor plant but also the ever-changing sensory environment (brightness, contrast etc.). These forward models therefore need to incorporate information on actual body states, issued motor commands, as well as incoming sensory information (and probably context information), a job that fits to the integrative position the cerebellum holds in the brain. Furthermore, its unique cellular architecture is best suited for the comparison of a predicted with an actual sensory afference that is necessary for recalibration.

In the case of the discussed global visual motion deficit, the precise forward model input to cortical areas involved in motion perception could be missing due to the cerebellar damage and thereby explain deficits in motion perception of these patients.

Support for this idea comes from work on the suprasylvian cortex of cats, in a region that contains cells that seem to represent the homolog of primate area MT responsible for motion perception. The cerebellar input to this area of cortex via the thalamus is as large as the purely visual afference. Given this tremendous cerebellar input to this part of cortex it stands to reason that the missing (predictive) cerebellar input could corrupt motion processing. A hint that this could also be the case in humans comes from an MEG study that found altered parieto-occipital activity of cerebellar patients in a coherent motion task, paralleling patients' perceptual impairment (Händel et al. 2009). Furthermore, in a recent study Sultan and colleagues have used electrical stimulation of the cerebellar output combined with functional magnetic resonance imaging and found connections between the cerebellar output and areas involved in motion processing (Sultan et al. 2012).

### ***10.3.2 Are There Other Deficits in Visual Perception?***

In the last decades many studies have been trying to identify other perceptual or cognitive deficits in cerebellar patients (Baumann et al. 2015). In fact, the idea of forward models predicting upcoming sensory afference based on current state and contextual information can be theoretically easily transferred to the cognitive/perceptual domain without the explicit need for motor behavior (Ito 2005, 2008). But separating motor from perceptual or cognitive effects can be hard and often experimentally impossible because the ability to move and therefore explore ones environment is the basis for much of our perceptual system.

However, the notion to use a system like the cerebellum that is mostly used for optimizing (visually guided) actions and therefore has all the necessary information and computational abilities to predict upcoming sensory events on the basis of current state information in combination with internally stored models and to update these models also for closely related perceptual tasks, seems parsimonious. Especially since such sensory events are usually important for subsequent movements (Baumann et al. 2015). A study by Roth and colleagues recently investigated

the question whether the cerebellum also plays a role in forward models about external motion, which likewise need to undergo adaptation to reflect the ever-changing (sensory) environment (Roth et al. 2013). In this study, participants had to form predictions about the spatiotemporal behavior of a partly occluded visual target. Cerebellar patients showed a clear deficit in updating their spatiotemporal predictions in response to changed stimulus statistics compared to healthy controls, while this difference was not due to eye movement differences (Fig. 10.2c). A recent similar study seems to support these findings (Deluca et al. 2014). Additionally, the cerebellar output seems to be functionally coupled to many areas that are also involved in motion processing (Sultan et al. 2012).

In general, predicting upcoming visual events is a very crucial ability of our central nervous system. It allows us, for example, to direct attention, to react faster to predictable stimuli and to attenuate or even cancel out self-induced sensory afference. And it seems likely that at least some parts of the already existing machinery used predominantly for action could additionally be employed in predicting – and especially recalibrating predictions about – upcoming (visual) sensory events because these predictions are highly informative and in fact used by the motor system to perform appropriate actions.

## 10.4 Conclusion

The cerebellum receives massive input from visual and oculomotor regions in cerebral cortex and also from subcortical regions. Projections from these areas thereby mainly take the route through the pontine nuclei (PN). From there, neurons project through the middle cerebellar peduncle to the granular layer of cerebellar cortex and make up the mossy fibers. The most important oculomotor and visual regions of cerebellar cortex that have been identified so far are lobuli VII and VIc of the posterior vermis and the dorsal paraflocculus. Damage to these areas lead to imprecise saccadic and smooth pursuit eye movements and absent adaptation of these movements. Such adaptation is believed to depend on updating of forward models of movement commands. Also for perceptual purposes such forward models are important in order to cancel or attenuate self-induced retinal image slip and therefore contribute to the perception of a stable world despite eye movements. Compatible with this idea, cerebellar patients show deficits in coherent motion perception, supporting the importance of the cerebellum also for such perceptual tasks. Furthermore, recent evidence suggests that the cerebellum is involved in optimizing perceptual predictions about visual motion also in non-motor tasks. It therefore seems that the existing machinery of the cerebellum mostly involved in visual information processing for the sake of eye movements can in addition be used for optimizing (visual) perception. The pattern of cerebellar projections to cerebral cortex strengthens this notion.

## References

- Andersen RG, Bracewell RM, Barash S, Gnadt JW, Fogassi L (1990) Eye position effects on visual, memory, and saccade-related activity in areas LIP and 7a of macaque. *J Neurosci* 10:1176–1196
- Barash S, Bracewell RM, Fogassi L, Gnadt JW, Andersen RG (1991a) Saccade-related activity in the lateral intraparietal area. I. Temporal properties; comparison with area 7a. *J Neurophysiol* 66:1095–1108
- Barash S, Bracewell RM, Fogassi L, Gnadt JW, Andersen RG (1991b) Saccade-related activity in the lateral intraparietal area. II. Spatial properties. *J Neurophysiol* 66:1109–1124
- Barash S, Melikyan A, Sivakov A, Zhang M, Glickstein M, Thier P (1999) Saccadic dysmetria and adaptation after lesions of the cerebellar cortex. *J Neurosci* 19:10931–10939
- Bastian AJ (2006) Learning to predict the future: the cerebellum adapts feed forward movement control. *Curr Opin Neurobiol* 16:645–649
- Bastian AJ (2011) Moving, sensing and learning with cerebellar damage. *Curr Opin Neurobiol* 21:596–601
- Baumann O, Borra RJ, Bower JM, Cullen KE, Habas C, Ivry RB, Leggio M, Mattingley JB, Molinari M, Moulton EA et al (2015) Consensus paper: the role of the cerebellum in perceptual processes. *Cerebellum* 14:197–220
- Brodman K (1909) Vergleichende Lokalisationslehre der Grosshirnrinde in ihren Prinzipien dargestellt auf Grund des Zellenbaues. Barth, Leipzig
- Bruce CJ, Goldberg ME, Bushnell MC, Stanton GB (1985) Primate frontal eye fields. II. Physiological and anatomical correlates of electrically evoked eye movements. *J Neurophysiol* 54:714–734
- Cooper MH, Fox CA (1976) The basilar Pontine gray in the adult monkey (*Macaca mulatta*): a Golgi study. *J Comp Neurol* 168:145–173
- Deluca C, Golzar A, Santandrea E, Gerfo Lo E, Eštočinová J, Moretto G, Fiaschi A, Panzeri M, Mariotti C, Tinazzi M et al (2014) The cerebellum and visual perceptual learning: evidence from a motion extrapolation task. *Cortex* 58:52–71
- Dursteler MR, Wurtz RH (1988) Pursuit and optokinetic deficits following chemical lesions of cortical areas MT and MST. *J Neurophysiol* 60:940–965
- Glickstein DM (2013) Visual circuits from cerebral cortex to cerebellum; the link through pons. In: Manto M, Schmahmann JD, Rossi F, Gruol DL, Koibuchi N (eds) *Handbook of the cerebellum and cerebellar disorders*. Springer, Dordrecht, pp 469–478
- Glickstein M, May JG, Mercier BE (1985) Corticopontine projection in the macaque: the distribution of labelled cortical cells after large injections of horseradish peroxidase in the pontine nuclei. *J Comp Neurol* 235:343–359
- Golla H, Thier P, Haarmeier T (2005) Disturbed overt but normal covert shifts of attention in adult cerebellar patients. *Brain* 128:1525–1535
- Golla H, Tziridis K, Haarmeier T, Catz N, Barash S, Thier P (2008) Reduced saccadic resilience and impaired saccadic adaptation due to cerebellar disease. *Eur J Neurosci* 27:132–144
- Gottlieb JP, MacAvoy MG, Bruce CJ (1994) Neural responses related to smooth-pursuit eye movements and their correspondence with electrically elicited smooth eye movements in the primate frontal eye field. *J Neurophysiol* 72:1634–1653
- Haarmeier T, Thier P (1999) Impaired analysis of moving objects due to deficient smooth pursuit eye movements. *Brain* 122(Pt 8):1495–1505
- Haarmeier T, Bunjes F, Lindner A, Berret E, Thier P (2001) Optimizing visual motion perception during eye movements. *Neuron* 32:527–535
- Händel B, Thier P, Haarmeier T (2009) Visual motion perception deficits due to cerebellar lesions are paralleled by specific changes in cerebro-cortical activity. *J Neurosci* 29:15126–15133
- Heinen SJ (1995) Single neuron activity in the dorsomedial frontal cortex during smooth pursuit eye movements. *Exp Brain Res* 104:357–361

- Ito M (2005) Bases and implications of learning in the cerebellum – adaptive control and internal model mechanism. In: *Creating coordination in the cerebellum*. Progress in brain research. Amsterdam, Boston: Elsevier, pp 95–109
- Ito M (2008) Control of mental activities by internal models in the cerebellum. *Nat Rev Neurosci* 9:304–313
- Jokisch D, Troje NF, Koch B, Schwarz M, Daum I (2005) Differential involvement of the cerebellum in biological and coherent motion perception. *Eur J Neurosci* 21:3439–3446
- Kawano K, Shidara M, Watanabe Y, Yamane S (1994) Neural activity in cortical area MST of alert monkey during ocular following responses. *J Neurophysiol* 71:2305–2324
- Martin TA, Keating JG, Goodkin HP, Bastian AJ, Thach WT (1996) Throwing while looking through prisms. I. Focal olivocerebellar lesions impair adaptation. *Brain* 119(Pt 4):1183–1198
- Matano S, Stephan H, Baron G (1985) Volume comparisons in the cerebellar complex of primates. I Ventral pons. *Folia Primatol* 44:171–181
- May JG, Keller EL, Suzuki DA (1988) Smooth-pursuit eye movement deficits with chemical lesions in the dorsolateral pontine nucleus of the monkey. *J Neurophysiol* 59:952–977
- Nawrot M, Rizzo M (1995) Motion perception deficits from midline cerebellar lesions in human. *Vision Res* 35:723–731
- Newsome WT, Wurtz RH (1988) Probing visual cortical function with discrete chemical lesions. *Trends Neurosci* 11:394–400
- Newsome WT, Wurtz RH, Komatsu H (1988) Relation of cortical areas MT and MST to pursuit eye movements. II. Differentiation of retinal from extraretinal inputs. *J Neurophysiol* 60:604–620
- Rosina A, Provini L, Bentivoglio M, Kuypers HGJM (1980) Ponto-neocerebellar axonal branching as revealed by double fluorescent retrograde labeling technique. *Brain Res* 195:461–466
- Roth MJ, Synofzik M, Lindner A (2013) The cerebellum optimizes perceptual predictions about external sensory events. *Curr Biol* 23:930–935
- Schlag J, Schlag-Rey M (1985) Unit activity related to spontaneous saccades in frontal dorsomedial cortex of monkey. *Exp Brain Res* 58:208–211
- Schlag J, Schlag-Rey M (1987) Evidence for a supplementary eye field. *J Neurophysiol* 57:179–200
- Straube A, Deubel H, Ditterich J, Eggert T (2001) Cerebellar lesions impair rapid saccade amplitude adaptation. *Neurology* 57:2105–2108
- Sultan F, Augath M, Hamodeh S, Murayama Y, Oeltermann A, Rauch A, Thier P (2012) Unravelling cerebellar pathways with high temporal precision targeting motor and extensive sensory and parietal networks. *Nat Commun* 3:924
- Takagi M, Zee DS, Tamargo RJ (2000) Effects of lesions of the oculomotor cerebellar vermis on eye movements in primate: smooth pursuit. *J Neurophysiol* 83:2047–2062
- Thier P (2011) *The oculomotor cerebellum*. The Oxford handbook of eye movements. Oxford: Oxford University Press, Oxford
- Thier P, Andersen RA (1997) Multiple parietal ‘eye fields’: insights from electrical microstimulation. In: Thier P, Karnath H-O (eds) *Parietal lobe contributions to orientation in 3D space*. Springer, Heidelberg/Germany, pp 95–108
- Thier P, Andersen RG (1998) Electrical microstimulation distinguishes distinct saccade-related areas in the posterior parietal cortex. *J Neurophysiol* 80:1713–1735
- Thier P, Erickson RG (1992) Responses of visual-tracking neurons from cortical area MST-I to visual, eye and head motion. *Eur J Neurosci* 4:539–553
- Thier P, Möck M (2006) The oculomotor role of the pontine nuclei and the nucleus reticularis tegmenti pontis. In: *Neuroanatomy of the oculomotor system*. Progress in brain research. Elsevier, Amsterdam/Oxford, pp 293–320
- Thier P, Haarmeier T, Treue S, Barash S (1999) Absence of a common functional denominator of visual disturbances in cerebellar disease. *Brain* 122(Pt 11):2133–2146
- Tomasch J (1969) The numerical capacity of the human cortico-pontocerebellar system. *Brain Res* 13:476–484



- Tseng Y-W, Diedrichsen J, Krakauer JW, Shadmehr R, Bastian AJ (2007) Sensory prediction errors drive cerebellum-dependent adaptation of reaching. *J Neurophysiol* 98:54–62
- von Holst E, Mittelstaedt H (1950) Das Reafferenzprinzip. *Naturwissenschaften* 37:464–476
- Wolpert DM, Flanagan JR (2001) Motor prediction. *Curr Biol* 11:R729–R732
- Wolpert DM, Ghahramani Z (2000) Computational principles of movement neuroscience. *Nat Neurosci* 3(Suppl):1212–1217
- Wolpert DM, Miall RC, Kawato M (1998) Internal models in the cerebellum. *Trends Cogn Sci (Regul Ed)* 2:338–347
- Zihl J, von Cramon D, Mai N (1983) Selective disturbance of movement vision after bilateral brain damage. *Brain* 106(Pt 2):313–340

# Chapter 11

## The Cerebrocerebellar System

Jeremy D. Schmahmann

**Abstract** The cerebellum has massive reciprocal interconnections with the cerebral cortex and with cerebral subcortical structures that complement its interconnections with the spinal cord and brainstem. The major cerebrocerebellar link is mediated by the feedforward/afferent corticopontine projections and mossy fibers emanating from the pontocerebellar projections, and the feedback/efferent cerebellothalamic and thalamocortical projections. These highly arranged connections link sensorimotor, associative and limbic regions of cerebral cortex with the cerebellum and the intervening pontine nuclei and thalamus in a topographically precise manner. The cerebellum also has reciprocal links with the basal ganglia and hypothalamus, and with structures in the limbic circuit. In addition to these mossy fiber afferents to cerebellum, the inferior olive receives indirect input from motor and associative regions of the cerebral cortex by way of the red nucleus and zona incerta, and it conveys these inputs to cerebellum via climbing fibers. The cerebrocerebellar pathways are organized into segregated loops of information processing and stand in contrast to the cerebellar cortical architecture that is essentially uniform. Knowledge of cerebrocerebellar circuits is critical to understanding theories of the cerebellar contribution to motor and nonmotor function, and to the diagnosis and management of patients with lesions in these pathways.

**Keywords** Cerebellum • Cerebral • Anatomy • Connections • Projections • Neural circuits • Corticopontine • Pontocerebellar • Cerebellothalamic • Thalamocortical • Pons • Thalamus • Olive

The cerebellum has massive reciprocal interconnections with the cerebral hemispheres. The cerebrocerebellar circuit consists of a two-stage feedforward, or afferent limb, and a two-stage feedback, or efferent limb. The feedforward limb synapses in the nuclei of the basis pontis, and comprises the corticopontine projections and the pontocerebellar pathway. The feedback limb originates in the deep cerebellar

---

J.D. Schmahmann (✉)  
Ataxia Unit, Cognitive Behavioral Neurology Unit, Laboratory for Neuroanatomy and Cerebellar Neurobiology, Department of Neurology, Massachusetts General Hospital, Harvard Medical School, Boston, MA, USA  
e-mail: [jschmahmann@mgh.harvard.edu](mailto:jschmahmann@mgh.harvard.edu)

nuclei (DCN) with an obligatory synaptic step in thalamus; the thalamocortical projection forms the final stage of this feedback system. The cerebral cortex communicates mostly with the contralateral cerebellum. Cerebral cortex projects to the ipsilateral pons, pontocerebellar fibers cross to the other side of the pons and course through the middle cerebellar peduncle to the contralateral cerebellum. The cerebellar feedback travels via the superior cerebellar peduncle, decussates in the brachium conjunctivum, and terminates in the contralateral thalamus; the thalamocortical projection is ipsilateral. This chapter provides an overview of the connective anatomy of the cerebrocerebellar circuit derived from tract tracing studies in animal models, mostly the monkey, with a particular focus on the feedforward limb of the circuit. Further details and discussion of important earlier studies can be found in the references cited here.

## **11.1 The Feedforward Limb of the Cerebrocerebellar System**

Corticopontine projections arise from neurons in layer Vb (Glickstein et al. 1985), and course in the anterior limb of the internal capsule from prefrontal regions, and in the sagittal stratum and/or posterior limb of the internal capsule from posterior regions (Schmahmann and Pandya 1992, 1997a, 2006). They course above and then medial to the lateral geniculate nucleus before descending into the cerebral peduncle where prefrontal fibers are most medial, premotor and motor cortices occupy its middle third, and parietal, temporal and occipital fibers are in the lateral third (Schmahmann and Pandya 1992, 1997a). The relative size of the cerebral peduncle comprised of fibers derived from association cortices is larger in human than monkey, reflecting evolutionary expansion (Ramnani et al. 2006).

### ***11.1.1 Patterns of Termination in the Pons***

Each cortical area gives rise to topographically arranged terminations in a unique mosaic of patches around the neurons of the basis pontis, distributed within transverse and rostrocaudal dimensions. Terminations interdigitate with each other but do not overlap.

### ***11.1.2 Neurons of the Basis Pontis***

Pontine neurons in monkey are arranged in nuclei according to location and cytoarchitecture. These are the dorsal tier (the dorsomedial, dorsal, dorsolateral and extreme dorsolateral nuclei), intermediate tier (median, paramedian, intrapeduncular and peri-peduncular, and lateral nuclei), and a ventral pontine nucleus (Nyby and Jansen 1951; Schmähmann and Pandya 1989). The nucleus reticularis tegmenti pontis (NRTP), is immediately adjacent to the dorsal tier nuclei. In human, these architectonic features are less persuasive (Schmähmann et al. 2004a).

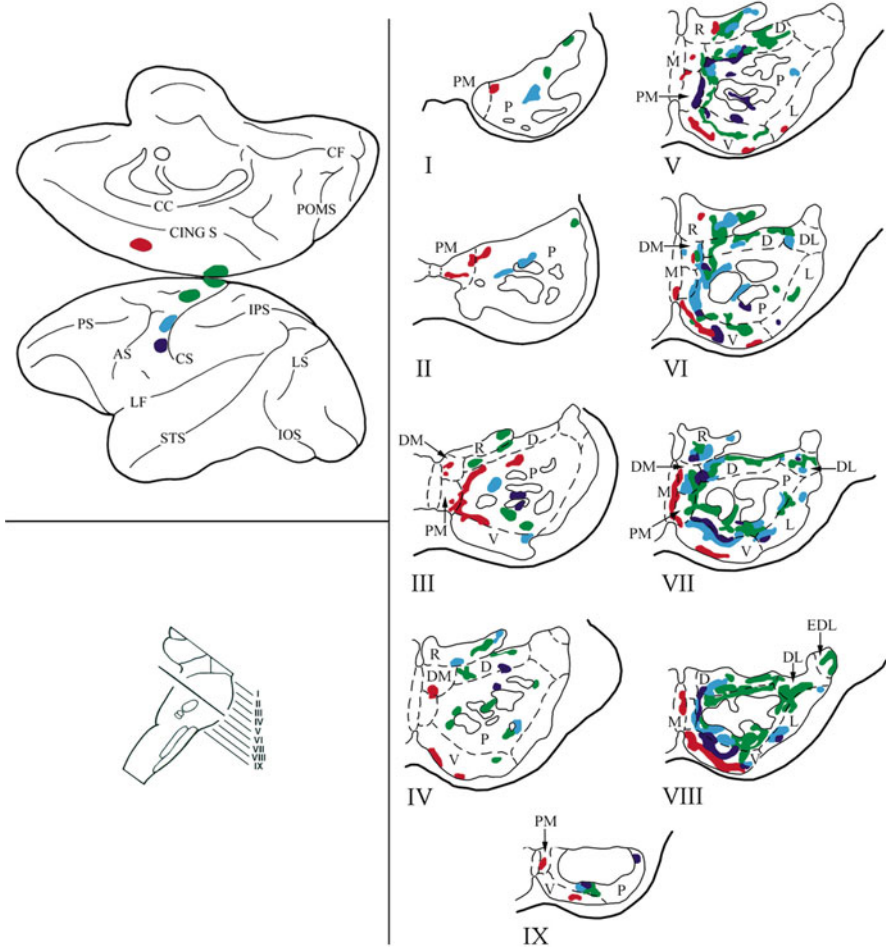
### ***11.1.3 Corticopontine Projections***

Projections from motor cortices terminate preferentially in the caudal half of the pons, in close proximity to traversing corticofugal fibers (Nyby and Jansen 1951; Brodal 1978; Wiesendanger et al. 1979; Hartmann-von Monakow et al. 1981; Schmähmann et al. 2004b). Projections from the face region of the supplementary motor area (SMA) are most medial. Projections from the ventral precentral gyrus (M1 face representation) are also medial, but lateral to those from SMA-face. M1 hand projections are in medially placed curved lamellae in mid and caudal pons. Dorsal trunk projections are in medial and ventral locations, ventral trunk/hip projections encircle the peduncle in the caudal pons, and projections from the foot representation are heaviest caudally in laterally placed curved lamellae (Schmähmann et al. 2004b) (Fig. 11.1). Corticopontine projections from the sensory cortex also terminate mostly in the caudal half of the pons (Brodal 1978; Brodal and Bjaalie 1992).

Motor topography is apparent in the human pons as shown in structure-function correlations in patients with stroke (Schmähmann et al. 2004a) (Fig. 11.2). Face movement and articulation are in rostral and medial basilar pons, hand coordination and dexterity are medial and ventral in rostral and mid-pons, and arm coordination is represented ventral and lateral to the hand. Leg coordination is in the caudal half of the pons, with lateral predominance. Gait is represented in medial and lateral locations throughout the rostral-caudal extent of the pons.

The pons receives heavy projections from multiple cerebral association areas (Fig. 11.3).

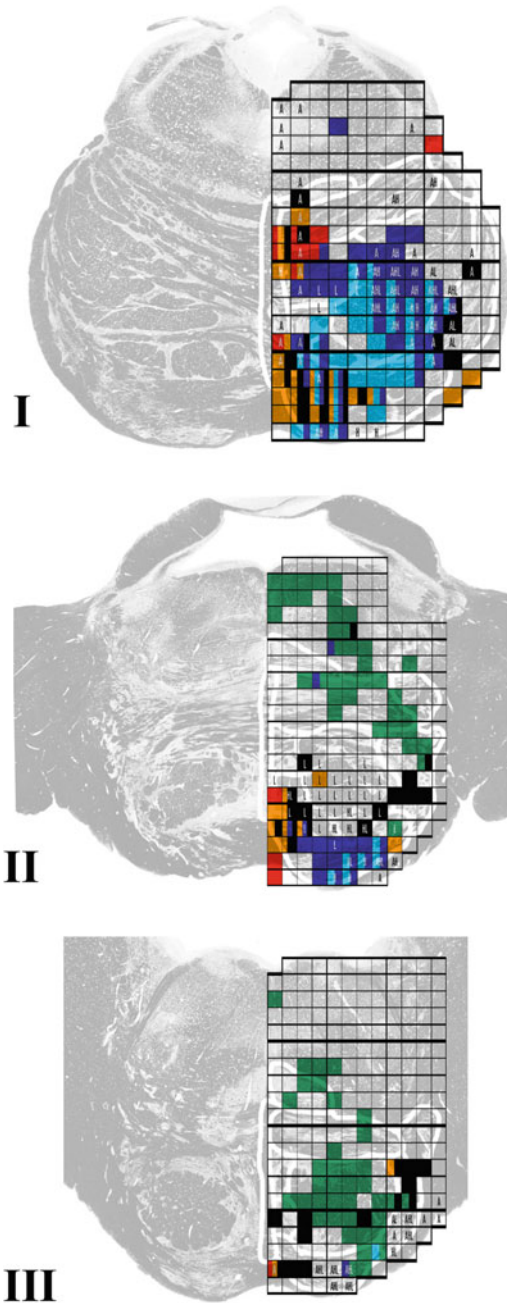
- Prefrontal projections to pons arise mostly in dorsolateral and dorsomedial prefrontal cortices from areas concerned with attention as well as with conjugate eye movements (area 8), the spatial attributes of memory and working memory (area 9/46d), planning, foresight, and judgment (area 10), motivational behavior and decision making capabilities (areas 9 and 32), and from areas considered to be homologous to the language area in human (areas 44 and 45). Terminations are in the medial pons in its rostral third, favoring the median, paramedian, dorsomedial and medial part of the peripeduncular pontine nuclei (Schmähmann and Pandya 1995, 1997b).

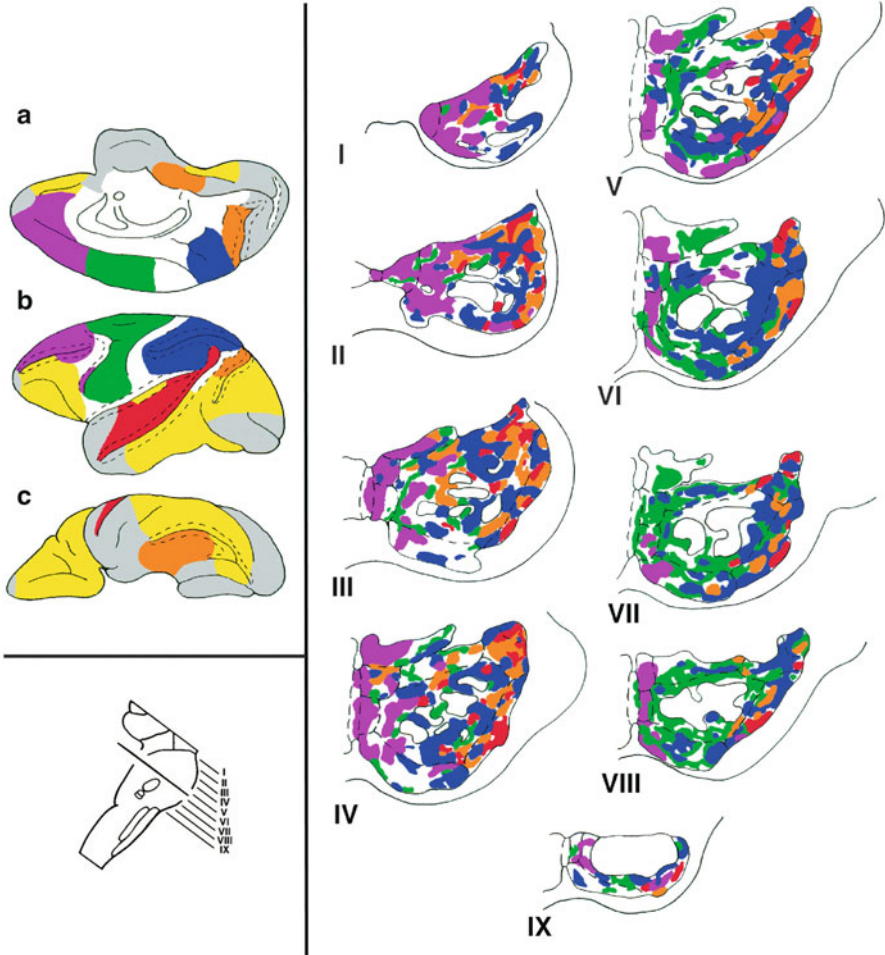


**Fig. 11.1** Composite color coded summary diagram of projections to the basis pontis from motor and supplementary motor cortices in the rhesus monkey. Injection sites in the cerebral cortex (*top left*) are shaded in *solid colors*. The corresponding termination patterns in the nine rostro-caudal levels of the pons taken at the level shown in the brainstem view (*lower left*), are represented by similarly colored regions. SMA – *red*; Trunk and Leg – *green*; Hand – *light blue*; Face-Hand overlapping area – *dark blue*. The terminations are predominantly in the caudal half of the pons, each cortical area projecting to a unique subpopulations of neurons within the pons. The SMA projections are most medial, and the face, hand, and leg projections are progressively more laterally situated (From Schmahmann et al. 2004b)

- Posterior parietal projections arise from both gyral and sulcal cortices including the multimodal caudal regions. Inferior parietal lobule projections to pons are predominantly rostral, those from superior parietal lobule distribute throughout the rostro-caudal extent of the pons. Parietal projections are mostly in the intermediate and lateral sectors of the pons, with topographic organization deter-

**Fig. 11.2** Color-coded composite summary diagram to illustrate the topographic map of motor representations in the human pons derived from analysis of ischemic stroke in the basis pontis. Pontine levels I through III from rostral to caudal pons. Face – red; dysarthria – orange; hand dexterity – dark blue; arm dysmetria – light blue; leg dysmetria – green; gait – black. *A* arm strength, *H* hand strength, *L* leg strength (From Schmahmann et al. 2004a)





**Fig. 11.3** Color-coded summary diagram illustrating the distribution within the nuclei of the basis pontis (levels I–IX) of the rhesus monkey of projections derived from association and paralimbic cortices in the prefrontal (*purple*), posterior parietal (*blue*), temporal (*red*), and parastriate and parahippocampal regions (*orange*), and from motor, premotor and supplementary motor areas (*green*). The medial (**a**), lateral (**b**) and ventral (**c**) surfaces of the cerebral hemisphere are shown above. Cerebral areas that have been shown to project to the pons by other investigators using either anterograde or retrograde tracers are depicted in *white*. Areas that have no pontine projections (according to anterograde and retrograde studies) are shown in *yellow*; those with no pontine projections according to retrograde studies are in *gray*. *Dashed lines* on the hemispheres represent sulcal cortices. *Dashed lines* in the pons represent pontine nuclei, and *solid lines* demarcate corticospinal fibers (From Schmahmann 1996)

mined by their site of origin (May and Andersen 1986; Schmahmann and Pandya 1989).

- Temporal lobe projections arise from the multimodal regions of the cortex of the upper bank of the superior temporal sulcus, the superior temporal gyrus and

supratemporal plane, and terminate in lateral and dorsolateral pontine regions (Schmahmann and Pandya 1991, 1992).

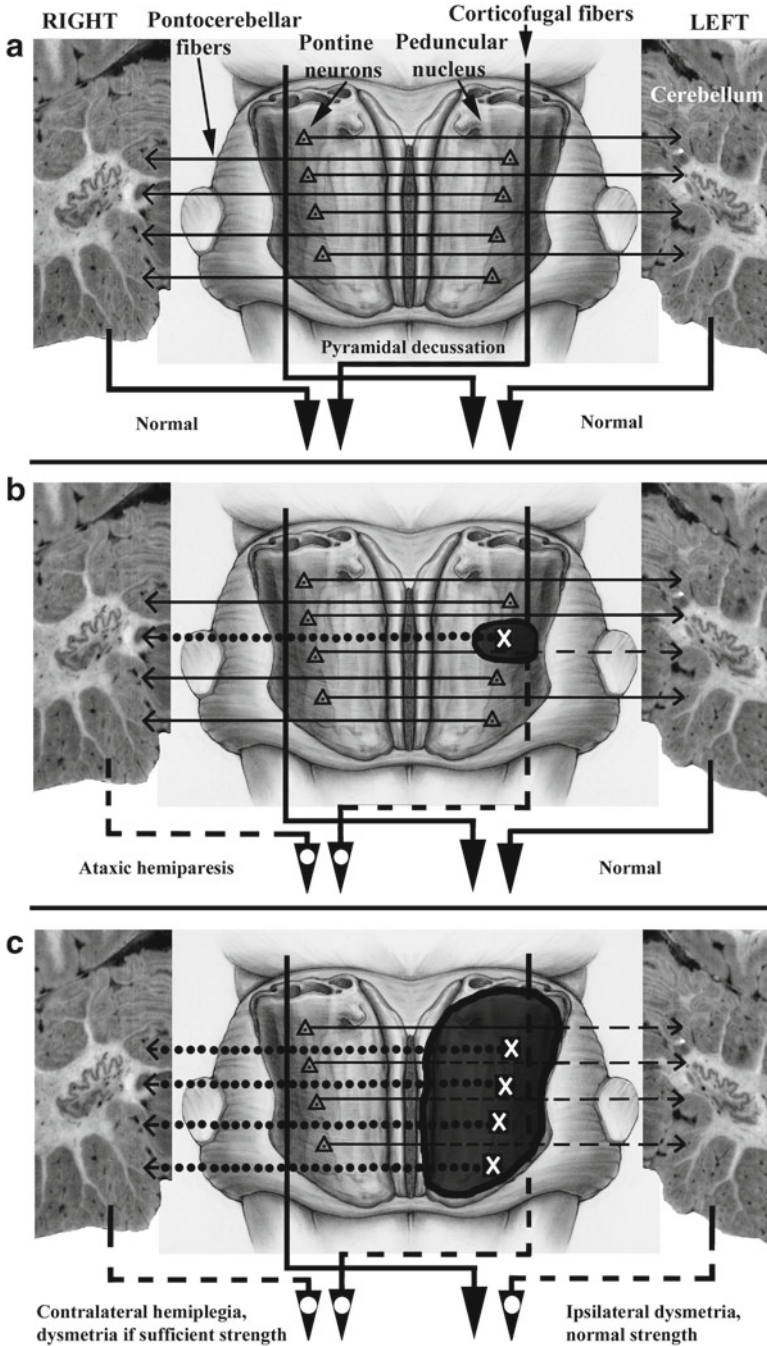
- Parastriate cortices at the dorsomedial and dorsolateral convexity, as well as the posterior parahippocampal gyrus, project to the lateral and dorsolateral pontine regions (Schmahmann and Pandya 1993).
- Rostral cingulate projections are directed to the medial pontine nuclei, the caudal cingulate to more lateral regions (Vilensky and Van Hoesen 1981; Schmahmann and Pandya 2006).
- Pontine projections arise also from the anterior insular cortex (Glickstein et al. 1985).

There is a dichotomy in the corticopontine projections according to the dorsal versus ventral streams of cognitive processing (Schmahmann and Pandya 1997a). Visual areas concerned with visual motion and the peripheral visual field (the “where” pathway) project to pons (dorsal part of the prelunate gyrus, caudal lower bank of the cortex in the superior temporal sulcus, polymodal convergence zones in the lower bank of the cortex in the intraparietal sulcus, and paralimbic parts of the caudal inferior parietal lobule). Cortical regions concerned with visual feature discrimination and the central visual field (the “what” pathway) do not have pontine projections (ventral prelunate gyrus, rostral lower bank of the superior temporal sulcus, middle and inferior temporal gyri, lateral aspects of the posterior parahippocampal gyrus). In the frontal lobe, pontine projections arise from the dorsolateral and dorsomedial prefrontal cortices that are concerned with spatial features of working memory, but not from the ventral prefrontal and orbitofrontal cortices that are part of the ventral stream of cognitive operations (Pandya et al. 2015). These anatomic arrangements suggest that the cerebellum plays a role in spatial awareness, and in attentional, executive, auditory and linguistic functions subserved by the dorsal stream of cognitive processing. They complement the cerebellar connections with the cingulate gyrus, posterior parahippocampal gyrus, and with subcortical limbic structures (discussed below) that form part of the anatomical basis of the cerebellar role in emotional processing.

#### ***11.1.4 Pontocerebellar Projections***

Pontocerebellar fibers course to the contralateral cerebellum by first running horizontally in a focused aggregate toward the midline. They then fan out in multiple directions to travel in most of the transverse pontocerebellar fiber bundles across the entire extent of the opposite side of the basis pontis at approximately the same rostro-caudal level. They then regroup in the middle cerebellar peduncle before entering the cerebellum (Schmahmann et al. 2004c). This anatomical arrangement has clinical implications for the phenomenon of ataxic hemiparesis arising from lesions of the basis pontis in patients (Fisher and Cole 1965; Schmahmann et al. 2004a) (Fig. 11.4).





**Fig. 11.4** Schematic diagram of the motor consequences of basis pontis infarction. A ventral view of the monkey pons is shown with the median, paramedian and peduncular pontine nuclei represented. Partial views of coronal sections of human cerebellum are seen on either side. (a) Normal arrangement, showing the pontine neurons, pontocerebellar fibers, and descending corticofugal

Neurons in the caudal pons project mainly to the cerebellar anterior lobe, and the intrapeduncular nucleus projects to vermal lobule VIII B (Brodal and Walberg 1977). Thus the anterior lobe (particularly lobules IV and V) and paramedian lobule (lobule VIII) which contain sensorimotor representations of the upper and lower extremities (Snider and Stowell 1944; Snider 1952), receive afferents from pericentral motor and sensory cortices. The dorsolateral pontine region and the NRTP project to lobule VIII and IX (dorsal paraflocculus, uvula) and the vermal visual area in lobule VII. Neurons in the dorsomedial nucleus also project to the vermal visual area (Brodal 1979).

The rostral pons receives input from cerebral association areas, and is linked with the cerebellar posterior lobe. Medial parts of the rostral pons project to crus I, and neurons in the medial, ventral, and lateral pons send their axons to crus II (Brodal 1979). Crus I therefore receives inputs from premotor and prefrontal cortices, crus II is linked with posterior parietal areas, but also with prefrontal cortices (Kelly and Strick 2003). These anatomical observations are consistent with conclusions derived from earlier physiological studies (Allen and Tsukahara 1974).

The pattern of divergence and convergence in the corticopontine and pontocerebellar pathways suggests that information from functionally diverse parts of the cerebral cortex and subcortical nuclei are brought together and integrated in the cerebellar cortex (Brodal and Bjaalie 1992; Schmahmann 1996).

## 11.2 The Feedback Limb of the Cerebrocerebellar System

### 11.2.1 The Cerebellar Corticonuclear Microcomplex

Apart from the vestibulocerebellum (lobule X – flocculus and nodulus, and the vermal part of lobule IX – uvula), that projects directly to the vestibular nuclei, efferents from the cerebellum are conveyed exclusively through the DCN (Voogd 2004). The cerebellar cortex projects to the DCN with a medio-lateral topography (Haines et al. 1997). Midline cortex projects to medial nuclear regions (fastigial nucleus), lateral hemisphere to the lateral/dentate nucleus, and intervening cortex to the interpositus nucleus (nucleus interpositus [NI] posterior, equivalent in human to globose nucleus, and NI anterior to emboliform nucleus).

---

←  
**Fig. 11.4** (continued) pathways to spinal cord. **(b)** Anatomical and clinical consequences following a small lesion in the basis pontis (*shaded black area*). Some pontine neurons are destroyed (marked by X), and the pontocerebellar fibers emanating from the lesioned neurons are affected (*dotted lines*). Pontocerebellar fibers arising from neurons in the contralateral hemipons are interrupted by the lesion (*dashed lines*), as are the descending corticofugal fibers (*heavy dashed lines*). **(c)** Large pontine lesions (*shaded black area*) destroy many pontine neurons and descending corticofugal fibers, and interrupt most of the pontocerebellar fibers traveling through the lesion from the normal hemipons (From Schmahmann et al. 2004c)

### ***11.2.2 Cerebellothalamic Projections***

The superior cerebellar peduncle (SCP) carries efferents from the DCN; fibers from the NIP are situated most medially, NIA fibers are intermediate, and dentate fibers are most lateral (Voogd 2004). Ascending axons from the fastigial nucleus course medially adjacent to the SCP. Each cerebellar nuclear region projects to three to seven rostrocaudally oriented rod-like aggregates within a dorsoventral curved lamella in the thalamus (Thach and Jones 1979).

Cerebellar projections from the DCN are directed to motor thalamic nuclei (pars oralis of the ventral posterolateral nucleus – VPLo, the caudal and pars postrema aspects of the ventrolateral nucleus – VLc and VLps, and nucleus X); intralaminar nuclei (including the central lateral, paracentral, paraventricular, and centromedian-parafascicular nuclei); and the medial dorsal thalamic nucleus in its paralaminar parts – the laterally situated pars multiformis (MDmf) and more caudal pars densocellularis (MDdc). Fastigial and lateral/dentate nucleus projections to thalamus are directed to motor, intralaminar and medial dorsal nuclei. Interpositus nucleus projections terminate in motor related ventrolateral and ventral anterior nuclei (Jones 2007; Ilinsky and Kultas-Ilinsky 1987; Schmahmann 1996).

### ***11.2.3 Thalamocortical Projections***

Motor thalamic nuclei project to motor-related cortices, as well as to multimodal association cortices in the temporal lobe (from VLc and VLps), posterior parietal cortex (from VLc, VLps, VPLo and nucleus X), and the prefrontal cortex (from VLc, VPLo and nucleus X). The cerebellar-recipient MDmf and MDdc thalamic nuclei project to prefrontal cortices (area 8, area 46 at both banks of the principal sulcus, and area 9), as well as to the cingulate gyrus, posterior parietal cortex, and multimodal parts of the superior temporal sulcus. Further, the intralaminar nuclei (notably centralis lateralis and paracentralis) project widely throughout the hemispheres to associative and paralimbic cortices in the cingulate and parahippocampal gyrus (see Schmahmann 1996; Schmahmann and Pandya 1990, 1997b).

### ***11.2.4 Cerebrocerebellar Loops***

Transynaptic viral tracing studies reveal that primary motor cortex is reciprocally connected with vermal and hemispheric lobules IV–VI, and lobules VIIIB and VIIIA; whereas dorsolateral prefrontal cortex areas 46 and 9 are linked with crus II of the cerebellar posterior lobe (Kelly and Strick 2003). The DCN projections back to the cerebral cortex are also topographically arranged (Middleton and Strick 1994; Dum and Strick 2003). Primary motor cortex receives projections via thalamus

from the dorsal part of the dentate nucleus (microgyric, large cells, phylogenetically older) at mid rostrocaudal levels, and from the caudal portions of the AIN – which contain neurons activated by arm movement (Thach 1978; Van Kan et al. 1993). Premotor cortex receives input from the mid-rostrocaudal part of the dentate, ventral to the M1 projecting neurons. Frontal eye field projecting neurons are located in the caudal third of the dentate that is correlated with saccadic eye movements. And the prefrontal cortex (areas 46 and 9) receives projections from the ventral part of the dentate nucleus (macrogyric, small cells, phylogenetically newer) mostly in its middle third rostrocaudally. Projections to the posterior parietal cortex arise from neurons in the ventral and lateral parts of the dentate nucleus (Dum et al. 2002).

### **11.3 Other Cerebral Hemisphere Connections with Cerebellum**

#### ***11.3.1 Basal Ganglia***

The cerebellum and basal ganglia are anatomically interconnected. Motor and non-motor domains of the subthalamic nucleus project by way of the pons to motor and non-motor regions of the cerebellar cortex (Bostan et al. 2010), and DCN projections via thalamus are directed back to sensorimotor and associative territories of the putamen and caudate nucleus (Hoshi et al. 2005). This has clinical relevance, for example, in the phenomenon of dystonia that occurs in some patients with cerebellar lesions (Batla et al 2015).

#### ***11.3.2 Inferior Olive***

The inferior olivary complex receives afferents via the central tegmental tract from the magnocellular division of the red nucleus (RNmc) linked with the precentral motor cortex, and from the parvocellular red nucleus (RNpc) linked with the supplementary motor cortices, the postcentral gyrus, and area 5 in the superior parietal lobule (Cintas et al. 1980; Saint-Cyr and Courville 1980). It also receives projections from the zona incerta which is linked with motor as well as with association and limbic cortices in the rostral cingulate cortex, posterior parietal cortex and dorsolateral and medial prefrontal regions (Shah et al. 1997). The inferior olive is the sole source of climbing inputs to the cerebellum. The olivocerebellar system is discussed in Chap. 8.

### ***11.3.3 Hypothalamus***

Posterior and dorsal hypothalamic regions project medially, dorsomedially and laterally within the caudal third of the pontine nuclei (Aas and Brodal 1988). Histaminergic neurons of the tuberomammillary nucleus in the posterior hypothalamus, the dorsomedial and ventromedial nuclei, and the periventricular zone terminate diffusely in the cerebellum. The ventromedial, dorsomedial and dorsal hypothalamic nuclei are linked with the cerebellar anterior lobe, and the lateral and posterior hypothalamic areas are linked with both anterior and posterior lobe (Haines and Dietrichs 1984). The DCN convey cerebellar projections back to the contralateral hypothalamus.

### ***11.3.4 Mammillary Body***

The medial mammillary nucleus (implicated in Korsakoff's amnesic syndrome) projects ventromedially at all rostrocaudal levels of the pontine nuclei (Aas and Brodal 1988). The lateral mammillary and supramammillary nuclei project directly to cerebellar anterior and posterior lobes.

### ***11.3.5 Septal Nuclei, Hippocampus, and Amygdala***

These regions important for memory and emotion are also interconnected with the cerebellum (Anand et al. 1959; Harper and Heath 1973; Snider and Maiti 1976). In addition, there are reciprocal connections between cerebellum and brainstem serotonin, norepinephrine and dopaminergic nuclei that have widespread projections to cerebral cortex (Dempsey et al. 1983; Marcinkiewicz et al. 1989).

Tract tracing studies in animal models thus reveal the rich complexity of cerebro-cerebellar communications. Different areas of the cerebral cortex – motor, associative and limbic, are reciprocally linked with the cerebellum via anatomical circuits, or closed loops, which demonstrate topographic precision at each stage of the feed-forward and feedback limbs. These anatomical connections are the essential substrates that enable cerebellar contributions to movement, cognition, emotion and autonomic control.

**Acknowledgements** Supported in part by the MINDlink, Birmingham, and Sidney R. Baer Jr Foundations, the National Ataxia Foundation and the Ataxia Telangiectasia Children's Project.

## References

- Aas J-E, Brodal P (1988) Demonstration of topographically organized projections from the hypothalamus to the pontine nuclei: an experimental study in the cat. *J Comp Neurol* 268:313–328
- Allen GI, Tsukahara N (1974) Cerebrocerebellar communication systems. *Physiol Rev* 54:957–1008
- Anand BK, Malhotra CL, Singh B, Dua S (1959) Cerebellar projections to limbic system. *J Neurophysiol* 22(4):451–457
- Batla A, Sánchez MC, Erro R, et al (2015) The role of cerebellum in patients with late onset cervical/segmental dystonia?—evidence from the clinic. *Parkinsonism Relat Disord* 21(11):1317–1322
- Bostan AC, Dum RP, Strick PL (2010) The basal ganglia communicate with the cerebellum. *Proc Natl Acad Sci U S A* 107(18):8452–8456
- Brodal P (1978) The corticopontine projection in the rhesus monkey. Origin and principles of organization. *Brain* 101(2):251–283
- Brodal P (1979) The pontocerebellar projection in the rhesus monkey: an experimental study with retrograde axonal transport of horseradish peroxidase. *Neuroscience* 4(2):193–208
- Brodal P, Bjaalie JG (1992) Organization of the pontine nuclei. *Neurosci Res* 13(2):83–118
- Brodal P, Walberg F (1977) The pontine projection to the cerebellar anterior lobe. An experimental study in the cat with retrograde transport of horseradish peroxidase. *Exp Brain Res* 29(2):233–248
- Cintas HM, Rutherford JG, Gwyn DG (1980) Some midbrain and diencephalic projections to the inferior olive in the rat. In: Courville J, de Montigny C, Lamarre Y (eds) *The inferior olivary nucleus: anatomy and physiology*. Raven Press, New York, pp 73–96
- Dempsey CW, Tootle DM, Fontana CJ, Fitzjarrell AT, Garey RE, Heath RG (1983) Stimulation of the paleocerebellar cortex of the cat: increased rate of synthesis and release of catecholamines at limbic sites. *Biol Psychiatr* 18:127–132
- Dum RP, Li C, Strick PL (2002) Motor and nonmotor domains in the monkey dentate. *Ann N Y Acad Sci* 978:289–301
- Dum RP, Strick PL (2003) An unfolded map of the cerebellar dentate nucleus and its projections to the cerebral cortex. *J Neurophysiol* 89(1):634–639
- Fisher CM, Cole M (1965) Homolateral ataxia and crural paresis: a vascular syndrome. *J Neurol Neurosurg Psychiatry* 28:48–55
- Glickstein M, May JG 3rd, Mercier BE (1985) Corticopontine projection in the macaque: the distribution of labelled cortical cells after large injections of horseradish peroxidase in the pontine nuclei. *J Comp Neurol* 235(3):343–359
- Haines DE, Dietrichs E (1984) An HRP study of hypothalamo-cerebellar and cerebello-hypothalamic connections in squirrel monkey (*Saimiri sciureus*). *J Comp Neurol* 229:559–575
- Haines DE, Dietrichs E, Mihailoff GA, McDonald EF (1997) The cerebellar-hypothalamic axis: basic circuits and clinical observations. In: Schmammann JD (ed) *The cerebellum and cognition*. Academic Press, San Diego. *Int Rev Neurobiol*:41:83–107
- Harper JW, Heath RG (1973) Anatomic connections of the fastigial nucleus to the rostral forebrain in the cat. *Exp Neurol* 39:285–292
- Hartmann-von Monakow K, Akert K, Künzle H (1981) Projection of precentral, premotor and prefrontal cortex to the basilar pontine grey and to nucleus reticularis tegmenti pontis in the monkey (*Macaca fascicularis*). *Schweiz Arch Neurol Neurochir Psychiatr* 129(2):189–208
- Hoshi E, Tremblay L, Féger J, Carras PL, Strick PL (2005) The cerebellum communicates with the basal ganglia. *Nat Neurosci* 8(11):1491–1493
- Ilinsky IA, Kultas-Ilinsky K (1987) Sagittal cytoarchitectonic maps of the *Macaca mulatta* thalamus with a revised nomenclature of the motor-related nuclei validated by observations on their connectivity. *J Comp Neurol* 262(3):331–364
- Jones EG (2007) *The thalamus*, 2nd edn. Cambridge University Press, Cambridge/New York

- Kelly RM, Strick PL (2003) Cerebellar loops with motor cortex and prefrontal cortex of a nonhuman primate. *J Neurosci* 23(23):8432–8444
- Marcinkiewicz M, Morcos R, Chretien M (1989) CNS connections with the median raphe nucleus: retrograde tracing with WGA-*apo*HRP-gold complex in the rat. *J Comp Neurol* 289:11–35
- May JG, Andersen RA (1986) Different patterns of corticopontine projections from separate cortical fields within the inferior parietal lobule and dorsal prelunate gyrus of the macaque. *Exp Brain Res* 63(2):265–278
- Middleton FA, Strick PL (1994) Anatomical evidence for cerebellar and basal ganglia involvement in higher cognitive function. *Science* 266(5184):458–461
- Nyby O, Jansen J (1951) An experimental investigation of the corticopontine projection in *Macaca mulatta*. *Skrifter utgitt av Det Norske Videnskaps-Akademi: Oslo; 1. Mat Naturv Klasse* 3:1–47
- Pandya DN, Seltzer B, Petrides M, Cipolloni PB (2015) Cerebral cortex: architecture, connections, and the dual origin concept. Oxford University Press, Oxford
- Ramnani N, Behrens TE, Johansen-Berg H et al (2006) The evolution of prefrontal inputs to the cortico-pontine system: diffusion imaging evidence from Macaque monkeys and humans. *Cereb Cortex* 16(6):811–818
- Saint-Cyr JA, Courville J (1980) Projections from the motor cortex, midbrain, and vestibular nuclei to the inferior olive in the cat: anatomical and functional correlates. In: Courville J, de Montigny C, Lamarre Y (eds) *The inferior olivary nucleus: anatomy and physiology*. Raven Press, New York, pp 97–124
- Schmahmann JD (1996) From movement to thought: anatomic substrates of the cerebellar contribution to cognitive processing. *Hum Brain Mapp* 4:174–198
- Schmahmann JD, Pandya DN (1989) Anatomical investigation of projections to the basis pontis from posterior parietal association cortices in rhesus monkey. *J Comp Neurol* 289:53–73
- Schmahmann JD, Pandya DN (1990) Anatomical investigation of thalamic projections to the posterior parietal cortices in rhesus monkey. *J Comp Neurol* 295:299–326
- Schmahmann JD, Pandya DN (1991) Projections to the basis pontis from the superior temporal sulcus and superior temporal region in the rhesus monkey. *J Comp Neurol* 308:224–248
- Schmahmann JD, Pandya DN (1992) Course of the fiber pathways to pons from parasensory association areas in the rhesus monkey. *J Comp Neurol* 326:159–179
- Schmahmann JD, Pandya DN (1993) Prelunate, occipitotemporal, and parahippocampal projections to the basis pontis in rhesus monkey. *J Comp Neurol* 337:94–112
- Schmahmann JD, Pandya DN (1995) Prefrontal cortex projections to the basilar pons: implications for the cerebellar contribution to higher function. *Neurosci Lett* 199:175–178
- Schmahmann JD, Pandya DN (1997a) The cerebrotocerebellar system. In: Schmahmann JD (ed) *The cerebellum and cognition*. Academic Press San Diego. *Int Rev Neurobiol* 41:31–60
- Schmahmann JD, Pandya DN (1997b) Anatomic organization of the basilar pontine projections from prefrontal cortices in rhesus monkey. *J Neurosci* 17:438–458
- Schmahmann JD, Pandya DN (2006) *Fiber pathways of the brain*. Oxford University Press, New York
- Schmahmann JD, MacMore J, Ko R (2004a) The human basis pontis. Clinical syndromes and topographic organization. *Brain* 127:1269–1291
- Schmahmann JD, Rosene DL, Pandya DN (2004b) Motor projections to the basis pontis in rhesus monkey. *J Comp Neurol* 478:248–268
- Schmahmann JD, Rosene DL, Pandya DN (2004c) Ataxia after pontine stroke: insights from pontocerebellar fibers in monkey. *Ann Neurol* 55:585–589
- Shah VS, Schmahmann JD, Pandya DN, Vaher PR (1997) Associative projections to the zona incerta: possible anatomic substrates for extension of the Marr-Albus hypothesis to non-motor learning. *Soc Neurosci Abstr* 23:1829
- Snider RS (1952) Interrelations of cerebellum and brainstem. In: Bard P (ed) *Patterns of organization of the central nervous system*. *Res Publ Ass Nerv Ment Dis* 30:267–281

- Snider RS, Maiti A (1976) Cerebellar contribution to the Papez circuit. *J Neurosci Res* 2:133–146
- Snider RS, Stowell A (1944) Receiving areas of the tactile, auditory, and visual systems in the cerebellum. *J Neurophysiol* 7:331–358
- Thach WT (1978) Correlation of neural discharge with pattern and force of muscular activity, joint position, and direction of intended next movement in motor cortex and cerebellum. *J Neurophysiol* 41:654–676
- Thach WT, Jones EG (1979) The cerebellar dentatohalamic connection: terminal field, lamellae, rods and somatotopy. *Brain Res* 169(1):168–172
- van Kan PL, Houk JC, Gibson AR (1993) Output organization of intermediate cerebellum of the monkey. *J Neurophysiol* 69:57–73
- Vilensky JA, van Hoesen GW (1981) Corticopontine projections from the cingulate cortex in the rhesus monkey. *Brain Res* 205(2):391–395
- Voogd J (2004) Cerebellum and precerebellar nuclei. In: Paxinos G, Mai JK (eds) *The human nervous system*, 2nd edn. Elsevier Academic Press, Amsterdam, pp 321–392
- Wiesendanger R, Wiesendanger M, Rüegg DG (1979) An anatomical investigation of the cortico-pontaine projection in the primate (*Macaca fascicularis* and *Saimiri sciureus*) – II. The projection from frontal and parietal association areas. *Neuroscience* 4(6):747–765



# Chapter 12

## Cerebello-Cerebral Feedback Projections

Kim van Dun, Mario Manto, and Peter Mariën

**Abstract** The functional neuroanatomy of cerebellar systems has been extensively studied during the past decades by means of experimental animal studies, anatomo-clinical studies, as well as structural and functional neuroimaging studies in patients and healthy subjects. Within a system of closed-loop circuits, this wealth of studies identified reciprocal projections between the cerebellar structures and the supratentorial areas subserving sensorimotor, cognitive, and affective function. It has been shown that cerebellar output is mediated by the deep cerebellar nuclei, mainly by the dentate nucleus (DN), which project to the supratentorial cortex via the thalamus (cerebello-thalamo-cortical pathway). In turn, the cortical areas that are the target of cerebellar output project back to the cerebellum via the pons (cortico-ponto-cerebellar pathway). Regions of the cerebellar cortex that receive input from a specific supratentorial area, are the same regions that project back to that supratentorial area, thus forming closed-loop circuits. These projections are largely crossed, connecting the cerebral hemispheres primarily with the contralateral cerebellar hemispheres.

**Keywords** Corticocerebellar pathways • Cerebello-cerebral network • Dentate nucleus • Functional neuroanatomy

---

K. van Dun

Department of Clinical Neurolinguistics (CLIN), Vrije Universiteit Brussel, Brussels, Belgium

M. Manto

FNRS, ULB-Erasme, 808 Route de Lennik, 1070 Bruxelles, Belgium

Service des Neurosciences, Université de Mons, 7000 Mons, Belgium

P. Mariën (✉)

Department of Clinical Neurolinguistics (CLIN), Vrije Universiteit Brussel, Brussels, Belgium

Department of Neurology and Memory Clinic, ZNA Middelheim Hospital, Antwerp, Belgium

e-mail: [peter.marien5@telenet.be](mailto:peter.marien5@telenet.be)

## 12.1 Introduction

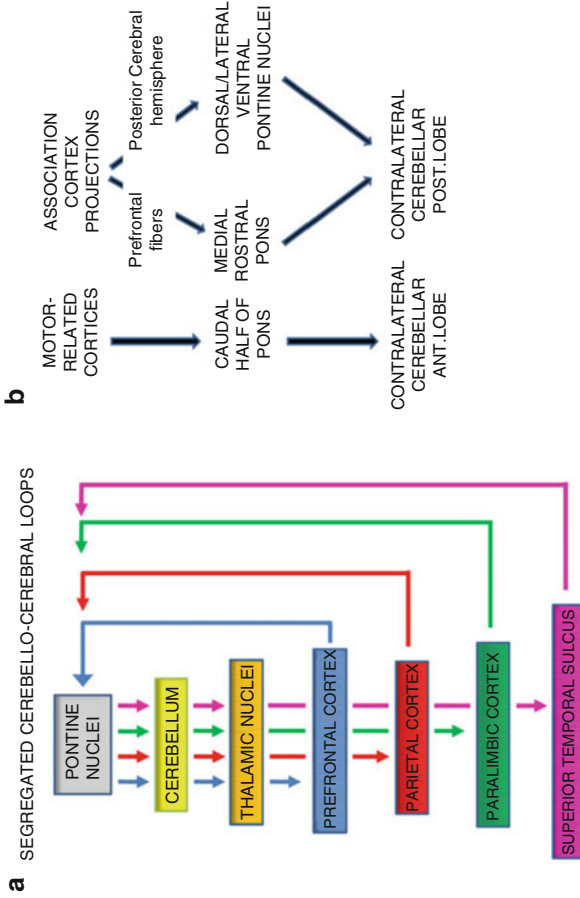
The functional neuroanatomy of cerebellar systems has been extensively studied during the past decades by means of experimental animal studies, anatomoclinical studies, as well as structural and functional neuroimaging studies in patients and healthy subjects. Within a system of closed-loop circuits, this wealth of studies identified reciprocal projections between the cerebellar structures and the supratentorial areas subserving sensorimotor, cognitive, and affective function. It has been shown that cerebellar output is mediated by the deep cerebellar nuclei, mainly by the dentate nucleus (DN), which project to the supratentorial cortex mainly via the thalamus (cerebello-thalamo-cortical pathway). In turn, the cortical areas that are the target of cerebellar output project back to the cerebellum via the pons (cortico-ponto-cerebellar pathway) (Schmahmann and Pandya 1995; Stoodley and Schmahmann 2010; Strick et al. 2009). Kelly and Strick (2003) demonstrated that the regions of the cerebellar cortex that receive input from a specific supratentorial area, are the same regions that project back to that supratentorial area, thus forming closed-loop circuits (Allen and Tsukahara 1974). These projections are largely crossed, connecting the cerebral hemispheres primarily with the contralateral cerebellar hemispheres (Stoodley and Schmahmann 2010). These crossed cerebello-cerebral projections are visualised in Fig. 12.1.

## 12.2 Projections

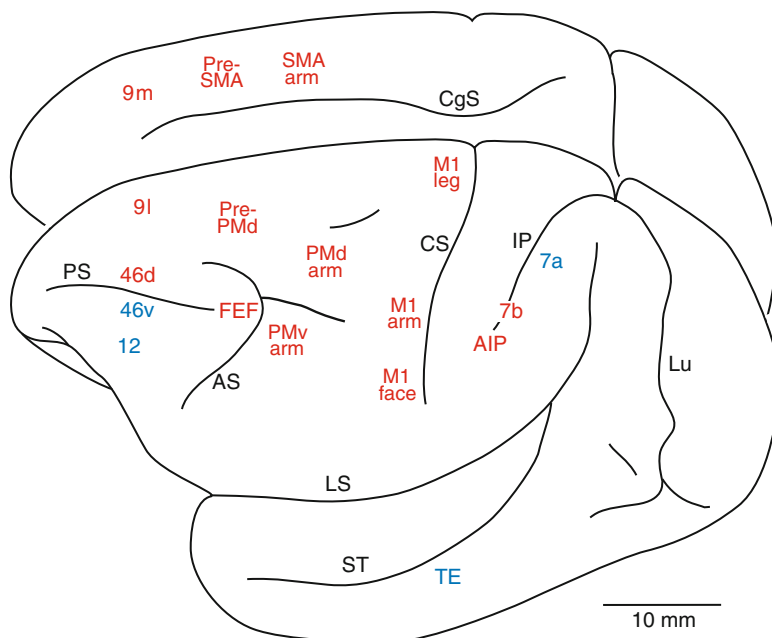
Over the past decades neuroanatomical studies established the foundation to substantially modify the traditional view of the cerebellum as a sole coordinator of sensorimotor function by showing that the cerebellum, in addition to the motor areas, also targets some associative areas crucially implicated in cognition and affect (Strick et al. 2009). Tracing methods in primates (Middleton and Strick 2001; Dum and Strick 2003; Akkal et al. 2007) linked the cerebellum to both frontal motor and premotor areas, and associative prefrontal and parietal regions (Strick et al. 2009; Habas et al. 2013). Some of the targeted cortical areas are visualised in Fig. 12.2.

Output channels from the DN are segregated. Projections to the motor areas originate from the dorsal portions of the DN, while projections to the associative cortices originate from the ventral portions of the DN (Dum and Strick 2003; Strick et al. 2009).

This means that the DN contains anatomically separate and functionally distinct motor and nonmotor domains (Dum and Strick 2009). This division is also represented by a neurochemically different composition within the DN, as shown by immunostaining with antibodies (Strick et al. 2009). Functional connectivity Magnetic Resonance Imaging (fcMRI) and Diffusion Tensor Imaging (DTI)-based tractography studies have confirmed these connections in primates, and in the



**Fig. 12.1** (a) Illustration of the segregated loops between the cerebellum and prefrontal cortex, parietal cortex, parahimbic cortex and superior temporal sulcus (Adapted from Grimaldi and Manto (2011)). (b) Topographic distribution of motor-related cortices and association cortex projections to the cerebellum. Both motor corticopontine projections and association cortex projections (from prefrontal, posterior parietal, superior temporal, parastriate, parahippocampal, and cingulate regions) are somatotopically organised in the pons (See also Stoodley and Schmahmann (2010). Adapted from Grimaldi and Manto (2012))



**Fig. 12.2** Targets of cerebellar output. *Red labels* indicate areas of the cerebral cortex that are the target of cerebellar output. *Blue labels* indicate areas that are not the target of cerebellar output. These areas are indicated on lateral and medial views of the cebus monkey brain. The numbers refer to cytoarchitectonic areas. *AIP* anterior intraparietal area, *AS* arcuate sulcus, *CgS* cingulate sulcus, *FEF* frontal eye field, *IP* intraparietal sulcus, *LS* lateral sulcus, *Lu* lunule sulcus, *M1*, face, arm, and leg areas of the primary motor cortex, *PMd arm* arm area of the dorsal premotor area, *PMv arm* arm area of the ventral premotor area, *PrePMd* predorsal premotor area, *PreSMA* presupplementary motor area, *PS* principal sulcus, *SMA arm* arm area of the supplementary motor area, *ST* superior temporal sulcus, *TE* area of inferotemporal cortex (Adapted from Strick et al. (2009))

human brain (Habas et al. 2013; Schlerf et al. 2014). DTI-based tractography is an important tool to track direct corticocerebellar pathways in humans. However, due to its low spatial resolution, partial coverage of the brain, and impossibility to track in low anisotropic regions, the technique faces a number of limitations preventing a full mapping of all the corticopontocerebellar fibers (Habas et al. 2009). Functional connectivity studies additionally indicate the existence of indirect connections that could be mediated by a third region. Both methods (functional connectivity and tractography) are therefore complementary and offer excellent opportunities to disentangle all cerebello-cerebral functional networks.

A motor/nonmotor subdivision also holds within the cerebellum. The sensorimotor cerebellum, which projects to the motor areas via the dorsal part of the DN, is primarily situated in the hemispheric parts of lobules IV/V/VI and VIII (Habas et al. 2013). There is little to no overlap between this sensorimotor network and the cognitive neocerebellar regions found to participate in the right/left executive control

networks involved in working memory, attention, response selection, and flexibility (especially crus I and II), the salience network required for processing and integration of interoceptive, autonomic, and emotional information (lobule VI), and the default-mode network involved in stream of consciousness, mental imagery, episodic memory retrieval, and self-reflection (lobule IX) (Habas et al. 2009, 2013). Therefore a functional dichotomy is suggested between the anterior cerebellum (lobules I-V) and lobule VIII, which are part of the sensorimotor network, and lobules VI and VII (including Crus I and II, and lobule VIIB), and possibly also lobule IX, contributing to higher-level processing (Stoodley and Schmahmann 2010).

### 12.2.1 *Sensorimotor Network*

Functional connectivity studies have shown that the sensorimotor network consists of cortical and subcortical structures comprising: the sensorimotor cortex (M1/S1), the premotor cortex (BA 6), the supplementary motor area (SMA), the anterior cingulate cortex (BA 24), the occipital cortex (BA 19/37), the temporal cortex (BA 21), the insula, the lentiform and caudate nuclei, the ventral thalami, the rostral part of the left red nucleus, and the bilateral hemispheric portions of lobules IV/V/VI and VIII of the cerebellum (Habas et al. 2009, 2013).

Virus tracing studies in primates found direct projections of the dorsal part of the DN to M1, the ventral premotor area (PMv), and the SMA (Strick et al. 2009). DTI-based tractography confirmed the connections between the DN and the supratentorial sensorimotor areas M1/S1 via the ventral part of the thalamus (Habas et al. 2013).

### 12.2.2 *Cognitive Networks*

Three different cognitive networks have been studied by means of functional connectivity studies: (1) *the default-mode network*, (2) *the executive network*, and (3) *the salience network*. *The default-mode network* consists at the cortical level of the prefrontal cortex (BA 9/10, 32), the superior parietal cortex (BA 7), the angular gyrus (BA 39), the posterior cingulate cortex (BA 23/31), the retrosplenial cortex (BA 29/30), the medial temporal lobe, and the ventral temporal cortex (BA 20). At the subcortical level this network includes the thalamus, the left red nucleus, the midbrain and both caudodorsal hemispheres of lobule IX, and a small cluster in the right hemisphere of lobule VIIB) of the cerebellum (Habas et al. 2009). *The executive network* consists of a right (RECN) and a left (LECN) executive network. These networks entail the following cortical and subcortical areas: the prefrontal cortex (LECN: BA 45/46, 9, and 8; RECN: BA 44/45/46), the orbitofrontal cortex (BA 47), the superior parietal cortex (BA 7), and the angular gyrus (BA 39), the caudate nucleus, and primarily crus I and crus II of the cerebellum with limited extensions into lobules VI and VIIB and the rostral hemisphere of lobule IX (Habas et al. 2009).

The RECN additionally activates the caudal cingulate cortex (BA 23 bilaterally), the supramarginal gyrus (BA 40), and the left red nucleus. **The salience network** comprises functional connectivity between the medial frontal cortex (BA 32), the dorsal anterior cingulate cortex (BA 24), the dorsolateral prefrontal cortex (BA 46), the frontoinsula cortex (BA 47/12), the thalamus, the red nuclei with a left predominance, and the lateral and ventral parts of both hemispheres of lobule VI of the cerebellum, more laterally located and closer to the posterosuperior fissure than the sensorimotor network (Habas et al. 2009).

Virus studies traced projections from the cerebellum to prefrontal areas BA 8A, 9/9 m, 10 and 46d (Strick et al. 2009; Schmahmann and Pandya 1995). Projections were also found to the preSMA, which can be regarded as a region of the associative prefrontal cortex instead of a motor area since it is densely interconnected with the prefrontal areas (Stoodley and Schmahmann 2010; Strick et al. 2009). In addition to the prefrontal cortex, the cerebellum is also connected with the posterior parietal cortex (BA 7b), the anterior intraparietal area, and possibly also with the medial and lateral banks of the intraparietal sulcus. Cerebellar projections to the parietal lobe, however, are complex and currently still incompletely understood (Strick et al. 2009). Tractography confirms the connectivity between the DN and the temporal, prefrontal (BA 9), and parietal (BA 7) cortices (Habas et al. 2013).

## 12.3 Conclusion

Neuroanatomical studies in primates, and functional connectivity analyses and DTI-based tractography studies in humans have confirmed a crossed closed-loop cerebello-cerebral feedback projection system. These dense connections not only link the cerebellum with the supratentorial motor areas such as M1/S1, but also with the associative cortical areas in the frontal, temporal, and parietal lobes. Due to these connections the cerebellum participates in the sensorimotor network, as well as in cognitive networks such as the default-mode network, the executive network, and the salience network.

## References

- Akkal D, Dum RP, Strick PL (2007) Supplementary motor area and presupplementary motor area: targets of basal ganglia and cerebellar output. *J Neurosci* 27:10659–10673
- Allen GI, Tsukahara N (1974) Cerebrocerebellar communication systems. *Physiol Rev* 54:957–1006
- Dum RP, Strick PL (2003) An unfolded map of the cerebellar dentate nucleus and its projections to the cerebral cortex. *J Neurophysiol* 89:634–639
- Grimaldi G, Manto M (2011) Clinical and pathophysiological features of cerebellar dysfunction. In: Jankovic J, Albanese A (eds) *Hyperkinetic disorders*. Blackwell Publishing Limited, Oxford

- Grimaldi G, Manto M (2012) Topography of cerebellar deficits in humans. *Cerebellum* 11:336–351
- Habas C, Kamdar N, Nguyen D, Prater K, Beckmann CF, Menon V, Greicius MD (2009) Distinct cerebellar contributions to intrinsic connectivity networks. *J Neurosci* 29:8586–8594
- Habas C, Shiner WR, Greicius MD (2013) Delineation of cerebrotocerebellar networks with MRI measures of functional and structural connectivity. In: Manto M, Gruol DL, Schmahmann JD, Koibuchi N, Ross F (eds) *Handbook of the cerebellum and cerebellar disorders*. Springer Science+Business Media, Dordrecht, pp 571–585
- Kelly RM, Strick PL (2003) Cerebellar loops with motor cortex and prefrontal cortex of a nonhuman primate. *J Neurosci* 23:8432–8444
- Middleton FA, Strick PL (2001) Cerebellar projections to the prefrontal cortex of the primate. *J Neurosci* 15:700–712
- Schlerf J, Wiestler T, Verstynen T, Diedrichsen J (2014) Big challenges from the “Little Brain” – imaging the cerebellum. In: Dorina Papageorgiou T, Christopoulos GI, Smirnakis SM (eds) *Advanced brain neuroimaging topics in health and disease – methods and applications*. Intech, pp 191–215. <http://cdn.intechopen.com/pdfs-wm/46098.pdf>
- Schmahmann JD, Pandya DN (1995) Prefrontal cortex projections to the basilar pons in rhesus monkey: implications for the cerebellar contribution to higher function. *Neurosci Lett* 199:175–178
- Stoodley CJ, Schmahmann JD (2010) Evidence for topographic organization in the cerebellum of motor control versus cognitive and affective processing. *Cortex* 46:831–844
- Strick PL, Dum RP, Fiez JA (2009) Cerebellum and nonmotor function. *Annu Rev Neurosci* 32:413–434

**Part III**  
**Embryology and Development of the**  
**Cerebellum**



# Chapter 13

## Cerebellar Neurogenesis

Ketty Leto, Richard Hawkes, and G. Giacomo Consalez

**Abstract** The mechanisms of cerebellar neurogenesis have been redefined in the last few years, showing the precise spatio-temporal sequence of neuronal generation from neurochemically heterogeneous pools of progenitors. Here we describe these processes, highlighting the principal strategies used within this system to generate appropriate cell numbers and phenotypes.

**Keywords** GABAergic neurogenesis • Glutamatergic neurogenesis • Purkinje cell type specification • Ptf1a • Atoh1 • Ebf2 • GABAergic interneurons • Deep cerebellar nuclei (DCN) neurons • Unipolar brush cells (UBCs) • Granule cells • Purkinje cells (PCs)

### 13.1 Introduction

The murine cerebellum represents an ideal model to study mechanisms of neural development and specification, as it is composed by a limited number of phenotypes, arranged in a finely patterned network and unambiguously identified by morphological features and by the expression of distinctive neurochemical markers (Ramon y Cajal 1911; Palay and Chan-Palay 1974; Miale and Sidman 1961; Ito 1984; Altman and Bayer 1997; Sotelo 2004). In addition, the principal dynamics

---

K. Leto

Department of Neuroscience Rita Levi Montalcini, University of Turin, Torino, Italy

Neuroscience Institute Cavalieri-Ottolenghi, University of Turin,  
Regione Gonzole 10, 10043 Orbassano, Torino, Italy

R. Hawkes

Cumming School of Medicine, Department of Cell Biology & Anatomy, Genes and Development Research Group, and Hotchkiss Brain Institute, Cumming School of Medicine, University of Calgary, 3330 Hospital Drive NW, Calgary, Alberta T2N 4N1, Canada

G.G. Consalez (✉)

Università Vita-Salute San Raffaele, Milan, Italy

Division of Neuroscience, San Raffaele Scientific Institute,  
Via Olgettina 60, 20132 Milan, Italy  
e-mail: [g.consalez@hsr.it](mailto:g.consalez@hsr.it)

regulating the whole period of cerebellar ontogenesis have been elucidated (Ramón y Cajal 1911; Hatten and Heintz 1995; Altman and Bayer 1997; Sotelo 2004; Carletti and Rossi 2008; Hoshino 2012).

Here we discuss the major features of cerebellar neurogenesis, highlighting both cell intrinsic programs and environmental influences governing neuronal generation and specification within developing cerebellar circuitries.

## 13.2 Cerebellar Territory and Germinal Zones

A series of studies that took advantage of the chick/quail chimeric approach have shown that the cerebellum arises from a specialized region at the midbrain/hind-brain boundary (Hallonet et al. 1990; Hallonet and Le Douarin 1993; Hallonet and Alvarado-Mallart 1997). Here, at embryonic day 8.5 (E8.5), the interaction between homeobox genes *Otx2* and *Gbx2* defines the Isthmic Organizer region (Broccoli et al. 1999; Li et al. 2005), which orchestrates the development of cerebellar structures via the morphogenic activity of two secreted factors, *Fgf8* and *Wnt1* (Martinez et al. 1991, 1999; Sotelo 2004). After territorial specification, cerebellar histogenesis starts at E9 in the mouse. At this age the cerebellar anlage is comprised of two separate and symmetric bulges that, during the following days, grow and fuse together, giving rise to the unitary cerebellar plate comprising the vermis and two hemispheres (Altman and Bayer 1997). This developmental process is also characterized by the formation of two germinative compartments just above the opening of the fourth ventricle: the rhombic lip (RL), located at the outer aspect of the cerebellar plate, adjacent to the roof plate and the ventricular zone (VZ), facing the lumen of the fourth ventricle. These germinative districts are defined by the region-specific expression of two basic helix-loop-helix transcription factors: the pancreas transcription factor 1-a (*PTF1A*), expressed in the VZ (Hoshino et al. 2005), and the mouse homolog of *Drosophila atonal* (*ATOH1*), present in the RL (Akazawa et al. 1995). This spatially-restricted expression pattern defines the neurochemical compartmentalization of cerebellar precursors, as all GABAergic neurons (Purkinje cells, PCs, nucleo-olivary projection neurons of deep cerebellar nuclei, DCN, and all inhibitory interneurons - basket, stellate, Golgi and Lugaro cells-) originate from *Ptf1a+* precursors (Hoshino et al. 2005; Seto et al. 2014; Yamada et al. 2014), while glutamatergic lineages (large projection neurons of DCN, unipolar brush cells, UBCs, and granule cells) derive from *Atoh1+* progenitors (Alder et al. 1996; Wingate 2001; Machold and Fishell 2005; Wang et al. 2005; Fink et al. 2006; Englund et al. 2006; Yamada et al. 2014). The two primary germinative epithelia disappear at birth. Dividing VZ precursors migrate into the cerebellar prospective white matter (PWM), whereas those of the RL move tangentially along the pial cerebellar surface, where they form the external granular layer (EGL). Postnatal neurogenesis is active in the secondary PWM and EGL epithelia up to the third postnatal week, in order to generate appropriate numbers of GABAergic and glutamatergic interneurons, respectively (Altman and Bayer 1997; Carletti and Rossi 2008).

The temporal schedule of generation of cerebellar phenotypes is also finely organized. Birthdating studies have shown that projection neurons are produced first, at the onset of cerebellar neurogenesis, while both inhibitory and excitatory interneurons are generated later, during late embryonic and early postnatal life (Miale and Sidman 1961; Altman and Bayer 1997; Sekerkova et al. 2004b).

### 13.3 Glutamatergic Neurogenesis

From the rostral portion of the RL (rRL), named the germinal trigone, distinct cerebellar glutamatergic cell populations are generated during subsequent embryonic phases, as demonstrated by genetic fate mapping experiments (Wingate and Hatten 1999; Wingate 2001; Lin et al. 2001; Machold and Fishell 2005; Machold et al. 2007). *Atoh1* expression in the RL begins at E9.5 in mice (Akazawa et al. 1995) and it is regulated by the antagonistic interaction between Notch1 in the cerebellar primordium and bone morphogenetic proteins secreted by the roof plate. Such interaction produces subsequent streams of migratory cells directed to the cerebellum: large glutamatergic DCN projection neurons, unipolar brush cells (UBCs) and granule cells (Machold and Fishell 2005; Machold et al. 2007). First, from E10.5 to E12.5, progenitors leaving the rRL give rise to large DCN projection neurons, which migrate to the surface of the cerebellar anlage and aggregate in the nuclear transitory zone (NTZ). From here, DCN neurons move inward below the developing Purkinje cell plate to form the three pairs of cerebellar nuclei (Wang et al. 2005; Fink et al. 2006; Morales and Hatten 2006; Machold and Fishell 2005; Machold et al. 2007). *Atoh1* expression is switched off as soon as these neurons leave the RL (Ben-Arie et al. 1997). Secondly, progenitors migrating from the rRL between E14 and E21 give rise to two different subsets of UBCs, distinguished on the basis of their birthdating and neurochemical profiles (Sekerkova et al. 2004; Nunzi et al. 2001; 2002). UBCs become regionally restricted during development through a non-cell-autonomous mechanism involving embryonic interactions with different Purkinje cell subtypes (Chung et al. 2009). Thirdly, the following wave exiting the rRL is represented by granule cell progenitors (GCPs) that migrate tangentially along the cerebellar surface, maintaining the expression of *Atoh1* and other transcription factor genes as *Zic1*, *Zic3* and *Zscan21*, encoding RU49 (Wingate 2001).

GCPs move tangentially towards their secondary germinal zone, the EGL, which by E16 covers the entire surface of the cerebellar anlage (Rakic 1990). It is initially composed of a single row of proliferating cells, but after birth it expands to a layer of about eight cells in thickness and its outer portion is occupied by actively proliferating GCPs (Miale and Sidman 1961; Fujita et al. 1966; Komuro et al. 2001). The proliferation window of murine GCPs closes at the end of the second postnatal week, when the last postmitotic granule cells from the deepest portion of the EGL migrate inward into the nascent IGL, marking the end of the EGL and extinguishing *Atoh1* expression (Acazawa et al. 1995; Helms and Johnson 1998; Ben-Arie et al. 2000). Evidence from transplantation (Gao and Hatten 1994), retroviral labelling

(Zhang and Goldman 1996a, b) and in vitro studies (Gao et al. 1991; Alder et al. 1996) demonstrates that the EGL gives rise to granule cells only. Interestingly, it has been shown that GCPs are also generated by some proliferative GFAP<sup>+</sup> astroglial cells present in the neonatal EGL (Silbereis et al. 2010).

Another salient feature of granule cell neurogenesis is the active control exerted by PC-derived mitogenic factors. In fact, the relative number of granule cells is abnormally reduced in animal models characterized by a primary PC degeneration (Sonmez and Herrup 1984; Vogel et al. 1989; Smeyne et al. 1995), whereas if the loss of PCs occurs later, in the postnatal period, the granule cell layer appears near-normal (Mullen et al. 1976; Smeyne et al. 1995). Sonic hedgehog (SHH), produced by PCs, is the most potent mitogen acting on granule cell development. Treatment of GCPs with SHH prevents their differentiation and induces a long-lasting proliferative response, while an inhibition of SHH signal dramatically reduces the mitotic activity of these precursors (Dahmane and Ruiz-i-Altaba 1999; Wallace 1999; Wechsler-Reya and Scott 1999; Lewis et al. 2004).

### 13.4 GABAergic Neurogenesis

GABAergic neurons are produced by *Ptf1a*<sup>+</sup> VZ progenitors according to a two-step process (Carletti and Rossi 2008). First, projection neurons (nucleo-olivary DCN neurons and PCs) are generated locally, from fate-committed precursor populations. Second, some progenitors become restricted to interneuron identities and migrate from the VZ to the nascent deep nuclei or cortical layers, where they acquire final phenotypic identities under the influence of instructive environmental cues.

Nucleo-olivary DCN neurons are generated between E10.5 and E12.5 in the mouse and join their glutamatergic counterparts (Palay and Chan-Palay 1974). PC progenitors undergo their terminal mitosis between E11 and E13 and populate different cortical regions according to their birthdate (Altman and Bayer 1997). Postmitotic PCs migrate radially towards the prospective cortex, where they form the multi-cell thick Purkinje cell plate (Morales and Hatten 2006). As early as E14–15, they aggregate in clusters and finally align into a monolayer through a process that is completed around P4 (Altman and Bayer 1997). The double-step migration allows the anteroposteriorly migrating PCs to constitute the adult parasagittal stripes, characterized by the expression of specific markers, which achieve a stable pattern in the third postnatal week (Larouche and Hawkes 2006; Consalez and Hawkes 2013).

GABAergic interneurons comprise multiple subsets of morphologically and neurochemically distinct phenotypes integrated at different levels of the cerebellar cortex and DCN. These cells are produced from the late embryonic life to the second postnatal week; the peak is reached around P5 and 75 % of all inhibitory interneurons are born prior to P7 (Weisheit et al. 2006). The origin of these cells has been controversial for a long time. Until a few years ago, molecular layer (ML) interneurons were thought to derive from the EGL, the only germinal layer known to be

active during postnatal development (Ramón y Cajal 1911; Altman 1972). More recently, the analysis of chick-quail chimeras, transplantation experiments and retroviral injections have demonstrated that the EGL only generates granule cells, suggesting that ML interneurons derive from the VZ (Hallonet et al. 1990; Napieralski and Eisenman 1993; Alvarez et al. 1993; Gao and Hatten 1994; Zhang and Goldman 1996a, b). Marichich and Herrup (1999) identified the progenitors of inhibitory interneurons as a population of PAX2<sup>+</sup> cells, which appear in the VZ around E12 and, later, migrate deep into the cerebellar cortex. Inhibitory interneuron precursors continue to proliferate during their migration in the PWM (Zhang and Goldman 1996a, b; Leto et al. 2006, 2009; Weisheit et al. 2006), and generate interneuron phenotypes according to an inside-out progression. DCN interneurons are the first to be born during embryonic and early postnatal life, followed by granular layer (GL) interneurons (Golgi and Lugaro cells) and, finally, by ML ones (basket and stellate cells; Marichich and Herrup 1999; Leto et al. 2006; Weisheit et al. 2006; Sudarov et al. 2011). Transplantation experiments have demonstrated that all types of cerebellar inhibitory interneurons derive from a single population of multipotent progenitors that acquire mature phenotypic traits under the influence of local instructive cues provided by the PWM microenvironment (Leto et al. 2006, 2009). It has been shown that proliferative progenitors of GABAergic interneurons in the PWM are *Ptf1a*<sup>+</sup> cells that start expressing *Pax2* during their last S phase (Marichich and Herrup 1999; Leto et al. 2009; Fleming et al. 2013). Importantly, it has been recently demonstrated that SHH delivered by PCs maintains the PWM niche and sustains the proliferation of neural stem cell-like primary progenitors able to generate both CD15<sup>+</sup> astroglial precursors and *Ptf1a*<sup>+</sup> GABAergic interneuron progenitors (Fleming et al. 2013). The same morphogen secreted by the choroid plexi in the embryonic cerebrospinal fluid is critically involved in the amplification of early VZ-derived GABAergic progenitors (Huang et al. 2010), suggesting that similar influences could sustain neurogenesis in the embryonic and postnatal cerebellum.

### 13.5 Neurogenesis and Purkinje Cell Type Specification

A regulatory network involving *Ptf1a*, Neurogenin 1/2 (*Neurog1/2*) and Early B-cell factor 2 (*Ebf2*) is implicated in PC differentiation and subtype specification (Zordan et al. 2008; Florio et al. 2012). By this model, the early-born PC cohort expresses neither *Neurog1/2* nor *Ebf2*, and expresses the ZII<sup>+</sup> phenotype in the adult. Soon after E11, *Neurog1/2* transcription is upregulated by PTF1A in the later-born PC progenitors (e.g. Henke et al. 2009). In this context, *Neurog2* regulates cell cycle progression, neuronal output and early dendritogenesis in PC progenitors (Florio et al. 2012), but neither *Neurog1* nor *2* deletions affect the specification of PC subtypes (R. Hawkes, unpublished observation). In turn, *Neurog1/2*<sup>+</sup> precursors express *Ebf2*, which represses the ZII<sup>+</sup> phenotype (Crocì et al. 2006; Chung et al. 2008): *Ebf2* deletion results in transdifferentiated PCs that express markers characteristic of both the ZII<sup>+</sup> and ZII<sup>-</sup> subtypes - the only manipulation known to alter a PC

subtype phenotype. In addition, *Ebf2* plays a subtype-specific anti-apoptotic role in ZII- PCs by locally regulating *Igf1* gene expression (Croci et al. 2011). As a result of these events, early-born PCs become ZII+ in the adult, while late-born PCs adopt the ZII- phenotype.

## 13.6 Concluding Remarks

Different strategies active within cerebellar neurogenic niches determine the precise sequence of phenotype generation: projection neurons are produced by defined pools of fate-restricted progenitors, whose specification programs mainly develop early in embryogenesis, while interneuron precursors proliferate until the second postnatal week, acquiring mature phenotypes under the influence of local instructive cues. The cellular/molecular mechanisms underlying these processes remain to be fully clarified. It is possible that these different mechanisms might support the correct establishment of topographically patterned long-distance connections on one hand, and of local experience-dependent networks on the other. Further analyses will be required to better clarify these issues.

**Acknowledgements** KL's research is funded by a grant from Ricerca Fondo per l'Incentivazione della Ricerca di Base (n. RBFR10A01S). GGC's cerebellar research is funded by the Italian Telethon Foundation.

## References

- Akazawa C, Ishibashi M, Shimizu C, Nakanishi S, Kageyama R (1995) A mammalian helix-loop-helix factor structurally related to the product of *Drosophila* proneural gene *atonal* is a positive transcriptional regulator expressed in the developing nervous system. *J Biol Chem* 270:8730–8738
- Alder J, Cho NK, Hatten ME (1996) Embryonic precursor cells from the rhombic lip are specified to a cerebellar granule neuron identity. *Neuron* 17:389–399
- Altman J (1972) Postnatal development of the cerebellar cortex in the rat. I. The external germinal layer and the transitional molecular layer. *J Comp Neurol* 145:353–398
- Altman J, Bayer SA (1997) Development of the cerebellar system in relation to its evolution, structures and functions. CRC, Boca Raton
- Alvarez Otero R, Sotelo C, Alvarado-Mallart RM (1993) Chick/quail chimeras with partial cerebellar grafts: an analysis of the origin and migration of cerebellar cells. *J Comp Neurol* 333:597–615
- Ben-Arie N, Bellen HJ, Armstrong DL, McCall AE, Gordadze PR, Guo Q, Matzuk MM, Zoghbi HY (1997) *Math1* is essential for genesis of cerebellar granule neurons. *Nature* 390(6656):169–172
- Ben-Arie N, Hassan BA, Bermingham NA, Malicki DM, Armstrong D, Matzuk M, Bellen HJ, Zoghbi HY (2000) Functional conservation of *atonal* and *Math1* in the CNS and PNS. *Development* 127(5):1039–1048

- Broccoli V, Boncinelli E, Wurst W (1999) The caudal limit of Otx2 expression positions the isthmic organizer. *Nature* 401(6749):164–168
- Carletti B, Rossi F (2008) Neurogenesis in the cerebellum. *Neuroscientist* 14:91–100
- Chung SH, Marzban H, Croci L, Consalez GG, Hawkes R (2008) Purkinje cell subtype specification in the cerebellar cortex: EBF2 acts to repress the zebrin II-negative Purkinje cell phenotype. *Neuroscience* 153:721–732
- Chung SH, Sillitoe RV, Croci L, Badaloni A, Consalez G, Hawkes R (2009) Purkinje cell phenotype restricts the distribution of unipolar brush cells. *Neuroscience* 164:1496–1508
- Consalez GG, Hawkes R (2013) The compartmental restriction of cerebellar interneurons. *Front Neural Circ* 6:123
- Croci L, Chung SH, Masserdotti G, Gianola S, Bizzoca A, Gennarini G, Corradi A, Rossi F, Hawkes R, Consalez GG (2006) A key role for the HLH transcription factor EBF2/COE2, O/E-3 in Purkinje neuron migration and cerebellar cortical topography. *Development* 133:2719–2729
- Croci L, Barili V, Chia D, Massimino L, van Vugt R, Masserdotti G, Longhi R, Rotwein P, Consalez GG (2011) Local insulin-like growth factor I expression is essential for Purkinje neuron survival at birth. *Cell Death Differ* 18:48–59
- Dahmane N, Ruiz-i-Altaba A (1999) Sonic hedgehog regulates the growth and patterning of the cerebellum. *Development* 126:3089–3100
- Englund CM, Kowalczyk T, Daza RAM, Dagan A, Lau C, Rose MF, Hevner RF (2006) Unipolar brush cells of the cerebellum are produced in the rhombic lip and migrate through developing white matter. *J Neurosci* 26:9184–9195
- Fink AJ, Englund C, Daza RAM, Pham D, Lau C, Nivison M, Kowalczyk T, Hevner RF (2006) Development of the deep cerebellar nuclei: transcription factors and cell migration from the rhombic lip. *J Neurosci* 26:3066–3076
- Fleming JT, He W, Hao C, Ketova T, Pan FC, Wright CC, Litingtung Y, Chiang C (2013) The Purkinje neuron acts as a central regulator of spatially and functionally distinct cerebellar precursors. *Dev Cell* 27(3):278–292
- Florio M, Leto K, Muzio L, Tinterri A, Badaloni A, Croci L, Zordan P, Barili V, Albieri I, Guillemot F, Rossi F, Consalez GG (2012) Neurogenin 2 regulates progenitor cell-cycle progression and Purkinje cell dendritogenesis in cerebellar development. *Development* 139:2308–2320
- Fujita S, Simada M, Nakanuna T (1966) 3H-thymidine autoradiographic studies on the cell proliferation and differentiation in the external and internal granular layers of the mouse cerebellum. *J Comp Neurol* 128:191–209
- Gao WO, Hatten ME (1994) Immortalizing oncogenes subvert the establishment of granule cell identity in developing cerebellum. *Development* 120:1059–1070
- Gao WO, Heintz N, Hatten ME (1991) Cerebellar granule cell neurogenesis is regulated by cell-cell interactions in vitro. *Neuron* 6(5):705–715
- Hallonet M, Alvarado-Mallart RM (1997) The chick/quail chimeric system: a model for early cerebellar development. *Perspect Dev Neurobiol* 5(1):17–31
- Hallonet ME, Le Douarin NM (1993) Tracing neuroepithelial cells of the mesencephalic and metencephalic alar plates during cerebellar ontogeny in quail-chick chimaeras. *Eur J Neurosci* 5:1145–1155
- Hallonet ME, Teillet MA, Le Douarin NM (1990) A new approach to the development of the cerebellum provided by the quail-chick marker system. *Development* 108:19–31
- Hatten ME, Heintz N (1995) Mechanisms of neural patterning and specification in the developing cerebellum. *Annu Rev Neurosci* 18:385–408
- Helms AW, Johnsons JE (1998) Progenitors of dorsal commissural interneurons are defined by MATH1 expression. *Development* 125(5):919–928
- Henke RM, Savage TK, Meredith DM, Glasgow SM, Hori K, Dumas J, MacDonald RJ, Johnson JE (2009) Neurog2 is a direct downstream target of the Ptf1a-Rbpj transcription complex in dorsal spinal cord. *Development* 136:2945–2954
- Hoshino M (2012) Neuronal subtype specification in the cerebellum and dorsal hindbrain. *Dev Growth Differ* 54(3):317–326

- Hoshino M, Nakamura S, Mori K, Kawauchi T, Terao M, Nishimura YV, Fukuda A, Fuse T, Matsuo N, Sone M, Watanabe M, Bito H, Terashima T, Wright CVE, Kawaguchi Y, Nakao K, Nabeshima YI (2005) Ptf1a, a bHLH transcriptional gene, defines GABAergic neuronal fates in cerebellum. *Neuron* 47:201–213
- Huang X, Liu J, Ketova T, Fleming JT, Grover VK, Cooper MK, Litingtung Y, Chiang C (2010) Transventricular delivery of Sonic hedgehog is essential to cerebellar ventricular zone development. *Proc Natl Acad Sci U S A* 107(18):8422–8427
- Ito M (1984) *The cerebellum and neural control*. Raven Press, New York
- Komuro H, Yacubova E, Yacubova E, Rakic P (2001) Mode and tempo of tangential cell migration in the cerebellar external granular layer. *J Neurosci* 21(2):527–540
- Larouche M, Hawkes R (2006) From clusters to stripes: the developmental origins of adult cerebellar compartmentation. *Cerebellum* 5(2):77–88
- Leto K, Carletti B, Williams IM, Magrassi L, Rossi F (2006) Different types of cerebellar GABAergic interneurons originate from a common pool of multipotent progenitor cells. *J Neurosci* 26:11682–11694
- Leto K, Bartolini A, Yanagawa Y, Obata K, Magrassi L, Schilling K, Rossi F (2009) Laminal fate and phenotype specification of cerebellar GABAergic interneurons. *J Neurosci* 29(21):7079–7091
- Lewis PM, Gritli-Linde A, Smeyne R, Kottmann A, McMahon AP (2004) Sonic hedgehog signaling is required for expansion of granule neuron precursors and patterning of the mouse cerebellum. *Dev Biol* 270:393–410
- Li JY, Lao Z, Joyner A (2005) New regulatory interactions and cellular responses in the isthmus organizer region revealed by altering Gbx2 expression. *Development* 132(8):1971–1981
- Lin JC, Cai L, Cepko CL (2001) The external granule layer of the developing chick cerebellum generates granule cells and cells of the isthmus and rostral hindbrain. *J Neurosci* 21(1):159–168
- Machold R, Fishell G (2005) Math1 is expressed in temporally discrete pools of cerebellar rhombic-lip neural progenitors. *Neuron* 48:17–24
- Machold RP, Kittell DJ, Fishell GJ (2007) Antagonism between notch and bone morphogenetic protein receptor signalling regulates neurogenesis in the cerebellar rhombic lip. *Neural Dev* 2:5
- Maricich SM, Herrup K (1999) Pax-2 expression defines a subset of GABAergic interneurons and their precursors in the developing murine cerebellum. *J Neurobiol* 41:281–294
- Martinez S, Wassef M, Alvarado-Mallart RM (1991) Induction of a mesencephalic phenotype in the 2-day-old chick prosencephalon is preceded by the early expression of the homeobox gene. *Neuron* 6(6):971–981
- Martinez S, Crossley PH, Cobos I, Rubenstein JL, Martin GR (1999) FGF8 induces formation of an ectopic isthmus organizer and isthmo-cerebellar development via a repressive effect on Otx2 expression. *Development* 126(6):1189–1200
- Miale IR, Sidman RL (1961) An autoradiographic analysis of histogenesis in the mouse cerebellum. *Exp Neurol* 4:277–296
- Morales D, Hatten ME (2006) Molecular markers of neuronal progenitors in the embryonic cerebellar anlage. *J Neurosci* 26:12226–12236
- Mullen RJ, Eicher EM, Sidman RL (1976) Purkinje cell degeneration, a new neurological mutation in the mouse. *Proc Natl Acad Sci U S A* 73(1):208–212
- Napierski JA, Eisenman LM (1993) Developmental analysis of the external granular layer in the meander tail mutant mouse: do cerebellar microneurons have independent progenitors? *Dev Dyn* 197(4):244–254
- Nunzi MG, Birnstiel S, Bhattacharyya BJ, Slater NT, Mugnaini E (2001) Unipolar brush cells form a glutamatergic projection system within the mouse cerebellar cortex. *J Comp Neurol* 434(3):329–341
- Nunzi MG, Shigemoto R, Mugnaini E (2002) Differential expression of calretinin and metabotropic glutamate receptor mGluR1 alpha defines subsets of unipolar brush cells in mouse cerebellum. *J Comp Neurol* 451(2):189–199



- Palay S, Chan-Palay V (1974) *Cerebellar cortex*. Springer, Berlin
- Rakic P (1990) Principles of neural cell migration. *Experientia* 46(9):882–891
- Ramon y Cajal S (1911) *Histologie du Système Nerveux de l'Homme et des Vertébrés*. Maloine, Paris
- Sekerková G, Ilijic E, Mugnaini E (2004) Time of origin of unipolar brush cells in the rat cerebellum as observed by prenatal bromodeoxyuridine labeling. *Neuroscience* 127:845–858
- Seto Y, Nakatani T, Masuyama N, Taya S, Kumai M, Minaki Y, Hamaguchi A, Inoue YU, Inoue T, Miyashita S, Fujiyama T, Yamada M, Chapman H, Campbell K, Magnuson MA, Wright CV, Kawaguchi Y, Ikenaka K, Takebayashi H, Ishiwata S, Ono Y, Hoshino M (2014) Temporal identity transition from Purkinje cell progenitors to GABAergic interneuron progenitors in the cerebellum. *Nat Commun* 5:3337
- Silbereis J, Heintz T, Taylor MM, Ganat Y, Ment LR, Bordey A, Vaccarino F (2010) Astroglial cells in the external granular layer are precursors of cerebellar granule neurons in neonates. *Mol Cell Neurosci* 44(4):362–373
- Smeyne RJ, Chu T, Lewin A, Bian F, Sanlioglu S, Kunsch C, Lira SA, Oberdick J (1995) Local control of granule cell generation by cerebellar Purkinje cells. *Mol Cell Neurosci* 6(3):230–251
- Sonmez E, Herrup K (1984) Role of staggerer gene in determining cell number in cerebellar cortex. II. Granule cell death and persistence of the external granule cell layer in young mouse chimeras. *Brain Res* 314(2):271–283
- Sotelo C (2004) Cellular and genetic regulation of the development of the cerebellar system. *Prog Neurobiol* 72:295–339
- Sudarov A, Turnbull RK, Kim EJ, Lebel-Potter M, Guillemot F, Joyner AL (2011) *Ascl1* genetics reveals insights into cerebellum local circuit assembly. *J Neurosci* 31(30):11055–11069
- Vogel MW, Sunter K, Herrup K (1989) Numerical matching between granule and Purkinje cells in *lurcher* chimeric mice: a hypothesis for the thropic rescue of granule cells from target-related cell death. *J Neurosci* 9(10):3454–3462
- Wallace VA (1999) Purkinje-cell-derived Sonic hedgehog regulates granule neuron precursor cell proliferation in the developing mouse cerebellum. *Curr Biol* 9:445–448
- Wang VY, Rose MF, Zoghbi H (2005) *Math1* expression redefines the rhombic lip derivatives and reveals novel lineages within the brainstem and cerebellum. *Neuron* 48:31–43
- Wechsler-Reya RJ, Scott MP (1999) Control of neuronal precursor proliferation in the cerebellum by Sonic hedgehog. *Neuron* 22:103–114
- Weisheit G, Gliem M, Endl E, Pfeffer PL, Busslinger M, Schilling K (2006) Postnatal development of the murine cerebellar cortex: formation and early dispersal of basket, stellate and Golgi neurons. *Eur J Neurosci* 24:466–478
- Wingate RJT (2001) The rhombic lip and early cerebellar development. *Curr Opin Neurobiol* 11:82–88
- Wingate RJT, Hatten ME (1999) The role of the rhombic lip in avian cerebellum development. *Development* 126(20):4395–4404
- Yamada M, Seto Y, Taya S, Owa T, Inoue YU, Inoue T et al (2014) Specification of spatial identities of cerebellar neuron progenitors by *ptf1a* and *atoh1* for proper production of GABAergic and glutamatergic neurons. *J Neurosci* 34:4786–47800
- Zhang L, Goldman JE (1996a) Generation of cerebellar interneurons from dividing progenitors in white matter. *Neuron* 16:47–54
- Zhang L, Goldman JE (1996b) Developmental fates and migratory pathways of dividing progenitors in the postnatal rat cerebellum. *J Comp Neurol* 370:536–550
- Zordan P, Croci L, Hawkes R, Consalez GG (2008) Comparative analysis of proneural gene expression in the embryonic cerebellum. *Dev Dyn* 237:1726–1735

# Chapter 14

## Zones and Stripes

Carol Armstrong and Richard Hawkes

**Abstract** The cerebellar cortex is built around different classes of Purkinje cell, which form an array of transverse zones, each of which is further divided into parasagittal stripes. There are >200 stripes, which are reproducible between individuals and the pattern is conserved across birds and mammals. Other features of cerebellar organization, including the topography of afferent projections and cerebellar interneurons, are built around the Purkinje cell framework. Zone and stripe architecture is established early in cerebellar development. Purkinje cells are born between E10 and E13 (in mouse) in the subventricular zone of the fourth ventricle. Purkinje cell subtype specification likely happens at this time. Postmitotic Purkinje cells migrate into the cerebellar anlage and form a stereotypical array of clusters (E14–E18). Clusters are the forebears of the stripes and are the targets of the ingrowing afferent projections. Reelin signaling at around birth triggers the rostrocaudal dispersal of the clusters into the adult stripes.

**Keywords** Zebrin • Zone • Stripe • Development

### 14.1 Zones and Stripes

The cerebellar cortex is traditionally described in terms of lobes and lobules separated by fissures. However lobulation does not reflect the functional organization of the cerebellum, its connectivity or its embryology. A more fundamental architecture is shown by intrinsic differences between subsets of Purkinje cells (PCs) through the expression of molecular markers such as zebrin II/aldolase C (Brochu et al. 1990), phospholipase C (PLC) $\beta$ 4 (Sarna et al. 2006; see Figure 1) and HSP25 (Armstrong et al. 2000). These reveal an elaborate and reproducible pattern of zones

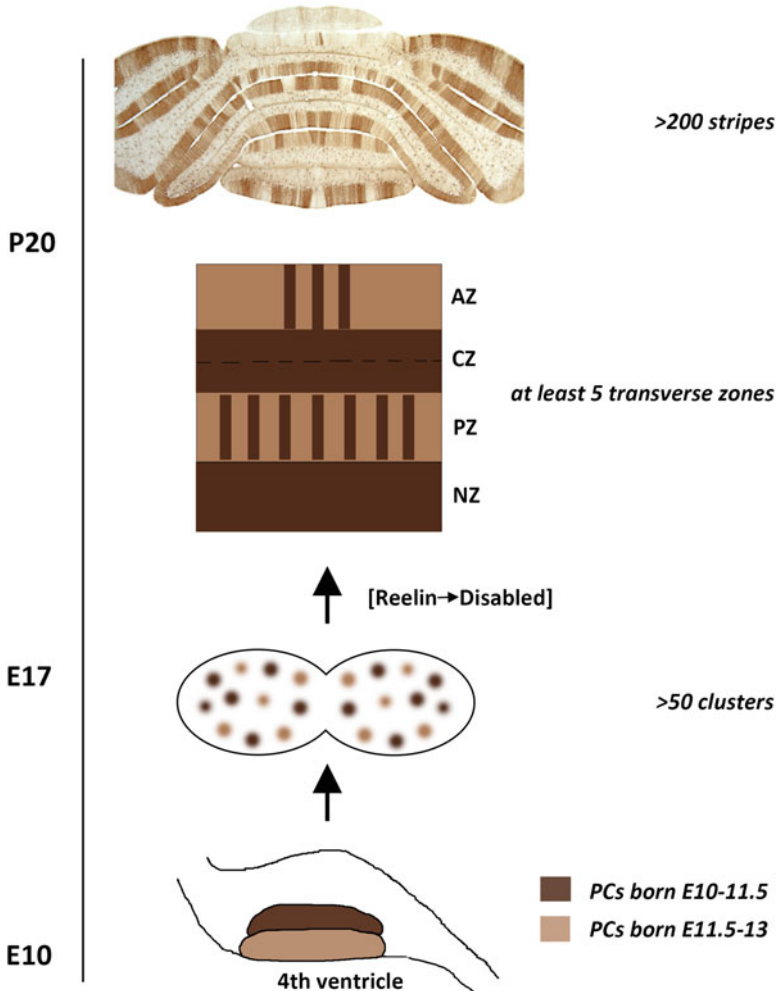
---

C. Armstrong

Department of Biology, Mount Royal University, Calgary, AB T3E 6K6, Canada

R. Hawkes (✉)

Cumming School of Medicine, Department of Cell Biology & Anatomy, Genes and Development Research Group, and Hotchkiss Brain Institute, Cumming School of Medicine, University of Calgary, 3330 Hospital Drive NW, Calgary, Alberta T2N 4N1, Canada  
e-mail: [rhawkes@ucalgary.ca](mailto:rhawkes@ucalgary.ca)



**Fig. 14.1** Zones and stripes. Newborn PCs exit the subventricular zone of the fourth ventricle and stack by birthdate. Subsequently, they migrate to form a symmetrical array of clusters. Reelin-Disabled signaling triggers cluster dispersal into the adult transverse zones and parasagittal stripes (seen here in an adult mouse transverse section immunoperoxidase-stained for PLC $\beta$ 4; Sarna et al. 2006)

and stripes that is conserved in birds and a diverse group of mammals (Sillitoe et al. 2005; Marzban and Hawkes 2011), and form the scaffold around which the rest of the cerebellar cortex is organized.

The mammalian cerebellum includes at least five zones (Fig. 14.1): regions of cerebellar cortex that extend anterior to posterior and can be distinguished as distinct expression domains separated by transverse boundaries that do not align with anatomical boundaries (Fig. 14.1). The anterior zone (AZ) is roughly equivalent to

lobules I–V (“roughly” because transverse zones interdigitate). The central zone (CZ) comprises lobules VI and VII and can be further divided into an anterior CZa (~lobule VI) and a posterior CZp (~lobule VII: Marzban et al. 2008). The posterior zone (PZ) occupies lobule VIII and the dorsal half of lobule IX. The nodular zone (NZ) includes the ventral half of lobule IX and lobule X. In birds, a sixth transverse zone – the lingular zone (LZ) – has been identified in lobule I (Pakan et al. 2007; Marzban et al. 2010).

Each transverse zone is further divided into parasagittal stripes (Armstrong and Hawkes 2013: Figure 1). For example, zebrin II+/- stripe arrays are found in the AZ and PZ (Hawkes and Leclerc 1987; Brochu et al. 1990) and HSP25+/- stripe arrays in the CZ and NZ (Armstrong et al. 2000). However, no single marker reveals the full complexity of the cerebellar architecture: distinct stripes illustrated by one marker are revealed as composite with another (e.g. zebrin II-/PLCβ4+ stripes subdivided by L7/pcp2-lacZ in the AZ – Ozol et al. 1999; zebrin II+ stripes subdivided by HSP25 in the PZ during development – Armstrong et al. 2001). The intrinsic zone-and-stripe organization of the cerebellar cortex also encompasses interneurons and glial cells (Consalez and Hawkes 2013), and PC death in cerebellar pathologies is typically restricted to particular PC subtypes (Sarna and Hawkes 2003).

Afferent tract tracing has shown that both climbing fiber and mossy fiber afferent terminal fields are also restricted to specific stripes (Ruigrok 2011). This patterned afferent input results in functional differences between stripes (witness the physiological classification of stripes/microzones: Apps and Hawkes 2009), and recent studies have also identified intrinsic functional differences between PC subtypes (e.g., Xiao et al. 2014; Zhou et al. 2014). The significance of cerebellar architecture to overall cerebellar function remains unclear: one speculation is that molecular differences between stripes may reflect alternative modes of long-term depression (Hawkes 2014).

## 14.2 Pattern Formation

The zone and stripe architecture of the adult cerebellum is established early in development (Fig. 14.1: Dastjerdi et al. 2012). PCs undergo terminal mitosis (E10–E13: Miale and Sidman 1961) within a *Ptf1a*+ expression domain in the ventricular zone of the fourth ventricle (Hoshino et al. 2005; Zordan et al. 2008). Birthdating studies reveal a direct correlation between PC birthdates and their final stripe location, suggesting that both subtype specification and positional information are acquired at this time (e.g., Hashimoto and Mikoshiba 2003; Chung et al. 2008).

Between E14 and E17, PCs undergo a choreographed migration into a reproducible array of numerous clusters that can be distinguished on the basis of differential expression of molecules (e.g. calbindin, engrailed, cadherins and neurogranin: Fujita et al. 2012; Armstrong and Hawkes 2013). These clusters are the targets of specific afferents and specify the adult connectivity (Sillitoe and Joyner 2007).

The PC clusters disperse between E18 and P20, triggered by Reelin secreted by the external granular layer (D'Arcangelo et al. 1995). Because dispersal is restricted to the rostrocaudal plane, each cluster is drawn out into a long, parasagittal stripe.

## References

- Apps R, Hawkes R (2009) Cerebellar cortical organization: a one-map hypothesis. *Nat Rev Neurosci* 10:670–681
- Armstrong CL, Hawkes R (2013) Pattern formation in the cerebellum. Colloquium digital library of life sciences. Morgan & Claypool. San Rafael
- Armstrong CL, Krueger-Naug AM, Currie RW et al (2000) Constitutive expression of the 25-kDa heat shock protein Hsp25 reveals novel parasagittal bands of Purkinje cells in the adult mouse cerebellar cortex. *J Comp Neurol* 416:383–397
- Armstrong CL, Krueger-Naug AM, Currie RW et al (2001) Expression of heat-shock protein Hsp25 in mouse Purkinje cells during development reveals novel features of cerebellar compartmentation. *J Comp Neurol* 429:7–21
- Brochu G, Maler L, Hawkes R (1990) Zebrin II: a polypeptide antigen expressed selectively by Purkinje cells reveals compartments in rat and fish cerebellum. *J Comp Neurol* 291:538–552
- Chung SH, Marzban H, Croci L et al (2008) Purkinje cell subtype specification in the cerebellar cortex: EBF2 acts to repress the zebrin II-negative Purkinje cell phenotype. *Neuroscience* 153:721–732
- Consalez GC, Hawkes R (2013) The compartmental restriction of cerebellar interneurons. *Front Neural Circ* 6:123
- D'Arcangelo G, Miao GG, Chen SC et al (1995) A protein related to extracellular matrix proteins deleted in the mouse mutant reeler. *Nature* 374:719–723
- Dastjerdi FV, Consalez GC, Hawkes R (2012) Pattern formation during development of the embryonic cerebellum. *Front Neuroanat* 6:10
- Fujita H, Morita N, Furuichi T et al (2012) Clustered fine compartmentalization of the mouse embryonic cerebellar cortex and its rearrangement into the postnatal striped configuration. *J Neurosci* 32:15688–15703
- Hashimoto M, Mikoshiba K (2003) Mediolateral compartmentalization of the cerebellum is determined on the “birth date” of Purkinje cells. *J Neurosci* 23:11342–11351
- Hawkes R (2014) Purkinje cell stripes and long-term depression at the parallel fiber-Purkinje cell synapse. *Front Syst Neurosci* 8:41
- Hawkes R, Leclerc N (1987) Antigenic map of the rat cerebellar cortex: the distribution of parasagittal bands as revealed by monoclonal anti-Purkinje cell antibody mabQ113. *J Comp Neurol* 256:29–41
- Hoshino M, Nakamura S, Mori K et al (2005) Ptf1a, a bHLH transcriptional gene, defines GABAergic neuronal fates in cerebellum. *Neuron* 47:201–213
- Marzban H, Hawkes R (2011) On the architecture of the posterior zone of the cerebellum. *Cerebellum* 10:422–434
- Marzban H, Kim CT, Doorn D et al (2008) A novel transverse expression domain in the mouse cerebellum revealed by a neurofilament-associated antigen. *Neuroscience* 153:1190–1201
- Marzban H, Chung SH, Pezhohu MK et al (2010) Antigenic compartmentation of the cerebellar cortex in the chicken (*Gallus domesticus*). *J Comp Neurol* 518:2221–2239
- Miale IL, Sidman RL (1961) An autoradiographic analysis of histogenesis in the mouse cerebellum. *Exp Neurol* 4:277–296
- Ozol K, Hayden JM, Oberdick J et al (1999) Transverse zones in the vermis of the mouse cerebellum. *J Comp Neurol* 412:95–111

- Pakan JMP, Iwaniuk AN, Wylie DRW et al (2007) Purkinje cell compartmentation as revealed by zebrin II expression in the cerebellar cortex of pigeons (*Columba livia*). *J Comp Neurol* 501:619–630
- Ruigrok TJ (2011) Ins and outs of cerebellar modules. *Cerebellum* 10:464–474
- Sarna JR, Hawkes R (2003) Patterned Purkinje cell death in the cerebellum. *Prog Neurobiol* 70:473–507
- Sarna JR, Marzban H, Watanabe M et al (2006) Complementary stripes of phospholipase C $\beta$ 3 and C $\beta$ 4 expression by Purkinje cell subsets in the mouse cerebellum. *J Comp Neurol* 496:303–313
- Sillitoe RV, Joyner AL (2007) Morphology, molecular codes, and circuitry produce the three-dimensional complexity of the cerebellum. *Ann Rev Cell Dev Biol* 23:549–577
- Sillitoe RV, Marzban H, Larouche M et al (2005) Conservation of the architecture of the anterior lobe vermis of the cerebellum across mammalian species. *Prog Brain Res* 148:283–297
- Xiao J, Cerminara NL, Kotsurovskyy Y et al (2014) Systematic regional variations in Purkinje cell spiking patterns. *PLoS One* 21(8):e105633
- Zhou H, Lin Z, Voges K et al (2014) Cerebellar modules operate at different frequencies. *Elife* 7(3):e02536
- Zordan P, Croci L, Hawkes R et al (2008) Comparative analysis of proneural gene expression in the embryonic cerebellum. *Dev Dyn* 237:1726–1735

# Chapter 15

## Specification of Cerebellar Neurons

Mikio Hoshino

**Abstract** The cerebellum consists of about ten types of neurons that have distinct characteristics in terms of their location, morphology, immunoreactivity and physiology. They can be categorized into two groups; glutamatergic excitatory and GABAergic inhibitory neurons. Excitatory neurons are comprised of glutamatergic deep cerebellar nuclei (DCN) neurons, granule cells and unipolar brush cells (UBCs). Inhibitory neurons include GABAergic DCN neurons, Purkinje cells, Golgi cells, Lugaro cells, basket cells, and stellate cells. GABAergic DCN neurons are interneurons that contribute to local circuitry and projection neurons that extend axons towards the inferior olivary nucleus. As all cerebellar GABAergic interneurons express Pax2 (Maricich and Herrup 1999), they are called Pax2+ interneurons (Pax2+ INs). Recent studies have partly uncovered the molecular machinery for neuronal subtype specification in the cerebellum.

**Keywords** Neural progenitor • Rhombic lip • Ventricular zone • Glutamatergic • GABAergic • bHLH • Transcription factor • Spatiotemporal regulation

### 15.1 Birthplaces and Birthdates of Cerebellar Neurons

The cerebellum consists of about ten types of neurons that have distinct characteristics in terms of their location, morphology, immunoreactivity and physiology. They can be categorized into two groups; glutamatergic excitatory and GABAergic inhibitory neurons. Excitatory neurons are comprised of glutamatergic deep cerebellar nuclei (DCN) neurons, granule cells and unipolar brush cells (UBCs). Inhibitory neurons include GABAergic DCN neurons, Purkinje cells, Golgi cells, Lugaro cells, basket cells, and stellate cells. GABAergic DCN neurons are

---

M. Hoshino (✉)

Department of Biochemistry and Cellular Biology, National Institute of Neuroscience,  
National Center of Neurology and Psychiatry,  
4-1-1 Ogawa-Higashi, Kodaira, Tokyo 187-8502, Japan  
e-mail: [hoshino@ncnp.go.jp](mailto:hoshino@ncnp.go.jp)

interneurons that contribute to local circuitry and projection neurons that extend axons towards the inferior olivary nucleus. As all cerebellar GABAergic interneurons express Pax2 (Maricich and Herrup 1999), they are called Pax2+ interneurons (Pax2+ INs).

All neurons in the cerebellum emerge from the cerebellar neuroepithelium that includes the dorsally located rhombic lip (RL) and the ventrally located ventricular zone (VZ). In the cerebellum, the RL produces all glutamatergic neurons (Ben-Arie et al. 1997; Machold and Fishell 2005; Wang et al. 2005). The VZ generates all GABAergic neurons (Hoshino et al. 2005), although postnatally produced neurons, such as stellate and basket cells, do not directly emerge from the VZ but from the prospective white matter (PWM) thought to be derived from the VZ (Leto et al. 2009).

Birthdates of GABAergic neurons can be estimated by BrdU or tritium incorporation studies or adenoviral infection studies (Chan-Palay et al. 1977; Batini et al. 1992; De Zeeuw and Berrebi 1995; Sultan et al. 2003; Leto et al. 2006; Hashimoto and Mikoshiba 2003). In mice, Purkinje cells are generated at embryonic day (E) 10.5–E13.5, GABAergic DCN neurons at E10.5–E11.5, and Golgi cells at approximately E13.5~ postnatal (peak around E13.5–E15.5). Late born GABAergic neurons, including stellate and basket cells, emerge from GABAergic progenitor cells in the PWM at later stages (approximately E13.5~ perinatal, peak around E17.5~ perinatal). Somatic recombination-based clonal analyses have revealed that Purkinje, Golgi and basket/stellate cells belong to the same lineage (Mathis et al. 1997; Mathis and Nicolas 2003). This suggests that not only Purkinje and Golgi cells but also GABAergic progenitors in the PWM are derived from the VZ. As to glutamatergic neurons, glutamatergic DCN neurons leave the RL at early stages (E10.5–12.5) and granule cells and UBCs at middle to late stages (granule cells; E13.5~, UBCs; E13.5–E18.5) (Machold and Fishell 2005; Wang et al. 2005; Englund et al. 2006).

## 15.2 Molecular Machinery to Specify Distinct Types of Cerebellar Neurons

Two basic-helix-loop-helix proteins are involved in specification of glutamatergic vs. GABAergic neurons. Atoh1 (also called Math1) is expressed in the RL and involved in producing glutamatergic neurons (Ben-Arie et al. 1997; Machold and Fishell 2005; Wang et al. 2005). Ptf1a is expressed in the VZ and specifies the GABAergic neuron lineage (Hoshino et al. 2005; Pascual et al. 2007). When the expression of Atoh1 and Ptf1a is switched, the RL and the VZ produce GABAergic and glutamatergic neurons, respectively (Yamada et al. 2014), suggesting that these two bHLH proteins are sufficient to specify glutamatergic and GABAergic fates. These observations imply that neural progenitors in the RL and the VZ have spatially-regulated distinct identities to produce glutamatergic and GABAergic neurons, respectively.

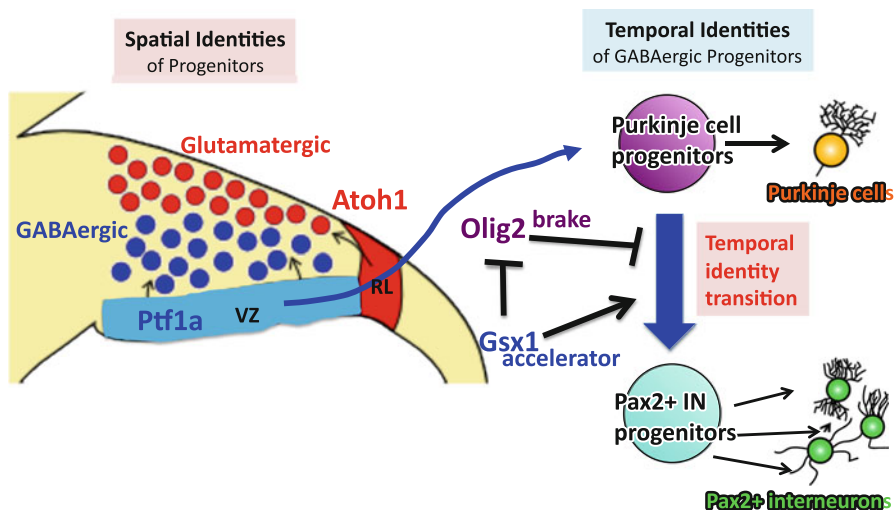


At early neurogenesis stages such as E11.5, there are two types of GABAergic neuron progenitors in the VZ that express *Ptf1a*; Pax2+ IN-producing progenitors (PIPs) and Purkinje cell-producing progenitors (PCPs). PIPs and PCPs express transcription factors, *Gsx1* (also called *Gsh1*) and *Olig2*, respectively. At the early stages, only a small number of PIPs are located at the ventralmost region within the VZ and a large number of PCPs occupy the remaining regions in the VZ. As development proceeds, PCPs gradually transit to become PIPs starting from ventral to dorsal regions. This temporal identity transition of cerebellar GABAergic neuron progenitor causes the loss of PCPs in the VZ by E14.5, correlating with the observations that Purkinje cells are produced only at early neurogenesis stages (E10.5–E13.5). The temporal identity transition of cerebellar GABAergic neuron progenitors from PCPs to PIPs is negatively regulated by *Olig2* and positively by *Gsx1*, which may contribute to proper numbers of distinct subtypes of neurons being produced (Seto et al. 2014). However, whether GABAergic projection neurons in the DCN are derived from PCPs or PIPs is unknown.

Considering the birthdates of distinct Pax2+ INs, PIPs may first produce GABAergic interneurons in the DCN (E10.5~), and then generate Golgi cells (E13.5~). PIPs at late neurogenesis stages may give rise to progenitor cells in the PWM that eventually generate stellate and basket cells. Previous transplantation studies suggested that distinct Pax2+ INs are derived from the same progenitor pool and that extrinsic instructive cues in the microenvironment may affect the terminal neuronal type commitment (Leto 2006, 2009). One candidate for the cue may be sonic hedgehog (SHH) (Fleming et al. 2013; De Luca et al. 2015). In addition, *Lhx1* and *Lhx5* as well as their cofactor *Lbd1* are known to postmitotically participate in Purkinje cell differentiation (Zhao et al. 2007).

In contrast to GABAergic neurons, the machinery to specify each cerebellar glutamatergic neuron subtype remains elusive. Some transcription factors, such as *Tbr1*, *Irx3*, *Meis2*, *Lhx2*, *Lhx9* and *Olig2* are expressed in subsets of postmitotic progenitors of glutamatergic DCN neurons, but their function is still unclear (Morales and Hatten 2006; Seto et al. 2014). As to granule cells, it is known that intrinsic and extrinsic molecules such as *Zic1* and SHH play important roles in cell migration, maturation and survival (Aruga et al. 1998; Dahmane and Ruiz-i-Altaba 1999; Lewis et al. 2004; Wallace 1999; Wechsler-Reya and Scott 1999), but the cell-type specification machinery remains to be identified. Although UBCs strongly express *Tbr2* (Englund et al. 2006), its function remains elusive.

The molecular machinery to specify cerebellar neuronal cell types is summarized in Fig. 15.1. Neuronal cell types seem to be defined according to the spatio-temporal identities of neural progenitors in the neuroepithelium. The bHLH transcription factors, *Atoh1* and *Ptf1a*, confer the spatial identities of the RL and the VZ on neural progenitors, letting them produce glutamatergic and GABAergic neurons, respectively. Glutamatergic and GABAergic neuron progenitors in the RL and the VZ change their temporal identities to produce distinct types of neurons during development. As to GABAergic neurons, PCPs at early stages gradually change their temporal identity to become PIPs, and this temporal identity transition is negatively and positively regulated by *Olig2* and *Gsx1*. PCPs may produce distinct



**Fig. 15.1** Specification of cerebellar neurons by spatiotemporal regulation of neural progenitor identities

types of Pax2+ INs according to extrinsic instructive cues. Temporal identities of glutamatergic neuron progenitors remain unclarified, and, further investigation will be required to fully understand the mechanisms underlying cerebellar neuronal type specification.

## References

- Aruga J, Minowa O, Yaginuma H, Kuno J, Nagai T, Noda T, Mikoshiba K (1998) Mouse *Zic1* is involved in cerebellar development. *J Neurosci* 18:284–293
- Batini C, Compoin C, Buisseret-Delmas C, Daniel H, Guegan M (1992) Cerebellar nuclei and the nucleocortical projections in the rat: retrograde tracing coupled to GABA and glutamate immunohistochemistry. *J Comp Neurol* 315:74–84
- Ben-Arie N, Bellen HJ, Armstrong DL, McCall AE, Gordadze PR, Guo Q, Matzuk MM, Zoghbi HY (1997) *Math1* is essential for genesis of cerebellar granule neurons. *Nature* 390:169–172
- Chan-Palay V, Palay SL, Brown JT, Van Itallie C (1977) Sagittal organization of olivocerebellar and reticulocerebellar projections: autoradiographic studies with <sup>35</sup>S-methionine. *Exp Brain Res* 30:561–576
- Dahmane N, Ruiz-i-Altaba A (1999) Sonic hedgehog regulates the growth and patterning of the cerebellum. *Development* 126:3089–3100
- De Luca A, Parmigiani E, Tosatto G, Martire S, Hoshino M, Buffo A, Leto K, Rossi F (2015) Exogenous Sonic hedgehog modulates the pool of GABAergic interneurons during cerebellar development. *Cerebellum* 14:72–85
- De Zeeuw CI, Berrebi AS (1995) Postsynaptic targets of Purkinje cell terminals in the cerebellar and vestibular nuclei of the rat. *Eur J Neurosci* 7:2322–2333
- Englund C, Kowalczyk T, Daza RA, Dagan A, Lau C, Rose MF, Hevner RF (2006) Unipolar brush cells of the cerebellum are produced in the rhombic lip and migrate through developing white matter. *J Neurosci* 26:9184–9195

- Fleming JT, He W, Hao C, Ketova T, Pan FC, Wright CV, Litingtung Y, Chiang C (2013) The Purkinje neuron acts as a central regulator of spatially and functionally distinct cerebellar precursors. *Dev Cell* 27:278–292
- Hashimoto M, Mikoshiba K (2003) Mediolateral compartmentalization of the cerebellum is determined on the “birth date” of Purkinje cells. *J Neurosci* 23:11342–11351
- Hoshino M, Nakamura S, Mori K, Kawauchi T, Terao M, Nishimura YV, Fukuda A, Fuse T, Matsuo N, Sone M, Watanabe M, Bito H, Terashima T, Wright CV, Kawaguchi Y, Nakao K, Nabeshima Y (2005) *Ptf1a*, a bHLH transcriptional gene, defines GABAergic neuronal fates in cerebellum. *Neuron* 47:201–213
- Leto K, Carletti B, Williams IM, Magrassi L, Rossi F (2006) Different types of cerebellar GABAergic interneurons originate from a common pool of multipotent progenitor cells. *J Neurosci* 26:11682–11694
- Leto K, Bartolini A, Yanagawa Y, Obata K, Magrassi L, Schilling K, Rossi F (2009) Laminae fate and phenotype specification of cerebellar GABAergic interneurons. *J Neurosci* 29:7079–7091
- Lewis PM, Gritli-Linde A, Smeyne R, Kottmann A, McMahon AP (2004) Sonic hedgehog signaling is required for expansion of granule neuron precursors and patterning of the mouse cerebellum. *Dev Biol* 270:393–410
- Machold R, Fishell G (2005) *Math1* is expressed in temporally discrete pools of cerebellar rhombic-lip neural progenitors. *Neuron* 48:17–24
- Maricich SM, Herrup K (1999) Pax-2 expression defines a subset of GABAergic interneurons and their precursors in the developing murine cerebellum. *J Neurobiol* 41:281–294
- Mathis L, Nicolas JF (2003) Progressive restriction of cell fates in relation to neuroepithelial cell mingling in the mouse cerebellum. *Dev Biol* 258:20–31
- Mathis L, Bonnerot C, Puelles L, Nicolas JF (1997) Retrospective clonal analysis of the cerebellum using genetic lacZ/lacZ mouse mosaics. *Development* 124:4089–4104
- Morales D, Hatten ME (2006) Molecular markers of neuronal progenitors in the embryonic cerebellar anlage. *J Neurosci* 26:12226–12236
- Pascual M, Abasolo I, Mingorance-Le Meur A, Martinez A, Del Rio JA, Wright CV, Real FX, Soriano E (2007) Cerebellar GABAergic progenitors adopt an external granule cell-like phenotype in the absence of *Ptf1a* transcription factor expression. *Proc Natl Acad Sci U S A* 104:5193–5198
- Seto Y, Nakatani T, Masuyama N, Taya S, Kumai M, Minaki Y, Hamaguchi A, Inoue YU, Inoue T, Miyashita S, Fujiyama T, Yamada M, Chapman H, Campbell KJ, Magnuson MA, Wright CV, Kawaguchi Y, Ikenaka K, Takebayashi H, Ishiwata S, Ono Y, Hoshino M (2014) Temporal identity transition from Purkinje cell progenitors to GABAergic interneuron progenitors in the cerebellum. *Nat Commun* 5:3337
- Sultan F, Czubyko U, Thier P (2003) Morphological classification of the rat lateral cerebellar nuclear neurons by principal component analysis. *J Comp Neurol* 455:139–155
- Wallace VA (1999) Purkinje-cell-derived Sonic hedgehog regulates granule neuron precursor cell proliferation in the developing mouse cerebellum. *Curr Biol* 9:445–448
- Wang VY, Rose MF, Zoghbi HY (2005) *Math1* expression redefines the rhombic lip derivatives and reveals novel lineages within the brainstem and cerebellum. *Neuron* 48:31–43
- Wechsler-Reya RJ, Scott MP (1999) Control of neuronal precursor proliferation in the cerebellum by Sonic Hedgehog. *Neuron* 22:103–114
- Yamada M, Seto Y, Taya S, Owa T, Inoue YU, Inoue T, Kawaguchi Y, Nabeshima Y, Hoshino M (2014) Specification of spatial identities of cerebellar neuronal progenitors by *Ptf1a* and *Atoh1* for proper production of GABAergic and glutamatergic neurons. *J Neurosci* 34:4786–4800
- Zhao Y, Kwan KM, Mailloux CM, Lee WK, Grinberg A, Wurst W, Behringer RR, Westphal H (2007) LIM-homeodomain proteins *Lhx1* and *Lhx5*, and their cofactor *Ldb1*, control Purkinje cell differentiation in the developing cerebellum. *Proc Natl Acad Sci U S A* 104:13182–13186

# Chapter 16

## Cerebellar Nucleus Development

Hong-Ting Prekop and Richard J.T. Wingate

**Abstract** The cerebellar nuclei are the final output structures of the cerebellum, integrating extra-cerebellar inputs from climbing fibres and mossy fibres with inhibitory signals from Purkinje cells. As in overlying cortical layers, cerebellar nuclei contain a mixture of glutamatergic and GABAergic neurons, which develop from the rhombic lip and ventricular zone, respectively.

**Keywords** Atoh (atonal) 1 • Ptf1a • Climbing fibre • Mossy fibre • GABAergic neuron • Glutamatergic neurons • Neuronal migration • Rhombic lip

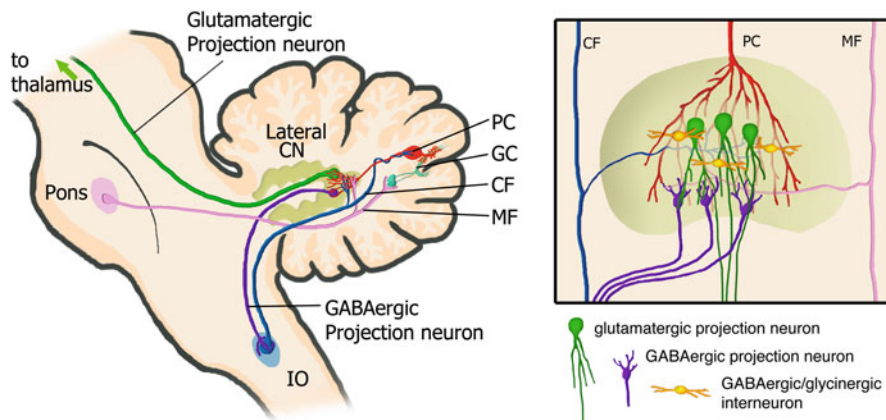
The cerebellar nuclei (CN) are the final output structures of the cerebellum, integrating inputs from the forebrain, brainstem and spinal cord with the cerebellar cortical output from Purkinje cells. In contrast to the remarkably evolutionarily conserved connectivity between granule cells and Purkinje cells in the cerebellar cortex, the size, foliation and number of CN varies between animals (one in amphibians, two in reptiles and birds, three to five in mammals) (Nieuwenhuys et al. 1998). In humans, there are four nuclei: the medial (fastigial), anterior and posterior interposed, and lateral (dentate) nuclei.

Much of what is known concerning CN cell morphologies and neuronal circuitry comes from Golgi and Nissl preparations of the mammalian lateral nucleus observed by light and electron microscopy (Chan-Palay 1977). Based on neurotransmitter content and neuronal connectivity, four main cell types have been identified: large excitatory glutamatergic projection neurons, inhibitory GABAergic projection neurons and local, inhibitory GABAergic and glycinergic interneurons (Fig. 16.1) (Batini et al. 1992; Chen and Hillman 1993; Fredette et al. 1992).

CN receive inhibitory projections from the Purkinje cells from the overlying cerebellar cortex in a broadly topographic manner. The lateral nuclei are innervated by the lateral cerebellum and medial nuclei by the medial vermis (Voogd and Glickstein 1998). CN also integrate collateral inputs from axons projecting from the

---

H.-T. Prekop (✉) • R.J.T. Wingate  
Department of Developmental Neurobiology, King's College London,  
4th floor New Hunts House, Guys Campus, London SE1 1UL, UK  
e-mail: [hong-ting.kwok@kcl.ac.uk](mailto:hong-ting.kwok@kcl.ac.uk)

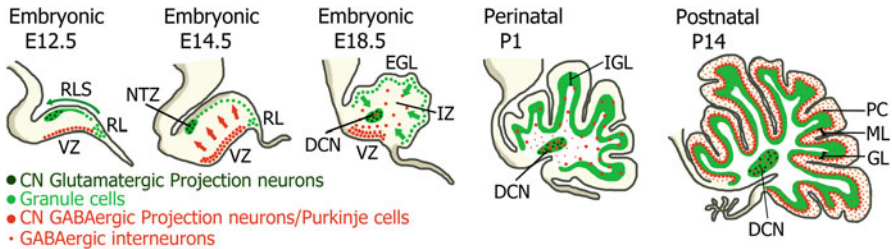


**Fig. 16.1** Connections and circuitry of the human lateral nucleus. *Left:* The lateral CN receives input from Purkinje Cells (PC) and innervates the thalamus, which in turn modulates cortical activity. The nucleus also receives climbing fibres (CF) collateral input from the inferior olive (IO), and mossy fibres (MF) collaterals, originating principally from the pons. Climbing and mossy fibres terminate on PC and granule cells (GC) in the cerebellar cortex, respectively. The CN also contains GABAergic projection neurons that send inhibitory signals to the IO. *Right:* Within the nucleus, each PC axon fans out into a cone that innervates a number of excitatory and GABAergic projection neurons. Small GABAergic and glycinergic interneurons provide local inhibition. Inputs from MF and CF collaterals run perpendicular to the afferent Purkinje cell axons (Adapted from Chan-Palay 1977)

pontine nucleus and inferior olive to the cerebellar cortex (Fig. 16.1). The output of each CN is then directed to different central neural systems as determined by the pattern of their efferent connections (Larsell and Jansen 1972). Of these, the connection from the lateral nucleus to ventrolateral thalamus is a uniquely mammalian adaptation and completes a closed-loop cortico-pontine-cerebellar relay circuit (Kelly and Strick 2003) that is heavily implicated in modulating higher cognitive function in humans (Schmahmann 2010).

## 16.1 Concepts of CN Development Have Changed Markedly in Recent Years

Cell types of the cerebellum arise from two germinal regions within the most anterior neuromere of embryonic hindbrain, rhombomere 1: the ventricular zone (VZ) and the rhombic lip (RL). The VZ is a neuroepithelial zone that lines the dorsolateral part of the fourth ventricle, while the rhombic lip comprises the interface of this neuroepithelium with the roof plate of the fourth ventricle (Wingate 2001). Until the last decade, it was thought that all CN neurons originate from the VZ then migrate radially into the white matter (Altman and Bayer 1985a, b; Goldowitz and Hamre 1998). It is now known that CN neurons of different neurotransmitter types are born from both the RL and VZ.



**Fig. 16.2** Cerebellar nucleus neurons have a dual origin. Different neuronal subtypes in the cerebellum develop from separate germinal regions. Precursors continue to migrate, proliferate, differentiate and mature postnatally. The CN glutamatergic cells form first at the RL and migrate via the nuclear transitory zone (NTZ). The RL also gives rise to granule cell precursors, which form the external granule layer (EGL) that later migrates in to form the inner granule layer (IGL). All cortical GABAergic cells originate from the VZ, migrate into the intermediate zone (IZ) and finally to the molecular (ML) and granule (GL) cell layers

Research by classical birth dating and genetic fate mapping has shown that all cerebellar excitatory neurons are derived from RL progenitors, specified by the expression of *Atoh1*, while inhibitory neurons arise from the VZ, where progenitors are specified by the early expression of *Ptfla* (Hoshino et al. 2005). The bHLH proteins, *Ptfla* and *Atoh1*, have both been shown to be necessary (Machold and Fishell 2005; Wang et al. 2005) and sufficient (Yamada et al. 2014) for the production of all GABAergic and glutamatergic neurons in the cerebellum, respectively (Fig. 16.2). The following description exemplifies CN development using the embryonic mouse model over its 21 days of gestation.

### 16.1.1 Glutamatergic Neurons Are Born at the Rhombic Lip

*Atoh1* expressing progenitor cells from the RL produce glutamatergic CN projection neurons between embryonic day (e)10–e12.5 prior to making granule cell precursors that populate the external granule layer (EGL) (Machold and Fishell 2005; Wang et al. 2005). From e12.5–e14.5, the CN cells migrate from the RL across the dorsal surface of rhombomere 1 via the subplial rhombic lip migratory stream (RLS), then congregate at the nuclear transitory zone (NTZ) at the boundary of the cerebellar anlage (Fig. 16.2). The NTZ is thought to be a transient differentiation zone (Altman and Bayer 1985a), where nuclear neurons are defined by specific, temporally restricted, developmental transcription factor profiles (Fink et al. 2006).

The CN are born in a lateral to medial sequence subsequent to the first-born RL derivatives, which become extra-cerebellar neurons (Machold and Fishell 2005). Like these extra-cerebellar neurons, nuclear cells in the lateral nucleus of mammals express the LIM-homeodomain gene *Lhx9* (Wang et al. 2005; Green and Wingate 2014). Both these early populations project to the thalamus suggesting a role for *Lhx9* in specifying axonal projection (Green and Wingate 2014). Subsequently, RL-derived projection neurons of the interposed and medial nuclei are defined by

their expression of *Tbr2* and *Tbr1*, respectively (Fink et al. 2006; Engelkamp et al. 1999; Landsberg et al. 2005) and extend axons to various hindbrain, midbrain and ventral diencephalic targets.

From e14.5–e16.5, CN cells in the NTZ descend into the white matter. It is unclear whether this is due to active migration towards the VZ (Altman and Bayer 1985a) or displacement by gross morphogenic changes to cerebellar shape as granule cell precursors in the EGL proliferate to produce the most abundant neuronal population in the brain.

### ***16.1.2 GABAergic Neurons Are Derived from the Ventricular Zone***

Fate-mapping studies indicate that GABAergic CN cells are derived from *Ptf1a*-positive precursors in the VZ in two phases (Hoshino et al. 2005). First, GABAergic neurons that project long axons from the CN to the inferior olive (Mugnaini and Oertel 1985; Ruigrok 1997) are born within a distinct temporal window alongside Purkinje cells (e10.5–e12.5), both characterised by the expression of *Olig2*. Very little is known about their subsequent temporal expression profiles or migration: for example, it is unclear whether they accumulate alongside excitatory projection neurons in the NTZ before descending to their destination.

From e13.5, *Olig2* is down regulated and subsequent populations of GABAergic neurons express *Gsx1* (Seto et al. 2014) and *Pax2* (Maricich and Herrup 1999; Weisheit et al. 2006). *Pax2*-positive precursors proliferate within the white matter through to P15 and migrate radially to sequentially form various GABAergic interneuron populations: first the CN interneurons, then Golgi cells of the granule cell layer and finally basket and stellate cells of the molecular layer (Leto et al. 2006). A growing body of evidence shows that specification is controlled post-mitotically by factors in the local microenvironment (Leto et al. 2009; Grimaldi et al. 2009; Zordan et al. 2008), although their identity, and the contribution, if any, of intrinsic cues are still largely undefined.

## **16.2 Future Studies Will Need to Address Fine-Grain Patterning of Different Nuclei**

Our current understanding outlines basic principles of CN development in terms of progenitor zones, temporal patterning and the function of a few key transcription factors. Recent studies have illustrated how the discovery of new molecular and genetic markers has allowed fate mapping of distinct cell types. Detailed studies of cell organisation within the lateral nucleus have revealed intricate cell arrangements and alignment of projections along a polarized axis within the nucleus (Chan-Palay 1977). How neuroblasts migrate, differentiate, and successfully form functional

circuits are important open questions. The identity of cues that shape CN circuits will be important targets for future research. This will also help in assessing the impact of CN dysgenesis on a broad spectrum of cerebellar disorders that can produce both classical motor symptoms and an emerging range of cognitive effects in syndromes such as Autistic Spectrum Disorder and Joubert Syndrome (Schmahmann 2010; Wang et al. 2014; Holroyd et al. 1991).

## References

- Altman J, Bayer SA (1985a) Embryonic development of the rat cerebellum. II. Translocation and regional distribution of the deep neurons. *J Comp Neurol* 231:27–41
- Altman J, Bayer SA (1985b) Embryonic development of the rat cerebellum. III. Regional differences in the time of origin, migration, and settling of Purkinje cells. *J Comp Neurol* 231:42–65
- Batini C, Compoin C, Buisseret-Delmas C, Daniel H, Guegan M (1992) Cerebellar nuclei and the nucleocortical projections in the rat: retrograde tracing coupled to GABA and glutamate immunohistochemistry. *J Comp Neurol* 315:74–84
- Chan-Palay V (1977) *Cerebellar dentate nucleus: organization, cytology and transmitters*. Springer, Berlin
- Chen S, Hillman DE (1993) Colocalization of neurotransmitters in the deep cerebellar nuclei. *J Neurocytol* 22:81–91
- Engelkamp D, Rashbass P, Seawright A, van Heyningen V (1999) Role of Pax6 in development of the cerebellar system. *Development* 126:3585–3596
- Fink AJ, Englund C, Daza RA, Pham D, Lau C, Nivison M, Kowalczyk T, Hevner RF (2006) Development of the deep cerebellar nuclei: transcription factors and cell migration from the rhombic lip. *J Neurosci* 26:3066–3076
- Fredette BJ, Adams JC, Mugnaini E (1992) GABAergic neurons in the mammalian inferior olive and ventral medulla detected by glutamate decarboxylase immunocytochemistry. *J Comp Neurol* 321:501–514
- Goldowitz D, Hamre K (1998) The cells and molecules that make a cerebellum. *Trends Neurosci* 21:375–382
- Green MJ, Wingate RJ (2014) Developmental origins of diversity in cerebellar output nuclei. *Neural Dev* 9:1
- Grimaldi P, Parras C, Guillemot F, Rossi F, Wassef M (2009) Origins and control of the differentiation of inhibitory interneurons and glia in the cerebellum. *Dev Biol* 328:422–433
- Holroyd S, Reiss AL, Bryan RN (1991) Autistic features in Joubert syndrome: a genetic disorder with agenesis of the cerebellar vermis. *Biol Psychiatry* 29:287–294
- Hoshino M, Nakamura S, Mori K, Kawauchi T, Terao M, Nishimura YV, Fukuda A, Fuse T, Matsuo N, Sone M et al (2005) Ptf1a, a bHLH transcriptional gene, defines GABAergic neuronal fates in cerebellum. *Neuron* 47:201–213
- Kelly RM, Strick PL (2003) Cerebellar loops with motor cortex and prefrontal cortex of a nonhuman primate. *J Neurosci* 23:8432–8444
- Landsberg RL, Awatramani RB, Hunter NL, Farago AF, Dipietrantonio HJ, Rodriguez CI, Dymecki SM (2005) Hindbrain rhombic lip is comprised of discrete progenitor cell populations allocated by pax6. *Neuron* 48:933–947
- Larsell O, Jansen J (1972) *The comparative anatomy and histology of the cerebellum: the human cerebellum, cerebellar connections, and cerebellar cortex*. University of Minnesota, Minnesota
- Leto K, Carletti B, Williams IM, Magrassi L, Rossi F (2006) Different types of cerebellar GABAergic interneurons originate from a common pool of multipotent progenitor cells. *J Neurosci* 26:11682–11694



- Leto K, Bartolini A, Yanagawa Y, Obata K, Magrassi L, Schilling K, Rossi F (2009) Laminar fate and phenotype specification of cerebellar GABAergic interneurons. *J Neurosci* 29:7079–7091
- Machold R, Fishell G (2005) Math1 is expressed in temporally discrete pools of cerebellar rhombic-lip neural progenitors. *Neuron* 48:17–24
- Maricich SM, Herrup K (1999) Pax-2 expression defines a subset of GABAergic interneurons and their precursors in the developing murine cerebellum. *J Neurobiol* 41:281–294
- Mugnaini E, Oertel W (1985) An atlas of the distribution of GABAergic neurons and terminals in the rat CNS as revealed by GAD immunohistochemistry. In: *Handbook of chemical neuroanatomy*, vol 4. Elsevier, Amsterdam, pp 436–622
- Nieuwenhuys R, ten Donkelaar HJ, Nicholson C (eds) (1998) *The central nervous system of vertebrates*. Springer, Berlin
- Ruigrok TJ (1997) Cerebellar nuclei: the olivary connection. *Prog Brain Res* 114:167–192
- Schmahmann JD (2010) The role of the cerebellum in cognition and emotion: personal reflections since 1982 on the dysmetria of thought hypothesis, and its historical evolution from theory to therapy. *Neuropsychol Rev* 20:236–260
- Seto Y, Nakatani T, Masuyama N, Taya S, Kumai M, Minaki Y, Hamaguchi A, Inoue YU, Inoue T, Miyashita S et al (2014) Temporal identity transition from Purkinje cell progenitors to GABAergic interneuron progenitors in the cerebellum. *Nat Commun* 5:3337
- Voogd J, Glickstein M (1998) The anatomy of the cerebellum. *Trends Neurosci* 21:370–375
- Wang VY, Rose MF, Zoghbi HY (2005) Math1 expression redefines the rhombic lip derivatives and reveals novel lineages within the brainstem and cerebellum. *Neuron* 48:31–43
- Wang SS, Kloth AD, Badura A (2014) The cerebellum, sensitive periods, and autism. *Neuron* 83:518–532
- Weisheit G, Gliem M, Endl E, Pfeffer PL, Busslinger M, Schilling K (2006) Postnatal development of the murine cerebellar cortex: formation and early dispersal of basket, stellate and Golgi neurons. *Eur J Neurosci* 24:466–478
- Wingate RJT (2001) The rhombic lip and early cerebellar development. *Curr Opin Neurobiol* 11:82–88
- Yamada M, Seto Y, Taya S, Owa T, Inoue YU, Inoue T, Kawaguchi Y, Nabeshima Y, Hoshino M (2014) Specification of spatial identities of cerebellar neuron progenitors by *ptf1a* and *atoh1* for proper production of GABAergic and glutamatergic neurons. *J Neurosci* 34:4786–4800
- Zordan P, Croci L, Hawkes R, Consalez GG (2008) Comparative analysis of proneural gene expression in the embryonic cerebellum. *Dev Dyn* 237:1726–1735

# Chapter 17

## Development of Glutamatergic and GABAergic Synapses

Marco Sassoè-Pognetto

**Abstract** Due to its stereotyped cellular architecture, the cerebellum has always constituted a useful model system for studying the basic organization and development of synaptic circuits. This chapter describes the current state of knowledge relating to the development of cerebellar glutamate and GABA synapses and reviews recent studies on the molecular and activity-dependent mechanisms that control the spatial specificity of synaptogenesis.

**Keywords** Glutamate synapse • GABA synapse • Synaptogenesis • Synaptic specificity

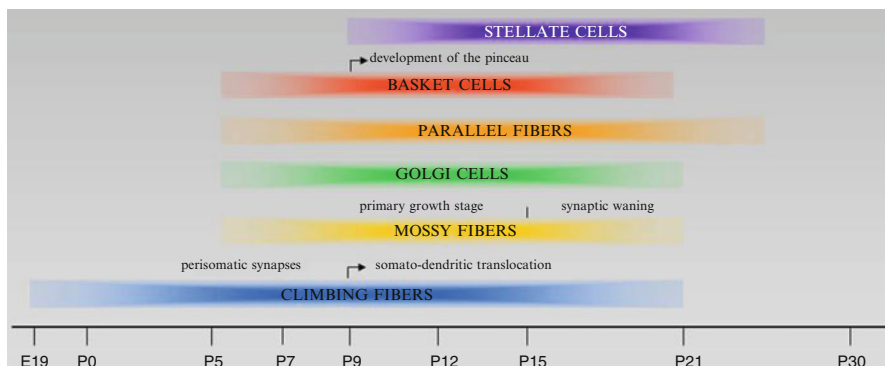
The cerebellum has a prolonged course of development, that largely extends into postnatal life (Wang and Zoghbi 2001). This feature, together with the availability of several natural mutants and of cell-specific genetic tools (Sotelo 2004; Sajan et al. 2010), makes the cerebellum one of the most accessible brain regions for studying synaptogenesis in situ. In the cerebellar cortex, synaptogenesis is entirely postnatal, although it occurs at rather different rates in different lobules (Altman 1972a, b, c). In both mice and rats, synapses start to form in the first postnatal week, and reach adult densities at the end of the third week (Fig. 17.1). The entire period of synaptogenesis is characterized by a progressive growth of the granular and molecular layers, and a proliferation of synapses from the bottom upward. Only a few studies have specifically investigated the development of synaptic connectivity in the deep cerebellar nuclei (Eisenman et al. 1991; Garin and Escher 2001). These investigations have suggested that synaptogenesis may start in the nuclei well before the emergence of the first synapses in the cerebellar cortex, but the precise pattern remains to be determined.

---

M. Sassoè-Pognetto (✉)

Department of Neuroscience, C.so Massimo d'Azeglio, 52, I-10126 Turin, Italy

e-mail: [marco.sassoe@unito.it](mailto:marco.sassoe@unito.it)



**Fig. 17.1** Graphic representation of the development of synapses made by different types of cerebellar neurons and by cerebellar cortical afferents. The diagram is based on studies of the mouse and rat cerebellum. There is still a lot of uncertainty about the precise dates of the onset and the conclusion of the synaptogenic period, as symbolized by the grading colors. Significant phases of the development of specific types of synapses are indicated

## 17.1 Development of Glutamate Synapses

The main types of glutamate synapses in the cerebellum are those established by mossy fibers (MFs), parallel fibers (PFs) and climbing fibers (CFs). In rodents, MFs invade the gray matter at P3–P5 and start establishing the first synapses onto granule cells at the end of the first postnatal week. However it is only during the second postnatal week that synapse number increases considerably, reaching a peak at P15 (Altman 1972c; Hamóri and Somogyi 1983). During development, MF synapses undergo an extensive structural remodeling, that is accompanied by changes of their electrophysiological properties (Larramendi 1969; Cathala et al. 2005). The formation of MF synapses and their developmental maturation depend on synaptogenic factors released by granule cells, such as *Wnt7a* and fibroblast growth factor 22 (Hall et al. 2000; Umemori et al. 2004).

PFs establish the first synapses as soon as their target neurons, the Purkinje cells (PCs), start growing their dendrites in the developing molecular layer at the end of the first postnatal week (Altman 1972a, b). The formation of PF synapses depends on trans-synaptic interactions between the  $\delta 2$  glutamate receptor (*GluD2*), that is expressed selectively by PCs, and cerebellin 1 (*Cbln1*), a C1q family member secreted from granule cell axons (Yuzaki 2010). *Cbln1* binds *GluD2* and also interacts with presynaptic neurexins, establishing a trimeric *trans*-synaptic complex that links pre- and postsynaptic specializations (Matsuda et al. 2010; Uemura et al. 2010).

CFs provide the earliest synaptic inputs to PCs in the developing cerebellar cortex (Fig. 17.1). CF synapses undergo a remarkable structural remodelling throughout development. During the first postnatal week, these afferents establish a dense plexus around the cell body of PCs (Cajal 1890). Subsequently, activity-dependent

competition among CFs results in regression of multiple innervation and dendritic translocation of a single “winner” CF from the soma to the proximal dendrites (Hashimoto et al. 2009). The remodeling of CFs involves also heterosynaptic competition with PFs. Thus, a decrease in PF innervation (e.g. in mutant mice with reduced numbers of granule cells or in mice lacking GluD2) results in retention of multiple CFs and an expansion of the CF innervation territory on PC distal dendrites (Cesa and Strata 2009 and references therein). By contrast, a selective silencing of CFs (e.g. after lesioning the inferior olive) causes the emergence of supernumerary spines in the proximal dendrites of PCs, which become innervated by PFs. Interfering with GABAergic inhibition also impairs CF synapse elimination (Nakayama et al. 2012). Therefore, synapse refinement in PCs requires appropriate levels of electrical activity evoked by CFs, PFs and GABAergic inputs.

## 17.2 Development of GABA Synapses

Synaptic inhibition in the supragranular layers is mediated mainly by basket and stellate cells. Basket cells make synapses with the cell body and the proximal dendrites of PCs, and also form a unique plexus around the axon initial segment (AIS), called a *pinneau* (Cajal 1911). In contrast, stellate cells establish contacts with the dendrites of PCs and of other cerebellar interneurons (Briatore et al. 2010). Basket cells start innervating the cell body of PCs at the end of the first postnatal week (Sotelo 2008; Viltono 2008). The number of perisomatic synapses then increases, together with a strong decrease in the number of somatic spines innervated by CFs. In the same period, basket cell synapses undergo a process of “waning” (Larramendi 1969), consisting in a fragmentation of long synaptic appositions into multiple shorter active zones. These morphological rearrangements are accompanied by a gradual loss of the scaffolding molecule gephyrin from postsynaptic specializations (Viltono et al. 2008), as well as a decrease in the amplitude of IPSCs recorded from PCs (Pouzat and Hestrin 1997).

Formation of the *pinneau* involves a displacement of basket cell axons from the cell body of PCs to the AIS (Sotelo 2008). The targeting of basket axons to the AIS depends a subcellular gradient of neurofascin 186, a cell adhesion molecule of the L1 immunoglobulin family, along the PC soma-AIS axis, and such gradient requires ankyrinG, a membrane adaptor protein that recruits neurofascin (Ango et al. 2004). Interestingly, another member of the same family of adhesion molecules, CHL1, is localized along Bergmann glia fibers and stellate cells during the formation of stellate axon arbors. In the absence of CHL1, stellate axons show aberrant branching and orientation, and synapse formation with PC dendrites is impaired (Ango et al. 2008). Thus different members of the L1 family contribute to axon patterning and subcellular synapse organization in different types of interneurons.

The axon collaterals of PCs also establish GABA synapses with different types of cerebellar neurons, including other PCs (Cajal 1911; Palay and Chan-Palay 1974). According to a recent study, PC-PC synapses are established early during

postnatal development (from P4). These synapses are believed to be ontogenetically transient, and to represent a substrate for waves of activity that propagate along chains of connected PCs (Watt et al. 2009). These travelling waves are absent in adult mice, therefore it has been proposed that they may have a developmental role in wiring cerebellar networks.

Golgi cells mediate synaptic inhibition in the granular layer. Their axon terminals surround the glomeruli and make synapses with the dendrites of granule cells (Palay and Chan-Palay 1974). Most Golgi cells contain both GABA and glycine, and can mediate GABAergic or glycinergic inhibition based on differential expression of either GABA<sub>A</sub> or glycine receptors in the target neurons (Dugué et al. 2005). Immunohistochemical investigations have revealed that Golgi cell synapses matures with a time course similar to that of MF synapses (McLaughlin et al. 1975). Other types of interneurons that mediate synaptic inhibition in the cerebellar cortex include Lugaro, globular and candelabrum cells (Schilling et al. 2008). Like Golgi cells, these neurons are situated in the granule cell layer and have a dual GABAergic/glycinergic phenotype. However, unlike Golgi cells, their axons are not restricted to the granule cell layer, but they distribute throughout the molecular layer. Knowledge of the connectivity and physiology of these cerebellar neurons is fragmentary, and very little is known about their development.

## References

- Altman J (1972a) Postnatal development of the cerebellar cortex in the rat. I. The external germinal layer and the transitional molecular layer. *J Comp Neurol* 145:353–398
- Altman J (1972b) Postnatal development of the cerebellar cortex in the rat. II. Phases in the maturation of Purkinje cells and of the molecular layer. *J Comp Neurol* 145:399–464
- Altman J (1972c) Postnatal development of the cerebellar cortex in the rat. III. Maturation of the components of the granular layer. *J Comp Neurol* 145:465–514
- Ango F, di Cristo G, Higashiyama H et al (2004) Ankyrin-based subcellular gradient of neurofascin, an immunoglobulin family protein, directs GABAergic innervation at Purkinje axon initial segment. *Cell* 119:257–272
- Ango F, Wu C, Van der Want JJ et al (2008) Bergmann glia and the recognition molecule CHL1 organize GABAergic axons and direct innervation of Purkinje cell dendrites. *PLoS Biol* 6:e103
- Briatore F, Patrizi A, Viltono L et al (2010) Quantitative organization of GABAergic synapses in the molecular layer of the mouse cerebellar cortex. *PLoS ONE* 5:e12119
- Cajal S (1890) Sobre ciertos elementos bipolares del cerebelo joven y algunos detalles mas acerca del crecimiento y evolución de las fibras cerebelosas. *Gaceta Sanitaria*, Barcelona, pp 1–20
- Cajal S (1911) *Histologie du système nerveux de l'homme et des vertébrés*. Maloine, Paris
- Cathala L, Holderith NB, Nusser Z et al (2005) Changes in synaptic structure underlie the developmental speeding of AMPA receptor-mediated EPSCs. *Nat Neurosci* 8:1310–1318
- Cesa R, Strata P (2009) Axonal competition in the synaptic wiring of the cerebellar cortex during development and in the mature cerebellum. *Neuroscience* 162:624–632
- Dugué GP, Dumoulin A, Triller A et al (2005) Target-dependent use of co-released inhibitory transmitters at central synapses. *J Neurosci* 25:6490–6498
- Eisenman LM, Schalekamp MP, Voogd J (1991) Development of the cerebellar cortical efferent projection: an in-vitro anterograde tracing study in rat brain slices. *Dev Brain Res* 60:261–266

- Garin N, Escher G (2001) The development of inhibitory synaptic specializations in the mouse deep cerebellar nuclei. *Neuroscience* 105:431–441
- Hall AC, Lucas FR, Salinas PC (2000) Axonal remodeling and synaptic differentiation in the cerebellum is regulated by WNT-7a signaling. *Cell* 100:525–535
- Hámori J, Somogyi J (1983) Differentiation of cerebellar mossy fiber synapses in the rat: a quantitative electron microscope study. *J Comp Neurol* 220:367–377
- Hashimoto K, Ichikawa R, Kitamura K et al (2009) Translocation of a “winner” climbing fiber to the Purkinje cell dendrite and subsequent elimination of “losers” from the soma in developing cerebellum. *Neuron* 63:106–118
- Larramendi LMH (1969) Analysis of synaptogenesis in the cerebellum of the mouse. In: Llinás R (ed) *Neurobiology of cerebellar evolution and development*. American Medical Association, Chicago
- Matsuda K, Miura E, Miyazaki T et al (2010) Cbln1 is a ligand for an orphan glutamate receptor delta2, a bidirectional synapse organizer. *Science* 328:363–368
- McLaughlin BJ, Wood JG, Saito K (1975) The fine structural localization of glutamate decarboxylase in developing axonal processes and presynaptic terminals of rodent cerebellum. *Brain Res* 85:355–371
- Nakayama H, Miyazaki T, Kitamura K et al (2012) GABAergic inhibition regulates developmental synapse elimination in the cerebellum. *Neuron* 74:384–396
- Palay S, Chan-Palay V (1974) *Cerebellar cortex: cytology and organization*. Springer, Berlin
- Pouzat C, Hestrin S (1997) Developmental regulation of basket/stellate cell→Purkinje cell synapses in the cerebellum. *J Neurosci* 17:9104–9112
- Sajan SA, Waimey KE, Millen KJ (2010) Novel approaches to studying the genetic basis of cerebellar development. *Cerebellum* 9:272–283
- Schilling K, Oberdick J, Rossi F et al (2008) Besides Purkinje cells and granule neurons: an appraisal of the cell biology of the interneurons of the cerebellar cortex. *Histochem Cell Biol* 130:601–615
- Sotelo C (2004) Cellular and genetic regulation of the development of the cerebellar system. *Prog Neurobiol* 72:295–339
- Sotelo C (2008) Development of “Pinceaux” formations and dendritic translocation of climbing fibers during the acquisition of the balance between glutamatergic and gamma-aminobutyric acidergic inputs in developing Purkinje cells. *J Comp Neurol* 506:240–262
- Uemura T, Lee SJ, Yasumura M et al (2010) Trans-synaptic interaction of GluRDelta2 and Neurexin through Cbln1 mediates synapse formation in the cerebellum. *Cell* 141:1068–1079
- Umemori H, Linhoff MW, Ornitz DM et al (2004) FGF22 and its close relatives are presynaptic organizing molecules in the mammalian brain. *Cell* 118:257–270
- Viltono L, Patrizi A, Fritschy JM et al (2008) Synaptogenesis in the cerebellar cortex: differential regulation of gephyrin and GABA<sub>A</sub> receptors at somatic and dendritic synapses of Purkinje cells. *J Comp Neurol* 508:579–591
- Wang VY, Zoghbi HY (2001) Genetic regulation of cerebellar development. *Nat Rev Neurosci* 2:484–491
- Watt AJ, Cuntz H, Mori M et al (2009) Traveling waves in developing cerebellar cortex mediated by asymmetrical Purkinje cell connectivity. *Nat Neurosci* 12:463–473
- Yuzaki M (2010) Synapse formation and maintenance by C1q family proteins: a new class of secreted synapse organizers. *Eur J Neurosci* 32:191–197

# Chapter 18

## Synaptogenesis and Synapse Elimination in Developing Cerebellum

**Kouichi Hashimoto, Masahiko Watanabe, and Masanobu Kano**

**Abstract** Purkinje cells (PCs) are the sole output neurons of the cerebellar cortex and play pivotal roles in coordination, control, and learning of movements. In the adult cerebellum, they receive two distinctive excitatory synaptic inputs from parallel fibers (PFs), the axons of granule cells (GCs), and climbing fibers (CFs) arising from the inferior olivary nucleus in the medulla oblongata. Each PC receives functionally weak but numerous (c.a. 100,000 in mice) PF synapses, on spines of distal dendrites. In contrast, most PCs are innervated by single but functionally very strong CFs on stubby spines of their proximal dendrites. PCs receive GABAergic inhibitory synaptic inputs from basket and stellate cells (BCs and SCs) in the molecular layer. These synaptic organizations are established mostly during the first 3 weeks of rodent's life. In this article, we briefly review how these microcircuits around PCs are organized, maintained and modified during postnatal development.

**Keywords** Purkinje cell • Basket cell • Stellate cell • Granule cell • Parallel fiber • Climbing fiber • Synaptogenesis • Synapse elimination • Cerebellum

---

K. Hashimoto

Department of Neurophysiology, Graduate School of Biomedical and Health Sciences, Hiroshima University, 1-2-3 Kasumi, Minami-ku, Hiroshima 734-8551, Japan  
e-mail: [hashik@hiroshima-u.ac.jp](mailto:hashik@hiroshima-u.ac.jp)

M. Watanabe

Department of Anatomy, Hokkaido University Graduate School of Medicine, 060-8638 Sapporo, Japan  
e-mail: [watamasa@med.hokudai.ac.jp](mailto:watamasa@med.hokudai.ac.jp)

M. Kano (✉)

Department of Neurophysiology, Graduate School of Medicine, The University of Tokyo, 7-3-1 Hongo, Bunkyo-ku, Tokyo 113-0033, Japan  
e-mail: [mkano-ty@m.u-tokyo.ac.jp](mailto:mkano-ty@m.u-tokyo.ac.jp)

## 18.1 Synaptogenesis and Refinement of CF to PC Synapses

### 18.1.1 Synaptogenesis of CFs to Immature PCs

Olivocerebellar axons reach the immature cerebellum around E18 (Hashimoto and Kano 2013; Watanabe and Kano 2011). They start to form synapses just after their arrival, but do not have the typical “climbing” morphology at this stage. Immature olivocerebellar axons extensively ramify in the white matter and the GC layer, and give rise to many collaterals around PCs (creeper stage) (Chedotal and Sotelo 1993). Since immature PCs are devoid of large primary dendrites, CFs mainly form terminals on abundant perisomatic protrusions and thorns emerging from PC somata.

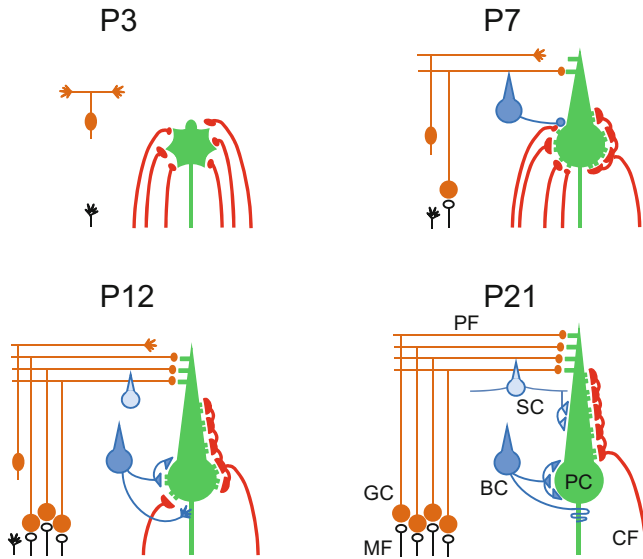
### 18.1.2 Postnatal Refinement of CF to PC Synapses

While most PCs are innervated by single CFs in the adult cerebellum, each PC receives synaptic inputs from multiple CFs at birth. Adult-like mono innervation is gradually established during postnatal development by elimination of surplus CFs, which proceeds in at least four distinct phases (Hashimoto and Kano 2013; Watanabe and Kano 2011).

Around P2–P3, individual multiply-innervating CFs form synapses with relatively similar strengths (Fig. 18.1). During the first postnatal week, a single CF is selectively strengthened on the soma of each PC both functionally and morphologically (termed “functional differentiation”). Mice deficient in Cav2.1, the  $\alpha$ -subunit of the P/Q-type voltage-dependent  $\text{Ca}^{2+}$  channel (VDCC), show impairment in the selective strengthening of a single CF, suggesting that activity-dependent  $\text{Ca}^{2+}$  influx through VDCCs is crucial for establishing a single “winner” CF in each PC.

Then, the strongest CF extends its innervation territory from the soma to dendrites, which is known as “CF translocation” (Fig. 18.1). As mentioned above, CFs initially establish synaptic contacts on the fine processes emerging from the soma, and form a plexus on the lower part of the PC somata (“pericellular nest” stage) (Ramon y Cajal 1911). While the stem dendrite of PCs starts to grow into the molecular layer from around P6, multiple CFs continue to innervate PC somata until P9. After the functional differentiation of CFs, only the strongest (winner) CF extends its innervation territory from the soma to stem dendrites from P9 (“capuchin” stage) (Ramon y Cajal 1911). In the “dendritic” stage (Ramon y Cajal 1911), CF synapses progressively translocate to growing PC dendrites. On the other hand, weaker (loser) CFs remain around the soma, and are eventually eliminated in two distinct phases (the “early and late phases of CF elimination”) mediated by distinct mechanisms (Hashimoto and Kano 2013; Watanabe and Kano 2011; Crepel 1982). The early phase of CF synapse elimination starts at around P7 just after the functional differentiation. Unlike the late phase of CF synapse elimination, the early phase is not





**Fig. 18.1** Synaptogenesis and synapse elimination around PCs during postnatal development. *PC* Purkinje cell, *CF* climbing fiber, *PF* parallel fiber, *BC* basket cell, *SC* stellate cell, *GC* granule cell, *MF* mossy fiber. Note that PF synapses onto BCs and SCs are not illustrated for simplicity

dependent on proper generation of GCs and PF-PC synapses. Several lines of evidence suggest that the neuronal activity is crucial for this event (Hashimoto and Kano 2013; Watanabe and Kano 2011).

The late-phase of CF synapse elimination starts at around P12 (Hashimoto and Kano 2013; Watanabe and Kano 2011; Crepel 1982). This process is critically dependent on proper formation of excitatory PF synapses and inhibitory BC synapses on PCs. In mice deficient in the type 1 metabotropic glutamate receptor (*mGluR1*) or any of its downstream signaling molecules (*G $\alpha$ q*, *PLC $\beta$ 4*, *PKC $\gamma$* ), the late-phase of CF elimination is severely impaired. A recent study has revealed that postsynaptic *Sema7A*, a GPI linked subtype of Semaphorin, and its receptors (*ItgB1* and *PlxnC1*) on CFs are involved in the cascade downstream of *mGluR1* (Uesaka et al. 2014). Moreover, a neurotrophin receptor, *TrkB*, is also involved in CF synapse elimination that starts at around P10–P12.

## 18.2 Synaptogenesis of PF to Immature PCs

During the prenatal period, GC precursors migrate to the cerebellar surface and form the external granular layer. After birth, they descend in the molecular and PC layers and form the internal granular layer (Altman and Bayer 1997; Rubenstein and Rakic 2013). In the premigratory zone, postmitotic spindle-shaped GCs extend

future PFs to both directions in the transverse plane parallel to the cortical surface (Fig. 18.1). Then, GCs start to migrate along Bergmann fibers in the molecular layer by extending downward fibers. As a consequence, T-shaped axons of GCs are constructed. At P7, the PF to PC synaptogenesis has already started on the immature PC dendrites, but the density of PF-PC synapses is low. Concomitant with active outgrowth of PC dendrites and migration of GCs, the density of PF-PC synapses is explosively increased thereafter. Formation and maturation of PFs in the molecular layer proceeds in an “inside-out” manner.

Mutant mice deficient in GluD2 or Cbln1 display similar defects in the PF synapse formation (Mishina et al. 2012; Yuzaki 2011). GluD2 is a member of ionotropic glutamate receptors but does not function as glutamate-gated ion channel. GluD2 is expressed predominantly in PCs. Cbln1 belongs to the C1q/tumor necrosis factor superfamily, and is highly expressed in cerebellar GCs. In GluD2 or Cbln1 knockout mice, the density of PF synapses is reduced to about a half of that in wild-type mice. Moreover, the number of free spines and mismatching of pre- and post-synaptic specialization at PF synapses are conspicuous. Recent studies have revealed that the molecular complex formed by GluD2 on PC dendritic spines, Cbln1 released from GCs and neurexin on PF terminals acts as a bidirectional synaptic organizer that stabilizes PF-PC synapses.

### 18.3 Synaptogenesis of SCs and BCs to PCs

BCs innervate the soma and construct the pinceau formation around the axon initial segment (AIS) of PCs in the mature cerebellum (Fig. 18.1). On the other hand, SCs mainly form synapses on PC dendrites (Fig. 18.1). The BC starts to form synapses on the PC soma at the end of the first postnatal week (Ango et al. 2004). Around P9, most of the perisomatic synapses are from CFs, but thereafter until P20, BC axons take over somatic synaptic sites with progress of somatic CF synapse elimination. From around P9, BC axons reach the AIS of PCs and begin to form the pinceau. Targeting of basket cell axons to the AIS is mediated by several molecules including membrane-associated adaptor protein ankyrin-G and one of its binding partner, neurofascin 186 (NF186) (Ango et al. 2004; Huang et al. 2007; Williams et al. 2010). NF186 exhibits subcellular concentration gradient highest at the AIS (Ango et al. 2004). Ankyrin-G is expressed exclusively at AISs in PCs. Ankyrin-G deficient mice show a defect in distribution of NF186 and abnormal widespread coverage of AISs with BC axons instead of the focal ensheathment of AIS in wild-type mice (Ango et al. 2004; Huang et al. 2007; Williams et al. 2010).

SC precursors migrate into the molecular layer a few days after the migration of BC precursors, which continue until around P14. Between P12 and P16, SCs extend neurites in horizontal orientation (Ango et al. 2008). Then, at P16 to P18, SC axons send ascending and descending collaterals strictly associating with the radial process of Bergmann glia, which are further elaborated with appearance of plexus of finer branches up to P40. In Close Homologue of L1 (CHL1) knockout mice, SC

axons exhibit abnormal trajectories and orientation, and aberrant innervations of PC dendrites (Williams et al. 2010; Ango et al. 2008), whereas the formation of the pinneau by BC axons is normal. Importantly, SC specific abnormalities are also observed in Bergmann glia-specific CHL1-deleted mice. These lines of evidence demonstrate that CHL1 expressed in the Bergmann glia works as guiding scaffolds to organize SC axon arbors and synapse formation (Williams et al. 2010; Ango et al. 2008).

## References

- Altman J, Bayer SA (1997) Development of the cerebellar system: in relation to its evolution, structure, and functions. CRC Press, Boca Raton
- Ango F, di Cristo G, Higashiyama H, Bennett V, Wu P, Huang ZJ (2004) Ankyrin-based subcellular gradient of neurofascin, an immunoglobulin family protein, directs GABAergic innervation at Purkinje axon initial segment. *Cell* 119(2):257–272. doi:10.1016/j.cell.2004.10.004
- Ango F, Wu C, Van der Want JJ, Wu P, Schachner M, Huang ZJ (2008) Bergmann glia and the recognition molecule CHL1 organize GABAergic axons and direct innervation of Purkinje cell dendrites. *PLoS Biol* 6(4):e103. doi:10.1371/journal.pbio.0060103
- Chedotal A, Sotelo C (1993) The ‘creeper stage’ in cerebellar climbing fiber synaptogenesis precedes the ‘pericellular nest’ – ultrastructural evidence with parvalbumin immunocytochemistry. *Brain Res Dev Brain Res* 76(2):207–220
- Crepel F (1982) Regression of functional synapses in the immature mammalian cerebellum. *Trends Neurosci* 5:266–269
- Hashimoto K, Kano M (2013) Synapse elimination in the developing cerebellum. *Cell Mol Life Sci* 70(24):4667–4680. doi:10.1007/s00018-013-1405-2
- Huang ZJ, Di Cristo G, Ango F (2007) Development of GABA innervation in the cerebral and cerebellar cortices. *Nat Rev Neurosci* 8(9):673–686. doi:10.1038/nrn2188
- Mishina M, Uemura T, Yasumura M, Yoshida T (2012) Molecular mechanism of parallel fiber–Purkinje cell synapse formation. *Front Neural Circ* 6:90. doi:10.3389/fncir.2012.00090
- Ramon y Cajal S (1911) *Histologie du système nerveux de l’homme et des vertèbres*, vol II. Maloine, Paris
- Rubenstein J, Rakic P (2013) *Neural circuit development and function in the brain: comprehensive developmental neuroscience*. Academic Press, San Diego. doi:10.1016/B978-0-12-397267-5.09994-5
- Uesaka N, Uchigashima M, Mikuni T, Nakazawa T, Nakao H, Hirai H, Aiba A, Watanabe M, Kano M (2014) Retrograde semaphorin signaling regulates synapse elimination in the developing mouse brain. *Science* 344(6187):1020–1023. doi:10.1126/science.1252514
- Watanabe M, Kano M (2011) Climbing fiber synapse elimination in cerebellar Purkinje cells. *Eur J Neurosci* 34(10):1697–1710. doi:10.1111/j.1460-9568.2011.07894.x
- Williams ME, de Wit J, Ghosh A (2010) Molecular mechanisms of synaptic specificity in developing neural circuits. *Neuron* 68(1):9–18. doi:10.1016/j.neuron.2010.09.007
- Yuzaki M (2011) Cbln1 and its family proteins in synapse formation and maintenance. *Curr Opin Neurobiol* 21(2):215–220. doi:10.1016/j.conb.2011.01.010

# Chapter 19

## Cerebellar Epigenetics: Transcription of MicroRNAs in Purkinje Cells

Neal H. Barmack

**Abstract** Climbing fiber activity is often associated with cerebellar plasticity. However, seemingly simple and short-lasting examples of neuronal plasticity such as Long-Term Potentiation (LTP) are associated with the translation and translocation of as many as 100 proteins. One means of controlling protein translation is through the interaction of microRNAs with mRNAs. MicroRNAs are small non-coding nucleotides that repress translation of mRNAs with complementary nucleotide sequences. A single microRNA may share nucleotide complementarity with as many as 30 different mRNAs, enhancing the scope of its regulatory impact. While microRNAs play an important role in cellular development, apoptosis and microbial defense, the role of microRNAs in the regulation of neuronal activity in adult nervous systems has been unexplored. Possibly, translation of many proteins necessary for neuronal plasticity is regulated by the repressive action of only a few microRNAs. Here we consider how the transcription of microRNAs in cerebellar Purkinje cells is influenced by activation of its climbing fiber synapses. We use horizontal optokinetic stimulation (HOKS) to chronically regulate climbing fiber excitation of floccular Purkinje cells in mice for 0–30 h. We investigate how this activity influences the transcription of microRNAs in Purkinje cells with enhanced climbing fiber signals compared to Purkinje cells with merely spontaneous climbing fiber inputs. HOKS evokes increases in 12 microRNA transcripts in floccular Purkinje cells. One of these microRNAs, miR335, increases 18-fold after 24 h of HOKS. After HOKS is stopped, miR335 transcripts decay with a time constant of ~2.5 h. HOKS evokes a 28-fold increase in pri-miR335 transcripts. These data indicate that the evoked increase in mature miR335 transcripts can be attributed to increased transcription of microRNAs.

**Keywords** Flocculus • Plasticity • Climbing fiber

---

N.H. Barmack (✉)

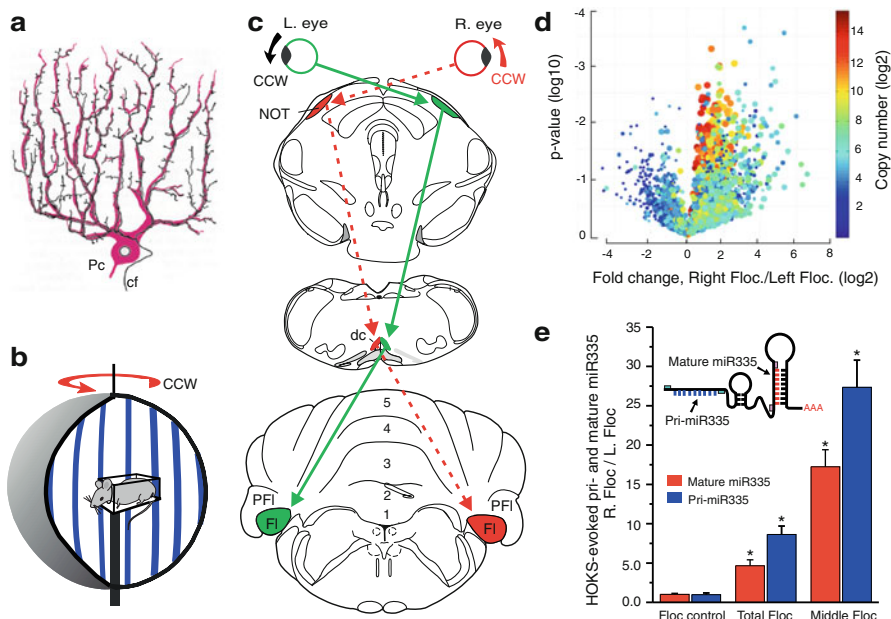
Department of Physiology and Pharmacology, Oregon Health & Science University,  
3181 S.W. Sam Jackson Park Road, Portland, OR 97239, USA

e-mail: [barmackn@ohsu.edu](mailto:barmackn@ohsu.edu)

Climbing fiber activity is often associated with cerebellar changes in synaptic efficacy of Purkinje cells. Long-term depression (LTD) in Purkinje cells provides an example of decreased synaptic efficacy of a set of pre-synaptic afferent, parallel fibers, following their conjunctive pairing with a climbing fiber (Ito et al. 1982; Ekerot and Kano 1985; Linden and Connor 1993). The changes in synaptic efficacy observed during LTD last seconds to tens of minutes. These seemingly simple and short-lasting examples of neuronal plasticity are associated with the translation or translocation of as many as 100 proteins (Sanes and Lichtman 1999). Longer-term changes in synaptic efficacy, lasting tens of hours, may involve not only redistribution and targeting of proteins, but changes in gene transcription as well. Here we consider how Purkinje cell activity evoked by natural stimulation of cerebellar climbing fibers causes increased transcription of microRNA.

Conceptually the problem of controlling gene transcription, translation and targeting of multiple proteins could be simplified if the proteins were regulated by common precursors such as microRNAs; small, non-coding RNAs derived from “junk” DNA. A single microRNAs can target the 3'-untranslated regions of as many as 5–30 mRNAs and limit their translation by complementary repression and degradation (Cullen 2004; Robins and Press 2005; Landgraf et al. 2007; Hobert 2008; Eulalio et al. 2009; Guo et al. 2010). While the transcription of microRNAs has been linked to cellular development, apoptosis (Ambros 2004; Reinhart et al. 2000; Harfe 2005; Cullen 2004; Kosik 2006; Schratt et al. 2006; Bushati and Cohen 2007) and microbial defense (Cullen 2004; Bartel 2004; Zeng et al. 2005). microRNAs also regulate functions of adult neurons (Smalheiser and Lugli 2009; Schratt 2009; Konopka et al. 2011; Tognini et al. 2011; Mellios et al. 2011; Barmack et al. 2010).

Each Purkinje cell receives synaptic input from only one climbing fiber that makes ~500 glutamatergic synaptic contacts as it envelopes the dendritic tree (Cajal 1911; Granit and Phillips 1956; Konnerth et al. 1990; Harvey and Napper 1991). The climbing fiber evokes the largest EPSP of any known central synapse (Eccles et al. 1967). Activation of climbing fiber synapses on Purkinje cells offers a powerful model system for examining how naturally-evoked neuronal activity influences the transcription of microRNAs and mRNAs. Controlled modulation of climbing fiber activity can be achieved using horizontal optokinetic stimulation (HOKS) to modulate the activity of floccular Purkinje cells. To achieve this objective unanesthetized mice are restrained at the center of a rotating optokinetic sphere (Fig. 19.1b). Rotation of the optokinetic sphere about its vertical axis in the CCW direction excites direction-selective “on” ganglion cells in the right eye while disfacilitating these cells in the left eye (Oyster et al. 1980). Ganglion cell axons from the right eye project to the left nucleus of the optic tract (NOT) in the dorsal midbrain. The axons of neurons in the left NOT descend to the inferior olive where they excite neurons in the left dorsal cap (Maekawa and Simpson 1973; Alley et al. 1975; Barmack and Hess 1980; Simpson et al. 1988). Neurons in the left dorsal cap project as climbing fibers to the right flocculus where they excite Purkinje cells (Fig. 19.1c) (Leonard et al. 1988; Schonewille et al. 2006). Since the visual projections to the flocculus are lateralized HOKS causes increased climbing fiber excitation in one flocculus while reducing it in the other.



**Fig. 19.1** Horizontal optokinetic stimulation (HOKS) evokes climbing fiber induced increases in microRNA transcription in the flocculus. **(a)** Mice are restrained at the center of an optokinetic sphere. Counter clockwise (CCW) rotation of the sphere (HOKS at 6 deg/s) excites direction-selective “on” ganglion cells in the right eye and “disfacilitates” ganglion cells in the left eye. **(b)** A cartoon shows that a single climbing fiber makes extensive synaptic terminals on a Purkinje cell dendritic tree (Redrawn from Cajal 1911). **(c)** A cartoon depicts functional optokinetic pathway from the retina to the ipsilateral flocculus (see text for details). The *dashed lines* indicate the excitatory pathway that originates from the right eye. The *solid lines* indicate the “disfacilitated” pathway from the left eye. **(d)** RNA samples from left and right flocculi are analyzed initially on a microRNA microarray that includes 616 human and 361 mouse mature miRNAs. Captured microRNAs are plotted in a Volcano plot, representing four variables: (1) The fold change for each microRNA is represented on abscissa (right floc/left floc), (2) Statistical probability transcription difference (p-value) of a miRNA between the left and right flocculi is represented on left ordinate, (3) Average copy number (color coded) is represented on right ordinate and (4) Frequency of occurrence a miRNA relative to all other sampled miRNAs is represented as data point diameter. **(e)** Specific microRNAs are measured using qPCR. For miR335 both pri-miR335 and mature miR335 are identified using specific primer pairs. Both pri-miR335 and mature miR335 transcripts increase. The location of qPCR primers that flank the targeted nucleotide sequences is indicated for both sets of primers by boxes. Abbreviations: *dc* dorsal cap of the inferior olive, *FI* flocculus, *NOT* nucleus of the optic tract, *PFI* paraflocculus

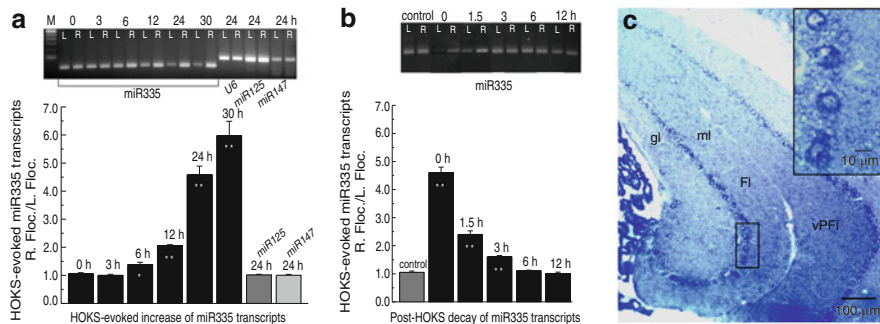
*Climbing fiber activity increases the transcription of microRNAs in Purkinje cells.* HOKS can be maintained for 0–30 h. When it is stopped mice are anesthetized, the left and right flocculi are removed and total RNA is extracted from each flocculus. Changes in microRNA transcripts in “stimulated” and “non-stimulated” flocculi are measured using a microarray (GeneChip® microRNA 2.0, Affymetrix Co).

Three criteria are used to discriminate levels of microRNA transcripts; (1) Fold changes between the left and right flocculus must exceed twofold. (2) The  $P$ -value of a  $t$ -test for significance must be  $<0.005$ . (3) The average copy number must exceed 256. These three criteria identify 12 microRNAs (miR133, miR7a, miR199a-5p, let71, miR100, miR15a, miR21, miR335-5p, miR361, miR379, miR22, miR126-3p) with increased transcripts in the right flocculus following 24 h of CCW HOKS (Barmack et al. 2010). Three of these microRNAs (miR126, miR335 and miR379) have  $p$ -values  $<0.001$  (Fig. 19.1d).

The microRNAs identified by microarrays can be measured with greater accuracy and at reduced cost using quantitative Polymerase Chain Reaction (qPCR). RNA is extracted from the flocculi. cDNAs are synthesized and amplified using primer pairs that identify and amplify specific target sequences. Using qPCR, the transcripts of miR335 increase 18-fold in the “stimulated” vs “unstimulated” flocculus after 24 h of HOKS (Fig. 19.1e).

Proof of climbing fiber-evoked increases in microRNA transcripts is not necessarily proof of increased microRNA transcription. Several enzymatic post-transcriptional factors could contribute to the regulation of microRNAs. However, the transcription of larger pri-microRNAs precedes the action of intra-nuclear enzyme Drosha/Pasha that digests pri-microRNA converting it into pre-microRNA (Lee et al. 2003; Cai et al. 2004). It also precedes the action of cytoplasmic enzymes such as Dicer, that cut pre-microRNA into a microRNA duplex (Lund and Dahlberg 2006) and Argonaut, that selects the mature microRNA strand from the microRNA duplex (Ghildiyal and Zamore 2009; Johnston and Hutvagner 2011). If climbing fiber-evoked depolarization of Purkinje cells increases mature microRNA transcripts by increasing transcription of pri-microRNAs rather than by post-transcriptional regulatory mechanisms, then it should be possible to measure changes in both pri-microRNAs and mature microRNAs during climbing fiber-evoked Purkinje cell activity. This question can be answered by measuring transcripts of pri-miR335 and mature miR335 in floccular RNA samples extracted from “stimulated” and “non-stimulated” flocculi. Primer binding sites for pri-miR335 are not present on mature miR335 and the primer binding sites on mature miR335 are not accessible until the duplex RNA is cleaved into two strands (Fig. 19.1e). Following 24 h of HOKS, pri-miR335 transcripts from the middle zone of the stimulated (right) flocculus are 28X more than those in the unstimulated (left) flocculus. Mature miR335 transcripts are 18X more. In samples taken from the whole flocculus pri-miR335 transcripts are 9X more in the right flocculus and mature miR335 transcripts are 5X more. In control samples taken from mice not exposed to HOKS, the ratio of right flocculus/left flocculus for pri-miR335 and mature miR335 is 1 (Barmack et al. 2014). Consequently, we can conclude that climbing fiber excitation increases the transcription of miR335 in Purkinje cells.

*Minimal HOKS time to detect climbing fiber evoked increases in microRNA transcription is 6 h.* It is useful to know the minimal duration of HOKS necessary to evoke a detectable increase in microRNA transcripts. This question is answered in experiments where mice receive HOKS for different durations (0, 3, 6, 12, 24, 30 h).



**Fig. 19.2** Increased transcription of miR335 by HOKS and its subsequent decay. **(a)** Increasing the duration of HOKS increases the transcription of miR335. Mice receive binocular HOKS for fixed durations of 0–30 h. After HOKS is stopped ward the mice are anesthetized and euthanized. The flocculi are dissected for RNA extraction. cDNAs are synthesized and amplified by PCR. U6 is co-amplified as a loading control. Each reaction is run on a gel and the optical density of the bands is measured photometrically. When the ratio of PCR band density (R. Flocc./L. Flocc.) is >1 it indicates increased transcription of miR335 in the right flocculus. Two microRNAs, miR125 or miR147 (gray bars), are run as controls. Their transcription is not affected by HOKS. HOKS duration is indicated above each gel pair and for each *histogram bar*. **(b)** Transcripts of miR335 in the right flocculus decay rapidly. The transcripts are measured at the indicated times after HOKS is stopped. Three control mice (gray bar) receive no HOKS. For both **a** and **b**, each *histogram bar* indicates the mean for three mice. *Error bars* indicate standard error of the mean. *Asterisks* indicate statistical significance using a single factor ANOVA at  $P < 0.020$  (\*) or  $P < 0.001$  (\*\*). **(c)** A digoxigenin-labeled oligonucleotide complementary to miR335 and immunolabeled with an antibody to digoxigenin hybridizes with the cytoplasmic component of Purkinje cells. The area denoted by the *small box* is shown at higher magnification in the larger insert. Abbreviations: *Fl*, flocculus, *gl* granule cell layer, *ml* molecular layer, *vPFI* ventral paraflocculus (Modified from (Barmack et al. 2010))

Climbing fiber evoked transcription of miR335 can be detected after 6 h of HOKS. The transcription of miR335 increases linearly from 6 to 30 h (Fig. 19.2a).

*miR335 transcripts decay following climbing fiber activation with a time constant of 2.5 h.* It is important to know for how long the increases in microRNA transcripts persist after HOKS stops. This question can be addressed specifically by exposing mice to a constant duration of HOKS for 24 h. When HOKS stopped, the mice remain within the illuminated sphere for 0.0, 1.5, 3.0, 6.0, or 12 h. Transcripts of miR335 are then measured with qPCR at each of the specified post-stimulus intervals. Using this regimen miR335 transcripts decay to control levels with a time-constant of ~2.5 h (Fig. 19.2b). This rapid decay suggests that while microRNA transcripts cannot account singularly for long-lasting changes in Purkinje excitability observed after HOKS is stopped.

*Hybridization histochemistry localizes microRNA transcripts to Purkinje cells.* While HOKS increases microRNA transcripts in the flocculus, it is by no means certain that the transcripts are localized exclusively to Purkinje cells. This localization can be tested using “locked nucleic acid-modified oligonucleotide probes” to examine whether they hybridize with mature microRNAs. A probe for miR335



hybridizes with Purkinje cell soma, but not with Purkinje cell nuclei (Fig. 19.2c). This confirms the cytoplasmic location of the mature miR335 in Purkinje cells, rather than the nuclear location of the unedited longer pri-miR335. Probes for other microRNA transcripts that increase with HOKS, miR15, miR21 and miR361, also hybridize with Purkinje cells and weakly with stellate cells (not shown). A scrambled probe, having the same GC content as the probe for miR335, fails to hybridize with either Purkinje cells or other cerebellar neurons (not shown). These data confirm that the microRNAs evoked by climbing fiber activity are localized primarily to Purkinje cells.

*Screens for discovering mRNAs targeted by microRNAs.* Having established that microRNA transcription in Purkinje cells is influenced by climbing fiber activity, it would be useful to identify the proteins whose translation is repressed by miR335. The nucleotide sequence of miR335 offers the first clue to the identity of target mRNAs that have complementary sequences. However, the set of complementary mRNA targets for a particular microRNA is unacceptably large. A stringent screening of two data bases ([microRNA Registry](#) and [EnsEMBL](#)) reveals more than 149 mRNAs with sequence complementarity to miR335. Second, we can functionally reduce the number of potential mRNAs targeted by miR335 by using an mRNA array (Genome 430 2.0, Affymetrix) in conjunction with same duration HOKS used to identify miRNAs. This functional mRNA screen identifies mRNAs whose transcripts decrease following HOKS. It allows that not all such decreases can be attributed to increased miR335 repression. This screen reveals a total of 42 mRNA transcripts that decrease after HOKS (Barmack and Qian 2002; Barmack et al. 2010). Third, we can microinject specific miR335 inhibitors directly into the cerebellum and identify mRNA transcripts that increase as a consequence of the microinjection, again using an mRNA microarray. This approach generates 28 mRNAs whose transcripts increase following microinjection of miR335 inhibitors. In sum, we can identify 149 mRNA transcripts with nucleotide sequences complementary to that of miR335. We can detect 42 mRNA transcripts that decrease following HOKS and we can identify 28 mRNA transcripts that increase following a microinjection of microR335 inhibitors. This approach yields two mRNAs that satisfy all three screens; 14-3-3- $\theta$  and calbindin (Barmack et al. 2010, 2014).

*microRNAs and cerebellar function.* Cerebellar plasticity will not be explained by reference to a single microRNA. Rather it seems likely that multiple microRNAs act in parallel to control a common target mRNA. Furthermore, a specific mRNA may have a nucleotide sequence that offers complementary targets to several microRNAs. Gaining a functional understanding of the interactions between microRNAs and mRNAs may prove useful in treating cerebellar disorders. Already microRNA dysfunction has been linked to neurological diseases such as cerebellar ataxia (Schaefer et al. 2007; Barnes et al. 2011), spinal muscular atrophy (Haramati et al. 2010) and polyglutamine-induced neurodegeneration (Bilen et al. 2006). Pharmacological treatments that target specific microRNAs or proteins, whose translation is repressed by microRNAs, may provide novel therapeutic approaches for treating the consequences of aberrant neuronal excitability.

## References

- Alley K, Baker R, Simpson JI (1975) Afferents to the vestibulo-cerebellum and the origin of the visual climbing fibers in the rabbit. *Brain Res* 98:582–589
- Ambros V (2004) The functions of animal microRNAs. *Nature* 431:350–355
- Barmack NH, Hess DT (1980) Multiple-unit activity evoked in dorsal cap of inferior olive of the rabbit by visual stimulation. *J Neurophysiol* 43:151–164
- Barmack NH, Qian Z (2002) Activity-dependent expression of calbindin in rabbit floccular Purkinje cells modulated by optokinetic stimulation. *Neuroscience* 113:235–250
- Barmack NH, Qian Z, Yakhnitsa V (2010) Climbing fibers induce microRNA transcription in cerebellar Purkinje cells. *Neuroscience* 171:655–665
- Barmack NH, Qian Z, Yakhnitsa V (2014) Long-term climbing fibre activity induces transcription of microRNAs in cerebellar Purkinje cells. *Philos Trans R Soc Lond B Biol Sci* 369:1652–1664
- Barnes JA, Ebner BA, Duvick LA, Gao W, Chen G, Orr HT, Ebner TJ (2011) Abnormalities in the climbing fiber-Purkinje cell circuitry contribute to neuronal dysfunction in ATXN1[82Q] mice. *J Neurosci* 31:12778–12789
- Bartel DP (2004) MicroRNAs: genomics, biogenesis, mechanism, and function. *Cell* 116:281–297
- Bilen J, Liu N, Burnett BG, Pittman RN, Bonini NM (2006) MicroRNA pathways modulate polyglutamine-induced neurodegeneration. *Mol Cell* 24:157–163
- Bushati N, Cohen SM (2007) microRNA functions. *Annu Rev Cell Dev Biol* 23:175–205
- Cai X, Hagedorn CH, Cullen BR (2004) Human microRNAs are processed from capped, polyadenylated transcripts that can also function as mRNAs. *RNA* 10:1957–1966
- Cajal SR (1911) *Histologie du système nerveux de l'homme et des vertébrés*. Maloine, Paris
- Cullen BR (2004) Transcription and processing of human microRNA precursors. *Mol Cell* 16:861–865
- Eccles JC, Ito M, Szentágotthai J (1967) *The cerebellum as a neuronal machine*. Springer, New York
- Ekerot CF, Kano M (1985) Long-term depression of parallel fibre synapses following stimulation of climbing fibres. *Brain Res* 342:357–360
- Eulalio A, Huntzinger E, Nishihara T, Rehwinkel J, Fauser M, Izaurralde E (2009) Deadenylation is a widespread effect of miRNA regulation. *RNA* 15:21–32
- Ghildiyal M, Zamore PD (2009) Small silencing RNAs: an expanding universe. *Nat Rev Genet* 10:94–108
- Granit R, Phillips CG (1956) Excitatory and inhibitory processes acting upon individual Purkinje cells of the cerebellum in cats. *J Physiol Lond* 133:520–547
- Guo H, Ingolia NT, Weissman JS, Bartel DP (2010) Mammalian microRNAs predominantly act to decrease target mRNA levels. *Nature* 466:835–840
- Haramati S, Chapnik E, Sztainberg Y, Eilam R, Zwang R, Gershoni N, McGlenn E, Heiser PW, Wills AM, Wirguin I, Rubin LL, Misawa H, Tabin CJ, Brown R Jr, Chen A, Hornstein E (2010) miRNA malfunction causes spinal motor neuron disease. *Proc Natl Acad Sci U S A* 107:13111–13116
- Harfe BD (2005) MicroRNAs in vertebrate development. *Curr Opin Genet Dev* 15:410–415
- Harvey RJ, Napper RM (1991) Quantitative studies on the mammalian cerebellum. *Prog Neurobiol* 36:437–463
- Hobert O (2008) Gene regulation by transcription factors and microRNAs. *Science* 319:1785–1786
- Ito M, Sakurai M, Tongroach P (1982) Climbing fibre induced depression on both mossy fibre responsiveness and glutamate sensitivity of cerebellar Purkinje cells. *J Physiol Lond* 324:113–134
- Johnston M, Hutvagner G (2011) Posttranslational modification of Argonautes and their role in small RNA-mediated gene regulation. *Silence* 2:5

- Konnerth A, Llano I, Armstrong CM (1990) Synaptic currents in cerebellar Purkinje cells. *Proc Natl Acad Sci U S A* 87:2662–2665
- Konopka W, Schütz G, Kaczmarek L (2011) The microRNA contribution to learning and memory. *Neuroscientist* 17:468–474
- Kosik KS (2006) The neuronal microRNA system. *Nat Rev Neurosci* 7:911–920
- Landgraf P et al (2007) A mammalian microRNA expression atlas based on small RNA library sequencing. *Cell* 129:1401–1414
- Lee Y, Ahn C, Han J, Choi H, Kim J, Yim J, Lee J, Provost P, Radmark O, Kim S, Kim VN (2003) The nuclear RNase III Drosha initiates microRNA processing. *Nature* 425:415–419
- Leonard CS, Simpson JI, Graf W (1988) Spatial organization of visual messages of the rabbit's cerebellar flocculus. I. Typology of inferior olive neurons of the dorsal cap of Kooy. *J Neurophysiol* 60:2073–2090
- Linden DJ, Connor JA (1993) Cellular mechanisms of long-term depression in the cerebellum. *Curr Opin Neurobiol* 3:401–406
- Lund E, Dahlberg JE (2006) Substrate selectivity of exportin 5 and Dicer in the biogenesis of microRNAs. *Cold Spring Harb Symp Quant Biol* 71:59–66
- Maekawa K, Simpson JI (1973) Climbing fiber responses evoked in vestibulocerebellum of rabbit from visual system. *J Neurophysiol* 36:649–666
- Mellios N, Sugihara H, Castro J, Banerjee A, Le C, Kumar A, Crawford B, Strathmann J, Tropea D, Levine SS, Edbauer D, Sur M (2011) miR-132, an experience-dependent microRNA, is essential for visual cortex plasticity. *Nat Neurosci* 14:1240–1242
- Oyster CW, Simpson JI, Takahashi ES, Soodak RE (1980) Retinal ganglion cells projecting to the rabbit accessory optic system. *J Comp Neurol* 190:49–61
- Reinhart BJ, Slack FJ, Basson M, Pasquinelli AE, Bettinger JC, Rougvie AE, Horvitz HR, Ruvkun G (2000) The 21-nucleotide let-7 RNA regulates developmental timing in *Caenorhabditis elegans*. *Nature* 403:901–906
- Robins H, Press WH (2005) Human microRNAs target a functionally distinct population of genes with AT-rich 3' UTRs. *Proc Natl Acad Sci U S A* 102:15557–15562
- Sanes JR, Lichtman JW (1999) Can molecules explain long-term potentiation? *Nat Neurosci* 2:597–604
- Schaefer A, O'Carroll D, Tan CL, Hillman D, Sugimori M, Llinas R, Greengard P (2007) Cerebellar neurodegeneration in the absence of microRNAs. *J Exp Med* 204:1553–1558
- Schonewille M, Luo C, Ruigrok TJ, Voogd J, Schmolesky MT, Rutteman M, Hoebeek FE, De Jeu MT, De Zeeuw CI (2006) Zonal organization of the mouse flocculus: physiology, input, and output. *J Comp Neurol* 497:670–682
- Schratt G (2009) microRNAs at the synapse. *Nat Rev Neurosci* 10:842–849
- Schratt GM, Tuebing F, Nigh EA, Kane CG, Sabatini ME, Kiebler M, Greenberg ME (2006) A brain-specific microRNA regulates dendritic spine development. *Nature* 439:283–289
- Simpson JI, Leonard CS, Soodak RE (1988) The accessory optic-system – analyzer of self-motion. *Ann NY Acad Sci* 545:170–179
- Smalheiser NR, Lugli G (2009) microRNA regulation of synaptic plasticity. *Neuromol Med* 11:133–140
- Tognini P, Putignano E, Coatti A, Pizzorusso T (2011) Experience-dependent expression of miR-132 regulates ocular dominance plasticity. *Nat Neurosci* 14:1237–1239
- Zeng Y, Cai X, Cullen BR (2005) Use of RNA polymerase II to transcribe artificial microRNAs. *Methods Enzymol* 392:371–380

**Part IV**  
**Cerebellar Circuits: Biochemistry,  
Neurotransmitters and Neuromodulation**

# Chapter 20

## Granule Cells and Parallel Fibers

Egidio D'Angelo

**Abstract** The granule cells (GrC) are the smallest and most numerous neurons of the brain and constitute the main elements of the granular layer of cerebellum, where they are thought to determine a complex spatio-temporal reconfiguration of incoming signals. GrC functioning is based on some specific properties (D'Angelo, Cerebellar granule cell. In: Handbook of the cerebellum and cerebellar disorders (Springer, ed). Springer, Berlin, pp 765–791, 2013):

1. GrCs have a special structure and connectivity pattern allowing fast combinatorial processing
2. GrC are connected to mossy fibers (MFs) and Golgi cells (GoCs) in glomeruli allowing neurotransmitter spillover and crosstalk
3. GrCs are silent at rest and respond with spike bursts to MF activity by exploiting specific ionic channel properties
4. GrCs are at the core of a complex NMDA- and NO-dependent system that regulates long-term synaptic plasticity in MFs and parallel fibers (PFs).
5. GrCs have a peculiar postnatal development determining their connectivity with MFs and Purkinje cells (PCs) (see Chaps. 13, 15, 17, 18).

**Keywords** Granule cells • Parallel fibers • Cerebellum

### 20.1 Granule Cell Structure and Electroresponsiveness

GrCs are composed of a small soma emitting four short unbranched dendrites on average and receive excitatory inputs from MFs and inhibitory inputs from GoCs (Eccles et al. 1967). GrCs are excitatory and transmit their output through the ascending axon (AA) that then bifurcates into the parallel fibers (PF). The AA contacts GoCs on their basal dendrites and the PF contacts both GoCs, PCs and

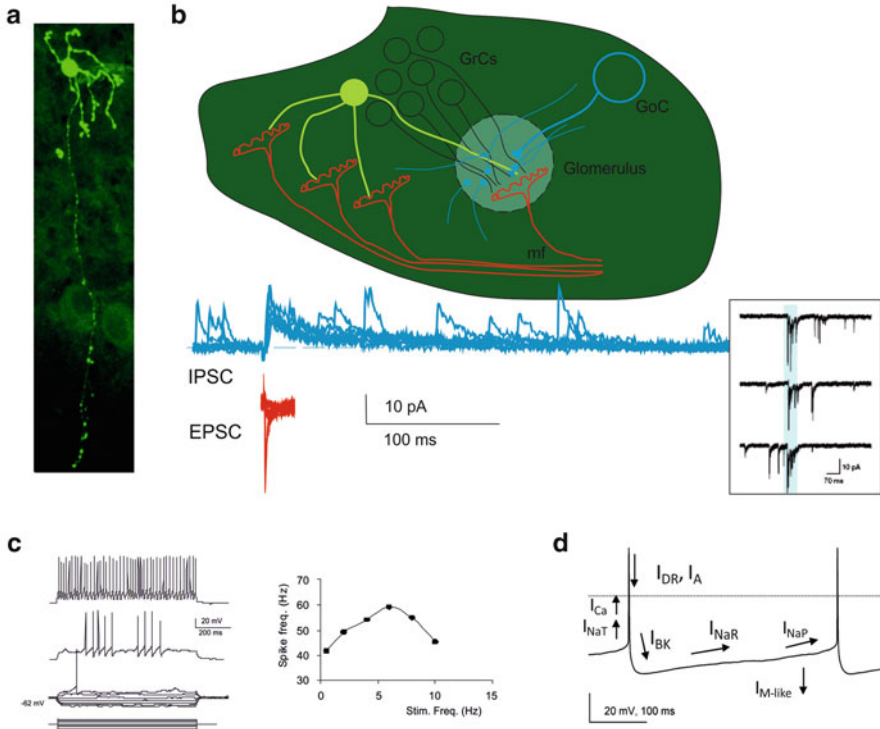
---

E. D'Angelo (✉)

Department of Brain and Behavioral Sciences, Department of Physiology,  
University of Pavia, Pavia, Italy

Brain Connectivity Center, C. Mondino National Neurological Institute,  
via Forlanini 6, 27100 Pavia, Italy

e-mail: [dangelo@unipv.it](mailto:dangelo@unipv.it); [egidiougo.dangelo@unipv.it](mailto:egidiougo.dangelo@unipv.it)



**Fig. 20.1** Cerebellar granule cell properties. **(a)** Confocal microscope reconstruction of a GrC injected with neurobiotin. The image shows the dendrites with terminal digitizations and the thin axon ascending through the granular layer into the molecular layer (D Gall and E D'Angelo, unpublished). **(b)** Synaptic transmission at GrC synapses. In this schematic drawing, a GrC receives activation from 4 MFs and 2 GoCs. In the glomerulus, spillover generates slow responses. Several GrC excitatory synaptic currents (EPSC; red) and inhibitory synaptic currents (IPSC; blue) generated in responses to minimal stimulation are shown superimposed (Redrawn from D'Angelo 2013). Note spontaneous activity generated by GoC discharge. The inset shows the in vivo response of a GrC to air-puff stimulation of the whisker-pad, revealing EPSC bursts with short-term depression (Reprinted from Rancz et al. 2007). **(c)** The GrC is silent at rest and generates repetitive spike discharge during current injection. It can generate bursts and is resonant at theta frequency (Modified from D'Angelo et al. 2001). **(d)** Ionic currents involved in GrC spike electrogenesis (Adapted from D'Angelo et al. 2001). INaT (Transient Na<sup>+</sup> current), INaR (Resurgent Na<sup>+</sup> current), INaP (Persistent Na<sup>+</sup> current), I<sub>Ca</sub> (Ca<sup>2+</sup> current), IDR (Delayed Rectifier K<sup>+</sup> current), IBK (Ca<sup>2+</sup>-dependent K<sup>+</sup> current), IM-like (M-like K<sup>+</sup> current)

molecular layer interneurons (MLIs) in the molecular layer (Fig. 20.1; Mapelli et al. 2014).

GrCs express ionic channels conferring specific electroresponsive properties (D'Angelo et al. 2001). Nav1.6 have the highest concentration in the axon initial segment (AIS), where action potentials are initiated, and are located along the axon but are almost absent from soma (Goldfarb et al. 2007). The Nav1.6 sodium channels, in addition to the transient component generating the spike upstroke, produce a persistent current, which amplifies theta-frequency oscillations and resonance.

Moreover, Nav1.6 channels produce a resurgent current reinforcing burst generation. The  $\text{Ca}^{2+}$  channels are of the high voltage-activated type: in the soma, N-type  $\text{Ca}^{2+}$  channels are activated during the action potential upstroke and regulate a BK  $\text{Ca}^{2+}$ -dependent  $\text{K}^+$  current, while in the synaptic terminals P/Q and R type  $\text{Ca}^{2+}$  channels regulate neurotransmitter release (Galliano et al. 2013). A-type  $\text{K}^+$  channels regulate spike initiation and M-type  $\text{K}^+$  channels determine oscillations and resonance. Finally, GIRK type  $\text{K}^+$  channels control GrC resting membrane potential and input conductance. These properties have been incorporated into realistic models (D'Angelo et al. 2001) demonstrating that GrCs are indeed designed to rapidly respond to incoming MF inputs with short spike bursts raising up to about 300 Hz. The spikes are propagated from initial segment backward to GrC dendrites and forward to AA synapses in about 0.1 ms, thus generating a close coincidence between excitation of GrCs and of PCs (Diwakar et al. 2011).

## 20.2 Glomerular Organization of GrCs Synaptic Inputs

GrC activity is determined by the interplay of excitatory and inhibitory inputs, which impinge onto a specialized structure called *cerebellar glomerulus*. Each glomerulus is made of a glial sheet enwrapping a MF terminal and as many as 50 GrC dendrites, as well as GoC axonal terminals and dendrites. In the glomerulus, in addition to fast synaptic transmission between axonal terminals and GrC dendrites, neurotransmitter diffusion in the glomerulus determines spillover effects and metabotropic activation on all the elements involved, setting up a complex regulatory mechanism (Mapelli et al. 2014).

MFs release glutamate and activate GrC AMPA and NMDA receptors (AMPA and NMDARs), regulating membrane depolarization and  $\text{Ca}^{2+}$  influx (D'Angelo et al. 1990; Silver et al. 1992). AMPARs contain GluR2, have fast kinetics and are  $\text{Ca}^{2+}$  impermeable. NMDARs contain NR2A and NR2C subunit conferring specific voltage-dependence and kinetics (Rossi et al. 2002; Schwartz et al. 2012). GoC terminals release GABA activating GrC GABA-A receptors (Mapelli et al. 2009). Metabotropic receptors on granule cells (mGluR1 and GABA-B), on MF terminals (mGluR2 and GABA-B) and on GoC axon terminals (mGluR2 and GABA-B), regulate neurotransmitter release and GrC ionic channels (Mapelli et al. 2014).

## 20.3 Synaptic Transmission and Plasticity

The MF-GrC synapse is enriched with synaptic vesicles and can release quanta at high rate for sustained time periods. During bursts, the postsynaptic response (i.e., excitatory postsynaptic current (EPSC)) shows a marked short-term depression due both to vesicle depletion and AMPAR desensitization (Nieus et al. 2014). Glutamate spillover activates NMDARs and contributes to generate a slow of AMPAR-dependent component (Rossi et al. 2002). The GoC-GrC synapse also

shows a marked short-term depression during burst transmission (Mapelli et al. 2009). Both synapses show complex regulatory mechanisms based on metabotropic receptors (Mapelli et al. 2014).

The MF-GrC relay is site of long-term synaptic plasticity, which is manifest as LTP or LTD depending on input bursts patterns: long high-frequency bursts generate LTP, and vice versa (Gall et al. 2005; D'Errico et al. 2009). This LTP and LTD depend on NMDARs and metabotropic glutamate receptors (mGluRs) receptors depending on the input patterns and require  $\text{Ca}^{+2}$  entry and NO (Gall et al. 2005). MF-GrC plasticity is expressed presynaptically through an increase in release probability and can fine tune the delay to first spike in GrCs by controlling quantal release and EPSC short-term plasticity (Nieus et al. 2014). Following patterned input bursts, GrCs also show persistent changes in intrinsic excitability (see Chap. 38).

## 20.4 Spike Coding and Transmission of GrC Output to the Molecular Layer Through AA and PF

By exploiting their ionic channels and synaptic properties, the GrCs efficiently recode input spikes trains into burst with precise timing and number of emitted spikes (Billings et al. 2014; Nieus et al. 2014). GrCs transmit their output spike patterns through the AA and PFs to PCs, GoCs and MLIs (Mapelli et al. 2013). AA and PFs are normally myelinated and conduct spikes at around 0.1 m/s. The PF-PC synapse has normally a low release probability and shows short-term facilitation, so that it responds better to spike doublets or triplets. Moreover, following patterned activity, the PF terminals generate various forms of long-term synaptic plasticity, some of which are presynaptic and involve NMDARs and NO production. Neurotransmission at synapses with MLIs and GoCs also involve forms of short- and long-term plasticity but these are less known (D'Angelo 2014) (see Chaps. 43 and 45).

## 20.5 Functional Activation of GrCs In Vitro and In Vivo

Experiments in vitro have revealed complex patterns of granule cell activation, which occurs in center surround and can generate combinatorial operations (D'Angelo 2013; Gandolfi et al. 2014). Recordings in vivo have confirmed that the properties observed in vitro actually regulate GrC activity during responses to sensori-motor inputs (Rancz et al. 2007). Most GrCs are normally silent and then respond in short burst or long spike sequences depending on the input MF patterns. Computational modeling has allowed to investigate the implications of GrC properties for the granular layer and cerebellar function (Solinas et al. 2010). The picture that emerges is that of a fast relay neuron, which can regulate timing and intensity of spike transmission to PCs exploiting long-term synaptic plasticity and glomerular interactions.



**Acknowledgments** We thank Leda Roggeri for technical assistance. This work was supported by European Union grants to ED [CEREBNET FP7-ITN238686, REALNET FP7-ICT270434, Human Brain Project (HBP-604102)].

## References

- Billings G, Piasini E, Lorincz A, Nusser Z, Silver RA (2014) Network structure within the cerebellar input layer enables lossless sparse encoding. *Neuron* 83:960–974
- D’Angelo E (2013) Cerebellar granule cell. In: *Handbook of the cerebellum and cerebellar disorders* (Springer, ed). Springer, Berlin, pp 765–791
- D’Angelo E (2014) The organization of plasticity in the cerebellar cortex: from synapses to control. *Prog Brain Res* 210:31–58. doi:10.1016/B978-0-444-63356-9.00002-9
- D’Angelo E, Rossi P, Garthwaite J (1990) Dual-component NMDA receptor currents at a single central synapse. *Nature* 346:467–470
- D’Angelo E, Nieuws T, Maffei A, Armano S, Rossi P, Taglietti V, Fontana A, Naldi G (2001) Theta-frequency bursting and resonance in cerebellar granule cells: experimental evidence and modeling of a slow  $K^+$ -dependent mechanism. *J Neurosci* 21:759–770
- D’Errico A, Prestori F, D’Angelo E (2009) Differential induction of bidirectional long-term changes in neurotransmitter release by frequency-coded patterns at the cerebellar input. *J Physiol* 587:5843–5857
- Diwakar S, Lombardo P, Solinas S, Naldi G, D’Angelo E (2011) Local field potential modeling predicts dense activation in cerebellar granule cells clusters under LTP and LTD control. *PLoS ONE* 6:e21928
- Eccles JC, Ito M, Szentagothai J (1967) *The cerebellum as a neural machine*. Springer, Berlin
- Gall D, Prestori F, Sola E, D’Errico A, Roussel C, Forti L, Rossi P, D’Angelo E (2005) Intracellular calcium regulation by burst discharge determines bidirectional long-term synaptic plasticity at the cerebellum input stage. *J Neurosci* 25:4813–4822
- Galliano E, Gao Z, Schonewille M, Todorov B, Simons E, Pop AS, D’Angelo E, van den Maagdenberg AM, Hoebeek FE, De Zeeuw CI (2013) Silencing the majority of cerebellar granule cells uncovers their essential role in motor learning and consolidation. *Cell Rep* 3:1239–1251
- Gandolfi D, Pozzi P, Tognolina M, Chirico G, Mapelli J, D’Angelo E (2014) The spatiotemporal organization of cerebellar network activity resolved by two-photon imaging of multiple single neurons. *Front Cell Neurosci* 8:92. doi: 10.3389/fncel.2014.00092. eCollection 2014.
- Goldfarb M, Schoorlemmer J, Williams A, Diwakar S, Wang Q, Huang X, Giza J, Tchetchik D, Kelley K, Vega A, Matthews G, Rossi P, Ormitz DM, D’Angelo E (2007) Fibroblast growth factor homologous factors control neuronal excitability through modulation of voltage-gated sodium channels. *Neuron* 55:449–463
- Mapelli L, Rossi P, Nieuws T, D’Angelo E (2009) Tonic activation of GABA(B) receptors reduces release probability at inhibitory connections in the cerebellar glomerulus. *J Neurophysiol* 101:3089–3099
- Mapelli L, Solinas S, D’Angelo E (2014) Integration and regulation of glomerular inhibition in the cerebellar granular layer circuit. *Front Cell Neurosci* 8:55. doi:10.3389/fncel.2014.00055. eCollection2014
- Nieuws TR, Mapelli L, D’Angelo E (2014) Regulation of output spike patterns by phasic inhibition in cerebellar granule cells. *Front Cell Neurosci* 8:246. doi: 10.3389/fncel.2014.00246. eCollection 2014.
- Rancz EA, Ishikawa T, Duguid I, Chadderton P, Mahon S, Hausser M (2007) High-fidelity transmission of sensory information by single cerebellar mossy fibre boutons. *Nature* 450:1245–1248

- Rossi P, Sola E, Taglietti V, Borchardt T, Steigerwald F, Utvik JK, Ottersen OP, Kohr G, D'Angelo E (2002) NMDA receptor 2 (NR2) C-terminal control of NR open probability regulates synaptic transmission and plasticity at a cerebellar synapse. *J Neurosci* 22:9687–9697
- Schwartz EJ, Rothman JS, Dugue GP, Diana M, Rousseau C, Silver RA, Dieudonne S (2012) NMDA receptors with incomplete  $Mg^{2+}$  block enable low-frequency transmission through the cerebellar cortex. *J Neurosci* 32:6878–6893
- Silver RA, Traynelis SF, Cull-Candy SG (1992) Rapid-time-course miniature and evoked excitatory currents at cerebellar synapses in situ. *Nature* 355:163–166
- Solinas S, Nieuwenhuis T, D'Angelo E (2010) A realistic large-scale model of the cerebellum granular layer predicts circuit spatio-temporal filtering properties. *Front Cell Neurosci* 4:12. doi: 10.3389/fncel.2010.00012. eCollection 2010.

# Chapter 21

## The Purkinje Cell: As an Integrative Machine

Anais Grangeray, Kevin Dorgans, Sebastien Roux, and Jean-Louis Bossu

**Abstract** The aim of this chapter is to discuss how the spontaneous activity, the simple spike and the complex spike are generated and modulated depending on the channel types expressed on the somatic and dendritic Purkinje cell membranes. Finally, we will briefly address the role of Purkinje cells in the pathology of autism.

**Keywords** Cerebellum • Purkinje cell • Spontaneous activity • Simple spike • Complex spike • Ionic channels • Autism

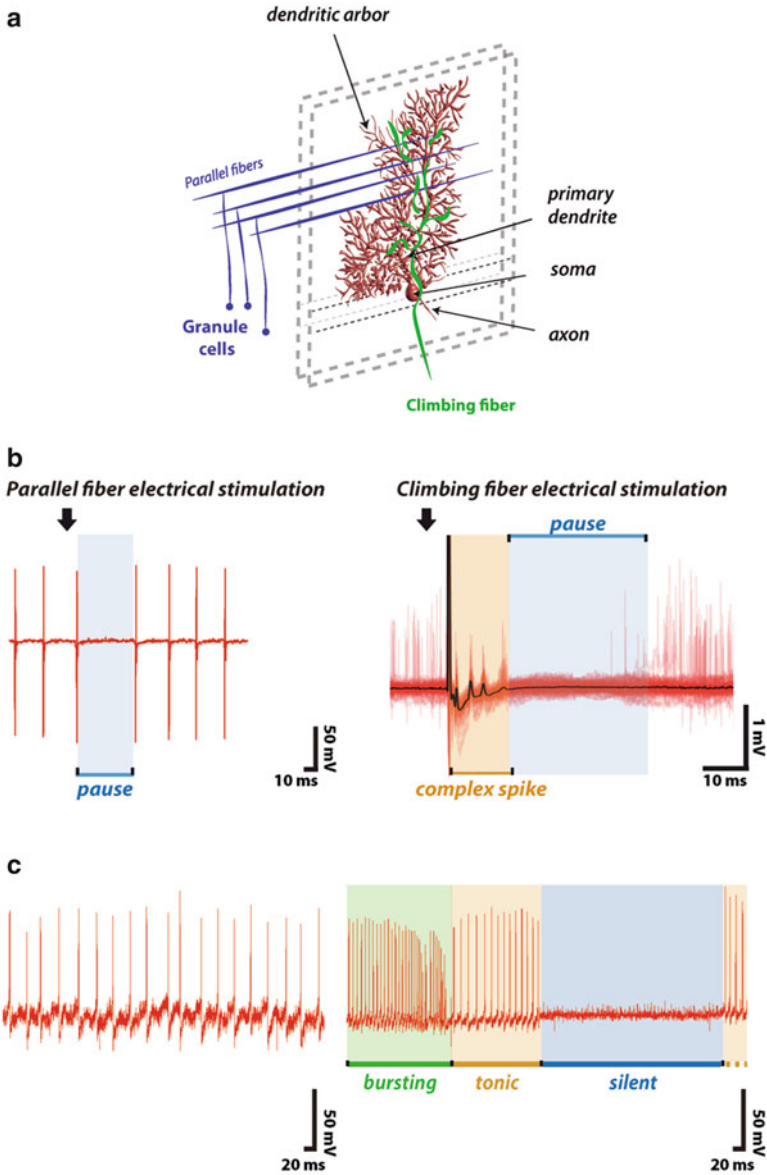
### 21.1 Introduction

Purkinje cells (PCs) were discovered in 1837 by a Czech anatomist, Jan Evangelista Purkyně and further nicely illustrated by Ramón y Cajal in 1899 using Golgi's staining method. PCs have a large dendritic arbor decorated with little spines. The dendritic arbor stems from a primary dendrite that emerges from a pear-shaped cell body with a single axon originating from the other end (Fig. 21.1a). PC somas align in the cerebellar cortex to form the PC layer.

PCs which are spontaneously active, receive two excitatory inputs: from the parallel fibers (PFs) and climbing fibers (CFs) (Fig. 21.1a). Those inputs provide electrical signals that are integrated and modulated along the PC dendritic tree and soma due to the presence of ionic channels. Each PC receives converging inputs from about 200,000 PF synapses. Stimulation of PF releases glutamate and produces simple spikes (SS) in PCs (Fig. 21.1b, left panel) at various frequencies. In adult animals, each PC receives one single CF originating from the inferior olive nucleus. Stimulation of CF releases glutamate on PC giving rise to a complex spike (CS): a massive electrical firing event (Fig. 21.1b, right panel). Action potentials (APs) propagate along the PC axon and trigger GABA release on their target: deep cerebellar nuclei (DCN) neurons.

---

A. Grangeray • K. Dorgans • S. Roux • J.-L. Bossu (✉)  
Institut des Neurosciences Cellulaires et Integratives CNRS et Université Louis Pasteur,  
UPR 3212, 5 rue Blaise Pascal, F-67084 Strasbourg Cedex 03, France  
e-mail: [jlbossu@inci-cnrs.unistra.fr](mailto:jlbossu@inci-cnrs.unistra.fr)



**Fig. 21.1** (a) 3D reconstruction of PC, afferences are also drawn. (b) Evoked responses of PC induced by parallel-fiber (*left*) and climbing-fiber stimulation (*right*). (c) Spontaneous activity of PC: an irregular discharge of AP (*left*) and a trimodal pattern of discharge (*right*)

## 21.2 Spontaneous Activity of PCs

In vivo the spontaneous activity of PCs consists in tonic SS trains at frequencies ranging between 50 and 125 Hz and CS at 1 Hz (Latham and Paul 1971). SS as well as CS are synchronized for pairs of PCs localized in the same cortical zone, this synchronization is under the control of sensory inputs (Wise et al. 2010).

This activity has a pacemaker component characterized in vitro as an irregular pattern of discharge with a frequency of 40 Hz (Fig. 21.1c, left panel). A trimodal pattern of pacemaker activity (tonic, bursting and silent modes, Fig. 21.1c, right panel) is also depicted and is probably induced by the lack of CF input.

### 21.2.1 Ionic Mechanism of the Pacemaker Activity of PCs

PC pacemaker activity was driven by low threshold TTX sensitive  $\text{Na}^+$ -current and TEA sensitive  $\text{K}^+$ -current (Nam and Hockberger 1997; Raman and Bean 1999). Furthermore, hyperpolarization-activated current (I<sub>h</sub>) maintains the membrane potential within a range where the inward  $\text{Na}^+$ -current responsible for the generation of AP firing can be activated. Thus, inhibition of the I<sub>h</sub> current leads to quiescent periods (Williams et al. 2002). Apamin sensitive small conductance  $\text{Ca}^{2+}$ -activated  $\text{K}^+$  channels (SK) activated by  $\text{Ca}^{2+}$  entering through P-type  $\text{Ca}^{2+}$  channels control the pacemaker firing frequency (Edgerton and Reinhart 2003). In PCs with a trimodal pattern, blockade of large conductance  $\text{Ca}^{2+}$ -activated  $\text{K}^+$  channels (BK) shortened the duration of the trimodal pattern whereas dendritic  $\text{Ca}^{2+}$ -T-type, BK and SK channels contribute to interspike and interburst intervals. P/Q  $\text{Ca}^{2+}$  channels are required to sustain spontaneous bursting. A partial blockade of P/Q channels eliminates dendritic  $\text{Ca}^{2+}$ -spikes and causes a switch from regular bursting to tonic firing or irregular bursting (Womack et al. 2009).

### 21.2.2 Modulation of the Spontaneous Activity of PCs

CFs and PFs activation can modulate the PC spontaneous activity. In vivo stimulation of CFs is immediately followed by a pause in the spontaneous discharge. This effect is also depicted in PCs recorded in acute slices (Fig. 21.1b, right panel). After the pause an increase in SS activity is regularly observed and is often followed by a reduction of the SS frequency (De Zeeuw et al. 2011). In vivo removal of CF input induces an increase of spontaneous discharge frequency or even a slow oscillatory pattern of discharge. Repetitive CFs discharge can also convert the spontaneous trimodal PC discharge pattern (recorded in vitro) to a non-bursting pattern (Engbers et al. 2013).

Concerning the PFs modulation of the PC discharge, in vivo when excitatory inputs from granule cells are chronically reduced the SS firing regularity increased without alteration of the spiking frequency. Furthermore, in vitro, when the PFs are stimulated an inhibition of the spontaneous activity is depicted (Fig. 21.1b, left panel; De Zeeuw et al. 2011).

### **21.2.3 *Physiological Role of the Spontaneous Activity of PCs***

The PC activity plays a role in sensory-motor calibration (Medina 2011). Interestingly, using optogenetic inhibition of PCs activity in awake mice, Heiney et al. (2014) show that a transient suppression of the spontaneous activity in a sub-population of PCs causes discrete movements with variations in size, speed and timing depending on the duration and intensity of the inhibition.

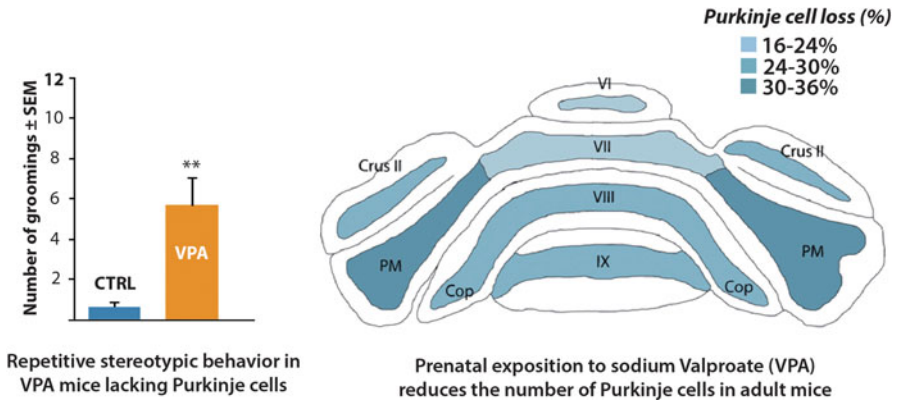
## **21.3 The Simple Spike and the Complex Spike**

### **21.3.1 *The Simple Spike Induced by PFs Stimulation***

A simple electrical stimulation of PFs releases glutamate and produces small depolarizing synaptic potentials (DSPs) at many synaptic sites dispersed on the PC dendritic arborization. DSPs temporally and spatially summate to reach the proximal axon where a discharge of SS is generated (Palmer et al. 2010). The DSPs are modified in amplitude and shape during their passive propagation in the dendritic tree and are also modulated by ionic-channel conductances on the PC membrane. This integration is conditioned by PCs morphology but especially by the expression of many channel types such as P/Q (Cav2.1) and T type (Cav3) Ca<sup>2+</sup> channels, voltage-gated K<sup>+</sup> channels (Kv1, Kv3.3) Ca<sup>2+</sup>-activated K<sup>+</sup> channels (BK, SK) and Ih. For example, the Cav3 associated with an intermediate conductance Ca<sup>2+</sup>-activated K<sup>+</sup> channels suppresses the temporal summation of DSPs generated by PFs activation (Engbers et al. 2012).

### **21.3.2 *The Complex Spike Induced by CF Stimulation***

Stimulation of CFs results in a massive depolarization of dendrites giving rise to a CS in the soma. The CS is primarily mediated by Na<sup>+</sup> channels and in some extent by Ca<sup>2+</sup> channels. It consists of a large depolarization inducing one initial fast action potential followed by one to six smaller spikelets. The CS is followed by an hyperpolarization mediated by Ca<sup>2+</sup>-activated K<sup>+</sup>-channels (De Zeeuw et al. 2011). T-type



**Fig. 21.2** Repetitive stereotypic behavior (*left*) and loss of PCs (*right*) in valproate treated CD1 mice

$\text{Ca}^{2+}$  channels activated by CF stimulation participate to the CS waveform, whereas somatic  $\text{Kv}3.3$  channels are required for spikelet generation (Kitamura and Kano 2013). The fast initial spike and the spikelets (driven by  $\text{Na}^+$ ) are initiated in the initial axon (Palmer et al. 2010). Stimulation of CF also triggers dendritic  $\text{Ca}^{2+}$  spikes mediated by P/Q type  $\text{Ca}^{2+}$ -channels.  $\text{Ca}^{2+}$ -spikes are not necessary for CS generation but regulate the pause in firing following the CS, probably by activating  $\text{Ca}^{2+}$ -dependent  $\text{K}^+$ -channels (Davie et al. 2008).

## 21.4 PCs and Autistic Syndromes

Imaging and autopsy studies of autistic patients have shown cerebellar abnormalities. Interestingly, it has been shown in mice that a PC loss is associated with autistic syndromes such as repetitive behaviors and increased activity (Martin et al. 2010). Prenatal exposition to sodium-valproate induces several autistic symptoms in mice (Roulet et al. 2013) including repetitive behaviors (Fig. 21.2, left panel). Using the autistic model of valproate-treated mice, we show a global PC loss of about 25% (Fig. 21.2, right panel). One important challenge would be to determine how a PCs loss can induce autistic syndromes.

## References

- Davie JT, Clark BA, Häusser M (2008) The origin of the complex spike in cerebellar Purkinje cells. *J Neurosci* 28:7599–7609
- De Zeeuw CI, Hoebeek FE, Bosman LW et al (2011) Spatiotemporal firing patterns in the cerebellum. *Nat Rev Neurosci* 12:327–344

- Edgerton JR, Reinhart PH (2003) Distinct contributions of small and large conductance  $\text{Ca}^{2+}$ -activated  $\text{K}^+$  channels to rat Purkinje neuron function. *J Physiol* 548:53–69
- Engbers JD, Anderson D et al (2012) Intermediate conductance calcium-activated potassium channels modulate summation of parallel fiber input in cerebellar Purkinje cells. *Proc Natl Acad Sci U S A* 109:2601–2606
- Engbers JD, Fernandez FR, Turner RW (2013) Bistability in Purkinje neurons: ups and downs in cerebellar research. *Neural Netw* 47:18–31
- Heiney SA, Kim J et al (2014) Precise control of movement kinematics by optogenetic inhibition of Purkinje cell activity. *J Neurosci* 34:2321–2330
- Kitamura K, Kano M (2013) Dendritic calcium signaling in cerebellar Purkinje cell. *Neural Netw* 47:11–17
- Latham A, Paul DH (1971) Spontaneous activity of cerebellar Purkinje cells and their responses to impulses in climbing fibres. *J Physiol* 213:135–156
- Martin LA, Goldowitz D, Mittleman G (2010) Repetitive behavior and increased activity in mice with Purkinje cell loss: a model for understanding the role of cerebellar pathology in autism. *Eur J Neurosci* 31:544–555
- Medina JF (2011) The multiple roles of Purkinje cells in sensori-motor calibration: to predict, teach and command. *Curr Opin Neurobiol* 21:616–622
- Nam SC, Hockberger PE (1997) Analysis of spontaneous electrical activity in cerebellar Purkinje cells acutely isolated from postnatal rats. *J Neurobiol* 33(1):18–32
- Palmer LM, Clark BA, Gründemann J et al (2010) Initiation of simple and complex spikes in cerebellar Purkinje cells. *J Physiol* 588:1709–1717
- Raman IM, Bean BP (1999) Ionic currents underlying spontaneous action potentials in isolated cerebellar Purkinje neurons. *J Neurosci* 19:1663–1674
- Rouillet FI, Lai JK, Foster JA (2013) In utero exposure to valproic acid and autism – a current review of clinical and animal studies. *Neurotoxicol Teratol* 36:47–56
- Williams SR, Christensen SR, Stuart GJ et al (2002) Membrane potential bistability is controlled by the hyperpolarization-activated current  $I(H)$  in rat cerebellar Purkinje neurons in vitro. *J Physiol* 539:469–483
- Wise AK, Cerminara NL, Marple-Horvat DE et al (2010) Mechanisms of synchronous activity in cerebellar Purkinje cells. *J Physiol* 588:2373–2390
- Womack MD, Hoang C, Khodakhah K (2009) Large conductance calcium-activated potassium channels affect both spontaneous firing and intracellular calcium concentration in cerebellar Purkinje neurons. *Neuroscience* 162:989–1000



# Chapter 22

## Stellate Cells

Siqiong June Liu and Christophe J. Dubois

**Abstract** Stellate cells are inhibitory interneurons located in the molecular layer of the cerebellar cortex. Stellate cells receive excitatory inputs from parallel fibers (PF) and climbing fibers and suppress the activity of Purkinje cells through feed-forward inhibition in the cerebellar cortex. A variety of mechanisms regulate GABA release at inhibitory synapses in the cerebellar cortex cells and consequently motor tasks.

**Keywords** Inhibitory interneurons • Stellate cells • Synaptic plasticity • AMPA receptors • GABA release

### 22.1 Introduction

In vivo studies reveal that cerebellar interneurons are vitally important during behavioral tasks such as motor coordination because a selective increase in GABA<sub>A</sub> receptor activity in Purkinje cells causes deficits in motor coordination (Wulff et al. 2007) and mutations in Kv1.1 channels enhance GABA release from stellate cells, causing type 1 episodic ataxia (Herson et al. 2003). Genetic deletion of GABA receptors on Purkinje cells impairs the consolidation of vestibulo-cerebellar motor learning (Wulff et al. 2009), and thus inhibitory transmission is critical for motor learning. Associative learning in the cerebellum, such as fear conditioning (Scelfo et al. 2008), enhances GABA release and associative eye-blink conditioning reduces the activity of Purkinje cells. Given the importance of inhibitory transmission in cerebellar function, GABA release at inhibitory synapses in the cerebellum is closely regulated.

---

S.J. Liu (✉) • C.J. Dubois  
Department of Cell Biology and Anatomy, Louisiana State University Health Sciences  
Center, New Orleans, LA 70112, USA  
e-mail: [sliu@lsuhsc.edu](mailto:sliu@lsuhsc.edu)

## 22.2 Stellate Cells and Synaptic Transmission

### 22.2.1 *Excitatory Synaptic Transmission*

Stellate cells are electrically compact and can be activated by a single excitatory input, triggering GABA release onto Purkinje cells. Because PFs also innervate Purkinje cells, feed-forward inhibition via stellate cells gives rise to a delayed inhibition and thereby restrict the excitation of Purkinje cells to the onset of excitatory input. Excitatory transmission at the PF to stellate cell synapse is mediated by postsynaptic AMPA receptors, which do not contain GluA2 subunits and are permeable to  $\text{Ca}^{2+}$ . Synaptic currents display rapid kinetics and an increased current amplitude when activated by two consecutive stimuli, allowing stellate cells to respond to high frequency excitatory inputs, such as occurs during sensory stimulation (Chadderton et al. 2004).  $\text{Ca}^{2+}$  entry via AMPA receptors triggers the release of endocannabinoids from stellate cells, which reduce glutamate release from PFs (Soler-Llavina and Sabatini 2006). Consequently this lowers the excitatory drive for feed-forward inhibition in the cerebellar circuit. Stimulation of climbing fiber also evokes excitatory synaptic response in stellate cells. Co-stimulation of these two excitatory inputs *in vivo* induces a lasting increase in EPSPs at the PF-stellate cell synapse, which is reversed by stimulation of PFs alone (Jörntell and Ekerot 2003). Thus stellate cells mediate associative learning-induced change.

Synaptic AMPA receptors in stellate cells undergo dynamic changes in response to presynaptic activity. Repetitive stimulation of PFs triggers a long lasting increase in synaptic GluA2 content, which replace GluA2-lacking AMPA receptors (Liu and Cull-Candy 2000) in stellate cells. This not only reduces the amplitude and prolongs the decay time of EPSCs, but also lowers the  $\text{Ca}^{2+}$ -permeability of AMPA receptors, producing a qualitative change in synaptic transmission. The switch is triggered by activation of synaptic AMPA or extrasynaptic NMDA receptors, and requires a  $\text{Ca}^{2+}$ -rise that activates PKC, leading to a PICK-dependent insertion of GluA2-containing receptors (Liu and Cull-Candy 2000; Sun and Liu 2007). Activation of mGluRs can also induce a switch in AMPA receptor subtypes via a mechanism that requires protein synthesis (Kelly et al. 2009). The switch in synaptic AMPA receptor phenotype reduces the ability of sensory stimulation to evoke multiple action potentials in stellate cells and thereby weakens the feed-forward inhibition.

Acute stress can also enhance gene transcription of GluA2 in stellate cells (Liu et al. 2010). Stress causes increased synaptic input to the cerebellum from norepinephrine containing fibers. Release of norepinephrine in the cerebellum activates  $\beta$ -adrenergic receptors and elevates cAMP levels. This increases  $\text{Ca}^{2+}$  entry during action potentials, activates ERK pathways and promotes GluA2 transcription in stellate cells. Consequently the elevated GluA2 expression prolongs the synaptic current duration and enhances the ability of each synaptic input to evoke an action potential and thus the feed-forward inhibition (Savtchouk and Liu 2011). Therefore acute stress can induce a lasting change in the activity and computation within the cerebellar circuitry.

### ***22.2.2 Inhibitory Synaptic Transmission***

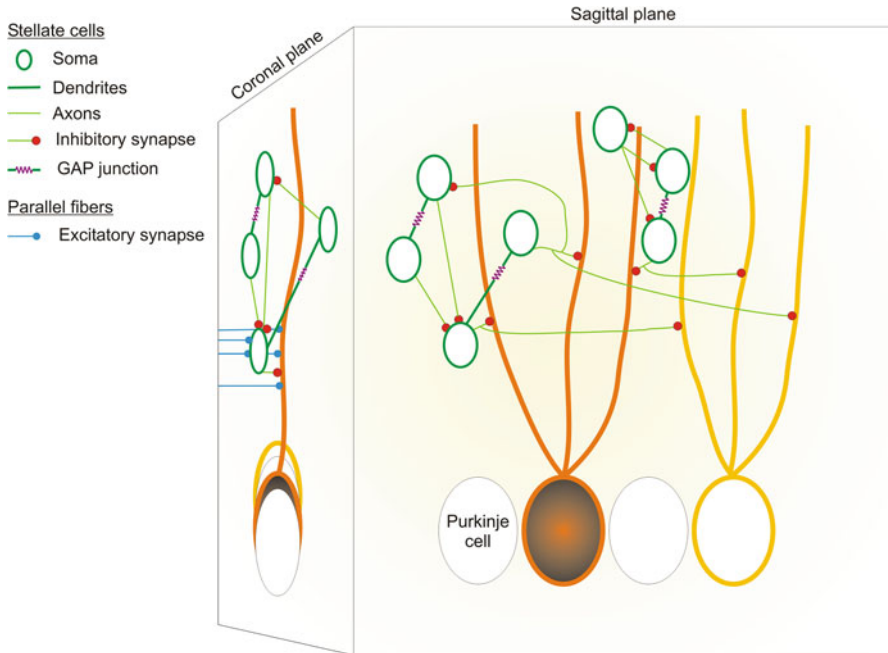
Interneurons innervate each other to form inhibitory networks and provide the inhibitory inputs to Purkinje cells. Enhanced GABA release by the inhibitory interneurons is thought to promote synchronous activity of interneuron network and suppress Purkinje cell activity. Glutamate released from PFs and Purkinje cell dendrites enhance GABA release (Duguid and Smart 2004; Liu and Lachamp 2006), altering the balance between excitatory and inhibitory transmission. A train of PF stimulation triggers glutamate spillover which activates presynaptic NMDA receptors, inducing a lasting increase in GABA release via a mechanism that requires PKA and an active zone protein, RIM1 $\alpha$  (Lachamp et al. 2009; Dubois et al. 2016). This alters the pattern and reduces the frequency of action potential firing in synaptically connected stellate cells. Neuromodulators, including noradrenaline (Liano and Gerschenfeld 1993) and neuropeptide Y (Dubois et al. 2012) also induce a sustained increase in GABA release. Such activity-dependent potentiation may underlie the associative learning-induced increase in GABA release.

### ***22.2.3 Presynaptic Regulation***

Endocannabinoids are critically involved in learning and extinction and dysregulation of endocannabinoid metabolism leads to cerebellar ataxia in PHARC disease (Fiskerstrand et al. 2010). In the cerebellar cortex depolarization of Purkinje cells triggers the release of endocannabinoids which activate the G-protein coupled CB1 receptors at the presynaptic terminal of interneurons (Yoshida et al. 2002; Beierlein and Regehr 2006). This decreases GABA release and reduces action potential firing in stellate cells (Kreitzer et al. 2002). The axons of interneurons extend over several hundred micrometers in a parasagittal plane and inhibit neighboring Purkinje cells, producing lateral inhibition. Thus inhibition of interneuron firing can lead to lateral excitation in the cerebellar cortex.

## **22.3 Gap Junctions**

Interneurons are connected via gap junctions allowing current flow between neighboring cells. These electrical connections play a key role in temporal synchronization of neuronal activity (Mann-Metzer and Yarom 1999). Each stellate cell is directly connected to one neighboring interneuron in the sagittal plane (Alcami and Marty 2013). Thus changes in membrane potential could spread among the interneurons. The pattern of connections (Rieubland et al. 2014) contributes to the spatial convergence onto Purkinje cells where seven interneurons form functional synapses onto a single Purkinje cell (Kim et al. 2014). Therefore electrical networks



**Fig. 22.1** Schematic of the connections made by molecular layer interneurons

spatially and temporally coordinate interneurons, which ultimately influence convergence of synaptic inhibition onto Purkinje cells, the only output neurons in the cerebellar cortex. In conclusion, both chemical and electrical synapses are critical in shaping the activity of Purkinje cells and controlling information processing in the cerebellum (Fig. 22.1).

## References

- Alcami P, Marty A (2013) Estimating functional connectivity in an electrically coupled interneuron network. *PNAS* 110:E4798–E4807
- Beierlein M, Regehr WG (2006) Local interneurons regulate synaptic strength by retrograde release of endocannabinoids. *J Neurosci* 26:9935–9943
- Chadderton P, Margrie TW, Häusser M (2004) Integration of quanta in cerebellar granule cells during sensory processing. *Nature* 428:856–860
- Dubois C, Ramamoorthy P, Whim M, Liu S (2012) Activation of NPY type 5 receptors induces a long-lasting increase in spontaneous GABA release from cerebellar inhibitory interneurons. *J Neurophysiol* 107:1655–1665
- Dubois CJ, Lachamp PM, Sun L, Mishina M, Liu SJ (2016) Presynaptic GluN2D receptors detect glutamate spillover and regulate cerebellar GABA release. *J Neurophysiol* 115:271–285
- Duguid IC, Smart TG (2004) Retrograde activation of presynaptic NMDA receptors enhances GABA release at cerebellar interneuron-Purkinje cell synapses. *Nat Neurosci* 7:525–533

- Fiskerstrand T et al (2010) Mutations in ABHD12 cause the neurodegenerative disease PHARC: an inborn error of endocannabinoid metabolism. *Am J Hum Genet* 87:410–417
- Herson PS, Virk M, Rustay NR, Bond CT, Crabbe JC, Adelman JP, Maylie J (2003) A mouse model of episodic ataxia type-1. *Nat Neurosci* 6:378–383
- Jörntell H, Ekerot C-F (2003) Receptive field plasticity profoundly alters the cutaneous parallel fiber synaptic input to cerebellar interneurons in vivo. *J Neurosci* 23:9620–9631
- Kelly L, Farrant M, Cull-Candy SG (2009) Synaptic mGluR activation drives plasticity of calcium-permeable AMPA receptors. *Nat Neurosci* 12:593–601
- Kim J, Lee S, Tsuda S, Zhang X, Asrican B, Gloss B, Feng G, Augustine GJ (2014) Optogenetic mapping of cerebellar inhibitory circuitry reveals spatially biased coordination of interneurons via electrical synapses. *Cell Rep* 7:1601–1613
- Kreitzer AC, Carter AG, Regehr WG (2002) Inhibition of interneuron firing extends the spread of endocannabinoid signaling in the cerebellum. *Neuron* 34:787–796
- Lachamp PM, Liu Y, Liu SJ (2009) Glutamatergic modulation of cerebellar interneuron activity is mediated by an enhancement of GABA release and requires protein kinase A/RIM1alpha signaling. *J Neurosci* 29:381–392
- Liu S, Cull-Candy SG (2000) Synaptic activity at calcium-permeable AMPA receptors induces a switch in receptor subtype. *Nature* 405:454–458
- Liu SJ, Lachamp P (2006) The activation of excitatory glutamate receptors evokes a long-lasting increase in the release of GABA from cerebellar stellate cells. *J Neurosci* 26:9332–9339
- Liu Y, Formisano L, Savtchouk I, Takayasu Y, Szabó G, Zukin RS, Liu SJ (2010) A single fear-inducing stimulus induces a transcription-dependent switch in synaptic AMPAR phenotype. *Nat Neurosci* 13:223–231
- Llano I, Gerschenfeld HM (1993) Beta-adrenergic enhancement of inhibitory synaptic activity in rat cerebellar stellate and Purkinje cells. *J Physiol* 468:201–224
- Mann-Metzer P, Yarom Y (1999) Electrotonic coupling interacts with intrinsic properties to generate synchronized activity in cerebellar networks of inhibitory interneurons. *J Neurosci* 19:3298–3306
- Rieubland S, Roth A, Häusser M (2014) Structured connectivity in cerebellar inhibitory networks. *Neuron* 81:913–929
- Savtchouk I, Liu SJ (2011) Remodeling of synaptic AMPA receptor subtype alters the probability and pattern of action potential firing. *J Neurosci* 31:501–511
- Scelfo B, Sacchetti B, Strata P (2008) Learning-related long-term potentiation of inhibitory synapses in the cerebellar cortex. *PNAS* 105:769–774
- Soler-Llavina GJ, Sabatini BL (2006) Synapse-specific plasticity and compartmentalized signaling in cerebellar stellate cells. *Nat Neurosci* 9:798–806
- Sun L, Liu SJ (2007) Activation of extrasynaptic NMDA receptors induces a PKC-dependent switch in AMPA receptor subtypes in mouse cerebellar stellate cells. *J Physiol* 583:537–553
- Wulff P et al (2007) From synapse to behavior: rapid modulation of defined neuronal types with engineered GABA receptors. *Nat Neurosci* 10:923–929
- Wulff P et al (2009) Synaptic inhibition of Purkinje cells mediates consolidation of vestibulo-cerebellar motor learning. *Nat Neurosci* 12:1042–1049
- Yoshida T, Hashimoto K, Zimmer A, Maejima T, Araishi K, Kano M (2002) The cannabinoid CB1 receptor mediates retrograde signals for depolarization-induced suppression of inhibition in cerebellar Purkinje cells. *J Neurosci* 22:1690–1697

# Chapter 23

## Basket Cells

Masahiko Watanabe

**Abstract** Santiago Ramón y Cajal provided a definitive description of the basket cells of the cerebellum. Ramón y Cajal discovered a characteristic terminal plexus of basket cells around Purkinje cell somata, naming this the pericellular nest or nid. This was the first clear observation of an axon terminal in the central nervous system; the discovery cultivated his ideas that nerve cells need only be in contact, not in continuity, with one another to transmit nerve impulse, and that the flow of the impulse is directed from the axon of one cell to the cell body of another. These ideas later came to fruition as his Neuron Doctrine (Palay S, Chan-Palay V Cerebellar cortex cytology and organization. Springer, Berlin, 1974).

**Keywords** Basket cell • Purkinje cell • interneuron

### 23.1 General

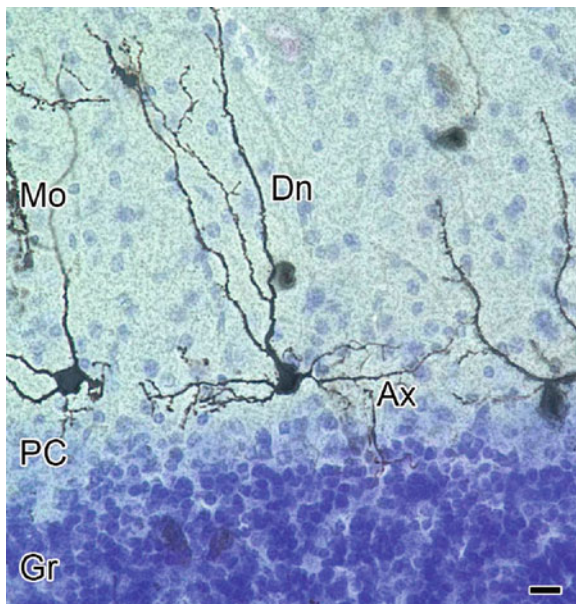
Basket and stellate cells are often collectively called molecular layer interneurons. Both are GABAergic interneurons that cast feed-forward inhibition to Purkinje cells, share similar developmental, molecular, and firing profiles, and are thought to represent a gradually varying cellular continuum (Zhang and Goldman 1996; Sultan and Bower 1998; Schilling et al. 2008). Nevertheless, basket and stellate cells have been distinguished neuroanatomically (Ramón y Cajal 1911; Palay and Chan-Palay 1974). Basket cells are situated in the basal one-third of the molecular layer, and target the soma and axon initial segment of Purkinje cells. In comparison, stellate cells reside in the superficial two-thirds of the molecular layer, and target Purkinje cell dendrites. Reflecting their distinct geometrical targeting, the two interneuron types are predicted to have different postsynaptic effects on Purkinje cells (Bower 2010). The basket-type somatic inhibition powerfully and rapidly influences on Purkinje cell spiking output, while the stellate-type dendritic inhibition

---

M. Watanabe (✉)

Department of Anatomy, Hokkaido University Graduate School of Medicine,  
060-8638 Sapporo, Japan  
e-mail: [watamasa@med.hokudai.ac.jp](mailto:watamasa@med.hokudai.ac.jp)

**Fig. 23.1** Golgi staining of cerebellar basket cells in adult mice. Basket cells are situated in a basal one-third of the molecular layer, and extend moderately straight dendrites (*Dn*) in the parasagittal plane (this plane). Basket cell axons (*Ax*) originate from the soma or from one the major dendrites of basket cells. *Gr* granular layer, *Mo* molecular layer, *PC* Purkinje cell layer



counterbalances the parallel fiber excitation in local regions of Purkinje cell dendrites with no direct influence on Purkinje cell spiking output.

## 23.2 Cytology

The dendrites of basket cells are arborized in the parasagittal plane, and thus they are parallel to those of Purkinje cells and at right angles to the direction of parallel fibers (Fig. 23.1). The axons of basket cells also traverse in the parasagittal plane; they extend horizontally above Purkinje cell somata, and give off descending axon collaterals. Axon collaterals originating from three to seven basket cells form GABAergic perisomatic synapses on individual Purkinje cells, and further embrace the Purkinje cell axon initial segment by constructing the pinceau formation: an inverted cone-shaped structure beneath Purkinje cell somata (Sotelo and Llinas 1972).

## 23.3 Inputs

The soma and dendrites of basket cells receive excitatory inputs from parallel fibers, the bifurcated axons of granule cells. Parallel fiber-basket cell synapses are asymmetrical synapses formed mostly on dendritic shafts and occasionally dendritic

spines (Palay and Chan-Palay 1974). Parallel fiber-basket cell synapses show a unique form of synaptic plasticity. Activation of extrasynaptic NMDA receptors on interneurons induces long-term synaptic plasticity by changing postsynaptic AMPA receptors from GluA2-lacking ( $\text{Ca}^{2+}$ -permeable) to GluA2-containing ( $\text{Ca}^{2+}$ -impermeable) receptors (Liu and Cull-Candy 2000). Parallel fiber-basket cell synapses also express the delta-type glutamate receptor GluD1, which strengthens the connectivity of this synapse (Konno et al. 2014). Basket cells also receive inhibitory inputs from basket and stellate cells and recurrent Purkinje cell axons.

Although several studies reported the presence of climbing fiber-interneuron synapses in the molecular layer, their contact lacks any kind of conventional synaptic specialization (Hámori and Szntágothai 1980; Kollo et al. 2006). When stimulating climbing fibers, no excitatory postsynaptic currents are elicited in molecular layer interneurons, but interneurons are activated via glutamate spillover from nearby climbing fibers (Szapiro and Barbour 2007). In turn, molecular layer interneurons send climbing fiber-driven feed-forward inhibition to Purkinje cells to prolong the post-complex spike pause (Mathews et al. 2012).

## 23.4 Outputs

Basket cells form a number of symmetrical synapses on the soma and axon hillock of Purkinje cells, but such synapses are rare along the axon initial segment of Purkinje cells (Palay et al. 1968; Somogyi and Hamori 1976; Iwakura et al. 2012). GABAergic molecules, including glutamic acid decarboxylase for GABA synthesis, vesicular inhibitory amino acid transporter for GABA filling into synaptic vesicles, and plasmalemmal GABA transporter GAT-1 for re-uptake of GABA, are highly concentrated in basket cell terminals synapsing on Purkinje cell somata, but are loosely organized in the pinceau formation (Iwakura et al. 2012). Likewise, GABA<sub>A</sub> receptor  $\alpha 1$  and neuroligin-2, a synaptic adhesion molecule selective at inhibitory synapses, are highly accumulated on the postsynaptic membrane of perisomatic basket cell synapses, but virtually lacking in the axon initial segment (Iwakura et al. 2012). This distinct organization strongly suggests that the major target of GABAergic inhibition by basket cell outputs is the soma of Purkinje cells.

From around birth, climbing fibers constitute a dense plexus around Purkinje cell somata called the pericellular nest, and innervate perisomatic spine-like protrusions or thorns (Ramón y Cajal 1911; Larramendi 1969). By the end of the second postnatal week of rodent's life, mono-innervation by single climbing fibers is established in most Purkinje cells by dendritic translocation of single 'winner' climbing fibers and subsequent elimination of perisomatic climbing fiber synapses (Hashimoto et al. 2009). Almost simultaneously, axon collaterals of basket cells descend to form inhibitory pericellular synapses (Larramendi and Victor 1967), and further construct the pinceau formation in the third postnatal week (Ango et al. 2004). A subcellular gradient of the cell adhesion molecule neurofascin, which is formed along



the axon initial segment-soma axis of Purkinje cells with the aid of Ankyrin-G, guides basket cell axon collaterals to the specific sites (Ango et al. 2004).

During the reorganization of perisomatic synapses, a considerable fraction of somatic spines innervated initially by climbing fibers are succeeded by basket cell axons and Bergmann glia, and the switching of postsynaptic receptor phenotypes from glutamatergic to GABAergic proceeds under the coverage of basket cell axons (Ichikawa et al. 2011). The establishment of perisomatic basket cell synapses influences climbing fiber-induced  $\text{Ca}^{2+}$  transients in the soma of Purkinje cells, and regulates the elimination of surplus climbing fiber synapses from Purkinje cell somata (Nakayama et al. 2012).

### 23.5 Pinceau Formation

The pinceau formation is composed of finger-like processes of basket cell axons and astrocytes. Given the strategic location and similarity to the axon cap of teleost Mauthner cells, the pinceau formation is thought to control the ultimate output of Purkinje cells, through either GABAergic inhibition, electrical inhibition by imposing a passive hyperpolarizing potential on the axon initial segment (Korn and Axelrad 1980), or both. Unique features of the pinceau formation have been taken to support the hypothesis of electrical inhibition. The lack of  $\text{Na}^+$  channels (Laube et al. 1996) and dense localization of *Shaker*-type  $\text{K}^+$  channels  $\text{K}_v1.1$  and  $\text{K}_v1.2$ , together with their scaffolding protein PSD-95 (Laube et al. 1996), may prevent active impulse conduction in the pinceau formation. Similarly, septate-like junctions between finger-like processes of basket cells, which should provide the pinceau formation with high resistance (Sotelo and Llinas 1972; Faber and Korn 1989), may allow currents to preferentially channel into the axon initial segment, thus leading to passive hyperpolarization. A recent electrophysiological study has shown that the pinceau formation exerts ultra-rapid axon-axon ephaptic inhibition of Purkinje cells (Blot and Barbour 2014).

## References

- Ango F, di Cristo G, Higashiyama H et al (2004) Ankyrin-based subcellular gradient of neurofascin, an immunoglobulin family protein, directs GABAergic innervation at Purkinje axon initial segment. *Cell* 119:257–272
- Blot A, Barbour B (2014) Ultra-rapid axon-axon ephaptic inhibition of cerebellar Purkinje cells by the pinceau. *Nat Neurosci* 17:289–295
- Bower JM (2010) Model-funded explorations of the roles of molecular layer inhibition in regulating Purkinje cell responses in cerebellar cortex: more trouble for the beam hypothesis. *Front Cell Neurosci* 4:1–7
- Faber DS, Korn H (1989) Electrical field effects: their relevance in central neural networks. *Physiol Rev* 69:821–863

- Hámori J, Szentágothai J (1980) Lack of evidence of synaptic contacts by climbing fibre collaterals to basket and stellate cells in developing rat cerebellar cortex. *Brain Res* 186:454–457
- Hashimoto K, Ichikawa R, Kitamura K, Watanabe M, Kano M (2009) Translocation of a “Winner” climbing fiber to the Purkinje cell dendrite and subsequent elimination of “Losers” from the soma in developing cerebellum. *Neuron* 63:106–118
- Ichikawa R, Yamasaki M, Miyazaki T et al (2011) Developmental switching of perisomatic innervation from climbing fibers to basket cell fibers in cerebellar Purkinje cells. *J Neurosci* 31:16916–16927
- Iwakura A, Uchigashima M, Miyazaki T, Yamasaki M, Watanabe M (2012) Lack of molecular-anatomical evidence for GABAergic influence upon axon initial segment of cerebellar Purkinje cells by the pinceau formation. *J Neurosci* 32:9438–9448
- Kollo M, Holderith NB, Nusser Z (2006) Novel subcellular distribution pattern of A-type K<sup>+</sup> channels on neuronal surface. *J Neurosci* 26:2684–2691
- Konno K, Matsuda K, Nakamoto C et al (2014) Enriched expression of GluD1 in higher brain regions and its involvement in parallel fiber-interneuron synapse formation in the cerebellum. *J Neurosci* 34:7412–7424
- Korn H, Axelrad H (1980) Electrical inhibition of Purkinje cells in the cerebellum of the rat. *Proc Natl Acad Sci U S A* 77:6244–6247
- Larramendi LM (1969) Analysis of synaptogenesis in the cerebellum of the mouse. In: Llinas R (ed) *Neurobiology of cerebellar evolution and development*. American Medical Association, Chicago, pp 803–843
- Larramendi E, Victor T (1967) Synapses on the Purkinje cell spines in the mouse. An electron microscopic study. *Brain Res* 5:15–30
- Laube G, Roper J, Pitt JC et al (1996) Ultrastructural localization of shaker-related potassium channel subunits and synapse-associated protein 90 to septate-like junctions in rat cerebellar pinceaux. *Mol Brain Res* 42:51–61
- Liu SQ, Cull-Candy SG (2000) Synaptic activity at calcium-permeable AMPA receptors induces a switch in receptor subtype. *Nature* 405:454–458
- Mathews PJ, Lee KH, Peng Z, Houser CR, Otis TS (2012) Effects of climbing fiber driven inhibition on Purkinje neuron spiking. *J Neurosci* 32:17988–17997
- Nakayama H, Miyazaki T, Kitamura K et al (2012) GABAergic inhibition regulates developmental synapse elimination in the cerebellum. *Neuron* 74:384–396
- Palay S, Chan-Palay V (1974) *Cerebellar cortex cytology and organization*. Springer, Berlin
- Palay SL, Sotelo C, Peters A, Orkand PM (1968) The axon hillock and the initial segment. *J Cell Biol* 38:193–201
- Ramón y Cajal S (1911) *Histology of the nervous system of man and vertebrates*. Oxford University Press, Oxford
- Schilling K, Oberdick J, Rossi F, Baader SL (2008) Besides Purkinje cells and granule neurons: an appraisal of the cell biology of the interneurons of the cerebellar cortex. *Histochem Cell Biol* 130:601–615
- Somogyi P, Hámori J (1976) A quantitative electron microscopic study of the Purkinje cell axon initial segment. *Neurosci* 1:361–365
- Sotelo C, Llinas R (1972) Specialized membrane junctions between neurons in the vertebrate cerebellar cortex. *J Cell Biol* 53:271–289
- Sultan F, Bower JM (1998) Quantitative Golgi study of the rat cerebellar molecular layer interneurons using principal component analysis. *J Comp Neurol* 393:353–373
- Szapiro G, Barbour B (2007) Multiple climbing fibers signal to molecular layer interneurons exclusively via glutamate spillover. *Nat Neurosci* 10:735–742
- Zhang L, Goldman JE (1996) Generation of cerebellar interneurons from dividing progenitors in white matter. *Neuron* 16:47–54

# Chapter 24

## Golgi Neurons

Stéphane Dieudonné

**Abstract** The Golgi cell is an essential cellular component of the cerebellar cortex and the only source of inhibition to the billions of granule cells forming the cortical input layer. Golgi cells are part of feed-forward, feedback and associative inhibitory circuits onto granule cells. Golgi cells are thus ideally placed to control the gain and temporal pattern of granule cell discharge in response to afferent mossy fibers activity. Although several theoretical frames have been proposed, the impact of Golgi cell activity on the granular layer encoding capacity is still debated.

**Keywords** Interneuron • GABA • Glycine • Inhibitory transmission • Feed-forward inhibition • Feed-back inhibition • Gain control • oscillations

### 24.1 Golgi Cells Within the Cerebellar Microcircuit

#### 24.1.1 Golgi Cell Morphology and Diversity

Golgi cells of the cerebellum, first described by Camillo Golgi in 1874 (Golgi 1874), are the main inhibitory interneuron of the granular layer (Eccles et al. 1964; Simat et al. 2007). Golgi cells are the only source of inhibition for billions of granule cells, which receive in average one inhibitory synapse per dendrite, inside the glomeruli (Jakab and Hamori 1988). Golgi cells are characterized by their extensive axonal plexus confined to the granular layer (Golgi 1874), with an estimated divergence of  $10^4$ . Golgi cells axons overlap extensively and many Golgi cells axons converge in one glomerulus.

---

S. Dieudonné (✉)

Inhibitory Transmission Team, IBENS, Ecole Normale Supérieure, CNRS UMR 8197;  
INSERM U 1024, 46 rue d'Ulm, 75005 Paris, France  
e-mail: [dieudon@biologie.ens.fr](mailto:dieudon@biologie.ens.fr)

Golgi cells are multipolar neurons with four to ten dendrites emerging from their soma. During their course through the GCL, these basolateral dendrites remain relatively thick and contorted (Dieudonné 1998). Eventually one to four dendrites reaches the Purkinje cell layer and divides into thin apical branches rising through the molecular layer towards the pial surface (Dieudonné 1998). Apical dendrites may not cross the boundaries of parasagittal Purkinje cell zebrin-like bands (Sillitoe et al. 2008), suggesting a modular organization of Golgi cells in the cerebellar microcircuit.

Golgi cells are neurochemically diverse. The majority of Golgi cells stain for the two inhibitory amino-acids GABA and glycine but about 20% contain GABA only (Simat et al. 2007). Golgi cells can exert functional mixed GABA/glycine inhibition on one of their minor target, the Unipolar Brush Cell (Dugué 2005), but granule cells express only GABA-A receptors (Brickley et al. 1996), questioning the role of glycine at this synapse. Immunostainings for various markers have further highlighted the diversity of Golgi cells (Geurts et al. 2003). Strikingly, neurogranin labels all Golgi cells expressing the GABA synthesis enzyme GAD67 while mGluR2 is expressed in all glycinergic Golgi cells (Simat et al. 2007). The neurochemical diversity of Golgi cells provides evidence for the complexity of granule cells inhibitory control.

### ***24.1.2 Excitatory Synaptic Inputs to Golgi Cells***

Golgi cells receive three types of excitatory inputs. Mossy fibers (MF) contact the basolateral dendrites of Golgi cells within the glomeruli (Palay and Chan-Palay 1974; Cesana et al. 2010), forming a feed-forward inhibitory circuit on granule cells. The ascending axons of granule cells make synapses on the somata and dendrites of Golgi cells, on their way to the molecular layer (ML) (Cesana et al. 2010). These numerous contacts provide the anatomical substrate for a feedback inhibitory circuit, whereby granule cells can evoke fast retroactive inhibition from local Golgi cells. Finally, the parallel fibers of distant granule cells contact the apical dendrites of Golgi cells in the molecular layer (Cesana et al. 2010; Palay and Chan-Palay 1974). This associative circuit could coordinate the level of activity amongst distant parasagittal modules along parallel fiber beams (Vos et al. 1999a). Climbing fibers do not contact Golgi cells (Galliano et al. 2013).

All three excitatory synapses on Golgi cells contain AMPA and NMDA receptors (Dieudonné 1998; Cesana et al. 2010; Kanichay and Silver 2008). Glutamate spillover generates a slow component of the AMPA excitatory post-synaptic currents (EPSCs) (Kanichay and Silver 2008; Cesana et al. 2010) at morphologically complex MF synapses within the glomerulus. AMPA receptors at ascending axon synapses decay with a single fast component (Dieudonné 1998; Cesana et al. 2010), but distal PF EPSCs are passively filtered by the thin apical dendrites of Golgi cells (Dieudonné 1998; Vervaeke et al. 2012).

### ***24.1.3 Inhibitory Synaptic Inputs to Golgi Cells***

Lugaro cells provide a major inhibitory input to Golgi cells via their parasagittal and longitudinal axonal plexus in the ML (Dumoulin et al. 2001; Lainé and Axelrad 1996). Mixed inhibitory transmission is the rule at this synapse in the rat (Dumoulin et al. 2001). The Lugaro cell synapses are ideally placed to shunt Golgi cells apical dendrites and could participate to the synchronisation of Golgi cells along PFs observed in vivo (Vos et al. 1999a). Surprisingly, Golgi cells are neither contacted by Purkinje cells nor by ML interneurons. However they contact each other with a probability of 20% (Hull and Regehr 2012).

## **24.2 Golgi Cell Function**

The main function of the granular layer is to expand and separate the patterns of mossy fiber activity (Marr 1969). Golgi cells, the ablation of which causes ataxia (Watanabe et al. 1998), have been proposed to participate in several ways in the enrichment of granular layer patterns.

### ***24.2.1 Gain Control***

Sparse granule cell activity is mandatory for pattern separation. Golgi cell may control dynamically the gain of the granular layer to match ongoing MF activity (Marr 1969; Billings et al. 2014). The activity of Golgi cells is indeed modulated with brain state and sensori-motor performance (Edgley and Lidieth 1987; Prsa et al. 2009; Heine et al. 2010) in vivo.

### ***24.2.2 Combinatorial Pattern Enrichment***

The overlap and convergence of many Golgi cells in the granular layer creates in the granule cell population a rich combination of possible inhibitory inputs, which could enrich granule cells activity patterns (Mapelli et al. 2010). The presence of receptive fields for Golgi cell responses supports this hypothesis (Edgley and Lidieth 1987; Prsa et al. 2009; Heine et al. 2010; Vos et al. 1999b). Computational models have attempted to extend this hypothesis to the temporal domain (Yamazaki and Tanaka 2007). This temporal hypothesis is supported by the complex time course of Golgi cell responses to peripheral stimulations (Holtzman 2006a; Vos et al. 1999b).

### 24.2.3 *Temporal Windowing and Oscillations*

Finally Golgi cells may sharpen the temporal response of granule cells to MF inputs by providing feed-forward and feedback inhibition (D'Angelo and De Zeeuw 2009). This temporal windowing may occur on the slower timescale of theta/beta oscillations, for which Golgi cells show resonance thanks to their gap-junction connections (Dugué et al. 2009) and intrinsic excitability (Solinas et al. 2007b).

## 24.3 Conclusion

While our knowledge of the connectivity of Golgi cells within the cerebellar microcircuit has greatly improved, much remains to be understood of the functional role of Golgi cells. The putative existence of multiple Golgi subtypes is of particular interest for future investigations.

**Acknowledgements** This work was supported by the ANR grant INNET to S.D.

## References

- Billings G, Piasini E, Lorincz A, Nusser Z, Silver RA (2014) Network structure within the cerebellar input layer enables lossless sparse encoding. *Neuron* 83(4):960–974. doi:[10.1016/j.neuron.2014.07.020](https://doi.org/10.1016/j.neuron.2014.07.020)
- Brickley S, Cull-Candy S, Farrant M (1996) Development of a tonic form of synaptic inhibition in rat cerebellar granule cells resulting from persistent activation of GABA<sub>A</sub> receptors. *J Physiol* 15(497):753–759
- Cesana E, Dieudonné S, Isope P, Bidoret C, D'Angelo E, Forti L (2010) Novel granule cell-Golgi cell excitatory inputs in the cerebellar granular layer. In: FENS Abstr. pp 052–057
- D'Angelo E, De Zeeuw CI (2009) Timing and plasticity in the cerebellum: focus on the granular layer. *Trends Neurosci* 32(1):30–40. doi:[S0166-2236\(08\)00245-2](https://doi.org/S0166-2236(08)00245-2) [pii] [10.1016/j.tins.2008.09.007](https://doi.org/10.1016/j.tins.2008.09.007)
- Dieudonné S (1998) Submillisecond kinetics and low efficacy of parallel fibre-Golgi cell synaptic currents in the rat cerebellum. *J Physiol* 510(3):845–866
- Dugué GP (2005) Target-dependent use of coreleased inhibitory transmitters at central synapses. *J Neurosci* 25(28):6490–6498. doi:[10.1523/jneurosci.1500-05.2005](https://doi.org/10.1523/jneurosci.1500-05.2005)
- Dugué GP, Brunel N, Hakim V, Schwartz E, Chat M, Levesque M, Courtemanche R, Lena C, Dieudonné S (2009) Electrical coupling mediates tunable low-frequency oscillations and resonance in the cerebellar Golgi cell network. *Neuron* 61(1):126–139. doi:[S0896-6273\(08\)01021-0](https://doi.org/S0896-6273(08)01021-0) [pii] [10.1016/j.neuron.2008.11.028](https://doi.org/10.1016/j.neuron.2008.11.028)
- Dumoulin A, Triller A, Dieudonné S (2001) IPSC kinetics at identified GABAergic and mixed GABAergic and glycinergic synapses onto cerebellar Golgi cells. *J Neurosci* 21(16):6045–6057
- Eccles IC, Llinas R, Sasaki K (1964) Golgi cell inhibition in the cerebellar cortex. *Nature* 204:1265–1266

- Edgley SA, Lidieth M (1987) The discharges of cerebellar Golgi cells during locomotion in the cat. *J Physiol* 392:315–332
- Galliano E, Baratella M, Sgritta M, Ruigrok TJ, Haasdijk ED, Hoebeek FE, D'Angelo E, Jaarsma D, De Zeeuw CI (2013) Anatomical investigation of potential contacts between climbing fibers and cerebellar Golgi cells in the mouse. *Front Neural Circ* 7:59. doi:10.3389/fncir.2013.00059
- Geurts FJ, De Schutter E, Dieudonne S (2003) Unraveling the cerebellar cortex: cytology and cellular physiology of large-sized interneurons in the granular layer. *Cerebellum* 2(4):290–299. doi:10.1080/14734220310011948
- Golgi C (1874) Sulla fina anatomia del cervello umano. *Arch Ital Mal Nerv* 2:90–107
- Heine SA, Highstein SM, Blazquez PM (2010) Golgi cells operate as state-specific temporal filters at the input stage of the cerebellar cortex. *J Neurosci* 30(50):17004–17014
- Holtzman T (2006) Different responses of rat cerebellar Purkinje cells and Golgi cells evoked by widespread convergent sensory inputs. *J Physiol* 574(2):491–507. doi:10.1113/jphysiol.2006.108282
- Hull C, Regehr WG (2012) Identification of an inhibitory circuit that regulates cerebellar Golgi cell activity. *Neuron* 73(1):149–158. doi:10.1016/j.neuron.2011.10.030
- Jakab RL, Hamori J (1988) Quantitative morphology and synaptology of cerebellar glomeruli in the rat. *Anat Embryol (Berl)* 179(1):81–88
- Kanichay RT, Silver RA (2008) Synaptic and cellular properties of the feedforward inhibitory circuit within the input layer of the cerebellar cortex. *J Neurosci* 28(36):8955–8967. doi:10.1523/jneurosci.5469-07.2008
- Lainé J, Axelrad H (1996) Morphology of the Golgi-impregnated Lugaro cell in the rat cerebellar cortex: a reappraisal with a description of its axon. *J Comp Neurol* 375:618–640
- Mapelli J, Gandolfi D, D'Angelo E (2010) Combinatorial responses controlled by synaptic inhibition in the cerebellum granular layer. *J Neurophysiol* 103(1):250–261
- Marr D (1969) A theory of cerebellar cortex. *J Physiol* 202(2):437–470
- Palay SL, Chan-Palay V (1974) Cerebellar cortex. Springer, New York
- Prsa M, Dash S, Catz N, Dicke PW, Thier P (2009) Characteristics of responses of Golgi cells and mossy fibers to eye saccades and saccadic adaptation recorded from the posterior vermis of the cerebellum. *J Neurosci* 29(1):250–262. doi:10.1523/jneurosci.4791-08.2009
- Sillitoe RV, Chung SH, Fritschy JM, Hoy M, Hawkes R (2008) Golgi cell dendrites are restricted by Purkinje cell stripe boundaries in the adult mouse cerebellar cortex. *J Neurosci* 28(11):2820–2826. doi:10.1523/jneurosci.4145-07.2008
- Simat M, Parpan F, Fritschy JM (2007) Heterogeneity of glycinergic and gabaergic interneurons in the granule cell layer of mouse cerebellum. *J Comp Neurol* 500(1):71–83. doi:10.1002/cne.21142
- Solinas S, Forti L, Cesana E, Mapelli J, De Schutter E, D'Angelo E (2007) Fast-reset of pacemaking and theta-frequency resonance patterns in cerebellar Golgi cells: simulations of their impact in vivo. *Front Cell Neurosci* 1:4. doi:10.3389/neuro.03.004.2007
- Vervaeke K, Lorincz A, Nusser Z, Silver RA (2012) Gap junctions compensate for sublinear dendritic integration in an inhibitory network. *Science* 335(6076):1624–1628. doi:10.1126/science.1215101
- Vos BP, Maex R, Volny-Luraghi A, De Schutter E (1999a) Parallel fibers synchronize spontaneous activity in cerebellar Golgi cells. *J Neurosci* 19(11):RC6
- Vos BP, Volny-Luraghi A, De Schutter E (1999b) Cerebellar Golgi cells in the rat: receptive fields and timing of response to facial stimulation. *Eur J Neurosci* 11:2621–2634
- Watanabe D, Inokawa H, Hashimoto K, Suzuki N, Kano M, Shigemoto R, Hirano T, Toyama K, Kaneko S, Yokoi M, Moriyoishi K, Suzuki M, Kobayashi K, Nagatsu T, Kreitman RJ, Pastan I, Nakanishi S (1998) Ablation of cerebellar Golgi cells disrupts synaptic integration involving GABA inhibition and NMDA receptor activation in motor coordination. *Cell* 95(1):17–27. doi:S0092-8674(00)81779-1 [pii]
- Yamazaki T, Tanaka S (2007) A spiking network model for passage-of-time representation in the cerebellum. *Eur J Neurosci* 26(8):2279–2292. doi:10.1111/j.1460-9568.2007.05837.x

# Chapter 25

## Lugaro Cells

Moritoshi Hirono

**Abstract** Lugaro cells that have typical spindle-shape cell bodies were discovered in the cerebellar granule cell layer more than 100 years ago. Although their electrophysiological properties were recently investigated, Lugaro cells are not well established. This chapter will review the morphological and electrophysiological characteristics of Lugaro cells, and introduce a Lugaro cell-incorporated microcircuit, which may contribute to the cerebellar motor control.

**Keywords** Lugaro cell • Globular cell • Calretinin • Serotonin • Axon collateral • Microcircuit

### 25.1 Introduction

Characterizing individual cells and their synaptic connections in the cerebellum helps to understand the mechanisms underlying cerebellar motor control (Ito 2011). The canonical neuronal network of the cerebellar cortex consists of only five-types of neurons: Purkinje cells (PCs), granule cells, Golgi cells, basket cells, and stellate cells. Recent evidence, however, suggests that inhibitory interneurons in the cerebellar granule cell layer are more heterogeneous than acknowledged in the traditional classification (Lainé and Axelrad 2002; Simat et al. 2007; Schilling et al. 2008). Among them are the Lugaro cells, which are first described in the cat cerebellum as a unique morphologically distinct interneuron located underneath the PC layer (Lugaro 1894).

---

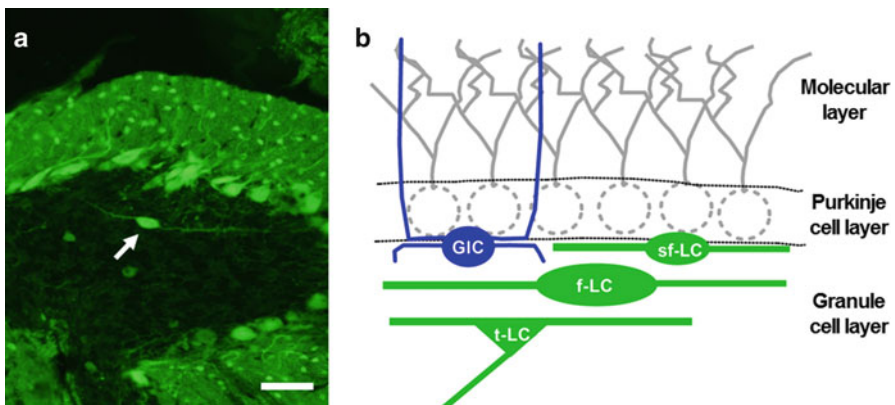
M. Hirono (✉)

Organization for Research Initiatives and Development, Doshisha University,  
Kyotanabe, Kyoto 619-0394, Japan  
e-mail: [mhirono@mail.doshisha.ac.jp](mailto:mhirono@mail.doshisha.ac.jp)



## 25.2 Morphological Characteristics of Lugaro Cells

Typical Lugaro cells have spindle-shaped cell bodies with dendrites extending on both side of the soma (Lugaro 1894; Fox 1959; Fig. 25.1), and their axons go into the molecular layer, and thereafter extend long in the mediolateral direction in parallel to the parallel fibers (Palay and Chan-Palay 1974; Lainé and Axelrad 1996). Lugaro cells are glycinergic/GABAergic interneurons expressing a calcium binding protein, calretinin, at a relatively higher level than other cerebellar neurons, and hence, an anti-calretinin antibody has been used for immunohistochemical characterization of Lugaro cells (Rogers 1989; Arai et al. 1991). There are very few Lugaro cells (Sahin and Hockfield 1990) and the ratio per PC is 1:15 in the rat cerebellar cortex (Dieudonné and Dumoulin 2000). Lugaro cell bodies are distributed more abundantly in the posterior lobules (VII to X) in the rat vermis and are often identified in the sulcus between lobules, but rarely at the apex of the lobules (Dieudonné 2001). On the basis of their cell body morphology, Lugaro cells are divided into four subgroups (Fig. 25.1): Large-sized Lugaro cells (typical fusiform Lugaro cells, and triangular Lugaro cells) are located in the middle of the granule cell layer (Lugaro 1894; Geurts et al. 2001; Melik-Musyan and Fanardzhyan 2004; Crook et al. 2006), while small-sized Lugaro cells (small fusiform Lugaro cells, and globular cells with a small and globular-shaped cell body) are located underneath the PC layer (Lainé and Axelrad 2002; Simat et al. 2007; Schilling et al. 2008; Hirono et al. 2012). Although a specific chemical marker for Lugaro cells has not yet been identified, antibodies against Rat303, Kv4.3, mGluR1 $\alpha$ , SMI311, and chondroitin sulfate proteoglycan, have been used for their detailed anatomical studies (Sahin and Hockfield 1990; Geurts et al. 2001; Hsu et al. 2003; Víg et al. 2003; Crook et al. 2007).



**Fig. 25.1** Morphological characteristics of Lugaro cells. **(a)** A typical fusiform Lugaro cell (*arrow*) in a sagittal cerebellar slice derived from a GAD67<sup>+/GFP</sup> knock-in mouse expressing GFP specifically in GABAergic neurons. Scale bar, 50  $\mu$ m (Modified from Ito 2011) **(b)** Schematic of Lugaro cells showing the relative size and location of the four cell types. *GIC* globular cell, *sf-LC* small fusiform Lugaro cell, *f-LC* fusiform Lugaro cell, *t-LC* triangular Lugaro cell

## 25.3 Electrophysiological Characteristics of Lugaro Cells

It is difficult to identify the soma of Lugaro cells under the Nomarski optical microscopy because of very few Lugaro cells and the size of their cell body being similar to that of Golgi cells. Recently whole-cell patch-clamp recordings were applied to Lugaro cells in the rat acute cerebellar slices to observe electrical responses to serotonin (Dieudonné and Dumoulin 2000). An electrophysiological characterization of Lugaro cells shows robust firing following the activation of serotonin receptors, while they are normally silent at rest (Dieudonné and Dumoulin 2000; Dumoulin et al. 2001; Dean et al. 2003; Hirono et al. 2012), suggesting that Lugaro cells are the primary targets of serotonin released from serotonergic axon terminals in the cerebellar cortex.

Lugaro cells display high inhibitory synaptic activity compared to Golgi cells (Dieudonné 2001; Hirono et al. 2012). Because the somata and proximal dendrites of fusiform Lugaro cells and globular cells are surrounded by axon collateral terminals of PCs, labeled by the calbindin-antibody, Lugaro cells likely receive recurrent PC axon collaterals (Lainé and Axelrad 2002; Crook et al. 2007; Simat et al. 2007; Hirono et al. 2012). Electrophysiological experiments exactly demonstrate that PCs make functional GABAergic synaptic contacts with globular cells, suggesting that outputs from several PCs converge on a Lugaro cell in the cerebellar cortex (Hirono et al. 2012). In contrast, Lugaro cells receive few fast glutamatergic excitatory synaptic inputs (Dieudonné 2001; Hirono et al. 2012). The excitatory synaptic inputs in globular cells show paired-pulse depression only at the short inter-pulse interval (<100 ms), suggesting that Lugaro cells receive mossy fiber inputs (Hirono et al. 2012). However, other excitatory synaptic connections with Lugaro cells have not been well established physiologically.

The parasagittal axonal plexus of Lugaro cells contact basket/stellate cells (Lainé and Axelrad 1998), and the long transverse branches of Lugaro cells make functional connections with Golgi cells (Dieudonné and Dumoulin 2000; Dumoulin et al. 2001). One Golgi cell receives inhibitory synaptic inputs from approximately ten Lugaro cells, and each Lugaro cell presumably make synaptic contacts divergently with around 150 Golgi cells (Dieudonné and Dumoulin 2000; Dieudonné 2001; Dumoulin et al. 2001), proposing a possibility that Lugaro cells can synchronize activity among Golgi cells. Although Lugaro cells have also been proposed to synaptically inhibit PCs (Dean et al. 2003), it remains controversial whether they innervate PCs (Lainé and Axelrad 1998, 2002; Simat et al. 2007).

## 25.4 Possible Physiological Meanings

Lugaro cells form a cerebellar transverse microcircuit that involves not only PC-Lugaro cell pairs but also other connections of Lugaro cell to basket/stellate cell and to Golgi cell-granule cell pairs (Dieudonné 2001; Simat et al. 2007). The basal

firing of PCs can regulate excitability of Lugaro cells through PC-Lugaro cell feedback loop. Firing of Lugaro cells, elicited by excitatory mossy fiber or serotonergic inputs, therefore, leads to rectifying the firing of PC (Hirono et al. 2012). Thus, the Lugaro cell-incorporated microcircuit could synchronize activity of PC clusters in different microzones, and likely contributes to the cerebellar motor control.

## References

- Arai R, Winsky L, Arai M, Jacobowitz DM (1991) Immunohistochemical localization of calretinin in the rat hindbrain. *J Comp Neurol* 310:21–44
- Crook J, Hendrickson A, Robinson FR (2006) Co-localization of glycine and gaba immunoreactivity in interneurons in macaca monkey cerebellar cortex. *Neuroscience* 141:1951–1959
- Crook JD, Hendrickson A, Erickson A, Possin D, Robinson FR (2007) Purkinje cell axon collaterals terminate on Cat-301+ neurons in macaca monkey cerebellum. *Neuroscience* 149:834–844
- Dean I, Robertson SJ, Edwards FA (2003) Serotonin drives a novel GABAergic synaptic current recorded in rat cerebellar Purkinje cells: a Lugaro cell to Purkinje cell synapse. *J Neurosci* 23:4457–4469
- Dieudonné S (2001) Serotonergic neuromodulation in the cerebellar cortex: cellular, synaptic, and molecular basis. *Neuroscientist* 7:207–219
- Dieudonné S, Dumoulin A (2000) Serotonin-driven long-range inhibitory connections in the cerebellar cortex. *J Neurosci* 20:1837–1848
- Dumoulin A, Triller A, Dieudonné S (2001) IPSC kinetics at identified GABAergic and mixed GABAergic and glycinergic synapses onto cerebellar golgi cells. *J Neurosci* 21:6045–6057
- Fox CA (1959) The intermediate cells of lugaro in the cerebellar cortex of the monkey. *J Comp Neurol* 112:39–51
- Geurts FJ, Timmermans JP, Shigemoto R, De Schutter E (2001) Morphological and neurochemical differentiation of large granular layer interneurons in the adult rat cerebellum. *Neuroscience* 104:499–512
- Hirono M, Saitow F, Kudo M et al (2012) Cerebellar globular cells receive monoaminergic excitation and monosynaptic inhibition from Purkinje cells. *PLoS One* 7:e29663
- Hsu YH, Huang HY, Tsaor ML (2003) Contrasting expression of Kv4.3, an A-type K<sup>+</sup> channel, in migrating Purkinje cells and other post-migratory cerebellar neurons. *Eur J Neurosci* 18:601–612
- Ito M (2011) *The cerebellum. Brain for an implicit self.* FT Press, Upper Saddle River, NJ
- Lainé J, Axelrad H (1996) Morphology of the golgi-impregnated Lugaro cell in the rat cerebellar cortex: a reappraisal with a description of its axon. *J Comp Neurol* 375:618–640
- Lainé J, Axelrad H (1998) Lugaro cells target basket and stellate cells in the cerebellar cortex. *Neuroreport* 9:2399–2403
- Lainé J, Axelrad H (2002) Extending the cerebellar Lugaro cell class. *Neuroscience* 115:363–374
- Lugaro E (1894) Sulle connessioni tra gli elemente nervosa della corteccia cerebellare con considerazioni generali sulsignificato fisiologico dei rapporti tra gli elementi nervosi. *Riv Sper Freniatr* 20:297–331
- Melik-Musyan AB, Fanardzhyan VV (2004) Morphological characteristics of Lugaro cells in the cerebellar cortex. *Neurosci Behav Physiol* 34:633–638
- Palay SL, Chan-Palay V (1974) Cerebellar cortex: cytology and organization. In: *Cerebellar cortex: cytology and organization.* Springer, Berlin
- Rogers JH (1989) Immunoreactivity for calretinin and other calcium-binding proteins in cerebellum. *Neuroscience* 31:711–721

- Sahin M, Hockfield S (1990) Molecular identification of the Lugaro cell in the cat cerebellar cortex. *J Comp Neurol* 301:575–584
- Schilling K, Oberdick J, Rossi F, Baader SL (2008) Besides Purkinje cells and granule neurons: an appraisal of the cell biology of the interneurons of the cerebellar cortex. *Histochem Cell Biol* 130:601–615
- Simat M, Parpan F, Fritschy JM (2007) Heterogeneity of glycinergic and gabaergic interneurons in the granule cell layer of mouse cerebellum. *J Comp Neurol* 500:71–83
- Víg J, Takacs J, Vastagh C, Baldauf Z, Veisenberger E, Hamori J (2003) Distribution of mGluR1alpha and SMI311 immunoreactive lugaro cells in the kitten cerebellum. *J Neurocytol* 31:217–227

# Chapter 26

## Unipolar Brush Cells

Marco Martina and Gabriella Sekerková

**Abstract** The unipolar brush cells (UBCs) are excitatory interneurons in the granule cell layer of the cerebellar cortex. They amplify extra-cerebellar inputs from vestibular origin as well as other inputs whose origin is the focus of ongoing research. The UBCs are classified in two functionally and chemically distinct subclasses. Type I UBCs express calretinin, are regularly firing, and are located in lobules IX and X. Type II UBCs are characterized by expression of mGluR1 $\alpha$ , are burst firing and are present throughout the cerebellum, although they are enriched in the vestibulo-cerebellum. Both UBC types show peculiarly slow glutamatergic currents in response to synaptic activation. This electrophysiological property suggests a critical role for these cells in determining the timing of the response of the cerebellar cortex to the peripheral inputs. Recent data also suggest that cerebellar UBCs may be involved in cerebellar ataxias and represent a potential cellular substrate for the generation of tinnitus.

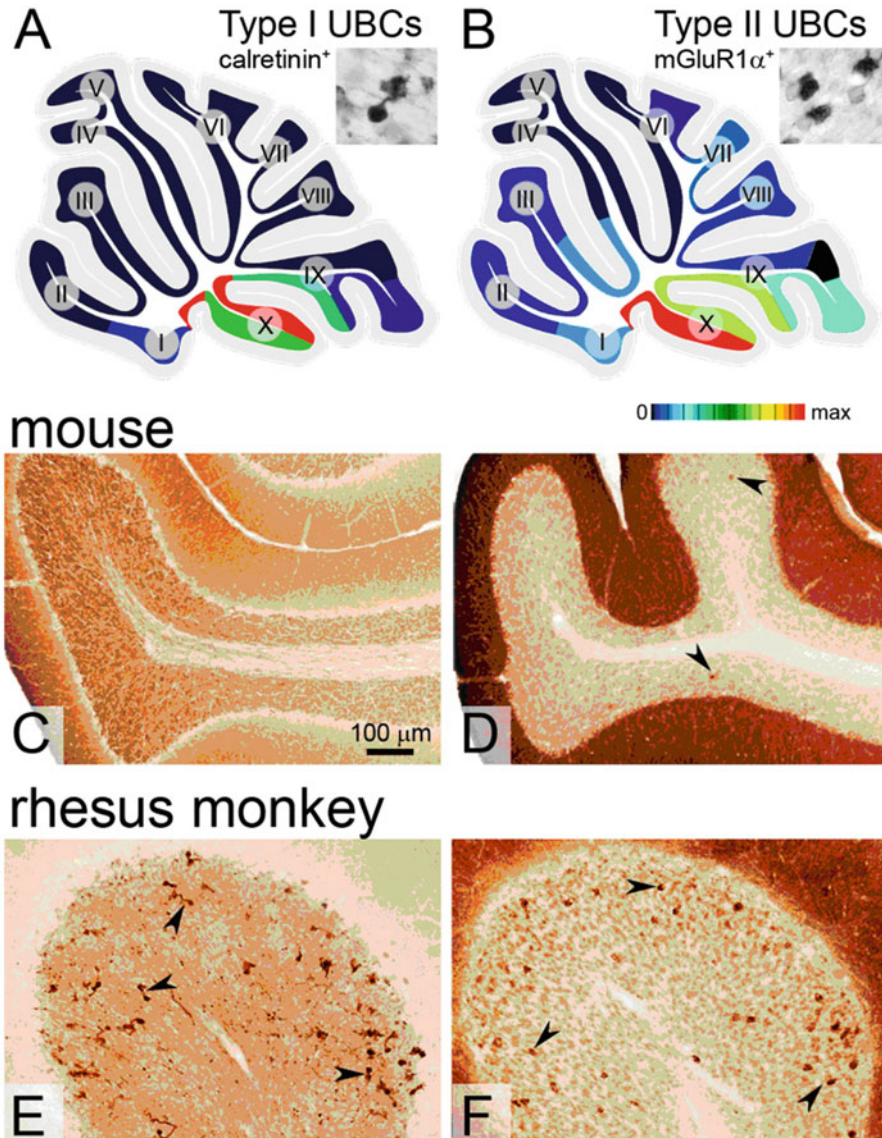
**Keywords** mGluR • Mossy fibers • Calretinin • Tinnitus • Ataxia

### 26.1 Morphology and Spatial Distribution

UBCs are already present in teleostei and are virtually unchanged in all mammals, including humans (Mugnaini et al. 2011). Intriguingly, their density increases with phylogenetic evolution as their density is considerably higher in monkeys than in rodents (Fig. 26.1). UBCs are excitatory interneurons in the cerebellum and cochlear nuclear (CN) complex (Mugnaini et al. 2011). They have one short dendrite terminating in a brush of fine dendrioles, which form a specialized giant synaptic junction with a single mossy fiber (MF) terminal. UBC axons stay within the cerebellar granule cell layer where they terminate in several MF rosettes and generate a web of intrinsic MFs superimposed on the canonical extrinsic MF system (Mugnaini

---

M. Martina (✉) • G. Sekerková  
Department of Physiology, Northwestern University Feinberg School of Medicine,  
300 E. Superior, Chicago, IL 60611, USA  
e-mail: [m-martina@northwestern.edu](mailto:m-martina@northwestern.edu)



**Fig. 26.1** Density map of UBC distribution in mouse cerebellum. Type I (**A**) and type II (**B**) UBCs distribution (based on calretinin and mGluR1 $\alpha$  immunostaining, respectively). Insets show UBC immunolabeling with these antibodies. Images from mouse cerebellar cortex illustrate the absence of type I UBCs in lobule V (**C**). Type II UBCs are rare in this lobule (**D**). In contrast to the mouse, the cerebellum of Rhesus monkey contains UBCs in all lobules and at higher density (**E**, **F**). These images are from lobule V, to facilitate comparison with **C**, **D**. *Arrowheads* indicate type I (**E**) and II (**F**) UBCs

et al. 2011). The morphological properties of UBCs are well-suited to amplify input signals that can be transmitted through their extended intrinsic MF network to downstream granule cell clusters and create a feed-forward amplification system for sensory afferents.

## 26.2 UBC Subtypes

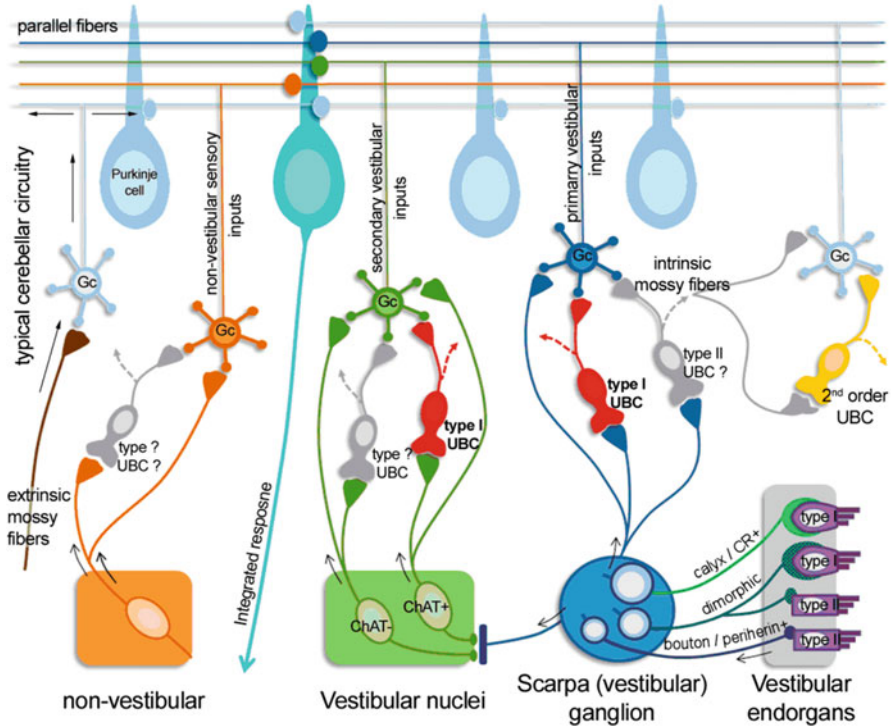
The UBC population comprises two chemically distinct subclasses: calretinin-positive type I and mGluR1 $\alpha$ -positive type II UBCs (Sekerková et al. 2014). The topographical distributions of the two subtypes overlap only in part: type II cells are distributed across cerebellar lobules, while expression of type I UBCs is limited to the vestibulo-cerebellum (Fig. 26.1; Sekerková et al. 2014). The electrophysiological properties of the two UBC subclasses also differ (Kim et al. 2012). Type I UBCs are intrinsically firing and show a nearly monotonic input/output function thus providing linear amplification of the vestibular inputs. In contrast, type II UBCs are often silent and exhibit burst firing when stimulated (Diana et al. 2007; Kim et al. 2012); therefore any input large enough to cross threshold will lead to a burst of action potentials, potentially enhancing the downstream signal. This conclusion is supported by recent data showing that, based on their differential response to glutamatergic inputs, type I and type II UBCs may be considered functional equivalents of OFF and ON retinal cells, respectively (Borges-Merjane and Trussell 2015).

## 26.3 UBC Connectivity

The inputs and outputs of the UBC subtypes are still largely unknown (Fig. 26.2). Because type I UBCs are present in the vestibulo cerebellum and their distribution is in register with the vestibular afferent fibers (Mugnaini et al. 2011), it is likely that these UBCs provide feed-forward amplification of single vestibular afferent signals. Accordingly, c-Fos expression can be elicited in type I UBCs following vestibular stimulation (Sekerková et al. 2005). Type I UBCs receive primary vestibular fibers from the ganglion of Scarpa (Diño et al. 2001) as well as fibers from the medial vestibular nucleus and the nucleus prepositushypoglossi (Mugnaini et al. 2011). The afferent partners of type II UBCs are unknown; however, it is likely that these cells receive vestibular as well as non-vestibular afferents (Mugnaini et al. 2011).

## 26.4 Function

Studies of afferent connectivity together with their high density in the median cerebellar cortex and the flocculus/paraflocculus complex suggest that UBCs contribute to the regulation of body posture, head position and eye movements (Mugnaini et al. 2011). The UBC brush forms an extensive contact with an individual MF



**Fig. 26.2** UBC circuitry in the vestibulo-cerebellum. The classical cerebellar circuitry is illustrated on the *left side* of the schematic: extrinsic MF terminals contact granule cells (Gc), which relay the input to Purkinje cells. UBCs modify this circuitry by introducing a further node between afferent MFs and granule cells. Moreover UBCs provide a parallel intrinsic MF system (*dashed-lines with arrows*) superimposed on the extrinsic system. This schematic depicts both demonstrated (*red UBCs*) and hypothesized (*grey UBCs*) circuitries in the vestibulocerebellum. *Yellow UBCs* are second order UBCs (Reviewed in Mugnaini et al. 2011)

terminal. As a consequence of the extensive apposition surface, the UBC synaptic response is unusually long-lasting (~3 s; Rossi et al. 1995). In response to synaptic excitation, type II UBCs generate an extended action potential burst that is believed to cause long-lasting activation of downstream neurons (Diño et al. 2000). Type I UBCs, on the other hand, are capable of spontaneous firing, which is down-regulated by group II mGluRs (Russo et al. 2008). Thus, glutamate entrapment in the synaptic space generates a biphasic response: an initial increased UBC firing followed by prolonged silencing. Both UBC subtypes seem tuned to respond to synaptic stimulation by generating highly spaced signals that introduce delays in the circuitry. Accordingly, recent data show that the slow synaptic currents of UBCs are ideally suited for the generation of responses with delays varying from zero up to hundreds of milliseconds depending on the stimulus frequency (van Dorp and De Zeeuw 2014). Considering that the intrinsic MFs may contribute up to 50% of the MF terminals in lobule X, it is likely that multiple UBCs are serially connected within an individual circuit, thus having the capability to generate an even wider range of temporal patterns.



## 26.5 UBCs and Disease

**Tinnitus:** while tinnitus is associated with several known conditions, the most common being noise-induced hearing loss, the cellular mechanisms of tinnitus are still unknown. Recently, it has been suggested that cerebellar UBCs may play a role in the generation of tinnitus (Baizer et al. 2012; Bauer et al. 2013). In this context, type I UBCs appear particularly intriguing. First, they are highly enriched in the cerebellar areas associated with tinnitus generation. Second, they are capable of autonomous firing (Russo et al. 2007; Kim et al. 2012). Third, after deafferentation UBCs not only survive, but they extend a mesh of newly formed intrinsic MFs (Mugnaini et al. 2011) that take over areas deprived of extrinsic MF inputs. Thus, it may be hypothesized that following acoustic deafferentation intrinsic MFs originating from type I UBCs take over the circuitry and generate phantom signals through their intrinsic activity.

**Ataxia:** the moonwalker (Mwk) mouse is recently identified a model of human ataxia (Becker et al. 2009) originally attributed to Purkinje cell loss. However, the phenotype is fully expressed at 1 month of age, when Purkinje cell loss is still absent, but UBC loss is massive (Sekerková et al. 2013). Thus it may be suggested that at least part of the phenotype is caused by the UBC loss and that the UBC-dependent transmission delays have an important role in motor coordination.

## References

- Baizer JS, Manohar S, Paolone NA, Weinstock N, Salvi RJ (2012) Understanding tinnitus: the dorsal cochlear nucleus, organization and plasticity. *Brain Res* 1485:40–53
- Bauer CA, Wisner KW, Baizer JS, Brozoski TJ (2013) Tinnitus, unipolar brush cells, and cerebellar glutamatergic function in an animal model. *PLoS One* 8:e64726
- Becker EB, Oliver PL, Glitsch MD et al (2009) A point mutation in TRPC3 causes abnormal purkinje cell development and cerebellar ataxia in moonwalker mice. *Proc Natl Acad Sci U S A* 106:6706–6711
- Borges-Merjane C, Trussell LO (2015) ON and OFF unipolar brush cells transform multisensory inputs to the auditory system. *Neuron* 85(5):1029–1042
- Diana MA, Otsu Y, Maton G et al (2007) T-type and L-type  $Ca^{2+}$  conductances define and encode the bimodal firing pattern of vestibulocerebellar unipolar brush cells. *J Neurosci* 27:3823–3838
- Diño MR, Schuenger RJ, Liu Y, Slater NT, Mugnaini E (2000) Unipolar brush cell: a potential feedforward excitatory interneuron of the cerebellum. *Neurosci* 98:625–636
- Diño MR, Perachio AA, Mugnaini E (2001) Cerebellar unipolar brush cells are targets of primary vestibular afferents: an experimental study in the gerbil. *Exp Brain Res* 140:162–170
- Kim J-A, Sekerková G, Mugnaini E, Martina M (2012) Electrophysiological, morphological, and topological properties of two histochemically distinct subpopulations of cerebellar unipolar brush cells. *Cerebellum* 11:1012–1025
- Mugnaini E, Sekerková G, Martina M (2011) The unipolar brush cell: a remarkable neuron finally receiving deserved attention. *Brain Res Rev* 66:220–245
- Rossi DJ, Alford S, Mugnaini E, Slater NT (1995) Properties of transmission at a giant glutamatergic synapse in cerebellum: the mossy fiber-unipolar brush cell synapse. *J Neurophysiol* 74:24–42

- Russo MJ, Mugnaini E, Martina M (2007) Intrinsic properties and mechanisms of spontaneous firing in mouse cerebellar unipolar brush cells. *J Physiol* 581:709–724
- Russo MJ, Yau HJ, Nunzi MG, Mugnaini E, Martina M (2008) Dynamic metabotropic control of intrinsic firing in cerebellar unipolar brush cells. *J Neurophysiol* 100:3351–3360
- Sekerková G, Ilijic E, Mugnaini E, Baker JF (2005) Otolith organ or semicircular canal stimulation induces c-fos expression in unipolar brush cells and granule cells of cat and squirrel monkey. *Exp Brain Res* 164:286–300
- Sekerková G, Kim JA, Nigro MJ et al (2013) Early onset of ataxia in moonwalker mice is accompanied by complete ablation of type II unipolar brush cells and Purkinje cell dysfunction. *J Neurosci* 33:19689–19694
- Sekerková G, Watanabe M, Martina M, Mugnaini E (2014) Differential distribution of phospholipase C beta isoforms and diacylglycerol kinase-beta in rodents cerebella corroborates the division of unipolar brush cells into two major subtypes. *Brain Struct Funct* 219:719–749
- van Dorp S, De Zeeuw CI (2014) Variable timing of synaptic transmission in cerebellar unipolar brush cells. *Proc Natl Acad Sci U S A* 111:5403–5408

# Chapter 27

## Glial Cells

**Katharine L. Dobson and Tomas C. Bellamy**

**Abstract** The term “glia” describes the non-neuronal, electrically passive cells of the central nervous system, which were first defined as a distinct cell type by Rudolph Virchow in 1856, and derive their name from the Greek for “glue” due to their presumed primary function as connective tissue. The term is misleading however, as it implies a single cell type when it in fact encompasses three cell classes: oligodendrocytes, astrocytes, and microglia. The origins and roles of these different glial classes are quite distinct, but they have collectively been viewed as supportive cells that maintain a healthy microenvironment favourable to neuronal function, and play structural and protective roles throughout development. This traditional conception is now giving way to an appreciation that glial cells play an active and dynamic role in neurophysiology, in addition to providing passive support. This chapter outlines the origins, anatomy and primary roles of the major glial cells in the cerebellum.

**Keywords** Astrocyte • Oligodendrocyte • Microglia • Gliotransmission • Homeostasis

### 27.1 Gliogenesis and Glial Lineages

Gliogenesis is the developmental process by which all glial cell types are generated; both the production of glial progenitor cells and their differentiation into mature glia. There are two routes via which cerebellar glia develop, with macroglia (astrocytes and oligodendrocytes) deriving from the neuroepithelium (along with neurons), and microglia originating from the mesodermal haematopoietic lineage.

Neuroepithelial cells, which are embryonic stem cells capable of both neuronal and glial fates, undergo morphological and epigenetic modification such that by mid-gestation they have differentiated to become radial glial cells. It is from these

---

K.L. Dobson • T.C. Bellamy (✉)  
School of Life Sciences, Queen’s Medical Centre, University of Nottingham Medical School,  
Nottingham NG7 2UH, UK  
e-mail: [tomas.bellamy@nottingham.ac.uk](mailto:tomas.bellamy@nottingham.ac.uk)

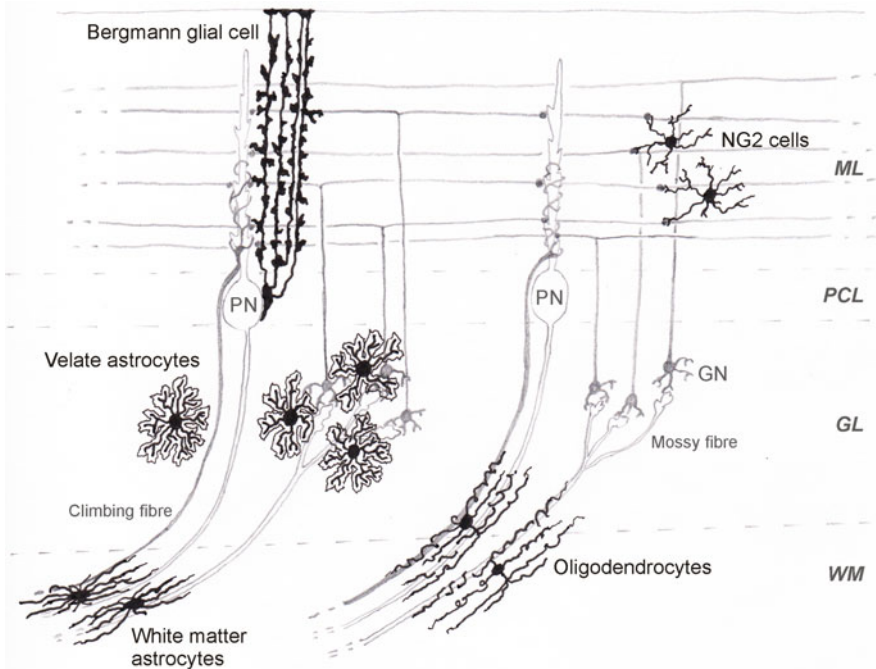
progenitor cells that astrocytes and oligodendrocytes arise (Rowitch and Kriegstein 2010). Radial glia undergo either direct differentiation into astrocytes, or form oligodendrocyte precursor cells which are subsequently capable of further specialization into oligodendrocytes.

Microglia enter the cerebellum early in embryogenesis as circulating foetal macrophages, and are thought to ‘seed’ the developing brain (Ginhoux et al. 2013). Further transformation results in embryonic microglia that mature in early post-natal life.

## 27.2 Oligodendrocytes and Microglia

Oligodendrocytes are the myelinating cells of the central nervous system. In the cerebellar cortex, they myelinate the mossy and climbing fibre inputs, and the Purkinje neuron axons that are the sole output of the cerebellar cortex. Accordingly, oligodendrocytes are most commonly located in the lower granular layer and the white matter (Fig. 27.1). In the rat cerebellum, approximately seven axons are myelinated by each mature oligodendrocyte (Bakiri et al. 2011).

In addition to the classic myelinating oligodendrocytes, another class of non-myelinating cells also originate from oligodendrocyte precursors, but do not lose



**Fig. 27.1** Diagram of the cerebellar cortical layers with the most abundant macroglial cells present in each layer illustrated in black. PN Purkinje neuron, GN granule neuron, ML molecular layer, PCL Purkinje cell layer, GL granular layer, WM white matter

expression of the proteoglycan NG2 during differentiation. These cells are therefore referred to as NG2 cells (or polydendrocytes) and could potentially represent a fourth major class of central nervous system glial cell (Nishiyama et al. 2009). NG2 cells are found throughout the cortex, and have been shown to receive synaptic input from parallel and climbing fibres (Fig. 27.1). Their role and function is currently a matter of active debate.

The microglia of the cerebellum function in much the same way as elsewhere in the central nervous system. Under physiological conditions, microglia exist in a resting state, with each cell body possessing several fine ramified processes that encompass an individual domain or territory. Under pathophysiological conditions, such as following injury or disease, the cell retracts these processes and enters an activated state. Activated microglia are highly mobile, such that they are able to rapidly translocate to the site of injury and, if required, perform phagocytic duties. In addition to their immune response function, microglia also play a critical role during development by engulfing and eliminating synapses to refine network connectivity in the maturing brain (Paolicelli et al. 2011).

### 27.3 Astrocytes

Astrocytes are a heterogeneous population of cerebellar glia, comprising fibrous astrocytes of the white matter tracts and protoplasmic astrocytes of the grey matter (Fig. 27.1). In addition to anatomical location, these two classes of astroglia are also distinguished on a morphological basis – protoplasmic astrocytes have more heavily branched processes than fibrous astrocytes. The astrocyte population of the cerebellum functions as an interconnected network known as a syncytium, with individual cells connected via gap junctions that allow the controlled diffusion of small molecules between neighbouring cells.

Fibrous astrocyte somata within regions of white matter are arranged in rows between axonal bundles, with their processes forming perivascular endfeet and perinodal contacts. The protoplasmic astrocytes found in the granular layer are termed “velate” astrocytes, due to the sheet-like projections that spread through the neuropil, enclosing the mossy fibre glomeruli and so limiting diffusion of transmitter away from sites of release. The velate astrocytes are therefore thought to demarcate glomeruli and associated granule neurons into anatomical compartments, with the hypothesized function of segregating specific mossy fibre inputs (Hoogland and Kuhn 2010).

### 27.4 Bergmann Glia

In the molecular layer, the predominant astroglial cell is a type unique to the cerebellum: the Bergmann glial cell. Bergmann glia (sometimes termed Golgi epithelial cells) are classed as protoplasmic astrocytes, but retain much in common with the radial glia from which they are derived (Fig. 27.1).

Bergmann glial somata align with Purkinje neuron somata between the granular and molecular layers, and extend two or more long radial processes through the molecular layer to the pial surface, where they terminate in bulbous endfeet. After maturation, each of these primary Bergmann fibres becomes decorated with multiple elaborate membrane protrusions known as microdomains, which sprout from the fibre and project into the neuropil of the molecular layer as complex leaf-like structures with high surface area to volume ratios. These processes enclose all of the synapses within the molecular layer, both excitatory and inhibitory, thus restricting diffusion of neurotransmitter away from active synapses. In the rat cerebellum there are approximately eight Bergmann glia to every Purkinje neuron, with each glial cell providing coverage of up to 6000 synapses.

## 27.5 Astroglial Functions in the Cerebellum

Cerebellar astroglia carry out the same core roles as astrocytes elsewhere in the central nervous system. Many of these roles are supportive, and only key roles are covered here for brevity; see Kettenmann and Ransom (2012) for more details.

$K^+$  buffering is a major homeostatic mechanism by which increased extracellular  $K^+$  released during action potential propagation is rapidly taken up by astrocytes (by virtue of their characteristically high  $K^+$  membrane permeability at rest), and redistributed through the astrocyte syncytium to sites of lower concentration. Another key role is the recycling of neurotransmitters: astroglia express transporters for both glutamate and GABA positioned near sites of release that rapidly clear the transmitters from the extrasynaptic space. Within the cytosol, the transmitters are metabolized to glutamine, which is released back into the extracellular space for reuptake by neurons. Finally, astrocytes can undergo a phenotypic change in response to noxious stimuli, adopting a quasi-immune cell state; a process known as reactive gliosis. This “activation” of astrocytes accompanies neuropathology, and can be both beneficial and detrimental to resolution of the injury or infection.

In addition to these general functions of astrocytes, Bergmann glia also play a crucial role in directing neuronal migration during development. Granule neuron precursor cells in the immature cerebellum are initially positioned as an external layer, but migrate along the radial Bergmann glial fibres (at that stage, lacking microdomain protrusions), to reach the internal granular layer in the adult cerebellum.

Finally, a major development in our understanding of astroglia that has emerged over the last few decades is the realization that these cells also play an active role in modulating neuronal function. In addition to expression of neurotransmitter transporters, astroglial processes also express both ionotropic and metabotropic receptors. These receptors are commonly linked to calcium signalling pathways, and so enable the astrocytes to detect and respond to synaptic transmission.

Calcium elevation can lead to release of neuromodulators from astrocytes that feed back to the neuronal network, modifying activity – a process termed

“gliotransmission” – which has been implicated in a wide range of neuronal processes, including synaptogenesis, neurovascular coupling, synchronization of network activity, and synaptic plasticity (Haydon 2001). In Bergmann glia, disruption of glutamate-evoked calcium signalling causes dysregulation of synaptic transmission to Purkinje neurons and motor defects, confirming the active role that neuron-glia signalling has in establishing proper connectivity and regulation of the cortical microcircuit. It is becoming increasingly clear that such bi-directional communication between neurons and glia is essential for proper cerebellar function, throughout development.

## References

- Bakiri Y, Káradóttir R, Cossell L, Attwell D (2011) Morphological and electrical properties of oligodendrocytes in the white matter of the corpus callosum and cerebellum. *J Physiol* 589:559–573
- Ginhoux F, Lim S, Hoeffel G, Low D, Huber T (2013) Origin and differentiation of microglia. *Front Cell Neurosci* 7:45
- Haydon PG (2001) Glia: listening and talking to the synapse. *Nat Rev Neurosci* 2:185–193
- Hoogland T, Kuhn B (2010) Recent developments in the understanding of astrocyte function in the cerebellum in vivo. *Cerebellum* 9:264–271
- Kettenmann H, Ransom B (2012) *Neuroglia*, 3rd edn. Oxford University Press, New York
- Nishiyama A, Komitova M, Suzuki R, Zhu X (2009) Polydendrocytes (NG2 cells): multifunctional cells with lineage plasticity. *Nat Rev Neurosci* 10:9–22
- Paolicelli RC, Bolasco G, Pagani F, Maggi L, Scianni M, Panzanelli P, Giustetto M, Ferreira TA, Guiducci E, Dumas L, Ragozzino D, Gross CT (2011) Synaptic pruning by microglia is necessary for normal brain development. *Science* 333:1456–1458
- Rowitch DH, Kriegstein AR (2010) Developmental genetics of vertebrate glial-cell specification. *Nature* 468:214–222

# Chapter 28

## GABA Pathways and Receptors

Tomoo Hirano

**Abstract** GABAergic neurons including Purkinje cells play critical roles in cerebellar neuronal circuits. In the cerebellar cortex, molecular layer interneurons (stellate and basket cells) provide feedforward inhibitory loops between parallel fibers and Purkinje cells, and granular layer interneurons (Golgi cells) form feedback inhibition loops between granule cells. Some GABAergic neurons in the cerebellar nuclei inhibit inferior olive neurons, which send excitatory climbing fibers to the cerebellum. The cerebellar nuclear neurons and Purkinje cells are rare examples of GABAergic projection neurons. Cerebellar neurons express various types of ionotropic and metabotropic GABA receptors, which mediate the effects of GABA, and granule cells express extrasynaptic ionotropic GABA receptors that play a role in tonic inhibition. Both excitatory synapses on GABAergic neurons and GABAergic synapses show neuronal activity dependent plasticity, which contribute to motor learning. Several types of mutant mice defective in GABAergic neurons or synaptic functions have been found or generated, and they show failures in motor coordination and/or motor learning. Dysfunctions of cerebellar GABAergic system have been suggested to be causes of ataxia, and a GABA-mimetic drug improves motor coordination in some ataxic patients.

**Keywords** GABA • GABA<sub>A</sub> receptor • GABA<sub>B</sub> receptor • Purkinje cell • Stellate cell • Basket cell • Golgi cell

### 28.1 GABA Pathways in the Cerebellum

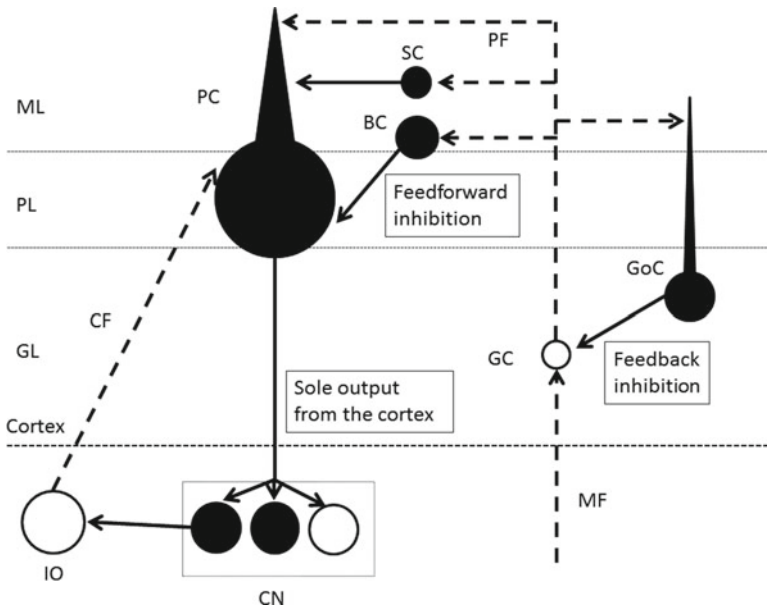
There are several types of GABAergic inhibitory neurons in the cerebellum (Fig. 28.1). Among them, Purkinje cells are sole output neurons of the cortex and send output to the deep cerebellar nuclei. Other GABAergic neurons are the interneurons, stellate, basket cells, and Golgi cells. Major inputs to the cerebellum are

---

T. Hirano (✉)

Department of Biophysics, Graduate School of Science, Kyoto University,  
Sakyo-ku, Kyoto 606-8502, Japan  
e-mail: [thirano@neurosci.biophys.kyoto-u.ac.jp](mailto:thirano@neurosci.biophys.kyoto-u.ac.jp)





**Fig. 28.1** Cerebellar neuronal circuits. *Filled* and *open* symbols represent GABAergic and glutamatergic neurons, respectively, and *solid* and *broken lines* indicate GABAergic and glutamatergic axons, respectively. *ML* molecular layer, *PL* Purkinje cell layer, *GL* granular layer, *IO* inferior olive nuclei, *CN* cerebellar nuclei, *CF* climbing fiber, *MF* mossy fiber, *PF* parallel fiber, *PC* Purkinje cell, *SC* stellate cell, *BC* basket cell, *GC* granule cell, *GoC* Golgi cell

glutamatergic and come through the excitatory mossy and climbing fibers. Mossy fibers form synapses on granule cells in the cortical granular layer and also on neurons in the cerebellar nuclei. A granule cell extends an axon to the molecular layer, where it forms a parallel fiber that sends excitatory glutamatergic output to Purkinje cells and also to two types of GABAergic interneurons, stellate and basket cells, which in turn send inhibitory output to Purkinje cells. A basket cell forms synapses on the axon hillocks of Purkinje cells and effectively suppresses action potential generation. On the other hand, a stellate cell forms synapses on dendrites of Purkinje cells and might selectively suppress the effect of nearby parallel fiber synapses. Stellate and basket cells form feed-forward inhibitory loops between parallel fibers and Purkinje cells. Golgi cells are located in the granular layer. They receive parallel fiber input and inhibit granule cells, thus forming an inhibitory feedback loop.

There are glutamatergic and GABAergic neurons in the deep cerebellar nuclei, and some of them are regulated by GABAergic output of Purkinje cells. One type of GABAergic nuclear neuron sends output to the inferior olive nuclei, which in turn send climbing fibers to the cerebellum. Purkinje cells and GABAergic nuclear neurons innervating the inferior olive are rare examples of inhibitory projection neurons in the central nervous system.

## 28.2 GABA Receptors in the Cerebellum

GABA receptors, which mediate the effects of GABA, are classified into ionotropic GABA<sub>A</sub> and GABA<sub>C</sub> receptors, and metabotropic GABA<sub>B</sub> receptors. An ionotropic GABA receptor is composed of five subunits. There are 19 genes for ionotropic GABA receptor subunits. They are  $\alpha$ 1-6,  $\beta$ 1-3,  $\gamma$ 1-3,  $\delta$ ,  $\epsilon$ ,  $\theta$ ,  $\pi$ , and three types of  $\rho$  subunits.  $\rho$  subunits form GABA<sub>C</sub> receptors, and others form GABA<sub>A</sub> receptors (Olsen and Sieghart 2009). The majority of GABA<sub>A</sub> receptors are composed of  $\alpha$ ,  $\beta$  and  $\gamma$  subunits. GABA<sub>A</sub> receptors consisting of different subunits contribute to differential effects of GABA in the cerebellum (Wisden et al. 1996). A Purkinje cell expresses  $\alpha$ 1,  $\beta$ 2,  $\beta$ 3 and  $\gamma$ 2 subunits; basket and stellate cells express  $\alpha$ 1,  $\beta$ 2 and  $\gamma$ 2 subunits; a granule cell expresses  $\alpha$ 1,  $\alpha$ 6,  $\beta$ 2,  $\beta$ 3,  $\gamma$ 2 and  $\delta$  subunits. In a granule cell,  $\alpha$ 1,  $\alpha$ 6,  $\beta$ 2 and  $\gamma$ 2 subunits are found in synapses formed by a Golgi cell and also on extrasynaptic membrane at low levels. The  $\delta$ -containing GABA receptors are found only on extrasynaptic membrane and show single channel currents with small conductance, long open time and little desensitization, contributing tonic inhibition of a granule cell (Olsen and Sieghart 2009).

The metabotropic GABA<sub>B</sub> receptors are hetero-dimers composed of GABA<sub>B1</sub> and GABA<sub>B2</sub>, and coupled with Gi protein suppressing the activity of adenylyl cyclase. Both GABA<sub>B1</sub> and GABA<sub>B2</sub> show high level expression around glutamatergic synapses between parallel fibers and a Purkinje cell. Presynaptically, GABA<sub>B</sub> receptors are found on extrasynaptic membrane of parallel fibers, and postsynaptically both on postsynaptic and extrasynaptic membrane of a Purkinje cell (Lujan and Shigemoto 2006). These GABA<sub>B</sub> receptors around glutamatergic synapses seem to be activated by ambient GABA. Granule, basket, stellate and Golgi cells also express GABA<sub>B</sub> receptors.

## 28.3 Regulation of GABAergic Neurons and Synapses

Firing patterns of cerebellar GABAergic neurons are modulated by neuronal activities. Synaptic transmission between parallel fibers and a Purkinje cell undergoes long-term depression after coupled activation of parallel fibers and a climbing fiber. Long-term depression has been considered as a primary cellular mechanism for motor learning. Parallel fiber input to a stellate cell is also modulated by activities of parallel and climbing fibers (Dean et al. 2010).

GABAergic synapses in the cerebellum also show plasticity. Synaptic transmission between a stellate cell and a Purkinje cell undergoes short-term and long-term plasticity depending on neuronal activities (Hirano and Kawaguchi 2014). Among them, rebound potentiation is long-lasting potentiation of the GABAergic transmission. It is induced by the climbing fiber activity followed by the increase in intracellular Ca<sup>2+</sup> concentration of a Purkinje cell. Both rebound potentiation at GABAergic synapses and long-term depression at excitatory synapses work to depress the

activity of a Purkinje cell depending on the climbing fiber input, which suggests a possible cooperation of the two types of synaptic plasticity in the cortical information processing. Indeed, suppression of rebound potentiation affects motor learning (Tanaka et al. 2013). Synaptic plasticity has also been reported at GABAergic and glutamatergic synapses in the cerebellar nuclei, and GABAergic Purkinje cell output is involved in regulation of synaptic plasticity (Zeng and Raman 2010).

## 28.4 Mutant Mice Affected in GABAergic Neurons or GABA Receptors

There are some mutant mouse lines affected in GABAergic neurons or synapses in the cerebellum. Lurcher mice and Purkinje cell degeneration (PCD) mice lose most of Purkinje cells during development and show motor dis-coordination. A transgenic mouse line in which Golgi cells can be ablated at a desired timing was raised (Watanabe et al. 1998). Golgi-cell ablation induces severe motor dis-coordination followed by partial recovery, which is accompanied with suppressed NMDA-receptor mediated synaptic response in granule cells. This suppression of excitatory response seems to counteract the loss of GABAergic inhibition caused by Golgi cell ablation, and to contribute to the partial recovery of motor coordination.

Transgenic mouse lines in which GABAergic synaptic transmission onto Purkinje cells are depressed have also been generated. In one type, GABA<sub>A</sub> receptor  $\gamma 2$  subunit was knocked out (Wulff et al. 2009). The mice show suppressed GABAergic synaptic response in a Purkinje cell and motor learning defects. However, they show apparently normal motor coordination. A previous study reported that acute suppression of GABAergic synaptic transmission by drug application causes severe motor dis-coordination (Wulff et al. 2007). Therefore, relatively mild effect of chronic suppression of GABAergic transmission might be ascribed to some compensatory mechanisms in the cerebellum.

## 28.5 GABA in Cerebellar Ataxia

As mice models with defects in GABAergic neurons or synapses show motor dis-coordination and/or motor learning failures, some dysfunction in the cerebellar GABAergic systems might be a cause of cerebellar ataxia in human patients. Indeed, some patients have auto-antibody against glutamate decarboxylase, an enzyme catalyzing production of GABA from glutamate (Vianello et al. 2003). The antibody suppresses GABA release from basket cells depressing inhibitory synaptic transmission to Purkinje cells. An agrypnia patient showing ataxia has auto-antibody against GABA<sub>B</sub> receptor, which might affect GABA systems in the cerebellum (Frisullo et al. 2007).

In a mouse model of episodic ataxia type 1, mutation of K<sup>+</sup> channel increases the frequency and amplitude of spontaneous GABAergic synaptic currents in a Purkinje cell, which might be a cause of episodic ataxia (Herson et al. 2003). On the other hand, GABA-mimetic drug gabapentin improves motor coordination in some spinocerebellar ataxia type 6 patients (Nakamura et al. 2009), suggesting that drug treatment to support GABA system is therapeutically effective in some ataxic patients.

## References

- Dean P, Porrill J, Ekerot CF, Jörntell H (2010) The cerebellar microcircuit as an adaptive filter: experimental and computational evidence. *Nat Rev Neurosci* 11:30–43
- Frisullo G, Marca GD, Mirabella M, Caggiula M, Broccolini A, Rubino M, Mennuni G, Tonali PA, Batocchi AP (2007) A human anti-neuronal autoantibody against GABA<sub>B</sub> receptor induces experimental autoimmune agrypnia. *Exp Neurol* 204:808–818
- Herson PS, Virk M, Rustay N, Bond CT, Crabbe JC, Adelman JP, Maylie J (2003) A mouse model of episodic ataxia type-1. *Nat Neurosci* 6:378–383
- Hirano T, Kawaguchi S (2014) Regulation and functional roles of rebound potentiation at cerebellar stellate cell – Purkinje cell synapses. *Front Cell Neurosci* 8(42):1–8
- Lujan R, Shigemoto R (2006) Localization of metabotropic GABA receptor subunits GABA<sub>B1</sub> and GABA<sub>B2</sub> relative to synaptic sites in the rat developing cerebellum. *Eur J Neurosci* 23:1479–1490
- Nakamura K, Yoshida K, Miyazaki D, Morita H, Ikeda S (2009) Spinocerebellar ataxia type 6 (SCA6): clinical pilot trial with gabapentin. *J Neurol Sci* 278:107–111
- Olsen RW, Sieghart W (2009) GABA<sub>A</sub> receptors: subtypes provide diversity of function and pharmacology. *Neuropharmacology* 56:141–148
- Tanaka S, Kawaguchi S, Shioi G, Hirano T (2013) Long-term potentiation of inhibitory synaptic transmission onto cerebellar Purkinje neurons contributes to adaptation of vestibulo-ocular reflex. *J Neurosci* 33:17209–17220
- Vianello M, Tavalato B, Armani M, Giometto B (2003) Cerebellar ataxia associated with anti-glutamic acid decarboxylase autoantibodies. *Cerebellum* 2:77–79
- Watanabe D, Inokawa H, Hashimoto K, Suzuki N, Kano M, Shigemoto R, Hirano T, Toyama K, Kaneko S, Yokoi M, Moriyoshi K, Suzuki M, Kobayashi K, Nagatsu T, Kreitman RJ, Pastan I, Nakanishi S (1998) Ablation of cerebellar Golgi cells disrupts synaptic integration involving GABA inhibition and NMDA receptor activation in motor coordination. *Cell* 95:17–28
- Wisden W, Korpi ER, Bahn S (1996) The cerebellum: a model system for studying GABA<sub>A</sub> receptor diversity. *Neuropharmacology* 35:1139–1160
- Wulff P, Goetz T, Leppa E, Linden A, Renzi M, Swinney JD, Vekovischeva OY, Sieghart W, Somogyi P, Korpi ER, Farrant M, Wisden W (2007) From synapse to behavior: rapid modulation of defined neuronal types with engineered GABA<sub>A</sub> receptors. *Nat Neurosci* 10:923–929
- Wulff P, Schonewille M, Renzi M, Viltono L, Sassoè-Pognetto M, Badura A, Gao Z, Hoebeek F, van Dorp S, Wisden W, Farrant M, De Zeeuw C (2009) Synaptic inhibition of Purkinje cells mediates consolidation of vestibulo-cerebellar motor learning. *Nat Neurosci* 12:1042–1049
- Zeng N, Raman IM (2010) Synaptic inhibition, excitation, and plasticity in neurons of the cerebellar nuclei. *Cerebellum* 9:56–66

# Chapter 29

## Glutamatergic Pathways and Receptors

Susumu Tomita

**Abstract** Glutamate is a major excitatory neurotransmitter in the vertebrate brain and is utilized at distinct synapses in the cerebellum. Glutamate released from pre-synaptic terminals binds to various types and classes of glutamate receptors at pre- and postsynapses. Glutamate receptors are classified as metabotropic (mGluR) or ionotropic (iGluR). iGluRs function as glutamate-gated cation channels and are classified pharmacologically as AMPA-, NMDA-, or kainite-types. AMPA receptors determine synaptic strength, whereas NMDA receptors induce synaptic plasticity. Kainate receptors play multiple roles in regulating synaptic transmission and plasticity. mGluRs are G protein-coupled receptors that modulate postsynaptic signaling by the type I mGluRs through Gq signaling and modulate glutamate release via the type II and III mGluRs acting via Gi/o signaling. Combinatory action among the glutamate receptors coordinates synaptic transmission and synaptic plasticity. Disruption of receptor activities causes various neurological disorders including epilepsy, mental retardation and neurodegenerative diseases, and controlling glutamate receptor activities is used as a therapeutic strategy for these disorders. This chapter covers topics of glutamate receptors and its auxiliary subunits.

**Keywords** Glutamate receptor • Synapse • Metabotropic glutamate receptor • AMPA receptor • Kainate receptor • NMDA receptor

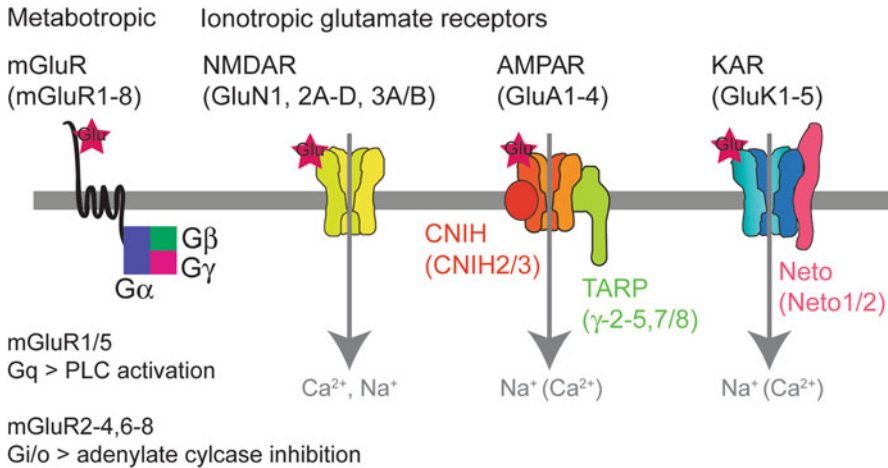
### 29.1 Glutamatergic Pathways and Synaptic Transmission

Neurons communicate with each other at synapses through the release and uptake of neurotransmitters. One major excitatory neurotransmitter in the vertebrate brain is glutamate. In the cerebellum, glutamate is used as a neurotransmitter at various synapses such as mossy fiber to granule cells, parallel fiber to Golgi cells, parallel fiber to stellate cells, parallel fiber to Basket cells, parallel fiber to Purkinje cells,

---

S. Tomita (✉)

Program in Cellular Neuroscience, Neurodegeneration and Repair (CNNR), Department of Cellular and Molecular Physiology, Yale University School of Medicine, 295 Congress Avenue BCMM441, New Haven, CT 06510, USA  
e-mail: [Susumu.Tomita@yale.edu](mailto:Susumu.Tomita@yale.edu)



**Fig. 29.1** Glutamate receptor complex. Glutamate receptors are classified as metabotropic and ionotropic receptors. mGluRs mediates various G protein signaling dependent on mGluR isoforms. Each ionotropic receptor is a hetero-tetramer with distinct auxiliary subunits that modulate receptor properties and/or localization. AMPA receptor (AMPA) interacts with transmembrane AMPA receptor regulatory protein (TARP) and kainate receptor (KAR) interacts with Neuropilin and Tolloid-like protein (Neto)

and climbing fiber to Purkinje cells (Ito 2006; Jakab and Hamori 1988). Synaptic transmission is initiated when glutamate is released from the presynaptic terminals upon depolarization of the terminals by the arrival of an action potential. Subsequently, glutamate binds to and activates glutamate receptors at pre- and post-synaptic membranes. At each synapse, unique classes of glutamate receptors are expressed and localized to mediate characteristic synaptic properties.

## 29.2 Glutamate Receptors

The various subtypes of metabotropic and ionotropic glutamate receptors are illustrated in Fig. 29.1 (Hollmann and Heinemann 1994; Nakanishi 1992; Wisden and Seeburg 1993).

### 29.2.1 Metabotropic Glutamate Receptors (mGluRs)

mGluRs are classic G protein-coupled receptors (GPCRs) that contain a conserved seven transmembrane domain and play major roles in modulating intracellular second messenger signaling. Upon glutamate binding, type I (1/5) mGluR activates protein kinase C (PKC) and inositol triphosphate (IP<sub>3</sub>) signaling through

Gq-mediated phospholipase C (PLC) activation. Subsequently, the phosphorylation of PKC substrates or an increase in intracellular calcium ( $\text{Ca}^{2+}$ ) mediated via IP3 receptors modulates postsynaptic functions. Type II (2/3) and III (4/6/7/8) mGluRs couple with Gi/o to reduce cAMP levels through Gi/o-mediated adenylate cyclase inhibition. In addition, type II/III mGluRs are primarily localized on presynaptic membranes where these receptors modulate neurotransmitter release.

mGluRs are implicated in various neurological diseases, including depression, schizophrenia, pain, epilepsy and neurodegenerative diseases (Bear et al. 2004; Niswender and Conn 2010). The disruption of mGluR expression is associated with multiple neurological diseases. For example, mGluR1 knockout mice show severe ataxia (Aiba et al. 1994). In addition, the disruption of mGluR functions is observed in Fragile X mental retardation, and mGluR5 knockout mice show mental retardation-like phenotypes (Bear et al. 2004; Dolen et al. 2007). Therefore, mGluRs are recognized as a therapeutic target for the treatment of various neurological disorders.

## 29.2.2 *Ionotropic Glutamate Receptors (iGluRs)*

iGluRs are glutamate-gated cationic channels and are further classified pharmacologically as AMPA-, NMDA-, and kainate-sensitive glutamate receptors (Fig. 29.1) (Hollmann and Heinemann 1994; Nakanishi 1992; Wisden and Seeburg 1993). The AMPA and kainate receptors can be activated by glutamate at the neuron resting potential of approximately  $-70$  mV. In contrast, at the resting potential magnesium ( $\text{Mg}^{2+}$ ) binds to the NMDA receptor to block the channel pore preventing a response to glutamate. Upon membrane depolarization by repetitive stimulation,  $\text{Mg}^{2+}$  is removed from the NMDA receptor, enabling activation of the receptor. The activated NMDA receptor possesses high  $\text{Ca}^{2+}$  conductivity, which is implicated in synaptic plasticity. All iGluR subunits have three transmembrane domains with 1 pore-loop, and a tetramer of these receptors forms a glutamate-gated cationic channel. In the brain, several iGluRs contain auxiliary subunits that stably bind to the receptors and modulate receptor localization and/or channel properties including pharmacology and activity.

### 29.2.2.1 AMPA Receptors (AMPA Rs)

AMPA Rs are composed of four subunits (GluA1-4), and all AMPA Rs can form homotetramers. However, in hippocampal and other neurons, AMPA Rs form heteromeric  $\text{Ca}^{2+}$ -impermeable channels of GluA2 with GluA1/3/4 (Sommer and Seeburg 1992). Importantly, GluA2 is subjected to RNA editing and the resulting protein has an R (glutamine) instead of a Q (arginine) in the pore-loop. This R/Q editing affects the ion permeability as GluA2(R) is  $\text{Ca}^{2+}$  impermeable, whereas GluA2(Q) is  $\text{Ca}^{2+}$  permeable. Several neurons, including cerebellar stellate cells,

express  $\text{Ca}^{2+}$ -permeable AMPARs, indicating that GluA2 is absent in these AMPARs (Liu and Cull-Candy 2000). Furthermore, to add to the complexity of this system, each subunit has splicing isoforms, termed the flip/flop isoforms, and the splicing site is located on the extracellular domain and modulates receptor kinetics (Sommer and Seeburg 1992).

In the brain, AMPARs contain auxiliary subunits (e.g., TARPs, CNIHs and CKAMP44) (Jackson and Nicoll 2011; Yan and Tomita 2012). TARPs have six isoforms ( $\gamma$ -2/3/4/5/7/8) that display distinct expression patterns in the brain, whereas CNIHs and CKAMP44 are abundantly expressed in the hippocampus. TARPs interact with AMPARs to modulate receptor properties, pharmacology and localization. For example, no synaptic AMPAR activity is observed in the cerebellar granule cells and in Purkinje cells disrupting expression of TARP $\gamma$ -2 and both  $\gamma$ -2/7, respectively (Hashimoto et al. 1999; Yamazaki et al. 2010), indicating essential roles of TARPs in synaptic AMPAR activity. Furthermore, AMPARs expressed in heterologous cells do not respond to kainic acid, whereas both native AMPAR in the brain and AMPAR co-expressed with TARPs respond to kainic acid (Tomita et al. 2005). To study AMPAR in the brain, the incorporation of TARPs into the receptors is required.

#### 29.2.2.2 NMDA Receptors (NMDARs)

NMDAR is a heteromer of GluN1 and GluN2/3 that has high  $\text{Ca}^{2+}$  permeability. Due to the blockage of the channel pore by  $\text{Mg}^{2+}$  at the resting potential, both glutamate binding and  $\text{Mg}^{2+}$  removal by membrane depolarization are required for NMDAR activation.  $\text{Ca}^{2+}$  influx through NMDAR plays critical roles in synaptic plasticity. In long-term potentiation (LTP), postsynaptic  $\text{Ca}^{2+}$  through NMDAR activates calmodulin (CaM) kinase II to increase synaptic AMPARs.

#### 29.2.2.3 Kainate Receptors (KARs)

KARs have five isoforms (GluK1-5). GluK1-3 form a homo-tetramer; however, GluK4/5 cannot form a tetramer and require GluK1-3 to function as a hetero-tetramer. Similar to AMPARs, GluK1-3 can be subjected to Q/R editing to alter  $\text{Ca}^{2+}$  permeability. Unlike AMPARs, KARs localize at both pre- and postsynapses (Lerma 2006; Nicoll and Schmitz 2005). At presynapses, KARs function as auto-receptors to modulate glutamate release, and at post-synapses, KARs function as membrane depolarizers, similar to AMPARs. Furthermore, KARs and AMPARs play redundant roles at post-synapses (Yan et al. 2013). In addition, KARs display distinctly slow kinetics, which are determined by Neto1/2 auxiliary subunits (Copits and Swanson 2012; Tomita and Castillo 2012). Neto1/2 interacts with KARs and slows the decay kinetics of synaptic KARs without changes in KAR localization.



### 29.3 Concluding Remarks

At excitatory synapses in the cerebellum, glutamate binds to various types and classes of glutamate receptors. Each of these receptors shows distinct expression, localization and properties, and combinatory receptor activity causes excitatory synaptic transmission. In addition to neurons, Bergmann glia also express glutamate receptors and modulate synaptic transmission. Furthermore, glutamate receptor disruption causes various neurological disorders. For example, the disruption of NMDAR or both AMPAR and KAR causes mouse lethality, whereas TARP $\gamma$ -2 disruption causes severe ataxia phenotypes. Furthermore, genome-wide association study (GWAS) findings have identified mutations in these receptor components in various neurological disorders, including schizophrenia, epilepsy and ataxia; therefore, glutamate receptor complex components are considered to be drug targets for neurological disorders.

### References

- Aiba A, Kano M, Chen C, Stanton ME, Fox GD, Herrup K, Zwingman TA, Tonegawa S (1994) Deficient cerebellar long-term depression and impaired motor learning in mGluR1 mutant mice. *Cell* 79:377–388
- Bear MF, Huber KM, Warren ST (2004) The mGluR theory of fragile X mental retardation. *Trends Neurosci* 27:370–377
- Copits BA, Swanson GT (2012) Dancing partners at the synapse: auxiliary subunits that shape kainate receptor function. *Nat Rev Neurosci* 13:675–686
- Dolen G, Osterweil E, Rao BS, Smith GB, Auerbach BD, Chattarji S, Bear MF (2007) Correction of fragile X syndrome in mice. *Neuron* 56:955–962
- Hashimoto K, Fukaya M, Qiao X, Sakimura K, Watanabe M, Kano M (1999) Impairment of AMPA receptor function in cerebellar granule cells of ataxic mutant mouse stargazer. *J Neurosci* 19:6027–6036
- Hollmann M, Heinemann S (1994) Cloned glutamate receptors. *Annu Rev Neurosci* 17:31–108
- Ito M (2006) Cerebellar circuitry as a neuronal machine. *Prog Neurobiol* 78:272–303
- Jackson AC, Nicoll RA (2011) The expanding social network of ionotropic glutamate receptors: TARPs and other transmembrane auxiliary subunits. *Neuron* 70:178–199
- Jakab RL, Hamori J (1988) Quantitative morphology and synaptology of cerebellar glomeruli in the rat. *Anat Embryol (Berl)* 179:81–88
- Jerma J (2006) Kainate receptor physiology. *Curr Opin Pharmacol* 6:89–97
- Liu SQ, Cull-Candy SG (2000) Synaptic activity at calcium-permeable AMPA receptors induces a switch in receptor subtype. *Nature* 405:454–458
- Nakanishi S (1992) Molecular diversity of glutamate receptors and implications for brain function. *Science* 258:597–603
- Nicoll RA, Schmitz D (2005) Synaptic plasticity at hippocampal mossy fibre synapses. *Nat Rev Neurosci* 6:863–876
- Niswender CM, Conn PJ (2010) Metabotropic glutamate receptors: physiology, pharmacology, and disease. *Annu Rev Pharmacol Toxicol* 50:295–322
- Sommer B, Seeburg PH (1992) Glutamate receptor channels: novel properties and new clones. *Trends Pharmacol Sci* 13:291–296

- Tomita S, Castillo PE (2012) Neto1 and Neto2: auxiliary subunits that determine key properties of native kainate receptors. *J Physiol* 590:2217–2223
- Tomita S, Adesnik H, Sekiguchi M, Zhang W, Wada K, Howe JR, Nicoll RA, Brecht DS (2005) Stargazin modulates AMPA receptor gating and trafficking by distinct domains. *Nature* 435:1052–1058
- Wisden W, Seeburg PH (1993) Mammalian ionotropic glutamate receptors. *Curr Opin Neurobiol* 3:291–298
- Yamazaki M, Fukaya M, Hashimoto K, Yamasaki M, Tsujita M, Itakura M, Abe M, Natsume R, Takahashi M, Kano M et al (2010) TARPs gamma-2 and gamma-7 are essential for AMPA receptor expression in the cerebellum. *Eur J Neurosci* 31:2204–2220
- Yan D, Tomita S (2012) Defined criteria for auxiliary subunits of glutamate receptors. *J Physiol* 590:21–31
- Yan D, Yamasaki M, Straub C, Watanabe M, Tomita S (2013) Homeostatic control of synaptic transmission by distinct glutamate receptors. *Neuron* 78:687–699

# Chapter 30

## Norepinephrine and Synaptic Transmission in the Cerebellum

Gerard Zitnik, Daniel J. Chandler, and Barry D. Waterhouse

**Abstract** Although the presence of norepinephrine (NE) in the mammalian cerebellum was initially controversial, there is now substantial evidence of a role for the NE system in modulating the response properties of individual cerebellar neurons to synaptic inputs rather than transmitting moment-to-moment details of modality specific information. As a result of these cellular actions the system is capable of regulating cerebellar circuit functions within the context of ongoing voluntary and reflex motor activities and in a manner appropriate to the behavioral state of the organism. The evidence for this mode of operation derives from extensive anatomical, physiological and pharmacological investigations over a period of more than 40 years. This chapter summarizes those studies and the development of this concept.

**Keywords** Noradrenergic • Locus coeruleus • Neuromodulation • Purkinje cells • Coeruleo-cerebellar pathway

---

G. Zitnik

Division of Stress Neurobiology, Department of Anesthesiology, Abramson Research Center, Children's Hospital of Philadelphia, 3416 Civic Center Blvd., Suite 402A, Philadelphia, PA 19106, USA  
e-mail: [zitnikg@email.chop.edu](mailto:zitnikg@email.chop.edu)

D.J. Chandler

Center for Neurobiology and Behavior, Department of Psychiatry, Translational Research Laboratories, University of Pennsylvania, 125 S 31st Street, Philadelphia, PA 191043, USA  
e-mail: [dancha@mail.med.upenn.edu](mailto:dancha@mail.med.upenn.edu)

B.D. Waterhouse (✉)

Department of Neurobiology and Anatomy, Drexel University College of Medicine, 2900 Queen Lane, Philadelphia, PA 19129, USA  
e-mail: [waterhouse@drexelmed.edu](mailto:waterhouse@drexelmed.edu)

## 30.1 Anatomical Considerations

Early fluorescent histochemical (Anden et al. 1967) and biochemical (Iversen and Glowinski 1966) studies provided the first evidence of norepinephrine (NE)-containing fibers within the cerebellar cortex. Later anatomical, physiological, and pharmacological experiments (Bloom et al. 1971; Hoffer et al. 1971a, b; Siggins et al. 1971a, b) confirmed the existence of a prominent NE pathway from the brainstem nucleus locus coeruleus (LC) to all regions of the cerebellar cortex and deep cerebellar nuclei (Olson and Fuxe 1971). Within the cortex, NE fibers arising from LC terminate primarily in the inner portion of the molecular, granule and Purkinje cell layers, with no contact made in the cerebellar white matter (Bloom et al. 1971). The pathway arises exclusively from NE-containing cell bodies in the ipsilateral LC and axons are distributed to virtually every Purkinje cell in every region of the cerebellar cortex. Because of the small number of LC neurons, approximately 1600 per nucleus in rat (Swanson and Hartman 1975), and the broad expanse of cerebellar tissue, it must be assumed that individual LC cells give rise to axons that collateralize extensively throughout the cerebellum.

## 30.2 Physiology of NE in Cerebellum

NE was initially viewed as an inhibitory transmitter in the cerebellum. However, later studies demonstrated differential effects of NE on spontaneous and evoked discharge of Purkinje neurons that are best described as neuromodulatory (Freedman et al. 1977; Moises et al. 1979; Woodward et al. 1979). NE suppresses Purkinje cell spontaneous discharge but reduces mossy fiber- or climbing fiber evoked excitation to a lesser extent or not all, yielding a net increase in signal to noise ratio, i.e. the ratio of the change in stimulus evoked versus spontaneous discharge. In addition, NE augments inhibitory responses of Purkinje neurons to afferent pathway stimulation (Freedman et al. 1976, 1977). Thus, NE is capable of producing a relative or absolute enhancement of stimulus driven activity in the primary output cells of the cerebellar cortex. Beyond these actions, a 'gating' effect has been observed whereby Purkinje cells exhibiting little or no response to peripheral stimuli become responsive to such inputs in the presence of NE (cf Fig. 5 – Moises et al. 1990). Collectively the evidence indicates that NE can produce a spectrum of effects on spontaneous and evoked discharge of Purkinje neurons, all of which serve to regulate the responsiveness of these cells to synaptically-driven inputs.

Further tests showed that NE's neuromodulatory action on inhibitory transmission was specific for GABA. For example, Moises et al. (1979) showed that glycine-induced inhibition of Purkinje cell firing was not enhanced by NE application and Yeh et al. (1981) showed that NE did not enhance Purkinje cell inhibition elicited by direct application of taurine or beta-alanine, inhibitory amino acids that are structurally similar to GABA. Despite these demonstrations of specificity for GABA, NE can also enhance Purkinje neuron responses to the excitatory amino acid transmitter glutamate (Moises et al. 1979). Importantly, the facilitating effects of NE on amino acid evoked responses in Purkinje neurons have been demonstrated in waking ani-

mals (West and Woodward 1984) suggesting these actions are indeed physiologically relevant.

Activation of the noradrenergic input pathway from the LC results in modulatory actions similar to those observed following local application of NE to Purkinje neurons. For example, phasic patterns of LC electrical stimulation that mimic physiologic discharge along the coeruleo-cerebellar pathway result in prominent modulation of Purkinje neuron responses to excitatory and inhibitory synaptic inputs; both climbing fiber and parallel fiber excitation as well as inhibition mediated by local inhibitory interneurons (cf Fig. 5- Moises et al. 1981, cf Fig. 2 – 1983). In addition, LC stimulation increases the probability of Purkinje cell discharge in response to otherwise sub-threshold activation of the climbing fiber input pathway (cf Fig. 5 – Moises et al. 1981). As in other brain regions (Berridge and Waterhouse 2003), these LC-NE modulatory effects follow an inverted-U function (Moises et al. 1981) suggesting that state dependent fluctuations in LC output can adjust cerebellar circuit operations across a dynamic range, one that is capable of optimizing or minimizing function as behavioral contingencies change.

### 30.3 Noradrenergic Receptors in Cerebellum

The net effect of NE on cerebellar network properties not only depends on the cellular type on which it acts, but also the receptor expression and localization, and concurrent excitatory or inhibitory afferent drive impinging on the neuron. Three main subtypes of adrenergic receptors exist in cerebellum:  $\alpha_1$ ,  $\beta$ , and  $\alpha_2$ , each of which is coupled to a distinct intracellular signaling pathway.

Noradrenergic modulation of inhibitory synaptic activity and GABAergic inhibitory responses in cerebellum are mediated by  $\beta$ -receptor activation (Waterhouse et al. 1982). Binding of NE to this G-protein coupled receptor (GPCR) activates  $G_s$  proteins, stimulating intracellular adenylate cyclase, which produces cAMP and activates protein kinase A (PKA). This leads to downstream phosphorylation of an intracellular domain of the GABA receptor, which increases GABA dependent chloride current leading to greater GABA-mediated hyperpolarization of the neuron (Cheun and Yeh 1996; Sweetnam et al. 1988; Kirkness et al. 1989). The modulatory actions associated with activation of cerebellar  $\alpha_1$  and  $\alpha_2$  receptors are less well characterized, but no doubt contribute to NE regulation of cerebellar function.

### 30.4 Functional Implications

Several reflexes mediated by the cerebellum are modulated by NE, indicating that the effects of NE on individual neuron and neural network properties impact the motor related output of the cerebellum significantly. The vestibular ocular reflex (VOR) stabilizes images on the retina during a head movement by proportionately rotating the eyes in the opposite direction. It has been shown experimentally that  $\beta$  receptor agonists and antagonists are capable of increasing and decreasing,

respectively, the ability of this reflex to keep a visual stimulus stabilized on the retina (van Neeven et al. 1990).

In addition to cerebellar reflexes and general motor coordination, motor learning is also heavily influenced by NE in the cerebellum. It has been shown that rats trained to walk across a series of regularly spaced horizontal pegs are able to perform the same task without impairment following 6-OHDA infusion into the brain to destroy NE fibers. The same held true when the pegs were irregularly spaced before and after 6-OHDA infusion. However, when rats were trained initially to walk across the regularly spaced pegs, then received a NE-specific lesion, and later tested on the irregularly spaced pegs, their performance was significantly lower when compared to those performing the same sequence of tasks without the NE-specific lesion (Watson and McElligott 1984). This suggests that the ability of the rats to learn a novel motor task is largely dependent on projections from the LC-NE system to the cerebellum.

### 30.5 Summary

The cerebellum is prominently innervated by NE fibers arising from the brainstem nucleus LC. The responses of Purkinje neurons in the cerebellar cortex to afferent synaptic inputs are subject to modulation by release of NE from these fibers. Thus, the factors that influence output from the LC also impact the network properties of the cerebellum, e.g. changes in arousal, exposure to stressors. The net outcome of LC-NE regulation of cerebellar circuit operations may be that voluntary and reflex motor activities are optimized with respect to ongoing behaviors and unexpected environmental challenges.

### References

- Anden N, Fuxe K, Ungerstedt U (1967) Monoamine pathways to the cerebellum and cerebral cortex. *Experientia* 23(10):838–839
- Berridge C, Waterhouse B (2003) The locus coeruleus-noradrenergic system: modulation of behavioral state and state-dependent cognitive processes. *Brain Res: Brain Res Rev* 42(1):33–84
- Bloom F, Hoffer B, Siggins G (1971) Studies on norepinephrine-containing afferents to purkinje cells of rat cerebellum. I. Localization of the fibers and their synapses. *Brain Res* 25(3):501–521
- Cheun J, Yeh H (1996) Noradrenergic potentiation of cerebellar Purkinje cell responses to GABA: cyclic AMP as intracellular intermediary. *Neuroscience* 74(3):835–844
- Freedman R, Hoffer BJ, Puro D, Woodward DJ (1976) Noradrenaline modulation of the responses of the cerebellar Purkinje cell to afferent synaptic activity. *Br J Pharmacol* 57(4):603–605
- Freedman R, Hoffer B, Woodward D, Puro D (1977) Interaction of norepinephrine with cerebellar activity evoked by mossy and climbing fibers. *Exp Neurol* 55(1):269–288
- Hoffer B, Siggins G, Bloom F (1971a) Studies on norepinephrine-containing afferents to purkinje cells of rat cerebellum. II. Sensitivity of Purkinje cells to norepinephrine and related substances administered by microiontophoresis. *Brain Res* 25(3):523–534

- Hoffer B, Siggins G, Woodward D, Bloom F (1971b) Spontaneous discharge of Purkinje neurons after destruction of catecholamine-containing afferents by 6-hydroxydopamine. *Brain Res* 30(2):425–430
- Iversen L, Glowinski J (1966) Regional studies of catecholamines in the rat brain – II. *J Neurochem* 13(8):671–682
- Kirkness E, Bovenkerk C, Ueda T, Turner A (1989) Phosphorylation of gamma-aminobutyrate (GABA)/benzodiazepine receptors by cyclic AMP-dependent protein kinase. *Biochem J* 259(2):613–616
- Moises H, Woodward D, Hoffer B, Freedman R (1979) Interactions of norepinephrine with Purkinje cell responses to putative amino acid neurotransmitters applied by microiontophoresis. *Exp Neurol* 64(3):493–515
- Moises H, Waterhouse B, Woodward D (1981) Locus coeruleus stimulation potentiates purkinje cell responses to afferent input: the climbing fiber system. *Brain Res* 222(1):43–64
- Moises H, Waterhouse B, Woodward D (1983) Locus coeruleus stimulation potentiates local inhibitory processes in rat cerebellum. *Brain Res Bull* 10(6):795–804
- Moises H, Burne R, Woodward D (1990) Modification of visual response properties of cerebellar neurons by norepinephrine. *Brain Res* 514(2):259–275
- Olson L, Fuxe K (1971) On the projections from the locus coeruleus noradrenaline neurons: the cerebellar innervation. *Brain Res* 28(1):165–171
- Siggins G, Hoffer B, Bloom F (1971a) Studies on norepinephrine-containing afferents to Purkinje cells of rat cerebellum. 3. Evidence for mediation of norepinephrine effects by cyclic 3',5'-adenosine monophosphate. *Brain Res* 25(3):535–553
- Siggins G, Oliver A, Hoffer B, Bloom F (1971b) Cyclic adenosine monophosphate and norepinephrine: effects on transmembrane properties of cerebellar Purkinje cells. *Science* 171(967):192–194
- Swanson L, Hartman B (1975) The central adrenergic system. An immunofluorescence study of the location of cell bodies and their efferent connections in the rat utilizing dopamine- $\beta$ -hydroxylase as a marker. *J Comp Neurol* 163(4):467–505
- Sweetnam P, Lloyd J, Gallombardo P, Malison R, Gallager D, Tallman J, Nestler E (1988) Phosphorylation of the GABA<sub>A</sub>/benzodiazepine receptor alpha subunit by a receptor-associated protein kinase. *J Neurochem* 51(4):1274–1284
- van Neeven J, Pompeiano O, Collewijn H, van der Steen J (1990) Injections of beta-noradrenergic substances in the flocculus of rabbits affect adaptation of the VOR gain. *Exp Brain Res* 79(2):249–260
- Waterhouse B, Moises H, Yeh H, Woodward D (1982) Norepinephrine enhancement of inhibitory synaptic mechanisms in cerebellum and cerebral cortex: mediation by beta adrenergic receptors. *J Pharmacol Exp Ther* 221(2):495–506
- Watson M, McElligott J (1984) Cerebellar norepinephrine depletion and impaired acquisition of specific locomotor tasks in rats. *Brain Res* 296(1):129–138
- West M, Woodward D (1984) Iontophoresis in the freely moving rat: norepinephrine in the cerebellum. *Soc Neurosci Abstr* 10:71
- Woodward D, Waterhouse B, Hoffer B, Freedman R (1979) Modulatory actions of norepinephrine in the central nervous system. *Fed Proc* 38(7):2109–2116
- Yeh H, Moises H, Waterhouse B, Woodward D (1981) Modulatory interactions between norepinephrine and taurine,  $\beta$ -alanine,  $\lambda$ -aminobutyric acid and muscimol, applied microiontophoretically to cerebellar Purkinje cells. *Neuropharmacology* 20(6):549–560

# Chapter 31

## Serotonin in the Cerebellum

Marlies Oostland and Johannes A. van Hooft

**Abstract** Serotonin (5-hydroxytryptamine, 5-HT) was first described as the ‘serum tonic factor’, and was therefore named serotonin. Serotonin is widely present in the brain, including in the cerebellum, which is richly innervated by serotonergic fibres. A variety of serotonin receptors mediate the effects of serotonin in the cerebellum. These serotonin receptors all have their own specialized role, but with some similar main effects. It is through the temporally and spatially restricted expression of these different serotonin receptors in the cerebellum that such a widely expressed neurotransmitter as serotonin can exert very specific functions. These functions include regulation of neuronal activity, synaptic transmission and cerebellar development.

**Keywords** Cerebellum • Serotonin • 5-HT<sub>3</sub> receptor • Development • Lugaro cells • Neuromodulation • Synaptic plasticity • Circuit formation • Cerebellar cortex • Deep cerebellar nuclei

### 31.1 Serotonergic Innervation in the Cerebellum

The cerebellum is richly innervated by serotonin: serotonergic fibres are the third main afferent fibres into the cerebellum, after the mossy fibres and the climbing fibres. Serotonergic fibres that innervate the cerebellum originate mainly in the medullary- and pontine reticular formation, although some serotonergic inputs originate from the raphe nuclei and the gigantocellular reticular formation adjacent to the raphe nuclei. These serotonergic fibres form a dense network in the granular

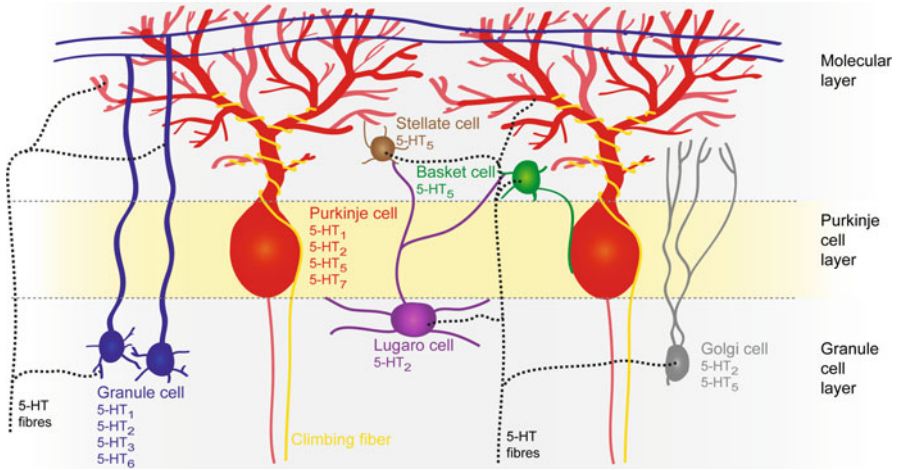
---

M. Oostland  
Swammerdam Institute for Life Sciences, University of Amsterdam,  
P.O. Box 94232, 1090 GE Amsterdam, The Netherlands

Centre for Integrative Physiology, University of Edinburgh,  
Hugh Robson Building Edinburgh EH8 9XD, United Kingdom

J.A. van Hooft (✉)  
Swammerdam Institute for Life Sciences, University of Amsterdam,  
P.O. Box 94232, 1090 GE Amsterdam, The Netherlands  
e-mail: [j.a.vanhooft@uva.nl](mailto:j.a.vanhooft@uva.nl)





**Fig. 31.1** Localization of serotonin receptors in the cerebellar cortex (Reproduced with permission from Oostland and van Hooft 2013, based on Geurts et al. 2002)

layer and are found around the somata of Purkinje cells, and in the overlying molecular layer, which contains the dendrites of Purkinje cells. Serotonin axon terminals innervate Purkinje cell dendrites, granule cell dendrites, parallel fibres, and basket, stellate and Golgi cells. Different serotonin receptors have distinct functions and can mediate both excitatory and inhibitory neurotransmission. The expression of the different serotonin receptors is summarized in Fig. 31.1. There is a great diversity in serotonin receptors, of which serotonin 1–2 and 4–7 receptors are all G protein coupled receptors. The serotonin 3 (5-HT<sub>3</sub>) receptor is the only ligand-gated ion channel for serotonin. Not all receptors are always expressed: some are only present during development while others start to be expressed when the cerebellum reaches a more mature stage (see also Sect. 31.4).

## 31.2 Serotonergic Modulation of the Cerebellar Cortex

In the cerebellar cortex, serotonin depresses Purkinje cell discharges and excites the granule cells (Bloom et al. 1972; Strahlendorf et al. 1979). The reduction in Purkinje cell output due to serotonin occurs by both decreasing excitatory inputs and increasing inhibitory inputs to Purkinje cells. Serotonin can tonically inhibit endogenous glutamate release from parallel fibres to Purkinje cells, via 5-HT<sub>1</sub> and 5-HT<sub>2</sub> receptors (Maura et al. 1988). Application of serotonin results in long-lasting enhancement of GABA-mediated inhibitory postsynaptic currents observed in Purkinje cells (Mitoma et al. 1994). 5-HT<sub>2</sub> receptors expressed by granule cells are involved in mediating stability and short- and long-term synaptic plasticity at the parallel fibre – Purkinje cell synapse (Oostland et al. 2014). Serotonin also inhibits

hyperpolarization-activated cyclic nucleotide-gated (HCN) channels in Purkinje cells, thereby reducing their spontaneous firing rate (Li et al. 1993).

One other cell type involved in the serotonergic control of the neuronal activity in the cerebellar cortex is the Lugaro cell. Lugaro cells are glycinergic/GABAergic interneurons located directly beneath the Purkinje cell layer, which innervate stellate cells, basket cells, Golgi cells and Purkinje cells (Lainé and Axelrad 1998, 2002; Dieudonné and Dumoulin 2000; Dean et al. 2003). Lugaro cells are specifically innervated by serotonin and viewed as the primary target of serotonergic input into the cerebellar cortex. Lugaro cells in the rat cerebellum are electrically silent and become intensively active following the application of serotonin (Dieudonné and Dumoulin 2000). By making long-distance connections with the other cerebellar inhibitory interneurons and Purkinje cells, Lugaro cells may control the pattern of activity in granule and Purkinje cells, allowing for a serotonin-operated intracortical switch. Taken together, this indicates strong serotonergic control of the cerebellar output via presynaptic inhibitory (from Lugaro cells) and excitatory (from granule cells) inputs to and postsynaptic modulations in Purkinje cells.

### 31.3 Serotonergic Modulation of Deep Cerebellar Nuclei (DCN)

Serotonergic innervation to the DCN is independent from the serotonergic innervation to the cerebellar cortex (Kitzman and Bishop 1994). In 2-week-old rats, serotonin decreases the amplitude of stimulation-evoked excitatory and inhibitory postsynaptic currents in DCN neurons via 5-HT<sub>1B</sub> receptors (Saitow et al. 2009; Murano et al. 2011). Furthermore, serotonin increases the firing rate of DCN neurons (Gardette et al. 1987; Saitow et al. 2009). This is because serotonin induces a slow depolarization resulting in an inward current in DCN neurons, presumably by the activation of 5-HT<sub>5</sub> receptors, thereby increasing spike frequency (Saitow et al. 2009). Similar to results in the cerebellar cortex, serotonin regulates long-term synaptic plasticity in the DCN, at mossy fibre–DCN synapses (Murano et al. 2011).

### 31.4 The Role of Serotonin in the Developing Cerebellum

Serotonin is one of the factors involved in brain development. Serotonin is associated with cognitive processes and malfunctioning of the serotonergic system is involved in neurodevelopmental disorders such as autism and schizophrenia (Dayer 2014). There is a developmentally critical window during which altered serotonin levels permanently influence neuronal circuitry (Daubert and Condrón 2010). This developmentally critical window is in rodents during the early postnatal period. This early postnatal period is also the timeframe during which the cerebellum

shows the greatest development, and serotonin proves to play an essential role in this development.

Serotonin controls cerebellar development in three phases: (1) stimulation of dendritic growth and formation of synapses, (2) hard-wiring of neuronal connections with limits to dendritic growth but ensuring synaptic plasticity, and (3) stabilization of synapses (Oostland and van Hooft 2013). During the first postnatal week, activation of 5-HT<sub>1</sub> receptors expressed by both granule cells and Purkinje cells stimulates dendritic growth and synapse formation. Later, activation of 5-HT<sub>3</sub> receptors expressed by granule cells limits the dendritic growth of Purkinje cells via mediating the secretion of reelin, influences physiological maturation of Purkinje cells, modulates synaptic plasticity at parallel fibre–Purkinje cell synapses and thereby affects competition with the climbing fibres on Purkinje cell dendrites resulting in proper climbing fibre elimination. Last, activation of 5-HT<sub>2</sub> receptors expressed by granule cells and Purkinje cells both during late postnatal development and in the mature cerebellum promotes the stability of synaptic activity.

## 31.5 Concluding Remarks

In this chapter we describe a powerful role for serotonin in the modulation of the physiology in the cerebellar cortex and in the deep cerebellar nuclei, both during development and in adulthood, through distinct temporal expression of its receptors. New research in this direction can help us to understand better how serotonin affects the function of the cerebellum, and may provide insight into pathophysiological conditions in which the serotonergic system is compromised.

## References

- Bloom FE, Hoffer BJ, Siggins GR et al (1972) Effects of serotonin on central neurons: microiontophoretic administration. *Fed Proc* 31:97–106
- Daubert EA, Condron BG (2010) Serotonin: a regulator of neuronal morphology and circuitry. *Trends Neurosci* 33:424–434
- Dayer A (2014) Serotonin-related pathways and developmental plasticity: relevance for psychiatric disorders. *Dialogues Clin Neurosci* 16:29–41
- Dean I, Robertson SJ, Edwards FA (2003) Serotonin drives a novel GABAergic synaptic current recorded in rat cerebellar Purkinje cells: a Lugaro cell to Purkinje cell synapse. *J Neurosci* 23:4457–4469
- Dieudonné S, Dumoulin A (2000) Serotonin-driven long-range inhibitory connections in the cerebellar cortex. *J Neurosci* 20:1837–1848
- Gardette R, Krupa M, Crepel F (1987) Differential effects of serotonin on the spontaneous discharge and on the excitatory amino acid-induced responses of deep cerebellar nuclei neurons in rat cerebellar slices. *Neuroscience* 23:491–500
- Geurts FJ, De Schutter E, Timmermans JP (2002) Localization of 5-HT<sub>2A</sub>, 5-HT<sub>3</sub>, 5-HT<sub>5A</sub> and 5-HT<sub>7</sub> receptor-like immunoreactivity in the rat cerebellum. *J Chem Neuroanat* 24:65–74

- Kitzman PH, Bishop GA (1994) The origin of serotonergic afferents to the cat's cerebellar nuclei. *J Comp Neurol* 340:541–550
- Lainé J, Axelrad H (1998) Lugaro cells target basket and stellate cells in the cerebellar cortex. *Neuroreport* 9:2399–2403
- Lainé J, Axelrad H (2002) Extending the cerebellar Lugaro cell class. *Neuroscience* 115:363–374
- Li SJ, Wang Y, Strahlendorf HK et al (1993) Serotonin alters an inwardly rectifying current (I<sub>h</sub>) in rat cerebellar Purkinje cells under voltage clamp. *Brain Res* 617:87–95
- Maura G, Roccatagliata E, Ulivi M et al (1988) Serotonin-glutamate interaction in rat cerebellum: involvement of 5-HT<sub>1</sub> and 5-HT<sub>2</sub> receptors. *Eur J Pharmacol* 145:31–38
- Mitoma H, Kobayashi T, Song SY et al (1994) Enhancement by serotonin of GABA-mediated inhibitory synaptic currents in rat cerebellar Purkinje cells. *Neurosci Lett* 173:127–130
- Murano M, Saitow F, Suzuki H (2011) Modulatory effects of serotonin on glutamatergic synaptic transmission and long-term depression in the deep cerebellar nuclei. *Neuroscience* 172:118–128
- Oostland M, van Hooft JA (2013) The role of serotonin in cerebellar development. *Neuroscience* 248:201–212
- Oostland M, Buijink MR, Teunisse GM et al (2014) Distinct temporal expression of 5-HT<sub>1A</sub> and 5-HT<sub>2A</sub> receptors on cerebellar granule cells in mice. *Cerebellum* 13:491–500
- Saitow F, Murano M, Suzuki H (2009) Modulatory effects of serotonin on GABAergic synaptic transmission and membrane properties in the deep cerebellar nuclei. *J Neurophysiol* 101:1361–1374
- Strahlendorf JC, Strahlendorf HK, Barnes CD (1979) A possible interplay of GABA with serotonergic and noradrenergic systems in the cerebellum. *Proc West Pharmacol Soc* 22:219

# Chapter 32

## Nitric Oxide

Sho Kakizawa

**Abstract** Nitric oxide (NO) is a gaseous molecule with chemical formula NO. In biological systems, NO is produced from L-arginine by three distinct NO synthases (NOSs), two of which, neuronal (nNOS) and endothelial (eNOS), are calcium dependent, whereas inducible NOS (iNOS) is calcium independent. In the cerebellum, expressions of all types of NOS are observed in physiological and/or pathological conditions. Although recognized originally as the endothelium-derived relaxing factor (EDRF), it is now well recognized that NO is involved in a wide range of neurobiological functions such as neurogenesis, synaptic plasticity, cerebellar-dependent learning, neuroprotection and neuronal-cell death.

**Keywords** Nitric oxide • cGMP • Soluble guanylyl cyclase • S-nitrosylation • Nitric oxide synthase • Granule cell • Synaptic plasticity • Parallel fiber • Purkinje cell • Motor learning

### 32.1 Nitric Oxide Synthase

Nitric oxide synthase (NOS) catalyzes the conversion of L-Arginine to NO and L-citrulline, in the presence of nicotinamide adenine dinucleotide phosphate (NADPH), O<sub>2</sub> and various cofactors (Abbott and Nahm 2004). NOS exist in three major isoforms. These are named type I/neuronal NOS (NOS1/nNOS), type II/inducible NOS (NOS2/iNOS) and type III/endothelial NOS (NOS3/eNOS) (Alderton et al. 2001; Stuehr et al. 2004). Two of them, nNOS and eNOS, are constitutively expressed mainly in the nervous system and the vascular endothelium, respectively, and synthesize NO in a calcium-dependent manner under basal conditions and upon stimulation. By contrast, iNOS is induced when stimulated by microbial endotoxins or certain proinflammatory cytokines and produces NO in a calcium-independent manner.

---

S. Kakizawa (✉)

Department of Biological Chemistry, Kyoto University Graduate School of Pharmaceutical Science, 46-29 Yoshida-Shimo-Adachi-cho, Sakyo-ku, Kyoto 606-8501, Japan  
e-mail: [sho-kaki@pharm.kyoto-u.ac.jp](mailto:sho-kaki@pharm.kyoto-u.ac.jp)

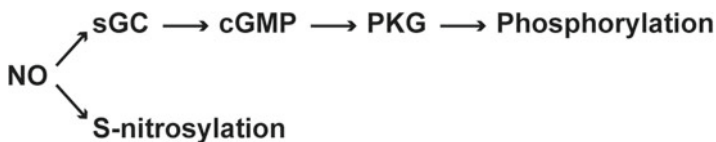
Among the three enzymatic isoforms of NOSs, nNOS and eNOS are expressed in the cerebellum in physiological condition, while iNOS starts to appear in pathologic states. High levels of nNOS are detected in cerebellar granule, basket and stellate cells. Glial cells also express NOS. Specifically, iNOS has been detected in microglia and astrocytes upon stimulation by cytokines and other compounds (Schilling et al. 1994; Stojkovic et al. 1998). Mutant mice lacking each NOS isoform as well as triple-knockout mice have been developed (Tsutsui et al. 2010).

## 32.2 Signal Transduction

The effects of NO on cellular functions are mediated by two pathways (Fig. 32.1). One is activation of soluble guanylyl cyclase (sGC), resulting in the production of cyclic guanosine monophosphate (cGMP). Another pathway for NO signal transduction is mediated by reversible post-translational modification of proteins, S-nitrosylation of thiol groups in cysteine (a term “S-nitrosation” is also used for this modification, Iyer et al. 2014). Although another type of post-translational modification of proteins, tyrosine nitration, is well known, this is an irreversible modification, and is not direct reaction of NO, but reaction of peroxynitrite ( $\text{ONOO}^-$ ) produced from NO and superoxide ( $\text{O}_2^-$ ) (Pacher et al. 2007; Ischiropoulos 2009).

The activation of sGC by NO results in surge of cellular cGMP, which is the main cellular transducer of NO signals whose concentration and kinetics are affected by phosphodiesterases, a catalytic enzyme for cGMP. In addition to regulating various channel proteins by direct binding, cGMP activates protein kinases G (PKGs) regulating functions of a wide range of other proteins through phosphorylation (Fig. 32.1, upper) (Friebe and Koesling 2003; Garthwaite 2010).

S-nitrosylation is a covalent addition of an NO group to a cysteine thiol/sulfhydryl (-SH), which results in formation of an S-nitrosothiol derivative (-SNO). S-nitrosylation is now well established as a major source of NO bioactivity, and proteins shown to be modified *in situ* by S-nitrosylation participate in a wide range of biological processes (Fig. 32.1, lower) (Foster et al. 2009; Shahani and Sawa 2011).



**Fig. 32.1** Two pathways for NO signaling. NO signal is mediated by activation of soluble guanylyl cyclase (sGC) and resulting increase in cyclic GMP (cGMP) level (*upper*), or by S-nitrosylation (also called S-nitrosation) of thiol groups in cysteine residue (*lower*). PKG, protein kinase G

## 32.3 Physiological and Pathophysiological Functions

### 32.3.1 Granule Cell Neurogenesis

In mammals, NO has been shown to down-regulate adult neurogenesis, occurring in granule cells in hippocampal dentate gyrus, for example.

In the cerebellum, negative regulation of cerebellar granule cells precursor proliferation by NO is indicated from several lines of studies *in vitro*. In neonatal rat cerebellar slices, NOS inhibition maintains an age-dependent higher proliferation rate among neuronal precursors localized in external granular layer. In primary cultures of dissociated cerebellar granule cells, NOS inhibition increases precursor proliferation (Contestabile 2012).

### 32.3.2 Synaptic Plasticity in the Cerebellar Cortex

Purkinje cell (PC), a principle neuron in the cerebellar cortex, receives two types of excitatory inputs: climbing fibers (CF), originate from inferior olive, and parallel fibers (PF), axons of granule cells. Both CF-PC synapse and PF-PC synapse show bidirectional plasticity, long-term depression (LTD) and long-term potentiation (LTP). However, neither LTD nor LTP at CF-PC synapse show NO-dependency, consistent with the negative staining of these architectures with nNOS antibody. On the other hand, many studies indicate that both LTD and LTP at PF-PC synapse are dependent on NO signals.

A currently accepted model for induction of the LTD is that NO produced by PF activity diffuses into PC where it stimulates guanylyl cyclase and activates PKG, increasing phosphorylation level of AMPA receptors which results in their de-clustering and endocytotic recycling, thus lowering excitatory response to glutamate (Ito 2002).

In addition to LTD, involvements of NO signals in LTP at PF-PC synapse are indicated. However, in contrast to the LTD, the LTP is not inhibited by a selective inhibitor of sGC activation by NO (ODQ, 1H-[1,2,4]oxadiazolo[4,3-a]quinoxalin-1-one) that abolishes the LTD (Lev-Ram et al. 2002). Instead, the action of NO is mediated by S-nitrosylation of N-ethyl maleimide sensitive factor (NSF) and type 1 ryanodine receptor (RyR1), a Ca<sup>2+</sup> release channel expressed in the membrane of sarco/endoplasmic reticulum, intracellular Ca<sup>2+</sup> store (Kakegawa and Yuzaki 2005; Kakizawa et al. 2012). S-nitrosylation of NSF results in the insertion of AMPA receptor to plasma membrane and increases the response to glutamate. S-nitrosylation of RyR1 elicits NO-induced Ca<sup>2+</sup> release from the intracellular store, which is essential for the induction of the LTP.

### 32.3.3 *Involvement in Cerebellar-Dependent Learning*

The LTD at CF-PC synapse is implicated to be involved in specific forms of motor learning such as adaptation of vestibule-ocular reflex (VOR), for example. Because NO signal is indicated to be necessary for the LTD, it is reasonable to speculate that NO signals are involved in the cerebellar-dependent motor learning such as VOR (Yuzaki 2013; Ito et al. 2014).

Actually, several lines of studies indicate possible involvement of NO signals in the motor learning. NOS inhibitors or NO scavengers, which block cerebellar LTD, impair some forms of motor learning, such as adaptation of the horizontal VOR, smooth pursuit eye movement, coordinated locomotion and eyeblink conditioning. Moreover, adaptation of optokinetic response eye movements is impaired in nNOS-knockout mice.

### 32.3.4 *Neurotoxic and Neuroprotective Roles of NO in the Cerebellum*

Numerous studies implicate that NO is neuroprotective, facilitating normal neuronal function, or neurotoxic, contributing to neuronal damage or death (Abbott and Nahm 2004).

NO reacts with superoxide to form peroxynitrite (ONOO<sup>-</sup>), a strong oxidizing agent inducing various neurotoxic effects through tyrosine nitration.

On the other hand, NO is also indicated to function as an antioxidant by scavenging oxygen free radicals. For example, NO is demonstrated to protect against CNS lesions induced by 1-methyl-4-phenyl-1,2,3,6-tetrahydropyridine (MPTP), an inhibitor of complex I in mitochondria inducing overproduction of reactive oxygen species.

## References

- Abbott LC, Nahm SS (2004) Neuronal nitric oxide synthase expression in cerebellar mutant mice. *Cerebellum* 3:141–151
- Alderton WK, Cooper CE, Knowles RG (2001) Nitric oxide synthases: structure, function and inhibition. *Biochem J* 357:593–615
- Contestabile A (2012) Role of nitric oxide in cerebellar development and function: focus on granule neurons. *Cerebellum* 11:50–61
- Foster MW, Hess DT, Stamler JS (2009) Protein S-nitrosylation in health and disease: a current perspective. *Trends Mol Med* 15:391–404
- Friebe A, Koesling D (2003) Regulation of nitric oxide-sensitive guanylyl cyclase. *Circ Res* 93:96–105
- Garthwaite J (2010) New insight into the functioning of nitric oxide-receptive guanylyl cyclase: physiological and pharmacological implications. *Mol Cell Biochem* 334:221–232



- Ischiropoulos H (2009) Protein tyrosine nitration – an update. *Arch Biochem Biophys* 484:117–121
- Ito M (2002) The molecular organization of cerebellar long-term depression. *Nat Rev Neurosci* 3:896–902
- Ito M, Yamaguchi K, Nagao S et al (2014) Long-term depression as a model of cerebellar plasticity. *Prog Brain Res* 210:1–30
- Iyer AK, Rojanasakul Y, Azad N (2014) Nitrosothiol signaling and protein nitrosation in cell death. *Nitric Oxide* 42C:9–18
- Kakegawa W, Yuzaki M (2005) A mechanism underlying AMPA receptor trafficking during cerebellar long-term potentiation. *Proc Natl Acad Sci U S A* 102:17846–17851
- Kakizawa S, Yamazawa T, Chen Y et al (2012) Nitric oxide-induced calcium release via ryanodine receptors regulates neuronal function. *EMBO J* 31:417–428
- Lev-Ram V, Wong ST, Storm DR et al (2002) A new form of cerebellar long-term potentiation is postsynaptic and depends on nitric oxide but not cAMP. *Proc Natl Acad Sci U S A* 99:8389–8393
- Pacher P, Beckman JS, Liaudet L (2007) Nitric oxide and peroxynitrite in health and disease. *Physiol Rev* 87:315–424
- Schilling K, Schmidt HH, Baader SL (1994) Nitric oxide synthase expression reveals compartments of cerebellar granule cells and suggests a role for mossy fibers in their development. *Neurosci* 59:893–903
- Shahani N, Sawa A (2011) Nitric oxide signaling and nitrosative stress in neurons: role for S-nitrosylation. *Antioxid Redox Signal* 14:1493–1504
- Stojkovic T, Colin C, Le Saux F et al (1998) Specific pattern of nitric oxide synthase expression in glial cells after hippocampal injury. *Glia* 22:329–337
- Stuehr DJ, Santolini J, Wang ZQ et al (2004) Update on mechanism and catalytic regulation in the NO synthases. *J Biol Chem* 279:36167–36170
- Tsutsui M, Shimokawa H, Otsuji Y et al (2010) Pathophysiological relevance of NO signaling in the cardiovascular system: novel insight from mice lacking all NO synthases. *Pharmacol Ther* 128:499–508
- Yuzaki M (2013) Cerebellar LTD vs. motor learning—lessons learned from studying GluD2. *Neural Netw* 47:36–41

# Chapter 33

## Cerebellar Circuits: Biochemistry, Neurotransmitters and Neuromodulators

### Cannabinoids as Modulators in the Cerebellum

Gary J. Stephens

**Abstract** Cannabinoid CB<sub>1</sub> receptors (CB<sub>1</sub>Rs) are the most widespread G-protein-coupled receptors (GPCRs) in the mammalian CNS. CB<sub>1</sub>Rs are present on inhibitory and excitatory presynaptic terminals supplying Purkinje cells (PCs), the sole output of the cerebellar cortex, where CB<sub>1</sub>R activation suppresses transmitter release. CB<sub>1</sub>Rs are part of the endocannabinoid (eCB) system, activated by the lipid mediator 2-arachidonoyl glycerol (2-AG) via retrograde transmission within the cerebellum. CB<sub>1</sub>Rs also mediate synaptic plasticities to modulate cerebellar learning. This review will discuss the latest knowledge regarding CB<sub>1</sub>R circuitry and signalling and their potential modulation.

**Keywords** CB<sub>1</sub> receptor • Endocannabinoid • Purkinje cells

#### 33.1 Introduction

The release of excitatory glutamate, from parallel fibres (PF) and climbing fibres (CF), and inhibitory GABA, predominantly from basket cell interneurons (INs), onto output PCs, is intimately controlled by CB<sub>1</sub>Rs in the cerebellar cortex (Stephens 2009). CB<sub>1</sub>Rs are activated by eCBs and may be modulated by exogenous synthetic cannabinoids and plant-derived phytocannabinoids (Pertwee et al. 2010; Hill et al. 2012). The major effect of presynaptic CB<sub>1</sub>R activation is suppression of neurotransmitter release (Kano et al. 2009). Cannabinoids also activate CB<sub>2</sub> receptors, expressed predominantly in microglia within the CNS, and potentially GPR55 receptors (Pertwee et al. 2010). However, key known effects of cannabinoids on synaptic function are mediated via presynaptic CB<sub>1</sub>Rs (see Hoffmann and Lupia 2013).

---

G.J. Stephens (✉)

School of Pharmacy, University of Reading, Whiteknights, Reading RG6 6AJ, UK  
e-mail: [g.j.stephens@reading.ac.uk](mailto:g.j.stephens@reading.ac.uk)

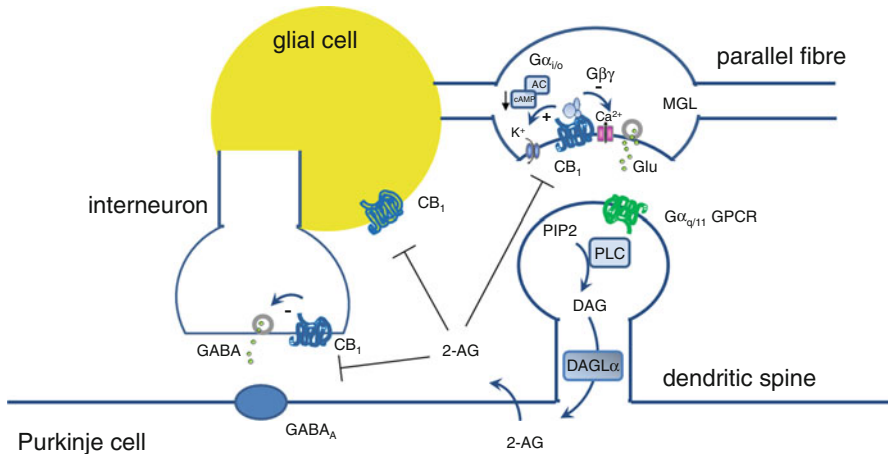
### 33.2 CB<sub>1</sub>R Expression Within the Cerebellum

CB<sub>1</sub>Rs are expressed at presynaptic terminals onto PCs, the principal neurons of the cerebellar cortex, which provide inhibitory innervation of deep cerebellar nuclei. Thus, CB<sub>1</sub>Rs are uniquely positioned to control cerebellar function and, in particular, modulation of fine motor co-ordination. CB<sub>1</sub>Rs are expressed on perisynaptic PF membranes, with lower expression at CF inputs onto dendritic shafts (Kawamura et al. 2006). CB<sub>1</sub>Rs are expressed at higher levels on inhibitory IN presynaptic terminals, predominantly on basket cells, which form specialized ‘pinneau’ regions surrounding the PC axon initial segment (Rodríguez-Cueto et al. 2014). In the cerebellar cortex, CB<sub>1</sub>Rs are activated preferentially by 2-AG (Szabo et al. 2006), over the other major brain eCB, arachidonylethanolamide (anandamide). The 2-AG biosynthetic enzyme diacylglycerol lipase- $\alpha$  (DAGL $\alpha$ ) is localized to PC somatodendritic regions, with a subcellular distribution at the base of postsynaptic spines (Yoshida et al. 2006). The 2-AG degrading enzyme monoacylglycerol lipase (MGL) is localised to PF terminals (Tanimura et al. 2012). CB<sub>1</sub>R expression has also been reported on microglial and astrocytes within the cerebellar cortex (Rodríguez-Cueto et al. 2014); the role of the CB<sub>1</sub>R at such tripartite synapses will be of clear future interest.

In PC postsynaptic dendritic spines, 2-AG is synthesised by DAGL $\alpha$  from DAG (produced from phosphatidylinositol 4,5-bisphosphate (PIP<sub>2</sub>) by phospholipase C (PLC)) in turn activated by G $\alpha_{q/11}$  GPCRs. 2-AG is released retrogradely to act on presynaptic CB<sub>1</sub>Rs at excitatory PF and inhibitory IN terminals to suppress release of glutamate (Glu) or GABA, respectively. Astrocytes and microglial also express CB<sub>1</sub>Rs. CB<sub>1</sub>Rs are predominantly coupled to G $\alpha_{i/o}$  to inhibit VGCCs (via G $\beta\gamma$ ) and/or activate K<sup>+</sup> channels (via AC inhibition and subsequent reduction in cAMP). 2-AG is catabolised by MGL produced by PF terminals.

### 33.3 CB<sub>1</sub>R Signalling in the Cerebellum

During retrograde transmission, 2-AG is synthesised *de novo* from diacylglycerol (DAG) by DAGL $\alpha$  and released ‘on-demand’ from postsynaptic somatodendritic PC regions to act on presynaptic CB<sub>1</sub>Rs (Urbanski et al. 2010; see Fig. 33.1). Release of 2-AG, by not yet fully resolved pathways, is triggered predominantly by increases in postsynaptic Ca<sup>2+</sup> concentration via depolarization-induced opening of voltage-gated Ca<sup>2+</sup> channels (VGCCs) and/or synaptically-driven activation of ionotropic AMPA receptors and certain G $\alpha_{q/11}$ -coupled GPCRs (Ohno-Shosaku and Kano 2014). Presynaptic CB<sub>1</sub>Rs couple predominantly to G $\alpha_{i/o}$  subunits, which inhibit adenylyl cyclase (AC)-mediated generation of cyclic adenosine monophosphate (cAMP) and liberate G $\beta\gamma$  subunits (Pertwee et al. 2010). CB<sub>1</sub>Rs activation causes pertussis toxin-sensitive inhibition of VGCCs and activation of inwardly rectifier K<sup>+</sup> channels (Guo and Ikeda 2004), CB<sub>1</sub>Rs can also link directly to the vesicular release machinery; these effects are mediated by G $\beta\gamma$  subunits (Stephens 2009).



**Fig. 33.1** 2-AG is fundamental to cannabinoid signalling in the cerebellar cortex

CB<sub>1</sub>R activation by synthetic agonists such as WIN55212-2 (WIN55) and CP55940, inhibits action potential-evoked, and spontaneous, inhibitory postsynaptic currents (IPSCs) at IN-PC synapses or excitatory postsynaptic currents (EPSCs) at PF-PC and CF-PC synapses; CB<sub>1</sub>R activation also reduces frequency of ‘miniature’ IPSCs (mIPSCs) at IN-PC synapses (Takahashi and Linden 2000). CB<sub>1</sub>R antagonists/inverse agonists increase mIPSCs (Ma et al. 2008); such effects are consistent with the presence of a strong, modulatable eCB tone in the cerebellum (Kreitzer et al. 2002).

Release of 2-AG causes short-term or long-term modulation of neurotransmitter release, offering the potential to fine-tune motor learning in the cerebellum. A prominent form of short-term modulation is the suppression of inhibitory GABA release from IN terminals (depolarization-induced suppression of inhibition, DSI) or suppression of excitatory glutamate release (depolarization-induced suppression of excitation, DSE) (Kreitzer and Regehr 2001). A major presynaptic effect in DSE is inhibition of VGCCs (Brown et al. 2004). eCBs also mediate long-term synaptic plasticity, due to repeated stimulation of synaptic inputs, but also in response to prolonged postsynaptic activity, and requiring additional activity to augment CB<sub>1</sub>R effects (Ohno-Shosaku and Kano 2014). Both long-term depression and potentiation are modulated by CB<sub>1</sub>R at PF-PC synapses, the balance of effects is proposed to underlie cerebellar learning (Vogt and Canepari 2010).

### 33.4 Association of CB<sub>1</sub>R with Cerebellar Dysfunction

Disruption of cerebellar circuitry is commonly associated with ataxia, a spectrum of diseases associated with motor co-ordination deficits. Whilst animals lacking CB<sub>1</sub>R have no gross deformities, they have deficits in eyeblink conditioning, suggesting that CB<sub>1</sub>R control discrete cerebellar-dependent, motor learning processes

(Kishimoto and Kano 2006). In fact, CB<sub>1</sub>R agonists cause severe motor incoordination and can be used to induce ataxia (Patel and Hillard 2001). We have shown that *du<sup>2j</sup>* ‘duffy’ ataxic mouse mutants exhibit irregular PC firing and disrupted CB<sub>1</sub>R-mediated signalling that could contribute to disease phenotype (Wang et al. 2013). In post-mortem spinocerebellar ataxia brain tissue, CB<sub>1</sub>R expression was increased in glial and PCs (Rodríguez-Cueto et al. 2014); therefore, up-regulated CB<sub>1</sub>R could be useful disease marker and/or may serve a neuroprotective function (Stephens 2016).

CB<sub>1</sub>R antagonists/inverse agonists have been shown to increase inhibitory neurotransmission at IN-PC synapses (Ma et al. 2008). Such agents have potential to dampen cerebellar excitability. These agents included rimonabant; however, rimonabant withdrawal as a therapeutic anti-obesity agent, due to fears of increased suicide and depression, has curtailed several related drug development programmes. Potential alternatives are CB<sub>1</sub>R negative allosteric antagonists, such as Org-27569 and PSNCBAM-1 (Ross 2007). These agents, somewhat paradoxically, increase binding of orthosteric ligands, but decrease their efficacy; this occurs in a ligand-dependent fashion (Baillie et al. 2013). We have shown such ‘functional selectivity’ for PSNCBAM-1 at IN-PC synapses (Wang et al. 2011). Moreover, unlike CB<sub>1</sub>R antagonists/inverse agonists, PSNCBAM-1 had no intrinsic effects on inhibitory transmission. These studies indicate that negative allosteric antagonists offer potential advantages including reduced side effects and toxicity and present future potential for selective manipulation of the eCB system within the cerebellar cortex.

## References

- Baillie GL, Horswill JG, Anavi-Goffer S et al (2013) CB<sub>1</sub> receptor allosteric modulators display both agonist and signaling pathway specificity. *Mol Pharmacol* 83:322–338
- Brown SP, Safo PK, Regehr WG (2004) Endocannabinoids inhibit transmission at granule cell to Purkinje cell synapses by modulating three types of presynaptic calcium channels. *J Neurosci* 24:5623–5631
- Guo J, Ikeda SR (2004) Endocannabinoids modulate N-type calcium channels and G-protein-coupled inwardly rectifying potassium channels via CB<sub>1</sub> cannabinoid receptors heterologously expressed in mammalian neurons. *Mol Pharmacol* 65:665–674
- Hill AJ, Williams CM, Whalley BJ, Stephens GJ (2012) Phytocannabinoids as novel therapeutic agents in CNS disorders. *Pharmacol Ther* 133:79–97
- Hoffman AF, Lupica CR (2013) Synaptic targets of  $\Delta^9$ -tetrahydrocannabinol in the central nervous system. *Cold Spring Harb Perspect Med* 3 pii: a012237.
- Kano M, Ohno-Shosaku T, Hashimoto-dani Y et al (2009) Endocannabinoid-mediated control of synaptic transmission. *Physiol Rev* 89:309–380
- Kawamura Y, Fukaya M, Maejima T et al (2006) CB<sub>1</sub> is the major cannabinoid receptor at excitatory presynaptic site in the hippocampus and cerebellum. *J Neurosci* 26:2991–3001
- Kishimoto Y, Kano M (2006) Endogenous cannabinoid signaling through the CB<sub>1</sub> receptor is essential for cerebellum-dependent discrete motor learning. *J Neurosci* 26:8829–8837
- Kreitzer AC, Regehr WG (2001) Cerebellar depolarization-induced suppression of inhibition is mediated by endogenous cannabinoids. *J Neurosci* 21:RC174

- Kreitzer AC, Carter AG, Regehr WG (2002) Inhibition of interneuron firing extends the spread of endocannabinoid signaling in the cerebellum. *Neuron* 34:787–796
- Ma YL, Weston SE, Whalley BJ, Stephens GJ (2008) The phytocannabinoid  $\Delta^9$ -tetrahydrocannabinol modulates inhibitory neurotransmission in the cerebellum. *Br J Pharmacol* 154:204–215
- Ohno-Shosaku T, Kano M (2014) [Endocannabinoid-mediated retrograde modulation of synaptic transmission](#). *Curr Opin Neurobiol* 29:1–8
- Patel S, Hillard CJ (2001) Cannabinoid CB<sub>1</sub> receptor agonists produce cerebellar dysfunction in mice. *J Pharmacol Exp Ther* 297:629–637
- Pertwee RG, Howlett AC, Abood ME et al (2010) International union of basic and clinical pharmacology. LXXIX. Cannabinoid receptors and their ligands: beyond CB<sub>1</sub> and CB<sub>2</sub>. *Pharmacol Rev* 62:588–631
- Rodríguez-Cueto C, Benito C, Fernández-Ruiz J et al (2014) Changes in CB1 and CB2 receptors in the post-mortem cerebellum of humans affected by spinocerebellar ataxias. *Br J Pharmacol* 171:1472–1489
- Ross RA (2007) Allosterism and cannabinoid CB<sub>1</sub> receptors: the shape of things to come. *Trends Pharmacol Sci* 11:567–572
- Stephens GJ (2009) G-protein-coupled-receptor-mediated presynaptic inhibition in the cerebellum. *Trends Pharmacol Sci* 8:421–430
- Stephens GJ (2016) Does modulation of the endocannabinoid system have potential therapeutic utility in cerebellar ataxia? *J Physiol* [Epub ahead of print Mar 11]
- Szabo B, Urbanski MJ, Bisogno T et al (2006) Depolarization-induced retrograde synaptic inhibition in the mouse cerebellar cortex is mediated by 2-arachidonoylglycerol. *J Physiol* 577:263–280
- Takahashi KA, Linden DJ (2000) Cannabinoid receptor modulation of synapses received by cerebellar Purkinje cells. *J Neurophysiol* 83:1167–1180
- Tanimura A, Uchigashima M, Yamazaki M et al (2012) Synapse type-independent degradation of the endocannabinoid 2-arachidonoylglycerol after retrograde synaptic suppression. *Proc Natl Acad Sci U S A* 109:12195–12200
- Urbanski MJ, Kovacs FE, Szabo B (2010) Endocannabinoid-mediated synaptically evoked suppression of GABAergic transmission in the cerebellar cortex. *Neuroscience* 169:1268–1278
- Vogt KE, Canepari M (2010) On the induction of postsynaptic granule cell-Purkinje neuron LTP and LTD. *Cerebellum* 9:284–290
- Wang X, Horswill JG, Whalley BJ, Stephens GJ (2011) Effects of the allosteric antagonist 1-(4-chlorophenyl)-3-[3-(6-pyrrolidin-1-ylpyridin-2-yl)phenyl]urea (PSNCBAM-1) on CB1 receptor modulation in the cerebellum. *Mol Pharmacol* 79:758–767
- Wang X, Whalley BJ, Stephens GJ (2013) The *du*<sup>2j</sup> mouse model of ataxia and absence epilepsy has deficient cannabinoid CB<sub>1</sub> receptor-mediated signalling. *J Physiol* 591:3919–3933
- Yoshida T, Fukaya M, Uchigashima M et al (2006) Localization of diacylglycerol lipase- $\alpha$  around postsynaptic spine suggests close proximity between production site of an endocannabinoid, 2-arachidonoyl-glycerol, and presynaptic cannabinoid CB<sub>1</sub> receptor. *J Neurosci* 26:4740–4751

# Chapter 34

## Purinergic Signalling in the Cerebellum

Mark J. Wall

**Abstract** Purinergic signalling is a complex and evolutionarily conserved mechanism of extracellular communication involved in many physiological and pathological functions. The complexity arises from a large number of purine receptor subtypes and multiple endogenous purine receptor ligands (including ATP, ADP, UTP, UDP UDP-glucose and adenosine) which can be directly released or arise from extracellular metabolism. Although much work has defined the distribution of purine receptors in the cerebellum and the cellular effects of purine receptor activation, relatively little is known about how and when purines are released in the cerebellum, the role of purinergic signalling in controlling cerebellar circuit output and the importance of purines in cerebellar motor control.

**Keywords** ATP • Adenosine • P2 receptors • P1 receptors • Neuromodulation

### 34.1 Introduction

Purines are important extracellular signalling molecules that mediate diverse physiological and pathological effects via cell-surface receptors (for review see Burnstock 2007). There are several potential endogenous purine receptor ligands but this review will concentrate on ATP and adenosine.

### 34.2 Mechanisms of ATP Release

All cells contain ATP (as energy currency) and hence they are all potential sources of ATP for extracellular signalling. But how does ATP get from the intracellular compartment into the extracellular space? ATP can be co-released from neurons by vesicular exocytosis, together with *classical* neurotransmitters such as glutamate

---

M.J. Wall (✉)

School of Life Sciences, University of Warwick, Gibbet Hill CV4 7AL, UK

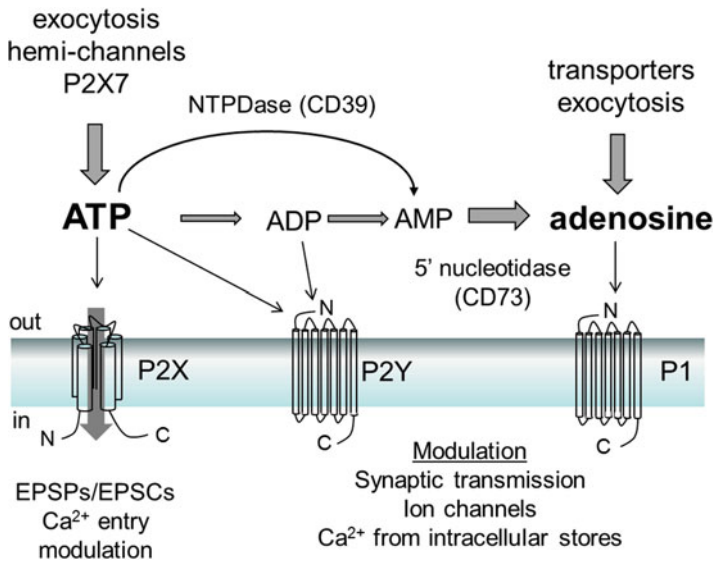
e-mail: [Mark.wall@warwick.ac.uk](mailto:Mark.wall@warwick.ac.uk)

and GABA. ATP can also be released by exocytosis from glial cells, via hemi-channels (pannexins and connexions, the latter of which combine together to form gap junctions between cells) and by a subset of ATP receptors (PX7), which undergo pore dilatation.

### 34.3 ATP (P2) Receptors

Following release, ATP activates two types of receptor, termed P2X and P2Y, which are both expressed by neurons and glia throughout the brain (Fig. 34.1). P2X receptors are ligand-gated ion channels. Seven P2X receptor subunits have been cloned (P2X1-7) and can combine to produce either homomeric or heteromeric receptors with distinct properties and pharmacology. P2X receptors are permeable to monovalent cations such as  $\text{Na}^+$  and  $\text{K}^+$  and divalent cations such as  $\text{Ca}^{2+}$ . For full review of the molecular physiology of P2X receptors see (Burnstock and Kennedy 2011). Since the synaptic responses to P2X receptor activation are often very small, when compared to GABA and glutamate, this has led to the idea that their role is to modulate other neurotransmitter systems rather than produce postsynaptic depolarisation.

P2Y receptors are G protein-coupled receptors with seven transmembrane domains. At least eight P2Y receptor subtypes have been cloned and modulate synaptic transmission, regulate ion channels and release  $\text{Ca}^{2+}$  from intracellular stores. For a comprehensive review of P2Y receptors see (von Kugelgen 2006).



**Fig. 34.1** Actions of ATP and adenosine. ATP activates P2 receptors and is then metabolised to adenosine which activates P1 receptors. Adenosine can also be directly released



## 34.4 ATP (P2) Receptors in the Cerebellum

Many of the possible P2 receptor subtypes appear to be expressed in the cerebellum, although the functional relevance of individual receptor subtypes is often not clear. Several studies have shown that activation of P2 receptors increases intracellular  $\text{Ca}^{2+}$  concentration in Purkinje cells, granule cells and glial cells, with P2 receptor activation initiating  $\text{Ca}^{2+}$  waves that can spread between coupled glial cells *in vitro* and *in vivo*. A recent study has shown that increases in  $\text{Ca}^{2+}$  concentration in Bergmann glial cells enhances the removal of extracellular  $\text{K}^+$  leading to changes in Purkinje cell firing. The rise in intracellular  $\text{Ca}^{2+}$  concentration probably stems from P2Y receptor activation ( $\text{Ca}^{2+}$  coming from intracellular stores) although whole cell and single channel P2X receptor currents have also been recorded in Purkinje cells, granule cells and astrocytes.

Activation of presynaptic P2 receptors (probably both P2X and P2Y) on basket cells, parallel fibres and Lugaro cells modulates excitatory and inhibitory synaptic transmission to Purkinje cells (reviewed in Deitmer et al. 2006). The P2Y receptors present on Purkinje cells can also enhance  $\text{GABA}_A$  receptor sensitivity. The mixed effects of P2 receptor activation on excitatory and inhibitory cells makes it difficult to predict the overall effect on cerebellar circuit output.

## 34.5 Extracellular Metabolism of ATP

Once released into the extracellular space, ATP is rapidly metabolised to adenosine by enzymes called ectonucleotidases (reviewed in Zimmermann et al. 2012). These enzymes include ecto-ATPase (CD39, converts ATP directly to AMP without liberating ADP) which is expressed in the soma and dendrites of Purkinje cells and weakly in the granule cell layer and ecto-5'-nucleotidase CD73 (converts AMP to adenosine) which is localized in glial cells and parallel and climbing fibre synapses.

## 34.6 Adenosine Release in the Brain

Extracellular adenosine arises from ATP metabolism (as outlined above) but adenosine can also be directly released into the extracellular space via specific nucleoside transporters (equilibrative and concentrative) and by exocytosis (see below). The extracellular concentration of adenosine in the brain can be increased by a number of stimuli including hypoxia, ischemia, hypoglycemia, epileptic seizures and prolonged wakefulness. More recent studies have shown that adenosine can also be released by brief trains of action potentials and thus is potentially important in controlling physiological network activity.

### 34.7 Adenosine (P1) Receptors in the Cerebellum

Once produced, extracellular adenosine activates G protein-coupled receptors (P1) that are divided into four subtypes:  $A_1$ ,  $A_{2A}$ ,  $A_{2B}$ , and  $A_3$  (Fredholm et al. 2001). The  $A_1$  receptor is the most widely expressed adenosine receptor in the brain and is inhibitory, as upon activation it opens  $K^+$  channels and closes voltage-gated  $Ca^{2+}$  channels, leading to hyperpolarisation of the membrane potential and inhibition of transmitter release. Activation of  $A_{2A}$  and  $A_{2B}$  receptors can facilitate transmitter release and modulate synaptic plasticity.

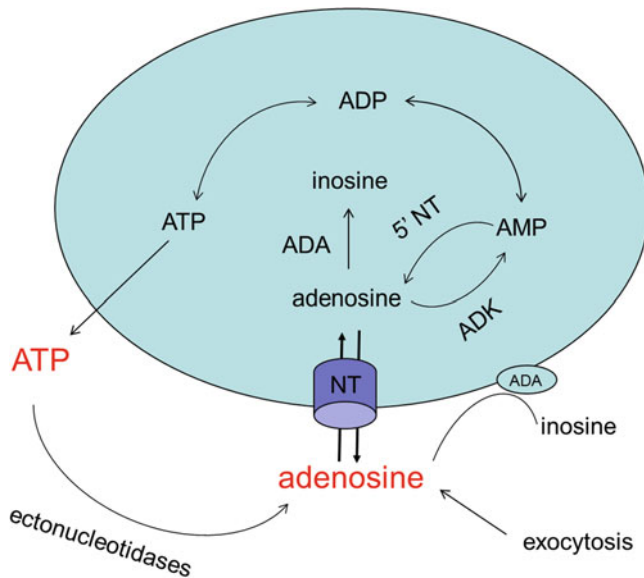
The cerebellum contains high levels of the  $A_1$  adenosine receptor, possibly the  $A_3$  receptor (diffuse expression), but not  $A_{2A}$  or  $A_{2B}$  receptors. Activation of  $A_1$  receptors reduces glutamate release at parallel fibre-Purkinje cell synapses with a similar but smaller effect at climbing fibre synapses. Adenosine also inhibits GABA release at Golgi cell-granule cell synapses via  $A_1$  receptor activation.

### 34.8 Adenosine Release in Cerebellum

Adenosine is released in the molecular layer of the cerebellum by focal electrical stimulation and can be directly measured using adenosine biosensors. This adenosine release is both action potential and  $Ca^{2+}$ -dependent with at least a proportion directly released from parallel fibres by exocytosis (Klyuch et al. 2012). Enough adenosine is released to activate  $A_1$  receptors and inhibit transmitter release at the parallel fibre synapse. This potentially represents an important feedback mechanism for controlling neural activity in the cerebellum. Adenosine is also released by hypoxia and inhibits parallel fibre-Purkinje cell transmission via  $A_1$  receptor activation which is probably neuroprotective.

### 34.9 Breakdown and Uptake of Adenosine

The extracellular concentration of adenosine is controlled by several mechanisms including specific equilibrative and concentrative transporters which transport adenosine into neurons and glia (Fig. 34.2). Adenosine can then be inactivated, by metabolism to inosine (by adenosine deaminase, ADA) or phosphorylated to AMP (by adenosine kinase, ADK), maintaining low concentrations of intracellular adenosine. ADK is exclusively expressed in glial cells with ADA present in glia and neurons and to a smaller extent in the extracellular space. In common with many brain regions, ADK activity is the major determinant of the basal extracellular concentration of adenosine in the cerebellum, with adenosine deaminase playing only a minor role.



**Fig. 34.2** Control of extracellular adenosine concentration. Adenosine is removed from the extracellular space by nucleoside transporters (NT) and can then be converted to AMP by adenosine kinase (ADK) or metabolised to inosine by adenosine deaminase (ADA). There is a small amount of extracellular ADA. ADK dominates adenosine clearance during basal conditions, leading to replenishment of intracellular ATP

### 34.10 The Role of Purinergic Signalling in the Cerebellum and in Motor Control

The role that purinergic signalling plays in cerebellar function remains unclear. Experiments in which Bergmann glia (which utilise ATP signalling to produce  $\text{Ca}^{2+}$  waves) were transgenically removed, showed defects in long term depression and eye blink conditioning although motor co-ordination was unaffected. It is tempting to suggest that glial ATP signalling is important for correct cerebellar function, but it could be that other roles of glia (such as glutamate uptake) underlie the deficits. There are several P2Y receptor knockout mice but they show no obvious cerebellar phenotype. Knockout of the adenosine  $\text{A}_1$  receptor also has little effect on co-ordination and locomotion. There is however evidence that adenosine signalling in the cerebellum is involved in the ataxia produced by alcohol and cannabinoid intoxication and is impaired in the neurodegenerative disease Niemann–Pick Type C.

### 34.11 Conclusions and Future Work

A great deal of work has defined the distribution of purine receptors and their effects on cellular function within the cerebellum but many questions remain unanswered. What effect does purine signalling have on cerebellar neural network activity,

cerebellar output and motor control? Mixed excitatory effects (P2X, P2Y) and inhibitory effects (A1 and P2Y) on both excitatory (glutamatergic) and inhibitory (GABAergic) neurons and on glial cells makes this difficult to predict. What is the source of ATP and adenosine and what form of cerebellar activity results in their release? ATP is probably released from Bergmann glia, astrocytes and maybe from molecular layer interneurons. Adenosine appears to be released from parallel fibres although there are probably other sources. Currently neither ATP nor adenosine release has been directly linked to a motor behaviour.

## References

- Burnstock G (2007) Physiology and pathophysiology of purinergic neurotransmission. *Physiol Rev* 87:659–797
- Burnstock G, Kennedy C (2011) P2X receptors in health and disease. *Adv Pharmacol* 61:333–372
- Deitmer JW, Brockhaus J, Casel D (2006) Modulation of synaptic activity in Purkinje neurons by ATP. *Cerebellum* 5:49–54
- Fredholm BB, Ijzerman AP, Jacobson KA, Klotz KN, Linden J (2001) International union of pharmacology. XXV. Nomenclature and classification of adenosine receptors. *Pharmacol Rev* 53:527–552
- Klyuch BP, Dale N, Wall MJ (2012) Deletion of ecto-5'-nucleotidase (CD73) reveals direct action potential-dependent adenosine release. *J Neurosci (Rapid Commun)* 32:3842–3847
- von Kugelgen I (2006) Pharmacological profiles of cloned mammalian P2Y-receptor subtypes. *Pharmacol Ther* 110:415–432
- Zimmermann H, Zebisch M, Sträter N (2012) Cellular function and molecular structure of ecto-nucleotidases. *Purinergic Signal* 8:437–502

# Chapter 35

## Neuropeptides in the Cerebellum

Georgia A. Bishop and James S. King

**Abstract** To truly understand cerebellar function, it is essential to address the effect of the numerous peptides present within cerebellar circuits and the role they play in modulating neuronal activity in the cerebellum. To date, at least 22 neuropeptides have been identified in the cerebellum. However, relatively little is conclusively known about the modulatory role of the vast majority of these peptides. The potential role of three peptides is reviewed. Future research should focus on defining transduction pathways activated following binding of these peptides to their G-protein-coupled receptors, defining the function of peptides produced by cerebellar neurons such as Purkinje cells or Golgi cells, and describing how neuropeptides modulate cerebellar nuclear neurons, which represent the output of the cerebellum.

**Keywords** Cerebellar nuclei • Climbing fiber • Corticotropin releasing factor • Orexin • Calcitonin gene related peptide • Purkinje cell

### 35.1 Introduction

The existence of neuropeptides in the central nervous system has been known since the 1970s (Hokfelt 1991). Today, at least 100 neuropeptides have been identified (Ito 2009). Neuropeptides are polypeptides that almost exclusively bind to G-protein coupled receptors. Thus, their actions require activation of second messenger pathways, which utilize complex intracellular pathways to alter the response properties of neurons. Neuropeptides are often characterized as neuromodulators.

An overview of neuropeptide synthesis, transport, release and removal may be found in a neuropharmacology textbook. A unique feature of neuropeptide synthesis is that it occurs entirely within the cell bodies of neurons and requires active

---

G.A. Bishop (✉) • J.S. King  
Department of Neuroscience, The Ohio State University,  
333 W. 10th Avenue, Columbus, OH 43210, USA  
e-mail: [bishop.9@osu.edu](mailto:bishop.9@osu.edu)

transport to an axon terminal. Further, a single gene may produce several different related neuropeptides in different brain regions. Within the presynaptic terminal, large dense core vesicles that contain neuropeptides tend to be located away from the active zone. The mechanism of peptide release is the same as for vesicles containing amino acids, requiring influx of calcium. However, for peptides to be released, more calcium influx is required than that needed for release of amino acid neurotransmitters. One way to accomplish this by a longer train of action potentials coming down the axon. Whereas a single action potential may result in release of amino acids, a prolonged train may be required to allow greater influx of calcium and subsequent release of peptides into the synaptic cleft. Thus peptide release, is activity dependent.

The method for terminating peptide activity is through endopeptidases and exopeptidases. The concentration of these peptidases is relatively low so neuropeptides may diffuse great distances from the site of their release to remote receptors thus giving them the opportunity to effect larger populations of neurons.

## 35.2 Neuropeptides in the Cerebellum

Table 35.1 shows several peptides that have been identified in the cerebellum and their localization in diverse components of cerebellar circuitry based on a review by Ito (2009).

**Table 35.1** Summary of neuropeptide distribution in different neuronal components in the cerebellum

Purkinje cell	Climbing fiber	Mossy fiber	Beaded fiber	Receptors on granule cells
Lugaro cell				
Golgi cell				
Atrial natriuretic peptide	Corticotropin releasing Factor	Corticotropin releasing factor	Angiotensin II	A-melanocyte stimulating hormone
Cerebellin	Insulin-like growth factor 1	Cholecystokinin	Dynorphin	Melanin-concentrating hormone
Motilin	Calcitonin gene related peptide	Calcitonin gene related peptide	Leu-Enkephalin	Neuronal neurotensin
		Leu-Enkephalin		
Galanin	Atrial natriuretic peptide	Met-Enkephalin	Met-Enkephalin	Somatostatin
		Substance P	Orexin	Neuropeptide Y

Several neurons within the cerebellar cortex express different neuropeptides. Neuropeptides also have been found in afferent systems to the cerebellum including climbing fibers, mossy fibers and a beaded plexus of axons. Granule cells express receptors for peptides; the origin is yet to be conclusively determined (Adapted from Ito 2009)

### 35.3 Role of Peptides in the Cerebellum

One of the major challenges to understanding of the role for peptides in the cerebellum is the fact that their distribution varies between and within species. This chapter will describe some of the potential roles for three peptides in regulating cerebellar circuitry.

#### 35.3.1 *Corticotropin Releasing Factor (CRF)*

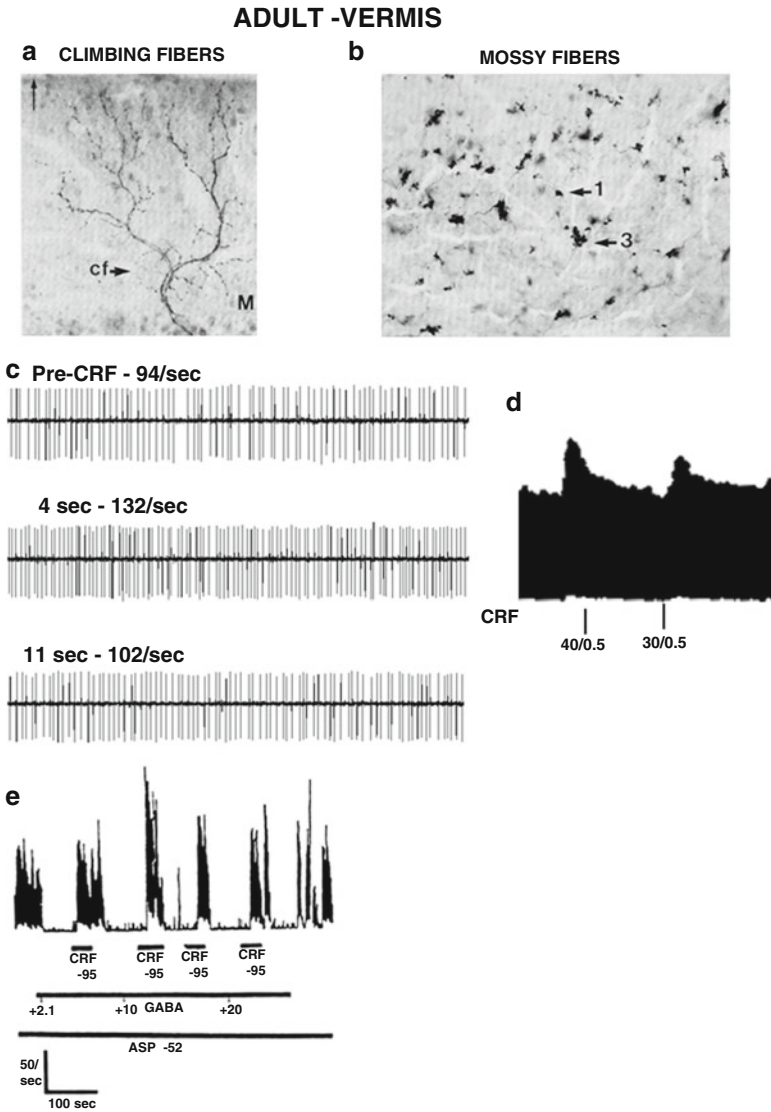
CRF is present in climbing and mossy fiber afferent systems in all mammalian species studied to date (Fig. 35.1a, b). CRF in climbing fibers originates from neurons in the inferior olive whereas CRF in mossy fibers originates from the vestibular complex and the reticular formation (Errico and Barmack 1993; Bishop 1998). Neurophysiological studies have shown that CRF is essential in the generation of long-term depression, a mechanism associated with cerebellar learning (Miyata and Ito 1999). Further, CRF has been shown to increase the firing rate of Purkinje cells (Fig. 35.1c, d) by decreasing the amplitude and duration of the after hyperpolarizing potential (Fox and Gruol 1993) and blocking GABA induced inhibition (Bishop 1990) (Fig. 35.1e).

#### 35.3.2 *Orexin*

Orexin is present in a beaded plexus of axons that originate from neurons located in the perifornical area and the lateral hypothalamus (Zhang et al. 2013). These axons terminate primarily within the flocculus of the cerebellum (Nisimaru et al. 2013). Zhang et al. (2013) suggested that the orexinergic system participates in motor control and integration of somatic motor and non-somatic (e.g., visceral, emotional) systems. They postulated that a somatic-non-somatic integration was critical for generation of a coordinated behavioral response to changes in the internal and external environment. The primary effect of orexin was on neurons located in the vestibular nuclei and the cerebellar interpositus nucleus (Yu et al. 2010) which represent a peptidergic effect on the output neurons of the cerebellum and closely related vestibular system.

#### 35.3.3 *Calcitonin Gene Related Peptide (CGRP)*

CGRP is transiently expressed in climbing fibers during rodent development (Morara et al. 1992). The CGRP receptor, which mediates the effect of this peptide, is present on astrocytes during early stages of development and on Purkinje cells at



**Fig. 35.1** (a) CRF-immunolabeled climbing fiber in the opossum cerebellum. (b) CRF-immunolabeled mossy fiber in the opossum cerebellum. (c) Extracellular recording from a Purkinje cell in the rat's cerebellum. Baseline firing rate was 94 spikes/s. 4 s after application of CRF the firing rate increased to 132 spikes/s. The unit recovered to baseline 11 s after application of CRF. (d) Histogram derived from data shown in C. X axis is time. Y axis is spikes/s. The dashed lines indicate application of CRF at the designated pressure and time. Following application of CRF the firing rate of the Purkinje cell increases and remains elevated for a prolonged period of time. The effect is dose dependent. (e) Histogram documenting interactions between CRF and GABA. This is from a recording in the rat's cerebellum. Application of aspartate causes the neuron to fire at approximately 60 spikes/s. Application of GABA blocks the aspartate induced excitation. Co-application of CRF during the GABA induced inhibition blocks the suppressive effect of GABA, even if the inhibitory transmitter is applied at higher doses



later stages (Morara et al. 2008). Studies demonstrate that CGRP modulates calcium in astrocytes during development (Morara et al. 2008). During later stages of development, CGRP was shown to stimulate Purkinje cell dendrite growth in culture (D'Antoni et al. 2010), an effect that was dependent on activation of CGRP receptors on astrocytes.

A different pattern of CGRP expression was observed in the cat's cerebellum, compared to the rat's, consistent with unique distributions and functions of peptides in different species. In the cat (Bishop 1992), CGRP was found in mossy fibers in the adult animal. Physiological studies demonstrated that CGRP suppressed spontaneous and excitatory amino acid-induced activity (Bishop 1995). In addition, there was a heterogeneous distribution of CGRP mossy fibers in the cat's cerebellum suggesting that the effect of this peptide is restricted to specific populations of cerebellar neurons (Bishop 1992).

## 35.4 Conclusion and Future Directions

To truly understand cerebellar function, it is essential to understand the functional role of the numerous peptides present within cerebellar circuits. Likely, many of the peptides expressed in the cerebellum are involved in modulating the activity of Purkinje cells and one, CRF, is essential for generation of long-term depression in the cerebellar cortex. However, to date, relatively little is conclusively known about the modulatory role of the vast majority of these peptides on intact cerebellar circuits. Functionally, it is essential to identify specific second messenger and associated signal transduction pathways and to determine differential roles for peptides during different stages of development and in the adult. Finally, defining the role of neuropeptides in regulating the activity of cerebellar nuclear neurons, which represent the output of the cerebellum, is essential.

## References

- Bishop GA (1990) Neuromodulatory effects of corticotropin releasing factor on cerebellar Purkinje cells: an in vivo study in the cat. *Neuroscience* 39:251–257
- Bishop GA (1992) Calcitonin gene related peptide in cerebellar afferents: distribution and origin. *J Comp Neurol* 322:201–212
- Bishop GA (1995) Calcitonin gene related peptide modulates neuronal activity in the mammalian cerebellar cortex. *Neuropeptides* 28:85–97
- Bishop GA (1998) Brainstem origin of corticotropin releasing factor afferents to the nucleus interpositus anterior of the cat. *J Chem Neuroanat* 15:134–153
- D'Antoni S, Zambusi L, Codazzi F, Zacchetti D, Grohovaz F, Provini L, Catania MV, Morara S (2010) Calcitonin gene-related peptide (CGRP) stimulates Purkinje cell dendrite growth in culture. *Neurochem Res* 35:2135–2143
- Errico P, Barmack NH (1993) Origins of cerebellar mossy and climbing fibers immunoreactive for corticotropin-releasing factor in the rabbit. *J Comp Neurol* 336:307–320

- Fox EA, Gruol DL (1993) Corticotropin-releasing factor suppresses the after hyperpolarization in cerebellar Purkinje neurons. *Neurosci Lett* 149:103–107
- Hokfelt T (1991) Neuropeptides in perspective: the last ten years. *Neuron* 7:867–879
- Ito M (2009) Functional roles of neuropeptides in cerebellar circuits. *Neuroscience* 162:666–672
- Miyata M, Ito M (1999) Corticotropin-releasing factor plays a permissive role in cerebellar long-term depression. *Neuron* 22:763–775
- Morara S, Rosina A, Provini L (1992) CGRP as a marker of the climbing fibers during the development of the cerebellum in the rat. *Ann NY Acad Sci* 657:461–463
- Morara S, Wang LP, Filippov V, Dickerson IM, Grohovaz F, Provini L, Kettenmann H (2008) Calcitonin gene-related peptide (CGRP) triggers Ca<sup>2+</sup> responses in cultured astrocytes and in Bergmann glial cells from cerebellar slices. *Eur J Neurosci* 28:2213–2220
- Nisimaru N, Mittal C, Shirai Y, Sooksawate T, Anandaraj P, Hashikawa T, Nagao S, Arata A, Sakurai T, Yamamoto M, Ito M (2013) Orexin-neuromodulated cerebellar circuit controls redistribution of arterial blood flows for defense behavior in rabbits. *Proc Natl Acad Sci U S A* 110:14124–14131
- Yu L, Zhang XY, Zhang J, Zhu JN, Wang JJ (2010) Orexins excite neurons of the rat cerebellar nucleus interpositus via orexin 2 receptors in vitro. *Cerebellum* 9:88–95
- Zhang XY, Yu L, Zhuang QX, Zhang J, Zhu JN, Wang JJ (2013) Hypothalamic histaminergic and orexinergic modulation on cerebellar and vestibular motor control. *Cerebellum* 12:294–296

# Chapter 36

## Neurosteroids

C. Fernando Valenzuela

**Abstract** Neurosteroids are steroids that are produced locally within the central nervous system independently of adrenal glands and gonads. Enzymes involved in neurosteroid biosynthesis are expressed in the cerebellum. These agents modulate the development of cerebellar neurons as well as glial cells. Neurosteroids exert neuroprotective actions and modulate synaptic transmission and plasticity in mature neurons. Deficits in cerebellar neurosteroid production may play a role in the pathophysiology of neuropsychiatric disorders.

**Keywords** Neurosteroids • Neuroactive • Steroids • Cerebellum • Neuron • Glia • Purkinje cells • Granule cells

Steroids produced locally in the brain are denoted as neurosteroids. Neurosteroids modulate neuronal and glial cells via regulation extracellular and intracellular receptors. Several of the enzymes involved in neurosteroid biosynthesis are expressed in the cerebellum (Fig. 36.1) (Ukena et al. 1998, 1999; Agis-Balboa et al. 2006; Kiyokage et al. 2014; Sakamoto et al. 2003; Kriz et al. 2005; Yarim and Kabakci 2004).

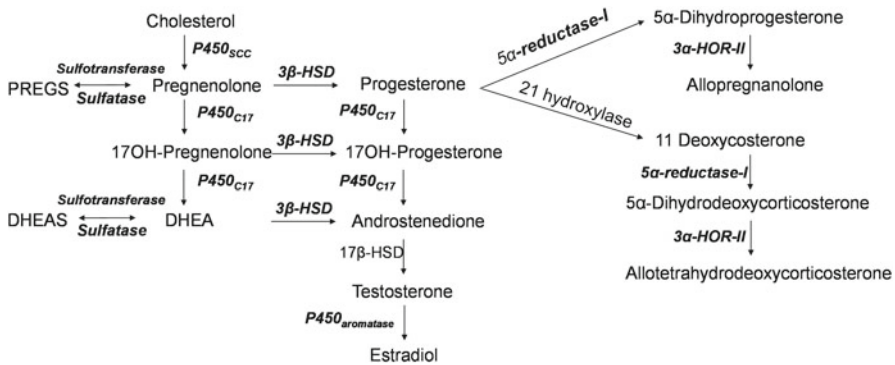
Purkinje cells (PCs) express cholesterol side chain cleavage enzyme (P450<sub>scC</sub>) during neonatal life and adulthood (Ukena et al. 1998). During neonatal life, rat PCs and external granule cells (GrCs) express 3 $\beta$ -hydroxysteroid dehydrogenase (3 $\beta$ -HSD) and generate progesterone (Ukena et al. 1999). Progesterone promotes dendritic outgrowth and increases spine density in PCs via intracrine and/or paracrine activation of nuclear receptors (Sakamoto et al. 2001). Progesterone and its metabolites also promote cerebellar myelination (Ghoumari et al. 2003).

Allopregnanolone has also been detected in the neonatal cerebellum where it promotes survival of PCs and GrCs (Tsutsui et al. 2011; Sakamoto et al. 2001;

---

C.F. Valenzuela (✉)

Department of Neurosciences, MSC08 4740, 1 University of New Mexico,  
87131-0001 Albuquerque, NM, USA  
e-mail: [fvalenzuela@salud.unm.edu](mailto:fvalenzuela@salud.unm.edu)



**Fig. 36.1** Neurosteroid Biosynthetic Pathway. Enzymes shown in bold and italics have been identified in the cerebellum. Steroid 17 alpha-hydroxylase/17,20 lyase (*P450<sub>C17</sub>*); pregnenolone sulfate (PREGS); dehydroepiandrosterone (DHEA); DHEA sulfate (DHEAS). For other enzyme abbreviations, see text

Yawno et al. 2009). In juvenile quails, allopregnanolone generated in the pineal gland promotes PC survival (Haraguchi et al. 2012). In a mouse model of Niemann-Pick type C disease, a lysosomal lipid storage disorder, expression of 3 $\alpha$ -hydroxysteroid oxidoreductase II (3 $\alpha$ -HOR-II) activity was found to be reduced in the cerebellum and neonatal administration of allopregnanolone increased survival of both PCs and GrCs by a mechanism involving nuclear pregnane X receptors (Griffin et al. 2004; Langmade et al. 2006).

In PCs and external GrCs from neonatal rats, high levels of both aromatase (*P450<sub>aromatase</sub>*) and estrogen can be detected (Sakamoto et al. 2003). Estradiol injection near the vermis of postnatal day 6–9 rats increased dendritic growth and spine density in PCs, perhaps via nuclear estrogen receptor-driven production of brain-derived neurotrophic factor (Sakamoto et al. 2003; Sasahara et al. 2007). In 10–12 day-old rats, intracerebral injection of prostaglandin E2 stimulated *P450<sub>aromatase</sub>* activity and estradiol synthesis; this was associated with a decrease in dendritic length, reduced spinophilin content, and altered excitability of PCs (Dean et al. 2012). Mice deficient in reelin, which have been used to model some aspects of schizophrenia and autism, displayed alterations in cerebellar neurosteroid levels as well as PC degeneration that could be corrected by estrogen administration (Biamonte et al. 2009).

In GrCs, estrogen rapidly activates ERK1/2 via a G protein-dependent mechanism; protein phosphatase 2A is also activated by estradiol through a different mechanism of action (Belcher 2008). The endocrine disruptor bisphenol A was shown to mimic and occlude these effects. Estrogen regulates the invasiveness of medulloblastoma, a malignant brain tumor that originates at GrC-like precursors (Belcher 2008).

Pregnenolone sulfate potentiates glutamatergic transmission at climbing fiber-PC synapses in neonatal rats, an effect that is mediated by an increase in presynaptic Ca<sup>2+</sup> levels mediated by steroid-sensitive transient receptor potential melastatin 3 receptors (Zamudio-Bulcock et al. 2011).

Adult mice express  $5\alpha$ -reductase type I and  $3\alpha$ -HSD-II mRNA in PCs and to a lesser extent in GrCs (Agis-Balboa et al. 2006). In samples from adolescent rats, immunohistochemical studies showed that  $5\alpha$ -reductase type I protein is expressed in glial cells (Kiyokage et al. 2014). The cerebellum of mature rodents can produce allopregnanolone (Griffin et al. 2004; Caruso et al. 2013). Allopregnanolone and allotetrahydrodeoxycorticosterone potentiate synaptic GABA<sub>A</sub> receptor function in PCs and GrCs (Cooper et al. 1999; Kelley et al. 2011). In GrCs and stellate cells, the effect of allotetrahydrodeoxycorticosterone on synaptic GABA<sub>A</sub> receptors depends on the presence of  $\delta$  subunits (Vicini et al. 2002). Allotetrahydrodeoxycorticosterone potentiates tonic currents mediated by  $\delta$  subunit-containing extrasynaptic GABA<sub>A</sub> receptors in rat cerebellar GrCs (Hamann et al. 2002). The potentiating effects of allopregnanolone and related neurosteroids on GABA<sub>A</sub> receptors may exert neuroprotective actions in the cerebellum (Ardeshiri et al. 2006; Kelley et al. 2011).

Mature cerebellar PCs and GrCs express estrogen receptors (Hedges et al. 2012). Estrogen exerts rapid modulatory effects on locomotor activity-induced PC firing in female rats (Smith et al. 1989). Estradiol facilitates the induction of long-term potentiation and increases synaptic density at parallel fiber-PC synapses; activation of  $\beta$ -estrogen receptors in PCs enhances gain-decrease vestibulo-ocular reflex learning (Andreescu et al. 2007). Optical imaging studies indicate that endogenous estrogen facilitates glutamatergic transmission at parallel fiber-PC synapses (Hedges et al. 2012). Cerebellar injury upregulates expression of P450<sub>aromatase</sub> in birds (Mirzaton et al. 2010). Estrogen treatment reduced PC death and improved motor coordination in ethanol withdrawn rats (Jung et al. 2002).

## References

- Agis-Balboa RC, Pinna G, Zhubi A, Maloku E, Veldic M, Costa E, Guidotti A (2006) Characterization of brain neurons that express enzymes mediating neurosteroid biosynthesis. *Proc Natl Acad Sci U S A* 103:14602–14607
- Andreescu CE, Milojkovic BA, Haasdijk ED, Kramer P, De Jong FH, Krust A, De Zeeuw CI, De Jeu MT (2007) Estradiol improves cerebellar memory formation by activating estrogen receptor beta. *J Neurosci* 27:10832–10839
- Ardeshiri A, Kelley MH, Korner IP, Hurn PD, Herson PS (2006) Mechanism of progesterone neuroprotection of rat cerebellar Purkinje cells following oxygen-glucose deprivation. *Eur J Neurosci* 24:2567–2574
- Belcher SM (2008) Rapid signaling mechanisms of estrogens in the developing cerebellum. *Brain Res Rev* 57:481–492
- Biamonte F, Assenza G, Marino R, D'Amelio M, Panteri R, Caruso D, Scurati S, Yague JG, Garcia-Segura LM, Cesa R, Strata P, Melcangi RC, Keller F (2009) Interactions between neuroactive steroids and reelin haploinsufficiency in Purkinje cell survival. *Neurobiol Dis* 36:103–115
- Caruso D, Pesaresi M, Abbiati F, Calabrese D, Giatti S, Garcia-Segura LM, Melcangi RC (2013) Comparison of plasma and cerebrospinal fluid levels of neuroactive steroids with their brain, spinal cord and peripheral nerve levels in male and female rats. *Psychoneuroendocrinology* 38:2278–2290

- Cooper EJ, Johnston GA, Edwards FA (1999) Effects of a naturally occurring neurosteroid on GABAA IPSCs during development in rat hippocampal or cerebellar slices. *J Physiol* 521(Pt 2):437–449
- Dean SL, Wright CL, Hoffman JF, Wang M, Alger BE, McCarthy MM (2012) Prostaglandin E2 stimulates estradiol synthesis in the cerebellum postnatally with associated effects on Purkinje neuron dendritic arbor and electrophysiological properties. *Endocrinology* 153:5415–5427
- Ghousari AM, Ibanez C, El-Etr M, Leclerc P, Eychenne B, O'Malley BW, Baulieu EE, Schumacher M (2003) Progesterone and its metabolites increase myelin basic protein expression in organotypic slice cultures of rat cerebellum. *J Neurochem* 86:848–859
- Griffin LD, Gong W, Verot L, Mellon SH (2004) Niemann-Pick type C disease involves disrupted neurosteroidogenesis and responds to allopregnanolone. *Nat Med* 10:704–711
- Hamann M, Rossi DJ, Attwell D (2002) Tonic and spillover inhibition of granule cells control information flow through cerebellar cortex. *Neuron* 33:625–633
- Haraguchi S, Hara S, Ubuka T, Mita M, Tsutsui K (2012) Possible role of pineal allopregnanolone in Purkinje cell survival. *Proc Natl Acad Sci U S A* 109:21110–21115
- Hedges VL, Ebner TJ, Meisel RL, Mermelstein PG (2012) The cerebellum as a target for estrogen action. *Front Neuroendocrinol* 33:403–411
- Jung ME, Yang SH, Brun-Zinkernagel AM, Simpkins JW (2002) Estradiol protects against cerebellar damage and motor deficit in ethanol-withdrawn rats. *Alcohol* 26:83–93
- Kelley MH, Kuroiwa M, Taguchi N, Herson PS (2011) Sex difference in sensitivity to allopregnanolone neuroprotection in mice correlates with effect on spontaneous inhibitory post synaptic currents. *Neuropharmacology* 61:724–729
- Kiyokage E, Toida K, Suzuki-Yamamoto T, Ishimura K (2014) Cellular localization of 5alpha-reductase in the rat cerebellum. *J Chem Neuroanat* 59–60:8–16
- Kriz L, Bicikova M, Hill M, Hampl R (2005) Steroid sulfatase and sulfuryl transferase activity in monkey brain tissue. *Steroids* 70:960–969
- Langmade SJ, Gale SE, Frolov A, Mohri I, Suzuki K, Mellon SH, Walkley SU, Covey DF, Schaffer JE, Ory DS (2006) Pregnane X receptor (PXR) activation: a mechanism for neuroprotection in a mouse model of Niemann-Pick C disease. *Proc Natl Acad Sci U S A* 103:13807–13812
- Mirzatonli A, Spence RD, Naranjo KC, Saldanha CJ, Schlinger BA (2010) Injury-induced regulation of steroidogenic gene expression in the cerebellum. *J Neurotrauma* 27:1875–1882
- Sakamoto H, Ukena K, Tsutsui K (2001) Effects of progesterone synthesized de novo in the developing Purkinje cell on its dendritic growth and synaptogenesis. *J Neurosci* 21:6221–6232
- Sakamoto H, Mezaki Y, Shikimi H, Ukena K, Tsutsui K (2003) Dendritic growth and spine formation in response to estrogen in the developing Purkinje cell. *Endocrinology* 144:4466–4477
- Sasahara K, Shikimi H, Haraguchi S, Sakamoto H, Honda S, Harada N, Tsutsui K (2007) Mode of action and functional significance of estrogen-inducing dendritic growth, spinogenesis, and synaptogenesis in the developing Purkinje cell. *J Neurosci* 27:7408–7417
- Smith SS, Woodward DJ, Chapin JK (1989) Sex steroids modulate motor-correlated increases in cerebellar discharge. *Brain Res* 476:307–316
- Tsutsui K, Ukena K, Sakamoto H, Okuyama S, Haraguchi S (2011) Biosynthesis, mode of action, and functional significance of neurosteroids in the Purkinje cell. *Front Endocrinol (Lausanne)* 2:61
- Ukena K, Usui M, Kohchi C, Tsutsui K (1998) Cytochrome P450 side-chain cleavage enzyme in the cerebellar Purkinje neuron and its neonatal change in rats. *Endocrinology* 139:137–147
- Ukena K, Kohchi C, Tsutsui K (1999) Expression and activity of 3beta-hydroxysteroid dehydrogenase/delta5-delta4-isomerase in the rat Purkinje neuron during neonatal life. *Endocrinology* 140:805–813
- Vicini S, Losi G, Homanics GE (2002) GABA(A) receptor delta subunit deletion prevents neurosteroid modulation of inhibitory synaptic currents in cerebellar neurons. *Neuropharmacology* 43:646–650

- Yarim M, Kabakci N (2004) Neurosteroidogenesis in oligodendrocytes and Purkinje neurones of cerebellar cortex of dogs. *Anat Histol Embryol* 33:151–154
- Yawno T, Hirst JJ, Castillo-Melendez M, Walker DW (2009) Role of neurosteroids in regulating cell death and proliferation in the late gestation fetal brain. *Neuroscience* 163:838–847
- Zamudio-Bulcock PA, Everett J, Harteneck C, Valenzuela CF (2011) Activation of steroid-sensitive TRPM3 channels potentiates glutamatergic transmission at cerebellar Purkinje neurons from developing rats. *J Neurochem* 119:474–485

# Chapter 37

## Cerebellar Modules and Networks Involved in Locomotion Control

Carla da Silva Matos<sup>#</sup>, María Fernanda Vinueza Veloz<sup>#</sup>, Tom J.H. Ruigrok, and Chris I. De Zeeuw

**Abstract** Modern neuroscience is paving the way for new insight into cerebellar functions including the control of cognitive, autonomic and emotional processes. Yet, how the cerebellum coordinates basic motor behavior such as locomotion is still only partly understood. Here, we will review the role of the cerebellum in locomotion from the perspective of neuro-anatomical and clinical reports as well as cell-specific rodent studies. Evidence has been emerging that different modules and networks exert synergistic roles in the preparation, performance, adaptation and consolidation of locomotion, highlighting their contribution to interlimb coordination and the accuracy, efficiency and regularity of locomotion patterns.

**Keywords** Cerebellar modules networks • Locomotion • Interlimb coordination

### 37.1 Introduction

Whereas the cerebellum does not initiate movement, it does facilitate the acquisition and performance of well-timed, smooth and efficient movements aimed at a specific target in space and/or proper coordination with respect to other body parts.

---

<sup>#</sup>Author contributed equally to this work

C. da Silva Matos  
Royal Netherlands Academy of Arts & Sciences, Netherlands Institute for Neuroscience,  
Amsterdam, The Netherlands

M.F. Vinueza Veloz • T.J.H. Ruigrok  
Department of Neuroscience, Erasmus MC Rotterdam,  
2040, 3000 CA Rotterdam, The Netherlands

C.I. De Zeeuw (✉)  
Royal Netherlands Academy of Arts & Sciences, Netherlands Institute for Neuroscience,  
Amsterdam, The Netherlands

Department of Neuroscience, Erasmus MC Rotterdam,  
2040, 3000 CA Rotterdam, The Netherlands  
e-mail: [c.de.zeeuw@nin.knaw.nl](mailto:c.de.zeeuw@nin.knaw.nl)



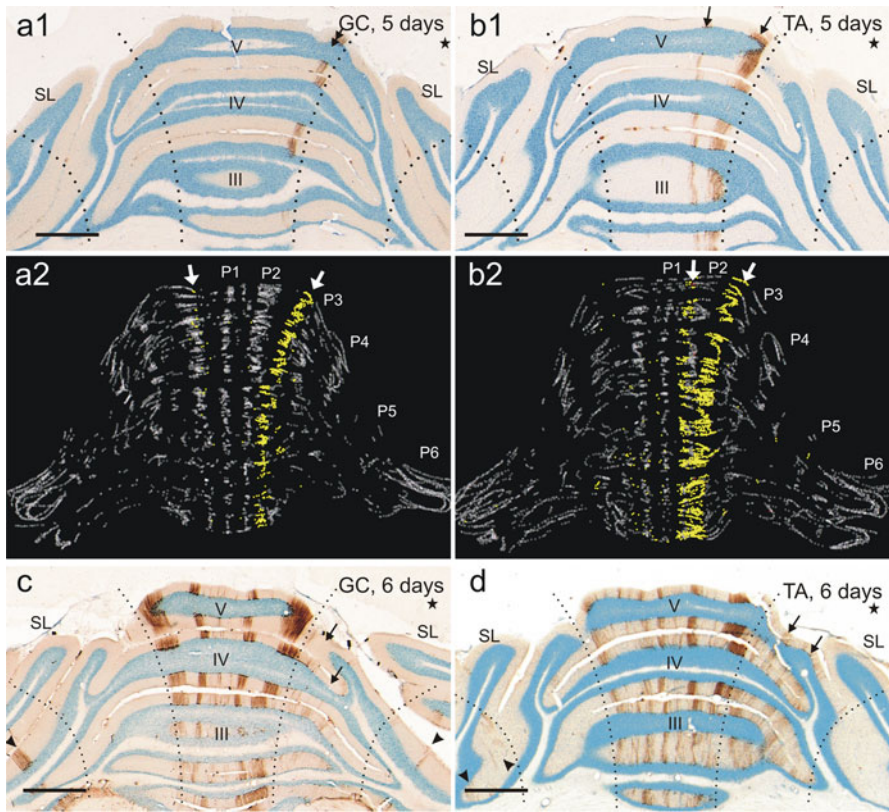
Accordingly, typical signs of cerebellar dysfunction include deficits in the acquisition and performance of such movements. In the initial stages of mild cerebellar disease, deficits are predominantly reflected in the inability to adapt the amplitude and timing of movements to new environmental challenges or to acquire new associative motor behaviors. However, when cerebellar degeneration progresses, performance deficits emerge, often leading to full-blown ataxia (De Zeeuw et al. 2011). The name *ataxia* literally means “without order” and highlights the robust coordination deficits of this disorder, while setting it apart from the inability to move (*paralysis*), a disorder occurring in non-cerebellar diseases such as amyotrophic lateral sclerosis or stroke of the cerebral motor cortex.

### 37.2 Modular Organization: Evidence from Neuro-Anatomical and Clinical Studies

The cerebellar cortex can be divided into distinct functional sagittal zones identified by their specific afferent and efferent connections (Voogd and Glickstein 1998). Each zone of cerebellar Purkinje-cells projects to a specific cerebellar or vestibular nucleus, which in turn inhibits the olivary subnucleus that provides the climbing fibers to the Purkinje-cells of the corresponding zone (De Zeeuw et al. 2011). These topographically organized triangular loops are referred to as olivocerebellar modules.

Lesion studies of the cerebellum or inferior olive in mammals suggest that most, if not all, modules are involved in locomotion, but probably each in a specific way. The medial zones of the cerebellum (A, B) regulate posture and balance by controlling extensor tone and modulate related rhythmic muscular activity by controlling spinal interneurons (Mori et al. 1999; Pijpers et al. 2008; Horn et al. 2010). By contrast, the intermediate zones (C1 to C3) are more relevant for controlling the trajectory, reflexes, timing and amplitude of limb movements (Chambers and Sprague 1955; Yu and Eidelberg 1983). Finally, the lateral zones (D1 and D2) are important in the adaptation of locomotion patterns to unusual and complex circumstances, especially when visual guidance is needed (Thach et al. 1992; Aoki et al. 2013). Indeed, retrograde transneuronal tracer studies show that multiple modules are involved in the control of individual hindlimb muscles (Fig. 37.1; Ruigrok et al. 2008).

Clinical studies of cerebellar patients suffering from focal lesions following stroke or resection of tumors also indicate that all olivocerebellar modules contribute to locomotion in specific ways. Here, too, lesions in the medial zones affect balance, posture and undisturbed gait, whereas those in the intermediate and lateral zones deregulate leg placement and interlimb coordination as well as planning and gait adaptation to demanding circumstances (Schoch et al. 2006; Morton and Bastian 2007; Ilg et al. 2008). Moreover, similar to animal studies, lesions affecting the cerebellar nuclei in humans are more difficult to compensate for than lesions



**Fig. 37.1** Multiple cerebellar modules are involved in the control of single hindlimb muscles. (**a1**, **b1**) Injection of the retrogradely and transneuronally transported rabies virus into either the gastrocnemius (GC) or anterior tibial (TA) muscles of the rat resulted in zonal labeling of vermal Purkinje cells after 5 days survival time. (**a2**, **b2**) These zones adhered to the zebrin pattern as demonstrated in a plot of the anterior lobe based on ten superposed double labeled sections. This enabled identification of the labeled zones. Note that virtually all rabies-labeled cells are zebrin-negative. Minor differences exist between patterns resulting from GC and TA injections. *Yellow dots*, rabies-labeled Purkinje cells; *grey dots*, zebrin-positive cells; *red dots*, double labeled cells. (**c**, **d**) Lengthening the survival time to allow for a single more transsynaptic passage also labeled Purkinje cells in the paravermis (*arrows*) and hemispheres (*arrowheads*). III, IV, V, vermal lobules, SL simple lobule; *star*, injected side; *stippled lines* indicate approximate lateral border of vermis and paravermis; scale bar: 500  $\mu$ m (Adapted from Ruigrok et al. 2008)

affecting solely the cerebellar cortex (Morton and Bastian 2004; Konczak et al. 2005; Schoch et al. 2006). Together, the cerebellar cortex and nuclei may act as an internal model of the motor apparatus, allowing sensorimotor predictions of body state in the future following particular motor commands (Wolpert et al. 1995; Bastian 2006).

### 37.3 Network Organization: Evidence from Cell-Specific Rodent Studies

The cerebellar cortex is a continuous sheet of repeated networks of neurons folded into folia. Its most remarkable structural feature is the orthogonal arrangement of many of its cells and afferents. The dendrites and axons of Purkinje-cells, axons of molecular layer interneurons, ascending axons of granule-cells, dendritic domains of Golgi-cells as well as the climbing-fibers and Bergmann glia-sheaths are all predominantly oriented in sagittal planes, whereas the parallel-fibers originating from the ascending granule cell axons are orthogonally oriented in a medio-lateral direction (De Zeeuw et al. 2011). In this respect, the mossy-fibers exhibit a somewhat ambiguous distribution in that they can show sagittally oriented input patterning as occurs in large parts of the anterior lobe, whereas in other parts they traverse multiple modules (Gao et al. 2012). Interestingly, the sagittally oriented mossy-fiber inputs also entail some of the areas involved in locomotion, such as those receiving input from the spinal cord and dorsal column nuclei (Gerrits et al. 1985).

Purkinje-cells are most critical for operations at the network level of the cerebellar cortex; deleting these cells in rodents leads to irregular and smaller movements of the limbs just like those of other body parts such as the eyes (De Zeeuw et al. 2011; Vinueza Veloz et al. 2014). Their climbing-fiber input has been suggested to carry an error signal affecting the strength of their parallel-fiber inputs (Marr 1969; Albus 1971). With regard to adaptation of locomotion patterns, intrinsic plasticity of Purkinje-cells and long-term potentiation (LTP), but not long-term depression (LTD), of the parallel fiber-Purkinje-cell synapse appear to be essential (Schonewille et al. 2011; Vinueza Veloz et al. 2014). Moreover, processing at the level of the interneurons in both the granular layer and molecular layer also appears to contribute to gait patterns, albeit less prominently and predominantly during demanding tasks (Galliano et al. 2013; Vinueza Veloz et al. 2014). Likewise, electrotonic coupling of neurons in the inferior olive is also critical for fast modification of locomotion reflexes (Van Der Giessen et al. 2008). Thus, although Purkinje-cells and their potentiation are most critical for generating accurate, efficient, and consistent walking patterns, their input structures also all play a relevant role; and this role is most prominent during interlimb coordination and obstacle crossings (Stroobants et al. 2013; Vinueza Veloz et al. 2014). Indeed, the cerebellar networks operate in a distributed synergistic fashion allowing for ample possibilities of compensation (Gao et al. 2012).

**Acknowledgements** This work was supported by the Dutch Organization for Medical Sciences (ZonMw), Life Sciences (ALW), Senter (Neuro-Bsik) and ERC-adv of the European Community.

## References

- Albus JS (1971) A theory of cerebellar function. *Math Biosci* 10:25–61
- Aoki S, Sato Y, Yanagihara D (2013) Lesion in the lateral cerebellum specifically produces overshooting of the toe trajectory in leading forelimb during obstacle avoidance in the rat. *J Neurophysiol* 110:1511–1524
- Bastian AJ (2006) Learning to predict the future: the cerebellum adapts feedforward movement control. *Curr Opin Neurobiol* 16:645–649
- Chambers WW, Sprague JM (1955) Functional localization in the cerebellum. II. Somatotopic organization in cortex and nuclei. *AMA Arch Neurol Psychiatry* 74:653–680
- De Zeeuw CI, Hoebeek FE, Bosman LW, Schonewille M, Witter L, Koekkoek SK (2011) Spatiotemporal firing patterns in the cerebellum. *Nat Rev Neurosci* 12:327–344
- Galliano E, Gao Z, Schonewille M, Todorov B, Simons E, Pop AS, D'Angelo E, van den Maagdenberg AM, Hoebeek FE, De Zeeuw CI (2013) Silencing the majority of cerebellar granule cells uncovers their essential role in motor learning and consolidation. *Cell Rep* 3:1239–1251
- Gao Z, van Beugen BJ, De Zeeuw CI (2012) Distributed synergistic plasticity and cerebellar learning. *Nat Rev Neurosci* 13:619–635
- Gerrits NM, Voogd J, Nas WS (1985) Cerebellar and olivary projections of the external and rostral internal cuneate nuclei in the cat. *Exp Brain Res* 57:239–255
- Horn KM, Pong M, Gibson AR (2010) Functional relations of cerebellar modules of the cat. *J Neurosci* 30:9411–9423
- Ilg W, Giese MA, Gizewski ER, Schoch B, Timmann D (2008) The influence of focal cerebellar lesions on the control and adaptation of gait. *Brain* 131:2913–2927
- Konczak J, Schoch B, Dimitrova A, Gizewski E, Timmann D (2005) Functional recovery of children and adolescents after cerebellar tumour resection. *Brain* 128:1428–1441
- Marr D (1969) A theory of cerebellar cortex. *J Physiol* 202:437–470
- Mori S, Matsui T, Kuze B, Asanome M, Nakajima K, Matsuyama K (1999) Stimulation of a restricted region in the midline cerebellar white matter evokes coordinated quadrupedal locomotion in the decerebrate cat. *J Neurophysiol* 82:290–300
- Morton SM, Bastian AJ (2004) Cerebellar control of balance and locomotion. *Neuroscientist* 10:247–259
- Morton SM, Bastian AJ (2007) Mechanisms of cerebellar gait ataxia. *Cerebellum* 6:79–86
- Pijpers A, Winkelman BH, Bronsing R, Ruigrok TJ (2008) Selective impairment of the cerebellar CI module involved in rat hind limb control reduces step-dependent modulation of cutaneous reflexes. *J Neurosci* 28:2179–2189
- Ruigrok TJ, Pijpers A, Goedknecht-Sabel E, Coulon P (2008) Multiple cerebellar zones are involved in the control of individual muscles: a retrograde transneuronal tracing study with rabies virus in the rat. *Eur J Neurosci* 28:181–200
- Schoch B, Dimitrova A, Gizewski ER, Timmann D (2006) Functional localization in the human cerebellum based on voxelwise statistical analysis: a study of 90 patients. *Neuroimage* 30:36–51
- Schonewille M, Gao Z, Boele HJ, Veloz MF, Amerika WE, Simek AA, De Jeu MT, Steinberg JP, Takamiya K, Hoebeek FE, Linden DJ, Huganir RL, De Zeeuw CI (2011) Reevaluating the role of LTD in cerebellar motor learning. *Neuron* 70:43–50
- Stroobants S, Gantois I, Pooters T, D'Hoooge R (2013) Increased gait variability in mice with small cerebellar cortex lesions and normal rotarod performance. *Behav Brain Res* 241:32–37
- Thach WT, Goodkin HP, Keating JG (1992) The cerebellum and the adaptive coordination of movement. *Annu Rev Neurosci* 15:403–442
- Van Der Giessen RS, Koekkoek SK, van Dorp S, De Gruijl JR, Cupido A, Khosrovani S, Dortland B, Wellershaus K, Degen J, Deuchars J, Fuchs EC, Monyer H, Willecke K, De Jeu MT, De Zeeuw CI (2008) Role of olivary electrical coupling in cerebellar motor learning. *Neuron* 58:599–612

- Vinueza Veloz MF, Zhou K, Bosman LW, Potters JW, Negrello M, Seepers RM, Strydis C, Koekkoek SK, De Zeeuw CI (2014) Cerebellar control of gait and interlimb coordination. *Brain Struct Funct* 220:3513–3536
- Voogd J, Glickstein M (1998) The anatomy of the cerebellum. *Trends Neurosci* 21:370–375
- Wolpert DM, Ghahramani Z, Jordan MI (1995) An internal model for sensorimotor integration. *Science* 269:1880–1882
- Yu J, Eidelberg E (1983) Recovery of locomotor function in cats after localized cerebellar lesions. *Brain Res* 273:121–131

# Chapter 38

## Distributed Plasticity in the Cerebellar Circuit

Egidio D'Angelo

**Abstract** In contrast with the original Motor Learning Theory that included a single form of plasticity at the parallel fiber – Purkinje cell synapse, recent experimental work has revealed at least nine forms of long-term synaptic and non-synaptic plasticity (some of which bidirectional) distributed among the cerebellar cortex and deep cerebellar nuclei). Thus, understanding cerebellar plasticity requires now that the spatio-temporal interplay of these multiple mechanisms are analyzed during specific behaviors. A recent set of experimental and modeling investigations has opened a new view on how the multiple forms of long-term synaptic plasticity might cooperate to generate cerebellar learning and memory in sensori-motor control tasks.

**Keywords** Long-term synaptic plasticity • Cerebellum • Motor control

### 38.1 Introduction

*Learning and control* have been integrated into the *Motor Learning Theory* (Marr 1969; Albus 1971), in which the cerebellum has been proposed to learn sensori-motor contingencies and then to act as a *forward controller* predicting the consequences of motor acts and correcting intervening errors (Raymond et al. 1996; Ito 1984). Multiple processes may contribute to motor skill acquisition, which proceeds through a rapid convergence toward a stable state before being consolidated into persistent memory (Lee and Schweighofer 2009; Shadmehr et al. 2010). Although multi-rates models can indeed explain the cerebellar learning process (Smith et al. 2006), the specific role of plastic mechanisms remained unclear. These plastic mechanisms include long-term potentiation (LTP) and long-term depression (LTD)

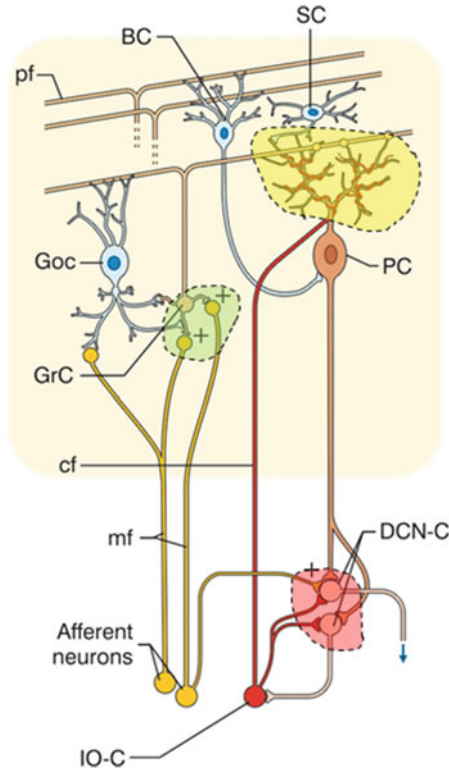
---

E. D'Angelo (✉)

Department of Brain and Behavioral Sciences, Department of Physiology,  
University of Pavia, Pavia, Italy

Brain Connectivity Center, C. Mondino National Neurological Institute,  
via Forlanini 6, 27100 Pavia, Italy

e-mail: [dangelo@unipv.it](mailto:dangelo@unipv.it); [egidiougo.dangelo@unipv.it](mailto:egidiougo.dangelo@unipv.it)



**Fig. 38.1** Schematic drawing of the cerebellar circuit and its forms of plasticity. The principal elements of the cerebellar circuit and associate structures are indicated: mossy fiber (*mf*), parallel fiber (*pf*), climbing fiber (*cf*), granule cell (*GrC*), Golgi cell (*GoC*), Purkinje cell (*PC*), stellate cell (*SC*), basket cell (*BC*), deep cerebellar nuclei cell (*DCN-C*), inferior olive cell (*IO-C*). The cerebellar cortex is indicated by a shadowed area. The cerebellar circuit expresses at least nine recognized forms of plasticity, some of which bidirectional, included into three main subcircuits. (1) Granular layer (*green area*): *mf* – *GrC* LTP and LTD; *GrC* LTP of intrinsic excitability. (2) Molecular layer circuit (*yellow area*): presynaptic *pf* – *PC* LTP and LTD; postsynaptic *pf* – *PC* LTP and LTD; *cf* – *PC* LTD; *SC/BC* inhibitory LTP; *PC* LTP of intrinsic excitability. (3) Deep cerebellar nuclei (*red area*): *mf* – *DCN-C* LTP and LTD; *PC* – *DCN-C* inhibitory LTP and LTD; *DCN* cell LTP of intrinsic excitability (Taken with permission from D'Angelo 2014)

at the mossy fiber (*mf*) – granule cell (*GrC*) synapse, at the synapses formed by parallel fibers (*pf*), climbing fibers (*cf*) and molecular layer interneurons (MLI: stellate and basket cells) on Purkinje cells (*PC*), and at the synapses formed by *mfs* and *PCs* on deep-cerebellar nuclear cells (*DCN-C*), as well as LTP of intrinsic excitability in *GrC*, *PC* and *DCN-C* (Fig. 38.1) (for details see Hansel et al. 2001; DeZeeuw and Yeo 2005; D'Angelo and DeZeeuw 2009; Gao et al. 2012; D'Angelo 2014).

Mf-*GrC* LTP and LTD are expressed through mechanisms altering the synaptic strength and dynamics of repetitive signal transmission in the granular layer. Multiple forms of *pf-PC* LTP and LTD, along with plasticity at molecular interneuron synapses,

control the state of PC activation. PC-DCN and mf-DCN LTP and LTD are regulated by mfs and PCs. In addition, plastic changes affect intrinsic excitability in granule cells, PCs and DCN cells. In front of this complexity, how does cerebellar learning occur? Are all these forms of plasticity required to learn and control complex behaviors? How are these forms of plasticity engaged during a learning task (Mauk 1997; Llinas et al. 1997)?

## 38.2 Evidence for Distributed Cerebellar Plasticity During Behavior

The properties of cerebellar learning can be investigated through adaptation of the eye-blink classical conditioning (EBCC) reflex (Garcia and Mauk 1998; Medina et al. 2001), which combines the three major aspects of cerebellar activity: *learning, prediction and timing*. In EBCC, the cerebellum allows learning of appropriate timing between conditioned (CS) and unconditioned stimuli (US), such that of US can be precisely predicted based on the occurrence of CS. The functions of cerebellar cortex and nuclei in EBCC have been dissected using micro-injection of the GABA<sub>A</sub> receptor agonist muscimol (Attwell et al. 2002; Cooke et al. 2004) and computational modeling has shown that the cerebellar cortex can account for the faster component and the deep cerebellar nuclei for slower components of EBCC learning (Medina and Mauk 2000). Moreover, dynamic transfer of plasticity among multiple sites has been suggested to rebalance synaptic weights moving associative learning from cortical to nuclear sites (Medina et al. 2001; Garrido et al. 2013a). We have recently faced the issue of EBCC learning in humans by using cerebellum transcranial magnetic stimulation (TMS) (Monaco et al. 2014). Interestingly, TMS pulses delivered over the oculo-motor cerebellum just after EBCC training, were able to disrupt the fast mechanism but not the slow mechanism of learning or even consolidation, suggesting that memory was acquired in superficial structures and dynamically transferred to deeper structures, according to the multi-rate model (Shadmehr et al. 2010).

## 38.3 Distributed Plasticity in Computational Models

In order to investigate the interplay of multiple plasticities in the cerebellum under realistic operating conditions, we have integrated cerebellar network models into the feed-back and feed-forward circuits of a robot (Garrido et al. 2013a; Casellato et al. 2014) generating both the motor commands (simulating cerebral cortex activity) and sensory signals (derived from various sensors measuring the consequences of movement). In robotic simulations, multiple plasticities played different roles on different timescales (Garrido et al. 2013a). Plasticity at the pf-PC synapse rapidly



acquired sensori-motor correlations but was labile and was overwritten by new signals. As soon as pf-PC plasticity was formed, PC firing changed and modified the synapses in the DCN. By transferring plasticity into the DCN, the whole system became more stable. Moreover, error feed-back through sensory reafferences and the entire control system allowed plasticity self-rescaling preventing pf-PC synapse saturation. A remarkable acceleration of learning was achieved through plasticity in the internal feed-forward loop passing from the inferior olive (IO) to DCN (Luque et al. 2014), which allowed system errors to be learnt in the DCN without the need of complex signal processing through the cortical loop (granular and molecular layers). These robotic simulations thus suggest that the multiple forms of plasticity observed in the cerebellar network are needed to obtain flexible, fast and stable learning as observed in biological systems.

It should be noted that these cerebellar models did not include granular layer plasticity. Plasticity at the mf-GrC synapse is critical to regulate the number and precision of spikes generated by granule cells (D'Angelo and DeZeeuw 2009) and may be assisted by plastic changes at the mf-Golgi cell (GoC) synapse and at the GoC-GrC synapses (Garrido et al. 2013b). Moreover, changes in synaptic strength at the mf-GrC synapse are critical to determine the variety of granular layer response patterns generated by the granular layer (Rossert et al. 2014). Thus, since granular layer plasticity is critical to process time-dependent multi-dimensional inputs, three problems need to be solved before including it into adaptive sensori-motor controllers: (i) the coding scheme should be based on timing rather than firing rates, (ii) the input dimensionality should be increased, (iii) the learning rules should be determined experimentally. The development of large-scale spiking networks coupled to extended sensory and command systems, as well as the inclusion of local oscillations coupled with STDP learning rules, may help solving the issue.

## 38.4 Conclusions

A new picture is emerging beyond the original intuition that learning had to occur at the pf-PC synapse of the cerebellum under guidance of CF signals in order to allow motor control. Cerebellar plasticity is distributed and dynamically transferred through the different synaptic sites and can perform various operations: it is probably needed for expansion recoding in the granular layer, then it allows fast signal association in the Purkinje cell layer, finally it allows slow memory stabilization in the DCN. The plasticity transfer into deep structures requires internal and external feedback, and it is possible that memory traces are also transferred outside the cerebellum, e.g. in the cerebral cortex and brainstem (Koch et al. 2008). Cerebellar plasticity seems therefore unavoidably bound to local circuit dynamics (D'Angelo and DeZeeuw 2009) and to the extended recurrent networks formed by the cerebellum with extracerebellar areas.

**Acknowledgments** We thank Leda Roggeri for technical assistance. This work was supported by European Union grants to ED [CEREBNET FP7-ITN238686, REALNET FP7-ICT270434, Human Brain Project (HBP-604102)].

## References

- Albus JS (1971) A theory of cerebellar function. *Math Biosci* 10:25–61
- Attwell PJE, Cooke SF, Yeo CH (2002) Cerebellar function in consolidation of a motor memory. *Neuron* 34:1011–1020
- Casellato C, Antonietti A, Garrido JA et al (2014) Adaptive robotic control driven by a versatile spiking cerebellar network. *PLoS One* 9(11):e112265
- Cooke SF, Attwell PJ, Yeo CH (2004) Temporal properties of cerebellar-dependent memory consolidation. *J Neurosci* 24:2934–2941
- D’Angelo E (2014) The organization of plasticity in the cerebellar cortex: from synapses to control. *Prog Brain Res* 210:31–58
- D’Angelo E, De Zeeuw CI (2009) Timing and plasticity in the cerebellum: focus on the granular layer. *Trends Neurosci* 32:30–40
- De Zeeuw CI, Yeo CH (2005) Time and tide in cerebellar memory formation. *Curr Opin Neurobiol* 15:667–674
- Gao Z, van Beugen BJ, De Zeeuw CI (2012) Distributed synergistic plasticity and cerebellar learning. *Nat Rev Neurosci* 13:619–635
- Garcia KS, Mauk MD (1998) Pharmacological analysis of cerebellar contributions to the timing and expression of conditioned eyelid responses. *Neuropharmacology* 37:471–480
- Garrido JA, Luque NR, D’Angelo E, Ros E (2013a) Distributed cerebellar plasticity implements adaptable gain control in a manipulation task: a closed-loop robotic simulation. *Front Neuroci Circ* 7:159
- Garrido JA, Ros E, D’Angelo E (2013b) Spike timing regulation on the millisecond scale by distributed synaptic plasticity at the cerebellum input stage: a simulation study. *Front Comput Neurosci* 7:64
- Hansel C, Linden DJ, D’Angelo E (2001) Beyond parallel fiber LTD: the diversity of synaptic and non-synaptic plasticity in the cerebellum. *Nat Neurosci* 4:467–476
- Ito M (1984) *The cerebellum and neural control*. Raven Press, New York
- Koch G, Mori F, Marconi B et al (2008) Changes in intracortical circuits of the human motor cortex following theta burst stimulation of the lateral cerebellum. *J Clin Neurophysiol* 119:2559–2569
- Lee JY, Schweighofer N (2009) Dual adaptation supports a parallel architecture of motor memory. *J Neurosci* 29:10396–10404
- Llinas R, Lang EJ, Welsh JP (1997) The cerebellum, LTD, and memory: alternative views. *Learn Mem* 3:445–455
- Luque NR, Garrido JA, Carrillo RR et al (2014) Fast convergence of learning requires plasticity between inferior olive and deep cerebellar nuclei in a manipulation task: a closed-loop robotic simulation. *Front Comput Neurosci* 8:97
- Marr D (1969) A theory of cerebellar cortex. *J Physiol* 202:437–470
- Mauk MD (1997) Roles of cerebellar cortex and nuclei in motor learning: contradictions or clues? *Neuron* 18:343–346
- Medina JF, Mauk MD (2000) Computer simulation of cerebellar information processing. *Nat Neurosci* 3(Suppl):1205–1211
- Medina JF, Garcia KS, Mauk MD (2001) A mechanism for savings in the cerebellum. *J Neurosci* 21:4081–4089

- Monaco J, Casellato C, Koch G et al (2014) Cerebellar theta burst stimulation dissociates memory components in eyeblink classical conditioning. *Eur J Neurosci* 40(9):3363–3370
- Raymond JL, Lisberger SG, Mauk MD (1996) The cerebellum: a neuronal learning machine? *Science* 272:1126–1131
- Rössert C, Solinas S, D'Angelo E et al (2014) Model cerebellar granule cells can faithfully transmit modulated firing rate signals. *Front Cell Neurosci* 8:304
- Shadmehr R, Smith MA, Krakauer JW (2010) Error correction, sensory prediction, and adaptation in motor control. *Annu Rev Neurosci* 33:89–108
- Smith MA, Ghazizadeh A, Shadmehr R (2006) Interacting adaptive processes with different timescales underlie short-term motor learning. *PLoS Biol* 4(6):e179

**Part V**  
**Basic Physiology**

# Chapter 39

## Oscillation in the Inferior Olive Neurons: Functional Implication

Rodolfo R. Llinas

**Abstract** The inferior olives represent one of the omnipresent bulbar nuclei in vertebrates.

Their axonal projection to cerebellar nuclei, and its powerful synaptic input to Purkinje cells, (the so-called climbing fibers), serve as a powerful excitatory input deeply related to the timing of motor execution. Inferior olive neuronal activity is synchronized by intrinsic membrane oscillatory activity, via voltage dependant calcium channel activation, and their interconnectivity via neuronal electrical coupling.

**Keywords** Climbing fiber • Electrical coupling • Intrinsic electrical properties • Motor coordination • Motor timing • Purkinje cell • P-type calcium conductance • T-type calcium conductance

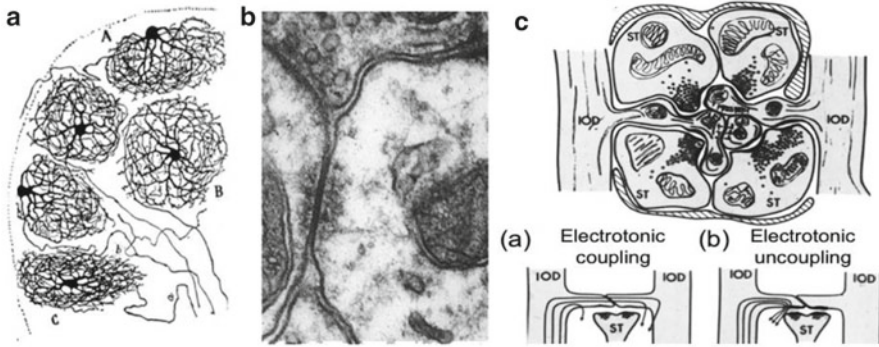
### 39.1 The Olivocerebellar System

The inferior olive nuclei, a set of two symmetrical neuronal groups, located on each side of the bulbar region, are the cells of origin of the cerebellar climbing fiber system (Szentagothai and Rajkovits 1959) and are one of two major afferent pathways on to the cerebellar cortex (Cajal 1904). Their axons traverse the midline to enter the cerebellum via the inferior peduncle where they form climbing fiber contacts on Purkinje cells (PC) establishing the most powerful chemical synaptic contact in the central nervous system (Eccles et al. 1966). Each inferior olive (IO) neuron generates ten or so climbing fibers that, in addition to innervating the cerebellar cortex, also produce collateral branches that terminate in all cerebellar nuclei. The conduction times of climbing fibers are modulated such that their activation of Purkinje cells are independent of location and distance in the cerebellar cortex (Sugihara et al. 1993).

---

R.R. Llinas (✉)

Department of Neuroscience and Physiology, NYU School of Medicine, New York, USA  
e-mail: [Rodolfo.llinas@med.nyu.edu](mailto:Rodolfo.llinas@med.nyu.edu)



**Fig. 39.1** Inferior olivary neurons. (a) Golgi stain of IO neurons in the IO nucleus. Note that cell bodies are located in the center of a spherically distributed dendritic tree, except when the cell body is next to the outer limit of the nucleus (Cajal 1888) (b) Electron micrograph showing gap junction at a point of contact between IO dendritic branches (Sotelo et al. 1974). The synaptic shunting occurs due to the increased membrane conductance. (c) Drawing of an IO glomerulus showing inhibitory synaptic terminal (ST) arising from the cerebellar nuclei. The glomerulus is the site of electrical junction. The diagrams below show electrotonic coupling between IO dendrites (a) and its shunting by synaptic inhibition (b)

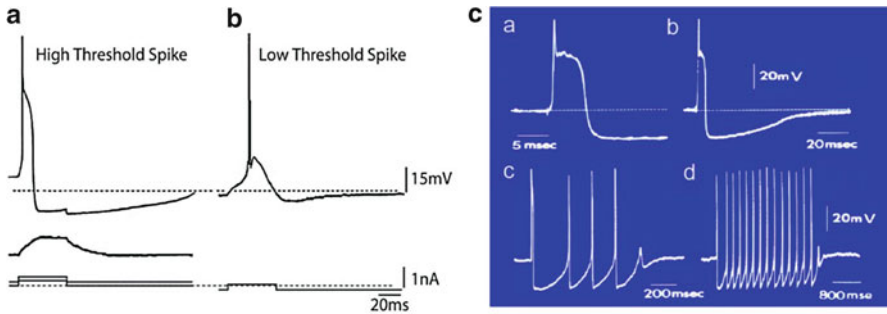
## 39.2 IO Single Cell Anatomy

IO neurons are characterized by their spherical dendritic trees (Fig. 39.1a). Within the IO nucleus their dendrites intermingle and are electronically coupled via gap junctions (Llinas et al. 1974; Sotelo et al. 1974) (Fig. 39.1b). The point of electrical junction between dendrites (Fig. 39.1c) is surrounded by inhibitory terminals arising from the cerebellar nuclei neurons. These junctions modulate electrotonic coupling by shunting current through an increase in membrane conductance (Llinas 1974; Lefler et al. 2014) (Fig. 39.1a–c).

## 39.3 Single Cell Electrophysiology

IO neurons fire spontaneously at 4–10 Hz and can exhibit rhythmic oscillatory activity near 10 Hz (Llinas and Yarom 1981a, b). The fact that IO neurons are electrically coupled and tend to fire in groups lends support to the proposal that climbing fibers have a timing function in motor coordination (Llinas 1974). Furthermore, simultaneous recordings from multiple PCs have shown that complex spikes occur synchronously within groups of PCs (Fig. 39.2).

The synchronous nature of IO oscillations have been shown to be important in determining the timing and spatial organization of motor sequences (Llinas 1988; Lampl and Yarom 1997; Welsh and Llinas 1997). In addition, a temporal correlation between the firing of the olivocerebellar system and the execution of movements

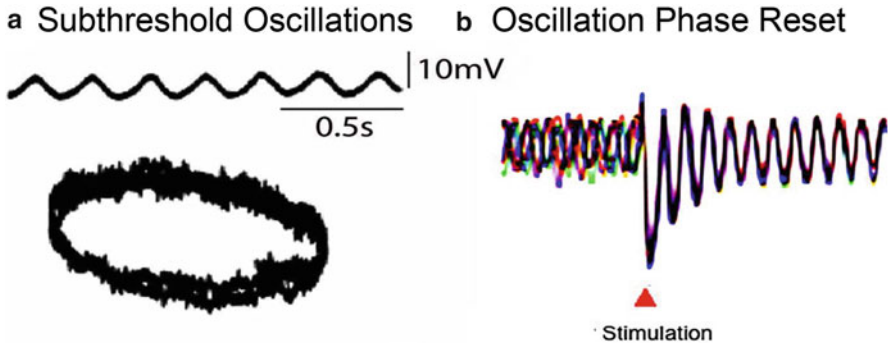


**Fig. 39.2** Electrical characteristics of IO neurons. (a, b) Two levels of IO spike activation. (a) From the resting membrane potential (*dashed line*) the high threshold spike has a large afterdepolarization generated by activation of a P-type calcium current followed by a prolonged afterhyperpolarization activated by a calcium-gated potassium conductance (*top trace*). No spike is elicited when a lower intensity current pulse is applied (*middle trace*). *Bottom traces* show injected current pulses. (b) The low threshold calcium spike is generated by activation of a T-type calcium current when the cell is depolarized from a hyperpolarized membrane potential. (c) High threshold IO spikes (*a, b*) producing spontaneous spike firing involving both low and high threshold calcium currents (*c, d*). Action potentials shown in *a* and *b* are the first action potential in *c* and *d*, respectively

has been demonstrated experimentally (Welsh et al. 1995). The ability of the olivocerebellar system to generate synchronous rhythmic activity has been attributed to the intrinsic oscillatory properties of the IO neurons (Llinas and Yarom 1981a, b; Benardo and Foster 1986; Bal and McCormick 1997) and their electrotonic coupling (Llinas 1974; Sotelo et al. 1974; Llinas and Yarom 1981b; Lampl and Yarom 1997; Makarenko and Llinas 1998; Yarom and Cohen 2002). In particular, several types of voltage-dependent calcium and potassium conductances, in addition to those involved in action potential generation, enable IO cells to oscillate and fire rhythmically at 1–10 Hz. These conductances include a high-threshold calcium conductance (P-type channels), a low-threshold calcium conductance (T-type channels), a calcium-gated potassium conductance, and a hyperpolarization-activated cationic conductance (Llinas and Yarom 1981a, b, 1986; Bal and McCormick 1997).

### 39.4 Electrical Coupling

Electrical coupling between IC neurons has been assumed to play a crucial role in synchronizing IO oscillations and in generating groups of concurrently oscillating neurons (Llinas and Yarom 1986). Originally, the degree of coupling was proposed to be controlled by return glomerular inhibition (Llinas 1974) that served to shunt the electrotonic coupling between IO dendrites. The pathway was found to originate from cerebellar nuclear GABAergic neurons (Sotelo et al. 1986; de Zeeuw et al.



**Fig. 39.3** Oscillations in IO cells recorded in vitro. (a) *Top trace.* Intracellular recording from IO neurons demonstrate regular the existence of spontaneous subthreshold membrane potential oscillations. (a) *Bottom.* The oscillation is regular enough in amplitude and frequency that a Lissajou figure could be generated. (b) A second property, quite fundamental to IO function is the ability to reset its phase following extracellular stimulation. Note that extracellular stimulation only modified the phase of the spontaneous oscillations without affecting their amplitude or frequency. (Superposition of six individual intracellular traces of stimulus-evoked oscillations reset) (Modified from Choi et al. 2010)

1989, 1996; Fredette and Mugnaini 1991; Medina et al 2002) and, surprisingly, represent almost 50 % of the total neuronal population of the cerebellar nuclei.

### 39.5 Membrane Potential Subthreshold Oscillation and Phase Resetting

In addition to uniform membrane potential oscillatory properties, IO neurons have the unique ability to reset their oscillatory phase when activated (Leznik et al. 2002; Lefler et al. 2013).

The functional significance of the oscillatory properties illustrated in Fig. 39.3 is an increased probability of PC complex spike activation relating to rapid recovery of motor execution following stumbling, or other unpredicted motor events.

### 39.6 Pathology

The single neurological condition related to the inferior olive is IO hypertrophy, associated with large synchronous movements of both midline musculature (palatal myoclonus) and multi-limb abnormal motricity especially in progressive supranuclear palsy.



## 39.7 Functional Implications

Four main issues are central of IO neurons: (1) their subthreshold oscillatory properties, relating to the control of motor timing. (2) The intrinsic electrical properties with electrical coupling allowing neuronal synchronization clusters. (3) The electronic decoupling by inhibition and (4) the resetting of oscillatory phase by synaptic input. These four elements allow simultaneous temporal control supporting rapid correction such as on the fly recovery from stumbling.

## References

- Bal T, McCormick DA (1997) Synchronized oscillations in the inferior olive are controlled by the hyperpolarization-activated cation current  $I(h)$ . *J Neurophysiol* 77:3145–3156
- Benardo LS, Foster RE (1986) Oscillatory behavior in inferior olive neurons, modulation, cell aggregates. *Brain Res Bull* 17:773–784
- Cajal R (1888) Sobre las fibras de la capa molecular del cerebelo. *Rev Trimest Hist Norm Patol* 2:343–353
- Cajal R (1904) *La Textura del Sistema nervioso del Hombre y los vertebrados*. Ed. Moya, Madrid
- Choi S, Yu E, Kim D, Urbano FJ, Makarenko V, Shin HS, Llinas RR (2010) Subthreshold membrane potential oscillations in inferior olive neurons are dynamically regulated by P/Q and T-type calcium channels: a study in mutant mice. *J Physiol* 588:3031–3043
- de Zeeuw CI, Holstege JC, Ruigrok TJ, Voogd J (1989) Ultrastructural study of the GABAergic, cerebellar, and mesodiencephalic innervation of the cat medial accessory olive: anterograde tracing combined with immunocytochemistry. *J Comp Neurol* 284:12–35
- De Zeeuw C, Lang EJ, Sugihara I, Ruigrok TJ, Eisenman IM, Mugnaini et al (1996) Morphological correlates of bilateral synchrony in the rat cerebellar cortex. *J Neurosci* 16:3412–3426
- Eccles JC, Llinas R, Sasaki K (1966) The excitatory synaptic action of climbing fibres on the Purkinje cells of the cerebellum. *J Physiol* 182:268–296
- Fredette BJ, Mugnaini E (1991) The GABAergic cerebello-olivary projection in the rat. *Anat Embryol* 184:225–243
- Lamp I, Yarom Y (1997) Subthreshold oscillations and resonant behavior: two manifestations of the same mechanism. *Neuroscience* 78:325–341
- Lefler Y, Torben-Nielsen B, Yarom Y (2013) Oscillatory activity, phase differences, and phase resetting in the inferior olive. *Front Syst Neurosci* 7:1–8
- Lefler Y, Yarom Y, Yoe-Uusisaari M (2014) Cerebellar inhibitory input to the inferior olive decreases electrical coupling and blocks subthreshold oscillation. *Neuron* 81:1389–1400
- Leznik E, Makarenko V, Llinas R (2002) Electrotonically mediated oscillatory patterns in neuronal ensembles. An in vitro voltage-dependent dye-imaging study in the inferior olive. *Neuroscience* 22:2804–2815
- Llinas R (1974) Eighteenth Bowditch lecture: motor aspects of cerebellar control. *Physiologist* 17:19–46
- Llinas R (1988) The intrinsic electrophysiological properties of mammalian neurons: insight into central nervous system function. *Science* 242:1654–1664
- Llinas R, Yarom Y (1981a) Electrophysiology of mammalian inferior olivary neurones in vitro. Different types of voltage-dependent ionic conductances. *J Physiol (Lond)* 315:549–567
- Llinas R, Yarom Y (1981b) Properties and distribution of ionic conductances generating electrosensiveness of mammalian inferior olivary neurones in vitro. *J Physiol (Lond)* 315:569–584
- Llinas R, Yarom Y (1986) Oscillatory properties of guinea-pig inferior olivary neurones and their pharmacological modulation: an in vitro study. *J Physiol* 376:163–182
- Llinás R, Baker R, Sotelo C (1974) Electrotonic coupling between neurons in cat inferior olive. *J Neurophysiol* 37:560–571

- Makarenko V, Llinas R (1998) Experimentally determined chaotic phase synchronization in a neuronal system. *Proc Natl Acad Sci U S A* 95:15747–15752
- Medina JF, Nores WL, Mauk MD (2002) Inhibition of climbing fibers is a signal for the extinction of conditioned eyelid reponse. *Nature* 62:330–333
- Sotelo C, Llinas R, Baker R (1974) Structural study of inferior olivary nucleus of the cat: morphological correlates of electrotonic coupling. *J Neurophysiol* 37:541–559
- Sotelo C, Gotow T, Wassef M (1986) Localization of glutamic-acid-decarboxylase-immunoreactive axon terminals in the inferior olive of the rat, with special emphasis on anatomical relations between GABAergic synapses and dendrodendritic gap junctions. *J Commun Neurol* 252:32–50
- Sugihara I, Lang EJ, Llinás R (1993) Uniform olivocerebellar conduction time underlies Purkinje cell complex spike synchronicity in the rat cerebellum. *J Physiol* 470:243–271
- Szentagothai J, Rajkovits K (1959) Ueber den Ursprung der Kletterfasern des kleinhirns. *Z Anat Entwicklungsgeschichte* 121:130–141
- Welsh JP, Llinas R (1997) Some organizing principles for the control of movement based on olivocerebellar physiology. *Prog Brain Res* 144:449–461, de Zeeuw, Strata and Voogd (Eds.)
- Welsh JP, Lang EJ, Sugihara I, Llinas R (1995) Dynamic organization of motor control within the olivocerebellar system. *Nature* 374:453–457
- Yarom Y, Cohen D (2002) The olivocerebellar system as a generator of temporal patterns. *Ann N Y Acad Sci* 978:122–134

# Chapter 40

## Simple Spikes and Complex Spikes

Thomas S. Otis

**Abstract** Cerebellar Purkinje neurons communicate with downstream circuit elements by generating two distinct types of electrical activity. Purkinje neurons fire conventional action potentials, termed *simple spikes*, and they also intermittently fire a highly stereotyped burst of decrementing spikes, called a *complex spike*. Each of these types of electrical activity arises from an interaction between synaptic input and distinct excitability mechanisms intrinsic to Purkinje neurons. Simple spikes occur at very high frequencies in the range of 50 spikes per second and are driven by pacemaking ion channels expressed by Purkinje neurons. This high simple spike rate is then modulated by excitatory and inhibitory synaptic input. Complex spikes occur in response to excitatory synaptic input from the climbing fiber; these compound electrical events are driven in part by the large voltage-gated calcium conductance in the dendrites of Purkinje neurons. Finally, the two forms of excitability interact; complex spikes can exert indirect effects on simple spike firing rate. Together, these two firing behaviors endow Purkinje neurons with a range of signaling behaviors critical for cerebellar contributions to motor coordination and motor learning.

**Keywords** Motor learning • Purkinje neuron • Excitability • Ion channel • Resurgent current • Climbing fiber

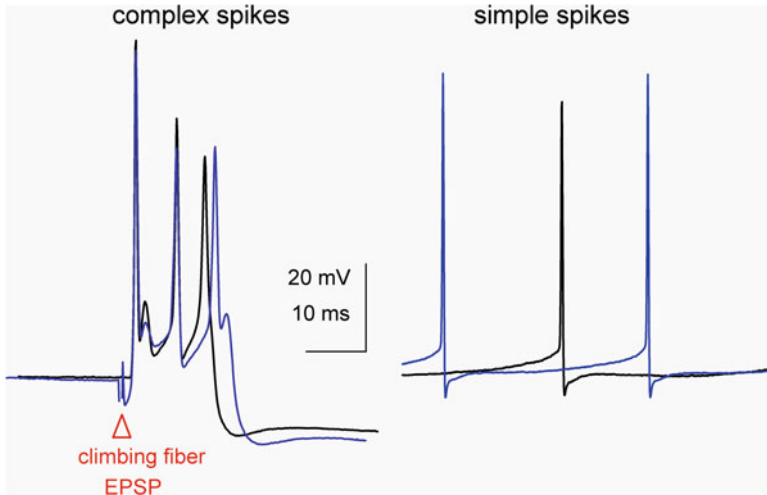
### 40.1 Simple and Complex Spikes

Purkinje neurons (PNs) are unusual neurons and this is particularly true of their highly distinctive electrical excitability. PNs generate two types of regenerative electrical behavior. As do most other neurons, they fire typical, voltage-gated sodium channel-dependent action potentials which are termed simple spikes. In addition, they also generate distinctive burst responses that are characterized by sodium channel driven “spikelets” riding on a depolarized plateau potential (see


---

T.S. Otis (✉)

Department of Neurobiology and Integrated Center for Learning and Memory, Geffen School of Medicine at UCLA, Los Angeles, CA 90095, USA  
e-mail: [otist@ucla.edu](mailto:otist@ucla.edu)



**Fig. 40.1** Examples of complex spikes in response to electrical stimulation of the climbing fiber input (red triangle) and spontaneously occurring simple spikes. Each panel shows two superimposed trials, one blue and one black



**Fig. 40.2** Extracellular recording of PN pacemaking under the indicated conditions

Fig. 40.1). Such bursts, which are known as complex spikes, occur in response to the very large excitatory synaptic input provided by the single climbing fiber axon that innervates each PN. Below we discuss fundamental physiological features of these two types of signals and their importance for information processing within the cerebellum.

### 40.1.1 *Simple Spikes Occur at High Rates and Are Driven in Part by Intrinsic Pacemaking*

Unlike conventional neurons, PNs fire action potentials constantly, even in the absence of synaptic inputs. These simple spikes occur at high rates, ranging from 40 to 100 spikes per second in resting animals. Moreover, with synaptic inputs blocked, simple spikes occur at these same high rates and with remarkable regularity (Hausser and Clark 1997)- see also Fig. 40.2. This metronome-like ability of PNs to

pacemake is a key aspect of the physiology of the cerebellum as it allows PNs to tonically inhibit their target neurons in the deep cerebellar nuclei and vestibular nuclei. Populations of PNs thus cooperate to influence motor behavior by increasing or decreasing this baseline blanket of tonic inhibition.

The ion channels responsible for this intrinsic pacemaking activity are known in some detail. The most important is a subtype of voltage-gated sodium channel called the “resurgent” sodium channel, assembled from pore-forming NaV1.6 and accessory  $\beta 4$  subunits (Grieco et al. 2005). Resurgent sodium channels are so named because they pass inward current as they recover from inactivation at hyperpolarized potentials between spikes, thereby generating a pacemaking drive current. In mice, missense mutations in or loss of the NaV1.6 gene result in reduced resurgent sodium current, impaired PN pacemaking activity, and ataxia (Raman et al. 1997).

Other ionic currents are also critical for pacemaking because they ensure that simple spikes are extremely brief, an important factor allowing rapid, cyclic activation of resurgent sodium channels. Spike brevity is ensured by large potassium conductances with rapid gating kinetics generated by Kv3.3, Kv3.4, and calcium activated BK channel subtypes (Raman and Bean 1999; Martina et al. 2007).

Interestingly, slowed pacemaking in Purkinje neurons is a common physiological deficit observed in transgenic mouse models of spinocerebellar ataxia (Hourez et al. 2011; Shakkottai et al. 2011; Hansen et al. 2013). These results strongly suggest that simple spike pacemaking is necessary for normal motor behavior.

### ***40.1.2 Complex Spikes Occur in Response to Climbing Fiber Input***

Mature PNs receive input from the terminal arbor of a single olivary neuron, the climbing fiber, which forms a powerful excitatory synapse onto the proximal dendritic tree. The postsynaptic response in the PN to climbing fiber input is a complex spike (Eccles et al. 1964). This burst response activates CaV3 type (a.k.a. T type) and CaV2.1 (a.k.a. P/Q type) voltage-gated calcium channels which are densely distributed throughout PN dendrites (Swensen and Bean 2003). Although dependent on membrane potential, the complex spike waveform is remarkably stereotyped (Davie et al. 2008). In this way, a single climbing fiber input can serve as a salient, cell-wide signal leading to increased calcium concentrations throughout much of the PN dendritic tree and cell soma (Tank et al. 1988; Kitamura and Hausser 2011). This is an important capability as climbing fibers convey a teaching signal to the cerebellum that drives circuit changes underlying associative forms of motor learning (Mauk et al. 1986; Raymond et al. 1996; Medina and Lisberger 2008).

### 40.1.3 *Complex Spikes Transiently Inhibit Simple Spike Firing*

Complex spikes are known to slow simple spike firing on two time scales. On a rapid time scale, complex spike transiently inhibit simple spike firing. This either results in fewer simple spikes immediately following a complex spike, termed a “post-CS pause”, or it results in a period reset in which simple spike firing is phase shifted (Bell and Grimm 1969). Such rapid inhibition is due to a combination of climbing fiber-driven feedforward inhibition, and activation of SK calcium-activated potassium channels in PNs (Mathews et al. 2012). Post-CS pauses may play a role in transmitting the teaching signal to the deep cerebellar nucleus, thereby enabling circuit-wide modifications known to occur during learning (Otis et al. 2012).

On a slower time scale, complex spike rates, which typically average 1 Hz but can be suppressed or driven experimentally, show an inverse relationship with simple spike rates (Cerminara and Rawson 2004). Indeed, rates of complex spikes and simple spikes are often strongly anticorrelated in response to periodic sensory stimuli (Barmack and Yakhnitsa 2011). This anticorrelation likely arises from the same mechanisms mentioned above; however, it may also reflect learning. Repeated occurrence of complex spikes with specific patterns of parallel fiber synaptic input would result in long term changes in excitability of PNs in response to those parallel fiber inputs. In this way, the intrinsic mechanisms linking complex and simple spikes can be solidified and reinforced through experience.

## References

- Barmack NH, Yakhnitsa V (2011) Topsy turvy: functions of climbing and mossy fibers in the vestibulo-cerebellum. *Neuroscientist* 17:221–236
- Bell CC, Grimm RJ (1969) Discharge properties of Purkinje cells recorded on single and double microelectrodes. *J Neurophysiol* 32:1044–1055
- Cerminara NL, Rawson JA (2004) Evidence that climbing fibers control an intrinsic spike generator in cerebellar Purkinje cells. *J Neurosci* 24:4510–4517
- Davie JT, Clark BA, Hausser M (2008) The origin of the complex spike in cerebellar Purkinje cells. *J Neurosci* 28:7599–7609
- Eccles J, Llinas R, Sasaki K (1964) Excitation of cerebellar Purkinje cells by the climbing fibres. *Nature* 203:245–246
- Grieco TM, Malhotra JD, Chen C, Isom LL, Raman IM (2005) Open-channel block by the cytoplasmic tail of sodium channel beta4 as a mechanism for resurgent sodium current. *Neuron* 45:233–244
- Hansen ST, Meera P, Otis TS, Pulst SM (2013) Changes in Purkinje cell firing and gene expression precede behavioral pathology in a mouse model of SCA2. *Hum Mol Genet* 22:271–283
- Hausser M, Clark BA (1997) Tonic synaptic inhibition modulates neuronal output pattern and spatiotemporal synaptic integration. *Neuron* 19:665–678
- Hourez R, Servais L, Orduz D, Gall D, Millard I, de Kerchove d’Exaerde A, Cheron G, Orr HT, Pandolfo M, Schiffmann SN (2011) Aminopyridines correct early dysfunction and delay neurodegeneration in a mouse model of spinocerebellar ataxia type 1. *J Neurosci* 31:11795–11807

- Kitamura K, Hausser M (2011) Dendritic calcium signaling triggered by spontaneous and sensory-evoked climbing fiber input to cerebellar Purkinje cells in vivo. *J Neurosci* 31:10847–10858
- Martina M, Metz AE, Bean BP (2007) Voltage-dependent potassium currents during fast spikes of rat cerebellar Purkinje neurons: inhibition by BDS-I toxin. *J Neurophysiol* 97:563–571
- Mathews PJ, Lee KH, Peng Z, Houser CR, Otis TS (2012) Effects of climbing fiber driven inhibition on Purkinje neuron spiking. *J Neurosci* 32:17988–17997
- Mauk MD, Steinmetz JE, Thompson RF (1986) Classical conditioning using stimulation of the inferior olive as the unconditioned stimulus. *Proc Natl Acad Sci U S A* 83:5349–5353
- Medina JF, Lisberger SG (2008) Links from complex spikes to local plasticity and motor learning in the cerebellum of awake-behaving monkeys. *Nat Neurosci* 11:1185–1192
- Otis TS, Mathews PJ, Lee KH, Maiz J (2012) How do climbing fibers teach? *Front Neural Circ* 6:95
- Raman IM, Bean BP (1999) Ionic currents underlying spontaneous action potentials in isolated cerebellar Purkinje neurons. *J Neurosci* 19:1663–1674
- Raman IM, Sprunger LK, Meisler MH, Bean BP (1997) Altered subthreshold sodium currents and disrupted firing patterns in Purkinje neurons of Scn8a mutant mice. *Neuron* 19:881–891
- Raymond JL, Lisberger SG, Mauk MD (1996) The cerebellum: a neuronal learning machine? *Science* 272:1126–1131
- Shakkottai VG, do Carmo Costa M, Dell’Orco JM, Sankaranarayanan A, Wulff H, Paulson HL (2011) Early changes in cerebellar physiology accompany motor dysfunction in the polyglutamine disease spinocerebellar ataxia type 3. *J Neurosci* 31:13002–13014
- Swensen AM, Bean BP (2003) Ionic mechanisms of burst firing in dissociated Purkinje neurons. *J Neurosci* 23:9650–9663
- Tank DW, Sugimori M, Connor JA, Llinas RR (1988) Spatially resolved calcium dynamics of mammalian Purkinje cells in cerebellar slice. *Science* 242:773–777

# Chapter 41

## Rebound Depolarization and Potentiation

Steven Dykstra and Ray W. Turner

**Abstract** The deep cerebellar nuclei (DCN) are critical in defining the output of cerebellum. The DCN are positioned at the base of cerebellum where they receive collateral input from afferent excitatory mossy and climbing fiber inputs and GABAergic inhibitory input from Purkinje cells of cerebellar cortex. DCN cells exhibit a form of rebound membrane depolarization following a hyperpolarization that gives rise to a rebound spike burst. Intracellular recordings and calcium imaging have established roles for virtually all classes of calcium channels in the rebound response, with additional roles for sodium, HCN, and potassium channels. Long-term potentiation of mossy fiber inputs is further known to rely on ion channels involved in the rebound response, revealing a complex interplay that determines DCN cell excitability and thus the final output from cerebellum.

**Keywords** Deep cerebellar nuclei • Rebound burst • Long-term potentiation • Calcium channel

### 41.1 Encoding Purkinje Cell Input

The final output of all signal processing in cerebellar cortex (not including vestibular input) is communicated by neurons in the DCN, identified as medial, interposed and lateral nuclei in rodents. DCN cells receive collateral excitatory projections from mossy and climbing fibers ascending to cerebellar cortex and extensive GABAergic inhibition from cerebellar cortical Purkinje cells. To encode Purkinje cell inhibitory input DCN cells exhibit a rather unique capability of generating a rebound increase in firing following a membrane hyperpolarization. Recent work has further identified how long-term potentiation (LTP) of synaptic inputs depends on an interplay with the ion channels that underlie a rebound response.

---

S. Dykstra • R.W. Turner (✉)  
University of Calgary,  
3330 Hospital Drive NW, HRC 1AA14, Calgary, AB T2N 4N1, Canada  
e-mail: [rwturner@ucalgary.ca](mailto:rwturner@ucalgary.ca)

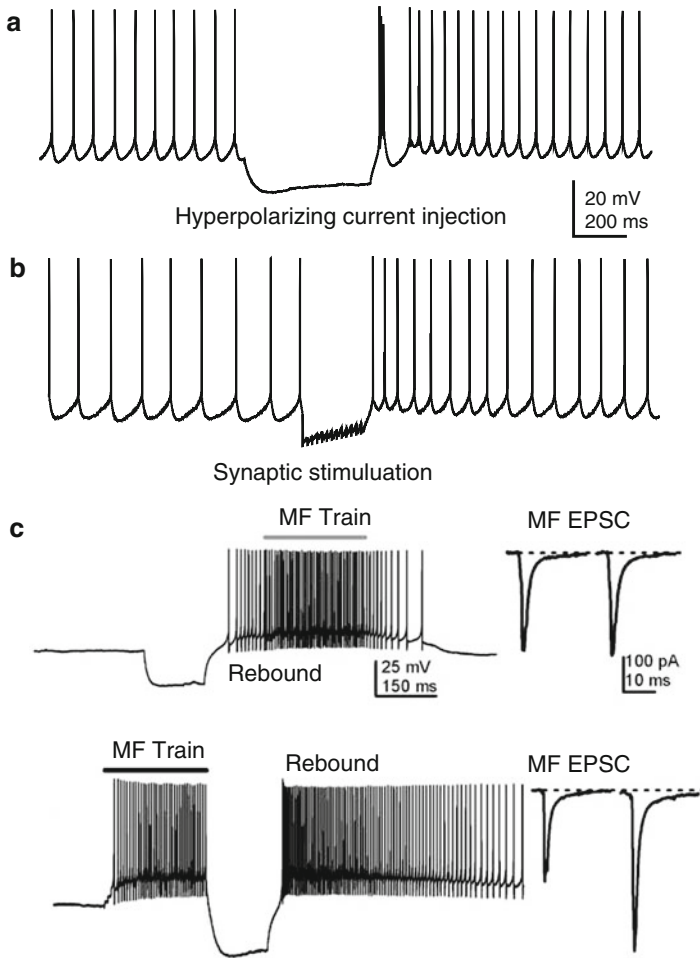


### ***41.1.1 Rebound Responses***

Membrane hyperpolarizations invoke rebound responses in DCN cells that are reflected in an early peak increase in firing frequency (within 100 ms) and a second late phase of rebound firing that can last for seconds. The role(s) for rebound responses in DCN cells is not entirely understood. Rebound firing has been implicated in rate and phase coding of Purkinje cell input, as well as modifying the timing, reliability, and precision of spike firing following a hyperpolarization (Hoebeek et al. 2010; Pedroarena 2010; Engbers et al. 2011; Person and Raman 2012; Steuber and Jaeger 2012). Most work in vitro on rebound discharge has focused on presumed excitatory “large diameter” cells (>15  $\mu\text{m}$ ), although the activity of more cell types is being distinguished through labeling of GABAergic and glycinergic cell types (Uusisaari et al. 2007, Uusisaari and Knopfel 2012). Different rebound phenotypes are still being defined, with several different patterns reported following hyperpolarizing stimuli (Fig. 41.1a, b) (Czubayko et al. 2001; Hoebeek et al. 2010; Pedroarena 2010; Tadayonnejad et al. 2010; Engbers et al. 2011).

### ***41.1.2 Ionic Basis for Rebound Responses***

Several ion channels are known to contribute to rebound responses. T-type calcium channels are partially inactivated during the resting tonic discharge of DCN cells, with hyperpolarizations acting to remove inactivation. A return to resting potential then triggers a larger T-type current (calcium spike) to drive a rebound depolarization (Molineux et al. 2006, 2008; Alvina et al. 2009; Tadayonnejad et al. 2010; Engbers et al. 2011; Steuber and Jaeger 2012; Schneider et al. 2013). The hyperpolarization-activated cyclic nucleotide-gated (HCN) channel is directly activated by membrane hyperpolarization in DCN cells, and upon return to resting potential deactivates slowly enough to generate a depolarization that controls first spike latency and spike precision, and augments the role of T-type current by shortening the membrane time constant (Raman et al. 2000; Sangrey and Jaeger 2010; Engbers et al. 2011). Non-inactivating sodium current(s) are proposed to contribute to at least the slow phase of rebound, as these channels will also undergo inactivation at rest and recovery from inactivation during a hyperpolarization. Return to resting potential then evokes a slowly inactivating sodium current that helps drive the late rebound component (plateau depolarization) (Jahnsen 1986; Llinas and Muhlethaler 1988; Aman and Raman 2007; Sangrey and Jaeger 2010). Recent work suggests a contribution by virtually all classes of high voltage-activated calcium channels, as defined by selective pharmacological blockers (Zheng and Raman 2009). The role of potassium channels has been considered, with pharmacological, knockout animal, and dynamic clamp studies uncovering differences in the role of



**Fig. 41.1** (a, b) Representative recordings of spike output from two large diameter DCN cells exhibiting spontaneous discharge. (a) Injecting a 500 ms current step elicits a transient rebound response. (b) A 25 pulse 50 Hz train of synaptic inhibitory inputs elicits a weak rebound response. (c) Induction of LTP of mossy fiber (MF) inputs. At *left* are responses evoked by different induction protocols and on *right* EPSCs before and after the induction protocols. Protocols consisted of a 250 ms, 133 Hz stimulation of excitatory afferents and a 150 ms current injection to  $\sim -85$  mV. LTP of EPSCs occurs in relation to synaptic input trains that precede a rebound spike response. Data in (c) was modified from Pugh and Raman (2008) (Republished with permission of the Society for Neuroscience, from Mechanisms of Potentiation of Mossy Fiber EPSCs in the Cerebellar Nuclei by Coincident Synaptic Excitation and Inhibition, Pugh and Raman (2008); permission conveyed through Copyright Clearance Center, Inc)

voltage- or calcium-gated potassium channels in controlling tonic firing vs rebound responses (Aizenman and Linden 1999; Alvina and Khodakhah 2008; Molineux et al. 2008; Joho and Hurlock 2009; Pedroarena 2011; Feng et al. 2013).

## 41.2 LTP of Mossy Fiber Input and Rebound Responses

The ion channels that are activated during the rebound response also help shape synaptic plasticity in the DCN. One example is the induction of mossy fiber LTP onto DCN cells that requires co-activation of excitatory and inhibitory synaptic inputs, but not according to classical Hebbian rules of coincidence. Rather, LTP at this synapse is induced if a train of mossy fiber input precedes a hyperpolarization and rebound response (Fig. 41.1c) (Pugh and Raman 2008; Person and Raman 2010; Zheng and Raman 2010). Potentiation thus follows a priming rule of synaptic plasticity, where potentiation is dependent on the timing of stimuli that trigger specific calcium-dependent signalling cascades that act as either a local priming signal or as a global potentiating signal. Specifically, mossy fibers prime a subset of synaptic inputs through a pathway that is dependent on activation of NMDA receptors and the phosphatase calcineurin. If the DCN cell is then hyperpolarized due to Purkinje cell input, calcium influx through L-type calcium channels normally present during tonic resting discharge is reduced, with a subsequent rebound response activating  $\alpha$ -CaMKII as the global triggering signal for LTP (Pugh and Raman 2008; Person and Raman 2010; Zheng and Raman 2010). A unique aspect of this form of LTP is the extent to which it fits models of cerebellar learning and memory formation in a system that is tonically active under resting conditions (Zheng and Raman 2010), and highlights how a rebound response can be utilized in novel ways to control the output of cerebellum at the level of the DCN.

## References

- Aizenman CD, Linden DJ (1999) Regulation of the rebound depolarization and spontaneous firing patterns of deep nuclear neurons in slices of rat cerebellum. *J Neurophysiol* 82:1697–1709
- Alvina K, Khodakhah K (2008) Selective regulation of spontaneous activity of neurons of the deep cerebellar nuclei by N-type calcium channels in juvenile rats. *J Physiol* 586:2523–2538
- Alvina K, Ellis-Davies G, Khodakhah K (2009) T-type calcium channels mediate rebound firing in intact deep cerebellar neurons. *Neuroscience* 158:635–641
- Aman TK, Raman IM (2007) Subunit dependence of Na channel slow inactivation and open channel block in cerebellar neurons. *Biophys J* 92:1938–1951
- Czubayko U, Sultan F, Thier P, Schwarz C (2001) Two types of neurons in the rat cerebellar nuclei as distinguished by membrane potentials and intracellular fillings. *J Neurophysiol* 85:2017–2029
- Engbers JD, Anderson D, Tadayonnejad R, Mehaffey WH, Molineux ML, Turner RW (2011) Distinct roles for I(T) and I(H) in controlling the frequency and timing of rebound spike responses. *J Physiol* 589:5391–5413

- Feng SS, Lin R, Gauck V, Jaeger D (2013) Gain control of synaptic response function in cerebellar nuclear neurons by a calcium-activated potassium conductance. *Cerebellum* 12:692–706
- Hoebeek FE, Witter L, Ruigrok TJ, De Zeeuw CI (2010) Differential olivo-cerebellar cortical control of rebound activity in the cerebellar nuclei. *Proc Natl Acad Sci U S A* 107:8410–8415
- Jahnson H (1986) Extracellular activation and membrane conductances of neurones in the guinea-pig deep cerebellar nuclei in vitro. *J Physiol* 372:149–168
- Joho RH, Hurllock EC (2009) The role of Kv3-type potassium channels in cerebellar physiology and behavior. *Cerebellum* 8:323–333
- Llinas R, Muhlethaler M (1988) Electrophysiology of guinea-pig cerebellar nuclear cells in the in vitro brain stem-cerebellar preparation. *J Physiol* 404:241–258
- Molineux ML, McRory JE, McKay BE, Hamid J, Mehaffey WH, Rehak R, Snutch TP, Zamponi GW, Turner RW (2006) Specific T-type calcium channel isoforms are associated with distinct burst phenotypes in deep cerebellar nuclear neurons. *Proc Natl Acad Sci U S A* 103:5555–5560
- Molineux ML, Mehaffey WH, Tadayonnejad R, Anderson D, Tennent AF, Turner RW (2008) Ionic factors governing rebound burst phenotype in rat deep cerebellar neurons. *J Neurophysiol* 100:2684–2701
- Pedroarena CM (2010) Mechanisms supporting transfer of inhibitory signals into the spike output of spontaneously firing cerebellar nuclear neurons in vitro. *Cerebellum* 9:67–76
- Pedroarena CM (2011) BK and Kv3.1 potassium channels control different aspects of deep cerebellar nuclear neurons action potentials and spiking activity. *Cerebellum* 10:647–658
- Person AL, Raman IM (2010) Deactivation of L-type Ca current by inhibition controls LTP at excitatory synapses in the cerebellar nuclei. *Neuron* 66:550–559
- Person AL, Raman IM (2012) Purkinje neuron synchrony elicits time-locked spiking in the cerebellar nuclei. *Nature* 481:502–505
- Pugh JR, Raman IM (2008) Mechanisms of potentiation of mossy fiber EPSCs in the cerebellar nuclei by coincident synaptic excitation and inhibition. *J Neurosci* 28:10549–10560
- Raman IM, Gustafson AE, Padgett D (2000) Ionic currents and spontaneous firing in neurons isolated from the cerebellar nuclei. *J Neurosci* 20:9004–9016
- Sangrey T, Jaeger D (2010) Analysis of distinct short and prolonged components in rebound spiking of deep cerebellar nucleus neurons. *Eur J Neurosci* 32:1646–1657
- Schneider ER, Civillico EF, Wang SS (2013) Calcium-based dendritic excitability and its regulation in the deep cerebellar nuclei. *J Neurophysiol* 109:2282–2292
- Steuber V, Jaeger D (2012) Modeling the generation of output by the cerebellar nuclei. *Neural Netw* 47:112–119
- Tadayonnejad R, Anderson D, Molineux ML, Mehaffey WH, Jayasuriya K, Turner RW (2010) Rebound discharge in deep cerebellar nuclear neurons in vitro. *Cerebellum* 9:352–374
- Uusisaari MY, Knopfel T (2012) Diversity of neuronal elements and circuitry in the cerebellar nuclei. *Cerebellum* 11:420–421
- Uusisaari M, Obata K, Knopfel T (2007) Morphological and electrophysiological properties of GABAergic and non-GABAergic cells in the deep cerebellar nuclei. *J Neurophysiol* 97:901–911
- Zheng N, Raman IM (2009) Ca currents activated by spontaneous firing and synaptic disinhibition in neurons of the cerebellar nuclei. *J Neurosci* 29:9826–9838
- Zheng N, Raman IM (2010) Synaptic inhibition, excitation, and plasticity in neurons of the cerebellar nuclei. *Cerebellum* 9:56–66

# Chapter 42

## Cerebellar Nuclei

Dieter Jaeger and Huo Lu

**Abstract** Understanding the basic physiology of cerebellar nuclei (CN) is essential to the understanding of cerebellar function and disorders as they provide the only output from the cerebellum along with the vestibular nuclei. In addition to integrating the inhibitory input from cerebellar cortical Purkinje cells, CN neurons also receive direct excitation from mossy fibers and this direct excitatory input to the CN may in fact drive a number of behaviorally relevant activities. The complete picture is considerably more complex than that of a simple relay of incoming excitation and inhibition, however. Specifically, the functional significance of synaptic plasticity in the CN, high spontaneous spike rates, post-inhibitory rebound firing, and multiple output pathways including GABAergic inhibition feeding back to the inferior olive remain to be elucidated.

**Keywords** Deep cerebellar nuclei • Inhibition • Excitation • Rebound spiking • Long-term plasticity • Short-term plasticity • Ion channel • GABA • Synchrony • Complex spike • Collateral • Climbing fiber • Mossy fiber • Pacemaker • Eye movement • Vestibular • Timing

---

D. Jaeger (✉)  
Department of Biology, Emory University, Atlanta, GA 30322, USA  
e-mail: [djaeger@emory.edu](mailto:djaeger@emory.edu)

H. Lu  
Department of Biomedical Sciences, Philadelphia College of Osteopathic Medicine,  
GA Campus, Suwanee, GA, USA  
e-mail: [huolu@pcom.edu](mailto:huolu@pcom.edu)

## 42.1 Basic Physiology of CN Neurons

### 42.1.1 Cellular Physiology

CN neurons recorded in brain slices from any of the 4 nuclei present in rodents (lateral, anterior interposed, posterior interposed, and medial) are spontaneously regularly spiking (Jahnsen 1986), a property which is due to an intrinsic depolarizing plateau current (Raman et al. 2000). A robust property of CN neurons is their ability to fire rebound spike bursts following strong hyperpolarization induced by current injection (Llinas and Muhlethaler 1988; Jahnsen 1986; Aizenman and Linden 1999). The rebound activity has an initial fast burst component carried by T-type calcium currents (Molineux et al. 2006) and a longer-lasting 2–5 s increase of spike rate associated with persistent sodium currents (Sangrey and Jaeger 2010). The functional implications of CN rebound properties are still hotly debated (Alvía et al. 2008; Hoebeek et al. 2010). While these basic properties are present in excitatory and inhibitory CN neurons, GABAergic cells can be distinguished physiologically by a broader spike width, a slower spike-afterhyperpolarization, and higher spike rate accommodation, and further differences are present between morphologically larger and smaller non-GABAergic neurons (Uusisaari et al. 2007).

### 42.1.2 Synaptic Physiology and Synaptic Plasticity

Early in vitro studies provided direct evidence that Purkinje cell spiking causes monosynaptic inhibitory post-synaptic potentials (IPSPs) in the CN (Ito et al. 1964). These IPSPs are characterized by a large amplitude, a fast decay, and pronounced short term depression (Person and Raman 2012). A single CN neuron receives large IPSPs from about 40 Purkinje cells, while smaller IPSPs may derive from many more Purkinje cells with fewer and/or more distal synaptic terminals (Person and Raman 2012). Robust excitatory postsynaptic potentials (EPSPs) can be elicited by stimulation of mossy fibers (Llinas and Muhlethaler 1988), which are collaterals of the same fibers projecting to cerebellar cortex (Shinoda et al. 1992). Climbing fibers also collateralize in the CN (Sugihara et al. 1999), and may induce a spike response in vivo (Blenkinsop and Lang 2011).

Long-term plasticity has also been observed for synaptic inputs to the CN. Excitatory mossy fibers undergo long-term potentiation as a result of a distinct combination of inhibitory and excitatory inputs “that resemble the activity of Purkinje and mossy fiber afferents that is predicted to occur during cerebellar associative learning tasks” (Pugh and Raman 2009). Inhibitory Purkinje cell input can undergo either long-term potentiation or long-term depression, which is dependent on the amount of rebound depolarization produced by a burst of Purkinje cell inputs (Aizenman et al. 1998). The plasticity inducing protocols in the CN generally require complex temporal conditions of excitation and inhibition, which may relate to the commonly hypothesized role of the cerebellum in motor timing.

## **42.2 A View at CN Function**

### ***42.2.1 Behavioral Correlates of CN Activity Changes***

A substantial number of studies has been undertaken to study the spiking activity of CN neurons in behaving animals, often revealing complex relationships between CN spike rate increases or decreases and sensory stimuli as well as movements. One of the most studied behaviors with respect to CN activity is the delayed eye blink reflex, where CN activity is clearly related to the learnt timing of the motor command (Thompson and Steinmetz 2009). In a more general sense CN output activity is congruent with representing an internal or forward model of movement execution (Lisberger 2009; Miall and Reckess 2002) that is important in the predictive control of behavior.

### ***42.2.2 Multiple Functional Areas in the CN and Microzonal Organization***

Each CN nucleus and to some degree different areas in each nucleus will be engaged in controlling behaviors related to the anatomical inputs of the respective nucleus, such as the vestibulo-ocular reflex and control of balance in the vestibular nuclei (Lisberger and Miles 1980), limb movements in the interposed and dentate nuclei (Strick 1983), and cognitive aspects of timing tasks such as finger tapping also in the dentate nucleus (Stefanescu et al. 2013). The microzonal organization of the cerebellar cortex is preserved in the CN (Apps and Garwicz 2000). This allows for functionally relevant climbing fiber synchrony evoking complex spikes in cerebellar cortical microzones to converge in the CN and elicit behaviorally relevant responses that may depend on this synchrony (De Gruijl et al. 2014; Person and Raman 2012).

### ***42.2.3 Output of the CN Is Split into Distinctive Pathways***

GABAergic neurons in CN solely project to the inferior olive where they often terminate near gap junctions in olivary glomeruli (De Zeeuw et al. 1998). This arrangement allows CN output to influence both the occurrence and the synchrony of olivary spikes (Lefler et al. 2014), which may be important in controlling olivary motor error signals (Simpson et al. 1996).

Excitatory CN neurons project to a variety of targets, notably the motor thalamus, red nucleus, and brainstem motor nuclei. The functional impact of CN activity on these targets is often not clearly understood, but given the high tonic rates of CN firing in vivo and behaviorally related phasic and tonic changes in CN firing a temporally highly precise effect on motor performance is expected (Heck et al. 2013).

## References

- Aizenman CD, Linden DJ (1999) Regulation of the rebound depolarization and spontaneous firing patterns of deep nuclear neurons in slices of rat cerebellum. *J Neurophysiol* 82(4):1697–1709
- Aizenman CD, Manis PB, Linden DJ (1998) Polarity of long-term synaptic gain change is related to postsynaptic spike firing at a cerebellar inhibitory synapse. *Neuron* 21(4):827–835
- Alvía K, Walter JT, Kohn A, Ellis-Davies G, Khodakhah K (2008) Questioning the role of rebound firing in the cerebellum. *Nat Neurosci* 11(11):1256–1258
- Apps R, Garwicz M (2000) Precise matching of olivo-cortical divergence and cortico-nuclear convergence between somatotopically corresponding areas in the medial C1 and medial C3 zones of the paravermal cerebellum. *Eur J Neurosci* 12(1):205–214
- Blenkinsop TA, Lang EJ (2011) Synaptic action of the olivocerebellar system on cerebellar nuclear spike activity. *J Neurosci* 31(41):14708–14720
- De Gruilj JR, Hoogland TM, De Zeeuw CI (2014) Behavioral correlates of complex spike synchrony in cerebellar microzones. *J Neurosci* 34(27):8937–8947
- De Zeeuw CI, Hoogenraad CC, Koekkoek SKE, Ruigrok TJH, Galjart N, Simpson JI (1998) Microcircuitry and function of the inferior olive. *TINS* 21(9):391–400
- Heck DH, De Zeeuw CI, Jaeger D, Khodakhah K, Person AL (2013) The neuronal code(s) of the cerebellum. *J Neurosci* 33(45):17603–17609
- Hoebek FE, Witter L, Ruigrok TJ, De Zeeuw CI (2010) Differential olivo-cerebellar cortical control of rebound activity in the cerebellar nuclei. *Proc Natl Acad Sci U S A* 107(18):8410–8415
- Ito M, Yoshida M, Obata K (1964) Monosynaptic inhibition of the intracerebellar nuclei induced from the cerebellar cortex. *Experientia* 20:575–576
- Jahnsen H (1986) Electrophysiological characteristics of neurones in the guinea-pig deep cerebellar nuclei in vitro. *J Physiol* 372:129–147
- Lefler Y, Yarom Y, Uusisaari MY (2014) Cerebellar inhibitory input to the inferior olive decreases electrical coupling and blocks subthreshold oscillations. *Neuron* 81(6):1389–1400
- Lisberger SG (2009) Internal models of eye movement in the floccular complex of the monkey cerebellum. *Neuroscience* 162(3):763–776
- Lisberger SG, Miles FA (1980) Role of primate medial vestibular nucleus in long-term adaptive plasticity of vestibuloocular reflex. *J Neurophysiol* 43(6):1725–1745
- Llinas R, Muhlethaler M (1988) Electrophysiology of guinea-pig cerebellar nuclear cells in the in vitro brain stem-cerebellar preparation. *J Physiol* 404:241–258
- Miall RC, Reckess GZ (2002) The cerebellum and the timing of coordinated eye and hand tracking. *Brain Cogn* 48(1):212–226
- Molineux ML, McRory JE, McKay BE, Hamid J, Mehaffey WH, Rehak R, Snutch TP, Zamponi GW, Turner RW (2006) Specific T-type calcium channel isoforms are associated with distinct burst phenotypes in deep cerebellar nuclear neurons. *Proc Natl Acad Sci U S A* 103(14):5555–5560
- Person AL, Raman IM (2012) Purkinje neuron synchrony elicits time-locked spiking in the cerebellar nuclei. *Nature* 481(7382):502–505
- Pugh JR, Raman IM (2009) Nothing can be coincidence: synaptic inhibition and plasticity in the cerebellar nuclei. *TINS* 32(3):170–177
- Raman IM, Gustafson AE, Padgett D (2000) Ionic currents and spontaneous firing in neurons isolated from the cerebellar nuclei. *J Neurosci* 20(24):9004–9016
- Sangrey T, Jaeger D (2010) Analysis of distinct short and prolonged components in rebound spiking of deep cerebellar nucleus neurons. *Eur J Neurosci* 32(10):1646–1657
- Shinoda Y, Sugiuchi Y, Futami T, Izawa R (1992) Axon collaterals of mossy fibers from the pontine nucleus in the cerebellar dentate nucleus. *J Neurophysiol* 67(3):547–560
- Simpson JI, Wylie DR, DeZeeuw CI (1996) On climbing fiber signals and their consequence(s). *Behav Brain Sci* 19(3):384



- Stefanescu MR, Thürling M, Maderwald S, Wiestler T, Ladd ME, Diedrichsen J, Timmann D (2013) A 7T fMRI study of cerebellar activation in sequential finger movement tasks. *Exp Brain Res* 228(2):243–254
- Strick PL (1983) The influence of motor preparation on the response of cerebellar neurons to limb displacements. *J Neurosci* 3(10):2007–2020
- Sugihara I, Wu HS, Shinoda Y (1999) Morphology of single olivocerebellar axons labeled with biotinylated dextran amine in the rat. *J Comp Neurol* 414(2):131–148
- Thompson RF, Steinmetz JE (2009) The role of the cerebellum in classical conditioning of discrete behavioral responses. *Neuroscience* 162(3):732–755
- Uusisaari M, Obata K, Knopfel T (2007) Morphological and electrophysiological properties of GABAergic and non-GABAergic cells in the deep cerebellar nuclei. *J Neurophysiol* 97(1):901–911

# Chapter 43

## Plasticity of the Cerebellum

Ying Shen

**Abstract** Since 1990s, long-term depression of (LTD) at parallel fiber-Purkinje cell synapses has been regarded as a cellular phenomenon for motor learning. However, parallel fiber LTD by itself cannot account for motor learning. Here, I review a rich variety of use-dependent plasticity in the cerebellar cortex and nuclei, including long-term potentiation (LTP) and LTD at excitatory and inhibitory synapses, and persistent modulation of intrinsic excitability. Intrinsic and extrinsic factors, including neuronal excitation, specific molecular mechanisms and theta oscillation, and external neuromodulators, are essential to different forms of plasticity.

**Keywords** Cerebellum • Long-term potentiation • Long-term depression • Purkinje cell • Motor learning

### 43.1 Parallel Fiber LTD

A persistent attenuation of parallel fiber-Purkinje cell synapse is produced when parallel fiber and climbing fiber inputs to a Purkinje cell are stimulated together at low frequency (Ito et al. 1982). The parallel fiber LTD is associative and saturable upon repeated parallel fiber stimulation. Strong parallel fiber stimulation or conjunctive climbing fiber/parallel fiber stimulation induces parallel fiber LTD through the activation of postsynaptic metabotropic glutamate receptors (mGluR) and  $\alpha$ -amino-3-hydroxy-5-methyl-4-isoxazolepropionic acid receptors (AMPA receptors), and subsequent rise of internal  $\text{Ca}^{2+}$ . The activation of protein kinase C $\alpha$  (PKC $\alpha$ ) and  $\alpha$ -Ca $^{2+}$ /calmodulin-dependent protein kinase II ( $\alpha$ CaMKII) are required. The cytosolic phospholipase A $_2$  $\alpha$  (cPLA $_2$  $\alpha$ )/cyclooxygenase-2 cascade plays important roles in this LTD by acting on upstream PKC $\alpha$ . Cannabinoid receptor 1 (CB1R) and nitric oxide/soluble guanylyl cyclase/cGMP-dependent protein kinase/phosphatase

---

Y. Shen (✉)

Department of Neurobiology, Zhejiang University School of Medicine,  
Hangzhou 310058, People's Republic of China  
e-mail: [yshen@zju.edu.cn](mailto:yshen@zju.edu.cn)

pathways are also involved (Bear and Linden 2000; Safo and Regehr 2005). Parallel fiber LTD is expressed postsynaptically, as a reduction in the number of surface AMPARs produced by clathrin-dependent endocytosis (Wang and Linden 2000).

### 43.2 Parallel Fiber LTP

Parallel fiber-Purkinje cell synapses undergo two forms of homosynaptic LTP, depending on stimulus frequency. Four to 8 Hz parallel fiber stimulation induces presynaptically-expressed LTP, which is associated with a decrease in paired-pulse facilitation (Salin et al. 1996) and evoked glutamate transport currents in glial cells (Linden 1998). Furthermore, 4–8 Hz LTP is mediated by the presynaptic adenylyl cyclase/cyclic adenosine monophosphate (cAMP)/protein kinase A (PKA) pathway (Hansel et al. 2001). Evidence from cerebellar cultures shows that 4-Hz LTP is mediated by PKA-mediated phosphorylation of the active zone protein RIM1 $\alpha$  (Lonart et al. 2003).

In contrast, 1-Hz parallel fiber stimulation induces a postsynaptically-expressed LTP. This LTP requires a low level of Ca<sup>2+</sup> in Purkinje cells (Coemans et al. 2004), which leads to the activation of cPLA<sub>2</sub> $\alpha$ , the liberation of arachidonic acid, and the production of 2-arachidonoylglycerol (2-AG). Activated CB1R on presynaptic terminals by 2-AG triggers the activation of nitric oxide synthase and produces a low-level release of nitric oxide from parallel fiber terminals (Wang et al. 2014). Afterwards, nitric oxide works postsynaptically with serine/threonine phosphatases to promote the required trafficking of AMPARs. Since 1-Hz LTP and parallel fiber LTD are both expressed postsynaptically, it is suggested that 1-Hz LTP is a resetting mechanism for motor learning and causes the extinction of learned associations.

### 43.3 Climbing Fiber LTD

5 Hz tetanization of climbing fibers evokes a LTD at climbing fiber-Purkinje cell synapse, which is homosynaptic and saturable (Hansel and Linden 2000). Climbing fiber LTD requires intracellular Ca<sup>2+</sup> and the activation of mGluR1 and PKC, and is expressed postsynaptically (Shen et al. 2002). Climbing fiber LTD is hypothesized to control the integrative response of Purkinje cell because complex spikes are attenuated after 5 Hz tetanization. Interestingly, 5 Hz tetanization at climbing fibers also induces a LTP of glutamate transporter EAAT4 (Shen and Linden 2005).

### 43.4 Interneuron-Purkinje Cell Synaptic LTP

LTP of GABA<sub>A</sub> receptor-mediated inhibitory postsynaptic currents in Purkinje cells is induced by repetitive climbing fiber activation (Kano et al. 1992). This inhibitory LTP requires a postsynaptic Ca<sup>2+</sup> transient from internal Ca<sup>2+</sup> stores and the

activation of CaMKII and PKA. An early study showed that simultaneous activity of inhibitory synapses is needed for the induction of inhibitory LTP (Kano 1996), but another study showed that simultaneous inhibitory activity suppresses the inhibitory LTP (Kawaguchi and Hirano 2000). Interneuron-Purkinje cell synaptic LTP has a major influence on Purkinje cells throughput, as it modulates the spike firing pattern in Purkinje cells (Häusser and Clark 1997).

### 43.5 Plasticity of Mossy Fiber-Granule Cell Synapses

Mossy fiber-granule cell synapses provide a large potential substrate for information storage. Activation of mossy fibers combined with postsynaptic depolarization of granule cells results in mossy fiber LTP (D'Angelo et al. 1999), which requires postsynaptic depolarization,  $\text{Ca}^{2+}$  influx and activation of NMDA receptors, mGluR, and PKC. The inhibitory input by Golgi cells also affects the expression of mossy fiber LTP. In contrast, protracted low-frequency stimulation causes mossy fiber LTD (Gall et al. 2005). Mossy fiber LTP and LTD promote the population (summed) and sparse (local) coding, respectively, in the granular layer.

### 43.6 Plasticity in the Deep Cerebellar Nuclei (DCN)

Mossy fiber-DCN plasticity depends on the excitation of DCN cells (Pugh and Raman 2006) while Purkinje cell-DCN plasticity depends on the excitation of both DCN cells and Purkinje cells (Aizenman et al. 1998). DCN cells can also generate a plasticity of intrinsic excitability. Mossy fiber-DCN plasticity and intrinsic excitability can work together to generate a coincidence detector driven by intracellular calcium transients.

### 43.7 Plasticity of Intrinsic Excitability in Purkinje Cells

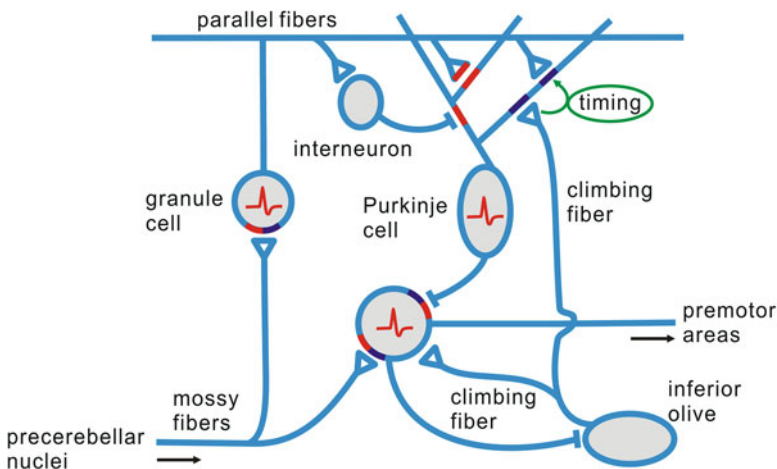
Purkinje cell excitability can be enhanced by somatic current injections or parallel fiber stimulation. Signal cascades for LTP of intrinsic excitability include local  $\text{Ca}^{2+}$  in spines and protein phosphatases. The interactions between these molecules and PKA and casein kinase 2 result in a downregulation of small conductance  $\text{Ca}^{2+}$ -activated potassium channels, thereby reducing an intrinsic inhibitory influence. LTP of intrinsic plasticity occludes subsequent parallel fiber LTP, but facilitates parallel fiber LTD (Coesmans et al. 2004). LTP of intrinsic plasticity can be locally restricted to one synapse, but can also affect a large number of synapses, depending on the identity and location of intrinsic conductances altered.

### 43.8 Spike-Timing Dependent Plasticity (STDP) in Cerebellum

Since the first report by Ekerot and Kano (1989), a series of studies have determined that parallel LTD is induced best when parallel fiber stimulation precedes climbing fiber-evoked complex spikes in Purkinje cells by 50–250 ms, suggesting an anti-Hebbian STDP mechanism in the cerebellum. Cerebellar STDP differs from that at hippocampal synapses, in that it is independent of axonal spike output. Rather, external climbing fiber stimulation and locally elicited  $Ca^{2+}$  spikes play a key role.

### 43.9 Conclusions

It is clear now that cerebellar learning is an integrated process involving numerous forms of synaptic plasticity in the cerebellar cortex and nuclei, where various specific spatial patterns are organized. Channeling begins from granular layer and is concluded in the molecular layer, where Purkinje cells integrate signals from different inputs. Plasticity is also organized in specific temporal patterns in the granular and molecular layer. In this view, the mechanisms for cerebellar learning should be viewed as the integration of various plasticities in the cerebellar cortex and nuclei (Fig. 43.1).



**Fig. 43.1** A summary of plasticity in the cerebellar circuit (Modified with permission from Hansel et al. 2001). The occurrence of long-term plasticity is coded with color: *red* indicating potentiation and *blue* indicating depression. The intrinsic excitability is labeled with action potentials in somata, whereas conventional synaptic LTP or LTD is labeled with *bars of colors* at synapses

## References

- Aizenman CD, Manis PB, Linden DJ (1998) Polarity of long-term synaptic gain change is related to postsynaptic spike firing at a cerebellar inhibitory synapse. *Neuron* 21:827–835
- Bear MF, Linden DJ (2000) The mechanisms and meaning of long-term synaptic depression in the mammalian brain. In: Cowan WM, Davies K (eds) *The synapse*. Johns Hopkins University Press, Baltimore, pp 455–516
- Coesmans M, Weber JT, De Zeeuw CI et al (2004) Bidirectional parallel fiber plasticity in the cerebellum under climbing fiber control. *Neuron* 44:691–700
- D'Angelo E, Rossi P, Armano S et al (1999) Evidence for NMDA and mGlu receptor-dependent long-term potentiation of mossy fibre–granule cell transmission in rat cerebellum. *J Neurophysiol* 81:277–287
- Ekerot CF, Kano M (1989) Stimulation parameters influencing climbing fibre induced long-term depression of parallel fibre synapses. *Neurosci Res* 6:264–268
- Gall D, Prestori F, Sola E et al (2005) Intracellular calcium regulation by burst discharge determines bidirectional long-term synaptic plasticity at the cerebellum input stage. *J Neurosci* 25:4813–4822
- Hansel C, Linden DJ (2000) Long-term depression of the cerebellar climbing fiber–Purkinje neuron synapse. *Neuron* 26:473–482
- Hansel C, Linden DJ, D'Angelo E (2001) Beyond parallel fiber LTD: the diversity of synaptic and nonsynaptic plasticity in the cerebellum. *Nat Neurosci* 4:467–475
- Häusser M, Clark BA (1997) Tonic synaptic inhibition modulates neuronal output pattern and spatiotemporal synaptic integration. *Neuron* 19:665–678
- Ito M, Sakurai M, Tongroach P (1982) Climbing fiber induced depression of both mossy fiber responsiveness and glutamate sensitivity of cerebellar Purkinje cells. *J Physiol (Lond)* 324:113–134
- Kano M (1996) Long-lasting potentiation of GABAergic inhibitory synaptic transmission in cerebellar Purkinje cells: its properties and possible mechanisms. *Behav Brain Sci* 19:354–361
- Kano M, Rexhausen U, Dreessen J et al (1992) Synaptic excitation produces a long-lasting rebound potentiation of inhibitory synaptic signals in cerebellar Purkinje cells. *Nature* 356:601–604
- Kawaguchi S, Hirano T (2000) Suppression of inhibitory synaptic potentiation by presynaptic activity through postsynaptic GABAB receptors in a Purkinje neuron. *Neuron* 27:339–347
- Linden DJ (1998) Synaptically-evoked glutamate transport currents may be used to detect the expression of long-term potentiation in cerebellar culture. *J Neurophysiol* 79:3151–3156
- Lonart G, Schoch S, Kaeser PS et al (2003) Phosphorylation of RIM1alpha by PKA triggers presynaptic long-term potentiation at cerebellar parallel fiber synapses. *Cell* 115:49–60
- Pugh JR, Raman IM (2006) Potentiation of mossy fiber EPSCs in the cerebellar nuclei by NMDA receptor activation followed by postinhibitory rebound current. *Neuron* 51:113–123
- Safo PK, Regehr WG (2005) Endocannabinoids control the induction of cerebellar LTD. *Neuron* 48:647–659
- Salin PA, Malenka RC, Nicoll RA (1996) cAMP mediates a presynaptic form of LTP at cerebellar parallel fiber synapses. *Neuron* 16:797–803
- Shen Y, Linden DJ (2005) Long-term potentiation of neuronal glutamate transporters. *Neuron* 46:715–722
- Shen Y, Hansel C, Linden DJ (2002) Glutamate release during LTD at cerebellar climbing fiber–Purkinje cell synapses. *Nat Neurosci* 5:725–726
- Wang YT, Linden DJ (2000) Expression of cerebellar long-term depression requires postsynaptic clathrin-mediated endocytosis. *Neuron* 25:635–647
- Wang DJ, Su LD, Wang YN et al (2014) Long-term potentiation at cerebellar parallel fiber–Purkinje cell synapses requires presynaptic and postsynaptic signaling cascades. *J Neurosci* 34:2355–2364

# Chapter 44

## Physiology of Olivo-Cerebellar Loops

Robin Broersen, Beerend H.J. Winkelman, Ozgecan Ozyildirim,  
and Chris I. De Zeeuw

**Abstract** The connections between the cerebellar cortex, the complex of cerebellar and vestibular nuclei and the inferior olive form a closed loop that is organized in parallel modules. In this chapter, we describe general physiological aspects of its primary components, highlighting parts of the neocerebellum and vestibulocerebellum that are involved in the generation of eye blinks and compensatory eye movements, respectively.

**Keywords** Cerebellar module • Physiological microcircuit • Eyeblink conditioning • Compensatory eye movements

### 44.1 Olivo-Cerebellar Circuitry

The olivo-cerebellar loop consists of three interconnected regions: the complex of cerebellar and vestibular nuclei (CN-VN), inferior olive (IO) and cerebellar cortex (CC) (Fig. 44.1a). Specific zones of Purkinje cells (PCs) in the CC send inhibitory projections to defined clusters of target neurons in the CN-VN, while receiving excitatory glutamatergic climbing fiber (CF) input from specifically that part of the IO that, in turn, receives inhibitory GABAergic nucleo-olivary projections from target neurons in the CN-VN (Ruigrok 2011). Neuronal signals thus flow between these regions in a closed-loop circuit (Fig. 44.1a), called a cerebellar module. A module can comprise multiple microzones, which are defined as clusters of neighboring PCs that are coherently active during particular physiological operations

---

R. Broersen • C.I. De Zeeuw (✉)

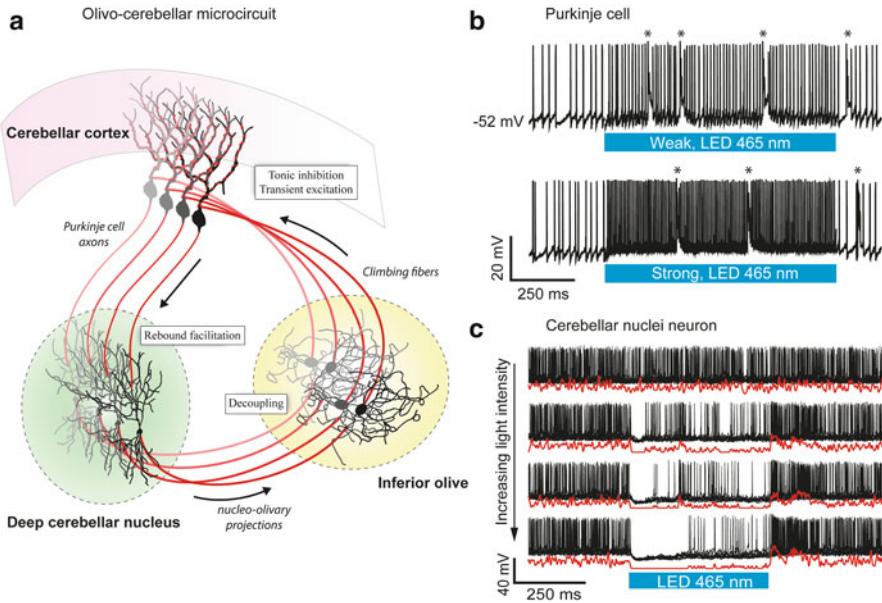
Royal Netherlands Academy of Arts & Sciences, Netherlands Institute for Neuroscience,  
Amsterdam, The Netherlands

Department of Neuroscience, Erasmus MC, Rotterdam, The Netherlands

e-mail: [c.de.zeeuw@nin.knaw.nl](mailto:c.de.zeeuw@nin.knaw.nl)

B.H.J. Winkelman • O. Ozyildirim

Netherlands Institute for Neuroscience, Royal Netherlands Academy of Arts & Sciences,  
Amsterdam, The Netherlands



**Fig. 44.1** (a) Anatomy of the olivo-cerebellar microcircuit. (b) Purkinje cell activity during optogenetic stimulation of the cerebellum. Stimulation of ChR2-expressing Purkinje cells leads to increases in simple and complex spike (*asterisks*) frequency proportional to light intensity. (c) Activity of a cerebellar nuclei neuron is inhibited during activation of Purkinje cells. With sufficiently strong stimulation, cessation of the light stimulus causes a well-timed burst of post-inhibitory rebound spikes (Modified from: Witter et al. 2013, with permission)

(Oscarsson 1979; De Zeeuw et al. 2011). The state of one of the components of a module generally affects the state of the other components.

In the IO, neuronal discharges generate small bursts of axonal spikes that travel along the CF to cerebellar PCs. This CF input evokes a complex spike (CS), but also influences simple spike (SS) activity of PCs. Abolishing spontaneous CS activity by IO inactivation or lesioning causes a steady rise in SS frequency (Cerminara and Rawson 2004). CFs thus exert both transient excitation (evoking CSs) and tonic inhibition (suppressing SSs) on PCs. Further downstream, increased SS activity resulting from IO inactivation inhibits activity in the nuclei (Benedetti et al. 1983), as GABAergic input from PCs hyperpolarizes CN neurons. If the hyperpolarizing current is sufficiently strong, cessation of the current causes *post-inhibitory rebound spiking* in these neurons (Fig. 44.1c). Strong hyperpolarization can occur when synchronized activity of several PC inputs converges at a CN neuron (Person and Raman 2011). Synchronization of CS activity depends on electrotonic coupling of Connexin36 gap-junctions between olivary neurons. Synchronous CS activity can also occur following strong transient stimuli inducing conjunctive afferent input to the IO.

The level of gap-junction coupling between olivary neurons is regulated by inhibitory nucleo-olivary fibers. Lowering the release of GABA at the olivary gap-junctions, achieved by artificially raising SS activity in the CC, results in



elevated CS synchrony (Marshall and Lang 2009). Reducing SS rate results in less CS synchrony and a lower CS frequency. These changes are restricted to the affected cortical region. Similar increases in SS and CS frequencies (Fig. 44.1b) are observable during optogenetic stimulation of PCs (Witter et al. 2013). CN neurons are inhibited during PC activation (Fig. 44.1c) and rebound excitation is observed when the light stimulation is stopped. The increase in CS frequency is therefore a direct consequence of increased PC activity.

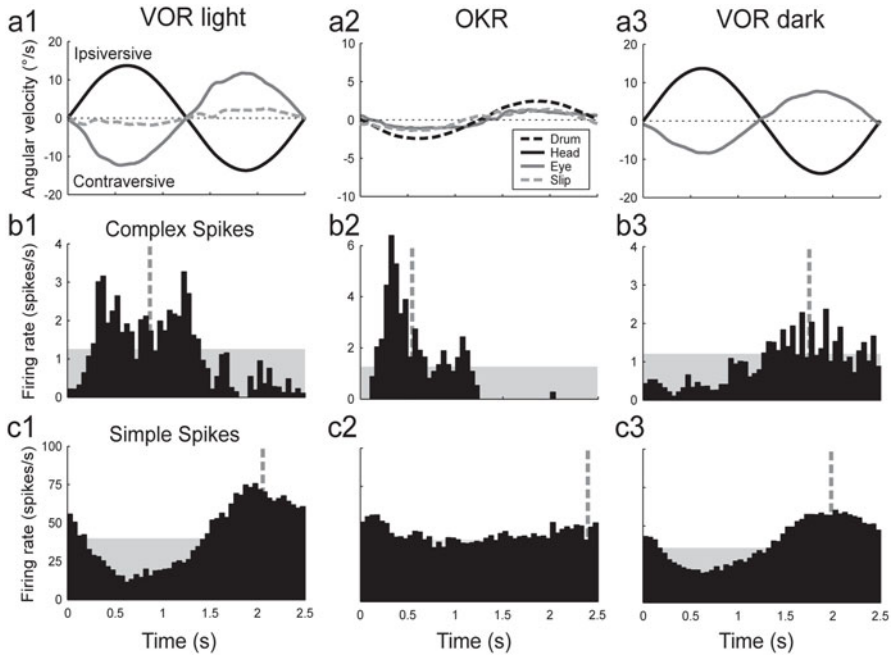
## 44.2 Olivo-Cerebellar Interactions in the Eyeblink Circuit

The modular connections of the neocerebellum follow the closed-loop format described above, including the zones involved in eyeblink conditioning. Many PCs in these eyeblink zones fire at high rates (Zhou et al. 2014) and respond to periocular stimulation. During eyeblink conditioning a neutral stimulus (conditioned stimulus, CoSt), such as an auditory cue, leads to an anticipatory eyeblink response upon repeated pairing with a subsequent blink-inducing unconditioned stimulus (UnSt), such as an airpuff onto the eye. The UnSt is relayed to the cerebellum via CF input, while the CoSt enters the cerebellum via the mossy fiber pathway. During repeated pairing of the CoSt and the UnSt, PCs develop a marked decrease in SS activity coinciding with the emergence of a conditioned eyelid response (CoRs) (De Zeeuw and Ten Brinke *in press*).

This process is reversible; when the CoSt and UnSt are randomly paired, the CoRs as well as the SS response are concurrently extinguished. By developing a suppression of SS activity in response to the CoSt, PCs disinhibit neurons in the cerebellar interposed nucleus (IPN), which in turn may result in rebound activity in these cells. IPN output is relayed via the red nucleus to the eyelid muscles, effectively closing the eye lid before the UnSt arrives. Rebound activity of IPN neurons may be facilitated by excitatory inputs from MF and/or CF collaterals (De Zeeuw et al. 2011). Indeed, the rebound temporally coincides with excitatory input to the CN (Witter et al. 2013). The projection from the IPN to the IO plays an important role in extinction of the CoRs. Blocking the inhibitory input to the IO prevents extinction of the CoRs (Medina et al. 2002) and stimulation of these projections during pairing of the CoSt and UnSt leads to altered olivary transmission, resulting in gradual extinction of the CoR (Bengtsson et al. 2007).

## 44.3 Olivo-Cerebellar Interactions in the Compensatory Eye Movement Circuit

Olivo-cerebellar loops that include the flocculus of the vestibulocerebellum have a more complex format than the layout depicted above. Some of the target nuclei of the floccular PC axons (e.g. ventral dentate nucleus, group Y) project to the part of the IO that subsequently projects to the corresponding floccular zone, thus



**Fig. 44.2** (a) Sinusoidal stimulation about the vertical axis at 0.4 Hz in rabbit: whole-body rotation in the light (column 1), optokinetic stimulation (column 2), and whole-body rotation in the dark (column 3). Average angular velocity of the head (*black line*), the slow-phase eye movement (*gray line*), and the residual retinal slip (*light-gray dashed line*). (b) Average complex spike firing rate relative to the background rate (*gray area*) of a single-unit Purkinje cell. *Vertical dashed line* indicates the average phase of the CS activity on the stimulus cycle. (c) Average simple spike firing rate (From: Winkelman et al. 2014, with permission)

completing a closed pathway (De Zeeuw et al. 1994). However, the medial and superior vestibular nucleus do not project directly back to the olivary subnuclei that innervate the flocculus.

Visual floccular zones are involved in control and plasticity of eye stabilization reflexes, e.g. the vestibulo-ocular reflex (VOR) and the optokinetic reflex (OKR). These reflexes minimize retinal image slip, which is otherwise detrimental to clear and stable vision. Figure 44.2 shows floccular PC activity during vestibular and optokinetic stimulation. Excitatory input to the IO causes the CSs to respond to retinal slip (contraversive to the recorded PC), present during whole-body rotation in the light (column 1) and optokinetic stimulation (column 2). However, whole-body rotation in darkness (column 3) causes CS activity to reverse in polarity, so that the CSs fire in-phase with the SSs. This non-visual CS modulation is a consequence of the inhibitory input signal to the IO (Winkelman et al. 2014), which originates in the prepositus hypoglossal nucleus (De Zeeuw et al. 1993).

The importance of the CF input to the CC for shaping the PC output has been explicitly demonstrated in a mouse model in which the CF projection was developmentally

rerouted towards the ipsilateral CC instead of the natural contralateral projection. Besides the observation that the CS signals were reversed in response to optokinetic stimulation also the SS modulation was reversed, so that reciprocity between CS and SS activity was maintained (Badura et al. 2013).

## References

- Badura A, Schonewille M, Voges K et al (2013) Climbing fiber input shapes reciprocity of Purkinje cell firing. *Neuron* 78:700–713
- Benedetti F, Montarolo PG, Strata P, Tempia F (1983) Inferior olive inactivation decreases the excitability of the intracerebellar and lateral vestibular nuclei in the rat. *J Physiol* 340:195–208
- Bengtsson F, Jirenhed DA, Svensson P, Hesslow G (2007) Extinction of conditioned blink responses by cerebello-olivary pathway stimulation. *Neuroreport* 18:1479–1482
- Cerminara NL, Rawson JA (2004) Evidence that climbing fibers control an intrinsic spike generator in cerebellar Purkinje cells. *J Neurosci* 24:4510–4517
- De Zeeuw CI, Wentzel P, Mugnaini E (1993) Fine structure of the dorsal cap of the inferior olive and its GABAergic and non-GABAergic input from the nucleus prepositus hypoglossi in rat and rabbit. *J Comp Neurol* 327:63–82
- De Zeeuw CI, Wylie DR, DiGiorgi PL, Simpson JI (1994) Projections of individual Purkinje cells of identified zones in the flocculus to the vestibular and cerebellar nuclei in the rabbit. *J Comp Neurol* 349:428–447
- De Zeeuw CI, Hoebeek FE, Bosman LWJ et al (2011) Spatiotemporal firing patterns in the cerebellum. *Nat Rev Neurosci* 12:327–344
- De Zeeuw CI, Ten Brinke MM (in press) Motor learning and the cerebellum. In: Mayford MR, Dudai Y (ed) *Learning & memory by Kandel*. CSH press, New York
- Marshall SP, Lang EJ (2009) Local changes in the excitability of the cerebellar cortex produce spatially restricted changes in complex spike synchrony. *J Neurosci* 29:14352–14362
- Medina JF, Nores WL, Mauk MD (2002) Inhibition of climbing fibres is a signal for the extinction of conditioned eyelid responses. *Nature* 416:330–333
- Oscarsson O (1979) Functional units of the cerebellum – sagittal zones and microzones. *Trends Neurosci* 2:143–145
- Person AL, Raman IM (2011) Purkinje neuron synchrony elicits time-locked spiking in the cerebellar nuclei. *Nature* 481:502–505
- Ruigrok TJH (2011) Ins and outs of cerebellar modules. *Cerebellum* 10:464–474
- Winkelman BHJ, Belton T, Suh M et al (2014) Nonvisual complex spike signals in the rabbit cerebellar flocculus. *J Neurosci* 34:3218–3230
- Witter L, Canto CB, Hoogland TM et al (2013) Strength and timing of motor responses mediated by rebound firing in the cerebellar nuclei after Purkinje cell activation. *Front Neural Circuits* 7:133
- Zhou H, Lin Z, Voges K et al (2014) Cerebellar modules operate at different frequencies. *eLife* 3:e02536

# Chapter 45

## Long-Term Depression at Parallel Fiber-Purkinje Cell Synapses

Kazuhisa Kohda, Wataru Kakegawa, and Michisuke Yuzaki

**Abstract** Long-term depression (LTD) at parallel fiber (PF) -Purkinje cell (PC) synapses is thought to play an important role in cerebellar motor learning. LTD is mediated by postsynaptic AMPA receptor endocytosis. Concurrent activation of PF and climbing fibers generates specific temporal and spatial  $\text{Ca}^{2+}$  dynamics in PC dendritic spines leading to activation of signaling cascade required for LTD.

**Keywords** Albus • Climbing fiber • LTD • Long-term depression • Marr • Motor learning • Nitric oxide • Parallel fiber

### 45.1 Introduction

According to the Marr-Albus-Ito theory of motor learning, climbing fiber (CF) activity serves as a “teacher” signal to induce long-term depression (LTD) at concomitantly activated parallel fiber (PF)-Purkinje cell (PC) synapses (Ito et al. 2014). Consistent with this theory, motor learning is impaired in animals treated with various pharmacological reagents or genetically engineered to modify signaling cascades involved in LTD (Yuzaki 2013). Although multiple types of synaptic plasticity can mediate motor learning (Schonewille et al. 2011), experimental evidence and theoretical consideration support the view that LTD at PF-PC synapses (PF-LTD) likely plays an important role in motor learning (Ito et al. 2014). Here, we summarize the current understanding about molecular mechanisms underlying PF-LTD.

---

K. Kohda • W. Kakegawa • M. Yuzaki (✉)  
Department of Physiology, School of Medicine, Keio University,  
35 Shinanomachi, Shinjuku-ku, 160-8582 Tokyo, Japan  
e-mail: [myuzaki@a5.keio.jp](mailto:myuzaki@a5.keio.jp)

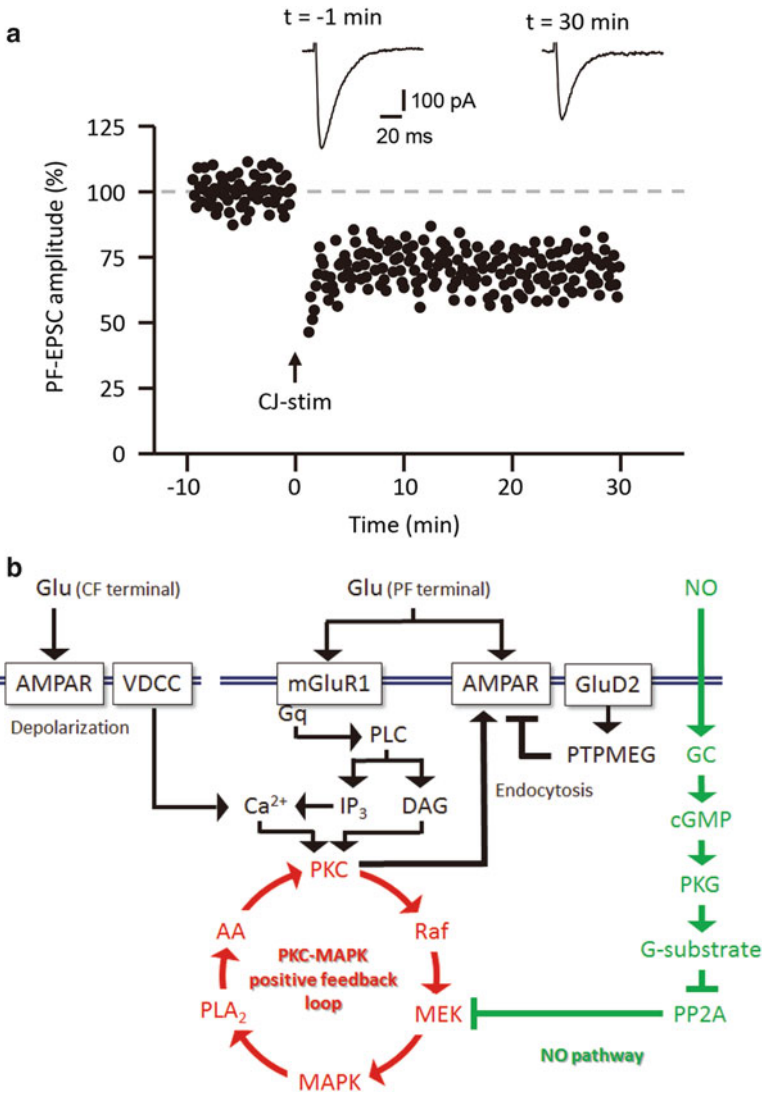
## 45.2 LTD-Dependent Endocytosis of AMPA Receptors

Like LTD in other brain regions, PF-LTD is mediated by clathrin-dependent endocytosis of postsynaptic AMPA receptors. A key event triggering this is phosphorylation of the GluA2 subunit of AMPA receptors at serine 880 residue (GluA2-S880) by protein kinase C $\alpha$  (PKC; Fig. 45.1b) (Matsuda et al. 2000; Xia et al. 2000). AMPA receptors are stabilized at synapses via their binding with glutamate interacting protein (GRIP). Phosphorylation at S880 drastically reduces GluA2's affinity for GRIP, but not for protein interacting with C kinase 1 (PICK1), another anchoring protein that promotes AMPA receptor endocytosis. Therefore, inhibiting GluA2 interactions with GRIP or PICK1 impairs LTD induction (Matsuda et al. 2000; Xia et al. 2000; Steinberg et al. 2006).

PF inputs activate postsynaptic metabotropic glutamate receptor subtype 1 (mGluR1), leading to phospholipase C activation and production of inositol 1, 4, 5-trisphosphate (IP<sub>3</sub>) and diacylglycerol. IP<sub>3</sub> then induces Ca<sup>2+</sup> release through IP<sub>3</sub> receptors, while diacylglycerol stimulates PKC $\alpha$  in coordination with Ca<sup>2+</sup>. On the other hand, CF inputs generate large depolarizations triggering Ca<sup>2+</sup> influx through voltage-gated Ca<sup>2+</sup> channels. Interestingly, combined PF and CF activity is detected by the supralinear summation of signals coming from two Ca<sup>2+</sup> sources: IP<sub>3</sub>-mediated Ca<sup>2+</sup> release from intracellular stores and Ca<sup>2+</sup> influx through Ca<sup>2+</sup> channels. Temporal and spatial Ca<sup>2+</sup> dynamics in dendritic spines can explain several features of LTD, such as synapse specificity and dependence on the timing of PF and CF activation (Finch et al. 2012). Moreover, concurrent activation of PF and CF inputs induces a sustained (>20 min) increases in PKC activity by the positive-feedback cycle, consisting of mitogen-activated protein kinase (MAPK), phospholipase A2 (PLA2), and their related molecules (Fig. 45.1b) (Tanaka and Augustine 2008).

For AMPA receptors endocytosis, the receptors freed from postsynaptic sites need to associate with clathrin adaptor protein complex-2 (AP-2). AP-2 binds to dephosphorylated forms of transmembrane AMPA receptor regulatory proteins (TARPs) (Matsuda et al. 2013; Nomura et al. 2012). Thus, the process of AMPA receptor endocytosis begins when an LTD-inducing stimuli activates the Ca<sup>2+</sup>-dependent phosphatase calcineurin, which then dephosphorylates TARPs to recruit AP-2 to the AMPA receptor-TARP complex.

Aside from activity-dependent changes, morphological changes are also observed at PF-PC synapses after motor learning *in vivo* (Aziz et al. 2014). In cultured PCs, LTD reportedly transits into a late phase (> ~60 min), which requires transcription of mRNAs, such as Arc (Smith-Hicks et al. 2010). However, whether and how late-phase LTD is induced *in vivo* remains elusive.

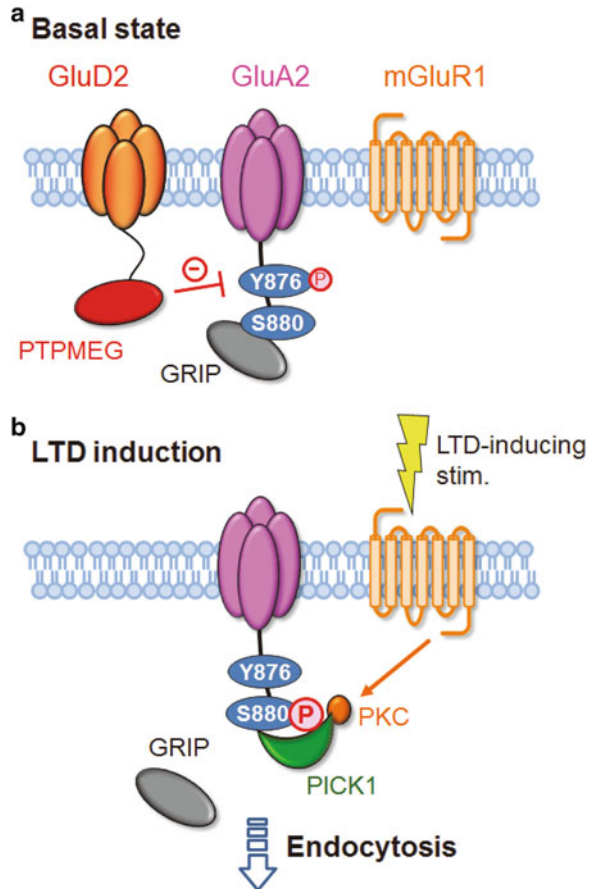


**Fig. 45.1** LTD and its signaling cascades. **(a)** A typical diagram of LTD in a whole-cell patch-clamp recording. Excitatory post-synaptic currents (EPSCs; insets) of a Purkinje cell were elicited by stimulating parallel fibers (PFs) and their amplitudes are plotted against time. Conjunctive stimulations (CJ-stim) of PFs and a climbing fiber induced enduring reduction of PF-EPSCs. **(b)** A positive-feedback model together with NO and GluD2 pathways for LTD induction

### 45.3 Unique Features of Cerebellar LTD

Nitric oxide (NO), which is produced by NO synthase following  $\text{Ca}^{2+}$  influx through NMDA receptors, serves as a retrograde messenger to induce long-term potentiation (LTP) in hippocampal neurons (Padamsey and Emptage 2014). Interestingly, NO is involved in LTD in the cerebellum (Ito et al. 2014). Such different effects may be partly attributable to the fact that PCs show low expression of functional NMDA receptors and NO synthase. NO up-regulates the MAPK pathway through a G-substrate in the positive-feedback loop of LTD induction (Fig. 45.1b). However, LTD is found to be largely intact in *G-substrate*-null mice (Endo et al. 2009). NO is also necessary for postsynaptic LTP at PF-PC synapses (Kakegawa and Yuzaki 2005). Thus, NO may not be directly involved in LTD induction, but rather plays a role in other aspects, such as the spread of plasticity across synapses.

**Fig. 45.2** A proposed model of how GluD2 regulates LTD. (a) Basal state. GluD2 maintains low phosphorylation levels at Y876 of the GluA2 subunit of AMPA receptors via PTPMEG, a protein tyrosine phosphatase. (b) LTD induction. LTD-inducing stimuli further dephosphorylate this tyrosine residue. Y876 dephosphorylation allows S880 phosphorylation by protein kinase C, which leads to the replacement of GRIP, a membrane anchoring protein, with PICK1 to allow AMPA receptor endocytosis



Another unique feature of PF-LTD is its absolute requirement of the  $\delta 2$  glutamate receptor (GluD2). GluD2 is highly and predominantly expressed in PC dendrites. While GluD2's channel activities are not required for LTD induction, its intracellular C-terminal region is indispensable (Kohda et al. 2007; Kakegawa et al. 2008) since it binds to PTPMEG, a protein tyrosine phosphatase that dephosphorylates a tyrosine residue (Y876) of GluA2. Interestingly, prior phosphorylation of Y876 hindered subsequent phosphorylation at S880 by PKC (Kohda et al. 2013). Thus, in *GluD2*-null or *PTPMEG*-null PCs, GluA2-Y876 is highly phosphorylated and LTD-inducing stimuli fail to phosphorylate S880 (Fig. 45.2). Therefore, GluD2 controls LTD induction by regulating interactions between the two phosphorylation sites of GluA2. Cbln1, a C1q family protein released from PFs, binds to the extracellular N-terminal region of GluD2 (Matsuda et al. 2010). Although it remains unclear why LTD is impaired in *Cbln1*-null mice (Hirai et al. 2005), PTPMEG signaling at the C-terminus may be regulated by binding of Cbln1 at the N-terminus of GluD2.

**Acknowledgements** This work was supported by the Grant-in-Aid from the MEXT of Japan (15H05772, 23240053) and the CREST from the JST.

## References

- Aziz W, Wang W, Kesaf S, Mohamed AA, Fukazawa Y, Shigemoto R (2014) Distinct kinetics of synaptic structural plasticity, memory formation, and memory decay in massed and spaced learning. *Proc Natl Acad Sci U S A* 111(1):E194–E202
- Endo S, Shutoh F, Dinh TL, Okamoto T, Ikeda T, Suzuki M, Kawahara S, Yanagihara D, Sato Y, Yamada K, Sakamoto T, Kirino Y, Hartell NA, Yamaguchi K, Itohara S, Nairn AC, Greengard P, Nagao S, Ito M (2009) Dual involvement of G-substrate in motor learning revealed by gene deletion. *Proc Natl Acad Sci U S A* 106(9):3525–3530
- Finch EA, Tanaka K, Augustine GJ (2012) Calcium as a trigger for cerebellar long-term synaptic depression. *Cerebellum* 11(3):706–717
- Hirai H, Pang Z, Bao D, Miyazaki T, Li L, Miura E, Parris J, Rong Y, Watanabe M, Yuzaki M, Morgan JI (2005) Cbln1 is essential for synaptic integrity and plasticity in the cerebellum. *Nat Neurosci* 8(11):1534–1541
- Ito M, Yamaguchi K, Nagao S, Yamazaki T (2014) Long-term depression as a model of cerebellar plasticity. *Prog Brain Res* 210:1–30
- Kakegawa W, Yuzaki M (2005) A mechanism underlying AMPA receptor trafficking during cerebellar long-term potentiation. *Proc Natl Acad Sci U S A* 102(49):17846–17851
- Kakegawa W, Miyazaki T, Emi K, Matsuda K, Kohda K, Motohashi J, Mishina M, Kawahara S, Watanabe M, Yuzaki M (2008) Differential regulation of synaptic plasticity and cerebellar motor learning by the C-terminal PDZ-binding motif of GluRdelta2. *J Neurosci* 28(6):1460–1468
- Kohda K, Kakegawa W, Matsuda S, Nakagami R, Kakiya N, Yuzaki M (2007) The extreme C-terminus of GluRdelta2 is essential for induction of long-term depression in cerebellar slices. *Eur J Neurosci* 25(5):1357–1362
- Kohda K, Kakegawa W, Matsuda S, Yamamoto T, Hirano H, Yuzaki M (2013) The delta2 glutamate receptor gates long-term depression by coordinating interactions between two AMPA receptor phosphorylation sites. *Proc Natl Acad Sci U S A* 110(10):E948–E957



- Matsuda S, Launey T, Mikawa S, Hirai H (2000) Disruption of AMPA receptor GluR2 clusters following long-term depression induction in cerebellar Purkinje neurons. *EMBO J* 19(12):2765–2774
- Matsuda K, Miura E, Miyazaki T, Kakegawa W, Emi K, Narumi S, Fukazawa Y, Ito-Ishida A, Kondo T, Shigemoto R, Watanabe M, Yuzaki M (2010) Cbln1 is a ligand for an orphan glutamate receptor delta2, a bidirectional synapse organizer. *Science* 328(5976):363–368
- Matsuda S, Kakegawa W, Budisantoso T, Nomura T, Kohda K, Yuzaki M (2013) Stargazin regulates AMPA receptor trafficking through adaptor protein complexes during long-term depression. *Nat Commun* 4:2759
- Nomura T, Kakegawa W, Matsuda S, Kohda K, Nishiyama J, Takahashi T, Yuzaki M (2012) Cerebellar long-term depression requires dephosphorylation of TARP in Purkinje cells. *Eur J Neurosci* 35(3):402–410
- Padamsey Z, Emptage N (2014) Two sides to long-term potentiation: a view towards reconciliation. *Philos Trans R Soc Lond B Biol Sci* 369(1633):20130154
- Schonewille M, Gao Z, Boele HJ, Veloz MF, Amerika WE, Simek AA, De Jeu MT, Steinberg JP, Takamiya K, Hoebeek FE, Linden DJ, Huganir RL, De Zeeuw CI (2011) Reevaluating the role of LTD in cerebellar motor learning. *Neuron* 70(1):43–50
- Smith-Hicks C, Xiao B, Deng R, Ji Y, Zhao X, Shepherd JD, Posern G, Kuhl D, Huganir RL, Ginty DD, Worley PF, Linden DJ (2010) SRF binding to SRE 6.9 in the Arc promoter is essential for LTD in cultured Purkinje cells. *Nat Neurosci* 13(9):1082–1089
- Steinberg JP, Takamiya K, Shen Y, Xia J, Rubio ME, Yu S, Jin W, Thomas GM, Linden DJ, Huganir RL (2006) Targeted in vivo mutations of the AMPA receptor subunit GluR2 and its interacting protein PICK1 eliminate cerebellar long-term depression. *Neuron* 49(6):845–860
- Tanaka K, Augustine GJ (2008) A positive feedback signal transduction loop determines timing of cerebellar long-term depression. *Neuron* 59(4):608–620
- Xia J, Chung HJ, Wihler C, Huganir RL, Linden DJ (2000) Cerebellar long-term depression requires PKC-regulated interactions between GluR2/3 and PDZ domain-containing proteins. *Neuron* 28(2):499–510
- Yuzaki M (2013) Cerebellar LTD vs. motor learning—lessons learned from studying GluD2. *Neural Netw* 47:36–41

# Chapter 46

## Regulation of Calcium in the Cerebellum

Donna L. Gruol

**Abstract**  $\text{Ca}^{2+}$  is an important ion in CNS biology, where it plays a critical role in basic functions of neurons, glia and other cell types. In CNS neurons,  $\text{Ca}^{2+}$  is a participant in the generation of electrical signals, an inducer and regulator of synaptic transmission, and a second messenger that controls many biochemical processes.  $\text{Ca}^{2+}$  is also a signal transmitter and second messenger in glial cells.  $\text{Ca}^{2+}$  levels in neurons and glia are dynamic but judiciously controlled in order to maintain biological processes at a level compatible with life. An excess or deficit of  $\text{Ca}^{2+}$  can result in cell damage or death. A variety of cellular mechanisms contribute to or enable the changes in intracellular  $\text{Ca}^{2+}$ , referred to as  $\text{Ca}^{2+}$  signaling, that are essential for normal cell function, some of which are present in all cells and others that are unique to a particular class of cells. This chapter will briefly describe the cellular mechanisms that contribute to  $\text{Ca}^{2+}$  signaling in cerebellar and other CNS neurons. These mechanisms are located at presynaptic sites (e.g., axon terminals), where they regulate transmitter release, and/or at postsynaptic sites (e.g., dendrites), where they influence synaptic responses and other physiological functions.

**Keywords**  $\text{Ca}^{2+}$  channels •  $\text{Ca}^{2+}$  signaling • Second messenger • Intracellular  $\text{Ca}^{2+}$  stores • Glutamate receptors

### 46.1 Introduction

$\text{Ca}^{2+}$  signaling is essential for cerebellar function (Lamont and Weber 2012). In cerebellar and other CNS neurons,  $\text{Ca}^{2+}$  has two primary roles, as a charge carrier and as a second messenger. As a charge carrier,  $\text{Ca}^{2+}$  influx through the plasma membrane produces a depolarizing influence on the membrane potential. The change in membrane potential serves as an electrical signal and also a regulator of the activity of other ion channels, for example  $\text{K}^{+}$  channels that play a role in repolarizing the membrane potential. As a second messenger,  $\text{Ca}^{2+}$  can alter the

---

D.L. Gruol (✉)

Molecular and Cellular Neuroscience Department, The Scripps Research Institute,  
La Jolla, CA, USA

e-mail: [gruol@scripps.edu](mailto:gruol@scripps.edu)

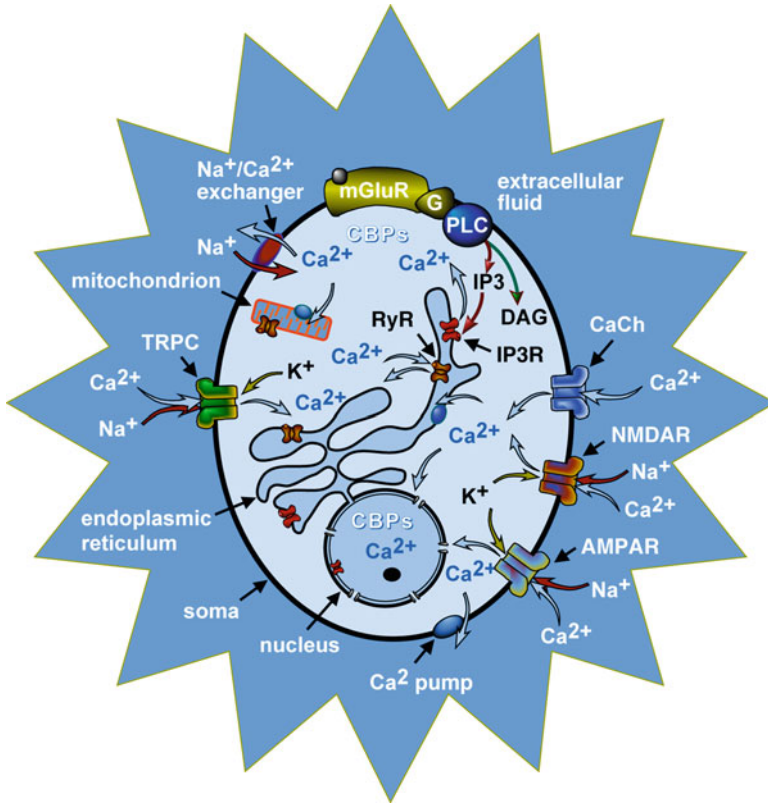
activity of other ion channels such as  $\text{Ca}^{2+}$  activated  $\text{K}^+$  channels, and regulate important biochemical processes such as mechanisms involved in synaptic plasticity and gene transcription. Through these actions,  $\text{Ca}^{2+}$  can couple electrical signals at the cell surface to physiological events in both the cytosol and nucleus of neurons. Glial cells are not electrically excitable but have several mechanisms for  $\text{Ca}^{2+}$  signaling, which also regulates a variety of glial functions (Metea and Newman 2006).

$\text{Ca}^{2+}$  is widely but unequally distributed in the cerebellum. In particular,  $\text{Ca}^{2+}$  levels are considerably higher in the extracellular fluid that bathes the cells (~1–2 mM) than in the cytosol of the cells (~100 nM). In addition, two organelles within the cytosol serve as  $\text{Ca}^{2+}$  storage vessels, the endoplasmic reticulum and mitochondria, and have higher levels of  $\text{Ca}^{2+}$  than the cytosol. These pronounced concentration differences are a consequence of the impermeability of the cellular membranes to  $\text{Ca}^{2+}$  and the actions of various cell mechanisms that regulate influx and efflux of  $\text{Ca}^{2+}$  from the cytosol.

## 46.2 Membrane Proteins That Mediate $\text{Ca}^{2+}$ Influx to the Cytosol

Several molecules located in the plasma membrane enable  $\text{Ca}^{2+}$  to transverse the otherwise impermeable cell membrane and enter the cytosol (Fig. 46.1). Of these, voltage-gated  $\text{Ca}^{2+}$  channels (VGCC) and ligand-gated channels play a primary role. VGCC are primarily expressed in neurons, whereas ligand-gated channels are expressed by both neurons and glia (Metea and Newman 2006). Both VGCC and ligand-gated channels require stimulation to be functional and enable  $\text{Ca}^{2+}$  flux. VGCCs are activated by changes in resting membrane potential, whereas ligand-gate channels are activated by neurochemicals, such as neurotransmitters. In the unstimulated state, VGCC and ligand-gated channels are typically closed and impermeable to  $\text{Ca}^{2+}$ . When activated, the channels open and  $\text{Ca}^{2+}$  influx occurs due to the large driving force for  $\text{Ca}^{2+}$  resulting from the prominent concentration difference for  $\text{Ca}^{2+}$  between the inside (nM range) and outside (mM range) of the neuron. In the case of ligand-gated channels, other ions may also flux through the channel in addition to  $\text{Ca}^{2+}$ .

$\text{Ca}^{2+}$  channels are divided into three gene subfamilies (Cav1, Cav2, and Cav3), which are further subdivided into 6 classes (L, N, P, Q, R, and T) based on the physiological and pharmacological properties of the  $\text{Ca}^{2+}$  current mediated by the channel. The properties of the currents mediated by the different  $\text{Ca}^{2+}$  channel types, such as voltage-sensitivity and kinetics, the location of the channel on the neuronal surface (e.g., axon, soma, dendrite), and the number and type of  $\text{Ca}^{2+}$  channels expressed by the neuron play key roles in defining the physiological properties of the neuron. For example, P-type  $\text{Ca}^{2+}$  channels, which were first identified in Purkinje neurons, are highly expressed in Purkinje neurons, particularly in the large dendritic tree (Lin et al. 1990). The functioning of P-type  $\text{Ca}^{2+}$  channels in Purkinje neurons is critical to the unique physiological properties and functional role of this



**Fig. 46.1**  $\text{Ca}^{2+}$  signaling components in cerebellar neurons.  $\text{Ca}^{2+}$  influx from the extracellular fluid occurs through several types of ion channels including  $\text{Ca}^{2+}$  channels (CaCh), NMDAR channels,  $\text{Ca}^{2+}$  permeable AMPA receptors and TRPC. Increases in cytosolic  $\text{Ca}^{2+}$  levels can also occur by  $\text{Ca}^{2+}$  release from intracellular  $\text{Ca}^{2+}$  stores through the IP3R and RyR channels.  $\text{Ca}^{2+}$  is removed from the cytosol by  $\text{Ca}^{2+}$  pumps and  $\text{Na}^{+}/\text{Ca}^{2+}$  exchanger located on the plasma membrane and by various  $\text{Ca}^{2+}$  pumps located on the endoplasmic reticulum and mitochondria.  $\text{Ca}^{2+}$  binding proteins (CBP) at different concentrations are located in all cell regions

neuronal type in cerebellar function (Llinas and Sugimori 1980; Kitamura and Kano 2013; Hartmann and Konnerth 2005). Depolarizing or hyperpolarizing the membrane potential can result in  $\text{Ca}^{2+}$  channel activation, depending on  $\text{Ca}^{2+}$  channel type. For example, T-type  $\text{Ca}^{2+}$  channels are activated by depolarization from a hyperpolarized membrane potential, whereas P-type  $\text{Ca}^{2+}$  channels are activated by depolarization from resting membrane potential ( $\sim 60$  mV).

The most prominent ligand-gated,  $\text{Ca}^{2+}$  permeable channels in the cerebellum are NMDA receptor (NMDAR) channel and some subtypes of AMPA receptor channels. These ligand-gated channels are activated by the neurotransmitter glutamate, although NMDARs also have a voltage requirement for activation, and produce a membrane depolarization. In addition to  $\text{Ca}^{2+}$ , these channels are permeable to  $\text{Na}^{+}$

and  $K^+$ , a property that is relevant to the degree of depolarization that can be produced when the receptor is activated.

Another type of glutamate receptor, the metabotropic glutamate receptor (mGluR), and in particular mGluR subtypes 1 and 5 (mGluR1/5), also play a key role in  $Ca^{2+}$  signaling in the cerebellum. mGluR1/5 are G-protein coupled receptors and do not contain an ion channel in their structure. However, when activated they induce an increase in cytosolic  $Ca^{2+}$  through the actions of phospholipase C (PLC), which is a downstream signaling partner of mGluR1 (Fig. 46.1). PLC activation results in the production of two second messengers, inositoltrisphosphate ( $IP_3$ ) and diacylglycerol (DAG).  $IP_3$  binds to its receptor, the  $IP_3R$ , which is located on the endoplasmic reticulum and contains a  $Ca^{2+}$  permeable channel.  $IP_3R$  activation results in efflux of  $Ca^{2+}$  through the receptor channel from  $Ca^{2+}$  stores in the endoplasmic reticulum and an increase in cytosolic  $Ca^{2+}$ .  $IP_3R$  activation also requires  $Ca^{2+}$  as a co-agonist. Thus,  $IP_3$  and  $Ca^{2+}$  act co-operatively to induce  $Ca^{2+}$  release from intracellular stores via  $IP_3Rs$ . In Purkinje neurons (but not in granule neurons),  $IP_3Rs$  are also present on the inner nuclear membrane where they appear to function in nuclear  $Ca^{2+}$  signaling (Marchenko and Thomas 2006; Gruol et al. 2010). The nuclear membrane is contiguous with endoplasmic reticulum. Nuclear  $Ca^{2+}$  signaling can also occur by  $Ca^{2+}$  influx from the cytosol through nuclear pores (Fig. 46.1).

In addition to  $IP_3Rs$ , a second receptor that contains a  $Ca^{2+}$  channel, the ryanodine receptor (RyR), is located on the endoplasmic reticulum and plays an important role in  $Ca^{2+}$  signaling. RyRs are activated by  $Ca^{2+}$  and, when activated,  $Ca^{2+}$  efflux occurs through the receptor channel. Thus, RyRs act as  $Ca^{2+}$  amplifiers that enhance cytosolic  $Ca^{2+}$  signals produced by other mechanisms such as VGCCs, NMDARs or  $IP_3Rs$ . mGluR1 and downstream signaling molecules, PLC,  $IP_3R$ , and RyR are highly expressed in the Purkinje neurons of the cerebellum (Shigemoto et al. 1992; Furuichi et al. 1989; Nakamura et al. 2004).

In addition to producing  $Ca^{2+}$  release from intracellular stores, mGluR1 activation can result in  $Ca^{2+}$  signaling through another pathway, activation of plasma membrane cationic channels called transient receptor potential canonical (TRPC) channels. TRPC channels are permeable to  $Ca^{2+}$ ,  $Na^+$  and  $K^+$  and when activated produce a membrane depolarization and  $Ca^{2+}$  influx.

### 46.3 Proteins That Reduce $Ca^{2+}$ Levels in the Cytosol

Increases intracellular levels of  $Ca^{2+}$  during  $Ca^{2+}$  signaling are typically transient in nature.  $Ca^{2+}$  levels recover through a variety of mechanisms.  $Ca^{2+}$  transport mechanisms on the plasma membrane (plasma membrane  $Ca^{2+}$ -ATPase (PMCA);  $Na^+$ - $Ca^{2+}$  exchanger) remove  $Ca^{2+}$  from the cytosol to the extracellular fluid, whereas transport mechanisms located on the endoplasmic reticulum (sarco-endoplasmic  $Ca^{2+}$ -ATPase (SERCA)) and mitochondria (mitochondrial  $Ca^{2+}$  uniporter and the  $H^+$ / $Ca^{2+}$  exchanger) import  $Ca^{2+}$  into these organelles for storage. In addition, a variety of cell proteins bind  $Ca^{2+}$  and act as  $Ca^{2+}$  buffers including calbindin, parvalbumin, calmodulin and calretinin.

## References

- Furuichi T, Yoshikawa S, Miyawaki A, Wada K, Maeda N, Mikoshiba K (1989) Primary structure and functional expression of the inositol 1,4,5-trisphosphate-binding protein P400. *Nature* 342(6245):32–38. doi:10.1038/342032a0
- Gruol DL, Netzeband JG, Nelson TE (2010) Somatic Ca<sup>2+</sup> signaling in cerebellar Purkinje neurons. *J Neurosci Res* 88(2):275–289. doi:10.1002/jnr.22204
- Hartmann J, Konnerth A (2005) Determinants of postsynaptic Ca<sup>2+</sup> signaling in Purkinje neurons. *Cell Calcium* 37(5):459–466. doi:10.1016/j.cecca.2005.01.014
- Kitamura K, Kano M (2013) Dendritic calcium signaling in cerebellar Purkinje cell. *Neural Netw* 47:11–17. doi:10.1016/j.neunet.2012.08.001
- Lamont MG, Weber JT (2012) The role of calcium in synaptic plasticity and motor learning in the cerebellar cortex. *Neurosci Biobehav Rev* 36(4):1153–1162. doi:10.1016/j.neubiorev.2012.01.005
- Lin JW, Rudy B, Llinas R (1990) Funnel-web spider venom and a toxin fraction block calcium current expressed from rat brain mRNA in *Xenopus* oocytes. *Proc Natl Acad Sci U S A* 87(12):4538–4542
- Llinas R, Sugimori M (1980) Electrophysiological properties of in vitro Purkinje cell dendrites in mammalian cerebellar slices. *J Physiol* 305:197–213
- Marchenko SM, Thomas RC (2006) Nuclear Ca<sup>2+</sup> signalling in cerebellar Purkinje neurons. *Cerebellum* (London) 5(1):36–42. doi:10.1080/14734220600554438
- Metaea MR, Newman EA (2006) Calcium signaling in specialized glial cells. *Glia* 54(7):650–655. doi:10.1002/glia.20352
- Nakamura M, Sato K, Fukaya M, Araishi K, Aiba A, Kano M, Watanabe M (2004) Signaling complex formation of phospholipase Cbeta4 with metabotropic glutamate receptor type 1 alpha and 1,4,5-trisphosphate receptor at the perisynapse and endoplasmic reticulum in the mouse brain. *Eur J Neurosci* 20(11):2929–2944. doi:10.1111/j.1460-9568.2004.03768.x
- Shigemoto R, Nakanishi S, Mizuno N (1992) Distribution of the mRNA for a metabotropic glutamate receptor (mGluR1) in the central nervous system: an in situ hybridization study in adult and developing rat. *J Comp Neurol* 322(1):121–135. doi:10.1002/cne.903220110

**Part VI**  
**Neuroimaging of the Cerebellum**

# Chapter 47

## Cerebellar Closed-Loops

Christophe Habas

**Abstract** Data from histological tracing studies in non-human primate strongly support the view that the cerebellar system is organized into distinct, motor and non-motor, parallel closed-loop circuits interconnecting the cerebellum and the cerebral cortex. Functional imaging data in human seem to confirm this specific network organization in human, and to extend the role of the cerebellum from motor control to regulation of cognition and emotion.

**Keywords** Cerebellum • Closed-loops • Tracing • Fmri • Resting-state

### 47.1 Histological Tracing in Animal Models

In the cerebellar system, cerebral cortex projects via pontine nuclei within the basis pontis to contralateral cerebellum (deep nuclei and cortex), which, in turn, sends it back projections via the thalamus. The closed-loop architecture of the cerebellar system relies on three main results. First, separate and non-overlapping territories of the dentate nuclei (DN), the main output source of the primate cerebellum, specifically target distinct thalamic and associated motor, premotor and associative cortical areas (Strick et al. 2009). In particular, cerebellar projections to prefrontal and pre-supplementary motor cortices originate in the ventral part of DN, whereas cerebellar projections to (pre-)motor cortex arise from the dorsal part of DN (Middleton and Strick 2001). Second, viral transneuronal tracing investigations in the macaque have demonstrated two closed-loops interconnecting via the dentate nucleus, motor cortex and lobules III-VI/VIII, and prefrontal cortex (BA 46) and lobule VII (crus II) (Kelly and Strick 2003). Third, except primary visual cortex and some ventrolateral prefrontal and orbitofrontal cortices, the rest of the cerebral cortex innervates the cerebellum via pontine nuclei (Schmahmann and Pandya 1997). Therefore, the cerebellum would take part in several closed-loops whose cortico-ponto-cerebellar

---

C. Habas (✉)

Service de NeuroImagerie, Centre Hospitalier National d'Ophtalmologie des Quinze-Vingts,  
Paris, France

e-mail: [chabas@quinze-vingts.fr](mailto:chabas@quinze-vingts.fr)



afferents remain to be firmly established, for major part of them, but whose efferents are successively (Clower et al. 2001; Middleton and Strick 2001; Dum and Strick 2003):

1. Dorsal DN, caudal ventrolateral thalamus, motor cortex (BA 4),
2. Lateral DN, X thalamus, lateral and medial premotor cortex (BA 6, supplementary motor area),
3. Caudal DN, X thalamus, prefrontal eye field cortex (BA 8),
4. Ventromedial DN, caudal ventrolateral and mediodorsal thalamus, dorsolateral prefrontal cortex (BA 9 medial and lateral),
5. Ventrolateral DN, caudal ventrolateral and mediodorsal thalamus, dorsolateral prefrontal cortex (BA 46 dorsal),
6. Lateral DN, caudal ventrolateral thalamus, inferior parietal cortex (BA 7b).

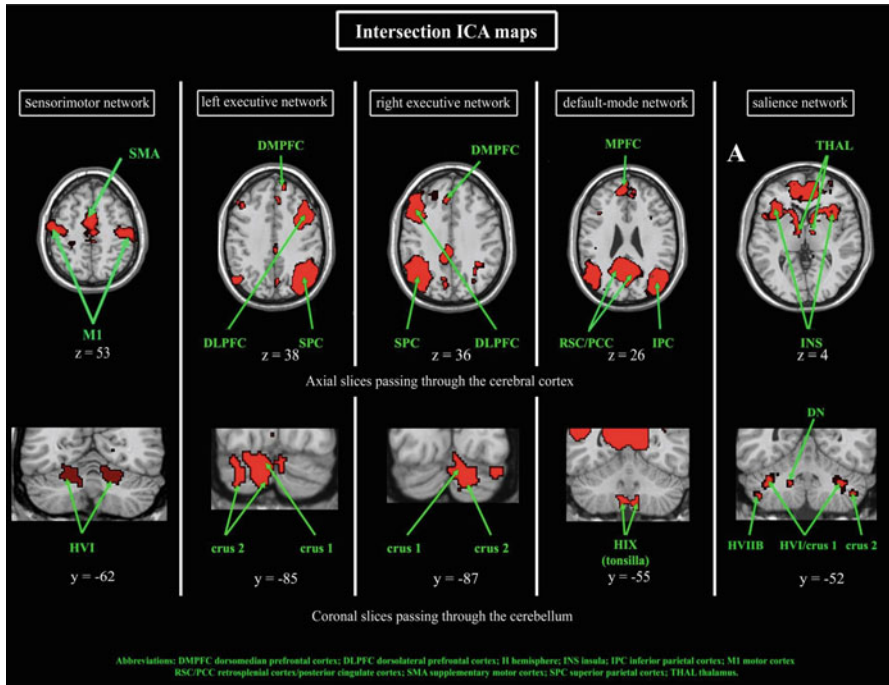
In addition to cerebello-cortical loops, cerebello-subcortical loops may exist as well, especially through reticular, red and bulbar olivary nuclei. Recently, potential motor and associative striato-cerebellar loops have been also traced: DN projects to the external pallidum via intralaminar and anterior/lateral ventral thalamus in rat (Hoshi et al. 2005), while subthalamic nucleus projects back to cerebellar cortex (crus II and lobule VIIb) via pontine nuclei in monkey (Bostan et al. 2010).

## 47.2 Functional Neuroimaging Data

Has this closed-loop organization of the cerebellar system been observed in human? Up to now, only partial arguments can be put forth in favor of such network architecture since no histological tracing data are available. Resting state functional connectivity and diffusion tensor imaging have provided some in vivo results in support of cerebellar closed-loops.

### 47.2.1 Cerebellar Subregional Connectivity

Cerebellar cortex can be parcellated into separate and non- or very narrow overlapping regions encompassing mainly sensorimotor (anterior lobe and lobule VIII), executive (lobules VI caudal, VII with crus I and II and IX) and limbic (lobule VI/VII especially the vermis) (Habas et al 2009; Krienen and Buckner 2009; O'Reilly et al. 2009; Buckner et al. 2011). It is noteworthy however that the oculomotor cerebellum must overlap part of the executive/limbic cerebellum (Voogd et al. 2012). These regions are in functional coherence with specific zones of the cerebral cortex which may represent cortico-ponto-cerebellar connections. For instance, motor and premotor cortex are linked to the sensorimotor cerebellum, and prefrontal and parietal cortex to the executive cerebellum. Moreover, functional connectivity of DN that may reflect cerebellar outputs, implicates prefrontal, temporal, cingulate and



**Fig. 47.1** The main cerebro-cerebellar networks determined by independent component analysis (ICA) applied to brain resting-state data

parietal cortices and thalamus and striatum (Allen et al. 2005; Bernard et al. 2014), in accordance with tractographic data (Habas and Cabanis 2007; Jissendi et al. 2008; Salmi et al. 2010; Palesi et al. 2015) and partly reciprocating cortical inputs.

### 47.2.2 Cerebellar Circuits

Independent component analysis-based functional connectivity has delineated specific parallel cerebro-cerebello-cortical networks including (Habas et al. 2009) (Fig. 47.1):

1. The sensorimotor network (motor and premotor cortex, cerebellar lobules V–VI and VIII),
2. The right and left executive networks (dorsolateral prefrontal and parietal prefrontal cortices, crus I and II),

3. The limbic “salience” network (frontal and insular cortices, lobules VI/VII) involved in interoception, emotional and autonomic regulation,
4. The “default-mode network” (dorsomedian prefrontal, posterior cingulate, retrosplenial and parahippocampal cortices, precuneus, lobules IX and VII) devoted to consciousness, self-agency, memory, and mental imagery.

Thus, it can be hypothesized that all these circuits may correspond to cerebellar closed-loops first identified in animals, even if further studies are still required.

### 47.3 Conclusion

Altogether, available data from animal and human studies agree with the existence of anatomical and functional well-segregated parallel cerebro-ponto-cerebello-thalamo-cortical circuits which may function as distinct modules applying a common type of computation (putatively internal models or timing function) to different mental activities from motor coordination and automation to cognition (Ramnani 2006).

### References

- Allen G, McColl R, Holly B, Ringe WK, Fleckenstein J, Cullum CM (2005) Magnetic resonance imaging of cerebellar-prefrontal and cerebellar-parietal functional connectivity. *Neuroimage* 28:39–48
- Bernard JA, Peltier SJ, Benson BI, Wiggins JL, Jaeggi SM, Buschkuhl M, Jonides J, Monk CS, Seidler RD (2014) Dissociable networks of the human dentate nucleus. *Cereb Cortex* 24:2151–2159
- Bostan AC, Dum RP, Strick PL (2010) The basal ganglia communicates with the cerebellum. *PNAS USA* 107:8452–8456
- Buckner RL, Krienen FM, Castellanos A et al (2011) The organization of the human cerebellum estimated by intrinsic functional connectivity. *J Neurophysiol* 106:1125–1165
- Clower DM, West RA, Lynch JC et al (2001) The inferior parietal lobule is the target of output from superior colliculus, hippocampus, and cerebellum. *J Neurosci* 21:6283–6291
- Dum RP, Strick PL (2003) An unfolded map of the cerebellar dentate nucleus and its projection to the cerebral cortex. *J Neurophysiol* 89:634–639
- Habas C, Cabanis EA (2007) Anatomical parcellation of the brainstem and cerebellar white matter: a preliminary probabilistic tractography study at 3 T. *Neuroradiology* 49:849–863
- Habas C, Kamdar N, Nguyen D, Prater K, Beckmann CF, Menon V, Greicius MD (2009) Distinct cerebellar contributions to intrinsic connectivity networks. *J Neurosci* 29:8586–8594
- Hoshi E, Tremblay L, Féger J, Carras PL, Strick PL (2005) The cerebellum communicates with the basal ganglia. *Nat Neurosci* 8:1491–1493
- Jissendi P, Baudry S, Balériaux D (2008) Diffusion tensor imaging (DTI) and tractography of the cerebellar projections to prefrontal and posterior parietal cortices: a study at 3 T. *J Neuroradiol* 35:42–50
- Kelly RM, Strick PL (2003) Cerebellar loops with motor cortex and prefrontal cortex of a nonhuman primate. *J Neurosci* 23: 8432–8444

- Krienen FM, Buckner RL (2009) Segregated fronto-cerebellar circuits revealed by intrinsic functional connectivity. *Cerebr Cortex* 19:2485–2497
- Middleton FA, Strick PL (2001) Cerebellar projections to the prefrontal cortex of the primate. *J Neurosci* 15:700–712
- O'Reilly JX, Beckmann CF, Tomassini V, Ramnani N, Johansen-Berg H (2009) Distinct and overlapping functional zones in the cerebellum defined by resting state functional connectivity. *Cereb Cortex* 20:953–965
- Palesi F, Tournier J-D, Calamante F et al (2015) Contralateral cerebello-thalamo-cortical pathways with prominent involvement of associative areas in humans in vivo. *Brain Struct Funct* 220:3369–3384
- Ramnani N (2006) The primate cortico-cerebellar system: anatomy and function. *Nat Rev Neurosci* 7:511–522
- Salmi J, Pallesen KJ, Neuvonen T, Brattico E, Korvenoja A, Salonen CS (2010) Cognitive and motor loops of the human cerebro-cerebellar system. *J Cogn Neurosci* 22:2663–2676
- Schmahmann JD, Pandya DN (1997) The cerebrocerebellar system. *Int Rev Neurobiol* 41:31–60
- Strick PL, Dum RP, Fiez JA (2009) Cerebellum and nonmotor function. *Annu Rev Neurosci* 32:413–434
- Voogd J, Schraa-Tam CKL, van der Geest JN et al (2012) Visuomotor cerebellum in human and non human primates. *Cerebellum* 11:392–410

# Chapter 48

## MRI Aspects: Conventional, SWI, DTI

Thomas M. Ernst, Marc Schlamann, and Dagmar Timmann

**Abstract** Despite the good quality of new generation computerized tomography (CT), magnetic resonance imaging (MRI) is the method of choice for visualization of structures within the posterior fossa and spinal canal. Different to CT bone artefacts are not a problem in MRI. The cerebellum, the brainstem and the spinal cord are shown in much more detail. This chapter will focus on structural MRI in degenerative cerebellar ataxias. These are slowly progressive degenerative disorders which involve the cerebellum and cerebellar pathways to varying extents. Structural MRI in focal cerebellar disease, such as stroke, tumors or multiple sclerosis, will not be addressed. T1 weighted MRI images have the best gray matter/white matter contrast. Therefore, T1 weighted MRI images are commonly used to reveal atrophy of the cerebellar cortex, the brainstem and spinal cord. In a subset of cerebellar ataxias there is white matter disease. Proton density (PD), T2 weighted, and fluid attenuated inversion recovery (FLAIR) MRI images are sensitive to show white matter lesions. MRI contrast enhancement is uncommon in cerebellar degeneration. Susceptibility weighted imaging (SWI) and diffusion weighted imaging (DWI), more specifically diffusion tensor imaging (DTI), are newer developments. SWI images are helpful to show abnormal brain iron deposition, but also accompanying atrophy of the iron-rich cerebellar nuclei. DTI is helpful to show changes of the integrity of cerebellar white matter and cerebellar peduncles.

**Keywords** Structural MRI • Cerebellar degeneration • White matter • Gray matter

---

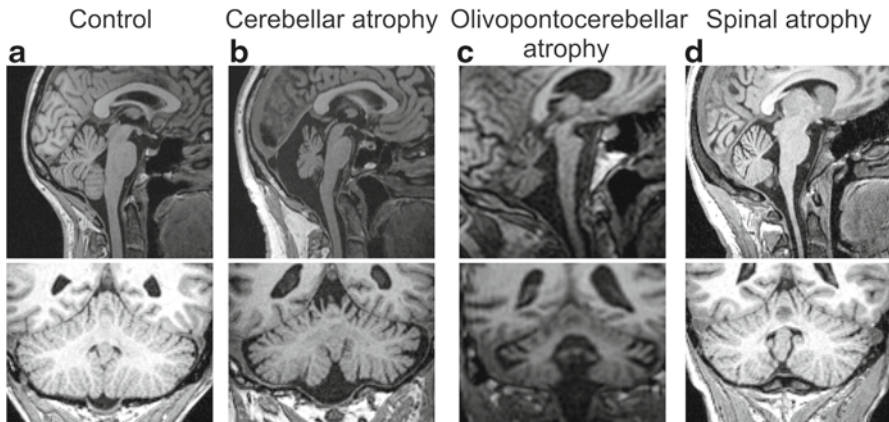
T.M. Ernst (✉) • D. Timmann  
Department of Neurology, University of Duisburg-Essen,  
Hufelandstrasse 55, 45147 Essen, Germany  
e-mail: [thomas.ernst@uk-essen.de](mailto:thomas.ernst@uk-essen.de); [dagmar.timmann-braun@uni-duisburg-essen.de](mailto:dagmar.timmann-braun@uni-duisburg-essen.de)

M. Schlamann  
Institute of Diagnostic and Interventional Radiology and Neuroradiology, University of  
Duisburg-Essen, Essen, Germany

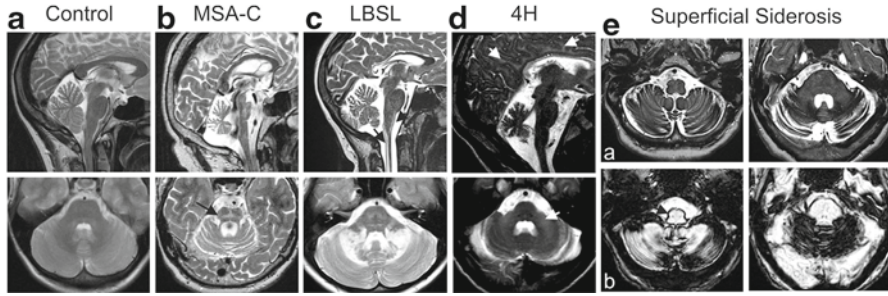
Department of Neuroradiology, University of Giessen-Marburg,  
Klinikstrasse 33, 35392 Giessen, Germany  
e-mail: [marc.schlamann@radiol.med.uni-giessen.de](mailto:marc.schlamann@radiol.med.uni-giessen.de)

## 48.1 Introduction

Despite the good quality of new generation computerized tomography (CT), magnetic resonance imaging (MRI) is the method of choice for visualization of structures within the posterior fossa and spinal canal. Different to CT bone artefacts are not a problem in MRI. The cerebellum, the brainstem and the spinal cord are shown in much more detail. This chapter will focus on structural MRI in degenerative cerebellar ataxias. These are slowly progressive degenerative disorders which involve the cerebellum and cerebellar pathways to varying extents. Structural MRI in focal cerebellar disease, such as stroke, tumors or multiple sclerosis, will not be addressed. T1 weighted MRI images have the best gray matter/white matter contrast. Therefore, T1 weighted MRI images are commonly used to reveal atrophy of the cerebellar cortex, the brainstem and spinal cord (Fig. 48.1). In a subset of cerebellar ataxias there is white matter disease. Proton density (PD), T2 weighted, and fluid attenuated inversion recovery (FLAIR) MRI images are sensitive to show white matter lesions (Fig. 48.2). MRI contrast enhancement is uncommon in cerebellar degeneration. Susceptibility weighted imaging (SWI) and diffusion weighted imaging (DWI), more specifically diffusion tensor imaging (DTI), are newer developments. SWI images are helpful to show abnormal brain iron deposition, but also accompanying atrophy of the iron-rich cerebellar nuclei. DTI is helpful to show changes of the integrity of cerebellar white matter and cerebellar peduncles.



**Fig. 48.1** Characteristic MRI patterns of degenerative cerebellar ataxias based on T1 weighted images. Sagittal views are shown in the upper row, coronal views in the lower row. (a) Healthy control subject; (b) pure cerebellar atrophy in a patient with spinocerebellar ataxia type 6 (SCA6); (c) olivopontocerebellar atrophy (OPCA) in a patient with advanced spinocerebellar ataxia type 3 (SCA3), note accompanying atrophy of the spinal cord; (d) pure atrophy of the spinal cord in a patient with Friedreich ataxia



**Fig. 48.2** Characteristic MRI abnormalities in degenerative cerebellar ataxias based on T2 weighted images (a–e) and SWI images (e). Sagittal views are shown in the upper row, axial views in the lower row in (a–d), axial views in (e). (a) Healthy control subject; (b) olivopontocerebellar atrophy (OPCA) in a patient with the cerebellar type of multiple system atrophy (MSA-C), note “hot cross bun” sign in the pons (black arrow); (c) cerebellar atrophy and white matter hyperintensities in the cerebellum and cerebellar peduncles (axial view), spinal cord (dorsal column, see lower black arrow in sagittal view) and brainstem (pyramidal tract, see upper black arrow in sagittal view) in a patient with leukoencephalopathy with brainstem and spinal cord involvement and lactate elevation (LBSL); (d) cerebellar atrophy and hyperintensities in cerebellar peduncles (white arrow in axial view) in 4H leukodystrophy, see also diffuse hypomyelination of the cerebral cortex (white arrows in sagittal view); (e) T2 (a) and SWI (b) axial images in a patient with superficial siderosis. See marked hypointensities (black signal) covering the surface of the cerebellum and brainstem (e.g. black arrow in b)

## 48.2 Brief Description of Magnetic Resonance Imaging (MRI) Sequences

In almost all modern clinical MRI the atomic nucleus of hydrogen  $^1\text{H}$ , the most abundant nuclide in the human body is used as a probe. In a strong external magnetic field hydrogen displays a small nuclear magnetization that can be specifically manipulated by an application of alternating electromagnetic fields at a specific frequency (usually radio frequency, RF). Classically, information about the sample is deduced from the system’s very small RF response following a very strong and short (that is, pulsed) RF excitation. Additional inhomogeneous magnetic fields (gradients) are applied to localize the signal’s source, allowing to subsequently scan through the sample to acquire full three dimensional information where each point in the image represents the signal of a volume element of a given size (“voxel”) (McRobbie 2007).

The decisive attribute of each image is the contrast between the relevant features displayed. In human tissues the local density of hydrogen atoms (“proton density”) and the electric environment of the individual atoms vary. By well-chosen sequential applications of RF and gradient pulses (that is, MRI sequences) this can be utilized to generate a choice of different contrasts that in combination yield a broad spectrum of information about a given biological sample. As a number of physical properties of the sample tissue influence the contrast, it is common practice to set up a sequence in such a way, that for the target tissue the influence of one of these

**Table 48.1** MR image appearance of a selection of human tissues

Tissue	Image appearance in weighted images				
	PD	T1	T2	FLAIR	T2*/SWI
CSF	Bright	Dark	Very bright	Dark	Bright
Gray matter	Bright gray	Dark gray	Bright gray	Bright gray	Bright
White matter	Dark gray	Bright gray	Dark gray	Dark gray	Bright
Fat	Bright	Very bright	Bright	Bright <sup>b</sup>	Bright
Bone	Very dark	Very dark	Very dark	Very dark	Very dark
Calcification	Dark	Dark <sup>a</sup>	Dark	Dark	Dark
Edema	Bright	Dark	Bright	Bright	Bright

CSF cerebrospinal fluid, PD proton density weighted, FLAIR fluid attenuated inversion recovery (FLAIR), SWI susceptibility weighted imaging (SWI)

<sup>a</sup>Under certain conditions bright

<sup>b</sup>In clinic practice often used with additional fat saturation. In this case: dark

properties is prominent (that is, weighting). A range of methods allow to optimize image acquisition for specific questions or to reduce the acquisition time. The pure quantity of different approaches and the accompanying – often vendor-specific – acronyms tend to confuse beginners as well as experienced MRI professionals. This is why we will focus on the most common contrasts in clinical neuroradiology practice: PD, T1, T2, including FLAIR sequences, susceptibility (SWI) and diffusion (DWI) weighting. Diffusion tensor imaging (DTI) constitutes a special case of DWI and while it is not generally an approach used in clinical practice it does allow unique insight into the anatomy of brain connectivity and is a valuable tool in research.

In PD weighted images the influence of relaxation effects is reduced and the contrast is dominated by the local density of hydrogen nuclei (“protons”). PD weighted images usually display a good gray matter/white matter contrast, but gray matter and cerebrospinal fluid (CSF) cannot be differentiated. However, they can be acquired very time efficiently and especially in the posterior fossa they are less prone to artifacts than e.g. FLAIR images (see below).

The T1 relaxation (spin-lattice relaxation) time, is the system’s time constant to return to the equilibrium following a RF excitation. In T1 weighted images long T1 times (e.g. CSF) are displayed dark, while short T1 (e.g. fat) appear bright (Table 48.1). As T1 in gray and white matter differs strongly and CSF is dark, T1 weighted images have a very good gray matter/white matter contrast. T1 can be artificially shortened by Gadolinium-based contrast agents.

The detectable macroscopic signal depends on the coherence of the microscopic magnetizations within each voxel. The loss of this spin coherence over time is another relaxation process, and can for example be caused by molecular collisions (spin-spin relaxation, T2). Most brain lesions increase the local extracellular water content, correspondingly rising T2. The relative T2 change is larger in the white matter than in the gray matter and the lesions appear hyperintense (bright) (Table 48.1). However, the dominant bright feature in the T2 weighted image is usually the



CSF. To compensate, the FLAIR sequence is set up in such a way, that signal from material with a T1 time near the T1 time of CSF is efficiently suppressed and does not contribute to the image. The result is a T2-like contrast where the CSF is displayed dark instead of bright, allowing to clearly distinguish hyperintense edema, gliosis or plaques from the CSF (Wattjes et al. 2006).

If local magnetic inhomogeneities are not compensated by the sequence applied, they reduce the effective relaxation time ( $T2^* < T2$ ). This can also be utilized to generate a  $T2^*$  weighted contrast sensitive to magnetic inhomogeneities (e.g. hemorrhages or abnormal brain iron deposition).

Differences in the magnetic susceptibility (i.e. the measure how strongly an material is magnetized by an applied magnetic field) of tissues cause phase differences between neighboring voxels, i.e. the signal of those voxels is in different stages of the oscillation cycle. In SWI this is used to increase the  $T2^*$  contrast, resulting in images with venous vessels and hemorrhages displayed prominently dark (Mittal et al. 2009). Due to their intrinsically high iron content this method is especially useful to visualize the anatomy of the cerebral and cerebellar nuclei.

Diffusion describes the undirected movement of a molecule within its surrounding. To do DWI a spatially varying magnetic pattern (gradient) is temporarily applied to the sample and consecutively inverted before the signal measurement. Stationary molecules will experience no resultant effect while molecules that moved along the direction of the gradient will be dephased and contribute the less to the signal intensity the further they moved. Thus the reduction in signal intensity is a measure for the local proton mobility. The direction of the magnetic gradient can be freely chosen. In DTI a large number of different gradient directions are applied, yielding for each voxel some directions with high and some with low molecular mobility. Arguing that water diffuses faster along the direction of nerve fibers than perpendicular to them this can be used to find the most probable fiber tracts within the white matter (tractography) (Le Bihan 2003; Smith et al. 2006).

### 48.3 T1 Weighted MRI Images

There are three main patterns of cerebellar degeneration which can be distinguished based on T1 weighted MRI images (Wüllner et al. 1993). The first pattern is “pure” cerebellar degeneration. Here MRI scans show predominant atrophy of the cerebellar cortex, with the brainstem, spinal cord and cerebrum being largely intact. Characteristic examples are spinocerebellar ataxia type 6 (SCA6; Fig. 48.1b), one of the most common autosomal dominant spinocerebellar ataxias, and sporadic adult onset ataxia of unknown etiology (SAOA). In addition, predominant cerebellar atrophy is a characteristic finding in some of the more recently described recessive spinocerebellar ataxias (spinocerebellar ataxia, autosomal recessive type 8 and 10, SCAR8 and SCAR10, with mutations in the SYNE1 and ANO10 genes, respectively; (Renaud et al. 2014; Dupré et al. 2007)).

The second pattern is cerebellar atrophy with accompanying atrophy of the brainstem, in particular the pons. This MRI pattern is called olivopontocerebellar atrophy (OPCA). The flattening of the pons is seen most easily on sagittal views (Fig. 48.1c). Examples are spinocerebellar ataxia type 1 and 2 (SCA1, SCA2), and the cerebellar type of multiple system atrophy (MSA-C) (Bürk et al. 1996). In spinocerebellar ataxia type 3 (SCA3), OPCA is often less prominent, and enlargement of the fourth ventricle is a characteristic finding. In SCA1, 2 and 3 there is accompanying atrophy of the spinal cord.

The third pattern is predominant atrophy of the spinal cord with the brainstem and cerebellum being largely intact (Fig. 48.1d). The best known example is Friedreich ataxia (Klockgether et al. 1991). Brain scans in Friedreich ataxia show atrophy of the visible part of the cervical spinal cord. Cerebellar atrophy is uncommon in Friedreich ataxia.

The degree of cerebellar, brainstem and spinal atrophy can be quantified using conventional volumetry and voxel-based morphometry (VBM) (Schulz et al. 2010). Both require further computations, and are not part of the clinical routine. Furthermore, VBM is performed at the group level. As yet, few studies have tried to analyze degeneration on the level of individual cerebellar lobules. The pattern of degeneration of individual cerebellar lobules appears to be different between patients with pure cerebellar degeneration (SCA6, SAOA), and patients with OPCA (SCA1,2) (Jung et al. 2012).

#### **48.4 T2 Weighted, Proton Density (PD) Weighted and FLAIR MRI Images**

Many of the degenerative cerebellar ataxias are disorders of the gray matter, and much of the pathology is seen on T1 weighted MRI images. There is, however, a subset of cerebellar ataxias which are accompanied by white matter abnormalities in conventional MRI images (Wolf 2012). White matter abnormalities are seen as hyperintensities (brighter signal) in T2, PD and FLAIR images. Some patterns of white matter disease are suggestive of certain types of ataxias.

The most frequent ataxia, which is accompanied by typical white matter abnormalities, is likely the cerebellar type of multiple system atrophy (MSA-C). Here, hyperintensities are present in the pons (“hot cross bun” sign; Fig. 48.2b) and the middle cerebellar peduncles (Schulz et al. 1994). Note that additional hypointensities (darker signal) in T1 weighted images can be present in the basal ganglia. Hyperintensities in T2, FLAIR and PD MRI images reflect degeneration and gliosis of pontocerebellar fibers. They develop only later in the disease. Although a “hot cross bun” sign is highly suggestive of MSA-C, it can be present in other spinocerebellar ataxias (SCAs) as well. Likewise, hyperintensities in the middle cerebellar peduncles are not specific to MSA-C. They are, for example, also a characteristic finding in fragile X tremor/ataxia syndrome (FXTAS; “MCP”-sign) (Brown and

Stanfield 2015), an adult onset genetic leukoencephalopathy, and leukoencephalopathy with brainstem and spinal cord involvement and lactate elevation (LBSL, see below; Fig. 48.2c) (Wolf 2012). Furthermore, hyperintensities in the middle cerebellar peduncles accompanied by linear pontine hypointensities are characteristic findings in autosomal recessive spastic ataxia of Charlevoix Saguenay (ARSACS).

Many inherited metabolic leukodystrophies can present with accompanying MRI hyperintensities in the cerebellar white matter (for example, metachromatic leukodystrophy and adrenoleukodystrophy; note that contrast enhancement occurs in the latter) or in the region of the dentate nuclei (for example, Krabbe disease and cerebrotendinous xanthomatosis) (Wolf 2012). Hyperintense signal in the region of the dentate nuclei can also be found in Wilson disease and the neurodegenerative form of Langerhans cell histiocytosis (Prosch et al. 2007).

There are other leukodystrophies (which are by definition hereditary disorders) in which ataxia can be one of the presenting symptoms (Vanderver et al. 2015). One example is LBSL (DARS2 gene mutation; Fig. 48.2c). In LBSL a characteristic MRI pattern can be found with hyperintensities of the pyramidal tract, sensory tracts, cerebellar peduncles and cerebellar white matter (with accompanying cerebellar atrophy). Another example is 4H leukodystrophy caused by POLR3A and POLR3B mutations with hyperintense cerebellar white matter and cerebellar atrophy (4H = hypomyelination, hypodontia, and hypogonadotropic hypogonadism; Fig. 48.2d).

In addition, many mitochondrial disorders can be accompanied by white matter abnormalities of the cerebellum and brainstem including POLG-associated ataxia (that is, mutations in the mitochondrial DNA polymerase gamma, POLG) (Kohlschütter et al. 2010).

More comprehensive lists of leukodystrophies and genetic leukoencephalopathies with ataxia can be found in (Wolf 2012; Vanderver et al. 2015; Kinghorn et al. 2013). As a rule of thumb none of these disorders are pure cerebellar diseases.

## 48.5 T2\* MRI Images

Increased iron deposition leads to hypointensities (darker signal) on T2 weighted images. Iron-related hypointensities are most easily observed in T2\* weighted images or SWI images. Superficial siderosis of the central nervous system (CNS) has a very characteristic pattern in T2 and T2\* weighted images (Wang and Gong 2011). Caused by chronic hemorrhage, hemosiderin deposition in the subpial layers presents as hypointensities alongside the surface of the brain and spinal cord. One common site is the surface of the cerebellum (Fig. 48.2e). Of note, superficial siderosis can easily be missed on CT scans. Common neurological manifestations are cerebellar ataxia and hearing loss.

Syndromes of neurodegeneration with brain iron accumulation (NBIA) are genetic disorders with abnormal iron deposition within the basal ganglia (Tonekaboni and Mollamohammadi 2014). Although ataxia and cerebellar atrophy accompany

some of the known NBIA, increased iron deposition within the cerebellum is rare. Hypointense dentate nuclei can be observed in aceruloplasminemia.

Susceptibility weighted imaging (SWI) has recently been applied to visualize the iron-rich cerebellar nuclei and to assess their volume in hereditary ataxias. Atrophy of the dentate nuclei was found in SCA3 and Friedreich ataxia, but also SCA6 (Stefanescu et al. 2015). In addition to visualization of the cerebellar nuclei, T2\* imaging and further developments such as quantitative susceptibility mapping (QSM) can be used to quantify iron content. This is of potential interest in disorders with known iron dysmetabolism, for example in Friedreich ataxia (but see also (Solbach et al. 2014)).

## 48.6 DTI Images

Diffusion tensor imaging (DTI) is used to quantify the integrity of white matter and white matter pathways (Smith et al. 2006; Assaf and Pasternak 2008). Most commonly, maps of the fractional anisotropy (FA), apparent diffusion coefficient (ADC), or radial diffusion are computed. Regarding cerebellar disease, DTI allows to quantify the integrity of the cerebellar white matter and cerebellar peduncles. Different to T1, T2 and T2\* weighted images, which are visually analyzed by the neuroradiologist, DTI requires further computations and, as yet, is not part of the clinical routine. DTI studies, however, reveal consistent abnormalities in hereditary and non-hereditary cerebellar ataxias. For example, FA has been found to be reduced in SCA1,2,3, Friedreich ataxia, SAOA and MSA-C (Prakash et al. 2009; Clemm von Hohenberg et al. 2013). FA, ADC, and radial diffusion, however, do not permit to assign the cause of possible changes. More recent developments, such as neurite orientation dispersion and density imaging (NODDI; Zhang et al. 2012) allow to quantify axonal damage.

## 48.7 Conclusions and Outlook

Structural T1 weighted MRI is a powerful diagnostic tool to reveal cerebellar degeneration. Signal abnormalities in T2, FLAIR, proton density and T2\* weighted MRI images can be of additional help to determine the diagnosis. T1 weighted MRI, however, may be inconclusive at early stages of the disease. Reasons are the slowly progressive course of many degenerative cerebellar ataxias and significant variability between individual healthy subjects including normal aging. Future studies are needed to evaluate whether newer developments, such as voxel-based or semiautomatic conventional volumetric measures of the cerebellar cortex and nuclei, MRI measures of iron content of the cerebellar nuclei and/or DTI parameters of white matter integrity, are more sensitive to reveal early changes of the disease. Likewise,

these measures may be useful as biomarkers to monitor the natural progression of the disease and treatment effects (Baldaçara et al. 2015).

## References

- Assaf Y, Pasternak O (2008) Diffusion tensor imaging (DTI)-based white matter mapping in brain research: a review. *J Mol Neurosci* 34:51–61
- Baldaçara L, Currie S, Hadjivassiliou M, Hoggard N, Jack A, Jackowski AP, Mascalchi M, Parazzini C, Reetz K, Righini A, Schulz JB, Vella A, Webb SJ, Habas C (2015) Consensus paper: radiological biomarkers of cerebellar diseases. *Cerebellum* 14:175–196
- Brown SS, Stanfield AC (2015) Fragile X premutation carriers: a systematic review of neuroimaging findings. *J Neurol Sci* 352:19–28
- Bürk K, Abele M, Fetter M, Dichgans J, Skalej M, Laccone F, Didierjean O, Brice A, Klockgether T (1996) Autosomal dominant cerebellar ataxia type I clinical features and MRI in families with SCA1, SCA2 and SCA3. *Brain* 119:1497–1505
- Clemm von Hohenberg C, Schocke MF, Wigand MC, Nachbauer W, Guttmann CR, Kubicki M, Shenton ME, Boesch S, Egger K (2013) Radial diffusivity in the cerebellar peduncles correlates with clinical severity in Friedreich ataxia. *Neurol Sci* 34:1459–1462
- Dupré N, Gros-Louis F, Chrestian N, Verreault S, Brunet D, de Verteuil D, Brais B, Bouchard JP, Rouleau GA (2007) Clinical and genetic study of autosomal recessive cerebellar ataxia type 1. *Ann Neurol* 62:93–98
- Jung BC, Choi SI, Du AX, Cuzzocreo JL, Geng ZZ, Ying HS, Perlman SL, Toga AW, Prince JL, Ying SH (2012) Principal component analysis of cerebellar shape on MRI separates SCA types 2 and 6 into two archetypal modes of degeneration. *Cerebellum* 11:887–895
- Kinghorn KJ, Kaliakatsos M, Blakely EL, Taylor RW, Rich P, Clarke A, Omer S (2013) Hypertrophic olivary degeneration on magnetic resonance imaging in mitochondrial syndromes associated with POLG and SURF1 mutations. *J Neurol* 260:3–9
- Klockgether T, Petersen D, Grodd W, Dichgans J (1991) Early onset cerebellar ataxia with retained tendon reflexes. Clinical, electrophysiological and MRI observations in comparison with Friedreich's ataxia. *Brain* 114:1559–1573
- Kohlschütter A, Bley A, Brockmann K, Gärtner J, Krägeloh-Mann I, Rolfs A, Schöls L (2010) Leukodystrophies and other genetic metabolic leukoencephalopathies in children and adults. *Brain Dev* 32:82–89
- Le Bihan D (2003) Looking into the functional architecture of the brain with diffusion MRI. *Nat Rev Neurosci* 4:469–480
- McRobbie DW (2007) MRI from picture to proton, 2nd edn. Cambridge University Press, Cambridge, UK
- Mittal S, Wu Z, Neelavalli J, Haacke EM (2009) Susceptibility-weighted imaging: technical aspects and clinical applications, part 2. *AJNR Am J Neuroradiol* 30:232–252
- Prakash N, Hageman N, Hua X, Toga AW, Perlman SL, Salamon N (2009) Patterns of fractional anisotropy changes in white matter of cerebellar peduncles distinguish spinocerebellar ataxia-1 from multiple system atrophy and other ataxia syndromes. *Neuroimage* 47(Suppl 2):T72–T81
- Prosch H, Grois N, Wnorowski M, Steiner M, Prayer D (2007) Long-term MR imaging course of neurodegenerative Langerhans cell histiocytosis. *AJNR Am J Neuroradiol* 28:1022–1028
- Renaud M, Anheim M, Kamsteeg EJ, Mallaret M, Mochel F, Vermeer S, Drouot N, Pouget J, Redin C, Salort-Campana E, Kremer HP, Verschuuren-Bemelmans CC, Muller J, Scheffer H, Durr A, Tranchant C, Koenig M (2014) Autosomal recessive cerebellar ataxia type 3 due to ANO10 mutations: delineation and genotype-phenotype correlation study. *JAMA Neurol* 71:1305–1310

- Schulz JB, Klockgether T, Petersen D, Jauch M, Müller-Schauenburg W, Spieker S, Voigt K, Dichgans J (1994) Multiple system atrophy: natural history, MRI morphology, and dopamine receptor imaging with 123IBZM-SPECT. *J Neurol Neurosurg Psychiatry* 57:1047–1056
- Schulz JB, Borkert J, Wolf S, Schmitz-Hübsch T, Rakowicz M, Mariotti C, Schöls L, Timmann D, van de Warrenburg B, Dürr A, Pandolfo M, Kang JS, Mandly AG, Nägele T, Grisoli M, Boguslawska R, Bauer P, Klockgether T, Hauser TK (2010) Visualization, quantification and correlation of brain atrophy with clinical symptoms in spinocerebellar ataxia types 1, 3 and 6. *Neuroimage* 49:158–6
- Smith SM, Jenkinson M, Johansen-Berg H, Rueckert D, Nichols TE, Mackay CE, Watkins KE, Ciccarelli O, Cader MZ, Matthews PM, Behrens TE (2006) Tract-based spatial statistics: voxelwise analysis of multi-subject diffusion data. *Neuroimage* 31:1487–1505
- Solbach K, Kraff O, Minnerop M, Beck A, Schöls L, Gizewski ER, Ladd ME, Timmann D (2014) Cerebellar pathology in Friedreich's ataxia: atrophied dentate nuclei with normal iron content. *NeuroImage Clin* 6:93–99
- Stefanescu MR, Dohnalek M, Maderwald S, Thürling M, Minnerop M, Beck A, Schlamann M, Diedrichsen J, Ladd ME, Timmann D (2015) Structural and functional magnetic resonance imaging abnormalities of cerebellar cortex and nuclei in spinocerebellar ataxia type 3, spinocerebellar ataxia type 6, and Friedreich's ataxia. *Brain* 138:1182–1197
- Tonekaboni SH, Mollamohammadi M (2014) Neurodegeneration with brain iron accumulation: an overview. *Iran J Child Neurol* 8:1–8
- Vanderver A, Prust M, Tonduti D, Mochel F, Hussey HM, Helman G, Garbern J, Eichler F, Labauge P, Aubourg P, Rodriguez D, Patterson MC, Van Hove JL, Schmidt J, Wolf NI, Boespflug-Tanguy O, Schiffmann R, van der Knaap MS, GLIA Consortium (2015) Case definition and classification of leukodystrophies and leukoencephalopathies. *Mol Genet Metab* 114:494–500
- Wang J, Gong X (2011) Superficial siderosis of the central nervous system: MR findings with susceptibility-weighted imaging. *Clin Imaging* 35:217–221
- Wattjes M, Lutterbey G, Harzheim M, Gieseke J, Träber F, Klotz L, Klockgether T, Schild H (2006) Imaging of inflammatory lesions at 3.0 Tesla in patients with clinically isolated syndromes suggestive of multiple sclerosis: a comparison of fluid-attenuated inversion recovery with T2 turbo spin-echo. *Eur Radiol* 16:1494–1500
- Wolf NI (2012) Ataxia in metabolic and white matter disorders. In: Boltshauser E, Schmähmann J (eds) *Cerebellar disorders in children*. Clinics in developmental medicine No. 191–192. Mac Keith Press, London, pp 269–281
- Wüllner U, Klockgether T, Petersen D, Naegele T, Dichgans J (1993) Magnetic resonance imaging in hereditary and idiopathic ataxia. *Neurology* 43:318–325
- Zhang H, Schneider T, Wheeler-Kingshott CA, Alexander DC (2012) NODDI: practical in vivo neurite orientation dispersion and density imaging of the human brain. *Neuroimage* 61:1000–1016

# Chapter 49

## SPECT and PET

**Martina Minnerop**

**Abstract** Both single photon emission computed tomography (SPECT) and positron emission tomography (PET) are tomographic imaging procedures using tracers to facilitate the evaluation of disease processes. Numerous PET and SPECT studies have been performed in disorders or conditions involving the cerebellum, focussing on changes of regional glucose metabolism, cerebral blood flow or receptor binding. While these methods allow studying specific functional and metabolic changes in detail, their spatial resolution is lower than that of MRI; anatomical localisation of the observed cerebellar changes using these methods often lacks precision. Their value for differential diagnosis of cerebellar disorders mainly depends on characterizing disease-specific patterns of involved extracerebellar brain structures. However, next to the investigation of disease-related functional changes, SPECT and in particular PET studies support detecting target structures for potential therapeutic interventions and visualising therapeutic effects.

**Keywords** SPECT • PET • Tracer • FDG • Receptor binding

### 49.1 Technical Aspects of SPECT and PET

The major molecular imaging modalities used in nuclear medicine are positron emission tomography (PET) and single photon emission computed tomography (SPECT) with PET having a higher sensitivity than SPECT. Both are tomographic imaging procedures facilitating by the use of radioactive-labelled tracers the evaluation of disease processes based on functional and metabolic information of organs and cells (Rahmim and Zaidi 2008; Jones et al. 2012). Radiopharmaceuticals relevant for the cerebellum are listed in Table 49.1.

The wide spread use of PET and SPECT for investigating brain functions and disorders in humans can be grouped into three distinct applications: (1) PET and SPECT studies investigating regional cerebral blood flow (rCBF), (2) PET studies

---

M. Minnerop (✉)

Institute of Neuroscience and Medicine (INM-1), Research Centre Juelich, Juelich, Germany  
e-mail: [m.minnerop@fz-juelich.de](mailto:m.minnerop@fz-juelich.de)

**Table 49.1** SPECT and PET radiotracers relevant for the cerebellum

Radiotracer	Abbreviation	Target class	Specific target
<b>SPECT</b>			
[ <sup>99m</sup> Tc]hexamethylpropylene-amine oxime	[ <sup>99m</sup> Tc]HMPAO	Blood flow	Cell components (exact target unknown)
[ <sup>123</sup> I]iomazenil	[ <sup>123</sup> I]IMZ	Receptor	Central benzodiazepine receptor (GABA receptor)
[ <sup>123</sup> I]5IA-85380	[ <sup>123</sup> I]5IA-85380	Receptor	Nicotinic acetylcholine receptor
<b>PET</b>			
2-[ <sup>18</sup> F]Fluoro-2-deoxy-D-glucose	[ <sup>18</sup> F]FDG	Glucose metabolism	Glucose utilization
[ <sup>15</sup> O]water	[ <sup>15</sup> O]H <sub>2</sub> O	Blood flow	Oxygen utilization
[ <sup>11</sup> C]flumazenil	[ <sup>11</sup> C]FMZ	Receptor	Central benzodiazepine receptors (GABA receptor)
2-[ <sup>18</sup> F]A-85380	[ <sup>18</sup> F]A-85380	Receptor	Nicotinic acetylcholine receptor (nAChR)
[ <sup>11</sup> C]N-methylpiperidin-4-yl propionate	[ <sup>11</sup> C]PMP	Receptor	Acetylcholinesterase (AChE)
[ <sup>11</sup> C]α-methyl-L-tryptophan	[ <sup>11</sup> C]AMT	Receptor	Serotonin synthesis/tryptophan activity
N-[2-(3-cyano-phenyl)-3-(4-(2-[ <sup>18</sup> F]-fluorethoxy)phenyl)-1-methylpropyl]-2-(5-methyl-2-pyridyloxy)-2-methylpropanamide	[ <sup>18</sup> F]CB1	Receptor	Cannabinoid receptor CB1

investigating glucose metabolism, and (3) PET and SPECT studies investigating receptor binding.

## 49.2 Cerebellar Regional Blood Flow (rCBF)

### 49.2.1 Cerebellar Disorders

Several studies demonstrate abnormal rCBF in the cerebellum and elsewhere in patients with acute or chronic ataxia (Mascalchi and Vella 2012). This includes patients with SCA3, SCA6, FRDA, EOCA, AT, superficial siderosis, sporadic OPCA, MSA-C and ILOCA; in the latter even correlating with frontal lobe hypo-perfusion. For SCA3 and FRDA the cerebellar hypo-perfusion does not correlate with cerebellar atrophy, while for SCA6 cerebellar hypo-perfusion is associated with cerebellar atrophy and clinical parameters.

The results of SPECT perfusion studies investigating acute cerebellitis are controversial. Some studies report diffusely decreased rCBF in the cerebellum. Others document increased perfusion in the acute stage of paraneoplastic cerebellar



degeneration and in gluten ataxia after treatment with intravenous immunoglobulin therapy; this exhibited a trend towards correlation with clinical improvement in gluten ataxia.

Another SPECT perfusion study indicates that thyrotropin-releasing hormone therapy may increase cerebellar rCBF in SCA6 patients and patients with LOCA and CCA, but not in MSA-C.

### ***49.2.2 Other Movement Disorders***

Cerebellar rCBF is increased in various forms of tremor. Ethanol intake in essential tremor patients responding to ethanol leads to a bilateral decrease of cerebellar blood flow and is associated with tremor suppression (Deuschl and Elble 2000). In patients with Parkinson's disease (PD) treated with deep brain stimulation of the subthalamic nucleus (STN-DBS) a decrease of the cerebellar rCBF is observed. Furthermore, while PD patients show an under-activation of the cerebellum when speaking, this normalises after STN-DBS according to another PET study (Ballanger et al. 2009). In primary and tardive dystonia an elevated cerebellar rCBF was observed and DBS reduced cerebellar rCBF in tardive dystonia (Ballanger et al. 2009).

### ***49.2.3 Stroke***

Unilateral cerebellar hypo-perfusion can result from direct vascular damage to one of the cerebellar arteries, crossed cerebellar hypo-perfusion after ischaemic stroke of the contralateral cerebral hemisphere or chronic contralateral major cerebral arterial occlusive disease (Baron et al. 1981; Matsumoto et al. 2013).

### ***49.2.4 Psychiatric Disorders***

Next to abnormalities in other brain regions the cerebellum is shown to be involved in several psychiatric disorders. Cerebellar hypo-perfusion is found in attention deficit hyperactivity disorder patients; involving the more medial part of cerebellar cortices in one study and associated with the degree of motor impairment and cognitive test results in another (Di Tommaso 2012). Hypo-perfusion within cerebellar hemispheres is also observed in autism (Rumsey and Ernst 2000). In contrast, hyper-perfusion is observed in depression (anterior cerebellum) and in tics (Fitzgerald et al. 2008; Neuner et al. 2013). Imaging addiction, Marijuana-induced changes in time sense are associated with altered rCBF, and after high doses rCBF is increased. However, it has to be taken into account that measuring rCBF may be confounded by the vasoactive properties of marijuana (Volkow et al. 2003).

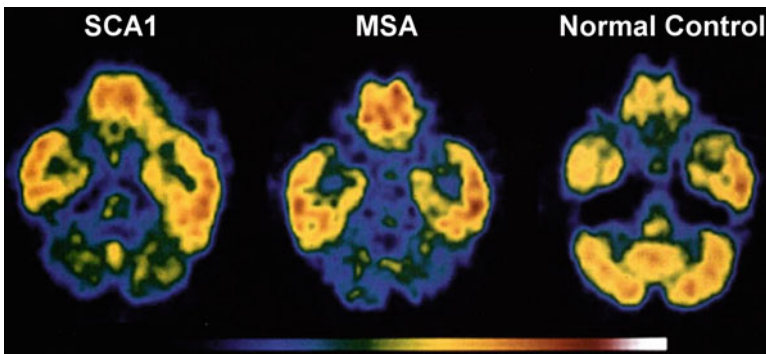
### 49.2.5 Cognition

With functional MRI increasingly widely available, rCBF PET studies requiring radiotracer injections to elucidate the role of the cerebellum (and other brain regions) in cognition are decreasing. However, several PET studies demonstrate significance of the (lateral) cerebellum in a variety of cognitive domains as well as in musical performance, processing of musical rhythm and pitch discrimination (Cabeza and Nyberg 2000; Parsons 2001).

## 49.3 Cerebellar Glucose Metabolism

### 49.3.1 Cerebellar Disorders

Most PET studies in patients with cerebellar disorders use FDG to investigate glucose metabolism and often demonstrate cerebellar hypo-metabolism in variable combination with further regions with reduced glucose consumption (Mascalchi and Vella 2012). This holds true for inherited and sporadic OPCA, MSA, SCA1,2,3,6,17, EOCA, paraneoplastic cerebellar degeneration and alcoholic cerebellar degeneration (superior cerebellar vermis) (Fig. 49.1). Cerebellar hypo-metabolism is also observed in asymptomatic carriers of SCA2 and SCA3 mutations and correlates with clinical features in inherited or sporadic OPCA. In FRDA patients with mild to moderate impairment a diffuse hyper-metabolism is described,



**Fig. 49.1** The PET scans reveal reduced glucose metabolism in a 72-year-old male with SCA1 (*left image*), a 68-year-old male with MSA (diagnosis confirmed post mortem, *middle image*) and a 74-year-old male control subject (*right image*). The scans show horizontal sections at the level of the cerebellum and the base of the temporal and frontal lobes. The *colour bar* indicates the relative rate of glucose metabolism for all scans illustrated, with colours at the right end of the scale indicating high rates and at the left end low rates. The scans of the patients with SCA1 and MSA show reduced glucose metabolism in the cerebellum and brainstem as compared to the control subject (Reprinted from Gilman et al. (1996))

while patients with more severe deficits show either a normal pattern or regional hypo-metabolism, including the cerebellum. The diffuse hyper-metabolism in (early) FRDA is a distinctive pattern and has been explained by the abnormalities in the mitochondrial function caused by the genetic defect of FRDA. For the acute stage of paraneoplastic cerebellar degeneration and Wernicke encephalopathy cerebellar hyper-metabolism is described; the latter decreases with recovery of cerebellar function. FDG uptake at rest and during gait is measured in patients with OPCA in the early phase, revealing hyper-metabolism during walk in the posterior cerebellar lobe (and brainstem) as compared with healthy controls. This data might suggest compensatory mechanisms for the instability during ataxic gait.

### ***49.3.2 Other Movement Disorders***

In PD patients receiving treatment (L-dopa infusion or DBS) a decline of regional glucose metabolism – including cerebellar vermis – is observed (Ballanger et al. 2009).

### ***49.3.3 Psychiatric Disorders***

Depression is associated with hyper-metabolism in the anterior cerebellum (Fitzgerald et al. 2008) and marijuana abuse with cerebellar hypo-metabolism (Volkow et al. 2003).

## **49.4 Cerebellar Receptor Binding**

### ***49.4.1 Cerebellar Disorders***

Several studies investigating patients with cerebellar disorders apply various SPECT and PET tracers, including those binding within the dopaminergic system. Due to lack of respective binding sites within the cerebellum these studies only detect extracerebellar disease related changes. [<sup>123</sup>I]IMZ SPECT in SCA3 patients find decreased binding within the cerebellum, suggesting that GABAergic function may be impaired. Further [<sup>11</sup>C]FMZ PET studies observe reduced binding within cerebellum (and brainstem) in patients with sporadic OPCA, MSA-C (not MSA-P), EOCA and alcoholic cerebellar degeneration (cerebellar vermis). In contrast, benzodiazepine receptor distribution in SCA1 and FRDA is normal. One study demonstrates a significant decrease of AchE in the posterior lobe of the cerebellar cortex in MSA-C

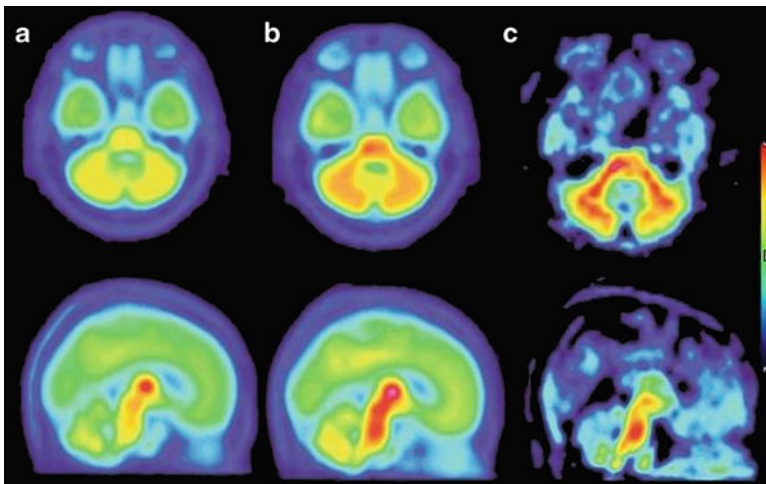
patients, suggesting that cholinergic modulating drugs may be helpful (Mascalchi and Vella 2012).

#### 49.4.2 Other Movement Disorders

In Huntington disease a decreased uptake for type 1 cannabinoid receptor has been found inter alia within the cerebellum (van Laere et al. 2010).

#### 49.4.3 Psychiatric Disorders

In Autism focal abnormalities of the serotonergic function, including elevated serotonin synthesis in the cerebellum (dentate nuclei) has been shown with [ $^{11}\text{C}$ ] AMT-PET (Rumsey and Ernst 2000). The nicotinic acetylcholine receptors  $\alpha 4\beta 2$ , present throughout the entire human brain, is prominently upregulated in chronic nicotine abuse, leading to an increased cerebellar uptake of the PET tracer 2- $^{18}\text{F}$  A-85380 in chronic smokers (Wüllner et al. 2008; Fig. 49.2). Further [ $^{123}\text{I}$ ]5IA-85380 SPECT studies show that the upregulation declines again to levels of non-smokers over the first 3 weeks of smoking cessation (Mamede et al. 2007).



**Fig. 49.2** Summation images of PET scans targeting the nicotinic AChR. (a) Non-smoker, (b) smoker, (c) Subtraction image (smoker vs. non-smoker). The colour-coded scale corresponds to distribution volume values 0–9.5 (min-max) of the tracer. A pronounced increase of [ $^{18}\text{F}$ ]-A85380 uptake in the cerebellum and brainstem in smokers is visible (Reprinted from Wüllner et al. (2008))

## References

- Ballanger B, Jahanshahi M, Broussolle E et al (2009) PET functional imaging of deep brain stimulation in movement disorders and psychiatry. *J Cereb Blood Flow Metab* 29:1743–1754
- Baron JC, Bousser MG, Comar D et al (1981) “Crossed cerebellar diaschisis” in human supratentorial brain infarction. *Trans Am Neurol Assoc* 105:459–461
- Cabeza R, Nyberg L (2000) Imaging cognition II: an empirical review of 275 PET and fMRI studies. *J Cogn Neurosci* 12:1–47
- Deuschl G, Elble RJ (2000) The pathophysiology of essential tremor. *Neurology* 54:S14–S20
- Di Tommaso MC (2012) A comparative study of bipolar disorder and attention deficit hyperactivity disorder through the measurement of regional cerebral blood flow. *J Biol Regul Homeost Agents* 26:1–6
- Fitzgerald PB, Laird AR, Maller J et al (2008) A meta-analytic study of changes in brain activation in depression. *Hum Brain Mapp* 29:683–695
- Gilman et al (1996) Spinocerebellar ataxia type 1 with multiple system degeneration and glial cytoplasmic inclusions. *Ann Neurol* 39:241–255
- Jones T, Rabiner EA, PET Research Advisory Company (2012) The development, past achievements, and future directions of brain PET. *J Cereb Blood Flow Metab* 32:1426–1454
- Mamede M, Ishizu K, Ueda M et al (2007) Temporal change in human nicotinic acetylcholine receptor after smoking cessation: 5IA SPECT study. *J Nucl Med* 48:1829–1835
- Mascalchi M, Vella A (2012) Magnetic resonance and nuclear medicine imaging in ataxias. *Handb Clin Neurol* 103:85–110
- Matsumoto Y, Ogasawara K, Saito H et al (2013) Detection of misery perfusion in the cerebral hemisphere with chronic unilateral major cerebral artery steno-occlusive disease using crossed cerebellar hypoperfusion: comparison of brain SPECT and PET imaging. *Eur J Nucl Med Mol Imaging* 40:1573–1581
- Neuner I, Schneider F, Shah NJ (2013) Functional neuroanatomy of tics. *Int Rev Neurobiol* 112:35–71
- Parsons LM (2001) Exploring the functional neuroanatomy of music performance, perception, and comprehension. *Ann N Y Acad Sci* 930:211–231
- Rahmim A, Zaidi H (2008) PET versus SPECT: strengths, limitations and challenges. *Nucl Med Commun* 29:193–207
- Rumsey JM, Ernst M (2000) Functional neuroimaging of autistic disorders. *Ment Retard Dev Disabil Res Rev* 6:171–179
- Van Laere K, Casteels C, Dhollander I et al (2010) Widespread decrease of type 1 cannabinoid receptor availability in Huntington disease in vivo. *J Nucl Med* 51:1413–1417
- Volkow ND, Fowler JS, Wang GJ (2003) Positron emission tomography and single-photon emission computed tomography in substance abuse research. *Semin Nucl Med* 33:114–128
- Wüllner U, Gündisch D, Herzog H et al (2008) Smoking upregulates alpha4beta2\* nicotinic acetylcholine receptors in the human brain. *Neurosci Lett* 430:34–37

# Chapter 50

## MR Spectroscopy

Vladimír Mlynárik

**Abstract** Localized *in vivo* magnetic resonance spectroscopy (MRS) is useful for obtaining information on brain metabolism. Many neurological diseases are associated with more or less specific changes of metabolite concentrations, which can be determined from integral peak intensities in MR spectra. The normal neurochemical profile and its changes in pathological conditions including spinocerebellar ataxias, other neurological diseases and psychiatric disorders were measured *in vivo* on series of patients and compared with normal values obtained on control subjects. It was shown that changes in cerebellar concentrations of some metabolites could be used as markers for the diagnosis and follow-up of diseases.

**Keywords** MR spectroscopy of human cerebellum • Normal neurochemical profile • Neurochemical profile in cerebellar ataxias • Neurochemical profile in psychiatric disorders

### 50.1 Introduction

MR spectroscopy provides information on metabolic composition of a brain structure in normal or pathological condition. The MR signal is acquired from a preselected volume of interest in an organ. Since the integral intensity of spectroscopic lines is proportional to the amount of specific hydrogen atoms in the volume, peak intensities can be used for estimating concentrations of a series of metabolites.

In spectroscopic methods based on spin echo, a time delay between excitation of the MR signal and its acquisition is called echo time (TE). With localization methods having TE longer than 20–30 ms, spectroscopic peaks having multiplet structure are distorted and their detection and quantification is difficult. In addition, intensity of spectroscopic peaks decays exponentially during TE with the T<sub>2</sub> relaxation time specific for each type of hydrogen atoms. Thus, methods utilizing long

---

V. Mlynárik (✉)

High Field MR Center, Department of Biomedical Imaging and Image-guided Therapy,  
Medical University of Vienna, Waehringer Guertel 18-20, 1090 Vienna, Austria  
e-mail: [vladimir.mlynarik@meduniwien.ac.at](mailto:vladimir.mlynarik@meduniwien.ac.at)

TE provide only integral ratios of peaks, in most cases ratios of singlets of N-acetylaspartate (NAA), creatine + phosphocreatine (total creatine, tCr) and choline-containing compounds (Cho).

## 50.2 Normal Metabolic Profile of Cerebellum

Absolute and relative concentrations of NAA, Cho, myo-inositol (mI), glutamine (Gln), and glutamate (Glu) in cerebellum are found to be similar with those previously reported in cerebrum. The concentration of tCr is markedly higher in cerebellar hemisphere than in other brain regions, which might be related to higher neural cell density (Minati et al. 2010). In a high field study of Öz and Tkáč (2011), absolute concentrations of 14 metabolites in vermis and 11 in hemispheres are reported. Along with the increased tCr, a higher cerebellar concentration of Cho and a high level of mI in the vermis compared to cerebral grey and white matter are observed.

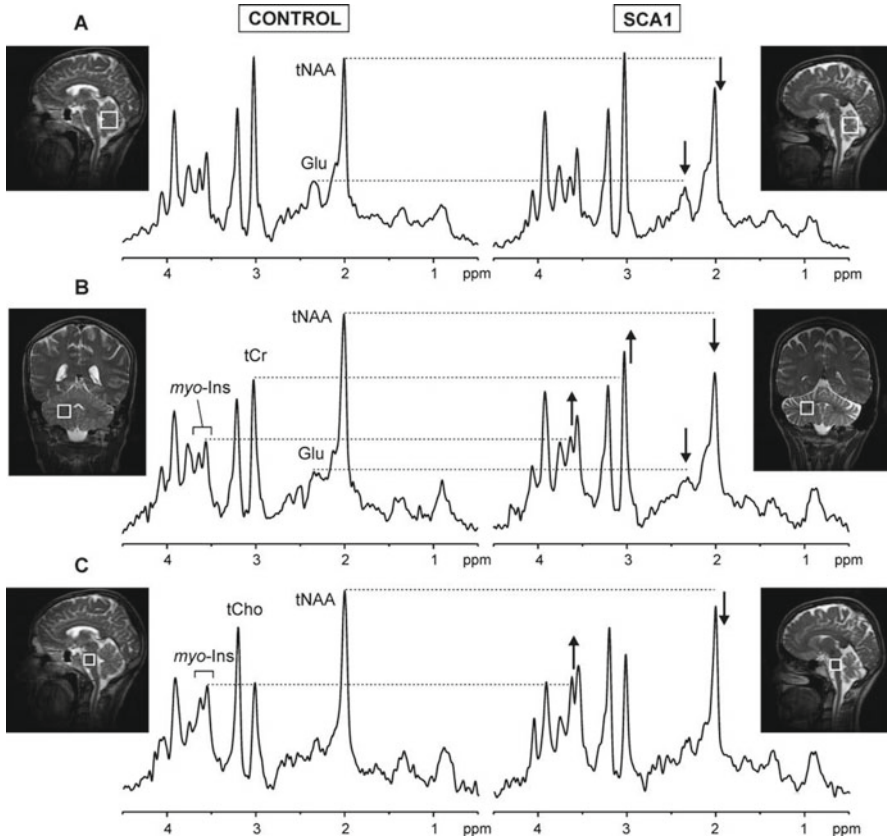
Cerebellar glucose concentration is found to be twice as high in the cerebellum than in the cerebrum after overnight fasting. During acute hyperglycemia, the glucose concentration increases by 3 mmol/l and is the same as in the cortex (Heikkilä et al. 2010).

Proton MRS of the cerebellar hemispheres in childhood (3–18 years) shows that the NAA/tCr tends to increase with age, and the tCr concentration, NAA/H<sub>2</sub>O, tCr/H<sub>2</sub>O and Cho/H<sub>2</sub>O ratios are higher in the hemispheres than those in parietoccipital white matter (Costa et al. 2002). In a study of neonatal brain (Tomiyasu et al. 2013), tCr, NAA and Glu + Gln increase, mI decreases, and Cho does not correlate with postconceptional age.

## 50.3 MR Spectroscopy in Cerebellar Ataxias

Spinocerebellar ataxias (SCA) are the most frequent disorders studied by MRS of cerebellum. In general, a decrease in the NAA concentration or in NAA/tCr is observed in all forms of SCA, which indicates neuronal dysfunction or loss. In SCA1, lower Glu and higher Gln, mIns and tCr concentrations compared to controls (Fig. 50.1) are observed in cerebellar hemispheres (Öz et al. 2010). Patients with SCA1, 2 and 6 and with cerebellar multiple system atrophy (MSA-C) show distinct neurochemical profiles. In particular, mIns in vermis and mIns, NAA, tCr, Glu and Gln in hemispheres are different between the patient groups (Öz et al. 2011). In a long-TE study, specific NAA/tCr, NAA/Cho and Cho/tCr ratios are found in SCA1, 2, 3, 6, 17 and MSA-C patients (Lirng et al. 2012).

Patients with most frequent autosomal recessive cerebellar ataxias, Friedreich's ataxia and oculomotor apraxia type 2, have lower NAA levels in vermis and hemispheres. Additionally, specific changes in mIns and tCr (potential gliosis markers) and in Gln and Glu concentrations (indicators of altered glutamatergic



**Fig. 50.1** Localized proton MR spectra obtained from the vermis (A), cerebellar hemispheres (B), and pons (C). *Left*: healthy volunteer; *right*: patient with SCA1. The alterations in total NAA, Glu, mIns, and tCr are visible in the spectra of the patient (Reproduced from Öz et al. 2010)

neurotransmission) are observed in various parts of cerebellum in the respective disorders (Iltis et al. 2010). MR spectra in gluten, Friedreich's and SCA6 ataxias show significant differences in metabolite ratios (Hadjivassiliou et al. 2012). A higher level of tCr observed in various degenerative ataxias is ascribed to substitutive gliosis.

The ataxia due to mitochondrial respiratory chain deficiency leads to increased cerebellar lactate (Boddaert et al. 2008). Cerebellar tCr is lower in patients with episodic ataxia type 2 than in controls (Harno et al. 2005). The decrease of cerebellar NAA/tCr is also observed in chronic recurrent cerebellar ataxia (Ichikawa et al. 2009). In acute hemicerebellitis, the Glu+Gln signal is increased while NAA and mIns are decreased at the disease onset. After 25 days, these peaks recover to normal values but Cho is increased (Tomiya et al. 2012).



## 50.4 MRS of Cerebellum in Other Neurological Diseases

Patients with familial hemiplegic migraine type 1 show a decrease in NAA/tCr in cerebellum and the NAA concentration in cerebellar vermis. The Glu concentration is decreased and mIns is increased in vermis, and the decrease in NAA correlates significantly with cerebellar scores (Dichgans et al. 2005).

Patients with benign adult familial myoclonic epilepsy exhibit an elevated Cho/tCr ratio in the cerebellar cortex but no changes in NAA ratios (Striano et al. 2009). In Lafora disease, Altindag et al. (2009) reported increased cerebellar NAA/Cho in patients relative to controls. They also observed a correlation of this ratio with myoclonus and ataxia scores. Patients with multiple sclerosis associated with cognitive deterioration show lower cerebellar NAA levels during follow-up than those without cognitive deterioration (Zaaraoui et al. 2011).

## 50.5 MRS of Cerebellum in Psychiatric Disorders

Phospholipid metabolism was studied in schizophrenia by  $^{31}\text{P}$  MRS. Psychotic symptoms correlate with phosphocholine concentration in the cerebral cortex whereas depression correlated with the phosphocholine levels in cerebellum (Weber-Fahr et al. 2013). In autism spectrum disorder, a significant decrease of NAA in cerebellum across age categories and differences in tCr as a function of age and brain region are observed (Ipser et al. 2012). In adult attention deficit/hyperactivity disorder (ADHD), a significant increase of (Glu+Gln)/tCr was found in the left cerebellar hemisphere (Perlov et al. 2010).

In summary, changes of the neurochemical profile in cerebellum or in its parts can be specific in some neurological disorders and can serve as markers of the disease. At the same time, MRS of cerebellum can be useful for understanding mechanisms of various inherited diseases, for monitoring progress of the disease and response to therapy.

## References

- Altindag E, Kara B, Baykan B et al (2009) MR spectroscopy findings in Lafora disease. *J Neuroimaging* 19:359–365
- Boddaert N, Romano S, Funalot B et al (2008)  $^1\text{H}$  MRS spectroscopy evidence of cerebellar high lactate in mitochondrial respiratory chain deficiency. *Mol Genet Metab* 93:85–88
- Costa MO, Lacerda MT, Garcia Otaduy MC et al (2002) Proton magnetic resonance spectroscopy: normal findings in the cerebellar hemisphere in childhood. *Pediatr Radiol* 32:787–792
- Dichgans M, Herzog J, Freilinger T et al (2005)  $^1\text{H}$ -MRS alterations in the cerebellum of patients with familial hemiplegic migraine type 1. *Neurology* 64:608–613
- Hadjivassiliou M, Wallis LI, Hoggard N et al (2012) MR spectroscopy and atrophy in Gluten, Friedreich's and SCA6 ataxias. *Acta Neurol Scand* 126:138–143

- Harno H, Heikkinen S, Kaunisto MA et al (2005) Decreased cerebellar total creatine in episodic ataxia type 2: a 1H MRS study. *Neurology* 64:542–544
- Heikkilä O, Mäkimattila S, Timonen M et al (2010) Cerebellar glucose during fasting and acute hyperglycemia in nondiabetic men and in men with type 1 diabetes. *Cerebellum* 9:336–344
- Ichikawa K, Kikuchi M, Takeshita S et al (2009) A case of chronic recurrent cerebellar ataxia responding to steroid therapy. *Brain Dev* 31:83–85
- Iltis I, Hutter D, Bushara KO et al (2010) <sup>1</sup>H MR spectroscopy in Friedreich's ataxia and ataxia with oculomotor apraxia type 2. *Brain Res* 1358:200–210
- Ipsier JC, Syal S, Bentley J et al (2012) 1H-MRS in autism spectrum disorders: a systematic meta-analysis. *Metab Brain Dis* 27:275–287
- Lirng JF, Wang PS, Chen HC et al (2012) Differences between spinocerebellar ataxias and multiple system atrophy-cerebellar type on proton magnetic resonance spectroscopy. *PLoS One* 7(10):e47925
- Minati L, Aquino D, Bruzzone MG et al (2010) Quantitation of normal metabolite concentrations in six brain regions by *in-vivo* <sup>1</sup>H-MR spectroscopy. *J Med Phys* 35:154–163
- Öz G, Tkáč I (2011) Short-echo, single-shot, full-intensity proton magnetic resonance spectroscopy for neurochemical profiling at 4 T: validation in the cerebellum and brainstem. *Magn Reson Med* 65:901–910
- Öz G, Hutter D, Tkáč I et al (2010) Neurochemical alterations in spinocerebellar ataxia type 1 and their correlations with clinical status. *Mov Disord* 25:1253–1261
- Öz G, Iltis I, Hutter D et al (2011) Distinct neurochemical profiles of spinocerebellar ataxias 1, 2, 6, and cerebellar multiple system atrophy. *Cerebellum* 10:208–217
- Perlov E, Tebarzt van Elst L, Buechert M et al (2010) <sup>1</sup>H<sup>1</sup>-MR-spectroscopy of cerebellum in adult attention deficit/hyperactivity disorder. *J Psychiatr Res* 44:938–943
- Striano P, Caranci F, Di Benedetto R et al (2009) <sup>1</sup>H-MR spectroscopy indicates prominent cerebellar dysfunction in benign adult familial myoclonic epilepsy. *Epilepsia* 50:1491–1497
- Tomiyasu M, Aida N, Mitani T et al (2012) Acute hemicerebellitis in a pediatric patient: a case report of a serial MR spectroscopy study. *Acta Radiol* 53:223–227
- Tomiyasu M, Aida N, Endo M et al (2013) Neonatal brain metabolite concentrations: an in vivo magnetic resonance spectroscopy study with a clinical MR system at 3 Tesla. *PLoS ONE* 8:e82746
- Weber-Fahr W, Englisch S, Esser A et al (2013) Altered phospholipid metabolism in schizophrenia: a phosphorus 31 nuclear magnetic resonance spectroscopy study. *Psychiatry Res* 214:365–373
- Zaaroufi W, Reuter F, Rico A et al (2011) Occurrence of neuronal dysfunction during the first 5 years of multiple sclerosis is associated with cognitive deterioration. *J Neurol* 258:811–819

# Chapter 51

## Functional Topography of the Human Cerebellum

Catherine J. Stoodley and Jeremy D. Schmahmann

**Abstract** Cerebellar functions are topographically arranged, enabling cerebellar modulation of vestibular, sensorimotor, and cognitive/limbic domains via cerebro-cerebellar circuits. The primary sensorimotor cerebellum linked with cerebral sensorimotor areas is in the anterior lobe – lobules II through V, and adjacent parts of lobule VI; the secondary sensorimotor representation is in lobule VIII. Leg and foot are represented in lobules II, III and VIII; hand in lobules IV, V and VIII; and orofacial movements in paravermal lobules V and VI. The cognitive cerebellum in the posterior lobe is interconnected with association and paralimbic cerebral cortices, and includes lobules VI, VIIA at the vermis, Crus I and II in the hemispheres, and lobule VIIB. Executive function and working memory paradigms engage lobules VI and VII, language recruits the right posterolateral cerebellum, and visual-spatial tasks the left. Lobule IX is coupled with the default mode network. The limbic cerebellum in the posterior vermis regulates affective/emotional processing and autonomic functions. Consistent with this topography, the cerebellar motor syndrome follows damage to cerebellar sensorimotor regions; the cerebellar cognitive affective/Schmahmann syndrome from damage to the cognitive-limbic cerebellum; and vestibular symptoms from damage to the vestibulocerebellum. These syndromes may coexist, or occur in isolation following circumscribed lesions.

**Keywords** Cerebellum • Functional topography • Cerebellar cognitive affective syndrome • Cerebellar motor syndrome • Ataxia • Dysmetria • Vestibular

---

C.J. Stoodley (✉)

Department of Psychology and Center for Behavioral Neuroscience,  
American University, Washington, DC, USA

e-mail: [stoodley@american.edu](mailto:stoodley@american.edu)

J.D. Schmahmann

Ataxia Unit, Cognitive Behavioral Neurology Unit, Laboratory for Neuroanatomy  
and Cerebellar Neurobiology, Department of Neurology, Massachusetts General  
Hospital, Harvard Medical School, Boston, MA, USA

e-mail: [jschmahmann@mgh.harvard.edu](mailto:jschmahmann@mgh.harvard.edu)

Just like the cerebral cortex, the cerebellum is topographically arranged and contributes to a wide array of behaviors. This functional heterogeneity is possible because of the highly organized anatomical connections of the cerebellum with the spinal cord, brainstem nuclei, and cerebral hemispheres engaged in vestibular, sensorimotor, cognitive and emotional processing. Unlike cerebral cortex, however, cerebellar cortex does not have areas with unique cytoarchitectonic properties; instead, it is defined by its ubiquitous trilaminar architecture and corticonuclear microcircuits that form tight, reciprocal links with the cerebellar nuclei (fastigial, globose, emboliform, and dentate, and the lateral vestibular nucleus in the brainstem). The repeating architecture of the cerebellar cortex is the basis for the dysmetria of thought hypothesis and the concept of the universal cerebellar transform (Schmahmann 1991, 2000), the idea that the cerebellum performs the same computation on the multiple streams of information to which it has access.

The three lobes of the cerebellum are divided into ten lobules. Lobules I through V comprise the anterior lobe, lobules VI through IX the posterior lobe, and the hemispheric and vermal parts of lobule X comprise the flocculonodular lobe (Table 51.1, Schmahmann et al. 2000). Vestibular syndromes of vertigo, nausea, vomiting, disequilibrium and nystagmus result from lesions of the flocculonodular lobe (Hotson and Baloh 1998); gait ataxia follows lesions of the anterior superior vermis (Victor and Adams 1953); appendicular dysmetria follows lesions that involve hemispheric parts of the anterior lobe (Holmes 2007); and the cerebellar cognitive affective (CCAS)/Schmahmann syndrome results from damage to the cerebellar posterior lobe (Schmahmann and Sherman 1998; Levisohn et al. 2000; Manto and Mariën 2015).

The three cornerstones of clinical ataxiology (Manto and Mariën 2015) – vestibular, sensorimotor and cognitive-limbic domains – are evident from connective anatomy and neurophysiology to clinical neurology, neuropsychology and neuropsychiatry. Resting state functional connectivity magnetic resonance imaging (fcMRI) and task-based functional MRI in humans also support these structural and functional connectivity patterns. The details are presented below and their relevant citations are found in the referenced reports.

Anatomical studies show three major cerebellar connectivity patterns (see Chap. 11).

1. Peripheral and brainstem vestibular afferents form connections with the flocculonodular lobe, fastigial nucleus, and the oculomotor vermis in lobule VII.
2. Spinal cord and sensorimotor regions of the cerebral cortex are linked with primary sensorimotor areas in the cerebellar anterior lobe (lobules I–V), medial lobule VI, and a second representation in the posterior lobe in lobule VIII, together with the related sensorimotor nuclei (globose, emboliform, and dorsal part of the dentate nucleus). This is reflected in electrophysiological studies showing the cerebellar homunculus as an upside-down body map in the anterior lobe (I–V) and a second body map in lobule VIII bilaterally (Snider and Eldred 1951).

**Table 51.1** Cerebellar fissures and lobules. The ten cerebellar lobules at the midline (vermis) and hemispheres are shown, along with the major fissures that demarcate each lobule from adjacent lobules

VERMIS Lobule I,II	FISSURE	HEMISPHERE Lobule I,II
III	Precentral	III
IV	Preculminate	IV
V	Intraculminate	V
VI	Primary	VI
VIIAf	Superior Posterior	Crus I
VIIAt	Horizontal	Crus II
VIIIB	Ansoparamedian	VIIIB
VIIIA	Prepyramidal/Prebiventer	VIIIA
VIIIB	Intrabiventer	VIIIB
IX	Secondary	IX
X	Posterolateral	X

Reproduced with permission from Schmahmann et al. (2000)

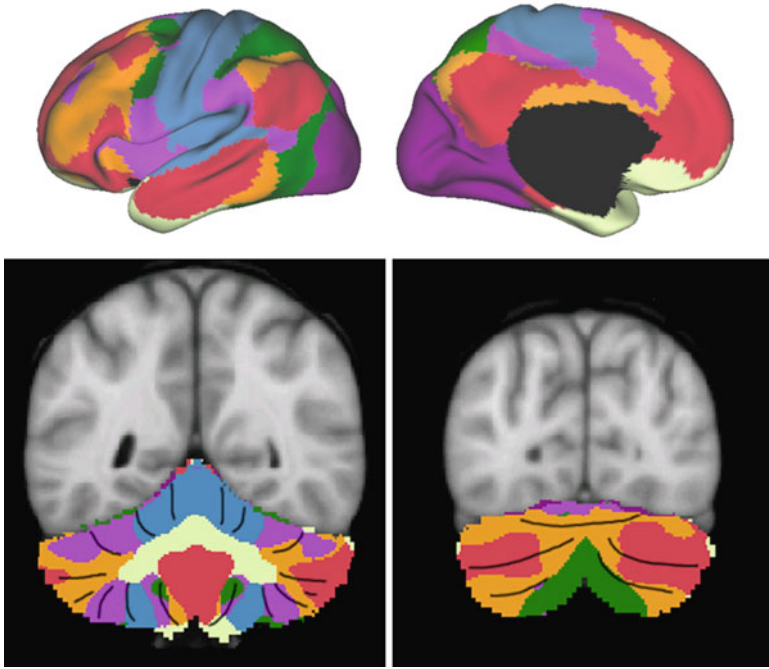
3. Prefrontal, posterior parietal, temporal and cingulate association and paralimbic cortices are reciprocally linked with the posterior cerebellum in lobules VI and VII (including vermal and hemispheric extensions of lobule VIIA – i.e., Crus I and Crus II; and lobule VIIB), and the ventral part of the dentate nucleus. The cerebellar hemispheres are linked with cerebral association areas, whereas the posterior vermis and fastigial nucleus are interconnected with limbic system structures including hypothalamus, septum, and amygdala.

## 51.1 Vestibular Cerebellum

The vestibular cerebellum is in vermal lobule IX (uvula), vermal and hemispheric parts of lobule X (nodulus and flocculus, respectively), and vermal lobule I/II (lingula). It receives input from the five peripheral vestibular end organs; the cristae in the three orthogonally oriented semicircular canals which detect angular rotation in the horizontal, pitch and roll planes, and the maculae in the two otoliths that sense the effect of the linear acceleration of gravity during roll-tilt (utricle) and pitch (sacule) (Barmack and Yakhnitsa 2013). Vermal lobule IX receives primary vestibular afferents from the otolith and vermal lobule X from the semicircular canals. Both the vermal and hemispheric parts of lobules IX and X (and the anterior vermis) receive secondary vestibular afferents from the vestibular nuclei in the medulla. Tertiary vestibular afferents from the medial accessory olive terminate in lobules IX and X in discrete parasagittal zones. The vestibular nuclei receive direct projections back from the flocculonodular lobe, and indirect projections from the anterior vermis via the oculomotor-relevant caudal part of the fastigial nucleus (Voogd and Barmack 2006). The vestibular system is critical for the control of eye movements for orientation in intra-personal and extra-personal space, and for control of axial musculature essential for posture, balance and equilibrium. Vestibulocerebellar connections provide the cerebellum with a topographic map of space, predicting spatial environments, and serving as an anatomic substrate for modulation of postural reflexes evoked by vestibular and optokinetic stimulation.

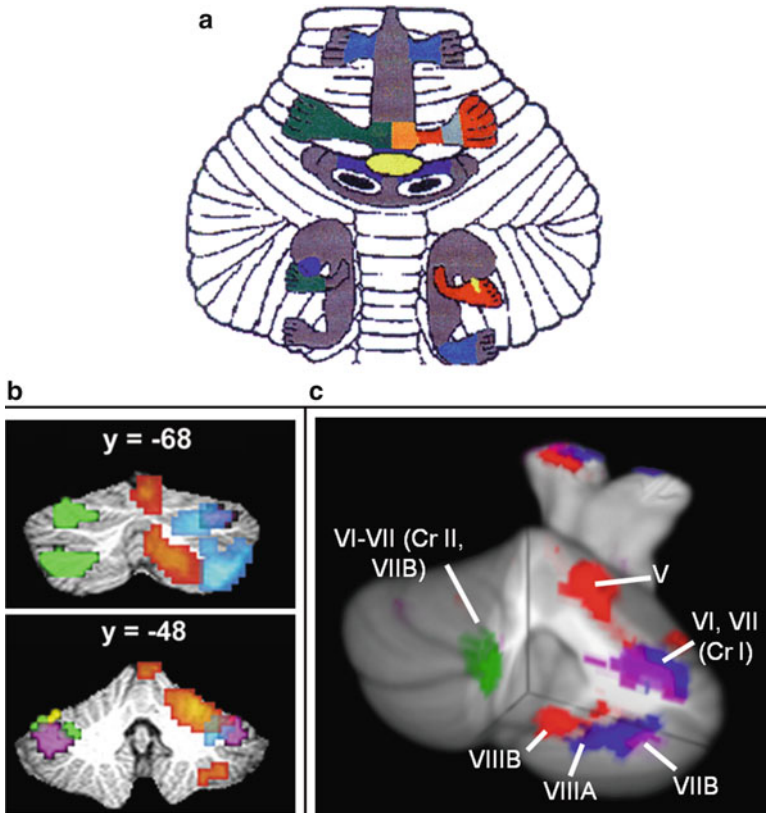
## 51.2 Sensorimotor Cerebellum

Gait ataxia, arm and leg dysmetria, and cerebellar dysarthria arise following strokes in the anterior lobe, and lobule VIII. Voxel-based lesion-symptom mapping confirms that lesions in vermal and paravermal regions of lobules II, III and IV cause impaired posture and ataxic gait; lobules III and VI produce lower limb ataxia; lobules IV–V and VI produce upper limb ataxia; and dysarthria results from paravermal lesions in lobules V and VI (Schoch et al. 2006). Eye movements are represented in vermal lobules VI and VII – the oculomotor vermis. Vergence eye movements are represented in vermal lobules IV/V.



**Fig. 51.1** Cerebellar functional topography revealed through resting-state fMRI. *Top*, the 7-network solution of the cerebral cortical networks described by Yeo et al. (2011); *bottom*, functional mapping of these networks in the cerebellum, based on a winner-takes-all algorithm at the voxel level (Buckner et al. 2011). Networks are color coded as follows: *blue*, somatomotor; *red*, default mode; *orange*, fronto-parietal; *green*, dorsal attention; *violet*, ventral attention; *cream*, limbic; *dark purple*, visual (Figures reproduced with permission from Yeo et al. (2011) and Buckner et al. (2011))

Cerebral sensorimotor cortices are functionally connected (using fcMRI) with contralateral cerebellar lobules III–V, VI and VIII B (Fig. 51.1, blue; Buckner et al. 2011). Cerebellar areas activated by movement are in the anterior lobe, the adjacent part of lobule VI, and lobule VIII (Fig. 51.1). Meta-analysis of task-based fMRI and multiple functional studies within the same individuals show that the sensorimotor homunculus localizes to anterior lobe (lobules III–V) extending into lobule VI, and lobule VIII (Fig. 51.2a) (Stoodley and Schmahmann 2009; Grodd et al. 2001). There is an upside-down somatotopic representation in the anterior lobe: leg and foot sensorimotor representations are localized to lobules II and III, hand representations in lobule V, and orofacial movements activate medial regions of lobule VI (Grodd et al. 2001). Cerebellar activation is ipsilateral to the body part being moved. Tactile stimulation of the hand and foot leads to activation in lobule V with a second activation cluster in lobules VIII B and IX. Orofacial movement and sensory stimulation also overlap in medial lobule VI. Articulation engages a preparation network, in which activity precedes articulation, in lobules IV–VI and the pre-supplementary motor



**Fig. 51.2** Cerebellar functional topography is evident in task-based fMRI studies. (a) Schematic of the sensorimotor homunculi in the anterior lobe and lobule VIII (Reproduced with permission from Grodd et al. (2001), an adaptation of the schematic in Snider and Eldred (1951)). (b) Meta-analysis of fMRI studies reveal anterior lobe and lobule VIII activation during motor tasks (*red-orange*), and posterior lobe activation that is right-lateralized activation for language (*cyan*) and left-lateralized activation during visual-spatial tasks (*green*), and bilateral for working memory tasks (*purple*; Reproduced with permission from Stoodley and Schmahmann (2009)). (c) This topography is also reflected in activation patterns in a prospective fMRI study while participants performed finger tapping (*red*), verb generation (*blue*), mental rotation (*green*), and n-back working memory (*purple*) tasks (Stoodley et al. 2012)

area and prefrontal cortex, and an execution network in which lobule VIII is engaged together with the primary motor cortex, the thalamus, and striatum (Riecker et al. 2005). In addition to these areas involved in movement execution, motor learning activates cerebellar lobules VI and parts of Crus I and II involved in planning and sequencing responses, and associative learning assessed with eyeblink conditioning also activates lobule VI and Crus I (e.g. Ramnani et al. 2000).



### 51.3 Cognitive/Limbic Cerebellum

The CCAS results from lesions of the posterior lobe, with impairments in executive function, spatial cognition, language and regulation of affect and emotion. Language deficits tend to follow lesions of the right cerebellum, and visual-spatial deficits from left cerebellar injury. The limbic connections of the vermis and fastigial nucleus underlie alterations in emotional control from midline cerebellar injury.

fMRI studies show that lobule VII (VIIA at the vermis, its hemispheric extensions Crus I and Crus II, and lobule VIIB) is functionally connected with association areas in the prefrontal, posterior parietal, temporal and cingulate cortices (O'Reilly et al. 2010). The dorsolateral prefrontal cortex is coupled with lobule VII (Crus I, Crus II, and VIIB), the medial prefrontal cortex with Crus I, and the anterior prefrontal cortex with lobules VI and Crus I/II (Fig. 51.1). Using a network approach, lobules VI, VII (Crus I and Crus II), and IX correlate with the executive control network, lobule VI with the salience network, and lobule IX with the default, or mentalizing, network (Habas et al. 2009). Similar analyses reveal that the attention (violet, green, Fig. 51.2), fronto-parietal (orange), limbic (cream) and default mode networks (red) are functionally coupled in a topographically precise manner with the cerebellar posterior lobe (Buckner et al. 2011). Task-based fMRI studies of cognition reveal activation in lateral regions of lobules VI and VII (Crus I, Crus II, and lobule VIIB), whereas emotional processing engages midline posterior vermis in lobule VIIA and lobules VI and Crus I (Fig. 51.2b, c Stoodley and Schmahmann 2009). Language activation is right-lateralized in lobules VI, Crus I and Crus II, contralateral to the language-dominant left cerebral cortex. Language tasks that activate the cerebellum include semantic and phonemic fluency and processing, word stem completion, verb-for-noun generation, verbal fluency, and silent reading. These functions are impaired in patients with right posterior lobe focal lesions (Mariën et al. 2014). Visual-spatial processing engages lobules VI and VII, particularly Crus I, usually on the left. This includes spatial navigation, spatial orientation, encoding of shape and color combinations, mental rotation and mental transformation tasks.

Working memory engages lobules VI, Crus I and VIIA bilaterally. Executive functions produce bilateral activation in cerebellar lobules VI and VII (Crus I and VIIB), usually in concert with dorsolateral prefrontal cortex, in planning tasks such as the Tower of London, random number generation, inhibition tasks such as go/no-go, set-shifting in the Wisconsin Card Sorting Test, complex decision-making, and working memory tasks, Paced Auditory Serial Addition Task, and verbal and visual n-back tasks (Fig. 51.2b, c; Stoodley and Schmahmann 2009; Stoodley et al. 2012).

Emotion regulation, social cognition, and neuropsychiatric phenomena are linked to the posterior vermis – the limbic cerebellum. Vermal lobule VII and lateral parts of lobules VI and Crus I are activated by processing emotion including viewing facial expressions, emotional images, and emotional vocal intonations, and in studies of empathy, panic, sadness, grief, and aversion to unpleasant stimuli (Stoodley and Schmahmann 2009).

Autonomic features including vasovagal tone, blood pressure, and heart rate localize to the fastigial nucleus and vermal cortex.

## 51.4 Summary

Cerebellar functions are topographically arranged, enabling cerebellar modulation of vestibular, sensorimotor, and cognitive/limbic domains via cerebrocerebellar circuits. The primary sensorimotor cerebellum linked with cerebral sensorimotor areas is in the anterior lobe – lobules II through V, and adjacent parts of lobule VI; the secondary sensorimotor representation is in lobule VIII. Leg and foot are represented in lobules II, III and VIII; hand in lobules IV, V and VIII; and orofacial movements in paravermal lobules V and VI. The cognitive cerebellum in the posterior lobe is interconnected with association and paralimbic cerebral cortices, and includes lobules VI, VIIA at the vermis and Crus I and II in the hemispheres, and lobule VIIB. Executive function and working memory paradigms engage lobules VI and VII, language recruits the right posterolateral cerebellum, and visual-spatial tasks the left. Lobule IX is coupled with the default mode network. The limbic cerebellum in the posterior vermis regulates affective/emotional processing and autonomic functions. The anterior lobe motor vs. posterior lobe cognitive dichotomy extends to the dentate nucleus: its dorsal part is engaged in motor control, its ventral part in cognitive functions including verb generation and working memory (Thürling et al. 2011). The globose and emboliform nuclei are sensorimotor. The fastigial nucleus regulates the vestibular system, posture, gait and eye movements, emotional processing and autonomic phenomena. Consistent with this topography, the cerebellar motor syndrome follows damage to cerebellar sensorimotor regions; the cerebellar cognitive affective/Schmahmann syndrome from damage to the cognitive-limbic cerebellum; and vestibular symptoms from damage to the vestibulocerebellum. These syndromes may coexist, or occur in isolation following circumscribed lesions.

**Acknowledgements** Supported in part by RO1 MH067980, the National Ataxia Foundation, Ataxia Telangiectasia Children's Project, and the Birmingham, MINDlink, and Sidney R. Baer Jr Foundations.

## References

- Barmack NH, Yakhnitsa V (2013) Vestibulocerebellar connections. In: Manto M, Gruol DL, Schmahmann JD, Koibuchi N, Rossi F (eds) *Handbook of the cerebellum and cerebellar disorders*. Springer, New York, pp 357–375
- Buckner RL, Krienen FM, Castellanos A, Diaz JC, Yeo BT (2011) The organization of the human cerebellum estimated by intrinsic functional connectivity. *J Neurophysiol* 106(5):2322–2345
- Grodd W, Hulsmann E, Lotze M et al (2001) Sensorimotor mapping of the human cerebellum: fMRI evidence of somatotopic organization. *Hum Brain Mapp* 13:55–73
- Habas C, Kamdar N, Nguyen D et al (2009) Distinct cerebellar contributions to intrinsic connectivity networks. *J Neurosci* 29:8586–8594
- Holmes G (2007) The croonian lectures on the clinical symptoms of cerebellar disease and their interpretation. Lecture II. 1922. *Cerebellum* 6(2):148–153, discussion 141

- Hotson JR, Baloh RW (1998) Acute vestibular syndrome. *N Engl J Med* 339(10):680–685
- Levisohn L, Cronin-Golomb A, Schmahmann J (2000) Neuropsychological consequences of cerebellar tumour resection in children: cerebellar cognitive affective syndrome in a paediatric population. *Brain* 123:1041–1050
- Manto M, Mariën P (2015) Schmahmann's syndrome – identification of the third cornerstone of clinical ataxiology. *Cerebellum Ataxias* 2:2
- Mariën P, Ackermann H, Adamaszek M et al (2014) Consensus paper: language and the cerebellum: an ongoing enigma. *Cerebellum* 13(3):386–410
- O'Reilly JX, Beckmann CF, Tomassini V et al (2010) Distinct and overlapping functional zones in the cerebellum defined by resting state functional connectivity. *Cereb Cortex* 20:953–965
- Ramnani N, Toni I, Josephs O et al (2000) Learning- and expectation-related changes in the human brain during motor learning. *J Neurophysiol* 84:3026–3035
- Riecker A, Mathiak K, Wildgruber D et al (2005) fMRI reveals two distinct cerebral networks subserving speech motor control. *Neurology* 64:700–706
- Schmahmann JD (1991) An emerging concept: the cerebellar contribution to higher function. *Arch Neurol* 48:1178–1187
- Schmahmann JD (2000) The role of the cerebellum in affect and psychosis. *J Neurolinguistics* 13:189–214
- Schmahmann JD, Sherman JC (1998) The cerebellar cognitive affective syndrome. *Brain* 121:561–579
- Schmahmann JD, Doyon J, Toga A et al (2000) MRI atlas of the human cerebellum. Academic, San Diego
- Schoch B, Dimitrova A, Gizewski ER et al (2006) Functional localization in the human cerebellum based on voxelwise statistical analysis: a study of 90 patients. *Neuroimage* 30:36–51
- Snider R, Eldred E (1951) Electro-anatomical studies on cerebro-cerebellar connections in the cat. *J Comp Neurol* 95:1–16
- Stoodley CJ, Schmahmann JD (2009) Functional topography in the human cerebellum: a meta-analysis of neuroimaging studies. *NeuroImage* 44:489–501
- Stoodley CJ, Valera EM, Schmahmann JD (2012) Functional topography of the cerebellum for motor and cognitive tasks: an fMRI study. *Neuroimage* 59(2):1560–1570
- Thürling M, Küper M, Stefanescu R et al (2011) Activation of the dentate nucleus in a verb generation task: a 7 T MRI study. *Neuroimage* 57(3):1184–1191
- Victor M, Adams RD (1953) The effect of alcohol on the nervous system. *Res Publ Assoc Res Nerv Ment Dis* 32:526–573
- Voogd J, Barmack NH (2006) Oculomotor cerebellum. *Prog Brain Res* 151:231–268
- Yeo BT, Krienen FM, Sepulcre J et al (2011) The organization of the human cerebral cortex estimated by intrinsic functional connectivity. *J Neurophysiol* 106(3):1125–1165

**Part VII**  
**Functional Properties of the Cerebellum**

# Chapter 52

## Cerebro-Cerebellar Networks

Iolanda Pisotta and Marco Molinari

**Abstract** Considering the cerebellum an independent structure devoted mainly in motor control functions, traditionally neuroscience research has considerably neglected the importance of cerebellar contribution to non-motor functions. However, the cerebellar anatomo-functional connections to different large scale networks of the neocortex -including frontal and parietal regions typically involved in high-order cognitive processing- suggests its primary role also outside the motor control. Histologically the cerebellum contains about 50 billion neurons— roughly half of the total number of neurons in the whole brain, and this impressive order of magnitude supports extremely powerful mechanisms for processing information (Ramnani, *Nat Rev Neurosci* 7:511–522, 2006). The definition of input-output organization between cerebellum and cerebral cortex will help to clarify the role of the cerebellum in higher cognitive functions because these connections provide the means through which association areas and the cerebellum may influence each other's operations (Ramnani, *Cerebellum* 11:366–383, 2012).

**Keywords** Sequencing • Cognition • Cognitive affective syndrome • Functional connectivity

### 52.1 Neurophysiology of Cerebello-Cortical Circuits

Considering the cerebellum an independent structure devoted mainly in motor control functions, traditionally neuroscience research has considerably neglected the importance of the cerebellar contribution to non-motor functions. However, the cerebellar anatomo-functional connections to different large scale networks of the neocortex -including frontal and parietal regions typically involved in high-order cognitive processing- suggests its primary role also outside the motor control. Istologically the cerebellum contains about 50 billion neurons—roughly half of the

---

I. Pisotta (✉)  
IRCCS Santa Lucia Foundation, Rome, Italy  
e-mail: [i.pisotta@hsantalucia.it](mailto:i.pisotta@hsantalucia.it)

M. Molinari  
Clinical Translational Research, Santa Lucia Foundation, Rome, Italy

total number of neurons in the whole brain, and this impressive order of magnitude supports extremely powerful mechanisms for processing information (Ramnani 2006). The definition of input-output organization between cerebellum and cerebral cortex will help to clarify the role of the cerebellum in higher cognitive functions because these connections provide the means through which association areas and the cerebellum may influence each other's operations (Ramnani 2012).

Anatomical evidence demonstrating the large connections through the dentate nuclei with the prefrontal, temporo-parietal, and limbic areas (Schmahmann 2010; D'Angelo and Casali 2013) prompted a number of cerebellar non-motor function. These wealth of study recently leads to the general acceptance of cerebellar role in modulating cognitive and emotional behaviors (Schmahmann and Sherman 1998). However, already back in 1998 Schmahmann argued that the overshoot and the inability of the motor system to check parameters of movements may be equated in the cognitive/affective realm with "dysmetria of thought", that is a mismatch between reality and perceived reality, and erratic attempts to correct errors of thought or behavior (Schmahmann and Sherman 1998). In the same vein, the involvement of the cerebellum in cognitive functions has been supported by studies showing that cerebellar lesions can produce cognitive deficits (Tedesco et al. 2011) in a variety of domains ranging from language, working memory, spatial data elaborations, procedural learning as well as action inhibition (Koziol et al. 2014).

Tedesco et al. (2011) examined the expression of cerebellar cognitive affective syndrome with regard to lesion topography in a large group of subjects with cerebellar damage, by analyzing the neuropsychological assessment compared with the lesion. Based on the collected data the authors concluded that the locations of lesions provide an understanding of the connectivity between cerebellum and cortical areas involved in each cognitive domain. Of the various cognitive domains, the ability to sequence was the most adversely affected in nearly all subjects, supporting the hypothesis that sequencing is a basic cerebellar operation. Traditionally, sequencing has not been recognized as a discrete cognitive function, it can be defined as a "supramodal function", but the relationship with other cortical functions, such as working memory and timing, is still unknown. Molinari et al. (2008) proposed to consider sequencing the basic mechanism that allows cerebellar prediction ability in all functional domains (Molinari et al. 2008) (see chapter by Molinari about sequencing in this book).

Altogether, this evidence supports the functional connectivity to be a key determinant of cerebellar functions, however little is known about the precise mechanisms through which the cerebellum exerts its influence upon the cerebral cortex. In spite of all the advances in the framework of cerebellar research and the enormous amount of data available on cerebral cortex physiology (Manto et al. 2006); (Manto and Haines 2012), the functional electrophysiology of the human cerebellum remains poorly characterized according to (Dalal et al. 2013).

By applying neurophysiological techniques in subjects suffering of focal unilateral cerebellar damage it has been possible to address the role of cerebellar input on motor (Di Lazzaro et al. 1995, 1994a, b) and somatosensory cortices in human (Restuccia et al. 2001, 2007). In the first study, Di Lazzaro et al. tested the effects of electrical stimuli over the base of the skull on the motor responses evoked by cortical magnetic stimulation in two patients with unilateral cerebellar

lesions. In both patients no inhibition of motor responses was present in the muscles ipsilateral to the lesion, whereas an inhibition, similar to that observed in controls, was evident on the opposite side. The authors suggested the cerebellar origin of the motor effects seen after electrical stimulation of the base of the skull and further clarify the physiological cerebro-cerebellar interactions in humans. Di Lazzaro et al. (1994a) evaluated, in seven patients with cerebellar lesions and in 20 control subjects, the excitability of the motor cortex to magnetic stimulation. In all but one of the patients with a hemispheric cerebellar lesion, the threshold was higher in the motor cortex contralateral to the impaired hemispheric cerebellum and the right/left threshold asymmetry was greater than normal. The authors suggested that the increase in the magnetic threshold of the motor cortex functionally related to the impaired hemispheric cerebellum can confirm the existence of a facilitating tonic action of the cerebellum on central motor circuits that might act at the cortical, or spinal level, or both.

Diffusion Tensor Imaging (DTI) allows investigators to use Magnetic resonance imaging (MRI) to study the trajectories of fiber pathways in the living brain (Le Bihan 2003). Ramnani and colleagues (2006) used this approach to compare the anatomical organization of cortico-pontine fibres in primate and human brains. The results showed that the fibers were topographically arranged both in humans and monkeys but the proportion of the cerebral peduncle occupied by fibers from the prefrontal cortex was much larger in humans than in macaque monkeys.

The cerebellum also modulates the cortical excitability. In 2005, Ben Taib and colleagues, demonstrated, by testing rats, that motor cortex excitability can be modulated largely by Transcranial Direct Current Stimulation (tDCS) of cerebellar cortex or deep cerebellar nuclei, corroborating the importance of cerebellar processing for sensory modulation of cortical excitability (Ben Taib et al. 2005). In rodents, Ben Taib and Manto (2013) argued that tDCS of the cerebellum modulates the excitability of both motor cortex and spinal cord. The authors examined the effects of anodal/cathodal direct current stimulation (DCS), applied epidurally over the cerebellum. The Anodal tDCS decreased the excitability of the motor cortex, reduced the excitability of F waves, exerted a “smoothing effect” on corticomotor maps, reshaping the representation of muscles on the motor cortex, and enhanced the afferent inhibition of conditioned motor evoked responses. Cathodal tDCS of the cerebellum exerted partially reverse effects. This study is the first demonstration that, in rodents, cerebellar tDCS tunes the shape of corticomotor maps, providing a mechanism by which tDCS of the cerebellum exerts a remote neuromodulatory effect upon motor cortex (Ben Taib and Manto 2013).

In line with cerebellar involvement in cortical processing, Tesche and Karhu (2000), but also Ivry (2000), suggested that the cerebellum is able to evaluate the predictability of incoming somatosensory stimuli and, accordingly, of modulating the somatosensory cerebral cortex (Tesche and Karhu 2000; Ivry 2000). By analyzing early latency somatosensory evoked potentials (SEPs) in patients with lateralized cerebellar lesions, Restuccia et al. (2001) demonstrated that inhibitory circuitries, whose activation follows the primary depolarization of granular layer cells, are low-functioning in cerebellar patients (Restuccia et al. 2001). These findings confirmed that the cerebellum influences the activity of inhibitory circuit-

ries in the primary somatosensory cortex and that the cerebellum is able to modulate the excitability of the primary sensory cortex at very early stages of somatosensory input processing.

To verify whether the cerebellum participates in somatosensory input processing and, more specifically, whether the presence/absence of cerebellar processing affects the somatosensory cortex's ability to recognize the similarity/diversity of incoming inputs, Restuccia et al. (2007) investigated the somatosensory mismatch negativity (S-MMN), component of event-related potentials (ERPs), in six patients with unilateral cerebellar lesions. When unattended, deviant acoustic stimuli are interspersed between regular, frequent acoustic stimuli; the deviant ones usually elicit a frontotemporal negative response (in the 120–180 ms latency range) labelled MMN (see (Naatanen and Escera 2000) for review). MMN was clearly abnormal in the cerebellar patients (Restuccia et al. 2007). This is a strong indication that the cerebellum plays a role in mechanisms generating the S-MMN and that subjects with cerebellar damage may be altered in their capacity to correctly process somatosensory information at cortical level.

## 52.2 Conclusions

The cerebellum receives massive higher-order input via the cortico-ponto-cerebellar pathway, and it sends projections back to the associative cerebral cortical areas via the thalamus. It follows that the cerebello-cortical network allows the cerebellar contribution not only to the coordination of movements, as once thought, but also to the modulation and integration of all higher cortical functions. There is an increasing interest in the scientific community to deeper understand cortico-cerebellar interactions, also for cerebellar supposed involvement in the pathophysiology of behavioral disturbances of high incidences, such as schizophrenia and autism (Sudarov 2013; Shakiba 2014).

## References

- Ben Taib NO, Manto M (2013) Trains of epidural DC stimulation of the cerebellum tune cortico-motor excitability. *Neural Plast* 2013:613197
- Ben Taib NO, Manto M, Pandolfo M, Brotchi J (2005) Hemicerebellectomy blocks the enhancement of cortical motor output associated with repetitive somatosensory stimulation in the rat. *J Physiol* 567:293–300
- D'Angelo E, Casali S (2013) Seeking a unified framework for cerebellar function and dysfunction: from circuit operations to cognition. *Front Neural Circuit* 6:116
- Dalal SS, Osipova D, Bertrand O, Jerbi K (2013) Oscillatory activity of the human cerebellum: the intracranial electrocerebellogram revisited. *Neurosci Biobehav Rev* 37:585–593
- Di Lazzaro V, Molinari M, Restuccia D et al (1994a) Cerebro-cerebellar interactions in man: neurophysiological studies in patients with focal cerebellar lesions. *Electroencephalogr Clin Neurophysiol* 93:27–34



- Di Lazzaro V, Restuccia D, Molinari M et al (1994b) Excitability of the motor cortex to magnetic stimulation in patients with cerebellar lesions. *J Neurol Neurosurg Psychiatry* 57:108–110
- Di Lazzaro V, Restuccia D, Nardone R et al (1995) Motor cortex changes in a patient with hemi-cerebellectomy. *Electroencephalogr Clin Neurophysiol* 97:259–263
- Ivry R (2000) Exploring the role of the cerebellum in sensory anticipation and timing: commentary on Tesche and Karhu [comment]. *Hum Brain Mapp* 9:115–118
- Koziol LF, Budding D, Andreassen N et al (2014) Consensus paper: the cerebellum's role in movement and cognition. *Cerebellum* 13:151–177
- Le Bihan D (2003) Looking into the functional architecture of the brain with diffusion MRI. *Nat Rev Neurosci* 4:469–480
- Manto M, Oulad BT, Luft AR (2006) Modulation of excitability as an early change leading to structural adaptation in the motor cortex. *J Neurosci Res* 83:177–180
- Manto M, Haines D (2012) Cerebellar research: two centuries of discoveries. *Cerebellum* 11:446–448
- Molinari M, Chiricozzi F, Clausi S, Tedesco A, De Lisa M, Leggio M (2008) Cerebellum and detection of sequences, from perception to cognition. *Cerebellum* 7:611–615
- Naatanen R, Escera C (2000) Mismatch negativity: clinical and other applications. *Audiol Neuro Otol* 5:105–110
- Ramnani N (2006) The primate cortico-cerebellar system: anatomy and function. *Nat Rev Neurosci* 7:511–522
- Ramnani N (2012) Frontal lobe and posterior parietal contributions to the cortico-cerebellar system. *Cerebellum* 11:366–383
- Ramnani N, Behrens TEJ, Johansen-Berg H et al (2006) The evolution of prefrontal inputs to the cortico-pontine system: diffusion imaging evidence from macaque monkeys and humans. *Cereb Cortex* 16:811–818
- Restuccia D, Valeriani M, Barba C et al (2001) Functional changes of the primary somatosensory cortex in patients with unilateral cerebellar lesions. *Brain* 124:757–768
- Restuccia D, Della MG, Valeriani M, Leggio MG, Molinari M (2007) Cerebellar damage impairs detection of somatosensory input changes. A somatosensory mismatch-negativity study. *Brain* 130:276–287
- Schmahmann J (2010) The role of the cerebellum in cognition and emotion: personal reflections since 1982 on the dysmetria of thought hypothesis, and its historical evolution from theory to therapy. *Neuropsychol Rev* 20:236
- Schmahmann JD, Sherman JC (1998) The cerebellar cognitive affective syndrome. *Brain* 121(Pt 4):561–579
- Shakiba A (2014) The role of the cerebellum in neurobiology of psychiatric disorders. *Neurol Clin* 32:1105–1115
- Sudarov A (2013) Defining the role of cerebellar Purkinje cells in autism spectrum disorders. *Cerebellum* 12(6):950–955
- Tedesco AM, Chiricozzi FR, Clausi S, Lupo M, Molinari M, Leggio MG (2011) The cerebellar cognitive profile. *Brain* 134:3672–3678
- Tesche CD, Karhu JJ (2000) Anticipatory cerebellar responses during somatosensory omission in man [see comments]. *Hum Brain Mapp* 9:119–142

# Chapter 53

## Clinical Functional Topography in Cognition

**Maria Leggio**

**Abstract** In the last 15 years increasing evidence has been added on non-motor cerebellar functions. In 1998 Schmahmann and Sherman defined a new clinical entity, the “cerebellar cognitive affective syndrome” (also called Schmahmann’s syndrome). In 2011 Tedesco et al. characterized the cognitive profile of subjects affected by focal cerebellar damage. The most adversely affected functions in focal cerebellar damage are sequencing, language, executive function, and visuospatial abilities.

**Keywords** Cerebellum • Laterality effect • SCA • PICA • Deep cerebellar nuclei • Posterior lobe

In 1998 Schmahmann and Sherman defined a new clinical entity, the “cerebellar cognitive affective syndrome”, to refer to the behavioural and cognitive symptoms that can be encountered in patients affected by cerebellar pathologies.

In the last 15 years increasing evidence has been added on non-motor cerebellar functions and in 2011 Tedesco et al. characterized the cognitive profile of subjects affected by focal cerebellar lesion.

The focal cerebellar lesions consist of ischemic or hemorrhagic stroke or surgical ablation due to arteriovenous malformations or tumors; they involve discrete portions of cerebellar lobuli and thus, differently from the degenerative pathologies, subjects with focal damage represent the best model to analyze cerebellar functional topography.

### 53.1 The Cerebellar Cognitive Profile

In general, subjects with cerebellar damage have a preserved intellectual level with poor performance with regard to definite cognitive abilities. All major cognitive domains can be affected by cerebellar damage but the cognitive scores generally

---

M. Leggio (✉)

Department of Psychology, Sapienza University of Rome, Rome, Italy

Ataxia Laboratory, IRCCS Santa Lucia Foundation, Rome, Italy

e-mail: [maria.leggio@uniroma1.it](mailto:maria.leggio@uniroma1.it)

result in the lower range of normal limits (Schmahmann and Sherman 1998; Tedesco et al. 2011). This evidence is consistent with the hypothesis that cerebellar injury does not abolish specific cognitive functions—instead rendering them less efficient (Courchesne and Allen 1997; Hokkanen et al. 2006).

It is worth noting that, among all cognitive domains, the most affected by the cerebellar damage are sequencing, linguistic, executive and visuospatial functions.

The cerebellar cognitive impairment is not linked to the motor deficits as demonstrated by the lack of correlations between cognitive and motor scores (Tedesco et al. 2011) and by the evidences of better cognitive performances in patients with higher motor impairment, i.e. patients with cerebellar atrophy (Leggio et al. 2000).

### 53.2 Laterality Effects

In recent years, consistent with the discovery of segregated parallel cerebello-cortico-cerebellar loops (Middleton and Strick 1998), several groups have demonstrated the importance of the topography of cerebellar lesions in cognition (Stoodley and Schmahmann 2010), suggesting differences in cognitive impairments between right or left focal cerebellar damage (Gottwald et al. 2004; Hokkanen et al. 2006; Scott et al. 2001).

However, this laterality effect is not clearly defined (Molinari et al. 1997; Leggio et al. 2000; Chiricozzi et al. 2008; Tedesco et al. 2011).

The cerebellum acts within the complex cortical-subcortical network, which mediates cognitive functions (Middleton and Strick 1998). Based on the functional lateralization of the cerebral cortex and the crossing of cerebello-cortico-cerebellar connections, the right cerebellar hemisphere should be involved in verbal performance, and the left hemisphere should be critical for spatial performance. Cerebral cortex functions are not completely lateralized, however, and bilateral cortical activation during linguistic and spatial tasks has been reported in fMRI studies (van Ettinger-Veenstra et al. 2010).

Consistent with this evidence of bilateral activation, studies on lesions have observed deficits in language after right and left cerebellar damage (Leggio et al. 2000; Fabbro et al. 2004). Further, specific language-related impairments have been demonstrated after the development of left cerebellar lesions (Cook et al. 2004).

How is this possible? It has been suggested that cerebellar processing is not linked to a specific subcomponent of a given function but instead provides support to all components, particularly in smoothing their interplay (Leggio et al. 2011). Thus, a function whose subcomponents are distributed bilaterally, such as language, should be affected by right and left lesions. However, in spite of the bilateral impairment, in-depth analyses have often demonstrated right-left specificity (Molinari et al. 2004; Leggio et al. 2008).

These differences have been interpreted to mean that within a distributed function, modules can be differentially affected by cerebellar damage (Molinari and Leggio 2007).

### 53.3 Vascular Territory Effects

Anatomical, developmental, and neuropsychological data indicate the existence of cerebellar motor functions in the anterior lobe and of cognitive functions in the posterior lobe (Stoodley and Schmahmann 2010; Timmann et al. 2008). The vascular territory of the Superior Cerebellar Artery (SCA) primarily involves the anterior lobe, and that of the Posterior Inferior Cerebellar Artery (PICA) mostly involves the posterior lobe. Thus, a comparison between patients with stroke lesions in the SCA or PICA territory allows one to evaluate anterior versus posterior cerebellar lesions.

Indeed, literature data indicate that PICA subjects perform worse than SCA patients on all cognitive domains, particularly with regard to verbal memory, language, visuospatial and executive functions (Tedesco et al. 2011).

Leiner et al. (1986) emphasized the contribution of phylogenetically new posterior components of the cerebellum to “mental skills”. Their hypothesis was based on the observation that the dentate nucleus enlarges in parallel with the frontal cortex during phylogenetic and ontogenetic development. This model was proposed by several groups implicating the cerebellar posterior lobe and dentate nucleus in various cognitive domains.

In a series of studies, Strick and colleagues (Middleton and Strick 1998; Strick et al. 2009) observed that the output channels to the prefrontal and posterior parietal areas are clustered in the ventral and caudal region of the dentate nucleus. These output channels are segregated from those in the dorsal dentate that target motor areas of the cortex (Habas 2010). Current evidence supports a model of a motor anterior lobe versus a “cognitive” posterior lobe, providing clinical indications, consistent with recent reports (Grimaldi and Manto 2012; Tedesco et al. 2011), that SCA and PICA territory lesions can be differentiated based on motor or cognitive symptoms.

All in all the reconstruction of the lobules that are affected by focal lesions confirms the general pattern of the involvement of posterior lobules in various cognitive functions (Stoodley and Schmahmann 2009; Tedesco et al. 2011).

### 53.4 Deep Cerebellar Nuclei Effects

The deep cerebellar nuclei (DCN) facilitate cerebello-thalamo-cortical projections, and the cerebellar cortex, by inhibiting the activity of the nuclei, blocks cerebellar activation of the cerebral cortex (Tarnecki 2003). Thus, cortical cerebellar lesions should effect disparate symptoms than lesions that involve the DCN.

Recently, in addition to its relevance in motor recovery (Schoch et al. 2006), the importance of DCN in cognition has been demonstrated by anatomical (Strick et al. 2009) and fMRI data (Habas 2010).

In clinical studies, it has been demonstrated that patients with or without damage to the DCN differently perform in cognitive tasks (Tedesco et al. 2011; Brunamonti

et al. 2014). Indeed, subjects with spared DCN have better scores than those with damage to the DCN.

### 53.5 Lobular Distribution of Impairments in Performance

Functional distribution in cerebellar lobules has been addressed by several neuroimaging and lesion studies.

However, even if both kind of studies implicate the posterior lobe as relevant in cognition, the activation peaks and overlap of lesions differ. The highest number of instances of significant activation during cognitive tasks is observed in lobules VI and VII (Crus I and II) (see *Ale* values in Table 3 of Stoodley and Schmahmann 2009). Clinical lesion overlap data indicate a more widespread distribution of cognition-relevant lobules (Tedesco et al. 2011). The lesion cognition map involved lobules VII (Crus I and II), VIIB, and VIIIA, with only partial involvement of lobule VI. Thus, both approaches have limitations, for which prospective studies are needed to further map cerebellar cognitive topography.

### 53.6 Conclusions

In patients affected by focal cerebellar damage sequencing, language, executive function, and visuospatial abilities, are the most adversely affected functions (Schmahmann and Sherman 1998; Tedesco et al. 2011).

Subjects with lesions in the PICA territory exhibit the worst cognitive patterns, similar to those with lesions of the DCN. Further, the cerebellar patients, with the notable exception of those in whom the DCN are spared, demonstrate the worst performance with regard to sequencing abilities.

Cerebellar damage impairs sequencing in all modalities, although modality differences are observed in relation to the anatomical distribution of the damage (Leggio et al. 2008; Molinari et al. 2008).

According to Courchesne and Allen (1997), a cerebellar lesion do not eliminate cognitive function, but it increases suboptimal variability when motor or mental tasks are performed. This model is consistent with findings of low, but not clearly pathological, functions in many domains. The cognitive profiles of patients affected by cerebellar lesion implicate the cerebellum as the “optimization structure” (Courchesne and Allen 1997) of cognitive operations, indicating the various domains in which the cerebellar “dysmetria of thought” (Schmahmann and Sherman 1998) can be seen.

## References

- Brunamonti E, Chiricozzi FR, Clausi S, Olivito G, Giusti MA, Molinari M, Ferraina S, Leggio M (2014) Cerebellar damage impairs executive control and monitoring of movement generation. *PLoS One* 9(1):e85997
- Chiricozzi FR, Clausi S, Molinari M, Leggio MG (2008) Phonological short-term store impairment after cerebellar lesion: a single case study. *Neuropsychologia* 46:1940–1953
- Cook M, Murdoch BE, Cahill L, Whelan BM (2004) Higher-level language deficits resulting from left primary cerebellar lesions. *Aphasiology* 18:771–784
- Courchesne E, Allen G (1997) Prediction and preparation, fundamental functions of the cerebellum. *Learn Mem* 4:1–35
- Fabbro F, Tavano A, Corti S, Bresolin N, De Fabritiis P, Borgatti R (2004) Longterm neuropsychological deficits after cerebellar infarctions in two young twins. *Neuropsychologia* 42:536–545
- Gottwald B, Wilde B, Mihajlovic Z, Mehdorn HM (2004) Evidence for distinct cognitive deficits after focal cerebellar lesions. *J Neurol Neurosurg Psychiatry* 75:1524–1531
- Grimaldi G, Manto M (2012) Topography of cerebellar deficits in humans. *Cerebellum* 11(2):336–351
- Habas C (2010) Functional imaging of the deep cerebellar nuclei: a review. *Cerebellum* 9:22–28
- Hokkanen LSK, Kauranen V, Roine RO, Salonen O, Kotila M (2006) Subtle cognitive deficits after cerebellar infarcts. *Eur J Neurol* 13:161–170
- Leggio MG, Silveri MC, Petrosini L, Molinari M (2000) Phonological grouping is specifically affected in cerebellar patients: a verbal fluency study. *J Neurol Neurosurg Psychiatry* 69:102–106
- Leggio MG, Tedesco AM, Chiricozzi FR, Clausi S, Orisini A, Molinari M (2008) Cognitive sequencing impairment in patients with focal or atrophic cerebellar damage. *Brain* 131:1332–1343
- Leggio MG, Chiricozzi FR, Clausi S, Tedesco AM, Molinari M (2011) The neuropsychological profile of cerebellar damage: the sequencing hypothesis. *Cortex* 47:137–144
- Leiner HC, Leiner AL, Dow RS (1986) Does the cerebellum contribute to mental skills? *Behav Neurosci* 100:443–454
- Middleton FA, Strick PL (1998) Cerebellar output: motor and cognitive channels. *Trends Cogn Sci* 2:348–354
- Molinari M, Leggio MG (2007) Cerebellar information processing and visuospatial functions. *Cerebellum* 6:214–220
- Molinari M, Leggio MG, Solida A, Corra R, Misciagna S, Silveri MC, Petrosini L (1997) Cerebellum and procedural learning: evidence from focal cerebellar lesions. *Brain* 120:1753–1762
- Molinari M, Petrosini L, Misciagna S, Leggio MG (2004) Visuospatial abilities in cerebellar disorders. *J Neurol Neurosurg Psychiatry* 75:235–240
- Molinari M, Chiricozzi FR, Clausi S, Tedesco AM, De Lisa M, Leggio MG (2008) Cerebellum and detection of sequences, from perception to cognition. *Cerebellum* 7:611–615
- Schmahmann JD, Sherman JC (1998) The cerebellar cognitive affective syndrome. *Brain* 121:561–579
- Schoch B, Dimitrova A, Gizewski ER, Timmann D (2006) Functional localization in the human cerebellum based on voxelwise statistical analysis: a study of 90 patients. *Neuroimage* 30:36–51
- Scott RB, Stoodley CJ, Anslow P, Paul C, Stein JF, Sugden EM, Mitchell CD (2001) Lateralized cognitive deficits in children following cerebellar lesions. *Dev Med Child Neurol* 43:685–691
- Stoodley CJ, Schmahmann JD (2009) Functional topography in the human cerebellum: a meta-analysis of neuroimaging studies. *Neuroimage* 44:489–501
- Stoodley CJ, Schmahmann JD (2010) Evidence for topographic organization in the cerebellum of motor control versus cognitive and affective processing. *Cortex* 46:831–844

- Strick PL, Dum RP, Fiez JA (2009) Cerebellum and nonmotor function. *Annu Rev Neurosci* 32:413–434
- Tarnecki R (2003) Responses of the red nucleus neurons to limb stimulation after cerebellar lesions. *Cerebellum* 2:96–100
- Tedesco AM, Chiricozzi FR, Clausi S, Lupo M, Molinari M, Leggio MG (2011) The cerebellar cognitive profile. *Brain* 134(Pt 12):3672–3686
- Timmann D, Brandauer B, Hermsdörfer J, Ilg W, Konczak J, Gerwig M, Gizewski ER, Schoch B (2008) Lesion-symptom mapping of the human cerebellum. *Cerebellum* 7:602–606
- van Ettinger-Veenstra HM, Ragnehed M, Hällgren M, Karlsson T, Landtblom AM, Lundberg P, Engström M (2010) Right-hemispheric brain activation correlates to language performance. *Neuroimage* 49:3481–3488

# Chapter 54

## Sequencing

Marco Molinari

**Abstract** Sequencing is the fundamental ability of acquiring knowledge of the structure of sequences by acting on a sequence of events – incidentally through experience or intentionally through explicit effort. To acquire sequence knowledge it must be recognized if stimuli are presented in a certain order and which are the ordering rules. To this aim, the information on a single stimulus must be kept active in a working memory system and compared with subsequent stimuli. Furthermore, information on time and space relations among stimuli must be acquired. Once sequence structure has been identified, it has to be stored for subsequent use.

**Keywords** Cognition • Perception • Behaviour

Sequencing is the fundamental ability of acquiring knowledge of the structure of sequences by acting on a sequence of events – incidentally through experience or intentionally through explicit effort. To acquire sequence knowledge it must be recognized if stimuli are presented in a certain order and which are the ordering rules. To this aim, the information on a single stimulus must be kept active in a working memory system and compared with subsequent stimuli. Furthermore, information on time and space relations among stimuli must be acquired. Once sequence structure has been identified, it has to be stored for subsequent use.

In spite of its importance for brain functioning, particularly for feed forward control (Pisotta and Molinari 2014), sequencing is not recognized as a discrete cognitive function. Nevertheless, sequencing abilities have been examined in various fields of cognitive neuroscience, as have the neuronal circuits that are involved—for example, frontal/predictive functions (Bubic et al. 2010), spatial hippocampal (Igloi et al. 2010) and cerebellar processing (Leggio et al. 2011). At present sequencing can be defined as a supramodular function whose relationships with other such functions, such as working memory and timing, remain unknown. As a supramodal function, impairment in sequencing would affect many domains although the deficit

---

M. Molinari (✉)

Clinical Translational Research, Santa Lucia Foundation, Rome, Italy

e-mail: [m.molinari@hsantalucia.it](mailto:m.molinari@hsantalucia.it)



would be discrete and functional compensation quite effective. Thus is not surprising if sequencing impairment has never been described in isolation.

Considering involvement in prediction of sensory events and the long-standing idea that the cerebellum acts as a comparator, participation of the cerebellum among the brain structures involved in sequencing is conceivable and indeed early in cerebellar research, sequence processing was proposed as the basic functional mechanism of the motor (Braitenberg et al. 1997) and cognitive (Molinari and Petrosini 1997) domains. Within this framework, it has been proposed that comparisons among actual input and preceding stimuli, as well as detection of similarities and discordances between predicted and actual sequences, happen within the cerebellum (Molinari et al. 2009). Results of this cerebellar processing would then be funneled to the cortex. If the incoming stimulus corresponds to the predicted one, cerebellar output would be minimal; if a discrepancy–error signal is detected then activity in the cerebellum increases and a large area of the cerebral cortex would be alerted with enhancing of neuronal excitability.

If the above described mechanism corresponds to the basic mode of cerebellar functioning than sequencing deficits should be present in all cerebellar functional domains. Indeed sequencing has been reported has the most affected domain in large cohort of subjects with focal or degenerative cerebellar damage (Tedesco et al. 2011).

The relevance of the cortico-striatal-cerebellar networks in motor sequence learning is well established (Doyon et al. 2003). Within this network cortico-striatal and cortico-cerebellar circuits are considered to work in parallel in order to mediate motor sequence learning. Striatal involvement has been considered more pronounced in implicit motor sequence learning (Karabanov et al. 2010), while cerebellar activity has been related to the computation of prediction errors which takes place during the early stage of learning but less when the motor sequence is already established (Doyon et al. 2009). Interestingly a cerebellar role has been demonstrated more in sequence detection than in sequence execution in serial reaction time task (SRTT) in which subjects learn a sequential pattern of finger presses (Molinari et al. 1997). This latter evidence highlights the importance of the cerebellum more as a sensory than a motor structure in line with Bower's theories (Bower 1997b).

The role of the cerebellum in sensory processing has long been demonstrated (Gao et al. 1996), as has its function in predicting somatosensory events (Bower 1997a). The importance of the cerebellum in sequencing incoming sensory inputs has been elegantly demonstrated more than 10 years ago in a magnetoencephalographic study (Tesche and Karhu 2000) and subsequently confirmed in two mismatch negativity studies (Restuccia et al. 2007; Moberget et al. 2008). If a random omission is inserted in a regular train of somatosensory stimuli, thus creating unpredictable omissions, the cerebellum presents much higher activity when the stimulus is absent than when it is present. This clearly indicates that the cerebellar activity codes change in expectancy (Ivry 2000). Reviewing the role of the cerebellum in sensory processing, Nixon proposed sensory prediction as a fundamental cerebellar function that could contribute to many of the behavioral processes with which the

cerebellum has been implicated also outside the motor-sensory domain (Nixon 2003).

Cognitive sequencing functions are often analyzed by processing behavioral sequences. Different terms, such as action script or semantic sequencing, have been used indiscriminately to refer to such a function. Script sequencing can be defined as the process that allows for recognition of correct spatial and temporal relations among behaviorally relevant actions. Script sequencing has been considered to be sustained by the frontal lobe and basal ganglia circuits, and it requires the ability to plan (Tinaz et al. 2006).

Card-sequencing tasks, as for instance the Picture Arrangement (PA) subtest of the Wechsler Adult Intelligence Scale Revised (WAIS-R), requires examination of visual or verbal material to understand spatial, temporal, and/or semantic relationships and to reconstruct the strings in logical sequences. In other words, subjects have to extract elements to predict the next card in the sequence from a complex array of sensory information. We reported deficits in card-sequencing tasks after cerebellar damage either in the PA or in new developed test with material controlled contents (Leggio et al. 2008). In the PA test, patients with degenerative or focal cerebellar pathologies generally score within the normal range. Nevertheless, if performances are carefully analyzed, impairments can be identified. Cerebellar patients only rearrange small string fragments, and their performance differs significantly from that of matched controls. The sequencing impairment became more apparent when using the new test which allows to evaluate the sequencing performance according to the material used: verbal-script, pictorial-script, or spatial-abstract. Script sequencing requires the use of both spatial and temporal information, while abstract sequencing can rely exclusively on spatial information. Subjects with cerebellar lesions are impaired with all testing materials. Nevertheless, differences emerge considering the etiology and lesion topography. While cerebellar degenerative disorders uniformly affect performance throughout modalities, focal lesions evoke different profiles depending on the affected side. Patients with lesions of the left hemiserebellum perform poorly on script sequences, based on pictorial material, and patients with lesions of the right hemiserebellum fail to generate script sequences that require verbal elaboration.

Sequencing is required for a number of language functions and sequencing deficits reported in different language pathologies either developmental (Peter et al. 2013; Stoodley and Stein 2013) or of adult onset (Robinson 2013). Cerebellar dependent language impairments have been reported since early 1990s (Silveri et al. 1994) and are still matter of debate (Marien et al. 2014). Among cerebellar language deficits verbal fluency impairment is the most commonly reported (Tedesco et al. 2011).

Verbal fluency is routinely studied using tasks which measure the ability to generate words through different word searching methods, i.e. associative processes—phonological or semantic—and strategic abilities (Abwender et al. 2001). Production of words in a specific semantic category (e.g., birds, furniture, etc.) tests semantic association. Production of words that begin with a specific letter (e.g., F, A, etc.) tests phonemic association. In retrieving words from a lexicon under forced

conditions, peak performance requires the ability to organize words strategically into burst of words (clusters) that can be semantically or phonemically related. In phonemic and semantic fluency tasks both semantic and phonemic clusters can be produced, with more phonemic than semantic clusters produced in phonemic fluency tasks and vice versa in the semantic fluency tasks. Cerebellar patients can be impaired in their ability to generate lists of words according to the phonemic but not semantic rule. This modality-specific deficit is also present in clustering, i.e. cerebellar damage impairs selectively phonological clustering (Stoodley and Schmahmann 2009; Leggio et al. 2000). The selective phonological impairment indicates that cerebellar fluency impairment is due to a deficit in sequencing. Differences between semantic and phonological association strategies are attributed to differences in lexical representation and retrieval cue properties (Rosser and Hodges 1994; Troster et al. 1995). The semantic system contains knowledge of the physical and functional properties of objects and the activation of an initial and usually highly prototypical exemplar effects the automatic activation of closely related semantic neighbours. Letter fluency relies on phonological level of word representation, without reference to meaning, the mechanism is less automatic and it represents and unusual means of word searching and requires to form novel category neighbours (Martin et al. 1994; Rosser and Hodges 1994). Thus, while semantic rule is based on a well learned automatic strategy, the phonemic rule requires a novel strategy. The acquisition of a novel word retrieval strategy requires similar steps as those for the acquisition of sequence knowledge. To obtain a correct phonemic cluster, a subject has to sequentially couple the last word with the new ones. i.e. to keep the prototypical sound active within the working memory system, and to recognize the last word sound–next word sound phonemic correspondence.

In the last 20 years, data from disparate fields of neuroscience highlighted the importance of cerebellar processing in several non-motor domains, such as cognition, emotion, and affective processing (Kozioł et al. 2014). In turn, this revolution has necessitated a complete reconsideration of the mechanisms through which the cerebellum exerts its influence on the cerebral cortex. Among different theories, a role for the cerebellum in sequencing incoming sensory patterns and outgoing responses has been proposed (Leggio et al. 2011) underscoring the central position of cerebellar circuits in sequence processing, regardless of whether the material that is processed is sensory (Bower 1997a), motor (Thach et al. 1992) or behavioral (Molinari et al. 2008). Overall, cerebellar sequencing can be viewed as the basic functional mechanism that allows optimization of brain functions and it can explain on one hand the complexity of the motor and cognitive cerebellar profile and on the other the discreteness of cerebellar cognitive impairments.

## References

- Abwender DA, Swan JG, Bowerman JT, Connolly SW (2001) Qualitative analysis of verbal fluency output: review and comparison of several scoring methods. *Assessment* 8:323–338

- Bower JM (1997a) Control of sensory data acquisition. *Int Rev Neurobiol* 41:489–513
- Bower JM (1997b) Is the cerebellum sensory for motor's sake, or motor for sensory's sake: the view from the whiskers of a rat? *Prog Brain Res* 114:463–496
- Braitenberg V, Heck D, Sultan F (1997) The detection and generation of sequences as a key to cerebellar function: experiments and theory. *Behav Brain Sci* 20:229–277
- Bubic A, von Cramon DY, Schubotz RI (2010) Prediction, cognition and the brain. *Front Hum Neurosci* 4:25
- Doyon J, Penhune V, Ungerleider LG (2003) Distinct contribution of the cortico-striatal and cortico-cerebellar systems to motor skill learning. *Neuropsychologia* 41:252–262
- Doyon J, Bellec P, Amsel R et al (2009) Contributions of the basal ganglia and functionally related brain structures to motor learning. *Behav Brain Res* 199:61–75
- Gao JH, Parsons LM, Bower JM, Xiong J, Li J, Fox PT (1996) Cerebellum implicated in sensory acquisition and discrimination rather than motor control. *Science* 272:482–483
- Igloi K, Doeller CF, Berthoz A, Rondi-Reig L, Burgess N (2010) Lateralized human hippocampal activity predicts navigation based on sequence or place memory. *Proc Natl Acad Sci U S A* 107:14466–14471
- Ivry R (2000) Exploring the role of the cerebellum in sensory anticipation and timing: commentary on Tesche and Karhu (comment). *Hum Brain Mapp* 9:115–118
- Karabanov A, Cervinka S, de Manzano O, Forssberg H, Farde L, Ullén F (2010) Dopamine D2 receptor density in the limbic striatum is related to implicit but not explicit movement sequence learning. *PNAS* 107:7574–7579
- Kozioł LF, Budding D, Andreassen N et al (2014) Consensus paper: the cerebellum's role in movement and cognition. *Cerebellum* 13:151–177
- Leggio MG, Silveri MC, Petrosini L, Molinari M (2000) Phonological grouping is specifically affected in cerebellar patients: a verbal fluency study. *J Neurol Neurosurg Psychiatry* 69:102–106
- Leggio MG, Tedesco AM, Chiricozzi FR, Clausi S, Orsini A, Molinari M. (2008) Cognitive sequencing impairment in patients with focal or atrophic cerebellar damage. *Brain* 131:1332–1343
- Leggio MG, Chiricozzi FR, Clausi S, Tedesco AM, Molinari M (2011) The neuropsychological profile of cerebellar damage: the sequencing hypothesis. *Cortex* 47:137–144
- Marien P, Ackermann H, Adamaszek M et al (2014) Consensus paper: language and the cerebellum: an ongoing enigma. *Cerebellum* 13:386–410
- Martin A, Wiggs CL, Lalonde F, Mack C (1994) Word retrieval to letter and semantic cues: a double dissociation in normal subjects using interference tasks. *Neuropsychologia* 32:1487–1494
- Moberget T, Karns CM, Deouell LY, Lindgren M, Knight RT, Ivry RB (2008) Detecting violations of sensory expectancies following cerebellar degeneration: a mismatch negativity study. *Neuropsychologia* 46:2569–2579
- Molinari M, Petrosini L (1997) Is sequence in/sequence out a cerebellar mode of operation in cognition too? *Behav Brain Sci* 20:259–260
- Molinari M, Leggio MG, Solida A et al (1997) Cerebellum and procedural learning: evidence from focal cerebellar lesions. *Brain* 120:1753–1762
- Molinari M, Chiricozzi F, Clausi S, Tedesco A, De Lisa M, Leggio M (2008) Cerebellum and detection of sequences, from perception to cognition. *Cerebellum* 7:611–615
- Molinari M, Restuccia D, Leggio MG (2009) State estimation, response prediction, and cerebellar sensory processing for behavioral control. *Cerebellum* 8:399–402
- Nixon PD (2003) The role of the cerebellum in preparing responses to predictable sensory events. *Cerebellum* 2:114–122
- Peter B, Button L, Stoel-Gammon C, Chapman K, Raskind WH (2013) Deficits in sequential processing manifest in motor and linguistic tasks in a multigenerational family with childhood apraxia of speech. *Clin Linguist Phon* 27:163–191

- Pisotta I, Molinari M (2014) Cerebellar contribution to feedforward control of locomotion. *Front Hum Neurosci* 8:475
- Restuccia D, Della MG, Valeriani M, Leggio MG, Molinari M (2007) Cerebellar damage impairs detection of somatosensory input changes. A somatosensory mismatch-negativity study. *Brain* 130:276–287
- Robinson GA (2013) Primary progressive dynamic aphasia and Parkinsonism: generation, selection and sequencing deficits. *Neuropsychologia* 51:2534–2547
- Rosser A, Hodges JR (1994) Initial letter and semantic category fluency in Alzheimer's disease, Huntington's disease, and progressive supranuclear palsy. *J Neurol Neurosurg Psychiatry* 57:1389–1394
- Silveri MC, Leggio MG, Molinari M (1994) The cerebellum contributes to linguistic production: a case of agrammatic speech following a right cerebellar lesion (see comments). *Neurology* 44:2047–2050
- Stoodley CJ, Schmahmann JD (2009) The cerebellum and language: evidence from patients with cerebellar degeneration. *Brain Lang* 110:149–153
- Stoodley C, Stein J (2013) Cerebellar function in developmental dyslexia. *Cerebellum* 12:267–276
- Tedesco AM, Chiricozzi FR, Clausi S, Lupo M, Molinari M, LEGGIO MG (2011) The cerebellar cognitive profile. *Brain* 134:3672–3678
- Tesche CD, Karhu JJ (2000) Anticipatory cerebellar responses during somatosensory omission in man (see comments). *Hum Brain Mapp* 9:119–142
- Thach WT, Goodkin HP, Keating JG (1992) The cerebellum and the adaptive coordination of movement. *Annu Rev Neurosci* 15:403–442
- Tinaz S, Schendan HE, Schon K, Stern CE. (2006) Evidence for the importance of basal ganglia output nuclei in semantic event sequencing: an fMRI study. *Brain Res.* 1067: 239–249.
- Troster AI, Warmflash V, Osorio I, Paolo AM, Alexander LJ, Barr WB (1995) The roles of semantic networks and search efficiency in verbal fluency performance in intractable temporal lobe epilepsy. *Epilepsy Res* 21:19–26

# Chapter 55

## Speech and Language

Peter Mariën and Kim van Dun

**Abstract** The traditional view of the cerebellum as the sole coordinator of sensorimotor function has been substantially redefined during the past decades. Neuroanatomical, neuroimaging and clinical studies have extended the role of the cerebellum to the modulation of cognitive, affective and social processing. Neuroanatomical studies have demonstrated cerebellar connectivity with the supratentorial association areas involved in higher cognitive, affective and social functioning, while functional neuroimaging and clinical studies have provided evidence of cerebellar involvement in a variety of cognitive, affective and social tasks. This chapter provides an overview of the recently acknowledged role of the cerebellum in speech and language processing.

**Keywords** Cerebellum • Language • Speech • Cognition • Affect

### 55.1 Introduction

Clinical and experimental research on the cerebellum has been overshadowed for more than two centuries by an overwhelming interest in the role of the cerebellum in sensorimotor control (Manto et al. 2012; Mariën et al. 2014). A wealth of experimental and clinical evidence supports the view that the cerebellum coordinates movement, resulting in various cerebellar ataxic syndromes in cases where the motor zones of the cerebellum sustain neurological damage. However, during the past decades, the long-standing view of the cerebellum as a pure coordinator of

---

P. Mariën (✉)

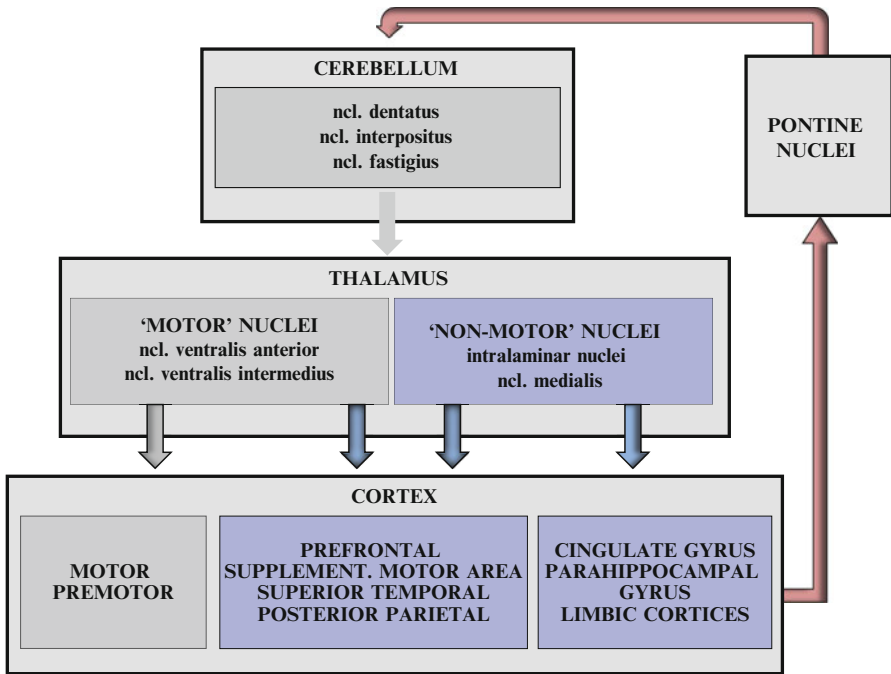
Department of Neurology and Memory Clinic, ZNA Middelheim Hospital,  
Antwerp, Belgium

Department of Clinical Neurolinguistics (CLIN), Vrije Universiteit Brussel,  
Brussels, Belgium

e-mail: [peter.marien5@telenet.be](mailto:peter.marien5@telenet.be)

K. van Dun

Department of Clinical Neurolinguistics (CLIN), Vrije Universiteit Brussel,  
Brussels, Belgium



**Fig. 55.1** Diagram depicting the cerebello-cerebral connectivity network underlying cognitive and affective processes. The feedback or efferent loop originates from the deep nuclei of the cerebellum that project to the motor (*grey arrows*) and nonmotor (*blue arrows*) nuclei of the thalamus. In turn, the motor nuclei of the thalamus (ncl. ventralis anterior and intermedius) project to motor and premotor cortices (*grey arrows*) but also to nonmotor areas among which the prefrontal cortex, the supplementary motor area, the superior temporal, and posterior parietal regions (*blue arrows*). The nonmotor nuclei of the thalamus project to the cingulate gyrus, the parahippocampal region, and the limbic cortices (*blue arrows*). The feedforward or afferent system of the cerebello-cerebral circuit is composed of corticopontine and pontocerebellar mossy fiber pathways (*red arrows*) (After Schmahmann and Pandya (1997) and from Mariën et al. (2013))

sensorimotor function has been modified. From the late 1970s onwards, major advances have been made in elucidating the many functional neuroanatomical connections of the cerebellum with the supratentorial association cortices that subserve nonmotor language, cognition, and affect (Fig. 55.1). In addition, neuroimaging studies in healthy subjects and neurophysiological and neuropsychological research in patients showed that the cerebellum is critically implicated in a large spectrum of cognitive and affective impairments. As a result, converging evidence derived from these different strands of research substantially extended the sensorimotor role of the cerebellum to include that of a crucial modulator of cognitive and affective processes.

## 55.2 Motor Speech Production: Planning and Coordination of Articulatory Movements

At the beginning of the twentieth century Gordon Holmes put forward the view that the cerebellum plays a crucial role in motor speech production. *Ataxic dysarthria* is a typical cerebellar motor speech disorder characterized by distorted articulation and prosody (Spencer and Slocomb 2007). Ataxic dysarthria shares a number of characteristics with *apraxia of speech*, a motor speech planning and coordination disorder that typically follows from injury to the language dominant motor speech regions. These similarities led some researchers to believe that both conditions are related phenomena resulting from disruption of the motor speech planning and coordinating network subserved by the motor speech areas of the language dominant hemisphere and the cerebellum (Mariën et al. 2006).

## 55.3 Verbal Fluency and Lexical/Semantic Retrieval

The right lateral cerebellum has been consistently implicated in *word generation* tasks. Papathanassiou et al. (2000) used positron emission tomography (PET) to show activation in the right cerebellum during a covert verb generation task. Silveri et al. (1998) found *verbal short-term memory* deficits after surgical removal of the right cerebellar hemisphere in an 18-year-old patient. They identified the functional locus of the deficit at the level of the phonological output buffer. Leggio et al. (1995, 2000) studied patients with focal or degenerative left and right cerebellar lesions and showed that cerebellar damage specifically affects phonological fluency. These findings were confirmed by Schweizer et al. (2010) who also showed that patients with right cerebellar lesions were significantly more impaired than patients with left cerebellar lesions.

## 55.4 Syntax Impairment

Agrammatism has been repeatedly observed in patients with focal cerebellar lesions. Silveri et al. (1994) described a patient who, following ischemic damage of the right cerebellum, presented with expressive agrammatism. Single photon emission computed tomography (SPECT) showed a relative hypoperfusion (cerebellocerebral diaschisis) in the entire left cerebral hemisphere (Silveri et al. 1994). Several other studies subsequently showed that the right cerebellar hemisphere is embedded within a distinct neural network devoted to the processing of grammar, together with the basal ganglia and the language dominant left prefrontal, temporal and parietal cortex (Mariën et al. 2001).



## 55.5 Aphasia

The co-occurrence of deficits affecting different linguistic levels may give rise to cerebellar-induced aphasia (Mariën et al. 1996). Mariën et al. (1996) described a 73-year-old, right-handed patient with a dynamic aphasia-like language disorder after an ischemic lesion in the vascular territory of the right superior cerebellar artery. SPECT revealed a significant hypoperfusion in the anatomoclinically suspected prefrontal language region of the left hemisphere. Impairment of linguistic functions after cerebellar lesions may therefore result from a decrease of excitatory impulses through the cerebello-ponto-thalamo-cortical pathways causing functional depression of the supratentorial regions subserving linguistic functions (cerebello-cerebral diaschisis). Other cases have been published of adult patients who suffered from various aphasic symptoms (Mariën et al. 2009; Baillieux et al. 2010). A more skeptical opinion on the role of the cerebellum in linguistic processing has been advanced by Timmann and co-workers who address the limitations of lesion studies and negative findings in patients with cerebellar lesions in a number of studies (e.g. Frank et al. 2007).

## 55.6 Acquired and Developmental Dyslexia

*Acquired dyslexia* (alexia) following cerebellar lesions is typically related to non-linguistic disturbances such as imperfect oculomotor control (nystagmus) (Moretti et al. 2002) or functional disruption of the cerebellar-encephalic projections involved in attentional and alerting mechanisms (Mariën et al. 2009; Moretti et al. 2002).

However, Nicolson et al. (1995, 2001) included the cerebellum in the pathogenesis of *dyslexia*. They introduced the “cerebellar deficit hypothesis” to explain dyslexia as a disruption of the automatization of learned skills such as articulation, reading, spelling, and phonological abilities, caused by cerebellar dysfunction. Several neuroimaging studies of dyslexic subjects have demonstrated abnormal cerebellar function in a range of cognitive and linguistic tasks (Brown et al. 2001; Rae et al. 2002; Nicolson et al. 1999; Baillieux et al. 2009).

## 55.7 Peripheral and Central Agraphia

Cerebellar damage might induce motor writing disorders such as *afferent dysgraphia* and *macrographia* (Silveri et al. 1997). However, central agraphias may be observed following cerebellar damage as well. The patient of Mariën et al. (2009) presented with *surface dysgraphia* after a right superior cerebellar artery infarction. Supported by SPECT findings they hypothesized that the writing deficits resulted from functional disruption of the cerebellar-encephalic pathways connecting the

cerebellum to the frontal supratentorial areas, which subserve attentional and planning processes. Clinical evidence suggests involvement of the cerebellum in the neural network of *graphomotor planning*. Distortion of the spatiotemporal features of handwriting (*apraxic agraphia*) has been observed after disruption of the cerebello-cerebral network subserving the planning and execution of skilled motor actions (Mariën et al. 2007; De Smet et al. 2011).

## 55.8 Conclusion

Clinical and experimental evidence shows that different neuroanatomic parts of the cerebellum are critically implicated in a variety of speech and language functions. The neuroanatomical substrate subserving the role of the cerebellum in nonmotor language processing is a dense and reciprocal network of crossed cerebro-cerebellar pathways that establish a close connection between the cerebellum and the supratentorial autonomic, limbic, and association cortices. In addition, the majority of anatomoclinical studies of patients with linguistic impairments following focal cerebellar lesions and experimental neuroimaging studies consistently show a lateralized involvement of the right lateral cerebellar regions in nonmotor linguistic processes. The exact underlying pathophysiological mechanisms, however, remain to be elucidated.

## References

- Baillieux H, Vandervliet EJM, Manto M, Parizel PM, De Deyn PP, Mariën P (2009) Developmental dyslexia and widespread activation across the cerebellar hemispheres. *Brain Lang* 108:122–132
- Baillieux H, De Smet HJ, Dobbeleir A, Paquier PF, De Deyn PP, Mariën P (2010) Cognitive and affective disturbances following focal cerebellar damage in adults: a neuropsychological and SPECT study. *Cortex* 46:869–879
- Brown WE, Eliez S, Menon V, Rumsey JM, White CD, Reiss AL (2001) Preliminary evidence of widespread morphological variations of the brain in dyslexia. *Neurology* 56:781–783
- De Smet HJ, Engelborghs S, Paquier PF, De Deyn PP, Mariën P (2011) Cerebellar-induced apraxic agraphia: a review and three new cases. *Brain Cogn* 76:424–434
- Frank B, Schoch B, Hein-Kropp C, Dimitrova A, Hövel M, Ziegler W, Gizewski ER, Timmann D (2007) Verb generation in children and adolescents with acute cerebellar lesions. *Neuropsychologia* 45:977–988
- Leggio MG, Solida A, Silveri MC, Gainotti G, Molinari M (1995) Verbal fluency impairments in patients with cerebellar lesions. *Soc Neurosci Abstracts* 21:917
- Leggio MG, Silveri MC, Petrosini L, Molinari M (2000) Phonological grouping is specifically affected in cerebellar patients: a verbal fluency study. *J Neurol Neurosurg Psychiatry* 69:102–106
- Manto M, Bower JM, Conforto AB, Delgado-García JM, da Guarda SN, Gerwig M, Habas C, Hagura N, Ivry RB, Mariën P, Molinari M, Naito E, Nowak DA, Oulad Ben Taib N, Pelisson D, Tesche CD, Tilkete C, Timmann D (2012) Consensus paper: roles of the cerebellum in motor control – the diversity of ideas on cerebellar involvement in movement. *Cerebellum* 11:457–487

- Mariën P, Saerens J, Nanhoe R, Moens E, Nagels G, Pickut B, Dierckx RA, De Deyn PP (1996) Cerebellar induced aphasia: case report of cerebellar induced prefrontal aphasic language phenomena supported by SPECT findings. *J Neurol Sci* 144:34–43
- Mariën P, Engelborghs S, Fabbro F, De Deyn PP (2001) The lateralized linguistic cerebellum: a review and a new hypothesis. *Brain Lang* 79:580–600
- Mariën P, Verhoeven J, Engelborghs S, Rooker S, Pickut BA, De Deyn PP (2006) A role for the cerebellum in motor speech planning: evidence from foreign accent syndrome. *Clin Neurol Neurosurg* 108:518–522
- Mariën P, Verhoeven J, Brouns R, De Witte L, Dobbeleir A, De Deyn PP (2007) Apraxic agraphia following a right cerebellar hemorrhage. *Neurology* 69:926–929
- Mariën P, Baillieux H, De Smet HJ, Engelborghs S, Wilssens I, Paquier P, De Deyn PP (2009) Cognitive, linguistic and affective disturbances following a right superior cerebellar artery infarction: a case study. *Cortex* 45:527–536
- Mariën P, De Smet HJ, Wijgerde E, Verhoeven J, Crols R, De Deyn PP (2013) Posterior fossa syndrome in adults: a new case and comprehensive survey of the literature. *Cortex* 49:284–300
- Mariën P, Ackermann H, Adamaszek M, Barwood CHS, Beaton A, Desmond J, De Witte E, Fawcett AJ, Hertrich I, Küper M, Leggio M, Marvel C, Molinari M, Murdoch BE, Nicolson RI, Schmahmann JD, Stoodley CJ, Thürling M, Timmann D, Wouters E, Ziegler W (2014) Consensus paper: language and the cerebellum: an ongoing enigma. *Cerebellum* 13:386–410
- Moretti R, Bava A, Torre P, Antonello RM, Cazzato G (2002) Reading errors in patients with cerebellar vermis lesions. *J Neurol* 249:461–468
- Nicolson RI, Fawcett AJ, Dean P (1995) Time estimation deficits in developmental dyslexia: evidence of cerebellar involvement. *Proc R Soc Lond Ser B Biol Sci* 259:43–47
- Nicolson RI, Fawcett AJ, Berry EL, Jenkins IH, Dean P, Brooks DJ (1999) Association of abnormal cerebellar activation with motor learning difficulties in dyslexic adults. *Lancet* 353:1662–1667
- Nicolson RI, Fawcett AJ, Dean P (2001) Developmental dyslexia: the cerebellar deficit hypothesis. *Trends Neurosci* 24:508–511
- Papathanassiou D, Etard O, Mellet E, Zago L, Mazoyer B, Tzourio-Mazoyer N (2000) A common language network for comprehension and production: a contribution to the definition of language epicenters with PET. *Neuroimage* 11:347–357
- Rae C, Harasty JA, Dzendrowskyj TE, Talcott JB, Simpson JM, Blamire AM et al (2002) Cerebellar morphology in developmental dyslexia. *Neuropsychologia* 40:1285–1292
- Schmahmann JD, Pandya DN (1997) The cerebrocerebellar system. In: Schmahmann JD (ed) *The cerebellum and cognition, international review of neurobiology*. Academic, San Diego, pp 31–60
- Schweizer TA, Alexander MP, Gillingham S, Cusimano M, Stuss DT (2010) Lateralized cerebellar contributions to word generation: a phonemic and semantic fluency study. *Behav Neurol* 23:31–37
- Silveri MC, Leggio MG, Molinari M (1994) The cerebellum contributes to linguistic production: a case of agrammatic speech following a right cerebellar lesion. *Neurology* 44:2047–2050
- Silveri MC, Misciagna S, Leggio MG, Molinari M (1997) Spatial dysgraphia and cerebellar lesion: a case report. *Neurology* 48:1529–1532
- Silveri MC, Di Betta AM, Filippini V, Leggio MG, Molinari M (1998) Verbal short-term store-rehearsal system and the cerebellum. Evidence from a patient with a right cerebellar lesion. *Brain* 121:2175–2187
- Spencer KA, Slocomb DL (2007) The neural basis of ataxic dysarthria. *Cerebellum* 6:58–65

**Part VIII**  
**Cellular and Animal Models of Cerebellar**  
**Disorders**

# Chapter 56

## The Zebrafish Cerebellum

Jan Kaslin and Michael Brand

**Abstract** The overall architecture and cell types are highly conserved from mammals to teleost fish. The rapid transparent *ex utero* development in zebrafish allows direct access and precise visualization of all the major events in cerebellar development. The superficial position of the cerebellar primordium and cerebellum further facilitates *in vivo* imaging of cerebellar structures and developmental events at cell resolution. Furthermore, zebrafish model have a comprehensive genetic toolbox that allow forward and reverse genetic approaches to study and manipulate gene function. Consequently, zebrafish is emerging as an excellent vertebrate model for studies of molecular, cellular and physiological mechanisms involved in cerebellar development and function at gene, cell and circuit level.

**Keywords** Zebrafish • Teleost • Fish • Adult neurogenesis • Mutant • Screening • Eurydendroid cell • Genetic model • Cerebellar development • Morphogenesis • Mid-hindbrain-boundary • Isthmic organizer • *in vivo* imaging

### 56.1 Introduction

The rapid transparent *ex utero* development in zebrafish allows direct access and precise visualization of all the major events in cerebellar development. The superficial position of the cerebellar primordium and cerebellum further facilitates *in vivo* imaging of cerebellar structures and developmental events at single cell resolution. Furthermore, zebrafish is amenable to high-throughput screening techniques and

---

J. Kaslin (✉)

Australian Regenerative Medicine Institute, Monash University,  
Wellington road, Bld 75, Clayton, VIC 3800 Melbourne, Australia  
e-mail: [jan.kaslin@monash.edu](mailto:jan.kaslin@monash.edu)

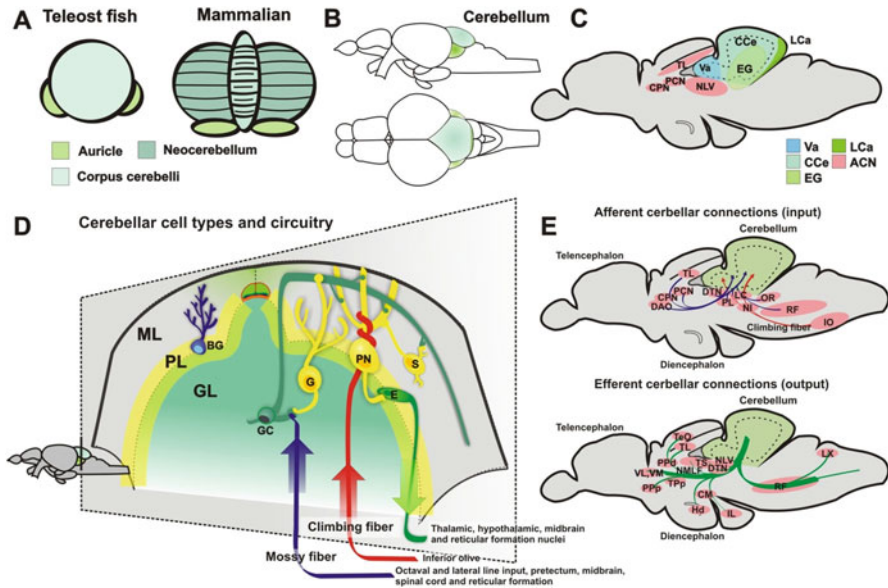
M. Brand (✉)

Biotechnology Center and Center for Regenerative Therapies Dresden,  
Technische Universität Dresden, Fetscherstr. 105, 01307 Dresden, Germany  
e-mail: [michael.brand@biotec.tu-dresden.de](mailto:michael.brand@biotec.tu-dresden.de)

forward genetics because of its fecundity and easy keeping. Forward genetics screens in zebrafish have resulted in several isolated cerebellar mutants and substantially contributed to the understanding of the genetic networks involved in hind-brain development (Bae et al. 2009; Brand et al. 1996). Recent developments in genetic tools, including the use of site specific recombinases, efficient transgenesis, inducible gene expression systems, and the targeted genome lesioning technologies TALEN and Cas9/CRISPR has opened up new avenues to manipulate and edit the genome of zebrafish (Hans et al. 2009; Jungke et al. 2013, 2016; Scott 2009; Suster et al. 2009; Goll et al. 2009; Hwang et al. 2013; Sander et al. 2011; Huang et al. 2011; Bedell et al. 2012). These tools enable the use of genome-wide genetic approaches, such as enhancer/exon traps and cell specific temporal control of gene expression in zebrafish. Several seminal papers have used these technologies to successfully elucidate mechanisms involved in the morphogenesis, neurogenesis and cell migration in the cerebellum (Bae et al. 2009; Chaplin et al. 2010; Hans et al. 2009; Kaslin et al. 2009, 2013; Volkmann et al. 2010, 2008). In addition, the use of genetically encoded sensors and probes that allows detection and manipulation of neuronal activity using optical methods have open up new means to study the physiology and function of the cerebellum (Simmich et al. 2012; Matsui et al. 2014). Taken together, these features have allowed zebrafish to emerge as an excellent model for studies of molecular, cellular and physiological mechanisms involved in cerebellar development and function at both cell and circuit level.

## 56.2 The Cerebellar Anatomy and Architecture

The general organization and cellular architecture of the cerebellum is highly conserved in vertebrates. The cerebellum of all jawed vertebrates consists of a major lobe, the corpus cerebelli (cerebellar corpus) and two bilateral lobes, the auricle (also known as the vestibulocerebellum, (Fig. 56.1a; Altman and Bayer 1997)). The architecture of cerebellum is highly similar to other vertebrates but there are some notable differences. The most striking differences are the lack of deep cerebellar nuclei and a well-defined white matter. Furthermore, the zebrafish fish have additional precerebellar and cerebelloid structures. The zebrafish cerebellum can be divided in three major parts, the valvula cerebelli, the corpus cerebelli and the vestibulolateral lobe (Fig. 56.1b–c; Finger 1983; Meek 1998; Wullimann 1997). The eminentia granularis and the caudal lobe together form the vestibulolateral lobe that has been suggested to be homologous to the auricle of other vertebrates (Wullimann 1997). The cerebellar corpus in zebrafish consists of a single folia and it has an anterior extension, the valvula cerebelli, which extends into the tectal ventricle below the optic tectum. The cerebellar corpus is laterally flanked by the eminentia granularis and posteriorly by the caudal lobe. In addition, zebrafish have extra structures associated to the cerebellum such as cerebelloid structures (cerebellar-like) and additional precerebellar nuclei that are not found in other vertebrates. Zebrafish has two precerebellar nuclei, the nucleus valvula lateralis and the nucleus



**Fig. 56.1** (a) The vertebrate cerebellum consists of a major lobe, the corpus cerebelli (cerebellar corpus) and two bilateral lobes, the auricle (flocculus in tetrapods). In addition, mammals display a large lateral expansion of the corpus cerebelli, the neocerebellum. (b) Schematic drawing of the zebrafish brain seen from the side and top. Light green illustrates the cerebellar corpus and the darker green the auricle. (c) Schematic parasagittal overview of the zebrafish brain showing the major cerebellar parts and associated cerebellar structures. *ACN* accessory cerebellar nuclei, *CCe* cerebellar corpus, *CPN* central pretectal nucleus, *EG* eminentia granularis, *LCa* caudal lobe of cerebellum, *NLV* nucleus lateralis valvulae, *PCN* paracommissural nucleus, *TL* torus longitudinalis, *Va* valvula cerebelli. (d) The zebrafish cerebellum has a simple laminar three layered architecture consisting of a molecular layer (*ML*), purkinje cell layer (*PL*) and a granule cell layer (*GL*). The granule layer is consisting of small densely packed excitatory granule cells and inhibitory Golgi neurons (*G*). The Purkinje cell layer is inhabited with Purkinje neurons (*PN*), a specialized macroglia type, Bergmann glia (*BG*) and excitatory eurydendroid cells (*E*). The *ML* is mainly consisting of nerve fibers and scattered inhibitory stellate cells (*S*). Mossy and climbing fibers excite Purkinje and granule cells. Granule cell axons provide excitatory input to Purkinje cells and their dendrites as well as the Golgi and stellate cells. Purkinje cells inhibit eurydendroid cells. Eurydendroid cell axons project to various targets outside the cerebellum. Stellate cells provide inhibitory input to the dendrites of Purkinje cells and Golgi cells inhibit granule cells. Dendrites from granule cells together with Golgi cell axons and mossy fiber terminals form a specialized synaptic structure known as the glomerulus. (e) Cerebellar afferents and efferents in teleost fish. *CM* mammillary body, *CPN* central pretectal nucleus, *DAO* dorsal accessory optic nucleus, *Hd* dorsal zone of periventricular hypothalamus, *DTN* dorsal tegmental nucleus, *IL* inferior lobe of the hypothalamus, *IO* inferior olive, *LC* locus coeruleus, *LX* vagal lobe, *NI* isthmus nucleus, *NLV* nucleus lateralis valvulae, *NMLF* nucleus of the medial longitudinal fascicle, *OR* octavolateral region, *PCN* paracommissural nucleus, *PPd* dorsal periventricular pretectal nucleus, *PPp* posterior parvocellular preoptic nucleus, *RF* reticular formation, *PL* perilemmiscal nucleus, *TL* torus longitudinalis, *TS* semicircular torus, *TeO* optic tectum, *TPp* periventricular nucleus of the posterior tuberculum, *VL* ventrolateral thalamic nucleus, *VM* ventromedial thalamic nucleus

paracommissuralis (Fig. 56.1c). The precerebellar nuclei are closely associated with the cerebellum through significant fiber projections. Cerebelloid structures are architecturally thought to be very similar to the cerebellum, although they are spatially well separated from the cerebellum. Cerebelloid structures are found in all vertebrate lineages except reptiles and birds (Bell 2002; Bell et al. 2008). Two cerebelloid structures are found in zebrafish. In the hindbrain the medial octavolateral nucleus, eminentia granularis and the cerebellar crest (crista cerebellaris) form one cerebelloid structure. The torus longitudinalis together with the optic tectum forms the second cerebelloid structure in zebrafish. Like the cerebellum the cerebelloid structures process sensory signals, receive input from the periphery to the deep layers and parallel fiber input to the molecular layer.

The general vertebrate cerebellum consists of a three-layered cortex and an underlying white matter (Altman and Bayer 1997). This three layered arrangement is well recognizable in zebrafish (Fig. 56.1d). However, the eminentia granularis and caudal lobe consists of a single granule cell layer. In contrast, to tetrapods zebrafish lack a well-defined white matter beneath the cerebellum. In teleost fish three distinct subtypes of inhibitory neurons have been found in the cerebellar cortex: stellate, Golgi and Purkinje cells. Stellate and Golgi cells are interneurons and only project within the cerebellum. The stellate cells are scattered in the molecular cell layer of teleost fish, while Golgi cells primarily are found in the granule cell layer (Fig. 56.1d; Butler and Hodos 2005; Delgado and Schmachtenberg 2008; Hans et al. 2009; Meek et al. 2008). In most vertebrates the Purkinje cell is the sole cell type that projects outside the cerebellum to the deep cerebellar nuclei. The deep cerebellar nuclei are located in the white matter beneath the cerebellum. In zebrafish and other teleosts this configuration is different. Firstly, teleost fish have an additional efferent cell type in the cerebellar cortex, the eurydendroid cell (Fig. 56.1d; Nieuwenhuys et al. 1974; Alonso et al. 1992; Bae et al. 2009; Meek 1992). Secondly, teleost fish lack deep cerebellar nuclei. However, the eurydendroid cells directly innervate similar targets in the brain stem and spinal cord as the deep cerebellar nuclei of other vertebrates. Furthermore, the eurydendroid cells receive input from Purkinje cells (Butler and Hodos 2005; Bae et al. 2009; Ikenaga et al. 2005; Murakami and Morita 1987). Based on these similarities to the deep cerebellar nuclei it is possible to imply that eurydendroid cells have an equivalent function in the cerebellar circuitry. Similar to other vertebrates abundant glutamergic granule cells are found in the granule cell layer of zebrafish (Bae et al. 2009; Kaslin et al. 2009). Other less abundant cerebellar interneuron types such as unipolar brush, Lugaro, and basket cells have not yet been identified in zebrafish.

The vertebrate cerebellum receives afferent input from two principal sources, mossy and climbing fibers (Fig. 56.1e; Altman and Bayer 1997). In zebrafish the climbing fibers originate in the inferior olive in the caudal hindbrain and predominantly terminate on the soma and the proximal dendrites of Purkinje neurons (Fig. 56.1e; Bae et al. 2009; Folgueira et al. 2006; Wullimann and Northcutt 1988; Xue et al. 2008). Similar to other vertebrates the mossy fiber-like pathway in teleost fish originates from multiple sources such as the spinal cord, reticular formation and tegmentum (Fig. 56.1e; Finger 1978; Folgueira et al. 2006; Kani et al. 2010;

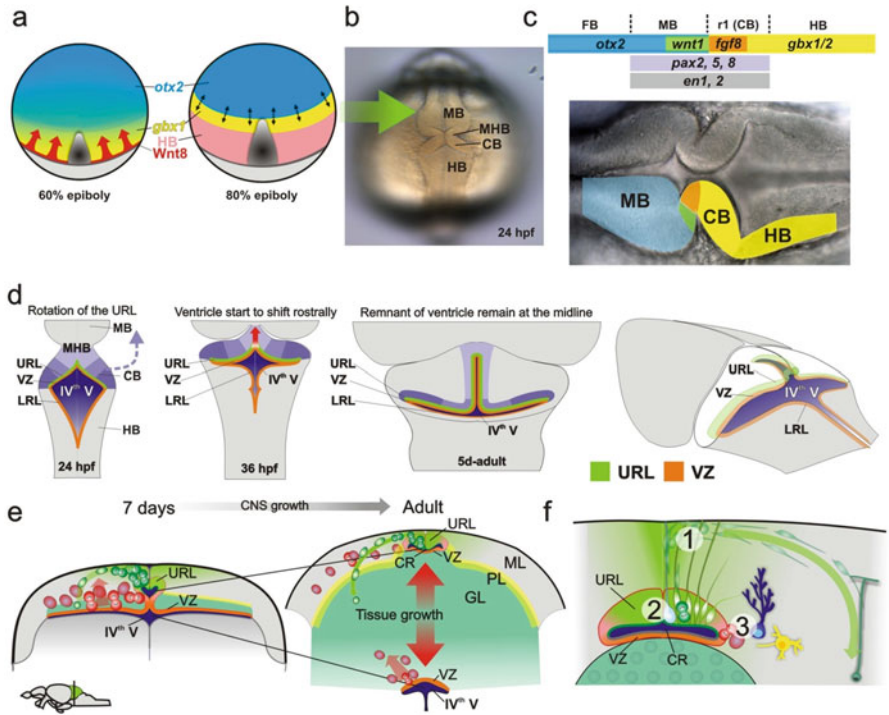


Volkman et al. 2010; Wullmann and Northcutt 1988, 1989). Systematic retrograde tracing experiments have not yet been undertaken in zebrafish but in agreement above mentioned studies, mossy fiber-like input from several precerebellar nuclei has been reported in juvenile zebrafish (Bae et al. 2009; Kani et al. 2010; Volkman et al. 2010). The cerebellar output from the eurydendroid cells in zebrafish has recently been mapped by genetic methods (Matsui et al. 2014) and is in agreement with studies from other teleosts and targets such as the thalamus, pretectal nuclei, tegmental nuclei and motor and premotor centers are innervated by the eurydendroid cells (Folgueira et al. 2006; Ikenaga et al. 2002; Ito and Yoshimoto 1990; Wullmann and Northcutt 1988).

### 56.3 Cerebellar Development and Neurogenesis

The initial phase of midbrain and cerebellar development in vertebrates depends on the formation and function of the isthmic organizer which lies at the midbrain-hindbrain boundary (MHB, Fig. 56.2). The MHB organizer formation and maintenance is defined by an intricate cascade of genetic interactions that are marked by complex temporal and spatial patterns of gene expression (Fig. 56.2). Initially the MHB is positioned along the anterior-posterior axis early within the neural plate by the opposing boundary created by mutual repression between the transcription factors *otx2* and *gbx2* (Broccoli et al. 1999; Millet et al. 1999; Rhinn and Brand 2001; Simeone 2000). In contrast to other vertebrates, *gbx1* and not *gbx2* positions the MHB in zebrafish (Rhinn et al. 2009, 2005). At the end of gastrulation, a complex genetic network with several region-specific transcription factors such as *Pax2/5* and *En1/2*, and the secreted molecules Wnt1 and Fgf8 are expressed at the *Otx/Gbx* interface (Rhinn and Brand 2001). The secreted signals from the isthmic organizer in turn determine the development of the surrounding mid and hindbrain tissue. Studies in different vertebrates show that three parallel signaling pathways, involving *Pax2/pax2.1*, *Wnt1* and *Fgf8*, are activated independently at this interface during early embryonic stages (Fig. 56.2c; Canning et al. 2007; Lun and Brand 1998; Raible and Brand 2004; Reifers et al. 1998). During later somitogenesis stages the three pathways become mutually dependent (Rhinn and Brand 2001). The expression of the region-specific transcription factors is later under the control of Fgf8, 17, 18 and Wnt1, 8b 10, secreted by the isthmic organizer itself (Raible and Brand 2004; Foucher et al. 2006; Buckles et al. 2004; Lekven et al. 2003; O'Hara 2005, #488). These factors are involved in regulating cell proliferation and patterning of the cerebellum as well as cell differentiation and maintenance.

The cerebellar neurons and glia originate from two principal germinal zones in the hindbrain, the rhombic lip (RL) and the ventricular zone (VZ (Wingate 2001)). Excitatory neurons are generated by the RL and the inhibitory neurons are generated from the VZ (Hoshino et al. 2005). The transcription factor Ptf1a marks progenitors of inhibitory neurons in the VZ, while the transcription factor Ato1 labels progenitors for excitatory cells in the RL and subsequent EGL (Ben-Arie et al.



**Fig. 56.2** (a) Positioning of the midbrain–hindbrain boundary organizer in the neural plate of zebrafish. The interface between cells expressing *otx* and *gbx* transcription factors marks the location in the neural plate where the midbrain–hindbrain boundary organizer forms. During gastrulation, *Wnt8* is secreted by the blastoderm margin (red arrows). It is required for the initial subdivision of the neuroectoderm, including onset of the posterior *gbx1* (yellow) expression and establishment of the posterior border of *otx2* (blue) expression. Towards the end of gastrulation, the *otx2* and *gbx1* expression domains are sharp and complementary. Grey area=developing axial mesoderm. Light grey=yolk. Black arrows indicate the mutually repressive interactions. (b–c) Morphogenetic events of the cerebellar primordium. At 24 hpf the midbrain–hindbrain boundary, midbrain structures and the cerebellar primordium are clearly distinguishable in the zebrafish embryo. (c) At the end of gastrulation, a complex genetic network with several region-specific transcription factors and the secreted molecules *Wnt1* and *Fgf8* are expressed at the *otx/gbx* interface. The secreted signals from the isthmic organizer in turn determine the development of the surrounding mid and hindbrain tissue. (d) Summary of the early morphogenetic events and the establishment of the progenitor domains. There is a morphogenetic rotation of the cerebellar primordium (blue arrow). From 36 hpf onwards the dorsomedial part of the IVth ventricle is shifted anteriorly creating a dorsomedial extension of the IVth ventricle (red arrow). Ventricularly located progenitors (orange line) are found in the LRL of the hindbrain and in the VZ of the cerebellum. Cerebellar progenitors adjacent to the roof plate are induced to turn in to granule cell progenitors (URL, green line). (e) Schematic summary of tissue growth and displacement of the progenitor niche. Displacement of the URL progenitor niche through tissue growth begins around 7 dpf. During juvenile stages there is vast generation of granule cells and massive expansion of the granule cell layer. URL progenitors (green) are maintained dorsal to the cerebellar recessus in adult zebrafish while ventricular zone derived progenitors and glia (orange) are found ventral to the recessus around the IVth ventricle. (f) Schematic summary of the zebrafish cerebellar progenitor niche. Neural progenitors derived from the URL are maintained in the dorsomedial part of the cerebellum around a remnant of the IVth ventricle (the cerebellar recessus). These progenitors

1997; Hoshino et al. 2005). In zebrafish the cerebellar primordium becomes morphologically distinguishable during mid-segmentation stages (Fig. 56.2b). The upper and lower rhombic lip parts are well recognizable one day after fertilization and *atoh1a-b* expression is detected in the whole RL (Adolf et al. 2004; Kani et al. 2010; Kim et al. 1997; Koster and Fraser 2001), while *ptf1a* expression is confined to the lower part of the RL (Elsen et al. 2008; Kani et al. 2010; Volkmann et al. 2008; Zecchin et al. 2004). Initiation of layer formation starts at three days after fertilization when the first differentiated Purkinje cells are detected (Bae et al. 2009; Katsuyama et al. 2007; Volkmann et al. 2008). Granule cell production starts at two days after fertilization when granule cell precursors leave the URL (Adolf et al. 2004; Bae et al. 2009; Chaplin et al. 2010; Koster and Fraser 2001; Toyama et al. 2004; Volkmann et al. 2008). They rapidly migrate in chain-like structures over long distance and start to differentiate (Koster and Fraser 2006; Volkmann et al. 2008). All the three cortical layers can be distinguished 5 days after fertilization.

Cerebellar progenitor activity and neurogenesis continue into adulthood in zebrafish (Grandel et al. 2006; Kaslin et al. 2009, 2013). The adult cerebellar stem cell niche consists of polarized neuroepithelial-like cells that inhabit the dorsal part of the IVth ventricle (Fig. 56.2e). Produced cells rapidly migrate in a distinct outside-in fashion into the granule cell layer where they differentiate into granule cells. In the adult cerebellum the granule precursors migrate into the granule cell layer within 3 days (Kaslin et al. 2009). Although several subtypes of inhibitory and excitatory cells are found in the zebrafish cerebellum, mainly granule cells are produced in the adult (Kaslin et al. 2013). In amniotes granule cell precursors migrate from the URL to the cerebellar surface where they transiently form a highly proliferative second germinal zone, the external granule layer (EGL). Sonic hedgehog secreted from Purkinje neurons act as the major mitogenic signal for granule precursors in the external granule layer (Dahmane et al. 1999; Wechsler-Reya and Scott 1999). In contrast to amniotes, sonic hedgehog signaling and a prominent external granule cell layer is lacking in the developing and adult zebrafish cerebellum (Chaplin et al. 2010; Kaslin et al. 2009). The advent of a secondary zone of transient amplification (eg the external granule cell layer) seems to be an amniote specific developmental adaptation because shark, teleost fish and frogs lack an obvi-



**Fig. 56.2** (continued) give rise to granule neurons in a distinct outside-in fashion. (1) Polarized neuroepithelial-like progenitors (*green*) are restricted to the midline of the dorsal cerebellum. The progenitors give rise to rapidly migrating granule precursors (*dark green*) that initially migrate dorsolaterally. During this initial phase the granule precursors still may proliferate. After reaching the meninge the granule precursors change to a unipolar morphology and start to migrate in ventrolateral direction towards the GL. The granule precursors migrate into the GL and differentiate in to granule neurons. (2) A few glia with a radial morphology (*light blue*) are found close to the midline and they are used as scaffolds during the initial dorsal migration of granule precursors. (3) Bergmann glia-like cells are interspersed in the PL (*dark blue*). A low amount of Bergmann glia-like cells and inhibitory neurons (*yellow*) are generated from VZ progenitors that are found lateral and ventral to the progenitor niche. VZ progenitors are also found ventrally around the IVth ventricle (see e). *CB* cerebellar primordium, *HB* hindbrain, *GL* granule cell layer, *IVth V* IVth ventricle, *LRL* lower rhombic lip, *MHB* midbrain–hindbrain boundary, *ML* molecular layer, *PL* Purkinje cell layer, *URL* upper rhombic lip, *VZ* ventricular zone

ous external granule cell layer (Chaplin et al. 2010; Butts et al. 2014a, b). This suggests that neurogenesis and production of granule cells in zebrafish is more likely to be controlled on the level of the primary progenitors (Kaslin et al. 2013; Kaslin and Brand, unpublished observations).

## References

- Adolf B, Bellipanni G, Huber V, Bally-Cuif L (2004) *Atoh1.2* and *beta3.1* are two new bHLH-encoding genes expressed in selective precursor cells of the zebrafish anterior hindbrain. *Gene Expr Patterns* 5:35–41
- Alonso JR, Arevalo R, Brinon JG, Lara J, Weruaga E, Aijon J (1992) Parvalbumin immunoreactive neurons and fibres in the teleost cerebellum. *Anat Embryol (Berl)* 185:355–361
- Altman J, Bayer SA (1997) Development of the cerebellar system: in relation to its evolution, structure, and functions. CRC Press, Boca Raton
- Bae YK, Kani S, Shimizu T, Tanabe K, Nojima H, Kimura Y, Higashijima S, Hibi M (2009) Anatomy of zebrafish cerebellum and screen for mutations affecting its development. *Dev Biol* 330:406–426
- Bedell VM, Wang Y, Campbell JM, Poshusta TL, Starker CG, Krug RG II, Tan W, Penheiter SG, Ma AC, Leung AYH, Fahrenkrug SC, Carlson DF, Voytas DF, Clark KJ, Essner JJ, Ekker SC (2012) In vivo genome editing using a high-efficiency TALEN system. *Nature* 491:114–118
- Bell CC (2002) Evolution of cerebellum-like structures. *Brain Behav Evol* 59:312–326
- Bell CC, Han V, Sawtell NB (2008) Cerebellum-like structures and their implications for cerebellar function. *Annu Rev Neurosci* 31:1–24
- Ben-Arie N, Bellen HJ, Armstrong DL, Mccall AE, Gordadze PR, Guo Q, Matzuk MM, Zoghbi HY (1997) *Math1* is essential for genesis of cerebellar granule neurons. *Nature* 390:169–172
- Brand M, Heisenberg CP, Jiang YJ, Beuchle D, Lun K, Furutani-Seiki M, Granato M, Haffter P, Hammerschmidt M, Kane DA, Kelsh RN, Mullins MC, Odenthal J, Van Eeden FJ, Nusslein-Volhard C (1996) Mutations in zebrafish genes affecting the formation of the boundary between midbrain and hindbrain. *Development* 123:179–190
- Broccoli V, Boncinelli E, Wurst W (1999) The caudal limit of *Otx2* expression positions the isthmus organizer. *Nature* 401:164–168
- Buckles GR, Thorpe CJ, Ramel MC, Lekven AC (2004) Combinatorial Wnt control of zebrafish midbrain-hindbrain boundary formation. *Mech Dev* 121:437–447
- Butler AB, Hodos W (2005) Comparative vertebrate neuroanatomy. Wiley, New York
- Butts T, Hanzel M, Wingate RJ (2014a) Transit amplification in the amniote cerebellum evolved via a heterochronic shift in *NeuroD1* expression. *Development* 141:2791–2795
- Butts T, Modrell MS, Baker CV, Wingate RJ (2014b) The evolution of the vertebrate cerebellum: absence of a proliferative external granule layer in a non-teleost ray-finned fish. *Evol Dev* 16:92–100
- Canning CA, Lee L, Irving C, Mason I, Jones CM (2007) Sustained interactive Wnt and FGF signaling is required to maintain isthmus identity. *Dev Biol* 305:276–286
- Chaplin N, Tendeng C, Wingate RJ (2010) Absence of an external germinal layer in zebrafish and shark reveals a distinct, an amniote ground plan of cerebellum development. *J Neurosci* 30:3048–3057
- Dahmane N, Ruiz I, Altava A (1999) Sonic hedgehog regulates the growth and patterning of the cerebellum. *Development* 126:3089–3100
- Delgado L, Schmachtenberg O (2008) Immunohistochemical localization of GABA, GAD65, and the receptor subunits GABAA $\alpha$ 1 and GABAB1 in the zebrafish cerebellum. *Cerebellum* 7:444–450

- Elsen GE, Choi LY, Millen KJ, Grinblat Y, Prince VE (2008) *Zic1* and *Zic4* regulate zebrafish roof plate specification and hindbrain ventricle morphogenesis. *Dev Biol* 314:376–392
- Finger TE (1978) Efferent neurons of the teleost cerebellum. *Brain Res* 153:608–614
- Finger TE (1983) Organization of the teleost cerebellum. In: Northcutt RG, Davis RG (eds) *Fish neurobiology*. University of Michigan Press, Ann Arbor
- Folgueira M, Anadon R, Yanez J (2006) Afferent and efferent connections of the cerebellum of a salmonid, the rainbow trout (*Oncorhynchus mykiss*): a tract-tracing study. *J Comp Neurol* 497:542–565
- Foucher I, Mione M, Simeone A, Acampora D, Bally-Cuif L, Houart C (2006) Differentiation of cerebellar cell identities in absence of Fgf signalling in zebrafish *Otx* morphants. *Development* 133:1891–1900
- Goll MG, Anderson R, Stainier DY, Spradling AC, Halpern ME (2009) Transcriptional silencing and reactivation in transgenic zebrafish. *Genetics* 182:747–755
- Grandel H, Kaslin J, Ganz J, Wenzel I, Brand M (2006) Neural stem cells and neurogenesis in the adult zebrafish brain: origin, proliferation dynamics, migration and cell fate. *Dev Biol* 295:263–277
- Hans S, Kaslin J, Freudenreich D, Brand M (2009) Temporally-controlled site-specific recombination in zebrafish. *PLoS ONE* 4:e4640
- Hoshino M, Nakamura S, Mori K, Kawauchi T, Terao M, Nishimura YV, Fukuda A, Fuse T, Matsuo N, Sone M, Watanabe M, Bito H, Terashima T, Wright CV, Kawaguchi Y, Nakao K, Nabeshima Y (2005) *Ptf1a*, a bHLH transcriptional gene, defines GABAergic neuronal fates in cerebellum. *Neuron* 47:201–213
- Huang P, Xiao A, Zhou M, Zhu Z, Lin S, Zhang B (2011) Heritable gene targeting in zebrafish using customized TALENs. *Nat Biotech* 29:699–700
- Hwang WY, Fu Y, Reyon D, Maeder ML, Tsai SQ, Sander JD, Peterson RT, Yeh JRJ, Joung JK (2013) Efficient genome editing in zebrafish using a CRISPR-Cas system. *Nat Biotech* 31:227–229
- Ikenaga T, Yoshida M, Uematsu K (2002) Efferent connections of the cerebellum of the goldfish, *Carassius auratus*. *Brain Behav Evol* 60:36–51
- Ikenaga T, Yoshida M, Uematsu K (2005) Morphology and immunohistochemistry of efferent neurons of the goldfish corpus cerebelli. *J Comp Neurol* 487:300–311
- Ito H, Yoshimoto M (1990) Cytoarchitecture and fiber connections of the nucleus lateralis valvulae in the carp (*Cyprinus carpio*). *J Comp Neurol* 298:385–399
- Jungke P, Hans S, Brand M (2013) The zebrafish CreZoo: an easy-to-handle database for novel CreER(T2)-driver lines. *Zebrafish* 10(3):259–263. doi:10.1089/zeb.2012.0834, Epub 13 May 2013
- Jungke P, Hans S, Gupta M, Machate A, Zöller D, Brand M (2016) Generation of a conditional *lima1a* allele in zebrafish using the FLEEx switch technology. *Genesis* 54(1):19–28. doi:10.1002/dvg.22909, Epub 6 Dec 2015
- Kani S, Bae YK, Shimizu T, Tanabe K, Satou C, Parsons MJ, Scott E, Higashijima S, Hibi M (2010) Proneural gene-linked neurogenesis in zebrafish cerebellum. *Dev Biol* 343:1–17
- Kaslin J, Ganz J, Geffarth M, Grandel H, Hans S, Brand M (2009) Stem cells in the adult zebrafish cerebellum: initiation and maintenance of a novel stem cell niche. *J Neurosci* 29:6142–6153
- Kaslin J, Kroehne V, Benato F, Argenton F, Brand M (2013) Development and specification of cerebellar stem and progenitor cells in zebrafish: from embryo to adult. *Neural Dev* 8:9
- Katsuyama Y, Oomiya Y, Dekimoto H, Motooka E, Takano A, Kikkawa S, Hibi M, Terashima T (2007) Expression of zebrafish ROR alpha gene in cerebellar-like structures. *Dev Dyn* 236:2694–2701
- Kim CH, Bae YK, Yamanaka Y, Yamashita S, Shimizu T, Fujii R, Park HC, Yeo SY, Huh TL, Hibi M, Hirano T (1997) Overexpression of neurogenin induces ectopic expression of HuC in zebrafish. *Neurosci Lett* 239:113–116
- Koster RW, Fraser SE (2001) Direct imaging of in vivo neuronal migration in the developing cerebellum. *Curr Biol* 11:1858–1863

- Koster RW, Fraser SE (2006) FGF signaling mediates regeneration of the differentiating cerebellum through repatterning of the anterior hindbrain and reinitiation of neuronal migration. *J Neurosci* 26:7293–7304
- Lekven AC, Buckles GR, Kostakis N, Moon RT (2003) Wnt1 and wnt10b function redundantly at the zebrafish midbrain-hindbrain boundary. *Dev Biol* 254:172–187
- Lun K, Brand M (1998) A series of no isthmus (noi) alleles of the zebrafish pax2.1 gene reveals multiple signaling events in development of the midbrain-hindbrain boundary. *Development* 125:3049–3062
- Matsui H, Namikawa K, Babaryka A, Koster RW (2014) Functional regionalization of the teleost cerebellum analyzed in vivo. *Proc Natl Acad Sci U S A* 111:11846–11851
- Meek J (1992) Comparative aspects of cerebellar organization. From mormyrids to mammals. *Eur J Morphol* 30:37–51
- Meek J (1998) Holosteans and teleosts. In: Nieuwenhuys R, T. D. H J, Nicholson C (eds) *The central nervous system of vertebrates*. Springer, Berlin
- Meek J, Yang JY, Han VZ, Bell CC (2008) Morphological analysis of the mormyrid cerebellum using immunohistochemistry, with emphasis on the unusual neuronal organization of the valvula. *J Comp Neurol* 510:396–421
- Millet S, Campbell K, Epstein DJ, Losos K, Harris E, Joyner AL (1999) A role for Gbx2 in repression of Otx2 and positioning the mid/hindbrain organizer. *Nature* 401:161–164
- Murakami T, Morita Y (1987) Morphology and distribution of the projection neurons in the cerebellum in a teleost, *Sebastiscus marmoratus*. *J Comp Neurol* 256:607–623
- Nieuwenhuys R, Pouwels E, Smulders-Kersten E (1974) The neuronal organization of cerebellar lobe C1 in the mormyrid fish *Gnathonemus petersii* (teleostei). *Z Anat Entwicklungsgesch* 144:315–336
- O'Hara FP, Beck E, Barr LK, Wong LL, Kessler DS, Riddle RD (2005) Zebrafish Lmx1b.1 and Lmx1b.2 are required for maintenance of the isthmus organizer. *Development* 132:3163–3173
- Raible F, Brand M (2004) Divide et Impera—the midbrain-hindbrain boundary and its organizer. *Trends Neurosci* 27:727–734
- Reifers F, Bohli H, Walsh EC, Crossley PH, Stainier DY, Brand M (1998) Fgf8 is mutated in zebrafish acerebellar (ace) mutants and is required for maintenance of midbrain-hindbrain boundary development and somitogenesis. *Development* 125:2381–2395
- Rhinn M, Brand M (2001) The midbrain–hindbrain boundary organizer. *Curr Opin Neurobiol* 11:34–42
- Rhinn M, Lun K, Luz M, Werner M, Brand M (2005) Positioning of the midbrain-hindbrain boundary organizer through global posteriorization of the neuroectoderm mediated by Wnt8 signaling. *Development* 132:1261–1272
- Rhinn M, Lun K, Ahrendt R, Geffarth M, Brand M (2009) Zebrafish gbx1 refines the midbrain-hindbrain boundary border and mediates the Wnt8 posteriorization signal. *Neural Dev* 4:12
- Sander JD, Cade L, Khayter C, Reyon D, Peterson RT, Joung JK, Yeh J-RJ (2011) Targeted gene disruption in somatic zebrafish cells using engineered TALENs. *Nat Biotech* 29:697–698
- Scott EK (2009) The Gal4/UAS toolbox in zebrafish: new approaches for defining behavioral circuits. *J Neurochem* 110:441–456
- Simeone A (2000) Positioning the isthmus organizer where Otx2 and Gbx2 meet. *Trends Genet* 16:237–240
- Simmich J, Staykov E, Scott E (2012) Zebrafish as an appealing model for optogenetic studies. *Prog Brain Res* 196:145–162
- Suster ML, Sumiyama K, Kawakami K (2009) Transposon-mediated BAC transgenesis in zebrafish and mice. *BMC Genomics* 10:477
- Toyama R, Gomez DM, Mana MD, Dawid IB (2004) Sequence relationships and expression patterns of zebrafish zic2 and zic5 genes. *Gene Expr Patterns* 4:345–350

- Volkman K, Rieger S, Babaryka A, Koster RW (2008) The zebrafish cerebellar rhombic lip is spatially patterned in producing granule cell populations of different functional compartments. *Dev Biol* 313:167–180
- Volkman K, Chen YY, Harris MP, Wullimann MF, Koster RW (2010) The zebrafish cerebellar upper rhombic lip generates tegmental hindbrain nuclei by long-distance migration in an evolutionary conserved manner. *J Comp Neurol* 518:2794–2817
- Wechsler-Reya RJ, Scott MP (1999) Control of neuronal precursor proliferation in the cerebellum by sonic hedgehog. *Neuron* 22:103–114
- Wingate RJ (2001) The rhombic lip and early cerebellar development. *Curr Opin Neurobiol* 11:82–88
- Wullimann MF (1997) The central nervous system. In: Evans DH, Claiborne JB (eds) *Physiology of fishes*. CRC Press, Boca Raton
- Wullimann MF, Northcutt RG (1988) Connections of the corpus cerebelli in the green sunfish and the common goldfish: a comparison of perciform and cypriniform teleosts. *Brain Behav Evol* 32:293–316
- Wullimann MF, Northcutt RG (1989) Afferent connections of the valvula cerebelli in two teleosts, the common goldfish and the green sunfish. *J Comp Neurol* 289:554–567
- Xue HG, Yang CY, Yamamoto N (2008) Afferent sources to the inferior olive and distribution of the olivocerebellar climbing fibers in cyprinids. *J Comp Neurol* 507:1409–1427
- Zecchin E, Mavropoulos A, Devos N, Filippi A, Tiso N, Meyer D, Peers B, Bortolussi M, Argenton F (2004) Evolutionary conserved role of *ptf1a* in the specification of exocrine pancreatic fates. *Dev Biol* 268:174–184

# Chapter 57

## The Teleost Fish

Takanori Ikenaga

**Abstract** In vertebrates, the basic structure of the central nervous systems, including the cerebellum, is conserved from mammals to teleosts. The cerebellum of teleost fish is subdivided into three parts: the corpus cerebelli, valvula cerebelli, and vestibulolateral lobe. Although the existence of basket cells remains unconfirmed, the teleost cerebellum possesses intra cerebellar neurons that are similar to those of other vertebrates. Additionally, there are similarities in the pattern of connectivity of these neurons and the neurotransmitters that are used. In the teleost cerebellum, the structure corresponding to the deep cerebellar nuclei is absent. Instead, the teleost cerebellar efferent neurons do not make clusters and are distributed within the ganglionic layer, which is equivalent to the Purkinje cell layer of other vertebrates. Efferent neurons use excitatory neurotransmitters and project their axons outside of the cerebellum. These efferent neurons are unique to the teleost cerebellum, so a detailed understanding of their structure and function may yield important clues about the evolution and function of the teleost cerebellum. Afferent and efferent fiber connection patterns suggest that the basic functions of the teleost cerebellum are similar to those of other vertebrates, but each subdivision of the teleost cerebellum is functionally separated. The functional role of the teleost cerebellum is still not fully understood, but research suggests that the teleost cerebellum has an important role in the execution of swimming gait and emotional learning.

**Keywords** Corpus cerebelli • Valvula cerebelli • Caudal lobe • Teleost • Evolution • Goldfish • Efferent cell • Purkinje cell • Deep cerebellar nuclei • Neurotransmitter • Fiber connection • Motor control • Fair conditioning • Zebrafish • Actinopterygian fish

The actinopterygii (ray finned fish) includes approximately 27,000 species, the majority of which are teleost fish (approximately 26,800 species) (Nelson 2006). The basic organization of the central nervous system of teleost fish is similar to that of other vertebrates including the cerebellum. In this chapter, I review the

---

T. Ikenaga (✉)

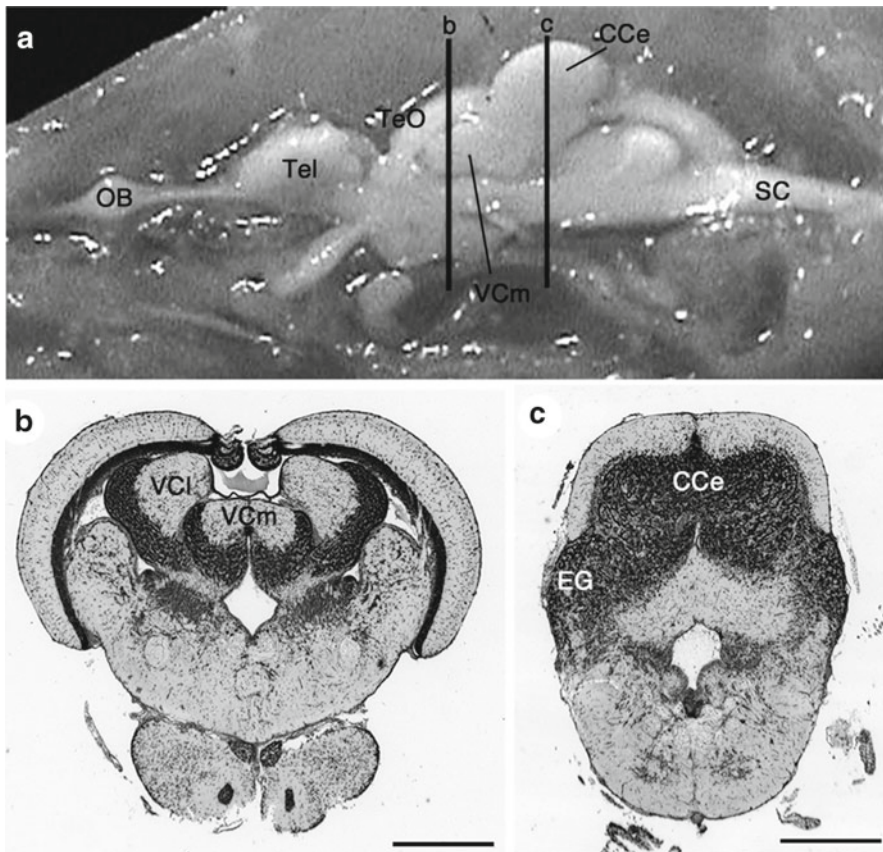
Department of Chemistry and Bioscience, Graduate School of Science and Engineering,  
Kagoshima University, Kagoshima, Japan  
e-mail: [ikenaga@sci.kagoshima-u.ac.jp](mailto:ikenaga@sci.kagoshima-u.ac.jp)



morphology, cellular organization, fiber connections, and functions of the teleost cerebellum.

### 57.1 Morphology, Cellular Organization, and Neural Circuits of the Teleost Cerebellum

The cerebellum of teleosts is subdivided into three major parts: the corpus cerebelli, valvula cerebelli, and the vestibulolateral lobe (including the eminentia granularis and lobus caudalis) (Fig. 57.1). The corpus cerebelli, considered to be homologous



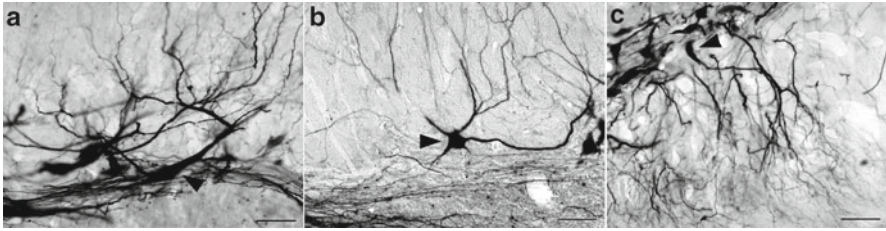
**Fig. 57.1** (a) Mid-sagittal plane of the goldfish brain. (b, c) Transverse sections of the goldfish brain including the cerebellum through lines indicated in (a). *Abbreviations:* *CCe* corpus cerebelli, *EG* eminentia granularis, *OB* olfactory bulb, *SC* spinal cord, *Tel* telencephalon, *TeO* optic tectum, *VCl* lateral lobe of valvula cerebelli, *VCm* medial lobe of valvula cerebelli. Scale bar = 500  $\mu\text{m}$  (Adapted from Ikenaga et al. 2006)

to the vermis of other vertebrates (Ito 1978), lies in the central portion of the teleost cerebellum and extends dorsally and curves either rostrally (e.g., mormyrids, catfish) or caudally (e.g., cyprinids, salmonids) (Fig. 57.1a, c). The valvula cerebelli is unique to actinopterygian fish and is not an obvious homologue of any cerebellar components of other vertebrates. It protrudes rostrally into the mesencephalic ventricle and is covered by the optic tectum (Fig. 57.1a, b). In some species, including goldfish, the valvula is subdivided into medial and lateral lobes (Fig. 57.1b). The vestibulolateral lobe consists of the eminentia granularis and lobus caudalis. In goldfish, the eminentia granularis is located in the ventro-lateral region of the corpus cerebelli as a granular cell mass (Fig. 57.1c). The lobus caudalis is an easily distinguishable structure in mormyrid fish, and protrudes from the caudal edge of the corpus cerebelli (Campbell et al. 2007). On the basis of its strong morphological relationship with the central lateral line sensory region, it is suggested that the vestibulolateral lobe is homologous with the tetrapodian flocculus (Meek 1992).

The teleost corpus cerebelli consists of three layers, which is consistent with the structure in other vertebrates (Fig. 57.1c). Parallel fibers from granule cells and dendrites of Purkinje cells represent the major components of the molecular layer of the teleost cerebellum. The presence of stellate cells has been reported (Nieuwenhuys et al. 1974; Han and Bell 2003), but to date there is no evidence to indicate the existence of basket cells in the teleost. The Purkinje cell layer in the teleost cerebellum is referred to as the ganglionic layer in some studies. This is because it contains both Purkinje cells and efferent cells termed eurydendroid cells (Meek 1992; Han and Bell 2003). The morphology of teleost Purkinje cells is basically similar to those of other vertebrates; one thick primary dendrite emerges from the apical part of the cell body and branches are distributed into the molecular layer and oriented sagittally. Axons of Purkinje cells of the corpus cerebelli run within the ganglionic layer and terminate onto the somata and main dendrites of the efferent cells (Nieuwenhuys et al. 1974; Ikenaga et al. 2005; Bae et al. 2009), and also onto other Purkinje cells (Meek and Nieuwenhuys 1991). The climbing fiber makes glutamatergic inputs onto somata or the proximal region of the primary dendrites of Purkinje cells, but does not climb to the distal section of dendrites, unlike in mammals (Han and Bell 2003). Efferent cells, another kind of neuron in the ganglionic layer, will be mentioned in detail later. The granule cell layer is located in the deepest portion of the teleost corpus cerebelli (Fig. 57.1c) and contains granule cells and Golgi cells.

## 57.2 Efferent Neurons of the Teleost Cerebellum

One unique feature of the teleost cerebellum is the lack of deep cerebellar nuclei. Instead, cerebellar efferent neurons are distributed in the ganglionic layer. The cerebellar efferent cells of teleost fish have two or more primary dendrites (Fig. 57.2) (Nieuwenhuys et al. 1974; Murakami and Morita 1987; Ikenaga et al. 2005). Like Purkinje cells, the efferent cells have an extensive dendritic arbor along the parasagittal dimension and are spread within the molecular layer. The shape of the efferent



**Fig. 57.2** Photomicrographs of retrogradely labeled cerebellar efferent neurons in the goldfish corpus cerebelli. (a) Fusiform type neurons. (b) Polygonal type neurons. (c) Monopolar type neurons. Arrowheads indicate cell bodies of efferent neurons. Scale bar = 50  $\mu\text{m}$  (Adapted from Ikenaga et al. 2006)

cells can vary even within a single species; in goldfish, they are classified into three types according to their morphology (Fig. 57.2) (Ikenaga et al. 2005). The efferent cell dendrites have fewer spines than those of the Purkinje cells (Nieuwenhuys et al. 1974; Murakami and Morita 1987; Campbell et al. 2007). In the goldfish corpus cerebelli, large numbers of neurons in the ganglionic layer were labeled with anti-GABA antibody, but retrograde labeled efferent cells were not labeled with same antibody, suggesting that Purkinje cells utilize GABA as a neurotransmitter whereas efferent cells are mediated by different one (Ikenaga et al. 2005). In zebrafish, some efferent neurons strongly express *vglut2alb* mRNA (vesicular glutamate transporter), suggesting that teleost cerebellar efferent neurons are glutamatergic (Bae et al. 2009). The axons of Purkinje cells terminate onto the somata and the main dendrites of the efferent cells in the mormyrid corpus cerebelli (Nieuwenhuys et al. 1974). Experiments combining retrograde labeling and immunohistochemistry indicate that efferent cells receive GABAergic inputs from Purkinje cells in the goldfish corpus cerebelli (Ikenaga et al. 2005). This relationship between the efferent cells and Purkinje cells is similar to that between the deep cerebellar nuclei and Purkinje cells in the mammalian cerebellum. Therefore, teleost cerebellar efferent neurons have some similarities with neurons of the deep cerebellar nuclei of mammals. The information about the cerebellar efferent system used by other fish is not sufficient. There is a need for additional studies of the cerebellar efferent systems of other fish to gain further insight into cerebellar evolution in vertebrates.

### 57.3 Afferent and Efferent Fiber Connections

The teleost cerebellum receives inputs via climbing fibers and origin of them is in the inferior olive, as is the case in other vertebrates. Additionally, the corpus receives inputs from the diencephalon, pretectal area, mesencephalon, rhombencephalon, and spinal cord in goldfish (see detail in Wullimann and Northcutt 1988). The afferent source of the lateral lobe of the valvula in goldfish partially overlaps with that of the corpus (Wullimann and Northcutt 1989).

The efferent targets of the goldfish corpus cerebelli are also widely distributed and include the diencephalon, pretectal area, mesencephalon, and rhombencephalon (see detail in Wullimann and Northcutt 1988; Ikenaga et al. 2002). The efferent targets of the medial lobe of the valvula cerebelli are very similar to those of the corpus cerebelli. Conversely, the lateral lobe of the valvula cerebelli projects only to a limited area (see detail in Ikenaga et al. 2002). These observations suggest that the roles of the corpus and the medial lobe of the valvula include both motor control and functions carried out by the mammalian higher cerebellum. It is also suggested that there are functional divisions between the medial and lateral lobes of the valvula cerebelli.

## 57.4 Functions of the Teleost Cerebellum

Ablation of the corpus in rainbow trout resulted in individuals being unable to maintain a steady position and subsequently being swept backwards in fast flowing water, suggesting that the corpus cerebelli is essential for smooth shifts between different motor programs, but has no role in the generation of motor programs (Roberts et al. 1992). Matsumoto et al. (2007) reached a similar conclusion based on observations of the swimming performance of goldfish with a partially ablated corpus cerebelli. In addition to the function in motor control, recent studies also suggest that the teleost corpus cerebelli has a critical role in learning, memory, and cognition. Ablation of the corpus cerebelli of goldfish impairs classical fear conditioning and spatial cognition (Yoshida et al. 2004; Gómez et al. 2010). Additionally, local anesthetization of the corpus cerebelli with drug application resulted in similar impairment (Yoshida and Hirano 2010). In contrast to the corpus, little is known about the function of the valvula. The valvula is covered by the optic tectum (Fig. 57.1), so is difficult to ablate without damaging other brain regions. To address this issue, genetic manipulation of the nervous system using zebrafish or medaka which is known as model animal must be useful. The combined application of new techniques and traditional electrophysiology and behavioral analysis continues to improve our understanding of the function of the teleost cerebellum.

## References

- Bae YK, Kani S, Shimizu T, Tanabe K, Nojima H, Kimura Y, Higashijima S, Hibi M (2009) Anatomy of zebrafish cerebellum and screen for mutations affecting its development. *Dev Biol* 330:406–426
- Campbell HR, Meek J, Zhang J, Bell CC (2007) Anatomy of the posterior caudal lobe of the cerebellum and the eminentia granularis posterior in a mormyrid fish. *J Comp Neurol* 502:714–735
- Gómez A, Durán E, Salas C, Rodríguez F (2010) Cerebellum lesion impairs eyeblink-like classical conditioning in goldfish. *Neuroscience* 166:49–60

- Han VZ, Bell CC (2003) Physiology of cells in the central lobes of the mormyrid cerebellum. *J Neurosci* 23:11147–11157
- Ikenaga T, Yoshida M, Uematsu K (2002) Efferent connections of the cerebellum of the goldfish, *Carassius auratus*. *Brain Behav Evol* 60:36–51
- Ikenaga T, Yoshida M, Uematsu K (2005) Morphology and immunohistochemistry of efferent neurons of the goldfish corpus cerebelli. *J Comp Neurol* 487:300–311
- Ikenaga T, Yoshida M, Uematsu K (2006) Cerebellar efferent neurons in teleost fish. *Cerebellum* 5:268–274
- Ito H (1978) A catalogue of histological preparations of the teleost brains. *Med J Osaka Univ* 28:219–228
- Matsumoto N, Yoshida M, Uematsu K (2007) Effects of partial ablation of the cerebellum on sustained swimming in goldfish. *Brain Behav Evol* 70:105–114
- Meek J (1992) Comparative aspects of cerebellar organization. From mormyrids to mammals. *Eur J Morphol* 30:37–51
- Meek J, Nieuwenhuys R (1991) Palisade pattern of mormyrid Purkinje cells: a correlated light and electron microscopic study. *J Comp Neurol* 306:156–192
- Murakami T, Morita Y (1987) Morphology and distribution of the projection neurons in the cerebellum in a teleost, *Sebastiscus marmoratus*. *J Comp Neurol* 256:607–623
- Nelson JS (2006) *Fishes of the world*. Wiley, Hoboken
- Nieuwenhuys R, Pouwels E, Smulders-Kersten E (1974) The neuronal organization of cerebellar lobe C1 in the mormyrid fish *Gnathonemus petersii* (Teleostei). *Z Anat Entwickl-Gesch* 144:315–336
- Roberts BL, Van Rossem A, de Jager S (1992) The influence of cerebellar lesions on the swimming performance of the trout. *J Exp Biol* 167:171–178
- Wullimann MF, Northcutt RG (1988) Connections of the corpus cerebelli in the green sunfish and common goldfish: a comparison of perciform and cypriniform teleost. *Brain Behav Evol* 32:293–316
- Wullimann MF, Northcutt RG (1989) Afferent connections of the valvula cerebelli in two teleosts, the common goldfish and the green sunfish. *J Comp Neurol* 289:554–567
- Yoshida M, Hirano R (2010) Effect of local anesthesia of the cerebellum on classical fear conditioning in goldfish. *Behav Brain Funct* 6:20
- Yoshida M, Okamura I, Uematsu K (2004) Involvement of the cerebellum in classical fear conditioning in goldfish. *Behav Brain Res* 153:143–148

# Chapter 58

## Lurcher Mouse

Jan Cendelin, Jan Tuma, and Zdenka Purkartova

**Abstract** Lurcher mutant mouse is a natural model of hereditary cerebellar degeneration which is caused by a mutation in the  $\delta 2$  glutamate receptor encoding gene. Heterozygous Lurcher mice suffer from virtually complete loss of Purkinje cells and the degeneration of cerebellar interneurons, deep cerebellar nuclei and inferior olive neurons. Progressive cerebellar degeneration in Lurcher mice affects motor and cognitive functions as well as emotional processing.

**Keywords** Ataxia • Cerebellar degeneration • *Grid2*<sup>Lc</sup>

### 58.1 Introduction

The Lurcher mouse, one of the most studied animal models of cerebellar ataxia, was discovered as a spontaneous mutant in a colony at the Medical Research Council Radiobiological Research Unit at Harwell, England in 1954, and was first described by Phillips in 1960 (Phillips 1960). The cerebellar degeneration is caused by a semi-dominant *Grid2*<sup>Lc</sup> mutation in the  $\delta 2$  glutamate receptor (*GluR $\delta$ 2*) encoding gene on chromosome 6 (Phillips 1960; Zuo et al. 1997). Later, a second Lurcher allele (*Lc*<sup>L</sup>), which is phenotypically indistinguishable from *Grid2*<sup>Lc</sup>, was found (De Jager et al. 1997). Homozygous Lurcher mice (*Lc/Lc*) die shortly after birth due to the massive degeneration of mid- and hindbrain neurons during late embryogenesis, which results in their inability to suck after birth (Cheng and Heintz 1997). Heterozygous Lurcher mice (+/*Lc*) are viable with a normal life-span, but suffer from

---

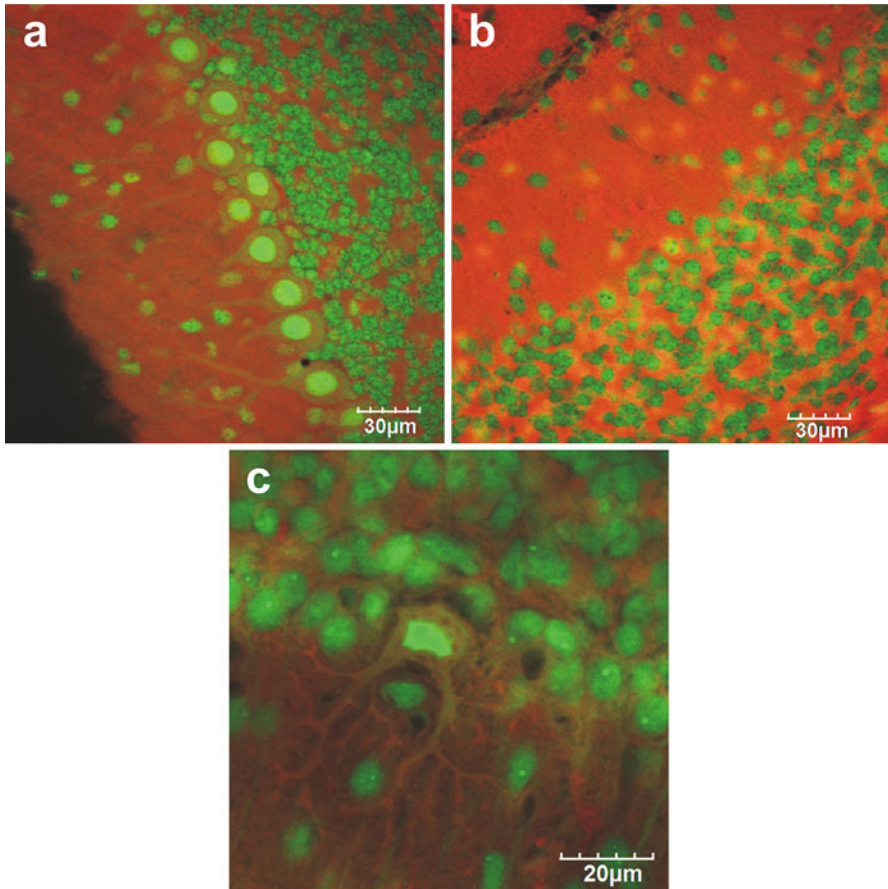
J. Cendelin, M.D., Ph.D. (✉) • J. Tuma

Department of Pathophysiology, Faculty of Medicine in Pilsen, Charles University, alej Svobody 1655, 304 60 Plzen, Czech Republic

Laboratory of Neurodegenerative Disorders, Biomedical Center, Faculty of Medicine in Pilsen, Charles University, Plzen, Czech Republic  
e-mail: [jan.cendelin@lfp.cuni.cz](mailto:jan.cendelin@lfp.cuni.cz)

Z. Purkartova

Department of Pathophysiology, Faculty of Medicine in Pilsen, Charles University, alej Svobody 1655, 304 60 Plzen, Czech Republic



**Fig. 58.1** Cerebellar cortex of a wild type mouse (**a**) and the cerebellum of a Lurcher mouse with residua of Purkinje cells (**b**) aged 20 days. Degenerating Purkinje cell, with two main dendrites, in a 17-day-old Lurcher mouse (**c**). Double staining with Lucifer yellow and DiD oil

olivocerebellar degeneration (Fig. 58.1). Wild type (+/+) littermates are normal, healthy mice, which can serve as controls.

## 58.2 Morphological Changes in the Lurcher Mutant Central Nervous System

Heterozygous Lurcher mouse pathology consists of early onset postnatal loss of cerebellar Purkinje cells and the degeneration of cerebellar interneurons, deep cerebellar nuclei and inferior olive neurons. About 95 % of Purkinje cells die between postnatal days 8 and 25 and virtually all of them degenerate by 3 months after birth

(Caddy and Biscoe 1979). Nevertheless, in the paraflocculus, flocculus and nodular zone, several hundred surviving Purkinje cells can be found as late as postnatal day 146 (Duffin et al. 2010). Degenerating Purkinje cells show typically hyperspinous dendrites, increased numbers of nucleoli, multiple primary dendrites, and, after postnatal day 10, decreased rates of synaptogenesis with parallel fibers (Doumesnil-Bousez and Sotelo 1992; Caddy and Biscoe 1979; Purkartova and Vozeh 2013) (Fig. 58.1c).

About 56 % of granule cells die between postnatal days 8 and 12, and by day 60, only 10 % are still alive (Caddy and Biscoe 1979). There is also extensive loss of Golgi, stellate and basket cells (Zanjani et al. 2006; Caddy and Biscoe 1979). On the other hand, degeneration of the deep cerebellar nuclei is relatively mild (Heckroth 1994). Loss of inferior olive neurons becomes apparent by postnatal day 11 and represents about 70–75 % of the population (Caddy and Biscoe 1979).

### 58.3 Pathogenesis of the Neurodegeneration in Lurcher Mice

GluR $\delta$ 2 is expressed at high levels in Purkinje cells and at lower levels in some hindbrain neurons (Araki et al. 1993). The *Grid2*<sup>Lc</sup> mutation is a base-pair substitution (G-to-A) that replaces a non-polar alanine with a polar threonine in the transmembrane domain III of the GluR $\delta$ 2 (Zuo et al. 1997). It is a gain-of-function mutation, changing the receptor into a leaky membrane channel (Zuo et al. 1997). Therefore, Lurcher Purkinje cells have a depolarized resting potential due to the presence of a constitutive inward Na<sup>+</sup> current (Zuo et al. 1997). Permanent excitation of the cells accompanied by Na<sup>+</sup>–K<sup>+</sup> ATPase over-activation increases the demand of energy and induces ATP depletion (Nishiyama and Yuzaki 2010). Depolarization is probably the primary reason for cell-autonomous Purkinje cell death in Lurcher mice (Zuo et al. 1997; Wetts and Herrup 1982a, b).

Zuo et al. (1997) suggested excitotoxic apoptosis as the mechanism of Purkinje cell extinction. The role of apoptosis is supported by the presence of apoptotic bodies engulfed by glial cells, the absence of infiltration with leucocytes (Norman et al. 1995) and by the increase in pro-caspase 3 expression (Selimi et al. 2000). On the other hand, some ultrastructural signs, including enlarged mitochondria with dilated cristae, indicate necrotic cell death (Doumesnil-Bousez and Sotelo 1992). Yue et al. (2002) suggested an autophagic death mechanism and Wang et al. (2006) described an accumulation of autophagosomes in axonal dystrophic swellings of Lurcher Purkinje cells. Induction of autophagy could be a response to lack of ATP (Nishiyama and Yuzaki 2010). Finally, there is some evidence that multiple cell death pathways are induced (Nishiyama and Yuzaki 2010; Zanjani et al. 2013).

Apoptosis of granule cells and inferior olive neurons, and probably the degeneration of stellate and basket cells as well, is target-related (transsynaptic) cell death secondary to the extinction of Purkinje cells (Wetts and Herrup 1982a, b; Vogel et al. 1989; Zanjani et al. 2006).



## 58.4 Functional Impairments

Progressive cerebellar degeneration in Lurcher mutant mice affects a broad spectrum of neural functions and provides insights into the role of the cerebellum in circuitries related to motor, cognitive and emotional processing.

### 58.4.1 *Motor Functions*

Lurcher mice are characterized by marked cerebellar ataxia. The gait is wobbly, lurching and with a tendency to fall to either side. It is not accompanied by trembling to the extent seen in other cerebellar mutants, but rather by a jerky up and down movements (Phillips 1960). The step ratio and inter-limb coupling are highly variable and disorganization of cyclic limb movements accompanied by an irregular EMG pattern is seen during walking, but not during swimming (Fortier et al. 1987). The motor disabilities of Lurchers result in poor performances on many of the tests that assess various aspects of motor function. Affected dynamic equilibrium and motor coordination were observed on the rotarod (Cendelin et al. 2014; Hilber and Caston 2001; Thullier et al. 1997). The wooden beam (Le Marec et al. 1997) and unstable platform (Hilber et al. 1999) tests showed impaired static equilibrium. Furthermore, Lurcher mice have decreased muscle strength (Cendelin et al. 2014; Hilber and Caston 2001; Lalonde et al. 1992). Although Lurcher mice possess both optokinetic and vestibulo-ocular compensatory reflexes, they exhibited altered dynamics and an inability to modify these reflexes in the course of training (Van Alphen et al. 2002). Despite their motor deficits and an age-related decline in learning ability, Lurchers are still capable of some motor task learning (Hilber and Caston 2001).

### 58.4.2 *Cognitive and Behavioral Abnormalities*

Massive loss of Purkinje cells induces cognitive and behavioral disturbances in Lurcher mice. In the Morris water maze, Lurchers show impairment in both hidden and visible platform tasks (Cendelin et al. 2014; Lalonde et al. 1988); therefore, the deficit in visuomotor coordination has been suggested as a key factor (Lalonde and Thifault 1994). Belzung et al. (2001) found that both spatial working memory and reference memory are impaired. All of these findings suggest that Lurcher mutants are unable to construct a cognitive map and use an associative route strategy rather than a true spatial strategy based on cognitive mapping (Hilber et al. 1998). Changes in classically conditioned eyelid responses have also been reported (Porras-Garcia et al. 2005).

The contrast between less anxiety-like behavior and elevated levels of corticosterone during stressful situations suggest that Lurcher mice have reduced capacity to inhibit selective components of natural behaviors (Hilber et al. 2004; Frederic et al. 1997). An inhibition deficit was demonstrated by their inability to produce prepulse inhibition of the acoustic startle response (Porrás-García et al. 2005) or the immobility response (Lalonde 1998). The discrepancy between the hypothalamo-pituitary-adrenal axis reaction and the disproportional neural control of behavior could be due to an affection of the sensorimotor gating mechanism (Porrás-García et al. 2005). Behavioral disinhibition and loss of motivation could also influence exploratory behavior, which is significantly reduced despite an increase in spontaneous activity (Caston et al. 1998).

## 58.5 Concluding Remarks

Lurcher mice can come from one of several background strains, e.g. B6CBA, C3H, and B6×BALB. Even though the genetic background affects the complex features of the mice, the *Grid2*<sup>Lc</sup> mutation leads to a strong pathological phenotype that is independent of the strain of origin (Cendelin et al. 2014). For this reason as well as for well-defined neuron loss, Lurcher mice are still a valuable model for experimental therapy of cerebellar degenerations.

## References

- Araki K, Meguro H, Kushiya E, Takayama C, Inoue Y, Mishina M (1993) Selective expression of the glutamate receptor channel delta 2 subunit in cerebellar Purkinje cells. *Biochem Biophys Res Commun* 197:1267–1276
- Belzung C, Chapillon P, Lalonde R (2001) The effects of the lurcher mutation on object localization, T-maze discrimination, and radial arm maze tasks. *Behav Genet* 31:151–155
- Caddy KWT, Biscoe TJ (1979) Structural and quantitative studies on the normal C3H and Lurcher mutant mouse. *Philos Trans R Soc London Ser B Biol Sci* 287:167–201
- Caston J, Chianale C, Delhaye-Bouchaud N, Mariani J (1998) Role of the cerebellum in exploration behavior. *Brain Res* 808:232–237
- Cendelin J, Tuma J, Korelusova I, Vozeh F (2014) The effect of genetic background on behavioral manifestation of *Grid2*(Lc) mutation. *Behav Brain Res* 271:218–227
- Cheng SS, Heintz N (1997) Massive loss of mid- and hindbrain neurons during embryonic development of homozygous Lurcher mice. *J Neurosci* 17:2400–2407
- De Jager PL, Zuo J, Cook SA, Heintz N (1997) A new allele of the lurcher gene, *lurcher*<sup>l</sup>. *Mamm Genome* 8:647–650
- Duffin CA, McFarland R, Sarna JR, Vogel MW, Armstrong CL (2010) Heat shock protein 25 expression and preferential Purkinje cell survival in the lurcher mutant mouse cerebellum. *J Comp Neurol* 518:1892–1907
- Dumesnil-Bousez N, Sotelo C (1992) Early development of the Lurcher cerebellum: Purkinje cell alterations and impairment of synaptogenesis. *J Neurocytol* 21:506–529

- Fortier PA, Smith AM, Rossignol S (1987) Locomotor deficits in the mutant mouse, Lurcher. *Exp Brain Res* 66:271–286
- Frederic F, Chautard T, Brochard R, Chianale C, Wollman E, Oliver C, Delhaye-Bouchaud N, Mariani J (1997) Enhanced endocrine response to novel environment stress and endotoxin in Lurcher mutant mice. *Neuroendocrinology* 66:341–347
- Heckroth JA (1994) A quantitative morphological analysis of the cerebellar nuclei in normal and lurcher mutant mice. I. Morphology and cell number. *J Comp Neurol* 343:173–182
- Hilber P, Caston J (2001) Motor skills and motor learning in Lurcher mutant mice during aging. *Neuroscience* 102:615–623
- Hilber P, Jouen F, Delhaye-Bouchaud N, Mariani J, Caston J (1998) Differential roles of cerebellar cortex and deep cerebellar nuclei in learning and retention of a spatial task: studies in intact and cerebellectomized lurcher mutant mice. *Behav Genet* 28:299–308
- Hilber P, Lalonde R, Caston J (1999) An unsteady platform test for measuring static equilibrium in mice. *J Neurosci Methods* 88:201–205
- Hilber P, Lorivel T, Delarue C, Caston J (2004) Stress and anxious-related behaviors in Lurcher mutant mice. *Brain Res* 1003:108–112
- Lalonde R (1998) Immobility responses in Lurcher mutant mice. *Behav Genet* 28:309–314
- Lalonde R, Thifault S (1994) Absence of an association between motor coordination and spatial orientation in lurcher mutant mice. *Behav Genet* 24:497–501
- Lalonde R, Lamarre Y, Smith AM (1988) Does the mutant mouse lurcher have deficits in spatially oriented behaviours? *Brain Res* 455:24–30
- Lalonde R, Botez MI, Joyal CC, Caumartin M (1992) Motor abnormalities in lurcher mutant mice. *Physiol Behav* 51:523–525
- Le Marec N, Caston J, Lalonde R (1997) Impaired motor skills on static and mobile beams in lurcher mutant mice. *Exp Brain Res* 116:131–138
- Nishiyama J, Yuzaki M (2010) Excitotoxicity and autophagy: lurcher may not be a model of “autophagic cell death”. *Autophagy* 6:568–570
- Norman DJ, Feng L, Cheng SS, Gubbay J, Chan E, Heintz N (1995) The lurcher gene induces apoptotic death in cerebellar Purkinje cells. *Development* 121:1183–1193
- Phillips RJS (1960) “Lurcher”, new gene in linkage group XI of the house mouse. *J Genet* 57:35–42
- Porras-Garcia E, Cendelin J, Dominguez-del-Toro E, Vozeh F, Delgado-Garcia JM (2005) Purkinje cell loss affects differentially the execution, acquisition and prepulse inhibition of skeletal and facial motor responses in Lurcher mice. *Eur J Neurosci* 21:979–988
- Purkartova Z, Vozeh F (2013) Cerebellar degeneration in Lurcher mice under confocal laser scanning microscope. *Microsc Res Tech* 76:545–551
- Selimi F, Doughty M, Delhaye-Bouchaud N, Mariani J (2000) Target-related and intrinsic neuronal death in Lurcher mutant mice are both mediated by caspase-3 activation. *J Neurosci* 20:992–1000
- Thullier F, Lalonde R, Cousin X, Lestienne F (1997) Neurobehavioral evaluation of lurcher mutant mice during ontogeny. *Brain Res Dev Brain Res* 100:22–28
- Van Alphen AM, Schepers T, Luo C, De Zeeuw CI (2002) Motor performance and motor learning in Lurcher mice. *Ann NY Acad Sci* 978:413–424
- Vogel MW, Sunter K, Herrup K (1989) Numerical matching between granule and Purkinje cells in lurcher chimeric mice: a hypothesis for the trophic rescue of granule cells from target-related cell death. *J Neurosci* 9:3454–3462
- Wang QJ, Ding Y, Kohtz DS, Mizushima N, Cristea IM, Rout MP, Chait BT, Zhong Y, Heintz MP, Yue Z (2006) Induction of autophagy in axonal dystrophy and degeneration. *J Neurosci* 26:8057–8068
- Wetts R, Herrup K (1982a) Interaction of granule, Purkinje and inferior olivary neurons in lurcher chimeric mice. I. Qualitative studies. *J Embryol Exp Morphol* 68:87–98
- Wetts R, Herrup K (1982b) Interaction of granule, Purkinje and inferior olivary neurons in lurcher chimeric mice. II. Granule cell death. *Brain Res* 250:358–362

- Yue Z, Horton A, Bravin M, DeJager PL, Selimi F, Heintz N (2002) A novel protein complex linking the  $\delta 2$  glutamate receptor and autophagy: implications for neurodegeneration in Lurcher mice. *Neuron* 35:921–933
- Zanjani SH, Selimi F, Vogel MW, Haerberle AM, Boeuf J, Mariani J, Bailly YJ (2006) Survival of interneurons and parallel fiber synapses in a cerebellar cortex deprived of Purkinje cells: studies in the double mutant mouse *Grid2<sup>Lc/-</sup>;Bax<sup>-/-</sup>*. *J Comp Neurol* 497:622–635
- Zanjani HS, Lohof AM, McFarland R, Vogel MW, Mariani J (2013) Enhanced survival of wild-type and Lurcher Purkinje cells in vitro following inhibition of conventional PKCs or stress-activated MAP kinase pathways. *Cerebellum* 12:377–389
- Zuo J, De Jager PL, Takahasi KJ, Jiang W, Linden DJ, Heintz H (1997) Neurodegeneration in Lurcher mice caused by mutation of  $\delta 2$  glutamate receptor gene. *Nature* 388:769–773

# Chapter 59

## The Tottering Mouse

Russell E. Carter and Timothy J. Ebner

**Abstract** In the late 1950s, a novel spontaneous mutation was found in the same litter of mice while breeding by Green and Sidman at the Roscoe B. Jackson Memorial Laboratory in Maine. Mice harboring this mutation, which was found to be recessive, were termed tottering (*tg/tg*) mice, and exhibited a series of neurological abnormalities, including a paroxysmal motor disturbances (dyskinesia/dystonia), a wobbly ataxic gait, and absence seizures. Since the initial discovery of this mutation, numerous studies have investigated the underlying genetics and behavioral consequences in the *tg/tg* mouse, and this mouse has proven useful in our understanding of several episodic neurological disorders involving the cerebellum. Caused by a mutation in the *Cacna1a* gene that encodes the P/Q-type voltage-gated Ca channel, the *tg/tg* mouse is a model for the human disorder episodic ataxia type 2 (EA2), and has provided insights into the mechanisms of episodic cerebellar dysfunction.

**Keywords** Ataxia • EA2 • Channelopathies • Dystonia • CACNA1A

### 59.1 Introduction

In the late 1950s, a novel spontaneous mutation was found in the same litter of mice while breeding at the Roscoe B. Jackson Memorial Laboratory in Maine (Green and Sidman 1962). Mice harboring this mutation, which was found to be recessive, were termed *tottering* (*tg/tg*) mice, and exhibited a series of neurological abnormalities, including paroxysmal motor disturbances (dyskinesia/dystonia), a wobbly ataxic gait, and absence seizures (Green and Sidman 1962; Noebels and Sidman 1979). Since the initial discovery of this mutation, numerous studies have investigated the underlying genetics and behavioral consequences in the *tg/tg* mouse, and this mouse has proven useful in our understanding of several episodic neurological disorders involving the cerebellum.

---

R.E. Carter • T.J. Ebner (✉)  
Department of Neuroscience, University of Minnesota,  
2001 6th St SE, Rm 421 LRB, Minneapolis, MN 55455, USA  
e-mail: [recarter@umn.edu](mailto:recarter@umn.edu); [ebner001@umn.edu](mailto:ebner001@umn.edu)

## 59.2 Tottering Mouse: A Calcium Channelopathy

The spontaneous recessive mutation was identified as a missense mutation, resulting in a substitution of leucine for proline, in the *Cacna1a* gene encoding the  $\alpha_{1A}$  subunit of the P/Q-type voltage-gated  $\text{Ca}^{2+}$  channel ( $\text{Ca}_v2.1$ ) (Fletcher et al. 1996). This mutation results in an approximate 30–40% reduction in P/Q-type  $\text{Ca}^{2+}$  channel current without changes in the kinetics of the channel (Wakamori et al. 1998). Many neurological disorders are caused by mutations in genes encoding ion channels, termed channelopathies. A common feature among channelopathies is the occurrence of episodic symptoms, including hemiplegic migraine, seizures, periodic paralysis, paroxysmal dyskinesia/dystonia, and episodic ataxia (for reviews see (Jen et al. 2004; Ptacek and Fu 2001; Pietrobon 2010; Ryan and Ptacek 2010)). These episodic symptoms can often have external triggering factors, such as fatigue, exercise, ethanol, caffeine, and emotional or psychological stress (Ptacek and Fu 2001; Ryan and Ptacek 2010). However, the mechanisms by which a permanent abnormality in an ion channel leads to transient dysfunction of the nervous system are generally unknown.

The *tg/tg* mouse has been a widely used model to investigate an autosomal dominant  $\text{Ca}^{2+}$  channelopathy that occurs in humans called episodic ataxia type 2 (EA2). Over 70 known mutations in the human *CACNA1A* gene encoding the  $\alpha_{1A}$  subunit of the P/Q-type  $\text{Ca}^{2+}$  channel can lead to the development of EA2 (Jen et al. 2004; Pietrobon 2010; Rajakulendran et al. 2010). EA2 patients suffer from episodic cerebellar dysfunction, and for periods lasting from tens of minutes to days at a time, they can exhibit severe ataxia and dyskinesia/dystonia (Jen et al. 2004; Baloh et al. 1997). In addition to these episodic cerebellar symptoms, patients also show non-cerebellar symptoms including migraine, hemiplegic paralysis, vertigo, and weakness (Jen et al. 2004). Stress, caffeine, and alcohol act as triggers for the episodic dysfunction in *tg/tg* mice and EA2 patients (Fureman et al. 2002; Raike et al. 2005). Additionally, the episodic motor dysfunction in EA2 patients and *tg/tg* mice is decreased by both carbonic anhydrase inhibitors, such as acetazolamide (Griggs et al. 1978), as well as 4-aminopyridine (Strupp et al. 2004), further suggesting that studying the underlying mechanisms in the *tg/tg* mouse can be a useful tool to understand and develop further treatments for EA2.

## 59.3 Tottering Behavioral Phenotype

The behavioral phenotype of the *tg/tg* mouse is quite complex, and typically has three major components that appear 3–4 weeks after birth (Green and Sidman 1962). One of the main neurological features of the *tg/tg* mouse is absence seizures, defined by bilateral, synchronous 6–7 Hz cortical spike-and-wave or polyspike discharges in electroencephalographic (EEG) recordings (Noebels and Sidman 1979),

which can last for 1–3 sec at a time and can occur very frequently, more than 30 times per hour.

Secondly, and most striking of the neurological symptoms in the *tg/tg* mouse, is the occurrence of paroxysmal motor attacks. Originally referred to as a focal seizure (Green and Sidman 1962), these motor attacks have more recently been confirmed to be episodic dyskinesia/dystonia, as they have no comparable seizure-like EEG activity and do not respond to antiepileptic drugs (Noebels and Sidman 1979; Campbell and Hess 1999). The episodic attacks progress from the hind limbs towards the head (a “jacksonian march”), until the entire body is undergoing the dystonic attack. Recovery occurs in the same order that the attack started, with the hind limbs recovering first and progressing towards the head. These attacks can last from 30 to 60 min and occur one to two times a day (Green and Sidman 1962).

The final major feature of the *tg/tg* mouse is a baseline mild ataxia that primarily involves the hind limbs and tail, and was originally described as a wobbly gait (Green and Sidman 1962). Recently, a study using high-speed video and EMG documented poorly coordinated movements and reduced muscle activity during treadmill locomotion in the *tg/tg* mice (Scholle et al. 2010).

## 59.4 P/Q-Type $\text{Ca}^{2+}$ Channel and Cerebellar Dysfunction

P/Q-type  $\text{Ca}^{2+}$  channels have a wide distribution in the nervous system and are found in the presynaptic terminals, soma, and dendrites of neurons (Mintz et al. 1992; Fletcher et al. 1996; Westenbroek et al. 1995), with moderate to high levels of expression in the cerebellum, cerebral cortex, hippocampus, and olfactory bulb. With high expression levels in the presynaptic terminals, P/Q-type  $\text{Ca}^{2+}$  channels are the major contributors of neurotransmitter release (for review, see (Pietrobon 2010)). There is abundant expression of P/Q-type  $\text{Ca}^{2+}$  channels in cerebellar granule and Purkinje cells (Westenbroek et al. 1995; Mintz et al. 1992). With the decreased current flow through the P/Q-type  $\text{Ca}^{2+}$  channels in *tg/tg* mice, there is an impairment in the parallel fiber-Purkinje cell synaptic transmission (Matsushita et al. 2002; Chen et al. 2009). This decrease in synaptic transmission is age-related, and develops in parallel with the behavioral phenotype. Additionally, one of the outputs of Purkinje cells, the simple spikes, exhibits higher variability in *tg/tg* mice compared to wild-type, and similar variability can be induced in wild-type mice by blocking P/Q-type  $\text{Ca}^{2+}$  channels (Walter et al. 2006; Hoebeek et al. 2005). While these changes in cerebellar synaptic transmission are static, and likely contribute to the baseline ataxia in *tg/tg* mice, it remains unclear how episodic dysfunctions such as the dystonic attacks can arise.

Recently, episodic, low-frequency neuronal oscillations (0.03–0.1 Hz) were observed spontaneously in the cerebellar cortex of *tg/tg* mice in vivo (Chen et al. 2009). While present, the oscillations disrupted the beam-like response evoked by parallel fiber stimulation, suggesting that cerebellar cortical physiology is highly

abnormal during the oscillations. Additionally, in awake animals, caffeine administration significantly increased the oscillations and induced the episodic dystonic attack (Chen et al. 2009). Recently, it was found that similar low-frequency oscillations are also prominent in the cerebral cortex, implying that the *tg/tg* mutation can lead to instabilities throughout the entire CNS (Cramer et al. 2015). These low-frequency oscillations provide a potential mechanism for how cerebellar and non-cerebellar episodic dysfunctions occur in the *tg/tg* mouse.

## 59.5 Beyond P/Q-Type Channels

Several other alterations in cerebellar protein expression have been reported in the *tg/tg* mouse. There is an increased expression of L-type  $\text{Ca}^{2+}$  channels in the cerebellum, and it was observed that blocking L-type  $\text{Ca}^{2+}$  channels in the cerebellum alleviated the episodic dystonia (Campbell and Hess 1999). Additionally, blocking L-type  $\text{Ca}^{2+}$  channels was effective in reducing the low-frequency oscillations observed in the *tg/tg* mouse cerebellar and cerebral cortices (Chen et al. 2009; Cramer et al. 2015), suggesting that L-type  $\text{Ca}^{2+}$  channels are involved in the episodic motor phenotype of the *tg/tg* mouse.

There are also alterations in GABA<sub>A</sub> receptors in the adult *tg/tg* mouse. In the cerebellum there is a 40% reduction in the number of GABA<sub>A</sub> receptors in the granular layer (Kaja et al. 2007). Recently, a study found that there was a compromised development of GABA signaling in the hippocampus of *tg/tg* mice (Nakao et al. 2015), however, it remains to be determined if these alterations affect cerebellar function in the *tg/tg* mouse. Additional changes have been reported for neuronal nitric oxide synthase (nNOS) (Rhyu et al. 2003), tyrosine hydroxylase (Hess and Wilson 1991), calcitonin and ryanodine receptor type 1 (Cicale et al. 2002). How these changes affect cerebellar function or their involvement in the *tg/tg* phenotype remains unclear.

## 59.6 Effectiveness of EA2 Therapies in the Tottering Mouse

Both acetazolamide and 4-aminopyridine have been shown to significantly reduce the frequency and severity of the episodic cerebellar symptoms in EA2 (Strupp et al. 2004; Griggs et al. 1978), and these drugs have also shown to be effective in alleviating the episodic dystonia and low-frequency oscillations in *tg/tg* mice (Chen et al. 2009; Cramer et al. 2015). It remains to be determined how these two drugs act to provide the beneficial effects, but the common overlap between the *tg/tg* mouse and EA2 patients suggests that the *tg/tg* mouse has the potential to serve as a model for testing new EA2 therapeutic agents.



## 59.7 Conclusion

In conclusion, the *tgtg* mouse is an extremely useful model and has the potential to provide insights into a class of genetic disorders that exhibit cerebellar dysfunction, including EA2. However, there is a great deal more to learn from this model. Understanding how the episodic neurological symptoms initiate and progress would not only be beneficial towards better treatment of EA2 patients, but could also help us understand how episodic neurological dysfunction occurs in numerous other disorders.

## References

- Baloh RW, Yue Q, Furman JM, Nelson SF (1997) Familial episodic ataxia: clinical heterogeneity in four families linked to chromosome 19p. *Ann Neurol* 41:8–16
- Campbell DB, Hess EJ (1999) L-type calcium channels contribute to the tottering mouse dystonic episodes. *Mol Pharmacol* 55:23–31
- Chen G, Popa LS, Wang X, Gao W, Barnes J, Hendrix CM, Hess EJ, Ebner TJ (2009) Low frequency oscillations in the cerebellar cortex of the tottering mouse. *J Neurophysiol* 101:234–245
- Cicale M, Ambesi-Impiombato A, Cimini V, Fiore G, Muscettola G, Abbott LC, de Batolomeis A (2002) Decreased gene expression of calretinin and ryanodine receptor type 1 in tottering mice. *Brain Res Bull* 59:53–58
- Cramer SW, Popa LS, Carter RE, Chen G, Ebner TJ (2015) Abnormal excitability and episodic low frequency oscillation in the cerebral cortex of the *tottering* mouse. *J Neurosci* 35:5664–5679
- Fletcher CF, Lutz CM, O’Sullivan TN, Shaughnessy JD Jr, Hawkes R, Frankel WN, Copeland NG, Jenkins NA (1996) Absence epilepsy in tottering mutant mice is associated with calcium channel defects. *Cell* 87:607–617
- Fureman BE, Jinnah HA, Hess EJ (2002) Triggers of paroxysmal dyskinesia in the calcium channel mouse mutant tottering. *Pharmacol Biochem Behav* 73:631–637
- Green MC, Sidman RL (1962) Tottering – a neuromuscular mutation in the mouse and its linkage with oligosyndacylism. *J Hered* 53:233–237
- Griggs RC, Moxley RT III, Lafrance RA, McQuillen J (1978) Hereditary paroxysmal ataxia: response to acetazolamide. *Neurology* 28:1259–1264
- Hess EJ, Wilson MC (1991) Tottering and leaner mutations perturb transient developmental expression of tyrosine hydroxylase in embryologically distinct Purkinje cells. *Neuron* 6:123–132
- Hoebeek FE, Stahl JS, van Alphen AM, Schonewille M, Luo C, Rutteman M, van den Maagdenberg AM, Molenaar PC, Goossens HH, Frens MA, De Zeeuw CI (2005) Increased noise level of purkinje cell activities minimizes impact of their modulation during sensorimotor control. *Neuron* 45:953–965
- Jen J, Kim GW, Baloh RW (2004) Clinical spectrum of episodic ataxia type 2. *Neurology* 62:17–22
- Kaja S, Hann V, Payne HL, Thompson CL (2007) Aberrant cerebellar granule cell-specific GABA(A) receptor expression in the epileptic and ataxic mouse mutant, Tottering. *Neuroscience* 148:115–125
- Matsushita K, Wakamori M, Rhyu IJ, Arii T, Oda S, Mori Y, Imoto K (2002) Bidirectional alterations in cerebellar synaptic transmission of tottering and rolling Ca<sup>2+</sup> channel mutant mice. *J Neurosci* 22:4388–4398

- Mintz IM, Adams ME, Bean BP (1992) P-type calcium channels in rat central and peripheral neurons. *Neuron* 9:85–95
- Nakao A, Miki T, Shimono K, Oka H, Numata T, Kiyonaka S, Matsushita K, Ogura H, Niidome T, Noebels JL, Wakamori M, Imoto K, Mori Y (2015) Compromised maturation of GABAergic inhibition underlies abnormal network activity in the hippocampus of epileptic Ca(2+) channel mutant mice, tottering. *Pflugers Arch* 467:737–752
- Noebels JL, Sidman RL (1979) Inherited epilepsy: spike-wave and focal motor seizures in the mutant mouse tottering. *Science* 204:1334–1336
- Pietrobon D (2010) Ca<sub>v</sub>2.1 channelopathies. *Pflugers Arch* 460:375–393
- Ptacek LJ, Fu YH (2001) Channelopathies: episodic disorders of the nervous system. *Epilepsia* 42(Suppl 5):35–43
- Raike RS, Jinnah HA, Hess EJ (2005) Animal models of generalized dystonia. *NeuroRx* 2:504–512
- Rajakulendran S, Graves TD, Labrum RW, Kotzadimitriou D, Eunson L, Davis MB, Davies R, Wood NW, Kullmann DM, Hanna MG, Schorge S (2010) Genetic and functional characterisation of the P/Q calcium channel in episodic ataxia with epilepsy. *J Physiol* 588:1905–1913
- Rhyu IJ, Nahm SS, Hwang SJ, Kim H, Suh YS, Oda SI, Frank TC, Abbott LC (2003) Altered neuronal nitric oxide synthase expression in the cerebellum of calcium channel mutant mice. *Brain Res* 977:129–140
- Ryan DP, Ptacek LJ (2010) Episodic neurological channelopathies. *Neuron* 68:282–292
- Scholle HC, Jinnah HA, Arnold D, Biedermann FH, Faenger B, Grassme R, Hess EJ, Schumann NP (2010) Kinematic and electromyographic tools for characterizing movement disorders in mice. *Mov Disord* 25:265–274
- Strupp M, Kalla R, Dichgans M, Freilinger T, Glasauer S, Brandt T (2004) Treatment of episodic ataxia type 2 with the potassium channel blocker 4-aminopyridine. *Neurology* 62:1623–1625
- Wakamori M, Yamazaki K, Matsunodaira H, Teramoto T, Tanaka I, Niidome T, Sawada K, Nishizawa Y, Sekiguchi N, Mori E, Mori Y, Imoto K (1998) Single tottering mutations responsible for the neuropathic phenotype of the P-type calcium channel. *J Biol Chem* 273:34857–34867
- Walter JT, Alvina K, Womack MD, Chevez C, Khodakhah K (2006) Decreases in the precision of Purkinje cell pacemaking cause cerebellar dysfunction and ataxia. *Nat Neurosci* 9:389–397
- Westenbroek RE, Sakurai T, Elliott EM, Hell JW, Starr TV, Snutch TP, Catterall WA (1995) Immunochemical identification and subcellular distribution of the alpha 1A subunits of brain calcium channels. *J Neurosci* 15:6403–6418

# Chapter 60

## The Rolling Nagoya Mouse

Jaap J. Plomp, Arn M.J.M. van den Maagdenberg, and Else A. Tolner

**Abstract** The natural mutant mouse *rolling Nagoya* is severely ataxic and frequently shows body roll-overs. A missense mutation was identified in *Cacna1a*, the gene encoding the  $\alpha_1$  pore subunit of  $\text{Ca}_v2.1$  type voltage-gated  $\text{Ca}^{2+}$  channels. We here discuss the main phenotypic and neuronal characteristics of this mutant, with relevance to the human neurological disorders associated with  $\text{Ca}_v2.1$  dysfunction (' $\text{Ca}^{2+}$ -channelopathies').

**Keywords** Ataxia • *Cacna1a* mutation •  $\text{Ca}_v2.1$   $\text{Ca}^{2+}$  channel • Cerebellum • Lambert-Eaton myasthenic syndrome • Migraine • *Rolling Nagoya* mouse • Synaptic transmission

### 60.1 *Rolling Nagoya* Phenotype

The *rolling Nagoya* (RN) mouse was identified as a natural recessive mutant more than 40 years ago (Oda 1973). Homozygous mice are severely ataxic with abnormal hind limb movements and typical sideway lurching (Fig. 60.1a). Early symptoms can be detected already in the second postnatal week (Takahashi et al. 2010b). There is no epilepsy, contrasting other natural *Cacna1a* mouse mutants (Van Den Maagdenberg et al. 2007). Adult homozygous RN mice have 25–30% reduced body-weight (Nakamura et al. 2005; Kaja et al. 2007). Although fertile, their motor

---

J.J. Plomp (✉)

Department of Neurology, Leiden University Medical Centre,  
Research Building, S5P, P.O.B. 9600, 2300 RC Leiden, The Netherlands  
e-mail: [j.j.plomp@lumc.nl](mailto:j.j.plomp@lumc.nl)

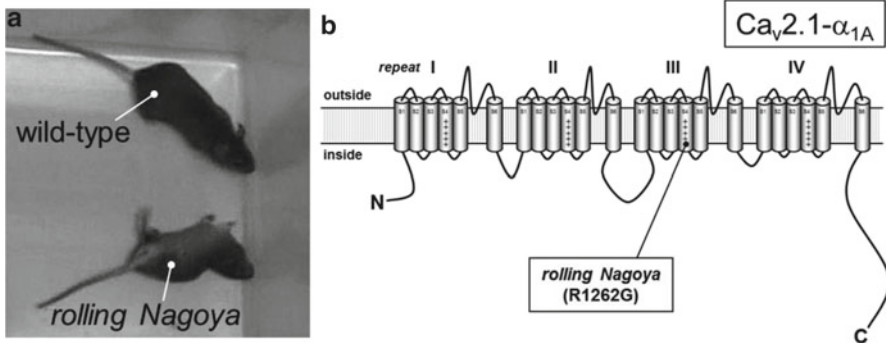
A. M.J.M. van den Maagdenberg

Department of Neurology, Leiden University Medical Centre,  
Research Building, S5P, P.O.B. 9600, 2300 RC Leiden, The Netherlands

Department of Human Genetics, Leiden University Medical Centre,  
P.O.B. 9600, NL-2300 RC Leiden, The Netherlands

E.A. Tolner

Department of Human Genetics, Leiden University Medical Centre,  
P.O.B. 9600, NL-2300 RC Leiden, The Netherlands



**Fig. 60.1** (a) Picture of a typical sideways body roll of a homozygous *rolling Nagoya* mouse. (b) Schematic representation of the  $\text{Ca}_v2.1\text{-}\alpha_{1A}$  pore-forming subunit, with indication of the position of the *rolling Nagoya* R126G mutation in the voltage sensing segment of the third repeating domain

disturbances hamper reproduction and breeding is therefore best achieved by heterozygous mating. Most homozygous RN mice have a normal life span, but some die in the first few postnatal weeks.

The disturbed motor coordination is paralleled by fatigable muscle weakness (Kaja et al. 2007). Furthermore, autonomic dysregulation seems present as heart rate is decreased by ~20% (Ohba et al. 2009) and breathing rate by ~35% (JJ Plomp, unpublished). In addition, RN mice have higher pain thresholds (Fukumoto et al. 2009).

Heterozygous RN mice develop motor and memory deficits at old age, indicating that the phenotype is not purely recessive. Increase in relative expression of RN-mutated versus wild-type  $\text{Ca}_v2.1\text{-}\alpha_{1A}$  mRNA may be underlying this late-onset effect in heterozygotes (Takahashi et al. 2009a, b).

## 60.2 The *Rolling Nagoya* Mutation Resides in *Cacna1a* Encoded $\text{Ca}_v2.1$ Ion Channels

Neuronal voltage-gated  $\text{Ca}^{2+}$  channels are membrane proteins which translate electrical signals into  $\text{Ca}^{2+}$  influx, thereby influencing many crucial processes such as excitability, transmitter release, gene regulation and axonal growth.  $\text{Ca}_v2.1$  channels reside in the membrane of neuronal cell bodies but are particularly present in presynaptic nerve terminals, governing neurotransmitter release (Westenbroek et al. 1995). Although distributed throughout the brain, the channels are particularly highly expressed in the cerebellum (Westenbroek et al. 1995). The channel contains a pore-forming  $\alpha_1$  subunit and modulatory  $\alpha_2\delta$ ,  $\beta$  and  $\gamma$  subunits, each encoded by different genes (Dolphin 2009). The  $\text{Ca}_v2.1\text{-}\alpha_{1A}$  pore-forming subunit is encoded by the *Cacna1a* gene, located on mouse chromosome 8. The RN mutation is a C-to-G change at nucleotide 3784, causing an arginine to glycine change at amino acid

1262 of the protein (Mori et al. 2000) (Fig. 60.1b). The R1262G mutation localizes in a voltage sensing segment of the channel and disturbs its function. A number of other neurological mouse mutants carry *Cacn1a* mutations (Van Den Maagdenberg et al. 2007). Importantly, human *CACNA1A* mutations exist in inherited forms of migraine, episodic ataxia and epilepsy (de Vries et al. 2009; Jen et al. 2007; Van Den Maagdenberg et al. 2007).

### 60.3 Rolling Nagoya Brain Morphology

Some older studies showed reduced RN cerebellum volume, weight and cell numbers, but this was not confirmed by others (for summary, see Tomoda et al. 1992). Later studies reported normal cerebellar anatomy without apoptosis and normal cell densities (Mori et al. 2000; Sawada et al. 2001), while others observed apoptosis (Rhyu et al. 1999). Deep cerebellar nuclei neurons showed increased  $\text{Ca}_v2.1\text{-}\alpha_1$  expression, possibly compensating for reduced  $\text{Ca}_v2.1$  channel function (see below) (Sawada et al. 2001).

Tyrosine hydroxylase (TH) in cerebellar Purkinje cells is normally expressed only transiently but persists in RN mice (Mori et al. 2000; Sawada et al. 2001). Disturbed intracellular  $\text{Ca}^{2+}$  concentration may be a key factor here. Levels of some other proteins are changed in the RN cerebellum as well. Corticotropin-releasing factor is increased, correlating with TH-positive Purkinje cells (Sawada et al. 2001). This factor modulates glutamate and  $\gamma$ -aminobutyric acid (GABA) sensitivity in Purkinje cells (Bishop et al. 2000). It also potentiates  $\text{Ca}_v1$  currents (Kanno et al. 1999), perhaps influencing TH expression in this way. In addition, levels of ryanodine receptors (channels which allow  $\text{Ca}^{2+}$  efflux from the endoplasmic reticulum) are altered in RN cerebella (Sawada et al. 2008). This may also underlie aberrant TH expression.

Synaptic abnormalities likely exist in RN brains.  $\text{GABA}_A$  and adenosine  $A_1$  receptors in the cerebellum and  $A_1$  receptors in the cerebral cortex and caudate-putamen were found reduced in RN mice (Onodera et al. 1988). However,  $\text{GABA}_A$  receptors in forebrain remain unaltered (Nielsen and Kaja 2014). Deformations were observed in RN cerebellar synapses (Oda et al. 2010; Rhyu et al. 1999) and  $\text{Ca}^{2+}$ /calmodulin-dependent protein kinase II is downregulated at hippocampal nerve terminals (Takahashi et al. 2010a).

### 60.4 Effect of the Rolling Nagoya Mutation on the Electrophysiology of $\text{Ca}_v2.1$ Channels and Neuronal Behaviour

Electrophysiological studies showed that expression of RN-mutated  $\text{Ca}_v2.1$  channels is reduced and that their activation voltage is shifted in the positive direction, i.e. mutated channels are less sensitive to voltage stimuli (Fukumoto et al. 2012;

Mori et al. 2000). The resulting diminished  $\text{Ca}_v2.1$  activity in cerebellum (and possibly other brain areas) likely triggers the events leading to ataxia. One secondary effect may be premature abortion of action potential firing in RN Purkinje cells due to insufficient stimulation of  $\text{Ca}^{2+}$ -activated  $\text{K}^+$ -channels, important for post-spike repolarization. Furthermore,  $\text{Ca}^{2+}$  spikes are hard to evoke and not followed by the usual  $\text{Na}^+$  action potential burst (Mori et al. 2000). These findings suggest impaired RN Purkinje cell responses to (integrated) synaptic excitation, affecting neuronal network function. Besides, considering the presynaptic function of  $\text{Ca}_v2.1$  channels, cerebellar synapses in RN mice presumably have aberrant neurotransmitter release. Neurochemistry studies indeed showed neurotransmitter level changes (Muramoto et al. 1981; Nakamura et al. 2005). Glutamatergic synaptic currents in RN brain slices are enhanced or reduced, depending on the synapse type assessed (Matsushita et al. 2002). Similarly, synaptic defects are present at the RN NMJ in the periphery, a synapse where neurotransmitter release fully depends on  $\text{Ca}_v2.1$  channels (Kaja et al. 2007). A >50% reduction of nerve stimulation-evoked acetylcholine release was found, accompanied by a ~3-fold *increase* of spontaneous quantal release. These opposing effects suggest a complex influence of the mutation on different channel parameters. The severely reduced evoked acetylcholine release at RN NMJs most likely underlies the fatigable muscle weakness.

## 60.5 Relevance of the *Rolling Nagoya* Mouse to Human $\text{Ca}_v2.1$ Channelopathies?

The RN mouse is a rather 'pure' ataxia model (i.e. no associated epilepsy) and may be used for ataxia drug testing, particularly related to human *CACNA1A* mutation-associated cerebellar ataxia (Jen et al. 2007). Two studies have shown anti-ataxic effects of thyrotropin-releasing hormone or analogues in RN mice, possibly due to unknown neuroprotective or metabolic effects (Kinoshita et al. 1995; Nakamura et al. 2005).  $\text{Ca}^{2+}$ -activated  $\text{K}^+$ -channels might be interesting drug targets, regarding their likely involvement in aborted action potential firing of RN Purkinje cells (Mori et al. 2000). Use of RN mice in ataxia drug studies may be limited by the fatigable muscle weakness interfering with motor performance testing.

Human *CACNA1A* mutations underlie familial hemiplegic migraine type-1 (FHM1), an inherited monogenic migraine variant that also models the more common, multifactorial migraine forms (de Vries et al. 2009). Interestingly, ~20% of FHM1 patients have (permanent) cerebellar ataxia. However, the electrophysiological behaviour of FHM1-mutated  $\text{Ca}_v2.1$  channels differs from that of RN-mutated channels, e.g. there are opposite shifts in activation voltage (Van Den Maagdenberg et al. 2007). Therefore, the RN mouse seems not a good model for (familial hemiplegic) migraine.

RN mice show certain similarities with Lambert-Eaton myasthenic syndrome (LEMS), in which auto-antibodies target NMJ  $\text{Ca}_v2.1$  channels and cause muscle

weakness. Acetylcholine release at LEMS NMJs is greatly reduced, as it is in RN (Kaja et al. 2007). A similar NMJ phenotype is present in some congenital myasthenic syndrome patients (without anti-Ca<sub>v</sub>2.1 antibodies or identified *CACNA1A* mutations, but with ataxia), as well as in episodic ataxia type-2 patients with *CACNA1A* mutation (Maselli et al. 2003). Conversely, some LEMS patients have cerebellar ataxia (Titulaer et al. 2008). Thus, RN mice model some aspects of LEMS and may be useful for drug studies.

## References

- Bishop GA, Seelandt CM, King JS (2000) Cellular localization of corticotropin releasing factor receptors in the adult mouse cerebellum. *Neuroscience* 101:1083–1092
- de Vries B, Frants RR, Ferrari MD et al (2009) Molecular genetics of migraine. *Hum Genet* 126:115–132
- Dolphin AC (2009) Calcium channel diversity: multiple roles of calcium channel subunits. *Curr Opin Neurobiol* 19:237–244
- Fukumoto N, Obama Y, Kitamura N et al (2009) Hypoalgesic behaviors of P/Q-type voltage-gated Ca<sub>2+</sub> channel mutant mouse, rolling mouse Nagoya. *Neuroscience* 160:165–173
- Fukumoto N, Kitamura N, Niimi K et al (2012) Ca<sub>2+</sub> channel currents in dorsal root ganglion neurons of P/Q-type voltage-gated Ca<sub>2+</sub> channel mutant mouse, rolling mouse Nagoya. *Neurosci Res* 73:199–206
- Jen JC, Graves TD, Hess EJ et al (2007) Primary episodic ataxias: diagnosis, pathogenesis and treatment. *Brain* 130:2484–2493
- Kaja S, van de Ven RC, van Dijk JG et al (2007) Severely impaired neuromuscular synaptic transmission causes muscle weakness in the *Cacna1a*-mutant mouse rolling Nagoya. *Eur J Neurosci* 25:2009–2020
- Kanno T, Suga S, Nakano K et al (1999) Corticotropin-releasing factor modulation of Ca<sub>2+</sub> influx in rat pancreatic beta-cells. *Diabetes* 48:1741–1746
- Kinoshita K, Watanabe Y, Asai H et al (1995) Anti-ataxic effects of TRH and its analogue, TA-0910, in Rolling mouse Nagoya by metabolic normalization of the ventral tegmental area. *Br J Pharmacol* 116:3274–3278
- Maselli RA, Books W, Dunne V (2003) Effect of inherited abnormalities of calcium regulation on human neuromuscular transmission. *Ann N Y Acad Sci* 998:18–28
- Matsushita K, Wakamori M, Rhyu IJ et al (2002) Bidirectional alterations in cerebellar synaptic transmission of tottering and rolling Ca<sub>2+</sub> channel mutant mice. *J Neurosci* 22:4388–4398
- Mori Y, Wakamori M, Oda S et al (2000) Reduced voltage sensitivity of activation of P/Q-type Ca<sub>2+</sub> channels is associated with the ataxic mouse mutation rolling Nagoya (tg(rol)). *J Neurosci* 20:5654–5662
- Muramoto O, Kanazawa I, Ando K (1981) Neurotransmitter abnormality in Rolling mouse Nagoya, an ataxic mutant mouse. *Brain Res* 215:295–304
- Nakamura T, Honda M, Kimura S et al (2005) Taltirelin improves motor ataxia independently of monoamine levels in rolling mouse nagoya, a model of spinocerebellar atrophy. *Biol Pharm Bull* 28:2244–2247
- Nielsen EO, Kaja S (2014) GABA receptor expression in the forebrain of ataxic mice. *Biol Med (Aligarh)* 6:198
- Oda S (1973) The observation of rolling mouse Nagoya (rol), a new neurological mutant, and its maintenance (author's transl). *Jikken Dobutsu* 22:281–288
- Oda S, Lee KJ, Arai T et al (2010) Differential regulation of Purkinje cell dendritic spines in rolling mouse Nagoya (tgrol/tgrol), P/Q type calcium channel (*alpha1A/Cav2.1*) mutant. *Anat Cell Biol* 43:211–217

- Ohba T, Takahashi E, Murakami M (2009) Modified autonomic regulation in mice with a P/Q-type calcium channel mutation. *Biochem Biophys Res Commun* 381:27–32
- Onodera H, Takase S, Oda S et al (1988) Neurotransmitter receptors of the rolling mouse Nagoya: a quantitative autoradiographic study. *Neurosci Res* 5:316–324
- Rhyu JJ, Oda S, Uhm CS et al (1999) Morphologic investigation of rolling mouse Nagoya (tg(rol)/tg(rol)) cerebellar Purkinje cells: an ataxic mutant, revisited. *Neurosci Lett* 266:49–52
- Sawada K, Sakata-Haga H, Ando M et al (2001) An increased expression of Ca(2+) channel alpha(1A) subunit immunoreactivity in deep cerebellar neurons of rolling mouse Nagoya. *Neurosci Lett* 316:87–90
- Sawada K, Hosoi E, Bando M et al (2008) Differential alterations in expressions of ryanodine receptor subtypes in cerebellar cortical neurons of an ataxic mutant, rolling mouse Nagoya. *Neuroscience* 152:609–617
- Takahashi E, Niimi K, Itakura C (2009a) Age-related spatial and nonspatial short-term memory in Cav2.1alpha1 mutant mice, Rolling Nagoya. *Behav Brain Res* 204:241–245
- Takahashi E, Niimi K, Itakura C (2009b) Motor coordination impairment in aged heterozygous rolling Nagoya, Cav2.1 mutant mice. *Brain Res* 1279:50–57
- Takahashi E, Niimi K, Itakura C (2010a) Interaction between Ca(v)2.1alpha (1) and CaMKII in Ca (v)2.1alpha (1) mutant mice, Rolling Nagoya. *J Mol Neurosci* 41:223–229
- Takahashi E, Niimi K, Itakura C (2010b) Neonatal motor functions in Cacna1a-mutant rolling Nagoya mice. *Behav Brain Res* 207:273–279
- Titulaer MJ, Wirtz PW, Kuks JB et al (2008) The Lambert-Eaton myasthenic syndrome 1988–2008: a clinical picture in 97 patients. *J Neuroimmunol* 201–202:153–158
- Tomoda H, Kato M, Sakata S et al (1992) Striatal dysfunction in Rolling mouse Nagoya: an electrophysiological study. *J Neurol Sci* 112:106–112
- Van Den Maagdenberg AM, Haan J, Terwindt GM et al (2007) Migraine: gene mutations and functional consequences. *Curr Opin Neurol* 20:299–305
- Westenbroek RE, Sakurai T, Elliott EM et al (1995) Immunochemical identification and subcellular distribution of the alpha 1A subunits of brain calcium channels. *J Neurosci* 15:6403–6418



# Chapter 61

## Ataxic Syrian Hamster

Kenji Akita

**Abstract** A spontaneous genetic model of cerebellar ataxia in the Syrian hamster (*Mesocricetus auratus*) is described. The homozygous mutant hamsters are smaller than the unaffected littermates but have a normal appearance. They develop progressive, but moderate ataxia beginning at 7 weeks of age. The major pathologic change in the ataxic mutants is significant cerebellar atrophy, including a rapid and substantial loss of Purkinje cells. In the homozygous hamster brain, expression of *Nna1*, the gene responsible for the Purkinje cell degeneration (*pcd*) phenotype in mice, is selectively suppressed.

**Keywords** Ataxia • Syrian hamster • Purkinje cell • *Nna1*

### 61.1 Introduction

To date, numerous laboratory animals with neurological mutations have been described. These animal models are characterized by selective neuronal loss and/or dysfunctions resulting from discrete, genetically induced lesions, and they have served as valuable experimental models for the developmental, differentiative, and degenerative phases of neuronal systems. The ataxic mutation in the Syrian hamster is characterized by substantial corticocerebellar atrophy with rapid loss of the cerebellar Purkinje cell (PC) population, occurring after the third postnatal week. Importantly, expression of *Nna1* (nervous system nuclear protein induced by axotomy 1), the causal gene of the Purkinje cell degeneration (*pcd*) mutation reported in mice, is almost completely suppressed in the brain of mutant hamsters (Akita et al. 2007; Akita and Arai 2009). General properties, similarities and discrepancies between the ataxic hamster and well-characterized *pcd* mutant mice are described.

---

K. Akita (✉)  
R&D Center, Hayashibara Co., Ltd., 675-1 Fujisaki, Naka-ku, Okayama 702-8006, Japan  
e-mail: [kenji.akita@hb.nagase.co.jp](mailto:kenji.akita@hb.nagase.co.jp)

## 61.2 General Properties

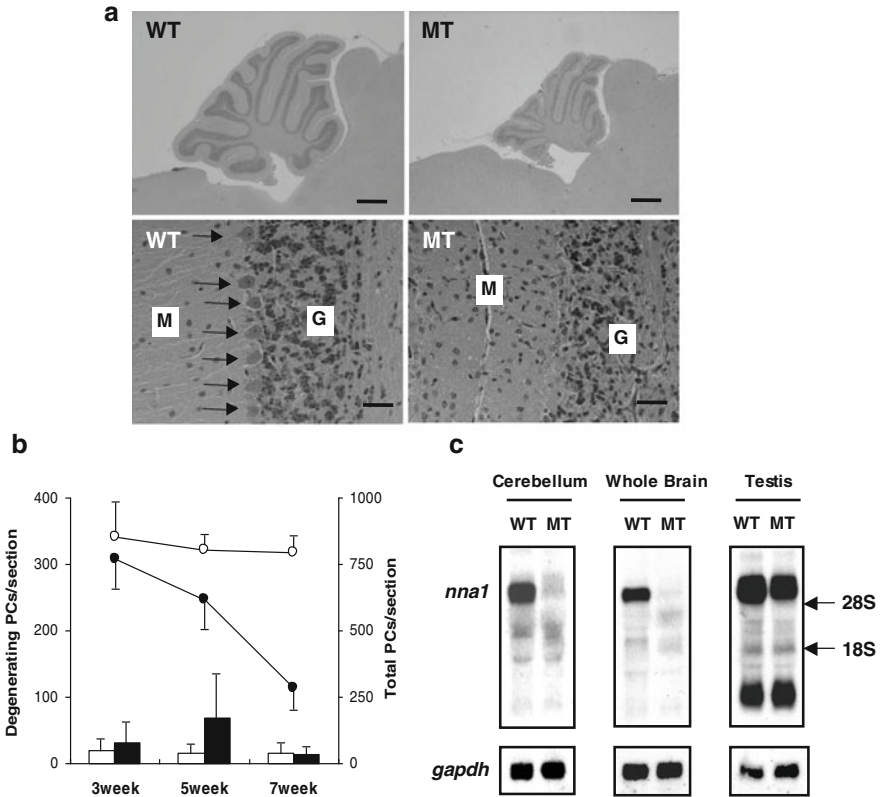
The body size of the ataxic mutants is comparable to that of wild-types at the time of weaning (third postnatal week), but they are about 20% smaller at 10 weeks of age. They have an otherwise normal appearance, exhibit no other peculiar disease symptoms, and live a normal lifespan (~2 years) under conventional breeding conditions. Both homozygous males and females are fertile. The major clinical sign of the mutant hamster is moderate ataxia of gait, including unsteady walking and stumbling as well as a slight trembling of the head. Symptoms become obvious in the mutants around 7 weeks of age and fixed after another 1 or 2 weeks, then progress slowly. Other than ataxia-related symptoms, no other behavioral abnormalities have been confirmed, including circadian coordination or body temperature regulation. Interestingly, they can hibernate normally when they are kept under a condition of short photoperiod (light:dark = 2 h:22 h) and low ambient temperature (4 °C).

## 61.3 Histology

The adult ataxic hamsters exhibited significant atrophy in the cerebellum compared with wild-type hamsters (Fig. 61.1a). The cerebellar volume was also significantly smaller in the mutants. The average weight of cerebellum in the adult mutant female hamster was approximately 50% compared with that in age- and sex-matched wild-type hamsters. In spite of this, mutant hamsters retained basic structure of the cerebellum. There was a remarkable reduction in the cerebellar cortical region, that is, a reduction in the thickness of both molecular and granule cell layers; however, the area of the deep cerebellar nuclei was not changed significantly. The PC number started to decrease after 3 weeks of age over several weeks. A remarkable degeneration of PCs was observed at 5 weeks of age in the ataxic mutants (Fig. 61.1b). By the time ataxic hamsters reached 18 months of age, almost all PCs disappeared in all lobules of the cerebellum. In contrast to the rapid degeneration of PCs, a slow and moderate reduction of cerebellar granule cells was also observed in older mutants. These observations suggest that a progressive, although mild degeneration of cerebellar granule cells occurs in the mutant hamsters probably due to a lack of support from PCs.

## 61.4 Genetics

Most of the murine mutations affecting the cerebellum are viewed as recessive, including *pcd*, *staggerer*, *reeler*, *nervous*, *scrambler*, *yotari*, *rolling mouse Nagoya*, *tottering*, and *leaner*, with *lurcher* and *weaver* as exceptions. The expression profile



**Fig. 61.1** Histology and genetics of the ataxic hamsters. (a) Mid-sagittal cerebella of adult wild-type (WT) and ataxic mutant (MT) hamsters. *Upper panels* indicate a substantial cerebellar atrophy in the ataxic mutant. *Arrows* indicate PCs. *G* granule cell layer, *M* molecular layer. Bars: 600  $\mu$ m (*upper*); 30  $\mu$ m (*lower*). (b) Time courses of the number of cerebellar PCs of WT (*open legend*) and MT (*closed legend*). The number of PCs was counted in all lobules of the cerebellar sections. Degenerating PCs were also counted with FluoroJade B staining and represented as bars. Data are presented as mean  $\pm$  SD. (c) Northern hybridization analysis of *nna1* transcript(s) in the cerebellum, whole brain, and testis. A 4-kb transcript was absent in the brain of the mutant hamsters, whereas 4-kb and 1-kb transcripts were detected in the testis of both WT and MT. *gapdh*: loading control

of five previously identified ataxia-related genes (*pcd/Nna1*, *weaver/Girk2*, *staggerer/Rora*, *reeler/Rln*, and *lurcher/Grid2*) was examined in wild-type and mutant hamsters. Within these five genes, only the *Nna1* was significantly silenced in the cerebellum of mutant hamsters. The suppression of *Nna1* gene expression in the homozygous mutant was seen not only in the cerebellum but also in the whole brain (Fig. 61.1c). This result strongly suggests that silenced *Nna1* gene expression is implicated in the primary loss of cerebellar PCs in mutant hamsters, similar to the previously reported *pcd* mutant mice.

## 61.5 Comparison to *pcd* Mice

*Pcd* is a mouse mutant characterized by postnatal degeneration of selective cell types, originally described by Mullen et al. (1976). This neurological mutant has been studied extensively for more than 30 years as an animal model for hereditary ataxia in humans. More than ten distinct phenotypic alleles of *pcd* mutation have been reported so far and a line of evidence strongly suggests that the loss-of-function of *Nna1* protein would be a critical factor for developing ataxia (Chakrabarti et al. 2006, 2008; Wang and Morgan 2007). In addition, testicular expression of *Nna1* may correlate with spermatogenesis, because the ataxic hamsters with stable *Nna1* expression in the testis are fertile and a non-sterile strain of *pcd* mice (*pcd<sup>21</sup>*) also expresses testicular *Nna1* exceptionally (Fernandez-Gonzalez et al. 2002).

The ataxic symptom in the *pcd* mice is moderate, beginning in the third to fourth postnatal week. In contrast, the mutant hamster develops ataxia at the seventh postnatal week, much later than the *pcd* mice. Therefore, the timing of the onset of ataxia is substantially different. Time courses of PC loss in these two animal models provide reasonable support for this notion. In *pcd* mice, the death of PCs occurs within a relatively brief period of time. PC death begins in authentic *pcd* mice (*pcd<sup>11</sup>*) at 18 days of age. In 22- and 24-day-old mutants, 25–50% of the PCs in the cerebellum had been lost. By 29 days of age, they had lost >90% of the PCs (Mullen et al. 1976). In the ataxic hamsters, however, there was no significant sign of PC death in third postnatal week; approximately 80% of PCs were alive in fifth postnatal week; and more than 30% were still alive in seventh postnatal week (Fig. 61.1b). Thus, degeneration of PCs progresses considerably slower in the ataxic hamsters compared with the authentic (and other types of) *pcd* mice.

## 61.6 Concluding Remarks

The ataxic Syrian hamster bears many similarities to the *pcd* mutant mice, and it appears certain that the *pcd*-type mutation is involved in ataxia pathogenesis in the mutant hamsters because *Nna1* expression is almost completely suppressed in the brain. Although detailed investigations are required to obtain conclusive proof, the ataxic hamster can be assumed to be an animal model homologous to the *pcd* mutant mice. The ataxic phenotype of the mutant hamsters develops slower and milder compare to those reported for most alleles of the *pcd* mice; therefore, the ataxic hamster might be a preferable alternative experimental model for hereditary ataxia. In fact, we successfully evaluated the neuroprotective effect of bioactive dyes against neuronal degeneration using this line of ataxic hamsters (Ohta et al. 2011). Given that *pcd* is one of the well-investigated mutated alleles for hereditary cerebellar ataxia and that *pcd* mutant mice have yielded significant insights into the treatment of chronic neurodegenerative disorders, the ataxic Syrian hamster could be applied in related field of research.

## References

- Akita K, Arai S (2009) The ataxic Syrian hamster: an animal model homologous to the *pcd* mutant mouse? *Cerebellum* 8:202–210
- Akita K, Arai S, Ohta T et al (2007) Suppressed *Nna1* gene expression in the brain of ataxic Syrian hamsters. *J Neurogenet* 21:19–29
- Chakrabarti L, Neal JT, Miles M et al (2006) The Purkinje cell degeneration 5J mutation is a single amino acid insertion that destabilizes Nna1 protein. *Mammal Genome* 17:103–110
- Chakrabarti L, Eng J, Martinez RA (2008) The zinc-binding domain of Nna1 is required to prevent retinal photoreceptor loss and cerebellar ataxia in Purkinje cell degeneration (*pcd*) mice. *Vision Res* 48:1999–2005
- Fernandez-Gonzalez A, La Spada AR, Treadaway J et al (2002) Purkinje cell degeneration (*pcd*) phenotypes caused by mutations in the axotomy-induced gene, *Nna1*. *Science* 295:1904–1906
- Mullen RJ, Eicher EM, Sidman RL (1976) Purkinje cell degeneration, a new neurological mutation in the mouse. *Proc Natl Acad Sci U S A* 73:208–212
- Ohta H, Arai S, Akita K et al (2011) Neurotrophic effects of a cyanine dye via the PI3K-Akt pathway: attenuation of motor discoordination and neurodegeneration in an ataxic animal model. *PLoS One* 6:e17137
- Wang T, Morgan JI (2007) The Purkinje cell degeneration (*pcd*) mouse: an unexpected molecular link between neuronal degeneration and regeneration. *Brain Res* 1140:26–40

# Chapter 62

## Lesions of the Cerebellum

Maria Teresa Viscomi and Marco Molinari

**Abstract** Since the end of nineteenth century, the simplicity of neuronal architecture of the cerebellar system has attracted neuroscientist and thus cerebellum has become one of the favorite targets for testing the cellular or systemic functional hypothesis of neural function. Thus the classical lesion approach, which consists in damaging a structure to test the function, has been applied many times.

**Keywords** Cerebellar system • Lesion • Brain plasticity • Neuronal degeneration

Since the end of nineteenth century, the simplicity of neuronal architecture of the cerebellar system has attracted neuroscientist and thus cerebellum has become one of the favorite targets for testing the cellular or systemic functional hypothesis of neural function. Thus the classical lesion approach, which consists in damaging a structure to test the function, has been applied many times.

Much of what is known about cerebellar function comes from findings on experimental approaches using small selective lesions, as well large lesions removing the entire cerebellum. One of the most employed paradigm of cerebellar lesion is the hemispherectomy (HCb), consisting in the ablation of half of the cerebellum. This approach is widely employed by many groups in various contexts of neuroscience and over the decades has provided interesting results on cerebellar functions, as well as structural plasticity and functional recovery and on mechanisms of neuronal degeneration.

### 62.1 Hemicerebellectomy

Hemicerebellectomy (HCb) is an experimental model of cerebellar lesion characterized by surgical ablation of half the vermis with one cerebellar hemisphere, including the deep cerebellar nuclei and cerebellar peduncle, while sparing the vestibular

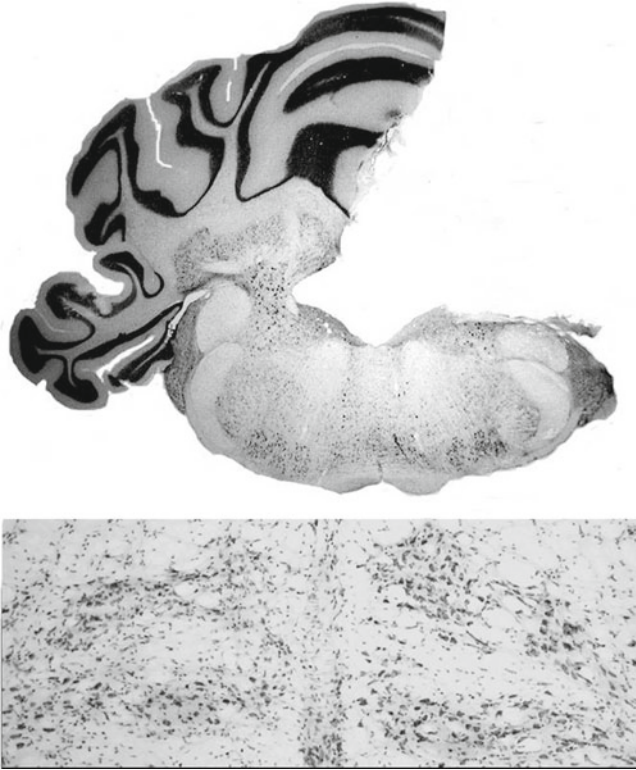---

M.T. Viscomi (✉)

Laboratory of Experimental Neurorehabilitation Santa Lucia Foundation, Rome, Italy  
e-mail: [mt.viscomi@hsantalucia.it](mailto:mt.viscomi@hsantalucia.it)

M. Molinari

Clinical Translational Research, Santa Lucia Foundation, Rome, Italy



**Fig. 62.1** Hemicerebellectomy in rat. *Upper part*: macrophotograph of a coronal section through the cerebellum and brain stem of an adult rat that has received a right HCb. Note the absence of the right cerebellar hemisphere, with complete sparing of the left cerebellar nuclei and brain stem structures. *Lower part*: microphotograph of a Nissl-stained section, showing retrograde degeneration in the inferior olive 21 days after right HCb. Note that the left side of the IO shows decreased neuronal density

nuclei and all surrounding structures (Fig. 62.1). This model of cerebellar damage can be considered as a mixed experimental model of both deafferentation and axotomy of CNS. In fact, this type of lesion by removing the cerebellar cortex and deep cerebellar nuclei (DCN) of one side produces a complete axotomy of both mossy and climbing afferent fiber systems and lesions all efferent projections from Deep Cerebellar Nuclei (DCN) to red nucleus and thalamus as well as to brain stem pre-cerebellar nuclei (deafferentation).

Based on the unilaterality of the lesion and the nearly complete crossover of the cerebellar input-output organization, it is possible to study an intact and a lesioned cerebellar circuit in the same animal using this model.

This approach is simple, effects low mortality, and has a high degree of reproducibility. Because in human pathology, focal cerebellar lesions due to stroke, bleeding, trauma, or surgery are often unilateral, HCb is suitable for examining

neurophysiological, functional, structural and morphological changes occurring after a focal cerebellar lesion.

## **62.2 Effects of Cerebellar Lesion on Precerebellar Nuclei: Inferior Olive and Pontine Nuclei**

Cerebellar focal lesion has effects on the main target of cerebellar output system, namely red nucleus and thalamus, and profoundly affects cerebro-cerebellar functional interactions (Giannetti and Molinari 2002). Effects of cerebellar damage on red nucleus anatomy and functions have been addressed by Tsukahara (Tsukahara et al. 1983) and were among the first demonstration of postlesional brain plasticity mechanisms in the brain. Thalamic and cortical changes have been addressed by many authors in humans (Jissendi et al. 2008; Clausi et al. 2009), but seldom analyzed in animal models.

The well-described anatomical efferent-afferent organization of the cerebellar system and the density of the major afferent sources in two well-defined brainstem structures—the inferior olive and pontine nuclei—constitute an optimal model that can be used to examine the mechanism of trans-synaptic degeneration—retrograde or anterograde—occurring in brain regions that are far, but functionally connected to the lesion site. Because of the crossed input-output cerebellar organization, HCb damages the axons of all neurons of the contralateral inferior olive (IO) and pontine nuclei (Pn)—retrograde effects—and nearly deprives the contralateral cerebral cortex of cerebellar input—anterograde effects.

After unilateral HCb extensive neuronal death occurs in all neurons of contralateral inferior olive and pontine nuclei (Fig. 62.1). Death signals from the area of damage are conveyed to neurons by the axons that are primarily involved in the damage. Interestingly, death of axotomized inferior olive and pontine nuclei neurons is not immediate but delayed. Neuronal death persists for approximately 2 months, during which the olivary and pontine neuronal cell populations progressively fade (Buffo et al. 1998; Viscomi et al. 2004). Furthermore, before dying Pn and IO neurons present a series of morphological changes such as chromatolysis, reduction of basophilic cytoplasmic substances, nuclear eccentricity, nuclear and nucleolar enlargement, cell swelling, and retraction of dendrites. After HCb, concomitant with neuronal degeneration, precerebellar nuclei experience robust astrocytic and microglial activation (Viscomi et al. 2008a, b). Also in this case the glial reaction is not immediate. Glial activation is evident by 7 days, peaking at 3 weeks and progressively decreasing in intensity. Olivary and pontine nuclei contain densely stained and hypertrophic astrocytes that have long processes with frequent ramifications, as well as microglial cells that have short and knotty processes with few short ramifications. Although the exact relationship between glial activation and neuronal cell death has not fully elucidated, after HCb glial activation is suspected of participating in degeneration of olivary and pontine nuclei.



### **62.3 HCb and Postlesional Structural Plasticity**

HCb approach demonstrated functionally relevant, lesion-induced structural changes and highlighted the importance of the rewiring of connections for functional recovery. In this regard, the studies by several groups on postlesional brain plasticity after HCb are of particular interest. The presence of abnormal cerebellar projections to the ipsilateral red nucleus and ventral thalamus has been shown after neonatal HCb in rats (Castro 1978). Furthermore, several groups have documented aberrant projections to the red nucleus and thalamus after HCb in the early postnatal period in describing the axonal collateralization of aberrant cerebellothalamic projections to the ipsilateral thalamus (Molinari et al. 1986) and the synaptic organization of the cerebello-rubral synapses that sprout (Gramsbergen and Ijkema-Paassen 1982). These aberrant ipsilateral projections maintain the topographic specificity of the normal contralateral route, at the least for the cerebellorubral projection (Naus et al. 1984).

With regard to anatomical brain organization after HCb, the developmental time frame during which a lesion develops highly influences postlesional brain plasticity after HCb (Castro 1978). When HCb is performed early in development induces rewiring not only in spared cerebellar efferents but also in systems that project to the cerebellar stations. Neonatal HCb is associated with anomalous increases in crossed sensorimotor cortico-pontine (O'Donoghue et al. 1987) and rubro-olivary projections (Swenson and Castro 1982). This pattern is also observed in ascending pathways. Spinal projections to the Deiters' nuclei are crossed. After early HCb, the surviving Deiters' nucleus receives increased amounts of ipsilateral spinal fibers (Castro and Smith 1979). Notably, these plastic changes do not involve the systems that originate from the surviving precerebellar nuclei. Specifically, the rubro-spinal, vestibulo-spinal, and reticulo-spinal pathways do not undergo significant changes after neonatal HCb (Petrosini et al. 1988). Conversely, in adulthood, HCb induces unilateral retrograde degeneration in the major precerebellar stations: the inferior olive, pontine nuclei, vestibular nuclei, and various brain stem nuclei. These retrograde phenomena deprive many pathways of their natural targets and the pathway that is deprived degenerates, spreading trans-synaptically and the connections are not rewired.

### **62.4 Effects of Cerebellar Lesion Performed at Different Developmental Stages**

The age at which animals received cerebellar lesions affects the motor performance (Petrosini et al. 1988, 1990; Molinari et al. 1990). Although classical cerebellar symptoms, such as decomposition of movements, dysmetria, tremor and asthenia were displayed by all operate groups, less disrupting effects were observed in neonatal operate animals than in weanling and adult lesioned animals.

The neonatal lesioned rats exhibited the posture, which most closely approached the normal pattern. They displayed only a slight extensor hypotonia, contralateral to the lesion side during standing and very efficient locomotion. Conversely, even several months after the lesion, the oldest operated animals displayed a markedly asymmetrical posture, with body tilt to the lesion side and a hampered locomotion with a wide base.

Interestingly, kinematic analysis of rats with a cerebellar lesion performed on the first postnatal day demonstrates that during stance, neonatal lesioned rats showed a clear hyperextension of both hindlimbs but not of the forelimbs. Their locomotor posture was characterized by spinal flexion with the head held lower than normal. During swing, they showed a tendency towards 'high stepping'. Their steps were regular and symmetrical but hypometric. Adult lesioned animals displayed a marked extensor hypotonia, ipsilateral to the lesion during stance and a relevant hyperflexion affecting both sides, during swing. Alteration of the interlimb coordination and modified sequence of steps were also observed. Thus, adult lesioned animals displayed a highly asymmetrical, impaired and unstable locomotion than young animals.

Finally, regarding motor function it has been shown that HCB in the early postnatal period affects normal motor development (Petrosini et al. 1990). All these aspects are closely related to the postnatal development of the cerebellum and to the fact that important steps of motor functions occur postnatally (Altman and Winfree 1977).

However, after early HCB motor competencies are affected differently. The emergence of the quadruped stance, placing reactions, and the ability to swim develop normally despite the cerebellar lesion. Conversely, the evolution of other motor competence skills such as cliff avoidance, pivoting, and crawling is delayed, but they recover nearly completely. Finally, complex functions, such as crossing a narrow path or remaining suspended on a wire, are permanently impaired after HCB (Petrosini et al. 1990).

Another peculiar effect of early HCB is characterized by normal development followed by the appearance of a deficit at a later stage. This phenomenon is evidenced by the progressive reduction in grasping ability and the development of a directional bias in the vestibular drop response. Overall, the most significant event in this phenomenon is the shift in postural asymmetry after HCB from the side of the lesion to the contralateral side in the third postnatal week (Petrosini et al. 1990).

Furthermore, the HCB model is a reliable model for demonstrating how the extent of recovery after lesions is highly dependent on the age at lesion. Although most of the motor symptoms elicited by cerebellar damage gradually compensate over time, independently of the age at lesion, other symptoms compensate less consistently over a longer time course and to a lesser extent. Specifically, in rats that received HCB in adulthood the severity of static symptoms, such as eye and head nystagmus and head and body tilt decrease progressively, while the dynamic symptoms, including complex and coordinated behaviors, compensate less consistently and to a lesser extent than in adult rats that received HCB at birth. This latest group presents efficient locomotion, characterized by spinal flexion with the head held

low, high stepping during swing, and symmetric regular and hypometric stepping (Molinari and Petrosini 1993). The functional differences in gait after HCb at various developmental stages are attributed to the use of disparate compensatory motor strategies, as well as to the different degree of anatomical remodelling (Molinari et al. 1986; O'Donoghue et al. 1987; Gramsbergen and Ijkema-Paassen 1991).

## 62.5 Conclusions

HCb is an animal model that has provided important insights into cerebellar function and mechanisms of brain plasticity. Despite its long history, dating back to Luciani's work in 1891 (Manni and Petrosini 1997), HCb remains a widely used model and continues to generate novel findings in neurobiology (Viscomi et al. 2009; Viscomi and Molinari 2014) of cerebellar functions (Mandolesi et al. 2010).

## References

- Altman J, Winfree AT (1977) Postnatal development of the cerebellar cortex in the rat. V. Spatial organization of purkinje cell perikarya. *J Comp Neurol* 171:1–16
- Buffo A, Fronte M, Oestreicher AB, Rossi F (1998) Degenerative phenomena and reactive modifications of the adult rat inferior olivary neurons following axotomy and disconnection from their targets. *Neuroscience* 85:587–604
- Castro AJ (1978) Projections of the superior cerebellar peduncle in rats and the development of new connections in response to neonatal hemicerebellectomy. *J Comp Neurol* 178:611–627
- Castro AJ, Smith DE (1979) Plasticity of spinovestibular projections in response to hemicerebellectomy in newborn rats. *Neurosci Lett* 12:69–74
- Clausi S, Bozzali M, Leggio MG, Di Paola M, Hagberg GE, Caltagirone C, Molinari M (2009) Quantification of gray matter changes in the cerebral cortex after isolated cerebellar damage: a voxel-based morphometry study. *Neuroscience* 162:827–835
- Giannetti S, Molinari M (2002) Cerebellar input to the posterior parietal cortex in the rat. *Brain Res Bull* 58:481–489
- Gramsbergen A, Ijkema-Paassen J (1982) CNS plasticity after hemicerebellectomy in the young rat. Quantitative relations between aberrant and normal cerebello-rubral projections. *Neurosci Lett* 33:129–134
- Gramsbergen A, Ijkema-Paassen J (1991) Increased cell number in remaining cerebellar nuclei after cerebellar hemispherectomy in neonatal rats. *Neurosci Lett* 124:97–100
- Jissendi P, Baudry S, Balériaux D (2008) Diffusion tensor imaging (DTI) and tractography of the cerebellar projections to prefrontal and posterior parietal cortices: a study at 3T. *J Neuroradiol* 35:42–50
- Mandolesi L, Foti F, Cutuli D, Laricchiuta D, Gelfo F, De Bartolo P, Petrosini L (2010) Features of sequential learning in hemicerebellectomized rats. *J Neurosci Res* 88:478–486
- Manni E, Petrosini L (1997) Luciani's work on the cerebellum a century later. *Trends Neurosci* 20:112–116
- Molinari M, Petrosini L (1993) Hemicerebellectomy and motor behaviour in rats. III. Kinematics of recovered spontaneous locomotion after lesions at different developmental stages. *Behav Brain Res* 54:43–55

- Molinari M, Bentivoglio M, Granato A, Minciacchi D (1986) Increased collateralization of the cerebellothalamic pathway following neonatal hemicerebellectomy. *Brain Res* 372:1–10
- Molinari M, Petrosini L, Gremoli T (1990) Hemicerebellectomy and motor behaviour in rats. II. Effects of cerebellar lesion performed at different developmental stages. *Exp Brain Res* 82:483–492
- Naus CG, Flumerfelt BA, Hryciyshyn AW (1984) Topographic specificity of aberrant cerebellorubral projections following neonatal hemicerebellectomy in the rat. *Brain Res* 309:1–15
- O'Donoghue DL, Kartje-Tillotson G, Castro AJ (1987) Forelimb motor cortical projections in normal rats and after neonatal hemicerebellectomy: an anatomical study based upon the axonal transport of WGA/HRP. *J Comp Neurol* 256:274–283
- Petrosini L, Molinari M, Gremoli T, Granato A (1988) Neonatal versus adult hemicerebellectomy: a behavioral and anatomical analysis. In: Flohr E (ed) *Postlesional neural plasticity*. Springer, Berlin, pp 213–220
- Petrosini L, Molinari M, Gremoli T (1990) Hemicerebellectomy and motor behaviour in rats. I. Development of motor function after neonatal lesion. *Exp Brain Res* 82:472–482
- Swenson RS, Castro AJ (1982) Plasticity of meso-diencephalic projections to the inferior olive following neonatal hemicerebellectomy in rats. *Brain Res* 244:169–172
- Tsukahara N, Bando T, Murakami F, Oda Y (1983) Properties of cerebello-precerebellar reverberating circuits. *Brain Res* 274:249–259
- Viscomi MT, Molinari M (2014) Remote neurodegeneration: multiple actors for one play. *Mol Neurobiol* 50:368–389
- Viscomi MT, Florenzano F, Conversi D, Bernardi G, Molinari M (2004) Axotomy dependent purinergic and nitrenergic co-expression. *Neuroscience* 123:393–404
- Viscomi MT, Florenzano F, Latini L, Amantea D, Bernardi G, Molinari M (2008a) Methylprednisolone treatment delays remote cell death after focal brain lesion. *Neuroscience* 154:1267–1282
- Viscomi MT, Latini L, Florenzano F, Bernardi G, Molinari M (2008b) Minocycline attenuates microglial activation but fails to mitigate degeneration in inferior olive and pontine nuclei after focal cerebellar lesion. *Cerebellum* 7:401–405
- Viscomi MT, Florenzano F, Latini L, Molinari M (2009) Remote cell death in the cerebellar system. *Cerebellum* 8:184

# Chapter 63

## Cellular and Animal Models of Cerebellar Disorders: Staggerer Mouse

N. Morellini, A.M. Lohof, R.M. Sherrard, and J. Mariani

**Abstract** The *staggerer* mutant mouse carries a spontaneous mutation in the ligand-binding domain of the rora gene. ROR $\alpha$  is expressed in many tissues and its loss leads to diverse abnormalities. In the cerebellum of *staggerer* mice, there is severe early degeneration of Purkinje cells and associated death of their afferent neurons (granule and olivary neurons). Thus *staggerer* mice have atrophic cerebella and associated severe ataxia. In contrast, although heterozygote *staggerer* mice develop apparently normally, there is premature Purkinje cell atrophy and death in adulthood. Given that recent links have been demonstrated between ROR $\alpha$  and spinocerebellar ataxia and autism spectrum disorders, the *staggerer* mouse is a particularly interesting model for cerebellar pathologies.

**Keywords** Purkinje Cell • Neuroprotection • Autism Spectrum Disorders • Anti-Inflammatory Action • Orphan Nuclear Receptor • Spinocerebellar Ataxia

### 63.1 The *Staggerer* Mouse

The *staggerer* mouse results from a spontaneous mutation and was first described as having a phenotype similar to that of cerebellar cortical neurodegenerative disease, characterized by a staggering gait, mild tremor and hypotonia in association with profound cerebellar atrophy (Sidman et al. 1962).

---

R.M. Sherrard and J. Mariani are co-senior authors.

N. Morellini (✉) • A.M. Lohof • R.M. Sherrard  
Sorbonne Universités UPMC-Univ Paris 6 and CNRS, IBPS-B2A and DHU FAST,  
UMR8256 Biological Adaptation and Ageing, Paris, France  
e-mail: [jean.mariani@upmc.fr](mailto:jean.mariani@upmc.fr)

J. Mariani  
Sorbonne Universités UPMC-Univ Paris 6 and CNRS, IBPS-B2A and DHU FAST,  
UMR8256 Biological Adaptation and Ageing, Paris, France

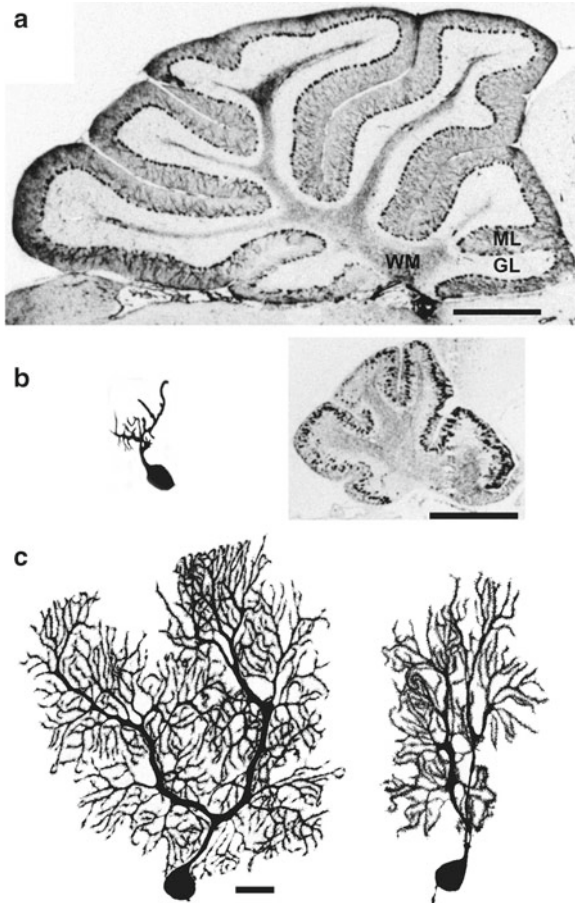
Institut de la Longévité, Hôpital Charles Foix, Ivry-sur-Seine, France

The mutation responsible for the *staggerer* phenotype is found in the retinoid-related orphan receptor alpha (ROR $\alpha$ ) gene (Hamilton et al. 1996). ROR $\alpha$  is a transcription factor that binds to DNA response elements and regulates transcription. The *staggerer* mutation causes a 122-bp deletion in the *rora* ligand-binding domain, resulting in its loss of function (Hamilton et al. 1996). ROR $\alpha$  is expressed in a variety of tissues; in the cerebellum, ROR $\alpha$  is expressed at high levels in Purkinje cells, at lower levels in the basket and stellate cells and also in astrocytes (Hamilton et al. 1996; Journiac et al. 2009). ROR $\alpha$  has been implicated in many roles within cerebellar development and plays an important role in Purkinje cell development, maintenance and survival (Boukhtouche et al. 2006; Chen et al. 2013). At birth, *staggerer* mice have the same number as Purkinje cells as wild-type mice (Yoon 1972). However in the first post-natal week Purkinje cells begin to die, and by the end of the first month there is 75–90% Purkinje cell loss, the surviving cells being atrophic and ectopically positioned (Fig. 63.1; Vogel et al. 2000). Surviving Purkinje cells in adult *staggerer* mice retain immature properties, with dendrites lacking spiny branchlets (Sotelo and Changeux 1974) and retaining multiple climbing fibre innervation (Mariani and Changeux 1980). These Purkinje cells also receive very few parallel fibre synapses, and these synapses lack the normal signalling by metabotropic glutamate receptors (Mitsumura et al. 2011). Due to the loss of the Purkinje cells, there is almost complete degeneration of granule cells (Herrup 1983) and 60% of inferior olive neurons (Blatt and Eisenman 1985; Zanjani et al. 2007) as well as a reduction in soma size of deep cerebellar nuclei neurons (Roffler-Tarlov and Herrup 1981). Consequently, the cerebellum of the adult *staggerer* is atrophic containing small folia with shallow fissures and indistinct lamination of the cortical grey matter (Fig. 63.1; Sidman et al. 1962).

The dysgenesis of the cerebellar cortex is associated with severe ataxia, tremor and hypotonia (Sidman et al. 1962). Behaviour tests show that *staggerer* mice have impaired balance and motor coordination and fail to learn motor tasks (Lalonde et al. 1996a). *Staggerer* mice are also less active in a T-maze and show less spontaneous alternation, which may be due to a deficit in response inhibition or spatial orientation (Lalonde et al. 1988). In addition, *staggerer* mice have a deficit in spatial learning, with increased path length and escape latencies compared to wild-type mice when searching for a submerged platform in a water maze (Lalonde et al. 1996b).

### 63.1.1 ROR $\alpha$ and Spinocerebellar Ataxia

Because of the severe cerebellar atrophy, Purkinje cell degeneration and congenital ataxia, the *staggerer* mouse is considered as an extreme model of developmental neurodegeneration, such as is found in spinocerebellar ataxia type-1 (SCA1), a polyglutamine repeat expansion disorder. In Purkinje cells of mice expressing the mutant ATXN1 (SCA1[82Q]), there was a significant reduction of ROR $\alpha$  mRNA and protein, as well as decreased ROR $\alpha$  target gene expression (Serra et al. 2006). Furthermore, when SCA1[82Q] mice were crossed onto a ROR $\alpha$  *staggerer*



**Fig. 63.1** Cerebellar and Purkinje cell size is very different between wild-type and *staggerer* mice. (a) A midsagittal section of the normal adult cerebellum labelled with calbindin, showing the Purkinje cells and their dendrites in the molecular layer. Bar = 1 mm. (b) In the adult *staggerer* cerebellum labelled with calbindin (on right), there are few surviving Purkinje cells, almost no granular layer and small poorly developed folia. Bar = 1 mm The remaining Purkinje cells are extremely atrophic (left-hand image at the same magnification as c). (c) Adult Purkinje cells from normal (left) and heterozygote (right)  $ROR\alpha^{sg/+}$  mice. Although there are no gross abnormalities in the  $ROR\alpha^{sg/+}$  cerebellum, adult  $ROR\alpha^{sg/+}$  Purkinje cells have slightly smaller dendritic arbors. Bar = 20  $\mu$ m. GL granular layer, ML molecular layer, WM central cerebellar white matter

heterozygote background ( $SCA1[82Q]/ROR\alpha^{sg/+}$ ), the Purkinje cell pathology in adulthood was more severe than in mice expressing  $SCA1[82Q]$  alone (Serra et al. 2006). Therefore, it is possible that a significant component of the mutant  $ATXN1$ -induced Purkinje cell degeneration is via reduced expression of  $ROR\alpha$  and  $ROR\alpha$  mediated genes that are critical for Purkinje cell maintenance and function (Serra et al. 2006). This effect would be exacerbated by the loss of  $ROR\alpha$ 's direct

anti-inflammatory and neuroprotective actions that are mediated through its expression in glia and ROR $\alpha$ 's consequent regulation of cytokine IL-6 expression (Journiac et al. 2009).

### 63.2 The Heterozygote *Staggerer*

In contrast to the homozygote, the heterozygote *staggerer* (ROR $\alpha^{+/-}$ ) shows a clinically normal phenotype, and its cerebellar structure is indistinguishable from wild-type during development and young adulthood (Doulazmi et al. 1999; Mitsumura et al. 2011). However, as early as 3 months of age, ROR $\alpha^{+/-}$  mice develop a deficit in motor coordination and balance, performing poorly on a rotarod compared to wild-type mice (Caston et al. 2003). This is followed by accelerated Purkinje cell dendritic atrophy (Fig. 63.1), and molecular layer thinning at 4 months (Hadj-Sahraoui et al. 2001). In ROR $\alpha^{+/-}$  mice, approximately 25–35% of Purkinje cells die between 6 and 12 months of age, whereas in wild-types Purkinje cell degeneration only begins at 18 months and only 25% of Purkinje cells are lost by 24 months (Doulazmi et al. 1999). Furthermore the time course of Purkinje cell loss is gender dependent and occurs earlier in males (Doulazmi et al. 1999), presumably due to their premature loss of neuroprotective sex steroids (Janmaat et al. 2011). Because of this gender difference and more subtle pathology, the heterozygote *staggerer* mouse has recently been proposed as a model for autism spectrum disorder (ASD), in which late developmental Purkinje cell loss, abnormal neurotransmission, hypoplastic deep nuclei and chronic neuroinflammation consistently occur (Fatemi et al. 2012). Given that these features are observed in ROR $\alpha$  deficient mice (see *staggerer* above) and that ROR $\alpha$  expression is reduced in the brains of ASD patients (Sarachana et al. 2011), studies of the ROR $\alpha^{+/-}$  may further our understanding of the role of the cerebellum in ASD.

### 63.3 Conclusion

The *staggerer* mutation is caused by a deletion in the ROR $\alpha$  gene. Importantly, ROR $\alpha$  is expressed in many tissues, and has been linked to atherosclerosis, osteopenia, muscle atrophy, increased inflammation and associated immune dysfunction (Jarvis et al. 2002). However, within the cerebellum, ROR $\alpha$  is crucially involved in the development, maturation and survival of Purkinje cells and ROR $\alpha$ 's absence leads to severe cerebellar degeneration resulting in ataxia. Furthermore, ROR $\alpha$  is involved in the inflammatory response of neurons and astrocytes and has a neuroprotective effect. The role of ROR $\alpha$  in cerebellar disease in humans is unknown; however recent studies show a link with the development of spinal cerebellar ataxia-1 and ASD. As ROR $\alpha$  is a transcription factor, it may also be involved in other genetic disorders of the cerebellum; however more research needs to be conducted.



## References

- Blatt GJ, Eisenman LM (1985) A qualitative and quantitative light microscopic study of the inferior olivary complex in the adult staggerer mutant mouse. *J Neurogenet* 2:51–66
- Boukhtouche F, Doulazmi M, Frederic F, Dusart I, Brugg B, Mariani J (2006) RORalpha, a pivotal nuclear receptor for Purkinje neuron survival and differentiation: from development to ageing. *Cerebellum* 5:97–104
- Caston J, Hilber P, Chianale C, Mariani J (2003) Effect of training on motor abilities of heterozygous staggerer mutant (Rora(+)/Rora(sg)) mice during aging. *Behav Brain Res* 141:35–42
- Chen X, Heck N, Lohof AM, Rochefort C, Morel MP, Wehrle R, Doulazmi M, Cannaya V, Avci HX, Mariani J, Rondi-Reig L, Vodjdani G, Sherrard RM, Sotelo C, Dusart I (2013) Mature Purkinje cells require the retinoic acid-related orphan receptor alpha (ROR $\alpha$ ) to maintain climbing fiber monoinnervation and other adult characteristics. *J Neurosci* 33(22):9546–9562
- Doulazmi M, Frederic F, Lemaigre-Dubreuil Y, Hadj-Sahraoui N, Delhaye-Bouchaud N, Mariani J (1999) Cerebellar Purkinje cell loss during life span of the heterozygous staggerer mouse (Rora(+)/Rora(sg)) is gender-related. *J Comp Neurol* 411:267–273
- Fatemi SH, Aldinger KA, Ashwood P, Bauman ML, Blaha CD, Blatt GJ, Chauhan A, Chauhan V, Dager SR, Dickson PE, Estes AM, Goldowitz D, Heck DH, Kemper TL, King BH, Martin LA, Millen KJ, Mittleman G, Mosconi MW, Persico AM, Sweeney JA, Webb SJ, Welsh JP (2012) Consensus paper: pathological role of the cerebellum in Autism. *Cerebellum* 11:777–807
- Hadj-Sahraoui N, Frederic F, Zanjani H, Delhaye-Bouchaud N, Herrup K, Mariani J (2001) Progressive atrophy of cerebellar Purkinje cell dendrites during aging of the heterozygous staggerer mouse (Rora(+)/sg). *Dev Brain Res* 126:201–209
- Hamilton BA, Frankel WN, Kerrebrock AW, Hawkins TL, FitzHugh W, Kusumi K, Russell LB, Mueller KL, van Berkel V, Birren BW, Kruglyak L, Lander ES (1996) Disruption of the nuclear hormone receptor RORalpha in staggerer mice. *Nature* 379:736–739
- Herrup K (1983) Role of staggerer gene in determining cell number in cerebellar cortex. I. Granule cell death is an indirect consequence of staggerer gene action. *Brain Res* 313:267–274
- Janmaat S, Akwa Y, Doulazmi M, Bakouche J, Gautheron V, Liere P, Eychenne B, Pianos A, Luiten P, Groothuis T, Baulieu EE, Mariani J, Sherrard RM, Frederic F (2011) Age-related Purkinje cell death is steroid dependent: RORalpha haplo-insufficiency impairs plasma and cerebellar steroids and Purkinje cell survival. *Age* 33:565–578
- Jarvis CI, Staels B, Brugg B, Lemaigre-Dubreuil Y, Tedgui A, Mariani J (2002) Age-related phenotypes in the staggerer mouse expand the RORalpha nuclear receptor's role beyond the cerebellum. *Mol Cell Endocrinol* 186(1):1–5
- Journiac N, Jolly S, Jarvis C, Gautheron V, Rogard M, Trembleau A, Blondeau JP, Mariani J, Vernet-der Garabedian B (2009) The nuclear receptor ROR(alpha) exerts a bi-directional regulation of IL-6 in resting and reactive astrocytes. *Proc Natl Acad Sci U S A* 106:21365–21370
- Lalonde R, Manseau M, Botez MI (1988) Spontaneous alternation and exploration in staggerer mutant mice. *Behav Brain Res* 27:273–276
- Lalonde R, Filali M, Bensoula AN, Lestienne F (1996a) Sensorimotor learning in three cerebellar mutant mice. *Neurobiol Learn Mem* 65:113–120
- Lalonde R, Filali M, Bensoula AN, Monnier C, Guastavino JM (1996b) Spatial learning in a Z-maze by cerebellar mutant mice. *Physiol Behav* 59:83–86
- Mariani J, Changeux JP (1980) Multiple innervation of Purkinje cells by climbing fibers in the cerebellum of the adult staggerer mutant mouse. *J Neurobiol* 11:41–50
- Mitsumura K, Hosoi N, Furuya N, Hirai H (2011) Disruption of metabotropic glutamate receptor signalling is a major defect at cerebellar parallel fibre–Purkinje cell synapses in staggerer mutant mice. *J Physiol* 589:3191–3209
- Roffler-Tarlov S, Herrup K (1981) Quantitative examination of the deep cerebellar nuclei in the staggerer mutant mouse. *Brain Res* 215:49–59

- Sarachana T, Xu M, Wu R, Hu VW (2011) Sex hormones in autism: androgens and estrogens differentially and reciprocally regulate RORA, a novel candidate gene for autism. *PLoS One* 6:e17116
- Serra HG, Duvick L, Zu T, Carlson K, Stevens S, Jorgensen N, Lysholm A, Burright E, Zoghbi HY, Clark HB, Andresen JM, Orr HT (2006) RORalpha-mediated Purkinje cell development determines disease severity in adult SCA1 mice. *Cell* 127:697–708
- Sidman RL, Lane PW, Dickie MM (1962) Staggerer, a new mutation in the mouse affecting the cerebellum. *Science* 137:610–612
- Sotelo C, Changeux JP (1974) Transsynaptic degeneration ‘en cascade’ in the cerebellar cortex of staggerer mutant mice. *Brain Res* 67:519–526
- Vogel MW, Sinclair M, Qiu D, Fan H (2000) Purkinje cell fate in staggerer mutants: agenesis versus cell death. *J Neurobiol* 42:323–337
- Yoon CH (1972) Developmental mechanism for changes in cerebellum of “staggerer” mouse, a neurological mutant of genetic origin. *Neurology* 22:743–754
- Zanjani HS, Mariani J, Herrup K (2007) Cell loss in the inferior olive of the staggerer mutant mouse is an indirect effect of the gene. *J Neurogenet* 21(4):257–269

**Part IX**  
**Human Cerebellar Symptoms: From**  
**Movement to Cognition**

# Chapter 64

## Cerebellum and Oculomotor Deficits

Amir Kheradmand, Ji Soo Kim, and David Zee

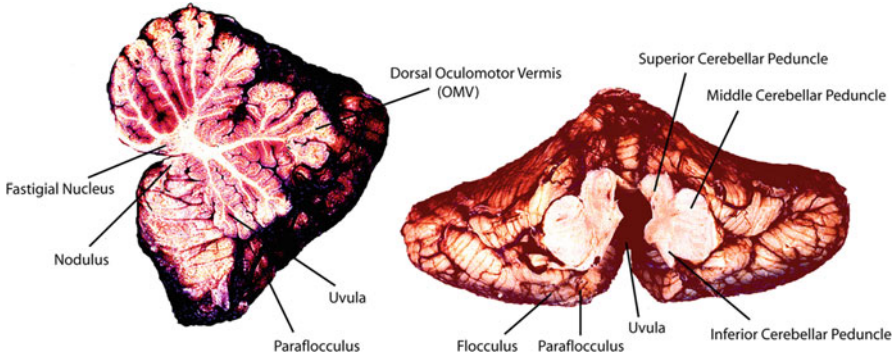
**Abstract** The cerebellum is a key structure within a widely distributed neural network that controls movements including those of the eyes. Both the immediate, on-line control of movement and more long-term adaptive functions are within the purview of the cerebellum. Ocular motor abnormalities are prominent in patients with cerebellar disorders and aid clinical anatomical localization. Assigning specific functions to structures within the cerebellum, however, is more problematic. For example, each of the ocular motor subsystems – saccades, pursuit, vestibular, and vergence – has multiple representations in different parts of the cerebellum, and a functional distinction is not always possible. Furthermore, the cerebellum is so richly interconnected with other parts of the brain that understanding its function depends on considering the entire motor control circuit within which it resides. There are three major structural units in the cerebellum associated with control of eye movements: (1) the flocculus and paraflocculus (tonsil), (2) nodulus and uvula, and (3) the dorsal vermis (lobules VI–VII) and underlying fastigial nuclei. Here we review the main ocular motor deficits associated with cerebellar lesions and infer function accordingly.

**Keywords** Cerebellum • Oculomotor • Saccades • Pursuit • Vestibular • Vergence

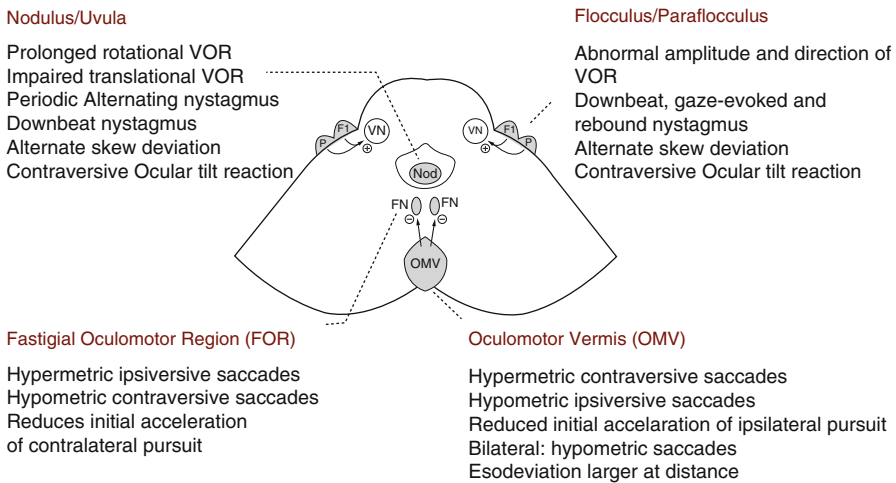
The cerebellum is a key structure within a widely distributed neural network that controls movements including those of the eyes. Both the immediate, on-line control of movement and more long-term adaptive functions are within the purview of the cerebellum. Ocular motor abnormalities are prominent in patients with cerebellar disorders and aid clinical anatomical localization. Assigning specific functions

---

A. Kheradmand (✉) • J.S. Kim • D. Zee  
Neurovestibular Lab, Department of Neurology, The Johns Hopkins Hospital,  
Path 2-210, 600 N Wolfe Street, Baltimore, MD 21287, USA  
e-mail: [akherad@jhu.edu](mailto:akherad@jhu.edu)



**Fig. 64.1** Major cerebellar structures for oculomotor control (Modified from Leigh and Zee, *The Neurology of Eye Movements* (Leigh and Zee 2015))



**Fig. 64.2** Topical oculomotor localization with cerebellar lesions, *VN* Vestibular nucleus, *FN* Fastigial nucleus, *VOR* vestibulo-ocular reflex (Modified from Leigh and Zee, *The Neurology of Eye Movements* (Leigh and Zee 2015))

to structures within the cerebellum, however, is more problematic. For example, each of the ocular motor subsystems – saccades, pursuit, vestibular, and vergence – has multiple representations in different parts of the cerebellum, and a functional distinction is not always possible. Furthermore, the cerebellum is so richly interconnected with other parts of the brain that understanding its function depends on considering the entire motor control circuit within which it resides (Voogd et al. 2012). Here we review the main ocular motor deficits associated with cerebellar lesions and infer function accordingly. Figure 64.1 shows the three major structural units in the cerebellum associated with control of eye movements: (1) the flocculus and paraflocculus (tonsil), (2) nodulus and uvula, and (3) the dorsal vermis (lobules VI-VII) and underlying fastigial nuclei. Figure 64.2 summarizes ocular motor deficits associated with specific cerebellar lesions.

*Saccades* are the rapid eye movements that promptly bring images of objects of interest onto the fovea for visual analysis. Control of saccade accuracy is a major function of the cerebellum, and the dorsal (oculomotor) vermis (OMV) and its underlying projection site, the posterior fastigial nucleus (FOR; fastigial oculomotor region) are the key structures. The activity of Purkinje neurons in the OMV facilitates ipsiversive saccades and the termination of contraversive saccades. FOR neurons, which are inhibited by the Purkinje cells of the OMV, send their axons *through* the contralateral FOR and then to the brainstem. They facilitate contralateral saccades and help stop ipsilateral saccades. Bilateral lesions of OMV produce saccade undershooting (hypometria) and bilateral lesions of the FOR, overshooting (hypermetria). Current hypotheses suggest that as the saccade unfolds, the cerebellum steers the saccade to the visual target and stops it there. This is accomplished using an internal model of the brain's estimate of where the eye is, and to where it must go, based on an efference copy of the premotor saccade commands (Zee and Shaikh 2013; Xu-Wilson et al. 2009; Daye et al. 2014). By comparing actual behavior with expected sensory feedback, the cerebellum also derives error signals to adjust saccade innervation in the long-term to optimize accuracy. Thus the cerebellum adjusts saccades trajectory as needed, both "online" and as part of long-term motor learning.

*Pursuit* movements are used to smoothly track targets that are moving in the environment, whether the head is still or moving. In the latter case pursuit is used to suppress the vestibulo-ocular reflex in order to keep the line of sight on a stationary object within the environment. Two areas in the cerebellum are strongly associated with pursuit. First is the flocculus/paraflocculus complex which projects to the brainstem areas controlling pursuit in the vestibular nuclei (VN), nucleus prepositus hypoglossi (NPH) and the interstitial nucleus of Cajal (INC). Lesions in the flocculus/paraflocculus impair smooth tracking, with the head still or moving, but primarily during the sustained phase of pursuit when the eyes should match the motion of the target. The second area is the OMV, where lesions impair primarily the initiation phase of pursuit, or whenever the eyes must respond promptly to an unexpected change in the speed or direction of the target. The OMV and its projection site in the FOR show a similar ipsilateral-contralateral dichotomy for pursuit as discussed above for saccades. Lesions in the nodulus/uvula may also lead to pursuit deficits, primarily vertical. A study in a patient with an acute unilateral lesion in the cerebellar tonsil (dorsal paraflocculus equivalent in the monkey) suggests a more specific role for the tonsil in pursuit (Lee et al. 2014).

*Vestibular* eye movements or the vestibulo-ocular reflex (VOR) acts to stabilize gaze during head rotations (rotational or rVOR) or translations (translational or tVOR). The VOR may also be affected by cerebellar lesions, including the nodulus/uvula and the flocculus/paraflocculus. A clear separation of function for the rVOR between these two general areas is not yet possible, but the flocculus seems more concerned with high-frequency, rapid VOR responses and the nodulus/uvula with lower frequency, sustained responses (Park et al. 2013). Lesions in the flocculus/paraflocculus may produce changes in the amplitude and direction of the VOR (typically causing an inappropriate upward component with horizontal head rotations)

(Kheradmand and Zee 2011). Lesions in the nodulus/uvula produce many vestibular abnormalities (see Fig. 64.2); some are related to the so-called velocity storage mechanism (VSM). The VSM, acting as an integrator, improves the inherently poor, low-frequency performance of the rVOR. The labyrinth cannot accurately transduce sustained motion because of limitations in its inherent mechanical properties. Accordingly, there is a mechanism in the vestibular nuclei (VN) that integrates signals from the semicircular canals and improves the fidelity of the brain's estimate of self-rotation. The nodulus controls the time constant of the VSM integrator, and nodulus lesions, by removing GABA-B related Purkinje cell inhibition to the VN, prolong the action of the VSM, leading to instability that may cause periodic alternating nystagmus (PAN). PAN is due to the combined effect of vestibular nucleus disinhibition, producing a unidirectional nystagmus, and an intact adaptive mechanism that attempts to null the nystagmus, causing it to change direction every few minutes. The nodulus is also important for combining head orientation information from the otoliths (with respect to gravity) and the semicircular canals, to help the brain distinguish tilt (from the pull of gravity) and translation (from self-motion), both of which rely on otolith activation (Angelaki and Yakusheva 2009). The nodulus/uvula also integrates linear acceleration inputs from the otoliths into velocity signals for the tVOR (Walker et al. 2010). Diffuse cerebellar lesions profoundly impair the tVOR whereas an rVOR can still be generated though its amplitude and direction may be incorrect. Abnormalities of the VSM are often reflected in unusual patterns of nystagmus after sustained head shaking or with positional testing (Leigh and Zee 2015).

The cerebellum also plays an important role in holding the eyes still when steady fixation is required. To hold an eccentric position of gaze, the brain must generate a tonic eye position signal to overcome orbital elasticity. This is accomplished by a neural integrator (NI) that integrates, in the mathematical sense, eye velocity signals into the necessary eye position signals to hold the eye still at the end of a movement. A crude, imperfect form of this integrator (with a time constant of about 2 s) is in the brainstem (VN and NPH for horizontal movements) but the flocculus/paraflocculus monitors and improves its performance (to a time constant of 30 s or more). The flocculus/paraflocculus also correctly matches the output of the integrator (the step) to the rapid 'pulse' of innervation that moves the eye rapidly from one position to another. In this way the eye does not drift after the saccade. Consequently, lesions in the flocculus/paraflocculus usually lead to a 'leaky' horizontal integrator, causing gaze-evoked nystagmus in which the eyes drift centripetally, requiring centrifugal saccades to take the eyes back to the desired eccentric position. In the vertical plane the neural integrator may become leaky or even unstable leading to runaway, velocity increasing, slow phases. After sustained eccentric gaze, upon return to the straight ahead position, there is often a transient "rebound" nystagmus with slow phases directed in the direction of prior eccentric gaze.

*Downbeat nystagmus* is often produced by diseases of the cerebellum but has many potential causes and lesion sites (Fig. 64.2). It can arise from an imbalance in the neural integrator mechanism, in vestibular pathways, either from the tVOR or

the rVOR, or from a vertical pursuit imbalance (Leigh and Zee 2015; Leigh et al. 2002).

The cerebellum also influences *vergence* and control of *eye alignment*. Distinctive is a horizontal misalignment, usually an eso (inward) deviation for distant viewing, and an alternating skew deviation, in which on eccentric horizontal gaze there is a *vertical* misalignment with the abducting eye usually higher. Occasionally there is an ocular tilt reaction (OTR) in which one eye is higher than the other, the head is tilted toward the side of the lower eye and there is a counterrolling (torsion) of the eyes such that the higher eye is intorted and the lower eye extorted. Lesions in various parts of the cerebellum have been associated with this finding (Leigh and Zee 2015).

In sum, eye movements serve as a biological marker, par excellence, for the study of the cerebellum, both its functional role in normal individuals and as a clinical tool in neurological diseases.

## References

- Angelaki DE, Yakusheva TA (2009) How vestibular neurons solve the tilt/translation ambiguity. Comparison of brainstem, cerebellum, and thalamus. *Ann N Y Acad Sci* 1164:19–28
- Daye PM, Optican LM, Blohm G, Lefèvre P (2014) Hierarchical control of two-dimensional gaze saccades. *J Comput Neurosci* 36:355–382
- Kheradmand A, Zee DS (2011) Cerebellum and ocular motor control. *Front Neurol* 2:53
- Lee S-H et al (2014) Isolated unilateral infarction of the cerebellar tonsil: ocular motor findings. *Ann Neurol* 75:429–434
- Leigh RJ, Zee DS (2015) *The neurology of eye movements*, 5th ed. Oxford University Press, Oxford
- Leigh RJ, Das VE, Seidman SH (2002) A neurobiological approach to acquired nystagmus. *Ann N Y Acad Sci* 956:380–390
- Park H-K, Kim J-S, Strupp M, Zee DS (2013) Isolated floccular infarction: impaired vestibular responses to horizontal head impulse. *J Neurol* 260:1576–1582
- Voogd J, Schraa-Tam CKL, van der Geest JN, De Zeeuw CI (2012) Visuomotor cerebellum in human and nonhuman primates. *Cerebellum* 11:392–410
- Walker MF, Tian J, Shan X, Tamargo RJ, Ying H, Zee DS (2010) The cerebellar nodulus/uvula integrates otolith signals for the translational vestibulo-ocular reflex. *PLoS One* 5:e13981
- Xu-Wilson M, Chen-Harris H, Zee DS, Shadmehr R (2009) Cerebellar contributions to adaptive control of saccades in humans. *J Neurosci* 29:12930–12939
- Zee DS, Shaikh A (2013) Neurology of eye movements: from control systems models to ion channels and genetics to targeted pharmacotherapy. In: Werner JS, Chalupa LM (eds) *The new visual neurosciences*. MIT Press, Cambridge, MA, pp 997–990



# Chapter 65

## Speech Deficits

**Maria Caterina Silveri**

**Abstract** Speech disorders characterize the cerebellar syndrome. In classical descriptions speech is reported as scanning, hesitant, explosive due to a lack of coordination of both articulation and phonation within a broader ataxic syndrome (ataxic dysarthria). Speech disorders are commonly observed in the presence of atrophic damage; they have been less frequently described in the presence of focal lesions confined to the cerebellum, primarily in the SCA territory. Cerebellar damage also produces disorders of covert articulation, which affect the planning of speech production at a “prearticulatory” level. The cerebellum is also responsible for time information processing during speech production and discrimination of perceptual components of speech.

**Keywords** Cerebellum • Articulation • Covert articulation • Speech production • Speech perception • Timing

Speech disorders characterize the cerebellar syndrome. In classical descriptions speech is reported as scanning, hesitant, explosive (Darley et al. 1975) due to a lack of coordination of both articulation and phonation within a broader ataxic syndrome (ataxic dysarthria) (Duffy 2013). Speech disorders are commonly observed in the presence of atrophic damage (Schalling and Hartelius 2013); they have been less frequently described in the presence of focal lesions confined to the cerebellum, primarily in the SCA territory (Urban 2013). Cerebellar damage also produces disorders of covert articulation (Silveri et al. 1998), which affect the planning of speech production at a “prearticulatory” level (Ackermann et al. 2007).

Evidence of cerebellar involvement in processing speech time parameters and in discriminating perceptual components of speech suggests that the role of the cerebellum transcends the articulatory level (Ackermann et al. 2007; Mariën et al. 2014) also in the perspective of evolution and acquisition of language. Time is a crucial parameter in discriminating speech sounds, particularly sound categorical stimuli.

---

M.C. Silveri (✉)

Department of Psychology, Catholic University, Largo A. Gemelli 1, 20123 Milano, Italy  
e-mail: [mariacaterina.silveri@unicatt.it](mailto:mariacaterina.silveri@unicatt.it)

Linguistic perception is, in fact, categorical (Lieberman et al. 1967); we are able to perceive stimuli that we learned as different by means of a categorization process which, during language acquisition, “mapped” continuous sensorial phenomena such as acoustic stimuli onto a limited number of sound categories (phonemes) which vary across languages. Thus, the brain assigns acoustic stimuli to qualitatively different categories (and never to intermediate categories). In particular, Voice-Onset-Time (VOT), i.e., the interval between the start of a stop consonant and the onset of the vibration of the vocal folds (voicing), allows perceiving sounds as different. For example, different length VOT allow the listener to distinguish the sound/ba/ (VOT <30) (voiced) from/pa/(VOT >30) (voiceless) (the phoneme boundary effect). In humans, the vocal tract is divided into independent components (articulation) (Studdert-Kennedy 1998). Speech sounds produced by each of these components are combined in various ways and each sound is influenced by both the preceding and the following ones (coarticulation).

Perception of speech has to be integrated with visual articulatory information (McGurk and MacDonald 1976. The “motor theory of speech perception” (Lieberman et al. 1967; Lieberman and Whalen 2000) assumes that perception of verbal sounds requires identification of the “articulatory gestures” the vocal tract is supposed to perform to pronounce those verbal sounds by evoking the motor representation in the listener’s motor cortex. Thus, “articulatory gestures” are the objects of both production and perception, which develop together in evolution; their representations are immediately linguistic and do not require the intervention of other components of the linguistic system (Lieberman and Whalen 2000). In other words, “speech” does not merely consist of sounds as such (Lieberman and Whalen 2000); instead, “speech” has to be intended as the only natural human communication system (Rizzolatti and Craighero 2007).

The identification of a mirror neurons system in the premotor cortex of humans (Rizzolatti et al. 1996) provided experimental support for Lieberman’s “motor theory of speech perception” because this system represents the structural basis of the direct link between speaker and listener. The existence of mirror neurons that respond to sounds produced by the orolaryngeal tract of the speaker (echo-mirrors) has also been hypothesized (Fadiga et al. 2002). This echo-mirror neurons system might also have a role in evolution. In the F5 human (Broca’s) area echo mirror neurons might have evolved to simultaneously code “gestures” generated in the vocal tract (speech articulatory movements) and in the body (actions), which is a prerequisite for the development of a relationship between phonetics and semantics (Rizzolatti and Craighero 2007).

The cerebellum has been considered as a “timing system” in both movement and perception (Keele and Ivry 1991). Ivry and Keele (1989) demonstrated that the ability to estimate the duration of time intervals is impaired when cerebellar damage is present. In fact, patients (unlike normal subjects) were unable to discriminate different intervals of time demarked by two clicks. VOT was confirmed to be altered in

speech production (Ackermann and Hertrich 1997), and an impaired phoneme boundary effect was demonstrated in patients with cerebellar atrophy by adopting acoustic stimuli that differed only in terms of a duration parameter (occlusion time), independently of voicing (Ackermann et al. 1997).

Despite the need for further experimental evidence, these data seem to confirm that the cerebellum acts as an internal clock (Keele and Ivry 1991) and intervenes to differentiate speech sounds in both production and perception. Thus, it contributes to accessing the phonological aspects of language and indirectly supports language functions in which the “timing” of phonological components has a role, such as in the application of syntactic rules (Silveri et al. 1994) and in working memory (Silveri et al. 1998). Cerebellar “timing” might also contribute to the correct combination of sounds in coarticulation processes by coordinating movements of the components of the vocal tract (where the cerebellum controls about 100 muscles) (Ackermann et al. 2007).

The reciprocal connectivity between the phylogenetically newest portion of the cerebellum and the anterior cerebral cortex (primarily Brodmann area 44-45-Broca’s area and premotor cortex) (Leiner et al. 1991; Stoodley et al. 2012) represents the neural basis of the cerebellar contribution to speech. But, as clinical studies suggest (Kumral et al. 2007) speech is a distributed function that requires the integrity of both cortical and subcortical structures. Among the subcortical structures, the basal ganglia make the greatest contribution to speech (Kotz et al. 2009) but with a different role than the cerebellum (Booth et al. 2007).

In conclusion, within a broad functional system that includes both cortical and subcortical structures, the cerebellum is responsible for time information processing during speech production and discrimination of perceptual components of speech. Thus cerebellar damage can be followed by disorders of speech production and perception and, in turn, by disorders of linguistic and cognitive processes connected to speech production and perception.

If the “articulatory gestures” represent, by means of the (echo) mirror neurons mechanism, the direct link between speaker and listener, allowing that type of communication from which language evolved (parity and direct comprehension between speaker and listener) (Rizzolatti and Arbib 1998), then a contribution to language evolution should also be attributed to the cerebellum to the extent that it modulates the temporal components of speech. Likewise, congenital damage of the cerebellum might account for disorders of speech/language acquisition (Misciagna et al. 2010).

## References

- Ackermann H, Hertrich I (1997) Voice onset time in ataxic dysarthria. *Brain Lang* 56:321–333
- Ackermann H, Gräber S, Hertrich I, Daum I (1997) Categorical speech perception in cerebellar disorders. *Brain Lang* 60:323–331
- Ackermann H, Mathiak K, Riecker A (2007) The contribution of the cerebellum to speech production and speech perception: clinical and functional imaging data. *Cerebellum* 6:202–213
- Booth JR, Wood L, Lu D, Houk JC, Bitan T (2007) The role of the basal ganglia and cerebellum in language processing. *Brain Res* 1133:136–144

- Darley FL, Aronson AE, Brown JR (1975) *Motor speech disorders*. W.B. Saunders, Philadelphia
- Duffy JR (2013) *Motor speech disorders: substrates, differential diagnosis, and management*, 3rd edn. Elsevier, Mosby, St Louis
- Fadiga L, Craighero L, Buccino G, Rizzolatti G (2002) Speech listening specifically modulates the excitability of tongue muscles: a TMS study. *Eur J Neurosci* 15:399–402
- Ivry RB, Keele SW (1989) Timing functions of the cerebellum. *J Cogn Neurosci* 1:136–152
- Keele SW, Ivry R (1991) Does the cerebellum provide a common computation for diverse tasks? A timing hypothesis. *Ann NY Acad Sci* 608:179–211
- Kotz SA, Schwartze M, Schmidt-Kassow M (2009) Non-motor basal ganglia functions: a review and proposal for a model of sensory predictability in auditory language perception. *Cortex* 45:982–990
- Kumral E, Celebisoy M, Celebisoy N, Canbaz DH, Calli C (2007) Dysarthria due to supratentorial and infratentorial ischemic stroke: a diffusion-weighted imaging study. *Cerebrovasc Dis* 23:331–338
- Leiner HC, Leiner AL, Dow RS (1991) The human cerebro-cerebellar system: its computing, cognitive, and language skills. *Behav Brain Res* 44:113–128
- Lieberman AM, Whalen DH (2000) On the relation of speech to language. *Trends Cogn Sci* 4:187–196
- Lieberman AM, Cooper FS, Shankweiler DP, Studdert-Kennedy M (1967) Perception of the speech code. *Psychol Rev* 6:431–461
- Mariën, Ackermann, Adamaszek et al (2014) Consensus paper: language and the cerebellum: an ongoing enigma. *Cerebellum* 13:386–410
- McGurk H, MacDonald J (1976) Hearing lips and seeing voices. *Nature* 264:746–748
- Misciagna S, Juvone L, Silveri MC (2010) Verbal short-term memory and the cerebellum; evidence from a patient with congenital cerebellar vermis hypoplasia. *Neurocase* 16:119–124
- Rizzolatti G, Arbib MA (1998) Language within our grasp. *Trends Neurosci* 21:188–194
- Rizzolatti G, Craighero L (2007) Language and mirror neurons. In: Gaskell G (ed) *Oxford handbook of psycholinguistics*. Oxford University Press, Oxford
- Rizzolatti G, Gallese V, Fadiga L, Fogassi L (1996) Premotor cortex and the recognition of motor actions. *Brain Res Cogn Brain Res* 3:131–141
- Schalling E, Hartelius L (2013) Speech in spinocerebellar ataxia. *Brain Lang* 127:317–322
- Silveri MC, Leggio MG, Molinari M (1994) The cerebellum contributes to linguistic production: a case of agrammatic speech following a right cerebellar lesion. *Neurology* 44:2047–2050
- Silveri MC, Di Betta AM, Filipini V, Leggio MG, Molinari M (1998) [Verbal short-term store-rehearsal system and the cerebellum. Evidence from a patient with a right cerebellar lesion.](#) *Brain* 21:2175–2187
- Stoodley CJ, Valera EM, Schmahmann JD (2012) Functional topography of the cerebellum for motor and cognitive tasks: an fMRI study. *Neuroimage* 59:1560–1570
- Studdert-Kennedy M (1998) The particulate origins of language generativity: from syllable to gesture. In: Hurford J, Studdert-Kennedy M, Knight C (eds) *Approaches to the evolution of language*. Cambridge University Press, Cambridge
- Urban PP (2013) Speech motor deficits in cerebellar infarctions. *Brain Lang* 127:323–326

# Chapter 66

## Deficits of Limbs Movements

Giuliana Grimaldi

**Abstract** This chapter provides a clinical description of the deficits involving limbs movements in cerebellar patients. The following cerebellar signs are described: dysmetria (hypermetria and hypometria); cerebellar tremor (kinetic, postural and isometric tremor); decomposition of movements; disorders of muscle tone (hypotonia, cerebellar fits); dysdiadochokinesia and dysrhythmokinesia; loss of check and rebound; isometrataxia; handwriting abnormalities and megalographia. Also, an explanation of the manoeuvres and tests currently used for clinical evaluation of limb deficits in cerebellar patients is provided.

**Keywords** Dysmetria • Cerebellar tremor • Decomposition of movements • Hypotonia • Dysdiadochokinesia • Clinical evaluation

### 66.1 Introduction

Ataxia of limbs may be defined as unsteadiness or incoordination of limbs, encompassing an impairment of the control of force and timing of movements. These abnormalities generate errors in speed, range, rhythm, starting, and stopping motor activity (Walker 1990), thus resulting in a jerky or poorly coordinated character of motion in the absence of muscle weakness or sensory deficit. The main deficits involving limb movements in cerebellar patients include: dysmetria, tremor, decomposition of movements, disorders of muscle tone, dysdiadochokinesia (Grimaldi and Manto 2012; Grimaldi 2013). Limb ataxia together with ataxic dysarthria and postural/gait deficits define the so called cerebellar motor syndrome (CMS). These symptoms share a lack of motor coordination between muscles resulting in undershoot or overshoot of the intended target position (Manto and Mariën 2015). This chapter provides a description of the deficits of limb movements occurring in cerebellar diseases and an overview of the manoeuvres and tests used for clinical examination during daily practice.

---

G. Grimaldi, M.D., Ph.D. (✉)  
Unité d'Etude du Mouvement, Hôpital Erasme-ULB, Bruxelles, Belgium  
e-mail: [giulianagrim@yahoo.it](mailto:giulianagrim@yahoo.it)

## 66.2 Dysmetria: Hypermetria and Hypometria

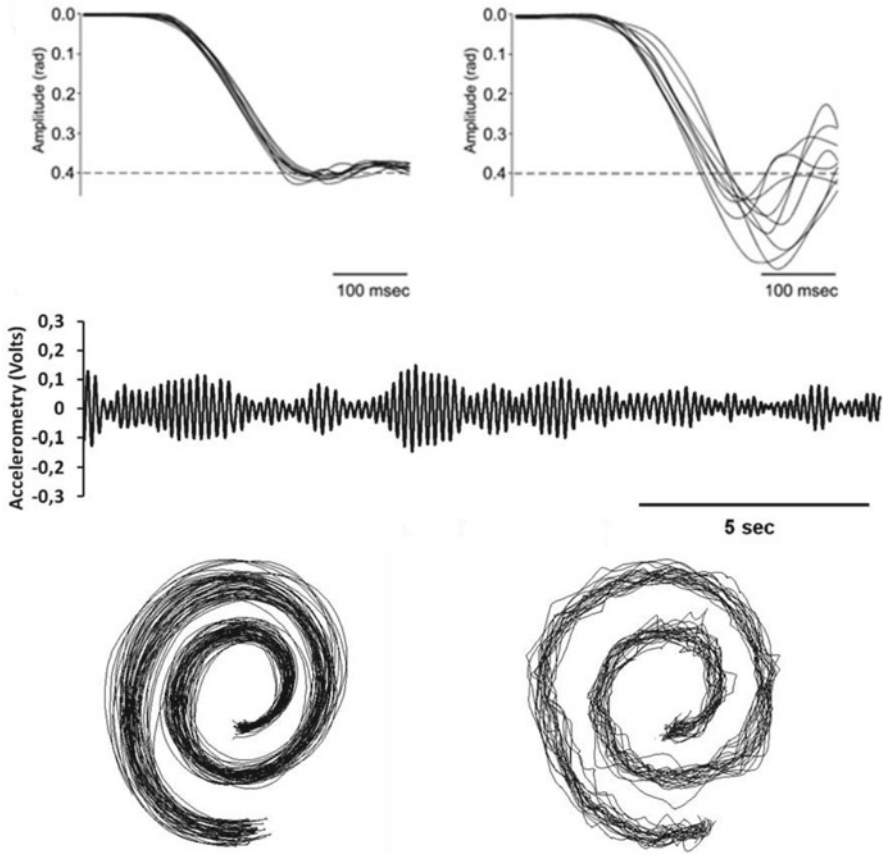
*Dysmetria* is an error in trajectory due to a disturbed range, rate, and force of movement (Holmes 1917, 1922; Gilman et al. 1981). In most cases, dysmetria occurs both for proximal and distal joints and is often followed by corrective movements (Hore et al. 1991). Both hypermetria and hypometria occur in cerebellar patients. *Hypermetria* refers to the overshoot of the target (Fig. 66.1, top panel) and is largest when the movement is made as fast as possible and when the inertia of the moving limb is increased (Manto et al. 1994, 1995a, b). Hypermetria is often associated with abnormal patterns of electromyographic (EMG) activities, namely a delayed onset latency of the antagonist EMG activity. *Hypometria*, is less common. Hypometric movements are characterized by a premature arrest before reaching the aimed target (Grimaldi and Manto 2012)

## 66.3 Cerebellar Tremor

Tremor in cerebellar disease is mainly composed of low frequency oscillations. Tremor may be bilateral. In most cases, oscillations are observed ipsilaterally to the cerebellar lesion. Eye closure and body displacements tend to enhance the oscillations. Action tremor is common in cerebellar disorders. The term “action tremor” refers to any tremor produced by voluntary contraction of muscles. It includes kinetic tremor (also named intention tremor), postural tremor and isometric tremor (Grimaldi and Manto 2008). The following criteria have to be fulfilled to diagnose cerebellar action tremor: pure or dominant intention tremor; tremor frequency below 5 Hz; postural tremor may be present, but not resting tremor (Deuschl et al. 2007).

*Kinetic tremor* appears during the execution of a movement and is usually maximal as the limb approaches the target (Holmes 1939). Kinetic tremor tends to involve predominantly the proximal musculature (Gilman et al. 1981; Lechtenberg 1993) and decreases with inertia, unlike cerebellar dysmetria (Chase et al. 1965; Hewer et al. 1972). Kinetic tremor has a frequency between 2 and 7 Hz in the large majority of cases. In most cases, oscillations are perpendicular to the main direction of the intended movement.

*Postural tremor* appears during postural tasks. Its frequency is usually between 4 and 12 Hz (Fig. 66.1, middle panel). Tremor appears immediately, but increases in amplitude after a few seconds in the line of gravity. Postural tremor in cerebellar disease can be further described as: (a) precision tremor, with a frequency of 2–5 Hz, occurring during the execution of precision tasks and involving the distal musculature; (b) asthenic tremor, which is precipitated by fatigue; (c) axial postural tremor; (d) midbrain tremor (Brown et al. 1997).



**Fig. 66.1** *Top panel:* cerebellar hypermetria. Superimposition of 9 fast wrist flexion movements. *Left:* control subject. *Right:* cerebellar patient. Movements (*lines*) are accurate in the control subject and hypermetric in the patient (overshoot of the target). Aimed target (*dotted lines*) located at 0.4 rad from the start position corresponding to a neutral position of the joint. The target is visually displayed (Adapted from Manto 2009). *Middle panel:* postural tremor recorded with accelerometer affixed to the right index of a right-handed 49-year-old right-handed woman affected with SCA2; the patient maintains upper limbs motionless, horizontally and parallel to the floor, in front of her (Adapted from Grimaldi et al. 2014). *Bottom panel:* superimposition of Archimedes' spirals drawn on a digitized tablet. *Left:* control subject. *Right:* patient affected with kinetic tremor. Notice that Archimedes' spirals performed by the patient are irregular and present swerves (Adapted from Grimaldi and Manto 2010)

*Isometric tremor* is defined as involuntary oscillations of one or more body regions occurring in situations of isometric muscle contraction against a rigid resistance, e.g. pressing the hand and arm against a heavy table, standing on the feet or hands (orthostatic tremor), or simply holding an object between thumb and other fingers in opposition (Findley and Koller 1995; Nowak et al. 2013).

## 66.4 Decompositions of Movement

*Decomposition of movement* into elementary components is due to a lack of synergy between joints, resulting in a lack of fluidity in motion and in ataxic movements (Topka et al. 1998). Decomposition of movement may be assessed by the index-to-wrist maneuver, during which cerebellar patients demonstrate asynchronous movements of the shoulder and the elbow. For slow multi-joint movements, decomposition is manifested by errors in the direction and rate of the movement. Decomposition of movement is often accompanied by an inability to generate independent finger movements, as during the index-thumb test. The attempt to move the thumb and the index alone induces successive flexion of the other fingers (“sign of the piano”) (Manto 2002, 2010). For details about index-to-wrist maneuver and index-thumb test see paragraph Clinical examination of limbs movements.

## 66.5 Dysdiadochokinesia and Dysrhythmokinesia

*Dysdiadochokinesia* (also called *adiadochokinesia*) denotes the inability to perform rapid successive movements (Babinski 1902), resulting in irregular and slow alternating sequential movements. The successive pronation/supination task is typically used to evaluate this deficit. In advanced cases, *dysdiadochokinesia* often results in an abnormal sway of the elbow, and the alternate character of the task may therefore not be detectable (Manto 2002). *Dysrhythmokinesia*, which is one of the characteristics of *adiadochokinesia*, consists of a disturbed rhythm associated to repetitive sequential movements (Wertham 1929). *Dysrhythmokinesia* can be detected in a tapping test (Manto 2010). Interestingly a relatively preserved accuracy of movements may be found although the presence of *dysrhythmokinesia* (Grimaldi 2013).

## 66.6 Loss of Check and Rebound

Impaired check causes a large movement called *rebound*. Disturbed check is assessed by asking the patient to maintain the upper limbs extended with the hands pronated. The examiner exerts a tap on the wrist thus causing a large displacement of the limb, immediately followed by an overshoot at the initial position followed by oscillations (Manto 2002). The lack of check can be evaluated during the Stewart-Holmes maneuver (1904) (see paragraph Clinical examination of limbs movements).



## 66.7 Disorders of Muscle Tone: Hypotonia and Cerebellar Fits

*Hypotonia* is a decreased resistance to passive manipulation of the limbs. It might be normally present in children, while in adult it is usually associated with cerebellar damage, namely at the acute stage of disease (Manto 2002). The decline in resistance to the passive manipulation of limbs tends to be more pronounced in proximal joints (Manto 2010). Due to this reduced resistance, pendular tendon reflexes may be observed, notably at the knee, characterized by the distal leg continuing to swing (like a pendulum) five times or more following elicitation of the patella tendon reflex (Holmes 1922, 1939). Disorder of muscle tone in cerebellar injury may also present as “*cerebellar fits*”, spasms associated with intermittent opisthotonos (Stewart and Holmes 1904), which are included in the category of the cerebellar seizures (Manto 2010).

## 66.8 Isometrataxia

*Isometrataxia* is the inability to maintain constant force (impaired isotonic force production) during skilled tasks, especially when requiring hand or finger use (Mai et al. 1989). Isometrataxia may be associated with action tremor. Isometric tremor often masks isometrataxia, which, therefore, is underestimated. However, isometrataxia can be differentiated from the isometric tremor thanks to two major features: it is not a rhythmic phenomenon and it occurs during slight contractions (Grimaldi 2013).

## 66.9 Handwriting Abnormalities and Megalographia

Cerebellar patients show difficulties in handwriting resulting in irregular writing (Fig. 66.1, bottom panel) (Grimaldi 2013). The observation of letters “unequal in size and irregularly spaced” was reported by Holmes in 1917 in patients with cerebellar lesions following gunshot injuries (Holmes 1917). *Megalographia* (also called macrographia), characterized by abnormally large handwriting, is another sign of cerebellar dysfunction (Frings et al. 2010).

## 66.10 Clinical Examination of Limbs Movements

Here is a list of the most common tests and maneuvers used for clinical evaluation of limb movements in cerebellar patients.

The following maneuvers are used for the clinical assessment of kinetic tremor (Manto 2002). These tests allow an evaluation of dysmetria (a target has to be reached along a trajectory).

*Finger-to-nose test*: patient (in a seated position) performs movements of one upper limb with the hand initially on the ipsilateral thigh and then touching the nose with the index;

*Finger-to-finger test*: patient touches the examiner's finger, which is moved and stopped in different locations in space;

*Knee-tibia test*: this test is executed in the supine position. The patient raises one leg and places the heel on the contralateral knee, which is kept motionless. The patient slides the heel down the tibial surface in a regular way towards the ankle. The heel is then raised again up to the resting knee.

The following maneuvers are used for the clinical assessment of postural tremor (Grimaldi 2013):

*Arm outstretched task*: holding the upper limbs outstretched with the hands in supination, parallel to the floor at the height of the shoulder;

*Index-to-index test*: the patient is asked to maintain the two index fingers medially, pointing at each other at a distance of about 1 cm. Forearms are maintained horizontally at the height of the shoulders;

*Heel-to-knee test*: the patient is asked to maintain the heel on the knee for several seconds (Stewart and Holmes 1904; Holmes 1922). The oscillations appearing during the heel-to-knee test rapidly evolve into lateral sways in severe cases.

The following tests are used to assess decomposition of movements (Manto 2002):

*Index-to-wrist test*: the patient performs a pointing movement towards the wrist of the examiner which is maintained horizontally at the height of the patient's shoulder and at an approximate distance of 85 % of the patient's upper limb's height;

*Index-thumb test*: the patient performs repeated tapping of the index against the thumb (see decomposition of movements and the "sign of the piano").

The pronation/supination movements is investigated through the *pronation/supination task*: patients maintains the upper limbs vertically and perform successive pronations/supinations movements of the hands. Alternate movements of the hands can be tested also with the tapping test over the thigh, by placing the palmar and the dorsal surfaces alternately (Manto 2010).

*Stewart-Holmes maneuver* (1904) allows the evaluation of the lack of check. The patient is asked to perform a forceful flexion of the elbow while the examiner attempts to extend the joint. When the examiner abruptly releases the forearm, the arm flexion continues unopposed and the patient is at risk of hitting him/herself in the shoulder, chest, or face. Possibility which is, of course, prevented by the examiner placing his/her other arm between the patient's limb and face prior to abruptly releasing the patient's limb that is being tested.

Muscle tone is assessed by passively moving the wrists, elbows, shoulders, ankles, knees and hips of the patient and by grasping the patient's forearm and shaking the relaxed arm.

Isometrataxia is tested by asking the patient to exert a slight and constant pinch force (using his index finger and thumb) on the lateral parts of the examiner's thumb. The examiner feels an irregular pressure in absence of tremor of the hand (Manto 2002).

Handwriting abnormalities is assessed by asking the patient to write standard sentences, and drawing the *Archimedes' spiral*: the subject is comfortably seated in front of a table, and a sheet of paper with a pre-drawn spiral is fixed on the table with tape to avoid motion artifacts. The subject copies the spiral three times, executing the task with his dominant hand without timing requirements (Grimaldi and Manto 2008).

## References

- Babinski J (1902) Sur le rôle du cervelet dans les actes volitionnels nécessitant une succession rapide de mouvements (diadococinésie). *Rev Neurol* 10:1013–1015
- Brown P, Rothwell JC, Stevens JM et al (1997) Cerebellar axial postural tremor. *Mov Disord* 12(6):977–984
- Chase RA, Cullen JK Jr, Sullivan SA et al (1965) Modification of intention tremor in man. *Nature* 206(983):485–487
- Deuschl G, Volkman J, Raethjen J (2007) Tremors: differential diagnosis, pathophysiology, and therapy. In: Jankovic J, Tolosa E (eds) *Parkinson's disease and movement disorders*, 5th edn. Lippincott Williams & Wilkins, Philadelphia, pp 298–320
- Findley LJ, Koller WC (1995) *Handbook of tremor disorders*. Marcel Dekker, New York
- Frings M, Gaertner K, Buderath P et al (2010) Megalographia in children with cerebellar lesions and in children with attention-deficit/hyperactivity disorder. *Cerebellum* 9(3):429–432
- Gilman S, Dloedel JR, Lechtenberg R (1981) *Disorder of the cerebellum (contemporary neurology series)*. F.A. Davis, Philadelphia
- Grimaldi G (2013) Cerebellar motor disorders. In: Manto M, Schmahmann JD, Rossi F, Gruol DL, Koibuchi N (eds) *Handbook of the cerebellum and cerebellar disorders*, Springer Netherlands, Springer Science+Business Media Dordrecht, p 1595–1625
- Grimaldi G, Manto M (2008) *Tremor: from pathogenesis to treatment*. Morgan and Claypool, San Rafael
- Grimaldi G, Manto M (2010) Neurological tremor: sensors, signal processing and emerging applications. *Sensors* 10(2):1399–1422
- Grimaldi G, Manto M (2012) Clinical and pathophysiological features of cerebellar dysfunction. In: Jankovic J, Albanese A (eds) *Hyperkinetic disorders*. Blackwell, Oxford
- Grimaldi G, Oulad Ben Taib N, Manto M, Bodranghien F (2014) Marked reduction of cerebellar deficits in upper limbs following transcranial cerebello-cerebral DC stimulation: tremor reduction and re-programming of the timing of antagonist commands. *Front Syst Neurosci* 8:9
- Hewer RL, Cooper R, Morgan MH (1972) An investigation into the value of treating intention tremor by weighting the affected limb. *Brain* 95:579–590
- Holmes G (1917) The symptoms of acute cerebellar injuries from gunshot wounds. *Brain* 40:461–535
- Holmes G (1922) Clinical symptoms of cerebellar disease and their interpretation. The Croonian lecture III. *Lancet* 2:59–65

- Holmes G (1939) The cerebellum of man. The Hugglings Jackson memorial lecture. *Brain* 62:1–30
- Hore J, Wild B, Diener HC (1991) Cerebellar dysmetria at the elbow, wrist and fingers. *J Neurophysiol* 65:563–571
- Lechtenberg R (1993) Signs and symptom of cerebellar diseases. In: Lechtenberg R (ed) *Handbook of cerebellar diseases*. Marcel Dekker, New York
- Mai N, Diener HC, Dichgans J (1989) On the role of feedback in maintaining constant grip force in patients with cerebellar disease. *Neurosci Lett* 99(3):340–344
- Manto M (2002) Clinical signs of cerebellar disorders. In: Manto MU, Pandolfo M (eds) *The cerebellum and its disorders*. Cambridge University Press, Cambridge
- Manto M (2009) Mechanisms of human cerebellar dysmetria: experimental evidence and current conceptual bases. *J Neuroeng Rehabil* 6:10
- Manto M (2010) *Cerebellar disorders a practical approach to diagnosis and management*. Cambridge University Press, Cambridge
- Manto M, Mariën P (2015) Schmahmann's syndrome – identification of the third cornerstone of clinical ataxiology. *Cerebellum Ataxias* 2:2
- Manto M, Godaux E, Jacquy J (1994) Cerebellar hypermetria is larger when the inertial load is artificially increased. *Ann Neurol* 35:45–52
- Manto M, Godaux E, Jacquy J (1995a) Detection of silent cerebellar lesions by increasing the inertial load of the moving hand. *Ann Neurol* 37(3):344–350
- Manto M, Jacquy J, Hildebrand J et al (1995b) Recovery of hypermetria after a cerebellar stroke occurs as a multistage process. *Ann Neurol* 38(3):437–445
- Nowak DA, Gdynia HJ, Raethjen J (2013) Isometric tremor. In: Grimaldi G, Manto M (eds) *Mechanisms and emerging therapies in tremor disorders*. Contemporary clinical neuroscience. Springer, New York, pp 153–166
- Stewart TG, Holmes G (1904) Symptomatology of cerebellar tumors: a study of forty cases. *Brain* 27:522–591
- Topka H, Konczak J, Schneider K et al (1998) Multijoint arm movements in cerebellar ataxia: abnormal control of movement dynamics. *Exp Brain Res* 119(4):493–503
- Walker HK (1990) The cerebellum. In: Walker HK, Hall WD, Hurst JW (eds) *Clinical methods: the history, physical, and laboratory examinations*. Butterworths, Boston
- Wertham FI (1929) A new sign of cerebellar disease. *J Nerv Ment Dis* 69:486–493

# Chapter 67

## Lesion-Symptom Mapping

Dagmar Timmann, Thomas M. Ernst, Winfried Ilg, and Opher Donchin

**Abstract** A traditional approach to studying cerebellar function is examining impairment in human subjects with cerebellar disease. High-resolution structural brain imaging coupled with tools that perform lesion-symptom mapping produced major advances in localization of function within the human cerebellum. Lesion-symptom mapping is also called lesion-behavior mapping and lesion-deficit mapping. To localize function, patients should be included who have lesions restricted to the cerebellum. These patients are rare. Group sizes are commonly much smaller than in comparable studies with cerebral stroke. Methods will be discussed which are currently available to perform lesion-symptom mapping in patients with focal and degenerative cerebellar disease.

**Keywords** Cerebellar function • Mapping • Lesion-symptom • Lesion-deficit • Lesion-behavior

---

D. Timmann (✉) • T.M. Ernst  
Department of Neurology, University of Duisburg-Essen,  
Hufelandstrasse 55, 45147 Essen, Germany  
e-mail: [dagmar.timmann-braun@uni-duisburg-essen.de](mailto:dagmar.timmann-braun@uni-duisburg-essen.de); [thomas.ernst@uk-essen.de](mailto:thomas.ernst@uk-essen.de)

W. Ilg  
Section Computational Sensomotrics, Department of Cognitive Neurology, Hertie Institute  
for Clinical Brain Research, Otfried-Mueller-Str 25, 72076 Tübingen, Germany

Centre for Integrative Neuroscience, University of Tübingen,  
Otfried-Mueller-Str 25, 72076 Tübingen, Germany  
e-mail: [winfried.ilg@uni-tuebingen.de](mailto:winfried.ilg@uni-tuebingen.de)

O. Donchin  
Department of Biomedical Engineering and Zlotowski Center for Neuroscience, Ben-Gurion  
University of the Negev, Be'er Sheva 84105, Israel  
e-mail: [donchin@bgu.ac.il](mailto:donchin@bgu.ac.il)

## 67.1 Introduction

A traditional approach to studying cerebellar function is examining impairment in human subjects with cerebellar disease. High-resolution structural brain imaging coupled with tools that perform lesion-symptom mapping produced major advances in localization of function within the human cerebellum (Timmann et al. 2009, 2013). Lesion-symptom mapping is also called lesion-behavior mapping and lesion-deficit mapping. To localize function, patients should be included who have lesions restricted to the cerebellum. These patients are rare. Group sizes are commonly much smaller than in comparable studies with cerebral stroke. Methods will be discussed which are currently available to perform lesion-symptom mapping in patients with focal and degenerative cerebellar disease.

## 67.2 “Pure” Human Cerebellar Lesion Conditions

Although some might argue no patients have pure cerebellar lesions, there are conditions that affect the human cerebellum primarily. Lesion-symptom mapping studies are best done on patients with circumscribed focal lesions of the cerebellum. These include patients with cerebellar stroke and patients with benign tumor surgery (Timmann et al. 2009, 2013). Alternatively, patients with degenerative cerebellar disease can be studied. Cerebellar degeneration is more diffuse, and it commonly affects all parts of the cerebellum. Table 67.1 summarizes the pros and cons of the different patient populations that are available for studying localization of cerebellar function.

### 67.2.1 *Cerebellar Stroke*

Cerebellar stroke is a common lesion condition for lesion-symptom mapping. Because the three main cerebellar arteries supply parts of the cerebellum and the brainstem, brainstem lesions need to be excluded based on magnetic resonance brain imaging (MRI) (Tatu et al. 1996). Widespread use of MRI has shown that many such strokes are limited to the cerebellum and that they have a benign course. One must also exclude accompanying cerebral vascular disease. Cerebellar stroke is most common in the territories of the superior cerebellar artery (SCA) and the posterior inferior cerebellar artery (PICA). Strokes of the anterior inferior cerebellar artery (AICA) are rare and usually do affect the brainstem.

**Table 67.1** Pros and cons of available “pure” human cerebellar lesion conditions

Cerebellar lesion condition	Pros	Cons
Cerebellar stroke	Lesion-symptom mapping in acute stage is possible	Old age
SCA-stroke		Brainstem and cerebral vascular lesions need to be excluded
PICA-stroke		
Cerebellar tumor surgery	Young age	Delineation and normalization of acute lesions not reliable
Pilocytic astrocytoma	Accompanying cerebral disease unlikely	Possible sequelae of hydrocephalus
Vascular tumors		Possible influence of still developing brain
Chronic focal lesions	Easy lesion delineation on T1-weighted images	Study of fully compensated stage
Cerebellar stroke	Stable disease allowing use continuous variables in statistics (e.g. t tests)	
Cerebellar tumor surgery		
Acute focal lesions	Maximal deficits with no or incomplete compensation	Crossed cerebello-cerebral diaschisis as possible confounder
Cerebellar stroke		Special MRI sequences needed to show full lesion extent (eg DWI, FLAIR, Perfusion MRI or ASL)
Cerebellar degeneration	Good availability in many labs	Old age
SCA6		Mild extracerebellar involvement frequently present
SAOA		More diffuse disease

*Abbreviations:* SCA superior cerebellar artery, PICA posterior inferior cerebellar artery, SCA6 spinocerebellar ataxia type 6, SAOA sporadic adult onset ataxia, DWI diffusion weighted imaging, FLAIR Fluid Attenuated Inversion Recovery (FLAIR), ASL arterial spin labeling

### 67.2.2 Cerebellar Tumors

Study of patients with benign tumors is much preferred. First, patients with metastasis of the cerebellum (the most common cerebellar tumor in adults) are frequently too sick to perform behavioral studies. Second, malign tumors require chemo- and radiotherapy which damages the nervous system. Pilocytic astrocytoma and vascular tumors (e.g. hemangioblastomas and arteriovenous malformations) do allow successful lesion-symptom mapping. Then, it is best to test behavior in the chronic stage after surgical removal of the tumor. Mass effects exacerbate the symptoms of cerebellar tumors so that the exact lesion site is difficult to determine with the tumor still in place (Karnath and Steinbach 2011). Furthermore, mass effects within the posterior fossa frequently cause accompanying hydrocephalus. In acute surgical lesions, there is usually a significant shift in neuronal structures because of edema, air and cell detritus.

### **67.2.3 Cerebellar Degeneration**

There are many different forms of hereditary, non-hereditary and acquired degenerative cerebellar ataxias. Only very few are primarily confined to the cerebellum. The two most common “pure” cerebellar ataxias are spinocerebellar ataxia type 6 (SCA6), with an autosomal dominant inheritance, and sporadic adult onset ataxia (SAOA). For some other, rare forms of hereditary ataxias, a benign course with a more cerebellar phenotype has been described as well (Klockgether 2011). Although SCA6 and SAOA are considered “pure” cerebellar ataxias mild extracerebellar involvement is common (e.g. mild polyneuropathy, brisk tendon reflexes, mild polyuria). Cerebellar cortical degeneration is the hallmark of both ataxias. Newer studies show that there is (likely secondary) degeneration of the cerebellar nuclei as well, at least in SCA6 (Stefanescu et al. 2015).

## **67.3 Lesion-Symptom Mapping in Focal Cerebellar Disease**

The general idea is to delineate lesions on high resolution structural MRI images. Next, in order to allow group analysis, the delineated lesions are normalized into a standard stereotaxic space, very similar to normalization of functional MRI data. If lateralization is not part of the scientific question, lesions are frequently mirrored to the same side of the cerebellum to increase group size. Finally lesion sites and behavioral data are compared using descriptive and statistical methods. These results are displayed as overlays on atlases of the cerebellum for localization. Because analysis is based on spatially normalized lesions, atlases are used which show the cerebellum in the same stereotaxic space.

### **67.3.1 Lesion Delineation**

The gold standard of lesion delineation remains manual tracing. This is most commonly done on T1-weighted MRI scans using image processing software such as the freely available MRICroN program ([www.cabiatl.com/mricro/mricron/](http://www.cabiatl.com/mricro/mricron/)). Cerebellar nuclei are not seen in T1-weighted images. Susceptibility weighted imaging (SWI) can be used to visualize the cerebellar nuclei directly and delineate their lesions (Maderwald et al. 2012). Limitations of automatic tracing methods are discussed in (Wilke et al. 2011).



### **67.3.2 Lesion Normalization**

The individual cerebellum and the traced lesion are simultaneously spatially normalized into a standard stereotaxic space. Normalization of the cerebellum is performed while the lesioned region is ignored (“masked”; (Brett et al. 2001)). The freely available SPM program is one of a number of software packages available for this purpose (<http://www.fil.ion.ucl.ac.uk/spm/>). Best practice is to use the Spatially Unbiased Infra-Tentorial atlas template (SUIT template) of the human cerebellum which allows optimized normalization of the cerebellum (Diedrichsen 2006). The SUIT template and software is freely available as a toolbox for SPM and other image analysis software ([www.icn.ucl.ac.uk/motorcontrol/imaging/suit.htm](http://www.icn.ucl.ac.uk/motorcontrol/imaging/suit.htm)). Normalization with the SUIT template has been extended for specific normalization of the dentate nuclei (Diedrichsen et al. 2011).

### **67.3.3 Descriptive Statistical Analysis**

The simplest use of normalized lesions is to collect patients with the same disorder and superimpose lesions. Because locations of brain damage are not randomly distributed, simple overlay plots may be biased, that is they may simply show commonly damaged areas. A more advanced method is the comparison of lesion site between two groups of patients with and without impairment in a given task (Rorden and Karnath 2004). Subtraction analysis is a way to quantify group differences (Karnath et al. 2002). In MRICroN, for each lesioned voxel the percentage of unimpaired patients with a lesion in that voxel is subtracted from the percentage of impaired patients with a lesion in that voxel. For example, in case 80% of the impaired patients and 40% of the unimpaired patients are lesioned for a voxel, then subtraction of the two numbers gives 40% consistency. Subtraction analysis is a useful tool in small patient populations which is frequently the case in human cerebellar lesion studies. The method, however, is descriptive. Furthermore, behavior is classified as normal or abnormal, and the severity of the abnormality is not considered.

### **67.3.4 Inferential Statistical Analysis**

Binomial statistical tests can be applied when behavior can be categorized as either normal or abnormal based on a specific threshold of performance. These include Fisher’s exact test, chi-square test and Liebermeister test. For example, the Liebermeister test can be performed to support the descriptive results of subtraction analysis. If symptom severity is a continuous variable, multiple t-tests or a non-parametric alternative (e.g. the Brunner-Munzel test) can be applied without the

need to group patients by a behavioral cut-off (Bates et al. 2003; Rorden et al. 2007). A *t* test is conducted at each voxel comparing the behavioral scores of the patients for whom that voxel is intact and lesioned on the parameter of interest. Voxel-wise lesion-symptom mapping has the same multiple-comparison problem as standard techniques in functional MRI. Bonferroni correction can be applied, and less conservative methods like false discovery rate (FDR) and permutation thresholding are also available to correct for this. Focusing analysis on a specific region of interest or only on those voxels where some patients have lesions (Rorden et al. 2009) are other ways to reduce the number of comparisons. Some authors include lesion size as nuisance regressor (Karnath and Smith 2014).

## 67.4 Lesion-Symptom Mapping in Cerebellar Degeneration

Conventional MRI volumetry and voxel-based morphometry (VBM) are two options to assess the correlation of behavioral data and regional atrophy of the cerebellar cortex. Both methods are based on T1-weighted MRI images. Conventional MRI volumetry accesses atrophy in predefined cerebellar regions, for example the anterior and posterior lobes or individual cerebellar lobules. Different manual, semiautomatic and automatic methods are available (e.g. Weier et al. 2012; Makris et al. 2005). SWI images can be used to assess changes in volume of the cerebellar nuclei (Stefanescu et al. 2015). No anatomical regions need to be predefined in VBM. Local concentration of gray matter is assessed on a voxel-wise basis. Furthermore, analysis is automatized. VBM data, however, need to be normalized to standard stereotaxic space (e.g. SUI space). Furthermore, it has the same multiple-comparison problem as outlined above. VBM is also of interest in patients with chronic focal cerebellar disorders. Here, VBM is a useful option to access secondary changes in preserved cerebellar tissue and in connected cerebral areas (Clausi et al. 2009). MR diffusion tensor imaging (DTI) enables the study of abnormalities in white matter tracts of the cerebellum. Similar to gray matter changes of the cerebellar cortex, alterations in structural connectivity of the cerebellar peduncles can be correlated with behavioral findings.

## 67.5 Atlases of the Cerebellum in Stereotaxic Space

For many years, Schmahmann et al.'s MRI atlas of an individual cerebellum was a major tool in identifying cerebellar lobules and fissures in functional and structural imaging studies (Schmahmann et al. 2000). Diedrichsen et al. (2009) have published a probabilistic atlas of the cerebellar cortex. This atlas is also available as a flat representation of the cerebellar cortex. Furthermore, recent versions include the cerebellar nuclei (Diedrichsen et al. 2011). These atlases are available for imaging data normalized to different stereotaxic spaces including SUI space. Finally, a

cerebellar template based on resting state networks, that is cerebellar regions that are functionally coupled to cerebral networks, has been made available (Buckner et al. 2011). These templates can be downloaded at <http://www.icn.ucl.ac.uk/motor-control/imaging/suit.htm>.

## 67.6 Limitations

Several limitations of lesion-symptom mapping in general and of human cerebellar lesion conditions and analysis methods in particular have to be taken in mind. The cerebellum is part of a more extended brain circuitry. Thus, a specific behavioral deficit following a localized cerebellar lesion may result from functional disruption anywhere within that circuitry. Furthermore, in patients with chronic lesions, plastic changes have occurred and behavior is confounded by compensatory effects. In patients with acute focal lesions a temporary dysfunction in connected brain areas (i.e. crossed cerebro-cerebellar diaschisis) after abrupt changes in input can be a confounder. Furthermore, much of recovery is happening in the very initial days and weeks after an acute brain injury. Unless patients are tested at the same time after the injury statistical tests using continuous variables are biased by lesions in patients with less time of recovery (Rorden and Karnath 2004). Therefore, subtraction analysis and binomial statistical tests are more reliable in acute lesions. Lesion delineation is another problem in acute lesions. In acute surgical lesions there is usually a significant shift in neuronal structures which hampers reliable lesion delineation and normalization. In acute stroke special MRI sequences are needed to show the full extent of the lesion. In very early stages, lesions may only be visualized on diffusion weighted (DWI) or Fluid Attenuated Inversion Recovery (FLAIR) images (Wintermark et al. 2013). Furthermore to show areas that are structurally intact but not functioning normally, perfusion MRI or arterial spin labeling is required (Rorden and Karnath 2004). Voxel-wise lesion-symptom mapping cannot fully rule out the possible bias by the natural distribution of the underlying brain lesions, e.g. stroke territories (Mah et al. 2014). Furthermore, voxel-wise lesion-symptom mapping has limitations when multiple regions are involved in a given task. In order to deal with these problems multivariate pattern analysis has recently been introduced (Karnath and Smith 2014; Mah et al. 2014). Large data sets, however, are required which are commonly not available in human cerebellar lesion studies. Despite these limitations, it remains of major scientific and clinical interest if lesions of a given cerebellar area lead to specific behavioral deficits.

## References

- Bates E, Wilson SM, Saygin AP, Dick F, Sereno MI, Knight RT, Dronkers NF (2003) Voxel-based lesion-symptom mapping. *Nat Neurosci* 6:448–450

- Brett M, Leff AP, Rorden C, Ashburner J (2001) Spatial normalization of brain images with focal lesions using cost function masking. *Neuroimage* 14:486–500
- Buckner RL, Krienen FM, Castellanos A, Diaz JC, Yeo BT (2011) The organization of the human cerebellum estimated by intrinsic functional connectivity. *J Neurophysiol* 106:2322–2345
- Clausi S, Bozzali M, Leggio MG, Di Paola M, Hagberg GE, Caltagirone C, Molinari M (2009) Quantification of gray matter changes in the cerebral cortex after isolated cerebellar damage: a voxel-based morphometry study. *Neuroscience* 162:827–835
- Diedrichsen J (2006) A spatially unbiased atlas template of the human cerebellum. *Neuroimage* 33:127–138
- Diedrichsen J, Balsters JH, Flavell J, Cussans E, Ramnani N (2009) A probabilistic MR atlas of the human cerebellum. *Neuroimage* 46:39–46
- Diedrichsen J, Maderwald S, Küper M, Thürling M, Rabe K, Gizewski ER, Ladd ME, Timmann D (2011) Imaging the deep cerebellar nuclei: a probabilistic atlas and normalization procedure. *Neuroimage* 54:1786–1794
- Karnath HO, Smith DV (2014) The next step in modern brain lesion analysis: multivariate pattern analysis. *Brain* 137:2405–2407
- Karnath HO, Steinbach JP (2011) Do brain tumours allow valid conclusions on the localization of human brain functions? – objections. *Cortex* 47:1004–1006
- Karnath HO, Himmelbach M, Rorden C (2002) The subcortical anatomy of human spatial neglect: putamen, caudate nucleus and pulvinar. *Brain* 125:350–360
- Klockgether T (2011) Update on degenerative ataxias. *Curr Opin Neurol* 24:339–345
- Maderwald S, Thürling M, Küper M, Theysohn N, Müller O, Beck A, Aurich V, Ladd ME, Timmann D (2012) Direct visualization of cerebellar nuclei in patients with focal cerebellar lesions and its application for lesion-symptom mapping. *Neuroimage* 63:1421–1431
- Mah YH, Husain M, Rees G, Nachev P (2014) Human brain lesion-deficit inference remapped. *Brain* 137:2522–2531
- Makris N, Schlerf JE, Hodge SM, Haselgrove C, Albaugh MD, Seidman LJ, Rauch SL, Harris G, Biederman J, Caviness VS Jr, Kennedy DN, Schmahmann JD (2005) MRI-based surface-assisted parcellation of human cerebellar cortex: an anatomically specified method with estimate of reliability. *Neuroimage* 25:1146–1160
- Rorden C, Karnath HO (2004) Using human brain lesions to infer function: a relic from a past era in the fMRI age? *Nat Rev Neurosci* 5:813–819
- Rorden C, Karnath HO, Bonilha L (2007) Improving lesion-symptom mapping. *J Cogn Neurosci* 19:1081–1088
- Rorden C, Fridriksson J, Karnath HO (2009) An evaluation of traditional and novel tools for lesion behavior mapping. *Neuroimage* 44:1355–1362
- Schmahmann JD, Doyon J, Toga AW, Petrides M, Evans A (2000) MRI atlas of the human cerebellum. Academic, San Diego
- Stefanescu MR, Dohnalek M, Maderwald S, Thürling M, Minnerop M, Beck A, Schlamann M, Diedrichsen J, Ladd ME, Timmann D (2015) Structural and functional MRI abnormalities of cerebellar cortex and nuclei in SCA3, SCA6 and Friedreich's ataxia. *Brain* 138:1182–1197
- Tatu L, Moulin T, Bogousslavsky J, Duvernoy H (1996) Arterial territories of human brain: brainstem and cerebellum. *Neurology* 47:1125–1135
- Timmann D, Konczak J, Ilg W, Donchin O, Hermsdörfer J, Gizewski ER, Schoch B (2009) Current advances in lesion-symptom mapping of the human cerebellum. *Neuroscience* 162:836–851
- Timmann D, Küper M, Gizewski ER, Schoch B, Donchin O (2013) Lesion-symptom mapping of the human cerebellum. In: Manto M, Gruol DL, Schmahmann JD, Koibuchi N, Rossi F (eds) *Handbook of the cerebellum and cerebellar disorders* (pp. 1627–1656). Springer Netherlands
- Weier K, Beck A, Magon S, Amann M, Naegelin Y, Penner IK, Thürling M, Aurich V, Derfuss T, Radue EW, Stippich K, Kappos L, Timmann D, Sprenger T (2012) Evaluation of a new approach for semi-automatic segmentation of the cerebellum in patients with multiple sclerosis. *J Neurol* 259:2673–2680

- Wilke M, de Haan B, Juenger H, Karnath HO (2011) Manual, semi-automated, and automated delineation of chronic brain lesions: a comparison of methods. *Neuroimage* 56:2038–2046
- Wintermark M, Sanelli PC, Albers GW, Bello J, Derdeyn C, Hetts SW, Johnson MH, Kidwell C, Lev MH, Liebeskind DS, Rowley H, Schaefer PW, Sunshine JL, Zaharchuk G, Meltzer CC (2013) Imaging recommendations for acute stroke and transient ischemic attack patients: a joint statement by the American Society of Neuroradiology, the American College of Radiology, and the Society of NeuroInterventional Surgery. *AJNR Am J Neuroradiol* 34:E117–E127

# Chapter 68

## The Cerebellar Cognitive Affective Syndrome and the Neuropsychiatry of the Cerebellum

Jeremy D. Schmahmann

**Abstract** Cognitive and limbic functions are represented in the cerebellar posterior lobe and vermis. Lesions of these areas produce dysmetria of thought, manifesting as the cerebellar cognitive affective syndrome (CCAS; Schmahmann's syndrome). This is the counterpart to the cerebellar motor syndrome which results from lesions of the motor representation in the cerebellar anterior lobe and lobule VIII. The CCAS is characterized by impairments in executive function, visual spatial processing, linguistic deficits, and regulation of affect. The affective component of the CCAS, conceptualized as the neuropsychiatry of the cerebellum, is grouped according to five major domains: attentional control, emotional control, autism spectrum disorders, psychosis spectrum disorders, and social skill set. Within each of these domains, behaviors may reflect cognitive overshoot or undershoot, akin to the disorder of motor control seen in the cerebellar motor syndrome. This chapter focuses on the behavioral neurology and neuropsychiatry of the cerebellum and emphasizes the clinically relevant manifestations for adults and children with a wide range of cerebellar disorders. Recognition of the CCAS throughout the age spectrum is important for patient care, and it highlights the promise that new insights into cerebellar function hold for novel interventions in patients with neurobehavioral and psychiatric diseases linked to the cerebellum.

**Keywords** Cognition • Emotion • Limbic • Cerebellar cognitive affective syndrome • Neuropsychiatry • Mutism

The cerebellar cognitive affective syndrome (CCAS; Schmahmann's syndrome) represents a disruption of the cerebellar contribution to distributed neural circuits linking different regions within the cerebellar posterior lobe with cerebral cortical

---

J.D. Schmahmann (✉)

Ataxia Unit, Cognitive Behavioral Neurology Unit, Laboratory for Neuroanatomy and Cerebellar Neurobiology, Department of Neurology, Massachusetts General Hospital, Harvard Medical School, Boston, MA, USA

e-mail: [jschmahmann@mgh.harvard.edu](mailto:jschmahmann@mgh.harvard.edu)

association and paralimbic areas that subserve higher order perceptual processing, intellectual function, and emotion (see Chap. 11 for anatomical tract tracing studies in nonhuman primates) (Schmahmann et al. 1997; Schmahmann 2010). Clinical observations of changes in behavior and intellect following cerebellar injury are further supported by resting state functional connectivity MRI showing topographically precise arrangement of cerebellar connections with motor and nonmotor areas of human cerebral cortex, (Buckner et al. 2011) and task based functional MRI of cerebellar engagement in executive functions, spatial tasks, language, and emotional processing (see also Chap. 51 for details) (Stoodley and Schmahmann 2009b; Stoodley et al. 2012).

## 68.1 The Initial Description

The CCAS was described by Schmahmann and Sherman (1998) in 20 patients with lesions confined to cerebellum. The neurobehavioral observations identified arose from lesions involving predominantly the cerebellar posterior lobe, characterized by clinically relevant deficits in executive function, visual spatial performance, linguistic processing and dysregulation of affect (Table 68.1). The CCAS has since been named eponymously as Schmahmann's syndrome (Manto and Mariën 2015).

Neurobehavioral tests performed as part of the neurological examination showed that 18 patients had problems with executive functions, including poor working memory (in 11 of 16 tested), motor or ideational set shifting (in 16 of 19), and perseveration of actions or drawings (in 16 of 20). Verbal fluency was impaired in 18 patients, presenting as telegraphic speech, occasionally so limited as to resemble mutism.

**Table 68.1** Deficits that characterize the cerebellar cognitive affective syndrome

<b>Executive function</b>
Deficient planning, mental flexibility, multi-tasking, abstract reasoning, working memory. Decreased verbal fluency, to the point of telegraphic speech or mutism. Perseverative ideation
<b>Spatial cognition</b>
Visuospatial disintegration with impaired attempts to draw or copy a diagram. Disorganized conceptualization of figures. Impaired visual-spatial memory. Simultanagnosia in some
<b>Linguistic difficulties</b>
Anomia, agrammatic speech, abnormal syntactic structure, abnormal prosody including high pitched, hypophonic whining
<b>Personality change</b>
Aberrant modulation of behavior and personality when posterior lobe lesions involve midline structures. Flattening or blunting of affect alternating or coexistent with disinhibited behaviors such as over-familiarity, flamboyant and impulsive actions, and humorous but inappropriate and flippant comments. Regressive, childlike behaviors and obsessive-compulsive traits. (See neuropsychiatry of the cerebellum, Table 68.2)
The net effect of these disturbances in cognitive functioning is lowering of overall intellectual function.

Decreased verbal fluency was unrelated to dysarthria. Visuospatial disintegration was found in 19 patients, who were disorganized in their sequential approach to drawing and conceptualization of figures (Fig. 68.1, left panel). Four patients had simultanagnosia. Naming was impaired in 13 patients, usually being spared in those with smaller lesions. Six with bilateral acute disease had agrammatic speech, and elements of abnormal syntactic structure were noted in others. Prosody was abnormal in eight patients, with tone of voice characterized by a high pitched, whining, childish and hypophonic quality. Mental arithmetic was deficient in 14 patients. Verbal learning and recall were slightly abnormal in 11, and visual learning and recall were impaired in 4 (of 13 patients tested). Ideational apraxia was evident in two individuals.

Difficulty modulating behavior and personality style was a prominent feature in 15 patients, particularly those with large or bilateral infarcts in the territory of the posterior inferior cerebellar artery, and in a patient with surgical excision of the vermis and paravermian structures. Flattening of affect or disinhibition manifested as overfamiliarity, flamboyant and impulsive actions, and humorous but inappropriate and flippant comments. Behavior was regressive and childlike, and obsessive-compulsive traits were occasionally observed.

Autonomic changes occurred in a patient with stroke involving the fastigial nucleus and paravermian cortex, with spells of hiccupping and coughing precipitating bradycardia and syncope.

Neuropsychological testing confirmed the neurological observations, demonstrating impaired executive function (planning, set-shifting, abstract reasoning, verbal fluency, working memory), often with perseveration, distractibility or inattention; visual-spatial disorganization and impaired visual-spatial memory; personality change with blunting of affect or disinhibited and inappropriate behavior; and difficulties with language production including dysprosodia, agrammatism and mild anomia. The net effect of these disturbances in cognitive abilities was a general lowering of intellectual function. Findings were more pronounced in patients with bilateral and acute disease. Posterior lobe lesions were particularly important in the generation of the syndrome and the vermis was consistently involved in patients with pronounced affective presentations. Patients with stroke improved over time, although executive function remained abnormal. The CCAS was hypothesized to reflect dysmetria of thought, analogous to dysmetria of movements resulting from damage to the motor cerebellum in the anterior lobe.

## 68.2 Subsequent Reports

The principal features and clinical relevance of the CCAS were confirmed in patients with cerebellar stroke or hemorrhage. Findings include problems with frontal/executive function such as impaired cognitive control, multitasking, mental flexibility, and working memory (reverse digit span and n-back task); deficits in visuospatial planning, visuomotor tasks and visual memory; anomia, irregularity of speech, agrammatism, dysprosodia, acquired dyslexia, and impaired verbal fluency (phonemic > semantic), as well as metalinguistic deficits – problems with metaphor,



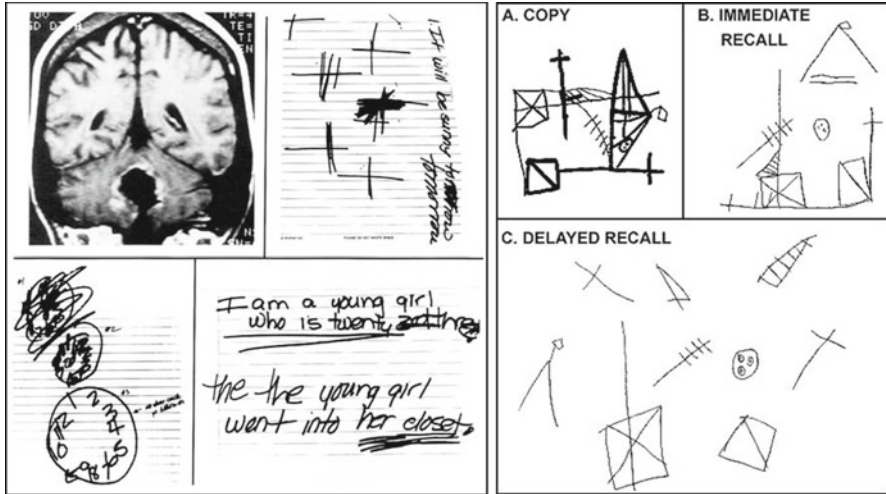
inference, ambiguity, and verbal expression of complex thoughts; (Güell et al. 2015) and apathy, disinhibition, and impaired emotional intelligence. Impaired focused and sustained attention, delayed recall of verbal or visual information, facial agnosia, amusia, and temporal disorientation, and limb kinetic apraxia are also reported (Schmahmann and Sherman 1998; Malm et al. 1998; Leggio et al. 2000; Neau et al. 2000; Exner et al. 2004; Gottwald et al. 2004; Hoffmann and Schmitt 2004; Kalashnikova et al. 2005; Hokkanen et al. 2006; Ravizza et al. 2006; Richter et al. 2007; Ziemus et al. 2007; Hoffmann and Cases 2008; Manes et al. 2009; Stoodley and Schmahmann 2009a; Schweizer et al. 2010; Alexander et al. 2011; Tedesco et al. 2011).

### 68.3 The Cerebellar Cognitive Affective Syndrome in Children

Levisohn et al. (2000) first studied cognition in children who underwent resection of cerebellar tumors without receiving radiation therapy or methotrexate which can lead to poor cognitive outcome. The cohort consisted of 19 children, ages 3–14 with medulloblastoma, astrocytoma, and ependymoma. Problems were noted with attention and executive function as evidenced by deficits in digit span (57% of the 14 tested), sequencing, and planning. Establishing and maintaining set was hampered by perseveration. Deficits in expressive language, present in 58% of the cohort, included brief responses, lack of elaboration, reluctance to engage in conversation, long response latencies, and word finding difficulties. Language initiation and word finding difficulties occurred in the context of average scores on verbal tests. Confrontation naming deficits were ameliorated with phonemic cues. Many demonstrated difficulty with initiation of responses and problem-solving strategies. Visual spatial difficulties were present in 37%, characterized by impaired planning and organizational aspects of tasks (Fig. 68.1, right panel). Verbal memory was impaired in 33% of 15 children tested, particularly for unstructured recall of information. Story retrieval improved with multiple-choice prompts. There was failure to organize verbal or visual-spatial material for encoding, which impacted retrieval of information. Impaired regulation of affect was particularly evident when cerebellar damage included the vermis, manifesting as irritability, impulsivity, disinhibition, and lability of affect with poor attentional and behavioral modulation.

The CCAS in children has also been confirmed by others. Deficits include executive dysfunction with impaired planning, sequencing, mental flexibility and hypothesis generation and testing, visual-spatial function, expressive language, and verbal memory (Karatekin et al. 2000; Grill et al. 2004; Turkel et al. 2004; Berger et al. 2005; Ronning et al. 2005; Vaquero et al. 2008). Impairments in verbal intelligence, auditory sequential memory, and language follow right-sided tumors; deficient non-verbal tasks including spatial and visual sequential memory and impaired prosody after left cerebellar hemisphere tumors (Riva and Giorgi 2000).

The affective component of the CCAS in children includes mood disturbances, pathologic laughing and crying (Kossorotoff et al. 2010), disinhibition, impulsivity



**Fig. 68.1** *Left panel:* T1-weighted coronal MRI of the brain of a patient showing the site of excision of a ganglioglioma, and her responses when asked to bisect a line, draw a clock and write a sentence (From Schmahmann and Sherman 1998) *Right panel:* drawings of the Rey-Osterrieth figure by a 6-year old boy 11 months following resection of a left cerebellar cystic astrocytoma (From Levisohn et al. 2000)

and irritability (Maryniak and Roszkowski 2005). dysphoria, inattention and irritability (Turkel et al. 2004), anxiety and aggression (Richter et al. 2005), hyperspontaneous and disinhibited behavior, and flattened affect with apathy and poverty of spontaneous movement (Aarsen et al. 2004). Emotional lability may be marked, with rapid fluctuation of emotional expression gravitating between irritability with inconsolable crying and agitation, to giggling and easy distractibility. Surgically induced vermal lesions may result in autistic features such as avoidance of physical and eye contact, complex repetitive and rhythmic rocking movements, stereotyped linguistic utterances, and lack of empathy (Riva and Giorgi 2000). Attention deficit disorder, addiction, anorexia, uncontrolled temper tantrums and phobias are also reported (Steinlin et al. 2003).

#### 68.4 Postoperative Pediatric Cerebellar Mutism Syndrome (CMS)

More than half the children in Levisohn et al. (2000) with surgical damage to the vermis developed mutism or markedly reduced speech 1–2 days after the surgery, often with hypotonia and oropharyngeal dysfunction/dysphagia. The CMS is frequently accompanied by the cerebellar motor syndrome, cerebellar cognitive affective syndrome and brain stem dysfunction including long tract signs and cranial neuropathies. The mutism is transient, but recovery from CMS may be prolonged,

speech and language may not return to normal, and the motor dysfunction and CCAS often persist (Gudrunardottir 2016). CMS has had other names, including posterior fossa syndrome (Daly and Love 1958; Wisoff and Epstein 1984; Rekate et al. 1985; Dietze and Mickle 1990; Catsman-Berrevoets et al. 1992; van Dongen et al. 1994; Kingma et al. 1994; Kirk et al. 1995; Pollack et al. 1995; Schmahmann and Sherman 1997, 1998; Schmahmann 1998; Levisohn et al. 2000; Sadeh and Cohen 2001).

## 68.5 Neuropsychiatry of the Cerebellum; the Affective Component of the CCAS

Emotional dysregulation occurs when lesions involve the limbic cerebellum – the vermis and fastigial nucleus (Schmahmann 1991; Schmahmann and Sherman 1998; Richter et al. 2007), with altered regulation of mood and personality, psychotic thinking, and behaviors that meet criteria for diagnoses of attention deficit hyperactivity disorder, obsessive compulsive disorder, depression, bipolar disorder, disorders on the autism spectrum, atypical psychosis, anxiety and panic disorder (Schmahmann et al. 2007). These manifestations segregate into five neuropsychiatric domains – attentional control, emotional control, social skill set, autism spectrum disorders, and psychosis spectrum disorders (Table 68.2) (Schmahmann et al. 2007). The behaviors are conceptualized as either excessive (hypermetric) or reduced (hypometric) responses to the external or internal environment. Deficits in social skill set likely reflect altered social cognition, defined as the set of mental processes required to understand, generate and regulate social behavior (Garrard et al. 2008; Sokolovsky et al. 2010; D'Agata et al. 2011; Hoche et al. 2015). Prominent affective changes are seen, for example in opsoclonus myoclonus syndrome which produces mood changes and inconsolable irritability with lability, aggression and night terrors, dysphoric mood, disinhibition and poor affect regulation, disruptive behaviors and temper tantrums as well as cognitive and language impairments (Turkel et al. 2006; Gorman 2010). Pathological laughing and crying occurs after stroke in the pontocerebellar circuit (Tei and Sakamoto 1997; Gondim et al. 2001; Parvizi et al. 2001; Schmahmann et al. 2004a; Jawaid et al. 2008), in post-infectious cerebellitis (Dimova et al. 2009), and in the cerebellar form of multiple system atrophy (Parvizi et al. 2007).

## 68.6 Cognition in Ataxic Disorders

Cognitive changes occur in most of the spinocerebellar ataxias (SCAs) (Geschwind 1999). Neuropathology in many SCAs involves brainstem, basal ganglia, thalamus, and sometimes the cerebral cortex, so the cerebellar lesion may not be solely

**Table 68.2** Neuropsychiatric manifestations in patients with cerebellar disorders, arranged according to major domains, each with positive and negative symptoms

	Positive (exaggerated) symptoms	Negative (diminished) symptoms
Attentional control	Inattentiveness	Ruminativeness
	Distractibility	Perseveration
	Hyperactivity	Difficulty shifting focus of attention
	Compulsive and ritualistic behaviors	Obsessional thoughts
Emotional control	Impulsiveness, disinhibition	Anergy, anhedonia
	Lability, unpredictability	Sadness, hopelessness
	Incongruous feelings, pathological laughing/crying	Dysphoria
	Anxiety, agitation, panic	Depression
Autism spectrum	Stereotypical behaviors	Avoidant behaviors, tactile defensiveness
	Self stimulation behaviors	Easy sensory overload
Psychosis spectrum	Illogical thought	Lack of empathy
	Paranoia	Muted affect, emotional blunting
	Hallucinations	Apathy
Social skill set	Anger, aggression	Passivity, immaturity, childishness
	Irritability	Difficulty with social cues and interactions
	Overly territorial	Unawareness of social boundaries
	Oppositional behavior	Overly gullible and trusting

From Schmahmann et al. 2007

responsible for the cognitive deficits. CCAS features include mild generalized cognitive impairment, impaired executive functions, deficits in verbal short-term memory (Kish et al. 1988; Burk et al. 2001; Tedesco et al. 2011), visual and verbal attention, verbal fluency, planning and strategy (Zawacki et al. 2002; Braga-Neto et al. 2011), concentration problems, impaired conceptual reasoning, and emotional instability and impulsivity (Gambardella et al. 1998; Storey et al. 1999; Lilja et al. 2005; Suenaga et al. 2008; Cooper et al. 2010; Sokolovsky et al. 2010; Horton et al. 2011). Developmental cognitive impairment occurs in SCA 13 (Herman-Bert et al. 2000), and dementia in SCA 17 (Koide et al. 1999; Nakamura et al. 2001) and SCA 21 (White et al. 2000). The cognitive profile in Friedreich's Ataxia is variable – some report normal cognition (Botez-Marquard and Botez 1993) whereas others describe impaired visual-perceptual and visual-constructive abilities, slowed information processing, decreased attention, reduced verbal span, deficits in letter fluency, and impaired acquisition and consolidation of verbal information (Devos et al. 2001; Wollmann et al. 2002), as well as irritability, poor impulsive control, or blunting of affect (Mantovan et al. 2006).

## 68.7 Cerebellar Lesions Impair Cognition in the Developing Brain

The cerebellum has a protracted developmental trajectory, and is vulnerable to environmental influences (Limperopoulos et al. 2005a). Adolescents born very pre-term (<33 weeks gestation) have reduced cerebellar volumes, and deficits in executive, visual-spatial and language skills including impaired reading (Allin et al. 2001). Malformations, agenesis and hypoplasia of the cerebellum are associated with motor, linguistic, intellectual and emotional manifestations (Chheda et al. 2002; Richter et al. 2005; Gross-Tsur et al. 2006; Tavano et al. 2007) including delayed milestones, mild motor impairments, and intellectual handicap (Gardner et al. 2001). Children with cerebellar hypoplasia and non-progressive cerebellar ataxia may have the developmental CCAS with decreased general intelligence scores, alertness and sustained attention, and difficulties with visuoconstructive tasks and visual perception (Steinlin et al. 1998). Autistic features and speech delay, together with ataxia, hypotonia, and ocular signs correctly predict 86% of children with cerebellar hypoplasia (Wassmer et al. 2003), and autistic features are seen in more than 40% of preterm children who suffered prenatal cerebellar hemorrhage (Limperopoulos et al. 2007).

Children with complex malformations of the cerebellum may have cognitive and emotional deficits in addition to the motor disorders, as seen in rhombencephalosynapsis, Joubert syndrome, some cases of Dandy Walker syndrome, and Chiari malformations, among others.

## 68.8 Clinical Implications

Clinicians should recognize the CCAS/Schmahmann syndrome because it can be assessed with mental state tests of cognitive and emotional domains, and patients and families can be informed about nonmotor aspects of cerebellar function which may have meaningful long-term impact. Current therapeutic interventions for CCAS include behavioral measures, psychopharmacology, and emerging therapies such as brain modulation, to improve the lives of patients with cerebellar disorders.

**Acknowledgements** Supported in part by RO1 MH067980, the National Ataxia Foundation, Ataxia Telangiectasia Children's Project, and the Birmingham, MINDlink, and Sidney R. Baer Jr, Foundations.

## References

- Aarsen FK, Van Dongen HR, Paquier PF et al (2004) Long-term sequelae in children after cerebellar astrocytoma surgery. *Neurology* 62(8):1311–1316
- Alexander MP, Gillingham S, Schweizer T et al (2012) Cognitive impairments due to focal cerebellar injuries in adults. *Cortex* 48(8):980–990
- Allin M, Matsumoto H, Santhouse AM et al (2001) Cognitive and motor function and the size of the cerebellum in adolescents born very pre-term. *Brain* 124(Pt 1):60–66
- Berger A, Sadeh M, Tzur G et al (2005) Task switching after cerebellar damage. *Neuropsychology* 19(3):362–370
- Botez-Marquard T, Botez MI (1993) Cognitive behavior in hereditary degenerative ataxias. *Eur Neurol* 33(5):351–357
- Braga-Neto P, Pedroso JL, Alessi H et al (2011) Cerebellar cognitive affective syndrome in Machado Joseph disease: core clinical features. *Cerebellum* 11:549–56
- Buckner RL, Krienen FM, Castellanos A et al (2011) The organization of the human cerebellum estimated by intrinsic functional connectivity. *J Neurophysiol* 106:2322–2345
- Burk K, Bosch S, Globas C et al (2001) Executive dysfunction in spinocerebellar ataxia type 1. *Eur Neurol* 46(1):43–48
- Catsman-Berrevoets CE, van Dongen HR, Zwetsloot CP (1992) Transient loss of speech followed by dysarthria after removal of posterior fossa tumour. *Dev Med Child Neurol* 34(12):1102–1109
- Chheda M, Sherman J, Schmahmann JD (2002) Neurologic, psychiatric and cognitive manifestations in cerebellar agenesis. *Neurology* 58(Suppl 3):356
- Cooper FE, Grube M, Elsegood KJ et al (2010) The contribution of the cerebellum to cognition in Spinocerebellar Ataxia Type 6. *Behav Neurol* 23(1–2):3–15
- D'Agata F, Caroppo P, Baudino B et al (2011) The recognition of facial emotions in spinocerebellar ataxia patients. *Cerebellum* 10(3):600–610
- Daly DD, Love JG (1958) Akinetic mutism. *Neurology* 8(3):238–242
- Devos D, Schraen-Maschke S, Vuillaume I et al (2001) Clinical features and genetic analysis of a new form of spinocerebellar ataxia. *Neurology* 56(2):234–238
- Dietze DD Jr, Mickle JP (1990) Cerebellar mutism after posterior fossa surgery. *Pediatr Neurosurg* 16(1):25–31, discussion 31
- Dimova PS, Bojinova VS, Milanov IG (2009) Transient mutism and pathologic laughter in the course of cerebellitis. *Pediatr Neurol* 41(1):49–52
- Exner C, Weniger G, Irlé E (2004) Cerebellar lesions in the PICA but not SCA territory impair cognition. *Neurology* 63(11):2132–2135
- Gambardella A, Annesi G, Bono F et al (1998) CAG repeat length and clinical features in three Italian families with spinocerebellar ataxia type 2 (SCA2): early impairment of Wisconsin Card Sorting Test and saccade velocity. *J Neurol* 245(10):647–652
- Gardner RJ, Coleman LT, Mitchell LA et al (2001) Near-total absence of the cerebellum. *Neuropediatrics* 32(2):62–68
- Garrard P, Martin NH, Giunti P et al (2008) Cognitive and social cognitive functioning in spinocerebellar ataxia: a preliminary characterization. *J Neurol* 255(3):398–405
- Geschwind DH (1999) Focusing attention on cognitive impairment in spinocerebellar ataxia. *Arch Neurol* 56(1):20–22
- Gondim FA, Parks BJ, Cruz-Flores S (2001) “Fou rire prodromique” as the presentation of pontine ischaemia secondary to vertebrobasilar stenosis. *J Neurol Neurosurg Psychiatry* 71(6):802–804
- Gorman MP (2010) Update on diagnosis, treatment, and prognosis in opsoclonus-myoclonus-ataxia syndrome. *Curr Opin Pediatr* 22(6):745–750
- Gottwald B, Wilde B, Mihajlovic Z et al (2004) Evidence for distinct cognitive deficits after focal cerebellar lesions. *J Neurol Neurosurg Psychiatry* 75(11):1524–1531

- Grill J, Viguier D, Kieffer V et al (2004) Critical risk factors for intellectual impairment in children with posterior fossa tumors: the role of cerebellar damage. *J Neurosurg* 101(2 Suppl):152–158
- Gross-Tsur V, Ben-Bashat D, Shalev RS et al (2006) Evidence of a developmental cerebello-cerebral disorder. *Neuropsychologia* 44(12):2569–2572
- Gudrunardottir T, Morgan AT, Lux AL, et al. Iceland Delphi Group (2016) Consensus paper on postoperative pediatric cerebellar mutism syndrome: the Iceland Delphi results. *Childs Nerv Syst.* May 3. [Epub ahead of print]
- Güell X, Hoche F, Schmahmann JD (2015) Metalinguistic deficits in patients with cerebellar dysfunction: empirical support for the dysmetria of thought theory. *Cerebellum* 14(1):50–58
- Herman-Bert A, Stevanin G, Netter JC et al (2000) Mapping of spinocerebellar ataxia 13 to chromosome 19q13.3-q13.4 in a family with autosomal dominant cerebellar ataxia and mental retardation. *Am J Hum Genet* 67(1):229–235
- Hoche F, Güell X, Sherman JC, Vangel MG, Schmahmann JD (2015) Cerebellar contribution to social cognition. *Cerebellum*. [Epub ahead of print]
- Hoffmann M, Cases LB (2008) Etiology of frontal network syndromes in isolated subtentorial stroke. *Behav Neurol* 20(3):101–105
- Hoffmann M, Schmitt F (2004) Cognitive impairment in isolated subtentorial stroke. *Acta Neurol Scand* 109(1):14–24
- Hokkanen LS, Kauranen V, Roine RO et al (2006) Subtle cognitive deficits after cerebellar infarcts. *Eur J Neurol* 13(2):161–170
- Horton LC, Frosch MP, Schmahmann JD (2011) Spinocerebellar ataxia type 7 (SCA7): a 13-year longitudinal study of clinical course, neuropathological features, and phenotype-genotype correlations. In: 63rd annual meeting of the American Academy of Neurology, Honolulu
- Jawaid A, Rauf MA, Usman U et al (2008) Post-infarct cerebellar cognitive affective syndrome: a case report. *J Pak Med Assoc* 58(7):415–417
- Kalashnikova LA, Zueva YV, Pugacheva OV et al (2005) Cognitive impairments in cerebellar infarcts. *Neurosci Behav Physiol* 35(8):773–779
- Karatekin C, Lazareff JA, Asarnow RF (2000) Relevance of the cerebellar hemispheres for executive functions. *Pediatr Neurol* 22(2):106–112
- Kingma A, Mooij JJ, Metzemaekers JD et al (1994) Transient mutism and speech disorders after posterior fossa surgery in children with brain tumours. *Acta Neurochir (Wien)* 131(1–2):74–79
- Kirk EA, Howard VC, Scott CA (1995) Description of posterior fossa syndrome in children after posterior fossa brain tumor surgery. *J Pediatr Oncol Nurs* 12(4):181–187
- Kish SJ, el-Awar M, Schut L et al (1988) Cognitive deficits in olivopontocerebellar atrophy: implications for the cholinergic hypothesis of Alzheimer's dementia. *Ann Neurol* 24(2):200–206
- Koide R, Kobayashi S, Shimohata T et al (1999) A neurological disease caused by an expanded CAG trinucleotide repeat in the TATA-binding protein gene: a new polyglutamine disease? *Hum Mol Genet* 8(11):2047–2053
- Kossorotoff M, Gonin-Flambois C, Gitiaux C et al (2010) A cognitive and affective pattern in posterior fossa strokes in children: a case series. *Dev Med Child Neurol* 52:626–631
- Leggio MG, Silveri MC, Petrosini L et al (2000) Phonological grouping is specifically affected in cerebellar patients: a verbal fluency study. *J Neurol Neurosurg Psychiatry* 69(1):102–106
- Levisohn L, Cronin-Golomb A, Schmahmann JD (2000) Neuropsychological consequences of cerebellar tumour resection in children: cerebellar cognitive affective syndrome in a paediatric population. *Brain* 123(Pt 5):1041–1050
- Lilja A, Hamalainen P, Kaitaranta E et al (2005) Cognitive impairment in spinocerebellar ataxia type 8. *J Neurol Sci* 237(1–2):31–38
- Limperopoulos C, Soul JS, Gauvreau K et al (2005) Late gestation cerebellar growth is rapid and impeded by premature birth. *Pediatrics* 115(3):688–695

- Limperopoulos C, Bassan H, Gauvreau K et al (2007) Does cerebellar injury in premature infants contribute to the high prevalence of long-term cognitive, learning, and behavioral disability in survivors? *Pediatrics* 120(3):584–593
- Malm J, Kristensen B, Karlsson T et al (1998) Cognitive impairment in young adults with infratentorial infarcts. *Neurology* 51(2):433–440
- Manes F, Villamil AR, Ameriso S et al (2009) “Real life” executive deficits in patients with focal vascular lesions affecting the cerebellum. *J Neurol Sci* 283(1–2):95–98
- Manto M, Mariën P (2015) Schmahmann’s syndrome – identification of the third cornerstone of clinical ataxiology. *Cerebellum Ataxias* 2:2. doi:10.1186/s40673-015-0023-1, eCollection 2015
- Mantovan MC, Martinuzzi A, Squarzanti F et al (2006) Exploring mental status in Friedreich’s ataxia: a combined neuropsychological, behavioral and neuroimaging study. *Eur J Neurol* 13(8):827–835
- Maryniak A, Roszkowski M (2005) Cognitive and affective disturbances in children after surgical treatment of cerebellar tumors. *Neurol Neurochir Pol* 39(3):202–206
- Nakamura K, Jeong SY, Uchihara T et al (2001) SCA17, a novel autosomal dominant cerebellar ataxia caused by an expanded polyglutamine in TATA-binding protein. *Hum Mol Genet* 10(14):1441–1448
- Neau JP, Arroyo-Anllo E, Bonnaud V et al (2000) Neuropsychological disturbances in cerebellar infarcts. *Acta Neurol Scand* 102(6):363–370
- Parvizi J, Anderson SW, Martin CO et al (2001) Pathological laughter and crying: a link to the cerebellum. *Brain* 124(Pt 9):1708–1719
- Parvizi J, Joseph J, Press DZ et al (2007) Pathological laughter and crying in patients with multiple system atrophy-cerebellar type. *Mov Disord* 22(6):798–803
- Pollack IF, Polinko P, Albright AL et al (1995) Mutism and pseudobulbar symptoms after resection of posterior fossa tumors in children: incidence and pathophysiology. *Neurosurgery* 37(5):885–893
- Ravizza SM, McCormick CA, Schlerf JE et al (2006) Cerebellar damage produces selective deficits in verbal working memory. *Brain* 129(Pt 2):306–320
- Rekate HL, Grubb RL, Aram DM et al (1985) Muteness of cerebellar origin. *Arch Neurol* 42(7):697–698
- Richter S, Dimitrova A, Maschke M et al (2005) Degree of cerebellar ataxia correlates with three-dimensional mri-based cerebellar volume in pure cerebellar degeneration. *Eur Neurol* 54(1):23–27
- Richter S, Aslan B, Gerwig M et al (2007) Patients with chronic focal cerebellar lesions show no cognitive abnormalities in a bedside test. *Neurocase* 13(1):25–36
- Riva D, Giorgi C (2000) The cerebellum contributes to higher functions during development: evidence from a series of children surgically treated for posterior fossa tumours. *Brain* 123(Pt 5):1051–1061
- Ronning C, Sundet K, Due-Tonnessen B et al (2005) Persistent cognitive dysfunction secondary to cerebellar injury in patients treated for posterior fossa tumors in childhood. *Pediatr Neurosurg* 41(1):15–21
- Sadeh M, Cohen I (2001) Transient loss of speech after removal of posterior fossa tumors – one aspect of a larger neuropsychological entity: the cerebellar cognitive affective syndrome. *Pediatr Hematol Oncol* 18(7):423–426
- Schmahmann JD (1991) An emerging concept. The cerebellar contribution to higher function. *Arch Neurol* 48(11):1178–1187
- Schmahmann JD (1998) Dysmetria of thought. Clinical consequences of cerebellar dysfunction on cognition and affect. *Trends Cogn Sci* 2:362–370
- Schmahmann JD (2010) The role of the cerebellum in cognition and emotion: personal reflections since 1982 on the dysmetria of thought hypothesis, and its historical evolution from theory to therapy. *Neuropsychol Rev* 20(3):236–260



- Schmahmann JD, Pandya DN (1997) The cerebrotocerebellar system. In: Schmahmann JD (ed) *The cerebellum and cognition*. San Diego, Academic Press. *Int Rev Neurobiol* 41:31–60
- Schmahmann JD, Sherman JC (1997) Cerebellar cognitive affective syndrome. In: Schmahmann JD (ed) *Cerebellum and cognition*. Academic Press, San Diego. *Int Rev Neurobiol* 41:433–440
- Schmahmann JD, Sherman JC (1998) The cerebellar cognitive affective syndrome. *Brain* 121(Pt 4):561–579
- Schmahmann JD, Ko R, MacMore J (2004) The human basis pontis: motor syndromes and topographic organization. *Brain* 127(Pt 6):1269–1291
- Schmahmann JD, Weilburg JB, Sherman JC (2007) The neuropsychiatry of the cerebellum – insights from the clinic. *Cerebellum* 6(3):254–267
- Schweizer TA, Alexander MP, Susan Gillingham BA et al (2010) Lateralized cerebellar contributions to word generation: a phonemic and semantic fluency study. *Behav Neurol* 23(1–2):31–37
- Sokolovsky N, Cook A, Hunt H et al (2010) A preliminary characterisation of cognition and social cognition in spinocerebellar ataxia types 2, 1, and 7. *Behav Neurol* 23(1–2):17–29
- Steinlin M, Zangger B, Boltshauser E (1998) Non-progressive congenital ataxia with or without cerebellar hypoplasia: a review of 34 subjects. *Dev Med Child Neurol* 40(3):148–154
- Steinlin M, Imfeld S, Zulauf P et al (2003) Neuropsychological long-term sequelae after posterior fossa tumour resection during childhood. *Brain* 126(Pt 9):1998–2008
- Stoodley CJ, Schmahmann JD (2009a) The cerebellum and language: evidence from patients with cerebellar degeneration. *Brain Lang* 110(3):149–153
- Stoodley CJ, Schmahmann JD (2009b) Functional topography in the human cerebellum: a meta-analysis of neuroimaging studies. *Neuroimage* 44(2):489–501
- Stoodley CJ, Valera EM, Schmahmann JD (2012) Functional topography of the cerebellum for motor and cognitive tasks: an fMRI study. *Neuroimage* 59(2):1560–1570
- Storey E, Forrest SM, Shaw JH et al (1999) Spinocerebellar ataxia type 2: clinical features of a pedigree displaying prominent frontal-executive dysfunction. *Arch Neurol* 56(1):43–50
- Suenaga M, Kawai Y, Watanabe H et al (2008) Cognitive impairment in spinocerebellar ataxia type 6. *J Neurol Neurosurg Psychiatry* 79(5):496–499
- Tavano A, Grasso R, Gagliardi C et al (2007) Disorders of cognitive and affective development in cerebellar malformations. *Brain* 130(Pt 10):2646–2660
- Tedesco AM, Chiricozzi FR, Clausi S et al (2011) The cerebellar cognitive profile. *Brain* 134:3672–86
- Tei H, Sakamoto Y (1997) Pontine infarction due to basilar artery stenosis presenting as pathological laughter. *Neuroradiology* 39(3):190–191
- Turkel SB, Shu Chen L, Nelson MD et al (2004) Case series: acute mood symptoms associated with posterior fossa lesions in children. *J Neuropsychiatry Clin Neurosci* 16(4):443–445
- Turkel SB, Brumm VL, Mitchell WG et al (2006) Mood and behavioral dysfunction with opsoclonus-myoclonus ataxia. *J Neuropsychiatry Clin Neurosci* 18(2):239–241
- van Dongen HR, Catsman-Berrevoets CE, van Mourik M (1994) The syndrome of ‘cerebellar’ mutism and subsequent dysarthria. *Neurology* 44(11):2040–2046
- Vaquero E, Gomez CM, Quintero EA et al (2008) Differential prefrontal-like deficit in children after cerebellar astrocytoma and medulloblastoma tumor. *Behav Brain Funct* 4:18
- Wassmer E, Davies P, Whitehouse WP et al (2003) Clinical spectrum associated with cerebellar hypoplasia. *Pediatr Neurol* 28(5):347–351
- White M, Lalonde R, Botez-Marquard T (2000) Neuropsychologic and neuropsychiatric characteristics of patients with Friedreich’s ataxia. *Acta Neurol Scand* 102(4):222–226
- Wisoff JH, Epstein FJ (1984) Pseudobulbar palsy after posterior fossa operation in children. *Neurosurgery* 15(5):707–709
- Wollmann T, Barroso J, Monton F et al (2002) Neuropsychological test performance of patients with Friedreich’s ataxia. *J Clin Exp Neuropsychol* 24(5):677–686

- Zawacki TM, Grace J, Friedman JH et al (2002) Executive and emotional dysfunction in Machado-Joseph disease. *Mov Disord* 17(5):1004–1010
- Ziemus B, Baumann O, Luerding R et al (2007) Impaired working-memory after cerebellar infarcts paralleled by changes in BOLD signal of a cortico-cerebellar circuit. *Neuropsychologia* 45(9):2016–2024

# Chapter 69

## Ataxia Scales for the Clinical Evaluation

**Katrin Bürk**

**Abstract** The International Cooperative Ataxia Rating Scale (ICARS), the Friedreich Ataxia Rating Scale (FARS), the Brief Ataxia Rating Scale (BARS), and the Scale for the Assessment and Rating of Ataxia (SARA) represent validated scales for the assessment of disease severity and progression in cerebellar disease. Each scale has its strengths and weaknesses. Extensive scales are certainly useful for thorough documentation of specific features of certain phenotypes, but this gain of information is not always essential for the purpose of a study. Therefore, compact and manageable scales like SARA are often preferred to more complex scales in observational and therapeutic studies.

**Keywords** Ataxia • Scales • SARA • ICARS • FARS • BARS

### 69.1 Introduction

Several clinical scales have been validated for the assessment of disease severity and progression in cerebellar disease. There are several quality characteristics for clinical scales: The inter-rater reliability covers the variation of the ratings on the same subject between independent investigators while test-retest reliability describes the concordance between the ratings of an individual rater at different time points. The quality of inter-rater and test-retest reliability are depicted as intraclass correlation coefficients (ICC) with numerical values above  $> 0.8$  being considered reliable. Internal consistency corresponds to the score consistency across the various items of a scale: all items that are thought to refer to the same theoretical construct should not differ significantly in their scoring. The quality of internal consistency is expressed as Cronbach's  $\alpha$ . It is assessed by comparing the scores referring to the same theoretical construct. Numerical values of 0.8 or above correspond to a good

---

The author does not have any potential conflict of interest.

K. Bürk (✉)

Department of Neurology, Philipps University of Marburg,  
Baldingerstraße, 35043 Marburg, Germany  
e-mail: [buerk@med.uni-marburg.de](mailto:buerk@med.uni-marburg.de)

internal consistency. Validity describes the extent to which a scale actually measures what it claims to measure: Internal construct validity of a scale is determined by a principal component analysis that evaluates whether the number of factors and the loadings of the variables measured on them correspond to what is expected on the basis of the proposed theoretical concept. Furthermore, the factor analysis assesses the variability of observed variables with respect to unobserved variables (the so-called ‘factors’) by investigating whether these factors mainly account for associated variations in a series of observed variables. Linearity of a scale and particularly of the differences between ratings is essential to capture a wide spectrum of clinical severity. A scale should also not have significant floor (when data cannot take a value lower than some particular number) or ceiling effects (all scores are localized in the high end of the distribution). Last, but not least, the acquisition of a scale should not be complicated and time-consuming. The most common clinical rating scales are the International Cooperative Ataxia Rating Scale (ICARS), the Friedreich Ataxia Rating Scale (FARS), the Scale for the Assessment and Rating of Ataxia (SARA) and the Brief Ataxia Rating Scale (BARS).

## 69.2 ICARS

ICARS hypothesizes that all of its 19 items are grouped into four multi-item subscales reflecting core cerebellar features:

- (a) **posture and gait** disturbances (items 1–7, maximum score 34),
- (b) **limb ataxia** (‘kinetic functions’, items 8–14, maximum score 52) with each side of the body being assessed separately. The sum of both sides is added to the total score,
- (c) **dysarthria** (‘speech disturbances’, items 15 and 16, maximum score 8), and
- (d) **oculomotor disorders** (items 17–19, maximum score 6).

A maximum total score of 0 indicates complete absence of cerebellar symptoms. ICARS rating takes about 20 min (Schmitz-Hubsch et al. 2006b). To date, ICARS has been applied in a number of clinical and therapeutic trials (Lynch et al. 2010; Artuch et al. 2002; Pineda et al. 2008, 2010; Ristori et al. 2010; Kearney et al. 2009; Kimura et al. 2011; Nakamura et al. 2009; Cooper et al. 2008; Bradley et al. 2004; Heo et al. 2008; Di Prospero et al. 2007; Bier et al. 2003; Mori et al. 2002).

Cano first established reliability and validity of total ICARS scores and the subscale ‘posture and gait’ in FA (Cano et al. 2005). All other subscales failed standard criteria for scaling assumptions, reliability and validity.

Video based ICARS rating in patients with spinocerebellar ataxia (SCA), FA and controls yielded high inter-rater reliability for ICARS sum and subscores as well as a good test-retest (live vs. videotaped rating) reliability (Storey et al. 2004). In a large cohort of SCA patients, ICARS inter-rater reliability, test-retest reliability and internal consistency were found to be good (Schmitz-Hübsch et al. 2006b). Testing for validity (with ataxia disease stages or Barthel indices serving as external criteria) yielded that several ICARS items were redundant and overlapping. Furthermore,

rating scores appeared determined by four different factors that did not coincide with ICARS subscales. Therefore, ICARS subscore structure has to be questioned.

Schoch evaluated reliability, criterion-related validity and internal construct validity in focal cerebellar lesions and degenerative ataxia (Schoch et al. 2007). Test-retest reliability for total ICARS scores was good while it was highly variable for ICARS subscores. Internal consistency for all 19 ICARS items and criterion related validity were good. However, progression over time was only captured by subscore analysis in focal cerebellar lesions, but not in degenerative ataxia.

A cross-sectional analysis of internal consistency, factor structure and correlation with UPDRS-III scores in multiple system atrophy (MSA), Parkinson's Disease, and controls (Tison et al. 2002; Goetz et al. 2008) questioned the applicability of ICARS in MSA due to interference of basal ganglia symptoms.

### 69.3 FARS

FARS had originally been developed for the application in FA (Subramony et al. 2005). The scale is composed of

1. a *physical examination* covering *bulbar* (maximum score 11), *upper* (maximum score 36) and *lower limb* (maximum score 16), *peripheral nerve* (maximum score 26) and *upright stability/gait* (maximum score 28) (maximum sum score 117)
2. *functional staging* of overall mobility (score 0–6)
3. *activities of daily living (ADL)* (score 0–36), and
4. *three timed activities*:
  - (a) the '*PATA*' rate (number of repetitions of the bisyllabic phrase '*PATA*' within 10 s)
  - (b) the *nine-hole pegboard test* (time taken to place and retrieve pegs on a nine-hole pegboard tested for each side)
  - (c) *timed-walk of 50 ft* (25 ft one way, turn and walk back with or without device or 8 m)

The whole FARS protocol can be completed within 30 min. FARS has been applied in therapeutic trials (Lynch et al. 2010; Boesch et al. 2007).

FARS had initially been evaluated in a small FA sample (Subramony et al. 2005). Disease severity ranged from almost normal to severely impaired gait ambulation. Inter-rater variability was low for all parameters but 'bulbar' and 'peripheral nerve' scores. Only two factors explained almost 90% of the data variance. These findings were interpreted to reflect the global nature of FARS with one set of items reflecting *lower body dysfunction* and the other *upper body dysfunction*. Indeed, the factors 'stage of disease', 'lower limb score' and 'peripheral nerve score' and 'upright stability' were highly correlated thereby implicating a common underlying construct. A similar correlation was found for 'bulbar', 'upper limb', 'PATA rate' and

‘pegboard’ scores. Correlation of the ‘neurological examination’ and most subscores with ‘ADL’ as well as ‘mobility measures’ indicates construct validity of FARS.

The original FARS version had been questioned for the application in advanced FA stages (Subramony et al. 2005). Therefore, the original protocol was adapted. Validity of the examination-based FARS scale and the timed performance measures were correlated with potential surrogate markers of disease severity (‘disease duration’, ‘functional disability’, ‘ADL’) as well as the factors ‘age’, and ‘length of the smaller repeat expansion’. In addition, the informative value of testing low-contrast letter acuity using Sloan charts was assessed (Lynch et al. 2005). Total examination scores were found to correlate significantly with ‘disease duration’, ‘disability’ and ‘ADL’ scores thereby establishing construct validity for capturing progression in FA. Correlation coefficients for all individual examination subscores except ‘upright stability’ were lower than for total FARS scores. Interestingly, all performance scores were only weakly correlated to ‘disease duration’ while examination-based FARS was also correlated to ‘disease duration’ and ‘repeat length’. Functional tests of hand coordination and timed walking were correlated to ‘disease severity’ and ‘ADL’. Visual acuity retained its sensitivity even in late stages when other measures had ‘maxed out’ despite moderate correlations of visual acuity with ‘disability’ and ‘ADL’ scores. Composite measures (combination of 9HPT and T25FW with or without visual acuity) were shown to complement, but not to replace FARS assessment.

Fahey compared FARS scores to ‘age’, ‘age of onset’, ‘disease duration’, ‘ICARS scores’, and ‘activities of daily living’ (Modified Barthel Index (MBI) and the Functional Independence Measure (FIM)) at baseline and after 12 months (Fahey et al. 2007; Keith et al. 1987). Concurrent criterion validity was established for FARS through correlations with these well-established measures of disability. A strong correlation between all four measurements also suggested a common underlying construct. On a cross-sectional base, correlations of FARS, ICARS, MBI and FIM scores and ‘disease duration’ were all significant, but best correlation was achieved for FARS sum scores. FARS also captured clinical progression after 12 months. It had the greatest effect size and required a smaller number of patients for an equivalently powered clinical trial than ICARS. More recently, another study has corroborated ICARS applicability in FA. Interestingly, changes on FARS (and ICARS) seem to be greater during the first 20 years after onset than in later stages (Tai et al. 2014).

## 69.4 SARA

SARA has eight items with a total score of up to 40 (most severe ataxia) (Schmitz-Hübsch et al. 2006a):

1. *gait* (score 0–8),
2. *stance* (score 0–6),

3. *sitting* (score 0–4),
4. *speech disturbance* (score 0–6),
5. *finger chase* (score 0–4)\*
6. *nose-finger test* (score 0–4)\*
7. *fast alternating hand movements* (score 0–4)\*
8. *heel-shin slide* (score 0–4)\*

\* As rated independently for both sides; mean of both sides is considered for total scores.

The time needed to complete varies between 4 and 40 min (Schmitz-Hübisch et al. 2006a; Yabe et al. 2008). SARA has been applied in several therapeutic trials (Boesch et al. 2007; Broccoletti et al. 2011; Lohle et al. 2008; Gazulla and Benavente 2007).

SARA has primarily been validated in SCA (Schmitz-Hübisch et al. 2006a, 2010). In SCA, it did not show major ceiling effects. Inter-rater variability was significant and better than for ICARS with significant ICCs for all single items. Test-retest reliability and internal consistency were excellent (Cronbach's  $\alpha$  0.94). Factorial analysis yielded a single factor that determined all items and accounted for 80% of the variance. So, in contrast to ICARS, SARA appears to assess a common underlying construct – namely ataxia. Linearity was demonstrated by the linear relation between SARA total ratings and the differences between individual ratings. When comparing SARA to ICARS scores, 'disease stages', 'Barthel indices', and part IV of the Unified Huntington's Disease Rating Scale (UHDRS-IV), scores were found to be correlated to UHDRS-IV and Barthel indices and to increase with disease stages (Huntington-Study-Group 1996; Klockgether et al. 1998; Schmitz-Hübisch et al. 2008a). A weak correlation between SARA scores and disease duration was attributed to differences in the individual progression rate of various SCA genotypes. However, SARA does not reliably capture all symptoms at onset. Concerning longitudinal assessment, SARA clearly displays decline after 12 months. Standardized response means were good: A two-arm trial that aims to decrease progression by 50% would require a sample size of 250 patients with various SCAs, 57 with SCA2, 70 with SCA1 and 75 with SCA3 per group (Schmitz-Hübisch et al. 2008b; Tezenas du Montcel et al. 2012). SARA has also been validated in a variety of cerebellar disorders including sporadic ataxia, MSA, focal cerebellar lesions and FA (Weyer et al. 2007; Yabe et al. 2008; Bürk et al. 2009).

## 69.5 Brief Ataxia Rating Scale (BARS)

BARS is a short five-item scale, covering

1. Gait (score 0–8).
2. Kinetic function leg (score 0–4), with each side of the body being assessed separately. The sum of both sides is added to the total score.

3. Kinetic function arm (score 0–4), with each side of the body being assessed separately. The sum of both sides is added to the total score.
4. Speech (score 0–4).
5. Eye movements (score 0–2).

The maximum total score of 30 indicates most severe ataxia.

BARS was derived from a modified version of ICARS (MICARS) that includes seven tests of cerebellar dysfunction (kinetic function, speech, oculomotor) in addition to the original ICARS scale (Schmahmann et al. 2009). Statistical search of MICARS for a five-test subset that would correlate best with the total MICARS score without any constraints yielded several thousand potentially significant and reliable combinations of five items in a cohort of 91 patients (48 % of possible combinations). In a second step, analysis was repeated applying the clinical constraint with one test each of gait, ataxia of upper and lower limbs, speech, and eye movements. Correlation with MICARS-minus BARS was excellent. Factor analysis yielded five factors that matched the clinically determined grouping exactly. The resulting scale BARS was then validated in a second cohort of 32 patients. Inter-rater reliability as assessed in a third cohort was found to be excellent. Cronbach's  $\alpha$  was 0.90 for BARS (and 0.92 for SARA in the same cohort).

In a study of 44 children ages 4–18 years who had undergone surgical resection for a posterior fossa tumour, patients were independently rated by two therapists using SARA and BARS and a Paediatric Evaluation of Disability Index (PEDI) mobility domain (Hartley et al. 2015). Inter-rater reliability was good for both scales, demonstrating strong correlations (SARA,  $r=0.94$ ; BARS,  $r=0.91$ ) and good consistency (93 % of SARA and 90 % of BARS paired scores differing by less than 2 points) between two raters. Both ataxia scales demonstrated a strong negative correlation with the mobility domain of the PEDI (SARA,  $r=-0.77$ ; BARS,  $r=-0.76$ ), indicating that more severe ataxia was associated with worse mobility. The mean time for completion of SARA was 4.5 min and 2.7 min for BARS.

## References

- Artuch R, Aracil A, Mas A, Colome C, Rissech M, Monros E, Pineda M (2002) Friedreich's ataxia: idebenone treatment in early stage patients. *Neuropediatrics* 33(4):190–193. doi:[10.1055/s-2002-34494](https://doi.org/10.1055/s-2002-34494)
- Bier JC, Dethy S, Hildebrand J, Jacquy J, Manto M, Martin JJ, Seeldrayers P (2003) Effects of the oral form of ondansetron on cerebellar dysfunction. A multi-center double-blind study. *J Neurol* 250(6):693–697. doi:[10.1007/s00415-003-1061-9](https://doi.org/10.1007/s00415-003-1061-9)
- Boesch S, Sturm B, Hering S, Goldenberg H, Poewe W, Scheiber-Mojdehkar B (2007) Friedreich's ataxia: clinical pilot trial with recombinant human erythropoietin. *Ann Neurol* 62(5):521–524. doi:[10.1002/ana.21177](https://doi.org/10.1002/ana.21177)
- Bradley JL, Homayoun S, Hart PE, Schapira AH, Cooper JM (2004) Role of oxidative damage in Friedreich's ataxia. *Neurochem Res* 29(3):561–567
- Broccoletti T, Del Giudice E, Cirillo E, Vigliano I, Giardino G, Ginocchio VM, Bruscoli S, Riccardi C, Pignata C (2011) Efficacy of very-low-dose betamethasone on neurological symptoms in ataxia-telangiectasia. *Eur J Neurol* 18(4):564–570. doi:[10.1111/j.1468-1331.2010.03203.x](https://doi.org/10.1111/j.1468-1331.2010.03203.x)



- Bürk K, Mälzig U, Wolf S, Heck S, Dimitriadis K, Schmitz-Hübsch T, Hering S et al (2009) Comparison of three clinical rating scales in Friedreich ataxia (FRDA). *Mov Disord* 24(12):1779–1784. doi:[10.1002/mds.22660](https://doi.org/10.1002/mds.22660)
- Cano SJ, Hobart JC, Hart PE, Korlipara LV, Schapira AH, Cooper JM (2005) International Cooperative Ataxia Rating Scale (ICARS): appropriate for studies of Friedreich's ataxia? *Mov Disord* 20(12):1585–1591. doi:[10.1002/mds.20651](https://doi.org/10.1002/mds.20651)
- Cooper JM, Korlipara LV, Hart PE, Bradley JL, Schapira AH (2008) Coenzyme Q10 and vitamin E deficiency in Friedreich's ataxia: predictor of efficacy of vitamin E and coenzyme Q10 therapy. *Eur J Neurol* 15(12):1371–1379. doi:[10.1111/j.1468-1331.2008.02318.x](https://doi.org/10.1111/j.1468-1331.2008.02318.x)
- Di Prospero NA, Baker A, Jeffries N, Fischbeck KH (2007) Neurological effects of high-dose idebenone in patients with Friedreich's ataxia: a randomised, placebo-controlled trial. *Lancet Neurol* 6(10):878–886. doi:[10.1016/S1474-4422\(07\)70220-X](https://doi.org/10.1016/S1474-4422(07)70220-X)
- Fahey MC, Corben L, Collins V, Churchyard AJ, Delatycki MB (2007) How is disease progress in Friedreich's ataxia best measured? A study of four rating scales. *J Neurol Neurosurg Psychiatry* 78(4):411–413. doi:[10.1136/jnnp.2006.096008](https://doi.org/10.1136/jnnp.2006.096008)
- Gazulla J, Benavente I (2007) Single-blind, placebo-controlled pilot study of pregabalin for ataxia in cortical cerebellar atrophy. *Acta Neurol Scand* 116(4):235–238. doi:[10.1111/j.1600-0404.2007.00912.x](https://doi.org/10.1111/j.1600-0404.2007.00912.x)
- Goetz CG, Tilley BC, Shaftman SR, Stebbins GT, Fahn S, Martinez-Martin P, Poewe W et al (2008) Movement Disorder Society-sponsored revision of the Unified Parkinson's Disease Rating Scale (MDS-UPDRS): scale presentation and clinimetric testing results. *Mov Disord* 23(15):2129–2170. doi:[10.1002/mds.22340](https://doi.org/10.1002/mds.22340)
- Hartley H, Pizer B, Lane S, Sneade C, Pratt R, Bishop A, Kumar R (2015) Inter-rater reliability and validity of two ataxia rating scales in children with brain tumours. *Childs Nerv Syst* 31(5):693–697
- Heo JH, Lee ST, Chu K, Kim M (2008) The efficacy of combined estrogen and buspirone treatment in olivopontocerebellar atrophy. *J Neurol Sci* 271(1–2):87–90. doi:[10.1016/j.jns.2008.03.016](https://doi.org/10.1016/j.jns.2008.03.016)
- Huntington-Study-Group (1996) Unified Huntington's disease rating scale: reliability and consistency. *Mov Disord* 11(2):136–142. doi:[10.1002/mds.870110204](https://doi.org/10.1002/mds.870110204)
- Kearney M, Orrell RW, Fahey M, Pandolfo M (2009) Antioxidants and other pharmacological treatments for Friedreich ataxia. *Cochrane Database Syst Rev* 4:CD007791. doi:[10.1002/14651858.CD007791.pub2](https://doi.org/10.1002/14651858.CD007791.pub2)
- Keith RA, Granger CV, Hamilton BB, Sherwin FS (1987) The functional independence measure: a new tool for rehabilitation. *Adv Clin Rehabil* 1:6–18
- Kimura N, Kumamoto T, Masuda T, Nomura Y, Hanaoka T, Hazama Y, Okazaki T (2011) Evaluation of the effects of thyrotropin releasing hormone (TRH) therapy on regional cerebral blood flow in the cerebellar variant of multiple system atrophy using 3DSRT. *J Neuroimaging* 21(2):132–137. doi:[10.1111/j.1552-6569.2009.00411.x](https://doi.org/10.1111/j.1552-6569.2009.00411.x)
- Klockgether T, Lüdtke R, Kramer B, Abele M, Bürk K, Schöls L, Riess O et al (1998) The natural history of degenerative ataxia: a retrospective study in 466 patients. *Brain* 121(Pt 4):589–600
- Lohle M, Schrepf W, Wolz M, Reichmann H, Storch A (2008) Potassium channel blocker 4-aminopyridine is effective in interictal cerebellar symptoms in episodic ataxia type 2 – a video case report. *Mov Disord* 23(9):1314–1316. doi:[10.1002/mds.22071](https://doi.org/10.1002/mds.22071)
- Lynch DR, Farmer JM, Wilson RL, Balcer LJ (2005) Performance measures in Friedreich ataxia: potential utility as clinical outcome tools. *Mov Disord* 20(7):777–782. doi:[10.1002/mds.20449](https://doi.org/10.1002/mds.20449)
- Lynch DR, Perlman SL, Meier T (2010) A phase 3, double-blind, placebo-controlled trial of idebenone in Friedreich ataxia. *Arch Neurol* 67(8):941–947. doi:[10.1001/archneurol.2010.168](https://doi.org/10.1001/archneurol.2010.168)
- Mori M, Adachi Y, Mori N, Kurihara S, Kashiwaya Y, Kusumi M, Takeshima T, Nakashima K (2002) Double-blind crossover study of branched-chain amino acid therapy in patients with spinocerebellar degeneration. *J Neurol Sci* 195(2):149–152
- Nakamura K, Yoshida K, Miyazaki D, Morita H, Ikeda S (2009) Spinocerebellar ataxia type 6 (SCA6): clinical pilot trial with gabapentin. *J Neurol Sci* 278(1–2):107–111. doi:[10.1016/j.jns.2008.12.017](https://doi.org/10.1016/j.jns.2008.12.017)

- Pineda M, Arpa J, Montero R, Aracil A, Dominguez F, Galvan M, Mas A et al (2008) Idebeneone treatment in paediatric and adult patients with Friedreich ataxia: long-term follow-up. *Eur J Paediatr Neurol* 12(6):470–475. doi:[10.1016/j.ejpn.2007.11.006](https://doi.org/10.1016/j.ejpn.2007.11.006)
- Pineda M, Montero R, Aracil A, O'Callaghan MM, Mas A, Espinos C, Martinez-Rubio D et al (2010) Coenzyme Q(10)-responsive ataxia: 2-year-treatment follow-up. *Mov Disord* 25(9):1262–1268. doi:[10.1002/mds.23129](https://doi.org/10.1002/mds.23129)
- Ristori G, Romano S, Visconti A, Cannoni S, Spadaro M, Frontali M, Pontieri FE, Vanacore N, Salvetti M (2010) Riluzole in cerebellar ataxia: a randomized, double-blind, placebo-controlled pilot trial. *Neurology* 74(10):839–845. doi:[10.1212/WNL.0b013e3181d31e23](https://doi.org/10.1212/WNL.0b013e3181d31e23)
- Schmitz-Hübisch T, du Montcel ST, Baliko L, Berciano J, Boesch S, Depondt C, Giunti P et al (2006a) Scale for the assessment and rating of ataxia: development of a new clinical scale. *Neurology* 66(11):1717–1720. doi:[10.1212/01.wnl.0000219042.60538.92](https://doi.org/10.1212/01.wnl.0000219042.60538.92)
- Schmitz-Hübisch T, Tezenas du Montcel S, Baliko L, Boesch S, Bonato S, Fancellu R, Giunti P et al (2006b) Reliability and validity of the International Cooperative Ataxia Rating Scale: a study in 156 spinocerebellar ataxia patients. *Mov Disord* 21(5):699–704. doi:[10.1002/mds.20781](https://doi.org/10.1002/mds.20781)
- Schmitz-Hübisch T, Coudert M, Bauer P, Giunti P, Globas C, Baliko L, Filla A et al (2008a) Spinocerebellar ataxia types 1, 2, 3, and 6: disease severity and nonataxia symptoms. *Neurology* 71(13):982–989. doi:[10.1212/01.wnl.0000325057.33666.72](https://doi.org/10.1212/01.wnl.0000325057.33666.72)
- Schmitz-Hübisch T, Giunti P, Stephenson DA, Globas C, Baliko L, Sacca F, Mariotti C et al (2008b) SCA functional index: a useful compound performance measure for spinocerebellar ataxia. *Neurology* 71(7):486–492. doi:[10.1212/01.wnl.0000324863.76290.19](https://doi.org/10.1212/01.wnl.0000324863.76290.19)
- Schmitz-Hübisch T, Fimmers R, Rakowicz M, Rola R, Zdzenicka E, Fancellu R, Mariotti C et al (2010) Responsiveness of different rating instruments in spinocerebellar ataxia patients. *Neurology* 74(8):678–684. doi:[10.1212/WNL.0b013e3181d1a6c9](https://doi.org/10.1212/WNL.0b013e3181d1a6c9)
- Schoch B, Regel JP, Frings M, Gerwig M, Maschke M, Neuhauser M, Timmann D (2007) Reliability and validity of ICARS in focal cerebellar lesions. *Mov Disord* 22(15):2162–2169. doi:[10.1002/mds.21543](https://doi.org/10.1002/mds.21543)
- Schmahmann JD, Gardner R, MacMore J, Vangel MG (2009) Development of a brief ataxia rating scale (BARS) based on a modified form of the ICARS. *Mov Disord* 24:1820–1828
- Storey E, Tuck K, Hester R, Hughes A, Churchyard A (2004) Inter-rater reliability of the International Cooperative Ataxia Rating Scale (ICARS). *Mov Disord* 19(2):190–192. doi:[10.1002/mds.10657](https://doi.org/10.1002/mds.10657)
- Subramony SH, May W, Lynch D, Gomez C, Fischbeck K, Hallett M, Taylor P, Wilson R, Ashizawa T, Group Cooperative Ataxia (2005) Measuring Friedreich ataxia: interrater reliability of a neurologic rating scale. *Neurology* 64(7):1261–1262. doi:[10.1212/01.WNL.0000156802.15466.79](https://doi.org/10.1212/01.WNL.0000156802.15466.79)
- Tai G, Corben LA, Gurrin L, Yiu EM, Churchyard A, Fahey M, Hoare B, Downie S, Delatycki MB (2014) A study of up to 12 years of follow-up of Friedreich ataxia utilising four measurement tools. *J Neurol Neurosurg Psychiatry*. doi:[10.1136/jnnp-2014-308022](https://doi.org/10.1136/jnnp-2014-308022)
- Tezenas du Montcel S, Charles P, Goizet C, Marelli C, Ribai P, Vincitorio C, Anheim M et al (2012) Factors influencing disease progression in autosomal dominant cerebellar ataxia and spastic paraplegia. *Arch Neurol* 69(4):500–508. doi:[10.1001/archneurol.2011.2713](https://doi.org/10.1001/archneurol.2011.2713)
- Tison F, Yekhelef F, Balestre E, Chrysostome V, Quinn N, Wenning GK, Poewe W (2002) Application of the International Cooperative Ataxia Scale rating in multiple system atrophy. *Mov Disord* 17(6):1248–1254. doi:[10.1002/mds.10290](https://doi.org/10.1002/mds.10290)
- Weyer A, Abele M, Schmitz-Hübisch T, Schoch B, Frings M, Timmann D, Klockgether T (2007) Reliability and validity of the scale for the assessment and rating of ataxia: a study in 64 ataxia patients. *Mov Disord* 22(11):1633–1637. doi:[10.1002/mds.21544](https://doi.org/10.1002/mds.21544)
- Yabe I, Matsushima M, Soma H, Basri R, Sasaki H (2008) Usefulness of the Scale for Assessment and Rating of Ataxia (SARA). *J Neurol Sci* 266(1–2):164–166. doi:[10.1016/j.jns.2007.09.021](https://doi.org/10.1016/j.jns.2007.09.021)

**Part X**  
**Human Cerebellar Disorders: From**  
**Prenatal Period to Elderly**

# Chapter 70

## Differential Diagnosis of Cerebellar Ataxias on the Basis of the Age at Onset

Francesc Palau and Javier Arpa

**Abstract** Ataxias are a complex and heterogeneous group of disorders characterized by the absence of order and coordination of voluntary movements and loss of equilibrium. The major clinical criteria for diagnosis include disease extension (focal vs non focal), etiology (hereditary vs symptomatic or idiopathic), progression rate, age at onset, and neurological and systemic symptoms that support the diagnosis of specific disorders. Age at onset is a very important clinical tool that along with inheritance are useful address the proper differential diagnosis. In this way three major categories of cerebellar ataxias may be recognized: (i) congenital ataxias in infancy and young children (<2 years), (ii) early-onset in childhood, adolescence and young adulthood (<25 years), and (iii) late-onset cerebellar ataxias.

**Keywords** Cerebellar ataxias • Differential diagnosis • Cerebellar Ataxias in Infancy • Cerebellar Ataxias in Young Children • Cerebellar Ataxias in Childhood • Cerebellar Ataxias in Adolescence • Cerebellar Ataxias in Young Adulthood • Late-Onset Cerebellar Ataxias

---

F. Palau (✉)

Department of Genetic & Molecular Medicine and Pediatric Institut of Rare Diseases (IPER),  
Sant Joan de Déu Children's Hospital, Pg. Sant Joan de Déu 2, 08950 Barcelona, Spain

CIBER on Rare Diseases (CIBERER), Instituto de Salud Carlos III, Valencia, Spain

Department of Pediatrics, University of Barcelona School of Medicine, Barcelona, Spain

e-mail: [fpalau@hsjdbcn.org](mailto:fpalau@hsjdbcn.org)

J. Arpa

Hospital Clínico San Carlos, Madrid, Spain

Department of Anatomy, Histology and Neurosciences, Autonomous University of Madrid

School of Medicine, Madrid, Spain

e-mail: [jarpag@ctv.es](mailto:jarpag@ctv.es)

## 70.1 Introduction

Cerebellar ataxias represent a wide group of disorders involving the cerebellum and spinocerebellar pathways. Classically recognition of these diseases and nosological conditions has been based on the clinical features and associated pathology.

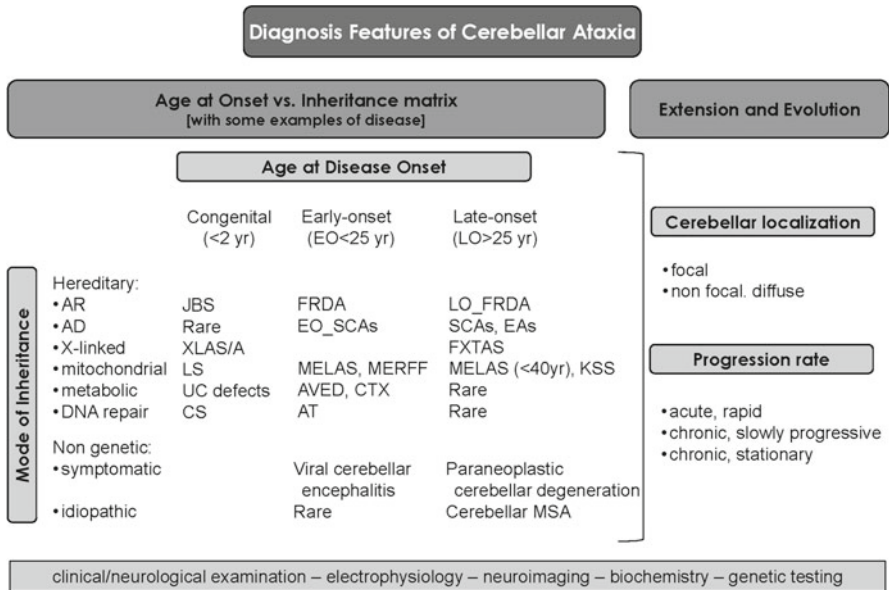
Modern diagnostic criteria and classification of ataxias started in 1983 when Anita Harding (1983, 1993) proposed a classification of inherited ataxias based on clinical data and genetic information obtained from the family history and genealogical pedigree. This author distinguished congenital disorders associated with non-progressive ataxia, ataxic disorders with known metabolic cause or defective DNA repair, and ataxic disorders of unknown etiology, most of them following a progressive evolution rate. The latter group included early-onset cerebellar ataxias that usually begin before the age of 20 years (most of them with autosomal recessive inheritance, and currently referred to autosomal recessive cerebellar ataxias or ARCAs) and late-onset cerebellar ataxias (onset usually after 20 years), which includes autosomal dominant cerebellar ataxias (ADCAs), periodic autosomal dominant ataxias (episodic ataxias, EA), and idiopathic late-onset cerebellar ataxias (ILOCA). In addition, hereditary ataxias also include the group of mitochondrial diseases expressing ataxic symptoms and the rare X-linked disorders. This classification has been modified by gene discovery and the use of molecular genetic diagnosis in clinical practice (Bird 2016; Mancuso et al. 2016). Since the discovery of the first ataxia-associated genes *SCAI* (spinocerebellar ataxia type 1) and *FXN* (Friedreich ataxia) in the 1990s of the past century, the genetic definition of an ataxia has moved from the inheritance pattern criterion towards the characterization and genetic testing of the causative gene mutation. However, clinical criteria still remain relevant to orient the diagnosis of patient with ataxia. An overview of phenotypes and genetics of cerebellar ataxias can be seen at the Washington University Neuromuscular Disease Center website (<http://neuromuscular.wustl.edu/ataxia/aindex.html>) and GeneReviews website (Bird 2016).

A rational diagnostic approach to the ataxic patients starts with proper orientation of the natural history of the disease, clinical symptoms and neurological and systemic examinations. Critical aspects are (i) distinction between focal (tumor, abscess, hemorrhage, ischemia, focal demyelination) and nonfocal (degenerative, metabolic, toxic, infectious, paraneoplastic syndrome) cerebellar disorder, (ii) progression rate (acute, chronic non-progressive, chronic progressive, intermittent), (iii) age at onset (early onset, late onset), and (iv) evidence for a characteristic neurological phenotype and systemic involvement. Moreover, most of chronic, either non-progressive congenital/developmental ataxias or progressive degenerative ataxias, are caused by gene mutations and segregate with a specific Mendelian or mitochondrial (maternal) inheritance pattern as mentioned above (Palau and Espinós 2013). Nevertheless, the cause of the disease is not achieved in a number of sporadic patients with idiopathic ataxia.

Electrophysiological studies, neuro-otology tests, neuro-ophtalmology tests, neuroimaging (e.g., magnetic resonance imaging – MRI), and cardiac studies are also relevant on diagnosis to define the altered neural structures and heart

involvement. Biochemical tests and, more recently, genetic testing of phenotype-oriented genes or the search for gene mutations by next generation sequencing (e.g. exome sequencing or a panel of ataxic genes) may be necessary to confirm clinical diagnosis, to perform a proper differential diagnosis and to provide genetic counselling to patients and families.

In this chapter, we discuss the approach to diagnosis of cerebellar ataxias based on the age at onset of the disease (Harding 1983, 1993). We are taking into account the inheritance pattern and the temporal course and progression. We are also distinguishing between hereditary ataxias and symptomatic or acquired ataxia (Anheim et al. 2012; Dürr 2010; Mancuso et al. 2014; Palau and Espinós 2006). Based on the age at onset we recognize three major categories: very early onset in infancy and young children (under 2 years), childhood to early adulthood, and late-onset after the age of 25 years. There is no a perfect division among each age category but it is realistic to take into account several considerations: (i) most of very early onset ataxias in children under 2 years used to be a developmental or congenital defect



**Fig. 70.1** Diagram of clinical diagnostic criteria in cerebellar ataxias. The drawing is designed in an attempt to integrate age at onset with other clinical criteria in a working process. As wide overlapping exists in cerebellar ataxias the authors are aware that reality is more complex. *AR* autosomal recessive, *AD* autosomal dominant, *EO* early onset, *LO* late onset, *AT* ataxia telangiectasia, *AVED* isolated ataxia with vitamin E deficiency, *CTX* cerebrotendinous xanthomatosis, *CS* Cockayne syndrome, *EAs* episodic ataxias, *FRDA* Friedreich ataxia, *FXTAS* fragile X with tremor/ataxia syndrome, *JBS* Joubert syndrome, *KSS* Kern-Sayre syndrome, *LS* Leigh syndrome, *MELAS* mitochondrial encephalopathy, lactic acidosis and stroke-like episodes, *MERFF* myotonic epilepsy with ragged-red fibers, *SCAs* spinocerebellar ataxias, *UC defects* urea cycle disorders, *XLAS/A* X-linked ataxia syndrome with anemia. Mitochondrial inheritance refers to disorders involving mitochondrial DNA genes that affect oxidative phosphorylation

that segregate as an autosomal recessive trait; (ii) chronic early-onset ataxias in childhood, adolescence and young adults under 25 years may be acquired or hereditary with autosomal recessive, maternal inheritance or rarely X-linked inheritance, and include progressive degenerative ataxias, inherited metabolic diseases, and mitochondrial disorders; (iii) late-onset ataxias after the age of 25 years may be hereditary, usually segregating as an autosomal dominant trait (less frequently as autosomal recessive and X-linked traits), symptomatic as the consequence of different primary acquired causes, or idiopathic. Among these idiopathic late-onset cerebellar ataxias, the cerebellar type (OPCA variant) of multiple system atrophy (MSA) is an important diagnosis (Klockgether 2010). A working diagram for differential diagnosis is proposed in Fig. 70.1.

## **70.2 Cerebellar Ataxias in Infancy and Young Children (< 2 Years)**

Congenital ataxias present hypotonia, delay of motor milestones and non-progressive cerebellar ataxia associated with vermis or cerebellar aplasia. There are a large number of clinical pictures and syndromes (Bird 2016; Mancuso et al. 2014). Most of them are autosomal recessive but a few are autosomal dominant or X-linked. Joubert-Boltshauser syndrome (JBS) is a clinically and genetically heterogeneous group of disorders (more than 15 genes) involving primary cilia, characterized by hypoplasia of the cerebellar vermis with the characteristic neuroradiologic “molar tooth sign”, and accompanying neurologic symptoms: ataxia, intellectual disability, oculomotor apraxia, dysregulation of breathing pattern, and developmental delay. Among other rare disorders it can be mentioned Gillespie syndrome, congenital ataxias with intellectual disability, Dandy-Walker malformation, Walker-Warburg syndrome, Cayman ataxia, carbohydrate deficient glycoprotein syndrome type 1a or the X-linked disorders associated with ataxia such as ataxia with sideroblastic anemia, Pelizaeus-Merzbacher disease, Arts syndrome and Rett syndrome. Metabolic ataxias in infancy include Hartnup disorder, argininosuccinic acidemia, citrullinemia and biotinidase deficiency (Fogel and Perlman 2007).

## **70.3 Cerebellar Ataxias in Childhood, Adolescence and Young Adulthood**

In childhood and young patients viral cerebellar encephalitis is the most frequent cause of acute ataxia. By contrast, progressive ataxia suggests an inherited ataxia likely with autosomal recessive inheritance, which may be suspected when the disease is running two or more affected sibs or there is consanguinity (pseudodominant pattern also suggest recessive inheritance) in the genealogical information provided by parents or relatives. Pathogenic mechanisms causing these ataxias include

mitochondrial dysfunction, DNA repair dysfunction, altered intermediate metabolism, protein misfolding and chaperone dysfunction, and less frequently altered function of calcium homeostasis and altered vesicle trafficking (Vermeer et al. 2011). Friedreich ataxia (FRDA) is the most frequent autosomal recessive cerebellar ataxia in Caucasians. FRDA is a sensory and cerebellar ataxia with characteristic clinical phenotype expressing both peripheral sensory neuropathy and spinocerebellar syndrome with signs of posterior columns dysfunction and dentate nucleus neuropathology, dysarthria, heart disease, diabetes mellitus or glucose intolerance, and skeletal deformities. Genetic testing of *FXN* gene provides definite diagnosis by demonstration of homozygosity of two GAA expanded alleles (98 % of patients) or compound heterozygosity of one expanded allele and one point mutation (2 % of patients) (Dürr et al. 1997). Based on prevalence, other ARCA to be considered are ataxia with ocular apraxia (AOA types 1 and 2), isolated vitamin E deficiency (AVED), abetalipoproteinemia (ABL), autosomal recessive spastic ataxia of Charlevoix-Saguenay (ARSACS), sensory ataxic neuropathy, dysarthria and ophthalmoparesis (SANDO), cerebrotendinous xanthomatosis (CTX), autosomal recessive cerebellar ataxia 2 (ARCA2 or SCAR9), Marinesco-Sjögren syndrome (MSS), cerebellar ataxia with coenzyme Q (CoQ) deficiency (Anheim et al. 2012; Fogel and Perlman 2007; Palau and Espinós 2006; Vermeer et al. 2011). Both vitamin E and CoQ deficiencies could be the consequence of gene mutations or secondary to acquired disorders such as disorders associated with malabsorption syndrome in case of vitamin E deficiency.

Among ataxias caused by defects in DNA repair ataxia-telangiectasia (AT) – the second most frequent ARCA type –, ataxia-telangiectasia-like disorder 1, Cockayne syndrome (CS), xeroderma pigmentosum (XP), and spinocerebellar ataxia with axonal neuropathy (SCAN1). Cockayne syndrome and xeroderma pigmentosum show locus genetic heterogeneity and may be diagnosed during infancy. AOA1 and AOA2 pathogenesis also involves DNA repair defects. AOA1 is the most ARCA form in Japan and Portugal.

Inherited metabolic diseases with enzymatic biochemical defects may also present with intermittent or progressive ataxia. In some disorders ataxia is a frequent sign but in others it is not relevant in the clinical picture. Most of them are autosomal recessive traits but X-linked inheritance may occur as well. Metabolic ataxias usually begin in infancy or childhood. Metabolic ataxias in the childhood period (2–12 years) include carnitine acetyltransferase deficiency, X-linked ornithine transcarbamylase deficiency and other defects of the urea cycle, Niemann-Pick type C disease, infantile Refsum disease, and ataxia with selective vitamin E deficiency (AVED) caused by mutations in the  $\alpha$ -TTP gene. Clinical metabolic entities in adolescence and adulthood are abetalipoproteinemia, hypobetalipoproteinemia,  $\alpha$ -methylacyl-CoA racemase deficiency, cerebrotendinous xanthomatosis, gamma-glutamyl cysteine synthetase deficiency, adolescent or young adult Refsum disease and Wilson disease.

Mitochondrial oxidative phosphorylation (OXPHOS) provides energy to most of the organs and tissues. Ataxia is one of the major neurological symptoms of OXPHOS defects due to mutations in the mitochondrial DNA, which used to



become symptomatic in childhood or young adulthood. Examples of manifesting with ataxia include MELAS syndrome (mitochondrial myopathy, encephalopathy, lactacidosis, stroke syndrome), MERRF (myoclonic epilepsy with ragged red fibers), NARP (neurogenic muscle weakness, ataxia, and retinitis pigmentosa), and KSS (Kearns-Sayre syndrome) (Fogel and Perlman 2007).

## 70.4 Late-Onset Cerebellar Ataxias

A primary cause may be found in cerebellar ataxia with onset after the age of 25 years. The etiology may be genetic or symptomatic because a gene mutation or an acquired disorder that is expressed with ataxia. However, the cause is not evident in a number of sporadic patients, for which idiopathic late-onset cerebellar ataxia is the working diagnosis.

Whereas symptomatic ataxia may appear in infancy and childhood (cerebellar tumors, metabolic deficiencies and immunological disease – e.g. opsoclonus/myoclonus syndrome), they are more frequent in adult individuals. Symptomatic ataxias in adulthood may be caused by vascular disease, hypoxia, mass lesion (neoplasm, abscess, sarcoid nodules), cervico-occipital hinge anomalies, hypothyroidism, hypoparathyroidism, vitamin deficiency (B1, B12, E), immune disease (acute cerebellar ataxia, paraneoplastic cerebellar degeneration, celiac disease, anti-GAD ataxia, multiple sclerosis, Bickerstaff encephalitis, Miller-Fisher syndrome), infections (acute cerebellar encephalitis, meningitis, HIV, Whipple's disease, Creutzfeldt-Jakob disease), drugs (e.g., ethanol, phenytoin, 5-fluorouracil), metals (lead, mercury, manganese, bismuth, siderose), toxics (toluene, methyl bromide, triorthocresyl phosphate), toxins (buckthorn fruit), paroxysmal causes (epilepsy, migraine, fever, heat stroke), and other systemic disorders (amyloid).

Most of the late-onset ataxias segregate as autosomal dominant cerebellar ataxias (ADCAs) (Dürr 2010). Two major groups are recognized: spinocerebellar ataxias (SCAs) with 40 defined genes/loci, and episodic ataxias (EAs) with seven genetic clinical variants. The CAG trinucleotide expansion is the major mutation in the most common forms of spinocerebellar ataxia, i.e. SCA1, SCA2, SCA3, SCA6, SCA7, SCA12, SCA17 and DRPLA (dentate-rubro-pallido-luysian atrophy). Other nucleotide expansions are observed in SCA8 (CTG), SCA10 (ATTCT), SCA31 (TGGAA) and SCA36 (intronic GGCCTG). The phenotypic classification by Harding (1993) that categorized three groups of ADCAs may be useful to perform an accurate genetic testing. ADCA type I refers to ataxia plus impairment of other neuronal systems, ADCA type II is ataxia plus retinal degeneration and ADCA type III is described as pure cerebellar ataxias. For ADCA type I the first genes to be tested are SCA1, SCA2 and SCA3. ADCA type II is almost exclusively associated with SCA7 mutations. And finally, for ADCA type III SCA6 and SCA12 should be the first genes to be analyzed. The most frequent types of episodic ataxias are due to mutations in ion channels: EA-1 manifests without vertigo and is associated with inter-

ictal myokymia, and EA-2 manifests with vertigo and is associated with interictal nystagmus, and in these patients acetazolamide often dramatically stops the spells.

Non-dominant inherited ataxias may present in individuals older than 25 years. The fragile X tremor/ataxia syndrome (FXTAS) is a frequent ataxic syndrome in adults and elderly people, and is due to short but abnormal CGG expansions in the *FMR-1* gene classically associated with fragile X intellectual disability syndrome. Rarely, mitochondrial (e.g. cerebellar ataxia, deafness and narcolepsy syndrome) and metabolic ataxias (e.g. hypobetalipoproteinemia, gamma-glutamyl cysteine synthetase deficiency) may also become symptomatic in individuals older than 25 years. In this way, it is very important to recognize that FRDA may express first symptoms in adult individuals older than 40 years.

## References

- Anheim M, Tranchant C, Koenig M (2012) The autosomal recessive cerebellar ataxias. *N Engl J Med* 366:636–646
- Bird TD (2016) Hereditary ataxia overview. 1998 Oct 28 [updated 2016 Mar 2016]. In: Pagon RA, Adam MP, Ardinger HH et al (eds) GeneReviews® [internet]. University of Washington, Seattle, pp 1993–2016. Available from: <http://www.ncbi.nlm.nih.gov/books/NBK1138/>
- Dürr A (2010) Autosomal dominant cerebellar ataxias: polyglutamine expansions and beyond. *Lancet Neurol* 9:885–894
- Dürr A, Cossée M, Agid Y et al (1997) Clinical and genetic abnormalities in patients with Friedreich's ataxia. *N Engl J Med* 335:1169–1175
- Fogel BL, Perlman S (2007) Clinical features and molecular genetics of autosomal recessive cerebellar ataxias. *Lancet Neurol* 6:245–257
- Harding AE (1983) Classification of the hereditary ataxias and paraplegias. *Lancet* 1:1151–1155
- Harding AE (1993) Clinical features and classification of inherited ataxias. *Adv Neurol* 61:1–14
- Klockgether T (2010) Sporadic ataxia with adult onset: classification and diagnostic criteria. *Lancet Neurol* 9:94–104
- Mancuso M, Orsucci D, Siciliano G, Bonuccelli U (2014) The genetics of ataxia: through the labyrinth of the Minotaur looking for Ariadne's thread. *J Neurol* 261(Suppl 2):S528–S541
- Palau F, Espinós C (2006) Autosomal recessive cerebellar ataxias. *Orphanet J Rare Dis* 1:47
- Palau F, Espinós C (2013) Approach to the differential diagnosis of cerebellar ataxias. In: Manto M, Gruol DL, Schamahmann JD, Koibuchi N, Rossi F (eds) *Handbook of the cerebellum and cerebellar disorders*. Springer + Business Media, Dordrecht, pp 1799–1817
- Vermeer S, van de Warrenburg BPC, Willemsen MAAP, Cluitmans M, Scheffer H, Kremer BP, Knoers NVAM (2011) Autosomal recessive cerebellar ataxias: the current state of affairs. *J Med Genet* 48:651–659

# Chapter 71

## Overview of Ataxias in Children

Andrea Poretti and Eugen Boltshauser

**Abstract** In children, ataxia may be caused by a wide number of hereditary or acquired diseases. The prevalence varies significantly in causes between pediatric and adult ataxia. Pediatric ataxia may be classified as acute, progressive, non-progressive, intermittent, and episodic. Cerebellar dysfunction is the leading cause of pediatric ataxia, while sensory (afferent) and vestibular ataxias are less common in children. A careful history and neurological examination are essential in classifying pediatric ataxia based on the course of symptoms and involved systems and narrowing the differential diagnosis. Neuroimaging plays a key role in the further work-up of pediatric ataxia and may be diagnostic or allow planning targeted further investigations.

**Keywords** Ataxia • Children • Cerebellum • Acute • Progressive • Non-progressive

Ataxia is a relatively common presentation in children and may have a genetic cause or be acquired. The duration and dynamic of symptoms vary greatly and allow the classification of ataxia as acute, non-progressive, progressive, episodic, or intermittent. Additionally, pediatric ataxia may be categorized by the affected system (e.g. cerebellum, sensory, vestibular) or etiology. In children, cerebellar dysfunctions cause the majority of ataxia cases (Boltshauser and Schmahmann 2012).

---

A. Poretti (✉)

Section of Pediatric Neuroradiology, Division of Pediatric Radiology, Russell H. Morgan Department of Radiology and Radiological Science, The Johns Hopkins University School of Medicine, Baltimore, MD, USA

Division of Pediatric Neurology, University Children's Hospital, Zurich, Switzerland  
e-mail: [aporett1@jhmi.edu](mailto:aporett1@jhmi.edu)

E. Boltshauser

Division of Pediatric Neurology, University Children's Hospital, Zurich, Switzerland  
e-mail: [eugen.boltshauser@kispi.uzh.ch](mailto:eugen.boltshauser@kispi.uzh.ch)

In this chapter, we provide some general information about the work-up and review the most common causes of pediatric ataxia. We classify pediatric ataxia according to duration and dynamic of symptoms and affected systems.

## 71.1 Diagnostic Work-Up

A careful history is essential. The age of onset and nature of symptoms (e.g. pure cerebellar, extra-cerebellar) suggest different etiologies. The temporal course of symptoms allows classifying ataxia as acute, non-progressive, progressive, episodic, or intermittent. History taking requires knowledge about the potential differential diagnoses.

The neurological examination should include cerebellar functions and other systems to reveal additional findings (ataxia plus). The neurological examination should be seen within the context of the age of the child. In young children, much of the neurological examination comes from observation. A brief general examination may provide systemic clues such as organomegaly or cardiac involvement.

Further investigations including neuroimaging, different laboratory assays, genetic analysis, electroencephalography, and nerve conduction study may be needed. Magnetic resonance imaging (MRI) plays a key role in the diagnostic work-up of ataxic children. MRI may provide the final diagnosis in cerebellar malformations or narrow significantly the differential diagnosis in neurometabolic disorders.

## 71.2 Acute Ataxia

In acute ataxia symptoms develop over a few hours or a few (1–2) days (Poretti et al. 2013). Acute post-infectious cerebellar ataxia (APCA) is the most common form. The onset of symptoms follows a (mostly viral) infection. APCA is a self-limiting, pure cerebellar dysfunction with an excellent prognosis without treatment. The diagnosis is made clinically and neuroimaging is not indicated.

Intoxication is the second most frequent cause and occurs most commonly in young children (accidental ingestion). Symptoms are accompanied by reduced level of consciousness of variable severity, seizures, and/or vomiting. Because a history of ingestion or exposure may not be given, a high index of suspicion is needed. Blood or urine “tox screen” may confirm the diagnosis.

Less common causes include cerebellitis, acute disseminated encephalomyelitis (ADEM), multiple sclerosis (MS), cerebellar stroke, and opsoclonus-myoclonus syndrome (OMS).

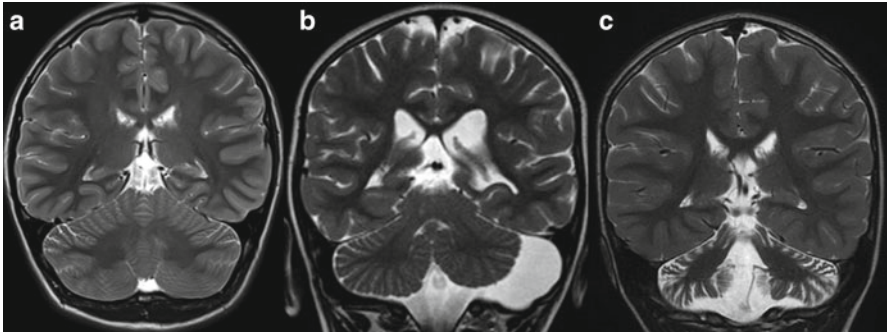
Acute pediatric ataxia may be caused by dysfunction of the vestibular and sensory systems. Vestibular migraine is the most common cause of acute vestibular ataxia, while acute unilateral vestibular dysfunction is rare. Acute sensory ataxia is the presenting symptom in about 15 % of children with Guillain-Barré syndrome.

### 71.3 Non-progressive Ataxia

Non-progressive ataxia refers to children with early (“congenital”) evidence of ataxia without progression on follow-up (Table 71.1). First obvious features of ataxia are preceded by hypotonia and delayed motor (and often language) milestones. Ataxia is thus not “congenital” in the strict sense. Non-progressive cerebellar ataxia (NPCA) may result from inherited (genetic) and prenatal or neonatal acquired (disruptive) causes. A *Malformation* is a morphologic anomaly due to an alteration of the primary developmental program caused by a genetic defect. Gene mutations causing malformations may be “de novo” or be inherited following different patterns that imply a different recurrence risk for further offspring. A

**Table 71.1** Differential diagnosis of non-progressive cerebellar ataxia

Disease	
NPCA outside a defined syndrome	Autosomal recessive inheritance (examples of genes: <i>VLDLR</i> , <i>CA8</i> , <i>ZNF592</i> , <i>KCNJ10</i> , <i>NEUROD1</i> , <i>KIAA0226</i> , <i>WDR81</i> , <i>ATP8A2</i> , <i>WWOX</i> ); several families with pedigree compatible with autosomal recessive inheritance and unknown gene
	Autosomal dominant inheritance (examples of genes: <i>ITPR1</i> , <i>CAMTA1</i> , <i>KCNC3</i> , <i>CACNA1A</i> )
	X-linked (examples of genes: <i>ATPB3</i> , <i>ABCB7</i> )
Cerebellar malformations	Dandy-Walker malformation
	Joubert syndrome
	Rhombencephalosynapsis
	Cerebellar hypoplasia
Congenital ocular motor apraxia type Cogan	
Cerebellar disruptions	Unilateral cerebellar hypoplasia
	Extreme prematurity
Metabolic disorders mimicking NPCA at onset	L-2-Hydroxyglutaric aciduria
	Glutaric aciduria type 1
	Congenital disorders of glycosylation Ia
	Pyruvate dehydrogenase deficiency
Infantile onset progressive ataxias that may mimic NPCA at onset	Glucose transporter type 1 (GLUT1) deficiency
	Ataxia teleangiectasia
	Infantile-onset spinocerebellar ataxia
	Mitochondrial disorders
White matter disorders that may mimic NPCA at onset	Marinesco-Sjögren syndrome
	Vanishing white matter disease (early childhood-onset form)
	Hypomyelination and congenital cataract
Syndromes that may mimic NPCA at onset	4H syndrome
	Rett syndrome
Benign hereditary chorea ( <i>NKX2-1</i> gene)	Angelman syndrome
	Midline tumors in the posterior fossa



**Fig. 71.1** Coronal T2-weighted images in three children with non-progressive cerebellar ataxia (NPCA) show normal cerebellar findings in (a), cerebellar hypoplasia involving mostly the left hemisphere in (b), and enlarged interfolial spaces remembering cerebellar atrophy, but static course in (c)

*Disruption* is a morphologic anomaly due to the breakdown of a body structure that had a normal developmental potential. Disruptive causes include e.g. prenatal infection and hemorrhage.

NPCA may be caused by well-defined cerebellar malformations such as Dandy-Walker malformation (DWM) and Joubert syndrome (JS). DWM is defined by (1) hypoplasia of the vermis, which is elevated and upwardly rotated and (2) dilatation of the cystic-appearing fourth ventricle. The majority of patients present before 1 year of age with hydrocephalus. Ataxia is present in about one half of the patients. Terms such as “Dandy-Walker variant” have been introduced to classify malformations that do not fulfill the DWM criteria. These terms lack specificity, are highly confusing, and should be avoided.

JS is defined by the presence of the “molar tooth sign”, which is characterized by elongated, thickened and horizontally orientated superior cerebellar peduncles, a deep interpeduncular fossa, and vermian hypoplasia and dysplasia. Children with JS present with hypotonia, ataxia, ocular motor apraxia, neonatal breathing dysregulation, and intellectual disability. Systemic involvement (renal, eye, liver, and skeleton) may be present. More than 30 genes coding for proteins of the primary cilia have been associated with JS.

NPCA may occur outside a well-defined cerebellar malformation. An increasing number of genes have been associated with NPCA such as *CA8*, *ATP8A2*, *WDR81*, and *ZNF592* (Poretti et al. 2014). Recessive inheritance is the most common. Ataxia presents in the second year of age. Intellectual disability is common and is the most limiting factor in older children. Neuroimaging findings are variable and range between normal, small cerebellum with widened interfolial spaces (remembering cerebellar atrophy, but static on follow-up), and classic cerebellar hypoplasia (Fig. 71.1).

The long and complex development place the immature cerebellum at high risk for acquired injury such as prenatal hemorrhages or infections. NPCA is a feature of some forms of cerebellar disruptions including unilateral cerebellar hypoplasia,

unilateral cerebellar cleft, and disruption of cerebellar development in preterm infants (Poretti et al. 2009). Recognition of disruptions and their differentiation from malformations is important for prognosis and genetic counseling.

Hereditary sensory neuropathy may mimic NPCA. If areflexia is present, nerve conduction studies are recommended.

## 71.4 Progressive Ataxia

Progressive ataxia implies progressive cerebellar dysfunction and may result from “intrinsic” (genetic and metabolic) and “extrinsic” (acquired) causes (Table 71.2). The list of pediatric diseases that may present with progressive ataxia is very long and the progresses of genetic analysis led to the delineation of several new entities in the last years (Anheim et al. 2012). Friedreich ataxia and ataxia teleangiectasia are the most common progressive ataxias in children. Other relatively common diseases are ataxia-ocular apraxia type 1 and 2, late-onset GM2 gangliosidosis, neuronal ceroid lipofuscinoses, Niemann-Pick disease type C, autosomal recessive spastic ataxia of Charlevoix-Saguenay, some leukodystrophies (e.g. metachromatic leukodystrophy, vanishing white matter disease, and 4H syndrome), and some mitochondrial encephalopathies (e.g. *POLG1* related disorders and Kearns Sayre disease). Dominantly inherited spinocerebellar ataxias (SCA) are rare in children. The prevalence of the single disorders differs in various ethnic groups. The context of history and findings, particularly “ataxia plus” symptoms (e.g. spasticity and polyneuropathy) often allow targeted diagnostic investigations. However, despite extensive work-up the final diagnosis remains unknown in considerable proportion (about 50%) of progressive ataxias. It is particularly important not to miss the rare treatable causes including Refsum disease, vitamin E deficiency, abetalipoproteinemia, and coenzyme Q10 deficiency.

Cerebellar atrophy (CA) is a common, but non-specific finding in several progressive ataxias and implies loss of cerebellar parenchyma with secondary enlargement of the interfolial spaces (Fig. 71.2) (Poretti et al. 2008). In the evaluation of neuroimaging data, a pattern-recognition approach considering isolated CA versus CA associated with other neuroimaging findings (e.g. hypomyelination or basal ganglia involvement) is helpful to narrow the differential diagnosis, plan further appropriate investigations, and interpret their results. Progressive ataxia, however, is not synonymous with CA. In some disorders with progressive ataxia such as Friedreich ataxia, Refsum disease, vitamin E deficiency and abetalipoproteinemia there is no evidence of CA.

Cerebellar tumors account for 45–60% of all pediatric brain tumors (Poretti et al. 2012). Ataxia is a common symptom and evolves typically over several days to weeks (subacute course). Accordingly, we included cerebellar neoplasms into progressive, not acute ataxia. Depending on the tumor location, symptoms of increased intracranial pressure are usually associated. Pilocytic astrocytoma,

**Table 71.2** Differential diagnosis of pediatric progressive ataxia

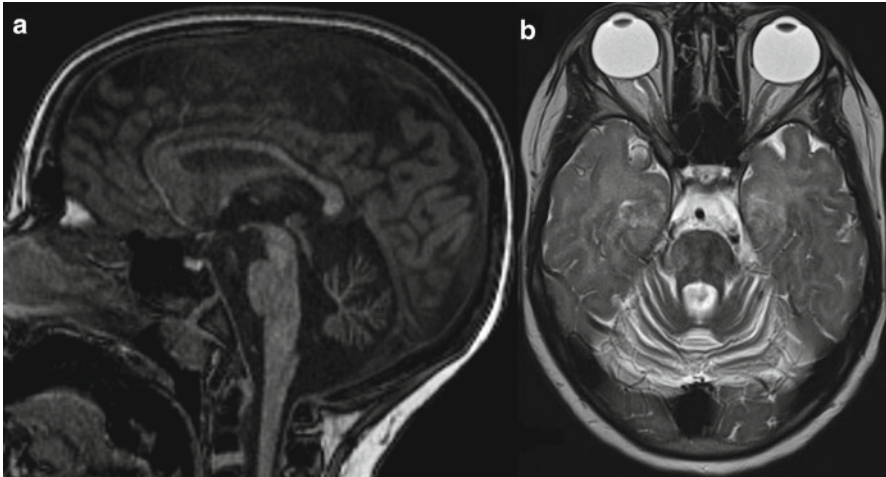
Disease	
Sphingolipidoses	Late-onset GM2 gangliosidosis
	Niemann Pick disease type C
	Late-infantile metachromatic leukodystrophy <sup>a</sup>
	Krabbe disease (late infantile and juvenile) <sup>a</sup>
Neuronal ceroid lipofuscinosis (late infantile and juvenile forms)	
Giant axonal neuropathy <sup>a</sup>	
Abnormalities of DNA repair	Ataxia teleangiectasia
	Cockayne syndrome type 1
Mitochondrial	Kearns-Sayre syndrome
	Myoclonic epilepsy with ragged red fibres (MERRF)
	Neurogenic muscle weakness, ataxia, and retinitis pigmentosa (NARP)
	Coenzyme Q10 deficiency
Peroxisomal	Adrenoleukodystrophy
	Refsum disease
Other metabolic	Abetalipoproteinemia
	Vitamin E deficiency
	Cerebrotendinous xanthomatosis
	Mevalonic aciduria
	L-2-hydroxyglutaric aciduria
Hypomyelinating disorders and leukodystrophies	Pelizaeus-Merzbacher disease
	Vanishing white matter disease
	Megalencephalic leukoencephalopathy with subcortical cysts
	Salla disease
	4H syndrome
	Hypomyelination and congenital cataract
Spinocerebellar degenerations	Friedreich ataxia
	Ataxia-oculomotor apraxia type 1 (AOA1)
	Ataxia-oculomotor apraxia type 2 (AOA2)
	Spinocerebellar ataxias, particularly type 7
Midline tumours in the posterior fossa	

<sup>a</sup>Ataxia is not the leading sign

medulloblastoma, and ependymoma are the most common pediatric posterior fossa tumors. The management and outcome depend on the tumor type and grade.

Charcot-Marie-Tooth disease, a heterogeneous group of hereditary motor and sensory neuropathies, may present with progressive sensory ataxia. Progressive vestibular ataxias (e.g. Menière disease) are exceptionally rare in children.





**Fig. 71.2** 8.5-year-old girl with progressive ataxia caused by 4H syndrome and *POLR3A* mutation. (a) Midsagittal T1- and (b) axial T2-weighted images show enlarged fissures (interfolial spaces) within the cerebellar vermis and hemispheres representing cerebellar atrophy. In addition, the white matter shows a T2-hyperintense signal representing hypomyelination

### 71.5 Intermittent Ataxia

Intermittent ataxia refers to recurrent ataxic events in patients who are symptom-free in the interval. At the first attack, intermittent ataxia resembles acute ataxia. Intoxications, metabolic, inflammatory (MS or multiphasic ADEM), or paraneoplastic (relapsing OMS) disorders may feature intermittent ataxia. Metabolic disorders that may present with intermittent ataxia include maple syrup urine disease, pyruvate dehydrogenase deficiency, Glut1-deficiency, urea cycle disorders, methylmalonic acidemia, and propionic acidemia.

### 71.6 Episodic Ataxia

Episodic ataxia (EA) refers to dominantly inherited channelopathies characterized by intermittent episodes of cerebellar dysfunction with or without interictal neurologic dysfunction. The first episode may mimic acute ataxia. Seven different types have been reported (Jen et al. 2007). EA1 and EA2 are relevant in pediatric ataxology.

## References

- Anheim M, Tranchant C, Koenig M (2012) The autosomal recessive cerebellar ataxias. *N Engl J Med* 366(7):636–646
- Boltshauser E, Schmähmann JD (2012) *Cerebellar disorders in children*. Mac Keith Press, London
- Jen JC, Graves TD, Hess EJ et al (2007) Primary episodic ataxias: diagnosis, pathogenesis and treatment. *Brain* 130(Pt 10):2484–2493
- Poretti A, Wolf NI, Boltshauser E (2008) Differential diagnosis of cerebellar atrophy in childhood. *Eur J Paediatr Neurol* 12(3):155–167
- Poretti A, Prayer D, Boltshauser E (2009) Morphological spectrum of prenatal cerebellar disruptions. *Eur J Paediatr Neurol* 13(5):397–407
- Poretti A, Meoded A, Huisman TA (2012) Neuroimaging of pediatric posterior fossa tumors including review of the literature. *J Magn Reson Imaging* 35(1):32–47
- Poretti A, Benson JE, Huisman TA et al (2013) Acute ataxia in children: approach to clinical presentation and role of additional investigations. *Neuropediatrics* 44(3):127–141
- Poretti A, Boltshauser E, Doherty D (2014) Cerebellar hypoplasia: differential diagnosis and diagnostic approach. *Am J Med Genet C: Semin Med Genet* 166(2):211–226

# Chapter 72

## Cerebellar Pathology in Autism

S. Hossein Fatemi

**Abstract** Autism is a severe brain disorder with a rising prevalence rate. Both genetic and environmental etiologies contribute to the development of this disorder. While autistic pathology involves multiple brain sites, the focus in this chapter will be on summarizing cerebellar pathology in autism.

**Keywords** Cerebellum • Autism • GABA • FMRP • mGluR5

Autism is a severe neurodevelopmental disorder which is characterized by deficits in communication, cognition and behavior (American Psychiatric Association 2013). Both genetic and environmental etiologies contribute to development of autism (Meek et al. 2013). As the prevalence rate for autism is rising steadily (CDC 2014), numerous environmental causes have been proposed recently (Gregory et al. 2013; Lyall et al. 2014; Rossignol et al. 2014). Additionally, genetic data point to a large number of genes and chromosomal loci in causation of autism (Devlin and Scherer 2012; Ronemus et al. 2014; Rosti et al. 2014). Autism is a heterogeneous disorder which is often comorbid with a number of other disorders including fragile X syndrome (Hagerman et al. 2005), seizure disorder (Tuchman and Rapin 2002), tuberous sclerosis (Wiznitzer 2004), and Down Syndrome (Starr et al. 2005). Brain structural abnormalities have been identified in several areas including prefrontal cortex, parietal cortex, amygdala, hippocampus and cerebellum (Bauman and Kemper 2005; Nickl-Jockschat et al. 2012; Travers et al. 2012). This chapter will focus on some of the brain structural and biochemical abnormalities of cerebellum in subjects with autism.

There is increasing evidence that cerebellar function is not restricted to motor control but extends to many higher function tasks including working memory, executive function and language (Stoodley and Schmahmann 2009). Thus, involvement of cerebellum with cognitive tasks may be a reflection of its extensive connections

---

S.H. Fatemi (✉)

Departments of Psychiatry and Neuroscience, University of Minnesota Medical School,  
420 Delaware St SE, MMC 392, Minneapolis, MN 55455, USA  
e-mail: [fatem002@umn.edu](mailto:fatem002@umn.edu)

to frontal cortex via the cerebello-thalamo-cortical and cortico-ponto-cerebellar loops (Schmahmann and Pandya 1989; Kelly and Strick 2003).

Several structural studies have demonstrated significant reductions in gray matter volume in the cerebella of individuals with autism (McAlonan et al. 2005; Rojas et al. 2006; Toal et al. 2009). Purkinje cell (PC) loss has been reported to occur in subjects with autism (Palmen et al. 2004; Wegiel et al. 2014). Wegiel et al. (2014) described decreases in total number and density of PC by 25 % and 24 % in autistic individuals, respectively. However, other studies have failed to report any differences in PC density in subjects with autism (Fatemi et al. 2002a; Whitney et al. 2008). Fatemi et al. (2002a) reported on a reduction in cross-sectional area of PC's in subjects with autism suggesting atrophy of these cells in these subjects. There is evidence that connectivity between the cerebellum and other brain regions in subjects with autism is also impaired. Sivaswamy et al. (2010) have shown abnormal microstructural connections between cerebellum and frontal cortex in subjects with autism. A recent proteomic analysis of post-mortem brain demonstrated significant alterations in several markers of myelination and synaptic vesicle release and astrocyte maturation in cerebella of autistic individuals confirming the previous brain structural abnormalities (Broek et al. 2014) indicative of disconnectivity between cerebellum and frontal cortex in autism.

An important inhibitory neurotransmitter in the brain is gamma-aminobutyric acid (GABA). Fatemi and colleagues have studied the expression of GABA receptors (Fatemi et al. 2009a, b, 2010, 2014) as well as GABAergic molecules Reelin and glutamic acid decarboxylases (GADs) in postmortem brains of subjects with autism (Fatemi et al. 2001, 2002b, 2005). Significant global downregulation of many GABA receptors were observed in several brain areas including cerebellum in autism. As seen in Table 72.1, protein expression abnormalities for GABA receptor subunits  $\alpha_1$ ,  $\beta_3$ , and GABA<sub>B</sub> receptors R1 and R2 and GAD 65 kDa protein were observed in subjects with autism (Fatemi et al. 2002b, 2009a, b, 2010, 2014). Additionally, Blatt and colleagues reported on reductions in mRNA for GAD65 in subpopulations of cells in cerebellar dentate nuclei as well as mRNA reductions for GAD67 in PC of subjects with autism (Yip et al. 2007, 2009).

Expression of Reelin, an important glycoprotein involved in neuronal migration and synaptic plasticity was reduced in cerebellum of subjects with autism (Fatemi et al. 2005). Interestingly, mRNA for very low-density lipoprotein receptor (VLDLR), one of several receptors for Reelin was significantly upregulated in the cerebellum of subjects with autism (Fatemi et al. 2005, Table 72.1). Additionally, mRNA for disabled 1 (DAB1) a downstream signaling partner for Reelin was reduced significantly in cerebellum of subjects with autism providing further evidence of Reelin signaling dysfunction in autism (Fatemi et al. 2005, Table 72.1).

In a similar vein, several reports have provided data showing abnormalities in other markers of brain plasticity [fragile X mental retardation protein (FMRP), metabotropic glutamate receptor 5 (mGluR5) and downstream cognates ras-related C3 botulinum toxin substrate 1 (RAC1), amyloid beta A4 precursor protein (APP), striatal-enriched protein tyrosine phosphatase (STEP), and homer 1], apoptosis [B-cell CLL/lymphoma 2 (Bcl-2), p53], and inflammation [Glial fibrillary acidic

**Table 72.1** Changes in selected proteins in cerebellum of subjects with autism

Protein	Change	Reference
GABR $\alpha$ 1	↓	Fatemi et al. (2009a)
GABR $\beta$ 3	↓	Fatemi et al. (2009a)
GABRR1	↓	Fatemi et al. (2009b)
GABRR2	↓	Fatemi et al. (2009b)
GAD65	↓	Fatemi et al. (2002b)
Reelin (410 kDa and 180 kDa)	↓	Fatemi et al. (2001, 2005)
VLDLR (mRNA)	↑	Fatemi et al. (2005)
DAB1 (mRNA)	↓	Fatemi et al. (2005)
FMRP	↓	Fatemi et al. (2011)
mGluR5	↑	Fatemi et al. (2011)
RAC1	↑	Fatemi et al. (2013)
APP 120 kDa	↓	Fatemi et al. (2013)
STEP (66 kDa and 27 kDa)	↓	Fatemi et al. (2013)
Homer 1	↓	Fatemi et al. (2013)
GFAP	↑	Fatemi et al. (2011), Laurence and Fatemi (2005)
BCL-2	↓	Araghi-Niknam and Fatemi (2003), Fatemi et al. (2001)
P53	↑	Araghi-Niknam and Fatemi (2003)

↑, increase; ↓, decrease

protein (GFAP)] (Table 72.1) in cerebellum of subjects with autism, demonstrating a large array of molecular abnormalities in this important brain site in autism (Araghi-Niknam and Fatemi 2003; Fatemi et al. 2001, 2011, 2013; Laurence and Fatemi 2005).

In conclusion, cerebellum is the site of extensive pathology (Fatemi et al. 2012) in autism spectrum disorders including abnormalities in cerebellar structural brain connections to other brain sites as well as in various proteins and neurotransmitters affecting multiple functional domains. Further studies should extend and confirm these findings and provide appropriate treatments based on cerebellar abnormalities relevant to autistic pathology.

**Acknowledgments** Grant support from NICHD (5R01HD052074-05 and 3R01HD052074-03S1), the Bernstein Endowed Chair in Adult Psychiatry, the Ewald Bipolar Disease Research and the Winston and Maxine Wallin Neuroscience Discovery funds to SHF is gratefully acknowledged.

## References

American Psychiatric Association (2013) Diagnostic and statistical manual of mental disorders, 5th edn. American Psychiatric Publishing, Washington, DC

- Araghi-Niknam M, Fatemi SH (2003) Levels of Bcl-2 and P53 are altered in superior frontal and cerebellar cortices in autistic subjects. *Cell Mol Neurobiol* 23:945–952
- Bauman ML, Kemper TL (2005) Structural brain anatomy in autism: what is the evidence? In: Bauman ML, Kemper TL (eds) *The neurobiology of autism*, 2nd edn. Johns Hopkins University Press, Baltimore, pp 121–135
- Broek JA, Guest PC, Rahmoune H, Bahn S (2014) Proteomic analysis of post mortem brain tissue from autism patients: evidence for opposite changes in prefrontal cortex and cerebellum in synaptic connectivity-related proteins. *Mol Autism* 5:41
- Centers for Disease Control and Prevention (CDC) (2014) Prevalence of autism spectrum disorder among children aged 8 years – autism and developmental disabilities monitoring network, 11 sites, United States. *MMWR Surveill Summ* 63:1–21
- Devlin B, Scherer SW (2012) Genetic architecture in autism spectrum disorder. *Curr Opin Genet Dev* 22:229–237
- Fatemi SH, Stary JM, Halt AR, Realmuto G (2001) Dysregulation of Reelin and Bcl-2 proteins in autistic cerebellum. *J Autism Dev Disord* 6:529–535
- Fatemi SH, Halt AR, Realmuto G, Earle J, Kist DA, Thuras P, Merz A (2002a) Purkinje cell size is reduced in cerebellum of patients with autism. *Cell Mol Neurobiol* 22:171–175
- Fatemi SH, Halt AR, Stary JM, Kanodia R, Schulz SC, Realmuto GR (2002b) Glutamic acid decarboxylase 65 and 67 kDa proteins are reduced in autistic parietal and cerebellar cortices. *Biol Psychiatry* 52:805–810
- Fatemi SH, Snow AV, Stary JM, Araghi-Niknam M, Reutiman TJ, Lee S, Brooks AI, Pearce DA (2005) Reelin signaling is impaired in autism. *Biol Psychiatry* 57:777–787
- Fatemi SH, Reutiman TJ, Folsom TD, Thuras PD (2009a) GABA(A) receptor downregulation in brains of subjects with autism. *J Autism Dev Disord* 39:223–230
- Fatemi SH, Folsom TD, Reutiman TJ, Thuras PD (2009b) Expression of GABA(B) receptors is altered in brains of Subjects with autism. *Cerebellum* 8:64–69
- Fatemi SH, Reutiman TJ, Folsom TD, Rooney RJ, Patel DH, Thuras PD (2010) mRNA and protein levels for GABA(A) alpha 4, alpha 5, beta 1, and GABA(B)R1 receptors are altered in brains from subjects with autism. *J Autism Dev Disord* 40:743–750
- Fatemi SH, Folsom TD, Kneeland RE, Liesch SB (2011) Metabotropic glutamate receptor 5 upregulation in children with autism is associated with underexpression of both Fragile X mental retardation protein and GABAA receptor beta 3 in adults with autism. *Anat Rec* 294:1635–1645
- Fatemi SH, Aldinger KA, Ashwood P, Bauman ML, Blaha CD, Blatt GJ, Chauhan A, Chauhan V, Dager SR, Dickson PE, Estes AM, Goldowitz D, Heck DH, Kemper TL, King BH, Martin LA, Millen KJ, Mittleman G, Mosconi MW, Persico AM, Sweeney JA, Webb SJ, Welsh JP (2012) Consensus paper: pathological role of the cerebellum in autism. *Cerebellum* 11:777–807
- Fatemi SH, Folsom TD, Kneeland RE, Yousefi M, Liesch S, Thuras PD (2013) Impairment of fragile X mental retardation protein-metabotropic glutamate receptor 5 signaling and its downstream cognates ras-related C3 botulinum toxin substrate 1, amyloid beta A4 precursor protein, striatal-enriched protein tyrosine phosphatase, and homer 1, in autism: a postmortem study in cerebellar vermis and superior frontal cortex. *Mol Autism* 4:21
- Fatemi SH, Reutiman TJ, Folsom TD, Rustan OG, Rooney RJ, Thuras PD (2014) Downregulation of GABA<sub>A</sub> receptor protein subunits  $\alpha 6$ ,  $\beta 2$ ,  $\epsilon$ ,  $\gamma 2$ , and  $\rho 2$  in superior frontal cortex of subjects with autism. *J Autism Dev Disord* 44:1833–1845
- Gregory SG, Anthonopolos R, Osgood CE, Grotgut CA, Miranda ML (2013) Association of autism with induced or augmented childbirth in North Carolina Birth Record (1990–1998) and Education Research (1997–2007) databases. *JAMA Pediatr* 167:959–966
- Hagerman RJ, Ono MY, Hagerman PJ (2005) Recent advances in fragile X: a model for autism and neurodegeneration. *Curr Opin Psychiatry* 18:490–496
- Kelly RM, Strick PL (2003) Cerebellar loops with motor cortex and prefrontal cortex of a nonhuman primate. *J Neurosci* 23:8432–8444

- Laurence JA, Fatemi SH (2005) Glial fibrillary acidic protein is elevated in superior frontal, parietal, and cerebellar cortices of autistic subjects. *Cerebellum* 4:206–210
- Lyall K, Schmidt RJ, Hertz-Picciotto I (2014) Maternal lifestyle and environmental risk factors for autism spectrum disorders. *Int J Epidemiol* 43:443–464
- McAlonan GM, Cheung V, Cheung C, Suckling J, Lam GY, Tai KS, Yip L, Murphy DG, Chua SE (2005) Mapping the brain in autism. A voxel-based MRI study of volumetric differences and intercorrelations in autism. *Brain* 128:268–276
- Meek SE, Lemery-Chalfant K, Jahromi LB, Valiente C (2013) A review of gene-environment correlations and their implications for autism: a conceptual model. *Psychol Rev* 120:497–521
- Nickl-Jockschat T, Habel U, Michel TM, Manning J, Laird AR, Fox PT, Schneider F, Eickhoff SB (2012) Brain structure anomalies in autism spectrum disorder – a meta-analysis of VBM studies using anatomic likelihood estimation. *Hum Brain Mapp* 33:1470–1489
- Palmen SJ, van England H, Hof PR, Schmitz C (2004) Neuropathological findings in autism. *Brain* 127:2572–2583
- Rojas DC, Peterson E, Winterrowd E, Reite ML, Rogers SJ, Tregellas JR (2006) Regional gray matter volumetric changes in autism associated with social and repetitive behavior symptoms. *BMC Psychiatry* 6:56
- Ronemus M, Iossifov I, Levy D, Wigler M (2014) The role of de novo mutations in the genetics of autism spectrum disorders. *Nat Rev Genet* 15:133–141
- Rossignol DA, Genus SJ, Frye RE (2014) Environmental toxicants and autism spectrum disorders: a systematic review. *Trans Psychiatry* 4:e360
- Rosti RO, Sadek AA, Vaux KK, Gleeson JG (2014) The genetic landscape of autism spectrum disorders. *Dev Med Child Neurol* 56:12–18
- Schmahmann JD, Pandya DN (1989) Anatomical investigation of projections to the basis points from posterior parietal association cortices in rhesus monkey. *J Comp Neurol* 289:53–73
- Sivaswamy L, Kumar A, Rajan D, Behen M, Muzik O, Chugani D, Chugani H (2010) A diffusion tensor imaging study of the cerebellar pathways in children with autism spectrum disorder. *J Child Neurol* 25:1223–1231
- Starr EM, Berument SK, Tomlins M, Papanikolaou K, Rutter M (2005) Brief report: autism in individuals with down syndrome. *J Autism Dev Disord* 35:665–673
- Stoodley CJ, Schmahmann JD (2009) Functional topography in the human cerebellum: a meta-analysis of neuroimaging studies. *Neuroimage* 44:489–501
- Toal F, Daly EM, Page L, Deeley Q, Hallahan B, Bloemen O, Cutter WJ, Brammer MJ, Curran S, Robertson D, Murphy C, Murphy KC, Murphy DG (2009) Clinical and anatomical heterogeneity in autistic spectrum disorder: a structural MRI study. *Psychol Med* 40:1171–1181
- Travers BG, Adluru N, Ennis C, Tromp do PM, Destiche D, Doran S, Bigler ED, Lange N, Lainhart JE, Alexander AL (2012) Diffusion tensor imaging in autism spectrum disorder: a review. *Autism Res* 5:289–313
- Tuchman R, Rapin I (2002) Epilepsy in autism. *Lancet Neurol* 1:352–358
- Wegiel J, Flory M, Kuchna I, Nowicki K, Ma S, Imaki H, Wegiel J, Cohen IL, London E, Wisniewski T, Brown W (2014) Stereological study of the neuronal number and volume of 38 brain subdivisions of subjects diagnosed with autism reveals significant alterations restricted to the striatum, amygdala and cerebellum. *Acta Neuropathol Comm* 2:141
- Whitney ER, Kemper TL, Bauman ML, Rosene DL, Blatt GJ (2008) Cerebellar Purkinje cells are reduced in a subpopulation of autistic brains: a stereological experiment using calbindin-D28k. *Cerebellum* 7:406–416
- Wiznitzer M (2004) Autism and tuberous sclerosis. *J Child Neurol* 19:675–679
- Yip J, Soghomonian JJ, Blatt GJ (2007) Decreased GAD67 mRNA levels in cerebellar Purkinje cells in autism: pathophysiological implications. *Acta Neuropathol* 113:559–568
- Yip J, Soghomonian JJ, Blatt GJ (2009) Decreased GAD65 mRNA levels in select subpopulations in the cerebellar dentate nuclei in autism: an in situ hybridization study. *Autism Res* 2:50–59

# Chapter 73

## Autosomal Recessive Ataxias

Marie Beaudin and Nicolas Dupré

**Abstract** Since the description of Friedreich ataxia more than 140 years ago, the phenotypic description of the autosomal recessive cerebellar ataxias has been a perpetually evolving field. These disorders classically present with a varying combination of gait disturbance, truncal and appendicular ataxia, dysarthria, eye movement abnormalities, sensorimotor neuropathy, pyramidal and extra-pyramidal tracts involvement, and other systemic manifestations. The progress of genetics has recently allowed a more accurate diagnostic work-up, which brought to light the great phenotypical heterogeneity of the genetically defined disease entities. We review here the clinical, genetic and molecular features of the most frequent and best-defined autosomal recessive ataxias: Friedreich ataxia, autosomal recessive spastic ataxia of Charlevoix-Saguenay, ataxia-telangiectasia, ataxia-telangiectasia-like disorder, autosomal recessive cerebellar ataxia types 1 and 2, ataxia with oculomotor apraxia types 1 and 2, ataxia with vitamin E deficiency, and abetalipoproteinemia. Emphasis will be placed on the key clinical features that enable discrimination between these complex diseases.

**Keywords** Hereditary ataxias • Cerebellar ataxias • Autosomal recessive • Friedreich ataxia • Ataxia-telangiectasia

### 73.1 Introduction

Autosomal recessive cerebellar ataxias (ARCAs) form a very heterogeneous group that has grown considerably in the last decades with the identification of many causative mutations in various disease-associated genes (Table 73.1). Some of these disorders are restricted to isolated populations or small geographic areas whereas

---

M. Beaudin (✉) • N. Dupré  
Faculty of Medicine, Laval University, CHU de Québec, 1401 18th street,  
Québec City, QC G1J 1Z4, Canada  
e-mail: [marie.beaudin.1@ulaval.ca](mailto:marie.beaudin.1@ulaval.ca); [nicolas.dupre.cha@sss.gouv.qc.ca](mailto:nicolas.dupre.cha@sss.gouv.qc.ca)



**Table 73.1** Autosomal recessive cerebellar ataxias

Disorder	Gene	Protein	Discriminating features
Ataxias with pure sensory neuropathy			
FRDA	<i>FXN</i>	Frataxin	Bilateral Babinski sign, square-wave jerks, scoliosis, hypertrophic cardiomyopathy, absence of cerebellar atrophy on MRI
AVED	<i>TTPA</i>	$\alpha$ -tocopherol transfer protein	Retinitis pigmentosa, head titubation, decreased vitamin E level
ABL	<i>MTTP</i>	Microsomal triglyceride transfer protein	Fat malabsorption symptoms, hypocholesterolemia, hypotriglyceridemia, acanthocytosis
SANDO	<i>POLG1</i>	Polymerase $\gamma$	Ophthalmoparesis, myoclonus
MIRAS	<i>POLG1</i>	Polymerase $\gamma$	Epilepsy, cognitive impairment, psychiatric symptoms
IOSCA	<i>C10orf2</i>	Twinkle	Athetosis, epilepsy, optic atrophy, hearing loss, hypogonadism
Ataxias with sensorimotor neuropathy			
A-T	<i>ATM</i>	Serine-threonine kinase	Telangiectasias, oculomotor apraxia, photosensitivity, predisposition for infections and cancer, elevation of $\alpha$ -foetoprotein
A-TLD	<i>MRE11</i>	Meiotic recombination 11	Oculomotor apraxia
AOA1	<i>APTX</i>	Aprataxin	Oculomotor apraxia, cognitive impairment, hypoalbuminemia, hypercholesterolemia
AOA2	<i>SETX</i>	Senataxin	Chorea, dystonia, elevation of $\alpha$ -foetoprotein
ARSACS	<i>SACS</i>	Sacsin	Spastic paraparesis, retinal striation
SCAN1	<i>TDP1</i>	Tyrosyl-DNA phosphodiesterase-1	Distal amyotrophy, pes cavus
Ataxias without neuropathy			
ARCA1	<i>SYNE1</i>	Synaptic nuclear envelope-1	Pure cerebellar ataxia
ARCA2	<i>ADCK3 (CABC1)</i>	Aarf-domain containing kinase 3	Exercise intolerance, mental retardation, epilepsy, myoclonus
ARCA3	<i>ANO10</i>	Anoctamin 10	Cognitive impairment
MSS	<i>SIL1</i>	Nucleotide exchange factor SIL1	Cataracts, mental retardation, myopathy, short stature
CA	<i>ATCAY</i>	Caytaxin	Psychomotor retardation

Most metabolic disorders that have ataxia as an associated feature are excluded *ABL* abetalipoproteinemia, *AOA1* ataxia with oculomotor apraxia type 1, *AOA2* ataxia with oculomotor apraxia type 2, *ARCA1* autosomal recessive cerebellar ataxia 1, *ARCA2* autosomal recessive cerebellar ataxia 2, *ARCA3* autosomal recessive cerebellar ataxia 3, *ARSACS* autosomal recessive spastic ataxia of Charlevoix-Saguenay, *A-T* ataxia-telangiectasia, *A-TLD* ataxia-telangiectasia-like disorder, *AVED* ataxia with vitamin E deficiency, *CA* Cayman ataxia, *FRDA* Friedreich ataxia, *MIRAS* mitochondrial recessive ataxia syndrome, *MSS* Marinesco-Sjogren syndrome, *SANDO* sensory ataxic neuropathy with dysarthria and ophthalmoparesis, *SCAN1* spinocerebellar ataxia with axonal neuropathy 1

others are found worldwide, and the relative frequency of each subtype varies greatly depending on the geographical and ethnical setting. Nevertheless, recessive ataxias remain rare diseases with a pooled prevalence estimate of 3,3/100,000 population, with Friedreich ataxia representing the most common type worldwide (Ruano et al. 2014). Although the preferred classification of ARCAs since the multiplication of the phenotypes, the molecular pathogenetic classification has recently outlived its usefulness with the description of new diseases whose unique molecular pathways do not fit within any of the previously defined categories (e.g. ARCA-1 and ARCA-3). Thus, physicians have turned towards a more practical clinical-electrophysiological classification that divides ARCAs according to the presence of associated sensory and/or motor neuropathy (Anheim et al. 2012).

### 73.2 Cerebellar Ataxias with Pure Sensory Neuropathy

**Friedreich Ataxia (FRDA)** is the most common of the recessive cerebellar ataxias, and it is almost exclusively restricted to individuals of European, North African, Middle Eastern or Indian origin. Age at onset is in average 15 years, although the range is very large with some patients presenting as early as age 2 while others with late-onset FRDA present in their 40s or 50s. The early clinical picture is that of a cerebellar syndrome consisting of truncal and limb ataxia with absent tendon reflexes in the lower limbs. Dorsal column neuropathy with loss of joint position and vibration sense is a quasi-universal feature in FRDA, but it might not be present initially. Pyramidal weakness and wasting, especially of the lower limbs, as well as extensor plantar reflexes and dysarthria, are also frequently observed. Scoliosis and hypertrophic cardiomyopathy are present in a majority of cases and can occasionally precede neurological symptoms (Noreau et al. 2013). Other associated features that are less frequent include type II diabetes, hearing loss, pes cavus, and eye movement abnormalities such as square-wave jerks and nystagmus. Disease progression is relentless, with patients becoming wheelchair-bound in average 15 years after disease onset (Anheim et al. 2012). Premature death typically occurs when patients reach their 40s, mainly from cardiac complications.

The disorder is caused by an unstable GAA triplet repeat expansion in the first intron of the *FXN* gene, situated on chromosome 9q13, which encodes the highly conserved 220-amino-acid mitochondrial protein frataxin. This repeat expansion creates a different conformation called *triplex* or *sticky DNA*, which interferes with transcription, thereby reducing gene expression and protein concentration. Frataxin's deficiency causes disruption of iron-sulfur cluster enzymes, mitochondrial iron overload, and increased sensitivity to oxidative stress. The large majority of FRDA patients are homozygous for this expanded trinucleotide repeat whereas only 4% are compound heterozygotes for this expansion and a point mutation (Noreau et al. 2013). Greater phenotype severity, for example younger age at onset and more incapacitating symptoms, is known to correlate with longer triplet expansions. Current treatment strategies include frataxin-level modifiers, antioxidants, and iron-chelators,

but to this date, no treatment has demonstrated a clinically significant diminution of neurological symptoms or alteration of disease progression despite improvements in cardiac parameters (Kearney et al. 2012).

**Ataxia with Vitamin E Deficiency (AVED)** is highly prevalent in Japan and around the Mediterranean sea. The phenotypes presented by different populations vary as regards to age of onset, disease progression, and symptoms severity due to differences in the type of mutation across populations. In general, the clinical picture is very similar to that of FRDA, although with a slower disease progression, more salient head titubation, and milder sensory neuropathy. Indeed, cerebellar ataxia, areflexia, dysarthria, posterior column involvement, positive bilateral Babinski signs, and skeletal abnormalities compose a clinical syndrome that could easily be mistaken for FRDA. One notable difference is that retinitis pigmentosa is a frequent feature in AVED, especially in patients from Japan. The biochemical hallmark of AVED is the very low serum vitamin E concentration in the absence of intestinal fat malabsorption as corroborated by a normal lipidic profile. The disease results from truncating or missense mutations in the gene *TTPA*, which codes for  $\alpha$ -tocopherol transfer protein (Noreau et al. 2013). This protein is involved in the incorporation of  $\alpha$ -tocopherol (the most biologically active form of vitamin E) into lipoproteins, hence the reduced vitamin E concentrations. The role of vitamin E in neuroprotection remains unclear, although its antioxidant properties are expected to be crucial in neuronal function. Treatment with vitamin E supplementation halts disease progression and could slightly improve cerebellar ataxia (Noreau et al. 2013).

**Abetalipoproteinemia (ABL)**, also called Bassen-Kornzweig syndrome, is a disorder of lipoprotein metabolism that presents at birth with symptoms of fat malabsorption such as vomiting, diarrhea, and steatorrhea. Neurological and ophthalmological symptoms identical to those of AVED then develop in the first or second decade. Biochemical findings include hypocholesterolemia, hypotriglyceridemia, acanthocytosis, and evidence of vitamins E, A, and K deficiency. Mutations in *MTTP*, which encodes a microsomal triglyceride transfer protein essential for the assembly and secretion of apolipoprotein B, are responsible for the disease. Treatment with vitamin supplementation, a low-fat diet, and medium-chain triglycerides is essential (Fogel and Perlman 2007).

### 73.3 Cerebellar Ataxias with Sensorimotor Neuropathy

**Ataxia-Telangiectasia (A-T)** is a severe multi-system disorder characterized by progressive truncal appendicular ataxia, oculocutaneous telangiectasias, and immunological deficiencies. It is the most frequent cerebellar ataxia in children under 5, and the most prevalent ARCA at all ages in Norway (Ruano et al. 2014). A-T is caused by a mutation in the ataxia-telangiectasia mutated gene (*ATM*), which encodes a serine-threonine kinase essential for coordination of the cell's DNA double strand breaks (DSB) repair mechanisms (Fogel and Perlman 2007). As such, it

is part of a group of DNA-repair defect ataxias that also includes A-TLD, AOA1, and AOA2. These disorders share common clinical features such as oculomotor apraxia, which presents as oculocephalic dissociation during head rotation, axonal sensorimotor neuropathy, and extra-pyramidal involvement in the form of chorea, dystonia, and tremor (Anheim et al. 2012). In A-T, ataxia typically appears around 2 or 3 years of age and is followed by dysarthria, loss of deep tendon reflexes, chorea, dystonia, and oculomotor apraxia. Humoral and cellular immunological deficiencies are responsible for recurrent infections. The patients' greater sensibility to ionizing radiations is directly linked to the latter's tendency to cause DSB. Moreover, the cell's inability to recognize and repair DNA damage leads to a greater predisposition for malignancies, especially T-cell lymphomas. Death typically occurs in the second or third decade from cancer or respiratory failure. On biochemical investigations, elevation of  $\alpha$ -foetoprotein is almost ubiquitous. No specific treatment is currently available (Vermeer et al. 2011).

**Ataxia-Telangiectasia-Like Disorder (A-TLD)** is a pathogenetic entity that resembles very closely ataxia-telangiectasia, but without telangiectasias, immunodeficiency or elevation of  $\alpha$ -foetoprotein. The disease course is also milder with later onset, slower progression, and moderate radiosensitivity. The resemblance of the phenotype with A-T is explained by the great functional interdependency of *ATM* and the *MRN* complex, which is deficient in A-TLD. Indeed, truncating and missense mutations in the meiotic recombination 11 gene (*MRE11*), which forms the core of the *MRN* complex, are known to cause A-TLD (Fogel and Perlman 2007).

**Ataxia with Oculomotor Apraxia Type 1 (AOA1)** has been mainly described in Japan and Portugal, where it is the second most frequent ARCA (Ruano et al. 2014). The clinical picture corresponds to what has been described in other DNA-repair defect ataxias, with early-onset gait and limb ataxia, oculomotor apraxia, chorea, and dystonic posturing. The peculiar finding in AOA1 is cognitive impairment that ranges from mild deficits indicative of a subcortical syndrome to frank mental retardation (Vermeer et al. 2011). The biochemical hallmark of AOA1 is hypoalbuminemia with hypercholesterolemia, and serum creatine kinase levels tend to be elevated as well. Mutations in the ubiquitously expressed aprataxin-encoding gene *APT*X are responsible for the disease (Noreau et al. 2013). The analysis of the functional domains of aprataxin has suggested its role in DNA single strand break (SSB) repair, and AOA1 patients' cells show accumulation of SSB under conditions of oxidative stress (Vermeer et al. 2011).

**Ataxia with Oculomotor Apraxia Type 2 (AOA2)** is a clinically heterogeneous disease with onset around 15 years and slower progression than AOA1. A variable combination of upper motor neuron signs, chorea, dystonia, and head tremor forms the neurological picture. It is notable that oculomotor apraxia is found in only less than half of patients, and convergent strabismus is a more frequent oculomotor abnormality (Vermeer et al. 2011). Cerebellar atrophy on MRI is pronounced, particularly in the vermis, and is often already present at clinical onset. Biochemical studies almost universally reveal elevated serum  $\alpha$ -foetoprotein levels, which may lead to confusion with A-T. The disease is caused by mutations in *SETX*, which

codes for the nuclear protein senataxin, a putative DNA/RNA helicase involved in SSB repair (Noreau et al. 2013). Of interest, autosomal dominant mutations of SETX may cause a juvenile form of amyotrophic lateral sclerosis (ALS4) (Vermeer et al. 2011).

**Autosomal Recessive Spastic Ataxia of Charlevoix-Saguenay (ARSACS)** was first described in a genetically isolated population of the Charlevoix and Saguenay regions in Quebec, Canada, where the carrier frequency is 1/22 (Noreau et al. 2013). This disorder presents in early childhood with progressive lower limb spasticity, cerebellar ataxia, and distal muscle atrophy. Other signs of pyramidal involvement are usually present such as increased deep tendon reflexes, clonus, and extensor plantar response. Mild oculomotor abnormalities and dysarthria are also frequently observed as well as foot deformity and urinary tract dysfunction. A peculiar finding in ARSACS, especially in patients from Quebec, is the presence of retinal striation at fundoscopy, which consists of prominent streaks radiating from the optic disk and embedding the retinal vessels (Vermeer et al. 2011). Once the *SACS* gene was identified in 2000, patients from other regions of the world were diagnosed with ARSACS, and over 70 different mutations were subsequently characterised (Vermeer et al. 2011). The encoded protein, sascin, is thought to be involved in chaperone-assisted protein folding.

**Other Cerebellar Ataxias with Sensorimotor Neuropathy** include Refsum's disease and cerebrotendinous xanthomatosis, two metabolic disorders that can be treated; hence early recognition is essential.

### 73.4 Cerebellar Ataxias Without Neuropathy

**Autosomal Recessive Cerebellar Ataxia Type 1 (ARCA1)**, also called recessive ataxia of Beauce, is a pure cerebellar ataxia of middle-age onset (17–46 years) that was first identified in the French-Canadian population. The cerebellar syndrome includes gait and limb ataxia, dysarthria, brisk reflexes in the lower limbs, and oculomotor abnormalities, including slow and jerky pursuit, abnormal saccades, and nystagmus. The responsible gene, *SYNE 1*, is one of the largest genes in the human genome (Noreau et al. 2013), and it encodes the 8797-amino-acid protein synaptic nuclear envelope-1. It is part of the spectrin superfamily of proteins that link the plasma membrane to the actin skeleton, which also contains dystrophine (Duchenne muscular dystrophy) and  $\beta$ -III-spectrin (spinocerebellar ataxia type 5).

**Autosomal Recessive Cerebellar Ataxia Type 2 (ARCA2)** due to coenzyme Q10 (coQ10) deficiency is a rare condition that presents as a childhood-onset gait ataxia with exercise intolerance, mental retardation, epilepsy, and myoclonus. Paraclinical evaluation reveals cerebellar atrophy on MRI, elevated serum lactate, and coQ10 deficiency. It is caused by a mutation in the AARF-domain containing kinase 3 (*ADCK3*), also called chaperone activity of BCI complex-like (*CABCI*), which encodes a mitochondrial protein essential for coQ10 synthesis (Vermeer et al.

2011). Ubiquinone (coQ10) supplementation has produced mild subjective improvement and stabilisation of the cerebellar ataxia at examination in one patient (Noreau et al. 2013).

## 73.5 Conclusion

Diagnostic work-up of patients presenting with progressive ataxia and a seemingly autosomal recessive or sporadic mode of inheritance should focus on the locally most prevalent subtypes and try to rule out those ARCAs for which a treatment may be available. Nonetheless, despite great developments in the molecular pathogenetics of autosomal recessive ataxias, about half of patients still do not receive any molecular diagnosis (Ruano et al. 2014), highlighting the need for future research and better characterisation of the clinical phenotypes.

## References

- Anheim M, Tranchant C, Koenig M (2012) The autosomal recessive cerebellar ataxias. *N Engl J Med* 366(7):636–646. doi:[10.1056/NEJMra1006610](https://doi.org/10.1056/NEJMra1006610)
- Fogel BL, Perlman S (2007) Clinical features and molecular genetics of autosomal recessive cerebellar ataxias. *Lancet Neurol* 6(3):245–257. doi:[10.1016/S1474-4422\(07\)70054-6](https://doi.org/10.1016/S1474-4422(07)70054-6)
- Kearney M, Orrell Richard W, Fahey M, Pandolfo M (2012) Antioxidants and other pharmacological treatments for Friedreich ataxia. *Cochrane Database of Syst Rev*. doi:[10.1002/14651858.CD007791.pub3](https://doi.org/10.1002/14651858.CD007791.pub3)
- Noreau A, Dupré N, Bouchard J-P, Dion P, Rouleau G (2013) Autosomal recessive cerebellar ataxias. In: Manto M, Schmähmann J, Rossi F, Gruol D, Koibuchi N (eds) *Handbook of the cerebellum and cerebellar disorders*. Springer, Dordrecht, pp 2177–2191
- Ruano L, Melo C, Silva MC, Coutinho P (2014) The global epidemiology of hereditary ataxia and spastic paraplegia: a systematic review of prevalence studies. *Neuroepidemiology* 42(3):174–183
- Vermeer S, van de Warrenburg BP, Willemsen MA, Cluitmans M, Scheffer H, Kremer BP et al (2011) Autosomal recessive cerebellar ataxias: the current state of affairs. *J Med Genet* 48(10):651–659. doi:[10.1136/jmedgenet-2011-100210](https://doi.org/10.1136/jmedgenet-2011-100210)

# Chapter 74

## X-Linked Ataxias

Josef Finsterer

**Abstract** X-linked ataxias are clinically and genetically heterogeneous. Clinically, ataxia may be the sole, the dominant, or a non-dominant phenotypic feature of X-linked ataxias. Ataxia is most commonly of the cerebellar type. Other manifestations in addition to ataxia may be neurological or non-neurological. Ataxia as the exclusive phenotypic feature has been described in X-linked ataxia due to PAMC3 mutations, X-linked adrenoleukodystrophy, and X-linked pyruvate-dehydrogenase deficiency. X-linked ataxias, in which ataxia dominates include fragile X-tremor ataxia syndrome, X-linked sideroplastic anemia with ataxia, and X-linked ataxia due to GJB1 mutations. Additionally, a number of X-linked disorders with ataxia as a non-dominant feature have been described. The number of X-linked ataxias is steadily increasing and it is quite likely that their number will further increase. Therapy of X-linked ataxias is symptomatic. Genetic counselling not only depends on the X-linked trait of inheritance but also on the presence or absence of germline mosaicism or if the mutation concerns a trinucleotide expansion. Early recognition of X-linked ataxias is warranted to prevent long-term misdiagnosis and application of ineffective treatment.

**Keywords** X-chromosomal • Hereditary • Multisystem disease • Genetic heterogeneity • Phenotypic heterogeneity • Genetic counseling

### 74.1 Introduction

X-linked ataxias are hereditary disorders following an X-chromosomal trait of transmission in which ataxia is the sole manifestation or one among others (Finsterer 2011). Among the latter, ataxia may be the dominant clinical feature or a non-dominant feature. Generally, ataxia may be of the cerebellar, spinal, or sensory type. Compared to autosomal dominant and autosomal recessive ataxias, X-linked ataxias are relatively rare (Sandford and Burmeister 2014). The most frequent of the

---

J. Finsterer (✉)  
Krankenanstalt Rudolfstiftung, Postfach 20, 1180 Vienna, Austria  
e-mail: [fifigs1@yahoo.de](mailto:fifigs1@yahoo.de)

X-linked ataxias is fragile X-associated tremor ataxia syndrome (FXTAS) (Sandford and Burmeister 2014). In X-linked spinocerebellar ataxia (SCA) due to the PMCA3 mutation, X-linked PDH-deficiency, and in X-linked adrenoleukodystrophy (X-ALD) ataxia may be the sole clinical manifestation (Zanni et al. 2012; Bertini et al. 2000). X-linked ataxias in which ataxia is the dominant phenotypic feature include FXTAS, X-linked sideroblastic anemia with ataxia (XLSA), and X-linked ataxia due to GJB1 mutations (Finsterer 2011; Caramins et al. 2013). X-linked disorders, in which ataxia is a non-dominant feature are listed in Table 74.1. Except for FXTAS and Rett syndrome, all other X-linked ataxias are rare and restricted to single families (Table 74.1) (Sandford and Burmeister 2014).

### ***74.1.1 Fragile X-Associated Tremor Ataxia Syndrome (FXTAS)***

FXTAS is clinically characterized by the triade of late-onset (usually past 50 years), progressive cerebellar ataxia (gait ataxia), kinetic tremor, and progressive intellectual disability and dementia (Finsterer 2011; Sandford and Burmeister 2014). The neuropsychological profile of FXTAS is consistent with a dysexecutive fronto-subcortical syndrome. Rare, additional phenotypic features include parkinsonism, proximal paraparesis of the lower limbs, and neuropathy with autonomic involvement. Four percent of the patients develop all three cardinal phenotypic features, 20% develop two cardinal phenotypic features, and 50% only a single cardinal feature (Finsterer 2011). Tremor is usually the initial manifestation followed by ataxia 2 years later (Finsterer 2011). Life expectancy ranges from 5 to 25 years after onset (Finsterer 2011). MRI shows symmetric regions of T2-hyperintensities in the middle cerebellar peduncles and adjacent peridentate white matter or non-specific symmetric signal changes in the cerebral white matter (Finsterer 2011). Usually, the cerebellar volume is decreased and the ventricular volume increased. Female carriers manifest clinically in 20% of the cases with premature ovarian insufficiency, resulting in premature onset of menopause or fertility problems (Sandford and Burmeister 2014).

FXTAS is caused by an intronic CGG-repeat expansion in the 5' untranslated region of the FMR1 gene on chromosome Xq27.3 (Sandford and Burmeister 2014). Rarely, FXTAS is due to point mutations. Patients with FXTAS carry a repeat number of 55–200 (FMR1 premutation) (Sandford and Burmeister 2014). If the expansion size exceeds 200, males present with fragile-X syndrome, a severe disorder completely different from FXTAS (Sandford and Burmeister 2014). The normal length of the CGG-repeat is 5–40 (Finsterer 2011) and transmitted in a stable fashion without increase or decrease in the repeat number between generations (Finsterer 2011). In normal alleles, every ninth or tenth CGG-repeat is interrupted by an AGG triplet repeat, which is assumed to maintain repeat integrity by preventing DNA strand slipping during replication (Finsterer 2011). In intermediate alleles (41–54



**Table 74.1** X-linked ataxias

Type of XL-ataxia	Gene	AP	Additional phenotypic features	MC	NF
FXTAS	FMR1	DA	Tremor, dysexecutive syndrome, ID, dementia, PS, NP, paraparesis	Yes	>100
XLSA	ABCB7	DA	Anemia, tremor, dysarthria, strabism, UMNS	No	4
X-linked ataxia	GJB1	DA	NP, scoliosis, foot deformity, spasticity	Yes	2
SCA	PMCA3	PA	None	uk	1
Adrenoleucodystrophy	ABCD1	PA, NDA	UMNS, hypogonadism	Yes	>5
PDH deficiency	PDHA1	PA, NDA	Lactacidosis; Leigh syndrome, encephalopathy, dystonia, epilepsy	No	>20
Rett syndrome	MECP2	NDA	DR, autism, epilepsy, paraparesis, stereotypies, microcephaly	Yes	>100
PMD	PLP1	NDA	DR, ID, tremor, spasticity, hypotonia, weakness	Yes	>20
Joubert syndrome	21 genes	NDA	DR, molar tooth sign, hypotonia, ocular motor apraxia, retina, kidney, skeleton	No	>10
MTS	TIMM8A	NDA	Hypoacusis, optic atrophy, dystonia, dementia	Yes	>10
Incontinentia pigmenti	NEMO	NDA	ID, epilepsy, ophthalmic abnormalities, skin lesions, microrcephaly	Yes <sup>a</sup>	>10
Christiansen syndrome	SLC9A6	NDA	DR, epilepsy, autism, dystonia, aphonia, weakness, microcephaly	uk	7
MCT8 deficiency	MCT8	NDA	DR, ID, hypotonia, spasticity, weakness	No	7
MECP2 duplication	MECP2	NDA	Dystonia, spasticity, ID, dementia, epilepsy	Yes	6
Arts syndrome	PRPS1	NDA	DR, ID, hypoacusis, hypotonia, optic atrophy, hyperuricemia	Yes	3
CMT1X	GJB1	NDA	NP, dysarthria, hemiparesis, quadraparesis	uk	2
Spastic paraplegia	PLP1	NDA	Spasticity, weakness, NP	Yes	2
XLMR	CUL4B	NDA	DR, ID, dysmorphism, hypogonadism, short stature, pes cavus	uk	1
X-linked ichthyosis	STS	NDA	Ichthyosis, tremor, dysarthria, anxiety disorder, baldness	No	1

*XL* X-linked, *AP* ataxia phenotype, *MC* manifesting carriers, *NF* number of affected families reported, *MTS* Mohr Tranebjaerg syndrome (deafness dystonia, optic neuropathy syndrome), *PMD* Pelizaeus Merzbacher disease, *XLMR* X-linked mental retardation, *CMT1X* X-linked Charcot-Marie-Tooth (*CMT1X*) disease, *PA* pure ataxia, *DA* ataxia dominates the phenotype, *NDA* ataxia is a non-dominant feature, *ID* intellectual disability, *PS* parkinsonism, *NP* neuropathy, *UMNS* upper motor neuron signs, *DR* developmental retardation, *uk* unknown

<sup>a</sup>Lethal in males

repeats) the likelihood to become unstable in successive generations increases with the number of uninterrupted CGG-repeats (Finsterer 2011). Retraction of the CGG-repeat expansion between generations is rare (Finsterer 2011).

### **74.1.2 X-Linked Sideroblastic Anemia with Ataxia (XLSA)**

XLSA is a rare mitochondrial disorder (MID), characterized by mild, non-symptomatic, early-onset sideroblastic anemia with hypochromia, microcytosis, marked poikilocytosis, reticulocytosis, and heavy stippling [tüfelung]. Bone marrow examination in affected males and occasionally in female carriers may show ring siderocytes (Finsterer 2011). In addition to anemia cerebellar ataxia predominates the phenotype (Finsterer 2011). Ataxia is either non-progressive (Kang et al. 2014) or slowly progressive on from the fifth decade (Finsterer 2011). In addition to gait and trunk ataxia, patients present with dysmetria, dysdiadochokinesia, dysarthria, nystagmus, hypometric saccades, strabism, or kinetic tremor (Finsterer 2011). Single patients develop lower limb spasticity. Cerebral imaging may show cerebellar atrophy or hypoplasia (Finsterer 2011). Female carriers are neurologically normal but may show a dimorphic blood smear with both hypochrome, microcytic and normal red blood cells.

XLSA is caused by mutations in the mitochondrial ATP-binding cassette transporter ABCB7 gene (Finsterer 2011). Point mutations have been detected in exons 5–16 and at the intron/exon boundaries (Finsterer 2011). The gene product, ABCB7, is like frataxin, involved in the biosynthesis of iron-sulfur clusters. There are indications that ABCD7 transports components required for the maturation of cytosolic iron-sulfur clusters from the mitochondrion to the cytosol (Finsterer 2011).

### **74.1.3 X-Linked Ataxia Due to a GJB1 Mutation**

X-linked ataxia due to GJB1 mutations is a recently identified disorder with predominant ataxia but also involvement of the peripheral nerves (wasting, sensory and motor nerve abnormalities) (Caramins et al. 2013). Patients additionally presented with scoliosis, foot deformity, or spasticity (Caramins et al. 2013). The phenotype is due to missense mutations in the GJB1 gene and has been described in two families so far (Caramins et al. 2013).

### **74.1.4 Spinocerebellar Ataxia Due to PMCA3 Mutations**

Spinocerebellar ataxia (SCA) due to PMCA3 mutations is one of the X-linked ataxias with a pure cerebellar phenotype and characterized by congenital-onset ataxia, cerebellar atrophy, hypotonia, and slow eye movements (Zanni et al. 2012; Bertini et al. 2000). This type of SCA was reported in a single Italian family so far. The

exact pathogenesis of PMCA3 mutations is unknown but they seem to disrupt the intracellular calcium-metabolism (Bertini et al. 2000; Caramins et al. 2013).

### ***74.1.5 X-Linked Adrenoleukodystrophy***

X-linked adrenoleukodystrophy (X-ALD) is clinically characterized by dysarthria, cerebellar ataxia, and mild spastic paraparesis. Additionally, adrenal and gonadal impairment may supplement the phenotype (Finsterer 2011). Cerebral and spinal cord imaging may show atrophy of the cerebellum and upper cervical spinal cord (Finsterer 2011) or cerebral demyelination (Finsterer 2011). Rarely, X-ALD may manifest as a pure cerebellar syndrome with demyelination of the dentate nucleus or the cerebellum (Kang et al. 2014). X-ALD is due to point mutations or deletions in the ABCD1 gene (Finsterer 2011).

### ***74.1.6 X-Linked Pyruvate-Dehydrogenase (PDH) Deficiency***

X-linked PDH-deficiency manifests clinically with a wide range of presentation from neonatal lactacidosis to severe leucoencephalopathy (Leigh syndrome) (Finsterer 2011). Less severe cases may present with intermittent ataxia exclusively (Finsterer 2011). X-linked PDH-deficiency is due to missense mutations, deletions or duplications in the PDHA1 gene encoding the E1-subunit of the PDH complex (Finsterer 2011). The genotype-phenotype correlation is poor.

### ***74.1.7 X-Linked Ataxias with Ataxia as a Non-dominant Feature***

A number of X-linked disorders present with ataxia as a non-dominant phenotypic feature (Table 74.1). Most of them are rare and have been described only in a few families (Table 74.1).

## **74.2 Management**

X-linked ataxias are usually diagnosed upon the clinical presentation and genetic studies. Supportive information may derive from blood chemical investigations, cerebral imaging, and nerve conduction studies (Finsterer 2011). Only symptomatic treatment, such as physiotherapy, speech therapy, or computed devices to manage difficulties with handwriting can be offered. In X-linked PDH-deficiency carbohydrate-free diet together with thiamine, carnitine, and vitamin E may have a

beneficial effect with an excellent outcome in single patients. Genetic counselling relies on the X-chromosomal transmission of the disorders. Affected males pass the mutation to all their daughters but not to their sons. The father of an affected male will neither be affected nor a carrier. Female carriers are clinically unaffected and have a 50% chance to transmit the mutation in each pregnancy. If the mother of an affected male does not carry the mutation, the mutation has to be classified as *de-novo*. If a mother has two affected sons but does not carry the mutation, germline mosaicism has to be considered. The risk of the sibs of a proband depends on the carrier status of the mother. Male sibs carrying the mutation will be affected, female sibs carrying the mutation will be carriers. Prenatal testing of fetuses at risk is possible on DNA from amnion cells. Preimplantation diagnosis is available in families with known mutation.

### 74.3 Conclusion

X-linked ataxias are clinically and genetically heterogeneous. Clinically, ataxia may be the sole, the dominant, or a non-dominant phenotypic feature. Ataxia is most commonly of the cerebellar type. Other manifestations in addition to ataxia may be neurological or non-neurological in nature. Ataxia as the exclusive phenotypic feature has been described in X-linked ataxia due to PAMC3 mutations, X-ALD, and X-linked PDH-deficiency. X-linked ataxias, in which ataxia dominates include FXTAS, XLSA, and X-linked ataxia due to GJB1 mutations. The number of X-linked ataxias is steadily increasing and it is quite likely that their number will further increase in the future. Therapy of X-linked ataxias is symptomatic. Genetic counselling not only depends on the X-linked trait of inheritance but also on the presence or absence of germline mosaicism or if X-linked ataxia is due to a trinucleotide expansion. Early recognition of X-linked ataxias is warranted to prevent long-term misdiagnosis and application of ineffective treatment.

### References

- Bertini E, Des Portes V, Zanni G, Santorelli F, Dionisi-Vici C, Vicari S, Fariello G, Chelly J (2000) X-linked congenital ataxia: a clinical and genetic study. *Am J Med Genet* 92:53–56
- Caramins M, Colebatch JG, Bainbridge MN, Scherer SS, Abrams CK, Hackett EL, Freidin MM, Jhangiani SN, Wang M, Wu Y, Muzny DM, Lindeman R, Gibbs RA (2013) Exome sequencing identification of a GJB1 missense mutation in a kindred with X-linked spinocerebellar ataxia (SCA-X1). *Hum Mol Genet* 22:4329–4338
- Finsterer J (2011) X-linked ataxias. In: Manto M, Gruol D, Rossi F, Schmähmann J, Koibuchi N (eds) *Handbook of cerebellum and cerebellar disorders*. Springer: Heidelberg, Germany
- Kang JW, Lee SM, Koo KY, Lee YM, Nam HS, Quan Z, Kang HC (2014) Isolated cerebellar variant of adrenoleukodystrophy with a *de novo* adenosine triphosphate-binding cassette D1 (ABCD1) gene mutation. *Yonsei Med J* 55:1157–1160.

- Sandford E, Burmeister M (2014) Genes and genetic testing in hereditary ataxias. *Genes (Basel)* 5:586–603
- Zanni G, Cali T, Kalscheuer VM, Ottolini D, Barresi S, Lebrun N, Montecchi-Palazzi L, Hu H, Chelly J, Bertini E, Brini M, Carafoli E (2012) Mutation of plasma membrane Ca<sup>2+</sup> ATPase isoform 3 in a family with X-linked congenital cerebellar ataxia impairs Ca<sup>2+</sup> homeostasis. *Proc Natl Acad Sci U S A* 109:14514–14519

# Chapter 75

## Imaging of Malformations of the Hindbrain and Craniocervical Junction

Christian Herweh

**Abstract** Primary hindbrain malformations are much less frequent than those of the cerebrum or combined anomalies. Cerebellar malformations may affect both hemispheres such as rhombencephalosynapsis or molar tooth malformations. Dysplastic gangliocytoma in Lhermitte-Duclos-Cowden syndrome is a typical unilateral malformation. Unilateral hypoplasia usually represents cerebellar disruption, i.e. an impact during intrauterine development. The Dandy-Walker complex (DWC) as well as the Chiari malformations are often accompanied by hydrocephalus, either infra- or supratentorial. DWC is a malformation of the fourth ventricle and its CSF outflow with hydrocephalus as the major complication. In Chiari I malformation CSF hydrodynamics are disturbed and frequently lead to syringomyelia, whereas Chiari malformations II and III are associated with spinal dysraphism which significantly affects the prognosis.

**Keywords** Blake's pouch cyst • Dandy-Walker malformation • Megacisterna magna • Rhombencephalosynapsis • Molar tooth malformations • Dysplastic gangliocytoma • Cerebellar disruption

### Abbreviations

BPC	Blake's pouch cyst
CSF	Cerebrospinal fluid
DWC	Dandy-Walker complex
DWM	Dandy-Walker malformation
MCM	Megacisterna magna
MMC	Myelomeningocele
PF	Posterior fossa

---

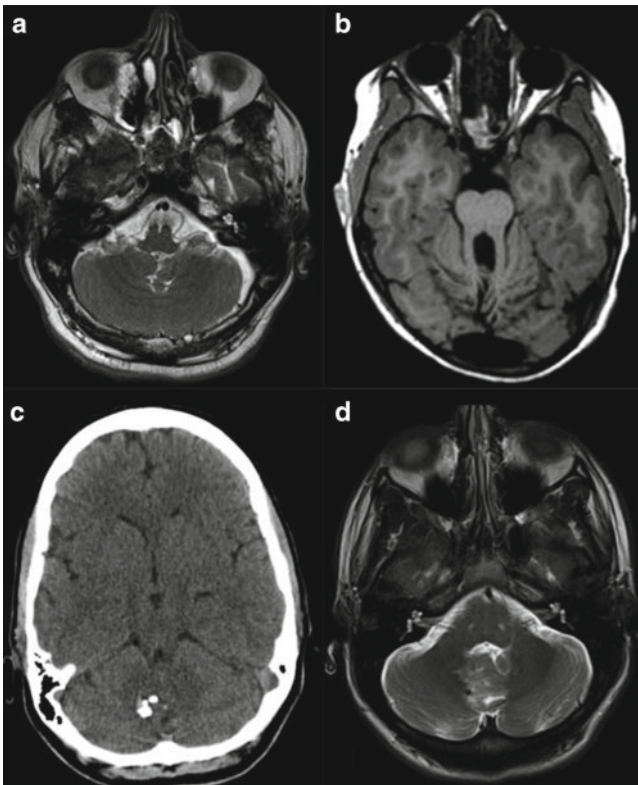
C. Herweh (✉)  
Department of Neuroradiology, University of Heidelberg,  
Im Neuenheim Feld 400, 69120 Heidelberg, Germany  
e-mail: [Christian.Herweh@med.uni-heidelberg.de](mailto:Christian.Herweh@med.uni-heidelberg.de)

## 75.1 Introduction

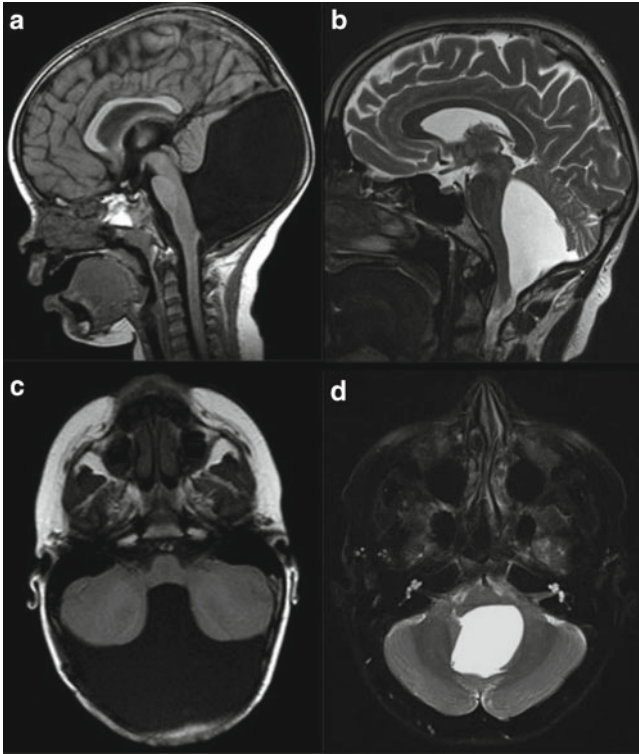
Malformations of the hindbrain and craniocervical junction can be separated into those restricted to the cerebellum and brainstem and those which are associated with other malformations, i.e. of the supratentorial brain. These associated anomalies largely determine the clinical presentation while isolated infratentorial anomalies result in less impairment (Barkovich 2005).

Primary malformations can be further separated into those affecting neuronal structures only and those associated with mesenchymal anomalies such as the Dandy Walker complex and the Chiari malformations (Figs. 75.1, 75.2, and 75.3).

According to Patel and Barkovich (2002) generalized cerebellar dysplasia as a result of abnormal neuronal migration is typically seen together with other malformations of the supratentorial brain, concerning either grey or white matter or both.



**Fig. 75.1** Different forms of cerebellar dysplasia. Rhombencephalosynapsis with absence of the vermis and medial fusion of the cerebellar hemispheres (**a**). Molar tooth malformation in Joubert syndrome, note the stretched aspect of the superior cerebellar peduncles and absent vermis (**b**). Dysplastic cerebellar gangliocytoma of the right hemisphere, note T2 hyperintense mass with irregular architecture and calcifications (**c, d**)



**Fig. 75.2** Differentiation between Dandy-Walker malformation (DWM; **a, c**) and posterior fossa arachnoid cyst (**b, d**). In DWM the hypoplastic vermis is rotated upward and the fourth ventricle shows a wide communication with a large CSF collection in the posterior fossa (PF). In the present example of a PF arachnoid cyst (**b, d**) there is a large cyst lying adjacent to the fourth ventricle which is compressed as the medial portions of the cerebellar hemispheres

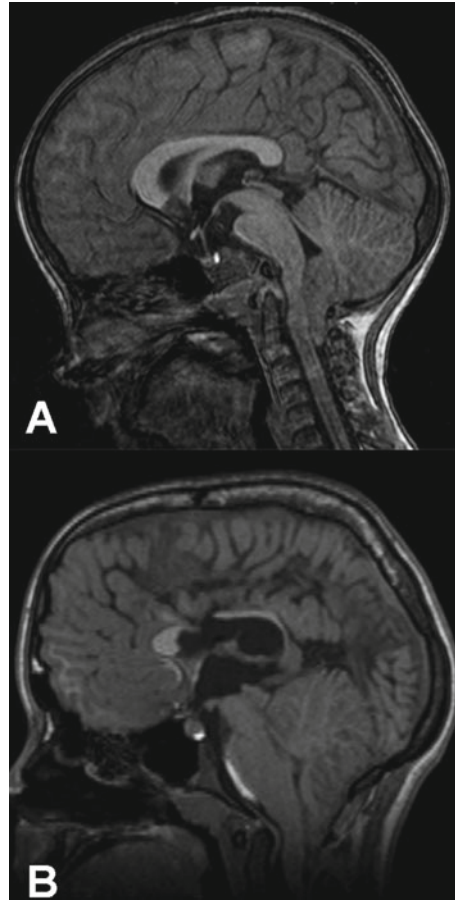
Focal cerebellar dysplasias either affect the vermis, such as rhombencephalosynapsis and molar tooth malformations, or one hemisphere, such as Lhermitte-Duclos-cowden syndrome. The most common malformations involving the cerebellum are listed in Table 75.1.

## 75.2 Rhombencephalosynapsis

Rhombencephalosynapsis as a dysgenesis of both cerebellar hemispheres and is characterized by the fusion of the cerebellar hemispheres in the midline together with fusion of the superior cerebellar peduncle and the dentate nucleus. This is most easily confirmed by inspecting the cerebellar foliae on coronal images. Clinical signs may vary from mild ataxia to severe mental retardation, especially if associated with other CNS malformations.



**Fig. 75.3** Chiari I and II malformation. In Chiari I malformation (**a**) cerebellar tonsils herniate downwards through the foramen magnum pushing the brainstem forward towards the clivus. In Chiari II malformation (**b**) larger parts of the caudal hemispheres herniate outward a small posterior fossa (PF) with a steep tentorium. Note the basilar invagination as well as the hypoplastic corpus callosum with a lesion from former shunt placement in the rostral portion



### 75.3 Molar Tooth Malformations

First described in Joubert syndrome which is defined clinically by episodic hyperpnea, abnormal eye movements, ataxia and mental retardation (Joubert et al. 1969), the molar tooth sign has meanwhile been described in several other syndromes comprising cerebral malformations and even anomalies in other organ systems. It is best observed on axial sectional images and is constituted by an absent or hypoplastic vermis, a tegmental cleft causing the superior cerebellar peduncles to run parallel to one another in the antero-posterior direction. This is due to the fact that their axons do not cross the midline (Poretti et al. 2007) which seems to be a general feature of all midbrain-hindbrain nerve fibers in these syndromes.

**Table 75.1** Main malformations involving the cerebellum

		Malformation	Common signs and characteristics
Cerebellar malformations	Symmetrical	Rhombencephalosynapsis	Apalasia of vermis Medial fusion of hemispheres
		Molar tooth malformation	Vermian aplasia Tegmental cleft
	Hemispherical	Dysplastic cerebellar gangliocytoma	Dysgenetic tumor
		Cerebellar disruption (antenatal impact)	Unilateral hypoplasia
	Dandy-Walker complex	Dandy-Walker malformation	Vermian hypoplasia infra- and supratentorial Hydrocephalus
	Malformations of the craniocervical junction	Chiari malformations	Chiari I
Syringomyelia			
Platybasia			
Chiari II		Lumbar myelomeningocele	
		Small posterior fossa	
		Cerebellar herniation	
		Brainstem compression	
		Hydrocephalus	
Callosal dysplasia			
Chiari III	Cervical Myelomeningocele with cerebellar herniation		

### 75.4 Lhermitte Duclos Cowden Syndrome

Originally described by Lhermitte and Duclos in 1920, the cerebellar feature of this syndrome is a dysplastic cerebellar gangliocytoma, a hemispherical cerebellar dysgenesis. It typically appears as a mass of thickened cerebellar cortex with disturbance of cortical organisation within one hemisphere. The T1 signal is low and T2 signal is increased, contrast enhancement is rare and CT may show calcifications. It may be found in patients with Cowden syndrome, otherwise it can be discovered incidentally.

## 75.5 Cerebellar Hypoplasia

Cerebellar hypoplasia may affect the vermis, one or both hemispheres or the entire cerebellum. If not associated with other malformations pure cerebellar hypoplasia may cause only little or no symptoms at all (Bolduc and Limperopoulos 2009). MRI is the method of choice to evaluate cerebellar hypoplasia with sagittal orientation for the vermis and coronal images to check the cerebellar hemispheres and their foliae. In case of true cerebellar hypoplasia the pons often is hypoplastic as well and should be inspected thoroughly.

In contrast to genetically determined forms of cerebellar hypoplasia, i.e. small cerebellum with normal shape, cerebellar disruption indicates a presumably vascular insult to the developing cerebellum. This is predominantly if not exclusively the cause for the unilateral small cerebellum (Boltshauser 2004). Due to the underlying etiology, it typically seen in preterm children with low birth weight and is therefore often accompanied by other cerebral sequelae such as periventricular leukomalacia and therefore neurodevelopmental deficits are common to these children (Messerschmidt et al. 2005).

## 75.6 Dandy-Walker Complex

The Dandy-Walker complex comprises a spectrum ranging from clinically relevant malformations such as the actual Dandy-Walker malformation (DWM) to Blake's pouch cyst (BPC), or to asymptomatic variants such as the megacisterna magna (MCM). Hypoplasia (primarily of the vermis) is the common feature of all variants (Barkovich et al. 1989). DWM features are (i) a hypoplastic or absent vermis, which is rotated upward in a counter-clockwise direction; (ii) an enlarged fourth ventricle and (iii) an elevated tentorium and torcular. Furthermore, it is regularly associated with a supratentorial hydrocephalus. Again, intellectual outcome may be poor, if the DWM is associated with other CNS anomalies (Klein et al. 2003).

BPC can be difficult to be distinguished from MCM because the cyst which communicates with the fourth ventricle protrudes into the cisterna magna and the separating septum may be overlooked. The MCM in contrast to the aforementioned entities does not communicate with fourth ventricle, is not regularly associated with vermian hypoplasia and most often discovered incidentally.

## 75.7 Chiari Malformations

In the outgoing nineteenth century Hans Chiari, an Austrian physician, described three different malformations of the hindbrain and craniocervical junction, respectively, which will be discussed below.

### **75.7.1 *Chiari I Malformation***

In Chiari I malformation, the cerebellar tonsils herniate through the foramen magnum which may lead to compression of the brainstem as well as the lower cranial nerves. This type may be discovered incidentally, especially in adults. In childhood it is more often discovered as a symptomatic lesion. Symptoms can either be unspecific such as headache or be attributed to the affected structures, i.e. brainstem (nystagmus, vertigo) or cranial nerves (otoneurologic deficits). Furthermore, syringohydromyelia with consecutive senso-motoric deficits can develop. There is often association with bony malformations of the cranio-cervical junction such as platybasia or basilar invagination. A steep configuration of the tentorium is frequently encountered.

### **75.7.2 *Chiari II Malformation***

Chiari II malformations are regularly associated with lumbar myelomeningoceles (MMC) and are therefore more and more often detected prenatally by ultrasound. The posterior fossa is typically small also due to a steep tentorium and the cerebellar hemispheres and vermis, not only the tonsils as in Chiari I malformation, are “squeezed” out downward leading to stretching and compression of the brainstem. Bony malformations of the craniocervical junction are also common. Another feature differing from Chiari I malformation is the variable occurrence of supratentorial anomalies. These are different degrees of callosal dysplasia as well as a large massa intermedia. Mesenchymal abnormalities besides a dysplastic tentorium comprise fenestration of the falx leading to gyral interdigitation between hemispheres (Miller et al. 2008). Hydrocephalus is found in all patients, sometimes by prenatal ultrasound but at the latest after surgical closure of the neural tube defect. Recently, a randomized controlled clinical trial has shown convincingly that Chiari II patients may benefit from antenatal MMC repair at many aspects. The necessity of shunt placement as well as the degree of hindbrain herniation was reduced and consecutively the ability to walk was improved (Adzick et al. 2011).

### **75.7.3 *Chiari III Malformation***

In Chiari III malformation a MMC is located at the upper cervical spine leading to herniation of contents of the posterior fossa.

A common feature of all Chiari malformations is the development of hydro- or syringomyelia which typically responds well to decompressive surgery at the craniocervical junction.

The Chiari IV malformation is an extremely rare hypoplasia of the cerebellum, initially not described by Hans Chiari.

## References

- Adzick NS, Thom EA, Spong CY et al (2011) A randomized trial of prenatal versus postnatal repair of myelomeningocele. *N Engl J Med* 364:993–1004
- Barkovich AJ (2005) *Pediatric neuroimaging*, 4th edn. Lippincott Williams & Wilkins, Philadelphia
- Barkovich AJ, Kjos BO, Norman D, Edwards MS (1989) Revised classification of posterior fossa cysts and cystlike malformations based on the results of multiplanar MR imaging. *AJR Am J Roentgenol* 153:1289–1300
- Bolduc ME, Limperopoulos C (2009) Neurodevelopmental outcomes in children with cerebellar malformations: a systematic review. *Dev Med Child Neurol* 51:256–267
- Boltshauser E (2004) Cerebellum-small brain but large confusion: a review of selected cerebellar malformations and disruptions. *Am J Med Genet A* 126A:376–385
- Joubert M, Eisenring JJ, Robb JP, Andermann F (1969) Familial agenesis of the cerebellar vermis. A syndrome of episodic hyperpnea, abnormal eye movements, ataxia, and retardation. *Neurology* 19:813–825
- Klein O, Pierre-Kahn A, Boddaert N, Parisot D, Brunelle F (2003) Dandy-Walker malformation: prenatal diagnosis and prognosis. *Child's Nerv Syst: ChNS: Off J Int Soc Pediatr Neurosurg* 19:484–489
- Messerschmidt A, Brugger PC, Boltshauser E et al (2005) Disruption of cerebellar development: potential complication of extreme prematurity. *AJNR Am J Neuroradiol* 26:1659–1667
- Miller E, Widjaja E, Blaser S, Dennis M, Raybaud C (2008) The old and the new: supratentorial MR findings in Chiari II malformation. *Child's Nerv Syst: ChNS: Off J Int Soc Pediatr Neurosurg* 24:563–575
- Patel S, Barkovich AJ (2002) Analysis and classification of cerebellar malformations. *AJNR Am J Neuroradiol* 23:1074–1087
- Poretti A, Boltshauser E, Loenneker T et al (2007) Diffusion tensor imaging in Joubert syndrome. *AJNR Am J Neuroradiol* 28:1929–1933

# Chapter 76

## Cerebellar Stroke

Keun-Hwa Jung and Jae-Kyu Roh

**Abstract** Cerebellar stroke consists of cerebellar infarction and hemorrhage. The two entities have similar symptoms and signs depending on structures involved. Vertebrobasilar atherosclerosis and cardioembolism cause the cerebellar infarction, while hypertensive microangiopathy and arteriovenous malformation generate cerebellar hemorrhage. The increasing availability of new imaging techniques helps to better identify the etiology of cerebellar stroke and predict the risk of progression and recurrence. Special attention should be paid to the patients with cerebellar stroke because of potential complications including brainstem compression, acute hydrocephalus, and brainstem infarction. Optimal medical therapy, endovascular procedures, or surgical interventions improve patients' outcomes. This chapter summarizes current understanding of cerebellar stroke, and clinical features, diagnosis and treatment of patients.

**Keywords** Cerebellar • Stroke • Infarction • Hemorrhage • Superior cerebellar artery • Posterior inferior cerebellar artery • Anterior inferior cerebellar artery • Vertigo • Dysmetria • Gait disturbance • Nystagmus • Dysarthria • Hearing loss • Mechanism • Cardioembolism • Artery to artery embolism • In situ branch atheromatous disease • Dissection • Venous thrombosis • CT • MRI • Diffusion-weighted imaging • Conventional angiography • CT angiography • Doppler • Coma • Edema • Brainstem compression • Hydrocephalus • Hemorrhagic transformation • Extraventricular drainage • Craniotomy • Prognosis

---

K.-H. Jung

Department of Neurology, Seoul National University Hospital, Seoul, South Korea

J.-K. Roh (✉)

Department of Neurology, Seoul National University Hospital, Seoul, South Korea

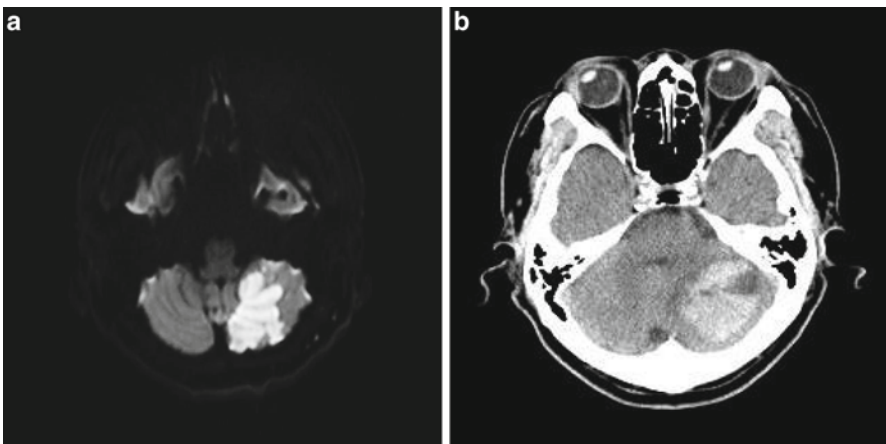
Department of Neurology, The Armed Forces Capital Hospital,

177, Saemaeyul-ro, Bundang-gu, Seongnam, Gyeonggi-do 463-040, South Korea

e-mail: [rohjk777@gmail.com](mailto:rohjk777@gmail.com)

## 76.1 Introduction

This part includes the essentials of clinical aspects of cerebellar stroke. The readers can refer to an extended version for more details (Jung and Roh 2013). Cerebellar stroke includes infarction (Fig. 76.1a) and hemorrhage (Fig. 76.1b). Cerebellar infarction accounts for 2–10% of cases in clinical series of cerebral infarction (Tohgi et al. 1993; Amarenco et al. 1994). The mean age of patients is 60–70 years and about two-thirds of patients are men (Tohgi et al. 1993). Along with the population aging, the incidence of cerebellar infarction is rising. Overall, the infarction in posterior inferior cerebellar arteries (PICA) territory is more common than that in the superior cerebellar artery (SCA) and anterior inferior cerebellar artery (AICA) territories (Tohgi et al. 1993). Bilateral cerebellar infarcts are not rare, constituting 31% of all cerebellar infarcts (Tohgi et al. 1993). While the relative contribution of the different etiologies depends on ethnic origin, age, and sex, the common etiologies of cerebellar infarction are cardioembolism and large artery atherosclerosis (Amarenco et al. 1990a; Bogousslavsky et al. 1993). Cerebellar infarction may occur in association with vertebral artery dissection, especially in younger patients (Schievink 2001). Rare causes include vasculitis (McLean et al. 1993), hypercoagulable states (Amarenco et al. 1994), acute drug intoxication (Aggarwal and Byrne 1991) and migraine (Reid et al. 2006). Cerebellar hemorrhage is the rarest type of intracerebral hemorrhage (ICH) constituting 10% of all ICH cases (Flaherty et al. 2005). The mortality rate of cerebellar hemorrhage is relatively high ranging from 20% to 75% because of possible swelling in the restricted posterior fossa (Salvati et al. 2001). Hypertension is the major risk factor of cerebellar hemorrhage (60–89% of all cases). Other causes include vascular malformations, aneurysms, coagulopathy, and amyloid angiopathy (St Louis et al. 1998).



**Fig. 76.1** Type of cerebellar stroke. Cerebellar stroke consists of cerebellar infarction and hemorrhage. Diffusion-weighted magnetic resonance image demonstrates cerebellar infarction in the left PICA territory (a). Brain CT (b) shows hemorrhage in the left cerebellar hemisphere

## 76.2 Clinical Features

Cerebellar stroke syndromes depend on the vascular territory, infarct size, and concurrent lesions in the brainstem (Lee 2009). The main clinical features include vertigo/dizziness, nausea and vomiting, headache, and gait instability. Vertigo/dizziness occurs in nearly three quarters of patients with cerebellar stroke (Tohgi et al. 1993; Kumral et al. 2005a, b). The territory of cerebellar infarction associated with dizziness frequently involves the medial PICA (medPICA) (Norrving and Magnusson 1995). Over half of patients with cerebellar strokes have nausea and vomiting in association with dizziness (Tohgi et al. 1993). Additionally, about 40% of patients with cerebellar infarction suffer from headache (Kumral et al. 2005a, b). Limb ataxia is present in about 40% of patients with cerebellar stroke and is a sign of infarction in the lateral SCA and PICA territories (Ye et al. 2010). About half of patients with cerebellar stroke complain of gait instability (Tohgi et al. 1993). While most patients with unilateral cerebellar lesions fall towards the side of the lesion, some patients fall to the contralateral side of the lesion or bilaterally (Lee et al. 2006; Ye et al. 2010). Truncal ataxia is more severe in infarctions in the medial superior cerebellar artery branch (medSCA) and medPICA territories compared to lateral SCA (latSCA) and lateral PICA (latPICA) (Sohn et al. 2006). Dysarthria is also a common sign (50%) among patients with cerebellar stroke (Tohgi et al. 1993; Kumral et al. 2005a, b). Cerebellar-type dysarthria is characterized by ataxic and slurred speech, explosive staccato scanning vocalization and wavering modulation and occurs in the medSCA lesion (Urban et al. 2003). Oculomotor signs include nystagmus, impaired smooth pursuit, and ocular tilt reaction (OTR). Half of patients with cerebellar infarction have nystagmus, which is more common in medPICA compared to latPICA and SCA infarction (Barth et al. 1994; Ye et al. 2010). Horizontal smooth pursuit eye movements are impaired in patients with lesions in the uvula and the pyramid of the vermis (Baier et al. 2009). The symptoms of cerebellar infarction often begin simultaneously with brainstem symptoms or signs, e.g., Horner's syndrome, weakness, paresthesia, hearing loss, tinnitus, dysphagia, or mental clouding. Specifically, a classical syndrome of AICA territory infarction includes vestibular and acoustic dysfunction, hearing loss, tinnitus, facial weakness, trigeminal sensory loss, and sensory dissociation in the face (Amarenco and Haww 1990a). A localized cerebellar infarction may lead to a specific affect deficit (Schmahmann and Sherman 1998) and executive functioning abilities (Manes et al. 2009). The crossed cerebello-cerebral diaschisis phenomenon may support the nature of cerebellar cognitive dysfunction. Although the majority of cerebellar infarcts have a benign clinical course, acute hydrocephalus and brainstem compression by evolving edema are often associated with a high morbidity and mortality.



## 76.3 Cerebellar Infarction

### 76.3.1 Mechanism

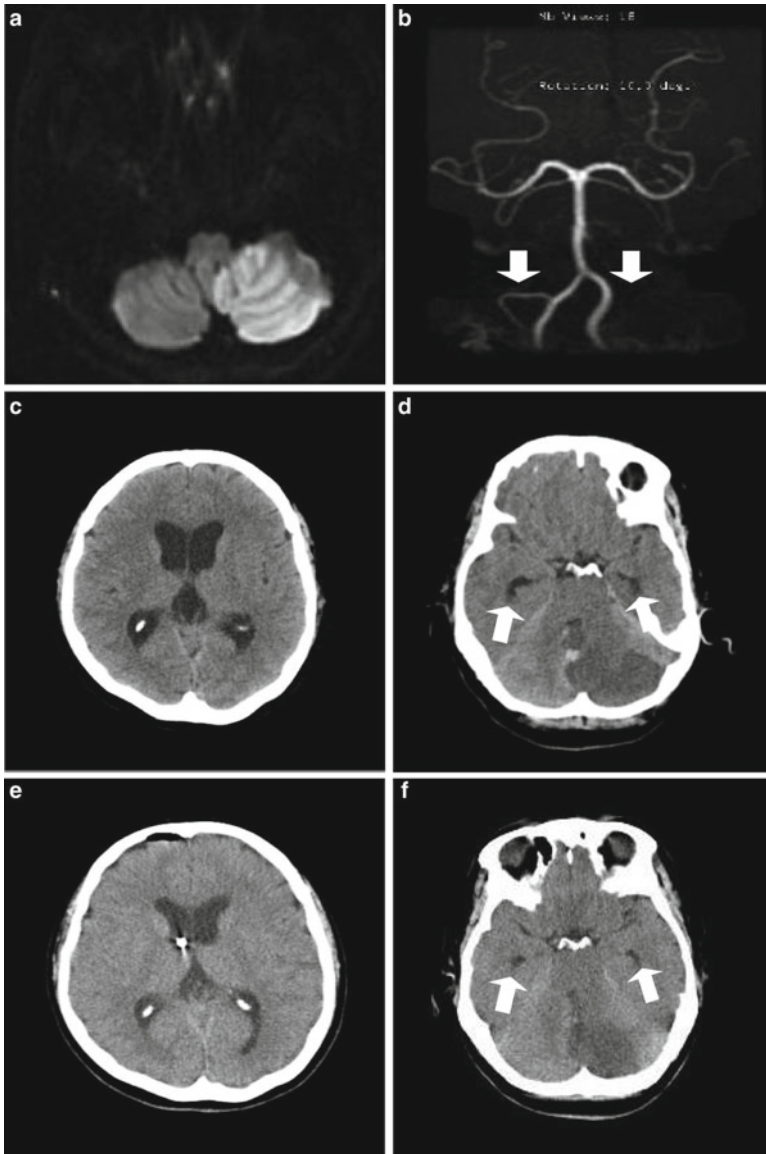
Cerebellar infarctions can be divided into territorial infarcts and nonterritorial infarcts, which are either unilateral or bilateral. The leading cause of cerebellar infarcts are emboli arising from cardiac or intra-arterial sources at the orifice of the vertebral artery (Caplan et al. 2004). In unilateral PICA infarction, cardioembolism is found in one fifth of the cases (Kumral et al. 2005b). More than one third of patients have steno-occlusive subclavian- vertebral atherosclerotic disease, which may cause multiple artery to artery embolisms or hemodynamic compromise (Min et al. 1999; Shin et al. 1999). In situ branch disease is present in one fifth of PICA infarction. In situ branch disease often induces PICA territorial or nonterritorial lesions. However, Kim et al. (1998) have found that cerebellar involvement is rare in patients with isolated PICA disease, supporting the concept that the collateral circulation system is effective within the cerebellum through the AICA or the SCA. In more than two-thirds of cases, the main cause of AICA infarction is the thrombotic occlusion of AICA itself or the progression of vertebrobasilar system atherosclerosis into the AICA (Tohgi et al. 1993; Kumral et al. 2006). In one-fifth of patients, the causes of cardioembolism are detectable, but more than three-fourth of these patients also have a concomitant vertebrobasilar atherosclerosis (Kumral et al. 2006). The most common mechanism of SCA infarction is embolic, resulting from either cardioembolism or artery-to-artery embolism. Cardioembolic source can be detected in one third of the patients with the SCA infarction (Kumral et al. 2005a) and atherosclerotic disease of the vertebrobasilar system in one third of cases (Amarenco et al. 1994). Small cerebellar infarcts are frequently associated with large artery disease involving the basilar or vertebral arteries and cardioembolism (Amarenco et al. 1993b, 1994). Small cerebellar infarcts are usually located in cortical areas, not within well-defined arterial regions, and thus are regarded as border zone infarcts (Amarenco et al. 1993b). Border zone infarction can be explained by a combination of hemodynamic mechanism and embolism (Caplan and Hennerici 1998). Alternatively, small cerebellar infarcts may be end artery area infarcts from the small artery disease in patients with no embolic source from the heart or large arteries (Canaple and Bogousslavsky 1999). A previous pathologic report showed that the deep cerebellum is one of the predilection sites of lacunar infarction (Fisher 1965). Bilateral cerebellar infarctions have similar characteristics in the territory involved as compared to unilateral cerebellar infarction, but they are more likely to have a stroke mechanism of large artery atherosclerosis, and have a higher rate of stroke recurrence (Hong et al. 2008).

### 76.3.2 *Diagnosis*

The widely used brain imaging technique is CT, which provides images very quickly and accurately excludes acute hemorrhage. However, this technique is hampered by a low sensitivity for acute ischemic stroke within the first few hours, especially for infarctions in the posterior fossa (Chalela et al. 2007). MRI is a more sensitive method for visualization of affected cerebellar structures within the posterior fossa (Schmahmann et al. 2000), and thus enables to establish various types of stroke, including small and large territorial infarcts, hemorrhages, and venous infarcts, and to correlate them with the clinical findings and outcome (Barth et al. 1993; Canaple and Bogousslavsky 1999). MRI becomes more sensitive when diffusion weighted imaging (DWI) is added, having 80–95% sensitivity in the first 24 h (Chalela et al. 2007). DWI can detect small ischemic lesions in the very early time window after the onset of symptoms, in contrast to the CT and conventional MRI (Roh et al. 2000; Kang et al. 2000). The methods to evaluate cerebrovascular status include Doppler ultrasound, CT angiography (CTA), MRA, and conventional angiography. Doppler ultrasound has advantages of early availability, monitoring, and low cost, whereas it is limited by a relatively poor accuracy in the posterior circulation as compared to the anterior circulation. CTA is known to be more sensitive than Doppler ultrasound and MRA in patients with vertebral artery pathology (Bash et al. 2005). However, the exposure of a potentially toxic dye and radiation limit the use of this technique. MRA overcomes this limitation, but it is less available and requires more time to acquire images compared with CTA. Conventional angiography can demonstrate the exact pathology of cerebellar vessels but this technique has procedure-related complications, in addition to all the disadvantages of CTA. As in cases of other strokes, cardiac evaluations such as echocardiography and Holter monitoring are useful to identify a potential cardioembolic source.

### 76.3.3 *Space-Occupying Infarction*

Subsequent edema formation from the initial infarct often becomes space occupying within the posterior fossa, leading to brainstem compression, hydrocephalus, cardiorespiratory distress, altered consciousness, and death (Koh et al. 2000). This complication occurs in 10–25% of patients, peaking on the third day after the infarction (Hornig et al. 1994; Koh et al. 2000). The critical factors for this process include the infarct size, vasculopathy type, association with hemorrhagic transformation, and lack of collateral flow. Figure 76.2 shows a representative large PICA infarction with hydrocephalus and brainstem compression. A progressive decline in level of consciousness and secondary brain stem signs are common clinical manifestations (Hornig et al. 1994). The outcome after sizeable cerebellar infarction



**Fig. 76.2** Natural course of space-occupying cerebellar infarction in a woman. Brain MRI (a) and MRA (b) showed left cerebellar infarction in the PICA territory and occlusion of the left PICA (arrow). Her consciousness worsened 2 days after onset, and brain CT (c, d) showed acute hydrocephalus (arrow) and brainstem compression. Ventricular drainage (e, f) resolved the hydrocephalus and her mental status returned to normal

depends mainly on the level of consciousness (Hornig et al. 1994). Therefore, close monitoring for signs of mental alteration is crucial. If deterioration occurs, the progression from the original vascular lesion with or without brainstem ischemia must be differentiated from brainstem compression or hydrocephalus, because the treatments for each status might be different. Hemorrhagic transformation also increases the likelihood of mass effect (Koh et al. 2000). Hemorrhagic transformation usually occurs within the first week of stroke onset, but sometimes in the second and third week after stroke onset (Chaves et al. 1996). The main mechanism of cerebellar hemorrhagic infarction is embolic, from cardiac or proximal artery sources, similar to the mechanism in the anterior circulation (Chaves et al. 1996).

### **76.3.4 Treatment**

Treatment guidelines correspond to the general recommendations for acute ischemic stroke. Airway, breathing, and circulation should be maintained as first priorities. Arterial hypertension should be managed with different threshold pressures depending on the individual hemodynamic profile. Patients whose blood pressure is greater than 220/120 mmHg should be treated with antihypertensive drugs, while, in the occasional patient with hemodynamically fluctuating symptoms, therapy to augment cerebral blood flow might be considered (Adams et al. 2007). Patients with cerebellar infarction can be treated with intravenous thrombolysis according to the NINDS criteria (1995) and others (Köhrmann et al. 2009). However, randomized trials specific for cerebellar stroke are scarce, and most trials have generally excluded patients with cerebellar infarction. Nonetheless, thrombolysis might be equally beneficial for both territories, because an embolic etiology is more frequently observed in cerebellar infarction (Tohgi et al. 1993). Endovascular balloon angioplasty, stenting, and stent-assisted coiling are being increasingly used. These interventions have been effective in patients with vertebral artery dissections, and extracranial and intracranial vertebral artery atherosclerosis, sometimes in combination with intra-arterial thrombolysis. The recommended therapy given in international guidelines is surgical intervention in case of a space-occupying infarction. Surgical procedures include external ventricular drainage (EVD), suboccipital craniotomy, or staged or combined procedures. Craniotomy should be considered in patients with mental deterioration and clinical and neuroimaging signs of brainstem compression (Mathew et al. 1995). In patients with altered consciousness and hydrocephalus, hydrocephalus should be treated with EVD (Raco et al. 2003). However, EVD in patients with posterior fossa mass lesions may paradoxically increase the risk of upward transtentorial herniation (Kase and Wolf 1993). If consciousness does not improve, decompression of the posterior fossa should be urgently undertaken (Raco et al. 2003). Corticosteroid is known to be ineffective and the effects of hyperventilation or osmotic diuretics are controversial or transient (Adams et al. 2007). Elevation of the head can improve venous drainage, but the effect is not dramatic.

## 76.4 Cerebellar Hemorrhage

Cerebellar hemorrhage is another presentation of the spectrum of the cerebellar stroke. Patients have similar clinical features to cerebellar infarction on initial examination. However, patients with a cerebellar hemorrhage are at higher risk of neurologic deterioration and mortality (St Louis et al. 1998). Spontaneous cerebellar hemorrhage occurs most frequently in the area of the dentate nucleus and can spread to involve most of a cerebellar hemisphere and occasionally cross the midline. They often extend into cerebellar peduncles, and rupture into the fourth ventricle, potentially inducing a hydrocephalus, even though the size of hemorrhage is small, if it involves the vermis (Jensen and St Louis 2005). In addition, the aqueduct of Sylvius may be obliterated due to upward herniation of cerebellar vermis through the tentorial notch. As for cerebellar infarction, the patients with cerebellar hemorrhage have a high risk of atherosclerosis such as hypertension. About two thirds of cerebellar hemorrhage patients have hypertension. Amyloid angiopathy is one of causes of cerebellar hemorrhage, but its incidence is likely to be low, because cerebellar hemorrhage frequently occurs under age of 60 (Itoh et al. 1993). In spite of unclear mechanisms of cerebellar hemorrhage, it is important to maintain optimal blood pressure to prevent progression and recurrence. The predictors associated with outcome of cerebellar hemorrhage include abnormal corneal and oculoccephalic reflexes, a Glasgow Coma Scale (GCS) score less than 8, and systolic blood pressure greater than 200 mmHg (Mezzadri et al. 1993; Kobayashi et al. 1994). Moreover, the CT scan features suggesting a poor prognosis are a hematoma size greater than 3 cm in diameter, clear visualization of distorted brainstem, progressive hydrocephalus and the presence of intraventricular hemorrhage on initial CT (Jensen and St Louis 2005). In contrast to patients with cerebellar infarction, the course of neurological worsening in cerebellar hemorrhage develops more rapidly. A widely accepted surgical intervention is to evacuate a cerebellar hemorrhage by suboccipital craniotomy. Neurosurgical treatment will be considered in cases of deterioration over 24 h, especially with a hematoma larger than 3 cm and/or moderate hydrocephalus on the CT scan. The findings of ongoing clinical trials emphasize the importance of hypertension management and urgent correction of coagulopathy (Elijovich et al. 2008). Adequate control of blood pressure is likely to minimize the chances of hemorrhage re-bleeding.

## References

- Adams HP Jr, del Zoppo G, Alberts MJ et al (2007) Guidelines for the early management of adults with ischemic stroke: a guideline from the American Heart Association/American Stroke Association Stroke Council, Clinical Cardiology Council, Cardiovascular Radiology and Intervention Council, and the Atherosclerotic Peripheral Vascular Disease and Quality of Care Outcomes in Research Interdisciplinary Working Groups: the American Academy of Neurology

- affirms the value of this guideline as an educational tool for neurologists. *Stroke* 38:1655–1711
- Aggarwal S, Byrne BD (1991) Massive ischemic cerebellar infarction due to cocaine use. *Neuroradiology* 33:449–450
- Amarenco P, Hauw JJ (1990) Cerebellar infarction in the territory of the anterior and inferior cerebellar artery. *Brain* 113:139–155
- Amarenco P, Hauw JJ, Gautier JC (1990) Arterial pathology in cerebellar infarction. *Stroke* 21:1299–1305
- Amarenco P, Kase CS, Rosengart A et al (1993) Very small (border zone) cerebellar infarcts: distribution, causes, mechanisms and clinical features. *Brain* 116:161–186
- Amarenco P, Levy C, Cohen A et al (1994) Causes and mechanisms of territorial and nonterritorial cerebellar infarcts in 115 consecutive patients. *Stroke* 25:105–112
- Baier B, Stoeter P, Dieterich M (2009) Anatomical correlates of ocular motor deficits in cerebellar lesions. *Brain* 132:2114–2124
- Barth A, Bogousslavsky J, Regli F (1993) The clinical and topographic spectrum of cerebellar infarcts: a clinicalmagnetic resonance imaging correlation study. *Ann Neurol* 33:451–456
- Barth A, Bogousslavsky J, Regli F (1994) Infarcts in the territory of the lateral branch of the posterior inferior cerebellar artery. *J Neurol Neurosurg Psychiatry* 57:1073–1076
- Bash S, Villablanca JP, Jahan R et al (2005) Intracranial vascular stenosis and occlusive disease: evaluation with CT angiography, MR angiography, and digital subtraction angiography. *AJNR Am J Neuroradiol* 26:1012–1021
- Bogousslavsky J, Regli F, Maeder P et al (1993) The etiology of posterior circulation infarcts: a prospective study using magnetic resonance imaging and magnetic resonance angiography. *Neurology* 43:1528–1533
- Canaple S, Bogousslavsky J (1999) Multiple large and small cerebellar infarcts. *J Neurol Neurosurg Psychiatry* 66:739–745
- Caplan LR, Hennerici M (1998) Impaired clearance of emboli (washout) is an important link between hypoperfusion, embolism, and ischemic stroke. *Arch Neurol* 55:1475–1482
- Caplan LR, Wityk RJ, Glass TA et al (2004) New England Medical Center Posterior Circulation registry. *Ann Neurol* 56:389–398
- Chalela JA, Kidwell CS, Nentwich LM et al (2007) Magnetic resonance imaging and computed tomography in emergency assessment of patients with suspected acute stroke: a prospective comparison. *Lancet* 369:293–298
- Chaves CJ, Pessin MS, Caplan LR et al (1996) Cerebellar hemorrhagic infarction. *Neurology* 46:346–349
- Elijovich L, Patel PV, Hemphill JC 3rd (2008) Intracerebral hemorrhage. *Semin Neurol* 28:657–667
- Fisher CM (1965) Lacunes: small, deep cerebral infarcts. *Neurology* 15:774–784
- Flaherty ML, Woo D, Haverbusch M et al (2005) Racial variations in location and risk of intracerebral hemorrhage. *Stroke* 36:934–937
- Hong JM, Bang OY, Chung CS et al (2008) Frequency and clinical significance of acute bilateral cerebellar infarcts. *Cerebrovasc Dis* 26:541–548
- Hornig CR, Rust DS, Busse O et al (1994) Space-occupying cerebellar infarction. *Clin Course Prognosis Stroke* 25:372–374
- Itoh Y, Yamada M, Hayakawa M et al (1993) Cerebral amyloid angiopathy: a significant cause of cerebellar as well as lobar cerebral haemorrhage in the elderly. *J Neurol Sci* 116:135–141
- Jensen MB, St Louis EK (2005) Management of acute cerebellar stroke. *Arch Neurol* 62:537–544
- Jung KH, Roh JK (2013) Cerebellar stroke. In: Manto M et al (eds) *Handbook of the cerebellum and cerebellar disorders*. Springer, New Delhi, pp 1959–1983

- Kang DW, Lee SH, Bae HJ et al (2000) Acute bilateral cerebellar infarcts in the territory of posterior inferior cerebellar artery. *Neurology* 55:582–584
- Kase CS, Wolf PA (1993) Cerebellar infarction: upward transtentorial herniation after ventriculostomy letter. *Stroke* 24:1096–1098
- Kim JS, Lee JH, Choi CG (1998) Patterns of lateral medullary infarction: vascular lesion-magnetic resonance imaging correlation of 34 cases. *Stroke* 29:645–652
- Kobayashi S, Sato A, Kageyama Y et al (1994) Treatment of hypertensive cerebellar hemorrhage: surgical or conservative management? *Neurosurgery* 34:246–251
- Koh MG, Phan TG, Atkinson KL, Wijdicks EF (2000) Neuroimaging in deteriorating patients with cerebellar infarcts and mass effect. *Stroke* 31:2062–2067
- Köhrmann M, Sauer R, Huttner HB et al (2009) MRI mismatch-based intravenous thrombolysis for isolated cerebellar infarction. *Stroke* 40:1897–1899
- Kumral E, Kisabay A, Atac C (2005a) Lesion patterns and etiology of ischemia in superior cerebellar artery territory infarcts. *Cerebrovasc Dis* 19:283–290
- Kumral E, Kisabay A, Atac C et al (2005b) Spectrum of the posterior inferior cerebellar artery territory infarcts. Clinical-diffusion-weighted imaging correlates. *Cerebrovasc Dis* 20:370–380
- Kumral E, Kisabay A, Atac C (2006) Lesion patterns and etiology of ischemia in the anterior inferior cerebellar artery territory involvement: a clinical-diffusion weighted MRI study. *Eur J Neurol* 13:395–401
- Lee H (2009) Neuro-otological aspects of cerebellar stroke syndrome. *J Clin Neurol* 5:65–73
- Lee H, Sohn SI, Cho YW et al (2006) Cerebellar infarction presenting isolated vertigo: frequency and vascular topographical patterns. *Neurology* 67:1178–1183
- Mathew P, Teasdale G, Bannan A, Oluoch-Olunya D (1995) Neurosurgical management of cerebellar haematoma and infarct. *J Neurol Neurosurg Psychiatry* 59:287–292
- Manes F, Villamil AR, Ameriso S et al (2009) “Real life” executive deficits in patients with focal vascular lesions affecting the cerebellum. *J Neurol Sci* 283:95–98
- McLean CA, Gonzales MF, Dowling JP (1993) Systemic giant cell arteritis and cerebellar infarction. *Stroke* 24:899–902
- Mezzadri JJ, Otero JM, Ottino CA (1993) Management of 50 spontaneous cerebellar haemorrhages: importance of obstructive hydrocephalus. *Acta Neurochir Wien* 122:39–44
- Min WK, Kim YS, Kim JY et al (1999) Atherothrombotic cerebellar infarction: vascular lesion-MRI correlation of 31 cases. *Stroke* 30:2376–2381
- Norrving B, Magnusson M (1995) Isolated acute vertigo in the elderly; vestibular or vascular disease? *Acta Neurol Scand* 91:43–48
- Raco A, Caroli E, Isidori A, Vangelista T (2003) Management of acute cerebellar infarction: one institution’s experience. *Neurosurgery* 53:1061–1066
- Reid J, Riding M, Purdy A, Phillips S (2006) Acute migraine-associated borderzone cerebellar infarction. *Cephalalgia* 26:1247–1251
- Roh JK, Kang DW, Lee SH et al (2000) Significance of acute multiple brain infarction on diffusion-weighted imaging. *Stroke* 31:688–694
- Salvati M, Cervoni L, Raco A, Delfini R (2001) Spontaneous cerebellar hemorrhage: clinical remarks on 50 cases. *Surg Neurol* 55:156–161
- Schievink WI (2001) Spontaneous dissection of the carotid and vertebral arteries. *N Engl J Med* 344:898–906
- Schmahmann JD, Sherman JC (1998) The cerebellar cognitive affective syndrome. *Brain* 121:561–579
- Schmahmann JD, Doyon J, Toga AW et al (2000) MRI atlas of the human cerebellum. Academic, San Diego
- Shin HK, Yoo KM, Chang HM, Caplan LR (1999) Bilateral intracranial vertebral artery disease in the New England Medical Center Posterior Circulation Registry. *Arch Neurol* 56:1353–1358
- Sohn SI, Lee H, Lee SR, Baloh RW (2006) Cerebellar infarction in the territory of the medial branch of the superior cerebellar artery. *Neurology* 66:115–117

- St Louis EK, Wijdicks EF, Li H (1998) Predicting neurologic deterioration in patients with cerebellar hematomas. *Neurology* 51:1364–1369
- The national institute of neurological disorders and stroke rt-PA stroke study group (1995) Tissue plasminogen activator for acute ischemic stroke. *N Engl J Med* 333:1581–1587
- Tohgi H, Takahashi S, Chiba K, Hirata Y (1993) Cerebellar infarction. Clinical and neuroimaging analysis in 293 patients. The Tohoku Cerebellar Infarction Study Group. *Stroke* 24:1670–1697
- Urban PP, Marx J, Hunsche S et al (2003) Cerebellar speech representation: lesion topography in dysarthria as derived from cerebellar ischemia and functional magnetic resonance imaging. *Arch Neurol* 60:965–972
- Ye BS, Kim YD, Nam HS et al (2010) Clinical manifestations of cerebellar infarction according to specific lobular involvement. *Cerebellum* 9:571–579, In press



# Chapter 77

## Immune Diseases

Marios Hadjivassiliou

**Abstract** The cerebellum can be the primary organ for immune mediated insults perhaps more commonly than the rest of the brain. The reasons for this remain unclear. Perhaps this relates to the morphologically distinct classes of cells that are very different to the rest of the brain, as well as the complex and multiple connections it has with almost the whole of the rest of the central nervous system. This chapter will discuss a number of such immune mediated ataxias that include primary autoimmune cerebellar ataxia, gluten ataxia, anti-GAD ataxia and post infectious cerebellitis.

**Keywords** Immune ataxias • Primary autoimmune cerebellar ataxia • Anti-GAD ataxia • Gluten ataxia • Post infective cerebellitis

### 77.1 Primary Autoimmune Cerebellar Ataxia (PACA)

There is emerging evidence to suggest that the cerebellum can at times be an organ specific autoimmune disease termed Primary Autoimmune Cerebellar Ataxia (PACA). The evidence in support of PACA comes from a number of observations. First, The Human Lymphocyte Antigen (HLA) type DQ2 is significantly overrepresented in patients with idiopathic sporadic ataxia (Hadjivassiliou et al. 2008a). This HLA type has been shown to have a strong association with autoimmune diseases. Secondly it has been shown that there is a significantly higher prevalence of one or more autoimmune diseases in patients with idiopathic sporadic ataxia when compared to the general population and to patients with genetic ataxias, 47%, 3% and 5% respectively (Hadjivassiliou et al. 2008b). Thirdly antibodies against cerebellar neurons are present in at least 60% of patients with idiopathic sporadic ataxia by contrast to 5% in patients with genetic ataxias (Hadjivassiliou et al. 2008a). Finally, studies have shown that idiopathic sporadic cerebellar ataxia is consistently associated with the presence of a number of different autoantibodies (e.g. anti-GAD).

---

M. Hadjivassiliou (✉)

Academic Department of Neurosciences, Royal Hallamshire Hospital, Sheffield, UK  
e-mail: [m.hadjivassiliou@sheffield.ac.uk](mailto:m.hadjivassiliou@sheffield.ac.uk)

The diagnosis of PACA is at present problematic. As the HLA DQ 2 is found in up to 35 % of healthy individuals, this test alone cannot serve as the only marker of patients with autoimmune ataxia. Furthermore it is likely that PACA may exist without HLA DQ2. The presence of additional autoimmune diseases in either the patient or their first-degree relatives may be another clue. Further characterisation of the antibodies mentioned above may prove to be helpful in the diagnosis of PACA.

Patients with PACA tend to develop ataxia in their early 50s. They exhibit pure ataxia that, in general, tends to be slowly progressive. They almost always have cerebellar atrophy on MRI with a particular predilection for the vermis. The severity of atrophy depends on disease duration. There are small series or case reports reporting improvement of the ataxia with immune treatments such as intravenous immunoglobulins (Takeguchi et al. 2006).

## 77.2 Gluten Ataxia

Gluten ataxia (GA) was originally defined as otherwise idiopathic sporadic ataxia with positive serological markers for gluten sensitivity (Hadjivassiliou et al. 1998, 2003a). It is one of the commonest immune mediated ataxias and accounts for up to 40 % of ataxias amongst patients with sporadic idiopathic ataxia. Gluten ataxia is part of the spectrum of Gluten Related Diseases in which Coeliac Disease (also known as gluten sensitive enteropathy) is the best characterised entity.

GA usually presents with pure cerebellar ataxia or rarely ataxia in combination with myoclonus (Sarrigiannis et al. 2014). GA is usually of insidious onset with a mean age at onset of 53 years. All patients have gait ataxia and the majority have limb ataxia. Less than 10 % of patients with GA will have any gastrointestinal symptoms but 40 % will have evidence of enteropathy on duodenal biopsy. Anti-TG2 IgA antibodies (TG: transglutaminase; a marker for coeliac disease) are present in up to 40 % of patients. A more specific marker, anti-TG6 antibodies is present in over 70 % of GA patients (Hadjivassiliou et al. 2013).

Up to 60 % of patients (depending on time of diagnosis and duration of ataxia) have evidence of cerebellar atrophy on MR imaging and all of them have abnormal spectroscopy of the vermis. Like other autoimmune ataxias the vermis appears to be the primary target.

The response to treatment with a gluten-free diet depends on the duration of the ataxia prior to the diagnosis. Whilst the benefits of a gluten-free diet in the treatment of patients with coeliac disease have long been established, there are very few studies, mainly case reports, of the effect of gluten-free diet on the ataxia. These studies suggest variable but overall favourable responsiveness to a gluten-free diet. A small, uncontrolled study showed improvement with intravenous immunoglobulins in 4 patients with GA without enteropathy (Bürk et al. 2001). Only one large systematic study of the effect of gluten-free diet on a cohort of patients presenting with ataxia, with or without an enteropathy, has been published (Hadjivassiliou et al. 2003b). This showed significant improvement in performance of ataxia tests scores and in

the subjective global clinical impression scale in the treatment group when compared to the control group.

The current recommendations are that patients presenting with sporadic idiopathic and progressive cerebellar ataxia should be screened for gluten sensitivity using anti-gliadin IgG and IgA, anti-TG2 antibodies, endomysium and if available anti-TG6 antibodies. Patients positive for any of these antibodies with no alternative cause for their ataxia should undergo gastroscopy and duodenal biopsy and be offered a strict gluten free diet irrespective of the presence of an enteropathy, with regular follow up to ensure that the antibodies are eliminated (usually takes 1 year). Stabilisation or improvement of the ataxia at 1 year, often associated with improvement of the spectroscopic findings on MR spectroscopy, would be a strong indicator that the patient should continue on a gluten free diet for life. The commonest reason for lack of response is compliance with the diet. If patients are indeed strict with their gluten free diet yet continue to progress the use of immunosuppressive medication should be considered.

The pathophysiology of GA has an immunological basis. An immune response directed against the brain-expressed transglutaminase TG6 may be responsible for the cerebellar damage (Hadjivassiliou et al. 2008b). There is evidence of cross-reactivity of TG6 and other gluten related antibodies with neural tissue as well as evidence of induction of ataxia in mice using serum from patients with GA (Hadjivassiliou et al. 2002; Boscolo et al. 2010).

### 77.3 Anti-GAD Antibodies and Ataxia

Glutamic acid decarboxylase (GAD) is the rate-limiting enzyme in the synthesis of the inhibitory neurotransmitter gamma-aminobutyric acid (GABA). GAD is found in both the central and peripheral nervous systems. Anti-GAD antibodies are usually found in patients with multiple autoimmune diseases. They were first identified in type 1 diabetes, and subsequently found in patients with stiff person syndrome (SPS). Evidence for anti-GAD antibodies being a marker of multiple autoimmunity comes from the observation that one or more additional autoimmune disorders are present in 60% of anti-GAD positive patients with SPS versus 6% in anti-GAD negative patients (Ellis and Atkinson 1996). Thus the finding of high prevalence of anti-GAD antibodies in patients with idiopathic sporadic ataxia who often have an additional autoimmune disease may signify that the ataxia in these cases is due to autoimmunity. It has been suggested that anti-GAD antibodies are not simply an epiphenomenon but may be a predisposing factor or a marker for the development of multiple autoimmune diseases. For example anti-GAD antibodies can predict the development of insulin dependent diabetes (Tuomilehto et al. 1994).

Anti-GAD antibodies have also been reported in some cases of sporadic ataxia. A number of case reports followed, culminating in the publication of a study of 14 patients with anti-GAD antibodies and ataxia (Honnorat et al. 2001). The prevalence of these antibodies amongst patients with sporadic ataxia varies. One study

found no evidence of such antibodies in 112 patients with sporadic ataxia (Abele et al. 2002). Based on the series of patients from the Sheffield ataxia clinic the prevalence of anti-GAD antibodies amongst idiopathic sporadic ataxia cases was 24/293 (8%).

The ataxia associated with GAD antibodies is usually slowly progressive. Interestingly most patients with SPS have a degree of cerebellar atrophy on MR imaging but in these patients it is the stiffness and spasms that cause the disability. Immunomodulation can be beneficial (Lauria et al. 2003; Virgilio et al. 2009).

Is there a direct pathogenic role for anti-GAD antibodies in causing cerebellar dysfunction? Clearly anti-GAD antibodies are found in a number of diverse autoimmune systemic and neurological conditions. Such diversity may be explained by different epitope recognition by these antibodies. A pathogenic role has been suggested in *in vitro* experiments using serum from patients and looking at cerebellar synapses, as well as *in vivo* studies in rodents (Ishida et al. 1999; Manto et al. 2007). In such experiments however, the use of serum from patients with SPS does not necessarily imply that it is the anti-GAD antibody that exerts such effects.

## 77.4 Post-Infectious Cerebellitis

Post-infectious cerebellitis refers to an immune mediated ataxia that usually follows on from a bacterial or viral infection. It accounts for as much as 0.4% of neurological presentations in children but is less common in adults. Data from the Sheffield ataxia clinic show that presumed post-infectious cerebellitis accounted for 17/286 (6%) of all idiopathic sporadic ataxias.

The first description of an acute cerebellar syndrome associated with infection (smallpox) was published in 1872 (Westbhal 1872). Since then, there have been numerous reports of post-infectious cerebellitis, predominantly in children, associated with specific infections, commonly viral such as influenza, parainfluenza, mumps, measles, rubella, poliomyelitis, variola, cytomegalovirus, vaccinia, ECHO, coxsackie, varicella, herpes simplex, herpes zoster and Epstein-Barr virus (EBV). Ataxia has also been associated with bacterial infections such as pertussis, typhoid, scarlet fever, Q fever, diphtheria, leptospirosis, mycoplasma and Legionaire's disease.

Post-infectious cerebellitis makes up 50% of all neurological sequelae of varicella infection in children. It is estimated that 0.1% of patients with varicella infection will develop neurological dysfunction (Kennedy 1987). A large series of 73 patients with acute cerebellitis in childhood reported varicella virus as the commonest infective agent (26%). In adults the commonest preceding infection is EBV.

The cerebellitis is thought to be immunologically mediated. One study demonstrated the presence of antineuronal antibodies following EBV infection (Ito et al. 1994). Another demonstrated antibodies against triosephosphate isomerase in 8 out of 23 patients with acute cerebellitis due to EBV. The titre of this antibody correlated with clinical improvement (Uchobori et al. 2005).

Case reports of fatal cerebellitis usually due to severe swelling and brain herniation are the only source of pathology. The neuropathological findings are compatible with an acute meningoencephalitis whilst other reports are more in favour of a post-infectious immune reaction similar to acute disseminated encephalomyelitis (Sawaishi and Takada 2002). Such reports need to be treated with caution as they are based on fulminant illness unlike most of the cases where full recovery is the norm.

The clinical features of a series of paediatric cases consisted of predominantly gait and lower limb ataxia. The peak incidence was at 3 years of age. Thirty four percent of the children had severe gait ataxia with inability to walk. The mean latency from onset of prodromal illness to onset of ataxia was 9.9 days. The recovery period averaged at about 2 months with the majority of the patients (88 %) making a full recovery (Connolly et al. 1994). In adult series the clinical features were very similar. However, the latency from onset of prodromal illness to development of ataxia was longer at 3.5 weeks. Complete recovery was observed in 9/11 (82 %) of these patients within a mean of 12 weeks (Klockgether et al. 1993). Cerebrospinal fluid examination showed elevation of white cell count, predominantly lymphocytes, in 50 % of patients and high protein in about 30 % of patients.

There is no evidence to suggest that treatment of the underlying infective agent impacts on the neurological sequelae. Management is supportive in the form of physiotherapy and occupational therapy during the symptomatic phase of the illness.

## References

- Abele M, Bürk K, Schöls L et al (2002) The aetiology of sporadic adult-onset ataxia. *Brain* 125:961–968
- Boscolo S, Lorenzon A, Sblattero D et al (2010) Anti Transglutaminase antibodies cause ataxia in mice. *PLoS One* 5(3):e9698. doi:[10.1371/journal.pone.0009698](https://doi.org/10.1371/journal.pone.0009698)
- Bürk K, Melms A, Schulz JB (2001) Effectiveness of intravenous immunoglobulin therapy in cerebellar ataxia associated with gluten sensitivity. *Ann Neurol* 50:827–828
- Connolly AM, Dodson WE, Prensky AL et al (1994) Course and outcome of acute cerebellar ataxia. *Ann Neurol* 35:673–679
- Ellis TM, Atkinson MA (1996) The clinical significance of an autoimmune response against glutamic acid decarboxylase. *Nat Med* 2:148–153
- Hadjivassiliou M, Grunewald RA, Chattopadhyay AK et al (1998) Clinical, radiological, neurophysiological and neuropathological characteristics of gluten ataxia. *Lancet* 352:1582–1585
- Hadjivassiliou M, Boscolo S, Davies-Jones GAB et al (2002) The humoral response in the pathogenesis of gluten ataxia. *Neurology* 58:1221–1226
- Hadjivassiliou M, Grünewald RA, Sharrack B et al (2003a) Gluten ataxia in perspective: epidemiology, genetic susceptibility and clinical characteristics. *Brain* 126:685–691
- Hadjivassiliou M, Davies-Jones GAB, Sanders DS et al (2003b) Dietary treatment of gluten ataxia. *J Neurol Neurosurg Psychiatry* 74(9):1221–1224
- Hadjivassiliou M, Boscolo S, Tongiorgi E et al (2008a) Cerebellar ataxia as a possible organ specific autoimmune disease. *Mov Disord* 23(10):1270–1377

- Hadjivassiliou M, Aeschlimann P, Strigun A et al (2008b) Autoantibodies in gluten ataxia recognise a novel neuronal transglutaminase. *Ann Neurol* 64:332–343
- Hadjivassiliou M, Aeschlimann P, Sanders DS et al (2013) Transglutaminase 6 antibodies in the diagnosis of gluten ataxia. *Neurology* 80:1–6
- Honnorat J, Saiz A, Giometto B et al (2001) Cerebellar ataxia with anti-glutamic acid decarboxylase antibodies. *Arch Neurol* 58:225–230
- Ishida K, Mitroma H, Song SY et al (1999) Selective suppression of cerebellar GABAergic transmission by an autoantibody to glutamic acid decarboxylase. *Ann Neurol* 46:263–267
- Ito H, Sayama S, Irie S et al (1994) Antineuronal antibodies in acute ataxia following Epstein-Barr infection. *Neurology* 44:1506–1507
- Kennedy PGE (1987) Neurological complications of varicella zoster virus. In: Kennedy PGE, Johnson RT (eds) *Infections of the nervous system*. Butterworths, London, pp 177–208
- Klockgether T, Döller G, Wüllner U et al (1993) Cerebellar encephalitis in adults. *J Neurol* 240:17–20
- Lauria G, Pareyson D, Pitzolu MG et al (2003) Excellent response to steroid treatment in anti-GAD cerebellar ataxia. *Lancet* 2:634–635
- Manto M, Laure M, Aguera M et al (2007) Effects of anti-glutamic acid decarboxylase antibodies associated with neurological diseases. *Ann Neurol* 61:544–551
- Sarrigiannis PG, Hoggard N, Aeschlimann D et al (2014) Myoclonus ataxia and refractory coeliac disease. *Cerebellum & Ataxias* 1;1:11. doi: 10.1186/2053-8871-1-11
- Sawaishi Y, Takada G (2002) Acute cerebellitis. *Cerebellum* 1:223–228
- Takeguchi M, Nanri K, Okita M et al (2006) Efficacy of intravenous immunoglobulin for slowly progressive cerebellar atrophy. *Rinsho Shinkeigaku (Japanese)* 46:467–474
- Tuomilehto J, Zimmet P, Mackay IR (1994) Antibodies to glutamic acid decarboxylase as predictors of insulin dependent diabetes mellitus before clinical onset of disease. *Lancet* 343:1383–1385
- Uchibori A, Sakuta M, Kusunoki S et al (2005) Autoantibodies in postinfectious acute cerebellar ataxia. *Neurology* 65:1114–1116
- Virgilio R, Corti S, Agazzi P et al (2009) Effect of steroid treatment in cerebellar ataxia associated with anti-GAD antibodies. *J Neurol Neurosurg Psychiatry* 80:95–96
- Westbhal C (1872) Über eine Affection des Nervensystems nach Pocken und Typhus. *Arch Psychiatr Nervenkr* 3:376–406

# Chapter 78

## Paraneoplastic Cerebellar Degeneration

Raffaele Iorio and Peter Sillevs Smitt

**Abstract** Paraneoplastic neurological syndromes (PNS) are an extensive group of neurologic disorders that occur in patients with cancer and can affect any part of the nervous system.

Paraneoplastic cerebellar degeneration (PCD) is one of the most common PNS. PCD can be associated with any cancer, although it most commonly occurs in the setting of small cell lung cancer, gynecologic and breast cancer, and Hodgkin lymphoma. PCD can be associated with autoantibodies binding to intracellular or plasma-membrane neural antigens. Most of the antibodies that can be associated with PCD can also be detected in other PNS, but each antibody predicts the presence of specific types of cancers. Thus the detection of a specific antibody should guide the cancer search. Early diagnosis of PCD is critical because it offers the unique opportunity to discover an occult and potentially treatable neoplasm. In this chapter the immunobiology and the clinical characteristics of PCD are presented.

**Keywords** Ataxia • Autoantibodies • Autoimmune diseases • Cancer

### 78.1 Introduction

Paraneoplastic neurological syndromes (PNS) can be defined as remote effects of cancer that are not caused by invasion of the tumor and its metastases, or by metabolic and nutritional deficits, infections, coagulopathy or side effects of cancer therapy (Darnell and Posner 2003). PNS are rare, occurring in less than 1% of patients with cancer. However, the diagnosis of these syndromes is important because it can lead to the discovery of an occult and not yet diffuse neoplasm. Evidence has mounted that the majority of PNS is immune-mediated.

---

R. Iorio (✉)

Institute of Neurology, Department of Geriatrics, Neuroscience and Orthopedics, Catholic University, L.go Gemelli, 8, 00168 Rome, Italy  
e-mail: [raffaele.iorio@policlinicogemelli.it](mailto:raffaele.iorio@policlinicogemelli.it)

P. Sillevs Smitt

Erasmus University Medical Center, Rotterdam, Netherlands

Immunoglobulin G (IgG) autoantibodies specific for neural proteins expressed by the neoplasms (e.g. onconeural antigens) have been documented in several PNS and their identification helps direct the cancer search and provides prognostic information. Since most antigenic targets are expressed diffusely through the nervous system, PNS can involve multiple levels of the neuraxis from cerebral cortex to the neuromuscular and autonomic synapses and muscle (Graus et al. 2004).

The molecular identification of these antigenic targets has provided insights into the pathogenic mechanisms underlying many autoimmune neurological disorders (Iorio and Lennon 2012).

Autoantibodies specific for neural antigens are classifiable generically on the basis of the target antigen location in:

- (i) Intracellular (nuclear or cytoplasmic); these autoantibodies are not pathogenic, and are considered surrogate markers of an autoimmune response mediated by CD8+ cytotoxic T cells.
- (ii) Plasma membrane; these autoantibodies with extracellular domain specificity have pathogenic potential.

The two classes of antibody can coexist.

Paraneoplastic cerebellar ataxia (PCD) is the most common PNS. It can be associated with any cancer, although some types of neoplasms (e.g. ovarian and breast cancer, small cell lung cancer and Hodgkin lymphoma) are more common (Shams'ili et al. 2003). The neurologic symptoms frequently precede the diagnosis of cancer, sometimes by an interval of years.

This chapter focuses on the immunobiology and the clinical characteristics of PCD.

## **78.2 Autoantibodies Associated with PCD**

### ***78.2.1 Antibodies Binding to Intracellular Antigens***

#### **78.2.1.1 Anti-Yo/PCA-1**

The anti-Yo antibody (also known as Purkinje cell cytoplasmic autoantibody, PCA-1) binds to the 52 kDa cerebellar degeneration related protein 2 (cdr2) which down-regulates DNA transcription through inhibition of c-Myc (Sakai et al. 1990). This autoantibody is found virtually exclusively in the setting of gynecological cancers: Mullerian carcinoma of the uterus or ovary and breast carcinoma.

#### **78.2.1.2 Anti-Hu/ANNA-1**

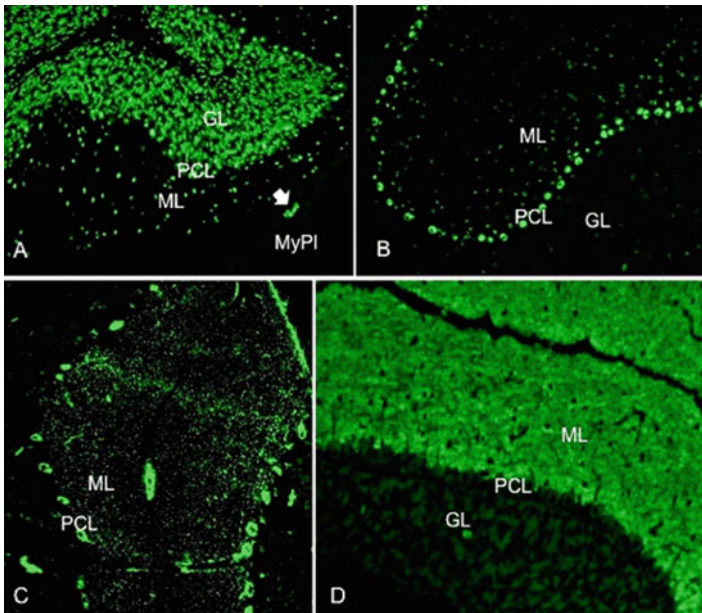
The antigen of this antibody (also known as Anti-neuronal nuclear antibody 1, ANNA-1) is the Hu family of RNA-binding proteins, which participate in



post-transcriptional regulation of RNA in postmitotic neurons (Darnell 2010). The expression of these proteins is restricted to neurons and neuroendocrine malignancies exemplified by small-cell carcinoma (Table 78.1 and Fig. 78.1).

**Table 78.1** Neural autoantibodies associated with paraneoplastic cerebellar degeneration

Antibody	Antigen	Oncological association
Anti-Yo/PCA-1	CDR2	Gynecological cancers (ovary, fallopian tube, uterus) breast adenocarcinoma
Anti-Hu/ANNA-1	Hu family of RNA binding proteins	Small cell carcinoma
Anti-Ri/ANNA-2	NOVA family of RNA binding proteins	Small-cell carcinoma, breast carcinoma
PCA-Tr	Delta/notch-like epidermal growth factor-related receptor	Hodgkin lymphoma
VGCC-IgG	P/Q-type	Small cell carcinoma
mGluR1-IgG	mGluR1	Hodgkin lymphoma, prostate adenocarcinoma



**Fig. 78.1** Immunofluorescence staining patterns yielded by antibodies associated with PCD on mouse cerebellum (a–d) and myenteric plexus (a). Anti-Hu binds to nuclei and perikaryonic cytoplasm of Purkinje, granular, and molecular layer neurons (a), and enteric ganglionic neurons (a, arrow); anti-Yo binds to Purkinje cells cytoplasm and to Golgi neurons (b). PCA-Tr immunoreactivity is restricted to cerebellar Purkinje neurons, and as fine synaptic puncta in dendritic shafts of the molecular layer (c). Antibodies binding to mGluR1 yield a strong immunoreactivity of the neuropil of the cerebellar molecular layer (d). GL= granular layer, ML= molecular layer, MyPI= Myenteric plexus, PCL= Purkinje cell layer

### 78.2.1.3 Anti-Ri/ANNA-2

Anti-Ri antibody (also known as Anti-neuronal nuclear antibody 2, ANNA-2) binds to the NOVA family of RNA binding proteins (NOVA-1 [55 kDa] and NOVA-2 [80 kDa]) responsible for alternative splicing of neuronal transcripts that encode synaptic proteins (Ueki et al. 1997; Yang et al. 1998). Associated primarily with small-cell lung cancer and breast cancer this antibody is less commonly detected compared to anti-Hu.

## 78.3 Other Autoantibodies

Other autoantibodies that can be rarely detected in patients with PCD are the Purkinje cell antibody type-2 (PCA2) and an IgG specific for the zinc-finger protein 4 (ZIC-4).

PCA2 is associated with cerebellar ataxia and other neurological disorders (encephalopathy, Lambert-Eaton myasthenic syndrome and peripheral neuropathies) occurring in the context of small cell carcinoma (Vernino and Lennon 2000).

An antibody binding to ZIC4 has been described in some patients with small-cell lung carcinoma and PCD. Seropositive patients usually have coexisting antibodies predictive of small-cell carcinoma (e.g. anti-Hu) (Bataller et al. 2004), and thus clinical utility of ZIC4 antibodies is limited.

### 78.3.1 *Antibodies Binding to Plasma-Membrane Antigens*

#### 78.3.1.1 PCA-Tr

The antibody was initially described by and named for the late Dr. John Trotter (hence the designation ‘Tr’) (Trotter et al. 1976). The PCA-Tr antibody has been considered specific for an intracellular protein until recently when its target antigen was demonstrated to be The Delta/Notch-like epidermal growth factor-related receptor, an antigen expressed on the neuronal plasma membrane (de Graaff et al. 2012). PCA-Tr-positive patients present most commonly with cerebellar ataxia in the setting of Hodgkin lymphoma.

### 78.3.1.2 mGluR1-IgG

Metabotropic glutamate receptors (mGluR) 1 is a G-protein-coupled receptor that is highly expressed in the Purkinje cells dendrites of the cerebellar molecular layer. Antibodies specific for mGluR1 have been described in five patients, two of whom had Hodgkin's lymphoma (Sillevis Smitt et al. 2000) and one prostate adenocarcinoma (Iorio et al. 2013). Interestingly mGluR1 receptor expression has been demonstrated in prostate adenocarcinoma and its expression has been correlated with cancer progression (Koochekpour et al. 2012).

### 78.3.1.3 VGCC-IgG

Autoantibodies targeting the P/Q type voltage-gated calcium channels (VGCC) are detected in over 85 % of cases of Lambert-Eaton myasthenic syndrome (LEMS) which are paraneoplastic in >70 % of the patients. Recent studies have demonstrated that the frequency of cerebellar ataxia in patients with LEMS is higher than that expected by chance, and that LEMS with cerebellar ataxia is usually associated with cancer. Antibodies specific for the P/Q type VGCC have also been found in patients with small cell lung cancer and isolated PCD (Sabater et al. 2013).

## 78.4 Clinical Characteristics and Therapeutic Strategies

The pathological hallmark of PCD is an extensive Purkinje cell loss with or without visible inflammatory infiltrate throughout the cerebellum (Giometto et al. 1997). Patients may present in a similar fashion to vestibular neuronitis or posterior circulation stroke with nausea, vomiting, diplopia, vertigo or dizziness. However the commonest clinical presentation is subacutely progressive ataxia associated with dysmetria and dysarthria. Blurred vision with oscillopsia (caused by nystagmus) is a typical symptom. Once onset has occurred rapid deterioration within weeks to months is typical.

Commonly associated neoplasms include: small cell lung carcinoma (anti-Hu, VGCC-IgG, anti-Ri), Hodgkins' lymphoma (PCA-Tr, mGluR1-IgG) and gynaecological and breast malignancies (anti-Yo, anti-Ri) (1, 4).

Occasional early transient MRI and PET abnormalities have been described such as transient diffuse cerebellar hemispheric swelling and hypermetabolism on PET-CT followed by late cerebellar atrophy and hypometabolism (de Andres et al. 2006; Choi et al. 2006). Other important differential diagnoses to consider include: chronic alcohol abuse or vitamin deficiency (e.g. vitamin E), iatrogenic cerebellar disorder (e.g. anti-epileptic drugs), infectious or post-infectious cerebellitis, Creutzfeldt-Jacob disorder, coeliac disease-related ataxia, Miller-Fisher syndrome and if the patient is known to have had cancer: cerebellar metastases or chemotherapy associated toxicity.

There is no consensus on the best management of patients with PCD. Initial treatment is aimed at eradicating the underlying cancer followed by immunotherapy. The majority of patients will stabilize at best.

Corticosteroids, IVIg, plasmapheresis (PLEX), cyclophosphamide and tacrolimus have all failed to show significant promise in treatment trials. However there are occasional case reports of successful treatment. PCA-Tr and anti-Ri associated PCD are more responsive than anti-Hu or anti-Yo disease. In theory those associated with intraneuronal antibodies are T-cell mediated and therefore should respond better to corticosteroids and/or cyclophosphamide. By contrast patients harboring cell surface antibodies (with pathogenic potential) may respond to antibody-depleting therapies (e.g. PLEX). Survival is dependent on the underlying cancer with patients harboring anti-Yo and anti-Hu surviving  $\leq 1$  year and anti-Ri and anti-Tr surviving 5–10 years after onset (Shams'ili S et al. 2003).

## References

- Bataller L, Wade DF, Graus F, Stacey HD, Rosenfeld MR, Dalmau J (2004) Antibodies to Zic4 in paraneoplastic neurologic disorders and small-cell lung cancer. *Neurology* 62(5):778–782
- Choi KD, Kim JS, Park SH, Kim YK, Kim SE, Smitt PS (2006) Cerebellar hypermetabolism in paraneoplastic cerebellar degeneration. *J Neurol Neurosurg Psychiatry* 77:525–528, 53
- Darnell RB (2010) RNA regulation in neurologic disease and cancer. *Cancer Res Treat* 42:125–129
- Darnell RB, Posner JB (2003) Paraneoplastic syndromes involving the nervous system. *N Engl J Med* 349:1543–1554
- de Andres C, Esquivel A, de Villoria JG, Graus F, Sanchez-Ramon S (2006) Unusual magnetic resonance imaging and cerebrospinal fluid findings in paraneoplastic cerebellar degeneration: a sequential study. *J Neurol Neurosurg Psychiatry* 77:562–563
- de Graaff E, Maat P, Hulsenboom E et al (2012) Identification of delta/notchlike epidermal growth factor-related receptor as the Tr antigen in paraneoplastic cerebellar degeneration. *Ann Neurol* 71(6):815–824
- Giometto B, Marchiori GC, Nicolao P et al (1997) Sub-acute cerebellar degeneration with anti-Yo autoantibodies: immunohistochemical analysis of the immune reaction in the central nervous system. *Neuropathol Appl Neurobiol* 23:468–474
- Graus F, Delattre JY, Antoine JC et al (2004) Recommended diagnostic criteria for paraneoplastic neurological syndromes. *J Neurol Neurosurg Psychiatry* 75:1135–1140
- Iorio R, Lennon VA (2012) Neural antigen-specific autoimmune disorders. *Immunol Rev* 248(1):104–121
- Iorio R, Damato V, Mirabella M et al (2013) Cerebellar degeneration associated with mGluR1 autoantibodies as a paraneoplastic manifestation of prostate adenocarcinoma. *J Neuroimmunol* 263(1–2):155–158
- Koochekpour S, Majumdar S, Azabdaftari G et al (2012) Serum glutamate levels correlate with Gleason score and glutamate blockade decreases proliferation, migration, and invasion and induces apoptosis in prostate cancer cells. *Clin Cancer Res* 18(21):5888–5901
- Sabater L, Höftberger R, Boronat A et al (2013) Antibody repertoire in paraneoplastic cerebellar degeneration and small cell lung cancer. *PLoS One* 8(3):e60438
- Sakai K, Mitchell DJ, Tsukamoto T, Steinman L (1990) Isolation of a complementary DNA clone encoding an autoantigen recognized by an antineuronal cell antibody from a patient with paraneoplastic cerebellar degeneration. *Ann Neurol* 28:692–698

- Shams'ili S, Grefkens J, de Leeuw B et al (2003) Paraneoplastic cerebellar degeneration associated with antineuronal antibodies: analysis of 50 patients. *Brain* 126(6):1409–1418
- Sillevis Smitt P, Kinoshita A, De Leeuw B et al (2000) Paraneoplastic cerebellar ataxia due to autoantibodies against a glutamate receptor. *N Engl J Med* 342:21–27
- Trotter JL, Hendin BA, Osterland CK (1976) Cerebellar degeneration with Hodgkin disease. An immunological study. *Arch Neurol* 33:660–661
- Ueki K, Ramaswamy S, Billings SJ, Mohrenweiser HW, Louis DN (1997) ANOVA, a putative astrocytic RNA-binding protein gene that maps to chromosome 19q13.3. *Neurogenetics* 1:31–36
- Vernino S, Lennon VA (2000) New Purkinje cell antibody (PCA-2): marker of lung cancer-related neurological autoimmunity. *Ann Neurol* 47:297–305
- Yang YY, Yin GL, Darnell RB (1998) The neuronal RNA-binding protein Nova-2 is implicated as the autoantigen targeted in POMA patients with dementia. *Proc Natl Acad Sci U S A* 95:13254–13259

# Chapter 79

## Essential Tremor

Elan D. Louis

**Abstract** Essential tremor (ET) is a chronic, progressive neurologic disease. Its central feature is a 4- to 12-Hz kinetic tremor (i.e., tremor occurring during voluntary movement). Along with an emerging appreciation of the presence of etiological, clinical, and pathological heterogeneity, there is growing support for the notion that ET itself may be a family of diseases whose central defining feature is kinetic tremor of the arms, and which might more accurately be referred to as “the essential tremors”. Clinical and scientific advances have increasingly placed the seat of the disease in the cerebellum and cerebellar system.

**Keyword** Tremor


### 79.1 Introduction

Essential tremor (ET) is a chronic, progressive neurologic disease. Its central feature is a 4- to 12-Hz kinetic tremor (i.e., tremor occurring during voluntary movement) (Fig. 79.1) (Louis 2001). Along with an emerging appreciation of the presence of etiological, clinical, and pathological heterogeneity, there is growing support for the notion that ET itself may be a family of diseases whose central defining feature is kinetic tremor of the arms, and which might more accurately be referred to as “the essential tremors” (Louis 2014a). Clinical and scientific advances have increasingly placed the seat of the disease in the cerebellum and cerebellar system.

---

E.D. Louis (✉)

Division of Movement Disorders, Department of Neurology,  
Yale School of Medicine, Yale University, New Haven, CT 06405, USA  
e-mail: [elan.louis@yale.edu](mailto:elan.louis@yale.edu)



**Fig. 79.1** Spiral drawn by a patient with ET who has moderate arm tremor

## 79.2 Epidemiology

ET is among the most prevalent movement disorders, with a pooled population prevalence across all ages of 0.9% (Louis and Ferreira 2010). Prevalence increases markedly with age, and among persons aged 95 and older, reached values in excess of 20% (Louis and Ferreira 2010). The incidence rate is 619/100,000 person-years among persons age 65 and older (Benito-León et al. 2005). Established risk factors for ET include older age and family history of ET.

## 79.3 Etiology

The precise causes of ET are unclear, yet genetic and environmental factors are likely contributors. There are numerous large kindreds, with an autosomal dominant pattern of inheritance, and first-degree relatives of ET patients are nearly five times more likely to develop ET than are members of the population (Louis et al. 2001). A variant in the *Lingo-1* gene has been most consistently associated with ET; (Stefansson et al. 2009) however, no major causal genes have been identified to date, and this is likely due to a variety of issues including phenocopies, incomplete penetrance, bilineal inheritance, or possibly other modes of inheritance (Ma et al.

2006). The existence of cases without apparent family history and lack of complete disease concordance in monozygotic twins (Tanner et al. 2001) argue for nongenetic (i.e., environmental) causes as well. A number of environmental toxins are under investigation, including  $\beta$ -carboline alkaloids (e.g., harmane, a dietary toxin) and lead (Louis 2008). One epidemiological study indicated a possible protective role of cigarette smoking and another indicated that higher levels of pre-morbid ethanol consumption raise the risk of developing ET, with the presumed mechanism being Purkinje cell toxicity (Louis et al. 2008, 2009).

## 79.4 Pathobiology

The olivary model of ET, initially proposed in the early 1970s, posited that a tremor pacemaker in the inferior olivary nucleus was driving the tremor in ET. However, given the major problems with this model, there has been trend to move on to other more plausible mechanisms (Louis 2014b). Recent research on ET has focused on the cerebellum and the role it seems to play in the biology of ET. Interest in the cerebellum was initially motivated by neuroimaging studies, which strongly implicate the importance of this brain region in ET, and clinical studies, which frequently note the presence of cerebellar signs (e.g., intention tremor, gait ataxia) in patients with ET. More recently, controlled postmortem studies have revealed a broad array of degenerative changes in the cerebellar cortex, primarily involving the Purkinje cells and surrounding neuronal populations, in the majority of ET cases. In some studies, there is Purkinje cell loss (Louis et al. 2007). A smaller group of ET cases demonstrate a pattern of Lewy bodies that are relatively restricted to the locus ceruleus, and of mechanistic interest is that noradrenergic neurons of the locus ceruleus project to the cerebellum and synapse with Purkinje cells. Given these data, there is growing support for the notion that the cerebellum may be central to a disease pathobiology that is neurodegenerative.

## 79.5 Clinical Features

The cardinal clinical feature of ET is kinetic tremor, evidenced during a variety of activities on neurological examination (e.g., finger-nose-finger maneuver, spiral drawing). In approximately 50% of patients, the tremor has an intentional component, worsening on finger-nose-finger maneuver as the patient approaches the target. Postural tremor also occurs in patients with ET and is generally greatest in amplitude at the wrist joint rather than more proximal or distal joints, and generally involves wrist flexion extension rather than wrist rotation-supination. As a rule, the amplitude of kinetic tremor exceeds that of postural tremor, and the converse pattern should raise questions about the diagnosis. Tremor at rest, without other cardinal features of parkinsonism, occurs in approximately 20% of ET patients who are



attending specialty clinics, but in contrast to that of Parkinson disease (PD), it is a late feature. Another motor feature of ET is gait ataxia, with tandem gait difficulty that is in excess of that seen in similarly-aged control subjects. Although in most patients, this is mild, in some ET patients, it may be of moderate severity. There is some evidence that such gait ataxia is more pronounced in patients who have mid-line cranial tremors (e.g., neck, jaw, voice). Saccadic eye movement abnormalities have also been detected in ET patients in several physiological studies, but these are of a subclinical nature. Recent years have also witnessed a growing awareness of the presence of nonmotor features in ET patients, which may broadly be divided into cognitive, psychiatric, and sensory. The extent to which the cognitive features are cerebellar- or cerebral-based is not clear.

Initially the tremor may be mild and asymptomatic, and it may not worsen for years, but in most individuals, the tremor worsens over time. There are few prospective, longitudinal natural history studies, yet the best estimates indicate that arm tremor worsens by 2–5% per year. With the passage of time, there is a tendency for the spread of tremor beyond the arms, with patients developing cranial tremors (neck, voice, jaw).

While in the past, ET was often viewed as a “benign” problem, the term “benign essential tremor” is no longer considered an appropriate term. In fact, the majority of patients have tremor-related disability, and 15–25% are sufficiently disabled by high-amplitude shaking that they cannot continue to work.

ET patients have about a fourfold increased risk of developing incident PD, thus developing what is commonly referred to as ET-PD (Benito-León et al. 2009). The pathobiology of this particular connection is not fully understood.

## 79.6 Treatment

The tremor of ET may be severe enough to result in embarrassment and functional disability, and these are the main motivations for treatment.  $\beta$ -Blockers (esp. propranolol) and primidone, alone or in combination, are the most effective pharmacologic therapies, although many patients chose to discontinue these medications due to their limited efficacy (Zesiewicz et al. 2011). Other agents that have been used include topiramate, gabapentin, and benzodiazepines (alprazolam or clonazepam). Many patients note that tremor is temporarily suppressed by drinking ethanol. High-frequency thalamic stimulation markedly reduces the severity of the tremor and has replaced stereotactic thalamotomy as the treatment of choice for severe pharmacologically refractory tremor. Several other emerging surgical therapies are also currently under evaluation, with all of these therapies serving to interrupt the presumed abnormal cerebellar-thalamic output.

## 79.7 Conclusions

ET is an extraordinarily common neurological disorder that is both chronic and progressive. Patients exhibit a variety of features on examination that suggest a cerebellar dysfunction, and new science is linking the disease to the cerebellum. As such, this progressive disease (or diseases) seems to involve a slow form of cerebellar degeneration. This presumed pathobiology raises real challenges for the development of effective pharmacotherapies.

## References

- Benito-León J, Bermejo-Pareja F, Louis ED (2005) Incidence of essential tremor in three elderly populations of central Spain. *Neurology* 64(10):1721–1725
- Benito-León J, Louis ED, Bermejo-Pareja F (2009) Risk of incident Parkinson's disease and parkinsonism in essential tremor: a population based study. *J Neurol Neurosurg Psychiatry* 80(4):423–425
- Louis ED (2001) Clinical practice. Essential tremor. *N Engl J Med* 345(12):887–891
- Louis ED (2008) Environmental epidemiology of essential tremor. *Neuroepidemiology* 31(3):139–149
- Louis ED (2014a) 'Essential tremor' or 'the essential tremors': is this one disease or a family of diseases? *Neuroepidemiology* 42(2):81–89
- Louis E (2014b) Re-thinking the biology of essential tremor: from models to morphology. *Parkinsonism Relat Disord* 20(Suppl 1):S88–S93
- Louis ED, Ferreira JJ (2010) How common is the most common adult movement disorder? Update on the worldwide prevalence of essential tremor. *Mov Disord* 25(5):534–541
- Louis ED, Ford B, Frucht S, Barnes LF, X-Tang M, Ottman R (2001) Risk of tremor and impairment from tremor in relatives of patients with essential tremor: a community-based family study. *Ann Neurol* 49(6):761–769
- Louis ED, Faust PL, Vonsattel JP, Honig LS, Rajput A, Robinson CA et al (2007) Neuropathological changes in essential tremor: 33 cases compared with 21 controls. *Brain* 130(Pt 12):3297–3307
- Louis ED, Benito-León J, Bermejo-Pareja F (2008) Population-based prospective study of cigarette smoking and risk of incident essential tremor. *Neurology* 70(19):1682–1687
- Louis ED, Benito-León J, Bermejo-Pareja F (2009) Population-based study of baseline ethanol consumption and risk of incident essential tremor. *J Neurol Neurosurg Psychiatry* 80(5):494–497
- Ma S, Davis TL, Blair MA, Fang JY, Bradford Y, Haines JL et al (2006) Familial essential tremor with apparent autosomal dominant inheritance: should we also consider other inheritance modes? *Mov Disord* 21(9):1368–1374
- Stefansson H, Steinberg S, Petursson H, Gustafsson O, Gudjonsdottir IH, Jonsdottir GA et al (2009) Variant in the sequence of the LINGO1 gene confers risk of essential tremor. *Nat Genet* 41(3):277–279
- Tanner CM, Goldman SM, Lyons KE, Aston DA, Tetrud JW, Welsh MD et al (2001) Essential tremor in twins: an assessment of genetic vs environmental determinants of etiology. *Neurology* 57(8):1389–1391
- Zesiewicz TA, Elble RJ, Louis ED, Gronseth GS, Ondo WG, Dewey RB Jr et al (2011) Evidence-based guideline update: treatment of essential tremor: report of the Quality Standards subcommittee of the American Academy of Neurology. *Neurology* 77(19):1752–1755

# Chapter 80

## Toxic Agents

**Mario Manto**

**Abstract** Cerebellum is vulnerable to intoxication and poisoning, especially in elderly patients and patients presenting structural lesions. The most common toxic agent is ethanol. Cerebellotoxic drugs include anti-epileptics, antineoplastics, lithium salts and heroin. Regarding environmental factors, chronic exposure to heavy metals, benzene derivatives and hyperthermia cause a cerebellar syndrome. Cerebellotoxicity should be listed in the differential diagnosis of cerebellar ataxia of unknown origin.

**Keywords** Ataxia • Intoxication • Ethanol • Anti-epileptics • Antineoplastics • Lithium • Heroin

Cerebellar ataxias of toxic origin are often overlooked, especially because the symptoms may be mild or part of a more complex syndrome (Manto 2010). The most common causes are ethanol intake, drug ingestion and environmental sources (Table 80.1). Elderly patients are particularly susceptible. Because the cerebellar syndrome may be irreversible and in some cases is life-threatening, early identification is mandatory.

### 80.1 Ethanol Intake

The prevalence of ethanol dependence has been estimated around 0.5–3% of the population in Europe and in the USA. There is a complex interaction between genetic contributions, environment and alcohol dependence. For instance, an increased thickness of lobule I of the cerebellum is associated with a greater consumption of drugs and hard liquor in young adults (Anderson et al. 2010). Recent animal studies highlight the role of epigenetic mechanisms in the regulation of ethanol intake (Qiang et al. 2014).

---

M. Manto (✉)

FNRS, ULB-Erasme, 808 Route de Lennik, 1070 Bruxelles, Belgium

Service des Neurosciences, Université de Mons, 7000 Mons, Belgium

e-mail: [mmanto@ulb.ac.be](mailto:mmanto@ulb.ac.be)

**Table 80.1** Cerebellar ataxia induced by toxic agents

(A) <i>Ethanol ingestion</i>
(B) <i>Drugs</i>
Anticonvulsants (phenytoin, carbamazepine, phenobarbital, vigabatrin)
Antineoplastics (5-FU, capecitabine, Ara-C, methotrexate, cisplatin)
Lithium salts
Amiodarone
Calcineurin inhibitors
Mefloquine
Isoniazid
Metronidazole
Drug abuse and addiction (cocaine, heroin, phenylclidine, methadone)
(C) <i>Environmental causes</i>
Metals (Mercury, lead, manganese, copper, gadolinium (?))
Benzene derivatives
Hyperthermia
Carbon monoxide
Chemical weapons
Insecticides/herbicides (Chlordecone, paraquat, phosphine, carbon disulfide)
Dimethylamine borane
Saxitoxin
Scorpion sting

Adapted from Manto (2013)

Neurological complications are multiple. Cerebellar ataxia is a clinical hallmark of acute ethanol intoxication (Gilman et al. 1981). Patients show a loss of balance, lack of coordination in lower limbs and walking difficulties. A gaze-evoked nystagmus is common, as well as slurred speech. The association of mental confusion, oculomotor deficits and ataxic gait raises the diagnosis of Wernicke's encephalopathy. In Korsakoff's syndrome, memory deficits and confabulation are at the forefront.

Chronic ethanol ingestion causes a progressive cerebellar syndrome evolving over a few months. The ataxia is usually most severe in case of malnutrition. A pontine or extra-pontine myelinolysis may occur, affecting cerebellum, midbrain, thalamus, basal ganglia and periventricular white matter (Kim et al. 2007). Laboratory findings (macrocytic anemia, platelet reduction, impaired liver function tests, sideropenia, decreased levels of blood transketolase) do not predict the development or the severity of cerebellar ataxia.

Cerebellar atrophy is detected in about 30% of patients with a daily intake of 150 g of ethanol during a period of 10 years (Haubek and Lee 1979). Cerebral cortex often shows variable degrees of atrophy. Brain MRI demonstrates a pattern of cerebellar atrophy predominating in the anterior lobe. In addition, it shows widening of cerebral sulci, dilatation of ventricles, symmetric lesions in the periventricular areas and dorsal thalamus, atrophy of mamillary bodies or enhancement with gadolinium injection (Gallucci et al. 1990). A pattern of global cerebral atrophy may develop (“chronic brain atrophy”). Fetal alcohol syndrome is associated with atrophy of the anterior region of the vermis (lobules I–V) and a relative sparing lobules VI–X (Sowell et al. 1996).

Neuropathological studies show lesions in the mamillary bodies, in diencephalon/mesencephalon, temporal lobes and frontal lobes. Cerebellar lesions are conspicuous in the anterior lobe.

The mechanisms of ethanol-induced cerebellar toxicity are multiple. In particular, ethanol affects neurotransmission and brain metabolism (Manto 2013; Volkow et al. 2013). Neurons containing GABA-A/benzodiazepine receptors in the superior vermis are vulnerable and cerebellar glucose metabolic rates are impaired (Gilman et al. 1996). Nutritional deficits contribute to the degeneration of neurons. Thiamine is a co-factor of enzymes of the energy metabolism. Chronic alcoholics have a low intake of thiamine. Moreover, ethanol blocks its conversion into the active form (Laforenza et al. 1990). Glia is also affected (de la Monte and Kril 2014).

Patients developing a Wernicke encephalopathy should be treated immediately with thiamine 50–100 mg IV, with a correction of electrolyte deficits. Ataxia of stance and gait may subside in case of abstinence (Diener et al. 1984), otherwise an irreversible syndrome dominated by gait difficulties develops.

## 80.2 Drugs

### 80.2.1 Anticonvulsants

#### 80.2.1.1 Phenytoin

Cerebellar ataxia induced by phenytoin intake can manifest with a minor cerebellar syndrome characterized by nystagmus and lack of balance (Selhorst et al. 1972). However, a severe pancerebellar syndrome may be observed. The deficits are either transient or permanent. Cerebellar ataxia is more common in case of silent cerebellar disease and myoclonic epilepsy is considered as a predisposing factor. Phenytoin has been incriminated as a teratogenic agent causing a ponto-cerebellar hypoplasia (Squier et al. 1990).

Cerebellar atrophy has been documented following an acute overdose and following a chronic treatment (Kuruville and Bharucha 1997). Purkinje cells and granule cells are particularly vulnerable.

### **80.2.1.2 Carbamazepine**

Carbamazepine causes a cerebellar syndrome which is dose-dependent. Dizziness is the commonest symptom. Patients show a gaze-evoked nystagmus, action tremor and ataxia of stance/gait (Masland 1982). The cerebellar syndrome is overlooked in case of impaired consciousness. The association of carbamazepine and lithium salts necessitates a close monitoring. Severe intoxication requires a monitoring in an intensive care unit.

### **80.2.1.3 Other Anticonvulsivants**

Phenobarbital may cause a gaze-evoked nystagmus, kinetic tremor and ataxia of stance and gait. Most patients show drowsiness. Vigabatrin (an inhibitor of GABA transaminase) triggers a mild ataxic posture in about 5–10% of adults with poorly controlled epilepsy. Gabapentin enhances GABAergic inhibition and is currently administered for neuropathic pain. Although about 8% of patients exhibit ataxia, the drug may improve the ataxia in patients with an isolated cerebellar atrophy (paradoxical effect).

## ***80.2.2 Antineoplastics***

### **80.2.2.1 5-FU and Capecitabine**

High doses of 5-FU cause a disabling pancerebellar syndrome (Moertel et al. 1964). Cerebellar ataxia may be part of a global encephalopathy. Capecitabine is an oral prodrug of 5-FU which can induce a diffuse toxic encephalopathy with seizure-like symptoms and disseminated white matter alterations affecting supra- and intratentorial structures (Niemann et al. 2004).

### **80.2.2.2 Ara-C (Cytarabine)**

Cerebellar toxicity is dose-dependent. In many cases, ataxia develops for cumulative doses superior to 24 g. In some cases, cerebellar deficits are irreversible (Herzig et al. 1987). Other neurological signs include somnolence and pyramidal deficits.

### **80.2.2.3 Methotrexate**

Methotrexate is cerebello-toxic, especially with intra-thecal administration. A leucoencephalopathy affecting the cerebellum may occur with oral doses (González-Suárez et al. 2014). The drug inhibits dihydrofolate reductase. Part of the toxicity is mediated by a folate deficiency.

## **80.2.3 Other Drugs**

### **80.2.3.1 Lithium Salts**

Lithium salts have a narrow therapeutic range (0.6–1.2 mM). Cerebellar ataxia develops either after an acute intoxication or during a chronic therapy. Side effects include hypothyroidism and affect the cardiovascular, renal, gastrointestinal and/or nervous system (Simard et al. 1989). Enhanced physiological tremor affecting the hands is a common observation. Dehydration and hyperthermia are risk factors for neurotoxicity. Neurological signs are multiple: coma, seizures, extra-pyramidal syndrome, pyramidal deficits, cerebellar ataxia. Cerebellar syndrome is reversible or associated with permanent sequelae.

### **80.2.3.2 Amiodarone**

Amiodarone is a lipophilic antiarrhythmic drug. Side effects include respiratory failure, liver toxicity, thyroid dysfunction, corneal deposits, as well as neurological side effects. Postural tremor, peripheral neuropathy and cerebellar deficits are the most common (Orr and Ahlskog 2009). There is a striking relationship between the long-term amiodarone maintenance dose and the frequency of neurotoxic effects, especially in the elderly. Cerebellar ataxia may subside very slowly following drug discontinuation.

### **80.2.3.3 Calcineurin Inhibitors**

Classical neurological side-effects are behavioral disorders, aphasia, seizures, cerebellar ataxia, vestibular deficits, motor spinal cord syndrome, paresthesia (Palmer and Toto 1991; Belli et al. 1993). The ataxia may be triggered by hypomagnesemia (Thompson et al. 1984).

Reversible posterior leucoencephalopathy syndrome is characterized by white matter lesions predominating in the posterior regions of cerebral hemispheres (Hinchey et al. 1996). Patients present with impaired mental status, headache, seizures, visual disturbances and cerebellar ataxia (Wong et al. 2003). Brain MRI is

particularly useful to establish the diagnosis, especially FLAIR sequence. Acute cerebellar edema requires brainstem decompression.

#### **80.2.3.4 Metronidazole**

Cerebellar toxicity affects nuclei. MRI demonstrates bilateral edema with increased diffusion coefficients in cerebellar nuclei (Chatzkel and Vossough 2010). Cerebellar ataxia may resolve after cessation of the treatment.

### ***80.2.4 Drug Abuse and Addiction***

#### **80.2.4.1 Cocaine**

Seizures, drowsiness, delirium and cerebellar ataxia are amongst the clinical presentation of cocaine intoxication. Cerebellar infarction is a complication of cocaine intake (Aggarwal and Byrne 1991). Other toxic agents, such as phenytoin, may be added to ‘crack’ cocaine and contribute to the neurological deficits.

#### **80.2.4.2 Heroin**

Heroin ingestion causes a toxic spongiform leukoencephalopathy (Weber et al. 1998). Cerebellar ataxia may be prominent. Lesions are typically symmetrical, usually predominating in white matter. Intoxication may be fatal (Ryan et al. 2005).

#### **80.2.4.3 Herbs**

Ceremonial herbs are used during social events. Kava causes postural ataxia and limbs tremor, probably via a disruption of GABAergic pathways (Singh and Singh 2002). Ingestion of Peganum harmala seed extract (containing beta-carboline alkaloids) triggers a reversible neurological syndrome characterized by psychomotor agitation, hallucinations, postural and kinetic tremor, limbs dysmetria, ataxia and vomiting (Frison et al. 2008).

#### **80.2.4.4 Methadone**

Accidental ingestion causes an acute toxic encephalopathy presenting with impaired consciousness. Patients develop obstructive hydrocephalus due to a severe cerebellar edema (Anselmo et al. 2006). A delayed syndrome has been described (Zanin et al. 2010). Administration of methylprednisolone and external drainage of



cerebrospinal fluid are recommended, but urgent decompressive occipital craniotomy may be necessary.

## **80.3 Environment**

### **80.3.1 Metals**

#### **80.3.1.1 Mercury**

Patients exhibit a very suggestive association of constricted visual fields (tunnel vision), hearing deficits, sensory deficits in the extremities caused by a peripheral neuropathy and cerebellar deficits (Korogi et al. 1998). The calcarine region, the post- and pre-central gyri, and the temporal gyri are particularly affected, as well as the inferior and middle parts of the vermis and cerebellar hemispheres.

#### **80.3.1.2 Lead**

The main causes of lead intoxication are ingestion of paints, sniffing of leaded gasoline, flour contamination, exposure to lead stearate and contamination from automobile batteries. Toxicity is greater in children. Patients often complain of abdominal pain and anemia is common. Lead is toxic for the central (especially frontal cortex, hippocampus and cerebellum) and the peripheral nervous system (peripheral motor neuropathy). Extreme lead exposure cause convulsions and coma. Cerebellar ataxia may be prominent in adults (Mani et al. 1998). Cerebellar intoxication may present as a pseudo-tumor with obstructive hydrocephalus due to edema (Johnson et al. 1993). Cerebral calcifications and hyperintense lesions on brain MRI are common. Chelation therapy is required when lead intoxication is confirmed.

#### **80.3.1.3 Gadolinium**

Gadolinium deposits have been identified in cerebellar nuclei following repeated administration of gadolinium-based contrast agents (Kanda et al. 2014). Preclinical and clinical studies are ongoing to assess a possible cerebellotoxic effect.

### **80.3.2 Toluene/Benzene Derivatives**

Intoxication is common in glue-sniffing and following chronic exposure in working areas poorly ventilated. An acute encephalopathy with coma, seizures, behavioural abnormalities and cerebellar ataxia occurs in children (King 1982). In adults, the

intoxication presents with headache, hyperactivity, memory impairment and cerebellar ataxia. Cerebellar ataxia may be prominent and irreversible (Damasceno and de Capitani 1994). Teenagers and young adults who develop cerebellar ataxia and decreased visual acuity should be suspected of a thinner intoxication (Uchino et al. 2002).

### **80.3.3 Hyperthermia**

Cerebellum is vulnerable to hyperthermia (above 40.5 °C). Heat stroke and neuroleptic malignant syndrome are causes of disabling ataxia. Although symptoms may resolve within 3–10 days, a cerebellar atrophy often develops after a few months, probably because of a peculiar vulnerability of Purkinje cells to high fever (Bazille et al. 2005). Treatment includes cooling of the body and monitoring of vital functions.

### **80.3.4 Chemical Weapons**

Marked brainstem-cerebellar symptoms have been described in patients exposed to diphenylarsinic acid poisoning (Ishii et al. 2004). Symptoms include ataxia, diplopia, myoclonus as well as symptoms related to hemokinetic dysfunction.

### **80.3.5 Insecticides/Herbicides/Pesticides**

Deliberate self-harm by ingestion of organophosphate insecticides, such as dimethoate, is common in Sri Lanka (Fonseka et al. 2003). A cholinergic crisis is followed by various neurological and psychiatric manifestations. Cerebellar signs may appear about a week after ingestion or start 5–6 weeks after intoxication.

### **80.3.6 Others**

#### **80.3.6.1 Saxitoxin (Shellfish Poisoning)**

Saxitoxin is a neurotoxin contaminating a mollusc and binding to voltage-sensitive sodium channels found at high densities in cerebellar cortex (Purkinje cells, parallel fibers, basket cells) (Mourre et al. 1990). Patients develop gastrointestinal and neurological symptoms, especially a cerebellar syndrome of benign course (Rhodes et al. 1975). Paresthesias are common.

## 80.4 Animal Related Cerebellar Toxicity

### 80.4.1 *Scorpions*

Myoclonus and cerebellar ataxia are the main neurological deficits in some series. Complications can be severe (Gadwalkar et al. 2006). Cerebellar stroke is a potential complication. Treatment includes supportive care and anti-venom serum administration.

## References

- Aggarwal S, Byrne BD (1991) Massive ischemic cerebellar infarction due to cocaine use. *Neuroradiology* 33:449–450
- Anderson CM, Rabi K, Lukas SE, Teicher MH (2010) Cerebellar lingula size and experiential risk factors associated with high levels of alcohol and drug use in young adults. *Cerebellum* 9(2):198–209
- Anselmo M, Campos Rainho A, do Carmo Vale M, Estrada J, Valente R, Correia M, Vieira JP, Barata D (2006) Methadone intoxication in a child: toxic encephalopathy? *J Child Neurol* 21:618–620
- Bazille C, Megarbane B, Bensimhon D, Lavergne-Slove A, Baglin AC, Loirat P, Woimant F, Mikol J, Gray F (2005) Brain damage after heat stroke. *J Neuropathol Exp Neurol* 64:970–975
- Belli LS, De Carlis L, Romani F, Rondinara GF, Rimoldi P, Alberti A, Bettale G, Dughetti L, Ideo G, Sberna M et al (1993) Dysarthria and cerebellar ataxia: late occurrence of severe neurotoxicity in a liver transplant recipient. *Transpl Int* 6:176–178
- Chatzkel JA, Vossough A (2010) Metronidazole-induced cerebellar toxicity. *Pediatr Radiol* 40(8):1453
- Damasceno BP, de Capitani EM (1994) Cerebellar atrophy related to chronic exposure to toluene. Case report. *Arq Neuropsiquiatr* 52:90–92
- de la Monte SM, Kril JJ (2014) Human alcohol-related neuropathology. *Acta Neuropathol* 127(1):71–90
- Diener HC, Dichgans J, Bacher M, Guschlbauer B (1984) Improvement of ataxia in alcoholic cerebellar atrophy through alcohol abstinence. *J Neurol* 231:258–262
- Fonseka MM, Medagoda K, Tillakaratna Y, Gunatilake SB, de Silva HJ (2003) Self-limiting cerebellar ataxia following organophosphate poisoning. *Hum Exp Toxicol* 22:107–109
- Frison G, Favretto D, Zancanaro F, Fazzin G, Ferrara SD (2008) A case of beta-carboline alkaloid intoxication following ingestion of *Peganum harmala* seed extract. *Forensic Sci Int* 179(2–3):e37–e43
- Gadwalkar SR, Bushan S, Pramod K, Gouda C, Kumar PM (2006) Bilateral cerebellar infarction: a rare complication of scorpion sting. *J Assoc Physicians India* 54:581–583
- Gallucci M, Bozzao A, Splendiani A, Masciocchi C, Passariello R (1990) Wernicke encephalopathy: MR findings in 5 patients. *Am J Neuroradiol* 11:887–892
- Gilman S, Bloedel JR, Lechtenberg R (1981) Disorders of the cerebellum, Contemporary Neurology series. FA. Davis, Philadelphia
- Gilman S, Koeppe RA, Adams K et al (1996) Positron emission tomographic studies of cerebral benzodiazepine-receptor binding in chronic alcoholics. *Ann Neurol* 40:163–171
- González-Suárez I, Aguilar-Amat MJ, Trigueros M, Borobia AM, Cruz A, Arpa J (2014) Leukoencephalopathy due to oral methotrexate. *Cerebellum* 13(1):178–183

- Haubek A, Lee K (1979) Computed tomography in alcoholic cerebellar atrophy. *Neuroradiology* 18:77–79
- Herzig RH, Hines JD, Herzig GP et al (1987) Cerebellar toxicity with high-dose cytosine arabinoside. *J Clin Oncol* 5:927–932
- Hinchey J, Chaves C, Appignani B, Breen J, Pao L, Wang A, Pessin MS, Lamy C, Mas JL, Caplan LR (1996) A reversible posterior leukoencephalopathy syndrome. *N Engl J Med* 334(8):494–500
- Ishii K, Tamaoka A, Otsuka F et al (2004) Diphenylarsinic acid poisoning from chemical weapons in Kamisu, Japan. *Ann Neurol* 56:741–745
- Johnson LM, Hubble JP, Koller WC (1993) Effect of medications and toxins on cerebellar function. In: Lechtenberg R (ed) *Handbook of cerebellar diseases*. Marcel Dekker, New York
- Kanda T, Ishii K, Kawaguchi H, Kitajima K, Takenaka D (2014) High signal intensity in the dentate nucleus and globus pallidus on unenhanced T1-weighted MR images: relationship with increasing cumulative dose of a gadolinium-based contrast material. *Radiology* 270(3):834–41
- Kim J, Song T, Park S, Choi IS (2007) Cerebellar peduncular myelinolysis in a patient receiving hemodialysis. *J Neurol Sci* 253(1–2):66–68
- King MD (1982) Neurological sequelae of toluene abuse. *Hum Toxicol* 1:281–287
- Korogi Y, Takahashi M, Okajima T, Eto K (1998) MR findings in Minamata disease. *J Magn Reson Imaging* 8:308–316
- Kuruvilla T, Bharucha NE (1997) Cerebellar atrophy after acute phenytoin intoxication. *Epilepsia* 38:500–502
- Laforenza U, Patrini C, Gastaldi G, Rindi G (1990) Effects of acute and chronic ethanol administration on thiamine metabolizing enzymes in some brain areas and in other organs of the rat. *Alcohol Alcohol* 25(6):591–603
- Mani J, Chaudhary N, Kanjalkar M, Shah PU (1998) Cerebellar ataxia due to lead encephalopathy in an adult. *J Neurol Neurosurg Psychiatry* 65:797
- Manto M (2010) *Cerebellar disorders. A practical approach to diagnosis and management*. Cambridge University Press, Cambridge, UK
- Manto M (2013) Cerebellotoxic agents. In: Manto M, Gruol DL, Schmähmann JD, Koibuchi N, Rossi F (eds) *Handbook of the cerebellum and cerebellar disorders*. Springer, Dordrecht, pp 2079–2117
- Masland RL (1982) Carbamazepine neurotoxicity. In: Woodbury DM, Penry JK, Pippenger CE (eds) *Antiepileptic drugs*, 2nd edn. Raven Press, New York, pp 521–531
- Moertel CG, Reitemeier RJ, Bolton CE, Shorter RG (1964) Cerebellar ataxia associated with fluorinated pyrimidine therapy. *Cancer Chemother Rep* 41:15–18
- Mourre C, Widmann C, Lazdunski M (1990) Saxitoxin-sensitive Na<sup>+</sup> channels: presynaptic localization in cerebellum and hippocampus of neurological mutant mice. *Brain Res* 533:196–202
- Niemann B, Rochlitz C, Herrmann R, Pless M (2004) Toxic encephalopathy induced by capecitabine. *Oncology* 66:331–335
- Orr CF, Ahlskog JE (2009) Frequency, characteristics, and risk factors for amiodarone neurotoxicity. *Arch Neurol* 66:865–869
- Palmer BF, Toto RD (1991) Severe neurologic toxicity induced by cyclosporine A in three renal transplant patients. *Am J Kidney Dis* 1:116–121
- Qiang M, Li JG, Denny AD, Yao J, Lieu M, Zhang K, Carreon S (2014) Epigenetic mechanisms are involved in the regulation of ethanol consumption in mice. *Int J Neuropsychopharmacol*. 18(2). pii: pyu072
- Rhodes FA, Mills CG, Popei K (1975) Paralytic shellfish poisoning in Papua New Guinea. *P N G Med J* 18:197–202
- Ryan A, Molloy FM, Farrell MA, Hutchinson M (2005) Fatal toxic leukoencephalopathy: clinical, radiological, and necropsy findings in two patients. *J Neurol Neurosurg Psychiatry* 76:1014–1016
- Selhorst JB, Kaufman B, Horwitz SJ (1972) Diphenylhydantoin-induced cerebellar degeneration. *Arch Neurol* 27:452–455

- Simard M, Gumbiner B, Lee A, Lewis H, Norman D (1989) Lithium carbonate intoxication. A case report and review of the literature. *Arch Intern Med* 149:36–46
- Singh YN, Singh NN (2002) Therapeutic potential of kava in the treatment of anxiety disorders. *CNS Drugs* 16:731–743
- Sowell ER, Jernigan TL, Mattson SN et al (1996) Abnormal development of the cerebellar vermis in children prenatally exposed to alcohol: size reduction in lobules I-V. *Alcohol Clin Exp Res* 20:31–34
- Squier W, Hope PL, Lindenbaum RH (1990) Neocerebellar hypoplasia in a neonate following intra-uterine exposure to anti-convulsants. *Dev Med Child Neurol* 32:737–742
- Thompson CB, June CH, Sullivan KM, Thomas ED (1984) Association between cyclosporin neurotoxicity and hypomagnesemia. *Lancet* ii:1116–1120
- Uchino A, Kato A, Yuzuriha T, Takashima Y, Hiejima S, Murakami M, Endoh K, Yoshikai T, Kudo S (2002) Comparison between patient characteristics and cranial MR findings in chronic thinner intoxication. *Eur Radiol* 12:1338–1341
- Volkow ND, Kim SW, Wang GJ, Alexoff D, Logan J, Muench L, Shea C, Telang F, Fowler JS, Wong C, Benveniste H, Tomasi D (2013) Acute alcohol intoxication decreases glucose metabolism but increases acetate uptake in the human brain. *Neuroimage* 64:277–283
- Weber W, Henkes H, Moller P, Bade K, Kuhne D (1998) Toxic spongiform leucoencephalopathy after inhaling heroin vapour. *Eur Radiol* 8:749–755
- Wong R, Beguelin GZ, de Lima M, Giralt SA, Hosing C, Ippoliti C, Forman AD, Kumar AJ, Champlin R, Couriel D (2003) Tacrolimus-associated posterior reversible encephalopathy syndrome after allogeneic haematopoietic stem cell transplantation. *Br J Haematol* 122(1):128–134
- Zanin A, Masiero S, Severino MS, Calderone M, Da Dalt L, Laverda AM (2010) A delayed methadone encephalopathy: clinical and neuroradiological findings. *J Child Neurol* 25(6):748–751

# Chapter 81

## Endocrine Disorders

Mario Manto and Christiane S. Hampe

**Abstract** This chapter discusses the links between hormonal disorders and cerebellar symptoms. Hormonal disorders impact on cerebellar functions and may cause cerebellar ataxia. In particular, thyroid and parathyroid disorders, diabetes mellitus and diabetes insipidus may be associated with cerebellar deficits. In case of hypothyroidism, cerebellar deficits are usually reversible with hormonal replacement. Hormonal investigations should be included in the general work-up of cerebellar ataxias of undetermined origin.

**Keywords** Cerebellum • Endocrine • Hormones • Thyroid

Hormonal disorders may cause or worsen cerebellar syndromes (Manto 2013). The classical example is a dysfunction of the thyroid gland, which worsens a chronic cerebellar ataxia of other origin such as a genetic ataxia. Table 81.1 lists the main endocrine disorders associated with cerebellar ataxia in daily practice. This chapter summarizes the main links between endocrine disorders and cerebellar ataxia from a clinical standpoint.

### 81.1 Thyroid Disorders

Thyroid hormones play a critical role on cerebellar circuitry (Koibuchi 2013) and modulate many aspects of cerebellar neurons (Manto 2010; Ahmed et al. 2010; Pasquini and Adamo 1994). TRH (thyrotropin-releasing hormone) is produced in the hypothalamus and not only controls the production of TSH (thyrotropin stimulating hormone) in the thyroid, but also activates noradrenergic cerebellar neurons

---

M. Manto (✉)

FNRS, ULB-Erasme, 808 Route de Lennik, 1070 Bruxelles, Belgium

Service des Neurosciences, Université de Mons, 7000 Mons, Belgium

e-mail: [mmanto@ulb.ac.be](mailto:mmanto@ulb.ac.be)

C.S. Hampe

University of Washington, Seattle, USA

**Table 81.1** Main endocrine disorders associated with cerebellar ataxia

A. Thyroid disorders
<i>Hypothyroidism</i>
<i>Hyperthyroidism</i>
<i>Hashimoto ataxia</i>
<i>Drug-induced (amiodarone, lithium salts)</i>
B. Parathyroid disorders
<i>Hypoparathyroidism</i>
<i>Pseudohypoparathyroidism</i>
<i>Pseudopseudohypoparathyroidism</i>
<i>Hyperparathyroidism</i>
C. Cerebellar ataxia and diabetes mellitus
<i>Friedreich ataxia</i>
<i>Mitochondrial diseases</i>
<i>Anti-GAD antibodies<sup>a</sup></i>
<i>APS syndromes<sup>b</sup></i>
<i>Aceruloplasminemia</i>
<i>Von Hippel-Lindau disease</i>
<i>Wolfram disease (DIDMOAD syndrome)</i>
<i>Infections (CMV)</i>
D. Cerebellar ataxia and diabetes insipidus
<i>Erdheim-Chester disease</i>
<i>Langerhans histiocytosis</i>
<i>Wolfram disease (DIDMOAD syndrome)</i>
<i>Septo-optic dysplasia</i>
E. Cerebellar ataxia and hypogonadism
<i>Holmes ataxia</i>
<i>Boucher-Neuhäuser syndrome</i>
<i>Marinesco-Sjögren syndrome</i>
<i>Septo-optic dysplasia</i>
<i>Kallman syndrome</i>
<i>Congenital disorders of glycosylation</i>
<i>4H syndrome</i>
<i>Oliver-McFarlane syndrome</i>
<i>Laurence-Moon syndrome</i>
<i>Usher syndrome</i>

Adapted from Manto (2013)

<sup>a</sup>Anti-glutamic acid decarboxylase

<sup>b</sup>Auto-immune polyendocrine syndromes

(Shibusawa et al. 2008), which may have an anti-ataxia effect in animal models (Muroga et al. 1982). In humans, the ataxia associated with thyroid disorders predominates for trunk and limbs movements. TRH treatment of patients with spinocerebellar degeneration improved ataxia in these patients (Sobue et al. 1980). The neurological effect of abnormally high (hyper) or low (hypo) levels of thyroid hormones are discussed in the following sections.

### **81.1.1 Hypothyroidism**

The three forms of hypothyroidism are congenital hypothyroidism, endemic cretinism and adult-onset hypothyroidism. General signs are common (Van Vliet and Deladoëy 2014). Congenital hypothyroidism is associated with a growth deficit. Endemic cretinism is characterized by delayed skeletal maturation, and neuronal dysfunctions, including cerebellar ataxia. Major neurological symptoms in adult-onset hypothyroidism are myoclonus, peripheral and entrapment neuropathy, and cerebellar ataxia (Manto 2013). It is noteworthy that cerebellar ataxia may be the first manifestation of hypothyroidism, although this is a rare presentation (Gilman et al. 1981). Neurological deficits have usually a slowly progressive presentation and stance/gait difficulties are the commonest complaints (Harayama et al. 1983; Pinelli et al. 1990). The ataxia has both a central and a peripheral component (Barnard et al. 1971; Manto 2010).

The successful reversal of cerebellar symptoms by hormone replacement suggests that the pathogenesis is due to endocrine dysfunction of the cerebellum.

However, some cases of hypothyroidism-associated cerebellar ataxia do not benefit from thyroid hormone replacement (Selim and Drachman 2001), suggesting non-endocrine pathogenic factors, such as autoimmune attacks.

### **81.1.2 Hyperthyroidism**

In adults, neurological symptoms of hyperthyroidism include physiological tremor, which may show a kinetic component highly suggestive of a cerebellar dysfunction, seizures and pyramidal deficits. Ocular flutter, myoclonus and truncal ataxia have been reported in Graves' disease (Kuwahara et al. 2013).

Treatment is based on anti-thyroid drugs aimed at the reduction of thyroid hormones, radioactive iodine therapy (especially in the elderly and in case of active toxic multinodular goiter) and surgical ablation of the hyperactive tissue. Beta-blockers are valuable to decrease cardiac symptoms and reduce tremor. Ophthalmopathy is managed with symptomatic therapies, including corticosteroids and immunosuppression. Cessation of smoking is recommended in Graves' disease, as smoking is a major risk factor in the development of Graves' ophthalmopathy (Hägg and Asplund 1987). Patients with Graves' disease often present stimulating thyroid autoantibodies and benefit from anti-thyroid drug treatment (Laurberg 2006).

### **81.1.3 Hashimoto Thyroiditis and Ataxia**

Hashimoto thyroiditis is an auto-immune disorder affecting more commonly women. The neurological presentation is either an encephalopathy with a fluctuating course (dementia, psychotic behaviour, seizures, impaired consciousness) or a



vascular-like syndrome, which may affect the cerebellum (Kothbauer-Margreiter et al. 1996; Aydin-Ozemir et al. 2006; Hoffmann et al. 2007). Cerebellar ataxia associated with Hashimoto thyroiditis may have a subacute onset or may even be recurrent. Ataxia is thought to result of the auto-immune attack to the cerebellar neurons, rather than a result of hormonal instability, as the disease occurs in euthyroid state (Selim and Drachman 2001; Shneyder et al. 2012).

Antibodies against thyroglobulin (TG), thyroid peroxidase enzyme (TPO), TSH-receptor and the amino terminal of the alpha-enolase (anti-NAE antibodies) are found in patients' blood (Yoneda et al. 2007). The latter are useful diagnostic biomarkers of Hashimoto encephalopathy (Nakagawa et al. 2009). It remains unclear whether anti-thyroid autoantibodies crossreact with targets in the cerebellum, or whether the cerebellar defects are the results of a widespread autoimmune response and/or inflammatory response. Ultrasonography of the thyroid gland shows a hypochoic structure (Seipelt et al. 1999), suggestive of thyroid autoimmunity (Schiemann et al. 1999). While certain clinical findings are similar to Creutzfeldt-Jakob disease, the characteristic absence of protein 14-3-3 in the CSF rules out the latter (Seipelt et al. 1999). A slowing of background activity is common on EEG recordings, suggestive of preceding seizures. Indeed, epileptic discharges may be observed (Lin and Liao 2009). However, periodic sharp waves, as often observed in epilepsy, are absent. Brain MRI shows focal hyperintense areas, diffuse subcortical lesions, and atrophy of the gray matter (Bohnen et al. 1997). The pattern of brain perfusion on SPECT is often diffuse with patchy defects.

Steroid treatment (Shaw et al. 1991) leads to improvement of MRI abnormalities and lowering of autoantibody titers (Bohnen et al. 1997). Other symptoms, such as myoclonus, may be responsive to clonazepam or piracetam. Immunosuppressants, plasmapheresis and administration of immunoglobulins are used in refractory cases (Boers and Colebatch 2001), while thyroidectomy is an option in poorly controlled relapses (Yuceyar et al. 2007).

### ***81.1.4 Drug-Induced Dysfunction***

Amiodarone and lithium salts are potential causes of hormonal disturbances and cerebellar ataxia. Amiodarone is an antiarrhythmic drug causing both hypothyroidism and thyrotoxicosis. About 5 % of patients develop a cerebellar toxicity (Garretto et al. 1994). Lithium salts are mainly used to treat bipolar disorders (Lazarus 2009). The thyroid concentrates lithium (Berens et al. 1970), where lithium inhibits thyroid hormone release (Spaulding et al. 1972). This inhibition causes an increase in TSH concentration, which together with lithium-induced cell proliferation (Rao et al. 2005) leads to an enlargement of the thyroid. Indeed, goitre develops in up to 40 % and hypothyroidism in up to 20 % of lithium-treated patients (Lazarus 2009). Thus, lithium salts can cause hyperthyroidism and exacerbate a pre-existing auto-immune

thyroid disease. Patients treated with these medications should be monitored for development of thyroid disorders and ataxia. Cessation of treatment is recommended when ataxia develops.

## **81.2 Parathyroid Disorders**

### ***81.2.1 Hypoparathyroidism***

Hypoparathyroidism is idiopathic or acquired (glands resection, thalassemia, autoimmune polyglandular syndrome, 22q11.2 deletion syndrome) (Cao et al. 2011) and is characterized by abnormally low levels of parathyroid hormones (PTH), resulting in hypocalcemia and hyperphosphoremia. Hypocalcemia reduces the threshold potential of neuronal axons, resulting in increased excitability of the neuromuscular system, manifested with tetany and muscle cramps. Patients may also exhibit seizures, dystonic posturing and parkinsonism. Cerebellar syndrome is characterized by dysarthria, dysmetria, dysdiadochokinesia, and ataxia of gait (Ertas et al. 1997).

In chronic hypoparathyroidism, deposits of calcium occur in the cerebellum. These are easily detected with a brain CT-scan. Cerebellar deficits may subside with calcium administration and vitamin D supplements.

### ***81.2.2 Pseudohypoparathyroidism and Pseudopseudohypoparathyroidism***

Pseudohypoparathyroidisms is due to a resistance to PTH. Patients have mutations in the alpha-subunit of the stimulatory G protein, a signaling protein essential for the actions of PTH (Bastepe 2008), and show increased PTH levels. The resulting hypocalcemia and hyperphosphoremia are associated with extensive symmetrical calcifications in the brain, especially in cerebral sulci, basal ganglia and dentate nuclei (Nyland and Skre 1977; Araki et al. 1990). Patients with type Ia (Albright osteodystrophy) show short stature, brachydactyly, heterotopic calcifications, and cognitive deficits, while in type Ib the hormone resistance occurs in absence of the above phenotypic manifestations, and patients with pseudopseudohypoparathyroidism show Albright's phenotype without hormone resistance. Neurological symptoms are variable: extra-pyramidal syndrome, syndrome of raised intracranial pressure with papilledema and paroxysmal kinesigenic dyskinesias (Thomas et al. 2010). A bilateral cerebellar syndrome has been reported (Nyland and Skre 1977).

### **81.2.3 *Hyperparathyroidism***

In hyperparathyroidism an excess of PTH is secreted. This endocrine disorder is either primary (adenoma), secondary (vitamin D deficiency, malabsorption) or tertiary (renal failure). It may also be part of the Von Hippel-Lindau disease, which typically includes cerebellar hemangioblastomas. Cerebellar syndrome associated with hyperparathyroidism is subtle.

## **81.3 Cerebellar Ataxia and Diabetes**

The brain is especially sensitive to hypoglycaemia and neurological manifestations include confusion, behavioural change, seizures and coma. These temporary functional brain failures can be corrected by normalization of blood glucose levels. Severe hypoglycaemia due to an overdose in insulin (Berz and Orlander 2008) or pancreatic insulinoma may cause prolonged cerebellar ataxia and lesions of the middle cerebellar peduncle and the anterior limb of the internal capsule, consistent with extra-pontine myelinolysis (Schwaninger et al. 2002).

### **81.3.1 *Friedreich Ataxia***

Friedreich ataxia is an autosomal recessive disease caused by mutations of the frataxin gene. Frataxin is a mitochondrial protein and mutations result in inefficient energy production and production of reactive oxygen species (Armstrong et al. 2010). While this in itself leads to neuronal degeneration, the presence of diabetes mellitus in 10–12% of patients is an additional factor contributing to the development of ataxia (Manto 2010).

### **81.3.2 *Anti-GAD Antibodies***

Autoantibodies directed against glutamate decarboxylase (GADA) are associated with type 1 diabetes mellitus (T1D), stiff-person syndrome and cerebellar ataxia (Saiz et al. 1997). GADA inhibit the function of GAD and may thereby impair GABAergic neurotransmission (Manto et al. 2011; Hampe et al. 2013). The severity of GADA-associated cerebellar ataxia ranges from mild to severe. The cerebellar syndrome may be restricted to ocular movements (vestibulo-cerebellar syndrome) or extend to limbs and gait. Brain MRI shows cerebellar atrophy after a several years of disease (Ishida et al. 1999). Intracerebellar administration of GADA induces hyperexcitatory motor cortex activity (Manto et al. 2007, 2011). Cerebellar

syndrome may respond to intravenous immunoglobulins, plasma exchanges, and immunosuppressive therapy (Abele et al. 1999; Ishida et al. 1999). Rituximab appears as a novel option, associated with temporal reduction in antibody levels (Planche et al. 2014). Derivatives of GABA, such as baclofen and gabapentin are recommended for oculomotor disturbances.

### **81.3.3 APS Syndromes (Auto-immune Polyglandular Syndromes)**

These syndromes are divided in three forms (Kahaly 2009): (a) type I (APECED syndrome) is a juvenile form characterized by a mucocutaneous candidiasis and various auto-immune disorders (hypoparathyroidism, Addison's disease, thyroiditis, alopecia universalis); (b) type 2 (Schmidt syndrome) is characterized by the association of Addison's disease with thyroiditis and T1D, (c) type 3 is associated with T1D, auto-immune gastritis, vitiligo, alopecia, pernicious anemia and myasthenia gravis.

The neurological deficits are caused by multiple auto-antibodies, endocrinopathies (discussed above for diabetes mellitus, hypoparathyroidism, hypothyroidism), vitamin deficits (especially vitamin B12 and vitamin E) and sprue.

Cerebellar ataxia may be prominent in APS type I and type II. In APS type II, the ataxic syndrome may have a subacute course (Manto and Jissendi 2012). Brain MRI discloses pancerebellar atrophy.

### **81.3.4 Aceruloplasminemia**

This autosomal recessive disease is characterized by mutations in the ceruloplasmin gene, resulting in defective iron metabolism. Serum levels of iron and copper are decreased, whereas ferritin concentrations are increased in a context of microcytic anemia. Brain imaging shows iron accumulation in dentate nuclei, thalamus, striatum. Neurons are especially susceptible to iron overload and iron accumulation causes neurodegeneration (Zecca et al. 2004), probably through reactive-oxygen species. The retinal pigmented epithelium is atrophied. An isolated cerebellar atrophy may occur in heterozygous cases. The disease is characterized by a triad in adults between 25 and 60 years: diabetes mellitus, retinal degeneration and neurological deficits. Movement disorders include cerebellar ataxia and extrapyramidal signs (blepharospasm, torticollis, chorea) (Miyajima et al. 1987, 2003).

Treatment may include iron-chelating agents (desferrioxamine; deferiprone) (Miyajima et al. 2003). Alternative therapies include fresh-frozen plasma and oral administration of zinc sulfate (Kuhn et al. 2007).

## 81.4 Cerebellar Ataxia and Hypogonadism

Holmes ataxia and Boucher-Neuhäuser syndrome are the commonest forms of these complex associations. Holmes ataxia is characterized by nystagmus, dysarthria, tendon hyperreflexia and mental deficits (Manto 2010). Boucher-Neuhäuser syndrome presents with a spinocerebellar syndrome, chorioretinal dystrophy and hypogonadotropic hypogonadism (Tarnutzer et al. 2014). Atrophy of the retinal pigment epithelium and degeneration of fundi are common. Neuronal defects may be caused by mutations of the PNPLA6 gene. PNPLA6 is involved in neuronal differentiation. Additional mutations of the RNF216 gene have been found in patients with Holmes ataxia and dementia (Margolin et al. 2013). Suboptimal neuronal development (caused by mutations of PNPLA6) may result in reduced secretion of LHRH in the hypothalamus, leading to the observed low blood levels of LH and FSH hormones. However, the lack of a robust response to LHRH suggests additional pituitary involvement (Seminara 2002). Brain MRI shows cerebellar atrophy. A mild axonal neuropathy is found in some patients with Holmes ataxia (Manto 2010). A deficiency in cytochrome c oxidase in Holmes ataxia may be discovered (De Michele et al. 1993).

**Acknowledgments** Mario Manto is supported by the FNRS-Belgium.

## References

- Abele M, Weller M, Mescheriakov S, Bürk K, Dichgans J, Klockgether T (1999) Cerebellar ataxia with glutamic acid decarboxylase autoantibodies. *Neurology* 52(4):857–859
- Ahmed OM, Abd El-Tawab SM, Ahmed RG (2010) Effects of experimentally induced maternal hypothyroidism and hyperthyroidism on the development of rat offspring: I. The development of the thyroid hormones-neurotransmitters and adenosinergic system interactions. *Int J Dev Neurosci* 28(6):437–454
- Araki Y, Furukawa T, Tsuda K, Yamamoto T, Tsukaguchi I (1990) High field MR imaging of the brain in pseudohypoparathyroidism. *Neuroradiology* 32(4):325–327
- Armstrong JS, Khdour O, Hecht SM (2010) Does oxidative stress contribute to the pathology of Friedreich's ataxia? A radical question. *FASEB J* 24(7):2152–2163
- Aydin-Ozemir Z, Tüzün E, Baykan B, Akman-Demir G, Ozbey N, Gürses C, Christadoss P, Gökyiğit A (2006) Autoimmune thyroid encephalopathy presenting with epilepsia partialis continua. *Clin EEG Neurosci* 37(3):204–209
- Barnard RO, Campbell MJ, McDonald WI (1971) Pathological findings in a case of hypothyroidism with ataxia. *J Neurol Neurosurg Psychiatry* 34(6):755–760
- Bastepe M (2008) The GNAS locus and pseudohypoparathyroidism. *Adv Exp Med Biol* 626:27–40
- Berens SC, Wolff J, Murphy DI (1970) Lithium concentration by the thyroid. *Endocrinology* 87:1085–1087
- Berz JP, Orlander JD (2008) Prolonged cerebellar ataxia: an unusual complication of hypoglycemia. *J Gen Intern Med* 23(1):103–105
- Boers PM, Colebatch JG (2001) Hashimoto's encephalopathy responding to plasmapheresis. *J Neurol Neurosurg Psychiatry* 70(1):132

- Bohnen NI, Parnell KJ, Harper CM (1997) Reversible MRI findings in a patient with Hashimoto's encephalopathy. *Neurology* 49(1):246–247
- Cao Z, Yu R, Dun K, Burke J, Caplin N, Greenaway T (2011) 22q11.2 deletion presenting with severe hypocalcaemia, seizure and basal ganglia calcification in an adult man. *Intern Med* J 41(1a):63–66
- De Michele G, Filla A, Striano S, Rimoldi M, Campanella G (1993) Heterogeneous findings in four cases of cerebellar ataxia associated with hypogonadism (Holmes' type ataxia). *Clin Neurol Neurosurg* 95(1):23–28
- Ertas NK, Hanoğlu L, Kirbaş D, Hatemi H (1997) Cerebellar syndrome due to hypoparathyroidism. *J Neurol* 244(5):338–339
- Garretto NS, Rey RD, Kohler G et al (1994) Cerebellar syndrome caused by amiodarone. *Arq Neuropsiquiatr* 52:575–577
- Gilman S, Bloedel JR, Lechtenberg R (1981) Disorders of the cerebellum, Contemporary Neurology series. FA. Davis, Philadelphia
- Hägg E, Asplund K (1987) Is endocrine ophthalmopathy related to smoking? *Br Med J (Clin Res Ed)* 295(6599):634–635
- Hampe CS, Petrosini L, De Bartolo P, Caporali P, Cutuli D, Laricchiuta D, Foti F, Radtke JR, Vidova V, Honnorat J, Manto M (2013) Monoclonal antibodies to 65 kDa glutamate decarboxylase induce epitope specific effects on motor and cognitive functions in rats. *Orphanet J Rare Dis* 8:82
- Harayama H, Ohno T, Miyatake T (1983) Quantitative analysis of stance in ataxic myxoedema. *J Neurol Neurosurg Psychiatry* 46(6):579–581
- Hoffmann F, Reiter K, Kluger G, Holthausen H, Schwarz HP, Borggraefe I, Bonfig W (2007) Seizures, psychosis and coma: severe course of hashimoto encephalopathy in a six-year-old girl. *Neuropediatrics* 38(4):197–199
- Ishida K, Mitoma H, Song SY, Uchihara T, Inaba A, Eguchi S, Kobayashi T, Mizusawa H (1999) Selective suppression of cerebellar GABAergic transmission by an autoantibody to glutamic acid decarboxylase. *Ann Neurol* 46(2):263–267
- Kahaly GJ (2009) Polyglandular autoimmune syndromes. *Eur J Endocrinol* 161(1):11–20
- Koibuchi N (2013) The role of thyroid hormone on functional organization in the cerebellum. *Cerebellum* 12(3):304–306
- Kothbauer-Margreiter I, Sturzenegger M, Komor J, Baumgartner R, Hess CW (1996) Encephalopathy associated with Hashimoto thyroiditis: diagnosis and treatment. *J Neurol* 243(8):585–593
- Kuhn J, Bewermeyer H, Miyajima H, Takahashi Y, Kuhn KF, Hoogenraad TU (2007) Treatment of symptomatic heterozygous aceruloplasminemia with oral zinc sulphate. *Brain Dev* 29(7):450–453. Epub 2007 Feb 20
- Kuwahara H, Suzuki S, Matsumura K, Watanabe M, Yakushiji F, Fujigasaki H (2013) Ocular flutter, generalized myoclonus, and truncal ataxia in a patient with Graves' ophthalmopathy. *J Neurol* 260(11):2906–2907
- Laurberg P (2006) Remission of Graves' disease during anti-thyroid drug therapy. Time to reconsider the mechanism? *Eur J Endocrinol* 155(6):783–786
- Lazarus JH (2009) Lithium and thyroid. *Best Pract Res Clin Endocrinol Metabol* 23:723–733
- Lin YT, Liao SC (2009) Hashimoto encephalopathy presenting as schizophrenia-like disorder. *Cogn Behav Neurol* 22:197–201
- Manto M (2010) Cerebellar disorders. A practical approach to diagnosis and management. Cambridge University Press, Cambridge
- Manto M (2013) Endocrine disorders. In: Manto M, Gruol DL, Schmahmann JD, Koibuchi N, Rossi F (eds) *Handbook of the cerebellum and cerebellar disorders*. Springer, Dordrecht, pp 2009–2025
- Manto M, Jissendi P (2012) Brain imaging in cerebellar ataxia associated with autoimmune polyglandular syndrome type 2. *J Neuroimaging* 22(3):308–311

- Manto MU, Laute MA, Aguera M, Rogemond V, Pandolfo M, Honnorat J (2007) Effects of anti-glutamic acid decarboxylase antibodies associated with neurological diseases. *Ann Neurol* 61(6):544–551
- Manto MU, Hampe CS, Rogemond V, Honnorat J (2011) Respective implications of glutamate decarboxylase antibodies in stiff person syndrome and cerebellar ataxia. *Orphanet J Rare Dis* 6:3
- Margolin DH, Kousi M, Chan YM, Lim ET, Schmahmann JD, Hadjivassiliou M, Hall JE, Adam I, Dwyer A, Plummer L, Aldrin SV, O'Rourke J, Kirby A, Lage K, Milunsky A, Milunsky JM, Chan J, Hedley-Whyte ET, Daly MJ, Katsanis N, Seminara SB (2013) Ataxia, dementia, and hypogonadotropism caused by disordered ubiquitination. *N Engl J Med* 368(21):1992–2003
- Miyajima H, Nishimura Y, Mizoguchi K, Sakamoto M, Shimizu T, Honda N (1987) Familial apoceruloplasmin deficiency associated with blepharospasm and retinal degeneration. *Neurology* 37(5):761–767
- Miyajima H, Takahashi Y, Kono S (2003) Aceruloplasminemia, an inherited disorder of iron metabolism. *Biomaterials* 16(1):205–213
- Muroga T, Adachi K, Konagaya M, Takayanagi T, Sobue I (1982) Effects of thyrotropin releasing hormone on cerebellar mutant mice – a kinesiological comparison between rolling mouse Nagoya, weaver and reeler. *Jpn J Med* 21(2):101–108
- Nakagawa H, Yoneda M, Fujii A, Kinomoto K, Kuriyama M (2009) Hashimoto encephalopathy presenting with progressive cerebellar ataxia. *BMJ Case Rep.* 2009, pii: bcr06.2009.2005.
- Nyland H, Skre H (1977) Cerebral calcinosis with late onset encephalopathy. Unusual type of pseudo-pseudohypoparathyroidism. *Acta Neurol Scand* 56(4):309–325
- Pasquini JM, Adamo AM (1994) Thyroid hormones and the central nervous system. *Dev Neurosci* 16(1–2):1–8
- Pinelli P, Pisano F, Miscio G (1990) Ataxia in myxoedema: a neurophysiological reassessment. *J Neurol* 237(7):405–409
- Planche V, Marques A, Ulla M, Ruivard M, Durif F (2014) Intravenous immunoglobulin and rituximab for cerebellar ataxia with glutamic acid decarboxylase autoantibodies. *Cerebellum* 13(3):318–322
- Rao AS, Kremenevskaja N, Resch J, Brabant G (2005) Lithium stimulates proliferation in cultured thyrocytes by activating Wnt/beta-catenin signalling. *Eur J Endocrinol* 153(6):929–938
- Saiz A, Arpa J, Sagasta A, Casamitjana R, Zarranz JJ, Tolosa E, Graus F (1997) Autoantibodies to glutamic acid decarboxylase in three patients with cerebellar ataxia, late-onset insulin-dependent diabetes mellitus, and polyendocrine autoimmunity. *Neurology* 49(4):1026–1030
- Schiemann U, Gellner R, Riemann B, Schierbaum G, Menzel J, Domschke W, Hengst K (1999) Standardized grey scale ultrasonography in Graves' disease: correlation to autoimmune activity. *Eur J Endocrinol* 141(4):332–336
- Schwaninger M, Haehnel S, Hess K, Fohr B, Nawroth P, Hacke W (2002) Cerebellar ataxia after repeated hypoglycemia. *Eur J Neurol* 9(5):544–545
- Seipelt M, Zerr I, Nau R, Mollenhauer B, Kropp S, Steinhoff BJ, Wilhelm-Gössling C, Bamberg C, Janzen RW, Berlit P, Manz F, Felgenhauer K, Poser S (1999) Hashimoto's encephalitis as a differential diagnosis of Creutzfeldt-Jakob disease. *J Neurol Neurosurg Psychiatry* 66(2):172–176
- Selim M, Drachman DA (2001) Ataxia associated with Hashimoto's disease: progressive non-familial adult onset cerebellar degeneration with autoimmune thyroiditis. *J Neurol Neurosurg Psychiatry* 71:81–87
- Seminara SB, Aciermo JS Jr, Abdulwahid NA, Crowley WF Jr, Margolin DH (2002) Hypogonadotropic hypogonadism and cerebellar ataxia: detailed phenotypic characterization of a large, extended kindred. *J Clin Endocrinol Metab* 87(4):1607–1612
- Shaw PJ, Walls TJ, Newman PK, Cleland PG, Cartledge NE (1991) Hashimoto's encephalopathy: a steroid-responsive disorder associated with high anti-thyroid antibody titers – report of 5 cases. *Neurology* 41(2 (Pt 1)):228–33

- Shibusawa N, Hashimoto K, Yamada M (2008) Thyrotropin-releasing hormone (TRH) in the cerebellum. *Cerebellum* 7(1):84–95
- Shneyder N, Lyons MK, Driver-Dunckley E, Evidente VG (2012) Cerebellar ataxia from multiple potential causes: hypothyroidism, hashimoto's thyroiditis, thalamic stimulation, and essential tremor. *Tremor Other Hyperkinet Mov (N Y)*. 2012;2. pii: tre-02-44-309–2
- Sobue I, Yamamoto H, Konagaya M, Iida M, Takayanagi T (1980) Effect of thyrotropin-releasing hormone on ataxia of spinocerebellar degeneration. *Lancet* 1(8165):418–9
- Spaulding SW, Burrow GN, Bermudez F, Himmelhoch JM (1972) The inhibitory effect of lithium on thyroid hormone release in both euthyroid and thyrotoxic patients. *J Clin Endocrinol Metab* 35(6):905–911
- Tarnutzer AA, Gerth-Kahlert C, Timmann D, Chang DI, Harmuth F, Bauer P, Straumann D, Synofzik M (2014) Boucher-Neuhäuser syndrome: cerebellar degeneration, chorioretinal dystrophy and hypogonadotropic hypogonadism: two novel cases and a review of 40 cases from the literature. *J Neurol*. 2014 Oct 31 [Epub ahead of print]
- Thomas KP, Muthugovindan D, Singer HS (2010) Paroxysmal kinesigenic dyskinesias and pseudohypoparathyroidism type Ib. *Pediatr Neurol* 43:61–64
- Van Vliet G, Deladoëy J (2014) Diagnosis, treatment and outcome of congenital hypothyroidism. *Endocr Dev* 26:50–59
- Yoneda M, Fujii A, Ito A, Yokoyama H, Nakagawa H, Kuriyama M (2007) High prevalence of serum autoantibodies against the amino terminal of alpha-enolase in Hashimoto's encephalopathy. *J Neuroimmunol* 185(1–2):195–200
- Yuceyar N, Karadeniz M, Erdogan M, Copur A, Akgun A, Kumral E, Ozgen G (2007) Thyrotoxic autoimmune encephalopathy in a female patient: only partial response to typical immunosuppressant treatment and remission after thyroidectomy. *Clin Neurol Neurosurg* 109(5):458–462
- Zecca L, Youdim MB, Riederer P, Connor JR, Crichton RR (2004) Iron, brain ageing and neurodegenerative disorders. *Nat Rev Neurosci* 5(11):863–873



**Part XI**  
**Therapies of Cerebellar Ataxias**

# Chapter 82

## Drugs in Selected Ataxias

Dagmar Timmann and Winfried Ilg

**Abstract** Options for drug treatment are very limited in patients with degenerative forms of ataxias. Drug treatments are available in a few metabolic disorders and vitamin deficiencies that can cause ataxia. These diseases have to be excluded in all cases of ataxias of unknown origin. Despite the huge increase in knowledge in the underlying genetics and pathophysiology, however, causal treatments are currently not available for the large majority of hereditary and non-hereditary degenerative ataxias. Most preclinical and clinical studies have been done in Friedreich's ataxia, and findings will be briefly summarized. Likewise, no symptomatic drug treatment is available which ameliorates the clinical signs and symptoms of ataxia. The only exceptions are aminopyridines for treatment of downbeat nystagmus, and acetazolamide and aminopyridines for treatment of episodic ataxias. A number of other drugs have been tried for symptomatic treatment of ataxias, but without provable effects.

**Keywords** Aminopyridine • Causative therapy • Idebeneone • Medication • Symptomatic treatment

### 82.1 Introduction

Options for drug treatment are very limited in patients with degenerative forms of ataxias. Drug treatments are available in a few metabolic disorders and vitamin deficiencies that can cause ataxia. These diseases have to be excluded in all cases of

---

D. Timmann (✉)  
Department of Neurology, University of Duisburg-Essen,  
Hufelandstrasse 55, 45147 Essen, Germany  
e-mail: [dagmar.timmann-braun@uni-duisburg-essen.de](mailto:dagmar.timmann-braun@uni-duisburg-essen.de)

W. Ilg  
Section Computational Sensomotrics, Department of Cognitive Neurology, Hertie Institute  
for Clinical Brain Research, Otfried-Mueller-Str 25, 72076 Tübingen, Germany

Centre for Integrative Neuroscience, University of Tübingen,  
Otfried-Mueller-Str 25, 72076 Tübingen, Germany  
e-mail: [winfried.ilg@uni-tuebingen.de](mailto:winfried.ilg@uni-tuebingen.de)

ataxias of unknown origin (Ramirez-Zamora et al. 2015). Despite the huge increase in knowledge in the underlying genetics and pathophysiology, however, causal treatments are currently not available for the large majority of hereditary and non-hereditary degenerative ataxias. Most preclinical and clinical studies have been done in Friedreich's ataxia, and findings will be briefly summarized. Likewise, no symptomatic drug treatment is available which ameliorates the clinical signs and symptoms of ataxia (Ilg et al. 2014). The only exceptions are aminopyridines for treatment of downbeat nystagmus, and acetazolamide and aminopyridines for treatment of episodic ataxias. A number of other drugs have been tried for symptomatic treatment of ataxias, but without provable effects.

## **82.2 Treatable Causes of Ataxia**

### **82.2.1 *Vitamin Deficiency***

Vitamin B12 deficiency is a cause of sensory ataxia. Sensory ataxia is also characteristic of vitamin E deficiency. Vitamin E deficiency can be due to malnutrition or metabolic disorders (that is, abetalipoproteinemia, and ataxia with vitamin E deficiency, AVED). It is mandatory to exclude Vitamin B1 deficiency in chronic alcoholics with cerebellar ataxia to prevent occurrence of a Korsakoff's syndrome.

### **82.2.2 *Metabolic Disorders***

There are a couple of metabolic disorders which can cause ataxia and are potentially treatable with drugs: abetalipoproteinemia, AVED, cerebrotendinous xanthomatosis, Niemann Pick disease type C, Refsum disease and Wilson disease (Ramirez-Zamora et al. 2015). Similar to abetalipoproteinemia and AVED sensory ataxia is typical in Refsum disease. Ataxia in the three other disorders is of the cerebellar type. Metabolic testing and drug treatment options are summarized in Table 82.1. Primary coenzyme Q10 deficiency is another potentially treatable cause of ataxia.

### **82.2.3 *Endocrine Disorders***

Hypothyroidism can be accompanied by cerebellar ataxia.

### **82.2.4 *Autoimmune Disorders***

Whether autoimmune disease can lead to cerebellar ataxia is a matter of ongoing discussion. Likewise it is an open question whether corticoids or intravenous immunoglobulin are advantageous. Evidence is best for anti-glutamic acid decarboxylase (GAD)-associated cerebellar ataxia in patients with polyglandular autoimmune

**Table 82.1** Metabolic disorders which can cause ataxia and are potentially treatable with drugs. These are autosomal-recessive diseases. Diagnosis is confirmed by genetic testing

Metabolic disorder	Laboratory test	Genetic mutation	Treatment option
Abetalipoproteinemia	Acanthocytes in blood smear; low serum level of vitamin E; low low-density lipoproteins (LDL) in cholesterol tests; absent betalipoproteins in lipoprotein electrophoresis	MTP (microsomal triglyceride transfer protein) gene	Low-fat diet; high doses of vitamin E; vitamin A and K
AVED	Reduced serum vitamin E	TTPA ( $\alpha$ -tocopherol transfer protein) gene	High doses of vitamin E
Cerebrotendinous xanthomatosis	Increased serum cholestanol	CYP27A1 gene	Chenodeoxycholic acid; statins
Niemann Pick disease type C	Increased serum chitotriosidase and oxysterols	NPC1 and NPC2 genes	Miglustat
Refsum disease	Increased serum phytanic acid	PHYH (phytanoyl-CoA hydroxylase) gene	Phytanic acid-restricted diet; plasmapheresis
Wilson disease	Low serum ceruloplasmin; low serum copper; elevated urine copper (collected for 24 h)	ATP7B gene	Copper chelators (penicillamine); zinc
Primary coenzyme Q10 deficiencies	Low coenzyme Q10 in muscle tissue	Various genes: COQ2; PDSS1; PDSS2; COQ8; COQ9; COQ6	High dose coenzyme Q10

disorder (Saiz et al. 2008). One has to be aware, however, that antibody titers are already high in diabetes mellitus type 1 and have to be significantly higher in anti-GAD associated cerebellar ataxias. They should also be present in CSF. Whether gluten- and thyroid-related antibodies in coeliac and Hashimoto's disease can cause cerebellar ataxia is unclear.

### 82.3 Friedreich's Ataxia

Friedreich's ataxia is the most common hereditary ataxia. Since the discovery of the genetic mutation in 1996 much has been learned about the underlying pathophysiology (Pandolfo 2012). Friedreich's ataxia is a mitochondriopathy. Frataxin levels are

abnormally low. Frataxin is involved in regulation of the mitochondrial iron metabolism. There is reduced biosynthesis of iron-sulfur clusters leading to disordered cell respiration, and there is iron overload within the mitochondria. As a consequence, oxidative stress is increased which results in subsequent cell death (apoptosis). Based on this known pathophysiology a number of preclinical and clinical drug trials have been initiated.

Firstly, antioxidant drugs are tested, in particular idebenone, but also vitamin E and coenzyme Q10. Idebenone is a derivative of coenzyme Q10. Initial studies suggested that idebenone reduces the degree of accompanying cardiomyopathy based on echocardiographic measures. Although subsequent studies indicated additional effects on some neurological signs, most recent placebo-controlled trials in large patient populations were unable to show significant effects on cardiac or neurological outcome parameters (Lagedrost et al. 2011). To date, idebenone cannot generally be recommended in the treatment of Friedreich's ataxia.

Secondly, iron chelators are tested to reduce the iron content of the mitochondria. Deferiprone is preferred to deferoxamine because it can penetrate cellular membranes and is thought to redistribute iron out of the mitochondria and into extracellular environment. Iron chelators have the problem of major side effects, in particular iron-deficient anemia, and close monitoring of blood parameters is needed. Agranulocytosis is a major risk factor of deferiprone. In a recent placebo-controlled study deferiprone showed no significant effects on neurological outcome parameters in Friedreich's ataxia at a low and medium dose, at higher doses ataxia became even worse (Pandolfo et al. 2014). At low and medium doses the degree of accompanying cardiomyopathy based on echocardiographic measures improved, but it was unclear whether this had an impact on cardiac function. As yet, the intake of deferiprone cannot be recommended outside study protocols.

Thirdly, treatments are tested which increase the frataxin level. In preclinical studies and clinical pilot studies erythropoietin led to increased frataxin levels. In subsequent placebo-controlled studies, however, no significant effects on frataxin levels or neurological outcome parameters could be observed (Mariotti et al. 2012). Potential side effects, in particular increases in hematocrit requiring phlebotomies, are another limitation. To date, treatment with erythropoietin cannot be recommended in Friedreich's ataxia.

The most recent development are clinical pilot trials with histone deacetylase inhibitors (HDACi). The idea of this epigenetic treatment is to reactivate the frataxin gene and therefore to increase expression of frataxin mRNA and frataxin levels. HDACi have been shown to increase frataxin levels in various human cell models as well as buccal cells of Friedreich's ataxia patients. A recent exploratory study was able to show that high doses of nicotinamide (that is, niacin or vitamin B3) increase frataxin levels in blood samples in patients with Friedreich's ataxia (Libri et al. 2014). The main side effect was nausea. Nicotinamide was given up to 8 weeks and no effects on neurological scores could be observed. Future studies are needed to evaluate effects of prolonged treatment on cardiac and neurological parameters, as well as side effects of long-term treatment with high doses of nicotinamide.

## 82.4 Symptomatic Treatment of Ataxias

To date, symptomatic drug treatment of ataxia is basically not available. Several drugs and food supplements have been used, including 5-hydroxytryptophane, buspirone, creatine, L-carnitine, vitamin E, coenzyme Q10, idebenone and amantadine with no convincing effects. In a placebo-controlled trial, positive effects of daily zinc supplementation together with neurorehabilitation therapy was found in SCA2 patients with reduced zinc concentrations in serum and CSF (Velázquez-Pérez et al. 2011). In a placebo-controlled trial, riluzole was found to be beneficial in patients with various forms of ataxias (Ristori et al. 2010). Experience of many ataxia clinics, however, is negative. Findings need to be confirmed in a second placebo-controlled study. Varenicline was assessed in a randomized controlled trial in SCA3 patients (Zesiewicz et al. 2012). Although positive effects on neurological outcome were reported, drop-out rate was high and results need to be treated cautiously. Furthermore side effects are common. Positive effects of acetyl-DL-leucine on neurological outcome parameters have been reported in a case series (Strupp et al. 2013). Experience of many ataxia clinics, however, is not convincing. Findings need to be validated in a placebo-controlled study. Current studies in patients with spinocerebellar ataxias evaluate lithium and immunoglobulines.

## 82.5 Aminopyridines

Aminopyridines are of help in a significant subset of patients with downbeat nystagmus (DBN) and episodic ataxia type 2 (EA2) (Ilg et al. 2014). Downbeat nystagmus is a common accompanying sign in degenerative ataxias.

Initial studies have been performed using 3,4-diaminopyridine (Strupp et al. 2003). In subsequent studies 4-aminopyridine (4-AP) was used. Because 4-AP appears to cross the blood-brain-barrier more easily, to date 4-AP is usually recommended. Most recent studies are performed with the slow-release form of 4-AP (fampridine or dalfampridine).

The therapeutic effect of aminopyridines has been demonstrated in placebo-controlled studies in DBN and EA2 (Strupp et al. 2011). Whether aminopyridines have a beneficial effect on other symptoms of ataxia, for example ataxia of stance and gait, is unclear. Results of ongoing placebo-controlled studies have to be awaited.

In EA2, as yet, acetazolamide is the treatment of choice, which has originally been used to treat arterial hypertension. Acetazolamide has a number of side-effects including the development of kidney stones, and aminopyridines are a useful alternative. An ongoing study compares the therapeutic effects of acetazolamide and fampridine (EAT-2-TREAT).

Common side effects of aminopyridines are vertigo, headache and nausea. Life-threatening cardiac arrhythmias are a rare but a severe side effect. Seizures are

reported in high doses. Patients with prolonged QTc intervals on electrocardiogram or known epilepsy should not receive aminopyridines. Tests of kidney function should be performed in particular in patients older than 50 years.

## 82.6 Conclusions

As yet, causal or symptomatic drug treatment is available only in a very small subset of patients with ataxia. Given the increased knowledge about the genetics and pathophysiology of many ataxias, this may well change in the future. Patients should be evaluated for downbeat nystagmus because aminopyridines can be helpful. In patients with episodic ataxia type 2 aminopyridines are a useful alternative for acetazolamide. SCA2 patients should be checked for lack of zinc concentration and Zn supplementation may be started. Ataxia is frequently accompanied by extracerebellar symptoms, such as restless legs syndrome, depression, spasticity, neuropathic pain, bladder dysfunction, sleeping disorders, dystonia and parkinsonism, which should be treated according to standard medications.

## References

- Ilg W, Bastian AJ, Boesch S, Burciu RG, Celnik P, Claaßen J, Feil K, Kalla R, Miyai I, Nachbauer W, Schöls L, Strupp M, Synofzik M, Teufel J, Timmann D (2014) Consensus paper: management of degenerative cerebellar disorders. *Cerebellum* 13:248–268
- Lagedrost SJ, Sutton MS, Cohen MS, Satou GM, Kaufman BD, Perlman SL, Rummey C, Meier T, Lynch DR (2011) Idebenone in Friedreich ataxia cardiomyopathy—results from a 6-month phase III study (IONIA). *Am Heart J* 161:639–645
- Libri V, Yandim C, Athanasopoulos S, Loyse N, Natisvili T, Law PP, Chan PK, Mohammad T, Mauri M, Tam KT, Leiper J, Piper S, Ramesh A, Parkinson MH, Huson L, Giunti P, Festenstein R (2014) Epigenetic and neurological effects and safety of high-dose nicotinamide in patients with Friedreich's ataxia: an exploratory, open-label, dose-escalation study. *Lancet* 384:504–513
- Mariotti C, Fancellu R, Caldarazzo S, Nanetti L, Di Bella D, Plumari M, Lauria G, Cappellini MD, Duca L, Solari A, Taroni F (2012) Erythropoietin in Friedreich ataxia: no effect on frataxin in a randomized controlled trial. *Mov Disord* 27:446–449
- Pandolfo M (2012) Friedreich ataxia. *Handb Clin Neurol* 103:275–294
- Pandolfo M, Arpa J, Delatycki MB, Le Quan Sang KH, Mariotti C, Munnich A, Sanz-Gallego I, Tai G, Tamopolsky MA, Taroni F, Spino M, Tricta F (2014) Deferiprone in Friedreich ataxia: a 6-month randomized controlled trial. *Ann Neurol* 76:509–521
- Ramirez-Zamora A, Zeigler W, Desai N, Biller J (2015) Treatable causes of cerebellar ataxia. *Mov Disord* 30(5):614–623
- Ristori G, Romano S, Visconti A, Cannoni S, Spadaro M, Frontali M, Pontieri FE, Vanacore N, Salvetti M (2010) Riluzole in cerebellar ataxia: a randomized, double-blind, placebo-controlled pilot trial. *Neurology* 74:839–845
- Saiz A, Blanco Y, Sabater L, González F, Bataller L, Casamitjana R, Ramió-Torrentà L, Graus F (2008) Spectrum of neurological syndromes associated with glutamic acid decarboxylase antibodies: diagnostic clues for this association. *Brain* 131:2553–2563

- Strupp M, Schüler O, Krafczyk S, Jahn K, Schautzer F, Büttner U, Brandt T (2003) Treatment of downbeat nystagmus with 3,4-diaminopyridine: a placebo-controlled study. *Neurology* 61:165–170
- Strupp M, Kalla R, Claassen J, Adrion C, Mansmann U, Klopstock T, Freilinger T, Neugebauer H, Spiegel R, Dichgans M, Lehmann-Horn F, Jurkat-Rott K, Brandt T, Jen JC, Jahn K (2011) A randomized trial of 4-aminopyridine in EA2 and related familial episodic ataxias. *Neurology* 77:269–275
- Strupp M, Teufel J, Habs M, Feuerecker R, Muth C, van de Warrenburg BP, Klopstock T, Feil K (2013) Effects of acetyl-DL-leucine in patients with cerebellar ataxia: a case series. *J Neurol* 260:2556–2561
- Velázquez-Pérez L, Rodríguez-Chanfrau J, García-Rodríguez JC, Sánchez-Cruz G, Aguilera-Rodríguez R, Rodríguez-Labrada R, Rodríguez-Díaz JC, Canales-Ochoa N, Gotay DA, Almaguer Mederos LE, Laffita Mesa JM, Porto-Verdecia M, Triana CG, Pupo NR, Batista IH, López-Hernandez OD, Polanco ID, Novas AJ (2011) Oral zinc sulphate supplementation for six months in SCA2 patients: a randomized, double-blind, placebo-controlled trial. *Neurochem Res* 36:1793–1800
- Zesiewicz TA, Greenstein PE, Sullivan KL, Wecker L, Miller A, Jahan I, Chen R, Perlman SL (2012) A randomized trial of varenicline (Chantix) for the treatment of spinocerebellar ataxia type 3. *Neurology* 78:545–550



# Chapter 83

## Cerebellar Stimulation

Giuliana Grimaldi

**Abstract** Non invasive brain stimulation (NIBS), encompassing Transcranial Magnetic Stimulation (TMS) and Transcranial Direct Current Stimulation (tDCS), is becoming more and more promising as a novel procedure to modulate cerebellar functions and as therapy for cerebellar patients. This chapter provides the elementary concept of this therapeutic approach, which is based on the modulation of the cerebellar brain inhibition (CBI), and reports a brief overview of the studies focusing on the therapeutic potentials and effectiveness of these techniques. Evidences of the effectiveness of this appealing therapeutic approach are growing, but many issues remain to be clarified to include these treatments in the standard management of the cerebellar patients.

**Keywords** Modulation of the Cerebellar Brain Inhibition (CBI) • Non Invasive Brain Stimulation (NIBS) • Transcranial Magnetic Stimulation (TMS) • Transcranial Direct Current Stimulation (tDCS)

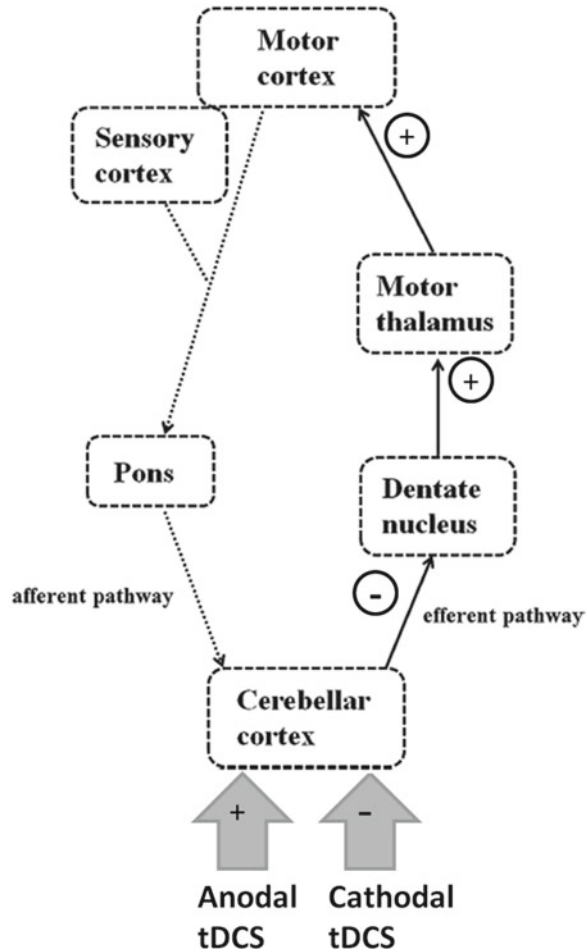
### 83.1 Introduction

There is a consensus that both Transcranial Magnetic Stimulation (TMS) and Transcranial Direct Current Stimulation (tDCS) can effectively influence cerebellar functions, not only in the motor domain, but also for the cognitive and affective operations handled by the cerebrocerebellar circuits (Grimaldi et al. 2014a). The cerebellum plays important roles in movement execution and motor control by modulation of the activity of the primary motor cortex (M1) through cerebello-thalamo-cortical connections (Fig. 83.1) (Ito 1984). The dentato-thalamo-cortical pathway itself is facilitatory. However, Purkinje cells of the cerebellar cortex inhibit cerebellar nuclei. Therefore, activation of Purkinje cells results in disfacilitation of the motor cortex (i.e. decreased excitability of the motor cortex: cerebellar brain inhibition – CBI). Both TMS and tDCS -non invasive brain stimulation (NIBS)

---

G. Grimaldi, M.D., Ph.D. (✉)  
Unité d'Etude du Mouvement, Hôpital Erasme-ULB, Bruxelles, Belgium  
e-mail: [giulianagrim@yahoo.it](mailto:giulianagrim@yahoo.it)

**Fig. 83.1** Simplified scheme of the fronto-ponto-cerebello-thalamo-cortical loop. *Solid lines* indicate the cerebellar efferent pathways and *dotted lines* the cerebellar afferent pathways. The *sign plus (+)* indicates facilitatory effect. The *sign minus (-)* indicates inhibitory effect. Anodal tDCS increases cerebellar cortical excitability (*arrow +*), while cathodal decreases it (*arrow -*) (Adapted from Grimaldi et al. 2014a)



through electromagnetic induction and direct electrical current, respectively- modulate the electrical properties of the networks between the cerebellum and M1, tuning cerebellar excitability (Grimaldi et al. 2014a). This is the basic concept for therapeutic applications of neuromodulation techniques in cerebellar patients. Studies show that the normal effects of CBI are reduced or absent in patients with degeneration or lesions of the efferent system from the cerebellum, confirming the clinical potential of NIBS to manage motor deficits in cerebellar ataxias (Pope and Miall 2014).

## 83.2 Transcranial Magnetic Stimulation (TMS)

TMS is based on electromagnetic induction by means of a magnetic field generator (the coil) which is placed over the scalp and produces small electric currents. This technique has been used in the last decades to investigate neural networks in human

by stimulating/inhibiting neural structures non-invasively. Single pulse TMS on the M1 and the recording of the motor evoked potential (MEP, generated in response to the TMS pulse: test stimulus), are used to measure motor cortical excitability. Applying a conditioning stimulus over the cerebellum before the test stimulus over the contralateral M1 allows to study the CBI (i.e. the cerebellar regulatory effects on M1) (Grimaldi et al. 2014a). Low frequency repetitive TMS (rTMS) has an inhibitory effect on cerebellar cortex thus decreasing CBI, high frequency rTMS has an excitatory effect (Pope and Miall 2014).

Safety and feasibility of repetitive transcranial magnetic stimulation (rTMS, 1 Hz) over the cerebellum in ataxic patients with posterior circulation stroke have been demonstrated (Kim et al. 2014). rTMS, more specifically the iTBS protocol (intermittent theta burst stimulation, interstimulus interval of 15 ms), applied over the injured cerebellar hemisphere of stroke patients induces both neurophysiological changes (a decrease in CBI and an increase in intra-cortical facilitation) and a clinical improvement, thus suggesting that cerebellar iTBS could be a promising tool to promote recovery of cerebellar stroke patients (Bonnì et al. 2014). Improved cognition has been demonstrated using TMS (21 daily sessions of TMS over the cerebellum) in an ataxic patient (affected by idiopathic late-onset cerebellar atrophy) presenting speech and gait difficulties. The TMS-induced reduction in CBI resulted in the improvements in the patients' functional mobility (postural control and walking) and dual-tasking (naming supermarket items while walking) after treatment (Farzan et al. 2013). Decreasing cortical excitability by administering 1 Hz rTMS for 10 min over the right (unaffected) cerebellum in a patient with a left cerebellar lesion and a selective deficit in procedural learning induces a recovery of the deficit and an improvement of the task performance (Torriero et al. 2007).

### 83.3 Transcranial Direct Current Stimulation (tDCS)

tDCS is based on the application of a steady current of small intensity (usually between 0.5 and 2 mAmp; anodal or cathodal) between two large electrodes fixed on the scalp (Tomlinson et al. 2013). The current causes a polarity-dependent modulation of brain activity which is site-specific (Nitsche et al. 2003). When applied over the cerebellum, tDCS can effectively modulate CBI by changing tonic Purkinje cell activity and thus resulting in modulation of cerebral cortical excitability (Fig. 83.1). Cathodal tDCS over the cerebellum reduces cortical excitability and leads to a lasting inhibition of CBI for up to 30 min after stimulation. On the other hand, anodal cerebellar tDCS, which increases cortical excitability, increases the magnitude of CBI (Galea et al. 2009). Anodal ctDCS causes walking adaptation to occur more rapidly, whereas cathodal ctDCS slowed it down relative to sham stimulation (Jayaram et al. 2012).

Recently, Pozzi et al. showed that anodal tDCS over the motor cortex in ataxic patients induced an improvement of the symmetry of step execution and reduction of base-width. This was associated with patients' perception of improvement, lasting 30 days after stimulation (Pozzi et al. 2014). A study on the effect of anodal

tDCS applied over the cerebellum in ataxic patients showed that tDCS exerts a favourable effect on upper limb stretch reflexes, reducing significantly the amplitudes of long-latency stretch reflexes (Grimaldi and Manto 2013). The effectiveness of tDCS on cerebellar patients improves when combining tDCS over the cerebellum and tDCS over the motor/premotor cerebral cortex (transcranial cerebello-cerebral DCS – tCCDCS). tCCDCS reduces both postural and action tremor, cancels hypermetria and restores EMG activity associated with fast goal-directed movements (decrease of the onset latency of the antagonist EMG activity) (Grimaldi et al. 2014b). These findings suggest that tCCDCS impacts on the distorted timing of muscle discharges which is considered as a signature of a cerebellar lesion involving the cerebello-thalamo-cortical pathway.

tDCS is now considered a potential therapeutic tool as well as a valuable clinical tool for neurorehabilitation interventions. tDCS also raises researchers' interest as a technique to provide novel information on cerebellar functions and to promote neuroplasticity (Grimaldi et al. 2014a). Moreover, this technique (similarly to TMS) is non-invasive, well tolerated and safe, provided an appropriate current intensity is used and inter-stimulation intervals are applied. However, important questions about therapeutic application of tDCS still remain open (Grimaldi et al. 2016): what is the optimal intensity? Are there any differences in responsiveness among cerebellar patients? How long the effects last? Is the effectiveness influenced by the extent of cerebellum volume loss in patients with cerebellar atrophy? Should tDCS be applied on a daily basis? Which are the optimal sites of stimulation and how to combine them? Could we consider a combination of stimulation of the cerebellum and the spinal cord (Priori et al. 2014)?

## References

- Bonni S, Ponzo V, Caltagirone C, Koch G (2014) Cerebellar theta burst stimulation in stroke patients with ataxia. *Funct Neurol* 7:1–5
- Farzan F, Wu Y, Manor B, Anastasio EM, Lough M, Novak V et al (2013) Cerebellar TMS in treatment of a patient with cerebellar ataxia: evidence from clinical, biomechanics and neurophysiological assessments. *Cerebellum* 12:707–712
- Galea JM, Jayaram G, Ajagbe L, Celnik P (2009) Modulation of cerebellar excitability by polarity-specific noninvasive direct current stimulation. *J Neurosci* 29(28):9115–9122
- Grimaldi G, Manto M (2013) Anodal Transcranial Direct Current Stimulation (tDCS) decreases the amplitudes of long-latency stretch reflexes in cerebellar ataxia. *Ann Biomed Eng* 41:2437–2447
- Grimaldi G, Argyropoulos GP, Boehringer A, Celnik P, Edwards MJ, Ferrucci R, Galea JM, Groiss SJ, Hiraoka K, Kassavetis P, Lesage E, Manto M, Miall RC, Priori A, Sadnicka A, Ugawa Y, Ziemann U (2014a) Non-invasive cerebellar stimulation – a consensus paper. *Cerebellum* 13(1):121–138
- Grimaldi G, Oulad Ben Taib N, Manto M, Bodranghien F (2014b) Marked reduction of cerebellar deficits in upper limbs following transcranial cerebello-cerebral DC stimulation: tremor reduction and re-programming of the timing of antagonist commands. *Front Syst Neurosci* 8:9

- Grimaldi G, Argyropoulos GP, Bastian A, Cortes M, Davis NJ, Edwards DJ, Ferrucci R, Fregni F, Galea JM, Hamada M, Manto M, Miall RC, Morales-Quezada L, Pope PA, Priori A, Rothwell J, Tomlinson SP, Celnik P (2016) Cerebellar Transcranial Direct Current Stimulation (ctDCS): a novel approach to understanding cerebellar function in health and disease. *Neuroscientist* 22(1):83–97
- Ito M (1984) *Cerebellum and neural control*. Raven, New York
- Jayaram G, Tang B, Pallegadda R, Vasudevan EV, Celnik P, Bastian A (2012) Modulating locomotor adaptation with cerebellar stimulation. *J Neurophysiol* 107(11):2950–2957
- Kim WS, Jung SH, Oh MK, Min YS, Lim JY, Paik NJ (2014) Effect of repetitive transcranial magnetic stimulation over the cerebellum on patients with ataxia after posterior circulation stroke: a pilot study. *J Rehabil Med* 46(5):418–423
- Nitsche MA, Schauenburg A, Lang N, Liebetanz D, Exner C, Paulus W, Tergau F (2003) Facilitation of implicit motor learning by weak transcranial direct current stimulation of the primary motor cortex in the human. *J Cogn Neurosci* 15:619–626
- Pope PA, Miall RC (2014) Restoring cognitive functions using non-invasive brain stimulation techniques in patients with cerebellar disorders. *Front Psychiatry* 5:33
- Pozzi NG, Minafra B, Zangaglia R, De Marzi R, Sandrini G, Priori A, Pacchetti C (2014) Transcranial direct current stimulation (tDCS) of the cortical motor areas in three cases of cerebellar ataxia. *Cerebellum* 13(1):109–112
- Priori A, Ciocca M, Parazzini M, Vergari M, Ferrucci R (2014) Transcranial cerebellar direct current stimulation and transcutaneous spinal cord direct current stimulation as innovative tools for neuroscientists. *J Physiol* 592(Pt 16):3345–3369
- Tomlinson S, Davis N, Bracewell R (2013) Brain stimulation studies of non-motor cerebellar function: a systematic review. *Neurosci Biobehav Rev* 37:766–789
- Torriero S, Oliveri M, Koch G, Lo Gerfo E, Salerno S, Petrosini L et al (2007) Cortical networks of procedural learning: evidence from cerebellar damage. *Neuropsychologia* 45:1208–1214

# Chapter 84

## Motor Rehabilitation of Cerebellar Disorders

Winfried Ilg and Dagmar Timmann

**Abstract** Cerebellar dysfunction can induce a variety of motor impairments including limb movement, speech, oculomotor control, balance and walking (Diener and Dichgans, *Clinical disorders of posture and gait*, Arnold, London; 1996). Causes for cerebellar impairments can be various, including stroke, tumors, multiple sclerosis, and degenerative disease. Motor rehabilitation is challenging for this patient population, since the cerebellum is known to play an important role in motor learning (Bastian, *Curr Opin Neurobiol* 21:596–601; 2011; Ilg, *Cerebellum* 13:248–268; 2014). However, recent results deliver evidence that patients with degenerative cerebellar diseases can benefit from motor training.

**Keywords** Neurorehabilitation • Motor training • Cerebellar ataxia • Dynamic stability • Coordination

### 84.1 Introduction

Cerebellar dysfunction can induce a variety of motor impairments including limb movement, speech, oculomotor control, balance and walking (Diener and Dichgans 1996). Causes for cerebellar impairments can be various, including stroke, tumors, multiple sclerosis, and degenerative disease. Motor rehabilitation is challenging for this patient population, since the cerebellum is known to play an important role in motor learning (Bastian 2011; Ilg et al. 2014). However, recent results deliver

---

W. Ilg (✉)

Section Computational Sensomotorics, Department of Cognitive Neurology, Hertie Institute for Clinical Brain Research, Otfried-Mueller-Str 25, 72076 Tübingen, Germany

Centre for Integrative Neuroscience, University of Tübingen,

Otfried-Mueller-Str 25, 72076 Tübingen, Germany

e-mail: [winfried.ilg@uni-tuebingen.de](mailto:winfried.ilg@uni-tuebingen.de)

D. Timmann

Department of Neurology, University of Duisburg-Essen,

Hufelandstrasse 55, 45147 Essen, Germany

e-mail: [dagmar.timmann-braun@uni-duisburg-essen.de](mailto:dagmar.timmann-braun@uni-duisburg-essen.de)

evidence that patients with degenerative cerebellar diseases can benefit from motor training.

This chapter will review briefly the state of the art of motor rehabilitation in cerebellar ataxia, focusing on gait and posture. More reviews can be found in (Cassidy et al. 2009; Bastian 2011; Marsden 2011; Ilg et al. 2014).

## 84.2 General Predictions of Functional Recovery

The cause, site and extent of brain lesions are generally thought to be important predictors of the degree of functional recovery. For example, functional deficits seem more marked following a hemorrhage compared to an ischemic infarct, but have better chances of recovery if survived. In focal cerebellar lesions, either due to tumor surgery or stroke, lesion site appears to be more important than extent. For example, functional recovery is worse in lesions affecting the deep cerebellar nuclei (e.g. Konczak et al. 2005).

In many degenerative cerebellar ataxias neuronal loss is caused by genetic factors with autosomal dominant inheritance as in the spinocerebellar ataxias (SCA) (Schöls et al. 2004) or a recessive trait like in Friedreich's ataxia. Many sporadic cases of cerebellar degeneration escape the detection of causative factors and are currently classified as sporadic adult onset ataxia of unknown etiology.

In general, degenerative ataxias are the most difficult group to treat, due to the progressive nature. In addition, virtually all parts of the cerebellum are affected although degeneration is frequently most prominent in the midline. In contrast, ataxia following stroke, neurosurgery or trauma affects only circumscribed regions of the cerebellum, but leaves other regions intact. These regions likely compensate for the defective parts. Thus, in patients with progressive degenerative diseases it would be a major achievement to stay on the current status of motor function as long as possible or to slow down progression of functional impairment.

## 84.3 Ataxia-Specific Impairments and Rehabilitation Strategies

### 84.3.1 *Motor Impairments*

Cerebellar damage does not cause loss of movement, but instead leads to increased movement variability and poor accuracy (Bastian 2006). In the case of limb movements typical ataxia symptoms are dysmetria, cerebellar tremor and dyssynergia (Bastian et al. 1996). Cerebellar ataxic gait is typically characterized by increased step width, irregular foot trajectories and a resulting instable walking path (Morton and Bastian 2004; Ilg and Timmann 2013) with a high risk of falling.

### 84.3.2 Motor Rehabilitation

Since the cerebellum plays an important role in motor learning, benefits from motor rehabilitation for patients with cerebellar damage were under debate for a long time and only few studies have evaluated interventions for these patients (Table 84.1).

**Table 84.1** Overview of studies examining motor rehabilitation in cerebellar disease

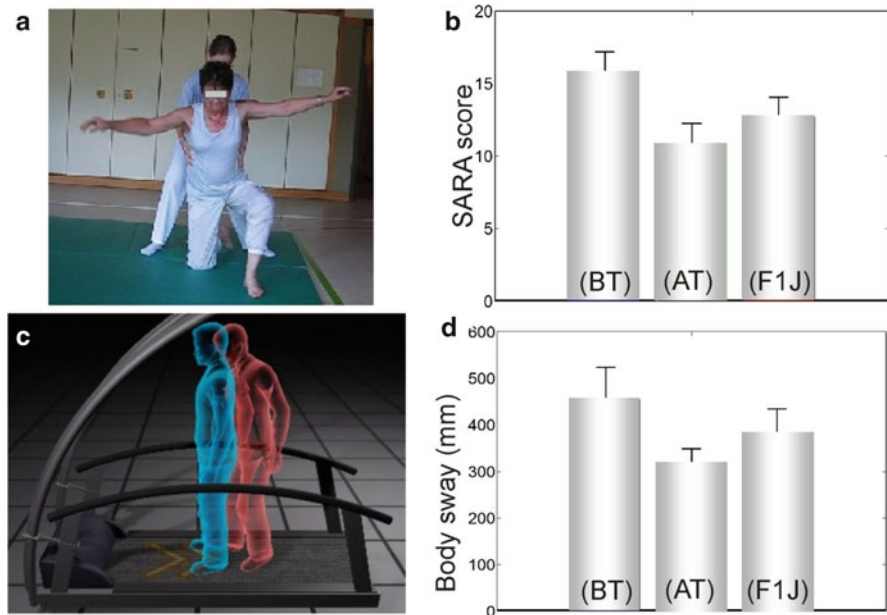
Reference	Patient group	Main result
Balliet et al. (1987)	5 patients after traumatic brain injury with cerebellar involvement	Using increasingly demanding balance and gait tasks, improvements were reached for increased postural stability in clinical measures and less dependency on walking aids in everyday life
Gill-Body et al. (1997)	Two patients with different cerebellar etiologies	Individualized treatment programs to train balance. The outcomes suggest that patients with cerebellar lesions, acute or chronic, may be able to learn to improve their postural stability
Cernak et al. (2008)	One child after cerebellar/brainstem infarct	Locomotion training on treadmill with weight support in conjunction with physical therapy can be an effective way to improve ambulatory function in individuals with severe cerebellar ataxia
Ilg et al. (2009)	16 patients (10 cerebellar, 6 afferent degeneration)	4 weeks intensive coordination training improves gait in terms of velocity, lateral sway and variability of intralimb coordination pattern, improvements in subjective important movements in daily life
Miyai et al. (2012)	42 patients with pure cerebellar degeneration	4 weeks physiotherapy in combination with occupational therapy improves gait speed and fall frequency
Ilg et al. (2012)	10 children with cerebellar degeneration	6 weeks video-gamed based coordination training in children improves velocity, step length variability, dynamic balance
Keller and Bastian (2014)	14 patients with cerebellar ataxia	Improvement in locomotor performance observed after a 6-week home balance exercise program. Exercises are individually designed to provide a significant challenge to the person's balance
Burciu et al. (2013)	19 patients with pure cerebellar degeneration	2 weeks training on a balance task increased balance performance in cerebellar patients. In contrast to controls, patients revealed significantly more post-training gray matter volume in the dorsal premotor cortex
Bunn et al. (2014)	12 patients with spinocerebellar ataxia type 6	Participants undertook balance exercises in front of optokinetic stimuli during weeks 4–8, training intervention was feasible, outcome measures reveal trends towards balance improvements

(continued)



**Table 84.1** (continued)

Reference	Patient group	Main result
Fonteyn et al. (2014)	10 patients with cerebellar ataxia	Training gait adaptability training on a treadmill with virtual obstacles projected on the belt's surface can lead to increased obstacle avoidance capacity and dynamic stability
Kaut et al. (2014)	17 patients with spinocerebellar ataxia types 1, 2, 3, and 6	Whole body vibrations (WBV) can lead to improvements of gait and posture. The use of stochastic WBV could provide a supplementation to treat ataxia and can be combined with physiotherapeutical training



**Fig. 84.1** (a) Snapshot of a demanding exercise: training of dynamic balance and multi-joint coordination. (b) Group data of the clinical ataxia score SARA before training intervention (BT), after the 4 weeks training intervention (AT) and for follow-up assessment after 1 year. (c) Illustration of an experiment testing dynamic balance capacities. Patients have to compensate the perturbation of the accelerating treadmill (accelerating phase 1 s) by anterior directed steps. The red and the blue character show one and the same patient before (red) and after (blue) the intervention period. After intervention patients were able to compensate the perturbation more efficiently and in a more secure way. (d) Quantitative measurement for the body sway in the perturbation experiment for the three assessment points (Ilg et al. 2009, 2010)

Recently, rehabilitation in cerebellar disease has been examined more systematically. In an intra-individual case-control design, the benefits of intensive coordination training have been tested in 16 patients suffering from cerebellar degeneration or degeneration of afferent pathways (Ilg et al. 2009, 2010). Results indicated that patients' benefits can be meaningful for their everyday life and persisted after 1 year. The specificity of motor improvements is shown by measures reflecting intra-limb coordination (see Fig. 84.1c, d). Furthermore, continuous training has been shown

to be crucial in for patients with degenerative diseases: Importantly, the degree of long-term retention depend on training intensity.

A similar study combining physiotherapy with occupational therapy in 42 patients with degenerative cerebellar ataxia revealed improvements of ataxia, gait speed, fall frequency, and activities of daily living (Miyai et al. 2012).

Inspired by these positive results, further studies have been performed recently, examining the effects of different training strategies (Table 84.1) and the relationship between functional improvements and changes in neural substrate (Burciu et al. 2013).

## 84.4 Discussion

### 84.4.1 *Current Practice of Motor Rehabilitation*

Recent studies give evidence, that intensive motor training can reduce ataxia symptoms in patients suffering from degenerative cerebellar disease equivalent to gaining back functional performance of 2 or more years of disease progression (Ilg et al. 2010). However, motor rehabilitation in degenerative cerebellar disease remains a challenge and requires a careful analysis of the patient's current motor capacities and condition in everyday life. In general, a combination of restorative and compensatory techniques may be utilized; the relative emphasis depend on the severity of cerebellar ataxia and its pattern of progression (Bastian 1997; Cassidy et al. 2009; Marsden and Harris 2011).

Best evidence for beneficial interventions exist for coordination training, which is (i) adapted on the severity of the ataxia and (ii) consists in increasingly demanding exercises for multi-joint coordination and balance. These approaches, to activate the remaining coordination capabilities should be used as long as possible, in order to potentially decelerate the process of degeneration of motor capabilities (which has yet shown only in animal studies (Fryer et al. 2011)). However, these types of exercise might be limited to stages of disease in which the patients are able to stand without help and have some gait capabilities.

In more severe cases, in which free standing and walking is not possible anymore, treadmill training with potential weight support may be helpful to increase walking capabilities and to preserve general fitness as far as possible. In such stages, compensatory techniques like replacing rapid multi-joint arm movements with slower movements with sequential single joint movements (Bastian 1997) might be useful.

The use of mobility aids is dependent on disease stage and individual preferences. Furthermore, in severe cases of upper limb ataxia, when basic activities of daily living like eating are impaired, the use of orthotics can help to improve functional performance (Cassidy et al. 2009).

## 84.4.2 *Open Questions*

There is common agreement that continuous motor training is necessary for patients with degenerative ataxia (Ilg et al. 2014). This should include physiotherapeutic treatments as well as training at home, e.g. by exergame-based coordination training (Ilg et al. 2012). There is a need of long-term studies to evaluate the benefits of rehabilitation strategies in patients' everyday life. When performing long-term studies with patients suffering from degenerative disease, one has to keep in mind, that progression in degeneration is different for specific types of diseases (Jacobi et al. 2011). Such studies should examine (i) whether patients with more severe impairments would also benefit from physiotherapeutical training and (ii) whether motor training in very early stage and preclinical stages of the disease could slow down degeneration. Animal studies indicate, that degeneration processes in the cerebellum could be decelerated by motor training (e.g. Fryer et al. 2011 SCA 1, mouse model).

### 84.4.2.1 **Motor Rehabilitation for Upper Extremities**

There is a lack of rehabilitation studies for upper limb movements in ataxia. In principle, the concept of training with increasingly demanding coordination exercises could also be transferred to goal-directed upper limb movements. Another promising approach (Bhanpuri et al. 2014) tries to model the dysmetric reaching behavior to develop individualized robotic training interventions.

### 84.4.2.2 **Studies on Mechanisms of Motor Learning and Rehabilitation**

It is not yet known to what extent functional improvements following rehabilitation efforts are related to motor learning. Further studies including modern brain imaging and modeling techniques are needed in order to clarify (i) whether associated changes in neural substrates could be identified either within the cerebellum and its connections or in other brain structures compensating the cerebellar deficit; and (ii) in which way functional improvements are related to motor learning.

These studies will help lead to a more detailed understanding of the potential of motor rehabilitation in degenerative ataxia and will enable individualized training concepts, which could involve different training modalities (dual task training) and potentially rehabilitation technology such as biofeedback (Cakrt et al. 2012) and non-invasive stimulation (Galea et al. 2009).

## References

- Balliet R et al (1987) Retraining of functional gait through the reduction of upper extremity weight-bearing in chronic cerebellar ataxia. *Int Rehabil Med* 8:148–153
- Bastian AJ (1997) Mechanisms of ataxia. *Phys Ther* 77:672–675

- Bastian AJ (2006) Learning to predict the future: the cerebellum adapts feedforward movement control. *Curr Opin Neurobiol* 16:645–649
- Bastian AJ (2011) Moving, sensing and learning with cerebellar damage. *Curr Opin Neurobiol* 21:596–601
- Bastian AJ et al (1996) Cerebellar ataxia: abnormal control of interaction torques across multiple joints. *J Neurophysiol* 76:492–509
- Bhanpuri NH et al (2014) Predicting and correcting ataxia using a model of cerebellar function. *Brain* 137:1931
- Bunn LM et al (2014) Training balance with opto-kinetic stimuli in the home: a randomized controlled feasibility study in people with pure cerebellar disease. *Clin Rehabil* 28(8):730
- Burciu RG et al (2013) Brain changes associated with postural training in patients with cerebellar degeneration: a voxel-based morphometry study. *J Neurosci* 33:4594–4604
- Cakr O et al (2012) Balance rehabilitation therapy by tongue electrotactile biofeedback in patients with degenerative cerebellar disease. *NeuroRehabilitation* 31:429–434
- Cassidy E et al (2009) Management of the Ataxias: towards best Clinical Practice – Physiotherapy Supplement. In: Ataxia UK
- Cernak K et al (2008) Locomotor training using body-weight support on a treadmill in conjunction with ongoing physical therapy in a child with severe cerebellar ataxia. *Phys Ther* 88:88–97
- Diener HC, Dichgans J (1996) Cerebellar and spinocerebellar gait disorders. In: Bronstein AM, Brandt T, Woollacott (eds) *Clinical disorders of posture and gait*, 1st edn. Arnold, London, pp 147–155
- Fonteyn EM et al (2014) Gait adaptability training improves obstacle avoidance and dynamic stability in patients with cerebellar degeneration. *Gait Posture* 40:247–251
- Fryer JD et al (2011) Exercise and genetic rescue of SCA1 via the transcriptional repressor capicua. *Science* 334:690–693
- Galea JM et al (2009) Modulation of cerebellar excitability by polarity-specific noninvasive direct current stimulation. *J Neurosci* 29:9115–9122
- Gill-Body KM et al (1997) Rehabilitation of balance in two patients with cerebellar dysfunction. *Phys Ther* 77:534–552
- Ilg W, Timmann D (2013) Gait ataxia-specific cerebellar influences and their rehabilitation. *Mov Disord* 28:1566–1575
- Ilg W et al (2009) Intensive coordinative training improves motor performance in degenerative cerebellar disease. *Neurology* 73:1823–1830
- Ilg W et al (2010) Long-term effects of coordinative training in degenerative cerebellar disease. *Mov Disord* 25:2239–2246
- Ilg W et al (2012) Video game-based coordinative training improves ataxia in children with degenerative ataxia. *Neurology* 79:2056–2060
- Ilg W et al (2014) Consensus paper: management of degenerative cerebellar disorders. *Cerebellum* 13:248–268
- Jacobi H et al (2011) The natural history of spinocerebellar ataxia type 1, 2, 3, and 6: a 2-year follow-up study. *Neurology* 77:1035–1041
- Kaut O et al (2014) A randomized pilot study of stochastic vibration therapy in spinocerebellar ataxia. *Cerebellum* 13:237–242
- Keller JL, Bastian AJ (2014) A home balance exercise program improves walking in people with cerebellar ataxia. *Neurorehabilitation and neural repair*.
- Konczak J et al (2005) Functional recovery of children and adolescents after cerebellar tumour resection. *Brain* 128:1428–1441
- Marsden J, Harris C (2011) Cerebellar ataxia: pathophysiology and rehabilitation. *Clin Rehabil* 25:195–216
- Miyai I et al (2012) Cerebellar ataxia rehabilitation trial in degenerative cerebellar diseases. *Neurorehabil Neural Repair* 26:515–522
- Morton SM, Bastian AJ (2004) Cerebellar control of balance and locomotion. *Neuroscientist* 10:247–259
- Schöls L et al (2004) Autosomal dominant cerebellar ataxias: clinical features, genetics, and pathogenesis. *Lancet Neurol* 3:291–304

# Index

## A

Actinopterygian fish, 425  
Adenosine, 257, 261–266, 318, 445  
Adult neurogenesis, 251  
Affect, 11, 83, 118, 131, 145, 228, 233, 246, 280, 287, 319, 324, 379, 388, 397, 399, 404, 405, 432, 433, 440, 457–459, 477, 490, 500–505, 525, 563, 566, 571, 603, 605, 606, 616, 642  
Aminopyridine, 59, 438, 440, 628, 631–632  
AMPA receptors (AMPArs), 179, 190, 197, 202, 233–234, 251, 257, 317, 330–332, 337  
Anatomy, 2, 8, 9, 25, 26, 33–38, 64, 102, 118, 294, 324, 352, 353, 374, 412–415, 445, 457  
Angiography, 573  
Anterior inferior cerebellar artery(AICA), 40–42, 44, 46–49, 490, 570–572  
Anti-epileptics, 591  
Anti-GAD ataxia, 528  
Anti inflammatory action, 466  
Antineoplastics, 602, 604–605  
Artery to artery embolism, 572  
Articulation, 103, 377, 405, 406, 477, 478  
Astrocyte, 198, 219–222, 250, 256, 263, 266, 269, 271, 457, 464, 466, 540  
Ataxia, 7, 92, 172, 189, 203, 217, 228–229, 233, 257, 265, 280, 301, 350, 360, 368–369, 374, 429, 438, 445, 450, 464, 481, 491, 505, 513–517, 523–529, 531–537, 545–551, 553–558, 563, 571, 581, 590, 597, 602, 613, 627–632, 636, 642  
Ataxia-telangiectasia(AT), 527, 546, 548, 549  
AtoH1, 66, 128, 129, 144, 145, 151  
ATP, 261–263, 265, 266, 338, 431, 556, 629

Autism, 10, 11, 245, 274, 361, 364, 370, 388, 466, 504, 505, 539–541, 555  
Autism spectrum disorders (ASD), 370, 466, 504, 541  
Autoantibodies, 446, 581, 588–591, 615, 616, 618, 619  
Autoimmune diseases, 581–583, 628  
Autosomal recessive, 353, 355, 368, 524–527, 533, 535, 545–551, 553, 618, 619, 629  
Axon collateral, 58, 75, 157, 196–198, 209

## B

BARS. *See* Brief Ataxia Rating Scale (BARS)  
Basic helix-loop-helix (bHLH), 128, 144, 145, 151  
Basilar artery (BA), 40–42, 44, 46, 47, 50  
Basket cell (BC), 8, 143–145, 156, 157, 163–165, 195–198, 207, 225, 226, 228, 231, 245, 255, 256, 263, 286, 413, 425, 431, 608  
Behaviour, 266, 391, 445–446, 464, 607, 615, 618  
Blake's pouch cyst (BPC), 561, 566  
Brain plasticity, 457, 458, 460, 540  
Brainstem, 9, 11, 12, 47, 48, 50, 69, 71–73, 80, 82, 83, 85, 90, 104, 112, 149, 238, 240, 288, 313, 350, 351, 353–355, 362–364, 374, 457, 473–475, 490, 491, 504, 562, 564, 565, 567, 571, 573–576, 606, 608, 643  
compression, 565, 571, 573–575  
Branching, 42, 47, 58, 157  
Brief Ataxia Rating Scale (BARS), 514, 517–518

**C**

- Ca<sup>2+</sup> channels, 179, 185–187, 257, 264, 330, 336, 337, 439, 440, 444
- CACNA1A*, 438, 443–447, 533
- Calcitonin gene related peptide (CGRP), 268–271
- Calcium channel, 301, 306
- Calretinin, 208, 214, 338, 440
- Cancer, 546, 549, 587–592
- Cardioembolism, 570, 572
- Ca<sup>2+</sup> signaling, 335–338
- Caudal lobe, 412–414
- Causative therapy, 631
- Ca v 2.1 Ca<sup>2+</sup> channel, 438, 444–447
- Cerebellar anatomy, 2, 412–414, 445
- Cerebellar arteries, 40–51, 361, 490, 570
- Cerebellar ataxia(s), 92, 172, 191, 228–229, 350, 351, 354–356, 368–369, 403, 429, 432, 446, 447, 452, 466, 492, 506, 523–537, 545–551, 554, 557, 581–585, 588, 601–609, 613–620, 628, 629, 631, 636, 643–644
- in adolescence, 526–528
- in childhood, 526–528
- infancy, 526
- in young adulthood, 526–528
- in young children, 526
- Cerebellar cognitive affective syndrome (CCAS), 10–11, 13, 374, 379, 386, 391, 499–506
- Cerebellar cortex, 7–9, 12, 23, 42, 56–58, 64, 80, 84, 85, 90, 93, 97, 109, 111, 118, 130, 131, 137–139, 149, 150, 155, 156, 158, 191, 192, 207–209, 214, 215, 220, 238, 240, 244–246, 251, 255, 256, 258, 268, 271, 280–282, 286, 287, 293, 305, 312, 313, 320, 323, 344, 345, 350, 353, 356, 363, 374, 387, 393, 413, 430, 439, 456, 464, 494, 565, 597, 608, 635, 637
- Cerebellar degeneration, 13, 92, 280, 350, 353, 354, 356, 362, 363, 429, 430, 432, 433, 466, 490–492, 494, 528, 536, 587–593, 614, 642–644
- Cerebellar development, 10, 246, 411, 412, 415–418, 464, 534
- Cerebellar disruption, 533, 534, 565, 566
- Cerebellar function, 6, 21–27, 64, 139, 172, 180, 189, 223, 239, 256, 265, 271, 335, 337, 363, 398, 406, 440, 455, 490, 506
- Cerebellar module, 57, 279–293, 323
- Cerebellar motor syndrome (CMS), 10, 11, 380, 481, 501, 503–504
- Cerebellar nuclei, 7, 11, 26, 50, 56–59, 64, 74, 81, 83–86, 91, 128, 129, 143, 155, 159, 183, 238, 243, 245, 246, 256, 280, 286, 287, 293, 294, 296, 301, 307, 311–313, 319, 350, 353, 356, 374, 387, 393–394, 412–414, 425, 426, 430, 431, 445, 450, 455, 456, 464, 492, 494, 606, 607, 635, 642
- Cerebellar system, 9, 13, 55, 59, 343, 344, 456, 457, 595
- Cerebellar tremor, 482–483, 642
- Cerebello-cerebral network, 407
- Cerebellothalamic, 110
- Channelopathies, 438, 446–447, 537
- Children, 10, 11, 14, 112, 485, 502–503, 506, 525, 526, 531–537, 566, 584, 585, 607, 643
- Circuit formation, 245
- Climbing fiber (CF), 7, 8, 13, 56, 58, 59, 64, 72, 74, 83, 139, 150, 156, 162, 163, 168–172, 183, 184, 190, 198, 202, 220, 221, 226–228, 238, 239, 243, 246, 251, 255, 263, 264, 268–270, 280, 282, 286, 293, 294, 299–301, 305, 312, 313, 317, 323, 329, 413, 414, 426, 456, 464
- neuron, 64–66
- Clinical evaluation, 485, 513–517, 550
- Closed-loops, 343–346
- Coeruleo-cerebellar pathway, 239
- Cognition, 10, 11, 112, 118, 362, 379, 391–394, 400, 404, 427, 502, 504–506, 637
- Coma, 576, 605, 607, 618
- Compartments, 57–59, 128, 261
- Compensatory eye movements, 325–327
- Complex spike, 58, 183, 186–187, 296, 301, 302, 324, 326
- Computerized tomography (CT), 50, 350, 355, 565, 570, 573, 574, 576, 591
- Coordination, 6, 10, 92, 103, 189, 217, 228, 229, 240, 256, 257, 265, 275, 279, 280, 282, 294, 330, 346, 388, 405, 432, 444, 450, 459, 464, 466, 481, 516, 548, 602, 643–645
- Corpus cerebelli, 26, 27, 412, 414, 424–427
- Corticocerebellar pathways, 120
- Corticopontine, 9, 90, 101–107, 109, 119, 404
- Corticospinal tract, 81, 84
- Corticotropin releasing factor (CRF), 268–271, 445
- Craniotomy, 575, 607
- CT angiography (CTA), 573

**D**

- Dandy-Walker malformation (DWM), 526, 533, 534, 561, 563, 565, 566

- Decomposition of movements, 458, 481, 486
- Deep cerebellar nuclei (DCN), 7, 91, 102, 109–112, 118, 128–131, 143–145, 155, 183, 225, 226, 238, 245, 246, 256, 286–288, 301, 305–308, 319, 387, 393–394, 412, 413, 425, 426, 430, 431, 445, 450, 455, 456, 464
- Dentate nucleus, 7, 9, 10, 13, 48, 50, 109–111, 118, 313, 325, 343, 374, 376, 380, 393, 527, 557, 563, 576
- Development, 6, 11, 26, 27, 58–59, 64–66, 127–131, 139, 145, 149–153, 155–158, 162, 163, 168, 177, 221–223, 228, 244–246, 258, 269, 271, 288, 392, 393, 411, 412, 415–418, 438, 440, 458, 459, 464, 466, 478, 534, 539, 567, 583, 585, 599, 602, 615, 617, 618, 620, 630, 631
- Differential diagnosis, 523–529, 532, 533, 535, 536
- Diffusion-weighted imaging (DWI), 350, 352, 353, 491, 495, 573
- Direct current stimulation (tDCS), 387, 635–638
- Dissection, 12, 35, 570, 575
- Doppler, 573
- Dynamic stability, 644
- Dysarthria, 10, 11, 105, 376, 501, 514, 527, 546–550, 555–557, 571, 591, 617, 620
- Dysidiadochokinesia, 481, 484, 556, 617
- Dysmetria, 11, 13, 24, 92, 105, 374, 376, 386, 394, 458, 481, 482, 486, 501, 556, 591, 606, 617, 642
- Dysplastic gangliocytoma, 562
- Dystonia, 111, 361, 437–440, 546, 549, 555, 632
- E**
- EA2. *See* Episodic ataxia type 2 (EA2)
- Early B-cell factor 2 (Ebf2), 131, 132
- ECN. *See* External cuneate nucleus (ECN)
- Edema, 352, 353, 491, 571, 573, 606, 607, 617
- Efferent cell, 413, 425, 426
- Electrical coupling, 295–297
- Emotion, 11, 112, 379, 400, 500
- Endocrine, 274, 613–620, 628
- Episodic ataxia type 2 (EA2), 369, 438, 440, 441, 447, 528, 537, 631, 632
- Ethanol, 275, 361, 438, 528, 597, 598, 601–603
- Eurydendroid cell, 413, 414
- Evolution, 213, 426, 459, 477–479, 524
- Excitability, 171, 172, 180, 204, 210, 258, 274, 286, 299, 302, 319, 320, 387, 388, 398, 444, 617, 635–637
- Excitation, 72, 168, 170, 179, 190, 191, 196, 216, 238, 239, 257, 270, 307, 312, 319, 324, 325, 351, 352, 367, 431, 446
- External cuneate nucleus (ECN), 64, 66, 70, 71, 82, 83
- Extraventricular drainage, 574, 606
- Eyeblink conditioning, 189, 252, 257, 325, 378
- Eye movement, 71, 89–95, 97, 103, 215, 252, 325–327, 376, 380, 472, 473, 475, 547, 556, 564, 571, 598
- F**
- FDG. *See* Fluoro-2-deoxy-D-glucose (FDG)
- Fear conditioning, 189, 427
- Feed-back inhibition, 202, 204
- Feed-forward inhibition, 190, 195, 197
- Fiber connection, 424, 426–427
- Fish, 412–414, 417, 423–427
- Fissures, 25–27, 34, 36, 50–52, 90, 93, 122, 137, 375, 464, 494, 537
- Flocculus, 34, 36, 37, 41, 46–48, 57, 70, 72, 74, 92, 109, 168–171, 215, 269, 325, 326, 376, 414, 425, 431, 472–474
- Fluoro-2-deoxy-D-glucose (FDG), 360, 362, 363
- fMRI. *See* Functional magnetic resonance imaging (fMRI)
- FMRP. *See* Fragile X mental retardation protein (FMRP)
- Forward models, 94, 96, 97, 313
- Fragile X mental retardation protein (FMRP), 540, 541
- Friedreich ataxia, 350, 354, 356, 524, 525, 527, 535, 536, 546, 547, 614, 618, 629, 630
- Friedreich Ataxia Rating Scale (FARS), 514–516
- Functional connectivity, 12, 118, 120–122, 344, 345, 374, 386, 500
- Functional magnetic resonance imaging (fMRI), 11, 96, 377–379, 392, 393
- Functional neuroanatomy, 118
- Functional topography, 373–380, 391–394
- G**
- GABA. *See* Gamma-aminobutyric acid (GABA)
- GABA<sub>A</sub> receptor, 179, 189, 197, 202, 227, 228, 263, 275, 287, 318, 440, 445
- GABA<sub>B</sub> receptor, 227, 228, 540

GABAergic, 56, 69, 74, 75, 128, 131,  
143–145, 149–152, 155–158, 196–198,  
208, 209, 225–229, 239, 245, 266, 295,  
305, 306, 312, 313, 323, 324, 363, 426,  
540, 604, 606, 618

GABAergic interneurons, 130, 131, 144, 145,  
195, 208, 226, 245

GABAergic neurogenesis, 130–131

GABAergic neuron, 56, 128, 130, 144, 145,  
152, 208, 225–228, 266, 295, 312, 313

Gain control, 203

Gait disturbance, 514

Gamma-aminobutyric acid (GABA), 158, 197,  
202, 222, 225–229, 238, 239, 244, 255,  
256, 262, 269, 270, 324, 426, 440, 445,  
540, 604, 619

  release, 179, 183, 189–191, 228, 257, 264

  synapse, 157–158

Ganule cells, 273

Genetic counseling, 525, 535, 558

Genetic heterogeneity, 527

Genetic model, 450–451

Glia, 219, 221, 223, 262, 264, 265, 336,  
415–417, 466, 603

Gliotransmission, 223

Globular cell, 208

Glutamate receptors, 156, 163, 197, 232, 235,  
330, 333, 338, 429, 540

Glutamatergic, 64, 85, 128–130, 144, 145,  
149, 151, 155–158, 168, 198, 209, 219,  
226–228, 231–235, 266, 274, 275, 323,  
368, 425, 426, 446

Glutamatergic neurogenesis, 129–130

Glutamate synapse, 156–157

Gluten ataxia, 361, 582–583

Glycine, 158, 202, 238, 444

Gold fish, 424–427

Golgi dell, 225–228

Gordon Holmes, 10, 21–27, 405

Granule cells, 7, 8, 59, 64, 70, 128–131, 143,  
144, 149–152, 156–158, 163, 171,  
177–180, 186, 192, 201–204, 207–209,  
213, 215, 216, 226–228, 231, 234,  
244–246, 251, 263, 264, 268, 273, 282,  
286, 319, 413, 414, 416–418, 425, 431,  
450, 451, 464

Gray matter, 156, 350, 352, 354, 494, 540,  
616, 643

*Grid2<sup>lc</sup>*, 429, 431, 433

## H

Hearing loss, 217, 355, 546, 547, 571

Hemorrhage, 353, 355, 501, 506, 524, 534,  
570, 573, 576, 642

Hemorrhagic transformation, 573, 575

Hereditary, 355, 356, 452, 492, 524–526, 533,  
535, 537, 553, 628, 629

  ataxias, 356, 492, 524, 525

Heroin, 602, 606

Historical background, 5–14

History of neuroscience, 21, 22

Homeostasis, 527

Hormones, 613–615, 617, 620

5-HT 3 receptor, 244, 246

Hydrocephalus, 491, 534, 565–567, 571,  
573–576, 606, 607

Hypotonia, 6, 23, 459, 463, 464, 485, 503,  
506, 526, 533, 534, 555, 556

## I

ICARS. *See* International Cooperative Ataxia  
Rating Scale (ICARS)

Idebenone, 630, 631

Immune ataxias, 584

Infarction, 42, 108, 406, 570–576, 606

Inferior olive, 7, 55–59, 64, 70, 71, 73–75, 80,  
81, 83, 111, 150, 152, 157, 168, 169,  
183, 226, 251, 269, 280, 282, 286, 288,  
293–297, 313, 323, 413, 414, 426, 430,  
431, 456–458, 464

Inferior olive nucleus (ION), 56, 64, 66, 183

Inhibition, 72, 130, 150, 157, 158, 185, 186,  
190–192, 195, 197, 198, 201, 202, 204,  
227, 228, 233, 238, 239, 251, 256, 257,  
264, 269, 270, 294, 295, 297, 301, 302,  
305, 307, 312, 324, 379, 386, 387, 433,  
464, 474, 588, 604, 616, 637

Inhibitory interneurons, 128, 130, 131, 191,  
207, 239, 245

Inhibitory transmission, 189, 191, 203, 238, 258

Interlimb coordination, 280, 282, 459

International Cooperative Ataxia Rating Scale  
(ICARS), 514–517

Interneuron, 81, 84, 128–132, 139, 144, 145,  
149, 150, 152, 157, 158, 189, 191, 192,  
195, 197, 201, 203, 207, 208, 213, 225,  
226, 239, 245, 255, 266, 280, 282, 286,  
413, 430

Intoxication, 265, 532, 537, 570, 602,  
604–608

Intracellular Ca<sup>2+</sup> stores, 251, 337

Intrinsic electrical properties, 297

*In vivo* imaging, 411

ION. *See* Inferior olive nucleus (ION)

Ion channel, 164, 178–180, 183, 186, 244,  
262, 301, 305, 306, 308, 335–338, 438,  
444–445, 528

Isthmic organizer, 128, 415, 416



**K**

Kainate receptor (KAR), 232–235

**L**

Lambert-Eaton myasthenic syndrome, 446, 590, 591

Language, 11, 103, 378–380, 386, 392–394, 399, 403–407, 477–479, 500–502, 504, 506, 533, 539

Larsell, O., 21–27

Late-onset cerebellar ataxias, 524, 526, 528–529

Laterality effect, 392

Lateral reticular nucleus (LRN), 64, 66, 73, 82

Lesion

- behavior, 490
- deficit, 490
- symptom, 376, 389–495, 567

Limbic, 9, 11, 107, 111, 112, 344, 346, 376, 377, 379, 380, 386, 404, 407, 504

Lithium, 602, 604, 605, 614, 616, 631

Lobules, 9, 25–27, 34–38, 42, 47, 50, 57, 82, 85, 86, 92, 104, 107, 109–111, 120–122, 137, 139, 155, 208, 214–216, 281, 343–346, 354, 374–380, 393, 394, 450, 451, 472, 494, 601, 603

Locomotion, 6, 10, 85, 252, 265, 279–282, 439, 459, 643

Locus coeruleus, 51, 238, 414

Long-term depression (LTD), 139, 168, 180, 227, 251, 252, 257, 265, 269, 271, 282, 285–287, 312, 317–320, 329–333

Long-term plasticity, 180, 197, 227, 244, 245, 257, 312, 320

Long-term potentiation (LTP), 180, 234, 251, 275, 282, 285–287, 305, 307, 308, 312, 318–320, 332

LRN. *See* Lateral reticular nucleus (LRN)

LTD. *See* Long-term depression (LTD)

Lugaro cells, 7, 128, 131, 143, 203, 207–210, 245, 263, 268

**M**

Magnetic resonance imaging (MRI), 11, 12, 36, 44, 45, 47, 49, 50, 52, 96, 349–357, 362, 374, 387, 490–492, 494, 495, 500, 503, 524, 532, 546, 549, 550, 554, 566, 573, 574, 582, 591, 603, 605–607, 616, 618–620

Mapping, 120, 129, 151, 152, 356, 376, 377, 432, 489–495

Medication, 14, 583, 598, 617, 632

Megacisterna magna (MCM), 566

Metabotropic glutamate receptor 5 (mGluR5), 233, 338, 540, 541

Metabotropic glutamate receptor (mGluR), 180, 190, 216, 232–233, 317, 319, 338, 464, 591

MHB. *See* Mid-hindbrain-boundary (MHB)

Microcircuit, 201–204, 209, 210, 223, 324, 374

Microglia, 219–221, 250, 255

Mid-hindbrain-boundary (MHB), 128, 415–417

Migraine, 370, 438, 445, 446, 528, 532, 570

Modulation of the cerebellar brain inhibition (CBI), 637

Molar tooth malformations, 562–565

Morphogenesis, 412

Mossy fibers (MFs), 7, 8, 13, 56, 64–66, 72, 74, 80–82, 90, 97, 139, 150, 156, 158, 163, 179, 180, 202–204, 209, 210, 213, 215–217, 221, 226, 231, 238, 243, 245, 268–271, 282, 286, 307, 308, 312, 319, 325, 404, 414

neuron, 7, 64–66

Motor control, 6, 11, 57, 84, 207, 265, 266, 269, 288, 380, 385, 427, 472, 539, 635, 641

Motor coordination, 189, 217, 228, 229, 240, 275, 294, 346, 432, 444, 464, 466, 481

Motor learning, 329, 330

Motor timing, 294, 297, 312

Motor training, 642, 645, 646

Mouse cerebellum, 33, 36, 37, 214, 589

MRI. *See* Magnetic resonance imaging (MRI)

MR spectroscopy of human cerebellum, 368, 370

Multisystem disease, 555

Mutant, 155, 157, 164, 228, 250, 258, 412, 429–432, 443, 445, 449–452, 464, 465

Mutism, 10, 500, 501, 503–504

**N**

Neural circuits, 424–425, 499

Neural progenitor, 144–146, 416

Neuroactive, 275

Neurochemical profile

- in cerebellar ataxias, 368
- in psychiatric disorders, 370

Neuroepithelial domain, 66

Neuromodulation, 238, 636

Neuronal degeneration, 452, 455, 457, 618

Neuronal migration, 222, 540, 562

Neuroprotection, 466, 548

Neuropsychiatry, 374, 499–506

Neurorehabilitation, 631, 638, 646

Neurosteroids, 273–275

- Neurotransmitter, 149, 150, 179, 222, 231, 233, 255–258, 261, 262, 268, 336, 337, 426, 439, 444, 446, 540, 541, 583
- N-methyl-D-aspartate receptor (NMDAR), 179, 180, 190, 191, 197, 202, 228, 233–235, 308, 319, 332, 337, 338
- Nna1, 449, 451, 452
- Nodulus, 27, 35, 36, 42, 48, 57, 74, 109, 376, 472–474
- Non invasive brain stimulation (NIBS), 635, 636
- Noradrenergic, 239, 597, 613
- Nystagmus, 374, 406, 459, 474, 528, 547, 550, 556, 567, 571, 591, 602–604, 620
- O**
- Oculomotor, 73, 74, 86, 91, 93, 97, 344, 368, 374, 376, 406, 471–475, 514, 526, 546, 549, 550, 571, 602, 619, 641
- Oligodendrocyte, 219–221
- Olive, 9, 44, 57, 83, 376
- Orexin, 268, 269
- Orphan nuclear receptor, 464
- Oscillations, 58, 178, 179, 204, 288, 293–297, 353, 439, 440, 482–484, 486
- P**
- PACA. *See* Primary autoimmune cerebellar ataxia (PACA)
- Pacemaker, 13, 185, 597
- Pancreas transcription factor 1-a ( Ptf1a), 66, 128, 131, 144, 145, 151, 415, 417
- Parallel fibers (PFs), 8, 9, 34, 90, 156, 157, 163, 164, 168, 177–180, 183–186, 190, 191, 196, 202, 203, 208, 226, 227, 231, 239, 244, 251, 255, 256, 263, 264, 266, 282, 286, 302, 317–320, 329–333, 413, 425, 431, 439, 464, 608
- Perception, 13, 87, 94–97, 478, 479, 637
- PET. *See* Positron emission tomography (PET)
- Phenotypic heterogeneity, 558
- Physiological microcircuit, 323
- PICA. *See* Posterior inferior cerebellar artery (PICA)
- Plasticity, 59, 168, 172, 179–180, 227, 251, 282, 285–288, 312, 317–320, 326, 332, 455, 457, 458, 460, 540
- Pons, 9, 40, 41, 44, 46, 47, 51, 89, 90, 102–109, 111, 118, 119, 150, 351, 354, 369, 566
- Pontine gray nucleus (PGN), 64, 66
- Pontocerebellar, 101, 102, 107–109, 354, 404, 504
- Positron emission tomography (PET), 359–364, 405, 591
- Posterior inferior cerebellar artery (PICA), 23, 40–46, 393, 394, 490, 491, 501, 570–574
- Posterior lobe, 6, 9–11, 26, 27, 34, 109, 110, 112, 363, 374, 378–380, 393, 394, 494, 500, 501
- Post-infectious cerebellitis, 584–585
- P1 receptors, 262, 264
- P2 receptors, 262, 263
- Precerebellar system, 64, 65
- Primary autoimmune cerebellar ataxia (PACA), 581–582
- Projections, 9, 55, 56, 59, 71–75, 80, 83, 86, 89–91, 97, 103, 104, 106, 110, 111, 118–122, 128–130, 144, 152, 221, 240, 325, 473
- Ptf1a. *See* Pancreas transcription factor 1-a (Ptf1a)
- P-type calcium conductance, 295
- Purkinje cells (PCs), 8, 9, 36, 56, 57, 64, 72, 80, 85, 90, 91, 128, 129, 137, 143, 144, 149, 150, 163, 167–172, 183–187, 189, 190, 195–198, 202, 203, 207, 216, 217, 220, 225, 226, 231, 238, 244, 251, 263, 268, 273, 280, 286, 293, 305–308, 312, 317, 323, 324, 329–333, 413, 425, 430, 439, 445, 449, 464, 473, 540, 588, 597, 603, 635
- Purkinje cell type specification, 131–132
- Pursuit, 90–92, 94, 95, 97, 252, 472, 473, 475, 550, 571
- R**
- Rebound burst, 307
- Rebound spiking, 324
- Receptor binding, 360, 363–364
- Reinnervation, 59
- Resting-state, 12, 221, 344, 345, 374, 377, 495, 500
- Resurgent current, 179, 301
- Reticulospinal tract (RST), 80, 85
- Reticulotegmental nucleus (RTN), 64, 66
- Rhombencephalosynapsis, 506, 533, 562–565
- Rhombic lip, 128, 144, 150–152, 415, 417
- Rhombomere, 56, 64, 66, 150, 151
- Rolling Nagoya mouse, 443–447
- Rubrospinal tract (RbST), 81, 84

**S**

Saccades, 90–93, 472–474, 550, 556  
 SCA. *See* Spinocerebellar ataxia (SCA)  
 Scale for the Assessment and Rating of Ataxia (SARA), 514, 516–517, 644  
 Scales, 10, 302, 362, 364, 385, 513–517, 583  
 Screening, 172, 411  
 Second messenger, 232, 267, 271, 335, 336, 338  
 Sensory predictions, 96, 398  
 Sequencing, 13, 378, 386, 392, 394, 397–400, 502, 525  
 Serotonin, 112, 209, 243–246, 360, 364  
 Short-term plasticity, 180  
 Simple spike, 183, 186–187, 299–302, 324, 326, 439  
 Single photon emission computed tomography (SPECT), 359–364, 405, 406, 616  
 Spatiotemporal regulation, 146  
 Speech  
   perception, 478  
   production, 405, 477, 479  
 Spinocerebellar ataxia (SCA), 10, 13, 40, 41, 47, 50, 51, 258, 301, 353, 354, 368, 464–466, 504, 514, 525, 527, 528, 533, 536, 546, 550, 554, 556–557, 631, 642  
 Spinocerebellar tracts, 9  
 Spino-olivocerebellar tracts, 81, 83  
 Spontaneous activity, 178, 184–186, 433  
 Stellate cells, 8, 131, 143, 144, 152, 157, 163, 172, 189–192, 195, 197, 207, 209, 226, 227, 231, 233, 245, 250, 275, 286, 413, 414, 425, 464  
 Steroids, 273, 274, 466, 616  
 Stripe, 58, 130, 137–140  
 Stroke, 7, 10, 103, 105, 280, 350, 361, 376, 393, 456, 490–491, 495, 501, 504, 569–576, 591, 608, 637, 641, 642  
 Superior cerebellar artery, 40, 41, 47–52, 393, 406, 490, 491, 569–571  
 Synapse, 81, 101, 155–158, 162–165, 168, 178–180, 189–192, 196–198, 201–203, 221, 222, 226–228, 231, 232, 235, 244–246, 251, 252, 256–258, 263, 264, 274, 275, 282, 286–288, 301, 308, 317–320, 329–333, 445, 446, 458, 464, 584, 588, 597  
 Synapse elimination, 157, 161–165  
 Synaptic plasticity, 180, 197, 223, 228, 233, 234, 244–246, 251, 257, 264, 308, 312, 320, 329, 336, 540  
 Synaptic specificity, 156

Synaptic transmission, 178–180, 190–191, 222, 223, 227, 228, 231–232, 235, 237–240, 262, 263, 439  
 Synaptogenesis, 155, 161–165, 223, 431  
 Synchrony, 58, 313, 325  
 Syrian hamster, 449–452

**T**

tDCS. *See* Transcranial direct current stimulation (tDCS)  
 Teleost, 198, 413, 414, 417, 423–427  
 Thalamocortical, 102, 110, 636  
 Thalamus, 9, 40, 73, 74, 81, 84, 96, 102, 110, 111, 118, 121, 122, 150, 151, 313, 343–345, 378, 388, 404, 415, 456–458, 504, 602, 603, 619  
 Thyroid, 605, 613–617  
 Timing, 13, 180, 186, 228, 280, 287, 288, 294, 297, 306, 308, 312, 313, 320, 330, 346, 386, 397, 452, 478, 479, 481, 487, 638  
 Tinnitus, 217, 571  
 TMS. *See* Transcranial magnetic stimulation (TMS)  
 Tracer, 90, 93, 106, 280, 359, 363, 364  
 Tracing, 9, 66, 80, 102, 110, 112, 118, 121, 139, 343–344, 415, 492, 500  
 Transcranial direct current stimulation (tDCS), 387, 635–638  
 Transcranial magnetic stimulation (TMS), 12, 287, 635–638  
 Transcription factor, 65, 66, 128, 129, 145, 151, 152, 415, 416, 464, 466  
 Tremor, 7, 14, 24, 354, 361, 458, 463, 464, 481–483, 485–487, 525, 529, 549, 554–556, 595–599, 604–606, 615, 638, 642  
 T-type calcium conductance, 295

**U**

Unipolar brush cells (UBCs), 7, 8, 128, 129, 143, 145, 202, 213–217  
 Uvula, 6, 35, 36, 42, 109, 376, 472–474, 571

**V**

Valvula cerebelli, 412, 414, 424, 425, 427  
 Venous thrombosis, 573  
 Ventricular zone, 128, 139, 144, 150, 152, 415–417  
 Vergence, 376, 472, 475

Vermis, 6, 7, 10, 11, 25, 27, 34–36, 41, 42, 50, 56, 57, 72, 80, 83, 85, 91, 97, 128, 149, 208, 274, 281, 344, 362, 363, 368–370, 374–376, 379, 380, 425, 455, 472, 501–504, 526, 534, 537, 549, 562–567, 571, 576, 582, 603, 607

Vertebral artery, 41, 44, 570, 572, 573, 575

Vertigo, 10, 374, 438, 528, 567, 571, 591, 631

Vestibular, 6, 9, 10, 13, 23, 26, 36, 44, 48, 58, 69–75, 82, 85, 86, 89, 109, 215, 239, 269, 301, 305, 313, 326, 374, 376, 380, 455, 458, 459, 472–474, 531, 532, 537, 571, 591, 605

Vestibular complex, 70–74, 85, 269

Vestibulospinal tracts, 75, 80, 85

Visual perception, 91, 94–97, 506

**W**

White matter, 7, 8, 12, 34, 36–38, 50, 56, 59, 83, 128, 144, 150, 152, 162, 220, 221, 238, 350–356, 368, 412, 413, 465, 494, 533, 535–537, 554, 562, 602, 604–606

**X**

X-chromosomal, 533, 558

**Z**

Zebrafish, 411–418, 426, 427

Zebrin, 137, 139, 281

Zone, 6, 7, 36, 43, 44, 46, 48, 51, 72, 81, 83, 86, 107, 112, 128–129, 137–140, 150–152, 157, 163, 170, 185, 191, 268, 280, 281, 318, 323, 325, 326, 344, 376, 403, 414–417, 431, 572