

Clinical Cases in Dermatology  
Series Editor: Robert A. Norman

Porcia B. Love  
Roopal V. Kundu *Editors*

# Clinical Cases in Skin of Color

Medical, Oncological and Hair  
Disorders, and Cosmetic  
Dermatology

 Springer

# Clinical Cases in Dermatology

**Series Editor**

Robert A. Norman  
Tampa, Florida, USA



Porcia B. Love • Roopal V. Kundu  
Editors

# Clinical Cases in Skin of Color

Medical, Oncological and Hair  
Disorders, and Cosmetic  
Dermatology

 Springer

*Editors*

Porcia B. Love  
Montgomery Dermatology, PC  
Montgomery  
AL  
USA

Roopal V. Kundu  
Feinberg School of Medicine  
Northwestern University  
Chicago  
IL  
USA

Clinical Cases in Dermatology

ISBN 978-3-319-23614-8 ISBN 978-3-319-23615-5 (eBook)

DOI 10.1007/978-3-319-23615-5

Library of Congress Control Number: 2015957248

Springer Cham Heidelberg New York Dordrecht London

© Springer International Publishing Switzerland 2016

This work is subject to copyright. All rights are reserved by the Publisher, whether the whole or part of the material is concerned, specifically the rights of translation, reprinting, reuse of illustrations, recitation, broadcasting, reproduction on microfilms or in any other physical way, and transmission or information storage and retrieval, electronic adaptation, computer software, or by similar or dissimilar methodology now known or hereafter developed.

The use of general descriptive names, registered names, trademarks, service marks, etc. in this publication does not imply, even in the absence of a specific statement, that such names are exempt from the relevant protective laws and regulations and therefore free for general use.

The publisher, the authors and the editors are safe to assume that the advice and information in this book are believed to be true and accurate at the date of publication. Neither the publisher nor the authors or the editors give a warranty, express or implied, with respect to the material contained herein or for any errors or omissions that may have been made.

Printed on acid-free paper

Springer International Publishing AG Switzerland is part of Springer Science+Business Media ([www.springer.com](http://www.springer.com))

# Prelude

Clinical cases are a key component in modern medical education, assisting the trainee or recertifying clinician to work through unusual cases using best practice techniques. Dermatology is an important discipline in this regard since it is a highly visual specialty requiring the reader to describe subtle differences in the presentation of patients and accurately define the diagnostic and management criteria to base their clinical decision making on.

Census projections predict that by the year 2042, people with skin of color (including Africans, African Americans, Asians, Native Americans, and Hispanic/Latinos) will represent more than half of the US population. There is now an increasing demand for dermatologic treatments in patients with skin of color, as well as an accompanying need for education and training in this quickly expanding market. Skin of color is a key topic within dermatology as specific conditions can be harder to diagnose effectively in darker skin, and their treatment can be compromised by this. Conditions such as psoriasis, eczema, and atopic dermatitis may be more difficult to diagnose in darker skin. There are various other conditions that can provide a challenge in management, including postinflammatory hyperpigmentation, melasma, scarring, alopecias, and pseudofolliculitis barbae. If these skin disorders are not diagnosed and treated properly, the initial lesions can become darker as they heal, and the darker spots can last for years in some cases. Scarring may also occur.

This book will identify the top dermatological conditions for patients with skin of color and provide essential features

which contrast these conditions in darker skin types. The reader will be able to formulate informed treatment regimens for patients with skin of color. This book will also provide clinical pearls to guide decision making, as well as important cultural beliefs that must be considered in order to provide optimal care to patients with skin of color.

Montgomery, AL, USA

Porcia B. Love, MD

# Contents

## Part I Medical Conditions

- 1 Discoid Lupus Erythematosus** . . . . . 3  
Michelle E. Oboite and Porcia B. Love
- 2 Sarcoidosis** . . . . . 15  
Chikoti M. Wheat, Ginette A. Okoye,  
and Porcia B. Love

## Part II Hair Disorders

- 3 Traction Alopecia** . . . . . 31  
Kirsten L. Cottingham and Porcia B. Love
- 4 Androgenetic Alopecia** . . . . . 41  
Yolanda M. Lenzy and Alfreda F. Batts
- 5 Central Centrifugal Cicatricial Alopecia** . . . . . 51  
Yolanda M. Lenzy and Julia R. Fiore

## Part III Keloids

- 6 Keloids** . . . . . 63  
Olabola D. Awosika and Porcia B. Love

## Part IV Skin Cancer

- 7 Basal Cell Carcinoma** . . . . . 79  
Laura K. Ibeto and Porcia B. Love



<b>8 Squamous Cell Carcinoma</b> . . . . .	89
Laura K. Ibeto and Porcia B. Love	
<b>9 Melanoma</b> . . . . .	99
Laura K. Ibeto and Porcia B. Love	
<b>10 Cutaneous T-Cell Lymphoma</b> . . . . .	111
Chikoti M. Wheat and Ginette A. Okoye	
<b>11 Dermatofibrosarcoma Protuberans</b> . . . . .	125
Porcia B. Love	
<b>Part V Cosmetic Concerns</b>	
<b>12 Dermatitis Papulosa Nigra</b> . . . . .	137
Porcia B. Love	
<b>13 Chemical Peels</b> . . . . .	145
Porcia B. Love	
<b>14 Laser Hair Removal</b> . . . . .	159
Oge Onwudiwe	
<b>15 Dermal Fillers</b> . . . . .	171
Porcia B. Love	
<b>Index</b> . . . . .	179

# Contributors

**Olabola D. Awosika, MD, MS** Mercy Medical Center,  
University of Maryland, Baltimore, MD, USA

**Alfreda F. Batts, BS** University of Texas Medical Branch  
at Galveston, Houston, TX, USA

**Kirsten L. Cottingham, BS** Tuskegee University, Tuskegee,  
AL, USA

**Laura K. Ibetto, BS, MS** University of North Carolina  
at Chapel Hill, Chapel Hill, NC, USA

**Yolanda M. Lenzy, MD, MPH** Department of Dermatology,  
Lenzy Dermatology & Hair Loss Center, University of  
Connecticut, Chicopee, MA, USA

**Porcia B. Love, MD** Montgomery Dermatology,  
Montgomery, AL, USA

**Michelle E. Oboite, MD** University of Pennsylvania  
Health System, Philadelphia, PA, USA

**Oge Onwudiwe, MD** Department of Dermatology,  
Wellman Center for Photomedicine, Massachusetts  
General Hospital, Harvard Medical School,  
Boston, MA, USA

**Ginette A. Okoye, MD** Department of Dermatology,  
Johns Hopkins Medicine, Baltimore, MD, USA

**Chikoti M. Wheat, MD** Department of Dermatology,  
Johns Hopkins Medicine, Baltimore, MD, USA

**Part I**  
**Medical Conditions**

# Chapter 1

## Discoid Lupus Erythematosus

**Michelle E. Oboite and Porcia B. Love**

### Case Presentation

A 30-year old African American woman presents with multiple scarred plaques on her scalp, ears, and neck. The lesions are occasionally pruritic and even painful, especially in the early stages when they first appear. She notes that outbreaks are worse during the summer, and she admits that she is very conscious of her appearance year-wide, often wearing her hair past her shoulders and clothing that covers her neck to help hide her skin. She denies joint pain, shortness of breath, chest pain, or ever noticing any ulcers in her mouth.

---

M.E. Oboite, MD  
University of Pennsylvania Health System,  
Philadelphia, PA, USA

P.B. Love, MD (✉)  
Montgomery Dermatology, PC,  
4712 Berry Boulevard, Montgomery, AL 36106, USA  
e-mail: [porcialove@gmail.com](mailto:porcialove@gmail.com)

P.B. Love, R.V. Kundu (eds.), *Clinical Cases in Skin of Color: Medical, Oncological and Hair Disorders, and Cosmetic Dermatology*, Clinical Cases in Dermatology, DOI 10.1007/978-3-319-23615-5\_1, 3  
© Springer International Publishing Switzerland 2016

## Physical Examination

On examination, polymorphic, round to oval shaped hyper- and hypopigmented patches are found scattered on her face and neck, some with adherent scale (Fig. 1.1a). She also has indurated, atrophic, scarred, depigmented plaques on the eyebrows, cheeks, and conchal bowls of the ears (Fig. 1.1a). A scarred, indurated plaque is noted on the occipital scalp (Fig. 1.1a).

## Differential Diagnosis

During its earlier stages, discoid lesions may not have developed characteristic features such as follicular plugging, and they may present as erythematous and inflamed indurated plaques. At this point, they can be confused with psoriasis, although psoriasis presents with well demarcated erythematous plaques with silvery scale and well-defined edges on the scalp, elbows and knees. The plaques of lichen planus are more violaceous with characteristic Wickham's striae. Polymorphous

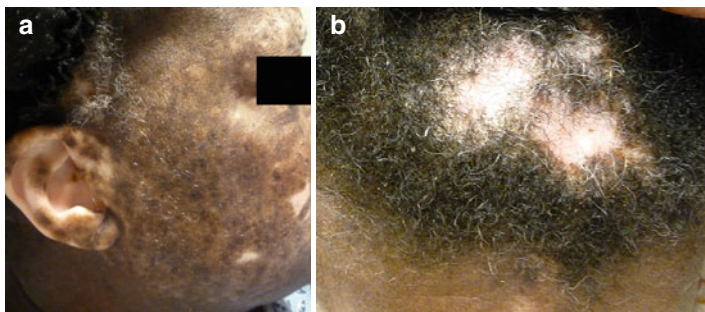


FIGURE 1.1 (a, b) Discoid lupus of the scalp and face. Polymorphic, round to oval shaped hyper- and hypopigmented patches are found scattered on her face and neck, some with adherent scale. She also has indurated, atrophic, scarred, depigmented plaques on the eyebrows, cheeks, and conchal bowls of the ears (a). A scarred, indurated plaque is noted on the occipital scalp (b)

light eruption presents with tiny erythematous papules or plaques on sun exposed areas and burning or pruritus; however, the face is usually spared. Granuloma annulare presents with erythematous indurated annular plaques with a raised border, typically on the dorsal surface of the fingers, hands, feet, or elbows. Both early and late stages of discoid lesions may also be confused with sarcoidosis (Walling and Sontheimer 2009). However, sarcoidosis is characterized by erythematous or violaceous, indurated plaques and nodules that usually affect the nose, cheeks, ears, and lips. Sarcoidosis may be accompanied by pulmonary abnormalities.

## Pathology

Punch biopsy of an active lesion on the ear revealed the following characteristics: (1) epidermal atrophy, (2) hyperkeratosis, (3) mononuclear inflammatory cell infiltrate (mostly lymphocytes) at the subepidermal junction, and (4) thickening of the basement membrane containing mucin vacuoles. Scalp biopsy revealed (1) follicular plugging with keratin, (2) reduced number of follicle units, (3) dermal perivascular and perifollicular lymphocytic infiltrate, (4) interstitial fibrosis, and (5) basal membrane degeneration with keratinocyte necrosis (Elder 2009).

Direct immunofluorescence of a lesional site is positive for immunoglobulin (mainly IgM) and complement deposition at the dermoepidermal junction (Elder 2009).

## Laboratory Studies

Blood serological testing was negative for ANA, anti-Ro, anti-Sm, and dsDNA.

## Diagnosis

Discoid lupus erythematosus (subtype of chronic cutaneous lupus erythematosus)

## Case Treatment

A thorough discussion of the diagnosis, natural history, and treatment options for discoid lupus were discussed with the patient. The patient was started on a high dose prednisone taper for 1 month. After having an ophthalmology exam, she was started on hydroxychloroquine 200 mg twice daily. Side effects, including retinopathy and liver function abnormalities were discussed. Clobetasol 0.05 % ointment was recommended on the discoid lesions twice a day. She was given strict instructions regarding daily sun protection, including a wide brimmed hat, sunglasses, sun protective clothing, and a broad spectrum sunscreen with an SPF of 30. She was also advised to avoid excess sun exposure between the hours of 10 am and 2 pm. Smoking should also be avoided as patients with lupus who smoke do not respond well to treatment.

## Discussion

Discoid lupus erythematosus (DLE) is the most common form of cutaneous lupus erythematosus (CLE), accounting for the largest subtype of chronic CLE (1). It is slightly more common in African Americans, Hispanics, and Asians than Caucasians (Petri 2005) and more common in women than men. The most common time of onset is in the third-fourth decade of life, and the highest prevalence is in persons in the fifth-seventh decade (Hordinsky 2008). Clinical signs of DLE include erythematous to violaceous scaly plaques, follicular plugging, and scarring with atrophy. New lesions typically appear as indurated erythematous to violaceous papules or plaques with adherent scale. As these lesions spread over time, follicular dilatation and plugging from the adherent keratin scale and dyspigmentation (hyperpigmented borders, hypopigmentation at center) (Fig. 1.2a) can be seen. Older, healed lesions present with dermal atrophy and telangiectasia in the center, leaving behind a depressed scar (Fig. 1.2b) (Hordinsky 2008). The most common site of involvement in

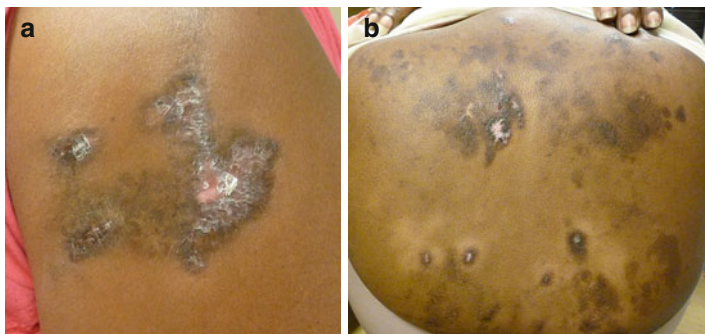

FIGURE 1.2 (a, b) Discoid lupus of the body. Hyperpigmented plaques with scarring, atrophy, and depigmentation are noted on the arm (a) and back (b) with atrophy. As these lesions spread over time, plugging from the adherent keratin scale can be seen as well as dyspigmentation (hyperpigmented borders, hypopigmentation at center) (a). Older, healed lesions present with dermal atrophy and telangiectasia in the center, leaving behind a depressed scar (b)

discoid lupus is the scalp, present in over 60 % of patients (Fig. 1.3) (Hordinsky 2008).

Cutaneous lupus erythematosus (CLE) encompasses a broad spectrum of lupus-specific skin pathology characterized by inflammation primarily mediated by infiltrating T lymphocytes incited by an unclear mechanism comprising of a number of genetic, environmental, and hormonal factors (Hordinsky 2008). A proposed mechanism is UV light-mediated induction of keratinocyte apoptosis in the epidermis leads to antigen presentation and autoantibody formation that, depending on genetic and hormonal predisposition, can result in an unregulated inflammatory response (Lin et al. 2007).

CLE can be present with or without systemic lupus erythematosus (SLE). Different forms of CLE carry different risks of systemic involvement. Discoid lupus carries the lowest risk compared to other forms of CLE (Hordinsky 2008). CLE can be divided into three categories based on the morphology and average lifespan of skin lesions (acute, subacute,



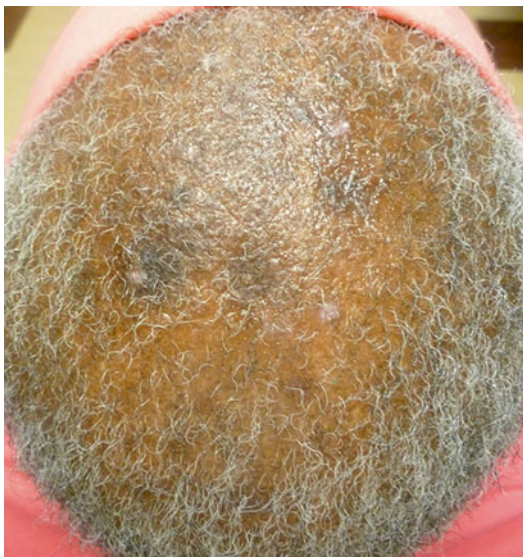

FIGURE 1.3 Discoid lupus of the scalp. Hyperpigmented plaques with adherent scale and dyspigmentation are noted on the scalp

chronic). An additional classification divides each CLE category into “localized” versus “generalized” disease: patients with localized disease have lesions confined to the neck and above, whereas those with generalized disease have lesions distributed both above and below the neck. This “localized” vs. “generalized” classification can be helpful in identifying a patient’s risk of systemic lupus erythematosus (SLE), depending on the form of CLE. For example, acute cutaneous lupus erythematosus (aCLE) typically presents as the classically-known malar ‘butterfly’ facial rash generally sparing the nasolabial folds (i.e. localized aCLE), or a diffuse morbilliform rash with erythema and edema of the hands sparing the joints (generalized aCLE). Acute cutaneous lupus erythematosus is highly associated with the presence of SLE, with localized aCLE more indicative than generalized (Walling and Sontheimer 2009). Likewise, subacute cutaneous lupus erythematosus, which often presents as coalescing annular or

psoriasiform plaques with fine scale typically found on the upper back, shoulders, neck, and anterior chest, often sparing the face and scalp (an important distinction from DLE)—may be a predictor of SLE development (Lin et al. 2007). Although patients with chronic cutaneous lupus erythematosus are less likely to have co-existing SLE or serological abnormalities at the time of diagnosis, there are recent studies that suggest that a portion of patients diagnosed with discoid lupus may develop SLE within 3 years of diagnosis. In contrast to aCLE, “generalized” DLE patients are more likely than those with “localized” DLE to have serological and immunological abnormalities and develop SLE (Walling and Sontheimer 2009).

It is important to note that in patients with skin of color who have systemic lupus erythematosus (SLE), skin involvement may be the predominant clinical finding, particularly discoid lupus. The Hopkins Lupus cohort followed over 1500 SLE patients in Baltimore and found that African Americans with SLE were more likely to have cutaneous manifestations compared to Caucasians. DLE was significantly more common in African Americans, whereas photosensitivity, malar rash, and mouth ulcers were less common compared to their Caucasian counterparts (Petri 2005). A separate comparative study of Latin and African American patients with SLE found that although skin involvement occurred with similar frequency in both Latin and African American patients (83 % and 84 %, respectively), the prevalence of discoid lupus was more common in African American patients than Latin Americans (25 % versus 9 %), while photosensitivity (56 % versus 30 %) and livedo reticularis (12 % versus 10 %) were more frequently seen in Latin Americans (Molina et al. 1997). If clinical suspicion for SLE is high based on history and exam findings, screening for serological markers (ANA, anti-Ro, anti-Sm, and dsRNA) or referral for more extensive work-up is indicated.

One of the most devastating complications of discoid lupus is permanent scarring. Over half of patients with DLE

develop significant and destructive scarring, and over one-third develop scarring alopecia (Walling and Sontheimer 2009). This is in contrast to acute or subacute CLE which often heals without scarring. There are also case reports of squamous cell carcinoma developing in the scars of Black and Chinese patients with longstanding DLE; it is postulated that melanin loss and chronic inflammation places patients of color at increased risk. Squamous cell carcinoma of the scalp, in particular, has been found to have a higher incidence in black patients, with a 21 % recurrence rate and 30 % metastatic rate (Hordinsky 2008). Ultimately, early treatment is critical in reducing both morbidity and mortality.

### *Treatment*

The goals of management of discoid lupus erythematosus are to improve the patient's appearance, to control existing lesions and limit scarring, and to prevent the development of further lesions. The patient should also be advised that the development of serious systemic disease is possible, although rare.

Since chronic CLE is exacerbated by sunlight and other UV exposure, therapy begins with the use of sun-protective measures, including sunscreens, sunglasses, protective clothing, and avoiding the excess sun exposure between the hours of 10 am and 2 pm when the rays are the strongest. Patients should avoid artificial light sources, such as tanning beds. Cosmetic measures, such as cover-up makeup or wigs, may be suggested for appropriately selected patients. Makeup used for camouflage includes Covermark and Dermablend (Jessop et al. 2009). Smoking should also be avoided as patients with lupus who smoke do not respond well to treatment. Inform the patient that although these behavioral modifications are beneficial, they are not sufficient alone in themselves.

Standard medical therapy includes topical or intralesional corticosteroids and antimalarials. Steroids are typically reserved for acute flares and short-term use. Although oral is most effective, there is a much higher risk of systemic side

effects; therefore, switching to medium to high potency topical steroids or intra-lesional steroids is recommended. Side effects of chronic topical steroid use include atrophy and striae (Jessop et al. 2009). Oral antimalarial agents, including hydroxychloroquine or chloroquine, can be considered as maintenance therapy. Antimalarial therapy seems to lessen the progression to SLE and is associated with response rates from 50 to 85 % (Wahie and Meggitt 2013). Hydroxychloroquine is the first-line systemic agent for discoid lupus erythematosus (DLE), whereas chloroquine is considered second-line antimalarial therapy in the United States. Quinacrine may be added to either hydroxychloroquine or chloroquine for additional benefit in some patients. Given the ability of both hydroxychloroquine and chloroquine to deposit in the retina and cause irreversible retinopathy, these two agents should not be used concomitantly because of the increased risk of ocular toxicity when used in combination. Hydroxychloroquine seems to have less retinopathy than chloroquine (Wahie and Meggitt 2013). However, given the risk of retinopathy, it is important for patients on an antimalarial to be monitored by Ophthalmology for retinal deposits (Marmor et al. 2011). Traditionally, antimalarials have been considered to be less effective in patients who smoke; however, it is also possible that DLE is worse in these patients (Jewell and McCauliffe 2000).

Topical calcineurin inhibitors, including tacrolimus ointments at 0.03 and 0.1 % and 1.0 % pimecrolimus cream, have also been used in patients with cutaneous lupus erythematosus for acute flare or maintenance therapy. They are better for lesions in areas prone to atrophy, i.e. facial lesions (Sardy et al. 2009). Topical retinoids have been reported to be helpful in skin of color (Seiger et al. 1991), particularly hyperkeratotic lesions; however, they can cause irritation. For recalcitrant, severe disease, immunosuppressants and immunomodulators, including methotrexate, mycophenolate mofetil, azathioprine, and thalidomide, amongst others, should be considered (Jessop et al. 2009). The severe teratogenic effects of thalidomide in women of childbearing age must be considered prior to starting this medication (Holm et al. 1993).

## Key Points

- Discoid lupus erythematosus can affect individuals of different ethnicities, gender, and ages; however, it is becoming increasingly common in young to middle-aged African American women.
- Early diagnosis and treatment is necessary to prevent the discomfort associated with the lesions and late-stage complications (irreversible skin dyspigmentation, disfiguring scarring, and increased risk of squamous cell carcinoma) prone to patients with skin of color.
- Of all the types of cutaneous lupus erythematosus, discoid lupus is less likely to be associated with the presence of or progression to systemic lupus erythematosus. However, discoid lesions are most likely to result in significant and destructive scarring if untreated.
- The scalp is the most common area affected in discoid lupus. Delayed treatment can lead to irreversible scarring alopecia. Squamous cell carcinomas developed in scars on the scalp can be aggressive.
- Patients with 'generalized' discoid lupus are more likely to have or develop systemic lupus erythematosus.

## References

- Elder D. *Lever's histopathology of the skin*. 10th ed. Philadelphia: Lippincott Williams & Wilkins; 2009.
- Holm AL, Bowers KE, McMeekin TO, Gaspari AA. Chronic cutaneous lupus erythematosus treated with thalidomide. *Arch Dermatol*. 1993;129(12):1548–50.
- Hordinsky M. Cicatricial alopecia: discoid lupus erythematosus. *Dermatol Ther*. 2008;21(4):245–8.
- Jessop S, Whitelaw DA, Delamere FM. Drugs for discoid lupus erythematosus. *Cochrane Database Syst Rev*. 2009;(4):CD002954.
- Jewell ML, McCauliffe DP. Patients with cutaneous lupus erythematosus who smoke are less responsive to antimalarial treatment. *J Am Acad Dermatol*. 2000;42(6):983–7.

- Lin JH, Dutz JP, Sontheimer RD, Werth VP. Pathophysiology of cutaneous lupus erythematosus. *Clin Rev Allergy Immunol.* 2007;33(1-2):85-106.
- Marmor MF, Kellner U, Lai TY, Lyons JS, Mieler WF. Revised recommendations on screening for chloroquine and hydroxychloroquine retinopathy. *Ophthalmology.* 2011;118(2):415-22.
- Molina JF, Molina J, Garcia C, Gharavi AE, Wilson WA, Espinoza LR. Ethnic differences in the clinical expression of systemic lupus erythematosus: a comparative study between African-Americans and Latin Americans. *Lupus.* 1997;6(1):63-7.
- Petri M. Lupus in Baltimore: evidence-based 'clinical pearls' from the Hopkins Lupus Cohort. *Lupus.* 2005;14(12):970-3.
- Sardy M, Ruzicka T, Kuhn A. Topical calcineurin inhibitors in cutaneous lupus erythematosus. *Arch Dermatol Res.* 2009;301(1):93-8.
- Seiger E, Roland S, Goldman S. Cutaneous lupus treated with topical tretinoin: a case report. *Cutis.* 1991;47(5):351-5.
- Wahie S, Meggitt SJ. Long-term response to hydroxychloroquine in patients with discoid lupus erythematosus. *Br J Dermatol.* 2013;169(3):653-9.
- Walling HW, Sontheimer RD. Cutaneous lupus erythematosus: issues in diagnosis and treatment. *Am J Clin Dermatol.* 2009;10(6):365-81.

# Chapter 2

## Sarcoidosis

**Chikoti M. Wheat, Ginette A. Okoye, and Porcia B. Love**

### Case History

A 46-year-old female presented with a 1 year history of persistent papules on her nose and around her mouth. She had been diagnosed with adult acne by her primary care physician and treated with topical clindamycin with no success. The facial lesions were asymptomatic; however, she notes mild fatigue, occasional dyspnea on exertion, and a mild cough.

### Physical Examination

Multiple 2 mm red to violaceous macules and papules are noted on the nasal tip and alar rim. Scattered violaceous papules coalescing into a thin plaque were noted on the upper

---

C.M. Wheat, MD • G.A. Okoye, MD  
Department of Dermatology, Johns Hopkins Medicine,  
Baltimore, MD, USA

P.B. Love, MD (✉)  
Montgomery Dermatology, PC,  
4712 Berry Boulevard, Montgomery, AL, USA  
e-mail: [porcialove@gmail.com](mailto:porcialove@gmail.com)

P.B. Love, R.V. Kundu (eds.), *Clinical Cases in Skin of Color: Medical, Oncological and Hair Disorders, and Cosmetic Dermatology*, Clinical Cases in Dermatology, DOI 10.1007/978-3-319-23615-5\_2, © Springer International Publishing Switzerland 2016 15

cutaneous lip. She also had hypopigmented 1 cm patches on the forehead, malar cheeks, and chin (Fig. 2.1).

## Differential Diagnosis

The clinical presentation was felt to be consistent with sarcoidosis. Granulomatous rosacea is a rare variant of rosacea that typically presents as erythematous or skin colored papules on

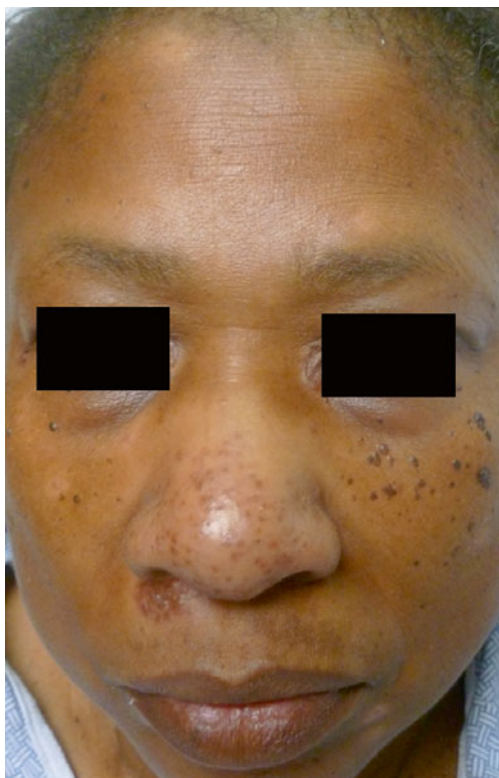


FIGURE 2.1 Maculopapular sarcoidosis. Multiple 2 mm red to violaceous macules are noted on the nose. Scattered violaceous papules coalescing into a thin plaque were noted on the upper cutaneous lip. She also has hypopigmented 1 cm patches on the forehead, malar cheeks, and chin



the forehead, periorbital area, and the nose. Patients typically do not have a history of flushing. Lupus erythematosus may present with erythematous papules and plaques on the face. Many of these patients have sun sensitivity. Patients with granuloma annulare present with erythematous or skin colored grouped papules that coalesce into annular plaques, typically on the dorsal surface of the extremities. Infectious cutaneous disorders that present with erythematous or violaceous papules or plaque on the body include tertiary syphilis, lepromatous leprosy, and cutaneous tuberculosis (Haimovic et al. 2012).

## Histopathology

Punch biopsy revealed superficial and deep dermal epithelioid granulomas without a surrounding lymphocytic infiltrate or central caseation (Haimovic et al. 2012).

## Chest X-Ray

Bilateral hilar lymphadenopathy and interstitial fibrosis are noted.

## Laboratory Results

Complete blood cell count, comprehensive metabolic panel, antinuclear antibodies, and double stranded DNA are all within normal limits. Serum angiotensin-converting enzyme (ACE) level and serum calcium are elevated. Electrocardiogram was within normal limits.

## Diagnosis

Cutaneous sarcoidosis, maculopapular subtype, with systemic involvement

## Case Treatment

The diagnosis, natural history, and treatment of the condition was discussed. Given the presence of cutaneous and systemic involvement, the patient was started on a high dose prednisone taper for 1 month, in addition to a high potency topical corticosteroid twice daily for her cutaneous lesions. After clearance from Ophthalmology, she was also started on hydroxychloroquine 200 mg twice daily. Given the bilateral hilar lymphadenopathy and interstitial fibrosis noted on chest X-ray, the patient was referred to Pulmonology. Her cutaneous lesions and lung involvement improved with hydroxychloroquine and prednisone. In addition to Dermatology and Pulmonology, she was followed every 6 months by Ophthalmology while on hydroxychloroquine.

## Discussion

Sarcoidosis is a multisystem, granulomatous and inflammatory disease that, depending on the organ involved, has different clinical presentations, with varying degrees severity. The most common organs involved include the lungs, lymph nodes and skin, with the skin being involved in 20–35 % of cases (Haimovic et al. 2012). Additional organs involved include the eyes, heart, liver, spleen, kidneys, and the central nervous system. The most common symptoms of systemic sarcoidosis are low-grade fever, weight loss, cough, dyspnea, chronic fatigue, arthralgia, and lymphadenopathy. Histologically, cutaneous sarcoid is characterized by superficial and deep dermal epithelioid granulomas without a surrounding lymphocytic infiltrate and with absence of central caseation (“naked or noncaseating granulomas”). Sarcoidosis is also characterized by the presence of eosinophilic stellate inclusions (asteroid bodies) and laminated basophilic inclusions (Schumann bodies) within multinucleated giant cells (Haimovic et al. 2012).

Several studies have documented the higher incidence of sarcoidosis in African Americans compared to Caucasians. In a population based study in a major metropolitan area in the United States, Rybicki et al. found the age-adjusted incidence in African Americans to be 35.5/100,000 compared to 10.9/100,000 in Caucasians. Approximately 20 % of African American patients reported an affected family member (Rybicki et al. 1997). Sarcoidosis has also been found to occur at an earlier age and have a more severe course in African Americans compared to Caucasians (Haimovic et al. 2012). In addition, Black patients are more likely to have cutaneous involvement than Caucasians (Guss et al. 2014).

The incidence of sarcoidosis may also be higher in other skin of color populations (Heath et al. 2012). In a retrospective survey of Caucasian, Black West Indian/African, and Indo-Pakistan Asian patients treated at South London hospitals, the incidence of sarcoidosis was similar in Blacks and Asians, and these two groups had more widespread extrathoracic disease compared to Caucasians (Edmondstone and Wilson 1985).

No causative agent has been identified for sarcoidosis; however, T cells play a central role in the disease (Facco et al. 2011), and both tumor necrosis factor (TNF) and TNF receptors (Yee and Pochapin 2001) are increased in patients with the disease. There are reports that genetically predisposed individuals who are exposed to different mycobacterial, viral, and other environmental antigens are susceptible to developing the disease, and this may initiate the immunologic cascade that produces the noncaseating granulomas most commonly found in the lung, skin, heart, and liver (McKinley-Grant et al. 2009). Recent genetic epidemiology studies from the Black Women's Health Study support the role of the *BTNL2* gene and the 5q31 locus in the etiology of sarcoidosis, and also demonstrate that percent African ancestry is associated with disease risk (Cozier et al. 2013).

Cutaneous sarcoidosis may present as a part of systemic disease but may also only involve the skin. Skin involvement manifests with a wide variety of morphologies; therefore,

being aware of the diverse presentations is crucial to a practicing dermatologist. Table 2.1 highlights the different morphologic types of cutaneous sarcoidosis.

Some of the more common lesions presenting in patients with skin of color include the maculopapular (Fig. 2.1), lupus pernio (Fig. 2.2), plaque, nodular ulcerative, and

TABLE 2.1 Morphologic subtypes of cutaneous sarcoidosis

<b>Subtype</b>	<b>Clinical features</b>	<b>Characteristics</b>
Maculopapular sarcoidosis	Reddish brown macules and papules involving the cheeks, periorbital area, nasolabial folds. Lesions may resolve without scarring	Most common manifestation of cutaneous sarcoidosis, especially in black women. Commonly associated with hilar lymphadenopathy, acute uveitis, and parotid enlargement [3]
Lupus pernio	Red and violaceous, indurated papules, plaques, and nodules that usually affect the nose, lips, cheeks, and ears. Nasal ulceration and septal perforation may occur	More common in black women [3]. Higher frequency of pulmonary and ocular disease
Plaque sarcoidosis	Annular, erythematous, brown or violaceous, infiltrated plaques that may be atrophic or scaly. Angiolupoid plaques may have large telangiectasias. Plaques may heal with scarring and alopecia	Patients usually have more chronic and severe systemic involvement [8]

(continued)

<b>Subtype</b>	<b>Clinical features</b>	<b>Characteristics</b>
Subcutaneous nodular sarcoidosis (Darier-Roussy)	Nontender, firm, skin colored or violaceous mobile subcutaneous nodules commonly found on the trunk or extremities. Usually appear in the early stages of the disease. Nodules may resolve spontaneously	Usually associated with less severe systemic disease [8]
Scar associated sarcoidosis	Scars from previous trauma, surgery, venipuncture, or tattoo may become infiltrated with sarcoidosis and show a red or violaceous color. These lesions may be tender	May appear early in the disease or parallel chronic systemic findings [8]
Erythema nodosum	Tender, erythematous subcutaneous nodules on the extremities (most commonly anterior tibias)	Associated with a good prognosis and spontaneous resolution of the disease. More common in Scandinavian women [8]
Lofgren syndrome	Triad of erythema nodosum, polyarthritis, and hilar adenopathy. Anterior uveitis, fever, ankle peri-arthritis, arthralgias, and pulmonary involvement	Acute syndrome with excellent prognosis [8]

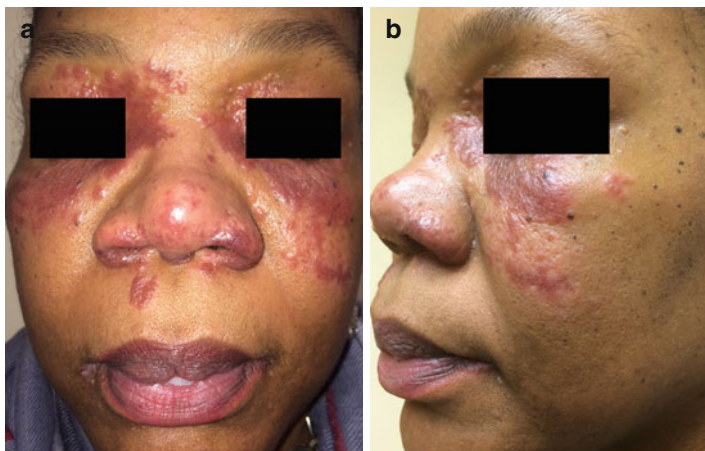

FIGURE 2.2 (a, b) Lupus pernio. Multiple disfiguring coalescing 2–4 mm violaceous papules and plaques are noted on the periorbital, malar cheeks, upper cutaneous lip and bilateral nasal rims

hypopigmented (Fig. 2.3) forms of sarcoidosis. Maculopapular sarcoidosis is the most common lesion seen in cutaneous sarcoidosis, especially in black women (Heath et al. 2012). Lupus pernio is usually more common in black women with long standing systemic disease (Heath et al. 2012). Sarcoidosis is often called the “great imitator” because it can present with almost any morphology. Less common cutaneous manifestations of sarcoidosis include psoriasiform, annular, lichenoid, ichthyosiform, verrucous, tumoral, ulcerative, angiolupoid, and erythrodermic forms. Scarring alopecia and nail dystrophy may also occur.

The lungs are affected in nearly all cases (90 %) of sarcoidosis and are characterized by granulomatous involvement of the interstitium, alveoli, blood vessels, and bronchioles. A third to half of all patients experience dyspnea, dry cough, and chest pain. Bilateral hilar adenopathy is the most common diagnostic radiographic finding. Overall, blacks tend to have more severe lung disease as compared with Caucasians on presentation, a higher likelihood of progressive pulmonary

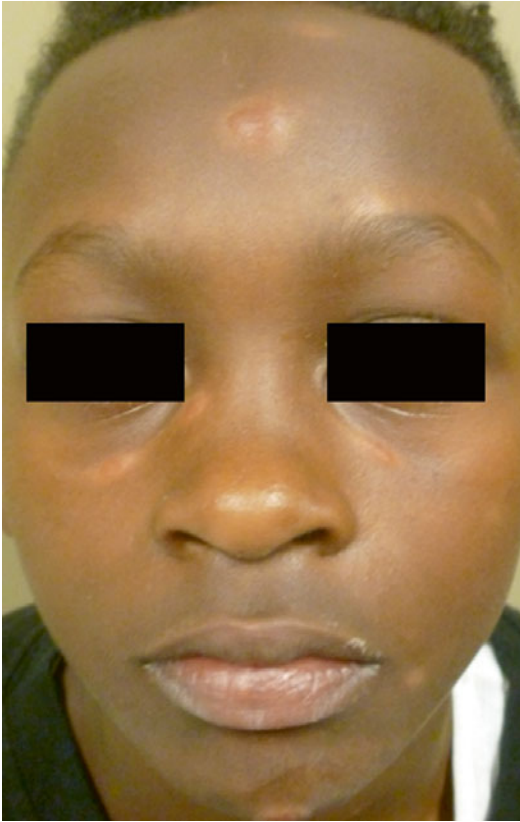


FIGURE 2.3 Hypopigmented sarcoidosis. Scattered 1 cm hypopigmented subcutaneous nodules are noted on the forehead, cheeks, and chin

dysfunction, and a poorer long-term prognosis (Rybicki et al. 1997; Heath et al. 2012).

In addition to the lungs and the skin, sarcoidal granulomatous infiltration may also present in the central nervous system, musculoskeletal system, liver, gastrointestinal tract, parotid glands, reproductive organs, and the kidneys. The frequency of sarcoid lesions involving lymph nodes, liver,

skin, and eyes is higher in Blacks as compared with Caucasians (Edmondstone and Wilson 1985). Black patients also have a higher rate of chronic uveitis and cystic bone lesions (Heath et al. 2012). Japanese patients have been found to have a higher incidence of ocular lesions, cardiac sarcoidal granulomas, and death related to cardiac sarcoidosis compared to Blacks and Caucasians (Pietinalho et al. 1995). The clinical presentation of cardiac sarcoidosis ranges from benign arrhythmias or heart block to sudden death.

Given the multiorgan system manifestations of sarcoidosis, a comprehensive diagnostic workup includes skin biopsy, complete blood cell count (which may reveal modest leukopenia or anemia), serum urea nitrogen, creatinine, liver enzymes, serum calcium, antinuclear antibodies, chest x-ray, pulmonary function tests, electrocardiogram, and serum angiotensin-converting enzyme. Patients should also be referred to rheumatology, pulmonology, and ophthalmology for evaluation (Heath et al. 2012).

### *Treatment*

The goal of therapy is to alleviate symptoms by minimizing the inflammatory process. Treatment is selected based on the type of lesion, the cosmetic disfigurement and symptoms (Haimovic et al. 2012). In general, patients presenting with cutaneous disease in the setting of systemic involvement benefit from being treated systemically. In cases where disease is localized to the skin, more conservative approaches are usually adequate.

For localized cutaneous disease, ultrapotent topical steroids or intralesional steroid injections are first line treatments. Corticosteroids have an anti-inflammatory effect and aid in suppressing granuloma formation. Intralesional injections are most appropriate for papule or plaque sarcoidal lesions. Side effects of topical and intralesional corticosteroid therapy include skin atrophy and hypopigmentation. Steroid-sparing topical agents such as the topical immunomodulators,



topical tacrolimus and pimecrolimus, can be alternated with topical steroids to decrease the risk of side effects.

Patients with severely scarring sarcoidosis, lesions refractory to local treatment, or those experiencing cutaneous and systemic involvement, may require systemic corticosteroids. There are a number of risks with prolonged oral corticosteroid therapy, including adrenal insufficiency, Cushing syndrome, osteoporosis, and peptic ulceration (Heath et al. 2012). Minocycline or doxycycline may also be used as first line treatment (Bachelez et al. 2001).

Widespread, cutaneous disease (especially lupus pernio, mucosal, and nail disease) may require oral corticosteroids or antimalarial agents, such as hydroxychloroquine or chloroquine. Antimalarial agents halt the body's inflammatory response by preventing the antigen presentation necessary for the process of granuloma formation. Antimalarials are often used in conjunction with corticosteroids or alone in patients where long-term steroids are not necessary or tolerable. Possible adverse effects of antimalarials include hematologic abnormalities, corneal opacity, renal damage, and hepatotoxicity. Given the potential for ocular toxicity, patients should be followed by an ophthalmologist with an eye examination every 6–12 months to monitor for the development of corneal deposits and retinopathy. Hydroxychloroquine 200–400 mg daily is more commonly prescribed than chloroquine because it is thought to have a better safety profile. Patients of color of African, Mediterranean, or Southeastern Asian descent should be screened for glucose-6-phosphate-dehydrogenase deficiency before prescribing antimalarial medication to avoid precipitating a hemolytic episode (Heath et al. 2012; Jones and Callen 1990).

Recalcitrant disease may require the addition of methotrexate, a folate analog that suppresses granuloma formation by acting as an anti-inflammatory agent, at a dose of 5–25 mg weekly. Baseline renal and hepatic function must be assessed prior to starting therapy. Follow-up care includes close monitoring for adverse effects, including pancytopenia, hepatic toxicity, gastrointestinal disturbances, and hypersensitivity

pneumonitis (Webster et al. 1991). Azathioprine and mycophenolate mofetil have been used anecdotally, but concerns about the side effects including opportunistic infections and malignancy may limit their use. Tumor necrosis factor (TNF) plays an important role in both formation and maintenance of the sarcoidal granulomas, and the TNF-alpha inhibitors, infliximab and adalimumab, have been used successfully in some patients with sarcoidosis (Crommelin et al. 2014). However, it is important to note that there have been cases of TNF alpha inhibitor-induced sarcoidosis (Scailteux et al. 2015).

## Key Points

- Cutaneous sarcoidosis can present with a wide range of morphologies.
- It has been well documented that in African Americans, sarcoidosis occurs at an earlier age, and may have a more severe course than in Caucasians.
- African Americans have more severe lung disease as compared with Caucasians on presentation, a higher likelihood of progressive pulmonary dysfunction, and a poorer long-term prognosis.
- Japanese patients have been found to have a higher incidence of ocular lesions, cardiac sarcoidal granulomas, and cardiac sarcoid induced death compared to African Americans and Caucasians.

## References

- Haimovic A, Sanchez M, Judson MA, Prystowsky S. Sarcoidosis: a comprehensive review and update for the dermatologist: part I. Cutaneous disease. *J Am Acad Dermatol.* 2012;66(5):699.e1–18. quiz 717–8.
- Rybicki BA, Major M, Popovich Jr J, Maliarik MJ, Iannuzzi MC. Racial differences in sarcoidosis incidence: a 5-year study in a health maintenance organization. *Am J Epidemiol.* 1997; 145(3):234–41.

- Guss L, Ghazarian S, Daya N, Okoye G. Sarcoidosis in African Americans. *Austin J Dermatol.* 2014;1(6):1028.
- Heath CR, David J, Taylor SC. Sarcoidosis: are there differences in your skin of color patients? *J Am Acad Dermatol.* 2012;66(1):121.e1–14.
- Edmondstone WM, Wilson AG. Sarcoidosis in Caucasians, Blacks and Asians in London. *Br J Dis Chest.* 1985;79(1):27–36.
- Facco M, Cabrelle A, Teramo A, Olivieri V, Gnoato M, Teolato S, et al. Sarcoidosis is a Th1/Th17 multisystem disorder. *Thorax.* 2011;66(2):144–50.
- Yee AM, Pochapin MB. Treatment of complicated sarcoidosis with infliximab anti-tumor necrosis factor-alpha therapy. *Ann Intern Med.* 2001;135(1):27–31.
- McKinley-Grant L, Warnick M, Singh S. Cutaneous manifestations of systemic diseases. In: Kelly A, Taylor S, editors. *Dermatology for Skin of Color.* China: McGraw-Hill Companies, Inc.; 2009.
- Cozier Y, Ruiz-Narvaez E, McKinnon C, Berman J, Rosenberg L, Palmer J. Replication of genetic loci for sarcoidosis in US black women: data from the Black Women's Health Study. *Hum Genet.* 2013;132(7):803–10.
- Pietinalho A, Hiraga Y, Hosoda Y, Lofroos AB, Yamaguchi M, Selroos O. The frequency of sarcoidosis in Finland and Hokkaido, Japan. A comparative epidemiological study. *Sarcoidosis.* 1995;12(1):61–7.
- Bachelez H, Senet P, Cadranet J, Kaoukhov A, Dubertret L. The use of tetracyclines for the treatment of sarcoidosis. *Arch Dermatol.* 2001;137(1):69–73.
- Jones E, Callen JP. Hydroxychloroquine is effective therapy for control of cutaneous sarcoidal granulomas. *J Am Acad Dermatol.* 1990;23(3 Pt 1):487–9.
- Webster GF, Razsi LK, Sanchez M, Shupack JL. Weekly low-dose methotrexate therapy for cutaneous sarcoidosis. *J Am Acad Dermatol.* 1991;24(3):451–4.
- Crommelin HA, Vorselaars AD, van Moorsel CH, Korenromp IH, Deneer VH, Grutters JC. Anti-TNF therapeutics for the treatment of sarcoidosis. *Immunotherapy.* 2014;6(10):1127–43.
- Scailteux LM, Guedes C, Polard E, Perdriger A. Sarcoidosis after adalimumab treatment in inflammatory rheumatic diseases: a report of two cases and literature review. *Presse Med.* 2015;44(1):4–10.

# **Part II**

# **Hair Disorders**

# Chapter 3

## Traction Alopecia

**Kirsten L. Cottingham and Porcia B. Love**

### Case Presentation

A 23 year old African American female presents with a 6 month history of thinning of the hair on the front of the scalp. She wore tight ponytails as a child and has a history of microbraids usage, sewn-in wefted hair extensions, and permanent hair dye. She has had a chemical relaxer applied to her hair every 6 weeks since the age of 6. She believes her scalp is inflamed and often very tender. She frequently flat irons her hair in the front.

### Physical Examination

During examination, a markedly decreased density of hair is noted on the frontal and temporal scalp (Fig. 3.1a). The presence of retained hairs on the frontal and temporal region

---

K.L. Cottingham, BS  
Tuskegee University, Tuskegee, AL USA

P.B. Love, MD (✉)  
Montgomery Dermatology, PC, Montgomery, AL 36106, USA  
e-mail: [porcialove@gmail.com](mailto:porcialove@gmail.com)

P.B. Love, R.V. Kundu (eds.), *Clinical Cases in Skin of Color: Medical, Oncological and Hair Disorders, and Cosmetic Dermatology*, Clinical Cases in Dermatology, DOI 10.1007/978-3-319-23615-5\_3, © Springer International Publishing Switzerland 2016 31

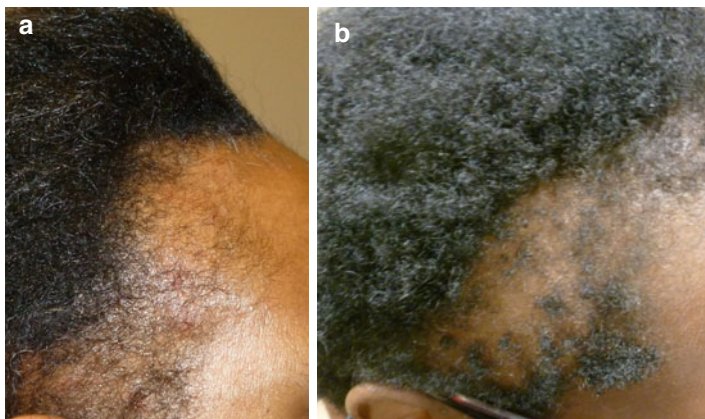

FIGURE 3.1 Traction alopecia. Markedly decreased density of hair is noted on the frontal and temporal scalp (a). The presence of retained hairs on the frontal and temporal region (b), mild inflammation, and follicular markings are also observed

(Fig. 3.1b), mild inflammation, and follicular markings are also observed. Mild scale, papules, pustules, and erythema were also noted.

## Differential Diagnosis

The patient's clinical presentation was felt to be most consistent with traction alopecia. Alopecia areata is a recurrent nonscarring type of hair loss that presents as patches of hair loss; it can affect any hair-bearing area. The ophiasis pattern of alopecia areata occurs when the hair loss is localized to the temporal and occipital scalp. Androgenetic alopecia is a genetically determined form of nonscarring alopecia characterized by gradual thinning of the hair, typically over the vertex of the scalp. The frontal hairline is often preserved in women, and temporal hair loss occasionally occurs in women. Central centrifugal cicatricial alopecia is a form of scarring alopecia in which hair loss typically begins at the vertex and

extends outward in a centrifugal manner. Tenderness, pruritus, and burning are common. Frontal fibrosing alopecia is a form of scarring hair loss characterized by hair loss on the frontal and temporal scalp. Patients may also have loss of the lateral eyebrows. At the margins of the areas of alopecia, perifollicular erythema and scaling may be seen. Frontal fibrosing alopecia usually affects post-menopausal women over the age of 50 (Quinn 2009).

## Histopathology

In early stages of this disorder, the histologic findings are similar to trichotillomania. The density of follicles is normal, and premature conversion of anagen hairs to catagen occurs. Pigment casts and trichomalacia are sometimes found. Later stages show loss of terminal follicles, with replacement of follicular tracts by scar tissue (Elder 2009).

## Diagnosis

Traction alopecia

## Case Treatment

The diagnosis, etiology, natural history, and treatment of the disorder was thoroughly discussed with the patient. She was counseled that her hair care practices, including her history of tight ponytails, microbraids, sew-in wefted hair extensions, and frequent chemical relaxers, likely contributed to her hair loss. In order to prevent further damage to the hair follicles, it was recommended that she terminate all hairstyles of this type and limit heat and chemical use. A good moisturizing conditioner was also recommended to prevent breakage. Given the presence of erythema and pustules on exam, doxycycline 100 mg twice daily was started for 3 months. Biotin

5000 mcg once a day was also recommended. Topical fluocinonide 0.05 % ointment to the affected areas of hair loss was recommended daily. The patient also received intralesional triamcinolone acetonide 10 mg/mL injections every 6 weeks for three cycles. At 6 months follow-up, moderate hair growth was noted.

## Discussion

Traction alopecia is a form of acquired hair loss that results from prolonged or repetitive tension on the scalp hair. Traction alopecia can be caused by regular wearing of tight chignons, cornrows, dreadlocks, weaves, braids, hair extensions, chemical relaxers, and rollers. It can also be due to the weight of excessively long hair. Traction alopecia affects people of any ethnic background or age (Khumalo et al. 2007); however, the hair care practices of females of African descent predispose this population to hair shaft damage from traction.

In a cross-sectional study of 1042 South African schoolchildren, the majority of girls (78 %) had chemically relaxed hair, which was usually combed back or tied in ponytails. Traction alopecia was significantly more common with relaxed than natural hair, with an overall prevalence of 17 % in girls, in whom it increased with age from 8 % in the first year of school to 21 % in the last year of high school. The proportion with traction alopecia in participants with a history of braids on natural hair was lower (22 %) than among those with a history of braids on relaxed hair (32 %) (Khumalo et al. 2007). Population studies also reported a prevalence of traction alopecia of 17.1 % in African schoolgirls (6–21 years) and 31.7 % in women (18–86 years), demonstrating that the likelihood of developing traction alopecia increases with age, likely due to a prolonged history of these hair practices (Khumalo et al. 2008).

In a survey of 201 African American girls, ponytails, braids, and cornrows were worn by 81 %, 67 %, and 49 % of



girls, respectively. Cornrows were significantly related to traction alopecia (Rucker Wright et al. 2011). The stronger association with cornrows was likely due to the fact that this technique pulls at the root whereas braids or ponytails can be worn looser. Girls who had chemical relaxers were twice as likely to report traction alopecia. It is well known that chemical relaxers weaken the hair shaft's tensile strength and cause hair fragility; therefore, it is plausible that the added mechanical stress of pulling hair into cornrows or braids increases the risk of traction alopecia (Rucker Wright et al. 2011).

Wefted hair extensions that consist of multiple strands of hair held together by a band of fine threads that are attached directly to the hairline by being sewn, glued, or clipped are often a cause of traction alopecia (Fig. 3.2) and may also cause a horseshoe pattern of traction alopecia (Ahdout and Mirmirani 2012). Traction alopecia has also been described in South Asian Sikh males who twist their uncut scalp hair tightly on the scalp (resulting in scalp alopecia) or their uncut beard below the chin (causing submandibular traction alopecia) (Karimian-Teherani et al. 2011).

Traction alopecia is a biphasic alopecia, as initially, traction alopecia is noncicatricial (without scarring), but prolonged and excessive tension leads to destruction of the hair follicles and permanent scarring alopecia (Quinn 2009). Traction alopecia often results in hair loss of the frontal and temporal scalp (Fig. 3.1a, b). Perifollicular papules and pustules may also be present at symmetric areas of traction. Hair casts can be seen with severe cases of traction (Quinn 2009). Patients may present with itching, erythema, scaling, and multiple short broken hairs.

The “fringe sign,” characterized by retention of some hair along the frontal and temporal rim of the hairline (Fig. 3.3), is commonly found in patients with traction alopecia of the marginal hairline. In a retrospective single-center review in a California clinic where the majority of patients were Hispanic, 100 % of women who had traction alopecia involving the marginal hairline had the fringe sign (Samrao et al. 2011).

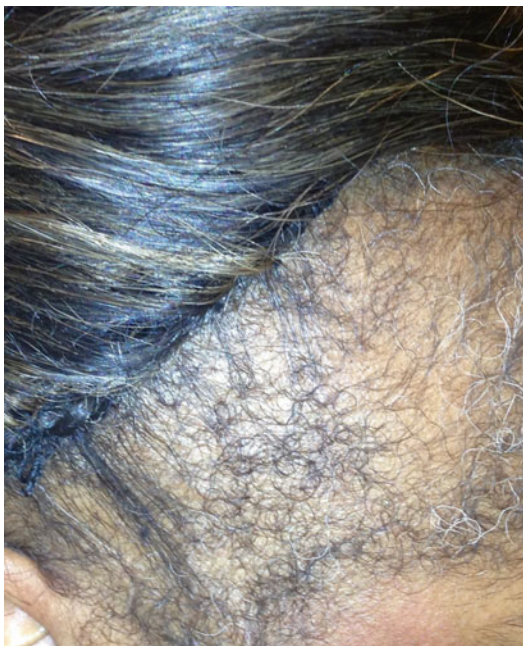

FIGURE 3.2 Patient with wefted hair extensions and traction alopecia. Wefted hair extensions that consist of multiple strands of hair held together by a band of fine threads that are attached directly to the hairline by being sewn, glued, or clipped are often the cause traction alopecia

### *Treatment*

The most common causes of traction alopecia are tight or traction type hairstyles, such as weaves, braids, and tight ponytails. In order to prevent further damage to the hair follicles, it is important to terminate all hairstyles of this type and limit heat and chemical use. Heat and chemicals, such as relaxers or dyes, generally weaken the hair and increase the risk of breakage. Therefore, good moisturizing conditioners are necessary to restore the hair's moisture, strengthen hair, and prevent breakage.

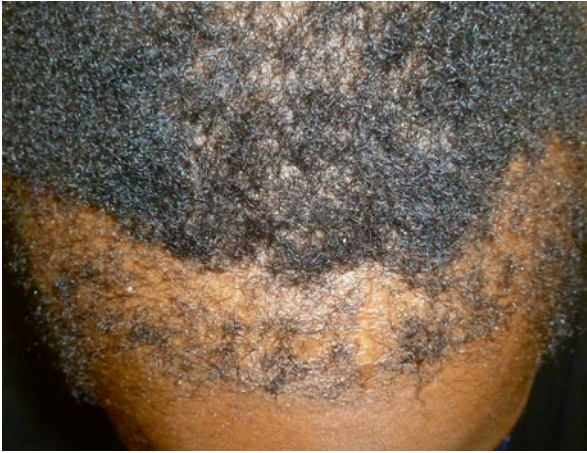

FIGURE 3.3 Fringe sign. The “Fringe sign,” characterized by retention of some hair along the frontal and temporal rim of the hairline, is commonly found in patients with traction alopecia of the marginal hairline

Oral and topical antibiotics (tetracyclines and topical clindamycin) are often given at the earlier stages of traction alopecia, especially if perifollicular papules and pustules are present. Topical and intralesional corticosteroids are also used for their anti-inflammatory effect (Callender et al. 2004). Topical minoxidil appears to lengthen the duration of the anagen phase, and it may increase the blood supply to the follicle (Olsen et al. 1985). Biotin deficiency is associated with alopecia (Camacho and Garcia-Hernandez 1999); therefore, biotin is often recommended in order to strengthen and increase thickness of the hair. Hair transplants, including mini-grafting, micro-grafting, and follicular unit transplantation (Earles 1986), are also a treatment for the final stages of the disorder. Patients with the best results histologically display a lack of inflammation on scalp biopsy (Callender et al. 2014).

Data suggest that the pre-teen years are an ideal public education target for traction alopecia prevention (Khumalo 2012). Table 3.1 includes recommendations for preventing traction alopecia.

TABLE 3.1 Recommendations for preventing traction alopecia

---

Traction-based hairstyles should be painless – pain is an indication to undo the hair

Traction hairstyles on relaxed hair should be avoided or done at least 2 weeks after processing – relaxed hair is weak and prone to breakage

Relaxers should be avoided, especially in children – hair damage increases with exposure duration

If used, relaxers should be applied according to package instructions, taking care to only process the new growth or “virgin hair” – no “smoothing” of the cream through previously relaxed hair. In addition, the hair should be thoroughly rinsed and neutralized after processing or immediately if scalp tingling or burning occurs

Using both relaxers and dyes compound hair damage; it should be avoided or done at least 2 weeks apart

Heat on relaxed hair should be avoided – air dry or use low-heat hairdryer settings. Hot combs and flat irons should be avoided or limited; their very high temperatures can cause significant hair damage

Conditioners and the use of non-occlusive petroleum-free moisturizers for dry hair may reduce the risk of hair breakage during grooming

---

Adapted from Khumalo (2012)

## Key Points

- Educating patients on avoiding hair care practices that promote tension is key in early stages of alopecia.
- Excessive traction, especially to chemically processed hair, may reduce the risk of developing traction alopecia.
- Educating parents about the risks associated with weaves, braids, tight ponytails, and pulling relaxed hair into tight hair styles may help to prevent traction alopecia.

## References

- Ahdout J, Mirmirani P. Weft hair extensions causing a distinctive horseshoe pattern of traction alopecia. *J Am Acad Dermatol*. 2012;67(6):e294–5.
- Callender VD, McMichael AJ, Cohen GF. Medical and surgical therapies for alopecias in black women. *Dermatol Ther*. 2004;17(2):164–76.
- Callender VD, Lawson CN, Onwudiwe OC. Hair transplantation in the surgical treatment of central centrifugal cicatricial alopecia. *Dermatol Surg Off Publ Am Soc Dermatol Surg*. 2014;40(10):1125–31.
- Camacho FM, Garcia-Hernandez MJ. Zinc aspartate, biotin, and clobetasol propionate in the treatment of alopecia areata in childhood. *Pediatr Dermatol*. 1999;16(4):336–8.
- Earles RM. Surgical correction of traumatic alopecia marginalis or traction alopecia in black women. *J Dermatol Surg Oncol*. 1986;12(1):78–82.
- Elder D. *Lever's histopathology of the skin*. 10th ed. Philadelphia: Lippincott Williams & Wilkins; 2009.
- Karimian-Teherani D, El Shabrawi-Caelen L, Tanew A. Traction alopecia in two adolescent Sikh brothers—an underrecognized problem unmasked by migration. *Pediatr Dermatol*. 2011;28(3):336–8.
- Khumalo NP. The “fringe sign” for public education on traction alopecia. *Dermatol Online J*. 2012;18(9):16.
- Khumalo NP, Jessop S, Gumedze F, Ehrlich R. Hairdressing is associated with scalp disease in African schoolchildren. *Br J Dermatol*. 2007;157(1):106–10.
- Khumalo NP, Jessop S, Gumedze F, Ehrlich R. Determinants of marginal traction alopecia in African girls and women. *J Am Acad Dermatol*. 2008;59(3):432–8.
- Olsen EA, Weiner MS, Delong ER, Pinnell SR. Topical minoxidil in early male pattern baldness. *J Am Acad Dermatol*. 1985;13(2 Pt 1):185–92.
- Quinn C. Alopecia. In: Kelly A, Taylor S, editors. *Dermatology for skin of color*. China: McGraw-Hill Companies, Inc.; 2009.
- Rucker Wright D, Gathers R, Kapke A, Johnson D, Joseph CL. Hair care practices and their association with scalp and hair disorders in African American girls. *J Am Acad Dermatol*. 2011;64(2):253–62.
- Samrao A, Price VH, Zedek D, Mirmirani P. The “Fringe Sign” – a useful clinical finding in traction alopecia of the marginal hair line. *Dermatol Online J*. 2011;17(11):1.

# Chapter 4

## Androgenetic Alopecia

**Yolanda M. Lenzy and Alfreda F. Batts**

### Case History

A 36-year old Latina female presented with a 5 year history of progressive thinning of the vertex scalp. She previously tried over the counter hair growth preparations and biotin, without any improvements.

### Physical Examination

On examination, diffuse thinning was noted over the fronto-parietal scalp with preservation of the frontal hairline (Fig. 4.1a). There was no scalp erythema or scaling and the pull test was negative. Variability in the diameter of the hairs

---

Y.M. Lenzy, MD, MPH (✉)

Department of Dermatology, Lenzy Dermatology & Hair Loss  
Center & University of Connecticut, Chicopee, MA, USA  
e-mail: [Yolanda\\_lenzy@yahoo.com](mailto:Yolanda_lenzy@yahoo.com)

A.F. Batts, BS

University of Texas Medical Branch at Galveston,  
12255 West Marsham Circle, Houston, TX 77066, USA  
e-mail: [ms.alfredabatts@gmail.com](mailto:ms.alfredabatts@gmail.com)

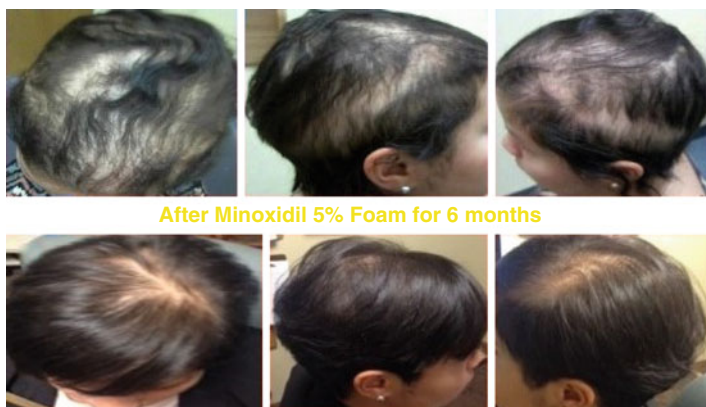

FIGURE 4.1 Androgenetic alopecia and treatment with minoxidil 5 % foam. Diffuse thinning is noted over the fronto-parietal scalp with preservation of the frontal hairline (a). After 6 months of topical minoxidil 5 % foam, there was significant re-growth in the fronto-parietal scalp (b)

and miniaturization were noted on dermoscopy. In addition, a horse-shoe shaped linear band of hair loss was noted extending from the frontal to occipital scalp, corresponding to the location of the adhesive attachment of the patient's hair replacement unit.

## Clinical Differential Diagnosis

The clinical differential diagnosis included androgenic alopecia, central centrifugal cicatricial alopecia (CCCA), chronic telogen effluvium and alopecia areata (Callender et al. 2004). CCCA and traction alopecia are the most common causes of hair loss in African American females (Rogers and Callender 2014). Diagnostic clues in differentiating the different causes of hair loss include the pattern of hair loss, symptomatology, and dermoscopy findings.

## Histopathology

Histologically, miniaturization of terminal hairs into vellus hairs, a decreased anagen-to-telogen ratio, decreased follicular density in long-standing cases, and an absence of inflammation was noted. It is important to indicate the patient ethnicity on the scalp biopsy requisition as African-American patients have been noted to have a lower normal follicular density compared to Caucasians (22 vs 36 follicles) on a 4 mm punch biopsy (Blumeyer et al. 2011).

## Diagnosis

Androgenetic Alopecia

## Case Treatment

The nature of the condition was discussed with the patient, and emphasis was placed on the importance of initiating treatment early. Treatment options discussed include topical minoxidil 2 % solution or foam bid, minoxidil 5 % solution or foam once daily and oral spironolactone. Risks and benefits were discussed regarding each. The patient decided to begin with topical minoxidil 5 % foam daily for a trial of 6 months. The patient noticed significant regrowth at her 6 month follow up (Fig. 4.1b) and has continued it for the past 2 years, without further clinical progression of the miniaturization.

## Discussion

Hair loss is a common problem that challenges patients from all cultural backgrounds, especially in females of color. In fact, Halder et al. reported that alopecia is the fifth most



common condition seen in a dermatologic private practice that treats mainly African-American patients (Halder et al. 1983). Androgenic alopecia (AGA), also known as androge-netic alopecia, alopecia androgenetica, female pattern hair loss (FPHL), and male pattern hair loss (MPHL), is the most common form of hair loss (McElwee and Shapiro 2012); although the exact prevalence in black males and females is not known.

The pathogenesis of androgenic alopecia is multifactorial with both hormonal and hereditary mechanisms involved. Elevated levels of  $5\alpha$  reductase type-2 ( $5\alpha$ R-II) are located in the hair follicles of patients with AGA (Cowper and Knopp 2012). Dihydrotestosterone, formed from the action of  $5\alpha$ R-II on testosterone, binds to the androgen receptor (AR) and the hormone-receptor complex then activates genes responsible for the gradual transformation of large, terminal follicles to small, miniaturized ones (Cowper and Knopp 2012). Although the biochemical composition of hair is similar among racial and ethnic groups, hair in people of African descent is known to have an elliptical, curly morphology with lower total hair density, total number of terminal follicles, and terminal anagen hairs making management of this process in skin of color more challenging (Rogers and Callender 2014).

There is a paucity of data on the genetics of this type of hair loss, yet proposed theories on the inheritance pattern include autosomal dominance with incomplete penetrance and polygenic inheritance. This is suggested by twin studies identifying genetics for an estimated 80 % of the predisposition to pattern baldness and the clinical observations of patients' families that are diagnosed with AGA (Cowper and Knopp 2012).

The clinical manifestations are the same across all ethnic groups with noticeable differences between genders. MPHL in men tends to start in the bitemporal scalp, then progresses to involve the vertex and frontal hairline. FPHL in females shows diffuse thinning over the crown and frontal scalp with preservation of the anterior hairline (Fig. 4.2) referred to as the "Christmas tree" pattern (Blumeyer et al. 2011).

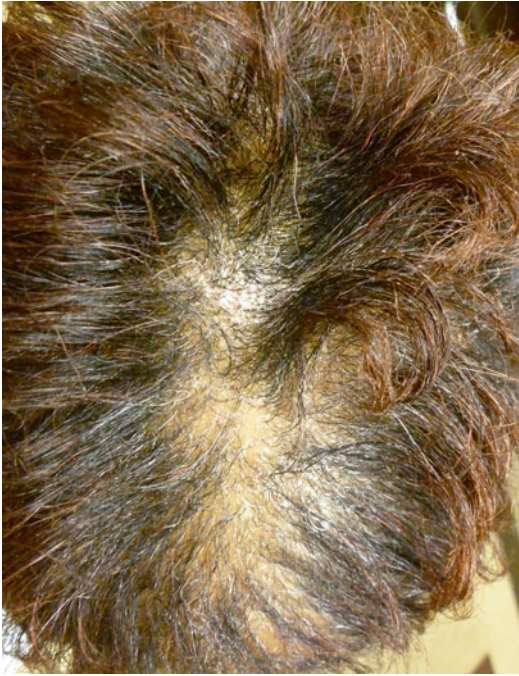

FIGURE 4.2 Androgenetic alopecia and the Christmas tree pattern. Female pattern hair loss in females shows diffuse thinning over the crown and frontal scalp with preservation of the anterior hairline, referred to as the “Christmas tree” pattern

It is important to note that AGA is not only a cosmetic issue, but it may entail many psychological and medical issues in its process. Many affected patients develop negative self-esteem and experience social problems causing major effects in their quality of life (QoL) (Callender et al. 2004). Chen et al. reported that the most common concerns of African-American females with alopecia are everyday functioning (i.e. hairstyling), emotional issues, and concerns with the appearance of the scalp (Callender et al. 2004). Therefore, early diagnosis and initiation of therapies in patients of African descent are essential in minimizing the overall effects on the patient.

There are several disorders that have been linked to androgenic alopecia including: polycystic ovary syndrome, postmenopausal ovarian hyperthecosis, administration of adrenocorticotrophic hormone, and prostate cancer (Cowper and Knopp 2012). These disorders are linked to overproduction of androgens and should be further worked up based on the clinical decision of the provider.

## Treatment

Androgenetic alopecia has several therapeutic options, both surgical and medical. The morphological structure of African-American hair presents specific challenges and special considerations when choosing an effective treatment plan for AGA. The elliptical, curly morphology, lower total hair density, total number of terminal follicles, and terminal anagen hairs are all factors that must be considered when treating African-American patients with hair loss (Rogers and Callender 2014).

Across all ethnicities topical minoxidil (5 % BID in males and 2 % BID or 5 % daily in females) is the mainstay medical therapy for treatment of AGA (Callender et al. 2004; Blumeyer et al. 2011). Its exact mechanism of promoting hair growth is unclear but it is known to convert miniaturized hairs into terminal hairs with a near normal morphology. In addition, minoxidil has Level 1 evidence of high rates of efficacy in preventing progression of hair loss and improving hair growth with high safety profiles and practicability for the patient (Blumeyer et al. 2011). Topical minoxidil is commercially available as a solution and foam and can be compounded into a gel or ointment. The solution or foam formulations may cause hair to return to its natural curly state in the black female patient with thermally straightened hair. To decrease this effect, the ointment formulation can be used as an alternative (Callender et al. 2004).

Anti-androgens are the second most popular treatment for AGA. Finasteride, a potent and highly selective synthetic  $5\alpha$  reductase type-2 inhibitor, prevents the conversion of testosterone into dihydrotestosterone (DHT), the hormone responsible for the miniaturization seen in AGA. Double blinded, placebo-controlled trials examined the 1 mg dose in patients. While a significant increase in hair counts were noted in men with AGA after 6–12 months, there were no differences in the terminal to miniaturized hair ratio in females. Camacho and colleagues reported significant hair growth using finasteride 2.5 mg/day in 41 females with AGA and SAHA (seborrhea, acne, hirsutism and alopecia) (Camacho 2001). Some studies have shown greater efficacy in the treatment of AGA with dutasteride, a  $5\alpha$  reductase type-1 inhibitor. However, dutasteride is not FDA approved in the treatment of AGA and Phase III clinical trials are currently ongoing. Spironolactone, a competitive aldosterone antagonist, has mild antiandrogenic effects by blocking the androgen receptor and preventing its interaction with DHT. Spironolactone may have a preventative effect in FPHL and may reduce shedding in females without hyperandrogenism. It is not FDA approved in the treatment of AGA and should not be used in men due to its anti-androgen effects. It requires concurrent contraception in fertile females and monitoring for menstrual disturbances and hyperkalemia (Blumeyer et al. 2011).

Hair transplantation as an option in black patients is increasing in popularity. The surgical correction of hair loss in patients of African descent poses many considerations and challenges when compared to patients of other ethnicities. Black patients have curved hair follicles, a lower hair density, lower number of follicular units with a higher number of hairs within each unit and a higher risk of keloid formation when compared to others (Callender et al. 2004). Therefore, the use of larger punch grafts (minigrafts and micrografts), donor harvesting with a bended Personna blade or flexible Dermablades, and transplanting hairs from the frontal area

caudally is a better option for this population (Rogers and Callender 2014). Patients with a known medical or family history of keloids can benefit from test transplantation to observe for thick scar formation. Therefore, in black patients with AGA refractory to medical treatment, transplantation can be a safe and a long-term therapeutic option.

Low-level light/laser therapy and platelet-rich plasma (PRP) are innovative hair loss therapies that are gaining popularity (Gkini et al. 2014). Paradoxical hair growth occurred has occurred in patients undergoing laser hair removal when relatively low fluences were used (Nusbaum et al. 2013). The mechanism of action of this phenomenon is unknown but one theory includes the absorption of photons by cytochrome oxidase, modulating gene regulation to decrease apoptosis and prolongation of the anagen phase (Nusbaum et al. 2013). Improvement in terminal hair density was observed with treatment with low-level laser device versus a sham device on the entire scalp three times weekly for 26 weeks in both males and females (Jimenez et al. 2014). Over the counter home-use handheld devices include HairMax LaserComb<sup>®</sup>, Sunetics Laser Hair Brush<sup>®</sup>, and the X5 Hair Laser<sup>®</sup>. LaserCap<sup>®</sup> is also a home-use system that must be prescribed. The in-office systems include the Sunetics Model G<sup>®</sup> and MEP90<sup>®</sup> system. PRP therapy includes injecting autologous platelets into the scalp that are known to release growth factors. There is insufficient evidence to support direct stimulation of hair growth but one clinical trial noted that PRP showed an increase in target hair counts compared with control (Nusbaum et al. 2013). If PRP is administered with dalteparin and protamine microparticles as carriers, hair shaft diameter and target hair counts are proposed to increase (Nusbaum et al. 2013). Further studies are needed to evaluate PRP as a FDA approved hair loss therapy.

Scalp prostheses are practical for patients with extensive hair loss without significant improvement with medical therapies who are not candidates for surgical hair restoration therapy.

## Key Points

- Androgenic alopecia is the most common cause of hair loss.
- It is characterized by non-scarring hair loss under the influence of androgens, miniaturization of terminal hairs into vellus hairs, a decreased anagen-to-telogen ratio, decreased follicular density in long-standing cases, and an absence of inflammation.
- There are several therapies to choose from when managing AGA with the most popular being topical minoxidil, oral finasteride, low-level laser/light therapies, and hair transplantation.
- More research is needed to effectively guide the treatment of AGA in patients with skin of color.

## References

- Blumeyer A, Tosti A, Messenger A, Reygagne P, Del Marmol V, Spuls PI, et al. Evidence-based (S3) guideline for the treatment of androgenetic alopecia in women and in men. *J Dtsch Dermatol Ges.* 2011;9 Suppl 6:S1–57.
- Callender VD, McMichael AJ, Cohen GF. Medical and surgical therapies for alopecias in black women. *Dermatol Ther.* 2004;17(2):164–76.
- Camacho F. Hirsutismo. Enfoque clinico terapeutico. *Act Terap Dermatol (Arg).* 2001;24:190–206.
- Cowper S, Knopp E. Androgenetic alopecia. In: Sperling L, editor. *An atlas of hair pathology with clinical correlations.* 2nd ed. Boca Raton: CRC; 2012. p. 42–51.
- Gkini MA, Kouskoukis AE, Tripsianis G, Rigopoulos D, Kouskoukis K. Study of platelet-rich plasma injections in the treatment of androgenetic alopecia through an one-year period. *J Cutan Aesthet Surg.* 2014;7(4):213–9.
- Halder RM, Grimes PE, McLaurin CI, Kress MA, Kenney Jr JA. Incidence of common dermatoses in a predominantly black dermatologic practice. *Cutis.* 1983;32(4):388, 90.
- Jimenez JJ, Wikramanayake TC, Bergfeld W, Hordinsky M, Hickman JG, Hamblin MR, et al. Efficacy and safety of a low-level laser

- device in the treatment of male and female pattern hair loss: a multicenter, randomized, sham device-controlled, double-blind study. *Am J Clin Dermatol.* 2014;15(2):115–27.
- McElwee KJ, Shapiro JS. Promising therapies for treating and/or preventing androgenic alopecia. *Skin Therapy Lett.* 2012;17(6):1–4.
- Nusbaum AG, Rose PT, Nusbaum BP. Nonsurgical therapy for hair loss. *Facial Plast Surg Clin North Am.* 2013;21(3):335–42.
- Rogers NE, Callender VD. Advances and challenges in hair restoration of curly Afrocentric hair. *Dermatol Clin.* 2014;32(2):163–71.

# Chapter 5

## Central Centrifugal Cicatricial Alopecia

**Yolanda M. Lenzy and Julia R. Fiore**

### Case Presentation

A 43-year-old African American female presented with a focal area of hair loss on the vertex scalp that she had noticed gradually expanding in size over the past 3–4 years. She denied a history of any systemic diseases. She had a positive history of hair relaxer use every 6–8 weeks since age 16. She also reported a 5-year history of braids as an adolescent for about 1 month at a time for most of the year. In addition, she reported wearing sew-in weaves every 4 months for the past 2 years. A family history of hair loss in her mother was also noted. She complained of occasional pruritus, and had not tried anything for treatment.

---

Y.M. Lenzy, MD, MPH (✉) • J.R. Fiore, MHS, PA-C  
Department of Dermatology, Lenzy Dermatology & Hair Loss  
Center & University of Connecticut, Chicopee, MA, USA  
e-mail: [Yolanda\\_lenzy@yahoo.com](mailto:Yolanda_lenzy@yahoo.com)

P.B. Love, R.V. Kundu (eds.), *Clinical Cases in Skin of Color: Medical, Oncological and Hair Disorders, and Cosmetic Dermatology*, Clinical Cases in Dermatology, DOI 10.1007/978-3-319-23615-5\_5, 51  
© Springer International Publishing Switzerland 2016



## Physical Examination

On examination, a focal, symmetric area of hair loss with smooth appearing areas (Fig. 5.1), and loss of follicular orifices on dermoscopy (Fig. 5.2) was noted on the vertex scalp. Evidence of hair breakage was also noted on the scalp throughout.

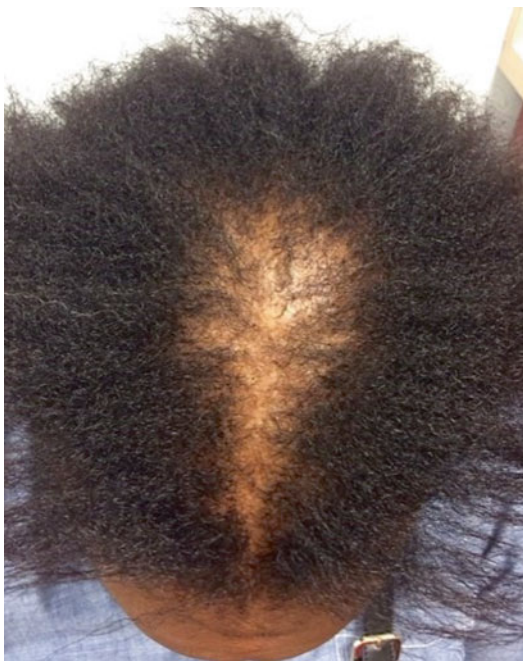


FIGURE 5.1 Central centrifugal cicatricial alopecia. On examination, a focal, symmetric area of hair loss with smooth appearing areas was noted on the vertex scalp. Evidence of hair breakage is also noted on throughout the scalp

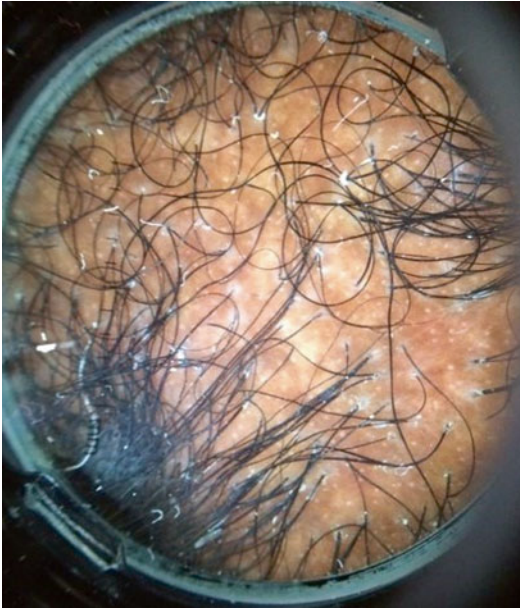


FIGURE 5.2 Dermoscopic presentation of central centrifugal cicatricial alopecia. Loss of follicular orifices, peripilar *white/gray* halos, white patches, and pinpoint white dots are noted on dermoscopy

## Differential Diagnosis

Based on the patient's history, her hair loss was felt to be most consistent with central centrifugal cicatricial alopecia (CCCA). Other cicatricial alopecias include lichen planopilaris (LPP), frontal fibrosing alopecia (FFA), folliculitis decalvans (FD), and discoid lupus erythematosus (DLE). Androgenetic alopecia must also be considered in the differential of early CCCA. LPP frequently exhibits clinical signs of inflammation such as perifollicular erythema and scaling, and may occur anywhere on the scalp. Frontal fibrosing alopecia involves the frontotemporal hairline and eyebrows.

Folliculitis decalvans may affect the occipital scalp and presents with follicular-based papules and pustules with surrounding areas of hair loss. Discoid lupus histologically has changes at the dermal-epidermal junction and often shows dermal deposition of mucin. Androgenetic alopecia does not have loss of follicular orifices on dermoscopy, but in early stages of CCCA it may be difficult to differentiate thus exemplifying the importance of biopsy for diagnostic confirmation (Madu and Kundu 2014).

## Histopathology

A scalp biopsy was performed, revealing a lymphocytic scarring alopecia. Pathology revealed a focal loss of sebaceous glands, perifollicular fibrosis and perifollicular lymphocytic infiltrate.

## Diagnosis

Central Centrifugal Cicatricial Alopecia (CCCA)

## Case Treatment

The nature of the condition was discussed with the patient, and emphasis was placed on the importance of preventing its progression. Treatment options discussed included topical steroids, intralesional steroids, and oral anti-inflammatories. Risks and benefits were discussed regarding each. The patient decided to begin with topical steroids, specifically clobetasol 0.05 % ointment, to be used daily for 1 month, then every other day. The patient was to schedule a follow up appointment for 2 months, and consider intralesional steroids or oral anti-inflammatory agents if symptoms were not improved or clinical progression was noted.

## Discussion

Hair loss is a common complaint seen in dermatology offices, affecting individuals of all ages, races, and ethnicities. Central Centrifugal Cicatricial Alopecia (CCCA) is the most common form of hair loss in African American women. It is a progressive form of scarring alopecia that involves the central or vertex scalp and expands centrifugally with time. A study by Olsen et al. developed a standardized photographic scale of central hair loss to evaluate the patterns of hair loss in African American women (Olsen et al. 2008).

The precise incidence and prevalence of CCCA has been somewhat difficult to ascertain. A study by Olsen and colleagues showed that hair loss patterns consistent with CCCA, though not histologically confirmed, occurred in 5.6 % of 233 African American women studied, which was felt to be indicative of the general population (Olsen et al. 2011). In a similar study by Khumalo et al., 2.7 % of 207 African American women studied exhibited clinical evidence of CCCA (Khumalo et al. 2007). It is proposed, however, based on clinical experience that the incidence and prevalence of this condition is largely underestimated. In a small study of 39 female patients in Nigeria seeking treatment for hair loss, 15.4 % of cases were confirmed histologically as CCCA (Ogunleye et al. 2014). Further epidemiologic data do show that CCCA occurs most commonly in African American women, though there have been few case reports in men. Onset is typically between the second and fourth decade of life, though a considerable amount of hair loss and thinning may occur prior to noticeable changes by the patient. This often accounts for delays in treatment, until hair loss is more extensive and scarring has already occurred (Ogunleye et al. 2014).

The etiology and risk factors associated with CCCA continue to require further elucidation. Many theories exist as to its pathogenesis, with several studies discussing environmental and genetic predisposing factors for the development of the condition.

It has long been proposed that traumatic hair styling practices such as tight braids, weaves, and the use of relaxers play a significant role in the development of CCCA. Traction hairstyles produce an inflammatory reaction of the scalp, which can lead to scarring if prolonged. It is common practice in many African American women to maintain traction hairstyles for extended periods of time, leading to prolonged inflammation and thus scarring. In a study by Kyei et al., it was found that hair-grooming practices that resulted in traction were associated with the most severe cases of central hair loss. In the same study, it was also found that 94 % of patients with CCCA had a history of chemical relaxer use. This was not statistically significant, however, in comparison to the control group (Kyei et al. 2011). Chemical relaxers do play a role in weakening the hair shaft, leading to breakage. In a recent study, hair breakage was found to be being a sign of early, occult CCCA. Of eight biopsies performed, five of them exhibited multiple histopathologic features consistent with CCCA, while two others showed histopathologic evidence of cicatricial alopecias, not specific for CCCA. Hair breakage, however, is associated with traumatic hair care practices, and is a non-specific finding with a broad differential diagnosis. This may be an area for future research (Ogunleye et al. 2014).

Hair care in individuals of color frequently involves multiple styling practices at the same time, contributing to the difficulty in identifying independent risk factors. Discerning the risk factors associated with hair care practices is further confounded by a lack of subjects without exposure to these practices at some point in their life, making it difficult to find appropriate controls.

Genetics have also been implicated as a risk factor in the development of CCCA. Dlova and coworkers expressed that CCCA may exhibit an autosomal dominant mode of inheritance with partial penetrance, and a modifying effect of hairstyling and gender. This study looked at 14 index African families with 31

immediate family members diagnosed with CCCA on clinical and histopathological grounds. While there was a significant correlation between history of traction hairstyles and the severity of the condition, six patients with a confirmed histological diagnosis of CCCA had a history of solely natural styling. This further lends to the suggestion of genetic factors playing a role in disease development (Dlova et al. 2014). Other studies have also shown genetic etiologies, but results may have been confounded by the use similar hair styling practices within familial generations (Madu and Kundu 2014).

A thorough clinical history is essential to the diagnosis of any alopecia. A thorough history should include: onset, duration, type of hair loss (thinning, breakage, shedding), hair care practice history (relaxers, traction hairstyles, breakage), and family history. Asking about associated symptoms such as burning, itching or tenderness is important. Patients may or may not exhibit scalp dysesthesia, but their presence if positive is important in regards to diagnosis and management (Summers et al. 2011).

Dermatoscopic findings in CCCA are also of significant importance. These include loss of follicular orifices honeycomb pigmented network, peripilar white/gray halos, white patches, and pinpoint white dots (consistent with scarring), broken hairs, and hair shaft variability (Fig. 5.2). Overt evidence of inflammation, such as perifollicular erythema or scaling, is often absent (Madu and Kundu 2014; Ogunleye et al. 2014).

Biopsies are frequently performed in early CCCA to confirm diagnosis and delineate the extent of inflammation and scarring. Early histologic changes exhibit perifollicular lymphocytic infiltrate and a reduction in terminal hair follicles and associated increase in fibrous tracts. Premature desquamation of the inner root sheath is an important histological marker, though not specific to CCCA as it may be seen in other cicatricial alopecias. Late stage histological findings may be indistinguishable from other scarring alopecias. These findings include destruction of pilosebaceous units, dermal scarring, and dermal lymphocytic infiltrate (Madu and Kundu 2014; Ogunleye et al.

2014). In a study of 51 cases of CCCA, premature desquamation of the inner root sheath was found in 96 % of cases. Goggles, or structures formed by the union of outer root sheaths with surrounding perifollicular fibrosis, is an evident and diagnostic feature of CCCA (Madu and Kundu 2014).

### *Treatment*

The goal of treatment in CCCA is the reduction of associated symptoms and prevention of disease progression. Once the hair follicle has been replaced by scarring, it is irreversible. Patients should be informed of this and should be educated about realistic treatment goals.

To prevent expansion, the mainstay of treatment is the use of anti-inflammatory agents. In the beginning stages of treatment, potent topical corticosteroids, such as clobetasol, are used as frequently as daily and then slowly tapered down to at least once weekly depending on disease severity.

Intralesional corticosteroids (2.5–10 mg/mL every 4–8 weeks) may be indicated in patients who exhibit progression at follow up or who have not had success in controlling symptoms with topical corticosteroids alone. Target areas for injections should include the periphery of the hair loss areas at the edge of normal hair to prevent further expansion outwards (Madu and Kundu 2014; Ogunleye et al. 2014).

Other anti-inflammatory agents include oral tetracyclines and antimalarials such as hydroxychloroquine. Studies of the effectiveness of these agents has been mixed, but may be an appropriate next step for those refractory to more traditional methods of treatment (Ogunleye et al. 2014).

Minoxidil may be added to a regimen once the condition is stable to help increase the density of the remaining hair follicles, which aids in hair growth and helps provide coverage for areas of hair loss (Madu and Kundu 2014).

As certain hair care practices have been associated with this condition, it is recommended that individuals avoid traction hairstyles and the use of chemical relaxers. Natural styles should

be encouraged. This, however, may not be ideal for patients. Encouraging patients to at least diminish the frequency of traction styles and increasing the intervals between them in order to give the hair a rest is recommended (Summers et al. 2011).

It is important to establish appropriate follow up for patients due to the progressive nature of CCCA. Intervals for follow up vary depending on disease severity. If a patient is a candidate for intralesional triamcinolone injections, visits may occur at more frequent intervals of every 4–8 weeks. If patients are well controlled, follow up should occur approximately every 2–3 months. Of note, it is good practice to obtain images at each visit to assess adequacy of the treatment regimen (Madu and Kundu 2014; Ogunleye et al. 2014).

## Key Points

- Central centrifugal cicatricial alopecia is the most common form of hair loss affecting African American women.
- African American hair care practices continue to be linked to the development of this condition, though the causes seem to be multifactorial in nature as there may be a genetic predisposition as well.
- Treatment goals are aimed at prevention progression and symptom control, as this form of hair loss is irreversible once scarring occurs.
- There is still a considerable amount of research that needs to be done in order obtain more insight into the specific etiologies and treatments for this condition.

## References

- Dlova NC, Jordaan FH, Sarig O, Sprecher E. Autosomal dominant inheritance of central centrifugal cicatricial alopecia in black South Africans. *J Am Acad Dermatol.* 2014;70(4):679–82.e1.
- Khumalo NP, Jessop S, Gumedze F, Ehrlich R. Hairdressing is associated with scalp disease in African schoolchildren. *Br J Dermatol.* 2007;157(1):106–10.



- Kyei A, Bergfeld WF, Piliang M, Summers P. Medical and environmental risk factors for the development of central centrifugal cicatricial alopecia: a population study. *Arch Dermatol.* 2011;147(8):909–14.
- Madu P, Kundu RV. Follicular and scarring disorders in skin of color: presentation and management. *Am J Clin Dermatol.* 2014;15(4):307–21.
- Ogunleye TA, McMichael A, Olsen EA. Central centrifugal cicatricial alopecia: what has been achieved, current clues for future research. *Dermatol Clin.* 2014;32(2):173–81.
- Olsen EA, Callender V, Sperling L, McMichael A, Anstrom KJ, Bergfeld W, et al. Central scalp alopecia photographic scale in African American women. *Dermatol Ther.* 2008;21(4):264–7.
- Olsen EA, Callender V, McMichael A, Sperling L, Anstrom KJ, Shapiro J, et al. Central hair loss in African American women: incidence and potential risk factors. *J Am Acad Dermatol.* 2011;64(2):245–52.
- Summers P, Kyei A, Bergfeld W. Central centrifugal cicatricial alopecia – an approach to diagnosis and management. *Int J Dermatol.* 2011;50(12):1457–64.

# **Part III**

## **Keloids**

# Chapter 6

## Keloids

**Olabola D. Awosika and Porcia B. Love**

### Case History

A 40 year old African American female presents with a firm, brown plaque on her anterior neck. She had previously undergone thyroid surgery in the area approximately 3 years ago. The plaque itches constantly and is occasionally tender. The patient would like the area removed. Other than her thyroid surgery, she has no history of previous surgeries.

### Physical Examination

A firm, brown,  $7 \times 1.5 \times 1$  cm plaque extending beyond the incision line is noted on the anterior neck (Fig. 6.1a).

---

O.D. Awosika, MD, MS  
Mercy Medical Center, University of Maryland,  
Baltimore, MD, USA

P.B. Love, MD (✉)  
Montgomery Dermatology,  
4712 Berry Boulevard, Montgomery, AL 36106, USA  
e-mail: [porcialove@gmail.com](mailto:porcialove@gmail.com)

P.B. Love, R.V. Kundu (eds.), *Clinical Cases in Skin of Color: Medical, Oncological and Hair Disorders, and Cosmetic Dermatology*, Clinical Cases in Dermatology, DOI 10.1007/978-3-319-23615-5\_6, © Springer International Publishing Switzerland 2016 63

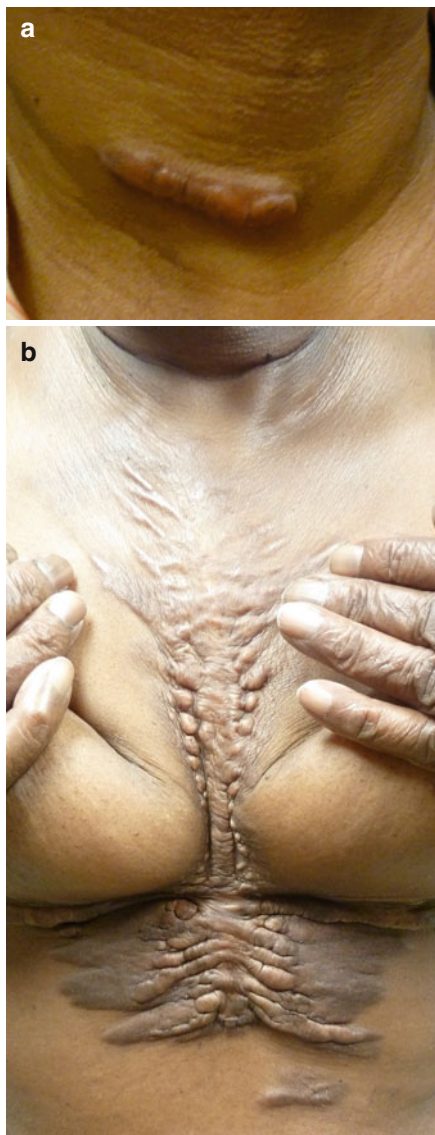


FIGURE 6.1 Keloid in surgical scar. A firm, *brown*, plaque extending beyond the incision line is noted on the anterior chest after thyroid surgery (**a**). Multiple keloids are noted after midline sternotomy for open heart surgery (**b**)

## Differential Diagnosis

The major differential diagnosis for keloids is a hypertrophic scar. Hypertrophic scars are erythematous, pruritic, firm plaques that do not extend beyond the borders of the original wounds and may regress spontaneously. Dermatofibromas typically present as pruritic, solitary, dark brown, firm nodules with characteristic tethering of the overlying epidermis to the underlying lesion with lateral compression ('dimple sign'), and they frequently occur on the extremities. Dermatofibrosarcoma protuberans is a rare malignancy that presents as a large indurated plaque with firm irregularly shaped reddish brown nodules. It most commonly occurs on the trunk. Lobomycosis is a cutaneous fungal infection endemic in rural regions of South American and Central America. Lesions present as firm, reddish brown papules or plaques (Burton and Escaravage 2008).

## Histopathology

A biopsy of a keloid may be performed if there is concern for dermatofibrosarcoma protuberans. On pathology, there is a normal epidermal layer. The reticular layer of the dermis consists mainly of hyalinized collagen and fibroblasts. There are horizontal cellular fibrous bands in the upper reticular dermis, with prominent fascialike fibrous bands (Burton and Escaravage 2008).

## Diagnosis

Keloid

## Case Treatment

The diagnosis, natural history, and treatment of the condition was discussed with the patient. Simple reexcision of the lesion most likely would be complicated by lesion reoccurrence;

therefore, intralesional triamcinolone acetonide was recommended. Side effects, including skin atrophy, hypopigmentation, and development of telangiectasias, were discussed with the patient. Intralesional triamcinolone acetonide 40 mg/ml combined with 5-flourouracil 50 mg/ml (2:1 ratio) was injected into the keloid plaque using a 27 gauge needle. Subsequent injections with triamcinolone acetonide 25 mg/ml and 5-flourouracil 50 mg/ml were performed every 4 weeks for four cycles. The patient was also given a topical fluocinonide 0.05 % ointment to apply each night for pruritus. At 4 month follow-up, the patient noted significant flattening of her keloid. The patient was counseled that she was at risk of developing keloids at sites of future piercings, tattoos, or surgeries.

## Discussion

Keloids are the overgrowth of dense fibrous tissue that develops after healing of a skin injury. Keloids extend beyond the borders of the original wound (i.e., the previous surgery, trauma, or acne) usually do not regress spontaneously, and tend to recur after excision. In contrast, hypertrophic scars typically do not expand beyond the boundaries of the initial injury and may undergo partial spontaneous resolution. Keloids occur more frequently in individuals of African and Asian descent. The most frequently involved sites of keloids are the earlobes, anterior chest, shoulders, and anterior neck, particular areas of the body that are constantly subjected to high skin tension or trauma (Love and Kundu 2013). Compared with mature scar tissue, keloids have an increased blood density, higher mesenchymal cell density, a thickened epidermal layer, and increased mucinous ground substance (Bux and Madaree 2012).

A strong genetic predisposition to the development of keloids is suggested by the increased prevalence in skin of color, increased concordance among identical twins, and increased familial clustering. In one familial study, 14 pedigrees

with keloids spanning 3–5 generations were observed. They concluded that single gene mutations can predispose an individual to keloids and proposed an autosomal dominant mode of inheritance with incomplete clinical penetrance and variable expression (Marneros et al. 2001).

There are four main subtypes of keloids. Postincisional keloids are the most common (Fig. 6.1b). They often occur in high tension areas, such as the sternum, shoulder, and upper back. Earlobe keloids mainly occur after ear piercing (Fig. 6.2). Spontaneous keloids are often due to unidentified trauma or inflammatory events (Fig. 6.3). They may occur in old scars (i.e., acne), develop from previously treated keloids, or arise spontaneously. Acne keloidalis nuchae (AKN) is a chronic inflammation of hair follicles that causes fibrosing papules that eventually coalesce into a keloidlike scarring alopecia. AKN presents in the occipital region of the scalp, typically in men of African or Hispanic descent. The pathogenesis of AKN is unknown; however, it is proposed to be due to chronic irritation and inward growth of curved coarse hairs from repetitive close shaving or irritation from shirt collars or athletic equipment. The naked hair becomes exposed, which, in the dermis, causes a granulomatous reaction. The treatment of AKN is more responsive to surgical excision than are keloids in other locations, and the postsurgical recurrence is minimal (Shockman et al. 2010).

### *Treatment*

Despite their common occurrence, keloids remain one of the most challenging dermatologic conditions to successfully treat. They are often symptomatic and can have a significant psychosocial burden for the patient. Treatment of keloids in patients with skin of color is challenging for both physicians and patients due to the etiology and side effects of therapies. Normalization of skin color, surface texture, and height are important treatment goals in treatment of scars (Visscher et al. 2014). Skin differences and the influence of skin type on

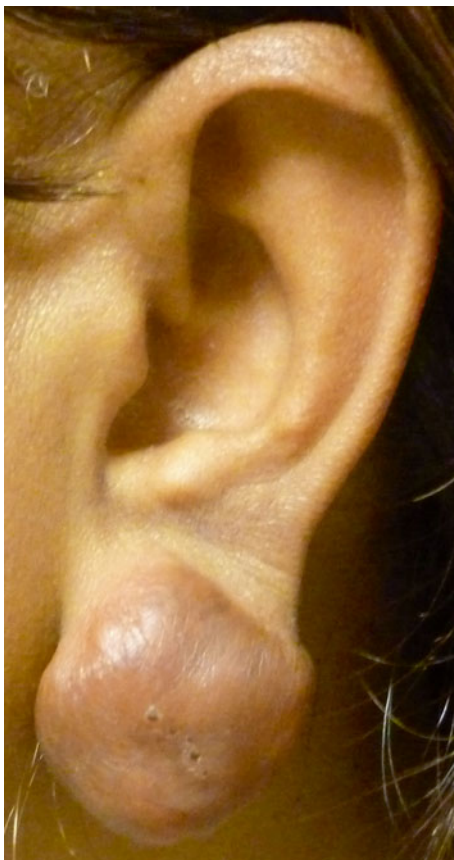

FIGURE 6.2 Keloid after ear piercing. A firm, *brown* plaque is noted on the earlobe after ear piercing

various modalities must be considered in treatment planning to achieve optimal results (Visscher et al. 2014). For darker skinned patients, it is of great importance to minimize the potential for hyperpigmentation and hypopigmentation as a side effect of treatment.

Only two evidence based treatments are recommended by the International Advisory Panel on hypertrophic scar and



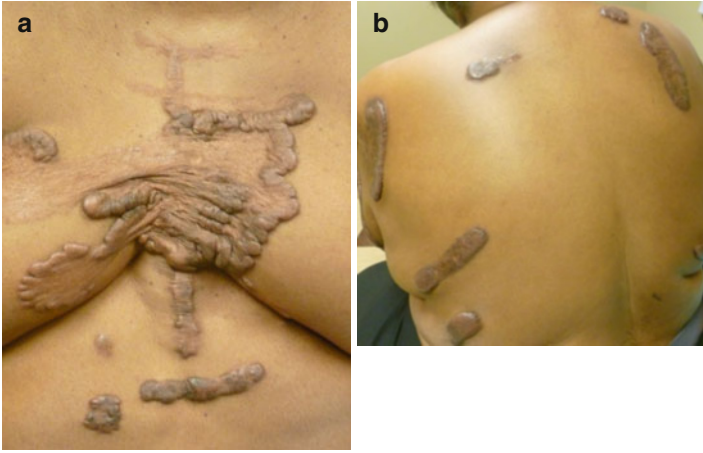


FIGURE 6.3 Spontaneous keloids. Spontaneous keloid plaques are noted on the chest (**a**) and back (**b**). The patient could not identify any preceding trauma or inflammatory events

keloid management: intralesional triamcinolone injection and silicone gel sheeting (McCarty 2010; Tziotzios et al. 2012). Intralesional triamcinolone acetonide is the treatment of choice for small and younger keloids (Fig. 6.4a, b) due to effective symptomatic relief (reduction of itching and pain) and size reduction (Visscher et al. 2014; Tziotzios et al. 2012; Gauglitz 2013). Intralesional triamcinolone acetonide suppresses inflammation, reduces collagen and glycosaminoglycan synthesis, inhibits fibroblast growth, causing vasoconstriction, and enhances fibroblast degeneration. Insoluble triamcinolone acetonide may be injected alone or in combination with lidocaine, which decreases the pain of injections and helps to immobilize the lesion leading to decreased tension and inhibition of further scar formation. Successful application requires injection into the scar itself which can pose a challenge in older, thicker lesions; dosages are administered monthly for up to 6 months (Sidle and Kim 2011). Complications include skin atrophy, hypo- or hyperpigmentation, and development of telangiectasias (McCarty 2010).

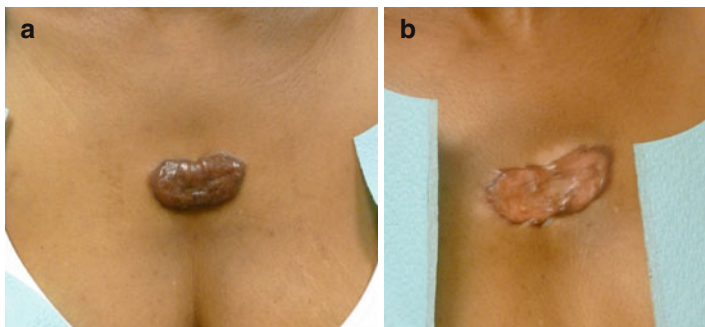


FIGURE 6.4 Keloid after treatment with intralesional triamcinolone acetone and 5-fluorouracil. A firm, keloid plaque was noted on the anterior chest after cyst surgery (a). The patient was treated with four sessions of intralesional triamcinolone combined with 5-fluorouracil spaced 4 weeks apart. Note the hypopigmentation in the posttreatment lesion (b)

Reduction of adverse effects, such as dermal atrophy and hypopigmentation, have been achieved through combination with 5-fluorouracil and the pulsed dye laser, mainly due to lower required doses of steroid (McCarty 2010).

Silicone gel sheeting has demonstrated the best improvement with smaller lesions (Shaffer et al. 2002). The exact mechanism is unknown but it has been suggested that occlusion and hydration of the stratum corneum are key factors to improvement of texture, pigmentation, and height of keloids seen with silicone gel sheeting (McCarty 2010). The need for the silicone gel sheets to be worn constantly (12 hours at minimum) for good effect, difficulty in keeping the sheets in place around joints and the face, and the possibility for local irritation may also limit compliance in patients (Chike-Obi et al. 2009). However, the relative benign nature of silicone gel sheeting and cost-efficacy (sheets can be washed and reused over a 2–3 month course of treatment) make a suitable alternative to intralesional therapy in the pediatric population (McCarty 2010; Shaffer et al. 2002). There is little to no risk for hypo or hyperpigmentation.

Cryosurgery has long been used for keloids to induce scar tissue destruction by direct cell freezing effects and vascular stasis after thawing. In the past, surface cryotherapy was not favored for skin of color patients due to the commonality for hypopigmentation after treatment. Intralesional cryotherapy achieves destruction of keloids through direct anoxia and tissue necrosis by creating a lethal freezing zone ( $-22^{\circ}\text{C}$ ) around the inserted probe in the dermis (Barara et al. 2012). Intralesional cryotherapy reportedly achieves better results (significant reduction in scar volume, deformity, discoloration, tenderness, and itching) and shorter healing time in comparison to surface cryotherapy. With intralesional cryosurgery, keloids in darker skin may exhibit less depigmentation compared to the contact method (Goldenberg and Lubert 2013).

Surgical excision of keloids is not recommended without an adjunct treatment because of high recurrence rates (50–100 %) (Fig. 6.5) (Tziotzios et al. 2012; Chike-Obi et al. 2009). Subtotal excisions, where a rim of keloid is left behind, often results in a better outcome because of low wound tension and decreased collagen synthesis (Chike-Obi et al. 2009). Surgery should be combined with an adjunct treatment, for example intralesional corticosteroids, pressure devices, magnets, or postoperative radiation.

Radiotherapy is usually reserved for keloids that are resistant to other treatments and may be used as monotherapy or an adjunct to surgical excision. Radiotherapy induces apoptosis in fibroblasts and subsequent restoration of balance between formation and breakdown of scar collagen (Tziotzios et al. 2012). Recurrence rates are lower when radiotherapy is used as an adjuvant to surgery, and response varies according to the site of the lesion (Klumpar et al. 1994). Radiotherapy is not widely used, mainly because of concerns of carcinogenic potential. Side effects tend to be minimal consisting of hyperpigmentation, radiation dermatitis, atrophy, and telangiectasias.

Excellent clinical results have been achieved with pulsed dye laser monotherapy and in combination with intralesional

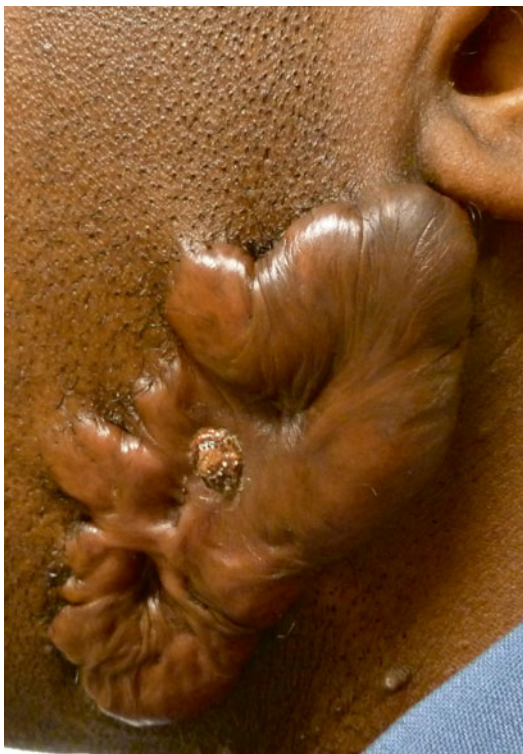

FIGURE 6.5 Keloid recurrence after surgical excision. The keloid plaque reoccurred larger after surgical excision

steroids or pressure therapy. The pulsed dye laser reportedly decreases TGF- $\beta$  and increases matrix metalloproteinase-13, leading to apoptosis of keloid fibroblasts. Lasers are also thought to decrease mast cell proliferation. The pulsed dye laser is best for Fitzpatrick skin types I to III with red postin-cisional keloids (Alster and Williams 1995). Other lasers that have been used in keloids include the CO<sub>2</sub>, argon, and Nd:YAG, with varying response rates.

Chemotherapeutic agents induce cell death in rapidly dividing cells, thus slowing the rate of proliferation in keloidal fibroblasts. Clinicians have found intralesional 5-fluorouracil

(5-FU) to provide a greater rate in reduction of size of keloids, decreased average number of sessions needed to achieve a satisfactory therapeutic response, and decreased recurrence rate (Nanda and Reddy 2004). Bleomycin has also been reported to improve the appearance of keloids (España et al. 2001). Efficacy and the reduction of side effects improves with both 5-FU and bleomycin when they are combined with triamcinolone or the pulsed dye laser. The main concern when using chemotherapeutic agents is the rate of leukopenia, anemia, and thrombocytopenia, which is rarely seen with either, but both have high rates of postinflammatory hyperpigmentation (Saha and Mukhopadhyay 2012).

Imiquimod 5 % cream is an immune response modifier that enhances the local production of immune stimulating cytokines and IL-6 and IL-12. It is often used after surgical excision to reduce recurrence of keloids (Berman and Kaufman 2002). Local irritation requires rest periods during treatment.

## Key Points

- Despite their common occurrence, keloids remain one of the most challenging dermatologic conditions to successfully treat.
- Intralesional triamcinolone acetonide is the treatment of choice for small and younger keloids.
- Surgical excision of keloids should be combined with an adjunct treatment, for example intralesional corticosteroids, pressure devices, magnets, or postoperative radiation, because of high recurrence rates.
- Excellent clinical results have been achieved with pulse dye laser monotherapy and in combination with intralesional steroids or pressure therapy. However, the pulsed dye laser is best for Fitzpatrick skin types I to III with red postincisional keloids.
- Prevention is always the best therapy for keloids; identify any past triggers (ear piercing, shaving, or trauma) and encourage patients to abstain from them.

## References

- Alster TS, Williams CM. Treatment of keloid sternotomy scars with 585 nm flashlamp-pumped pulsed-dye laser. *Lancet*. 1995;345 (8959):1198–200.
- Barara M, Mendiratta V, Chander R. Cryotherapy in treatment of keloids: evaluation of factors affecting treatment outcome. *J Cutan Aesthet Surg*. 2012;5(3):185–9.
- Berman B, Kaufman J. Pilot study of the effect of postoperative imiquimod 5% cream on the recurrence rate of excised keloids. *J Am Acad Dermatol*. 2002;47(4 Suppl):S209–11.
- Burton C, Escaravage V. Dermal hypertrophies. In: Bologna J, Jorizzo J, Rapini R, editors. *Dermatology*. 2nd ed. Madrid: Mosby Elsevier; 2008. p. 1497–504.
- Bux S, Madaree A. Involvement of upper torso stress amplification, tissue compression and distortion in the pathogenesis of keloids. *Med Hypotheses*. 2012;78(3):356–63.
- Chike-Obi CJ, Cole PD, Brissett AE. Keloids: pathogenesis, clinical features, and management. *Semin Plast Surg*. 2009;23(3):178–84.
- Espana A, Solano T, Quintanilla E. Bleomycin in the treatment of keloids and hypertrophic scars by multiple needle punctures. *Dermatol Surg Off Publ Am Soc Dermatol Surg et al*. 2001;27(1): 23–7.
- Gauglitz GG. Management of keloids and hypertrophic scars: current and emerging options. *Clin Cosmet Investig Dermatol*. 2013;6:103–14.
- Goldenberg G, Luber AJ. Use of intralesional cryosurgery as an innovative therapy for keloid scars and a review of current treatments. *J Clin Aesthet Dermatol*. 2013;6(7):23–6.
- Klumpar DI, Murray JC, Anscher M. Keloids treated with excision followed by radiation therapy. *J Am Acad Dermatol*. 1994;31(2 Pt 1):225–31.
- Love PB, Kundu RV. Keloids: an update on medical and surgical treatments. *J Drugs Dermatol JDD*. 2013;12(4):403–9.
- Marneros AG, Norris JE, Olsen BR, Reichenberger E. Clinical genetics of familial keloids. *Arch Dermatol*. 2001;137(11): 1429–34.
- McCarty M. An evaluation of evidence regarding application of silicone gel sheeting for the management of hypertrophic scars and keloids. *J Clin Aesthet Dermatol*. 2010;3(11):39–43.

- Nanda S, Reddy BS. Intralesional 5-fluorouracil as a treatment modality of keloids. *Dermatol Surg Off Publ Am Soc Dermatol Surg et al.* 2004;30(1):54–6; discussion 6–7.
- Saha AK, Mukhopadhyay M. A comparative clinical study on role of 5-fluorouracil versus triamcinolone in the treatment of keloids. *Indian J Surg.* 2012;74(4):326–9.
- Shaffer JJ, Taylor SC, Cook-Bolden F. Keloidal scars: a review with a critical look at therapeutic options. *J Am Acad Dermatol.* 2002;46(2 Suppl Understanding):S63–97.
- Shockman S, Paghdal KV, Cohen G. Medical and surgical management of keloids: a review. *J Drugs Dermatol JDD.* 2010;9(10):1249–57.
- Side DM, Kim H. Keloids: prevention and management. *Facial Plast Surg Clin North Am.* 2011;19(3):505–15.
- Tziotzios C, Profyris C, Sterling J. Cutaneous scarring: pathophysiology, molecular mechanisms, and scar reduction therapeutics Part II. Strategies to reduce scar formation after dermatologic procedures. *J Am Acad Dermatol.* 2012;66(1):13–24; quiz 5–6.
- Visscher MO, Bailey JK, Hom DB. Scar treatment variations by skin type. *Facial Plast Surg Clin North Am.* 2014;22(3):453–62.

**Part IV**  
**Skin Cancer**



# Chapter 7

## Basal Cell Carcinoma

**Laura K. Ibeto and Porcia B. Love**

### Case Presentation

A 65 year old Latino male presents with a 2 year history of an enlarging growth on his right temple. The growth is tender and has been bleeding. He is a farmer. He wears a hat when working outside.

### Physical Examination

There is a 2 cm brown, pearly plaque with telangiectasias on his right temple. A large erythematous, scaly patch surrounds the pearly plaque (Fig. 7.1).

---

L.K. Ibeto, BS, MS  
University of North Carolina at Chapel Hill, Chapel Hill, NC, USA

P.B. Love, MD (✉)  
Montgomery Dermatology,  
4712 Berry Boulevard, Montgomery, AL 36106, USA  
e-mail: [porcialove@gmail.com](mailto:porcialove@gmail.com)

P.B. Love, R.V. Kundu (eds.), *Clinical Cases in Skin of Color: Medical, Oncological and Hair Disorders, and Cosmetic Dermatology*, Clinical Cases in Dermatology, DOI 10.1007/978-3-319-23615-5\_7, © Springer International Publishing Switzerland 2016 79

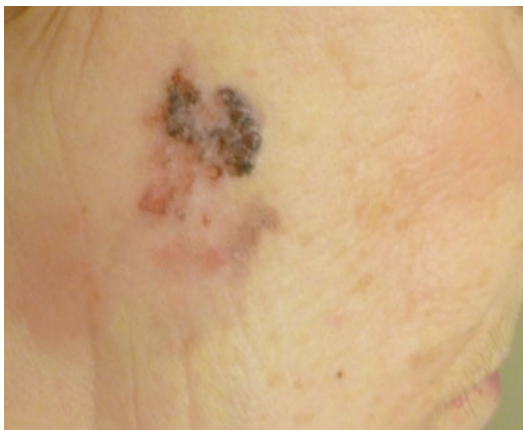


FIGURE 7.1 Pigmented basal cell carcinoma in Hispanic. There is a 2 cm *brown*, pearly plaque with telangiectasias on the right temple. A large erythematous, scaly patch surrounds the pearly plaque

## Differential Diagnosis

Benign melanocytic nevi can often be confused with basal cell carcinomas; however, these typically lack the translucency or telangiectasias of basal cell carcinomas. Sebaceous hyperplasia are yellowish, soft papules with a central dell typically found on the forehead, cheeks, and nose. Seborrheic keratoses are tan to dark brown greasy appearing papules. Angiofibromas are firm tiny papules that occur on the face in patients with tuberous sclerosis. Fibrous papules are skin colored papules that occur on the nose. Squamous cell carcinomas classically present as shallow ulcers with heaped-up edges, often covered by a thin plaque (Rubin et al. 2005).

## Histopathology

A shave biopsy of a portion of the plaque demonstrated large islands of hyperchromatic basaloid cells with oval nuclei and little cytoplasm within the dermis, with an epidermal attachment. Artificial retraction of the tumor islands from the surrounding stroma was noted.

## Diagnosis

Basal cell carcinoma

## Case Treatment

After discussion of the diagnosis, natural history, and treatment options with the patient, it was recommended that he have Mohs micrographic surgery. After surgery, the patient was followed every 6 months for 5 years, then annually. The patient was advised to wear a broad spectrum sunscreen with an SPF of 30 or above. Sun protection, including a wide-brimmed hat, sun protective clothing, and sun avoidance between the hours of 10 am and 2 pm was recommended.

## Discussion

Nonmelanoma skin cancer most commonly affects the Caucasian population and is uncommon in darker skinned individuals. However, darker skinned patients often experience a higher level of morbidity and mortality. Numerous research studies have confirmed that fairer skin correlates to a higher incidence of the majority of skin cancer (Sng et al. 2009). For example, in a study assessing the skin cancer trends among Asians living in Singapore from 1968 to 2006, skin cancer rates among the fairer skinned Chinese were higher than in Malays and Indians, who generally have darker complexions (Sng et al. 2009). Given the observation that skin cancer is most common in fairer skin, it is commonly thought among patients, as well as some physicians, that darker pigmentation inherently affords complete protection from skin cancer development. This low index of suspicion contributes to delayed diagnosis and poorer outcomes (Ahluwalia et al. 2012).

Basal cell carcinoma (BCC) is the most common form of skin cancer. It is also the most common type of skin cancer that affects Hispanic and Asian populations and the second most common type of skin cancer that affects populations of African descent (Bradford 2009). The majority of BCCs in a

clinical series at Howard University in Washington, D.C. from 1960 to 1986 occurred in light-complexioned, as opposed to darker, blacks (Halder and Bang 1988). Thus, the frequency of BCC appears to be directly correlated with the degree of pigmentation in the skin, being most common in fair Caucasians and least common in African blacks (Bradford 2009).

Ultraviolet radiation exposure (UVR) is the primary risk factor for BCC development (Gallagher et al. 1995). The lower incidence of skin cancer in darker skin is primarily a result of photoprotection provided by increased melanin in the epidermis, which filters twice as much ultraviolet radiation compared to Caucasian skin, providing an inherent sun protective factor of 13.4 in black skin (Montagna and Carlisle 1991). Darker skin also has increased melanocyte activity and larger melanosomes, which absorb and scatter more light energy than the smaller melanosomes of Caucasians (Brenner and Hearing 2008). The darker the pigmentation in the skin, the more that protection is afforded.

Basal cell carcinoma is associated with long-term, cumulative UVR (Gallagher et al. 1995). Thus, the typical patient developing these tumors is over the age of 50, regardless of skin pigmentation. The head and neck region is the most common location of BCCs in all ethnicities. Africans and African-Americans with lighter skin have an increased propensity to develop actinic damage and BCCs. Various studies in Africa have consistently shown higher incidences of BCCs in albino African patients than darker-pigmented blacks (Kiprono et al. 2014). In addition to ultraviolet radiation exposure, phenotypic risk factors for BCC include a family history, blonde hair, and blue eyes. In skin of color, other risk factors for BCC include scarring processes (particularly in discoid lupus erythematosus) (Mora and Perniciaro 1981), ulcers (Abreo and Sanusi 1991), chronic infections, immunosuppression, previous radiation treatment, and both physical and thermal trauma (Gloster and Neal 2006). Patients with genetic conditions, such as xeroderma pigmentosum (Bradford et al. 2011), albinism, and

nevus basal cell carcinoma syndrome, are at risk of developing basal cell carcinomas. BCCs that have arisen in scars or ulcers often develop in sun-exposed sites, suggesting a synergistic role between these existing processes and UVR.

There are five clinicopathologic types of basal cell carcinoma, including nodular (the most common type), which usually presents as a round, pearly, flesh-colored papule with telangiectasias, infiltrative, micronodular, morpheaform, and superficial. The nodular form is also the most common in skin of color; however, when BCC does occur in patients with skin of color, pigmentation is present in more than 50 % of the tumors (Fig. 7.2) (Bigler et al. 1996). Pigmentation is only present in 5 % of Caucasians with BCC. In a recent study, a cross sectional analysis of BCCs diagnosed in Fitzpatrick types IV-V, a predominance of pigmented BCCs was found in sun exposed areas of these older individuals (Ahluwalia et al. 2012). The clinical features of BCC are similar in Blacks, Asians, Hispanics, and Caucasians. Most patients with BCC are elderly and present with asymptomatic, translucent, solitary nodules with central ulceration. Telangiectasias and a pearly, rolled border in dark skin or in a pigmented tumor may be difficult to discern. When pigmented BCC presents in people of color, there are often incorrect diagnoses, such as seborrheic keratoses, malignant melanoma, or nevus sebaceous (Halder and Bridgeman-Shah 1995). The anatomic distribution of BCC tends to be similar in Caucasians and people of color. In a review of BCC's in Washington, D.C, Halder and Bang showed that 89 % of BCC's in people of color occurred on the head and neck regions (Halder and Bang 1988).

One of the major concepts in prevention of all forms of skin cancer is that limiting sun exposure reduces the risk of developing skin cancer. Patients can protect themselves and lower their risk of developing skin cancer by wearing a broad spectrum sunscreen with an SPF of 30 or above, practicing skin self-examinations, wearing sun protective clothing such as wide-brimmed hats and sunglasses, and avoiding tanning salons. Many people of color are sometimes under

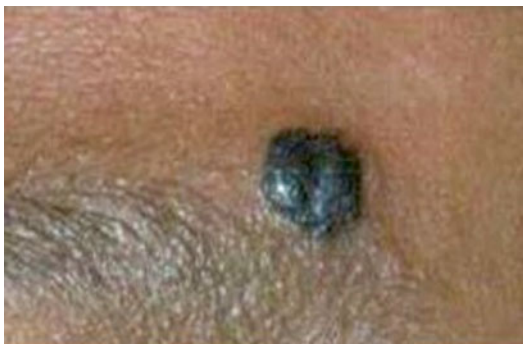

FIGURE 7.2 Pigmented basal cell carcinoma in African American. A dark brown, round, firm, pearly papule is noted above the eyebrow

the false impression that they are immune to skin cancer because such populations tend to commonly have darker skin pigmentations. Patients with skin of color are advised to wear sunscreen but to take vitamin D supplementation due to the deficiency in vitamin D that wearing sunscreen can cause in populations of darker pigment (Agbai et al. 2014).

### *Treatment*

Treatment for BCC for all races is identical (Kiprono et al. 2014) and include cryosurgery, electrodesiccation and curettage, excision, and Mohs micrographic surgery. Treatments vary according to cancer size, depth, and location. Local therapy with chemotherapeutic and immune-modulating agents are useful for small and superficial BCC may respond to these compounds. Topical 5 % imiquimod is approved by the US Food and Drug Administration (FDA) for the treatment of nonfacial superficial BCCs that are less than 2 cm in diameter (Beutner et al. 1999). Likewise, topical 5-fluorouracil is approved by the FDA for the treatment of

superficial BCC (Gross et al. 2007). For recurrent BCC or those in which sparing normal tissue is paramount, Mohs micrographic surgery should be considered (Connolly et al. 2012). Radiation should be considered for advanced lesions and nonsurgical candidates. Chemotherapy should be considered for metastatic basal cell carcinoma. Photodynamic therapy may be used as an adjunct for tumor recurrence, elderly patients, ill-defined tumors, and tumors requiring extensive oculoplastic surgery (Braathen et al. 2007). Vismodegib was recently FDA-approved drug for advanced forms of basal cell carcinoma. It selectively inhibits smoothened, a key transmembrane protein involved in hedgehog signal transduction of cancerous epithelial cells (Sekulic et al. 2012).

Metastatic BCC is rare in all races, with rates ranging from 0.0028 to 0.55 % (Rubin et al. 2005). However, risk factors for metastasis include a tumor diameter greater than 2 cm, location on the central part of the face or ears, longstanding duration, and incomplete excision. The prognosis for metastatic disease is poor, with mean survival ranging from 8 months to 3.6 years (Rubin et al. 2005).

## Key Points

- Basal cell carcinoma is the most common skin cancer in Caucasians, Hispanics and Asians.
- Risk factors for basal cell carcinoma in skin of color include excessive sun exposure, fair skin, scars, ulcers, previous radiation therapy, and genetic disorders (i.e. albinism, nevoid basal cell carcinoma syndrome, xeroderma pigmentosum).
- Approximately 50 % of basal cell carcinomas in skin of color are pigmented with “brown or black, pearly appearance.”
- Basal cell carcinomas typically occur in the head and neck regions in skin of color.

## References

- Abreo F, Sanusi ID. Basal cell carcinoma in North American blacks. Clinical and histopathologic study of 26 patients. *J Am Acad Dermatol.* 1991;25(6 Pt 1):1005–11.
- Agbai ON, Buster K, Sanchez M, Hernandez C, Kundu RV, Chiu M, et al. Skin cancer and photoprotection in people of color: a review and recommendations for physicians and the public. *J Am Acad Dermatol.* 2014;70(4):748–62.
- Ahluwalia J, Hadjicharalambous E, Mehregan D. Basal cell carcinoma in skin of color. *J Drugs Dermatol JDD.* 2012;11(4):484–6.
- Beutner KR, Geisse JK, Helman D, Fox TL, Ginkel A, Owens ML. Therapeutic response of basal cell carcinoma to the immune response modifier imiquimod 5 % cream. *J Am Acad Dermatol.* 1999;41(6):1002–7.
- Bigler C, Feldman J, Hall E, Padilla RS. Pigmented basal cell carcinoma in Hispanics. *J Am Acad Dermatol.* 1996;34(5 Pt 1):751–2.
- Braathen LR, Szeimies RM, Basset-Seguín N, Bissonnette R, Foley P, Pariser D, et al. Guidelines on the use of photodynamic therapy for nonmelanoma skin cancer: an international consensus. International Society for Photodynamic Therapy in Dermatology, 2005. *J Am Acad Dermatol.* 2007;56(1):125–43.
- Bradford PT. Skin cancer in skin of color. *Dermatol Nurs.* 2009;21(4):170–7, 206; quiz 178.
- Bradford PT, Goldstein AM, Tamura D, Khan SG, Ueda T, Boyle J, et al. Cancer and neurologic degeneration in xeroderma pigmentosum: long term follow-up characterises the role of DNA repair. *J Med Genet.* 2011;48(3):168–76.
- Brenner M, Hearing VJ. The protective role of melanin against UV damage in human skin. *Photochem Photobiol.* 2008;84(3):539–49.
- Connolly SM, Baker DR, Coldiron BM, Fazio MJ, Storrs PA, Vidimos AT, et al. AAD/ACMS/ASDSA/ASMS 2012 appropriate use criteria for Mohs micrographic surgery: a report of the American Academy of Dermatology, American College of Mohs Surgery, American Society for Dermatologic Surgery Association, and the American Society for Mohs Surgery. *J Am Acad Dermatol.* 2012;67(4):531–50.
- Gallagher RP, Hill GB, Bajdik CD, Fincham S, Coldman AJ, McLean DI, et al. Sunlight exposure, pigmentary factors, and risk of non-melanocytic skin cancer. I. Basal cell carcinoma. *Arch Dermatol.* 1995;131(2):157–63.



- Gloster Jr HM, Neal K. Skin cancer in skin of color. *J Am Acad Dermatol.* 2006;55(5):741–60; quiz 61–4.
- Gross K, Kircik L, Kricorian G. 5% 5-Fluorouracil cream for the treatment of small superficial basal cell carcinoma: efficacy, tolerability, cosmetic outcome, and patient satisfaction. *Dermatol Surg Off Publ Am Soc Dermatol Surg et al.* 2007;33(4):433–9; discussion 40.
- Halder RM, Bang KM. Skin cancer in blacks in the United States. *Dermatol Clin.* 1988;6(3):397–405.
- Halder RM, Bridgeman-Shah S. Skin cancer in African Americans. *Cancer.* 1995;75(2 Suppl):667–73.
- Kiprono SK, Chaula BM, Beltraminelli H. Histological review of skin cancers in African Albinos: a 10-year retrospective review. *BMC Cancer.* 2014;14:157.
- Montagna W, Carlisle K. The architecture of black and white facial skin. *J Am Acad Dermatol.* 1991;24(6 Pt 1):929–37.
- Mora RG, Perniciaro C. Cancer of the skin in blacks. I. A review of 163 black patients with cutaneous squamous cell carcinoma. *J Am Acad Dermatol.* 1981;5(5):535–43.
- Rubin AI, Chen EH, Ratner D. Basal-cell carcinoma. *N Engl J Med.* 2005;353(21):2262–9.
- Sekulic A, Migden MR, Oro AE, Dirix L, Lewis KD, Hainsworth JD, et al. Efficacy and safety of vismodegib in advanced basal-cell carcinoma. *N Engl J Med.* 2012;366(23):2171–9.
- Sng J, Koh D, Siong WC, Choo TB. Skin cancer trends among Asians living in Singapore from 1968 to 2006. *J Am Acad Dermatol.* 2009;61(3):426–32.

# Chapter 8

## Squamous Cell Carcinoma

**Laura K. Ibeto and Porcia B. Love**

### Case Presentation

A 65 year old African-American female presents with a 1 year history of a scar on her lower leg that has been increasing in size. It is nontender, but occasionally pruritic and bleeds often. She grew up in Wisconsin and on further questioning, reported frequent use of well water.

### Physical Examination

On exam, there is a 2 cm erythematous to violaceous, round, thin plaque on the left lower leg. There are shallow ulcers in the center of the plaque (Fig. 8.1).

---

L.K. Ibeto, BS, MS

University of North Carolina at Chapel Hill, Chapel Hill, NC, USA

P.B. Love, MD (✉)

Montgomery Dermatology, PC, 4712 Berry Boulevard,

Montgomery, AL 36106, USA

e-mail: [porcialove@gmail.com](mailto:porcialove@gmail.com)

P.B. Love, R.V. Kundu (eds.), *Clinical Cases in Skin of Color:* 89

*Medical, Oncological and Hair Disorders, and Cosmetic*

*Dermatology*, Clinical Cases in Dermatology,

DOI 10.1007/978-3-319-23615-5\_8,

© Springer International Publishing Switzerland 2016

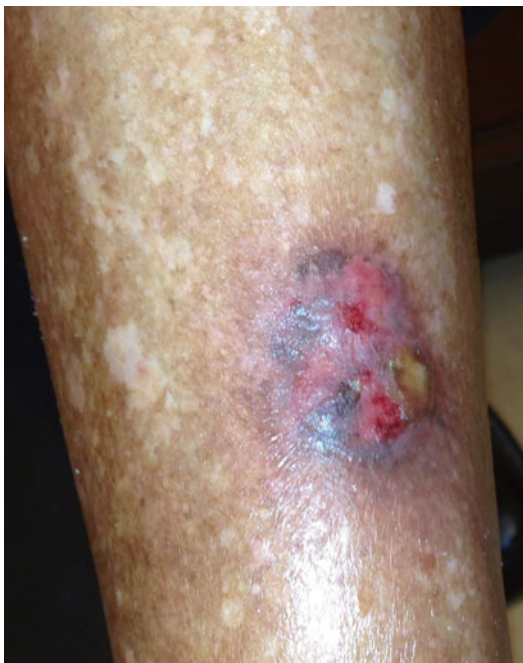

FIGURE 8.1 SCC in African American with arsenic exposure. There is a 2 cm erythematous and violaceous, round, thin plaque on the left lower leg. There are shallow ulcers in the center of the plaque

## Differential Diagnosis

Squamous cell carcinoma can easily be confused with basal cell carcinomas. The nodular subtype is the most common type of basal cell carcinoma and presents as a round, pearly, flesh-colored papule with telangiectasias. Discoid lupus presents as erythematous atrophic plaques with mild scale; they may develop hypopigmentation in the center and hyperpigmentation at the active border. Pyoderma gangrenosum is characterized by a deep ulceration with a violaceous border that overhangs the ulcer bed; it typically occurs on the legs. Atypical fibroxanthoma present as red, firm, dome-shaped

nodules that may be ulcerated. They typically appear on the head and neck in sun exposed areas in patients with significant sun exposure or previous radiation damage (Alam and Ratner 2001).

## Histopathology

Shave biopsy of a portion of the lesion revealed lobules and detached islands of glassy, brightly eosinophilic keratinocytes containing nuclei with some degree of pleomorphism and mitoses that proliferate downward into the dermis.

## Diagnosis

Invasive squamous cell carcinoma

## Case Treatment

After discussion of the diagnosis, natural history, and treatment options with the patient, given the size and location of her tumor, it was recommended that she have Mohs micrographic surgery. Mohs Surgery is recommended for high risk or recurrent tumors, sites where tissue preservation is needed, and ill-defined tumors. Mohs Surgery is also recommended for tumors >2 cm in diameter or >4 mm in depth, tumors with perineural or perivascular invasion, and in previously irradiated skin (Connolly et al. 2012). Her exposure to well water in Wisconsin, which is associated with arsenic, was thought to contribute to her development of squamous cell carcinoma (Knobeloch et al. 2006). After surgery, the patient was followed every 6 months for 5 years, then annually. The patient was advised to wear a broad spectrum sunscreen with an SPF of 30 or above. Sun protection, including a wide-brimmed hat, sun protective clothing, and sun avoidance between the hours of 10 am and 2 pm was recommended.

## Discussion

Overall, squamous cell carcinoma (SCC) accounts for ~20 % of all skin cancers, and excluding melanoma, ~75 % of all deaths attributed to skin cancers (Alam and Ratner 2001). Squamous cell carcinoma is the most common type of skin cancer that occurs in individuals of African and Indian-Asian descent (Agbai et al. 2014). It is the second most common skin cancer in Caucasians, Latinos, and the remainder of the Asian population that includes nationalities such as Chinese and Japanese (Agbai et al. 2014).

Exposure to ultraviolet radiation is the most common cause of SCC (Fears and Scotto 1983). Other causes of SCC in patients with skin of color include genetic disorders like albinism (Kromberg et al. 1989) and xeroderma pigmentosum (Bradford et al. 2011). Patients who have been exposed to radiation (Davis et al. 1989), the human papillomavirus (Wang et al. 2014), and arsenic (Yeh et al. 1968) are also at an increased risk of SCC. Increased levels of skin cancer have been associated with arsenic exposure from groundwater in Wisconsin, even at levels below the ten parts per billion drinking water standard (Knobeloch et al. 2006). Organ transplant recipients (Ruiz and Hsieh 2015) and patients with chronically diseased skin (ulcers, sinus tracts, osteomyelitis, radiation dermatitis) have increased risk of SCC.

Other predisposing factors for SCC in people of color include scars from thermal and chemical burns (Copcu et al. 2003) and chronic leg ulcers (Kong et al. 2008). Patients with chronic inflammation, such as osteomyelitis, hidradenitis suppurativa, or lupus vulgaris, are also at increased risk for SCC (Halder and Bridgeman-Shah 1995). In Blacks, the most important risk factors for the development of SCC are chronic scarring processes and areas of chronic inflammation (Bradford 2009). In fact, chronic scarring processes are noted in 20–40 % of cases of SCC in Blacks (Gloster and Neal 2006). Cases of SCC developing in Black (Sherman et al. 1993) and Chinese patients (Ee et al. 2006) with chronic discoid lupus erythematosus have also been reported.

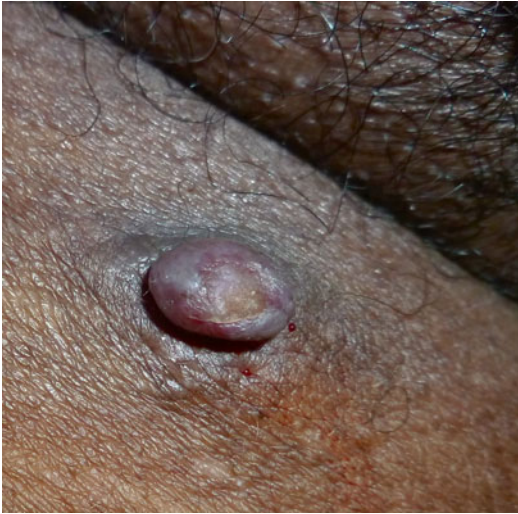

FIGURE 8.2 SCC in African American on right thigh. Squamous cell carcinomas are often solitary, firm, erythematous papules with central ulceration arising from an indurated, rounded, and elevated base. People of color develop SCC predominantly in areas infrequently exposed to the sun, such as the legs

Squamous cell carcinomas are often solitary, firm, erythematous papules with central ulceration arising from an indurated, rounded, and elevated base (Fig. 8.2) (Alam and Ratner 2001). Some lesions are pruritic or painful nonhealing wounds that bleed. The principal precursor of SCC is actinic keratosis. Other precancerous conditions that may evolve into SCC include bowenoid papulosis, which is associated with HPV 16 and 18, and epidermodysplasia verruciformis, which are widespread, flat warts that may degenerate into carcinoma in situ or invasive SCC. The most common forms of SCC in situ are Bowen's disease, in which patients present with sharply demarcated erythematous, velvety, or scaly plaques (Fig. 8.3) on sun exposed areas, and erythroplasia of Queryat, which is less common and occurs on the glans penis of uncircumcised men as red, smooth plaques. Most invasive SCCs occur on the head

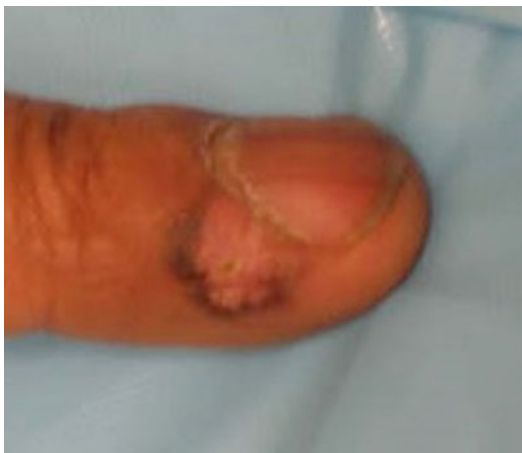

FIGURE 8.3 Bowen's disease in African American. A sharply demarcated erythematous, thin plaque with a hyperpigmented border is noted on the finger

and neck, followed by the trunk (Alam and Ratner 2001). Nonhealing ulcers on the skin of people of color, regardless of original etiology, should be biopsied if present for a significant amount of time (Halder and Bridgeman-Shah 1995). There is variation in the latency period, but many studies report at least two to three decades between the injury and malignant transformation (Tobin and Sanger 2014).

People of color develop SCC predominantly in areas infrequently exposed to the sun, such as the legs (Figs. 8.1 and 8.2), in contrast to Caucasians, who develop them in chronically sun-exposed skin (Halder and Bang 1988). For example, in one Howard University series, 15 % of SCC occurred in the anus in Blacks (Halder and Bang 1988).

### *Treatment*

Treatment for SCC includes cryosurgery, electrodesiccation and curettage, surgical excision, Mohs micrographic surgery, and radiation therapy. Low-risk SCC (<1 cm in diameter) on

the trunk and extremities can be treated with electrodesiccation and curettage (ED&C), and cure rates are as high as 96 % (Alam and Ratner 2001). For invasive SCC, surgical excision is preferred. Mohs micrographic surgery offers the highest rates of cure for high risk or recurrent tumors, sites where tissue preservation is needed, and ill-defined tumors (Connolly et al. 2012).

Radiation therapy is typically used as an adjuvant to surgery to provide improved locoregional control for patients with nodal disease. It may also be used as the primary therapy in patients who are unable to undergo surgical excision. Chemotherapy may be considered as adjuvant therapy in metastatic SCC. Prevention is an important aspect of managing SCC. Given the central role that ultraviolet radiation (UVR) plays in the pathogenesis of SCC, methods aimed at decreasing UVR exposure are key to SCC prevention.

Invasive SCC has the potential to metastasize. The disparity in metastatic rates of SCC between people of color and Caucasians may reflect the tendency for people of color to present with more advanced disease, presumably as a result of delays in diagnosis, or it may be related to the presence of inherently more aggressive tumors (Gloster and Neal 2006). Unfortunately, SCC that develops within a chronic scarring process, tends to be more aggressive and is associated with a 20–40 % risk of metastasis, compared with the 1–4 % metastatic rate of sun induced SCC in Caucasians (Gloster and Neal 2006). In one series of patients with SCC, the greatest mortality was seen in patients with perianal tumors (Mora and Perniciaro 1981). SCC that arises from lesions of chronic discoid lupus erythematosus also appear to metastasize at a greater rate than SCC that arises from other preexisting lesions (Halder and Bridgeman-Shah 1995); therefore, hyperkeratotic or poorly healing lesions in areas of chronic discoid lupus erythematosus in people of color should be biopsied immediately. Most patients with primary SCC have an excellent prognosis. However, if metastatic disease is present, 10-year survival rates are less than 20 % for patients with regional lymph node involvement and less than 10 % for patients with distant metastases (Alam and Ratner 2001).



## Key Points

- Squamous cell carcinoma is the most common type of skin cancer that occurs in individuals of African and Indian-Asian descent. It is the second most common skin cancer in Caucasians, Latinos, and the remainder of the Asian population that includes nationalities such as Chinese and Japanese.
- Risk factors for patients with skin of color include chronic scarring inflammation from burns, leg ulcers, radiation, lupus, immunosuppression, and human papillomavirus.
- Squamous cell carcinoma in skin of color is most common on areas infrequently exposed to the sun (i.e., legs or mucosal areas).

## References

- Agbai ON, Buster K, Sanchez M, Hernandez C, Kundu RV, Chiu M, et al. Skin cancer and photoprotection in people of color: a review and recommendations for physicians and the public. *J Am Acad Dermatol.* 2014;70(4):748–62.
- Alam M, Ratner D. Cutaneous squamous-cell carcinoma. *N Engl J Med.* 2001;344(13):975–83.
- Bradford PT. Skin cancer in skin of color. *Dermatol Nurs.* 2009; 21(4):170–7, 206; quiz 178.
- Bradford PT, Goldstein AM, Tamura D, Khan SG, Ueda T, Boyle J, et al. Cancer and neurologic degeneration in xeroderma pigmentosum: long term follow-up characterises the role of DNA repair. *J Med Genet.* 2011;48(3):168–76.
- Connolly SM, Baker DR, Coldiron BM, Fazio MJ, Storrs PA, Vidimos AT, et al. AAD/ACMS/ASDSA/ASMS 2012 appropriate use criteria for Mohs micrographic surgery: a report of the American Academy of Dermatology, American College of Mohs Surgery, American Society for Dermatologic Surgery Association, and the American Society for Mohs Surgery. *J Am Acad Dermatol.* 2012;67(4):531–50.
- Copcu E, Aktas A, Sisman N, Oztan Y. Thirty-one cases of Marjolin's ulcer. *Clin Exp Dermatol.* 2003;28(2):138–41.

- Davis MM, Hanke CW, Zollinger TW, Montebello JF, Hornback NB, Norins AL. Skin cancer in patients with chronic radiation dermatitis. *J Am Acad Dermatol.* 1989;20(4):608–16.
- Ee HL, Ng PP, Tan SH, Goh CL. Squamous cell carcinoma developing in two Chinese patients with chronic discoid lupus erythematosus: the need for continued surveillance. *Clin Exp Dermatol.* 2006;31(4):542–4.
- Fears TR, Scotto J. Estimating increases in skin cancer morbidity due to increases in ultraviolet radiation exposure. *Cancer Invest.* 1983;1(2):119–26.
- Gloster Jr HM, Neal K. Skin cancer in skin of color. *J Am Acad Dermatol.* 2006;55(5):741–60; quiz 61–4.
- Halder RM, Bang KM. Skin cancer in blacks in the United States. *Dermatol Clin.* 1988;6(3):397–405.
- Halder RM, Bridgeman-Shah S. Skin cancer in African Americans. *Cancer.* 1995;75(2 Suppl):667–73.
- Knobeloch LM, Zierold KM, Anderson HA. Association of arsenic-contaminated drinking-water with prevalence of skin cancer in Wisconsin's Fox River Valley. *J Health Popul Nutr.* 2006;24(2):206–13.
- Kong MF, Jogia R, Nayyar V, Berrington R, Jackson S. Squamous cell carcinoma in a heel ulcer in a patient with diabetes. *Diabetes Care.* 2008;31(7), e57.
- Kromberg JG, Castle D, Zwane EM, Jenkins T. Albinism and skin cancer in Southern Africa. *Clin Genet.* 1989;36(1):43–52.
- Mora RG, Perniciaro C. Cancer of the skin in blacks. I. A review of 163 black patients with cutaneous squamous cell carcinoma. *J Am Acad Dermatol.* 1981;5(5):535–43.
- Ruiz DELAM, Hsieh C. Yearly burden of skin cancer in non-Caucasian and Caucasian solid-organ transplant recipients. *J Clin Aesthet Dermatol.* 2015;8(3):16–9.
- Sherman RN, Lee CW, Flynn KJ. Cutaneous squamous cell carcinoma in black patients with chronic discoid lupus erythematosus. *Int J Dermatol.* 1993;32(9):677–9.
- Tobin C, Sanger JR. Marjolin's ulcers: a case series and literature review. *Wounds.* 2014;26(8):248–54.
- Wang J, Aldabagh B, Yu J, Arron ST. Role of human papillomavirus in cutaneous squamous cell carcinoma: a meta-analysis. *J Am Acad Dermatol.* 2014;70(4):621–9.
- Yeh S, How SW, Lin CS. Arsenical cancer of skin. Histologic study with special reference to Bowen's disease. *Cancer.* 1968;21(2):312–39.

# Chapter 9

## Melanoma

**Laura K. Ibeto and Porcia B. Love**

### Case Presentation

An 80 year old African American female presents with a 1 year history of an enlarging black patch on her left foot. Over the last 3 months, the lesion has become painful. She has been treating the lesion with an antibiotic ointment. She noticed that the place on her foot has also been increasing in size with associated scale over the last 3 months.

### Physical Examination

There are two ill-defined patches with associated scale measuring  $2 \times 1.5$  and  $2.8 \times 2$  cm on the plantar surface of the left foot. There are scattered hyperpigmented macules coalescing into patches noted on the medial aspect of the left foot (Fig. 9.1).

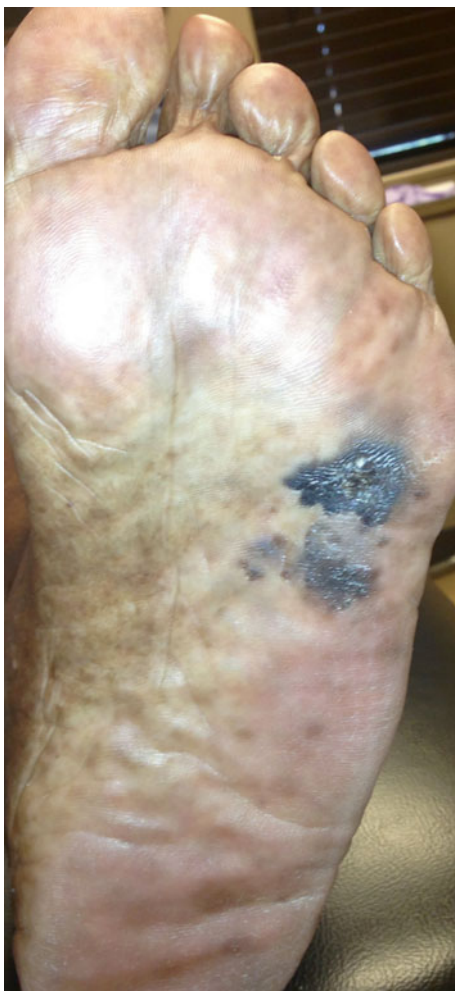---

L.K. Ibeto, BS, MS  
University of North Carolina at Chapel Hill, Chapel Hill, NC, USA

P.B. Love, MD (✉)  
Montgomery Dermatology, PC,  
4712 Berry Boulevard, Montgomery, AL 36106, USA  
e-mail: [porcialove@gmail.com](mailto:porcialove@gmail.com)

P.B. Love, R.V. Kundu (eds.), *Clinical Cases in Skin of Color: Medical, Oncological and Hair Disorders, and Cosmetic Dermatology*, Clinical Cases in Dermatology, DOI 10.1007/978-3-319-23615-5\_9, © Springer International Publishing Switzerland 2016 99

FIGURE 9.1 Acral lentiginous melanoma in African American. There is are two ill-defined black patches with associated scale on the plantar surface of the left foot. There are scattered hyperpigmented macules coalescing into patches noted on the medial aspect of the left foot



## Differential Diagnosis

The differential diagnosis includes melanocytic nevi, which present as brown to dark brown, round, symmetrical macules or papules with well-defined borders and no color irregularity. Dysplastic nevi are acquired variants of benign

melanocytic nevi that present as brown, flat or thin papules, with irregular borders that are greater than 6 mm. Tinea nigra presents as a mottled brown-black patch with irregular borders on the palms and soles. Scaling may be present (Nestle and Halpern 2008).

## Histopathology

Biopsies of both lesions demonstrated atypical melanocytes with cytologic atypia and large, pleomorphic, hyperchromic nuclei and rare poorly formed nests haphazardly arranged along the basal zone of the epidermis. Confluent growth pattern and pagetoid spread of the melanocytes are noted. Numerous mitotic figures are noted. The atypical melanocytes extend to the dermis, with a Breslow depth of 0.44 mm. Immunohistochemistry stains for HMB-45, MART-1, and Tyrosinase were all positive. Given the size of the lesion on her foot, a left groin sentinel lymph node biopsy was performed and revealed metastatic melanoma, with one positive node.

## Radiographic Results

PET/CT Scan of the chest, abdomen, and pelvis was negative.

## Diagnosis

Invasive Melanoma, acral lentiginous subtype, Breslow thickness of 0.44 mm, Stage III-T1a, N1, M0.

## Case Treatment

A thorough discussion of the diagnosis, natural history, and etiology of melanoma was held with the patient. She underwent wide local excision with healing by second intention by Surgical Oncology. Given the fact that she had a single

metastatic tumor cell in the subcapsular space in the lymph node without any extranodal extension and numerous comorbidities, no adjuvant therapy was recommended by Surgical or Medical Oncology. She has follow up with Dermatology and Surgery Oncology every 3 months for 1 year, then every 6 months for 5 years. Sun protection, including a wide brimmed hat, sunglasses, and sunscreen with an SPF of 30 or above, was discussed.

## Discussion

Melanoma is the third and most deadly form of skin cancer in all racial groups. During the 1970s, the incidence rate of cutaneous melanoma increased rapidly by 6 % per year, but slowed to 3 % per year from 1981 to 2000 and has remained stable since then (Bradford 2009). Melanoma most commonly affects Caucasians and rarely affects individuals of African, Asian, Latin-American, and American-Indian descent (Byrd-Miles et al. 2007). However, rates of invasive melanoma have increased markedly among Hispanics in California since 1988, with a 1.8 % per year increase in incidence of invasive melanomas among Hispanic males between 1988 and 2001, and a 7.3 % annual increase in the period between 1996 and 2001 (Cockburn et al. 2006). Although melanoma is rare in skin of color, the diagnosis is often associated with significant morbidity and mortality (Byrd-Miles et al. 2007).

Major risk factors for melanoma include intermittent excessive ultraviolet radiation exposure (i.e. tanning outdoors), tanning salons and chronic cumulative dosages of UVR (i.e.—outdoor workers). Host susceptibility factors include dysplastic nevi, increased number of nevi, freckling, family history of melanoma, fair complexion, light eyes, and blonde or red hair (Tucker and Goldstein 2003). In African Americans and Asians, ultraviolet radiation does not appear to be a significant risk factor for melanoma, unlike Caucasians and Latinos (Bradford et al. 2009).

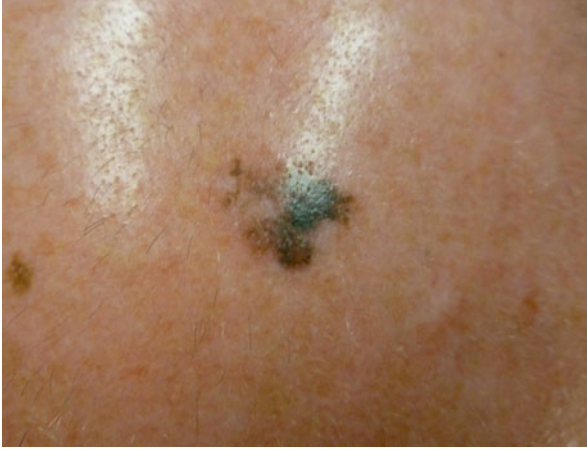


FIGURE 9.2 Superficial spreading melanoma in Hispanic. There is an 8 mm ill-defined *brown-dark brown* patch on the scalp of a Hispanic farmer. The incidence rates of melanoma in Hispanics is increasing in the United States

Clinically, melanomas typically present as asymmetric, ill-defined, dark brown or black patches greater than 6 mm in diameter (Fig. 9.2). There are four main clinicopathologic types of melanoma, including superficial spreading (the most common form), lentigo maligna, nodular, and acral lentiginous. The most common histologic type among blacks is acral lentiginous melanoma among, and superficial spreading melanoma is the most common among all other racial and ethnic groups (Wu et al. 2011). Acral lentiginous melanoma (ALM) represents approximately 36 % of melanoma subtypes in blacks (Bradford et al. 2009). It has been reported that over 90 % of blacks have nevi, and the majority of melanocytic nevi among blacks are acral, which may be related to the high number of ALM among blacks (Coleman et al. 1980a).

In Caucasians and to a lesser extent, Hispanics, melanomas predominantly occur in sun exposed skin, whereas in Asians and Blacks, the majority occur in non-sun-exposed skin (i.e. — subungual, palmar and plantar surfaces, mucus membranes)

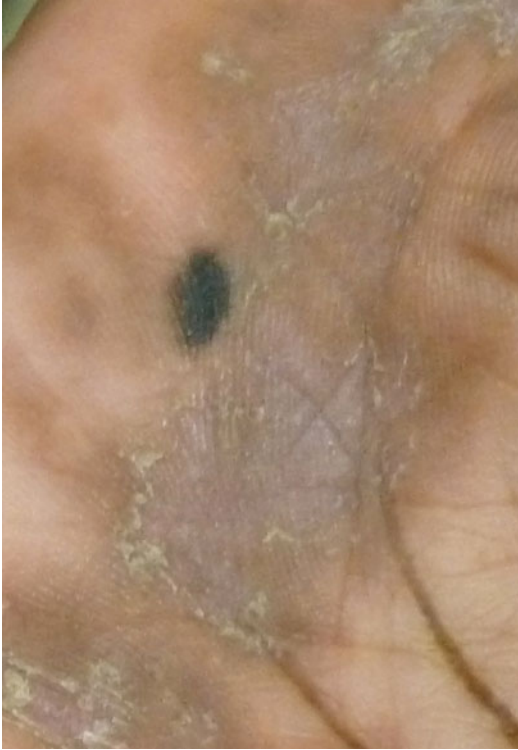

FIGURE 9.3 Melanoma in situ in African American. There is a *black* well circumscribed macule noted on the palm of the right hand. The patient has underlying tinea nigra. Acral sites are common sites of melanoma in skin of color

(Bradford et al. 2009). Clues to the diagnosis of subungual (under the nail) melanoma include a pigmented band on the nail with width greater than 3 mm (Hutchinson's sign), variable pigment, rapid increase in size, and the presence of solitary lesions (Gloster and Neal 2006). Oral melanomas represent ~7.5 % of all melanomas in Asians, and two-thirds of these tumors arise from oral melanosis (Collins 1984).

Melanoma in skin of color has been shown to have a predilection for acral locations (Fig. 9.3) (Bradford et al. 2009; Cormier et al. 2006). The predilection for melanoma on plantar



locations has led many to believe that trauma may be important in the etiology for acral melanoma because sun exposure has not been shown to be a risk factor for ALM (Feibleman et al. 1980). The sole of the foot is constantly exposed to pressure, friction, maceration, and irritation. In two retrospective ALM case series in which a trauma history was taken, 13 % of 119 patients (Phan et al. 2006) and 25 % of 35 patients (Coleman et al. 1980b) reported prelesional trauma (i.e., puncture wounds, stonebruises, friction blisters, contact dermatitis). Another factor that may play a role in the predilection of ALM for plantar locations is the fact that the density of melanocytes is 50 % higher there than on the palm (Coleman et al. 1980a).

Multiple studies have demonstrated that 5-year melanoma survival rates of Asians, Blacks and Hispanics are consistently lower than those of Caucasians (Byrd-Miles et al. 2007; Wu et al. 2011; Reintgen et al. 1982). Compared with Caucasians, patients with skin of color tend to present with more advanced, thicker tumors and thus tend to have a poorer prognosis, with higher mortality (Bradford et al. 2009). In a review of California melanoma cases, tumors thicker than 1.5 mm at presentation increased at 11.6 % per year and 8.9 % per year among Hispanic males and females, respectively (Cockburn et al. 2006). In a retrospective analysis of case reports in the Florida Cancer Data system, late stage melanoma (regional and distant) was more common among Hispanic (26 %) and Black patients (52 %) compared with Caucasians (16 %) (Hu et al. 2006). Interestingly, in a review of California melanoma cases, it was shown that even after adjustments for age, sex, histology, stage, anatomic site, treatment, and socioeconomic status, a statistically significant increased risk of death was observed for Blacks compared with Caucasians (Zell et al. 2008). Hence, the poor survival for Black patients with melanoma is not fully explained by differences in treatment or socioeconomic status (Bradford 2009).

### *Treatment*

Wide local excision is the treatment for early-stage melanoma. Sentinel lymph node biopsy (with elective lymph node dissection) is recommended for staging in patients diagnosed with

intermediate-thickness melanoma (1.01–4.0 mm) (Doecker and Zager 2015). Medical management is reserved for adjuvant therapy of patients with advanced melanoma (>4 mm) or regional lymph node involvement. Interferon alfa is approved for adjuvant treatment after excision in patients who are free of disease but are at high risk for recurrence (Kirkwood et al. 1996). Treatment of patients with advanced-stage melanoma (stage IV) has not improved significantly in recent years, although there are now biologic therapies being used alone and with chemotherapy regimens. Dacarbazine is the most widely used chemotherapy agent; however, it yields only a 10–15 % response rate (Mignot et al. 2014). High dose IL-2, a recombinant hormone of the immune system used as a lymphokine-activated cell killer therapy, is also FDA approved for metastatic melanoma (Stoter et al. 1991).

In recent years, Vemurafenib, a BRAF -V600E inhibitor, has been FDA approved for the treatment of unresectable or metastatic melanoma with BRAF -V600 mutations. BRAF mutations are present in approximately 40–60 % of melanomas (Chapman et al. 2011). Additional BRAF inhibitors that have been approved for metastatic melanoma include Dabrafenib and Trametinib, a mitogen-activated, extracellular signal-regulated kinase (MEK) inhibitor (Flaherty et al. 2012).

Anti-cytotoxic T-lymphocyte associated protein 4 (CTLA-4) is a humanized antibody directed at a down-regulatory receptor on activated T-cells. Ipilimumab, a CTLA-4 blocker, has also been FDA approved for unresectable or metastatic melanoma (Hodi et al. 2010). Pembrolizumab is the first monoclonal antibody for inhibition of programmed cell death-1 protein (PD-1). It is indicated for unresectable or metastatic melanoma and disease progression following the use of ipilimumab, and if BRAF V600 mutation positive, a BRAF inhibitor (Robert et al. 2014).

### *Prevention*

The focus of melanoma prevention is avoidance of sun exposure. People with skin of color should be advised to use a daily broad spectrum sunscreen of at least SPF 30 and

practice sun-protective behavior such as seeking shade and use of protective clothing, wide brimmed hat, and sunglasses. Sunscreens should be applied liberally and reapplied every 2 h while outdoors. Patients should be advised to avoid tanning salons. A thorough skin examination, including the nails, oral cavity, gums, palms, soles, groin, and perianal area should be regularly performed by a dermatologist. Pigmented lesions on the gums and streaks in nails are normal in people with skin of color, but should be monitored regularly for changes as malignant transformation can occur (Agbai et al. 2014).

## Key Points

- Melanoma is the third most common skin cancer in people of color; however, incidence rates are increasing in Hispanics.
- Melanoma is often found on palmar and plantar surfaces in people of color.
- The high percentages of advanced and thicker melanomas among nonwhites highlight the need to improve melanoma awareness for all race and ethnicities in the United States.
- To reduce the burden of melanoma, it is crucial to promote prevention by reducing sun exposure and the use of tanning beds, as well as improving early recognition of melanoma among all ethnic groups.
- Given the poorer melanoma survival rates in people of color, it is important that physicians maintain a high index of suspicion in all ethnic groups and closely examine a patient's palms, soles, and nail beds.

## References

- Agbai ON, Buster K, Sanchez M, Hernandez C, Kundu RV, Chiu M, et al. Skin cancer and photoprotection in people of color: a review and recommendations for physicians and the public. *J Am Acad Dermatol.* 2014;70(4):748–62.
- Bradford PT. Skin cancer in skin of color. *Dermatol Nurs.* 2009; 21(4):170–7, 206; quiz 178.

- Bradford PT, Goldstein AM, McMaster ML, Tucker MA. Acral lentiginous melanoma: incidence and survival patterns in the United States, 1986-2005. *Arch Dermatol.* 2009;145(4):427-34.
- Byrd-Miles K, Toombs EL, Peck GL. Skin cancer in individuals of African, Asian, Latin-American, and American-Indian descent: differences in incidence, clinical presentation, and survival compared to Caucasians. *J Drugs Dermatol JDD.* 2007;6(1):10-6.
- Chapman PB, Hauschild A, Robert C, Haanen JB, Ascierto P, Larkin J, et al. Improved survival with vemurafenib in melanoma with BRAF V600E mutation. *N Engl J Med.* 2011;364(26):2507-16.
- Cockburn MG, Zadnick J, Deapen D. Developing epidemic of melanoma in the Hispanic population of California. *Cancer.* 2006;106(5):1162-8.
- Coleman 3rd WP, Gately 3rd LE, Kremenz AB, Reed RJ, Kremenz ET. Nevi, lentiginos, and melanomas in blacks. *Arch Dermatol.* 1980a;116(5):548-51.
- Coleman 3rd WP, Loria PR, Reed RJ, Kremenz ET. Acral lentiginous melanoma. *Arch Dermatol.* 1980b;116(7):773-6.
- Collins RJ. Melanoma in the Chinese of Hong Kong. Emphasis on volar and subungual sites. *Cancer.* 1984;54(7):1482-8.
- Cormier JN, Xing Y, Ding M, Lee JE, Mansfield PF, Gershenwald JE, et al. Ethnic differences among patients with cutaneous melanoma. *Arch Intern Med.* 2006;166(17):1907-14.
- Doepker MP, Zager JS. Sentinel lymph node mapping in melanoma in the twenty-first century. *Surg Oncol Clin N Am.* 2015;24(2):249-60.
- Feibleman CE, Stoll H, Maize JC. Melanomas of the palm, sole, and nailbed: a clinicopathologic study. *Cancer.* 1980;46(11):2492-504.
- Flaherty KT, Infante JR, Daud A, Gonzalez R, Kefford RF, Sosman J, et al. Combined BRAF and MEK inhibition in melanoma with BRAF V600 mutations. *N Engl J Med.* 2012;367(18):1694-703.
- Gloster Jr HM, Neal K. Skin cancer in skin of color. *J Am Acad Dermatol.* 2006;55(5):741-60; quiz 61-4.
- Hodi FS, O'Day SJ, McDermott DF, Weber RW, Sosman JA, Haanen JB, et al. Improved survival with ipilimumab in patients with metastatic melanoma. *N Engl J Med.* 2010;363(8):711-23.
- Hu S, Soza-Vento RM, Parker DF, Kirsner RS. Comparison of stage at diagnosis of melanoma among Hispanic, black, and white patients in Miami-Dade County, Florida. *Arch Dermatol.* 2006;142(6):704-8.
- Kirkwood JM, Strawderman MH, Ernstoff MS, Smith TJ, Borden EC, Blum RH. Interferon alfa-2b adjuvant therapy of high-risk resected cutaneous melanoma: the Eastern Cooperative Oncology Group Trial EST 1684. *J Clin Oncol.* 1996;14(1):7-17.

- Mignot G, Hervieu A, Vabres P, Dalac S, Jeudy G, Bel B, et al. Prospective study of the evolution of blood lymphoid immune parameters during dacarbazine chemotherapy in metastatic and locally advanced melanoma patients. *PLoS One*. 2014;9(8), e105907.
- Nestle F, Halpern A. Melanoma. In: Bologna J, Jorizzo J, Rapini R, editors. *Dermatology*. 2nd ed. Madrid: Mosby Elsevier; 2008. p. 1745–70.
- Phan A, Touzet S, Dalle S, Ronger-Savle S, Balme B, Thomas L. Acral lentiginous melanoma: a clinicoprognostic study of 126 cases. *Br J Dermatol*. 2006;155(3):561–9.
- Reintgen DS, McCarty Jr KM, Cox E, Seigler HF. Malignant melanoma in black American and white American populations. A comparative review. *JAMA*. 1982;248(15):1856–9.
- Robert C, Ribas A, Wolchok JD, Hodi FS, Hamid O, Kefford R, et al. Anti-programmed-death-receptor-1 treatment with pembrolizumab in ipilimumab-refractory advanced melanoma: a randomised dose-comparison cohort of a phase 1 trial. *Lancet*. 2014;384(9948):1109–17.
- Stoter G, Aamdal S, Rodenhuis S, Cleton FJ, Iacobelli S, Franks CR, et al. Sequential administration of recombinant human interleukin-2 and dacarbazine in metastatic melanoma: a multicenter phase II study. *J Clin Oncol*. 1991;9(9):1687–91.
- Tucker MA, Goldstein AM. Melanoma etiology: where are we? *Oncogene*. 2003;22(20):3042–52.
- Wu XC, Eide MJ, King J, Saraiya M, Huang Y, Wiggins C, et al. Racial and ethnic variations in incidence and survival of cutaneous melanoma in the United States, 1999–2006. *J Am Acad Dermatol*. 2011;65(5 Suppl 1):S26–37.
- Zell JA, Cinar P, Mobasher M, Ziogas A, Meyskens Jr FL, Anton-Culver H. Survival for patients with invasive cutaneous melanoma among ethnic groups: the effects of socioeconomic status and treatment. *J Clin Oncol*. 2008;26(1):66–75.

# Chapter 10

## Cutaneous T-Cell Lymphoma

**Chikoti M. Wheat and Ginette A. Okoye**

### Case Presentation

A 31-year-old Black male presented with a 10-year history of a diffuse pruritic rash. He was initially diagnosed with pityriasis rosea and reported complete resolution of the eruption. However, a similar rash recurred eight years later. An alternative medicine specialist had prescribed an oral anti-fungal and later topical steroid without resolution.

### Physical Examination

Involving approximately 75 % body surface area (BSA), he had well-demarcated hyper- and hypopigmented discrete round and ovoid variably sized patches on the trunk, buttocks, thighs and the intertriginous areas. Some of the lesions had fine scale (Fig. 10.1a, b). A full lymph node examination revealed bilateral axillary non-tender lymphadenopathy.

---

C.M. Wheat, MD (✉) • G.A. Okoye, MD  
Department of Dermatology, Johns Hopkins Medicine,  
Baltimore, MD, USA  
e-mail: [chikotim@gmail.com](mailto:chikotim@gmail.com)

P.B. Love, R.V. Kundu (eds.), *Clinical Cases in Skin of Color: Medical, Oncological and Hair Disorders, and Cosmetic Dermatology*, Clinical Cases in Dermatology, DOI 10.1007/978-3-319-23615-5\_10, 111  
© Springer International Publishing Switzerland 2016

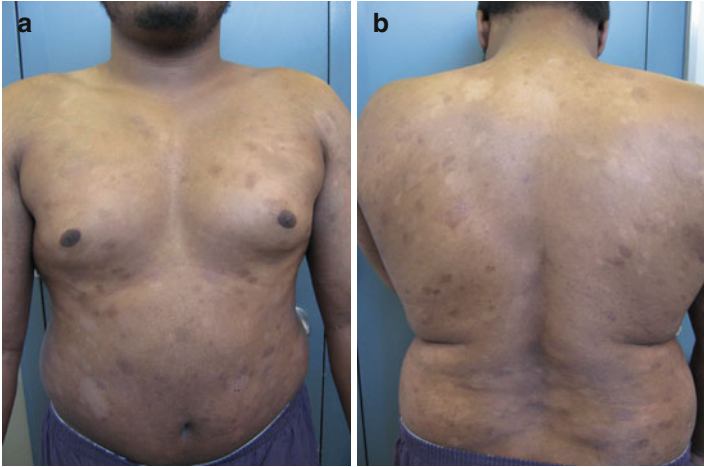


FIGURE 10.1 Patch stage mycosis fungoides. Well-demarcated hyper- and hypopigmented discrete round and ovoid variably sized patches are noted on the chest, stomach (a), back, buttocks, thighs and the intertriginous areas (b). Some of the lesions had fine scale

## Differential Diagnosis

The patient's clinical presentation was felt to be consistent with cutaneous T-cell lymphoma. Pityriasis rosea is a common skin disorder found in children and young adults and manifests as an acute, self-limiting, papulosquamous eruption, usually beginning with a "herald patch." Tinea versicolor is characterized by hypopigmented or hyperpigmented macules and patches on the chest and the back, typically in young active adults. Patients with inflammatory vitiligo have lesions with an erythematous, raised border, which is present from the onset of vitiligo or may appear several months or years after the initial onset; mild pruritus may be present. Pityriasis lichenoides chronica presents as small erythematous-to-reddish brown papules, with fine scale. Atopic dermatitis with post-inflammatory dyspigmentation is also included in the differential.

## Histopathology

A punch biopsy showed a moderately dense atypical lymphocytic infiltrate lining up at the dermoepidermal junction with exocytosis of cells and Pautrier microabscesses in the epidermis. Flow cytometry showed cluster of differentiation (CD)3+/CD4+/CD7-/CD8-/CD30- T lymphocytes.

## Imaging

A computed axial tomography scan of the chest, abdomen and pelvis revealed 6 mm left lower lobe pulmonary nodule, bilateral axillary, pelvic and inguinal lymphadenopathy. A positron emission tomography (PET) scan showed increased [18] F-fluorodeoxyglucose (FDG) uptake of the skin of the trunk, lower extremities, face and scalp as well as increased uptake of the lymph nodes of the neck, axillary, external iliac and inguinal areas. Right femoral lymph node biopsy revealed no abnormalities. A Sezary preparation of the blood showed no atypical cells.

## Diagnosis

Cutaneous T-cell lymphoma, Mycosis Fungoides subtype, Stage IIA ( $T_2, N_1, M_0, B_0$ )

## Case Treatment

A discussion of the diagnosis, natural history, and treatment was discussed. Because patients presenting with early stage disease very rarely have systemic involvement, skin-directed therapy is the appropriate choice. He was started on topical nitrogen mustard 0.02 % gel once a day. He was also started on narrow band UVB phototherapy three times a week. At 6 months follow-up, moderate improvement was noted in approximately 75 % of his lesions. He is followed by Dermatology every 6 months.



## Discussion

Cutaneous T-cell lymphoma (CTCL) is the most common type of primary cutaneous lymphoma. The term CTCL encompasses multiple heterogeneous neoplasms, all of which are composed of skin homing monoclonal T-cells with the potential to transform into high grade T cell lymphoma (Hinds and Heald 2009). Based on Surveillance, Epidemiology, and End Results (SEER) data in the United States collected in 2001–2005, Mycosis fungoides (MF) is the most common type of CTCL and affecting 54 % of all patients with CTCL (Bradford et al. 2009). The etiology of CTCL remains unknown; however, it is believed to result from chronic antigenic stimulation that leads to uncontrolled clonal expansion and the accumulation of memory helper T cells in the skin (Jawed et al. 2014). The human T-cell lymphotropic virus type I (HTLV-1), a virus that is endemic in the Caribbean, Japan, sub-Saharan Africa, and South America, has been associated with some forms of CTCL (Verdonck et al. 2007). Numerous environmental agents, such as exposure to aromatic halogenated hydrocarbons, have also been reportedly associated with a small proportion of CTCL (Morales-Suarez-Varela et al. 2005), but the cause remains largely unknown. The histologic findings found in the most classic CTCL biopsies are a band of atypical lymphocytes with hyperchromatic, convoluted nuclei in the upper dermis, epidermotropism, exocytosis with minimal spongiosis, and the formation of Pautrier microabscesses (Leboit et al. 2006).

Multiple studies have looked at the demographics of patients presenting with CTCL. A study by Criscione et al. 2009 looked at the incidence of CTCL in the United States from 1973 to 2002 and found that blacks have the highest incidence compared to whites, and that men were more affected than women (Criscione and Weinstock 2007). Though black patients are typically diagnosed at an earlier age they, unlike their white counterparts, present with more advanced disease and have poorer overall outcomes (Hinds and Heald 2009). It is postulated that late presentation occurs primarily

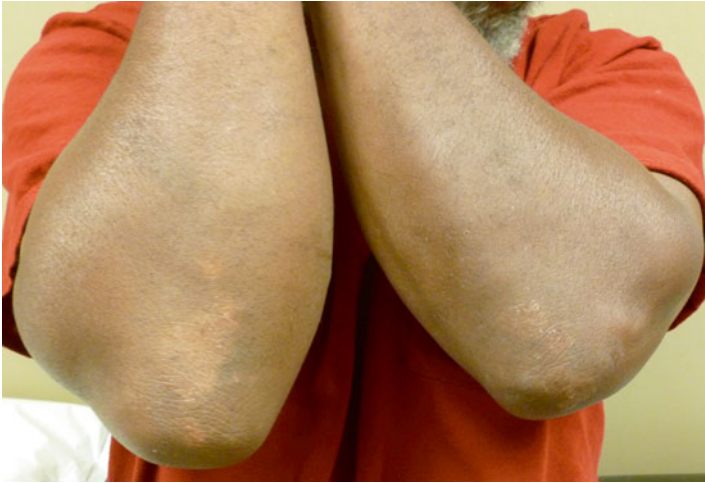

FIGURE 10.2 Hypopigmented mycosis fungoides. Hypopigmented patches are noted on the elbows and dorsal forearms

due to difficulty in clinical recognition that leads to misdiagnosis. It is therefore important that physicians recognize clinical appearance of CTCL in their skin of color patient so as to appropriately manage or refer the patient in a timely manner.

Early MF typically presents with patches that are poikilodermatous, slightly scaling, atrophic, annular or arcuate, and classically involve sun-shielded areas, also known as a “bathing suit distribution.” In skin of color, the dyspigmentation associated with MF can produce asymptomatic hypopigmented (Fig. 10.2) and hyperpigmented (Fig. 10.1a, b) lesions. In addition, some patients may present with lesions that mimic a more common dermatosis, such as psoriasis, atopic dermatitis, vitiligo, or lichen planus. Patients with skin of color may also present with pruritus and secondary lichenification and hyperpigmentation, which often masks clues to the presence of MF (Hinds and Heald 2009). Later stages of MF may have red to violaceous dome-shaped or ulcerated tumors (Fig. 10.3). The most severe form of CTCL is Sezary syndrome, which

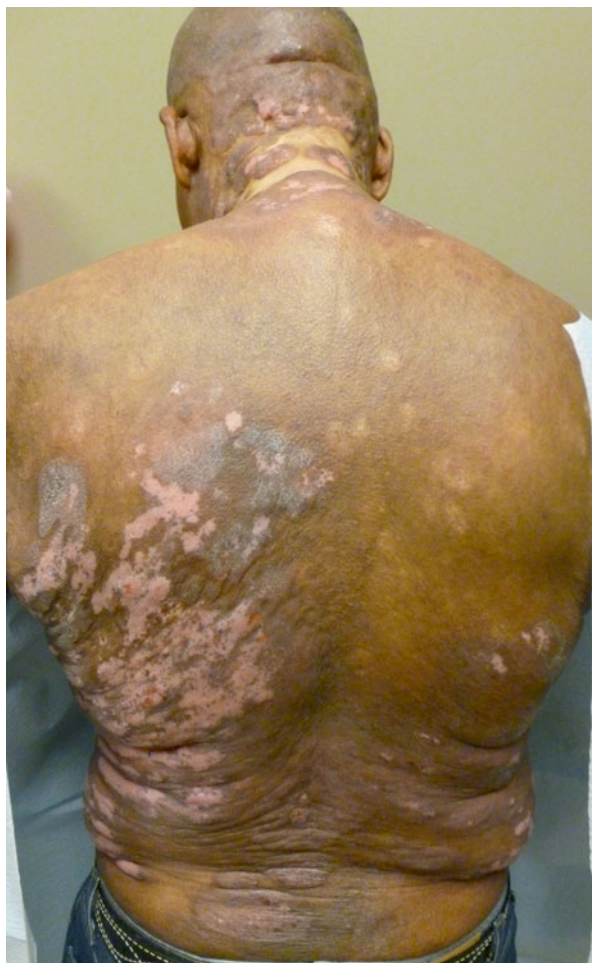

FIGURE 10.3 Tumor stage mycosis fungoides. Erythematous to violaceous dome-shaped and ulcerated tumors are noted on the occipital scalp, posterior neck, and back

is characterized by erythroderma, lymphadenopathy, and atypical T cells (Sezary cells) in the peripheral blood. Patients with Sezary syndrome may also have associated pruritus, exfoliation, edema, alopecia, and “leonine facies,” which is thickening of the facial folds (Jawed et al. [2014](#)).

The early recognition and diagnosis of CTCL in skin of color is facilitated by a combination of clinical and histologic findings and can decrease the morbidity and mortality currently associated with this disease. After a skin biopsy, demonstration of a dominant T cell clone in the specimen by a polymerase chain reaction (PCR) can help distinguish CTCL from inflammatory disorders. Additional tests that should be performed include a complete blood count with differential and review for Sezary cells, liver function tests, uric acid and lactate dehydrogenase levels, and a flow cytometric study of the blood to detect a circulating malignant clone. A chest X-ray should be performed to determine lung involvement, and a CT of the abdomen and pelvis may be performed in patients with advanced CTCL (Hinds and Heald 2009).

Treatment of CTCL is highly dependent on the type and stage of the disease. The disease stage, CTCL subtype as well as the patient's age, general health, and the goals of therapy (i.e. palliative versus curative therapy) determine the course of treatment. Like other malignancies, the stage of MF is determined by the tumor, node, metastasis, blood (TNMB) classification with a grading system that depends on the degree of skin, lymph node, visceral and blood involvement (Willemze 2008).

## Treatment for Early Stages Ia, Ib, Iia

Patients presenting with early stage disease very rarely have systemic involvement, making skin-directed therapy an appropriate choice. The most commonly used include topical steroids, topical nitrogen mustard (mechlorethamine hydrochloride) and topical retinoids.

### *Topicals*

Topical steroids may be used as single therapy or as adjuncts to other topical or systemic therapies in the early stages but also in the late stages of MF (Zackheim et al. 1998). Topical nitrogen mustard at concentrations of 0.01–0.02 % has been reported to achieve complete remission (CR) lasting at least

8 years. The 0.02 % gel formulation is now FDA approved for the treatment of stages IA/IIB (Lessin et al. 2013). Bexarotene 1 % gel and tazarotene 0.1 % gel are the two topical retinoids used for early stage MF. Bexarotene is FDA approved for early stage MF while tazarotene is reported to be an effective adjuvant to topical steroids especially in refractory or relapsed disease (Apisarnthanarax et al. 2004).

### *Phototherapy*

Phototherapy, either ultraviolet A (PUVA, 320–400 nm) or ultraviolet B (UVB, 290–320 nm) radiation, are effective treatment options for early stage MF (stage IA, IB, IIA) and also for refractory early stage MF (Oguz et al. 2003). Though narrowband UVB (311 nm) is used more frequently than PUVA in early stage MF, physicians frequently treating patients with Fitzpatrick skin types III–VI recommend PUVA therapy over UVB (Wongpraparut and Setabutra 2012). Not only do patients have longer remission but treatment of early MF with PUVA delays extracutaneous spread (Herrmann et al. 1995) and allows for easier tapering of the frequency of dosing after clearance has been achieved. PUVA therapy requires patients to take oral 8-methoxypsoralen 1 h prior to treatment, which sensitizes the skin to ultraviolet A radiation. Patients are required to have treatment sessions three times per week until complete followed by slowly tapered maintenance therapy.

### *Total Skin Electron Beam Therapy (TSEBT) and Local Radiation*

TSEBT involves the administration of 30–36 Gy ionizing radiation to the entire surface of the skin over an 8–10 week period (Navi et al. 2011). It is typically used as an initial treatment in patients with T2 or T3 MF or as an adjunct to nitrogen mustard, ECP or PUVA in those with refractory or relapsing

disease (Navi et al. 2011; Chinn et al. 1999). A single-institution study by Hinds et al. showed black females with early stage MF had higher odds of achieving a complete response to TSEBT, compared to black males and white males and females. Therefore, skin of color patients presenting with early stage MF, particularly black females, should be educated about TSEBT as a potential option for treatment (Hinds and Heald 2009). Local radiation, as single fraction of 700 cGy-800 cGy, is typically used for palliative treatment for refractory areas or tumors with a CR of 94.4 % (Thomas et al. 2013).

## Treatment for Advanced Stages IIB, III, IV

TSEBT and phototherapy, though primarily having skin-directed mechanisms, can also be used for more advanced stages. Other treatment options include systemic therapy such as oral retinoids, interferons, histone deacetylase inhibitors, extracorporeal photopheresis (ECP), antifolates, allogeneic stem cell transplant and a variety of combination therapies.

### *Retinoids*

Oral retinoids that have undergone or are currently undergoing investigation for treatment of CTCL/ MF include isotretinoin, acitretin and etretinate. Oral bexarotene is the only FDA approved oral retinoid for refractory CTCL at all stages.

### *Interferons*

IFN $\alpha$  has gained popularity owing to relatively fewer side effects in comparison to IFN $\beta$  or IFN $\gamma$ . In addition, these side effects can easily be ameliorated with dose reduction (Olsen and Bunn 1995) (Olsen). IFN $\alpha$  is given at low doses via subcutaneous injection of 1–3 million units [MUs] three times weekly with a gradual increase in dose to 9–12 MUs daily as tolerated.

Maintenance therapy is continued for at least 3 months and then tapered over 6–12 months (Olsen and Bunn 1995). It is administered as monotherapy but is even more effective when combined with PUVA therapy for stages IB-IIB (Kuzel et al. 1995). In skin of color patients with advanced stage disease that is refractory to treatment, combination of IFN $\alpha$  and PUVA is particularly worth trying given the good response to PUVA that is often observed in this population.

### *Histone Deacetylase Inhibitors*

Panobinostat and vorinostat both work by increasing acetylation of protein involved in oncogenic pathways. Vorinostat is FDA approved for advanced disease and given orally at 400 mg daily (Duvic et al. 2009). Panobinostat is given by mouth at 20 mg three times per week (Duvic et al. 2013). Both drugs have shown have a benign safety profile at these doses and are relatively effective for refractory MF.

### *Antifolates*

Methotrexate and pralatrexate are both FDA approved for treatment of refractory and relapsed CTCL. The mechanism of action for both involves inhibiting dihydrofolate reductase. Methotrexate is given at a median weekly dose of 25 mg (Zackheim et al. 2003), while pralatrexate is administered at a dose of 15 mg/m<sup>2</sup> weekly (Foss et al. 2012). The once weekly regimen allows for a manageable regimen and therefore medication adherence.

### *Extracorporeal Photopheresis (ECP)*

ECP involves separating circulating mononuclear cells by leukapheresis, mixing the cells with 8-methoxypsoralen, exposing the mixture with ultraviolet A light and then reinfusing into

the patient. It is approved for palliative treatment of CTCL given on 2 consecutive days every 2–4 weeks over a period of at least 6 months (Arulogun et al. 2008). It is also effective and recommended for erythrodermic CTCL (Edelson et al. 1987). Though a viable option with a relatively benign side-effect profile, a single institution study by Agi et al. showed ECP is less likely to be offered as a treatment option to black patients compared to white patients (Agi et al. 2015).

### *Chemotherapy*

Chemotherapeutic agents are used as palliative monotherapies in those with refractory or relapsing therapy that no longer responds to initial therapy. Monotherapies used for treatment of MF include gemcitabine and pegylated liposomal doxorubicin (Dummer et al. 2012; Duvic et al. 2006). Multiagent regimens consist of cyclophosphamide, doxorubicin, vincristine, VP-16 and prednisolone in various combinations. It is important to be aware that as combination therapy, these agents achieve complete and partial remission in tumor stage MF but do not maintain remission (Molin et al. 1980).

### Key Points

- Classic mycosis fungoides presents with patches and plaques on non sunexposed areas that may slowly evolve into tumors.
- Early CTCL in skin of color may resemble classic inflammatory dermatoses, such as psoriasis, atopic dermatitis, vitiligo, or lichen planus, with reactive T cells and other immune cells.
- The early recognition and diagnosis of CTCL in skin of color is facilitated by a correlation of clinical, histological, and cytomorphological findings, and can decrease the morbidity and mortality currently associated with this disease.



## References

- Agi C, Kuhn D, Chung J, Zampella J, Hinds G. Racial differences in the use of extracorporeal photopheresis for mycosis fungoides. *J Dermatol Treat.* 2015;26(3):266–8.
- Apisarnthanarax N, Talpur R, Ward S, Ni X, Kim HW, Duvic M. Tazarotene 0.1 % gel for refractory mycosis fungoides lesions: an open-label pilot study. *J Am Acad Dermatol.* 2004;50(4):600–7.
- Arulogun S, Prince HM, Gambell P, Lade S, Ryan G, Eaton E, et al. Extracorporeal photopheresis for the treatment of Sezary syndrome using a novel treatment protocol. *J Am Acad Dermatol.* 2008;59(4):589–95.
- Bradford PT, Devesa SS, Anderson WF, Toro JR. Cutaneous lymphoma incidence patterns in the United States: a population-based study of 3884 cases. *Blood.* 2009;113(21):5064–73.
- Chinn DM, Chow S, Kim YH, Hoppe RT. Total skin electron beam therapy with or without adjuvant topical nitrogen mustard or nitrogen mustard alone as initial treatment of T2 and T3 mycosis fungoides. *Int J Radiat Oncol Biol Phys.* 1999;43(5):951–8.
- Criscione VD, Weinstock MA. Incidence of cutaneous T-cell lymphoma in the United States, 1973-2002. *Arch Dermatol.* 2007;143(7):854–9.
- Dummer R, Quaglino P, Becker JC, Hasan B, Karrasch M, Whittaker S, et al. Prospective international multicenter phase II trial of intravenous pegylated liposomal doxorubicin monochemotherapy in patients with stage IIB, IVA, or IVB advanced mycosis fungoides: final results from EORTC 21012. *J Clin Oncol.* 2012;30(33):4091–7.
- Duvic M, Talpur R, Wen S, Kurzrock R, David CL, Apisarnthanarax N. Phase II evaluation of gemcitabine monotherapy for cutaneous T-cell lymphoma. *Clin Lymphoma Myeloma.* 2006;7(1):51–8.
- Duvic M, Olsen EA, Breneman D, Pacheco TR, Parker S, Vonderheid EC, et al. Evaluation of the long-term tolerability and clinical benefit of vorinostat in patients with advanced cutaneous T-cell lymphoma. *Clin Lymphoma Myeloma.* 2009;9(6):412–6.
- Duvic M, Dummer R, Becker JC, Poulalhon N, Ortiz Romero P, Grazia Bernengo M, et al. Panobinostat activity in both bexarotene-exposed and -naive patients with refractory cutaneous T-cell lymphoma: results of a phase II trial. *Eur J Cancer.* 2013;49(2):386–94.

- Edelson R, Berger C, Gasparro F, Jegasothy B, Heald P, Wintroub B, et al. Treatment of cutaneous T-cell lymphoma by extracorporeal photochemotherapy. Preliminary results. *N Engl J Med*. 1987; 316(6):297–303.
- Foss F, Horwitz SM, Coiffier B, Bartlett N, Popplewell L, Pro B, et al. Pralatrexate is an effective treatment for relapsed or refractory transformed mycosis fungoides: a subgroup efficacy analysis from the PROPEL study. *Clin Lymphoma Myeloma Leuk*. 2012; 12(4):238–43.
- Herrmann JJ, Roenigk Jr HH, Hurria A, Kuzel TM, Samuelson E, Rademaker AW, et al. Treatment of mycosis fungoides with photochemotherapy (PUVA): long-term follow-up. *J Am Acad Dermatol*. 1995;33(2 Pt 1):234–42.
- Hinds GA, Heald P. Cutaneous T-cell lymphoma in skin of color. *J Am Acad Dermatol*. 2009;60(3):359–75; quiz 76–8.
- Jawed SI, Myskowski PL, Horwitz S, Moskowitz A, Querfeld C. Primary cutaneous T-cell lymphoma (mycosis fungoides and Sezary syndrome): part I. Diagnosis: clinical and histopathologic features and new molecular and biologic markers. *J Am Acad Dermatol*. 2014;70(2):205 e1–16; quiz 21–2.
- Kuzel TM, Roenigk Jr HH, Samuelson E, Herrmann JJ, Hurria A, Rademaker AW, et al. Effectiveness of interferon alfa-2a combined with phototherapy for mycosis fungoides and the Sezary syndrome. *J Clin Oncol*. 1995;13(1):257–63.
- Leboit P, Burg G, Weedon D, Sarasin A. Pathology and genetics: skin tumors. Lyons: IARC Press; 2006.
- Lessin SR, Duvic M, Guitart J, Pandya AG, Strober BE, Olsen EA, et al. Topical chemotherapy in cutaneous T-cell lymphoma: positive results of a randomized, controlled, multicenter trial testing the efficacy and safety of a novel mechlorethamine, 0.02 %, gel in mycosis fungoides. *JAMA Dermatol*. 2013;149(1):25–32.
- Molin L, Thomsen K, Volden G, Groth O, Hellbe L, Holst R, et al. Combination chemotherapy in the tumour stage of mycosis fungoides with cyclophosphamide, vincristine, vp-16, adriamycin and prednisolone (cop, chop, cavop): a report from the Scandinavian Mycosis Fungoides Study Group. *Acta Derm Venereol*. 1980; 60(6):542–4.
- Morales-Suarez-Varela MM, Olsen J, Johansen P, Kaerlev L, Guenel P, Arveux P, et al. Occupational exposures and mycosis fungoides. A European multicentre case-control study (Europe). *Cancer Causes Control*. 2005;16(10):1253–9.

- Navi D, Riaz N, Levin YS, Sullivan NC, Kim YH, Hoppe RT. The Stanford University experience with conventional-dose, total skin electron-beam therapy in the treatment of generalized patch or plaque (T2) and tumor (T3) mycosis fungoides. *Arch Dermatol*. 2011;147(5):561–7.
- Oguz O, Engin B, Aydemir EH. The influence of psoralen + ultraviolet A treatment on the duration of remission and prognosis in mycosis fungoides. *J Eur Acad Dermatol Venereol*. 2003;17(4):483–5.
- Olsen EA, Bunn PA. Interferon in the treatment of cutaneous T-cell lymphoma. *Hematol Oncol Clin North Am*. 1995;9(5):1089–107.
- Thomas TO, Agrawal P, Guitart J, Rosen ST, Rademaker AW, Querfeld C, et al. Outcome of patients treated with a single-fraction dose of palliative radiation for cutaneous T-cell lymphoma. *Int J Radiat Oncol Biol Phys*. 2013;85(3):747–53.
- Verdonck K, Gonzalez E, Van Dooren S, Vandamme AM, Vanham G, Gotuzzo E. Human T-lymphotropic virus 1: recent knowledge about an ancient infection. *Lancet Infect Dis*. 2007;7(4):266–81.
- Willemze R. Cutaneous T-cell lymphoma. In: Bologna J, Jorizzo J, Rapini R, editors. *Dermatology*. 2. 2nd ed. Spain: Mosby Elsevier; 2008. p. 1867–86.
- Wongpraparut C, Setabutra P. Phototherapy for hypopigmented mycosis fungoides in Asians. *Photodermatol Photoimmunol Photomed*. 2012;28(4):181–6.
- Zackheim HS, Kashani-Sabet M, Amin S. Topical corticosteroids for mycosis fungoides. Experience in 79 patients. *Arch Dermatol*. 1998;134(8):949–54.
- Zackheim HS, Kashani-Sabet M, McMillan A. Low-dose methotrexate to treat mycosis fungoides: a retrospective study in 69 patients. *J Am Acad Dermatol*. 2003;49(5):873–8.

# Chapter 11

## Dermatofibrosarcoma Protuberans

**Porcia B. Love**

### Case Presentation

A 35 year old African American male with a history of coronary artery disease presented with a 3 month history of a large protuberant nodule on the right inguinal fold. At age five, he had a right inguinal hernia repair. At age 26, he suffered a myocardial infarction, and a heart catheterization was performed via access of the right femoral artery. He developed a keloid (size of a jelly bean) at the catheterization site. However, over the last 3 months, the mass has rapidly enlarged with occasional bleeding.

### Physical Examination

A large, indurated, approximately 10 cm plaque is noted on the right inguinal fold. Firm, irregular nodules varying in color from flesh to reddish brown are noted (Fig. 11.1).

---

P.B. Love, MD  
Montgomery Dermatology, PC,  
4712 Berry Boulevard, Montgomery, AL 36106, USA  
e-mail: [porcialove@gmail.com](mailto:porcialove@gmail.com)

P.B. Love, R.V. Kundu (eds.), *Clinical Cases in Skin of Color: Medical, Oncological and Hair Disorders, and Cosmetic Dermatology*, Clinical Cases in Dermatology, DOI 10.1007/978-3-319-23615-5\_11, © Springer International Publishing Switzerland 2016 125

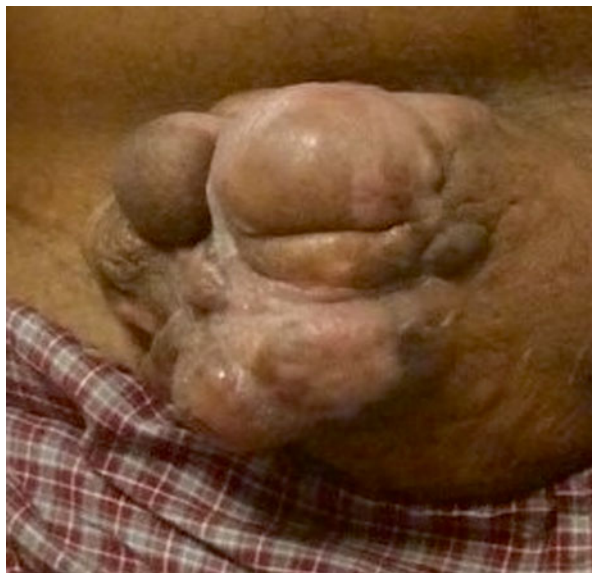

FIGURE 11.1 Dermatofibrosarcoma protuberans of the right inguinal fold after femoral vein access. A large, indurated, approximately 10 cm plaque is noted on the right inguinal fold. Firm, irregular nodules varying in color from flesh to reddish brown are noted

## Differential Diagnosis

Dermatofibromas are typically solitary nodules that arise on an extremity, particularly the lower leg. Many have characteristic tethering of the overlying epidermis to the underlying lesion with lateral compression. Atypical keloids present as firm, smooth nodules with clawlike projections, usually after some form of trauma. Lipomas present as soft, fluctuant, subcutaneous nodules. Plexiform neurofibroma present as noncircumscribed, thick, irregular, soft tumors and are specific for type 1 neurofibromatosis. A cutaneous metastasis may present as a firm, fixed, nontender nodule

with a variety of colors including red, blue, black and occasional ulceration. The patient may elicit a history of breast, lung, melanoma, or colon cancer. Soft tissue fibrosarcomas present as painless, subcutaneous masses that most commonly occur on the legs. Nodular fasciitis presents as a subcutaneous nodule over a period of three to 6 weeks that eventually regresses (Bogucki et al. 2012).

## Histopathology

A punch biopsy reveals numerous tumor cells with spindle shaped nuclei in the dermis with a storiform pattern. The tumor cells are immunoreactive for CD34 and vimentin, with cytoplasmic staining for beta-catenin and very weak staining for Bcl-2. The tumor cells are negative for Factor XIIIa, S-100, pan-keratin, EMA, and p16. Mitotic figures are noted.

## Diagnosis

Dermatofibrosarcoma protuberans

## Case Treatment

The diagnosis, natural history, and treatment of the tumor was discussed with the patient. Repeated trauma from his right inguinal hernia repair and subsequent right femoral vein access may have contributed to the development of the dermatofibrosarcoma protuberans. Given the size and rapid growth of the lesion, the patient underwent radical resection with 2 cm margins by Surgery Oncology. Delayed reconstruction with a tensor fascia lata fasciocutaneous flap was performed by Plastic Surgery. He has 6 month follow-up with Surgery Oncology and Dermatology.

## Discussion

Dermatofibrosarcoma protuberans (DFSP) is an uncommon low grade cutaneous sarcoma. It initially presents as a raised reddish-blue lesion and enters a more rapid growth phase that may result in one or more nodules (Bogucki et al. 2012). DFSP is characterized by its slow, infiltrative growth and marked tendency toward local recurrence after surgical excision (Gloster 1996). DFSP is a rare tumor that constitutes less than 0.1 % of all malignancies and approximately 1 % of all soft tissue sarcomas (Criscione and Weinstock 2007).

Although rare, DFSP accounts for ~10 % of all cases of skin cancer in Blacks (Halder and Bang 1988). A review of skin cancer cases in blacks at Howard University by Halder and Bang 35 in 1986, documented DFSP in 16 patients (12.1 %), which accounted for a higher frequency of skin cancer in blacks than melanoma (6 %), Bowen's disease (4.5 %), or Kaposi's sarcoma (3.8 %) (Bang et al. 1987). The high frequency of DFSP in the Howard University series prompted the authors to recommend that this tumor be included in the differential diagnosis of atypical appearing keloids in black patients. A study conducted by Criscione and Weinstock found that the annual incidence of DFSP among African Americans (6.5 cases per million population) was almost double the incidence among Caucasians (3.9 per million population) (Criscione and Weinstock 2007). DFSP most commonly occurs in adults between the ages of 20 and 50. The tumor is relatively rare in children (Kornik et al. 2012). Several studies of DFSP reveal an almost equal sexual distribution or a slight male predominance.

DFSP initially appears as an asymptomatic, indurated plaque that may be violaceous, red-brown, or flesh-colored (Fig. 11.2). The pigmented variant of DFSP, the Bednar tumor, has also been described to be more common in blacks, although it represents less than 5 % of cases (Criscione and Weinstock 2007). Although DFSP characteristically arises as a solitary lesion, multiple primary lesions have also been reported (Harvell 2003). Over a period, which varies from a few months

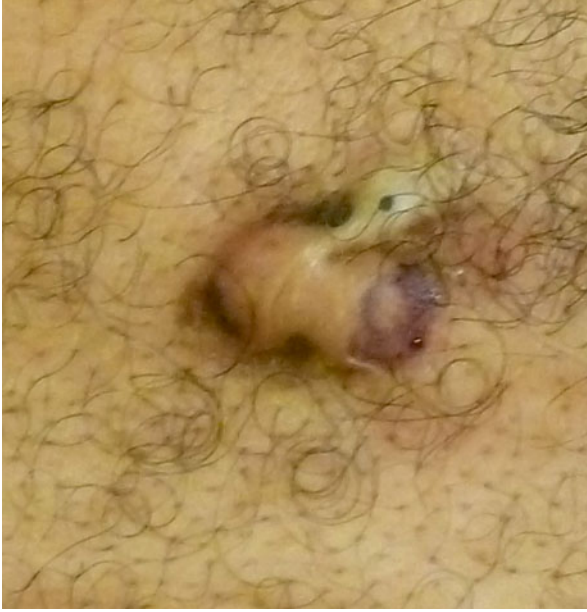

FIGURE 11.2 Dermatofibrosarcoma protuberans of the chest. DFSP initially appears as an asymptomatic, indurated plaque that may be violaceous, red-brown, or flesh-colored

to decades, DFSP slowly enlarges and develops protuberant nodules within the plaque. Once nodules appear, growth is often accelerated and the tumor may ulcerate, bleed, or become painful in 10–25 % of cases (Gloster 1996). Rarely, DFSP enlarges rapidly from onset. Rapid growth or ulceration often stimulates patients to seek medical attention. Although DFSP typically ranges in size from 1 to 5 cm, neglected lesions may grow as large as 20 cm in diameter and have multiple satellite nodules (Bogucki et al. 2012). The tumor is usually fixed to overlying skin but not to deeper structures. Recurrent or long-standing tumors, however, may invade fascia, striated muscle, and bone (Bogucki et al. 2012). The most common location of DFSP is the skin of the trunk; approximately 50–60 % of tumors arise in this area (Gloster 1996).



The cause of DFSP is unknown. There does not appear to be a hereditary or familial predisposition to DFSP. Approximately 15 % of cases have been in sites of prior trauma (Gloster 1996), including surgical scars (Coard et al. 1994), old burn scars (McPeak et al. 1967), and at the site of multiple immunizations (McPeak et al. 1967). Associations with acanthosis nigricans, long-term arsenic exposure, acrodermatitis enteropathica, and pregnancy have also been reported (Gloster 1996).

Histologic examination, often with the use of appropriate immunostains, is necessary for diagnosis. DFSP is thought to result from a translocation between platelet-derived growth factor beta (PDGFB,22q13.1) and type 1 collagen (COL1A1,17q2122) leading to a fusion protein (PDGFB) which stimulates the PDGF receptor (Gisselsson et al. 1998). Detection of this translocation in tissue via PCR or fluorescence in situ hybridization (FISH) can be helpful in difficult cases.

Despite its locally aggressive behavior, DFSP rarely metastasizes. Metastatic lesions may resemble the primary tumor or appear more pleomorphic like a fibrosarcoma. In the largest study to date examining the incidence of metastasis, Rutgers et al reviewed 913 cases of DFSP and found only 11 patients (about 1 %) with regional lymph node metastases and 37 patients (approximately 4 %) with distant metastases. In the majority of these cases, the time interval between diagnosis and metastasis was considerable. The appearance of metastasis was frequently preceded by multiple local recurrences after inadequate surgical excision; 32 patients with distant relapses had a total of 105 local recurrences. Thus, multiple local recurrences appeared to lead to the evolution of more aggressive tumors. The development of regional lymph node metastases was a sign of a poor prognosis; most patients died within 2 years of metastatic disease. The lung, via hematogenous spread, was the predominant site of distant metastases (34 of 37 patients) (Gloster 1996; Rutgers et al. 1992).

## *Treatment*

DFSP is characterized by its slow, infiltrative growth and marked tendency towards local recurrence after surgical excision. The occult spread of tumor by tentacle-like projections of neoplastic cells beneath clinically normal-appearing skin makes complete removal difficult. Published series of patients with DFSP have reported recurrence rates as high as 60 % (Mark et al. 1993) after standard surgical excision and ~2 % after wide excision with margins of more than 4 cm (McPeak et al. 1967). Given the infiltrating growth pattern and potential for extension into deep tissues and bone, negative margins may be difficult to obtain, and risk of recurrence is a concern. Therefore, the preferred treatment of choice is Mohs micrographic surgery. Wide local excision (WLE) with 2–4 cm margins may be performed for extremely large tumors (Gloster et al. 1996). In one study, the average recurrence rate of DFSP treated with Mohs micrographic surgery was 0.6 % (range, zero to 6.6 %) in 64 patients; the total recurrence rate was 1.6 % (1 of 64) (Gloster et al. 1996).

DFSP is thought to be radiosensitive; therefore, radiation treatment is recommended in cases of residual tumor after resection or large lesions with questionable tumor clearance (Dagan et al. 2005). Many cases of DFSP are not suitable for surgery, particularly larger or metastatic lesions. Because the majority of DFSPs are due to monogenic mutations, molecular targeting is being evaluated as an adjunctive therapeutic option. Imatinib mesylate is a tyrosine kinase inhibitor that exhibits activity against many proteins, including ABL, KIT, and PDGF receptors. Two phase II clinical trials in adults have shown effectiveness of imatinib against advanced or metastatic DFSP and neoadjuvant therapy before surgery (Labropoulos and Raziz 2007). The updated National Comprehensive Cancer Network guidelines for the management of DFSP recommend the use of radiation therapy or imatinib when clear surgical margins are unobtainable, in the event of a recurrence, or if there is concern about metastasis (Bichakjian et al. 2014).

## Key Points

- Dermatofibrosarcoma protuberans is a relatively uncommon tumor with intermediate to-low grade malignancy.
- Although rare, DFPS accounts for ~10 % of all cases of skin cancer in Blacks.
- Atypical keloids in people of color, such as those unusual in appearance or occurring in nontraumatized areas of skin or in nontension areas, and keloids with rapid clinical growth should be biopsied.
- Although metastasis rarely occurs, DFSP is a locally aggressive tumor with a high recurrence rate.
- Treatment for DFSP is primarily Mohs micrographic surgery.

## References

- Bogucki B, Neuhaus I, Hurst EA. Dermatofibrosarcoma protuberans: a review of the literature. *Dermatol Surg.* 2012;38(4):537–51.
- Gloster Jr HM. Dermatofibrosarcoma protuberans. *J Am Acad Dermatol.* 1996;35(3 Pt 1):355–74; quiz 75–6.
- Criscione VD, Weinstock MA. Descriptive epidemiology of dermatofibrosarcoma protuberans in the United States, 1973 to 2002. *J Am Acad Dermatol.* 2007;56(6):968–73.
- Halder RM, Bang KM. Skin cancer in blacks in the United States. *Dermatol Clin.* 1988;6(3):397–405.
- Bang KM, Halder RM, White JE, Sampson CC, Wilson J. Skin cancer in black Americans: a review of 126 cases. *J Natl Med Assoc.* 1987;79(1):51–8.
- Kornik RI, Muchard LK, Teng JM. Dermatofibrosarcoma protuberans in children: an update on the diagnosis and treatment. *Pediatr Dermatol.* 2012;29(6):707–13.
- Harvell JD. Multiple spindle cell lipomas and dermatofibrosarcoma protuberans within a single patient: evidence for a common neoplastic process of interstitial dendritic cells? *J Am Acad Dermatol.* 2003;48(1):82–5.
- Coard K, Branday JM, LaGrenade L. Dermatofibrosarcoma protuberans. A 10-year clinicopathological review of an uncommon tumour. *West Indian Med J.* 1994;43(4):130–3.

- McPeak CJ, Cruz T, Nicastrì AD. Dermatofibrosarcoma protuberans: an analysis of 86 cases--five with metastasis. *Ann Surg.* 1967;166(5):803-16.
- Gisselsson D, Hoglund M, O'Brien KP, Dumanski JP, Mertens F, Mandahl N. A case of dermatofibrosarcoma protuberans with a ring chromosome 5 and a rearranged chromosome 22 containing amplified COL1A1 and PDGFB sequences. *Cancer Lett.* 1998; 133(2):129-34.
- Rutgers EJ, Kroon BB, Albus-Lutter CE, Gortzak E. Dermatofibrosarcoma protuberans: treatment and prognosis. *Eur J Surg Oncol.* 1992;18(3):241-8.
- Mark RJ, Bailet JW, Tran LM, Poen J, Fu YS, Calcaterra TC. Dermatofibrosarcoma protuberans of the head and neck. A report of 16 cases. *Arch Otolaryngol Head Neck Surg.* 1993; 119(8):891-6.
- Gloster Jr HM, Harris KR, Roenigk RK. A comparison between Mohs micrographic surgery and wide surgical excision for the treatment of dermatofibrosarcoma protuberans. *J Am Acad Dermatol.* 1996;35(1):82-7.
- Dagan R, Morris CG, Zlotecki RA, Scarborough MT, Mendenhall WM. Radiotherapy in the treatment of dermatofibrosarcoma protuberans. *Am J Clin Oncol.* 2005;28(6):537-9.
- Labropoulos SV, Razis ED. Imatinib in the treatment of dermatofibrosarcoma protuberans. *Biologics.* 2007;1(4):347-53.
- Bichakjian CK, Olencki T, Alam M, Andersen JS, Berg D, Bowen GM, et al. Dermatofibrosarcoma protuberans, version 1.2014. *J Natl Compr Canc Netw.* 2014;12(6):863-8.

**Part V**  
**Cosmetic Concerns**

# Chapter 12

## Dermatosis Papulosa Nigra

**Porcia B. Love**

### Case Presentation

A 50 year old African American female presented with “moles” on her face. She began noticing them in her 30’s, but as she aged, they increased in number and size. They are asymptomatic. She notes that all of her sisters, as well as her mother, have these moles.

### Physical Examination

There are multiple soft, smooth, dark brown, flattened papules that measure 1–5 mm in diameter mainly on the malar and periorbital areas of the face. There is no associated scaling, crusting, or ulceration (Fig. 12.1).

---

P.B. Love, MD  
Montgomery Dermatology PC,  
4712 Berry Boulevard, Montgomery, AL 36106, USA  
e-mail: [porcialove@gmail.com](mailto:porcialove@gmail.com)

P.B. Love, R.V. Kundu (eds.), *Clinical Cases in Skin of Color: 137*  
*Medical, Oncological and Hair Disorders, and Cosmetic*  
*Dermatology*, Clinical Cases in Dermatology,  
DOI 10.1007/978-3-319-23615-5\_12,  
© Springer International Publishing Switzerland 2016

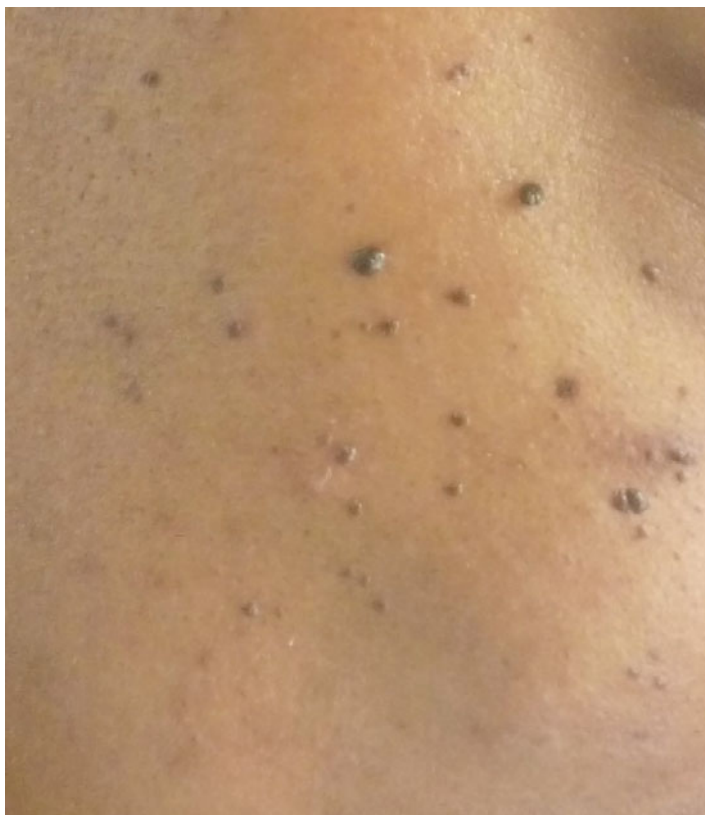

FIGURE 12.1 Dermatitis papulosa nigra. There are multiple soft, smooth, dark brown, flattened papules that measure 1–5 mm in diameter mainly on the malar and periorbital areas of the face

## Differential Diagnosis

The patient's clinical presentation was consistent with dermatosis papulosa nigra. Melanocytic nevi are the main differential diagnosis. Melanocytic nevi typically present as brown, well circumscribed, macules or papules, less than 1 cm in size. They are usually solitary lesions. Other lesions to consider in the differential include acrochordons, syringomas, solar

lentiginos, verrucae, trichoepitheliomas, and adenoma sebaceum (Collyer and Leu 2009).

## Histopathology

Dermatosi papulosa nigra is usually a clinical diagnosis; however, if a biopsy were performed on one of the lesions, it would display the histologic appearance of a seborrheic keratosis with hyperkeratosis, irregular acanthosis, keratin-filled invaginations of the epidermis (horn cysts), and marked hyperpigmentation of the basal layer. Although most lesions are of the acanthotic type and show thick interwoven tracts of epidermal cells, they may have a reticulated pattern in which the tracts consist of a double row of basaloid cells (Hafner et al. 2010).

## Diagnosis

Dermatosi papulosa nigra (DPN)

## Case Treatment

Topical anesthesia, consisting of Betacaine/lidocaine/tetracaine was placed on the patient's face 30 minutes prior to the procedure. Electrodesiccation with low voltage (0.4–0.8 W) was performed on the DPNs. After treatment, Aquaphor ointment was applied to the treated areas. The patient was advised to use a gentle cleanser with a broad spectrum sunscreen daily for 1 week. Three weeks after the procedure, the patient was started on tretinoin 0.025 % cream for postinflammatory hyperpigmentation and sunscreen for 1 month.

## Discussion

Dermatosi papulosa nigra (DPN) are superficial, benign papules that develop predominantly on the malar region, neck, and upper trunk, most commonly in African-Americans and



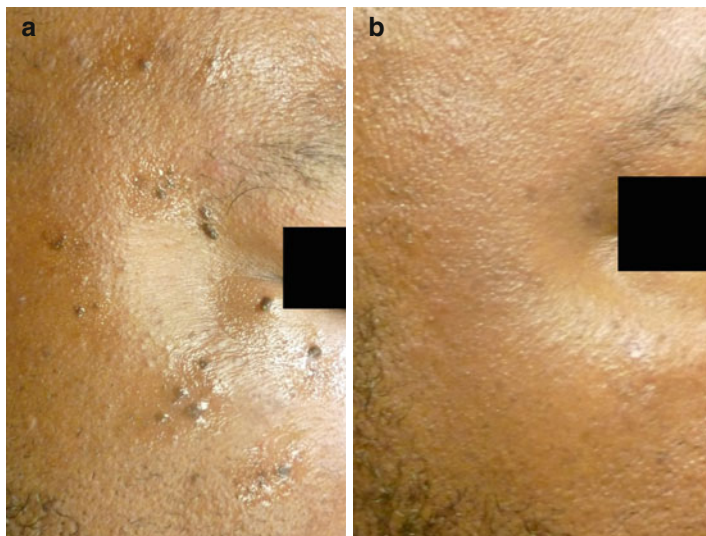


FIGURE 12.2 Dermatitis papulosa nigra treatment with electrocautery. There are multiple soft, smooth, dark brown papules on the malar area (a). The patient was treated with electrocautery (b)

Asians. The prevalence of DPNs in dark skinned patients has been reported to be between 10 and 35 % (Katz et al. 2009), with a gender ratio of 1:2 in favor of women (Grimes et al. 1983). Many patients note a family history of the lesions and the number of lesions increasing with age (Katz et al. 2009). DPNs increase in number and size over the years and do not resolve on their own. Dermatitis papulosa nigra are thought to be a variant of seborrheic keratoses; however, DPNs generally develop at an earlier age than seborrheic keratoses, but are usually not seen in children. DPNs are commonly referred to as “moles” by patients; however, it is important to educate the patient that these are not melanocytic nevi and reassure them that DPNs have no risk for malignant transformation.

Dermatitis papulosa nigra are characterized by multiple, firm, smooth, dark brown to black, flattened papules that measure 1–5 mm in diameter (Fig. 12.2). Lesions occur

mainly on the malar and periorbital areas of the face, although they also may be found on the neck, upper back, and chest. A small percentage of patients have similar lesions on the upper trunk. Scaling, crusting, and ulceration do not occur. As observed in seborrheic keratoses, the number of DPNs increases with age (Hafner et al. 2010).

DPNs are likely to be genetically determined, with 40–54 % of patients having a family history of involvement (Taylor et al. 2011). A study by Hafner et al analyzed whether the FGFR3 mutation found in seborrheic keratoses was also present in DPNs. Two DPN samples were analyzed, and both DPN samples harbored the FGFR3 mutation. Control tissues available for these samples did not show FGFR3 mutations, excluding germline mutations and indicating a strong genotype-phenotype correlation between the mutation and the lesion. Given the already well-known clinical and histological similarities of DPNs and seborrheic keratoses, these molecular genetic findings further support the concept that DPNs may be specific variants of seborrheic keratosis (Hafner et al. 2010).

### *Treatment*

Although dermatosis papulosa nigra is a benign skin condition, cosmetic disfigurement from the lesions may be substantial, causing patients concern and leading them to seek out treatment (Katz et al. 2009). Treatment modalities include cryotherapy, snip excision, curettage, and electrodesiccation, with electrodesiccation being the gold standard (Grimes et al. 1983). In electrodesiccation, the electrode contacts the skin, causing superficial tissue dehydration. Most damage is epidermal, and there is minimal risk of scarring as long as lower power settings are used. Higher power settings may cause superficial scarring, hypopigmentation, and electric burns. Light cryosurgery may be used in conjunction with light abrasive curettage; however, cryosurgery is used cautiously as melanocytes are more susceptible to destruction than keratinocytes, and patients may be left with hypopigmented lesions.

Given that DPNs are prevalent in patients with darker skin types, care must be taken to avoid hyperpigmentation, hypopigmentation, or scarring after treatment. In patients with numerous DPNs, it is often time consuming to treat individual lesions using the above-mentioned treatment options (Kundu et al. 2009); therefore, there have been several reports comparing the efficacy of lasers, including the CO<sub>2</sub>, Er:YAG, KTP, fractionated CO<sub>2</sub>, q-switched ruby, q-switched alexandrite, 532-nm diode laser, and the 1064 nm Nd:YAG laser (Kundu et al. 2009), to electrodesiccation. However, an understanding of basic laser principles, particularly in ethnic skin, is crucial when treating DPNs, as the increased melanin content in the epidermis of darker pigmented individuals can lead to hyper or hypopigmentation. One must be careful that the spot size does not exceed the diameter of the skin lesion to minimize any risk of damage to the surrounding skin. When using lasers for removal of DPNs in skin of color, lower energy settings should be used to avoid dyspigmentation (Collyer and Leu 2009).

One study found that the KTP laser for treatment of DPN was safe and well tolerated in skin phototypes IV to VI. KTP laser and standard-of-care electrodesiccation were found to be effective, and there was no statistically significant difference in efficacy between the two modalities. Although electrodesiccation resulted in greater subjective discomfort than KTP laser, a topical anesthetic was not used in this protocol. Although treatment of DPN with KTP laser and electrodesiccation are comparable in efficacy, KTP laser was preferable for patient comfort (Kundu et al. 2009).

In another study, the erbium-doped 1550-nm fractionated laser was used to treat a Pakistani patient with skin type IV. High energy settings (60–70 mJ) were chosen to treat this patient, as deeper penetration for papular lesions was desired. The treatment level was also high to cover a larger surface area per treatment (Katz et al. 2009). Fractional photothermolysis may also be a treatment modality for DPN. Although it was found that fractional photothermolysis required several treatments to achieve the best results, the risk of dyspigmentation was lower than that seen in other treatment modalities (Katz et al. 2009).

Another study compared the efficacy and complications of pulsed dye laser (PDL) therapy for the treatment of DPN with those of curettage and electrodesiccation. Ten patients completed the study. Mean lesion clearance was 96 % for curettage, 92.5 % for electrodesiccation, and 88 % for laser. There was no significant difference between the three treatment modalities. All three techniques had an overall cosmetic outcome of good for most patients; however, five of the ten patients preferred electrodesiccation. Patients rated the laser as the most painful treatment method. The most common adverse outcome was hyperpigmentation; however, there were no significant differences between the treatment groups for any of the measured outcomes (Garcia et al. 2010).

Because patients with DPNs often have numerous lesions to treat, topical anesthetic agents, such as the topical lidocaine preparations EMLA cream (containing a mixture of lidocaine 2.5 % and prilocaine 2.5 %; AstraZeneca LP, Wilmington, DE, USA) and L.M.X.4 cream (containing liposome-encapsulated lidocaine 4 %; Ferndale Laboratories Inc., Ferndale, MI, USA), have proven useful for local anesthesia prior to treatment. A recent study by Carter et al, found that EMLA and L.M.X.4 provide comparable levels of anesthesia after a single 30 min application under occlusion prior to electrodesiccation of superficial skin lesions (Carter et al. 2006).

Strict posttreatment skin care is essential. Patients should be advised to use a gentle cleanser, avoid picking or scratching the treated area, and to use a broad spectrum sunscreen with at least SPF 30 or above. Patients should return to clinic in one month to be evaluated for postinflammatory hyperpigmentation, in which topical retinoids or hydroquinone can be used (Collyer and Leu 2009).

## Key Points

- Despite the benign nature of dermatosis papulosa nigra, many patients seek out medical advice on management and treatment.

- Dermatoses papulosa nigra are commonly referred to as “moles” by patients; however, it is important to educate the patient that these are not melanocytic nevi and reassure them that DPNs have no risk for malignant transformation.
- While the known treatment modalities can be effective in treating dermatosis papulosa nigra, there are potential side effects, such as scarring and hyperpigmentation; therefore, risks and benefits of each treatment must be discussed.
- Electrodesiccation is the gold standard for treatment; however, lasers are becoming increasingly popular, though more studies on optimal settings are needed.

## References

- Collyer J, Leu S. Treatment of dermatosis papulosa nigra. In: Alam M, Bhatia A, Kundu RV, Yoo S, Chan H, editors. *Cosmetic dermatology for skin of color*. China: McGraw-Hill Companies; 2009.
- Hafner C, Landthaler M, Mentzel T, Vogt T. FGFR3 and PIK3CA mutations in stucco keratosis and dermatosis papulosa nigra. *Br J Dermatol*. 2010;162(3):508–12.
- Katz TM, Goldberg LH, Friedman PM. Dermatoses papulosa nigra treatment with fractional photothermolysis. *Dermatol Surg*. 2009;35(11):1840–3.
- Grimes PE, Arora S, Minus HR, Kenney Jr JA. Dermatoses papulosa nigra. *Cutis*. 1983;32(4):385–6, 92.
- Taylor SC, Averyhart AN, Heath CR. Postprocedural wound-healing efficacy following removal of dermatosis papulosa nigra lesions in an African American population: a comparison of a skin protectant ointment and a topical antibiotic. *J Am Acad Dermatol*. 2011;64(3 Suppl):S30–5.
- Kundu RV, Joshi SS, Suh KY, Boone SL, Huggins RH, Alam M, et al. Comparison of electrodesiccation and potassium-titanylphosphate laser for treatment of dermatosis papulosa nigra. *Dermatol Surg*. 2009;35(7):1079–83.
- Garcia MS, Azari R, Eisen DB. Treatment of dermatosis papulosa nigra in 10 patients: a comparison trial of electrodesiccation, pulsed dye laser, and curettage. *Dermatol Surg*. 2010;36(12):1968–72.
- Carter EL, Coppola CA, Barsanti FA. A randomized, double-blind comparison of two topical anesthetic formulations prior to electrodesiccation of dermatosis papulosa nigra. *Dermatol Surg*. 2006;32(1):1–6.

# Chapter 13

## Chemical Peels

**Porcia B. Love**

### Case Presentation

A 25 year old African American female presents with a 3 year history of acne vulgaris. She has been treated with a combination benzoyl peroxide/clindamycin antibiotic gel and topical tretinoin 0.1 % cream. Her menstrual cycles are regular. She has no history of herpes simplex.

### Physical Examination

There are erythematous and brown papules and pustules noted on the bilateral cheeks and chin. There are hyperpigmented macules noted on the forehead, cheeks, and chin. There are tiny ice pick scars noted on the bilateral temples (Fig. 13.1).

---

P.B. Love, MD  
Montgomery Dermatology, PC,  
4712 Berry Boulevard, Montgomery, AL 36106, USA  
e-mail: [porcialove@gmail.com](mailto:porcialove@gmail.com)

P.B. Love, R.V. Kundu (eds.), *Clinical Cases in Skin of Color: Medical, Oncological and Hair Disorders, and Cosmetic Dermatology*, Clinical Cases in Dermatology, DOI 10.1007/978-3-319-23615-5\_13, © Springer International Publishing Switzerland 2016 145

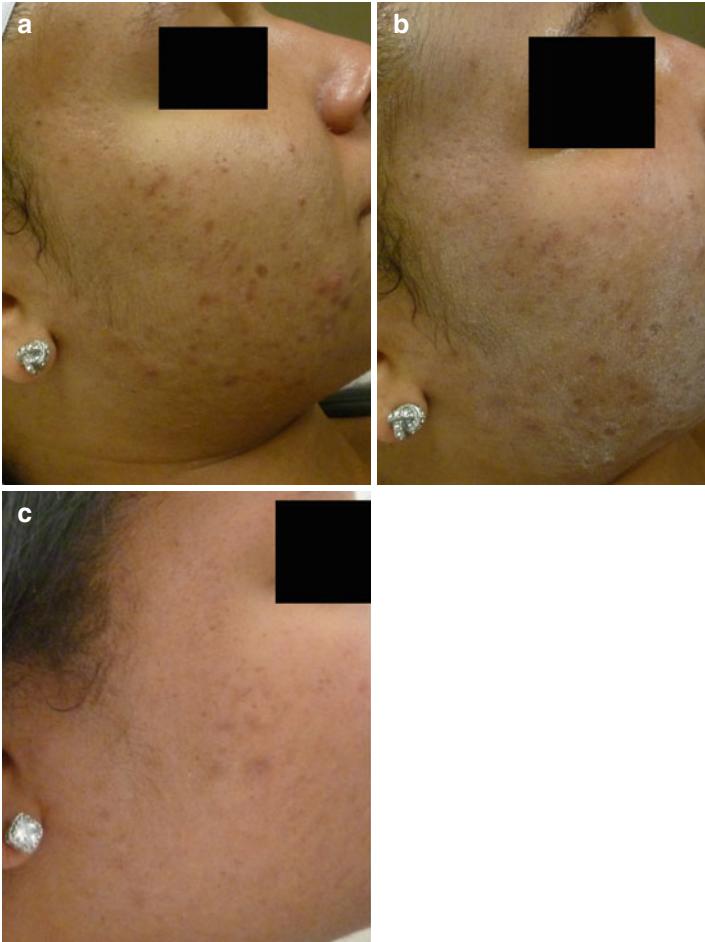

FIGURE 13.1 Patient with inflammatory acne and postinflammatory hyperpigmentation treated with chemical peels. After presenting with inflammatory papules and pustules and postinflammatory hyperpigmentation (**a**), the patient was treated with four salicylic acid peels spaced 4 weeks apart (**b**). Note the improvement in inflammatory lesions and postinflammatory hyperpigmentation (**c**)

## Diagnosis

Acne with Postinflammatory Hyperpigmentation

## Case Treatment

Treatment options were discussed with the patient. She wanted to avoid isotretinoin if at all possible. Given her inflammatory lesions, we recommended starting a sodium sulfacetamide/sulfur cleanser twice a day with doxycycline 100 mg twice a day. She was told to continue her benzoyl peroxide/antibiotic gel in the morning and topical retinoid at night. After 1 month of treatment, salicylic acid peels were performed. She was told to discontinue her acne regimen 1 week prior to the peel. She started with a 25 % salicylic acid peel and was told to use a gentle cleanser and moisturizer with a broad spectrum sunscreen with an SPF of 30 for 1 week, then return to her acne regimen. Afterwards, she had two 30 % Salicylic acid chemical peels spaced 4 weeks apart with improvement in her inflammatory lesions and her postinflammatory hyperpigmentation.

## Discussion

Cleopatra, the famous queen of ancient Egypt, can be considered the “mother of chemical peeling.” In addition to bathing in sour milk, which contains lactic acid, to smooth the skin, the Egyptians also applied alabaster and salt to their skin for rejuvenation. Other women of color in ancient times used pumice, urine, and other agents to effectively peel their skin (Roberts 2004).

The primary indication for chemical peeling in Fitzpatrick skin types III–VI is for pigmentation dyschromias (Roberts 2004). Biopsies of acne in African females have shown a high degree of histologic inflammation compared to



clinical inflammation, which may explain the frequency of postinflammatory hyperpigmentation (PIH) in darker skinned individuals. Medical treatment for PIH includes retinoids, hydroquinone, and azelaic acid. However, these therapies often require months of diligent use to see improvement, and concentrations may need to be titrated slowly to prevent the development of irritant dermatitis, which can easily cause PIH. Therefore, when medical therapies are insufficient, chemical peels may be added to augment the results (Leu 2009).

The indications for chemical peels can be broadly classified under pigmentary abnormalities, photodamage and textural concerns. Unlike skin types I and II, where peels are mostly used to treat skin changes associated with photoaging, peels in skin types IV–VI are used mostly for mottled dyschromia, acne vulgaris, postinflammatory hyperpigmentation, melasma, pseudofolliculitis barbae, and oily skin (Grimes 2012). Although darker skin has the advantage of added photoprotection, it is the often unpredictable response of melanocytes to injury that can cause disfiguring postinflammatory pigmentary changes. It is primarily this risk that makes chemical peels potentially disfiguring (Salam et al. 2013).

Chemical peels are classified as superficial, medium depth, or deep peels (Table 13.1). Superficial peels, including glycolic and salicylic acid peels, Jessner's solution, tretinoin, and trichloroacetic acid (TCA) in concentrations of 10–30 %, target the epidermis and are well tolerated in all skin types. Medium-depth peels, including TCA (35–50 %), combination glycolic acid 70 %/TCA 35 %, Jessner's/TCA 35 %, and phenol 88 % penetrate to the upper reticular dermis and may be used in ethnic skin. Deep peels, like the Baker-Gordon formula penetrate the midreticular dermis and should generally be avoided in skin of color due to the very high risk of dyschromia and scarring (Grimes 2012; Salam et al. 2013).

TABLE 13.1 Types of chemical peels

Type of peel	Target depth	Chemical peel	Indications	Considerations
Superficial (light)	Stratum spinosum	Glycolic acid 20–50 %; Salicylic acid 20–30 %	Melasma, solar lentigenes, acne, PIH, photoaging	Safe in all FPTs; erythema/scaling may last 1–3 days; salicylic acid particularly suitable for FPT IV–VI
Superficial (deeper)	Up to entire epidermis	TCA 10–30 %; Jessner's solution; Glycolic acid 60–70 %	Actinic keratoses, solar lentigenes, acne, photoaging, melasma, PIH, fine lines and wrinkles	Caution advised in darker skin types; higher risk of dyschromia
Medium	Upper reticular dermis	TCA 35–40 %; Phenol 88 %; Brady's combination (solid CO <sub>2</sub> + 35 % TCA); Monheit's combination (Jessner's + 35 % TCA); Coleman's combination (70 % glycolic acid + 35 % TCA)	Melasma, moderate photoaging, scars, actinic keratosis, lentigenes, PIH	Erythema/scaling typically lasts 8–10 days; not as suitable as superficial peels for acne vulgaris/rosacea
Deep	Mid reticular dermis	Baker–Gordon formula (phenol 88 % + tap water + liquid soap + croton oil)	Severe photoaging, dermal-type melasma, deep acne scarring, PIH, actinic keratoses	Best for FPT I and II and should be avoided in FPT IV–VI; risk of prolonged erythema and hyperpigmentation

Adapted from Salam et al. (2013)

Abbreviations: PIH postinflammatory hyperpigmentation, FPT Fitzpatrick skin type, TCA trichloroacetic acid

## Types of Chemical Peels

### *Glycolic Acid*

Glycolic acid is a naturally occurring alpha hydroxy acid that is present in sugarcane. Glycolic acid is epidermolytic within three minutes of application, followed by desquamation. The intensity of the glycolic acid peel is determined by the concentration of the acid (Brody 1999) and the amount of time it is applied to the skin. Chemical peeling by physicians is usually accomplished with a 30–70 % glycolic acid solution. Time is a very important factor to consider when peeling with glycolic acid because unless it is neutralized with water or 1 % bicarbonate solution, this acid will continue keratolysis and subsequent desquamation. Glycolic acid is an excellent peeling agent for the treatment of acne in all skin types and melasma for skin types III-IV (Wang et al. 1997). It is less favorable as a peeling agent for melasma and postinflammatory hyperpigmentation in skin types V and VI because it may induce PIH (Roberts 2004).

### *Salicylic Acid*

Salicylic acid is a beta-hydroxy acid that is found in the bark of the willow tree. It functions as a keratolytic and comedolytic agent, and it enhances the penetration of other peeling agents. Ethanol solutions of salicylic acid at concentrations of 20–30 % are excellent peeling agents for numerous conditions in dark-skinned individuals, including acne, melasma, pseudofolliculitis barbae, and PIH (Grimes 1999).

### *Trichloroacetic Acid*

Trichloroacetic acid (TCA) is an inorganic compound that precipitates epidermal proteins and causes cell necrosis. It is present in crystalline form and mixed with distilled water to create the desired concentration. In skin of color, the desired result is a

superficial peel, which is usually accomplished with a 10–30 % solution. Higher concentrations of TCA may be used in conjunction with other agents to create medium depth peels; however, the risk of PIH and scarring increase with higher concentrations of TCA. TCA is self-neutralizing, and the typical endpoint of a TCA peel is a white frost. In lighter complexions, this is sometimes a desirable effect; however, in skin types IV–VI, a frost is not desired and may carry risks of postpeel dyschromia and scarring. TCA peels work well to treat acne scarring in skin of color, and in combination with glycolic acid, it also rejuvenates uneven mottled facial pigmentation (Roberts 2004).

### *Jessner's Solution*

Formulated by Dr. Max Jessner, this combination of resorcinol (14 g), salicylic acid (14 g), and lactic acid (85 %) in ethanol (95 %) is an excellent superficial peeling agent. The advantages of this formulation are that there is a synergistic effect caused by three keratolytic agents, as well as the additional benefit of resorcinol, a phenolic skin-lightening agent. Unfortunately, resorcinol may also create some depigmentation problems in skin types V and VI (Roberts 2004). Although it may be used alone, Jessner's solution is most effective when combined with other peels (Monheit 1995).

### *Chemical Peels for Acne Vulgaris*

The decision to use chemical peeling as a therapeutic modality has many benefits: (1) It gives you the ability to target the pathogenic factors attributed to the development of acne as well as treat some of the existing primary and secondary lesions; (2) Topical antibiotics and keratolytics are more easily absorbed after an area is chemically peeled; (3) The PIH changes seen with acne are also improved (Fig. 13.1); and (4) it has been shown to speed up the time taken to restore skin to normal. When used as superficial peeling agents, both gly-

colic acid and salicylic acid have an excellent safety profile in all skin types (Roberts 2004).

### *Chemical Peels for Postinflammatory Hyperpigmentation*

PIH secondary to trauma or inflammatory skin disorders poses a therapeutic challenge and is often unresponsive to topical agents. Performing a series of three to six salicylic or glycolic acid peels is one way to remove this excess pigment (Burns et al. 1997). A 4–8 week regimen of a tretinoin-hydroquinone-corticosteroid combination preparation should follow (Roberts 2004).

### *Chemical Peeling for Melasma*

Chemical peeling can be used to remove excess epidermal pigment in the epidermal and mixed types of melasma (Fig. 13.2a, b). Chemical peeling for dermal pigment is not recommended in skin types IV–9VI. Different ethnicities within the IV–VI skin types have varied responses to chemical peeling. For example, Asians respond very well to staged glycolic peels (Lim and Tham 1997). However, African-Americans may do less well with glycolic acid in terms of development of PIH and have often have better outcomes with salicylic acid peels in skin types V–VI. Pretreatment of the affected area with a combination skin-lightening agent 1 month prior to peeling is critical. Peeling can then be accomplished with a 30 % salicylic acid solution or a 40–70 % glycolic acid solution (Roberts 2004).

### *Chemical Peels for Acne Scarring*

Acne scarring responds well to chemical peeling in skin of color. Because the atrophic, pitted, or ice-pick forms of acne

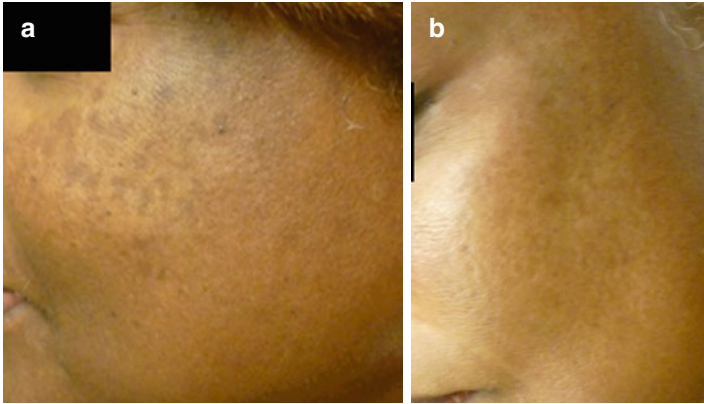
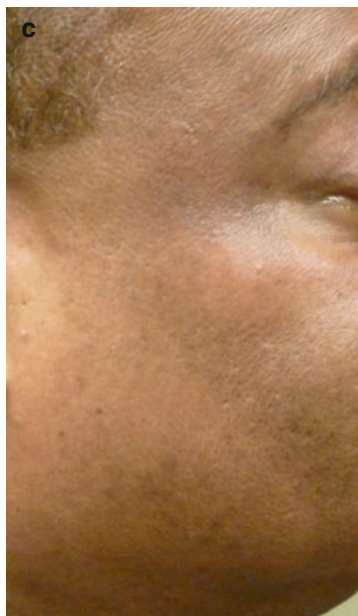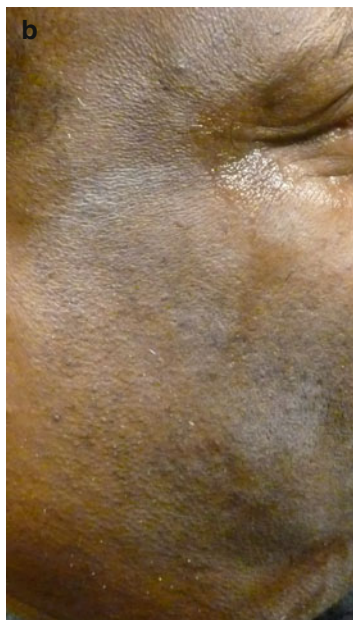

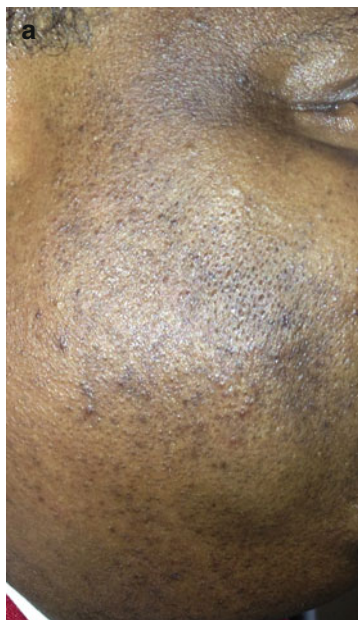
FIGURE 13.2 Patient with melasma treated with chemical peel. After presenting with brown, reticular patches on the bilateral cheeks (a), the patient was treated with a triple combination lightening compound for 2 months, then two 35 % glycolic acid peels spaced 4 weeks apart. Note the improvement in the hyperpigmented patches (b)

scars have a dermal component, a medium-depth peel is typically indicated (Roberts 2004). The most commonly used peel is TCA at concentrations of 35–100 % either alone or in combination with another peeling agent, such as Jessner’s solution. Lower concentrations are useful for atrophic boxcar scars or rolling scars while the CROSS method using 100 % TCA is useful for ice pick scars that are difficult to treat (Handog et al. 2012).

### *Chemical Peeling for Pseudofolliculitis Barbae*

Pseudofolliculitis barbae (PFB) is a foreign-body reaction surrounding an ingrown facial hair which results from shaving. Serial glycolic peels, which act as potent exfoliating agents (Perry et al. 2002) or salicylic acid peels (Fig. 13.3), which act as keratolytic and comedolytic peeling agents, have been reported to work well for PFB (Roberts 2004).



## *Chemical Peeling for Solar Lentigines and Mottling*

Solar lentigines and mottled hyperpigmentation may occur in darker-skinned individuals. Because this is typically done with a lighter-skinned patient, the peeling agent of choice is 25 % TCA. A complete white frost of the lentigo is achieved, and then the face is rinsed with cool water. The procedure may be repeated in three to six weeks. While glycolic acid is certainly indicated in the treatment of lentigines, it tends to spread diffusely across the face and offers no color discernment. In contrast, TCA will frost evenly over a discreet lesion and the outcome is easier to evaluate. Staged glycolic acid peels (50–70 %) are also efficacious for mottling. Excellent results have also been achieved with salicylic acid peels (20–30 %) (Roberts 2004).

Pre and post instructions are critical for patients receiving chemical peels. A peel date needs to be decided to plan the pretreatment preparation and priming regimen. This is usually initiated 2–4 weeks prior to peeling, and discontinued 3–7 days before the peel (Salam et al. 2013). Many dermatologists use a triple combination skin lightening preparation, including a topical retinoid and a low potency corticosteroid in combination with hydroquinone or kojic acid (Roberts 2004). It is also critical for the patient to use a broad spectrum sunscreen and a bland emollient post peel. One week after the peel, hydroquinone and topical retinoid therapy may be restarted (Salam et al. 2013).

---

←

FIGURE 13.3 Patient with pseudofolliculitis barbae and dyschromia treated with chemical peels. After presenting with follicular based papules of the jawline, enlarged pores of the cheeks, and hyperpigmentation of the cheeks and temples (**a**), the patient was treated with four salicylic acid peels spaced 4 weeks apart (**b**). Note the improvement in inflammatory papules, pore size, and postinflammatory hyperpigmentation (**c**)



Complications of superficial peels include skin dryness, irritation (leading to PIH) and erythema. PIH is most likely in patients with skin phototypes IV–VI, with medium-depth peels posing a greater risk than superficial peels. Deep peels in darker skin types must always be avoided. It is prudent to start with a low-potency peel and titrate up, as underpeeling is better than overpeeling (Salam et al. 2013)

## Key Points

- Serial superficial peels offer substantial benefits in skin of color for postinflammatory hyperpigmentation, melasma, acne, pseudofolliculitis barbae, oily skin, and texturally rough skin.
- When selecting a peeling agent, the benefits of the procedure should always substantially outweigh any associated risks or complications.
- Given the labile nature of melanocytes in skin of color, medium and deep peels are more likely to induce substantial complications and side effects.

## References

- Brody H. Chemical peeling. St Louis: Mosby-Yearbook; 1999.
- Burns R, Prevost-Blank P, Lawry M. Glycolic acid peels for post-inflammatory hyperpigmentation in black patients. A comparative study. *Dermatol Surg.* 1997;23:171–4.
- Grimes PE. The safety and efficacy of salicylic acid chemical peels in darker racial-ethnic groups. *Dermatol Surg.* 1999;25(1):18–22.
- Grimes P. Chemical peels in dark skin. In: Tosti A, Grimes P, De Padova M, editors. *Color atlas of chemical peels*. 2nd ed. London: Springer; 2012.
- Handog EB, Datuin MS, Singzon IA. Chemical peels for acne and acne scars in asians: evidence based review. *J Cutan Aesthet Surg.* 2012;5(4):239–46.
- Leu D, Yoo S. Epidermal and color improvement in ethnic skin: microdermabrasion and superficial peels. In: Alam M, Bhatia A,

- Kundu R, Yoo S, Chan H, editors. *Cosmetic dermatology for skin of color China*. McGraw-Hill Companies, Inc.; 2009.
- Lim JT, Tham SN. Glycolic acid peels in the treatment of melasma among Asian women. *Dermatol Surg*. 1997;23(3):177–9.
- Monheit GD. The Jessner's-trichloroacetic acid peel. An enhanced medium-depth chemical peel. *Dermatol Clin*. 1995;13(2):277–83.
- Perry PK, Cook-Bolden FE, Rahman Z, Jones E, Taylor SC. Defining pseudofolliculitis barbae in 2001: a review of the literature and current trends. *J Am Acad Dermatol*. 2002;46(2):S113–9.
- Roberts WE. Chemical peeling in ethnic/dark skin. *Dermatol Ther*. 2004;17(2):196–205.
- Salam A, Dadzie OE, Galadari H. Chemical peeling in ethnic skin: an update. *Br J Dermatol*. 2013;169 Suppl 3:82–90.
- Wang CM, Huang CL, Hu CT, Chan HL. The effect of glycolic acid on the treatment of acne in Asian skin. *Dermatol Surg*. 1997; 23(1):23–9.

# Chapter 14

## Laser Hair Removal

**Oge Onwudiwe**

### Case Presentation

A 45 year-old Hispanic female with skin phototype 4 presented with a chief complaint of unwanted hair on her legs. Her current depilatory methods included waxing and shaving without adverse events. She denied previous laser hair removal treatments.

### Physical Examination

A focused examination was performed and notable for numerous black terminal hairs of the lower leg bilaterally. There was no evidence of pigmentary alterations, folliculitis barbae or other acute inflammatory processes.

---

O. Onwudiwe, MD

Department of Dermatology, Wellman Center for Photomedicine,  
Massachusetts General Hospital, Harvard Medical School,  
Thier Building, #204, 50 Blossom Street, Boston, MA 02114, USA  
e-mail: [oonwudiwe@partners.org](mailto:oonwudiwe@partners.org)

P.B. Love, R.V. Kundu (eds.), *Clinical Cases in Skin of Color: 159*  
*Medical, Oncological and Hair Disorders, and Cosmetic*  
*Dermatology*, Clinical Cases in Dermatology,  
DOI 10.1007/978-3-319-23615-5\_14,  
© Springer International Publishing Switzerland 2016

## Differential Diagnosis

A thorough medical history and examination should be performed on all patients. In the appropriate setting, further work up with respect to endocrine imbalances, menstrual abnormalities, malnutrition, medication induced hair abnormalities and other underlying medical conditions such as porphyria should be conducted. Any patient with unexplained new onset hypertrichosis should be evaluated for an underlying malignancy (Kvedar et al. 1985).

## Diagnosis

Hypertrichosis

## Case Treatment

After reviewing risks, benefits and potential complications, the patient decided to proceed with laser hair removal. The long-pulse Nd:YAG 1064 nm laser with a 35 ms pulse duration, 30 J/cm<sup>2</sup> and 10 mm spot size was used. The endpoint achieved was perifollicular erythema and edema (Fig. 14.1). The patient underwent six treatment sessions approximately 6–8 weeks apart once hair regrowth was noted. The patient was counseled regarding the risk of regrowth and the possible need for maintenance treatments. Repeat treatments will only be performed when regrowth is seen, to capture the hairs while they are in the anagen phase, or actively growing, and therefore able to be destroyed more permanently.

## Discussion

Laser hair removal (LHR), commonly referred to as photoepilation, can be a gratifying procedure for many with unwanted hair. According to the American Academy of Plastic Surgery's

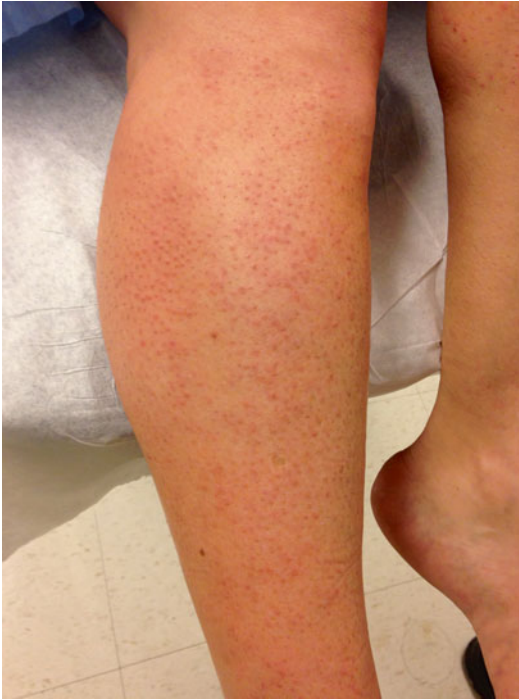

FIGURE 14.1 Laser hair removal. Note the resolution of hypertrichosis and the perfollicular erythema and edema achieved after six treatments with the Nd:YAG laser

most recent report, laser hair removal is one of the top five minimally invasive procedures performed in the United States with well over one million treatments being performed annually (Surgeons ASoP 2013). LHR eliminates or reduces the need for other depilatory methods such as shaving, waxing, tweezing and threading which need to be performed regularly. When performed correctly, LHR significantly reduces the risk for adverse events from these other procedures, which include post inflammatory hyperpigmentation, pseudofolliculitis barbae, and keloid formation; all of which can be challenging to treat and potentially leave permanent sequelae. The only alternative to LHR

for permanent hair reduction, is electrolysis. Electrolysis can be painful and tedious; however, it is user dependent, and need not be painful when performed correctly (Richards et al. 1986). It requires precise needle insertion into follicles, and appropriate duration and intensity of radiofrequency or direct current application through the needle. Side effects such as scarring have been reported with this hair removal modality. The primary advantage of electrolysis over LHR, is that hair color has no effect on efficacy. Electrolysis is also recommended in patients who have 20–25 hairs or less and if the patient has gray hair. A topical prescription, eflornithine, by inhibiting ornithine decarboxylase, slows down the growth rate of hairs and is synergistic when used in conjunction with photoepilation (Hamzavi et al. 2007).

### *Fundamentals of Laser Hair Removal*

Melanin serves as the target chromophore for LHR. Wavelengths in the red and near-infrared portion of the electromagnetic spectrum (Anderson and Parrish 1981) are used, which penetrate deeply into skin and preferentially absorbed by melanin. When factoring in the need for adequate depth of penetration with laser devices, the 700 nm region of the electromagnetic spectrum is considered to provide the most selective absorption by eumelanin (Lin et al. 1998) over other skin chromophores such as hemoglobins. At longer wavelengths, melanin absorption decreases.

The useful range of wavelengths for LHR extends from about 600 nm to about 1100 nm.

The 694 nm ruby laser, 755 nm alexandrite laser, 800 nm diode laser and the 1064 nm ND:YAG laser and some of the Intense Pulsed Light systems are all used in photoepilation. Studies have shown that among the three aforementioned laser systems, the 1064 nm devices are the least effective in hair reduction (Rao and Goldman 2005; Bouzari et al. 2004), probably because of lower absorption by eumelanin at this wavelength. In very dark brown or black hair, however, there is high melanin content such that 1064 nm Nd:YAG lasers are

an excellent choice for treatment of people with very dark hair color. Inheritance of skin color and hair color are often correlated; in general people with darker skin also have darker hair. In skin of color, the alexandrite, diode and Nd:YAG devices all have safely been used. However, the Nd:YAG laser is typically better tolerated, due to reduced absorption by epidermal melanin. In many ways, LHR is a “contest” between light absorption in the epidermis and light absorption in the hair follicles. All light reaching the hair follicles must first pass through epidermis.

As it relates to laser hair removal, the theory of selective photothermolysis, introduced by Anderson et al (Anderson and Parrish 1983), allows selective targeting of melanin within the hair follicle. Melanin in hair follicles is mainly in the hair shaft (which is not alive), and matrix (the deepest part of the follicle). To achieve permanent hair removal, destruction of the biological “target” must occur. This is likely the follicular stem cells located in the bulge region and/or dermal papilla. The “bulge hypothesis” purports a complex interaction between the bulge and the dermal papilla is needed to control the hair cycle (Cotsarelis et al. 1990) and thus, destruction via diffusion of heat to the stem cells, matrix cells and/or dermal papilla seemingly prevents the regeneration of hair.

Based on the spatial separation of the chromophore and desired target, an extended theory of selective photothermolysis was proposed which requires diffusion of heat from the chromophore to the desired target for destruction (Altshuler et al. 2001). The extended theory supports a thermal damage time (TDT), which is somewhat longer than the thermal relaxation time (TRT). Both TDT and TRT are longer for larger hair follicles. Thus, optimal LHR uses pulse widths in the range of about 3–10 ms for fine hair, and 10–100 ms for coarse hair. Since longer pulse widths are also less likely to cause epidermal injury, in general the best approach for skin of color is to use the longest effective pulse width. Very fine hair typically does not respond to long pulse widths, and is challenging to remove safely in skin of color (Altshuler et al. 2001; Ibrahim et al. 2011).

Immediately following laser irradiation to the hair follicle, the hair shaft can display fragmentation and increased eosinophilia. Increased eosinophilia is also seen in the follicular epithelium. With proper treatment, there should be little or no damage to the perifollicular dermis (Grossman et al. 1996). After a series of treatments, one expects to see histologically, reduced terminal hairs, but intact pilosebaceous units and epidermal melanin (Alster et al. 2001).

### *Characteristics of Hair That Effect Photoepilation*

**Hair Type:** Of the three hair types, only terminal hairs have been shown to adequately respond to laser pulses. Vellus hairs are likely too fine while lanugo hairs are both fine and depigmented.

**Hair color:** Hair color is determined by the amount of pigment in the hair shaft itself. Melanocytes produce two types of pigment: eumelanin (brown, black pigment) and pheomelanin (red pigment). Gray and white hairs which correspond to scarce melanin and absence of melanin, respectively, are not laser responsive.

**Caliber or thickness of hair fibers:** Hair shafts of terminal hairs typically range from 150  $\mu\text{m}$  to 300  $\mu\text{m}$  in cross sectional diameter. For comparison, the average vellus hair is 30  $\mu\text{m}$  (Ibrahimi et al. 2011). The thicker the hair, the more likely it will respond well to laser irradiation.

**Cause of hypertrichosis:** Hairs under hormonal influence, or as part of a nevus can be more challenging to treat. A patient with polycystic ovarian syndrome will likely require more treatment sessions as well as maintenance treatments to achieve successful hair reduction. Alster et al showed that areas characterized by thinner skin (e.g. axillae) were most responsive to laser treatments when compared to areas with thicker skin like the chin and legs. In addition, transient pigmentary alterations were limited to sun exposed areas like the chin and legs rather than the axillae (Alster et al. 2001).



### *Potential Adverse Events*

During photoepilation, epidermal melanin in richly pigmented patients act as a competing chromophore and if the proper laser device, laser parameters and adequate cooling are not utilized, a host of sequelae can ensue. Such effects include, but are not limited to, temporary and/or permanent hypo- and hyperpigmentation, ulcerations, scarring, paradoxical hypertrichosis (Ibrahimi et al. 2011; Mandt et al. 2005). Paradoxical hypertrichosis occurs when laser light stimulates vellus hairs to transition into terminal hairs. This is mainly seen on the face and neck of women of phototypes III–VI. This is thought to be due to suboptimal fluencies; post-treatment cooling is recommended. Unmasking the presence of an underlying untreated hormonal condition has been documented as well (Desai et al. 2010).

Although all skin types can safely and effectively be treated, the ideal candidate for LHR possesses fair skin with dark brown or black terminal hairs. Laser hair removal in skin of color is not without inherent challenges. As mentioned previously, melanin is preferentially absorbed at a number of wavelengths. The goal in photoepilation is to use wavelengths that penetrate deeply into the skin, bypassing as best as possible the epidermis. Adequate cooling mechanisms via dynamic cooling devices, forced cold air or sapphire cooling tips are warranted especially in skin of color. In addition, instituting practices such as the use of cold ultrasound gel, ice packs pre and/or post treatment, and the use of topical steroids post treatment all can aid in cooling the epidermis- potentially mitigating epidermal damage and risks of post treatment sequelae.

For inexperienced practitioners, or in very dark skin, or if the patient expresses a high level of worry, a test spot may be necessary before embarking on a full treatment area. Performing a test spot assures the patient that they can be treated safely, allows them to observe their response, and gives the practitioner some assessment. In very dark skin, it may be helpful to use sunscreen, with or without skin lightening medications to reduce epidermal pigmentation. Performing a

test spot allows the patient to comply with this approach for several weeks or more prior to LHR treatment.

Assessment of early treatment endpoints is very useful. For LHR, the therapeutic endpoint is perifollicular erythema and edema (Fig. 14.1). Of note, longer pulses with lower power densities, typically used in the darkest of phototypes may not display this endpoint (Ross 2001), and typically do not experience good efficacy. Hair singeing is another endpoint but does not predict response. It is recommended that hairs are shaven below the level of the epidermis as any hairs protruding through the epidermis can potentially absorb the energy-increasing the risk of epidermal damage and theoretically decreasing the amount of energy reaching the target which can result in less efficacious treatments. When done properly, typically 15–30 % long term hair loss occurs with each LHR treatment (Dierickx et al. 1998). A useful analogy for setting patient expectation, is to imagine taking  $\frac{1}{4}$  of the water away from a full glass of water, such that  $\frac{3}{4}$  remains. Even after doing this many times, there is always a little bit of water in the glass. Similarly, LHR typically leaves behind some hairs.

Patients with skin of color can be safely and effectively treated with laser devices for hair removal. Long pulsed, 1064 nm Nd:YAG lasers delivered with good skin cooling are considered the gold standard laser of choice when conducting laser hair removal in skin of color- particularly those of the darkest phototype. Skin of color patients with lighter phototypes can also be treated with other laser modalities such as the 810 nm diode and 755 nm alexandrite lasers. If the latter lasers are used in skin phototypes types 5 and 6, longer pulse durations and lower energies are necessary to minimize the risk of epidermal injury. One must recognize the challenges and potential pitfalls when treating darker skin types and look for classic endpoints when treating. Above all, a “cookbook” approach to LHR must be avoided – individual pigmentation of both skin and hair varies widely, even within a skin phototype, In addition, individuals have varying hair color, hair shaft diameter, depth, and sensitivity. Finally, laser hair removal is not permanent, and maintenance therapy is usually needed long-term, particularly on facial areas.

## Key Points

- Patients with skin of color can successfully be treated with laser devices for laser hair removal. The 1064 nm ND:YAG device is typically the laser modality of choice due to its deeper penetration and lower absorption within the epidermis. 755 nm alexandrite and 810 nm diode laser systems have been used successfully as well, in skin of color.
- In photoepilation, the extended theory of selective photothermolysis is necessary to achieve optimal more permanent hair reduction. The hair shaft effectively acts as a source of light absorption, allowing heat transfer to the regenerative system located in the bulb and/or bulge regions. A longer pulse duration is required to transfer heat from the chromophore to the intended target.
- Cooling the epidermis during treatment is of paramount importance. Cooling methods include sapphire chilled tips attached to the laser device, dynamic cooling devices with cryogen, and forced cold air.
- Side effects such as post inflammatory hyper- and hypopigmentation, ulcers, and scars have been reported with improper laser use and/or inadequate cooling. These side effects are almost always caused by unwanted epidermal damage, leading to injury, inflammation and/or wounds.
- In areas with very dense hairs, one should consider lower fluences initially to decrease the risk of collateral thermal damage to adjacent untargeted structures from the accumulation of heat from closely spaced hair follicles.
- Avoid any method of hair removal, which removes the hair shaft, such as waxing, approximately 3 weeks prior to photoepilation.
- Limiting the amount of and area to which topical anesthesia is applied is key in preventing lidocaine toxicity which can lead to seizures and even death.
- In the setting of hirsutism or new onset hypertrichosis, it is prudent that a work-up is conducted to find or rule out any underlying medical etiology.

## References

- Alster TS, Bryan H, Williams CM. Long-pulsed Nd:YAG laser-assisted hair removal in pigmented skin: a clinical and histological evaluation. *Arch Dermatol*. 2001;137(7):885–9.
- Altshuler GB, Anderson RR, Manstein D, Zenzie HH, Smirnov MZ. Extended theory of selective photothermolysis. *Lasers Surg Med*. 2001;29(5):416–32.
- Anderson RR, Parrish JA. The optics of human skin. *J Invest Dermatol*. 1981;77(1):13–9.
- Anderson RR, Parrish JA. Selective photothermolysis: precise microsurgery by selective absorption of pulsed radiation. *Science*. 1983;220(4596):524–7.
- Bouzari N, Tabatabai H, Abbasi Z, Firooz A, Dowlati Y. Laser hair removal: comparison of long-pulsed Nd:YAG, long-pulsed alexandrite, and long-pulsed diode lasers. *Dermatol Surg*. 2004;30(4 Pt 1):498–502.
- Cotsarelis G, Sun TT, Lavker RM. Label-retaining cells reside in the bulge area of pilosebaceous unit: implications for follicular stem cells, hair cycle, and skin carcinogenesis. *Cell*. 1990;61(7):1329–37.
- Desai S, Mahmoud BH, Bhatia AC, Hamzavi IH. Paradoxical hypertrichosis after laser therapy: a review. *Dermatol Surg*. 2010;36(3):291–8.
- Dierickx CC, Grossman MC, Farinelli WA, Anderson RR. Permanent hair removal by normal-mode ruby laser. *Arch Dermatol*. 1998;134(7):837–42.
- Grossman MC, Dierickx C, Farinelli W, Flotte T, Anderson RR. Damage to hair follicles by normal-mode ruby laser pulses. *J Am Acad Dermatol*. 1996;35(6):889–94.
- Hamzavi I, Tan E, Shapiro J, Lui H. A randomized bilateral vehicle-controlled study of eflornithine cream combined with laser treatment versus laser treatment alone for facial hirsutism in women. *J Am Acad Dermatol*. 2007;57(1):54–9.
- Ibrahimi OA, Avram MM, Hanke CW, Kilmer SL, Anderson RR. Laser hair removal. *Dermatol Ther*. 2011;24(1):94–107.
- Kvedar JC, Gibson M, Krusinski PA. Hirsutism: evaluation and treatment. *J Am Acad Dermatol*. 1985;12(2 Pt 1):215–25.
- Lin TY, Manuskiatti W, Dierickx CC, Farinelli WA, Fisher ME, Flotte T, et al. Hair growth cycle affects hair follicle destruction by ruby laser pulses. *J Invest Dermatol*. 1998;111(1):107–13.

- Mandt N, Troilius A, Drosner M. Epilation today: physiology of the hair follicle and clinical photo-epilation. *J Investig Dermatol Symp Proc.* 2005;10(3):271–4.
- Rao J, Goldman MP. Prospective, comparative evaluation of three laser systems used individually and in combination for axillary hair removal. *Dermatol Surg.* 2005;31(12):1671–6; discussion 7.
- Richards RN, McKenzie MA, Meharg GE. Electroepilation (electrolysis) in hirsutism. 35,000 hours' experience on the face and neck. *J Am Acad Dermatol.* 1986;15(4 Pt 1):693–7.
- Ross EV. Extended theory of selective photothermolysis: a new recipe for hair cooking? *Lasers Surg Med.* 2001;29(5):413–5.
- Surgeons ASoP. Top five cosmetic minimally-invasive procedures of 2013. 2013 [cited 2015 Feb 12]. Available from: <http://www.plastic-surgery.org/news/plastic-surgery-statistics/2013/top-five-cosmetic-minimally-invasive-procedures.html>.

# Chapter 15

## Dermal Fillers

**Porcia B. Love**

### Case Presentation

A 50 year old African American female presents with under eye darkening, sagging cheeks, and smile lines.

### Physical Examination

On examination, decreased fullness around the cheeks are noted. The malar fat pads are atrophic and have descended. She also has infraorbital hollowing, tear trough deformity, and deepening of the nasolabial folds (Fig. 15.1a).

### Case Treatment

The procedure of injecting hyaluronic acid filler into the dermis was discussed with the patient. Side effects of hyaluronic acid filler injections, including bruising, redness, swelling, nodules

---

P.B. Love, MD

Montgomery Dermatology, PC, 4712 Berry Boulevard,  
Montgomery, AL 36106, USA

e-mail: [porcialove@gmail.com](mailto:porcialove@gmail.com)

P.B. Love, R.V. Kundu (eds.), *Clinical Cases in Skin of Color: Medical, Oncological and Hair Disorders, and Cosmetic Dermatology*, Clinical Cases in Dermatology, DOI 10.1007/978-3-319-23615-5\_15, 171  
© Springer International Publishing Switzerland 2016

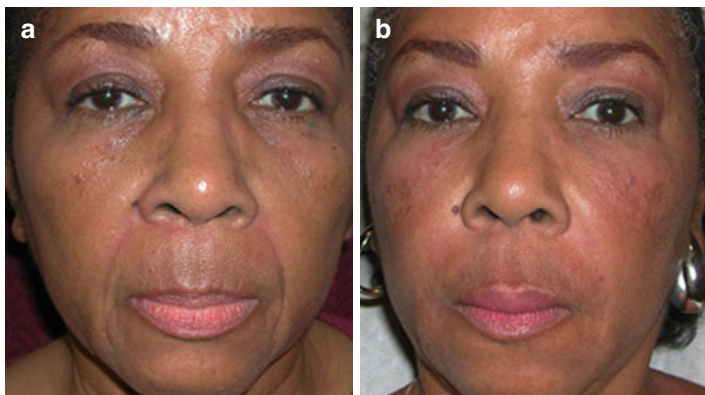


FIGURE 15.1 Dermal fillers. **(a)** The patient presented with infraorbital hollowing, tear trough deformity, and deepening of the nasolabial folds. **(b)** Hyaluronic acid injections were performed to correct the infraorbital hollows and nasolabial folds (Photos courtesy of Dr. Cheryl Burgess)

and the rare complications of necrosis and blindness, were discussed with the patient. After written consent was received, the patient was treated with 2.0 cc of hyaluronic acid filler to correct the infraorbital hollowing and nasolabial folds (Fig. 15.1b).

## Discussion

The popularity of dermal fillers has grown rapidly in recent years because they offer the rejuvenating and enhancing aesthetic improvements previously only achievable with surgery, but at lower cost and with limited-to-no recovery time (Gilbert et al. 2012). However, unlike surgery, the majority of dermal fillers are temporary and last anywhere from 6 months to 3 years, depending on the product. The main indications for fillers are the filling of rhytides and folds and correction of soft tissue loss due to disease or age. Increasingly, fillers are used for volume replacement and enhancement procedures, including cheek and chin augmentation, tear

trough correction, nose reshaping, midfacial volumization, lip enhancement, hand rejuvenation, and the correction of facial asymmetry (Funt and Pavicic 2013).

Soft tissue augmentation with dermal fillers can be particularly effective in treating the volume loss and soft tissue redistribution seen with intrinsic aging. Replacing lost volume has been accomplished using autologous fat transfers and human collagen, as well as with products from nonhuman sources such as bacteria-derived hyaluronic acid (HA), bovine or porcine collagen, and synthetic calcium hydroxylapatite or poly-L-lactic acid (Gilbert et al. 2012). The most popular filling agents are the HA derivatives.

Midfacial aging is a common pattern of age-related changes, particularly in darker-skinned populations. The malar fat pads, normally positioned over the infraorbital rim, atrophy and descend, leading to characteristic signs of midfacial aging such as infraorbital hollowing, tear trough deformity, and deepening of the nasolabial folds (Harris 2004). Changes in the underlying skeletal morphology may also play a role in the development of these features. Infraorbital maxillary hypoplasia can be found in patients of African, Hispanic, and Asian ancestry, and bone resorption due to the natural process of aging can work to undermine facial skeletal support (Shirakabe et al. 2003; Grimes et al. 2008). Darker-skinned individuals may develop greater gravitational descent of facial soft tissues with time from the combination of dense, heavy subcutaneous tissue and a weaker facial skeletal support (Grimes et al. 2008). Volume loss can also occur in the temporal regions, lateral chin, and lips, although the last location is not a typical concern in African Americans (Davis and Callender 2011).

Soft tissue augmentation with injectable fillers can be safe and effective in populations with dark skin. Multiple techniques are currently used to inject fillers, including linear threading, serial puncture, serial threading, the fan technique, and crosshatching. Patients with skin of color may develop erythema after injection; therefore, to decrease the risk of complications in skin of color, some authors have



recommended minimizing the number of punctures, such as with linear threading (Taylor et al. 2009) and mid-dermal placement of HA fillers to avoid disruption of the dermal-epidermal junction. One clinical study with approximately 20 % of subjects with skin of color found that injection techniques that disrupt the subepidermal plane, such as the fan technique; rapid injection rates; and higher volumes, increased the incidence of local adverse events (Glogau and Kane 2008). The use of cold compresses and massage can not only improve aesthetic outcomes, but also can help to decrease complications such edema and bruising (Ogunze et al. 2007). Most often, postinjection erythema does not require treatment and will resolve with sequelae, but if significant erythema occurs, application of a mid- to high-potency topical corticosteroid may decrease the risk of postinflammatory dyschromia (Davis and Callender 2011).

### *Safety and Efficacy Data*

Since 2003, the FDA has approved several dermal fillers with the condition that postapproval studies be conducted specifically in patients with Fitzpatrick skin type (FST) IV to VI. The goal of these studies was to assess the safety of dermal fillers, particularly rates of keloid formation, dyschromias, hypertrophic scarring, and hypersensitivity, in skin of color because this population was underrepresented in the premarket clinical studies and may be at a higher risk of developing these complications (Davis and Callender 2011).

Grimes and colleagues published the results of a subgroup analysis evaluating the safety and efficacy of multiple HA fillers in people with FST IV to VI using one of three highly concentrated HA fillers. Of the 439 study participants, 160 (36 %) were FST IV to VI, and there were no occurrences of hypersensitivity or hypertrophic scarring, keloid formation or hypopigmentation in non-Caucasian vs. Caucasian subjects. There were three instances of mild hyperpigmentation. All of the HA fillers were well tolerated in individuals with skin of

color and demonstrated effectiveness throughout the 24 week follow-up period (Grimes et al. 2009).

Postapproval safety studies have been conducted using HA and calcium hydroxylapatite fillers, and all have found that the rate of dyschromia was similar between Caucasian and non-Caucasian patients (Taylor et al. 2009; Grimes et al. 2009; Marmur et al. 2009). There were no reports of keloid formation and single cases of asymptomatic positive serum IgG antibody titer and mild hypertrophic scarring with HA fillers (Davis and Callender 2011).

Studies by Taylor et al compared the efficacy and tolerability of small-gel-particle and large-gel-particle HA in correcting nasolabial folds in 150 patients with FST IV to VI. Pigmentation changes occurred in 6–9 % of patients treated with large-gel particle and small-gel particle HA, respectively. There were 17 cases of hyperpigmentation. Most were mild or moderate and resolved within 12 weeks, except for three patients with postinflammatory hyperpigmentation. Treatments using minimal numbers of needle sticks (such as linear threading technique) were recommended to reduce the potential for pigmentation changes and local adverse events (Taylor et al. 2009).

In a study by Marmur et al evaluating the use of calcium hydroxylapatite in moderate to severe facial wrinkles and folds, including the nasolabial folds (NLFs) in 100 patients with Fitzpatrick skin types IV to VI, calcium hydroxylapatite was injected subdermally with a 25–27-gauge needle. There were no reports of keloid formation, hypertrophic scarring, hypo- or hyperpigmentation, or other clinically significant adverse events. Because of this safety feature, calcium hydroxylapatite was noted to be an attractive dermal filler in the skin of color population (Marmur et al. 2009).

Dermal fillers are typically safe; however, no medical procedure is without risks. Transient and self-limiting complications include erythema, bruising, and swelling. Nodules and granuloma formation can occur with any filler, but are less common with hyaluronic acid than poly-lactic acid and calcium hydroxyapatite and permanent fillers like

polymethylmethacrylate. Hyaluronidase can correct nodules from hyaluronic acid. Necrosis or even blindness are rare complications that can occur from inadvertent injection into the arterial circulation. Therefore, the injecting physician should inject slowly and watch for any signs of vascular compromise such as skin color change (blue or blanched) and immediately stop injection if this occurs. The area should be massaged, topical nitroglycerin paste should be applied, and a full dose of aspirin should be given (Lupo 2011).

## Key Points

- Midfacial aging is a common pattern of age-related changes, particularly in darker-skinned populations, that occurs when the malar fat pads, normally positioned over the infraorbital rim, atrophy and descend, leading to characteristic signs of midfacial aging such as infraorbital hollowing, tear trough deformity, and deepening of the nasolabial folds.
- Soft tissue augmentation with dermal fillers can be particularly effective and safe in treating the volume loss and soft tissue redistribution seen with intrinsic aging in patients with skin of color.
- Treatment using minimal numbers of needle sticks (such as the linear threading technique) is recommended to reduce the potential for pigmentation changes and local adverse events in patients with skin of color.

## References

- Davis EC, Callender VD. Aesthetic dermatology for aging ethnic skin. *Dermatol Surg*. 2011;37(7):901–17.
- Funt D, Pavicic T. Dermal fillers in aesthetics: an overview of adverse events and treatment approaches. *Clin Cosmet Investig Dermatol*. 2013;6:295–316.
- Gilbert E, Hui A, Waldorf HA. The basic science of dermal fillers: past and present part I: background and mechanisms of action. *J drugs Dermatol*. 2012;11(9):1059–68.

- Glogau RG, Kane MA. Effect of injection techniques on the rate of local adverse events in patients implanted with nonanimal hyaluronic acid gel dermal fillers. *Dermatol Surg.* 2008;34 Suppl 1:S105–9.
- Grimes P, Hexsel D, Rutowitsch M. The aging face in darker racial ethnic groups. In: Grimes P, Soriano T, Hexsel D, Kim J, editors. *Aesthetics and cosmetic surgery for darker skin types.* Philadelphia: Lippincott Williams & Wilkins; 2008. p. 27–36.
- Grimes PE, Thomas JA, Murphy DK. Safety and effectiveness of hyaluronic acid fillers in skin of color. *J Cosmet Dermatol.* 2009;8(3):162–8.
- Harris MO. The aging face in patients of color: minimally invasive surgical facial rejuvenation—a targeted approach. *Dermatol Ther.* 2004;17(2):206–11.
- Lupo M. Hyaluronic acid fillers. In: Beer K, Lupo M, Narurkar V, editors. *Cosmetic bootcamp primer: comprehensive aesthetic management.* London/New York: Informa Healthcare; 2011. p. 135–40.
- Marmur ES, Taylor SC, Grimes PE, Boyd CM, Porter JP, Yoo JY. Six-month safety results of calcium hydroxylapatite for treatment of nasolabial folds in Fitzpatrick skin types IV to VI. *Dermatol Surg.* 2009;35 Suppl 2:1641–5.
- Odunze M, Cohn A, Few JW. Restylane and people of color. *Plast Reconstr Surg.* 2007;120(7):2011–6.
- Shirakabe Y, Suzuki Y, Lam SM. A new paradigm for the aging Asian face. *Aesthetic Plast Surg.* 2003;27(5):397–402.
- Taylor SC, Burgess CM, Callender VD. Safety of nonanimal stabilized hyaluronic acid dermal fillers in patients with skin of color: a randomized, evaluator-blinded comparative trial. *Dermatol Surg.* 2009;35 Suppl 2:1653–60.

# Index

## A

- Acne keloidalis nuchae (AKN), 67
- Acne scarring, 151, 153–154
- Acne vulgaris, 145, 148, 151–152
- Acral lentiginous melanoma (ALM), 100, 103, 105
- Acute cutaneous lupus erythematosus (aCLE), 8, 9
- Androgenetic alopecia
  - case history, 41
  - case treatment, 43
  - “Christmas tree” pattern, 44, 45
  - clinical differential diagnosis, 42
  - clinical manifestations, 44
  - dihydrotestosterone, 44
  - genetics, 44
  - histopathology, 43
  - pathogenesis, 44
  - physical examination, 41–42
  - quality of life, 45
  - treatment, 46–48
- Antifolates, 120

- Antimalarial therapy, 11
- Azathioprine, 26

## B

- Basal cell carcinoma
  - in African American, 84
  - anatomic distribution, 83
  - case presentation, 79
  - case treatment, 81
  - clinical features, 83
  - clinicopathologic types, 83
  - darker skin, 82
  - differential diagnosis, 80
  - genetic condition, 82
  - Hispanic and Asian populations, 81
  - histopathology, 80
  - physical examination, 79–80
  - sunscreen, 84
  - treatment, 84–85
  - ultraviolet radiation exposure, 82
- Biotin deficiency, 37
- Bleomycin, 73
- Bowen’s disease, 93–94, 128

## C

## Central centrifugal cicatricial alopecia (CCCA), 42

- biopsies, 57
- case presentation, 51
- case treatment, 54
- chemical relaxers, 56
- clinical evidence, 55
- dermatoscopic findings, 57
- differential diagnosis, 53–54
- etiology and risk factors, 55
- genetics, 56
- hair loss, 55
- histopathology, 54
- incidence and prevalence, 55
- physical examination, 52–53
- traumatic hair styling practices, 56
- treatment, 58–59

## Chemical peels

- acne scarring, 153–154
- acne vulgaris, 151–152
- case presentation, 145
- case treatment, 147
- deep peels, 148, 149
- diagnosis, 147
- glycolic acid, 150
- histologic inflammation, 147
- indications, 147, 148
- Jessner's solution, 151
- medium-depth peels, 148, 149
- for melasma, 152
- physical examination, 145–146
- postinflammatory hyperpigmentation, 152
- pseudofolliculitis barbae, 154–155
- salicylic acid, 150
- solar lentigines and mottlingbarbae, 155–156
- superficial peels, 148, 149
- trichloroacetic acid, 150–151

## Chemotherapy, 121

“Christmas tree” pattern, 44, 45

## Cutaneous sarcoidosis

- maculopapular sarcoidosis, 22
- morphologic subtypes, 20–21
- skin involvement, 19

## Cutaneous T-cell lymphoma (CTCL)

- advanced stage disease (IIB, III, IV) treatment
  - antifolates, 120
  - chemotherapy, 121
  - extracorporeal photopheresis (ECP), 120–121
  - histone deacetylase inhibitors, 120
  - interferons, 119–120
  - retinoids, 119

## aromatic halogenated

- hydrocarbons, 114

## case presentation, 111

## case treatment, 113

## diagnosis, 113

## differential diagnosis, 112

## early stage disease (IA, IB, IIA) treatment

- phototherapy, 118
- topical steroids, 117–118
- TSEBT and local radiation, 118–119

## etiology, 114

## F-fluorodeoxyglucose (FDG), 113

## histologic findings, 114

## histopathology, 113

## hypopigmented mycosis

- fungoides, 115

## incidence, 114

## mycosis fungoides, 114

## physical examination, 111–112

## polymerase chain reaction, 117

## positron emission

- tomography, 113

## recognition and diagnosis, 117

- right femoral lymph node
    - biopsy, 113
  - Sezary syndrome, 115
  - skin of color, 115
  - tumor stage mycosis
    - fungoides, 116
- D**
- Dermal fillers
    - case presentation, 171
    - case treatment, 171–172
    - indications, 172
    - midfacial aging, 173
    - physical examination, 171–172
    - safety and efficacy data, 174–176
    - soft tissue augmentation, 173
    - volume replacement and enhancement
      - procedure, 172
  - Dermatofibrosarcoma
    - protuberans, 65
    - African Americans, 128
    - in Blacks, 128
    - case presentation, 125
    - case treatment, 127
    - cause, 130
    - differential diagnosis, 126–127
    - histologic examination, 130
    - histopathology, 127
    - local recurrences, 130
    - metastatic lesion, 130
    - physical examination, 125–126
    - treatment, 131
  - Dermatosis papulosa nigra (DPN)
    - in African-Americans, 139
    - in Asians, 140
    - case presentation, 137
    - case treatment, 139
    - differential diagnosis, 138–139
    - FGFR3 mutation, 141
    - histopathology, 139
    - physical examination, 137–138
    - prevalence, 140
    - treatment, 141–143
  - Dihydrotestosterone, 44, 47
  - Discoid lupus erythematosus (DLE)
    - in African American, 9
    - case presentation, 3
    - case treatment, 6
    - Chinese patients, 10
    - clinical signs, 6
    - complications, 9
    - diagnosis, 5
    - differential diagnosis, 4–5
    - laboratory studies, 5
    - pathology, 5
    - physical Examination, 4
    - prevalence, 6
    - of scalp, 8
    - treatment, 10–11
  - DLE. *See* Discoid lupus erythematosus (DLE)
  - DPN. *See* Dermatitis papulosa nigra (DPN)
- E**
- Earlobe keloids, 67
  - Electrolysis, 162
  - Erythema nodosum, 21
  - Extracorporeal photopheresis (ECP), 120–121
- F**
- F-fluorodeoxyglucose (FDG), 113
  - Fitzpatrick skin type (FST) IV, 174
- G**
- Granuloma annulare, 5
  - Granulomatous rosacea, 16
  - Glycolic acid, 148, 150, 152, 153

**H**

- Histone deacetylase inhibitors, 120
- Hydroxychloroquine, 6, 11, 25, 58

**I**

- Imiquimod, 73, 84
- Interferons, 119–120
- Intralesional corticosteroids, 10, 37, 58, 71

**J**

- Jessner's solution, 151

**K**

- Keloids
  - acne keloidalis nuchae, 67
  - case history, 63
  - case treatment, 65–66
  - differential diagnosis, 65
  - earlobe keloids, 67
  - histopathology, 65
  - physical examination, 63–64
  - postincisional keloids, 67
  - spontaneous keloids, 67
  - treatment
    - bleomycin, 73
    - chemotherapeutic agents, 72
    - complications, 69
    - cryosurgery, 71
    - hyperpigmentation and hypopigmentation, 68
    - imiquimod, 73
    - insoluble triamcinolone acetone, 69
    - intralesional triamcinolone acetone, 69, 70
    - radiotherapy, 71
    - recurrence rates, 71, 72
    - silicone gel sheeting, 70

- skin difference, 67
- surgical excision, 71

**L**

- Lichen planopilaris (LPP), 53
- Lobomycosis, 65
- Lofgren Syndrome, 20
- Lupus pernio, 20, 22

**M**

- Maculopapular sarcoidosis, 16, 22
- Melanocytic nevi, 138
- Melanoma
  - acral lentiginous melanoma, 103
  - in African Americans, 102, 104
  - in Asians, 102, 104
  - case presentation, 99
  - case treatment, 101–102
  - clinicopathologic types, 103
  - diagnosis, 101
  - differential diagnosis, 100–101
  - in Hispanic patients, 103
  - histopathology, 101
  - incidence rate, 102
  - physical examination, 99–100
  - prevention, 106–107
  - radiographic results, 101
  - risk factors, 102
  - skin of color, 103
  - treatment, 105–106
- Melasma, 150, 152, 153
- Methotrexate, 120
- Minoxidil, 37, 46, 58
- Mottlingbarbae, 155–156
- Mycosis fungoides (MF), 112–114, 116

**O**

- Oral antimalarial agents, 11



**P**

- Photodynamic therapy, 85
- Phototherapy, 113, 118
- Pityriasis rosea, 112
- Plaque sarcoidosis, 20
- Postincisional keloids, 67, 72
- Postinflammatory
  - hyperpigmentation, 152
- Pseudofolliculitis barbae,
  - 151, 154–155
- Pulsed dye laser (PDL)
  - therapy, 143

**Q**

- Quinacrine, 11

**R**

- Retinoids, 119
- Radiotherapy, 71
- Recalcitrant disease, 25

**S**

- Salicylic acid, 146, 148, 150, 152
- Sarcoidosis
  - in African Americans, 19
  - bilateral hilar
    - adenopathy, 22
  - in Blacks and Asians, 19
  - BTNL2 gene, 19
  - case history
    - case treatment, 18
    - chest X-ray, 17
    - diagnosis, 17
    - differential diagnosis,
      - 16–17
    - histopathology, 17
    - laboratory results, 17
    - physical examination,
      - 15–16
  - characteristics, 18
  - clinical presentation, 24
  - cutaneous sarcoidosis

- maculopapular
    - sarcoidosis, 22
  - morphologic subtypes,
    - 20–21
  - skin involvement, 19
  - hypopigmented
    - sarcoidosis, 23
  - incidence, 19
  - Japanese patients, 24
  - lungs, 22
  - lupus pernio, 22
  - 5q31 locus, 19
  - sarcoidal granulomatous
    - infiltration, 23
  - treatment, 24–26
  - tumor necrosis factor, 19
  - Sezary syndrome, 115, 116
  - Soft tissue augmentation, 173
  - Solar lentigines, 155–156
  - Spontaneous keloids,
    - 67, 69
  - Squamous cell carcinoma
    - actinic keratosis, 93
    - in African American, 93
    - Bowen's disease, 93–94
    - case presentation, 89
    - case treatment, 91
    - chronic scarring
      - processes, 92
    - differential diagnosis,
      - 90–91
    - histopathology, 91
    - physical examination,
      - 89–90
    - risk factors, 92
    - treatment, 94–95
    - ultraviolet radiation, 92
  - Steroids, 10–11, 25
  - Subcutaneous nodular
    - sarcoidosis, 21
- T**
- Thermal damage time
    - (TDT), 163

- Thermal relaxation time  
(TRT), 163
- Total skin electron beam therapy  
(TSBET), 118–119
- Traction alopecia  
biphasic alopecia, 35  
case presentation, 31  
case treatment, 33–34  
causes, 34  
cross-sectional study, 34  
differential diagnosis, 32–33  
“fringe sign,” 35  
histopathology, 33  
perifollicular papules and  
pustules, 35  
physical examination, 31–32  
population studies, 34  
in South Asian Sikh males, 35  
treatment, 36–38  
wefted hair extension, 36
- Trichloroacetic acid,  
148, 150–151
- Tumor necrosis factor (TNF), 26
- U**
- Ultraviolet radiation exposure  
(UVR), 82, 102
- V**
- Vemurafenib, 106
- Vitamin D supplementation, 84
- Vorinostat, 120