

Arne J. Venjakob

Proximal humeral fractures portray 5 % of all fractures in adults and represent the third most common fracture in adults over 65 years old [1]. Despite that there is no definite consensus in literature regarding the classification system so far.

In the following the most common classification systems will be presented:

Neer Classification

The Neer classification was established by Charles Neer II in 1970 [2]. This classification represents a modification of the Codman classification and implies the four-segment theory. This classification is based on the occurrence of displacement of one or more of the four major segments in terms of humeral shaft, humeral head, greater and lesser tuberosity. Six different fracture type groups have been introduced based on a patient collective of 300 patients with undislocated and dislocated proximal humeral fractures

treated in the New York Orthopaedic Hospital between 1953 and 1967.

The Neer classification may represent the most commonly used classification for proximal humeral fractures although several authors determined a low intraobserver reproducibility and interobserver reliability [3–7]. The Neer classification presents a descriptive classification without any recommendation of therapy for the different fracture types. In general for the Neer classification a segment is considered as displaced when a dislocation >1 cm or an angle >45° is present.

Group I consists of all undislocated fractures regardless of the number of fracture lines (see Fig. 8.1). Neer stated that the treatment of this group would be identical and in most cases of conservative character.

Group II includes a displacement of the articular-segment at the anatomical neck without separation of one or both tuberosities (see Fig. 8.1). Although being rare this fracture configuration needs to be identified by strict antero-posterior radiographs of the shoulder in order to prevent malunion and vascular necrosis.

Group III characterizes fractures at the level of the surgical neck being displaced more than 1 cm or angulated more than 45°. Three variations of this fracture have been described in terms of an (A) impacted and angulated surgical neck fracture, (B) separated surgical neck fracture and (C) comminuted surgical neck fracture. In 1970

A.J. Venjakob
Sports Orthopaedics Department,
Marienkrankenhaus Kaiserswerth,
Duesseldorf, Germany

Department of Trauma Surgery,
Klinikum rechts der Isar, Technical University
of Munich, Munich, Germany
e-mail: Arne.Venjakob@lrz.tu-muenchen.de

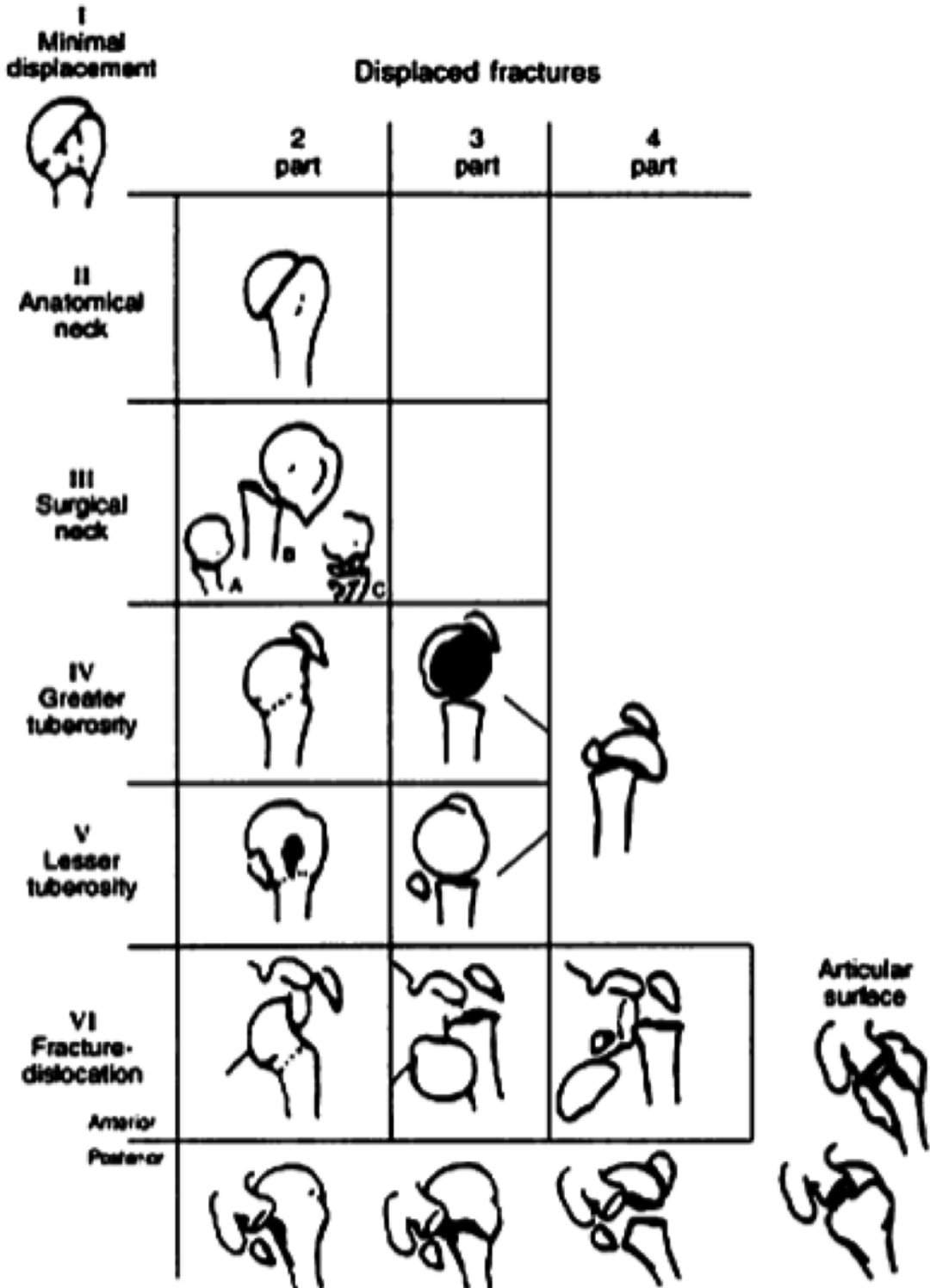


Fig. 8.1 Neer classification (Reprinted with permission from Neer [2])

conservative treatment options have been described by Charles Neer for group III fractures, whereas today displaced surgical neck fractures mainly are treated operatively.

In summary Group II and III fractures are classified as two-part fractures (see Fig. 8.1).

Group IV includes fractures of the greater tuberosity and may occur as two-, three- and four-part fractures (see Fig. 8.1). Two-part fractures reveal an articular segment which remains in normal position to the humeral shaft. A minimally displaced fracture of the surgical neck may be present as well. Three-part fractures are characterized by an additional fracture of the surgical neck often appearing due to an application of force by the subscapularis tendon resulting in internal rotation position. In four-part fractures a further detachment of the humeral head is present (see Fig. 8.1). Closed reduction of group IV fractures led to high rates of unsuccessful results mainly due to malunion [8].

In group V fractures a displacement of the lesser tuberosity is present. The two-part fracture of this group is characterized by a displacement of the lesser tuberosity, in some cases associated with an undisplaced fracture of the surgical neck. In three part fractures the surgical neck appears dislocated leading to abduction and external rotation position of the articular segment due to the attachment of the supraspinatus and infraspinatus tendon. The four-part fracture additionally reveals retraction of both tuberosities (see Fig. 8.1). Again closed reduction of group V fractures resulted in a high incidence of unsuccessful outcome.

In group VI fractures caused by a dislocation of the proximal humerus are summed up. Antero-inferior and posterior dislocation may occur in two-, three- and four-part fractures (see Fig. 8.1). It has been stated that a posterior displacement in combination with damage of more than 20 % of articular cartilage predisposes for recurrent shoulder instability and may require a so-called McLaughlin procedure in terms of a transplantation of the subscapularis tendon [9]. Defects greater than 50 % of the articular cartilage may even require prosthetic treatment.

Hertel Classification

The Hertel classification is predicated on the article “Fractures of the proximal humerus in osteoporotic bone” published by Ralph Hertel in the *Journal of Osteoporosis International* in 2005. In this article the author reviewed effective treatment options for proximal humeral fractures in patients suffering from severe osteoporosis [10]. In this context based on the original drawings [11] of Codman et al. a descriptive fracture classification was introduced by Hertel (see Fig. 8.2). In contrast to Neer’s classification [2] based on the four segment theory, this classification is based on five fracture planes.

In this context five questions have been released to identify the basic fracture planes:

1. Is there a fracture between the greater tuberosity and the humeral head?
2. Is there a fracture between the greater tuberosity and the humeral shaft?
3. Is there a fracture between the lesser tuberosity and the humeral head?
4. Is there a fracture between the lesser tuberosity and the humeral shaft?
5. Is there a fracture between the lesser and the greater tuberosity?

Consequently these fracture planes lie between the greater tuberosity and the humeral head, the greater tuberosity and the humeral shaft, the lesser tuberosity and the humeral head, the lesser tuberosity and the humeral shaft and the lesser and greater tuberosity. The combination of these fracture planes results in 12 possible fracture patterns as illustrated in Fig. 8.2. Hertel pointed out that several additional aspects need to be considered regarding an appropriate fracture classification: subsequently the length of the postero-medial metaphyseal head extension and the integrity of the medial hinge present the most important criteria (see Fig. 8.3). Furthermore the displacement of the tuberosities, the amount of angular displacement of the humeral head, the occurrence of glenohumeral dislocation, an impression fracture of the humeral head, a headsplitted component and the

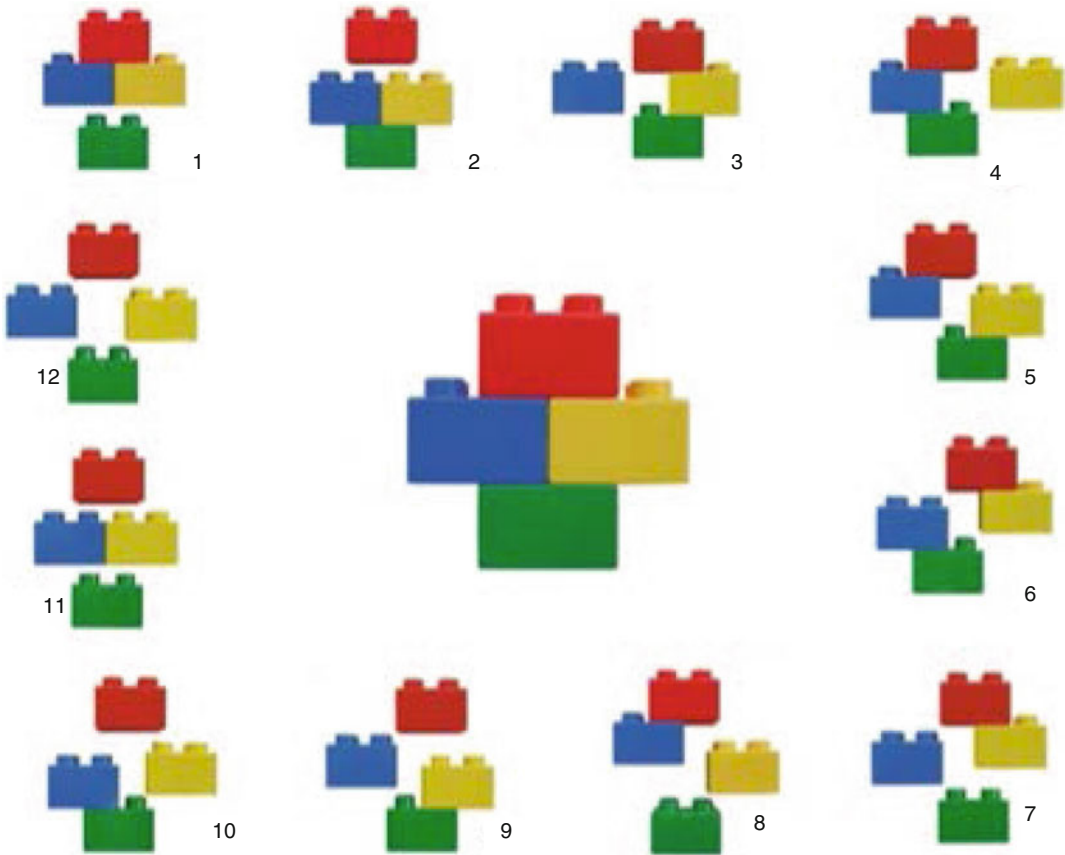


Fig. 8.2 Binary or “LEGO” descriptive system. The image illustrates the five basic fracture planes, resulting in 12 possible basic fractures: Six possible fractures divide the humerus into two fragments (figs. 1–6), five

possible fractures divide the humerus into three fragments (figs. 7–11) and one single fracture divides the humerus into four fragments (fig. 12) (Reprinted with permission from Hertel [10])

mechanical quality of the bone are of utmost importance. All criteria are considered as predictors for the perfusion of the humeral head. Accordingly 100 consecutive fractures were prospectively analysed by Hertel et al. [11] in respect of humeral head ischemia, revealing the length of the metaphyseal head extension and the integrity of the medial hinge as good predictors for ischemia (see Fig. 8.3).

AO (Association for Osteosynthesis)/ OTA (American Orthopaedic Trauma Association) Classification of Fractures and Dislocations

The AO classification (Association for Osteosynthesis, AO Foundation, Davos, Switzerland) for fractures of long bones was established in

1990 by Müller et al. [12]. Later this initial classification was further developed by surgeons and researchers of the AO and the American Orthopaedic Trauma Association (OTA) and is now officially named the AO/OTA Classification of Fractures and Dislocations.

This classification may contain the most accurate fracture-morphology compared to all other classification systems, being more comprehensive than the most commonly used Neer classification [13].

The first number of this classification represents the long bone (1 = humerus, 2 = radius/ulna, 3 = femur and 4 = tibia/fibula), the following defining the bone segment (1 = proximal, 2 = middle, 3 = distal and 4 = malleolar).

Proximal humeral fractures are therefore classified as 1.1-fractures and have been divided into extra-articular unifocal fractures (A), extra-

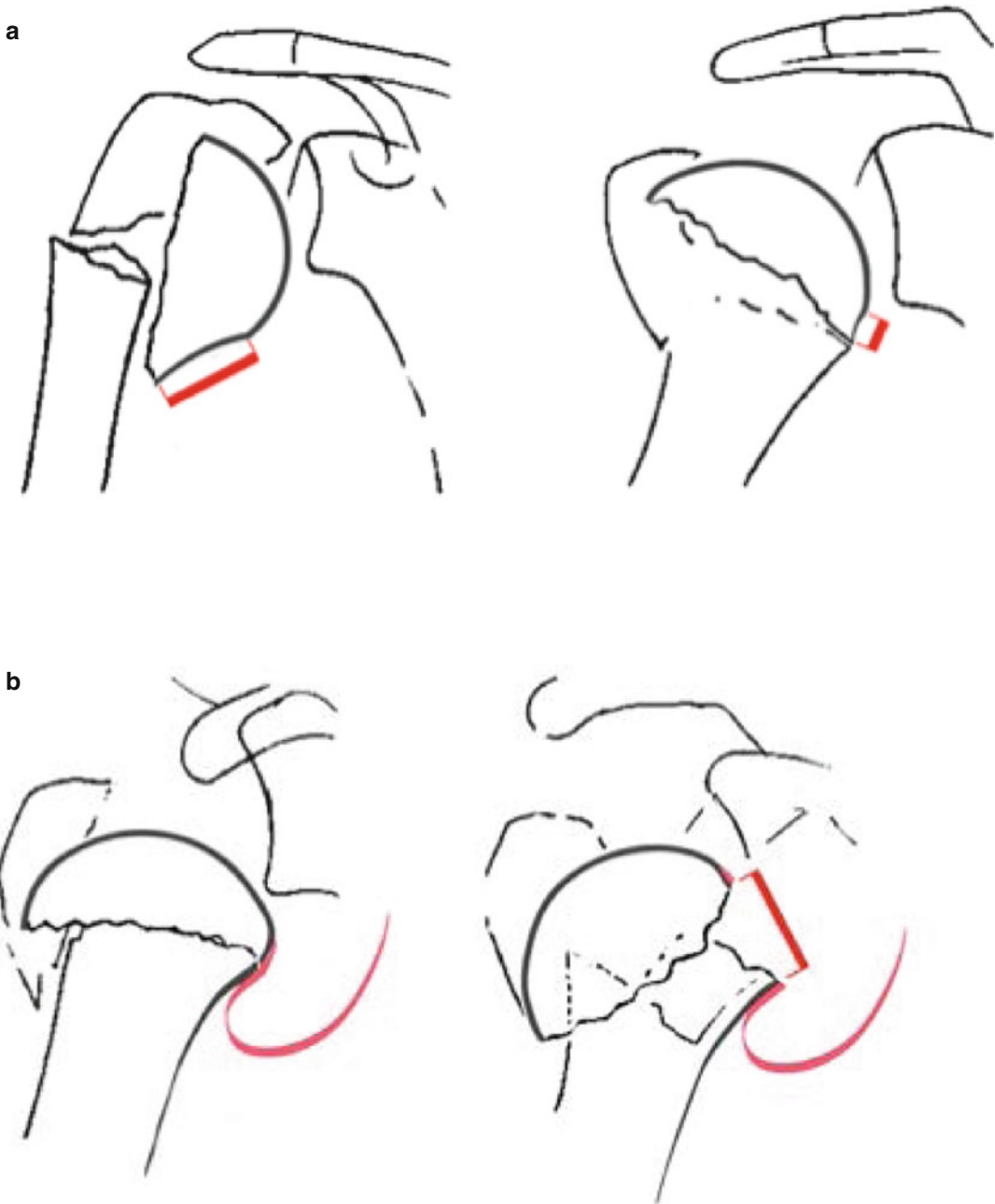


Fig. 8.3 Additional criteria as predictor for humeral head ischemia: (a) length of the medial metaphyseal head extension, (b) integrity of the medial hinge (Reprinted with permission from Hertel [10])

articular bifocal fractures (B) and articular fractures (C) (Fig. 8.4).

Type A fractures comprise non-articular, definite fractures which are rarely associated with the development of humeral head necrosis.

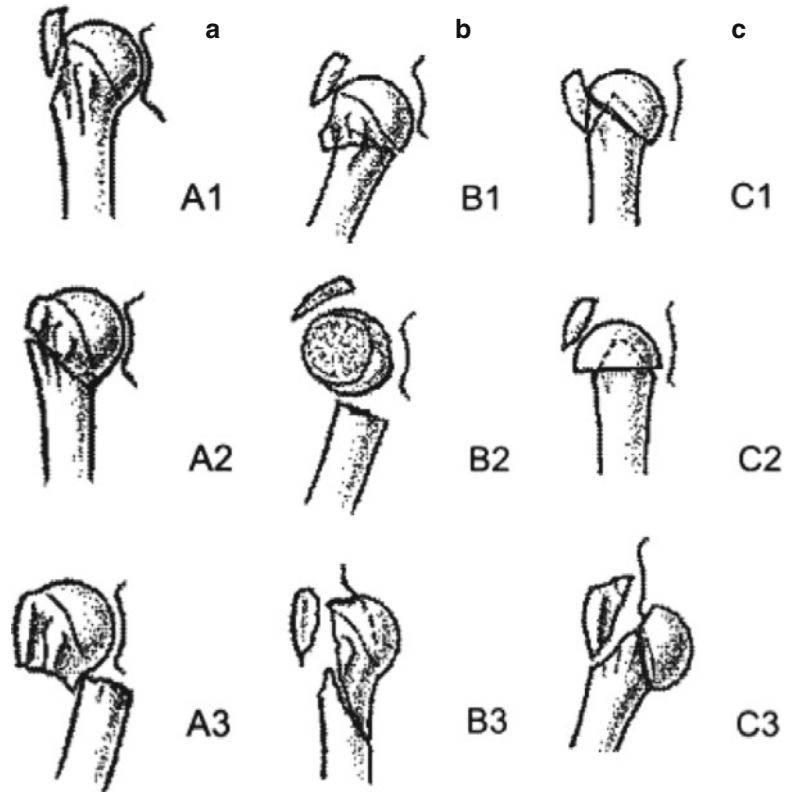
Type B fractures summarize bifocal fractures and type C fractures include severe, articular

fractures which are associated with a higher risk of osteonecrosis of the humeral head [12].

All groups (proximal/diaphysal/distal) have been divided into 9 additional subgroups resulting in 27 fracture types of the humerus.

Due to its high number of fracture types the AO/OTA Classification of Fractures and

Fig. 8.4 Depiction of the AO classification system showing an extra-articular fracture of the tuberosity (A1), an impacted metaphyseal fracture (A2) and a non impacted metaphyseal fracture (A3). Extra-articular bifocal fracture patterns include fractures with metaphyseal impaction (B1), without metaphyseal impaction (B2) and with glenohumeral dislocation (B3). Articular fractures are classified with slight displacement (C1), impacted with marked displacement (C2) and dislocated (C3) (Reprinted with permission from Muller et al. [12])



Dislocations is not as commonly used as the Neer classification. Furthermore a low reproducibility and reliability has been assessed in the literature with the AO/OTA Classification of Fractures and Dislocations [4, 14].

References

1. Baron JA, Barrett JA, Karagas MR. The epidemiology of peripheral fractures. *Bone*. 1996;18:209S–13.
2. Neer 2nd CS. Displaced proximal humeral fractures. I. Classification and evaluation. *J Bone Joint Surg Am*. 1970;52:1077–89.
3. Kristiansen B, Andersen UL, Olsen CA, Varmarken JE. The Neer classification of fractures of the proximal humerus. An assessment of interobserver variation. *Skeletal Radiol*. 1988;17:420–2.
4. Gumina S, Giannicola PA, Passaretti D, Cinotti G, Postacchini F. Comparison between two classifications of humeral head fractures: Neer and AO-ASIF. *Acta Orthop Belg*. 2011;77:751–7.
5. Sidor ML, et al. The Neer classification system for proximal humeral fractures. An assessment of interobserver reliability and intraobserver reproducibility. *J Bone Joint Surg Am*. 1993;75:1745–50.
6. Petit CJ, et al. Management of proximal humeral fractures: surgeons don't agree. *J Shoulder Elbow Surg*. 2010;19:446–51.
7. Shrader MW, Sanchez-Sotelo J, Sperling JW, Rowland CM, Cofield RH. Understanding proximal humerus fractures: image analysis, classification, and treatment. *J Shoulder Elbow Surg*. 2005;14:497–505.
8. Neer 2nd CS. Displaced proximal humeral fractures. II. Treatment of three-part and four-part displacement. *J Bone Joint Surg Am*. 1970;52:1090–103.
9. Mc LH. Posterior dislocation of the shoulder. *J Bone Joint Surg Am*. 1952;24-A-3:584–90.
10. Hertel R. Fractures of the proximal humerus in osteoporotic bone. *Osteoporos Int*. 2005;16 Suppl 2:65–72.
11. Hertel R, Hempfing A, Stiehler M, Leunig M. Predictors of humeral head ischemia after intracapsular fracture of the proximal humerus. *J Shoulder Elbow Surg*. 2004;13:427–33.
12. Müller ME, et al. The comprehensive classification of fractures of long bones. Berlin, Heidelberg, New York: Springer Verlag, 1990.
13. Court-Brown CM, Garg A, McQueen MM. The epidemiology of proximal humeral fractures. *Acta Orthop Scand*. 2001;72:365–71.
14. Sallay PI, et al. Reliability and reproducibility of radiographic interpretation of proximal humeral fracture pathoanatomy. *J Shoulder Elbow Surg*. 1997;6: 60–9.