

---

# Case 61: Older Clubfoot with Osteotomy Treated with MAC External Fixator

Michael M. Kheir, Anish G. R. Potty, and Richard S. Davidson

## Contents

1	<b>Brief Clinical History</b> .....	439
2	<b>Preoperative Clinical Photos and Radiographs</b> .....	440
3	<b>Preoperative Problem List</b> .....	440
4	<b>Treatment Strategy</b> .....	440
5	<b>Basic Principles</b> .....	440
6	<b>Images During Treatment</b> .....	440
7	<b>Technical Pearls</b> .....	441
8	<b>Outcome Clinical Photos and Radiographs</b> .....	441
9	<b>Avoiding and Managing Problems</b> .....	441
10	<b>See Also in Vol. 1</b> .....	444
	<b>References and Suggested Reading</b> .....	444

---

## Abstract

This case describes a 6 year old male with bilateral resistant clubfoot deformities related to be a variant of arthrogryptic clubfeet. The decision was made to treat with bilateral application of Biomet multiaxial correction (MAC) external fixation system with osteotomy. The use of the MAC external fixator allows for correction and adjustment of angular deformity and displacement in all three planes, including correction of residual or secondary deformities that occur during lengthening. The fixator can correct lower extremity deformities, including clubfoot, and allows the possibility of anatomic alignment within normal radiographic limits. Correction could be accomplished here with one MAC fixator on the midfoot bisector. The deformities can be corrected via a CORA-centric or CORA-perpendicular application. Correction can be accomplished through soft tissues if the joints are intact or osteotomy if the joints are degenerated and bone growth disturbances have occurred. The advantages of external fixation for clubfoot deformity are gradual correction, preservation of joints, correction through bone around deformed joints, post-operative adjustability, and reduced risk to nerves and vessels. Furthermore, if the osteotomy is not at the center of rotation of angulation (CORA), the external fixator can translate to compensate. For this patient's right foot, we performed a one-level application of the MAC external fixation system with lateral column closing wedge osteotomy of the calcaneus.

---

M.M. Kheir (✉)  
Perelman School of Medicine, University of Pennsylvania,  
Philadelphia, PA, USA  
e-mail: [mkheir@mail.med.upenn.edu](mailto:mkheir@mail.med.upenn.edu); [mikemkheir@gmail.com](mailto:mikemkheir@gmail.com)

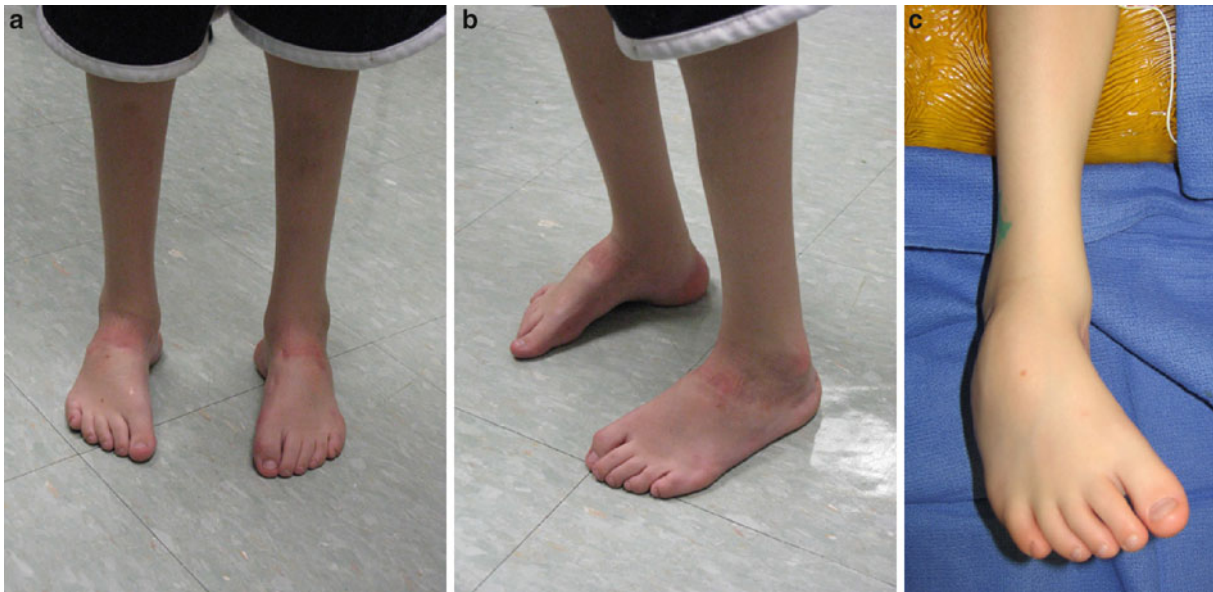A.G.R. Potty  
Department of Orthopaedics, The Children's Hospital of Philadelphia,  
Philadelphia, PA, USA  
e-mail: [potty@email.chop.edu](mailto:potty@email.chop.edu); [anish\\_potty@yahoo.co.uk](mailto:anish_potty@yahoo.co.uk)

R.S. Davidson  
Department of Orthopaedics/School of Medicine, Children's Hospital  
of Philadelphia/Hospital of the University of Pennsylvania,  
Philadelphia, PA, USA  
e-mail: [davidsonr@email.chop.edu](mailto:davidsonr@email.chop.edu); [davidson.richard.s@gmail.com](mailto:davidson.richard.s@gmail.com)

---

## 1 Brief Clinical History

A 6 year old boy was brought for a second opinion for bilateral residual and recurrent clubfoot deformities related to be a variant of arthrogryptic clubfeet. He has had two operations on each foot: one was likely to be a posterior medial Cincinnati incision circumferential release and the



**Fig. 1** (a–c) Pre-operative photograph demonstrating severe clubfoot in spite of previous corrective efforts

other an osteotomy of the calcaneus to correct the midfoot varus.

In spite of this, he is left with a foot where the hindfoot is reasonably well positioned but stiff at the ankle with plantar flexion varus deformity of the mid- and forefoot. He also demonstrated to have very weak calves and was using bilateral MAFOs to ambulate.

---

## 2 Preoperative Clinical Photos and Radiographs

See Figs. 1 and 2.

---

## 3 Preoperative Problem List

- Midfoot and forefoot plantar flexion and varus deformity

---

## 4 Treatment Strategy

The pre-operative plan included right foot one-level application of the Biomet multiaxial correction (MAC) external fixation system with lateral column closing wedge osteotomy of the calcaneus.

---

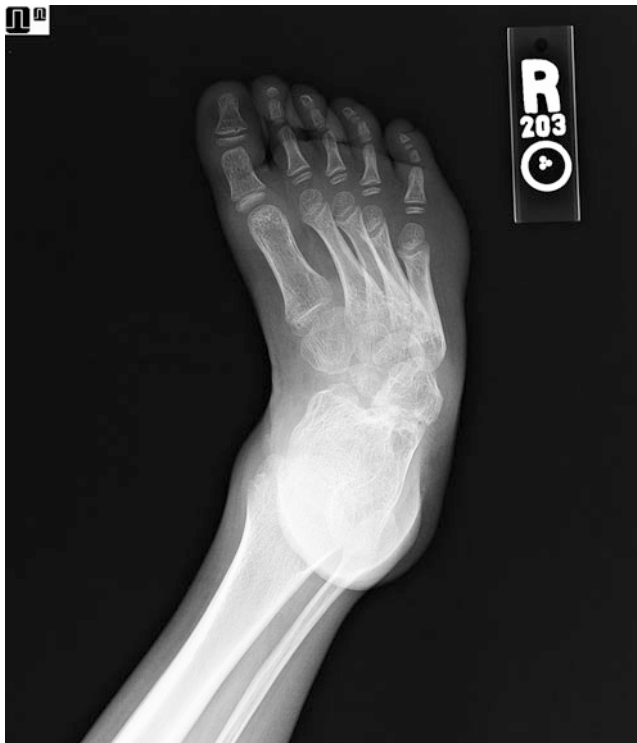## 5 Basic Principles

The use of the MAC external fixator allows for correction and adjustment of angular deformity and displacement in all three planes, including correction of residual or secondary deformities that occur during lengthening. The fixator can correct lower extremity deformities, including clubfoot, and allows the possibility of anatomic alignment within normal radiographic limits. Correction could be accomplished here with one MAC fixator on the midfoot bisector. The deformities can be corrected via a CORA-centric or CORA-perpendicular application. Correction can be accomplished through soft tissues if the joints are intact or osteotomy if the joints are degenerated and bone growth disturbances have occurred (Davidson 2011). An opening wedge osteotomy can avoid shortening an already small foot. The advantages of external fixation for clubfoot deformity are gradual correction, preservation of joints, correction through bone around deformed joints, post-operative adjustability, and reduced risk to nerves and vessels. Furthermore, if the osteotomy is not at the center of rotation of angulation (CORA), the external fixator can translate to compensate.

---

## 6 Images During Treatment

See Figs. 3 and 4.



**Fig. 2** Pre-operative dorsal-plantar radiograph demonstrating CAVE deformity

## 7 Technical Pearls

If the bottom of the foot is flat, perform an osteotomy through the talus or distal tibia. If the bottom of the foot is deformed (i.e., rocker sole), the osteotomy can be placed in the calcaneus (or supramalleolar) and the midfoot. For older children (older than 6 years of age), lateral closing wedge osteotomy (sliding osteotomy) of the calcaneus or cuboid can correct the heel valgus. It can also correct for lateral column varus and equinus (plantar flexion). Perform a resection arthrodesis of the calcaneocuboid joint if there is degenerative joint disease. Perform medial soft tissue release as needed, including the talonavicular joint.

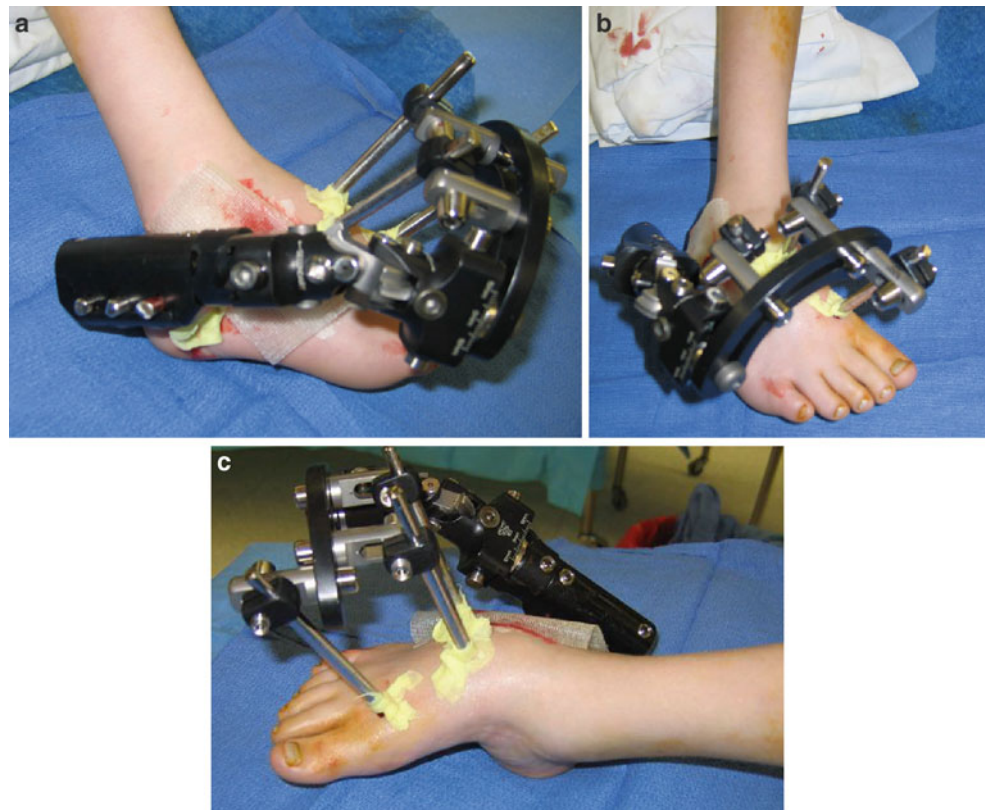
## 8 Outcome Clinical Photos and Radiographs

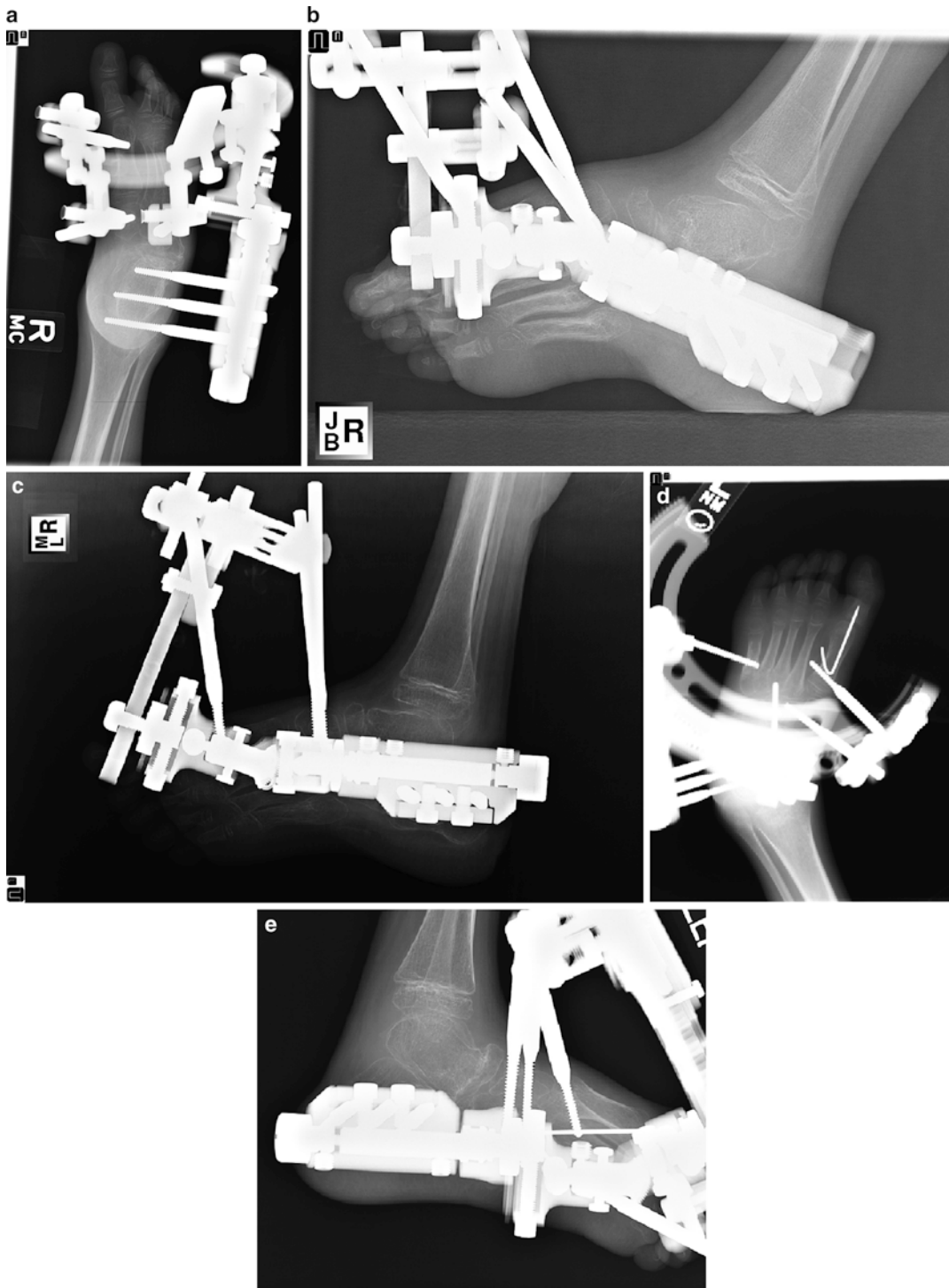
See Figs. 5 and 6.

## 9 Avoiding and Managing Problems

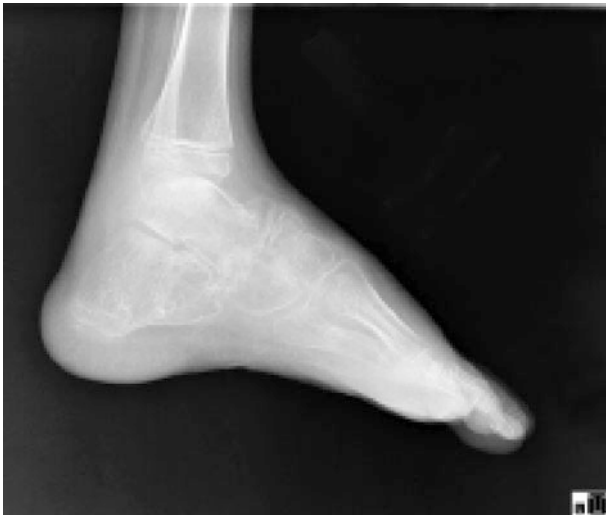The most common complications following the application of the MAC external fixation system are pin site infections and cellulitis, requiring antibiotics. Check pin sites at follow-up.

**Fig. 3** (a–c) Post-operative photograph demonstrating patient with external fixator





**Fig. 4** (a–e) Post-operative radiographs demonstrating gradual correction. Dorsal-plantar view of right foot (a), oblique view of right foot (b–d), and lateral view of right foot (e)

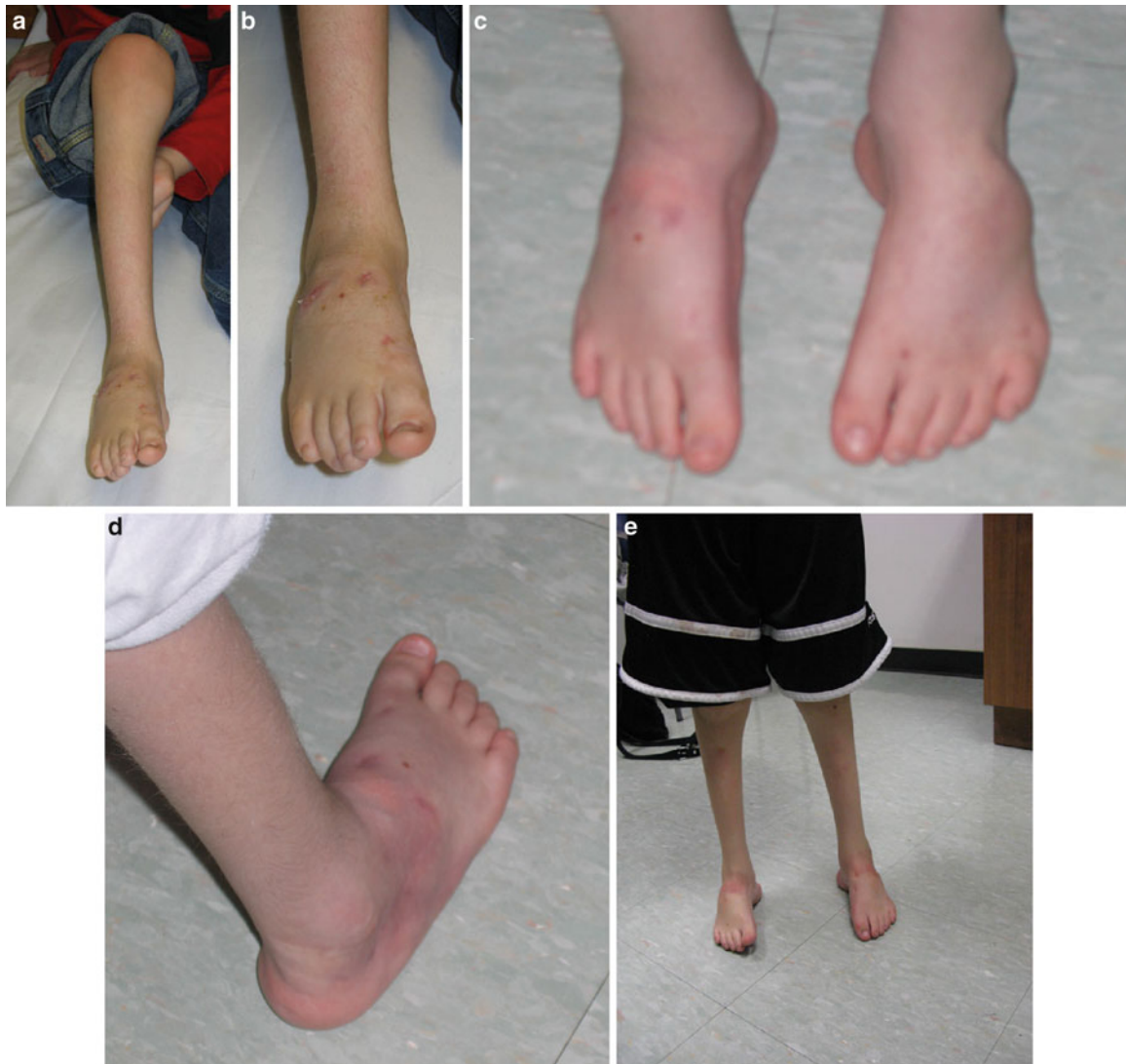

**Fig. 5** Lateral radiograph of the right foot

Take AP and lateral X-rays, and correct one direction at a time at  $1^\circ$  per day (or  $1/4$  mm four times per day).

Nerve palsy, leg length discrepancy, delayed union/nonunion, and compartment syndrome are rare complications. In general, major complications, including neurovascular complications, are extremely rare, given the gradual correction granted by the MAC external fixator compared to an acute correction. Although rare, a careful neurovascular examination must still be performed after the procedure.

Patients need to be followed up closely during the correction to avoid malalignment. Weekly X-rays are obtained until the deformities are corrected, usually in 2–3 weeks. Monthly X-rays are obtained from then on until consolidation is observed on radiographs, at which time the device can then be removed. As with all fixators, it can affect radiographic evaluation by directly obscuring the osteotomy site, which may lead to errors in measurements (Sabharwal et al. 2008). One must take account for these errors; oblique



**Fig. 6** (a–e) Photographs of the right foot with final correction

radiographs may be used to better visualize the osteotomy site and location of the CORA.

---

## 10 See Also in Vol. 1

Case 43: Tibial Hemimelia

Case 69: 13 year old with Unilateral Late-Onset Blount Disease

## References and Suggested Reading

- Davidson RS (2011) The MAC (multi-axial correcting) monolateral external fixation system (Biomet/EBI) technique: an easier way to correct deformity. *Oper Tech Orthop* 21(2):113–124
- Sabharwal S, Badarudeen S, McClemens E, Choung E (2008) The effect of circular fixation on limb alignment. *J Pediatr Orthop* 28:314–319