

Grégory Mesplé

Hand and Wrist Rehabilitation

Theoretical Aspects and
Practical Consequences

Foreword by
Marc Garcia-Elias

 Springer

Hand and Wrist Rehabilitation

Grégory Mesplié

Hand and Wrist Rehabilitation

Theoretical Aspects and Practical
Consequences

Foreword by Marc Garcia-Elias

 Springer

Grégory Mesplé
Biarritz
France

Original French edition published by Sauramps Medical, Montpellier, 2011–2013

Translation by Coline Geoffroy

ISBN 978-3-319-16317-8 ISBN 978-3-319-16318-5 (eBook)

DOI 10.1007/978-3-319-16318-5

Library of Congress Control Number: 2015939595

Springer Cham Heidelberg New York Dordrecht London

© Springer International Publishing Switzerland 2015

This work is subject to copyright. All rights are reserved by the Publisher, whether the whole or part of the material is concerned, specifically the rights of translation, reprinting, reuse of illustrations, recitation, broadcasting, reproduction on microfilms or in any other physical way, and transmission or information storage and retrieval, electronic adaptation, computer software, or by similar or dissimilar methodology now known or hereafter developed.

The use of general descriptive names, registered names, trademarks, service marks, etc. in this publication does not imply, even in the absence of a specific statement, that such names are exempt from the relevant protective laws and regulations and therefore free for general use.

The publisher, the authors and the editors are safe to assume that the advice and information in this book are believed to be true and accurate at the date of publication. Neither the publisher nor the authors or the editors give a warranty, express or implied, with respect to the material contained herein or for any errors or omissions that may have been made.

Printed on acid-free paper

Springer International Publishing AG Switzerland is part of Springer Science+Business Media
(www.springer.com)

Foreword

Professor Claude Verdan (1909–2006), true pioneer in reconstructive surgery of the injured hand, and founder of the *Musée de la Main* (Lausanne), devoted his entire life to studying the hand from all perspectives. The museum was inaugurated in 1997. In his inauguration speech, Dr. Verdan compared the hand to a family of five brothers, all similar, all looking alike, and yet different in terms of their role. Certainly, each finger has a specific protagonism in the overall function of the hand. They are all important, and yet there is a hierarchy among them: the thumb is the leader, the conductor of the orchestra, and the *sine qua non* of hand function. Thanks to its remarkable ability to oppose, the thumb ensures adequate manipulation of objects. The thumb possesses a skill that none of the other fingers have. Without that skill, any attempt to grasp an object is futile.

I was thinking about this, when I got an e-mail from Biarritz. It was my friend Grégory Mesplié. The good news was that, finally, his work on hand reeducation, so nicely published in French, would be made available also in English. What an excellent initiative! There are not that many knowledgeable upper limb therapists in the world for us to learn from, and he is one of the very best. Indeed, this man's work deserves to be on the shelves of all our libraries,...and I mean it!

The problem was that he wanted me to write a foreword for that book. I knew from the start that being asked was an honor that I could not refuse. My agenda, however, was about to explode with commitments. How could I find the time to write a meaningful preamble? Furthermore, how could I come up with the right words to express my admiration for what people like Grégory is doing? Of course, finding the time was not really a problem: there is always time for a good cause, and his cause is one of the best. The problem was the foreword itself. What should I say? How to cope with this assignment?

It was then when I thought about Verdan's analogy. If a hand is like a family, as stated by the prestigious Swiss surgeon, and if the ideal hand unit is also like a family, as defended by my friend Mesplié, a hand unit must be like a hand! (What an interesting syllogism!)

If we assume this thought to be correct, who would play the role of the five digits in an ideal hand unit? Well, I have spent some time trying to come up with an

answer; let's see if you agree with me. In my opinion, the index finger (the pointing finger) would be a surgeon who knows when not to operate. The middle finger would be a rheumatologist who believes on surgery and therapy. The ring finger would be a radiologist that does not need the "Netter's Atlas of Anatomy" to describe a complex carpal dislocation; a radiologist who does not copy-and-paste radiology reports. The little finger would be a multi-tasking nurse that is not afraid of speaking on behalf of the patients' needs. And finally, the thumb,...who would be the thumb? Who would be the *sine qua non* of an ideal hand unit? Doubtless, the thumb would be the hand therapist.

I am not saying that the other professionals are not important, they are, but the thumb is what gives meaning to the hand. A surgeon without a therapist is like a hand without the thumb, is like a car racer without trained mechanics in the boxes, is like a crane without a hook at the end of the cable. Certainly, a hand unit without a good team of hand therapists is a complication waiting to happen. Truly, when I send one of my patients to a fine therapist, I feel safe: my suboptimal repairs will be in good hands.

What do I like from this book? I like almost everything: the concise, matter-of-fact style of writing, the clarity of concepts, the didactic figures, the surplus of ideas for the future,...; but above all, I like the authors' insistence on team work, on sharing knowledge, on refusing isolation. The author's emphasis in setting multi-disciplinary groups is, in my opinion, the key to success. As my friend John Stanley's says: there is nothing more dangerous than a hand surgeon who does not believe in therapy. I am sure that this book will help reducing such prejudices.

In 1978, Jim Dobyns and Ron Linscheid stated that wrist surgery is, at best, a compromise between the ideal and the possible. They were absolutely right. However, there is no better way of reducing the distance between the ideal and the possible than collaborating in the dissemination of the hand therapy principles defended in this book. Such is my enthusiasm for the publication you have in your hands.

I will close this preface trying not to sound as overly transcendent as Isaac Newton when he uttered the famous sentence "In the absence of any other proof, the thumb alone would convince me of the existence of God". My closing statement will be more modest, but still certain: "In the absence of any other proof, this book convinces me of the existence of a bright future for those who suffer a hand injury". Indeed, this is a thorough, meticulous, extremely didactic publication, by a team of highly respected professionals. It is, undoubtedly, an important contribution to medical science.

And again,...I mean it!

Barcelona, Spain

Marc Garcia-Elias, MD, PhD

Contents

Part I Current Traumatic Pathologies of the Wrist

1 Functional and Biomechanical Anatomy of the Radioulnar Unity and the Wrist	3
1.1 Osseous Elements	3
1.1.1 Radius and Ulna	3
1.1.2 1st Carpal Row	6
1.1.3 2nd Carpal Row	11
1.2 Joint Anatomy and Physiology	14
1.2.1 Radioulnar Joints	14
1.2.2 Radiocarpal and Midcarpal Joints	25
1.2.3 Carpal Dynamics	36
1.3 Muscular Anatomy and Physiology	42
1.3.1 Muscular Anatomy	43
1.3.2 Physiology	49
Bibliography	61
2 Injuries of the Radioulnar Unity	63
2.1 Physiopathological Classification	63
2.1.1 Stage 1 = 1 Lock Damaged	63
2.1.2 Stage 2 = 2 Locks Damaged	64
2.1.3 Stage 3 = 3 Locks Damaged	65
2.1.4 Physiopathology	66
2.2 Clinical and Paraclinical Signs	67
2.2.1 Clinical Signs	67
2.2.2 Paraclinical Signs	68
2.3 Therapeutic Process and Surgical Treatment	69
2.3.1 Osseous Surgery	69
2.3.2 Proximal Radioulnar Surgery	69
2.3.3 Distal Radioulnar Surgery	70
2.3.4 Interosseous Membrane Surgery	70

2.4	Rehabilitation and Orthotic Treatment	70
2.4.1	Mobility of the Radioulnar Unity	70
2.4.2	Stability of the Radioulnar Unity	74
	Bibliography	84
3	Recent Fractures of the Scaphoid Bone	85
3.1	Physiopathology	85
3.2	Clinical and Paraclinical Signs	86
3.3	Therapeutical Process and Surgical Treatment	88
3.3.1	Orthopedic Treatment	88
3.3.2	Surgery	89
3.4	Rehabilitation and Orthotic Treatment	91
3.4.1	Rehabilitation Protocol	92
3.4.2	Orthotic Treatment	116
3.5	Complications	118
	Bibliography	125
4	Sprains of the Scapholunate Ligament	127
4.1	Physiopathology	127
4.2	Clinical and Paraclinical Signs	129
4.2.1	Clinical Signs	130
4.2.2	Paraclinical Signs	133
4.3	Therapeutical Process and Surgical Treatment	135
4.4	Rehabilitation and Orthotic Treatment	137
4.4.1	Rehabilitation Protocol	137
4.4.2	Orthotic Treatment	142
4.5	Complications	144
	Bibliography	144
5	Recent Fractures of the Inferior Extremity of the Radius	147
5.1	Physiopathology	147
5.2	Clinical and Paraclinical Signs	148
5.3	Therapeutic Process and Surgical Treatment	150
5.3.1	Reduction	150
5.3.2	Fixation	151
5.3.3	Indications	152
5.4	Rehabilitation and Orthotic Treatment	152
5.4.1	Rehabilitation Protocol	152
5.4.2	Orthotic Treatment	166
5.5	Complications	168
	Bibliography	168

Part II Osseous and Capsulo-ligamentous Injuries in the Hand and Thumb

6	Sprains of the Metacarpophalangeal Joint of the Thumb	173
6.1	Anatomical and Biomechanical Reminders	173
6.2	Physiopathology	175
6.3	Clinical and Paraclinical Signs	176
6.3.1	Clinical Signs	176
6.3.2	Paraclinical Signs	177
6.4	Therapeutic Process and Surgical Treatment	177
6.5	Rehabilitation and Orthosis	177
6.5.1	Rehabilitation Protocol of the Serious Medial Collateral Ligament Sprains (Postoperative)	178
6.5.2	Rehabilitation Protocols After Benign and Medium Sprains (No Surgery)	185
6.5.3	Orthotic Treatment	186
	Bibliography	188
7	Fractures of Metacarpals and Phalanges	189
7.1	Anatomical Reminders	189
7.1.1	Hand Architecture	189
7.1.2	Opposition of the Thumb	191
7.2	Types of Fractures	194
7.2.1	Fractures of the Metacarpals	194
7.2.2	Fractures of the Phalanges	197
7.3	Therapeutic Process	199
7.3.1	Orthopedic Treatment	199
7.3.2	Surgical Treatment	200
7.4	Rehabilitation and Orthosis	200
7.4.1	Orthotic Immobilization Treatment	200
7.4.2	Rehabilitation	206
7.4.3	Orthotic Treatment to Gain Amplitude	214
	Bibliography	216
8	Capsulo-ligamentous Injuries of the Proximal Interphalangeal Joint	217
8.1	Anatomical Reminders	217
8.2	Volar Plate Sprains	219
8.2.1	Rehabilitation	219
8.2.2	Orthotic Treatment	227
8.3	Collateral Ligaments Sprains	227
8.4	Dislocations	227
	Bibliography	232

Part III Tendon Injuries of the Hand

9	Injuries of the Extensor Tendons	237
9.1	Biomechanical and Physiological Reminders	237
9.2	Topographic Anatomy	237
9.2.1	Long Fingers	238
9.2.2	Thumb	242
9.3	Physiology	243
9.3.1	Nutrition of the Extensor Tendons	243
9.3.2	Biomechanics	243
9.3.3	Extension Dynamics and Tendon Race	246
9.4	Physiopathology	247
9.5	Clinical and Paraclinical Signs	248
9.6	Therapeutic Process and Surgical Treatment	249
9.6.1	Orthopedic Treatment	249
9.6.2	Surgical Treatment	250
9.6.3	Thumb	252
9.7	Rehabilitation and Orthosis	252
9.7.1	After an Orthopedic Treatment	252
9.7.2	After a Surgical Treatment	264
	Bibliography	274
10	Injuries of the Flexor Tendons	275
10.1	Biomechanical and Physiological Reminders	275
10.1.1	Topographic Anatomy	275
10.1.2	The Pulleys	279
10.1.3	Nutrition of the Flexor Tendons	279
10.1.4	Lag Time	281
10.1.5	The Quadriga Effect	283
10.1.6	Winding Dynamic and Tendon Gliding	283
10.1.7	The Essential Function of the Flexors	284
10.2	Physiopathology	284
10.2.1	Sharp Cut or Shredding	284
10.2.2	Contamination of the Injury	284
10.2.3	Clamping at the Moment of the Trauma	286
10.3	Clinical and Paraclinical Signs	287
10.4	Therapeutic Process and Surgical Treatment	287
10.4.1	The Lapse of Time	288
10.4.2	The Points of Access	288
10.4.3	The Suture Techniques	289
10.4.4	Particular Cases	292
10.5	Rehabilitation	292
10.5.1	Rehabilitation Protocols	292
10.6	Orthotic Treatment	302
10.6.1	Immobilization Phase	302
10.6.2	After D60	303

- 10.7 Particular Cases 304
 - 10.7.1 Injuries of the Flexor Pollicis Longus 304
 - 10.7.2 Jersey Finger (or Rugby Finger) 304
- Bibliography 305

Part IV Amputations

- 11 Amputations 309**
 - 11.1 Therapeutic Process and Surgical Treatment 309
 - 11.1.1 Amputations of the Long Fingers 310
 - 11.1.2 Amputation of the Thumb 312
 - 11.1.3 Poly-digital Amputations 312
 - 11.1.4 Transmetacarpal Amputations 312
 - 11.2 Rehabilitation and Orthotic Treatment 312
 - 11.2.1 Rehabilitation Protocol 312
 - 11.2.2 Orthotic Treatment 322
 - 11.3 Neurological Pain 324
 - 11.3.1 Phantom Pain 324
 - 11.3.2 Neuromas 325
- Bibliography 325

Part V Physiology and Rehabilitation of Sensorial and Motor Disorders

- 12 Physiology and Rehabilitation of Sensorial and Motor Disorders . . 329**
 - 12.1 Nerve Physiology 329
 - 12.2 Functional Classification of Nervous Injuries 330
 - 12.3 Sensorial Physiology 331
 - 12.3.1 Sensorial Receptors 331
 - 12.3.2 Sensitivity Types 333
 - 12.4 Assessment and Rehabilitation of Sensorial Disorders 337
 - 12.4.1 Hyposensitivity 337
 - 12.4.2 Sensorial Disorders (Not Allodynia) 344
 - 12.4.3 Allodynia 346
 - 12.5 Assessment and Rehabilitation of Motor Disorders 348
 - 12.5.1 Assessment of Peripheral Motor Disorders 349
 - 12.5.2 Rehabilitation of Peripheral Motor Disorders 350
- Bibliography 352

Part VI Entrapment Syndromes

- 13 Entrapment Syndromes of the Median Nerve 355**
 - 13.1 Anatomy 355
 - 13.2 Carpal Tunnel Syndrome 359
 - 13.2.1 Physiopathology 359
 - 13.2.2 Clinical and Paraclinical Signs 359

- 13.2.3 Medical and Surgical Treatment 360
- 13.2.4 Rehabilitation and Orthotic Treatment,
Without Surgery or Preoperative 361
- 13.2.5 Rehabilitation and Orthotic Treatment, Postoperative . . . 370
- 13.3 Other Entrapment Syndromes of the Median Nerve 378
 - 13.3.1 Arcade of Struthers 378
 - 13.3.2 Under the Lacertus Fibrosus 379
 - 13.3.3 Between the 2 Fascicles of the Pronator Teres 379
 - 13.3.4 Under the Arcade of the Flexor Digitorum
Superficialis 379
 - 13.3.5 Rehabilitation and Orthotic Treatment 380
 - 13.3.6 Important Points 384
- Bibliography 385
- 14 Entrapment Syndromes of the Ulnar Nerve 387**
 - 14.1 Functional Anatomy 387
 - 14.2 Entrapment Syndromes of the Ulnar Nerve 389
 - 14.2.1 Compression of the Ulnar Nerve at the Level
of the Elbow 389
 - 14.2.2 Compression of the Ulnar Nerve at the Level
of the Wrist 392
 - 14.3 Rehabilitation and Orthotic Treatment of the Compressions
of the Ulnar Nerve 392
 - 14.3.1 Without Surgery 392
 - 14.3.2 Postoperative 402
 - Bibliography 406
- 15 Entrapment Syndromes of the Radial Nerve 407**
 - 15.1 Anatomy 407
 - 15.2 Compression in the Humeral Groove 408
 - 15.3 Compression in the Elbow 409
 - 15.3.1 Radial Tunnel Syndrome 410
 - 15.3.2 Posterior Interosseous Nerve Syndrome 410
 - 15.4 Compression in the Wrist 410
 - 15.5 Rehabilitation and Orthotic Treatment 411
 - 15.5.1 Without Surgery 411
 - 15.5.2 Postoperative 418
 - Bibliography 425

Part VII Other Current Pathologies of the Hand

- 16 Dupuytren Disease 429**
 - 16.1 History 429
 - 16.2 Anatomical Reminders 430
 - 16.2.1 Medium Palmar Aponeurosis 430
 - 16.2.2 Digital Aponeurosis 432
 - 16.2.3 Aponeurosis System of the 1st Finger 435

- 16.3 Anatomopathology 436
 - 16.3.1 Anatomical Expression 436
 - 16.3.2 Epidemiology 436
- 16.4 Clinical and Paraclinical Signs 437
- 16.5 Therapeutic Process and Surgical Treatment 438
 - 16.5.1 Nonsurgical Treatment 438
 - 16.5.2 Surgical Treatment 438
- 16.6 Rehabilitation and Orthotic Treatment 443
 - 16.6.1 Rehabilitation Protocol 443
 - 16.6.2 Orthotic Treatment 451
- Bibliography 453
- 17 Complex Regional Pain Syndrome 455**
 - 17.1 Type 1 CRPS 455
 - 17.2 Type 2 CRPS 456
 - 17.3 Etiology and Physiopathology 456
 - 17.3.1 Etiology 456
 - 17.3.2 Physiopathology 456
 - 17.4 Diagnosis and Clinical Signs 457
 - 17.5 Evolution 458
 - 17.5.1 Stage 1 (Hot or Acute Phase) 458
 - 17.5.2 Stage 2 (Cold or Dystrophic Phase) 460
 - 17.5.3 Stage 3 (Sequelae Phase) 460
 - 17.6 Therapeutic Process 460
 - 17.7 Rehabilitation and Orthotic Treatment 461
 - 17.7.1 Hot Phase 461
 - 17.7.2 Cold Phase 466
 - Bibliography 468

Part VIII Protocols

- 18 Protocols 471**
 - 18.1 Current Traumatic Pathologies of the Wrist 471
 - 18.2 Osseous and Capsulo-ligamentous Injuries
of the Hand and Thumb 474
 - 18.3 Tendon Injuries of the Hand 478
 - 18.4 Amputations 482
 - 18.5 Entrapment Syndromes 482
 - 18.6 Other Current Pathologies of the Hand 484

Contributors

Baptiste Arrate Occupational Therapist, Institut Sud Aquitain de la Main et du Membre Supérieur, Aguiléra Clinic Biarritz, Biarritz, France

Jean-François Chauvet Hand Surgeon, Institut Sud Aquitain de la Main et du Membre Supérieur, Aguiléra Clinic Biarritz, Biarritz, France

Vincent Grelet Hand Surgeon, Institut Sud Aquitain de la Main et du Membre Supérieur, Aguiléra Clinic Biarritz, Biarritz, France

Olivier Léger Hand Surgeon, Institut Sud Aquitain de la Main et du Membre Supérieur, Aguiléra Clinic Biarritz, Biarritz, France

Stéphane Lemoine Hand Surgeon, Institut Sud Aquitain de la Main et du Membre Supérieur, Aguiléra Clinic, Biarritz, France

Démécia Maffray Physiotherapist, Institut Sud Aquitain de la Main et du Membre Supérieur, Aguiléra Clinic Biarritz, Biarritz, France

Grégory Mesplié Physiotherapist and Orthotist, Institut Sud Aquitain de la Main et du Membre Supérieur, Aguiléra Clinic Biarritz, Biarritz, France

Part I
Current Traumatic Pathologies
of the Wrist

Chapter 1

Functional and Biomechanical Anatomy of the Radioulnar Unity and the Wrist

Grégory Mesplié

The wrist is a joint complex essential in prehensions.

It orients and stabilizes the hand during activities thanks to its complex biomechanics, which is better understood since a few years due to the progress of medical imagery.

1.1 Osseous Elements [5, 11, 13, 14, 16, 17]

1.1.1 *Radius and Ulna*

1.1.1.1 Proximal Extremities

The part we will talk about only concerns the radioulnar unity, so the radial head and the radial notch of the ulna [2].

Radial Head

It's an irregular cylinder slightly ovoid at the end of the radial neck. It's about 4 mm larger than the radial neck. The axis of the neck is the same as the radial axis in the sagittal plane but forms an angle of 165° outwards in the frontal plane (Fig. 1.1).

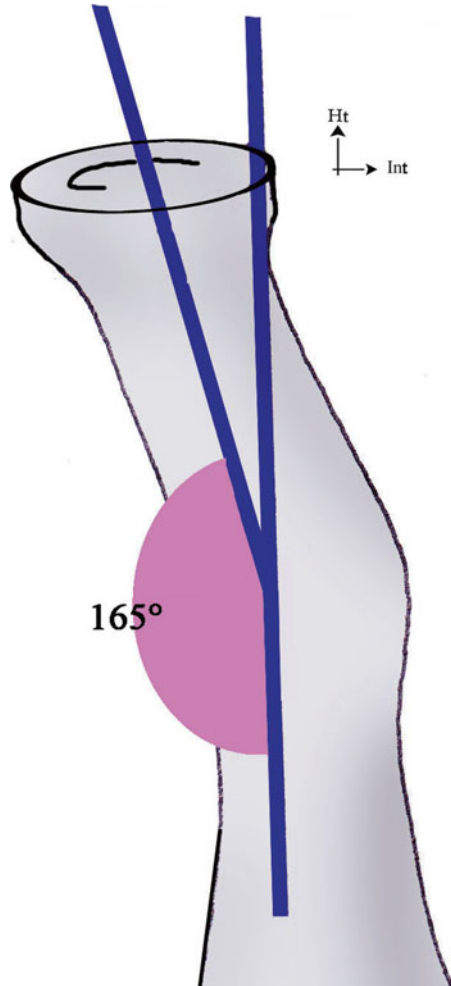
Thanks to this conformation, the radial head is positioned in the frontal plane.

The superior concavity, ovoid shape and head size vary from one individual to the other.

G. Mesplié

Physiotherapist and Orthotist, Institut Sud Aquitain de la Main
et du Membre Supérieur, Aguiléra Clinic Biarritz, Biarritz, France
e-mail: greg.mesplie@mac.com

Fig. 1.1 The radial head forms an angle of 165° with the radial neck axis



It has a sponge-like structure so it's fragile but reinforced by bone trabeculae whose homogeneous distribution avoids the formation of areas more fragile than others.

In supination, the ovoid axis is oriented inwards and frontwards, and the radial tuberosity is oriented inwards. The radial head tilts so that its internal part is higher than its external part.

Lesser Sigmoid Cavity (or Radial Notch)

It's a small cavity with a cartilaginous "crust" located under the greater sigmoid cavity (or trochlear notch). Both notches are separated by an anteroposterior ridge.

1.1.1.2 Diaphysis

The radial and ulnar diaphyses have special curvatures that allow important mobility in pronosupination.

In supination, the two bones are concave anteriorly but have opposite concavities in the frontal plane, where the ulna is concave outwards and the radius is concave inwards (Fig. 1.2).

1.1.1.3 Distal Extremities

Along with the triangular complex, they form a set that interfaces with the 1st carpal row.

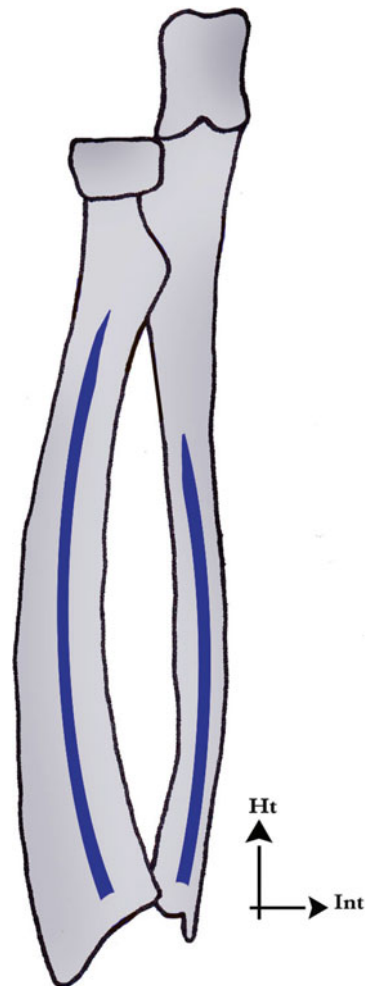


Fig. 1.2 The diaphysis of the two bones of the forearm have inverted concavities in the frontal plane, which allows their “winding” in pronation

Radial Epiphysis

It has the shape of a truncated pyramid whose anterior part is occupied by the pronator quadratus. Its posterior side contains Lister's tubercle, which separates two grooves: the extensor pollicis longus passes and changes direction in the medial one and the radial extensors of the carpus pass in the lateral one. On its lateral side, there is the radial styloid process, in front of which pass the tendons of the abductor pollicis longus and extensor pollicis brevis.

The inferior articular side has a medial part (relation with the lunate) and an external part (relation with the scaphoid). It is concave and globally oriented frontwards (10°) and inwards (25°) (Fig. 1.3).

The internal side receives the radial notch of the ulna (trochoid joint).

Mechanically, the radius absorbs 80 % of the axial constraints transmitted by the carpus. A 2 mm shortening is enough to transfer 20 % more load on the ulnar compartment.

Ulnar Epiphysis

Thinner than the radial epiphysis, it contacts with the radius by its external convex side to form the distal radioulnar joint.

Its inferior side has to do with the triangular complex, which articulates with the 1st carpal row.

1.1.2 1st Carpal Row (Fig. 1.4)

The mobility between the bones of the 1st carpal row is complex and gives it a huge adaptive capacity allowing it to absorb part of the constraints imposed on it. From lateral to medial, it's made of:

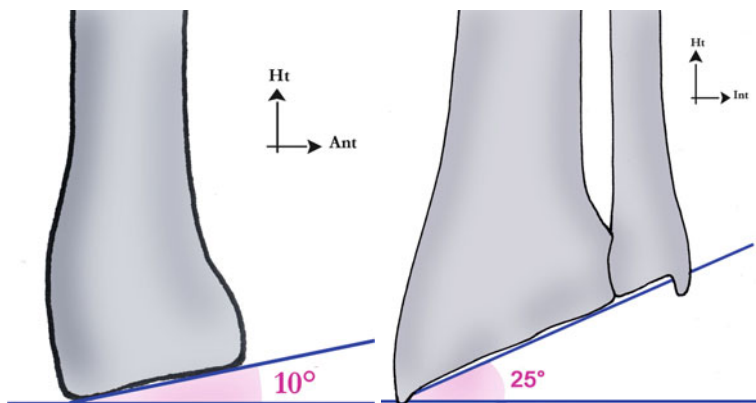


Fig. 1.3 Orientation of the radial socket downwards, frontwards and inwards

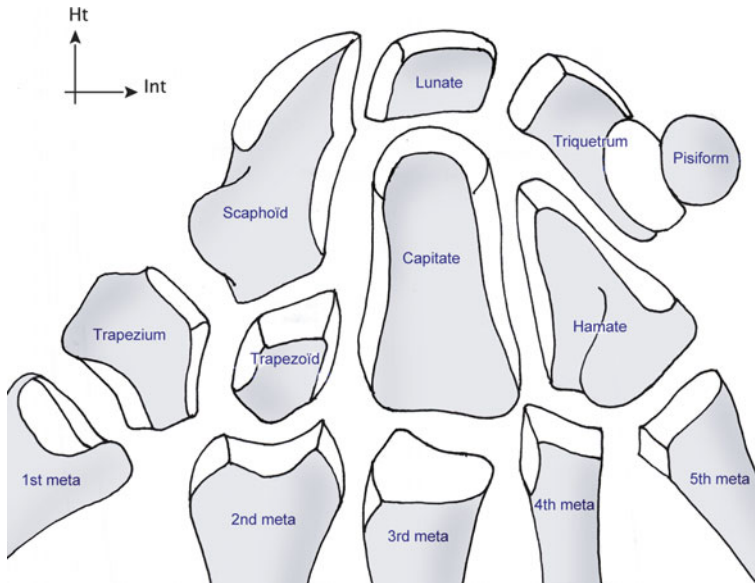


Fig. 1.4 Carpal bones

1.1.2.1 Scaphoid

The scaphoid has a “bean” shape. It’s the most lateral bone of the 1st carpal row. There are an angle of 30° between the distal and proximal parts viewed from the side and an angle of 40° viewed from the front (Figs. 1.5 and 1.5’).

More than 75 % of its surface is covered by cartilage.

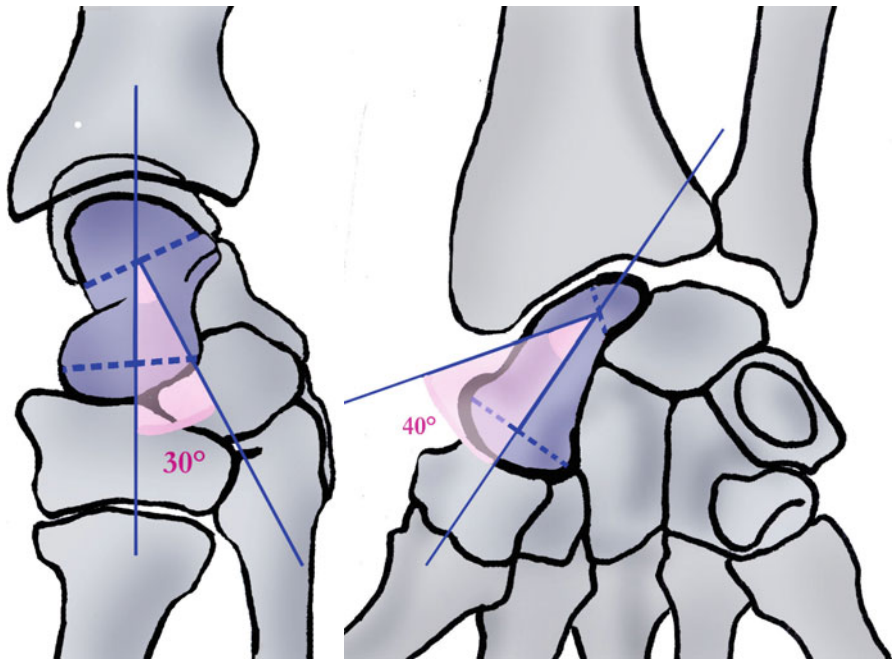
It’s the most voluminous bone of the 1st carpal row and the closest to the thumb, between the radius and the trapezo-trapezoidal joint.

Like for the lunate and triquetrum, there are no tendons attached on it, but it’s strongly attached to the radius and carpus by intrinsic and extrinsic ligaments.

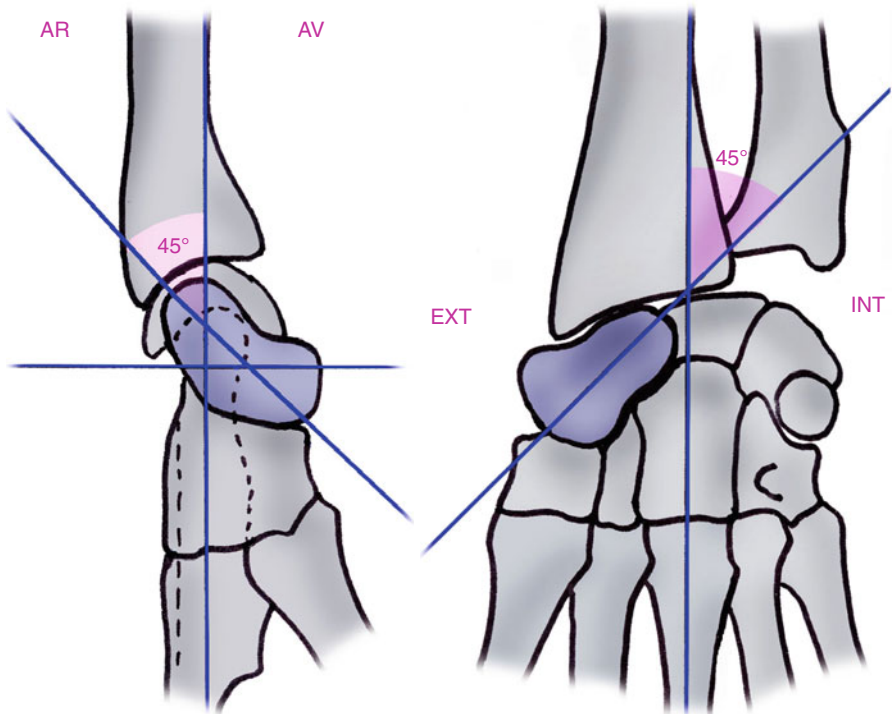
It forms a 45° angle with the radial axis in the frontal and sagittal plane. This orientation is the key element of the natural thumb opposition, essential in prehensions (Figs. 1.6 and 1.6’).

It’s made of three parts (Fig. 1.7):

- The proximal part is round, covered in cartilage and articulates with the lunate (plane joint). This joint forms the lateral part of the carpal condyle. The superior side of the proximal part articulates with the radius. It can be palpated in wrist flexion, when it dorsally peeks out from the radiocarpal groove in the Lister’s tubercle axis.
- The neck is the narrowest part of the bone (6 mm width). Its medial part articulates with the capitate. Its lateral part contacts with the radial artery and corresponds to the floor of the anatomical snuffbox.

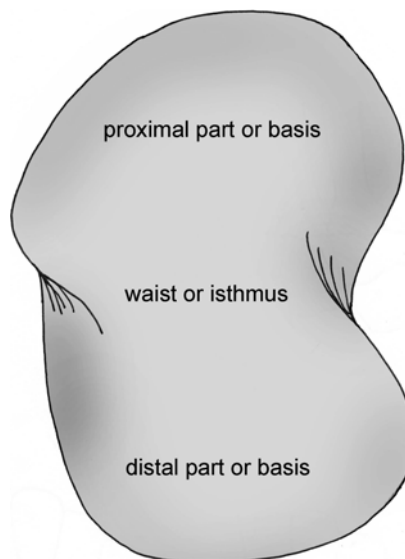


Figs. 1.5 and 1.5' Intra-scapoid angles



Figs. 1.6 and 1.6' Orientation of the scaphoid frontwards and outwards with respect to the radial axis

Fig. 1.7 The three parts of the scaphoid



- The base articulates with the trapezium and trapezoid distally and is anteriorly prolonged by the scaphoid's tubercle. On this tubercle are inserted the flexors retinaculum and the abductor pollicis brevis. There's a medial groove where the flexor carpi radialis passes. This muscle then ends on the scapho-trapezo-trapezoidal joint and on the bases of the 2nd and 3rd metacarpals. It's easily palpable in wrist extension.

Its vascularization is ensured by the branches of the radial artery, in two groups:

- The proximal group enters the scaphoid's neck and takes care of 70 % of the vascularization.
- The distal group enters the scaphoid's tubercle and takes care of 30 % of the vascularization (Fig. 1.8).

There are no vessel entering the proximal part, which explains why there is an important risk of pseudoarthrosis and necrosis in case of fractures at this level.


The scaphoid is "stuck" between the radius and the trapezo-trapezoidal joint and is under important compressive constraints as 80 % of the carpus load is transmitted to the radius and 20 % to the ulna. The scaphoid transmits 60 % of these constraints and the lunate 40 % (Fig. 1.9).

These axial constraints tend to bring the scaphoid to flexion because of its angle of 45° with the radius (Fig. 1.10).

However, several anatomical elements oppose this tendency (Fig. 1.11):

- The scapho-trapezo-trapezoidal ligamentous system and the scaphocapitate ligament (powerful distal anchor)
- The radioscapocapitate ligament that opposes the distal part of the scaphoid from going forward
- The flexor carpi radialis, sliding in front of the scaphoid and whose contraction brings the distal part of the scaphoid backwards

Fig. 1.8 The vascularization of the scaphoid is ensured by two groups given off by the radial artery. The proximal group enters by the waist and represents 70 % of this vascularization. There are no vessels that directly enter the head of the scaphoid



1.1.2.2 Lunate

It has the shape of an irregular lunar crescent with a distal concavity articulated with the capitate. Its anterior horn is bigger than the posterior one. Its lateral side articulates with the scaphoid and its internal side with the triquetrum.

When the wrist is straight, the two horns are at the same height, and the lunate axis is the same as the radial axis.

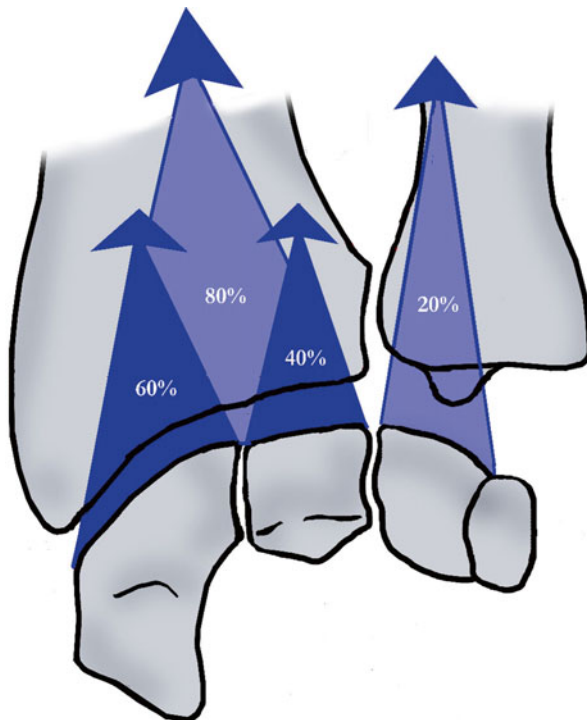
It's subjected to two opposite forces through the scaphoid that brings it to flexion and the triquetrum and capitate, which bring it to extension (Fig. 1.12).

This allows us to understand that in case of injury of the scapholunate ligament, the lunate won't be connected to the scaphoid and therefore will go to extension or dorsal intercalated segment instability. In case of injury of the lunotriquetral ligament, the lunate goes to flexion or ventral intercalated segment instability (Figs. 1.13 and 1.13') [7].

1.1.2.3 Triquetrum

It's the most internal bone of the 1st carpal row, in the shape of a pyramid lying down with an external base and an internal top.

Fig. 1.9 The radius bears 80 % of the longitudinal forces coming from the carpus. The scaphoid transmits 60 % of these forces to the radius



Its superior part is convex in every way and forms the carpal condyle with the lunate and scaphoid. The external side (2/3) of its inferior part is concave, and the internal side (1/3) is convex, to harmoniously articulate with the hamate.

1.1.2.4 Pisiform

It's a sesamoid bone, so it isn't really a part of the 1st carpal row. It's a sort of "patella" for the flexor carpi ulnaris; it helps the muscle to be more efficient by improving its tendinous angle.

It articulates with the triquetrum.

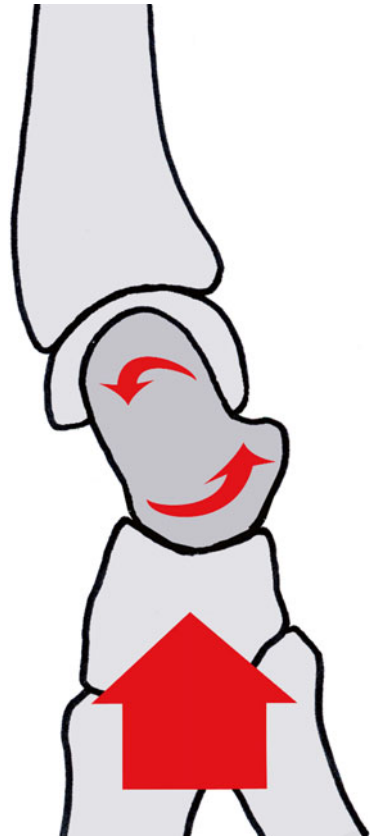
1.1.3 2nd Carpal Row (Fig. 1.4)

It's less mobile than the 1st carpal row and made from lateral to medial of:

1.1.3.1 Trapezium

It's cubical and articulates proximally with the scaphoid and distally with the first metacarpal. Its internal side articulates with the trapezoid (superior part) and 2nd metacarpal (inferior part).

Fig. 1.10 The scaphoid's orientation with respect to the radius in the sagittal plane causes a flexion of the radius because of the axial constraints coming from the carpus



Its external face isn't involved in any joint but is pierced with many vascular holes.

The anterior retinacular ligament, the superficial bundle of the flexor pollicis brevis and the opponens pollicis insert on its palmar side: it's the trapezium ridge, oblique downwards and outwards.

1.1.3.2 Trapezoid

It articulates proximally with the scaphoid and distally with the 2nd metacarpal. Its external part articulates with the internal part of the trapezium and its internal part with the external part of the capitate. The deep bundle of the flexor pollicis brevis and a few fibres of the adductor pollicis insert on its palmar side.

Fig. 1.11 Ligamentary (scapho-trapezo-trapezoidal system, scaphocapitate ligament, radioscaphocapitate ligament) and muscular (flexor carpi radialis) elements opposing the flexion of the scaphoid

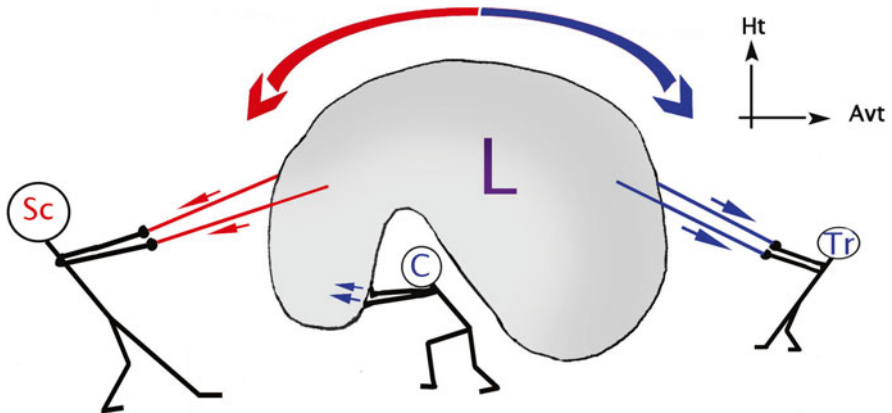
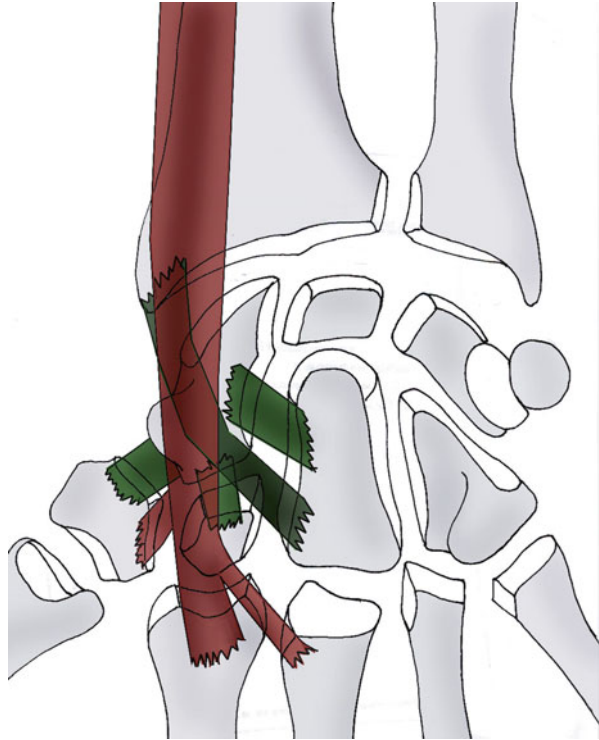


Fig. 1.12 The lunate bone is under opposite constraints; the scaphoid brings it in flexion with the scapholunate ligament, the triquetrum brings it in extension with the lunotriquetral ligament, and the capitate pressing on its posterior part brings it in extension

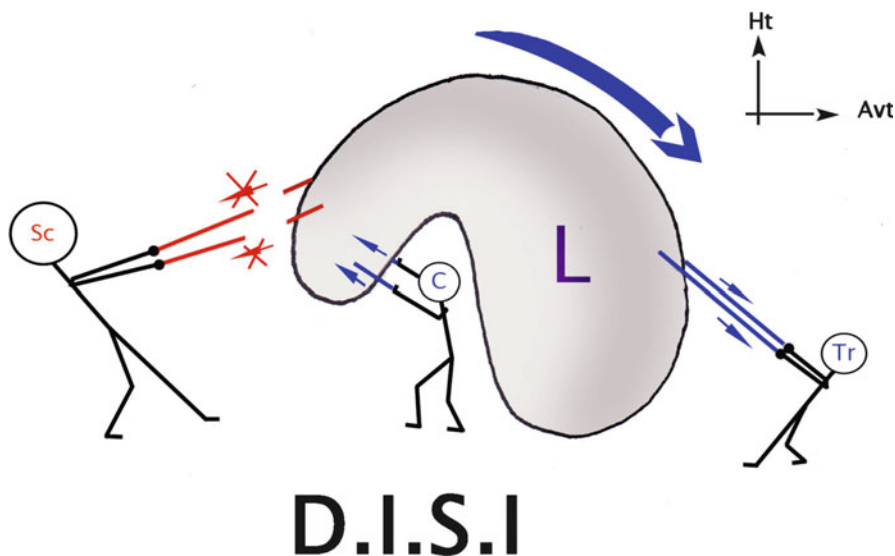


Fig. 1.13 Rupture of the scapholunate ligament, creating unbalance. The lunate tilts in DISI

1.1.3.3 Capitate

It's the biggest and central carpal bone. It articulates with every other carpal bone, except for the triquetrum. Parts of the deep bundle of the flexor pollicis brevis and adductor pollicis insert on its anterior part.

1.1.3.4 Hamate

It's prism-shaped and articulates proximally with the triquetrum and distally with the 4th and 5th metacarpals.

The flexor pollicis brevis and opponens digiti minimi insert on the hamulus on its anterior part.

1.2 Joint Anatomy and Physiology [8]

1.2.1 Radioulnar Joints

They stabilize and mobilize in order to efficiently direct the hand in pronosupination.

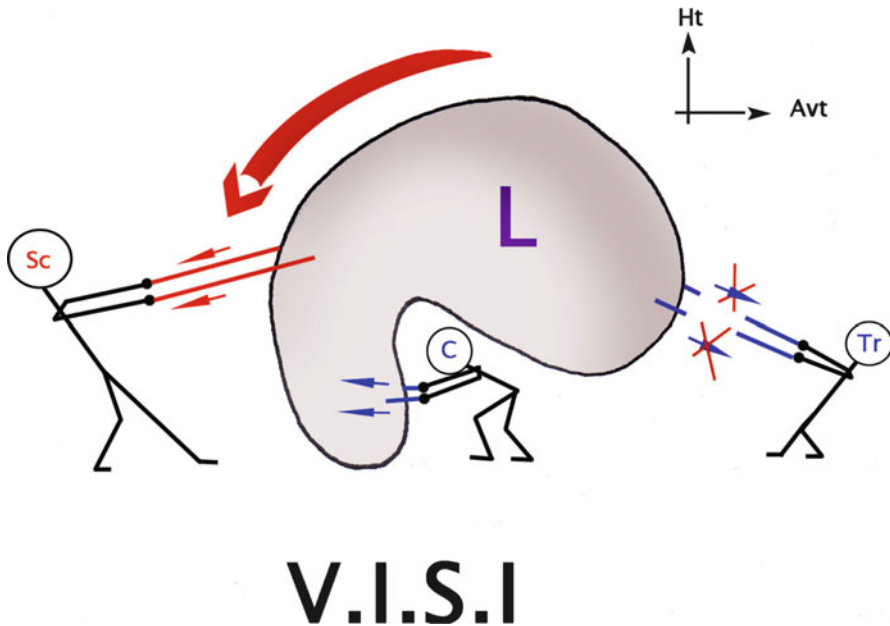


Fig. 1.13' Rupture of the lunotriquetral ligament causing a VISI

The amplitudes vary from one individual to the other, but it's usually 90° of supination and 85° of pronation. The pronosupination range of motion is measured with the elbow against the trunk, with 90° of flexion to prevent the shoulder from participating to the movement.

Some authors have recently proposed the concept of “radioulnar unity”, made of the radial and proximal radioulnar joints, and a third part, the interosseous membrane [15] and the ulnar and radial diaphyses (middle lock). Each component depends on the two others.

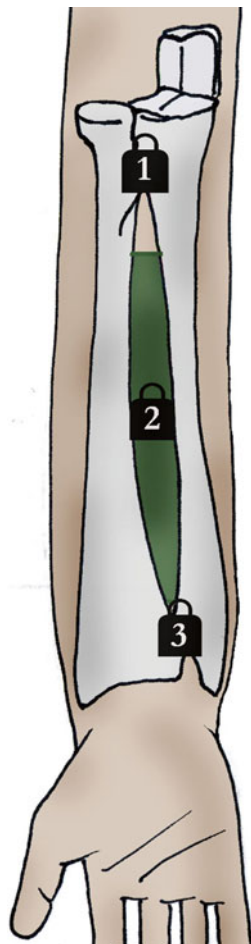
The three joints are complementary and inseparable “locks”. If one lock is blocked, it will block the rest of the forearm. Instability in only one lock can be compensated by the two others.

Therefore, we can't treat one of the radioulnar locks without checking the two others (Fig. 1.14).

1.2.1.1 Proximal Radioulnar Joint or Proximal Lock

It's a trochoid joint with only 1° of movement. Its congruence is maximal in an intermediary position, and it's stabilized by a powerful ligamentous complex.

Fig. 1.14 The three locks of the radioulnar unity



Annular Ligament (Fig. 1.15)

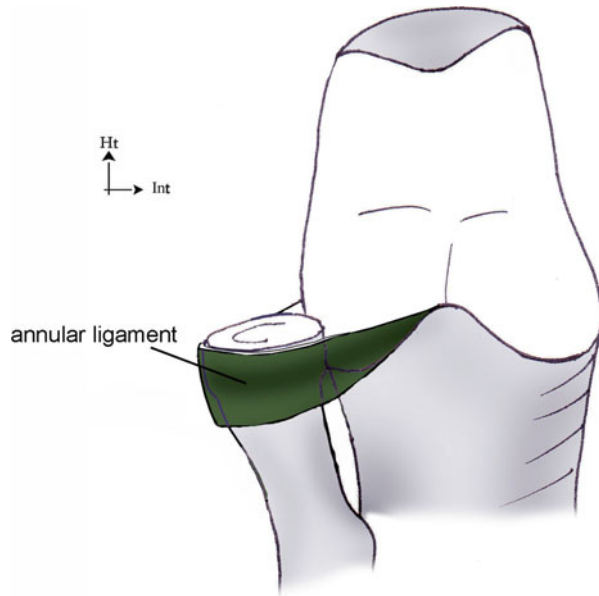
It inserts on the anterior and posterior parts of the ulnar radial notch and surrounds the radial head with its internal face covered with cartilage. Therefore, it plays the role of a joint surface as well as a ligament.

Quadrato Ligament or Ligament of Dénucé (Fig. 1.16)

It inserts on the inferior part of the ulnar radial notch and ends just below the radial head, above the radial tuberosity.

Its most anterior and posterior fibres mix with the most distal fibres of the annular ligament.

Fig. 1.15 The annular ligament surrounds the radial head. It's a predominant element in the proximal radioulnar stability



It's tensed in pronation because of its anterior fibres and in supination because of its posterior fibres.

1.2.1.2 Interosseous Membrane or Intermediate Radioulnar Joint

It's tensed on about 10 cm between the radius and the ulna. It's made of crossed connective fibres (collagen and elastin) that form a "network" efficiently opposed to the multidirectional constraints imposed on it:

Fibres Oriented Upwards from the Ulna Towards the Radius
(Upwards and Outwards)

They form two "membranous" parts, one distal and one proximal, and a middle "ligamentous" part thicker and more resistant.

They are the most important, as their orientation allows them to transfer part of the constraints imposed on the radius towards the ulna.

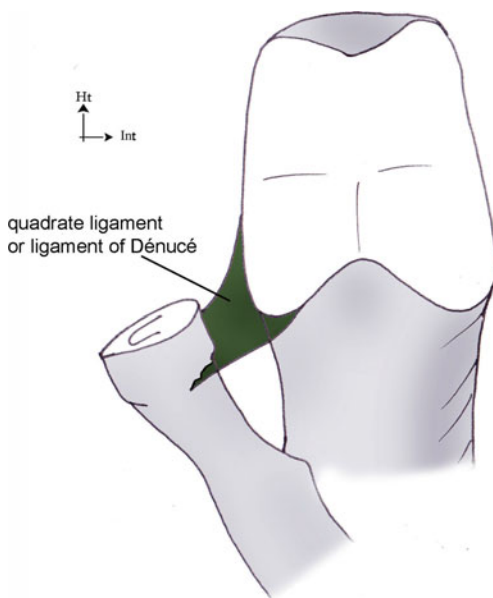
In fact, 80 % of the axial constraints are transmitted on the radius through the carpus, but in the elbow, 70 % of the constraints pass through the humeroulnar joint: the load transfer distribution is inverted between the elbow and the wrist (Fig. 1.17).

The triangular complex participates in this phenomenon at the distal level.

The interest of this load transfer is that the radial head is too fragile to bear 80 % of the constraints coming from the carpus, while the coronoid process can do it.

Recently, some studies have questioned this theory and don't find this load transfer from the radius to the ulna.

Fig. 1.16 The quadrate ligament is tensed between the radial notch of the ulna and the radial head



Fibre Oriented Downwards from the Ulna Towards the Radius (Downwards and Outwards)

They form 2 individualized structures: the oblique cord and the proximal band.

The interosseous membrane is always tensed during pronosupination: the proximal part is tensed in pronation, the middle part in neutral position and the distal part in supination (Fig. 1.18).

The middle lock is composed by the interosseous membrane and the two bones of the forearm described in the Sect. 1.1.

1.2.1.3 Distal Radioulnar Joint or Distal Lock

It's a trochoid joint that is neither concordant nor congruent (Fig. 1.19), which makes it particularly unstable, especially in pronation and supination. The intermediary position is the most stable one, like in the proximal radioulnar joint.

It's the radioulnar unity's distal lock, stabilized by a powerful ligamentous complex made of:

Triangular Complex or Triangular Ligament (Fig. 1.20) [12]

It's a biconcave fibrocartilage covered with cartilage, tensed between the ulnar styloid process and the internal side of the radial epiphysis.

Fig. 1.17 The interosseous membrane transmits part of the longitudinal forces from the radius to the ulna, avoiding any excessive constraints on the radial head that is a fragile spongy bone



It's made of an articular disc, a palmar and dorsal radioulnar ligamentous arch, a meniscus, fibres from the palmar and dorsal ulnotriquetral ligament, fibres from the ulnolunate ligament and from the extensor carpi ulnaris sheath.

It plays the role of a radioulnar ligament and the role of a meniscus hanging between the two bones of the forearm and the carpus.

Because of this, it's under important multidirectional constraints. It opposes these constraints in different ways:

- Cushioning the longitudinal constraints, as 20 % of the axial constraints of the wrist are transferred towards the ulna. It also participates to the transfer of the longitudinal forces from the radius towards the ulna, along with the interosseous membrane.

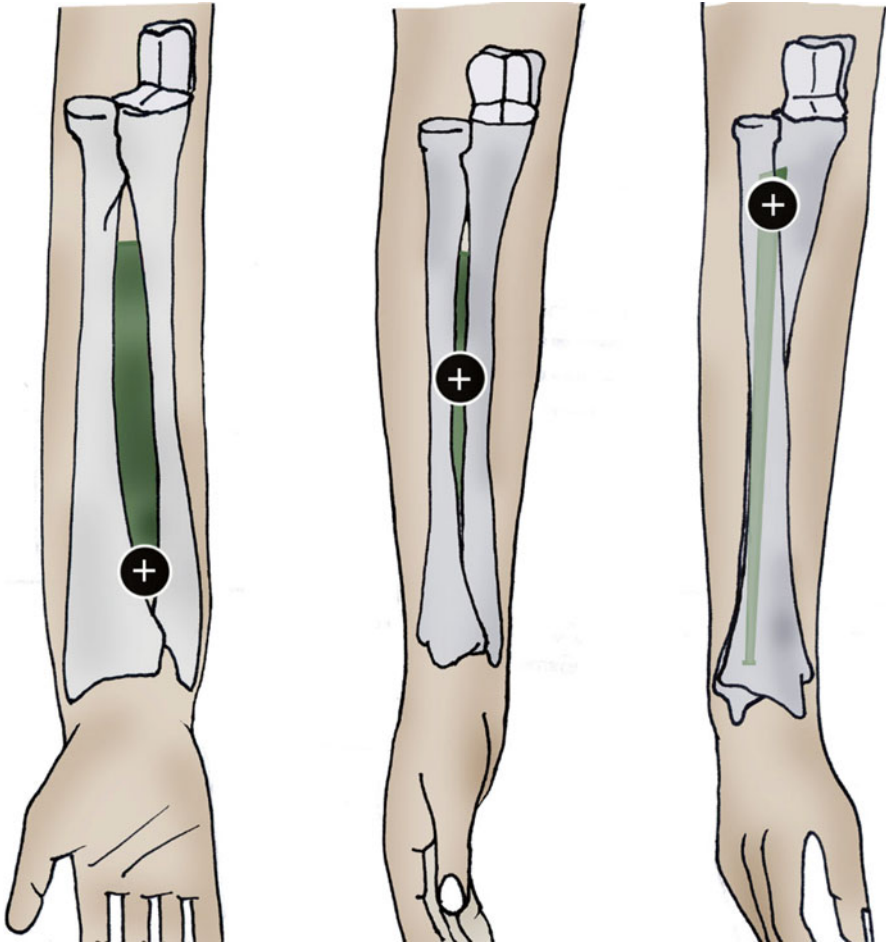


Fig. 1.18 The interosseous membrane is always tensed during pronosupination: its distal part during supination, its middle part during the intermediary position and its proximal part during pronation

- Limiting pronosupination, putting in tension the anterior fibres in supination and the posterior fibres in pronation. The most important tension is in the intermediary position, which is the most stable one.
- Preventing the radius and the ulna from moving away from each other, especially when clamping (which causes the capitate to go upwards, leading to constraints on the distal radioulnar joint) (Fig. 1.21).

The triangular ligament is only vascularized in 10–40 % of its ulnar part. The middle and radial parts don't receive any vascularization, which makes their spontaneous healing impossible.

It's sometimes perforated in the middle, without any traumatic cause.

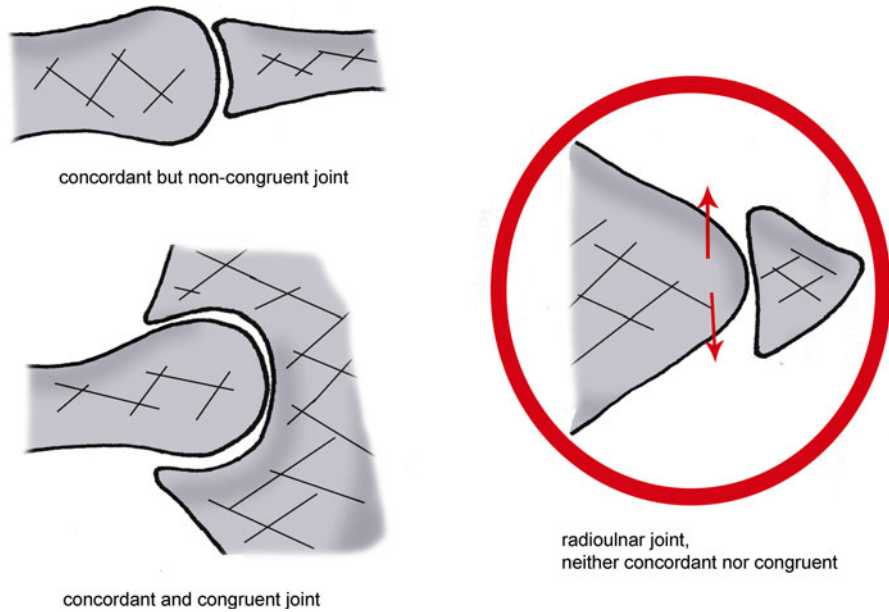
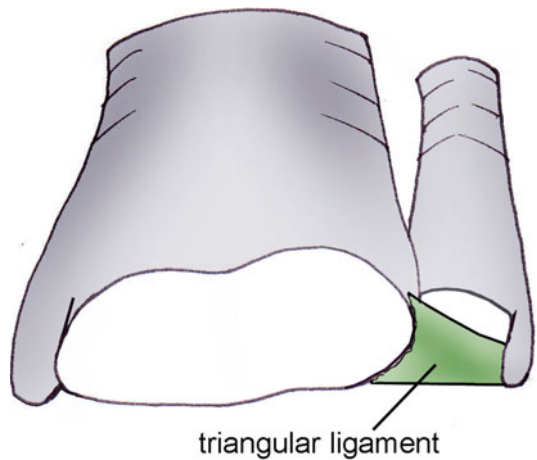


Fig. 1.19 The distal radioulnar joint is neither congruent (the bony elements don't "fit" together), nor concordant. This leads to joint instability

Fig. 1.20 The triangular ligament is a fibrocartilage, tensed between the radius and the ulna and bearing important constraints. It's an important element in radioulnar and ulnocarpal stability



Radioulnar Ligaments

For some authors, they are simple capsular thickenings. They have a moderate functional role on the distal radioulnar joint. They're located within the periphery of the triangular ligament, in a vascularized area.

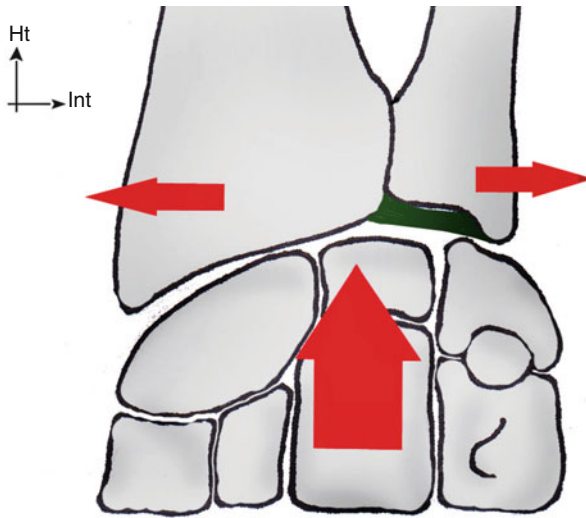


Fig. 1.21 Squeezing a ball for example, increases the longitudinal constraint on the carpus, which tends to move the ulnar apart from the radius

1.2.1.4 Biomechanics of the Radioulnar Unity

The pronosupination biomechanics depends on the conformation of the 2 forearm bones and the functional coupling of the radioulnar joints [6].

Opposite Concavity of the Two Bones of the Forearm

It's essential to maintain a normal pronation as it avoids the early block that would appear in pronation if the bones were straight (Fig. 1.22).

Pronosupination

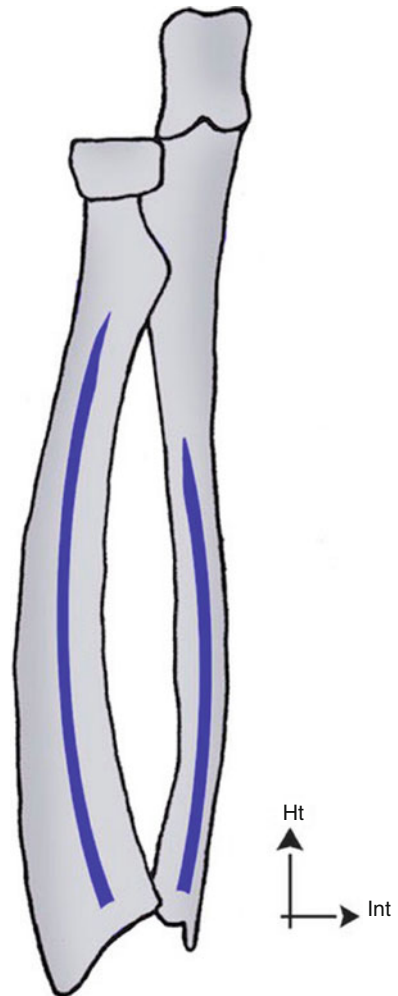
Pronosupination is realized according to a harmonious dynamics related to the functional coupling of the radioulnar joints.

Contrary to widespread opinion, the radius doesn't turn around the fixed ulna: pronosupination is realized around a non-materialized evolutionary axis passing near the radial and ulnar heads.

The two bones of the forearm realize a complex movement of circumduction, in opposite directions. The humerus participates in the movement in two different ways depending on the elbow's position (flexed or extended).

In pronation with the elbow in 90° of flexion, there's an external rotation of the humerus inducing an external translation of the ulna, while the radius rotates on its own axis (Fig. 1.23).

Fig. 1.22 The opposite concavity of the two bones of the forearm avoids their early blocking in pronation



In supination with the elbow in 90° of flexion, we observe the opposite movement: internal rotation of the humerus combined with an internal translation of the ulna and a rotation of the radius in the opposite direction (Fig. 1.24).

With the elbow extended, the amplitude of pronosupination is smaller, because of the tension of the humeroulnar ligaments and the loss of efficiency of the biceps and pronator teres placed in external race [4]. However, this loss is largely compensated by humeral the internal rotation in pronation and external rotation in supination, which allows the whole limb to reach $260\text{--}360^\circ$ depending on the authors (Fig. 1.25).

In this elbow position, the global axis of the forearm is in valgus in supination and considered as the extension of the humerus in pronation (Fig. 1.26).

During pronation, the radius goes upwards with respect to the ulna, which increases the distal radioulnar index and the axial constraints on the radial head. The radial head moves forwards with respect to the capitulum.

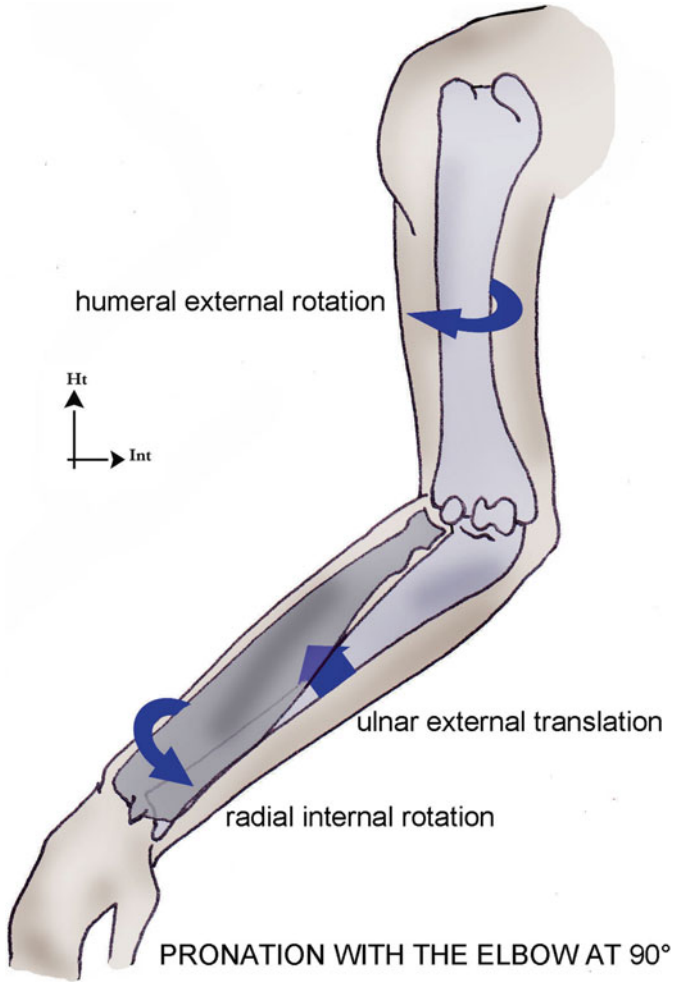


Fig. 1.23 In elbow flexion, the pronation is combined with an external rotation of the humerus

In pronation, the radial fovea presents its great axis, which leads to the radius moving apart from the ulna, allowing the passage of the radial tuberosity between the two bones.

In supination, we observe the opposite mechanism with a reduction of the distal radioulnar index.

The radioulnar joint are the most congruent in the intermediary position, which is also the position of maximal tension in the triangular complex and the middle part of the interosseous membrane. That's why it's the most stable position for the radioulnar unity.

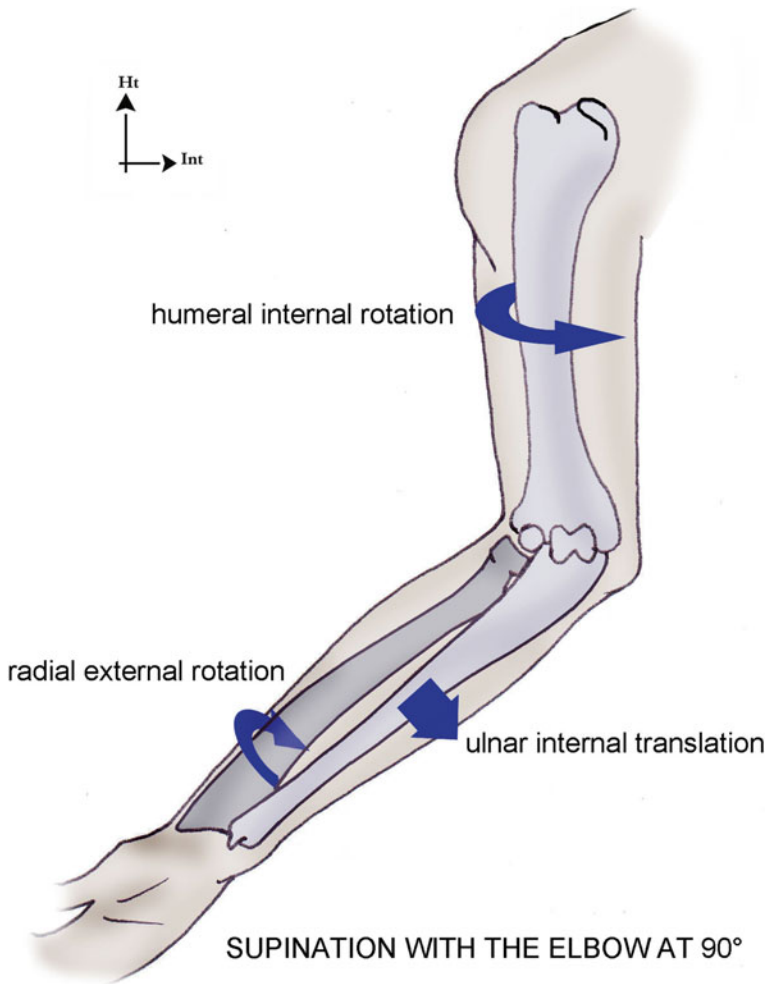


Fig. 1.24 In elbow flexion, the supination is combined with an internal rotation of the humerus

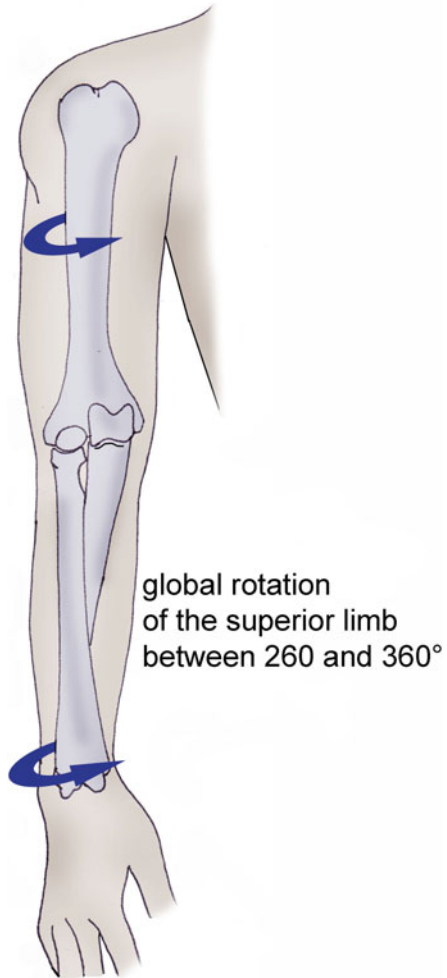
1.2.2 Radiocarpal and Midcarpal Joints [9]

The radiocarpal joint brings together the receiving cavity (radial epiphysis and triangular complex) with the carpal condyle. It's neither concordant nor congruent.

The midcarpal joint is extremely complex and would be a plane joint for its lateral part but rather a condyloid for its medial part. However, the opinions differ, and it seems that it works more like a screw thread allowing screwing and unscrewing of the 1st and 2nd carpal row around the capitate.

These 2 joints participate together to the global wrist mobility that is normally 45° of ulnar inclination, 15° of radial inclination and 90° of flexion/extension. In

Fig. 1.25 With the elbow extended, the amplitudes of pronosupination and humeral rotation are added and allow a global rotation between 260° and 360° , depending on the authors



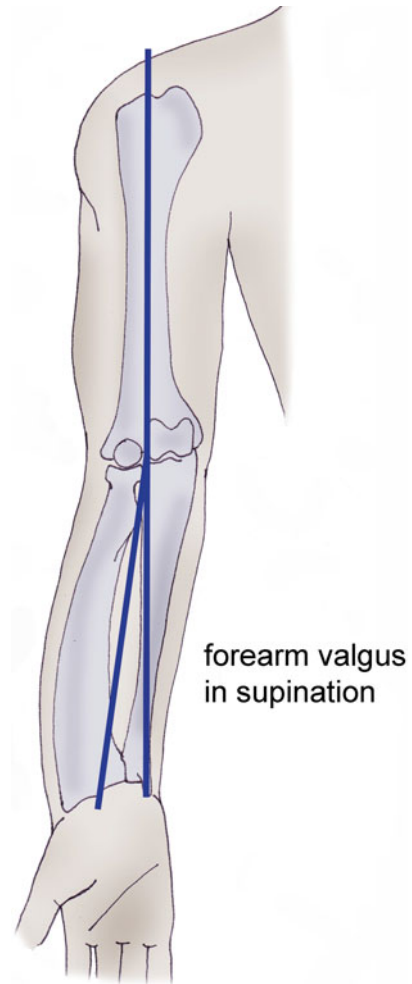
extension, the $2/3$ of the movement is realized in the midcarpal joint, because of the early block of the posterior part of the radius on the 1st carpal row (and especially on the scaphoid). In flexion, the $2/3$ of the movement is realized in the radiocarpal joint (Figs. 1.27 and 1.28).

Sixty percent of the ulnar inclination is radiocarpal while 60 % of the radial inclination is midcarpal.

However, according to recent studies, flexion would be more important at the scapho-trapezo-trapezoidal, radioulnar and ulnotriquetral levels and extension at the radioscapohoidal, lunocapital and triquetrohamate levels (Fig. 1.29).

There are no extrinsic tendinous insertions on the carpus, except on the pisiform (flexor carpi ulnaris). Therefore, the wrist stability is more related to the osseous conformations and extrinsic and intrinsic ligamentous systems.

Fig. 1.26 In elbow extension with the palm towards the front, there is a physiological valgus of the forearm with respect to the arm



1.2.2.1 Extrinsic Ligaments of the Wrist (Figs. 1.30 and 1.30')

They have a carpal insertion and a peripheral insertion.

The extrinsic ligamentous system is composed by ligaments tensed between the radius and the first carpal row and between the radius and the 2nd carpal row. This complex system stabilizes the carpus along with the intrinsic ligaments and allows it to adapt to the constraints imposed on it.

In the frontal plane, the palmar system is the more powerful than the dorsal system, as it has to oppose the anterior pressure of the carpus related to the radial slope (oblique downwards and backwards).

There's a powerful palmar and dorsal anchor point at the level of the triquetrum, fighting against the tendency of the 1st carpal row to slide towards the ulnar side

Fig. 1.27 The wrist extension is realized in the midcarpal (2/3) and radiocarpal (1/3), because of the early block of the carpus against the posterior part of the radius that is more distal than its anterior part

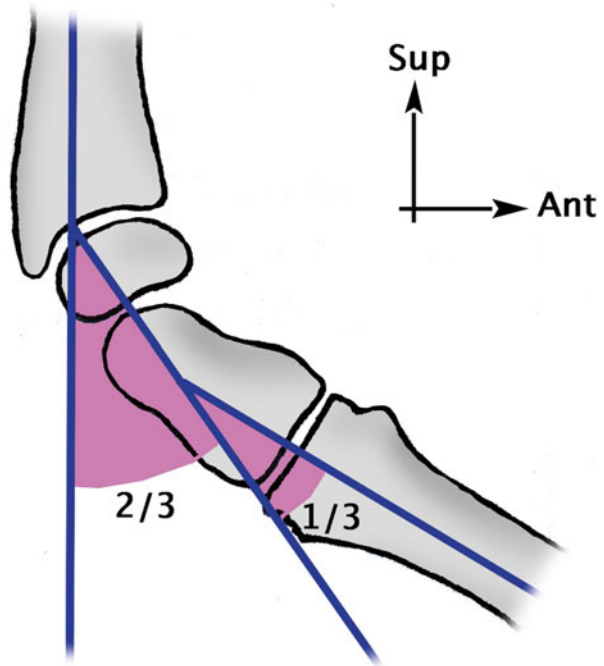
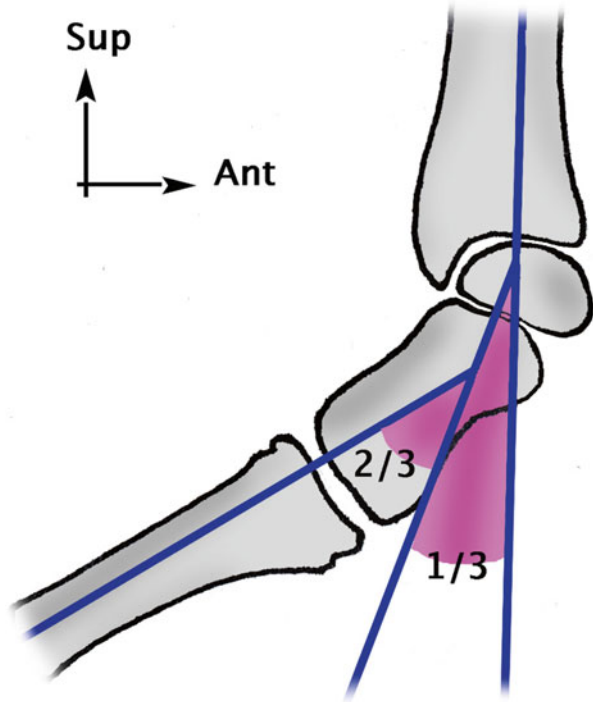
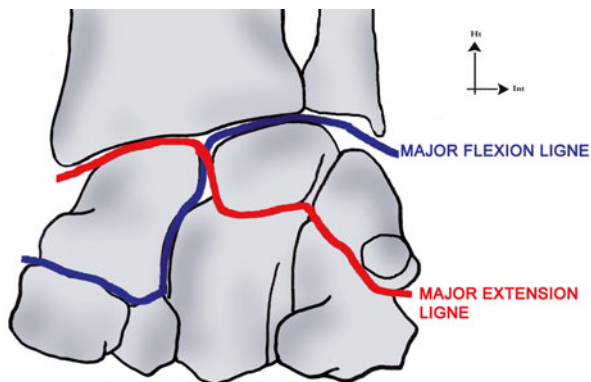


Fig. 1.28 In flexion, the participation of the midcarpal and radiocarpal joints are inverted

Fig. 1.29 Some studies describe a major flexion axis and a major extension axis in the flexo-extension of the wrist



because of the radial slope (oblique downwards and outwards) and the longitudinal muscle forces (Fig. 1.31).

This “pyramidal sling” is made of the anterior and posterior radiolunotriquetral ligaments, reinforced by the palmar ulnotriquetral ligament, the dorsal and palmar intercarpal ligaments and the triquetrohamatocapitate ligament (Fig. 1.32).

This tendency of the 1st carpal row to slide towards the ulnar side is increased in radial inclination, which is a naturally unstable position. It’s cancelled in ulnar inclination, which is a natural functional and stable wrist position, as the 1st row is centred and coapted by the contraction of the longitudinal muscles that are perpendicular to the radial slope in this position (Fig. 1.33).

The radioscaphocapitate ligament acts as a pivot and powerful stabilizer of the scaphoid, opposing the palmar translation of the distal part of the scaphoid (Fig. 1.34).

The radioscapholunate ligament has a poor mechanical resistance but carries radiocarpal vessels (Fig. 1.35).

In the sagittal plane, the wrist is stable when it’s straight as the anterior and posterior ligamentous systems are equally tensed.

In 30° of flexion, the wrist is in its most stable position as the lunate is centred under the radial epiphysis that is oriented downwards and frontwards and coapted by the longitudinal muscles.

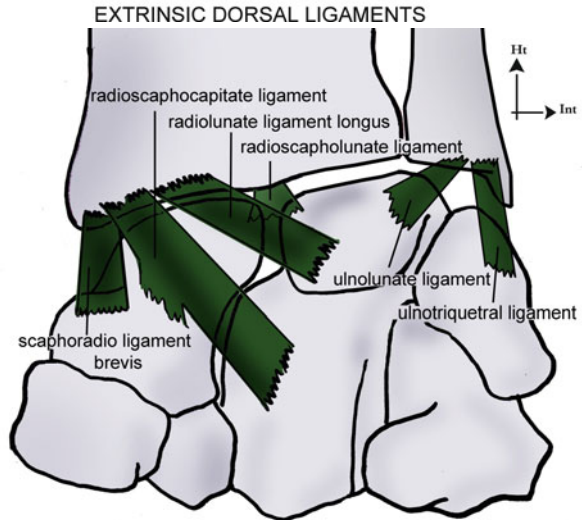
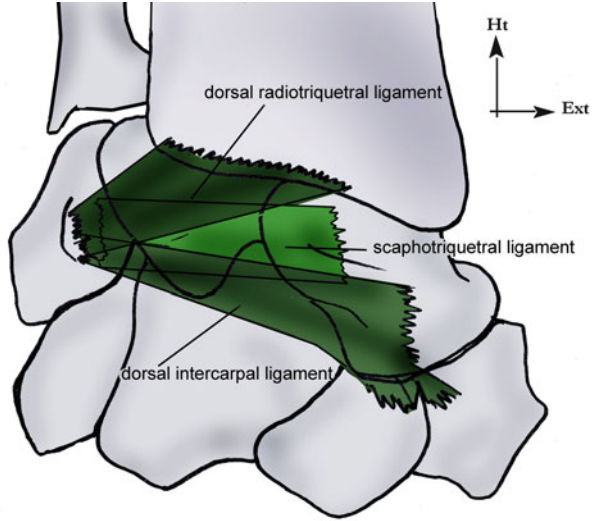
However in extension, the lunate slides frontwards along the radial slope and the longitudinal muscles favour this displacement. The anterior ligaments are important stabilizers and get tensed proportionally to the degree of extension to oppose this gliding (Fig. 1.36).

The most stable position is in flexion and 30° of ulnar inclination.

1.2.2.2 Interosseous Ligaments [3]

They’re particularly thick at the level of the 1st carpal row and allow transmitting the sagittal movements from one bone to the other.

Figs. 1.30 and 1.30' Main extrinsic ligaments of the wrist



EXTRINSIC VOLAR LIGAMENTS

The scapholunate ligament is made of 3 bundles with different mechanical resistances as the palmar portion has a resistance of 150 N, while the dorsal portion has a resistance of 300 N.

Its superior part is covered with cartilage, in continuity with the cartilage of the two adjacent bones.

Its elasticity allows 30° of freedom between the scaphoid and lunate, essential for the good functioning of the scapholunar pair.

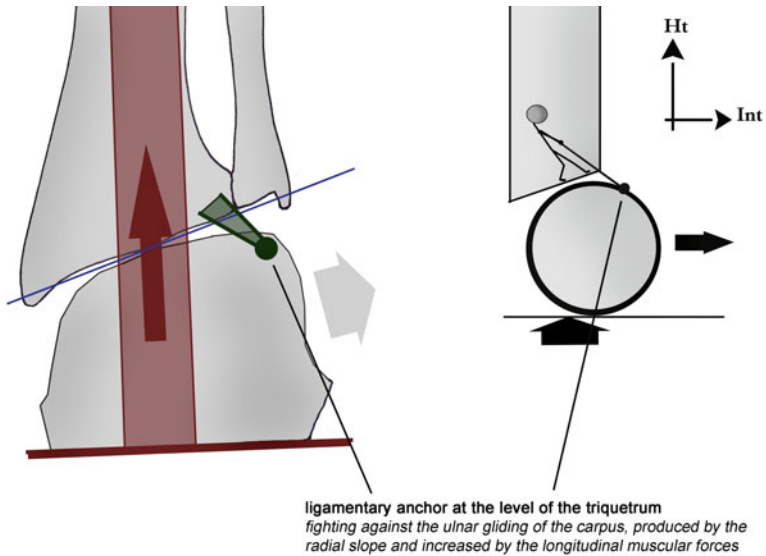
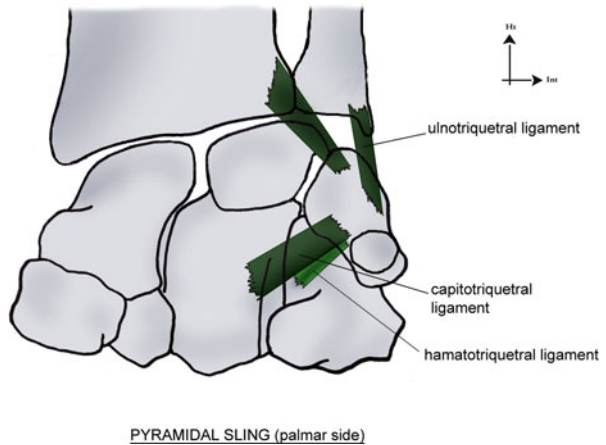


Fig. 1.31 The ulnar ligamentary anchor opposes the carpal physiological gliding occurring because of the longitudinal constraints and radial slope

Fig. 1.32 Composition of the triquetral sling



Its rupture leads to a scapholunate diastasis and a posterior tilt of the lunate, which then won't be pushed by the triquetrum towards extension. It also produces a secondary global collapse of the 1st carpal row.

The lunotriquetral ligament allows very little mobility between the lunate and the triquetrum. Its superior face is also covered with cartilage.

Contrary to the scapholunate ligament, its palmar part is the thickest and more resistant (approximately 300 N) than its dorsal part (150 N).

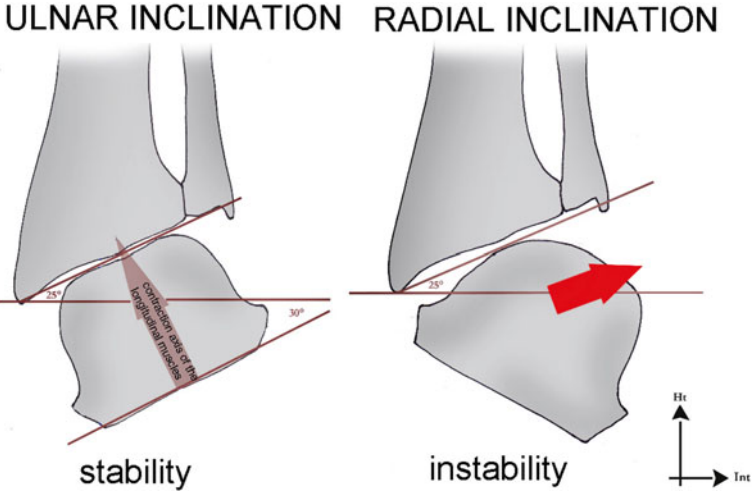
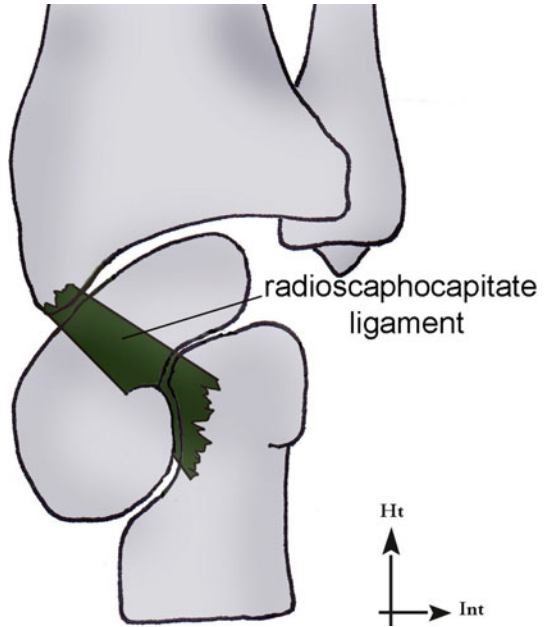


Fig. 1.33 In the frontal plane, the carpus is more stable in ulnar inclination as the ulnar gliding is null in this position. It's the opposite in radial inclination as the ulnar gliding is major in this position

Fig. 1.34 The radioscapocapitate ligament is a powerful anti-flexion stabilizer of the scaphoid



The lunate hangs in torsion between the scaphoid and the triquetrum that have antagonist ligaments with equivalent resistances.

However, the pressure constraints bringing the scaphoid to flexion are more important than the ones in extension on the triquetrum, as the scaphoid transmits 48 % of the longitudinal constraints while the triquetrum only transmits 20 %.

Fig. 1.35 The radioscapholunate ligament plays a vessel carrier role. Its mechanical action is very limited

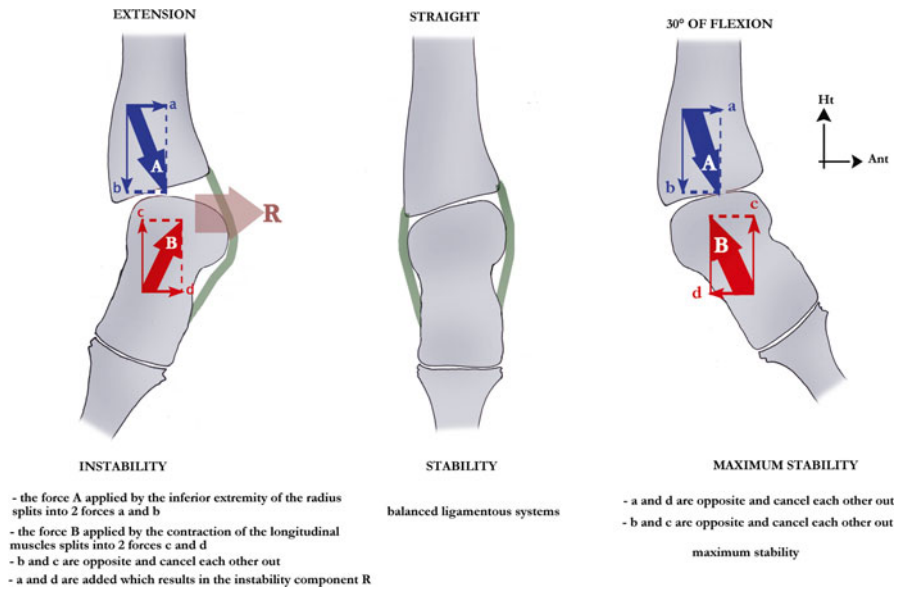
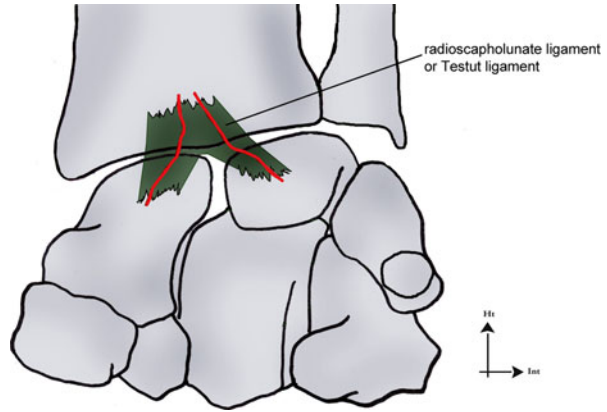


Fig. 1.36 In the sagittal plane, the carpus is more stable in flexion than in extension because the lunate is centred under the radius, and the anterior gliding of the carpus along the radial slope is null

Balance is maintained by the axial pressure of the capitate that brings the lunate in extension.

At the midcarpal level, ligaments are present in the lateral and medial parts of the joint but absent between the lunate and capitate.

Laterally, the distal scaphoid ligaments aren't very solicited in flexion. They limit the anterior tilt in neutral position and are tensed in abduction/dorsal inclination when they keep the scaphoid against the 2nd carpal row.

Medially, the triquetrohamatal system limits the triquetrum's gliding on the hamatal slope.

The arched ligament is made of the scaphocapitate and triquetrocapitate ligaments. It forms a central midcarpal lock essential in stability if we take into account the fragility area created by the lack of lunocapitate ligament (space of Poirier) (Fig. 1.37) [7].

In the 2nd row, ligaments lock the 4 distal carpal bones so that they biomechanically act like a monolithic block.

1.2.2.3 Organization in "V"

Various ligamentous systems have this type of organization:

- *Proximal palmar "V"*: radiolunate and ulnolunate ligaments
- *Distal palmar "V"*: scaphocapitate and triquetrocapitate ligaments (Fig. 1.38)
- *Dorsal triquetral "V"*: dorsal intercarpal and dorsal radiotriquetral ligaments
- *Palmar triquetral "V"*: palmar radiotriquetral and triquetrocapitate ligaments

1.2.2.4 "Active" Collateral Ligaments?

The anatomy of the collateral ligamentous systems is put into question, as they wouldn't allow movement in the frontal plane. It would seem that the muscular systems ensure collateral stability, as their capacity to extend doesn't restrain contralateral movements (Fig. 1.39).

This active system is made of the extensor and flexor carpi ulnaris for the ulnar side and the abductor pollicis longus, extensor pollicis brevis, extensor carpi radialis longus and flexor carpi radialis for the radial side.

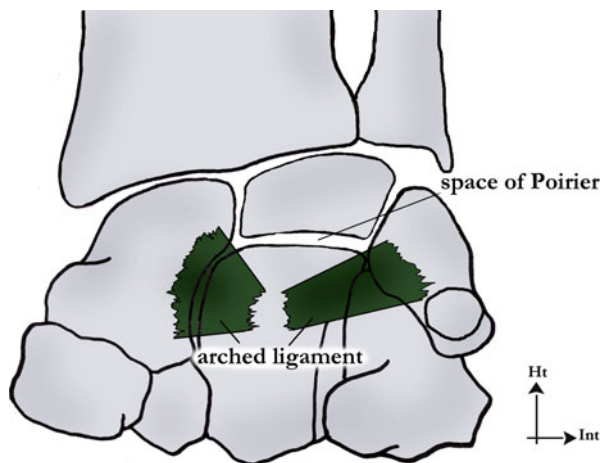


Fig. 1.37 The arched ligament stabilizes the midcarpal joint, which fragility zone is the space of Poirier between the lunate and capitate

Fig. 1.38 “V” shape of the extrinsic volar ligamentous system

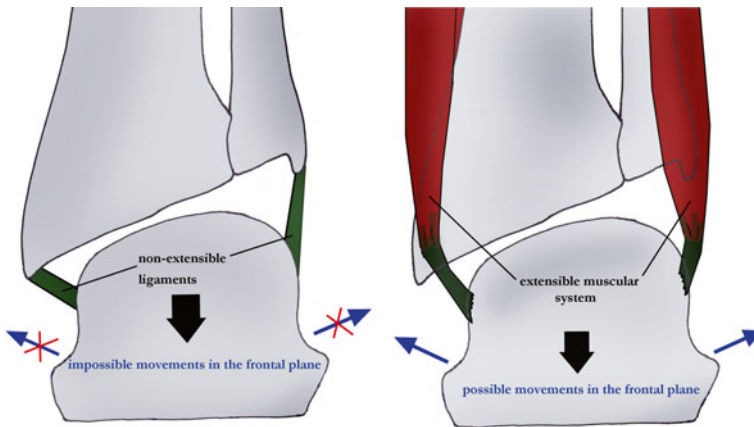
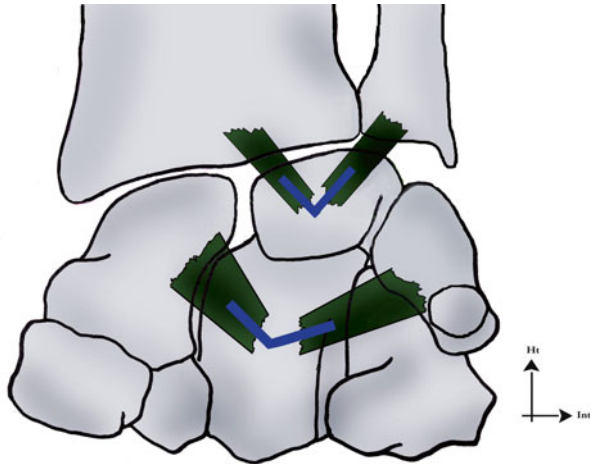


Fig. 1.39 The lateral stability of the carpus is ensured by muscular systems that don't hinder mobility in the frontal plane, thanks to their extensibility

1.2.2.5 Retinacular Ligaments

The flexors retinaculum only has a secondary role in the carpal stability and will be described in the Chap. 13. It's the most powerful reflexion pulley in the human body; it optimizes the angle of the flexor system and protects the carpal tunnel. It's also the anchor for the thenar and hypothenar muscles.

The extensors retinaculum is made of a transverse part and an oblique part. The transverse part plays the role of reflexion pulley for the six synovial slides of the

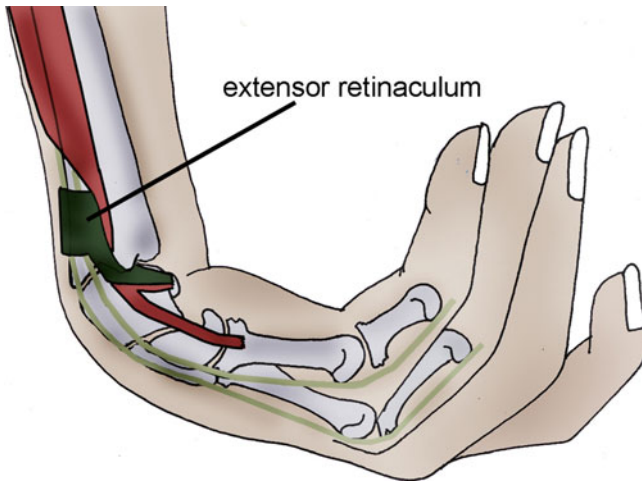


Fig. 1.40 The dorsal carpal ligament plays the role of a pulley for the extensor systems. Its oblique part ends on the pisiform and therefore participates in stabilizing the ulnar compartment of the carpus

extensors of the long fingers, thumb and wrist. The oblique part is oriented downwards and inwards and ties the ulnar side of the carpus and the extensor carpi ulnaris (with which it shares some fibres), before inserting on the pisiform.

This oblique portion participates in the formation of the triquetral anchor and therefore in the frontal carpal stabilization. It doesn't stabilize the ulnar head as it's more distal than this one (Fig. 1.40).

1.2.2.6 Triangular Complex

Already described in the paragraph about the distal radioulnar joint, it's a fibrocartilage covered with cartilage helping transmitting the axial constraints from the carpus towards the forearm frame.

1.2.3 Carpal Dynamics

1.2.3.1 Scapholunate Joint and Scapholunate Ligament

The scapholunate joint is a key element in the carpal dynamics, as their permanent adaptation maintains the spatial alignment of the carpus by filling the "empty spaces".

To obtain this result, their "working distance" (distance between the radius and the 2nd row) must adapt to the wrist positions.

In a straight position, the lunate's working distance is medium, and the scaphoid's is maximal.

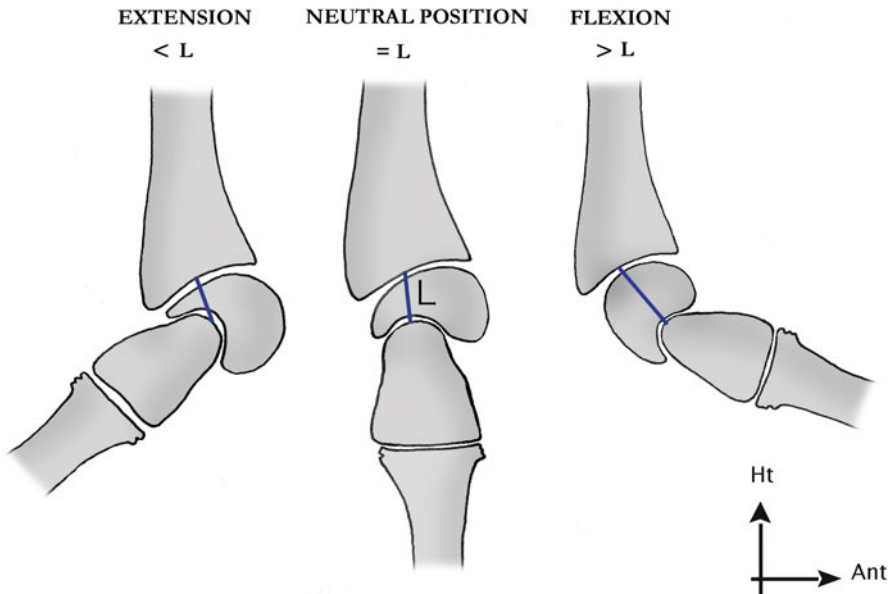


Fig. 1.41 The adaptability of the scapholunate pair allows modifying the space between the 2nd carpal row and the radius, guaranteeing a good spatial consistency in the carpus (According to Kapandji)

In flexion, it is maximal for the lunate as its anterior horn (the biggest) interposes and minimal for the scaphoid that is completely down.

In extension, it is minimal for the lunate that presents its posterior horn (the thinnest) and medium for the scaphoid that is right, but the trapezium slides dorsally to reduce the working distance (Figs. 1.41, 1.42).

There's asynchronicity between the lunate and scaphoid when locking in extension: the scaphoid is locked earlier because of the tension of the radioscaphoid and scaphotrapezoid ligaments and the block on the posterior part of the radius.

The lunate moves about 30° more after the scaphoid is locked due to the elasticity of the scapholunate ligament.

In flexion, the two bones are locked at the same time.

1.2.3.2 Global Movements

During wrist movements, there's an adaptive carpal dynamics maintain the joint cohesion. It's related to the conformation of the bones and the tension of the ligamentous systems.

During flexion, the 1st carpal row realizes a flexion/abduction/pronation, while the 2nd row realizes a flexion/adduction/supination. The two flexions are added, and the components of pronation/supination and abduction/adduction cancel each other out. This compensatory mechanism allows obtaining a global simple flexion.

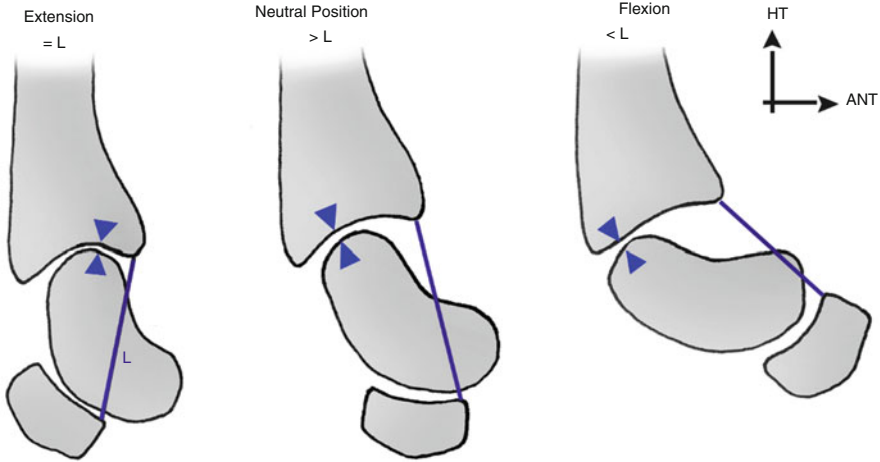


Fig. 1.42 The adaptability of the scapholunate pair allows modifying the space between the 2nd carpal row and the radius, guaranteeing a good spatial consistency in the carpus (According to Kapandji)

During extension, we observe the opposite movement of extension/adduction/supination in the 1st row and extension/abduction/pronation in the 2nd row. The two extensions are added, and the components of pronation/supination and abduction/adduction cancel each other out (Figs. 1.43 and 1.43').

During abduction, the 1st carpal row realizes a pronation/flexion, while the 2nd row realizes a supination/extension. These two components cancel each other out to obtain a “pure” abduction.

During adduction, the 1st row realizes a supination/extension while the 2nd row realizes a pronation/flexion. These two components also cancel each other out to obtain a “pure” adduction (Figs. 1.44 and 1.45).

These mechanisms are supposed to be related to two evolutionary oblique axes:

- A radiocarpal axis oblique frontwards and inwards
- A midcarpal axis oblique frontwards and outwards

This theory, described by Henke, would explain the movement combination previously described.

1.2.3.3 Analytical Movements of the Carpal Bones

During an ulnar inclination, the triquetrum slides in an ulnar and palmar direction along the hamate; this places it in extension. The ulnar column's height decreases.

The tension of the distal scaphoidal ligaments moves the trapezo-trapezoidal joint and the radius apart. This brings the scaphoid in extension to increase its working distance and fill the radio-trapezo-trapezoidal space.

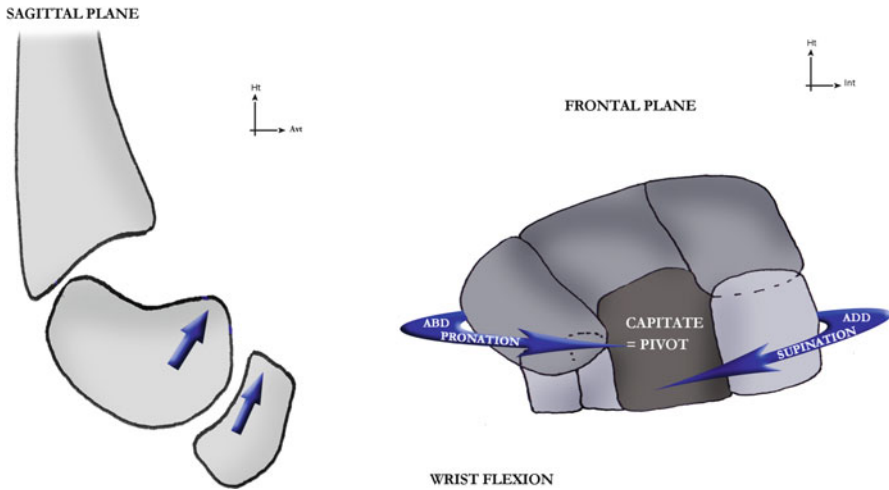


Fig. 1.43 In wrist flexion both carpal rows go to flexion, but the 1st row goes to pronation/abduction, while the 2nd row goes to supination/adduction, so the two components cancel each other out. The resulting movement is a “simple” flexion

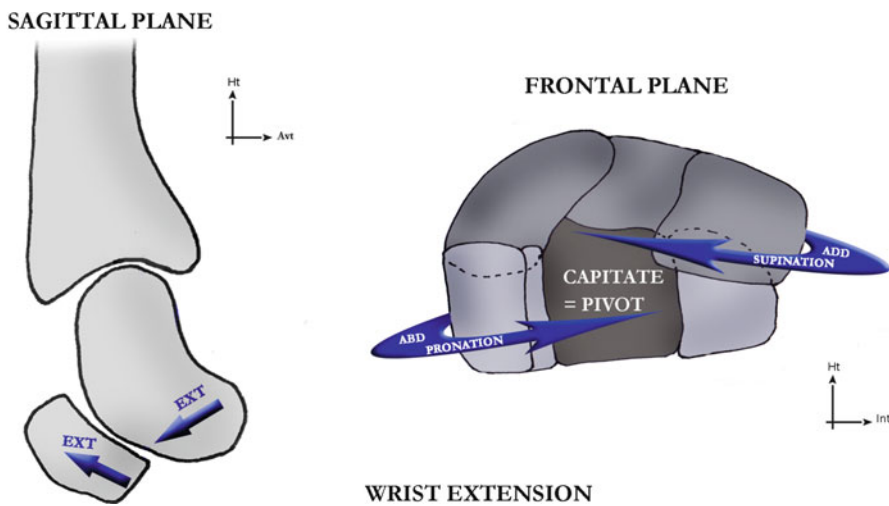


Fig. 1.43' In wrist extension both carpal rows go to extension, but the 1st row goes to supination/adduction while the 2nd row goes to pronation/abduction, so the two components cancel each other out. The resulting movement is a “simple” extension

The triquetrum slides towards the palmar ulnar side along the hamate slope, which places it in extension. The interosseous scapholunate and lunotriquetral ligaments transmit this extension component to the lunate. The 1st row tilts in extension. The lunate tilt brings the capitate and then the rest of the 2nd carpal row in flexion.

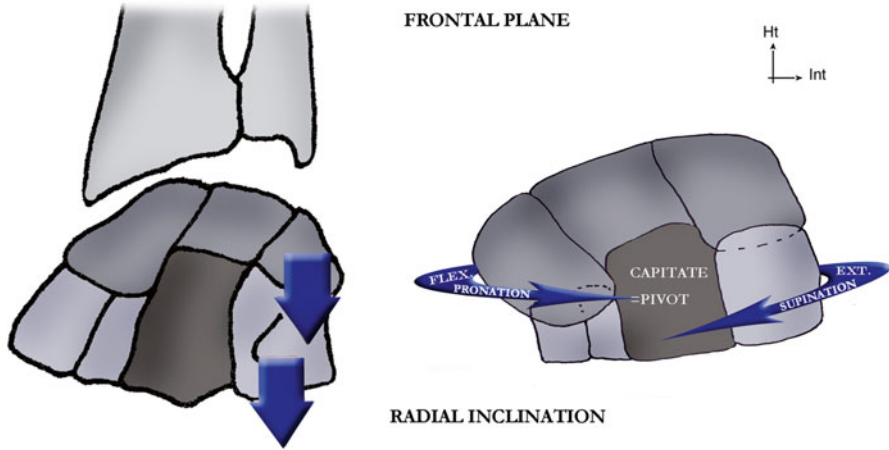


Fig. 1.44 In wrist radial inclination, both carpal rows go to abduction, but the 1st row goes to pronation/flexion, while the 2nd row goes to supination/extension, so the two components cancel each other out. The resulting movement is a “simple” radial inclination

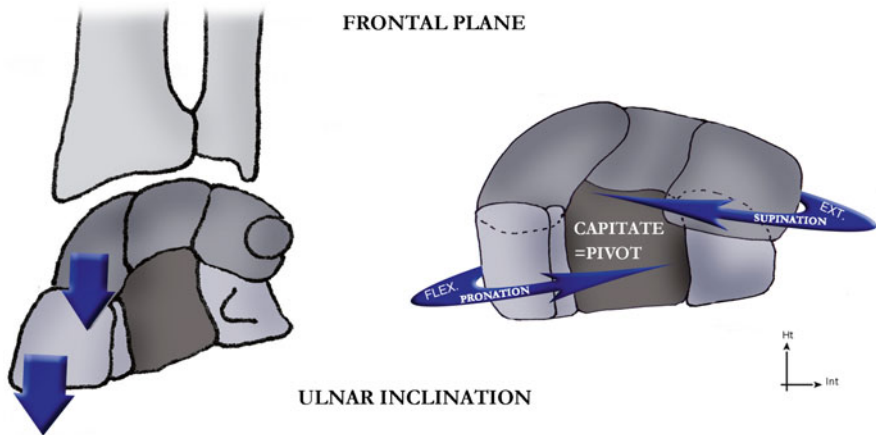


Fig. 1.45 In wrist ulnar inclination, both carpal rows go to adduction, but the 1st row goes to supination/extension, while the 2nd row goes to pronation/flexion, so the two components cancel each other out. The resulting movement is a “simple” ulnar extension

During a radial inclination, the trapezo-trapezoidal joint moves upwards, thus reducing the radio-trapezo-trapezoidal space; this brings the scaphoid to flexion. The triquetrum is maintained by the pyramidal “sling” and moves up the hamate slope towards the capitate; this also places it in flexion. Therefore, the radial column is reduced, and the ulnar column is increased.

The scapholunate and lunotriquetral ligaments transmit this flexion component to the lunate, making the 1st row tilt in flexion. The lunate tilt brings the capitate and then the rest of the 2nd carpal row in extension.

During extension, the radioscaphocapitate ligament is tensed and brings the scaphoid and capitate in extension. The scaphoid is locked thanks to the distal scaphoidal ligaments and transmits the movement to the lunate that also tilts in extension.

The scaphoid's extension stops before the lunate's, which keeps moving approximately 30°.

In this movement, the scaphoid's working distance decreases less than the lunate's, so the 1st carpal row realizes an adduction compensated by an abduction of the 2nd row.

Simultaneously, the 1st row realizes a pronation compensated by a supination of the 2nd row.

1.2.3.4 “Variable Geometry” of the Carpus

The 1st carpal row can be compared with a flexible and mobile meniscus that doesn't form a unique joint surface.

It has important adaptive capacities that allow managing the biomechanical constraints imposed on it and cushion part of them (Fig. 1.46).

The 2nd carpal row is a lot less mobile. It can be biomechanically compared with a monolithic block.

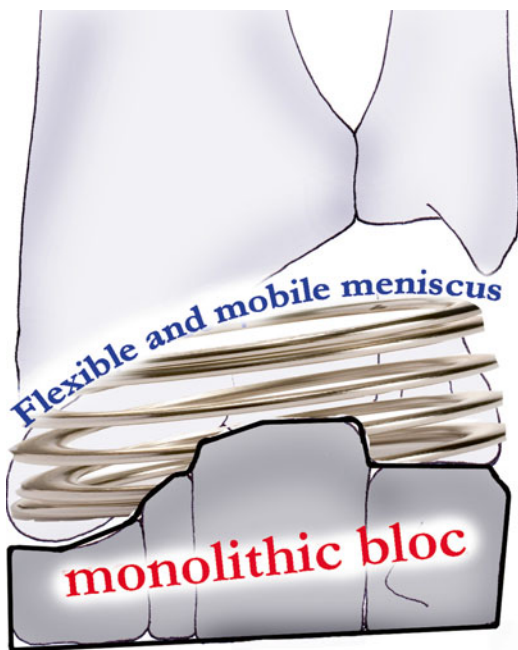


Fig. 1.46 The 1st carpal row is schematically identified as a flexible meniscus that adapts to the constraints imposed on it, while the 2nd row is compared to a monolithic block with no adaptive capacity

1.3 Muscular Anatomy and Physiology

The wrist and radioulnar frame orient and stabilize the hand in the three planes.

There are muscles whose characteristics are adapted to movement (fusiform) and others adapted to stability (pennate).

The main muscles of the radioulnar frame are short and fleshy with short tendons (pronator quadratus [10], pronator teres and supinator).

The wrist extensors (extensor carpi radialis longus and brevis, extensor carpi ulnaris) are fusiform muscles with longer tendons and pass like a bridge over the carpus. This architecture gives them good endurance and active amplitude but poor stabilizing capacity.

The main wrist flexors (flexor carpi radialis and ulnaris, palmaris longus) also have long tendons passing over the carpus. Their architecture is variable as the flexor carpi ulnaris is bipennate (adapted to stabilization but less to movement), while the other flexors are fusiform.

The long muscles of the fingers have a more important action on the wrist when they work in closed chain, as their distal fix point makes them more efficient in mobilizing and stabilizing the wrist.

The anterior muscles are flexors and the posterior ones extensors, the lateral ones realize radial inclination and the medial ones an ulnar inclination (Fig. 1.47).

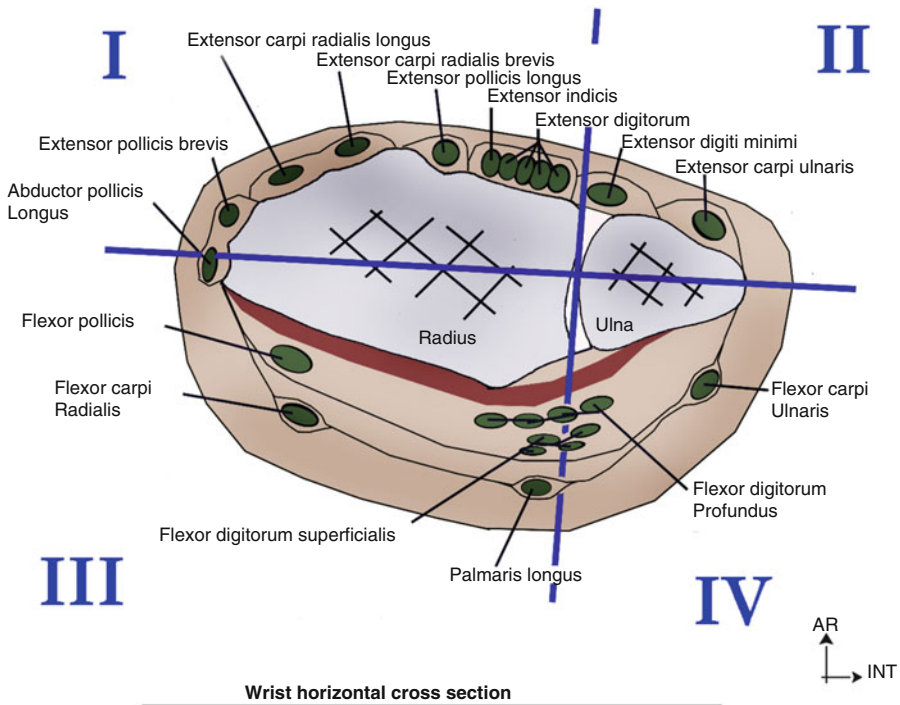


Fig. 1.47 Wrist cross-section

1.3.1 Muscular Anatomy [5, 11, 13, 14, 16, 17]

1.3.1.1 Main Muscles of the Radioulnar Frame (Fig. 1.48)

They work in synergy to ensure the cohesion of the three radioulnar locks. We'll only describe here the muscles that also have an action on the radio and midcarpal joints.

Pronator Teres

It's the most lateral superficial muscle of the forearm's anterior compartment. It has 2 heads, one from the medial humeral epicondyle (common epicondylar tendon) and the other from the medial part of the coronoid process. The muscle ends on the middle third of the radius' lateral side.

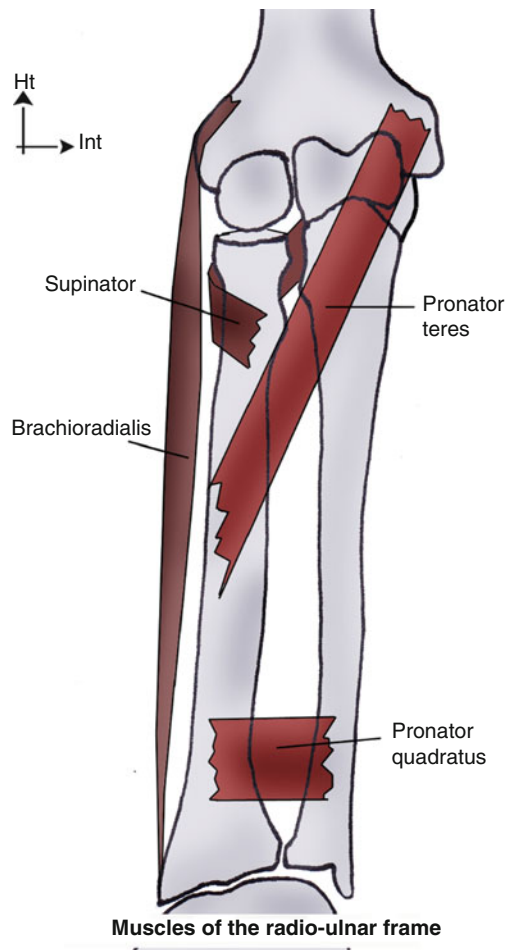


Fig. 1.48 Muscles of the radioulnar frame

Main action: forearm pronation

Secondary action: elbow flexion

Innervation: median nerve (C6–C7)

Pronator Quadratus (Fig. 1.49)

It's the deepest muscle in the forearm's anterior compartment. It has a quadrilateral shape and is flat against the interosseous membrane, from the radius to the ulna in their inferior quarter, next to the distal radioulnar joint. It's a short, powerful muscle. It has its own aponeurosis and is composed of two bundles:

- A *superficial bundle*, made of transversal fibres and is similar to a flat muscle
- A *deep bundle* made of fibres oblique downwards and outwards, twice as thick as the superficial bundle, similar to a pennate muscle (more stabilizing capacity)

The distal part of the muscle is larger than the proximal part and blends with the distal radioulnar joint capsule. From an anatomical point of view, the architecture and location of the deep bundle allow it to efficiently stabilize this distal radioulnar joint.

Main action: forearm pronation and stabilization of the distal radioulnar joint

Innervation: anterior interosseous nerve (C8–T1)

Brachioradialis

It's a muscle bulging in the lateral side of the forearm in forced elbow flexion. It has no action on the wrist and is the only muscle in the body to start on the inferior extremity of one bone and end on the inferior extremity of another bone. It goes

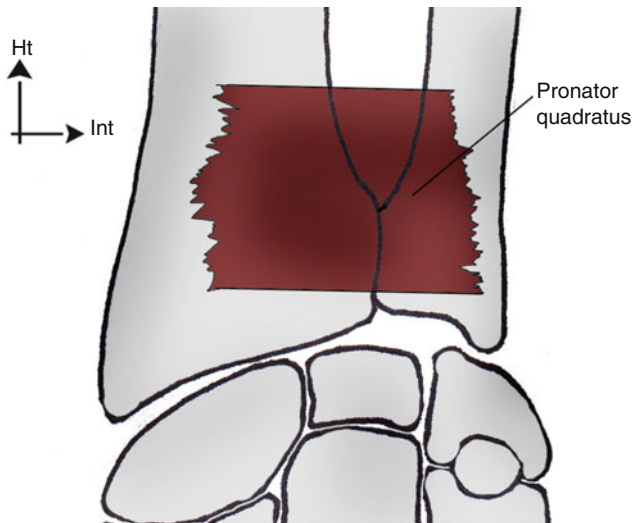


Fig. 1.49 The pronator quadratus is a short and fleshy muscle of the deep anterior compartment of the forearm

from the lateral supracondylar ridge of the humerus, to the lateral side of the radial styloid process.

Main action: elbow flexion (weak action because of its parallelism with the radius and its proximal insertion close to the elbow joint).

Secondary action: it's an accessory supinator in pronation and an accessory pronator in supination; it brings the forearm back in the intermediary position.

Innervation: radial nerve (C5–C6).

Supinator

Short and flat, this muscle is wrapped around the radial head. Its origin is split into two bundles: a superficial bundle from the lateral humeral epicondyle and a deep bundle from the supinator crest of the ulna. It ends on the superior third of the lateral radial side, covering part of its anterior and posterior sides.

Main action: forearm supination in any elbow position

Secondary action: coaptation of the lateral part of the elbow joint with its superficial head

Innervation: radial nerve (C5–C6–C7)

1.3.1.2 Wrist Muscles

Wrist Extensors (Fig. 1.50)

They are posterior muscles of the forearm, with a fusiform architecture and tendons sliding in a synovial sheath at the level of the extensors retinaculum.

Extensor Carpi Radialis Longus

It spreads from the lateral inferior part of the humerus to the dorsal base of the 2nd metacarpal. It's located outside the extensor carpi radialis brevis, above the brachioradialis. The muscle belly makes its way down the lateral part of the forearm and ends by a tendon in the middle third of the forearm. This tendon is right next to the extensor carpi radialis longus tendon, behind the brachioradialis. It then passes behind the radial styloid process, in the posterior groove on the lateral side of the inferior radial extremity.

Main action: wrist extension and radial inclination.

Secondary action: elbow flexion.

Functional aspect: it combines synergic-antagonist contractions with the flexor carpi radialis. It's the antagonist of the muscles realizing the ulnar inclination, and it stabilizes the radial side of the wrist.

Innervation: radial nerve (C6–C7).

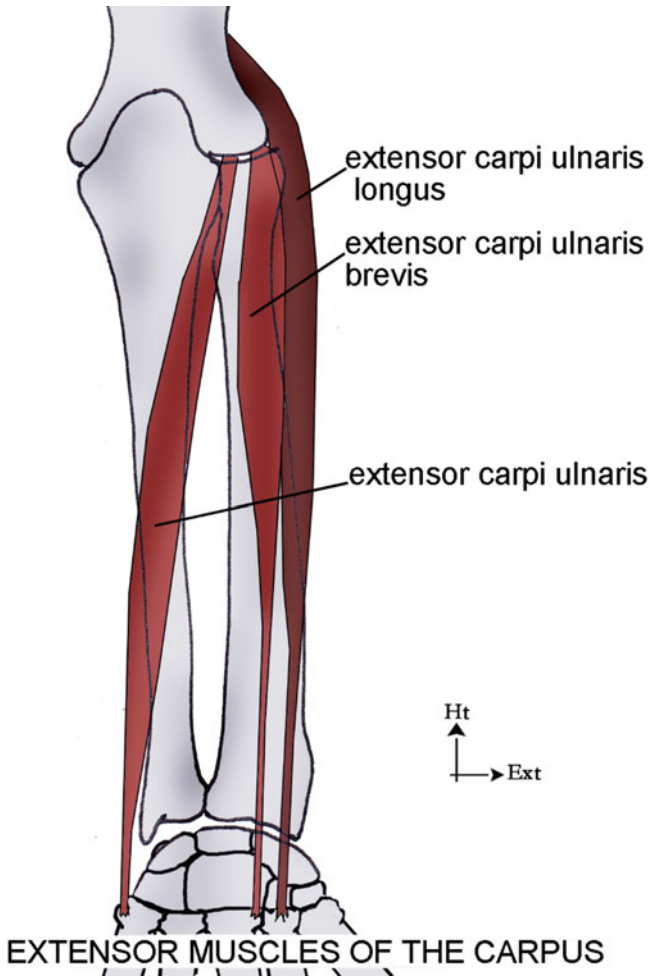


Fig. 1.50 Extensor muscles of the carpus

Extensor Carpi Radialis Brevis

This muscle spreads from the lateral epicondyle to the dorsal base of the 3rd metacarpal. Its origin is outside the supinator (common epicondylar tendon). The muscle belly is triangular, medial in relation with the extensor carpi radialis longus. Its tendon is right next to the extensor carpi radialis longus tendon and ends on the base of the 3rd metacarpal.

Main action: hand extension.

Functional aspect: it's synergic to the flexor digitorum profundus; its activity is reduced during the contraction of the fingers extensors.

Innervation: radial nerve (C6–C8).

Extensor Carpi Ulnaris [1]

It's fusiform.

Its origin is on the epicondyle (common epicondylar tendon) and on the posterior part of the ulna (aponeurotic blade).

On its pathway, it's not in contact with the forearm aponeurosis a lot. The muscle fibres are longitudinal in relation with the long end tendon. This tendon has its own sheath, independent from the dorsal retinaculum. It passes behind the ulnar styloid process in a resistant osteofibrous sheath and ends on the base of the 5th metacarpal.

Action: wrist extension and ulnar inclination.

Functional aspect: synergic contraction with the abductor pollicis longus.

Innervation: radial nerve (C6–C7–C8).

Wrist Flexors (Fig. 1.51)

They are anterior muscles of the forearm, fusiform (flexor carpi radialis and palmaris longus) or bipennate (flexor carpi ulnaris).

Flexor Carpi Radialis

It belongs to the superficial plane of the anterior forearm compartment. Its origin is on the medial epicondyle. It's a fusiform muscle, flat in the front and in the back. Its fleshy muscle belly is followed by a long and voluminous tendon that goes down in front of the median nerve. The muscle belly is oblique downwards and a little outwards, placed in front of the flexor digitorum superficialis. It's followed by a tendon that appears in the middle of the forearm. This long tendon follows the gutter of the pulse.

At the level of the wrist, it crosses the carpus in its own osteofibrous groove, outside the carpal tunnel, which contains the flexor tendons, limited in the back by the scaphoid and trapezium. The flexor carpi radialis tendon ends on the base of the 2nd metacarpal and partly on the trapezium and the base of the 3rd metacarpal.

Main action: wrist flexion and participates in the radial inclination.

Secondary action: elbow flexion and forearm pronation.

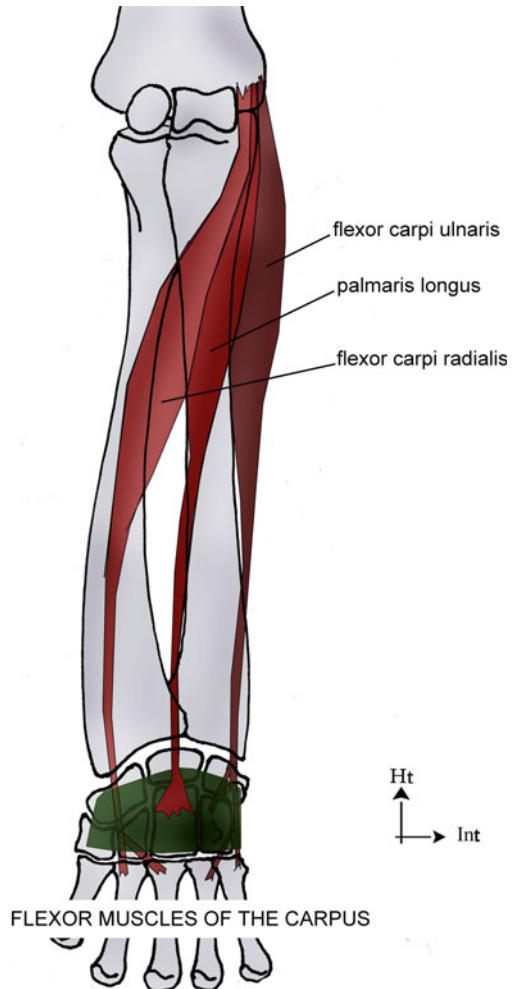
Functional aspect: it's synergic to the extensor digitorum when opening the hand. It realizes the radial inclination of the wrist in co-contraction with the extensor carpi radialis longus.

Innervation: median nerve (C8–T1).

Palmaris Longus

This muscle belongs to the superficial plane of the anterior forearm compartment. Its origin is on the medial epicondyle. It's a fusiform muscle, thin, and not very powerful. Its muscle belly corresponds to the superior 1/3 and its tendon to the inferior 2/3. The tendon goes down on the medial side of the flexor carpi radialis and

Fig. 1.51 Flexor muscles of the carpus



ends spreading on the flexors retinaculum. The median fibres continue on the superficial palmar aponeurosis and the lateral fibres on the palmar aponeurosis of the thenar and hypothenar eminences.

Main action: wrist flexion and puts tension in the superficial palmar aponeurosis.

Secondary action: small participation in the elbow flexion and forearm pronation.

Particularity: it's an inconstant muscle, absent in 13 % of the cases and with multiple anatomical variations.

Innervation: median nerve (C8–T1).

Flexor Carpi Ulnaris [1]

It's a bipennate muscle.

Its origin is epitrochlear (common epitrochlear tendon), with a tendinous blade on the internal part of the olecranon and on the superior 2/3 of the posterior ulnar part.

It sticks to the forearm aponeurosis. The insertion of the muscular fibres is oblique in relation with the tendon axis, and their end is purely tendinous, short and inserted on the pisiform. It has expansions spreading towards the hamate, the flexors retinaculum and the 4th and 5th metacarpals.

Action: wrist flexion and ulnar inclination.

Innervation: ulnar nerve (C7, C8, T1).

1.3.2 Physiology

The wrist muscles orient and stabilize the hand.

This double function requires a constant adaptation of their course and tension.

Stability is the dominant function of the wrist. As passive stability is moderate, the role of the active stabilizers is essential.

These stabilizers work with a co-contraction mode of the different muscular groups.

Here we differentiate the extrinsic stabilizers that work in synergy in a “puppet system” and the intrinsic stabilizers that act more directly on the two carpal rows (Fig. 1.52).

1.3.2.1 Extrinsic Wrist Stabilizers

They all end on the metacarpals and therefore don't have a direct action on the carpal bones, except the flexor carpi ulnaris.

Radial Stabilizers

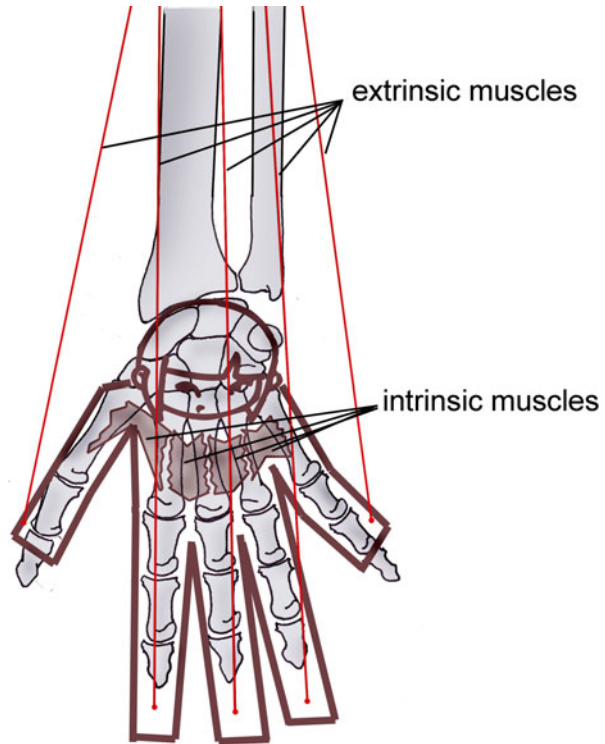
The main radial stabilizers are the flexor carpi radialis and the radial extensors of the carpus. They act in synergy to stabilize the wrist radially. Their tendons are about 3.5 cm long, and their length is maximal during wrist flexion/extension.

In the sagittal plane, they ensure the scaphoid's stability between their two tendons (Fig. 1.53).

In the frontal plane, their action is lesser due to the radial slope that puts important constraints on the ulnar compartment. However, they play the role of active ligaments, stabilizing the wrist without limiting ulnar inclination (cf. Figs. 1.39 and 1.40).

At the intracarpal level, the radial extensors realize a supination, allowing the coaptation of the scapholunate space and the relative opening of the lunotriquetral space. The anatomical situation of the flexor carpi radialis should give it the role of an intracarpal pronator, but its distal tendon, passing in front of the scaphoid's tubercle, opposes this tendency and stabilizes the scaphoid against its natural tendency to go to flexion.

Fig. 1.52 The carpus acts like a puppet (because of the action of the extrinsic muscles) that would have its own muscles (thanks to the intrinsic system)



Ulnar Stabilizers

The main ulnar stabilizers are the flexor and extensor carpi ulnaris [1].

They act on the carpus directly with their tendinous insertions and indirectly due to their anatomical continuity with the retinacular system.

These muscles' tendons are 3.5 cm long, in the sagittal plane for the flexor carpi ulnaris and in the frontal plane for the extensor carpi ulnaris.

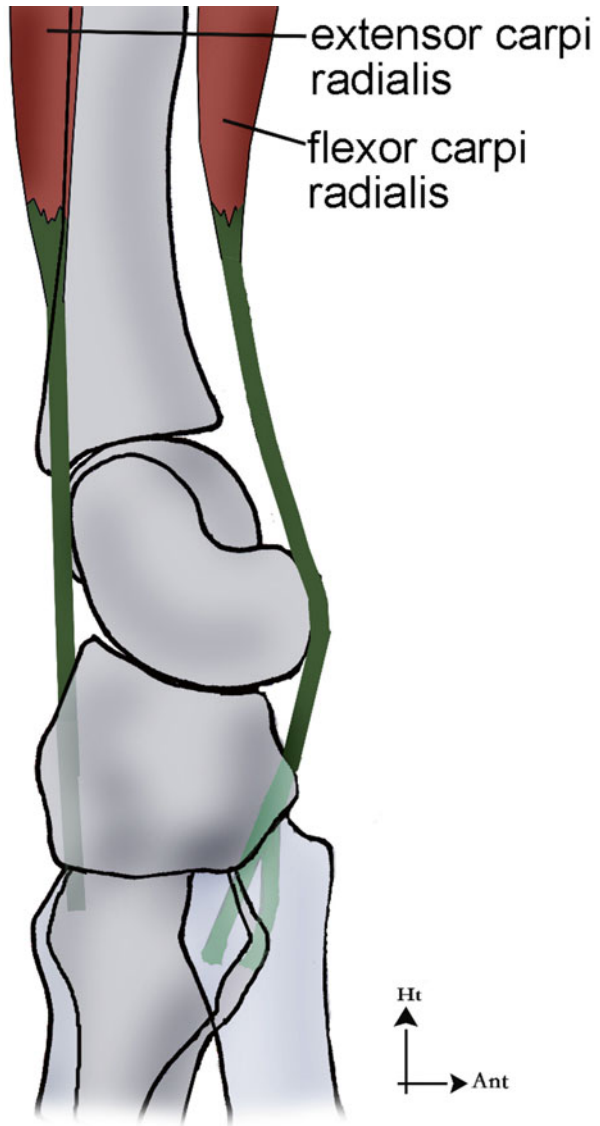
In the sagittal plane, the flexor carpi ulnaris supports important and prolonged constraints because of its bipennate architecture (low active amplitude, good capacity to hold back and good endurance). It actively participates in carrying loads and other force activities soliciting the wrist. This action is favoured by the pisiform that protects and optimizes the angle of the flexor carpi ulnaris tendon, making its contraction more efficient.

In the frontal plane, they oppose the ulnar gliding of the 1st carpal row during the radial inclination or because of axial constraints (Fig. 1.54).

Their contraction puts in tension the retinacular system that stabilizes the carpus (Fig. 1.55).

At the intracarpal level, the flexor carpi ulnaris causes an intracarpal supination, stabilizing the scapholunate space and putting in tension the lunotriquetral space,

Fig. 1.53 The flexor carpi radialis and the extensor carpi radialis longus participate in the active stability of the scaphoid in the sagittal plane
 Court extenseur radial du carpe: extensor carpi radialis brevis
 Fléchisseur radial du carpe: flexor carpi radialis

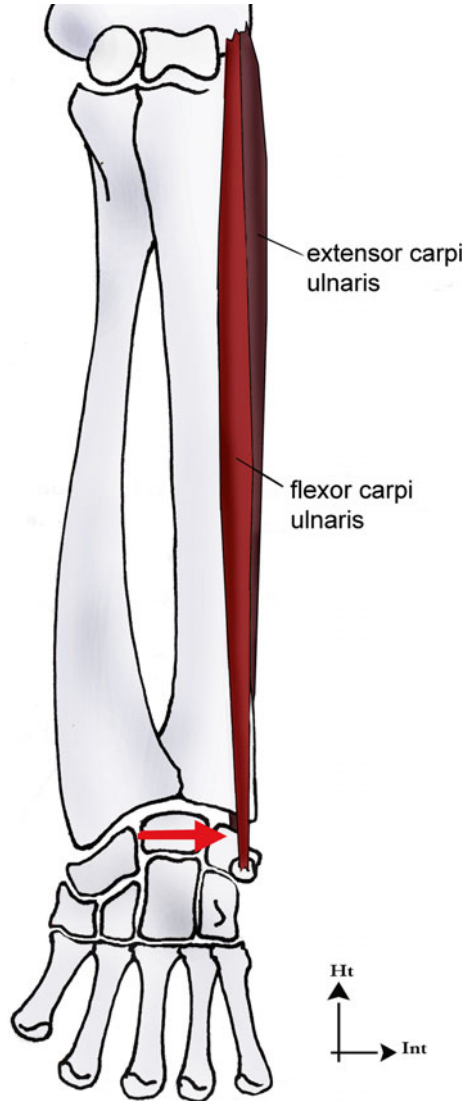


while the extensor carpi ulnaris stabilizes the lunotriquetral space and destabilizes the scapholunate one, producing an intracarpal pronation.

1.3.2.2 Intrinsic Carpal Stabilizers

The intrinsic carpal muscles are the thenar and hypothenar muscles.

Fig. 1.54 The flexor carpi ulnaris and the extensor carpi ulnaris are important active stabilizers of the carpus as they oppose its physiological ulnar gliding related to the radial slope and the axial constraints imposed on it



They fight against the carpus' tendency to dislocation, due to external forces or to compressive constraints caused by the powerful fingers flexors.

This stabilizing action, via the flexors retinaculum, is allowed by their osseous and retinacular insertions (Fig. 1.56).

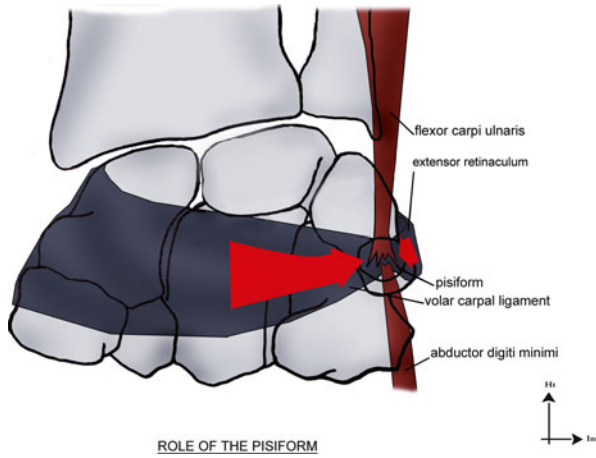


Fig. 1.55 Besides their direct action, the flexor carpi ulnaris and the extensor carpi ulnaris have an indirect action, putting in tension the retinacular systems

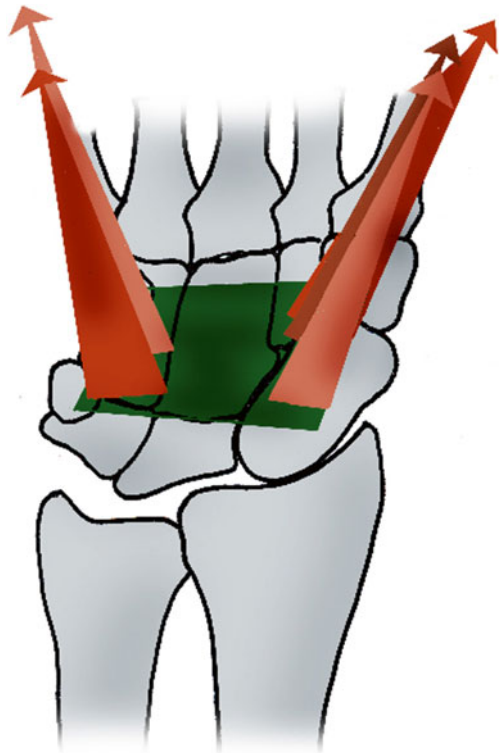


Fig. 1.56 The insertions of the thenar and hypothenar muscles on the bones and retinacula allow them to put in tension the flexors retinaculum, and counterbalance its tendency to dislocate

1.3.2.3 Role of the Fingers' Long Muscles on the Wrist Stability

A contraction in closed chain of the fingers' long muscles puts important constraints on the carpus. The carpus then transmits them to the two forearm bones.

Their main consequences are:

- A push of the capitate towards the lunate (which tends to tilt in extension) and the scapholunate space
- An increase of the constraints on the 1st carpal row and the two forearm bones
- A tendency of ulnar gliding for the 1st carpal row
- Shear constraints on the triangular complex and the interosseous membrane

Therefore, their contraction has a destabilizing effect on the wrist and radioulnar unity.

1.3.2.4 Active Stability of the Radioulnar Unity

The stability of the radioulnar unity depend on transverse and longitudinal “key muscles” that must be efficient in all the pronosupination amplitude.

Transverse Key Muscles

The pronator quadratus, the supinator and the pronator teres are short and fleshy tonic muscles that work in synergy to efficiently stabilize the radioulnar unity.

- *The pronator quadratus* is composed of two bundles (Fig. 1.57) and acts like an active ligament for the distal lock (distal radioulnar joint) as it has the anatomical position of a ligament and the mechanical capacities of a muscle. Its deep bundle is active in pronation and in supination, and its anatomical continuity with the

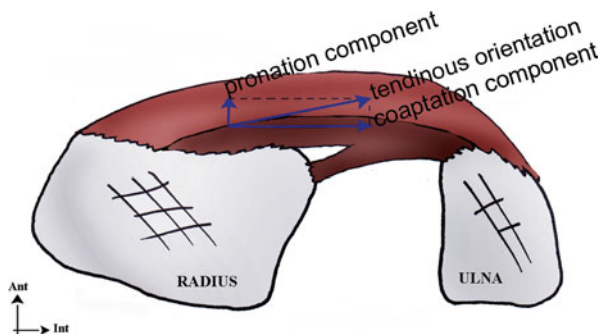
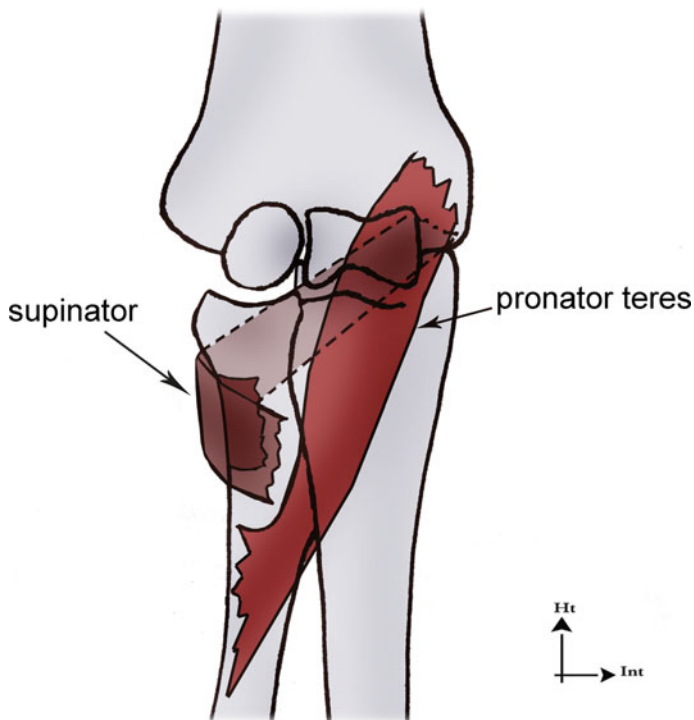


Fig. 1.57 The pronator quadratus is composed by two bundles; the superficial one mobilizes and the deep one stabilizes, as shown in its kinesiological analysis



RADIAL HEAD STABILIZERS

Fig. 1.58 The supinator wraps around the radial head to stabilize it efficiently

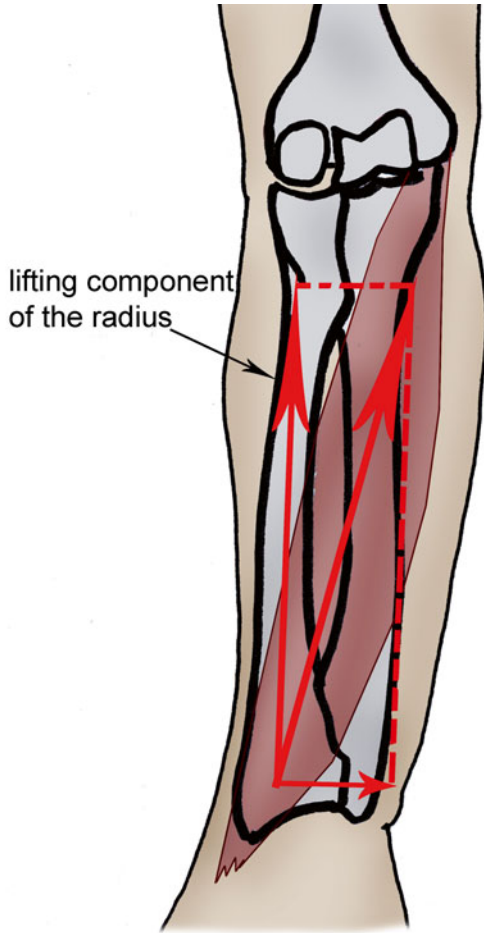
joint capsule allows it to have an indirect stabilizing effect, tensing the capsule when it contracts. It's the main active stabilizer of the distal lock (distal radioulnar joint).

- *The pronator teres* also has two heads. Its anatomical position allows it to stabilize the middle and proximal locks in synergy with the supinator.
- *The supinator* is wrapped around the radial head. It's the main active stabilizer of the proximal lock (Fig. 1.58).

Longitudinal Key Muscles

Their role is more complex as they sometimes have longitudinal destabilizing effects.

We don't think the palmaris longus, abductor pollicis longus, extensor pollicis longus and brevis and finger extensors are adapted to a stabilizing exercise of the radioulnar unity, due to their architectural characteristics.



Destabilizing action of the muscles oblique downwards and outwards

Fig. 1.59 The flexor carpi radialis has a coaptation component, like every muscle crossing the radioulnar space that has an oblique direction downwards and outwards. It also has a lifting component of the radius with respect to the ulna

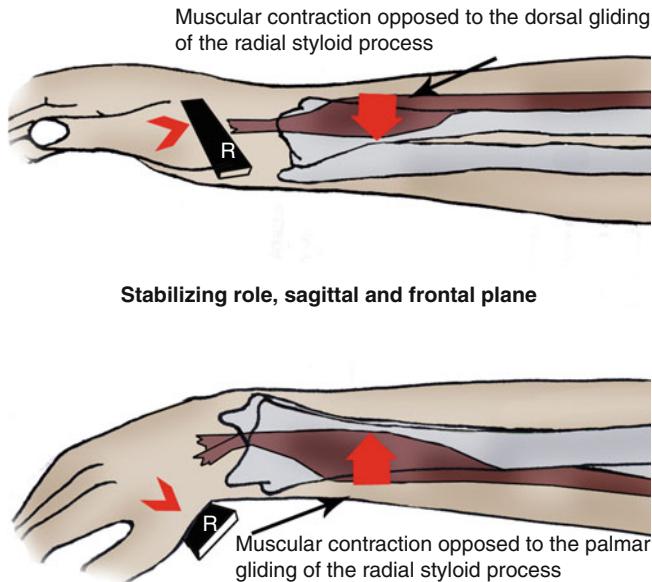


Fig. 1.60 In the sagittal plane, the flexor carpi radialis opposes the radius going forwards with respect to the ulna, while the extensor carpi radialis opposes it going backwards

- *The flexor carpi radialis* is an oblique epitrochlear muscle oriented downwards and outward: it has a coaptation effect on the radioulnar space and lifts the radius in relation with the ulna (Fig. 1.59). It's more palmar than the distal 1/3 of the radius, which allows it to forbid the radius from going frontwards (Fig. 1.60).
- *The radial extensors of the carpus* are epicondylar muscles that don't cross the radioulnar space. Therefore, they don't stabilize the radioulnar unity in the frontal plane but forbid the radius from going backwards. The radial stabilizers and pronator quadratus form a stabilizing trio essential in the stability of the distal lock (Fig. 1.61).
- *The flexor and extensor carpi ulnaris* only have a secondary role as they don't cross the radioulnar space and are inserted on the medial epicondyle and the ulna, which is the "fix" bony element of the radioulnar unity. This insertion on a "fix" bony element gives them more efficiency in stabilizing the carpus.

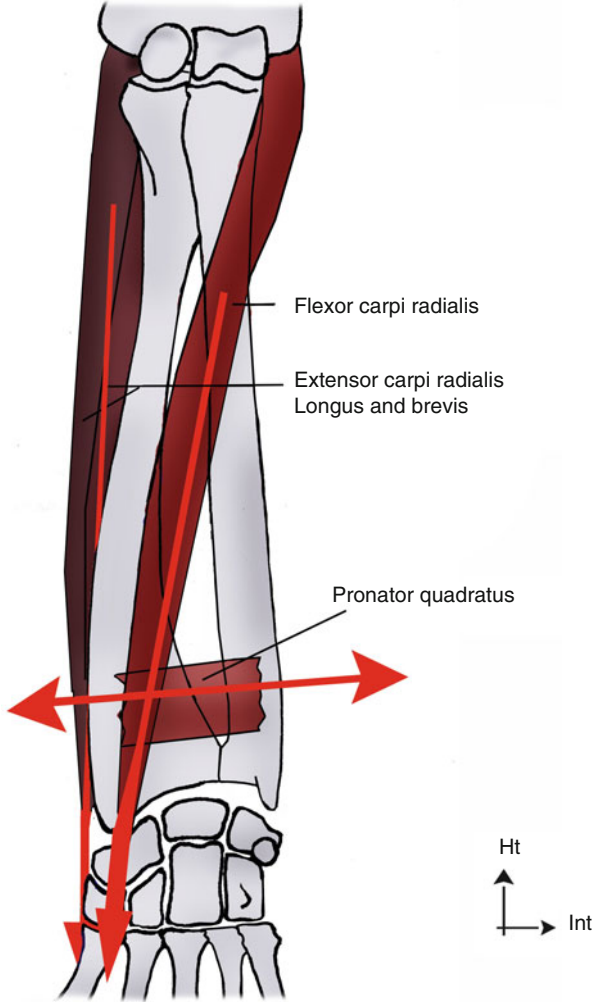
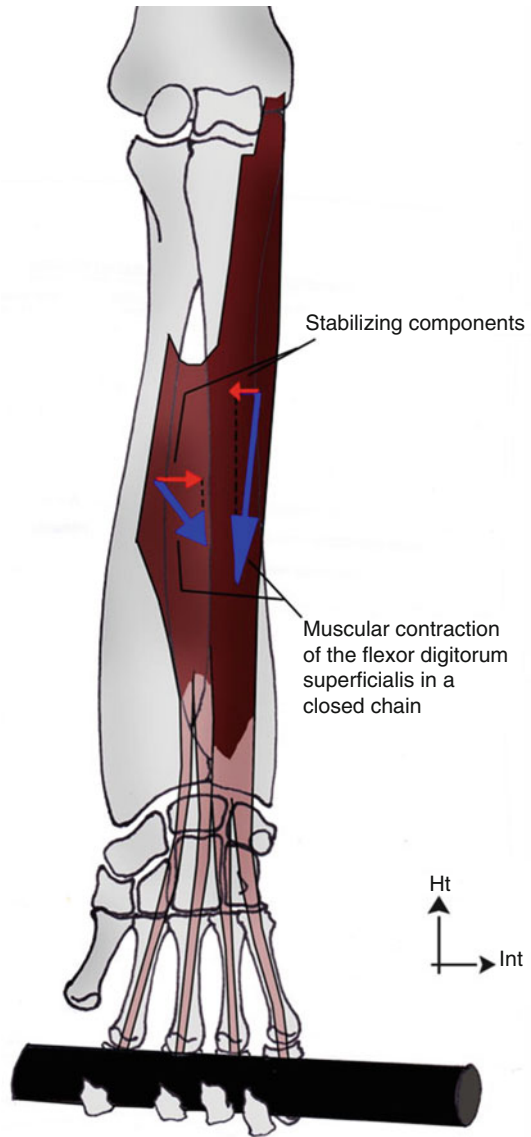


Fig. 1.61 The flexor carpi radialis, the extensor carpi radialis and the pronator quadratus form a stabilizing trio for the distal radioulnar joint. Their orientation (longitudinal for the radial stabilizers and transversal for the pronator quadratus) allows them to efficiently oppose the multidirectional constraints imposed on the distal lock

Fig. 1.62 The double radioulnar insertion of the flexor digitorum superficialis gives it a stabilizing component for the radioulnar unity



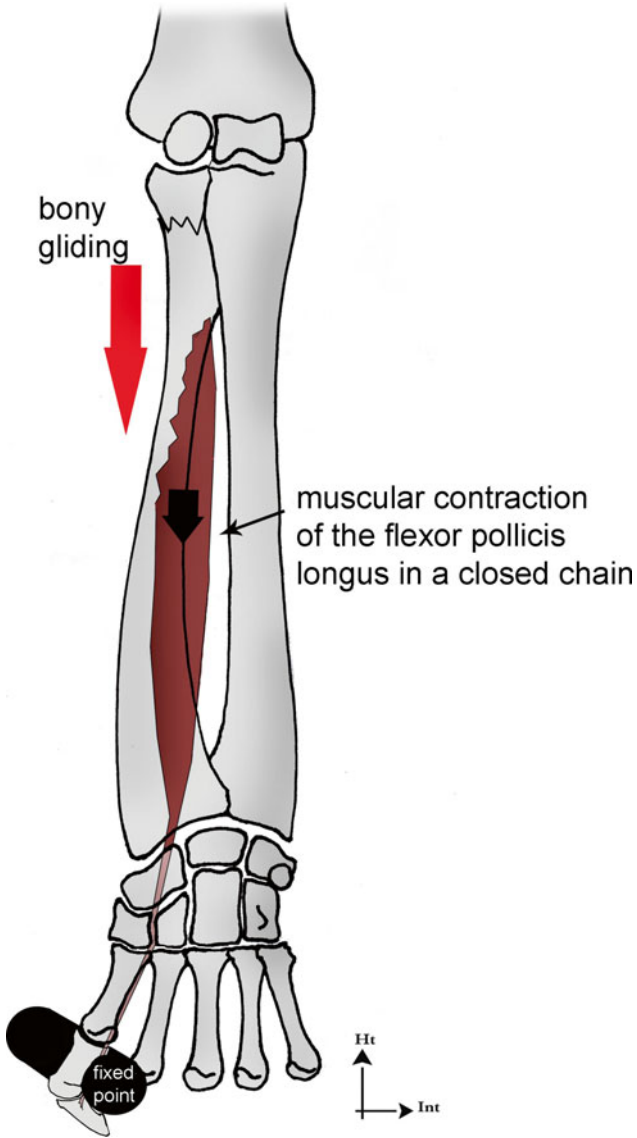


Fig. 1.63 The flexor pollicis longus creates a distal gliding of the radius with respect to the ulna in a closed chain

- *The flexor digitorum superficialis* doesn't cross the radioulnar space but has double insertion on the radius and the ulna, which gives it a role in coaptation due to its proximal insertion (Fig. 1.62).
- *The flexor digitorum profundus* doesn't cross the radioulnar space and has an ulnar insertion. These two factors limit its direct stabilizing action. However, its insertion on the interosseous membrane gives it an indirect stabilizing action.
- *The flexor pollicis longus* has a radial insertion but doesn't cross the radioulnar space. Therefore, it doesn't play an important role in the frontal plane but forbids the radius from going frontwards in the sagittal plane. In closed chain, it tends to produce a distal gliding of the radius (Fig. 1.63).

Bibliography

1. Boutan M (2005) La sangle ulnaire: Anatomie, physiologie et rééducation. Kinésithérapie, les cahiers 47-48:69-73
2. Brizon J, Castaing J (1995) Ostéologie du membre supérieur, in Les feuillets d'anatomie. Maloine, Paris
3. Camus EJ, Van Overstraeten L (2009) Chirurgie ligamentaire du carpe avant l'arthrose. In: Herzberg G (ed) Avant-bras post-traumatique, arthroscopie – arthroplasties (sous la direction). Sauramps medical, Montpellier
4. Chantelot C et al (2008) Intra-articular compressive stress of the elbow joint in extension: an experimental study using Fuji films. Surg Radiol Anat 30:103-111
5. Dufour M (ed) (2002) Anatomie de l'appareil locomoteur, vol 2. Masson, Issy-les-Moulineaux
6. Dufour M, Pillu M (eds) (2005) Biomécanique fonctionnelle. Masson, Issy-les-Moulineaux
7. Garcia-Elias M (2003) Lésions du complexe lunotriquetral : principes thérapeutiques. Chir Main 22:57-64
8. Kapandji AI (2007) Physiologie articulaire, vol 1. Maloine, Paris
9. Kuhlmann JN (2002) La stabilité et les instabilités radio- et médio-carpiennes. Sauramps médical, Montpellier
10. Mesplie G (2007) Stabilité de l'articulation radio-ulnaire distale: quid du carré pronateur. Kinésithérapie, la revue 68:58-62
11. Netter FH (ed) (2004) Atlas d'anatomie humaine. Masson, Paris
12. Palmer AK (1989) Triangular fibrocartilage complex lesions: a classification. J Hand Surg 14:594-606
13. Pechlaner S, Kerschbaumer F, Hussl H (eds) (2000) Atlas of hand surgery. Thieme, Stuttgart/ New York
14. Schunke M et al (eds) (2006) Atlas d'anatomie prométhée. Maloine, Paris
15. Soubeyrand M et al (2007) Pathologie traumatique de la membrane interosseuse de l'avant-bras. Chir Main 26:255-277
16. Brizon J, Castaing J Muscles du membre supérieur, in les feuillets d'anatomie. Maloine, Paris
17. Tubiana R, Thomine J-M. La main anatomie fonctionnelle et examen clinique, Masson 1990

Chapter 2

Injuries of the Radioulnar Unity

Grégory Mesplié and Vincent Grelet

The radioulnar unity is a whole anatomical entity between the elbow and wrist [1] and it's made of the two radioulnar joints and, a third part, the interosseous membrane [2] and the two bones of the forearm (see Chap. 1).

An injury in one of these elements can lead to stiffness during pronosupination [3], and an injury in two of them can lead to instability in the whole radioulnar frame.

Injuries of the radioulnar unity concern any damage of one of these elements [1].

2.1 Physiopathological Classification

M. Soubeyrand et al. classify the osteoligamentous injuries of the forearm depending on the number of damaged locks [4]:

2.1.1 Stage 1 = 1 Lock Damaged

It's a damage of the proximal lock (proximal radioulnar joint), middle lock (interosseous membrane), or distal lock (distal radioulnar joint).

If these injuries block the damaged lock, the global radioulnar mobility will be impaired.

G. Mesplié (✉)

Physiotherapist and orthotist, Institut Sud Aquitain de la Main et du Membre Supérieur, Aguiléra Clinic, Biarritz, France
e-mail: greg.mesplie@mac.com

V. Grelet

Hand surgeon, Institut Sud Aquitain de la Main et du Membre Supérieur, Aguiléra Clinic Biarritz, Biarritz, France

If these injuries destabilize the damaged lock, the global radioulnar stability will be preserved, thanks to the two other locks [4].

Taking the example of a door with three hinges helps in understanding this mechanism. If a hinge is rusted, the door can't be moved, but if a hinge is taken off or unscrewed, the door stays stable, thanks to the two other locks (Fig. 2.1).

Pathologies concerned by this stage are:

- *Fractures of the radial head*, resection of the radial head, radial head prosthesis, and injuries of the annular and quadrate ligaments for the proximal lock
- *Fractures of the ulnar or radial diaphyses*, isolated injuries of the interosseous membrane, considered rare, for the middle lock
- Fractures of the distal ulnar or radial extremity that damage the distal radioulnar joint and injuries of the triangular complex for the distal lock

2.1.2 Stage 2=2 Locks Damaged

These damages concern the proximal and middle, middle and distal, or proximal and distal locks.

These injuries can block the radioulnar frame if 1 or 2 locks are blocked or destabilize it if both locks become unstable.

Pathologies concerned by this stage are:

- *Fracture of Monteggia* that is an ulnar diaphyseal fracture combined with a dislocation of the proximal radioulnar joint. It's an injury of the middle (the fracture tears the interosseous membrane) and proximal locks (Fig. 2.2).

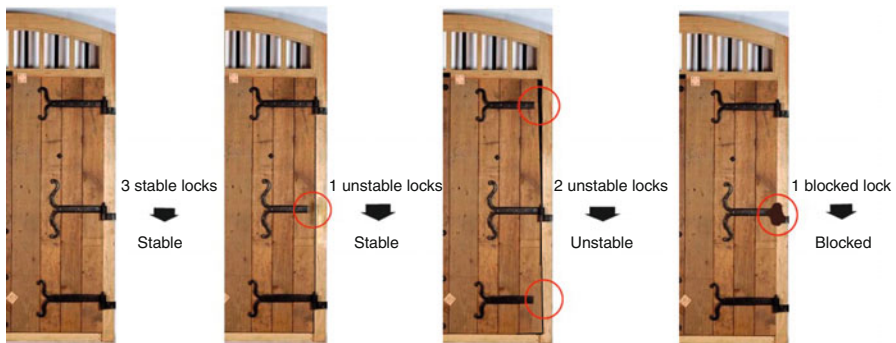
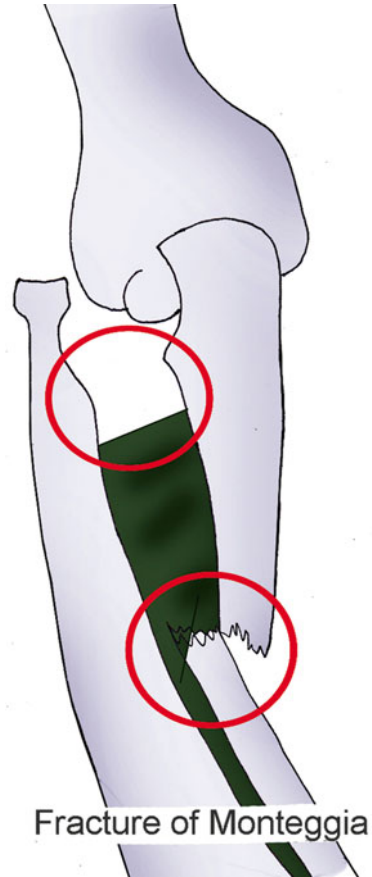


Fig. 2.1 The radioulnar unity acts like a door with three locks. If only one lock is blocked, the whole door is blocked. If 2 locks are taken away, the door is unstable

Fig. 2.2 Fracture of Monteggia combining an injury of the medium lock with one of the proximal locks

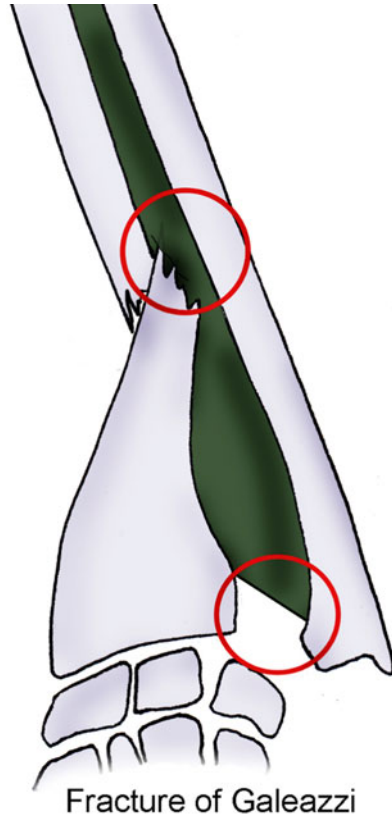


- *Fracture of Galeazzi* that is a radial diaphyseal fracture combined with a dislocation of the distal radioulnar joint. It's an injury of the middle (the fracture tears the interosseous membrane) and distal locks (Fig. 2.3).
- *Crisscross injuries* that are fractures of the radial head combined with dorsal dislocations of the ulnar head. They are injuries of the distal and proximal locks. The injury mechanism is a pivot of the two bones around an axis made by the middle part of the interosseous membrane (Fig. 2.4).

2.1.3 Stage 3=3 Locks Damaged

These damages concern the three locks which is an Essex-Lopresti syndrome combining a fracture of the radial head, a tear of the interosseous membrane [4], and a dislocation of the distal radioulnar joint (Fig. 2.5).

Fig. 2.3 Fracture of Galeazzi combining an injury of the distal lock with one of the medium locks



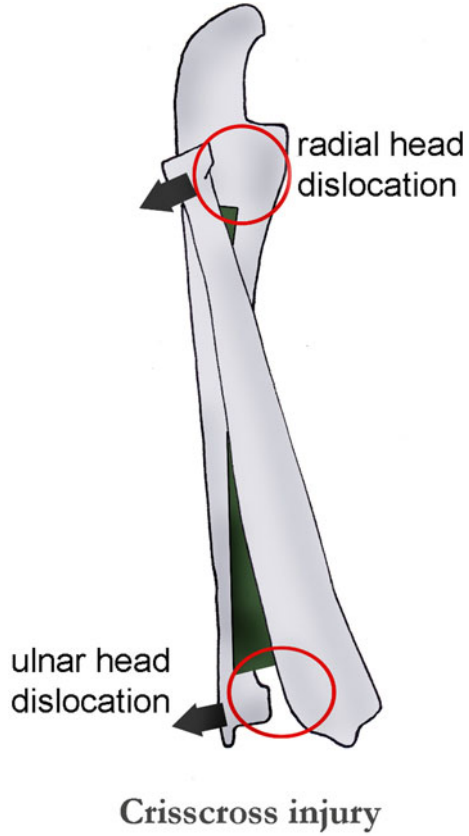
2.1.4 Physiopathology

At the physiopathological level, injuries of the radioulnar unity correspond to a fall with the wrist in extension. The grade of pronosupination during the fall defines the anatomical damages observed:

- *In total supination*, fractures of the two forearm bones are frequent.
- *In 45° of supination*, simple fractures of the radial head are more frequent.
- *In neutral position*, Essex-Lopresti syndromes.
- *In pronation*, complex fractures of the radial head.

These are tendencies and mustn't be taken literally, as the exact position of the forearm during the trauma can be uncertain. Moreover, other components like the violence of the trauma have an important influence on the nature of the injuries.

Fig. 2.4 Crisscross injury combining an injury of the distal lock with one of the proximal locks



2.2 Clinical and Paraclinical Signs

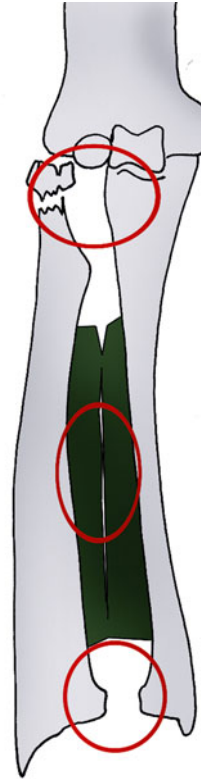
2.2.1 Clinical Signs [5]

It's important to differentiate acute and old injuries. Chronic injuries are harder to treat; that's why it's important to make an early diagnosis. Symptoms vary depending on the number of damaged locks.

The limitation of mobility concerns pronosupination [3] and the different amplitudes of the elbow and wrist, and it can evolve with time: formation of a posttraumatic synostosis and inversion of the distal radioulnar index after resection of the radial head.

The natural evolution of an injury of the interosseous membrane is unknown as well as its healing mechanism. Echographies and MRIs have been realized to try to get more precise indications for surgery and stabilization of the forearm.

Fig. 2.5 Essex-Lopresti syndrome with injuries of the three locks



Essex-Lopresti syndrome

2.2.2 Paraclinical Signs

2.2.2.1 Static X-Rays

An injury of the interosseous membrane can be affirmed in case of lift of the radius, combined with dislocations of the proximal and distal radioulnar joints [6]. If the injury seems isolated, we have to look for an associated injury.

2.2.2.2 Dynamic X-Rays

They help highlighting proximal or distal instabilities. Ideally, this exam is realized under general anesthesia.

2.2.2.3 MRI

This exam is actually considered to be the gold standard. We visualize directly the interosseous membrane with hyposignal T1 and T2 and a sensitivity above 87 % according to some authors.

2.2.2.4 Echography

It's an exam easily realized in case of emergency, but it has the disadvantage of being operator dependent. However, several authors say it has excellent sensitivity and specificity, which can be potentiated by a dynamic study of the interosseous membrane [6].

2.3 Therapeutic Process and Surgical Treatment

The treatment's results will be worse in old injuries.

2.3.1 Osseous Surgery

A radial or ulnar fracture requires perfect reduction and osteosynthesis with plate to avoid any rotation or angulation disorders that would have an immediate impact on pronosupination and joint stability [7]. This perfect reduction will spontaneously produce a reduction of the dislocated joint.

2.3.2 Proximal Radioulnar Surgery

In fractures of Monteggia, the reduction of the ulnar fracture automatically reduces the dislocation of the radial head, except in case of imprisonment of the annular ligament, which requires a direct approach.

In fractures of the radial head, we'll use osteosynthesis, looking for associated tears of the interosseous membrane, especially in comminuted fractures. In fractures of the radial head combined with a rupture of the interosseous membranes where we can't keep the radial head, we'll have to put a radial head prosthesis more or less associated to a ligamentoplasty of the interosseous membrane to decrease longitudinal constraints.

2.3.3 *Distal Radioulnar Surgery*

Reducing distal instabilities is usually done in supination. It can be maintained with a temporary radioulnar pin if the injuries are recent. The patients are often seen in chronic phase and we'll have to surgically shorten the ulna. If they are in an even more advanced phase, we'll realize less conservative procedures like the Sauve-Kapandji.

2.3.4 *Interosseous Membrane Surgery*

To repair the interosseous membrane, some authors have proposed ligamentoplasty techniques using the flexor carpi radialis tendon or the pes anserinus tendons with encouraging results [8].

2.4 Rehabilitation and Orthotic Treatment

Given the variety and complexity of the possible injuries, we won't detail a precise rehabilitation protocol but rather elements to work with in order to regain a good functionality of the radioulnar unity [1, 9].

These elements concern the post-immobilization phase, after the damaged elements are solid and the pain and trophic disorders have disappeared.

They're based on a global comprehension of the radioulnar unity [5, 10, 11], a "major" injury of one lock being possibly associated to a less important injury of another lock "hidden" during the paraclinical exam.

2.4.1 *Mobility of the Radioulnar Unity*

As seen in the Chap. 1, stiffness in one radioulnar lock blocks the whole radioulnar joint.

That's why it's essential to check the mobility of each radioulnar joint after any trauma in the forearm.

2.4.1.1 *Distal Radioulnar Joint*

It's a trochoid joint with a cylindrical ulnar surface and a radial cavity.

Glidings between the ulna and radius must have amplitudes similar to those of the sane side, without cracking or snapping.

To maintain or regain good dynamics, these specific mobilizations must be realized in all the pronosupination amplitude.

The therapist is in front of the patient whose elbow is flexed.

He/she grabs the ulna and the internal part of the carpus with one hand and the radius and the external part of the carpus with the other.

The goal is to apply differential glidings between the radius and the ulna, maintained between the therapist's thumbs and indexes (Fig. 2.6).

2.4.1.2 Interosseous Membrane

Fibrosis in the interosseous membrane can also produce stiffness in the radioulnar unity.

Several techniques are used but their efficiency on the interosseous membrane has yet to be demonstrated.

Deep Massage

These techniques don't have a direct effect on the membrane but can favor its mobilization, relaxing radioulnar muscles.

We use glided pressures, sanding, and palpating-rolling techniques.

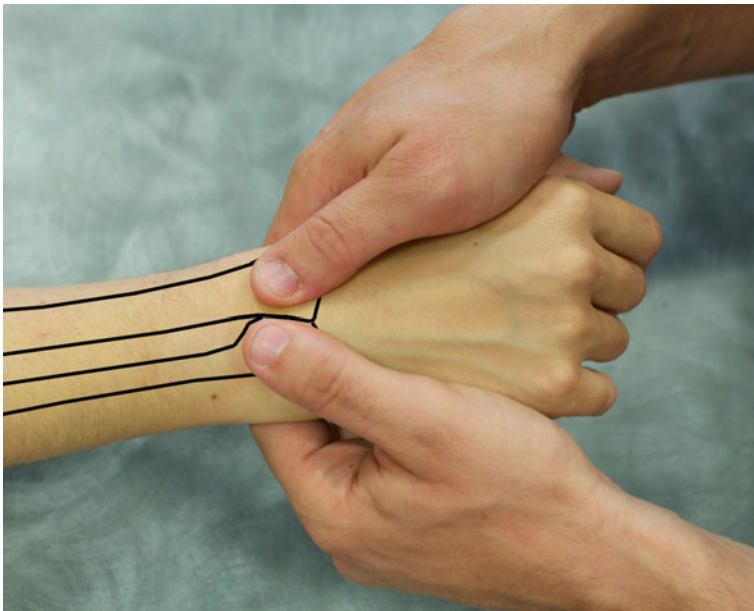


Fig. 2.6 Radioulnar mobilization technique. One hand does anteroposterior movements while the other realizes the opposite movement

Contraction-Stretching of the Muscles Inserted on the Interosseous Membrane

Alternating contractions and stretchings improves the local microcirculation (pumping effect), favors the fiber remodelling during the healing phase, and improves mobility in the different gliding planes.

We progressively use static intermittent, concentric, and eccentric contractions. Resistance and speed increase and adapted to the patient's progress.

These techniques concern:

Flexor Digitorum Profundus

Contractions are realized in all the pronosupination positions. The therapist places the resistance on the 3rd phalanges of the long fingers.

Stretchings are realized in the same position; the therapist applies soft, progressive pain-free stretchings (Fig. 2.7).

Flexor Digitorum Superficialis

It's in relation with the interosseous membrane through the oblique cord.

The modalities are the same than those for the flexor digitorum profundus, but the resistance is placed of the 2nd phalanges of the long fingers.

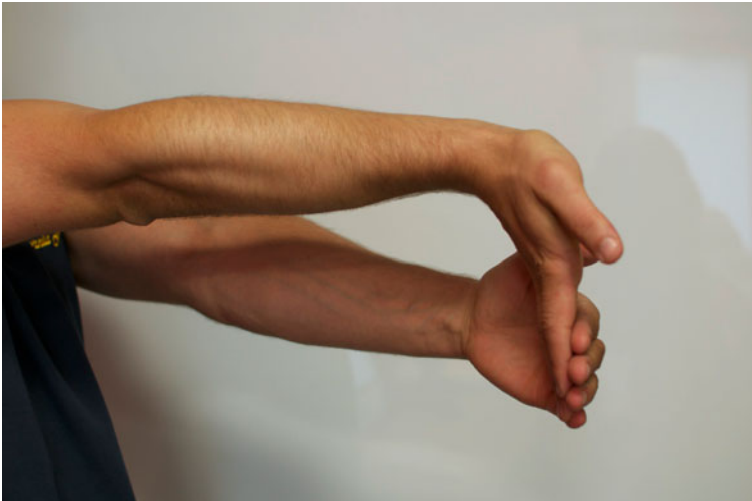

Fig. 2.7 Stretching of the fingers and wrist flexors. Resistance placed at the level of the 3rd phalanx. With a resistance on the 2nd phalanx, we don't stretch the flexor digitorum profundus, and with a resistance on the palmar side of the metacarpals, we don't stretch the flexor digitorum superficialis (only the wrist flexors)

Flexor Pollicis Longus

The modalities are the same than those described previously, but the resistance is placed on the 2nd phalanx of the thumb.

Extensor Pollicis Longus

Contractions are realized in all the pronosupination positions. The therapist places the resistance on the dorsal side of the 2nd phalanx of the thumb.

Stretchings are realized with the elbow extended and the forearm pronated; the therapist applies a radial inclination in the wrist, with his/her thumb against the palm.

Extensor Pollicis Brevis

The modalities are the same than the ones for the extensor pollicis longus, but the resistance is placed on the dorsal side of the 1st phalanx.

The stretching is the same as the one for the extensor pollicis longus.

Abductor Pollicis Longus

The modalities are the same than those described previously, but the resistance is placed on the dorsal side of the 1st metacarpal.

The stretching is the same as the one for the extensor pollicis longus.

Extensor Indicis

Contractions are realized in all the pronosupination positions. The therapist places the resistance on the dorsal side of the 1st phalanx of the index.

Stretchings are realized with the elbow extended and the forearm pronated; the therapist applies a flexion in the wrist and the metacarpophalangeal of the index.

Global Mobilization of the Radius in Relation with the Ulna

It mobilizes part of the fibers of the interosseous membrane. There are two types of mobilization:

- Mobilizations with longitudinal radial traction where the therapist sits in front of the patient, with the elbow flexed and the forearm pronated. With one hand, the therapist grabs the distal extremity of the radius, and with the other, he maintains the anterior part of the arm. The radial hand realizes a traction following the radial axis, while the other hand forbids the arm from going frontward.
- Mobilizations with pronosupination in all the authorized areas, as the interosseous membrane, are tensed throughout the whole movement [12].
- The flexor pollicis longus has a strong radial insertion, so its contractions in a closed chain produce a differential gliding between the radius and the ulna, with distal displacement of the radius (Figs. 2.8 and 2.9).



Fig. 2.8 Working in a closed chain with the flexor pollicis longus (resistance is stronger than contraction)

2.4.1.3 Proximal Radioulnar Joint

It's also a trochoid joint, with the cylindrical radial head and the concordant radial notch of the ulna.

To realize an anterior gliding of the radial head, the therapist is in front of the patient with the elbow in 90° of flexion and the forearm pronated.

With one hand he blocks the proximal part of the forearm in the first commissure.

The other hand grabs the radial head dorsally with the 4th long fingers, to apply an anterior gliding.

To realize a posterior gliding of the radial head, the therapist is on the patient's side. The patient's elbow is extended and his forearm is supinated.

With one hand, the therapist grabs the internal side of the ulna with the thumb frontward under the flexion crease.

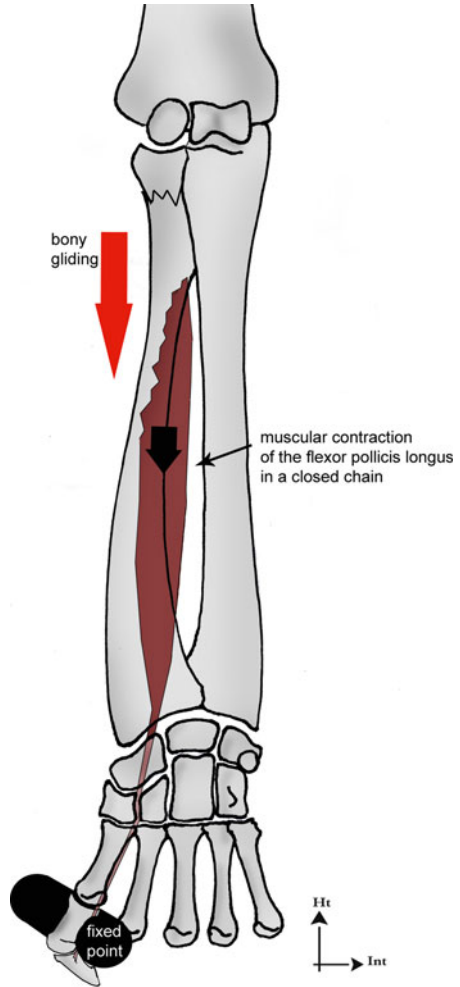
The other hand maintains the radial head so that the thumb is in front of the radial head to apply a posterior gliding.

2.4.2 Stability of the Radioulnar Unity

The instability or loss of one radioulnar lock can be compensated by the two other locks, but instability in 2 locks induces instability in the 3rd lock.

However, important instability in one lock can be clinically observed even when there are no diagnosed injuries in the two other locks.

Fig. 2.9 The contraction of the flexor pollicis longus in a closed chain induces a proximo-distal gliding of the radius with respect to the ulna



2.4.2.1 Key Muscles in Radioulnar Stability [13, 14]

Transverse Muscles

They play an essential role in coaptation.

They must be reinforced after any trauma in the forearm as they don't destabilize the radioulnar unity.

The supinator and pronator teres "surround" the superior extremity of the radius. They work in parallel to stabilize the radial head (Fig. 2.10).

These three muscles are short "tonic" muscles, so the reinforcement protocol is based on static or stato-eccentric progressive exercises, proprioception, and rhythmic stabilization.

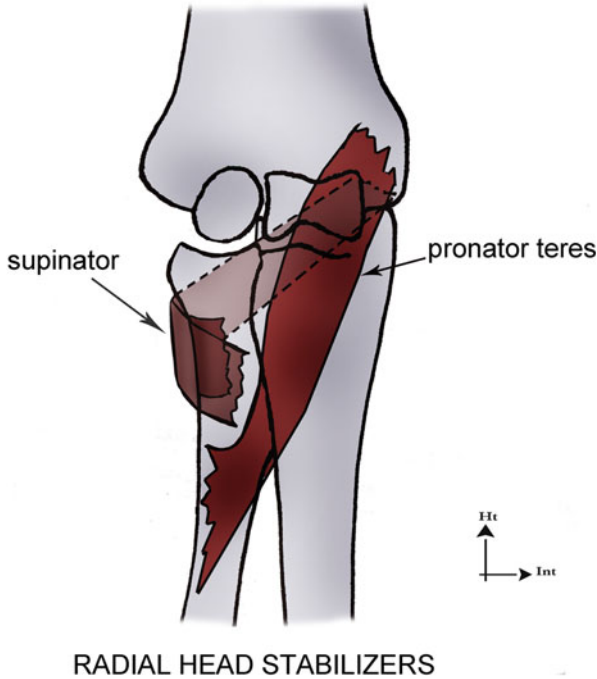


Fig. 2.10 The supinator and the pronator teres have a synergic action and work in parallel to stabilize the radial head

Pronator Quadratus [15]

It's a short, fleshy muscle against the interosseous membrane.

Its fibers are important for coaptation, especially since they're deep (Fig. 2.11).

Its superficial bundle is similar to a flat muscle, with activity during pronation but not during supination.

Its deep bundle is similar to a pennate muscle, with activity during pronation and supination. This makes it an "active ligament" of the distal radioulnar joint: this muscle has the anatomical situation of a ligament combined with the contractile capacity of a muscle.

Its action doesn't depend on the elbow's position.

Supinator

Its action depends on the elbow's position. Therefore, it's important to reinforce it in all the elbow's positions.

However, we know the biceps has a supination action that changes depending on the elbow's position. It's most efficient in 90° of elbow flexion, but its contraction has a dislocation effect on the radial head (Fig. 2.12).

Its action can be limited with a flexion of the glenohumeral joint.

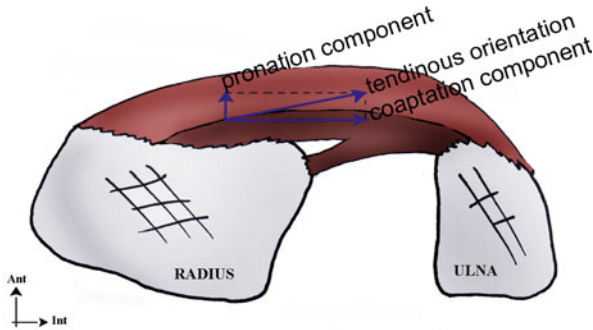
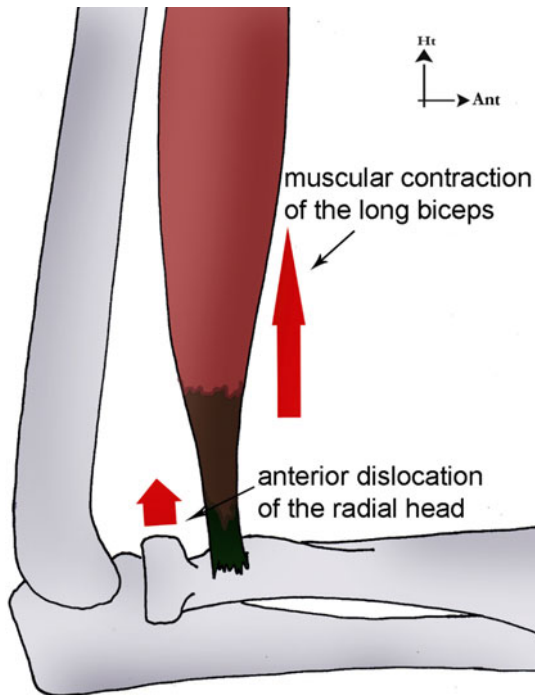


Fig. 2.11 The kinesiological study of the pronator quadratus demonstrates that its stabilizing action on the distal lock is more important than its pronation action. This action is particularly important for the deep fibers, which are perpendicular to the bony lever

Fig. 2.12 With 90° of elbow flexion, the biceps has an anterior dislocation component of the radial head



In case of important instability of the proximal radioulnar lock, we recommend avoiding a 90° flexion in the elbow or working with the glenohumeral in flexion.

Pronator Teres

Its action is favored with an elbow flexion; that's why this position is preferred for the reinforcement (even if we work in all of the elbow amplitudes).

Reinforcement exercises start with “manual” exercises: the therapist can control the applied resistance (Fig. 2.13).

Static reinforcement with feedback, proprioception, and feedforward are added to optimize muscle reinforcement and radioulnar stability (Figs. 2.14, 2.15, and 2.15’).

Longitudinal Muscles

Their role is more complex as they sometimes have destabilizing longitudinal effects. Like in transverse muscles, static exercises are preferred as it’s the type of contraction corresponding to the “locking” of the radioulnar unity.

We’ll talk here about the muscles whose architectural and anatomical characteristics stabilize (or destabilize) the radioulnar unity.

Working with “powerful” muscles is incompatible with an efficient stabilization work, so we choose not to treat them (palmaris longus, abductor pollicis longus, extensor pollicis longus and brevis, extensor indicis, and extensor digiti minimi).

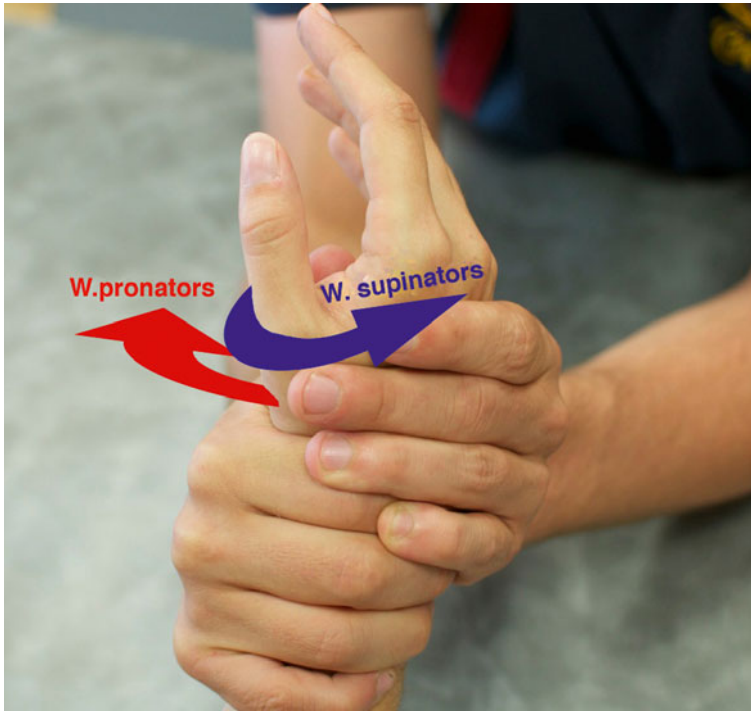


Fig. 2.13 Manual exercise with static and stato-eccentric contractions and rhythmical stabilizations, adapted to the tonic muscles



Fig. 2.14 Instrumental exercise with visual feedback and pronosupination dynamometer, precisely focusing on the muscular work we want

Fig. 2.15 Proprioceptive exercise pressing on a ball more and more inflated



The radial longitudinal muscles have a functional role more important than the ulnar longitudinal muscles, as the radial passive stability is lesser than the ulnar one (the ulna is the “stable” bone of the radioulnar unity).

Fig. 2.15' Instrumental exercise with a hammer allowing successive contractions (concentric-static-eccentric) of the supinator and pronator muscles



Flexor Carpi Radialis

It's an epitrochlear muscle, obliquely downward and outward. It ends on the bases of the 2nd and 3rd metacarpals.

This orientation gives it a longitudinal destabilizing action, favoring the radial head going upward (Fig. 2.16). Therefore, it must be reinforced carefully, especially in case of fractures of the radial head.

Radial Extensors of the Carpus

They don't cross the radioulnar space and therefore don't have any stabilizing role in the frontal plane, but they forbid the radius from going backward.

Flexor and Extensor Carpi Ulnaris [16]

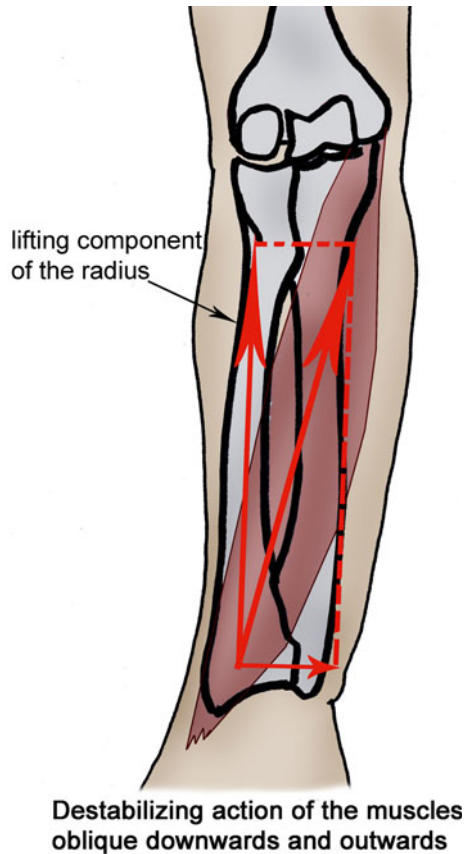
They don't cross the radioulnar space and therefore don't have effect on the global radioulnar stability in the frontal plane. However, they stabilize the ulna in the sagittal and horizontal planes.

As the ulna is a "stable" element in the radioulnar unity, their reinforcement can be useful, especially in case of ulnar fracture or any other injury making it unstable.

The flexor carpi ulnaris is an epitrochlear muscle ending on the pisiform and with expansions towards the hamate, the flexors retinaculum, and the 4th and 5th metacarpals. The therapist is in front of the patient, whose elbow is flexed. The resistance is placed on the palmar side of the 5th metacarpal, and we ask for a flexion/ulnar inclination.

The extensor carpi ulnaris is an epicondylar muscle ending on the dorsal side of the 5th metacarpal's base. The therapist is in front of the patient, whose elbow is flexed. The resistance is placed on the dorsal side of the 5th metacarpal, and we ask for an extension/ulnar inclination.

Fig. 2.16 The orientation downward and outward of the flexor carpi radialis gives it an important lifting component of the radius. Its reinforcement must therefore be realized very cautiously in case of fracture of the radial head, for example



A synergic contraction of these two elements improves their intermuscular coordination, useful for the stabilization of the radioulnar distal lock.

These exercises can be manual or instrumental (Figs. 2.17 and 2.18).

Flexor Pollicis Longus

It doesn't cross the radioulnar space, but it has notable longitudinal and anteroposterior components, thanks to its radial insertion.

In closed chain, it forbids the inferior part of the radius from going forward.

In fractures of the radial head, it's preferentially reinforced in closed chain to increase the radioulnar space.

The therapist is in front of the patient and puts a resistance at the level of the palmar side of the thumb's 2nd phalanx. He asks for a contraction against a fix resistance if he wants to work in closed chain and against a mobile resistance if he wants to work in open chain. This exercise is realized in all the pronosupination amplitude.

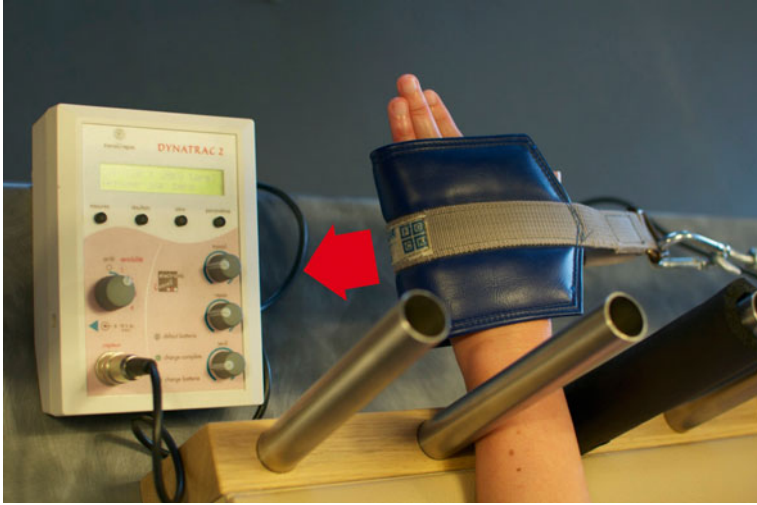

Fig. 2.17 Exercise for the ulnar stabilizers with a dynamometer and a visual feedback, precisely focusing on the muscular work we want (left wrist on the picture)

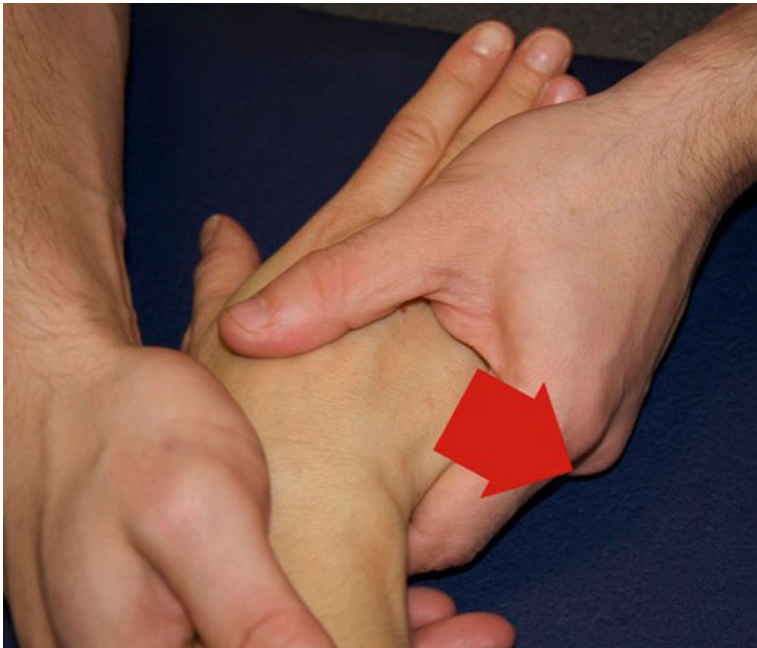

Fig. 2.18 Manual exercise for the ulnar stabilizers

Flexor Digitorum Superficialis

It doesn't cross the radioulnar space, but its double radioulnar insertion gives it a stabilizing role for the proximal part of the radioulnar frame, in all the planes.

In closed chain, its contraction stabilizes the radioulnar frame as it brings its radial and ulnar insertions closer together (Fig. 2.19).

In open chain, it has a destabilizing effect on the distal radioulnar joint as it improves the longitudinal constraints imposed on it.

Therefore, it must be reinforced cautiously in injuries of the distal radioulnar joint, avoiding working in open chain.

The therapist is in front of the patient and puts a resistance on the palmar side of the 2nd phalanx of the long fingers.

Flexor Digitorum Profundus

It has an ulnar insertion and doesn't cross the radioulnar space, which limits its direct stabilizing action. However, it has an indirect stabilizing effect due to its insertion on the interosseous membrane.

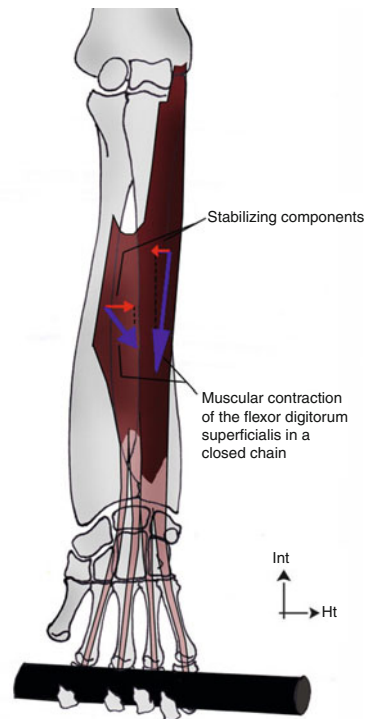


Fig. 2.19 Thanks to its ulnar and radial heads, the contraction of the flexor digitorum superficialis induces a radioulnar coaptation

The therapist places manual or instrumental resistances on the palmar side of the 3rd phalanges of the long fingers. This exercise is realized in closed chain, as it requires a displacement of the proximal muscle insertion.

Remember

- The radioulnar unity depends on 3 locks (distal, middle, and proximal).
- Blocking only 1 lock creates stiffness in pronosupination, and damaging 2 locks destabilizes the whole radioulnar unity.
- The therapist must take into account the whole radioulnar unity, or rehabilitation could be incomplete or inefficient.

Bibliography

1. Kapandji A (1998) L'unité radio-cubitale. Son importance dans les fractures des 2 os de l'avant-bras. *Chir Main* 17(4):348–361
2. Poitevin L (2001) Anatomy and biomechanics of the interosseous membrane: its importance in the longitudinal stability of the forearm. *Hand Clin* 17(1):97–110
3. Lastayo PC, Weiss S (2001) The GRIT: a quantitative measure of ulnar impaction syndrome. *J Hand Ther* 14:173–179
4. Soubeyrand M et al (2007) Pathologie traumatique de la membrane interosseuse de l'avant-bras. *Chir Main* 26:255–277
5. Paul C, Lee Michael J (2006) The forearm complex: anatomy, biomechanics and clinical considerations. *J Hand Ther* 19:137–145
6. Soubeyrand M et al (2006) The “muscular hernia sign”: an original ultrasonographic sign to detect lesions of the forearm's interosseous membrane. *Surg Radiol Anat* 28(3):372–378
7. Watanabe H, Berger RA, An KN, Berglund LJ, Zobitz ME (2004) Stability of the distal radioulnar joint contributed by the joint capsule. *J Hand Surg [Am]* 29A:1114–1120
8. Gabriel MT, Pfaeffle HJ, Stabile KJ et al (2004) Passive strain distribution in the interosseous ligament of the forearm: implications for injury reconstruction. *J Hand Surg [Am]* 29A:293–298
9. Millard GM, Budoff JE, Paravic V, Noble PC (2002) Functional brac-ing for distal radioulnar joint instability. *J Hand Surg [Am]* 27A:972–977
10. Werner F (1994) Biomechanics of the elbow and forearm. *Hand Clin* 10(3):357–373
11. Zimmerman NB (2002) Clinical application of advances in elbow and forearm anatomy and biomechanics. *Hand Clin* 18:1–19
12. Nakamura T, Yabe Y, Horiuchi Y (1999) In vivo MR studies of dynamic changes in the interosseous membrane of the forearm during rotation. *J Hand Surg* 24(2):245–248
13. Gofton WT, Gordon KD, Dunning CE, Johnson JA, King GJ (2004) Soft tissue stabilizers of the distal radioulnar joint: an in vitro kinematic study. *J Hand Surg [Am]* 29A:423–431
14. William BK (2007) Stability of the distal radioulnar joint: biomechanics, pathophysiology, physical diagnosis, and restoration of function what we have learned in 25 years. *J Hand Surg* 32A:1086–1106
15. Mesplie G (2007) Stabilité de l'articulation radio-ulnaire distale: quid du carré pronateur. *Kinésithérapie, la revue* 68:58–62
16. Boutan M (2005) La sangle ulnaire: Anatomie, physiologie et rééducation. *Kinésithérapie, les cahiers* 47–48:69–73

Chapter 3

Recent Fractures of the Scaphoid Bone

Grégory Mesplié and Vincent Grelet

Fractures of the scaphoid are frequent, especially in young men, and represent 70–80 % of the traumas on the carpus [1].

Their consolidation is difficult because of the important constraints imposed on the scaphoid and its precarious vascularization [2].

The efficiency of the treatment depends on an early diagnosis, which allows avoiding evolutions towards a scaphoid nonunion advanced collapse [3].

3.1 Physiopathology [4–7]

The fractures of the scaphoid concern most of the times the waist of the bone that is narrower and more fragile than the rest of the bone.

The injury is most often due to a trauma in compression/shearing in wrist hyperextension, combined with a radial or ulnar inclination.

This mechanism puts tension on the palmar radio-carpal ligaments that forbid the scaphoid from going frontward. The bone then suffers the shock from the posterior part of the radius at the level of the waist. The radioscapocapitate ligament can increase the displacement in flexion of the distal fragment, causing a shortening of the bone (Fig. 3.1).

This mechanism only occurs in fractures of the waist and doesn't concern the fractures of the proximal part [8].

The same mechanism puts important constraints on the scapholunate ligament, opposed to the differential gliding between the scaphoid and lunate.

G. Mesplié (✉)

Physiotherapist and Orthotist, Institut Sud Aquitain de la Main et du Membre Supérieur, Aguiléra Clinic Biarritz, Biarritz, France
e-mail: greg.mesplie@mac.com

V. Grelet

Hand Surgeon, Institut Sud Aquitain de la Main et du Membre Supérieur, Aguiléra Clinic Biarritz, Biarritz, France

© Springer International Publishing Switzerland 2015

G. Mesplié, *Hand and Wrist Rehabilitation: Theoretical Aspects and Practical Consequences*, DOI 10.1007/978-3-319-16318-5_3

Fig. 3.1 Action of the radioscaphocapitate ligament that can increase the displacement of the distal fragment in fractures of the scaphoid waist


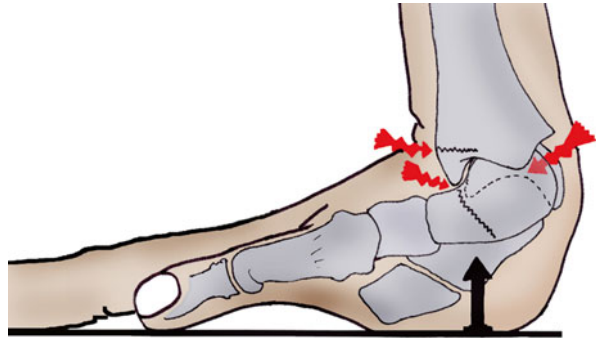


Fig. 3.2 Injury mechanism that can cause a rupture of the scapholunate ligament, a fracture of the scaphoid or the radius



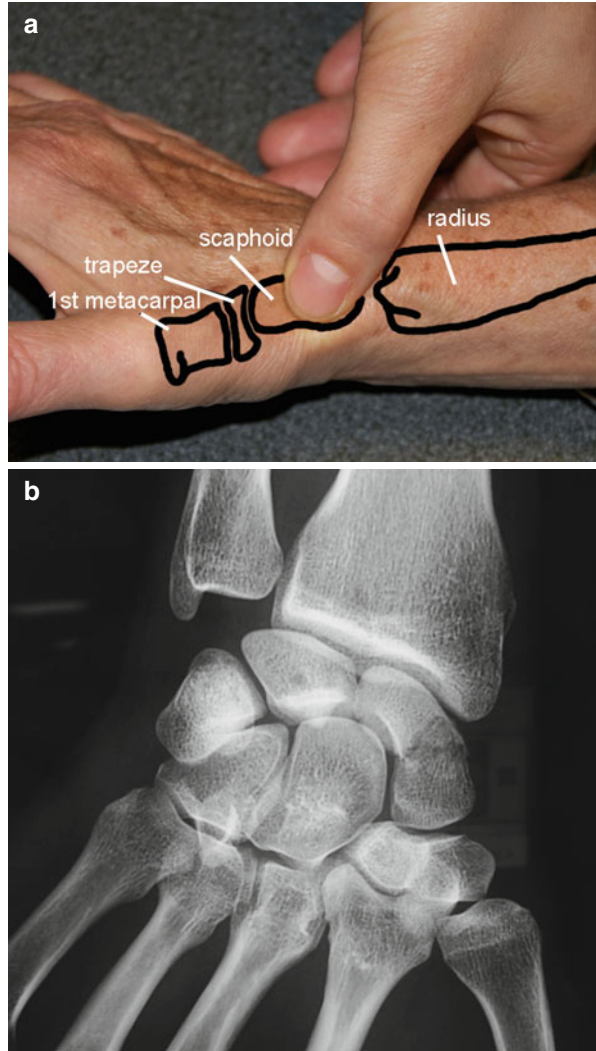
That’s why in a trauma in hyperextension, we can observe a fracture of the scaphoid, an injury of the scapholunate ligament, or a fracture of the radial epiphysis. The combination of these injuries is rare (Fig. 3.2).

3.2 Clinical and Paraclinical Signs

With the patient interview only, we can determine if there has been a “risky” trauma.

The most suggestive clinical sign is pain when palpating the anatomical snuffbox, (Fig. 3.3) but if there’s an edema in this area or in the radial side of the wrist and pain when putting load on the scaphoid, we’ll have to realize X-rays [9].

Fig. 3.3 (a) Palpation of the scaphoid in the anatomical snuffbox, between the first extensor gliding and the extensor pollicis longus. (b) Radiography showing a fracture of the scaphoid waist



Sometimes, the X-rays are clear and the diagnosis is easy, but it's possible that the fracture isn't visible on the X-ray on the day of the trauma.

In this case, a resting orthosis is realized and kept 15 days, and then other X-rays are realized to confirm the presence/absence of fracture.

However, we must keep in mind that the decalcification process around the fracture line that allows detecting a fracture after 15 days isn't systematic, especially in proximal fractures. When in doubt, we use MRI and scintigraphy.

Echography also has a certain interest in the diagnosis, but its efficiency is operator dependent.

3.3 Therapeutical Process and Surgical Treatment [4–7]

The treatment depends on the location of the fracture line, whether the fracture is displaced or not, and the patient's socioeconomic and sports context. This treatment can be orthopedic or surgical with conventional screwing, percutaneous technique, or simple pin.

3.3.1 Orthopedic Treatment [10]

The orthopedic treatment by prolonged immobilization stays the first-line indication to treat undisplaced fractures of the scaphoid, but the development of percutaneous osteosynthesis tends to progressively prevail over the cast. Several studies agree that there's a high rate of consolidation (more than 90 %); however, opinions differ more widely as regards the type of immobilization, the wrist position, and the duration of immobilization.

3.3.1.1 Immobilize the Elbow and the Thumb?

The SOFCOT's round table in 1988 gathers a series of 209 recent undisplaced fractures of the scaphoid treated with brachio-palmar immobilization in 41 % of the cases and antebrachio-palmar immobilization in 33 % of the cases. The 26 % left were treated with a combination of the 2 previous techniques (first brachio-palmar, then antebrachio-palmar). The conclusion of this study doesn't bring formal statistical elements to confirm the superiority of one treatment or the other.

In 1990, a study shows on 10 subjects that pronosupination doesn't put constraint on the scaphoid, unlike the flexion/extension and the radial and ulnar inclinations. Only two studies analyze the consolidation rate depending on whether the elbow is in the cast or not; they both conclude that the consolidation isn't improved when the elbow is immobilized.

The fact that the elbow must be immobilized in fractures of the scaphoid is strongly anchored in people's minds. In 1943 Watson-Jones recommends blocking the thumb's metacarpophalangeal joint, and we have to wait until 1991 for a randomized prospective study to obtain results identical between the group of patients immobilized until the interphalangeal and those with the thumb free.

3.3.1.2 Wrist Position

The most common method is the immobilization in a neutral position in the sagittal and frontal planes, with a slight radial inclination to avoid distraction in the fracture site.

3.3.1.3 Immobilization Duration

Several studies have evaluated the consolidation duration between 12 and 15 weeks. Some authors recommend only 2 months of immobilization for distal fractures as the distal part is more vascularized, but no clinical study confirms this.

In theory, only a proof of consolidation should allow us to stop the immobilization, but in practice this consolidation is hard to confirm and immobilizing during 3 months seems to be the most scientifically established and the most prudent approach.

3.3.1.4 Immobilization Type

The cast still seems to be the most used technique. However, the resins have several advantages: They're half as heavy as casts and they're more solid and resist to water. But they also have disadvantages: poor plasticity making compressions more frequent and hardness of the material that can irritate the skin.

Thermoformed custom-made orthosis provides more comfort in the patients' daily life and can be readjusted when the edema disappears.

In conclusion, 2–3 months of immobilization depending on the location of the fracture line, with the wrist in a neutral position and the thumb free in a thermoformed orthosis, is the first-line indication in undisplaced fractures of the scaphoid.

3.3.2 Surgery

Displaced fractures of the scaphoid and delayed bone healing are indications for surgery [11].

In 1968 the screwing with a spongy 4 mm screw has been described in the AO's osteosynthesis manual, but subsequent studies have shown technique difficulties due to the particular anatomy of this bone [12] and the equipment load. Since the beginning of the 1980s and the apparition of Herbert's headless screw, several screws have been developed to favor the compression and make the placement easier. In this chapter, we'll develop the main osteosynthesis techniques with traditional screws, percutaneous screws, and percutaneous pins.

3.3.2.1 Traditional Screws

Screwing can be realized in a retrograde way with an anterior approach or from proximal to distal with a posterior approach in proximal fractures.

We use an AO stainless steel screw with a 2 mm diameter with a long thread length to allow a good compression (Fig. 3.4). Perforated screws avoid multiple drilling, but have a wider diameter.

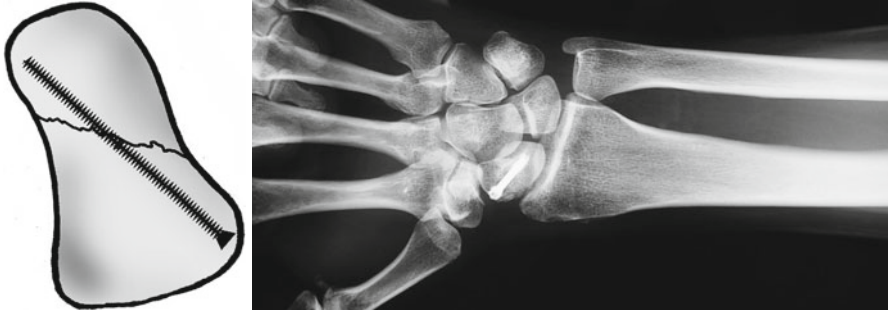
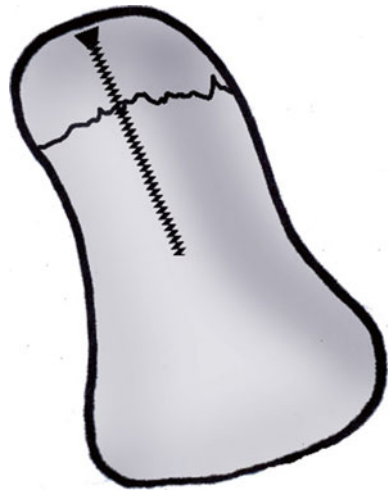
Fig. 3.4 Screw osteosynthesis

Fig. 3.5 Anterograde screwing with a small screw



In anterograde screwing from proximal to distal, we prefer screws with a smaller diameter considering the small size of the proximal fragment (Fig. 3.5).

The surgical follow-ups depend on the surgeon and go from no immobilization to a resin cuff during a month.

Consolidation rates vary between 90 and 100 %.

3.3.2.2 Percutaneous Screws [13]

Since a few years, little invasive surgical techniques have been developed to reduce morbidity and preserve the scaphoid's vascularization as well as the ligaments surrounding it.

The approach can be palmar (Fig. 3.6) or dorsal, and the reduction is controlled with radioscopy or coupled with arthroscopy. This technique uses perforated screws guided by a pin. The diameter of the screw varies from 2 to 3 mm.

Instable and displaced fractures are formal indications for osteosynthesis [11]. The percutaneous technique is reserved to fractures that are little displaced and is more and more used in undisplaced fractures based on economic, social, professional, and sports factors, as it reduces the duration of immobilization (0–30 days).

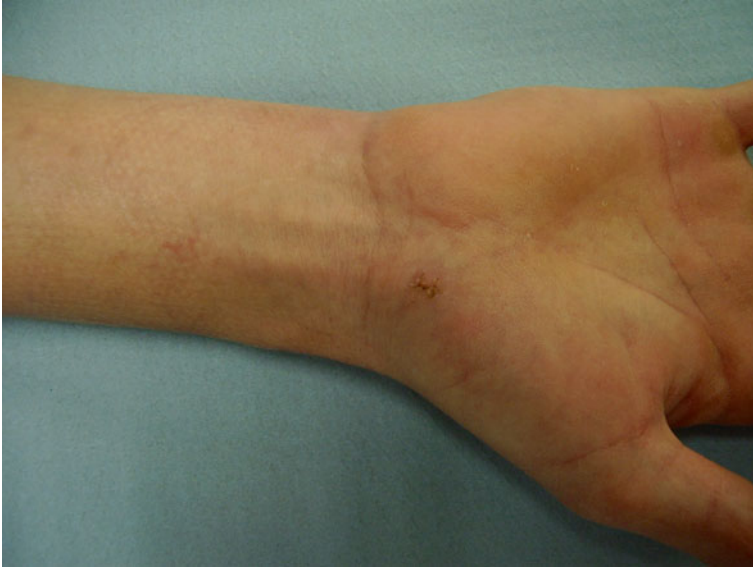

Fig. 3.6 Cutaneous aspect after percutaneous screwing

3.3.2.3 Percutaneous Pins [14, 15]

The pins seem to be the best osteosynthesis technique for the scaphoid, putting compression on the fracture site. However, some authors are now wondering if compression is necessary for the scaphoid. The natural tendency in median fractures is towards flexion, so we'll have to install a wiring during the synthesis. The pins allow a stable osteosynthesis without shortening of the scaphoid and avoid rotation disorders if we place at least 3 pins with a diameter between 14 and 16.

In conclusion, the surgical treatment is justified in undisplaced fractures when:

- The fracture concerns the proximal part.
- There's an associated injury requiring surgery.
- The fracture is open or unstable.
- The patient is a sportsman or motivated worker who wants to quickly go back to his activities.

3.4 Rehabilitation and Orthotic Treatment [4–7]

Rehabilitation can follow surgery or a longer immobilization in case of orthopedic treatment.

The different protocol stages can be modified depending on the bone healing, regularly controlled with X-rays.

In any case, the priorities are regaining physiological amplitudes and strength to restore optimal function.

There are many similar points between this protocol and the one for the fractures of the inferior extremity of the radius, but the concerned patients are usually very different.

The patients with a fracture of the inferior extremity of the radius are usually woman of more than 60 years old with osteoporosis, whereas the patients with a fracture of the scaphoid are usually young men who have suffered a high kinetic energy trauma.

Therefore, the rehabilitation goals for these two pathologies are often different, as they're related to the patient's anterior capacities and functional imperatives. The exercises are usually more intense in fractures of the scaphoid, especially in muscular reinforcement and proprioception exercises.

3.4.1 Rehabilitation Protocol (Fig. 3.7)

3.4.1.1 Immobilization Phase (D0 to D15/45 with Surgery or D0 to D60/90 Without Surgery)

The duration of immobilization after surgery depends on the surgical technique and varies from 15 (percutaneous screws) to 45 days (pins).

During all this phase, rehabilitation isn't essential and self-rehabilitation advices are given to the patient.

The treatment is based on the protocol PRICE that fights against trophic disorders resulting from the trauma and surgery:

- *P* for protection of the fracture line during the whole phase, realized immobilizing the wrist and informing the patient about the tissue fragility in this phase.
- *R* for rest of the damaged area that mustn't be solicited during the immobilization phase, aside from self-rehabilitation exercises explained by the therapist. These exercises are described in the Chap. 5, Fig. 5.20.
- *I* for ice, putting cold packs several times a day on the fracture zone. If there's a cast it's impossible, but if there is no wound, we immobilize the patient with a thermoformed orthosis, which allows cold bath against edema.
- *C* for compression that can be realized in the fingers if they're swollen.
- *E* for elevation of the wrist to avoid edema.

These exercises are combined with sensorimotor stimulations to maintain the body mapping and cutaneous receptors and with simple active mobilizations of the free joint (the metacarpophalangeals in the long fingers tend to get easily stiff). We stop these exercises if pain appears.

3.4.1.2 Pre-consolidation Phase (D15/45 to D90 with Surgery or D60/90 to D120 Without Surgery)

In this phase we start putting load on the scaphoid, and the patient progressively goes back to his daily activities. We fight against pain and trophic disorders if they are still present, try to regain functional amplitudes, and start the muscular awakening and reinforcement.

<i>Recent fractures of the scaphoid bone</i>			
	Phase 1: immobilization	Phase 2: pre- consolidation	Phase 3: consolidation
R E H A B I L I T A T I O N	<p>Therapeutic goals: immobilization.</p> <p>Techniques: - Monitoring of the orthosis (stability, comfort, pressure points). - PRICE protocol. - Mobilizations of the free joints (shoulder, elbow, fingers, interphalangeal of the thumb).</p> <p>Risks: trophic disorders, CRPS.</p>	<p>Therapeutic goals: progressive load, gain joint amplitude, progressive muscular reinforcement with fingers extended.</p> <p>Techniques: - Massages, manual and instrumental mobilization, fluidotherapy. - Relaxing of the scar (if surgery). - Electrostimulation, transcutaneous vibratory stimulations ++, intrinsic muscles and wrist stabilizers. - Exercises for fine prehensions, digital coordination.</p> <p>Risks: stiffness, muscle atrophy.</p>	<p>Therapeutic goals: regain total joint amplitude, muscular reinforcement, proprioceptive exercises, and functional goals.</p> <p>Techniques: - Specific intracarpal mobilizations. - Muscular reinforcement, exercises for the muscular chains. - Proprioception exercises. - Exercises for strong prehensions, professional or sports orientation.</p> <p>Risks: stiffness, loss of strength.</p>
OR TH ES IS	Immobilizing the wrist, worn all the time.	Functional for the wrist during activities.	Flexible for restarting work or sports activities.
	<p>If surgery: D0 to D15/45 If no surgery: D0 to D60/90</p>	<p>D15/45 to D 90 D60/90 to D120</p>	<p>After D90 After D120</p>

Fig. 3.7 Rehabilitation protocol

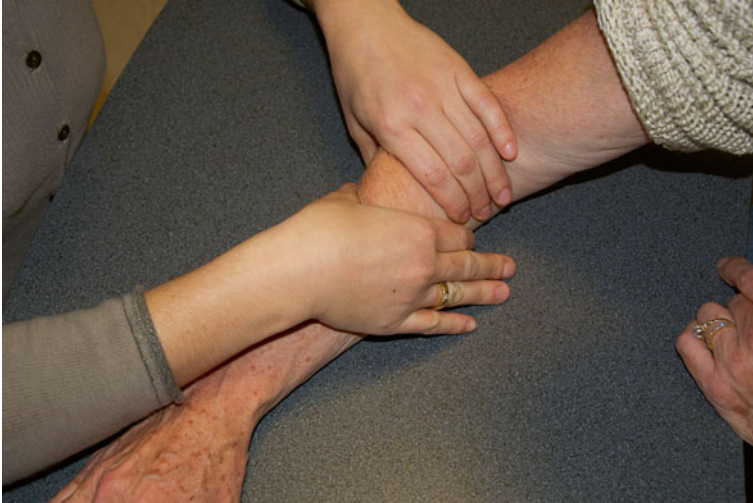

Fig. 3.8 Decontracting massage of the forearm muscles

Fight Against Trophic Disorders and Pain

It's essential to start with the rest of the rehabilitation.

We use the similar techniques than in fractures of the inferior extremity of the radius:

- *Draining massages* without slackening the scar in case of surgery. Decontracting massages for the forearm if we observe hypertonia in the extrinsic musculature, which is frequent (Fig. 3.8).
- *Analgesic electrotherapy* can be used.
- *Pressotherapy* from distal to proximal helps draining the wrist. In this phase, this technique can be badly tolerated by the patient; we'll then delay its use.
- *Transcutaneous vibratory stimulations and infrasounds* are used for their analgesic and vasomotor effect. Vibrations with more than 1 mm amplitude are realized far from the fracture site in order not to disturb the healing process.

Regaining Functional Amplitudes

It requires a good knowledge of the constraints transmitted to the scaphoid depending on the joint sector [16].

In flexion-extension, the ligaments are relaxed and the joint pressure minimal until 20°, to become significant at 40°. After that, the pressures increase to reach their maximal value around 80°. After 80°, they become pathogenic [6] (Fig. 3.9).

The normal amplitude in radial inclination is 15°. It induces compressive constraints on the scaphoid that tilts in flexion, which can encourage the formation of a vicious callus [17], closing the intrascaphoidal sagittal angle.

The normal amplitude in ulnar inclination is 45°. It creates traction constraints on the scaphoid that tilts in extension. The formation of a vicious callus [17] when the intrascaphoidal sagittal angle is open is rarer, but can happen.

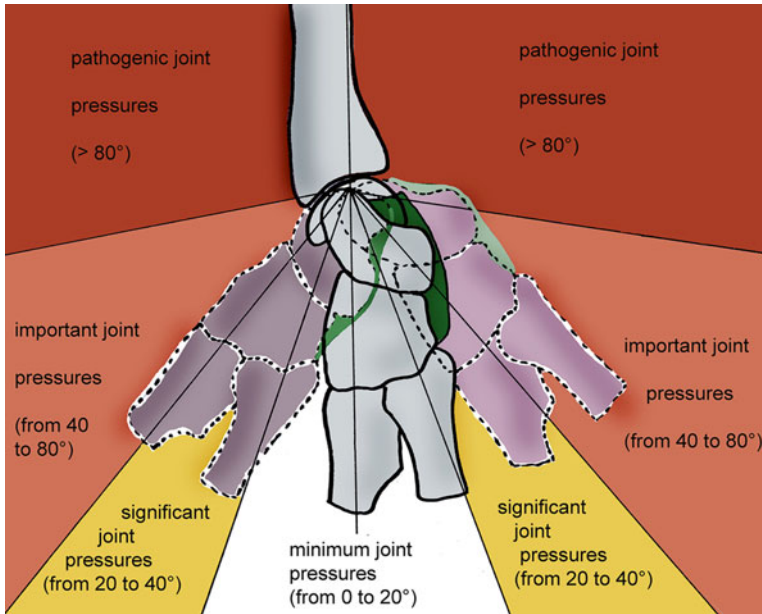


Fig. 3.9 Joint pressures depending on the amplitudes in flexion/extension, which become important after 40° (According to Kapandji)

Like for the fractures of the inferior extremity of the radius, these elements allow defining “risky” areas in which the exercises to regain amplitude will have to be realized very cautiously, without any force.

These areas are after 20° in flexion/extension and ulnar inclination and from 5° in radial inclination.

Trying to regain total amplitudes at all costs is, in this phase, useless and dangerous.

We use the same techniques than in fractures of the inferior extremity of the radius:

- *Fluidotherapy* to relax the muscles and tissues. We use it at the beginning of the session to warm up the wrist.
- *Passive manual mobilizations* are basic exercises to regain joint amplitude. They’re soft and pain-free and can be realized increasing the joint spaces a little. We work in all the authorized sectors, being particularly careful in extension and radial inclination where the constraints on the scaphoid are more important.
- *Active mobilizations* are realized after the passive ones, in various finger positions to improve tendinous glidings at the level of the wrist (Fig. 3.10).
- *Active-assisted mobilizations* can be assisted by an arthromotor. We ask the patient to participate actively in the movements applied by the device. This exercise is realized in amplitudes previously regained by the therapist in passive. It has an interest at the joint level, but also in draining the edema. It can be combined with icing (Fig. 3.11 and 3.11’).
- *Electrostimulation*, combined with an active movement (winding the fingers), can help regaining the last degrees of mobility in finger flexion if necessary (Fig. 3.12). The patient mustn’t clutch his fingers as it would put important constraints on the scaphoid.

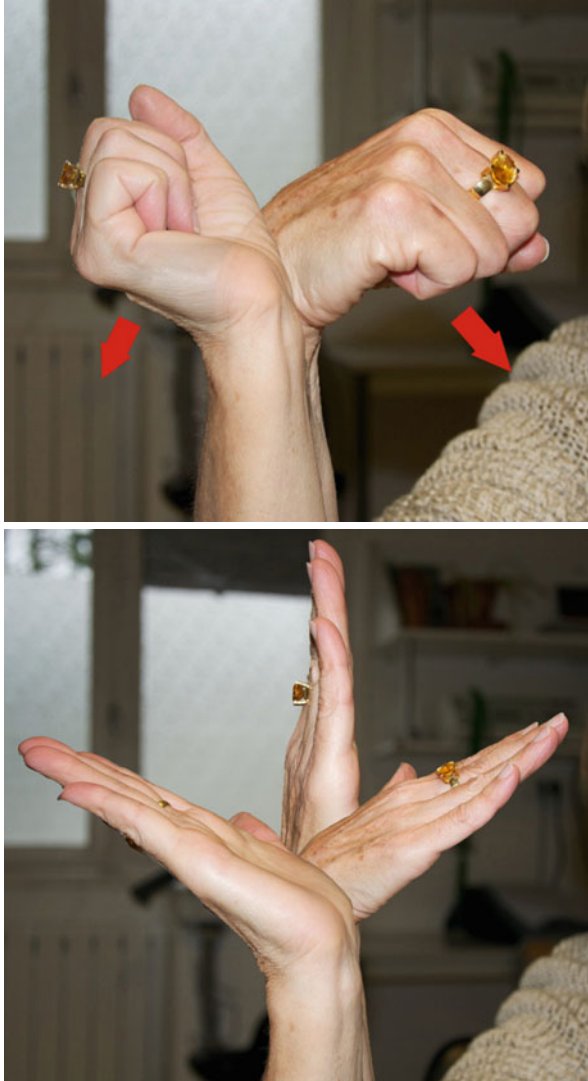

Fig. 3.10 Active mobilizations realized with the fingers extended and a closed fist to improve the tendon glidings in the flexor and extensor systems

Muscular Awakening and Reinforcement for the Stabilizing Muscles

Muscular awakening is realized with exercises with energy overload, which can be used at first to progressively stimulate atrophic muscles.

“Trigger” muscles are part of the intrinsic musculature to avoid increasing the longitudinal constraints of the carpus on the forearm [16]:

- Abductor pollicis brevis – pronator quadratus (Fig. 3.13)
- Flexor digiti minimi – flexor carpi ulnaris (Fig. 3.14)

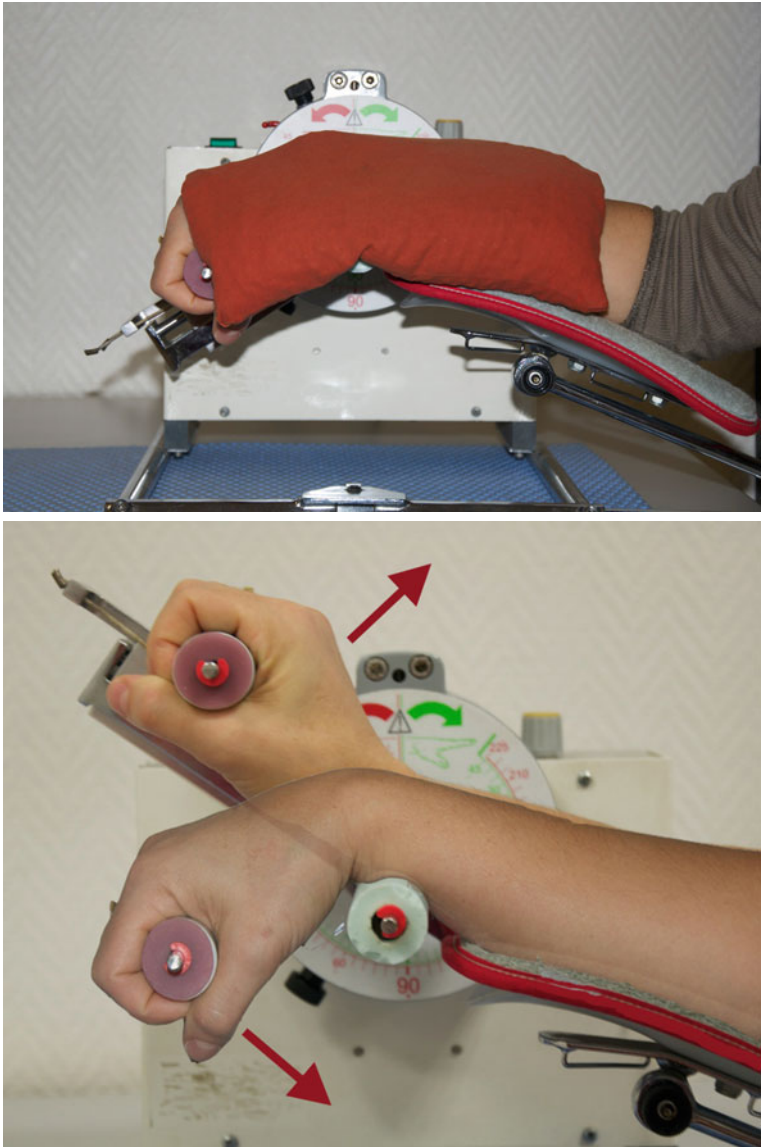


Fig. 3.11 and 3.11' Active-assisted mobilization with an arthromotor with or without ice depending on the trophic state of the wrist

- Thenar and hypothenar muscles – flexor carpi radialis (Fig. 3.15)
- Abductor digiti minimi and thumb extensors – ulnar and radial carpal stabilizers (Fig. 3.16) [18]

The reinforcement protocol itself starts when the previous exercises are easily realized by the patient.

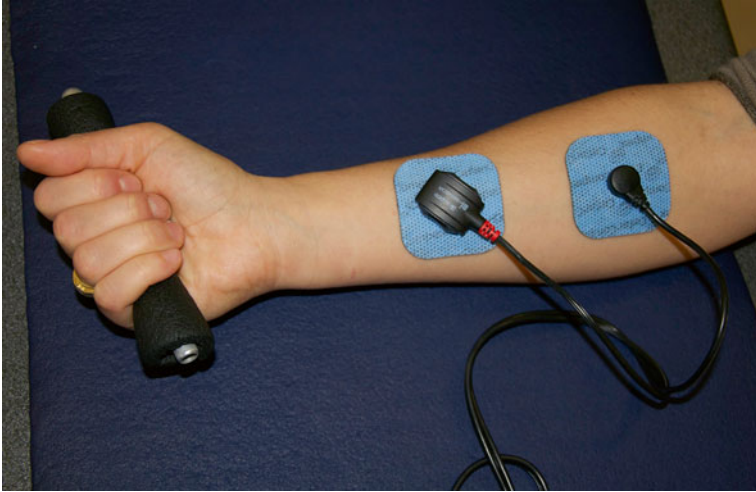

Fig. 3.12 Electroactive winding (without clamping) to avoid putting important constraints on the osseous callus

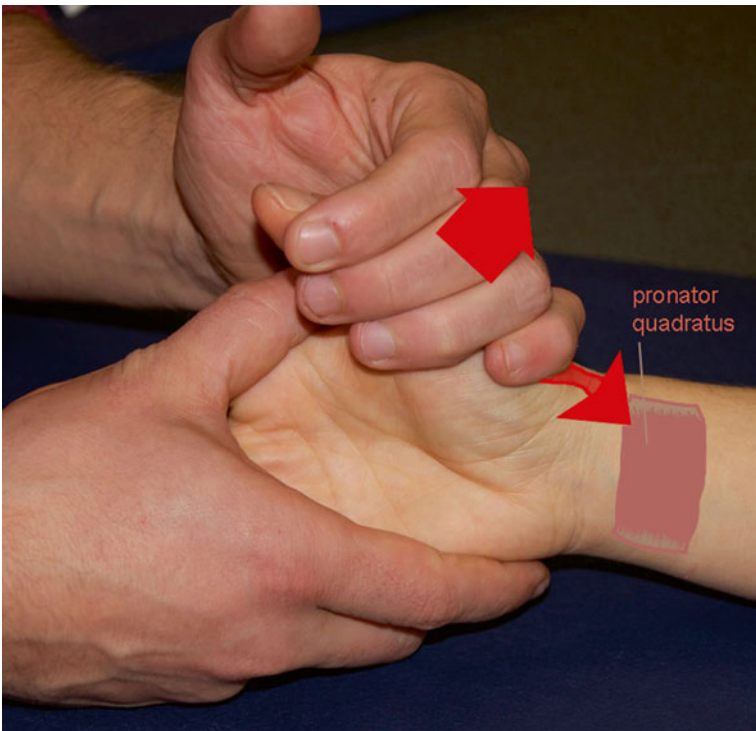


Fig. 3.13 Exercise with energy overload, where the trigger muscle is the abductor pollicis brevis and the target muscle the pronator quadratus

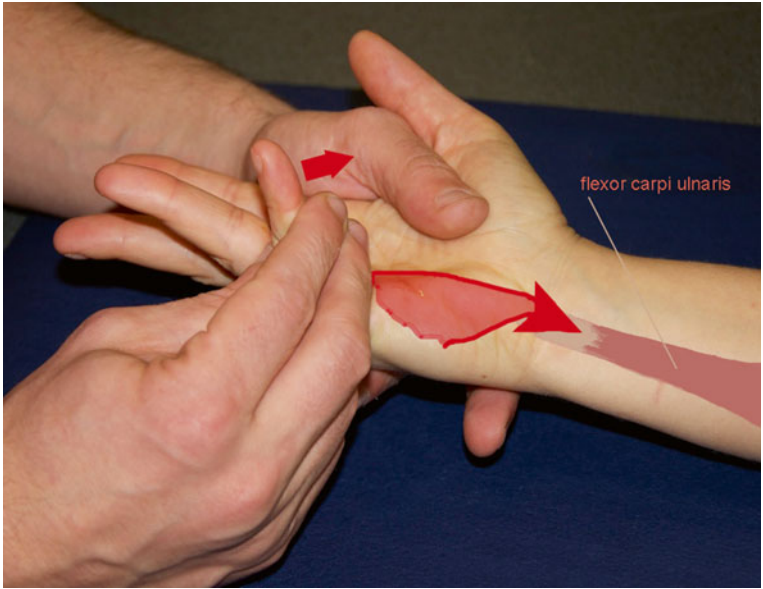


Fig. 3.14 Exercise with energy overload, where the trigger muscle is the flexor digiti minimi brevis and the target muscle the flexor carpi ulnaris

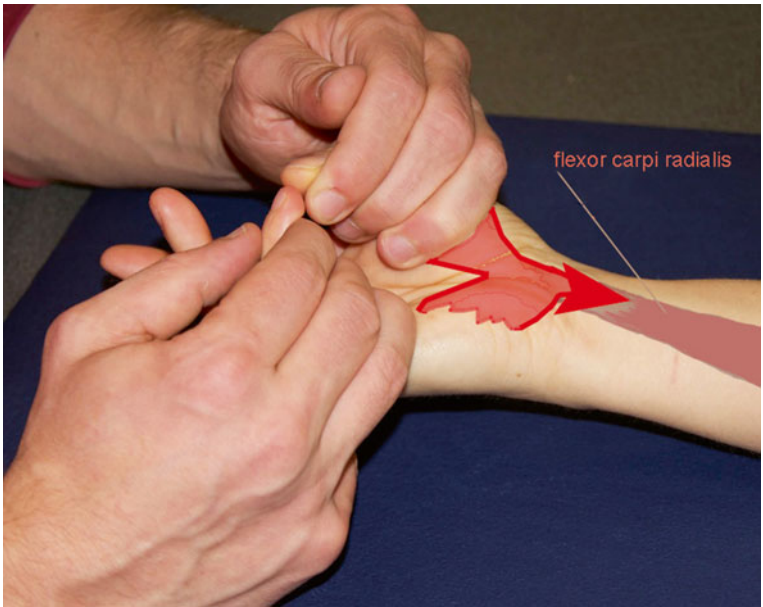


Fig. 3.15 Exercise with energy overload, from the opposition arch to the flexor carpi radialis

All the exercises are realized with the fingers in extension, the limit the axial constraints increased by the contraction of the finger flexors when clamping (Fig. 3.17).

The first solicited energy system is the aerobic one as it's the least constraining at the muscular and articular level.

“Pure” aerobic exercises can't be realized in this phase as the patient would be asked to realize long contraction (10–15 min), which in this phase would lead to tendinous and muscular disorders, as well as important pain. Therefore, we use

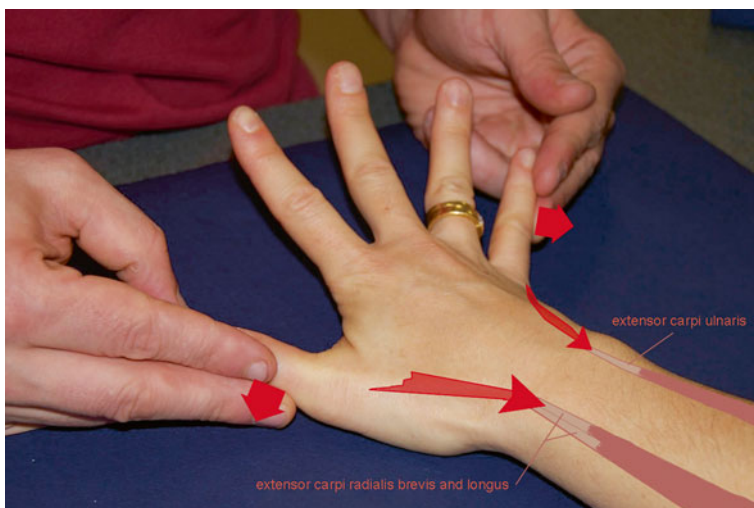


Fig. 3.16 Exercise with energy overload, from the extensors of the thumb and the abductors of the 5th finger to the radial and ulnar stabilizers of the carpus

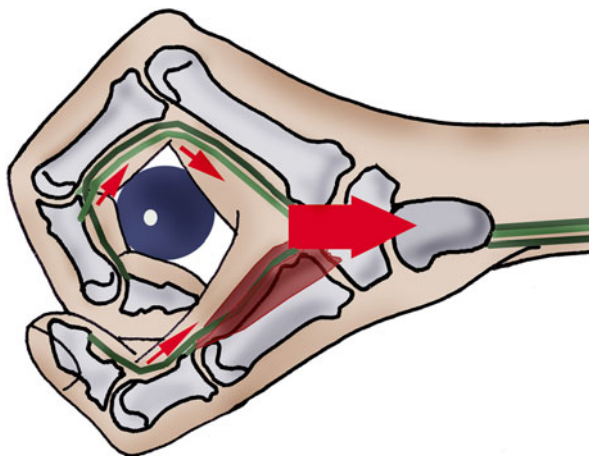


Fig. 3.17 The contraction of the finger flexors when clamping puts compressive constraints on the carpus that can affect the osseous healing of the scaphoid

static intermittent exercises adapted to the wrist's functional biomechanics, the relative fragility of the callus, and the wrist muscles' physiology.

At the beginning of the phase, we ask for low-intensity static contractions with series of 30 repetitions, held 6 s, and with 6 s of rest between the repetitions. The ideal contraction intensity is 20–30 % of the maximal strength, but as it can't be assessed in this phase, it's controlled by the therapist or the device.

We can't use the contralateral side to determine the usual strength of the injured side as there are often important differences between the 2 sides of a patient.

The parameters (number of repetitions, contraction duration, and modalities) evolve during the treatment, adapting to the patient's capacity and osseous consolidation.

A contraction with maximal resistance or clamping is never asked.

Dynamic contractions with wide amplitudes aren't in relation with the physiological role of the wrist orient and stabilize the hand during prehensions). Therefore, they're not included in the reinforcement protocol (except if there's a particular indication).

We realize a static reinforcement of the 4 sides of the wrist, with the wrist in a neutral position and the fingers in extension.

Wrist Flexors

The flexor carpi radialis passes in front of the radial epiphysis and the scaphoid. It forms the most powerful active complex stabilizing the radial column, along with the radial extensors (Fig. 3.18).

The flexor carpi ulnaris passes in front of the ulnar head and ends on the pisiform. It produces expansions towards the anterior retinacular ligament, the hamate, and the 4th and 5th metacarpals. It's prolonged along the internal column by the adductor digiti minimi. It forms the most powerful active complex stabilizing the ulnar column, along with the extensor carpi ulnaris (Fig. 3.19).

During these exercises, the flexor carpi radialis and ulnaris work in synergy, and the action of the finger flexors is limited as we place the fingers in extension.

We work with the espalier, with a contraction against an elastic band (moderate resistance). At the beginning of this rehabilitation phase, the patient brings the elastic band in the working position with his contralateral hand, to realize a pure static exercise.

The exercise is then realized only with the damaged side to alternate stato-concentric, static, and stato-eccentric contractions against a controlled resistance.


A visual feedback allows the patient to control the contraction and rest phases (Fig. 3.20).

Manually, the resistance is placed at the level of the palmar side of the metacarpal diaphyses, stabilizing the forearm with the contralateral hand. This grip allows us in controlling the osseous callus and limits the compression and shearing constraints imposed on it.

A digital grip with the fingers in extension is also possible (Fig. 3.21).

An ulnar or radial inclination can be asked to work with the flexor carpi ulnaris or radialis.

Fig. 3.18 Anatomical disposition of the flexor carpi radialis tendon, forbidding the distal part of the scaphoid to go forward



Wrist Extensors

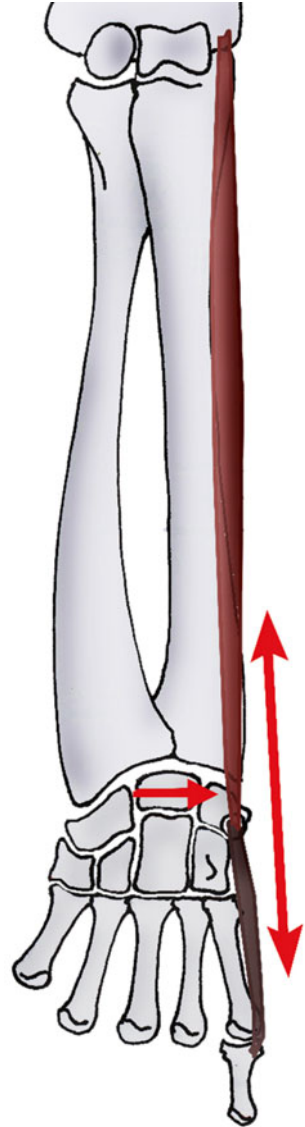
The extensor carpi radialis longus and brevis pass on the posterior side of the radial styloid process and in the anatomical snuffbox, before ending, respectively, on the posterior side of the 2nd and 3rd metacarpals. They participate in stabilizing the radial column, along with the flexor carpi radialis (Fig. 3.22).

The extensor carpi ulnaris passes with the extensors between the styloid process and the ulnar head before ending on the 5th metacarpal's posterointernal tubercle. It participates in stabilizing the ulnar column, along with the flexor carpi ulnaris.

The abductor pollicis longus and extensor pollicis brevis stabilize the radial column, but their analytical contraction is moderate in this phase as there are important risks of tendinopathy.

We use the espalier with an elastic band, according to the same modalities than for the wrist flexors, and always with visual feedback (Fig. 3.23).

Fig. 3.19 Stabilizing role of the flexor carpi ulnaris in the frontal plane, as opposed to the ulnar gliding of the 1st carpal row



Manually, the resistance is placed at the level of the dorsal side of the metacarpal diaphyses, stabilizing the ulnar side of the wrist with the contralateral hand (Fig. 3.24).

As for the reinforcement of the wrist flexors, we can associate a radial or ulnar inclination to work with the extensor carpi radialis or ulnaris.

Ulnar Stabilizers

The extensor and flexor carpi ulnaris can work in synergy in an exercise with the espalier (Fig. 3.25).



Fig. 3.20 Exercise for the wrist flexors with an espalier and visual feedback determining precisely the contraction time and the resting time. The exercise is realized with the fingers extended to limit the compressive constraints on the scaphoid




Fig. 3.21 Manual exercise for the wrist flexors with a digital grip. The interphalangeals are extended ad the metacarpals flexed. As the metacarpophalangeal flexion is ensured by the intrinsic system, there is no increase of the compressive constraints on the scaphoid

Fig. 3.22 Role of the radial muscles, forbidding the proximal part of the scaphoid to go backward


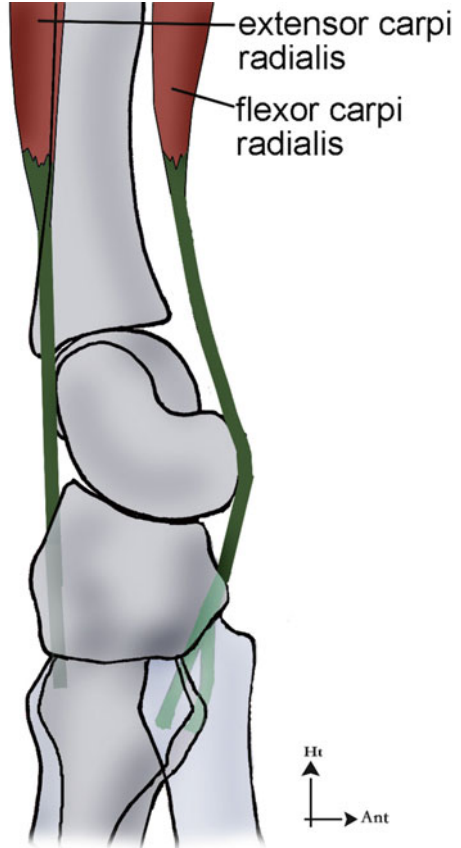


Fig. 3.23 Exercise for the wrist extensors with an espalier, with the same modalities than for the flexors

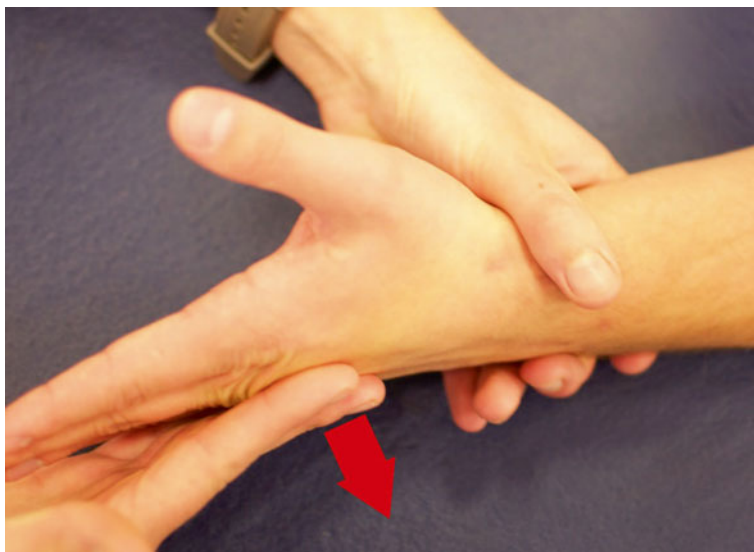

Fig. 3.24 Manual exercise for the wrist extensors



Fig. 3.25 Synergic exercise for the flexor carpi ulnaris and the extensor carpi ulnaris with an espalier

Manually, we can ask for a direct contraction against resistance at the level of the ulnar side of the carpus (triquetrum, hamate, and 5th metacarpal), stabilizing the scaphoid with the contralateral hand (Fig. 3.26).

Another exercise consists in working with the abductor digiti minimi brevis as it's in continuity with the flexor carpi ulnaris.

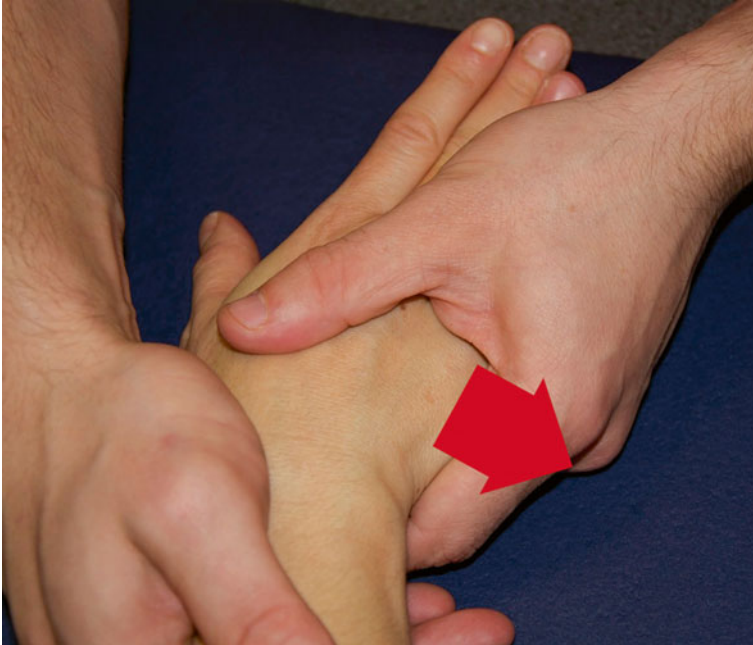

Fig. 3.26 Manual exercise for the ulnar stabilizers of the carpus with a stabilizing counter-grip on the radial compartment

Radial Stabilizers

The opposite exercise is proposed to solicit preferentially the wrist radial stabilizers. Resistances are placed on the radial side of the 2nd metacarpal to reduce the contraction of the thumb muscles.

This exercise is realized very carefully, and the patient is forbidden to mobilize his wrist in radial inclination during the contraction (Fig. 3.27).

Intrinsic Muscles

The contraction of the intrinsic muscles doesn't produce important axial constraints, unlike the contraction of the extrinsic muscles (Fig. 3.28).

We'll reinforce preferentially the interossei, the flexor pollicis brevis, and the adductor pollicis.

We ask the patient to realize a "vise" pinch against resistance, with visual feedback to manage the duration of contraction and rest (Fig. 3.29).

The same exercise can be realized manually.

The opposition arch between the thumb and the 5th finger can also be solicited manually (Fig. 3.30).

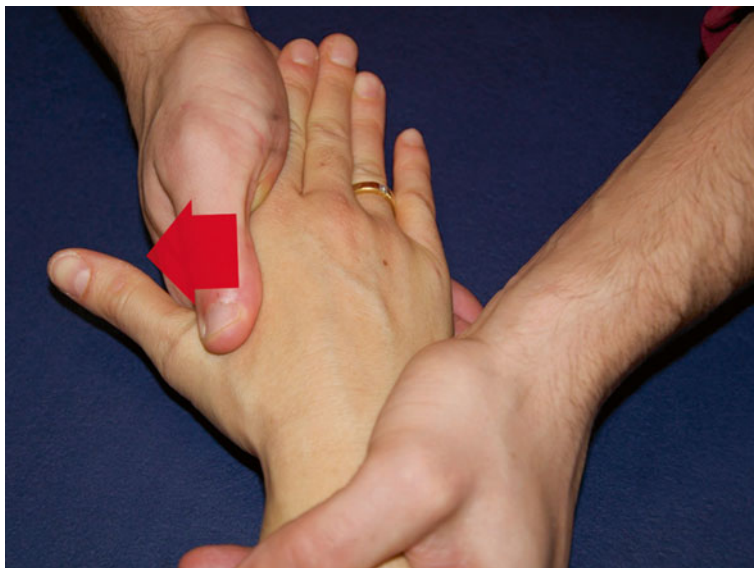


Fig. 3.27 Manual exercise for the radial stabilizers of the carpus with a stabilizing counter-grip on the ulnar compartment. The wrist mustn't be in an important radial inclination to limit the constraints on the scaphoid

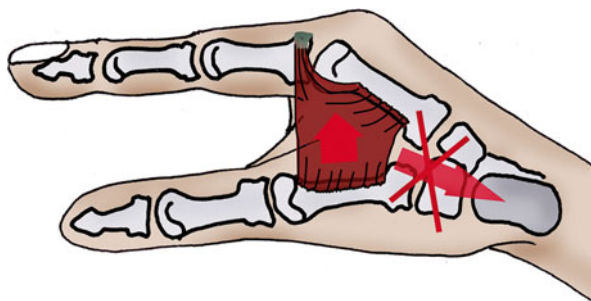


Fig. 3.28 The contraction of intrinsic muscles that don't have a longitudinal orientation doesn't put important compressive constraints on the scaphoid

Electrostimulation

Combined with an active contraction of the stimulated muscles, it improves motor recruitment and maintains body mapping, thus participating in the active wrist stabilization.

It can concern intrinsic or extrinsic muscles (Fig. 3.31).

Note: even if these techniques are the same as in fractures of the inferior extremity of the radius, there are some variations. We'll particularly insist on regaining strength in the radial muscles (flexor carpi radialis and radial extensors) that are important stabilizers of the scaphoid.



Fig. 3.29 Instrumental contraction exercise for the intrinsic muscles with a “vise” pinch and visual feedback




Fig. 3.30 Manual reinforcement of the muscles that are part of the arch of opposition between the thumb and the 5th finger

Prehensions

We work on prehensions to improve coordination and dexterity and therefore improve functional capacities in daily activities.

These exercises are realized without clamping or putting excessive constraints on the scaphoid.

For example, clamping a ball is forbidden (Fig. 3.32).

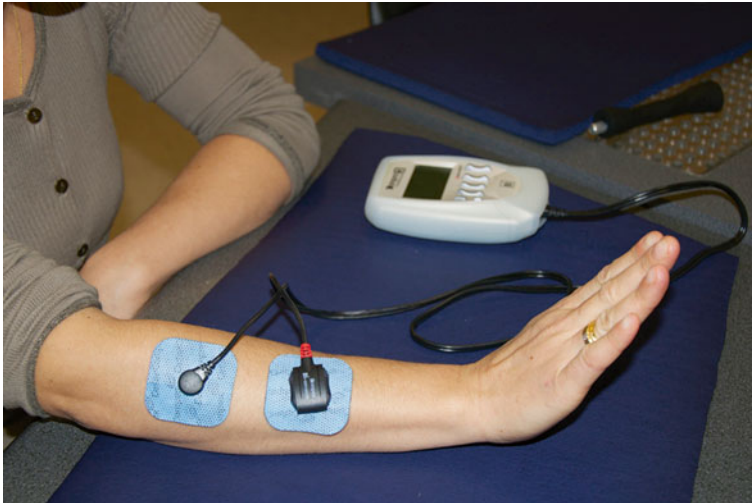


Fig. 3.31 Electrostimulation of the ulnar wrist stabilizers. The patient realizes a moderate active extension and controls the ulnar inclination produced by the electrostimulation. This exercises allows a co-contraction of the ulnar and radial stabilizers of the carpus

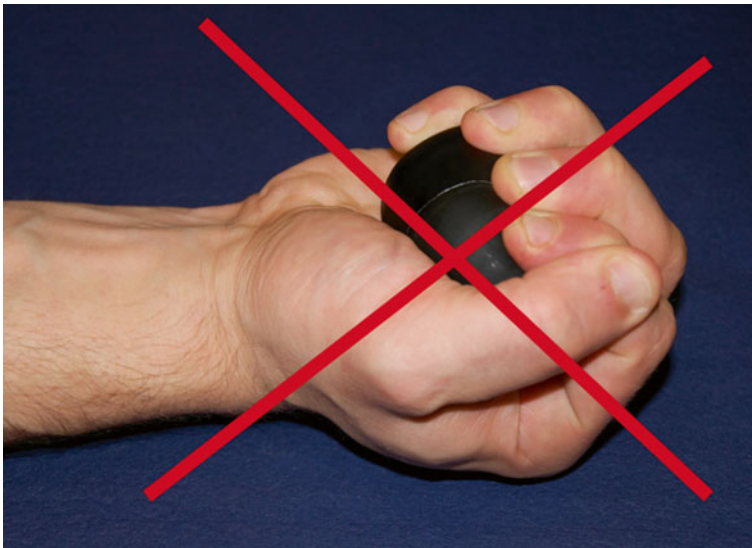

Fig. 3.32 Clamping a ball, forbidden during the healing phase as it puts compressive constraints on the scaphoid

Proprioception

In this phase, these exercises are only realized if there is no pain or trophic disorders. They improve the patient's proprioception without risk for the callus healing.

Table Tennis Racket

We ask the patient to maintain the ball on the racket, which implies a good sensorial analysis and a contraction adapted to the received informations.

Progressively, we ask the patient to throw the ball and receive it "softly" on the racket.

Exercises with a Plastic Ball

We use a light plastic ball and ask the patient to pass it from one hand to the other, to throw and catch it.

3.4.1.3 Consolidation (After D90 with Surgery, After D120 Without Surgery)

When the scaphoid is solid, we can start more intensive techniques (never aggressive).

In this phase, we aim to regain strength and wrist amplitudes. Rebalancing force ratios between the different muscular groups limits the risks of secondary tendinopathy.

Prehension and proprioception exercises help the patient in regaining the functionality he'll need in his work and sports activities.

Regaining Wrist Amplitudes

We keep realizing techniques from the previous phase and intensify them if necessary (pain-free) to completely regain the wrist amplitudes.

We use specific peri-scaphoidal mobilization techniques.

Specific Mobilizations

They require a good knowledge of the morpho-palpatoary anatomy [12] and the radio-carpal and intracarpal biomechanics [12, 18]. Traction glidings are realized between the radius and the 1st carpal row, between the 1st and 2nd carpal row, and between the scaphoid and the adjacent bones, insisting on the lunate with which it forms a pair essential in the good functioning of the wrist (cf. Chap. 4).

We realize mobilizations between the radius and the carpus and between the 2 carpal rows (described in the Chap. 5), to which we add analytical mobilizations between the scaphoid and the adjacent bones:

Mobilization Scaphoid/Radius

The patient keeps the wrist in a neutral position to avoid limiting mobility with the reduction of the space between the trapezo-trapezoidal joint and the radius during radial inclination or the tension in radial ligaments during ulnar inclination.

The scaphoid is maintained between the therapist's thumb and index, with the thumb on the scaphoid's tubercle and the index on the posterior side of the proximal part.

The other hand maintains the radius, and we apply anteroposterior glidings on the scaphoid (Fig. 3.33).

Mobilization Scaphoid/Lunate

The wrist is still in a neutral position; the patient places his forearm in pronation.

The scaphoid is maintained by the radial hand between the thumb (dorsal side of the proximal part) and the index (tubercle). The lunate is maintained by the ulnar hand between the thumb (dorsal side) and the pulp of the other fingers (palmar side). Each hand applies an opposite gliding to obtain maximal movement (Fig. 3.34).

Mobilization Scaphoid/Trapezium

In the same position than for the mobilization scaphoid/lunate, the scaphoid is maintained the same way and the trapezium is between the thumb (dorsal side) and the index (palmar side). We apply a differential gliding on each bone in a direction oblique backward and outward or frontward and inward, with the scaphoid oriented frontward and outward.

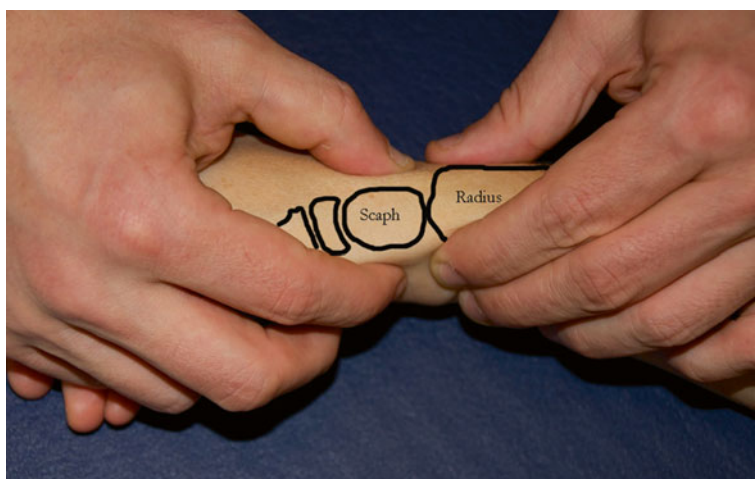


Fig. 3.33 Analytical mobilization of the scaphoid with respect to the radius, wrist in a neutral position

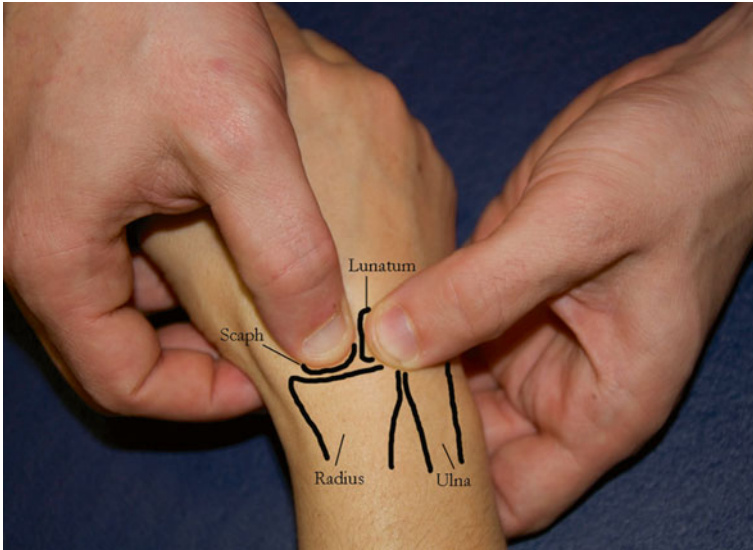


Fig. 3.34 Scapho-lunar mobilization with opposed glidings of the 2 mobilizing hands

Muscular Reinforcement

The scaphoid is healed so the muscular reinforcement can be realized with no other limit than the pain threshold and the progression of the techniques.

We use the same techniques as in the previous phase with more important loads, to regain strength comparable to the same side.

Chain work is realized according to the patient's functional needs (Fig. 3.35 and 3.35'). The assessment of the muscular ratios is essential, and we often observe weakness in the radial and extrinsic elements in relation with the ulnar and intrinsic ones. This difference is probably related to the limits imposed in the other phases to protect the scaphoid:

- Using a load cell and visual feedback allows accurately targeting the solicited energy system, modifying the load and duration of contraction and rest. The reinforcement is realized in flexion-supination and extension-pronation to improve muscular capacities and regain muscular balance, comparable to the same side (Fig. 3.36). If a comparison with the same side can't be done, our experience has determined that strength in flexion-supination is 1.8 times more important than strength in extension-pronation in men and 2.6 times in women.
- Using a dynamometer combined with a device allows regulating the duration of contraction and rest, with visual feedback to target the solicited energy system, reinforce and rebalance the pronators and supinators (Fig. 3.37). The same kind of device is used for the radial and ulnar stabilizers (Fig. 3.37').
- Global exercises for the superior limb can be done too, realizing a controlled contraction with visual feedback of the ulnar (Fig. 3.38) or radial stabilizers, and the wrist flexors (Fig. 3.39) and extensors.




Fig. 3.35 and 3.35' Example of an exercise in chain for the whole superior limb. The aim is to find exercises close to the patient's functional needs

- Using weights solicits flexors/extensors in half-open chain (Figs. 3.40 and 3.40'). It allows alternating concentric, static, and eccentric contractions whose parameters evolve depending on the patient's functional needs.
- Using a hammer solicits pronators/supinators in half-open chain (Fig. 3.41). Like with weights, we can alternate different contractile modes and the parameters evolve depending on the patient's functional needs and progress.
- Using a minibike in active mode improves the wrist flexors and extensors' endurance. The resistance and exercise duration evolve, adapting to the patient's needs and capacities (Fig. 3.42).
- Support exercises to work in closed chain (Fig. 3.43).
- Techniques using digito-antebrachial chains can be realized manually or instrumentally (Fig. 3.44).
- Electrostimulation can be associated with every exercise previously described, adapting the program to the energy system we want to work with.

Proprioception and Feedforward

It's essential in the functional recovery for the wrist and can be realized manually or with instrumental techniques.

We use exercises with oscillating poles, medicine balls, and rhythmical stabilization:

- Multidirectional proprioception and feedforward pressing on a plastic ball first poorly inflated and then progressively more inflated (Fig. 3.45).
- Rhythmical stabilization with an oscillating pole (Fig. 3.46).
- Exercises passing a weighted ball from one hand to the other, throwing and receiving it. We progressively increase the weight (Fig. 3.47).

Fig. 3.36 Reinforcement exercise for the wrist flexors with the forearm supinated, with load cell and visual feedback

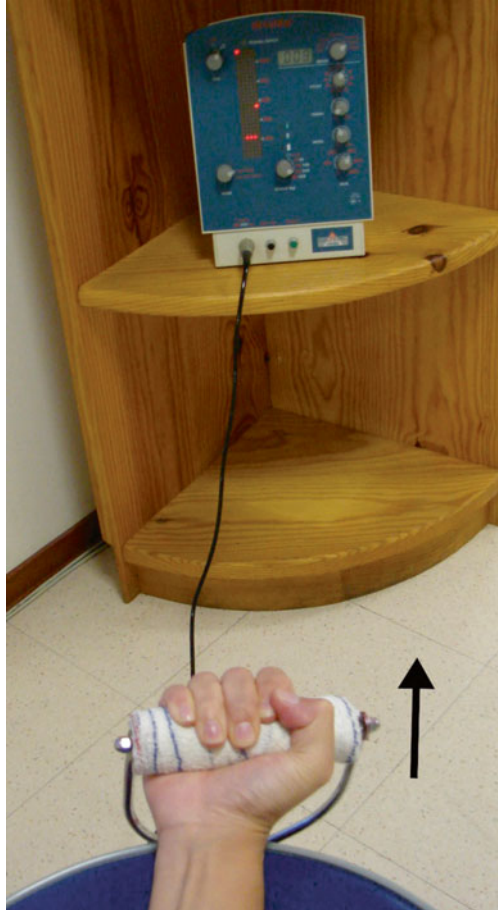
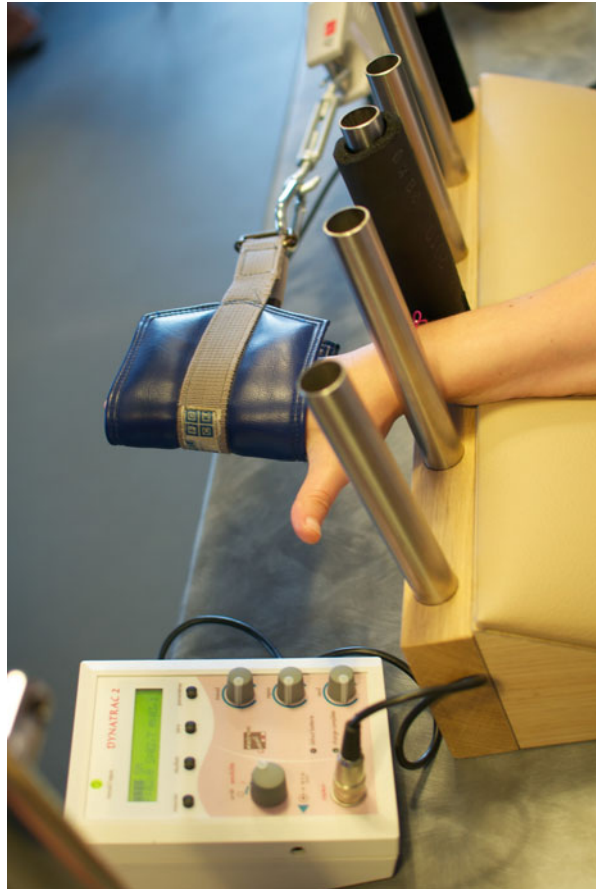

Fig. 3.37 Exercise for the pronators and supinators with dynamometer and a device regulating the contraction and rest duration and visual feedback

Fig. 3.37' Exercise for the radial stabilizers with load cell and visual feedback



Prehensions

We realize exercises to improve the types of prehensions the patient will need in his daily activities, work, and sports.

3.4.2 Orthotic Treatment

The orthotic treatment evolves in parallel in relation with the rehabilitation protocol:

3.4.2.1 Immobilization

It can be a cast or made of resin, but we prefer using perforated thermoformable plastic (2,4mm thick) to realize a non-removable orthosis.

Fig. 3.38 Exercise for the ulnar stabilizers of the wrist with load cell and visual feedback



We obtain a precise immobilization, 8 times lighter than with resin, that can go in water (if there is no wound), radiolucent, and with perforations that allow the skin to “breathe.”

As described in the chapter about immobilization, recent studies tend to demonstrate that letting the thumb free doesn’t affect the healing process, so we realize orthosis leaving the thumb free (Fig. 3.48).

3.4.2.2 Pre-consolidation

It’s not realized all the time, but a resting orthosis can be useful in case of nocturnal pain or in daily activities.

However, we make sure the patient gets progressively rid of the orthosis without impeding his functional evolution.

The orthosis lets the thumb free and maintains the wrist in a neutral position. The plastic is perforated and its thickness depends on the patient’s morphology (Fig. 3.49).

Fig. 3.39 Exercise for the wrist flexors with load cell and visual feedback



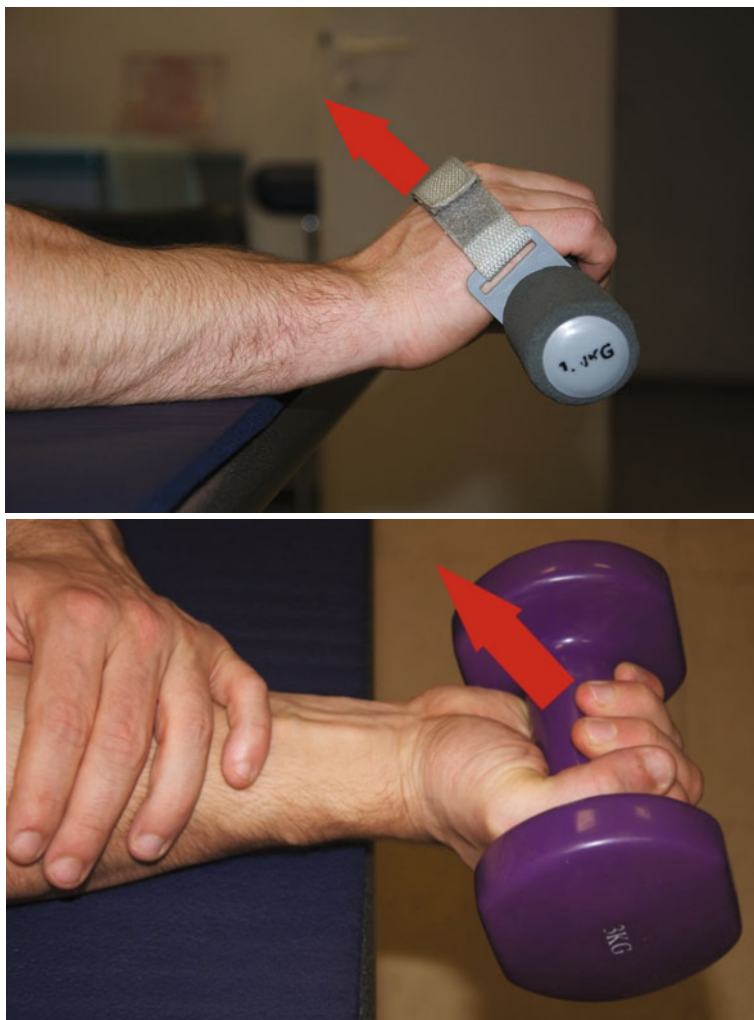3.4.2.3 Consolidation

A neoprene orthosis can be realized to go back to professional or sports activities. It protects the wrist from shocks and has an interesting contention effect, useful at a proprioceptive level and in the patient's apprehension. It is most of the times a wrapped on cuff and thermoformed plastic reinforcements can be added depending on the indications (Fig. 3.50).

3.5 Complications

Other than the usual complications related to surgery and immobilization, pseudoarthrosis is the main complication in fractures of the scaphoid [19].

They are more frequent in case of insufficient initial treatment, displaced fractures, or fractures localized in the proximal part, which vascularization is precarious.



Figs. 3.40 and 3.40' Exercise for the flexors and extensors with weights. It allows alternating concentric, static, and eccentric contractions whose parameters evolve depending on the patient's progresses

The treatment for pseudoarthrosis is surgical, most often realizing a bone graft from the hip bone or the radial epiphysis. The goal is to avoid the evolution towards an SNAC wrist. The rehabilitation after a graft uses the same principles as in simple fractures, modifying the durations depending on the case and the surgeon's indications.

Remember

- The scaphoid is a bone whose healing can be difficult as it is poorly vascularized, with important risks of pseudoarthrosis (proximal part).
- Compressive constraints must be avoided during the whole healing phase.
- The protocol is a lot like the one for fractures of the inferior extremity of the radius, but it's often more intense and centered around reinforcement and proprioception.




Fig. 3.41 Auxotonic exercise for the pronators and supinators




Fig. 3.42 Endurance exercise setting the resistance, speed, and duration

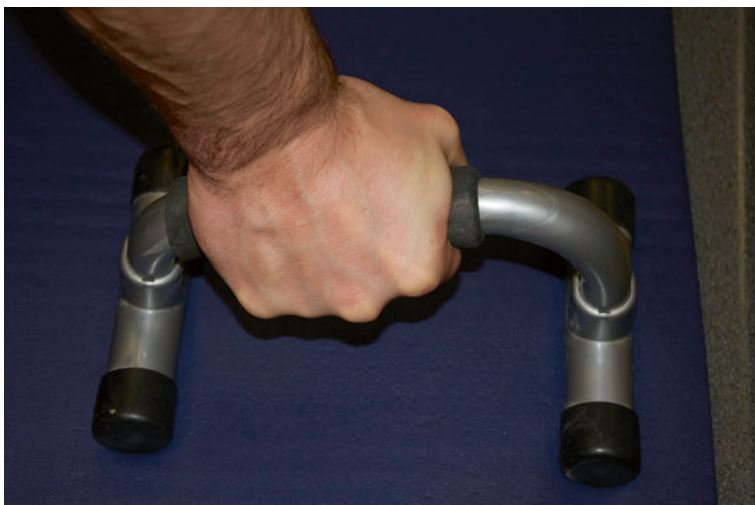

Fig. 3.43 Support exercise allowing working in a closed chain. Destabilizing maneuvers can be added to obtain an interesting proprioceptive exercise




Fig. 3.44 Exercise for the digito-antebrachial chains

Fig. 3.45 Proprioceptive exercise pressing on a ball more or less inflated



Fig. 3.46 Rhythmical stabilization exercise with an oscillating pole



Fig. 3.47 Proprioceptive exercise with weighted balls, increasing the weight depending on the patient's progress

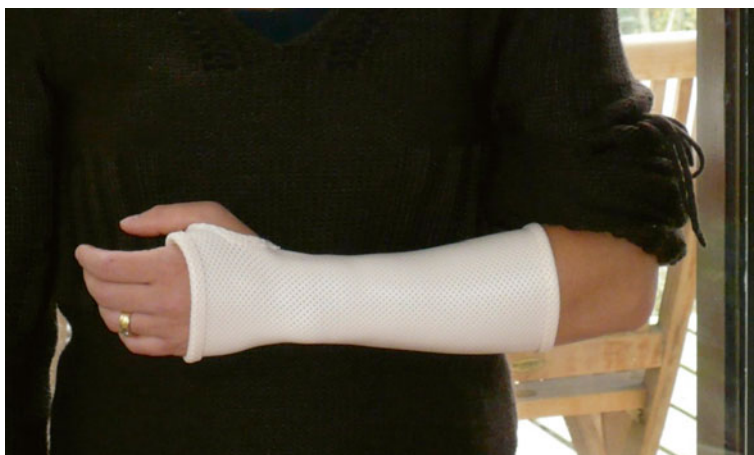

Fig. 3.48 Immobilization orthosis for the scaphoid with the thumb free

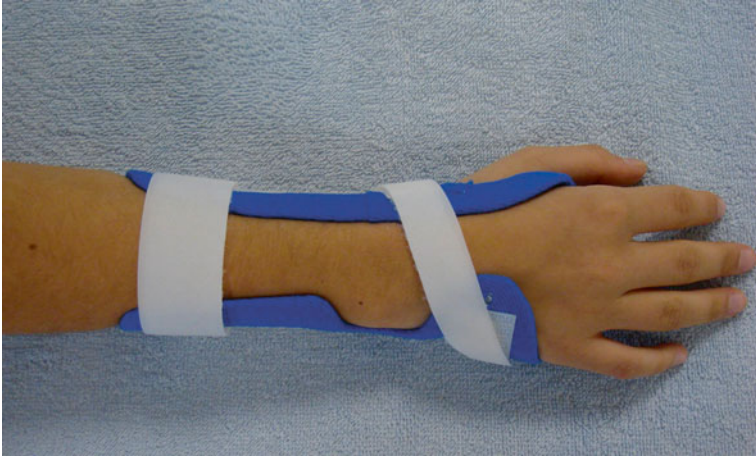


Fig. 3.49 Resting orthosis in the pre-consolidation phase. It isn't realized every time and isn't worn all the time

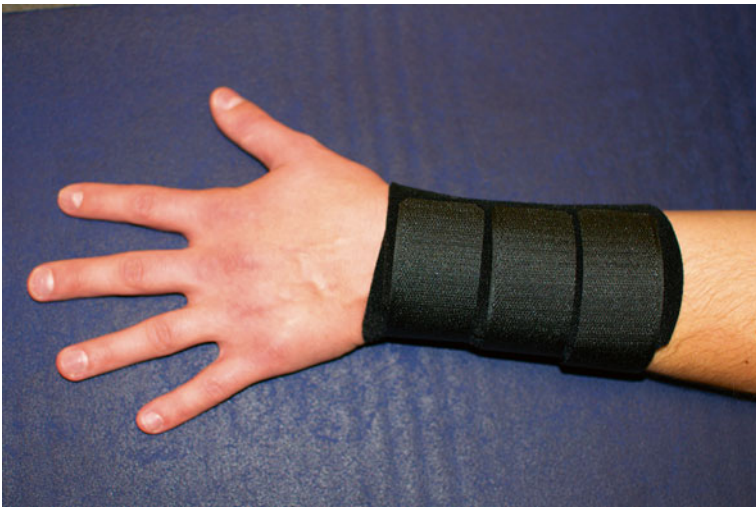

Fig. 3.50 Neoprene wrap-around cuff to restart sports and force activities. Plastic reinforcement can be added to increase the rigidity of the orthosis if needed

Bibliography

1. Schernberg F (2005) Fractures récentes du scaphoïde (moins de 3 semaines). *Chir Main* 24:117–130
2. Berger RA (2001) The anatomy of the scaphoid. *Hand Clin* 17(4):525–532
3. Nakamura R (2000) Scaphoid mal-union — current concept and perspectives. *Hand Surg* 5(2):155–160
4. Herbert T (1990) The fractured scaphoid. Quality medical publishing Inc, St-Louis
5. Merle M (ed) (2009) La main traumatique, vol 2. Elsevier Masson, Issy-les-Moulineaux, p 379
6. Schernberg F, Harisboure A, Gaston E (2000) Fractures des os du carpe. In: Masson E (ed) EMC appareil locomoteur, Elsevier, Paris pp 14-046-B-10
7. Schubert HE (2000) Scaphoid fracture. *Can Fam Physician* 46:1825–1832
8. Weber E (1980) Biomechanical implications of scaphoid waist fractures. *Clin Orthop* 149:83–89
9. Herzberg G, Foissier D, Falaise C (2003) Coronal fractures of the proximal scaphoid: the proximal ring sign. *J Hand Surg* 28B:500–503
10. Dickson R, Leslie IJ (1982) Traitement orthopédique des fractures du scaphoïde carpien. Monographie du GEM. Le poignet. Ed. Expansion scientifique Française - Paris. pp 82–95
11. Toh S, Nagao A, Harata S (2000) Severely displaced scaphoid fracture treated by arthroscopic assisted reduction and osteosynthesis. *J Orthop Trauma* 14:299–302
12. Tubiana R, Thomine J-M (1990) La main anatomie fonctionnelle et examen clinique, Masson
13. Holley B (2009) Intérêt de l'arthroscopie dans le traitement par vissage percutané des fractures du scaphoïde carpien, analyse retrospective de 31 cas
14. Schadel-Hopfner M, Bohringer G, Gotzen L (2000) Percutaneous osteosynthesis of scaphoid fracture with the Herbert-Whipple screw-technique and results. *Handchir Mikrochir Plast Chir* 32:271–276
15. Brutus JP, Baeten Y, Kinnen L, Moermans JP, Ledoux P (2002) Ostéosyn- thèse percutanée des fractures du scaphoïde par la vis de Herbert: revue de 30 cas. *Chir Main* 21:350–354
16. Horii E, Garcia-Elias M, Bishop AT et al (1990) Effect on force transmission across the carpus in procedures used to treat Kienboock's disease. *J Hand Surg* 15A:393–400
17. Saffar P (2008) Cal vicieux du scaphoïde. *Chir Main* 27(2–3):65–75
18. Kuhlmann JN (2002) La stabilité et les instabilités radio- et médio-carpiennes. Sauramps médical, Montpellier
19. Herzberg G (ed) (2006) Arthrose péri-scaphoïdienne. Sauramps medical, Montpellier, p 340

Chapter 4

Sprains of the Scapholunate Ligament

Grégory Mesplié and Olivier Léger

Injuries of the scapholunate ligament are the most frequent intracarpal ligamentous injuries.

They lead to instability in the carpus, evolving towards a scapholunate advanced collapse wrist [1].

4.1 Physiopathology [2–4]

The injury mechanism is related to a trauma in hyperextension/radial inclination, most often because of a fall on the thenar eminence.

In these conditions, the scaphoid is under two opposite constraints, towards the extension because of the wrist extension and towards the flexion because of the combined radial inclination (Figs. 4.1 and 4.1').

The posterior part of the radius presses on the scaphoid that transmits important constraints on the scapholunate ligament, which is opposed to the movement of the scaphoid's proximal part towards palmar.

The first carpal row is like a “mobile meniscus” that absorbs axial constraints as long as it forms a coherent set (Fig. 4.2).

When the scapholunate ligament breaks, the first carpal row is disunited and the whole carpal stability is compromised [5]:

G. Mesplié (✉)

Physiotherapist and Orthotist, Institut Sud Aquitain de la Main et du Membre Supérieur,
Aguiléra Clinic Biarritz, Biarritz, France
e-mail: greg.mesplie@mac.com

O. Léger

Hand Surgeon, Institut Sud Aquitain de la Main et du Membre Supérieur,
Aguiléra Clinic Biarritz, Biarritz, France

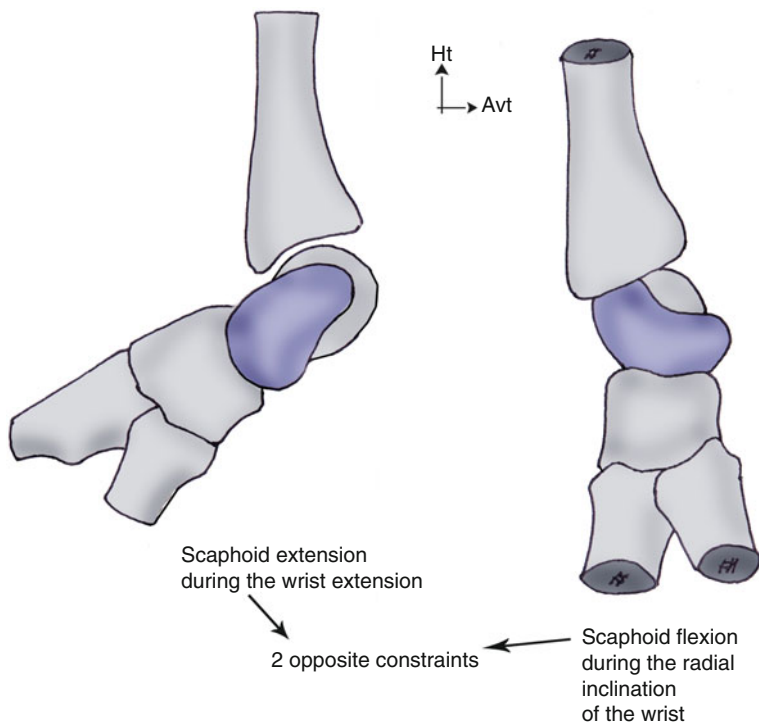


Fig. 4.1 A combination of wrist extension and radial inclination leads to opposed constraints on the scaphoid

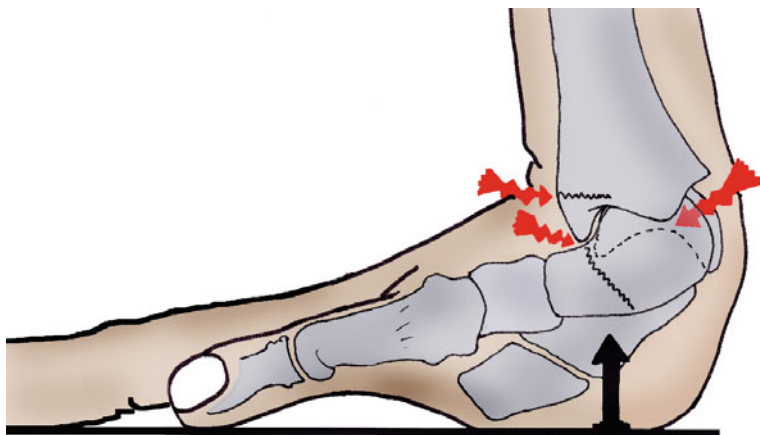


Fig. 4.1' The extension and radial inclination of the injury mechanism put constraints on the radius, the scaphoid, and the scapholunate ligament. In this mechanism, the scapholunate ligament forbids the proximal part of the scaphoid from going to palmar




Fig. 4.2 The first carpal row plays the role of a “flexible and mobile meniscus” that absorbs the longitudinal constraints from the carpus

- *The scaphoid* goes to flexion because of longitudinal constraints.
- *The lunate* goes to extension because of the triquetrum (dorsal intercalated segment instability).
- *The scapholunate space* increases, creating a scapholunate diastasis (Fig. 4.3).

These biomechanical changes lead to a decrease of the carpus height, as the scaphoid and lunate reduce their working distance. This causes the extrinsic ligamentous systems to become slack and the passive stability of the carpus to be compromised (Fig. 4.4) [5].

The biomechanical changes in the wrist after this type of injury lead to degenerative phenomena [6], even if it’s difficult to predict when they are going to appear.

4.2 Clinical and Paraclinical Signs

An early diagnosis is a crucial factor for the patient’s recovery as surgery is more difficult with an old injury [7].

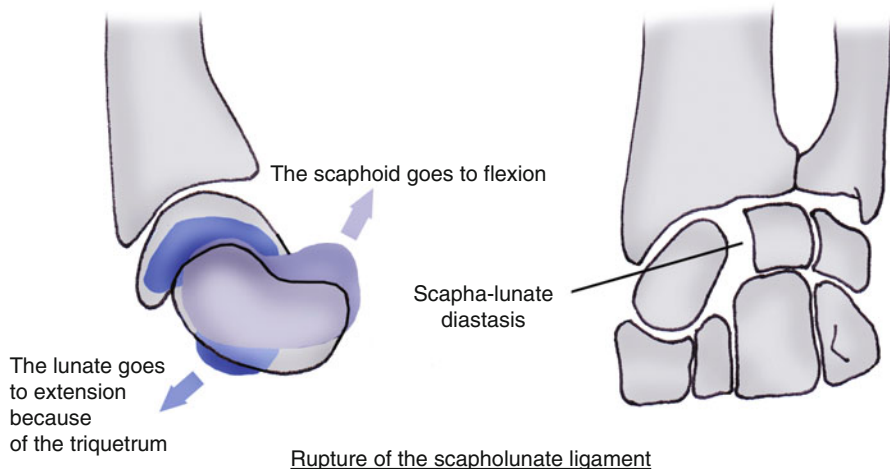


Fig. 4.3 The rupture of the scapholunate ligament is catastrophic for the cohesion of the first carpal row

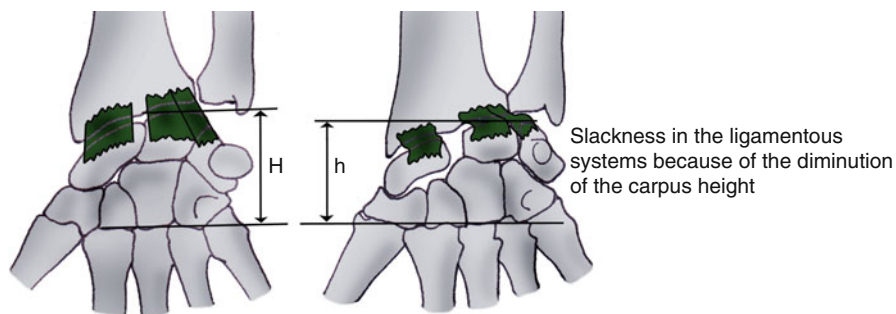


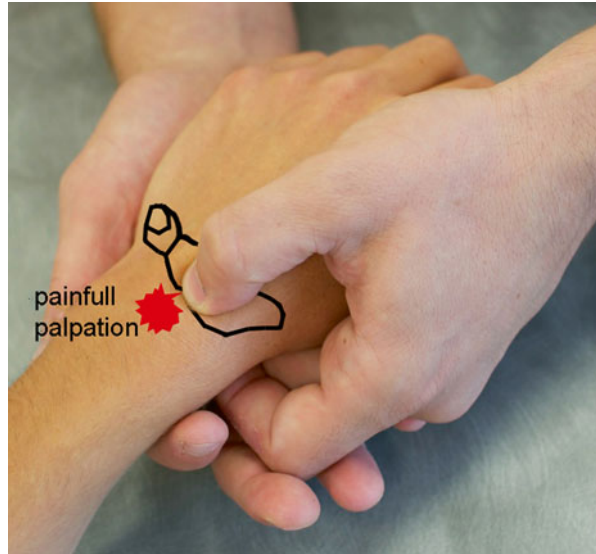
Fig. 4.4 The modifications of organization in the first carpal row after injury of the scapholunate ligament lead to a decrease of the carpus height, which causes slackness in the extrinsic capsular systems

4.2.1 Clinical Signs

The clinical exam allows finding several elements that, unfortunately, aren't specific to injuries of the scapholunate ligament:

- Pain on the radial side of the wrist, most often with intense pain when palpating the scapholunate interline (Fig. 4.5)
- Clicking and snapping when mobilizing, mainly related to the disconnection of the scaphoid and lunate
- Important strength loss
- Mobility loss (later)

Fig. 4.5 Palpation of the scapholunate interline



There also exist some clinical tests that can help the assessment:

- *Scapholunate instability test*: it consists in applying opposite glidings on the scaphoid and the lunate. Pain or abnormal movement guides the therapist towards an injury of the scapholunate ligament (Fig. 4.6).
- *Evaluation of the scaphoid dynamic (bell sign)*: it consists in assessing the scaphoid's mobility with the wrist in radial and ulnar inclination. The therapist places his/her thumb at the level of the scaphoid's tubercle and applies a radial and ulnar inclination in the wrist. If the scaphoid dynamic is good, the therapist feels the tubercle sticks out in radial inclination (the scaphoid goes to flexion) and goes in ulnar inclination (the scaphoid goes to extension) (Fig. 4.7).
- *Watson's test (scaphoid shear test)*: in this test, the therapist is facing the patient in an "arm wrestling" position. The therapist's index or fingers are placed on the dorsal side of the scaphoid's proximal part, and his thumb is on the palmar tuberosity. The other hand maintains the metacarpals. A firm pressure is applied on the palmar side of the scaphoid, while the wrist is placed in ulnar inclination, which makes the scaphoid go to extension. When passing in radial inclination, the scaphoid can't flex as it's maintained by the therapist's thumb. In case of scapholunate injury and in patients with great laxity, the scaphoid tends to go backward under the posterior part of the radius and therefore contacts with the therapist's index which revives pain. Pain can be present on its own or be associated to snapping. When pressure is released, the scaphoid gets back to its normal position, sometimes with an audible "thunck." In some cases, the lack of mobility with comparison to the same side can express an edematous and synovial reaction. To avoid false positives that are still too frequent, we must first put pressure on the posterior side of the scaphoid and see if there's spontaneous pain.

Fig. 4.6 Scapholunate instability test

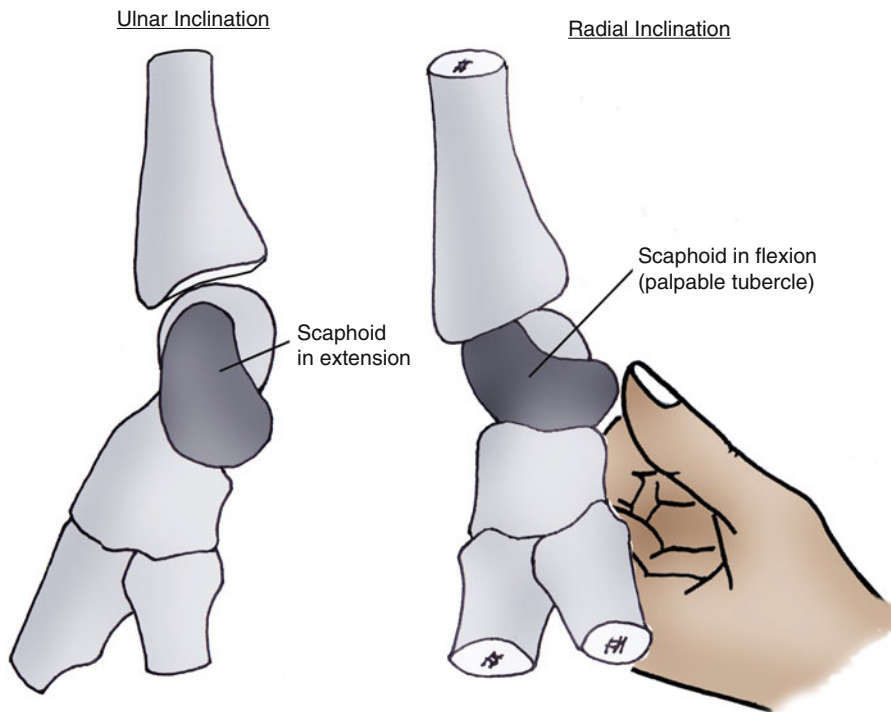
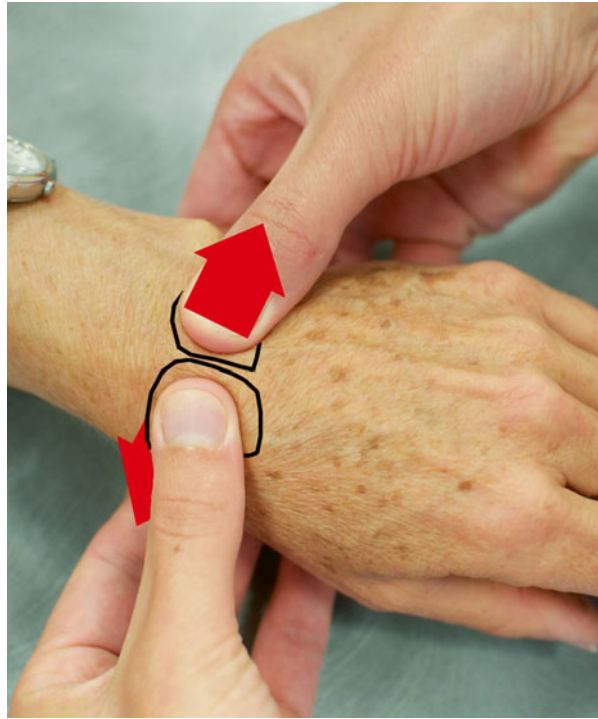

Fig. 4.7 Evaluation of the scaphoid dynamic

Even if it's the most well-known test, it has low sensitivity and specificity. It's positive in only 20 % of normal individuals. Lane proposed a modification (scaphoid shift test) realizing only an anteroposterior translation, which would increase the test's sensitivity.

4.2.2 Paraclinical Signs

After a complete clinical exam, these signs will confirm or reject the injury of the scapholunate ligament and its stage (Table 4.1).

4.2.2.1 X-Ray

Static

Frontal X-rays assess:

- The scapholunate diastasis (or gap), greater than 3 mm in case of injury
- The ring sign that means the scaphoid tilts in flexion
- The carpal height that can be reduced as the scaphoid tilt in flexion and the lunate tilt in extension decrease their working distance

Lateral X-rays assess:

- The scapholunate angle that is normally lower than 70° (Fig. 4.8)
- The displacement of the lunate in extension or DISI (dorsal intercalated segment instability)

Fist Closed

The patient clutches his fingers with the maximal intensity, which makes the capitate go towards the scapholunate space. If the scapholunate ligament is ineffective, it creates a diastasis between the scaphoid and the lunate (Fig. 4.9).

Table 4.1 Recapitulative table of the scapholunate instabilities (according to Ph. Saffar)

STAGE	EXAM
“Predynamic”	Clinical diagnosis, normal X-ray
Dynamic instability	Clinical diagnosis + dynamic X-ray
“Static” or constant (N. Barton)	Simple FP X-ray + control of the cartilage: arthroscan or arthroscopy
Static with arthrosis: arthrosis radio-scaphoid + luno-capitate (SLAC)	Simple FP X-ray ± control of the cartilage: arthroscan or arthroscopy

Fig. 4.8 Scapholunate angle superior to 70° that shows an injury of the scapholunate ligament

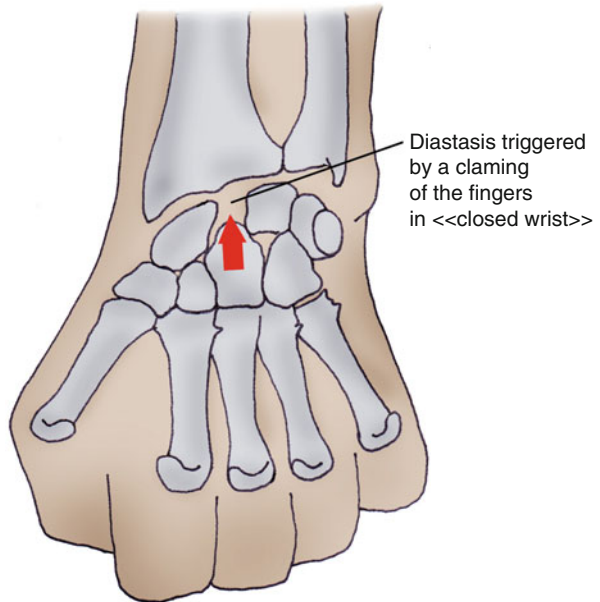
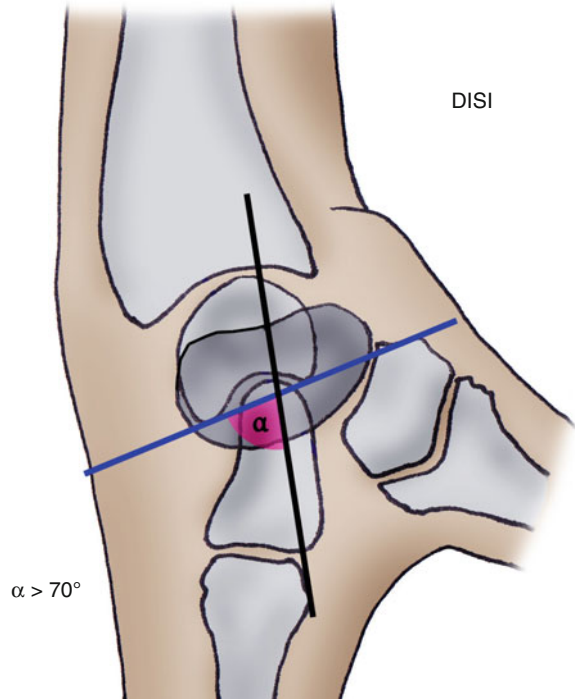


Fig. 4.9 An X-ray of the clamping hand can show a scapholunate diastasis

Dynamic

Dynamic X-rays in flexo-extension and inclinations of the wrist highlight injuries of the scapholunate ligament with rupture of the Gilula's lines, which don't appear on static X-rays. We talk about dynamic scapholunate instability.

4.2.2.2 Scintigraphy

In this stage, if no clinical or radiological element is accepted, a negative scintigraphy excludes serious injuries.

Otherwise, an arthrogram is proposed.

4.2.2.3 Arthrogram

It's a preferred technique that highlights chondral and ligamentous damages of the carp. However, there are false negatives (ligamentous perforation filled with scar tissue) and false positives (gap without instability, degenerative injury), and localization is often difficult. Therefore, arthroscopy stays important.

4.2.2.4 Arthroscopy

It confirms the diagnosis (visualization and palpation of the injury from the radio-carpal joint, dynamic test spreading the scapholunate space from the midcarpal joints). It also eliminates chondral consequences in the proximal part of the scaphoid, which would counter-indicate any repair procedure in favor of palliative care, like an arthroscopic radial styloidectomy.

4.2.2.5 Other Exams

The arthro-MRI obtains diagnosis comparable to the arthrogram, but its price and availability are important disadvantages.

The MRI results in this area are subject to controversy.

The arthroscopy precisely assesses the state of the ligamentous and cartilaginous injuries in the carpus, but it's an invasive technique that we can avoid, thanks to the arthrogram.

4.3 Therapeutical Process and Surgical Treatment [8–12]

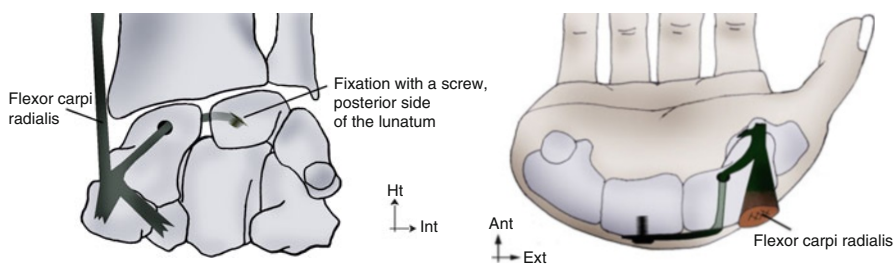
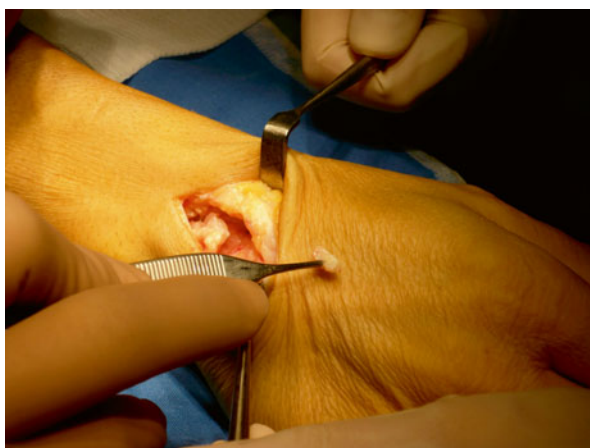Surgery depends on the type of injury.

We don't realize any particular surgery in case of injury of the medium part, as it's biomechanically secondary.

In complete injuries, we realize a ligamentous repair protected by a temporary double scapholunate pin and an immobilization orthosis during 45 days:

- Arthroscopic suture according to the technique proposed by Mathoulin if there is a scaphoid or lunar ligamentous shred (trans-ligamentous rupture; unfortunately it's fairly rare).
- Osseous reinsertion with micro-anchors in case of avulsion of the ligament. We often combine it with a capsulodesis using the proximal part of the transversal capsular flap realized during the initial posterior arthrotomy according to Berger's technique.
- When there aren't ligamentous residues, Cuenod's ligamentoplasty bone-ligament-bone hasn't given satisfactory results (Fig. 4.10). We're currently working on a ligamentoplasty acting on the distal part of the scaphoid as well as on the scapholunate ligament (Figs. 4.11 and 4.12).

Fig. 4.10 Ligamentoplasty bone-ligament-bone, type Cuenod



Figs. 4.11 and 4.12 Ligamentoplasty project using the flexor carpi radialis stopping the distal part of the scaphoid from going forward and opposing the scapholunate diastasis

4.4 Rehabilitation and Orthotic Treatment [3]

The rehabilitation of scapholunate injuries must allow regaining good wrist stability and avoiding evolution towards an SLAC wrist.

Immobilization can last between 45 and 60 days depending on the surgery realized.

4.4.1 Rehabilitation Protocol (Fig. 4.13)

4.4.1.1 Immobilization Phase (D0-D45/60)

As in other wrist injuries, rehabilitation isn't essential in this phase. Self-rehabilitation advices are given to the patient.

The treatment is based on the protocol PRICE that fights against trophic disorders resulting from the trauma and surgery:

- *P* for protection of the fracture line during the whole phase, realized immobilizing the wrist and informing the patient about the tissue fragility in this phase.
- *R* for rest of the damaged area that mustn't be solicited during the immobilization phase, aside from self-rehabilitation exercises explained by the therapist.
- *I* for ice, putting cold packs several times a day on the fracture zone. If there's a cast it's impossible, but if there is no wound, we immobilize the patient with a thermoformed orthosis, which allows cold bath against edema.
- *C* for compression that can be realized in the fingers if they're swollen.
- *E* for elevation of the wrist to avoid edema.

These exercises are combined with sensorimotor stimulations to maintain the body mapping and cutaneous receptors and with simple active mobilizations of the free joint (the metacarpophalangeals in the long fingers tend to get easily stiff). We stop these exercises if pain appears.

4.4.1.2 Relative Fragility Phase (D45/60-D90)

The goal in that phase is to eliminate pain in the wrist and regain stability and functional mobility.

We realize exercises comparable to those used in fractures of the scaphoid.

Fight Against Trophic Disorders and Pain

We apply the same modalities as for other traumatic injuries of the wrist.

Sprains of the scapholunate ligament			
	Phase 1: healing	Phase 2: relative fragility	Phase 3: solidity
R e h a b i l i t a t i o n	<p>Therapeutic goals: healing phase, strict immobilization, no load carrying.</p> <p>Techniques:</p> <ul style="list-style-type: none"> - Monitoring of the orthosis (comfort, pressure points). -PRICE protocol. -Mobilizations of the free joints (shoulder, elbow), mobilization without resistance of the digital chains (exercises at homes). <p>Risks: nonobservance of the immobilization and safety advices.</p>	<p>Therapeutic goals: pre-consolidation phase, progressively putting constraints on the scapholunate ligament, stability, fight against muscular atrophy.</p> <p>Techniques:</p> <ul style="list-style-type: none"> - Relaxing of the scar and skin (massage). -“De-rust” the joints, fluidotherapy. -Static reinforcement with an open palm (electrostimulation, wrist stabilizers, transcutaneous vibratory stimulations, simple active mobilizations). <p>Risks: no kneading, avoid axial compressions caused by oversoliciting the finger flexors. No analytical exercise for the extensor carpi ulnaris that can damage de scapholunate ligament.</p>	<p>Therapeutic goals: regain total joint amplitude, stability ++, and functional goals (work and sports activities).</p> <p>Techniques:</p> <ul style="list-style-type: none"> - Specific intracarpal mobilizations. -Static instrumental muscular reinforcement. -Dynamic muscular reinforcement with light weights. -Proprioception exercises and multidirectional resistances. <p>Risks: stiffness or instability of the wrist.</p>
	Or th e s is	Closed ante-brachio-palmar orthosis, wrist in 0° of flexo-extension and 5° of ulnar inclination, fingers free	Resting orthosis progressively taken off.
D0 to D45/60		D45/60 to D 90	After D90

Fig. 4.13 Rehabilitation protocol

Regaining Functional Amplitudes

Wrist mobilizations must be soft to avoid putting excessive tensions on the scapholunate ligament. These tensions are significant after 30° of flexion/extension.

If surgery is associated with capsuloplasty, the wrist mobility in flexion is limited and the therapist mustn't "force" on the wrist in flexion, as there's a risk of recreating instability (Fig. 4.14).

Mobilizations in inclination are combined with an analytical mobilization of the scaphoid that recreate the scaphoid dynamic [13].

Muscular awakening and reinforcement [14].

The exercises are progressive and realized with the fingers extended to limit axial constraints of the capitate on the scapholunate space (Fig. 4.15).

Fig. 4.14 Realizing a capsuloplasty allows stabilizing the scaphoid in the sagittal plane but can limit the amplitude in flexion. Therefore, the therapist mustn't "force" in flexion

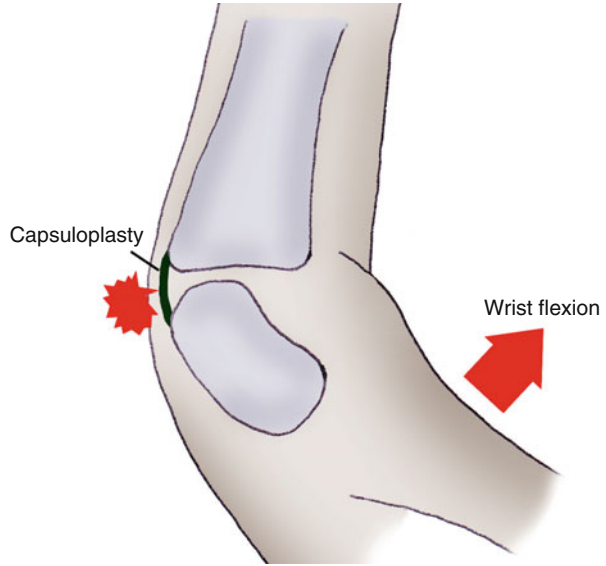
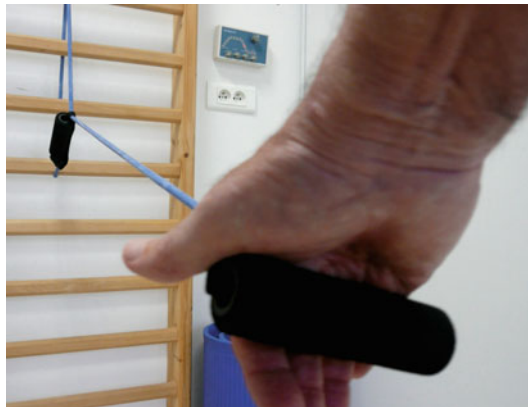
Fig. 4.15 Muscular awakening and reinforcement exercises are realized with the fingers extended during the healing phase of the scapholunate ligament



Clamping or kneading balls are forbidden as they increase the scapholunate diastasis (Fig. 4.15').

We reinforce mainly:

- The intrinsic muscles that help in regaining strength when clamping without producing axial constraints (Fig. 4.16)
- The flexor carpi radialis that opposes the flexion/pronation of the scaphoid, thanks to its distal tendon, and therefore stabilized the scapholunate space (Fig. 4.17) [15]
- The flexor carpi ulnaris [16] and radial extensors of the carpus that are intracarpal supinator muscles and stabilize the scapholunate joint

In this stage, it's harmful to realize an analytical exercise for the extensor carpi ulnaris as it's an intracarpal pronator and therefore destabilizes the scapholunate space (Fig. 4.18) [16, 17].

Proprioception and Prehensions

We apply the same modalities as in other traumatic injuries of the wrist.

Fig. 4.15' Kneading and clamping a ball is forbidden during the healing phase as they produce axial constraints increasing the scapholunate diastasis

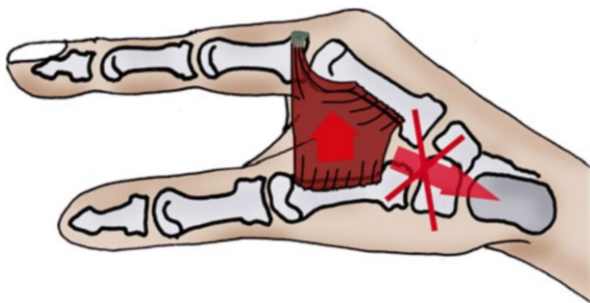
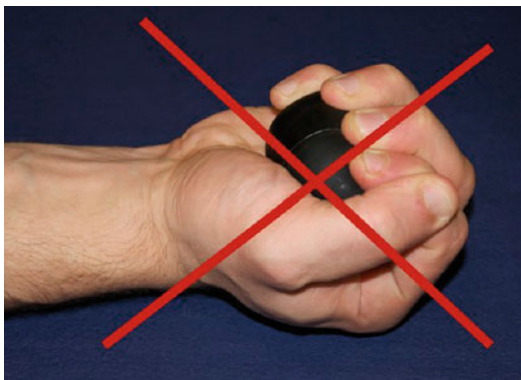


Fig. 4.16 The exercise for the intrinsic muscles doesn't produce axial constraints, whereas the work of the extrinsic muscles does

Fig. 4.17 Reinforcement of the flexor carpi radialis that forbids the distal part of the scaphoid to go forward and the extensor carpi radialis that forbids its proximal part to go backward



4.4.1.3 Solidity Phase (After D90)

Healing is acquired and the goal is to regain a functional wrist allowing the patient to go back to his normal activities.

The exercises realized are comparable to the ones used in fractures of the scaphoid.

Regaining Functional Amplitudes

Working on mobility must be done globally and analytically to regain good scaphoid dynamic if it isn't acquired yet.

We mustn't try to regain mobility "at all costs" as it can create scapholunate instability.

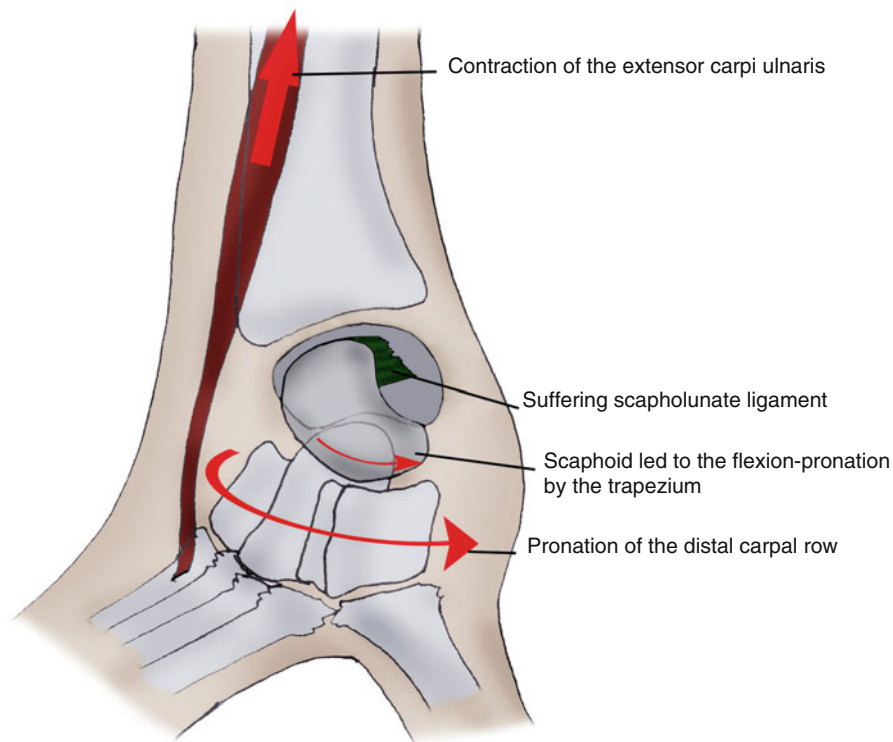


Fig. 4.18 The extensor carpi ulnaris causes an intracarpal pronation harmful for the healing of the scapholunate ligament

Muscular Awakening and Reinforcement [14]

Muscular reinforcement is intensified and controlled with dynamometers and visual feedback, which allow regaining muscular balance and strength comparable to those of the sane side.

Proprioception and Prehensions

These exercises help in regaining a good neuromuscular coordination and going back to professional and sports activities.

4.4.2 Orthotic Treatment

It evolves with the ligamentous healing.

4.4.2.1 Immobilization

It can be a cast or made of resin, but we prefer using perforated thermoformable plastic (2.4 mm thick) to realize a non-removable orthosis. The wrist is placed in a neutral flexo-extension and slight ulnar inclination; the fingers are free (Fig. 4.19).

4.4.2.2 Relative Fragility Phase

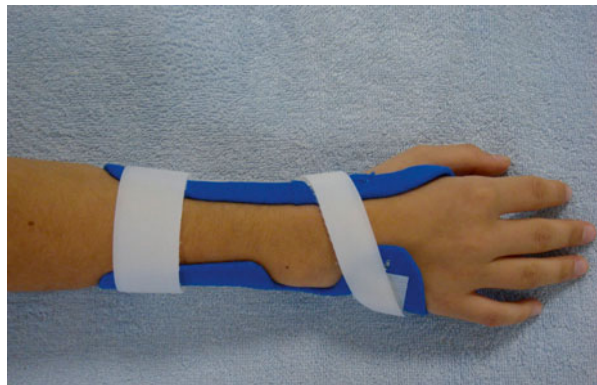
Even if it's not realized all the time, a removable resting orthosis can be useful in case of nocturnal pain or in daily activities. The wrist is placed in the same position as in the previous phase (Fig. 4.20).

However, we make sure the patient gets rid of the orthosis without impeding his functional evolution.

Fig. 4.19 Immobilization orthosis after repair of the scapholunate ligament

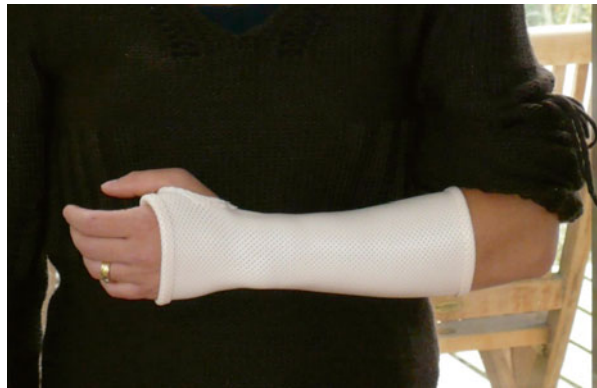

Fig. 4.20 Resting orthosis used after the immobilization phase during the night and in case of pain. It must be taken off rapidly in order not to hinder the functional evolution



4.4.2.3 Consolidation

A neoprene orthosis can be realized to go back to professional or sports activities, to protect the wrist against shocks. It also has an interesting contention effect, useful at a proprioceptive level and in the patient's apprehension. It's most often a wrap-around cuff, and thermoformed plastic reinforcements can be added depending on the indications.

4.5 Complications

Complications related to the injuries of the scapholunate ligament are mainly the evolution towards a SLAC wrist, when the cohesion of the 1st carpal row is compromised. This evolution must be avoided as the treatment for an SLAC wrist is complex and has uncertain results, especially in advanced stages.

Remember

- Injuries of the scapholunate joint compromise the cohesion of the 1st carpal row, possibly leading to arthrosis [6, 11].
- Rehabilitation must respect the ligamentous healing in order not to recreate a scapholunate instability.
- Gaining amplitude mustn't be done at the expense of stability, especially in wrist flexion if a capsuloplasty has been realized.

Bibliography

1. Saffar P. L'instabilité du carpe. www.maitrise-orthop.com
2. Drapé J et al (2009) Poignet et main. Société d'imagerie musculo-squelettique. Sauramps medical, Montpellier
3. Laulan J (2009) Désaxation scapholunaire: physiopathologie et orientations thérapeutique s. Chir Main 28(4):192–206
4. Herzberg G, Joudet T (1999) Entorses, subluxations et luxations du carpe. Encycl Méd Chir. In: Appareil locomoteur. Elsevier, Paris, 14-046-C-10, 13p
5. Kuhlmann JN (2002) La stabilité et les instabilités radio- et médio-carpiennes. Sauramps médical, Montpellier
6. Lane LB, Daher RJ, Leo AJ (2010) Scapholunate dissociation with radiolunate arthritis without radioscapoid arthritis. J Hand Surg 35A:1075–1081
7. Prosser R, Herbert R, LaStayo PC (2007) Current practice in the diagnosis and treatment of carpal instability – results of a survey of Australian hand therapists. J Hand Ther 20:239–242
8. Camus EJ, Van Overstraeten L (2009) Chirurgie ligamentaire du carpe avant l'arthrose. In: Herzberg G (ed) Avant-bras post-traumatique, arthroscopie – arthroplasties (sous la direction). Sauramps medical, Montpellier

9. Merle M, Dautel G (1995) La main traumatique. Vol. Tome 2 – Chirurgie secondaire – le poignet traumatique. Masson, Paris/Milan/Barcelona
10. Megerle K, Bertel D, Germann G, Lehnhardt M, Hellmich S (2012) Long-term results of dorsal intercarpal ligament capsulodesis for the treatment of chronic scapholunate instability. *J Bone Joint Surg Br* 94:1660–1665
11. Garcia-Elias M, Lluch AL, Stanley JK (2006) Three-ligament tenodesis for the treatment of scapholunate dissociation: indications and surgical technique. *J Hand Surg Am* 31:125–134
12. Garcia-Elias M (2011) Carpal instability. In: Wolfe S, Hotchkiss R, Pederson W, Kozin S (eds) *Green's operative hand surgery*, 6th edn. Churchill Livingstone Elsevier, Philadelphia, pp 465–521
13. Tang JB, Xu J, Xie RG (2011) Scaphoid and lunate movement in different ranges of carpal radioulnar deviation. *J Hand Surg Am* 36(1):25–30
14. Salva-Coll G, Garcia-Elias M, Leon-Lopez MT, Llusa-Perez M, Rodríguez-Baeza A (2011) Effects of forearm muscles on carpal stability. *J Hand Surg Eur* 36:553–559
15. Salva Coll G, Garcia-Elias M, Llusá Pérez M, Rodríguez Baeza A (2011) The role of the flexor carpi radialis muscle in scapholunate instability. *J Hand Surg Am* 36:31–36
16. Leon-Lopez MM, Salva-Coll G, Garcia-Elias M, Lluch-Bergada A, Llusa-Perez M (2013) Role of the carpi ulnaris in the stabilization of the lunotriquetral joint. An experimental study. *J Hand Ther* 26:312–317
17. Salva Coll G, Garcia-Elias M, Leon Lopez M, Lusa Pérez M, Rodriguez Baeza A (2012) Role of the extensor carpi ulnaris and its sheath on dynamic carpal stability. *J Hand Surg Eur* 37:544–548
18. Herzberg G (ed) (2006) *Arthrose péri-scaphoïdienne*. Sauramps medical, Montpellier, p 340

Chapter 5

Recent Fractures of the Inferior Extremity of the Radius

Grégory Mesplié and Stéphane Lemoine

5.1 Physiopathology [1]

Described by Castaing in 1964, the injury mechanism is related to a compression transmitted from the carpus towards the forearm frame. This mechanism can be associated to other components, explaining the different types of injuries we find in these cases.

There are three main fracture types:

- Traumas in compression-extension causing a dorsal displacement, like the Colles' fracture where there's a tilt of the inferior extremity of the radius (Fig. 5.1).
- Traumas in compression-flexion, rarer, causing a palmar displacement. For example, the Goyrand-Smith fracture, where there's a palmar displacement of the inferior extremity of the radius (Fig. 5.1').

Associated injuries are frequent and related to the inclination [2] and pronosupination during the trauma:

- *In radial inclination/supination*, the associated injuries are generally a fracture of the scaphoid or a sprain of the scapholunate ligament.
- *In ulnar inclination/pronation*, the associated injuries are generally injuries of the triangular complex, the ulnar styloid process (Gérard-Marchand fracture), or the lunotriquetral ligament (Fig. 5.2).

G. Mesplié (✉)

Physiotherapist and Orthotist, Institut Sud Aquitain de la Main et du Membre Supérieur, Aguiléra Clinic Biarritz, Biarritz, France
e-mail: greg.mesplie@mac.com

S. Lemoine

Hand Surgeon, Institut Sud Aquitain de la Main et du Membre Supérieur, Aguiléra Clinic Biarritz, Biarritz, France

Fig. 5.1 Mechanism in compression-extension causing Colles' fractures

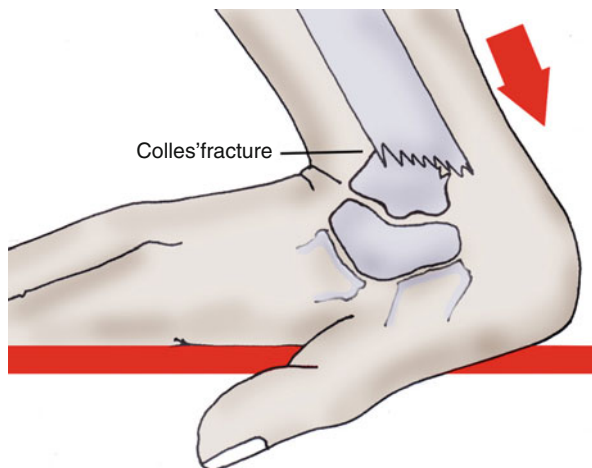
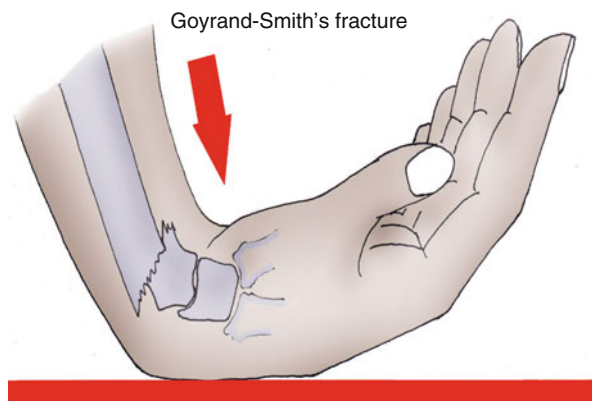


Fig. 5.1' Mechanism in compression-flexion causing Goyrand-Smith's fracture



In practice, fractures in old patients with osteoporosis will produce metaphyseal fractures without associated injuries, while fractures in young patients are often caused by more violent traumas and are frequently complex with associated injuries.

This kind of fracture can modify the radioulnar index with an injury of the triangular complex and/or another radioulnar lock, disturbing the dynamics and/or stability of the radioulnar frame (see Chap. 2).

In this chapter, we will only see the injuries of the inferior extremity of the radius that don't lead to these complications.

5.2 Clinical and Paraclinical Signs [3]

A radiological assessment must be realized after any trauma causing pain or wrist deformity (Fig. 5.3).

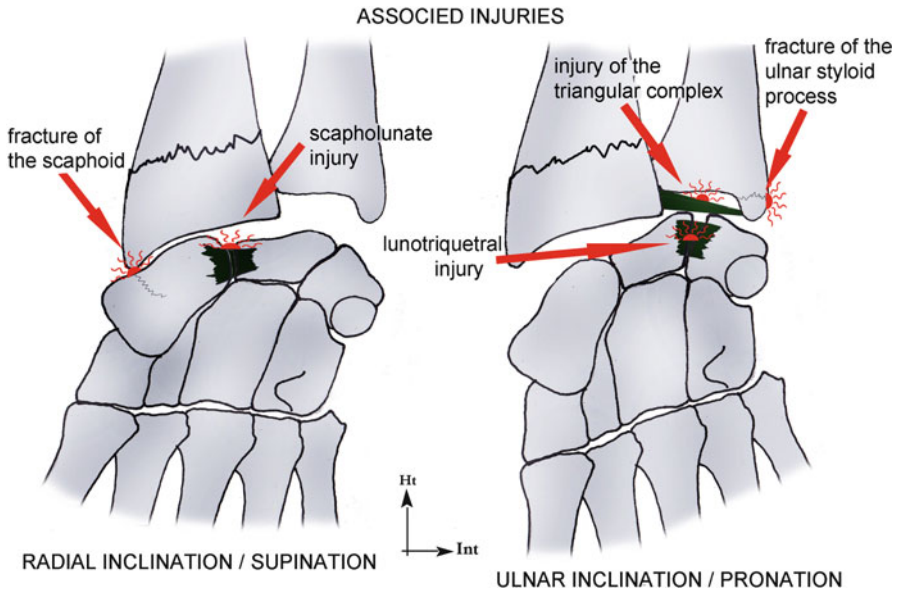


Fig. 5.2 Associated injuries are frequent and related to the inclination and prono-supination during the trauma

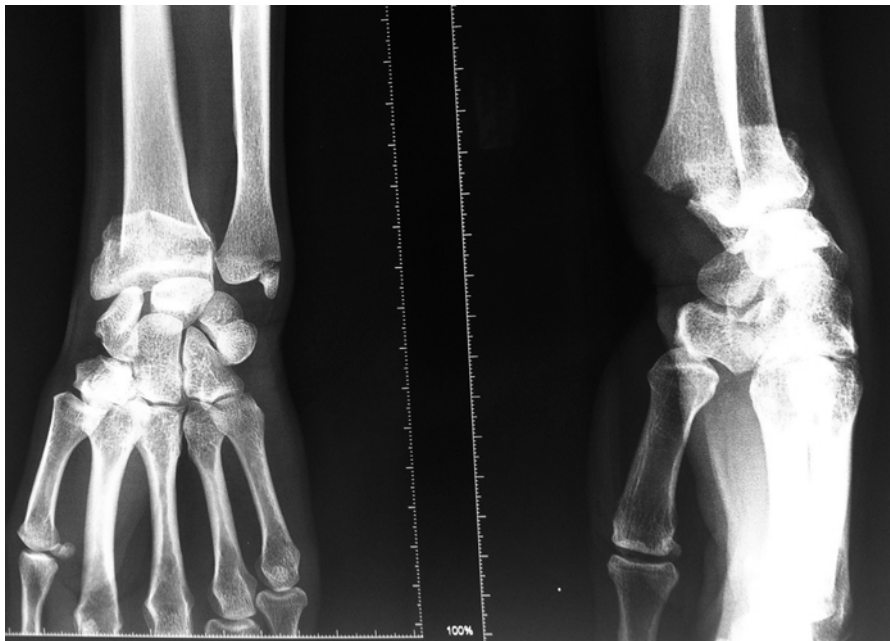


Fig. 5.3 Fracture of the radius with posterior tilt and associated injury of the ulnar styloid process

It's very rare to find a normal X-ray in case of a fracture of the radius, displaced or not.

We always check the radial pulse and the absence of injury of the median nerve. This verification can require a quick reduction of the fracture, or even emergency surgery.

If there's a doubt and pain persists, we immobilize during 15 days before realizing another clinical (palpation of the radial metaphysis, triangular complex, and anatomical snuffbox) and paraclinical (scintigraphy, scanner, MRI) exploration.

5.3 Therapeutic Process and Surgical Treatment [4–7]

Several classifications of the wrist fractures are proposed. They mainly depend on the position of the fracture line, the distal fragment's direction of displacement, and the fracture's complexity (comminuted fracture). These classifications guide the orthopedic and surgical treatment [6].

The orthopedic treatment is used in stable and non-displaced fractures of the distal radius. It always starts with a palmar immobilization of the forearm in order to immobilize the flexion/extension and the prono-supination.

On the other hand, surgery is used in displaced fractures of the metaphysis or joint surface, and that are instable after reduction [8].

The surgery aims to obtain an anatomical restitution of the joint surface and relative length of the 2 bones, to respect the forearm frame. They guarantee quality functional recovery.

5.3.1 Reduction

It's always realized with an external maneuver at first, with the help of an image intensifier.

We also take shots in traction to analyze better the fracture lines.

In joint fractures [8], arthroscopy can be interesting to check the quality of reduction.

If the fracture is stable, this reduction can be enough. For example, displaced fractures of the radial metaphysis in children are usually stable once reduced and don't require complementary surgical fixation.

Generally, in adults, fractures are unstable once reduced and require osteosynthesis in most cases.

There's an exception for fractures of very osteoporotic bones in old patients, to which no osteosynthesis will give enough stability. In these rare cases, the reduction is followed by a palmar immobilization of the forearm, without osteosynthesis.

If we obtain the reduction with the external maneuver, we can do the reduction with closed surgery.

If we don't do the reduction with the external maneuver, the fixation has to be realized with open surgery.

5.3.2 Fixation (Fig. 5.3')

The goal is to obtain a stable fixation allowing the consolidation without secondary displacement, ideally with an early mobilization of the wrist.

There are three ways to realize the osteosynthesis: the pins are generally put percutaneously and can only be dorsal or lateral. In fact, there's a major risk of injury for the noble palmar elements (radial artery and median nerve).

Screwed plates are more stable than pins, and this stability is all the more important since the screws can have an angular stability inside the plate (locked screws).

It would be more logical to place these elements on the side of the displacement to oppose it: dorsal pins for fractures with dorsal tilt and palmar plate for fractures with palmar tilt [9].

However, complications are frequent with plates placed on the dorsal radial side. In particular, there are many ruptures of the extensor tendons (extensor pollicis longus) that are very vulnerable when contacting with the osteosynthesis plate. These complications have made many surgical teams abandon this technique.

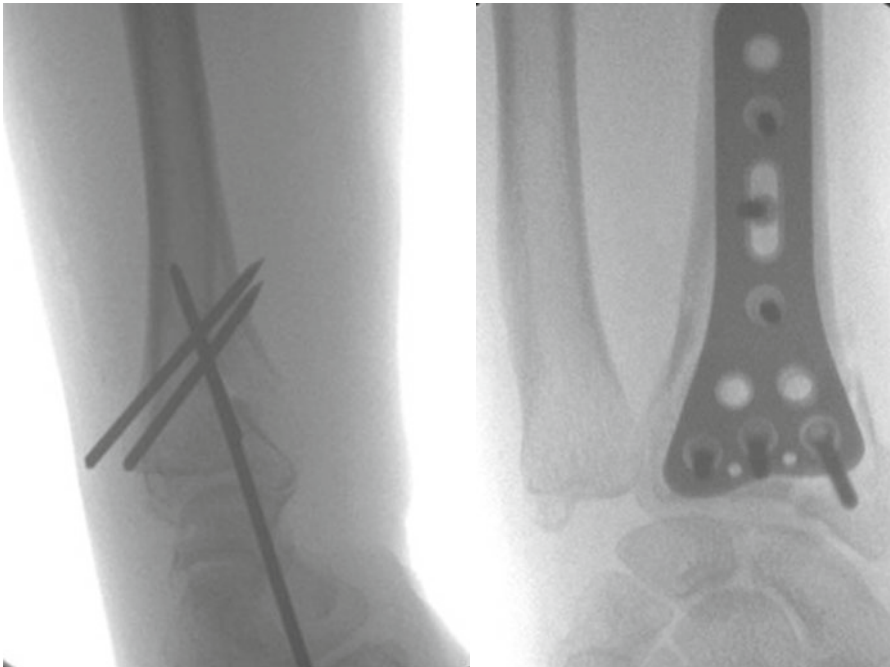


Fig. 5.3' Osteosynthesis with pins or plate

A third way to do it is putting an external fixator.

The principle is to use the ligamentotaxis induced by the wrist distraction. The problems of this technique are the high number of CRPS related to distraction and the inaccessibility of the posteromedial fragment of the radius on which no ligament is inserted.

To prevent these complications, it's recommended to realize a distraction as little as possible and to place at least one posteromedial pin combined with the external fixator.

5.3.3 Indications

They're mostly guided by classifications [6].

Open surgery with internal fixation (plate) must be mostly used in active patients, in whom the reduction and fixation must be optimal.

The use of external fixation must be moderate, as algodystrophy is particularly frequent [7].

5.4 Rehabilitation and Orthotic Treatment [4, 6, 10–12]

These fractures have the false reputation of being “benign,” but they can cause important losses of strength and mobility that can have functional aftereffects [13].

5.4.1 Rehabilitation Protocol (Fig. 5.4) [14, 15]

This protocol can follow the surgery or orthopedic treatment and can be modified depending on the healing evolution.

This evolution is regularly controlled with X-rays.

The protocol has many common points with the one for the fractures of the scaphoid; therefore, we won't describe here the techniques used in both pathologies.

In practice, the protocol is often more progressive as these injuries mainly occur in old people. Trophic disorders, pain, and stiffness are then often longer and more important.

From a symptomatic point of view, the patients often describe pain on the ulnar side of the wrist that can have various causes:

- Increase of the radial slope leading to overwork of the ulnar stabilizers
- Injury of the triangular complex
- Changes in the radioulnar index with a “long” ulna that increases the ulno-carpal constraints

Recent fractures of the inferior extremity of the radius			
	Immobilization phase	End of the immobilization	Consolidation phase
R e h a b i l i t a t i o n	<p>Therapeutic goals: immobilization of the wrist with a cast or a closed orthosis for a good healing, maintaining prehension schemas without constraints.</p> <p>Techniques: - PRICE protocol. - Mobilization advices for the free joints of the superior limb. - Vibralgic on the finger pulps, contacts between the palm and the pulps. - Control of the pressure points of the cast or orthosis and of the pins (if surgery).</p> <p>Risks: maladapted immobilization, CRPS, Volkmann, cutaneous disorders, stiffness if no digital mobilization.</p>	<p>Therapeutic goals: fight against trophic disorders and pain, progressively regain joint amplitudes, muscular awakening and maintaining prehension schemas.</p> <p>Techniques: - Trophic and analgesic massages, analgesic electrotherapy (100Hz), fluidotherapy, infrasounds, pressotherapy. - Passive and soft active mobilizations, Kinetic. - Electroactive exercises for the intrinsic and extrinsic muscles, muscular irradiation techniques then static exercises with light weights, soft occupational therapy.</p> <p>Risks: secondary displacement if the techniques are too aggressive are the muscles are too solicited, stiffness and exclusion syndrome in opposite cases.</p>	<p>Therapeutic goals: completely regain joint amplitude, muscular strength, and prehensions.</p> <p>Techniques: - Intensify the techniques from the previous phase. - Specific intracarpal mobilizations. - Proprioceptive exercises and feedforward. - More intensive occupational therapy.</p> <p>Risks: same + tendinopathy if work and sports activities are too intense at first.</p>
	Or th e s is	Cast, closed orthosis or opened orthosis.	Opened orthosis during the night if pain persists and during "risky" activities.
D0 to D21/45		D21/45 to D90	After D90

Fig. 5.4 Rehabilitation protocol

Fig. 5.5 The increase of the radial slope favors the carpal gliding towards the ulna, which increases the constraints at this level

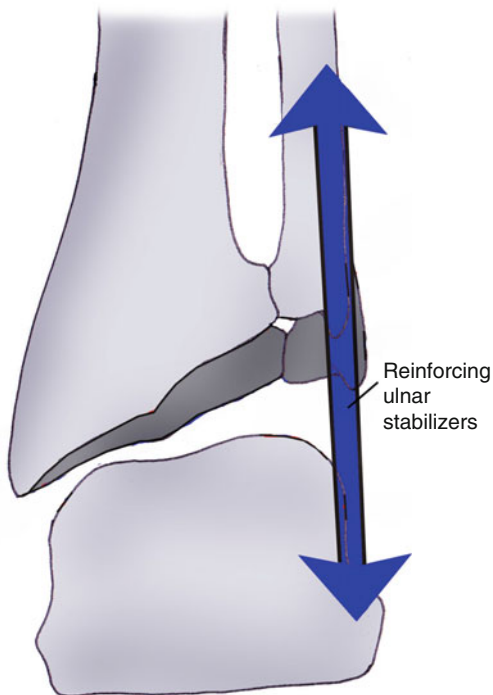
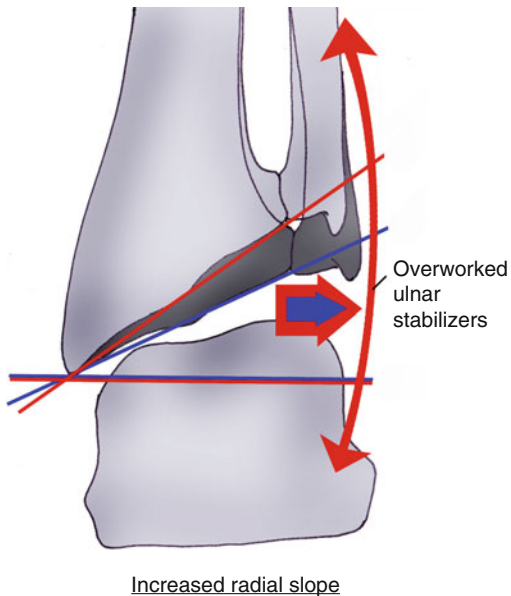


Fig. 5.5' In this case, the therapist must intensify reinforcement techniques for the ulnar stabilizers to oppose this phenomenon

The consequences of these unbalances for the therapist are:

- Predominant reinforcement of the ulnar stabilizers in case of increased radial slope (Figs. 5.5 and 5.5')
- Predominant reinforcement of the pronator quadratus in injuries of the triangular complex (Figs. 5.6 and 5.6')
- Exercises in ulnar decoaptation in case of long ulna (Figs. 5.7 and 5.7')

However, if the symptoms persist or if there's a risk of arthrosis, a corrective surgery can be required (Wafer procedure, osteotomy, arthroscopy of the triangular fibrocartilage complex).

5.4.1.1 Immobilization Phase (D0 to D21/45)

The duration of immobilization after surgery depends on the initial fracture, the type of surgery, and the evolution of the osseous healing.

During all this phase, rehabilitation isn't essential and self-rehabilitation advices are given to the patient.

Like in fractures of the scaphoid, the treatment is based on the protocol PRICE to fight against trophic disorders and pain.

Finger stiffness is more frequent than in fractures of the scaphoid, particularly in old patients.

After putting pins, it's important to regularly check the radial pin as there can be a conflict with the extensor pollicis longus that can lead to an injury or even a rupture (Fig. 5.8).

If there is pain at this level, we advise the patient to stop mobilizing the thumb and to see his surgeon, to eventually take the pin off.

5.4.1.2 Pre-consolidation Phase (D21/45 to D90)

In this phase we start putting load on the fracture site and the patient progressively goes back to his daily activities. We fight against pain and trophic disorders if they are still present, try to regain functional amplitudes, and start the muscular awakening and reinforcement.

Fight Against Trophic Disorders and Pain

It's essential as it sets the possibilities for other exercises. Therefore, it's the key element of this phase.

Fig. 5.6 An injury of the triangular complex can cause pain and instability if it's associated with an injury of one of the two other radioulnar locks

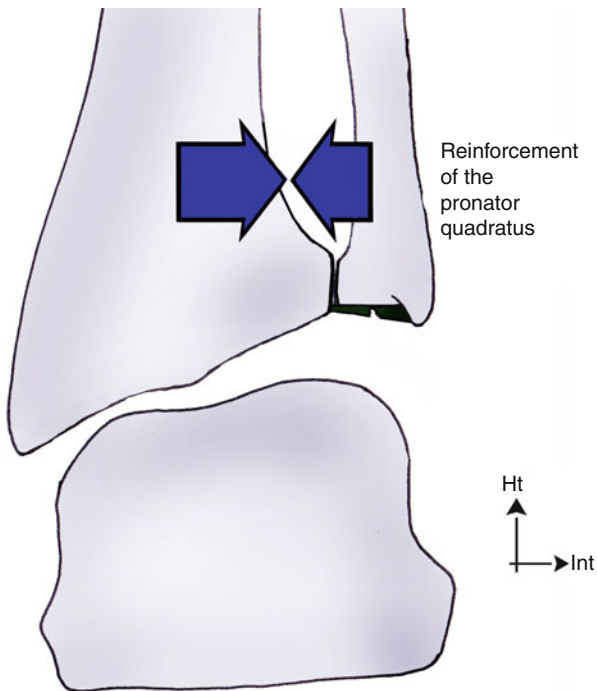
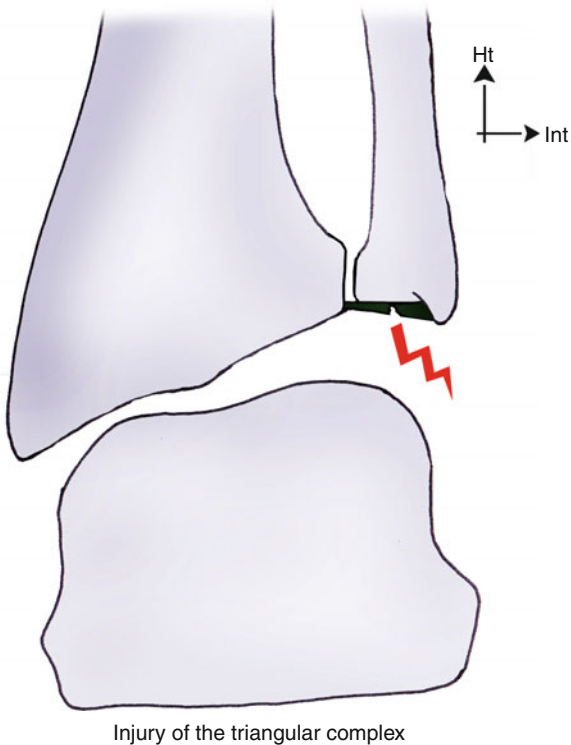
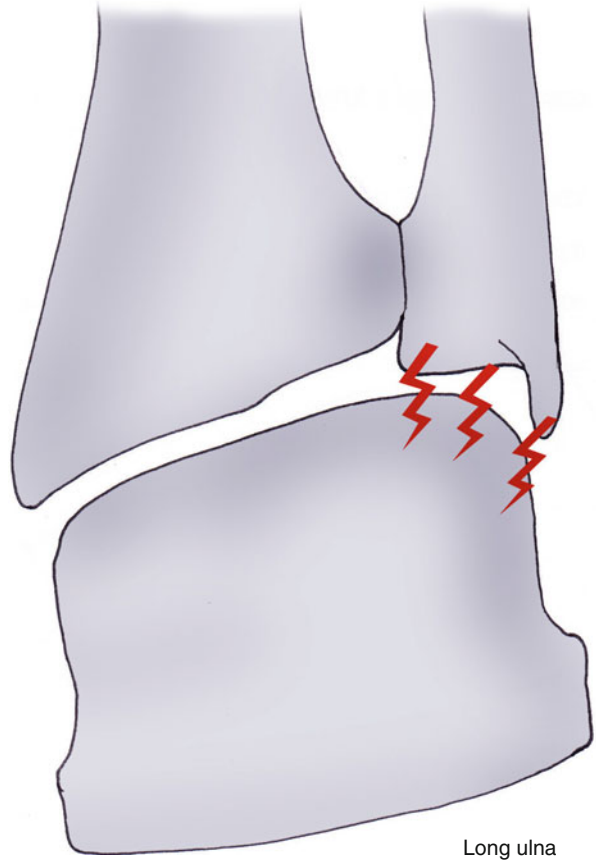


Fig. 5.6' Reinforcing the pronator quadratus participates in limiting pain and instability (combined with the other radioulnar "key" muscles) (see Chap. 2)

Fig. 5.7 A long ulna increases ulno-carpal constraints



We use the same techniques of massages, analgesic electrotherapy, distoproximal pressotherapy, and infrasounds than in fractures of the scaphoid.

Regaining Functional Amplitudes

Like in fractures of the scaphoid, mobilizations are necessary, without harming the healing process of the fracture site.

In fact, if the cartilaginous callus bears hypoxia well, the osseous callus doesn't. An excess of constraints on the fracture site during this phase can cause hypoxia and prevent the osseous callus from developing, leading to pseudoarthrosis.

Therefore, it's important to know the relation between joint amplitudes supported pressures (Fig. 5.9).

Fig. 5.7' Decompressive maneuvers are preferred as they limit this phenomenon

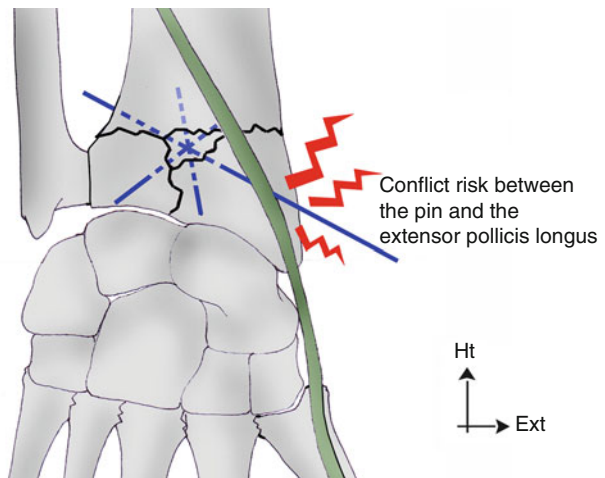
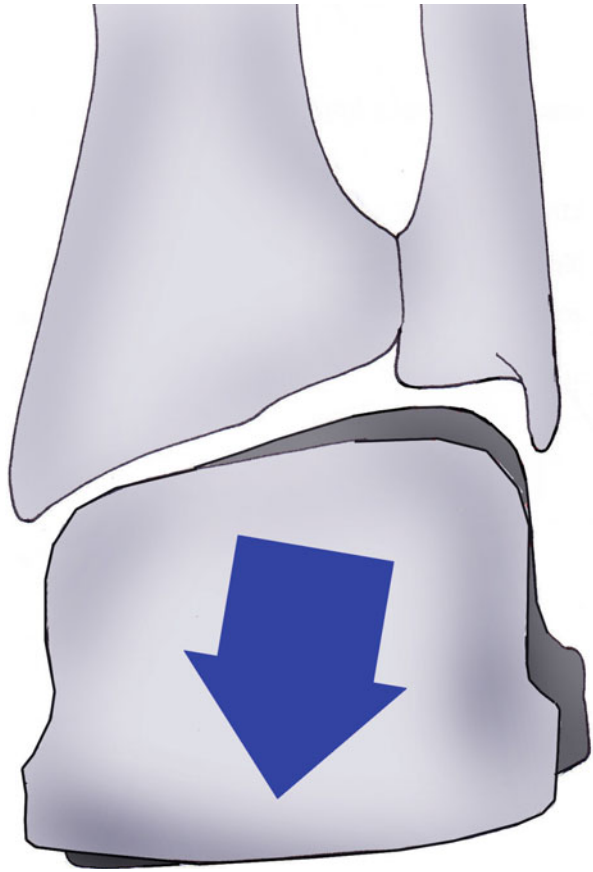


Fig. 5.8 After putting a pin, it's very important to check if there aren't any conflicts between the pin and the extensor pollicis longus. This conflict could lead to a rupture of the tendon

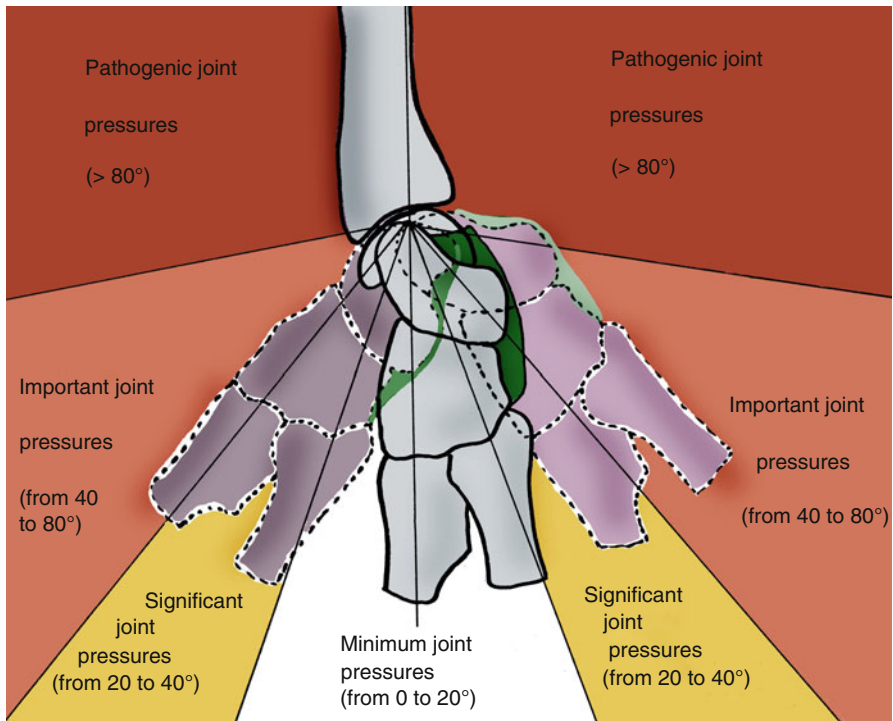


Fig. 5.9 Joint pressures depending on the wrist amplitudes

All these elements allow defining “risky” areas in which the exercises to regain amplitude will have to be realized very cautiously, without any force.

These areas are after 20° in flexion/extension and ulnar inclination and from 5° in radial inclination.

Trying to regain total amplitudes at all costs is, in this phase, useless and dangerous.

We use the same techniques than in fractures of the scaphoid, being more careful in prono-supination that often causes problems.

Muscular Awakening and Reinforcement of the Stabilizing Muscles

We use the same techniques as in fractures of the scaphoid, insisting on the ulnar stabilizers that have an important stabilizing role in this kind of injuries.

These exercises can be manual, analytical, or global (Fig. 5.10).

The muscular awakening for the pronator quadratus is done using the abductor pollicis brevis as “trigger” (Fig. 5.11). Its reinforcement with controlled manual and

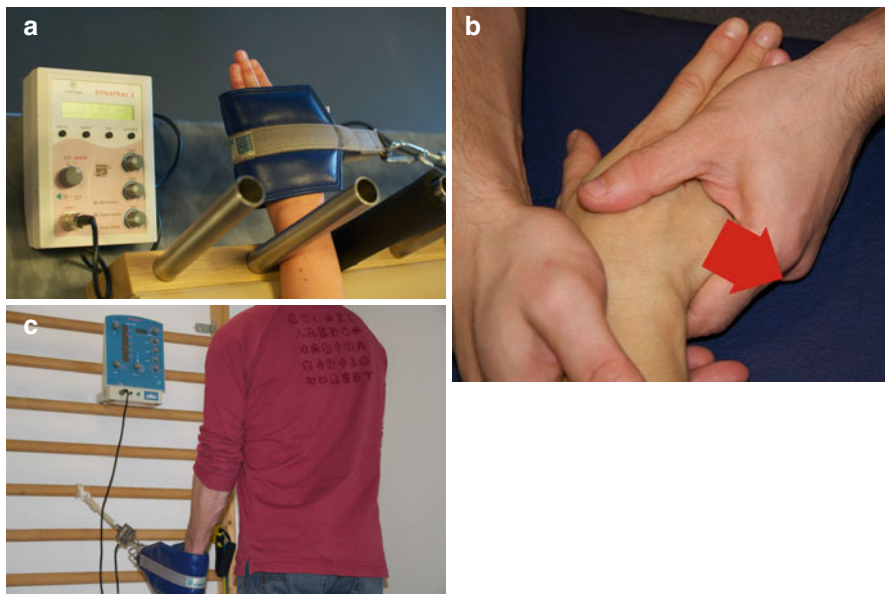


Fig. 5.10 (a) Manual exercise for the ulnar stabilizers. (b) Analytical instrumental exercise for the ulnar stabilizers with load cell and visual feedback for a better control of the contraction parameters. (c) Global instrumental exercise with a similar device

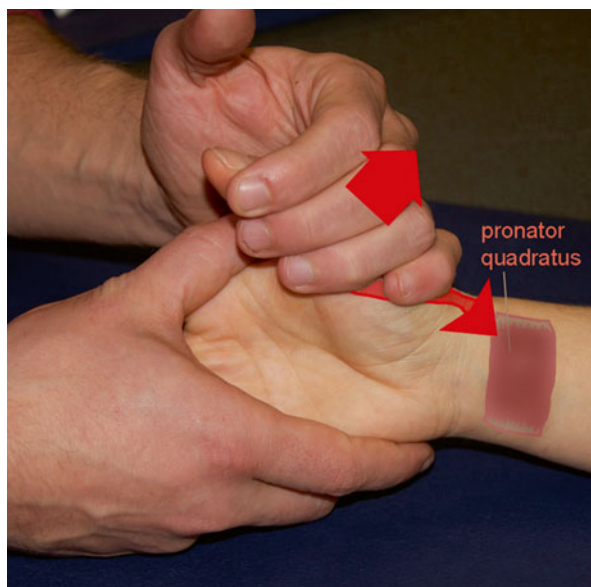


Fig. 5.11 Exercise for the pronator quadratus in irradiation from the abductor pollicis brevis

instrumental techniques (Figs. 5.12 and 5.12') complete the protocol and even more in case of injury of the triangular complex as the pronator quadratus is a powerful stabilizer of the distal radioulnar joint.

Like in every wrist injury, reinforcing the finger flexors is forbidden in this stage as it produces important compressive constraints on the carpus and forearm (Fig. 5.13).

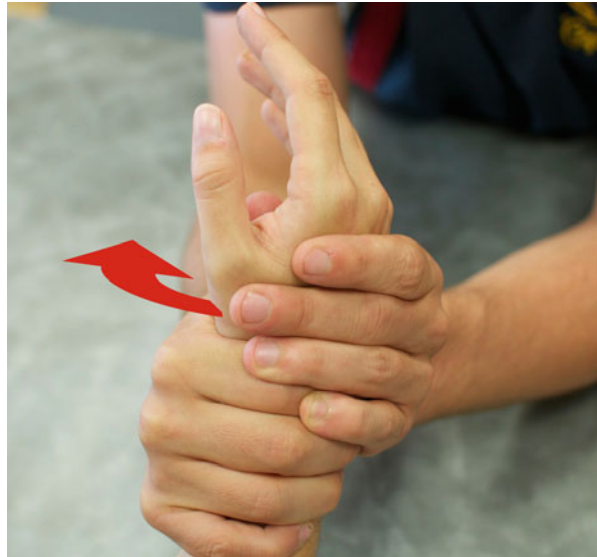

Fig. 5.12 Manual exercise for the pronator quadratus with direct resistance



Fig. 5.12' Reinforcement of the pronator quadratus with dynamometer and visual feedback

Fig. 5.13 Clamping a ball is forbidden during the healing phase as it puts important constraints on the wrist

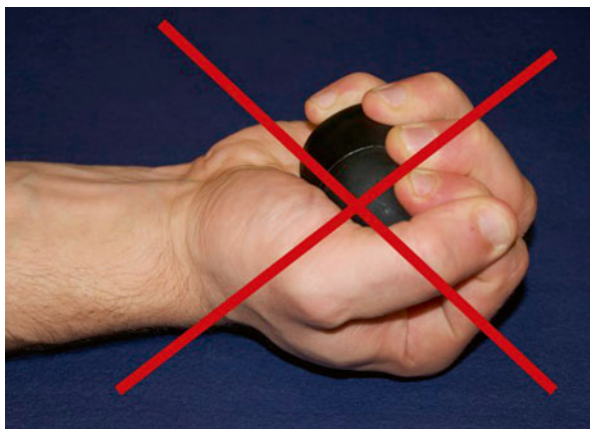

Fig. 14 and 14' Manipulating golf balls (rotation in one direction and in the other) or one bigger ball improves coordination and dexterity

Coordination and Dexterity

We work on prehensions to improve coordination and dexterity and therefore improve functional capacities in daily activities.

These exercises are realized without clamping or putting excessive constraints on the callus.

Manipulating golf balls or a small ball improves coordination and dexterity without excessive risks for the osseous healing (Figs. 14 and 14').

Proprioception

In this phase, proprioception exercises are realized only if there is no pain and/or trophic disorders. They improve the patient's proprioceptive capacities without risk for the callus healing.

We use exercises similar to those used in fractures of the scaphoid (plastic ball, table tennis racket) (Figs. 5.15 and 5.15').

Fig. 5.15 Passing a light ball from one hand to the other improves proprioception



Fig. 5.15' At first, the patient must stop the ball from falling down. Then he progressively realizes rotations of the golf ball on the racket and throws it repeatedly



5.4.1.3 Consolidation Phase (After D90)

When the callus is solid, we can start more intensive techniques.

In this phase we try to reach a total recovery of strength and amplitude in the wrist. Rebalancing the strength ratios between the different muscular groups limits the risks of secondary tendinopathies.

Regaining Amplitudes in the Wrist

We keep using the techniques from the previous phase, intensifying them if needed (always without pain).

In this phase, specific mobilizations are authorized and help with the carpal and radio-carpal dynamics.

Stretchings

Stretching the forearm muscles helps fight against muscular stiffness by stretching the wrist flexors (stiffness in extension) or extensors (stiffness in flexion) (Fig. 5.16).

Hypoextensibility is more frequent in the flexors after putting an anterior plate.

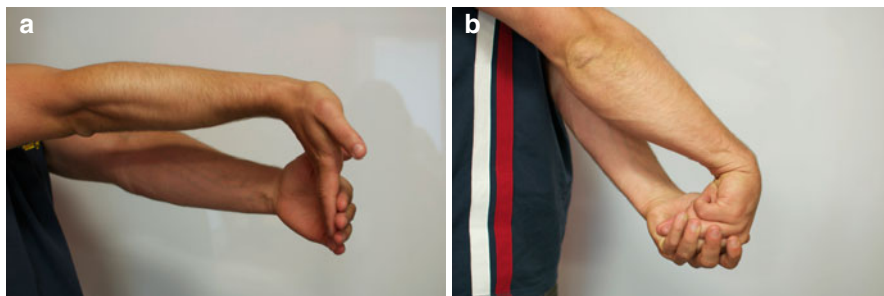


Fig. 5.16 (a) Stretching of the wrist and fingers flexors. It's even more important after putting an anterior plate (adherences or hypo-extensibility of the flexors). (b) Stretching of the extensors

Specific Mobilizations

They require a good knowledge of the morpho-palpatory anatomy and the radio-carpal and intracarpal biomechanics. Traction glidings are realized between the radius and the 1st carpal row, between the 1st and 2nd carpal row, and between the carpal bones if necessary.

- *Mobilization 1st row*: the patient puts his forearm in a neutral position and we grab the 1st carpal row. The radial counter-grip applies glidings, respecting the flexion/extension axis that is oblique downward and outward. The posterior gliding is combined with traction to avoid the early block between the 1st row and the posterior part of the radial epiphysis (Fig. 5.17). Latero-lateral glidings are smaller, as the radial gliding is limited by the radial styloid process.
- *Mobilization 2nd row/1st row*: according to the same principle, the proximal grip is on the 2nd carpal row and the distal grip is on the 1st carpal row at the level of the pisiform and the scaphoid's tubercle. We apply anteroposterior glidings and very small lateral glidings (Fig. 5.18).
- *Intracarpal mobilization*: these techniques are described in the Chap. 3.

Muscular Reinforcement

The osseous callus is solid; therefore, we can realize more intensive reinforcement techniques.

In this phase there's a deficit of the extrinsic muscles with respect to the intrinsic muscles. This unbalance is likely related to the limitations imposed during the previous phases to protect the scaphoid (exercises with the fingers extended).

Radial stabilizers are dominant with respect to ulnar stabilizers.

We use the same reinforcement techniques with force sensors than in fractures of the scaphoid.

Fig. 5.17 Specific mobilization of the 1st carpal row with respect to the two bones of the forearm, respecting the axes of movement (the radial slope is oblique downward and outward in the frontal plane and downward and backward in the sagittal plane)

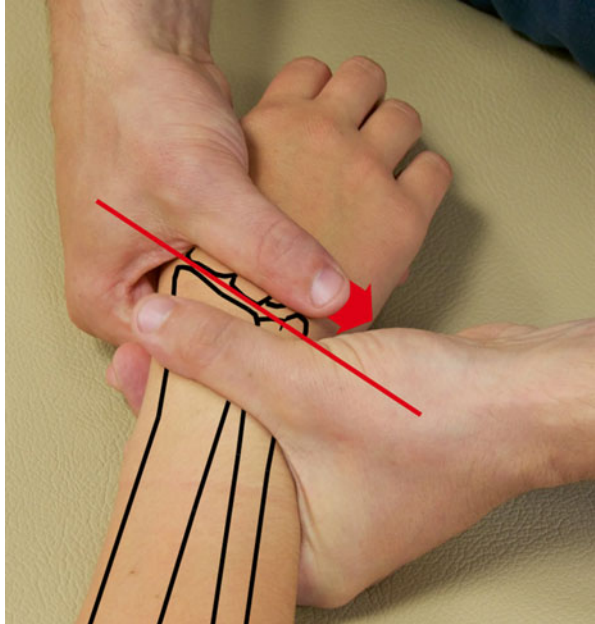


Fig. 5.18 Specific mobilization of the two carpal rows in all the planes



Proprioception and Feedforward

We intensify the techniques from the previous phase with rhythmical stabilizations.

Prehensions

We realize exercises to improve the types of prehensions the patient will need in his daily activities, work, and sports.

5.4.1.4 Important Note

There are frequent associated injuries of one other or the two other locks of the radioulnar unity. The treatment is described in the Chap. 2.

5.4.2 Orthotic Treatment [16]

5.4.2.1 Immobilization

It can be a cast or made of resin, but we prefer using perforated thermoformable plastic (2.4 mm thick) to realize a non-removable orthosis (Fig. 5.19).

We obtain a precise immobilization, eight times lighter than with resin, that can go in water (if there is no wound), radiolucent, and with perforations that allow the skin to “breathe.”

Advice sheets are always given to the patients. They are about the terms of use and maintenance of the orthosis and self-rehabilitation exercises the patient must realize during the immobilization phase (Fig. 5.20).

5.4.2.2 Pre-consolidation

It's not realized all the time, but a resting orthosis can be useful in case of nocturnal pain or in daily activities.

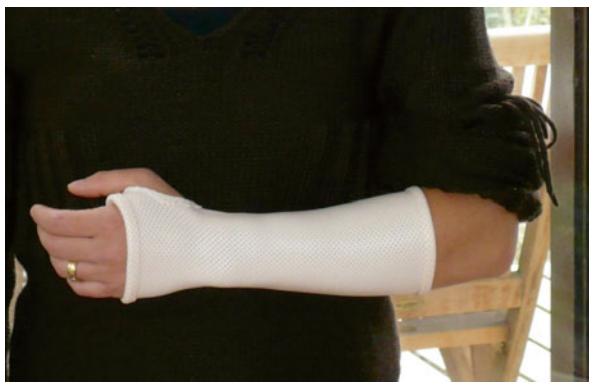

Fig. 5.19 Immobilization orthosis after a fracture of the radius

However, we make sure the patient gets rid of the orthosis without impeding his functional evolution.

The orthosis maintains the wrist in a neutral position. The plastic is perforated and its thickness depends on the patient’s morphology (Fig. 5.21).





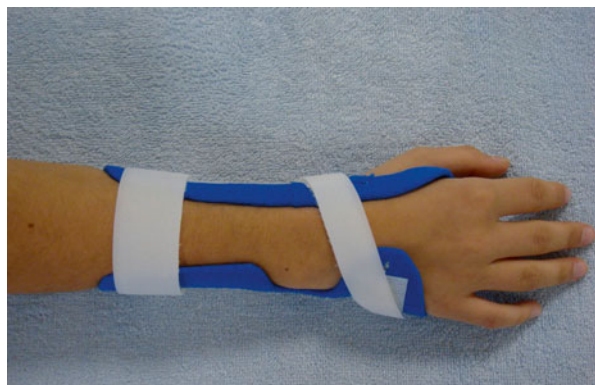<p>Vous venez de bénéficier d’une orthèse thermoformée de poignet suite à une fracture de poignet.</p>  <p>Buts de cette orthèse :</p> <ul style="list-style-type: none"> - antalgique - immobilisation du foyer de fracture pour favoriser la consolidation <p>Vous devez porter votre orthèse en permanence. Dans certains cas, le chirurgien peut vous autoriser à la quitter, avec prudence, le temps de la toilette.</p>	<p>Si le chirurgien vous a posé des broches, n’hésitez pas à contacter l’orthésiste si :</p> <ul style="list-style-type: none"> - la mobilisation du pouce est douloureuse - la broche crée un appui douloureux. <p>Plusieurs fois par jour pensez à faire ces exercices lentement et <u>sans</u> douleur:</p> <ul style="list-style-type: none"> ▪ Plier et tendre les doigts  ▪ Écarter les doigts et les resserrer (doigts tendus)  ▪ Toucher le bout des doigts avec le pouce 
<p>L’œdème, qui accompagne souvent le traumatisme, peut faire varier le volume de la main. En cas d’inconfort, ou si l’orthèse ne vous semble plus adaptée</p> <p>CONTACTEZ L’ORTHÉSISTE</p>	
<p>Ne pas utiliser la main, en dehors de ces exercices.</p>	
<p>C’est le chirurgien, qui décidera de l’ablation de l’orthèse, souvent après un contrôle radiologique.</p> <p><small>Pour plus de précision, vous pouvez poser vos questions sur notre site : www.espacemain.com</small></p>	

Fig. 5.20 Advice sheet given to the patient after giving him an orthosis

Fig. 5.21 Resting orthosis, not realized in every case but that can be useful in case of pain, especially during the night



5.4.2.3 Consolidation

A neoprene orthosis can be realized to go back to professional or sports activities.

It protects the wrist from shocks and has an interesting contention effect, useful at a proprioceptive level and in the patient's apprehension.

Thermoformed plastic reinforcements can be added depending on the indications.

5.5 Complications [17]

Complications in these types of fractures are frequent.

They can concern the surgical or orthopedic treatment:

- Injuries of the median nerve and/or ulnar nerve during the trauma or the immobilization (too compressive or with too much wrist flexion)
- Evolution towards arthrosis in case of bad rehabilitation or vicious callus [18]
- Tendinous injuries related to the trauma, or the friction of a pin or an osseous fragment on the tendon (the most frequently damaged is the extensor pollicis longus tendon)
- CPRS, particularly frequent in traumas of the wrist

Remember

- False reputation to be benign
- Frequent associated injuries (pain in the ulnar compartment)
- Compressive constraints forbidden in a joint fracture

Bibliography

1. Merle M, Dautel G (1995) *La main traumatique*. Masson, Paris/Milan/Barcelone
2. Tang JB, Xu J et al (2011) Scaphoid and lunate movement in different ranges of capral radio-ulnar deviation. *J Hand Surg Am* 36:25–30
3. Le Nen D, Laulan J (2001) *Sémiologie de la main et du poignet*. Sauramps médical, Montpellier
4. Boutan M, Rouzaud S (2006) Le poignet radial chirurgie et rééducation. *Kinésithérapie scientifique* 466:7–18
5. Castaing J (1964) Recent fractures of the lower extremity of the radius in adults. *Rev Chir Orthop Reparatrice Appar Mot* 50:581–696
6. Mathoulin C (1990) Les fractures de l'extrémité inférieure du radius. Description, classification, traitement. Conférences d'enseignement. Monographie n°2 des Ann Chir Main. Paris : Expansion scientifique française
7. Margaliot Z, Haase SC, Kotsis SV, Kim HM, Chung KC (2005) A meta-analysis of outcomes of external fixation versus plate osteosynthesis for unstable distal radius fractures. *J Hand Surg Am* 30:1185–1199

8. Herzberg G (2008) Fractures articulaires du radius distal. Sauramps medical, Montpellier
9. Dos Remedios C, Nebout J et al (2009) Pronator quadratus preservation for distal radius fractures with locking palmar plate osteosynthesis. Surgical technique. *Chir Main* 28(4):224–229
10. Della Santa D, Sennwald G (2001) Is there still a place for conservative treatment of distal radius fractures in the adult? *Chir Main* 20(6):426–435
11. Delprat J, Rongieres M et al (1999) Main et poignet traumatique. EMC kinésithérapie-médecine physique-réadaptation. Paris, Masson. 26-220-A-11
12. Wakefield AE, McQueen MM (2000) The role of physiotherapy and clinical predictor outcome after fracture of the distal radius. *J Bone Joint Surg Br* 82-B:972–976
13. Berthe A (2003) Les séquelles de fractures du poignet: présentation, évaluation, quelques points de la kinésithérapie selon les divers traitements. Les feuillets du GEMMSOR Trauma A-1. www.reeducation-main.com
14. Abramo A, Kopylov P et al (2008) Evaluation of a treatment protocol in distal radius fractures: a prospective study in 581 patients using DASH as outcome. *Acta Orthop* 79(3):376–385
15. Handoll HH, Madhok R, Howe TE (2006) Rehabilitation for distal radius fractures in adults. *Cochrane Data Base Syst Rev* (2):CD0003324
16. Bong M, Egol K, Leibman M, Kovak KJ (2006) A comparison of immediate post reduction splinting of fractures of the distal radius: a prospective randomized study of long-arm versus short-arm splinting. *J Hand Surg* 31A:766–770
17. McKay SD, MacDermid JC, Roth JH, Richards RS (2001) Assessment of complications of distal radius fractures and development of complication checklist. *J Hand Surg* 26:916–922
18. Safar P, Tafnkji Y (2005) Cal vicieux du radius en flexion. *Chir Main* 24(6):299–304

Part II
Osseous and Capsulo-ligamentous Injuries
in the Hand and Thumb

Chapter 6

Sprains of the Metacarpophalangeal Joint of the Thumb

Grégory Mesplié

6.1 Anatomical and Biomechanical Reminders [1]

The metacarpophalangeal joint is the intermediate joint of the thumb. Its main purpose is to ensure the stability of the grips between the thumb and the fingers and the cylindrical grabs using the palm.

It allows 60–70° of active flexion and until 80° of passive flexion. The amplitude of active and passive extension is 0°.

It's a condyloid joint, which means it has 2° of freedom (flexion/extension and varus/valgus), to which must be added a third one: the automatic axial rotation, essential in the pulp-to-pulp oppositions between the thumb and the fingers (with the participation of the trapezio-metacarpal and the interphalangeal joints).

This automatic rotation in pronation during the flexion is related to the combined action of various anatomical elements:

- *Capsulo-ligamentous*, because the ulnar collateral ligament is shorter than the radial collateral ligament. During the flexion, the ulnar collateral ligament slows the movement of the ulnar part of the first phalanx before the radial collateral ligament holds the radial part back, which creates an automatic pronation of the phalanx on the metacarpal. The same mechanism occurs in extension, leading to a supination of the metacarpophalangeal joint.
- *Muscular*, as the external thenar muscles are more active in flexion than the internal thenar muscles and provide a combined movement of flexion–pronation–radial inclination.
- *Osseous*, because the internal anterior part of the metacarpal head is higher than the external one. This makes the internal movement of the phalanx shorter than its external movement (Fig. 6.1).

G. Mesplié

Physiotherapist and Orthotist, Institut Sud Aquitain de la Main et du

Membre Supérieur, Aguiléra Clinic Biarritz, Biarritz, France

e-mail: greg.mesplie@mac.com

© Springer International Publishing Switzerland 2015

G. Mesplié, *Hand and Wrist Rehabilitation: Theoretical Aspects and Practical Consequences*, DOI 10.1007/978-3-319-16318-5_6

173

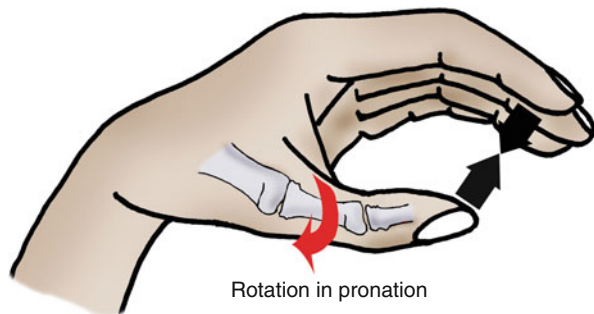


Fig. 6.1 The automatic rotation of the metacarpophalangeal of the thumb in pronation during the opposition between the thumb and the finger is related to ligamentous (ulnar collateral ligament shorter than radial collateral ligament), muscular (external thenar muscles more active), and osseous (external part of the first metacarpal head longer than the internal one) factors

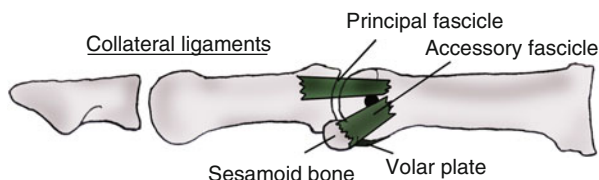


Fig. 6.2 Ligamentous system of the metacarpophalangeal of the thumb

The passive stability of the joint is mainly ensured by the collateral ligaments and the volar plate (Fig. 6.2).

The collateral ligaments are made of two fascicles:

- *The principal fascicle* goes from the head of the first metacarpal to the base of the first phalanx, slightly dorsal to the joint axis in flexion/extension. In flexion, it's tensed, ensuring the lateral stability.
- *The accessory fascicle* is oblique at the palmar and distal level; it goes from the head of the first metacarpal to the corresponding sesamoid, thus creating a common structure with the volar plate. It's tensed in extension, ensuring the lateral stability in this position.

The volar plate is a thick and resistant fibrocartilage, which contains the two sesamoid bones and opposes the metacarpophalangeal extension.

The most instable joint position is the intermediate flexion, as the collateral ligaments and the volar plate are relaxed.

The active joint stability is ensured by the internal (adductor pollicis, inconstant first palmar interosseous) and external (abductor brevis and flexor brevis) sesamoid muscles (Fig. 6.3).

The combined movement of flexion–radial inclination–pronation made by the external and internal thenar muscles allows optimizing the cylindrical grips with a full palm, increasing the contact surface.

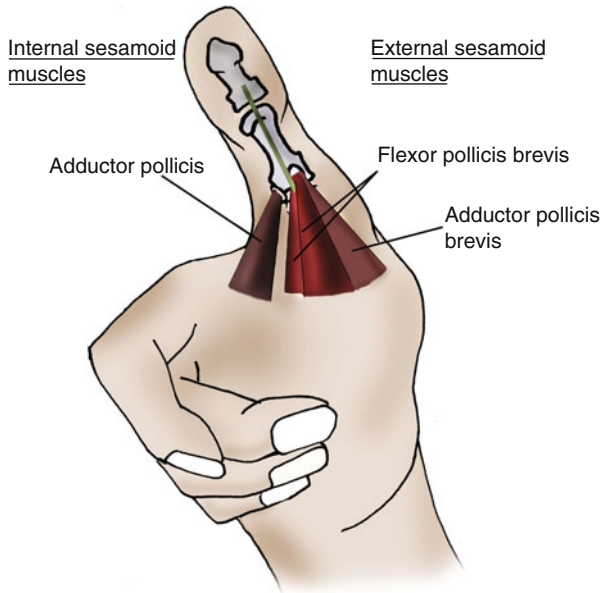


Fig. 6.3 Active stability of the metacarpophalangeal joint of the thumb, depending mainly on the internal and external sesamoid muscles

The opponens metacarpal pollicis, which ends on the palmar side of the first metacarpal, doesn't play a role in the stability of the metacarpophalangeal joint, and the extrinsic muscles only have a moderate action.

6.2 Physiopathology [2]

The metacarpophalangeal sprains are frequent in the thumb due to sports (skiing, handball, basketball, rugby, etc.) [3, 4] and are the results of injuries in the valgus in 90 % of the cases (damage of the medial collateral ligament).

The traumas in the varus damage the lateral collateral ligament, and the ones in hyperextension damage the volar plate. Injuries with a combination of various elements often occur.

In serious sprains of the medial collateral ligament (rupture), ligament healing is impossible and surgery is needed [5, 6], as the proximal extremity of the ligament passes over the adductor's expansion toward the extensor pollicis longus, making the healing impossible: it's the Stener effect (Fig. 6.4).

Even if it's rarer, the same phenomenon can be observed radially, with the expansion of the external thenar muscles.

The varus deformity in the injuries of the radial collateral ligament is more spectacular than the valgus deformity in the injuries of the ulnar collateral ligament [7],

Fig. 6.4 Physiological explanation of the Stener effect

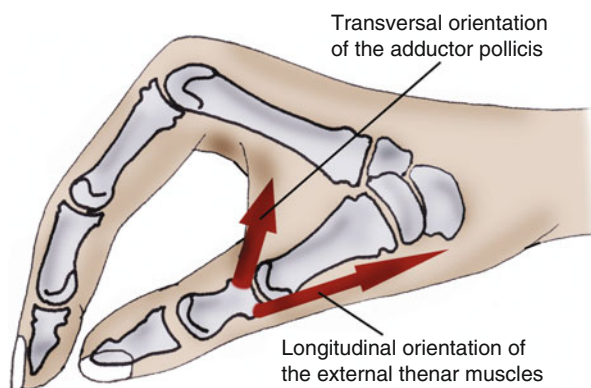
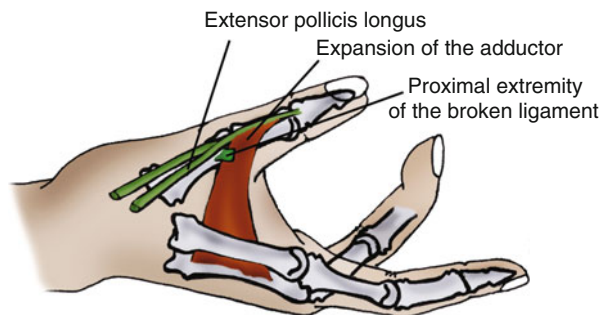


Fig. 6.5 The varus deformity in case of an injury of the radial collateral ligament is important because the adductor pollicis is transversal to the osseous lever, unlike the external sesamoid muscles

due to the longitudinal orientation of the external thenar muscles and the transversal orientation of the adductor pollicis, which will have an important tendency to lead to varus in case of an injury of the radial collateral ligament (Fig. 6.5).

6.3 Clinical and Paraclinical Signs

6.3.1 Clinical Signs

Other than the usual signs of a damaged ligament (pain when palpating and when putting it in tension, swelling, sensation of instability), we have to be careful to some specific clinical signs that allow suspecting a serious sprain with a Stener effect:

- Hematoma on the dorsal part of the interphalangeal joint (pathognomonic)
- Valgus 30 % superior to the contralateral side and metacarpophalangeal joint flexed to 30° (specific test of the metacarpophalangeal fascicle) (Fig. 6.6) [7]

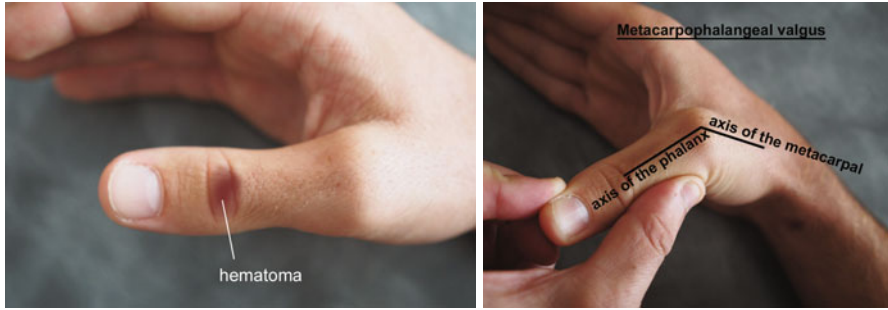

Fig. 6.6 Clinical signs leading to suspecting a Stener effect; hematoma on the dorsal side of the interphalangeal (*left*) and valgus 30 % superior to the contralateral side (*right*)

6.3.2 Paraclinical Signs

The bilateral test in valgus, under a radiological control, allows obtaining a better appreciation of the angular value than the simple clinical test.

The presence of a bone fragment at the level of the phalangeal insertion means there is a rupture of the ligament, with a Stener effect.

6.4 Therapeutic Process and Surgical Treatment [5, 6, 8, 9]

In the case of a benign sprain (ligamentous distension without important slackness or osseous avulsion), we suggest an immobilization of the metacarpophalangeal joint in a functional position (without any varus/valgus component), leaving the wrist and the interphalangeal joint free.

The Orthosis is realized in a thin plastic (1.6 mm) and kept for 3–4 weeks to allow ligamentous healing.

In the case of a serious sprain with a Stener effect (important slackness with or without osseous avulsion), the treatment is surgical.

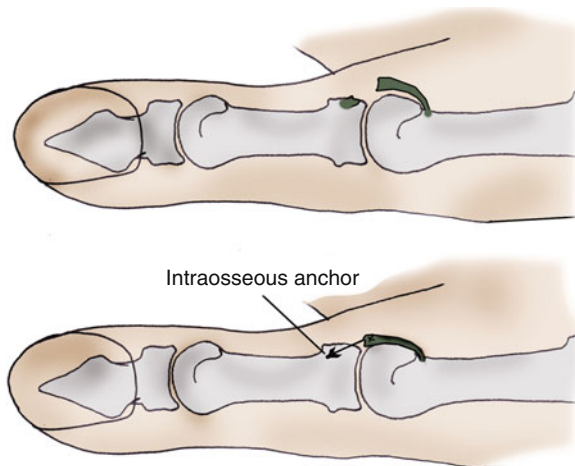
It consists in reinserting the ligament at the level of the first phalanx, with an intraosseous anchor, in order to regain good stability of the metacarpophalangeal (Fig. 6.7).

A postoperative Orthosis is realized with the same criteria as the one made for benign sprains. It's kept for 4 weeks.

6.5 Rehabilitation and Orthosis

The metacarpophalangeal joint of the thumb is a stabilizing joint. The aim of the rehabilitation is to improve active stability of the joint, particularly the muscles protecting the damaged ligament. The techniques to gain amplitude will be used

Fig. 6.7 Intraosseous anchor of the ligament in case of a serious sprain with Stener effect



very carefully during the healing period, in order not to weaken the passive stabilization structures.

In case of surgery, ultrasounds mustn't be used if a metallic intraosseous anchor has been used.

6.5.1 Rehabilitation Protocol of the Serious Medial Collateral Ligament Sprains (Postoperative) (Fig. 6.8)

6.5.1.1 Immobilization Phase (D0 to D30)

From D0 to D30, we have to fight against trophic disorders and pain and maintain mobility in the joints adjacent to the metacarpophalangeal.

Stimulations of the thumb's pulp can be added to limit the functional exclusion (rare in the thumb).

An informed self-rehabilitation is sufficient in this phase, ideally supported by some "tip sheets."

In case of an important inflammatory reaction, the rehabilitation can start to fight against pain and edema using massage, cryotherapy, and TENS.

6.5.1.2 Relative Fragility Phase (D30 to D60)

From D30 to D60, the relative fragility phase is marked by the beginning of the solicitations of the metacarpophalangeal, progressively reducing the immobilization. The ligament isn't totally healed so it's forbidden to put important constraints on it (stress constraints).

Serious sprains of the internal collateral ligament of the metacarpophalangeal of the thumb (surgery)			
	Immobilization phase (A)	Fragility phase (B)	Strength phase (C)
R E H A B I L I T A T I O N	<p>Therapeutic goals: immobilization, self-rehabilitation advices.</p> <p>Techniques:</p> <ul style="list-style-type: none"> - Monitoring of the orthosis (pressure points). - Active self-mobilizations of the interphalangeal, cryotherapy if global inflammation. <p>Risks: bad ligament healing, stiffness of the interphalangeal.</p>	<p>Therapeutic goals: same, and even intensify phase A if necessary (interphalangeal stiffness). Fight against pain and trophic disorders, regain the active amplitudes in the metacarpophalangeal and the interphalangeal joints, reinforcement of the metacarpophalangeal stabilizers, regain coordination and dexterity.</p> <p>Techniques:</p> <ul style="list-style-type: none"> - Progressively take off the orthosis. - Massages, fluidotherapy, transcutaneous vibratory stimulations, depressotherapy, electrotherapy - Active exercise to regain the active amplitudes in the metacarpophalangeal and the interphalangeal joints. - Electrostimulations, static exercise for the internal sesamoid muscles ++ and for the other stabilizers of the metacarpophalangeal joint. - Manipulations and occupational therapy. <p>Risks: same as in phase A + instabilities if the techniques are too intense.</p>	<p>Therapeutic goals: intensify the techniques from the 2 previous phases if necessary, regain clamping strength, complete functional recovery.</p> <p>Techniques:</p> <ul style="list-style-type: none"> - Specific joint mobilizations, and increase the intensities of the electrostimulation. - Exercise for the intrinsic and extrinsic strength. - Functional exercise according to the job and leisure activities. <p>Risks: same as in phases A and B.</p>
OR TH ES IS	<p>Orthosis blocking the metacarpophalangeal of the thumb, interphalangeal is free (worn all the time).</p>	<p>Progressively take off the orthosis.</p>	<p>“Alpine” orthosis if necessary to get back to activities.</p>
	D0 to D30	D30 to D60	After D60

Fig. 6.8 Rehabilitation protocol after surgery

Starting to move again in strict flexion/extension and reinforcing the stabilizing muscles of the metacarpophalangeal are the strong points of this phase. We keep mobilizing the adjacent joints until they are totally free.

Putting too much charge too soon on the damaged ligament leads to instability and pain.

Fight Against Trophic Disorders and Pain

- *Massages*: trophic and analgesic goal, around the ligament healing area. This area can stay inflamed during various months.
- *Transcutaneous vibratory stimulations*: 70 Hz frequency at the level of the extensor or flexor system if we want to improve proprioceptive aspect and 100 Hz at the level of the painful areas if we want an analgesic effect.
- *Depressotherapy*: at the level of the healing area, privileging disto-proximal movements (Fig. 6.9).
- *Electrotherapy*: 1 Hz to fight against inflammatory phenomena or electro-active to regain the active amplitudes (no excessive tension).
- *Compressive bandage*: along the thumb, with a decreasing tension from distal to proximal.

Amplitudes in Flexion/Extension

This exercise will be realized in amplitudes that don't put the ligamentoplasty realized by the surgeon in tension, as it could lead to a joint instability relaxing the stabilizing elements repaired during the surgery [1, 6].

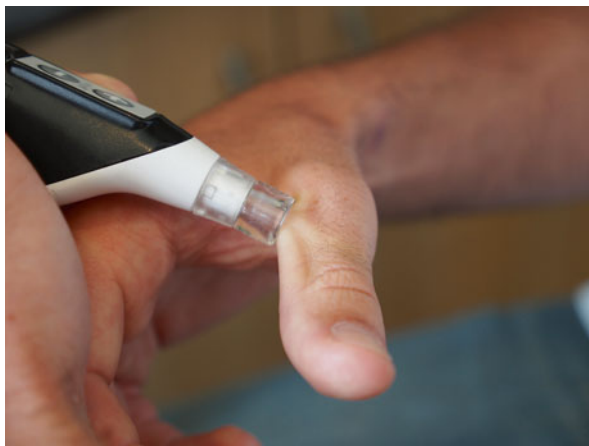

Fig. 6.9 Depressotherapy at the level of the scar area, moving disto-proximally (draining)

The mobilizations must never be realized with strength and must stay painless. They are as active as possible to allow the patient to control the tension put on the hypo-extensible tissues.

We don't make any specific mobilization in this phase, but the use of active electrostimulation can be considered (Fig. 6.10).

Reinforce the Active Stabilizers

The first function of the metacarpophalangeal joint of the thumb is to allow a good stability during the grips between fingers and thumb and during the cylindrical grasps with a full palm. Therefore, reinforcing the muscles participating in this function is the key element of this rehabilitation.

We start this reinforcement after the decrease of the trophic disorders and pain, in order not to maintain these phenomena.

The muscle reinforcement is mostly for the internal ones in the ulnar collateral ligament injuries.

However, it is essential to do a global stabilization work in the joint in order not to create a muscular imbalance, which is a pathogenic source.

The reinforcement must be done with progressive charges (lower than 30 % of the maximal strength in the beginning of the phase). The contraction will stay static during this phase. We realize a series of 30 repetitions, alternating 6 s of contraction and 6 s of rest.

Adductor Pollicis

We fix the first metacarpal with the proximal hand and put a resistance with the pulp of the distal hand's thumb at the level of the ulnar side of the first phalanx, as close as possible to the joint (especially before the end of the healing process), to limit the shear forces on the joint (Fig. 6.11).

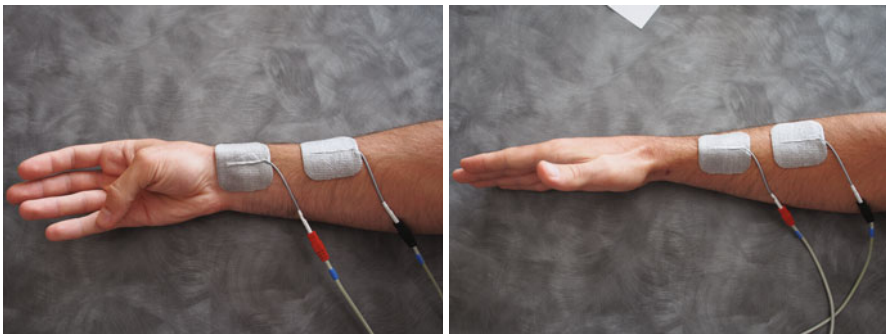


Fig. 6.10 Examples of active electrostimulations with metacarpophalangeal mobilizations in flexion (*left*) and extension (*right*)

External Sesamoid Muscles

The same modalities are applied for the external sesamoid muscles, except for the resistance, which is placed at the level of the radial side of the first phalanx (Fig. 6.12).

Synergic Exercise for the External and Internal Sesamoid Muscles

We ask for a clamping between the pulp of the thumb and the radial side of the second phalanx, controlling the full extension of the interphalangeal joint of the thumb.

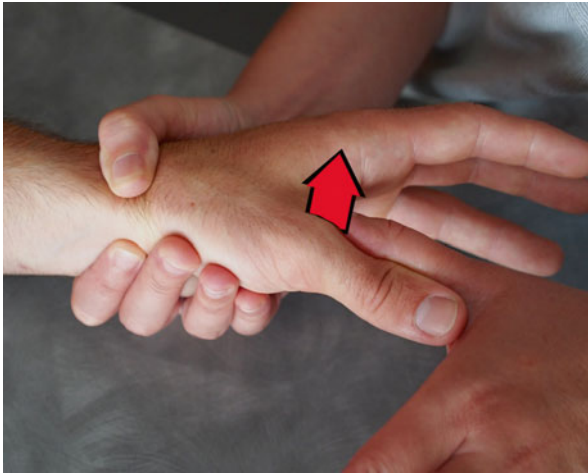

Fig. 6.11 Manual reinforcement of the adductor pollicis



Fig. 6.12 Manual reinforcement of the external sesamoid muscles

A pinch can provide a visual feedback of the contraction's intensity (Fig. 6.13).

NB: the interphalangeal flexion is a sign of compensation by the flexor pollicis longus and has to be avoided.

Electrostimulation

In theory, in case of a medial collateral ligament injury, it should be necessary to place the electrodes exclusively on the muscular group we want to reinforce (the internal thenar muscles).

In practice, we obtain a co-contraction of the internal and external sesamoid muscles regardless of the stimulated muscular group, as the antagonist muscle contracts to fight against the movement created by the electrical stimulation.

Therefore, we ask the patient to maintain the initial position during the electrical stimulation to obtain a co-contraction of the internal and external sesamoid muscles (Fig. 6.14).

It is therefore a global reinforcement technique for the metacarpophalangeal joint.




Fig. 6.13 Instrumental reinforcement of the tip-to-side pinch using a pinch (*left*), without an interphalangeal flexion, which is a sign of a flexor pollicis longus contraction (*right*)

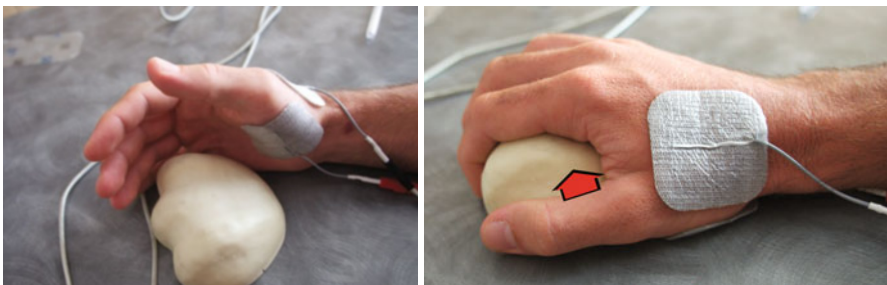


Fig. 6.14 Active electrostimulation of the sesamoid muscles. Placement of the electrodes (*left*). The patient must squeeze the handrest during the active phase, without soliciting the flexor pollicis longus (*right*)

Grips

We realize exercises that improve coordination and dexterity of the thumb and hand.

6.5.1.3 Strength Phase (After D60)

The ligament is healed and can stand more important constraints.

The goal of this phase is the complete recovery of the patient's aptitudes.

Full Recovery of the Joint Amplitudes

Specific Mobilizations

These techniques, used after the healing of the damaged ligament, allow getting back the joint glidings, essential for the proper functioning of the joint.

The proximal hand fixes the first metacarpal, and the distal hand maintains the first phalanx between its thumb and index, making it glide softly in various directions with a global or local widening of the joint space (Fig. 6.15).

Strength Recovery

We intensify the techniques described in phase two in order to regain muscular ratios comparable with the sane side.




Fig. 6.15 Specific mobilization of the metacarpophalangeal, associating a slight widening of the joint space

The use of a silicone (or other) cylinder allows a solicitation of the internal sesamoid muscles, appealing to their component of anti-pronation and anti-supination rotatory stabilization (Fig. 6.16).

Proprioceptive and Functional Recovery

Proprioceptive Exercise and Feed Forward

This exercise will be realized following the multidirectional solicitations imposed on the metacarpophalangeal joint and adapted to the professional and sports activities of each patient.

It's combined with dexterity and coordination exercises and adapted as well to the patient's functional needs.

6.5.2 Rehabilitation Protocols After Benign and Medium Sprains (No Surgery)

We will use the same techniques, adapting them to the healing time of a benign sprain (3–4 weeks). The rehabilitation phases are mainly the same, but the techniques can be intensified earlier if there is no trophic disorder or pain.




Fig. 6.16 Rotatory stability with a silicone cylinder, progressively decreasing the diameter of the cylinder

It should be noted that in lateral collateral ligament sprains, we reinforce more the external thenar muscles, as they have an anti-varus and anti-supination role (and therefore protect the lateral collateral ligament).

6.5.3 Orthotic Treatment [10]

6.5.3.1 Immobilization Phase

We realize an orthosis with thin thermoformable plastic (1.6 mms), keeping the interphalangeal joint free.

Its molding at the level of the metacarpophalangeal opposes the varus or valgus deformities.

It must be worn all the time and can be kept in water without any protection (Fig. 6.17).

6.5.3.2 Resuming Sports Activities and Career

An “alpine” orthosis can be made when the patient gets back to work and sports activities (Fig. 6.18).

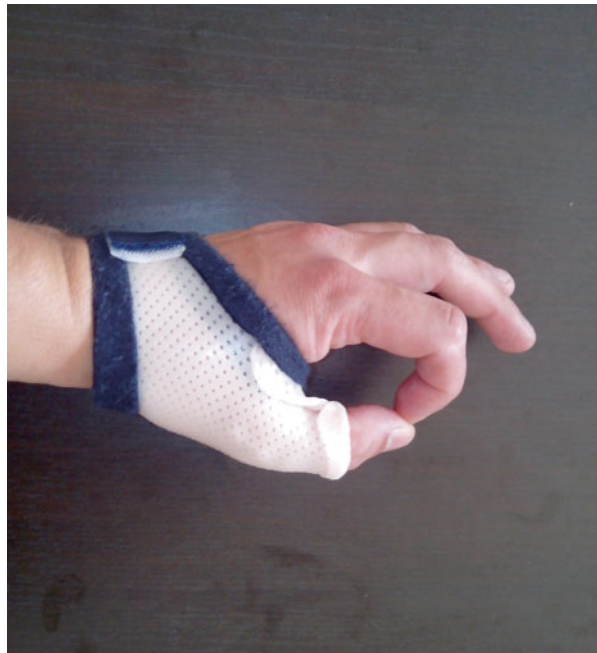

Fig. 6.17 Immobilization orthosis letting the interphalangeal free and opposing to varus/valgus deformities of the metacarpophalangeal

6.5.3.3 Dynamic Orthosis

A global winding dynamic orthosis of the thumb or an analytical dynamic orthosis of the metacarpophalangeal can be made after 8 weeks if there's a persisting stiffness [11].

It's worn shortly (15 min maximum), under the pain threshold, but repeatedly during the day.

A commissural opening orthosis can also be made if there's a deficit of movement when spreading the thumb. It is worn during the night and can be associated with a silicone sheet placed on the scar if it's inflamed (Fig. 6.19).

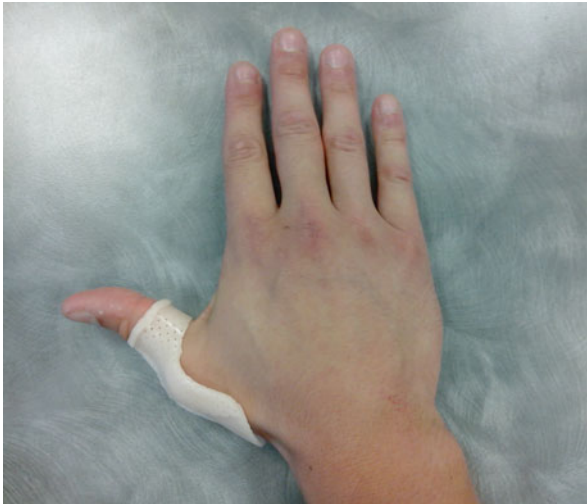

Fig. 6.18 Alpine orthosis made to return to sports and professional activities and associated to strapping

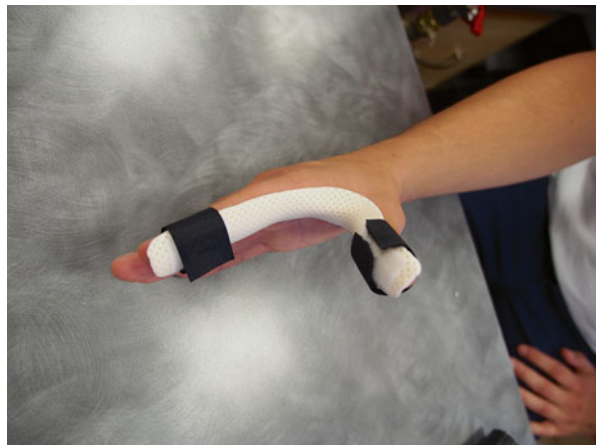

Fig. 6.19 Commissural opening orthosis associated to a silicone sheet if the scar is inflamed

Bibliography

1. Harley BJ, Werner FW, Green JK (2004) A biomechanical modeling of injury, repair, and rehabilitation of ulnar collateral ligament injuries of the thumb. *J Hand Surg [Am]* 29:915–920
2. Merle M, Dautel G (1997) *La main traumatique (L'urgence)*. Masson, Paris
3. Bousselmame N, Boussouga M, Kadi S, Benchebba D, Bouabid S, Taobane H, Moulay I (2000) A propos d'une série de 20 cas d'entorses graves de la métacarpophalangienne du pouce. *J Traumatol Sport-12-2000-17-4-0762-915X-101019-ART91*
4. Massart P, Bezes H (1984) L'entorse grave de la metacarpo-phalangienne du pouce au cours des accidents de ski. *Ann Chir Main* 3:101–112
5. Marin-Braun F, Merle M (1985) Conduite à tenir devant une entorse de la metacarpo-phalangienne du pouce. *Lettre chir n° 42*, 3–4
6. Glickel SZ (2002) Thumb metacarpophalangeal joint ulnar collateral ligament reconstruction using a tendon graft. *Tech Hand Upper Extrem Surg* 6:133–139
7. Abrahamsson SO, Sollerman C, Lundborg G et al (1990) Diagnosis of displaced ulnar collateral ligament of the metacarpophalangeal joint of the thumb. *J Hand Surg [Am]* 15:457–460
8. Moutut F, Guinard D, Lebrun C, Bellon-Champel P, Massart P (1989) Les endorses de la métacarpo-phalangienne du pouce. Une expérience de plus de 1000 cas. *Ann Chir Main* 8:99–109
9. Stener B (1984) Entorses récentes de l'articulation metacarpo-phalangienne du pouce. In: Tubiana R (ed) *Traité de chirurgie de la main*, vol 2. Masson, Paris
10. Merle M, Isel M, Célérier S (2012) *Orthèses de la main et du poignet*. Elsevier Masson, Issy-les-Moulineaux
11. Adams BD, Muller DL (1996) Assessment of thumb positioning in the treatment of ulnar collateral ligament injuries: a laboratory study. *Am J Sports Med* 24:672–675

Chapter 7

Fractures of Metacarpals and Phalanges

Grégory Mesplié

7.1 Anatomical Reminders [1]

The morphology of the hand is adapted to its function. The modification of its architecture that can happen after this type of injuries can have important functional consequences.

7.1.1 *Hand Architecture*

The hand's function is complex and depends on its architecture, which allows an adaptation to the different grips.

When grabbing voluminous objects, the hand has various arches (transverse, longitudinal, and oblique), anteriorly concave, which give the hand the shape of a cup, facilitating the grips (Fig. 7.1).

When the hand is pressed against a support, it can flatten and thus increase the surface of support.

The 2nd and 3rd metacarpals are relatively fixed, whereas the 4th and 5th are mobile, which allows an important adaptability of the ulnar side.

The length of each osseous segment is essential for a harmonious winding of the long fingers, describing an equiangular spiral described by Fibonacci, according to his numerical series [0, 1, 1, 2, 3, 5, 8, 13, 21, 34] (Fig. 7.2).

When the distal interphalangeal joints flex from an extension position, we can observe that the fingers converge toward the thumb, mainly because of the obliquity

G. Mesplié
Physiotherapist and Orthotist, Institut Sud Aquitain de la Main et du Membre Supérieur,
Aguiléra Clinic Biarritz, Biarritz, France
e-mail: greg.mesplie@mac.com

Fig. 7.1 The arches of the hand give it a cup shape, favoring the grips

- - - Longitudinal arch
- • - • - Oblique arch
- Transverse arch

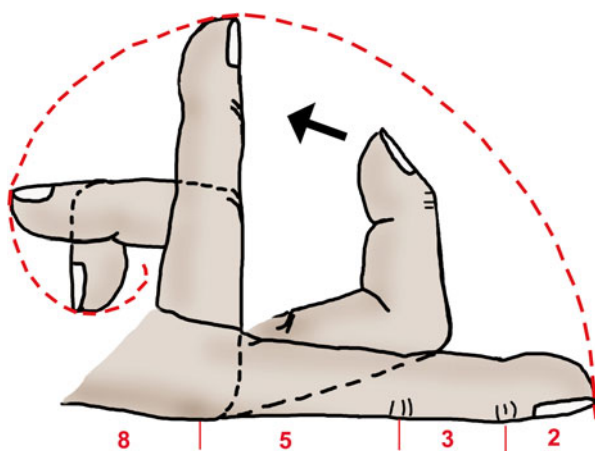
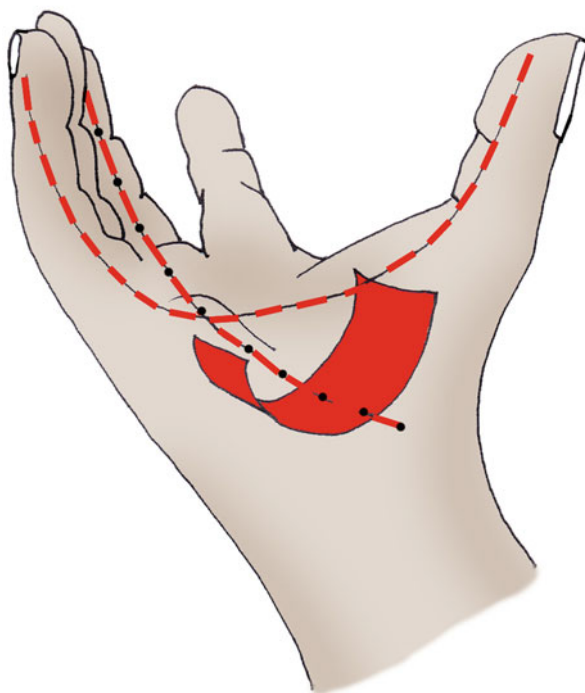
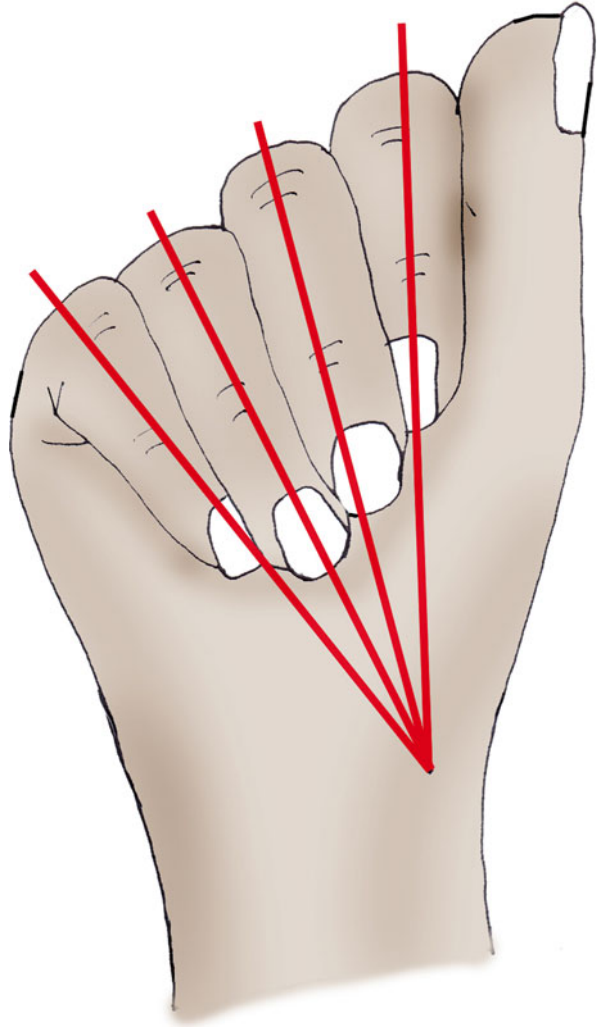


Fig. 7.2 The winding movement of the fingers describes an equiangular spiral because the lengths of the osseous segments follow the numeric series of Fibonacci, defined by the gold number (1,618, the “divine proportion”)

Fig. 7.3 During the winding of the fingers with the distal interphalangeal joint extended, the fingers converge toward the thumb



of the metacarpophalangeal and interphalangeal joints (in a downward and outward direction) (Fig. 7.3).

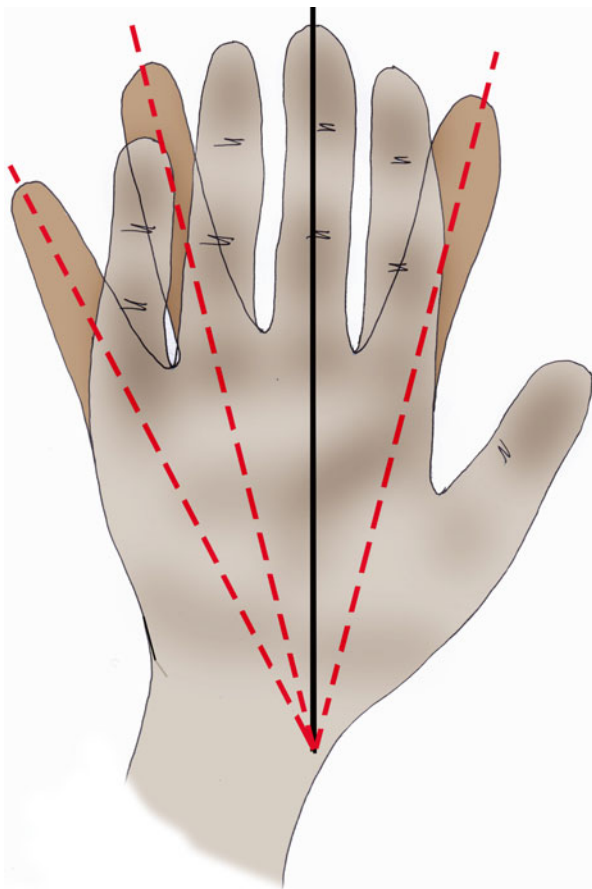
During the fingers' opening, the axis of the fingers converges toward the scaphoid tubercle. The axis of the 3rd finger stays still (Fig. 7.4).

7.1.2 *Opposition of the Thumb*

7.1.2.1 **Thumb**

The mobility of the thumb depends on the scapho-trapezium, trapeziometacarpal, metacarpophalangeal, and interphalangeal joints.

Fig. 7.4 When spreading the fingers, the 3rd finger stays still and the axis of the fingers converges toward the scaphoid's tubercle



These four joints, mobilized by the synergic action of the intrinsic and extrinsic muscles of the hand, participate in the opposition of the thumb. This opposition is composed by various actions, a protraction, an abduction, and a pronation, allowing the thumb to oppose its pulp to the long fingers.

This automatic pronation of the thumb is related to osseous (topography of the trapeziometacarpal joint surfaces, radial part of the metacarpophalangeal larger than the ulnar part), ligamentous (radial ligaments longer than the ulnar ones), and muscular (external thenar muscles stronger than the internal thenar muscles during the opposition) factors (Fig. 7.5).

7.1.2.2 Long Fingers

In the long fingers, the opposition between the pulps is allowed by an automatic rotation in supination during the flexion. It's related to the obliquity of the metacarpophalangeal and interphalangeal joints, the ulnar collateral ligaments longer than the radial collateral ligaments, and the predominant action of the ulnar interosseous muscle (Fig. 7.6).

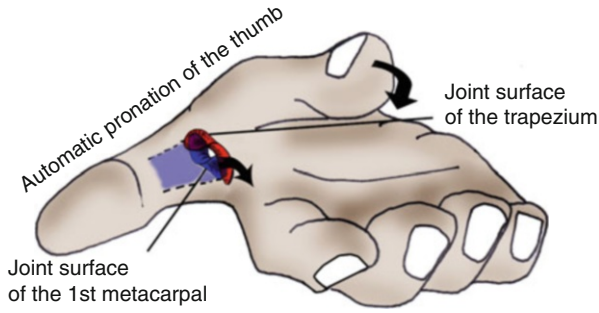
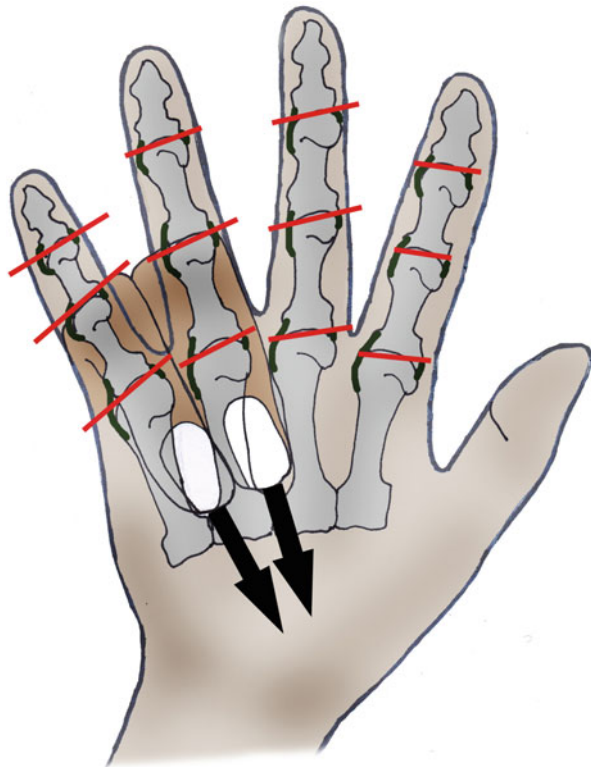


Fig. 7.5 The trapeziometacarpal joint allows automatically associating a pronation during the opposition between the thumb and the fingers, which leads to the pulp of the thumb contacting with the pulp of the finger. The metacarpophalangeal and interphalangeal joints participate too in this automatic rotation, even though they're less involved

Fig. 7.6 In the long fingers, the flexion is automatically associated with a supination, to favor the opposition between the pulp of the thumb and the pulp of the fingers



Automatic rotation in supination during the flexion

This automatic rotation (and the important anatomical particularities previously described) decreases from the 5th to the 2nd finger, as the segmental movement is more important in the 5th than in the 2nd finger.

7.2 Types of Fractures

7.2.1 Fractures of the Metacarpals [2]

7.2.1.1 Fractures of the Base

Stable and extra-articular fractures don't present an important risk of secondary displacement, if the treatment is correctly done.

On the contrary, joint fractures are potentially unstable and source of secondary arthrosis.

- The fracture of the base of the 5th metacarpal: the radial fragment stays in contact with the base of the 4th metacarpal and the hamate bone, while the extensor carpi ulnaris tends to move the rest of the metacarpal dorsally, proximally, and medially (Fig. 7.7).
- The joint fractures in the base of the 2nd and 3rd metacarpals present the same risk of instability, because of the action of the radial muscles.
- The joint fractures in the base of the 1st metacarpal can be of two types:
 - *The Bennett fracture*, with a medial fragment staying next to the base of the 2nd metacarpal. The rest of the base of the metacarpal moves because of the

Fracture of the base of the 5th metacarpal

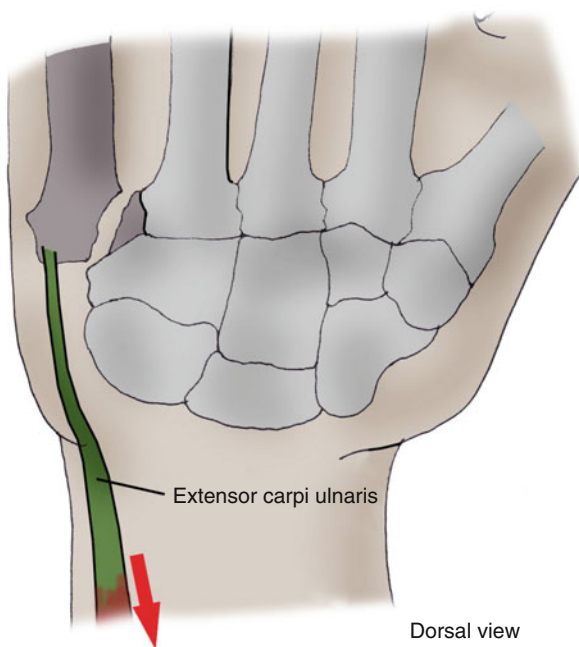
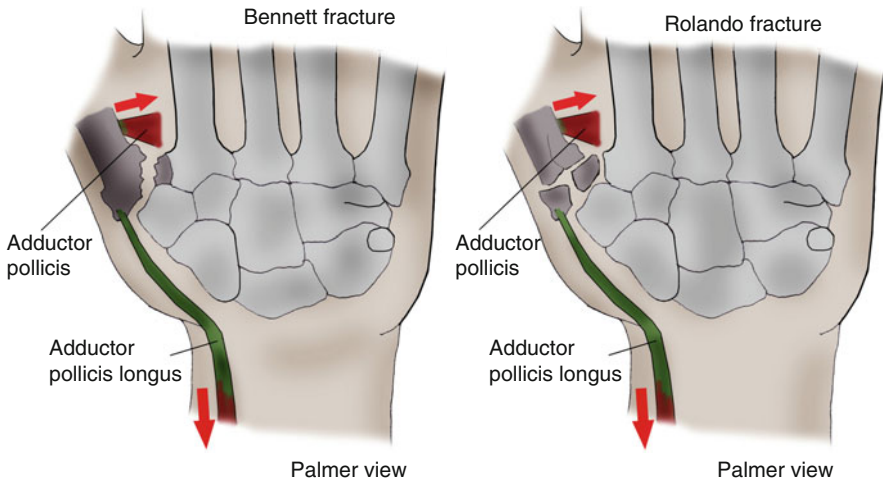


Fig. 7.7 In the fractures of the base of the 5th metacarpal, the extensor carpi ulnaris can cause instability of the fracture (left hand on the picture)

Dorsal view



Figs. 7.8 and 7.8' Fractures of the base of the thumb, possibly unstable because of the effect of the abductor pollicis brevis and the thenar muscles

effect of the abductor pollicis longus. The thenar muscles (mainly the adductor pollicis) tend to move the metacarpal toward adduction (Fig. 7.8).

- *The Rolando fracture*, which is a fracture with one metaphyseal fracture line and two epiphyseal fracture lines (T-shaped or V-shaped) (Fig. 7.8').

7.2.1.2 Fractures of the Diaphysis

Long Fingers

These fractures can lead to an anterior tilt of the part distal to the fracture, because of the action of the interossei and flexor muscles (Fig. 7.9).

Furthermore, the action of the interossei can lead to an axial rotation of the metacarpal, detectable by asking the patient to do a global winding of the fingers. We can then observe a lack of alignment of the metacarpal comparing to the adjacent fingers.

In this type of deformity, the two radial metacarpals are often excessively pronated, whereas the two ulnar metacarpals are more likely to be excessively supinated during the winding (Fig. 7.10).

Thumb

We can observe a palmar tilt of the distal part, because of the effect of the expansion made by the flexor pollicis brevis, the abductor pollicis brevis, and the adductor pollicis (Fig. 7.11).

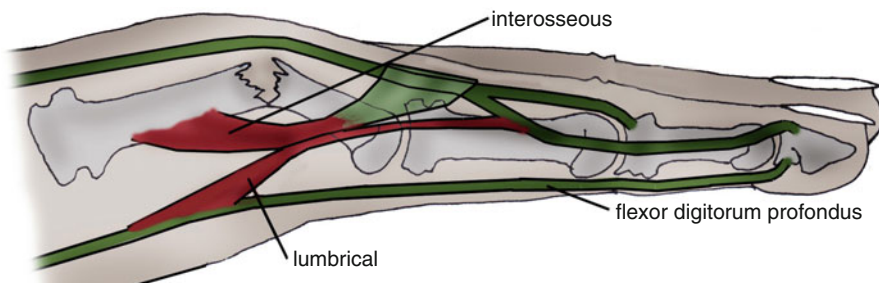
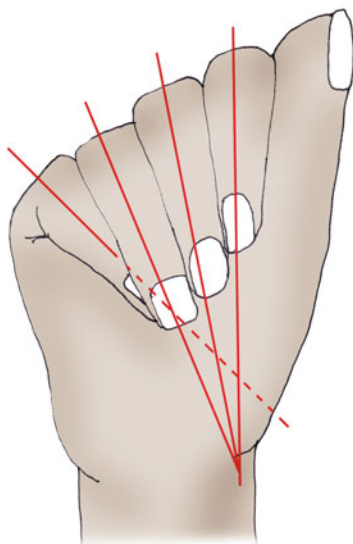
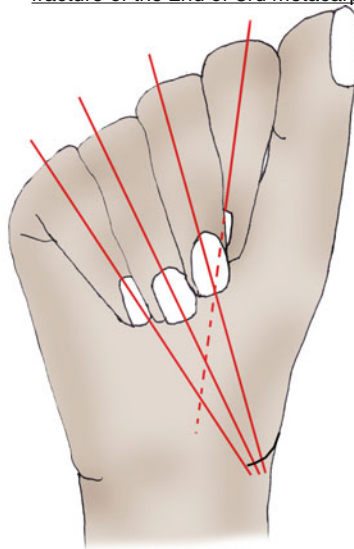


Fig. 7.9 Anterior tilt of the distal part of the fracture because of the action of the interossei and flexors

fracture of the 4th or 5th metacarpal



fracture of the 2nd or 3rd metacarpal



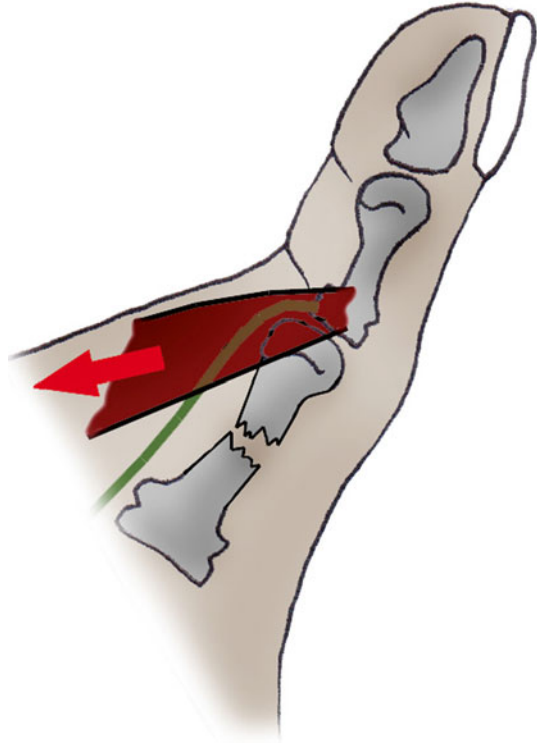
LACK OF ALIGNMENT OF THE FINGERS
AFTER A FRACTURE OF A METACARPAL

Fig. 7.10 In fractures of the metacarpal with vicious rotation, the radial metacarpals tend to have an excessive pronation, unlike the ulnar metacarpals

7.2.1.3 Boxer’s Fracture

The boxer’s fractures are the most frequently observed, mainly in the 4th and 5th metacarpals. This “bad boxer’s fracture” is due to a punch with an impact on the ulnar side (the “good boxers” usually use the two radial metacarpals that are more fixed), leading to an anterior tilt of the head of the 5th metacarpal.

Fig. 7.11 Anterior tilt of the distal fragment in the thumb



In that case, like in the fractures of the diaphysis, the dorsal expansion of the interossei (or the thenar muscles – except the opponens – of the thumb) increases the palmar displacement of the metacarpal head.

7.2.1.4 Joint Fractures of the Metacarpal Head

These fractures are a source of stiffness in case of prolonged immobilization and of arthrosis in case of badly reduced displacement, at the level of the thumb or the long fingers.

7.2.2 Fractures of the Phalanges [2–4]

7.2.2.1 Joint Fractures [5, 6]

Joint fractures, like in every other joint, present a risk of stiffness [7] and secondary arthrosis in case of prolonged immobilization and/or bad restoration of the joint surfaces.

We have to be very vigilant because some of these fractures are in fact ligamentous or tendinous injuries, which must be imperatively identified quickly. Here is a list of the most frequent cases (Fig. 7.12).

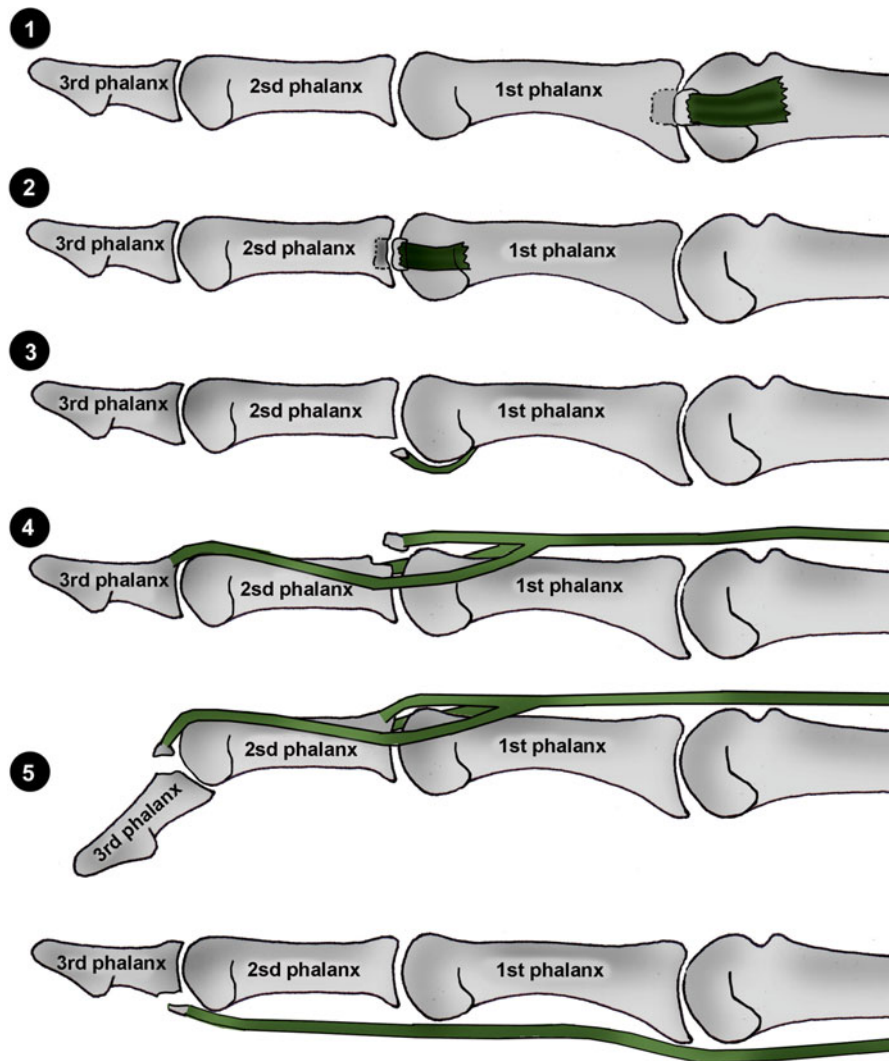


Fig. 7.12 Joint fractures

1. Fracture of the base of the 1st phalanx with lateral fragment; most of the time, it's a severe sprain of the corresponding collateral ligament
 2. Fracture of the base of the 2nd phalanx with lateral fragment; same situation as before
 3. Fracture of the base of the 2nd phalanx with palmar fragment; most of the time, it's a tear of the volar plate of the proximal interphalangeal phalanx (cf. Chap. 8)
 4. Fracture of the base of the 2nd phalanx with dorsal fragment; it's probably a tear of the median strip of the extensor system. It must be treated as such (cf. Chap. 9)
 5. Fracture of the base of the 3rd phalanx with dorsal fragment; it is a fracture/tear of the lateral strips (or osseous mallet finger), as seen in the Chap. 9
- Fracture of the base of the 3rd finger with palmar fragment; it is a Jersey finger (or rugby finger), where there is a tear of the base of the 3rd phalanx by the flexor digitorum profundus. It's a surgical emergency (cf. Chap. 10)

7.2.2.2 Fractures of the Diaphysis

First Phalanx

In this kind of fracture, there's a tendency of palmar displacement of the proximal fragment (because of the dorsal expansion of the interossei) and of dorsal displacement of the distal fragment (because of the extensor system).

Second Phalanx

When the fracture line is proximal to the end of the flexor digitorum superficialis, the proximal fragment is pulled backward by the median strip of the extensor system, and the distal fragment is pulled frontward by the flexor digitorum superficialis.

When the fracture line is distal to the end of the flexor digitorum superficialis, the proximal fragment moves frontward and the distal fragment moves backward.

Third Phalanx

The fractures of the diaphysis of the 3rd phalanx are often the consequence of a crushing trauma, leading to trophic disorders and prolonged pain. They usually don't cause residual stiffness.

7.3 Therapeutic Process [8]

Our therapeutic process depends on the type of injury. The first priority would be allowing the early mobilization of the damaged finger without disturbing the osseous healing.

7.3.1 Orthopedic Treatment

This treatment is based on the use of thermoformable orthosis, which ideally adapt to the patient's morphology and leave the unaffected joints free.

7.3.1.1 Allowing Early Mobilization

It's the treatment that obtains the best results, but it can be used only in stable fractures. The orthosis must allow the osseous healing and at the same time maintain the movements that don't put excessive constraints on the callus.

The evolution is regularly controlled (by clinical and radiological assessments [9]) to limit the risk of secondary displacements.

7.3.1.2 Immobilization

This is the default choice, when there is a contraindication for surgery and the fracture is displaced or unstable. The orthosis is more constraining and immobilizing in order to improve osseous healing, but it must allow a soft mobilization of the joints that aren't concerned by the fracture.

7.3.2 Surgical Treatment [10]

Surgical treatment is used in case of displaced fractures with a functional tolerance of 30° of tilt for the fractures of the diaphysis of the 4th or 5th metacarpal and 5° of tilt for the fractures of the diaphysis of the 2nd or 3rd metacarpal.

Every other displacement (phalangeal tilt, rotatory disorders, etc.) and unstable fractures need a surgical intervention.

7.3.2.1 Percutaneous Techniques [11]

They're used in case of reducible closed injuries.

Their interest is to limit the risk of secondary displacements and to allow an early mobilization, with an adapted orthosis.

7.3.2.2 Open Osteosynthesis [12]

These techniques concern the open and unstable fractures [13], or the non-reducible ones, and the joint fractures. Screwed plates, screws, Bilboquets, or external fixators can be used, among others.

7.4 Rehabilitation and Orthosis

7.4.1 Orthotic Immobilization Treatment

The type of orthosis depends on the location of the fracture, its displacement, and its stability. The described orthosis is the same with or without surgery.

7.4.1.1 Long Fingers [14]

- *Stable fracture of the metacarpal base:* we realize the orthosis putting the wrist in 30° of extension, combined with a syndactyly with the adjacent finger opposed to the tendency of bad rotation. If there isn't any tendency evaluated, the syndactyly is preferably realized between the 4th and 5th fingers or the 2nd and 3rd (Fig. 7.13).
- *Stable fracture of the metacarpal diaphysis:* a metacarpal gauntlet maintains the metacarpal architecture (transversal and longitudinal metacarpal arch), combined with a syndactyly, following the same principles as before (Fig. 7.14).
- *Unstable fracture of the metacarpals:* we realize a "Thomine" orthosis, placing the wrist in 30° of extension and the metacarpophalangeals in 70° of flexion. The interphalangeals stay free (Fig. 7.15).

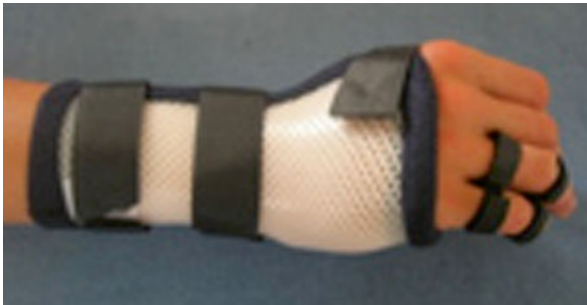
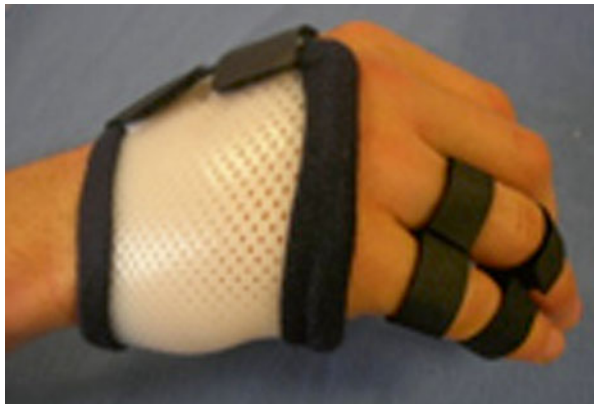
Fig. 7.13 Orthosis placing the wrist in 30° of extension and syndactyly between the 4th and 5th fingers after a stable fracture of the base of the 5th metacarpal

Fig. 7.14 Metacarpal gauntlet and syndactyly between the 4th and 5th fingers after a stable fracture of the diaphysis of the 5th metacarpal



- *Stable fracture of the 1st and 2nd phalanges:* a syndactyly is enough, associating the 2nd and 3rd fingers or the 4th and 5th (Fig. 7.16).
- *Unstable fracture of the base or diaphysis of the 1st phalanx:* we realize a metacarpal gauntlet that maintains the metacarpal arches and places the metacarpophalangeals in 70° of flexion (Fig. 7.17).
- *Unstable fracture of the head of the 1st or 2nd phalanx:* the orthosis realized is a digital tube. An early liberation of the distal interphalangeal joint is realized in case of a fracture of the head of the 1st phalanx or the base of the 2nd phalanx if the osseous callus evolves well (after a radiographic control).
- *Stable or unstable fracture of the 3rd phalanx:* a thermoformed “thimble” is realized, leaving the proximal interphalangeal joint free (Fig. 7.18). Letting the distal interphalangeal joint free in the distal injuries of the 3rd phalanx is

Fig. 7.15 Orthosis placing the wrist in 30° of extension, the metacarpophalangeal in 70° of flexion, and the interphalangeal free in flexion/extension after an unstable fracture of the metacarpals

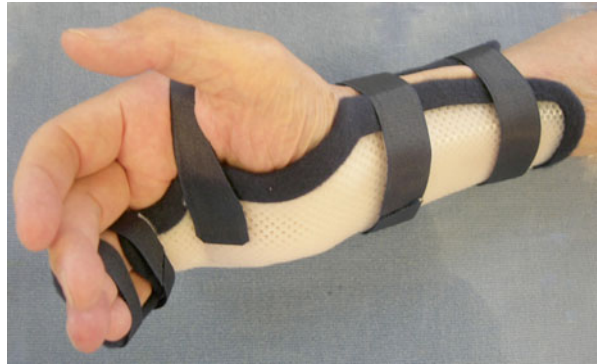

Fig. 7.16 Simple syndactyly after stable fractures of the 1st or 2nd phalanx

Fig. 7.17 Orthosis placing the metacarpophalangeals in 70° of flexion and conserving the metacarpal arches in unstable fractures of the base or the diaphysis of the 1st phalanx

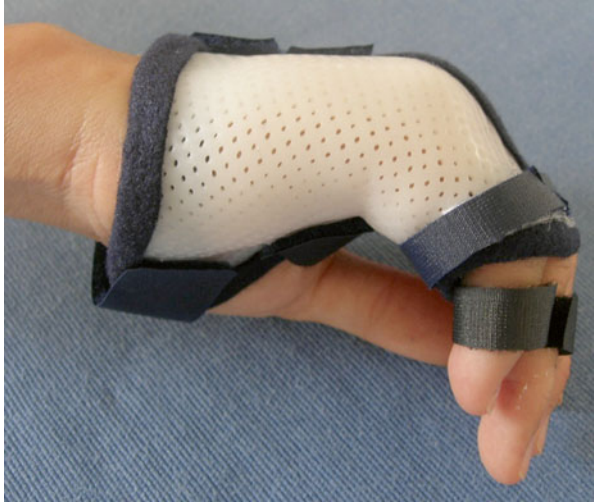
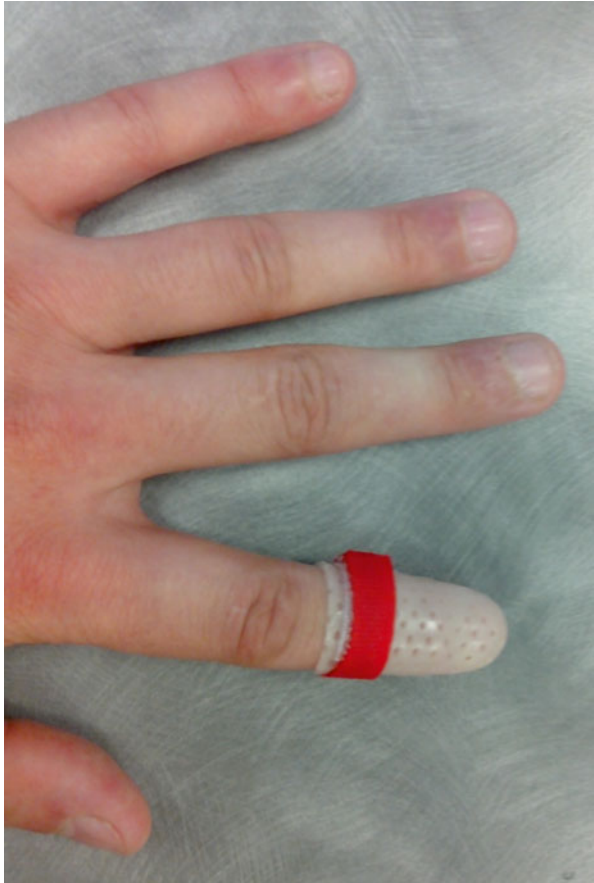
Fig. 7.18 Orthosis after a fracture of the 3rd phalanx letting the proximal interphalangeal joint free



technically very difficult and the patients tend to lose their orthosis, especially during the night.

7.4.1.2 Thumb

- *Stable fracture of the base of the 1st metacarpal*: we realize an orthosis placing the wrist in a neutral position and the metacarpophalangeal in a functional position (Fig. 7.19). We don't let the metacarpophalangeal of the thumb free in this case, as the patient can be tempted to grab things between the thumb and the fingers, which can lead to excessive constraints on the base of the 1st metacarpal.
- *Stable fracture of the diaphysis of the 1st metacarpal*: the orthosis lets the wrist free but maintains the thumb in a functional position, with a good commissural opening (Fig. 7.20).
- *Unstable fracture of the 1st metacarpal*: we realize the same orthosis for the fracture of the base of the 1st metacarpal.
- *Stable fracture of the base of the 1st phalanx*: the orthosis places the metacarpophalangeal in a functional position, with the interphalangeal free. Careful: some patients have a very wide 1st phalanx head, in comparison to the diaphysis. This particularity makes it impossible to mold the orthosis as close as possible to the 1st phalanx, as the orthosis could be impossible to take off. In these cases, we immobilize the interphalangeal straight, at least until the first radiologic control (D15).
- *Stable fracture of the diaphysis of the 1st phalanx*: we place the metacarpophalangeal in a functional position and the interphalangeal straight (Fig. 7.21).
- *Stable fracture of the head of the 1st phalanx*: the orthosis is a tube placing the interphalangeal straight (Fig. 7.22).

Fig. 7.19 Orthosis immobilizing the wrist and the metacarpophalangeal in a neutral position after a stable fracture of the base of the 1st metacarpal

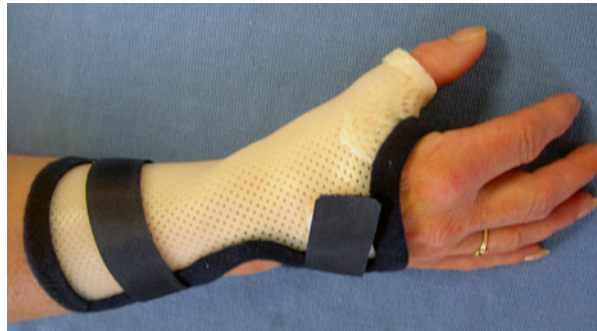

Fig. 7.20 Orthosis after a stable fracture of the diaphysis of the 1st metacarpal

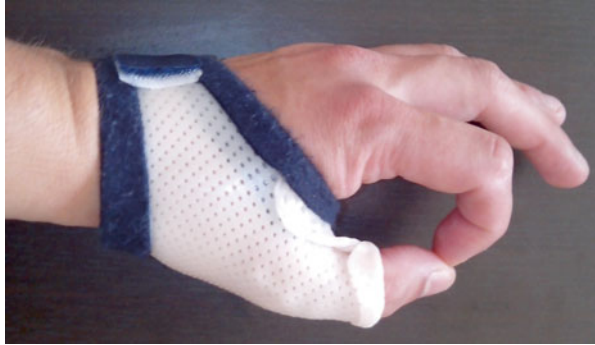
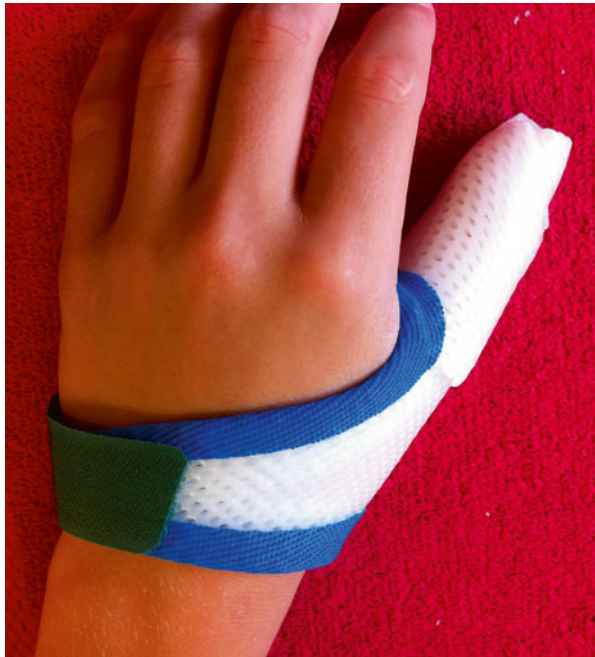
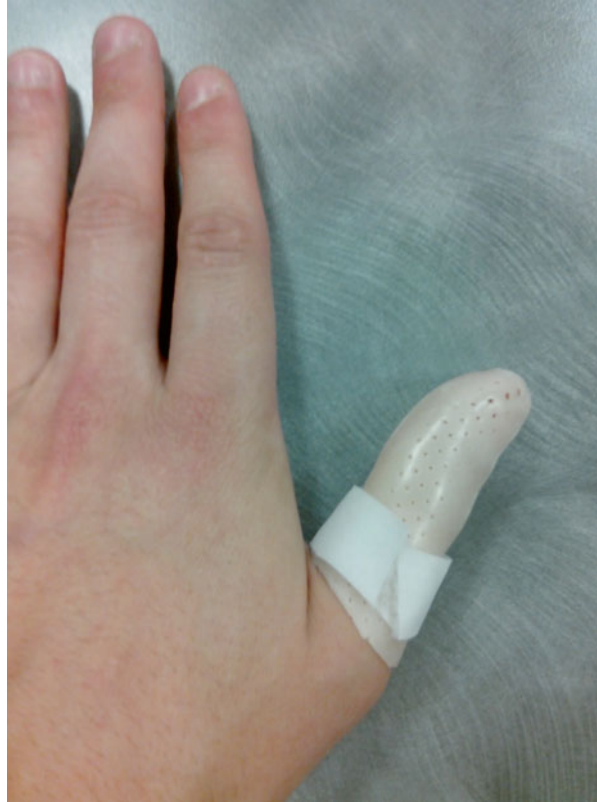Fig. 7.21 Orthosis after a stable fracture of the diaphysis of the 1st phalanx, metacarpophalangeal in a functional position, and interphalangeal straight



- *Unstable fracture of the 1st phalanx:* we immobilize the metacarpophalangeal in a functional position and the interphalangeal straight.
- *Stable or unstable fracture of the 2nd phalanx:* a tube of thin plastic (1.6 mm) places the interphalangeal straight.

Fig. 7.22 Orthosis placing the interphalangeal straight after a stable fracture of the head of the 1st phalanx



7.4.2 Rehabilitation [2]

Describing a specific protocol for each type of fracture doesn't have any practical interest. In this type of pathologies, the surgeon faces six different situations:

- Immediate mobilization
- Orthotic immobilization
- Orthopedic reduction and early mobilization
- Orthopedic reduction, percutaneous techniques, and immobilization
- Bloody reduction and “instable” osteosynthesis, leading to immobilization
- Strong osteosynthesis and early mobilization

The therapist is then left with two situations:

- Immediate mobilization, in case of stable fracture or after a strong osteosynthesis
- Immobilization after reduction, percutaneous techniques, and instable osteosynthesis after a bloody reduction

7.4.2.1 Rehabilitation Protocol (Fig. 7.23)

The described protocol concerns the fractures that need an immobilization. When the immediate mobilization is possible, the protocol starts in phase (B), or fragility phase, using techniques with an increasing intensity for trophic disorders and pain.

Immobilization Phase (D0 to D30/45)

In this phase, the rehabilitation is often limited to self-rehabilitation exercises and control of the orthosis. However, some other things can be done if there is a bad evolution or if the initial trophic disorders are important.

Fight Against Trophic Disorders and Pain

- Cryotherapy with gas or a sterilized ice bag if there's a wound
- Electrostimulation: trophic or analgesic goal
- Transcutaneous vibratory stimulations: analgesic, 100 Hz
- Analgesic and draining massages
- Compressive bandage worn only during the night in order not to disturb the daily mobilization (Fig. 7.24)

Active Self-Mobilizations of the Free Joints

These mobilizations allow maintaining the amplitudes in the sane joints and in the meantime improve global trophicity of the hand by a “vis a latere” stimulation (muscular and venous pump).

Orthosis Control and Fight Against an Eventual Angulation/Bad Rotation

A regular control of the orthosis is realized, in order to check if there aren't any problems of the fulcrum, bad rotation, or bad angulation.

When these troubles are moderate, the orthosis can be adapted to limit their evolution (foam spacers opposed to the angulation, syndactyly with the finger opposed to the rotatory trouble, etc.). But above all, it's important to inform the surgeon about this type of evolution, in order not to lose time if another surgery is necessary.

Relative Fragility Phase (D30/45 to D90)

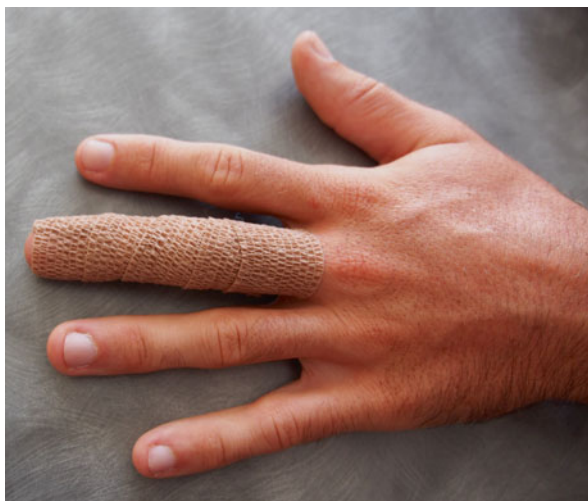Soft Recovery of the Amplitudes in the Immobilized Joints [15]

- *Fluidotherapy* (Fig. 7.25)
The fluidotherapy techniques (hot water, corn dust, hot air, etc.) increase the viscoelasticity of the tissues and, therefore, improve mobility. We ask the patient

Fractures of the metacarpals and phalanges			
	Immobilization phase (A)	Fragility phase (B) Beginning of the rehabilitation if no immobilization (D2)	Strength phase (C)
R E H A B I L I T A T I O N	<p>Therapeutic goals: fight against trophic disorders and pain, maintain mobility in the free joints, prevent vicious callus.</p> <p>Techniques:</p> <ul style="list-style-type: none"> - Ice (gaseous cryotherapy after the scar is closed or if there is no scar), analgesic transcutaneous vibratory stimulations, analgesic and draining massages, compressive bandages (if possible). - Active self-mobilizations of the free joints. - Learning protection rules when monitoring the orthesis (+ control by the orthotist once a week to control the rotation and the angle of the callus). <p>Risks: vicious callus (especially if there is an orthopaedic treatment), stiffness of the free joints.</p>	<p>Therapeutic goals: same as in phase A, intensify phase A if necessary (stiffness ++), softly regain joint amplitudes in immobilized/damaged joints, muscular awakening, maintain the body mapping.</p> <p>Techniques:</p> <ul style="list-style-type: none"> - Same techniques as in phase A, using more intensive techniques (pressotherapy, cold baths...). - Fluidotherapy, depressotherapy and massages against adherences, active electrotherapy, manual mobilizations. - Soft electrostimulation of the intrinsic muscles. - Manipulations, occupational therapy. <p>Risks: same as in phase A, functional exclusion.</p>	<p>Therapeutic goals: intensify the techniques from the 2 previous phases if necessary, regain clamping strength, complete functional recovery.</p> <p>Techniques:</p> <ul style="list-style-type: none"> - Specific joint mobilizations, increase the intensity of the electrostimulation, and stretching of the intrinsic muscles (B1). - Exercise for the intrinsic and extrinsic strengths, regain the muscular ratios. - Functional exercises depending on the job and leisure activities. <p>Risks: same as in phase B.</p>
OR TH ES IS	Orthesis adapted to the type of fracture.	Postural orthesis after the end of the trophic disorders and pain.	Same as in phase B.
	D0 to D30/45	D30/45 to D90	More than D90

Fig. 7.23 Rehabilitation protocol

Fig. 7.24 Compressive bandage to fight against trophic disorders



to realize slow active mobilizations until he feels a sensation of tension during the whole treatment (approximately 20’).

- *Depressotherapy*

It is mainly used after a surgery around the scar but can also be interesting if there are adhesions in the extensor system (frequent after this kind of injuries).

- *Massages against adhesions*

Like depressotherapy, these massages are important mainly after a surgery around the scar. They also help fight against fibrosis, which is present as well when there isn’t any surgery.

- *Active electrotherapy*

It is usually used after relaxing the retracted tissues, in order to limit the resistances when mobilizing, which can lead to tendinopathies of the “motor” muscles.

We ask the patient to actively mobilize his fingers during the electrostimulation, to maintain his motor pattern and optimize the recuperation of the joint amplitudes. This exercise is realized in all areas with a deficit of mobility (Fig. 7.26).

- *Active and passive manual mobilizations* [16]

Like electrotherapy, we use these techniques after relaxing the fingers using massages and fluidotherapy to limit the resistances when mobilizing, which can lead to tendinopathies in the working muscles.

During this relative fragility phase, we first use active exercises, which are more reassuring for the patient as he can control the tension in his retracted or adherent tissues.

Passive mobilizations are also used with grips close to the stiff joint, to avoid imposing shear force on it.

In case of a joint fracture, there can exist a “came effect” that limits the mobilization. In this case, strength techniques mustn’t be used, as it could

Fig. 7.25 Soft active mobilization in hot baths, improving viscoelasticity of the connective tissue

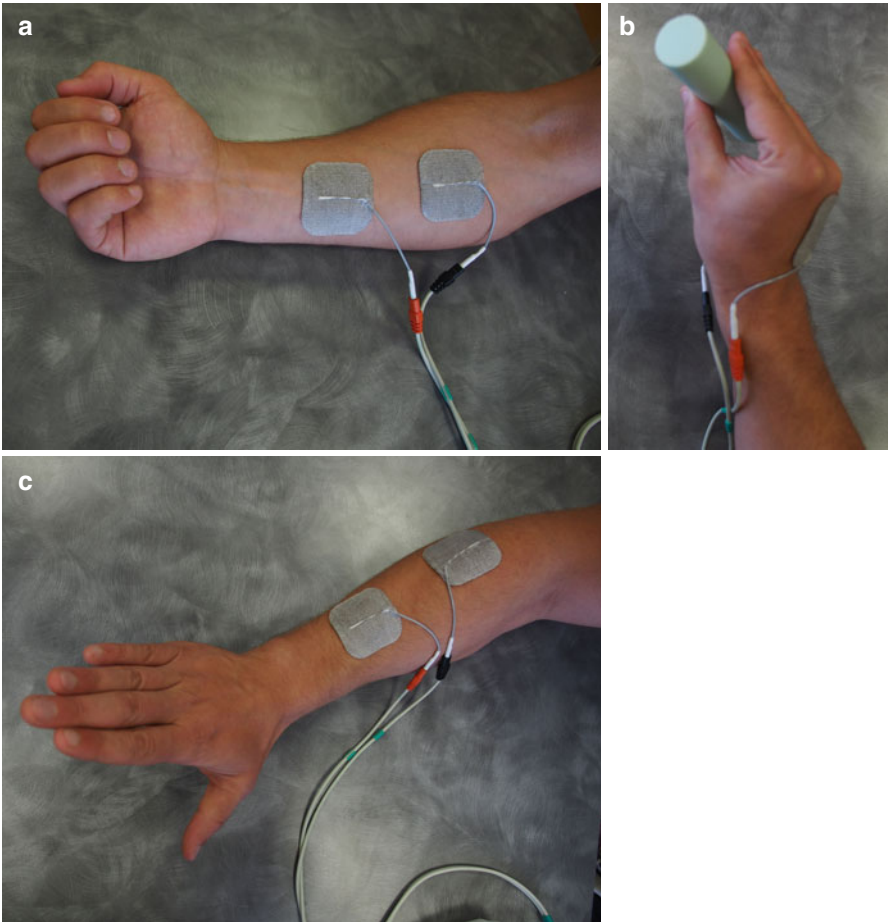



Fig. 7.26 Active electrostimulation in winding (a), extension of the interphalangeals (b), or extension of the metacarpals (c) depending on the goals of the rehabilitation

accelerate the degenerative processes occurring in the joint. A radiologic exam is therefore essential before starting to recuperate the amplitudes.

- *Stretching of the intrinsic muscles*

These stretchings are realized if the Finochietto test is positive, which means there is a retraction of the intrinsic muscles, quite frequent in these traumas (Fig. 7.27).

We stretch these muscles passively putting the hand in an “extrinsic +” position. This position has to be actively maintained to stretch the lumbrical muscles (Fig. 7.28).

These stretchings must be soft and well tolerated by the patient. If they aren’t tolerated in this phase, we postpone the application of this technique.

- *Computerized imitation exercises*

The patient has to imitate exercises displayed on a screen. The models are defined depending on the patient’s joint limitations.

Fig. 7.27 Positive Finochietto test; the retraction of the intrinsic muscles makes it impossible to realize active mobilizations in the extrinsic + position

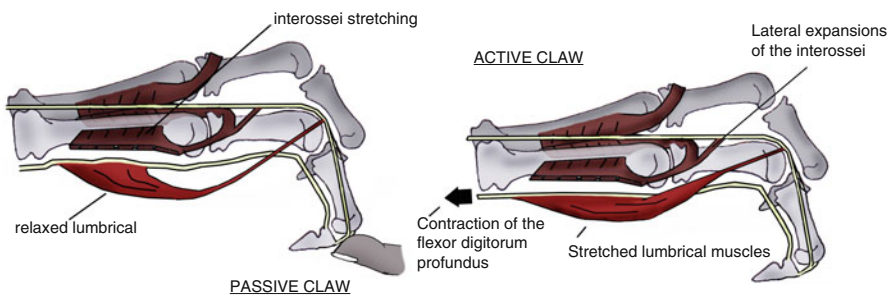



Fig. 7.28 The passive placement in the extrinsic + position doesn’t stretch the lumbrical muscles, unlike the active placement

Muscular Awakening

It's essential because it participates in the stabilization of the damaged joints and the joints peripheral to the fractured bone. It also improves callus healing by vascular pumping effect.

We ask the patient to realize isometric contractions with a low intensity during 6 s. Thirty repetitions or less are done, considering that it mustn't create any pain or secondary trophic disorder.

The contractions mustn't put torsion or distraction constraints on the callus, as it isn't strong in this phase.

The exercises depend on where the fracture is:

- *Fracture of the base of the 5th metacarpal:* exercise for the intrinsic muscles in the axis of the fingers, sustain of the palmar side of the metacarpals (Figs. 7.29). No solicitation of the extensor carpi ulnaris, which tends to displace the osseous fragment.
- *Fracture of the base of the 2nd and 3rd metacarpals:* exercise for the intrinsic muscles in the axis of the fingers, with a palmar sustain. No work with the radial extensors of the carp that end on the base of the 2nd and 3rd metacarpals (cf. Fig. 7.29).
- *Fracture of the base of the 1st metacarpal:* exercise for the opponet pollicis sustaining the palmar side of the 1st metacarpal. No work with the abductor pollicis longus that ends on the radial side of the base of the 1st metacarpal (cf. Figs. 7.8 and 7.8'). Working with the abductor pollicis brevis and the flexor pollicis brevis tends to displace the 1st metacarpal in a palmar direction and, therefore, is not recommended.
- *Fracture of the diaphysis of the metacarpals:* muscular awakening of the thenar and hypothenar muscles. No work with the interossei, because their role of flexion of the metacarpophalangeal tends to displace the distal fragment in a palmar direction (cf. Fig. 7.9).

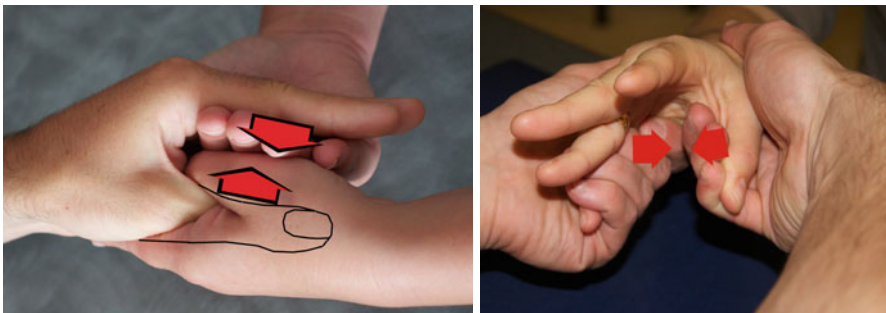


Fig. 7.29 Exercise for the intrinsic muscles after a fracture of the base of the metacarpals. This exercise isn't realized at this stage in the fractures of the diaphysis of the metacarpals, as it can favor the anterior tilt of the distal fragment

- *Fracture of the diaphysis of the 1st phalanx*: same as before, because the interossei tend to displace the proximal fragment in a palmar direction. We don't work with the extensor system that tends to displace the distal fragment dorsally.
- *Fracture of the diaphysis of the 2nd phalanx*: no work with the flexor digitorum superficialis and the extensor system that tend to displace the fragments in one direction or another depending on the localization of the fracture line.

The active electrostimulation of the muscles previously mentioned can also be done.

Maintaining the Body Mapping

It's done by employing grips, dexterity, and intermuscular coordination exercises.

Strength Phase (After D90)

Full Recovery of the Joint Amplitudes

We intensify the techniques used in the previous phase and add some specific mobilization techniques, realized in a decoaptation position, particularly in case of joint fractures (Fig. 7.30).

Recovery of the Strength and Muscular Balance

An auxotonic contraction is realized in the forearm and hand muscles in order to regain the initial strength and the muscular balance between the intrinsic and extrinsic muscles, often impaired in these traumas (Fig. 7.31).




Fig. 7.30 Specific mobilization of the proximal interphalangeal joint or the other joints with articular deficit after the consolidation of the callus, especially if it's a joint fracture



Fig. 7.31 Dynamometer allowing the evaluation and the reinforcement of the extrinsic (a) or intrinsic (b) muscles. The goal in this phase is to regain muscular ratios comparable with the sane side

Proprioceptive and Functional Exercises

A specific treatment adapted to the patient's needs is made, allowing him to regain an optimal function (proprioception, dexterity, coordination).

7.4.3 Orthotic Treatment to Gain Amplitude [14, 15, 17]

Since the 2nd phase of the rehabilitation and in the absence of contraindication related to the evolution of the osseous callus, it's sometimes necessary to realize an orthosis to gain amplitude, in order to optimize the rehabilitation. These orthosis are evolutionary and adapted to the healing, in order not to put any excessive constraint on the fracture site.

They should be worn, ideally, at least 6 h a day to be effective: it's the minimum duration for the histology of the connective tissue to be modified.

The extension orthosis are worn during the night and can be global or selective (Fig. 7.32).

The winding orthosis is worn during the day, shortly (15') and not too intensively because they're very demanding at the vascular level and therefore can be poorly tolerated by the patient (Fig. 7.33).

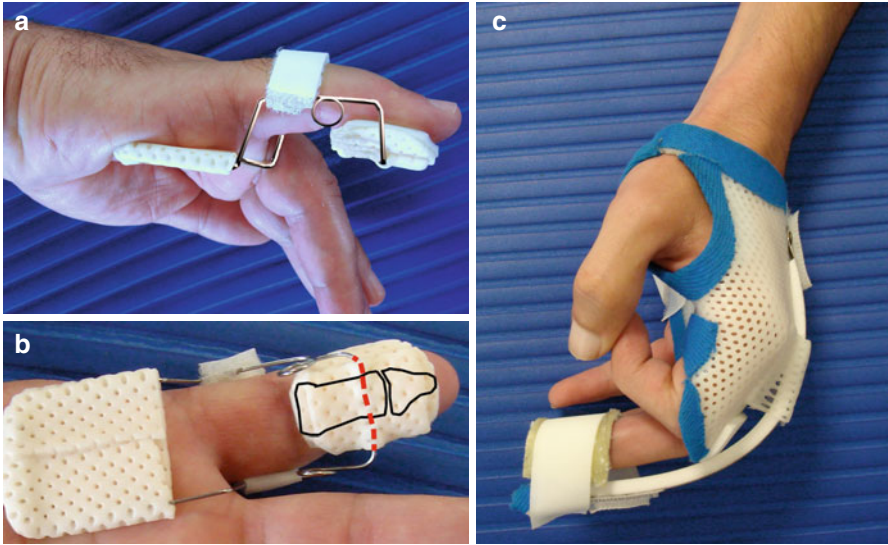


Fig. 7.32 Extension orthosis for the proximal interphalangeal joint (Capener) (a and b) or global extension orthosis (Levame) (c). They're worn during the night

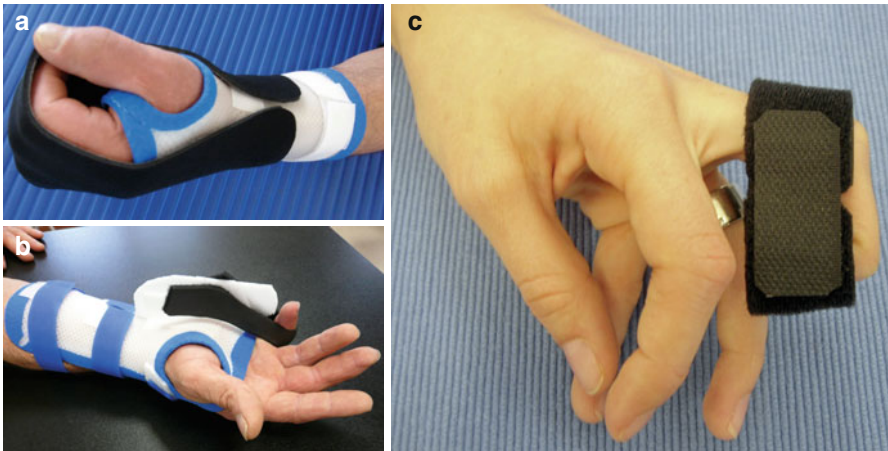


Fig. 7.33 Global winding orthosis (a), selective on the metacarpophalangeal (b) or on the interphalangeals (c). They're worn various times during the day, 15 min each time

Bibliography

1. Kapandji IA (2001) Anatomie fonctionnelle, vol 1, Maloine, Paris
2. Scougall P, Prosser R (2003) Metacarpal and phalangeal fractures. In: Prosser R, Conolly W (eds) Rehabilitation of the hand and upper limb. Butterworth-Heinemann, Eastbourne
3. Rouzaud JC, Allieu Y (1990) Les fractures articulaires de l'IPP. Ann kinésithérapie. Masson, t.17, n°5, P 223–227
4. Stern P, Roman R, Kiefhaber T, McDonough J (1991) Pilon fractures of the proximal interphalangeal joint. J Hand Surg 16:844–850
5. Kiefhaber TR, Stern PJ (1998) Fracture dislocations of the proximal interphalangeal joint. J Hand Surg Am 23:368–380
6. Glickel SZ, Barron OA (2000) Proximal interphalangeal joint fracture dislocations. Hand Clin 16:333–344
7. Curtis RM (1984) Raideurs des articulations interphalangiennes des doigts. In: Tubiana R (ed) Traité de chirurgie de la main, vol 2. Elsevier, Masson
8. Merle M, Dautel G (1997) La main traumatique: l'urgence. Masson, Issy-les-Moulineaux. p.35–65
9. Le Nen D, Laulan J (2001) Sémiologie de la main et du poignet. Sauramps médical, Montpellier
10. Blazar P, Robbe R, Lawton J (2001) Treatment of dorsal fracture/dislocations of the proximal interphalangeal joint by volar plate arthroplasty. Techn Hand Upper Extr Surg 5:148–152
11. Burkhalter WE (1989) Closed treatment of hand fractures. J Hand Surg [Am] 14(2 pt 2):390–393
12. Foucher G (1995) “Bouquet” osteosynthesis in metacarpal neck fractures: a series of 66 patients. J Hand Surg [Am] 20(3 pt 2):S86–S90
13. CHOW SP, Pun WK, So YC et al (1991) A prospective study of 245 open digital fractures of the hand. J Hand Surg [Br] 16:137–140
14. Vaissier M (2011) Traitement des raideurs post-traumatiques des doigts longs – Mémoire du DIU de rééducation et appareillage en chirurgie de la main. www.reeducation-main.com
15. Delprat J, Mansat M (1981) Rééducation des raideurs post-traumatiques des doigts longs. J réadaptation Méd
16. Ghossoub P, Dufour X, Barette G, Montigny JP (2009) Mobilisations spécifiques, EMC Kinésithérapie-Médecine physique-réadaptation
17. Tournaire H (2001) Les orthèses dynamiques des interphalangiennes proximales, Mémoire du DIU de rééducation et appareillage en chirurgie de la main. www.reeducation-main.com

Chapter 8

Capsulo-ligamentous Injuries of the Proximal Interphalangeal Joint

Grégory Mesplié

8.1 Anatomical Reminders [1, 2]

The proximal interphalangeal joint is a trochlear joint with one degree of freedom. The flexion axes are evolutionary: perpendicular in extension, they become oblique during the flexion to create a supination allowing the opposition between the pulp of the thumb and the pulp of the fingers. This obliquity is more important in the ulnar fingers, as the supination needed is more important (Fig. 8.1).

This automatic rotation is anatomically related to the asymmetry of the joint surface and a differential tensioning of the collateral ligaments.

The amplitude of the interphalangeals in flexion is approximately 90° (depending on the person). This amplitude increases from the 2nd finger to the 5th finger.

There is 0° of extension, even though there can be tendencies to the recurvatum in the most lax patients.

The stability of the joint is related to various anatomical elements [3, 4]:

- The *collateral ligaments*, spreading from the head of the 1st phalanx to the base of the 2nd phalanx, the volar plate and the flexor sheath. The principal fascicle is tensed between the head of the 1st phalanx and the base of the 2nd phalanx, with an insertion on the volar plate. The accessory fascicle is tensed from the head of the 1st phalanx to the volar plate and the flexor sheath. The collateral ligaments are tensed in extension (maximal tension in the accessory fascicle) and in complete flexion (phalangeal pulley wider

G. Mesplié

Physiotherapist and Orthotist, Institut Sud Aquitain de la Main et du Membre Supérieur,
Aguiléra Clinic Biarritz, Biarritz, France

e-mail: greg.mesplie@mac.com

Fig. 8.1 The flexion axis of the fingers is perpendicular in extension and becomes oblique in flexion, which leads to an automatic rotation allowing the opposition between the thumb and the fingers (according to Kapandji)

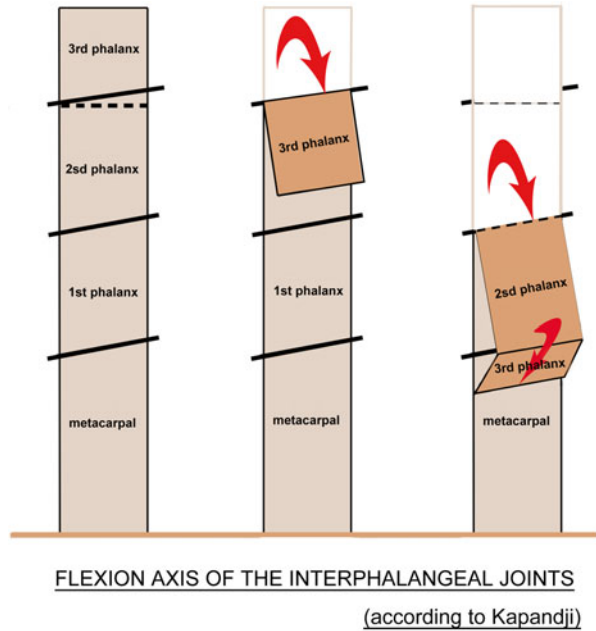
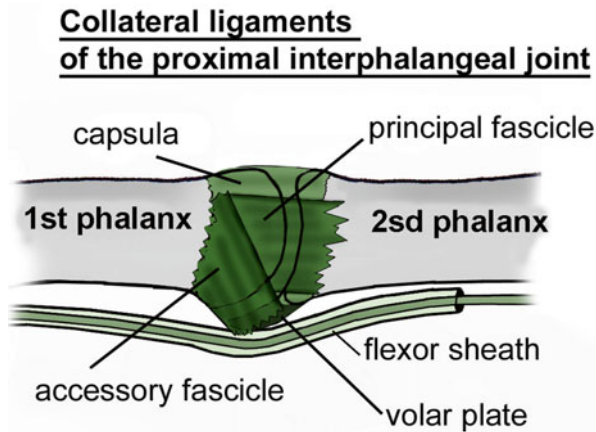


Fig. 8.2 Collateral ligaments of the proximal interphalangeal joint



frontwards than backwards). They are relatively relaxed in an intermediary position (Fig. 8.2) [5].

- The *volar plate* is a very resistant fibrocartilage, anchored between the 1st and 2nd phalanges on the palmar side by the “check reins”, which also are the insertion of the A3 pulley and flank the flexor sheath (Fig. 8.3). It’s tensed in extension and slides on the anterior side of the 1st phalanx in flexion (hinge system) to avoid its early abutment on the anterior side of the head of the 1st phalanx (Fig. 8.4).

Fig. 8.3 Volar plate

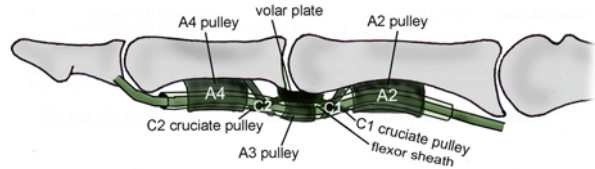
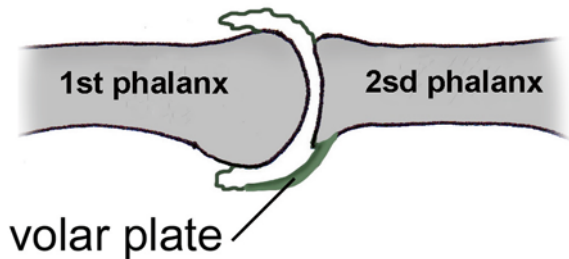
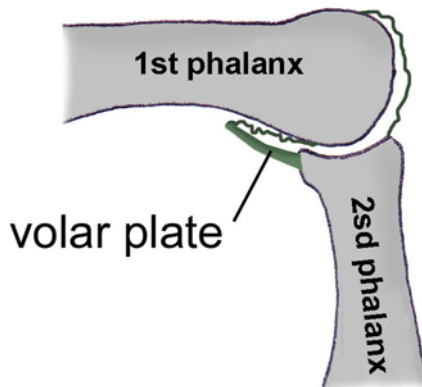


Fig. 8.4 Deployed in extension (tensioning position), the volar plate slides along the 1st phalanx during the flexion of the proximal interphalangeal joint, allowing a wider angular area

Extension of the proximal interphalangeal joint



Flexion of the proximal interphalangeal joint



8.2 Volar Plate Sprains (Fig. 8.5) [6]

8.2.1 Rehabilitation [7]

Volar plate injuries occur during a trauma in hyperextension (Fig. 8.6).

The clinical signs are an important periarticular oedema, associated to an anterior hematoma and pain when palpating the anterior part of the joint [8].

Severe injuries of the volar plate			
	Acute phase	Healing phase	Remodelling phase
R e h a b i l i t a t i o n	<p>Therapeutic goals: rest the volar plate, and limit the risks of stiffness, fight against trophic disorders and pain, maintain the body mapping.</p> <p>Techniques: - Cryotherapy, infrasounds, TENS (1-3 Hz or 100Hz), draining depressotherapy. -Draining massage -Passive exercise in flexion and simple active exercise in extension</p> <p>Risks: maladapted mobilizations = stiffness (flexum ++) and/or instability, even CRPS.</p>	<p>Therapeutic goals: progressively put charge on the damaged elements, regain joint amplitudes, fight against trophic disorders and pain, and maintain the body mapping.</p> <p>Techniques: - Same (depending on the evolution) + US (1MHz pulsed) + simple active exercise in flexion/extension + differential gliding of the distal and proximal interphalangeal joints + electrostimulation + massages of the scar + depressotherapy to relax the tissues + occupational therapy.</p> <p>Risks: flexum + maintain the inflammation (risks of scar hypertrophy), functional exclusion.</p>	<p>Therapeutic goals: gain amplitude and strength, fight against trophic disorders and pain, and maintain the body mapping.</p> <p>Techniques: - Same (depending on the evolution) + Menel technique + muscle reinforcement. -Functional exercise (occupational therapy + +).</p> <p>Risks: flexum + “big” proximal interphalangeal joint.</p>
	Or t h e s i s	<p>“Proximal interphalangeal stop” or digital tube in complete extension, syndactyly allowing a protected self-mobilization of the damaged finger.</p>	<p>Dynamic (Capener) or static in series in extension or flexion (snail, portuguese, etc.), worn daily (> 6h/j).</p>
D0 to D21		D21 to D60	After D60

Fig. 8.5 Rehabilitation protocol of the volar plate sprains

The radiographies can highlight the presence of a little osseous fragment, corresponding to a tearing of the volar plate.

If the observed fragment is voluminous, its surgical reinsertion will be realized.

If not, the treatment is orthotic, combined with an early or immediate mobilization depending on the pain and trophic disorders. The immobilization mustn't last longer than 48 h.

Fig. 8.6 Traumatism in hyperextension leading to volar plate injuries

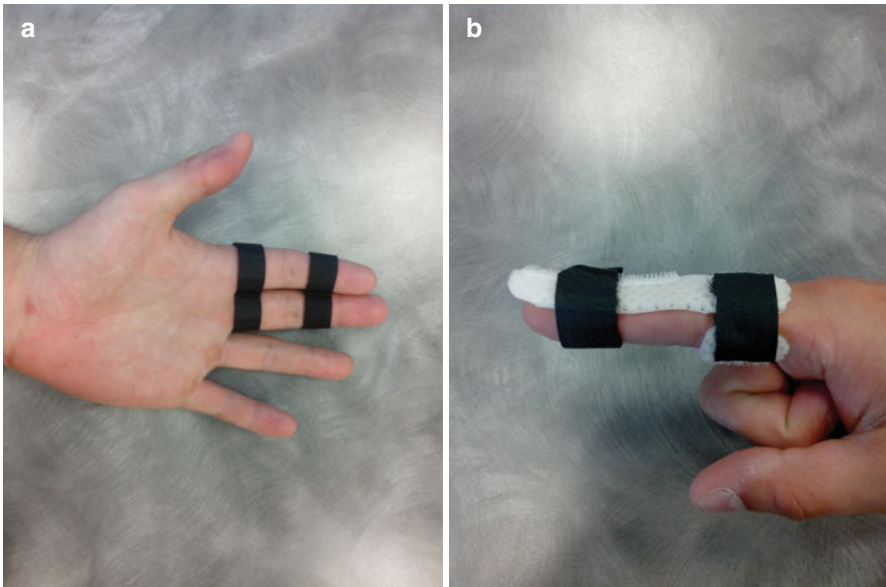
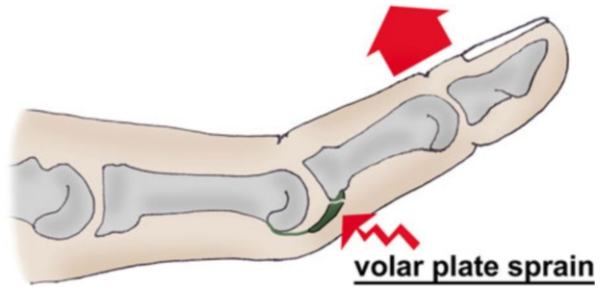


Fig. 8.7 The “proximal interphalangeal stop” in extension is worn during the night (a). Diurnal syndactyly liberating the flexion creases of the proximal interphalangeal to maintain mobility (b)

During the first 3 weeks, the orthotic treatment consists in realizing a “proximal interphalangeal stop” orthosis, placing the interphalangeal in extension. It will be worn during the night, while a syndactyly is worn during the day (Fig. 8.7).

The rehabilitation must be realized early and with very soft and progressive techniques in order not to “attack” the damaged tissues. As Madden reminds us, “tissues don’t know enthusiasm, but stress”.

8.2.1.1 Acute Phase (D0 to D21)

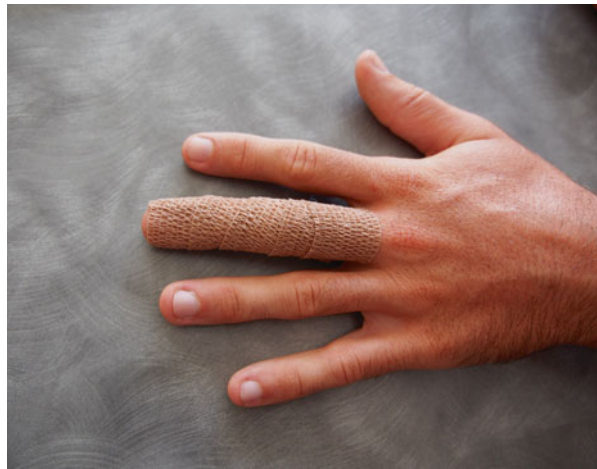Fight Against Pain and Trophic Disorders

- Draining massages from distal to proximal, following the neurovascular pedicles.

Fig. 8.8 Gaseous cryotherapy in front of the proximal interphalangeal joint, controlling the cutaneous temperature with an infrared thermometer



Fig. 8.9 Compressive bandage in case of important oedema



- Electrotherapy: 1 Hz on the oedematous area or 100 Hz for a precise analgesic effect.
- Gaseous cryotherapy allowing a very precise anti-oedematous effect on the interphalangeal joint (Fig. 8.8). Cryotherapy also has an interesting analgesic effect.
- Pressotherapy: the device realizes a compression from distal to proximal that drains the hand oedema. A soft painless posture in extension can be realized during the treatment. In this phase, this technique can be badly tolerated by the patient, in which case we delay its application.
- Compressive bandage during the night if the oedema is important and resistant to treatment (Fig. 8.9).
- Put the hand in an elevated position at home, especially when there's a global oedema of the hand (rare case).
- Transcutaneous vibratory stimulations (frequency 50–100 Hz, amplitude >1 mm) are applied on the painful area, moving along the sensitive nerve concerned by the painful area. If there is pain when contacting with the device, we place it

Fig. 8.10 Deep massages to relax the tissues



away from the painful area, still on the corresponding nerve. This type of mechanical vibration has a sensorimotor stimulation effect, limiting the risks of functional exclusion.

Progressive Recuperation of the Joint Amplitudes

- Passive mobilizations in flexion and active mobilizations in extension, then active in flexion/extension. The soft passive mobilizations in flexion relax the joint, before asking the patient to do an active exercise, which can easily lead to pain.
- Deep massages (punctiforme, palpate-roll) to relax the tissues of the palmar elements of the proximal interphalangeal joint, in order to improve glidings between the different anatomical planes (Fig. 8.10).

These techniques are realized without any inflammatory phenomena or pain.

Maintaining the Body Mapping

- Transcutaneous vibratory stimulations, varying the frequencies to solicit as much cutaneous and tendinous mechanoreceptors as possible
- Soft manipulation exercises, soliciting the sensorimotor buckles of prehensibility (Fig. 8.11)

8.2.1.2 Healing Phase (D21 to D60)

Maintaining the Techniques of the Acute Phase If Necessary

If the trophic disorders and pain persist, we keep applying the techniques from the previous phase.



Fig. 8.11 Soft manipulations maintaining the body mapping

Regaining the Mobility

Electrostimulation

This technique helps regaining the joint amplitudes in flexion or extension (Fig. 8.12).

We preferably use striomotor currents (150–200 μ s, 20 Hz). They are ideal for the muscles of the superior limb and stimulate the slow-twitch fibres (type 1).

The patient associates a voluntary contraction to the electric stimulation (electroactive exercise) to stimulate the motor command, sometimes disrupted after a surgery [9] or a prolonged immobilization.

Fluidotherapy

The fluidotherapy techniques participate in the global relaxation of the hand after this type of intervention. We ask the patient to realize flexion/extension movements and to separate the fingers, in association to the dry or wet fluidotherapy.

Specific Mobilizations

Decompression and gliding manoeuvres of the digital joints allow regaining a good joint mobility (Fig. 8.13).

Stretching of the Intrinsic Muscles

If there's stiffness in an extrinsic + position (positive Finochietto test), it's imperative to stretch the intrinsic muscles that are causing this deficit. We have to differentiate the interossei and lumbrical muscles that aren't stretched the same way.

The interossei can be stretched by positioning the hand in an extrinsic + position, reached in active or passive.

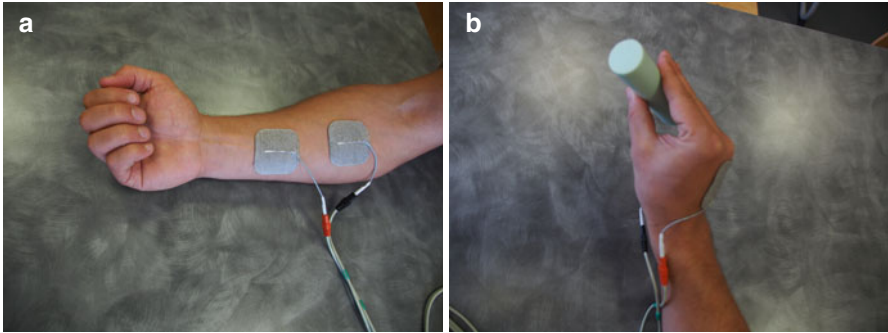
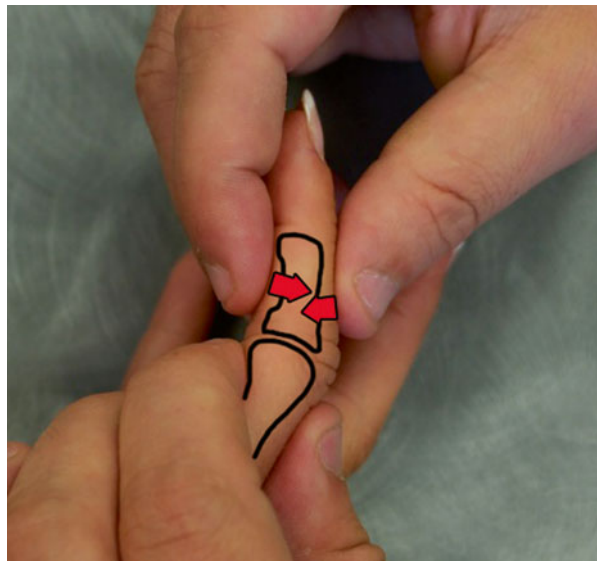


Fig. 8.12 Electroactive exercise winding the fingers, stimulating the corresponding finger flexor (a), and in extension of the proximal interphalangeal joint, stimulating the intrinsic muscles of the concerned finger (b). Example in the 4th finger on the pictures

Fig. 8.13 Specific mobilizations of the proximal interphalangeal joint



The lumbrical muscles are stretched only if this position is reached actively. This is related to the fact that the lumbrical muscles don't have an osseous proximal insertion but insert on the deep flexors that move from distal to proximal when placing the hand actively in the extrinsic+position, allowing their stretching.

Computerized Imitation Exercises

It consists of imitating the pictures on the screen while they're on display (Fig. 8.14).

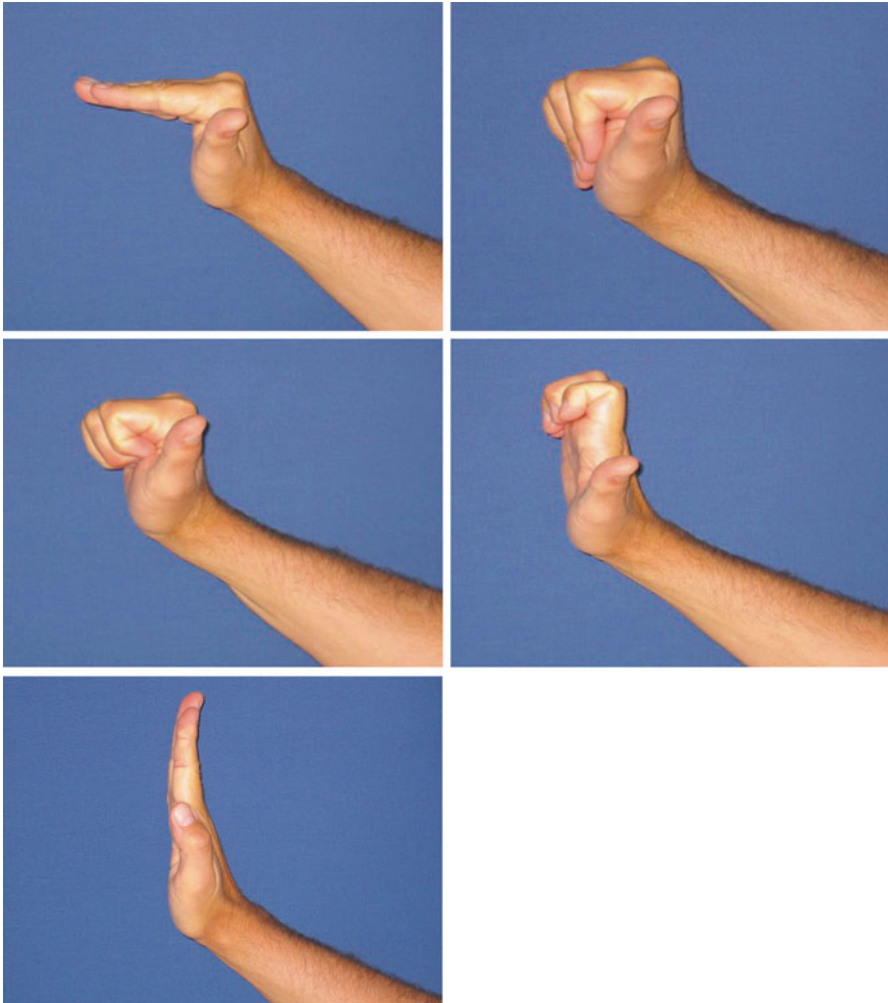


Fig. 8.14 Computerized imitation exercises

Working on the Grips

Manipulating objects improves coordination and dexterity of the operated hand more rapidly and efficiently.

8.2.1.3 Remodelling Phase (After D60)

All the previous techniques are used more intensively, so the patient can go back to his/her professional and sports activities. Proprioception, coordination and dexterity are the most important things to work with in this phase.

8.2.2 Orthotic Treatment [7]

8.2.2.1 Acute Phase (D0 to D21)

The orthotic treatment is composed of a tube-shaped orthosis (or “proximal interphalangeal stop”) in complete extension, worn during the night, and a diurnal syndactyly with the adjacent finger (2nd with 3rd fingers and 4th with 5th fingers) (Fig. 8.7).

8.2.2.2 Healing and Remodelling Phases

The orthosis used during these phases help regaining the normal joint amplitudes.

We realize static and then dynamic orthosis depending on the evolution of the trophic disorders and ligamentous healing (Fig. 8.15).

8.3 Collateral Ligaments Sprains (Fig. 8.16)

Collateral ligament injuries in the proximal interphalangeal joint occur when there’s a trauma on an extended finger (Fig. 8.17) [4].

In case of severe sprain, radiographies can highlight a small osseous fragment on the base of the 2nd phalanx.

A surgical reinsertion can be realized if the fragment is very voluminous or in case of a joint fracture.

In less severe cases, the treatment is mostly orthotic, realizing a syndactyly with the finger adjacent to the damaged collateral ligament (Fig. 8.18).

It allows the mobilization of the finger in flexion/extension, while limiting the constraints in varus/valgus. This syndactyly is kept between 15 and 21 days.

In severe sprains, a tube-shaped orthosis associated to a compressive bandage can be realized for the first 2 days if the pain and trophic disorders are important.

The rehabilitation protocol uses similar techniques than the ones used in the treatment of the volar plate injuries, adapting the protocol to the anatomical particularities of the collateral ligaments of the proximal interphalangeal joint [10].

8.4 Dislocations [11, 12]

The dislocations are severe injuries of the proximal interphalangeal joint and can lead to stiffness if they’re not treated well.

They can be palmar, lateral or dorsal:

- *Dorsal dislocations* occur when there is a trauma in hyperextension (similar to the one in injuries of the volar plate). These dislocations lead to an avulsion of

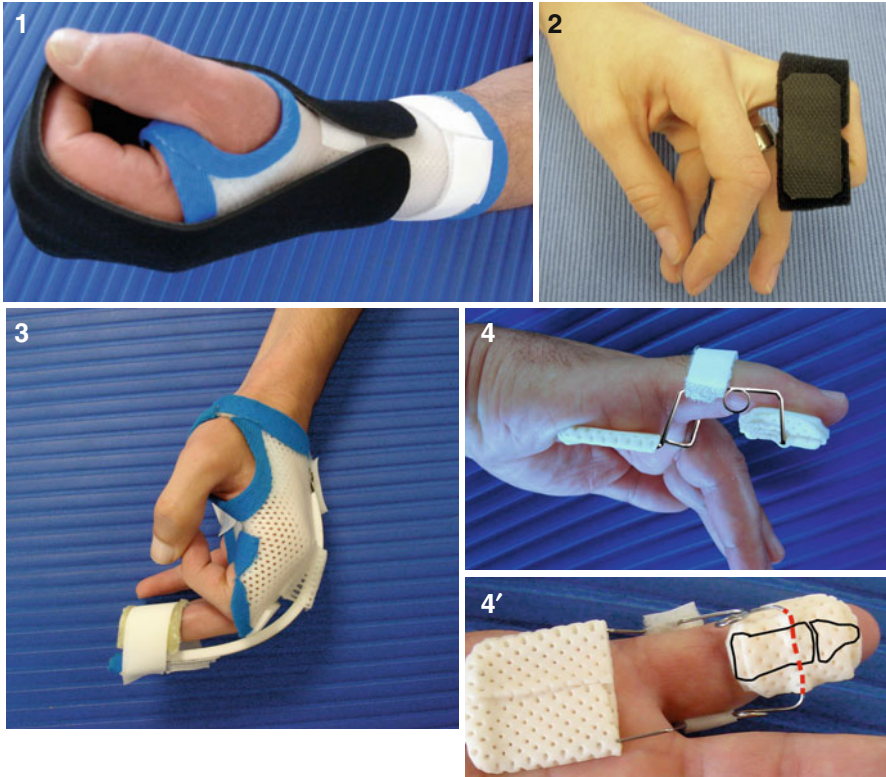


Fig. 8.15 Various dynamic orthoses, helping regaining functional amplitudes. Global finger winding (1), selective winding of the interphalangeals (2), extension of the proximal interphalangeal joint with a Levame blade (3) or Capener (4 and 4')

the volar plate at the level of its proximal insertion and associated injuries of the collateral ligaments (Fig. 8.19).

- *Lateral dislocations* occur on an extended finger (like in collateral ligaments sprains). They lead to a rupture of the collateral ligament and an associated injury of the volar plate (Fig. 8.20).
- *Palmar dislocations* occur when there is a trauma in hyperflexion. They lead to a rupture of the median strip of the extensor system and an associated injury of the principal collateral ligaments (dorsal fibres) (Fig. 8.21).

The rehabilitation and orthotic treatments of the dorsal and lateral dislocations are similar, respectively, to the treatments for the injuries of the volar plate and the collateral ligaments. The treatment of the palmar dislocations is very different. In fact, in these injuries, we realize a tubular orthosis liberating the distal interphalangeal joint

Collateral ligaments sprains in the proximal interphalangeal joints			
	Post-traumatic phase	Healing phase	Remodelling phase
R e h a b i l i t a t i o n	<p>Therapeutic goals: fight against pain and trophic disorders, prevent stiffness (flexum ++).</p> <p>Techniques: -TENS gate-control and endorphinic (100Hz and 2Hz), infrasounds, pulsed US , fluidotherapy, supple compression, draining massage. -Soft active mobilizations , active electrostimulation.</p> <p>Risks: CRPS if maladapted exercises+ flexum.</p>	<p>Therapeutic goals: same + regain amplitudes if necessary + maintain body mapping in a functional goal.</p> <p>Techniques: -Same. - More intense passive and active mobilizations, differential tendinous gliding. -Occupational therapy, manipulations for dexterity and coordination.</p> <p>Risks: same + flexum + functional exclusion.</p>	<p>Therapeutic goals: same+ global and strength exercises.</p> <p>Techniques: - Intensify the mobilization techniques (gain amplitude) , Menne), sports and professional rehabilitation - Intensify occupational therapy.</p> <p>Risks: flexum + functional exclusion + "big" proximal interphalangeal joint.</p>
Orthosis	Syndactyly 2nd-3rd fingers or 4th-5th fingers depending on the damaged ligament.	Syndactyly during risky activities -extension tube if flexum.	Dynamic pro-flexion / pro-extension orthosis.
	D0 to D21	D21 to D60	After D60

Fig. 8.16 Rehabilitation protocol for collateral ligaments sprains (no surgery)

if active extension is possible after reduction. This allows the healing of the median strip. If extension is impossible, the treatment is surgical, to reinsert the median strip. The rehabilitation and orthotic treatment of the palmar dislocations is similar to the injuries of the extensor system in zone 3. The associated injury of the posterior fibres of the collateral ligaments is one more obstacle to the recovery of the mobility.

Fig. 8.17 Injury mechanism (frontal plane)

**Collateral ligaments sprain
in the proximal interphalangeal joint**


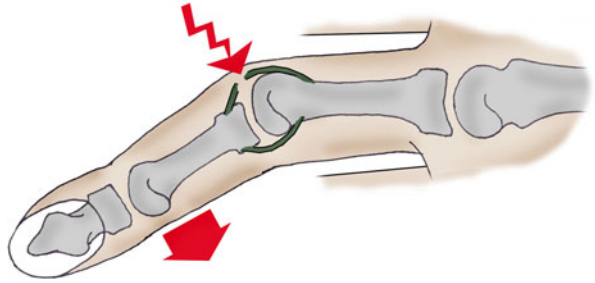


Fig. 8.18 In mild sprains, a syndactyly (15–21 days) allowing the mobility in flexion/extension can be enough

Fig. 8.19 Anatomical injuries in a dorsal dislocation (a) and radiography (b)

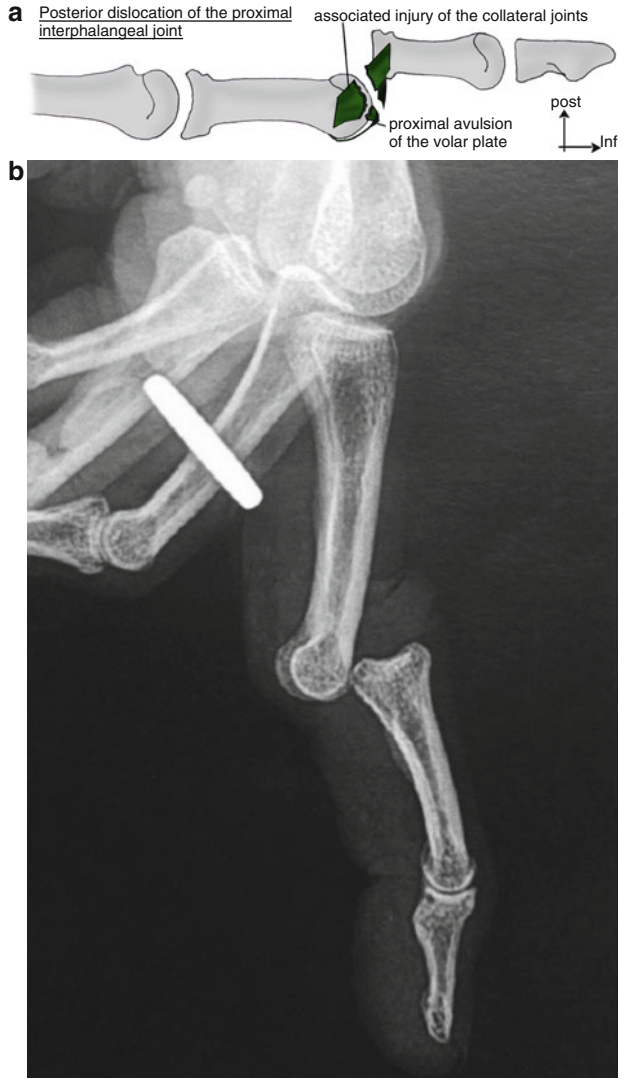

Fig. 8.20 Anatomical injuries in a lateral dislocation

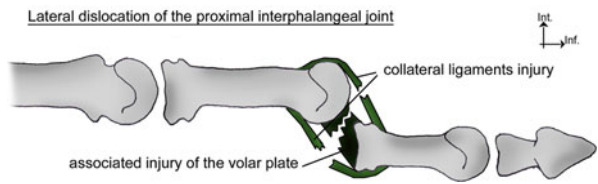
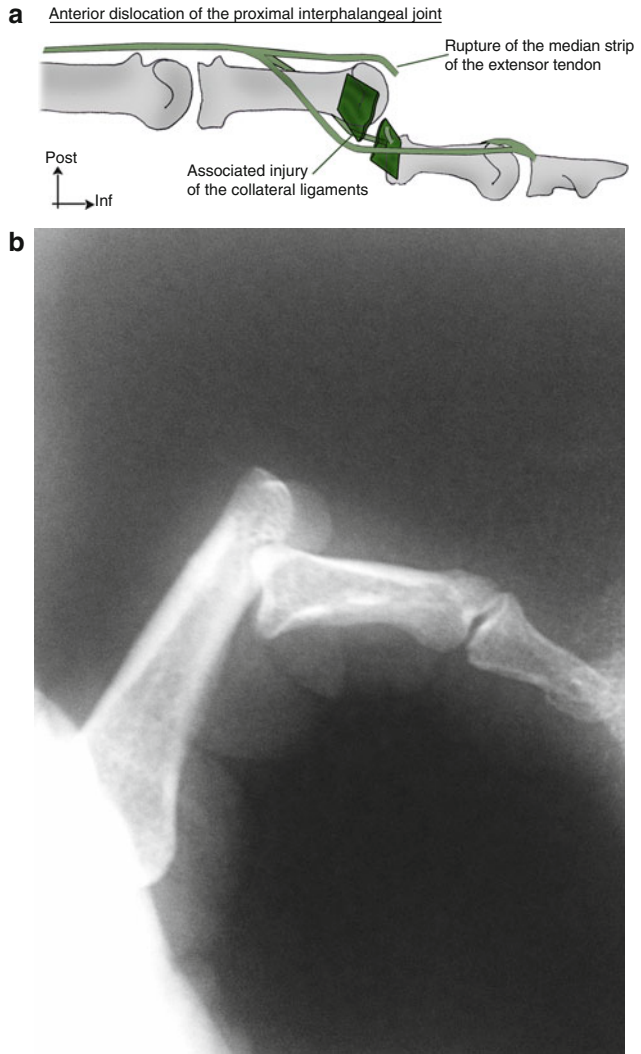


Fig. 8.21 Anatomical injuries in a palmar dislocation (a) and radiography (b)



Bibliography

1. Kapandji IA (1980) *Physiologie articulaire*, vol 1. Maloine, Paris
2. Leibovic SJ, Bowers WH (1994) Anatomy of the proximal interphalangeal joint. *Hand Clin* 10:169–178
3. Minamikawa Y, Horii E, Amadio PC et al (1993) Stability and constraint of the proximal interphalangeal joint. *J Hand Surg Am* 18:198–204
4. Kiefhaber TR, Stern PJ, Grood ES (1986) Lateral stability of the proximal interphalangeal joint. *J Hand Surg Am* 11:661–669
5. Rhee RY, Reading G, Wray RC (1992) A biomechanical study of the collateral ligaments of the proximal interphalangeal joint. *J Hand Surg Am* 17:157–163

6. Bowers WH (1986) Sprains and joint injuries in the hand. *Hand Clin* 2:93–98
7. Isel M, Merle M (2012) *Orthèses de la main et du poignet, protocoles de rééducation*. Issy-les-Moulineaux, Elsevier Masson
8. Nen L, Laulan J (2001) *Sémiologie de la main et du poignet*. Sauramps médical, Montpellier
9. Merle M, Dautel G (1995) *La main traumatique, chirurgie secondaire*. Masson, Paris
10. Egal V (1997) Entorses et luxations des doigts longs. *Revue de kinésithérapie scientifique*. 365:51, 53
11. Merle M, Dautel G (1997) *La main traumatique, L'urgence*. Masson, Paris
12. Chinchalkar SJ, Gan BS (2003) Management of proximal interphalangeal joint fractures and dislocations. *J Hand Ther* 16:117–128

Part III
Tendon Injuries of the Hand

Chapter 9

Injuries of the Extensor Tendons

Grégory Mesplié and Stéphane Lemoine

9.1 Biomechanical and Physiological Reminders

The extensor system is composed by an extrinsic system and an intrinsic system that work in synergy during the digital extension.

It is extra-synovial, except at the level of the extensor retinaculum where it is surrounded by a synovial sheath allowing its lubrication and nutrition (Fig. 9.1).

The tendons are flat, composed by longitudinal fibres and located directly under the skin.

9.2 Topographic Anatomy [1, 2]

The International Federation of Societies for Surgery of the Hand made a classification allowing us to study their physiology depending on their topography (Fig. 9.2).

G. Mesplié

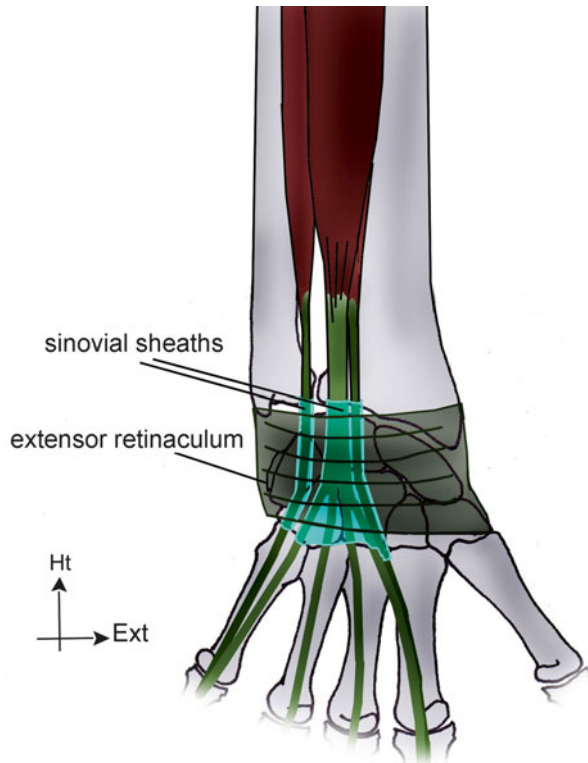
Physiotherapist and Orthotist, Institut Sud Aquitain de la Main et du Membre Supérieur,
Aguiléra Clinic Biarritz, Biarritz, France

e-mail: greg.mesplie@mac.com

S. Lemoine

Hand Surgeon, Institut Sud Aquitain de la Main et du Membre Supérieur,
Aguiléra Clinic Biarritz, Biarritz, France

Fig. 9.1 Synovial sheath of the extensor system, allowing its lubrication and nutrition



9.2.1 Long Fingers

Zone 1

It is the area where the lateral strips end and come together and insert on the base of the dorsal side of the 3rd phalanx. The tendon is not vascularized much at this level [3].

The injuries lead to a mallet finger, characterized by a drop in flexion of the distal phalanx (Fig. 9.3). These deformities can evolve to a swan-neck deformity, especially when the volar plate of the proximal interphalangeal joint is slack (Fig. 9.4).

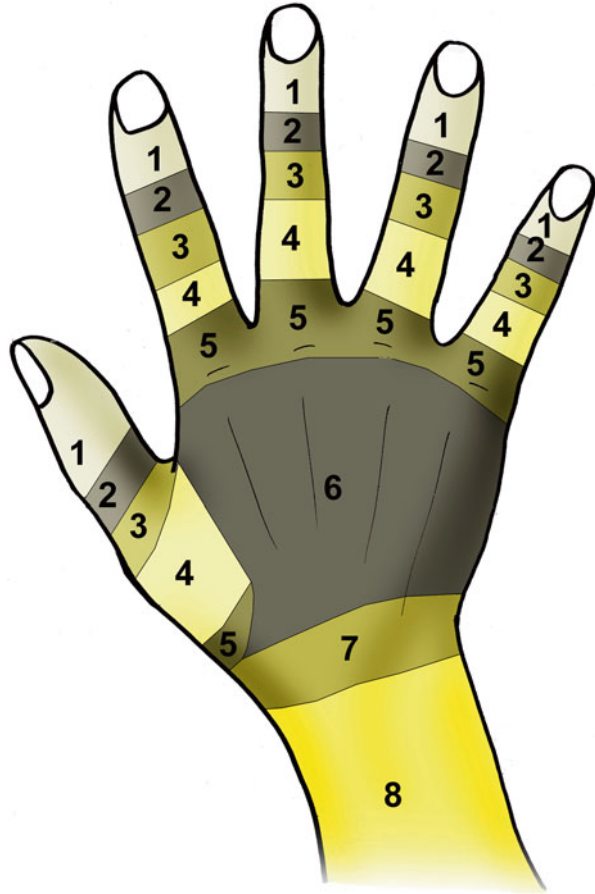
Zone 2

In this zone we find the lateral strips, next to the diaphysis of the 2nd phalanx. The deformity is the same as in zone 1, but there can be an associated injury of the oblique retinacular ligament, leading to a faster swan-neck deformity especially if the volar plate of the proximal interphalangeal joint is slack.

Zone 3

Next to the proximal interphalangeal joint is the area of trifurcation of the extensor system, forming the 2 lateral strips and the median strip ending on the base of the 2nd phalanx.

Fig. 9.2 Topographic classification of the extensors numbers of the finger zones described in the topographic anatomy



TOPOGRAPHIC CLASSIFICATION
OF THE EXTENSORS

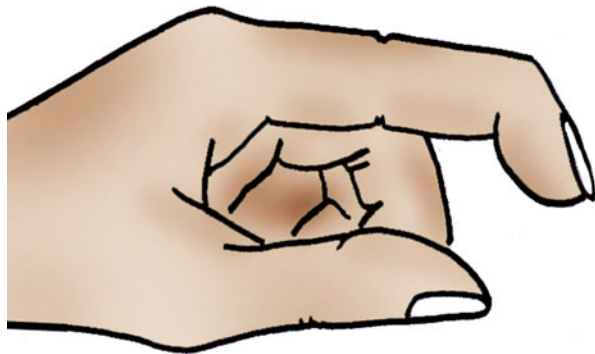


Fig. 9.3 Mallet finger

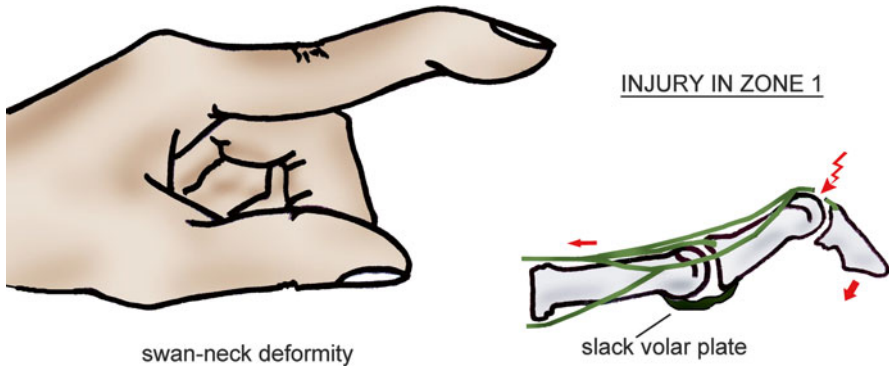
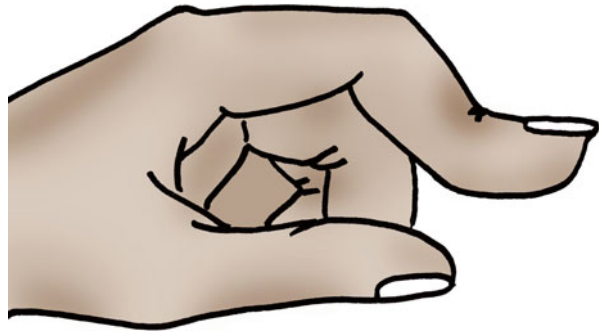


Fig. 9.4 Swan-neck deformity after a mallet finger badly treated. The tension normally applied on the 2nd and 3rd phalanges is now only applied on the 2nd phalanx. In case of slackness of the proximal interphalangeal joint, this excess of tension leads to a joint in hyperextension

Fig. 9.5 Boutonnière deformity



An isolated injury of the median strip leads to a boutonnière deformity (Fig. 9.5). The lateral strips bend towards the palm, putting the proximal interphalangeal joint in flexion and the distal interphalangeal joint in extension.

Zone 4

It is the zone next to the diaphysis of the 1st phalanx, at the level of the dorsal expansion of the interossei.

Zone 5

It is the zone next to the metacarpophalangeal joint. At this level, the extensor tendons are stabilized on the metacarpals by the sagittal strips that insert on both sides of the tendon on the inter-glenoidal ligaments (Fig. 9.6).

These stabilizing elements are tensed when the metacarpophalangeal is flexed and relaxed when it is extended.

An injury in the sagittal strip leads to a dislocation of the extensor tendon in the ulnar inter-metacarpal area, as the extensor system is decentred relative to the axis of the metacarpophalangeal joints. Therefore, the injuries of the ulnar sagittal strip do not lead to a dislocation of the extensor tendon in the radial inter-metacarpal area (Fig. 9.7).

Fig. 9.6 At the level of the metacarpophalangeal joints, the sagittal strips stabilize the extensor tendons in the frontal plane

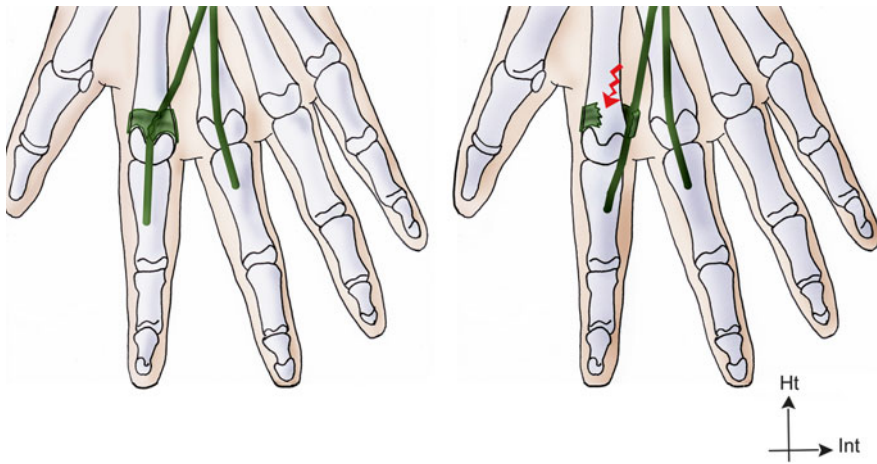
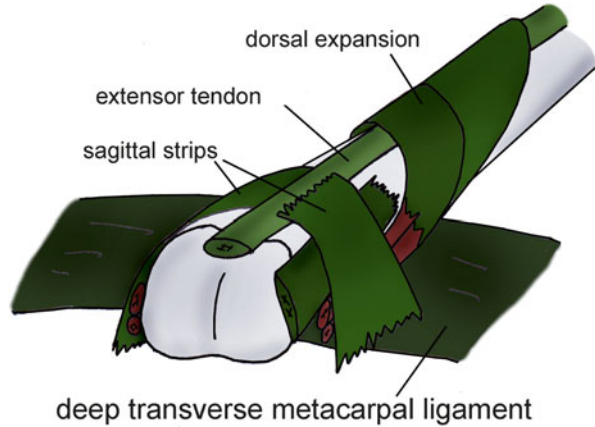


Fig. 9.7 Injury of the radial sagittal strip of the index, leading to a dislocation of the extensor tendon in the inter-metacarpal area

Zone 6

The extensor tendons pass along the dorsal side of the metacarpals. At this level, there are some inter-tendinous junctions that connect the extensor tendons. If there is an injury above the inter-tendinous junctions, the extension deficit will be small, because it is partly compensated by the adjacent tendons (Fig. 9.8).

Zone 7

The tendons slide in the synovial sheath next to the extensor retinaculum. Unlike the extensor indicis, the extensor digiti minimi has its own sheath (Fig. 9.9).

Zone 8

It is the zone above the extensor retinaculum, until the myotendinous junction.

Fig. 9.8 Inter-tendinous junctions in zone 6

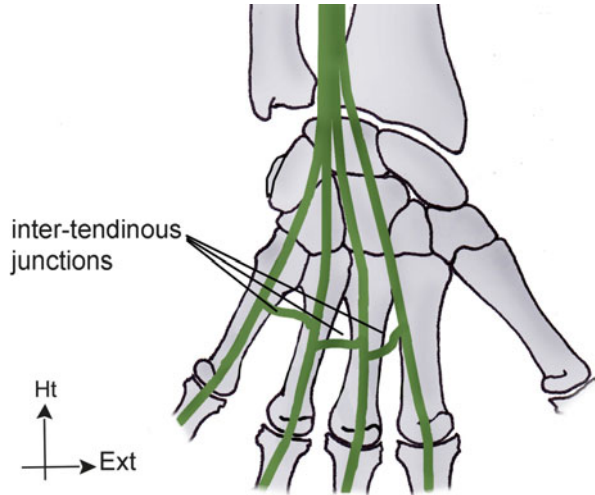
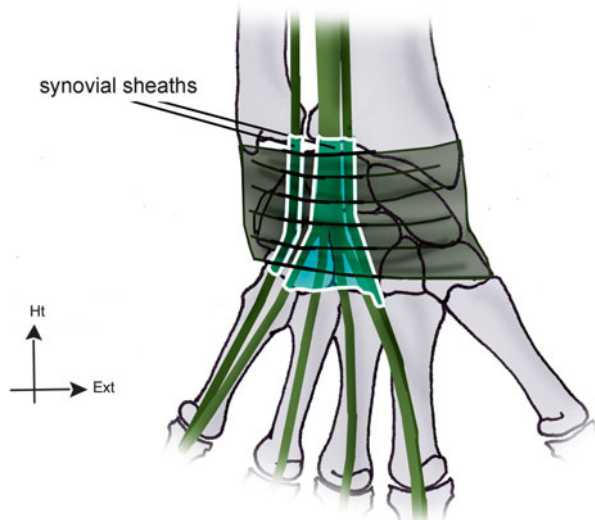


Fig. 9.9 Unlike the extensor indicis, the extensor digiti minimi has its own sheath



9.2.2 Thumb

The extensor system of the thumb also depends on an extrinsic system made by the extensor pollicis brevis and the extensor pollicis longus and an intrinsic system made by the sesamoid muscles. The abductor pollicis brevis and the flexor pollicis brevis form the radial part of the dorsal expansion, and the adductor pollicis forms the ulnar part.

9.3 Physiology

9.3.1 *Nutrition of the Extensor Tendons*

Like the flexor tendons, the nutrition of the extensor tendons depends on an intrinsic system and an extrinsic system. Unlike the flexor tendons, the extrinsic system is the main actor during the tendon healing.

The extensor system is, in fact, mostly extra-synovial, which limits the synovial imbibition role it has at the level of the extensor retinaculum (intrinsic healing by a “synovial pump” effect), and favours the extrinsic healing.

This type of healing leads to important adhesences.

9.3.2 *Biomechanics*

The finger extension depends on two synergic systems:

9.3.2.1 **Extrinsic System**

This system is made by the extensor digitorum, the extensor indicis and the extensor digiti minimi.

Its isolated contraction brings the metacarpophalangeal joint in extension but does not lead to an extension of the interphalangeal joints. The extensor digitorum exhausts its action on its proximal insertions, leading to a “claw” deformity.

9.3.2.2 **Intrinsic System**

It is composed by the interossei and the lumbrical muscles that join the extrinsic system at the level of the dorsal expansion of the interossei to form a complex group that ensures the harmony of the digital extension.

The interossei have various endings along the digital chain, which allows them to have various actions, depending on the situation:

- *On a deep plane*, the endings on the lateral tubercles of the 1st phalanx allow them to separate the fingers and bring them closer to each other and to participate in the lateral stability of the metacarpophalangeal joint.
- *On a superficial plane*, they form the dorsal expansion of the interossei next to the metacarpophalangeal joint and give off more distal fibres that reinforce the median strip of the extensor tendon and others associated to the corresponding lumbrical muscles to join the lateral strips. If the metacarpophalangeal joint is extended, the contraction of the interossei brings the interphalangeal joints in extension. If the metacarpophalangeal is flexed, it favours the interphalangeal flexion by relaxing the extensor system (Fig. 9.10).

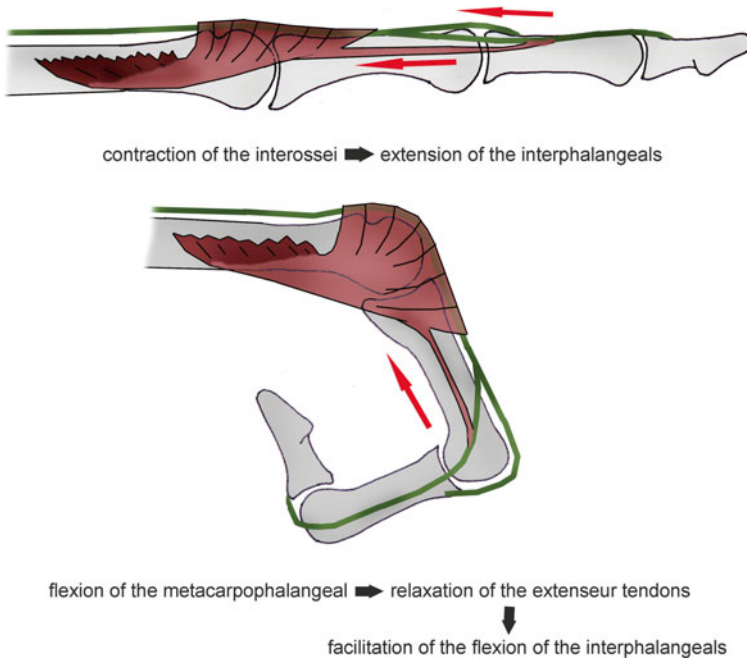


Fig. 9.10 The interossei realize an extension of the interphalangeals when the metacarpophalangeal is extended but favour the flexion of the interphalangeals when the metacarpophalangeal is flexed

The lumbrical muscles insert on the flexor digitorum profundus at the level of the palm, pass in front of the inter-glenoidal ligament on the radial side and end on the corresponding lateral strip. They play a proprioceptive role, dividing the tension between the 2 systems, which explains the incredible number of mechanoreceptors they contain (Fig. 9.11).

They also have an extension action in the distal phalanx, regardless of the position of the metacarpophalangeal joint.

9.3.2.3 Retinacular Ligaments

The retinacular ligaments also play an important role in the coordination of the 2 last phalanges by a tenodesis effect:

- *Transverse retinacular ligament*, anchored on the A3 pulley for the proximal half and on the volar plate and the capsule of the proximal interphalangeal joint for the distal part. It goes vertically towards the corresponding lateral strip of the extensor system. It favours the palmar movement of the lateral strips during the flexion of the proximal interphalangeal joint. It forms, with the oblique retinacular ligament, the lateral retinacular ligament (Fig. 9.12).
- *Oblique retinacular ligament*, anchored on the flexor sheath next to the diaphysis of the 1st phalanx. It passes in front of the flexion axis of the proximal

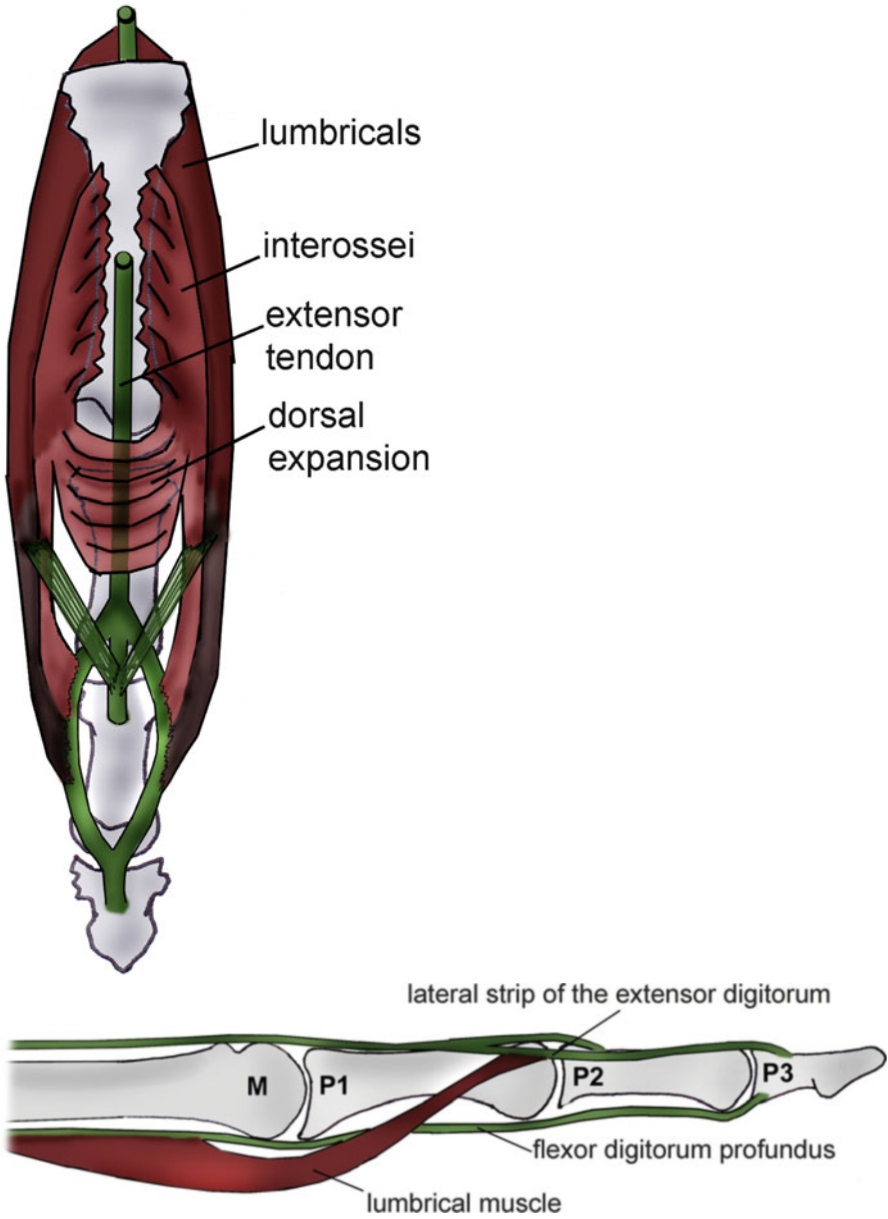


Fig. 9.11 The lumbrical muscles are very sarcomeric and contain a lot of mechanoreceptors. They play an important proprioceptive role regulating the tensions between the flexor system and the extensor system

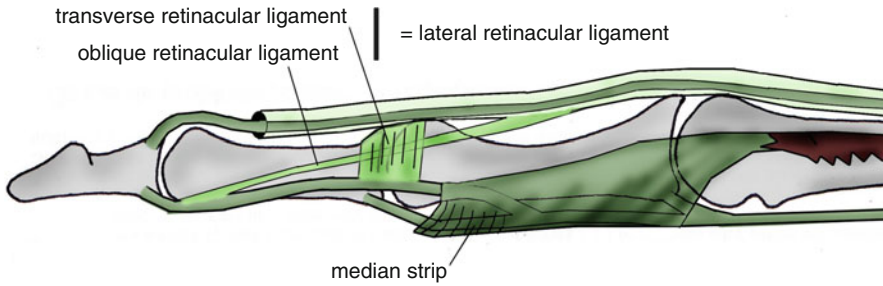


Fig. 9.12 The transverse retinacular ligament participates in the stabilization of the lateral strips, preventing their movement towards the dorsal area. The median strip prevents their movement towards ventral area

interphalangeal joint to join the extensor system at the level of the distal interphalangeal joint. This ligament allows the coordination of the distal and proximal interphalangeal joints in flexion and extension. During the flexion of the distal interphalangeal joint, the oblique retinacular ligament gets tensed, automatically leading to a flexion of the proximal interphalangeal joint. During the extension of the proximal interphalangeal joint, the oblique retinacular ligament gets tensed, automatically bringing the distal interphalangeal joint in extension (Figs. 9.13 and 9.14).

Thanks to those two elements, there is a functional coordination between the two interphalangeals that can move only in the same direction, forming a functional unit: the interphalangeal system.

9.3.3 *Extension Dynamics and Tendon Race [4, 5]*

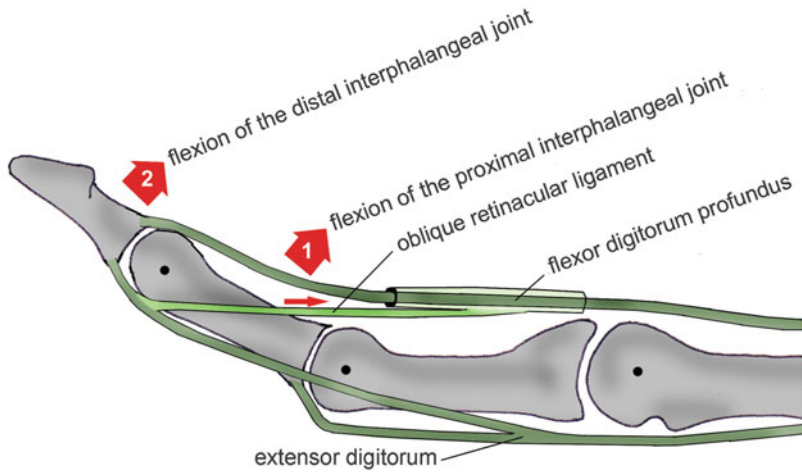
The extension of the fingers starts with the metacarpophalangeal joint, through the action of the extensor digitorum.

The contraction of the lumbrical muscles opposes the tension of the flexor digitorum profundus and therefore the formation of a “claw”.

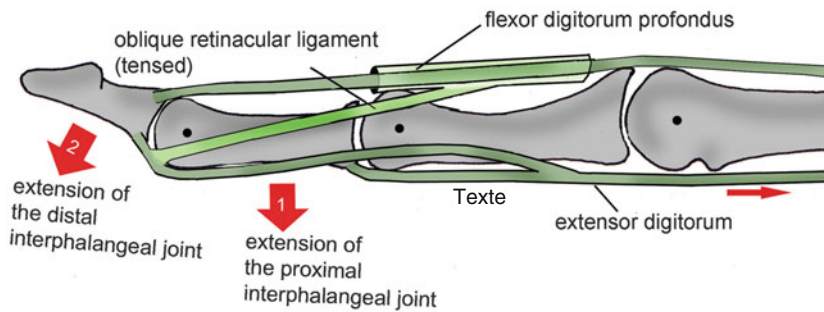
The contraction of the interossei also participates, through the dorsal expansion, in this fight against the “claw”. Combined with the contraction of the extensor digitorum, it brings the proximal interphalangeal joint in extension.

The extension of the proximal interphalangeal joint brings the distal interphalangeal joint in extension by putting the oblique retinacular ligament in tension (tenodesis effect).

The tendinous race of the extensor system during the complete extension of the fingers is 15 mm on the back of the hand, 4 mm on the back of the 1st phalanx, 6 mm at the level of the proximal interphalangeal joint and 3 mm at the level of the distal interphalangeal joint.



ACTION OF THE OBLIQUE RETINACULAR LIGAMENT IN THE FLEXION OF THE INTERPHALANGEALS



ACTION OF THE OBLIQUE RETINACULAR LIGAMENT IN THE EXTENSION OF THE INTERPHALANGEALS

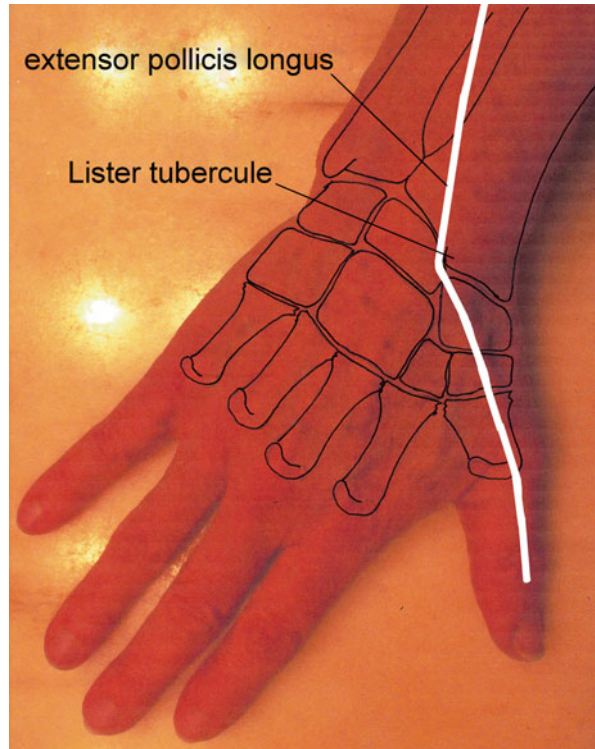
Figs. 9.13 and 9.14 The oblique retinacular ligament favours the functional coordination between the distal and proximal interphalangeal joints. The extension of the proximal interphalangeal joint tenses it, which leads to an extension of the distal interphalangeal joint. The flexion of the distal interphalangeal joint is only possible if the proximal interphalangeal joint is flexed (relaxation of the oblique retinacular ligament). The flexion of the distal interphalangeal joint is impossible while the proximal interphalangeal is in extension, as the oblique retinacular ligament is in tension

9.4 Physiopathology [6–8]

There are two types of injuries of the extensor system:

- *Subcutaneous rupture*: the most frequent is at the level of the distal interphalangeal joint and leads to a mallet finger. We can also observe this injury at the level of the metacarpophalangeal joint after a punch that causes a rupture of the sagittal strip and a dislocation of the extensor in the inter-metacarpal area. In the thumb, the injury is most often in the extensor pollicis longus at the level of the Lister tubercle, where the muscle changes its direction (Fig. 9.15).

Fig. 9.15 The Lister tubercle is a “risky” area for the extensor pollicis longus, as the muscle changes its direction at this level, which increases the constraints on it



- *Open traumas*: they most often affect the index or the thumb. The severity depends on the nature of the device that has damaged the extensor system and on the associated injuries. In traumas by crushing, the dorsal abrasions and infectious factors worsen the functional prognosis.

9.5 Clinical and Paraclinical Signs [9, 10]

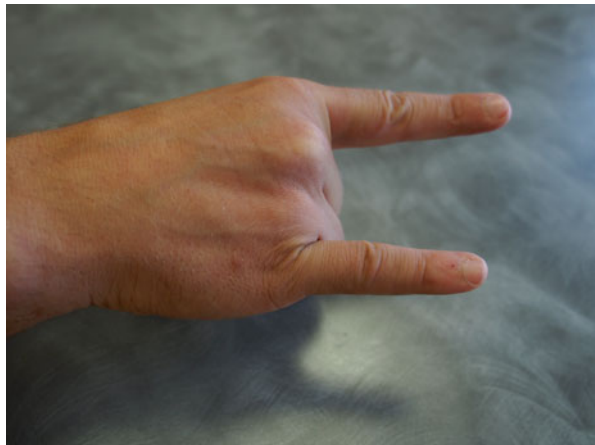
Various clinical tests make it possible to determine an injury of the extensor system:

- *Extensor pollicis longus*: with the hand lying flat on the table, the patient is asked to lift the thumb from the table (Fig. 9.16).
- *Extensor pollicis brevis*: we ask the patient to attempt an extension of the metacarpophalangeal joint.
- *Extensor indicis and extensor digiti minimi*: we ask the patient to make a selective extension of the index and the little finger (“make horns”) (Fig. 9.17).
- *Extensor digitorum*: the patient must be able to realize a selective extension of the phalanges against resistance. If there is an injury above the inter-tendinous junctions, a relative compensation can be realized by the adjacent extensor tendons. The extension of the 3rd phalanx can only be realized with the proximal interphalangeal

Fig. 9.16 If the patient cannot lift his thumb from the table, the extensor pollicis longus is probably broken



Fig. 9.17 “Horn” test verifying the integrity of the extensor indicis and extensor digiti minimi



joint in extension, thanks to the relaxation of the median strip allowing an action of the lateral strips. If the extension of the distal interphalangeal joint is possible with the proximal interphalangeal joint in flexion, it means there is a rupture of the median strip. The tension of the median strip relaxes the lateral strips, making them inactive on the distal interphalangeal joint (we say that the 3rd phalanx is “dangling”). This phenomenon is the physiological base of the Elson test (Fig. 9.18).

9.6 Therapeutic Process and Surgical Treatment

9.6.1 Orthopedic Treatment

The subcutaneous injuries in zones 1, 2, and 3 are most often treated by a strict immobilization during 8 weeks, with a nocturnal immobilization for 15 more days if the patient cannot lock in extension at the end of the 8 weeks.

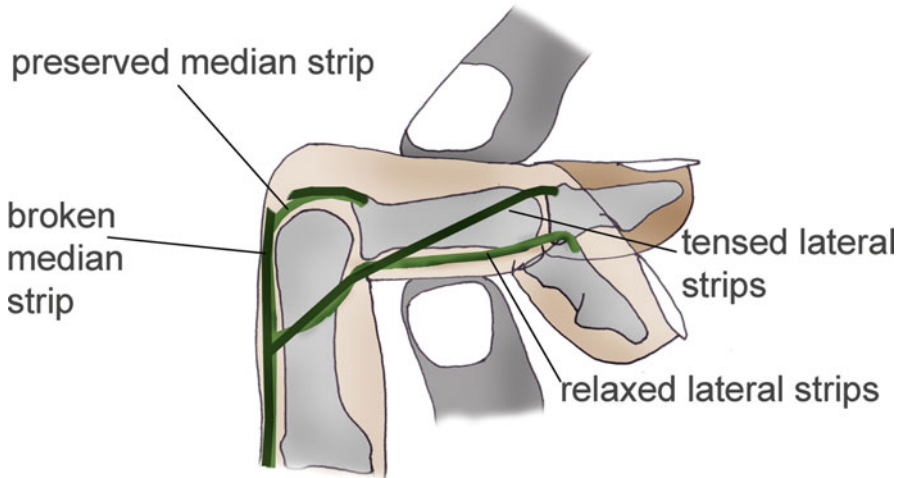


Fig. 9.18 Elson test: if the median strip is broken, the flexion of the proximal interphalangeal joint does not relax the lateral strips. The lateral strips keep their efficiency and are able to realize an extension of the distal interphalangeal joint

9.6.2 Surgical Treatment [11]

The wounds are the most frequent injuries of the extensor tendons. The extensor tendons are, in fact, very superficial, subcutaneous on the dorsal part of the hand and wrist. Therefore, they are very exposed in case of wound.

The proximity of the joints imposes the systematic search of an associated articular wound. As the integuments are very thin (mainly at the level of the fingers), the losses of cutaneous substances are frequent, which leads to realizing cutaneous flaps because of the articular or tendinous exposure.

The dissection will be atraumatic, and we will avoid delamination, which leads to secondary stiffness. If a tendinous trimming is necessary, it will have to be as economic as possible to avoid an excessive shortening of the tendon.

There also is a non-negligible proportion of subcutaneous ruptures (traumatic or degenerative) of the extensor tendons, which share a certain number of characteristics with the open injuries.

The tendinous repair will have to be strong enough to allow an immediate mobilization in a protected area.

The extensor tendons have different shapes and calibre depending on the area; therefore, the suture technique has to be adapted.

Zone 1

With the ending strip being flat and thin, we have to realize an overlock suture with a thin thread (5/0) with slow resorption. It is possible to put the distal interphalangeal

joint in hyperextension to draw the tendinous edges together while realizing the suture. The immobilization will place the distal interphalangeal joint straight for a minimal duration of 6 weeks.

Zone 2

In this zone, the lateral strips are also very thin; their repair will also be made with a thin thread with slow resorption. Realizing an overlock is not always possible, so we can use U- or X-shaped stitches that decrease the tension on each thread.

The immobilization is the same as in zone 1.

Zone 3

Next to the proximal interphalangeal joint, the isolated section of the median strip can lead to a boutonnière deformity.

In most cases, we use a trans-osseous reinsertion device (metallic or resorbing anchor) to firmly fix the median strip. Like in zone 1, we can use a temporary trans-articular oblique arthrodesis broche (3 weeks) that will allow a strict immobilization in extension of the proximal interphalangeal joint.

If the lateral strips are damaged too, they will be repaired in the same way as in zone 2.

Zone 4

In zone 4, the extensor tendon becomes thicker and larger, which allows the realization of overlocks with a slow resorption thread 4/0. We will make sure to search for an associated injury of the dorsal expansion of the interossei on the lateral sides of the extensor tendons.

Zone 5

The repair of the extensor tendon will be realized with multi-thread stitches, associated with a peripheral overlock. The difficulty here is to keep the sagittal balance of the tendon to avoid its dislocation in the inter-metacarpal area. In order to achieve this, we will have to systematically search and suture every injury of the sagittal strips.

Zone 6

In zone 6, the extensor tendons become rounder than at the level of the fingers. If there is a wound, there usually is not any retraction of the proximal edge, which is kept by the inter-tendinous junctions. We make the sutures with a slow resorption thread 4/0.

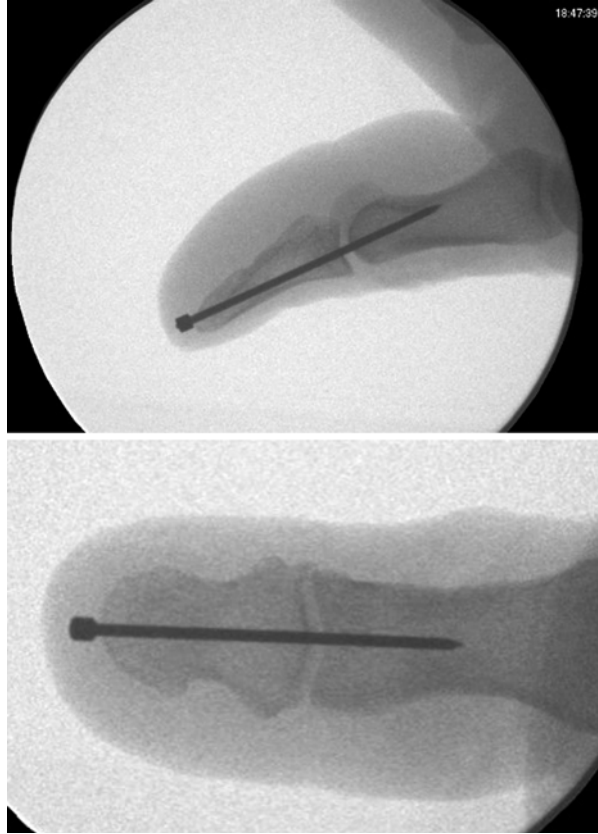
Zone 7

The repair of the tendon in zone 7 will be done with a multi-thread stitch, using a slow resorption thread 4/0 (Kessler or Tsuge), combined with a peripheral overlock with a thinner thread 5 or 6/0. At the end of the suture, we must ensure there is not any conflict against the extensor retinaculum, and a Z-plasty of the retinaculum may be necessary.

Zone 8

It is a rare injury, which repair is done with a classic suture with a slow resorption thread 4/0.

Figs. 9.19 and 9.20 Temporary arthrorise broche of the interphalangeal of the thumb, postoperative radiosopic control



9.6.3 Thumb

The repair of the tendons of the thumb follows the same rules as at the level of the similar zones of the long fingers. The immobilization of the interphalangeal joint for a rupture of the median strip in zone 1 can call for an arthrorisis pin (Figs. 9.19 and 9.20), given that the isolated immobilization of this joint is difficult.

9.7 Rehabilitation and Orthosis [8, 12]

9.7.1 After an Orthopedic Treatment [13–16]

9.7.1.1 Subcutaneous Injuries in Zones 1 and 2 (Mallet Finger)

(Protocol 9.1) [17]

The subcutaneous injuries in zones 1 and 2 correspond with a damage of the lateral strips of the extensor system (Fig. 9.21).

<i>Subcutaneous injury of the extensors in zones 1-2/Mallet finger</i>			
	Immobilization phase (A)	Fragility phase (B)	Solidity phase (C)
REHABILITATION	<p>Therapeutic goals: tendon healing, maintain the mobility of the proximal interphalangeal joint.</p> <p>Techniques:</p> <ul style="list-style-type: none"> - Learning the protection rules during the maintenance of the orthosis (+ control by the orthotist once a week). - Active self-mobilizations of the proximal interphalangeal joint. <p>Risks: bad tendon healing, stiffness of the proximal interphalangeal joint.</p>	<p>Therapeutic goals: same, intensifying the techniques from the phase A if necessary (stiffness). Fight against pain and trophic disorder, regain the active amplitudes of the distal interphalangeal joint, and maintain the body mapping.</p> <p>Techniques:</p> <ul style="list-style-type: none"> - Orthosis worn at night during 15 days (A1), specific and global mobilizations of the proximal interphalangeal joint (A2). - Massages, fluidotherapy, transcutaneous vibratory stimulations, depressotherapy, electrotherapy. - Active exercise in flexion of the distal interphalangeal joint returning to extension with an active-assisted movement, then simple active exercise (depending on the locking). Electrostimulation in winding if the extension locking is ok. - Electrostimulations. - Manipulations, occupational therapy. <p>Risks: same as in phase A, functional exclusion</p>	<p>Therapeutic goals: intensify the techniques from the 2 previous phases if necessary, regain clamping strength, complete functional recovery.</p> <p>Techniques:</p> <ul style="list-style-type: none"> - Specific joint mobilizations, increasing the electrostimulation's electric intensities, and stretching the intrinsic muscles (B2). - Exercise for the intrinsic and extrinsic strengths. - Functional and leisure exercises. <p>Risks: same as in phases A and B.</p>
	ORTHOSES	Stack orthosis (worn all the time).	Stack orthosis worn during the night if no locking.
D0 to D60		D60 to D90	After D90

Protocol 9.1 Protocol for the mallet finger

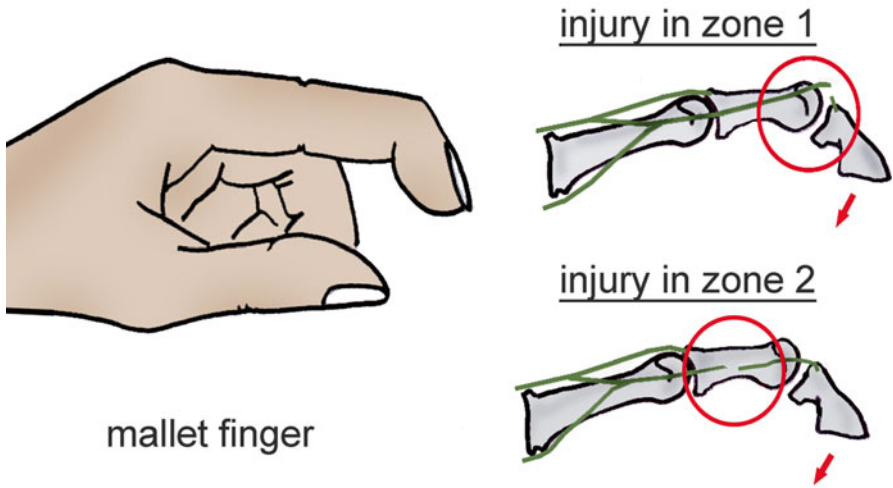
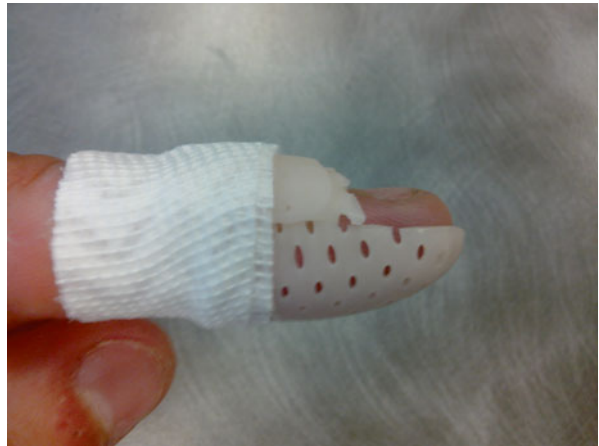

Fig. 9.21 The injuries in zone 2 are injuries of the lateral strips

Fig. 9.22 Stack orthosis



During the period of strict immobilization, we use a stack orthosis realized with a thin (1.6 mm) micro-perforated plastic (Fig. 9.22).

The strict immobilization lasts 8 weeks, controlling the orthosis and weekly changing the bandage.

We can prolong the wearing of the orthosis during the night for 2 weeks if there is an incomplete extension of the distal interphalangeal joint.

D0 to D60 (Immobilization)

Asides from the advice of self-mobilization of the proximal interphalangeal joint, the rehabilitation is not essential from D1 to D60, but we ask the patient to come in for a control of the orthosis once a week to limit the risks associated with this type of treatment (cutaneous state, observance of the instructions, etc.).

The active mobilization of the proximal interphalangeal joint does not tense the lateral strips of the extensor system (Fig. 9.23). It is essential in this phase to avoid stiffness.

D60 to D90 (Fragility)

This phase corresponds with the end of the immobilization, keeping the orthosis at night if the active extension locking of the distal interphalangeal joint is not reached.

The goals of the rehabilitation during this phase are as follows.

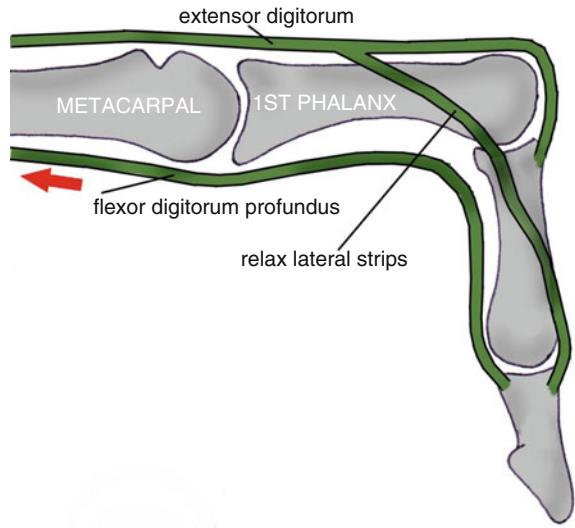
Fight Against Trophic Disorders and Pain

- *Massages*: trophic and analgesic goals, around the tendinous healing area. This area can stay inflammatory during various months.
- *Transcutaneous vibratory stimulations*: 70 Hz frequency on the extensor system if we want to improve the proprioceptive aspect or 100 Hz on the painful areas if we want an analgesic effect (Fig. 9.24).
- *Depressotherapy*: on the healing area, preferring to the disto-proximal movements of the hand (Fig. 9.25).
- *Electrotherapy*: 1 Hz to fight against inflammation or electroactive to regain the active amplitudes (without excessive tension).

Progressive Recuperation of the Joint Amplitudes

- *Recuperation of the active and passive amplitudes of the proximal interphalangeal joint*: this exercise is not always necessary, as it is part of the self-rehabilitation exercises proposed to the patient from D0 to D60.
- *Fluid therapy*: not if there is no inflammation anymore to improve viscoelasticity of the tissues and therefore mobility.
- *Active exercise for the flexion of the distal interphalangeal joint, active-assisted then active extension*: the flexion of the distal interphalangeal joint is realized actively only to limit the risks of excessive tension on the tendinous callus. In the first sessions, the patient returns to the extension position with passive and active-assisted movements then with a simple active movement when the active extension locking is reached (Fig. 9.26).
- *Specific mobilizations of the proximal interphalangeal joint*: realized if there still is stiffness in the joint (loss of the intra-articular glidings) (Fig. 9.27).

Fig. 9.23 The mobilization of the proximal interphalangeal joint puts the median strip in tension, which leads to a relaxation of the lateral strips



ACTIVE FLEXION OF THE PROXIMAL METACARPOPHALANGEAL JOINT (DORSAL VIEW)

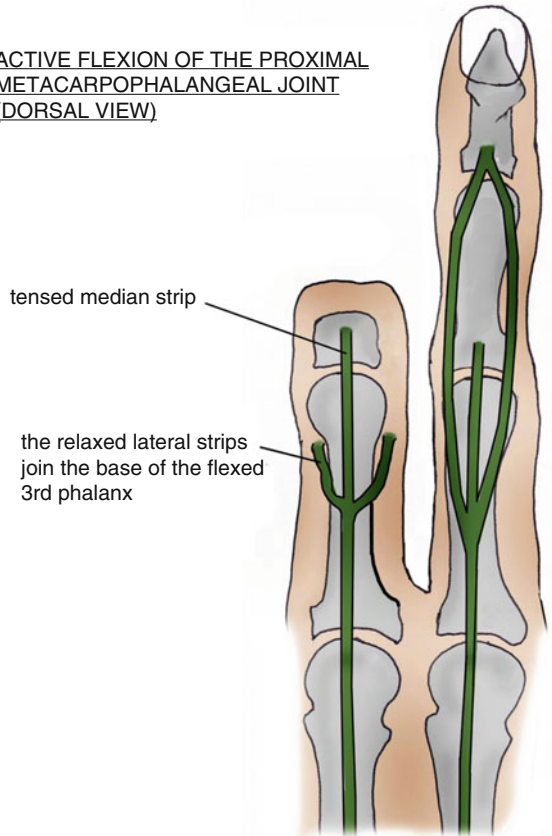


Fig. 9.24 Transcutaneous vibratory stimulation with a proprioceptive or analgesic effect, depending on the frequency



Fig. 9.25 Depressotherapy to relax the scar and fight against the oedema

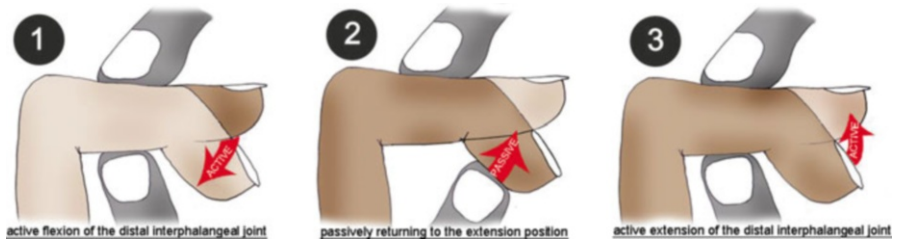
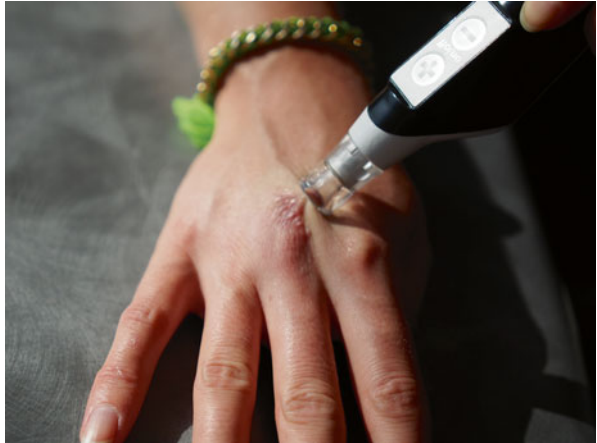

Fig. 9.26 Progressive mobilizations to limit the constraints on the tendinous callus

Fig. 9.27 Specific mobilizations of the proximal interphalangeal joint (Mennel)




Fig. 9.28 Functional exclusion of the index (rare, but must be carefully monitored)



Maintaining the Body Mapping

The “blinding” of the finger pulp during 2 months, related to the stack orthosis, can lead to a perturbation in the body mapping (until functional exclusion of the concerned finger).

These disorders essentially concern the index (Fig. 9.28) and are treated stimulating the mechanoreceptors of the pulp of the concerned finger and working with simple and complex grips.

The patient recognizing this trouble is an essential element in the treatment success (Fig. 9.29).

Fig. 9.29 Syndactyly participating in the reintegration of the index in the grips



Fig. 9.30 Finochietto test, the retraction of the intrinsic muscles makes it impossible to actively mobilize in the extrinsic + position



After D90 (Solidity)

This phase corresponds with the patient going back to doing all of his sports and professional activities.

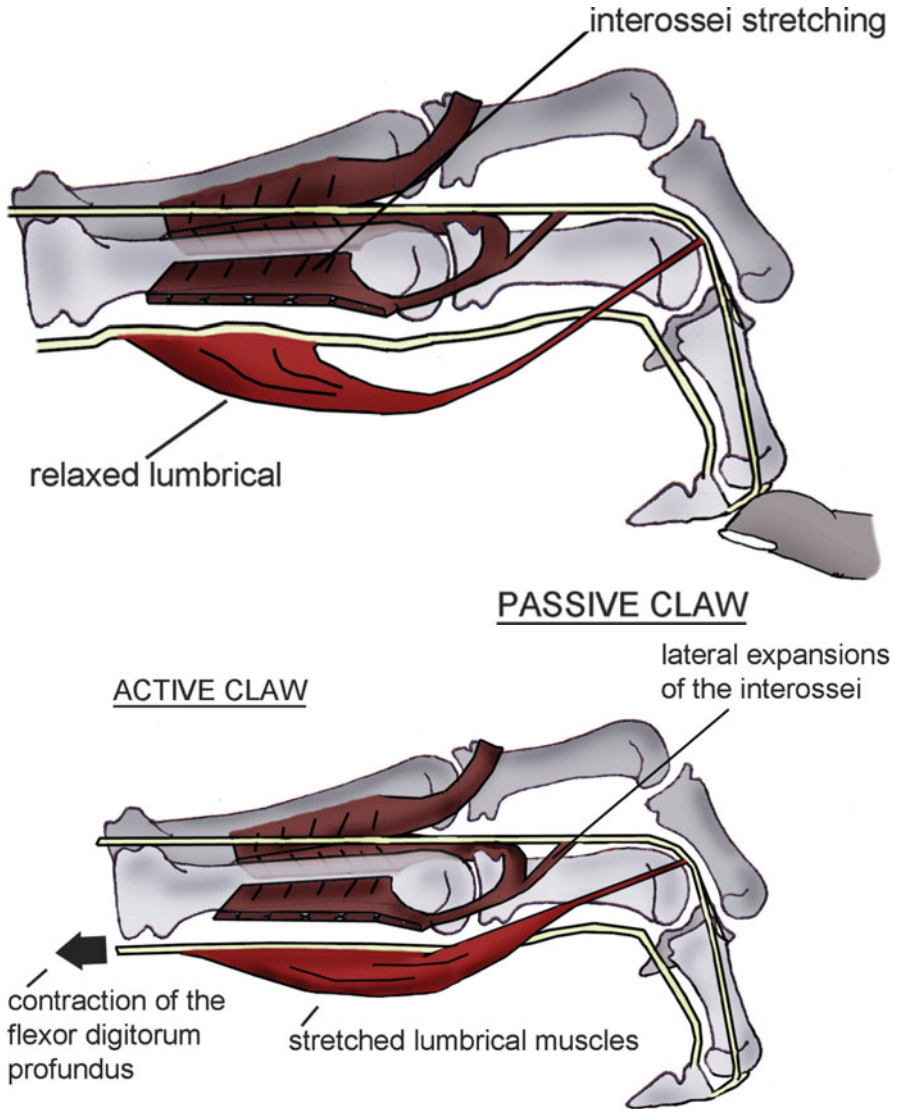
The rehabilitation is focused on the complete rehabilitation of the joint amplitudes, the strength of the hand and wrist, the complex grips, the proprioception and the digital dexterity.

Specific Mobilizations of the Proximal and Distal Interphalangeal Joints

Regaining the intra-articular glidings is essential in the good recuperation of the amplitudes and the decrease of the resistances to movement. These glidings are realized in all the planes, without pain or tension on the tendinous callus.

Stretching the Intrinsic Muscles

These stretchings are realized if the Finochietto test is positive, meaning there is a retraction of the intrinsic muscles (Fig. 9.30).



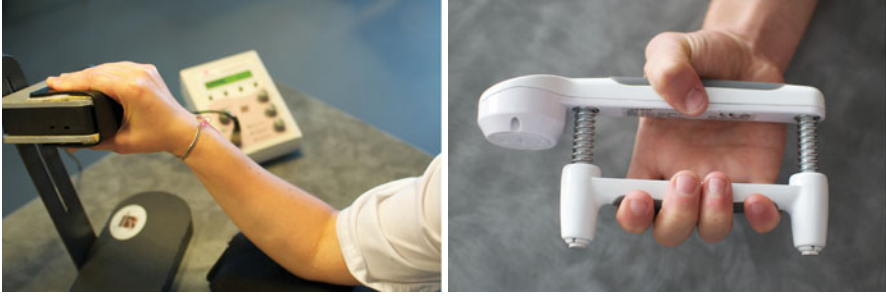Figs. 9.31 and 9.31' The lumbrical muscles are stretched if we actively place the fingers in the extrinsic + position and not if we place them passively

We stretch the interossei passively placing the hand in the “extrinsic +” position.

To stretch the lumbrical muscles, this position must be actively maintained (Figs. 9.31 and 9.31').

Recuperation of the Strength and Proprioception

Rebalancing the muscular ratios, in particular between the extrinsic and intrinsic systems, is realized comparing with the same side with dynamometers (Figs. 9.32 and 9.32'). It is combined with an exercise for dexterity and coordination, adapted to the patient's functional needs.



Figs. 9.32 and 9.32' Using dynamometers allows evaluating eventual muscular unbalances (here between the extrinsic (32') and intrinsic (32) forces)

9.7.1.2 Subcutaneous Injuries in Zone 3 (Boutonnière Deformity) (Protocol 9.2)

These injuries correspond with a damage of the median strip of the extensor system (Fig. 9.33).

We immobilize the proximal interphalangeal joint strictly in extension, leaving the distal interphalangeal joint free, by realizing a tube-shaped orthosis with a thin (1.6 mm) micro-perforated plastic. This orthosis is controlled every week to check the pressure points and adapt it to the trophic evolution of the damaged finger (Fig. 9.34).

D0 to D60 (Immobilization)

As for the subcutaneous injuries in zones 1 and 2, the rehabilitation is not necessary and only consists in a regular control of the orthosis and self-rehabilitation advices.

The analytic flexion of the distal interphalangeal joint tenses the lateral strips but not the median strip (Fig. 9.35).

It also puts in tension the oblique retinacular ligament, which tends to retract and fix the boutonnière deformity.

D60 to D90 (Fragility)

In this phase, we stop the immobilization, keeping the orthosis during the night if the active locking of the proximal interphalangeal joint in extension has not been reached.

The rehabilitation goals in this phase are:

Fight Against Trophic Disorders and Pain

The techniques used are identical to the ones used in the injuries in zones 1 and 2.

<i>Subcutaneous injury of the extensors in zone 3 Boutonnière deformity</i>			
	Immobilization phase (A)	Fragility phase (B)	Solidity phase (C)
R E H A B I L I T A T I O N	<p>Therapeutic goals: tendon healing, maintain the mobility of the distal interphalangeal joint.</p> <p>Techniques: - Learning the protection rules during the maintenance of the orthosis (+ control by the orthotist once a week). - Active self-mobilizations of the distal interphalangeal joint</p> <p>Risks: bad tendon healing, stiffness of the distal interphalangeal joint.</p>	<p>Therapeutic goals: same, intensifying the techniques from phase A if necessary (stiffness). Fight against pain and trophic disorders; regain the active amplitudes of the proximal interphalangeal joint.</p> <p>Techniques: - Orthosis worn at night during 15 days (A1), specific and global mobilizations of the distal interphalangeal joint (A2). - Massages, fluidotherapy, transcutaneous vibratory stimulations, depressotherapy, electrotherapy. - Active exercise in flexion of the proximal interphalangeal joint returning to extension with an active-assisted movement, then simple active exercise (depending on the locking). Electrostimulation in winding if the extension locking is ok. - Electrostimulations. - Manipulations, occupational therapy.</p> <p>Risks: same as in phase A.</p>	<p>Therapeutic goals: intensify the techniques from the 2 previous phases if necessary, regain clamping force, complete functional recovery.</p> <p>Techniques: - Specific joint mobilizations, increasing the electrostimulation's electric intensities, and stretching the intrinsic muscles (B2). - Exercise for the intrinsic and extrinsic strengths. - Functional and leisure exercises.</p> <p>Risks: same as in phases A and B.</p>
	OR TH ES IS	Digital orthosis liberating the distal interphalangeal joint (worn all the time).	Orthosis from phase (A) worn during the night if the locking isn't efficient.
	D0 to D60	D60 to D90	After D90

Protocol 9.2 Protocol for the boutonnière deformity

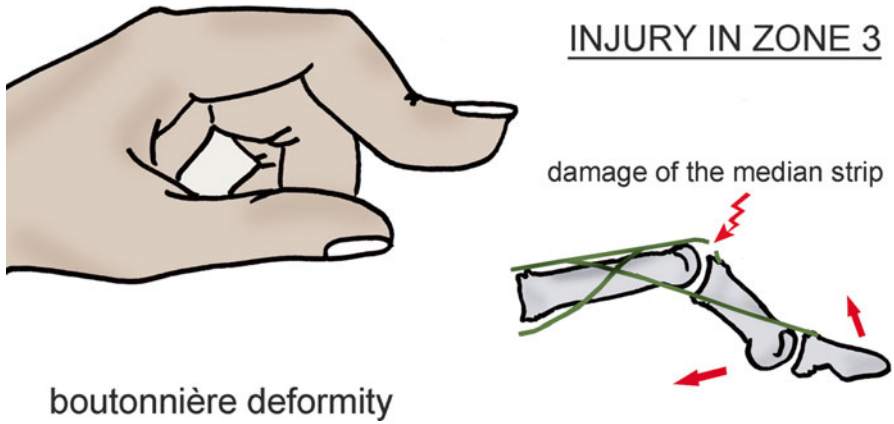


Fig. 9.33 The injuries in zone 3 correspond with a damage of the median strip

Fig. 9.34 Tube-shaped orthosis leaving the distal interphalangeal joint free

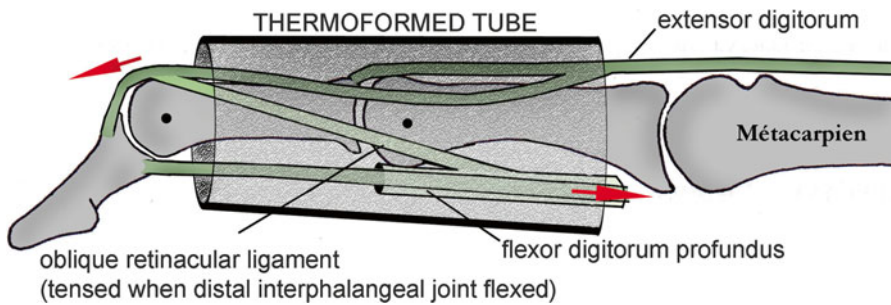
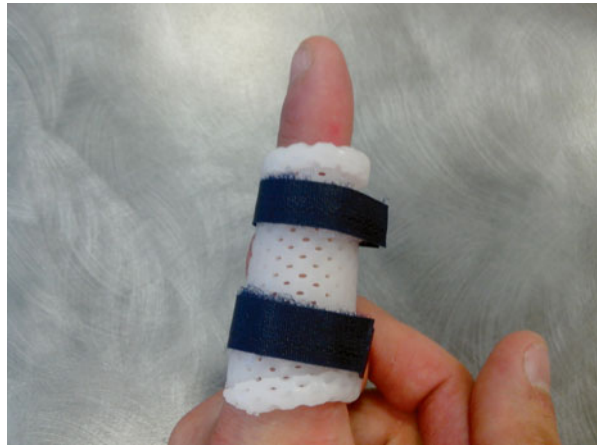

Fig. 9.35 The flexion of the distal interphalangeal joint tenses the lateral strips, which relaxes the median strip

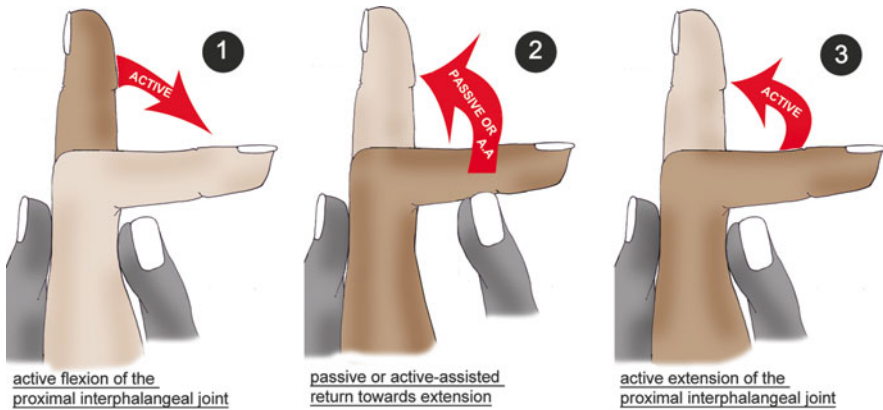


Fig. 9.36 Progressive mobilizations to limit the constraints on the median strip

Progressive Recuperation of the Joint Amplitudes

- *Fluid therapy*: hot, used if there is no inflammation anymore, to improve viscoelasticity of the tissues and therefore mobility.
- *Regain the active and passive amplitudes of the distal interphalangeal joint*: this exercise is not always necessary, as it is part of the self-rehabilitation exercises proposed to the patient from D0 to D60.
- *Active exercise for the flexion of the proximal interphalangeal joint, active-assisted then active extension*: the flexion of the proximal interphalangeal joint is realized only actively to limit the risks of excessive tension on the tendinous callus. Returning in extension is a passive movement and active-assisted in the first sessions then a simple active movement when the active extension locking is reached (Fig. 9.36).
- *Specific mobilizations of the distal interphalangeal joint*: realized if the stiffness persists in the distal interphalangeal joint.

After D90 (Solidity)

Like in the subcutaneous injuries in zones 1 and 2, in this phase the patient goes back to doing his work and sports activities. The rehabilitation is focused on the complete recuperation of the joint amplitudes, the strength, the complex grips and the proprioception.

The techniques used are comparable to the ones used in zones 1 and 2.

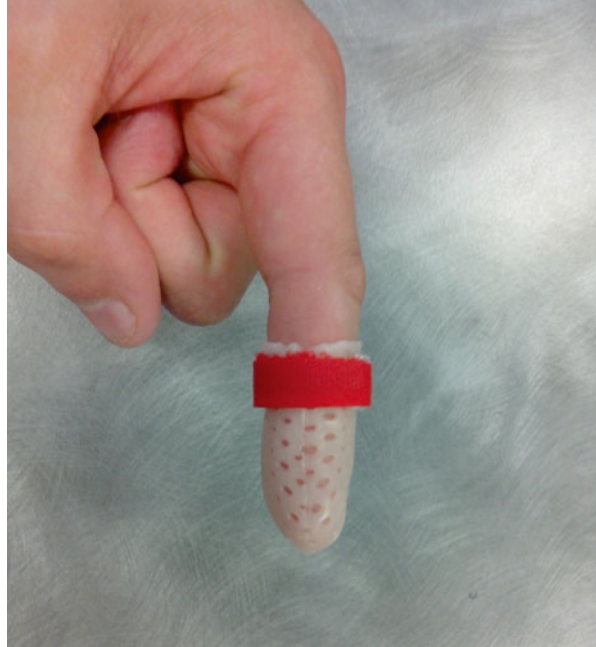
9.7.2 After a Surgical Treatment [13–16]

9.7.2.1 Orthotic Treatment

These orthoses are realized immediately after the surgery.

The bandages realized right after the surgery are as small as possible to make the moulding easier.

Fig. 9.37 Tube-shaped orthosis liberating the proximal interphalangeal joint for a surgery in zones 1 and 2



Zones 1 and 2

There is a scar on the dorsal side of the operated finger; therefore, a stack orthosis is not adapted as it presses against the dorsal side of the dorsal interphalangeal joint. We prefer to use a circular orthosis that immobilizes the distal interphalangeal joint in extension and lets the proximal interphalangeal joint free (Fig. 9.37).

Zone 3

We realize a tube-shaped orthosis blocking the proximal interphalangeal joint and letting the distal interphalangeal joint free, as in the subcutaneous injuries of this zone (cf. Fig. 9.34).

Zones 4 and 5

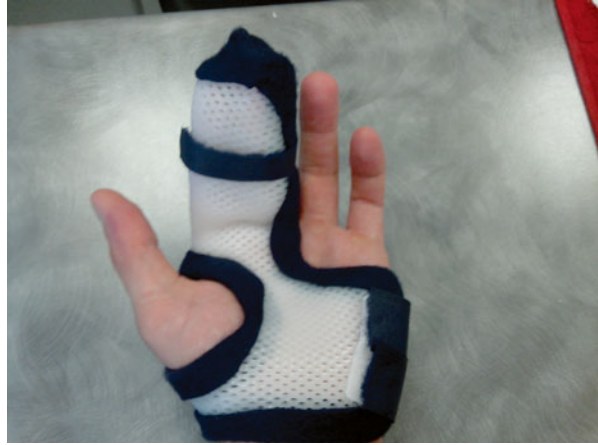We realize an orthosis placing the metacarpophalangeal in 60° of flexion, the interphalangeal in extension and letting the wrist free. This position of the metacarpophalangeal allows a distal tilt of the dorsal expansion of the interossei and therefore a relaxation of the extensor system at the digital level. So, the wrist immobilization is not necessary (Fig. 9.38).

Zone 6

The orthosis immobilizes the wrist in 30° of extension, the metacarpophalangeal in 30° of flexion and the interphalangeal in extension.

The immobilization of the adjacent finger depends on the location of the wound in relation to the inter-tendinous junctions:

Fig. 9.38 Orthosis for injuries in zones 4 and 5



- *If the injury is above the inter-tendinous junctions*, the flexion of the adjacent fingers produces a tension in the suture area, so it is better to immobilize them.
- *If the injury is below the inter-tendinous junctions*, the flexion of the adjacent fingers produces a relaxation of the suture, so the damaged finger must be immobilized alone (Fig. 9.39).

If we do not have any indication from the surgeon, we immobilize the adjacent fingers.

Zones 7 and 8

We realize an orthosis placing the wrist in 30° of extension, the metacarpophalangeal slightly flexed and the interphalangeal in extension (Fig. 9.40).

Thumb (Zones T1 and T2)

This injury resembles the mallet finger, so we immobilize the interphalangeal joint of the thumb in extension with the metacarpophalangeal free (Fig. 9.41).

Thumb (Zone T3)

We realize an orthosis placing the interphalangeal in extension and the metacarpophalangeal in 30° of flexion. The wrist is free.

Thumb (Zones T4, 5 and 7)

The orthosis immobilizes the interphalangeal in extension, the metacarpophalangeal slightly flexed and the wrist in slight extension.

9.7.2.2 Rehabilitation (Protocol 9.3)

The rehabilitation of the extensor tendons without surgery looks a lot like the one realized after a tendinous suture. However, the immobilization phase is shorter and less strict. As there is a cutaneous scar, the physiotherapist must do a specific work to fight against adhesences of the different gliding planes.

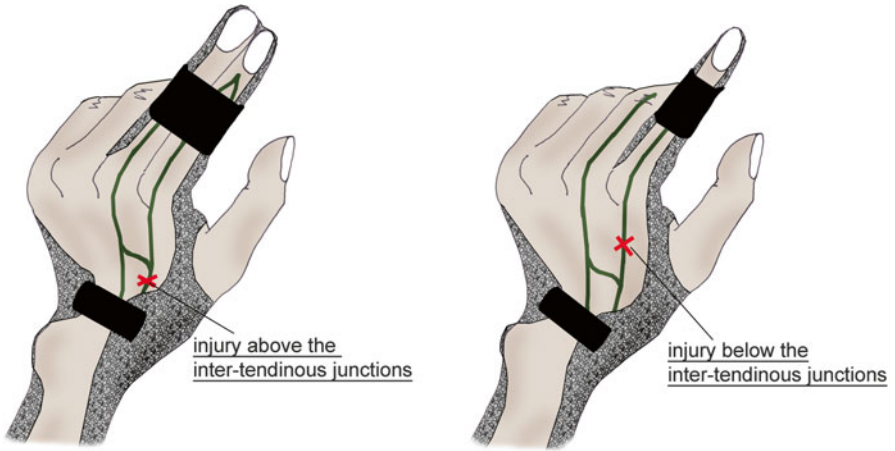


Fig. 9.39 Immobilization of the adjacent fingers depending on the location of the injury in relation with the inter-tendinous junctions (zone 6)

Fig. 9.40 Orthosis for injuries in zones 7 and 8

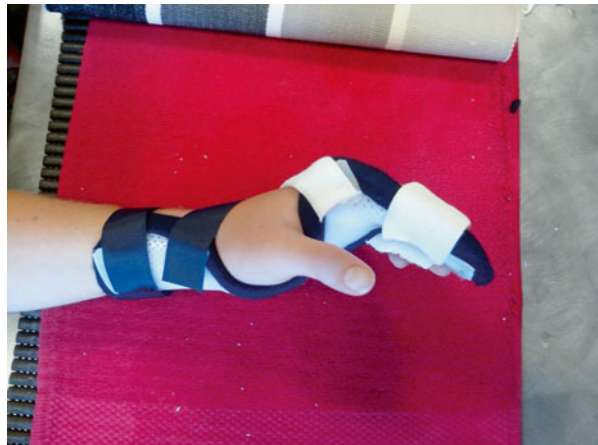
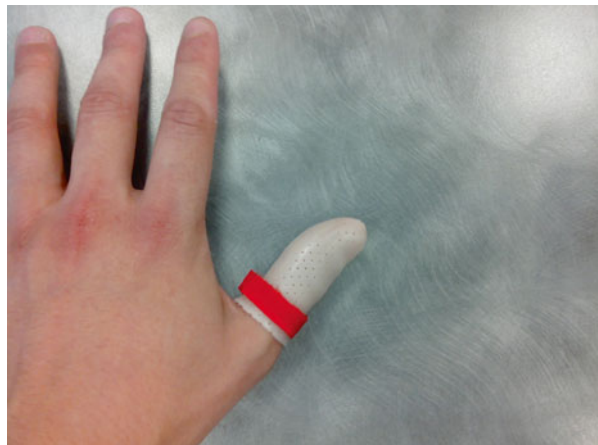
Fig. 9.41 Orthosis for injuries in zone T1



<i>Injuries of the extensor tendons (asides form orthopaedic treatment zones 1, 2 and 3)</i>			
	Immobilization phase (A)	Fragility phase (B)	Solidity phase (C)
R E H A B I L I T A T I O N	<p>Therapeutic goals: partial tendon healing, fight against trophic disorders and pain, mobilization in a protected area.</p> <p>Techniques:</p> <ul style="list-style-type: none"> - Learning the protection rules during the maintenance of the orthosis and the dressing changes (+ control by the orthotist once a week). - Transcutaneous vibratory stimulations, analgesic and soft electrotherapy, analgesic and draining massages - Passive, then active-assisted mobilization in extension of the immobilized joints. - Active exercise in flexion of each analytically concerned joint (NO GLOBAL FLEXION) until tension <p>Risks: bad healing and distension of the tendon, stiffness, CRPS.</p>	<p>Therapeutic goals: regain the active amplitudes, fight against trophic disorders, and maintain the body mapping.</p> <p>Techniques:</p> <ul style="list-style-type: none"> - Active exercise in extension. - Active exercise in global flexion until tension. - Massage around the scar and depressotherapy (adherences), fluidotherapy, infrasounds, ultrasounds, electrostimulation if good extension locking. - Specific mobilizations of the joints far from the injury. - Trophic massages, pressotherapy. - Rehabilitation of the prehensions, occupational therapy. <p>Risks: same as in phase A.</p>	<p>Therapeutic goals: same + complete recuperation of the amplitudes, regain clamping strength, complete functional recovery.</p> <p>Techniques:</p> <ul style="list-style-type: none"> - Intensify the techniques from phase 2, imitation exercises, specific mobilizations (Mennel) if joint stiffness, stretchings if tendon stiffness. - Exercise for the clamping strength. - Functional and leisure exercise. <p>Risks: same as in phase B.</p>
	OR TH ES IS	Immobilization orthosis (depending on the zone), digital orthosis liberating the distal interphalangeal joint (worn all the time).	orthosis worn by night if risk of distension.
	D0 to D21	D21 to D45	After D45

Protocol 9.3 Protocol after surgery

The protocol described below must be adapted to the injury area, especially for the mobilizations in a protected area.

D0 to D 21 (Immobilization)

This phase must improve tendon healing and limit trophic disorders and pain, while avoiding adhesions around the scar.

The orthosis must be worn all the time, except during the dressing replacement and the rehabilitation.

Fight Against Trophic Disorders and Pain

- *Transcutaneous vibratory stimulations* with a 70 Hz frequency next to the extensor system if we want to improve proprioceptive aspect or 100 Hz next to the painful areas if we want an analgesic effect
- *Electrotherapy* 100 Hz (TENS) to fight against pain or 1 Hz to fight against trophic disorders
- *Analgesic or draining massage*, staying away from the wound (risk of sepsis)

Mobility in Protected Area

We have to be careful with the joints distal to the injury.

In extension, we realize passive then active-assisted mobilizations of the joints distal to the injury. If the injury is simple, we can ask for a locking in extension of the immobilized joints.

In flexion, we ask for an analytical active flexion of each joint distal to the injury. This flexion is realized until there is tension to avoid any excessive constraint on the suture.

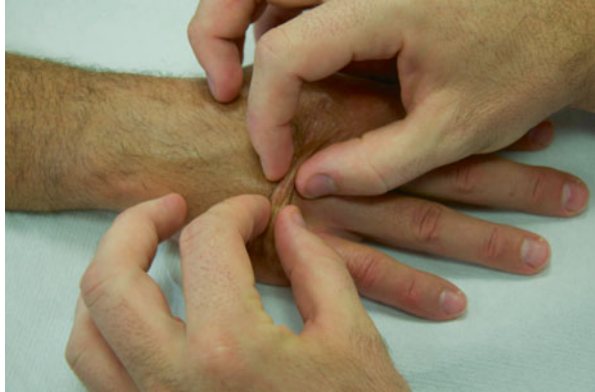D21 to D45 (Fragility)

We keep fighting against trophic disorders and pain if necessary, but the priority goal is to fight against stiffness, which is closely related to fibrosis around the scar.

Recuperation of the Active Amplitudes

- *Fluid therapy*: hot if there is no inflammation anymore and the scar has closed to increase the tissues viscoelasticity and therefore improve mobilization.
- *Massage around the scar*: to fight against adhesions (Fig. 9.42).
- *Depressotherapy*: adapted to the trophicity of the scar (pulsed or continuous) to avoid fibrosis.
- *Electrostimulation*: active if the locking in extension is reached in the joints distal to the injury. It's realized in winding and in extension (Fig. 9.43).

Fig. 9.42 Massages around the scar to mobilize the different gliding planes relative to each other



- *Active mobilizations in extension and global flexion:* the patient stops when he feels tension. These exercises are also realized by the patient outside the sessions, as often as possible, but without tension and in short series (every hour, 10 repetitions of each exercise, for each joint distal to the injury).

Maintaining the Body Mapping

Working on dexterity and coordination favours the reintegration of the damaged finger(s) in the body mapping of the hand (Figs. 9.44 and 9.44').

After D45 (Solidity)

In this phase, the patient starts doing his sports and professional activities (asides form strength activities, only at D60). The goal is the complete functional rehabilitation.

Total Recovery of the Active Amplitudes


The techniques of the previous phase are intensified if necessary, and we add:

- Imitation exercises, by doing sequences of movements allowing an optimal gliding of the different tendinous systems of the hand (Fig. 9.45)
- Specific mobilizations of the joints presenting troubles in the intra-articular glidings


After D60

- *Stretch the intrinsic muscles* (especially for injuries in zones 1, 2, 3, 4, 5 and 6): these stretchings are realized if the Finochietto test is positive, which means there is a retraction of the intrinsic muscles. We stretch the interossei passively

Fig. 9.43 Active electrostimulation in winding (a), in extension of the interphalangeals (b) or in extension of the metacarpophalangeals (c) depending on the goal



Figs. 9.44 and 9.44'
Exercise for dexterity and
prehensions



placing the hand in an “extrinsic +” position. We stretch the lumbrical muscles actively maintaining this position.

- *Stretch the extrinsic muscles* (especially for injuries in zones 7 and 8) (Fig. 9.46).

Recuperation of the Strength and Proprioception

As in the closed injuries, we realize a dynamometric reinforcement of the hand and wrist to regain the same strength characteristics and ratios as in the sane side.

A specific exercise adapted to the patient’s needs is realized, so that he can regain an optimal function (proprioception, dexterity, coordination).

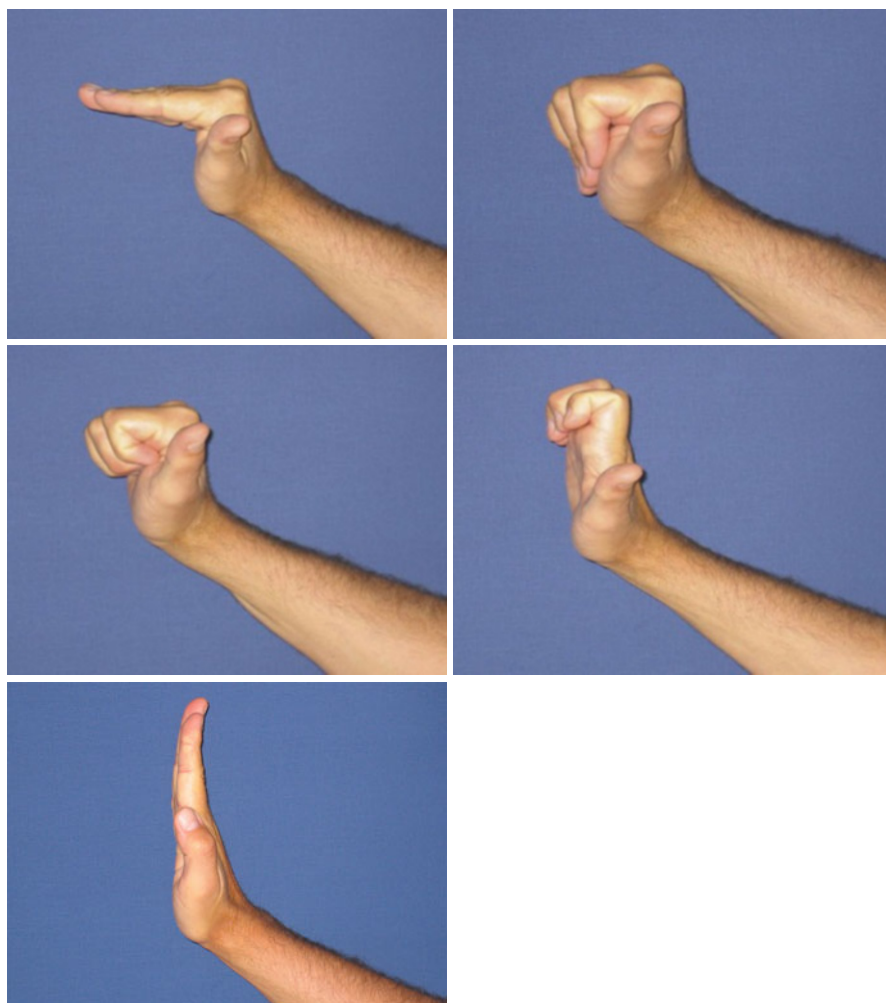
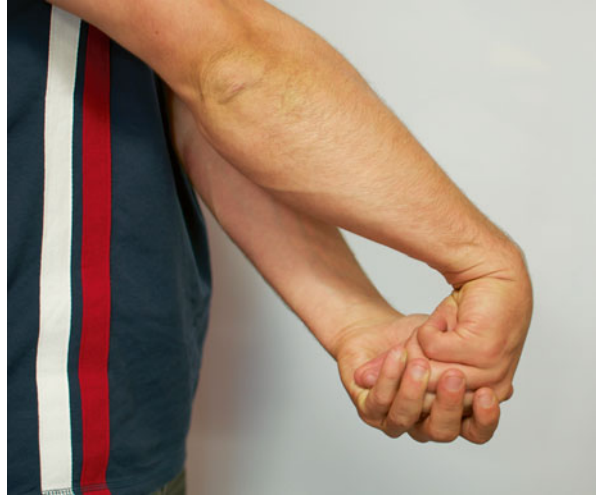

Fig. 9.45 Computerized imitation exercises favouring tendon glidings

Fig. 9.46 Stretching exercises for the extrinsic muscles, realized actively or passively



Bibliography

1. Landsmeer JMF (1949) The anatomy of the dorsal aponeurosis of the human finger and its functional significance. *Anat Rec* 104:31–44
2. Hirai Y, Yoshida K, Yamanaka K et al (2001) An anatomic study of the extensor tendons of the human hand. *J Hand Surg [Am]* 26:1009–1015
3. Warren RA, Kay NRM, Norris SH (1988) The microvascular anatomy of the distal digital tendon. *J Hand Surg* 13:161–163
4. Garcia-Elias M, An KM, Berglund L, Linscheid RL, Cooney WP, Chao EYS (1991) Extensor mechanism of the fingers. A quantitative geometric study. *J Hand Surg* 16:1130–1136
5. Evans RB, Burkhalter WE (1986) A study of the dynamic anatomy of extensor tendons and implications for treatment. *J Hand Surg [Am]* 11:774–779
6. Merle M, Dautel G (1997) *La main traumatique: l'urgence*. Masson, Paris
7. Liverneux PH, Chantelot C (2011) *La traumatology des parties molles de la main*. Springer, Paris
8. Rouzaud J-C, Allieu Y, Bénichou M (1990) Les lésions des tendons extenseurs de la main. *Ann Kinésithérapie* 17:255
9. Le Nen D, Laulan J (2001) *Sémiologie de la main et du poignet*. Sauramps médical, Montpellier
10. Tubiana R, Thomine J-M (1990) *La main, anatomie fonctionnelle et examen clinique*. Masson, Paris
11. Baratz ME, Schmidt CC, Hughes TB (2005) Extensor tendon injuries. In: Green DP, Hotchkiss RN, Pederson WC et al (eds) *Operative hand surgery*, 5th edn. Churchill Livingstone, New York
12. Isel M, Merle M (2012) *Orthèses de la main et du poignet, protocoles de rééducation*
13. Dovellet S, Heeter PK, Fisher DR, Chow JA (1989) Rehabilitation of extensor tendon injury of the hand by means of early controlled motion. *Am J Occup Ther* 43:115–119
14. Hung LK, Chan A, Chang J, Leung PC (1990) Early controlled active mobilization with dynamic splintage for extensor tendon injuries. *J Hand Surg Am* 15:251–257
15. Russell RC, Jones M, Grobbelaar A (2003) Extensor tendon repair: mobilise or splint? *Chir Main* 22:19–23
16. Howell JW, Merritt WH, Robinson SJ (2005) Intermediate controlled active motion following zone 4–7 extensor tendon repair. *J Hand Ther* 18:182–190
17. Abouna JM, Brown H (1968) The treatment of mallet finger: the results in a series of 148 consecutive cases and a review of the literature. *Br J Surg* 55:653–667

Chapter 10

Injuries of the Flexor Tendons

Grégory Mesplié and Vincent Grelet

A huge progress has been made these last years in the surgical treatment and rehabilitation of the flexor system. However, a good knowledge of the tendon healing process and some experience are required to limit the risks of tears or secondary adhesences.

10.1 Biomechanical and Physiological Reminders

The flexor tendons are part of the extrinsic system (from the forearm) and are responsible for the flexion of the proximal interphalangeal joint for the flexor digitorum superficialis and the distal interphalangeal joint for the flexor digitorum profundus.

Their helix structure gives them an important resistance to the constraints imposed on them.

10.1.1 Topographic Anatomy

The Verdan and Michon classification allows us to approach their physiology according to 5 topographic zones (Fig. 10.1):

G. Mesplié (✉)

Physiotherapist and Orthotist, Institut Sud Aquitain de la Main et du
Membre Supérieur, Aguiléra Clinic Biarritz, Biarritz, France
e-mail: greg.mesplie@mac.com

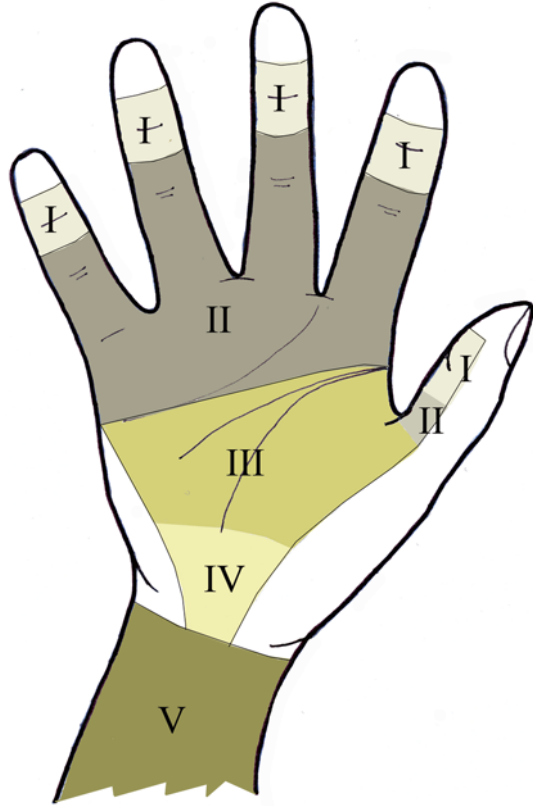
V. Grelet

Hand surgeon, Institut Sud Aquitain de la Main et du
Membre Supérieur, Aguiléra Clinic Biarritz, Biarritz, France

© Springer International Publishing Switzerland 2015

G. Mesplié, *Hand and Wrist Rehabilitation: Theoretical Aspects and Practical Consequences*, DOI 10.1007/978-3-319-16318-5_10

Fig. 10.1 Topographic classification of the flexor tendons according to Verdan and Michon



10.1.1.1 The Long Fingers

Zone 1

Located below the distal insertion of the flexor digitorum superficialis, it is the area of the distal insertion of the flexor digitorum profundus. It is one of the areas where the tendon is poorly vascularized, which makes its healing longer and random in case of injury.

Zone 2

Starts at the entrance of the digital sheath and ends at the medium part of the 2nd phalanx (lower than the 2 tendon strips of the flexor digitorum superficialis).

This zone used to be called the “no man’s land” by Bunnell, because it seemed impossible to repair the injuries that occurred there. The injuries in that zone are still the most complex to treat.

The 2 flexors divide the digital canal, made up of the periosteum and the palmar ligaments of the metacarpophalangeal and proximal interphalangeal joint from behind and the annular ligaments and cruciate pulleys in the front (Fig. 10.2).

The aim of these pulleys and annular ligaments is to maintain the flexors against the bone levers, thus permitting the complete finger winding and avoiding the bow-string effect.

Lastly, the flexor digitorum superficialis splits into two strips near the base of the 1st phalanx, to let the flexor digitorum profundus pass. Below this chiasma, the flexor digitorum profundus becomes superficial and the flexor digitorum superficialis becomes deep (Fig. 10.3).

Fig. 10.2 Location of the annular ligaments and cruciate pulleys

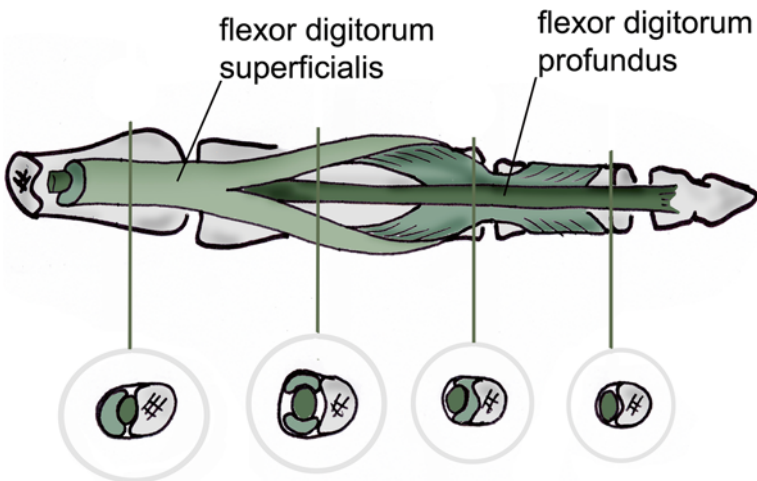
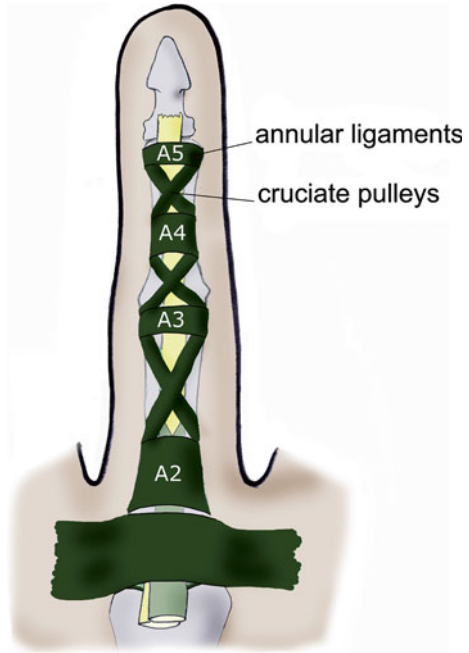


Fig. 10.3 Flexor digitorum superficialis' chiasma (area of frequent adherences) – according to Kapandji

Zone 3

Situated between the distal part of the flexor retinaculum (or transverse carpal ligament) and the entrance of the digital sheath.

Zone 4

Corresponds to the carpal tunnel where the flexor retinaculum acts as the first pulley for the flexor system.

Zone 5

Located between the musculotendinous junction proximally (inferior 1/3 of the forearm) and the proximal part of the flexor retinaculum.

10.1.1.2 The Thumb

The only extrinsic muscle that makes the flexion of the thumb is the flexor pollicis longus.

The T1 zone corresponds to the ending of the flexor pollicis longus, and the T2 zone is between the A1 pulley and the proximal part of the A2 pulley. The T3 zone is located at the level of the thenar eminence (possible area of adherences with the 2 heads of the flexor pollicis brevis) (Fig. 10.4). Zones 4 and 5 are the same than for the long fingers.

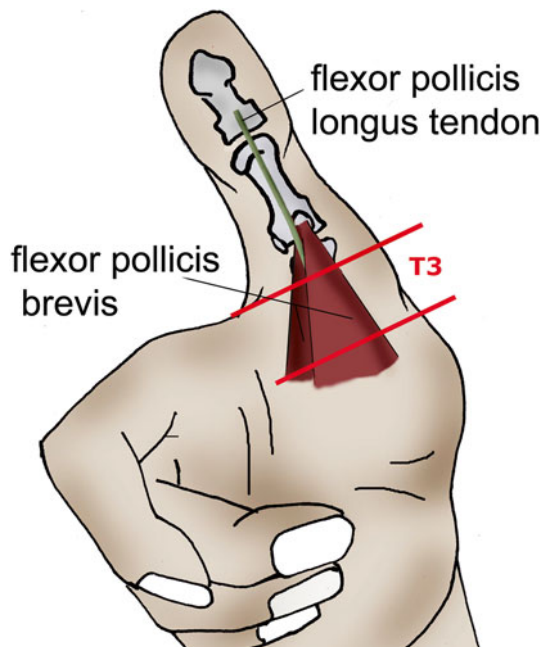


Fig. 10.4 Trajectory of the flexor pollicis longus between the 2 heads of the flexor pollicis brevis

10.1.2 *The Pulleys [1]*

They are fibrous bands maintaining the flexor system in contact with the skeleton and therefore avoiding the bowstring effect (Fig. 10.5).

There are 5 annular ligaments and 3 cruciate pulleys at the digital level, to which must be added the flexor retinaculum at the level of the carpal tunnel (Fig. 10.6).

They are essential for winding the fingers, especially the A2 and A4 pulleys. Their isolated tear is in fact enough to lower the mobility (Fig. 10.7).

10.1.3 *Nutrition of the Flexor Tendons*

It depends on 2 complementary systems:

10.1.3.1 *The Vascular System*

Outside the digital sheath: the flexor tendons are vascularized from their 2 endings (periosteum and musculotendinous junction) and by the intratendinous vascular system for the areas far from the extremities of the tendon.

The paratendon, surrounding the tendon, sends a structure to carry the vessels (the mesotendon) which enters the tendon, allowing its vascularization.

Inside the digital sheath: the mesotendon condenses to form the vincula, supplied by anastomosis with the collateral arteries.

The 2 flexors each have 2 vincula, a short one near their ending and a long one higher, which infuse their dorsal part.

There still are 3 areas that are badly vascularized, in front of the A2 and A4 pulleys. The first one is proximal to the flexor digitorum superficialis' chiasma, and the

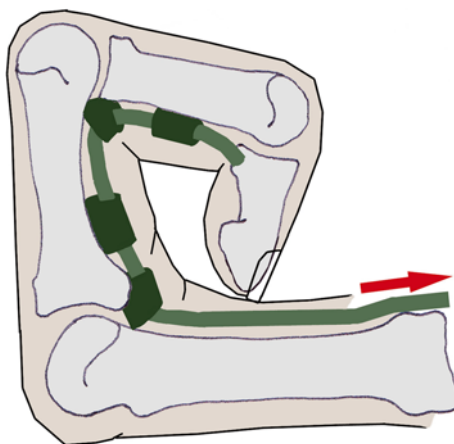
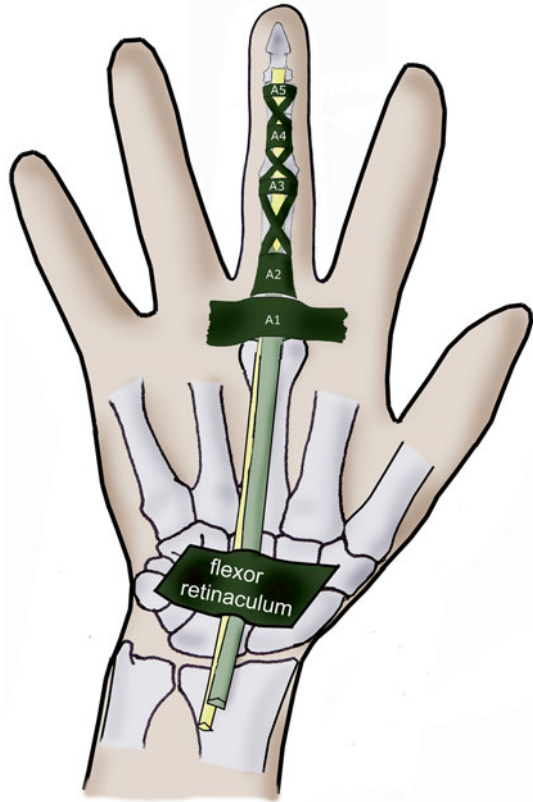


Fig. 10.5 The pulleys keep the flexor tendons against the skeleton to avoid the bowstring effect

Fig. 10.6 The flexor retinaculum participates in the action of the digital pulleys



2 others are above and below the vinculum longus that approaches the flexor digitorum profundus at the level of the proximal interphalangeal joint (Fig. 10.8).

10.1.3.2 The Synovial Pump [2]

The synovial sheaths have different organizations, depending on the finger (Fig. 10.9a). The flexor pollicis longus has its own sheath, from zone 4 to the T1 zone.

The index, middle and ring fingers share a sheath with the little finger in zone 4. They each have their individual sheath in the digital canal. The little finger's sheath, shared with the other long fingers, continues until the digital canal.

The synovial fluid in the sheaths plays an important role of lubrication and nutrition, by soaking the tendons in the digital canal (Fig. 10.9b).

It is important to note that, in the digital canal, the nutrition of the flexor digitorum superficialis is twice as important through this method as through the vascular system and 5 times more important for the flexor digitorum profundus.

Thanks to these 2 systems, we obtain the healing of the tendon by extrinsic healing (vascular mechanism) and intrinsic healing (synovial pump).

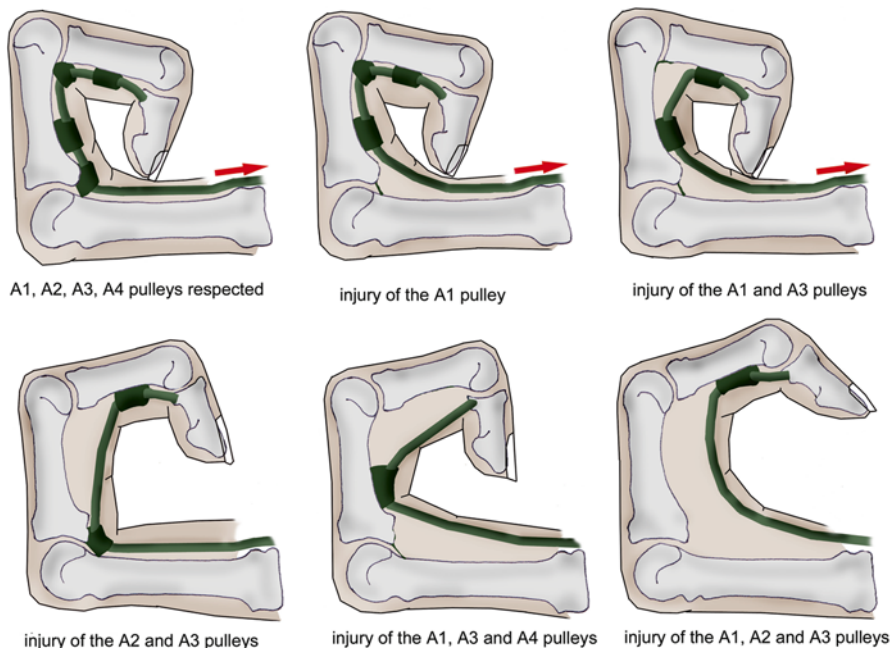
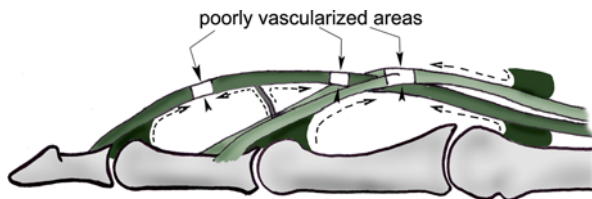


Fig. 10.7 The integrity of the annular ligaments, A2 and A4 in particular, is essential in the complete fingers winding

Fig. 10.8 Vincula system, participating in the vascularization of the flexor system but leaving some avascular areas



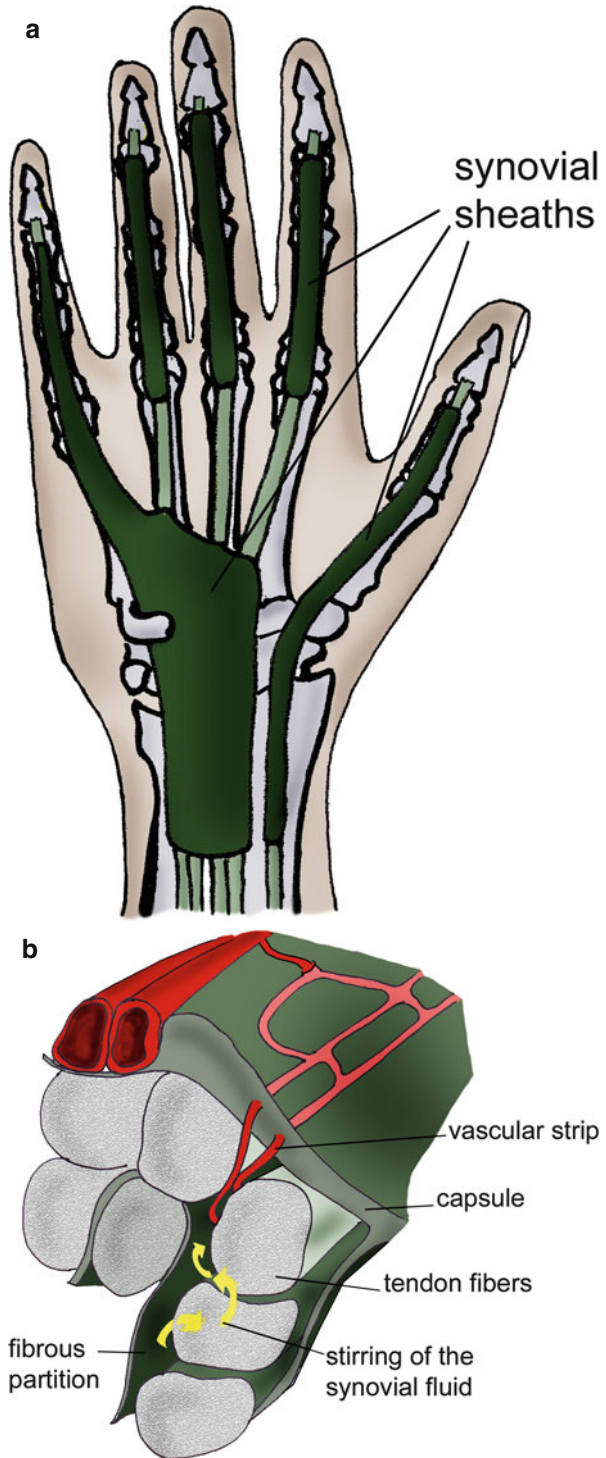
The extrinsic healing corresponds to a fibroblastic invasion, which causes adhesences. On the other hand, the intrinsic healing is related to a phenomenon of synovial imbibition that doesn't create adhesences.

A surgery as atraumatic as possible and an immediate active rehabilitation favour the intrinsic healing, providing a better functional recovery.

10.1.4 Lag Time

The lag time is the decrease of the resistance of the sutured tendon until the 5th postoperative day and then the improvement of this resistance until it reaches the immediate postoperative resistance on the 15th day.

Fig. 10.9 (a) Topography of the synovial sheaths. (b) Nutrition of the tendon by stirring the synovial fluid or synovial pump



This phenomenon can only be observed in case of postoperative immobilizations and doesn't exist in the active protocols.

10.1.5 *The Quadriga Effect*

Forcing the extension of 3 long fingers leads to a “blocking” of the free finger, which can mobilize the proximal interphalangeal joint in flexion but not the distal interphalangeal joint (Fig. 10.10).

This phenomenon can be explained by the fact that the flexor digitorum superficialis tendons are very well individualized in the forearm, whereas the flexor digitorum profundus tendons are individualized only in the hand, thus preventing (or limiting) their isolated contraction.

10.1.6 *Winding Dynamic and Tendon Gliding*

From an analytic point of view, the role of each tendon during the finger flexion is well known and defined:

- *Flexion of the distal interphalangeal joint* produced by the flexor digitorum profundus
- *Flexion of the proximal interphalangeal joint* produced by the flexor digitorum superficialis
- *Flexion of the metacarpophalangeal joint* produced by the interossei through the dorsal expansion

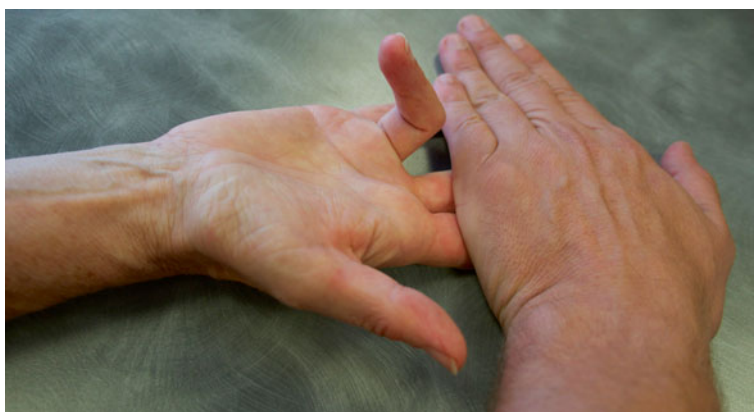

Fig. 10.10 The quadriga effect; it is impossible to flex the distal interphalangeal joint in one finger if the others are maintained in extension, because the flexor digitorum profundus is the same for all the long fingers and the proper tendons of each finger become separated very distally

The finger winding starts with the proximal interphalangeal joint which unlocks the distal interphalangeal joint by relaxing the lateral strips, putting in tension the median strip and relaxing the retinacular ligament.

The distal gliding of the extensor system, during this phase, puts in tension the interossei and the lumbrical muscles, which start a flexion of the metacarpophalangeal joint due to the tenodesis effect (related to the slant path of these tendons).

The flexion of the metacarpophalangeal joint moves the dorsal expansion of the interossei distally, in an efficient position to produce a flexion of the first phalanx (when the metacarpophalangeal joint is extended, the contraction of the interossei leads to an extension of the interphalangeal joints) (Fig. 10.11).

The finger winding is made according to an equiangular spiral, described by Littler in 1960.

This spiral respects the divine proportions from the Fibonacci sequence (1-1-2-3-5-8-13-21, etc.) (Fig. 10.12).

The path of the flexor tendons in complete flexion is 85 mm above the wrist.

The metacarpophalangeal joint takes care of 77 % of the movement, the proximal interphalangeal joint of 20 % and the distal interphalangeal joint of 3 %.

10.1.7 The Essential Function of the Flexors

The flexor muscles ensure that we can pick up and hold objects tight, with a cocontraction of the extensor and intrinsic systems. They usually work in closed chain, in a concentric way. It corresponds with maintaining and moving an object, for example (Fig. 10.13).

10.2 Physiopathology

It is most frequently due to direct traumas caused by sharp objects (knife, steel plate, etc.).

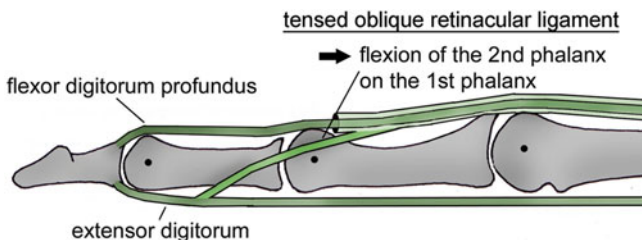
However, there are 3 seriousness factors that can lower the functional prognosis:

10.2.1 Sharp Cut or Shredding

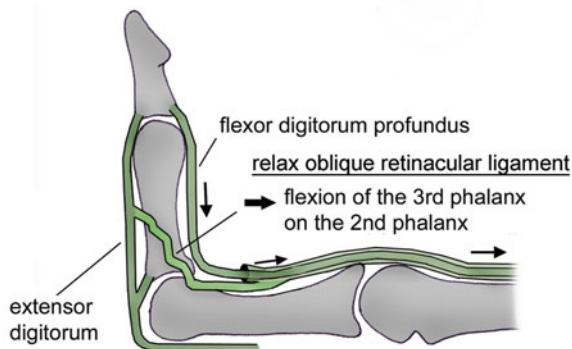
The surgical repair is easier in case of sharp cut.

10.2.2 Contamination of the Injury

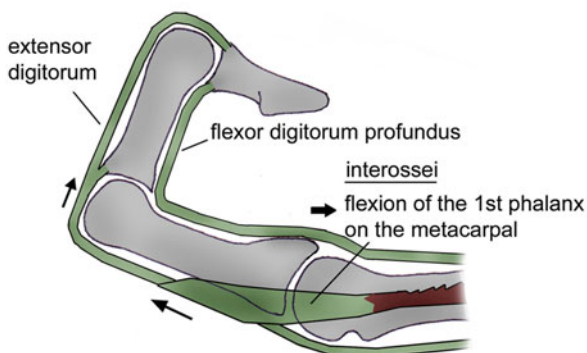
In case of infection, the risks of adhesences and breaks are far more important.



FLEXION OF THE 2ND PHALANX ON THE 1ST PHALANX



FLEXION OF THE 3RD PHALANX ON THE 2ND PHALANX



FLEXION OF THE 1ST PHALANX ON THE METACARPAL

Fig. 10.11 Dynamic of the winding in the long fingers. (1) The contraction of the flexor digitorum profundus doesn't allow the distal interphalangeal joint to move in flexion while the proximal interphalangeal joint is extended (tension in the retinacular ligament). (2) The flexion of the proximal interphalangeal joint relaxes the retinacular ligament and allows the flexion of the distal interphalangeal joint. (3) The combined flexion of the proximal and distal interphalangeal joints puts the dorsal expansion of the interossej distally in relation with the metacarpophalangeal joint. It then allows the flexion of this joint

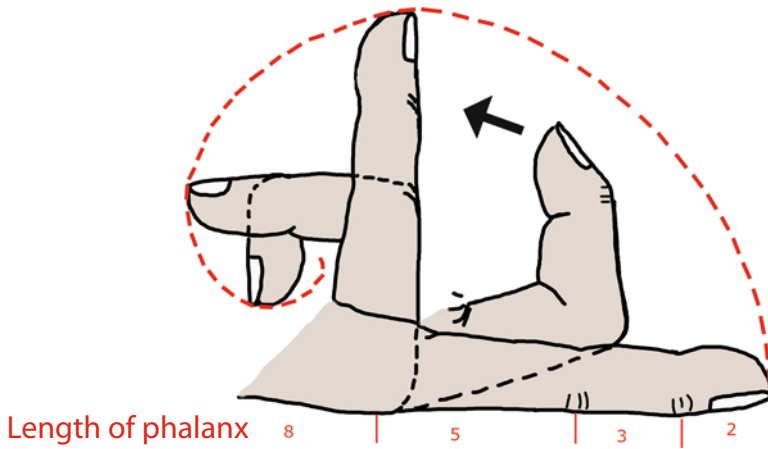


Fig. 10.12 The digital winding describes an equiangular spiral



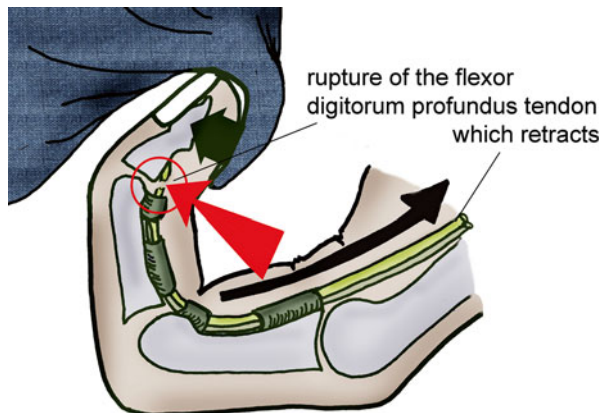
Fig. 10.13 The functional role of the flexors in a closed chain

10.2.3 Clamping at the Moment of the Trauma

The flexors can retract higher, pulling out the vincula, which makes the repair more difficult and the healing random.

The jersey finger (or rugby finger) is the typical example of this type of injury, where the player (often a rugby player) holds back his opponent by the jersey, which leads to a rupture of the flexor digitorum profundus (often in the ring finger). The tendon can retract until the palm of the hand (Fig. 10.14).

Fig. 10.14 Injury mechanisms in the jersey finger



The prognosis in this kind of injury is guarded and uncertain and depends on the rapidity of the medical care (to limit the retraction of the tendon).

Sadly, this kind of injury is often underestimated on the field.

10.3 Clinical and Paraclinical Signs

There are various reliable tests that help reveal a sectioning of the flexor tendons:

- *Tenodesis effect*: as the flexor tendons are polyarticular, the mobilization of the wrist in extension leads to a progressive flexion of the fingers (“in cascade”), from the index to the little finger if there is no rupture (Fig. 10.15).
- *The pressure* on the muscle masses of the forearm leads to a global flexion of the fingers if there is no rupture.
- *The test of the analytical active flexion of the distal interphalangeal joint*, with the other fingers free, to test the flexor digitorum profundus.
- *The test of the analytical active flexion of the proximal interphalangeal joint*, with the other fingers extended to short-circuit the flexor digitorum profundus with the quadriga effect, to test the flexor digitorum superficialis.
- *The test of the analytical active flexion of the interphalangeal joint of the thumb*, to test the flexor pollicis longus.

If there is any doubt, in particular in case of partial injury, the exploration of the wound and even the echography if it's a closed injury (jersey finger) are essential.

10.4 Therapeutic Process and Surgical Treatment

As always in the hand surgery, but even more in the tendon surgery, the gesture must be precise and meticulous to avoid tissue trauma, which leads to oedema and adhesences, as much as possible.

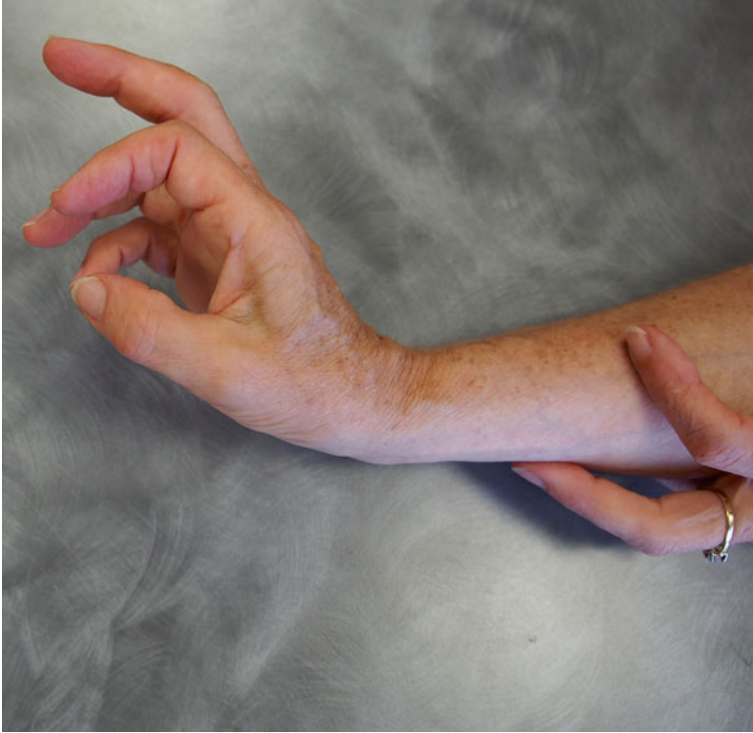

Fig. 10.15 Because of the tenodesis effect, the extension of the wrist leads to the flexion of the fingers. In case of rupture of the flexor tendon, there is no flexion of the affected finger (on the picture, the 3rd finger is affected)

The goal of this repair is to obtain a strong primary suture, allowing an immediate controlled rehabilitation, which is the only thing that can guarantee a good functional result. The best care is ideally given by the hand emergency services.

10.4.1 The Lapse of Time

Ideally, the repair must be done in emergency, as the results are better than in the case of a postponed repair. In practice, it can be done during the first 48 hours.

10.4.2 The Points of Access

A meticulous trimming is always done, and then enlarging incisions are made so that they aren't very extensive and don't cross the flexion creases with a right angle, to avoid cords.

Zigzag incisions (Bunnel) are used, avoiding delamination and making sure to protect the neurovascular pedicles (Fig. 10.16).

10.4.3 The Suture Techniques (Fig. 10.17)

The manipulation of the tendon's extremities must be as atraumatic as possible. If the rupture of the tendon has occurred in finger flexion, the distal extremity will have distally shifted from the wound of the synovial sheath, and it will be necessary to open said sheath.

The A2 and A4 pulleys must be respected as much as possible with, if necessary, partial lateral L-shaped openings. In case of a loss of the pulley's substance, a reconstruction with a strip of the flexor digitorum superficialis, a dorsal retinaculum transplant or a plastic surgery with the palmaris longus is necessary.

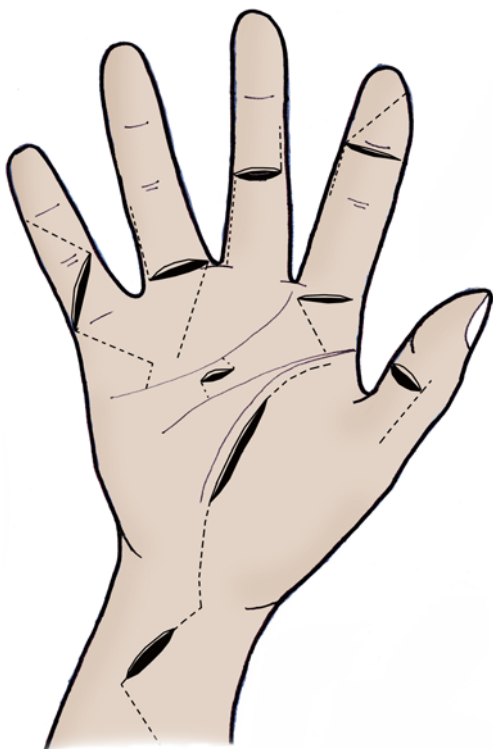

Fig. 10.16 Skin incision
(according to Merle and
Dautel)

SKIN INCISION

(according to Merle and Dautel)

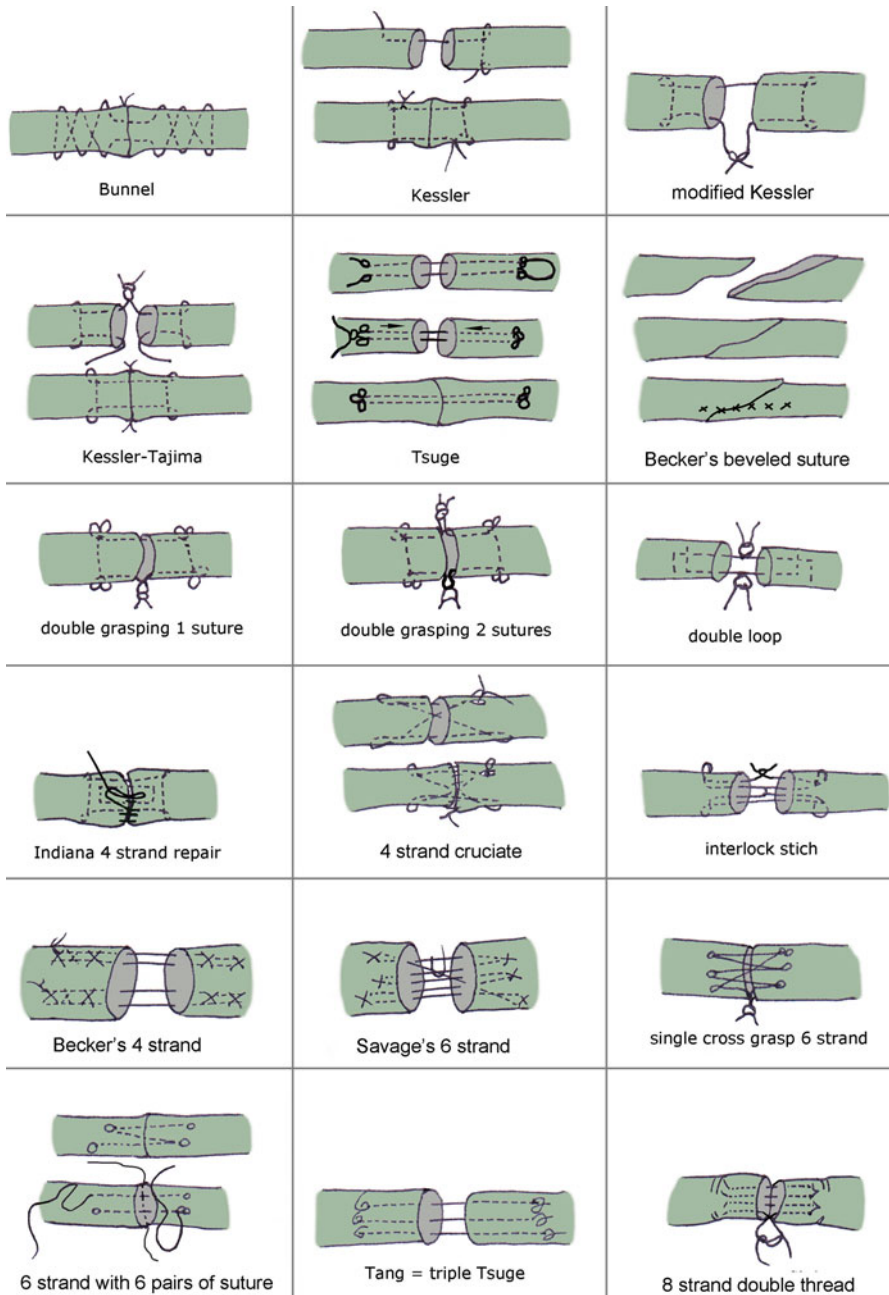


Fig. 10.17 Different types of suture of the flexor tendons

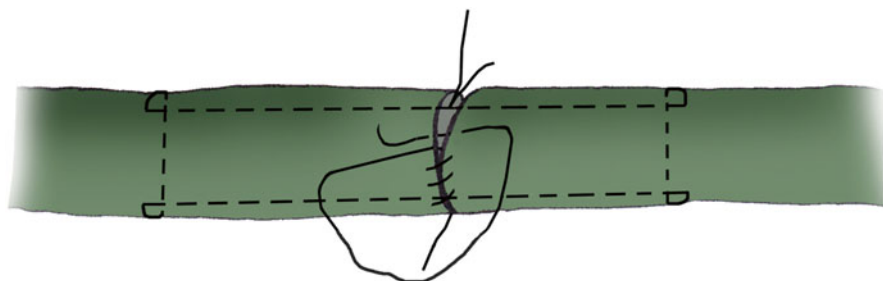
The tendon suture must have the highest resistance possible to avoid early ruptures and allow and immediate mobilization. The tendon's anchoring must be the best possible to avoid the shearing of the tendon fibres by the thread with the formation of a callus. The suture must be as thin as possible to allow the tendon gliding and not interfere with the healing process.

A thread with slow resorption, like a PDS with a 4/0 or 3/0 diameter, is the most used, depending on the size of the tendon, with a round needle which is less aggressive.

The classical stitch is the modified Kessler (Fig. 10.17'), in which a frame is made with 2 strands associated with a peritendinous overlock, using a 5/0 thread. By increasing the number of threads, we enhance the resistance, so the 4-strand sutures are the most used nowadays (Fig. 10.17''), like McLarney's cruciate suture or Tsuge's 2-strand looped suture.

The peripheral overlock, combined with the suture in the middle of the tendon, assures an optimal congruence and avoids friction at the level of the pulleys.

The healing of the flexor digitorum superficialis must always be associated with the healing of the flexor digitorum profundus, to keep the strength and independence of the finger in flexion. However, in zone 2, there is a risk of blocking of the 2 repaired tendons because of their volume, so the repair of only one strip of the flexor digitorum superficialis and the resection of the second one can be preferable.



MODIFIED KESSLER SUTURE AND PERITENDINOUS OVERLOCK

Fig. 10.17' Modified Kessler suture and peritendinous overlock

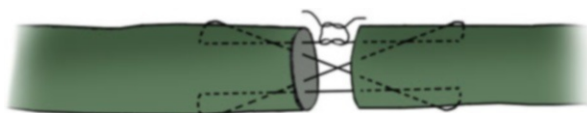


Fig. 10.17'' McLarney's 4-strand cruciate suture

MAC LARNEY'S 4 STRAND CRUCIATE SUTURE

10.4.4 Particular Cases

In zone 1: the avulsion of the flexor digitorum profundus on the last phalanx (jersey finger), or its distal rupture, needs a transosseous reinsertion by the pull-out technique or an intraosseous anchor.

Partial injury: the risks of adhesences, trigger finger or secondary rupture make us prefer a repair with a peripheral outlock if the injury is smaller than 50 % of the tendon and a suture directly in the tendon if it's bigger than that.

The flexor pollicis longus: its particularity is due to the frequent importance of the associated neurovascular injuries, because of the superficial location of the radial collateral pedicle. It is also due to a retraction of the proximal stump, because there is only one vinculum.

The associated multitissular injuries must be treated at the same time and allow an early rehabilitation.

The postoperative immobilization is carried out immediately, in a resting position for the flexor system. The early rehabilitation will be an integral part of the treatment and play an essential role in the final result.

10.5 Rehabilitation [3–6]

The rehabilitation has to limit the risks of adhesences and avoid any rupture of the suture in priority.

A badly measured rehabilitation will lead to one of these two complications.

There is a wide variety of rehabilitation protocols, depending on the physiotherapy centre. It also depends on the suture (type of suture, number of strands, etc.).

However, the immediate postoperative care and active exercises seem to be used in every centre, as they increase the intrinsic healing of the tendon.

These early mobilizations create a healing remodelling, with a longitudinal orientation of the collagen fibres and a faster maturation of the tendinous callus.

The mobilized tendons are therefore stronger and more mobile than the ones that are immobilized (Figs. 10.18 and 10.18').

10.5.1 Rehabilitation Protocols (Fig. 10.19) [7]

10.5.1.1 Relative Immobilization Phase (D0 to D45)

From D0 to D45, the patient has to keep his orthosis at all times, except during the rehabilitation session and when he does the exercises that he'll have to repeat every hour at home.

Fig. 10.18 Correlation between the type of suture mobilization and its strength through time

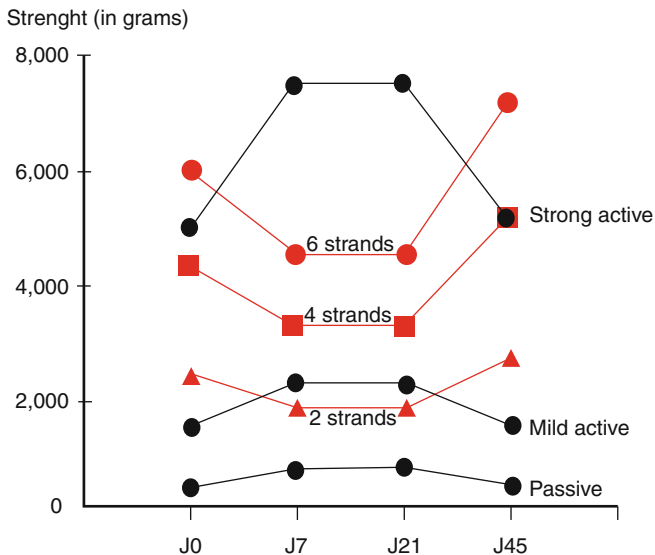
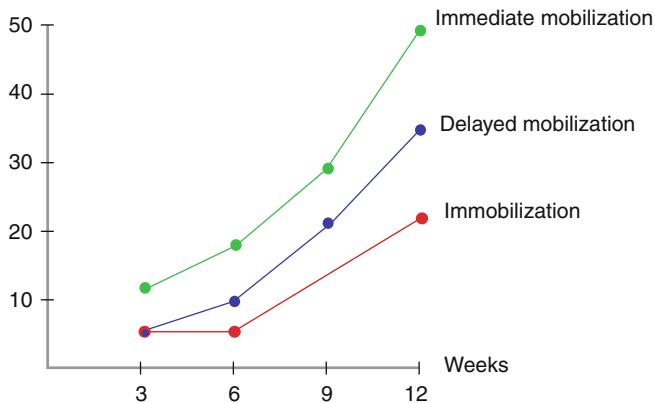


Fig. 10.18' Correlation between the immobilization time and the resistance of the suture through time



This is the key phase of that kind of rehabilitation, because it is a fragility and healing phase. The physiotherapist has to improve tendon gliding with as few constraints as possible, in order to limit the risks of adhesions and rupture.

The sessions are daily during at least the first month. During this phase, it is important to know exactly what type of injury and suture we are dealing with, in order to use the programme that best suits the fragility of the operated tendon.

It is thus possible to start an active exercise since the first days if the wound is sharp and if there isn't any vascular injury. On the other hand, the progress is slowed down if there are any aggravating factors. The notion of a surgeon-physiotherapist team is of key importance here to obtain the best results possible!

<i>Injuries of the flexor tendons</i>			
	Immobilization phase (A)	Fragility phase (B)	Strength phase (C)
REHABILITATION	<p>Therapeutic goals: fight against pain and scar disorders, maintain the passive mobility, fight against functional exclusions, and promote intrinsic healing.</p> <p>Techniques:</p> <ul style="list-style-type: none"> - Draining massages and massages of the scar, depressotherapy and ultrasounds after the scar is closed. - Analgesic electrotherapy (TENS). - Passive pain-free mobilization - Infrasounds – manual stimulations of the fingertips. - Placed and held in the free areas, analytically and globally. - Simple active mobilizations and Cooney from the 3rd week, depending on the case. <p>Risks: ruptures and adhesences.</p>	<p>Therapeutic goals: same, and even intensify phase 1 if necessary. Regain the active amplitudes, coordination and dexterity.</p> <p>Techniques:</p> <ul style="list-style-type: none"> - Pressotherapy at D60 if flexum, deep massages and mobilization of the scar (A1). - Simple active analytical and global mobilizations. - Electrostimulations. - Stretching of the intrinsic muscles. - Manipulations and occupational therapy. <p>Risks: same as in phase A, functional exclusion.</p>	<p>Therapeutic goals: intensify the techniques from the 2 previous phases if necessary, complete functional recovery.</p> <p>Techniques:</p> <ul style="list-style-type: none"> - Specific mobilizations of the joints, and increase the intensities of the electrostimulation (B1). - Functional exercises according to the job and leisure activities. <p>Risks: same as in phases A and B.</p>
	ORTHESES	Duran orthosis – Worn during the night after 1 month, depending on the surgeon’s instructions.	Postural orthosis after 2 months if there is a flexum or a lack of passive winding.
	D0 to D45	D45 to D90	After D90

Fig. 10.19 Rehabilitation protocol

Self-rehabilitation is essential and complements the daily sessions. The exercises must be realized every hour. They are explained to the patient and an “exercise sheet” is handed to him.

Fight Against the Oedema

- Draining massage above the injury, without any “risky” manoeuvre for the tendon (like going to extension).
- Cryotherapy without touching the wound for the non-sterile applications. In that case, we use a cold pillow of cherry stones and apply it on the palm of the oedematous hand during 15 to 20 min (with a bandage). The patient’s hand must be maintained in a protective position during all the application. Cryotherapy also has an interesting analgesic effect.
- Compressive bandage outside the periods of self-rehabilitation if the patient knows well what the “risky” positions are for his tendon. Otherwise, he mustn’t take the bandage off himself, which raises the issue of the self-mobilization at home, limited by this compressive system. We sometimes have to give it up, as the self-mobilization at home is essential to recuperate the mobility (Fig. 10.20).
- Electric currents (1Hz) that can be used since D21 on the oedematous areas with a moderate intensity.

Fight Against Pain

- Analgesic electrotherapy with a wobbled 100Hz frequency. The active (smallest) electrode is placed near the painful area and the indifferent electrode at the level of the corresponding vertebral level. The current intensity must be set in order to get a “tingling” sensation, but no muscle contraction.

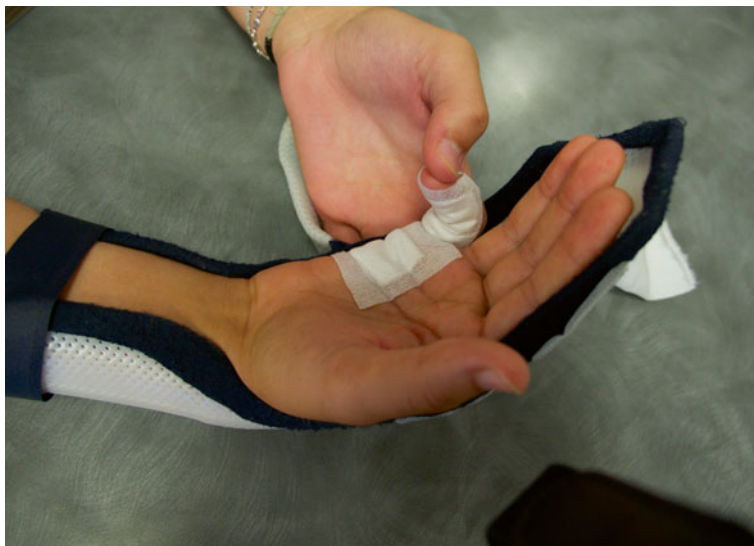

Fig. 10.20 Self-rehabilitation. The patient has to make 10 passive pain-free mobilizations of the affected finger every hour, without increasing the trophic disorders. An active exercise can also be done in some cases

- Transcutaneous vibratory stimulations with a low frequency (ideally 100Hz) and amplitude (lower than 1 mm) are applied on the painful area, moving along the trajectory of the sensitive nerve concerned by this area. In case of pain when applying the device directly on the skin, we place it far from the painful area, yet always on the trajectory of the corresponding nerve. With a 70Hz frequency, this type of mechanical vibration has a proprioceptive effect, creating an illusion of movement if we apply it along the operated tendon (Fig. 10.21).

Progressively Getting Mobility Back (Improving the Intrinsic Healing) (Fig. 10.22)

Passive Exercise in a Protected Area

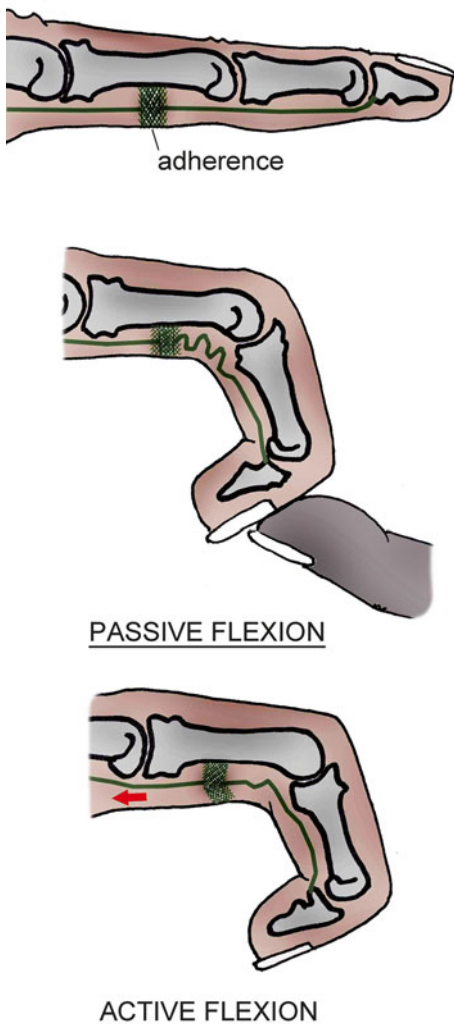
It is the mobilization of the affected segments, in areas that don't threaten the tendon suture. The flexion isn't limited, but the combined extension of various joints of the same segment is forbidden if it puts the suture in tension. The limits are different from one patient to another depending on the type of injury, the intraoperative tensioning of the suture, etc. Therefore, we have to be careful and stay focus during these mobilizations and be aware of the operative report.

The passive exercise alone can be insufficient to mobilize the tendon effectively, in particular in case of adherences when the "accordion effect" can be observed (Fig. 10.22). However, it is used to get the joint amplitudes back in flexion and to warm up the hand before using active techniques, which are essential in the good recuperation of the tendon gliding.

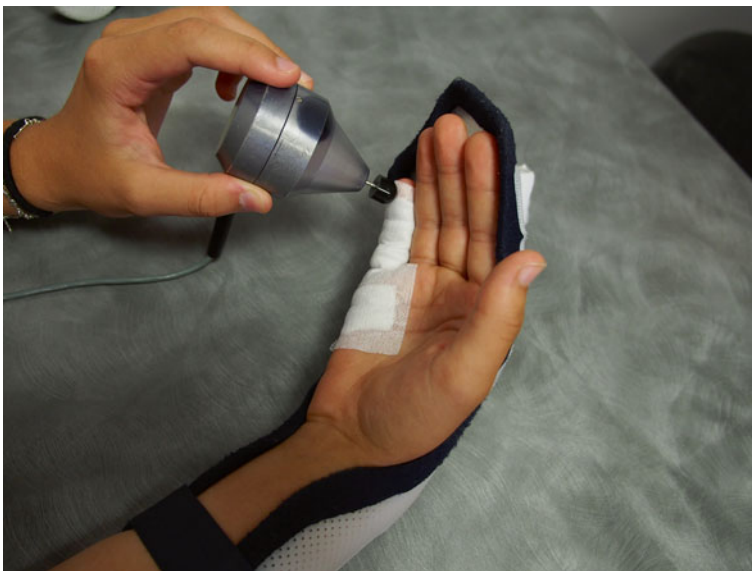

Fig. 10.21 Transcutaneous vibratory stimulations

Fig. 10.22 In case of adhesions, the passive mobilization alone doesn't allow moving the tendon suture, and an accordion effect can be observed



Semi-active Exercise

The finger winding is passive, but the patient actively returns to the extended position, still staying in protected areas. For example, we work on the interphalangeal extension with the metacarpophalangeals flexed to avoid any excessive constraint on the suture.

We use this exercise to progressively get back the amplitudes in extension, as the contraction of the extensor system is less “risky” than the passive mobilization for the suture. This exercise doesn't avoid the “accordion effect” as there isn't any contraction of the flexor system.

Placed and Held

This technique is used after warming up the hand with passive mobilizations, which limits the resistances during the contraction of the flexor tendon.

We place the finger in flexion and ask the patient to actively maintain this position. The evolution goes from an “easy” position in the intermediate race to more difficult positions in the inner or outer tendon race. In the inner race, the resistance of the flexor to contraction is more important than in the intermediate race because the extensor system is tensed, while it’s the pre-tension of the flexor that increases the constraints imposed on it in the outer race. Therefore, we have to be very careful with the exercise in the inner and outer race, which has to be realized after the exercise in the intermediate race.

We ask the patient to do 20 contractions, each of them lasting 3 s. He mustn’t realize these contractions with strength, so we ask him to avoid tremors and contractions of the muscles next to the one we’re working with. The goal is to insist on the quality of the motor command and to get the exact contraction we’re looking for. If the exercise is too difficult, we postpone it or we place the finger in a more favourable position, most of the time in the intermediate tendon race. In order to do this, the physiotherapist can change the position of each joint of the concerned segments separately, always staying in protected areas.

Active Exercise in a Protected Area

When there are only a few risks of rupture (no vascular injury, sharp and/or partial cut), it is possible to start a simple active exercise in a protected area. We realize it analytically and globally, without forcing the hand’s amplitudes, and always after a previous warm-up. The movements must be slow and smooth, and we ask for 10 repetitions per session. The active exercise, if it’s too aggressive, can lead to a rupture or a flabbiness of the scar. Working with the 4 long fingers at the same time makes the realization of the movement easier and limits the constraints on the suture.

Cooney Exercise (Since D21)

This technique consists in mobilizing the wrist in flexion/extension in order to make the flexor tendons glide below by tenodesis effect.

This exercise must be realized very carefully, asking an active mobilization of the wrist in moderated amplitudes, never going further than the tension, because the mobilization of the wrist is the source of gliding but also of notable constraints on the tendon.

Flexibility of the Scar (As Soon As It Is Closed)

Massage of the Scar

Without any distraction of the scar, we mobilize it to try to free the different gliding planes and soften the scar. We use sanding techniques, sliding pressures and palpating and rolling massage in the areas where it can be done.

Depressotherapy

We use this machine with the usual procedures for the treatment of scars, but with the orthosis to limit the risks of dangerous manoeuvres for the tendon.

10.5.1.2 Fragility Phase (D45 to D90)

During this phase, we keep doing the previous techniques, intensifying their application. The orthosis is removed for all the daily activities, but kept during “risky” activities.

The importance of the different techniques depends on the healing of the patient.

If the patient has an intrinsic healing, there are less adherences, and the active mobility can be satisfactory. There is less risk of stiffness than of rupture (which is still unusual in this phase).

If the patient has an extrinsic healing (big finger, hypertrophic scar), the finger isn't very mobile, and there still are trophic disorders. The risk of stiffness is important.

Of course, ideally, at D45 the patients should all have developed an intrinsic healing, but we note that it isn't always the case, even for the patients followed by a specialized team (genetic factor, associated injuries, waiting before medical care?).

Some new techniques are used in this phase:

Fight Against Trophic Disorders

Pressotherapy

Pressotherapy techniques with compression from distal to proximal can be used to fight trophic disorders that can still remain in this phase of the rehabilitation.

Getting Mobility Back

Electrostimulation

In this phase, we can use striomotor currents in order to accompany the patient's active contraction. It helps improving the tendon glidings and therefore fighting against eventual adherences.

They are particularly useful when the patient has a deficit of the motor control, because the current efficiently stimulates the targeted muscle even if the motor command isn't optimal.

The placement of the electrodes depends on the muscle we want to stimulate.

Intrinsic Muscle Stretching

If the winding is satisfactory but the extrinsic + position is more difficult or impossible (positive Finochietto test), it is important to stretch the intrinsic muscles, which are hypo-extensible. The interossei and lumbrical muscles should be differentiated, as their stretching modalities are different.

The interossei can be stretched by the extrinsic + position of the hand, actively or passively.

The lumbrical muscles are stretched only if this position is realized actively, as the lumbrical muscles don't have a proximal bone insertion: the insertion is on the flexor digitorum profundus that moves from distal to proximal during the placement in the extrinsic + position (Figs. 10.23 and 10.23').

Computerized Imitation Exercises

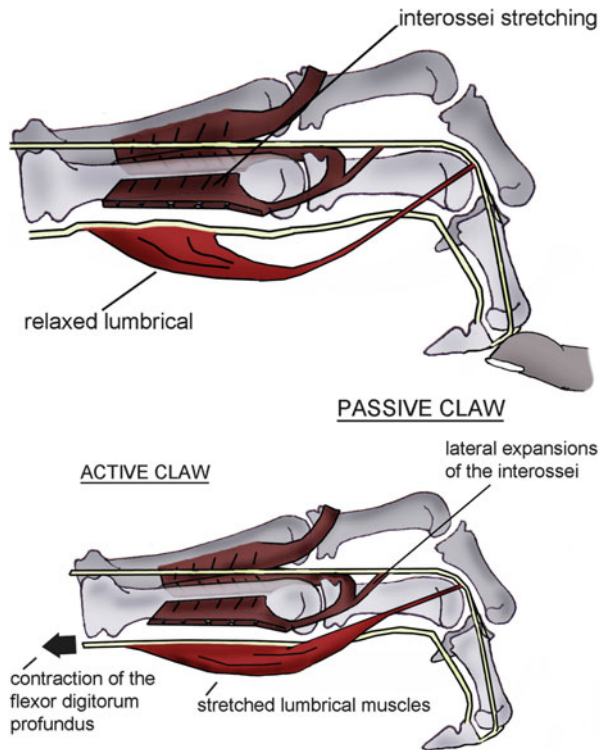
It consists in imitating the pictures on the screen during all the time they're on display.

The positions have been defined by Wehbé and allow obtaining a complete tendon gliding for the flexor digitorum superficialis and the flexor digitorum profundus and a maximal differential gliding between the two of them (Fig. 10.24).

Improving the Coordination and Dexterity

Manual Handling and Proprioception

We ask the patient to do manual handlings with different difficulties and intensities in order to improve coordination and dexterity.



Figs. 10.23 and 10.23' The passive placement of the lumbrical muscles in the extrinsic position doesn't stretch them, but the active placement does

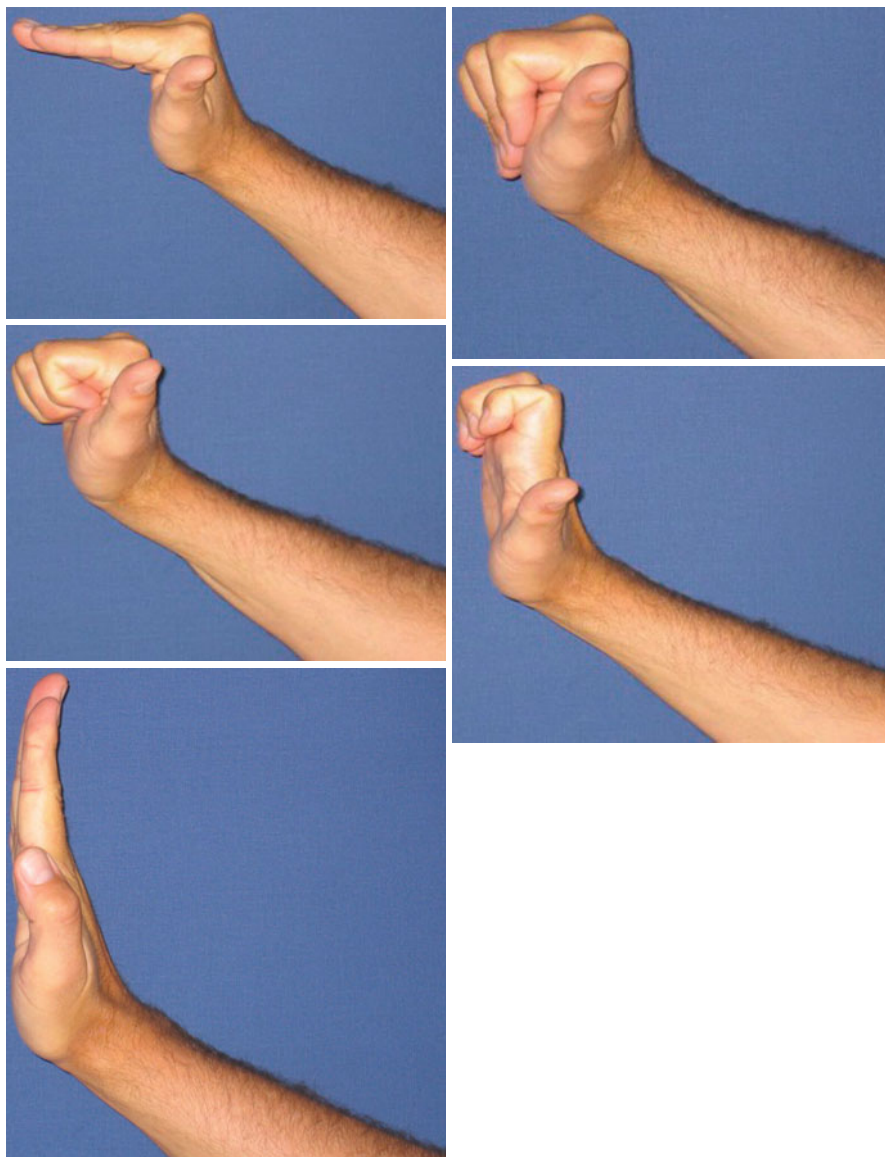



Fig. 10.24 Slide show for imitations of the positions defined by Wehbé, which allow a maximal differential gliding between the flexor digitorum profundus and the flexor digitorum superficialis

10.5.1.3 Strength Phase (After D90)

This phase corresponds with the patient getting back to work and doing sports.

We keep doing the previous techniques and intensify them in order to get closer to the patient's daily needs and the flexor tendons' function (Fig. 10.25).

Fig. 10.25 Functional exercises according to the patients' needs



10.6 Orthotic Treatment [7]

10.6.1 Immobilization Phase (Fig. 10.26)

Postoperatively, we use a Duran orthosis which shape depends on the affected area.

In case of injuries in zones 1, 2 and 3, we place the wrist in 30° of flexion and the metacarpophalangeal joints in 60° of flexion.

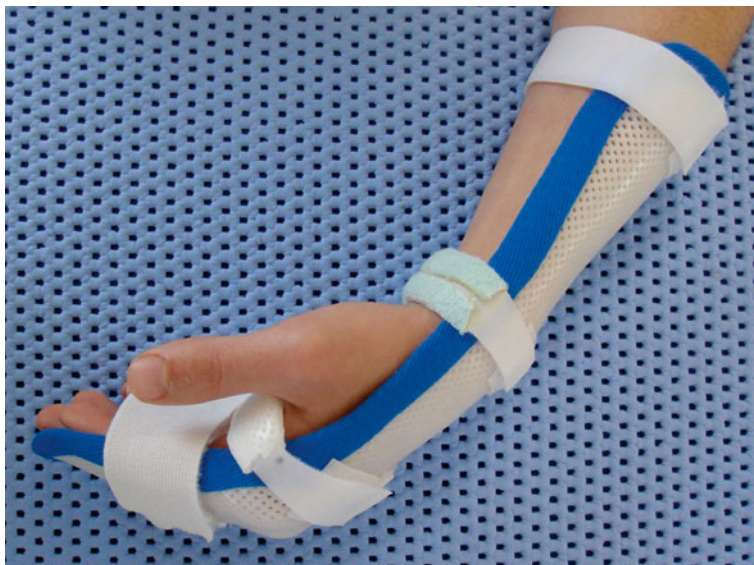

Fig. 10.26 Duran orthosis

In case of injuries in zones 4 and 5, the wrist is placed in 45° of flexion and the metacarpophalangeal joints in 60° of flexion.

The interphalangeal joints are placed straight, if that position is actively possible. If it's not, the suture may be under tension, and the orthosis is moulded in the position of maximal active extension of the patient. It is remoulded depending on the progress made in active extension. The finger must never be put in passive extension, because that could break the surgical repair!

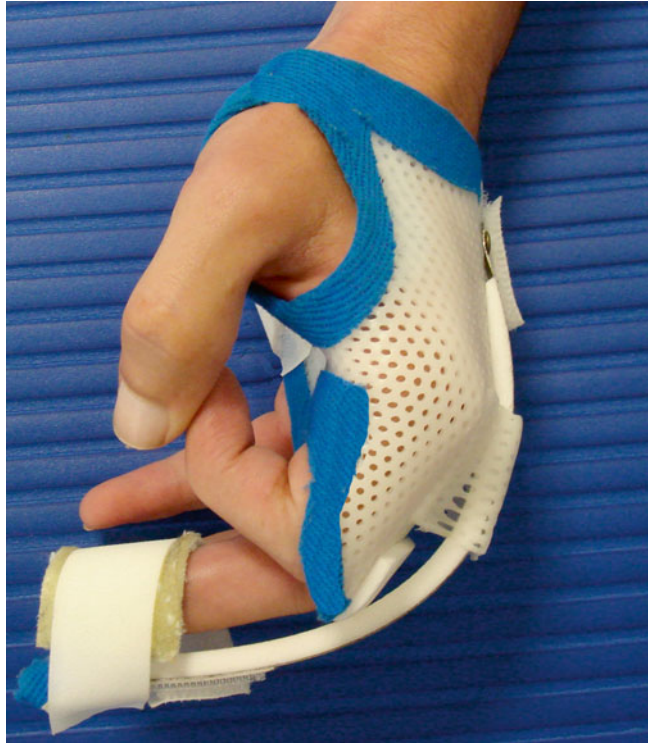After D21, the orthosis can be remoulded, placing the wrist in more extension, in particular if the flexed position of the wrist is poorly tolerated. The Duran orthosis is worn during 45 days.

10.6.2 After D60

In case of a flexum of the interphalangeal or metacarpophalangeal joints, we realize a postural orthosis (Fig. 10.27).

The use of a silicone tube can also be very beneficial, as it combines an anti-oedematous effect (by compression) and an anti-flexum effect and improves healing state (Fig. 10.28). The posture, maintained by the silicone tubes, isn't very intense, so we use these tubes since D45 if the trophic and healing disorders persist.

Fig. 10.27 Dynamic extension orthosis in case of flexum



10.7 Particular Cases

10.7.1 Injuries of the Flexor Pollicis Longus

The rehabilitation protocol follows the same principles as in the rehabilitation of the long fingers, adjusting to the physiological and architectural particularities of the flexor pollicis longus.

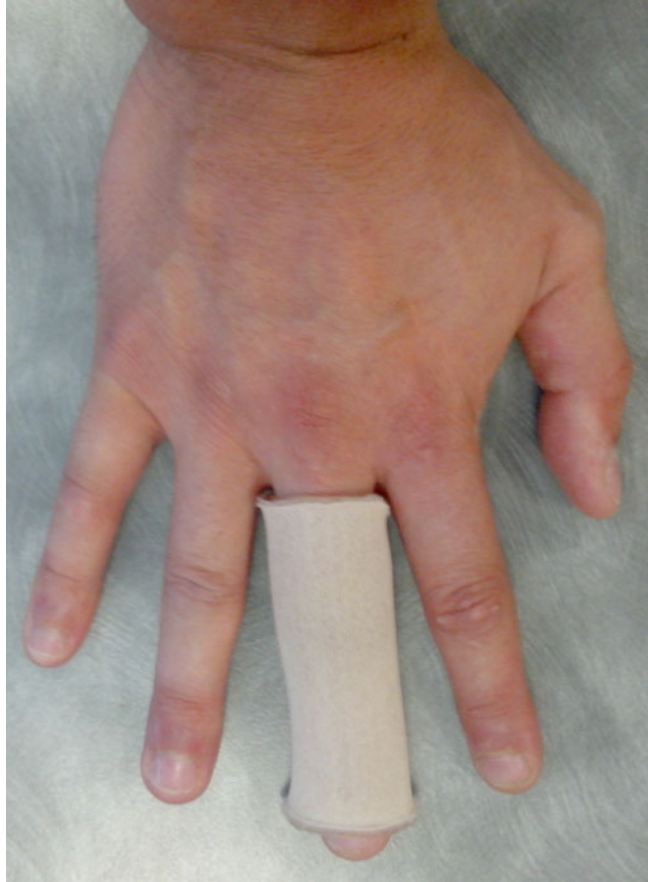There are a few things to keep in mind:

- The flexor pollicis longus is a very powerful muscle, so the patient has to control its contraction during the first phase to avoid any risk of rupture.
- In the T2 zone, its tendon can stick to the 2 heads of the flexor pollicis brevis, which can limit its gliding (cf. Fig. 10.4).

10.7.2 Jersey Finger (or Rugby Finger)

It's an injury of the flexor digitorum profundus in the ring finger, caused by a tear that occurs in a closed chain.

Fig. 10.28 Silicone muff for an anti-oedematous effect and healing improvement



Their classification allows us to know their gravity and surgical treatment.

The application of the rehabilitation protocol is more or less careful, depending on the vascular state of the tendon (tear of its short distal vincula).

Bibliography

1. Doyle JR (1988) Anatomy of the finger flexor tendon sheath and pulley system. *J Hand Surg Am* 13:473–484
2. Weber ER (1986) La repartition des tendons fléchisseurs dans le canal digital: rôle nutritionnel du liquide synovial. In: *Traité de chirurgie de la main*, vol 3. Masson, Paris
3. Delaquaize F (2003) Tendons fléchisseurs en zone II réparation et rééducation, méthodes actuelles et évolution des idées. Mémoire DIU de rééducation et appareillage en chirurgie de la main
4. Ovieve JM, Chapin-Bouscarat B (2005) Lésions des tendons fléchisseurs en zone 2. Evolution des idées et rééducation. KS 2005

5. Le Lardic C. Rééducation après suture des fléchisseurs des doigts, 40 ans d'évolution. KS octobre 2008
6. Creekmore H, Bellingnausen H, Young VL, Wray R, Weeks PM, Grasse PS (1985) Comparison of early passive motion and immobilisation after flexor tendon repairs. *Plast Reconstr Surg* 75:75–79
7. Isel M, Merle M (2012) *Orthèses de la main et du poignet – protocoles de rééducation*. Elsevier Masson, Issy-les-Moulineau

Part IV

Amputations

Chapter 11

Amputations

Demecia Maffray

“The hand is the tool of tools” (Aristotle), but it is also an important relational device. The partial or total amputation of a finger leads to the loss of the anatomical and/or functional integrity and must therefore be supported physically and psychologically by the patient.

The hand amputations (or mutilated hand) are often caused by work, handiwork, or public highway accidents. They are very diverse, as well as their severity and complications.

So, depending on the amputation level, the hand functions will be more or less compromised.

These patients should be treated by physiotherapists, working closely with orthotists and occupational therapists in order to reestablish their hand’s function, sometimes with compensatory mechanisms.

11.1 Therapeutic Process and Surgical Treatment [1]

The treatment for a digital amputation is always a surgery to remove a part or the whole finger that has irretrievably lost its anatomical or functional integrity. This surgery is repairing and functional.

It can have heavy functional consequences, regardless of the mutilation level.

In case of poly-digital amputations, it’s important to keep the thumb that is, functionally, the most important finger.

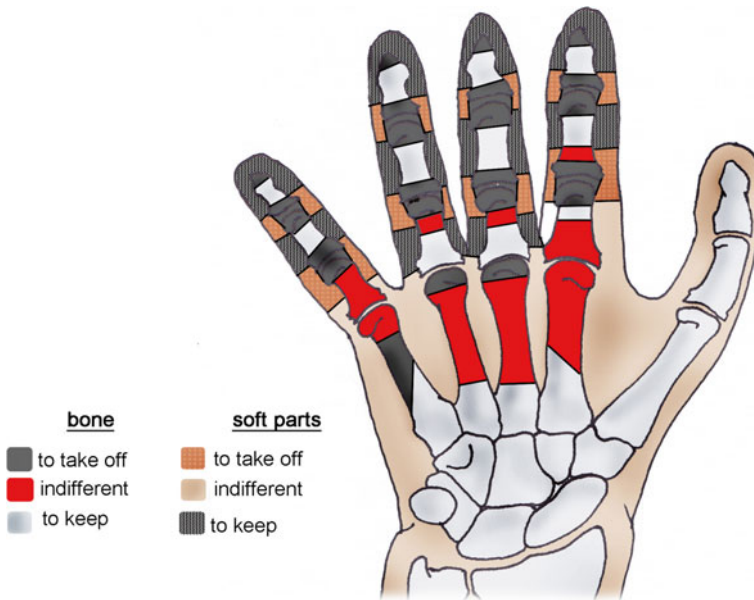
In this repairing and functional surgery, two amputation types can be distinguished: a “simple” or “complex” amputation.

D. Maffray

Physiotherapist, Institut Sud Aquitain de la Main et du Membre Supérieur,

Aguiléra Clinic Biarritz, Biarritz, France

e-mail: dmaffray@hotmail.com



Amputation levels for isolated digital amputations
(according to Gosset and Michon)

Fig. 11.1 Amputation levels for isolated digital amputations (according to Gosset and Michon)

The “simple” amputation is a sharp amputation of one or various parts of the limb.

We talk about a “complex” amputation when there is an extensive damage, but that still allows a functional or esthetic reconstruction.

These amputations must be carefully executed, as a neuroma on a stump that is too long will lead to various surgeries and therefore delay the recovery.

11.1.1 Amputations of the Long Fingers

The surgical treatment depends on the level of the mutilation (Fig. 11.1).

11.1.1.1 At the Level of the 3rd Phalanx

The amputation is always definitive; we distinguish 4 zones (Fig. 11.2).

In zones 1, 2, and 3, we keep the length of the 3rd phalanx that’s left.

In zone 4, it isn’t necessary to keep the base of the 3rd phalanx. We regularize the head of the 2nd phalanx (Fig. 11.3).

Fig. 11.2 Topography of the distal amputations at the level of the 3rd phalanx (zones 1 to 4)

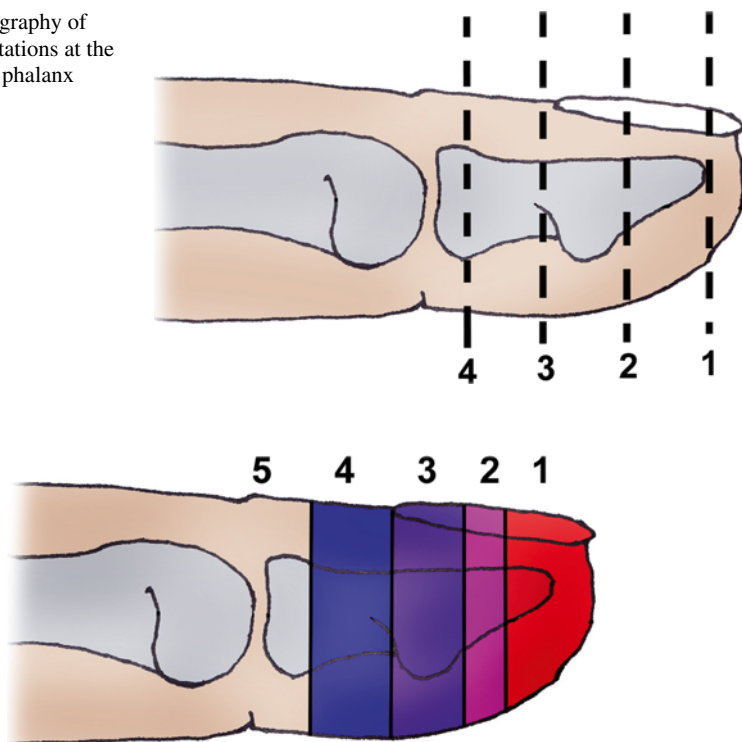


Fig. 11.3 Level and indication of the definitive amputations of the distal phalanx (long finger). 1 Preservation of the nail and pulp reconstruction with a sensorial flap. 2 Preservation of the nail to be discussed. 3 Preservation of the 3rd phalanx: eventual reconstruction with a sensorial flap, nail sterilization. 4 Preservation of the 3rd phalanx to be discussed, nail preservation. 5 Preservation of the 3rd phalanx contraindicated, amputation at the head of the 2nd phalanx

11.1.1.2 At the Level of the 2nd and 1st Phalanges

The amputation will be realized at the head of the phalanges or through the diaphyseal segment.

11.1.1.3 At the Level of the Metacarpophalangeal Joints

We try to keep the head of the metacarpal to keep the bone length and therefore keep the architecture of the metacarpal arch (integrity of the palm's width).

For the 3rd and 4th fingers, a new commissure is created. We can then realize a proximal resection of the segment or a digital translocation if a functional discomfort appears (or with an esthetic purpose).

11.1.1.4 At the Level of the Metacarpals (Proximal)

The amputation will never be realized as an emergency, except if the damage is too important.

11.1.2 Amputation of the Thumb

The thumb is, functionally, the most important finger of the hand; therefore, we can't apply the same rules than for the long fingers. Everything will be done to keep as much length as possible, even if it leads to joint stiffness (arthrodesis).

11.1.3 Poly-digital Amputations

In this case, everything will be done to keep as much stump length as possible, in a functional purpose.

11.1.4 Transmetacarpal Amputations

We will also try to keep as much length as possible.

11.2 Rehabilitation and Orthotic Treatment

The rehabilitation usually starts early to avoid eventual stiffness and regain the optimal function of the hand.

The priority goal is to regain the physiological joint amplitudes (without disturbing the tissue healing).

Once the scars are closed, we can add scar remodeling and sensorial exercises. We also start functional reintegration for the stump not to be excluded.

We'll have to watch carefully for pain to avoid the complex regional pain syndrome (CRPS).

11.2.1 Rehabilitation Protocol (Fig. 11.4) [3]

11.2.1.1 Cutaneous Healing Phase (d0 to d21)

In this phase, the patient still has bandages, so the rehabilitation is limited. It's important to fight against pain and stiffness.

Digital amputations		
	Cutaneous healing phase	Scar remodelling phase (closed scar)
R e h a b i l i t a t i o n	<p>Therapeutic goals: fight against pain and vasomotor disorders, prevent stiffness.</p> <p>Techniques: - Electrotherapy TENS (100Hz) and 1 Hz, transcutaneous vibratory stimulation, digital draining. - Passive and active mobilizations ++ of the proximal joints.</p> <p>Risks: CRPS if inadequate treatment, phantom limb, neuroma...</p>	<p>Therapeutic goals: regain strength and amplitude, scar relaxation, functional reintegration, rehabilitation to cold temperatures.</p> <p>Techniques: - Same + fluidotherapy, active electrostimulations. - Intensify the articular and muscular techniques. - Scar massages. - Desensitisation and padding of the stump. - Occupational therapy + rehabilitation to cold temperature (Lewis).</p> <p>Risks: functional exclusion.</p>
	Or th o s is	Protection orthosis.
D0 to 21		After D21

Fig. 11.4 Rehabilitation protocol

The patient must do some self-rehabilitation exercises at home.

We have to be alert for signs of CPRS (if inadequate treatment), phantom pain, or neuromas.

Fight Against Pain

Analgesic Electrotherapy: 100 Hz (TENS) or 1 Hz

The active electrode is placed as close as possible to the painful area and the other at the level of the corresponding vertebral level. The intensity will be regulated so that the patient feels a tingling sensation, not a muscular contraction.

Transcutaneous Vibratory Stimulation (Fig. 11.5) [2]

It will start early, through the bandages, as it has an analgesic effect and prevents painful and sensorial neuromas.

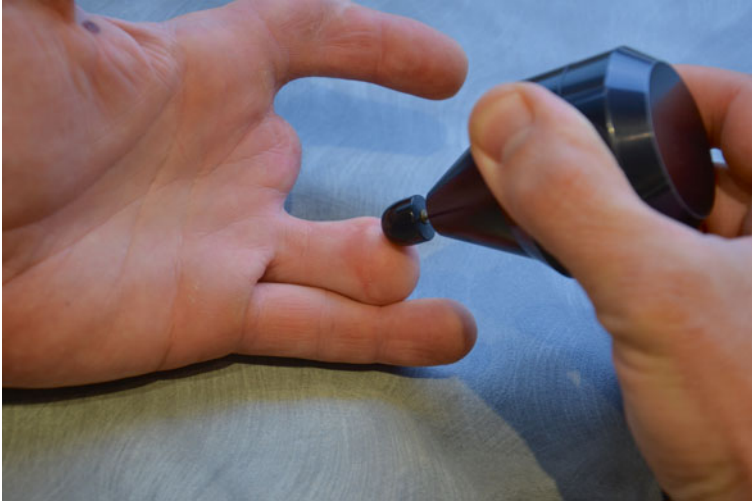


Fig. 11.5 Transcutaneous vibratory stimulation on the stump

For an analgesic effect, we use low-frequency vibrations (100 Hz) and with a low amplitude on the painful area. If the patient feels pain when contacting with the vibration, we'll use it far from the painful area. We'll try increasing the amplitude of the vibrations and getting closer to the painful area little by little, without creating any pain. We consider the result satisfying with a 100 Hz frequency and maximum amplitude.

The transcutaneous vibratory stimulation also has a proprioceptive action that creates an illusory sensation of movement by stimulating the cutaneous mechanoreceptors and exciting the muscle spindles. This will replace the lack of use of the hand and keep the movements intact. The active movements will be regained easier.

The early stimulation of the stump allows a better acceptance of the treatment when we remove the bandage. It also lowers the anxiety toward the trauma and its consequences.

Fight Against Vasomotor Disorders

- Circulatory massage once the scar is closed (Fig. 11.6a).
- *Pressotherapy* with disto-proximal compression to drain the superior limb (Fig. 11.6b)
- *Cryotherapy* (Fig. 11.6c)

Prevent Stiffness

Passive and Active Mobilizations of the Various Proximal Joints

We prefer the active mobilization to maintain the motor pattern and favor the tendon gliding.

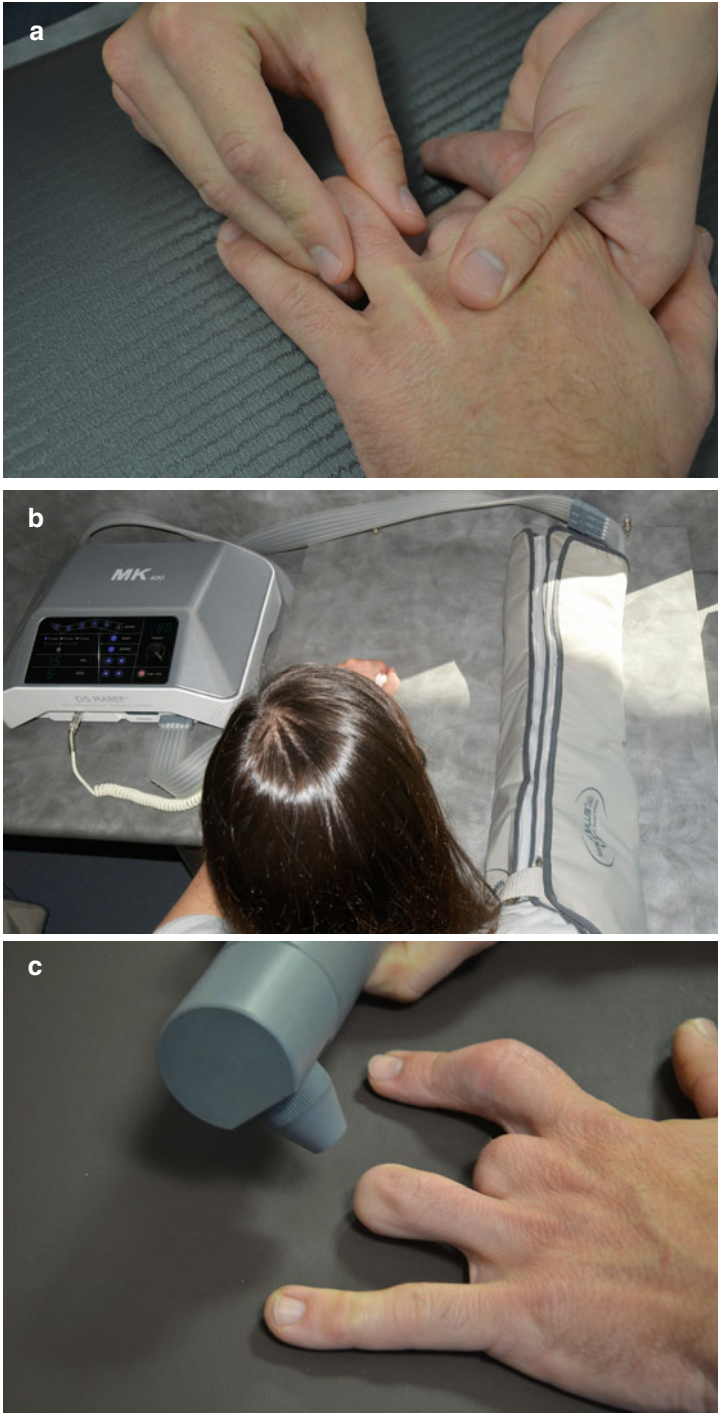


Fig. 11.6 (a) Scar massage of the stump, (b) pressotherapy, (c) cryotherapy

Electrostimulation

The electric stimulation, combined with an active contraction, favors the tendon gliding and therefore fights against eventual adhesences. The electrodes are placed depending on the muscle we want to stimulate (cf. *Volume 1 - Physiotherapy*).

Computerized Imitation Exercises

It consists in imitating the pictures on the screen during all the time they're on display.

They allow a complete tendon gliding (Fig. 11.7).

Exercises for Sensitivity

Transcutaneous Vibratory Stimulation [2]

The sensitive rehabilitation of the stump is important. In fact, early stimulating the scars (since D3, postoperative) through the bandages will get the stump used to receiving sensorial informations.

If there is hypersensitivity, we'll work with a low frequency and a low amplitude. The sensation felt by the patient should be neither painful nor unpleasant.

If there is hyposensitivity, we'll work with a high frequency (200 Hz) on the numb area.

Stereognosis (Wynn-Parry)

The patient stimulates his/her stump with objects made of different materials (hylognosis) and of different shapes, sizes, and surfaces (morphognosis) (Fig. 11.8a, b).

11.2.1.2 Cutaneous Remodeling Phase (Closed Scar) After D21

In this phase, the wound has healed, and the rehabilitation goals will be the same as in the first phase. We add the relaxation of the scar and the functional reintegration, and we intensify the sensorial rehabilitation.

It's important to watch for an eventual functional exclusion.

Regaining Strength and Amplitude

Passive and Active Mobilization

See first phase.

Fig. 11.7 Computerized imitation exercises






Fig. 11.8 (a) Work on hylagnosis. (b) Descriptive table of the different stages of stereognosis

Electrostimulation

See first phase.

Computerized Imitation Exercises

See first phase.

Thermotherapy

We use heated materials (bag of cherry stones or hot packs, paraffin) that fit the shape of the hand and improve tissue viscoelasticity. It relaxes the muscles and improves glidings between the different tissue planes of the hand.

With the bag of cherry stones, we can ask the patient to realize slow movements to realize a global warm-up of the hand.

With the paraffin baths, the patient can rest his/her hand or put it in maximal amplitude to realize a posture that will be more tolerated and eased by the hot temperature (Fig. 11.9a, b, b').

Of course, we don't realize these exercises on inflammatory or sensitive areas, but a more proximal application is authorized.



Fig. 11.9 (a) Cherry stones bag, (b, b') paraffin bath



Fig. 11.10 Depressotherapy

Fluidotherapy

Hot water helps obtaining a relaxation of the tissues and therefore improves joint amplitude. The patient can realize computerized imitation exercises in the water to make them easier.

Muscular Exercises

As the patient uses his/her hand less, he'll feel a loss of strength. Therefore, we'll reinforce the intrinsic muscles of the hand.

Relaxing the Scar

Massage of the Scar

We mobilize the scar to try liberating the different gliding planes and relax it. We use different techniques like sanding, glided pressures, or palpate-roll in areas where it can be done.

Depressotherapy

This device relaxes and drains the scars.

When the scar is still inflammatory, the patient will put the head away from it, which will mobilize and drain the tissues adjacent to the scar, without maintaining the inflammation.

When the scar isn't inflammatory anymore, we apply the head directly on it to relax it, decrease the edema, and make its evolution faster (Fig. 11.10).

Working on Sensitivity

Transcutaneous Vibratory Stimulations [2]

We continue with the exercise performed in the first phase, until there aren't symptoms left. Various sessions and habituation will allow the patient to bear more intensive stimulations.

Fluidotherapy

The Aerodyn® stimulates mechanoreceptors in the hand and stump (Fig. 11.11a).

The Kineroll® works on sensitivity, but also improves trophicity and has an analgesic effect (Fig. 11.11b).

High-Pressure Jet of Water

This jet has an adjustable pressure (maximum 3 bars) and stimulates precisely the area we want with hot or cold water. Working around and on the scar will help desensitize the stump.

It also has an effect on pain by stimulating the gate control and on trophicity by vasodilatation (hot water) or vasoconstriction (cold water) (Fig. 11.12).

Rehabilitation to Cold Temperatures [5]

After these traumas, we often observe a temporary intolerance to cold temperatures, related to a perturbation of the Lewis reaction that corresponds to a series of paradoxical vasoconstrictions and vasodilatations during an exposition to cold.

Daily immersion in cold baths (5–15 °C) can improve tolerance to cold temperatures, starting with the best tolerated temperature and progressively increasing the duration.

Various physiological and environmental factors (age, gender, tobacco, alcohol, circulatory pathologies...) can interfere on this rehabilitation.

Functional Reintegration

Improving Coordination and Dexterity

The patient has to realize manipulations, which become harder and harder (Fig. 11.13).

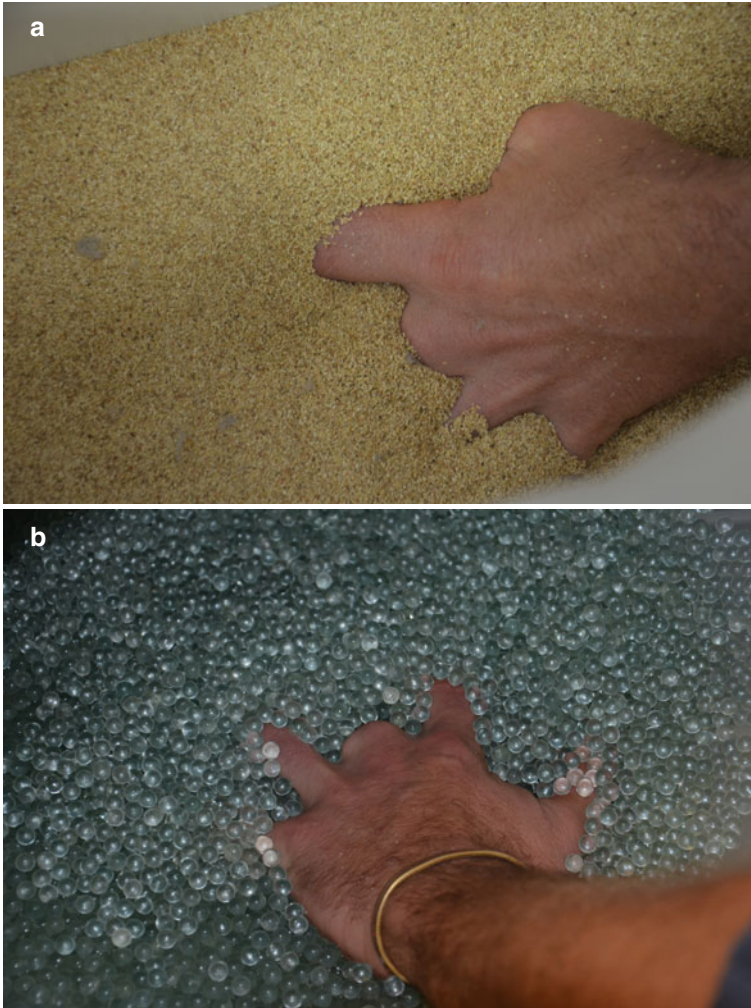


Fig. 11.11 (a) Aerodyn®: corn dust and hot air. (b) Kineroll®: wet fluidotherapy system combined with a massage with tiny glass beads mobilized by the rotation of the tank

Occupational Therapy

The patient can be advised to also see an occupational therapist if there is a functional exclusion.

11.2.2 Orthotic Treatment

11.2.2.1 Protection Orthosis

At first, it will be used to protect the stump during daily activities. The patient will have to stop using it rapidly to optimize his/her functional capacities (Fig. 11.14).



Fig. 11.12 High-pressure jet of water, with an analgesic and sensorial purpose



Fig. 11.13 Work on dexterity

11.2.2.2 Functional Orthosis

Its aim is to protect the stump from painful contacts while allowing the patient to have a normal activity.

There also exist compressive gloves or bandages to fight against vasomotor disorders and protect from hot and cold (Fig. 11.15).

In case of flexum or deficit of flexion, we can use dynamic or static orthosis to gain amplitude.




Fig. 11.14 Protection orthosis (silicone and thermoformable plastic)



Fig. 11.15 Compressive bandage

11.3 Neurological Pain

11.3.1 *Phantom Pain* [4]

Most of the amputated patients feel their amputated limb. This sensation comes along with phantom pain (the pain an amputee feels in his/her absent limb). The patients know these sensations are illusory.

Phantom pains are present in 50–80 % of the cases after an amputation.

There are also some painless sensations in the phantom limb: proprioceptive, exteroceptive, and motor.

There is a difference between phantom sensations and phantom pains:

- *The phantom sensations* are painless tingling, numbness, itching, and hot and cold sensations. Even if they are painless, they can cause discomfort.
- *The phantom pains* are painful sensations like cramps, tearing, and burning and electric shocks in the phantom limb.

The phantom pains are often distal in the phantom limb and mean there is muscular tension or vascular disorders in the residual limb. These painful phenomena can be ad hoc or permanent and have a neuropathic nature.

It is hard to treat, but there are different treatments, more or less efficient, to alleviate the pain:

- *Surgical treatments* obtain good results but are used only if every other treatment has failed.
- *Medications* can relieve or prevent pain, but it is hard to determine their efficiency.
- *TENS* also has beneficial effects.
- There are other techniques like acupuncture, hypnosis, or reflexology.

The transcutaneous vibratory stimulation is ideal in this type of pain.

11.3.2 Neuromas

A neuroma is an abnormal growth of nerve tissue that appears as a result of a peripheral nervous injury.

In amputations, a neuroma develops when a nerve has been cut. The fibers (axons) will grow back, but they're not guided in a nervous sheath anymore, so they will entangle and form the neuroma.

This bundle of peripheral nervous fibers sets off paroxysmal or neuropathic pain.

There are different treatments to alleviate the pain:

- *Surgical treatment: neurectomy*
- *Local anesthetic injection*
- *Medications*
- *Deep massages*
- *Transcutaneous vibratory stimulation*

Bibliography

1. Dautel G. Amputation d'attente et amputations définitives. In: Tome 1, Merle M, Dautel G (eds.) La main traumatique
2. Durand PA, Romain M (1993) La stimulation vibratoire transcutanée dans la rééducation de la main. Journal d'Ergothérapie, Masson.15:(2):44–46.

3. Xhardez Y et coll (2009) Vade-Mecum de Kinésithérapie et de Rééducation Fonctionnelle. Maloine, Paris
4. Haarer-Becker R, Schoer D (2010) Kinésithérapie en orthopédie et traumatology. Douleurs fantômes, boîte miroir et réalité virtuelle: une nouvelle approche pour le kinésithérapeute. Rev Questions Sci 181(3):273–304
5. Beyls Y (2005) Réactions physiologiques et adaptation de la main au froid – Mémoire du DIU de rééducation et appareillage en chirurgie de la main. www.reeducation-main.com

Part V
Physiology and Rehabilitation
of Sensorial and Motor Disorders

Chapter 12

Physiology and Rehabilitation of Sensorial and Motor Disorders

Gregory Mesplié

12.1 Nerve Physiology [2, 7]

A peripheral nerve is made by fascicles limited by the perineurium and surrounded by connective tissue (the endoneurium). These fascicles are gathered in another tissue, the epineurium, which ensures the fixation and gliding of the nerve respective to the adjacent structures. They describe a wavy path and therefore absorb the stretching constraints before they're transmitted to the proper fibres.

The peripheral nerves have a double vascularisation:

- *Extrinsic*, from the adjacent vascular systems
- *Intrinsic*, via a longitudinal web that anastomoses to create a link between the vessels of the epineurium and the perineurium

The low energetic needs of the nerve, the wavy path of the fascicles and the double vascularisation allow supporting a nerve elongation until a certain point. Beyond that point, the diameter of the fascicle decreases and the intrafascicular pressure increases. This can compromise the vascularisation and have irreversible side effects.

The importance of the constraints imposed on the nerve depends on the strength applied, its speed and duration.

G. Mesplié
Physiotherapist and Orthotist, Institut Sud Aquitain de la Main et du Membre Supérieur,
Aguiléra Clinic Biarritz, Biarritz, France
e-mail: greg.mesplie@mac.com

12.2 Functional Classification of Nervous Injuries (Fig. 12.1)

This classification was first made by Seddon in 1943 and includes three types of nervous injuries: neurapraxia, axonotmesis and neurotmesis. Sunderland then added two other stages:

1. *Neurapraxia* or Sunderland's first stage: damage of the myelin but preservation of the axonal continuity. There's usually a full recovery in 3–12 weeks.
2. *Axonotmesis* or Sunderland's second stage: damage of the fascicle, but conservation of the endoneurial tubes. Therefore, there's usually a full recovery except if the denervation lasts too long and causes irreversible damages in the motor plate or the sensorial receptors. The volar plate stays functional during approximately a year; the sensorial receptors can survive several years.
3. *Stage 3* with damage of the endoneurial tubes but preservation of the perineurium. The axon is damaged and the prognosis uncertain.
4. *Stage 4* with damage of the perineurium but preservation of the epineurium. The continuity of the nerve is only due to the epineurium. Surgery is necessary to have any hope of recovery.
5. *Neurotmesis* or Sunderland's fifth stage: total rupture of the nerve, there isn't continuity anymore and surgery is needed.

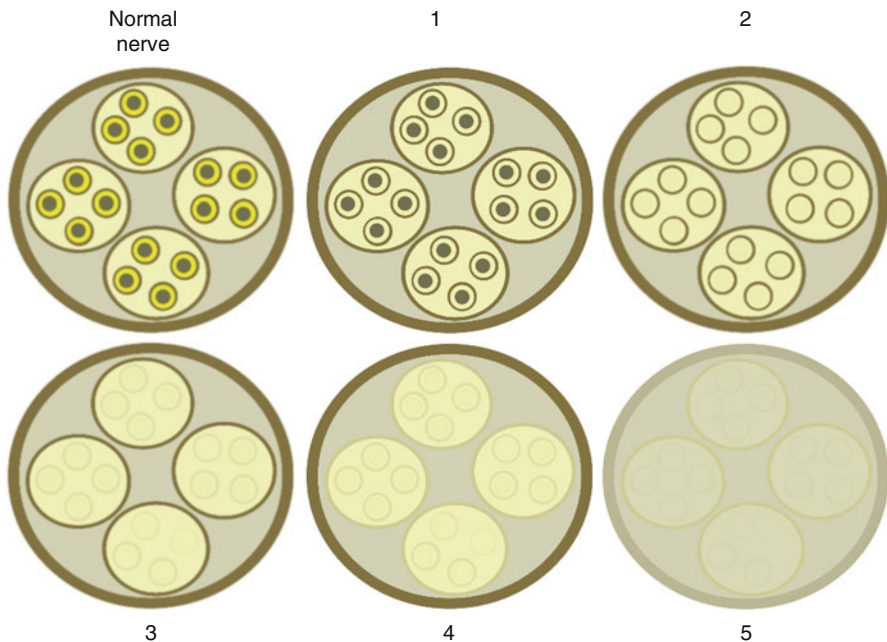


Fig. 12.1 Functional classification of nervous injuries

12.3 Sensorial Physiology [11]

The sensitivity of the hand allows transmitting to the cortex any information that brings an adapted motor answer. Therefore, it has a huge importance in every thin or strong prehension. The mechanoreceptors and thermoreceptors of the palmar side of the hand are the most precise and transform the mechanical stimulus in nervous impulse, which travels through different types of nervous fibres corresponding to different types of sensitivities.

12.3.1 Sensorial Receptors

The hand has approximately 17,000 tactile unities, which gives it important precision allowing precise prehensions. The discriminative sensitivity can be lower than 2 mm between the thumb and the radial index.

Very briefly, there are two big categories of receptors that work differently and don't react the same way when receiving a stimulus. The essential difference is that the fast-adapting receptors (FA) react to the stimulus with only 1 pulse, whereas the slow-adapting receptors (SA) modify the frequency of their pulses.

Hairless skin presents several types of receptors that react to mechanical, thermic or painful stimuli.

12.3.1.1 Mechanoreceptors (Fig. 12.2)

- *Meissner corpuscles* localised in the papillary groove between the epidermis and the dermis. They are fast-adapting receptors sensitive to low frequencies (30–40 Hz) and to exploratory touch.

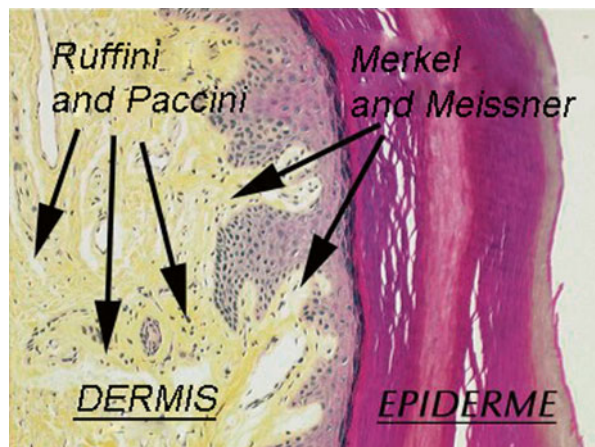


Fig. 12.2 Location of the mechanoreceptors in the palmar side of the hand

- *Pacinian corpuscles* localised in the deep dermis and the subcutaneous tissue. They are fast-adapting receptors, very sensitive to frequencies between 250 and 350 Hz.
- *Merkel cells* localised at the level of the junction between the epidermis and the dermis. They are slow-adapting receptors, and their capacity of modulating their pulses favours the touch and pressure evaluation. Cold temperatures increase their excitability, while hot temperatures inhibit them.
- *Ruffini corpuscles* localised in the dermis. They are slow-adapting receptors sensitive to pressure and play a role in detecting displacements and positions. They are more sensitive to cutaneous stretching than to vertical pressures and are excited by cold temperatures and inhibited by hot temperatures.

12.3.1.2 Thermoreceptors (Fig. 12.3)

- *Hot receptors* are point located, which explains why the thermo-sensitivity works by “stains” of approximately 1 mm. They are active from 30 °C, to liberate a pulse peak between 38 and 43 °C. They stop emitting this pulse below 32 °C or above 48 °C (then the nociceptive fibres are the ones that are active).
- *Cold receptors* are also point located, with a reception field of 1 mm. They are active from approximately 10 °C to liberate a pulse peak between 20 and 30 °C. They stop emitting this pulse below 10 °C and between 38 and 48 °C. Between 48 and 50 °C, they react paradoxically, creating a feeling of cold.

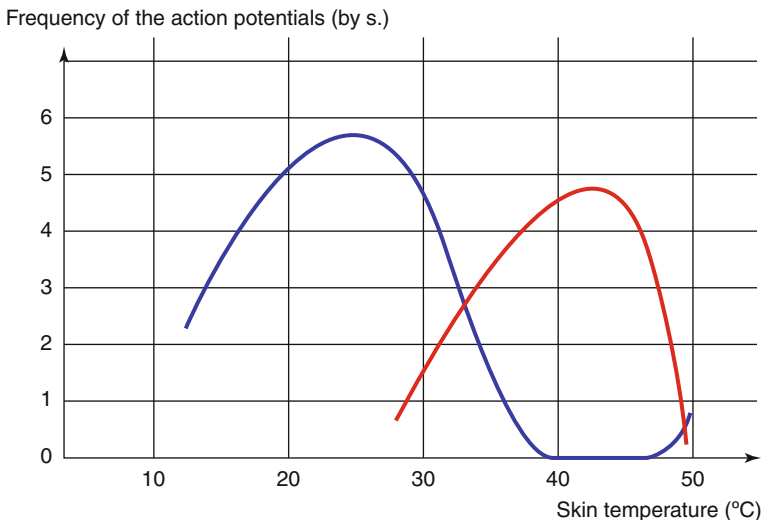


Fig. 12.3 Thermoreceptors' activity depending on the cutaneous temperature

When we put the hand in cold water, the thermoreceptors' activity is important at first, and then it decreases. This can explain the fact that water seems less cold after a short time. The same phenomenon exists with hot temperatures.

12.3.1.3 Nociceptors

They are activated by stimulations which excitement threshold is higher than for other types of receptors. They allow defining risky stimulations, potentially damaging. There are 3 types of receptors (mechanonociceptors, thermic and mechanic receptors, polymodal), related to fibres with different diameters, which permit transmitting a well-localised acute pain followed by a delayed burning pain, less localised but during longer.

12.3.2 Sensitivity Types

12.3.2.1 Nociceptive Sensitivity

Types of Pain

According to the medical dictionary Flammarion, pain is “an abnormal and unpleasant sensation caused by the excessive excitation of a living part of the organism, perceived and integrated at the highest level of the cerebral cortex, which gives it a characteristic of personal experience and an emotional nature”. This definition is in accordance with the fact that pain is related to physical factors, perceived differently depending on the individual.

It can be defined according to clinical or physiopathological criteria.

Clinically, we distinguish acute and chronic pain.

Acute pain is an alarm signal in response to an aggression that could jeopardise the integrity of the individual. When the injury heals, the painful message disappears. This system allows the subject to adapt his behaviour to the injuries he's suffering and therefore favours his recovery.

Chronic pain is pain that has been lasting more than 3–6 months. It works on its own without associated tissue injuries and causes structural modifications in the central nervous system, leading to modifications of the pain threshold. These modifications can make pain more intense (hyperalgesia), make painless stimuli painful (allodynia) or allow the apparition of spontaneous pains. This kind of pain can change the patient's behaviour with social and family consequences that can be catastrophic.

On a physiopathological level, we differentiate neuropathic pains and pains with excess of nociception.

The last ones are triggered by a stimulation of the nociceptors, are mechanical and are located on the damaged area without neurological topography.

Neuropathic pains are related to a peripheral or central nervous damage and can be continued or intermittent, without mechanical stress. They can feel like a burn, an electric shock or a dysesthesia and are located on the topographic area of the damaged nerve. They can be associated with hyperesthesias, allodynias, hypoesthesias or anaesthesia.

We also have to add to these two types of pain: the pains maintained by the sympathetic system (CRPS types 1 and 2) and the psychogenic pains (somatisation, hypochondria, delirium, etc.).

In practice, this classification raises problems as several types of pain can be involved. Sometimes we don't know the pain's origin, and a pain that seems psychogenic can in fact be a chronic pain with a side effect on the patient's psyche.

Transmission of the Nociceptive Message

The nociceptors are either mechanonociceptors A δ responding to mechanical and hot stimulations or polymodal nociceptors C responding to intense mechanical, thermal or chemical stimuli. They convey the pain message towards the spine through A δ fibres poorly myelinated (localised and sharp pain) or C fibres unmyelinated (delayed and widespread pain). These fibres have a moderate diameter and a conduction speed inferior to the A β fibres conveying sensitivity for fine touch (Table 12.1).

These fibres enter the dorsal horn of the spinal cord where there is a medullary relay with two types of neurons:

- *Specific nociceptive neurons* that convey only pain messages.
- *Polymodal neurons* that convey any kind of information, nociceptive or not, coming from the skin, the guts or the muscles. The convergence of informations at the cortical level can lead to a processing error that can cause referred pain, where we find a cutaneous metameric pain when the origin is visceral, articular or muscular.

Table 12.1 Characteristics of the sensorial fibres

Sensorial fibers	Roles	Myelination	Diameter (μm)	Conduction speed (m/s)
A β	Proprioception: neuromuscular bundles	+	12–20	70–120
	Golgi tendon organ	+		
	Cutaneous sensitivity: touch	+	5–12	30–70
A δ	Cutaneous pressure: temperature	+	2–5	12–30
C	Cutaneous pain: pain	–	0.4–1.2	0.5–2

When coursing towards the brain, the pain message is modulated by various factors that can amplify or inhibit it.

Nociceptors Sensitivity

The substances released around the damaged tissues can increase the inflammatory phenomena, lowering the excitability threshold and causing allodynia.

Pain Memory

The pain message lasts too long; the hormonal and chemical phenomena involved in the message transmission can “soak up” the nerve cells that “remember” this pain signal. Any other signal is then traduced as if it were nociceptive.

Axon Reflex

In the dorsal horn, the affluence of nociceptive messages can create a neurogenic inflammation that can maintain pain.

Gate Control or Melzack and Wall’s Theory

Large fibres have an inhibitory action on the nociceptive message conveyed by fibres A δ and C with antidromic conduction.

The Opioid System

The opioid receptors of the nervous system are present at the level of the central and peripheral systems and oppose nociceptive messages.

There is an integration of pain in the brain where there is also a modulation of the pain message that depends on the circumstances of the injury and the individual’s culture and background.

12.3.2.2 Protopathic Sensitivity Other Than Nociceptive

Besides the nociceptive message, A δ and C fibres convey informations about temperature and cutaneous pressure. The thermoreceptors react after 45 °C and under 10 °C and can convey a pain message in case of important stimulus. The informations arrive in the dorsal horn of the spinal cord at the level of convergent cells that receive nociceptive informations and other sensorial messages.

12.3.2.3 Epicritic Sensitivity

The epicritic sensitivity conveys informations of fine and discriminative displacements, pressure or vibration. Two types of mechanoreceptors collect mechanical informations and change them in nervous impulses:

- *Type 1 receptors* are small and cover a small skin surface.
- *Type 2 receptors* cover a wider surface and don't have precise limits.

Each of these receptor types can have a slow adaptation (and send the message during the whole stimulation) or a fast adaptation (and send the message at the beginning and at the end of the stimulation).

The cutaneous territory concerned by one receptor is small in the hand, which explains the important sensorial precision at this level.

The sensorial message coming from these receptors is conveyed by A β fibres that are large myelinated fibres with important conduction speeds.

12.3.2.4 Proprioceptive Sensitivity

It conveys informations concerning the limbs' position and movements, essential for the cortex to regulate the muscular tensions and adapt to every situation. The sensitivity relies on several mechanoreceptors at a muscular, tendinous and articular level, to which we must add cutaneous receptors that also participate in the formation of the proprioceptive message:

- *Golgi tendon receptors* that gives informations about the tendon tension and whose message is conveyed by A β fibres and has an inhibitory role on motoneurons during tendon stretching.
- Joint receptors at the level of the capsule and ligaments, which give information about the joint position and movements. They're made by three slow adaptation mechanoreceptors (Golgi organ, Ruffini corpuscles and free nerve endings) and one fast adaptation receptor (Pacinian corpuscles).
- *Neuromuscular bundle*, made by two types of receptors: nuclear chains fibres reacting to continuous stretching and nuclear bag fibres reacting to short stretching. The number of fibres in the bundle is very important in the hand for fine movements. In each extremity, the bundle is innervated by A γ motor fibres that regulate its tension.

12.3.2.5 Autonomic System

The autonomic system concerns the innervation of the guts and the endocrine and exocrine glands and the vasomotor activity.

The autonomic system is composed by two antagonist but complementary systems:

- *The parasympathetic system* whose role is to reduce the use of energy (trophotropism)
- *The sympathetic system* that produces energy (ergotropism)

Any disturbance in the balance between them can lead to important autonomic disorders, like the ones we can find in CPRS where the predominance of the sympathetic system causes vasomotor, pilomotor and sudoriparous disorders, as well as pain exacerbation by axon reflex.

12.4 Assessment and Rehabilitation of Sensorial Disorders

[3–5, 12, 17]

In axonal injuries of cutaneous nerves, the skin can develop two different states:

- It presents a decrease or even total loss of sensitivity, depending on the number of axons damaged in the nerve (no pain).
- It develops an unpleasant or even painful sensitivity (tingling, neuroma, allodynia, neuralgia, etc.), depending on the gravity of the phenomenon, with stimuli that aren't normally painful.

These two categories are assessed and treated in different ways, knowing that in case of pain there is also an underlying hypoesthesia that has to be treated later.

Therefore, we have to figure out if we're dealing with a "hypersensitive skin" or a "hypoesthetic skin".

12.4.1 Hyposensitivity

12.4.1.1 Assessment [8, 14]

Identification of a Hyposensitive Area (Esthesiography)

The first exam we realise in case of a partial nerve injury is an esthesiography that defines the hyposensitive area.

The pressure perception threshold in the palmar side of the hand is 0.1 g and the one in the dorsal side is 0.3 g. The one for the rest of the body is 0.6 g.

We, respectively, use aesthesiometers of 0.2, 0.4 and 0.7 g depending on the area we want to assess.

During the test, the patient must close his eyes and say "touch" when he feels the contact of the monofilament.

When touching the patient, the monofilament must bend under pressure, and the contact must last 2 s. We have to wait 10 s between two applications.

The assessment is realised in order to define an area as precise as possible, in relation to a reference point like a flexion crease, a scar, etc.

The first point is placed on the longitudinal axis of the damaged nerve branch. We progress centimetre by centimetre from distal to proximal, until the first point where the patient doesn't feel anything. The therapist then progresses from proximal to distal millimetre by millimetre until the first detected point, then one last time

from distal to proximal millimetre by millimetre until the first non-detected point. This point is transferred on the graph paper on which we realise the assessment.

The same process is realised to define the most proximal non-detected point and then the 2 transverse points of the area (Fig. 12.4).

Assessment of the Hyposensitivity Gravity

These measures define the stage of hypoesthesia in the area pre-established, according to Seddon's stages (Table 12.2).

Stage S0 corresponds to a complete anaesthesia.

Stage S1 corresponds to the sensitivity that protects against hot temperatures and pain. To assess this capacity, we try to determine if the patient feels important pressures and vibrations (e.g. 100 g and vibrations of 1 mm of amplitude), because if he can, it means he has this protective sensitivity. If the patient doesn't feel these stimulations, we evaluate his protection against pain and heat:

- *The protection against pain*, whose role is to protect against injuries, is tested with a simple needle. We apply a light contact on the skin and the patient must say "touch" when he feels a stimulus. A reaction time longer than 2 s isn't valid.

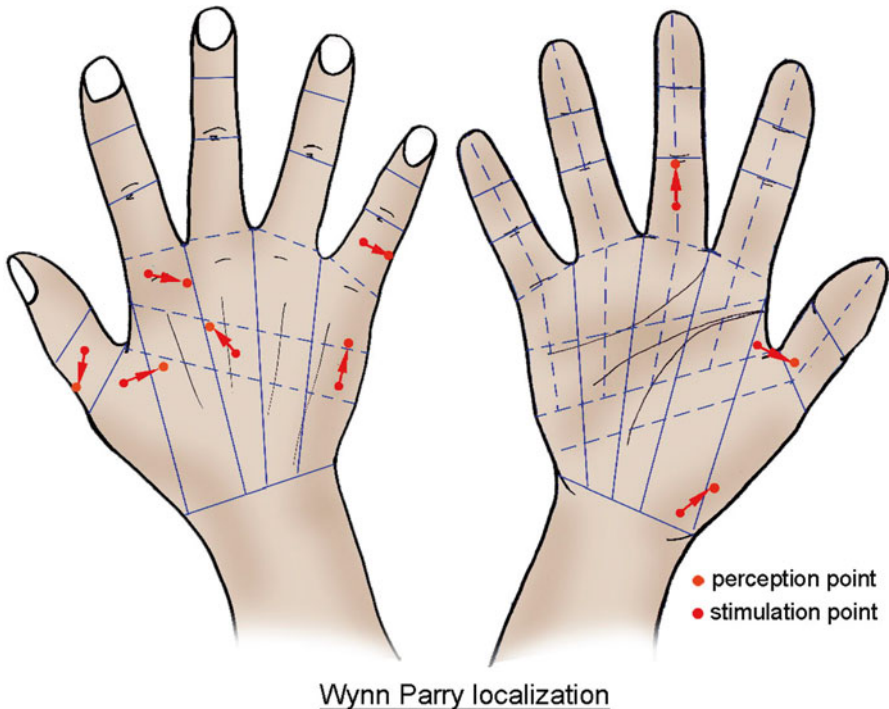


Fig. 12.4 Hand pattern reporting the damaged and perceived areas to objectify localisation errors

Table 12.2 Seddon's classification

Stages	Seddon's classification (1975)
S0	No protective sensitivity, no vibrotactile sensitivity
S1	Return of protective sensitivity to pain and heat No vibrotactile sensitivity
S2	Return of superficial pain sensitivity + Beginning of vibrotactile sensitivity (poor sensitivity) Perception of vibration at 30 Hz, 3 volt Perception of pressure between 100 and 5 g
S2+	S2 with dysesthesia
S3	Beginning of discriminative sensitivity between two mobile and static points between 30 and 15 mm and a pressure of 4.9–1 g (fair sensitivity)
S3+	S3 with good localization of stimuli between two mobile and static points between 15 and 7 mm and a pressure of 0.99–0.1 g (correct sensitivity)
S4	Normal sensitivity between two mobile and static points between 6 and 2 mm and a pressure of 0.1 g

- *The protection against heat*, whose role is to protect against burns, can be tested with a small glass bottle filled with hot water (the hottest tap water). The test modalities are identical as the ones for the protection against pain.

The stages S2, S3, S3+ and S4 need a more complete vibrotactile evaluation (Table 12.3):

- *Dellon's two-point mobile test*: it assesses the fast adaptation mechanoreceptors (Pacinian and Meissner corpuscles) and is realised before the two-point static test as the Meissner corpuscles recover before the Merkel discs. It's realised in the same conditions than the two-point static test and introduces a dynamic aspect that is important in prehensions. Combining Weber's and Dellon's tests allows an assessment of the functional discriminative sensitivity. In fact, the Weber's test is predictor for stable fine prehensions, whereas Dellon's test evaluates better the functional capacities of the hand for the manipulations of small objects.
- *Weber's two-point static test*: it evaluates the slow adaptation mechanoreceptors (Merkel discs and Ruffini corpuscles) responsible for the quality of posture when maintaining an object between the fingers. A damage of these receptors leads to a bad control of the objects taken in the hands, and the patients often complain about dropping things. It's a valid and sensitive test. The normal values depend on the individual, the explored territory and the thickness of the skin (corneous layer). The fingers pulp has the best discriminative values (between 2 and 4 mm). It varies between 5 and 8 mm in the palm and between 8 and 10 mm on the dorsal side of the hand. The test is realised with a divider calliper; the patient closes his eyes and tells the therapist whether he feels 1 or 2 needle points. In the initial reference series, the therapist looks for the distance in which the patient starts to make mistakes. He places at least one tip in the mapped area (when it's small). Once he reaches the distance between the tips defined as the reference distance,

Table 12.3 Correspondence between Seddon's classification and the observed vibrotactile capacities

Evaluation	S2	S3	S3+	S4
Vibrotactile sensitivity	Poor	Fair	Correct	Good
Threshold for the perception of pressure	100–3.6 g	3.5–1.6 g	1.5–0.2 g	0.1 g
Threshold for the perception of vibration	From 1.00 to 0.01 mm with vibradol or from 40 to 1% (minimal parameter of the device) with vibralgic 5			
Discrimination of two points	∅	≤30 mm	≤15 mm	≤6 mm
		>15 mm	>6 mm	

he asks a series of 10 questions (randomly: 5 times 1 tip, 5 times 2 tips), with 10 s between each question. The tips are applied on the skin during 2 s. Seven correct answers out of 10 are required for the test to be successful (Dellon 1988; Spicher et al. 2005). When we're evaluating hypoesthesia behind a mechanical allodynia, the test is shorter (5 questions instead of 10), to avoid producing pain. The normal values in the palmar side of the hand depend on the area and are related to the patient's functional needs (Fig. 12.5).

- *Pressure perception threshold (PPT)*: the PPT is realised alternating with the two-point mobile and two-point static tests, as realising both these tests in the same session requires a lot of concentration from the patient. It's realised on the area defined by the esthesiography during the 1st session. Like when realising the esthesiography, the patient closes his eyes and says "touch" when he feels the monofilament. When touching the skin, the monofilament must bend under pressure, and the contact must last 2 s. We have to wait for 10 s between two applications. The reference aesthesiometer is the last detected aesthesiometer (on the less sensitive area indicated by the patient), realising a decreasing series 75–11.7–3.6–1.2–0.2 g. Once we've determined the reference monofilament, we determine the PPT using the 3 bigger and the 3 smaller adjacent monofilaments: the test is realised with 7 monofilaments, as proposed by Annie Malenfant. We realise 6 series in one given point (the less sensitive indicated by the patient), alternating an increasing series (from the smallest to the biggest monofilament) and a decreasing series. For each series, we write down the first detected aesthesiometer. The 6 series can be memorised with the formula "IDIDID". The PPT is the mean value of the 6 applied forces detected during the test.
- *Vibratory perception threshold (VPT)*: it determines the capacity to feel the smallest vibration in a precise point, with a vibration generator. The frequency is 100 Hz and the amplitude 8 % (vibralgic 5) or 0.2 mm. If with this intensity the patient doesn't feel vibration, we use 40 % of amplitude (03 1 mm), which is the highest vibratory perception in stage S2. We apply vibration during 2 s, with 8 s of rest between 2 applications. We apply the stimulus decreasing by 1 % (or

Norm for the discrimination of 2 static points

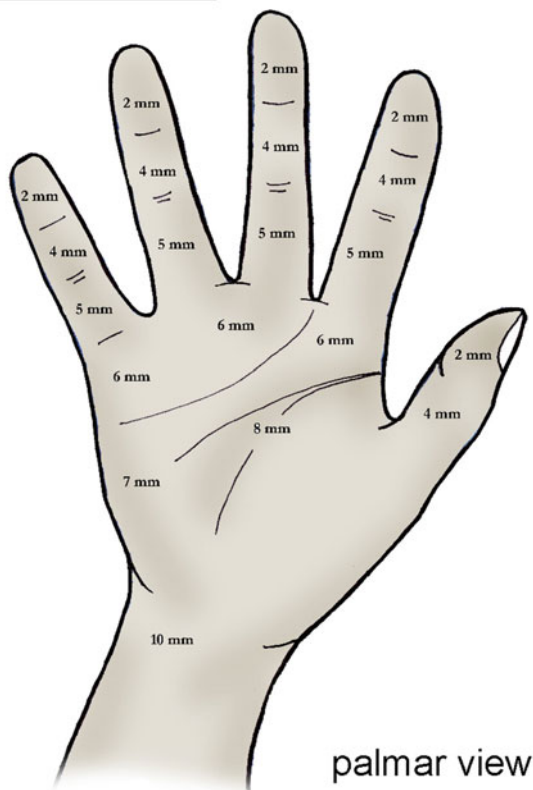


Fig. 12.5 Norm for the discriminative sensitivity of the palmar side of the hand

0.025 mm), then increasing and then decreasing again (DID). The VPT is the smallest amplitude perceived as a vibration.

- *Picking up test*: the patient has to pick up 12 metallic objects one by one as quickly as possible and put them in a box fixed in the middle. First, he realises it with the dominant hand with his eyes open. The test is timed and repeated 3 times. Then the patient repeats it 3 times with his eyes closed. Each time, we note the best time of the 3 repetitions. The test is then realised with the non-dominant hand, eyes open and eyes closed. Standards have been set depending on the gender for the 4 tests, which allows us to evaluate the patient in relation with the average time obtained in the normal population. This test is also useful to follow the sensorial recovery. Note: the hand must have an active mobility close to normal to realise this test.

	Women		Man	
	Minimum normal population	Average normal population	Minimum normal population	Average normal population
Dominant hand, eyes open	13 s	11 s	14 s	12 s
Dominant hand, eyes closed	26 s	20 s	29 s	22 s
Nondominant hand, eyes open	15 s	11 s	15 s	12 s
Nondominant hand, eyes closed	29 s	21 s	30 s	23 s

Excerpt from C. Spicher's "Manuel de rééducation sensitive du corps humain" [13]

Some variations for the picking up test:

- Seddon's coin test: recognising several coins with different values.
- Riddoch's test: distinguish several coins with smooth and serrated edges.
- Porter's test: recognising small letters (H, O, V, Y) in less than 30s. After 30s the test is negative.

Dexterity tests like the Purdue Pegboard test or the Minnesota test indicate well the sensorimotor performances of the patient's hand.

12.4.1.2 Hyposensitivity Rehabilitation [4, 5, 8, 9, 12, 13]

It's based on the brain's neuroplasticity that allows the somesthetic cortex, which reacts to tactile stimulations, to reorganise.

The patient will only be able to decode this new information with training. The new message is the result of the summons of mechanoreceptors whose number, variety and locations are different from the previous conditions.

The goal isn't to favour or produce axonal regrowth, but only to help making the new message understandable. The effort is realised at the level of the cortex, not at the level of the injury.

Vibrotactile Anaesthesia (S0 and S1)

The rehabilitation aims to protect the patient from traumas to which he's exposed and from which he's not protected in case of anaesthesia (hot and cold burns, sharp objects, etc.) and to limit risks of exclusion in and around the damaged area.

In these phases, we ask the patient to realise simple actions several times a day to maintain body mapping. These exercises must be simple enough not to make the patient fail every time, but mustn't produce articular or muscular compensations that can cause biomechanical disorders.

Vibrotactile Rehabilitation (S2 to S4)

Touch Exercise

We realise these exercises when the level of hypersensitivity is low ($PPT < 5\text{ g}$).

They consist in asking the patient to touch different kind of objects and analyse the sensations he gets, comparing with the sane side. First, the exercises are realised with visual control, and the eyes closed with everything accessible to the hand (trousers, jumper, blanket, face, etc.) (Fig. 12.6).

The analysis gets more complex with the patient's evolution, to get plurifactorial (shape and temperature, shape and texture, shape and weight, texture and temperature, etc.).

The exercises are realised 4 times a day during 5 min.

“Trace” Rehabilitation

We realise this rehabilitation when the level of hypersensitivity is important ($PPT > 5\text{ g}$).

With a pencil rubber, the patient must differentiate a fix point from a mobile point, then a straight line from a curved line. We can vary and increase the difficulty asking alternatively to locate and analyse the stimulus.

The exercises are realised 5 times a day during 5 min.



Fig. 12.6 Example of exercise for the touch

Transcutaneous Vibratory Stimulations [10, 15, 16]

They consist in stimulating the skin with a vibration generator with a frequency of 100 Hz. Its intensity is the VPT+0.1 mm (vibradol) or +4 % (vibralgic 5).

This technique is applied at the end of the session, during 5 min.

Complex Activities

Global exercises are used when the patient has recovered enough not to fail. They concern performances, sensorial functional exploration, fine prehensions, object and texture recognition.

The functional tests participate in this rehabilitation, in addition to assessing the patient's performances and progress:

- *Picking up test.*
- *Seddon's coin test.*
- *Riddoch's test.*
- *Porter's test.*
- *Identifying textures:* we can quantify and date the response rates in relation with the number of textures and materials presented during the test. Therefore, we have a basis of comparison to point out the patient's progress during rehabilitation.

12.4.2 Sensorial Disorders (Not Allodynia)

12.4.2.1 Terminology of the Concerned Disorders

They are sensorial disorders, frequent in hand rehabilitation but with different origins (scar, neuroma, entrapment syndrome, etc.). They are a priority in sensorial rehabilitation and must be treated before going any further:

Hyperesthesias: increased sensitivity to a stimulation, except for special senses. Hyperalgesia (increased reaction to a usually painful stimulation) and allodynia (pain produced by stimulations that usually to cause pain) are hyperesthesias, but allodynia is treated with distant vibrotactile counter stimulation, not with the techniques described in this paragraph.

Paresthesias: abnormal spontaneous or provoked sensation.

Dysesthesias: abnormal and unpleasant spontaneous or provoked sensation.

These sensorial disorders are rehabilitated according to a specific protocol, but the therapist must treat hyposensitivity first, as these abnormal sensations often disappear when hyposensitivity is treated.

12.4.2.2 Rehabilitation of Sensorial Disorders (Not Allodynia) [4, 5, 12]

These disorders are treated combining a desensitisation protocol with electrotherapy and also treating the present hypoesthesia according to the modalities described previously:

Desensitisation

The goal is to stimulate the damaged area with painless contacts to short-circuit the painful interpretation of the brain.

Painful contacts must be avoided as it would maintain pain phenomena.

We use massages, transcutaneous vibratory stimulations [10, 15, 16] and any other element allowing a progressive contact on the damaged area.

At the beginning of the protocol, we use superficial massages on the area or far from it if it's painful and contacts on the skin with soft elements.

Transcutaneous vibratory stimulations [10, 15, 16] are applied on the area if they don't produce pain, with 270 Hz frequency producing anaesthesia on the area of application and low amplitudes (1.5 mm) during 10 min. If modifications are well supported by the patient, we progressively decrease the frequency until 70 Hz, while increasing the amplitude until 4 mm and the duration until 20 min.

The other elements of the protocol evolve the same way: we realise deeper massages and less soft contacts as the patient progresses.

Electrotherapy

The nociceptive stimulus is transmitted by unmyelinated nervous fibres (small diameter) to the spinal cord, where a transmission control is realised in superior centres by inhibitory neurons.

Stimulating large fibres activates these neurons, blocking the transmission of the nociceptive impulse towards the superior centres ("gate control") (Fig. 12.7).

Analgesia is immediate and lasts from 30 min to a few hours.

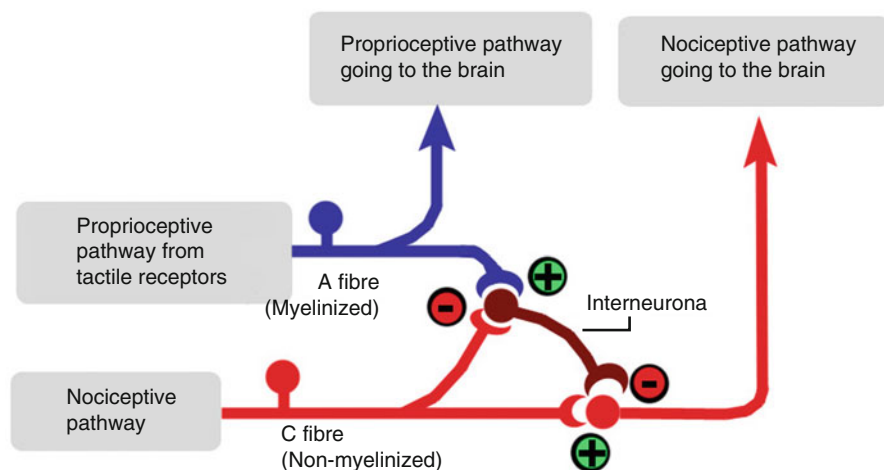


Fig. 12.7 Gate control mechanism

We use a 40–75-microsecond pulse width and a wobble frequency between 50 and 100 Hz (a wobbled current's frequency varies to limit habituation without increasing intensity).

We place two electrodes proximally in the area with sensorial disorders, according to the concerned nerve's path.

The intensity must produce “tingling” on the concerned area. We apply the current during 30 min.

Stimulating the large fibres can be done with other techniques like massage, active or passive mobilisation or any painless sensorimotor stimulation.

Treatment of Hypoesthesia in the Territory of the Nerve

As described in the Sect. 12.4.1.2 if necessary.

12.4.3 Allodynia

Allodynia is pain caused by a stimulus that doesn't normally produce pain.

There are two types of allodynia: mechanical (pain produced by a static stimulus like pressure) and dynamic (pain produced by a mobile stimulus like water or air on the skin).

12.4.3.1 Allodynia Assessment [13]

Allodynography: Determining an Area with Allodynia

We use two fix factors: pressure (15 g aesthesiometer) and pain intensity.

The tested territory is allodynic if a patient who doesn't have pain during rest feels a pain of 3 on the visual analogue scale (VAS) or if the intensity of pain increases by two when putting pressure with the aesthesiometer.

When realising this test, we ask the patient to locate the most painful area, from which we define the damaged nervous branch (the atlas of the body's cutaneous territories by C. Spicher, N. Desfoux and P. Sprumont can be very useful).

The pressure used is the minimal pressure bending the monofilament and the application lasts 2 s, with 10s between stimulations.

The assessments are realised in order to define the most precise territory possible, in relation with a reference point that can be a flexion crease, a scar, etc.

The first point is placed on the longitudinal axis of the damaged nervous branch, progressing from distal to proximal towards the affected area.

The patient is asked to say “it's starting” when we come close to the first allodynic point. From this point, we move the aesthesiometer millimetre by millimetre until the patient says “stop”, when he feels a pain intensity of three on the VAS (for

patients who don't have pain during rest) or increased by two (for patients with spontaneous pain).

The same process is realised to define the most proximal undetected point, the 2 transverse points of the area.

The allodyngography allows defining the allodynic area, but not its intensity that is defined by the pain rainbow.

Pain Rainbow

At the end of the allodyngography, we determine the allodynia intensity looking for the lightest aesthesiometer that produces a pain of 3 on the VAS on the most painful area described by the patient, starting with the lightest monofilament. We use 6 aesthesiometers: 0.03 g (red), 0.2 g (orange), 0.7 g (yellow), 1.5 g (green), 3.6 g (blue), 8.7 g (indigo) and 15 g (purple).

The stimulation is applied the same way than during the allodyngography: the pressure must bend the monofilament, which is applied 2 s with 10 s between stimulations.

During the next session, we use the aesthesiometer we've defined to limit the area of the pain rainbow that corresponds to the aesthesiometer.

The determined territory is smaller than the one in the allodyngography as the tested area and the "reference" pain (VAS=3) are the same, but the aesthesiometer is lighter.

We realise three pain rainbows after the first allodyngography and then a second allodyngography followed by 3 other pain rainbows.

12.4.3.2 Allodynia Rehabilitation [13]

Distant Vibrotactile Counter Stimulation (DVCS)

It's the first step. It's based on the DVCS, a technique developed by C. Spicher that uses a tactile and vibratory therapeutic agent to allow the patient to perceive a non-nociceptive stimulus on an allodynic territory.

This new concept comes from the counter stimulation of medullary neurostimulators, based on Melzack and Wall's gate control theory.

This technique "consists, for the patient, in perceiving a non-nociceptive stimulus in a non-nociceptive way, first on a non-allodynic territory and then on a surface closer and closer to the allodynic territory, until the allodynic territory" [18].

The first important point is to explain to the patient that he must avoid any contact with the allodynic territory in order not to maintain the painful phenomenon. This step is essential in the protocol's success and supposes a significant involvement from the patient.

With very soft materials (rabbit skin, very soft brush, alcantra, etc.), the patient has to stimulate a precise area during 45 s (or less if it becomes unpleasant), 8 times a day. This stimulation must never produce unpleasant sensations.

Vibrotactile stimulations can be localised in three areas, preferring the one closest to the allodynic territory:

- *Area proximal* to the allodynic territory: stimulations are realised proximally to the territory of the damaged nervous branch.
- “*Cousin*” area: we apply stimulations on “cousin” nervous branch of the damaged branch. They are part of the same brachial plexus cord (lateral, posterior or medial). In this kind of area, we stimulate proximally to the damaged branch, if there are no unpleasant sensations.
- *Segmental area*: stimulations are applied at the segmental level when “cousin” branches can’t be used (unpleasant sensations, pain, etc.). In the inferior limb, we stimulate the segmental level inferior to the damaged branch.

We can also realise a vibratory counter stimulation on the territories previously described using precise parameters: 0.06 mm with the vibradol, 0.9 V and 300 Hz with the old vibralgic and 2 % and 100 Hz with the new vibralgic.

Underlying Hypoesthesia

Once treated, the former allodynic area stays hyposensitive. We assess and treat this hypoesthesia the same way than for hypoesthesias without allodynia, adapting the tests and rehabilitation in order not to restart allodynia. Therefore, the tests are shorter with less stimulations and touch rehabilitation starts with rabbit skin and stimulations of 15 s during the first week. It progressively evolves towards “normal” hyposensitivity rehabilitation if there aren’t complications.

12.5 Assessment and Rehabilitation of Motor Disorders [6, 12]

The innervation of striated muscles is organised around $A\alpha$ and $A\gamma$ fibres, corresponding, respectively, to the muscular fibres and the muscle spindle.

Therefore, α motoneurons are responsible for the muscular contraction, while γ and β motoneurons regulate the tone through the γ loop.

Various muscular fibres depend on one motor neuron; together they form the motor unit.

Tonic muscles have a postural or stabilisation function. They have many muscular fibres for one neuron. These muscles don’t allow fine gestures as only one neuron has to “manage” a lot of muscular fibres.

On the contrary, phasic muscles have a very little number of fibres for one neuron. Therefore, they can realise very fine movements and are well represented in the hand.

12.5.1 Assessment of Peripheral Motor Disorders [14]

Before evaluating the motor ability, the appreciation of muscular trophicity can allow palpating a modification in the muscular tone (hypotonia in peripheral injuries) and a muscular atrophy (confirmed comparing with the sane side).

The 3 main nerves of the hand (median, ulnar and radial) are mix nerves and therefore have a motor, sensorial and autonomic role. Their damage can cause vaso-motor disorders (oedema, increased cutaneous temperature, excessive sweating, etc.) in addition to the sensorial and motor disorders.

The evaluation of motor ability can concern 3 elements:

12.5.1.1 Motor Reflexes

They correspond to motor reactions triggered by a well-identified sensorial stimulus and realised by predetermined neural circuits. They're evaluated with the tendon reflex.

To assess them, the patient must be relaxed and the muscle is placed in middle race. We realise a quick percussion on the muscle tendon and evaluate the intensity of the observed response:

- *Stage 0*: no response
- *Stage 1*: a little less than the sane side (if present)
- *Stage 2*: normal (compared to the sane side)
- *Stage 3*: stronger than the sane side
- *Stage 4*: a lot stronger than the sane side

The stages observed in peripheral nervous injuries are the stages 0, 1 and 2.

The stages 3 and 4 are usually related to a pyramidal damage, which we won't be treating here.

12.5.1.2 Automatic Motor Ability

It corresponds to stereotyped and reproducible movements produced by innate nervous networks (breathing, swallowing, etc.) or acquired through learning (driving, sports, etc.). Its assessment in the hand is difficult, but its alteration has an impact on the hand's dexterity.

12.5.1.3 Voluntary Motor Ability

It corresponds to intentional movements triggered by an external stimulus or an "internal order". It's the most complex motor ability, and there's a wide range of intentional movements that are differentiated by the number of mobilised segments,

their repetition, speed and precision. The assessment is complex and must take into account the different elements of the motor command with a precise neurological evaluation. We'll only talk about the assessment of peripheral nervous injuries based on the Daniels and Worthingham test.

It's made of 5 stages:

- *“Normal” or 5 and “good” or 4*: they can be differentiated if the contralateral muscles are normal. The resistance is applied in the whole range of motion. We ask the patient to “hold” a position and the therapist applies a force as opposite as possible to the muscular traction. This test mustn't cause pain.
- *“Fair” or 3*: it corresponds to the capacity to mobilise the concerned segment in all its amplitude against gravity.
- *“Mediocre” or 2*: it corresponds to the capacity to mobilise the concerned segment in all its amplitude without gravity or in part of its amplitude against gravity.
- *“Trace” or 1 and zero*: it requires a careful inspection and a precise palpation as we want to determine whether there's a contraction of the solicited muscle or not. This can be realised in superficial muscles but it's a lot more random (unrealistic?) for deeper muscles.

Mechanised muscular evaluation can compensate for the analytical muscular test's lack of precision. It requires a dynamometer (or any other system that measures force). It's undeniably useful for the forensic aspect, but it's only really useful for the stages “normal” and “good” as the muscle's capacities aren't sufficient in the other stages.

12.5.2 Rehabilitation of Peripheral Motor Disorders [4, 12]

The exercises realised after a peripheral nervous injury require a lot of concentration from the patient. We must be very attentive to the patient's tiredness and “morale”.

It's usually better to realise short sessions several times a day.

The rehabilitation techniques for peripheral motor disorders are directly related to the stages determined during the assessment:

12.5.2.1 Stages 0 and 1

The denervated muscle atrophies and the therapist's main goals are to fight against fibrosis and vicious attitudes.

We start working with analytical contractions of the concerned muscle as early as possible but avoiding making the patient permanently face failure (little repetitions, learning the gesture with the sane side, active-assisted work so the patient feels the movement, etc.).

Massages against fibrosis are realised with glided pressures and kneadings, avoiding areas of nerve regrowth that are usually painful.

Facilitation techniques based on percussions and stretchings can be realised when there are signs of regrowth and the nervous suture (if there is one) is not very fragile, usually after 1 month and after surgical advice.

The psychological interest of these techniques is to trigger an idio-muscular response related to the histological characteristics of the muscular fibres without fibrosis (percussions) and to trigger the tendon reflex (stretchings).

Therefore, stage 1 is essential to realise this technique.

Using electrostimulation for denervated (stage 0) or partially innervated (stage 1) muscles can be done to maintain muscular trophicity.

12.5.2.2 Stage 2

The exercises are realised analytically, active without gravity or active-assisted against gravity.

Facilitation techniques like PNF (proprioceptive neural facilitation) are started in this stage, as they stimulate damaged muscles.

They use “trigger” muscles preserved from the nervous injury and “target” damaged muscles.

Irradiation is realised working against a dynamic or static resistance for the “trigger” muscles and working with active (without gravity) or active-assisted (against gravity) contractions for the “target” muscles.

We complete this protocol with electrotherapy for partially innervated muscles.

Using visual feedback can improve the contraction quality. We ask the patient to reach a pre-established threshold and then to maintain the contraction during a certain duration. The threshold can be increased from one session to the other depending on the patient’s progress.

12.5.2.3 Stage 3

The exercises are analytical, active or active-assisted against gravity.

Facilitation techniques like PNF are prolonged, but the exercises for “target” muscles can be realised against gravity.

We complete this protocol with feedback systems and electrostimulation for partially innervated muscles.

12.5.2.4 Stages 4 and 5

The goal is to regain mechanical and physiological capacities in the damaged muscles.

We start a muscular reinforcement protocol adapted to the patient's capacities and needs, associated to proprioception and feedforward exercises.

Facilitation techniques like PNF are realised, placing adaptive resistances on "trigger" and "target" muscles.

The functional reintegration of the hand, including occupational therapy [1], is essential in this stage to optimise the functional result and help the patient go back to his sports and work activities.

Bibliography

1. Allieu Y, Durand PA, Romain M, Kizlik C (1986) L'ergothérapie dans la phase précoce des traumatismes de la main. In: Simon L, Pélissier J (eds) Ergothérapie et environnement. Masson, Paris
2. Antoine JC (1999) Anatomie et physiologie du nerf périphérique. EMC Appareil locomoteur. 14005-A-10. Elsevier, Paris
3. Blanchard B, Mitrénique B, Noel L, Valenbois B (2006) Rééducation des troubles de la sensibilité de la main. EMC Kinésithérapie-Médecine Physique-Réadaptation, éditions. Elsevier SAS, Paris
4. Dauzac C, Dumontier C, Froissart MT, Monet J, Sautet A (2002) Prise en charge et rééducation des lésions nerveuses périphériques. EMC Kinésithérapie-Médecine physique-Réadaptation, 26-465-A-10. Elsevier, Paris
5. Delprat J, Mansat M (1986) La sensibilité; Examens et principes de rééducation. J Réad Méd 6(1):9-18
6. Bioulac B (2004) Fonctions motrices EMC Kinésithérapie-médecine physique-réadaptation 17-002-D-10
7. Bruge C, Coudert A, Desoutter P, Desoutter E, Eyssette M (1991) Neurologie périphérique chez l'adulte et réadaptation. Dossiers de kinésithérapie. Masson, Paris
8. Orset G. Les tests d'évaluation sensitive cutanée de la main après lésion des nerfs périphériques, Les feuillets du GEMMSOR. www.reeducation-main.com
9. Payen J-F (2002) Bases physiopathologiques et évaluation de la douleur, Corpus Médical-Faculté de médecine de Grenoble, pp 1-15
10. Riera G (1986) Intérêt des stimulations vibratoires dans la pathologie traumatique des nerfs périphériques, Thèse de la faculté de médecine de l'université de Montpellier. 1 Décembre 1986, p. 7
11. Valat J. La somesthésie: sensibilités tactiles, thermiques et douloureuses, Université de Montpellier 2. Module de Psychophysiologie. www.electronic-conseil.com/docs/somesthésie.pdf
12. Sassoon D, Romain M (1999) Réadaptation de la main. Volume 26 de Monographie de la Société française de chirurgie de la main, ISSN 1292-3702. Monographies du Groupe d'étude de la main. Elsevier, Paris
13. Spicher C (2003) Manuel de rééducation sensitive du corps humain. Médecine et hygiène, Chêne-Bourg Suisse
14. Cauquil C, Thauray MN, Boussagol H, Ster F, Chammas M, Allieu Y (1999) Évaluation musculaire de la main. In: Sassoon D, Romain M (ed) Réadaptation de la main, Monographie de la société française de chirurgie de la main (GEM), Expansion Scientifique Publications, monographie du GEM n° 26, réadaptation de la main, pp 45 à 46
15. Romain M, Durand PA, Kizlik C, Allieu Y (1989) Question: Que peut-on attendre de la stimulation vibratoire transcutanée en rééducation? Ann Kinésithér 16:361-364
16. Tardy-Gervet MF, Guieu R, Ribot-Ciscar E, Roll JP (1994) Les vibrations mécaniques transcutanées. Kinésithér Sci 333:7-12
17. Tubiana R, Thomine JM (1990) Examen de la sensibilité. In: Tubiana R, Thomine JM (eds) La Main, Anatomie Fonctionnelle et Examen Clinique. Masson, Paris, pp 189-206
18. Spicher C, Quintal I (2013) La méthode de rééducation sensitive de la douleur. Sauramps Medical

Part VI
Entrapment Syndromes

Chapter 13

Entrapment Syndromes of the Median Nerve

Grégory Mesplié and Olivier Léger

13.1 Anatomy [5]

It's a mixed nerve (motor, sensorial, and neurovegetative role).

It comes from the roots C6 to T1 and passes through the posterior cord (C6–C7) and medial cord (C8–T1) and then through the brachial canal until the Struthers ligament (inconstant) above the medial epicondyle, to reach the bicipital groove.

It then passes between the two heads of the pronator teres where it gives off the anterior interosseous branch. This nerve innervates the flexor indicis profundus, the flexor pollicis longus, and the pronator quadratus, as well as a part of the wrist joints.

The median nerve then passes under the flexor digitorum superficialis.

The palmar cutaneous branch of the median nerve arises from its lateral side 6 cm above the palmar flexion crease of the wrist, passes between the flexor carpi radialis and the palmaris longus, and then passes through the antebrachial aponeurosis above the wrist to give off its terminal branches (sensitivity of the thenar compartment) (Fig. 13.1).

It enters the hand at the level of the carpal tunnel, which is an hourglass-shaped inextensible osteofibrous tunnel. Its narrow part is the hamulus.

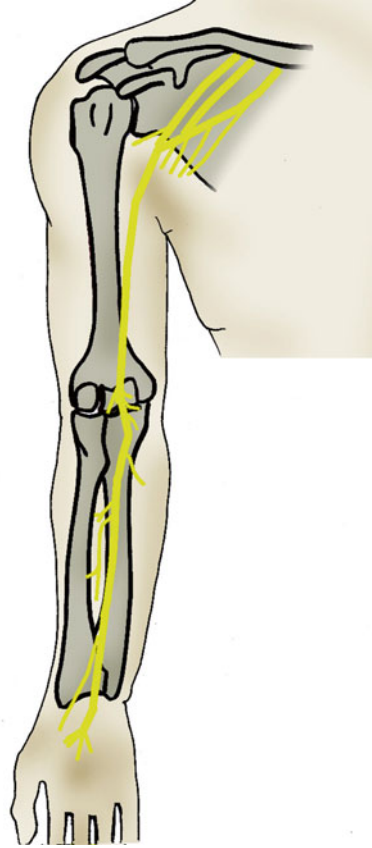
It's formed dorsally by the palmar concave osteo-ligamentous groove and closed in the front by the flexor retinaculum composed by two layers:

G. Mesplié (✉)

Physiotherapist and Orthotist, Institut Sud Aquitain de la Main et du Membre Supérieur, Aguiléra Clinic Biarritz, Biarritz, France
e-mail: greg.mesplie@mac.com

O. Léger

Hand Surgeon, Institut Sud Aquitain de la Main et du Membre Supérieur, Aguiléra Clinic Biarritz, Biarritz, France

Fig. 13.1 Schematic path of the median nerve

- *The superficial layer* and the antebrachial fascia prolonged distally by the palmar aponeurosis [9].
- *The deep layer* with the carpi volare proximally, then from the distal palmar crease of the wrist, from the flexor retinaculum [8, 11] that spreads from the pisiform bone to the apophysis of the sesamoid bone inward, and from the scaphoid's tubercle to the trapezium bone outward. Its distal part is covered by fat tissues that form the fat pad of Kaplan and Milford, which contains the superficial palmar arch.

Between these two layers and the two compartments, there is the fascia of Mirza.

Its most internal part forms the floor of Guyon's canal, limited inward by the insertion of the flexor carpi ulnaris on the pisiform bone and in the front by the antebrachial fascia.

The carpal tunnel contains the nine flexor tendons with their synovial sheath and the median nerve [11], organized in three planes:

- Deep plane with the four deep flexor tendons
- Medium plane with the superficial flexors (the tendons of the flexor indicis and flexor digiti minimi are deeper and more lateral than the flexor tendons of the third and fourth fingers)
- Superficial plane with the median nerve, located in front of the flexor indicis and outside the axis of the fourth finger

The flexor carpi radialis passes through its own canal, separated from the carpal tunnel by a sagittal connective partition.

Mechanically, the flexor retinaculum is the first flexion pulley of the flexor system and therefore optimizes the tendon's action, making them more efficient and avoiding the "bowstring" effect. It plays an important role in the strength of the grips.

Distally to the carpal tunnel, the median nerve gives off its terminal branches (Fig. 13.2):

- The thenar branch usually comes from the radial side of the nerve, half the time beyond the inferior side of the ligament, in 30 % of the cases behind the ligament bypassing its inferior part, and in 20 % of the cases behind the ligament, passing through it. It rarely comes from the anterior side or the medial part of the nerve.
- The proper palmar digital nerve of the thumb.
- Interdigital nerve: in 90 % of the cases, there is an anastomosis between the nerve of the third space and the one of the fourth space (terminal branch of the ulnar nerve from Guyon's canal). It's called the anastomosis of Berrettini, located in the fat pad and therefore exposed during surgery.

Therefore:

At the motor level, it innervates:

- The anterior compartment of the forearm, except the flexor carpi ulnaris and the two medial heads of the flexor digitorum profundus (innervated by the ulnar nerve)
- The two radial lumbrical muscles (branches from the first and second space) and the external thenar muscles (abductor pollicis and superficial fascicle of the flexor pollicis brevis, as the deep fascicle of the flexor pollicis brevis and the adductor pollicis is the medial thenar muscle innervated by the ulnar nerve) innervated by the thenar branch

At the sensorial level, it innervates:

- The palmar side of the three first fingers and the radial half of the fourth finger
- The dorsal side of the two distal phalanges of the index and the third finger and the radial side of the two distal phalanges of the fourth finger (Fig. 13.3)

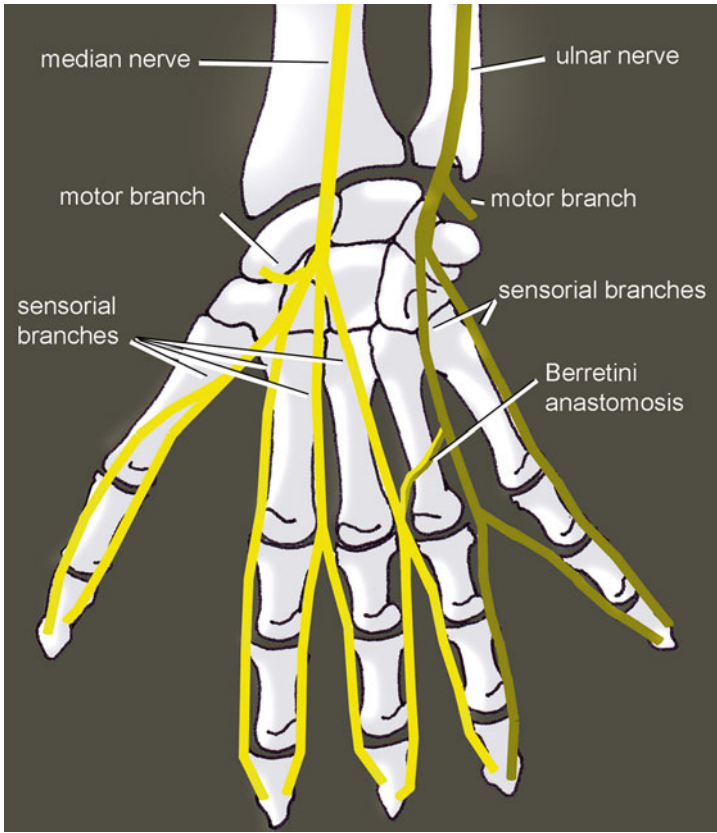


Fig. 13.2 The median nerve ends in 6 branches: 1 motor, 4 sensorial, and 1 anastomosed with the ulnar nerve (Berrettini)

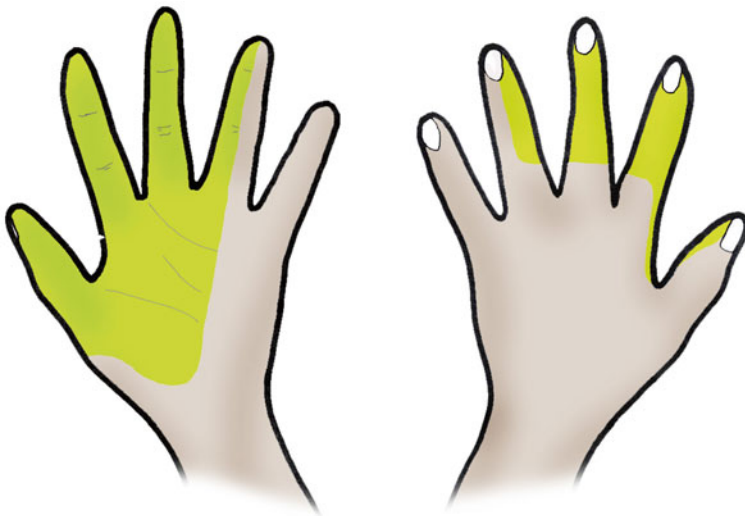


Fig. 13.3 Sensorial innervation by the median nerve

13.2 Carpal Tunnel Syndrome

Carpal tunnel syndrome is a set of clinical signs, meaning there is an entrapment of the median nerve at the level of the carpal tunnel.

It's the most frequent pathology of the hand and mostly occurs bilaterally in 50-year-old women [15].

13.2.1 *Physiopathology*

There is a dual physiopathology in this syndrome:

- Ischemia of the median nerve, which explains the increase of symptoms during the night and the alleviating maneuvers described by the patients [10].
- Intra-canal hyper-pressure (from 3 to 30 mmHg), causing the apparition of symptoms. It can be related to various causes:
 - Fractures of the inferior extremity of the radius.
 - Tenosynovitis of the flexors [11], inflammatory rheumatism, hormonal changes, and diabetes. Aside from obvious metabolic contexts, tenosynovitis is present only in 4 % of the cases, making the synovectomy useless.
 - Intra-canal tumors and muscular anomalies (hypertrophic lumbricals, palmaris longus or flexor digitorum superficialis with a distal or digastric muscle belly, Frohse palmaris profundus from the anterior side of the radius to the deep side of the superficial palmar aponeurosis).
 - Repeated flexion–extension movements, often related to a professional or sports activity.

Despite the large number of possible causes, it is most often idiopathic.

The two mechanisms are probably intricately linked. The preponderance of one or the other can explain the different electro-clinical observed forms. In fact, the median nerve at the level of the wrist is composed of 50 % big fibers, which are the only ones explorable by EMG and sensible to pressure. The small fibers (C fibers and fibers of the sympathetic system) are more sensible to ischemia.

13.2.2 *Clinical and Paraclinical Signs*

The presence of digital acroparesthesia, sometimes felt like pain and mostly during the night, seems to be the most characteristic sign. The fifth finger isn't usually damaged.

The reproduction of the signs with a cuff inflated above the venous pressure (Gilliat test), a prolonged flexion of the wrist (Phalen test), or the percussion of the nerve (Tinel pseudo-test) is evocative, but far from being constant.

Their respective predictive values are 100, 87, and 50 %. A hypoesthesia in the territory of the median nerve and an atrophy of the external thenar muscles make the diagnosis obvious but are, fortunately, very rare as they mean we're dealing with a severe deficit form of the syndrome.

Other than the following neurologic injuries, the Raynaud syndrome is the key element of the differential diagnosis.

The EMG is essential as it studies the distal motor latency and the speed of the sensorial conduction and allows [13, 19]:

- Confirming the diagnosis.
- Assessing the severity.
- Looking for an associated neurologic injury realizing a double crush syndrome, compression of the ulnar nerve in the elbow and radicular compression, or thoracic outlet syndrome, diabetic neuropathy, for example. In the case of double crush syndrome, it's hard to tell which pathology causes which symptoms. The carpal canal treatment is simple (contrary to the previous pathologies) and should therefore be proposed first.

There are 10 % false negatives. They are starting forms with damage of the small fibers that are explored on the exam or a transitory damage of a small number of big fibers. In these cases, a test infiltration is essential.

13.2.3 *Medical and Surgical Treatment*

A conservative treatment (orthosis, gestures, corticoid infiltration) is possible, with 30–75 % of improvement depending on the authors [17]. It is therefore difficult to know if this improvement is due to a lull in the pathology or is a therapeutic effect. Infiltration often betters the speed of the nervous conduction after 1 month but doesn't change the spontaneous evolution after 1 year, unlike the surgery that we realize after a loss of 2.7 m/s [16].

The surgical treatment is essential in three cases [1, 2]:

- *If there is a sensorial or motor deficit.* When there's deficit, there is little pain, with a major axonal loss. It occurs more often in old patients and may be a particular form of the pathology, the evolution from painful subjective forms to forms with deficit being poorly known. Surgery clearly improves symptoms.
- *In the case of neurogenic path* of the abductor pollicis brevis, the other parameters only reflecting the importance of the conduction block.
- *If the symptoms persist after 1 year.*

Surgery is very efficient, with an almost immediate relief. Aside from all the secondary effects that can happen in every hand surgery, some specific secondary effects are frequent and can persist until 6 months in 25 % of the cases, justifying the cessation of work because of loss of strength and pillar pain. They're related to

hypertrophic healing of the retinaculum or slight modifications in the architecture of the carpal bones.

Some publications demonstrate that complex surgeries of the root canal like synovectomy or endo-neurolysis are useless and that an incision in the axis of the fourth finger is safe [20, 23]. Therefore, several authors have suggested the endoscopic section of the retinaculum and have presented their results in the early 1990s [20, 22, 24].

The endoscopic technique allows a better postoperative comfort and an earlier use of the hand, as well as a shorter leave from work [12]. However, the results 6 months after surgery are the same, except maybe for the strength recovery.

The endoscopy is reliable, with a relapse rate comparable to the conventional technique and a close failure rate (0.05 %) [18].

The complications are more frequent than with the conventional technique but are resolving most of the time. In 2/3 of the cases, the complication is the contusion of the nerve or the branch of the third space occurring when preparing the ligament or introducing the endoscope [18].

The technique with one opening seems to have better results than the one with two openings, and it is logical to reduce the scar as much as possible, especially in a contact area [24].

Contrary to the conventional technique, the endoscopic liberation allows conserving the inter-thenar fascia and the superficial palmar aponeurosis.

To avoid any neuroma in the palmar cutaneous branch of the median nerve, the cutaneous incision must stay medial to the palmaris longus. However, similar branches intended to innervate the skin of the hypothenar eminence arise from the ulnar nerve (cutaneous palmar branch of the ulnar nerve and nerve of Henlé), and only a small incision (endoscopic) decreases the risk of neuroma.

13.2.4 Rehabilitation and Orthotic Treatment, Without Surgery or Preoperative

When the nerve damage is moderate, the rehabilitation and wearing a resting orthosis can delay or even avoid surgery. This treatment is only efficient in some cases, most of the time when the inflammation has mechanical causes.

We can observe temporary paresthesia, often nocturnal, without other neurologic disorders.

13.2.4.1 Rehabilitation

It's about fighting against inflammatory phenomena and, depending on the indications, mobilizing the median nerve.

Fight Against Trophic Disorders and Pain

This exercise is based on the association of cryotherapy, pressotherapy, analgesic vibrotherapy, and draining massages that can help reduce intra-canal edema, therefore participating in the decompression of the median nerve in the carpal tunnel.

Longitudinal Massages

These massages are applied on the accessible area of the nerve that is closest to the painful area.

It consists in realizing a longitudinal pressure along the nerve on 3–4 cm to improve vascularization and enable axonal flow.

The ideal pressure recreates the distal symptomatology without creating pain. It's maintained for a few minutes, until we obtain a variation of the initial response [14].

The preferential area is proximal to the flexor retinaculum, where the nerve isn't reachable.

In this area, the nerve is located on the ulnar side of the flexor pollicis longus [4] and the flexor carpi radialis and on the radial side of the palmaris longus.

The patient is placed in decubitus, with a 30° flexion of the elbow.

After finding the median nerve, longitudinal maneuvers are realized along it.

Another way to apply this technique consists in pressing the median nerve and slowly mobilizing the wrist in flexion/extension. It's not the finger but the nerve that moves, which can be better tolerated by the patient.

Fight Against Perineural Adherences

These exercises improve glidings between the median nerve and the adjacent tissues, which limit the compressive constraints and improve vascularization.

Nervous Mobilizations [6]

The goal of the mobilizations of the nerve is to mobilize the median nerve respective to the adjacent tissues to limit the risks of compression and ischemia.

The progression of the mobilization is based on the upper limb tension tests, described by Butler in 1991.

For the median nerve, the mobilization is described by the ULTT 1 or the ULTT 2a in several steps:

ULTT 1 based on a shoulder abduction of 90° or more (Fig. 13.4):

- 90° of shoulder abduction (110° for the roots C5 to C7)
- Slight shoulder depression
- Wrist supination and extension, finger extension, and elbow flexed
- 90° of shoulder external rotation

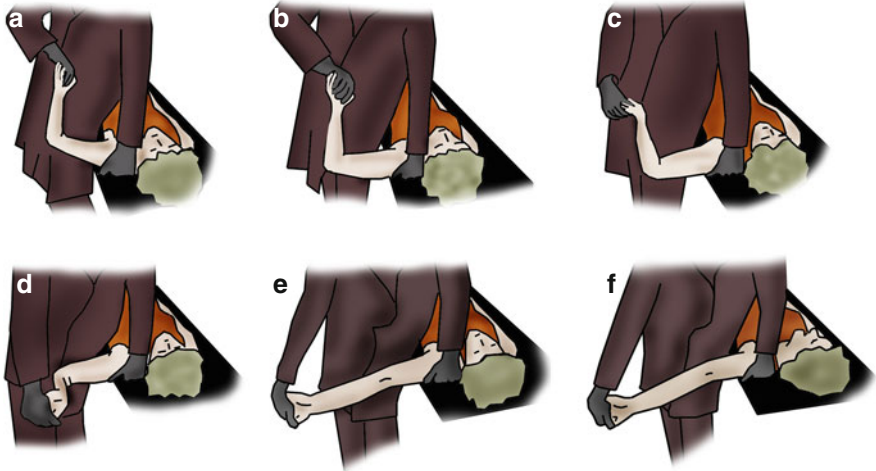


Fig. 13.4 Mobilization of the median nerve (ULTT1). (a) Ninety degrees of shoulder abduction (110° for the roots C5 to C7). (b) Slight shoulder depression. (c) Wrist supination and extension, finger extension, elbow flexed. (d) Ninety degrees of shoulder external rotation. (e) Elbow extension. (f) Contralateral head rotation

- Elbow extension
- Contralateral head rotation

ULTT 2a based on the association traction/external rotation of the shoulder (Fig. 13.5):

- Position with a “triple grip” (pelvis + 2 hands of the physiotherapist)
- Strong shoulder depression
- Elbow extension
- Shoulder supination and external rotation
- Wrist and finger extension
- Shoulder abduction until 30°

The two mobilizations can be done, but in any case, the steps are continued until the patient feels a bearable tension.

The last position is held 6 s to avoid any ischemic risk.

Mobilizations of the Tissues Adjacent to the Nerve

Alternating contraction–relaxation–stretching of the adjacent muscles allows a perineural pumping that improves local trophicity and maintains the inter-tissue glidings.

This mobilization of the tissues around the nerve can be realized by alternating movements in the wrist and fingers, allowing a dissociative contraction of the muscles adjacent to the median nerve.

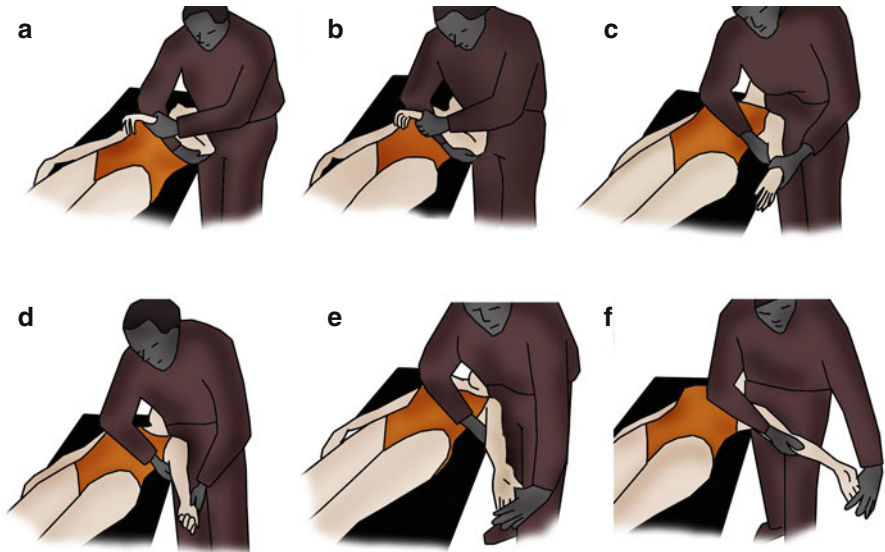


Fig. 13.5 Mobilization of the median nerve (ULTT 2a). (a) Position with a “triple grip” (pelvis + 2 hands of the physiotherapist). (b) Strong shoulder depression. (c) Elbow extension. (d) Shoulder supination and external rotation. (e) Wrist and finger extension. (f) Shoulder abduction until 30°

It can be obtained by imitating the animated images in a slideshow (Fig. 13.6). The patient maintains the position while the picture is on display.

Massages Against Fibrosis

They're realized along the median nerve, on the anterior part of the forearm, and at the level of the flexor retinaculum and the thenar muscles.

We use dot-shaped massages, glided pressures, and kneading that improve local trophicity, fight against perineural fibrosis, and relax the muscles adjacent to the nerve.

Self-Rehabilitation

Self-rehabilitation exercises include mobilizations, longitudinal self-massages, and cryotherapy.

The mobilizations are realized several times a day in all of the amplitudes of the wrist and elbow to improve perineural gliding.

The longitudinal massages are realized three times a day during 1–2 min (until there's a modification of the perception).

We put ice on the compression area after all the other exercises during 20 min, depending on the presence of pain.

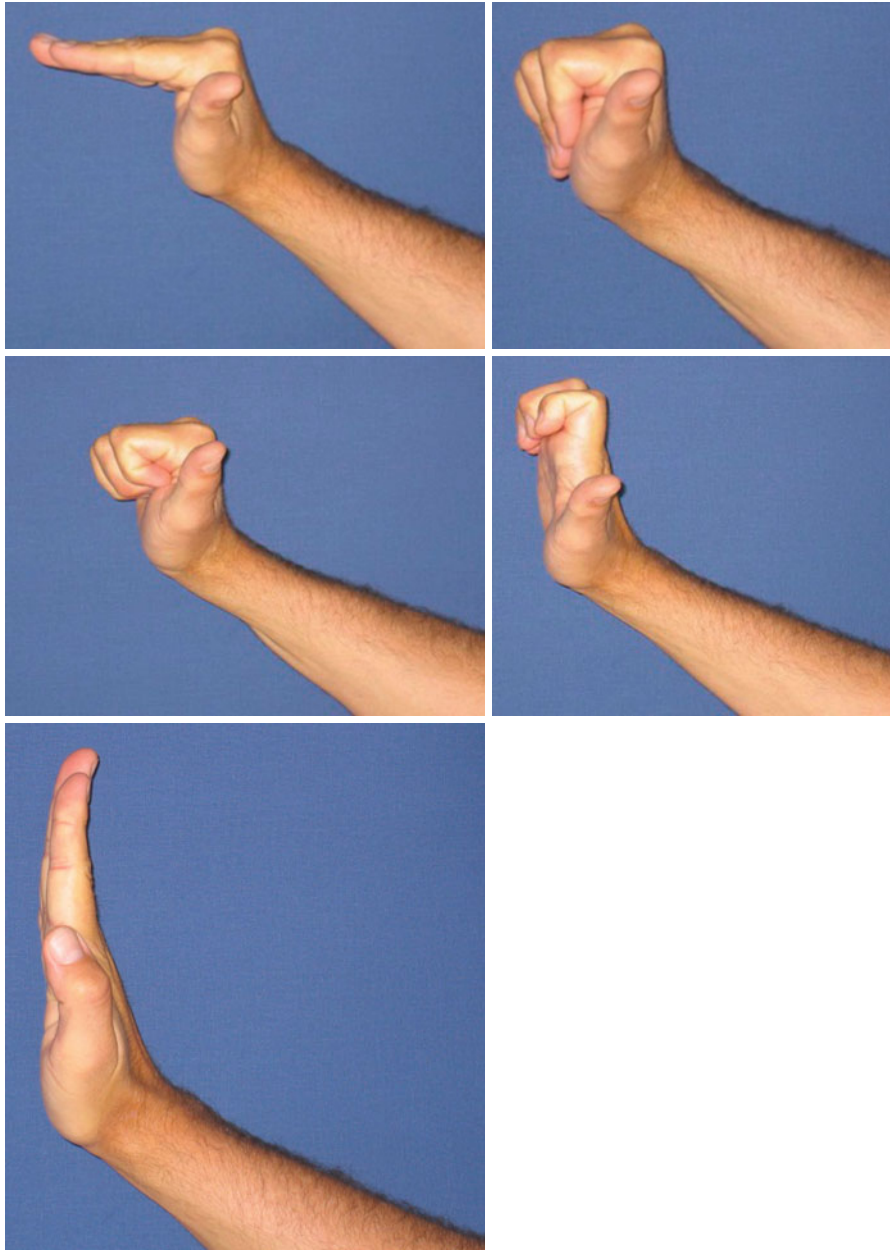


Fig. 13.6 Imitation exercises mobilizing the tissues adjacent to the median nerve



Fig. 13.7 Manual reinforcement of the external sesamoid muscles

Regaining Strength

At this level of compression, the injuries aren't beyond the stage of neurapraxia or stage 1 of Sunderland. The motor evaluation of Daniels and Worthingham is most often 4.

The muscles concerned by the compression of the median nerve in the carpal tunnel are the pollicis abductor brevis, the opponens pollicis, the short fascicle of the flexor pollicis brevis, and the two radial lumbrical muscles.

Therefore, we propose several exercises reinforcing these anatomical elements:

Internal Thenar Muscles

We ask the patient to realize an anteflexion of the thumb against a resistance placed on the radial side of the first phalanx to stimulate the external sesamoid muscles and on the radial side of the first metacarpal for the opponens pollicis (Fig. 13.7).

The reinforcement evolves depending on the progression, until 2 months, when the flexor retinaculum is healed.

We add electrotherapy to the voluntary contraction of the patient, with currents of wide amplitude (150–200 μ s) and a frequency of 20–30 Hz to stimulate type 1 muscle fibers (Fig. 13.8).

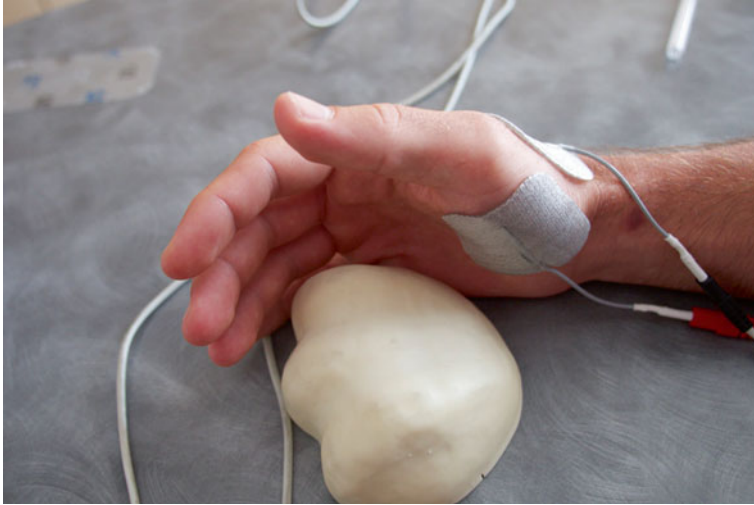

Fig. 13.8 Active electrostimulation of the external sesamoid muscles (placement of the reference electrode)

Global Exercise of the Intrinsic Muscles

This exercise limits the apparition of muscular unbalance, often created by compensation when the patient goes back to his daily activities.

It consists in reinforcing globally and progressively the intrinsic muscles of the hand to stimulate the functional synergies essential for the efficiency of the prehensions.

We ask for a contraction against resistance with a “wise” pinch (Figs. 13.9 and 13.9’): opposition thumb, fifth finger, and separation thumb, fifth finger.

This exercise can also be realized instrumentally, with or without visual feedback (Figs. 13.9 and 13.9’).

The electrostimulation of the muscles of the opposition arch (thumb, fifth finger) can be used combined with a voluntary contraction of the patient (Fig. 13.10).


Working on the tip-to-side pinch, without participation of the flexor pollicis longus, can also be realized with a visual feedback (Figs. 13.11 and 13.11’).

To complete the protocol, we can add exercises for the rotatory stability, which have a functional and proprioceptive interest (Figs. 13.12 and 13.12’).

Rebalancing the Muscle Balances

This reinforcement protocol must allow regaining muscular ratios comparable to the same side, particularly between the intrinsic and extrinsic systems, even if all ratios should be controlled.

The measures are controlled during the regular checkups realized with dynamometers.



Figs. 13.9 and 13.9' Global manual and instrumental exercise for the intrinsic muscles

Proprioception, Coordination, and Dexterity

We work on simple and then complex prehensions to improve proprioceptive, dexterity, and coordination aspects.

These exercises are adapted to the patient's functional needs.


Regaining Sensitivity [7]

This exercise is realized after defining exactly the patient's sensorial disorders (hypoesthesia, hyperesthesia, paresthesia, dysesthesia, allodynia, etc.).


The rehabilitation is then adapted to these disorders, according to the protocol described in the Chap. 12.



Fig. 13.10 Placement of the electrodes (*left*). Electro-active exercise for the muscles of the opposition arch of the thumb (*right*)



Figs. 13.11 and 13.11' Exercise for the termino-lateral pinch, without compensation from the flexor pollicis longus, in which innervation is proximal to the carpal tunnel



Figs. 13.12 and 13.12' Rotatory stabilization of the thumb, progressively decreasing the size of the cylinder

13.2.4.2 Orthotic Treatment [2]

A thermoformed orthosis can delay and even avoid surgery when it's realized at the onset of the symptoms.

Its role is to immobilize the wrist in a neutral position where the pressure in the carpal tunnel is less important and, therefore, to limit the constraints on the median nerve (Fig. 13.13).

An orthosis worn during the night avoids nocturnal compression of the median nerve by the lumbrical muscles and that in the carpal tunnel when the fingers are flexed (classical position during the night) (Fig. 13.14) [3].

The orthosis must be worn all the time during 6 weeks and then only during the night until the symptoms disappear – or until the surgery.

13.2.5 Rehabilitation and Orthotic Treatment, Postoperative

The goal of decompression surgery by section of the flexor retinaculum has several biomechanical consequences:

- Increase of the carpal tunnel volume, allowing the decompression of the median nerve and therefore opposing the ischemic disorders damaging it [12].
- Decrease of the friction in the nerve–tendon–synovial sheath inside the tunnel.

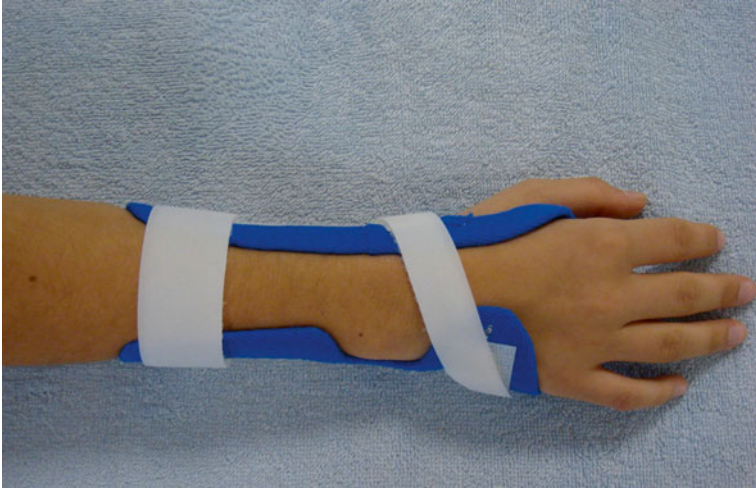


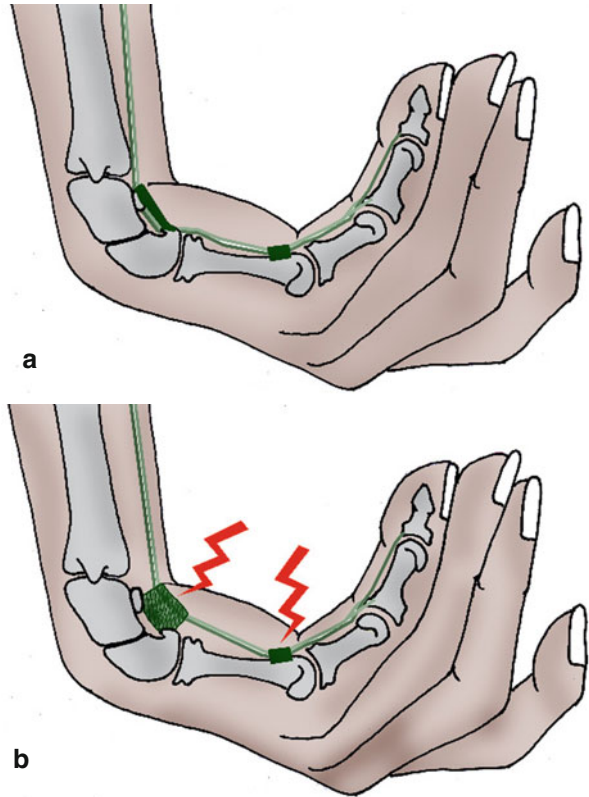
Fig. 13.13 Rest orthosis of the wrist in a neutral position, where the pressure in the carpal tunnel is the least important

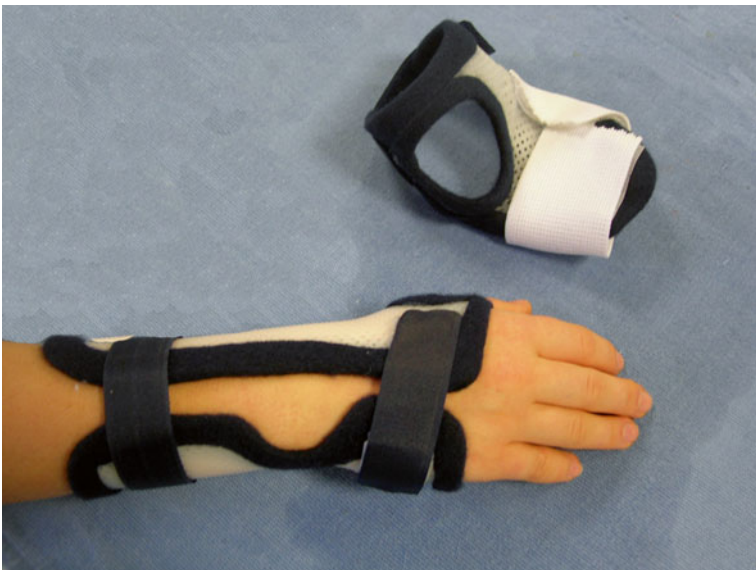

Fig. 13.14 Nocturnal device associated to the rest orthosis. It can be used to limit the compression of the median nerve by the lumbricals when the fingers are flexed

- Palmar translation of the flexors by “bowstring” effect, putting more constraints on the A1 pulley. This phenomenon can lead to a trigger finger after carpal tunnel surgery (Fig. 13.15).

Fig. 13.15 The retinacular ligament opposes to the “bowstring” effect of the flexor tendons at the level of the carpal tunnel (a). After surgery, we can observe a palmar translation of the flexors leading to a transfer of the constraints on the A1 pulley (b)



- Loss of the proximal fixing point of the thenar and hypothenar muscles that can cause a loss of strength in these muscles (Fig. 13.16).
- Possibility of hypertrophic healing of the flexor retinaculum causing pillar pain and perineural fibrosis (Fig. 13.17).
- Relative relaxation of the thenar muscles, which can decompensate a rhizarthrosis that already existed but wasn't causing any painful disorders.

Other than these mechanical disturbances, the operated patients sometimes have sensorial disorders that must be treated to regain an optimal prehension.

13.2.5.1 Rehabilitation (Fig. 13.18)

The rehabilitation aims to limit the negative impact of these biomechanical modifications on the patient's functions. However, it isn't systematic, as the postoperative evolution is usually positive without rehabilitation.

In the immediate postoperative phase (D0 to D21), rehabilitation isn't essential in most cases and is reduced to guided self-rehabilitation exercises and advice sheets.

Fig. 13.16 Loss of the proximal fix point of the thenar and hypothenar muscles

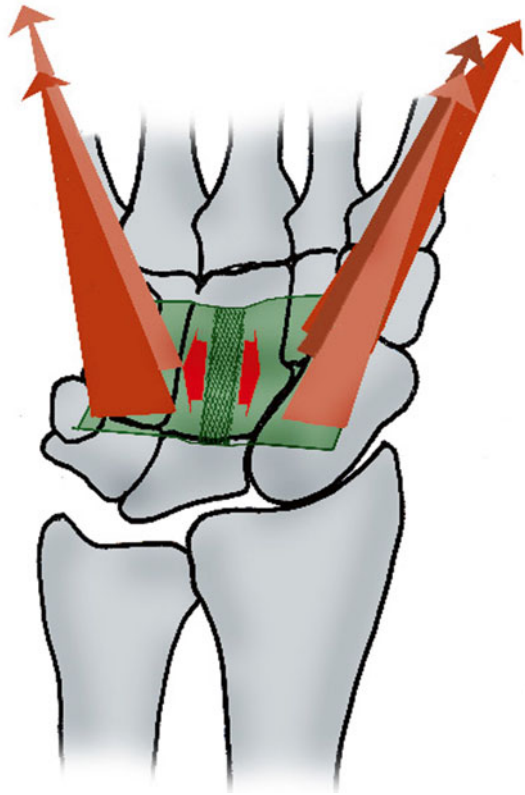
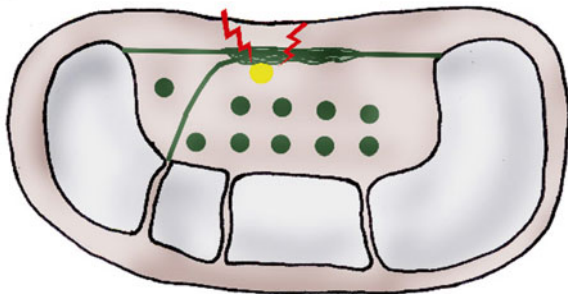


Fig. 13.17 Hypertrophic healing of the flexor retinacular ligament causing perineural fibrosis and “pillar pain”



These exercises consist in putting ice on the operated hand, mobilizing passively and then actively the fingers and the wrist without resistance, and stimulating the tips of the three radial fingers with various objects (tissue, soft brush, etc.). Strength activities are strictly forbidden as they disturb the healing process and increase the risks of complications. In some cases (important perioperative fibrosis, important risks of CRPS, important pre- or postoperative sensorial disorders), the rehabilitation starts

Operated carpal tunnel		
	Postoperative phase (A)	Healing phase (B)
R e h a b i l i t a t i o n	<p>Therapeutic goals: fight against inflammation and pain; prevent stiffness in the fingers and the wrist, self-rehabilitation.</p> <p>Techniques: - Transcutaneous vibratory stimulations, cryotherapy, disto-proximal pressotherapy, TENS (100 Hz), analgesic and draining massages around the scar. - Passive, then simple active mobilizations without resistance or pain in the wrist and the fingers.</p> <p>Risks: CRPS, slackness of the flexors retinaculum.</p>	<p>Therapeutic goals: same phase (4) if necessary, scar relaxation and mobility of the nerve, progressively regain the grip (since D21), rehabilitation of the sensitivity.</p> <p>Techniques: - Scar massage without distraction, progressive and pain-free Butler mobilization. - Progressive reinforcement of the thenar and hypothenar muscles (D21). - Sensorial stimulations, prehensions, coordination and dexterity.</p> <p>Risks: same + loss of intrinsic strength.</p>
Or t h e s i s	Resting orthosis for the wrist in 30° of extension.	Neoprene + silicone orthosis if healing problem.
D0 to 21		After D21

Fig. 13.18 Rehabilitation protocol after carpal tunnel surgery

in this phase with gaseous cryotherapy, disto-proximal pressotherapy, draining massages around the scar, and transcutaneous vibratory stimulations (100 Hz).

From D21, the scar is closed and the hand is usually less inflammatory and painful. In this phase, we fight against healing disorders that can cause fibrosis around the median nerve, mobilize the median nerve, and work for the progressive recuperation of the grip. The sensorial rehabilitation will also be key if there are disturbances in the sensitivity of the median territory.

Fight Against Healing Disorders

Healing disorders after a surgery of the carpal tunnel can cause important fibrosis, with consequences that can disturb the hand's functions.

The cutaneous scar usually causes few problems, but the healing of the flexor retinaculum can cause pillar pain or “trap” the median nerve, leading to a symptomatology similar to the one observed before the surgery.

Massages Around the Scar and in Fibrosis Areas

Their goal is to improve trophicity around the treated area and to relax the scar.

We realize disto-proximal glided pressures following the orientation of the fibers of the flexor retinaculum, thenar, and hypothenar muscles. This helps remodeling the scar tissue. We also use sanding on indurations to relax the areas with the most fibrosis.

Ultrasounds

Once the scar is closed, we use ultrasounds to fight against adhesences around the scar.

The ideal frequency is 1 MHz as it has a deeper affect than 3 MHz. We prefer using the pulse mode that has a “fibrolytic” effect.

Depressotherapy

Its application must be cautious and progressive.

We start using it when the scar is closed.

First, when the scar is still inflammatory, we apply the head of the device far from the scar in a disto-proximal direction.

When the scar isn't inflammatory anymore, we apply the head of the device directly on it, first with the alternative mode and then with the continuous mode if the patient tolerates it well.

Mobilization of the Median Nerve

These techniques are realized if the patient presents paresthesias without any other neurologic disorders on the median territory.

We use the same techniques than the ones described for the rehabilitation without surgery.

Longitudinal Massage

It's first applied fare from the operated area, then getting closer to the wrist, according to the same modalities as the ones described for the rehabilitation without surgery.

Regaining Strength

The carpal tunnel surgery is meant for compressive nervous injuries not exceeding the stage of the axonotmesis or stage 2 of Sunderland but that can cause motor disorders often rated between 2 and 4 on the Daniels and Worthingham scale described in the Chap. 12.

Stage 2

This stage corresponds with the capacity to mobilize the concerned segment in all its amplitude without gravity or in part of its amplitude against gravity.

We ask the patient to realize simple active mobilizations if the mobilization isn't against gravity and active-assisted contractions against gravity.

The interest here is to improve the trophic state of the muscle and to maintain the glidings in different anatomic planes.

Stage 3

This stage corresponds with the capacity of mobilizing the concerned segment in all its amplitude against gravity.

The interest is the same as in stage 2, but here we can start an intermittent static exercise against gravity to alternate the contractile modes, depending on the patient's capacities.

Stage 4

This stage marks the beginning of the reinforcement protocol, progressively putting charge on the flexor retinaculum, as the motor ability of the thenar muscles allows us to use manual or instrumental resistances.

The strength loss in this stage is constant, even if the muscles' motor ability is normal, because of the incision of the flexor retinaculum that weakens the proximal fixing point of the thenar muscles, which is an essential element for the efficiency of the grabs between the thumb and fingers (cf. Fig. 13.16).

Working with the external thenar muscles is part of a global reinforcement protocol for the intrinsic muscles of the hand. It must be progressive until 8 weeks in order not to damage the flexor retinaculum, which would distend it and limit the recuperation of strength or favor the appearance of fibrosis around the scar that could compress the median nerve.

The maximal contraction of the extrinsic muscles is forbidden until the end of healing as it multiplies by 3 the pressure in the carpal tunnel and tends to relax the flexor retinaculum because of the "bowstring" effect.

The exercises proposed in the stage are the same than the ones for the rehabilitation without surgery.

Sensorial Rehabilitation [7]

Sensorial disorders after a carpal tunnel surgery can appear when the nerve is a lot damaged before the intervention or in the case of hypertrophic healing of the flexor retinaculum that "traps" and compresses the median nerve.

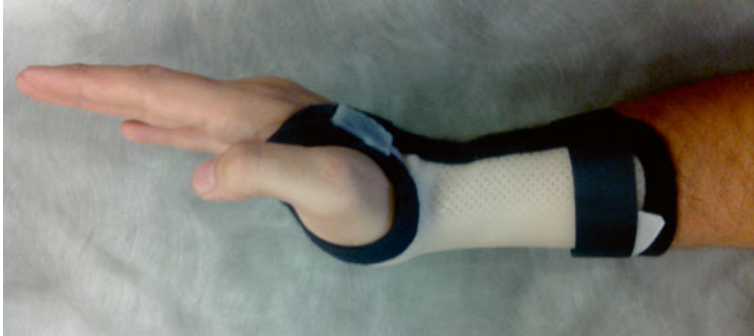

Fig. 13.19 Postoperative orthosis after carpal tunnel surgery, with a wrist extension to limit the risks of adhesions between the median nerve and the flexor retinaculum

This rehabilitation isn't always needed but is essential in the case of sensorial disorders on the median territory, which corresponds with the precise functions of the hand and needs an exceptional discriminative sensitivity.

This rehabilitation is realized following the modalities described in the Chap. 12.

Prehensions

Manipulation exercises allowing improving dexterity and coordination are realized, insisting on the precision of the thumb–index pinch.

13.2.5.2 Orthotic Treatment [2]

The orthosis realized places the wrist in 30° of extension to maintain the flexors and median nerve in contact with the carpal floor and therefore:

- Improves flexor retinaculum healing, limiting the “bowstring” effect of the finger flexors during the flexion of the wrist (especially in active flexion)
- Limits the risk of adherence between the median nerve and the flexor retinaculum (Fig. 13.19)

In the case of hypertrophic healing with pillar pain, a neoprene orthosis with a silicone pad on the scar can be realized once the scar is closed.

This orthosis allows progressively getting back to professional activities, while protecting the scar from painful contacts. It also improves healing with the silicone pad.

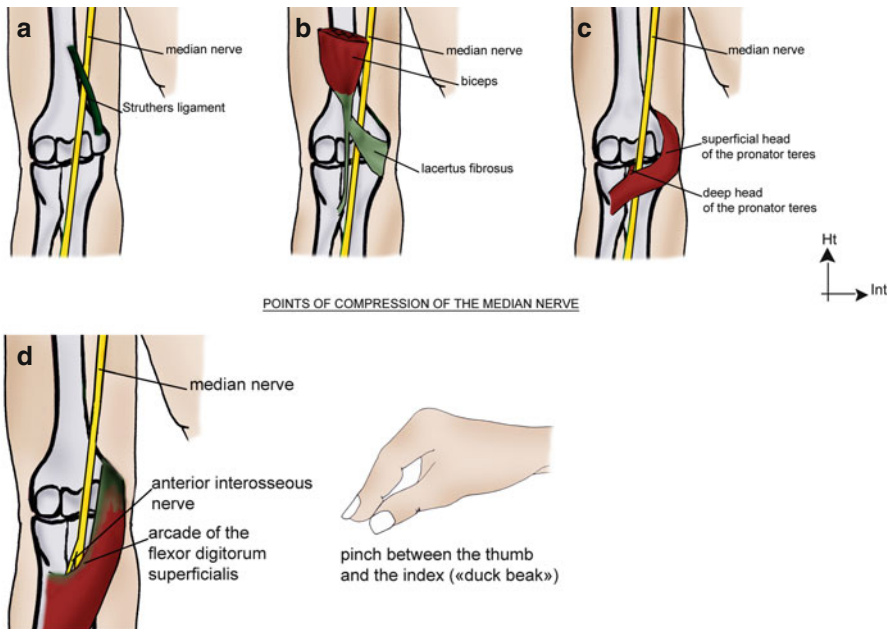
13.3 Other Entrapment Syndromes of the Median Nerve (Figs. 13.20 and 13.20')

Even if the carpal tunnel syndrome is, by far, the most common entrapment syndrome of the median nerve, other locations are possible, and several compression sites can be associated to generate a double crush syndrome that is a proximal compression of the nerve causing positive clinical signs distally on a second less important compression site.

13.3.1 Arcade of Struthers

The ligament of Struthers, very inconstant, forms an inextensible arch between the medial epicondyle and the supra-epicondyle apophysis, where injuries of the median nerve can occur.

Its compression at this level causes muscular and sensorial disorders in all its innervation territory, as there aren't collateral branches yet.



Figs. 13.20 and 13.20' Other points of compression of the median nerve. (a) The Struthers ligament. (b) Lacertus fibrosus of the biceps. (c) Pronator teres. (d) Arcade of the flexor digitorum superficialis

13.3.2 Under the Lacertus Fibrosus

The lacertus fibrosus is an accessory bicipital aponeurosis on the ulnar side of the principal biceps tendon that can be the source of a compression of the median nerve, in which its symptomatology is close to the one of the compressions at the level of the arcade of Struthers and the pronator teres.

13.3.3 Between the 2 Fascicles of the Pronator Teres

The pronator teres syndrome is a compression of the median nerve between the two heads of the pronator teres, causing a symptomatology close to the one we observe in the carpal tunnel syndrome.

However, the symptoms decrease during the night and the Tinel sign is positive in the elbow, which helps localize the injury.

13.3.4 Under the Arcade of the Flexor Digitorum Superficialis

The compression of the median nerve at this level is the source of a compression of the anterior interosseous nerve, which is a branch of the median nerve formed at the level of the pronator teres.

The anterior interosseous syndrome causes motor deficit in the flexor pollicis longus [4], flexor indicis profundus, and pronator quadratus. There is no associated sensorial disorder.

At an advanced stage, the pinch between the thumb and the index is in the shape of a “duck beak” (Fig. 13.21).

The Eversmann test and the dynamic tests of Spinner also take part in the localization of the injury:

- If clinical signs are triggered by a flexion against resistance of the elbow between 120 and 130° of flexion, the compression is probably at the level of the arcade of Struthers.
- If clinical signs are triggered by a flexion against resistance of the elbow + forearm supination, the compression is probably at the level of the lacertus fibrosus.
- If clinical signs are triggered by a pronation against resistance + elbow in 30° of flexion, the compression is probably at the level of the pronator teres.
- If clinical signs are triggered by a flexion against resistance of the proximal interphalangeal joint of the third finger + elbow extension, the compression is probably at the level of the arcade of the flexor digitorum superficialis.

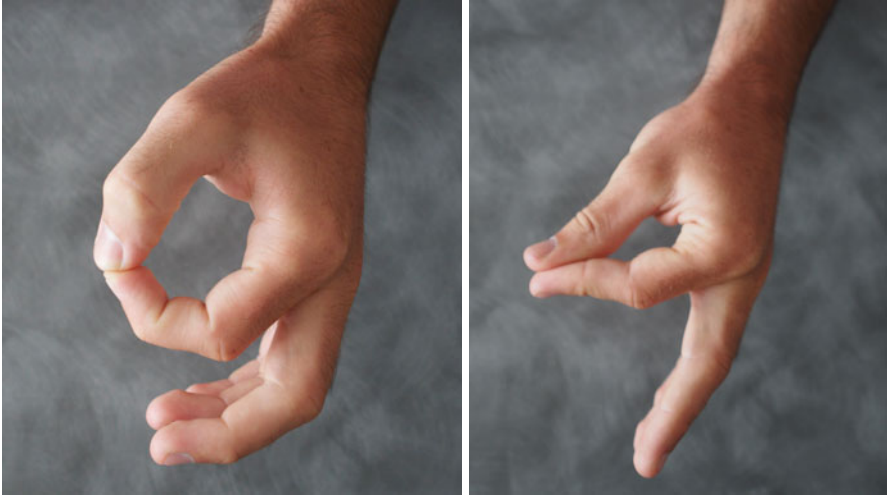


Fig. 13.21 The syndrome of the anterior interosseous nerve leads to a motor damage of the flexor pollicis longus and the flexor digitorum profundus of the second finger. The pinch between the thumb and the index isn't normal (*left*) but in the shape of a “duck beak” (*right*)

13.3.5 Rehabilitation and Orthotic Treatment

The rehabilitation of the entrapment syndromes of the median nerve only concerns the early stages of compression of the nerve; more severe stages need surgery.

It aims to improve tissue glidings around the nerve and sensitivity in the damaged areas and to maintain (and even regain) trophicity of the concerned muscles in the most advanced cases.

13.3.5.1 Fight Against Trophic Disorders and Pain

It's based on the association of cryotherapy, pressotherapy, analgesic vibrotherapy, and draining massages that can improve symptomatology.

Longitudinal Massage

They are realized on the accessible areas of the median nerve.

The median nerve goes along the internal side of the arm until it reaches the arcade of Struthers where it's easily accessible. We realize longitudinal massages along the nerve and transversal and dot-shaped massages on the areas with fibrosis.

The nerve then passes in the anterior part of the elbow under the lacertus fibrosus and passes between the two heads of the pronator teres and then under the flexor digitorum superficialis.

Here, we also use longitudinal massages on areas where the nerve is reachable and transversal and dot-shaped massages on areas with fibrosis.

Decontracting Massages

They are realized on the internal side of the arm and the anterior side of the forearm and based on glided pressures and kneading to improve local trophicity and muscular relaxation.

13.3.5.2 Improving Tissue Glidings Around the Nerve

The goal is to realize differential glidings between the nerve and the adjacent tissues, mobilizing the nerve directly or indirectly with myo-aponeurotic stretchings or muscular contractions.

The mobilizations of the median nerve are realized following the modalities described in previous paragraphs (ULTT1 and 2a), and contractions–rest–stretchings can concern the biceps, flexor digitorum superficialis, or pronator teres depending on the localization of the compression. Each stage of pumping is maintained 4–6 s to avoid risks of ischemia.

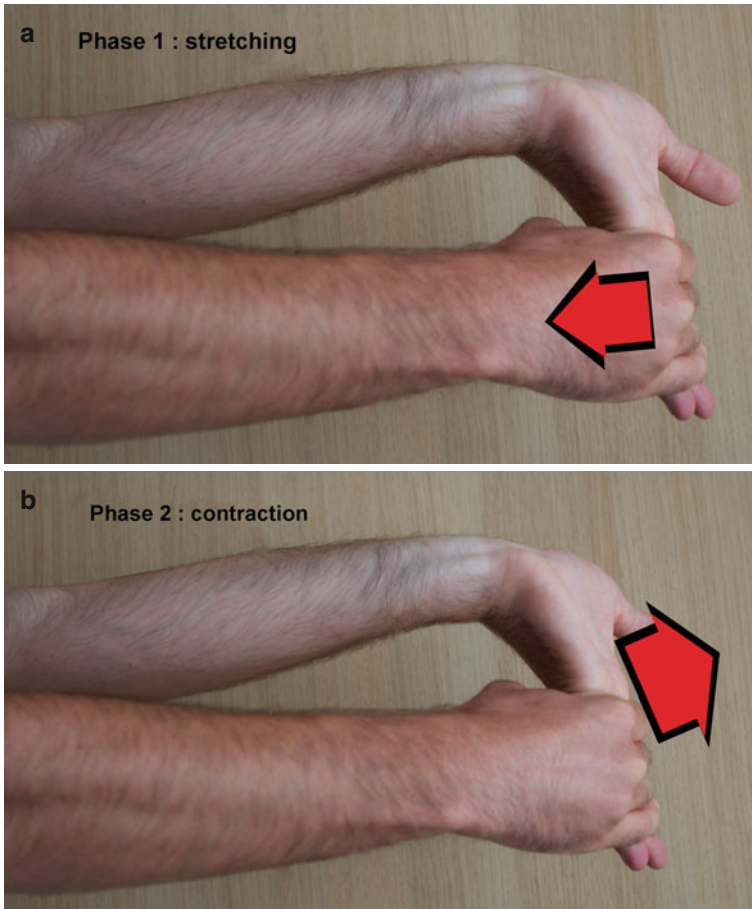
Flexor Digitorum Superficialis

The stretching is realized with the elbow extended, extending the wrist and fingers except the distal interphalangeal joint, in order not to put tension on the flexor digitorum profundus that isn't a compressive element for the median nerve (Figs. 13.22 and 13.22').

The contraction is realized in external race and closed chain to get a decompressive effect in the arcade of the flexor digitorum superficialis (Fig. 13.23).

Pronator Teres

Contraction–relaxation of the pronator teres are realized to create “pumping” around the median nerve, improving local trophicity. These maneuvers are realized with the elbow in 90° of flexion, which is the position where the pronator teres is solicited the most (Fig. 13.24).



Figs. 13.22 and 13.22' Stretching–contraction of the flexor digitorum superficialis mobilizing it in relation with the median nerve

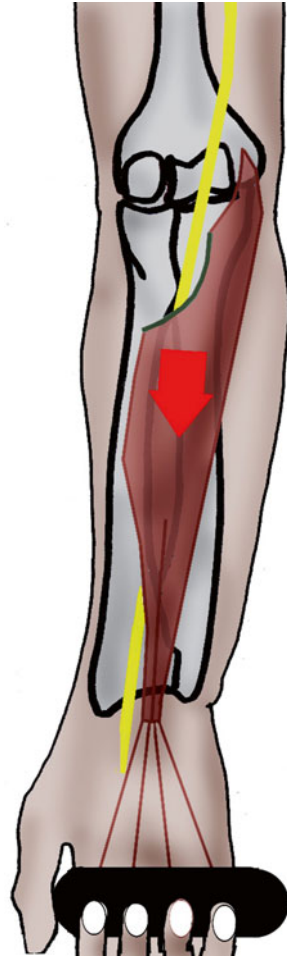Biceps

We alternate contraction–rest–stretching in every position of the elbow to favor glidings of the lacertus fibrosus.

13.3.5.3 Regaining Strength

This part of the treatment is adapted to the Daniels and Worthingham scale, following the same steps as in the rehabilitation after carpal tunnel surgery.

Fig. 13.23 Working in a closed chain for the flexor digitorum superficialis decompresses the median nerve at the level of its arcade



13.3.5.4 Regaining Sensitivity [7]


It is realized following the modalities described in the Chap. 12.

13.3.5.5 Self-Rehabilitation

Self-rehabilitation exercises based on mobilizations, longitudinal self-massages, and cryotherapy are explained to the patient.

The mobilizations are realized several times a day in all the amplitudes of the wrist and elbow to improve perineural glidings.

Fig. 13.24 Contraction–relaxation of the pronator teres, realizing a per-nervous vascular pumping



Longitudinal massages are realized three times a day during 1–2 min (until there's a modification of the perception) on the median nerve, depending on the compression site.

We put ice on the compression area after all the other exercises during 20 min, depending on pain.

13.3.6 Important Points

13.3.6.1 Diagnosis

The diagnosis of these injuries isn't easy as the different possible localizations are close from each other and the clinical signs can be unclear with a mixed or incomplete clinical picture.

For example, the anterior interosseous syndrome only affects the flexor pollicis longus and therefore can be confused with a rupture of this muscle [4].

We can also find a clinical picture that reminds us of a pronator teres syndrome, when the compression is really at the level of the arcade of flexor digitorum superficialis. Or we can find a clinical picture of anterior interosseous syndrome with a compression at the level of the pronator teres or even more proximal.

For these reasons, the surgical approach is the same for compressions related to the lacertus fibrosus, the pronator teres, and the arcade of the flexor digitorum superficialis, which allows the surgeon to evaluate the nerve state and specify the compression site.

There are also double crush syndromes, in which the nerve is compressed in several places.

Therefore, we mustn't stay focused on just one location, and it's essential to control the state of the nerve in its entire pathway. A painful area can correspond with another compression site of the nerve.

Some symptomatology is close to the ones we can observe in entrapment syndromes and yet are due to completely different causes, for example, the radicular compressions, referred pain, systemic pathologies, etc.

Therefore, it's essential to take complementary medical advice if the symptomatology doesn't evolve.

13.3.6.2 Rehabilitation Techniques

Nervous compressions are complex and need a precise and adaptive treatment.

Some techniques, like nervous mobilizations and longitudinal massages, can worsen the symptomatology if they aren't realized well. When in doubt, it's better to delay their application.

Bibliography

1. Merle M (2007) *Chirurgie de la main, Affections rhumatismales, dégénératives, syndromes canaux.* Elsevier-Masson
2. Gerritsen AA, de Krom MC, Struijs MA, Scholten RJ, de Vet HC, Bouter LM (2002) Conservative treatment options for carpal tunnel syndrome: a systematic review of randomised controlled trials. *J Neurol* 249(3):272–280
3. Lemoine S, Grelet V, Leger O, Mesplé G (2012) Intérêt du port nocturne d'une orthèse après chirurgie du canal carpien. Etude prospective sur 60 cas consécutifs, *Chirurgie de la main*, Vol. 31-N°6, (ed). Elsevier, Masson, p. 400
4. Duteille F, Amara B, Dautel G, Merle M (2000) Atteinte isolée du long fléchisseur du pouce dans le syndrome du nerf interosseux antérieur, quel mécanisme? *Revue de chirurgie orthopédique et traumatologique* RCO-06-2000-86-3-0035-1040-101019-ART80. Elsevier-Masson
5. Dufour M (2002) *Anatomie de l'appareil locomoteur T2.* Masson, Paris
6. Butler DS (2005) *Mobilisation of the nervous system.* Churchill, Livingstone
7. Valemois B (2006) Rééducation des troubles de la sensibilité de la main. In: Blanchard M, Mitermique B, Noel L. *EMC Kinésithérapie-Médecine physique réadaptation* 26-064-A-10. Elsevier-Masson
8. Cobb TK (1993) Anatomy of the flexor retinaculum. *J Hand Surg* 18A:91–99

9. Ferrari GP (1991) The superficial anastomosis on the palm of the hand between the ulnar and the median nerve. *J Hand Surg* 16B:511–514
10. Seiler JC (1989) Intraoperative assessment of median nerve blood flow during carpal tunnel release with laser Doppler flowmetry. *J Hand Surg* 14A:968–991
11. Kerr CD (1992) An analysis of the flexor synovium in idiopathic CTS: report of 625 cases. *J Hand Surg* 17A:1028–1030
12. Okutsu I (1989) Measurement of pressure in the carpal canal before and after endoscopic management of CTS. *J Bone Joint Surg* 71A:679–683
13. Stevens JC (1987) The electrodiagnosis of CTS. *Muscle Nerve* 10:99–113
14. Williams TM (1992) Verification of the pressure provocation test in CTS. *Ann Plast Surg* 29:8–11
15. Futami T (1992) Natural history of the carpal tunnel syndrome. *J Jpn Soc Surg Hand* 9:128–130
16. Serror P (1992) Nerve conduction studies after treatment for carpal tunnel syndrome. *J Hand Surg Br* 17:987–995
17. Gelberman RH (1986) Results of prospective trial of steroid injection and splinting. *J Bone Joint Surg* 68A:735–737
18. Nolan WB III (1992) Results of treatment of severe CTS. *J Hand Surg* 17A:1020–1023
19. Metral S (1986) EMG, EMC app loc, 14-001-R-10. 10p
20. Lowry WE (1988) Interfascicular neurolysis in the severe CTS: a prospective study randomized, double-blind, controlled study. *Clin Orthop* 227:251–254
21. Lanz U, Agee JM (1992) Endoscopic release of the carpal tunnel: a randomized prospective multicentric study. *J Hand Surg Am* 17:987–995
22. Chow JC (1993) The Chow technique of endoscopic release of the carpal ligament for CTS: four years of clinical results. *Arthroscopy* 9:301–314
23. Léger O (2000) Influence de la technique opératoire sur le coût du traitement chirurgical du syndrome du canal carpien. *Chirurgie de la Main mai* 19(2):95–99
24. Palmer DH (1993) Endoscopic carpal tunnel release: a comparison of two techniques with open release. *Arthroscopy* 9:498–508

Chapter 14

Entrapment Syndromes of the Ulnar Nerve

Grégory Mesplié and Olivier Léger

14.1 Functional Anatomy

The ulnar nerve is a mixed nerve and therefore has a motor, sensory, and neurovegetative function.

It originates from the C8 and T1 nerve roots and goes along the internal side of the arm, along the internal head of the triceps and crosses the arcade of Struthers toward the ulnar canal of the elbow [1, 2]. This canal is made of a ligamentous floor (medial collateral ligament), bony walls (epitrochlear–olecranon groove), and a fibrous roof (retinaculum of the ulnar canal).

The ulnar nerve then goes between the two heads of the flexor carpi ulnaris under Osborne's fascia (Fig. 14.1).

It continues its path under the flexor carpi ulnaris and above the flexor digitorum superficialis, behind the arcade of Amadio and Beckenbaugh.

In the middle part of the forearm, it gets ventral and goes along the flexor digitorum superficialis toward the Guyon's canal in the wrist (Fig. 14.2).

It then gives off four branches, the most ulnar being motor (hypothenar eminence, interossei, third and fourth lumbricals, adductor pollicis, deep bundle of the flexor pollicis brevis) [3].

The two medium branches are the sensory nerves of the 5th and half of the 4th finger (Fig. 14.3).

The most radial branch forms the Riche and Cannieu anastomosis (or Berrettini anastomosis).

G. Mesplié (✉)

Physiotherapist and Orthotist, Institut Sud Aquitain de la Main et du
Membre Supérieur, Aguiléra Clinic Biarritz, Biarritz, France
e-mail: greg.mesplie@mac.com

O. Léger

Hand Surgeon, Institut Sud Aquitain de la Main et du
Membre Supérieur, Aguiléra Clinic Biarritz, Biarritz, France

Fig. 14.1 Schematic location of the ulnar nerve

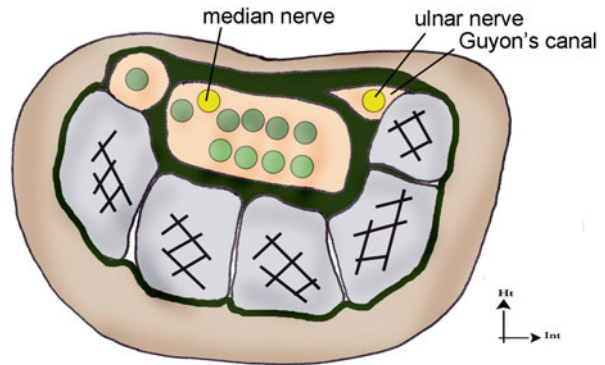
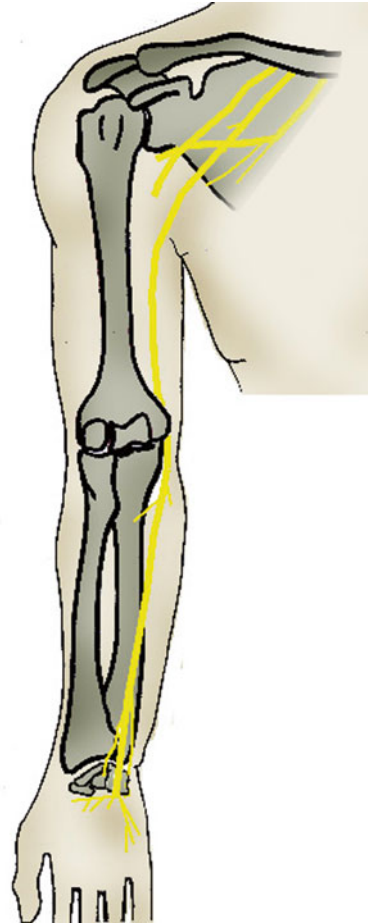


Fig. 14.2 Path of the ulnar nerve in the Guyon's canal

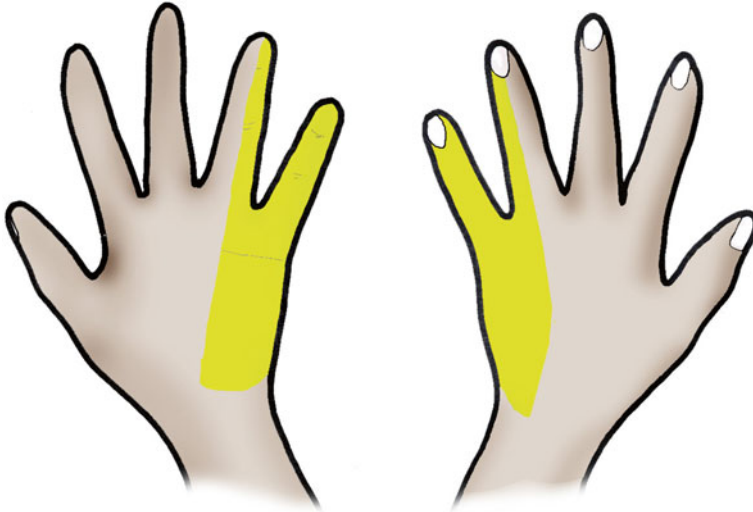


Fig. 14.3 Sensorial territory of the ulnar nerve

It innervates the flexor carpi ulnaris and the two medial heads of the flexor digitorum profundus in the forearm.

In the hand, it innervates all the intrinsic muscles except for the two radial lumbricals, the opponens pollicis, the abductor pollicis brevis, and the superficial bundle of the flexor pollicis brevis.

14.2 Entrapment Syndromes of the Ulnar Nerve [4]


14.2.1 *Compression of the Ulnar Nerve at the Level of the Elbow [1, 2]*

The vulnerability of the ulnar nerve, because of its anatomical path, has been known since the beginning of the twentieth century. A traumatic origin, or one secondary to a degenerative damage, was frequently found, and in 1957 Osborne described the concept of the cubital tunnel syndrome. He showed that opening this tunnel has positive effects on the symptomatology.

14.2.1.1 Etiology

- *Primitive forms* in a context of hyper-use
- *Traumatic forms* by direct contusion, fracture of the inferior extremity of the humerus, elbow dislocation, or prolonged compression [5]
- *Secondary forms*, nontraumatic with arthrosis, rheumatoid polyarthritis, osteochondromatosis, or tumor

Fig. 14.4 Froment's test: maintain a sheet of paper being pulled away is impossible without compensating with the flexor pollicis longus (innervated by the median nerve) as the adductor pollicis (innervated by the ulnar nerve) is inefficient. (1) Negative test and (2) positive test



14.2.1.2 Clinical Exam [6]

It must look for traumatic or nontraumatic factors that could be causing the symptoms. The symptomatology depends on the fibers concerned by the compression; it can be mostly sensorial or motor.

Paresthesias occur in the 5th finger and the ulnar side of the 4th finger, and they can be more important during the night as the elbow is flexed (around 90°) and becomes permanent.

For the motor function, we have to look for a global loss of the clamping strength and an ulnar paralysis with Froment's sign, revealed by a flexion of the interphalangeal joint of the thumb when pinching a sheet of paper between the pulps of the thumb and index. This compensation is related to the contraction of the flexor pollicis longus (innervated by the median nerve) that compensates the weakness of the adductor pollicis (innervated by the ulnar nerve) (Fig. 14.4).

The weakness of the interossei is brought to light by Wartenberg's sign, which is a permanent abduction of the 5th finger (Fig. 14.5).

Tinel's sign has a sensitivity of 62 % but is not enough to unsure the nerve suffering, as it is also present in patients with no neurological damage.

14.2.1.3 Complementary Exams

We look for signs of arthrosis or traumatic sequels with radiography of the elbow.

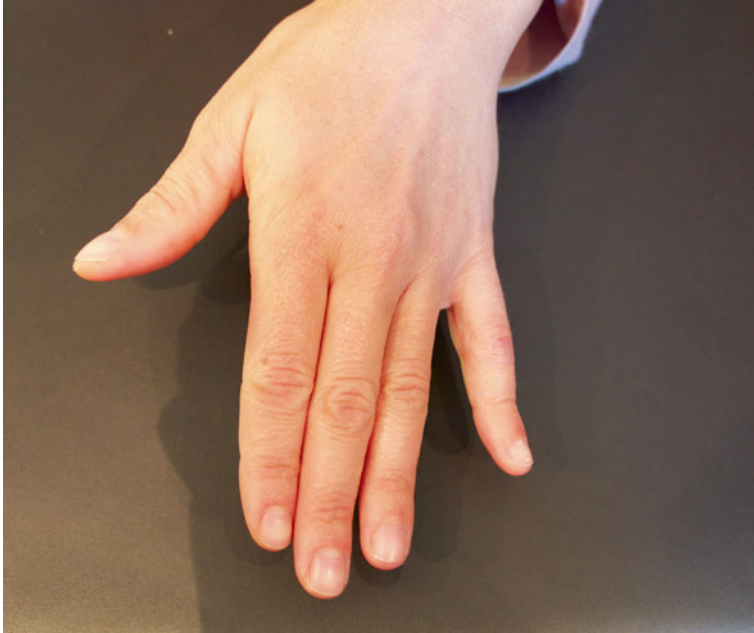

Fig. 14.5 Wartenberg's sign, meaning the 4th palmar interosseus is weak. The abduction of the 5th finger is permanent because of the effect of the extensor digiti minimi

The electromyogram is part of the systematic assessment in every entrapment syndrome and determines the seriousness and level of the injury.

14.2.1.4 Medical and Surgical Treatment

Medical Treatment

When symptomatology is intermittent with a minimal damage on the electromyogram, the medical treatment combines anti-inflammatories with an orthosis in 30° of elbow flexion, worn during the night. Compression phenomena must be reduced adapting the workstation.

Surgical Treatment [7–11]

Extra-articular neurolysis improves symptomatology in most of the cases; epicondylectomy and transposition of the ulnar nerve are used in case of relapse, nervous instability, or bony deformity.

Extra-articular neurolysis: realized with plexus block and pneumatic tourniquet. It consists in successively lifting every compression site, with section of the retinaculum of the ulnar canal, the Osborne's fascia, and the arcade of Amadio and

Beckenbaugh, while checking that there isn't any nervous subluxation that would require an anterior transposition or a medial epicondylectomy.

Medial epicondylectomy: [7], it consists in removing the medial epicondyle to decrease the path of the nerve and the intracanal pressure during the movements of flexion–extension [5].

Subcutaneous transposition: it consists in modifying the path of the nerve, placing it under the medial epicondyle and therefore decreasing the tension and stretching during the movements of flexion–extension of the elbow. This transposition can be subcutaneous or submuscular and is realized when simple neurolysis has failed and in case of degenerative or posttraumatic deformities.

14.2.2 Compression of the Ulnar Nerve at the Level of the Wrist

Damage of the ulnar nerve in the wrist is less frequent than in the elbow. It requires a paraclinical assessment with electromyogram and echography to look for the various possible causes of damage of the nerve in this anatomical area.

The ulnar nerve gets into the palm of the hand through Guyon's canal, which has a triangle shape and is limited by the flexor retinaculum in its superior part, the hook of the hamate laterally, and the insertion of the pisohamate ligament and the pisiform medially.

There are various etiologies, from a tumorous or vascular pathology to a traumatic or degenerative origin.

The medical treatment consists in wearing a resting orthosis during 6 weeks, followed by rehabilitation. However, most of the times the patients seek a consultation when they are already in an advanced stage, therefore needing surgery liberating the sensory branches and the motor branch.

14.3 Rehabilitation and Orthotic Treatment of the Compressions of the Ulnar Nerve [12]

14.3.1 Without Surgery [13]

As for the median nerve, this treatment concerns moderate damages of the nerve without important sensorial and motor disorders. The patient describes tingling sensations, most often during the night.

The rehabilitation and orthotic treatment delay and can even avoid surgery.

14.3.1.1 Rehabilitation

The techniques used are the same as for the median nerve, adapted to the anatomical situation of the ulnar nerve.

Fight Against Inflammation and Pain

It's based on a combination of cryotherapy, pressotherapy, and draining massages that can help decreasing the perineural inflammation.

Longitudinal Massage

This massage is applied at the level of the accessible area of the nerve closest to the damaged area.

It consists in realizing a longitudinal pressure along 3–4 cm of the nerve, to improve its vascularization and restart the axonal flow.

The ideal pressure recreates the distal symptomatology, without producing pain. It's maintained a few minutes, which allows obtaining a variation of the initial symptoms.

In epitrochlear–olecranon compressions, the patient is placed in decubitus with his elbow in 30° of flexion. After locating the groove (sometimes with an area with fibrosis), we realize longitudinal maneuvers along the ulnar nerve. Transversal maneuvers can also be done to relax the retinaculum of the epitrochlear–olecranon groove (or ulnar canal).

For compressions in the wrist, the patient is in the same position. We locate the external part of the flexor carpi ulnaris, where the ulnar nerve passes since the inferior 1/3 of the forearm, and realize the longitudinal massage there.

A different way of doing this technique consists in realizing a static pressure at the level of the damaged area and mobilizing the closest joint. The nerve is mobilized, which is sometimes better tolerated by the patient.

We realize this technique on the two possible compression sites, no matter where the “major” compression is.

Fight Against Perineural Fibrosis

It improves glidings between the ulnar nerve and the adjacent tissues, which limits the compressive constraints to which it is exposed and improves its vascularization.

Mobilization of the Nerve (Fig. 14.6) [14]

Nervous mobilizations aim to mobilize the nerve respective to the adjacent tissues to limit the risks of compression and ischemia.

The progression of the mobilization is based on the Upper Limb Tension Tests described by Butler in 1991.

For the ulnar nerve, the mobilization is based on the ULTT 3 and has several stages:

- 90° of shoulder abduction that can be combined with a slight shoulder depression
- Wrist extension and supination
- Blocking the shoulder anti-anteflexion and external rotation



Fig. 14.6 Mobilization of the ulnar nerve described by Butler

- Arm abduction with the palm of the hand touching the ear without losing the previous components
- Contralateral inclination of the head

These stages are realized until the patient feels a bearable tension. The last position is then maintained 6 s to avoid any ischemic risk.

Mobilizations of the Tissues Adjacent to the Nerve

Alternating contraction–relaxation–stretching of the adjacent muscles produces a perineural pumping that improves local trophicity and maintains glidings between tissues.

These mobilizations are realized preferentially on the flexor carpi ulnaris for proximal compressions, on the hypothenar muscles for distal compressions, and on the adductor pollicis for exclusively motor damages. Each step is maintained between 4 and 6 s to avoid any ischemic risk.

Imitation exercises improving movements between the different gliding planes participate in this fight against perineural fibrosis.

Massages Against Fibrosis and Contractures

They are realized along the ulnar nerve, on the internal side of the forearm, around the pisiform, and at the level of the hypothenar eminence.

We use dot-shaped massages, glided pressures, and kneading that improve local trophicity, fight against perineural fibrosis, and relax the muscles adjacent to the nerve.

Self-Rehabilitation

Self-rehabilitation exercises based on mobilization, self-longitudinal massages, and cryotherapy are explained to the patient.

Mobilizations are realized several times a day in every amplitude to improve perineural glidings.

Longitudinal massages are realized three times a day during 1–2 min (until there's a modification of perception).

Putting ice on the compression area is realized after the other exercises during 20 min depending on the appearance of pain.

Regaining Strength

At this stage of compression, the injuries remain at the stage of neurapraxia or stage 1 of Sunderland. The motor evaluation of Daniels and Worthingham is most often rated 4.

The muscles concerned by the compression of the ulnar nerve in the wrist are the hypothenar muscles, interossei, 2 ulnar lumbricals, adductor pollicis, and deep bundle of the flexor pollicis brevis.

In compressions at the level of the elbow, there is also a damage of the flexor carpi ulnaris and the deep flexors of the 4th and 5th fingers.

However, the symptoms are variable and depend on the fibers concerned by the compression.

The reinforcement protocol begins with an intermittent static work and progressively evolves toward more intensive exercises depending on the patient's functional needs.

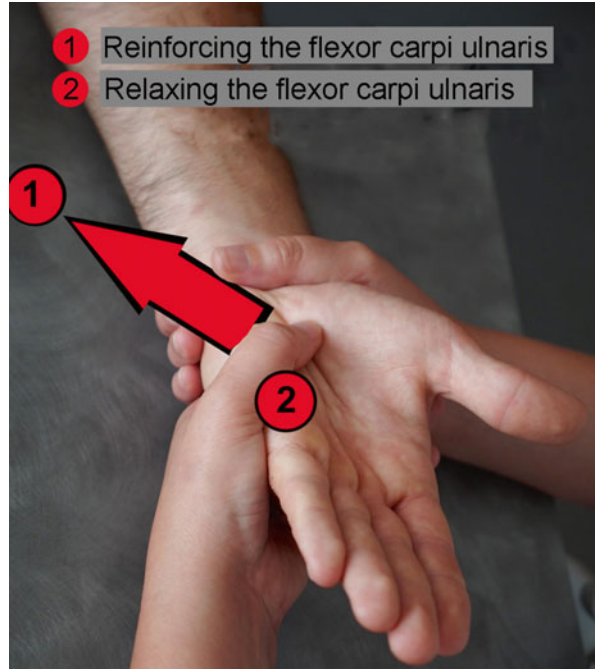
Flexor Carpi Ulnaris

We ask the patient to realize a flexion/ulnar inclination of the wrist against resistance (Fig. 14.7).

Deep Flexors of the 4th and 5th Fingers

The 4th and 5th fingers have a very important role in locking cylindrical prehensions in force activities.

Fig. 14.7 Contraction–relaxation–stretching of the flexor carpi ulnaris in case of compression in the forearm



We don't reinforce them analytically as the flexion of the distal interphalangeal joint against resistance doesn't have any functional interest.

It's better to realize a more global work of the grasp or base on the locking of cylindrical prehensions during functional activities (Fig. 14.8).

Hypothenar Muscles [3]

We ask the patient to realize a flexion of the metacarpophalangeal joint of the 5th finger against a resistance placed on the palmar side on the first phalanx to reinforce the flexor digiti minimi brevis (Fig. 14.9).

An abduction of the metacarpophalangeal against a resistance placed on the lateral side of the first phalanx is asked to reinforce the abductor digiti minimi (Fig. 14.10).

We ask for an anteflexion of the fifth metacarpal against a resistance placed on the palmar side of the metacarpal to reinforce the opponens digiti minimi (Fig. 14.11).



Fig. 14.8 Instrumental reinforcement of the flexor digitorum profundus of the 4th and 5th fingers (role of locking the grips), in synergy with the flexor carpi ulnaris

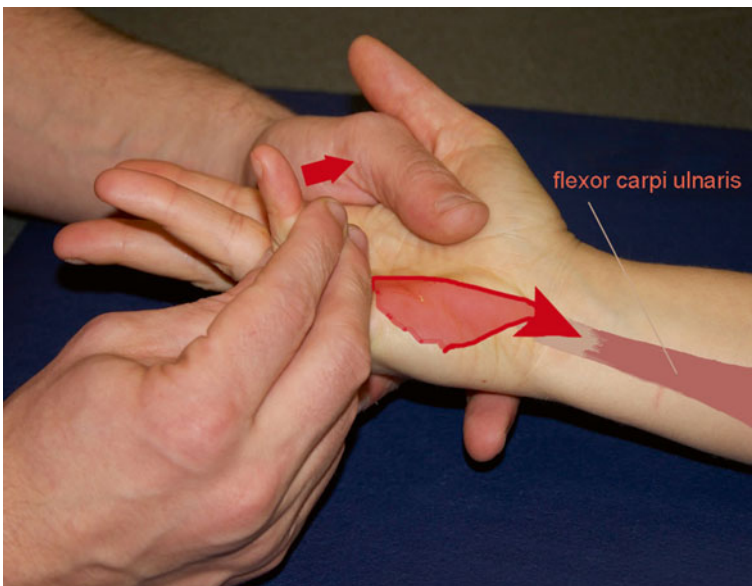


Fig. 14.9 Manual reinforcement of the flexor digiti minimi brevis with irradiation toward the flexor carpi ulnaris

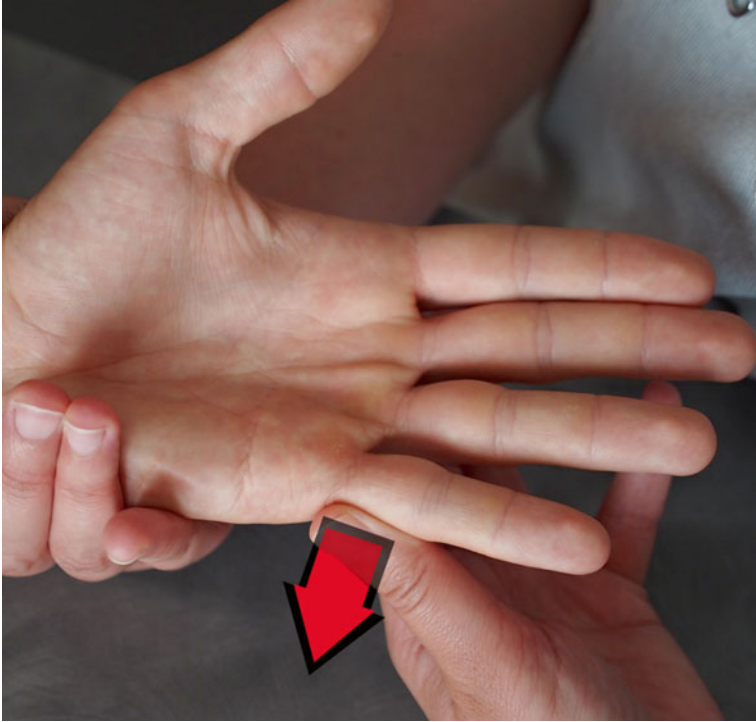



Fig. 14.10 Reinforcement of the abductor digiti minimi



Fig. 14.11 Reinforcement of the opponens digiti minimi



Figs. 14.12 and 14.12' Manual and instrumental reinforcement of the intrinsic muscles with dynamometer and strength captor

Intrinsic Muscles

We ask the patient to realize a “vise” pinch against manual or instrumental resistance with visual feedback (Figs. 14.12 and 14.12').

Exercises against resistance for the muscles of the arch of opposition between the thumb and 2nd finger are interesting and can be combined with active electrostimulation (Fig. 14.13).




Fig. 14.13 Reinforcement of the arch of opposition between the thumb and 5th finger

Adductor Pollicis

We realize an exercise derived from Froment's test.

The patient realizes an opposition between the tips of his thumb and index with visual feedback, without compensating with the flexor pollicis longus (Fig. 14.14).

Regaining Muscular Balance

This reinforcement protocol must help regaining muscular ratios comparable to the sane side, especially between the intrinsic and extrinsic systems.

We check the ratios during the regular checkups realized with dynamometers.

Regaining Sensitivity [15]

Sensorial disorders mainly occur on the sensorial territory of the ulnar nerve, mostly paresthesia. They are treated according to the protocol defined in the Chap. 12.

Proprioception, Coordination, and Dexterity

Proprioception exercises for the wrist and fingers are realized and improve muscular reactivity as well as coordination in the treated hand.




Fig. 14.14 Exercise for the adductor pollicis, derived from the Froment's test. The patient mustn't use the flexor pollicis longus, innervated by the median nerve

14.3.1.2 Orthosis

Their goal is to rest the nerve when the stage of the injury doesn't require surgery.

In compressions at the level of the elbow, an orthosis positioning the elbow in 30° of flexion is realized and worn during the night. It avoids a prolonged flexion of the elbow that causes ischemic phenomena and important stretching (Fig. 14.15).

In compressions at the level of the Guyon's canal, we realize an orthosis putting the wrist in a neutral position that is kept during 6 weeks (Fig. 14.16).

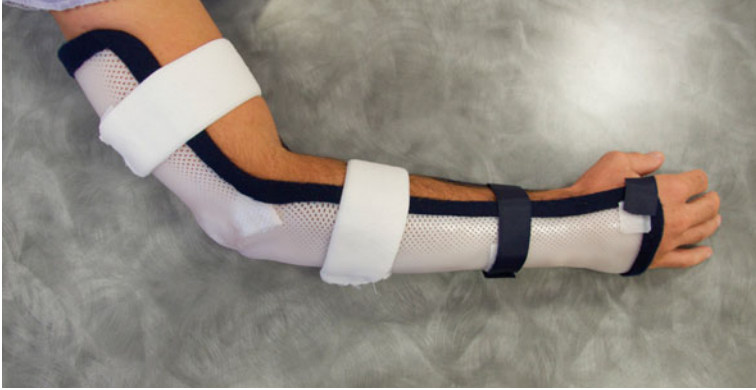

Fig. 14.15 Rest orthosis in case of compression in the elbow, realized in 30° of flexion

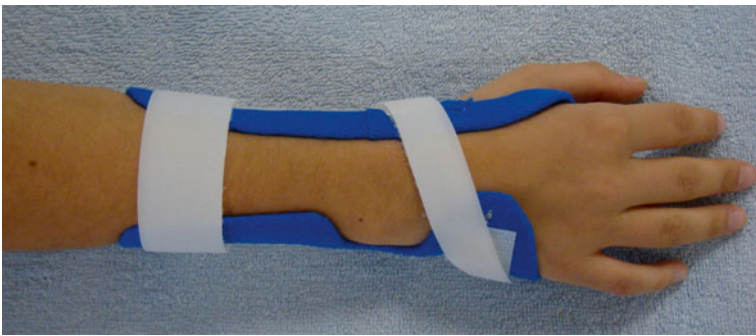

Fig. 14.16 Wrist orthosis in a neutral position in case of compression in the wrist

14.3.2 *Postoperative*

14.3.2.1 **Rehabilitation** (Fig. 14.17)

The main goal is to fight against perineural fibrosis that can have important functional consequences.

Therefore, the rehabilitation starts early or even immediately and is based on soft and progressive mobilizations in all the amplitudes of the wrist and elbow.

Immediate Postoperative Phase (D0 to D21)

In this phase, the most important is to fight against trophic disorders and pain and soft mobilizations of the wrist and elbow.

Operated entrapment syndrome of the ulnar nerve		
	Postoperative phase (A)	Healing phase (B)
R e e d u c a t i o n	<p>Therapeutic goals: fight against inflammation and pain; prevent stiffness in the fingers and the wrist and elbow, self-rehabilitation.</p> <p>Techniques: -Transcutaneous vibratory stimulations, cryotherapy, disto-proximal pressotherapy, TENS (100 Hz), analgesic and draining massages around the scar. - Passive, then simple active mobilizations without resistance and under the pain threshold for the wrist, elbow and fingers</p> <p>Risks: Complex Regional Pain Syndrome</p>	<p>Therapeutic goals: same as in phase (A) if necessary, relaxation of the scar and exercises for the mobility of the nerve, progressively regaining the grasp (from D21), rehabilitation of sensitivity.</p> <p>Techniques: -Scar massage against fibrosis (± ultrasounds), progressive and pain-free Butler mobilization. - Progressive reinforcement of the hypothenar muscles, the flexor carpi ulnaris and the adductor pollicis. - Sensorial stimulations; prehension, coordination and dexterity exercises.</p> <p>Risks: same + lack of intrinsic strength.</p>
O r t h e s i s	Resting orthosis for the elbow in 30° of flexion (compression in the elbow), orthosis for the wrist in a neutral position (compression in the wrist).	Functional orthosis if necessary.
	D0 to 21	After D21

Fig. 14.17 Postoperative rehabilitation protocol

Fight Atrophic Disorders and Pain

It's based on the combination of cryotherapy, pressotherapy, analgesic vibrotherapy, and draining and relaxing massages that improve local trophicity and symptomatology.

Mobilizations of the Elbow, Wrist, and Fingers

Passive then active mobilizations are realized from the joint farther away from the compression site toward the closest joint.

For example, to liberate the ulnar nerve in the elbow, we mobilize first the fingers and then the wrist, and we end with the elbow in all of the amplitudes and without pain.

It maintains joint mobility and perineural glidings.

Self-Rehabilitation

Self-rehabilitation exercises based on self-mobilization of the elbow and wrist and icing are described to the patient.

The mobilizations of the fingers, wrist, and elbow are repeated in all of the amplitudes if there isn't pain or swelling. We ask for ten repetitions for each movement of each mobilized segment. Icing is realized during 20 min three times a day with an ice bag in a damp cloth.

Healing Phase (After D21)

In this phase we keep fighting against trophic disorders and pain if necessary. We also fight against healing disorders and perineural fibrosis and try to regain strength and sensitivity in the ulnar part of the hand.

Fight Against Perineural Fibrosis

- *Massages around the scar and on the areas with fibrosis:* these massages aim to improve perineural trophicity, relax the scar, and limit the risks of fibrosis around the scar. They are realized around the scar, along the internal part of the arm and forearm, and at the level of the hypothenar muscles. We use disto-proximal glided pressures and soft kneading in the arm and forearm and glided pressures at the level of the hypothenar muscles.
- *Ultrasounds:* used after the scar is closed with a frequency of 1 MHz in the wrist or elbow. We prefer the pulsed mode as it has a more important "fibrolytic" effect. The head of the device is applied on and around the scar.
- *Depressotherapy:* its application must be progressive. We start using it after the scar is closed. First, when the scar is still inflammatory, we apply the head of the device far from the scar in a disto-proximal direction. When the scar isn't inflammatory anymore, we apply the head directly on it.
- *Mobilizations of the ulnar nerve:* these techniques have already been described in the paragraph about rehabilitation without surgery. They're realized after surgical advice that defines if the state of nerve observed during the surgery allows us to use these techniques. Clinically, it's most often patients with nocturnal paresthesia without any other neurological disorder [14].
- *Longitudinal massage:* it's realized with the same modalities than in the rehabilitation without surgery. It's first applied far from the operated area, then getting closer to this area if the scar isn't inflammatory or painful.

Regaining Strength

Surgery in entrapment syndromes of the ulnar nerve concerns nervous injuries that aren't beyond stage 2 of Sunderland (axonotmesis) and that can cause motor disorders rated between 2 and 4 on the scale of Daniels and Worthingham described in the Chap. 12.

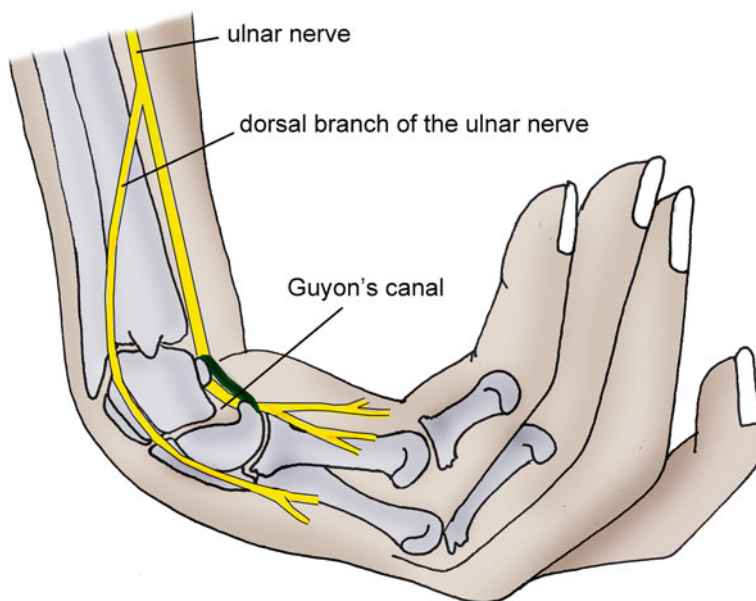


Fig. 14.18 Compressions of the ulnar nerve in the Guyon's canal don't cause sensorial disorders in the back of the hand, which depends on the dorsal branch

- *Stage 2*: this stage corresponds with the capacity to mobilize the concerned segment in all its amplitude without gravity or in part of the amplitude against gravity. We ask the patient to realize simple active contractions if the mobilization isn't against gravity and active-assisted contractions against gravity. This exercise improves the trophic state of the muscle and maintains the glidings in the different anatomical planes.
- *Stage 3*: this stage corresponds with the capacity to mobilize the concerned segment in all its amplitude against gravity. This exercise has the same interest as the one for stage 2, but here we can start an intermittent static exercise against gravity and alternate types of contraction depending on the patient's capacities.
- *Stage 4*: in this stage we realize reinforcement exercises against increasing resistances, alternating the types of contraction. The exercises are similar to the ones realized in the rehabilitation without surgery.

Regaining Sensitivity [15]

Sensorial disorders can persist several weeks after surgery, especially in advanced stages.

They can concern the whole sensorial territory of the ulnar nerve in compressions at the level of the elbow, but compressions in the Guyon's don't only concern the back of the hand as it's innervated by the dorsal branch that doesn't pass through this canal (Fig. 14.18).

The sensorial rehabilitation protocol is realized according to the modalities described in the Chap. 12.

Proprioception, Coordination, and Dexterity

Like in rehabilitation without surgery, these exercises allow the patient to regain coordination and dexterity according to his functional needs.

We particularly insist on exercises for strong cylindrical grips that suffer a greatest deficit in this type of injuries.

14.3.2.2 Orthotic Treatment

Postoperative orthosis aren't systematic but can be useful in case of important pain. As for the conservative treatment, they can be orthosis with the elbow in 30° of flexion or the wrist in a neutral position, depending on the site of surgery.

They are kept 15 days, but the patient gets self-mobilization recommendations that he/she must realize every hour to limit the risks of perineural fibrosis and stiffness.

Bibliography

1. Roulot E, Charlez C (2004) Le nerf ulnaire au coude. *Chirurgie de la main* Vol 23, n° S1:110–127. Elsevier-Masson, Paris
2. Apfelberg DB, Larson SJ (1973) Dynamic anatomy of the ulnar nerve at the elbow. *Plast Reconstr Surg* 51:76–81
3. Lebreton E (2010) Éminence hypothénar. *Chirurgie de la main* Vol 29, n° 4:213–223
4. Allieu Y, Chammas M, Roux JL (1997) Syndromes canalaires et des défilés (canal carpien exclu). *Appareil locomoteur*. 15-005 A-10
5. Byl C, Puttlitz C, Byl N et al (2002) Strain in the median and ulnar nerves during upper-extremity positioning. *J Hand Surg Am* 27:1032–1040
6. Novak CB, Lee GW, Mackinnon SE et al (1994) Provocative testing for cubital tunnel syndrome. *J Hand Surg Am* 19:817–820
7. Merl M, Dautel G, Dap F (1995) Chirurgie secondaire des plaies des nerfs périphériques. *La main traumatique* 2:147–177
8. Bartels RHMA, Menovsky T, Van Overbeeke JJ et al (1998) Surgical management of ulnar nerve compression at the elbow: an analysis of the literature. *J Neurosurg* 89:722–727
9. Dellon AL (1989) Review of treatment results for ulnar nerve entrapment at the elbow. *J Hand Surg Am* 14:688–700
10. Lowe JB, Novak CB, Mackinnon SE (2001) Current approach to cubital tunnel syndrome. *Neurosurg Clin N Am* 12:267–284
11. Mowlavi A, Andrews K, Lille S et al (2000) The management of cubital tunnel syndrome: a meta-analysis of clinical studies. *Plast Reconstr Surg* 106:327–334
12. Roulot E (2010) Conflit du nerf ulnaire: quel traitement. *Les conflits du membre supérieur chez le sportif*. 159–172. Elsevier-Masson. doi:[10.1016/B978-2-294-71290-6.50014-5](https://doi.org/10.1016/B978-2-294-71290-6.50014-5)
13. Dellon A (1993) Non operative management of the cubital tunnel syndrome: a 8 year prospective study. *Neurology* 43(9):1673–1677
14. Butler DS (2005) *Mobilisation of the nervous system*. Churchill, Livingstone
15. Spicher C (2003) *Manuel de rééducation sensitive du corps humain*. Sauramps medical

Chapter 15

Entrapment Syndromes of the Radial Nerve

Grégory Mesplié and Olivier Léger

15.1 Anatomy [1]

The radial nerve is a mixed nerve from the posterior branches of the spinal nerves C5, C6, C7, C8, and sometimes T1. After passing in the lower triangular space of the axilla, it enters the humeral groove. Then at about 10 cm above the epicondyle, it pierces the external intermuscular septum to enter the anterior compartment of the arm, coursing in the external bicipital compartment considered to be the “top floor” of the radial tunnel (Figs. 15.1 and 15.1’).

The “medium floor” goes from the humeral condyle to the inferior part of the radial head, and in this part the nerve splits into the posterior interosseous nerve (motor innervation) and the superficial branch of the radial nerve (sensorial innervation).

The anterior branch is anterointernal and courses on the brachialis muscle. The posterior branch courses laterally between the brachialis and the brachioradialis.

The “lower floor” corresponds to the posterior interosseous nerve passing between the superficial and deep bundles of the supinator, through a muscular or fibrous arcade called the arcade of Fröhse (30 % of the cases).

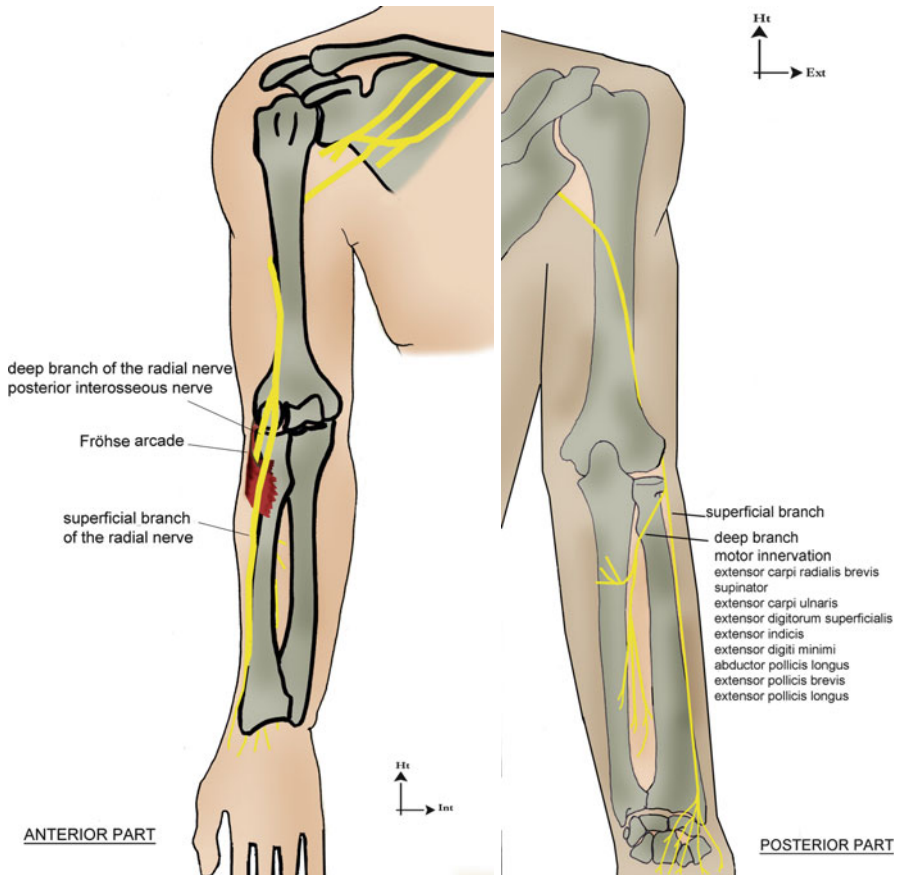
The radial nerve gives off a posterior branch that innervates the extensor carpi ulnaris, the extensor digitorum, and the extensor digiti minimi with its posterior branch and the abductor pollicis longus, the extensor pollicis brevis, the extensor pollicis longus, and the extensor indicis with its anterior branch.

G. Mesplié (✉)

Physiotherapist and Orthotist, Institut Sud Aquitain de la Main et du Membre Supérieur,
Aguiléra Clinic Biarritz, Biarritz, France
e-mail: greg.mesplie@mac.com

O. Léger

Hand Surgeon, Institut Sud Aquitain de la Main et du Membre Supérieur,
Aguiléra Clinic Biarritz, Biarritz, France



Figs. 15.1 and 15.1' Anatomical location of the radial nerve (anterior and posterior parts)

The anterior sensorial branch passes along the posterior side of the brachioradialis, then gets closer to the radial artery, and avoids the lateral side of the radius to cross the abductor pollicis longus, extensor pollicis brevis, and extensor carpi radialis tendons.

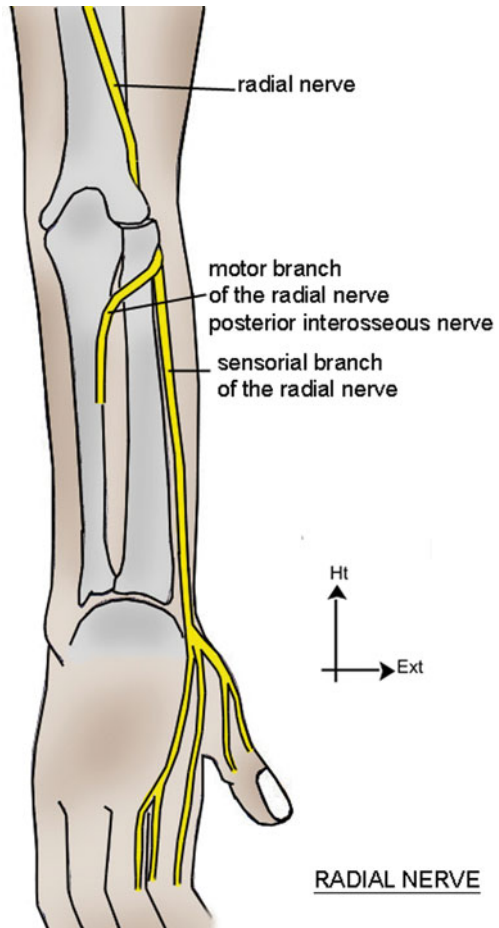
The nerve reaches the dorsal side of the wrist and then splits into four dorsal digital branches (Fig. 15.2).

15.2 Compression in the Humeral Groove [2, 3]

A radial palsy at this level can be secondary to three mechanisms:

- A traumatic damage caused by a fracture of the distal third of the humerus, which requires an exploration during the osteosynthesis.
- An extrinsic compression because of a prolonged pressure or an overinflated tourniquet kept too long.

Fig. 15.2 Sensorial innervation by the radial nerve (superficial branch)



- There are also “spontaneous” palsies corresponding to anatomical structures fixing the nerve to the distal part of the groove and causing mechanical conflicts during prolonged repetitive movements. This could lead to a surgical exploration if the patient doesn’t show signs of recovery after 2 months, with a disturbed EMG.

15.3 Compression in the Elbow [2–4]

In the elbow, the radial nerve is subjected to stretching and twisting constraints in flexo-extension and pronosupination. There are two distinguishable symptomatology.

15.3.1 Radial Tunnel Syndrome

It corresponds to a compression of the radial nerve in the radial tunnel, between the humeroradial joint and its emergence from the supinator.

There is pain at the level of the epicondyle, which can spread until the wrist without sensorimotor disorders and is increased by movements of extension and supination. The differential diagnosis with epicondylitis requires a meticulous exam as pain is located at approximately 5 cm below the epicondyle. The EMG is hard to interpret but allows doing the diagnosis, following a rigorous protocol.

A conservative treatment will always be recommended at first, along with rest, adaptation of the workstation and orthosis, NSAIDs, and muscle relaxants.

After an observation period of 3 months, surgery will be proposed with opening of the superficial bundle of the supinator and the deep part of the extensor carpi radialis brevis. An orthosis is given to the patient for 2–3 weeks, with the wrist in 20° of extension.

15.3.2 Posterior Interosseous Nerve Syndrome

It corresponds to the compression of the posterior interosseous nerve at the level of the supinator arch.

It causes a more or less partial loss of the wrist and finger extension that gets worse over time and can be secondary to repetitive movements in patients who have an anatomical predisposition (thick arcade of Fröhse) or a tumor.

An MRI allows the identification of swellings compressing the nerve, and an EMG is always realized to confirm the increase of the distal motor latency and the muscular integrity.

With surgery, we can realize a neurolysis of the posterior interosseous nerve in its entire pathway along the supinator, followed by 15 days of immobilization before starting the rehabilitation.

15.4 Compression in the Wrist [2, 3, 5]

Wartenberg's syndrome is the compression of the sensorial branch of the radial nerve between the brachioradialis and the extensor carpi radialis longus tendons, in pronation and ulnar inclination of the wrist.

The EMG confirms the diagnosis, comparing the sensorial conduction speed with the opposite side.

The treatment consists in resting the wrist in 20° of extension with an orthosis immobilizing the thumb. If the medical treatment fails, surgery allows excising at least 6 cm of the fascia between the brachioradialis and the extensor carpi radialis longus.

15.5 Rehabilitation and Orthotic Treatment

15.5.1 Without Surgery

As for the median and ulnar nerves, this treatment concerns moderate damages of the nerve without important sensorial and motor disorders. Its goal is to delay or even avoid surgery.

The patient often presents nocturnal paresthesias, without any other neurological disorder.

15.5.1.1 Rehabilitation

Fight Against Inflammation and Pain

It's based on a combination of cryotherapy, pressotherapy, and draining massages that can help decreasing the perineural inflammation.

Longitudinal Massage

This massage is applied at the level of the accessible area of the nerve closest to the damaged area.

It consists in realizing a longitudinal pressure along 3–4 cm of the nerve to improve its vascularization and restart the axonal flow.

The ideal pressure recreates the distal symptomatology, without producing pain. It's maintained a few minutes, which allows obtaining a variation of the initial symptoms.

For compressions in the humeral groove, the patient is placed in decubitus. The therapist grabs the posterior side of the elbow with one hand and looks for an area of induration in the lateral side of the arm with the other hand. We apply a “coma” movement to follow the path of the radial nerve.

The association of internal and external rotations of the arm effectively participates in this exercise.

For compressions in the elbow, the patient is in decubitus. The therapist maintains the forearm with one hand and places his thumb across, slightly above the flexion crease of the elbow, on its lateral side. He realizes the longitudinal massage with his thumb or alternates flexion/extension movements of the elbow, with the thumb still.

The radial nerve can also be manipulated 5 cm below the epicondyle, which is a particularly painful area in radial tunnel syndromes. The patient is in the same position as before, and the therapist grabs the forearm with both hands so that his thumbs contact with the painful area and the elbow in 100° of flexion.

He applies the longitudinal massage on the radial nerve with his thumbs or alternates flexion/extension movements of the elbow with the thumb still.

For compressions in the wrist, the patient is in the same position, and the therapist realizes longitudinal massages at the level of the emergence of the superficial branch of the radial nerve.

We can also mobilize the nerve alternating radial and ulnar inclinations, the thumb still.

Fight Against Perineural Fibrosis

It improves glidings between the radial nerve and the adjacent tissues, which limits the compressive constraints to which it is exposed and improves its vascularization.

Mobilization of the Nerve [6]

Nervous mobilizations aim to mobilize the nerve with respect to the adjacent tissues to limit the risks of compression and ischemia.

The progression of the mobilization is based on the upper limb tension tests described by Butler in 1991.

For the radial nerve, the mobilization is based on the ULTT 2b and has several stages (Fig. 15.3):

- Position with a “triple grip” (pelvis + 2 hands of the physiotherapist)
- Shoulder internal rotation, pronation, and strong depression
- Wrist flexion and ulnar inclination to put the superficial branch in tension
- Fingers and thumb flexion

These stages are realized until the patient feels a bearable tension. The last position is then maintained 6 s to avoid any ischemic risk.

Mobilization of the Adjacent Tissues

Alternating contraction–relaxation–stretching of the adjacent muscles produces a perineural pumping that improves local trophicity and maintains glidings between tissues.

These mobilizations are realized preferentially on the supinator muscle in posterior interosseous nerve syndromes, on the brachialis and brachioradialis in radial tunnel syndromes, and on the brachioradialis and extensor carpi radialis longus in Wartenberg’s syndromes.

Each step is maintained between 4 and 6 s to avoid any ischemic risk.

Imitation exercises improving movements between the different gliding planes participate in this fight against perineural fibrosis.

Massages Against Fibrosis and Contractures

They are realized along the radial nerve, on the posterior and lateral sides of the forearm and hand.

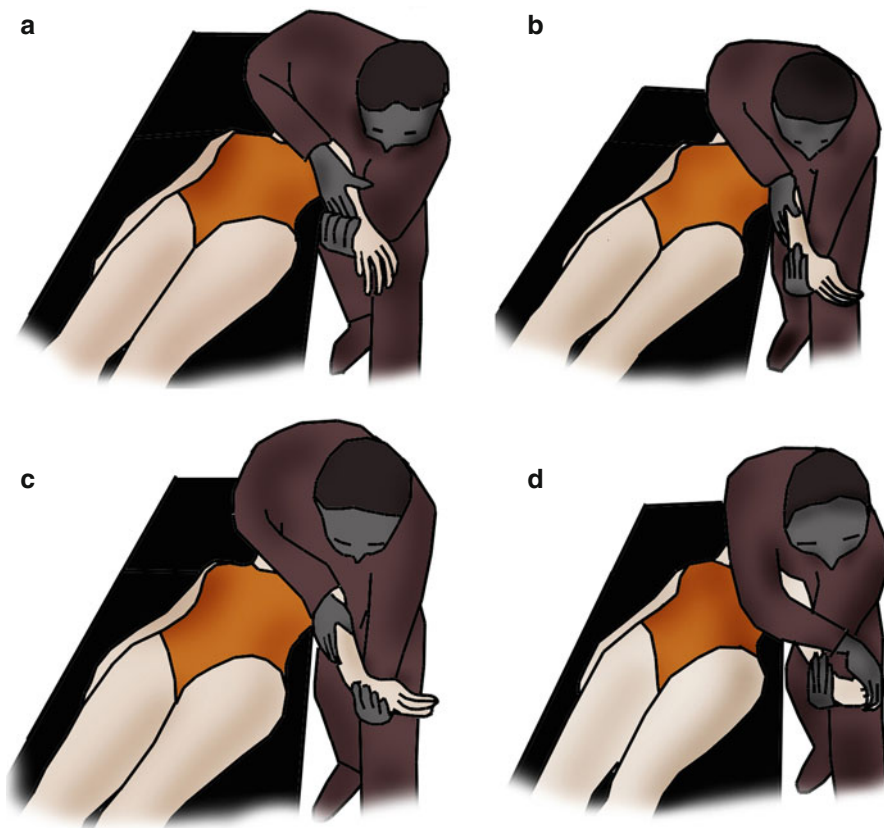


Fig. 15.3 Nervous mobilization technique by David S. Butler based on the upper limb tension tests. (a) Position with a “triple grip” (pelvis + 2 hands of the physiotherapist). (b) Shoulder internal rotation, pronation, and strong depression. (c) Wrist flexion and ulnar inclination to put the superficial branch in tension. (d) Finger and thumb flexion

We use dot-shaped massages, glided pressures, and kneading that improve local trophicity, fight against perineural fibrosis, and relax the muscles adjacent to the nerve. The massages are realized until the arm and cervical spine.

Self-Rehabilitation

Self-rehabilitation exercises based on mobilization, self-longitudinal massages, and cryotherapy are explained to the patient.

Mobilizations are realized several times a day in all of the amplitudes to improve perineural glidings.

Longitudinal massages are realized three times a day during 1–2 min (until there’s a modification of perception).

Putting ice on the compression area is realized after the other exercises during 20 min depending on the appearance of pain.

Regaining Strength

At this stage of compression, the injuries remain at the stage of neurapraxia or stage 1 of Sunderland. The motor evaluation of Daniels and Worthingham is most often rated 4.

The muscles concerned by the compression of the radial nerve in posterior interosseous nerve syndromes are the extensor carpi radialis brevis, the supinator, the extensor carpi ulnaris, the extensor digitorum, the extensor digiti minimi, the abductor pollicis longus, the extensor pollicis longus, the extensor pollicis brevis, and the extensor indicis. The extensor carpi radialis longus isn't damaged in these injuries, which explains why the wrist goes spontaneously to a slight radial inclination in complete palsies of the posterior interosseous nerve.

The radial tunnel syndrome and Wartenberg's syndrome don't cause any motor disorder.

The reinforcement protocol begins with an intermittent static work and progressively evolves toward more intensive exercises depending on the patient's functional needs.

Wrist Extensors

The main functional role of these muscles is to place the wrist in 30° of extension during strong grips, when the finger flexors aren't efficient. This should be taken into account when realizing reinforcement exercises.

These exercises can be realized against a manual resistance, more on the radial or ulnar side (Fig. 15.4).

The priority is to reinforce the extensor carpi ulnaris in case of spontaneous deviation of the wrist in radial inclination, because of the extensor carpi radialis longus that isn't damaged in posterior interosseous nerve syndromes related to a compression in the arcade of Fröhse.

Exercises with an elastic band fixed to an espalier allow alternating the contractile modes. We also use a visual feedback to control the duration of contraction and rest (Fig. 15.5).

We can favor the radial or the ulnar component in this exercise, but we prefer asking for a "pure" extension for a synergic exercise. Exercises with weights allow the same type of exercises, also working with a strong cylindrical prehension (Fig. 15.6).

Extensors of the Long Fingers

They aren't "strong" muscles but participate in cylindrical prehensions as they open the hand and therefore allow the flexors to be efficient.

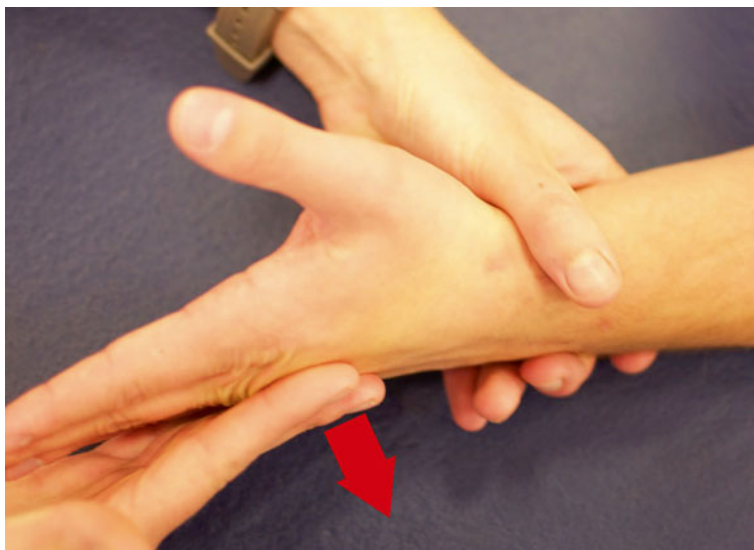

Fig. 15.4 Manual reinforcement of the extensor muscles of the wrist




Fig. 15.5 Reinforcement of the extensor muscles of the wrist with an elastic band, combined with a visual feedback allowing a precise regulation of the contraction and rest durations



Fig. 15.6 Reinforcement of the extensor muscles of the wrist with weight

Exercises for these muscles can be realized manually with a resistance on the dorsal side of the first phalanx of the fingers we work with (a resistance on the second and third phalanges reinforces the interosseous muscles, innervated by the ulnar nerve) (Fig. 15.7).

An exercise for the index or the fifth finger only allows working analytically with the extensor indicis or the extensor digiti minimi (Fig. 15.8).

Instrumental exercises are also possible.

Global Exercises

Exercises for the fingers with visual feedback are used and are synergic exercises for the wrist and finger extensors (Fig. 15.9).

Proprioception, Coordination, and Dexterity

Proprioception exercises for the wrist and fingers are realized and improve muscular reactivity as well as coordination in the treated hand (Fig. 15.10).

Regaining Sensitivity [7, 8]

Sensorial disorders only occur if the superficial branch of the radial nerve is damaged (Wartenberg's syndrome). They are treated according to the protocol defined in the Chap. 12.



Fig. 15.7 Manual exercise for the extensor digitorum



Fig. 15.8 Exercise for the extensor indicis and extensor digiti minimi




Fig. 15.9 Synergic exercise for the extensors of the fingers and wrist

15.5.1.2 Orthosis

They allow resting the elbow in compressions at the level of the elbow.

They are static resting orthosis placing the wrist in 20° of extension during between 6 weeks and 3 months. If there aren't any clinical improvement within this period of time, surgery is proposed.

15.5.2 Postoperative [4, 5, 9, 10]

15.5.2.1 Rehabilitation (Fig. 15.11)

The main goal is to fight against perineural fibrosis that can have important functional consequences.

Therefore, the rehabilitation starts early or even immediately and is based on soft and progressive mobilizations in all the amplitudes of the wrist and elbow.

Fig. 15.10 Global proprioceptive exercise for the superior limb. Here an example with an oscillating pole and anteroposterior movements to work with both the flexors and extensors of the wrist



Immediate Postoperative Phase (D0 to D21)

Fight Against Trophic Disorders and Pain

It's based on the combination of cryotherapy, pressotherapy, analgesic vibrotherapy, and draining and relaxing massages that improve local trophicity and symptomatology.

Mobilizations of the Wrist and Elbow

Passive then active mobilizations are realized from the joint farther away from the compression site toward the closest joint.

Operated entrapment syndrome of the radial nerve		
	Postoperative phase (A)	Healing phase (B)
R e d u c a t i o n	<p>Therapeutic goals: fight against inflammation and pain; prevent stiffness in the wrist and elbow, self-rehabilitation.</p> <p>Techniques:</p> <ul style="list-style-type: none"> - Transcutaneous vibratory stimulations, cryotherapy, disto-proximal pressotherapy, TENS (100 Hz), analgesic and draining massages around the scar. - Passive, the simple active mobilizations without resistance and under the pain threshold for the wrist, elbow and fingers. <p>Risks: CRPS.</p>	<p>Therapeutic goals: same as in phase (A) if necessary, relaxation of the scar and exercises for the mobility of the nerve, progressively regaining the grasp (from D21), rehabilitation of sensitivity.</p> <p>Techniques:</p> <ul style="list-style-type: none"> - Scar massages against fibrosis (\pm ultrasounds), progressive and pain-free Butler mobilization. - Progressive reinforcement of the wrist and fingers extensors. - Sensorial stimulations; prehension, coordination and dexterity exercises. <p>Risks: same + deficit of the extensors.</p>
Or th e s is	Resting orthosis for the wrist in 20° of extension (compression in the elbow), orthosis for the wrist and thumb (compression in the wrist).	Functional orthosis if necessary.
	D0 to 21	After D21

Fig. 15.11 Protocol after surgery

For example, to liberate the radial nerve in the elbow, we first mobilize the fingers and then the wrist, and we end with the elbow in all of the amplitudes and without pain.

It maintains joint mobility and perineural glidings.

Self-Rehabilitation

Self-rehabilitation exercises based on self-mobilization of the elbow and wrist and icing are described to the patient.

The mobilizations of the fingers, wrist, and elbow are repeated in all of the amplitudes if there isn't pain or swelling. We ask for ten repetitions for each movement of each mobilized segment.

Icing is realized during 20 min, three times a day with an ice bag in a damp cloth.

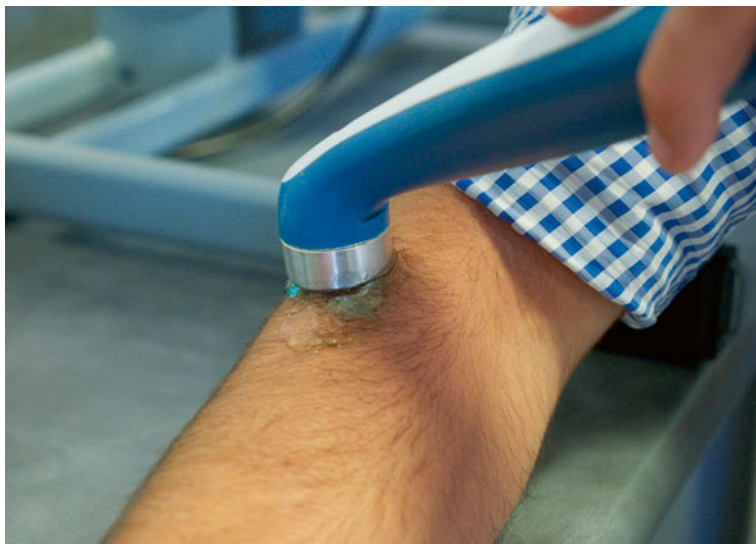

Fig. 15.12 Ultrasounds on the area with fibrosis if the scar is closed

Healing Phase (After D21)

In this phase we keep fighting against trophic disorders and pain if necessary. We also fight against healing disorders and perineural fibrosis and try to regain strength and sensitivity in the ulnar part of the hand.

Fight Against Perineural Fibrosis

Healing disorders can cause perineural fibrosis that can disturb the nerve function, so these techniques are very important after the surgery of an entrapment syndrome of the radial nerve:

- *Massage around the scar and on areas with fibrosis*: these massages aim to improve perineural trophicity, relax the scar, and limit the risks of fibrosis around the scar. They are realized around the scar along the nerve. We use disto-proximal glided pressures and soft kneading in the arm and forearm and glided pressures at the level of the postero-external part of the hand.
- *Ultrasounds*: used after the scar is closed with a frequency of 1 MHz in the wrist or elbow. We prefer the pulsed mode as it has a more important “fibrolytic” effect. The head of the device is applied on and around the scar (Fig. 15.12).
- *Depressotherapy*: its application must be progressive. We start using it after the scar is closed. First, when the scar is still inflammatory, we apply the head of the device far from the scar in a disto-proximal direction. When the scar isn’t inflammatory anymore, we apply the head directly on it.
- *Mobilizations of the radial nerve*: these techniques have already been described in the paragraph about rehabilitation without surgery. They’re realized after surgical advice that defines if the state of nerve observed during the surgery allows




Fig. 15.13 Active helped exercise in extension for the wrist and/or fingers on an arthromotor device

us to use these techniques. Clinically, it's most often patients with nocturnal paresthesias without any other neurological disorder.

- *Longitudinal massage*: it's realized with the same modalities than in the rehabilitation without surgery. It's first applied far from the operated area and then getting closer to this area if the scar isn't inflammatory or painful.

Regaining Strength

Surgery in entrapment syndromes of the radial nerve concerns nervous injuries that aren't beyond stage 2 of Sunderland (axotmesis) and that can cause motor disorders rated between 2 and 4 on the scale of Daniels and Worthingham described in the Chap. 12:

- *Stage 2*: this stage corresponds with the capacity to mobilize the concerned segment in all its amplitude without gravity or in part of the amplitude against gravity. We ask the patient to realize simple active contractions if the mobilization isn't against gravity and active-assisted contractions against gravity. This exercise improves the trophic state of the muscle and maintains the glidings in the different anatomical planes. It can be realized with an arthromotor mobilizing the wrist and/or fingers (Fig. 15.13).
- *Stage 3*: this stage corresponds with the capacity to mobilize the concerned segment in all its amplitude against gravity. This exercise has the same interest as the one for stage 2, but here we can start an intermittent static exercise against gravity and alternate types of contraction depending on the patient's capacities (Fig. 15.14).

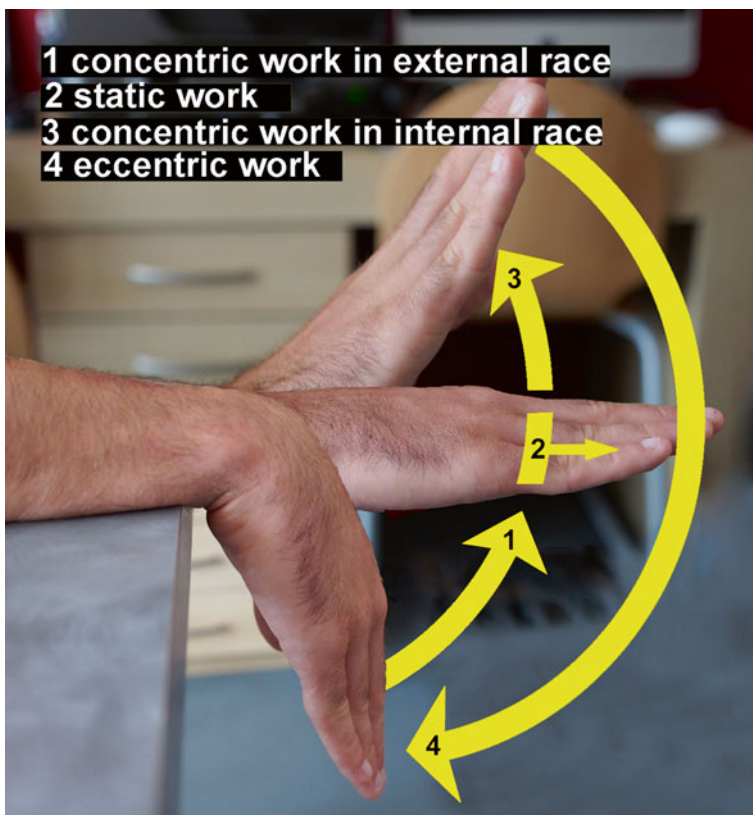


Fig. 15.14 Exercise against gravity for the extensors of the wrist and fingers with different types of contractions. The patient realizes an extension of the wrist and fingers from a wrist flexion (concentric exercise in external race), maintains the neutral position a few seconds (static exercise), keeps extending the wrist (concentric exercise in internal race), and then slows down when returning in flexion (eccentric exercise)

- *Stage 4:* the exercises are similar to the ones realized in the rehabilitation without surgery.

Proprioception, Coordination, and Dexterity

These exercises can be realized when the muscles are graded 4 and are identical to the ones realized without surgery.

Regaining Sensitivity [7, 8]

The sensorial rehabilitation only concerns the damages of the superficial branch of the radial nerve in Wartenberg's syndromes. The protocol is realized according to the modalities described in the Chap. 12.

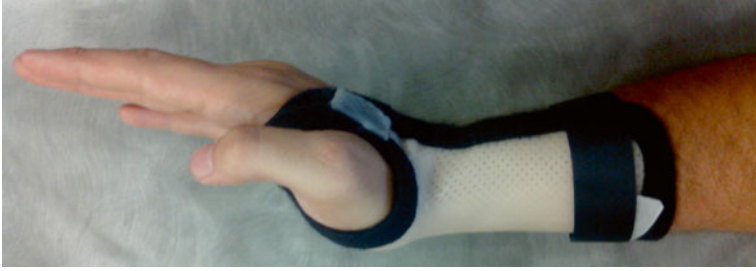

Fig. 15.15 Orthosis after surgery in the elbow, placing the wrist in 20° of extension, kept between 15 days and 3 weeks depending on the associated movements

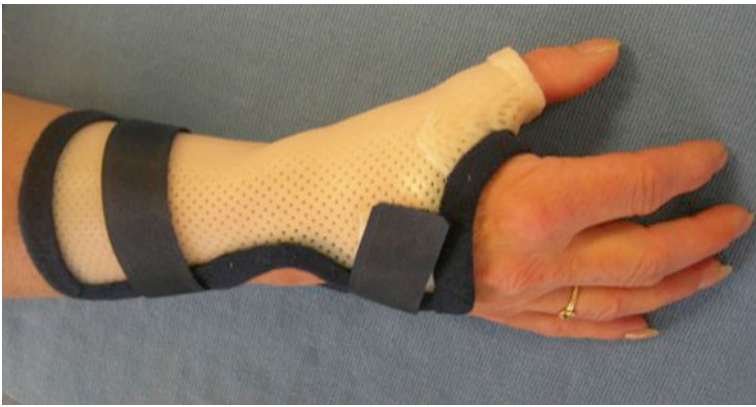

Fig. 15.16 Orthosis after surgery in the elbow, putting the wrist and thumb in a neutral position, kept for 1 week

15.5.2.2 Orthotic Treatment

After surgery of the radial nerve in the elbow, an immobilization orthosis is realized to place the wrist between 10° and 20° of extension (Fig. 15.15).

It's kept during about 15 days, unless there is also a radial tunnel syndrome (it's then kept for 3 weeks).

After surgery in the wrist, an immobilization orthosis is realized to place the wrist and the thumb in a resting position (Fig. 15.16).

It's kept for 1 week before starting rehabilitation.

Bibliography

1. Abrams RA, Brown RA, Botte MJ (1992) The superficial branch of the radial nerve: an anatomic study with surgical implications. *J Hand Surg Am* 17:1037–1041
2. Leclercq C (2010) Conflit du nerf radial: une entité mal connue. Les conflits du membre supérieur chez le sportif. doi: [10.1016/B978-2-294-71290-6.50016-9](https://doi.org/10.1016/B978-2-294-71290-6.50016-9). Elsevier-Masson, Paris
3. Cambon-Binder A, Sedel L, Hannouche D (2010). Syndromes canaux et des défilés. Appareil locomoteur. [15-005-A-10] Elsevier-Masson, Paris
4. Raimbeau G, Saint-Cast Y (2004) Compression de nerf radial au coude. *Chirurgie de la main* Vol 23, n° S1:86–101
5. Fontes D (2004) Compression du nerf radial au poignet. *Chirurgie de la main* Vol 23, n° S1:160–164
6. Butler DS (2005) Mobilisation of the nervous system. Churchill, Livingstone
7. Merle M, Isel M (2012) Plaies des nerfs et rééducation de la sensibilité. Orthèses de la main et du poignet doi: [10.1016/B978-2-294-71185-5.00016-3](https://doi.org/10.1016/B978-2-294-71185-5.00016-3). Elsevier-Masson, Paris
8. Spicher C (2003) Manuel de rééducation sensitive du corps humain. Medecine et hygiene
9. Merle M, Dautel G, Dap F (1995) Chirurgie secondaire des plaies des nerfs périphériques. *La main traumatique* 2:147–174, Masson
10. Dellon AL, Mackinnon SE (1986) Radial sensory nerve entrapment in the forearm. *J Hand Surg Am* 11:199–205

Part VII
Other Current Pathologies of the Hand

Chapter 16

Dupuytren Disease

Grégory Mesplié and Jean-François Chauvet

Dupuytren disease is a pathology affecting the medium palmar aponeurosis and the digital aponeurosis, leading to the formation of cords and nodules.

It can cause important retractions leading to flexion of the metacarpophalangeals, proximal interphalangeals, and more rarely distal interphalangeals.

16.1 History

On December 5, 1831, Baron Guillaume Dupuytren described this pathology during a lecture at the Dieu hospital [1].

He had previously performed a surgery on June 12, 1831, described as follows:

- *Transversal incision next to the 4th finger metacarpophalangeal*: section of the aponeurosis, easy extension of the 4th finger, nothing on the 5th finger, despite passing subcutaneously the scalpel toward the 5th finger.
- *Transversal incision at the level of the 5th finger proximal interphalangeal*: unfreeze the finger from the palm. Prolonging the incision of the 4th finger metacarpophalangeal and sectioning the aponeurosis don't better the extension.
- *Transversal incision in front of the first phalanx*: complete extension.
- *Bandage and extension splint*, renewed every 48 h.
- *Healing phase during 22 days*: the splint is kept for a month, then “self-rehabilitation” with progressive relaxation, and perfect result on December 5.

G. Mesplié (✉)

Physiotherapist and Orthotist, Institut Sud Aquitain de la Main et du Membre Supérieur, Aguiléra Clinic Biarritz, Biarritz, France

e-mail: greg.mesplie@mac.com

J.-F. Chauvet

Hand Surgeon, Institut Sud Aquitain de la Main et du Membre Supérieur, Aguiléra Clinic Biarritz, Biarritz, France

The end of the lecture and his conclusion:

... the cases I've been telling you about, as well as the surgery you've seen yourselves, establish without a doubt that this digital retraction, with the characteristics I've mentioned, is caused by a contracture of the palmar aponeurosis, and mainly of its extensions towards the base of the fingers. This medical condition can be treated by transversal incisions of these expansions and their origin on the palmar aponeurosis.

According to Dupuytren, this pathology was an occupational disease caused by microtraumas.

Some say this pathology was first described in 1777 by the British surgeon Henry Cline, who recommended a subcutaneous aponeurotomy as treatment.

The surgical treatment doesn't evolve much in the nineteenth century, except from a proposition from Ferguson in 1842 to do fasciectomy.

In 1900, Lexer proposes a dermofasciectomy of the whole palm, with skin graft.

In 1948, an extensive fasciectomy without cutaneous excision is realized. Its results would lead to lots of complications and stiffness.

At the same time, Skoog realizes selective fasciectomy, limiting dissections, which better the results.

Hueston proves that there is no recurrence under a skin graft (1960) [2].

Mc Cash, in 1964, describes an open palm technique, without closing or skin graft, thus updating the Dupuytren technique.

16.2 Anatomical Reminders [3, 4]

16.2.1 *Medium Palmar Aponeurosis* (Fig. 16.1) [5]

It spreads between the thenar and hypothenar aponeurosis, following the palmaris longus.

It's divided in four pre-tendinous strips that change direction at the level of the distal palmar crease to form various fibrous planes:

- *Superficial*, attaching to the dermis between the distal palmar crease and the proximal digital flexion crease (the crease of the metacarpophalangeal flexion)
- *Medium* that extends along each of the sides of the metacarpophalangeal joints to participate in the formation of the digital aponeurosis of the corresponding finger
- *Deep*, attaching to the palmar side of the metacarpophalangeal joint and more distally on the flexor sheath (at the level of the C1 pulley)

There are also some vertical partitions at the level of the proximal palmar crease, the partitions of Legueu and Juvara, connecting the medium and deep palmar aponeurosis.

These partitions delimit seven areas that contain alternatively the flexor system and the neurovascular pedicles with the corresponding lumbrical (Fig. 16.2).

PALMAR APONEUROSIS

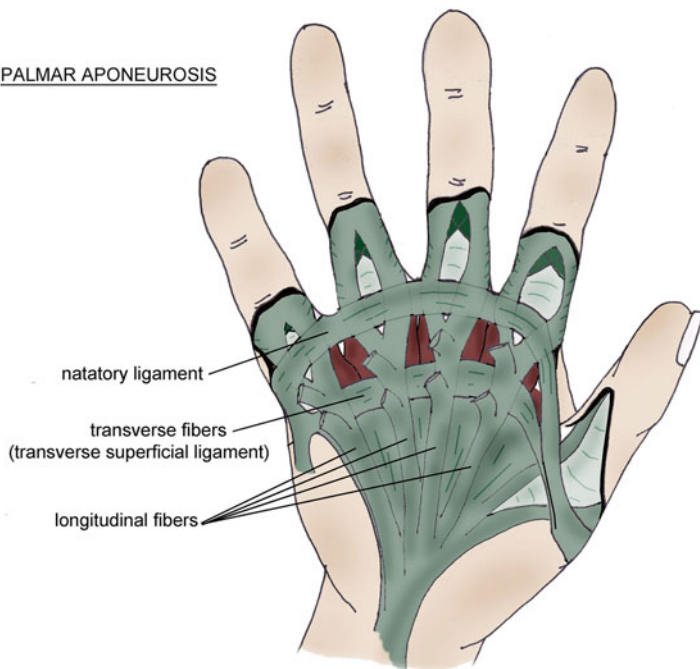


Fig. 16.1 Medium palmar aponeurosis

PARTITIONS OF LEGUEU AND JUVARA

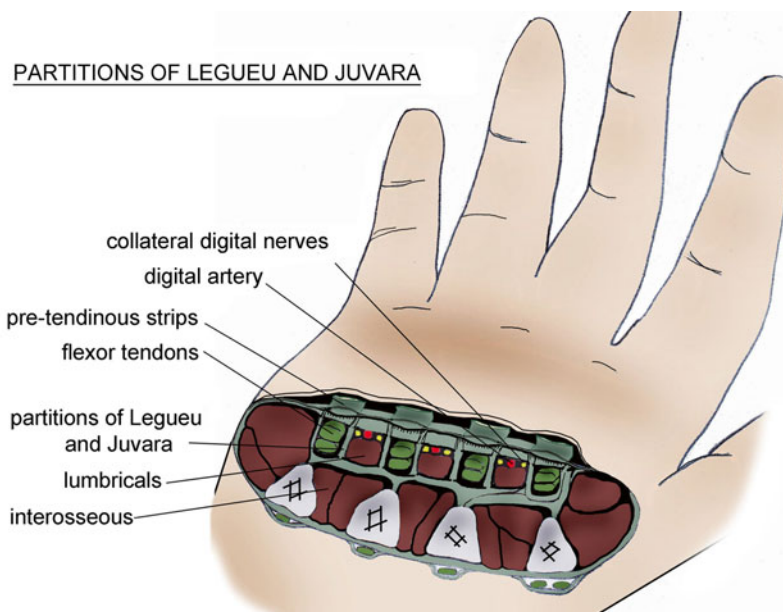
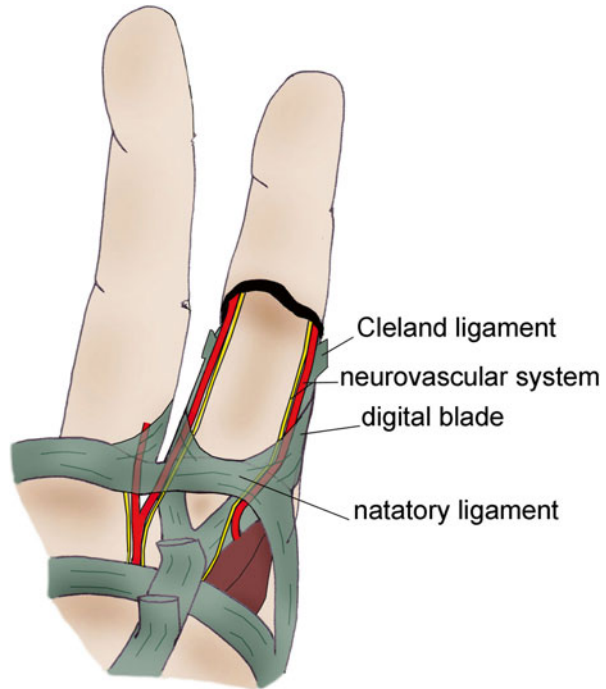


Fig. 16.2 Partitions of Legueu and Juvara delimiting alternatively the flexor system and the neurovascular pedicles + lumbrical

Fig. 16.3 At the level of the distal palmar crease, the medium fibrous plane of the palmar aponeurosis joins the expansions of the natatory ligament to form the digital blade



DIGITAL APONEUROSIS

16.2.2 Digital Aponeurosis [6]

The medium plane of the pre-tendinous strips forms two bundles laterally prolonging toward the corresponding finger to form the sagittal strips of the finger.

These sagittal strips receive expansions from the natatory ligament to form the digital blade that protects the digital neurovascular system and fixes the cutaneous coating (Fig. 16.3).

This blade emits fibers at the level of the proximal interphalangeal joint to form the retrovascular strip, the Cleland ligament, and the Grayson ligament.

At the level of the 2nd phalanx, its anterior fibers form the oblique retinacular ligament.

We should, however, individualize some of the elements of this aponeurosis:

- *The oblique retinacular ligament*, anchored on the flexor sheath next to the 1st phalanx diaphysis. It passes in front of the flexion axis of the proximal interphalangeal joint and joins the extensor system at the level of the distal interphalangeal joint. This ligament allows the coordination between the distal and proximal interphalangeal joints in flexion and extension. During the flexion of the distal interphalangeal joint, the oblique retinacular ligament gets tensed, automatically

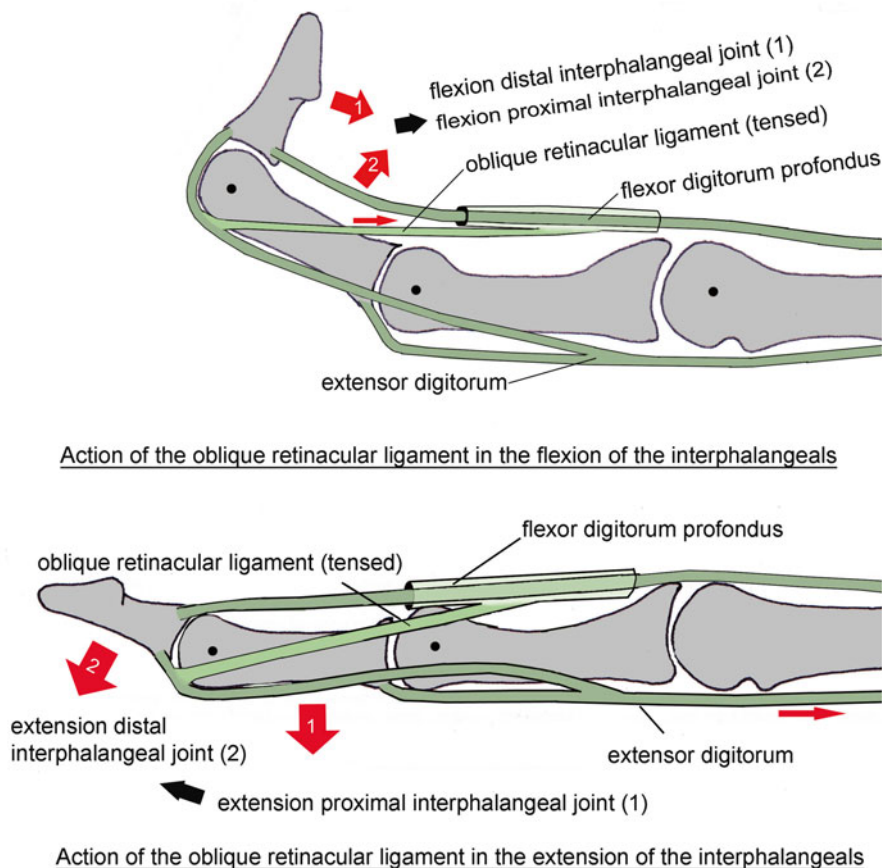


Fig. 16.4 The oblique retinacular ligament favors the functional coordination between the distal and proximal interphalangeal joints. The extension of the proximal interphalangeal joint puts it in tension, which leads to the extension of the distal interphalangeal joint. Meanwhile, the flexion of the distal interphalangeal joint is only possible if the proximal interphalangeal joint is flexed (relaxation of the oblique retinacular ligament)

causing the flexion of the proximal interphalangeal joint. During the extension of the proximal interphalangeal joint, the oblique retinacular ligament gets tensed, automatically causing the extension of the distal interphalangeal joint (Fig. 16.4).

- *The transverse retinacular ligament*: its proximal half is anchored on the A3 pulley, and its distal half on the volar plate and the capsule of the proximal interphalangeal joint. It goes vertically toward the lateral strip of the corresponding extensor system. It favors the palmar movement of the lateral strips during the flexion of the proximal interphalangeal joint (Fig. 16.5). It forms the lateral retinacular ligament (with the oblique retinacular ligament).

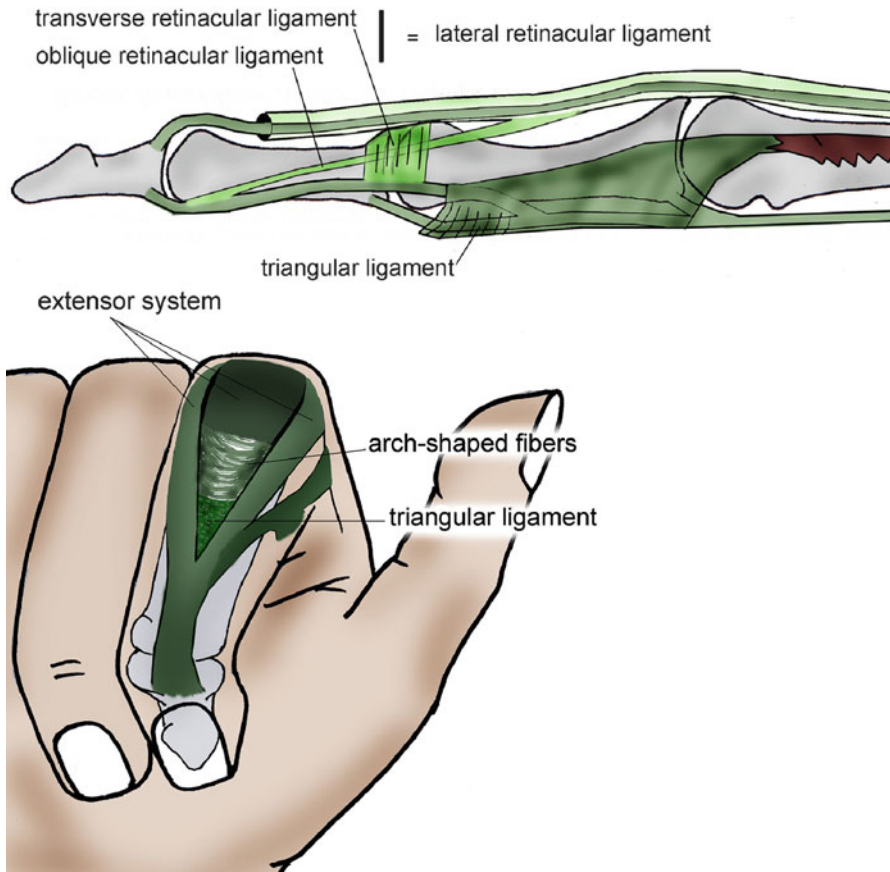


Fig. 16.5 The transverse retinacular ligament participates in the stabilization of the lateral strips of the extensor system, opposing their dorsalization (*up*). The triangular ligament opposes the ventralization of the lateral strips (*down*)

- *The dorsal retinacular ligament*: composed by the median strip and the arch-shaped fibers, it's tensed between the two strips of the extensor system. It favors the dorsal movement of the lateral strips during the extension of the proximal interphalangeal joint and limits their palmar gliding during the flexion (Fig. 16.5).
- *The Cleland ligament*: laterally tensed between the osseous skeleton and the dermis, it creates a frontal partition behind the neurovascular pedicle. In addition to its role of protecting the neurovascular pedicle, it fixes the dermis to the fibrous skeleton. Some authors don't differentiate it from the retrovascular strip (Fig. 16.6).
- *The retrovascular strip*: from the digital blade at the level of the proximal interphalangeal joint, it partitions the neurovascular pedicle (Fig. 16.6).
- *The Grayson ligament*: from the digital blade at the level of the proximal interphalangeal joint, it partitions the neurovascular pedicle (Fig. 16.6).
- *The longitudinal fibers*: next to the flexion creases of the fingers (between the fat pads), they fix the dermis to the fibrous skeleton, allowing an efficient grip.

Fig. 16.6 Cleland and Grayson ligaments. (AV) forward, (AR) backward

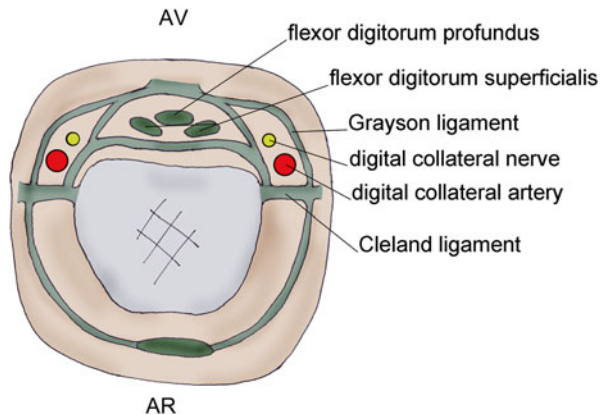
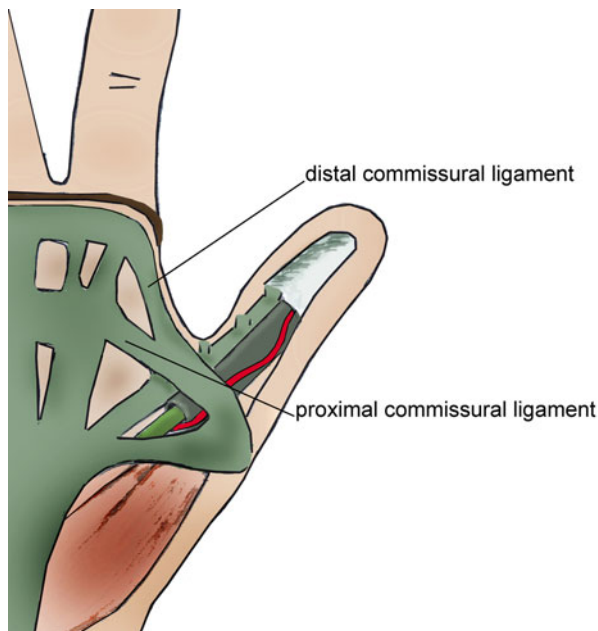


Fig. 16.7 Aponeurosis system of the 1st finger (According to M. Merle)



16.2.3 Aponeurosis System of the 1st Finger (Fig. 16.7)

The digital structures of the thumb can be compared to the ones of the long fingers, but we can still observe some differences.

The radial fibers of the palmar aponeurosis go toward the thumb and split into two planes (three in the long fingers), one superficial for the dermis and the other deeper for the flexor pollicis longus sheath.

The natatory ligament forms, on the radial side, the distal commissural ligament that inserts on each side of the flexor pollicis longus sheath.

The superficial transverse ligament forms, on the radial side, the proximal commissural ligament that inserts on the flexor pollicis longus sheath. With the end of the distal commissural ligament, it forms an important fibrous knot on the base of the thumb.

16.3 Anatomopathology

We describe three stages:

- Initial stages: fibroblastic proliferation
- Intermediate stage: fibroblastic and organization of the collagen by myofibroblastic proliferation
- Terminal stage: organization of mature collagen

16.3.1 Anatomical Expression [7]

The nodules: essentially palmar; they progressively invade the tissues and strongly stick to the skin.

They are never responsible for articular retraction.

The cords: they lead to articular retractions and are the expression of this pathology.

We can find pre-tendinous palmar cords and digital cords (median, spiral, lateral, and retrovascular).

They cause the retraction of the metacarpophalangeal, the proximal interphalangeal, and rarely the distal interphalangeal (which can even be in hyperextension because of a boutonnière deformity).

The proximal interphalangeal tends to get stiff, opposite to the metacarpophalangeal.

Anatomical repartition: by order of decreasing frequency for the long fingers (V, IV, III, II).

The thumb is damaged in 10–35 % of the cases.

16.3.2 Epidemiology [8]

Dupuytren disease is more frequent in white men from Northern Europe [9].

It is unusual in black people. In 25 % of the cases, there is a hereditary factor, related to a dominant autosomal recessive gene.

16.3.2.1 Related Affections [10]

Alcoholism doubles the risks, which are even more important in case of alcoholic cirrhosis.

Diabetes, Dupuytren is related to the duration of diabetes. After 20 years of evolution, 67 % of the diabetic patients have a Dupuytren disease. However, it is often limited and almost never needs surgery.

Epilepsy doubles the risks.

Traumas and manual activities: there are no statistic proofs, but it could be a triggering factor in patients with a predisposition.

16.3.2.2 Diathesis [11]

The pathology will be more severe and recurring if it starts early and is bilateral and if there is a hereditary and/or ethnic characteristic.

The association with knuckle pads, plantar fibromatosis, and damage in the lateral fingers are pejorative factors.

16.4 Clinical and Paraclinical Signs [12, 13]

The diagnostic can be done with a clinical exam alone.

We systematically observe retractions in flexion of the metacarpophalangeal and proximal interphalangeal that can be associated with a hyperextension of the distal interphalangeal.

The palpation shows a thickening of the damaged tissues and indurations at the level of the cords and nodules.

The natatory ligament is damaged (or distal commissural ligament in the thumb), so the commissural opening decreases, which can cause maceration.

If the patient can't put his hand flat on the table (Fig. 16.8), we should take a specialized advice to avoid important tissue retractions that can make the surgery complicated.

The topography of the injuries, which depends on the damaged elements of the aponeurosis, is resumed in the grading system of Tubiana and Michon (Fig. 16.9).

Some rare manifestations of this pathology are:

- *Knuckle pads* or dorsal nodules located next to the proximal interphalangeal joint that adhere to the skin but not to the extensor system. They can be painful and functionally disturbing.
- *Peyronie disease*, retraction of a conjunctive tissue at the level of the albuginea that creates a dorsal angulation in erection.
- *Plantar fibromatosis*, plantar equivalent of the Dupuytren and Peyronie disease.

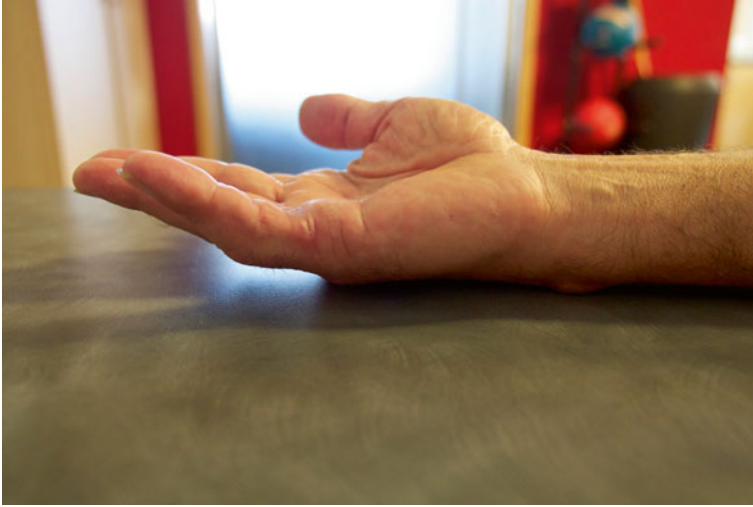

Fig. 16.8 Test of holding the hand flat on the table

16.5 Therapeutic Process and Surgical Treatment

16.5.1 Nonsurgical Treatment [14]

Various treatments have been tried without proving their efficiency.

These are massages using vitamin E oil, physiotherapy, ultrasounds, corticoids, anti-gout preparations, etc.

- Splints: dynamic or static
- Traumatic rupture of the cords
- Corticoid injections
- Interferon: alpha 2b and gamma
- 5-Fluorouracil
- Localized radiotherapy during an early stage
- Fibroblastic differentiation inhibitors

The XIAPEX is a new tool to treat Dupuytren disease.

It consists of two injectable forms of two collagenases isolated from *Clostridium histolyticum*.

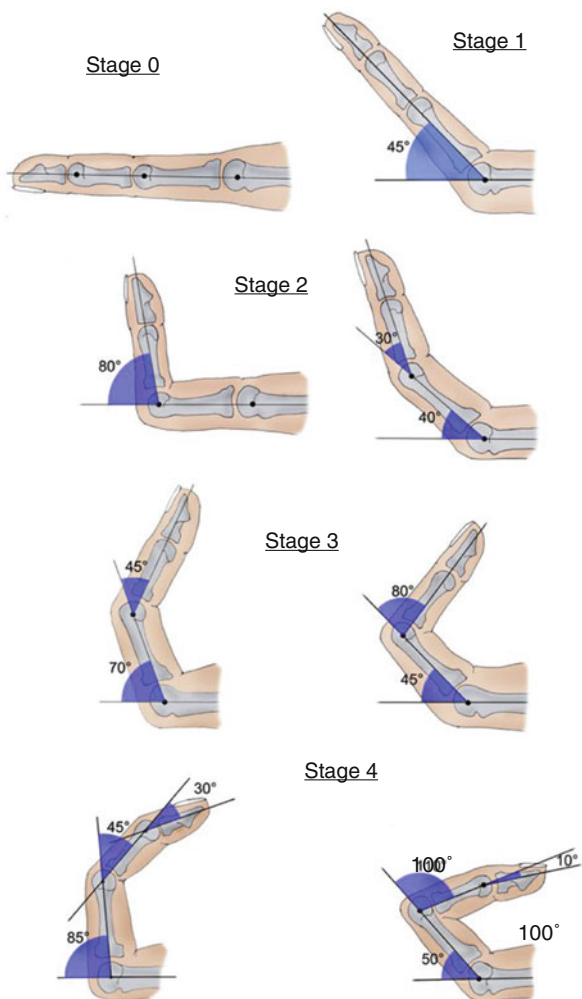
We realize a forced extension combined with a local injection.

The treatment is actually in phase III trial and seems promising.

16.5.2 Surgical Treatment

Like every hand surgery, the goal is to obtain a hand closer to the functional norm, without sequels.

Fig. 16.9 Grading system of Tubiana and Michon



This goal, however, is hard to reach, especially in damages of various fingers and relapses.

16.5.2.1 General Principles

The surgery must be done with optical magnification (magnifying glasses) and a pneumatic tourniquet in the superior limb previously drained without the help of an elastic band.

It's a precision surgery that requires special attention during the dissection of the neurovascular bundle, especially in the base of the fingers and next to the proximal interphalangeals, and of course in case of relapse.

Surgery is carried out under locoregional anesthesia.

16.5.2.2 Surgical Techniques [15]

Aponeurotomy

It's a little aggressive technique that intends to remove longitudinal tension by sectioning the cords. Transversal incisions are realized and associated to a traction of the fingers that reduces the retraction.

In general, a postoperative extension orthosis maintains the reduction.

This surgery is mainly used in severe retractions in old patients.

Aponeurotomy with a Needle [16]

This technique is only used if the palmar cord is well individualized. It is totally counter indicated in finger damages.

This technique leads to many neurovascular and tendinous complications and presents a high rate of relapse even though it's used in pathologies with low diathesis.

Aponeurectomy

It's the most complete resection of pathological tissues.

The excision of the non-pathological palmar aponeurosis has progressively been abandoned in favor of selective excisions of the pathological areas.

It can be done with longitudinal incisions in a broken line or transversal incisions.

We have to be particularly careful during the dissection of the neurovascular bundles.

Dermofasciectomy

It's the combination of the excision of the aponeurosis and the cutaneous tissue damaged by the disease.

The cutaneous resection is done according to the functional units, which will later be covered by a total skin graft (Hueston).

In some cases, we can let the area exposed for controlled healing, as suggested by Mac Cash.

If the tendons are too exposed, we'll choose a more limited excision or a cover with a skin flap.

16.5.2.3 Surgical Approach and Skin Flap

Two types of surgical approach:

- *Longitudinal incisions*: zigzag cut (Brüner or Palmen) or following the path of the cord associated with a Z-plasty if necessary.
- *Palmo-digital incisions*: allow realizing a selective aponeurectomy, with an excellent control of the neurovascular structures and without important delamination that causes hematomas.

They have their limitations if the skin is severely damaged, and we should not hesitate to change the technique (skin graft, open palm).

Transversal incisions also allow realizing aponeurectomy, but there are often important subcutaneous delaminations that cause hematomas and cutaneous necrosis. They can be directly closed if the skin is flexible and not damaged, but they need draining. When the suture is impossible, we use skin graft or flaps or choose an "open skin" technique.

In some cases, the use of mixed incision will give the best result.

16.5.2.4 Closure Techniques

Direct Suture

When it's possible, it's the technique that brings the fastest healing.

Skin Grafts

There is no relapse of Dupuytren disease under a skin graft, so we should not hesitate to use them, but they are subject to precise criteria.

Skin grafts are used in case of dermofasciectomy.

It's most often a total skin graft that covers the exposed noble structures.

They must respect the cutaneous functional units of the hand described by Michon.

The skin grafts must repair the unit in one single piece, reporting the sutures at the level of the neutral lines of their borders.

Flaps

Their goal is also to cover an exposed area.

- *Jacobsen flap*: it avoids the skin graft of the 1st phalanx of the 5th finger. It's used in evolved and very infiltrating forms. Obtaining the skin sample leaves a loss of the palmar substance that will be left for controlled healing like in the Mac Cash technique.
- *Tanzer-Bunnell-Colson flap*: taken on the lateral side of the 1st phalanx, this flap has a commissural base and covers the loss of substances in the base of the finger. The donor site will be covered by a skin graft.

Open Palm Techniques

Mac Cash described this technique in 1964, which is derived from the Dupuytren technique.

Principle:

- Long incision in the distal palmar crease
- Extension on the fingers, often by longitudinal incision
- Aponeurectomy
- Palm left for controlled healing
- Immediate mobilization and extension orthosis

No skin graft, which avoids maceration, hematoma, and sepsis.

Fast recuperation that still does not decrease the number of relapses.

16.5.2.5 Associated Gestures

Stiffness

They essentially occur in the proximal interphalangeal joint. Stiffness is the most important problem in the treatment of Dupuytren disease. Sometimes a total surgical resection of the pathological tissue can bring back a complete extension of the proximal interphalangeal joint.

Otherwise, we'll have to do an arthrolysis liberating the flexor tendons, with section of the check-reins and resection of the collateral ligaments.

16.5.2.6 Complications

Intraoperative Complications

Neurovascular wounds: wounds of the digital nerves that must be immediately repaired with a direct suture.

Arterial wounds: if only one artery is damaged and the finger isn't devascularized, we perform a hemostasis. If the wounds are bilateral, a repartition is obligatory, even if there's a risk of important trophic disorders or necrosis leading to an amputation.

Early Postoperative Complications

The hematomas could require a draining surgery. Cutaneous necroses that cause shrinking cords must be excised and covered by a skin graft or flap.

Infections are rare and require a surgical evacuation, draining, and antibiotic therapy.

Late Complications

Algodystrophy and joint stiffness.

Relapses and Extension of the Disease

Relapses occur in an operated area, whereas the extension happens in an intact area. They're related to the diathesis of the disease.

The extension can be treated by aponeurectomy, but the relapse requires most of the time a dermofasciectomy with skin graft avoiding relapse in the grafted area.

16.6 Rehabilitation and Orthotic Treatment

The rehabilitation always follows the surgery, which is the only efficient treatment for Dupuytren disease.

The rehabilitation fights against postoperative tissue retractions, regardless of the surgical technique employed (aponeurotomy with needle, aponeurectomy, Mac Cash technique).

Mobilization techniques and deep massages, combined with the nocturnal wear of an extension orthosis, lead to better results.

16.6.1 Rehabilitation Protocol (Fig. 16.10)

16.6.1.1 Postoperative Phase (D0 to D15)

From D0 to D15, the scar can be spectacular, especially in case of an open palm technique (Mac Cash).

The most important goals in the phase are the fight against pain and trophic disorders and the prevention of finger stiffness and functional exclusion.

Dupuytren disease			
	Postoperative phase	Scar phase (closed scar)	Remodelling phase
R e h a b i l i t a t i o n	<p>Therapeutic goals: fight against cutaneous trophic disorders and pain, prevent stiffness and exclusion syndrome (sensori-motor stimulation).</p> <p>Techniques:</p> <ul style="list-style-type: none"> - Simple active exercise in flexion/ extension and abduction / adduction of the fingers, stimulations contacting the palm. - Pressotherapy + vis a latere + electrotherapy (1 Hz). - Infrasons (vibralgic, nostrafon ...). -TENS (100 Hz). <p>Risks: CRPS, stiffness and healing disorders if maladapted immobilization.</p>	<p>Therapeutic goals: same + work on the scar</p> <p>Techniques:</p> <ul style="list-style-type: none"> - Same. - Relax the tissues (ultrasounds, hydrotherapy, depressotherapy massages) - Electrostimulation of the flexors and extensors. - Dry fluidotherapy + soft occupational therapy (coordination-dexterity) + rehabilitation of the grips. <p>Risks: healing disorders (inflammation, hypertrophy ...).</p>	<p>Therapeutic goals: same + functional rehabilitation.</p> <p>Techniques:</p> <ul style="list-style-type: none"> - Same - Intensify electrotherapy. - Gain amplitude. <p>Risks: same.</p>
	Or t h e s i s	Dynamic orthosis (Levame) worn during the night after the compressive bandage is removed (D2).	Same.
D0 to D15		D15 to D45	After D45

Fig. 16.10 Protocol

Fight Against Trophic Disorders

- Draining massages.
- Electrotherapy (1 Hz) on the edematous area.
- Soft active mobilization improving the evacuation of the edema and stimulating the “vis a latere.” The mobilizations, if they’re too intense and traumatizing for the tissues, can restart the inflammatory process and increase the edema.
- Cryotherapy without direct contact with the scar for non-sterile application modes. In this phase, the scar is open, so we use two cold bags of cherry stones

to “sandwich” the edematous area. The hand is placed higher than the forearm to optimize the draining effect. The patient keeps his bandage to avoid any infection risk. Cryotherapy also has an interesting analgesic effect.

- Depressotherapy, where the device causes a compression from distal to proximal, which drains the edema of the hand, and causes a soft and painless extension during the treatment. In this phase, this technique can be poorly supported by the patient, in which case we delay its application.
- Compressive bandage during the night, in case of important edema that resists to treatment.

Fight Against Pain

- Analgesic electrotherapy using the “gate control” or the liberation of endorphins.
- Transcutaneous vibratory stimulations (frequency 50–100 Hz, amplitude <1 mm) applied on the painful area, moving along the path of the concerned sensorial nerve. If contacting with the device causes pain, we apply it away from the painful area, still along the corresponding nervous path. This type of mechanical vibrations also has a sensorimotor stimulation effect limiting the risks of functional exclusion.
- Infrasonds (frequency >20 Hz, amplitude >1 mm) also fight against pain by relaxing the muscles and improving the local trophic state. They’re applied perpendicularly to the area we want to treat.

Prevent Stiffness

Painless passive mobilizations are performed before active exercises, which can already be combined with electrostimulation in this phase if it’s tolerated by the patient. We have to give the patient self-rehabilitation advices, based on passive then mobilizations of the fingers several times a day, in short and painless series.

16.6.1.2 Healing Phase (Scar Closed): D15 to D45

From D15 to D45, the scar is closed and the hand is usually less inflammatory and painful. The techniques from the previous phase can be prolonged if necessary. The key points are working with the scar, regaining joint amplitudes and improving the grips.

Fight Against the Edema

We can add cryotherapy with compressed air ($-50\text{ }^{\circ}\text{C}$), as the scar is closed. This quickly lowers the cutaneous temperature until $7\text{ }^{\circ}\text{C}$ (not less than $7\text{ }^{\circ}\text{C}$ as it can cause burning or nervous injury) in 30–60s and then maintains the temperature around $10\text{ }^{\circ}\text{C}$ during 16 min. It would seem that this modality is the most efficient for the anti-inflammatory and analgesic effects we’re looking for.

Work with the Scar

The palmar skin is thick and not very flexible. It's composed of papillary ridges that optimize the efficiency of the mechanoreceptors in the pulp of the fingers. This particular organization can make healing difficult, with an important hypertrophy of the scar and even retractions that impact greatly the grips, limiting the joint amplitudes and disturbing the sensitivity in the area around the scar.

Therefore, relaxing the scar is of particular importance in the treatment of the Dupuytren disease.

Massages Around and on the Scar

The goal is to improve trophicity around the treated areas and to relax the scar.

Therefore, we realize glided pressures from distal to proximal, getting closer to the scar. We progressively add sanding and palpating-rolling techniques.

Ultrasound

After the closure of the scar, we use ultrasound to fight against adherences around the scar.

The ideal frequency is 3 MHz, allowing a superficial effect in accordance with the anatomical location of the cutaneous scar and the superficial palmar aponeurosis. The pulsed mode has a more important "fibrolytic" effect than the continuous mode and should therefore be preferred.

Depressotherapy

We must be careful and progressive when applying this technique.

We start to use the depressotherapy after the closure of the scar.

First, when the scar is still inflammatory, we apply the head of the device away from the scar in a disto-proximal direction.

When the scar isn't inflammatory anymore, we apply the head directly on the scar, first in alternative mode and then in continuous mode if the patient tolerates it well (Fig. 16.11).

Regaining Mobility

These techniques, combined with the stretching of the scar, should allow us regaining joint amplitudes in the fingers. When the surgery has been delayed for a long time, the risks of stiffness are higher as the fingers have stayed blocked during months or even years!

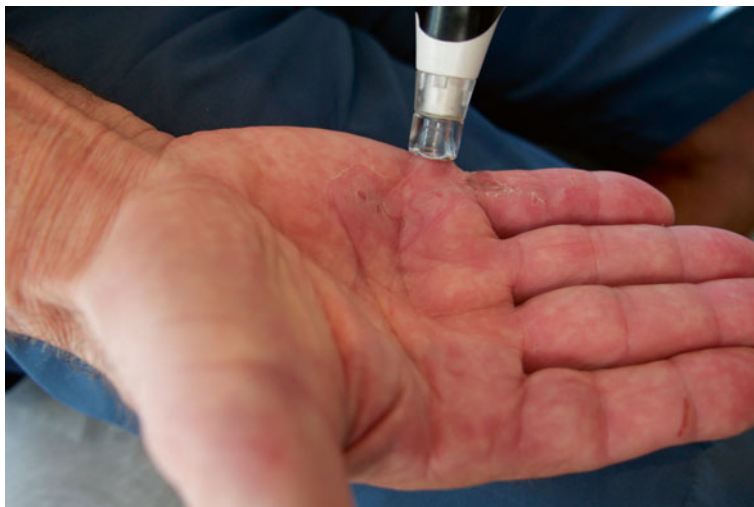

Fig. 16.11 Depressotherapy relaxing the scar tissue

Electrostimulation

This technique helps regaining the joint amplitudes in flexion or extension (Fig. 16.12).

We prefer using currents with a pulse width of 150–200 μs (ideal for the muscles of the superior limb) and a frequency of 20 Hz (stimulations of the slow fibers).

The patient combines the electric stimulation with a voluntary contraction (electro-active exercise) to stimulate the motor command, sometimes disturbed after a surgical intervention or a prolonged immobilization.

Fluidotherapy

These techniques participate in the global relaxation of the hand after this kind of intervention. We ask the patient to realize flexion/extension movements and to spread his fingers, in combination with dry or wet fluidotherapy.

Specific Mobilizations

Decompression and gliding maneuvers in the digital joints help regain a good joint harmony, especially in case of prolonged preoperative stiffness (Fig. 16.13).

Stretching of the Intrinsic Muscles

If there is stiffness in the extrinsic + position, it will be necessary to stretch the intrinsic muscles. The lumbricals and interossei aren't stretched the same way.

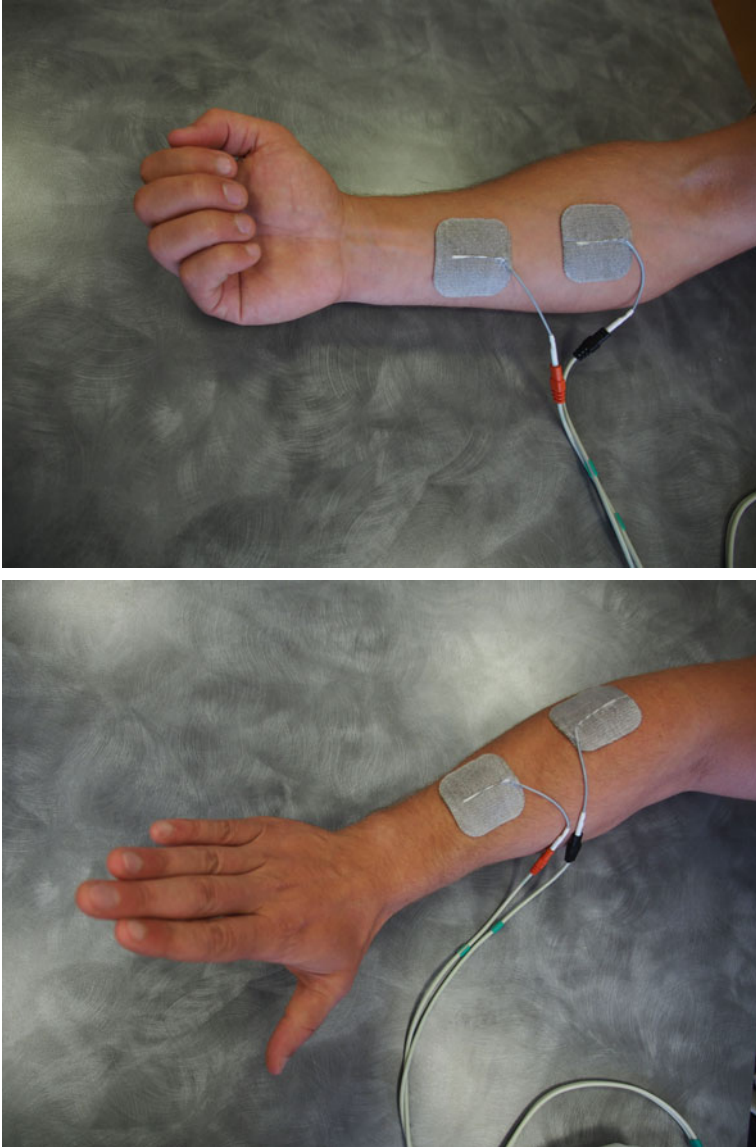


Fig. 16.12 Active electrostimulation regaining the amplitudes in flexion (*up, left*) and extension of the metacarpophalangeals (*down, left*) and the interphalangeals (*right*)




Fig. 16.12 (continued)


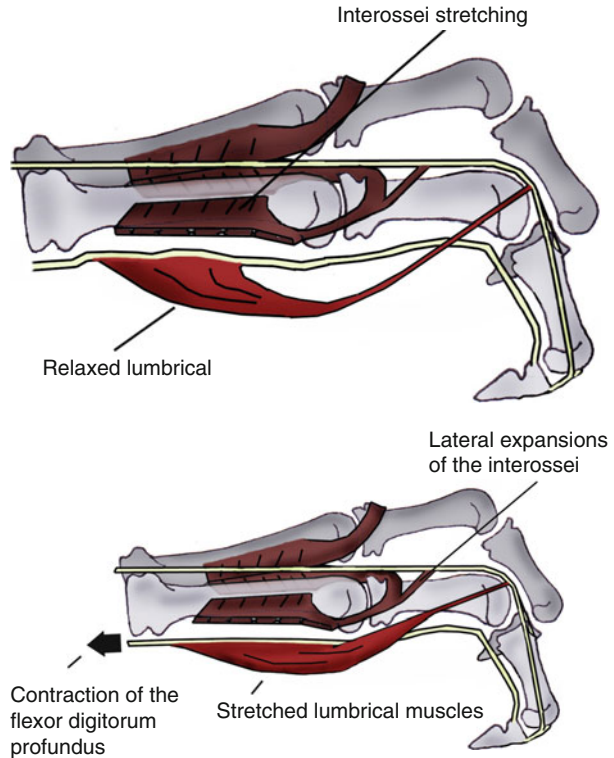


Fig. 16.13 Specific mobilizations (Mennel)

Figs. 16.14 and 16.14'

The passive placement of the hand in an extrinsic + position stretches the interossei but not the lumbricals, unlike the active placement that stretches the two muscular groups



The interossei are stretched placing the hand in the extrinsic + position, reached actively or passively.

The lumbricals are stretched only if this position is reached actively. This is related to the fact that the lumbricals don't have a proximal osseous insertion but insert on the flexor digitorum profundus that moves from distal to proximal when the hand reaches the extrinsic + position, which stretches the lumbricals (Figs. 16.14 and 16.14').

Grips

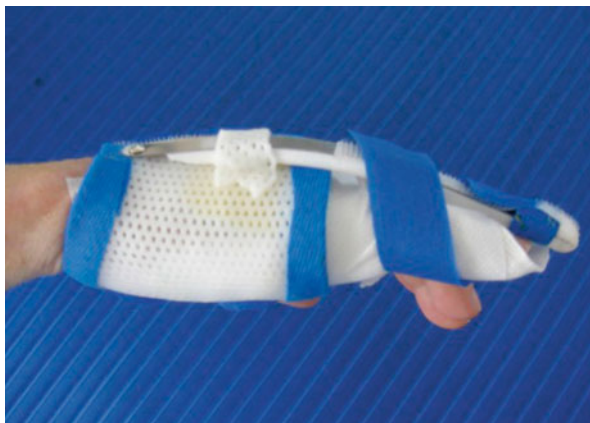Manipulations

Manipulating objects improves rapidly and efficiently coordination and dexterity in the operated hand.

16.6.1.3 Remodeling Phase (After D45)

After D45, the techniques from phases 1 and 2 are used more intensively (but still painlessly) if the disorders persist.

Fig. 16.15 Extension orthosis worn during the night (Levame)



Progressively regaining strength and starting to do professional and leisure activities again are the goals of this phase.

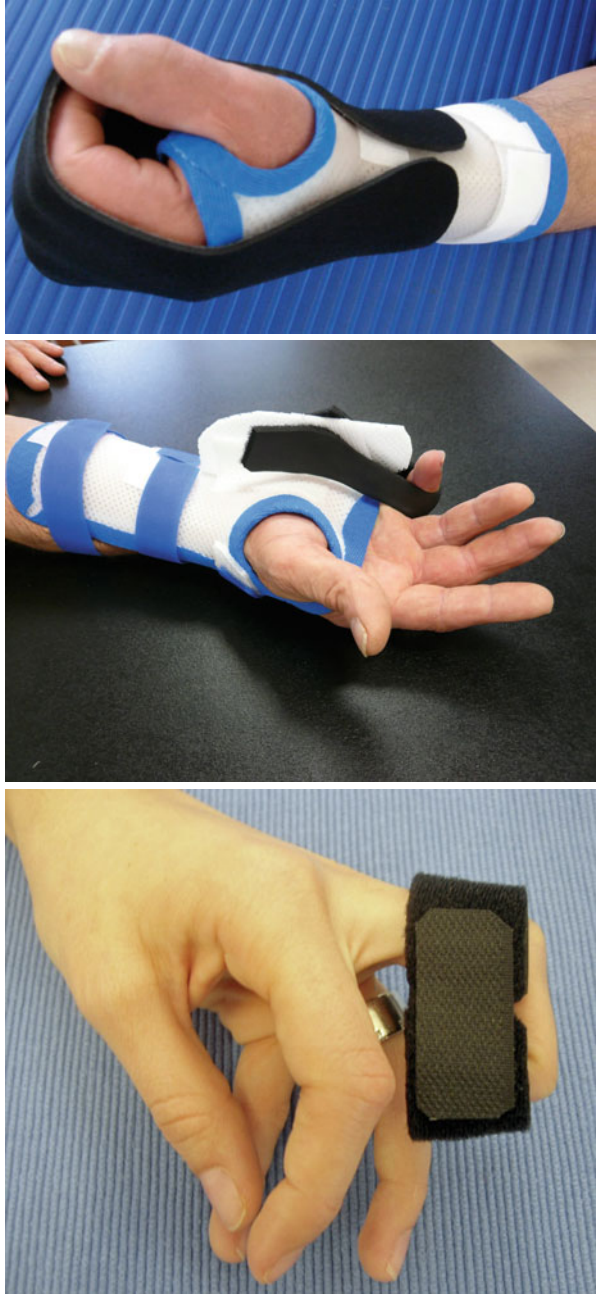16.6.2 Orthotic Treatment [17]

A dynamic extension orthosis is realized since the first postoperative days and worn during the night during the tissue healing.

When the scar is closed, we use a Levame orthosis with silicon pads on the scar (Fig. 16.15).

A winding orthosis can be used when the amplitudes are hard to regain in flexion. It can be a global or winding orthosis or local for the stiff joints. It's worn shortly (15 min) to limit the apparition of circulatory disorders but repeated several times a day (Fig. 16.16).

Fig. 16.16 Orthosis for global winding (*up, left*), selective winding of the metacarpophalangeal (*down, left*) and the interphalangeals (*right*)



Bibliography

1. Glicenstein J (2012) Maladie de Dupuytren, histoire d'un éponyme. *Chirurgie de la Main* (Impact Factor: 0.25). 31(3):107–112. doi:[10.1016/j.main.2012.04.007](https://doi.org/10.1016/j.main.2012.04.007)
2. Villani F, Choughri H, Pelissier P (2009) Intérêt de la greffe de peau dans la prévention des récidives de la maladie de Duuytren. *Chirurgie de la main*. doi:[10.1016/j.main.2009.08.006](https://doi.org/10.1016/j.main.2009.08.006)
3. Tubiana R, Thomine J-M (1990) *La main anatomie fonctionnelle et examen clinique*, Masson, Paris
4. Gosset J (1985) Dupuytren's disease and the anatomy of the palmo-digital aponeuroses. In: Hueston JT, Tubiana R (eds) *Dupuytren's disease*, 2nd edn. Churchill Livingstone, Edinburgh, pp 13–26
5. Bojsen-Moller F, Schmidt L (1974) The palmar aponeurosis and the central spaces of the hand. *J Anat* 117:55–68
6. Thomine JM (1965) Conjonctif d'enveloppe des doigts et squelette fibreux des commissures interdigitales. *Ann Chir Plast* 3:194–203
7. Beaudreuil J, Lellouche H, Roulot E, Orcel P, Bardin T (2011) Maladie de Dupuytren. *EMC appareil locomoteur*, Elsevier-Masson. [14-068-A-10] doi:[10.1016/S0246-0521\(11\)48224-3](https://doi.org/10.1016/S0246-0521(11)48224-3)
8. Hindocha S, McGrouther DA, Bayat A (2009) Epidemiological evaluation of Dupuytren's disease incidence and prevalence rates in relation to etiology. *Hand* 3:256–269
9. Wilbrand S, Ekbohm A, Gerdin B (1999) The sex ratio and rate of reoperation for Dupuytren's contracture in men and women. *J Hand Surg Eur* 4:456–459
10. Al-Qattan MM (2006) Factors in the pathogenesis of Dupuytren's contracture. *J Hand Surg Am* 31:1527–1534
11. Hindocha S, Stanley JK, Watson S, Bayat A (2006) Dupuytren's diathesis revised: evaluation of prognostic indicators for risk of disease recurrence. *J Hand Surg Am* 31A:1626–1634
12. Debet-Mejean A, Dumontier. *CCA Orthopédie Hôpital Saint-Antoine, Sémiologie de la main*
13. Zyluk A, Jagielski W (2007) The effect of the severity of the Dupuytren's contracture on the function of the hand before and after surgery. *J Hand Surg Eur* 3:326–329
14. Hurst LC, Badalamente MA (1999) Nonoperative treatment of Dupuytren's disease. *Hand Clin* 15:97–107
15. Merle M (2007) *Chirurgie de la main*, Tome 3. éditions Masson, Paris
16. Foucher G, Medina J, Navarro R (2003) Percutaneous needle aponeurotomy: complications and results. *J Hand Surg Br* 28:427–431
17. Merle M, Isel M, Célérier S (2012) *Maladie de Dupuytren. Orthèses de la main et du poignet*

Chapter 17

Complex Regional Pain Syndrome

Baptiste Arrate and Grégory Mesplié

The complex regional pain syndrome (CRPS) is also known as algodystrophy, sympathetic neuroalgodystrophy, or reflex sympathetic dystrophy [1]. These numerous changes in the name show the “blur” that still surrounds this syndrome.

Since 1994, the IASP (International Association for Study of Pain) proposes a definition: “Persistent pain in a segment of a limb secondary to a trauma or a tissue injury, particularly osseo-ligamentous or neurologic, and that doesn’t involve a big nervous trunk, associated to a sympathetic dysregulation” [2].

17.1 Type 1 CRPS [3]

First known as algoneurodystrophy, the type 1 CRPS is the most frequent pain syndrome. It appears after a minor event (surgery, prolonged immobilization, fracture, sprain, dislocation) in a limb or a joint. In the type 1 CRPS, there is no sensorial disorder in the painful territory as the peripheral and central nervous system isn’t damaged. However, there are some disorders in the cutaneous vascularization and the sweating and motor activity in the painful area, and edema.

B. Arrate (✉)

Occupational Therapist, Institut Sud Aquitain de la Main et du Membre Supérieur,
Aguiléra Clinic Biarritz, Biarritz, France
e-mail: baptiste.arrate@gmail.com

G. Mesplié

Physiotherapist and Orthotist, Institut Sud Aquitain de la Main et du Membre Supérieur,
Aguiléra Clinic Biarritz, Biarritz, France
e-mail: greg.mesplie@mac.com

17.2 Type 2 CRPS [3]

The difference between the type 2 CRPS and the type 1 CRPS is that the type 2 appears after an injury (section, contusion, avulsion) of a peripheral nerve, of one of its branches or the trunk. Therefore, there are sensory disorders in the pain territory. There are also alterations in vascularization, sudoriparous function, and edema.

In 1864, Weir Mitchell was one of the firsts to mention CRPS; however, his pathophysiological hypothesis wasn't stated before 1923 by Leriche and Renier JC.

17.3 Etiology and Physiopathology

17.3.1 Etiology

Algoneurodystrophy is more frequent in adults around 35 years old. It's more frequent in women and is very rare in children. Its apparition can be primary in 25 % of the cases, but most of the time, it is secondary to a trauma (35 % of the cases), central neurologic (hemiplegia, Parkinson) or cardiac (coronary heart disease) damage, pregnancy, or long treatment (chemotherapy, antiepileptic, or barbiturates). Diabetes, hyperuricemia, cholesterol, anxiety, depression, and alcoholism can be aggravating factors.

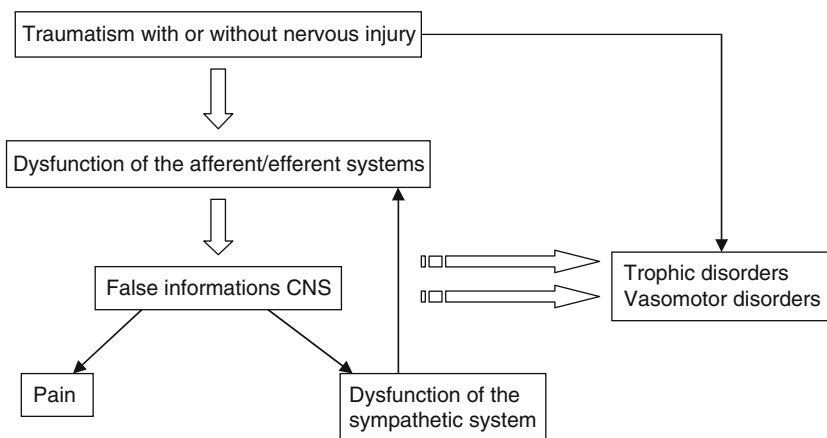
The hand and mostly the wrist are "risky" areas after a trauma, without knowing why (rich innervation, small vascular elements). Algodystrophy appears in these areas more often than in other areas (rachis, elbow). In fact, in 20 % of the fractures of the wrist, there is a pain syndrome [4].

17.3.2 Physiopathology

The activation of the sympathetic system after a trauma initiates the inflammatory phase of tissue healing, causing peripheral vasoconstriction increasing the edema and hyperalgesia to avoid worsening of the injuries.

This lasts from a few minutes to a few hours, but in algodystrophy it stays, establishing a painful vicious circle.

This sympathetic hyperactivity could be related to the formation of new synapses between the big sensorial fibers A β and the afferent sympathetic fibers, creating a sensorio-vegetative combination that causes the sympathetic hyperactivity and the permanent activation of the sensorial neurons.



Schema 17.1 Physiopathology of CRPS [5]

The nociceptive message intensifies and gets wider until it reaches the adjacent areas on its way towards the brain, because of sensitization of the nociceptors, pain memory, axon reflex, and convergent neuron mechanisms (Schema 17.1).

17.4 Diagnosis and Clinical Signs

The diagnosis is clinical and must be established early to rapidly set up a treatment. However, it's difficult to diagnose as there are some atypical and late forms.

The pain is described as severe, constant, burning, and disproportionate in relation to the traumatic event or secondary to a surgery. It can be present in several extremities with sometimes allodynia and/or hyperpathia.

Cutaneous modifications can also be observed: the skin seems shinier, dry, and even scaly. The nails become brittle, and the hairs on the damaged extremity are thicker. Either the sweat increases or the skin gets colder. The skin can also change color, from white to red with blue spots (because of the thermic changes) (Fig. 17.1).

There's an edema in the painful area. It can be soft, leaving a depression when we press on the area (venous edema), or hard (lymphatic edema).

There's also limitation of the movements with onset of dystonia, joint stiffness, tremor, or involuntary shaking, as well as coordination disorders.

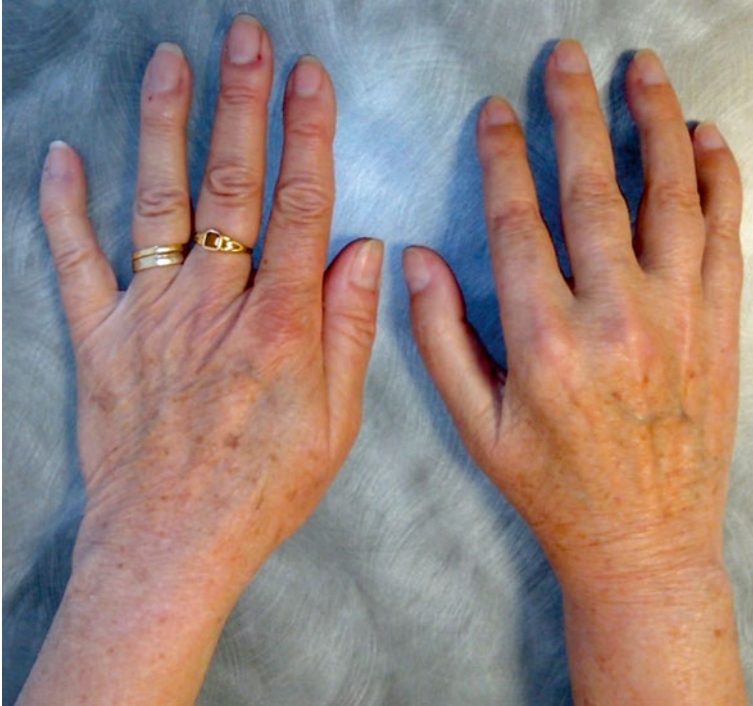

Fig. 17.1 Right hand with CRPS

Complementary exams can be realized to confirm the diagnosis:

- *Scintigraphy*: establishes an early diagnosis of CRPS, highlighting the isotopic hyper-fixation in the hand and carpal bones.
- *Radiology*: can show demineralization signs. It must be done comparing with the same side (Fig. 17.2) [6].

17.5 Evolution

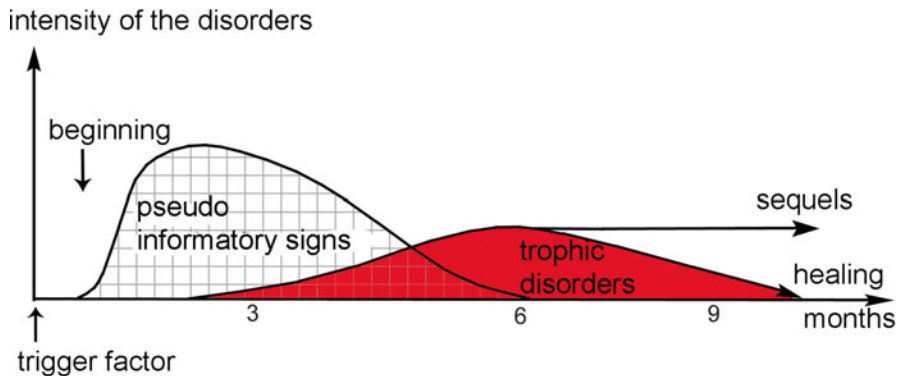
The evolution of the CRPS changes from one person to the other but usually spreads from 12 to 48 months. There are three evolution stages, and the apparition of the symptoms can stretch out over several months. Some patients don't reach the third stage (Schema 17.2).

17.5.1 Stage 1 (*Hot or Acute Phase*)

It can last for 6 months and is associated with the apparition of spontaneous pain, disproportionate in relation with the trauma. This pain is limited to the

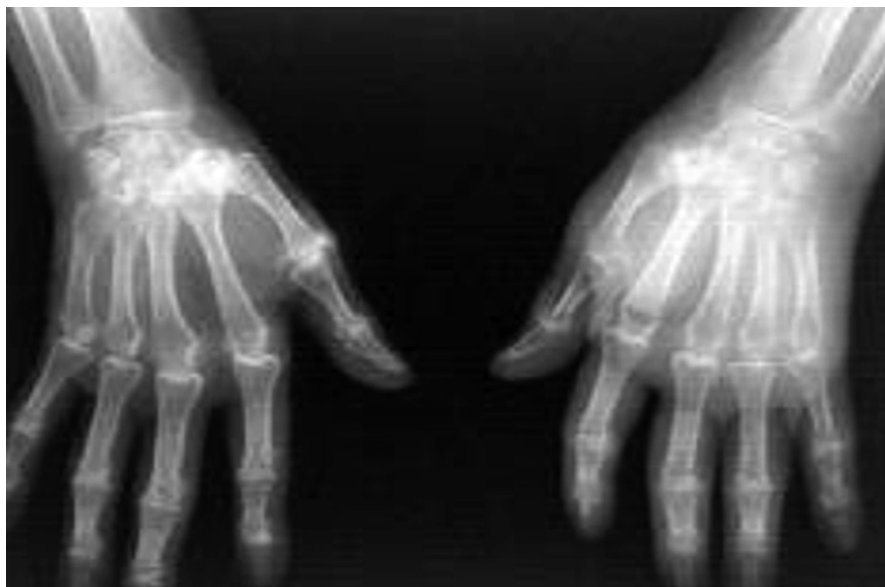

Fig. 17.2 Demineralization of the hand with CRPS



Schema 17.2 Evolution of the CRPS

wound area. Simple cutaneous pressures can cause pain (hyperesthesia). There's a localized edema. The skin becomes shiny with hyperhidrosis (increased sweating). Redness and hotness are frequent because the regional neurovegetative system is disturbed. The joint mobility is limited, which causes a functional discomfort for the patient.

17.5.2 Stage 2 (Cold or Dystrophic Phase)

The cold phase lasts 3 to 12 months. During this phase the skin can have a bluish color, with a local decrease of the temperature. The spontaneous pains progressively decrease but stay important when mobilizing. The fingers are sharp with brittle and stripped nails. The edema tends to decrease but becomes hard with tissue fibrosis that will cause joint discomfort. Muscular atrophy is frequent, and it's during this phase that fibrosis adhesences settle, leading to functional limitations. We can then observe a "claw" deformity.

In this stage, radiography allows observing a demineralization with disappearance of the bone material [6].

The patient evolves towards recovery or towards sequelae.

17.5.3 Stage 3 (Sequelae Phase)

During this phase that lasts from 6 to 24 months, the main symptom is a joint and tendinous stiffness that can be irreversible. This evolution justifies an early treatment of the CRPS, combining an analgesic treatment with a multidisciplinary rehabilitation.

17.6 Therapeutic Process

The early diagnosis of the CRPS leads to the development of a specific treatment. The main drugs found in this pathology are corticoids (infiltration), calcitonin (analgesic and vasoactive effect), and type I analgesics (during rehabilitation). Bisphosphate is also used as it fights against osseous demineralization, as well as sympatholytics that inhibit the adrenergic receptors α and β .

Rehabilitation should start the earlier possible to avoid the beginning of the vicious circle and decrease the risk of functional sequelae. However, some principles must be respected, like working under the pain threshold and mobilizing to avoid possible adhesences and retractions, decrease the edema, and avoid the functional exclusion of the damaged limb.

The relational aspect is also very important in a pain syndrome. It is essential for the multidisciplinary team to establish a relationship of trust with the patient.

17.7 Rehabilitation and Orthotic Treatment

(Fig. 17.3: Protocol)

17.7.1 Hot Phase

The priorities are treating pain and fighting against trophic disorders and stiffness.

For that, we use:

Complex regional pain syndrome		
	Hot phase	Cold phase
R e h a b i l i t a t i o n	<p>Therapeutic goals: fight against pain and vasomotor disorders + stimulation of the palmar mechanoreceptors, prevent stiffness and muscular atrophy.</p> <p>Techniques: TENS 100 Hz, vibralgic, Scottish baths; draining, analgesic and trophic massages. Soft and slow active-passive mobilizations, static exercises. Motor imagery program. Hypnosis if asked by the patient.</p> <p>Risks: maintain the vicious circle of Leriche if maladapted exercise intensity, functional exclusion.</p>	<p>Therapeutic goals: same + fight against established stiffness + sensorimotor reintegration.</p> <p>Techniques: Same + fluidotherapy + infrasounds (amplitude > vibralgic) + electrostimulation. Occupational therapy. Intensify articular and muscular techniques + exercises in compression-decompression (inspired by Watson).</p> <p>Risks: same.</p>
Or th e s is	Resting orthosis with an analgesic purpose (worn during the night ++).	Dynamic orthosis to regain joint amplitudes.

Fig. 17.3 Rehabilitation protocol

17.7.1.1 Physiotherapy

Analgesic Electrotherapy [7]

TENS currents have an interesting analgesic effect.

Scottish Baths

We obtain an analgesic and trophic effect. We put the hand in hot water for 4 min, then 1 min in cold water. We repeat this process four times and end with cold water (total duration: 20 min).

Cryotherapy

We use devices combining cryotherapy with pressotherapy when it's tolerated by the patient. If it's not, gaseous cryotherapy is a good solution.

Transcutaneous Vibratory Stimulations

They have an analgesic effect with a frequency of 100 Hz.

Maintain the Active/Passive Mobility

It should always be done under the pain threshold, in every joint in the superior limb.

17.7.1.2 Orthotic Treatment

In this phase, the orthosis have an analgesic purpose. They are rest orthosis as the patient wears them during the night to avoid vicious positioning in the damaged limb. It's an antebrachio-digital orthosis with the wrist in 30° of extension, the metacarpophalangeals in 60° of flexion, and the interphalangeals in 20° of flexion (Fig. 17.4).

17.7.1.3 Occupational Therapy

The role of the occupational therapist is to solicit the function of the damaged limb, working with both hands to avoid the exclusion of the limb. He/She also has to work on the grips and coordination on an inclined plane to improve the resorption of the edema.

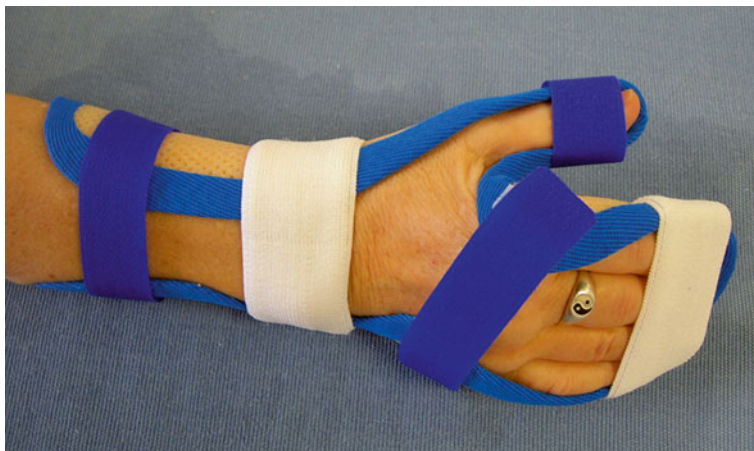

Fig. 17.4 Antebrachio-digital rest orthosis

17.7.1.4 Motor Imagery Program (MIP or Graduated Motor Imagery)

The GMI has proved to be efficient in patients with CRPS in hot phase, thanks to Moseley's study in 2004 [8–11]. This program consists in three phases that each lasts for 2 weeks. Ideally, the exercises must be realized every day, 10 min every hour:

- Left/right discrimination,
- Explicit motor imagery,
- Mirror therapy [12, 13].

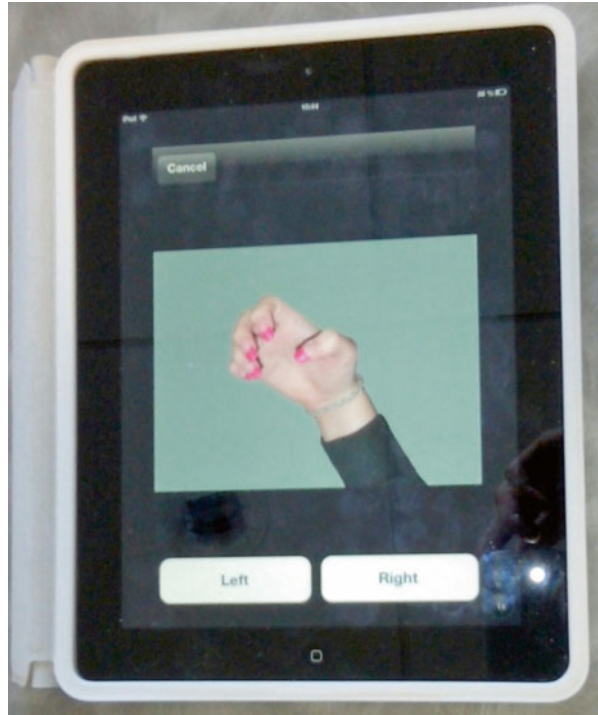
For the patients to stick better with the program, we give them the exercises so they can do them at home. It's a difficult therapy that needs to be explained correctly by the therapist before each phase.

We can make the needed tools ourselves: a mirror box or a set of photos of the right and left hands.

Left/Right Discrimination

During this phase we show the patient some photos of the right and left hands in different positions. The patient then has to determine what hand he/she's looking at (right or left). This stimulates the premotor cortex without activating the primary motor cortex, which could increase the edema and pain (Fig. 17.5).

Fig. 17.5 Left/right discrimination



Explicit Motor Imagery

The patient imagines placing his limb in different positions observed on the photos. He/She does three visualizations for each photo. He/She doesn't make any real movement with his hand. The explicit motor imagery activates the premotor cortex and the primary motor cortex.

Mirror Therapy [12, 13]

During this third and last phase, the patient places his damaged limb in the mirror box and his sane limb in front of the mirror. That way, he/she sees the reflection of his sane limb instead of his damaged limb. He/She then does simultaneous bimanual movements looking in the mirror, thus creating the illusion of a functional limb. The mirror therapy activates the mirror neurons and stimulates the primary motor cortex, thus fighting against motor disorders and functional exclusion syndrome. The analgesic effect of the mirror allows realizing movements without triggering painful mechanisms (Fig. 17.6).

Fig. 17.6 Mirror therapy

17.7.1.5 Treatment with Hypnosis

Hypnosis is a verbal technique making a person pass from a conscious to an unconscious state. He/She can then support pain better during the hypnosis sessions and outside the sessions with self-hypnosis.

Various techniques can be used:

- *Accompaniment in a pleasant memory*: the patient chooses an enjoyable memory, and the therapist, with his verbal technique, puts the patient into a trance. He/She is in a daze; his mind is in his pleasant memory. The therapist can then realize mobilizations easier. Active mobilization can also be better.
- *Analgesia*: we tell the hypnotized patient to feel analgesia in the painful limb and even to “disconnect” his pain with a verbal technique.
- *Well-chosen words*: the words used during a rehabilitation session are important. The patient is often stuck in time since the beginning of his CRPS, which consequences can be difficult to bear. We must try to get the patient to move again, pointing out what gets better, looking for pain-free movements, and making them more important.

17.7.2 Cold Phase

In this phase, pain and edema are less present; the first goal is regaining functional amplitudes.

17.7.2.1 Physiotherapy

All the techniques used during the hot phase can be used if necessary.

Fluidotherapy

Fluidotherapy exercises are associated with active mobilization to improve recuperation of the functional amplitudes (increase of the tissue viscoelasticity).

Ultrasound

They take part in the fight against adherences that have emerged during hot phase, when mobilizations are sometimes difficult to realize because of pain.

Electrostimulation

We ask the patient to do electroactive exercises to improve the body map and joint amplitudes (Fig. 17.7).

Regaining Joint Amplitudes

Mobilization techniques are intensified (but always under the pain threshold) to regain the physiological amplitudes. Specific mobilizations can be used in this phase if they are borne by the patient.

Progressive Muscular Reinforcement

It starts with an intermittent static exercise with 6 s of contraction and 6 s of rest with light weights (muscular awakening).

If it's well tolerated, we realize more intensive exercises with increasing loads.

17.7.2.2 Orthotic Treatment

In this stage the orthosis aims to regain the joint amplitudes. We use dynamic flexion or extension orthosis (Fig. 17.8).

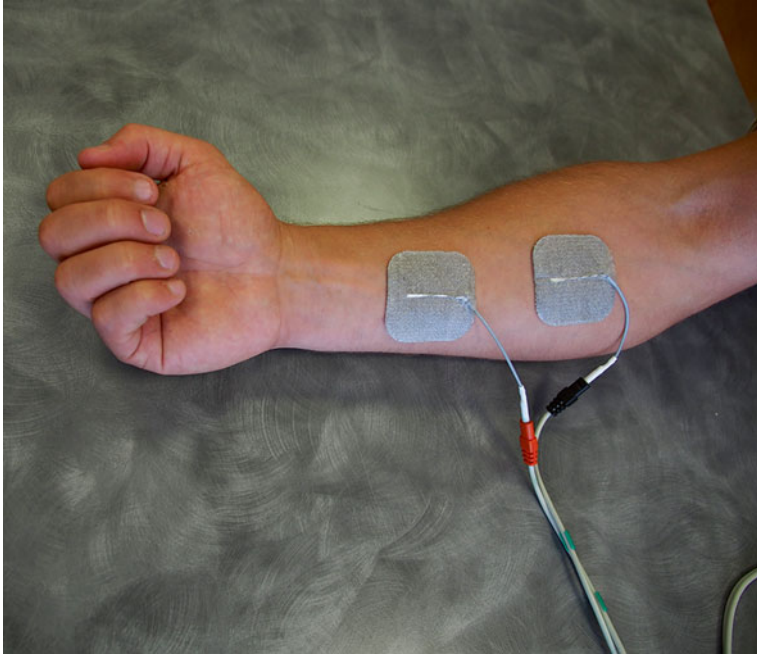


Fig. 17.7 Electrostimulation to regain joint amplitudes (painless)

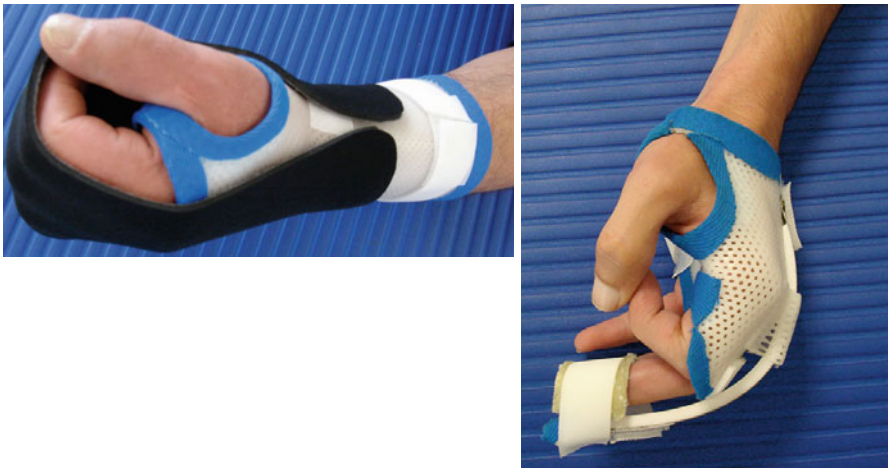

Fig. 17.8 Global winding orthosis worn shortly during the day (*left*) and extension orthosis worn during the night (*right*). These orthosis mustn't provoke edema or pain

17.7.2.3 Occupational Therapy

The occupational therapist will propose exercises to improve global and fine dexterity, strength, and endurance.

Bibliography

1. Grundberg AB, Reagan D (1991) Compression syndromes in reflex sympathetic dystrophy. *J Hand Surg [Am]* 16:731–736
2. International Association for the Study of Pain (1996) Classification of chronic pain. *Pain* 3(suppl):28–30
3. Vincent B, Wood C (2008) Douleur évaluation-diagnostic-traitement: Les syndromes douloureux régionaux complexes (SDRC) de type I et II. Masson Paris. Volume 9
4. Field J, Warwick D, Bannister GC (1992) Features of algodystrophy ten years after Colles' fracture. *J Hand Surg [Br]* 17:318–320
5. Scadding JW (1999) Complex regional pain syndrome. In: Wall PD, Melzack R (Eds.) *Textbook of pain* 4th ed. Edinburgh: Churchill Livingstone 835–49
6. Bickerstaff DR, Charlesworth D, Kanis JA (1993) Changes in cortical and trabecular bone in algodystrophy. *Br J Rheumatol* 32:46–51
7. Cooney WP (1997) Electrical stimulation and the treatment of complex regional pain syndromes of the upper extremity. *Hand Clin* 13:519–526
8. Moseley G.L (2006) Graded motor imagery for pathologic pain: a randomised controlled trial. *Neurology* Vol 67:2129–34
9. Moseley GL (2004) Graded motor imagery is effective for long-standing Complex Regional Pain Syndrome: a randomised controlled trial. *Pain* 108:192–198
10. Bowering KJ, O'Connell NE, Tabor A, Catley MJ, Leake HB, Moseley GL, Stanton TR (2013) The effects of graded motor imagery and its components on chronic pain: A systematic review and meta-analysis. *J Pain* 14:3–13
11. Walz AD, Usichenko T, Moseley GL, Lotze M (2013) Graded Motor Imagery and the Impact on Pain Processing in a Case of CRPS. *The Clinical Journal of Pain* 29(3):276–279
12. McCabe C, Haigh R, Ring E, Halligan P, Wall P, Blake D (2003) A controlled pilot study of the utility of mirror visual feedback in the treatment of Complex Regional Pain Syndrome Type One. *Rheumatology* 42:97–101
13. Marteau J (2011) La thérapie miroir, un moyen de lute contre la douleur dans le SDRC et l'algohallucinoze, mémoire non publié, Institut Régional de Formation aux Métiers de la Rééducation et Réadaptation des Pays de la Loire, section kinésithérapie

Part VIII
Protocols

Chapter 18

Protocols

Grégory Mesplié

18.1 Current Traumatic Pathologies of the Wrist

<i>Recent fractures of the scaphoid bone</i>			
	Phase 1: immobilization	Phase 2: pre-consolidation	Phase 3: consolidation
Rehabilitation	<p><i>Therapeutic goals:</i> immobilization</p> <p><i>Techniques:</i> Monitoring of the orthosis (stability, comfort, pressure points) PRICE protocol Mobilizations of the free joints (shoulder, elbow, fingers, interphalangeal of the thumb)</p> <p><i>Risks:</i> trophic disorders, CRPS</p>	<p><i>Therapeutic goals:</i> progressive load, gain joint amplitude, progressive muscular reinforcement with fingers extended</p> <p><i>Techniques:</i> Massages, manual and instrumental mobilization, fluidotherapy Relaxing of the scar (if surgery) Electrostimulation, transcutaneous vibratory stimulations ++, intrinsic muscles, and wrist stabilizers Exercises for fine prehensions, digital coordination</p> <p><i>Risks:</i> stiffness, muscle atrophy</p>	<p><i>Therapeutic goals:</i> regain total joint amplitude, muscular reinforcement, proprioceptive exercises, and functional goals</p> <p><i>Techniques:</i> Specific intracarpal mobilizations Muscular reinforcement, exercises for the muscular chains Proprioception exercises Exercises for strong prehensions, professional or sports orientation</p> <p><i>Risks:</i> stiffness, loss of strength</p>

G. Mesplié

Physiotherapist and Orthotist, Institut Sud Aquitain de la Main et du Membre Supérieur, Aguiléra Clinic Biarritz, Biarritz, France

e-mail: greg.mesplie@mac.com

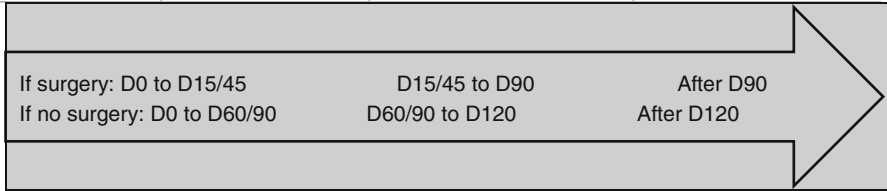
© Springer International Publishing Switzerland 2015

G. Mesplié, *Hand and Wrist Rehabilitation: Theoretical Aspects and Practical Consequences*, DOI 10.1007/978-3-319-16318-5_18

471

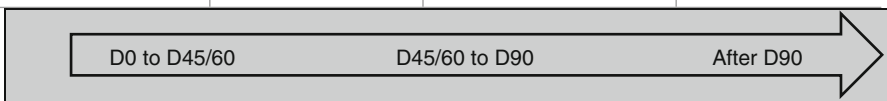
Recent fractures of the scaphoid bone

	Phase 1: immobilization	Phase 2: pre-consolidation	Phase 3: consolidation
Orthosis	Immobilizing the wrist, worn all the time	Functional for the wrist during activities	Flexible for restarting work or sports activities




Sprains of the scapholunate ligament

	Phase 1: healing	Phase 2: relative fragility	Phase 3: solidity
Rehabilitation	<p><i>Therapeutic goals:</i> healing phase, strict immobilization, <i>no load carrying</i></p> <p><i>Techniques:</i> Monitoring of the orthosis (comfort, pressure points) PRICE protocol Mobilizations of the free joints (shoulder, elbow), mobilization without resistance of the digital chains (exercises at home)</p> <p><i>Risks:</i> nonobservance of the immobilization and safety advices</p>	<p><i>Therapeutic goals:</i> pre-consolidation phase, progressively putting constraints on the scapholunate ligament, stability, fight against muscular atrophy</p> <p><i>Techniques:</i> Relaxing of the scar and skin (massage) “De-rust” the joints, fluidotherapy Static reinforcement with an open palm (electrostimulation, wrist stabilizers, transcutaneous vibratory stimulations, simple active mobilizations)</p> <p><i>Risks:</i> no kneading, avoid axial compressions caused by over-soliciting the finger flexors. <i>No analytical exercise for the extensor carpi ulnaris that can damage the scapholunate ligament</i></p>	<p><i>Therapeutic goals:</i> regain total joint amplitude, stability ++, and functional goals (work and sports activities)</p> <p><i>Techniques:</i> Specific intracarpal mobilizations Static instrumental muscular reinforcement Dynamic muscular reinforcement with light weights Proprioception exercises and multidirectional resistances</p> <p><i>Risks:</i> stiffness or instability of the wrist</p>
Orthosis	Closed antebrachio-palmar orthosis, wrist in 0° of flexo-extension and 5° of ulnar inclination, fingers free	Resting orthosis progressively taken off	Wraparound cuff when restarting activities



Recent fractures of the inferior extremity of the radius

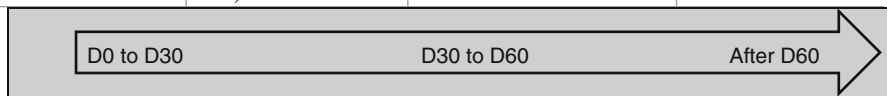
	Immobilization phase	End of the immobilization	Consolidation phase
Rehabilitation	<p><i>Therapeutic goals:</i> immobilization of the wrist with a cast or a closed orthosis for good healing, maintaining prehension schemas without constraints</p> <p><i>Techniques:</i> PRICE protocol Mobilization advices for the free joints of the superior limb Vibralgic on the finger pulps, contacts between the palm and the pulps Control of the pressure points of the cast or orthosis and of the pins (if surgery)</p> <p><i>Risks:</i> maladapted immobilization, CRPS, Volkmann, cutaneous disorders, stiffness if no digital mobilization</p>	<p><i>Therapeutic goals:</i> fight against trophic disorders and pain, progressively regain joint amplitudes, muscular awakening and maintaining prehension schemas</p> <p><i>Techniques:</i> Trophic and analgesic massages, analgesic electrotherapy (100 Hz), fluidotherapy, infrasounds, pressotherapy Passive and soft active mobilizations, Kinetec Electroactive exercises for the intrinsic and extrinsic muscles, muscular irradiation techniques then static exercises with light weights, soft occupational therapy</p> <p><i>Risks:</i> Displacement if the techniques are too aggressive and the muscles are too solicited, stiffness and exclusion syndrome if the techniques are too soft and the muscles are not solicited enough</p>	<p><i>Therapeutic goals:</i> completely regain joint amplitude, muscular strength, and prehensions</p> <p><i>Techniques:</i> Intensify the techniques from the previous phase Specific intracarpal mobilizations Proprioceptive exercises and feedforward More intensive occupational therapy</p> <p><i>Risks:</i> same + tendinopathy if work and sports activities are too intense at first</p>
Orthosis	Cast, closed orthosis or opened orthosis	Opened orthosis during the night if pain persists and during "risky" activities	Neoprene orthosis to progressively restart activities if necessary



18.2 Osseous and Capsulo-ligamentous Injuries of the Hand and Thumb

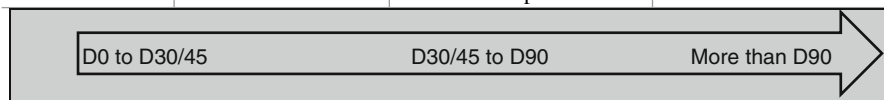
Serious sprains of the internal collateral ligament of the metacarpophalangeal of the thumb (surgery)

	Immobilization phase (A)	Fragility phase (B)	Strength phase (C)
Rehabilitation	<p><i>Therapeutic goals:</i> immobilization, self-rehabilitation advices</p> <p><i>Techniques:</i> Monitoring of the orthosis (pressure points) Active self-mobilizations of the interphalangeal, cryotherapy if global inflammation</p> <p><i>Risks:</i> bad ligament healing, stiffness of the interphalangeal</p>	<p><i>Therapeutic goals:</i> same and even intensify phase A if necessary (interphalangeal stiffness). Fight against pain and trophic disorders, regain the active amplitudes in the metacarpophalangeal and the interphalangeal joints, reinforcement of the metacarpophalangeal stabilizers, regain coordination and dexterity</p> <p><i>Techniques:</i> Progressively take off the orthosis Massages, fluidotherapy, transcutaneous vibratory stimulations, depressotherapy, electrotherapy Active exercise to regain the active amplitudes in the metacarpophalangeal and the interphalangeal joints Electrostimulations, static exercise for the internal sesamoid muscles ++ and for the other stabilizers of the metacarpophalangeal joint Manipulations and occupational therapy</p> <p><i>Risks:</i> same as in phase A + instabilities if the techniques are too intense</p>	<p><i>Therapeutic goals:</i> intensify the techniques from the 2 previous phases if necessary, regain clamping strength, complete functional recovery</p> <p><i>Techniques:</i> Specific joint mobilizations and increase the intensities of the electrostimulation Exercise for the intrinsic and extrinsic strength Functional exercise according to the job and leisure activities</p> <p><i>Risks:</i> same as in phases A and B</p>
Orthosis	<p>Orthosis blocking the metacarpophalangeal of the thumb, interphalangeal is free (worn all the time)</p>	<p>Progressively take off the orthosis</p>	<p>“Alpine” orthosis if necessary to get back to activities</p>



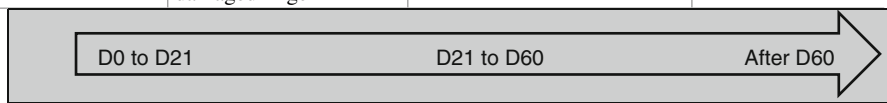
Fractures of the metacarpals and phalanges

	Immobilization phase (A)	Fragility phase (B) Beginning of the rehabilitation if no immobilization (D2)	Strength phase (C)
Rehabilitation	<p><i>Therapeutic goals:</i> fight against trophic disorders and pain, maintain mobility in the free joints, prevent vicious callus</p> <p><i>Techniques:</i> Ice (gaseous cryotherapy after the scar is closed or if there is no scar), analgesic transcutaneous vibratory stimulations, analgesic and draining massages, compressive bandages (if possible) Active self-mobilizations of the free joints Learning protection rules when monitoring the orthosis (+ control by the orthotist once a week to control the rotation and the angle of the callus)</p> <p><i>Risks:</i> vicious callus (especially if there is an orthopedic treatment), stiffness of the free joints</p>	<p><i>Therapeutic goals:</i> same as in phase A, intensify phase A if necessary (stiffness ++), softly regain joint amplitudes in immobilized/damaged joints, muscular awakening, maintain the body mapping</p> <p><i>Techniques:</i> Same techniques as in phase A, using more intensive techniques (pressotherapy, cold baths...)</p> <p>Fluidotherapy, depressotherapy and massages against adhesions, active electrotherapy, manual mobilizations</p> <p>Soft electrostimulation of the intrinsic muscles</p> <p>Manipulations, occupational therapy</p> <p><i>Risks:</i> same as in phase A, functional exclusion</p>	<p><i>Therapeutic goals:</i> intensify the techniques from the 2 previous phases if necessary, regain clamping strength, complete functional recovery</p> <p><i>Techniques:</i> Specific joint mobilizations, increase the intensity of the electrostimulation, and stretching of the intrinsic muscles (B1)</p> <p>Exercise for the intrinsic and extrinsic strengths, regain the muscular ratios</p> <p>Functional exercises depending on the job and leisure activities</p> <p><i>Risks:</i> same as in phase B</p>
Orthosis	Orthosis adapted to the type of fracture	Postural orthosis after the end of the trophic disorders and pain	Same as in phase B



Severe injuries of the volar plate

	Acute phase	Healing phase	Remodeling phase
Rehabilitation	<p><i>Therapeutic goals:</i> rest the volar plate, and limit the risks of stiffness, fight against trophic disorders and pain, maintain the body mapping</p> <p><i>Techniques:</i> Cryotherapy, infrasounds, TENS (1–3 or 100 Hz), draining depressotherapy Draining massage Passive exercise in flexion and simple active exercise in extension</p> <p><i>Risks:</i> maladapted mobilizations = stiffness (flexum ++) and/or instability, even CRPS</p>	<p><i>Therapeutic goals:</i> progressively put charge on the damaged elements, regain joint amplitudes, fight against trophic disorders and pain, and maintain the body mapping</p> <p><i>Techniques:</i> Same (depending on the evolution) + US (1 MHz pulsed) + simple active exercise in flexion/extension + differential gliding of the distal and proximal interphalangeal joints + electrostimulation + massages of the scar + depressotherapy to relax the tissues + occupational therapy</p> <p><i>Risks:</i> flexum + maintain the inflammation (risks of scar hypertrophy), functional exclusion</p>	<p><i>Therapeutic goals:</i> gain amplitude and strength, fight against trophic disorders and pain, and maintain the body mapping</p> <p><i>Techniques:</i> Same (depending on the evolution) + Mennel technique + muscle reinforcement Functional exercise (occupational therapy ++)</p> <p><i>Risks:</i> flexum + “big” proximal interphalangeal joint</p>
Orthosis	<p>“Proximal interphalangeal stop” or digital tube in complete extension, syndactyly allowing a protected self-mobilization of the damaged finger</p>	<p>Dynamic (Capener) or static in series in extension or flexion (snail, Portuguese, etc.), worn daily (>6 h/j)</p>	<p>Same, adapting the resistances depending on the results</p>



Collateral ligaments sprains in the proximal interphalangeal joints

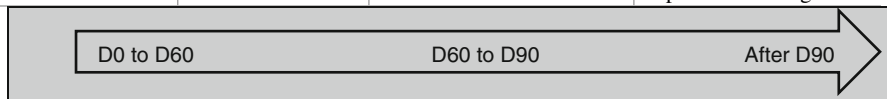
	Posttraumatic phase	Healing phase	Remodeling phase
Rehabilitation	<p><i>Therapeutic goals:</i> fight against pain and trophic disorders, prevent stiffness (flexum ++) <i>Techniques:</i> Gate-control and endorphinic TENS (100 and 2 Hz), infrasounds, pulsed US, fluidotherapy, supple compression, draining massage Soft active mobilizations, active electrostimulation <i>Risks:</i> CRPS if maladapted exercises + flexum</p>	<p><i>Therapeutic goals:</i> same + regain amplitudes if necessary + maintain body mapping in a functional goal <i>Techniques:</i> Same More intense passive and active mobilizations, differential tendinous gliding Occupational therapy, manipulations for dexterity and coordination <i>Risks:</i> same + flexum + functional exclusion</p>	<p><i>Therapeutic goals:</i> same + global and strength exercises <i>Techniques:</i> Intensify the mobilization techniques (gain amplitude), Mennel, sports and professional rehabilitation Intensify occupational therapy <i>Risks:</i> flexum + functional exclusion + “big” proximal interphalangeal joint</p>
Orthosis	<p>Syndactyly 2nd–3rd fingers or 4th–5th fingers depending on the damaged ligament</p>	<p>Syndactyly during risky activities – extension tube if flexum</p>	<p>Dynamic pro-flexion/pro-extension orthosis</p>

D0 to D21
D21 to D60
After D60

18.3 Tendon Injuries of the Hand

Subcutaneous injury of the extensors in zones 1–2/mallet finger

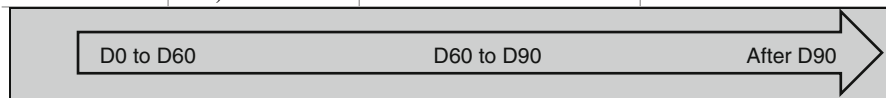
	Immobilization phase (A)	Fragility phase (B)	Solidity phase (C)
Rehabilitation	<p><i>Therapeutic goals:</i> tendon healing, maintain the mobility of the proximal interphalangeal joint</p> <p><i>Techniques:</i> Learning the protection rules during the maintenance of the orthosis (+ control by the orthotist once a week)</p> <p>Active self-mobilizations of the proximal interphalangeal joint</p> <p><i>Risks:</i> bad tendon healing, stiffness of the proximal interphalangeal joint</p>	<p><i>Therapeutic goals:</i> same, intensifying the techniques from the phase A if necessary (stiffness). Fight against pain and trophic disorder, regain the active amplitudes of the distal interphalangeal joint, and maintain the body mapping</p> <p><i>Techniques:</i> Orthosis worn at night during 15 days (A1), specific and global mobilizations of the proximal interphalangeal joint (A2)</p> <p>Massages, fluidotherapy, transcutaneous vibratory stimulations, depressotherapy, electrotherapy</p> <p>Active exercise in flexion of the distal interphalangeal joint returning to extension with an active-assisted movement, then simple active exercise (depending on the locking). Electrostimulation in winding if the extension locking is okay</p> <p>Electrostimulations</p> <p>Manipulations, occupational therapy</p> <p><i>Risks:</i> same as in phase A, functional exclusion</p>	<p><i>Therapeutic goals:</i> intensify the techniques from the 2 previous phases if necessary, regain clamping strength, complete functional recovery</p> <p><i>Techniques:</i> Specific joint mobilizations, increasing the electrostimulation's electric intensities, and stretching the intrinsic muscles (B2)</p> <p>Exercise for the intrinsic and extrinsic strengths</p> <p>Functional and leisure exercises</p> <p><i>Risks:</i> same as in phases A and B</p>
Orthosis	Stack orthosis (worn all the time)	Stack orthosis worn during the night if no locking	Same as in phase B, postural orthosis at 2 months if flexum or lack of passive winding



Subcutaneous injury of the extensors in zone 3

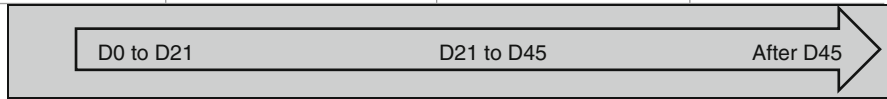
Boutonnière deformity

	Immobilization phase (A)	Fragility phase (B)	Solidity phase (C)
Rehabilitation	<p><i>Therapeutic goals:</i> tendon healing, maintain the mobility of the distal interphalangeal joint</p> <p><i>Techniques:</i> Learning the protection rules during the maintenance of the orthosis (+ control by the orthotist once a week) Active self-mobilizations of the distal interphalangeal joint</p> <p><i>Risks:</i> bad tendon healing, stiffness of the distal interphalangeal joint</p>	<p><i>Therapeutic goals:</i> same, intensifying the techniques from phase A if necessary (stiffness). Fight against pain and trophic disorders; regain the active amplitudes of the proximal interphalangeal joint</p> <p><i>Techniques:</i> Orthosis worn at night during 15 days (A1), specific and global mobilizations of the distal interphalangeal joint (A2) Massages, fluidotherapy, transcutaneous vibratory stimulations, depressotherapy, electrotherapy Active exercise in flexion of the proximal interphalangeal joint returning to extension with an active-assisted movement, then simple active exercise (depending on the locking). Electrostimulation in winding if the extension locking is okay Electrostimulations Manipulations, occupational therapy</p> <p><i>Risks:</i> same as in phase A</p>	<p><i>Therapeutic goals:</i> intensify the techniques from the 2 previous phases if necessary, regain clamping force, complete functional recovery</p> <p><i>Techniques:</i> Specific joint mobilizations, increasing the electrostimulation's electric intensities, and stretching the intrinsic muscles (B2) Exercise for the intrinsic and extrinsic strengths Functional and leisure exercises</p> <p><i>Risks:</i> same as in phases A and B</p>
Orthosis	<p>Digital orthosis liberating the distal interphalangeal joint (worn all the time)</p>	<p>Orthosis from phase (A) worn during the night if the locking isn't efficient</p>	<p>Same as in phase B, postural orthosis at 2 months if flexum or lack of passive winding</p>



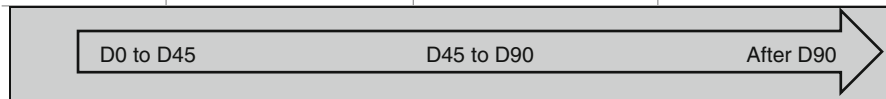
Injuries of the extensor tendons (asides form orthopedic treatment zones 1, 2, and 3)

	Immobilization phase (A)	Fragility phase (B)	Solidity phase (C)
Rehabilitation	<p><i>Therapeutic goals:</i> partial tendon healing, fight against trophic disorders and pain, mobilization in a protected area</p> <p><i>Techniques:</i> Learning the protection rules during the maintenance of the orthosis and the dressing changes (+ control by the orthotist once a week) Transcutaneous vibratory stimulations, analgesic and soft electrotherapy, analgesic and draining massages Passive, then active-assisted mobilization in extension of the immobilized joints Active exercise in flexion of each analytically concerned joint (NO GLOBAL FLEXION) until tension <i>Risks:</i> bad healing and distension of the tendon, stiffness, CRPS</p>	<p><i>Therapeutic goals:</i> regain the active amplitudes, fight against trophic disorders, and maintain the body mapping</p> <p><i>Techniques:</i> Active exercise in extension Active exercise in global flexion until tension Massage around the scar and depressotherapy (adherences), fluidotherapy, infrasounds, ultrasounds, electrostimulation if good extension locking Specific mobilizations of the joints far from the injury Trophic massages, pressotherapy Rehabilitation of the prehensions, occupational therapy <i>Risks:</i> same as in phase A</p>	<p><i>Therapeutic goals:</i> same + complete recuperation of the amplitudes, regain clamping strength, complete functional recovery</p> <p><i>Techniques:</i> Intensify the techniques from phase 2, imitation exercises, specific mobilizations (Mennel) if joint stiffness, stretchings if tendon stiffness Exercise for the clamping strength Functional and leisure exercise <i>Risks:</i> same as in phase B</p>
Orthosis	Immobilization orthosis (depending on the zone), digital orthosis liberating the distal interphalangeal joint (worn all the time)	Orthosis worn by night if risk of distension	Dynamic orthosis to gain amplitude if necessary (at 2 months)



Injuries of the flexor tendons


	Immobilization phase (A)	Fragility phase (B)	Strength phase (C)
Rehabilitation	<p><i>Therapeutic goals:</i> fight against pain and scar disorders, maintain the passive mobility, fight against functional exclusions, and promote intrinsic healing</p> <p><i>Techniques:</i> Draining massages and massages of the scar, depressotherapy and ultrasounds after the scar is closed Analgesic electrotherapy (TENS) Passive pain-free mobilization Infrasounds – manual stimulations of the fingertips Placed and held in the free areas, analytically and globally Simple active mobilizations and Cooney from the 3rd week, depending on the case <i>Risks:</i> ruptures and adhesences</p>	<p><i>Therapeutic goals:</i> same and even intensify phase 1 if necessary. Regain the active amplitudes, coordination, and dexterity</p> <p><i>Techniques:</i> Pressotherapy at D60 if flexum, deep massages, and mobilization of the scar (A1) Simple active analytical and global mobilizations Electrostimulations Stretching of the intrinsic muscles Manipulations and occupational therapy <i>Risks:</i> same as in phase A, functional exclusion</p>	<p><i>Therapeutic goals:</i> intensify the techniques from the 2 previous phases if necessary, complete functional recovery</p> <p><i>Techniques:</i> Specific mobilizations of the joints and increase the intensities of the electrostimulation (B1) Functional exercises according to the job and leisure activities <i>Risks:</i> same as in phases A and B</p>
Orthosis	<p>Duran orthosis – worn during the night after 1 month, depending on the surgeon’s instructions</p>	<p>Postural orthosis after 2 months if there is a flexum or a lack of passive winding</p>	<p>Same as in phase B</p>



18.4 Amputations

Digital amputations

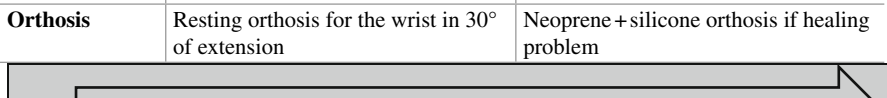
	Cutaneous healing phase	Scar remodeling phase (closed scar)
Rehabilitation	<p><i>Therapeutic goals:</i> fight against pain and vasomotor disorders, prevent stiffness</p> <p><i>Techniques:</i> Electrotherapy TENS (100 Hz) and 1 Hz, transcutaneous vibratory stimulation, digital draining Passive and active mobilizations ++ of the proximal joints <i>Risks:</i> CRPS if inadequate treatment, phantom limb, neuroma...</p>	<p><i>Therapeutic goals:</i> regain strength and amplitude, scar relaxation, functional reintegration, rehabilitation to cold temperatures</p> <p><i>Techniques:</i> Same + fluidotherapy, active electrostimulations Intensify the articular and muscular techniques Scar massages Desensitization and padding of the stump Occupational therapy + rehabilitation to cold temperature (Lewis) <i>Risks:</i> functional exclusion</p>
Orthosis	Protection orthosis	Functional orthosis if painful contact (progressively taking it off) – silk gloves (≠ cold)



18.5 Entrapment Syndromes


Operated carpal tunnel

	Postoperative phase (A)	Healing phase (B)
Rehabilitation	<p><i>Therapeutic goals:</i> fight against inflammation and pain, prevent stiffness in the fingers and the wrist, self-rehabilitation</p> <p><i>Techniques:</i> Transcutaneous vibratory stimulations, cryotherapy, disto-proximal pressotherapy, TENS (100 Hz), analgesic, and draining massages around the scar Passive, then simple active mobilizations without resistance or pain in the wrist and the fingers <i>Risks:</i> CRPS, slackness of the flexor retinaculum</p>	<p><i>Therapeutic goals:</i> same phase (4) if necessary, scar relaxation and mobility of the nerve, progressively regain the grip (since D21), rehabilitation of the sensitivity</p> <p><i>Techniques:</i> Scar massage without distraction, progressive and pain-free Butler mobilization Progressive reinforcement of the thenar and hypothenar muscles (D21) Sensorial stimulations, prehensions, coordination, and dexterity <i>Risks:</i> same + loss of intrinsic strength</p>
Orthosis	Resting orthosis for the wrist in 30° of extension	Neoprene + silicone orthosis if healing problem




Operated entrapment syndrome of the ulnar nerve

	Postoperative phase (A)	Healing phase (B)
Reeducation	<p><i>Therapeutic goals:</i> fight against inflammation and pain, prevent stiffness in the wrist and elbow, self-rehabilitation</p> <p><i>Techniques:</i> Transcutaneous vibratory stimulations, cryotherapy, disto-proximal pressotherapy, TENS (100 Hz), analgesic, and draining massages around the scar Passive, the simple active mobilizations without resistance and under the pain threshold for the wrist, elbow, and fingers</p> <p><i>Risks:</i> CRPS</p>	<p><i>Therapeutic goals:</i> same as in phase (A) if necessary, relaxation of the scar and exercises for the mobility of the nerve, progressively regaining the grasp (from D21), rehabilitation of sensitivity</p> <p><i>Techniques:</i> Scar massages against fibrosis (± ultrasounds), progressive and pain-free Butler mobilization Progressive reinforcement of the hypothenar muscles, the flexor carpi ulnaris, and the adductor pollicis Sensorial stimulations; prehension, coordination, and dexterity exercises</p> <p><i>Risks:</i> same + lack of intrinsic strength</p>
Orthosis	Resting orthosis for the elbow in 30° of flexion (compression in the elbow), orthosis for the wrist in a neutral position (compression in the wrist)	Functional orthosis if necessary



Operated entrapment syndrome of the radial nerve

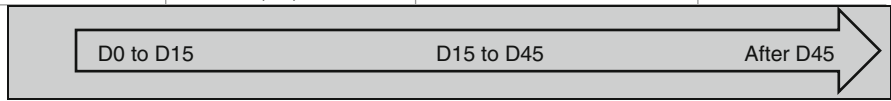
	Postoperative phase (A)	Healing phase (B)
Reeducation	<p><i>Therapeutic goals:</i> fight against inflammation and pain, prevent stiffness in the wrist and elbow, self-rehabilitation</p> <p><i>Techniques:</i> Transcutaneous vibratory stimulations, cryotherapy, disto-proximal pressotherapy, TENS (100 Hz), analgesic, and draining massages around the scar Passive, the simple active mobilizations without resistance and under the pain threshold for the wrist, elbow, and fingers</p> <p><i>Risks:</i> CRPS</p>	<p><i>Therapeutic goals:</i> same as in phase (A) if necessary, relaxation of the scar and exercises for the mobility of the nerve, progressively regaining the grasp (from D21), rehabilitation of sensitivity</p> <p><i>Techniques:</i> Scar massages against fibrosis (± ultrasounds), progressive and pain-free Butler mobilization Progressive reinforcement of the wrist and finger extensors Sensorial stimulations; prehension, coordination, and dexterity exercises</p> <p><i>Risks:</i> same + deficit of the extensors</p>
Orthosis	Resting orthosis for the wrist in 20° of extension (compression in the elbow), orthosis for the wrist and thumb (compression in the wrist)	Functional orthosis if necessary



18.6 Other Current Pathologies of the Hand

Dupuytren disease

	Postoperative phase	Scar phase (closed scar)	Remodeling phase
Rehabilitation	<p><i>Therapeutic goals:</i> fight against cutaneous trophic disorders and pain, prevent stiffness and exclusion syndrome (sensorimotor stimulation)</p> <p><i>Techniques:</i> Simple active exercise in flexion/extension and abduction/adduction of the fingers, stimulations contacting the palm Pressotherapy + vis a latere + electrotherapy (1 Hz) Infrasounds (vibralgic, nostrafon, etc.) TENS (100 Hz) <i>Risks:</i> CRPS, stiffness and healing disorders if maladapted immobilization</p>	<p><i>Therapeutic goals:</i> same + work on the scar</p> <p><i>Techniques:</i> Same Relax the tissues (ultrasounds, hydrotherapy, depressotherapy massages) Electrostimulation of the flexors and extensors Dry fluidotherapy + soft occupational therapy (coordination-dexterity) + rehabilitation of the grips <i>Risks:</i> healing disorders (inflammation, hypertrophy...)</p>	<p><i>Therapeutic goals:</i> same + functional rehabilitation</p> <p><i>Techniques:</i> Same Intensify electrotherapy Gain amplitude</p> <p><i>Risks:</i> same</p>
Orthosis	<p>Dynamic orthosis (Levame) worn during the night after the compressive bandage is removed (D2)</p>	<p>Same</p>	<p>Same + winding posture if necessary</p>



Complex regional pain syndrome

	Hot phase	Cold phase
Rehabilitation	<p><i>Therapeutic goals:</i> fight against pain and vasomotor disorders + stimulation of the palmar mechanoreceptors, prevent stiffness and muscular atrophy</p> <p><i>Techniques:</i> TENS 100 Hz, vibralgic, Scottish baths; draining, analgesic, and trophic massages</p> <p>Soft and slow active-passive mobilizations, static exercises</p> <p>Motor imagery program</p> <p>Hypnosis if asked by the patient</p> <p><i>Risks:</i> maintain the vicious circle of Leriche if maladapted exercise intensity, functional exclusion</p>	<p><i>Therapeutic goals:</i> same + fight against established stiffness + sensorimotor reintegration</p> <p><i>Techniques:</i> Same + fluidotherapy + infrasounds (amplitude > vibralgic) + electrostimulation</p> <p>Occupational therapy</p> <p>Intensify articular and muscular techniques + exercises in compression-decompression (inspired by Watson)</p> <p><i>Risks:</i> same</p>
Orthosis	Resting orthosis with an analgesic purpose (worn during the night ++)	Dynamic orthosis to regain joint amplitudes