

Analysis of OCT Images for Detection of Choroidal Neovascularization in Retinal Pigment Epithelial Layer

Sadaf Ayaz, Sadaf Sahar, Madeeha Zafar, Muhammad Usman Akram
, and Yasser Nadeem

College of Electrical and Mechanical Engineering,
National University of Sciences and Technology, Pakistan
{sadafayaz32,sadafsahar21,usmakram,yassernadeem}@gmail.com,
madeehazafar31eme@yahoo.com

Abstract. Choroidal Neovascularization (CNV) is an age related disease which deals with the Degeneration of Macular tissue. This degeneration causes acute drop in central vision as the age progresses. Therefore it is necessary to identify the changes caused by CNV for the Successful detection of this disease. In CNV the Retinal Pigment Epithelial (RPE) layer encounters changes in different attributes which can be identified with the help of Optical Coherence Tomography (OCT) Images. This paper focuses on analyzing the changes caused in the RPE layer due to CNV. The proposed system segments out RPE layer and observes the changes in RPE layer by calculating different features like Euler Number, Energy, Homogeneity and Correlation. The system is tested on locally gathered dataset of 50 images from different patients and has achieved an accuracy of 98%.

1 Introduction

Aging Macular Degeneration (AMD) is a common eye disease in people aging more than 50 years. This condition is caused because of the damage to the main visual field of the eye. This damage is caused because the macular tissues in the retina of the eye die out [1-2]. All over the world the population of the people suffering from age related diseases is around 25-30 million.

Digital fundus images are normally used for screening of retina to detect this disease but fundus images do not provide detailed imagery of retinal layers [2-4]. Optical Coherence Tomography (OCT) Imaging is a modern technique for taking cross sectional images with a very high resolution. OCT is just like ultrasound. The difference lies in method of imaging. Sound is used in ultra sound imaging whereas light is used when taking OCT images. OCT can provide images of tissues on a very small scale (a micron). OCT images has been very extensively used in the field of ophthalmology.[5]

Choroidal Neo Vascularization (CNV) is caused when the retinal tissues all deposit their waste normally in the form of fat particles in the choroid which




Fig. 1. (Left) Normal Vision, (Right) Loss of central Vision in patients with AMD

is the central visual area for the retina. These fat particles accumulate in the RPE layer resulting in growth of abnormal blood vessels and thickening of the capillaries in the retina as shown in Figure 2 [6].

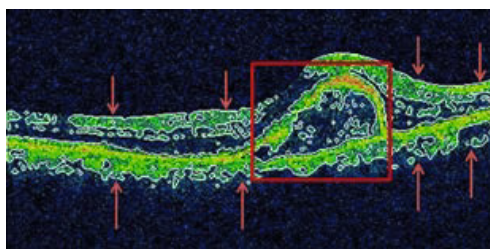


Fig. 2. OCT Image: RPE Layer (Red Arrows), Presence of CNV (Red Square)

In case of normal OCT the RPE layer is smooth with minimum distortions whereas in the OCT image of a patient suffering from CNV, the extra growth of capillaries can be seen in the RPE layer. Figure 3 shows the comparison of normal OCT image to the image of a patient suffering from CNV.

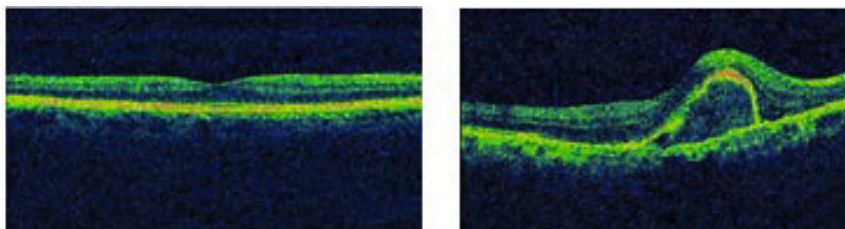


Fig. 3. (Left) OCT Image Of Normal Macula, (Right) OCT Image Of Patient With CNV

This paper consists of 5 sections. Some related work done is explained in section II. Section III explains the Methodology followed for the Segmentation

and Features extraction purpose. This section also explains the classification of the complete Dataset of images on the basis of extracted attributes. Section IV discusses the results of proposed system. Finally conclusion is given in the last section.

2 Related Work

There are many methods and groups all over the world who have worked on computer aided diagnostic systems for retinal diseases using digital fundus images but limited work is done in this field for Analysis of OCT images for the characterization of different diseases [7,8]. But some researchers have done very useful addition in this field for example Chen et al. in [9] have proposed a new approach for deforming registration of OCT retinal images with higher accuracy in comparison of existing 3D methods during the segmentations of the layers. In addition to that a quite simple approach for performing scaling of OCT images has also been introduced to start deformable registration by these researchers.

Texture analysis contains the ability to provide a way for the diagnoses and differentiation of tissue and Ali A.pouyan et al. in [10] have presented a method which could have an important role for the enhancement of computer based OCT quantification technique in future. Like thickness and volume of the retinal layers can help in the diagnosis of disease. Also their results show that it is possible to separate out the retina layers without using systems with ultrahigh resolutions. Another group of researchers in [7,8] have also made very important contribution in the field of OCT image analysis and their research is able to analyse and separate out the RPE layer and quantifies the changes associated with CNV by calculating the values of area for the RPE layer and thickness etc. According to them CNV can be differentiated from the normal OCT image which is important in the use of many ophthalmological practices.

An approach for an automated methodology was presented by authors in [11] for cyst detection in OCT retinal images by using watershed algorithm for the detection of candidate regions in the images and after that the discard of all the possible regions to reduce eligible candidates, which due to some of the properties can be considered as cysts. Finally, a classifier used for the determination of their correspondence to cystic regions or not on the basis of texture features extracted from them. The research in this paper is also a contribution in the area of OCT images Analysis for the detection and classification of CNV on the basis of changes in RPE layer by Analysis of OCT images.

3 Proposed Methodology

The proposed system consists of three phases; image acquisition and pre-processing, Area of interest segmentation and attribute comparison and classification. Figure 4 shows all the phases included in the methodology of our proposed research. Pre-Processing phase is used for the initial processing in order to segment the area of interest from the original image. The CNV detection is done by the analysis of this area of interest.

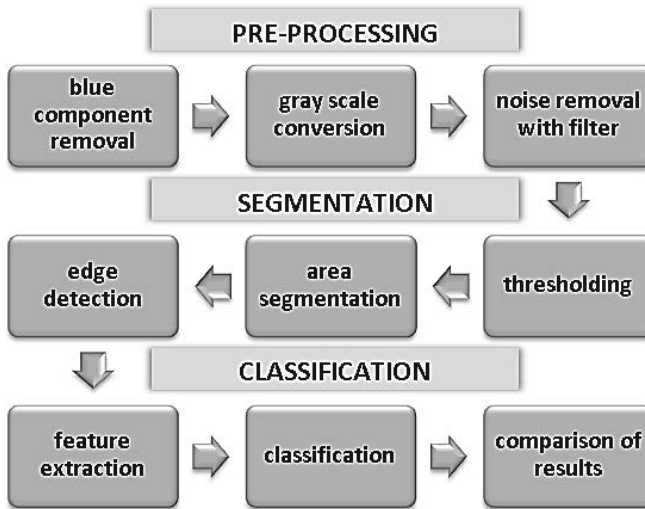


Fig. 4. Flow diagram of proposed system

3.1 Image Acquisition and Pre-processing

Fifty Persons were clinically examined by Ophthalmologist and OCT images are obtained for the observation of changes occurring in abnormal cases and then for the classification on the basis of changes in Normal and Abnormal cases. OCT images of size 240x480x3 of normal and patients suffering from CNV are selected for this study.

It is observed that the OCT image is a blend of primary colours red, green and blue as shown in Figure3. In the OCT images the blue component signifies the vitreous humour layer of the eye and does not provide any useful information hence the blue component is discarded from both normal and diseased image [9]. Only the images with green and red component are kept as further computations are based on these components of OCT images. The images are converted into gray scaled by averaging the red component and green component of the images.

3.2 Image Segmentation

A Threshold value is selected for the segmentation of the region of interest from the images. This threshold is calculated with reference to the Otsu's algorithm for calculating the gray level threshold for the images [13]. After the threshold is calculated the median filtered image is converted to a black and white image by assigning 1 to the values greater than threshold value and 0 to the values less than threshold value.

The Retinal Pigment Epithelial layer is segmented out as a result of thresholding. It is observed that the RPE layer is a thick layer and covers a minimum of 3000 pixels of the OCT image. This layer is segmented out and the boundary is

created using the canny edge detector. The edges obtained are then overlaid on the original image so that the assessment of the patient can be easily done clinically. Figure 6 shows the binary images after thresholding of normal and diseased images respectively and the highlighted normal and diseased OCT images.

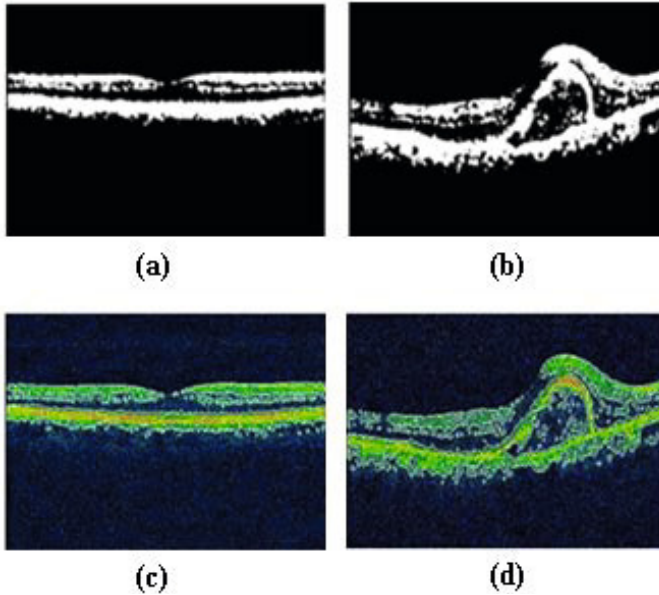


Fig. 5. (a) Binarized Image Of Normal OCT, (b) Binarized Image Of OCT With CNV, (c) Highlighted Edges Of Normal RPE Layer, (d) Highlighted Edges Of RPE With CNV

3.3 Attributes Extraction

For proper classification of OCT images as normal and abnormal, the proposed system extracts different features i.e. Euler Number, Energy, Homogeneity and Correlation.

1. Euler Number (f_1): The Euler Value of an Image gives a value proportional to the number of disruptions and holes in the segmented image.
2. Energy (f_2): Energy depicts how much uniform a certain image is. Energy of the normal OCT image is found out more than the one of the patient suffering from CNV [11].
3. Homogeneity (f_3): Homogeneity is a measure of how closely related are the pixels in an image. The lesser the difference of the values the more homogeneous is an image.
4. Correlation (f_4): Correlation value returns a measure of how correlated a pixel is to its neighbor over the whole image. Correlation is 1 or -1 for a perfectly positively or negatively correlated image.

Table 1 shows the mean values of the extracted features both for set of normal images and diseased images. These feature values are used further for the classification purpose.

Table 1. Mean and standard deviation of feature values of normal and abnormal classes

Attributes	Mean \pm Std Normal	Mean \pm Std Diseased
Euler Number	940.14 \pm 200.05	1483.10 \pm 276.29
Energy	0.93 \pm 0.01	0.90 \pm 0.0155
Homogeneity	0.98 \pm 0.0044	0.96 \pm 0.0065
Correlation	0.5314 \pm 0.0551	0.4445 \pm 0.0597

The significance and contribution of each feature vector member is calculated using Box Plot analysis. Euler value and Homogeneity does not have any Outlier in Box Plot that is why these are considered as most significant features and are assigned more weights during classification

3.4 Classification

After features extraction of each OCT image collected for classification, Gaussian Mixture Models (GMM) has been used for the classification of infected images with CNV. This classifier uses four extracted features as the Feature Vector for classification. GMM makes use of Nave Bayes' theorem and follows probabilistic techniques for the classification of data into classes on the basis of their features. For application of GMM in classification, the data set have two categories i.e. normal and diseased (R_1 & R_2). Training and testing data are the subsets of both these classes and this data is randomly selected during training so that the biasness of the data can be eliminated.

Sample belongs to R_1 if $p(v|R_1)P(R_1) > p(v|R_2)P(R_2)$ else it belongs to class R_2 . Where $p(v|R_n)$ is the probability density function(conditional) and is also called likelihood (v being the feature vector). $P(R_n)$ is the probability of occurrence of a class in the data set. GMM uses Gaussian functions for modeling the conditional probabilities of classes. These probabilities are represented as weighted sums of Gaussian functions and tell us the likelihood of the Gaussian Mixture Model:

$$p(v|R_i) = \sum_{j=1}^{k_i} N(v|\mu_j, \Sigma_j)w_j \quad (1)$$

Weights (w_j) are assigned on the basis of significance of different attributes used as feature vector [14]. Classification is also done by using some other classifiers for the comparison of results with GMM. This comparison is done using the Box Plot Thresholding, KNN, K-Means and Neural Networks.

4 Results and Discussion

The Complete Dataset of Images containing both Normal and Infected Eye images is classified into two classes named Normal and Diseased on the basis of extracted feature values using many different classifiers. The dataset is consisted of 50 total images having 41 Normal and 9 Diseased images. Feature Extraction is performed one by one on each image of Dataset and feature values of all images is collected as a result.

Out of total Images in the dataset, Half of Diseased and Same number of Normal images are used for the training of classifiers and the remaining others are used for the testing and Estimation of Accuracy of classifiers. The classification process is repeated 10 times and training images are selected randomly to avoid any kind of biasness which could affect the testing and accuracy of results. Table-2 shows the Sensitivity and Specificity values on the basis of mean value of total number of truly identified images. It also shows that the accuracy of GMM is much more as compared to others.

Table 2. Comparison of results between two classes using different classifier

Classifier	Sensitivity	Specificity	Accuracy
GMM	88.80%	100%	98%
Box Plot Thresholding	77.70%	95.10%	92%
KNN	50%	87.50%	92.50%
K-Means	33.30%	92.60%	82%
Neural Networks	0%	100%	90%

5 Conclusion

Analysis of Retinal Pigment Epithelium layer is necessary for the detection of Choroidal NeoVascularization causing vision loss with age. The work presented in this paper identifies changes in RPE layer due to CNV. These changes are identified on the basis of values of Euler Value, Energy, Homogeneity and Correlation of RPE layer. CNV has been differentiated from normal OCT image on the basis of these values. Higher Euler value suggests loss of continuity and presence of breaks in OCT image due to CNV. Also higher correlation value of normal image is due to fewer changes in RPE layer. Similarly lesser values of Energy and Homogeneity depict the loss of linearity in case of CNV. Classification of 50 images on the basis of these attribute values using various classifiers is done. The proposed system gives overall accuracy of 98% in the detection of CNV in OCT images.

References

1. Schmitt, J.M., Knuttel, A., Yadlowsky, M., Eckhaus, M.: Optical coherence tomography of a dense tissue - statistics of attenuation and backscattering. Phys. Med. Biol. 38 (1994)

2. Akram, M.U., Khalid, S., Tariq, A., Khan, S.A., Azam, F.: Detection and Classification of Retinal Lesions for Grading of Diabetic Retinopathy. *Computers in Biology and Medicines* 45(1), 161–171 (2014)
3. Tariq, M.U., Akram, A., Shaukat, S.A.: Khan, Automated Detection and Grading of Diabetic Maculopathy in Digital Retinal Images. *Journal of Digital Imaging* 26(4), 803–812 (2013)
4. Akram, M.U., Khalid, S., Khan, S.A.: Identification and Classification of Microaneurysms for Early Detection of Diabetic Retinopathy. *Pattern Recognition* 46(1), 107–116 (2013)
5. Fujimoto, J.G., Brezinski, M.E., Tearney, G.J., Boppart, S.A., Bouma, B., Hee, M.R., Southern, J.F., Swanson, E.A.: Optical biopsy and imaging using optical coherence tomography. *Nat. Med.* 1, 970–972 (1995) [PubMed]
6. Brezinski, M.E., Tearney, G.J., Bouma, B.E., Izatt, J.A., Hee, M.R., Swanson, E.A., Southern, J.F., Fujimoto, J.: Optical coherence tomography for optical biopsy: properties and demonstration of vascular pathology. *Circulation* 93, 1206–1213 (1996)
7. Prashanth, T.R., Paranjape, S.V., Ghosh, S., Dutta, P.K., Chatterjee, J.: Characterization of Changes in Retinal Pigment Epithelium Layer in Choroidal Neovascularization through Analysis of Optical Coherence. In: 2010 IEEE Students' Technology Symposium (TechSym), pp. 39–43 (2010)
8. Shahidi, M., Wang, Z., Zelkha, R.: Quantitative thickness measurement of retinal layers imaged by optical coherence tomography. *Am. J. Ophthalmol.* 1056–1062 (2005)
9. Chen, M., Lang, A., Sotirchos, E., Ying, H.S., Calabresi, P.A., Prince, J.L., Carass, A.: Deformable registration of macular OCT using A-mode scan similarity. In: 2013 IEEE 10th International Symposium on Biomedical Imaging (ISBI), pp. 476–479 (2013)
10. Pouyan, A.A., Naseri, A., Kavian, N.: An Image Processing Technique to Detecting Retina Layers. In: 2010 International Conference on Signal and Image Processing (ICSIP), pp. 7–10 (2010)
11. González, B., Remeseiro, M., Ortega, M.G., Penedo, P.: Automatic Cyst Detection in OCT Retinal Images Combining Region Flooding and Texture Analysis. In: 2013 IEEE 26th International Symposium on Computer-Based Medical Systems (CBMS), pp. 397–400 (2013)
12. Arevalo, J.F., Garcia, R.A., Sanchez, J.G., Fernandez, C.F., Mendoza, A.J., Wu, L., Shields, C.L., Shields, J.A., Fujimoto, J.G., Materin, M.A.: *Retinal Angiography and Optical Coherence Tomography*. Springer, New York (2009)
13. Otsu, N.: A threshold selection method from gray-level histograms. *IEEE Transactions on Systems, Man, and Cybernetics* 9(1), 62–66 (1979)
14. Usman Akram, M., Tariq, A., Almas Anjum, M., Younus Javed, M.: Automated detection of exudates in colored retinal images for diagnosis of diabetic retinopathy. *Applied. Optics.* 51(20) (July 2012)