Surgery for Gliomas

Matthew C. Tate

Abstract Surgical resection, with the goal of maximal tumor removal, is now standard of care for the overwhelming majority of newly diagnosed gliomas. In order to achieve this goal while minimizing the risk of postoperative neurologic deficits, intraoperative brain mapping remains the gold standard. Recent advances in technical aspects of preoperative and intraoperative brain mapping, as well as our understanding of the functional anatomy of the human brain with respect to language, movement, sensation, and cognition, particularly at the subcortical level, have improved our ability to safely perform aggressive resective surgeries in eloquent areas. In this chapter, the functional anatomy of the human brain relevant to intrinsic tumor resection is reviewed. In addition, general principles governing surgical management of patients are highlighted, with a particular emphasis on awake brain mapping.

Keywords Glioma surgery · Mapping

Contents

1 Introduction 31
2 Review of Human Cortical and Subcortical Functional Anatomy 32
  2.1 Motor 32
  2.2 Sensory 34
  2.3 Language 35
  2.4 Vision 37
  2.5 Spatial Cognition 37
3 Tumor Location and Extraoperative Assessment of Functional Regions 37
  3.1 Tumor Imaging 37
  3.2 Identifying Functional Brain Regions 38
4 Preoperative Considerations 41

M.C. Tate (✉)
Department of Neurological Surgery, Northwestern University Feinberg School of Medicine, 676 North Saint Clair Street Suite 2210, 60611 Chicago, IL, USA
e-mail: matthew.tate@northwestern.edu

© Springer International Publishing Switzerland 2015

J. Raizer and A. Parsa (eds.), *Current Understanding and Treatment of Gliomas*, Cancer Treatment and Research 163, DOI 10.1007/978-3-319-12048-5_3

5 Intraoperative Mapping Techniques 42
5.1 Patient Positioning and Incision 42
5.2 Awake Craniotomy 42
5.3 Asleep Craniotomy 43
5.4 Mapping Details 43
6 Neural Plasticity: Implications for Surgical Management of Gliomas 45
7 Conclusions 45
References 46

1 Introduction

Recent data from multiple series have demonstrated the importance of aggressive surgical resection for improved outcomes in glioma. In particular, increased volumetric extent of resection has been shown to directly improve survival in both low-grade [1–5] and high-grade gliomas [6–9]. The mechanism of improved survival is likely by delaying malignant transformation in low-grade gliomas and similarly delaying progression in high-grade gliomas. Given the clear benefit of surgery, the primary goal of glioma surgery is to maximize the extent of resection while minimizing morbidity. Thus, it is imperative that neurosurgeons and neurooncologists have an understanding of the relevant cortical and subcortical functional networks, not only to plan and execute a surgical plan, but also to counsel patients with respect to risks and benefits of surgery. Despite advances in preoperative functional assessment in brain tumor patients, including functional MRI (fMRI), diffusion tensor imaging (DTI), magnetoencephalography (MEG), and transcranial magnetic stimulation (TMS), direct cortical stimulation (DCS) in the operating room remains the gold standard for identifying indispensable functional pathways to preserve function. In this chapter, the relevant cortical and subcortical functional anatomy in the human brain is reviewed, with a particular focus on data from intraoperative DCS. Basic principles guiding the preoperative evaluation, management, and surgical planning for patients with gliomas are discussed. Finally, a detailed description of surgical technique, including modern cortical/subcortical mapping protocols which allow for optimal surgical resection while minimizing neurologic deficits is provided.

2 Review of Human Cortical and Subcortical Functional Anatomy

2.1 Motor

Motor networks in the human cortex are primarily located within the frontal lobe. The primary motor cortex (M1) within the precentral gyrus, is bounded by the central sulcus posteriorly and the precentral sulcus anteriorly. DCS of M1 in

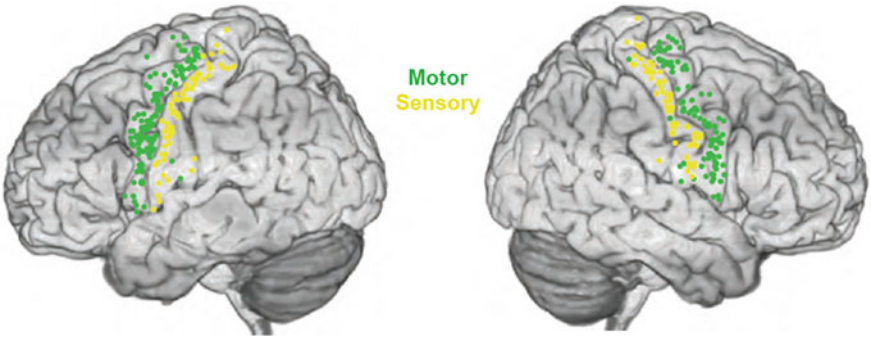

Fig. 1 Motor and sensory direct cortical stimulation data. Rendering of *left* and *right* hemisphere positive stimulation sites eliciting movement (*green*) and dysesthesias (*yellow*) within the precentral and postcentral gyri, respectively. Adapted from Tate et al. [41]

patients undergoing craniotomy reliably produces contralateral muscle contractions in a topographically organized fashion (Fig. 1). This phenomenon was first shown in humans by Sir Horsley in 1891 [10] and was followed by the demonstration of the motor homunculus by Penfield and Boldrey in 1937 [11]. At the subcortical level, DCS of M1 produces movement of a contralateral single muscle or limited group of muscles that is transmitted by the corticospinal tract (CST), and the patient is unable to suppress the movement. An exception to the general rule of contralateral contraction with M1 stimulation is that DCS within palate, pharynx, and tongue regions of M1 can cause bilateral muscle contractions.

In addition to the contribution of M1 to the CST, premotor and supplementary motor cortices anterior to M1 in the frontal lobe also contribute to the CST. The exact function of these so-called "higher-order" motor areas are less well understood, but recent studies have given some insight into their functional contributions. The premotor cortex (PMC), corresponding to Brodmann Area 6, is composed of a dorsal part (dPMC) that includes the posterior part of the superior and middle frontal gyri just anterior to the precentral sulcus, and a ventral part (vPMC) that is defined by the precentral gyrus from the Sylvian fissure to the level of the superior frontal sulcus. PMC lesions result in proximal muscle weakness and difficulty with sequencing of movements of the contralateral limb [12]. DCS of the vPMC in patients undergoing awake craniotomy for tumor resection reliably causes disorders of articulation [13], while DCS in the left hemisphere points to a role in language. The supplementary motor area (SMA), also a part of Brodmann area 6, is located in the medial/posterior portion of the superior frontal gyrus just anterior to leg motor cortex. The SMA is thought to be involved in motor planning, as SMA stimulation causes complex contralateral movements and resection of the SMA produces a stereotypical "SMA-syndrome" characterized by impairment of volitional movements, hemineglect, and dyspraxia of the contralateral limbs with preservation of muscle tone. If the SMA of the dominant (language) hemisphere is involved, difficulty initiating speech may also be observed. Deficits caused by SMA syndrome

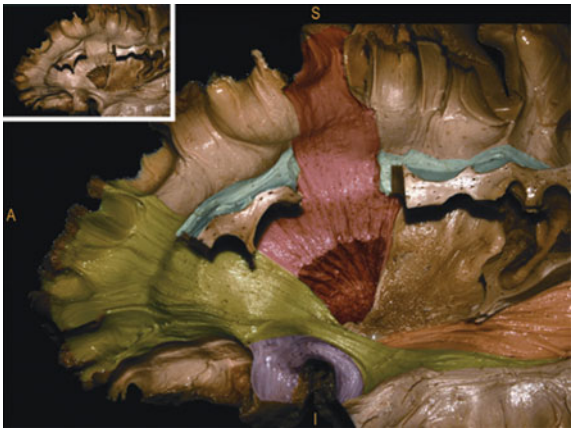

Fig. 2 Major white matter pathways. Dissected *left* hemisphere demonstrating main white matter pathways. Inferior frontal occipital fasciculus (IFOF, *green*); uncinated fasciculus (UF, *violet*); superior longitudinal fasciculus (SLF, *blue*); corticospinal tract (CST, *orange*). Inset shows colors prior to colorization. Adapted from De Benedictis et al. [42]

typically resolve within a few months postoperatively [14, 15]. As with M1, the SMA also demonstrates somatotopy: leg representation is most posterior, face is most anterior, and the arm region is located in between [14]. The frontal eye field (FEF) of the frontal lobe is located within the middle frontal gyrus just anterior to dPMC and is involved in saccadic eye movement. Lesions of the FEF impair voluntarily contralateral gaze, and DCS may elicit conjugate eye movements toward the contralateral side [16, 17].

In addition to motor regions located in the frontal lobe, the parietal lobe is involved in tuning of movement (preparation, control, adjustment). For example, the primary somatosensory area (S1), discussed further in the sensory section below, can produce complex motor movements when stimulated. Other proposed parietal lobe functions include visuomotor transformation and coding of motor acts such as grasping [18].

At the subcortical level, the major descending pathway is the corticospinal tract (CST) which originates as axons of pyramidal neurons within the layer V of M1 that travel through the centrum semiovale, corona radiata, posterior limb of the internal capsule, cerebral peduncle, pyramidal decussation in the medulla, and then descends as the lateral corticospinal spinal tract in the spinal cord (Fig. 2). The other major descending motor system is the corticobulbar tract, which originates in the cortical motor areas described above and descends alongside the corticospinal tracts before eventually projecting to brainstem motor cranial nerve nuclei bilaterally. The exception to this rule is innervation to the lower face, which is unilateral.

2.2 Sensory

The primary sensory pathway of relevance to glioma surgery is the posterior column–medial lemniscus pathway. Vibration, proprioceptive, and light touch sensory information from the periphery is detected by sensory neurons that have their cell

body in the dorsal root ganglion and axon that ascends within the posterior column of the spinal cord and synapse onto ipsilateral gracile and cuneatus nuclei that are devoted to lower body and upper body sensation, respectively, within the caudal medulla. Second-order axons then cross the midline and ascend within the medial lemniscus within the contralateral brainstem and midbrain before eventually synapsing onto neurons of the ventral posterior lateral (VPL) nucleus of the thalamus. Neurons of the VPL then project to the layers III and IV of S1 [19]. S1 is within the postcentral gyrus of the parietal lobe, and electrical stimulation of S1 causes sensory perception, typically described as tingling (Fig. 1), in a localized region of the contralateral body, as initially described by Cushing in 1909 [20].

2.3 Language

2.3.1 Hemispheric Dominance

The concept of left hemispheric dominance for language was first proposed by Paul Broca in 1865 [21]. Current data are that for 85 % of the population the left hemisphere is dominant, while 9 % of patients have bilateral representation, and 6 % have right-sided dominance. For right-handed patients, 98 % have left-sided dominance. Thus, clinical investigation of dominance, the gold standard being the Wada test, is typically reserved for left-handed or ambidextrous patients. In addition to language, the left hemisphere is typically involved in logical problem solving and calculation. Conversely, the right hemisphere is specifically devoted to facial recognition, tasks involving visuospatial manipulation, and musicality [22].

2.3.2 Comprehension

Language comprehension was described by Wernicke as residing in the posterior superior temporal gyrus [23]. DCS studies have further expanded the region of language comprehension to include the posterior portion of both the superior and middle temporal gyri, as well as the inferior parietal lobule superior to the Sylvian fissure. Damage to any of these areas can result in a receptive aphasia, in which the patient can still produce written or oral language with normal grammar/syntax/prosody, but the word content is incorrect, often with neologisms or word salad. In addition, the ability to repeat words and name pictures is compromised, although naming and language comprehension may be mediated by distinct regions of the posterior superior temporal lobe [24]. In addition, the ability to sing and to recite memorized passages is maintained. If similar areas are damaged in the nondominant hemisphere, dysprosody may occur, which is the inability to detect the pitch, rhythm, or emotional content of speech. More recent studies have aimed to further dissect various aspects of language within the parietal-temporal-occipital junction. From these studies, we have learned that the posterior temporal lobe is involved in reading and word retrieval but not particularly involved in word repetition.

2.3.3 Language Output

Classically, the final common pathway of language output is known as Broca's area, which encompasses the pars triangularis and pars opercularis within the posterior third of the inferior frontal gyrus. However, recent studies point to the ventral dPMC as the final common speech output region, while Broca's area may be more involved in higher order speech processing. Thus, stimulation of vPMC typically causes overt speech arrest, while stimulation at Broca's area causes dysnomias. Interestingly, the inferior frontal gyrus of the nondominant hemisphere appears to be involved in the speech prosody (rhythm/stress/intonation of speech), with lesions to this area causing flat, unemotional speech [25]. In addition, as mentioned earlier in the chapter, the SMA of the dominant hemisphere is involved in speech initiation, and stimulation can cause temporary speech arrest or vocalization. Finally, the dominant insular cortex may plan an important role in speech planning [26].

Recent insights from cortical stimulation studies have refined our understanding of the relationship of writing. While circuits involved in writing do correspond to the same hemisphere as oral language, at least some of the writing sites are partially distinct, as evidenced by the presence of writing deficits despite negative mapping at traditional language sites. Areas shown to be important for writing function include the dominant hemisphere superior parietal lobe, supramarginal gyrus, insula, middle and inferior frontal gyri, and SMA [27].

2.3.4 Subcortical Language Representation

The major subcortical pathways subserving oral language function as identified by direct intraoperative stimulation are the superior longitudinal fasciculus (SLF) and inferior occipito-frontal fasciculus (Fig. 2). The SLF connects the parietal/temporal region with the frontal lobe and is composed of two functionally distinct white matter pathways—the arcuate fasciculus (AF) and an indirect pathway parallel and lateral to the AF termed the lateral SLF (latSLF). The AF (also termed the dorsal phonologic stream) connects the posterior middle and inferior frontal gyri with the posterior portion of the middle and inferior temporal gyri, with interruption at any site along the pathway resulting in phonological disturbances. The latSLF, which connects the posterior superior temporal gyrus, supramarginal gyrus, and primarily vPMC, is involved in speech perception and articulation. The inferior frontal occipital fasciculus, also termed the ventral semantic stream, is involved with semantic aspects of speech and stimulation of the pathway intraoperatively produces semantic paraphasias. Finally, the subcallosal fasciculus, connecting the mesial frontal lobe structures (SMA, cingulate) to the caudate nucleus may mediate the control of language, with lesions resulting in transcortical motor aphasias characterized by nonfluent aphasia with intact repetition.

A number of studies have investigated the representation of languages in multilingual patients. A consistent finding is that both shared and language-specific sites are present in bilingual patients. While primary language and shared language

sites are found throughout the temporal, parietal, and frontal lobes, distinct secondary language sites are located in the posterior temporal and parietal regions [28]. Interestingly, a recent study using DCS in bilingual patients implicate the dominant posterior temporal area and SLF in mediating language switching [29].

2.4 Vision

Visual information enters the retina and is transmitted via axons of retinal ganglion cells in the optic nerves, which cross at the optic chiasm and continue as the optic tracts which synapse in the lateral geniculate nucleus (LGN) of the thalamus. Cells of the LGN then project to the primary visual cortex of the occipital lobe via a fan-like projection of fibers (optic radiations) that pass lateral and superior to the atria and temporal horn of the lateral ventricle. The inferior optic radiations (Meyer's loop) project through the temporal lobe, carrying visual information from the contralateral superior visual field, with lesions causing a "pie in the sky" contralateral homonymous superior quadrantanopsia, though the ipsilateral eye is typically affected to a greater extent because of the lateral position of ipsilateral relative to contralateral eye fibers in the optic radiations [19]. Superior optic radiations project through the inferior parietal lobe and carry visual information from the contralateral inferior quadrants. The primary visual cortex resides in the occipital lobe along both borders of the calcarine sulcus and is retinotopically organized.

2.5 Spatial Cognition

The nondominant parietal lobe has been implicated in visuospatial perception, with damage to this region in humans producing a clinical syndrome of unilateral neglect, where patients essentially ignore the left half of their visual field. Recent studies using a line bisection task in awake human patients undergoing DCS has further defined the regions responsible for spatial cognition as both the supramarginal gyrus and posterior superior temporal lobe of the nondominant hemisphere [30]. Subcortically, both the optic radiations and nondominant SLF are involved in visuospatial information transmission.

3 Tumor Location and Extraoperative Assessment of Functional Regions

3.1 Tumor Imaging

Preoperative image of patients harboring gliomas begin with standard MRI sequences, most importantly T1-weighted images with gadolinium and T2/FLAIR.

In addition to providing anatomic localization of the tumor, the presence of enhancing tumor presents a target for surgical resection, as tumor recurrence risk is greatest within 2 cm of the enhancing rim [31]. Also, enhancement generally indicates the presence of a high-grade tumor, although there are exceptions. FLAIR sequences demonstrate the extent of edema, although one cannot determine the relative contributions of tumor versus vasogenic edema. With that caveat, for the case of low-grade gliomas (LGG), FLAIR signal is generally considered the target of resection. MR spectroscopy may be a useful adjunct in the setting of previously treated patients for which the diagnosis of recurrence versus treatment effect is equivocal.

3.2 Identifying Functional Brain Regions

3.2.1 Anatomic Localization of Functional Regions with MRI and DTI

In order to determine the relationship of the tumor to the Rolandic (sensorimotor) cortices, it is imperative that the surgeon be able to localize the central sulcus from preoperative MRI. Multiple methods exist for identifying the central sulcus (CS). On high-vertex axial images, mirror-image transverse sulci that are nearly perpendicular to the midline represent the CS (Fig. 3). The "hand knob", an omega-shaped region of the precentral gyrus, can usually be seen anterior to the CS. Another method is to analyze a sagittal MRI image at the midline. The cingulate sulcus is identified and

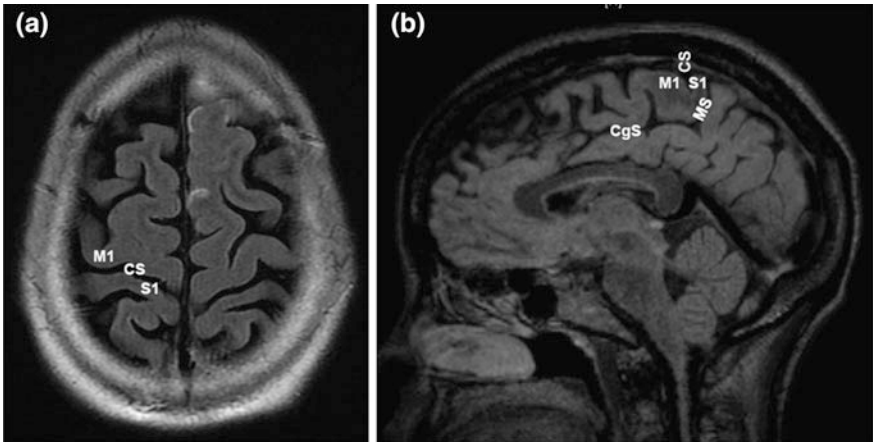

Fig. 3 Primary motor and sensory cortex landmarks on MRI. **a** Axial plane cut near the vertex illustrating hand knob within primary motor area (*M1*) of precentral gyrus and primary sensory area (*S1*) of postcentral gyrus anterior and posterior to central sulcus (*CS*), respectively. **b** Sagittal MRI slice just off *midline* showing paracentral lobule containing *M1*, *S1*, and *CS*. In this view, the cingulate sulcus (*CgS*) at its posterior extent angles superiorly to form the marginal sulcus (*MS*), which is continuous with the postcentral sulcus that forms the posterior border of *S1*

followed posteriorly and then superiorly where it terminates as the marginal sulcus. Immediately anterior to the marginal sulcus is the paracentral lobule, which is a medial extension of both the precentral (motor) and postcentral gyri of the lateral hemisphere. A third method utilizes a sagittal MRI image through the superficial portion of the inferior frontal gyrus, where pars triangularis and pars opercularis are identified. The vPMC is located just posterior to the precentral sulcus, and just posterior to vPMC is the inferior portion of the postcentral gyrus.

In addition to these topographic assessments of sensorimotor function, diffusion tensor imaging (DTI) is emerging as a routine part of preoperative evaluation of brain tumor patients as well as an important intraoperative adjunct to DCS. DTI fundamentally measures the degree of water diffusion within brain compartments, with more anisotropic regions such as white matter tracts having restricted directionality. The diffusion tensor can be evaluated for each MRI voxel of interest and a three-dimensional map is generated which accurately displays major white matter bundles, such as the CST, AF, SLF, IFOF, ILF, optic radiations, corpus callosum, and cingulum. While the process is associated with some inherent error and must be verified with direct stimulation in the operating room, in our experience DTI is helpful in determining the mapping strategy for a given tumor, discussing expectations with patients, and improving the efficiency of mapping in the operative room. As a general rule, DTI maps tend to be larger than that observed by direct stimulation, suggesting that resection of a significant part of a DTI-defined tract can be well tolerated in terms of maintaining function and highlighting the importance of direct stimulation during resection.

In contrast to preoperative localization of cortical and subcortical motor function, for which the standard MRI, DTI, and fMRI findings are relatively consistent between patients, functional language circuits are more diffuse and variable, making anatomic localization preoperatively more difficult. One particularly promising strategy is the use of preoperative DTI to localize language circuits. Recent data from a series of 230 patients undergoing glioma resection for whom the concordance of preoperative DTI with direct subcortical stimulation during surgery demonstrated a high concordance rate for the CST (motor), SLF (phonemic language), and frontal occipital fasciculus (semantic language) [32]. Thus, DTI is becoming an important preoperative and intraoperative adjunct to direct cortical mapping.

3.2.2 Functional Magnetic Resonance Imaging (fMRI)

fMRI is based on the principle that neurons of more active brain regions receive increased blood flow, which results in a localized increase of oxyhemoglobin (diamagnetic) relative to deoxyhemoglobin (paramagnetic). While localization of primary motor and sensory cortices by fMRI is accurate, several issues plague its widespread clinical use in brain tumor patients. First, at its most basic level, fMRI only demonstrates areas of increased blood flow, which is an indirect measure of neuronal activity. Also, the time lag between neuronal firing and diverted blood

flow may be problematic for interpretation, particularly for complex actions involving several brain regions or which have overlapping neural circuitry, such as language or higher order cognitive function. fMRI at best illustrates which brain regions are involved in a particular task, but it does not indicate which regions are functionally necessary.

3.2.3 Magnetoencephalography (MEG)

Another methodology for detecting recruited neural circuitry during a given activity is MEG. Unlike fMRI, MEG directly measures the magnetic field produced by electrical activity in the brain, specifically dendritic potentials. During a particular task, changes in the magnitude of α, β, and γ band cerebral oscillations can be detected, with higher and lower frequencies representing synchronization and re-synchronization, respectively [33]. For example, changes in the γ frequency band are associated with higher order cognitive processes such as language processing [34]. MSI, which refers to incorporating MEG-based functional data into intraoperative brain navigation software, is being utilized in some centers. A recent study demonstrated a 100 % negative predictive value and 64 % positive predictive value for correlation of intraoperative stimulation of functional sites with MEG [35]. Thus, MEG presents a promising technology for identifying function or absence of function near the tumor preoperatively, although additional validation with DCS and outcome data will be necessary before routine use is recommended.

3.2.4 Transcranial Magnetic Stimulation (TMS)

A more recent technology for mapping cortical function preoperatively is TMS. TMS is a noninvasive technique that generates a precise, local magnetic field that induces an action potential in a small population of neurons. In the outpatient setting, through a simple algorithm the patient's MRI data can be coregistered with the TMS software, allowing for precise delivery of the magnetic field to the cortical surface. A magnetic field is delivered to specific regions of the primary motor cortex using the MRI-based map, resulting in pyramidal neuron activation and subsequent movements of the relevant contralateral muscle groups, which can then be detected by EMG. Recent data indicate that TMS-based motor maps correlate well with DCS in the operating room [36]. TMS has also been investigated as preoperative test for localization of language functions, though these data are somewhat less consistent compared to motor mapping [37]. Nonetheless, TMS represents a very promising modality not only for preoperative mapping of various cerebral functions but also a tool to study cortical plasticity before and after tumor resection, an important consideration for surgical strategies following initial resection.

4 Preoperative Considerations

After initial imaging studies to evaluate the tumor characteristics location and its location to known functional pathways and a careful neurological examination, it is important to consider the goals of surgery. For patients with diffuse disease, poor performance status, or for tumors located in the basal ganglia, thalamus, or brainstem, a biopsy to establish diagnosis may be the most prudent course of action. For a patient with a tumor within the primary motor cortex that has imaging characteristics of a low-grade glioma and minimal or no functional deficit, observation with frequent serial MRI scans is reasonable, based on the concept that additional functional pathways may be recruited over time. In these patients, a worsening neurologic deficit or evidence of progression would be criteria for operative intervention. Otherwise, craniotomy with the goal of maximal resection while minimizing morbidity is typically the first course of action. Once the decision is made to proceed with resection, the next major decision is whether the patient needs direct cortical mapping. Given the broad distribution of functional areas in the human brain, the variation of function between patients, and the diffuse nature of intrinsic brain tumors, direct cortical and subcortical stimulation mapping can be justified for any intrinsic tumor, independent of hemisphere. At a minimum, tumors in the following regions require direct mapping, as they involve motor, sensory, or language areas: bilateral precentral and postcentral gyri, left middle/posterior temporal lobe, left inferior parietal lobule, and middle/posterior left superior/middle/inferior frontal gyri. With the exception of motor mapping, which can be performed with the patient under general anesthesia, these surgeries are performed under awake conditions. It is our tradition to also perform motor mapping in the awake state, as the efficiency and fidelity of the motor map are improved with the patient under local anesthesia. Patients with less than antigravity strength (0–2/5) or with significant preoperative language deficits (>25 % error rate) that do not improve with short-course steroids may not be good candidates for mapping. Also pediatric patients or more generally patients who may not be able to cooperate with the intraoperative tasks should not be offered awake craniotomy. For these scenarios, the approach would be able to perform either asleep mapping (for tumors in/near motor cortex) or to perform a more conservative resection based on anatomic imaging and available preoperative functional data. Finally, for the subset of patients with preoperative breakthrough seizures despite adequate anticonvulsant trials, electrocorticography can be used to guide resection of seizure foci in addition to the planned tumor resection. Such electrocorticography-guided glioma resections are particularly effective in reducing long-term seizure profiles in the pediatric population [38].

5 Intraoperative Mapping Techniques

5.1 Patient Positioning and Incision

The main considerations for positioning the patient in the operating room are related to the location of the tumor. A recent paper by Berger and Hadjipanayis [16] provides an excellent review of patient positioning and suggested skin incision as a function of tumor location. After appropriate positioning, all pressure points are padded. Importantly, the contralateral body must remain free of lines, blood pressure cuff, etc., so that it can be readily visualized during mapping. A heating blanket is placed to ensure temperature >36 °C. Intravenous steroids (4 mg decadron) and preoperative antibiotics (1–2 g cefazolin) are administered. Anticonvulsants are also administered, either the patient's home regimen or a dilantin load (15 mg/kg) if not previously on anticonvulsants. If elevated intracranial pressure is a concern, mannitol (1 g/kg) can be administered. Finally, a time-out procedure verifying patient characteristics, tumor side, surgical plan, expected blood loss, and details of the proposed mapping strategy is essential.

5.2 Awake Craniotomy

Ultimately, the success of awake craniotomy and language mapping relies on a cooperative patient. Given that the length of surgery may be several hours, it is important to have the patient comfortably sedated for the portions of the operation when mapping is not performed. While there are multiple options, a combination of propofol (≤100 μg/kg/min) and remifentanil (≥0.05 μg/kg/min) is common. It is important to ensure adequate ventilation and thus not to over sedate. For mild obstruction, a nasal airway can be helpful. Propofol is administered at the time of foley administration and just prior to Mayfield pin application. Lidocaine/bupivacaine local anesthetic is also administered at the three pin sites. Specifically, the local block should address the territories of the supraorbital (above midpoint of orbital rim), auriculotemporal (1.5 cm anterior to tragus), zygomaticotemporal (midway between supraorbital ridge and the posterior margin of the zygoma), and lesser/greater occipital nerves (along line extending from inion to mastoid), depending on the location of the anterior–posterior extent of the scalp incision. The propofol/remifentanil infusion is titrated during incision, muscle dissection, and craniotomy so that the patient remains comfortably sedated and breathing comfortably. After the bone flap is removed, all sedatives are discontinued and the patient is allowed to wake fully prior to opening the dura, as emergence can otherwise cause coughing and brain herniation, particularly for tumors with significant mass effect/edema. In addition, a 30-gauge needle is used to administer local to the dura along the middle meningeal artery. During mapping, propofol should be within six inches of the IV line and ice cold lactated Ringer's solution

should be available should seizures occur during stimulation. Following mapping, propofol/remifentanil infusions are used to slowly increase the level of sedation while avoiding respiratory depression.

5.3 Asleep Craniotomy

The patient is premedicated with midazolam and then brought to the operating room. Induction is performed using fentanyl and propofol. The patient is paralyzed prior to intubation and the blockade is reversed following skin incision. General anesthesia is maintained with nitrous oxide (70 %), low-dose inhalational agent (typically <0.5 MAC isoflurane), and a fentanyl infusion (2 μg/kg/hr). After bone flap removal, mannitol and/or hyperventilation can be utilized if the brain appears full. Prior to initiation of motor mapping, the contralateral arm and leg should be uncovered and adequate patient temperature (>36 °C), and full reversal of neuromuscular blockade should be confirmed. As with awake mapping, first cold saline and then propofol can be used to abort seizure activity during mapping. Following completion of motor mapping, neuromuscular blockade can be resumed and is not reversed until after Mayfield pin removal. Fentanyl infusion is continued through scalp closure.

5.4 Mapping Details

5.4.1 Sensory/Motor Mapping

Following dural opening, an Ojemann Cortical Stimulator (biphasic square wave, 60 Hz, 1 ms duration, current range 2–16 mA peak–peak) is brought into the field for motor mapping. Stimulation is performed by applying a bipolar electrode to the cortical surface for 2 s. For asleep motor mapping, a starting current of 4 mA (peak–peak) is applied the primary motor cortex (as localized on MRI as discussed above), and the current increased in intervals of 2 mA until either an overt motor response or reproducible EMG activity in the muscle is noted. This latter EMG-based method is more sensitive than muscle contraction, allowing for decreased stimulation threshold and thus decreased risk of intraoperative seizure activity [39]. Positive cortical sites are labeled with sterile numbered paper squares and/or captured and saved onto the patient's navigated MRI sequence. Typically, motor stimulation is elicited in the face or hand region of the motor strip. Following mapping of the primary motor area, sensory mapping may be performed within the postcentral gyrus at the same current intensity, with patients typically reporting dysesthesias. Respecting the positive motor and sensory sites, cortical window(s) are opened to provide adequate access to the intrinsic tumor below the surface. Subcortical motor mapping is performed once the resection nears the CST system

descending corticospinal fibers, internal capsule, cerebral peduncle. Prior to dural closure, a final stimulation at the cortical surface with preserved EMG activity distally provides confidence to the surgeon that the entire motor circuit is intact, whether subcortical stimulation was positive or not. Thus, even in the presence of a new postoperative motor deficit, the patient can be reassured that function will likely return.

5.4.2 Awake Language Mapping

For patients undergoing awake language mapping, all sedation is discontinued prior to dural opening. After the dura is opened and prior to mapping, orientation and counting are checked to ensure a baseline level of patient function and cooperation. The motor pathways are identified as described for asleep motor mapping, with the exception that stimulation is started at a lower current (1 mA) and increased in intervals of 0.5 mA. Language mapping begins a simple counting paradigm to investigate sites of speech arrest (typically within vPMC). Next, a picture naming task is employed where the patient looks at a computer screen and identifies simple objects presented at 4 s intervals. All sources of extraneous noise (suction tubing, pulse oximeter volume, etc.) are reduced to a minimum, and the patient is equipped with a microphone to ensure that the surgical team can hear all responses. The ability of the patient to correctly perform the task is verified prior to intratask stimulation to ensure that the sedation is adequately reversed and that there are no anesthesia-related changes from baseline language function. It may be necessary to adjust the draping, increase the time interval between picture refreshing, or adjust the patient's microphone setting to optimize patient comfort/cooperation and mapping efficiency. Once reliable picture naming is established, cortical stimulation is performed at 1 cm spacing throughout the exposed cortex. Stimulation is performed just prior to a picture change, and each stimulation-accompanied picture change is followed by one without stimulation to allow for recovery to baseline if an error is made and to serve as an internal control. A site is considered positive if stimulation-induced errors were present for at least 2 out of 3 trials. For each picture, the patient is asked to state "This is a …." followed by the object name, to enable the surgeon to distinguish speech arrest from anomia. After picture naming is complete, a similar stimulation paradigm is employed as the patient is asked to read a series of words presented on the computer screen, and sites with stimulation-induced alexia/dyslexia are recorded. For multilingual patients, given that some representation of each language is distinct, it is important to map each language separately, starting with the patient's primary language [28]. After localizing cortical representation of language, a corticectomy is planned utilizing these patient-specific functional data. During tumor resection, frequent subcortical stimulation, in conjunction with DTI tracts incorporated within the MRI-based navigation software and more importantly the surgeon's three-dimensional knowledge white matter anatomy, allows for reliable identification of the major language tracts, particularly the SLF/AF and IFOF. Subcortical stimulation of the SLF, AF, and IFOF at any

part of the pathway reproducibly elicits dysarthria, phonemic paraphasias, and semantic paraphasias, respectively. In addition to these awake mapping techniques, the patient is asked to perform relevant functional tasks continuously throughout the resection as a method of functional monitoring.

6 Neural Plasticity: Implications for Surgical Management of Gliomas

Given the increasing evidence for redistribution of neural function in patients harboring gliomas, particularly in the case of low-grade gliomas (LGG), taking advantage of this property is becoming an important aspect of tumor management. For example, patients with LGG in the primary motor cortex may be observed over some period of time to allow for unmasking of latent or parallel circuits so that when resection becomes mandatory due to tumor growth or worsened neurologic function, the primary motor circuits are farther away from the tumor center. More recently, a number of groups have endorsed a strategy pioneered by Duffau which takes advantage of surgery-induced plasticity for LGG [40]. For patients with a limited first resection due to positive mapping findings within the planned resection field, the patient is allowed to recover and functional mapping is continued post-operatively via fMRI. Over the course of a few years, the eloquent function redistributes, presumably triggered by the initial surgery and/or long-standing slowly progressive tumor infiltration. Thus, at a second surgery the cortical area once devoted to a functional pathway which has been redistributed can be safely resected after proper confirmation of this functional shift with DCS. Importantly, this functional plasticity allowing for a more complete resection can occur over a relatively short time period relative to the expected time scale of tumor transformation to a higher grade.

7 Conclusions

The goal of modern glioma surgery is to maximize extent of resection while minimizing neurologic deficits. For patients with tumors in or near eloquent brain regions, DCS during resection allows for accurate localization of functional circuits at both the cortical and subcortical levels, including motor, sensory, language, vision, and spatial attention. In addition to direct cortical/subcortical stimulation, recent advances in preoperative mapping techniques such as fMRI, magnetoencephalography, diffusion tensor imaging, and TMS allow neurosurgeons to tailor respective strategies based on an individual patient's occupation, goals, and hobbies, thereby achieving not only the oncologic goals of maximal resection but also allowing the patient to return to normal life postoperatively.

References

1. Capelle L et al (2013) Spontaneous and therapeutic prognostic factors in adult hemispheric World Health Organization Grade II gliomas: a series of 1097 cases: clinical article. J Neurosurg 118(6):1157–1168
2. Claus EB et al (2005) Survival rates in patients with low-grade glioma after intraoperative magnetic resonance image guidance. Cancer 103(6):1227–1233
3. Jakola AS et al (2012) Comparison of a strategy favoring early surgical resection vs a strategy favoring watchful waiting in low-grade gliomas. JAMA 308(18):1881–1888
4. Smith JS et al (2008) Role of extent of resection in the long-term outcome of low-grade hemispheric gliomas. J Clin Oncol 26(8):1338–1345
5. van Veelen ML et al (1998) Supratentorial low grade astrocytoma: prognostic factors, dedifferentiation, and the issue of early versus late surgery. J Neurol Neurosurg Psychiatry 64 (5):581–587
6. Keles GE, Anderson B, Berger MS (1999) The effect of extent of resection on time to tumor progression and survival in patients with glioblastoma multiforme of the cerebral hemisphere. Surg Neurol 52(4):371–379
7. Lacroix M et al (2001) A multivariate analysis of 416 patients with glioblastoma multiforme: prognosis, extent of resection, and survival. J Neurosurg 95(2):190–198
8. Sanai N et al (2011) An extent of resection threshold for newly diagnosed glioblastomas. J Neurosurg 115(1):3–8
9. Stummer W et al (2006) Fluorescence-guided surgery with 5-aminolevulinic acid for resection of malignant glioma: a randomised controlled multicentre phase III trial. Lancet Oncol 7 (5):392–401
10. Horsley V (1891) The Croonian Lecture: on the mammalian nervous system, its funcitions and their localization, determined by an electrical method. Philos Trans Royal Soc London 82:60
11. Penfield W, Boldrey E (1937) Somatic motor and sensory representation in the cerebral cortex of man as studied by electrical stimulation. Brain 60:55
12. Freund HJ, Hummelsheim H (1985) Lesions of premotor cortex in man. Brain 108(Pt 3):697–733
13. Duffau H et al (2003) The role of dominant premotor cortex in language: a study using intraoperative functional mapping in awake patients. Neuroimage 20(4):1903–1914
14. Fontaine D, Capelle L, Duffau H (2002) Somatotopy of the supplementary motor area: evidence from correlation of the extent of surgical resection with the clinical patterns of deficit. Neurosurgery 50(2):297–303 (discussion 303–305)
15. Rostomily RC et al (1991) Postoperative deficits and functional recovery following removal of tumors involving the dominant hemisphere supplementary motor area. J Neurosurg 75 (1):62–68
16. Berger MS, Hadjipanayis CG (2007) Surgery of intrinsic cerebral tumors. Neurosurgery 61(1 Suppl):279–304 (discussion 304–305)
17. Blanke O et al (2000) Location of the human frontal eye field as defined by electrical cortical stimulation: anatomical, functional and electrophysiological characteristics. NeuroReport 11 (9):1907–1913
18. Fogassi L, Luppino G (2005) Motor functions of the parietal lobe. Curr Opin Neurobiol 15 (6):626–631
19. Blumenfeld H (2002) Neuroanatomy through clinical cases, vol xxii. Sinauer, Sunderland, p 951
20. Cushing H (1909) A note upon the faradic stimulation of the postcentral gyrus in conscious patients. Brain 32:10
21. Broca P (1865) On the seat of the faculty of articulate language. Bulletin Soc Anat Paris 6:57
22. Nolte J, Sundsten JW (2002) The human brain: an introduction to its functional anatomy, vol xiii, 5th edn. Mosby, St. Louis, p 650
23. Wernicke C (1874) Der aphasische Symptomencomplex. Kohn und Weigert, Breslau

24. Gatignol P et al (2004) Double dissociation between picture naming and comprehension: an electrostimulation study. NeuroReport 15(1):191–195
25. Nolte J (2009) The human brain: an introduction to its functional anatomy, vol xii, 6th edn. Mosby/Elsevier, Philadelphia, p 720
26. Dronkers NF (1996) A new brain region for coordinating speech articulation. Nature 384 (6605):159–161
27. Scarone P et al (2009) Agraphia after awake surgery for brain tumor: new insights into the anatomo-functional network of writing. Surg Neurol 72(3):223–241
28. Lucas TH 2nd, McKhann GM 2nd, Ojemann GA (2004) Functional separation of languages in the bilingual brain: a comparison of electrical stimulation language mapping in 25 bilingual patients and 117 monolingual control patients. J Neurosurg 101(3):449–457
29. Moritz-Gasser S, Duffau H (2009) Evidence of a large-scale network underlying language switching: a brain stimulation study. J Neurosurg 111(4):729–732
30. de Schotten M Thiebaut et al (2005) Direct evidence for a parietal-frontal pathway subserving spatial awareness in humans. Science 309(5744):2226–2228
31. Wallner KE et al (1989) Patterns of failure following treatment for glioblastoma multiforme and anaplastic astrocytoma. Int J Radiat Oncol Biol Phys 16(6):1405–1409
32. Bello L et al (2010) Intraoperative use of diffusion tensor imaging fiber tractography and subcortical mapping for resection of gliomas: technical considerations. Neurosurg Focus 28 (2):E6
33. Pfurtscheller G (1992) Event-related synchronization (ERS): an electrophysiological correlate of cortical areas at rest. Electroencephalogr Clin Neurophysiol 83(1):62–69
34. Eulitz C et al (1996) Oscillatory neuromagnetic activity induced by language and non-language stimuli. Brain Res Cogn Brain Res 4(2):121–132
35. Martino J et al (2011) Resting functional connectivity in patients with brain tumors in eloquent areas. Ann Neurol 69(3):521–532
36. Picht T et al (2011) Preoperative functional mapping for rolandic brain tumor surgery: comparison of navigated transcranial magnetic stimulation to direct cortical stimulation. Neurosurgery 69(3):581–588
37. Devlin JT, Watkins KE (2007) Stimulating language: insights from TMS. Brain 130(Pt 3): 610–622
38. Berger MS et al (1989) Brain mapping techniques to maximize resection, safety, and seizure control in children with brain tumors. Neurosurgery 25(5):786–792
39. Yingling CD et al (1999) Identification of motor pathways during tumor surgery facilitated by multichannel electromyographic recording. J Neurosurg 91(6):922–927
40. Duffau H, Denvil D, Capelle L (2002) Long term reshaping of language, sensory, and motor maps after glioma resection: a new parameter to integrate in the surgical strategy. J Neurol Neurosurg Psychiatry 72(4):511–516
41. Tate MC, Herbet G, Moritz-Gasser S, Tate JE, Duffau H (2014) Probabilistic map of critical functional regions of the human cerebral cortex: Broca's area revisited. Brain 137 (10):2773–2782
42. De Benedictis A, Sarubbo S, Duffau H (2012) Subcortical surgical anatomy of the lateral frontal region: human white matter dissection and correlations with functional insights provided by intraoperative direct brain stimulation: laboratory investigation. J Neurosurg 117 (6):1053–1069