

Spondylitis

- A 35-year-old patient
- Dorsal and lumbar pain for more than 12 months
- Morning stiffness and limitation of motion in the frontal planes

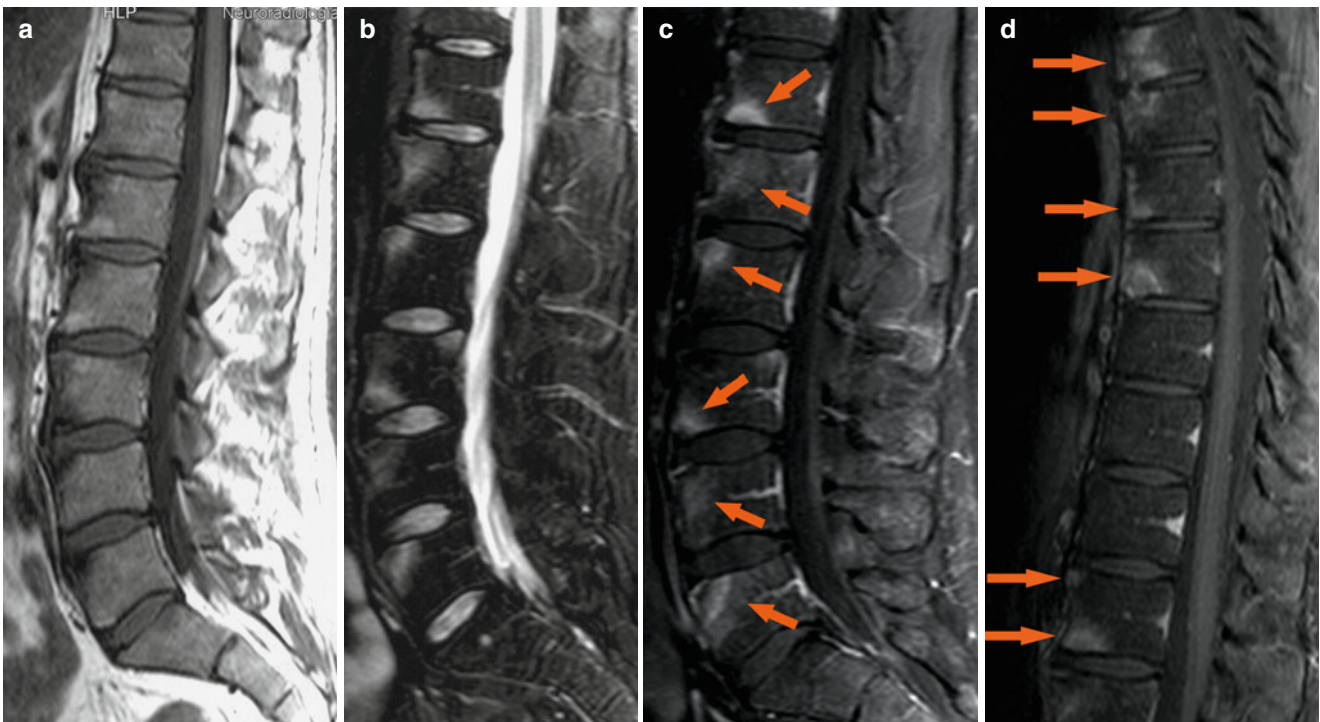


Fig. 1 Sagittal SE T1-weighted sequence (a), sagittal TSE T2-weighted sequence with fat saturation (b), sagittal SE T1-weighted images with fat saturation following the administration of contrast medium (c–d). The images show low signal and fat infiltration of the anterior corners of the lumbar spine (sign of chronic inflammation) (a), edema of the bone marrow of the anterior corners (b), contrast enhancement of the anterior and posterior corners, sign of active inflammation of the spine extended to the thoracic spine (c–d, arrows)

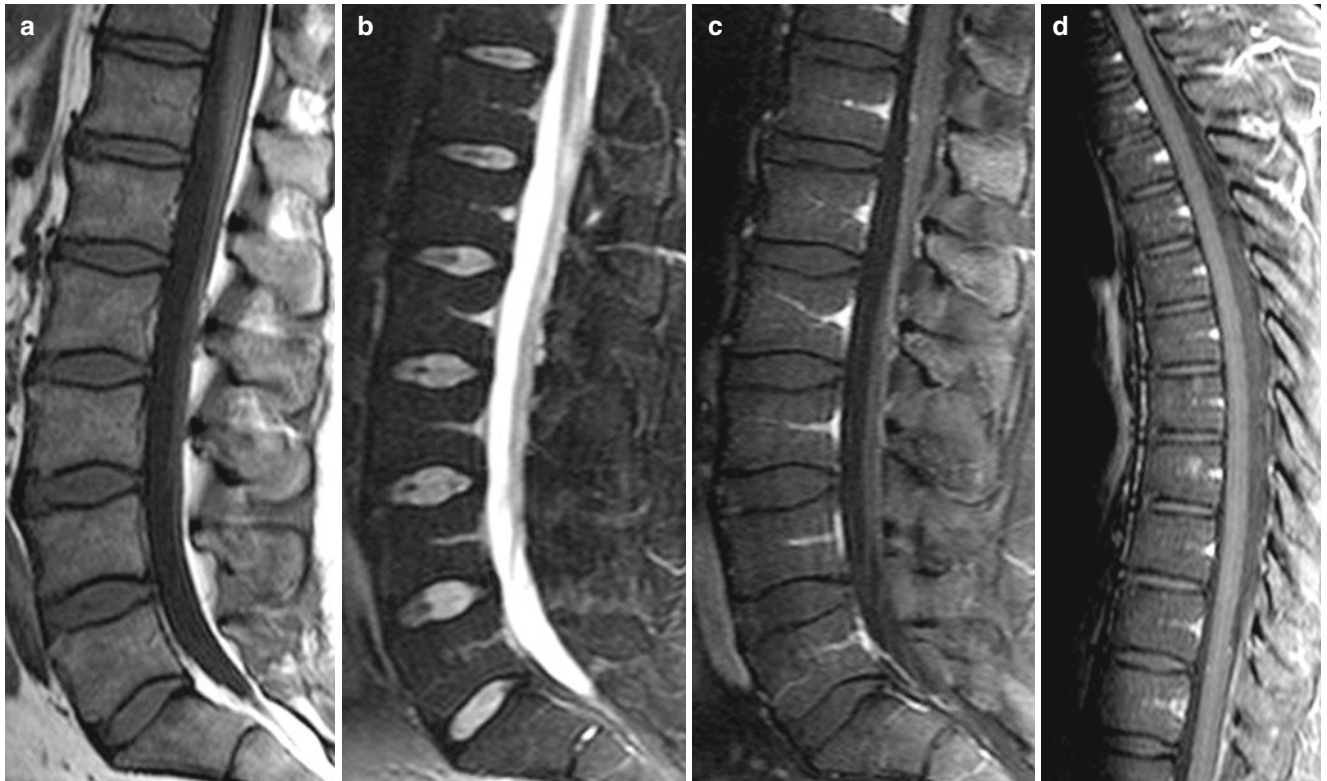
Follow-up after 14 months of TNF-blocker therapy

Fig. 2 Sagittal SE T1-weighted sequence (**a**), sagittal TSE T2-weighted sequence with fat saturation (**b**), sagittal SE T1-weighted image with fat saturation following the administration of contrast medium (**c-d**). The images show only fat

infiltration of the anterior corners of lumbar spine (**a**), a low signal of the spine (**b**), and the absence of acute inflammatory lesions of the thoracic and lumbar spine (**c-d**)