

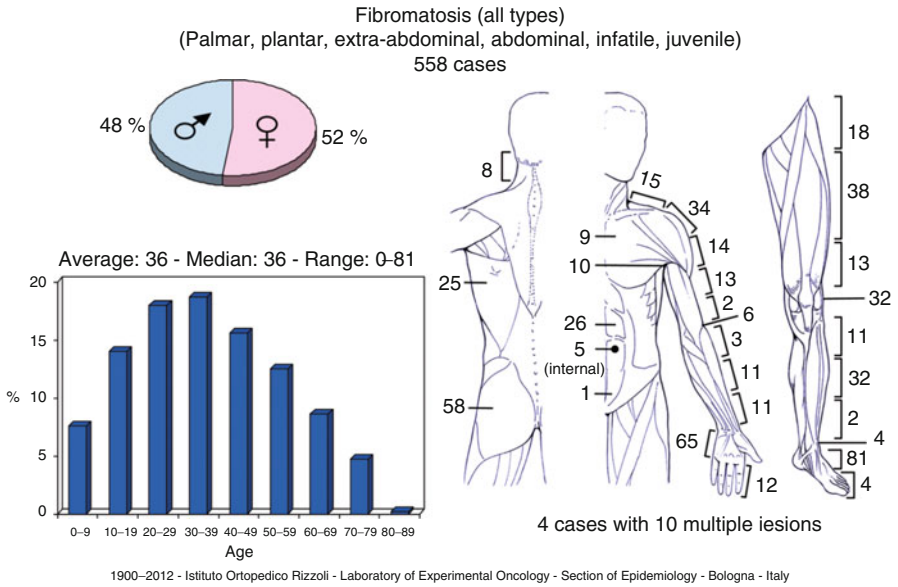
# Chapter 60

## Fibromatosis

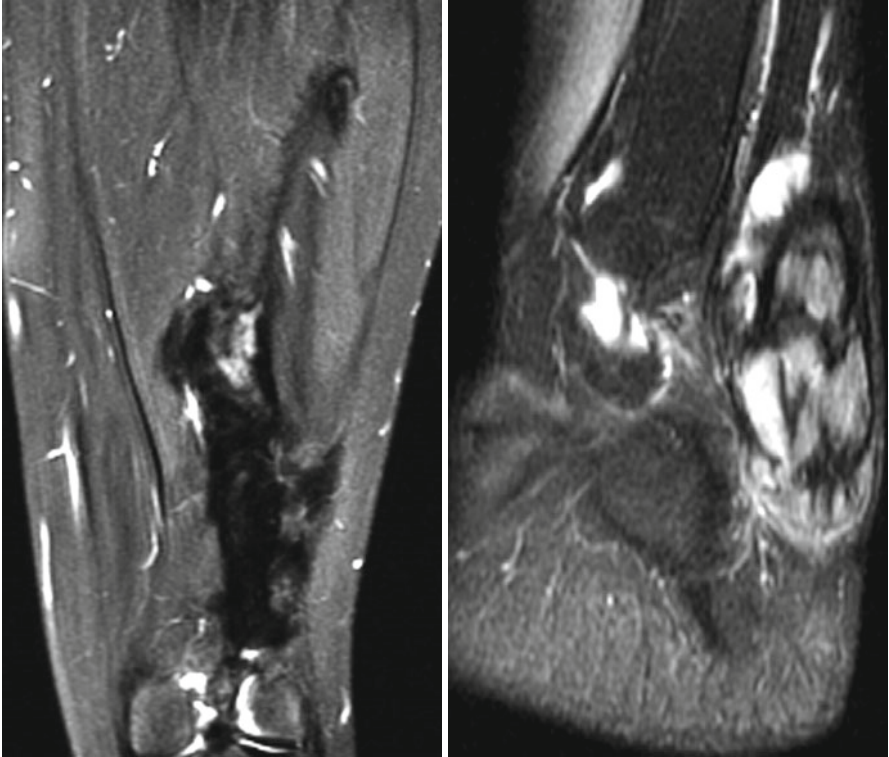
Nicola Fabbri

It covers a broad group of benign fibroblastic tissue proliferation of similar microscopic appearance.

- A. Superficial: (1) palmar f. (Dupuytren’s contracture), (2) plantar f. (Ledderhose’s disease), (3) penile f. (Peyronie’s disease) and (4) knuckle pads.
- B. Deep (desmoid-type fibromatosis): (1) extra-abdominal f. and (2) abdominal f.



N. Fabbri, MD  
 Department of Surgery, Orthopaedic Service, Memorial Sloan-Kettering Cancer Center,  
 1275 York Avenue, New York, 10065, NY, USA  
 e-mail: fabbrin@mskcc.org



T2 MR images, coronal of the thigh and sagittal of the foot. The thigh lesion has a low signal and infiltrates the muscles, whereas one in the foot is nodular with a high signal. Both behaviors are possible on different masses in the same patient