

Chapter 56

Case on Postoperative Abscess After Appendicectomy

Suzanne S. Gisbertz

Keywords Acute appendicitis • Laparoscopic appendicectomy • Percutaneous drainage • Abscess

Diagnosis and Operation Description

Six weeks before, this 58-year-old female manager had undergone a laparoscopic appendectomy because of a phlegmonous-inflamed appendix (Fig. 56.1). Through three trocars her appendix had been removed by using an endostapler white. The appendix was deposited in an endobag and consequently exteriorized. Hemostasia was good, and after closure of the trocar sites, the operation was completed.

Postoperative Course: Identification and Treatment of Complication

During the same hospital stay, her postoperative course was complicated by a small bowel ileus and fever. On the CT scan, an abscess was seen in the right paracolic area, being subsequently percutaneously drained (Fig. 56.2a, b). Patient improved, and once the drain was removed, she went home.

Presenting now some weeks later at the outpatient policlinic, she claimed not feeling well, having a poor intake, and diarrhea. She was readmitted to the hospital, now sick, with temperature 38.1 °C, heart rate 94 bpm, and on physical examination having localized pain in the right lower abdomen. The CRP was 250, and

S.S. Gisbertz, M.D.

Department of Surgery, Academic Medical Centre, Amsterdam, The Netherlands
e-mail: s.gisbertz@antoniuziekenhuis.nl

Fig. 56.1 US diagnosis acute appendicitis

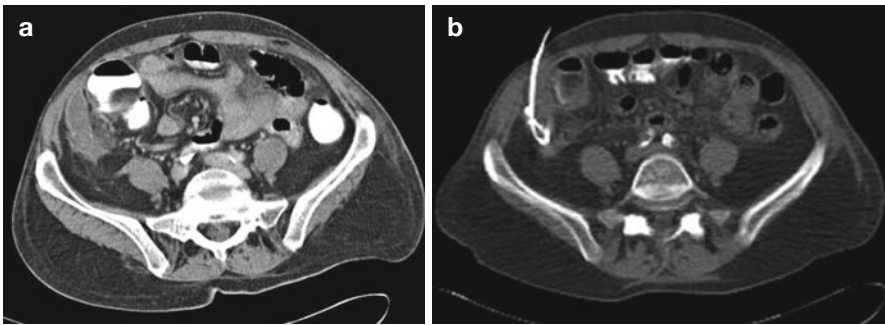
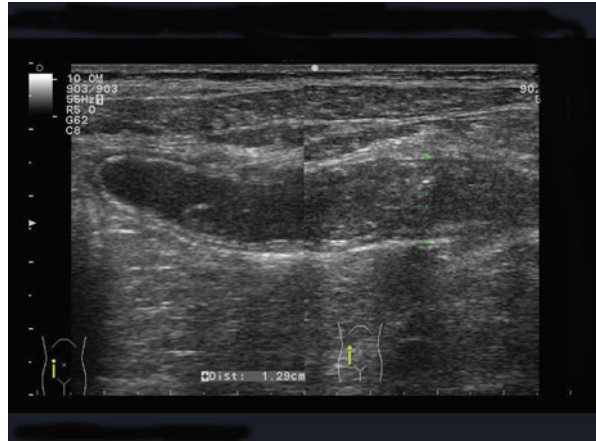
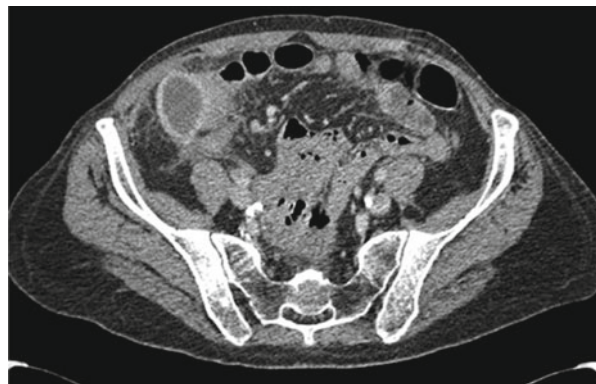

Fig. 56.2 (a) CT scan showing an abscess around cecum. (b) CT scan, percutaneous drainage abscess

Fig. 56.3 CT scan, new abscess, 3 weeks after 1st operation



leukocytosis of $12.5 \times 10^9/l$. On the CT scan an abscess was found paracolic space right, again being drained (Fig. 56.3) and treated by iv broad spectrum antibiotics (AB). Nutrition and general condition improved, and after retiring the drain, she could return home at the 10th day following readmission.

Discussion

The Cochrane reviews and meta-analysis comparing rates of open and laparoscopic appendectomies of postoperative abscesses show rates slightly higher for the laparoscopic group [1].

Pertaining lesson of this case is perhaps that before the first discharge following the requirement for checking clinically and by imaging whether the abscess has completely disappeared. Instead—after pressure by the patient to return home for reinitiating her work—this control had been omitted.

Reference

1. Sauerland S, Jaschinski T, Neugebauer EA. Laparoscopic versus open surgery for suspected appendicitis. *Cochrane Database Syst Rev.* 2010;6(10).