Decompression for Chiari type I-malformation (*with or without syringomyelia*) by extreme lateral foramen magnum opening and expansile duraplasty with arachnoid preservation: comparison with other technical modalities (Literature review)

M. Sindou and E. Gimbert

Department of Neurosurgery, Hôpital Neurologique Pierre Wertheimer,
University of Lyon, Lyon, France

With 3 Figures

Contents

Abstract

Posterior craniocervical decompression is the procedure most currently used for treating Chiari I malformation (alone or in association with syringomyelia in the absence of hydrocephalus). We reviewed the various technical modalities reported in the literature. We present a personal series of 44 patients harboring Chiari type I malformation (CM-I) operated with a suboccipital craniectomy and a C1 (or C1/C2) laminectomy, plus an extreme lateral Foramen Magnum opening, a "Y" shaped dural incision with preservation of the arachnoid membrane, and an expansile duraplasty employing autogenous periosteum. Outcomes were analyzed with follow-up ranging from 1 to 10 years (4 years on average).

The presented technique was compared with the other surgical modalities reported in the literature. This comparative study shows that this type of craniocervical decompression achieved the best results with minimal complications and side-effects. Syringomyelia associated with CM-I must be treated by craniocervical decompression alone. Shunting no longer appears to be an appropriate method of treatment for syringomyelia.

Keywords: Chiari type I malformation; foramen magnum decompression; syringomyelia; cerebrospinal flow; posterior fossa surgery.

Introduction/Definition

First described by Hans Chiari (1851–1916) in 1891 [9] in Deutsche Medizinische Wochenschrift and entitled "concerning alterations in the cerebellum resulting from cerebral hydrocephalus", this entity came to be known as Chiari type I-malformation (CM-I) [5]. Nowadays, CM-I is described as caudal descent of the cerebellar tonsils through the foramen magnum into the spinal canal, at least 5 mm below the plane of the foramen magnum, without involving the brainstem. In 32% to 73% of patients, CM-I is associated with syringomyelia [20, 28, 37, 46, 68, 69]. More recently, the Chiari type 1.5-malformation has been described [65, 66]. Its essential difference with CM-I is that in addition to tonsillar ectopia, patients with Chiari type 1.5-malformation also exhibit caudal descent of the brainstem [65]. Management of this subtype is the same as for CM-I.

When progressive syrinx enlargement and/or other symptoms related to CM-I is/are noted, a posterior decompression of the cervico-occipital junction is commonly offered. The aim of the surgery is to halt the progression of neurological signs and symptoms of the condition [12]. Whilst some improvement in the patient's condition often results from the procedure, patients must be aware that this is not the principal goal. The aim of the procedure it to relieve the compression of the neural structures, and to re-establish cerebrospinal fluid (CSF) circulation within cisterna magna, as this appears to be the most logical means of counteracting pathophysiology of syringomyelia.

In adults, it is commonly during the third decade that CM-I is highlighted, after several years of headache, neck pain, arm weakness, numbness, spasticity, and dissociated sensory loss. Headaches are typically aggravated by Valsalva manoeuvres. It is now well established that this pathology is the result of a particularly small and shallow posterior cranial fossa, which itself is due to an underdeveloped occipital bone [43, 55, 59, 62, 71].

Furthermore, intracranial hypotension syndrome may be mistaken for a CM-I and has to be excluded. Imaging also evidence descent of cerebellar tonsils. Usually, it is characterized by an orthostatic headache [29, 38, 45, 49]. In addition to headache, patients may experience nausea, vomiting, neck pain, dizziness, horizontal diplopia, or radicular symptoms, all of which are orthostatic in nature. There is strong evidence indicating that most cases of intracranial hypotension result from a persistent CSF leak (after dural puncture, ventricular shunt and any time the dura matter is violated) [30]. The major abnormalities demonstrated on MRI studies are diffuse thickening of the pachymeninges with gadolinium enhancement, engorgement of venous sinuses, and downward displacement of the cerebellar tonsils [39]. Intracranial hypotension generally is considered to be a benign condition, and most cases resolve with conservative management [45].

Surgical treatment of CM-I can be applied by several technical modalities, some of which are controversial. A suboccipital craniectomy is universally accepted, but combining it with laminectomy, opening or leaving dura matter closed, opening or respecting arachnoid, lysing of the arachnoid, shrinking or resecting cerebellar tonsils, stenting the fourth ventricle, plugging the obex, performing a duraplasty and the optimal material for it, leaving the dura open, and the need for cranioplasty are still debated.

Generalities

Chiari type I-malformation pathophysiology

It is now accepted that CM-I results from either a mesodermal defect after the closure of the neural folds, which leads to the underdevelopment of the basichondrocranium which in turn results in disproportion between the container (skull) and the contents (neural elements), or to an overgrowth of the supratentorial component and consequent shallow posterior fossa. Too bulky for this hypoplasic posterior fossa, the cerebellar tonsils herniate through the foramen magnum [31, 35, 42, 77] obstructing the normal venting of CSF in and out of the craniocervical subarachnoid space, throughout the systolic time of cardiac cycle [13]. Chronic occipital and/or posterior cervical pain may be due to reflex irritation of the dura of the posterior fossa. Headaches associated with Valsalva and all maneuvers that increase intracranial blood volume, induce temporary intracranial hypertension resulting from the trapped CSF by cerebellar tonsils impaction at the level of the Foramen Magnum.

Syringomyelia pathophysiology

Syringomyelia causes progressive myelopathy. Determination of the pathophysiological mechanisms underlying the progression of syringomyelia associated with the CM-I, should improve strategies to halt the progression of myelopathy. Despite many hypotheses, the pathophysiology of syringomyelia is still not well understood.

In 1981, Williams [74] used simultaneous measurements to demonstrate a differential pressure gradient between the intraventricular and the lumbar subarachnoid spaces. He later proposed the "craniospinal pressure dissociation theory", which suggests that CSF flow is obstructed in patients with CM-I at the craniocervical junction by the herniated cerebellar tonsils, resulting in a differential pressure gradient between the cranial and spinal cavities [75]. Significant pressure differentials between these two areas occur during the systolic cardiac cycle and Valsalva maneuvers. This effect increases the impact of tonsils at the craniocervical junction, creating a piston effect that drives CSF into the Virchow-Robin and interstitial spaces, thus leading to the formation of syringomyelia [37, 44, 57, 74, 75, 77]. The propagation of syrinx fluid caudally with each heartbeat, leads to syrinx progression [22].

Moreover, cisterna magna functions as a shock absorber against the pulsatile CSF waves coming from the cranial side. Reducing the temporary fluid storage capacity of the cisterna magna dramatically increases the pressure wave propagated along the central canal. The loss of the shock absorbing capacity of the cisterna magna and the subsequent increase of central canal wall pressure leads to syrinx progression in patients with CM-I [8, 44, 73].

Neuro-imaging

Brain and entire spinal cord MRI (magnetic resonance imaging) with T1 and T2 sequences is the modality of choice for evaluating cerebellar tonsils herniation through foramen magnum (Fig. 1a, b, and 3b). Moreover, MRI is able to search and show the associated hydrocephalus and/or syringomyelia degree

→

Fig. 1. Illustrative case: preoperative sagittal T1 (a) and T2-weighted MRI (b) revealing CM-I with cerebellar tonsils herniated to C-2 posterior arch (Grade IV); Postoperative cine-MRI (c) showing dynamic flow posterior to the cerebellar tonsils; Postoperative T2-weighted MRI (d) with CSF visible posterior to the cerebellar tonsils; Postoperative sagittal CT-scan with craniectomy, C-1 and C-2 laminectomy (e) and axial CT-scan with Foramen Magnum opened laterally condyle to condyle (f); Platybasia can be noted (a–b)

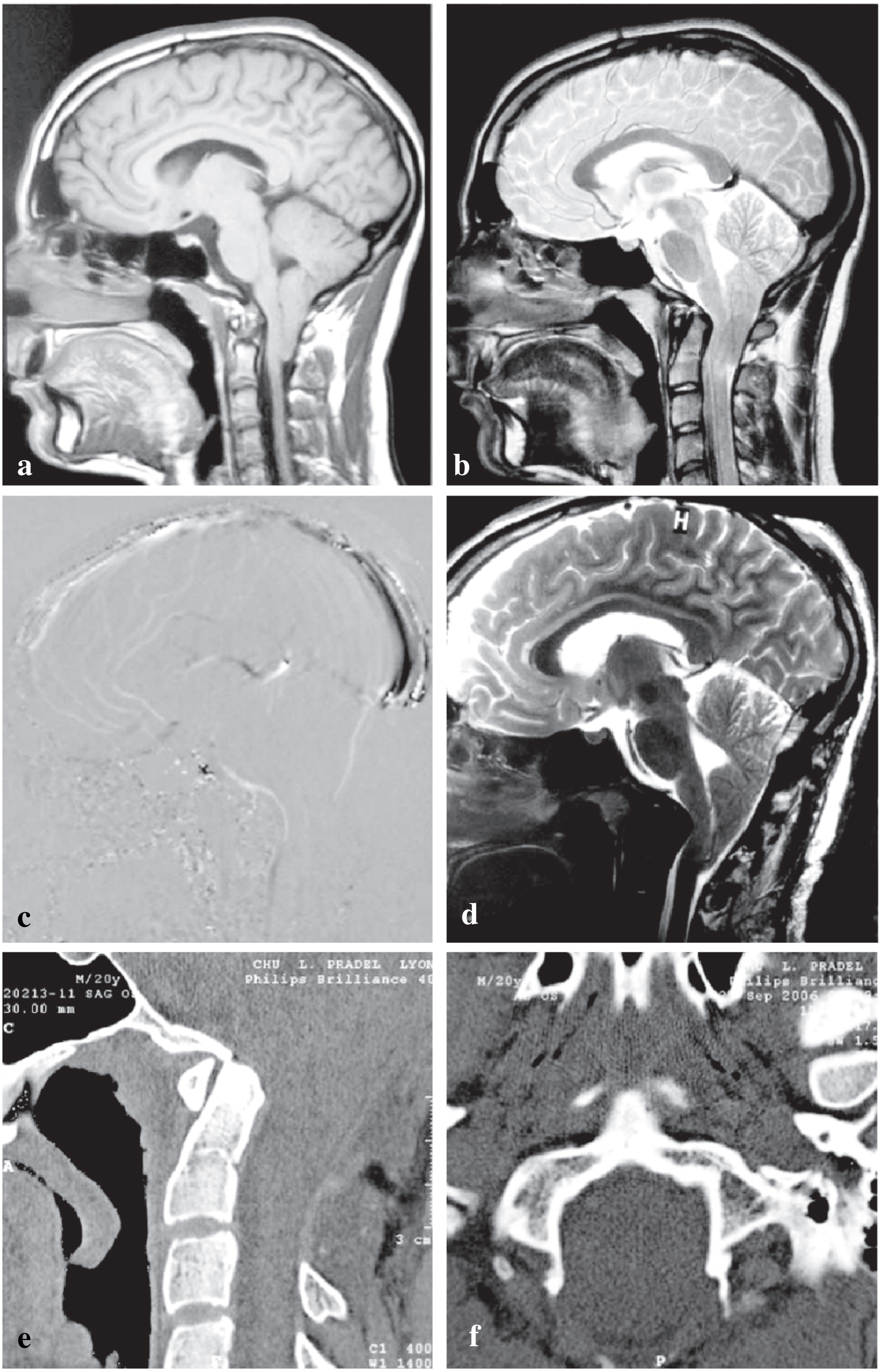
a
b
H
c
d
M/20y
20213-11 SAG O
30.00 mm
C
CHU L. PRADEL LYON
Philips Brilliance 40
A
3 cm
C1 400
W1 1400
e
M/20y
L. PRADEL
Philips Brillianc
Sep 2006
P
f

(Fig. 3a and b). In addition, a gadolinium-enhanced MRI is recommended to rule out the existence of any intramedullary tumor. Tonsillar herniations can be classified into four grades, corresponding to the degree to which they have descended through the foramen magnum [60]. Grade I corresponds to a level of tonsils descent between the foramen magnum and C-1, Grade II corresponds to descent to C-1 level, Grade III corresponds to descent to between C-1 and C-2 (Fig. 3b), and Grade IV corresponds to descent to C-2 level (Fig. 1a and b). The radiological assessment often reveals other bone anomalies of the skull base, such as basilar impression, atlanto-occipital fusion, atlanto-axial assimilation, platybasia (Fig. 1a and b), and Klippel-Feil syndrome [10, 35, 56]. Where present, syringomyelia can be classified into four groups. Group I corresponds to the cervical location, Group II to the thoracic location, Group III to the cervicothoracic location and Group IV to panmedullary extension.

Recent advances in MRI permit a cinematic analysis of CSF flow, posterior to the cerebellar tonsils at the foramen magnum (Fig. 1c), plotted in relation to the cardiac cycle, producing a flow velocity profile. A reduction of the flow velocity and a shorter period of caudal CSF flow are typical of CM-I [13]. The same MRI modality can be performed postoperatively to confirm the re-establishment of a normal CSF flow velocity.

Moreover, intraoperative Doppler ultrasonography anatomical and dynamical informations can be used as a guide for performing patient-specific posterior fossa decompressions.

If hydrocephalus is present, shunt insertion or endoscopic ventriculocisternostomy should precede consideration of other surgical intervention.

Overview of the various technical modalities

For more than one-hundred years, various modalities have been employed to manage CM-I decompression. Some authors limit themselves to performing only a simple suboccipital craniectomy, associated with a C-1 ± C-2 laminectomy [27, 40]. Others suggest enlargement of the dura of the posterior fossa in addition to the craniectomy [1, 2, 4, 6, 7, 11, 13, 14, 16–19, 21, 22, 24, 26, 28, 32, 33, 36, 40, 41, 44, 47, 48, 50–54, 60, 61, 63, 64, 68–70, 72]. One option is to incise only the external layer of the dura, leaving the internal layer intact [19, 24, 26, 41]. Another option is to open both layers of the dural sheath, along a vertical line [7], or in a Y-shaped manner [4, 13, 14, 36, 41, 52, 60, 63] and to patch the enlarged opening with a duraplasty of periosteum [4, 53, 60, 68, 69], fascia lata [7, 28], or artificial dura [52] rather than leaving it open [54, 70].

Dural incision may be accompanied by a large arachnoid opening to explore the foramen of Magendie [1–3, 6, 7, 11, 21, 28, 40, 47, 52, 53, 61, 64, 67, 69, 72] in order to ascertain its patency, especially in cases where hydrocephalus is also present, although arachnoid opening predisposes to pseudomeningocele and/or CSF fistulas.

Bilateral resection of the tonsils has been advocated by some authors in order to achieve an optimal decompression of the cervico-occipital junction [3, 7, 13, 17, 21, 48, 76]. A suboccipital cranioplasty is systematically done by Milhorat to cover and protect the duraplasty, and to limit the extent of extradural scarring [36].

In patients with a large-sized syrinx, some authors prefer to use syringo-subarachnoid shunt alone [1, 23, 24, 64, 70].

Recent advances in neuroimaging modalities and the widespread use of MRI has led to CM-I being diagnosed with increased frequency (0.56 [15] to 0.77% [34] of incidence on MRI studies). Therefore, we see many asymptomatic and minimally symptomatic patients with CM-I ± syringomyelia who pose problems of therapeutic strategy.

When CM-I and/or syrinx is/are incidentally identified, there is no scientific proof that they will become symptomatic in the future. Brain and entire spinal cord MRI assessment secures the follow up, because it can identify a radiological aggravation before symptoms are present, thus enabling surgical treatment to be carried out in time.

When performing dural incision and duraplasty, the arachnoid membrane may be opened, but one may prefer to preserve it, which avoids CSF leakage [6, 18, 24, 32, 44, 52, 53, 60, 63]. This is our preferred option when treating patients, and the surgical technique which we describe in more detail here.

Decompression with extreme lateral foramen magnum opening and expansile duraplasty with arachnoid preservation

This technique was carried out in a personal series of 44 adult patients with symptomatic CM-I.

Personal series

From 1990 to 2000, 44 adult patients were operated on using extreme lateral foramen magnum opening and expansile duraplasty with arachnoid preservation. 15 had CM-I with syringomyelia on MRI (34%) and 29 had CM-I without abnormal neuro-imaging of associated syringomyelia (66%). 13 (29%) were males and 31 (71%) females. Age ranged from 14 to 63 years, with the average age being 40. The mean duration of symptoms from origin to surgery was 3 years and 6 months, with extremes of 3 months and 15 years. Presenting symptoms, signs, functional status, and neuro-imaging are listed in Table 1.

Analysis of our results showed that a suboccipital craniectomy and C-1 laminectomy, with extreme lateral foramen magnum decompression, together with dural opening and arachnoid preservation, followed by enlargement duraplasty, was able to obtain improvement in 83% of patients with CM-I alone,

Table 1. *Presenting symptoms (A), signs (B), functional status (C), and neuro-imaging (D) in CM-I, without or with syringomyelia, listed in decreasing order. Personal series [60]*

A – Symptoms			
Pain:	86.4%	unsteadiness	4.5%
–Neck (occipito-cervical)	38.7%	diplopia	2.3%
–Trigeminal neuralgia	20.5%	hypo-acousia	2.3%
–Brachial neuralgia	15.9%	difficulty in swallowing	2.3%
–Headaches	6.8%	vomiting	2.3%
–Backpain	4.5%	micturition imperiosa	2.3%
Paresthesias	29.5%	attacks of unconsciousness	2.3%
Dizziness	18.2%		
B – Signs			
Pinprick altered sensation	27.3%	dysmetry	4.5%
Thermal altered sensation	15.9%	dysarthria	4.5%
Upper extremity weakness	13.6%	facial hemispasm	2.7%
Hand atrophy	9.1%	dysphonia	2.3%
Hyperactive lower reflexes	6.8%	hypopallesthesia	2.3%
Gait disturbances	6.8%	lower extremity weakness	2.3%
Hyperactive upper reflexes	4.5%	babinski sign	2.3%
Micturition imperiosa	4.5%	urinary incontinence	2.3%
C – Functional status (See table: Karnofsky Scale) Karnofsky Disability Scale: 37 patients (84%) scored above 70. (24 CM-I alone, and 13 CM-I + S). Karnofsky Disability Scale: 7 patients (16%) scored below 70. (5 CM-alone, and 2 CM-I + S).			
D – Neuro-imaging			
29 (66%) had CM-I alone		Tonsillar herniation:	31 patients (71%) Grade I
15 (34%) had CM-I + S:	panmedullary in 6 (40%).		8 patients (18%) Grade II
	cervical in 4 (27%) thoracic in 3 (20%)		3 patients (7%) Grade III
	cervicothoracic in 2 (13%)		2 patients (4%) Grade IV

Table 2. *Postoperative results. Personal series [60]*

		Clinical outcome: N (%)			Syrinx on postoperative MRI			
	N	IMP	STAB	AGG	IMP	STAB	AGG	Complications
CM	29	24 (83)	5 (17)	0 (0)	–	–	–	delayed wound healing 5 (12), CSF leak 3 (7)
S	15	12 (80)	3 (20)	0 (0)	9 (60)	6 (40)	0 (0)	

N Number of patient, *IMP* improved, *STAB* stabilized, *AGG* aggravated, *CM* Chiari type I malformation alone, *S* Chiari malformation with syringomyelia.

Table: Karnofsky Scale

Score	
100	normal; no complaints, no evidence of disease
90	able to carry on normal activity; minor symptoms
80	normal activities with effort; some symptoms
70	cares for self; unable to carry on normal activity
60	requires occasional assistance; cares for most needs
50	requires considerable assistance and frequent care
40	disabled; requires special care and assistance
30	severely disabled; hospitalised, death not imminent
20	very sick; active supportive care needed
10	moribund; fatal processes are progressing rapidly

and in 80% of patients with CM-I associated with syringomyelia. This technique did not provoke any neurological or other severe or lasting associated complication (Table 2).

Technical description

Patients are operated on under general anaesthesia with endotracheal intubation, in the sitting position. All of them previously undergo a Doppler transesophageal echocardiography to exclude a patent foramen ovale. During surgery, each patient is equipped with a right atrial central venous catheter and Doppler ultrasonography to monitor the possible occurrence of air embolism.

The goal of surgery is to re-establish normal patterns of CSF flow, by removing the brainstem compression. The strategy of the surgery is to increase the capacity of the occipito-cervical junction in its two axial-plane diameters (the antero-posterior and the transverse), so as to achieve an optimal decompression of the neural structures and obtain free cisternal spaces with good CSF circulation in the cisterna magna, and also around the brainstem and cervico-occipital junction.

The operation is performed in the sitting position, with the patient's head fixed by a Mayfield® three-pin headholder in a slightly flexed position. After antiseptic preparation, the hair is shaven to 2 cm either side of the incision draw.

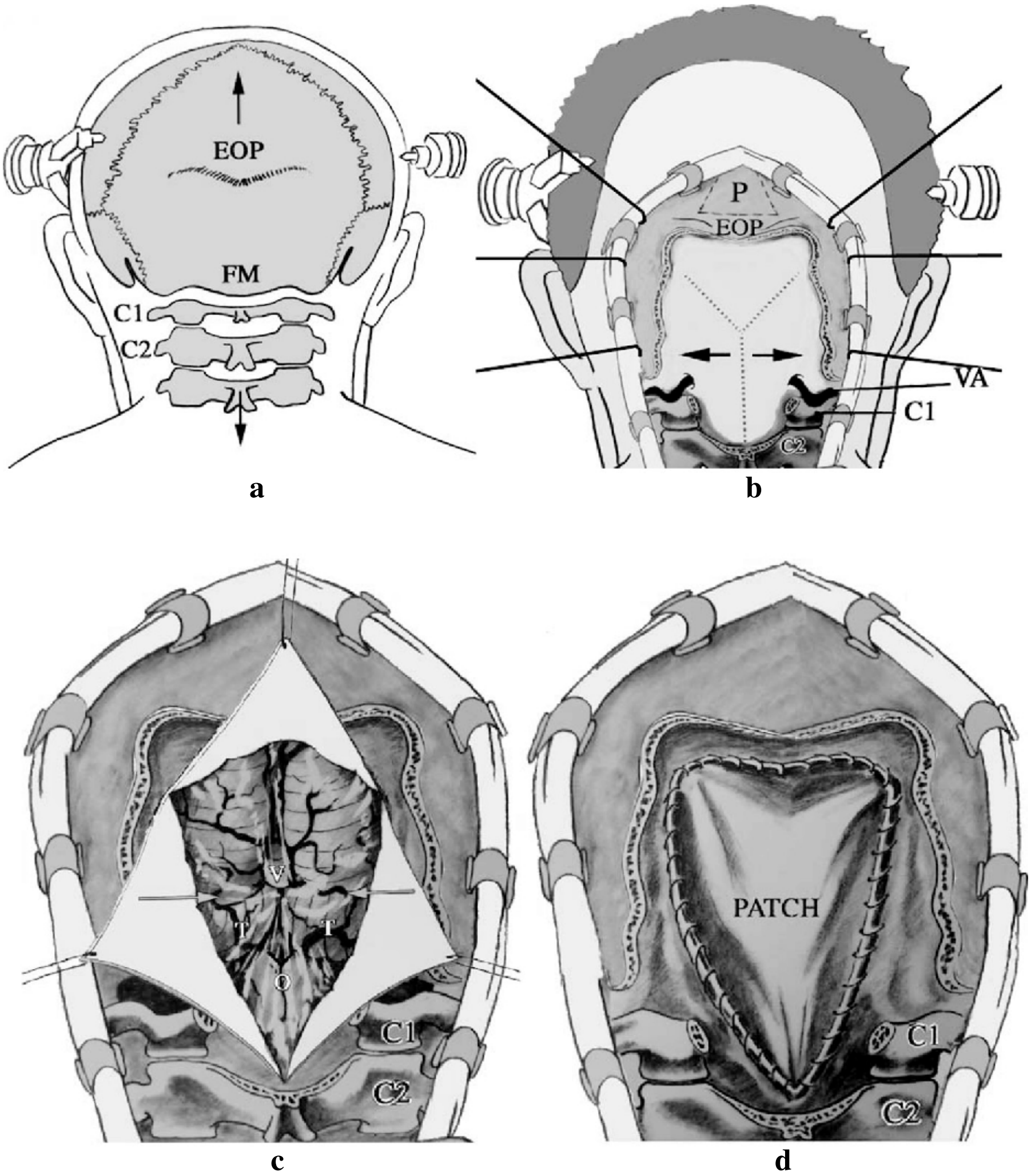

a b

c d

Fig. 2. Technique of cervico-occipital decompression (*schematic drawings*). Surgical steps are: (a) Skin incision (*vertical arrows*); Exposure of bony structures: external occipital process (*EOP*), foramen magnum (*FM*), C-1 and C-2 laminae. (b) Bone opening: sub-occipital craniotomy with extreme lateral opening of Foramen Magnum (*horizontal arrows*); Vertebral artery exposure (*VA*) on both sides; C-1 laminectomy; Periosteum for patching (*P*) above the external occipital process (*EOP*). (c) Y-shaped dural opening with arachnoid preservation; Exposure of herniated tonsils with marked engrooving by the posterior margin of foramen magnum (*arrows*); Obex (*O*), Vermis (*V*), Tonsils (*T*). (d) Enlargement duraplasty with periosteal patch (*PATCH*)

A midline occipito-cervical skin incision is made from 5 cm above the external occipital protuberance (to expose the supra-occipital periosteum), down to the level of the C-4 spinous process (Fig. 2a). The periosteum is preserved in the supra-occipital region so that it can be harvested to patch the dural opening at closure. Then posterior cervical muscles are elevated to expose the occipital bone and foramen magnum, as well as the posterior arch of C-1 in all cases, and where necessary of C-2, depending on the degree of tonsillar herniation. Special care is taken not to damage the occipital nerve on both sides.

The vertebral arteries at occipito-cervical level are identified and protected on both sides. Ligamentum flavum and epidural fat is removed, exposing the dura matter. Particular care has to be taken when disconnecting the dura from the undersurface of the foramen magnum. Once this is done, a sub-occipital craniectomy is made by removing a bone flap, the purpose of which is to decompress posteriorly the medullary-spinal cord junction and the tonsils. When the skull bone is thick, it can be drilled to facilitate the use of the rongeur. The craniectomy is completed with an extreme lateral opening of

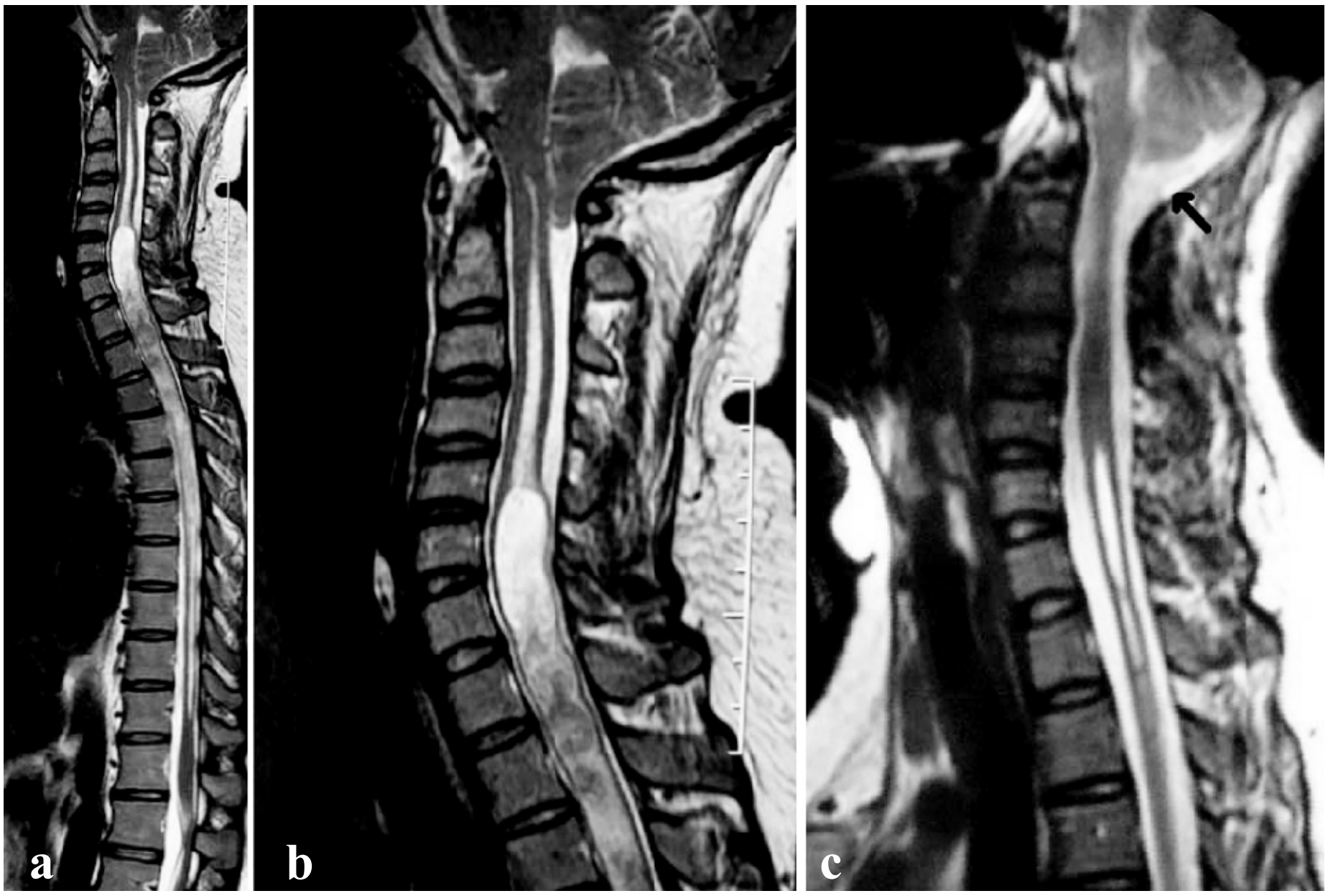

Fig. 3. Illustrative case: Sagittal T2-weighted MRI obtained before (a and b) and after (c) surgery. The cerebellar tonsil appears significantly pointed and inferiorly displaced (b). Effacement of CSF is ventral to the cervicomedullary junction and dorsal to the cerebellar tonsil (b). A large panmedullary syringomyelia is associated with CM-I (a). Three months after bone decompression and duraplasty, the cerebellar tonsil appears more rounded, a new cisterna magna can be seen (*black arrow*) and the resolution of the cervical syrinx is nearly complete (c)

the rim of the foramen magnum by bone resection with Kerrison® rongeurs to the level of the occipital condyles on both sides (Fig. 1f). The aim here is to achieve a good decompression of both tonsils, not only posteriorly but also laterally. The arch of C-1 (and C-2 if necessary) is/are then removed taking care not to compress the underlying dura (Fig. 2b). Even if in most of CM-I tonsils does not reach below C-1, we preferred to remove systematically the arch of C-1 to increase cisterna magna volume and improve its shock absorbing capacity.

A Y-shaped opening is then made to each bone resection limit, in order to enlarge the cisterna magna. Particular care has to be taken when opening both dural leaves at the level of the foramen magnum, because of the usual presence of dural occipital sinuses between the leaves of the dura. If bleeding occurs, it can be controlled by applying titanium clips to obtain definitive hemostasis by compressing the two leaves of the dura together. The arachnoid membrane is preserved to avoid CSF leakage and consequent brain collapse (Fig. 2c). To preserve the arachnoid membrane, the opening of the dura matter is made step by step, placing cottonoids between the dura and arachnoid space to achieve the aperture of both dural leaves. Nevertheless, accidental "pin-points" arachnoids openings resulting in small drops of CSF leakage often occur. However, their small sizes permit cessation within a few seconds.

Then, a duraplasty is made with periosteum patch, harvested from the supra-occipital region, in order to enlarge the posterior fossa and restore a spacious cisterna magna. The dural patch is tightened with three running sutures, in triangular-shaped manner with the base superior (Fig. 2d). Valsalva maneuvers are performed to ensure a watertight closure. Finally, the wound is closed, one layer at a time, muscles, fascia, subcutaneous tissue and skin, with interrupted sutures.

For post-operative care, the patient is placed in the intensive care unit for one night. A cervical collar is offered to the patient to keep his neck comfortable with a physiological lordosis and to reduce the pain. Analgesics and anticoagulation are given systematically. On average the patient is discharged on the 10th day. One month postoperatively, physiotherapy with particular mobilization of both upper limbs is undertaken to avoid frozen shoulders. At 2 months, an outpatient clinic visit is organized before a decision is taken as to the patient's readiness to return to work and resume a normal life.

Discussion from literature review

This technical modality has to be compared with the other varieties of cranio-cervical decompression techniques. Therefore, we reviewed 211 articles published during the past sixteen years (1990–2006), provided by the PUB-MED system (keywords for search were: Chiari, syrin*, I, decompression). Only 31 reports with information on the techniques used and their corresponding long-

Table 3. *Summary of literature results in CM-I alone, after surgical decompression*

Series	Technical modalities	N	Clinical outcome: N (%)		
			IMP	STAB	AGG
Pillay *et al.* [47]	FMD + DO + AO + DU	14	12 (86)	2 (14)	0 (0)
Bindal *et al.* [6]	FMD + DO + DU	9	9 (100)	0 (0)	0 (0)
Fisher [17]	FMD + DO + AO + RT + DU	3	2 (67)	1 (33)	0 (0)
Klekamp *et al.* [28]	FMD + DO + AO + DU	36	*	–	–
Blagodatsky *et al.* [7]	FMD + DO + AO + DU	16	14 (88)	1 (6)	1 (6)
Munshi *et al.* [40]	FMD + DO + AO + DU	11	10 (91)	1 (9)	0 (0)
	FMD	4	3 (75)	1 (25)	0 (0)
Alperin *et al.* [2]	FMD + DO + AO + DU	2	2 (100)	0 (0)	0 (0)
James and Brant [27]	FMD	3	3 (100)	0 (0)	0 (0)
Sindou *et al.* [60]	FMD + DO + DU	29	24 (83)	5 (17)	0 (0)
Sivaramakrishnan *et al.* [61]	FMD + DO + AO + DU	7	7 (100)	0 (0)	0 (0)
McGirt *et al.* [32]	FMD + DO + DU	17	13 (76)	4 (24)	0 (0)
Sakas *et al.* [54]	FMD + DO + AO + RT	5	2 (40)	3 (60)	0 (0)

IMP Improved, *STAB* stabilized, *AGG* aggravated, *FMD* foramen magnum decompression, *DO* dural opening, *AO* arachnoid opening, *DU* duraplasty, *RT* resection of tonsils.

* In Klekamp *et al.*'s series [28] average Karnofsky score passed from 68 (pre operatively) to 77 (at one year post-operatively) with large craniectomy and from 77 (pre op.) to 83 (at one year post op.) with small craniectomy. Kaplan-Meier analysis demonstrated that 9 of the 36 patients without a syrinx showed progressive worsening of at least some of their symptoms and signs after a mean follow-up of 39 ± 52 months.

term outcomes, were sufficiently detailed to allow comparison between series, and were therefore retained. These are listed in Table 3 for CM-I alone, Table 4 for CM-I with syringomyelia, and Table 5 for both.

In order to evaluate the effectiveness and risks of each of the various techniques, the literature series which corresponded to the same technical modality were grouped together. Separate inventories were made for CM-I alone and CM-I associated with syringomyelia.

Chiari type I malformation without syringomyelia (Tables 3 and 5)

Craniocervical bone resection without dural opening (technique No. 1) was performed in only 7 cases. 6 patients (86%) improved. Foramen magnum decompression with dural opening but with preservation of the arachnoid membrane and duraplasty to enlarge cisterna magna (Technique No. 3) was performed in 55 cases. An improvement was obtained in 84% (Table 3), with very few complications, as shown in Table 5. Systematic opening of the arach-

Table 4. *Summary of literature results in CM-I with syringomyelia, after surgical decompression and/or shunt. Clinical outcome and evolution of syrinx on post-operative MRI*

Series	Technical modalities	N	Clinical outcome			Syrinx on post-op MRI		
			IMP	STAB	AGG	IMP	STAB	AGG
Vaquero *et al.* [70]	FMD + DO + AO	15	4 (27)	6 (40)	5 (33)	14 (93)	1 (7)	0 (0)
	Shunt	15	10 (67)	2 (13)	3 (20)	15 (100)	0 (0)	0 (0)
Pillay *et al.* [47]	FMD + DO + AO + DU	17	9 (53)	6 (35)	2 (12)			
Fujii *et al.* [18]	FMD + DO + DU	5	4 (80)	0 (0)	1 (20)	3 (60)	1 (20)	1 (20)
	FMD + DO + DU + SH	8	8 (100)	0 (0)	0 (0)	6 (75)	2 (25)	0 (0)
Isu *et al.* [26]	FMD + DO (ext. Layer)	7	6 (86)	1 (14)	0 (0)	7 (100)	0 (0)	0 (0)
Tognetti and Calbucci [64]	FMD + DO + AO + DU	17	14 (82)	2 (12)	1 (6)	12 (100)	0 (0)	0 (0)
	Shunt	12	4 (33)	5 (42)	3 (25)	12 (100)	0 (0)	0 (0)
Raftopoulos *et al.* [48]	FMD + DO + AO + RT + DU	8	8 (100)	0 (0)	0 (0)	8 (100)	0 (0)	0 (0)
VanVelthoven *et al.* [67]	FMD + DO + AO + DU	25	10 (40)	9 (36)	6 (24)			
Versari *et al.* [72]	FMD + DO + AO + DU	40	25 (63)	9 (22)	6 (15)	28 (70)	12 (30)	0 (0)
Oldfield *et al.* [44]	FMD + DO + DU	7	5 (71)	2 (29)	0 (0)	7 (100)	0 (0)	0 (0)
Sahuquillo *et al.* [52]	FMD + DO + DU	10	8 (80)	2 (20)	0 (0)			
	FMD + DO + AO + DU	10	2 (20)	5 (50)	3 (30)			
Bindal *et al.* [6]	FMD + DO + AO + DU	12	7 (58)	5 (42)	0 (0)			
Fisher [17]	FMD + DO + AO + RT + DU	16	9 (56)	7 (44)	0 (0)	14 (93)	1 (7)	
Hida *et al.* [24]	FMD + DO (ext. Layer)	12	10 (83)			30 (94)		
	FMD + DO + DU	21	17 (81)	3 (14)	1 (5)			
	Shunt	37	36 (97)			37 (100)	0 (0)	0 (0)
Klekamp *et al.* [28]	FMD + DO + AO + DU	88	*					
Vanaclocha *et al.* [69]	FMD + DO + AO + DU (+ BR)	28	20 (73)	8 (27)	0 (0)	11 (39)		
Gambardella *et al.* [19]	FMD + DO (ext. Layer)	8	7 (87)	0 (0)	1 (13)	7 (87)		

Guyotat *et al.* [21]	FMD + DO + DU	50	18 (36)	14 (28)	18 (36)	14 (58)		
	FMD + DO + AO + RT + DU	8	7 (87)	1 (13)	0 (0)			
	FMD + DO + DU + SH	8	6 (75)	1 (13)	1 (12)			
Aghakhani *et al.* [1]	FMD + DO + AO + DU	242	92 (38)	121 (50)	29 (12)	36 (15)		
	Shunt	31	0 (0)	8 (71)	3 (29)	(7)		
Blagodatsky *et al.* [7]	FMD + DO + AO + DU	44	34 (78)	8 (18)	2 (5)			
	FMD + DO + AO + RT + DU	11	7 (64)	3 (27)	1 (9)			
Sakamoto *et al.* [53]	FMD + DO + DU + BR	20	20 (100)	0 (0)	0 (0)	20 (100)	0 (0)	0 (0)
	FMD + DO + AO + DU + BR	20	17 (85)	3 (15)	0 (0)	20 (100)	0 (0)	0 (0)
	FMD + DO + AO + DU + BR	4	3 (75)	1 (25)	0 (0)	3 (75)	1 (25)	0 (0)
Ellenbogen *et al.* [13]	FMD + DO + AO + RT + DU	51	49 (96)	2 (4)	0 (0)	49 (96)	2 (4)	0 (0)
Ergün [16]	FMD + DO + AO + DU + SH	18	16 (89)	2 (11)	0 (0)	18 (100)	0 (0)	0 (0)
Munshi *et al.* [40]	FMD + DO + AO + DU	12	10 (84)	2 (16)	0 (0)	9 (100)	0 (0)	0 (0)
	FMD	7	5 (71)	2 (29)	0 (0)	3 (50)	0 (0)	3 (50)
Alperin [2]	FMD + DO + AO + DU	1	1 (100)	0 (0)	0 (0)	1 (100)	0 (0)	0 (0)
Hida and Iwasaki [23]	Shunt	59	59 (100)	0 (0)	0 (0)	59 (100)	0 (0)	0 (0)
James and Brant [27]	FMD	1	1 (100)	0 (0)	0 (0)	0 (0)	1 (100)	0 (0)
Sindou *et al.* [60]	FMD + DO + DU	15	12 (80)	3 (20)	0 (0)	9 (60)	6 (40)	0 (0)
Takayasu *et al.* [63]	FMD + DO + DU	16	16 (100)	0 (0)	0 (0)	16 (100)	0 (0)	0 (0)
Sakas *et al.* [54]	FMD + DO + AO + RT	10	4 (40)	6 (60)	0 (0)	7 (70)	2 (20)	1 (10)

MP Improved, *STAB* stabilized, *AGG* aggravated, *FMD* foramen magnum decompression, *DO* dural opening, *AO* arachnoid opening, *DU* duraplasty, *SH* shunt, *RT* resection of tonsils, *BR* bone reconstructed.

* In Klekamp *et al.*'s series [28], Karnofsky score passed from 68 (pre op.) to 74 (at one year post op.) with large craniectomy and from 71 (pre op.) to 77 (at one year post op.) with small craniectomy. Kaplan-Meier analysis demonstrated that 16 of the 88 patients with a syrinx showed progressive worsening with time, but much less with a small craniectomy (14%) than with a large craniectomy (62%). There were actually two groups according to the size of craniectomy. In the group of patients with a small craniectomy the size of the syrinx decreased in 87%, was unchanged in 11% and increased in only 2% (versus 72, 6 and 22%, respectively, in the large craniectomy group).

noid in addition to dural opening (Technique No. 4) was performed in 86 cases. It did not reveal any superiority compared to the procedure without arachnoid opening. The improvement rate was 84% (compared with 84%) and there was 11% of aggravation (versus none). The results achieved with technique No. 3 indicated that dural opening with preservation of arachnoid membrane is preferable, as complications due to arachnoid opening were frequent and sometimes severe, as illustrated by Table 5.

Chiari type I malformation with syringomyelia (Tables 4 and 5)

Results with the various reported techniques are summarized in Tables 4 and 5. Statistical analysis (Confidence Interval 95% CI), showed that foramen magnum decompression with simple incision of the dural outer layer (modality No. 2), or complete dural opening followed by duraplasty (modalities No. 3–5 or 8), were significantly better ($p < 0.05$) than foramen magnum decompression with dural and arachnoid opening, but without duraplasty (modality No. 6 and No. 7). Modalities No. 6 and No. 7 were the worst options.

Interestingly, in a study comparing the effects of two varieties of craniectomy (one small and one large and both associated with dural opening, arachnoid opening and duraplasty) Klekamp *et al.* observed better results with the smaller bone resection. In the group with small craniectomy, syrinx was seen to have decreased in 87% of cases, it was unchanged in 11% of cases and had increased in 2%. This compared with 72%, 6% and 22%, respectively, in the large craniectomy group [28]. Foramen magnum decompression with dural opening and enlargement duraplasty, but without opening the arachnoid (modality No. 3), was the most effective and also the least dangerous modality. With this technique (which was performed in 94 cases), 87% of the patients were improved, whereas only 2% deteriorated either because of, or despite surgery having been performed. Furthermore, the complication rate was minimal, as shown in Table 5.

Bone decompression with dural incision of only the outer layer (modality No. 2), produced only marginally inferior results when compared with complete dural opening. This technique was performed in 27 cases. 85% of the patients showed improvement and 4% deteriorated. Foramen Magnum decompression without any dural opening at all (modality No. 1), was less effective. With this technique, which was performed in only 8 cases, the improvement rate was 75%. In the case of both techniques, complications were nil, as shown in Table 5.

Whether the dura was reconstructed (modalities No. 4 and No. 5), or left open (modality No. 6 and No. 7), opening of the arachnoid was followed by a number of complications. These complications were particularly severe when the dura was not closed, as shown in Table 5. The 7 patients who were reported in the literature as having died from complications [1, 7, 21, 28],

Table 5. *Summary of results in the literature, according to the technical modality used. Clinical outcome [N number; (%)]*

		N	Clinical outcome			Complications
			IMP	STAB	AGG	
1. FMD without DO						
James and Brant [27]	CM	3	3 (100)	0 (0)	0 (0)	
	S	1	1 (100)	0 (0)	0 (0)	
Munshi *et al.* [40]	CM	4	3 (75)	1 (25)	0 (0)	wound infection 1 (9)0
	S	7	5 (71)	2 (29)	0 (0)	
Total	CM	7	6 (86)	1 (14)	0 (0)	
	S	8	6 (75)	2 (25)	0 (0)	
2. FMD with DO (outer)						
Gambardella *et al.* [19]	S	8	7 (88)	0 (0)	1 (12)	
Hida *et al.* [24]	S	12	10 (83)	2 (17)	0 (0)	
Isu *et al.* [26]	S	7	6 (86)	1 (14)	0 (0)	
Total	S	27	23 (85)	3 (11)	1 (4)	
3. FMD + DO + DU (arachnoid integra)						
Bindal *et al.* [6]	CM	9	9 (100)	0 (0)	0 (0)	
Fujii *et al.* [18]	S	5	4 (80)	0 (0)	1 (20)	
Hida *et al.* [24]	S	21	17 (81)	3 (14)	1 (5)	motor deterioration (13)
McGirt *et al.* [32]	CM	17	13 (76)	4 (24)	0 (0)	
Oldfield *et al.* [44]	S	7	5 (71)	2 (29)	0 (0)	
Sahuquillo *et al.* [52]	S	10	8 (80)	2 (20)	0 (0)	aseptic meningitis 1 (5)
Sakamoto *et al.* [53]	S	20	20 (100)	0 (0)	0 (0)	
Sindou *et al.* [60]	CM	29	24 (83)	5 (17)	0 (0)	delayed wound healing 5 (12), CSF leak 3 (7)
	S	15	12 (80)	3 (20)	0 (0)	
Takayasu *et al.* [63]	S	16	16 (100)	0 (0)	0 (0)	
Total	CM	55	46 (84)	9 (16)	0 (0)	
	S	94	82 (87)	10 (11)	2 (2)	
4. FMD + DO + AO + DU						
Aghakhani *et al.* [1]	S	242	92 (38)	121 (50)	29 (12)	wound hematoma 17 (6), meningitis 17 (6)
Alperin *et al.* [2]	CM	2	2 (100)	0 (0)	0 (0)	
	S	1	1 (100)	0 (0)	0 (0)	
Bindal *et al.* [6]	S	12	7 (58)	5 (42)	0 (0)	

(*continued*)

Table 5 (*continued*)

		N	Clinical outcome			Complications
			IMP	STAB	AGG	
Blagodatsky *et al.* [7]	CM	16	14 (88)	1 (6)	1 (6)	
	S	44	34 (78)	8 (18)	2 (5)	
Guyotat *et al.* [21]	S	50	18 (36)	14 (28)	18 (36)	meningitis 1 (1)
Klekamp *et al.* * [28]	CM	36	27	0	9	Infection 5 (4), aseptic meningitis 13 (10), CSF leak 15 (12), hydrocephalus 1 (1), cerebellar 1 (1) and posterior cerebral 1 (1) infarction, apnea 2 (2), mesencephalic disturbances 2 (2) swallowing dysfunction 3 (2)
	S	88	72	0	16	
Munshi *et al.* [40]	CM	11	10 (91)	1 (9)	0 (0)	CSF leak 2 (9), aseptic meningitis 1 (4), subgaleal CSF 4 (17), infection 3 (13), occipital nerve pain 1 (4)
	S	12	10 (84)	2 (16)	0 (0)	
Pillay *et al.* [47]	CM	14	12 (86)	2 (14)	0 (0)	
	S	17	9 (53)	6 (35)	2 (12)	
Sahuquillo *et al.* [52]	S	10	2 (20)	5 (50)	3 (30)	hydrocephalus 1 (10)
Sakamoto *et al.* [53]	S	24	20 (83)	4 (17)	0 (0)	aseptic meningitis 1 (4)
Sivaramakrishnan *et al.* [61]	CM	7	7 (100)	0 (0)	0 (0)	
Tognetti and Calbucci [64]	S	17	14 (82)	2 (12)	1 (6)	
Vanaclocha *et al.* [69]	S	28	20 (73)	8 (27)	0 (0)	
VanVelthoven *et al.* [67]	S	25	10 (40)	9 (36)	6 (24)	
Versari *et al.* [72]	S	40	25 (63)	9 (22)	6 (15)	
Total	CM	86	72 (84)	4 (5)	10 (11)	
	S	610	334 (55)	193 (32)	83 (13)	

(*continued*)

Table 5 (*continued*)

		N	Clinical outcome			Complications
			IMP	STAB	AGG	
5. FMD + DO + AO + RT + DU						
Blagodatsky *et al.* [7]	S	11	7 (64)	3 (27)	1 (9)	
Ellenbogen *et al.* [13]	CM	14	14 (100)	0 (0)	0 (0)	subgaleal CSF 4 (6),
	S	51	49 (96)	2 (4)	0 (0)	CSF leak 2 (9)
Fisher [17]	S	16	15 (94)	1 (6)	0 (0)	aseptic meningitis 2 (11), kyphotic deformity 1 (5), mild hearing loss 1 (5)
Guyotat *et al.* [21]	S	8	7 (87)	1 (13)	0 (0)	meningitis 1 (1)
Raftopoulos *et al.* [48]	S	8	8 (100)	0 (0)	0 (0)	
Williams [76]	S	54	45 (83)	5 (9)	4 (8)	
Total	CM	14	14 (100)	0 (0)	0 (0)	
	S	148	131 (89)	12 (8)	5 (3)	
6. FMD + DO + AO						
Vaquero *et al.* [70]	S	15	4 (27)	6 (40)	5 (33)	cephalalgias 7 (47), meningitis 2 (13), neuralgia Vth 1 (7)
Total	S	15	4 (27)	6 (40)	5 (33)	
7. FMD + DO + AO + RT						
Sakas *et al.* [54]	CM	5	2 (40)	3 (60)	0 (0)	arachnoid adhesions and tethering 3 (20)
	S	10	4 (40)	6 (60)	0 (0)	
Total	CM	5	2 (40)	3 (60)	0 (0)	
	S	10	4 (40)	6 (60)	0 (0)	
8. FMD + DO + DU + SH						
Ergün *et al.* [16]	S	18	16 (89)	2 (11)	0 (0)	aseptic meningitis 2 (11), transient dysesthesias 4 (22)
Fujii *et al.* [18]	S	8	8 (100)	0 (0)	0 (0)	
Guyotat *et al.* [21]	S	8	6 (75)	1 (13)	1 (12)	
Total	S	34	30 (88)	3 (9)	1 (3)	

(*continued*)

Table 5 (*continued*)

		N	Clinical outcome			Complications
			IMP	STAB	AGG	
9. Shunt						
Aghakhani *et al.* [1]	S	31	7 (23)	15 (48)	9 (29)	
Hida *et al.* [24]	S	37	36 (97)	1 (3)	0 (0)	shunt malfunction 4 (11)
Hida and Iwasaki [23]	S	59	59 (100)	0 (0)	0 (0)	shunt malfunction 10 (17)
Tognetti and Calbucci [64]	S	12	4 (33)	5 (42)	3 (25)	leg dysesthesia 1 (8)
Vaquero *et al.* [70]	S	15	10 (67)	2 (13)	3 (20)	leg dysesthesia 8 (53)
Total	S	154	116 (75)	23 (15)	15 (10)	

IMP Improved, *STAB* stabilized, *AGG* aggravated, neuro neurological, *CM* Chiari type I malformation alone, *S* Chiari malformation with syringomyelia, *FMD* foramen magnum decompression, *DO* dural opening, *AO* arachnoid opening, *DU* duraplasty, *SH* shunt, *RT* resection of tonsils.

* For Klekamp *et al.*'s series see legends of Tables 3 and 4 for interpretation.

had large arachnoid openings. Opening of the arachnoid did not guarantee a more effective outcome as shown in Table 5. On the contrary, with technical modality No. 4, only 55% of the 610 patients improved, and in 13% their conditions worsened. The outcome was worst with modality No. 6 and No. 7 (25 patients reported), in which there was improvement in only 32% of cases, stabilization in 48% and aggravation in 20%.

Plugging the obex in addition to arachnoid opening (which we found reported in 106 patients in the literature [7, 47, 53, 67]), did not bring about any positive effect. The improvement rate was 66% and the aggravation rate was 9% (not shown in the table).

It appears from data in the literature that complementary tonsillar resection (modality No. 5), did not bring any significant improvement compared to Foramen Magnum decompression with enlargement duraplasty only. The improvement was obtained in 89% of the 148 patients and there was aggravation in 3% (compared with 87% and 2% with modality No. 3 for example). The same holds true for shunting in addition to foramen magnum decompression with duraplasty (modality No. 8); improvement was achieved in 88% of the 30 patients and aggravation occurred in 3% [1, 24, 64, 70].

Several authors [22, 36, 44, 58, 77] state that they use intraoperative colour doppler ultrasonography to adjust surgical procedure on the basis of real-time anatomic and physiological measurements. They first practice an occipital craniectomy ± a C-1 laminectomy. An intraoperative ultrasound device is then positioned so that the neuroradiologist can examine the craniocervical junction. Decompression is considered adequate when a CSF space is present anterior to the brainstem and dorsal to the cerebellar tonsils, and when there is no evidence of abnormal tonsillar piston activity. When decompression is inadequate, a more invasive type of surgery is performed, with duraplasty, tonsillar shrinkage, and/or more laminectomy.

In our experience, we have not been confronted with a symptomatic slump of the hindbrain following craniocervical decompression. Nevertheless, this complication is well-known and as such the clinician must be attentive to the possibility of it occurring, especially in case of large craniectomy and excessive enlargement duraplasty. Intractable headache and/or neurological deficits due to persistent or recurrent syringomyelia should evoke the diagnosis. Holly *et al.* suggest partial suboccipital cranioplasty, with or without intradural exploration, as an effective treatment for this condition [25].

Conclusion

- Foramen magnum decompression with extreme lateral rim resection, followed by dural enlargement, was revealed to be the most effective treatment for CM-I whether associated with syringomyelia or not. As pointed out by Klekamp *et al.* [28], small craniectomy offers better results than large craniectomy.
- Preservation of the arachnoid membrane, whenever there is no evidence of obstruction of the foramen of Magendie and/or arachnoiditis, decreases the risk of complications. That is to say the arachnoid should be dissected in cases of CM-I with syringomyelia and/or hydrocephalus, whenever simple decompression is unlikely to be sufficient to re-establish a good CSF flow, when there is evidence of blocking arachnoiditis.
- Tonsillar resection does not seem to add much value, provided foramen magnum decompression is performed not only posteriorly but also laterally, condyle to condyle.
- Large opening of the arachnoid, with exploration of the foramen of Magendie, and complementary subpial resection of the tonsils, may be considered as a secondary option in the rare cases in which CSF circulation at the cervico-occipital junction is judged to remain insufficient.
- Plugging the obex not only brings no positive benefit, it also entails significant additional risks.
- Syringomyelia associated to CM-I must be treated by craniocervical decompression alone.
- Shunting no longer appears to be an appropriate method of treatment for syringomyelia considered in relation to a dysfunctioning circulation due to CM-I.
- Intraoperative ultrasonography may help to find the least invasive but most effective surgical modality. Nevertheless, further evaluations are needed.

Acknowledgements

We thank Mrs. Cindy Chambaud for her precious assistance.

References

1. Aghakhani N, Parker F, Tadie M (1999) Syringomyelia and Chiari abnormality in the adult. Analysis of the results of a cooperative series of 285 cases. Neurochirurgie 45 Suppl 1: 23–36
2. Alperin N, *et al.* (2001) Analysis of magnetic resonance imaging-based blood and cerebrospinal fluid flow measurements in patients with Chiari I malformation: a system approach. Neurosurg Focus 11: E6
3. Alzate JC, Kothbauer KF, Jallo GI, Epstein FJ (2001) Treatment of Chiari I malformation in patients with and without syringomyelia: a consecutive series of 66 cases. Neurosurg Focus 11: E3
4. Batzdorf U (2000) Microsurgery of syringomyelia and syringomyelia cord syndrome. In: Schmidek HH, Sweet WH (eds) Operative neurosurgical techniques: indication, methods and results. WB Saunders Company, Philadelphia, pp 1946–54
5. Bejjani GK (2001) Definition of the adult Chiari malformation: a brief historical overview. Neurosurg Focus 11: E1
6. Bindal AK, Dunsker SB, Tew JM Jr (1995) Chiari I malformation: classification and management. Neurosurgery 37: 1069–74
7. Blagodatsky MD, Larionov SN, Alexandrov YA, Velm AI (1999) Surgical treatment of Chiari I malformation with or without syringomyelia. Acta Neurochir (Wien) 141: 963–68
8. Chang HS, Nakagawa H (2003) Hypothesis on the pathophysiology of syringomyelia based on simulation of cerebrospinal fluid dynamics. J Neurol Neurosurg Psychiatry 74: 344–47
9. Chiari H (1891) Üeber Veränderungen des Kleinhirns infolge von Hydrocephalie des Grosshirns. Dtsch Med Wochenschr 17: 1172–75
10. Chopra JS, Sawhney IM, Kak VK, Khosla VK (1988) Craniovertebral anomalies: a study of 82 cases. Br J Neurosurg 2: 455–64
11. Cristante L, Westphal M, Herrmann HD (1994) Cranio-cervical decompression for Chiari I malformation. A retrospective evaluation of functional outcome with particular attention to the motor deficits. Acta Neurochir (Wien) 130: 94–100
12. Dones J, De Jesus O, Colen CB, Toledo MM, Delgado M (2003) Clinical outcomes in patients with Chiari I malformation: a review of 27 cases. Surg Neurol 60: 142–47; discussion 147–48
13. Ellenbogen RG, Armonda RA, Shaw DW, Winn HR (2000) Toward a rational treatment of Chiari I malformation and syringomyelia. Neurosurg Focus 8: E6
14. Ellenbogen RG, Zeidman S (2000) Craniovertebral decompression for Chiari Malformation. In: Kaye A, Black P (eds) Operative neurosurgery. Churchill Livingston, London, pp 1725–41
15. Elster AD, Chen MY (1992) Chiari I malformations: clinical and radiologic reappraisal. Radiology 183: 347–53
16. Ergün R, *et al.* (2000) Surgical management of syringomyelia-Chiari complex. Eur Spine J 9: 553–57

17. Fisher E (1995) Posterior fossa decompression for Chiari I deformity, including resection of the cerebellar tonsils. Childs Nerv Syst 11: 625–29
18. Fujii K, Natori Y, Nakagaki H, Fukui M (1991) Management of syringomyelia associated with Chiari malformation: comparative study of syrinx size and symptoms by magnetic resonance imaging. Surg Neurol 36: 281–85
19. Gambardella G, Caruso G, Caffo M, Germano A, La Rosa G, Tomasello F (1998) Transverse microincisions of the outer layer of the dura mater combined with foramen magnum decompression as treatment for syringomyelia with Chiari I malformation. Acta Neurochir (Wien) 140: 134–39
20. Goel A, Bhatjiwale M, Desai K (1998) Basilar invagination: a study based on 190 surgically treated patients. J Neurosurg 88: 962–68
21. Guyotat J, Bret P, Jouanneau E, Ricci AC, Lapras C (1998) Syringomyelia associated with type I Chiari malformation. A 21-year retrospective study on 75 cases treated by foramen magnum decompression with a special emphasis on the value of tonsils resection. Acta Neurochir (Wien) 140: 745–54
22. Heiss JD, *et al.* (1999) Elucidating the pathophysiology of syringomyelia. J Neurosurg 91: 553–62
23. Hida K, Iwasaki Y (2001) Syringosubarachnoid shunt for syringomyelia associated with Chiari I malformation. Neurosurg Focus 11: E7
24. Hida K, Iwasaki Y, Koyanagi I, Sawamura Y, Abe H (1995) Surgical indication and results of foramen magnum decompression versus syringosubarachnoid shunting for syringomyelia associated with Chiari I malformation. Neurosurgery 37: 673–78; discussion 678–79
25. Holly LT, Batzdorf U (2001) Management of cerebellar ptosis following craniovertebral decompression for Chiari I malformation. J Neurosurg 94: 21–26
26. Isu T, Sasaki H, Takamura H, Kobayashi N (1993) Foramen magnum decompression with removal of the outer layer of the dura as treatment for syringomyelia occurring with Chiari I malformation. Neurosurgery 33: 844–49; discussion 849–50
27. James HE, Brant A (2002) Treatment of the Chiari malformation with bone decompression without durotomy in children and young adults. Childs Nerv Syst 18: 202–06
28. Klekamp J, Batzdorf U, Samii M, Bothe HW (1996) The surgical treatment of Chiari I malformation. Acta Neurochir (Wien) 138: 788–801
29. Lay CM (2002) Low cerebrospinal fluid pressure headache. Curr Treat Options Neurol 4: 357–63
30. Marcelis J, Silberstein SD (1990) Spontaneous low cerebrospinal fluid pressure headache. Headache 30: 192–96
31. Marin-Padilla M, Marin-Padilla TM (1981) Morphogenesis of experimentally induced Arnold-Chiari malformation. J Neurol Sci 50: 29–55
32. McGirt MJ, Nimjee SM, Floyd J, Bulsara KR, George TM (2005) Correlation of cerebrospinal fluid flow dynamics and headache in Chiari I malformation. Neurosurgery 56: 716–21; discussion 716–21
33. McGirt MJ, Nimjee SM, Fuchs HE, George TM (2006) Relationship of cine phase-contrast magnetic resonance imaging with outcome after decompression for Chiari I malformations. Neurosurgery 59: 140–146; discussion 140–46
34. Meadows J, Kraut M, Guarnieri M, Haroun RI, Carson BS (2000) Asymptomatic Chiari type I malformations identified on magnetic resonance imaging. J Neurosurg 92: 920–26

35. Menezes AH (1995) Primary craniovertebral anomalies and the hindbrain herniation syndrome (Chiari I): data base analysis. Pediatr Neurosurg 23: 260–69
36. Milhorat TH, Bolognese PA (2003) Tailored operative technique for Chiari type I malformation using intraoperative color Doppler ultrasonography. Neurosurgery 53: 899–905; discussion 905–896
37. Milhorat TH, *et al.* (1999) Chiari I malformation redefined: clinical and radiographic findings for 364 symptomatic patients. Neurosurgery 44: 1005–17
38. Mokri B (1999) Spontaneous cerebrospinal fluid leaks: from intracranial hypotension to cerebrospinal fluid hypovolemia-evolution of a concept. Mayo Clin Proc 74: 1113–23
39. Mokri B, Atkinson JL, Dodick DW, Miller GM, Piepgras DG (1999) Absent pachymeningeal gadolinium enhancement on cranial MRI despite symptomatic CSF leak. Neurology 53: 402–04
40. Munshi I, Frim D, Stine-Reyes R, Weir BK, Hekmatpanah J, Brown F (2000) Effects of posterior fossa decompression with and without duraplasty on Chiari malformation-associated hydromyelia. Neurosurgery 46: 1384–89; discussion 1389–90
41. Navarro R, Olavarria G, Seshadri R, Gonzales-Portillo G, McLone DG, Tomita T (2004) Surgical results of posterior fossa decompression for patients with Chiari I malformation. Childs Nerv Syst 20: 349–56
42. Nishikawa M, Sakamoto H, Hakuba A, Nakanishi N, Inoue Y (1997) Pathogenesis of Chiari malformation: a morphometric study of the posterior cranial fossa. J Neurosurg 86: 40–47
43. Nishizawa S, Yokoyama T, Yokota N, Tokuyama T, Ohta S (2001) Incidentally identified syringomyelia associated with Chiari I malformations: is early interventional surgery necessary? Neurosurgery 49: 637–40; discussion 640–31
44. Oldfield EH, Muraszko K, Shawker TH, Patronas NJ (1994) Pathophysiology of syringomyelia associated with Chiari I malformation of the cerebellar tonsils. Implications for diagnosis and treatment. J Neurosurg 80: 3–15
45. Paldino M, Mogilner AY, Tenner MS (2003) Intracranial hypotension syndrome: a comprehensive review. Neurosurg Focus 15: ECP2
46. Paul KS, Lye RH, Strang FA, Dutton J (1983) Arnold-Chiari malformation. Review of 71 cases. J Neurosurg 58: 183–87
47. Pillay PK, Awad IA, Little JR, Hahn JF (1991) Symptomatic Chiari malformation in adults: a new classification based on magnetic resonance imaging with clinical and prognostic significance. Neurosurgery 28: 639–45
48. Raftopoulos C, Sanchez A, Matos C, Baleriaux D, Bank WO, Brotchi J (1993) Hydrosyringomyelia-Chiari I complex. Prospective evaluation of a modified foramen magnum decompression procedure: preliminary results. Surg Neurol 39: 163–69
49. Raskin NH (1990) Lumbar puncture headache: a review. Headache 30: 197–200
50. Rhoton A (2000) Management of syringomyelia. In: Kaye A, Black P (eds) Operative neurosurgery. Churchill Livingston, London, pp 1743–54
51. Rhoton A (2000) Microsurgery of syringomyelia and the syringomyelia-Chiari complex. In: Schmidek HH, Sweet WH (eds) Operative neurosurgical techniques: indications, methods and results. WB Saunders Company, Philadelphia, pp 1955–69
52. Sahuquillo J, Rubio E, Poca MA, Rovira A, Rodriguez-Baeza A, Cervera C (1994) Posterior fossa reconstruction: a surgical technique for the treatment of Chiari I malformation and Chiari I/syringomyelia complex-preliminary results and magnetic resonance imaging

quantitative assessment of hindbrain migration. Neurosurgery 35: 874–84; discussion 884–75

53. Sakamoto H, *et al.* (1999) Expansive suboccipital cranioplasty for the treatment of syringomyelia associated with Chiari malformation. Acta Neurochir (Wien) 141: 949–960; discussion 960–941
54. Sakas DE, *et al.* (2005) Chiari malformation: CSF flow dynamics in the craniocervical junction and syrinx. Acta Neurochir (Wien) 147: 1223–33
55. Sansur CA, Heiss JD, DeVroom HL, Eskioglu E, Ennis R, Oldfield EH (2003) Pathophysiology of headache associated with cough in patients with Chiari I malformation. J Neurosurg 98: 453–58
56. Schady W, Metcalfe RA, Butler P (1987) The incidence of craniocervical bony anomalies in the adult Chiari malformation. J Neurol Sci 82: 193–203
57. Schijman E (2004) History, anatomic forms, and pathogenesis of Chiari I malformations. Childs Nerv Syst 20: 323–28
58. Scott RM (2004) Tailored operative technique for Chiari type I malformation using intraoperative color Doppler ultrasonography. Neurosurgery 55: 1008; author reply 1008
59. Sgouros S, Kountouri M, Natarajan K (2006) Posterior fossa volume in children with Chiari malformation type I. J Neurosurg 105: 101–06
60. Sindou M, Chavez-Machuca J, Hashish H (2002) Cranio-cervical decompression for Chiari type I-malformation, adding extreme lateral foramen magnum opening and expansile duroplasty with arachnoid preservation. Technique and long-term functional results in 44 consecutive adult cases – comparison with literature data. Acta Neurochir (Wien) 144: 1005–19
61. Sivaramakrishnan A, Alperin N, Surapaneni S, Lichtor T (2004) Evaluating the effect of decompression surgery on cerebrospinal fluid flow and intracranial compliance in patients with chiari malformation with magnetic resonance imaging flow studies. Neurosurgery 55: 1344–50; discussion 1350–1341
62. Stovner LJ, Bergan U, Nilsen G, Sjaastad O (1993) Posterior cranial fossa dimensions in the Chiari I malformation: relation to pathogenesis and clinical presentation. Neuroradiology 35: 113–18
63. Takayasu M, Takagi T, Hara M, Anzai M (2004) A simple technique for expansive suboccipital cranioplasty following foramen magnum decompression for the treatment of syringomyelia associated with Chiari I malformation. Neurosurg Rev 27: 173–77
64. Tognetti F, Calbucci F (1993) Syringomyelia: syringo-subarachnoid shunt versus posterior fossa decompression. Acta Neurochir (Wien) 123: 196–97
65. Tubbs RS, Iskandar BJ, Bartolucci AA, Oakes WJ (2004) A critical analysis of the Chiari 1.5 malformation. J Neurosurg 101: 179–83
66. Tubbs RS, McGirt MJ, Oakes WJ (2003) Surgical experience in 130 pediatric patients with Chiari I malformations. J Neurosurg 99: 291–96
67. Van Velthoven V, Jost M, Siekmann R, Eggert HR (1993) Surgical strategies and results in syringomyelia. Acta Neurochir (Wien) 123: 199–201
68. Vanaclocha V, Saiz-Sapena N (1997) Duraplasty with freeze-dried cadaveric dura versus occipital pericranium for Chiari type I malformation: comparative study. Acta Neurochir (Wien) 139: 112–19
69. Vanaclocha V, Saiz-Sapena N, Garcia-Casasola MC (1997) Surgical technique for cranio-cervical decompression in syringomyelia associated with Chiari type I malformation. Acta Neurochir (Wien) 139: 529–539; discussion 539–40

70. Vaquero J, Martinez R, Arias A (1990) Syringomyelia-Chiari complex: magnetic resonance imaging and clinical evaluation of surgical treatment. J Neurosurg 73: 64–68
71. Vega A, Quintana F, Berciano J (1990) Basichondrocranium anomalies in adult Chiari type I malformation: a morphometric study. J Neurol Sci 99: 137–45
72. Versari PP, D'Aliberti G, Talamonti G, Collice M (1993) Foraminal syringomyelia: suggestion for a grading system. Acta Neurochir (Wien) 125: 97–104
73. Wagshul ME, Chen JJ, Egnor MR, McCormack EJ, Roche PE (2006) Amplitude and phase of cerebrospinal fluid pulsations: experimental studies and review of the literature. J Neurosurg 104: 810–19
74. Williams B (1981) Simultaneous cerebral and spinal fluid pressure recordings. 2. Cerebrospinal dissociation with lesions at the foramen magnum. Acta Neurochir (Wien) 59: 123–42
75. Williams B (1991) Pathogenesis of syringomyelia. In: U B (eds) Syringomyelia. Current concepts in diagnosis and treatment. Williams, pp 90
76. Williams B (1993) Surgical treatment of syringobulbia. Neurosurg Clin N Am 4: 553–71
77. Yeh DD, Koch B, Crone KR (2006) Intraoperative ultrasonography used to determine the extent of surgery necessary during posterior fossa decompression in children with Chiari malformation type I. J Neurosurg 105: 26–32