

HYPOHIDROTIC ECTODERMAL DYSPLASIA (HED)

Martino Ruggieri and Ignacio Pascual-Castroviejo

Institute of Neurological Science, National Research Council, Catania and Department of Paediatrics, University of Catania, Catania, Italy (MR); Paediatric Neurology Service, University Hospital La Paz, University of Madrid, Madrid, Spain (IPC)

Definition of the ectodermal dysplasias

The ectodermal dysplasias (EDs) represent a complex and highly diverse group of congenital heritable disorders affecting tissues of ectodermal origin. The main characteristics of the group, which encompasses more than 170 conditions (Irvine 2006, OMIM 2006), consist in developmental abnormalities of two or more ectodermal appendages/structures including skin, hair, teeth, nail and sweat glands, many of which have overlapping clinical features (Irvine 2006). Other structures derived from embryonic ectoderm include the mammary gland, thyroid gland, thymus, anterior pituitary, adrenal medulla, central nervous system, external ear, melanocytes, cornea, conjunctiva, lacrimal gland and lacrimal duct. The broader definition endeavouring all ectodermal derived structures, according to a recent review (Irvine 2006), has definite benefits in that the problems encountered by many patients and families are similar regardless of the specific subtype of ED. In addition, the wide-ranging classification is also helpful as several EDs are now known to share similar genetic mechanisms (Irvine 2006).

History of terminology of ectodermal dysplasia

The first clinical report with features of what would be currently classified as ED is by Danz who in 1792 described two Jewish boys with congenital absence of hair and teeth (Danz 1792). The term “ectodermal dysplasia” did not appear in the literature until Weech coined it in 1929. Prior to this report isolated descriptions or small series of patients with hypotrichosis,

hypodontia, onychodysplasia and anhidrosis had been described under various terms including “dystrophy of hair and nails”, “imperfect development of skin, hair and teeth” and “congenital ectodermal defect”. The designation coined by Weech specified some essential aspects of EDs: (1) most disturbances affected tissues of ectodermal origin; (2) these disturbances were developmental; and (3) heredity played a causative role (Irvine 2006). When Weech published his report in the late ‘20 (Weech 1929) he had in mind the X-linked anhydrotic form of ED (Christ-Siemens-Touraine syndrome; CST; or hypohidrotic ectodermal dysplasia, HED, OMIM # 305100) in males but noted that it had also been reported in females and occasionally could be inherited as a non-sex-linked trait (Irvine 2006): since then many clinicians have used the term ED to refer to CST syndrome and to the autosomal recessive and dominant forms of HED. As more clinical reports of patients with similar but subtly distinct patterns of abnormalities were recorded, the term “ectodermal dysplasia” became extended to include many different genetic entities. In an attempt to encapsulate this heterogeneity and the diversity of symptoms, Touraine (1936) proposed the term “ectodermal polydysplasia”. Several other attempts, including hidrotic and anhidrotic forms soon followed but all failed to reflect the complexity of ectodermal appendages anomalies associated with the various forms of EDs. Currently, the most widely accepted and used definition of EDs is that reported in the paragraph below (Irvine 2006). Notably, many conditions that, by definition, lie within the broader spectrum of EDs (e.g., incontinentia pigmenti, Goltz syndrome) are often considered separately for practical reasons: these conditions are given in-depth coverage elsewhere.

Classification of the ectodermal dysplasias

More than 170 different pathological conditions have been reported as EDs (Irvine 2006, Freire-Maia and Pinheiro 1984, OMIM 2006, Pinheiro et al. 1994, Priolo et al. 2000, 2001), and these are often associated with a broad spectrum of anomalies of ectodermal-derived organs and systems including the central nervous system (Clarke 1987, Irvine 2006). Until the end of the 20th century, classification systems for EDs were, because of lack of molecular understanding, based on clinical features. The most comprehensive accounts of clinical features and inheritance patterns of EDs are to be found in the 1984 monograph by Freire-Maia and Pinheiro and subsequent publication by Pinheiro and Freire-Maia (1994). Their classification designated conditions by groups depending on the presence of features in hair, nails, teeth or sweat glands, and assigned conditions to groups using a "1234 system" to collate conditions that had involvement of the hair (1), teeth (2) nails (3) or sweat glands (4) to groups such as 1-2 or 1-2-3. We refer the reader to the thorough review by Irvine (2006) for a comprehensive contemporaneous consideration of the breadth of ED conditions in the tradition of Freire-Maia and Pinheiro (Irvine 2006).

The last decade has watched several important insights into the molecular basis of several of the EDs which have either confirmed clinical impressions or contributed to pool or split several ED forms (Irvine 2006). Thus, new approaches to classification have endeavoured these most recent molecular insights and classified EDs under the broad categories of; (a) defects in nuclear tumour necrosis factor-like- $\kappa\beta$ (*NF- $\kappa\beta$*) signalling pathways; (b) transcription factors (*TP63*-phenotypes) and homeobox genes; (c) gap junctions (*connexin* proteins: *GJA*, *GJB* and *GJC*); and (d) epithelial structural (*cytokeratins*) or adhesive (*desmosomal* components) molecules.

The X-linked, autosomal dominant and recessive hypohidrotic ectodermal dysplasias, whose phenotypic appearances are identical, are due to mutations in tumour necrosis factor-like/*NF- $\kappa\beta$* signalling pathways.

HYPHIDROTIC ECTODERMAL DYSPLASIA

Introduction

Hypohidrotic ectodermal dysplasia (HED) is the most common of the EDs and is characterised by hypotrichosis, hypodontia, hypohidrosis and distinctive facial features. HED is included in both classifications of EDs, the most permissive of Freire-Maia and Pinheiro (1984) and Pinheiro and Freire-Maia (1994) and the more restrictive ones of Priolo et al. (2000), including 46 entities, and Irvine (2006) which integrate either the molecular genetic data and the corresponding clinical findings.

Three inherited types of HED are known: (1) X-linked recessive HED (XLRHED; OMIM # 305100) which is the most frequent (Irvine 2006, Reed et al. 1970); and two rarer forms: (2) autosomal dominant HED (ADHED; OMIM # 129490) and autosomal recessive HED (ARHED; OMIM # 224900) (Baala et al. 1999, Irvine 2006, Munoz et al. 1997). The phenotypic appearance of the XLRHED and autosomal types (ADHED and ARHED) are identical. The autosomal forms of HED are caused by mutations in the *Downless* (DL) gene while the X-linked form is caused by mutations in the *EDA1* gene which maps to Xq12-13.1 and encodes two isoforms of a transmembrane protein, *ectodysplasin-A* (EDA), that has homology to the TNF family (Irvine 2006).

Historical perspective and eponyms

HED (also known as anhidrotic ectodermal dysplasia or Christ-Siemens-Touraine syndrome or Weech syndrome (Christ 1932, Siemens 1937, Weech 1929) was first reported by Thurman in 1848, but earlier descriptions may be found. Thedani (1921) determined that HED was an X-linked disorder and later reported that female carriers manifest varying signs of the conditions. Weech (1929) observed the depression of gland function and coined the term

“anhidrotic ectodermal dysplasia”, while Christ defined the condition as a “congenital ectodermal defect”, and Siemens named the disorder as “anhidrosis hypotrichotica”. Felsher (1944) pointed that the skin is rarely, if ever, completely anhidrotic and suggested the term “hypohidrotic” instead of “anhidrotic” which is most often used.

Incidence and prevalence

HED is a rare condition.

Clinical manifestations

Clinically, HED is characterized by: a) fine and sparse hair; b) few and often pointed teeth; c) diminished or absent eccrine function that mainly affects mucosal and sweat glands. The inability to sweat is responsible for the most dangerous consequences of the disorder with the chance of putting affected infants and children at risk for life-threatening and brain-damaging episodes of hyperthermia (Cambiaghi et al. 2000). Intolerance to heat, with severe incapacitation and hyperpyrexia may occur after only mild exertion or even following meals. In X-linked HED, the affected patients are most often hemizygous male individuals, since in heterozygous female carriers the severity of the disorder varies considerably; most females only have a mild or “partial” involvement and, most often, are not referred to a physician (Cambiaghi et al. 2000). Autosomal recessive HED is similar to the hemizygous form of X-linked HED from a clinical viewpoint except that males and females are equally affected.

Patients with HED most often show a quite characteristic phenotype and individuals from different families look enough alike as brothers.

Craniofacial features

The facies appears as an inverted triangle, with marked frontal bossing, concave midface, different degrees of depressed nasal bridge, saddle nose and

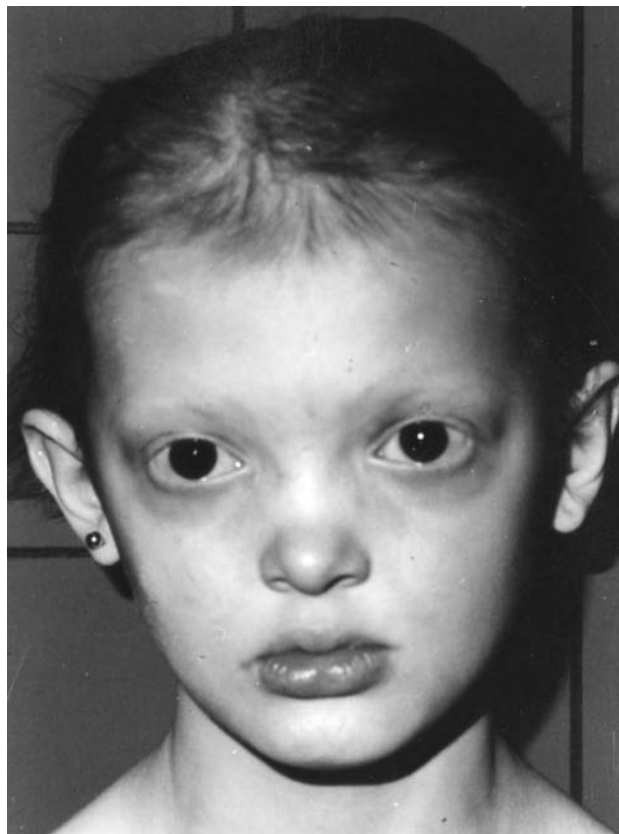

Fig. 1. Hypohidrotic ectodermal dysplasia in a 7-year-old girl: the facies is characterized by frontal bossing, depressed nasal bridge, thin hair, and pouting lips.

protuberant lips (Fig. 1). Fine linear wrinkles are often noted about the eyes and mouth, or evident periorbital pigmentation. A third of affected males have ears that are described as simple or satyr. The distinctive facial features may not be obvious at birth but become more noticeable with age. Carrier females may exhibit similar facial features.

Skin

In children and adults the skin is soft, thin and dry because of the absence of sebaceous glands (Fig. 2). Eczema is not uncommon, especially during the first years of life. At birth, affected males may demonstrate marked scaling or peeling of their skin that

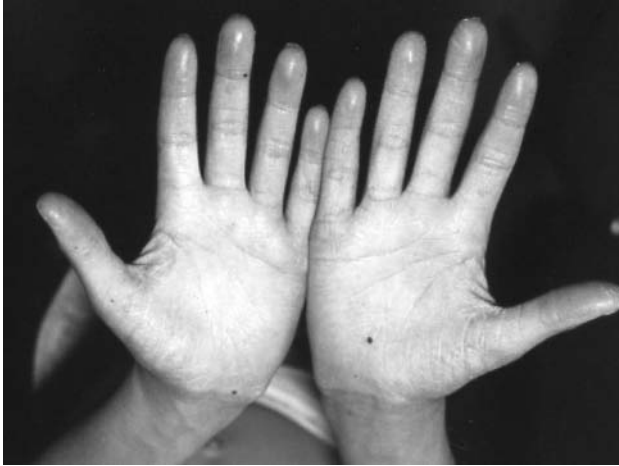

Fig. 2. The palms of the same patient as in Fig. 1 shows dry skin.

may be mistaken for a colloidon membrane. Periorbital hyperpigmentation around the eyes is a characteristic features of the disorder. Small milia-like papules may be found on the face.

Hair

Hair is scant, fine, stiff, short, and most often blond, in scalp, axillary and pubic regions, and may be completely lacking in the eyelashes, brows or in entire body. Secondary sexual hair in the beard, pubic and axillary regions is variably present. Approximately, 70% of obligate female carriers of X-linked HED describe their hair as being sparse or fine.

Oral manifestations

Oral manifestations consist of hypodontia or, more often, anodontia reflecting complete lack of dental ectoderm. Teeth is originate from both ectodermal and mesodermal tissue, while odontoblasts from, a mesodermal component, and do not differentiate in the absence of an ectodermal layer (Glasstone 1935–1936). The few teeth that may be present are often delayed in eruption (Fig. 3), and when present, the incisors, canines and bicuspid, are often conical in crown form (Gorlin and Pindborg 1964). The shape of the crown is determined by the inner enamel or ameloblastic layer of the tooth germ. Oral, pharyngeal

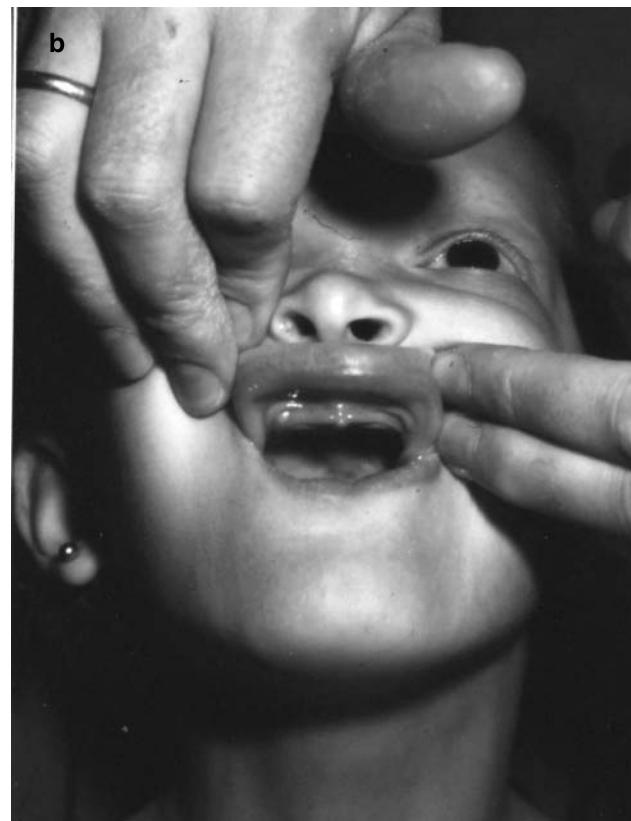
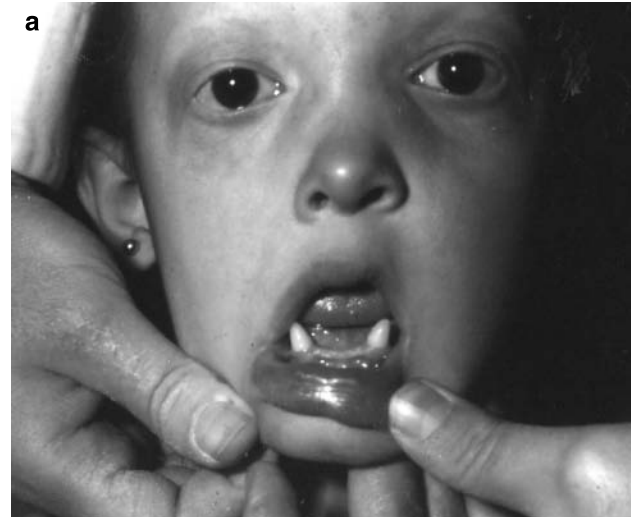
Fig. 3. Same patient as in Figs. 1 and 2. (a) Periorbital pigmentation and presence only of canines in the lower arcade; (b) Anodontia in the upper arcade.

and nasal mucosa most often appear dry and atrophic. Dental roentgenograms show the hypodontia or anodontia and the conical form of tooth crowns (Fig. 4).

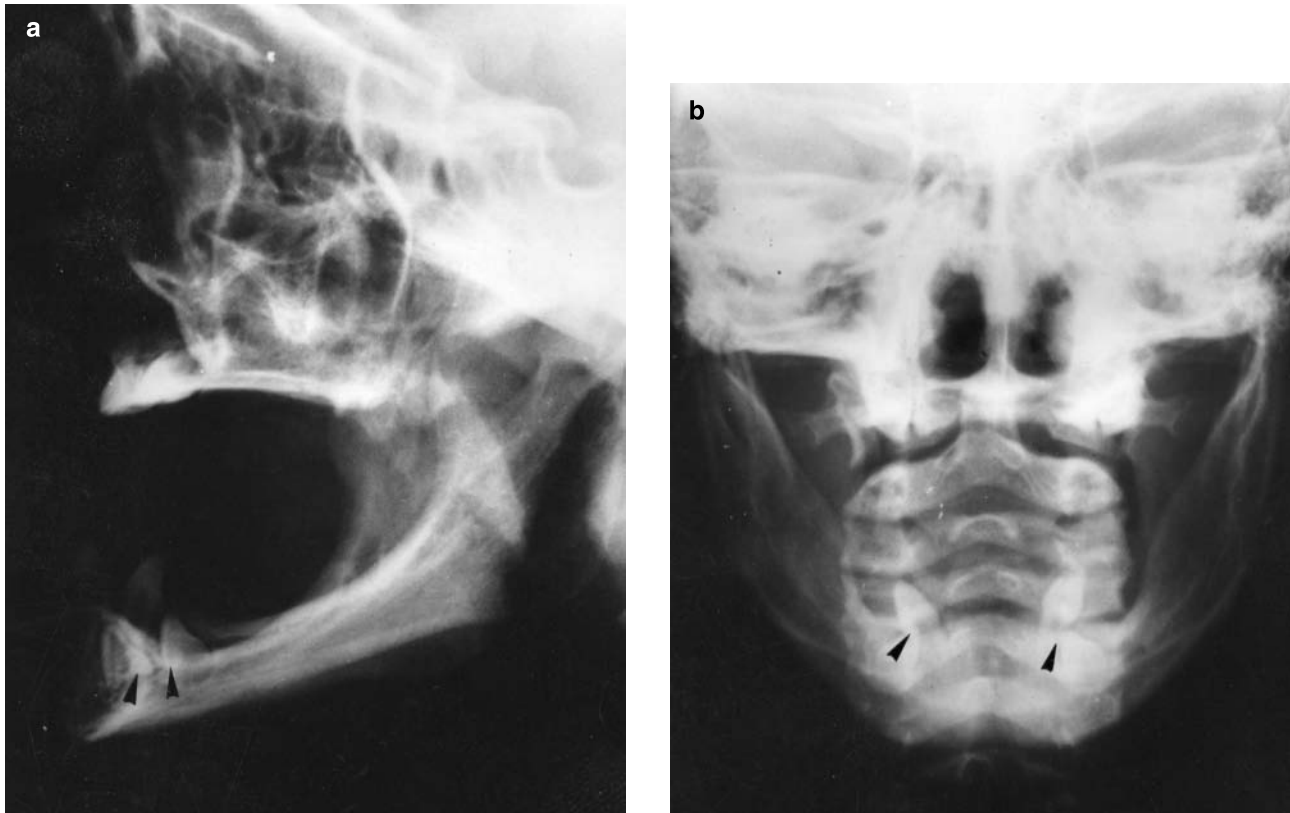

Fig. 4. Dental roentgenograms of the same patient. Sagittal and coronal views confirm the presence of two canines in the mandible (arrow heads) and anodontia of the other teeth.

Other ectodermal structures

Aplastic or hypoplastic mammary glands, and primary hypogonadism (Mohler 1959) have been also reported. The finger and the toe nails are usually normal. Thin, brittle nail plates with longitudinal ridges have been described in some individuals.

Eye involvement

Ocular symptoms and signs consist in alterations of the meibomian glands (95.45%) which are detected by meibomioscopy, reduction of eyebrows (94.4%), and lashes alterations (91.6%) (Kaercher 2004).

Other clinical features

Diminished or absent mucous glands of the tracheal, bronchial, oesophageal, gastric and colonic mucosa

cause problems with recurrent bronchitis, pneumonia, dysphagia, and gastro-oesophageal reflux and constipation. Reactive airways associated with wheezing are a common problem.

Individuals with HED most frequently show normal intelligence, and mental retardation is seldom associated with this condition.

Molecular genetics and pathogenesis

HED most frequently manifests as X-linked recessive form or more rarely, as autosomal recessive or autosomal dominant (Baala et al. 1999, Shimomura et al. 2004, Zonana et al. 2000).

The gene responsible for X-linked HED, known as *EDA1* gene (mouse model known as *tabby*), is located at Xq12-q13.1 and affects a transmembrane protein (*ectodysplasin-A* or EDA) (Na et al. 2004) expressed by keratinocytes, hair follicles, and sweat

glands, possibly having a key role in epithelial-mesenchymal signalling (Kere et al. 1996). Mutations in the domains of EDA are thought to have an effect on solubility or cleavage of ectodysplasin-A (EDA) rendering it non functional: cleavage of EDA is necessary to enable solubility and functionality of EDA. The two longest isoforms of EDA, EDA-1 and EDA-2 bind to two different receptors: EDA-1 binds to the EDAR protein and EDA-2 binds to another X-linked receptor, XEDAR.

The gene responsible for autosomal dominant/recessive HED, known as *Downless* (DL) (mouse model known as *downless*), has been mapped to chromosome 2q11-q13 (Monreal et al. 1999, Shimomura et al. 2004) and encodes a member of the tumour necrosis factor receptor (TNFR) super-family which functions as an ectodysplasin receptor (EDAR).

The EDA-EDAR pathway has been further refined when the molecular basis of a third mouse homologue has been identified: the *crinkled* mouse (*cr*) which is a spontaneous mouse mutant with an identical phenotype to *downless* and *tabby*. The causative gene of *crinkled* has been identified in an adapter protein (EDAR-associated death domain, termed *EDARADD*) for the EDA-EDAR complex (Fig. 5). Mutations in this gene have been also identified in patients with autosomal recessive HED. The EDARADD domain interacts with the intracellular domain of EDAR, linking to downstream signals leading to NF- κ B activation. In addition, EDARADD associates with TRAF (tumour necrosis factor receptor/TNFR-associated factor) 1, 2 and 3.

NF- κ B activation by the EDAR pathway is NEMO dependent: thus, loss of function mutations

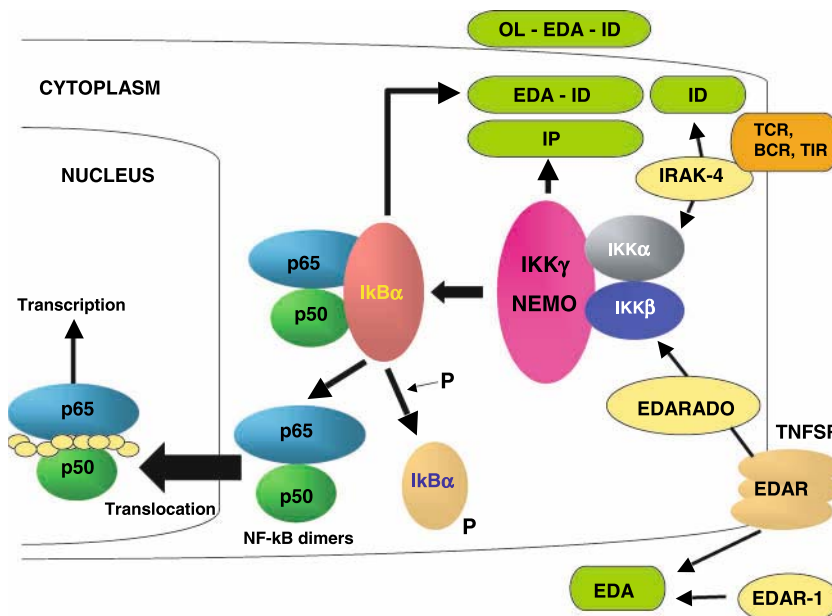


Fig. 5. Overview of the NF- κ B-related pathways and their role in human ectodermal dysplasias. EDA, hypohidrotic/anhidrotic ectodermal dysplasia; EDA-1, etodysplasin a; EDA-ID, anhidrotic ectodermal dysplasia with immunodeficiency; EDAR, EDA receptor; EDARADD, EDAR-associated death domain; ID, immune deficiency; $\kappa\beta\alpha$ (aka: NFKBIA), alpha nuclear factor of kappa light chain gene enhancer in B cells inhibitor; IKK α , alpha kinase of inhibitor of kappa light polypeptide gene enhancer in B cells; IKK β , beta kinase of inhibitor of kappa light polypeptide gene enhancer in E cells; IKK γ , gamma kinase of inhibitor of kappa light polypeptide gene enhancer in B cells; IP, incontinentia pigmenti; IRAK-4, interleukin-1-receptor-associated kinase-4; NEMO, (aka: IKK γ) NF κ B essential modulator (gamma kinase of inhibitor of kappa light polypeptide gene enhancer in B cells); NF κ B, nuclear factor kappa-B; OL-EDA-ID, anhidrotic ectodermal dysplasia with immunodeficiency, osteopetrosis and lymphoedema; TCR, T-cell receptor; BCR, B-cell receptor; TIR, Toll/IL-1 receptor superfamily; TNFSR, TNF superfamily (Adapted from Irvine 2006).

in the EDAR pathway are similar to those in the IKK γ gene (known as NEMO) which regulates the expression of multiple genes which functions in controlling the immune and stress response, cell adhesion, protection against apoptosis and inflammatory reactions. NF- κ B factor is composed of homo- and heterodimers of 5 proteins belonging to the *Rel* family and is sequestered in the cytoplasm by inhibitory proteins of the I κ B family. In response to various stimuli such as tumour necrosis factor (TNF), interleukin-1 (IL-1), and lipopolysaccharide, the inhibitory molecule is phosphorylated and then degraded, allowing NF- κ B to enter the nucleus and activate transcription of targeted genes. The kinase phosphorylating I κ B (IKK) is a complex of three molecules IKK1/IKK α , IKK2/IKK β , and NEMO. IKK1 and IKK2 act as catalytic subunits, while NEMO is a structural and regulatory subunit vital to the function of the unit as a whole (Fig. 5). The absence of NEMO results in no NF- κ B activity in response to stimuli (Bruckner 2004).

Several studies have shed light on how abnormalities in the NF- κ B pathway produce skin and systemic lesions in HED and/or in IP (reviewed in Bruckner 2004 and Irvine 2006). The activation of NF- κ B is critical in preventing apoptosis induced by TNF- α . Male NEMO knockout mice die early in utero and often demonstrate massive liver apoptosis. On the other hand, female mice heterozygous for NEMO deficiency (IKK γ^{\pm}) develop transitory skin changes that are phenotypically and histologically similar to those of HED and IP. The skin of these mice contains elevated levels of several cytokines and chemokines such as TNF- α (Makris et al. 2000). IP lesions of human skin strongly express eotaxin, an eosinophil-selective chemokine that is activated by NF- κ B (Jean-Baptiste et al. 2002). These findings suggest that in the vesicular stage of IP and in the skin of HED, IKK- γ^{-} cells undergo apoptosis, while IKK- γ^{+} cells in turn upregulate the production of TNF- α , IL-1, eotaxin and other cytokines and chemokines. This further drives apoptosis of IKK- γ^{-} cells and also produces an influx of eosinophils into the skin. As the population of IKK- γ^{-} cells declines, inflammation subsides, heralding the end of

the 1st stage of disease. Residual IKK- γ^{-} cells that undergo apoptosis in response to circulating cytokines explain the recurrence of vesicular lesions with febrile illnesses (Brucker 2004). The mechanism producing subsequent skin changes, as well as other findings associated with IP and HED, are poorly understood. The skin of NEMO knockout mice over expresses cytokeratins 6 and 17 which are markers of an inflammatory response, in part explaining the hyperkeratotic lesions. The pathogenesis of the hyperpigmented lesions is unclear, as these areas often do not correspond to preceding inflammation, making purely post inflammatory hyperpigmentation unlikely. Atrophic skin changes may represent residual scarring but may also be due to developmental malformation of the affected areas.

Hypohidrotic ectodermal dysplasia with immunodeficiency (EDA-ID)

Mutations in IKK-gamma (NEMO) have been shown to cause incontinentia pigmenti (IP) (Bloch-Sulzberger type) (Smahi et al. 2000). IKK-gamma is required for the activation of a transcription factor known as "nuclear factor Kappa B" and plays an important role in T- and B-cell function. Males with HED and immune-deficiency (ID) (HED-ID) (OMIM # 300291) from four families studied sequentially by Zonana et al. (2000) revealed 10 mutations affecting the carboxy-terminal end of IKK-gamma protein, a domain believed to connect the IKK signalsome complex to upstream activators. The findings defined this new-linked recessive immunodeficiency syndrome, distinct from other types of HED and immunodeficiency syndromes. Affected males with HED-ID have significant morbidity and mortality from recurrent infections despite therapy (Zonana et al. 2000). Even though the common IKK-gamma mutations seen in IP are lethal for males in utero, and only decrease the immunity in patients with X-linked HED-ID in the four families described by Zonana et al. (2000), it has been suggested that mutations that preserve some IKK-gamma function may be responsible for HED-ID (Zonana et al. 2000).

Diagnosis

The value of tests in supporting the diagnosis of HED has been studied and demonstrated that non-invasive trichogram and sweat testing results can support the diagnosis of HED, but are not sensitive or highly specific; horizontally sectioned 4-mm punch biopsy specimens of the scalp or palms that lack eccrine structures are diagnostic of HED; scalp biopsy shows more sensitivity (67%), with a specificity of 100%, than palmar biopsy, and a scalp biopsy specimen with detectable eccrine structures suggests that a patient does not have HED (Rouse et al. 2004).

Differential diagnosis

HED shows several facets in the clinical features that overlap with those observed in other neurocutaneous disorders. HED chondroectodermal dysplasia, focal dermal hypoplasia, and incontinentia pigmenti (IP) show almost identical conical teeth. Alopecia is seen in the progeria of Hutchinson-Gilford, Rothmund-Thomson syndrome, ichthyosis follicularis and sixteen additional overlapping entities (Mégarbané et al. 2004). The clinical features of HED also resemble Rapp-Hodgkin, Bowen-Amstrong and CHAND syndromes (Sahin et al. 2004), hypotrichosis and nail dysplasia syndrome (Harrison and Sinclair 2004), and the Johanson-Blizzard syndrome (1971) which is an autosomal recessive inherited disorder (Mardini et al. 1978) characterized by alae nasi hypoplasia, scalp and hair ectodermal abnormalities, absence of teeth, genito-urethro-anal anomalies, malabsorption, microcephaly, deafness and dwarfism (Schussheim et al. 1976).

Management

The intolerance of subjects with HED to heat requires these patients to take precautions to protect them from high temperatures, sun exposure and abundant meals.

The oral rehabilitation of patients with HED is important for better social living, self esteem, and oral function (Della Valle et al. 2004).

In the current absence of any effective treatment for HED, comprehensive, accurate prenatal or postnatal genetic testing and counselling can provide valuable information.

References

- Baala L, Hadj Rabia S, Zlogotora J, Kabbaj K, Chhoul H, Munnich A, Lyonnet S, Sefiani A (1999) Both recessive and autosomal dominant forms of anhidrotic/hypohidrotic ectodermal dysplasia map to chromosome 2q11-q13. *Am J Hum Genet* 64: 651–653.
- Bruckner AL (2004) Incontinentia pigmenti: a window to the role of NF- κ B function. *Semin Cut Med Surg* 23: 116–124.
- Cambiaghi S, Restano L, Pääkönen K, Caputo R, Kere J (2000) Clinical findings in mosaic carriers of hypohidrotic ectodermal dysplasia. *Arch Dermatol* 136: 217–224.
- Christ J (1932) Über die Korrelationen der Kongenitalen Defekte des Ectoderms untereinander mit besonderer Berücksichtigung ihrer Beziehungen zum Auge. *Zbl Haut Geschlkr* 40: 1–21.
- Clarke A (1987) Hypohidrotic ectodermal dysplasia. *J Med Genet* 24: 659–663.
- Danz DFG (1792) Sechste Bemerkung. Von Menschen ohne Haare und Zähne. *Stark Arch Geburtch Frauenz Neugeb Kinderkr* 4: 684.
- Della Valle D, Chevatarese AB, Maia LC, Farinhas JA (2004) Alternative rehabilitation treatment for a patient with ectodermal dysplasia. *J Clin Pediatr Dent* 28: 103–106.
- Felsher Z (1944) Hereditary ectodermal dysplasia. Report of a case with experimental study. *Arch Dermatol Syph* 49: 410–414.
- Freire-Maia N, Pinheiro M (1984) Ectodermal dysplasias: a clinical and genetic study. New York: Alan R. Liss.
- Glasstone S (1935–1936) Development of tooth germs in vitro. *J Anat* 70: 260–266.
- Gorlin RJ, Pindborg JJ (1964) Anhidrotic ectodermal dysplasia. In: Gorlin RJ, Pindborg JJ (eds.) *Syndromes of the head and neck*. New York: McGraw-Hill, pp. 303–311.
- Harrison S, Sinclair R (2004) Hypotrichosis and nail dysplasia: a novel hidrotic ectodermal dysplasia. *Australas J Dermatol* 45: 103–105.
- Irvine AD (2006) Ectodermal dysplasia. In: Harper J, Oranje A, Prose N (eds.) *Textbook of Pediatric Dermatology*. Oxford: Blackwell Science, pp. 1412–1466
- Jean-Baptiste S, O'Toole EA, Chen M, Guitart J, Paller A, Chan LS (2002) Expression of eotaxin, an eosinophil-selective chemokine, parallels eosinophil accumulation

- in the vesiculobullous stage of incontinentia pigmenti. *Clin Exp Immunol* 127: 470–478.
- Johanson A, Blizzard B (1971) A syndrome of congenital aplasia of the alae nasi, deafness, hypothyroidism, dwarfism, absent permanent teeth, and malabsorption. *J Pediatr* 79: 982–987.
- Kaercher T (2004) Ocular symptoms and signs in patients with ectodermal dysplasia syndromes. *Graefes Arch Clin Exp Ophthalmol* 242: 495–500.
- Kere J, Srivastava AK, Montonen O (1996) X-linked anhidrotic (hypohidrotic) ectodermal dysplasia is caused by mutation in a novel transmembrane protein. *Nat Genet* 13: 409–416.
- Makris C, Godfrey VL, Krahn-Senftleben G, Takahashi T, Roberts JL, Schwarz T, Feng L, Johnson RS, Karin M (2000) Female mice heterozygous for IKK gamma/NEMO deficiencies develop a dermatopathy similar to the human X-linked disorder incontinentia pigmenti. *Mol Cell* 5: 969–979.
- Mardini MK, Ghandour M, Sakati NA, Nyhan VL (1978) Johanson-Blizzard syndrome in a large inbred kindred with three involved members. *Clin Genet* 14: 247–250.
- Mégarbané H, Zablitz C, Waked N, Lefranc G, Tomb R, Mégarbané A (2004) Ichthyosis follicularis, alopecia, and photophobia (IFAP) syndrome: report of a new family with additional features and review. *Am J Med Genet* 124A: 323–327.
- Mohler DN (1959) Hereditary ectodermal dysplasia of the anhidrotic type associated with primary hypogonadism. *Am J Med* 27: 682–688.
- Monreal AW, Ferguson BM, Headon DJ, Street SL, Overbeek PA, Zonana J (1999) Mutations in the human homologue of mouse *dl* cause autosomal recessive and dominant hypohidrotic ectodermal dysplasia. *Nat Genet* 22: 366–369.
- Munoz F, Lestringant G, Sybert V, Frydman M, Alswaini A, Frossard PM, Jorgenson R, Zonana J (1997) Definitive evidence for an autosomal recessive form of hypohidrotic ectodermal dysplasia clinically indistinguishable from the more common X-linked disorder. *Am J Hum Genet* 61: 94–100.
- Na GY, Kim do W, Lee SJ, Chung SL, Park DJ, Kim JC, Kim MK (2004) Mutation in the ED1 gene, *A la* 349 Thr, in a Korean patient with X-linked hypohidrotic ectodermal dysplasia developing de novo. *Pediatr Dermatol* 21: 568–572.
- OMIM (2006) online Mendelian Inheritance in Man. Baltimore: Johns Hopkins University Press. <http://ncbi.nlm.nih.gov/omim>
- Pinheiro M, Freire-Maia N (1994) Ectodermal dysplasias: a clinical classification and a causal review. *Am J Med Genet* 53: 153–162.
- Priolo M, Silengo M, Lerone M, Ravazzolo R (2000) Ectodermal dysplasias: not only “skin” deep. *Clin Genet* 58: 415–431.
- Priolo M, Laganà C (2001) Ectodermal dysplasias: a new clinical-genetic classification. *J Med Genet* 38: 579–585.
- Reed WB, Lopez DA, Landing BH (1970) Clinical spectrum of anhidrotic ectodermal dysplasia. *Arch Dermatol* 102: 134–143.
- Rouse C, Siegfried E, Breer W, Nahass G (2004) Hair and sweat glands in families with hypohidrotic ectodermal dysplasia. Further characterization. *Arch Dermatol* 140: 850–855.
- Sahin MT, Turel-Ermertcan A, Chan I, McGrath JA, Ozturkcan S (2004) Ectodermal dysplasia showing clinical overlap between AEC, Rapp-Hodgkin and CHAND syndromes. *Clin Exp Dermatol* 29: 486–488.
- Schussheim A, Choi SJ, Silverberg M (1976) Exocrine pancreatic insufficiency with congenital anomalies. *J Pediatr* 89: 782–784.
- Shimomura Y, Sato N, Miyashita A, Hashimoto T, Ito M, Kuwano R (2004) A rare case of hypohidrotic ectodermal dysplasia caused by compound heterozygous mutations in the EDAR gene. *J Invest Dermatol* 123: 649–655.
- Siemens HW (1937) Studien über Vererbung von Hautkrankheiten. XII. Anhidrosis hypotrichotica. *Arch Dermat Syph* 175: 565.
- Smahi A, Courtois G, Vabres P, Yamaoka S, Hewertz S, Munnich A, Israel A, Heiss NS, Klauck SM, Kioschis P, Wiemann S, Poustka A, Esposito T, Bardaro T, Gianfrancesco F, Ciccodicola A, D’Urso M, Woffendin H, Jakins T, Donnai D, Stewart H, Kenwrick SJ, Aradhya S, Yamagata T, Levy M, Lewis RA, Nelson DL (2000) Genomic rearrangement in NEMO impairs NF-Kappa B activation and is a cause of incontinentia pigmenti: The International Incontinentia Pigmenti (IP) Consortium. *Nature* 405: 466–472.
- Thadani KI (1921) A toothless type of man. *J Hered* 12: 87–88.
- Thurman J (1848) Two cases in which skin, hair and teeth were very imperfectly developed. *Proc Roy Med Chir Soc* 31: 71–81.
- Touraine A (1936) L’anidrose héréditaires avec hypotrichose et anodontie (polydysplasie ectodermique héréditaire). *Presse Med* 44: 145–149.
- Weech AA (1929) Hereditary ectodermal dysplasia. *Am J Dis Child* 37: 766–790.
- Zonana J, Elder ME, Schneider LC, Orlow SJ, Moss C, Golabi M, Shapira SK, Farndon PA, Wara DW, Emmal SA, Ferguson BM (2000) A novel X-linked disorder of immune deficiency and hypohidrotic ectodermal dysplasia is allelic to incontinentia pigmenti and due to mutations in IKK-gamma (NEMO). *Am J Hum Genet* 67: 1555–1562.