



Clinical Manifestations of Early Disseminated Lyme Carditis

Andres F. Miranda-Arboleda, Juan G. Sierra-David,
Rachel Wamboldt, and Adrian Baranchuk

Abstract

Atrioventricular conduction abnormalities are the most common presentation of early disseminated Lyme carditis. Up to two-thirds of patients with Lyme carditis will progress to a high-degree atrioventricular block; however, it can reverse completely when early antibiotic treatment is provided. A systematic approach to early disseminated Lyme carditis is essential since the identification of Lyme as the etiology in patients with heart block will avoid the unnecessary implantation of permanent pacemakers. This chapter covers the clinical manifestation of early disseminated Lyme carditis.

Keywords

Early disseminated Lyme carditis • Atrioventricular blocks • SILC Score • Myocarditis • Pancarditis

1 Introduction

Lyme Disease (LD) is a zoonosis caused most typically by the gram-negative spirochete *Borrelia burgdorferi* sensu lato complex, transmitted by the Ixodes-tick. There are other less common types of *Borrelia* such as *B. garinii*, *B. afzelii*, and *B. spielmanii* which can also cause the disease. LD is the most commonly reported vector-borne disease in North America accounting for approximately 80% of tick-borne diseases reported in the US [1, 2]. In Canada, the number of LD cases has

A. F. Miranda-Arboleda (✉) · R. Wamboldt · A. Baranchuk
Division of Cardiology, Queen's University-Kingston Health Sciences Centre, Kingston, ON,
Canada
e-mail: andreas.miranda@queensu.ca

J. G. Sierra-David
Division of Cardiology, Naples Heart Institute-Naples Healthcare System, Naples, FL, USA

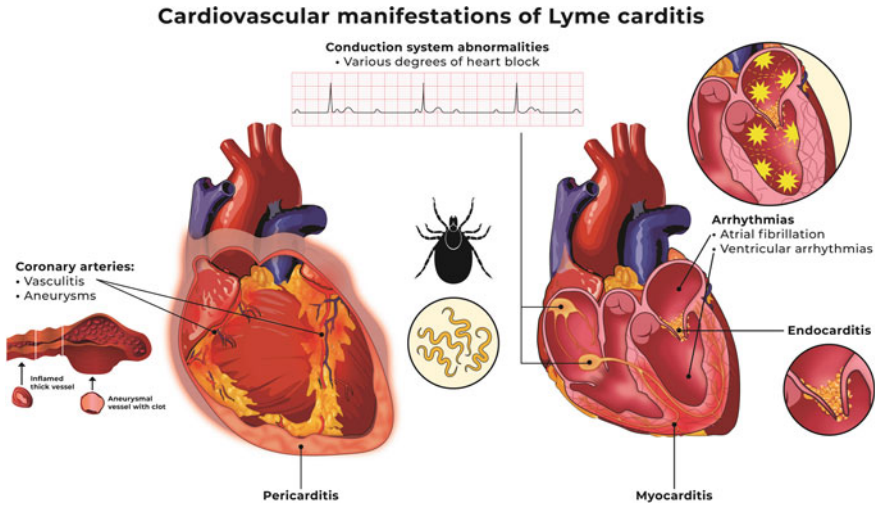


Fig. 1 Cardiovascular manifestations of early disseminated Lyme disease

climbed steadily, and risk modeling suggests that cases will continue to increase due to *I. scapularis*, as this tick is carried by migratory birds that are affected by climate change and will invade further into southern Canada [3, 4].

Early Disseminated Lyme Disease (EDLD) represents the stage when bacteria spreads to other organs and it may have cutaneous, cardiovascular, musculoskeletal, neurological, and/or ocular complications. Cardiac manifestations also called Lyme carditis (LC), are present in approximately 10% of patients with LD. The onset of LC typically occurs within one to two months after exposure as a form of EDLD. The most common type of cardiac involvement is atrioventricular block (AVB) which occurs in about 90% of patients hospitalized with LC [1]. Children mostly manifest carditis and myocardial involvement, and up to 30% have electrocardiographic (ECG) changes [5] (Fig. 1).

The purpose of this chapter is to describe the cardiovascular manifestations of patients with early disseminated Lyme carditis and provide a stepwise diagnostic algorithm.

2 Pathophysiology

Following the inoculation of *Borrelia sp.* in the skin by the tick, the spirochete invades subcutaneous tissue, and due to its marked tropism for the heart tissue advances via the bloodstream to the myocardium infiltrating collagen fibers in the extracellular matrix provoking an inflammatory response by the host [6]. Approximately two to three weeks after initial infection, evidence of this bacteria can be found in higher concentrations in the AV junction, however, other cardiac

structures such as the atrial root, atrial and ventricular myocardium, endocardium, myocardium, and the perivascular spaces can also be affected [6, 7].

The immunologic response is predominantly cellular and mediated by macrophages and lymphocytes which cause collateral damage to the cardiac structures and is responsible for most of the cardiac manifestations of LC. The valves or blood vessels are rarely affected in LC, and therefore, although previously described, it is uncommon to see valvular abnormalities or vasculitis as a clinical manifestation [7].

It is not currently known whether the borrelia spirochete can produce endo or exotoxins. However, cytokine release is facilitated by the phagocytosis of the bacteria, triggering the activation of natural killer cells, and generating a vicious circle of inflammation and tissue injury [7]. Increased immunogenicity can contribute to the LC pathophysiology. This is suggested by the presence of a few spirochetes causing significant lymphocytic myocardial infiltration in the absence of toxin or cell invasion [7].

Autoimmunity has been suggested to play a role in EDLC [8]. Research by *Raveche* et al., found that *Borrelia* protein OspA has properties of molecular mimicry in mice, and it can generate cross-reactivity against myosin. Self-component cross-reactivity can be important in future exposition that may react with self-constituents [8].

3 Clinical Findings—Early Disseminated Lyme Carditis (EDLC)

3.1 General Symptoms

Many patients with LC do not recall a tick bite. LD is primarily a clinical diagnosis, and a high index of suspicion is required. There is a small predominance of males. General symptoms and limited disease after the *Ixodes* tick have bitten the host are more common. Patients often present with erythema migrans, and general constitutional symptoms such as fever, fatigue, chills, and arthralgia (Table 1).

3.2 Atrioventricular Conduction Abnormalities

The most common manifestation is the atrioventricular block (AVB) in 90% of admitted patients with LC, and approximately 60% of those progress to high-degree AVB which is transient, and most often supra-hisian, in which conduction delays originate above the Bundle of His. The duration of AVB can last minutes, hours, or days. Other less common conduction or rhythm alterations include the presence of sinus node disease, atrial fibrillation, supraventricular tachycardia, ventricular tachycardia, fibrillation, and intraventricular conduction abnormalities [6] (Fig. 1).

Table 1 Clinical Manifestations of Lyme carditis

General signs and symptoms	Frequency reported, %
Documented rash	54
Fever	43
Fatigue/Malaise	39.8
<i>Cardiovascular signs and symptoms</i>	
Presyncope	63
Syncope	33
Shortness of breath	3
<i>Extracardiac manifestations</i>	
Arthralgia	23
Cranial neuritis	10
Arthritis	3
Meningitis	3
<i>Electrocardiographic findings</i>	
Third-degree Atrioventricular block	77.3
Second-degree Atrioventricular block	33.0
Asystole/Sinus Pauses	12.5
<i>Resolution</i>	
Atrioventricular block resolved	94.3

Modified from Besant G, Wan D, Yeung C, et al. Suspicious index in Lyme carditis: Systematic review and proposed new risk score. *Clin Cardiol* Dec 2018;41:1611–1616 and Shen RV, McCarthy CA, Smith RP. Lyme Carditis in Hospitalized Children and Adults, a Case Series. *Open Forum Infect Dis* Jul 2021;8:ofab140 [5, 15]

Progression from mild forms of AV block (first-degree or second-degree Mobitz I) to more advanced presentations (second-degree Mobitz II, high degree or complete heart block) in patients with LC may occur rapidly and patients need to be monitored closely in the hospital until evidence of conduction recovers is observed[9, 10].

Many factors are relevant when considering high-degree AVB in patients with LC;

- (1) It is a common presentation of this disease.
- (2) It is transient, particularly when timely treated with antibiotics.
- (3) The standard treatment of high-degree AVB due to other etiologies, once correctable causes have been ruled out, is the insertion of a permanent pacing device.
- (4) LC mostly affects young patients who will embark in a whole life engagement process with a permanent pacemaker that might be not needed [1, 6, 11, 12].

In that sense, identifying whether a high-degree AV block is caused by LC is of critical importance, and requires the appropriate clinical context, and a high suspicion index.

3.3 Myocarditis/Pericarditis

EDLC can also present with acute myocarditis, pericarditis, myopericarditis, endocarditis as well as pancarditis, and can mimic acute coronary syndromes. ST segment depression and T wave inversion in the inferolateral leads can be seen in up to 60% and remit after antibiotic therapy (Fig. 1). It has been hypothesized that some of the improvements in left ventricular dysfunction attributed to transient conduction system disease, have been identified in patients with LD [1, 6].

3.4 Miscellaneous Abnormalities

Case reports have described other uncommon manifestations of LC such as valve endocarditis, cardiogenic shock, and arteritis. (Fig. 1) [6, 13, 14]. However, their diagnosis is difficult due to the high suspicion index required to diagnose them and their high mortality rate.

4 Diagnosis

Our group, in publications led by *Besant* and *Yeung* et al. [15, 16] proposed the use of the Suspicious Index in Lyme Carditis (SILC) score as a systematic approach to patients presenting with HDAVB, aiming to early identify those at risk of LC to provide quick antibiotic treatment and postpone the implantation of permanent pacemakers (Fig. 2).

The SILC score components are summarized by the mnemonic COSTAR:

- Constitutional symptoms; fever, malaise: 2 points
- Outdoor activity: 1 point
- Sex; Male: 1 point
- Tick bite: 3 points
- Age < 50 years: 1 point
- Rash; Erythema migrans: 4 points.

A score 0–2 represents a low risk of HDAVB being caused by LC, 3–6 intermediate and, 7–12 a high risk, respectively (Table 2) [15]. If a SILC Score is low (0–2), no further testing is needed and if considered appropriate patients presenting with HDAVB can proceed with permanent pacemaker implantation. Whereas if the SILC score is 3 or more, *B. burgdorferi* serology testing with ELISA and/or Western Blot is warranted, and antibiotic therapy should be started immediately until the test results are available [15, 16]. For a more detailed review of the SILC score please refer to Chap. 7 of this book.

Serological testing includes ELISA to identify IgM or IgG antibodies against *B. burgdorferi*. Certain caveats need to be accounted for: false negative testing secondary to delayed immune response, this does not necessarily rule out LC.

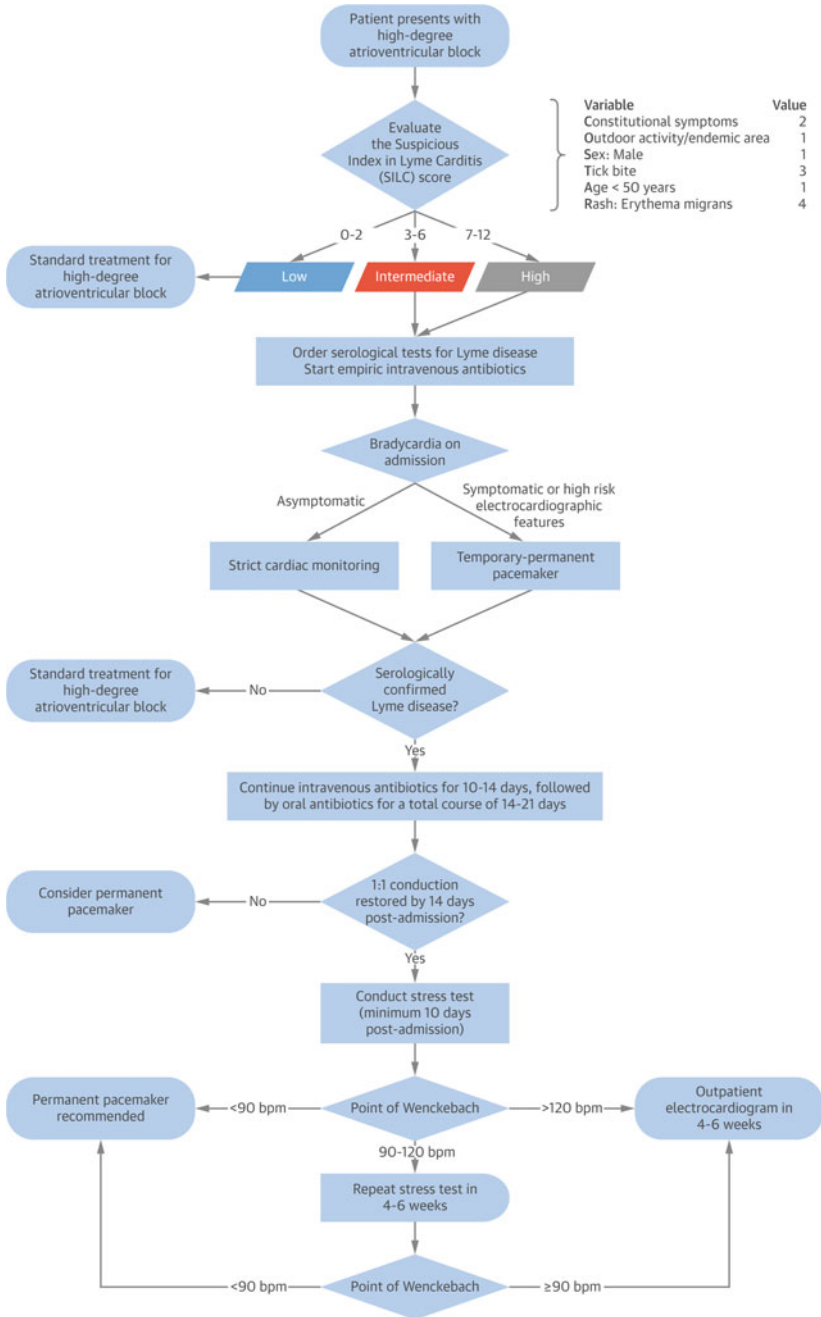


Fig. 2 A systematic approach to High-degree AV block in the setting of Lyme carditis. Reproduced with permission from this manuscript: Yeung C, Baranchuk A. Systematic Approach to the Diagnosis and Treatment of Lyme Carditis and High-Degree Atrioventricular Block. Healthcare (Basel) Sep 22 2018;6(16). Copyright Elsevier (2023)

Table 2 Suspicious index in Lyme carditis (SILC) score^a

Variable	Value
Constitutional symptoms (malaise, fever)	2
Outdoor activity/endemic area	1
Sex = Male	1
Tick bite	3
Age < 50 years old	1
Rash = Erythema migrans	4

Interpretation: Low risk score: 0–2, Intermediate risk score: 3–6, High-risk score: 7–12

^a Besant G, Wan D, Yeung C, et al. Suspicious index in Lyme carditis: Systematic review and proposed new risk score. *Clin Cardiol* Dec 2018;41:1611–1616[15]

On the other hand, positive serologies especially IgG may reflect a prior remote infection and therefore may not be the cause of the HDAVB in patients presenting without other symptoms of LC. A two-tiered approach usually involves an initial ELISA as a screening and if the results are positive or indeterminate a Western Blot can confirm the diagnosis. Of note, sensitivity significantly increases when extracutaneous manifestations such as LC are present (87–100%) [9].

Additional cardiac testing may be needed depending on the LC presentation. Abnormal echocardiographic findings may include left or right ventricular dilations and involvement of the left and ventricular function as a sign of myocarditis. Cardiac magnetic resonance imaging (MRI) may show signs of inflammation such as myocardial wall edema, either acute such as decreased signal intensity or sub-acute to chronic represented by late gadolinium enhancement with subendocardial sparing. Pericardial inflammation can be seen either on an echocardiogram or in MRI [1, 6, 17]. Our group uses exercise stress testing before discharge to prove recovery of 1:1 atrioventricular conduction at faster heart rates before discharge in selected patients admitted initially with HDAVB.

5 Treatment

Prevention is the cornerstone of the treatment of LC, most of the LD cases occur between June and December (in North America), therefore preventive strategies to minimize tick exposure should be adopted while doing outdoor activities. Wearing protective clothing such as long-sleeve shirts, and long pants; use repellent and adoption of a tick check and removal habitude after potential exposure to ticks. In the case of tick detection, it has been proved that during the first 72 h of a tick attachment, one dose of doxycycline decreases the chance of LD by approximately 90% [1, 3, 9].

Antibiotics are the cornerstone of LC treatment because their early initiation reduces the length of the symptoms and the risk of additional complications [18].

Based on the systematic approach to LC mentioned above [15, 16], in patients with SILC intermediate or high it is recommended to start intravenous antibiotics once the suspicion of LC rises and while the serology and additional cardiovascular test are obtained [15]. Ceftriaxone is the most used parenteral antibiotic for LC, it is usually administered during the hospital for 7–10 days until conduction abnormalities improved (1:1 AV conduction, PR interval < 300 ms) [1, 18]. Other parenteral antibiotic alternatives include Cefotaxime and Penicillin G (Table 3) [18]. Once conduction abnormalities have subsided, temporary pacemakers are removed, and LC patients can be transitioned to oral antibiotics to complete 14–21 days of total treatment time. Doxycycline is the standard oral antibiotic in adults, alternative options include amoxicillin, phenoxymethylpenicillin, cefuroxime, and azithromycin (Table 3) [1, 18]. Extended courses of antibiotics have not been translated into better outcomes and they may imply higher costs and risks of adverse effects [9].

The use of temporary pacing is the gold standard for patients who develop symptomatic high-degree AVB, depending on every center's expertise this can be achieved through temporary floating wires or temporary-permanent pacemakers. The biggest advantage of temporary-permanent pacemakers is their higher stability in position and threshold over the days and the fact that they allow earlier patient mobilization as has been previously reported in our center experience [12].

A deliberate implant of permanent pacemakers is not recommended in patients with LC because most of the patients recover conduction even weeks after their

Table 3 Commonly used antibiotics in patients with Lyme carditis

Drug	Adult dose	Pediatric dose
<i>Parenteral medications^a</i>		
Ceftriaxone	2 g IV once daily	50–70 mg/kg IV once daily ^b
Cefotaxime	2 g IV every 8 h	150–200 mg/kg per day divided into three–four daily doses ^c
Penicillin G	18–24 million units IV per day divided into six daily doses	250 000–400 000 U/kg per day divided into six daily doses IV ^d
<i>Oral medications^e</i>		
Doxycycline	100 mg two times a day	≥ 8 years—4 mg/kg per day divided into two doses a day
Amoxicillin	500 mg three times a day	50 mg/kg per day divided into three doses a day
Cefuroxime axetil	500 mg two times a day	30 mg/kg per day divided into two daily doses
Azithromycin	500 mg once daily	10 mg/kg per day

IV: intravenously

^a usually given during the first seven to ten days, ^b Maximum dose: 2 g IV daily, ^c Maximum dose: 6 g daily, ^d Maximum dose = 18–24 million units per day, ^e transition when the parenteral scheme is finished, usually given until completion of 14–21 days of the antibiotic course

initial presentation [1]. In a recent single-center observational study from Canada, Wang et al. showed that after 20 months of follow-up, all patients resolved AV conduction abnormalities, and none of them were on permanent pacing at discharge [12]. Permanent pacing is not usually recommended in LC unless conduction abnormalities persist despite adequate antibiotic therapy for at least three weeks [5].

6 Prognosis

LC can resolve spontaneously; however, since LC result from the dissemination of the bacteria to the cardiac structures and tissues, the early use of antibiotic therapy may help to shorten this period and its related complications [11, 19].

Once antibiotic therapy is initiated, the time to reach a PR interval of less than 300 ms, as a marker of progressive resolution of AV conduction disturbances has been established in an average of four days [5]. Occasionally LC may last up to six weeks before it recovers completely [9].

The self-limited nature of conduction abnormalities in LC has permitted consideration of the possibility of early pacemaker extraction in patients for whom the main indication of pacing was AVB in the context of LC. A recent case series described the successful explantation of permanent pacemakers in patients with previous LC. This raises the importance of detailed clinical analysis before definite pacing is considered in Lyme patients and highlighting the role of early device interrogation after implant to define possible device extraction, in order to avoid the long-term effects and complications associated with pacemakers [20].

The association of LC and chronic dilated cardiomyopathy is still a matter of controversy. Possible untreated or partially treated cases of LC may evolve into permanent myocardial dysfunction. A meta-analysis published by Motamed et al. concluded that current evidence suggests a role of chronic *Borrelia sp.* infection as a potential etiology of dilated cardiomyopathy, however, additional research needs to be performed in this field. A deeper analysis of the long-term cardiovascular complications of LC is provided in Chap. 14 of this book [19].

Previous series have reported cases of fatal presentation in LD, those cases have been mainly associated with fulminant myocarditis or coronary arteries affection; however mortality is an uncommon complication in this disease (5, 21).

7 Conclusion

Lyme carditis is a potential complication of early disseminated Lyme disease. It can affect almost any structure of the heart, but atrioventricular conduction abnormalities are the most common presentation. Atrioventricular block in Lyme carditis is a potentially reversible condition, therefore a systematic approach to identifying *B. burgdorferi* as the etiology of high-degree AVB will facilitate the early initiation of antibiotic therapy, temporary pacemakers, and ultimately minimize the

unnecessary implantation of permanent pacemakers with their potential long-term implications.

References

1. Yeung C, Baranchuk A. Diagnosis and treatment of Lyme Carditis: JACC review topic of the week. *J Am Coll Cardiol.* 2019;73(6):717–26.
2. Centers for Disease Control and Prevention. Lyme disease: data and surveillance. 2022 [cited 2022 Nov 11]. Available from: www.cdc.gov/lyme/stats/index.html.
3. Public Health Agency of Canada. Surveillance of Lyme disease. 2022 [cited 2022 Nov 11]. Available from: <https://www.canada.ca/en/public-health/services/diseases/lyme-disease/surveillance-lyme-disease.html>.
4. Ripoche M, Gasmi S, Adam-Poupart A, Koffi JK, Lindsay LR, Ludwig A, et al. Passive tick surveillance provides an accurate early signal of emerging Lyme disease risk and human cases in Southern Canada. *J Med Entomol.* 2018;55(4):1016–26.
5. Shen RV, McCarthy CA, Smith RP. Lyme Carditis in hospitalized children and adults, a case series. *Open Forum Infect Dis.* 2021;8(7):ofab140.
6. Robinson ML, Kobayashi T, Higgins Y, Calkins H, Melia MT. Lyme carditis. *Infect Dis Clin North Am.* 2015;29(2):255–68.
7. Montgomery RR, Booth CJ, Wang X, Blaho VA, Malawista SE, Brown CR. Recruitment of macrophages and polymorphonuclear leukocytes in Lyme carditis. *Infect Immun.* 2007;75(2):613–20.
8. Raveche ES, Schutzer SE, Fernandes H, Bateman H, McCarthy BA, Nickell SP, et al. Evidence of *Borrelia* autoimmunity-induced component of Lyme carditis and arthritis. *J Clin Microbiol.* 2005;43(2):850–6.
9. Krause PJ, Bockenstedt LK. Cardiology patient pages. Lyme disease and the heart. *Circulation.* 2013;127(7):e451–4.
10. Uzomah UA, Rozen G, Mohammadreza Hosseini S, Shaqdan A, Ledesma PA, Yu X, et al. Incidence of carditis and predictors of pacemaker implantation in patients hospitalized with Lyme disease. *PLoS ONE.* 2021;16(11):e0259123.
11. van der Linde MR. Lyme carditis: clinical characteristics of 105 cases. *Scand J Infect Dis Suppl.* 1991;77:81–4.
12. Wang CN, Yeung C, Enriquez A, Chacko S, Hanson S, Redfearn D, et al. Long-term outcomes in treated Lyme Carditis. *Curr Probl Cardiol.* 2022;47(10):100939.
13. Fatima B, Sohail MR, Schaff HV. Lyme disease-an unusual cause of a mitral valve endocarditis. *Mayo Clin Proc Innov Qual Outcomes.* 2018;2(4):398–401.
14. Duray PH. Histopathology of clinical phases of human Lyme disease. *Rheum Dis Clin North Am.* 1989;15(4):691–710.
15. Besant G, Wan D, Yeung C, Blakely C, Branscombe P, Suarez-Fuster L, et al. Suspicious index in Lyme carditis: systematic review and proposed new risk score. *Clin Cardiol.* 2018;41(12):1611–6.
16. Yeung C, Baranchuk A. Systematic approach to the diagnosis and treatment of Lyme Carditis and high-degree atrioventricular block. *Healthcare (Basel).* 2018;6(4).
17. Munk PS, Orn S, Larsen AI. Lyme carditis: persistent local delayed enhancement by cardiac magnetic resonance imaging. *Int J Cardiol.* 2007;115(3):e108–10.
18. Stanek G, Wormser GP, Gray J, Strle F. Lyme borreliosis. *Lancet.* 2012;379(9814):461–73.
19. Motamed M, Liblik K, Miranda-Arboleda AF, Wamboldt R, Wang CN, Cingolani O, et al. Disseminated Lyme disease and dilated cardiomyopathy: a systematic review. *Trends Cardiovasc Med.* 2022.
20. Wamboldt R, Wang CN, Miller JC, Enriquez A, Yeung C, Chacko S, et al. Pacemaker explanation in patients with Lyme Carditis. *JACC Case Rep.* 2022;4(10):613–6.

21. Muehlenbachs A, Bollweg BC, Schulz TJ, Forrester JD, DeLeon CM, Molins C, et al. Cardiac tropism of *Borrelia burgdorferi*: an autopsy study of sudden cardiac death associated with Lyme Carditis. *Am J Pathol.* 2016;186(5):1195–205.