




Considerations for Permanent Pacemaker Explantation in Resolved Lyme Carditis

Rachel Wamboldt , Sanoj Chacko , and Adrian Baranchuk 

Abstract

Permanent pacemakers should not be part of the treatment algorithm for Lyme carditis (LC), as LC is a transient cause of high-degree atrioventricular (AV) block that should resolve after 5–10 days of intravenous antibiotics. If LC is not suspected by the treating physicians, the patient may undergo the unnecessary implantation of a permanent pacemaker. If the diagnosis of LC is confirmed after permanent pacemaker implantation, the pacemaker may be safely explanted within the first year as long as the patient has completed a three-week course of antibiotics, no evidence of ventricular pacing on interrogation, and a stress-test confirming 1:1 AV conduction during exercise.

Keywords

Lyme carditis • Lyme disease • Pacemaker explantation • Heart block • Atrioventricular block

1 Introduction

Lyme carditis (LC) is a clinical manifestation of early disseminated Lyme disease (LD) that results in alterations in cardiac function, particularly the conduction system. Patients with any evidence of LC should be admitted to the hospital for monitoring and intravenous antibiotics. If symptomatic bradycardia occurs from

R. Wamboldt (✉) · S. Chacko · A. Baranchuk
76 Stuart Street, Kingston, Ontario K7L 3N6, Canada
e-mail: 17reaw@queensu.ca

S. Chacko
e-mail: Sanoj.Chacko@kingstonhsc.ca

A. Baranchuk
e-mail: Adrian.Baranchuk@kingstonhsc.ca

either a high-grade AV nodal conduction disturbance or sinus node dysfunction, patients may require treatment with a temporary pacing device to support their cardiac rhythm while their conduction system recovers [1, 2]. Permanent pacemakers should not be a part of the treatment algorithm for LC, unless in the exceedingly rare circumstance that their conduction abnormality does not recover following a course of guideline-directed antibiotics [1, 3].

The diagnosis of LC is made predominantly from clinical presentation, with confirmatory serological testing [1]. Unfortunately, making the diagnosis of LC can be challenging and requires a high degree of clinical suspicion, given that it typically manifests 1–2 months after the initial infection with *Borrelia burgdorferi*. [4] If LD is not considered within the differential diagnosis for symptomatic bradycardia or if physicians do not allow adequate time for conduction system recovery, following the administration of antibiotics, patients may undergo the unnecessary placement of a permanent pacing device. In such cases, if these patients are identified early, and their cardiac rhythm recovers following antibiotics, pacemaker explantation should be facilitated. Before device explantation is arranged, several considerations are required. This chapter will outline the risks associated with inappropriate pacemaker implantation and how device explantation can be facilitated safely.

2 Pacemakers in Lyme Carditis

The insertion of a permanent pacing device is an invasive procedure. Complications related to the procedure are rare but can be serious (Table 1) [5, 6] Given the young age of patients with LC, the unnecessary implantation of a permanent pacemaker can also lead to a lifetime of physical and psychological consequences, frequent device checks, and an accumulation of health care costs [1]. In the event that a patient has had a permanent pacing device implanted as part of their treatment for LC, regular follow-up with a cardiac device clinic is necessary to ensure that the pacemaker is functioning appropriately, to screen for complications and to assess for ventricular pacing. Once there is convincing evidence of complete recovery of the conduction system with resolution of ventricular pacing, pacemaker and lead explantation should be facilitated (Fig. 1). [2] If performed within the first year of implantation, lead explantation can be performed using simple traction techniques, using regular stylets [5]. Traction techniques in these cases have a high success rate with a low risk of complications [5].

Chronically implanted pacemaker leads (> 1-year duration) can develop fibrotic attachments at the tip of the wire as well as throughout its length [5, 6]. The presence of fibrotic attachments to the veins (access vein or superior vena cava) and endocardial structures (valves, papillary muscles, endocardium, electrode-myocardial interface), increase the risk of complications associated with lead removal [5]. Separating the lead from the encapsulating tissue is the most crucial step in the process of lead extraction. The lead extraction procedure can be performed using a variety of techniques including traction (simple, continuous),

Table 1 Procedural, short-term, and long-term complications associated with pacemaker insertion for Lyme carditis

Procedural complications	Short-term complications	Long-term complications
<ul style="list-style-type: none"> - Pocket hematoma - Pneumothorax - Hemothorax - Myocardial perforation/ cardiac tamponade - Massive pulmonary embolism - Arteriovenous (AV) fistula - Vascular laceration 	<ul style="list-style-type: none"> - Phlebitis - Thrombophlebitis - Tricuspid regurgitation - Pacemaker malfunction (failure to pace, failure to sense, failed capture, dysrhythmia, lead fracture) - Pocket infection - Lead dislodgement 	<ul style="list-style-type: none"> - Pacemaker malfunction - Tricuspid regurgitation - Endocarditis - Lead dislodgement - Pocket erosion - Twiddler syndrome - Myocardial perforation - Pectoral muscle stimulation - Intercostal/diaphragm pacing - Thrombosis (access vein, inferior vena cava, right atrium)

mechanical telescoping sheaths, powered sheaths, snares, locking stylets and laser/radiofrequency devices [5, 6]. However, regardless of the technique used, clinicians must be prepared to deal with the procedure which may vary from a relatively simple lead extraction to an extremely complicated one. Thus the procedure requires expert clinicians, with careful planning along with meticulous patient preparation, to prevent and manage complications that may arise during pacemaker lead extraction (Table 2) [5, 6].

The principle of patience is crucial when caring for patients with LC. Resolution of conduction abnormalities can take upwards of 10 days (range 3–42) with appropriate antibiotics [6]. Thus, allowing adequate time for the recovery of the conduction system, is vital to circumvent the disease and avoid unnecessary implantation of a permanent device. If a permanent pacemaker has been implanted as part of the management of LC, treating physicians should arrange explantation as soon as possible, as long as their conduction abnormality has resolved.

3 Review of Algorithm

The diagnosis of LC should ideally be made while the patient is still in the hospital. In some cases, patients are discharged before a formal diagnosis of LC is made, depending on the availability and speed of serological testing but also depending on whether the diagnosis of LC was considered. Patients diagnosed with LC should be started promptly on guideline-directed antibiotics. The Infectious Diseases Society of America (IDSA) recommends a 14–21 day course of antibiotics as covered in Chap. 8. Early treatment is associated with a good prognosis [1].

Following the treatment of LC with antibiotics, patients who have undergone placement of a permanent pacemaker device should receive early follow-up by an electrophysiologist and/or device clinic. The algorithm published by Wamboldt

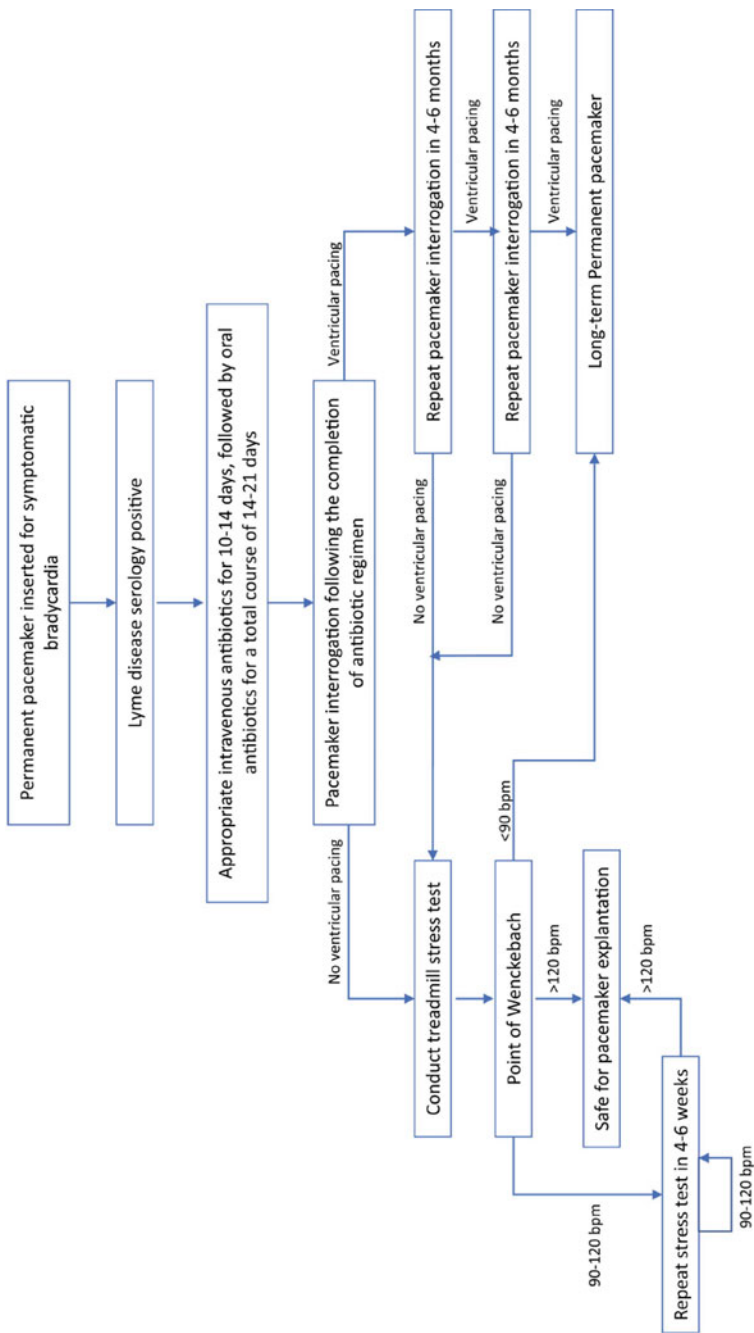


Fig. 1 Algorithm for permanent pacemaker explantation in Lyme carditis (JACC Case Reports)

Table 2 Complications associated with pacemaker extraction

Complications associated with pacemaker lead extraction
Pericardial effusion
Venous thrombosis
Migrated lead fragment
Hematoma/bleeding
AV fistula
Pulmonary embolism
Pneumothorax
Cardiac/respiratory arrest
Cerebrovascular accident
Vascular laceration
Death

et al. should be followed to facilitate the safe explantation of cardiac pacemakers for those where it is deemed clinically appropriate (Fig. 1) [2]. The first step is to organize a pacemaker interrogation, to assess for the presence of ventricular pacing. If ventricular pacing persists, a follow-up should be arranged in 4–6 months for re-interrogation. If the patient continues to be reliant on the pacemaker after two further assessments, they will likely require long-term pacing. Ongoing follow-up should be arranged by their cardiac device clinic and/or cardiologist.

For patients with no evidence of ventricular pacing on pacemaker interrogation, treadmill stress testing should be pursued to evaluate AV node function. A modified Bruce protocol should be used with continuous cardiac monitoring. If the patient can maintain 1:1 AV conduction at a heart rate greater than 120 beats per minute (bpm), device explantation can be safely arranged. If the patient is unable to maintain 1:1 AV conduction at a heart rate greater than 120 bpm, stress testing should be repeated. Those who are unable to achieve 1:1 conduction over a heart rate of 90bpm, will likely require a permanent pacemaker.

4 Conclusion

Pacemaker explantation is a safe option for patients who have undergone permanent pacemaker implantation as part of the management of LC. Explantation should ideally be performed within the first year. Patients should have received a full course of guideline-directed antibiotics, should have no evidence of ventricular pacing on device interrogation and should retain 1:1 AV conduction on treadmill stress testing.

References

1. Yeung C, Baranchuk A. Diagnosis and treatment of lyme carditis: JACC review topic of the week. *J Am Coll Cardiol.* 2019;73(6):717–26.
2. Wamboldt R, Wang C, Miller JC, Enriquez A, Yeung C, Chacki S, Foisy M, Baranchuk A. Pacemaker explantation in patients with lyme carditis. *JACC Case Rep.* 2022;4(10):613–6.
3. Lantos PM, Rumbaugh J, Bockenstedt LK, et al. Clinical practice guidelines by the infectious diseases society of America (IDSA), American academy of neurology (AAN), and American college of rheumatology (ACR): 2020 guidelines for the prevention, diagnosis and treatment of lyme disease. *Clin Infect Dis.* 2021;71:e1–48.
4. Bush LM, Vazquez-Pertejo MT. Tick borne illness-Lyme disease. *Dis Mon.* 2018;64:195–212.
5. Bongiorni MG, Burri H, Deharo JC, Starck C, Kennergren C, Saghy L, Rao A, Tascini C, Lever N, Kutarski A, Lozano IF, Strathmore N, Costa R, Epstein L, Love C, Blomstrom-Lundqvist C. EHRA expert consensus statement on lead extraction: recommendations on definitions, endpoints, research trial design, and data collection requirements for clinical scientific studies and registries: endorsed by APHRS/HRS/LAHRs. *Eur Soc Cardiol.* 2018;20:1217.
6. Perez AA, Woo FW, Tsang DC, Carrillo RG. Transvenous lead extractions: current approaches and future trends. *Arrhythm Electrophysiol Rev.* 2018;7(3):210–7.