

# Chapter 5

## Vestibular Neuritis



T. Logan Lindemann and Pamela C. Roehm

### Introduction

Vestibular neuritis, also referred to as vestibular neuronitis, labyrinthitis, and acute unilateral peripheral vestibulopathy (AUPVP) [1], is an acute vestibulopathy of the peripheral vestibular system. It is one of the most common causes of peripheral vertigo, following benign paroxysmal positional vertigo (BPPV) [2, 3]. Vestibular neuritis may follow a nonspecific viral illness, although symptoms may present several weeks following the initial illness. Patients complain of a rapid-onset vertigo that lasts for days and then resolves over the next few weeks. Residual dizziness and imbalance may continue for several months. While vestibular neuritis is benign and most often associated with complete resolution of symptoms, it can be very debilitating for patients during the acute phase.

---

T. L. Lindemann  
Lewis Katz School of Medicine at Temple University, Philadelphia, PA, USA  
e-mail: [logan.lindemann@temple.edu](mailto:logan.lindemann@temple.edu)

P. C. Roehm (✉)  
Division of Otolaryngology, St. Christopher's Hospital for Children,  
Philadelphia, PA, USA

## **Etiology**

Patients with vestibular neuritis typically experience acute peripheral vertigo in the absence of hearing loss, suggesting an isolated vestibular nerve dysfunction. This dysfunction is hypothesized to result from vestibular nerve inflammation. Postmortem histopathology, obtained after death from unrelated causes, revealed isolated demyelination of the vestibular nerve [4, 5]. Elevations in acute phase reactants, including plasma fibrinogen and C-reactive protein (CRP), and MRI enhancement of the vestibular nerve suggest that demyelination occurs as a result of local inflammation [5]. Several etiologies, including viral reactivation, autoimmune damage, and vascular occlusion, have been proposed to explain these observations [4]. However, it is unclear whether inflammation of the nerve is the cause of this disorder, and so the term acute unilateral peripheral vestibulopathy (AUPVP) has been proposed as a more unbiased descriptor of this syndrome of symptoms, signs and test results [6].

## ***Viral Inflammation***

Vestibular neuritis is generally considered to develop secondary to viral or postviral inflammation. The disorder is frequently associated with a recent viral illness, epidemics, and is most often diagnosed in the spring and summer seasons [4, 7]. However, patients exhibit no overt signs of systemic infection, and despite suggestive serology, no causative virus has been isolated [4, 8].

Interestingly, vestibular neuritis shares several similarities with Bell's palsy. Both present as an acute idiopathic cranial neuropathy that is suspected to be secondary to viral inflammation, and are commonly treated with corticosteroids [9]. Mounting evidence suggests that the reactivation of a neurotropic virus, specifically herpes simplex type 1 (HSV1), may be responsible for the development of both disorders [4]. A recent genome-wide association study linked vestibular neuritis to a particular mineralocorticoid and glucocorticoid receptor, which functions as a host factor for HSV1 replication [10]. HSV1 has been shown to establish latency not only in trigeminal ganglia, but also geniculate and vestibular ganglia [11, 12]. The virus was found to readily reactivate within rat vestibular ganglia due to a number of stimuli [13]. Latency of HSV1 has been further associated with an infiltration of CD8<sup>+</sup> T cells into vestibular ganglia, supporting an inflammation-induced vestibular nerve dysfunction [12].

While latent herpesvirus infection is the etiology most supported by evidence, confirmation of an inciting viral illness is obtained in less than half of patients [14].

## ***Autoimmune***

Vestibular neuritis frequently presents after the resolution of an upper respiratory illness. The delayed onset of symptoms suggests that the disorder may occur as a result of local, postinfectious inflammation, rather than as a direct result of infection [4]. Acute autoimmune neuropathies, such as Guillain–Barre syndrome, are well-known, and result from immunologic recognition and destruction of peripheral nerve myelin following infection or vaccination. However, local neuropathies following nonspecific respiratory illnesses are not well-described.

The autoimmune hypothesis is primarily supported by an elevated CD4/CD8 ratio accompanying inner ear pathologies of unknown origin, including vestibular neuritis [4, 15]. The CD4/CD8 ratio often increases in autoimmune disease (in contrast to viral infection). The increased ratio was shown to be caused by a relative decrease in T-suppressor (CD8) lymphocytes in patients with otoneurological disease [16]. It has been proposed that with relatively fewer T-suppressor lymphocytes, “forbidden” plasma cells become unsuppressed and produce autoantibodies against the vestibular nerve [4].

## ***Vascular Occlusion***

Vestibular neuritis often appears to develop secondary to acute inflammation. It has been suggested that vestibular neuritis patients suffer from an inherent proinflammatory state, leading to labyrinthine ischemia [4]. Elevated levels of acute phase reactants and proinflammatory peripheral blood mononuclear cells (PBMCs) have been measured in patients with acute vestibular neuritis [17]. Activated PBMCs induce endovascular adhesion and platelet-monocyte aggregation, potentially creating an environment favorable for microvascular occlusion [4].

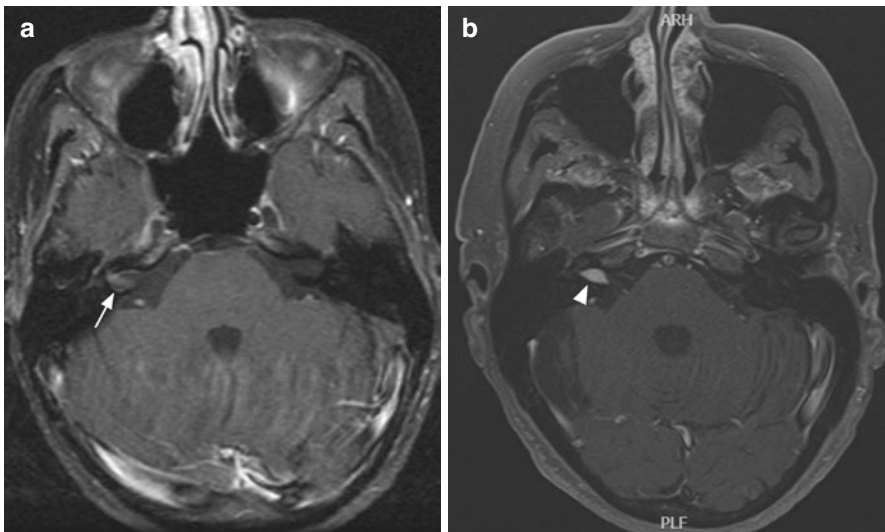
A similar environment has been observed in patients with cardiovascular risk factors [18, 19]. One retrospective cross-sectional study found a significantly increased prevalence of cardiovascular risk factors among hospitalized vestibular neuritis patients [20]. It is possible that cardiovascular disease may contribute to an endovascular inflammatory response, resulting in a compromised blood supply to the vestibular nerve. However, this mechanism does not directly explain vestibular nerve demyelination observed in histopathologic studies of this disorder.

## **Clinical Findings and Pathophysiology**

Clinical features (Table 5.1) are consistent with an acute vestibular syndrome (AVS), resulting from a unilateral disruption in afferent vestibular nerve signaling. Patients complain of rapid-onset vertigo, nausea and vomiting, and imbalance.

**Table 5.1** Clinical overview of vestibular neuritis

History	Examination	Vestibular testing	Treatment
<ul style="list-style-type: none"> <li>• Acute, prolonged vertigo, typically resolving in days to weeks</li> <li>• Classically following resolution of an upper respiratory illness</li> </ul>	<ul style="list-style-type: none"> <li>• Imbalance</li> <li>• Spontaneous horizontal-torsional nystagmus, beating away from the affected side</li> <li>• Positive head impulse test</li> <li>• Focal neurologic deficits absent</li> </ul>	<ul style="list-style-type: none"> <li>• Consistent with a unilateral peripheral vestibulopathy</li> <li>• Superior/horizontal SCC dysfunction with relative sparing of the inferior SCC</li> <li>• Negative HINTS exam</li> </ul>	<ul style="list-style-type: none"> <li>• Symptomatic relief: antivestibular medications, anticholinergics, and antiemetics</li> <li>• Corticosteroids to decrease inflammation</li> <li>• Vestibular rehabilitation</li> </ul>

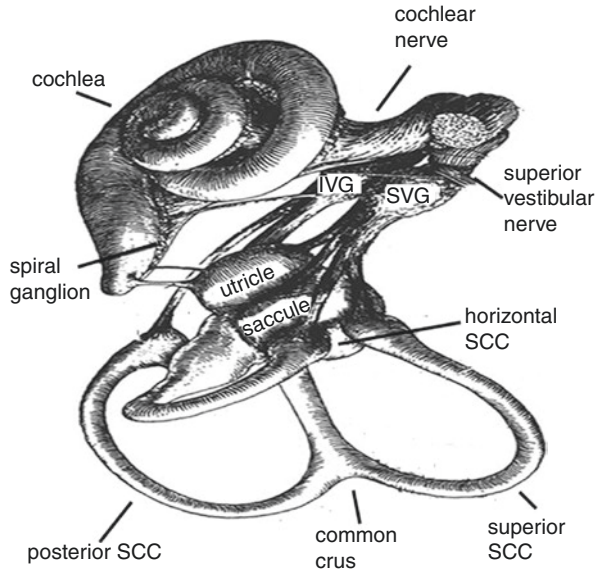


**Fig. 5.1** Comparison of MRIs of patients presenting with similar symptoms. (a) Typical appearance of nonspecific vestibular nerve enhancement (arrow) seen with vestibular neuritis in a patient with sudden onset of spinning vertigo (image courtesy of Barton Branstetter, MD). (b) MRI of the brain and internal auditory canals with gadolinium of a patient who presented with sudden onset of vertigo and hearing loss demonstrating a left acoustic neuroma (arrowhead)

Initial examination reveals spontaneous nystagmus, positive head impulse test (HIT), and gait instability [7]. Ipsilateral sensorineural hearing loss is rarely present, and in these cases, the disorder is termed “labyrinthitis” [7]. Other neurologic signs such as facial droop, asymmetric weakness or loss of sensation, and dysarthria are signs of central nervous system (CNS) pathology and should prompt immediate evaluation for cerebrovascular accident (CVA) and other central nervous system pathologies, including tumors [14] (see section “Differential Diagnosis”) (Fig. 5.1).

Key clinical signs in the acute phase of this disorder include a spontaneous horizontal-torsional nystagmus that beats away from the affected side [21].

**Fig. 5.2** Anatomy of the peripheral vestibular system. The superior vestibular nerve and its branches pass through more narrow and longer bony channels than the inferior vestibular nerve, and so it is more susceptible to injury. Abbreviations: *IVG* inferior vestibular ganglion, *SCC* semicircular canal, *SVG* superior vestibular ganglion. (Modified with permission from Lee and Kaylie, 2013 [48])



Nystagmus is independent of gaze direction and follows Alexander's law [14, 22]. HIT and caloric testing reveal impairment of the semicircular canals, preferentially affecting the superior and horizontal canals [21, 23]. Head tilt, skew deviation, and ocular torsion measurements reveal an ipsiversive (directed toward the ipsilateral side) ocular tilt reaction (OTR), resulting in an ipsiversive subjective visual vertical (SVV) tilt [24]. Finally, the affected side will show decreased or absent responses to vestibular-evoked myogenic potentials (VEMPs) [24].

Vestibular testing most often reveals superior and horizontal semicircular canal dysfunction with a relative sparing of the posterior semicircular canal [25]. This observation is likely explained by the natural course of the vestibular nerve divisions within the bony skull base (Fig. 5.2). The superior division, which innervates the superior and horizontal semicircular canals, runs within a bony canal that is longer and more restrictive than those in which the inferior division and singular nerves travel [23]. The superior division may be more susceptible to entrapment within the canal during periods of vestibular nerve inflammation, resulting in the unique exam findings described previously [4, 21, 23].

There are no specific diagnostic tests for vestibular neuritis. Diagnosis is made via careful consideration of the patient's history and physical exam findings discussed.

## Differential Diagnosis

A cerebellar or brainstem stroke may mimic vestibular neuritis. Patients over the age of 50 years and those with cardiovascular disease are of particular concern for infarction [14, 26]. While central nystagmus signs, including horizontal gaze, direction changing nystagmus and vertical or purely torsional nystagmus, are specific for stroke, they are not reliable indicators [27].

The HINTS triad (normal horizontal Head Impulse test, direction-changing Nystagmus, and deviation on Test of Skew) was shown to be 100% sensitive and 96% specific for detecting stroke [28]. The HIT, used to evaluate semicircular canal (SCC) function, is conducted by rapidly turning the patient's head in the plane of a SCC pair while the patient fixes their gaze on a stationary target. Patients with normal SCC function maintain gaze fixation on the target with smooth compensatory eye movements, while those with vestibular dysfunction generate corrective saccades back to the target after the head impulse [29]. Peripheral AVS is typically associated with a unidirectional nystagmus that becomes more intense when gazing in the direction of the fast phase. However, nystagmus that changes direction on eccentric gaze is a sign of central AVS [28]. Test of skew is performed by covering one eye for several seconds and then quickly uncovering to compare both eyes. Vertical skew, or vertical realignment of the eye once it is uncovered, is concerning for central pathology. Benign HINTS examination was shown to rule out stroke with 100% sensitivity, better than a negative MRI with diffusion weighted imaging (DWI) performed within the first 24–48 h after symptom onset [28].

A potential drawback to standard HINTS testing is that it relies on subjective observations made by the physician [29]. Video head impulse testing (vHIT), which measures each HINTS component, has been developed as an objective tool for accurate diagnosis of AVS [27]. During this test, the patient wears goggles with head velocity sensors and a mounted high-speed camera. This system can accurately calculate the vestibule-ocular response (VOR) gain, or eye velocity relative to head velocity, to measure the function of each SCC individually [29].

## Treatment

Management of vestibular neuritis typically begins with symptomatic vestibular suppressants (Table 5.2). These include antihistamines, anticholinergics, antiemetics, and in severe cases benzodiazepines, which help to control initial dizziness, nausea, and vomiting. The CNS works to compensate for the initial insult, however, by bringing the unbalanced vestibular signals into equilibrium over the following days [7]. Vestibular suppressants function as symptomatic therapies during the time that central compensation remains insufficient to quell acute symptoms. These medications should be used with caution, as vestibular suppression and sedation can prolong symptoms by inhibiting central compensatory mechanisms and should not

**Table 5.2** Common symptomatic treatments for acute vestibular neuritis

Drug	Route	Dose interval	Additional information
<i>Antihistamines</i>			Parenteral forms preferred in the emergent setting.
Dimenhydrinate	IV	50 mg	
	Oral	50–100 mg every 4–6 h	
Diphenhydramine	IV	10–50 mg	
	Oral	25–50 mg every 4–6 h	
Meclizine	Oral	25–50 mg 6–12 h	
<i>Antiemetics</i>			Parenteral forms preferred in the emergent setting.
Metoclopramide	IV	10 mg	
	Oral	5–10 mg every 6 h	
Ondansetron	IV	4–8 mg	
	Oral	4 mg every 8–12 h	
Prochlorperazine	IV	2.5–10 mg	
	Oral	5–10 mg every 6 h	
Promethazine	IM or IV	12.5–25 mg	
	Oral	12.5–25 mg every 4–6 h	
<i>Benzodiazepines</i>			Use with caution due to risk of dependency.
Alprazolam	Oral	0.5 mg every 8 h	
Clonazepam	Oral	0.25–0.5 mg 8–12 h	
Diazepam	Oral	1 mg every 12 h	
Lorazepam	Oral	1–2 mg every 8 h	

*IV* intravenous, *IM* intramuscular

be continued longer than 3 days [6]. Benzodiazepines should be reserved for symptomatic temporary initial treatment for severe vestibular neuritis, as they also carry a risk of dependency.

Treatment with corticosteroids accelerates recovery of the peripheral vestibular system, possibly by decreasing inflammation, edema, and compression of the vestibular nerve secondary to viral reactivation [4]. Immune system suppression would also decrease autoimmune inflammation, supporting a potential autoimmune etiology [4]. Recommendations range from lower dosages up to 1 mg/kg prednisone for 10 days.

Finally, vestibular exercises are recommended to enhance central compensatory mechanisms in patients recovering from vestibular neuritis. Vestibular therapy is typically designed to target the visual and optokinetic, vestibular, and somatosensory systems [30]. Exercises may include eye movements while following objects, head and body tilts and rotation, and balance exercises with eyes closed. Patients should develop an individualized rehabilitation program in collaboration with a

vestibular therapist, in addition to home exercises. Initially, exercises should occur in short intervals to cause tolerable dizziness without triggering nausea and vomiting [31]. Exercise duration and repetitions can steadily be increased and adjusted as the patient's symptoms improve.

## Prognosis

Patients typically experience acute dizziness over the span of days as the CNS gradually equilibrates mismatched peripheral vestibular signals. A prolonged interval of imbalance and dizziness typically follows the acute period, lasting for several weeks to months. Not all patients fully recover from vestibular neuritis. In fact, 30–50% of patients continue to suffer from varying dizziness and imbalance months to years after the initial episode [32–34].

Early initiation of vestibular rehabilitation is thought to accelerate recovery by enhancing central compensatory mechanisms. Vestibular exercises speed recovery of balance function and reduce perception of dizziness, thereby allowing patients to more quickly return to normal daily activities [30, 31]. Corticosteroids have similar early benefits, accelerating vestibular compensation [35]. Most evidence suggests that standard vestibular rehabilitation and corticosteroids yield similar outcomes for long-term recovery [36–38]. However, a recent study found that early vestibular rehabilitation, in addition to a 10-day prednisolone taper, significantly reduced perceived dizziness and improved daily function after 12 months when compared to 10 days of corticosteroids alone [31].

Long-term prognosis may also be explained by the patient's visual and psychological predisposition. Visual dependence, or the degree of weighting visual input relative to vestibular input in evaluation of spatial orientation, plays a large role in long-term recovery. Patients in one study of 28 patients at least 6 months following vestibular neuritis who displayed the worst residual dizziness on Dizziness Handicap Inventory (DHI) (scores from 36 to 80) had higher visual dependence on Rod-and-Disk Testing than controls ( $6.35^\circ$  v.  $3.39^\circ$ ). There was no significant difference on Rod-and-Disk Testing between controls and patients who had minimal residual dizziness on DHI [39]. Other studies have found similar delays in recovery for patients with strong visual dependence after vestibular neuritis. Psychological conditions, including anxiety and depression, have also been associated with worse long-term outcomes following vestibular neuritis over a 10-month period and these poor outcomes can be further exacerbated by high levels of autonomic arousal (as measured by symptoms such as diaphoresis and palpitations) [32, 33]. In addition to standard therapy, patients with psychological factors associated with poor recovery may require pharmacotherapy and cognitive therapy to improve clinical outcomes following acute vestibular neuritis [32].



## Recurrence Risk

Patients have a low risk of subsequent cases of vestibular neuritis. A study that followed 103 patients for an average of 10 years found only 2 patients (1.9%) developed a second case of vestibular neuritis [40]. Both patients developed subsequent vestibular neuritis in the contralateral ear and their symptoms were less severe during the second episode of this disorder [40].

## Additional Sequelae

Vestibular neuritis is one of the most common causes of secondary benign paroxysmal positional vertigo (BPPV) (15% of secondary BPPV) [41]. These secondary BPPV episodes affect the ipsilateral posterior semicircular canal to the initiating vestibular neuritis [42–45]. These findings suggest relative sparing of the inferior vestibular nerve division during vestibular neuritis, which innervates the posterior semicircular canal and is consistent with findings that the superior vestibular nerve branch is more susceptible to inflammatory damage due to vestibular neuritis [42]. Inflammatory damage to the macula and utricle may result in the displacement of otoliths, which collect in the dependent posterior semicircular canal, resulting in a pure posterior semicircular canal BPPV [42]. Additionally, the demyelinated superior vestibular nerve branch may be relatively unable to detect dislodged otoliths in the superior and horizontal SCCs.

Finally, most patients experience acute anxiety following an episode of vestibular neuritis. Approximately 15% ultimately develop a somatoform or panic disorder [46]. Interestingly, severity of vertigo is not correlated with the development of the disorders. Rather, patients with poor psychosocial support networks are at higher risk of subsequently developing somatoform or panic disorders [47].

## Summary

Vestibular neuritis is a unilateral vestibulopathy due to inflammation of the vestibular nerve. Patients experience a rapid-onset, prolonged vertigo that resolves over days to weeks, with residual dizziness persisting until central compensation occurs. Initial examination may reveal a spontaneous nystagmus beating away from the affected side and positive HIT. Signs of central neurologic dysfunction should be absent. Vestibular suppressants may be useful during the first few days for symptomatic relief but may inhibit central compensatory mechanisms if use continues beyond this period. Treatment typically includes a combination of corticosteroids to reduce inflammation and early vestibular exercises to enhance central compensation.

## References

1. Strupp M, Mandala M, Lopez-Escamez JA. Peripheral vestibular disorders: an update. *Curr Opin Neurol*. 2019;32(1):165–73. <https://doi.org/10.1097/WCO.0000000000000649>.
2. Neuhauser HK. The epidemiology of dizziness and vertigo. *Handb Clin Neurol*. 2016;137:67–82. <https://doi.org/10.1016/B978-0-444-63437-5.00005-4>.
3. Muellemann T, Shew M, Subbarayan R, Shum A, Sykes K, Staecker H, et al. Epidemiology of dizzy patient population in a neurotology clinic and predictors of peripheral etiology. *Otol Neurotol*. 2017;38(6):870–5. <https://doi.org/10.1097/MAO.0000000000001429>.
4. Greco A, Macri GF, Gallo A, Fusconi M, De Virgilio A, Pagliuca G, et al. Is vestibular neuritis an immune related vestibular neuropathy inducing vertigo? *J Immunol Res*. 2014;2014:459048. <https://doi.org/10.1155/2014/459048>.
5. Bartual-Pastor J. Vestibular neuritis: etiopathogenesis. *Rev Laryngol Otol Rhinol (Bord)*. 2005;126(4):279–81.
6. Strupp M, Magnusson M. Acute unilateral vestibulopathy. *Neurol Clin*. 2015;33(3):669–85, x. <https://doi.org/10.1016/j.ncl.2015.04.012>.
7. Baloh RW. Clinical practice. Vestibular neuritis. *N Engl J Med*. 2003;348(11):1027–32. <https://doi.org/10.1056/NEJMc021154>.
8. Matsuo T. Vestibular neuronitis—serum and CSF virus antibody titer. *Auris Nasus Larynx*. 1986;13(1):11–34. [https://doi.org/10.1016/s0385-8146\(86\)80020-7](https://doi.org/10.1016/s0385-8146(86)80020-7).
9. Fishman JM. Corticosteroids effective in idiopathic facial nerve palsy (Bell’s palsy) but not necessarily in idiopathic acute vestibular dysfunction (vestibular neuritis). *Laryngoscope*. 2011;121(11):2494–5. <https://doi.org/10.1002/lary.22327>.
10. Rujescu D, Hartmann AM, Giegling I, Konte B, Herrling M, Himmelein S, et al. Genome-wide association study in vestibular neuritis: involvement of the host factor for HSV-1 replication. *Front Neurol*. 2018;9:591. <https://doi.org/10.3389/fneur.2018.00591>.
11. Arbusow V, Schulz P, Strupp M, Dieterich M, von Reinhardstoettner A, Rauch E, et al. Distribution of herpes simplex virus type 1 in human geniculate and vestibular ganglia: implications for vestibular neuritis. *Ann Neurol*. 1999;46(3):416–9. [https://doi.org/10.1002/1531-8249\(199909\)46:3<416::aid-ana20>3.0.co;2-w](https://doi.org/10.1002/1531-8249(199909)46:3<416::aid-ana20>3.0.co;2-w).
12. Arbusow V, Derfuss T, Held K, Himmelein S, Strupp M, Gurkov R, et al. Latency of herpes simplex virus type-1 in human geniculate and vestibular ganglia is associated with infiltration of CD8+ T cells. *J Med Virol*. 2010;82(11):1917–20. <https://doi.org/10.1002/jmv.21904>.
13. Roehm PC, Camarena V, Nayak S, Gardner JB, Wilson A, Mohr I, et al. Cultured vestibular ganglion neurons demonstrate latent HSV1 reactivation. *Laryngoscope*. 2011;121(10):2268–75. <https://doi.org/10.1002/lary.22035>.
14. Hotson JR, Baloh RW. Acute vestibular syndrome. *N Engl J Med*. 1998;339(10):680–5. <https://doi.org/10.1056/NEJM199809033391007>.
15. Bumm P, Schlimok G. T-lymphocyte subpopulations and HLA-DR antigens in patients with Bell’s palsy, hearing loss, neuronitis vestibularis, and Meniere’s disease. *Eur Arch Otorhinolaryngol*. 1994;S447–8. [https://doi.org/10.1007/978-3-642-85090-5\\_178](https://doi.org/10.1007/978-3-642-85090-5_178).
16. Bumm P, Muller EC, Grimm-Muller U, Schlimok G. [T-lymphocyte subpopulation and HLA-DR antigens in hearing loss of vestibular neuropathy, Meniere’s diseases and Bell’s palsy]. *Laryngorhinootologie*. 1991;70(5):260–6. <https://doi.org/10.1055/s-2007-998033>.
17. Kassner SS, Schottler S, Bonaterra GA, Stern-Straeter J, Hormann K, Kinscherf R, et al. Proinflammatory activation of peripheral blood mononuclear cells in patients with vestibular neuritis. *Audiol Neurootol*. 2011;16(4):242–7. <https://doi.org/10.1159/000320839>.
18. Bonaterra GA, Hildebrandt W, Bodens A, Sauer R, Dugi KA, Deigner HP, et al. Increased cyclooxygenase-2 expression in peripheral blood mononuclear cells of smokers and hyperlipidemic subjects. *Free Radic Biol Med*. 2005;38(2):235–42. <https://doi.org/10.1016/j.freeradbiomed.2004.10.021>.
19. Bonaterra GA, Hildebrandt W, Bodens A, Sauer R, Dugi KA, Deigner HP, et al. Increased gene expression of scavenger receptors and proinflammatory markers in peripheral blood

- mononuclear cells of hyperlipidemic males. *J Mol Med (Berl)*. 2007;85(2):181–90. <https://doi.org/10.1007/s00109-006-0117-6>.
20. Oron Y, Shemesh S, Shushan S, Cinamon U, Goldfarb A, Dabby R, et al. Cardiovascular risk factors among patients with vestibular neuritis. *Ann Otol Rhinol Laryngol*. 2017;126(8):597–601. <https://doi.org/10.1177/0003489417718846>.
  21. Fetter M, Dichgans J. Vestibular neuritis spares the inferior division of the vestibular nerve. *Brain*. 1996;119(Pt 3):755–63. <https://doi.org/10.1093/brain/119.3.755>.
  22. Silvoniemi P. Vestibular neuronitis. An otoneurological evaluation. *Acta Otolaryngol Suppl*. 1988;453:1–72. <https://doi.org/10.3109/00016488809098974>.
  23. Gianoli G, Goebel J, Mowry S, Poomipannit P. Anatomic differences in the lateral vestibular nerve channels and their implications in vestibular neuritis. *Otol Neurotol*. 2005;26(3):489–94. <https://doi.org/10.1097/01.mao.0000169787.99835.9f>.
  24. Jeong SH, Kim HJ, Kim JS. Vestibular neuritis. *Semin Neurol*. 2013;33(3):185–94. <https://doi.org/10.1055/s-0033-1354598>.
  25. Aw ST, Fetter M, Cremer PD, Karlberg M, Halmagyi GM. Individual semicircular canal function in superior and inferior vestibular neuritis. *Neurology*. 2001;57(5):768–74. <https://doi.org/10.1212/wnl.57.5.768>.
  26. Norrving B, Magnusson M, Holtas S. Isolated acute vertigo in the elderly; vestibular or vascular disease? *Acta Neurol Scand*. 1995;91(1):43–8. <https://doi.org/10.1111/j.1600-0404.1995.tb05841.x>.
  27. Kattah JC. Use of HINTS in the acute vestibular syndrome. An overview. *Stroke Vasc Neurol*. 2018;3(4):190–6. <https://doi.org/10.1136/svn-2018-000160>.
  28. Kattah JC, Talkad AV, Wang DZ, Hsieh YH, Newman-Toker DE. HINTS to diagnose stroke in the acute vestibular syndrome: three-step bedside oculomotor examination more sensitive than early MRI diffusion-weighted imaging. *Stroke*. 2009;40(11):3504–10. <https://doi.org/10.1161/STROKEAHA.109.551234>.
  29. Halmagyi GM, Chen L, MacDougall HG, Weber KP, McGarvie LA, Curthoys IS. The video head impulse test. *Front Neurol*. 2017;8:258. <https://doi.org/10.3389/fneur.2017.00258>.
  30. Strupp M, Arbusow V, Maag KP, Gall C, Brandt T. Vestibular exercises improve central vestibulospinal compensation after vestibular neuritis. *Neurology*. 1998;51(3):838–44. <https://doi.org/10.1212/wnl.51.3.838>.
  31. Tokle G, Morkved S, Brathen G, Goplen FK, Salvesen O, Arnesen H, et al. Efficacy of vestibular rehabilitation following acute vestibular neuritis: a randomized controlled trial. *Otol Neurotol*. 2020;41(1):78–85. <https://doi.org/10.1097/MAO.0000000000002443>.
  32. Bronstein AM, Dieterich M. Long-term clinical outcome in vestibular neuritis. *Curr Opin Neurol*. 2019;32(1):174–80. <https://doi.org/10.1097/WCO.0000000000000652>.
  33. Cousins S, Kaski D, Cutfield N, Arshad Q, Ahmad H, Gresty MA, et al. Predictors of clinical recovery from vestibular neuritis: a prospective study. *Ann Clin Transl Neurol*. 2017;4(5):340–6. <https://doi.org/10.1002/acn3.386>.
  34. Adamec I, Krbot Skoric M, Ozretic D, Habek M. Predictors of development of chronic vestibular insufficiency after vestibular neuritis. *J Neurol Sci*. 2014;347(1–2):224–8. <https://doi.org/10.1016/j.jns.2014.10.001>.
  35. Batuecas-Caletrio A, Yanez-Gonzalez R, Sanchez-Blanco C, Perez PB, Gonzalez-Sanchez E, Sanchez LA, et al. Glucocorticoids improve acute dizziness symptoms following acute unilateral vestibulopathy. *J Neurol*. 2015;262(11):2578–82. <https://doi.org/10.1007/s00415-015-7918-x>.
  36. Shupak A, Issa A, Golz A, Margalit K, Braverman I. Prednisone treatment for vestibular neuritis. *Otol Neurotol*. 2008;29(3):368–74. <https://doi.org/10.1097/MAO.0b013e3181692804>.
  37. Goudakos JK, Markou KD, Psillas G, Vital V, Tsaligopoulos M. Corticosteroids and vestibular exercises in vestibular neuritis. Single-blind randomized clinical trial. *JAMA Otolaryngol Head Neck Surg*. 2014;140(5):434–40. <https://doi.org/10.1001/jamaoto.2014.48>.

38. Ismail EI, Morgan AE, Abdel Rahman AM. Corticosteroids versus vestibular rehabilitation in long-term outcomes in vestibular neuritis. *J Vestib Res.* 2018;28(5–6):417–24. <https://doi.org/10.3233/VES-180645>.
39. Cousins S, Cutfield NJ, Kaski D, Palla A, Seemungal BM, Golding JF, et al. Visual dependency and dizziness after vestibular neuritis. *PLoS One.* 2014;9(9):e105426. <https://doi.org/10.1371/journal.pone.0105426>.
40. Huppert D, Strupp M, Theil D, Glaser M, Brandt T. Low recurrence rate of vestibular neuritis: a long-term follow-up. *Neurology.* 2006;67(10):1870–1. <https://doi.org/10.1212/01.wnl.0000244473.84246.76>.
41. Baloh RW, Honrubia V, Jacobson K. Benign positional vertigo: clinical and oculographic features in 240 cases. *Neurology.* 1987;37(3):371–8. <https://doi.org/10.1212/wnl.37.3.371>.
42. Turk B, Akpınar M, Kaya KS, Korkut AY, Turgut S. Benign paroxysmal positional vertigo: comparison of idiopathic BPPV and BPPV secondary to vestibular neuritis. *Ear Nose Throat J.* 2019;100:145561319871234. <https://doi.org/10.1177/0145561319871234>.
43. Karlberg M, Halmagyi GM, Buttner U, Yavor RA. Sudden unilateral hearing loss with simultaneous ipsilateral posterior semicircular canal benign paroxysmal positional vertigo: a variant of vestibulo-cochlear neurolabyrinthitis? *Arch Otolaryngol Head Neck Surg.* 2000;126(8):1024–9. <https://doi.org/10.1001/archotol.126.8.1024>.
44. Mandala M, Santoro GP, Awrey J, Nuti D. Vestibular neuritis: recurrence and incidence of secondary benign paroxysmal positional vertigo. *Acta Otolaryngol.* 2010;130(5):565–7. <https://doi.org/10.3109/00016480903311278>.
45. Balatsouras DG, Koukoutsis G, Ganelis P, Economou NC, Moukos A, Aspris A, et al. Benign paroxysmal positional vertigo secondary to vestibular neuritis. *Eur Arch Otorhinolaryngol.* 2014;271(5):919–24. <https://doi.org/10.1007/s00405-013-2484-2>.
46. Godemann F, Schabowska A, Naetebusch B, Heinz A, Strohle A. The impact of cognitions on the development of panic and somatoform disorders: a prospective study in patients with vestibular neuritis. *Psychol Med.* 2006;36(1):99–108. <https://doi.org/10.1017/S0033291705005921>.
47. Godemann F, Schuller J, Uhlemann H, Budde A, Heinz A, Strohle A, et al. Psychodynamic vulnerability factors in the development of panic disorders—a prospective trial in patients after vestibular neuritis. *Psychopathology.* 2009;42(2):99–107. <https://doi.org/10.1159/000203342>.
48. Lee S, Kaylie DM. Balance (anatomy: vestibular nerve). In: Kountakis SE, editor. *Encyclopedia of otolaryngology, head and neck surgery.* Berlin: Springer; 2013. [https://doi.org/10.1007/978-3-642-23499-6\\_577](https://doi.org/10.1007/978-3-642-23499-6_577).