



# An Unusual Cause of Intracranial Hemorrhage: Cerebral Mucormycosis

*Yelco Chicote Carasa and Laura López García*

## Contents

- 16.1 Introduction – 164
- 16.2 Investigations – 165
- 16.3 Differential Diagnosis – 166
- 16.4 Treatment – 167
- 16.5 Evolution, Outcome, and Follow-up – 168
- 16.6 Discussion – 168
- References – 170

### Learning Objectives

- To consider diabetes mellitus as a cause of immunosuppression, especially in patients with poor glycemic control.
- To always look for the etiology of intracranial bleeding and not to be carried away by appearances.
- To suspect fungal infection as a cause of neuroinfection in the immunocompromised patient.
- To illustrate a case of apparent hemorrhagic stroke, in which the correct diagnosis arises from brain histopathology.
- To highlight the management of refractory intracranial hypertension, including to decompressive craniectomy and barbiturate coma.

## 16.1 Introduction

---

Mucormycosis is a fungal infection caused by filamentous fungi belonging to the order Mucorales. These are ubiquitous fungi that mainly affect severely immunocompromised hosts. The location of the disease varies according to the type of immunosuppression. Onco-hematological malignancies are the main risk factors in developed countries, while diabetes mellitus accounts for the majority of cases in developing areas [1].

Invasive mucormycosis includes different clinical entities, depending on the affected organs: gastrointestinal, cutaneous, renal, pulmonary, and rhino-orbito-cerebral mucormycosis. It is a relatively rare pathology, with variable incidences among different countries and populations [2].

The diagnosis of mucormycosis still relies on microbiological analyses of tissues obtained by surgical debridement or biopsy. Visualization of nonseptate broad hyphae with branching at right angles on direct microscopy strongly suggests infection with Mucorales [3]. Serum fungal biomarkers such as  $\beta$ -D-glucan and galactomannan are not relevant to the diagnosis. In recent years, new diagnostic tools have emerged, such as polymerase chain reaction (PCR) or mass spectrometry-based techniques, although their performance is still inferior to that of classical histopathological and microbiological tests [1].

As for treatment, it is based on two essential pillars: surgical debridement, which should be aggressive if possible; and systemic antifungal therapy, usually with a combination of liposomal amphotericin B and an azole with activity against Mucorales (isavuconazole or posaconazole) [4].

Mortality varies significantly depending on the location of the lesions. For example, according to the literature, mortality of rhino-orbito-cerebral mucormycosis varies between 25 and 60%, with better outcomes when limited to the paranasal sinuses, and higher mortality in case of angioinvasion and infiltration of central nervous system [2].

### Case Presentation

A 44-year-old man, from Honduras, with a personal history of poorly controlled diabetes mellitus (DM), presented to the emergency department with deteriorating level of consciousness. He had consulted at another hospital for somnolence and was diagnosed with diabetic ketoacidosis three days before. He was discharged after 24 h, once the acidosis was resolved and the insulin treatment was optimized.

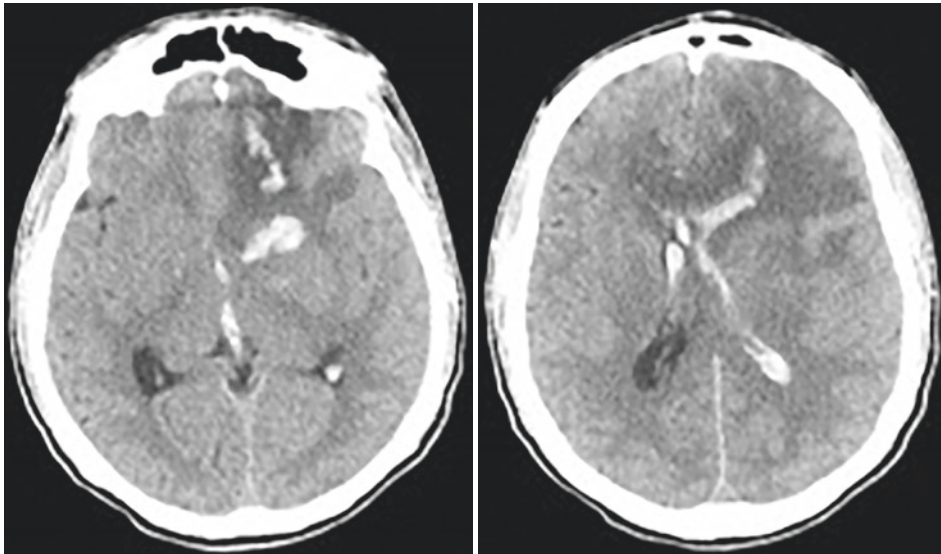
Upon arrival to our hospital, he was tachycardic, tachypneic, and febrile, with

normal arterial blood pressure. He was comatose (Glasgow coma scale (GCS) of 7 points) with risk of bronchial aspiration. A venous gas blood analysis was performed, demonstrating metabolic acidosis with a pH of 7.26 and a bicarbonate of 11 mmol/L.

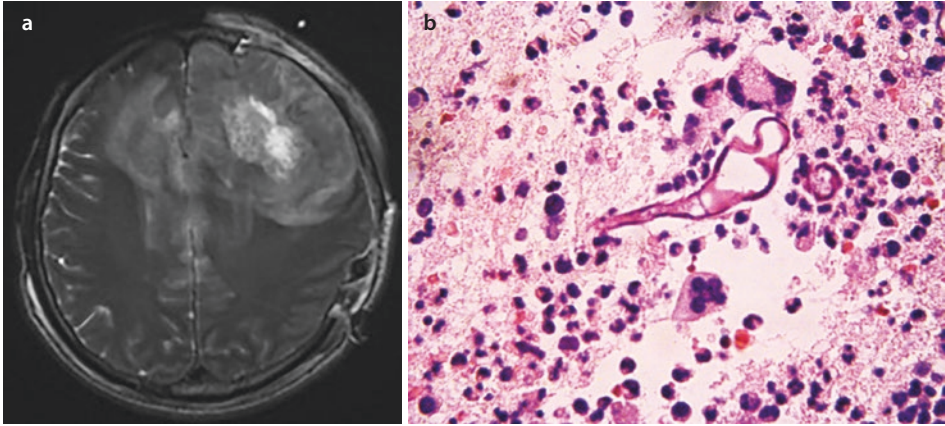
Given the situation, the patient was intubated for mechanical ventilation and was admitted to the intensive care unit (ICU).

## 16.2 Investigations

After initial stabilization, a computed tomography (CT) was performed, which revealed a large bilateral cerebral hemorrhage in the basal ganglia open to the ventricular system. It was associated with perilesional edema and an 8-mm midline shift. CT angiography was also obtained, which ruled out large vessel occlusion or vascular malformation (■ Fig. 16.1).



■ **Fig. 16.1** CT scan showing intraparenchymal hemorrhage in the basal ganglia and left frontal lobe open to the ventricular system, with mass effect and midline shift



■ **Fig. 16.2** a MR sequence T2 flair in axial cut showing bihemispheric involvement. b Mucor hyphae invading the cerebral parenchyma

Standard diagnostic tests (electrocardiogram, chest radiograph, and basic laboratory panel) revealed no abnormalities.

Neurosurgery was consulted, and the patient underwent urgent surgery to evacuate the hematoma; because of signs of herniation, the cranial vault bone was not replaced. Cerebral parenchyma samples were collected and sent to the laboratory for histopathological and microbiological analysis. During the procedure, indirect signs of venous sinus thrombosis were observed. A venous phase contrast-enhanced CT was performed after the intervention, which ruled out thrombosis of the venous system. Due to the persistence of radiological signs of intracranial hypertension, a parenchymal fiberoptic bolt was placed to invasively monitor his intracranial pressure (ICP).

Given that the etiology of the bleeding was not clarified, a cerebral magnetic resonance imaging (MRI) was ordered in the following days. It demonstrated extensive frontal cerebral parenchymal involvement, associated with cortical and subarachnoid hemorrhages, as well as images suggesting thrombosis of the venous sinus and cortical veins (■ Fig. 16.2A).

### 16.3 Differential Diagnosis

The differential diagnosis in this case includes the following:

- **Vascular causes.** This patient suffered from altered consciousness and a hemorrhagic stroke on imaging tests. The first clinical suspicion was an undiagnosed arterial hypertension. Likewise, in the MRI, there were signs of unnoticed venous thrombosis in venous phase CT, but they were incomplete thrombosis and, due to their topographic locations, they did not fully justify the involvement of all the damaged brain territories. The initial syndromic diagnosis was malignant cerebral infarction, with the suspicion that diabetic ketoacidosis was a secondary event.

- Infectious causes. Our patient was an immunocompromised individual because of his DM. The various etiologies of central nervous system (CNS) infection can begin with a nonspecific neurologic deterioration and, although rarely, can cause different types of intracranial bleeding, especially the fungal causes due to their tendency to angioinvasion, generating thromboses and hemorrhages along their progression.
- Immune mediated diseases. Within this group, we include immune mediated aseptic encephalitis, like anti-NMDA receptor encephalitis. These are rare etiologies, usually difficult to diagnose and with significant morbidity and mortality.

## 16.4 Treatment

---

The patient was admitted to the ICU, where neurocritical care was initiated, including sedation, analgesia, temperature control, and escalation to the barbiturate coma for optimization of cerebral perfusion pressure.

In addition, given the diabetic ketoacidosis that was observed upon admission, treatment of the latter was initiated with fluid and electrolyte administration, intravenous insulin, glycemic control, and ketonemia monitoring.

The surgeons evacuated the hematoma without bone replacement, leaving a large decompressive craniectomy. Following the CT scan performed 24 h after the surgery, which showed persistent signs of intracranial hypertension, a second neurointervention was performed during which biopsies were taken and a parenchymal fiberoptic bolt was placed.

Besides, given the suspicion of neuroinfection as one of the etiologies (lesion distribution on CT, not corresponding to vascular territories, and its infiltrative nature) empirical antimicrobial therapy was initiated. Antimicrobial therapy included meropenem 2 g every 8 h (the patient was immunocompromised and at risk of *Nocardia* infection among the possible etiologies) and linezolid 600 mg every 12 h, as well as corticosteroid therapy with dexamethasone 4 g every 6 h, taking into account the possibility of an immune-mediated encephalitis.

The patient's relatives denied recent traveling or risky behavior either nutritionally or sexually, but reported that the patient had a weeks-long history of dental and ear pain for which he did not consult. He was examined by maxillofacial surgery, and no lesions were found in the examined territory. At that point, Anatomical Pathology reported the discovery of hyphae compatible with *Mucor* in the brain biopsy (■ Fig. 16.2B), so antibiotic therapy and corticosteroids were stopped. Dual anti-fungal therapy with liposomal amphotericin B and isavuconazole were started (amphotericin B at doses of 10 mg/Kg every 24 h and isavuconazole with loading dose of 200 mg every 8 h for 6 doses and, then, 200 mg daily).

## 16.5 Evolution, Outcome, and Follow-up

---

The patient was admitted to the ICU with the diagnosis of extensive intraparenchymal hemorrhage associated with a significant mass effect, so he underwent urgent surgical intervention for its evacuation, and primary decompressive craniectomy was performed. Given the severity of the lesions, invasive monitoring of intracranial pressure was decided upon. Despite progressive escalation of treatment to third-level measures (including barbiturate coma) and targeted antifungal treatment, the patient developed refractory intracranial hypertension.

In this situation, with no other available therapeutic options available, and given the unfavorable prognosis of the established lesions, probably leading to severe neurological sequelae and death, the case was reassessed in a multidisciplinary meeting and, in accordance with the relatives, the team decided to withdraw life-sustaining treatment. The patient died after 7 days in the ICU.

## 16.6 Discussion

---

Invasive mucormycosis is a potentially fatal fungal infection that predominantly affects individuals with any degree of immunosuppression. Its rhino-orbito-cerebral variation is typical of patients with poorly controlled diabetes mellitus, especially those with episodes of ketoacidosis. Involvement of paranasal sinuses is the most frequent feature, although spread to the cerebral parenchyma is not unusual. Invasive mucormycosis is an uncommon entity, but it entails high rates of mortality and disability, thus the importance of a high level of suspicion that allows early initiation of antifungal therapy is clearly related to a better prognosis [1]. In the case of our patient, his DM treatment was suboptimal, and he had suffered from several episodes of ketoacidosis.

Clinical manifestations at the beginning of the clinical course can be indistinguishable from common sinusitis. At this stage, the presence of necrotic sloughs in oral or nasal mucosa is considered a sentinel sign that should alert to the possibility of a *Mucor* infection, although it is absent in almost half of cases. Less than 50% of the patients present with fever [3]. The development of neurological symptoms (*i.e.* deterioration in the level of consciousness, focal deficits, seizures, etc.) is indicative of fungal invasion of cerebral tissue. Although the temporal evolution is variable, progression to more advanced stages can occur rapidly, even within days [1].

Regarding the radiological tests, both CT and MRI can show unspecific thickening of sinus mucosa, as well as bone destruction and orbital involvement in more advanced cases. Two unique findings occur with intracranial involvement: cavernous sinus thrombosis and internal carotid occlusion. It is also possible to observe primary involvement of cerebral tissue, frequently associating bleeding/infarction areas [2].

The symptoms of our patient were exclusively neurological; nevertheless, his relatives reported that he had suffered from odontalgia and otalgia weeks prior to the admission. Initially, the CT and MRI did not report the possibility of fungal infection (probably because the initial suspicion level was low). Bilateral parenchymal involvement and the development of venous thrombosis and hemorrhages are described in the literature.

Treatment lies in the early administration of antifungal agents, surgical debridement, and correction of the underlying metabolic or immune dysfunction. The most commonly used drugs (although not supported by randomized controlled trials) are liposomal amphotericin B and azoles with activity against Mucorales (isavuconazole and posaconazole) [4]. Aggressive surgical debridement is not recommended in cases of cerebral involvement, given the limited benefit and the high risk of sequelae. Neurosurgical intervention is indicated in cases of intracranial hypertension, obstructive hydrocephalus, and spinal cord compression [2]. As for our patient, ketoacidosis and hyperglycemia were resolved within the first few hours after receiving fluid therapy and intravenous insulin. He underwent a surgical procedure to evacuate the hematoma, and a primary decompressive craniectomy was performed, and yet he developed refractory intracranial hypertension. Antifungal agents were initiated after the finding of hyphae in the biopsy samples sent from the operating room.

### Take-Home Messages

- Diabetes is a serious cause of immunosuppression.
- Once established, fungal invasion is a devastating disease with significant morbidity and mortality.
- MRI is a potentially helpful tool also in intensive care settings.
- Cerebral biopsy may be a potential diagnostic test if necessary.

### Summary

Mucormycosis is a fungal infection caused by fungi belonging to the order Mucorales. It is a disease of immunocompromised patients. It presents with different clinical pictures according to the affected organ. Most cases entail high morbidity and mortality, even if optimal treatment (combining debridement surgery and antifungal) is accomplished.

We presented the case of a young patient with a history of poorly controlled diabetes mellitus who was admitted to our center with neurological symptoms and diabetic ketoacidosis, with initial diagnosis of hemorrhagic stroke.

The patient developed intracranial hypertension refractory to the escalation of measures to the third tier. During etiological search of the cause of bleeding and in the series of imaging tests, the existence of an underlying lesion not congruent with vascular affectations was revealed.

Brain biopsy was performed, and it was this test that gave the diagnostic key by showing a brain tissue completely invaded by *Mucor* hyphae. Despite the diagnosis and adjusted antifungal treatment, surgical debridement was not an option, given the extensive brain involvement and the likely significant secondary brain damage due to refractory intracranial hypertension. Therefore, the withdrawal of measures was finally agreed, and the patient died 7 days after admission to the Intensive Care Unit.

Regarding this case, it is important to highlight diabetes as a cause of immunosuppression, as well as ketoacidosis as a predisposing factor to *Mucor* infection. On the other hand, the clinical picture of invasive mucormycosis can be highly unspecific, sometimes requiring many different evaluation tools, including invasive tests, such as biopsy, in almost all of the cases.

**Acknowledgements** We want to thank the entire team of the ICU of our hospital and especially the Polyvalent Unit where this patient was admitted.

We would also like to thank the Department of Anatomical Pathology for courteously providing us with the histopathological images provided in the case.

## References

---

1. Steinbrink J, Miceli M. Mucormycosis. *Infect Dis Clin N Am*. 2021;35(2):435–52.
2. Chikley A, Ben-Ami R, Kontoyiannis D. Mucormycosis of the central nervous system. *J Fungi*. 2019;5(3):59.
3. Reid G, Lynch J, Fishbein M, Clark N. Mucormycosis. *Semin Respir Crit Care Med*. 2020;41(01):099–114.
4. Brunet K, Rammaert B. Mucormycosis treatment: recommendations, latest advances, and perspectives. *J Mycol Med*. 2020;30(3):101007.