

# Interventions in Pulmonary Medicine

José Pablo Díaz-Jiménez  
Alicia N. Rodríguez  
*Editors*

*Third Edition*

 Springer

---

# Interventions in Pulmonary Medicine



---

José Pablo Díaz-Jiménez  
Alicia N. Rodríguez  
Editors

# Interventions in Pulmonary Medicine

Third Edition

 Springer

*Editors*

José Pablo Díaz-Jiménez  
Interventional Pulmonary  
Department Hospital  
Universitari de Bellvitge  
Hospitalet de Llobregat  
Barcelona, Spain

Department of Pulmonary  
Medicine - Research - MD  
Anderson Cancer Center  
Houston, TX, USA

Alicia N. Rodríguez  
School of Medicine  
National University of Mar del Plata  
Buenos Aires, Argentina

ISBN 978-3-031-22609-0      ISBN 978-3-031-22610-6 (eBook)  
<https://doi.org/10.1007/978-3-031-22610-6>

© The Editor(s) (if applicable) and The Author(s), under exclusive license to Springer Nature Switzerland AG 2013, 2018, 2023

This work is subject to copyright. All rights are solely and exclusively licensed by the Publisher, whether the whole or part of the material is concerned, specifically the rights of translation, reprinting, reuse of illustrations, recitation, broadcasting, reproduction on microfilms or in any other physical way, and transmission or information storage and retrieval, electronic adaptation, computer software, or by similar or dissimilar methodology now known or hereafter developed. The use of general descriptive names, registered names, trademarks, service marks, etc. in this publication does not imply, even in the absence of a specific statement, that such names are exempt from the relevant protective laws and regulations and therefore free for general use.

The publisher, the authors, and the editors are safe to assume that the advice and information in this book are believed to be true and accurate at the date of publication. Neither the publisher nor the authors or the editors give a warranty, expressed or implied, with respect to the material contained herein or for any errors or omissions that may have been made. The publisher remains neutral with regard to jurisdictional claims in published maps and institutional affiliations.

This Springer imprint is published by the registered company Springer Nature Switzerland AG  
The registered company address is: Gewerbestrasse 11, 6330 Cham, Switzerland

*To all the colleagues and people involved in medical care who died during the COVID-19 pandemic. Our appreciation and heartfelt thanks to those who gave their lives to save others.*

---

## Foreword

The care of patients with pulmonary disorders requires a combination of both cognitive expertise and procedural skills. My personal journey in this field began when asked to join the bronchoscopy team at Mayo Clinic. This small group of five clinicians was responsible for all the flexible and rigid bronchoscopies in adult and pediatric patients. It was a unique opportunity and privilege to be trained and mentored by some of the original pioneers of both flexible and rigid techniques. I have also been blessed to work with and train many physicians in the art of advanced pulmonary procedures. Several are the current and future leaders in this field and authors of this book.

One of the highlights of my professional journey has been developing a friendship with Professor José Pablo Díaz-Jiménez. I first met Dr. Díaz-Jiménez over 30 years ago when he took a 6-month sabbatical at Mayo Clinic to train in the application of photodynamic therapy for early lung cancer. It was during this sabbatical that we became lifelong colleagues and friends. I am privileged to witness Pablo's development from a young pulmonary physician with procedural interests into a master clinician and master educator in the artful application of both flexible and rigid bronchoscopy.

A Mayo Clinic tradition, as in other academic institutions, has been to share and learn new knowledge through collaborative relationships with national and international physicians. Dr. Diaz Jimenez exemplifies this principle as evidenced by his own travels and by the many physicians he has trained in the art and appropriate application of rigid bronchoscopy for various benign and malignant airway disorders. It was during one of many trips to Barcelona in 1998 that I met another young clinician Dr. Alicia N. Rodríguez from Mar de Plata, Argentina. Similar to Dr. Díaz-Jiménez, Dr. Rodriguez subsequently became an internationally recognized leader in the application of advanced pulmonary procedures and a master educator of physicians in this field.

The current edition of *Interventions in Pulmonary Medicine* again highlights new technologies and their application to pulmonary medicine and reviews the various pulmonary procedures and techniques in previous editions. Drs. Díaz-Jiménez and Rodriguez accomplish this by bringing together world experts in the field. Each author provides up-to-date scholarly information that will be useful to both beginners and experts.

Mayo Clinic  
Rochester, MN, USA

Eric Edell

---

## Preface

The third edition of the book *Interventions in Pulmonary Medicine* was entrusted to us in the midst of the COVID-19 pandemic, hard times for pulmonologists. The pandemic came to change our professional life and made us focus mainly on those pulmonary conditions related to the virus.

With this, the time of professional in-person meetings, congresses, symposiums, and even casual conversations was replaced by online meetings only, and we had a massive number of updates on the situation, day-to-day medical news that kept us up to date with the developments. Now is not the time to make a balance or arrive at conclusions; the future will tell the advantages or disadvantages that the confinement brought about. It is true that for almost 3 years we have learnt many things, even though our daily coexistence with colleagues was very limited.

Vulnerability, the most fragile aspect of humanity, suddenly appeared, highlighting aspects that taught us to reflect on how to manage critical situations, how to handle administrative and economic resources, and how to put in motion all the necessary scientific aspects to deal with the world pandemic. Many good things arose too: human values such as love, solidarity, empathy, and generosity toward those in need showed that we have an innate capacity to work together for the good of us all, to team up to alleviate the pain and suffering that this pandemic brought upon the human race.

In record time the virus was identified and mapped, facilitating the development of new therapies and vaccines that have borne fruit to the point that the disease is now, hopefully, almost under control.

As can be seen in the content of the book, there are many new developments in terms of scientific and practical repercussions that have occurred regarding the application of interventional techniques for pulmonary complications of COVID-19. Likewise, the reader will find, in accordance with the progress of endoscopic techniques, new chapters that will illustrate our knowledge and contributions on that matter.

We have come a long way since the first publications on knowledge and use of Bronchoscopy, from pioneers such as Gustav Killian and Chevalier Jackson at the end of the nineteenth century and the beginning of the twentieth century. It was at that time that the first foundations were laid out for what is now Modern Bronchoscopy.

In 1949, Robert Monod said, in the prologue to his magnificent French book *Bronchologie, Technique endoscopique et Pathologie trachéo-bronchique* by André Soulas and Pierre Mounier-Kuhn, that the most

transcendental acquisitions of Pulmonology had been auscultation and fine-tuning of the radiological techniques and later a third acquisition, peroral tracheo-bronchoscopy, giving way to the foundations and flourishing of Interventional Bronchoscopy.

The path of the first bronchoscopists, great experts in the extraction of foreign bodies, broncho-pulmonary suppurations, and bronchial obstruction mechanisms, was not easy at the beginning. They also had to manage pandemics, world wars full of suffering, and of great challenges. The current bronchoscopy field, now essential and involved in many modern advances in the diagnosis and treatment of respiratory diseases, was made easier thanks to the contribution of those pioneers.

Most recent technical advances in the industry have contributed much to the progress and improvement of bronchoscopes and their accessory equipment. With the expansion of modern bronchoscopy in the late sixties of the twentieth century, such as the development of the fiberoptic bronchoscope and its introduction into clinical practice by Shigeto Ikeda, and the advances brought by Prof. J.F. Dumon in the early eighties, the Modern Interventional Pulmonology was firmly established in the medical arena.

We like to consider Prof. J.F. Dumon as the Leonardo da Vinci of Rigid Bronchoscopy, a genius who designed the safest bronchoscope and incredible tools to perform treatments in the tracheobronchial tree in order to improve the patient's quality of life. Though he left us a year ago, it was an honor for us to learn from him, and to consider him a mentor and a friend for almost 40 years. Among his many qualities, we particularly value his willingness and generosity to teach in an easy way. He will be missed and remembered by all of us.

Dumon liked to define Interventional Bronchoscopy as “the art of Bronchoscopy,” and we, interventional pulmonologists, should call ourselves artisans in that regard. And so, we would like to thank all the artisan collaborators in the use of bronchoscopy who have participated sharing their expertise in this book, in spite of the overwhelming medical and personal demands during this difficult time. Without their invaluable work, the publication of this Third Edition of *Interventions in Pulmonary Medicine* would have been impossible.

Barcelona, Spain  
Mar del Plata, Buenos Aires, Argentina

José Pablo Díaz-Jiménez  
Alicia N. Rodríguez

---

# Contents

## Part I Basic Bronchoscopy Procedures

- 1 Tracheobronchial Anatomy** . . . . . 3  
Juan Antonio Moya Amorós and Anna Ureña Lluveras
- 2 Flexible Bronchoscopy** . . . . . 15  
Tarek Dammad, Vishal Singh, and Bilal A. Jalil
- 3 Ultrathin Bronchoscopy: Indications and Technique** . . . . . 37  
Marta Díez Ferrer and Antoni Rosell
- 4 Rigid Bronchoscopy** . . . . . 51  
José Pablo Díaz-Jiménez and Alicia N. Rodríguez
- 5 Anesthesia for Interventional Bronchoscopic Procedures** . . . . . 71  
Mona Sarkiss
- 6 Bronchoscopy Education: New Insights** . . . . . 87  
Henri G. Colt
- 7 Evaluation of Outcomes After Interventional Procedures** . . . . . 109  
Teruomi Miyazawa and Hiroki Nishine

## Part II Interventional Procedures During the COVID-19 Pandemic

- 8 Interventional Procedures During the COVID-19 Pandemics: Adaptations in the Interventional Pulmonology Department** . . . . . 117  
Fernando Guedes and António Bugalho
- 9 Bronchoscopy During the COVID-19 Pandemic** . . . . . 127  
Elizabeth S. Malsin and A. Christine Argento
- 10 Tracheostomy in COVID-19 Patients** . . . . . 141  
Laura K. Frye

## Part III Tracheobronchial Obstructions

- 11 Laser Bronchoscopy in Tracheobronchial Obstructions** . . . . . 151  
Michela Bezzi

<b>12</b>	<b>Cryotherapy and Cryospray</b> .....	169
	Enambir Josan and Jasleen Pannu	
<b>13</b>	<b>Brachytherapy</b> .....	189
	Sara Shadchehr and Ileana Iftimia	
<b>14</b>	<b>Photodynamic Therapy</b> .....	201
	José Pablo Díaz-Jiménez and Alicia N. Rodríguez	
<b>15</b>	<b>Benign Airways Stenosis</b> .....	227
	José Pablo Díaz-Jiménez and Rosa López Lisbona	
<b>16</b>	<b>Endobronchial Prosthesis</b> .....	257
	Claudia Freitas, Sean Stoy, and Septimiu Dan Murgu	
 <b>Part IV Lung Cancer, General Considerations</b>		
<b>17</b>	<b>Lung Cancer Screening and Incidental Lung Nodules</b> .....	293
	Javier J. Zulueta and Marta Marín	
<b>18</b>	<b>Tissue Acquisition in Patients with Suspected Lung Cancer: Techniques Available and Sampling Adequacy for Molecular Testing</b> .....	307
	Semra Bilaceroglu	
<b>19</b>	<b>The Newly Proposed Lung Cancer TNM Classification: Review and Clinical Implications</b> .....	327
	Roberto F. Casal and Rodolfo F. Morice	
 <b>Part V Diagnosing and Staging of Lung Cancer</b>		
<b>20</b>	<b>Bronchoscopy Role in the Evaluation of Peripheral Pulmonary Lesions: An Overview</b> .....	341
	Stefano Gasparini and Lina Zuccatosta	
<b>21</b>	<b>Early Lung Cancer: Methods for Detection</b> .....	363
	Takahiro Nakajima and Kazuhiro Yasufuku	
<b>22</b>	<b>Optical Coherence Tomography: A Review</b> .....	379
	Hamid Pahlevaninezhad and Stephen Lam	
<b>23</b>	<b>Endobronchial Ultrasound</b> .....	393
	Alberto A. Goizueta and George A. Eapen	
<b>24</b>	<b>Electromagnetic Navigation: A Review</b> .....	415
	Danai Khemasuwan and Atul C. Mehta	
<b>25</b>	<b>Cone Beam Computed Tomography-Guided Bronchoscopy</b> .....	433
	Bruce F. Sabath and Roberto F. Casal	
<b>26</b>	<b>Robotic Assisted Bronchoscopy</b> .....	453
	Tarek Dammad and Bilal A. Jalil	



<b>27</b>	<b>Mediastinoscopy, Its Variants and Transcervical Mediastinal Lymphadenectomy</b> . . . . .	465
	Ramón Rami-Porta and Sergi Call	
<b>28</b>	<b>Lung Cancer Staging Methods: A Practical Approach</b> . . . . .	483
	Travis L. Ferguson, Tejaswi R. Nadig, and Gerard A. Silvestri	
<b>Part VI Pleural Conditions</b>		
<b>29</b>	<b>Pleural Anatomy</b> . . . . .	507
	Juan Antonio Moya Amorós	
<b>30</b>	<b>Chest Ultrasound</b> . . . . .	521
	Rachid Tazi Mezalek and Pere Trias Sabrià	
<b>31</b>	<b>Overview of the Spectrum of Chest Tubes with a Focus on Indwelling Pleural Catheters: Disease-Specific Selection</b> . . . . .	545
	Audra J. Schwalk and Anastasiia Rudkovskaia	
<b>32</b>	<b>Empyema Thoracis</b> . . . . .	571
	David Shore and Jennifer W. Toth	
<b>33</b>	<b>Management of Malignant Pleural Effusions</b> . . . . .	585
	Carlos A. Jiménez and Vickie R. Shannon	
<b>34</b>	<b>Medical Thoracoscopy</b> . . . . .	605
	Melissa Tukey, KeriAnn Van Nostrand, and Gaëtane C. Michaud	
<b>Part VII Interventional Bronchoscopy for Specific Conditions</b>		
<b>35</b>	<b>Endoscopic Methods for Lung Volume Reduction</b> . . . . .	619
	Luis M. Seijo Maceiras	
<b>36</b>	<b>Bronchial Thermoplasty</b> . . . . .	633
	Ekaterina Yavarovich	
<b>37</b>	<b>Bronchoscopy Role in Interstitial Lung Disease</b> . . . . .	641
	Ana Gruss and María Molina-Molina	
<b>38</b>	<b>Interventional Pulmonology in the Pediatric Population</b> . . . . .	651
	Nathaniel Silvestri, Lonny B. Yarmus, and Christopher R. Gilbert	
<b>39</b>	<b>Aero-Digestive Fistulas: Endoscopic Approach</b> . . . . .	669
	Alicia N. Rodríguez and José Pablo Díaz-Jiménez	
<b>40</b>	<b>Foreign Bodies in the Airway: Endoscopic Methods</b> . . . . .	685
	Michael Simoff, Harmeet Bedi, and Bianka Eperjesiova	
<b>41</b>	<b>Hemoptysis, Endoscopic Management</b> . . . . .	713
	Rosa Cordovilla and Juan Alejandro Cascón	

---

**Part VIII Interventional Pulmonary Medicine – History  
And Future Perspective**

**42 History of Bronchoscopy – The Evolution  
of Interventional Pulmonology . . . . . 733**  
Tanmay S. Panchabhai, Michael Ghobrial, and Atul C. Mehta

**Index. . . . . 747**

---

## About the Editors



**José Pablo Díaz-Jiménez, MD, PhD**, is a Pulmonary Physician, dedicated to Interventional Pulmonology (IP) for more than 35 years. He trained as a Pulmonary Physician at Bellvitge University Hospital in Barcelona, Spain, and then he completed his interventional training with Dr. Dumon at Marseille (France) and Dr. Cortese at the Mayo Clinic, Rochester, Minnesota (USA).

He was Head of the Interventional Pulmonary Department at Bellvitge University from 1991, organizing training programs, international courses, and congresses in Interventional Pulmonology for more than 25 years. He is Adjunct Professor, Department of Pulmonary Medicine-Research, at the MD Anderson Cancer Center, Houston, Texas (USA).

He is recognized as one of the leaders of IP around the world. He is Former Chairman of the World Association for Bronchology and Interventional Pulmonology (WABIP) and Former President of the World Bronchology Foundation (WBF). He is also recipient of Dumon Award and Killian Centenary Medal for the World Association for Bronchology and Interventional Pulmonology (WABIP).

**Alicia N. Rodríguez, MD**, has been a Pulmonary Physician for more than 20 years. She trained in Internal Medicine and then completed her training in Pulmonary Medicine with Dr. Beamis at the Lahey Clinic in Burlington, MA (USA), and Interventional Pulmonary Medicine with Dr. Díaz-Jiménez at Bellvitge University Hospital in Barcelona (Spain). She settled in Mar del Plata (Argentina), where she became Head of the Pulmonary and Respiratory Endoscopy Department in Clínica Colón. She has taken part in many multicentric research projects and is also

performing independent research and teaching at the University of Mar del Plata Medical School.

She belongs to many scientific societies, such as the Argentinian Association of Respiratory Medicine (AAMR), the Argentinian Association of Bronchoesophagology (AABE), and Women in Interventional Pulmonology (WIIP).

She is a respected Senior Pulmonary Consultant, well known for both her academic work and dedication to her patients.

---

## Contributors

**Juan Antonio Moya Amorós** Department de Ciències Clínicas, Hospital Universitari de Bellvitge, Hospitalet de Llobregat, Barcelona, Spain  
Thoracic Surgery Department, Hospital Univeritari de Bellvitge, Hospitalet de Llobregat, Barcelona, Spain

**A. Christine Argento** Department of Medicine, Northwestern Memorial Hospital/Northwestern University, Chicago, IL, USA

**Harmeet Bedi** Stanford University, Stanford, CA, USA

**Michela Bezzi** Pneumologia a Indirizzo Endoscopico, ASST Spedali Civili di Brescia, Brescia, Italy

**Semra Bilaceroglu** Izmir Faculty of Medicine, Dr. Suat Seren Training and Research Hospital for Thoracic Medicine and Surgery, University of Health Sciences, Izmir, Turkey

**António Bugalho** Pulmonology Department, CUF Tejo Hospital and CUF Descobertas Hospital, Lisbon, Portugal

Comprehensive Health Research Centre, Chronic Diseases Research Center (CEDOC), NOVA Medical School, Lisbon, Portugal

**Sergi Call** Thoracic Surgery Service, Hospital Universitari Mútua Terrassa, University of Barcelona, Terrassa, Spain

Department of Morphological Sciences, Medical School, Autonomous University of Barcelona, Bellaterra, Spain

**Roberto F. Casal** Department of Pulmonary Medicine, The University of Texas M.D. Anderson Cancer Center, Houston, TX, USA

The University of Texas MD Anderson Cancer Center, Houston, TX, USA

**Juan Alejandro Cascón** Interventional Pulmonology Unit, Hospital Central de Asturias, Oviedo, Spain

**Henri G. Colt, MD, FAWM** University of California, Irvine, Orange, CA, USA

**Rosa Cordovilla** Interventional Pulmonology Unit, University Hospital of Salamanca, Salamanca, Spain

**Tarek Dammad** Houston Methodist, Houston, TX, USA

AdventHealth Orlando, Orlando, FL, USA

**José Pablo Díaz-Jiménez** Interventional Pulmonary Department, Hospital Universitari de Bellvitge, Hospitalet de Llobregat, Barcelona, Spain

**George A. Eapen** Department of Pulmonary Medicine, The University of Texas MD Anderson Cancer Center, Houston, TX, USA

**Bianka Eperjesiova** University of Florida, Health Shands Hospital System and VA, Gainesville, FL, USA

**Travis L. Ferguson** Department of Medicine, Division of Pulmonary and Critical Care, Allergy and Sleep Medicine, Medical University of South Carolina, Charleston, SC, USA

**Marta Díez Ferrer** Department of Respiratory Medicine, Hospital Universitari de Bellvitge, Hospitalet de Llobregat, Barcelona, Spain

**Claudia Freitas** Pulmonology Department, Centro Hospitalar e Universitário de São João and Faculty of Medicine, University of Porto, Porto, Portugal

**Laura K. Frye** Division of Pulmonary and Critical Care, University of Wisconsin, Madison, WI, USA

**Stefano Gasparini** Department of Public Health and Biomedical Sciences, Polytechnic University of Marche Region, Ancona, Italy

Pulmonary Diseases Unit, Department of Internal Medicine, Azienda “Ospedali Riuniti”, Ancona, Italy

**Michael Ghobrial** Department of Pulmonary Medicine, Respiratory Institute, Cleveland Clinic, Cleveland, OH, USA

**Christopher R. Gilbert** Thoracic Surgery and Interventional Pulmonology, Swedish Cancer Institute, Seattle, WA, USA

Center for Lung Research in Honor of Wayne Gittinger, Seattle, WA, USA

**Alberto A. Goizueta** Department of Pulmonary Medicine, The University of Texas MD Anderson Cancer Center, Houston, TX, USA

**Ana Gruss** ILD Unit, Department of Respiratory Medicine, Hospital Universitari de Bellvitge, Hospitalet de Llobregat, Barcelona, Spain

**Fernando Guedes** Pulmonology Department, Centre Hospitalier du Nord, Ettelbruck, Luxembourg

ICBAS, Instituto de Ciências Biomédicas Abel Salazar, Porto, Portugal

**Ileana Iftimia** Radiation Oncology, TUSM, Lahey Hospital and Medical Center, Burlington, MA, USA

**Bilal A. Jalil** Department of Pulmonary and Critical Care at West Virginia, University School of Medicine, Morgantown, West Virginia, US

Heart and Vascular Institute, West Virginia University, Morgantown, WV, USA

**Carlos A. Jiménez** Department of Pulmonary Medicine, The University of Texas MD Anderson Cancer Center, Houston, TX, USA

- Enambir Josan** The Ohio State University Hospital, Columbus, OH, USA
- Danai Khemasuwan** Pulmonary and Critical Care Division, Virginia Commonwealth University, Richmond, VA, USA
- Stephen Lam** Cancer Imaging Unit, Integrative Oncology Department, British Columbia Cancer Agency Research Centre and the University of British Columbia, Vancouver, BC, Canada
- Rosa López Lisbona** Bronchoscopy and Interventional Pulmonology Unit, Department of Respiratory Medicine, Hospital Universitari de Bellvitge, Hospitalet de Llobregat, Barcelona, Spain
- Anna Ureña Lluveras** Departament de Ciències Clíiques, Hospital Universitari de Bellvitge, Hospitalet de Llobregat, Barcelona, Spain
- Elizabeth S. Malsin** Department of Medicine, Northwestern Memorial Hospital/Northwestern University, Chicago, IL, USA
- Marta Marín** Pulmonary Medicine Service, Hospital Clinico-Universitario Lozano Blesa, Zaragoza, Spain
- Atul C. Mehta** Lerner College of Medicine, Buoncore Family Endowed Chair in Lung Transplantation, Respiratory Institute, Cleveland Clinic, Cleveland, OH, USA  
Department of Pulmonary Medicine, Respiratory Institute, Cleveland Clinic, Cleveland, OH, USA
- Rachid Tazi Mezalek** Bronchoscopy Unit and Interventional Pulmonology, Hospital Universitari Germans Trias i Pujol, Barcelona, Spain  
Gerència Metropolitana Nord, Institut Català de la Salut, Barcelona, Spain
- Gaëtane C. Michaud** Pulmonary, Critical Care and Sleep Medicine, University of South Florida, Tampa, FL, USA
- Teruomi Miyazawa** Division of Respiratory and Infectious Disease, Department of Internal Medicine, St Mariana University School of Medicine, Kawasaki, Kanagawa, Japan
- María Molina-Molina** ILD Unit, Department of Respiratory Medicine, Hospital Universitari de Bellvitge, Hospitalet de Llobregat, Barcelona, Spain
- Rodolfo F. Morice** Department of Pulmonary Medicine, The University of Texas M.D. Anderson Cancer Center, Houston, TX, USA
- Septimiu Dan Murgu** The University of Chicago Medicine, Chicago, IL, USA
- Tejaswi R. Nadig** Department of Medicine, Division of Pulmonary and Critical Care, Allergy and Sleep Medicine, Medical University of South Carolina, Charleston, SC, USA
- Takahiro Nakajima** Department of General Thoracic Surgery, Dokkyo Medical University, Mibu, Tochigi, Japan

**Hiroki Nishine** Division of Respiratory and Infectious Disease, Department of Internal Medicine, St Mariana University School of Medicine, Kawasaki, Kanagawa, Japan

**KeriAnn Van Nostrand** Pulmonary, Critical Care and Sleep Medicine, University of South Florida, Tampa, FL, USA

**Hamid Pahlevaninezhad** Cancer Imaging Unit, Integrative Oncology Department, British Columbia Cancer Agency Research Centre and the University of British Columbia, Vancouver, BC, Canada

**Tanmay S. Panchabhai** Norton Thoracic Institute, St. Joseph's Hospital and Medical Center, Phoenix, AZ, USA

**Jasleen Pannu** The Ohio State University Hospital, Columbus, OH, USA

**Ramón Rami-Porta** Thoracic Surgery Service, Hospital Universitari Mútua Terrassa, University of Barcelona, Terrassa, Spain

Network of Centres for Biomedical Research in Respiratory Diseases (CIBERES), Lung Cancer Group, Terrassa, Spain

**Alicia N. Rodríguez** School of Medicine, National University of Mar del Plata, Buenos Aires, Argentina

**Antoni Rosell** Hospital Universitari Germans Trias, Barcelona, Spain  
Gerència Metropolitana Nord, Institut Català de la Salut, Barcelona, Spain

**Anastasiia Rudkovskaia** Internal Medicine, Pulmonary and Critical Care Division, The University of Texas Southwestern Medical Center, Dallas, TX, USA

**Bruce F. Sabath** The University of Texas MD Anderson Cancer Center, Houston, TX, USA

**Pere Trias Sabrià** Bronchoscopy and Interventional Pulmonology Unit, Department of Respiratory Medicine, Hospital Universitari de Bellvitge, Hospitalet de Llobregat, Barcelona, Spain

**Mona Sarkiss** Department of Anesthesiology and Perioperative Medicine, The University of Texas MD Anderson Cancer Center, Houston, TX, USA  
Department of Pulmonary Medicine, The University of Texas MD Anderson Cancer Center, Houston, TX, USA

**Audra J. Schwalk** Internal Medicine, Pulmonary and Critical Care Division, The University of Texas Southwestern Medical Center, Dallas, TX, USA

**Luis M. Seijo Maceiras** Pulmonary Department, University Clinic, Navarra, Pamplona, Spain

**Sara Shadchehr** Interventional Pulmonology, TUSM, Lahey Hospital and Medical Center, Burlington, MA, USA

**Vickie R. Shannon** Department of Pulmonary Medicine, The University of Texas MD Anderson Cancer Center, Houston, TX, USA



**David Shore** Division of Pulmonary, Allergy, and Critical Care Medicine, Department of Medicine, Penn State Milton S. Hershey Medical Center, Hershey, PA, USA

**Gerard A. Silvestri** Department of Medicine, Division of Pulmonary and Critical Care, Allergy and Sleep Medicine, Medical University of South Carolina, Charleston, SC, USA

**Nathaniel Silvestri** Department of Pediatrics, The Johns Hopkins Hospital, Baltimore, MD, USA

**Michael Simoff** Department of Pulmonary and Critical Care Medicine, Bronchoscopy and Interventional Pulmonology, Henry Ford Hospital, Wayne State University, Detroit, MI, USA

**Vishal Singh, MD** Department of Critical Care Medicine At AdventHealth Orlando, Orlando, Florida, USA

**Sean Stoy** North Memorial Health, Robbinsdale, MN, USA

**Jennifer W. Toth** Division of Pulmonary, Allergy, and Critical Care Medicine, Department of Medicine, Penn State Milton S. Hershey Medical Center, Hershey, PA, USA

**Melissa Tukey** Pulmonary, Critical Care and Sleep Medicine, University of South Florida, Tampa, FL, USA

**Lonny B. Yarmus** Interventional Pulmonology, Division of Pulmonary Disease and Critical Care Medicine, The Johns Hopkins Hospital, Baltimore, MD, USA

**Kazuhiro Yasufuku** Division of Thoracic Surgery, Toronto General Hospital, University Health Network, University of Toronto, Toronto, Canada

**Ekaterina Yavarovich** Lahey Hospital & Medical Center, Pulmonary & Critical Care Medicine, Burlington, MA, USA

**Lina Zuccatosta** Pulmonary Diseases Unit, Department of Internal Medicine, Azienda “Ospedali Riuniti”, Ancona, Italy

**Javier J. Zulueta** Pulmonary, Critical Care, and Sleep Medicine, Icahn School of Medicine, Mount Sinai Morningside Hospital, New York, NY, USA

---

**Part I**

**Basic Bronchoscopy Procedures**



# Tracheobronchial Anatomy

# 1

Juan Antonio Moya Amorós  
and Anna Ureña Lluveras

## Trachea

### Introduction

The trachea or windpipe is a tube of approximately 12 cm length. Viewed laterally, it assumes an oblique course, running from superoanterior to inferoposterior, from 23° to 34° related to the body's major axis. It ends up by dividing into two bronchial tubes at the level of the tracheobronchial bifurcation, which usually has an angle of 60°. Changes in the degree of angulation can orient to diagnose some conditions located distally to the bifurcation such as enlarged lymph nodes, or left atrium dilatation in mitral stenosis. The tracheal tube extends from C6 to C7 (limited by the cricoid cartilage superiorly) to D4–D5, approximately at 1 or 2 cm below a horizontal plane passing through the Louis sternal angle. Topographically, its average length (12 cm as stated) is equally divided between the cervical and mediastinal region [1].

---

J. A. Moya Amorós (✉) · A. Ureña Lluveras  
Departament de Ciències clíniques, Hospital  
Univeritari de Bellvitge, Hospitalet de Llobregat,  
Barcelona, Spain  
e-mail: [jmoya@ub.edu](mailto:jmoya@ub.edu);  
[juan.moya@bellvitgehospital.cat](mailto:juan.moya@bellvitgehospital.cat);  
[aurena@bellvitgehospital.cat](mailto:aurena@bellvitgehospital.cat)

## External Morphology

The external tracheal configuration is characterized by the presence of roughness due to incomplete cartilage rings that are staggered, and horizontally and segmentally distributed. Usually 20 rings are identified in the trachea.

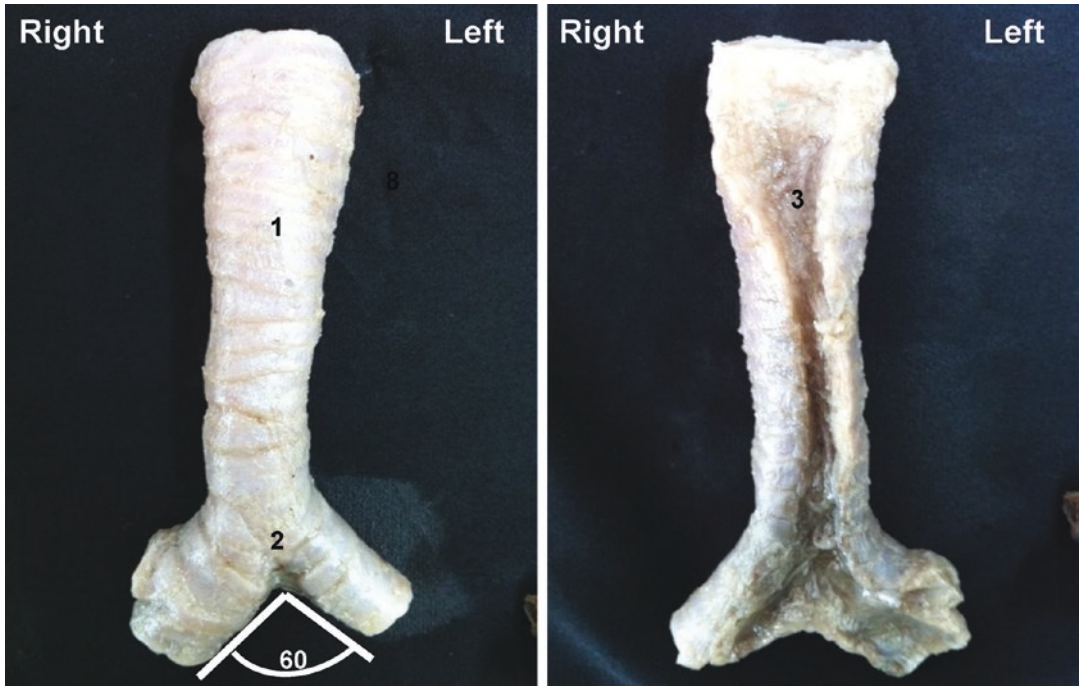In the cervical region, the tube has a flattened shape posteriorly, due to the absence of cartilage, so that the predominant diameter is sagittal or anteroposterior (approximately 16 mm), but inside the chest it predominates the transverse diameter (approximately 16 mm).

In the external tracheal wall, narrowing or depressions can be seen, produced by the imprint of organs in close proximity contacting the tracheal wall. In the left side, two of them are visible: one due to the left thyroid gland lobe (neck) and the other one due to the aortic arch (mediastinum).

The posterior membrane closing the entire tracheal canal is flat, soft, and depressible; it is known as the *membranous pars* (Fig. 1.1).

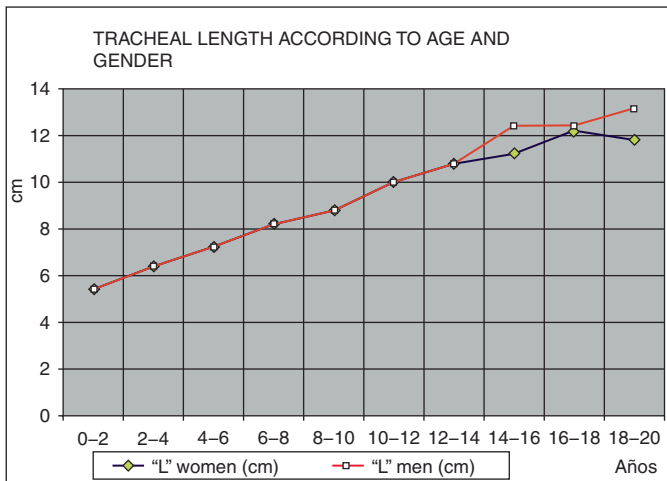
The special tracheal configuration and its elastic structure make it capable of elongating up to 1/3 of its length. This fact is of particular interest for tracheal reconstruction surgeries.

Dimensions of the trachea vary primarily according to age, and less so with gender. Figures 1.2, 1.3, 1.4, and 1.5 present the normal size variations in all three axes, internal size, area, and volume.



**Fig. 1.1** Anterior view of the dissected trachea. Note the tracheal bifurcation angle of 60°: (1) anterior view: trachea and tracheal cartilage; (2) tracheobronchial bifurcation; and

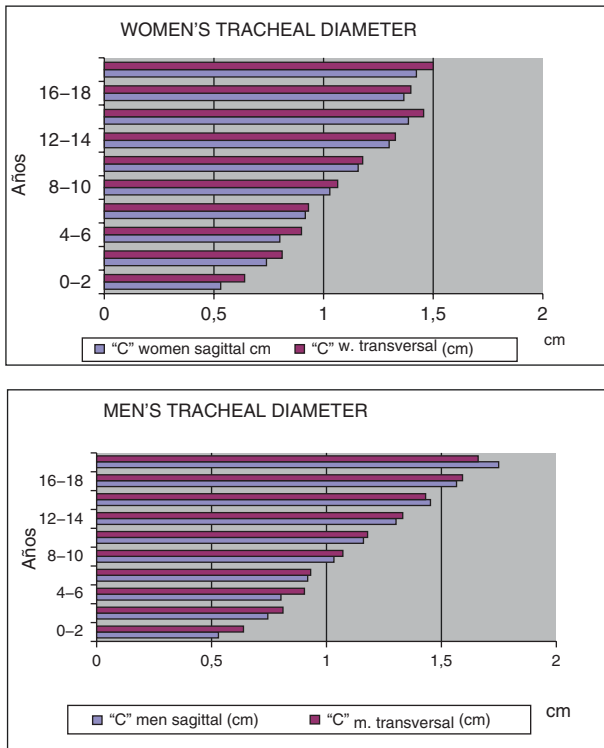
(3) membranous pars or tracheal muscle. Unit of Human Anatomy and Embryology, Department of Pathology and Experimental Therapeutics, Universitat de Barcelona



	"L" women (cm)	"L" men (cm)
0-2	5.4	5.4
2-4	6.4	6.4
4-6	7.2	7.2
6-8	8.2	8.2
8-10	8.8	8.8
10-12	10	10
12-14	10.8	10.8
14-16	11.2	12.4
16-18	12.2	12.4
18-20	11.8	13.1

Medium length of the trachea increases similarly in both genders until the age of 14. After that it only increases in men.

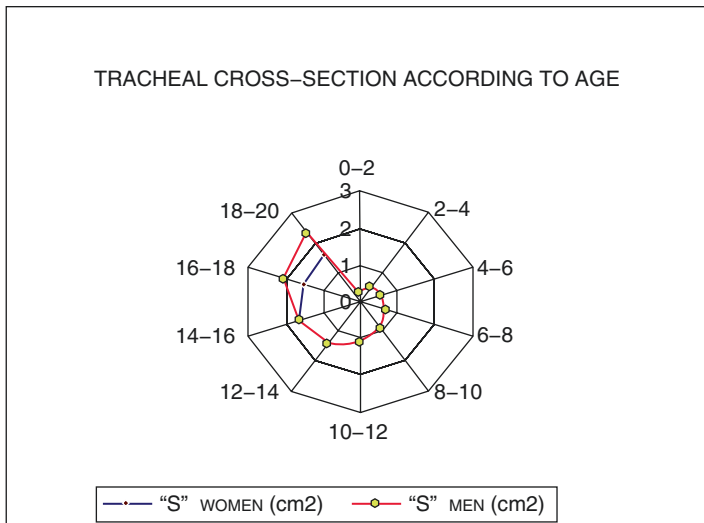
**Fig. 1.2** Medium length of the trachea increases similarly in both genders until the age of 14. After that it only increases in men



AGE in years	"C" sagittal women (cm)	"C" transv. women (cm)	"C" sagittal men (cm)	"C" transv. men (cm)
0-2	0.53	0.64	0.53	0.64
2-4	0.74	0.81	0.74	0.81
4-6	0.8	0.9	0.8	0.9
6-8	0.92	0.93	0.92	0.93
8-10	1.03	1.07	1.03	1.07
10-12	1.16	1.18	1.16	1.18
12-14	1.3	1.33	1.3	1.33
14-16	1.39	1.46	1.45	1.43
16-18	1.37	1.4	1.57	1.59
18-20	1.42	1.49	1.75	1.66

Medium tracheal diameter increases similarly in both genders until the age of 14. After that it only increases in men.

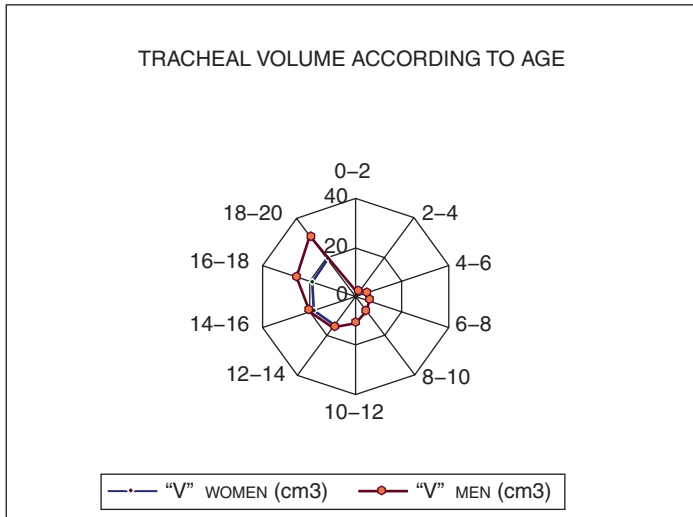
**Fig. 1.3** Medium tracheal diameter increases similarly in both genders until the age of 14. After that it only increases in men



AGE	"S" WOMEN (cm <sup>2</sup> )	"S" MEN (cm <sup>2</sup> )
0-2	0.28	0.28
2-4	0.48	0.48
4-6	0.58	0.58
6-8	0.69	0.69
8-10	0.89	0.89
10-12	1.1	1.1
12-14	1.39	1.39
14-16	1.62	1.62
16-18	1.54	2.01
18-20	1.59	2.3

- Medium tracheal area increases similarly in both genders until the age of 14.
- At age 20, tracheal area is 44.6% larger in men than in women.

**Fig. 1.4** Medium tracheal area increases similarly in both genders until the age of 14. At age 20, the tracheal area is 44.6% larger in men than in women



AGE	"V" WOMEN (cm <sup>3</sup> )	"V" MEN (cm <sup>3</sup> )
0-2	1.57	1.57
2-4	3.11	3.11
4-6	4.16	4.16
6-8	5.67	5.67
8-10	7.87	7.87
10-12	11.1	11.1
12-14	15.4	15.4
14-16	18.2	20.2
16-18	18.8	25.1
18-20	18.9	30.3

- Medium tracheal volumen increases similarly in both genders until the age of 14
- By age 20, men's tracheal volume is 60% larger than in women's.

**Fig. 1.5** Medium tracheal volume increases similarly in both genders until the age of 14. By age 20, men's tracheal volume is 60% larger than women's

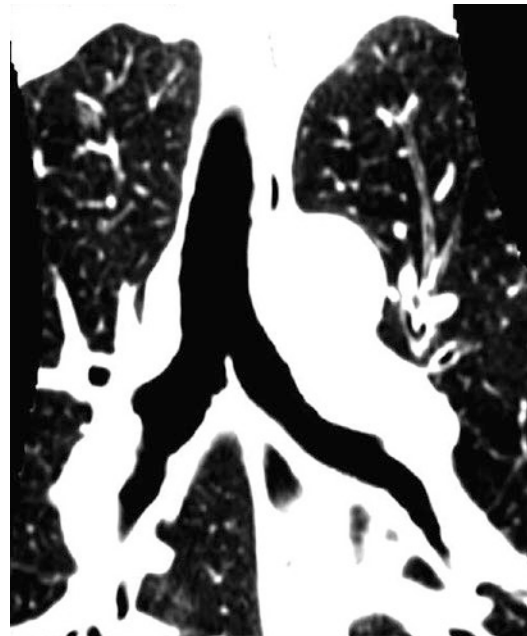
Among both genders, there are also differences in tracheal size, especially in the sagittal and transverse axes, which are evident in tomographies and three-dimensional (3D) reconstruction (Figs. 1.6 and 1.7).

## Internal Morphology

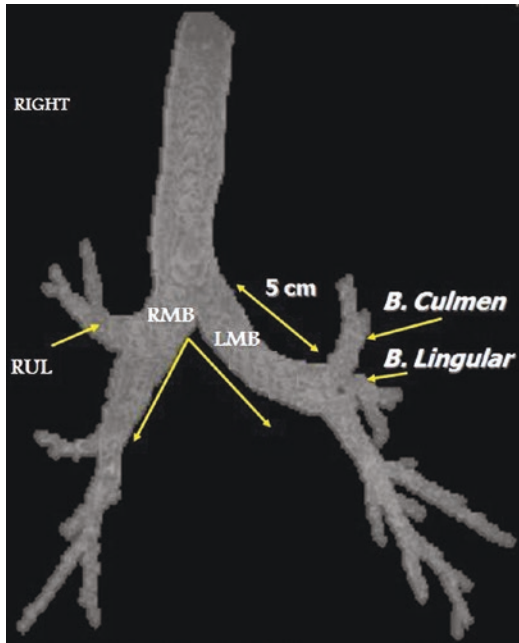
The tracheal tube has two covers or layers:

**Main, Fibro-Chondro Elastic Layer** It is a completely circular, soft, and elastic connective tissue fundamental matrix. It affects the entire circumference of the windpipe. It presents tiny holes that represent the point of vascular entrance or exit to and from inside the trachea.

Enclosed to this layer there are bands of incomplete hyaline cartilage rings, horseshoe-shaped. The cartilage forms about four-fifths of the circumference of the trachea. Given that the posterior border of the trachea is formed by a fibromuscular membrane, the tracheal cross-



**Fig. 1.6** At age 20, men's sagittal and transverse tracheal axes are 23% and 11.4% larger than women's, respectively. Coronal computerized tomography: view of mediastinal trachea, tracheobronchial bifurcation, and main bronchi



**Fig. 1.7** Medium tracheal diameter is 1.5 mm larger in men than in women. Medium bronchial diameter is 1 mm larger in men. Two-dimensional (2D) tomographic reconstruction of the tracheobronchial tree. Note that the intracardinal angle is 60°. Lengths are 5 cm for the left main bronchus, and 2.5 cm for the right main bronchus

sectional shape is similar to a letter D, with the flat side located posteriorly. These are known as the tracheal muscles, and have vegetative involuntary innervation. The tracheal muscles cross transversely and obliquely, forming continuous entangled fibers that constitute a large muscle: the common tracheal muscle. Contraction of this muscle produces adduction of the free cartilage edges, thus modulating the internal tracheal caliber. Wrapping the outer tracheal tube, we found the adventitia, a membrane that acts as a false pretracheal fascia. Between the adventitia and the tracheal wall vascular and nervous branches are located, and they incorporate to the tracheal tube wall at the level of the interchondral spaces.

### Mucous Layer

The trachea is lined by pseudostratified columnar epithelium that sits in an elastic *lamina propria*, and covers the inside of the tracheal tube. Goblet

mucous cells and small subepithelial glands that secrete into the luminal surface are interspersed among the ciliated columnar cells. The produced mucus adheres to inhaled foreign particles, which are then expelled by the action of cilia propelling the mucus lining upward toward the pharynx from which they can be coughed and sneezed out of the airway. At the end of the tracheal duct, when it is divided into the main bronchi, the mucosa presents a middle-line elevation known as carina, similar to a medial ridge. The tracheal carina indicates the entrance to the right and left main bronchi (Fig. 1.8a–c).

### Blood Supply

Arterial blood supply is established by two arterial systems on each side of the trachea, communicating the aorta artery with the subclavian artery:

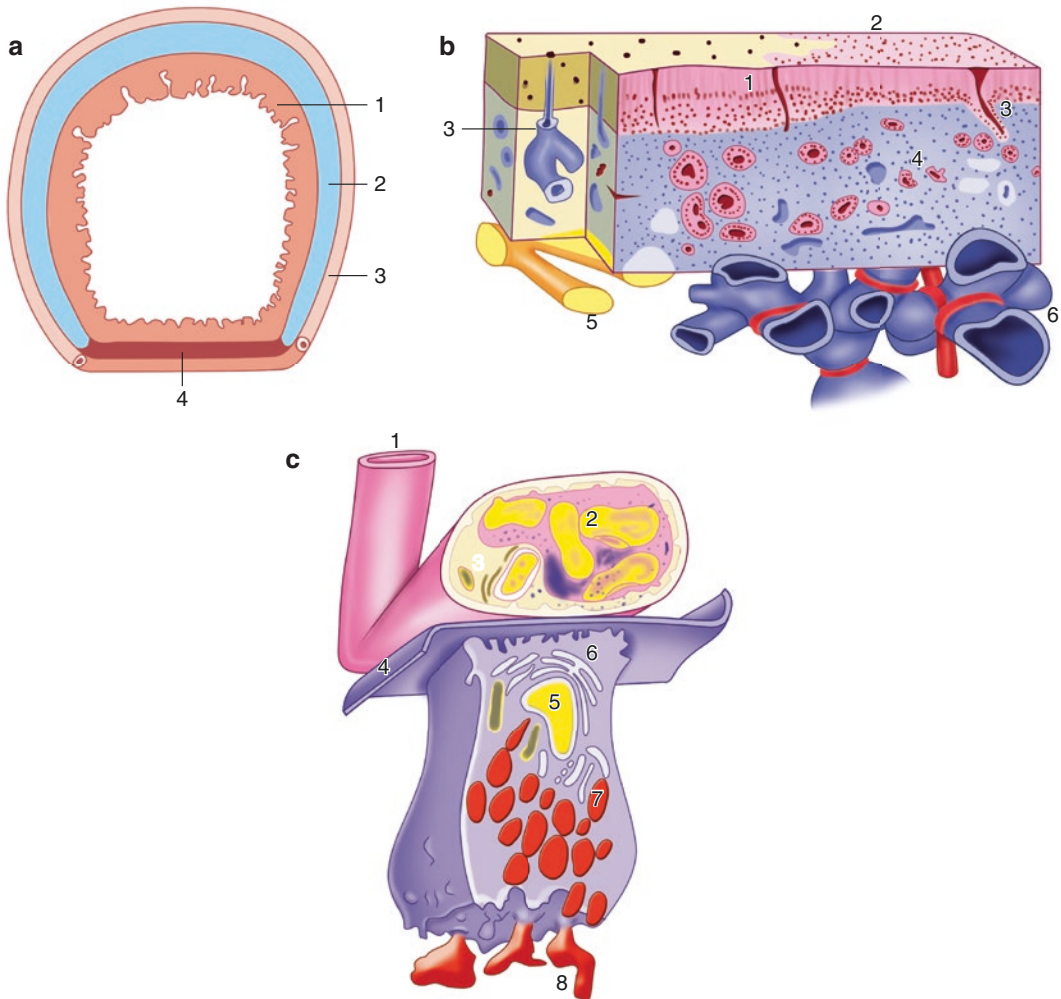
- From the aorta, originates the left paratracheal ascending artery (Demel arteries) and the tracheobronchial esophageal artery. Of the latter, the right bronchial artery, the esophageal artery, and the right paratracheal ascending artery are born.
- From both subclavian arteries, inferior thyroid arteries emerge and from these in turn emerge the right and left paratracheal descending arteries (Haller arteries).

Each paratracheal descending artery anastomoses with the paratracheal ascending artery of the corresponding side, closing the vascular circuit at the back of the tracheal wall and along its side edges. From these two vascular axes, tracheal perforating arteries are born that supply tracheal layers entering through the interchondral spaces.

### Anatomo-Clinical Relationships

The trachea is related to their surroundings through the peri-tracheal fascia, as if it were a hanger between the neck and the mediastinum [2]. Vascular and nerve structures are hung from or are in contact with it.





**Fig. 1.8** (a) Cross-section, trachea: (1) respiratory cylindrical epithelium and mucous glands; (2) horseshoe-shaped cartilage with a posterior opening; and (3) main layer, connective tissue fundamental matrix, surrounded by the adventitia. (b) Schematic illustration of the elements of the tracheal wall: (1) Pseudostratified columnar

epithelium; (2) gland drainage orifice; (3) gland duct; (4) submucosa; (5) vagus nerve; and (6) venules and arterioles. (c) Tracheal mucous gland: (1) arteriole; (2) erythrocyte; (3) endothelial cell; (4) basement membrane; (5) Golgi apparatus of a Goblet cell; (6) endoplasmic reticulum; (7) vacuole; and (8) mucus secretion

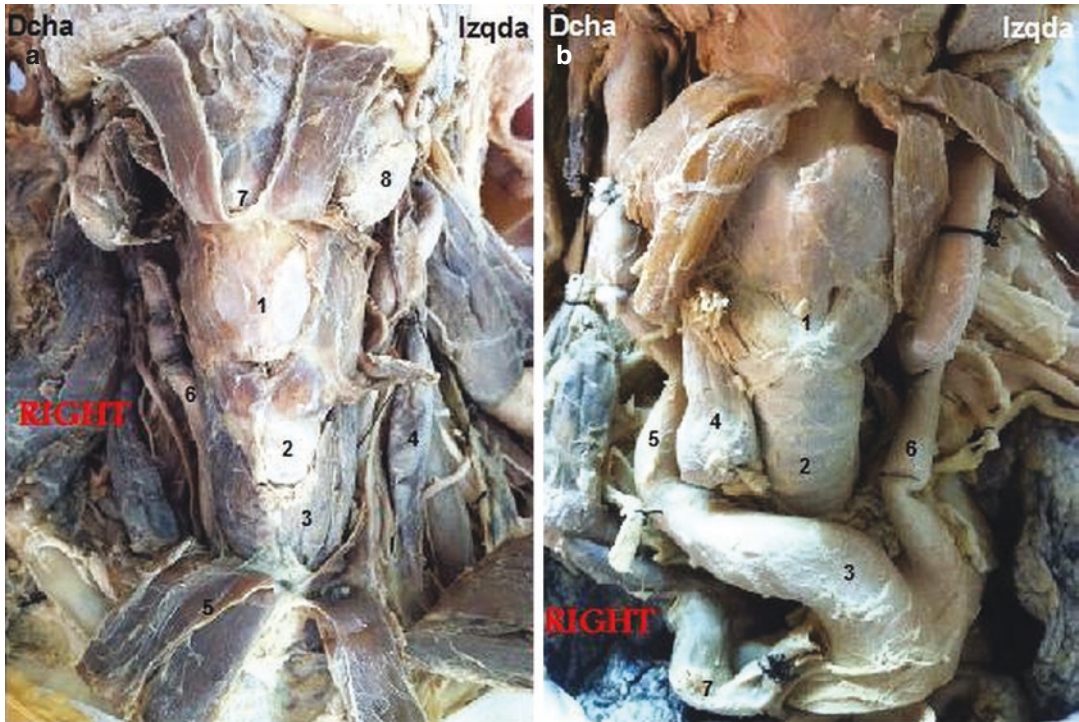
Regardless of the anatomical details, the tracheal relationships from inside out are:

- Posterior: recurrent nerve, esophagus, and vertebral bodies covered by deep cervical aponeurosis
- Anterior: thyroid gland, medium cervical aponeurosis, anterior jugular veins, and superficial cervical aponeurosis

- Lateral: thyroid gland, vessels and nerves, deep cervical aponeurosis, and superficial cervical aponeurosis (involving the sternocleidomastoid and trapezius muscles; Fig. 1.9a, b)

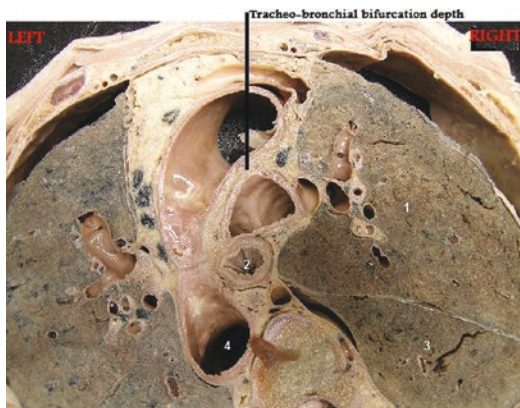The tracheobronchial bifurcation has similar topographical relationships in both genders, and it is located 7 cm deep from the skin of the anterior midline chest (Figs. 1.10 and 1.11).





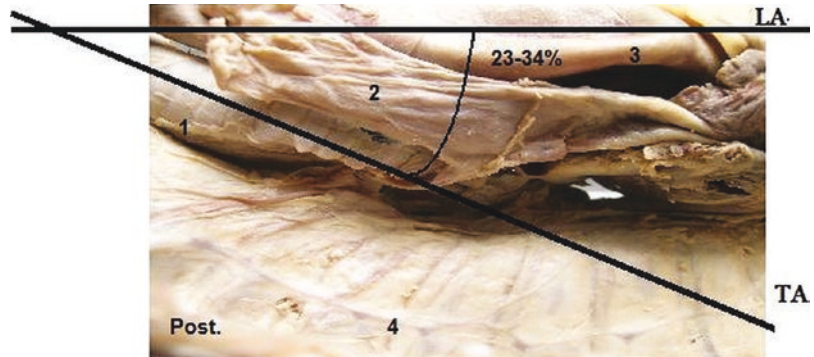
**Fig. 1.9** (a) Dissection of the cervical trachea: (1) larynx; (2) trachea; (3) left thyroid lobe; (4) left internal jugular vein; (5) right infrahyoid muscles; (6) right common carotid artery; (7) hyoid bone; and (8) left submandibular gland. (b) Dissection of the cervical trachea: (1) larynx; (2) trachea; (3) brachiocephalic arterial trunk; (4)

right internal jugular vein; (5) right common carotid artery; (6) left common carotid artery; and (7) left venous brachiocephalic trunk or innominate trunk. Unit of Human Anatomy and Embryology, Department of Pathology and Experimental Therapeutics, Universitat de Barcelona



**Fig. 1.10** Cranial view of thoracic cross-section at the level of D4. Note the location of the tracheobronchial bifurcation at a depth of 7 cm from the surface: (1) right upper lobe; (2) thoracic esophagus; (3) right lower lobe; and (4) descending thoracic aorta. Unit of Human Anatomy and Embryology, Department of Pathology and Experimental Therapeutics, Universitat de Barcelona

**Fig. 1.11** Right lateral view of mediastinum: TA tracheal axis; LA long axis of the body. (1) Trachea; (2) superior vena cava; (3) ascending aorta; and (4) dorsal spine. Unit of Human Anatomy and Embryology, Department of Pathology and Experimental Therapeutics, Universitat de Barcelona



## Bronchi

### Main Bronchi

Main bronchi are located in a compartment known as the mediastinum. The mediastinum is delimited by the pleural cavity. This space does not have a regular shape (mediastinum = “servant” or “heart and major vessels service area”). There are two main bronchi, left and right. Each main bronchus is related to some elements of the mediastinum and they are not equal in length or size.

**Left main bronchus (LMB)** is 5 cm in length. It is longer than the right main bronchus (RMB), passing beneath the aortic arch and the left pulmonary artery.

**Right main bronchus** is 2.5 cm in length. It is more vertical than the left bronchus and has a bigger diameter.

Inside the lung parenchyma, both bronchi will continue dividing into branches to the 24th order (Fig. 1.12).

### Bronchial Division

#### Left Main Bronchus (LMB)

- **Left upper lobe bronchus:** It divides into:
  - *Apicoposterior segmental bronchus (B1 + 2)*, from where B1 (Apical) and B2 (dorsal or posterior) bronchi are born

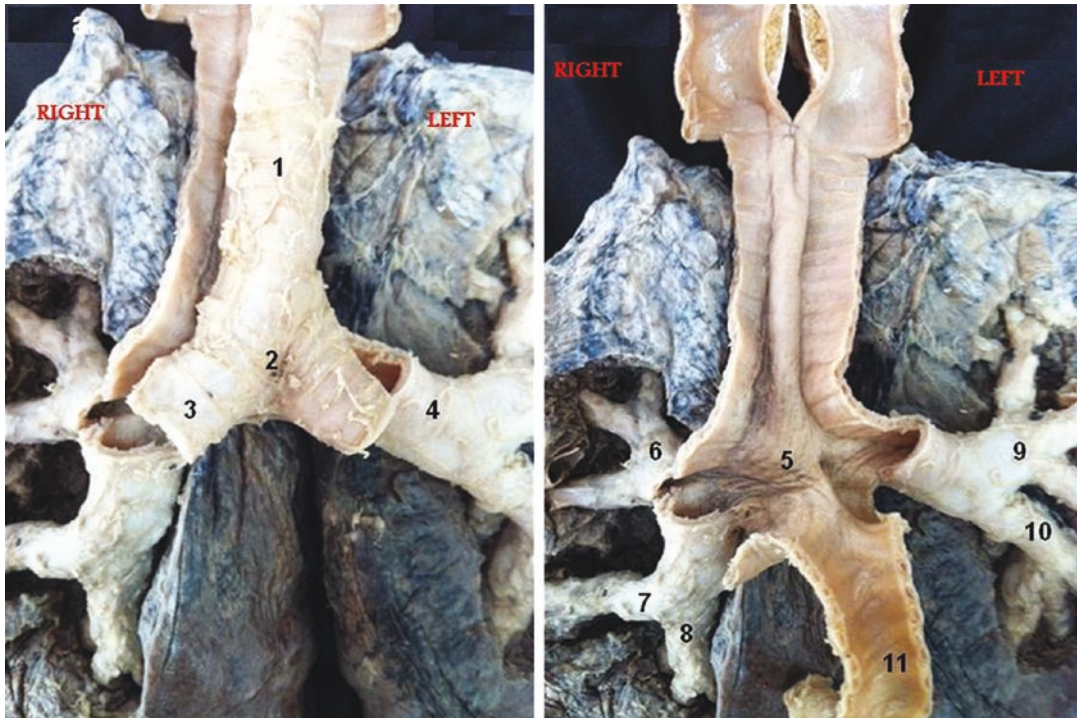
- *Anterior- or ventral-segmental bronchus (B3)*
- *Lingular bronchus*, divided into *superior lingular segmental bronchus (B4)* and *inferior lingular segmental bronchus (B5)*
- **Left lower lobe bronchus:** It divides into:
  - *Apical segmental bronchus*, which forms the *left lower lobe* or *Nelson’s bronchus (B6)*
  - *Posterior or dorsal bronchus (B10)*
  - *Lateral bronchus (B9)*
  - *Trunk (B7 + 8)* or *ventromedial bronchus*, from which *B7 (medial)* and *B8 (ventral)* originate

#### Right Main Bronchus (RMB)

- **Right upper lobe bronchus:** It divides into:
  - *Apical segmental bronchus (B1)*
  - *Anterior or ventral segmental bronchus (B3)*
  - *Dorsal segmental bronchus (B2)*
- **Right middle lobe bronchus:** It divides into:
  - *Medial segmental bronchus (B5)*
  - *Lateral segmental bronchus (B4)*
- **Right lower lobe bronchus:** It divides into:
  - *Apical bronchus of the right lower lobe (Nelson’s bronchus) (B6)*
  - *Posterior or dorsal bronchus (B10)*
  - *Lateral bronchus (B9)*
  - *Anterior bronchus (B8)*
  - *Paramediastinic bronchus (B7)*

The right main bronchus, after the superior lobe bronchus departure, is called *intermedius bronchus*. The intermedius bronchus after approximately 15 mm originates from the right middle lobe bronchus. From that on it is called the *right lower lobe bronchus*.





**Fig. 1.12** Tracheobronchial bifurcation. Notice in the image on the right a tracheal cross-section with anterior inclination of its ventral side: (1) trachea; (2) tracheobronchial bifurcation; (3) right main bronchus; (4) left main bronchus; (5) bronchial carina; (6) right upper lobe bronchus; (7) right

middle lobe bronchus; (8) right lower lobe bronchus; (9) left upper lobe bronchus; (10) left lower lobe bronchus; and (11) inner wall of the anterior trachea. Unit of Human Anatomy and Embryology, Department of Pathology and Experimental Therapeutics, Universitat de Barcelona

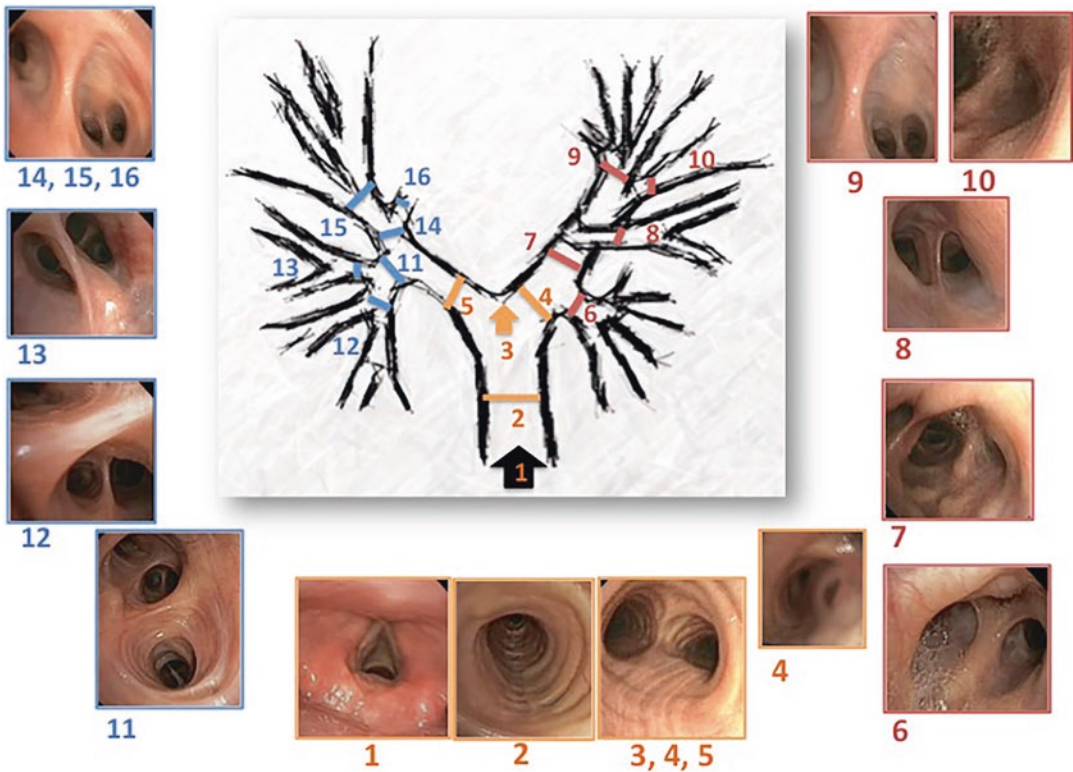
Each bronchial division is accompanied by the corresponding segmental pulmonary artery, giving place to the different bronchopulmonary segments.

### Endoscopic Vision of the Bronchial Tree and Anatomical Relationships

It is very important to learn the normal endoscopic view of the airways and keep in mind the anatomical relationships. Figure 1.13 depicts the tracheobronchial tree when inspected with a bronchoscope, with the patient in the supine position and the endoscopist located posteriorly. The camera is moving down from head to feet.

The most important anatomic relationships we have to consider are:

- **Cervical trachea:** Anteriorly, the thyroid gland is located at the level of the second, third, and fourth tracheal rings. Thyroid lobes are in contact with the side walls of the cervical trachea. The veins that drain the thyroid gland are located at the bottom, and head to the left innominate vein. In general these veins are arranged along the tracheal wall and do not constitute a serious hazard. The same occurs for the left innominate vein, which is located in front of the trachea behind the sternal manubrium. Bifurcation of the arterial brachiocephalic trunk is in close contact with the windpipe at the base of the neck, and the main right carotid artery is located right in front of cervical trachea. From behind, the cervical trachea is in close contact with the esophagus, which is slightly more to the left. The right



**Fig. 1.13** Endoscopic vision of the bronchial tree: (1) vocal cords; (2) trachea; (3) carina; (4) right main bronchus; and (5) left main bronchus. **Right:** (6) right upper lobe bronchus—three apical segments; (7) intermediate bronchus; (8) middle lobe bronchus; (9) basal pyramid; and (10) six right segment bronchus. **Left:** (11) left upper lobe bronchus; (12) Culmen bronchus; (13) lingular bronchus; (14) left lower lobe bronchus; (15) basal pyramid; and (16) six left segment bronchus

recurrent nerve meets the sixth-level windpipe cartilage ring, running parallel to its rear edge. The left recurrent nerve, coming from below the aortic arch, runs along the posterior tracheal wall in front of the esophagus. Laterally, apart from the thyroid gland, cervical trachea is close to the neurovascular structures of the neck (common carotid artery, internal jugular vein, vagus nerve). From the base of the neck these structures deviate from the windpipe. Only the common carotid artery is in virtual contact with the outer edge of the trachea. The internal jugular vein and vagus nerve are more superficial.

- Thoracic trachea: As already explained, the thoracic trachea is a bit longer than the cervical trachea, and has close contacts with the

large vessels of the mediastinum. The danger of massive bleeding at this level is very high. The most important anterior anatomical relationships are vascular. The venous system includes the left innominate vein, right innominate vein, and superior vena cava (which is located below and to the right of the windpipe). The azygos vein is located at the level of the right edge of the windpipe. Important arterial structures are in close contact with the trachea: the aortic arch passes directly from front to back and right to left along the left edge of the trachea, generating a mark on it and deviating it to the right. Then the aorta is curved on the left main bronchus and descends along the column. The arterial brachiocephalic trunk is born in front of the windpipe and

crosses obliquely to stand on its right edge. The left common carotid artery relates to the left edge of the windpipe, but is farther away, like the left subclavian artery, so it does not constitute a danger. The left vagus nerve descends along with the common carotid artery, crossing the left side of the aortic arch, generating the left recurrent nerve that ascends along the left edge of the trachea and the esophagus. On the back, the thoracic trachea continues in close contact with the esophagus that descends to the stomach and moves away to the left.

- **Carina:** At its inferior part, the trachea is divided into right and left main bronchi, looking like an inverted Y. The divergence angle thus formed is 70°. The carina has important neurovascular connections. Anteriorly to it, the pulmonary artery divides into right and left branches. Also anteriorly and to the right, we find the union of the azygos vein and the superior vena cava. Anteriorly and to the left, the carina is in contact with the aortic arch and the left recurrent nerve. Posteriorly, the carina also remains in contact with the esophagus.
- **Main right bronchus:** The most important vascular connection of the main right bronchus is the right pulmonary artery, which crosses horizontally and anteriorly of the ascending aorta and the superior vena cava, before passing in front of right main bronchus. The pulmonary vein is located slightly below the artery, but not in direct contact with the bronchi. This is very important to know because the use of lasers, for instance, is less dangerous when applied in the main right bronchus than in the left. For the rest, vascular distribution is practically superimposed on the bronchial tree, being parallel to the bronchial walls. Veins are more remote from the walls than the arteries, except in the inner edge of the middle and lower lobes, where they constitute a real danger during invasive procedures.
- **Main left bronchus:** The main left bronchus has a more horizontal path than the main right bronchus, and is also longer and thinner. It has important vascular relations—the aortic arch

is in contact with the superior and posterior aspects of it. Anteriorly, the aorta is separated from the bronchus by the main pulmonary artery.

The left pulmonary artery is short and its path is oblique, up, and backward to the origin of the left upper lobe bronchus. It depicts an “S” curve that wraps around the left main bronchus and then around the left upper lobe bronchus. The superior pulmonary veins cross the main left bronchus at the level of the origin of the upper lobe bronchus. The esophagus is posterior, in contact with the first few centimeters of the left main bronchus.

At the level of the main left bronchus, dangers are more numerous than the main right one, mainly due to the proximity of the aortic arch and pulmonary artery and veins. In the rest of the left bronchial tree, arteries are parallel to the bronchial walls.

## Blood Supply

Bronchial arterial supply depends upon the bronchial arteries, which are aortic branches. These bronchial arteries are small in size and are located at the posterior wall of the bronchus following the first bronchial divisions [3]. Bronchial arteries can be divided into:

- Right bronchial artery
- Left superior bronchial artery
- Left inferior bronchial artery

We can also see the *Demel artery* and the *Tracheobroncho-esophageal artery*, both aortic branches. The latter will divide into three more branches:

- *Ascending tracheal artery*
- *Esophageal artery*
- *Right bronchial artery*—it is a single artery located at the posterior bronchial wall that will be divided into two bronchial branches each time it finds a bronchial division.

There are anastomoses between arteries on each side, which close the territory between the left and right bronchial arteries.

---

## References

1. Chevrel JP. La trachée. In: Chevrel JP, Barbin JY, Bastide G, Bécue J, Bouchet A, Cabrol C, et al., editors. *Le Tronc (2). Anatomie Clinique*. Paris: Springer; 1994. p. 213–6. ISBN 2-287-00026-7.
2. Ugalde P, Miro S, Fréchette E, Deslauriers J. Correlative anatomy for thoracic inlet; glottis and subglottis; trachea, carina, and main bronchi; lobes, fissures, and segments; hilum and pulmonary vascular system; bronchial arteries and lymphatics. *Thorac Surg Clin*. 2007;17(4):639–59. Review.
3. Fréchette E, Deslauriers J. Surgical anatomy of the bronchial tree and pulmonary artery. *Semin Thorac Cardiovasc Surg*. 2006;18(2):77–84. Review.



# Flexible Bronchoscopy

# 2

Tarek Dammad, Vishal Singh, and Bilal A. Jalil

## Introduction

Flexible bronchoscopy (FB) describes the invasive, direct visualization of the airways via a flexible bronchoscope for diagnostic and therapeutic purposes. It is a safe procedure, usually performed by pulmonologists and thoracic surgeons to inspect the proximal and distal airways and perform diagnostic and therapeutic procedures in the airways and lung parenchyma. Its ease of use, minimal sedation requirement, and great safety profile account for its preference over more invasive alternatives [1, 2].

The uses and applications of FB have evolved over the last 50 years to various diagnostic and therapeutic modalities. This chapter will review the history of FB, its indications, and contraindications, and describe the procedure and its basic and advanced diagnostic and therapeutic techniques.

---

T. Dammad (✉)  
Houston Methodist, Houston, TX, USA

V. Singh  
Department of Critical Care Medicine At  
AdventHealth Orlando, Orlando, Florida, USA

B. A. Jalil  
Department of Pulmonary and Critical Care at West  
Virginia University School of Medicine,  
Morgantown, West Virginia, USA

## History

The history of exploring human airways dates back to Hippocrates. Hippocrates mentioned, “cannulas should be carried into the throat along the jaws so that air may be drawn into the lungs.” Internet.


However, it was not until 1897 when Gustav Killian in Freiburg, Germany, performed the first rigid bronchoscopy, examining the larynx and trachea to extract a pork bone from the right main-stem bronchus of a farmer. He then presented his experience in Heidelberg, Germany, branding it “direct bronchoscopy.” Gustav Killian is regarded today as the Father of Bronchoscopy [3].

Rigid bronchoscopy remained the standard practice for the next 70 years until Shigeto Ikeda, a thoracic surgeon from Tokyo, Japan, introduced the first prototype flexible fiberoptic bronchoscope in Copenhagen in 1966 [4] (Fig. 2.1).

The first commercially available flexible bronchoscope was manufactured by Machida in 1968 and comprised over 15,000 glass fibers. Further revisions and improvements by Machida and Olympus allowed an enhanced working channel, image quality, and maneuverability.

The invention of the flexible bronchoscope represented a paradigm shift in bronchoscopy. It was easier to perform than rigid bronchoscopy and allowed superior visualization of the distal airways. It continued to evolve with extensive technical and clinical applications.





**Fig. 2.1** Dr. Shigeto Ikeda, Surgeon at the National Cancer Center, Japan, 1977. (Photography: Burt Glinn Magnum Photos)

With Ikeda's contribution, Pentax produced the first video-flexible bronchoscope in 1987, where a miniature video camera at the tip of the bronchoscope replaced the fiber optic bundle, allowing for the bronchoscopy team to watch the procedure on a screen with tremendous definition and record it for documentation and educational purposes [5].

A second paradigm shift occurred with the introduction of endobronchial ultrasound (EBUS) bronchoscopy, another form of flexible bronchoscopy.

The usefulness of radial probe (RP)-EBUS was first reported by Hurter and Hanrath in 1992. They studied 74 patients with central tumors and 26 patients with peripheral carcinomas [6]. In 1996, Heinrich Becker demonstrated the great

potential of EBUS in assessing tumor infiltration of the bronchial wall and parabronchial structures, including lymph nodes [7].

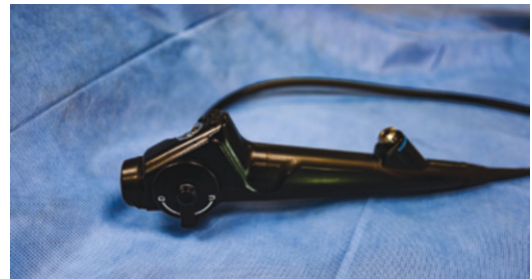In the early 2000s, Yasufuku and colleagues were the first to describe the high diagnostic yield of convex probe EBUS, enabling real-time visualization and sampling of the mediastinal, hilar adenopathy, and central lesions, changing how we diagnose and stage lung cancer forever [8, 9].

Significant technological innovations over the last few decades such as light amplification by stimulated emission of radiation (LASER) therapy, argon plasma coagulation (APC), transbronchial cryobiopsy, and electromagnetic navigational bronchoscopy (ENB) were specifically developed and designed to use with the flexible bronchoscope [10]. Finally, a significant innovation in the field of flexible bronchoscopy has emerged called robot-assisted bronchoscopy that we will discuss in a separate chapter of this book [11].

## Description

The flexible bronchoscope constitutes a flexible hollow vinyl tube called the "insertion tube" containing optical fibers and a longitudinal working channel for suction and ancillary instruments.

The proximal handle contains a control lever to maneuver the distal end of the scope and control buttons for the camera and suction (Fig. 2.2).



**Fig. 2.2** The bronchoscope handle with the control lever at the proximal end and working channel insertion point at the distal end



There are two light-transmitting bundles and one viewing bundle. Each bundle contains up to 30,000 ultrafine glass fibers (8–15  $\mu\text{m}$ ). In the fiber optic bronchoscope, the light entering the system is internally reflected and emitted at the opposite end.


However, a charged coupled device (CCD) has replaced the viewing bundle in the video bronchoscope. The CCD converts energy from light photons into digital information, allowing excellent image capture.

The current flexible video bronchoscope's outer diameter ranges from 2.8 mm for the ultrathin scope to 6.9 mm for convex probe EBUS.


The working channel ranges from 1.2 mm for the ultrathin bronchoscope to 3.0 mm for the therapeutic bronchoscope (Fig. 2.3).

The insertion tube length ranges from 400 to 600 mm, and the distal-end flexion angulation ranges from  $120^\circ$  to  $210^\circ$  in the latest-generation bronchoscopes [12]. On the other hand, the

distal-end extension angle ranges from  $60^\circ$  to  $130^\circ$  on the flexible bronchoscope (Fig. 2.4a, b). Of note, the flexible bronchoscope was designed to hold with the left hand since Dr. Ikeda was left-handed.



**Fig. 2.3** Distal ends of different bronchoscopes ranging from the therapeutic bronchoscope with a 3 mm working channel on the left to the thin bronchoscope with a 1.2 mm working channel on the right



**Fig. 2.4** (a) Distal end of the bronchoscope maximally extended at  $130^\circ$ . (b) Flexion of the distal end of the bronchoscope to  $210^\circ$

## Indications and Contraindications

Indications for flexible bronchoscopy are divided into diagnostic and therapeutic (Tables 2.1 and 2.2).

It is not uncommon that a diagnostic flexible bronchoscopy becomes both diagnostic and therapeutic in the same session, depending on unexpected findings that go undetected with pre-procedure imaging modalities or a change in the patient's condition.

Increasingly, therapeutic flexible bronchoscopic interventions are being performed by pulmonologists. In our opinion, it is due to an increased number of dedicated Interventional Pulmonology training programs and the more recent innovations in this field.

Flexible bronchoscopy, in general, has a great safety profile [1, 2]. Major complications such as bleeding, respiratory depression, cardiorespiratory arrest, arrhythmia, and pneumothorax occur in less than 1% of cases. Mortality is rare, with

**Table 2.1** Indications for diagnostic flexible bronchoscopy

Suspected malignancy:	Lung nodule/mass, airway lesion, hilar or mediastinal mass/adenopathy, lung cancer staging
Pulmonary infections:	Pneumonia in an immunocompromised host, cavitary lesions, non-resolving pneumonia, recurrent pulmonary infections
Diffuse lung disease:	Interstitial lung disease, pulmonary toxicity, suspected diffuse alveolar hemorrhage, inhalation lung injury
Symptoms and signs:	Hemoptysis, stridor, persistent cough, unexplained dyspnea, unilateral wheezing
Abnormal chest imaging:	Persistent lobar collapse, localized bronchiectasis, suspected airway obstruction/narrowing, suspected excessive expiratory airway collapse, tracheobronchomalacia
Miscellaneous:	Suspected aerodigestive fistula, bronchopleural fistula, chest trauma with suspected airway tear/injury, perioperative thoracic surgery, chemical and thermal burns of the airway, suspected foreign body aspiration, evaluation of post-transplant patients, endotracheal tube positioning

**Table 2.2** Indications for therapeutic flexible bronchoscopy

Central airway obstruction (CAO)	Benign disease: LASER coagulation, radial cuts, electrocautery, balloon dilatation of stenosis/stricture Malignant disease: tumor debulking/resection, LASER coagulation/ablation, argon plasma coagulation (APC), cryotherapy, photodynamic therapy, stenting (self-expandable stents)
Foreign body removal	Removal of an aspirated foreign body or broncholith extraction
Fiducial marker placement	Assisting in tumor localization for tumor resection or stereotactic body radiation therapy
Hemoptysis	Coagulation via LASER/APC or electrocautery of visible tumor/lesion, placement of airway blocker
Tracheobronchial toilet	Therapeutic lavage in necrotizing pulmonary infections
Bronchopleural fistula closure	Spigots, endobronchial valve placement, sealant placement
Aspiration of a cyst, drainage of abscess	EBUS-guided drainage of cysts and abscesses
Difficult airway intubation	Awake intubation for difficult airway and guidance in percutaneous dilatational tracheostomy
Bronchial thermoplasty	Treatment option in select asthmatics
Endoscopic lung volume reduction	Endobronchial one-way valve placement in select patients with emphysema

a reported death rate of 0–0.04% in more than 68,000 procedures [13]. Most contraindications are relative rather than absolute [13–15].

## Absolute Contraindications

- Life-threatening arrhythmia or hemodynamic collapse
- Profound refractory hypoxemia/inability to oxygenate patient during the procedure
- Lack of informed consent
- Lack of capable bronchoscopist
- Lack of adequate facility

## Relative Contraindications (Risk–Benefit Assessment)

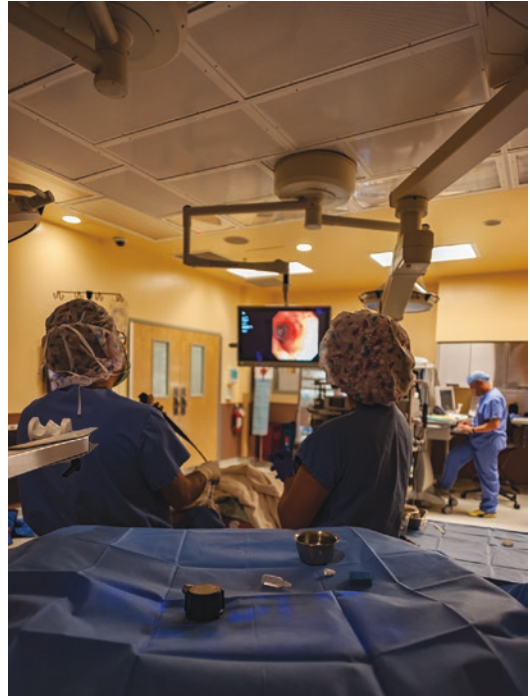- Bleeding diathesis: Platelet count less than 50,000/mm<sup>3</sup>, uremic platelet dysfunction, and international normalized ratio (INR) > 1.5 are relevant when brushing or biopsies are considered [16, 17]. Papin and colleagues demonstrated a significant incidence of bleeding in 24 patients who underwent transbronchial lung biopsy (TBLB) with a mean platelet count of 30,000/mm<sup>3</sup> [18]. Ernest and colleagues concluded that Clopidogrel use greatly increases the risk of bleeding after TBLB in humans and, therefore, should be discontinued five days before bronchoscopy with planned biopsies [19]. On the other hand, Herth et al. found that Aspirin does not increase bleeding complications after TBLB [20]. A small case series by Stather concluded that proceeding to EBUS-transbronchial needle aspiration (TBNA) without first withdrawing Clopidogrel should only be performed in situations where the risk of short-term thrombosis is believed to outweigh the (theoretical) risk of bleeding [21].
- Recent myocardial infarction or unstable angina: Most experts will postpone elective bronchoscopies for six weeks post-acute coronary syndrome [22].
- Lack of patient cooperation
- Pregnancy
- Asthma attack
- Increased intracranial pressure
- Inability to sedate

## Procedure Preparation

Flexible bronchoscopy can be performed in the endoscopy suite, operating room, intensive care unit, or even emergency room.

### 1. Equipment

The basic equipment needed is a bronchoscope and its accessories, light source and a video monitor, bronchoalveolar lavage (BAL) container, cytology brushes, biopsy forceps, needle aspiration catheters, syringes, normal



**Fig. 2.5** The bronchoscopy team in the procedure suite

saline aliquots, specimen containers, bronchoscope lubricant, bite block, suction apparatus, supplemental oxygen, continuous pulse oximetry, hemodynamic monitoring, and equipment for resuscitation including an endotracheal tube, laryngoscope, and chest tube insertion kit. Fluoroscopy can be valuable when performing TBLB, or advanced diagnostic or therapeutic FB (Fig. 2.5).

### 2. Personnel

The bronchoscopist, registered nurse, endoscopy technician or respiratory therapist (RT), and the anesthesiologist or certified registered nurse anesthetist should all be familiar with the patient's condition and the procedure being performed and appropriate handling of the specimens. This will maximize patient experience and outcome.

### 3. Patient Preparation

A consent form must be obtained after explaining the procedure, indication, risks, and benefits.

The bronchoscopist must perform a thorough history and physical exam before pro-



ceeding. Chest imaging and diagnostic tests should be reviewed carefully.

A few important concerns to mention:

- (a) Nil per os (NPO): Indicated for 2 h for clear liquids and 6–8 h for solids before FB [23].
- (b) Electrocardiograms are generally indicated for patients with suspected or known cardiac history.
- (c) Spirometry is not indicated before proceeding with bronchoscopy [24].
- (d) Premedication with atropine or glycopyrrolate is not beneficial in reducing bronchoscopy-related cough or secretions [13, 14].
- (e) Prophylactic antibiotics: FB is a rare cause of bacteremia and endocarditis [25]. Prophylactic antibiotics are indicated in patients with mechanical valves and a history of endocarditis.
- (f) Chest X-ray is indicated 1-h post trans-bronchial lung biopsy (TBLB) to rule out pneumothorax [26]. Alternatively, a thoracic ultrasound (US) exam documenting sliding lung sign will rule out pneumothorax post TBLB. Kumar and colleagues performed a total of 379 FB and 113 TBLB. Lung US exam detected all cases

of pneumothorax (PTX), whereas chest X ray (CXR) missed one PTX. The sensitivity, specificity, and overall accuracy for ultrasound were 100% as compared with a sensitivity of 87.5% and an accuracy of 99.6% for the CXR group [27].

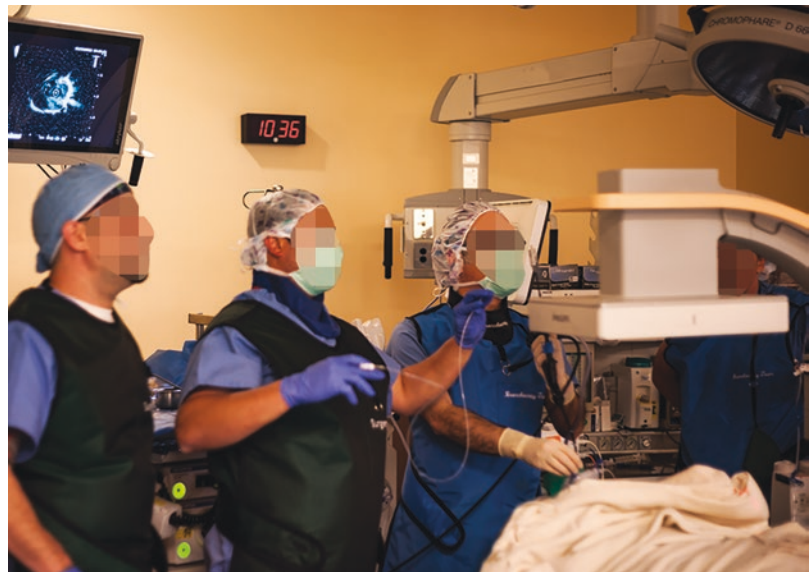#### 4. Anesthesia and Monitoring

The current guidelines do not address the type of anesthesia needed for each procedure but suggest that simple diagnostic FB procedures can be performed under local anesthesia or moderate conscious sedation. On the other hand, complex diagnostic and therapeutic bronchoscopy usually requires general anesthesia like total intra venous anesthesia (TIVA) [28].

The most used local/topical anesthetic for FB is lidocaine. Its plasma level of 5 µg/mL or dose greater than 8.2 mg/kg instilled in the airways can result in central nervous system (CNS) toxicity (restlessness, slurred speech, seizure), cardiovascular toxicity (atrioventricular block, hypotension), and methemoglobinemia.

Common sedative and opioid combinations used during conscious sedation are midazolam and fentanyl. Propofol, and to a lesser extent, ketamine, or dexmedetomidine coupled with fentanyl or remifentanyl are also used in TIVA (Fig. 2.6).

**Fig. 2.6** A bronchoscopy procedure in progress using ENB and radial EBUS through a laryngeal mask airway with general anesthesia



After the FB procedure, patients are observed in the recovery unit until they meet discharge criteria. Written discharge instructions and contact information are provided to the patient.

---

## Technique of FB Procedure

- Insertion route: According to an American College of Chest Physicians (ACCP) survey done in 1991, 33.8% of the total 871 responders/bronchoscopists preferred the nasal FB route, compared to 6.4% who preferred oral route only, and 42.6% had no preference [16]. Choi and colleagues in 2005 randomly assigned 307 patients to nasal vs. oral insertion route. They concluded that oral insertion of a flexible bronchoscope was associated with less discomfort for patients than nasal insertion, although the insertion route had no significant effect on outcome [29]. Beaudoin and colleagues assessed the feasibility of using the nasal route for linear endobronchial ultrasound performed on 196 patients, where in 73.5% of patients, nasal insertion was possible. The author concluded that linear EBUS could be performed safely and accurately via the nasal route [30].
- When ready to proceed with FB, the patient should be placed in either a semirecumbent or supine position after obtaining intravenous (IV) access. A topical anesthetic should be applied to the nasal passages and pharynx in case of nasal route insertion and only the pharynx if the oral route is chosen. Then, the bronchoscope is introduced either through the nose or mouth with a bite block in place to protect the bronchoscope. The oropharynx is examined, reaching the vocal cords, which are re-anesthetized topically. The vocal cords are examined for abduction and adduction. The bronchoscope is passed through the vocal cords to examine the tracheobronchial tree. We prefer to start with an inspection of normal airways, leaving the diseased area of interest to the end. A thorough, systematic approach to examining the airways is recommended. Description of airway configuration, mucosal membranes, secretions, location, extent, and

size of the abnormality is very valuable. Luminal narrowing/obstruction, whether intrinsic, extrinsic, combined, or dynamic, should be described; its length and distance from the closest carina should be documented in the report since it is very valuable if a surgical intervention may become an option.

- Both diagnostic and therapeutic bronchoscopic procedures can be performed during flexible bronchoscopy. Lengthy, complex diagnostic and therapeutic procedures are better performed under IV general anesthesia.
- Depending on the indication, the following diagnostic procedures can be performed: BAL, endobronchial or transbronchial biopsies, cytological washes or brushings, and conventional TBNA, endobronchial ultrasound (EBUS) TBNA, radial probe EBUS, cryobiopsy, navigational bronchoscopy, and narrow-band imaging (NBI) bronchoscopy. Therapeutic procedures including balloon dilatation, endobronchial LASER ablation/coagulation, electrocautery, photodynamic therapy, brachytherapy, self-expandable stent placement, and endobronchial valve placement can all be accomplished through flexible bronchoscopy [13, 15].

---

## Complications of FB Procedure

Flexible bronchoscopy, in general, has a great safety profile [1, 2, 31]. Major complications such as bleeding, respiratory depression, cardiorespiratory arrest, arrhythmia, and pneumothorax occur in less than 1% of cases [16]. Mortality is rare, with a reported death rate of 0–0.04% in more than 68,000 procedures [13].

It is important to mention that transient hypoxemia during and after bronchoscopy is the most common complication, especially when performing BAL in a patient with borderline cardiopulmonary reserve [2, 32]. Cardiac arrhythmia and risk of myocardial infarction are increased in elderly patients with cardiovascular comorbidities [33, 34].

Other complications of FB are adverse events of sedatives and narcotics, hypercapnia, hypoten-

sion, bronchospasm and laryngospasm, pneumothorax, and bleeding. Gas embolism has been reported using argon plasma coagulation [35].

## Basic Diagnostic Procedures

### Bronchoalveolar Lavage (BAL)

The bronchoalveolar lavage was first introduced to clinical practice by Reynolds in 1974 [36].

Standardization of BAL was addressed in a report by the European Respiratory Society task force in 1999. The report considers in detail the four main problems that prevent accurate quantification of components in alveolar epithelial lining fluid (ELF) using BAL:

1. An unknown amount of dilution during lavage.
2. Contamination of the ELF sample with material from the bronchi.
3. Inadequate sampling due to incomplete mixing.
4. Lung permeability varies, allowing loss of introduced lavage fluid into the tissues and increased leakage of soluble components from the blood capillaries and tissues into the ELF [37].

To perform a BAL, the bronchoscope is wedged in the target bronchus while keeping the working channel in the lumen of the bronchus. A total of 4 aliquots (30–60 mL each) are instilled in the alveoli for a total of at least 100 mL and a maximum of 240 mL of sterile normal saline. Subsequently, the fluid is suctioned into a trap with a pressure below 100 mmHg adjusted to avoid visible airway collapse.

In a healthy non-smoking subject, the BAL cellular composition is: macrophages (80–90%), lymphocytes (5–15%) with CD4/CD8 ratio of 1.5–1.8, neutrophils (1–3%), and eosinophils and mast cells <1% [38].

Cell counts on BAL can have non-specific results in many conditions such as cryptogenic organizing pneumonia and usual interstitial pneumonia, making its utility, to some extent, contro-

versial [39, 40]. On the other hand, BAL plays an important role in diagnosing pulmonary infections, especially in immunocompromised hosts and mycobacterial infections [41, 42]. A higher yield can be achieved by adding TBLB [43].

It is important to mention that the presence of more than 5% squamous or epithelial cells represents contamination of the sample with bronchial secretions, rendering it a non-representative sample of alveolar cells [37].

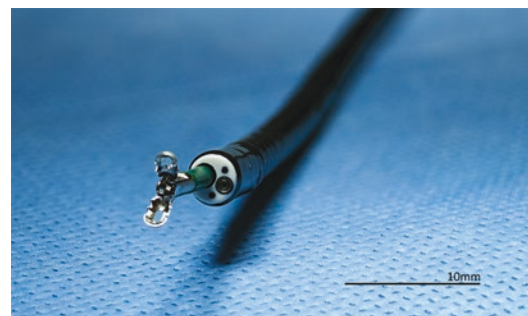### Transbronchial Lung Biopsy (TBLB)

TBLB refers to sampling the lung parenchyma via flexible biopsy forceps. Anderson and colleagues first described this method and their results in the 1960s and 1970s [44, 45].

It is usually performed by first wedging the bronchoscope in the bronchus. The forceps are then advanced in the closed position through the bronchoscope's working channel under fluoroscopic guidance, reaching the lung parenchyma where resistance is felt. The forceps are pulled back about 1 cm to open, re-advanced until the desired tissue is in contact with the forceps, and closed again to obtain a biopsy (Fig. 2.7).

The wedging position of the bronchoscope will facilitate further biopsies without the need to reposition the scope. It will also help isolate and tamponade any significant bleeding from the biopsy site.

The yield of TBLB increases with the number of biopsies taken. Descombes and colleagues showed that TBLB yield is increased from 38



**Fig. 2.7** Biopsy forceps used with the flexible bronchoscope

to 69% when 6 or more biopsies are performed [46]. The yield is also dependent on the pulmonary disease being investigated. The yield in usual interstitial pneumonitis (UIP) is only 30%, whereas higher yield of 70% or more is seen in pulmonary diseases with:

- A centrilobular distribution such as granulomatous lung diseases (hypersensitivity pneumonitis and sarcoidosis), eosinophilic pneumonia, and lymphangitic carcinomatosis [47, 48].
- Pulmonary infection in an immunocompromised host and mycobacterial infections [42, 43].
- Lung transplant patients with acute rejection or infection [49].

TBLB has a low complication rate with major bleeding (greater than 50 mL) averaging 1% and risk of pneumothorax between 1 and 4% [2, 50, 51].

### Transbronchial Needle Aspiration (TBNA)

TBNA refers to sampling through the tracheal or bronchial wall. The mediastinal and hilar lymph nodes and lung and mediastinal masses can be sampled via this method. A thorough review of the patient's chest computed tomography (CT) and knowledge of thoracic anatomy are essential before proceeding. A retractable hollow cytology needle (21 or 22 gauge) or histology needle (19 gauge) is used, with suction applied to the proximal end of the needle. Fluoroscopy should be used when performing TBNA of peripheral lung lesions.

Wang and colleagues in 1978 performed the first successful TBNA of a paratracheal tumor via the flexible bronchoscope. They later published their experience with TBNA for hilar and mediastinal adenopathy [52, 53].

Blind TBNA is the term used for standard TBNA without using EBUS guidance. The sensitivity of blind TBNA varies according to size, location, number of aspirates per lymph node's

station, and the bronchoscopist experience. A sensitivity of 78% and specificity of 99% has been reported for blind TBNA in patients with lung cancer [54, 55]. Baaklini and coworkers found a yield of 64% for pulmonary lesions located in the inner third of the lungs versus 35% for lesions located in the outer two-thirds of the lungs. They also showed a lower yield for smaller lesions (<2 cm) [56].

Blind TBNA also has a role in diagnosing peripheral lung masses and nodules, as Katis and colleagues first showed in 1995 [57].

Despite its great diagnostic utility, both ACCP and UK surveys have shown low routine use of blind TBNA in malignant and non-malignant diseases with 11.8% and 2.3% respectively in the ACCP survey [16] and 10% use in the UK survey [2].

The overall complication rate for blind TBNA is quite low at 0.8% [55]. The most common is damage to the bronchoscope working channel [16].

The introduction of EBUS-TBNA for mediastinal and hilar adenopathy and central tumors has replaced blind TBNA to a great extent. More guidance tools to reach peripheral lung nodules, like radial probe EBUS and virtual bronchoscopy, have changed the way pulmonologists perform TBNA.

A brief review of advanced diagnostic bronchoscopy is to follow.

### Bronchial Brushings

Bronchial brushings involve the introduction of a small-protected brush via the flexible bronchoscope to the visible endoluminal lesion or peripheral pulmonary nodule with assistance via fluoroscopy or guidance tools of bronchoscopy (radial EBUS or virtual bronchoscopy techniques). It is a useful tool to obtain both microbiological and cytological samples. Protected brushings have shown to increase the diagnostic yield in peripheral lung nodules [58].

A review of 30 studies published in 2003 assessed the performance characteristics of different modalities for suspected lung can-

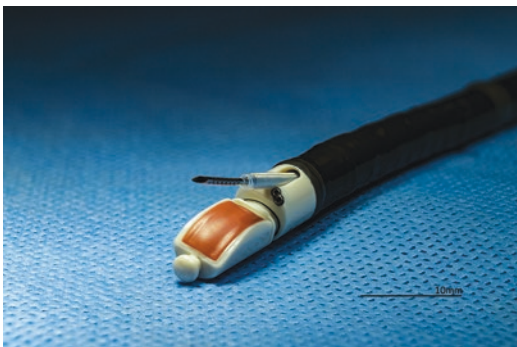cer. They found that the diagnostic yield of all modalities combined for central endobronchial disease is 88%. The highest sensitivity is for endobronchial biopsy (74%), followed by cytobrush (59%) and washings (48%). For peripheral lung lesions, cytobrush demonstrated the highest sensitivity (52%), followed by transbronchial biopsy (46%) and BAL/washings (43%). The overall sensitivity for all modalities was 69%. Peripheral lesions <2 cm or >2 cm in diameter showed sensitivities of 33% and 62%, respectively [59].

## Advanced Diagnostic Bronchoscopy

### EBUS-TBNA

EBUS-TBNA refers to the technique of obtaining needle aspiration biopsies under direct sonographic visualization using the EBUS bronchoscope (Fig. 2.8).

The special flexible bronchoscope incorporates an ultrasound transducer at its distal end, allowing real-time visualization and characterization of mediastinal and parabranchial structures and real-time needle aspiration of lymph nodes and lesions. The procedure is usually performed under moderate sedation. No advantage has been demonstrated by performing EBUS-TBNA under general anesthesia [60]. The reported safety profile is excellent. Gu et al. reported only two complications in 1299 patients (0.15%) [61] in their meta-analysis.



**Fig. 2.8** An endobronchial ultrasound bronchoscope

The current available needle sizes for EBUS-TBNA are 22G, 21G, and, most recently, 19G needles.

Nakajima and colleagues demonstrated no differences in the diagnostic yield between the 21G and 22G needles during EBUS-TBNA. However, more blood contamination was present in the 21G needle TBNA biopsies. The preserved histological structure of the samples obtained by the 21G needle may be useful for diagnosing mediastinal and hilar adenopathy of unknown etiology, which may be a challenge with a 22G needle [61].

Yarmus and colleagues retrospectively evaluated the results of 1299 patients from 6 centers who underwent EBUS-TBNA. No difference in diagnostic yield or sample adequacy was found when comparing 22G and 21G needles. However, EBUS-TBNA, in conjunction with rapid onsite cytological evaluation and a 21G needle, was associated with fewer needle passes than a 22G needle [62]. Jeyabalan and coworkers have recently confirmed the high clinical utility of EBUS-TBNA samples processed as histopathological specimens for epidermal growth factor receptor (EGFR) and anaplastic lymphoma kinase (ALK) genotyping in primary lung adenocarcinoma. The needle gauge did not affect genotyping efficacy [63].

In 2009, two meta-analyses and one systematic review reported the sensitivity and specificity of EBUS-TBNA. Adams et al. and Gu et al. reported that the pooled sensitivity for EBUS-TBNA was 88% and 93%, respectively [64, 65]. In their systematic review, Varela-Lema et al. reported that sensitivity for the diagnosis of malignancy ranged from 85 to 100% [66].

Therefore, the most recent ACCP guidelines in 2013 on the diagnosis and management of lung cancer recommend EBUS-TBNA over surgical staging as the best first invasive test in patients with intermediate or high suspicion of N2 or N3 involvement (Grade 1B) [67].

In a recent meta-analysis by Ge and colleagues comparing video-assisted mediastinoscopy (VAM) and EBUS-TBNA for lung cancer staging, 10 studies with 999 EBUS-TBNA patients and 7 studies with 915 VAM patients were included. The pooled sensitivities for EBUS-TBNA and VAM were 0.84 (95% con-



fidence interval [CI]: 0.79–0.88) and 0.86 (95% CI: 0.82–0.90), respectively. The analysis concluded that VAM and EBUS exhibited equally high diagnostic accuracy for mediastinal staging of lung cancer [68].

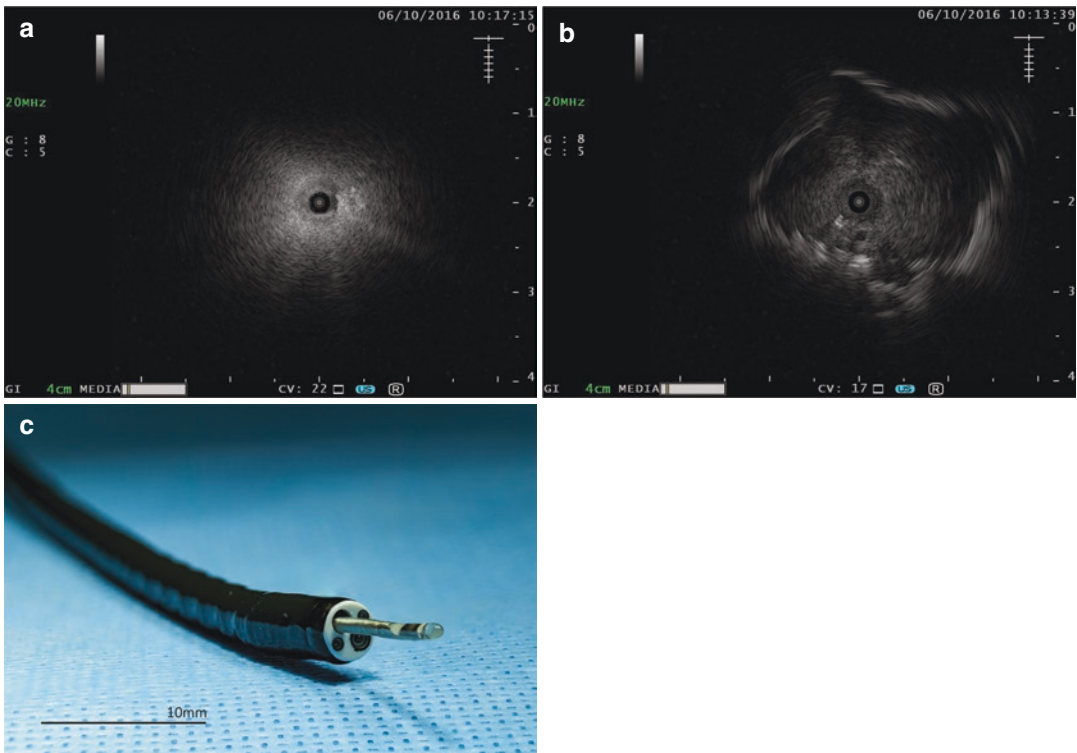
The role of EBUS-TBNA is less established for the diagnosis and subtyping of lymphoma. In a recent study by Grosu and colleagues, EBUS-TBNA was able to establish a diagnosis and subtype the lymphoma in 67% (95% CI: 0.45–0.88) of patients with de novo lymphoma and 81% (95% CI: 0.70–0.91) of patients with relapsed lymphoma [69].

EBUS-TBNA plays an important role in the diagnosis of sarcoidosis. The diagnostic yield ranges from 88 to 93% [70–73]. It is equally effective in identifying non-caseating granulomas compared with transbronchial/endobronchial lung biopsies combined with bronchoalveolar lavage [74].

### Radial Probe Endobronchial Ultrasound (RP-EBUS)

RP-EBUS utilizes a miniature ultrasound probe with a 1.4–1.7 mm diameter and provides a circumferential radial ultrasound image. It is inserted through the scope's working channel with or without a guidance sheath (GS). The characteristic “snowstorm-like” appearance represents a normal lung. The high resolution provided by the 20 MHz US probe allows detailed imaging of the peripheral lung lesion. A solid tumor will appear dark, homogenous, and well-differentiated from a normal lung with a bright border (Fig. 2.9a–c).

Once the target lesion is reached, the GS is left in place as an extending working channel of the bronchoscope. The US probe is removed, and sampling tools like biopsy forceps, protected brushes, and aspiration needles can be introduced



**Fig. 2.9** (a) Radial ultrasound of the lung, showing normal “snowstorm-like” appearance. (b) Radial ultrasound of a malignant lung mass. (c) Radial EBUS probe seen through the working channel of a bronchoscope

to obtain samples with or without fluoroscopic guidance.

RP-EBUS has increased the yield of FB in the diagnosis of peripheral lung lesions. Chen and colleagues showed that of all 467 nodules, 96% were successfully identified using radial probe EBUS. When the radial probe was within the target lesion, the diagnostic yield was 84% compared with 48% when the probe was positioned adjacent to the lesion [75].

A systematic review and meta-analysis with 1420 patients revealed significant inter-study variations in the RP-EBUS technique; however, the overall pooled sensitivity of RP-EBUS for detection of lung cancer in peripheral pulmonary lesions was 73% [76]. In a prospective randomized trial, Steinfert and colleagues demonstrated that the diagnostic accuracy of RP-EBUS transbronchial biopsy is not inferior to that of CT-guided transthoracic needle aspiration but with a significantly lower complication rate [77].

The lesion's size, the probe's position within the lesion, and the number of biopsies taken are all important factors that affect the diagnostic yield [78, 79]. Utilizing combined modalities like RP-EBUS and ENB has pushed the diagnostic yield to 88% for the diagnosis of peripheral lung nodules, compared to EBUS (69% yield) and ENB (59% yield) utilized alone [80]. In a multicenter randomized trial, Ishida et al. demonstrated virtual bronchoscopic navigation (VBN)-assisted RP-EBUS significantly improved the diagnostic yield of small (<30 mm) peripheral pulmonary nodules to 80.4%, 13% higher than the non-VBN-assisted group [81].

## Ultrathin Bronchoscopy

Peripheral pulmonary lesions are commonly encountered by the pulmonologist and require pathologic analysis to determine treatment options. Transbronchial biopsy has a low diagnostic yield for peripheral lesions <20 mm [82]. Thus, bronchoscopy is currently not recommended as a diagnostic technique for peripheral lesions <20 mm [83]. Transbronchial biopsy is

limited by the difficulty in guiding the bronchoscope and biopsy instrument to the peripheral lesion. Navigational bronchoscopy and radial probe EBUS with guidance sheath have been used to overcome this issue.

The ultrathin bronchoscope with a working channel has an external diameter of approximately 2.8 mm and is commercially available. It is used to diagnose peripheral pulmonary lesions and can be advanced to more peripheral bronchi than conventional bronchoscopes under direct observation. Ultrathin bronchoscopes have been reported to be advanced to sixth-generation bronchi and valuable in patients where a diagnosis is difficult using conventional bronchoscopy [84].

Oki et al. conducted a randomized controlled trial comparing ultrathin (3 mm) and thin bronchoscopy with guidance sheath (4 mm) bronchoscopy for peripheral lesions and found ultrathin bronchoscopy to be superior [84]. The combination of navigational bronchoscopy with ultrathin bronchoscopes was recently studied by Asano et al. and did not show a statistically significant difference [85].

## Transbronchial Lung Cryobiopsy (TBLC)

Cryobiopsy is the term used to describe the utilization of cryoprobes to obtain lung tissue. Cryosurgical equipment operates by the Joule-Thomson effect, which dictates that a compressed gas in a liquid state, released at high flow, rapidly expands and creates a very low temperature. The most commonly used cryogenic agents are carbon dioxide (CO<sub>2</sub>) or nitrous oxide. The gas at the tip expands due to the sudden difference in pressure relative to the atmospheric pressure, resulting in a drop in temperature at the tip of the probe (around -80°C). The size of cryobiopsies correlates positively with longer activation time and larger diameters of the cryoprobe.

The technique is simple. The cryoprobe (diameter of 1.1, 1.7, 1.9, or 2.4 mm) is introduced into the selected area under fluoroscopic guidance via a flexible bronchoscope. A distance of approximately 10–20 mm from the thoracic wall and a

perpendicular relation between the thoracic wall and the probe are considered optimal. Once the probe's tip is at the target area, the probe is activated for approximately 3–6 s. The frozen tissue attached to the probe's tip is removed by pulling the bronchoscope and cryoprobe together.

The advantage of TBLC over TBLB has been highlighted in several publications [86, 87].

Ravaglia and colleagues compared the diagnostic yield and safety of TBLC and surgical lung biopsy (SLB) in a large cohort of patients with interstitial lung disease (ILD). The diagnostic yield of TBLC was 82.8% compared to 98.7% in SLB with less median hospitalization time (2.6 days) in TBLC vs. (6.1 days) for SLB. Mortality due to adverse events was observed in 2.7% (SLB) and 0.3% (TBLC) of the patients. Pneumothorax was the most common complication after TBLC (20.2%). No severe bleeding was observed [88]. A meta-analysis of 15 investigations, including 781 patients, revealed an overall diagnostic yield of 81%. As retrieved from 15 studies including 994 patients, the overall pooled probability of developing a pneumothorax was 6% [88].

TBLC can also be utilized with the assistance of radial probe EBUS with goals to reduce the risk of bleeding by visualization of large vessels under ultrasound guidance. Berim et al. demonstrated a technique using TBLC with RP-EBUS to decrease the risk of major bleeding for diagnosis of ILD [89]. Gnass et al. performed a single-center prospective trial of TBLC with RP-EBUS to diagnose ILD in 20 patients, and their results showed a similar diagnostic yield at 80%. They only reported 5% of patients with minor bleeding and no moderate or severe bleeding [90].

Multiple single-center publications use TBLC with RP-EBUS to diagnose peripheral nodules, which confer a potential for a better diagnostic yield of tissue obtained than forceps [91]. However, large multicenter randomized trials still need to be performed to demonstrate efficacy.

It is important to recognize the higher rate of potential complications when using TBLC, like pneumothorax and bleeding. Therefore, TBLC should be performed by interventional pulmonologists who are trained to manage potential complications.

## **Cone-Beam Computed Tomography (CBCT)-Guided Biopsy**

Cone-beam computed tomography (CBCT) is a form of CT imaging compared to traditional CT imaging. In traditional CT imaging, a fan-beam X-ray is used with multiple linear detectors taking multiple images requiring overlap, in which a patient needs to be moved through the machine. In CBCT, a cone-shaped X-ray is used with a single detector that can capture a full image in a single rotation, which does not require the patient to be moved. It can be quickly performed with a C-Arm, and due to not requiring multiple overlapping images, it also provides less radiation to the patient and staff [92].

CBCT scans are obtained with a 200° turn around the patient taking up to 600 images ranging from 4 to 10 s [93].

CBCT has been used with growing popularity in oral and maxillofacial surgery, vascular surgery, and interventional radiology. Adapting this technology with existing bronchoscopic techniques for biopsies has proven beneficial in increasing diagnostic yield and minimizing complication rates. Using CBCT imaging, a bronchoscopist can localize the positioning of a transbronchial biopsy, improving accuracy and minimizing inaccurate attempts [94].

In initial studies, Hohenforst-Schmidt et al. reported a diagnostic yield of 73% in 33 patients with a mean lesion size of 25 mm [95]. CBCT can be combined with augmented fluoroscopy (AF) and ENB to increase diagnostic yield further. Pritchett et al. reported a diagnostic yield of 83.7% when using CBCT with AF with a median lesion size of 16 mm. At nearly 1.5 CBCT scans per case, the average effective radiation dose was 2.0 mSv per run [96].

Kheir et al. compared CBCT and ENB vs. ENB alone in 62 patients showing a diagnostic yield of 74.2 vs. 51.6 for a median lesion size of 16 mm, respectively. Following multivariate analysis, including distance from pleura, lesion size, and bronchus sign presence, the diagnostic odds ratio was noted to be 3.4. They also measured a decreased median procedure time of 76 vs. 90 min, respectively [97]. Ali et al. evalu-

ated the feasibility of using an ultrathin bronchoscope, VBN, and 2D-fluoroscopy with the addition of CBCT in 40 patients. The target was unable to be localized with conventional C-Arm fluoroscopy, but it was seen in all 40 patients with CBCT. They categorized the biopsy location into three categories: inside lesion, outside lesion, and indeterminate with goals of a CBCT target-forceps sign. The overall diagnostic yield was 90.0%. Diagnostic yield for CBCT target-forceps sign was 100%, 0%, and 75%, respectively [98]. Park et al. concluded that the only contributing factor that increases diagnostic yield is the forceps' position assessed by CBCT [94].

## Therapeutic Procedures Via FB

Therapeutic bronchoscopy refers mainly to managing central airway obstruction (CAO), which may be intrinsic, extrinsic, or combined. This entitles mechanical and non-mechanical tumor debulking in malignant and benign diseases, tracheobronchial dilatation of stenosis, deployment of airway stents, extraction and removal of foreign bodies, and management of hemoptysis. It also includes newer therapeutic applications like endobronchial valve placement for prolonged air leak post lobectomy or endoscopic lung volume reduction interventions in selected emphysema patients.

Therapeutic bronchoscopic interventions, to a certain degree, can be accomplished via the flexible bronchoscope (Fig. 2.10a–c).

However, the bronchoscopist must be competent and experienced with the use of rigid bronchoscopy and ready to use it when intervening on complex central airway obstruction. The rigid bronchoscope remains the tool of choice recommended by most experts in the field when treating CAO [15, 99].

In this chapter, we will outline a brief summary of some available interventional therapeutic

modalities that can be implemented for use with flexible bronchoscopy.

## LASER Bronchoscopy

The majority of publications on LASER bronchoscopy report the use of neodymium-doped yttrium aluminum garnet (Nd:YAG) LASER [100, 101]. Other LASERs like CO<sub>2</sub>, Nd:YAP neodymium doped yttrium aluminum perovskite (Nd:YAP), Holmium:YAG, and diode LASERs are utilized in bronchoscopic interventions.

In LASER therapy, the heat energy from the LASER light is used to coagulate and vaporize the endobronchial lesion.

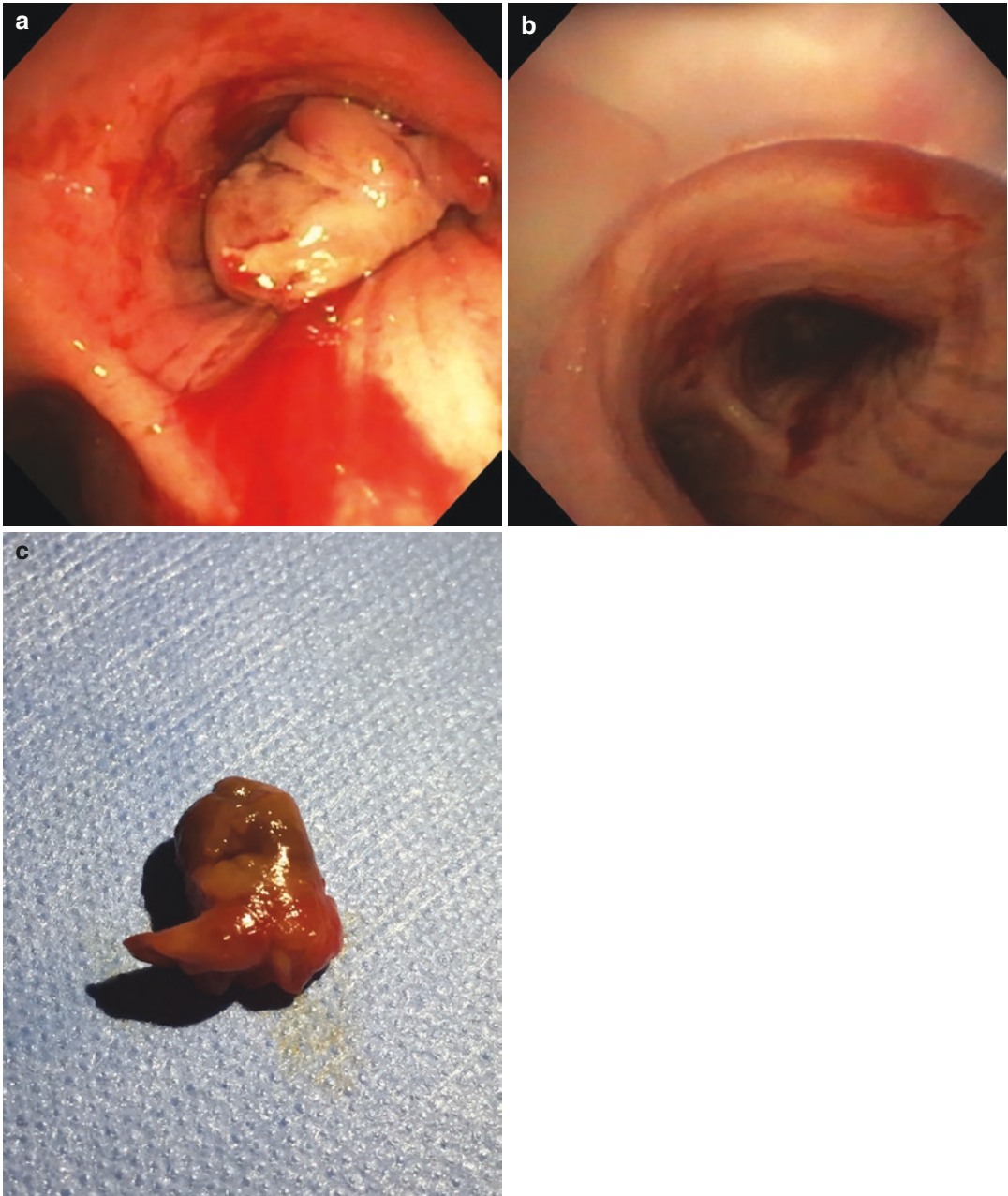
It is recommended to set LASER at low power (40 W) to coagulate the target lesion in anticipation to prevent bleeding.

The LASER fiber is introduced through the working channel of the FB. The LASER fiber tip should be at least 4 mm away from both the target lesion and the bronchoscope distal end. The inspired FiO<sub>2</sub> should be lowered to 40% or less, and frequent suctioning should be used to minimize the risk of endobronchial fire [102].

Then coagulation followed by mechanical resection with the flexible forceps can occur. In general, LASER treatments performed using a flexible bronchoscope are long and require a significant amount of patience. The flexible bronchoscope is not useful in severe obstruction or critical situations; they are better handled with the rigid bronchoscope [17]. Small lesions such as granulomas are easily treated with LASER application via flexible bronchoscopy.

LASER is very effective in restoring airway patency, with symptomatic improvement in around 70–80% of patients [100, 101, 103]. Complications related to LASER application include massive hemoptysis (1%), pneumothorax (0.4%), pneumomediastinum (0.2%), and endobronchial fire and peri-procedural death (2–3%) [101, 103, 104].





**Fig. 2.10** (a) Right main stem obstruction with squamous cell carcinoma causing post-obstructive pneumonia and severe hypoxemia. (b) The endobronchial component of the tumor resected via a flexible bronchoscope in an already intubated patient. (c) The resected tumor

## Electrocautery

Electrocautery is used to treat central airway obstructions from benign or malignant tumors of the airway [105]. It also acts through coagulation and vaporization. The electrical probe can be used to treat superficial lesions, while the snare can be applied to polypoid tumors protruding into the airway lumen. Similar to LASER, electrocautery is contraindicated when the obstruction arises from extrinsic compression without an intraluminal component [106].

Palliation of malignant obstructions using electrocautery is effective, with a rate of restoration of airway patency and symptomatic relief similar to LASER debulking (69–94%) [107–109].

Complications are similar to those of LASER application, with massive hemoptysis being the most concerning. Suggested settings to avoid fire during the procedure are:  $\text{FiO}_2$  equal to or less than 40% and low power (20–30 W).

## Argon Plasma Coagulation (APC)

APC is a non-contact mode of electrocautery that causes coagulation and vaporization. It is performed to treat exophytic endobronchial tumors and has good results treating bleeding tumors. APC can also be applied to other benign lesions compromising the airway, such as granulomas resulting from airway stents.

APC shows good results in central airway obstruction, with a partial or complete restoration of airway patency in 66% of patients. It has a reported success rate of 99% when treating hemoptysis [110].

Complications related to APC are airway perforation and gas embolism [35].

## Cryotherapy

Cryotherapy refers to the use of extreme cold to destroy abnormal or diseased tissue. The cryoprobe is inserted through the working channel of the flexible bronchoscope, and cycles of freezing and thawing are applied to the target, causing

delayed necrosis. Repeat bronchoscopy is performed three to seven days after the application to remove necrotic tissue. Cryotherapy does not open the airway rapidly, and it is not utilized in critical airway obstruction since its application generates edema that may worsen the degree of the obstruction.

Conventional cryotherapy is indicated in malignant airway obstruction as a palliative method. A success rate of 61% has been reported in airway restoration and significant improvement of symptoms such as hemoptysis, cough, and dyspnea [111, 112]. Complications related to cryotherapy are hemoptysis, bronchospasm, cardiac arrhythmia, and death [113].

A newer modality of cryotherapy called cryoextraction or cryorecanalization can be considered a rapid airway restoration method since tumor pieces attached to the cryoprobe are removed immediately [14].

## Photodynamic Therapy

It involves the administration of a photosensitizer substance (most commonly porfimer sodium) followed by its activation with LASER light of a given wavelength. This generates a photodynamic reaction that produces oxygen radicals that damage tumor cells, ultimately resulting in cellular death. Photodynamic therapy can be applied to early and advanced malignant lesions with good results [114].

Complications related to this procedure are photosensitivity (can last up to six weeks) and hemoptysis.

## Airway Stent Placement

The flexible bronchoscope can be used to deploy self-expandable metallic stents (SEMS) in the airway. Both bare and fully covered SEMS are commercially available.

The bare SEMS' application is limited to malignant conditions. Long-term permanence inside the airway has been linked to severe complications such as erosion and perforation of the airway wall, excessive granulation tis-

sue, bacterial colonization, stent disruption, and fracture [115].

The Food and Drug Administration (FDA) released very clear recommendations regarding the use of metallic airway stents in 2005 [116]. Experts recommend avoiding bare metallic stents and considering other therapeutic strategies. Placement of a silicon stent can be performed in most patients via rigid bronchoscopy and represents a safer alternative [117].

However, post-surgical stenosis that follows lung transplant or tracheal resection can be an indication for metallic stents. Bronchial dehiscence after lung transplantation can present as a life-threatening respiratory insufficiency, and deployment of a metallic stent can be life-saving and can favor healing, taking advantage of granulation tissue formation secondary to stent placement [118]. This indication is left to the team of experts managing lung-transplanted patients, not applicable to the general interventional bronchoscopy practice.

It is crucial to note that when bronchoscopists deploy a stent via flexible bronchoscopy approach, they must be skilled and ready to perform rigid bronchoscopy if needed.

## Endobronchial Valve Placement

Currently, two commercially FDA-approved valves for the treatment of emphysema exist.

- Zephyr Valve: This is a one-way silicone duckbill endobronchial valve attached to Nitinol self-expandable frame.
- Spiration Valve: This is an umbrella-shaped self-expanding one-way valve made of various metals, including a nickel-titanium frame. Distal anchors secure the valve against bronchial walls, with proximal struts keeping contact with the airway.

These valves can range in sizes, and depending on target airway size, they can be passed through a flexible bronchoscope with a channel > 2.6 mm.

The uses for endobronchial valve (EBV) are growing but most commonly limited to severe

emphysema and a non-surgical alternative to persistent air leaks.

Criner et al. studied patients with forced expiratory volume in the first second (FEV1) between 15 and 45% of predicted, TLC greater than 100% predicted, residual volume (RV) equal or greater than 175% predicted, and diffusion capacity of carbon monoxide (DLCO) equal or greater than 20% predicted in the lung function improvement after bronchoscopic lung volume reduction with pulmonx endobronchial valves used in the treatment of emphysema (LIBERATE) study, and demonstrated that the Zephyr EBV provides meaningful benefits in the lung function where FEV1 improved 0.106 L, and 6-min-walk distance +39.31 m. Also, the study demonstrated improvement in quality of life for these severe emphysema patients with intact fissure or lack of collateral ventilation of the target lobe [119].

The effectiveness and safety of the Spiration valves were evaluated in a multicenter, open-label, randomized controlled trial evaluation of the spiration valve system for emphysema to improve lung function (EMPROVE), including patients with severe heterogeneous emphysema with somewhat similar inclusion criteria to the LIBERATE study.

The primary effectiveness endpoint was a mean change in FEV1 post-bronchodilator from baseline to 6 months between treatment and control groups; 12-month results were also reported.

Mean FEV1 showed statistically significant improvements in the treatment group at 6 and 12 months, respectively, of 0.10 and 0.099 L and in health status quality of life questionnaires [120].

Pneumothorax is the most common complication, with rates ranging 12–34% without affecting survival rates [121, 122].

EBV can be used for patients with air leaks who are refractory to conventional treatments and not good surgical candidates. A balloon occlusion device is often placed in the airway to assess if the air leak has improved. If it does improve, an EBV can be considered for placement. Fiorelli et al. and Gilbert et al. both showed improvement in air leaks with EBV placement [123, 124].

Large prospective trials are ongoing to continue to evaluate efficacy and safety profile.

## Conclusion

The evolution of flexible bronchoscopy over the last 50 years has changed the field of diagnostic and therapeutic bronchoscopy. It started with basic diagnostic procedures that we must, as trainees and teachers, master and not forget. It continued to evolve with sophisticated, novel modalities that have proven to advance the care of our patients with thoracic and pulmonary diseases.

Today's pulmonologist needs to understand and learn some of the advanced techniques in flexible bronchoscopy. It is also vital for our interventional pulmonology trainees to utilize the current and future techniques to achieve the best possible outcomes for our patients.

## References

1. Suratt PM, Smiddy JF, Gruber B. Deaths and complications associated with fiberoptic bronchoscopy. *Chest*. 1976;69(6):747–51.
2. Smyth CM, Stead RJ. Survey of flexible fiberoptic bronchoscopy in the United Kingdom. *Eur Respir J*. 2002;19(3):458–63.
3. Becker HD. History of the rigid bronchoscope. In: Bolliger CT, Mathur PN, editors. *Interventional bronchoscopy*, vol. 30. Basel: Karger; 2000. p. 2–15.
4. Ikeda S. The flexible bronchofiberscope. *Keio J Med*. 1968;17:1–16.
5. Miyazawa T, Miyazu Y, Iwamoto Y. Interventional flexible bronchoscopy. Historical perspective. In: Beamis J, Mathur P, Mehta A, editors. *Interventional pulmonary medicine lung biology in health and disease*, vol. 189. New York, NY: Marcel Dekker; 2004. p. 33–48.
6. Hürter T, Hanrath P. Endobronchial sonography: feasibility and preliminary results. *Thorax*. 1992;47(7):565–7.
7. Becker HD. [Endobronchial ultrasound—a new perspective in bronchology]. *Ultraschall Med*. 1996;17(3):106–12.
8. Yasufuku K, Chhajed PN, Sekine Y, Nakajima T, Chiyo M, Iyoda A, et al. Endobronchial ultrasound using a new convex probe: a preliminary study on surgically resected specimens. *Oncol Rep*. 2004;11(2):293–6.
9. Yasufuku K, Chiyo M, Sekine Y, Chhajed PN, Shibuya K, Iizasa T, et al. Real-time endobronchial ultrasound-guided transbronchial needle aspiration of mediastinal and hilar lymph nodes. *Chest*. 2004;126(1):122–8.
10. Panchabhai TS, Mehta AC. Historical perspectives of bronchoscopy. Connecting the dots. *Ann Am Thorac Soc*. 2015;12(5):631–41.
11. Fielding DIK, Bashirzadeh F, Son JH, Todman M, Chin A, Tan L, et al. First human use of a new robotic-assisted fiber optic sensing navigation system for small peripheral pulmonary nodules. *Respiration*. 2019;98(2):142–50.
12. Hsia DW, Tanner NT, Shamblin C, Mehta HJ, Silvestri GA, Musani AI. The latest generation in flexible bronchoscopes: a description and evaluation. *J Bronchology Interv Pulmonol*. 2013;20(4):357–62.
13. Ernst A, Silvestri GA, Johnstone D, American College of Chest Physicians. *Interventional pulmonary procedures: guidelines from the American College of Chest Physicians*. *Chest*. 2003;123(5):1693–717.
14. Du Rand IA, Barber PV, Goldring J, Lewis RA, Mandal S, Munavvar M, et al. British Thoracic Society guideline for advanced diagnostic and therapeutic flexible bronchoscopy in adults. *Thorax*. 2011;66 Suppl 3:i11–21.
15. Bolliger CT, Mathur PN, Beamis JF, Becker HD, Cavaliere S, Colt H, et al. ERS/ATS statement on interventional pulmonology. *Eur Respir J*. 2002;19(2):356–73.
16. Prakash UB, Offord KP, Stubbs SE. Bronchoscopy in North America: the ACCP survey. *Chest*. 1991;100(6):1668–75.
17. Prakash UB, Stubbs SE. The bronchoscopy survey. Some reflections. *Chest*. 1991;100(6):1660–7.
18. Papin TA, Lynch JP, Weg JG. Transbronchial biopsy in the thrombocytopenic patient. *Chest*. 1985;88(4):549–52.
19. Ernst A, Eberhardt R, Wahidi M, Becker HD, Herth FJ. Effect of routine clopidogrel use on bleeding complications after transbronchial biopsy in humans. *Chest*. 2006;129(3):734–7.
20. Herth FJ, Becker HD, Ernst A. Aspirin does not increase bleeding complications after transbronchial biopsy. *Chest*. 2002;122(4):1461–4.
21. Stather DR, MacEachern P, Chee A, Tremblay A. Safety of endobronchial ultrasound-guided transbronchial needle aspiration for patients taking clopidogrel: a report of 12 consecutive cases. *Respiration*. 2012;83(4):330–4.
22. Matot I, Kramer MR, Glantz L, Drenger B, Cotev S. Myocardial ischemia in sedated patients undergoing fiberoptic bronchoscopy. *Chest*. 1997;112(6):1454–8.
23. American Society of Anesthesiologists Task Force on Sedation and Analgesia by Non-Anesthesiologists. Practice guidelines for sedation and analgesia by non-anesthesiologists. *Anesthesiology*. 2002;96(4):1004–17.
24. Beamis J Jr. Rigid bronchoscopy. In: Beamis J, Mathur P, editors. *Interventional pulmonology*. New York, NY: McGraw Hill; 1999. p. 17–28.



25. Jurado RL, Klein S. Infective endocarditis associated with fiberoptic bronchoscopy in a patient with mitral-valve prolapse. *Clin Infect Dis*. 1998;26(3):768–9.
26. Hanson RR, Zavala DC, Rhodes ML, Keim LW, Smith JD. Transbronchial biopsy via flexible fiberoptic bronchoscope; results in 164 patients. *Am Rev Respir Dis*. 1976;114(1):67–72.
27. Kumar S, Agarwal R, Aggarwal AN, Gupta D, Jindal SK. Role of ultrasonography in the diagnosis and management of pneumothorax following transbronchial lung biopsy. *J Bronchology Interv Pulmonol*. 2015;22(1):14–9.
28. Wahidi MM, Jain P, Jantz M, Lee P, Mackensen GB, Barbour SY, et al. American College of Chest Physicians consensus statement on the use of topical anesthesia, analgesia, and sedation during flexible bronchoscopy in adult patients. *Chest*. 2011;140(5):1342–50.
29. Choi CM, Yoon HI, Lee SM, Yoo CG, Kim YW, Han SK, et al. Oral insertion of a flexible bronchoscope is associated with less discomfort than nasal insertion for Korean patients. *Int J Tuberc Lung Dis*. 2005;9(3):344–8.
30. Beaudoin S, Ferland N, Martel S, Delage A. Feasibility of using the nasal route for linear endobronchial ultrasound. *Lung*. 2014;192(6):921–6.
31. Credle W, Smiddy J, Elliot R. Complications of fiberoptic bronchoscopy. *Am Rev Respir Dis*. 1976;109:67–72.
32. Dubrawsky C, Awe RJ, Jenkins DE. The effect of bronchofiberscopic examination on oxygenation status. *Chest*. 1975;67(2):137–40.
33. Katz A, Michelson E, Stawicki J, Holford F. Cardiac arrhythmias: frequency during fiberoptic bronchoscopy and correlation with hypoxemia. *Arch Intern Med*. 1981;141:603–6.
34. Davies L, Mister R, Spence DP, Calverley PM, Earis JE, Pearson MG. Cardiovascular consequences of fiberoptic bronchoscopy. *Eur Respir J*. 1997;10(3):695–8.
35. Reddy C, Majid A, Michaud G, Feller-Kopman D, Eberhardt R, Herth F, et al. Gas embolism following bronchoscopic argon plasma coagulation: a case series. *Chest*. 2008;134(5):1066–9.
36. Reynolds HY, Newball HH. Analysis of proteins and respiratory cells obtained from human lungs by bronchial lavage. *J Lab Clin Med*. 1974;84(4):559–73.
37. Haslam PL, Baughman RP. Report of ERS Task Force: guidelines for measurement of acellular components and standardization of BAL. *Eur Respir J*. 1999;14(2):245–8.
38. Heron M, Grutters JC, ten Dam-Molenkamp KM, Hijdra D, van Heugten-Roeling A, Claessen AM, et al. Bronchoalveolar lavage cell pattern from healthy human lung. *Clin Exp Immunol*. 2012;167(3):523–31.
39. Raghu G, Mageto YN, Lockhart D, Schmidt RA, Wood DE, Godwin JD. The accuracy of the clinical diagnosis of new-onset idiopathic pulmonary fibrosis and other interstitial lung disease: a prospective study. *Chest*. 1999;116(5):1168–74.
40. Collard HR, King TE. Demystifying idiopathic interstitial pneumonia. *Arch Intern Med*. 2003;163(1):17–29.
41. Baughman RP, Dohn MN, Frame PT. The continuing utility of bronchoalveolar lavage to diagnose opportunistic infection in AIDS patients. *Am J Med*. 1994;97(6):515–22.
42. Joos L, Chhajed PN, Wallner J, Battagay M, Steiger J, Gratwohl A, et al. Pulmonary infections diagnosed by BAL: a 12-year experience in 1066 immunocompromised patients. *Respir Med*. 2007;101(1):93–7.
43. Jain P, Sandur S, Meli Y, Arroliga AC, Stoller JK, Mehta AC. Role of flexible bronchoscopy in immunocompromised patients with lung infiltrates. *Chest*. 2004;125(2):712–22.
44. Andersen HA, Fontana RS, Harrison EG. Transbronchoscopic lung biopsy in diffuse pulmonary disease. *Dis Chest*. 1965;48:187–92.
45. Andersen HA, Fontana RS. Transbronchoscopic lung biopsy for diffuse pulmonary diseases: technique and results in 450 cases. *Chest*. 1972;62(2):125–8.
46. Descombes E, Gardiol D, Leuenberger P. Transbronchial lung biopsy: an analysis of 530 cases with reference to the number of samples. *Monaldi Arch Chest Dis*. 1997;52(4):324–9.
47. Ensminger SA, Prakash UB. Is bronchoscopic lung biopsy helpful in the management of patients with diffuse lung disease? *Eur Respir J*. 2006;28(6):1081–4.
48. Bradley B, Branley HM, Egan JJ, Greaves MS, Hansell DM, Harrison NK, et al. Interstitial lung disease guideline: the British Thoracic Society in collaboration with the Thoracic Society of Australia and New Zealand and the Irish Thoracic Society. *Thorax*. 2008;63(Suppl 5):v1–58.
49. Hopkins PM, Aboyou CL, Chhajed PN, Malouf MA, Plit ML, Rainer SP, et al. Prospective analysis of 1,235 transbronchial lung biopsies in lung transplant recipients. *J Heart Lung Transplant*. 2002;21(10):1062–7.
50. Simpson FG, Arnold AG, Purvis A, Belfield PW, Muers MF, Cooke NJ. Postal survey of bronchoscopic practice by physicians in the United Kingdom. *Thorax*. 1986;41(4):311–7.
51. Rademacher J, Suhling H, Greer M, Haverich A, Welte T, Warnecke G, et al. Safety and efficacy of outpatient bronchoscopy in lung transplant recipients—a single centre analysis of 3,197 procedures. *Transplant Res*. 2014;3:11.
52. Wang KP, Terry P, Marsh B. Bronchoscopic needle aspiration biopsy of paratracheal tumors. *Am Rev Respir Dis*. 1978;118(1):17–21.
53. Wang KP, Haponik EF, Gupta PK, Erozan YS. Flexible transbronchial needle aspiration. Technical considerations. *Ann Otol Rhinol Laryngol*. 1984;93(3 Pt 1):233–6.
54. Chin R Jr, McCain TW, Lucia MA, Cappellari JO, Adair NE, Lovato JF, et al. Transbronchial needle aspiration in diagnosing and staging lung cancer: how

- many aspirates are needed? *Am J Respir Crit Care Med.* 2002;166(3):377–81.
55. Holty JE, Kuschner WG, Gould MK. Accuracy of transbronchial needle aspiration for mediastinal staging of non-small cell lung cancer: a meta-analysis. *Thorax.* 2005;60(11):949–55.
  56. Baaklini WA, Reinoso MA, Gorin AB, Sharafkaneh A, Manian P. Diagnostic yield of fiberoptic bronchoscopy in evaluating solitary pulmonary nodules. *Chest.* 2000;117(4):1049–54.
  57. Katis K, Inglesos E, Zachariadis E, Palamidas P, Paraskevopoulos I, Sideris G, et al. The role of transbronchial needle aspiration in the diagnosis of peripheral lung masses or nodules. *Eur Respir J.* 1995;8(6):963–6.
  58. Boonsarngsuk V, Kanoksil W, Laungdamerongchai S. Diagnosis of peripheral pulmonary lesions with radial probe endobronchial ultrasound-guided bronchoscopy. *Arch Bronconeumol.* 2014;50(9):379–83.
  59. Schreiber G, McCrory DC. Performance characteristics of different modalities for diagnosis of suspected lung cancer: summary of published evidence. *Chest.* 2003;123(1 Suppl):115S–28S.
  60. Casal RF, Lazarus DR, Kuhl K, Noguera-González G, Perusich S, Green LK, et al. Randomized trial of endobronchial ultrasound-guided transbronchial needle aspiration under general anesthesia versus moderate sedation. *Am J Respir Crit Care Med.* 2015;191(7):796–803.
  61. Nakajima T, Yasufuku K, Takahashi R, Shingyoji M, Hirata T, Itami M, et al. Comparison of 21-gauge and 22-gauge aspiration needle during endobronchial ultrasound-guided transbronchial needle aspiration. *Respirology.* 2011;16(1):90–4.
  62. Yarmus LB, Akulian J, Lechtzin N, Yasin F, Kamdar B, Ernst A, et al. Comparison of 21-gauge and 22-gauge aspiration needle in endobronchial ultrasound-guided transbronchial needle aspiration: results of the American College of Chest Physicians Quality Improvement Registry, Education, and Evaluation Registry. *Chest.* 2013;143(4):1036–43.
  63. Jeyabalan A, Bhatt N, Plummeridge MJ, Medford AR. Adequacy of endobronchial ultrasound-guided transbronchial needle aspiration samples processed as histopathological samples for genetic mutation analysis in lung adenocarcinoma. *Mol Clin Oncol.* 2016;4(1):119–25.
  64. Gu P, Zhao YZ, Jiang LY, Zhang W, Xin Y, Han BH. Endobronchial ultrasound-guided transbronchial needle aspiration for staging of lung cancer: a systematic review and meta-analysis. *Eur J Cancer.* 2009;45(8):1389–96.
  65. Adams K, Shah PL, Edmonds L, Lim E. Test performance of endobronchial ultrasound and transbronchial needle aspiration biopsy for mediastinal staging in patients with lung cancer: systematic review and meta-analysis. *Thorax.* 2009;64(9):757–62.
  66. Varela-Lema L, Fernández-Villar A, Ruano-Ravina A. Effectiveness and safety of endobronchial ultrasound-transbronchial needle aspiration: a systematic review. *Eur Respir J.* 2009;33(5):1156–64.
  67. Dettlerbeck FC, Lewis SZ, Diekemper R, Addrizzo-Harris D, Alberts WM. Executive summary: diagnosis and management of lung cancer, 3rd ed: American College of Chest Physicians evidence-based clinical practice guidelines. *Chest.* 2013;143(5 Suppl):7S–37S.
  68. Ge X, Guan W, Han F, Guo X, Jin Z. Comparison of endobronchial ultrasound-guided fine needle aspiration and video-assisted mediastinoscopy for mediastinal staging of lung cancer. *Lung.* 2015;193(5):757–66.
  69. Grosu HB, Iliesiu M, Caraway NP, Medeiros LJ, Lei X, Jimenez CA, et al. Endobronchial ultrasound-guided transbronchial needle aspiration for the diagnosis and subtyping of lymphoma. *Ann Am Thorac Soc.* 2015;12(9):1336–44.
  70. Wong M, Yasufuku K, Nakajima T, Herth FJ, Sekine Y, Shibuya K, et al. Endobronchial ultrasound: new insight for the diagnosis of sarcoidosis. *Eur Respir J.* 2007;29(6):1182–6.
  71. Oki M, Saka H, Kitagawa C, Tanaka S, Shimokata T, Kawata Y, et al. Real-time endobronchial ultrasound-guided transbronchial needle aspiration is useful for diagnosing sarcoidosis. *Respirology.* 2007;12(6):863–8.
  72. Garwood S, Judson MA, Silvestri G, Hoda R, Fraig M, Doelken P. Endobronchial ultrasound for the diagnosis of pulmonary sarcoidosis. *Chest.* 2007;132(4):1298–304.
  73. Tournoy KG, Bolly A, Aerts JG, Pierard P, De Pauw R, Leduc D, et al. The value of endoscopic ultrasound after bronchoscopy to diagnose thoracic sarcoidosis. *Eur Respir J.* 2010;35(6):1329–35.
  74. Gupta D, Dadhwal DS, Agarwal R, Gupta N, Bal A, Aggarwal AN. Endobronchial ultrasound-guided transbronchial needle aspiration vs conventional transbronchial needle aspiration in the diagnosis of sarcoidosis. *Chest.* 2014;146(3):547–56.
  75. Chen A, Chenna P, Loiselle A, Massoni J, Mayse M, Misselhorn D. Radial probe endobronchial ultrasound for peripheral pulmonary lesions. A 5-year institutional experience. *Ann Am Thorac Soc.* 2014;11(4):578–82.
  76. Steinfurt DP, Khor YH, Manser RL, Irving LB. Radial probe endobronchial ultrasound for the diagnosis of peripheral lung cancer: systematic review and meta-analysis. *Eur Respir J.* 2011;37(4):902–10.
  77. Steinfurt DP, Vincent J, Heinze S, Antippa P, Irving LB. Comparative effectiveness of radial probe endobronchial ultrasound versus CT-guided needle biopsy for evaluation of peripheral pulmonary lesions: a randomized pragmatic trial. *Respir Med.* 2011;105(11):1704–11.
  78. Kikuchi E, Yamazaki K, Sukoh N, Kikuchi J, Asahina H, Imura M, et al. Endobronchial ultrasonography with guide-sheath for peripheral pulmonary lesions. *Eur Respir J.* 2004;24(4):533–7.

79. Yamada N, Yamazaki K, Kurimoto N, Asahina H, Kikuchi E, Shinagawa N, et al. Factors related to diagnostic yield of transbronchial biopsy using endobronchial ultrasonography with a guide sheath in small peripheral pulmonary lesions. *Chest*. 2007;132(2):603–8.
80. Eberhardt R, Anantham D, Ernst A, Feller-Kopman D, Herth F. Multimodality bronchoscopic diagnosis of peripheral lung lesions: a randomized controlled trial. *Am J Respir Crit Care Med*. 2007;176(1):36–41.
81. Ishida T, Asano F, Yamazaki K, Shinagawa N, Oizumi S, Moriya H, et al. Virtual bronchoscopic navigation combined with endobronchial ultrasound to diagnose small peripheral pulmonary lesions: a randomised trial. *Thorax*. 2011;66(12):1072–7.
82. Matsuno Y, Asano F, Shindoh J, Abe T, Shiraki A, Ando M, et al. CT-guided ultrathin bronchoscopy: bioptic approach and factors in predicting diagnosis. *Intern Med*. 2011;50(19):2143–8.
83. Rivera MP, Mehta AC, Physicians ACoC. Initial diagnosis of lung cancer: ACCP evidence-based clinical practice guidelines (2nd edition). *Chest*. 2007;132(3 Suppl):131S–48S.
84. Oki M, Saka H, Ando M, Asano F, Kurimoto N, Morita K, et al. Ultrathin bronchoscopy with multimodal devices for peripheral pulmonary lesions. A randomized trial. *Am J Respir Crit Care Med*. 2015;192(4):468–76.
85. Asano F, Shinagawa N, Ishida T, Shindoh J, Anzai M, Tsuzuku A, et al. Virtual bronchoscopic navigation combined with ultrathin bronchoscopy. A randomized clinical trial. *Am J Respir Crit Care Med*. 2013;188(3):327–33.
86. Poletti V, Casoni GL, Gurioli C, Ryu JH, Tomassetti S. Lung cryobiopsies: a paradigm shift in diagnostic bronchoscopy? *Respirology*. 2014;19(5):645–54.
87. Fruchter O, Fridel L, Rosengarten D, Rahman NA, Kramer MR. Transbronchial cryobiopsy in immunocompromised patients with pulmonary infiltrates: a pilot study. *Lung*. 2013;191(6):619–24.
88. Ravaglia C, Bonifazi M, Wells AU, Tomassetti S, Gurioli C, Piciocchi S, et al. Safety and diagnostic yield of transbronchial lung cryobiopsy in diffuse parenchymal lung diseases: a comparative study versus video-assisted thoracoscopic lung biopsy and a systematic review of the literature. *Respiration*. 2016;91(3):215–27.
89. Berim IG, Saeed AI, Awab A, Highley A, Colanta A, Chaudry F. Radial probe ultrasound-guided cryobiopsy. *J Bronchology Interv Pulmonol*. 2017;24(2):170–3.
90. Gnass M, Filarecka A, Pankowski J, Soja J, Bugalho A, Szlubowski A. Transbronchial lung cryobiopsy guided by endobronchial ultrasound radial miniprobe in interstitial lung diseases: preliminary results of a prospective study. *Pol Arch Intern Med*. 2018;128(4):259–62.
91. Gupta A, Youness H, Dhillon SS, Harris K. The value of using radial endobronchial ultrasound to guide transbronchial lung cryobiopsy. *J Thorac Dis*. 2019;11(1):329–34.
92. Kumar M, Shanavas M, Sidappa A, Kiran M. Cone beam computed tomography—know its secrets. *J Int Oral Health*. 2015;7(2):64–8.
93. Setser R, Chintalapani G, Bhadra K, Casal RF. Cone beam CT imaging for bronchoscopy: a technical review. *J Thorac Dis*. 2020;12(12):7416–28.
94. Park SC, Kim CJ, Han CH, Lee SM. Factors associated with the diagnostic yield of computed tomography-guided transbronchial lung biopsy. *Thorac Cancer*. 2017;8(3):153–8.
95. Hohenforst-Schmidt W, Zarogoulidis P, Vogl T, Turner JF, Browning R, Linsmeier B, et al. Cone beam computed tomography (CBCT) in interventional chest medicine—high feasibility for endobronchial realtime navigation. *J Cancer*. 2014;5(3):231–41.
96. Pritchett MA, Schampaert S, de Groot JAH, Schirmer CC, van der Bom I. Cone-beam CT with augmented fluoroscopy combined with electromagnetic navigation bronchoscopy for biopsy of pulmonary nodules. *J Bronchology Interv Pulmonol*. 2018;25(4):274–82.
97. Kheir F, Thakore SR, Uribe Becerra JP, Tahboub M, Kamat R, Abdelghani R, et al. Cone-beam computed tomography-guided electromagnetic navigation for peripheral lung nodules. *Respiration*. 2021;100(1):44–51.
98. Ali EAA, Takizawa H, Kawakita N, Sawada T, Tsuboi M, Toba H, et al. Transbronchial biopsy using an ultrathin bronchoscope guided by cone-beam computed tomography and virtual bronchoscopic navigation in the diagnosis of pulmonary nodules. *Respiration*. 2019;98(4):321–8.
99. Diaz-Jimenez J, Rodriguez A. *Broncoscopia rigida*. In: Diaz-Jimenez J, Rodriguez A, editors. *Neumologia intervencionista*. Barcelona: Ediciones Gea; 2000. p. 1–16.
100. Diaz-Jimenez JP, Ballarin JI, Muñoz EF, Kovitz KL, Serrano MJ, Shirakura K. Video endoscopy for laser photoresection in tracheobronchial pathology: some considerations after 9 years experience with 2105 treatments. *Diagn Ther Endosc*. 1995;2(2):79–87.
101. Cavaliere S, Foccoli P, Farina PL. Nd:YAG laser bronchoscopy. A five-year experience with 1,396 applications in 1,000 patients. *Chest*. 1988;94(1):15–21.
102. Lee P, Mehta A. Therapeutic flexible bronchoscopy: overview. In: Beamis J, Mathur P, Mehta A, editors. *Interventional pulmonary medicine*, vol. 189. New York, NY: Marcel Dekker; 2004.
103. Brutinel WM, Cortese DA, McDougall JC, Gillio RG, Bergstralh EJ. A two-year experience with the neodymium-YAG laser in endobronchial obstruction. *Chest*. 1987;91(2):159–65.
104. Katlic MR, Burick AJ, Lucchino DB. Experiences with laser bronchoscopy. *Pennsylvania Med*. 1991;94(6):24–7.
105. Marel M, Pekarek Z, Spasova I, Pafko P, Schutznier J, Betka J, et al. Management of benign stenoses

- of the large airways in the university hospital in Prague, Czech Republic, in 1998-2003. *Respiration*. 2005;72(6):622–8.
106. Van Boxem TJ, Venmans BJ, Schramel FM, van Mourik JC, Golding RP, Postmus PE, et al. Radiographically occult lung cancer treated with fiberoptic bronchoscopic electrocautery: a pilot study of a simple and inexpensive technique. *Eur Respir J*. 1998;11(1):169–72.
  107. De la Cruz L, Pereira A, Krieger B. Use of endobronchial electrocautery for the palliation of airway obstruction due to metastases from nonpulmonary malignancies. *J Bronchology Interv Pulmonol*. 2006;13:124–7.
  108. Sutedja G, van Kralingen K, Schramel FM, Postmus PE. Fiberoptic bronchoscopic electrosurgery under local anaesthesia for rapid palliation in patients with central airway malignancies: a preliminary report. *Thorax*. 1994;49(12):1243–6.
  109. Sutedja T, Van Boxem T, Schramel F. Endobronchial electrocautery is an excellent alternative for Nd:YAG laser to treat airway tumors. *J Bronchology Interv Pulmonol*. 1997;4:101–5.
  110. Reichle G, Freitag L, Kullmann H-J. Argon plasma coagulation in bronchology: a new method—alternative or complementary? *J Bronchology Interv Pulmonol*. 2000;7:109–17.
  111. Chan AL, Tharratt RS, Siefkin AD, Albertson TE, Volz WG, Allen RP. Nd:YAG laser bronchoscopy. Rigid or fiberoptic mode? *Chest*. 1990;98(2):271–5.
  112. Maiwand MO, Evans JM, Beeson JE. The application of cryosurgery in the treatment of lung cancer. *Cryobiology*. 2004;48(1):55–61.
  113. Vergnon JM, Schmitt T, Alamartine E, Barthelemy JC, Fournel P, Emonot A. Initial combined cryotherapy and irradiation for unresectable non-small cell lung cancer. Preliminary results. *Chest*. 1992;102(5):1436–40.
  114. Diaz-Jiménez JP, Martínez-Ballarín JE, Lluell A, Farrero E, Rodríguez A, Castro MJ. Efficacy and safety of photodynamic therapy versus Nd-YAG laser resection in NSCLC with airway obstruction. *Eur Respir J*. 1999;14(4):800–5.
  115. Rodriguez A, Diaz-Jimenez J, Edell E. Silicone stents versus metal stents for management of benign tracheobronchial disease Con: metal stents. *J Bronchology Interv Pulmonol*. 2000;7:184–7.
  116. Administration FaD. FDA public health notification: complications from metallic tracheal stents in patients with benign airway disorders. 2005. <http://www.fda.gov/cdrh/safety/072905-tracheal.html>.
  117. Lund ME, Force S. Airway stenting for patients with benign airway disease and the Food and Drug Administration advisory: a call for restraint. *Chest*. 2007;132(4):1107–8.
  118. Mughal MM, Gildea TR, Murthy S, Pettersson G, DeCamp M, Mehta AC. Short-term deployment of self-expanding metallic stents facilitates healing of bronchial dehiscence. *Am J Respir Crit Care Med*. 2005;172(6):768–71.
  119. Criner GJ, Sue R, Wright S, Dransfield M, Rivas-Perez H, Wiese T, et al. A multicenter randomized controlled trial of zephyr endobronchial valve treatment in heterogeneous emphysema (LIBERATE). *Am J Respir Crit Care Med*. 2018;198(9):1151–64.
  120. Criner GJ, Delage A, Voelker K, Hogarth DK, Majid A, Zgoda M, et al. Improving lung function in severe heterogenous emphysema with the spiration valve system (EMPROVE). A multicenter, open-label randomized controlled clinical trial. *Am J Respir Crit Care Med*. 2019;200(11):1354–62.
  121. Hartman JE, Vanfleteren LEGW, van Rikxoort EM, Klooster K, Slebos DJ. Endobronchial valves for severe emphysema. *Eur Respir Rev*. 2019;28(152).
  122. Gompelmann D, Benjamin N, Bischoff E, Kontogianni K, Schuhmann M, Hoffmann H, et al. Survival after endoscopic valve therapy in patients with severe emphysema. *Respiration*. 2019;97(2):145–52.
  123. Fiorelli A, D'Andrilli A, Cascone R, Occhiati L, Anile M, Diso D, et al. Unidirectional endobronchial valves for management of persistent air-leaks: results of a multicenter study. *J Thorac Dis*. 2018;10(11):6158–67.
  124. Gilbert CR, Casal RF, Lee HJ, Feller-Kopman D, Frimpong B, Dincer HE, et al. Use of one-way intrabronchial valves in air leak management after tube thoracostomy drainage. *Ann Thorac Surg*. 2016;101(5):1891–6.



# Ultrathin Bronchoscopy: Indications and Technique

# 3

Marta Díez Ferrer  and Antoni Rosell

## Introduction and Definition of the Procedure

Flexible bronchoscopes allow direct visualization of the airways. Depending on the indication for bronchoscopy, standard or therapeutic bronchoscopes can be used with outer diameters ranging 5–6 mm and inner diameters ranging 2–3 mm, respectively. In adult patients, standard and therapeutic bronchoscopes can therefore be advanced up to the third–fifth generation bronchi with some variation depending on both bronchoscope and airway anatomy.

Ultrathin bronchoscopy refers to the use of bronchoscopes with outer diameter of 3 mm or less, the thinness of which allows the exploration of the peripheral airways otherwise not reachable with conventional bronchoscopes and, particularly, the achievement of peripheral pulmonary lesions (PPLs). Although there is wide variation depending on the bronchial anatomy of every

patient, ultrathin bronchoscopes may allow airway visualization up to the 9th–12th bronchial generation of adult patients. A visual comparison of the thinness of therapeutic, standard, and ultrathin bronchoscopes is shown in Fig. 3.1.



**Fig. 3.1** Flexible bronchoscopes of different diameters: 2.8 mm ultrathin bronchoscope with a 1.2 mm channel, 4.9 mm standard bronchoscope with a 2.0 mm channel, and 6.0 mm therapeutic bronchoscope with a 2.8 mm channel

M. Díez Ferrer (✉)  
Department of Respiratory Medicine, Hospital  
Universitari de Bellvitge, Hospitalet de Llobregat,  
Barcelona, Spain  
e-mail: [marta.diez@bellvitgehospital.cat](mailto:marta.diez@bellvitgehospital.cat)

A. Rosell  
Thorax Department, Hospital Germans Trias i Pujol,  
Badalona, Barcelona, Spain  
e-mail: [arosellg.germanstrias@gencat.cat](mailto:arosellg.germanstrias@gencat.cat)

The main technical differences when performing ultrathin compared to standard bronchoscopy are related to mechanical constraints of the scope and the multiple bronchial divisions, the limitations inherent to the smaller diameter of the working channel, and the difficulty to obtain an optimal endoscopic view of the peripheral airways.

This chapter will review the history of ultrathin bronchoscopy, describe the indications and contraindications, provide step-by-step description of the procedure, and envision a possible evolution of the technique.

---

## History and Historical Perspective

The first ultrathin fiberoptic bronchoscope reported in medical literature was used through the working channel of a conventional bronchoscope. Developed by Tanaka et al. [1], the model Olympus BF-1.8T was composed of fine optical glass fibers and had a tip diameter of 1.8 mm that could go up to 180 mm past the tip of a conventional fiberoptic bronchoscope. It had no working channel and could be bent passively only. Attachment to a special camera allowed for the first photographs of peripheral airways of 2 mm or less and their first endoscopic classification [1, 2]. By the same time, Prakash was using a regular pediatric fiberoptic bronchoscope (Olympus BF-3C4) with an external diameter of 3.5 mm to explore and sample with a cell brush the abnormalities present in subsegmental airways of adult patients [3]. In 1990, Tanaka et al. developed a

second model of ultrathin bronchoscope with an outer diameter of 2.2 mm and distal tip that could be bended 120° upward and downward (Olympus BF-2.2T) [4]. Later, in 1994, a new bronchoscope (Olympus BF-2.7T) was released by the same authors with a tip diameter of 2.7 mm and the novelty of incorporating a 0.8 mm working channel that allowed small airways sampling under direct vision with a cell brush (Olympus BC-0.7T) [5]. Since then, newer ultrathin fiber bronchoscopes and video bronchoscopes with working channels up to 1.2 mm have been developed as well as various types of brushes and biopsy forceps that can be passed through these smaller working channels. Most recently, a new prototype of ultrathin hybrid bronchoscope with a working channel of 1.7 mm has been used that allows for radial probe endobronchial ultrasound (EBUS) insertion [6]. Pediatric bronchoscopes from other brands have also been used for exploring the peripheral airways of adult patients, although tube length might be a limitation if bronchoscopes are intended for the pediatric population only.

In essence, the concern to explore peripheral airways and to diagnose processes that occur beyond the physical limits of conventional bronchoscopes has led researchers to develop thinner versions of standard bronchoscopes. Ultrathin bronchoscopes are currently equipped with technologies that provide high-quality imaging, and wider working channels that allow using a greater number of instruments. A summary of the evolution of ultrathin bronchoscopes is shown in Table 3.1.

**Table 3.1** Evolution of ultrathin bronchoscopes in medical literature

Image <sup>a</sup>	Year	Type	Working length (mm)	External diameter (mm)	Internal diameter (mm)	Tip angulation (up/down)	Additional imaging techniques	Instruments
F	1984	Olympus BF-1.8T	950	1.8	–	–	–	–
F	1990	Olympus BF-2.2T	1150	2.2	–	120°/120°	–	–
F	1994	Olympus BF-2.7T	1200	2.7	0.8	120°/120°	–	Brush
F	1999	Olympus BF-XP40	600	2.8	1.2	180°/130°	–	
F	2004	Olympus BF-XP60	600	2.8	1.2	180°/130°	–	Brush and forceps
H	2004	Olympus BF-XP160F	600	2.8	1.2	180°/130°	–	
V	2014	Olympus BF-XP190	600	3.1	1.2	210°/130°	NBI	
H	2017	Olympus BF-MP190	600	3.0	1.7	210°/130°	–	Brush, forceps, and rEBUS <sup>a</sup>

F fiber optic bronchoscope, H hybrid bronchoscope, NBI Narrow Band Imaging, rEBUS radial probe endobronchial ultrasound, V video bronchoscope

<sup>a</sup> The Olympus UM-S20-17S radial miniature probe

## Indications and Contraindications

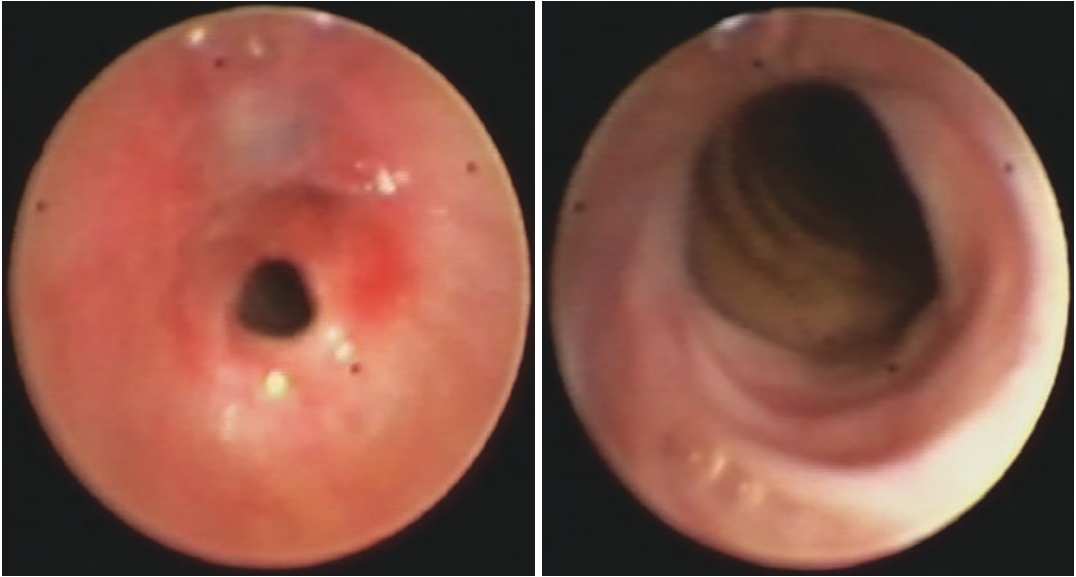
Unlike standard flexible bronchoscopy, which is used for both diagnostic and therapeutic purposes, the use of ultrathin bronchoscopy is mainly diagnostic of processes occurring in the middle and outer thirds of the tracheobronchial tree and, particularly, the diagnosis of peripheral pulmonary lesions. Although ultrathin bronchoscopes have occasionally been used for other purposes, such as accessing lung cavities or passing through stenotic areas, these potential indications are practically anecdotal compared to the large number of peripheral lesions that need to be studied. As to contraindications, these are very similar to those of standard flexible bronchoscopy.

Indications and contraindications of ultrathin bronchoscopy are detailed next.

## Indications of Ultrathin Bronchoscopy

The main indication of ultrathin bronchoscopy is the diagnosis of peripheral pulmonary lesions. In the latest American College of Chest Physicians (ACCP) guidelines, the overall sensitivity of flexible bronchoscopy for diagnosing central lesions was 88% compared to 78% for peripheral lesions [7]. This difference in the diagnostic yield between central and peripheral lesions is largely explained by the bronchoscope reaching the lesion. Therefore, it is logical that ultrathin bronchoscopes are used to diagnose peripheral pulmonary lesions.

Other uses of ultrathin bronchoscopy include the exploration of cavitated lesions, especially when aspergilloma formation is suspected, or the



**Fig. 3.2** Examination of critical stenosis with the ultrathin bronchoscope: view of the severe stenosis and distal trachea after passing through the stenosis with the ultrathin bronchoscope

study of critical stenosis (see Fig. 3.2), where the ultrathin scope allows minimal contact and air-flow limitation when introduced through the stenotic area thus avoiding asphyxia and even barotrauma. Other reported uses include volume reduction through suction application in a giant bulla [8] or peripheral nodule marking with barium prior to surgery [9].

However, as already mentioned, the ultrathin bronchoscope is mainly used for the study of peripheral pulmonary lesions and it is to this indication that we will refer from now on in this chapter.

### Contraindications of Ultrathin Bronchoscopy

Ultrathin bronchoscopy is a safe procedure. It should be considered though that the indications for ultrathin bronchoscopy are diagnostic and, mainly, of pulmonary nodules. Therefore, if at the time of the procedure the patient is undergoing any acute process that can be reversed, then the procedure should be postponed. Also, if there is the possibility that the patient will not be eligible for any potential treatment of the lesion after its diagnosis, i.e., oncospecific treatment,

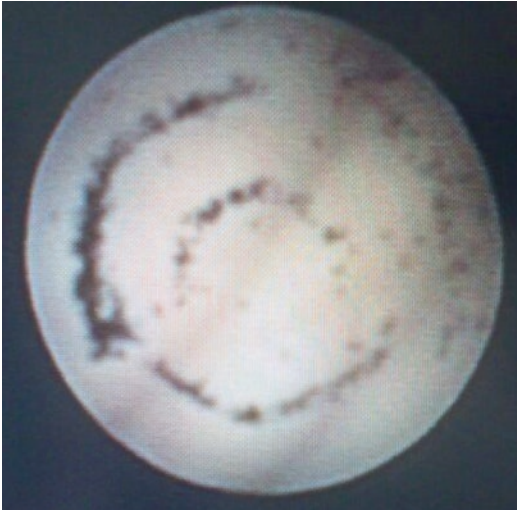then benefits of performing the procedure should be reconsidered.

On the other hand, it has to be taken into account that the ultrathin bronchoscope is a very fragile instrument and careful manipulation is imperative. Therefore, deep sedation may be necessary in order to prevent abrupt patient movements that could damage the fibers of the bronchoscope. If patient stillness cannot be guaranteed, ultrathin bronchoscopy is discouraged to avoid breaking of the fiber bronchoscope such as that shown in Fig. 3.3.

After these considerations, the contraindications for ultrathin bronchoscopy are basically the same as for any other flexible bronchoscopy. As already explained in Chap. 2, these include:

- Lack of informed consent.
- Lack of patient cooperation.
- Lack of an experienced bronchoscopist to perform or closely supervise the procedure.
- Lack of adequate facilities and personnel to care for emergencies that can occur, such as cardiopulmonary arrest, pneumothorax, or bleeding.
- Inability to adequately oxygenate the patient during the procedure.





**Fig. 3.3** Black dots corresponding to broken fibers after the ultrathin fiberoptic bronchoscope was accidentally bitten by a patient

- Uncorrected coagulopathy or bleeding diathesis.
- Severe refractory hypoxemia.
- Unstable hemodynamic status.
- Recent myocardial infarct or unstable angina.
- Acute superior vena cava syndrome.
- Increased intracranial pressure.

Relative contraindications (benefits should be weighed against potential risks) include:

- Partial obstruction of the central airways.
- Moderate to severe hypoxemia or any degree of hypercapnia.
- Uremia and pulmonary hypertension.
- Lung abscess.
- Debility and malnutrition.
- Known or suspected pregnancy.

### Description of the Equipment Needed

Ultrathin bronchoscopy may be performed in a bronchoscopy suite with the patient awake with topical anesthesia, under mild sedation or under general anesthesia. If general anesthesia is preferred, either nasal intubation, orotracheal intu-

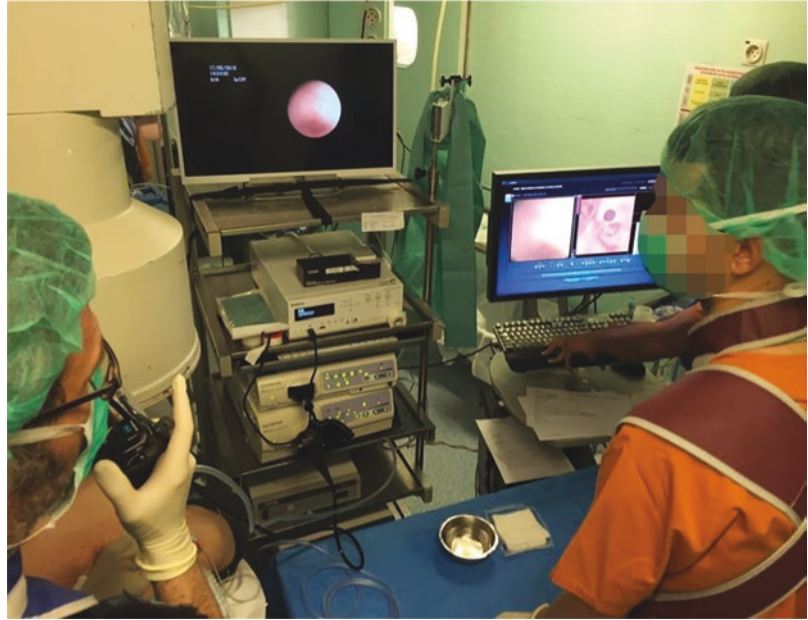bation, or a laryngeal mask can be used. The authors of the present text prefer performing ultrathin bronchoscopy under general anesthesia through a laryngeal mask in order to assure patient stillness during the procedure. This is further explained in the next paragraphs. In any case, intravenous access and patient monitoring of at least heart rate or electrocardiogram, respiratory rate, pulse oximetry, and blood pressure is mandatory. If general anesthesia is preferred, an anesthesiologist and qualified assistant as well as the necessary material for assisted ventilation and advanced cardiorespiratory monitoring must be guaranteed. In any case, resuscitation equipment should be available in the procedure room.

To perform ultrathin bronchoscopy, at least one skilled operator and two qualified assistants are needed.

The basic equipment needed for ultrathin bronchoscopy includes:

- Ultrathin bronchoscope and valve for the working channel.
- Suction valve and catheter.
- Light source and video processor.
- Syringes: 20 and 50 mL.
- Topical anesthesia: 2.5% lidocaine.
- Room-temperature saline in 50 mL syringes connected to a catheter and tip that can be connected to the valve of the working channel.
- Sampling instruments: Mini biopsy forceps and/or mini cytological brush (1 mm diameter). For scopes with a 1.7 mm working channel (Olympus BF-MP190), mini radial EBUS probes can be used.
- Specimen collection devices (bronchial washing receptacle, ThinPrep®Cytolyt, or similar buffered solution to support cells after biopsy).
- Cold saline should be ready to use in case of bleeding.
- Chest tube placement kit should be ready to use in case of pneumothorax.
- C-arm fluoroscopy or computed tomography (CT) should be available to track the position of bronchoscope and/or sampling instruments, as well as to confirm that no pneumothorax is present right after sampling.

**Fig. 3.4** Two bronchoscopists and one trained nurse performing ultrathin bronchoscopy with virtual bronchoscopic navigation (LungPoint®) in the endoscopy suite. Note that fluoroscopy is also used



Optional equipment:

- Cone-beam CT to corroborate the position of the ultrathin bronchoscope and the sampling instrument relative to the lesion.
- Virtual bronchoscopy, virtual bronchoscopic navigation, or electromagnetic navigation to assist procedure planning and guiding of the ultrathin bronchoscope to the peripheral pulmonary lesion.

In Fig. 3.4, ultrathin bronchoscopy with virtual bronchoscopic navigation is performed under general anesthesia in the endoscopy suite.

## Procedure Description

In general terms, the procedure starts by conducting an accurate planning of the bronchial route leading to the peripheral lesion, either through fine reading of a high-resolution chest CT or supported by a planning software. During the procedure of ultrathin bronchoscopy, target approximation can be accomplished after memorization of the planned bronchial route or assisted by navigation software. Fluoroscopy is usually used to track the position of the ultrathin bron-

choscope and to assist sampling, although CT or cone-beam CT can also be used to corroborate the position of the ultrathin bronchoscope and the sampling instrument relative to the lesion. Sampling is performed with instruments of limited size that can be passed through the working channel of the ultrathin bronchoscope.

To develop all the aforementioned aspects and to provide an integrated understanding of the technologies that can be coupled with ultrathin bronchoscopy, we have structured ultrathin bronchoscopy in the following steps: procedure planning, target approximation, position verification, and sampling.

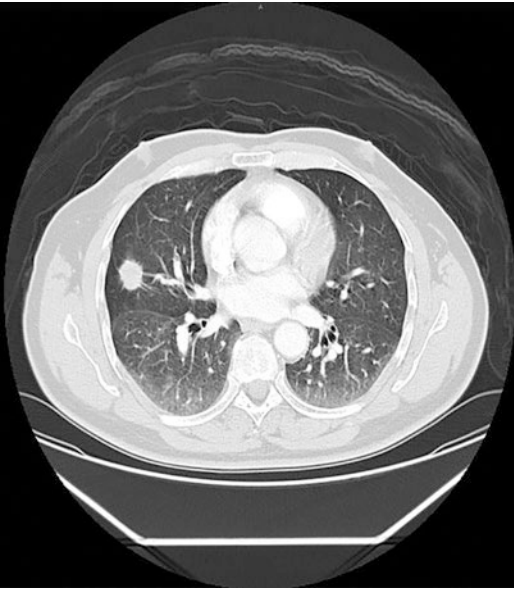
## Procedure Planning

First thing to consider when planning the procedure on a CT image is the presence of a bronchus or artery afferent or, within the peripheral lesion, the so called bronchus sign and artery sign. When present, the diagnostic yield of the procedure is significantly higher [10–12]. Examples of bronchus and artery signs are shown in Fig. 3.5.

If the slice thickness of the CT is sufficient to allow identification of small bronchi and if a bronchus leading to the lesions is present, then it

will be feasible to reconstruct a three-dimensional bronchial route to the peripheral nodule. With this information alone, highly trained bronchoscopists have the ability to reconstruct the bronchial route from the CT and mentally reproduce the route during the procedure. Fortunately, complementary technologies have been developed to assist procedure planning. The mainstay technology for procedure planning is virtual bronchoscopy. Dedicated software is used for multiplanar

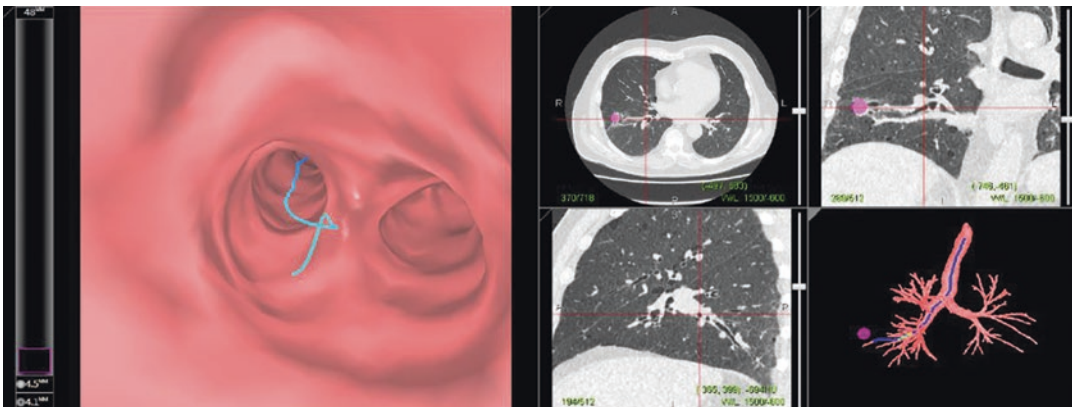
reconstruction of CT images and segmentation of the airways. After manual identification of the nodule in the CT, the bronchial route to the nodule can be followed through the inner lumen of the segmented airways. This route can be memorized by the bronchoscopist to be reproduced in the bronchoscopy suite. Otherwise, a virtual bronchoscopic navigation platform can be used to perform virtual bronchoscopy in the endoscopy suite and match virtual and endoscopic images during the procedure to facilitate orientation. A screenshot of a virtual bronchoscopy is shown in Fig. 3.6.



**Fig. 3.5** Chest CT showing both a bronchus and artery leading to a PPL (bronchus and artery signs, respectively)

### Target Approximation

In order to guarantee patient stillness during the procedure, the authors of the present text prefer performing ultrathin bronchoscopy under general anesthesia and laryngeal mask or endotracheal intubation. This facilitates bronchoscope manipulation in the smaller subsegmental bronchi, allows application of short controlled apneas to gain greater operator control during sampling, and may also avoid accidental damaging of the fiber bronchoscope due to abrupt patient movements. It has to be pointed out that, in some cases, cutting some centimeters of the proximal end of the orotracheal tube may be necessary to warrant full insertion of the 600 mm working length of the ultrathin bronchoscope and avoid falling

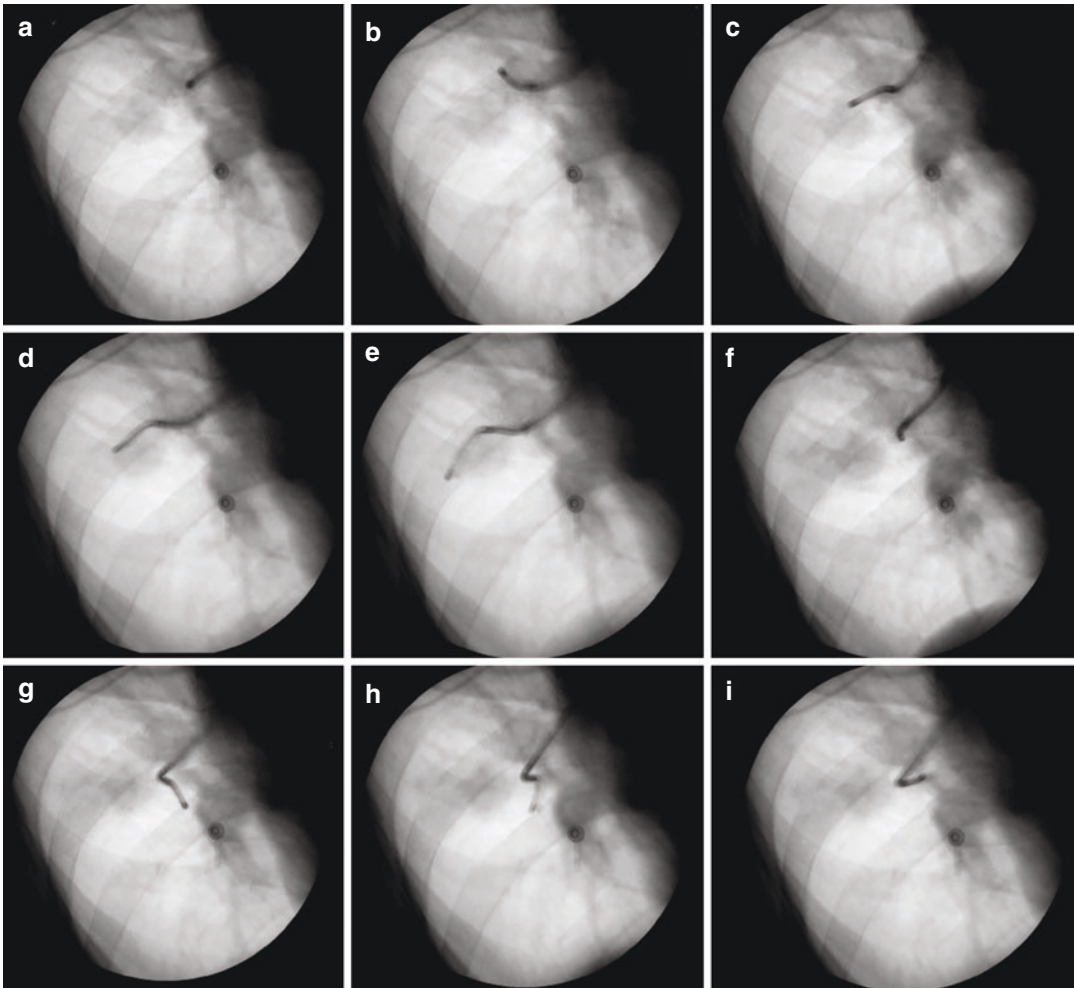


**Fig. 3.6** Procedure planification with a virtual bronchoscopy navigation system (LungPoint®). This system allows matching the virtual bronchoscopy seen in the Figure with the endoscopic images during the procedure

short to the lung periphery, especially in relatively tall patients. However, general anesthesia is not mandatory and moderate sedation is preferred in many centers.

As previously mentioned, target approximation can be accomplished after memorization of the planned bronchial route or assisted by virtual bronchoscopic navigation software. This software allows matching virtual and endoscopic images during the procedure to guide the ultrathin bronchoscope through every bifurcation leading to the afferent bronchus. In either case, fluoroscopy is usually used to track the real-time position of the ultrathin bronchoscope.

Fluoroscopy was the first imaging technique used for guiding the ultrathin bronchoscope to the nodule [1]. Biplanar fluoroscopy is desirable but, when not accessible, the C-arm must be rotated adequately. Although it is not a guidance tool per se, it can be useful to confirm the position and direction of the bronchoscope throughout the procedure and relative to the peripheral lesion, as long as the lesion is fluoroscopically visible (see Fig. 3.7). Unfortunately, peripheral pulmonary nodules are not always visible with fluoroscopy. In one study, the authors reported that from a population of 1369 individuals at high risk for lung cancer, 15 small peripheral lung



**Fig. 3.7** Fluoroscopy Fluoroscopy can be used to track down the path leading to the peripheral pulmonary lesion. To assure that the right direction is followed, fluoroscopy

is performed in every bifurcation (a–i). Whenever misdirected, the bronchoscope is pulled backward to the previous bifurcation and another bronchus followed



cancers were detected with low-dose CT. Of these, 73% had negative chest radiography [13]. Because CT allows for nodule detection independent of size, localization, and characteristics of the PPL, it has also been used for verifying the position of the instrument when exploring the peripheral airways [14].

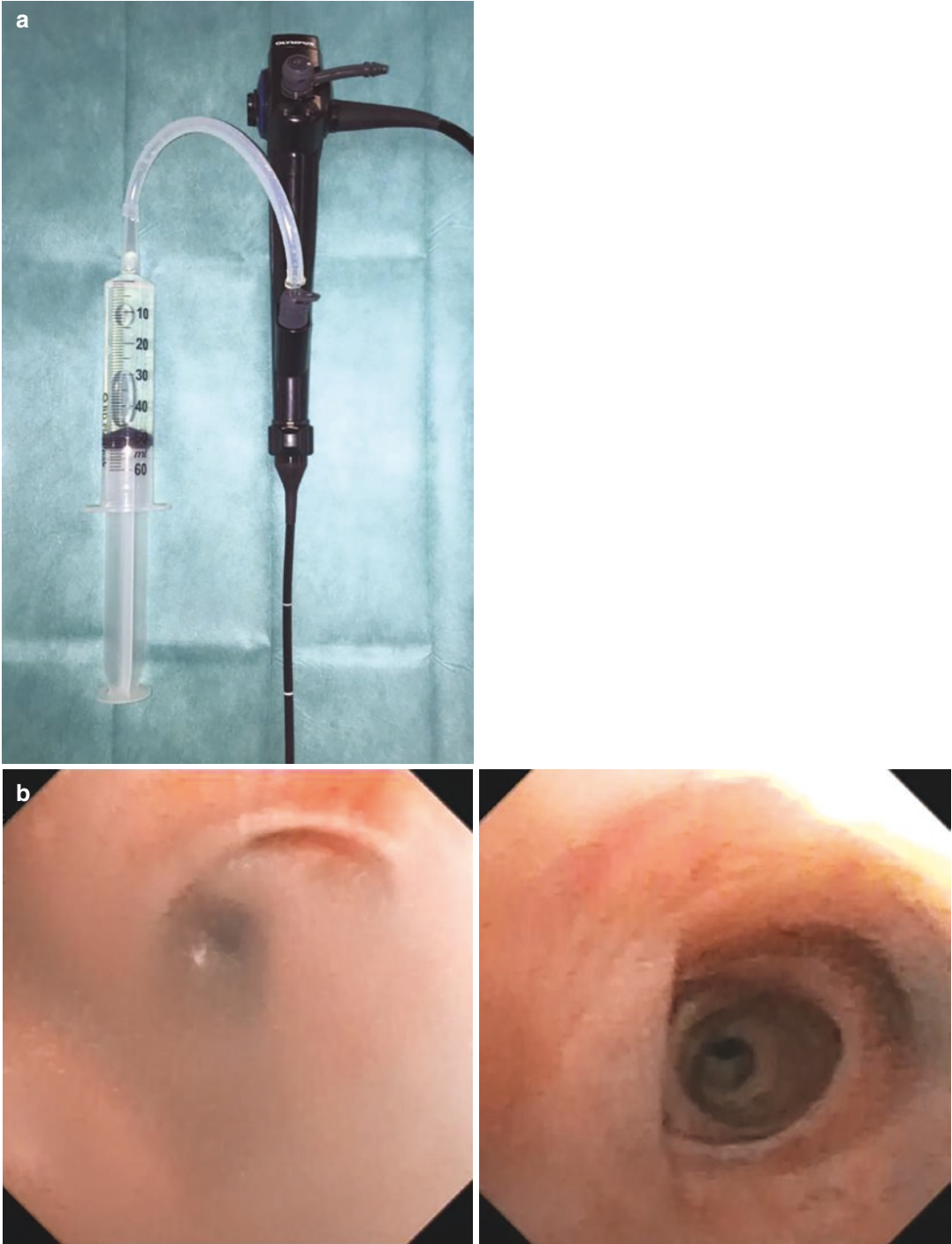
Virtual bronchoscopic navigation can also be used to assist in lesion approximation. When using virtual bronchoscopic navigation systems, a trained bronchoscopist is needed to perform the virtual bronchoscopy through the previously selected path. The assistant bronchoscopist will guide the operator through the airways and will indicate the right direction in each encountered bifurcation. To date, there is only one large randomized trial comparing ultrathin bronchoscopy with and without use of virtual bronchoscopic navigation. This study by Asano et al. showed no significant differences in diagnostic yield on both groups (67.1% vs. 59.9%;  $p = 0.173$ ) in 350 patients with peripheral nodules  $\leq 3$  cm. However, subgroup analysis of these data showed that the navigation system could be helpful for achieving nodules located in the peripheral third of the lung, those invisible in the postero-anterior radiographs and when located in the upper right lobe. Fluoroscopy was used in both groups to ensure location of the ultrathin bronchoscope and sampling of the desired location [15]. In a later study, we compared ultrathin bronchoscopy with and without virtual bronchoscopic navigation and evaluated the influence of segmentation on diagnostic yield [16]. We compared 55 cases of virtual bronchoscopic navigation-guided ultrathin bronchoscopy to 110 unguided controls. Although the diagnostic yield did not differ between both arms (47% and 40%, respectively;  $p = 0.354$ ), an 85% diagnostic yield was observed when segmentation was optimal and the peripheral nodule was endobronchial, compared to a 30% diagnostic yield when the segmentation was suboptimal and a 20% diagnostic yield when segmentation was optimal but the lesion extrabronchial. In fact, the position of the lesion relative to the bronchus, that is, if the lesion is endo- or extrabronchial, will determine the diagnostic yield of the procedure. This point is fur-

ther commented in the next section on position verification.

During target approximation with an ultrathin bronchoscope, several considerations should be made. First of all is the limited suction capability of the ultrathin bronchoscope due to the small working channel. Therefore, if abundant or thick secretions are present, it might be recommended that bronchial hygiene with a conventional bronchoscope is performed either prior to starting or during the procedure. Also, angulation of the tip of the ultrathin bronchoscope can be challenging in the upper lobes. Sometimes it might be simply impossible to overcome some anatomical angulations with the ultrathin bronchoscope. Leaving the biopsy forceps inside the working channel may provide greater stiffness to the bronchoscope in some cases. Finally, another disadvantage of ultrathin compared to conventional bronchoscopes is the quality of the endoscopic vision, not only in regard to technical manufacturing details but also to bronchial anatomy in the lung periphery. Particularly, a greater collapsibility is found in the periphery due to progressive loss of stiffness in the intrapulmonary airways. To overcome bronchial collapsibility and improve endoscopic vision in the peripheral airways, it is recommended that secretions are not aspirated and saline is continuously instilled instead. In our institution, a 50 mL syringe with room-temperature saline is connected to the working channel of the ultrathin bronchoscope. The assistant instills saline as requested, thus facilitating bypassing of secretions and bronchial lumen widening. A view of ultrathin bronchoscopy in peripheral airways under saline infusion is shown in Fig. 3.8.

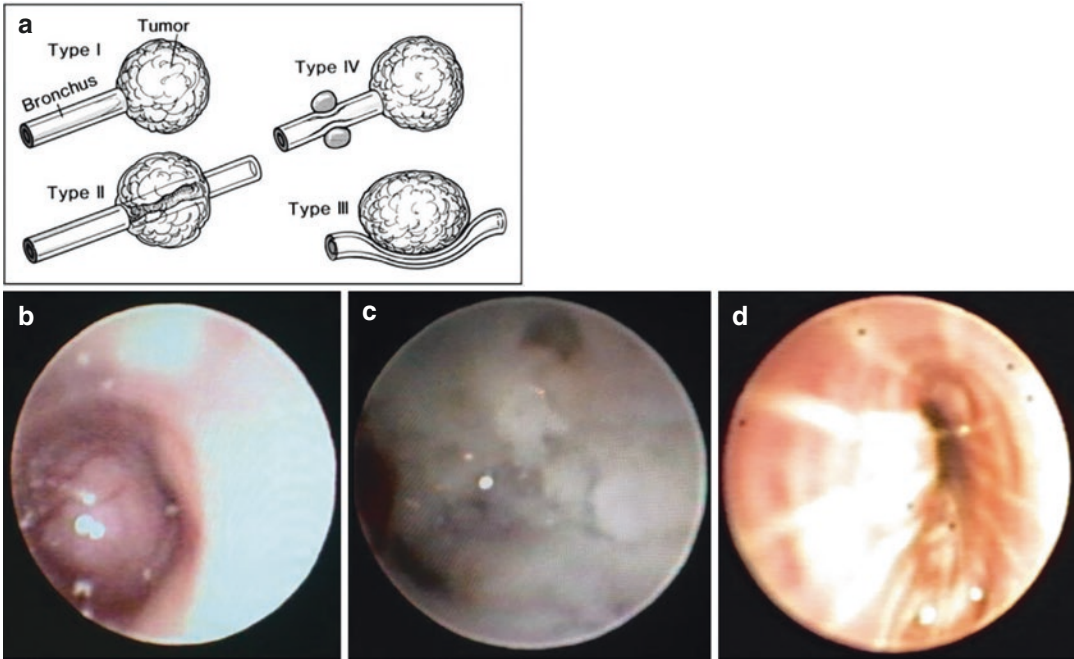
### Position Verification

Once the peripheral pulmonary lesion is approximated and no endobronchial abnormality is visualized, then two issues might have occurred: either approximation to the lesion has not been accurate enough, or the lesion is extrabronchial. At this point, fluoroscopy, CT, or cone-beam CT can be used to verify the position of the ultrathin bronchoscope relative to the lesion. Also, a radial



**Fig. 3.8** Ultrathin bronchoscopy in peripheral airways: (a) 50 mL aliquot with saline connected to the working channel. (b) Views before and after saline infusion





**Fig. 3.9** Tsuboi's classification of the relationship between the bronchus and the nodule (a). *Type I*: bronchus leads to the nodule. *Type II*: the bronchus is completely surrounded by the nodule. *Type III*: extrinsic compression without bronchial mucosal invasion. *Type IV*: the bron-

chus is proximaly obstructed either by the peribronchial disease or by lymphadenopathy and then continues on to communicate with the tumor distally [17]. Figure from reference [18]. Bronchoscopic examples of each type: (b) Type I; (c) Type II; (d) Type III/IV

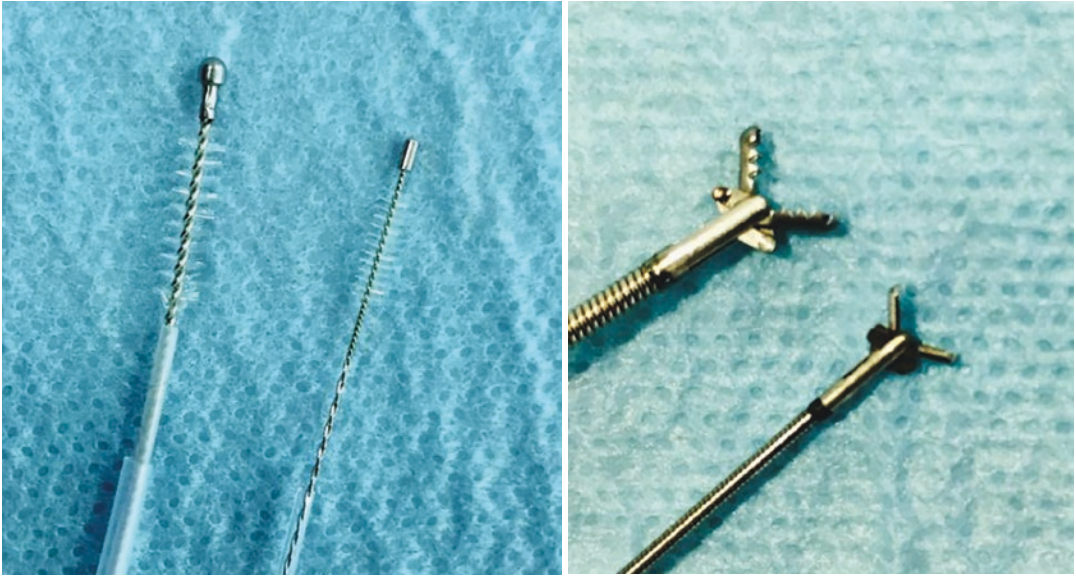
miniature endobronchial ultrasound (EBUS) probe could be used to locate an extrabronchial lesion [6, 19], although it has to be noted that the radial miniature EBUS probe mentioned in these studies was used through a novel prototype ultrathin bronchoscope that had a 1.7 mm working channel. Otherwise, if the problem is that approximation was not accurate enough, then renavigation is mandatory, when possible.

In Fig. 3.9, a classification of the relationship between the bronchus and the lesion is shown.

### Sampling

Concerning the instruments that can be passed through the working channel of an ultrathin

bronchoscope, the only commercialized and widely available sampling tools are “mini” versions of the cytological brush and biopsy forceps: the mini cytology brush (Olympus BC-201C-1006) and the mini biopsy forceps (Olympus FB-56D-1). Caution must be taken to manipulate the forceps as they can break more easily than larger ones and their cost is relatively high (around €1000 in Europe). A visual comparison of the sizes of the sampling instruments is shown in Fig. 3.10. The limited size of these mini sampling instruments implies that a greater number of samples need to be taken. In our institution, four to six biopsies along with cytological brush and bronchial washing samples are performed when studying peripheral pulmonary lesions.



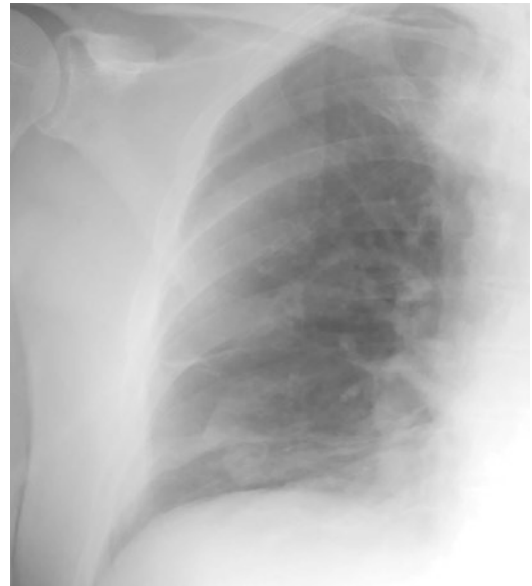**Fig. 3.10** Sampling instruments of different sizes: regular cytology brush and biopsy forceps compared to the 1 mm wide “mini” versions

## Complications

Ultrathin bronchoscopy is a very safe procedure. Since it is a scheduled diagnostic procedure in the great majority of cases, complications are not frequent. However, like any invasive technique, it is not without risks. Most frequent complications of ultrathin bronchoscopy include:

- Transient fever and pneumonia, especially if a relatively high amount of saline is retained and in those patients with purulent secretions. In our institution, if purulent secretions are observed during bronchoscopy, prophylactic antibiotics with 2 g of amoxicillin/clavulanate (or equivalent in patients with penicillin allergy) are administered during the procedure.
- Pneumothorax can occur during or after sampling. Performance of a chest X-ray or thoracic echography is recommended when biopsies are performed without fluoroscopic control. A pneumothorax is seen in Fig. 3.11.

Overall, the reported complication rate for ultrathin bronchoscopy is 3% and includes pneu-



**Fig. 3.11** Apical laminar pneumothorax after sampling a peripheral pulmonary nodule in the right lower lobe with an ultrathin bronchoscope

monia, bleeding, bradycardia, chest pain, extensive coughing, hypertension, lidocaine intoxication, lung abscess, and pneumothorax (in 1% of cases) [6, 11, 12, 15, 20–25].

## Future Directions

Ultrathin bronchoscopes are and will be very relevant tools for the diagnosis of pulmonary nodules. Historical perspective offers a clear tendency to design wider working channels that allow use of diagnostic tools with higher diagnostic yield. These include mini probes to confirm the location and the relation to the bronchial lumen, mini cryoprobes (1.1 mm) to sample intra- and peribronchial nodules, or the expected bendable, thin, and short needles for extrabronchial lesions. One of the robotic bronchoscopy platforms (Ion™ Endoluminal System Intuitive Surgical) uses a 3.5 mm outer diameter bronchoscope with a 2.0 mm diameter working channel and few mechanical constrictions as the catheter can articulate 180° in any direction. These characteristics are unbeatable, but its costs (€1 M approximately) are currently unaffordable for most centers.

As for mini cryoprobes, these may allow sampling intra- and extrabronchial lesions and may therefore improve the quality and quantity of tissue obtained [26]. A French randomized trial comparing mini cryobiopsy vs. forceps has been recently initiated ([ClinicalTrials.gov](https://clinicaltrials.gov/ct2/show/study/NCT05230992) Identifier: NCT05230992, March 2022) and results are expected by next year.

Nevertheless, the significant change will be the introduction of single-use ultrathin bronchoscopes. Since the Coronavirus Disease-2019 (COVID-19) pandemic, single-use scopes have experienced a substantial boost and are considered a substitute for conventional bronchoscopes in some settings (intensive care units, operating rooms, etc.). The different brands (Boston Scientific, Ambu, Bronchoflex, or Vathin) have similar external diameters of 3.8 mm with inner diameter of 1.2 mm. These single-use scopes can perfectly substitute the conventional ultrathin reusable bronchoscopes because they are cheaper (cost of acquisition and maintenance) and do not suffer a prolonged repair time when damaged. Nevertheless, the authors consider that the evolution of these scopes to longer working length

(from 60 to 70 cm) and bigger inner diameter of the working channel (from 1.2 to 1.7 mm), with less image resolution if needed to maintain the outer diameter of 3.8 mm, can let the proceduralists achieve better results with different diagnostic tools, and even consider therapeutic probes.

---

## Summary and Recommendations

The ultrathin bronchoscope is a versatile instrument that is mainly used for diagnosing peripheral pulmonary lesions. Although it is a flexible bronchoscope, just like the standard, its small diameter allows exploring the peripheral airways and selecting the bronchial route at each bifurcation encountered. To advance the bronchoscope through the peripheral airways, however, infusion of saline might be necessary to maintain an optimal endoscopic view, facilitating bypass of secretions and bronchial lumen widening. Finally, the limited size of the working channel of ultrathin bronchoscopes implies not only that the suctioning capacity is limited but also that smaller sampling instruments must be used.

Ultrathin bronchoscopy procedure can be broken down into four steps: (1) procedure planning, which can be performed after fine reading of a high-resolution chest CT or can be supported by a planning software; (2) target approximation, which can be accomplished after memorization of the planned bronchial route or assisted by navigation software; (3) position verification, with either fluoroscopy, CT, or cone-beam CT; and (4) sampling, using small instruments that can be passed through the working channel of the ultrathin bronchoscope.

To get the utmost of ultrathin bronchoscopy in the diagnosis of peripheral pulmonary lesions, the combination of various technologies is recommended to increase the diagnostic yield.

The single-use slim bronchoscopes are more affordable than the conventional reusable flexible scopes and will progressively let this technique be broadly used.

## References

1. Tanaka, Mitsuru, Masaru Satoh, Oichi Kawanami, Kaoru Aihara. 1984. A new bronchofiberscope for the study of diseases of very peripheral airways. *Chest* 85(5):590-594 <https://doi.org/10.1378/chest.85.5.590>.
2. Tanaka M, Kawanami O, Satoh M, Yamaguchi K, Okada Y, Yamasawa F. Endoscopic observation of peripheral airway lesions. *Chest*. 1988;93(2):228-33.
3. Prakash UB. The use of the pediatric fiberoptic bronchoscope in adults. *Am Rev Respir Dis*. 1985;132(3):715-7.
4. Tanaka M, Kohda E, Satoh M, Yamasawa F, Kawai A. Diagnosis of peripheral lung cancer using a new type of endoscope. *Chest*. 1990;97(5):1231-4.
5. Tanaka M, Takizawa H, Satoh M, Okada Y, Yamasawa F, Umeda A. Assessment of an ultrathin bronchoscope that allows cytodiagnosis of small airways. *Chest*. 1994;106(5):1443-7.
6. Oki M, Saka H, Ando M, Asano F, Kurimoto N, Morita K, Kitagawa C, Kogure Y, Miyazawa T. Ultrathin bronchoscopy with multimodal devices for peripheral pulmonary lesions. A randomized trial. *Am J Respir Crit Care Med*. 2015;192(4):468-76.
7. Rivera, MP Atul C. Mehta, Momen M. Wahidi. 2013. Establishing the diagnosis of lung cancer. *Chest* 143(5 Suppl):e142S-e165S <https://doi.org/10.1378/chest.12-2353>.
8. Asai N, Ohkuni Y, Kaneko N. A case of giant bulla successfully treated by bronchoscopic lung volume reduction therapy. *J Bronchol Interven Pulmonol*. 2014. <https://doi.org/10.1097/lbr.000000000000026>.
9. Asano F, Shindoh J, Shigemitsu K, Miya K, Abe T, Horiba M, Ishihara Y. Ultrathin bronchoscopic barium marking with virtual bronchoscopic navigation for fluoroscopy-assisted thoracoscopic surgery. *Chest*. 2004;126(5):1687-93.
10. Naidich, David P., Robert Sussman, William L. Kutcher, Conrado P. Aranda, Stuart M. Garay, Norman A. Ettenger. 1988. Solitary pulmonary nodules. *Chest* 93(3):595-598 <https://doi.org/10.1378/chest.93.3.595>.
11. Shinagawa N, Yamazaki K, Onodera Y, Asahina H, Kikuchi E, Asano F, Miyasaka K, Nishimura M. Factors related to diagnostic sensitivity using an ultrathin bronchoscope under CT guidance. *Chest*. 2007;131(2):549-53.
12. Shinagawa N, Yamazaki K, Onodera Y, Asano F, Ishida T, Moriya H, Nishimura M. Virtual bronchoscopic navigation system shortens the examination time--feasibility study of virtual bronchoscopic navigation system. *Lung Cancer*. 2007;56(2):201-6.
13. Kaneko M, Eguchi K, Ohmatsu H, Kakinuma R, Naruke T, Suemasu K, Moriyama N. Peripheral lung cancer: screening and detection with low-dose spiral CT versus radiography. *Radiology*. 1996;201(3):798-802.
14. Asano F, Yoshihiko M, Chihito K, Tatsuo K, Masatoshi I, Tomoki K, Joe S, Michiaki H. [CT-guided transbronchial diagnosis using ultrathin bronchoscope for small peripheral pulmonary lesions]. *Nihon Kokyuki Gakkai zasshi*. 2002;40(1):11-6.
15. Asano F, Shinagawa N, Ishida T, Shindoh J, Anzai M, Tsuzuku A, Ozumi S, Morita S. Virtual bronchoscopic navigation combined with ultrathin bronchoscopy. A randomized clinical trial. *Am J Respir Crit Care Med*. 2013;188(3):327-33.
16. Díez-Ferrer M, Morales A, Tebé C, Cubero N, López-Lisbona R, Padrones S, Aso S, et al. Ultrathin bronchoscopy with and without virtual bronchoscopic navigation: influence of segmentation on diagnostic yield. *Respiration*. 2019;97(3):252-8.
17. Tsuboi E, Ikeda S, Tajima M, Shimosato Y, Ishikawa S. Transbronchial biopsy smear for diagnosis of peripheral pulmonary carcinomas. *Cancer*. 1967;20(5):687-98.
18. Ranes JL, Arroliga AC, Mehta AC. Role of bronchoscopy in the Evaluation of Solitary Pulmonary Nodule. *Clin Pulm Med*. 2003;10(1):34-8.
19. Zheng, Xiaoxuan, Fangfang Xie, Ying Li, Junxiang Chen, Yifeng Jiang, Jiayuan Sun. 2021. Ultrathin bronchoscope combined with virtual bronchoscopic navigation and endobronchial ultrasound for the diagnosis of peripheral pulmonary lesions with or without fluoroscopy: a randomized trial. *Thorac Cancer* 12(12):1864-1872 <https://doi.org/10.1111/1759-7714.13995>.
20. Ali EAA, Takizawa H, Kawakita N, Sawada T, Tsuboi M, Toba H, Takashima M, et al. Transbronchial biopsy using an ultrathin bronchoscope guided by cone-beam computed tomography and virtual bronchoscopic navigation in the diagnosis of pulmonary nodules. *Respiration*. 2019;98(4):321-8.
21. Eberhardt, Ralf, Nikolas Kahn, Daniela Gompelmann, Felix J. Herth. 2010. LungPoint: a new approach to peripheral lung lesions. *Chest* 138(4), 1026 <https://doi.org/10.1378/chest.10265>.
22. Franzen D, Diacon AH, Freitag L, Schubert PT, Wright CA, Schuurmans MM. Ultrathin bronchoscopy for solitary pulmonary lesions in a region endemic for tuberculosis: a randomised pilot trial. *BMC Pulm Med*. 2016;16(1):62.
23. Matsuno Y, Asano F, Shindoh J, Abe T, Shiraki A, Ando M, Suzuki T, Seko A, Moriwaki H. CT-guided ultrathin bronchoscopy: bioptic approach and factors in predicting diagnosis. *Intern Med*. 2011;50(19):2143-8.
24. Oki M, Saka H, Asano F, Kitagawa C, Kogure Y, Tsuzuku A, Ando M. Use of an ultrathin vs thin bronchoscope for peripheral pulmonary lesions: a randomized trial. *Chest*. 2019;156(5):954-64.
25. Sumi T, Ikeda T, Sawai T, Shijubou N, Kure K, Yamada Y, Nakata H, Mori Y, Takahashi H. Comparison of ultrathin bronchoscopy with conventional bronchoscopy for the diagnosis of peripheral lung lesions without virtual bronchial navigation. *Respir Investig*. 2020;58(5):376-80.
26. Franke KJ, Linzenbold W, Boesmueller H, Nilius G, Hetzel J. A new tool for transbronchial cryobiopsies in the lung: an experimental feasibility ex-vivo study. *Pneumologie*. 2016. <https://doi.org/10.1055/s-0036-1572197>.





## Introduction and History

Bronchoscopy is the invasive procedure most commonly indicated to diagnose and treat pulmonary problems. There are two kinds of bronchoscopes: the flexible bronchoscope (FB), and the rigid bronchoscope (RB). The first one is the most utilized in clinical practice. However, the rigid bronchoscope is a very important instrument for the diagnosis and treatment of many pulmonary disorders, and has been applied to the airway for many decades.

The interest in reviewing the airway goes back to 1823, when Horace Green introduced first a sponge and then a rubber catheter into the bronchi, applying silver nitrate to burn lesions located at the level of the larynx and trachea. Later, Joseph O'Dwyer introduced a tube to release adhesions of the lower airways caused by diphtheria, and he also constructed a thin-walled tube to assist in the removal of foreign bodies.

The first rigid bronchoscopy was introduced by Gustav Killian (Germany) in 1897, who became the Father of Bronchoscopy, after performing the first rigid bronchoscopy for

the extraction of a foreign body (a small piece of a pig bone) in a 63-year-old patient. For the procedure, Killian used an esophagoscope and rigid forceps [1]. Chevalier Jackson, from Philadelphia, Pennsylvania, USA, popularized this new bronchoscopic technique and developed the most widely used rigid bronchoscope at the time. His idea of placing a small light in the distal part of the endoscope revolutionized the endoscopist's ability to examine the airways. In 1916, he established bronchoesophagology departments in five hospitals in Philadelphia, training many well-known bronchoesophagology professionals [2, 3].

During more than 70 years, the rigid bronchoscope or open tube was the only available instrument to review the airway. At first, it was mainly used to remove foreign bodies or dilate strictures, but later new applications were described: aspiration of secretions, hemoptysis treatment, biopsies, etc.

Shigeto Ikeda's flexible bronchoscope (FB) development in the 1960s [4] has been the most significant advance in the area of bronchoscopy, and has changed the practice to our days, allowing the pulmonology physicians to develop ability in performing flexible bronchoscopy and also gave place to the introduction of new technologies specifically designed to assist with FB.

Shortly after its invention, the FB almost replaced the RB in clinical practice. However, the rigid bronchoscope is still a very important

J. P. Díaz-Jiménez (✉)

Interventional Pulmonary Department, Hospital Universitari de Bellvitge, Hospitalet de Llobregat, Barcelona, Spain  
e-mail: [pablodiaz@pablodiaz.org](mailto:pablodiaz@pablodiaz.org)

A. N. Rodríguez

School of Medicine, National University of Mar del Plata, Buenos Aires, Argentina

instrument in the study and treatment of airway disorders.

Rigid and flexible bronchoscopes complement each other in many indications, and there is no reason to see their application in opposite terms, since each instrument has strengths and limitations. In this chapter, we will review our experience on RB, along with a complete discussion on indications and contraindications.

---

## Overview of RB

The RB is a stainless steel open tube with variable lengths and widths. It has a distal end, beveled and smooth, and a proximal end that can be adapted to a metallic universal head with several side ports. The distal end is used to lift the epiglottis during intubation, and is also very useful to dilate strictures and to “core” tumors. Lateral openings or fenestrations are present to allow contralateral lung ventilation while working.

The RB is the preferred instrument for endoscopic resections. The rigid tube is the only device that allows a complete control on the airway, assuring proper oxygenation and ventilation while performing, for instance, a laser resection. Aspiration of blood, secretions, and smoke can be easily achieved at the same time that an excellent view of the central airway is depicted.

One of its main strengths is the ability to confront serious hemorrhagic accidents, or airway obstruction from various etiologies: benign or malignant conditions, foreign bodies, mucus plugs, etc. Although unusual, massive hemorrhages can occur even in routine fiber bronchoscopies. The RB allows the application of pressure on the hemorrhagic area until hemostasis occurs, giving sufficient time to apply other therapeutic modalities, which can bring a definitive solution to the problem. It is also particularly useful in the pediatric population. Children’s airway diameter is very small, and it is preferable to use a hollow tube in order to allow spontaneous breathing or assisted ventilation. The FB blocks the airway, and the patient has to breathe around it, increasing significantly the airway resistance and work of breathing, making the procedure more diffi-

cult. The RB, in turn, allows the patient to breathe through it, favoring spontaneous breathing and mechanical ventilation while performing the procedure.

The rigid bronchoscope has undergone modifications over time, particularly after laser resection and stent placement became regular indications for different airway conditions. The most used brand names today are Efer(R), Storz(R), and Wolf® and Novatech.

---

## Innovations

The first rigid bronchoscope for laser application was designed by Jean François Dumon (Fig. 4.1), from Marseille, France, for the brand Wolf. In contrast to other rigid bronchoscopes, the Wolf system has two lateral ports (one for the laser fiber and the other one for the suction catheter) and a rotating ventilation connector that allows assisted ventilation without interrupting the treatment. All ports can be occluded to allow closed

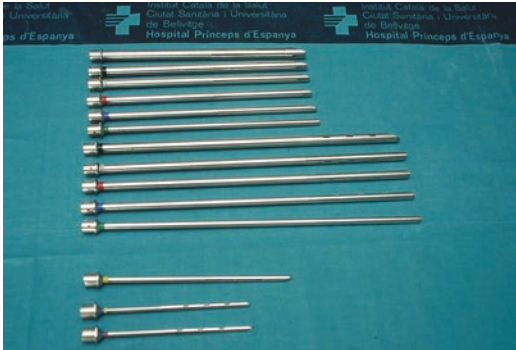


**Fig. 4.1** Dr. J.F. Dumon

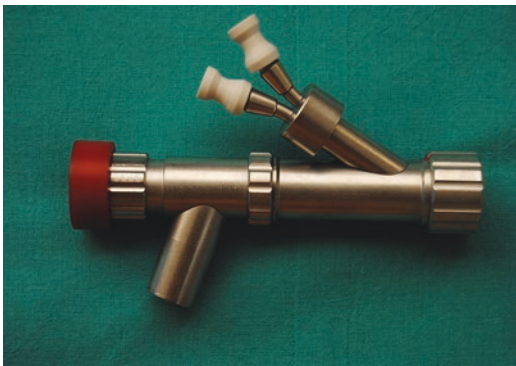


circuit ventilation. Based on this experience, the Dumon-Harrel (Efer) universal rigid bronchoscope was later developed. It associated modifications already present in the Wolf system with other advantages, such as the possibility of using a series of 11 interchangeable tubes with increasing diameters available in 2 different lengths: the short tubes (Fig. 4.2) for endotracheal treatments, with no side orifices (diminishing the air lost in the trachea); and the long tubes for endobronchial treatments, with lateral orifices that allow an adequate ventilation even when the bronchoscope is placed in a peripheral bronchus. Internal and external diameters are color coded on each tube (from 3.5 to 10 mm internal diameter and from 4 to 12 mm external diameter). Available tubes for pediatric use have an internal diameter from 3 to 5 mm and are 20 cm in length.

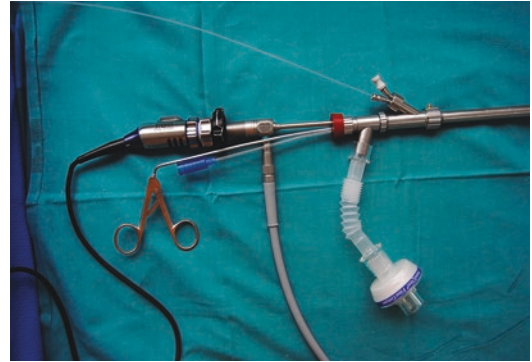The head of the rigid bronchoscope can be adapted to the desired tube, according to the different needs (Figs. 4.3 and 4.4).




**Fig. 4.2** Dumon's rigid bronchoscope



**Fig. 4.3** Universal head of the rigid bronchoscope



**Fig. 4.4** Rigid bronchoscope with ancillary tools and connection for ventilation

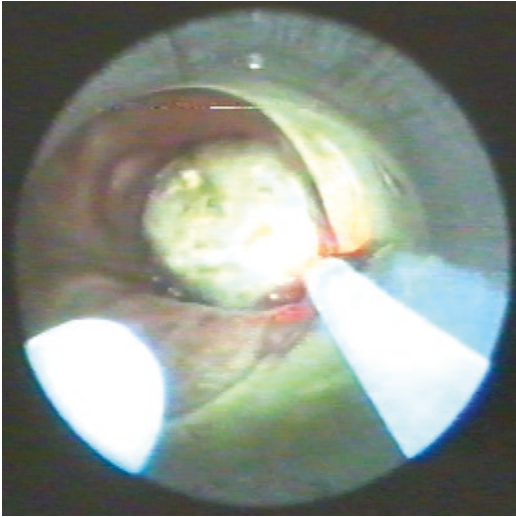


**Fig. 4.5** Rigid telescope (optic)

The Dumon-Harrel rigid bronchoscope comes with a separate deployment system for the silicone (Dumon) prosthesis.

Another Dumon-Harrel system innovation is the fact that it is possible to lift the superior part of the lateral door, allowing the aspiration of large tumor fragments without modifying the position of the suction catheter. The securing caps are made of silastic, with one or several orifices of different sizes. These caps are much more solid than the usual rubber ones, allowing a more hermetic closure, optimizing ventilation.

The rigid optics offer direct 0° vision (Fig. 4.5); they come in three diameters, 3.5, 5.5, and 7 mm, and they are not fixed. There is also a smaller optics for pediatric use. These instruments easily slide through the silastic caps, and can be moved back and forth according to need. It is a very useful feature to avoid sudden move-



**Fig. 4.6** Correct position of the suction catheter and laser fiber into the rigid bronchoscope (RB). It is important to always see the tip of the bronchoscope during the procedure

ments that can injure the airway. The rigid optic can be pulled back to avoid midst, or loss of visualization due to blood or detritus. The rigid optic, suction catheter, and laser fiber are independent inside the rigid tube, making handling easier.

The most comfortable position when applying laser is placing the tip of the laser fiber advanced within the airway, the suction catheter located slightly back to the laser tip, and the rigid optic further back from the working field (Fig. 4.6). The independence of these elements allows modifying at any time their position according to the intervention needs.

The RB has been designed to present a universal character; in other words, to adapt to multiple endoscopic situations. In addition to laser application settings described above, this instrument can take other configurations: all or some of the entrance ports can be used (from one to three), open or closed ventilation circuit (for “jet ventilation,” manually assisted ventilation, or spontaneous ventilation), use of short or long tubes, adult or pediatric tubes, and allowing diagnostic and/or therapeutic procedures on practically any group of patients.

Thinking that the rigid bronchoscopy technique had to be simplified in order to be more

easily used among the interventional bronchoscopy community, H. Dutau, from J.F. Dumon’s team in Marseille, developed a new RB system in collaboration with Karl Storz (manufacturer) and Novatech (distributor): the Dutau-Novatech Rigid Bronchoscope (DNRB) (Fig. 4.7). This new model is more simple to use and it adapts better to new technologies and facilitates the association with FB.


Among the new features that this system provides, one can list: a snap fit connection of the tubes to the head allowing easier attachment and detachment; an iso-connection of the tubes (once the head has been detached) to the ventilation circuit, which improves ventilation while preventing air leak when spontaneous ventilation is used during general ventilation—this iso-connection allows an easier utilization of the FB (Fig. 4.8); a smaller detachable head allowing easier handling (Fig. 4.9); and a 45° angled bevel tip of the tubes, which are less traumatic without reducing the possibility to core out endoluminal lesions. Graduations on the outer surface of the tubes allow measurements of lesions and facilitate stent dimension decision.

The complete DNRB adult set will include 3 tracheal tubes (14, 13, and 12 outer diameter) and 5 bronchial tubes (14, 13, 12, 11, and 9 outer diameter), a detachable head including the body’s head, the ventilation connector, and a 3-divided detachable side port including 1 channel for the suction, 1 for flexible probes (such as laser, electrocautery, or cryotherapy probes), and 1 for the jet ventilation connection (Fig. 4.7).

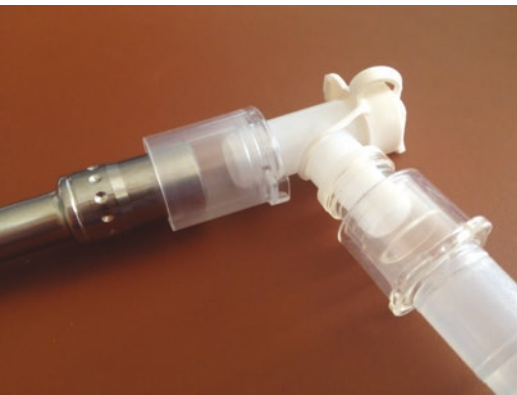The DNRB is compatible with all the Karl Storz rigid instruments and with the Tonn silicone stent loading and insertion system.

The variant of Storz rigid bronchoscope for laser bronchoscopy was designed by Shapshay from Boston, USA. It is specially manufactured for jet ventilation, and for this reason it has a fixed port designed to serve this purpose. It is available in 10 mm internal diameter size (12 mm external diameter), presenting also a connection for ventilation and two additional ports [5].

A recently introduced rigid bronchoscope, called Rigid Integrated Bronchoscope developed by Wolf, presents separate channels for optics



**Fig. 4.7** The Dutau-Novatech Rigid Bronchoscope (DNRB)



**Fig. 4.8** An iso-connection of the tubes (once the head has been detached) to the ventilation circuit, which improves ventilation while preventing air leak when spontaneous ventilation is used during general ventilation. This iso-connection allows an easier utilization of the flexible bronchoscope (FB)



**Fig. 4.9** A smaller detachable head allowing easier handling

and instruments, and integrates the operator head with the camera. It has also an irrigation port to wash the distal lens. It has the advantage of increasing the working space and thus

improves manipulation within the bronchoscope. However, the vision is limited since the camera does not go further distal to the end of the rigid bronchoscope.

It is clear that the RB, although keeping its original basic shape, has suffered several modifications to adapt to specialized procedures,

like laser application, prosthesis placements, and dilatation of tracheobronchial strictures. The RB allows flexible bronchoscopes to get through it, taking advantage of both instruments at the same time.

## Ancillary Equipment

**Suction Catheters** They play a very important role during procedures. In addition to suction of blood, smokes, and debris, they are useful in palpating lesions to give an idea on consistency. They are also used to instillate medications such as saline, epinephrine, and lidocaine. It is recommended that they do not exceed 3 mm in diameter, and are made of rigid transparent material. In

that way the laser beam will not burn them, and they will not collapse during suction.

Other ancillary instruments that should be available are: foreign bodies rigid forceps (used to retrieve different elements from the airway and to adjust position of silicone stents), scissors, scalpel, balloons, mechanical dilators, endoscopic resectors, and prostheses and laser equipment, most of them designed by Dumon (Fig. 4.10).

The capability of project images is very important as well. That serves various purposes: it allows all the team to follow the procedure in detail and anticipate steps. It also permits recording the procedure, for both educational and documentation purposes.



**Fig. 4.10** Ancillary equipment designed by Dr. Dumon



## Applications and Contraindications

RB's most important applications are therapeutic, and include: laser application, electrocautery, argon plasma coagulation or cryotherapy, dilatation of tracheobronchial stenosis using balloon dilatation or directly with the rigid tube, airway stent placement, and foreign bodies' removal, particularly in children. Massive hemoptysis is also another therapeutic indication. Diagnostic applications are: hemoptysis and the need for deep biopsies, better obtained with the rigid biopsy forceps (Table 4.1, [6]).

There are not many absolute contraindications for the use of the rigid bronchoscope: unstable cardiovascular state, significant cardiac arrhythmias, severe hypoxemia that will not improve with the procedure, and cervical spine instability. The most important contraindication is lack of appropriately trained personnel [7].

Some clinic situations, however, must be considered as relative contraindications for RB. An unstable neck that makes unsafe the excessive mobilization during the bronchoscopy, microstomy, maxillofacial trauma or other oral lesions that prevent an appropriate mouth opening to introduce the rigid tube, and technical difficulties related with cervical ankylosis and severe kyphoscoliosis, among the most important ones.

**Table 4.1** Indications for rigid bronchoscopy<sup>a</sup>

Foreign body removal
Hemoptysis
Tracheobronchial stenosis
Tracheobronchomalacia
Central airway obstruction
Extrinsic compression
Therapeutic procedures:
Stents
Laser
Electrocautery
Cryotherapy
Argon plasma coagulation
Dilatational balloons

<sup>a</sup> Modified from Lamb and Beamis [6]

## Rigid Bronchoscopy Applications

### Laser Bronchoscopy

Laser bronchoscopy application has diminished in the last few years. Reasons include high cost of the equipment, lack of adequate training, need for RB in most of the cases, long procedure time, the absence of improvement in mortality when applied to malignant conditions (even though quality of life and survival definitely get better), and the insufficient number of patients in some centers. In addition to this, other therapeutic modalities such as electrocautery and argon plasma coagulation have become more popular given their availability, low cost, and similar good results.

However, the application of laser therapy through the RB has not been replaced in some indications and it is still the technique offering the best results. RB laser resection is an important tool in treating central airway obstructions (benign or malignant) and provides an immediate reopening of the trachea or bronchus when stenotic lesions are found. For most of the treatments, Neodymium-Yttrium-Aluminum-Garnet (Nd-YAG) or Neodymium-Yttrium-Aluminum-Phosphate (Nd-YAP) is used. Diodos laser is also equally useful and has become more popular given its lower cost.

In a published series about laser applications in malignant lesions, 1585 patients were treated with 2253 therapy sessions of Nd-YAG laser during a period of 11 years. More than 93% showed immediate good results. Complications included 18 hemorrhages, 6 pneumothorax, and 10 deaths [8].

Similar results have been published on low-grade malignant tumors that are unresectable or present in nonsurgical candidates with advanced age or severe cardiorespiratory insufficiency. In a prospective study on 19 patients who presented with carcinoid tumor and cylindroma with inoperability criteria, the use of laser was associated with an immediate symptomatic improvement

following the treatment in 100% of the cases. Fifteen patients were free from disease during a follow-up time of average 20 months (from 6 to 50 months) and 2 patients died of unrelated causes at 21 and 6 months of treatment. Although low-grade malignant tumor recurrence is hard to predict, the use of laser is an excellent way to keep inoperable patients free from symptoms [9].

In a retrospective review on laser bronchoscopy application, laser resection was offered to 17 patients with inoperable lung carcinoma requiring mechanical ventilation secondary to acute respiratory failure. All of them received Nd-YAG laser treatment through an RB, with respiratory assistance (jet ventilation) at the operating room. A subgroup of seven patients could be weaned from mechanical ventilation and were able to receive other therapies showing an improved survival. The rest of the patients had tumoral extrinsic compression of the airway or submucosal growing of the tumor and had almost no benefit from laser application. They died on mechanical ventilation or after being extubated when the order “comfort measures only” was established. Survival improvement seen in the first group of patients ( $p = 0.0038$ ) was associated with the presence of obstructive endobronchial tumor as the cause of respiratory insufficiency [10]. These results show that even those patients with acute respiratory failure due to obstructive lesions can be treated with laser bronchoscopy with good results.

## Tracheobronchial Prosthesis

In the last years, tracheobronchial stenosis has received much interest from bronchoscopists due to the several available techniques to treat this problem. Endoscopic treatment of tracheobronchial stenosis can be achieved through balloon dilatation, stent placements, laser resection, and even with dilatation with the rigid bronchoscope.

Balloon dilatation can be done through an RB or through a fiber bronchoscope with a wide working channel. The balloons are designed for esophagus dilatation but are also used in the airway; angioplasty balloons can be used as well.

RB dilatation is performed by applying a smooth rotation to the rigid tube, simultaneously advancing, and passing through the stenotic area several times until a safe airway diameter is achieved. Laser resection can be applied before this dilatation if needed. All fibrous stenoses treated by mechanical dilatation have the tendency to recur and repeated procedures are needed to keep the airway open. In addition, sometimes forceful maneuvers cause mucosal damage with more scar formation, and in the long term they can worsen the stenosis. Thus, mechanical dilatation is only recommended to solve an acute situation and as a bridge to a more definitive treatment. Benign airway stenosis is discussed in detail in a dedicated chapter of this book.

Tracheobronchial prostheses can be indicated in benign or malignant airway stenosis [11].

Several types of prosthesis are available to use with both the RB and the flexible bronchoscope. Many of the auto-expandable metallic prostheses have been designed specially to allow placement with the flexible bronchoscope under fluoroscopic control. Airway prosthesis is discussed in detail elsewhere in this book. However, we have to say that the RB is the only instrument suited for silicone prosthesis placement. We recommend the use of silicone prosthesis to treat most of the airway lesions, particularly benign conditions since metallic stents are associated with significant complications that have been recognized by many experts and made clear by the U.S. Food and Drug Administration (FDA) during 2005, when it recommended against metallic stent application to airway benign conditions. (Available at: [www.fda.gov/cdrh/safety/072905-tracheal.html](http://www.fda.gov/cdrh/safety/072905-tracheal.html).)

Results on the application of the RB are presented in a study where this instrument was used under general anesthesia to insert silicone prostheses (Dumon) in 31 adult patients with more than 50% malignant airway obstruction. After laser resection, a stent was placed and all patients presented immediate improvement in respiratory symptoms. All patients but three tolerated the prostheses well. Stents were placed in the trachea in 14 cases, right main bronchus 13,



left main bronchus 8, and intermedius bronchus 3. Complications included: migration 5, mucous obstruction 2, and hemoptysis in 1 patient [12].

We consider training in RB use crucial to any interventional pulmonologist. Regardless of the type of stent selected for a given treatment, expertise working with the RB will be needed at some point during the course of therapy. For instance, when a complication arises (i.e., migration, stent disruption) and the prosthesis needs to be removed or replaced, the best instrument to retrieve it is the RB. In addition, most of the prostheses placed via FB are very difficult to remove with fibrobronchoscope, requiring the application of the RB to extract or adjust them. When metallic uncovered stents stay for a given period of time within the airway, they become embedded in the mucosa. In order to remove them, the beveled end of the RB should be placed between the metallic stent wall and the tracheal mucosa, and with soft rotating movements the RB is advanced distally “dissecting” the stent from the airway wall until it is totally detached. Then it can be removed with forceps (Fig. 4.11).

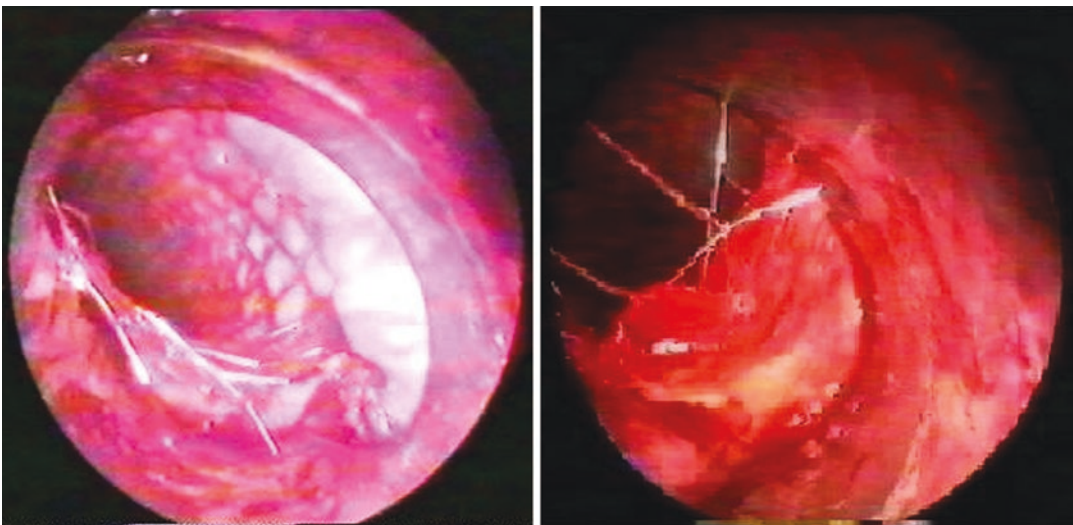
Likewise, the growth of tumor tissue through uncovered metallic stents requires RB and laser to relieve the obstruction, remove the prosthesis, and replace it in case of need. Training in RB is one of the most important skills that an interven-

tionist has to learn and be proficient at, and is a requisite when placing silicone (Dumon) prosthesis [12, 13]. Such training also involves the staff assisting and collaborating during the procedure: assisting nurse or scrub nurse, anesthesiologist, circulating assistant, etc.

### Transbronchial Needle Aspiration (TBNA)

TBNA of subcarinal and paratracheal nodules was described in 1950. Wang, in 1978, reported a diagnostic sensibility of 90% for this technique when applied with the RB [14]. After the introduction of the FB during the 1960s, most of the bronchoscopists have been using this instrument to perform TBNA in lymph nodes located subcarinal and parahilar. Diagnostic sensibility for TBNA when performed with the FB has been reported as 80–89%, especially when the 19-gauge needle is used [15, 16].

The appearance of endobronchial ultrasound (EBUS) has completely changed the approach to lymph node sampling, and this technique has virtually replaced all blind procedures given the high diagnostic yield, particularly in mediastinal sampling [17]. However, in spite of EBUS generalized use, it can still be a place for blind TBNA



**Fig. 4.11** Metallic prosthesis removal with the rigid bronchoscope

applied both with the RB and the FB, particularly where EBUS is not available given its high cost.

A study published in 1996 described results on needle aspiration through the RB. Twenty-four procedures were performed in 24 patients using RB and a 2-cm long rigid needle, under general anesthesia and guided with computerized tomography. Samples taken were: tracheal wall ( $n = 11$ ), main carina ( $n = 3$ ), right secondary carina ( $n = 3$ ), left principal bronchus ( $n = 2$ ), and right principal bronchus ( $n = 3$ ). The average amount of samples was 6 (from 1 to 19). An *in situ* cytopathologist immediately reviewed the samples to determine the number of samples needed. Diagnostic sensibility and specificity was 88% and 100%, respectively. TBNA was diagnostic in 18 patients. Findings helped in therapeutic decisions in 21 patients. There were no false-positives during a follow-up period of six months. Three false-negatives were present, and follow-up showed that these three patients ultimately had malignant lesions. There were no complications [18]. Those findings suggest that even though the technique has been improved by using EBUS or blind TBNA with the FB, the RB can have a role in the diagnosis of intrathoracic lymphadenopathies if no other method is available.

### **Rigid Bronchoscope in Other Treatments for Bronchial Obstruction**

Laser treatments in tracheobronchial obstructions are effective, but expensive. As a result, other therapeutic options have been developed and applied with good results. Electrocautery is broadly available and results in airway resections comparable to laser. Also, cryotherapy and argon plasma coagulation can be applied with RB.

Results on electrocautery application with the RB are depicted in a study that performed this procedure under general anesthesia in 29 patients with tracheobronchial obstruction, 24 of which had malignant conditions. In nine patients, stents were placed immediately after electrocoagulation. All patients but one presented immediate improvement in the symptoms, and an objective

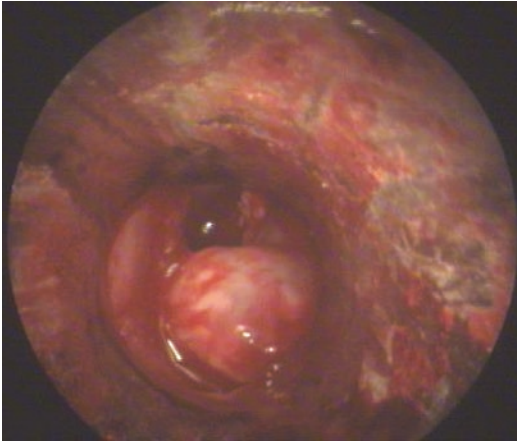
improvement in the pulmonary function was also observed in eight patients who had been tested with spirometry before surgery. There were neither intraoperative deaths nor complications [19]. Electrocautery can be also applied through the FB, but, similar to laser applications, procedures are more time consuming since the RB allows better vision, optimal suction, and the possibility to remove large tumoral pieces. Cryotherapy has been presented as an alternative therapy for obstructions. However, it is called a “slow” opening method since it lacks immediate effects. Initially, all treatments with cryotherapy were performed with RB but more recently, the cryotherapy probes have been designed for application with the FB and new modalities of cryotherapy are available, such as cryoextraction or cryoresection and also cryospray, which makes this technique more versatile and can be applied as a fast method to open the airway.

Balloon dilatation can be applied both with the RB and FB.

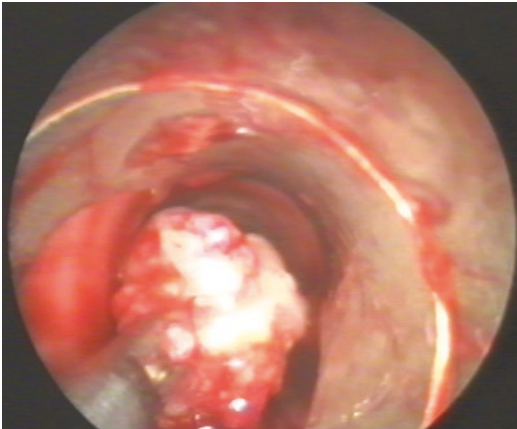
### **Mechanical Debridement**

Even though laser, electrocautery, cryotherapy, and argon plasma coagulation are useful for coagulating during debridement of airway lesions, most of the obstructive tumors are generally extracted in a mechanical mode. In fact, all opening procedures involve the use of forceps. When performed with an FB, this procedure is invariably long and tedious, especially if large tumors are involved. The removal of big tumor pieces through the narrow channel of FB is very complicated, since the biggest pieces that can be extracted fit in small biopsy forceps. It is obvious that a bigger channel such as the one of the RB will accomplish the same task in a shorter period of time.

Most of the experienced bronchoscopists use laser only to coagulate the tumor and when that is accomplished, dissect large tumoral pieces with the beveled rigid tube (Figs. 4.12 and 4.13), obtaining a much efficient procedure [20]. Grillo et al. [21] affirm that the use of auxiliary methods like laser is not necessary to reopen the airway



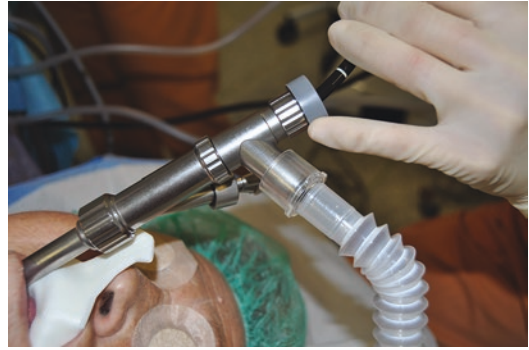**Fig. 4.12** Resection of a tumor with the beveled end of the rigid bronchoscope



**Fig. 4.13** Aspiration of a tumor piece with the rigid aspiration catheter

and only adds costs and risks to the procedure. However, their study on 56 patients whose tumors were removed only by mechanical means showed a 7% mortality associated with the treatment—considerably higher than when other methods are applied, including laser.

The RB itself acts as an airway dilator, and can achieve reopening of an obstruction in a shorter time than required by the FB. There is an important and statistically significant difference in the total number of sessions needed to permeabilize the airway with RB and FB; the RB requires only one session and the FB an average of two [22]. In fact, bronchoscopists who use only FB to



**Fig. 4.14** Use of the flexible bronchoscope through the rigid bronchoscope (RB)

extract tumors usually require several sessions. The theoretical advantage of the FB in opening peripheral airway obstructions is rarely needed, since these cases are infrequent and the need of reopening a distal airway as a palliative measure is questionable, unless postobstructive infection is present. Even so, the FB can be more easily introduced through the RB (Fig. 4.14) and thus take advantage of the strengths of both instruments [23].

### Pediatric Rigid Bronchoscopy

In 1997, the Pediatric Bronchoscopy Group of the European Respiratory Society (ERS) presented the current pediatric bronchoscopy state in Europe. From the 125 contacted centers, it was informed that during the 12 months previous to the survey, 7446 bronchoscopies had been done on pediatric patients: 4587 (61.6%) of these bronchoscopies were completed with FB and 2859 with RB. While 29 centers were utilizing both techniques, 17 centers were using only FB and 5 centers just RB. Twenty-three centers were applying RB in the operating room, 7 centers in the intensive care unit (ICU), and 15 centers in a specially equipped room.

The most frequent indications included the following: persistent/recurrent pneumonia, wheezing refractory to medical treatment, persistent atelectasis, stridor, chronic cough, interstitial pneumonia, pulmonary tuberculosis, suspected foreign body, hemoptysis, and suspicion of pulmonary malfor-

mation, among others. The RB was completed under general anesthesia in 31 centers and under local anesthesia and intravenous sedation in 2. A bronchoalveolar lavage (BAL) was performed in 2231 children; 812 of them were immunosuppressed. The utility of the diagnostic varied with the type of procedure. For centers using only FB, only RB, and the combination of both (FB + RB), diagnostic application was almost invariably superior when the use of FB and RB were combined, except for persistent/recurrent pneumonia [24].

Advantages of the RB in the pediatric population are mainly due to the fact that, in a small-diameter airway, it is safer to use an instrument that does not produce increased resistance in the airway. The rigid scope provides complete airway control and at the same time, the possibility of applying diagnostic or therapeutic interventions.

### Tracheobronchial Dilatation

The RB has been used to perform tracheobronchial stenosis dilatation in children. The dilatation technique with an angioplasty catheter can be performed as follows: the catheter (6F, 8 mm diameter) is placed under direct vision with the RB and balloon inflation is controlled with a manometer. Children so treated showed a significant improvement in the size of the intraoperative lumen, and an important postoperative clinic improvement, confirmed with endoscopies and radiographies. Recurrence of stenosis many times requires a repeated procedure until a more definitive therapy can be offered, or the natural increment of the airway diameter as the child grows up relieves the stenosis without the need for further procedures [25].

Other therapeutic options include the progressive dilatation using the rigid bronchoscope.

### Foreign Bodies Removal

The RB is the instrument of choice to extract foreign objects in pediatric patients. It is a safe, effective, and a life-saving technique. The number of ancillary instruments such as forceps, bas-

kets to use with the RB is important; almost every type of foreign body can be extracted. However, the flexible 1-mm channel bronchoscope can also be utilized for the same purpose [26]. Urologic instruments (like ureteral baskets and forceps) can go easily through this narrow 1-mm channel and capture big foreign bodies.

Nevertheless, it is recognized that the RB is still the best instrument to extract foreign bodies from the pediatric airway and it is also preferred in adults. In a retrospective study on 60 adults presenting foreign bodies aspiration, the FB was successful in removal in 61% of cases, while the RB had a success rate of 96% [27]. In adults, however, the FB is frequently applied first to inspect and to try removal, and if it is not possible, then RB is considered [28].

Opinions about RB use on children, though, are divided. A prospective study evaluating the role of both instruments (rigid and flexible) showed that the predictive value of clinic and the radiologic findings in 83 children with foreign bodies in the airway were useful in deciding selection of RB or FB. The study concluded that the rigid bronchoscope must be used if any of the following clinical signs were present: asphyxia, a radio-opaque foreign body present in the radiography, and the association of decreased air sounds along with obstructive overinflation in the chest radiograph. The FB can be used in the rest of the cases, and if during the procedure a foreign body is identified, RB must be utilized for its extraction. Application of the RB was always successful, except in one child who required a second session for the extraction of the foreign body. Post-surgical complications included laryngospasm ( $n = 1$ ) and laryngeal edema ( $n = 6$ ), and two of them required brief intubation. The extracted foreign bodies comprised: peanuts, vegetables, inert metals, bones and teeth, plastic pieces, and other inorganic objects [29]. The authors conclude that following this protocol was cost effective, limiting the number of unsuccessful procedures and the use of RB. Many of the recommendations and conclusions of this study have been questioned, however. The study implies that the RB cannot examine the distal airway as good as the flexible bronchoscope.



However, with the rigid bronchoscopes and smaller optics, the presence of foreign bodies can be detected as much as with a flexible bronchoscope. Procedures performed with the RB versus the FB are not more time consuming at all; on the contrary, general anesthesia for RB can be completed with intravenous sedation and the required time is comparable to the fibrobronchoscopy time. In addition to this, most of the foreign bodies removal performed with FB are also under general anesthesia, introducing the FB through an endotracheal tube (ETT), making manipulation cumbersome. Besides, children who were treated with RB did not have longer hospitalizations than children treated with FB [30]. In conclusion, we prefer the RB for foreign body retrieval in the pediatric population since it is safer, easier to do, and the number of ancillary elements is such that virtually all foreign bodies can be removed in one session.

### **Rigid Bronchoscopy in Intensive Care Units (ICU)**

RB indications in the ICU are limited. The most common are: massive hemoptysis, large foreign bodies, obstructive lesions of the central airway, laser treatments, and prosthesis placement. All of these cases constitute relative indications, and the RB is, in practice, used only when the FB cannot fix the problem.

In the event of lung cancer patients ventilated for tumoral airway obstruction, the application of rigid laser bronchoscopy and airway stent according to need can result in a change in level of care allowing immediate discontinuation of mechanical ventilation, as was published by Colt et al. [31].

Two important inconveniences in applying the RB in an ICU are the need of the bronchoscopist to be situated behind the patient and the difficulty of positioning the patient to easily insert the device. If the RB is indicated, it may be better to transfer the patient to the operating room to proceed.

### **Other Indications**

The RB can be a life-saving instrument in situations other than massive hemoptysis and foreign body removal.

In difficult tracheal intubations, the FB is used to guide the endotracheal tube to the trachea. Occasionally, when this technique fails, the RB may act as endotracheal tube.

Impacted mucus plugs, difficult to aspirate with the FB, can be easily extracted with the RB. This is especially useful in pediatric patients with cystic fibrosis, asthma, and postoperative atelectasis.

### **Complications**

Most of the complications arise from a poor RB insertion technique: laryngeal or vocal cord trauma, hypercapnia, hypoxemia, or hemodynamic instability. The bronchoscopist must not forget that he/she shares the airway control with the anesthetists, and that oxygenation and ventilation have priority.

Complications associated with the use of RB include: teeth, lips, gums, and throat lesions. Moderate laryngeal edema is very common but rarely produces relevant problems. Post-procedure throat and neck pain are frequent, and usually last from 24 to 36 h. Vocal cord lesion is inversely related to the ability of the operator: on trained hands, it hardly occurs. Luxation of arytenoids may be also seen when a bad technique is used during intubation, or when the procedure is executed with a poor local anesthesia or with an awake patient. A very infrequent and severe complication is rupture of the posterior tracheal wall. This requires surgical repair. Minimum or massive bleeding may occur during tumor resections. Most of the complications diminish as the bronchoscopist's ability increases. Lack of training of the endoscopist or his/her assistants must be considered an absolute contraindication for the use of the RB [32] (Table 4.2, [6]).

**Table 4.2** Complications

Hypoxemia
Cardiovascular instability
Tracheobronchial perforation
Esophageal perforation
Laryngeal edema
Vocal cord damage
Dental trauma
Pneumothorax
Severe bleeding
Mediastinal emphysema
Laryngospasm
Bronchospasm

Drummond et al. published their eight years of experience using the RB in a university hospital [33]. During this time, 775 procedures were performed. The authors found that 13.4% of the patients experienced an associated complication. Most of them were minor complications. Patients presenting abnormal pulmonary function or basal hypoxemia, known cardiac disease, and those with coagulation abnormalities (prolonged prothrombin time or thrombocytopenia) were more susceptible to complications than those without comorbid conditions. Preoperative risk increased when the following parameters were present:

- PaO<sub>2</sub> <55 mmHg
- FEV1 <50% of the predicted value
- Unstable angina or cardiac failure
- Severe arrhythmia
- Heart attack during the six months prior to the procedure
- Thrombocytopenia < to 50.000 per µL [9]
- Abnormal prothrombin time

Patients presenting with any of these risk factors had a 37% rate of complication during rigid bronchoscopy. The group of patients with more complications presented malignant conditions involving the main carina. Also, those undergoing RB for airway obstruction had more chances to complicate. Only three deaths resulted from RB application. The cause of death was bleeding in two of the patients and respiratory insufficiency in the remaining one.

Complications were also frequent in the group of patients receiving RB to remove foreign bodies. The least complicated group was the one presenting benign conditions (benign tumor removal or benign stenosis treatment). In general, these patients showed less comorbidities.

One patient presented pneumothorax associated with the use of a laser for airway resection. Other complications were: those associated with anesthesia (hypoxemia, arrhythmia) and a dental piece rupture.

The experience published by this group reinforces the notion that patients must be carefully selected according to risk before performing RB. It also reminds us that the RB is a powerful therapeutic tool that can also cause damage.

## The Procedure

When rigid bronchoscopy was introduced, it used to be performed in awake patients. Nowadays, it would be an exception to proceed under those conditions. All patients we treat with RB are under general anesthesia, and they are carefully evaluated just as we do for any other surgical procedure. History taken should be detailed, noting all comorbid conditions and medications in use. Physical exam should focus on temporomandibular disorders, cervical spine mobility, and spine abnormalities. Minimum laboratory values must be obtained: coagulation profile, blood count, chemistry profile, acid base status, and electrocardiogram. Usually, patients already have images of the pulmonary lesions, chest radiograph and thoracic computerized tomography, which must be carefully reviewed before the procedure.

The patient and his/her family must receive a clear explanation about what will be done and sign informed consent.

The procedure can be performed in the bronchoscopy suite or the operating room, and a minimum of four persons are needed: bronchoscopist, anesthesiologist, assistant nurse, and a circulating assistant.

Preparation involves positioning the patient in a supine position, with a little pillow under the



head, and application of topical anesthesia, lidocaine, or tetracaine. Dental prosthesis should be removed, and proceed to the inspection of teeth and gums. Additional local anesthesia is also flushed on the cords and high trachea with a syringe, under direct view via laryngoscopy. Then, an oxygen mask is placed for pre-oxygenation, and anesthetic induction and muscle relaxant medications are administered according to the usual practice.

A protection for the superior teeth is placed; it can be made of plastic or simply be a thick folded gauze that works as the rigid tube support and protects teeth and gums (Table 4.3).

RB procedures have become common practice and the anesthetic techniques have evolved. All procedures are performed under general intravenous anesthesia. Muscular relaxation and paralysis can be avoided by administering appropriate sedation. This technique shortens the recovery period. We do not apply muscle relaxants since we have found that with appropriate sedation there is no need for administration of these agents. Many centers apply jet ventilation, but we prefer to perform all rigid procedures with manually assisted spontaneous ventilation. There is a special chapter in this book discussing in detail anesthesia in interventional procedures.

Once the equipment is prepared and the video camera system is connected, the conditions are given to initiate the procedure. The classic intu-

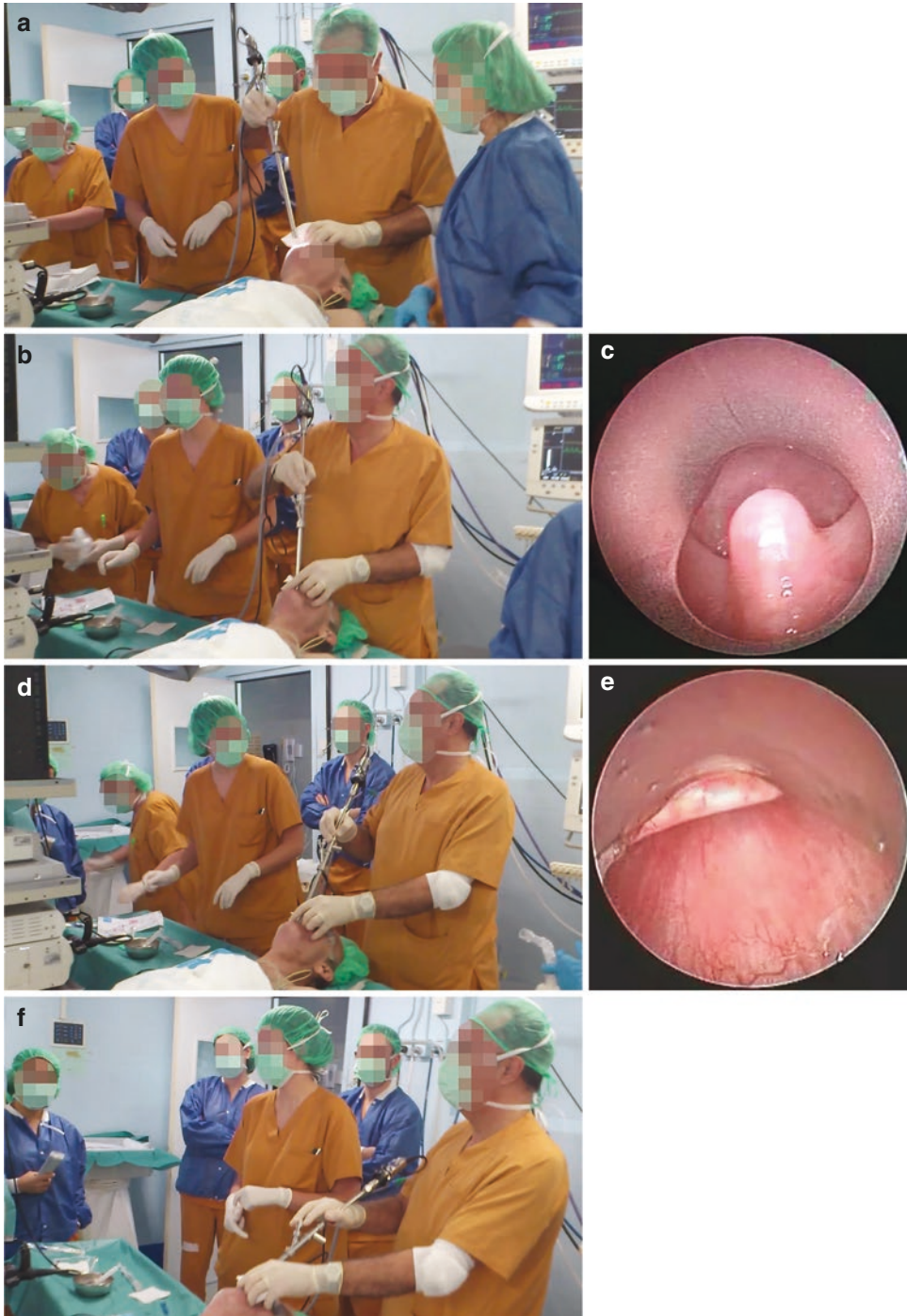bation technique requires considerable experience. It is performed with the RB and the rigid optic connected to the video system if available.

The steps are the following (Fig. 4.15a–i):

1. Figure 4.15a: The RB is held with a hand, adjusting the optic a little retracted in a way that the distal end of the RB is interiorly visible. The other hand is used to open the patient's mouth, advance the RB, and adjust the tongue. Then, with the index finger and thumb the tip of the RB is held to direct it and to keep it in the middle line at the same time. When initiating the maneuvers, the instrument edge must be looking forward, and an appropriate protection for the teeth must be observed.
2. Figure 4.15b: Keeping the instrument in the middle line, it is slowly advanced. Soft back and forth movements are simultaneously performed, in order to position it properly without causing any mouth injury and to get a better vision. The advance direction must be perpendicular to the operating table.
3. Figure 4.15c: The RB should be thus advanced until the uvula is visible in the 6 o'clock position.
4. Figure 4.15d, e: From there on, the advance angle is changed approximately 45° to the procedure table, and with soft rotation movements the RB is introduced until the epiglottis is visible in the 12 o'clock position.
5. Figure 4.15f, g: The RB tip is used then to softly lift the epiglottis, using the same rotation movements, and it is carefully crossed through until the vocal cords are visible.
6. Figure 4.15h: Moving forward to immediately above the vocal cords, the RB is given a 90° clockwise turn, so the beveled edge is softly leaned on a vocal cord while turning and simultaneously advancing through the cords to achieve the trachea.
7. Figure 4.15i: Once this is done, the trachea will already be intubated, and the RB is again rotated 90° counterclockwise. The rigid tube is then introduced further.
8. Figures 4.16 and 4.17: Following, the universal head is disconnected, and reconnected to a

**Table 4.3** Requirements to perform rigid bronchoscope (RB)

• Rigid bronchoscope and tracheoscope
• Light source
• Video monitor if available
• Rigid optic 0° angulation
• Ancillary equipment (alligator forceps, scissors, foreign body retrieval elements)
• Rigid suction catheter
• Ventilation system (jet ventilation, ventilation bag)
• Eye protection
• Mouth protection
• Flexible bronchoscope with additional light source and suction port
• Interventional application: stents and deployment systems, laser, electrocautery, dilatational balloons, etc., according to the procedure taking place



**Fig. 4.15** Sequence of rigid bronchoscope (RB) intubation: (a) Initial positioning, protection for teeth and tongue. (b) Slowly advancing with the RB perpendicular to the operation table until the uvula is in view. (c) Uvula. (d) Advancing from uvula, changing the angle to 45° until the epiglottis is in view. (e) Epiglottis. (f) The epiglottis is lifted changing to a more acute angle, until the arytenoids cartilages can be seen. (g) Once the arytenoids are in view,

the RB should be positioned more horizontally until the cords are visible. (h) When vocal cords are in view, the RB is rotated 90° clockwise to place the beveled end leaning on the right vocal cord to protect it, while simultaneously advancing. Once in the trachea, the RB is rotated counterclockwise and advanced further. (i) Finally, ventilation is connected to oxygenate the patient for a while

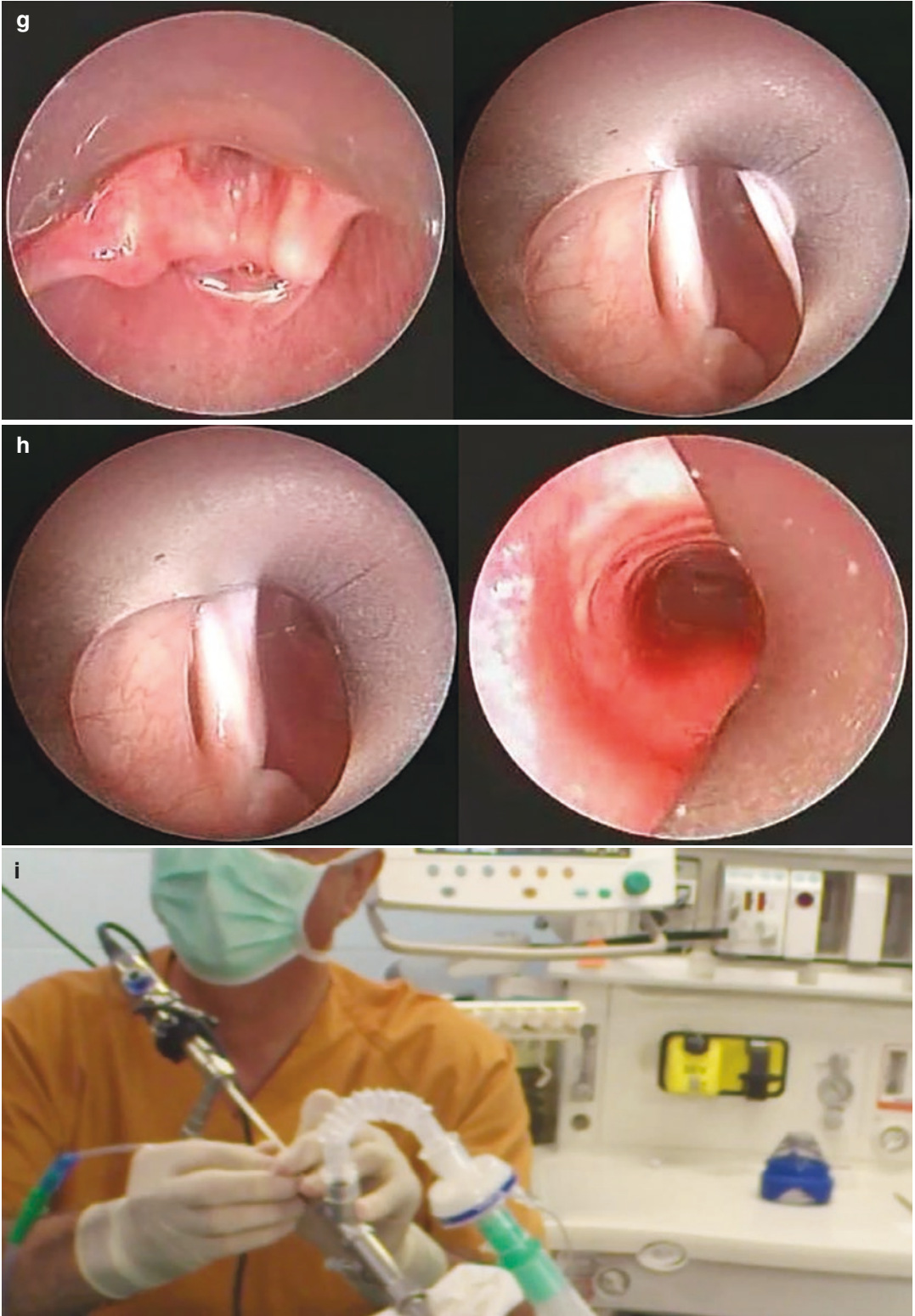
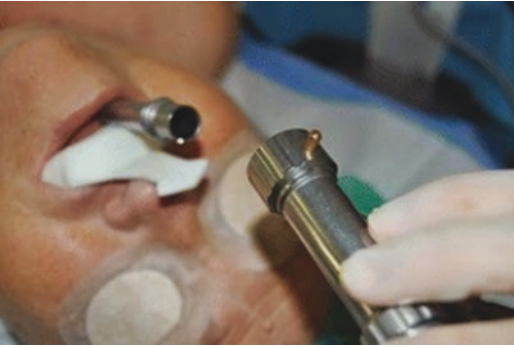
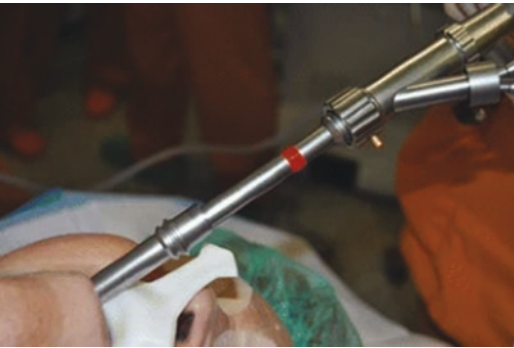
Fig. 4.15 (continued)



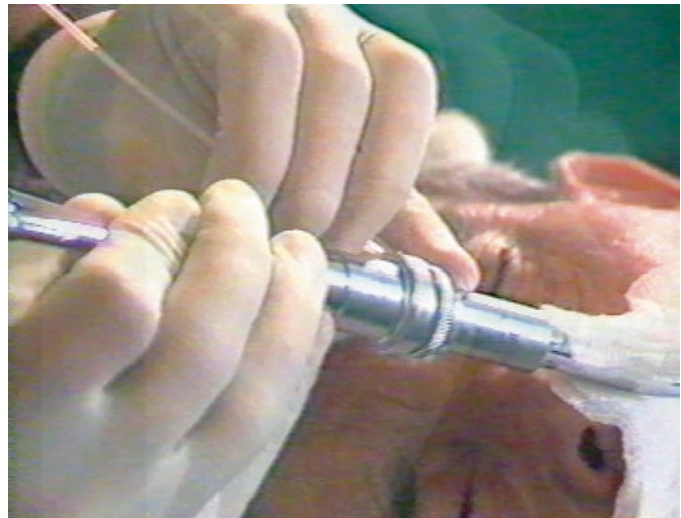

**Fig. 4.16** Once the rigid tracheoscope is in the airway, the head of the rigid bronchoscope (RB) is removed



**Fig. 4.17** Head of the rigid bronchoscope (RB) connected to a bronchial rigid tube. They are then introduced through the tracheal tube, and the procedure can start

**Fig. 4.18** Comfortable position of the hands for manipulation of ancillary tools



bronchial tube, which is then inserted through the tracheal tube.

9. Figure 4.18: Ventilation is connected and the therapeutic procedure can start. It is very important that the operator works in a comfortable position.

It takes time and experience to be able to perform rigid intubation as described above. There are other techniques to place a rigid bronchoscope that are very useful during the training period. The first of them implies to intubate the patient with a conventional endotracheal tube (ETT) and as a second step execute the intubation with the rigid tube, along the side of the ETT. This method has the advantage of giving the operator all the time needed to maneuver, since it does not require the patient to be in apnea like during the conventional technique, but ventilated until the tubes are changed.

The other alternative is to complete the intubation with the help of a laryngoscope.

This intubation is achieved by observing the cords with a conventional laryngoscope. After lifting the epiglottis with it, the RB is inserted by the side of the mouth, directing it toward the larynx. Then, it is introduced between the vocal cords and softly rotated to keep it on the middle

line without injuring the subglottic area. At this moment, the laryngoscope is removed and the rigid optic is placed through the RB, and advanced within the trachea under direct vision.

Intubation with RB through a tracheotomy is also possible. For this method, the rigid tube is introduced obliquely through the tracheotomy, previously numbed with local anesthetics. This maneuver must be carefully performed to avoid lesion of the posterior tracheal wall.

---

## Some Conclusions

Before the FB introduction, the use of RB was almost limited to surgeons. During a British study, it was observed that, even though only 2% of the 39,564 bronchoscopies completed between 1974 and 1986 used RB, more than 90% were performed by surgeons. This work also noted that 81% of the bronchoscopists used FB, 9% of them were using both techniques, and 8% used the FB through the RB [34].

In a review made by the American College of Chest Physicians, only 8% of the responding endoscopists were using RB [20]. The reasons are multiple, but some of the most important ones are that the FB is more available and easier to use than the RB, which requires special training not given routinely during training programs.

These data ratify a known fact: obtaining training on the RB technique is difficult, for several reasons. The first one is that its teaching is not part of the pulmonary specialist training as we discuss, while FB training is included. Besides, its use is generally associated with therapeutic procedures such as laser, stents placement, and that requires specific technology not always available. Another inconvenience is that the technique is indeed difficult, and requires full dedication to learn it. The number of procedures to become proficient varies from person to person. In addition, when proficiency is obtained, a number of regular procedures are required in order to maintain the ability, and to get the interest of the involved team: nurses and anesthesiologists. In general, it is advisable that the person who is interested in learning interventionism fol-

lows a formal training with an expert, in a place where adequate numbers of procedures are performed per year. Many experts agree that expertise on RB takes years, and that courses and seminars (although indispensable to a complete learning) are not enough to initiate the individual practice without supervision. The ACCP guidelines published in 2003 recommended that a trainee should perform at least 20 procedures in a supervised setting to establish basic competency in patients with normal airways, and then he/she should perform 10 procedures per year in order to maintain competency. They also recommended that program directors should decide whether or not the candidate is able to perform RB procedures without supervision [35].

The ideal bronchoscopist should be able to perform both FB and RB, on the pediatric and adult population. Given that lung cancer incidence continues rising and today the multimodality approach to treatment includes a pulmonary physician able to perform palliative procedures according to need, the RB will continue to be indicated. This instrument has unique features that make it irreplaceable and it is also complementary to many other tools, particularly when treating central airway diseases. Though still RB is performed by a minority of physicians, there is an increased interest to train and maintain proficiency in rigid bronchoscopy and we are sure that it will be more so in the future.

---

## References

1. Nakhosteen J. Removal of a tracheobronchial foreign body. Gustav Killian. (An actual translation of the first paper by Gustav Killian). *J Bronchol.* 1994;1:76.
2. Jackson C. The life of Chevalier Jackson—an autobiography. New York: Macmillan; 1938. p. 106.
3. Boyd AD. Chevalier Jackson: the father of american bronchoesophagoscopy. *Ann Thorac Surg.* 1994;57:502–5.
4. Ikeda S. The flexible bronchofiberscope. *Keio J Med.* 1968;17:1–16.
5. Dumon JF, Diaz-Jimenez JP. Accidents methodology and prevention. In: Dumon-Diaz-Jimenez, editor. *Respiratory endoscopy and laser.* Barcelona: Tecnograf S.A; 1991.
6. Lamb C, Beamis JF Jr. Rigid bronchoscopy. In: Beamis JF, Mathur PM, Mehta A, editors. *Interventional*



- pulmonary medicine, vol. 189. Amsterdam: Marcel Dekker; 2004. p. 13–31.
7. Prakash UBS, Díaz-Jimenez JP. The rigid bronchoscope (Chapter 4). In: Prakash UBS, editor. *Bronchoscopy*. New York: Raven Press. p. 53–9.
  8. Cavallieri S, Foccoli P, Toninelli C, et al. Nd-YAG laser therapy in lung cancer: an 11-year experience with 2,253 applications in 1,585 patients. *J Bronchol*. 1994;1:105–11.
  9. Diaz Jimenez JP, Canela-Cardona M, Maestre Alcazar J. Nd-YAG laser photoresection of low-grade malignant tumors of the tracheobronchial tree. *Chest*. 1997;4:920–2.
  10. Stanopoulos IT, Beamis JF, Martinez JF, Vergos K, Shaphay SM. Laser bronchoscopy in respiratory failure from malignant airway obstruction. *J Crit Care*. 1993;21:386–91.
  11. Martinez Ballarin JI, Diaz-Jimenez JP, Castro MJ, Moya JA. Silicone stents in the management of benign tracheobronchial stenosis. Tolerance and early results in 63 patients. *Chest*. 1996;109:626–9.
  12. Bolliger CT, Probst R, Tschopp K, Soler M, Perruchoud AP. Silicone stents in the managements of inoperable tracheobronchial stenosis. Indications and limitations. *Chest*. 1993;104:1653–9.
  13. Dumon JF. A dedicated tracheobronchial stent. *Chest*. 1990;97:328–32.
  14. Wang KP, Terry P, Marsh B. Bronchoscopic needle aspiration biopsy of paratracheal tumors. *Am Rev Respir Dis*. 1978;118:17–21.
  15. Schenk DA, Chambers SL, Derdak S, Komadina KH, Pickard JS, Strollo PJ, et al. Comparison of the Wang 19-gauge and 22-gauge needles in the mediastinal staging of lung cancer. *Am Rev Respir Dis*. 1993;147:1251–9.
  16. Schenk DA, Strollo PJ, Pickard JS, Santiago RM, Weber CA, Jackson CV, Burrell RS, Dew JA, Komadina KH, Segarra J, Porter DK. Utility of the Wang 18-gauge transbronchial histology needle in the staging of bronchogenic carcinoma. *Chest*. 1989;96:272–4.
  17. Varela-Lema L, Fernandez-Villar A, Ruano-Ravina A. Effectiveness and safety of endobronchial ultrasound-transbronchial needle aspiration: a systematic review. *Eur Respir J*. 2009;33:1156–64.
  18. Wilsher ML, Gurley AM. Transtracheal aspiration using rigid bronchoscopy and a rigid needle for investigating mediastinal masses. *Thorax*. 1996;51:197–9.
  19. Petrou M, Kaplan D, Goldstraw P. Bronchoscopic diathermy resection and stent insertion: a cost effective treatment for tracheobronchial obstruction. *Thorax*. 1993;48:1156–9.
  20. Prakash UBS, Stubbs SE. The bronchoscopy survey. Some reflections. *Chest*. 1991;100:1660–7.
  21. Mathisen DJ, Grillo H. Endoscopic relief of malignant airway obstruction. *Ann Thorac Surg*. 1989;48:469–73.
  22. Hetzel MR, Smith S. Endoscopic palliation of tracheobronchial malignancies. *Thorax*. 1991;46:325–33.
  23. Brutinel WM, Cortese D, Edell ES, McDougall JC, Prakash UBS. Complications of Nd:YAG laser therapy. *Chest*. 1988;94:902–3.
  24. Barbato A, Magarotto M, Crivellaro M, Novello A Jr, Cracco A, de Blic J, Scheinmann P, Warner JO, Zach M. Use of the pediatric bronchoscope, flexible and rigid, in 51 European centers. *Eur Respir J*. 1997;10:1761–6.
  25. Skedros DG, Chan KH, Siewers RD, Atlas AB. Rigid bronchoscopy balloon catheter dilation for bronchial stenosis in infants. *Ann Otol Rhinol Laryngol*. 1993;102:266–70.
  26. Castro M, Midhum DE, Edell ES, et al. Flexible bronchoscopic removal of foreign bodies from pediatric airways. *J Bronchol*. 1994;1:92–8.
  27. Limper AH, Prakash UBS. Tracheobronchial foreign bodies in adults. *Ann Intern Med*. 1990;112:604–9.
  28. Diaz-Jimenez JP. Bronchoscopic approach to tracheal bronchial foreign bodies in adults: pro rigid bronchoscopy. *J Bronchol*. 1997;4:168–72.
  29. Martinot A, Closset M, Marquette CH, Hue V, Deschildre A, Ramon P, Remy J, Leclerc F. Indications for flexible versus rigid bronchoscopy in children with suspected foreign body aspiration. *Am J Respir Crit Care Med*. 1997;155:1676–9.
  30. Prakash UBS, Midthum D, Edell ES. Indications for flexible versus rigid bronchoscopy in children with suspected foreign body aspiration. *Am J Respir Crit Care Med*. 1997;155:1676–9.
  31. Colt HG, Harrel JH. Therapeutic rigid bronchoscopy allows level of care changes in patients with acute respiratory failure from central airways obstruction. *Chest*. 1997;112:202–6.
  32. Diaz-Jimenez JP. Rigid bronchoscopy. *J Jpn Soc Bronchol*. 1996;18:767–76.
  33. Drummond M, Magalanes A, Hespanhol V, et al. Rigid bronchoscopy. complications in a University Hospital. *J Bronchol*. 2003;10:177–82.
  34. Simpson FG, Arnold AG, Purvis A, Belfield PW, Muers MF, Cooke NJ. Postal survey of bronchoscopic practice by physicians in the United Kingdom. *Thorax*. 1986;41:311–7.
  35. Ernst A, Silvestri GA, Johnstone D. American College of Chest Physicians. Interventional pulmonary procedures: guidelines from the American College of Chest Physicians. *Chest*. 2003;123(2):1693–717.



# Anesthesia for Interventional Bronchoscopic Procedures

# 5

Mona Sarkiss

## Introduction and Definition of Anesthesia for Interventional Bronchoscopy

Introducing the bronchoscope into the airway has proved to be a challenge since the invention of the first bronchoscope. Airway reflexes, such as the gag, cough, and laryngospasm, hemodynamic alteration, and anxiety induced by the passage of the bronchoscope into the airway forced the bronchoscopist to be skilled and hurried to perform the procedure [1]. As a result, interest in using anesthesia to ameliorate the airway reflexes and patient's anxiety associated with bronchoscopy has emerged. A wide range of anesthesia techniques were developed to accommodate a variety of interventional bronchoscopic procedures such as simple diagnostic bronchoscopy, advanced diagnostic bronchoscopy, therapeutic bronchoscopic interventions, and pleural procedures. The scope of depth of anesthesia needed for various interventional bronchoscopic procedures encompasses local anesthesia as the sole anesthetic modality, moderate sedation/

analgesia ("conscious sedation") with or without local anesthesia, and general anesthesia [2]. Moderate sedation/analgesia ("conscious sedation") is defined by the American Society of Anesthesiologist (ASA) as "a drug-induced depression of consciousness during which patients respond purposefully to verbal commands, either alone or accompanied by light tactile stimulation. No interventions are required to maintain a patent airway, and spontaneous ventilation is adequate. Cardiovascular function is usually maintained [3]." Moderate sedation may progress to deep sedation/analgesia or even general anesthesia during the same procedure. Once under deep sedation, "the patients cannot be easily aroused but respond purposefully following repeated or painful stimulation. The ability to independently maintain ventilatory function may be impaired. Patients may require assistance in maintaining a patent airway, and spontaneous ventilation may be inadequate. Cardiovascular function is usually maintained [3]." At the other end of the spectrum during general anesthesia "patients are not arousable, even by painful stimulation. The ability to independently maintain ventilatory function is often impaired. Patients often require assistance in maintaining a patent airway, and positive pressure ventilation may be required because of depressed spontaneous ventilation or drug-induced depression of neuromuscular function. Cardiovascular function may be impaired [3]."

M. Sarkiss (✉)

Department of Anesthesiology and Perioperative Medicine, The University of Texas MD Anderson Cancer Center, Houston, TX, USA

Department of Pulmonary Medicine, The University of Texas MD Anderson Cancer Center, Houston, TX, USA

e-mail: [msarkiss@mdanderson.org](mailto:msarkiss@mdanderson.org)

Although the current guidelines do not identify what depth of anesthesia is needed for various procedures, it is generally accepted that simple diagnostic and interventional airway procedures of short duration are well tolerated by the patient when performed under local anesthesia and/or moderate sedation. Meanwhile, more complex interventional bronchoscopic procedures that require a still field, have a longer duration, and entail more risk to the patient due to comorbidities or a compromised airway are best performed under general anesthesia. General anesthesia has the added advantage of the availability of special modes of ventilation and monitoring that can be provided and managed by anesthesia provider while the bronchoscopist focuses on the procedure. This chapter will provide a brief historical perspective, the indications and contraindications for different levels of anesthesia, the equipment required, and the application of the techniques. Finally, a summary and recommendations are presented.

---

## History and Historical Perspective

When the rigid bronchoscope was invented in 1865 by Dr. Killian, anesthesia had not been discovered and the procedure was performed on conscious patients. The patients were advised to repeatedly touch their pharynx and vocal cords for several weeks before the procedure to desensitize their airway reflexes. The physicians performing the procedures practiced on a corpse head or healthy volunteers. According to early reports, this practice allowed the bronchoscopists to become “extremely skilled and swift as operations had to be performed within seconds before the view disappeared [1].” Multiple attempts to anesthetize the airway with ammonia, iodine, belladonna, or potassium bromide had failed. In 1884, Jellinek introduced cocaine, the first local anesthetic, for airway exam and reported its benefits by stating that “by eliminating the reflexes of the pharynx and the larynx it was possible to perform some of the operations in which even the most skillful artists in surgery had failed. The procedure completely changed.

Virtuosity gave way to careful methodology, skill to exactness and the former almost endless preparation that so often tried the patience of the physician as well as of the patient could be almost completely abandoned” [1]. Similarly, Killian emphasized the advantages of using cocaine during bronchoscopy by stating that “whether one stops inspection with the rigid tube at the bifurcation or passes on for some distance into a major bronchus does not matter for the patient. If he is sufficiently cocainized he does not even realize it” [1].

In 1968, the flexible bronchoscope was invented by Ikeda and gradually replaced the rigid bronchoscope. Compared to the rigid bronchoscope, the flexible bronchoscope is better tolerated by the patient, even without anesthesia due to its small diameter and plasticity. Flexible bronchoscopy was initially used for simple diagnostic bronchoscopic procedures of short duration making local anesthetics an ideal technique for anesthesia. However, a subset of anxious patients remained unable to tolerate the procedure. As a result, conscious sedation with anxiolytics and opioids, to ameliorate anxiety and cough, respectively, became common practice for airway procedures in addition to local anesthetics. As the field of interventional bronchoscopy expanded, a growing number of lengthy and technically demanding procedures especially in patients with severe comorbidities and compromised central airway emerged. The use of the rigid bronchoscope was revived to aid in the management of large airway tumors, procedure-related complications, and to allow for ventilation during lengthy procedures. Accordingly, a renewed interest in monitored anesthesia care (MAC) or general anesthesia has emerged. Currently, some centers in the United States and Europe made it their standard practice to have an anesthesiologist provide either sedation or general anesthesia to selected patients undergoing interventional bronchoscopic procedures. This arrangement allows the interventionalist to direct his or her full attention to the procedure, with minimal or no discomfort to the patient, while the anesthesiologist vigilantly manages the patient’s airway, ventilation, medical condition, and the anesthesia.

## Indications and Contraindications

In its 2003 guidelines for interventional pulmonary procedures, the American College of Chest Physicians (ACCP) left the choice of anesthesia to the interventionalists, depending on the guidelines and resources available at their practice. This was due to the lack of evidence and consensus on what are the indications for different types of anesthesia. However general anesthesia was recommended “for rigid bronchoscopy and for pediatric bronchoscopic procedures” [4]. More specific guidelines on anesthesia for interventional pulmonology were published by the European Respiratory Society and the American Thoracic Society (ERS/ATS) in 2002. These guidelines alerted the interventional bronchoscopists “to be prepared to convert to general anesthesia, if the situation requires (page 358)” and recommended that “the design of the bronchoscopy suite should account for the presence of anesthesia equipment” [5]. It is important to note that the availability of anesthesia support in different practices, especially in nonacademic settings, remains limited. Some facilities have anesthesia support only when procedures are performed in the operating room, and others have anesthesia support in the bronchoscopy suite and/or the operating room, but some practices have no access to anesthesia support. Under all circumstances, preprocedural evaluation of the patient along with the nature of the procedure and consideration of the available resources should direct the interventionalist to determine the most appropriate form and location of anesthesia needed for a particular procedure.

## Preprocedural Evaluation and Preparation

*Medical history* focused on respiratory and cardiovascular diseases, exercise tolerance, performance status, drug allergy, current medication especially anticoagulants, tobacco, alcohol, or drug use should be documented. Specific history related to central airway disease such as stridor, hoarseness, snoring and sleep apnea, hemopty-

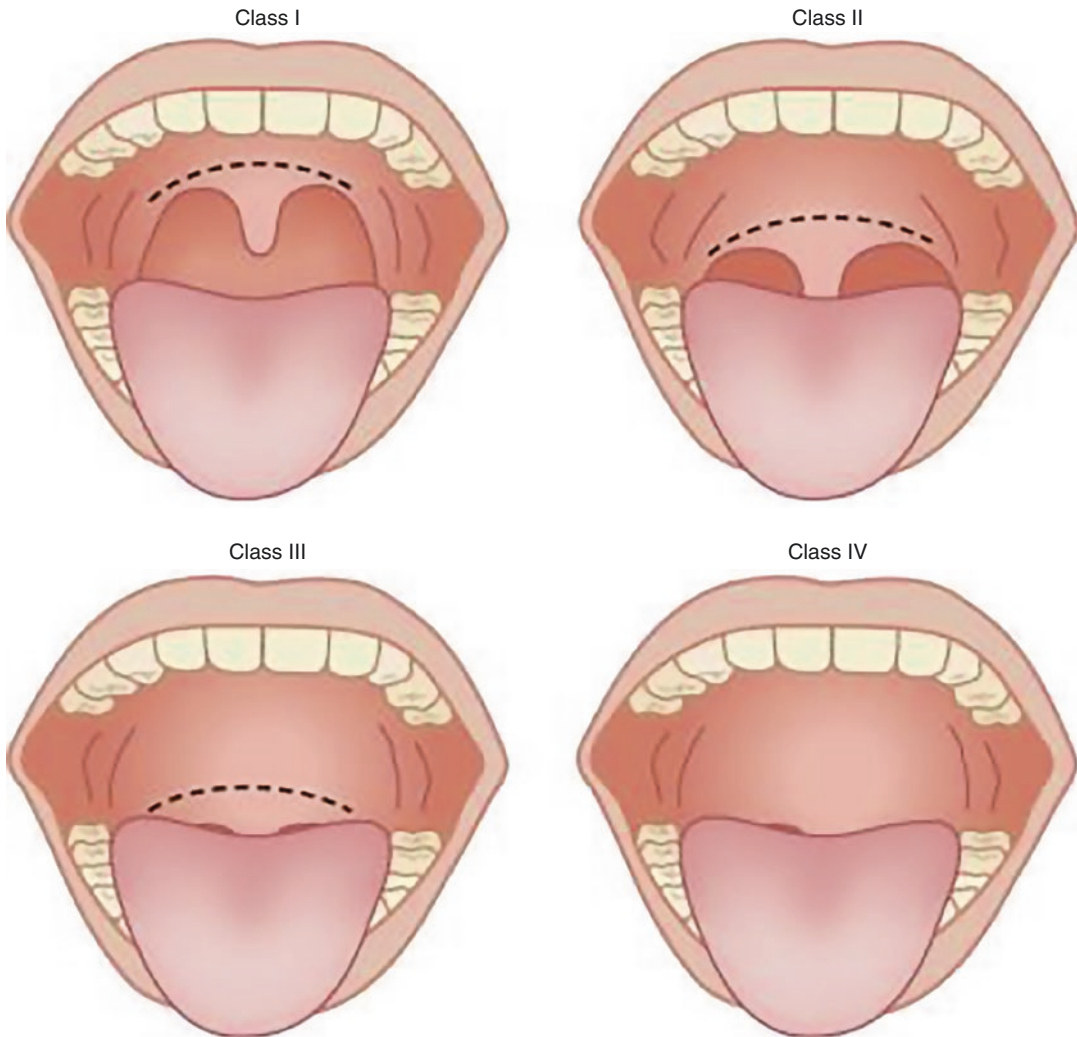
**Table 5.1** ASA physical status

<i>ASA physical status 1</i>	A normal healthy patient
<i>ASA physical status 2</i>	A patient with mild systemic disease
<i>ASA physical status 3</i>	A patient with severe systemic disease
<i>ASA physical status 4</i>	A patient with severe systemic disease that is a constant threat to life
<i>ASA physical status 5</i>	A moribund patient who is not expected to survive without the operation
<i>ASA physical status 6</i>	A declared brain-dead patient whose organs are being removed for donor purposes

sis, orthopnea, wheezing, and signs of superior vena cava syndrome (SVC) should be elicited. Additionally, anesthesia-related history such as complications of previous sedation and anesthesia, prolonged sedation, unplanned hospital admission, or intubation should be sought. The American Society of Anesthesiologist (ASA) score is commonly assigned to the patient to assess the patient’s physical status and severity of illness; however, the ASA status is not intended to predict anesthesia or procedure-related risk (Table 5.1). Women of childbearing age should be questioned about possibility of pregnancy and counseled regarding effect of anesthesia and the procedure on pregnancy [6].

## Physical Examination

*The airway* should be assessed to determine difficulty of intubation in case of airway compromise or if rigid bronchoscopy is planned. Direct inspection of pharyngeal structure when the mouth is wide open and the tongue is protruding as far as possible is used to determine the difficulty of intubation by direct laryngoscopy according to the Mallampati classification (Fig. 5.1). Other parameters that predict difficult intubation are: decreased extension of the atlanto-occipital joint by more than two-third (normally 35 degrees from neutral midline position), decreased mouth opening below the normal range of 50–60 mm, thyromental distance measured in an extended



**Fig. 5.1** The Mallampati classification

neck from the mentum to the notch of the thyroid cartilage  $\leq 6$  cm in adults, short muscular neck, and receding mandible.

*Dental inspection* is necessary to identify the presence of loose teeth, dental prosthesis, chipped, missing teeth, bridges, crowns, or dentures that can be dislodged or further damaged during direct laryngoscopy or rigid bronchoscopy. The presence of prominent or protruding maxillary incisors may alert the bronchoscopist to the possibility of difficult intubation.

*Respiratory system assessment* should be performed with emphasis on baseline saturation,

requirement of supplemental oxygen, and use of accessory respiratory muscle.

*Cardiovascular system exam* focused on baseline vital signs, signs of cardiovascular compromise due to intrathoracic disease, e.g., superior vena cava syndrome, pericardial effusion.

*Laboratory testing* should be performed based on the baseline comorbidities and nature of the procedure (e.g., complete blood count, electrolytes, coagulation profile).

*Radiographic studies*, e.g., chest X-ray, computed tomography (CT), and electrocardiogram are recommended.



*Pulmonary function tests* and assessment of arterial blood gases may be required depending on the nature of the procedure and/or the severity of the pulmonary compromise [5].

*Informed consent* should be obtained from the patient after detailed explanation of the risks, benefits, and possible alternatives of the procedure and sedation or anesthesia.

*Nothing per os* (NPO) is indicated for 2 h for clear liquids and 6–8 h for solids before the procedure according to the current ASA guidelines. Patients with history of uncontrolled or untreated acid reflux, postesophagectomy, or gastroparesis should be instructed to take their antireflux medication on the day of the procedure and can benefit from airway protection by endotracheal intubation.

### Procedure-Related Indications

Despite few reports of rigid bronchoscopy performed under local anesthesia [7] or general anesthesia with spontaneous ventilation, the most common practice is to perform rigid bronchoscopy under general anesthesia with muscle relaxation [4]. The rationale for utilizing general anesthesia for rigid bronchoscopy is the lengthy nature of the procedures and the concurrence of hypoxemia and hypercapnia [8]. Spontaneous, assisted, mechanical, or jet ventilation can be used during rigid bronchoscopy to maintain adequate oxygenation and carbon dioxide elimination [9].

Controversy exists over performing EBUS under moderate sedation or general anesthesia. The EBUS bronchoscope has a larger external diameter of 6.9 mm and is more tolerated when inserted through the mouth compared to the nose. Therefore, some practitioners prefer to perform all EBUS procedures or only the lengthy staging EBUS procedures under general anesthesia. Recent study showed that more lymph nodes per patient and smaller lymph nodes were sampled more often when EBUS was performed under deep sedation or general anesthesia. In addition, onsite cytology evaluation was used more frequently when general anesthesia was used [10]. However, several reports indicated no difference

in patient satisfaction, yield, sensitivity, or specificity of the EBUS procedure when performed under moderate sedation versus general anesthesia [11, 12].

## Application of the Technique

### Topical Anesthesia

Local anesthetics cause reversible block of the conduction of nerve impulses with subsequent sensory, motor, and autonomic blockade. Cocaine was the first topical anesthetic discovered, but it was soon found to cause topical irritation and psychological dependence. Subsequently, synthetic local anesthetics lacking such side effects were discovered. Procaine, the first synthetic local anesthetic, was introduced by Einhorn in 1905 and was followed by lidocaine, which was synthesized in 1943 by Löfgren. Synthetic local anesthetics have a lipophilic benzene ring linked via an amide or an ester bond to a hydrocarbon chain that is attached to a hydrophilic tertiary amine structure. Local anesthetics are classified according to the type of their linking bond to ester or amide local anesthetics. The nature of the linking bond affects the metabolism of the local anesthetic as well as its potential to produce an allergic reaction. Amide local anesthetics, which are commonly used in bronchoscopy, are metabolized by the liver microsomal enzymes and are also extracted through the lungs. The addition of epinephrine at 1:200,000 (5 µg/mL) concentration or 0.25% phenylephrine causes local vasoconstriction, which slows down the absorption of the local anesthetic, prolongs its duration of action, and decreases its systemic toxicity.

### Side Effects of Local Anesthetics

Absorption of large amounts of local anesthetics from the application site or direct accidental intravascular injection of large dose can result in systemic toxicity, e.g., lidocaine plasma level of (5 µg/mL) or greater than 8.2 mg/kg of lidocaine instilled in the airway can result in systemic toxicity [13].

Central nervous system (CNS) toxicity initially presents with symptoms of CNS excita-

tion such as restlessness, vertigo, tinnitus, and slurred speech. The symptoms may progress to tonic-clonic seizure followed by CNS depression in the form of coma and possibly death. Seizures should be immediately treated with small doses of intravenous benzodiazepine (diazepam or midazolam), intravenous thiopental, or propofol. Hypoxemia should be treated with supplemental oxygen. Additionally, hyperventilation with subsequent respiratory alkalosis causes hyperpolarization of the nerve membrane thus increasing the threshold for seizure and the amount of local anesthetic bound to protein causing a decrease in the delivery of free drug to the brain. If seizures continue despite treatment, intubation is warranted to protect the airway.

Cardiovascular toxicity due to blockade of the cardiac sodium channels can result in hypotension, long PR interval, and widening of the QRS complex. More severe cardiotoxicity can present with severe hypotension, cardiac arrhythmias, and atrioventricular heart block.

Methemoglobinemia occurs when local anesthetic oxidizes the iron molecule in the hemoglobin from the ferrous to ferric state. Hemoglobin with iron molecules in the ferric state is called methemoglobin and is characterized by its inability to release bound oxygen to tissue. Patients with methemoglobinemia present with cyanosis, chocolate-colored blood, stupor, coma, and death. Methemoglobinemia is easily treated by the administration of 1–2 mg/kg of methylene blue intravenously.

Allergic reactions to local anesthetics are rare but are more common with ester local anesthetic metabolite para-aminobenzoic acid (PABA). In addition, the preservatives used with either ester or amide local anesthetics (e.g., methylparaben) can be a source of allergic reaction. It is noteworthy that cross-sensitivity does not exist between ester and amide local anesthetics.

### **Anesthesia of the Nasal Mucosa and Nasopharynx**

Sensation to the nasal mucosa is provided by the middle division (V2) of the trigeminal nerve (CN V), the sphenopalatine ganglion, and the ethmoid

nerve. The nasal mucosa and the nasopharynx can be topicalized using a cotton-tipped applicator or pledgets soaked in a 1%, 2%, or 4% lidocaine solution with or without a vasoconstricting agent. The applicators are placed sequentially along the inferior turbinate, the middle turbinate, and the superior turbinate. Each applicator should be left in place for 5 min.

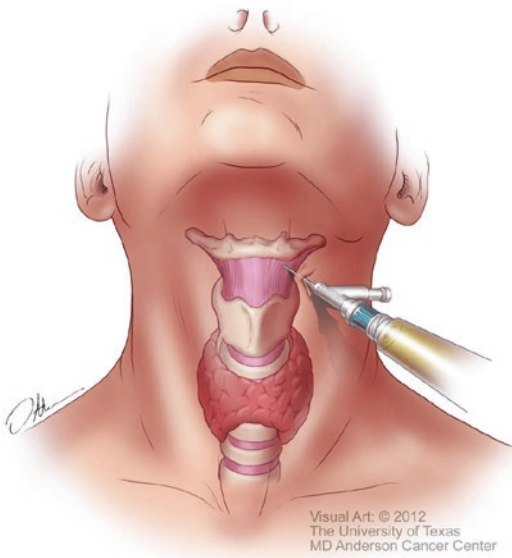
### **Anesthesia of the Mouth and Oropharynx**

Sensation of the mouth and oropharynx is supplied by branches of the glossopharyngeal, vagus, and facial nerves. The lingual branch of the glossopharyngeal nerve provides sensation to the posterior third of the tongue, the vallecula, and the anterior surface of the epiglottis. The pharyngeal branch provides sensation to the posterior and lateral walls of the pharynx, and the tonsillar branch supplies the tonsillar pillars. The tongue can be anesthetized by placing a tongue blade coated with lidocaine gel on the tongue for several minutes. Oral and pharyngeal mucosa are anesthetized by inhalation of nebulized 4% lidocaine or 0.5% tetracaine or by using a cetacaine atomizer spray (tetracaine and benzocaine combination). Gargle with 2–4 mL of viscous lidocaine for 30 s can provide additional anesthesia to the posterior pharyngeal wall.

### **Superior Laryngeal Nerve Block**

The superior laryngeal nerve (SLN) is a branch of the vagus nerve that divides lateral to the cornu of the hyoid bone into internal and external branches. The internal branch passes under the greater cornu of the hyoid bone before piercing the thyrohyoid membrane and entering the pyriform recess where it provides sensory innervation to the base of the tongue, the superior epiglottis, the aryepiglottic folds, the arytenoids, and the laryngeal mucosa above the vocal cords. The external branch supplies motor innervation to the cricothyroid muscle.

To perform SLN block, the patient should be placed in a supine position with the head slightly extended; the greater horn of the hyoid bone is palpated above the thyroid cartilage. The nee-



**Fig. 5.2** Superior laryngeal nerve block

dle (size 22 or 23 gauge) is inserted toward the greater horn of the hyoid bone and then moved caudally until a pop is felt when the thyroid ligament is pierced at a depth of about 1–2 cm. Negative aspiration is then followed by injecting 2–3 mL of 2% lidocaine with epinephrine. Bilateral blocks should be performed (Fig. 5.2).

### Recurrent Laryngeal Nerve Block (RLN)

The recurrent laryngeal provides motor innervation to the vocal cords and sensory innervation to both the trachea and vocal cords. In a supine patient with hyperextended neck, the skin over the cricothyroid membrane is anesthetized with lidocaine 1–2% with a 22-gauge needle. A 22-gauge IV catheter is then inserted through the cricothyroid membrane into the tracheal lumen at an angle of 45° caudally. Air should be aspirated to confirm intratracheal position. The needle should then be removed leaving the plastic catheter in the tracheal lumen. The patient is asked to take a deep breath followed by forced exhalation, while 3–4 cc of 1–2% or 4% lidocaine is injected through the catheter. This maneuver commonly results in coughing that aids in the spread of the local anesthetic over the vocal cords and the trachea.

### Conscious Sedation

The American College of Chest Physicians has suggested in its consensus statement in 2011 that all physicians performing bronchoscopy should consider using topical anesthesia, analgesic, and sedative agents, when feasible [14]. The advantages of conscious sedation are the reduction of patient anxiety, pain, airway reflexes such as cough and gag, and the dyspnea associated with the insertion of the bronchoscope. Amnesia from the procedure also increases patient satisfaction and willingness to undergo another bronchoscopic procedure. In addition, the ability of the bronchoscopist to adequately perform advanced diagnostic and therapeutic procedures in shorter duration improves with sedation.

Different drug regimens have been used, and they vary depending on the bronchoscopist's preference and experience. The most commonly used classes of drugs are benzodiazepines for anxiolysis and amnesia in combination with opioids for suppression of cough and pain. The combination of narcotics and benzodiazepines has an additive effect on the suppression of the respiratory drive and cardiovascular hemodynamics thus increasing the likelihood of apnea, desaturation, and hypotension. Therefore, these drugs should be titrated gradually to achieve the desired effect and avoid undesired side effects.

*Benzodiazepines* act primarily by enhancing the action of the inhibitory neurotransmitter  $\gamma$ -aminobutyric acid (GABA), causing increased resistance of neuronal excitation. This translates clinically to anxiolysis, sedation, anterograde amnesia, centrally mediated muscle relaxation, and minimal depression of the ventilation and the cardiovascular system. When compared with no sedation for bronchoscopy, benzodiazepine, as a single sedating agent, was associated with increased patient satisfaction and willingness to undergo another bronchoscopy. However, the postprocedure recovery time was longer in the benzodiazepine-treated patients without an increase in complication rates [15].

The three commonly used benzodiazepines for procedural sedation are midazolam, diazepam, and lorazepam. Midazolam is the most preferred

benzodiazepine because of its water solubility, absence of pain with injection, rapid onset, short duration of action, and rapid clearance. The average dose of midazolam is 0.06–0.07 mg/kg with special consideration to using lower doses in elderly patients. Diazepam is a water-insoluble drug that is dissolved in the organic solvent propylene glycol that causes pain on intravenous or intramuscular injection. Diazepam is metabolized by the liver into two active metabolites, desmethyldiazepam, and oxazepam. The activity of these metabolites may cause prolonged sedation for 2–4 days in elderly patients and in those with impaired liver function. Lorazepam is an intermediate-acting benzodiazepine with a stronger amnestic effect and a delayed peak effect, making it the least favored benzodiazepine for procedural sedation (Table 5.2).

Flumazenil is the only known benzodiazepine antagonist. A dose of 0.2 mg IV every 1 min to a total dose of 1–3 mg/1 h is commonly used. The onset of action is at 1–3 min, the peak is at 10 min, and the duration of action is 20 min. Additional doses may be required to maintain antagonism and prevent the recurrence of seda-

tion by longer-acting benzodiazepines. Side effects of flumazenil include nausea, vomiting, tachycardia, hypertension, headache, and rarely seizures.

**Opioids:** These are natural and synthetic substances that bind opioid receptors in the central nervous system and peripheral tissue, causing presynaptic inhibition of release of neurotransmitters (e.g., acetylcholine, dopamine, norepinephrine, and substance P). Activation of the opioid receptors mu, kappa, and delta results in varying degrees of analgesia and side effects such as depression of ventilation, urinary retention, constipation, miosis, and physical dependence. The naturally occurring opioid morphine and the synthetic opioids meperidine, fentanyl, sufentanil, alfentanil, and remifentanyl have been used for bronchoscopic procedural sedation. Fentanyl is the most commonly used opioid for bronchoscopy sedation due to its rapid onset of action and short half-life. Although therapeutic bronchoscopy is not associated with significant somatic pain, opioids were found to cause suppression of airway reflexes in particular cough, tachycardia, and hypertension associated with bronchoscopy [16]. See Table 5.3 for a comparison between the pharmacodynamics of different opioids. Noteworthy is that the combination of opioids and benzodiazepines is associated with better patient's tolerance of bronchoscopy when compared to each agent alone [17].

**Table 5.2** Pharmacodynamics of benzodiazepines

Drug	Dose (mg/kg)	Elimination half-life (h)
Midazolam	0.3–0.5	1–4
Lorazepam	0.05	10–20
Diazepam	0.15–0.3	21–37

**Table 5.3** Pharmacodynamics of commonly used opioids

	Onset (min)	Peak (min)	Duration (h)	Elimination (h)	Context-sensitive half-life (min)	Potency
Morphine	2–3	15–30	3 h	2–3		1
Meperidine	5	5–7	3 h	3–5		0.1
Fentanyl	1–2	3–5	0.5–1	3–6	260	75–125
Sufentanil	1–2	3–5	0.3	2–4	30	500–1000
Alfentanil	1–2	1.5–2	0.2–0.3	1.4–1.5	60	10–25
Remifentanyl	1–2	1.5–2	0.1–0.2	0.17–0.33	4	250

## Monitored Anesthesia Care (MAC)

MAC is defined as a specific anesthesia service in which an anesthesiologist has been requested to participate in the care of a patient undergoing a diagnostic or therapeutic procedure. However, MAC does not describe the depth of sedation. Under MAC, the anesthesiologist can either provide sedation or general anesthesia and the post procedure recovery care. Situations where MAC is valuable are:

1. When variable levels of sedation are needed to meet changes in the patient's and the bronchoscopist's needs during a procedure.
2. Patients sensitive to small doses of sedatives where respiratory or hemodynamic complications can occur and resuscitation will be required.
3. Patients who need a transient period of general anesthesia.

Therefore, the drugs of choice for MAC should be ultra-short-acting anesthetics that are easily titrated to match the patient tolerance to the procedure with rapid return to baseline status at the end of the procedure, e.g., remifentanyl, alfentanil, propofol, dexmedetomidine, and fospopofol. In addition, midazolam, fentanyl, and morphine can also be an acceptable choice [18].

## General Anesthesia

If general anesthesia is the chosen anesthesia technique for an interventional bronchoscopic procedure, an open discussion between the anesthesiologist and the bronchoscopist should take place before and throughout the procedure. The discussion should include procedure location (e.g., trachea vs. bronchi), degree of airway obstruction (e.g., complete vs. partial obstruction), depth of anesthesia needed (e.g., general

vs. sedation), airway device options (e.g., none, endotracheal tube, laryngeal mask airway, or rigid bronchoscope), and the most suitable mode of ventilation (e.g., spontaneous ventilation, non-invasive positive pressure, assisted ventilation, mechanical ventilation, or jet ventilation). In addition, the anesthesiologist should be familiar with the step-by-step plan the bronchoscopist has to manage the airway pathology and possible complications.

*Total intravenous anesthesia (TIVA)* is the anesthetic technique of choice for interventional bronchoscopic procedures when compared to inhalation anesthesia [12]. Inhalational anesthetics have multiple disadvantages, including the variable levels of anesthetic gas delivered because of frequent suctioning during the procedure and the contamination of the operating room air by inhalation agents. However, it is important to emphasize that inhalation agents can be a better choice in cases of bronchospasm or in patients with an anterior mediastinal mass, where maintenance of spontaneous ventilation is essential. The following medications are commonly used for TIVA.

*Propofol*, similar to benzodiazepines, acts to facilitate the inhibitory effect of GABA. When used for sedation for airway procedures, propofol has been shown to be superior to midazolam due to its short onset time of 30 s, metabolism independent of organ function, and rapid recovery time of 15 min after a 2 h infusion. In addition, propofol has been shown to result in significantly better neuropsychometric recovery than midazolam [19]. When compared to inhalation anesthetics, propofol has been shown to reduce coughing and the depression in ciliary function as well as the release of cytokines and the stress hormone response [20–22].

Propofol infusion rates of 100–150  $\mu\text{g}/\text{kg}/\text{min}$  can be used for anesthesia induction while maintaining spontaneous ventilation. The bispectral index monitor (BIS) can be used to titrate the



propofol infusion rates to achieve and sustain an appropriate depth of anesthesia.

*Remifentanyl* is the shortest acting narcotic available, with duration of action of 3–10 min and a rapid onset of action at 1 min. After interventional bronchoscopic procedures, patients do not suffer from postprocedure pain thus eliminating the need for the use of long-acting narcotics. Remifentanyl is ideal for blunting airway reflexes during the procedure with no residual effect in the recovery room [23].

*Ketamine* is a general anesthetic that induces a dissociative state in which sensory stimuli are blocked from reaching the cerebral cortex, causing amnesia and analgesia. Although ketamine is an old drug, its use has been revived because it has profound analgesic property. Ketamine-induced analgesia makes it a good adjunct to propofol that lacks any analgesic properties [24]. Ketamine is particularly valuable for bronchoscopic procedures because of its bronchodilator properties and absence of respiratory depressant effect.

*Dexmedetomidine* is an  $\alpha$ -2 agonist that inhibits norepinephrine release causing its unique ability to provide sedation and analgesia without respiratory depression [25]. Dexmedetomidine has also been found to offer cardio protective benefits during surgery by lowering perioperative oxygen consumption and the stress response [26].

*Muscle relaxants*, such as succinylcholine, rocuronium, or cisatracurium, can be used safely during general anesthesia to prevent laryngospasm and coughing associated with the insertion of the bronchoscope in the airway. The use of muscle relaxation for therapeutic bronchoscopic procedures has many advantages. These include facilitating the insertion of airway devices (e.g., LMA, endotracheal tube, and the rigid bronchoscope); better lung compliance during positive pressure ventilation or jet ventilation; providing the bronchoscopist with a still field when precise targeting of lesions adjacent to major vessels and the heart is needed; and maintaining the glottis aperture open during multiple insertion and removal of the bronchoscope and other instruments thus minimizing trauma to the vocal cord.

On the other hand, indiscriminate use of muscle relaxant in interventional bronchoscopy can be associated with severe complications. For example, there are several reports of loss of the airway patency after muscle relaxant was given in patients with large anterior mediastinal mass. Pneumothorax and/or pneumomediastinum can develop in patients with tracheoesophageal fistulas, bronchoesophageal fistulas, or airway tears when muscle relaxant is given, and positive pressure ventilation is used. In addition, prolonged unwanted muscle relaxation has been reported in patients with lung cancer and paraneoplastic Lambert–Eaton myasthenia syndrome.

In the event that muscle relaxation is deemed unsuitable, instillation of lidocaine on the vocal cords and the proximal airway is a better alternative to the use of muscle relaxation prior to insertion of the rigid bronchoscope or other airway devices.

*Fraction-inspired oxygen ( $FiO_2$ )* should be continuously adjusted to maintain patient oxygen saturation  $>90\%$  during interventional bronchoscopic procedure.  $FiO_2$  of 100% is commonly needed during an advanced bronchoscopic procedure especially in patients with advanced lung pathology, poor baseline oxygen saturation, and/or the use of supplemental oxygen. In addition,  $FiO_2$  of 100% is valuable when periods of complete airway occlusion and/or inability to provide mechanical ventilation is anticipated, e.g., during deployment or extraction of stents, balloon dilation of the airway, removal of a tumor mass where positive pressure ventilation can force the excised tumor down the airway causing acute obstruction, or during exchange of one rigid bronchoscope to a different type or size rigid bronchoscope.

It is important to note that low  $FiO_2$  of less than 40% is required during electrocautery, laser, and argon plasma coagulation (APC) in order to avoid airway fire.

## Monitoring the Depth of Anesthesia

Processed electroencephalograms can be used to monitor the depth of anesthesia and in combina-

tion with the patient's clinical signs can guide the titration of intravenous anesthetics to achieve adequate depth of anesthesia. Consequently, adequate sedation without undesired side effects, such as respiratory failure or cardiovascular instability associated with increased depth of anesthesia, is more likely to be attained [27].

## Description of the Equipment Needed

### Interventional Bronchoscopy Suites

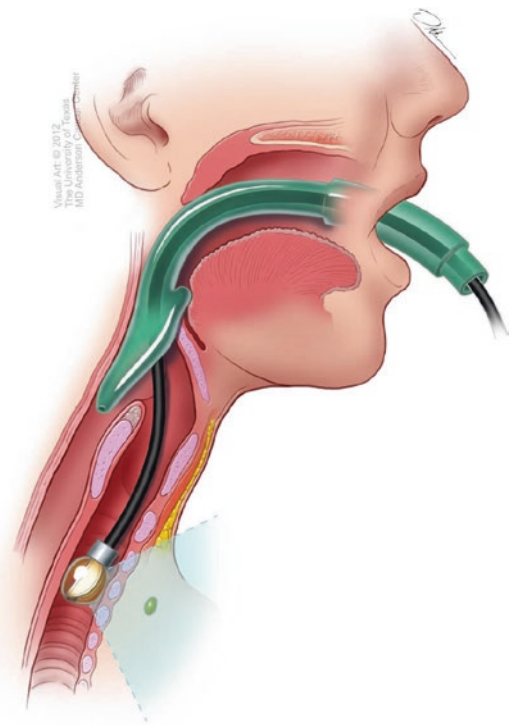
Interventional bronchoscopic procedures are commonly performed in an interventional bronchoscopy suite or the operating room. In most centers, the choice of the location of the procedure depends on the available resources and the anesthesia technique required. Interventional bronchoscopic procedures requiring local anesthesia and/or conscious sedation are usually performed in an interventional bronchoscopy suite where conscious sedation is administered by a trained bronchoscopy nurse under the supervision of the bronchoscopist. Meanwhile, rigid bronchoscopy or procedures that require general anesthesia are commonly performed in the operating room [28]. In recent years, interventional bronchoscopy departments that perform a large number of procedures on a daily basis have designed their interventional bronchoscopy suites in collaboration with the anesthesiologist at their practice to be a replica of an operating room. This has allowed the bronchoscopists to perform more procedures under MAC or general anesthesia in the bronchoscopy suites. Interventional bronchoscopy suites have been operational for several years with great success in several centers in the United States and Europe [29].

### Airway Devices

Procedures performed under conscious sedation or MAC require no invasive airway devices. However, the patient's oxygenation should be monitored by pulse oximetry, and supplemental oxygen should be delivered to maintain the patient's saturation above 90% during the procedure and in the recovery area [13].

### Laryngeal Mask Airway (LMA)

The LMA was first introduced more than 20 years ago and is still used today, with a consistently low incidence of complications. The LMA is an ideal airway device for advanced bronchoscopic procedures. The large diameter of the shaft of the LMA makes it easy to insert large therapeutic bronchoscopes without compromise to the ventilation (Fig. 5.3). The LMA also allows the bronchoscopist to inspect the entire length of the airway from the vocal cords to the distal large bronchi. Additionally, the LMA allows free mobility of the bronchoscope in the airway when compared to an ETT. A bite block needs to be inserted around the LMA. Alternatively, the I-gel version of the LMA has a built-in bite block. The disadvantages of the LMA are the lack of protection against aspiration and the inability to seat the LMA in patients with oral, pharyngeal, or laryngeal deformity or pathology or those who have received radiotherapy. It is important to note that the LMA was originally designed for spontaneously ventilating patients; however, mechanical

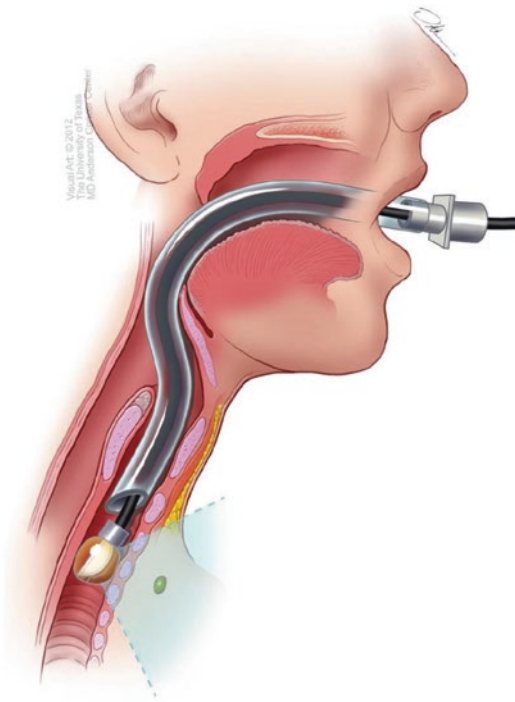


**Fig. 5.3** EBUS bronchoscope introduced through LMA

ventilation can be performed with a limitation of a maximum peak airway pressure of 20 cmH<sub>2</sub>O in order to avoid overcoming the tone of the lower esophageal sphincter and insufflating the stomach with oxygen [30, 31].

### Endotracheal Tube (ETT)

Although an ETT is the most definitive and most reliable airway device in patients undergoing general anesthesia, an ETT has challenges when inserted in a patient with central airway obstruction undergoing a therapeutic bronchoscopic procedure. Insertion of the ETT does not allow the bronchoscopist to examine the vocal cords and the upper part of the trachea for pathology. The large external diameter of the therapeutic flexible bronchoscope requires the insertion of an ETT with an internal diameter of 8.5 mm or 9 mm in order to deliver adequate ventilation around the bronchoscope (Fig. 5.4). The length of the ETT projecting from the patient's mouth limits the length of the flexible bronchoscope available for insertion into the airway, and the proximal end of the ETT is commonly cut off. Insertion



**Fig. 5.4** EBUS bronchoscope introduced through ETT

of an ETT in a patient with pre-existing tracheal or bronchial stents carries a risk of dislodging or deforming the stents, which can potentially result in airway compromise [32].

### Rigid Bronchoscope

The rigid bronchoscope is an ideal airway device in complicated interventional bronchoscopic procedures where instruments and stents are inserted in the airway. The distal end of the rigid bronchoscope is beveled to allow for lifting of the epiglottis and safer insertion through the vocal cords. The proximal end of the rigid bronchoscope can remain open to air to allow for simultaneous insertion of multiple instruments. Leak of the ventilating gas through the open end of the rigid bronchoscope makes jet ventilation or spontaneous ventilation the only possible modes of ventilation. Alternatively, when a cap is placed to seal the proximal end of the rigid bronchoscope, positive pressure ventilation from the anesthesia ventilator can be used. Leak is overcome by inserting a throat pack and Vaseline gauze to occlude the nostrils. A short stainless steel cylinder attached to the proximal end of the rigid bronchoscope has multiple side ports to accommodate a jet ventilator, an anesthesia circuit, and bronchoscopic instruments [33].

The rigid bronchoscope has many advantages over the flexible bronchoscope. These include the ability to provide positive pressure ventilation during lengthy airway procedures and the ability to insert instruments with a large diameter into the airway such as the microdebrider, large suction catheter, and the deployment device for silicone stents. The rigid bronchoscope can also be used as a coring device to debulk airway tumors, dilate stenotic areas, stent the airway open in the case of external airway compression by an anterior mediastinal mass, and tamponade airway bleeding [34].

### Modes of Ventilation

#### Spontaneous Ventilation

Spontaneous ventilation is necessary in cases when the integrity of the airway is compromised, such as tracheoesophageal fistulas, broncho-

esophageal fistulas, and iatrogenic tears in the airway. In such cases, positive pressure ventilation can result in leakage of the ventilating gas (oxygen and/or air) to the mediastinum, the thoracic cavity, and possibly the peritoneum. Anterior mediastinum mass is another indication for spontaneous ventilation because of multiple reports of worsening of the compressive obstruction of the central airway by the mass after a muscle relaxant was given. In addition, spontaneous ventilation is valuable during pleuroscopy, when collapse of the lung on the side of the procedure is essential for visualization.

Spontaneous ventilation can be easily achieved under conscious sedation, MAC, or general anesthesia. Inhalation anesthetics or intravenous anesthetics with adequate topical anesthesia can be used, without the muscle relaxant, for the insertion of the rigid bronchoscope, LMA, or the ETT. Alternatively, a small dose of the short-acting muscle relaxant succinylcholine can be used for the intubation with rapid regain of spontaneous ventilation.

### **Assisted Ventilation**

In a patient with an airway device in place, ventilation can be assisted by multiple modalities to overcome hypoxia and/or hypercapnia associated with spontaneous ventilation under general anesthesia. For example, intermittent handbag ventilation with a large tidal volume, pressure support, or synchronized intermittent mandatory ventilation can be used to overcome atelectasis and improve saturation and CO<sub>2</sub> elimination during bronchoscopic procedures.

### **Noninvasive Positive Pressure Ventilation (NIV)**

NIV, commonly used for patients with sleep apnea, has been described as beneficial in hypoxemic patients undergoing bronchoscopy with anesthesia. Modified nasal or full-face masks, with a special adaptor to allow for the insertion of the bronchoscope, can be used. NIV should be considered when endotracheal intubation and mechanical ventilation is suspected to carry an increased risk to the patient undergoing bronchoscopy. The use of NIV ventilation was shown

to improve oxygenation and reduce the risk of acute respiratory failure after bronchoscopy in patients with impaired baseline oxygenation, such as chronic obstructive pulmonary disease (COPD) patients with pneumonia or immunocompromised patients [35, 36].

### **Positive Pressure Controlled Mechanical Ventilation**

Patients undergoing interventional bronchoscopic procedures that require muscle relaxation need mechanical ventilation. Mechanical ventilation can be delivered through the LMA, ETT, or rigid bronchoscope. When the LMA is the airway device of choice, the peak airway pressure should be kept below 20 cmH<sub>2</sub>O to avoid opening the lower esophageal sphincter and inflating the stomach. Mechanical ventilation through the rigid bronchoscope is associated with leakage around and through the rigid bronchoscope. To overcome such leak, insertion of a throat pack, occlusion of the nostrils with Vaseline gauze, capping of the rigid bronchoscope ports, and high oxygen flow rates with high tidal volumes are needed.

### **Jet Ventilation**

Jet ventilation can be performed using a handheld device through which 100% oxygen is injected into a port at the proximal end of the rigid bronchoscope. The pressure of the injected oxygen can be adjusted with a dial; the frequency of ventilation is left to the operator to select and frequently ranges from 8 to 20 breaths per minute. Jet ventilation should be performed only when the proximal end of the rigid bronchoscope is open to air, to avoid barotrauma [37]. Air is entrained at the open proximal end of the rigid bronchoscope, causing variation in the delivered FiO<sub>2</sub>.

### **Electronic Mechanical Jet Ventilation**

The mechanical jet ventilator (Acutronic Medical Systems, Hirzel, Switzerland) has many advantages over the simple handheld jet ventilator [38]. The user can control the FiO<sub>2</sub>, the frequency of ventilation (up to 150 breaths per minute), and the driving pressure of ventilation (up to 40 mmHg). The inspired oxygen can be humidified up to

100%, enabling prolonged jet ventilation without the risks of airway mucosal dryness and necrosis or damage to ciliary function. In addition, the mechanical jet ventilator has two alarms to protect against barotrauma and will discontinue ventilation if the set maximum airway pressure limit is reached.

### Postprocedure Care

After interventional bronchoscopic procedures, patients should be transported to a standard designated recovery area with well-trained nursing staff. The recovery unit is generally equipped with wall oxygen, vital signs monitors, crash carts, and emergency intubation equipment. In patients who have undergone general anesthesia or who remain deeply sedated at the end of the procedure, supplemental oxygen should be continued via a face mask or a nasal cannula and weaned off gradually. Patients should be observed until they meet discharge criteria (i.e., for 30–45 min). Residual muscle relaxation or postprocedure respiratory failures for a variety of reasons are possible complications that may require intubation, unplanned hospital stay, and/or likely ICU admission.

Upon discharge, all patients should be advised in writing and verbally not to drive, sign legally binding documents, or operate machinery for 24 h after the procedure. The patient should be accompanied home by a responsible adult.

### Special Consideration

#### Anesthesia for Peripheral Diagnostic and Therapeutic Bronchoscopy

Several modalities have emerged to enable the bronchoscopist to reach peripheral lung nodules. These modalities require image guided navigation such as augmented fluoroscopy, electromagnetic navigation (ENB), radial endobronchial ultrasound (rEBUS), cone-beam computed tomography (CBCT), and most recently robotic bronchoscopy [39]. Preprocedural CT imaging is generally required to map the location of lesions and plan the navigation path. It has been noted

that the preprocedural CT images performed in an awake spontaneously ventilating patient do not mirror the imaging of the lung while the patient is under general anesthesia with muscle paralysis and mechanical ventilation. This divergence between the awake spontaneous ventilation versus asleep mechanical ventilation image has resulted in difficulty reaching the lesion and poor biopsy yield. The proposed mechanism of this divergence is the occurrence of atelectasis in the dependent areas of the lung within a few minutes of induction of general anesthesia. Additionally, suctioning of the airway secretions and installation of local anesthetic or normal saline in the airway during bronchoscopy can add to the severity of the atelectasis [40]. Noteworthy, patients with high body mass index were found to have increased risk of atelectasis. Peripheral lesions within an area of atelectasis become concealed by the surrounding collapsed lung and the airways leading to the lesion become distorted, narrowed, and shortened making the navigation difficult [41]. The following recommendations have been described to combat the atelectasis occurring under general anesthesia and closing the gap between awake versus asleep lung radiographic images in patients with posterior or lower lobe lesions as well as obese patients undergoing peripheral bronchoscopy [42].

- Preprocedural incentive spirometry especially in obese patients.
- Preoxygenation with 80–60% fractional inspired oxygen (FiO<sub>2</sub>).
- Induction and maintenance of anesthesia with muscle paralysis.
- Postintubation lung recruitment maneuvers, e.g., PEEP of 40 cmH<sub>2</sub>O for 40 s (adjust level and duration of PEEP to the patient's hemodynamic tolerance as high peep of long duration causes lung hyperinflation, decrease in the venous return, and cardiac output with resultant hypotension and possibly bradycardia due to a vagal reflex).
- During intraprocedural imaging requiring breath hold, the anesthesia ventilator should be set to manual mode at the peak inspiration



with the adjustable pressure-limiting (APL) valve set at a pressure tailored to the patient's tolerance.

- Maintain the same consistent ventilator settings throughout the procedure.

---

## Anesthesia for Interventional Bronchoscopic Procedures During the COVID-19 Pandemic

Bronchoscopy is considered an aerosol-generating procedure due to the coughing encountered during the procedure and the movement of the bronchoscope in and out of the airway. In patients undergoing bronchoscopic procedures under general anesthesia, the process of intubation and extubation is also considered aerosol generating. Additionally, the use of high flow nasal cannula and noninvasive positive pressure ventilation is known to aerosolize the virus into the procedure room air [43]. It has been generally recommended to have the patient undergoing bronchoscopic procedures tested for COVID-19 within 72 h before the procedure. These recommendations are based on the perception that preprocedural testing decreases the risk to both the patient and health care providers. It is also essential to comply with full personal protective equipment's PPE during the procedure to avoid spreading the virus outside the procedure room. Jet ventilation is believed to generate the most aerosolization, and attempts should be made to avoid it in patients testing positive for COVID-19 [44].

---

## Summary and Recommendations

### Conclusion

The field of interventional bronchoscopy has been evolving and becoming more sophisticated, as has the field of anesthesiology. As a result, the older techniques of local anesthesia may not be as well suited for new, complex, prolonged bronchoscopic procedures. Communication between interventional bronchoscopy depart-

ments and anesthesiology departments is necessary to delineate when anesthesia services are needed and where certain bronchoscopic procedures should be performed. Recent advances in the field of anesthesiology render both conscious sedation and general anesthesia for interventional bronchoscopy safe, and the use of these advances is invaluable for the continued growth of the field of interventional bronchoscopy.

---

## References

1. Becker HD. Bronchoscopy: the past, the present, and the future. *Clin Chest Med.* 2010;31(1):1–18, Table of Contents.
2. Sarkiss M. Anesthesia for bronchoscopy and interventional pulmonology: from moderate sedation to jet ventilation. *Curr Opin Pulm Med.* 2011;17(4):274–8.
3. Practice guidelines for sedation and analgesia by non-anesthesiologists. *Anesthesiology.* 2002;96(4):1004–17.
4. Ernst A, Silvestri GA, Johnstone D. Interventional pulmonary procedures: guidelines from the American College of Chest Physicians. *Chest.* 2003;123(5):1693–717.
5. Bolliger CT, et al. ERS/ATS statement on interventional pulmonology. *European Respiratory Society/American Thoracic Society. Eur Respir J.* 2002;19(2):356–73.
6. Bahhady IJ, Ernst A. Risks of and recommendations for flexible bronchoscopy in pregnancy: a review. *Chest.* 2004;126(6):1974–81.
7. Conacher ID, Curran E. Local anaesthesia and sedation for rigid bronchoscopy for emergency relief of central airway obstruction. *Anaesthesia.* 2004;59(3):290–2.
8. Perrin G, et al. Safety of interventional rigid bronchoscopy using intravenous anesthesia and spontaneous assisted ventilation. A prospective study. *Chest.* 1992;102(5):1526–30.
9. Ausseur A, Chalons N. Anesthesia in interventional bronchoscopy. *Rev Mal Respir.* 1999;16(4 Pt 2):679–83.
10. Ost DE, et al. Diagnostic yield of endobronchial ultrasound-guided transbronchial needle aspiration: results of the AQUIRE Bronchoscopy Registry. *Chest.* 2011;140(6):1557–66.
11. Herth FJ, et al. Endobronchial ultrasound-guided transbronchial needle aspiration of lymph nodes in the radiologically and positron emission tomography-normal mediastinum in patients with lung cancer. *Chest.* 2008;133(4):887–91.
12. Sarkiss M, et al. Anesthesia technique for endobronchial ultrasound-guided fine needle aspiration of mediastinal lymph node. *J Cardiothorac Vasc Anesth.* 2007;21(6):892–6.

13. British Thoracic Society Bronchoscopy Guidelines Committee, a Subcommittee of Standards of Care Committee of British Thoracic Society. British Thoracic Society guidelines on diagnostic flexible bronchoscopy. *Thorax*. 2001;56(Suppl 1):i1–21.
14. Wahidi MM, et al. American college of chest physicians consensus statement on the use of topical anesthesia, analgesia, and sedation during flexible bronchoscopy in adult patients. *Chest*. 2011;140(5):1342–50.
15. Maguire GP, et al. Patients prefer sedation for fibreoptic bronchoscopy. *Respirology*. 1998;3(2):81–5.
16. Greig JH, et al. Sedation for fibre optic bronchoscopy. *Respir Med*. 1995;89(1):53–6.
17. Fox BD, et al. Benzodiazepine and opioid sedation attenuate the sympathetic response to fiberoptic bronchoscopy. Prophylactic labetalol gave no additional benefit. Results of a randomized double-blind placebo-controlled study. *Respir Med*. 2008;102(7):978–83.
18. Abdelmalak B, et al. Dexmedetomidine as sole sedative for awake intubation in management of the critical airway. *J Clin Anesth*. 2007;19(5):370–3.
19. Clark G, et al. Titrated sedation with propofol or midazolam for flexible bronchoscopy: a randomised trial. *Eur Respir J*. 2009;34(6):1277–83.
20. Hohlrieder M, et al. Effect of total intravenous anaesthesia and balanced anaesthesia on the frequency of coughing during emergence from the anaesthesia. *Br J Anaesth*. 2007;99(4):587–91.
21. Ledowski T, et al. Bronchial mucus transport velocity in patients receiving propofol and remifentanyl versus sevoflurane and remifentanyl anesthesia. *Anesth Analg*. 2006;102(5):1427–30.
22. Ledowski T, et al. Neuroendocrine stress response and heart rate variability: a comparison of total intravenous versus balanced anesthesia. *Anesth Analg*. 2005;101(6):1700–5.
23. Purugganan RV. Intravenous anesthesia for thoracic procedures. *Curr Opin Anaesthesiol*. 2008;21(1):1–7.
24. Phillips W, et al. Propofol versus propofol/ketamine for brief painful procedures in the emergency department: clinical and bispectral index scale comparison. *J Pain Palliat Care Pharmacother*. 2008;24(4):349–55.
25. Ramsay MAE, Luteran DL. Dexmedetomidine as a total intravenous anesthetic agent. *Anesthesiology*. 2004;101(3):787–90.
26. Taittonen MT, et al. Effect of clonidine and dexmedetomidine premedication on perioperative oxygen consumption and haemodynamic state. *Br J Anaesth*. 1997;78(4):400–6.
27. Bruhn J, et al. Depth of anaesthesia monitoring: what's available, what's validated and what's next? *Br J Anaesth*. 2006;97(1):85–94.
28. Vaitkeviciute I, Ehrenwerth J. Con: bronchial stenting and laser airway surgery should not take place outside the operating room. *J Cardiothorac Vasc Anesth*. 2005;19(1):121–2. [http://www.ncbi.nlm.nih.gov/pubmed/15747283?ordinalpos=2&itool=EntrezSystem2.PEntrez.Pubmed.Pubmed\\_ResultsPanel.Pubmed\\_DefaultReportPanel.Pubmed\\_RVDocSum](http://www.ncbi.nlm.nih.gov/pubmed/15747283?ordinalpos=2&itool=EntrezSystem2.PEntrez.Pubmed.Pubmed_ResultsPanel.Pubmed_DefaultReportPanel.Pubmed_RVDocSum).
29. Amat B, Günther R, Carlos A, Antoni X, Antoni T. What is an interventional pulmonology unit in Europe? *Clin Pulm Med*. 2010;17(1):42–6.
30. Abdelmalak B, et al. Respiratory arrest after successful neodymium:yttrium-aluminum-garnet laser treatment of subglottic tracheal stenosis. *Anesth Analg*. 2002;95(2):485–6, table of contents.
31. Hung WT, Liao SM, Su JM. Laryngeal mask airway in patients with tracheal stents who are undergoing non-airway related interventions: report of three cases. *J Clin Anesth*. 2004;16(3):214–6.
32. Kirsner KM, Sarkiss M, Brydges GJ. Treatment of tracheal and bronchial tumors and tracheal and bronchial stent placement. *AANA J*. 2010;78(5):413–9.
33. Ayers ML, Beamis JF Jr. Rigid bronchoscopy in the twenty-first century. *Clin Chest Med*. 2001;22(2):355–64.
34. Wahidi MM, Herth FJ, Ernst A. State of the art: interventional pulmonology. *Chest*. 2007;131(1):261–74.
35. Clouzeau B, et al. Fiberoptic bronchoscopy under noninvasive ventilation and propofol target-controlled infusion in hypoxemic patients. *Intensive Care Med*. 2011;37:1969.
36. Ambrosino N, Guarracino F. Unusual applications of noninvasive ventilation. *Eur Respir J*. 2011;38(2):440–9.
37. Fernandez-Bustamante A, et al. High-frequency jet ventilation in interventional bronchoscopy: factors with predictive value on high-frequency jet ventilation complications. *J Clin Anesth*. 2006;18(5):349–56.
38. Kraincuk P, et al. A new prototype of an electronic jet-ventilator and its humidification system. *Crit Care*. 1999;3(4):101–10.
39. Practice Guidelines for Sedation and Analgesia by Non-Anesthesiologists. A report by the American Society of Anesthesiologists task force on sedation and analgesia by non-anesthesiologists. *Anesthesiology*. 1996;84(2):459–71.
40. Casal RF, et al. Cone beam computed tomography-guided thin/ultrathin bronchoscopy for diagnosis of peripheral lung nodules: a prospective pilot study. *J Thorac Dis*. 2018;10(12):6950–9.
41. Sagar AS, et al. Incidence and location of atelectasis developed during bronchoscopy under general anesthesia: the I-LOCATE trial. *Chest*. 2020;158(6):2658–66.
42. Pritchett MA, et al. Anesthesia considerations to reduce motion and atelectasis during advanced guided bronchoscopy. *BMC Pulm Med*. 2021;21(1):240.
43. Pritchett MA, et al. Society for advanced bronchoscopy consensus statement and guidelines for bronchoscopy and airway management amid the COVID-19 pandemic. *J Thorac Dis*. 2020;12(5):1781–98.
44. Gildea TR, Abdelmalak BB. Bronchoscopy challenges during the COVID-19 pandemic. *Cleve Clin J Med*. 2020. <https://doi.org/10.3949/ccjm.87a.ccc054>.



# Bronchoscopy Education: New Insights

# 6

Henri G. Colt

Tell me and I'll forget; show me and I may remember; involve me and I'll understand. (Chinese proverb)

## Background

I have always been amazed that medical education involved learning “on” patients as well as from them. Many years ago, surrounded by other medical students, I positioned myself so as to stand directly beside my senior resident as he prepared to perform a lumbar puncture. Erect in our long white coats, leaning inward with anticipatory curiosity and awe, we marveled at the way he told the patient what he was going to do before ordering her to turn onto her side. After prepping the skin, he inserted the spinal needle effortlessly. We cringed collectively, however, as it was repositioned, causing the patient to cry out in pain. We sighed with relief when a clear fluid suddenly appeared, and the procedure finished, we admired the authoritative tone with which our resident informed this small, frail, and frightened 18-year old girl with sweat-drenched hair and a poorly fitting hospital gown that uncovered her bare buttocks and lower back, that she must lay quietly for several hours and that everything was going to be fine. As we followed the resident out of the room (the ward had several patients, all of

whom had been watching us), we felt important in our white coats. Like a swarm of flies around a picnic table covered with food, we excitedly spoke about how cool the resident had been and how easy the procedure seemed. Later that afternoon, I recalled that we had never been told the patient's name, nor been introduced to her as she lay passively on her bed. We were not given much of an explanation about the procedure either, and I had not yet had the opportunity to watch others before I was told the very next morning to “go tap that patient in bed 3”.

Until very recently, medical training has followed guidelines established by Flexner and Halsted in the early twentieth century [1]: A step-wise postgraduate training program is designed within a “see one, do one, teach one” paradigm, with patients serving as teaching material. Trainees gradually achieve independence from faculty supervision as they progress through their years of apprenticeship. Competency is often presumed based on numbers of procedures performed, and objective measures of knowledge (high-stakes tests) are used for licensure and certification purposes [2].

Today, “see one, do one, teach one” is no longer an acceptable paradigm of procedure-related medical instruction, so patients need no longer suffer the burden of procedure-related training. Furthermore, teachers need no longer devote hours to enumerating facts and figures related to medical illnesses because educational media are

H. G. Colt (✉)  
University of California, Irvine, Orange, CA, USA

increasingly accessible, with information at the fingertips and on the computer screens of health care providers and patients alike [3]. Using inanimate and computer-based platforms, technical skills can be practiced independently or under supervision; structured curricula help assure a foundation of knowledge regardless of the diversity and variability of the clinical setting, and new norms and expectations governing professionalism help guide physician behaviors that promote respect for patient autonomy and shared-decision making.

These early twenty-first century learning environments empower both teacher and learner. Benefitting from a bidirectional learning process, they are able to explore together many new and exciting roles. Digital simulation allows students to practice procedures before ever going to the patient's bedside, and, as new delivery systems for instructional materials replace conventional textbooks, enhancing the portability, access, and design of information, both learners and teachers can devote more time to learning *how to think* or *how to teach*, rather than on rote memorization and content development [4]. The availability of web-based instruction, use of interactive case-based exercises, role-playing sessions, opportunities for individualized instruction, and an open forum where teachers serve more as coaches or wise elders frees teachers from their podiums. Low-stakes assessment tools and self-assessments can be used to identify areas that warrant remedial training, as well as to document one's progress toward competency and proficiency because at the bedside and in the classroom, the implementation of new models of instruction allows educators more time to build personal relationships with learners. Learners benefit from this because face time with instructors can be used to encourage learning through positive reinforcement, provide key insights into a procedure or management decision, enhance intrinsic motivation, and discover fun in learning. Learning curves may thus be climbed with greater confidence and comfort in a truly caring education environment.

Taking the liberty to depart from a conventional chapter devoted to science and literature

review, my objectives in the following paragraphs, are instead to: (1) address major elements of curricular structure and delivery, (2) provide an example of how a structured curricular approach using a combination of onsite and online materials such as those provided in the Bronchoscopy Education Project might facilitate learning, (3) describe how assessment tools might help guide the educational process and assure procedure-related competency, and (4) discuss how an ethics of teaching underlies and justifies the paradigm shift occurring in today's world of medical procedural education. While flexible bronchoscopy and airway procedures are used as models for discussion, much of what I write is applicable to other areas of procedure-related medicine.

---

## Curricular Structure and Delivery

Bronchoscopy is performed by a variety of medical and surgical specialists including pulmonologists, thoracic surgeons, ear, nose, and throat specialists, anesthesiologists, and intensivists. Indications vary from simple inspection to diagnosis of lung and airway disorders, assistance with intubation, and therapeutic procedures to remove foreign bodies, restore airway patency, treat emphysema, asthma, or cancer to name but a few. There does not appear to be a universally accepted convention by which to teach the technical skills required to perform this procedure, nor to introduce learners to the complexities of a bronchoscopy-related consultation.

In many institutions, the bronchoscopy learning experience is variable, in part because of diverse practice patterns and patient referrals, but also because of different teaching interests, methodologies, and time committed to the educational process [5]. In fact, despite its existence since the late 1960s, many questions remain regarding the clinical practice of flexible bronchoscopy. The variability of equipment used and resources available for teaching further complicates matters when contemplating a global approach to the educational process. Videobronchoscopes, for example, are used in most prosperous areas

of North America, Europe, and the Middle East, whereas flexible fiberoptic bronchoscopes are still the workhorses of South Americans and many developing countries in Asia. Techniques are also controversial: Should the scope be held in the left of the right hand? Where should assistants stand? Should the procedure be performed from the head or from in front of the patient? Should the patient be supine or semierect? What kind of sedation, if any should be used? Are universal precautions, including gown, gloves, and protective eyewear always necessary, and how should equipment be cleaned? Finally, who should be considered able and competent to perform the procedure? Could it be performed by nonphysician providers in specific settings such as an intensive care unit or as part of a lung donor eligibility assessment, or should bronchoscopy remain a physician-only performed procedure? Should training and certification processes be different depending on medical specialty? Should bronchoscopy privileges extend to all types of procedures, or should only certain specialists perform certain types of procedures? How many procedures should one perform to be deemed competent, and if numbers are used as a metric, how many must be performed each year to maintain competency? If they are not used as a metric, what assessment and testing tools might be employed to assure that procedures are performed safely and competently?

### What Is a Bronchoscopy Curriculum?

In most countries, there is no fixed curriculum pertaining to bronchoscopy education. See Table 6.1. It is assumed that physicians in various specialties become competent in the procedure as a result of their subspecialty training. In the United States, where more than 500,000 bronchoscopies are performed each year, there is no uniform structure for bronchoscopy training other than learning during residency or fellowship [6]. Nor is there a standardized method by which technical skills and procedure-related knowledge are assessed. In fact, very few questions (usually less than five) are devoted to bron-

**Table 6.1** What we know about bronchoscopy education today

- Various learning and teaching modalities are and can be complementary
- Didactic lectures can be conveniently accessed off-site though the use of the internet
- Well-edited videos can replace watching cases performed in real time, without jeopardizing patient care or programmatic structure
- A learner's active engagement time is maximized if less time is devoted to hands-off demonstrations, and more time is spent assisting learners with clearly identified hands-on skillsets and exercises
- Participation in problem-solving and critical thinking (practical approach, case based) exercises help assure procedural safety, effectiveness, efficiency, and systems-based practice, and tells instructors "how" learners think and process information
- The sacrifice of live animals for practice purposes has been rendered unnecessary because cadavers, inanimate models, and computer-based simulation are excellent, proven, and cost-efficient alternatives
- Assessments and outcome metrics help identify a learner's position along the experience curve, ascertain knowledge, and measure technical skill acquisition. Insights are provided regarding a program overall effectiveness, and assessments identify weaknesses that can be corrected through remedial, individualized training
- A "bronchoscopy university at your fingertips" is possible using portable tablets and mobile devices. This increases access to learning materials and helps achieve a democratization of knowledge whereby bronchoscopy training is more uniformly achievable regardless of one's place of work or practice

choscopy on subspecialty board examinations, even though it is the major minimally invasive procedure performed by chest physicians.

Surveys pertaining to flexible bronchoscopy in countries as diverse as Singapore, Great Britain, India, Poland, Egypt, and the United States consistently identify variations in practice and training [7–9]. This diversity derives from a lack of uniform requirements, paucity of structured curricula, absence of validated measures of competency and proficiency, unequal access to learning materials, variability of patient-based learning experiences, and differences in skill, interest, and teaching abilities of medical practitioners designated as bronchoscopy instructors. Furthermore, the lack of a uniform competency-based framework for bronchoscopy education makes it dif-



difficult for physicians already in practice to acquire new skills.

A curriculum (noun, plural of which is *curricula* or *curriculae*) can be defined as a group of related courses, often in a special field of study [10]. As such, it pertains to the purpose, content, activities, and organization inherent to an educational program [11]. There are many challenges that must be overcome, however, as one contemplates curricular structure [12]. Some of these are related to conceptualizing the instructional process and defining meaningful learning experiences. Others relate to tradition, availability of resources, variability of deeply held beliefs and teaching styles, and the paucity of bronchoscopy-education-related research.

### **Instructional Process and Defining Meaningful Learning Experiences**

John Dewey (born 1859–1952), probably one of America’s most influential philosophers, wrote “the belief that all genuine education comes about through experience does not mean that all experiences are genuinely or equally educative” [13]. For health care providers, being obliged to perform what might be for the first time, albeit with guidance, a procedure in a patient is both discomforting and anxiety provoking. A social mandate for accountability and truly informed consent will make it increasingly difficult for practitioners to learn by doing. In addition, such a learning environment creates an ethical dilemma for the competent instructor being asked to advocate for efficient, evidence-based, cost-effective quality of care, and who knows that he or she can perform the procedure more quickly, more efficiently, and with greater patient comfort than the learner. These arguments justify, whenever possible, a more widespread use of simulation-based bronchoscopy training.

Changes in the perception of the educational process have resulted from modifications of medical education systems. In the United States, for example, The Accreditation Council of Graduate Medical Education currently advocates a competency-based training model that replaces

one based on process and number of cases performed [14]. Great emphasis is placed on objective measurements of competency, including elements of professionalism, systems analysis, and health care team development. In designing a bronchoscopy curriculum, therefore, one must consider how learning processes reach beyond technical skill development to involve the cognitive, affective, and experiential forms of knowledge, as well as how knowledge acquisition and retention might be assessed both during and after training [15]. In my opinion, these arguments, particularly in view of the expansion of bronchoscopic practice,<sup>1</sup> give good reason for a more structured approach to bronchoscopy training. One such approach might include a curriculum that includes recommended reading assignments, case-based and problem-based learning exercises [16], hands-on simulation and real patient-based procedure performance, low-stakes assessments to document progress along the learning curve [17], individual learner-centric training opportunities, and outcome metrics [18] to identify strengths and weaknesses of continued medical education programs as well as the effectiveness of courses and seminars on both individuals and groups.

From a learner-centric perspective, therefore, bronchoscopy education should entail elements of critical thinking, problem-solving, ethical values and behaviors, mastery of critical facts and figures, mastery of certain technical skills unique to each type of procedure being performed, self-realization, self-esteem and emotional stability, safety, and an ability to effectively and efficiently integrate procedural practice into one’s institution-based medical practice. While much of this is presumed to be learned during

<sup>1</sup>Bronchoscopy is increasingly used to diagnose and treat patients with a variety of lung and airway disorders. Therapeutic procedures such as bronchial thermoplasty, endobronchial valve insertion, and airway stent placement have been added to the traditional interventional pulmonology armamentarium. Additionally, evolving acoustic and optical technologies augment diagnostic capabilities, and the need for greater amounts of tissue for tumor markers and other lung cancer-related analyses is expanding the role of bronchoscopists in the area of cancer management.

traditional apprenticeship-style training, various components are often not documented, and in most institutions, from what I have been told by many bronchoscopy experts, no precise written curricular structure is in place.

Despite increasing patient care responsibilities and the stress of providing cost and time-effective quality care, many bronchoscopists create time in their busy schedules in order to devote themselves to the educational process. From a teacher's perspective, such unselfish involvement might be enhanced if curricular elements were developed in a manner that is time and cost-efficient, nonalienating, and conducive to individualized and collective learning. Some educational methodologies and curricular content, for example, could be standardized to the extent that a generally accepted or more uniform foundation of facts and philosophies becomes available and can be integrated into various individual and group educational venues (i.e., clinical settings, online or computer-based programs, postgraduate seminars, online and onsite courses).

All of us, regardless of our experience and level of competence or expertise, can benefit from pedagogical technical assistance. As new concepts, learning materials, and techniques

are introduced into practice, faculty development programs could be used to enhance teaching skills, assure continuity and growth, and develop educational resources. During these venues, experiences could be shared regarding the advantages and challenges of moderating small group interactive learning sessions, using presentations and audience participation software, and integrating video, other media, real-time decision trees, instant messaging, Twitter, tablet PCs, or writing boards into educational programs (Figs. 6.1 and 6.2).

While a mentor's behaviors might readily be emulated after observation, it is unrealistic to expect that the ability to teach effectively comes naturally to everyone. Of course, many physicians are excellent teachers, but the assumption that a medical doctor is a natural born instructor represents, in my opinion, a significant shortcoming of our academic philosophy, and runs contrary to assumptions in other professions such as public education and sports, where particular emphasis is placed on learning how to teach. The purpose of faculty development programs, often referred to as train the trainer seminars, therefore, is to help motivate, stimulate, inspire, and train professionals interested in serving as role models, mentors and instructors in the use of diverse

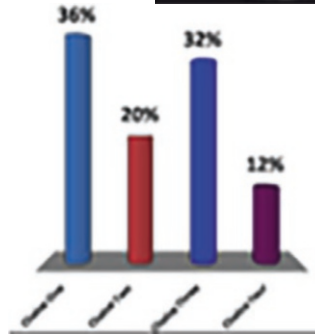
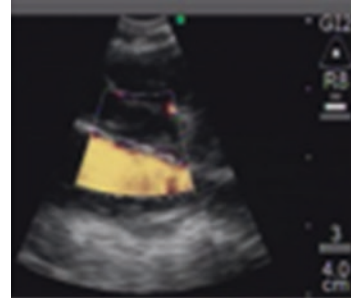
**Fig. 6.1** Example of instructor led small group discussion in Peru. Participants are debating the advantages of using Bronchoscopy skills and task assessment tool in background (BSTAT) quiz to develop a common language for airway secretions and mucosal abnormalities



**Fig. 6.2** Example of using audience participation software during an interactive question/answer session. In view of the wide variety of responses shown on the graph, the instructor will provide insight regarding each of the possible answers

A patient with a PET avid mediastinal and hilar lymphadenopathy is referred for EBUS-TBNA. The lower right paratracheal lymph node is shown. Which of the following sonographic characteristics is most specific for a metastatic lymph node?

1. Its heterogeneous echogenicity
2. Its short axis of 1.5 cm
3. The hypoechoic areas within the lymph node without blood flow
4. Its distinct margins



educational techniques and methodologies, and to develop, provide and study resources that are incorporated in whole or in part into various learning curricula.

### Tradition, Teaching Styles, and Beliefs

There is a grand tradition in bronchoscopy education. This tradition is twofold. In the first instance, we assume that learners will learn bronchoscopy during the course of their specialty training [19], and that learning will be satisfactory because learners are exposed to different faculty members who might each perform bronchoscopy in a different way (setup, positioning, sedation and medication use, techniques, etc.). Accompanying this is the idea that the complexities of a bronchoscopy-related consultation are always learned while rotating on a specialty consulta-

tion service and that all of the items pertinent to such a consultation are satisfactorily addressed, even if they are not explicitly reviewed with the attending faculty (i.e., indications and informed consent, procedure-related strategy and planning, technique and expected results, response to complications, postprocedure management, and follow-up).

The second tradition pertains to the popularity of 1 and 2-day postgraduate courses, devoted until recently and for the most part to physicians already in practice. We have always trusted that these courses were effective and met particular training objectives. For bronchoscopists, the tradition comes from decades of hands-on learning that began with the admired and effective patient-based rigid bronchoscopy instruction programs conducted by Gustav Killian and Chevalier Jackson. In such a program, the expert speaker lectures on a topic while the learner

group listens dutifully. Often, individual experts prepare their lectures with little information or fixed-in-advance knowledge regarding common purpose that might integrate their lectures with content from other talks given during the course. Popular hands-on sessions are organized using animal models and equipment loaned from equipment manufacturers. More recently, computer-based simulation and inanimate models have been introduced. Learners rotate from station to station, listening to experts tell them about a procedure or technique, then watch as he (until recently, most bronchoscopy experts have been male) demonstrates the technique. Then one after another, learners take the scope in hand and do something, some less well than others. Sometimes, live transmissions of cases are included in the program, with either the operator or other faculty member interacting with the audience to discuss indications and procedural techniques.<sup>2</sup>

During these programs, we had always assumed learners would learn by simply being present: preliminary or postcourse assessments are rarely performed, and little time is devoted to truly individualizing the learning process. An objective commentary about these programs, however, might include the following: (1) the complexities of bronchoscopy-related instruction and consultation are increasing in view of the rapid expansion of interventional pulmonology, (2) time constraints, accountability, concerns for cost-effectiveness and a mandate for enhanced patient safety and respect make patient-based instruction increasingly problematic, so complementary venues for learning are necessary, (3) passive learning from listening to a speaker giving a lecture is not as effective as when learn-

ers are actively engaged, (4) critical thinking and problem-solving are rarely addressed, yet these are major components of achieving procedure-related competency, (5) educational content and the effectiveness of its delivery depends on who prepares the lecture and how it is delivered, (6) active engagement time (the time the learner is actually devoting to learning by doing) is minimal, consisting of, for example, only 3–5 min per person for a group of five people during a 30 min station session, (7) specific tasks and learning objectives are often not made explicit at each hands-on station, decreasing the likelihood that a specific skill will actually be enhanced or acquired at the skill station, (8) substantial time is spent listening to lecturers during didactic as well as hands-on sessions, (9) baseline knowledge and skill levels of course participants are rarely assessed, making targeted individualized or problem-focused instruction difficult, and (10) after they return to their clinical practices, few resources are available to help participants apply and master what they have experienced.

A paucity of studies pertaining to the effectiveness, or lack thereof, of these traditional methods of bronchoscopy education, makes it challenging to step out of the box in order to view the above-mentioned traditional educational processes differently. It is equally challenging to introduce and potentially justify changing a well-entrenched educational system. The reality is, however, that an older paradigm frequently provides a dynamic vision for what is to come after it. Today, we know that: (1) different learning and teaching modalities are and can be complementary, (2) many lectures could be accessed offsite though the use of the internet, (3) well-edited videos could replace long periods of watching a transmitted “live” case, without jeopardizing patient care, (4) not all bronchoscopists, especially myself, are as good at teaching as they could be, (5) not all lectures provide a foundation of knowledge considered useful or required by learners, (6) active engagement time can be

<sup>2</sup>Live transmissions carry many challenges not the least of which are that cases may be selected based on the expectant participants, intraoperative decisions might be made solely on the basis of educational or theatrical need, and the operator may be distracted by questions or other interactions with the audience.

maximized if less time is devoted to demonstrations, and more time is spent assisting learners as they perform specific skill sets or exercises, (7) problem-solving and critical thinking needs to become a standard part of bronchoscopy courses because they are essential to the safety, effectiveness, and efficiency of bronchoscopic practice, (8) animals, veterinary services, cadavers, and animal laboratories are costly and regulated, also prohibiting instructional programs in hotels or congress halls, (9) the unnecessary sacrifice of live animals can almost always be avoided by using inanimate models and computer-based simulation, and (10) metrics are needed to help ascertain knowledge and skill acquisition as well as program effectiveness as part of a competency-oriented program of procedure-related learning.

This list is obviously not exclusive, and many other elements are important in rethinking traditional methods of bronchoscopy education. Agents of change are necessary to develop and implement different teaching strategies and methodologies across the globe. Industry support is essential to educational programs, and professional societies may need to work together, rather than compete, in order to foster a foundation of information and assure a greater democratization of knowledge. Finally, either/or debates and opposing points of view can be synthesized in a manner that promotes learning and choice, acknowledging both points of view in the context of a broadened educational perspective [20] (Fig. 6.3).

### **Bronchoscopy-Education-Related Research**

The bronchoscopy-related literature is gradually supporting the paradigm shift whereby patients will no longer bear the burden of procedure-related training. In a review pertaining to the use of simulation for bronchoscopy education [21], we noted that simulation helps learners improve procedural efficiency and economy of

movement, thoroughness and accuracy of airway examination, and decreases airway wall trauma [22]. In addition to increasing learner satisfaction and interest, simulation allows tasks to be practiced repeatedly without jeopardizing patient safety, and training scenarios can be individualized. Both low- and high-fidelity simulation have been shown to enhance competency in procedural skills while saving time and improving the learning curve [23, 24]. Furthermore, skills acquired through practice on simulators are transferable to the clinical setting [25]. Objective assessment identifies errors and provides opportunities for remedial training [26, 27].

High-fidelity simulation platforms using three-dimensional virtual anatomy and force feedback technology can be used to teach conventional and EBUS-guided transbronchial needle aspiration (TBNA), although less expensive, low-fidelity models comprised of molded silicone excised animal airways and ultrasound phantoms are also effective [28]. The efficacy of a low-fidelity hybrid airway model made of a porcine trachea and a plastic upper airway was demonstrated for learning transcranial and transbronchial needle aspiration [29]. This model gave learners an opportunity to practice needle insertion, positioning, safety measures, and communication with ancillary personnel. It has since been modified so that a plastic airway is used, obviating the need for discarded animal parts, and making the use of such training materials possible in hotel conference centers and nonhospital facilities. Models can also be used to teach scope manipulation and airway anatomy, foreign body removal, bronchoscopic intubation, EBUS-guided TBNA, and other interventional techniques, some of which can also be practiced using high-fidelity computer based simulation<sup>3</sup> (Fig. 6.4). New, portable computer-based bronchoscopy simulation is

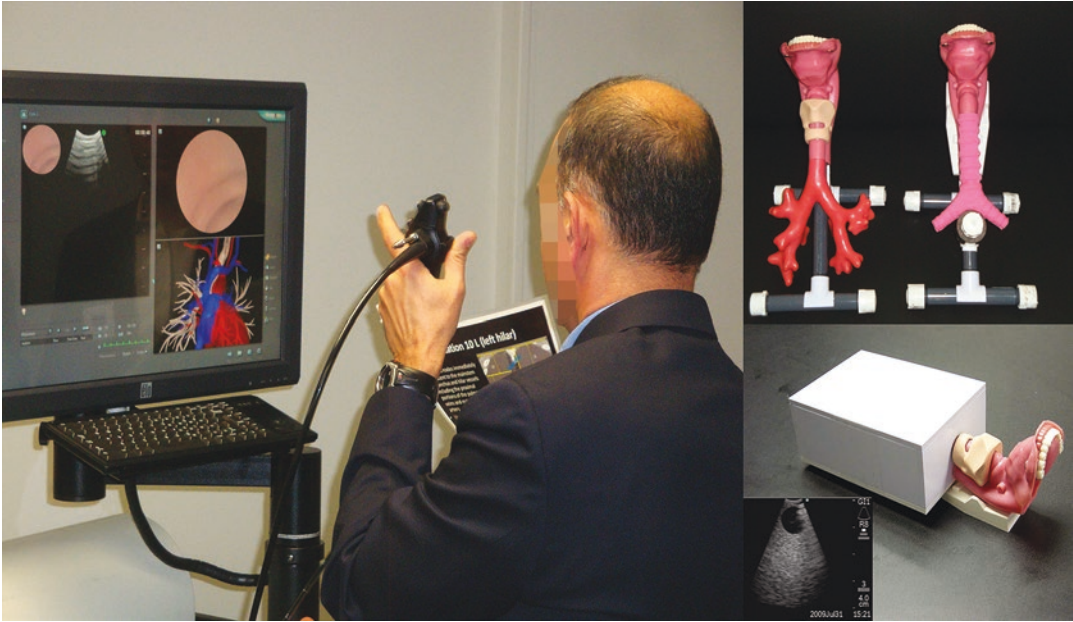
<sup>3</sup>See for example <http://symbionix.com/>



EITHER	OR	BOTH-AND SYNTHESIS
Scope handling with the left hand.	Scope handling with the right hand.	Both are correct and impact positioning of bronchoscopy assistants and handling of ancillary equipment. Operator comfort and the existing traditions with influence choice.
Operator position from the head of the patient.	Operator position from in front of the patient.	Both are correct and should be learned because either may be necessary depending on procedural setting and indication.
Tests	Assessments	Both are important in improving learning. How should competency be ascertained? Is there a role for Mastery learning? What kind of remedial training may be warranted? How can both be used in the setting of physicians-in-training as well as for physicians already in practice?
Teacher-centered instruction	Learner-centered learning	Teacher-learner relationships are important and allow teachers to assume various roles. New technological platforms create greater opportunities for independent study, collaboration, and long distance learning.
Apprenticeship-style learning	Competency-oriented learning	Both are important as learners take on greater responsibilities. Using new technologies and educational methodologies are likely to help accelerate quality patient care and safety, and allow a more rapid introduction of new procedures and techniques into the patient care arena.
Face-to-face instruction	Online learning	Both are important. Face-to-face instruction and active engagement time, especially during hands on training, takes on even greater value when learners learn using online resources. Face-to-face time can occur through videoconferencing as well as during onsite seminars, and of course at the patient's bedside or in the simulation center.
Learning on patients	Learning using simulation	Both are important. All facets of bronchoscopic knowledge and skill, including elements of professionalism, physician behaviors, procedural techniques, response to complications, and management decision making can be improved upon using inanimate models, computer-based simulation, and by helping learners work through the decision-making process during individual or group learning sessions. These can occur prior to or concurrent with patient-based experiences.
Reading conventional textbooks and articles	Media and technology	Both are important. Reading conventional textbooks may still be helpful, but media and technology are changing the way learners can interact with reading, both online and in print. Videos and interactive images and text (such as patient-centered exercises and clinical pathways) enliven the learning process and help learners analyze their performance. Articles are easily retrieved today using online informational databases and can be used to justify decision-making and enhance evidence-based quality care practice.
Competency determined based on single institution subspecialty training	Competency determined based on completing a core curriculum that might be applicable in part or in whole in many	Both are necessary. For example, a curriculum similar to one proposed in the Bronchoscopy Education Project and modified based on institutional needs or medical practice setting (see Figure 4) assures objective monitoring of trainees who attend onsite learning programs, clinical pathways, experience the advantages of simulation, and demonstrate skills using checklists and assessment tools in both the simulation and patient-care environment.

\*Inspired from reference #20: Chen M, Education Nation pg 23-24.

**Fig. 6.3** Examples of turning either/or debates into both/and syntheses



**Fig. 6.4** Examples of inanimate and computer-based simulation platforms for learning bronchoscopy. Shown are the simionix bronch mentor (EBUS module) and inanimate models assembled by bronchoscopy international: bronchoscopy airway inspection model using bifurcated normal airway from CLA, Germany, transbron-

chial needle aspiration model using silicone airway from Sawbones Seattle WA, USA, and inanimate EBUS model using Laerdal laryngeal structure and ATS laboratories ultrasound phantom with bifurcated airway and simulated lymph nodes at levels 2, 4, and 7 (ATS laboratories, Bridgeport, CT)

becoming available using laptop computers and proxy bronchoscopes.<sup>4</sup>

Demonstrating improvements in technical skill completes only part of the picture [30]. The increasing emphasis on competency-oriented education warrants that bronchoscopy courses also use competency-based measures to assess the efficacy of course curricula and training modalities [31]. Outcome measures might take the form of high or low-stakes testing in the various cognitive, technical, affective, and experiential elements of procedure-related knowledge [32–34]. Using quasi-experimental study design and a series of pretest/posttest assessments with cal-

culations of absolute, relative and class-average normalized gain, we have demonstrated the efficacy of a 1-day structured curriculum including a uniform set of didactic lectures, interactive sessions, workshops, and hands-on simulation-based training in flexible bronchoscopy and thoracoscopy [35, 36].

Assessment tools that objectively measure skill and knowledge acquisition will also need to be designed and validated in various learning settings and medical environments [37]. Ideally, their design should be flexible so that instructors with different habits or biases can still incorporate them into their programs without feeling compelled to radically modify their own way of performing procedures. As faculty development programs are integrated into curricular structures,

<sup>4</sup>See for example: <http://www.orsim.co.nz/>, and <http://www.anesthesia.utoronto.ca/edu/cme/bronch.htm>

it may become helpful to study their value and contributions to enhanced teaching and learning. Finally, research targeting curricular platforms and the results of educational interventions will contribute to the elaboration of new bronchoscopy instruction-related theories and processes.

---

## The Bronchoscopy Education Project

Developed by Bronchoscopy International<sup>5</sup> in collaboration with many experts from all over the world, The Bronchoscopy Education Project (BEP)<sup>6</sup> has been officially endorsed by several international bronchology and interventional pulmonology societies. Its aim is to complement and hopefully enhance existing educational programs by providing bronchoscopy instructors and training program directors with competency-oriented tools and materials. These may be used to help train bronchoscopists and assess progress along the learning curve from novice to competent practitioner. The curriculum includes The Essential Bronchoscopist™ series of books and eBooks [38, 39] a series of training manuals [40], an encyclopedia of Practical Approach© patient-centered exercises that integrate cognitive, affective and experiential knowledge pertinent to bronchoscopy-related consultation, Bronchoscopy step-by-step© lessons, a problem-oriented BranchAtlas™ video series,<sup>7</sup> a compilation of PowerPoint-based lecture programs

called Fundamentals of Bronchoscopy©, and a set of Bronchoscopy Assessment Tools© and Checklists. Material can be integrated in whole or in part, as needed by each program. Learning is based on individual and group study of training manuals, participating in didactic and interactive lecture programs delivered onsite and online, viewing instructional videos on social media sites such as YouTube and Facebook, and participating in deliberate hands-on practice sessions during postgraduate programs and in the course of subspecialty training. Officially supported by and in collaboration with professional medical societies, faculty development programs are being conducted across the globe to help an international group of bronchoscopists, early adopters, and agents of change use these learning materials, improve their presentation skills, create personalized curricula specific to the needs and medical culture of their region, and develop concepts that will strengthen future educational programs. Specific criteria exist by which instructors become certified. A brief description of some of the BEP resources built on the philosophy of using frequent, repeated group, and individual exposures to multimedia rather than single medium instruction [41] is found below:

- As part of the Essential Bronchoscopist™ Series of eBooks The *Essential Flexible Bronchoscopist*© and The *Essential EBUS Bronchoscopist*© are comprised of specific reading materials, learning objectives, and posttests. Each module contains 30 question–answer sets with information about major topics relating to bronchoscopic procedures. The aim of these modules is not to replace the apprenticeship model but to complement in-hospital subspecialty training and to encourage open dialogue between learners and faculty.
- A *Bronchoscopy Step-by-Step*© and *EBUS Step-by-Step*© series of graded exercises help

---

<sup>5</sup>Bronchoscopy International is a transnational group of educators and agents of change devoted to the development of educational resources and to the dissemination of bronchoscopy-related knowledge.

<sup>6</sup>The BEP is a work in progress with materials constantly being added. For more information, visit HONcode certified website at [www.Bronchoscopy.org](http://www.Bronchoscopy.org) and the BranchOrg page on YouTube.

<sup>7</sup>For example, video found at: <http://www.youtube.com/watch?v=-MP-WdVcCXY>

learners acquire technical skills necessary to perform these procedures.<sup>8</sup> Instructional videos are readily viewable on desktop computers as well as hand-held devices, IPADs, or cell phones. Specific training maneuvers help the learner practice incrementally difficult steps of bronchoscopy and EBUS-guided TBNA.<sup>9</sup> Steps are designed to enhance the development of “muscle memory” by breaking down complex moves into constituent elements and practicing the separate elements repeatedly before gradually combining them into more complex maneuvers.

- *The Fundamentals of Bronchoscopy*© lecture series includes a compilation of PowerPoint lectures and interactive slide presentations that can be delivered as part of online or onsite courses. Material has been developed with input from many generous experts worldwide and constitutes a uniform collection of learning resources that can be presented by speakers as part of local, regional, or international training programs.
- *The Introduction to Flexible Bronchoscopy* and *The Endobronchial Ultrasound and EBUS-Guided TBNA* are specific training manuals that are available in hard copy as well as in the form of eBooks. Each contains program materials, model schedules 1-day seminars, suggestions for elements of a program completion checklist, specific simulation scenarios, recommended reading assignments,

patient-centered practical approach exercises, checklists, and procedure-specific assessment tools. Volumes pertaining to other aspects of bronchoscopic practice are being developed.

- An encyclopedia of *Practical Approach patient-centered exercises* using a four-box approach to bronchoscopy-related consultation (includes elements from the initial evaluation, procedural strategies, techniques and results, and long-term management). Specific scenarios and case resolutions can be used for purposes of individual and group study, assessment, or as content for didactic or interactive lecture sessions.
- *BronchAtlas*<sup>TM</sup> includes a series of PowerPoint presentations and the *BronchAtlas*<sup>TM</sup> Video Series, a group of concise problem-oriented text files and short, hyperlinked videos designed to address specific issues encountered in daily bronchoscopic practice. Each text (PDF) file enunciates the problem (for example, bronchoscopy in patients with obstructive sleep apnea) and uses bullet lists to describe the problem with greater detail before providing solutions, a video, and a handful of relevant references. Files can be downloaded onto IPADs and mobile devices for easy review.
- A series of *Bronchoscopy Assessment Tools*© designed as learning instruments provides objective measures of knowledge acquisition. Fixed numeric scores are attributed to learners based on performance of technical skills that include dexterity, accuracy, anatomic recognition, navigation, posture and position, economy of movement, atraumatic instrument manipulation, pattern recognition, and image analysis (Fig. 6.5).

<sup>8</sup>Colt HG. *Bronchoscopy Lessons*. Instructional video pertaining to various aspects of bronchoscopy You Tube (posted 2010): <http://www.youtube.com/watch?v=phRv73Ik7fI&feature=related>

<sup>9</sup>For example, video found at [http://www.youtube.com/watch?v=Z9FdgVx\\_xrM](http://www.youtube.com/watch?v=Z9FdgVx_xrM)

**EBUS-STAT 10 Point Assessment Tool**

Learner: \_\_\_\_\_

Year of Training \_\_\_\_\_

Faculty: \_\_\_\_\_

Date \_\_\_\_\_

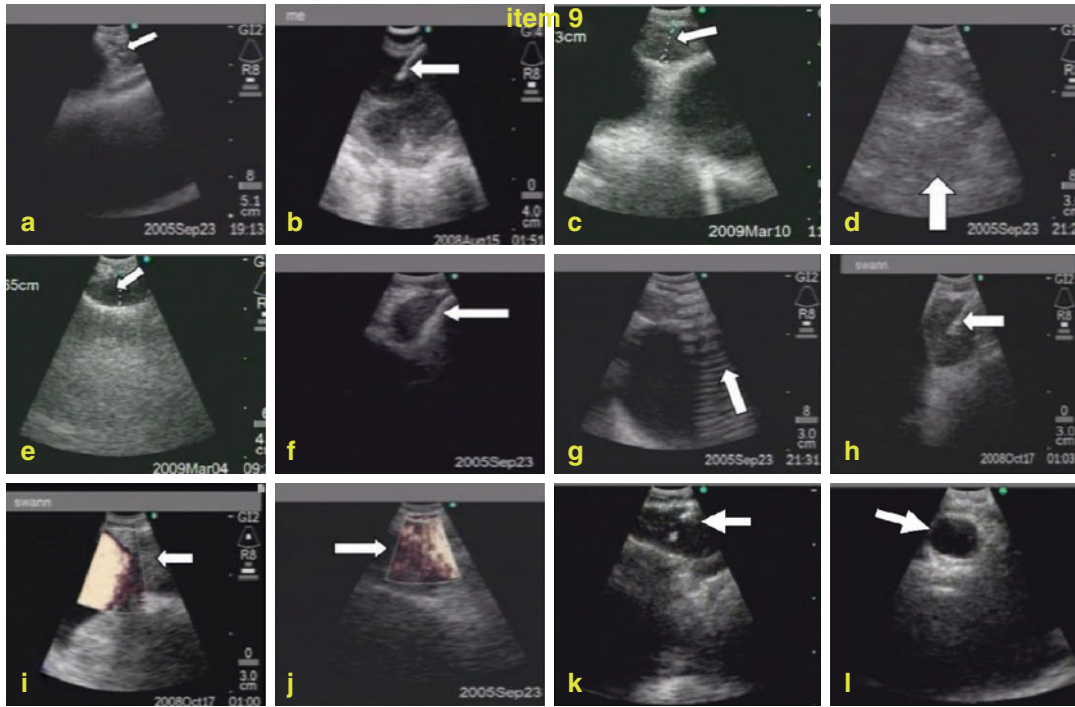
<p align="center"><b>Educational Item*</b> Items 1-10 each scored separately</p>	<p align="center"><b>Satisfactory Yes/No</b></p>
<p><b>1. Able to maneuver the scope through upper airway into trachea, without trauma or difficulty (5 points for single item tested)</b>  <input type="checkbox"/> Mouth and Vocal cords    <input type="checkbox"/> ET Tube    <input type="checkbox"/> Laryngeal mask airway</p>	<p align="center">Yes / No  Score ____/5</p>
<p><b>2. Able to maneuver scope using white light bronchoscopy within tracheobronchial tree without trauma (4 points, no partial points)</b>  <input type="checkbox"/> Scope centered in airway lumen avoiding airway wall trauma</p>	<p align="center">Yes / No  Score ____/4</p>
<p><b>3. Ultrasound image obtained without artifacts (5 points, no partial points)</b>  <input type="checkbox"/> Absence of artifacts on image, any target</p>	<p align="center">Yes / No  Score ____/5</p>
<p><b>4. Identify major mediastinal vascular structures (4 points per item)</b>  <input type="checkbox"/> Aorta    <input type="checkbox"/> Pulmonary artery    <input type="checkbox"/> Superior vena cava    <input type="checkbox"/> Azygos vein    <input type="checkbox"/> Left atrium</p>	<p align="center">Yes / No  Score ____/20</p>
<p><b>5. Identify lymph node station (Select 3 targets, 5 points each)</b>  <input type="checkbox"/> 2R    <input type="checkbox"/> 2L       <input type="checkbox"/> 4R    <input type="checkbox"/> 10R    <input type="checkbox"/> 7    <input type="checkbox"/> 4L       <input type="checkbox"/> 10L    <input type="checkbox"/> 11L    <input type="checkbox"/> 11Rs    <input type="checkbox"/> 11Ri</p>	<p align="center">Yes / No Score ____/15</p>
<p><b>6. Able to operate EBUS processor (2 points each item)</b>  <input type="checkbox"/> Gain    <input type="checkbox"/> Depth    <input type="checkbox"/> Doppler</p>	<p align="center">Yes / No Score ____/6</p>
<p><b>7. Performance of EBUS-TBNA (1 point each, target 15 points)</b>  <input type="checkbox"/> Advance needle through working channel (neutral position)    <input type="checkbox"/> Secure needle housing by sliding the flange    <input type="checkbox"/> Release sheath screw    <input type="checkbox"/> Advance and lock sheath                  When it touches wall    <input type="checkbox"/> Release needle screw    <input type="checkbox"/> Advance needle using jab technique    <input type="checkbox"/> Visualize needle entering target node    <input type="checkbox"/> Move stylet in and out a few times    <input type="checkbox"/> Remove stylet    <input type="checkbox"/> Attach syringe    <input type="checkbox"/> Apply suction    <input type="checkbox"/> Pass needle in and out of node 10-15 times    <input type="checkbox"/> Release suction    <input type="checkbox"/> Retract needle into sheath    <input type="checkbox"/> Unlock and remove needle and sheath</p>	<p align="center">Yes / No Score ____/15</p>
<p><b>8. Image analysis: CT scans (1 point each, target 10 points)</b>  <input type="checkbox"/> Image 1    <input type="checkbox"/> Image 2    <input type="checkbox"/> Image 3    <input type="checkbox"/> Image 4    <input type="checkbox"/> Image 5    <input type="checkbox"/> Image 6    <input type="checkbox"/> Image 7  <input type="checkbox"/> Image 8    <input type="checkbox"/> Image 9    <input type="checkbox"/> Image 10</p>	<p align="center">Yes / No Score ____/10</p>
<p><b>9. Image analysis: EBUS views (1 point each, target 10 points)</b>  <input type="checkbox"/> Image 1    <input type="checkbox"/> Image 2    <input type="checkbox"/> Image 3    <input type="checkbox"/> Image 4    <input type="checkbox"/> Image 5    <input type="checkbox"/> Image 6    <input type="checkbox"/> Image 7  <input type="checkbox"/> Image 8    <input type="checkbox"/> Image 9    <input type="checkbox"/> Image 10</p>	<p align="center">Yes / No Score ____/10</p>
<p><b>10. Decision-making tasks: (2 points each, target 10 points)</b>  <input type="checkbox"/> Image 1    <input type="checkbox"/> Image 2    <input type="checkbox"/> Image 3    <input type="checkbox"/> Image 4    <input type="checkbox"/> Image 5</p>	<p align="center">Yes / No Score ____/10</p>

\* The combined use of the 10 items tests competencies needed to climb the learning curve from novice to advanced beginner to intermediate to competent bronchoscopist able to independently perform EBUS-TBNA.

**FINAL GRADE**                      **PASS**                      **FAIL**                      **SCORE \_\_\_\_/100**

**Fig. 6.5** Example of EBUS-STAT (checklist and one component of the EBUS-STAT image quiz), an assessment tool for endobronchial ultrasound and EBUS-guided transbronchial needle aspiration. *STAT* skills and tasks assessment tool





ITEM 9: Match the photo (A-L) to the corresponding 10 EBUS views (Only one response per description)			
_____	_____	_____	_____
Station 4R adjacent to pulmonary artery superior vena cava and ascending aorta	Needle penetrating through and through	Needle missing target node	Station 4L adjacent to aorta and pulmonary artery
_____	_____	_____	_____
Station 4L adjacent to pulmonary artery	Needle within lymph node	Normal lung	Reverberation artifact
_____	_____	NO RESPONSE	
Station 7 adjacent to left atrium	Hilar node adjacent to normal lung		

Fig. 6.5 (continued)

## Using Assessment Tools to Guide the Educational Process

Whether learning to play a musical instrument, participate in a sporting activity, or perform a medical procedure, learning requires acquisition of technical skill, facts (cognition), experience, and an understanding about how we relate emotionally to what we are doing (affect). The effectiveness of the learning process depends, in part, on the frequency, variety, quality, and intensity of the learning encounter, as well as on the presence, quality, interest, skill, and demeanor of the teacher. One's natural talents and predisposition, motivation, and personality come into play, as do the various written, passive, visual, aural, interactive) ways that are used to present learning materials.

Just as tasting is a prerequisite to good cooking, assessments are a fundamental part of learning. In health profession education, written tests, performance tests, clinical observation, and other methods of evaluation such as chart reviews and oral examinations are used as in high-stakes tests for certification<sup>10</sup> or licensure but are also valu-

able as low-stakes assessments<sup>11</sup> that are part of the learning process during a learner's quest for competency.<sup>12</sup> In this case, they help document progress along the learning curve,<sup>13</sup> identify gaps in knowledge warranting remedial or individualized training, uncover strengths and weaknesses of an educational program, may help identify different knowledge levels among a group of trainees or course participants in order to design a more individualized sequence of training, and help determine congruence with self-assessments performed by learners as part of a feedback or debriefing session [42].

---

<sup>11</sup>*Low-stakes* testing usually does not have pass-fail thresholds or carry significant consequences. Such assessment would be consistent with an educational process that emphasizes a quest toward professionalism and competency (progress along the learning curve), but does not measure skill or knowledge with significant consequences. A *high-stakes* assessment, on the other hand, usually carries significant consequences, such as licensure or pass/fail certification.

<sup>12</sup>*Competency* is the ability gained from knowledge and skills, which forms a basis for performance. To be competent means having the ability to activate and utilize specific knowledge when faced with a problem.

<sup>13</sup>In medicine, a learning curve, also called an *experience curve*, applies to a process where performance improves as a function of practice. This curve may be more or less steep depending on the learner's skill and knowledge, circumstances, experience, and on whether the procedure being learned is new or established. We increasingly tend to differentiate learners into novices, beginners, intermediate learners (also referred to by some as advanced beginners), experienced, and experts, but simpler delineations of beginner, intermediate, and competent practitioner might also be used. Progress along the learning curve usually occurs in steps, with learners remaining, or choosing to remain on a particular plateau that itself may have its occasional dips and peaks.

---

<sup>10</sup>*Certification* is defined as a process that provides assurance to the public that a medical specialist has successfully completed an educational program and undergone some type of evaluation, which almost always includes a high-stakes written examination that is designed to test the knowledge, experience, and skills requisite to the provision of high-quality care in that specialty (see ACGME—Accreditation Council for Graduate Medical Education).

When cognitive knowledge is assessed using standardized tests with written multiple-choice questions or oral interviews, questions should ideally be validated using specific criteria that include testing for difficulty and internal reliability. This may not be absolutely necessary when designing assessment tools where learning is the major objective. Assessments, contrary to tests, have the primary purpose of giving feedback to both teachers and learners about gaps in knowledge and how to improve learning. Technical skill assessments, however, to be of valuable across a broad range of learners, should probably use measures that are validated in various learning settings, be reliable,<sup>14</sup> and have a strong correlation to the procedure being taught. Checklists can be used to ascertain progress toward competency in various components of a procedure such as ability to obtain informed consent or safe use of fluoroscopy. Checklists also democratize knowledge and have the potential to improve safety and quality of care [43].

It is noteworthy that validity evidence refers to the data and information collected in order to assign meaningful interpretation to assessment scores or outcomes designed for a specific purpose and at one specific point in time [44]. Hence, validity refers to score interpretations and not

to the assessment itself [45]. While validity has been traditionally divided into *construct*, *content*, *criterion*, and *face validity*, Downing and others consider construct validity (a test measuring what it is supposed to measure) as the whole of validity, and validity evidence as both case and time specific.<sup>15</sup>

The Bronchoscopy Education project stresses the importance of using a Mastery training paradigm, whereby the eventual expected score on an assessment reflects 100% correct responses because operators should ideally be able to master each of the constituent elements of a safe and effective procedure in order to achieve and document competency. The main variable that distinguishes different learners is the slope of the curve, i.e., the time each learner requires to reach a particular educational objective [46]. Different facets of the project, including introduction to bronchoscopy, endobronchial ultrasound, bronchoscopy in the intensive care unit, and interventional bronchoscopy curricula, can be integrated in part or in whole into ongoing training programs. A program completion checklist helps document a learner's participation as shown in this example pulled from the Introduction to Flexible Bronchoscopy Program (Fig. 6.6).<sup>16</sup>

<sup>14</sup>Reliability is defined as the proportion of reproducible data to random noise recorded by the assessment instrument. Using criterion-referenced testing, concrete criteria are established, and the individual is challenged to meet them. This explores what proportion of specific content of knowledge and skills the learners know or are able to perform, as opposed to norm-referenced tests that compare an individual's performance to the performances of a group (See <http://www.valparint.com/CRITERIO.HTM> reference downloaded May 25, 2012).

<sup>15</sup>In other words, the evidence presented to support or refute the interpretation assigned to assessment that can be used for one test administration and is not necessarily applicable to a different test administration (see Downing, reference 45 page 22–23).

<sup>16</sup>While user instructions, checklists, and assessment tools are provided in the Bronchoscopy Education Project Faculty Development Training Manual, they can also be obtained from various professional societies (such as the ASER and WABIP) and at [www.Bronchoscopy.org](http://www.Bronchoscopy.org)

**Introduction to Flexible Bronchoscopy Program  
Program Completion Checklist**

<b>Educational Item*</b>	<b>Completed Yes/No</b>	<b>Assessment Item</b>	<b>Pass / Fail / Incomplete</b>
1. Participation in regional introductory course	Yes / No	Post-test scores Target 12/20 (60% correct) Score _____%	Pass / Fail / Incomplete
2. Assigned reading: <i>The Essential Flexible Bronchoscopist</i>	Yes / No	Post-test scores Target 7/10 (70% correct)	Pass / Fail / Incomplete
Module 1	Yes / No	Score _____	Pass / Fail / Incomplete
Module 2	Yes / No	Score _____	Pass / Fail / Incomplete
Module 3	Yes / No	Score _____	Pass / Fail / Incomplete
Module 4	Yes / No	Score _____	Pass / Fail / Incomplete
Module 5	Yes / No	Score _____	Pass / Fail / Incomplete
Module 6	Yes / No	Score _____	Pass / Fail / Incomplete
3. <i>Sedation module</i>	Yes / No	Score _____	Pass / Fail / Incomplete
4. <i>Fluoroscopy Module</i>	Yes / No	Score _____	Pass / Fail / Incomplete
5. Informed consent, patient safety, and procedural pause simulation workshops	Yes / No Yes / No Yes / No	IC 10-pt Checklist Target 100% Score _____% on each	Pass / Fail / Incomplete
6. Informed consent, patient safety, and procedural pause patient-based scenarios	Yes / No Yes / No Yes / No	IC 10-pt Checklist Target 100% Score _____% on each	Pass / Fail / Incomplete
7. Practical Approach interactive workshop	Yes / No	Subjective scores Target Pass	Pass / Fail / Incomplete
8. Flexible bronchoscopy simulation workshop	Yes / No	Target scores 100% BSTAT _____%  TBLB/TBNA _____%	Pass / Fail / Incomplete
9. Flexible bronchoscopy patient-based scenario	Yes / No	Target scores 100% BSTAT _____%  TBLB/TBNA _____%	Pass / Fail / Incomplete
10. Proctored case bronchoscopy checklist	Yes / No	FB 10-pt Checklist Target 100% Score _____%	Pass / Fail / Incomplete

\*When completed, learners are assumed to be able to perform flexible bronchoscopy independently. Programs may still require observation and faculty presence based on training regulations and preferences.

**Fig. 6.6** Program completion checklist from the bronchoscopy education project's introduction to flexible bronchoscopy curriculum

## The Ethics of Teaching

“We’re Doctors” proclaims actor Harry Connick Jr., portraying Dr. Dennis Slamon<sup>17</sup> in his plea for continued research funding in the Lifetime television movie *Living Proof* (Dan Ireland, 2008), about the discovery of epidermal growth factor Her2 and subsequent development by Genentech of the antibreast cancer drug Herceptin. Perhaps this simple statement, more than any other, justifies taking a new look at how bronchoscopy is both taught and learned.

As medical practitioners dedicated to the health and well-being of our patients, it is paradoxical that for the past 40 years, patients have suffered the burden of bronchoscopy-related training. As availability to technology and computer-based learning increases around the world and the cost of using alternative learning materials such as instructional videos, training models, and simulation decreases; however, educational processes and philosophies inevitably change. Learners are already less dependent on rote memorization, referring frequently to web-based instruction, digital textbooks, electronic information delivery systems, and social communication media available through their computers and hand-held mobile devices.

Those interested in the advantages of “scaffolding,” a process by which instructional techniques, materials, and other resources are used to structure programs that are conducive to a learner’s more rapid ascent of the experience curve, can excitedly revisit ways to package and deliver educational materials. The world is rapidly becoming a global village. By altering our views and practices, health care education can better reflect society’s adoption of new technologies and fulfill an increasingly verbalized directive for provider competency, accountability, professionalism, and expert medical procedural practice.

Much of the intrinsic value physicians accord to medical education is derived from knowing that jobs are well done and that patients are well served. In this sense, both consequentialist

(to reduce suffering and avoid retribution) and nonconsequentialist ethical arguments (duty, obligation, and the respect of principles such as beneficence or justice) enhance intrinsic motivation and prompt learners freed from the classroom and the patient’s bedside, to improve their skills and knowledge by accessing educational resources using new technologies. Resistance to this shifting paradigm is futile in light of the increasing availability of learning materials on the internet. Learners cannot be denied access, nor be restrained from obtaining varying points of view regarding a certain procedure or technique. Because access is often free, teachers, rather than being fearful of their loss of power and control, should view them as shortcuts to the learning process. Embracing the digital age and encouraging learners to access these resources fosters dialogue and debate.<sup>18</sup> Faculty can thus use face time with learners, whether online or onsite, more productively to enhance understanding, rectify erroneous interpretations, and teach how to *think* and *process* information.

Curiously, doctors are unfairly expected to be good mentors and effective instructors without ever having learned to teach. As mentioned earlier, this presumption is, for the most part, absent in other areas such as public school, sports, or music education, and represents, in my opinion, a significant shortcoming of our academic institutions and profession. Very few bronchoscopists have been offered seminars specifically designed to teach educational methodologies [47], team dynamics, communication techniques, leadership, presentation skills, or conflict resolution. Even fewer have received formal instruction in behavioral psychology or learned to evaluate and

<sup>17</sup>Currently Director of clinical/translational research, UCLA Jonsson Comprehensive Cancer Center.

<sup>18</sup>Tinsley and Lebak expanded on Vygotsky’s constructivist theories, describing a zone of reflective capacity in which adults increased their ability for critical reflection through feedback, analyses, and evaluation of one another’s work in a collaborative environment (see Lebak, K. & Tinsley, R. Can inquiry and reflection be contagious? Science teachers, students, and action research. *Journal of Science Teacher Education*;2010;21;953–970).



relate to students with different individual propensities for learning.<sup>19</sup>

### When Learners Teach: The Journey from Novice to Mastery and Back Again

For those interested in teaching, a fascinating yet challenging journey lies ahead. Physicians already adept at bronchoscopic interventions, but less knowledgeable about education can experience the thrill and insecurity of becoming novices again. In addition to renewing interests in bronchoscopy-related knowledge and techniques, teachers can find out more about how social media facilitates communication with a new generation of learners at a time that is most convenient for both. We can become skillful using programs and devices for editing audio and video files, creating eBooks, constructing learning platforms, and delivering educational materials. We might also explore websites like Cool-math, SuccessMaker, and Kahn Academy to experience how interactive online programs effectively encourage learning.<sup>20</sup> During our quest, we will learn more about ourselves, and while not quite identical to Dorothy's journey along the yellow brick road to Oz, we will also become increasingly knowledgeable of five structural elements crucial to the educational process: curricular design, content development, instructional methodology, teach-

ing techniques, and flexible assessment tools that accurately measure what is learned and identify what remains to be taught.

In learning you will teach, and in teaching, you will learn. (From *Son of Man* (1999), lyrics by Phil Collins)

---

### The Future Is Now

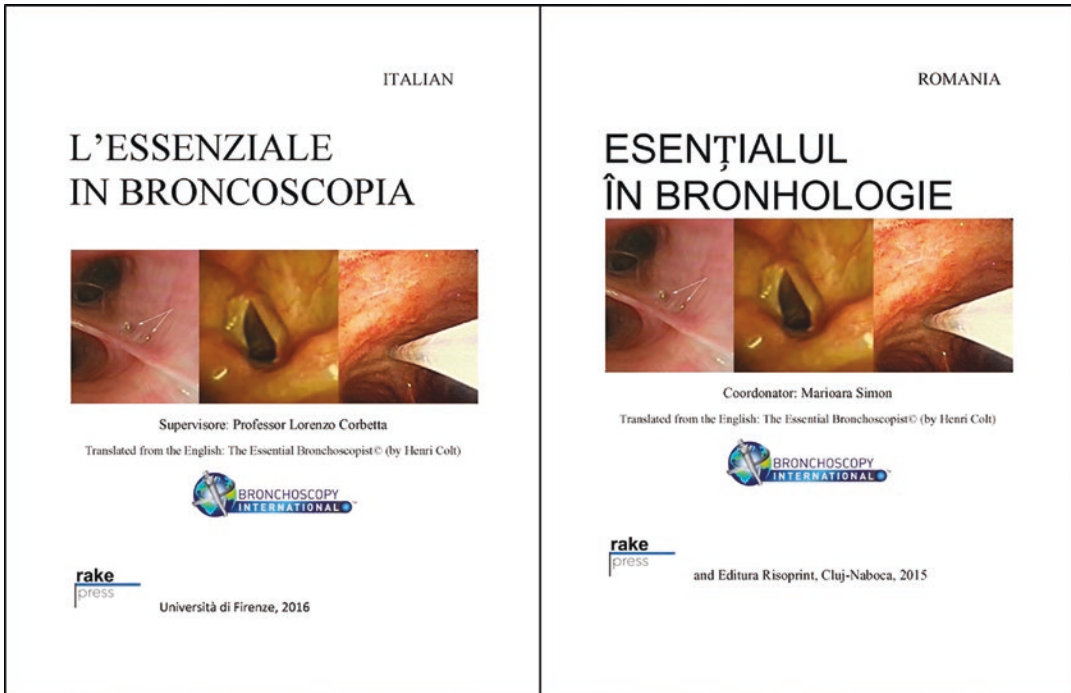
In this chapter, I provided a brief overview of curricular structure and delivery, described an example of a structured instructional program that is The WABIP-endorsed Bronchoscopy Education Project, explained how assessment tools and checklists are used to help guide the educational process, and argued that an ethics of teaching justifies the paradigm shift from a “see one, do one, teach one” bronchoscopy education model to one where learner-centric behaviors are the focus and target of a ladder learning philosophy. By freely using footnotes and supplemental tables, I tried to clarify terminologies and help enhance the reader's knowledge and understanding of educational processes (Fig. 6.7).

Change is a slow process, and by definition, incites resistance. During the last few years, however, and even since the last edition of this textbook, we have witnessed the enthusiastic adoption of new educational philosophies and innovative teaching modalities. Assessment tools and checklists are increasingly advocated, and physician-educators, recognizing that wearing a white coat in and of itself does not make one an “educator,” are obtaining advanced degrees in education. Programs are being designed and implemented to help bring a more uniform approach to the bronchoscopy educational process, including translations of key texts and videos, official endorsements of structured training modalities by national and international bronchology organizations, introduction of new assessment tools in other fields of interventional pulmonology (such as the UGSTAT developed and officially endorsed by the TSANZ [48]). Consistent with the move toward increasing use of artificial intelligence, long-distance learning, inverted classroom teaching modalities, and advancing

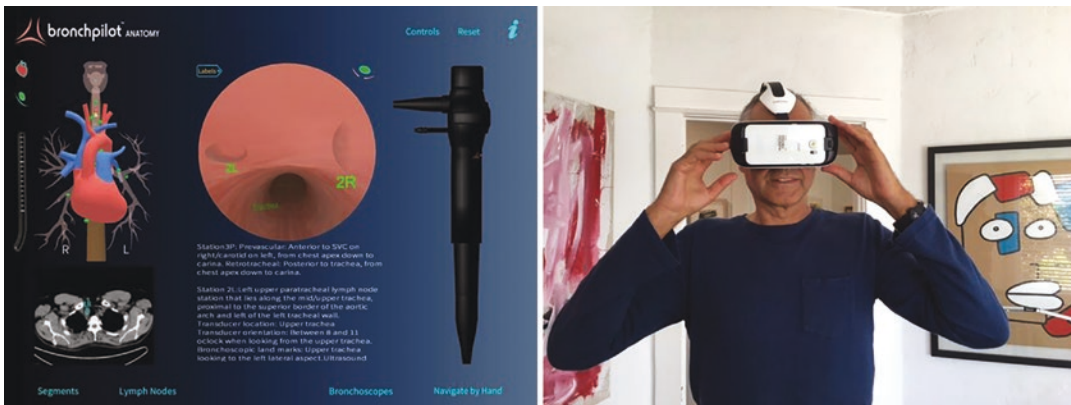
---

<sup>19</sup>Fenstermacher and Soltis describe a humanistic teaching approach, whereby teachers strive to impart knowledge within an environment in which learning has personal meaning for the learner. By adopting various teaching techniques; facilitator (*coaching*), executive (*modifying the curriculum based on review of assessment results*), or liberationist (*fostering discovery and creativity*), for example, liberationist educators might alter their teaching methods on the spot according to the medical learning environment and to fit the many different ways individual learners learn (italics are mine).

<sup>20</sup>David Ausubel (1918–2008) in his meaningful reception theory where, contrary to rote memorization or discovery learning based on problem solving, one's knowledge of new material is enhanced if the material is related to relevant ideas within the learner's existing cognitive structure (<http://tip.psychology.org/ausubel.html>, downloaded December 27, 2010).



**Fig. 6.7** Examples of translations of *the flexible essential bronchoscope* in Italian and Romanian



**Fig. 6.8** Example of the *sharp visions software* iPad-based BronchPilot anatomy and Samsung-based BronchPilot virtual programs help bring individualized learning to the forefront of the educational process

technology, educators are also working toward greater democratization, making learning materials globally available and accessible regardless of one’s place of work or practice. An example of using these new technologies is the WABIP-endorsed BronchPilot Anatomy program that is an iPad-based learning modality whereby learners can drive a flexible bronchoscope through

the airways, while simultaneously accessing 3D reconstructions of airway and mediastinal anatomy. The Samsung-based platform used for the new BronchPilot Virtual program is another step forward, using fully immersive virtual reality that allows the learner to virtually “be the bronchoscope” examining the airways through a self-guided tour (Fig. 6.8). These new teaching

modalities, accompanied by more accepted and conventional (how times change...for just a few years ago these modalities were considered to be innovative and new) methods providing access to internet-based learning materials and interactive presentation-like programs, provides learners of the future with a veritable *Bronchoscopy University* at their fingertips. That future, most excitingly, is already upon us, beckoning teachers and learners alike to become agents of change in a world where step by step, one person at a time, can indeed change the world.

**Disclosures** Henri G. Colt, MD, is Chairman of the World Association for Bronchology and Interventional Pulmonology, and is also the founder of Bronchoscopy International, a nonprofit group of professionals dedicated to the design, development study, and global dissemination of educational materials benefiting bronchoscopists and their patients. Dr. Colt has no financial or commercial conflicts of interests with any of the companies whose websites are listed in the text or footnotes.

## References

- Stratakos G. Contemporary bronchoscopy and assessment: a la recherché du professionalism perdu? *Respiration*. 2012;83(2):140–6. (editorial).
- Long DM. Competency-based residency training: the next advance in graduate medical education. *Acad Med*. 2000;75:1178–83.
- Dinscore A, Andres A. Surgical videos online: a survey of prominent sources and future trends. *Med Ref Serv Q*. 2010;29:10–27.
- Colt HG, Quadrelli S. Democratization of medical knowledge and technology: brief commentary on implications for medical education. *Simul Healthc*. 2006;1:238–9.
- Pastis N, Nietert P, Silvestri G. ACCP interventional chest diagnostic procedures network steering committee. Variation in training for interventional pulmonary procedures among U. S. pulmonary critical care fellowships, a survey of fellowship directors. *Chest*. 2005;127:1614–21.
- Haponik EF, Russell GB, Beamis JF, et al. Bronchoscopy training: current fellows, experiences, and some concerns for the future. *Chest*. 2000;118:572–3.
- Torrington KG. Bronchoscopy training and competency: how many are enough? *Chest*. 1999;118:572–3.
- Colt HG. Flexible bronchoscopy in Cairo, Egypt. *J Bronchol*. 2008;15(3):125–6.
- Pyng L, Loo CM, Jagadesan R, Colt HG. Survey of bronchoscopy practice in Singapore. *J Bronchol*. 2008;15(4):215–20.
- <http://www.thefreedictionary.com/curriculum>. Accessed 25 May 2012.
- Walker DF, Soltis JF. Curriculum and aims. New York: Teachers College, Columbia University; 2009. p. 1.
- Walker DF, Soltis JF. Curriculum and aims. New York: Teachers College Press; 2009. p. 55–79.
- Dewey J. Experience and education. The Kappa delta pi lecture series. New York: Touchstone Books; 1997. p. 25.
- Accreditation Council for Graduate Medical Education. ACGME Outcome Project <http://www.acgme.org/outcome/>. Accessed 22 Dec 2010.
- Carraccio C, Wolfsthal SD, Englander R, et al. Shifting paradigms: from flexner to competencies. *Acad Med*. 2002;77(5):361–7.
- Patel VL, Aroca JF, Zhang J. Thinking, and reasoning in medicine. In: Holyoake KJ, Morrison RG, editors. *The Cambridge handbook of thinking and reasoning*. Cambridge: University Press; 2005.
- High stakes testing. [http://en.wikipedia.org/wiki/High-stakes\\_testing](http://en.wikipedia.org/wiki/High-stakes_testing). Accessed 20 March 2008.
- Miller GE. The assessment of clinical skills, competence and performance. *Acad Med*. 1990;65(9 Suppl):S63–7.
- Mahmood K, Wahidi MM. Bronchoscopy education and training. *Pak J Chest Med*. 2012;18(1):89–94.
- Chen M. Education nation. San Francisco: Jossey-Bass, Wiley Imprint; 2010. p. 23.
- Davoudi M, Colt HG. Bronchoscopy simulation: a brief review. *Adv Health Sci Educ*. 2009;14:287–96.
- Colt HG, Crawford SW, Galbraith O. Virtual reality bronchoscopy simulation: a revolution in procedural training. *Chest*. 2001;120(4):1333–9.
- Konge L, Larsen KR, Clementsen P, Arendrup H, von Buchwald C, Ringsted C. Reliable and valid assessment of clinical bronchoscopy performance. *Respiration*. 2012;83(1):53–60.
- Ost D, DeRosiers A, Britt EJ, et al. Assessment of a bronchoscopy simulator. *Am J Respir Crit Care Med*. 2001;164(12):2248–55.
- Stather DR, MacEachem P, Chee A, Dumoulin E, Tremblay A. Evaluation of clinical endobronchial ultrasound skills following clinical versus simulation training. *Respirology*. 2012;17(2):291–9.
- Seymour NE. VR to OR: a review of the evidence that virtual reality simulation improves operating room performance. *World J Surg*. 2008;32(2):182–8.
- Konge L, Clementsen P, Larsen KR, Arendrup H, Buchwald C, Ringsted C. Establishing pass/fail criteria for bronchoscopy performance. *Respiration*. 2012;83(2):140–6.
- Goldberg R, Colt HG, Davoudi M, Cherisson L. Realistic and affordable lo-fidelity model for learning transbronchial needle aspiration. *Surg Endosc*. 2009;23(9):2047–52.

29. Davoudi M, Wahidi MM, Rohani NZ, Colt HG. Comparative effectiveness of low and high-fidelity bronchoscopy simulation for training in conventionaltransbronchial needle aspiration and user preferences. *Respiration*. 2010;80:327–34.
30. Crawford SW, Colt HG. Virtual reality and written assessments are of potential value to determine knowledge and skill in flexible bronchoscopy. *Respiration*. 2004;71:269–75.
31. Davoudi M, Quadrelli S, Osann K, Colt HG. A competency-based test of bronchoscopic knowledge using the essential bronchoscopist: an initial concept study. *Respirology*. 2008;13:736–43.
32. Wahidi MM, Silvestri GA, Coakley RD, Ferguson JS, Shepherd RW, Moses L, Conforti J, Que L, Anstrom KJ, McGuire F, Colt H, Downie GH. A prospective multi-center study of competency metrics and educational interventions in the learning of bronchoscopy among starting pulmonary fellows. *Chest*. 2009;137(5):1040–9.
33. Colt HG, Davoudi M, Quadrelli S. Pilot study of web-based bronchoscopy education using the essential bronchoscopist© in developing countries (Mauritania and Mozambique). *Respiration*. 2007;74:358–9.
34. Quadrelli S, Galíndez F, Davoudi M, Colt HG. Reliability of a 25 item *low stakes* multiple choice assessment of bronchoscopic knowledge. *Chest*. 2009;135:315–21.
35. Colt HG, Davoudi M, Murgu S, Rohani NZ. Measuring learning gain during a one-day introductory bronchoscopy course. *Surg Endosc*. 2011;25:207–16.
36. Colt HG, Davoudi M, Quadrelli S, Rohani N. Competency-based metrics to measure short-term knowledge and skill acquisition during a two-day thoracoscopy program. *Respiration*. 2010;80(6):553–9.
37. Davoudi M, Osann K, Colt HG. Validation of two instruments to assess technical bronchoscopy skill using virtual reality simulation. *Respiration*. 2008;76:92–101.
38. Colt HG. *The essential flexible bronchoscopist*. Laguna Beach, CA: Bronchoscopy International; 2012.
39. Colt HG, Murgu S. *The essential EBUS bronchoscopist*. Laguna Beach, CA: Bronchoscopy International; 2012.
40. Colt HG. *Introduction to flexible bronchoscopy training manual*. Laguna Beach, CA: Bronchoscopy International; 2012.
41. Bordage G, Carlin B, Mazmanian PE. Continuing medical education effect on physician knowledge: American college of chest physicians evidence-based clinical care guidelines. *Chest*. 2009;135:29S–36S.
42. Davis DA, Mazmanian PE, Fordis M, Harrison VR, Thorpe KE, Perrier L. Accuracy of physician self-assessment compared with observed measures of competence: a systematic review. *JAMA*. 2006;296:1094–102.
43. Winters BD, Gurses AP, Lehmann H, Sexton JB, Rampersad CJ, Pronovost PJ. Clinical review: checklists-translating evidence into practice. *Crit Care*. 2009;13(6):210.
44. Downing S. Validity: on the meaningful interpretation of assessment data. *Med Educ*. 2003;37:830–7.
45. Downing SM, Yudkowsky R, editors. *Assessment in health professions education*, vol. 50. New York: Routledge; 2009.
46. Zendejas B, Cook DA, Bingener J, Huebner M, Dunn WF, Sarr MG, Farley DR. Simulation-based mastery learning improves patient outcomes in laparoscopic inguinal hernia repair: a randomized controlled trial. *Ann Surg*. 2011;254:502–11.
47. Fenstermacher GD, Soltis JF. *Approaches to teaching*. 5th ed. New York: Teachers College Press; 2009. p. 31–56.
48. Salamonson M, McGrath D, Steiler G, et al. A new instrument to assess physician skill at thoracic ultrasound, including pleural effusion markup. *Chest*. 2013;144:930–4.



# Evaluation of Outcomes After Interventional Procedures

# 7

Teruomi Miyazawa and Hiroki Nishine

## Interventional Procedure

Inoperable central airway stenosis due to a malignant tumor is a relatively common condition and may be life threatening. Because of the poor prognosis, palliative methods are needed to maintain airway patency. In patients with severe malignant airway stenosis, interventional bronchoscopy is considered as a method of maintaining airway patency [1].

Flow limitation during forced expiration is affected by the relationship between transmural pressure ( $P_{tm}$ ) and the cross-sectional area ( $A$ ) of the airway. The wave speed is dependent on the stiffness of the airway wall, i.e.,  $dP_{tm}/dA$  and on the cross-sectional airway itself [2, 3]. The flow-limiting segment (FLS) occurs originally where the cross-sectional area of the airway is the narrowest. On the basis of wave-speed concepts of maximal expiratory flow limitation, stenting at the FLS improved expiratory flow limitation by increasing the cross-sectional area, supporting the weakened airway wall and relieving dyspnea [4, 5].

## Assessment of Flow–Volume Curve

The location of the FLS is assessed using flow–volume curves. Analysis of the flow–volume curve can be used to define the nature of the stenosis and provide reliable information on the efficacy of stenting [5–10]. In patients with tracheal stenosis, the flow–volume curve shows a marked reduction of the expiratory flow (fixed narrowing patterns) with a plateau. In patients with bronchial stenosis, the flow–volume curve shows decreased flow with expiratory choking (initial transient peak flow followed by acute flow deterioration and consecutive low flow, and dynamic collapse patterns). In patients with carinal stenosis, the flow–volume curve shows a descending expiratory limb with a plateau and choking (combined fixed and dynamic patterns). In patients with extensive stenosis from the trachea and carina, extending to the bronchi due to tumor and/or mediastinal lymphadenopathy, the flow–volume curve shows severe reduction of the expiratory flow (complex patterns containing elements of all the former).

T. Miyazawa (✉) · H. Nishine  
Division of Respiratory and Infectious Disease,  
Department of Internal Medicine,  
St Mariana University School of Medicine,  
Kawasaki, Kanagawa, Japan  
e-mail: [t.miyazawa@go5.enjoy.ne.jp](mailto:t.miyazawa@go5.enjoy.ne.jp);  
[Nishineh@marianna-u.ac.jp](mailto:Nishineh@marianna-u.ac.jp)

## Dyspnea

The degree of dyspnea depends on the degree of airway obstruction and becomes severe when well over 70% of the tracheal lumen is obstructed [11]. In cases with 50% *tracheal obstruction*, the



**Table 7.1** Relation between the baseline degree of *tracheal obstruction* and the change in MMRC after interventional bronchoscopy

Degree of tracheal obstruction (%)	$\Delta$ MMRC <sup>a</sup>		Responders <sup>b</sup> (%)
	$\leq 1$	$\geq 2$	
50–60		2	10/17 (58.8%)
61–70	2	2	
71–80	5	6	
81–90	2	9	11/13 (84.6%)
91–100		2	

<sup>a</sup> $\Delta$ MMRC = change in MMRC scale

<sup>b</sup> $\Delta$ MMRC responder = improvement in MMRC scale of 2 or more

highest velocities are in the jet, which are generated by glottic constriction. In cases with over 70% *tracheal obstruction*, peak velocities are generated at the stenosis and exceed velocities in the glottic area. Pressure differences changed dramatically from 70% *tracheal obstruction*.

The relation between the baseline degree of *tracheal obstruction* and the changes in MMRC ( $\Delta$ MMRC) is shown in Table 7.1. Any patient with an improvement in the MMRC scale of 2 or more was considered to be a clinical responder. The clinical responder rate was 84.6% for obstructions above 80% and 58.8% for obstructions between 50% and 80%. Preoperation measures by the baseline degree of *tracheal obstruction* could be used to predict the post-operation impact on dyspnea [12].

## Assessment of Lateral Airway Pressure

Analysis of the flow–volume curve could be used in defining the nature of the stenosis. However, flow–volume curves cannot identify the precise location of the lesion where airway resistance increases, nor can it immediately define the outcome of stenting.

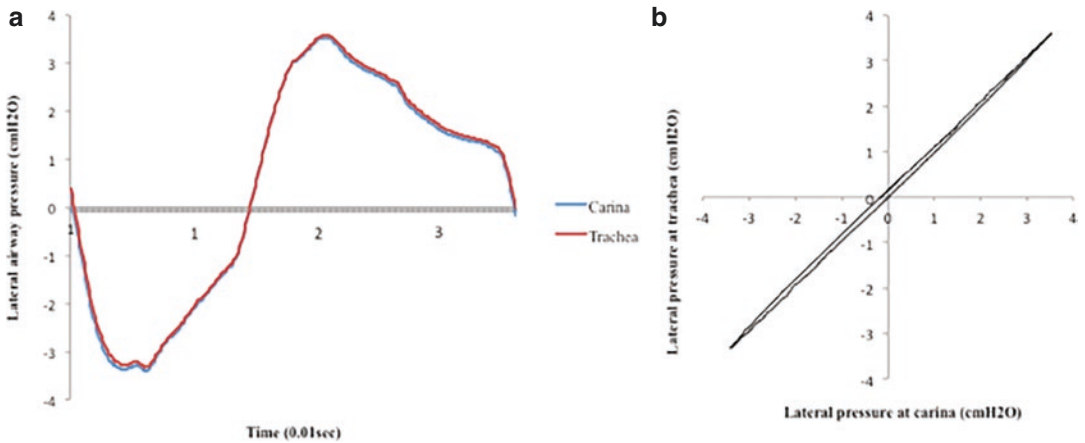
With the use of airway catheters in dogs [13–15] and in human subjects [16–18], the FLS could be located by measuring lateral airway pressure ( $P_{lat}$ ) during induced flow limitation generated by either an increase in pleural pressure or a decrease in downstream pressure. Healthy subjects have relatively uniform pressure drop down the bron-

chial tree during expiration. In patients with airway stenosis, the major pressure drop occurs across the stenosis. By measuring  $P_{lat}$  on each side of the stenosis, we could detect the pressure difference between two sites (proximal and distal) of the stenotic segment [12].

After intubation, a double lumen airway catheter was inserted into the trachea during bronchoscopy.  $P_{lat}$  was measured simultaneously at two points during spontaneous breathing with light general anesthesia before and after intervention.  $P_{lat}$  at the two points was plotted on an oscilloscope (pressure–pressure [P–P] curve). The angle of the P–P curve was defined as the angle between the peak inspiratory and expiratory pressure points and the baseline of the angle. If the cross-sectional area (CSA) was small, the angle was close to 0°; however, after intervention, the CSA significantly increased and the angle was close to 45°.

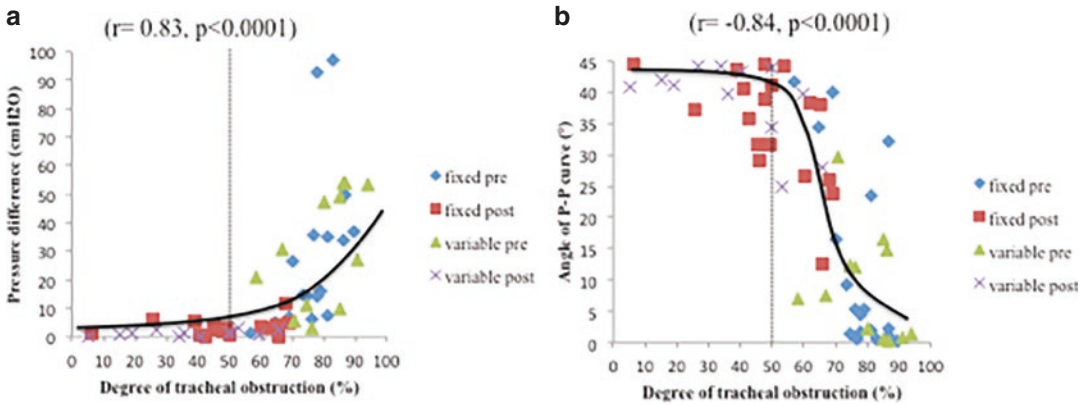
In healthy subjects, no pressure difference between the carina and trachea was observed ( $0.10 \pm 0.22$  cm H<sub>2</sub>O) during tidal breathing (Fig. 7.1a). The P–P curves were linear, and the angle of the P–P curve was close to 45° ( $44.6 \pm 0.98$ ) (Fig. 7.1b).

In patients with *tracheal obstruction*, dyspnea scale, pressure difference, and the angle changed significantly beyond 50% obstruction (Fig. 7.2a, b). After stenting, the pressure difference disappeared, and the angle was close to 45°. The degree of *tracheal obstruction* was significantly correlated with the pressure difference and the angle ( $r = 0.83$ ,  $p < 0.0001$  and  $r = -0.84$ ,  $p < 0.0001$ , respectively) [12].



**Fig. 7.1** Typical patterns of lateral airway pressure ( $P_{lat}$ ) measurements during tidal breathing in a healthy subject.  $P_{lat}$  is measured simultaneously at two points (upper trachea and carina). There are no pressure differences between the carina and upper trachea (a) Lateral airway pressure/time curve. (b) Lateral airway pressure/pressure

at carina curve. (Blue: carina; Red: upper trachea.) The angle of pressure–pressure (P–P) curve is defined as the angle between peak inspiratory and expiratory pressure points and the baseline of the angle. The P–P curves are linear, and the angle of P–P curve is close to 45° (Fig. 7.2b)

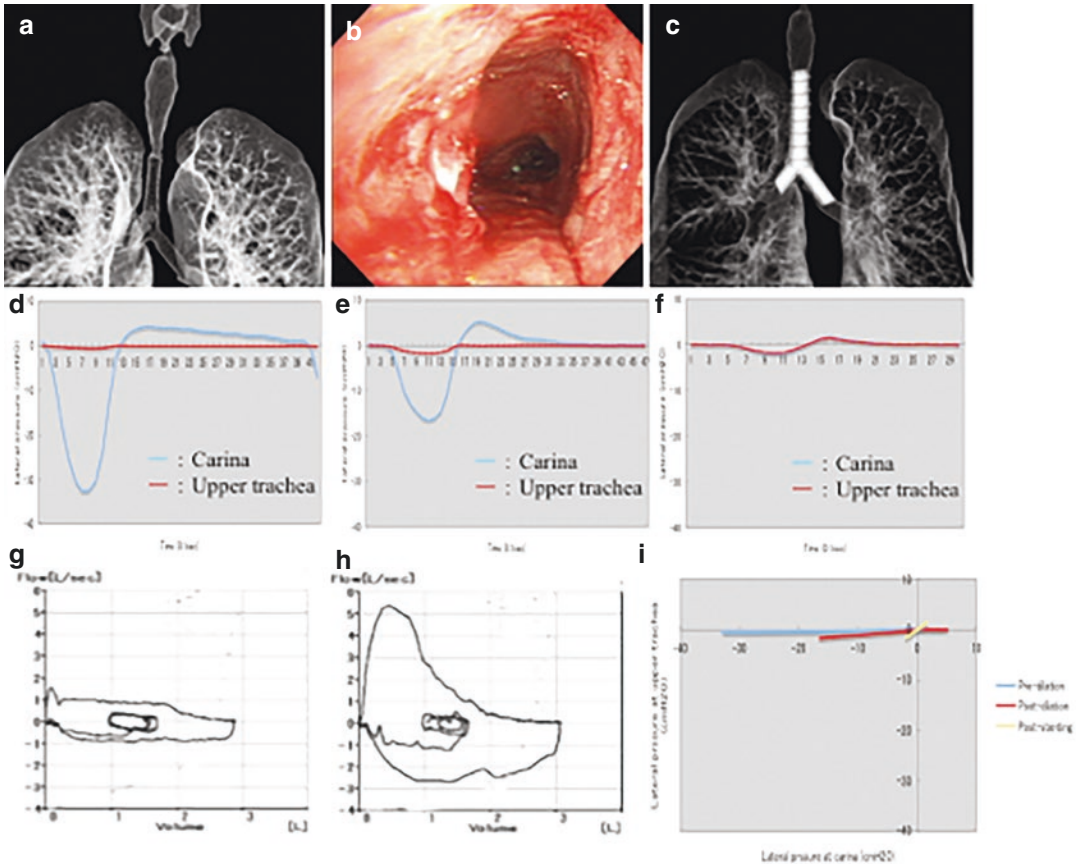


**Fig. 7.2** Scatter plot of pressure difference and the angle of the pressure–pressure (P–P) curve versus the degree of tracheal obstruction. Blue diamonds show before intervention and red squares indicate after intervention in cases with fixed stenosis. Green triangles show before intervention and purple X’s indicate after intervention in cases with variable stenosis. Dotted line shows the threshold for 50% tracheal obstruction. The pressure difference (a) and

the angle of P–P curves (b) are significantly correlated with the degree of tracheal obstruction. The pressure difference increased significantly above 50% obstruction (a). When the cross-sectional area was small, the angle of the P–P curve was close to 0°. After interventional bronchoscopy, the cross-sectional area increased and the angle of the P–P curve was close to 45° (b)

This approach identified a need for additional treatment during interventional bronchoscopy. In a patient with fixed intrathoracic stenosis due to tracheal tuberculosis, CT showed a tracheal stenosis at the middle trachea (Fig. 7.3a). Before treatment, a considerable pressure difference between the upper trachea and carina was noted

(Fig. 7.3d), and the angle of the P–P curve was 0.3° (Fig. 7.3i). The flow–volume curve shows marked reduction of the expiratory and inspiratory flow (Fig. 7.3g). After balloon dilation, bronchoscopic imaging revealed greater patency for the trachea (Fig. 7.3b). However, the pressure difference only decreased from 36.6 cm



**Fig. 7.3** Lateral airway pressure ( $P_{lat}$ ) measurements during interventional bronchoscopy with balloon dilation and silicone Y stent implantation in *fixed intrathoracic stenosis* due to tracheal tuberculosis (before treatment: panels **a**, **d**, and **g**; after balloon dilation: panels **b** and **e**; after stenting: panels **c**, **f** and **h**).  $P_{lat}$  was measured simultane-

ously at two points (upper trachea and carina). Blue line shows  $P_{lat}$  at carina and the red line indicates  $P_{lat}$  at upper trachea (**d–f**). After each treatment, the angle of P–P curve showed a stepwise improvement over the interventional procedures (**i**). See text for further explanation

$H_2O$  to 20.1 cm  $H_2O$  (Fig. 7.3e), and the angle of the P–P curve only increased from 0.3° to 5.0° (Fig. 7.3i). Subsequently, a silicone Y stent was implanted from the upper trachea to the both main stem bronchus. After stenting (Fig. 7.3c), pressure differences disappeared (Fig. 7.3f) and the angle of the P–P curve increased from 5.0° to 35.8° (Fig. 7.3i). The MMRC scale decreased from 2 to 0, and flow–volume curve returned to a near normal pattern (Fig. 7.3h). Measuring  $P_{lat}$  could estimate the need for additional procedures better than bronchoscopy alone. The direct measurement of the pressure difference and the angle of pressure–pressure curve is a new assessment modality for the success of interventional bronchoscopy.

### Analysis of Pressure–Pressure Curve

Central airway stenosis can be divided into four major types: *fixed*, *variable*, *extrathoracic*, and *intrathoracic stenosis*. In *fixed stenosis*, the CSA at the site of the lesion does not change during the respiratory cycle, and the P–P curve was linear. In *variable stenosis*, the configuration of the stenotic lesion changes between phases of respiration. Airway narrowing occurs during expiration in *intrathoracic stenosis*, whereas airway narrowing occurs during inspiration in *extrathoracic stenosis*. In *variable extrathoracic stenosis*, the angle of the P–P curve during inspiration is smaller than during expiration, and in

*variable intrathoracic stenosis*, the angle of the P–P curve during expiration is smaller than during inspiration.

---

## Conclusions

Placement of the stent at the flow-limiting segment (FLS) provided the greatest functional benefit to patients with central airway stenosis [4, 5]. Although bronchoscopic imaging showed that tracheal patency was restored after procedures, the angle of P–P curve did not always improve. It is difficult to estimate the outcome of interventional procedures by bronchoscopy alone. When the location of the FLS is assessed using flow–volume curves, the pressure difference and the angle of pressure–pressure curve are able to immediately estimate the outcomes of interventional bronchoscopy in real time.

---

## References

1. Seijo LM, Sterman DH. Interventional pulmonology. *N Engl J Med*. 2001;344:740–9.
2. Dawson SV, Elliott EA. Wave-speed limitation on expiratory flow a unifying concept. *J Appl Physiol*. 1977;43:498–515.
3. Mead J. Expiratory flow limitation: a physiologist's point of view. *Fed Proc*. 1980;39:2771–5.
4. Miyazawa T, Yamakido M, Ikeda S, Furukawa K, Takiguchi Y, Tada H, Shirakusa T. Implantation of Ultraflex nitinol stents in malignant tracheobronchial stenoses. *Chest*. 2000;118:959–65.
5. Miyazawa T, Miyazu Y, Iwamoto Y, Ishida A, Kanoh K, Sumiyoshi H, Doi M, Kurimoto N. Stenting at the flow-limiting segment in tracheobronchial stenosis due to lung cancer. *Am J Respir Crit Care Med*. 2004;169:1096–102.
6. Pedersen OF, Ingram RH Jr. Configuration of maximum expiratory flow-volume curve: model experiments with physiological implications. *J Appl Physiol*. 1985;58:1305–13.
7. Ohya N, Huang J, Fukunaga T, Toga H. Airway pressure-volume curve estimated by flow interruption during forced expiration. *J Appl Physiol*. 1989;67:2631–8.
8. Pedersen OF. The peak flow working group: physiological determinants of peak expiratory flow. *Eur Respir J*. 1997;10:11–6.
9. Aljuri N, Freitag L, Vegegas JG. Modeling expiratory flow from excised tracheal tube law. *J Appl Physiol*. 1999;87:1973–80.
10. Miller RD, Hyatt RE. Evaluation of obstructing lesions of the trachea and larynx by flow-volume loops. *Am Rev Respir Dis*. 1973;108:475–81.
11. Brouns M, Jayaraju ST, Lacor C, Mey JD, Noppen M, Vincken W, Verbanck S. Tracheal stenosis: a flow dynamics study. *J Appl Phys*. 2007;102:1178–84.
12. Nishine H, Hiramoto T, Kida H, Matsuoka S, Mineshita M, Kurimoto N, Miyazawa T. Assessing the site of maximum obstruction in the trachea using lateral pressure measurement during bronchoscopy. *Am J Respir Crit Care Med*. 2011;185:24–33.
13. Mink S, Ziesmann M, Wood JDH. Mechanisms of increased maximum expiratory flow during HeO<sub>2</sub> breathing in dogs. *J Appl Physiol*. 1979;47:490–502.
14. Smaldone GC, Itoh H, Swift DL, Wagner HN. Effect of flow-limiting segments and cough on particle deposition and mucociliary clearance in the lung. *Am Rev Respir Dis*. 1979;120:747–58.
15. Pedersen OF, Thiessen B, Lyager S. Airway compliance and flow limitation during forced expiration in dogs. *J Appl Physiol*. 1982;52:357–69.
16. Macklem PT, Fraser RG, Bates DV. Bronchial pressures and dimensions in health and obstructive airway disease. *J Appl Phys*. 1963;18:699–706.
17. Smaldone GC, Smith PL. Location of flow-limiting segments via airway catheters near residual volume in humans. *J Appl Physiol*. 1985;59:502–8.
18. Pedersen OF, Brackel HJ, Bogaard JM, Kerrebijn KF. Wave-speed-determined flow limitation at peak flow in normal and asthmatic subjects. *J Appl Physiol*. 1997;83:1721–32.

---

## **Part II**

# **Interventional Procedures During the COVID-19 Pandemic**





# Interventional Procedures During the COVID-19 Pandemics: Adaptations in the Interventional Pulmonology Department

Fernando Guedes and António Bugalho

## Introduction

Coronavirus disease (COVID) emerged in December 2019 as an important and worldwide infectious disease caused by a previous unknown pathogen, severe acute respiratory syndrome coronavirus 2 (SARS-CoV-2). The ability for human-to-human transmission, mainly through respiratory droplets or aerosols, facilitated its rapid dissemination [1].

According to the World Health Organization, as of December 2021, nearly 269 million people have been infected and more than 5 million people have died of this disease worldwide.

All airway and aerosol-generating procedures were immediately recognized as a major risk of spreading contaminated droplets, and health care facilities had to quickly adapt to this reality. Pulmonology departments and interventional pulmonology (IP) units were in the battle front of

this war since these are preferential locations to diagnose and treat respiratory and thoracic disorders.

The role of bronchoscopy in COVID-19 patients was rapidly evaluated after the beginning of the outbreak but is still a matter of debate. In patients with clinical and radiological suspicion of COVID-19 with negative nasopharyngeal swab specimen by real-time polymerase chain reaction with reverse transcription (RT-PCR), bronchoscopy can be useful, increasing sensitivity by obtaining samples from the lower respiratory tract [2]. On the other side, in patients with confirmed severe COVID-19, bronchoscopy can be required to manage complications such as atelectasis, hemoptysis, or to rule out superinfection [3].

Although many societies have drafted guidelines regarding this issue, none of the recommendations have a high level of evidence and some topics are quite incomplete and need further scientific data and evaluation [4–9].

The IP department is a particularly high-risk area, given the procedures performed with airway manipulation, mainly in patients with respiratory diseases and with multiple staff involved. Although dedicated and new settings were designed to deal with airborne infectious diseases, they were not prepared to systematically execute high-risk cases/procedures, which causes an increased strain to health care systems, with diminished productivity, higher workload, and need for additional resources.

---

F. Guedes (✉)

Pulmonology Department, Centre Hospitalier du Nord, Ettelbruck, Luxembourg

ICBAS, Instituto de Ciências Biomédicas Abel Salazar, Porto, Portugal

A. Bugalho

Pulmonology Department, CUF Tejo Hospital and CUF Descobertas Hospital, Lisbon, Portugal

Comprehensive Health Research Centre, Chronic Diseases Research Center (CEDOC), NOVA Medical School, Lisbon, Portugal

## Adaptations of the IP Department

Each IP unit must implement infection-control programs and rethink its administrative, environmental, logistic, and procedural circuits [10], as well as the type and timing of procedures to perform and personal protection equipment (PPE).

### Administrative and Organizational Issues

Administrative and organizational measures are crucial to assure safety while maintaining activity [10].

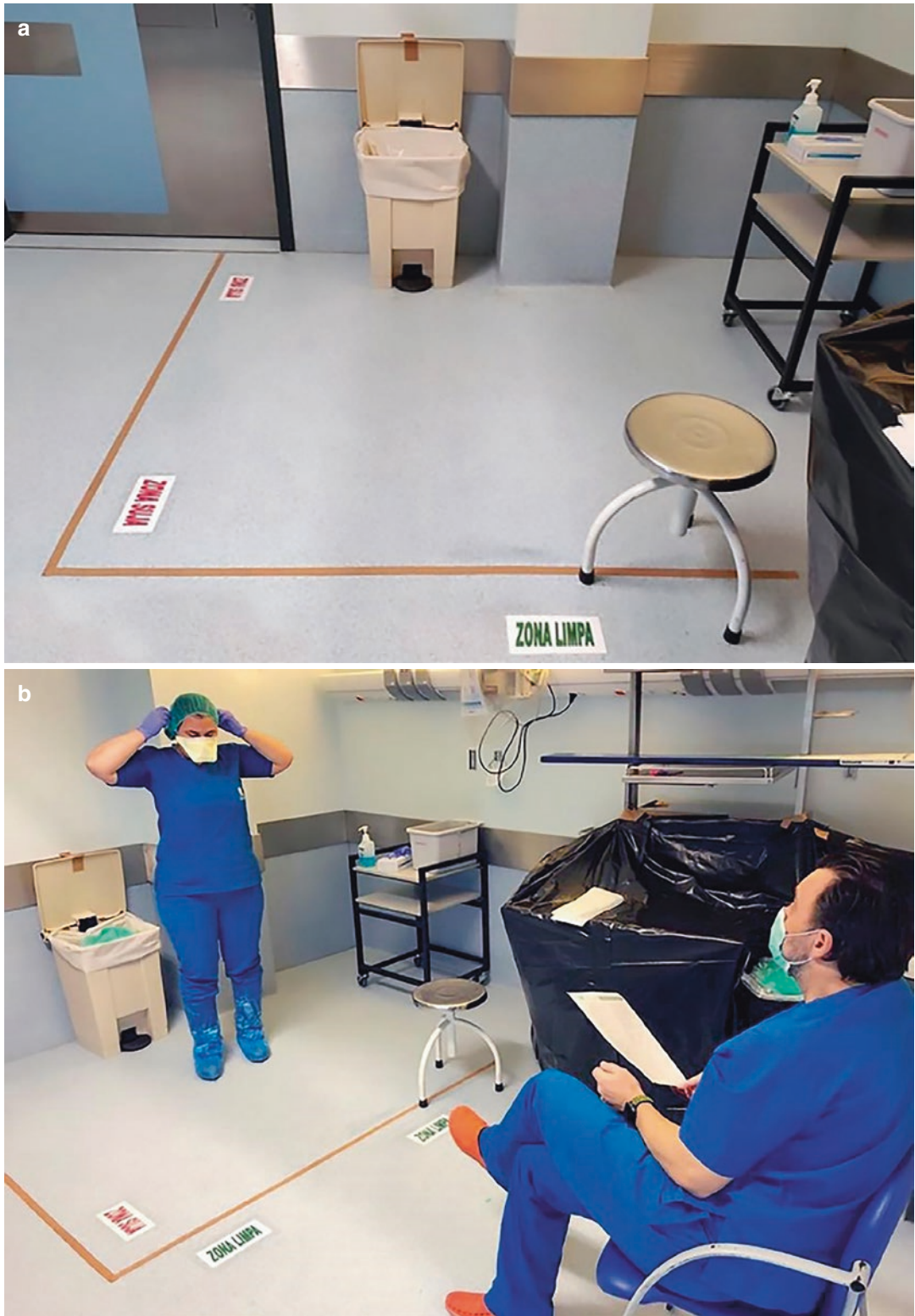All referrals and requests to the IP unit must be made preferably by telephone or digital means. Patients should be contacted by telephone 24–72 h prior to arrival to the IP unit and submitted to a pre-screening checklist that includes questions about recent symptoms suggestive of COVID-19; contact with suspicious/confirmed SARS-CoV-2 cases; or occupational exposure.

- The elective procedure in patients who have recent respiratory and infectious symptoms and/or chest imaging suggestive of COVID-19 should be postponed and rescheduled after all symptoms are solved.
- All patients must be asked for respiratory symptoms and temperature checked when arrived at IP unit.
- All patients should have at least one negative RT-PCR for SARS-CoV-2 in the hours/days preceding the exam (most hospitals recommend in the previous 24–48 h). In patients with a positive RT-PCR SARS-CoV-2, the decision to proceed with the intervention will be based on the procedure emergence (Flowchart 8.1 and Table 8.1).
- The IP unit should keep a record of deferred patients to reschedule their procedures according to the COVID-19 outbreak situation, as proposed in Table 8.2.

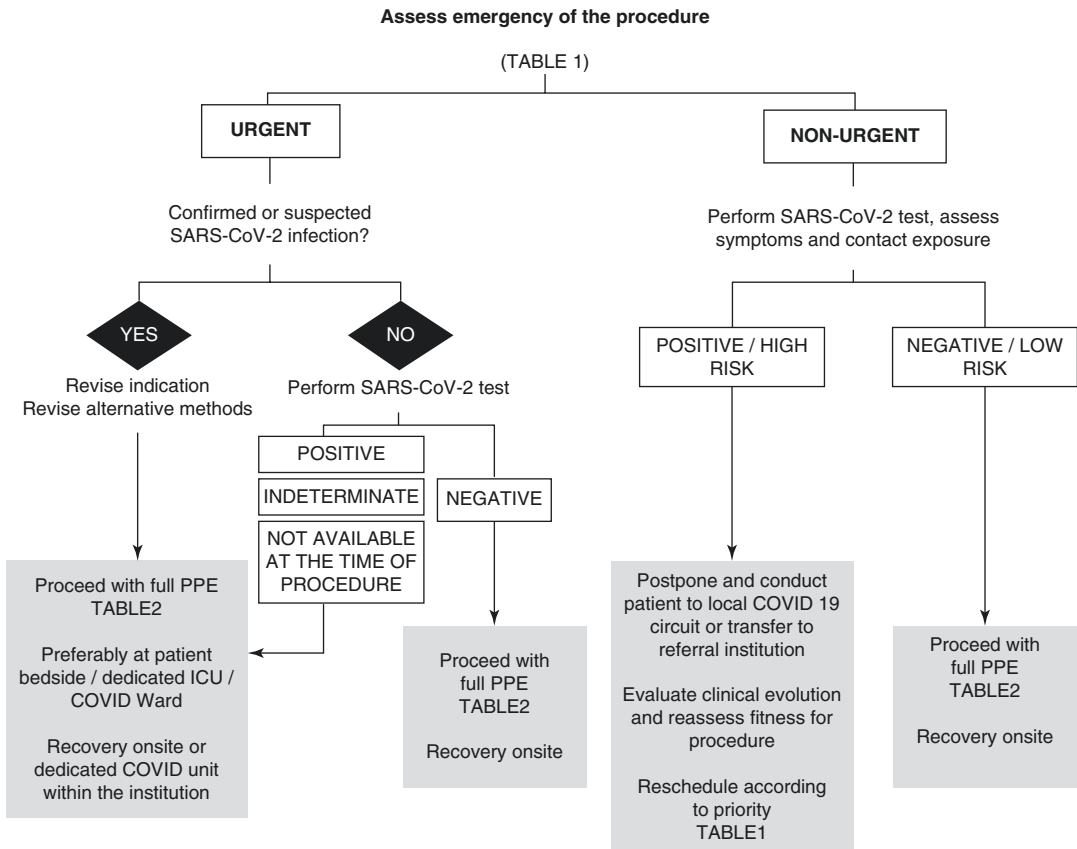
## Environmental Control

It is crucial to plan and correctly prepare the physical space of the IP unit [4].

- All areas of the IP unit should separate confirmed/high-risk patients from negative/low-risk ones. This must include reception, administrative, clinical, and waiting rooms. Inpatients and outpatients should be separated, either by time or physical location, to prevent cross infection.
- Specific circuits and written workflow plans must be prepared, covering the pre-procedural area, procedural room, post-procedural area, decontamination, and reprocessing. It is recommended the implementation of a flowchart with different areas and walking paths using a color visual zone system: red zone for contaminated areas and green zone for non-COVID-19 safe areas [11] (Fig. 8.1a).
- All items required for PPE should be stored in a defined and separated place inside the unit.
- A designated area in the unit should be selected, close to the procedural suite, for wearing and removal of all PPE, according to hospital protocol and standards, to reduce exposure to contaminated particles and droplets. When an anteroom is available, it may be used as an area for donning and doffing of PPE (Fig. 8.1b).
- Stations should be created to facilitate frequent hand hygiene.
- Waste containers should be distributed according to local infectious control recommendations.
- Posters and other visual aids should be placed at strategic locations around the intervention suite to act as reminders.
- Emergent procedures must be, if possible, performed in a negative pressure room environment, preferably under airway-controlled protection (e.g., laryngeal mask, endotracheal tube).



**Fig. 8.1** (a) Implementation of specific circuits with color visual zone system to distinguish contaminated (red) and safe cleaned areas (green). (b) Designated area for donning and doffing of PPE



**Flowchart 8.1** Proposed triage of IP procedures during the COVID-19 outbreak. (Adapted from F. Guedes et al., Recommendations for interventional pulmonology during

COVID-19 outbreak: a consensus statement from the Portuguese Pulmonology Society)

- Elective procedures should be reserved for COVID-19 negative patients (Flowchart 8.1 and Table 8.1).
- Even in COVID-19 negative patients, procedures should be performed in a dedicated negative pressure room (see below, ventilation requirement) with strict isolation precautions and adequate ventilation to avoid aerosol contamination [12]. If these requirements are not met in the bronchoscopy suite, they should be then sought in a different venue, such as an operating theatre, isolation room, or ICU with negative pressure, if available.
- If negative pressure rooms are unavailable throughout the institution, a specific and dedicated room with adequate natural ventilation (see requirement below) may be an alternative [6].
- Suspicious and confirmed cases of COVID-19 must be placed in an airborne infection isolation room with negative pressure before and after the procedure.
- Low-risk and negative patients can remain in the pre-procedural and recovery area, if there is adequate room ventilation, protective equipment (e.g., surgical mask), and physical distance (>2 m) from other negative patients.
- Patient source control strategies, such as wearing a mask and keeping a safety distance should be encouraged.
- Whenever feasible, it is recommended to perform procedures in a room that meets the ventilation requirements for airborne infection isolation (AII), ensuring the dilution and removal of contaminated air. The preferred

**Table 8.1** Type and prioritization of IP procedures

Risk stratification	SARS-CoV-2 status	Procedure indication	
Urgent procedures	COVID-19 negative or positive	<ul style="list-style-type: none"> <li>• Massive hemoptysis with airway compromise</li> <li>• Acute foreign body aspiration</li> <li>• Severe symptomatic central airway obstruction</li> <li>• Suspicion of alternative (non-COVID-19) acute and severe infectious disease</li> <li>• Airway management of difficult and nondelayable endotracheal intubation or complicated percutaneous tracheotomy</li> <li>• Large and symptomatic pleural occupation (air, fluid, blood, pus)</li> </ul>	
	COVID-19 positive or high risk	<ul style="list-style-type: none"> <li>• Removal of copious secretions and mucus plugs</li> <li>• Possibility of superinfection (community acquired or nosocomial)</li> <li>• Severe suspicious cases of COVID-19 that need to be confirmed by bronchoscopy after negative/inconclusive nasopharyngeal RT-PCR SARS-CoV-2 tests</li> </ul>	
Nonurgent procedures	COVID-19 negative or low-risk	Nondelayable (2–4 weeks)	<ul style="list-style-type: none"> <li>• Lung cancer diagnosis and staging</li> <li>• Increased mediastinal and/or hilar lymph nodes</li> <li>• Suspected pulmonary infection in immunosuppressed hosts</li> <li>• Suspicion of pulmonary tuberculosis (after negative sputum)</li> <li>• Interstitial lung disease in symptomatic and lung function deteriorating patients</li> <li>• Mild-to-moderate airway stenosis</li> <li>• Mild persistent hemoptysis</li> <li>• Pleurodesis or indwelling pleural catheter placement for recurrent and symptomatic pleural effusion</li> </ul>
		Delayable ( $\geq 4$ weeks)	<ul style="list-style-type: none"> <li>• Routine evaluation of tracheobronchial stenosis or endobronchial stent</li> <li>• Surveillance of lung transplant patients</li> <li>• Mild asymptomatic benign airway stenosis</li> <li>• Minor pulmonary CT abnormalities in an asymptomatic patient</li> <li>• Chronic cough evaluation (normal chest CT and lung function)</li> <li>• Interstitial lung disease differential diagnosis in nonsymptomatic or nondeteriorating patients</li> <li>• Bronchoscopic lung volume reduction</li> <li>• Bronchial thermoplasty</li> <li>• Minimal pleural effusion in asymptomatic patients</li> </ul>

system is a negative pressure room with at least 12 air changes per hour (ACH) with airflow direction control (single-pass or recirculation systems with HEPA filtration). Alternatively, natural ventilation with an airflow of at least 160 L/s is an option [11].

- Between procedures, it must be ensured that adequate time for air renewal is allowed (depending on ACH and disinfection methods, but at least 30 min). Local adaptations must be considered according to the characteristics of the IP unit.

Concerning cleaning and disinfection of the environment and equipment:

- Recommendations from the Centres for Disease Control and Prevention (CDC) on reprocessing equipment should be followed. These include precleaning, leak testing, manual cleaning, and visual inspection followed by disinfection/sterilization. A high-level disinfection, either manually or using an automated endoscope reprocessor is recommended.



- Storage and documentation are also an integral part of the reprocessing workflow.
- To minimize exposure, adequate packaging and proper pathways of contaminated equipment must be defined. Hermetic boxes are considered to be a good option.
- Disposable bronchoscopes are recommended in confirmed COVID-19 patients with clear advantage on portability, post-procedural handling, and cross-contamination risk [9].
- Disinfection of the floor and surfaces of the bronchoscopy suite must be performed after each procedure using intermediate-level disinfectants with proven activity against enveloped viruses include 0.1% sodium hypochlorite, 62–71% ethanol, 0.5% hydrogen peroxide, and quaternary ammonium compounds [13–15].

### Optimization of Circuits

The security of health care workers and patients is a priority. Defining proper rules and circuits in the IP unit is crucial.

For health professionals:

- The allocation of human resources in IP unit should be reduced and priorities according to the outbreak evolution and hospital needs. The minimal number of staff required to ensure a correct operation must be defined.
- It is essential that everyone is familiar and knows their specific role. Train and maintain competency on effective hand hygiene and every aspect of PPE (theoretical, training and simulation sessions) is fundamental.
- All interactions with patients must include the same level of care. The staff should not reduce the level of awareness and protection, and the idea that patients suspected of COVID-19 should be handled in the same manner as confirmed cases must be reinforced.
- The most experienced staff should be responsible for the procedure in SARS-CoV-2 positive patients, to reduce time and effectively

- deal with possible complications. Other healthcare personnel, medical students and visitors should not be inside the unit or in the examination room before, during, or after the procedure. Training physicians may be present if they have significant awareness of the procedure that is going to be performed and if they had previous training and proficiency in simulators and non-COVID-19 patients [16].
- All the exams must be performed in normal working hours and within an appropriate designated room that fulfils all the standards required for care, avoiding unnecessary increment of stress and risk for team and patient.

### Personal Protective Equipment

IP procedures are considered to undertake the highest risk of exposure so full precautions must be taken, regarding all different possible types of transmission (contact, droplet, and airborne) [17]. Personnel involved in the reprocessing procedure must also wear protective equipment consisting of eye protection, respiratory mask FFP2, long-sleeved gown, and double gloves [8].

The recommendations for the use of PPE are shown in Table 8.2.

**Table 8.2** Personal protective equipment. (Adapted from F. Guedes et al., Recommendations for interventional pulmonology during COVID-19 outbreak: a consensus statement from the Portuguese Pulmonology Society)

Type	Specifications
Respiratory	FFP2/N95, FFP3
Gloves	<ul style="list-style-type: none"> <li>• Single use</li> <li>• Waterproof</li> <li>• Double gloves               <ul style="list-style-type: none"> <li>– First: long-sleeved gloves</li> <li>– Second: nitrile gloves</li> </ul> </li> </ul>
Eye protection	<ul style="list-style-type: none"> <li>• Goggles with lateral protection</li> <li>• Face shield</li> <li>• Single use</li> </ul>
Gowns	<ul style="list-style-type: none"> <li>• Standard EN 14605:2009</li> <li>• Long sleeved</li> <li>• Waterproof</li> <li>• Single use</li> </ul>
Cap	<ul style="list-style-type: none"> <li>• Single use</li> </ul>
Shoe cover	<ul style="list-style-type: none"> <li>• Single use</li> </ul>

## Procedure Performance

All societies recommend postponing elective procedures in suspected or known COVID-19 patients. Bronchoscopy is considered to be a relatively contraindicated procedure in these situations as its benefit in face of infectious risk of operators is not clear [7].

Although rescheduling certain procedures is obvious, in other cases the decision is not straightforward and risks/benefits must be weighted [6, 9].

Nonelective bronchoscopic procedures are mainly performed for microbiological evaluation in suspected superinfection and obstructive atelectasis [3]. Elective procedures mostly represent diagnostic (oncologic and microbiologic purposes) and therapeutic reasons [18].

## Bronchoscopy in Nonintubated Patients

In an ideal scenario, it is safer to perform all the procedures in intubated patients and with general anesthesia to minimize droplet emission. In the real world, this situation may not be possible and the procedure must be done in spontaneous ventilation and in a nonintubated patient. Considering this last situation, some recommendations are listed below:

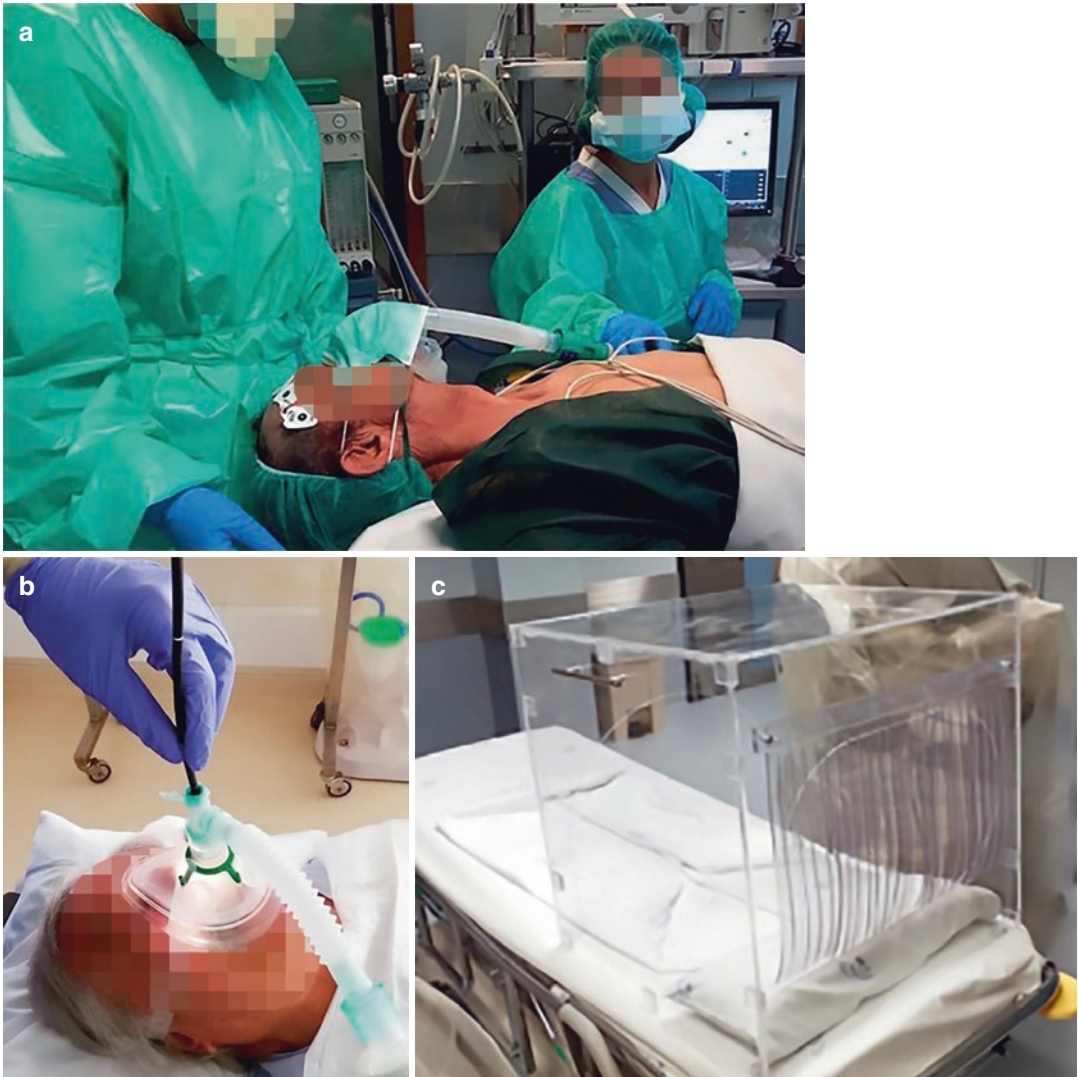- To reduce direct exposure, the operator should stand behind the patient.
- Oxygen supplementation should be done without humidification.
- Nebulized medications should be avoided before or after the procedure.
- Some guidelines suggest not to use lidocaine for pharyngeal anesthesia, while others suggest cough-suppressive drugs to reduce aerosolization [7].
- Appropriate sedation should be performed.
- A transnasal approach is preferred when possible, and a facial mask should be placed over the patients' mouth (Fig. 8.2a). An oral aspiration cannula should be available. The use of nonvented oronasal masks with a dedicated bronchoscopic entrance is also a possible option.
- In hypoxemic patients, bronchoscopy may be performed under noninvasive ventilation (NIV) (Fig. 8.2b).
- Other barrier systems have been used as alternatives to masks, with the aim of minimizing the dispersion of droplets, like the existence of a protective box placed over the patient's head, but they need further investigations to prove their efficacy (Fig. 8.2c).
- Bronchoscopy under high-flow oxygen is not recommended.

## Bronchoscopy in Intubated Patients

About 5% of COVID-19 patients can develop respiratory failure and need mechanical ventilation [1]. In critically ill patients under invasive ventilation, ventilator-associated pneumonia occurs in up to 30%, and lobar collapse causing atelectasis is frequent and multifactorial. The combination of predisposing factors related to the underlying pathology, sedation, position, inadequate secretion aspiration and the high fraction of inspired oxygen will contribute to pulmonary atelectasis [19].

Performing a bronchoscopy in an intubated patient has some advantages: offers a secure airway, it is easier to oxygenate and reduces muscular workout and fatigue [20]. Several considerations may be considered:

- It is always preferred to perform the procedure under general anesthesia. In specific and more complex cases, if there is no contraindication, consider muscle relaxation with a neuromuscular blocker.
- A cuffed endotracheal tube is preferred over the supraglottic devices; cuff pressure should be maintained between 25 and 30 cm H<sub>2</sub>O [21].
- The use of an adapter (e.g., swivel) may facilitate the entry of the bronchoscope, avoiding disconnection of the ventilator circuit and minimizing air leaks.
- Pressure-limited volumetric ventilatory modes with FIO<sub>2</sub> 100%, attempting to main-



**Fig. 8.2** (a) Facial mask placed over the patients' mouth. (b) Noninvasive ventilation mask. (c) Protective box

tain constant PEEP during the procedure are desirable. Variations in ventilatory parameters can be performed dynamically after adequate patient-related risk assessment.

- To avoid aerosol dispersion, a simple maneuver consists of clamping the ventilation circuit just before introduction of bronchoscope, repeating the same step just before withdrawal.
- When performing a bronchoalveolar lavage, the volume used should be reduced to a minimum, and it is worth mentioning that 2–3 mL

of recovery lavage is able to provide a SARS-CoV-2 diagnosis.

- Bronchoscope removal and reinsertion during the procedure should be avoided or reduced.

### Other Procedures in IP Unit

In patients with suspected or confirmed COVID-19, rigid bronchoscopy should be avoided, but there are scenarios where flexible

bronchoscopy would be considered difficult or even impossible, such as some foreign body aspiration, massive hemoptysis, severe central airway obstruction, or migrated airway stents. In those cases, the procedure should always be performed in a negative pressure room, with controlled ventilation (if possible utilizing closed ventilation systems instead of jet ventilation) and using rubber caps on the ports of rigid scope to avoid air leaks.

Pleural procedures are not listed as aerosol generating procedure in the CDC recommendations, and they do not appear to be a prominent feature of COVID-19 [22, 23].

Thoracoscopy is not recommended as a principle and the risk benefit must be assessed. When required, the use of one-way valve trocars should be preferred.

---

## Summary and Recommendations

The World Health Organization recommends the preparation of a checklist to be completed during the procedure to minimize the risk of infection by the participating staff. This vision must include the pre-procedure planning, the execution, and the post-procedure phase. It is mandatory that proper training be provided to all health care staff involved in IP.

The *pre-procedure* includes:

- Adaptation the IP (proper rooms and circuits);
- Revise prioritization of all the procedures;
- Perform pre-screening checklist (symptoms, contact history, and occupational exposure);
- RT-PCR nasopharyngeal swab for SARS-CoV-2 test 24–48 h preceding the exam; and
- Proceed according to priority and test results.

In the *procedure execution* phase:

- Gown adequate PPE and perform procedure at adequate endoscopy suite;
- Prepare in advance all equipment needed and plan the procedure;
- Minimize direct exposure:

- Stand behind the patient;
  - Use appropriate sedation;
  - Place surgical mask over patients' mouth;
  - Avoid nebulized drugs;
  - In ventilated patients, prefer endotracheal tubes and clamp ventilation circuit when introducing and removing bronchoscope;
  - Use disposable bronchoscopes in confirmed or highly suspicious COVID-19 patients; and
  - Minimize procedure duration.
- Reduce team to minimal necessary; and
  - Medical doctors in training can be present during exam if they have previous adequate formation.

In the *post-procedure* timing:

- Collect samples in closed circuits, according to local infectious control guidelines;
- Reprocessing of bronchoscopes must be considered an aerosol-generating procedure;
- Disinfect floor and surfaces after each procedure;
- Allow adequate time (30 min) between procedures; and
- Perform sequential remove of PPE in a designated area.

**Acknowledgements** The authors acknowledge H.N. Bastos and M. de Santis for the photos and H.N. Bastos, J.P. Boléo-Tomé, L.V. Rodrigues, S. Campaíña, and M. de Santis for the discussion of some topics.

---

## References

1. Wu Z, McGoogan JM. Characteristics of and important lessons from the coronavirus disease 2019 (COVID-19) outbreak in China: summary of a report of 72 314 cases from the Chinese Center for Disease Control and Prevention. *JAMA*. 2020;323(13):1239–42.
2. Wang W, et al. Detection of SARS-CoV-2 in different types of clinical specimens. *JAMA*. 2020;323(18):1843–4.
3. Arenas-De Larriva M, et al. The role of bronchoscopy in patients with SARS-CoV-2 pneumonia. *ERJ Open Res*. 2021;7(3).
4. Baldwin D, et al. Recommendations for day case bronchoscopy services during the COVID-19 pandemic. *Eur Assoc Bronchol Interven Pulmonol*; 2020.

5. Cordovilla R, et al. "Recomendaciones de consenso SEPAR y AEER sobre el uso de la broncoscopia y la toma de muestras de la vía respiratoria en pacientes con sospecha o con infección confirmada por COVID-19. *Arch Bronconeumol*. 2020;56:19–26.
6. Guedes F, et al. Recommendations for interventional pulmonology during COVID-19 outbreak: a consensus statement from the Portuguese Pulmonology Society. *Pulmonology*. 2020;26(6):386–97.
7. Lentz RJ, Colt H. Summarizing societal guidelines regarding bronchoscopy during the COVID-19 pandemic. *Respirology*. 2020;25(6):574.
8. Pritchett MA, et al. Society for Advanced Bronchoscopy Consensus Statement and Guidelines for bronchoscopy and airway management amid the COVID-19 pandemic. *J Thorac Dis*. 2020;12(5):1781.
9. Wahidi MM, et al. American Association for Bronchology and Interventional Pulmonology (AABIP) statement on the use of bronchoscopy and respiratory specimen collection in patients with suspected or confirmed COVID-19 infection. *J Bronchol Interv Pulmonol*. 2020;27(4):e52–4.
10. Center for Disease Control and Prevention. Interim infection prevention and control recommendations for patients with suspected or confirmed coronavirus disease 2019 (COVID-19) in healthcare settings. Atlanta, GA: Center for Disease Control and Prevention; 2020.
11. WHO. Strengthening the health systems response to COVID-19: technical guidance# 2: creating surge capacity for acute and intensive care, 6 April 2020. Geneva: World Health Organization. Regional Office for Europe; 2020.
12. Adhikari U, et al. A case study evaluating the risk of infection from Middle Eastern Respiratory Syndrome Coronavirus (MERS-CoV) in a hospital setting through bioaerosols. *Risk Anal*. 2019;39(12):2608–24.
13. WHO. Coronavirus disease 2019 (COVID-19): situation report, 73. Geneva: WHO; 2020.
14. Berríos-Torres SI, et al. Centers for disease control and prevention guideline for the prevention of surgical site infection, 2017. *JAMA Surg*. 2017;152(8):784–91.
15. Chen CC, Chi CY. Biosafety in the preparation and processing of cytology specimens with potential coronavirus (COVID-19) infection: perspectives from Taiwan. *Cancer Cytopathol*. 2020;128(5):309–16.
16. Kalchiem-Dekel O, et al. Impact of COVID-19 on interventional pulmonology training. *ATS Sch*. 2021;2(2):236–48.
17. Tran K, et al. Aerosol generating procedures and risk of transmission of acute respiratory infections to healthcare workers: a systematic review. *PLoS One*. 2012;7(4):e35797.
18. Du Rand I, et al. British Thoracic Society guideline for advanced diagnostic and therapeutic flexible bronchoscopy in adults. *Thorax*. 2011;66(Suppl 3):iii1–iii21.
19. Hellyer TP, et al. Biomarker-guided antibiotic stewardship in suspected ventilator-associated pneumonia (VAPrapid2): a randomised controlled trial and process evaluation. *Lancet Respir Med*. 2020;8(2):182–91.
20. Murgu SD, Pecson J, Colt HG. Bronchoscopy during noninvasive ventilation: indications and technique. *Respir Care*. 2010;55(5):595–600.
21. Biselli P, et al. Reductions in dead space ventilation with nasal high flow depend on physiological dead space volume: metabolic hood measurements during sleep in patients with COPD and controls. *Eur Respir J*. 2018;51(5):1702251.
22. Zhu J, et al. CT imaging features of 4121 patients with COVID-19: a meta-analysis. *J Med Virol*. 2020;92(7):891–902.
23. Salehi S, et al. Coronavirus disease 2019 (COVID-19): a systematic review of imaging findings in 919 patients. *Am J Roentgenol*. 2020;215(1):87–93.





# Bronchoscopy During the COVID-19 Pandemic

# 9

Elizabeth S. Malsin and A. Christine Argento

## Introduction

The severe acute respiratory syndrome coronavirus-2 (SARS-CoV-2) was identified in Wuhan City, Hubei Province, China in December 2019 and spread rapidly via human-to-human contact starting in 2020, with the World Health Organization (WHO) classifying SARS-CoV-2 infection and its resulting illness, coronavirus disease 2019 (COVID-19), as a global pandemic in March 2020. This highly transmissible virus led to high hospitalization rates throughout the world, with illness severity requiring hospitalization in up to 20% of those infected in the initial phase of the pandemic [1]. Cultural and geographic differences in practice, resources, comorbidities, and populations lead to wide variations in the level of care provided and patient outcomes. For example, in the initial hospitalized cohorts in China up to 26% required an intensive care unit (ICU) admission [2] but in the second year of the pandemic, less than 10% required intensive care due to better understanding, differing strains, treatments, and vaccinations. Global mortality in the first 2 months of the pandemic was approximately 3.4% worldwide, with a high degree of variation by country and region [3].

Though mortality rates decreased as the pandemic continued, the high transmissibility led to large portions of the global population becoming infected, again with high degree of variation at regional and national levels. At the time of this writing, approximately six million people worldwide have died from COVID-19 [4], though many experts think this an underestimate of the toll.

SARS-CoV-2 is a beta-coronavirus similar to the virus causing the original SARS epidemic in 2003. It has an incubation period of 14 days, with most symptoms beginning 4–5 days post-exposure [5, 6]. SARS-CoV-2 is usually transmitted via respiratory droplets, which are inhaled or deposited on mucous membranes, and do not usually travel more than 6 ft. Inhalation of contaminated aerosols is also a potential transmission route. Fever, fatigue, cough, and dyspnea are the most common presenting symptoms, though COVID-19 symptoms have proven highly variable. Asymptomatic transmission is common, and dependent on strain variant, with more recent strains such as Omicron having high transmissibility and low mortality. Comorbidities including obesity, diabetes mellitus, immunocompromised state, hypertension, and heart disease increase the likelihood of symptoms, hospitalization, and mortality, as does older age [5].

In the initial years of the pandemic, with growing understanding of SARS-CoV-2 and COVID 19 as well as the emergence of vaccinations, diver-

---

E. S. Malsin (✉) · A. C. Argento  
Department of Medicine, Northwestern Memorial  
Hospital/Northwestern University, Chicago, IL, USA  
e-mail: [elizabeth.malsin@nm.org](mailto:elizabeth.malsin@nm.org); [aargent1@jhu.edu](mailto:aargent1@jhu.edu)

gent strains, and COVID-19 specific treatment, multiple leading health organizations released guidelines including the WHO, the International Society for Infectious Disease (ISID), and the United States Centers for Disease Control (CDC) on multiple topics including travel, social distancing, vaccinations, and masking. Guidelines for the care of both inpatients and outpatients with known or suspected COVID-19 became available at multiple levels, including institution-specific policies, city guidelines, country guidelines, and worldwide recommendations.

Leading respiratory medical associations and societies, including the European Respiratory Society (ERS), a joint statement from the American College of Chest Physicians (CHEST)/American Association for Bronchology and Interventional Pulmonary (AABIP), the Society for Advanced Bronchoscopy (SAB), the Canadian Thoracic Society (CTS), the German Respiratory Society (DGP), the Chinese Thoracic Society (CMA), the Spanish Society of Pneumology and Thoracic Surgery (SEPAR), and the Argentinean Association for Bronchology (AABE) all released guidelines and reports with respect to the role of bronchoscopy in patients with known COVID-19 and those patient with a need for bronchoscopy with the incidental finding of COVID-19 positivity [6–12]. This chapter includes the approach to bronchoscopy in differing populations during the pandemic, as well as patient assessment and triage, safety measures and personal protection equipment (PPE), and questions remaining around bronchoscopy during a lengthy and challenging global pandemic.

---

## Safety

### Patient Safety

The same patient safety criteria and patient-specific factors should be used when considering bronchoscopy in patients with or without COVID-19. Multiple studies have evaluated the safety of bronchoscopy in both critically ill and noncritically ill patients with COVID-19 and found variable differences in outcomes

or adverse effects, with up to 8% having complications from the procedure, higher than in all-comers [13–16]. Similarly, patients recently recovered from COVID-19 also have increased surgical complications [17]. Overall, an individualized patient risk analysis accounting for patient- and procedure-specific risks should be done before proceeding with bronchoscopy during COVID-19 surges, as should be done in any infectious or noninfectious patient. Anticipating support needs, including personnel, support devices for oxygenation and/or ventilation, medication needs for analgesia and/or sedation, bronchoscopes, and other tools should all be discussed and accounted for.

### Provider Safety

During the initial phases COVID-19 pandemic, there were wide variations in the both availability and use of personal protective equipment (PPE). Subsequently, during the initial period of the pandemic, when many aspects of the disease were also unknown and testing not widely or quickly available, many outpatient bronchoscopy practices were closed given that bronchoscopy is an aerosol generating procedure. Current provider PPE recommendations from the CTS, SAB, and the AABIP/CHEST guidelines for bronchoscopy recommend PPE in patients with confirmed or suspected COVID-19 include an N95 mask with goggles or a powered air purifying respirator (PAPR), gown, and gloves [6–8]. For team members performing high-risk aerosol generating procedures when COVID-19 is not suspected, the SAB recommends the same PPE when overall community rates are high, though the definition for high rates is not explicitly given. The SAB guideline also reviews the importance of appropriate donning and doffing to minimize exposure to contaminated particles including the importance of training and practice. Multiple studies have revealed that bronchoscopy in COVID-19 positive patients is safe for providers in regard to procedural transmission [13, 15, 18], with additional studies showing positive testing in healthcare providers highly associated with pro-

vider uncertainty of proper donning and doffing protocols [19]. We recommend the most experienced team member perform bronchoscopy when needed for patients with known or highly suspected COVID-19, especially the critically ill. Experienced bronchoscopists are more procedurally efficient, minimizing procedural time and therefore aerosolization as well as complications including worsening or new hypoxemia; benefiting both the patient and healthcare team.

## Patient Selection and Screening

The initial stages of the pandemic resulted in many hospitals worldwide canceling all elective procedures due to concerns about patient and staff safety as well as equipment/staffing availability. While many bronchoscopies are elective, most are for acute and urgent issues, including the diagnosis and/or staging of malignancy. True emergent needs for bronchoscopy such as severe, symptomatic airway obstruction; massive hemoptysis; or foreign body aspiration are less common. During the pandemic, the need to risk stratify each procedure to minimize risk of infection transmission and, in many cases, optimize the utilization of limited resources, became of utmost importance. As both asymptomatic or incidentally found COVID-19 positivity rates and resource availability waxed and waned during the initial years of the pandemic, bronchoscopists faced continued changing challenges of triage.

Current recommendations include those from the SAB, which gives some of the most specific guidelines, recommending those procedures that are emergent as noted above continue to be done emergently in a same day procedure. They recommend remaining bronchoscopy procedures be stratified to urgent, acute, subacute, and elective procedures [7]:

- Urgent procedures, including those for neutropenic fevers and undiagnosed infiltrates without improvement on antibiotics as well as transplant patients with concerns for acute infection, be performed within 2 days

- Acute procedures including those for new lung mass or nodule, including those with adenopathy with no other target present, those for suspected disease progression, symptomatic suspected sarcoidosis, and acute lobar atelectasis, to be performed within 2 weeks.
- Subacute procedures including bronchoscopic inspections for cough or minor hemoptysis, chronic lobar atelectasis, and stent surveillance can be delayed greater than 2 weeks.
- Elective procedures such as bronchial thermoplasty, bronchoscopic lung volume reduction, lavage for nontuberculous mycobacteria, and other atypical chronic infections with minimal symptoms, tracheostomy changes, and lung transplant surveillance should be rescheduled when possible.

Other societies have similar recommendations, if slightly less detailed. The AABIP/CHEST guidelines also recommend considering local resource availability, including the availability of COVID-19 testing and PPE, as well as the possible need to utilize nearby resources, such as tertiary care centers, be taken into account [6]. Of course, there are multiple circumstances where a patient may not fit perfectly into one of the above categories. Figure 9.1 illustrates a triage strategy when bronchoscopy is needed during times of pandemic or endemic COVID-19.

## Lung Cancer Diagnosis and Staging

The role of bronchoscopy in lung cancer diagnosis, staging, repeat tissue sampling for molecular analysis and treatment response, and therapeutics via management of airway obstruction with debulking, stenting, photodynamic therapy, fiducial placement, and brachytherapy leaves this particular population especially vulnerable during the COVID-19 pandemic and its surges. The American Society of Clinical Oncology (ASCO) gave cautious guidelines directing clinicians toward standard infection control practices as well as individualized decision-making reflecting the patient's best interest [20]. The European Society for Medical Oncology (ESMO) offered

Triage level	COVID +	Pathology examples and timeframe
Emergent	<ul style="list-style-type: none"> <li>Airborne precautions</li> <li>PPE should include PAPR if available</li> </ul>	<ul style="list-style-type: none"> <li>Acute foreign body</li> <li>Massive hemoptysis without source for embolization</li> <li>Severe symptomatic airway obstruction</li> </ul> <p>Same day</p>
Urgent	<ul style="list-style-type: none"> <li>Minimize staff</li> <li>Minimize procedure time</li> </ul>	<ul style="list-style-type: none"> <li>Neutropenic fevers with unexplained, non-improving infiltrate</li> <li>Transplant patients with clinical decline despite antimicrobials</li> </ul> <p>24-48 hours</p>
Acute	If unable to await clinic clearance per facility protocol, perform as if COVID + above	<ul style="list-style-type: none"> <li>Lung nodule or mass, suspected early stage and a resection candidate</li> <li>Lung mass with adenopathy requiring staging</li> <li>New lesions or suspected progression of known cancer</li> <li>New suspicion for symptomatic sarcoid requiring tissue diagnosis</li> <li>New lobar atelectasis</li> </ul> <p>Within 2 weeks</p>
Subacute	Follow facility protocol, await COVID clearance based on patient characteristics such as immunosuppression	<ul style="list-style-type: none"> <li>Airway inspection for cough, dyspnea, minor hemoptysis with reassuring CT imaging</li> <li>Chronic lobar atelectasis</li> <li>Airway stent surveillance</li> </ul> <p>More than 2 weeks, dependent on resources</p>
Elective		<ul style="list-style-type: none"> <li>Bronchial thermoplasty</li> <li>Bronchoscopic lung volume reduction</li> <li>BAL for suspected nontuberculous mycobacteria with minimal symptoms</li> <li>Tracheostomy changes</li> <li>Transplant surveillance</li> </ul> <p>When possible and safe</p>

**Fig. 9.1** Triage of bronchoscopy in COVID-19 and positive patient considerations. Timing of bronchoscopy should be triaged on a case-by-case basis dependent on symptoms and pathology; COVID-19 status should then

be considered for each case dependent on these needs. Facility protocols and guidelines need to be considered when scheduling any bronchoscopy when COVID-19 community levels are elevated

prioritization of management of lung cancers, with tiers reflecting high, medium, and low priorities in care [21]. The American College of Surgeons guidelines for triage consider semi-urgent cases as those where “survivorship would be compromised if surgery not performed within three months, including lung cancer or presumed lung cancer measuring greater than two centimeters with negative or positive nodes, post-induction therapy, need for surgical staging to start treatment, symptomatic mediastinal tumors or those enrolled in therapeutic clinical trials” [22]. Current data regarding COVID-19 infection in thoracic cancer patients suggest a particularly high mortality and hospitalization rate in this vulnerable population [23], making the role of vaccinations and minimizing exposures also of utmost importance to all providers who care for them.

### Bronchoscopy for Outpatients

In patients suspected of both having COVID-19 and requiring bronchoscopy for a separate reason, a nasopharyngeal or salivary specimen

should be obtained to confirm the diagnosis of COVID-19. If negative, a second specimen after 24–48 h may be useful in ruling out early infection with false negative testing. If testing is again negative, alternatives to COVID-19 infection such as other infections (influenza, other respiratory viruses, noninfectious causes) should be considered and tested for. If positive, the proceduralist should review his/her/their institutional policies regarding how long to wait before a non-emergent procedure; as well as discuss with other care providers on the team including anesthesia, bronchoscopy staff, oncology, thoracic surgery, and radiation oncology. The guidelines above should not supersede institutional policy.

In those outpatients with transmissible COVID-19 requiring emergent bronchoscopy or bronchoscopy unable to await the above recommendations; PPE, bronchoscope processing, pre-, intra-, and post-procedure care should match that of every other SARS-CoV-2 patient including N95 respirators or PAPRs as well as negative air-flow during the entire time they are in the health-care facility which may affect the location of the pre-procedure time as well as the recovery prior to discharge.

## Inpatients

In inpatients suspected of having COVID-19, a nasopharyngeal or salivary specimen should be obtained first. Universally, organizations recommend against the use of bronchoscopy as the first line testing modality in those with suspected COVID-19. The AABIP/CHEST guidelines recommend that in the setting of severe or progressive disease requiring intubation with additional testing is needed, it is appropriate to obtain a lower respiratory specimen to establish a diagnosis of COVID-19 or other diagnosis which would change management [6]. Notably, this is an ungraded statement based on expert consensus from September 2020, prior to vaccine availability as well as prior to availability of several COVID-19 specific treatments. Initial data at that time suggested that bronchoalveolar lavage does have an increased sensitivity of 93%, compared to 72% in sputum and 63% in nasal swabs [24].

## Universal Screening of Asymptomatic Patients

In both inpatients and outpatients requiring bronchoscopy without a clinical concern for concomitant COVID-19 infection, multiple society recommendations are for a COVID-19 test within 72 h of the procedure when community transmission of COVID-19 is present [6, 7]. Additionally, consideration of repeating screening questions within 24 h of the procedure such as asking about symptoms, contacts, and travel history could be useful [7]. Again, as positivity rates, variant strains, and vaccination rates changed, there have been changes in data regarding the utility of testing. After initial uncertainty about transmission rates among asymptomatic persons, by late 2020 and early 2021, it was apparent that more than 50% of transmissions were among this population, confirming the need for public health measures to control the pandemic [25]. This verified the practice of many healthcare systems of screening all patients in an effort to prevent patient harm of operative complications related to COVID-19 and decrease exposure

and transmission to healthcare personnel [26]. Vaccination decreases asymptomatic infections found on pre-procedure screening, from 3.2% to 1.4% in a large study in the United States [27]. Indeed, the very idea of community transmission and the need for universal testing is difficult to assess as changes in viral strain and differences in population vaccination status vary throughout the pandemic.

## COVID-19 Clearance

Current RT-PCR tests have been demonstrated to detect RNA for prolonged periods of times, but do not automatically correlate with infectivity. Current recommendations from the American Society of Anesthesiologists (ASA) and Anesthesia Patient Safety Foundation (APSF), based on the NIH/CDC guidelines, for clearance recommend [28]:

- Classification by symptoms:
  - Asymptomatic.
  - Mild to moderately symptomatic (no pneumonia or hypoxemia).
  - Severe or critical illness (pneumonia, hypoxemic respiratory failure, or shock).
- Classifying severely immunocompromised patient separately, despite presence or absence of symptoms.
- In asymptomatic patients who are not severely immunocompromised, isolation and transmission-based precautions may be discontinued after a minimum of 10 days from their first positive viral test.
- Discontinuing isolation and other transmission-based precautions in mild to moderate patients who are not severely immunocompromised when:
  - 10 days have passed since symptom onset.
  - At least 24 h have passed since last fevers without antipyretics.
  - Symptoms are improved.
- In those with severe or critical illness or anyone who is severely immunocompromised, the CDC recommends discontinuing isolation and other symptom-based precautions when



- At least 10, and up to 20, days have passed since first symptoms.
- At least 24 h have passed since last fevers, without use of antipyretics.
- Symptoms are improved.

These recommendations should be integrated with information of other risks, especially pulmonary complications post-operatively, in decision making. A large, multi-country collaborative suggests that when possible, surgery should be delayed up to 7 weeks following COVID-19 and even longer in patients with persistent symptoms at 7 weeks [17]. There is now evidence that those requiring hospitalization for COVID-19 have residual changes in pulmonary function and radiographs for up to 6 months [29]. Using these data, the ASA/APSF guidelines suggest the following wait times for surgery:

- Four weeks for asymptomatic patients or recovery from only mild, non-respiratory symptoms.
- Six weeks for a symptomatic patient who did not require hospitalization.
- Eight to ten weeks for a symptomatic patient who is diabetic, immunocompromised, or hospitalized.
- Twelve weeks for a patient admitted to the ICU due to COVID-19.

The ASA/APSF acknowledges that these guidelines cannot be definitive and, again, each patient's perioperative risk assessment should be individualized [28]. Indeed, a side-by-side comparison of these recommendations with the triage levels and procedural timing recommended by the SAB reveals contrasting recommendations. The definition of severe immunocompromised is also variable, but usually includes those undergoing chemotherapy, those within 1 year of a stem cell or solid organ transplant, those with HIV and a CD4 count <200, those with combined primary immunodeficiency disorder, and those treated with prednisone >20 mg/day for more than 14 days. Though these are the most recent guidelines from the ASA/APSF, at the time of this writing the CDC has again updated their guidelines,

with those who are asymptomatic and not moderately or severely immunocompromised isolation could be discontinued at 5 days from first positive test. This certainly highlights the continued lack of data around safety of procedures in those with recent COVID-19 and the need for a thoughtful approach by a multi-disciplinary team that individualizing a plan for patient needs and urgency of a procedure.

---

## Bronchoscopy Procedure in COVID-19 Respiratory Failure

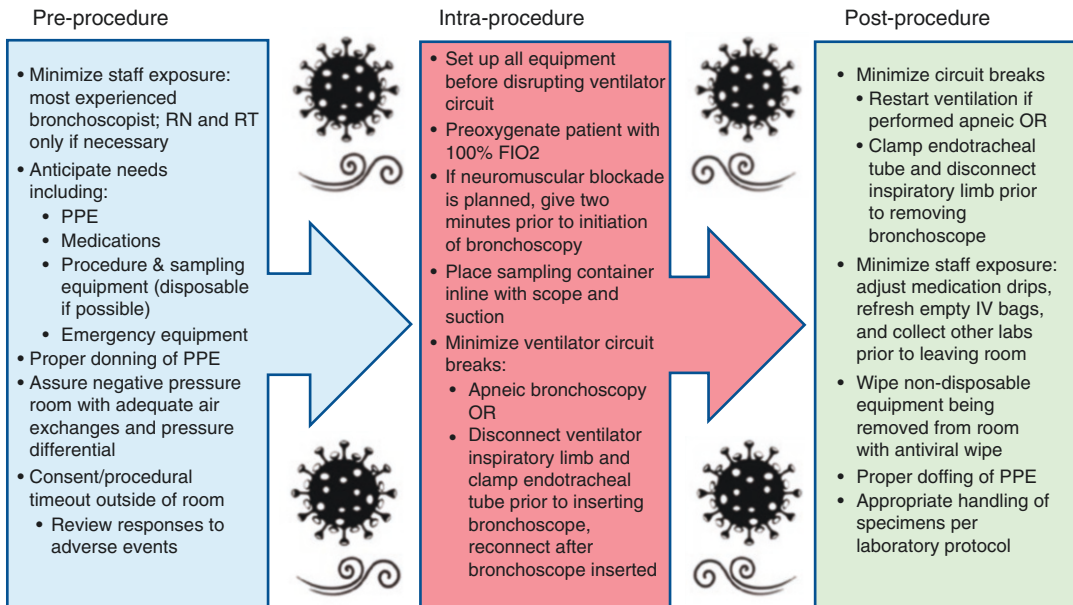
The role of bronchoscopy in any mechanically ventilated patient is variable by disease pathology, clinical parameters, and acuity. Data suggest bronchoscopy in COVID-19 patients requiring mechanical ventilation is performed more often than mechanically ventilated patients with ARDS due to other causes, but is highly institution specific, with many institutions avoiding all aerosol generating procedures, including bronchoscopy and many airway clearance treatments, in this population. For example, early in the pandemic in NYC, approximately 33% of intubated patients at one institution underwent bronchoscopy [13]. This is in contrast with the majority of other hospitals globally, where bronchoscopy in COVID-19 patients was not performed due to a combination of the overall overwhelming clinical burden on the healthcare systems and the fear of provider exposure [14, 15].

The potential benefits of bronchoscopy in COVID 19 for those requiring mechanical ventilation appear to fall into two categories: airway clearance of mucus and identification of secondary pathogens [16, 29–31]. Early bacterial co-infection is thought to affect up to 30% of patients with COVID-19 respiratory failure within the first 24 h of ventilation and bacterial pneumonia at any point during mechanical ventilation is associated with worse outcomes, with different pathogens identified more commonly at different time courses in COVID-19 patients [32, 33]. Fungal pneumonia, usually aspergillus species, has also be recognized as a pathogen in critically ill COVID patients and is associ-

ated with higher mortality [34]. It should be noted that the SAB guidelines recommend as 1C (strong recommendation/low quality evidence) bronchoscopy on inpatients with suspected or known COVID-19 be avoided, including routine toileting bronchoscopy. They use a 2C (weak recommendation/low quality evidence) that bronchoscopy be considered in selected situations including evaluation for alternative or co-infections, complication evaluation, and therapeutic aspiration [7].

When performing bronchoscopy in COVID 19 positive patients on the ventilator, the logistics and preparation is also institution dependent; variations include use of neuro-muscular blockade pre-procedure to minimize coughing, positioning including if patients who are in prone position are considered candidates for bronchoscopy, ventilator manipulations including circuit clamping, apnea for parts or all of the procedure, experience level of the bronchoscopist, and amount of fluid instilled for bronchoalveolar lavage. Identifying a strategy concordant with institution specific policies is a must for all proceduralists, and all team members should be comfortable with the preparation and plan.

Our approach to bronchoscopy in ICU patients with active COVID-19 includes the following: use of PPE according to the societal guidelines discussed above and illustrated in Fig. 9.2. Pre-procedure discussion with the proceduralist, bedside nurse, respiratory therapist and other team members should take place outside the patient room prior to the procedure, with goals of identifying any potential needs, including accounting for all equipment that might be needed, and any anticipated barriers. All equipment should be accounted for prior to entering the room. If available, a negative pressure room should be used. The team should be thoughtful to minimize post-procedure bedside care, which includes making sure continuous infusion medications supply is adequate and any lab draws are done prior to the procedure. Procedural timeout should be performed outside the room and only necessary staff should be in the room. At our institutions we've found a single attending physician provider, as the most experienced provider, is usually sufficient with additional staff available outside the room if needed. A disposable bronchoscope should be used if available. The patient should be preoxygenated with 100% FIO<sub>2</sub>. If the team



**Fig. 9.2** Pre-, intra-, and post-procedure considerations for bronchoscopy on COVID-19 positive patients. Adequate planning for all three phases will improve patient and provider safety

has decided the use neuromuscular blockade, it should be given approximately 2 min prior to initiation of bronchoscopy and the team should wait for complete ventilator synchrony to begin the procedure. The bronchoscope should be lubricated, connected to suction, and inserted into the bronchoscopy endotracheal tube adaptor prior to procedure start. If there is a plan to collect specimens, the collection container, such as a Lukens's trap, should be put in-line pre-procedure. To minimize aerosolization, the existing endotracheal tube should be clamped and the ventilator paused or the inspiratory limb disconnected. The bronchoscope and adaptor should be inserted and connected, the endotracheal tube unclamped, and ventilation resumed unless the procedure is being performed apneic. If the bronchoscopy is for specimen collection for secondary infectious workup, a brief inspection may be warranted but otherwise the lobe or segment of interest should be lavaged and specimen collected in quick succession to minimize overall scope time. Aerosol minimizing precautions should then be performed in reverse: the bronchoscope should be withdrawn into the proximal endotracheal tube which is then clamped below; with the ventilator paused or disconnected, the bronchoscope and adaptor can be removed from the circuit. If there is a concern for de-recruitment or high potential for post-procedure hypoxemia, a higher FIO<sub>2</sub> should be considered to be kept in place after the proceduralist leaves the room to minimize staff having to enter to adjust ventilator settings. Remote management of the ventilator can also be considered if available.

Special considerations in this population include when there is a need for bronchoscopy for airway clearance. Minimal data exist for success rates of use of mucolytics such as DNase and N-acetyl cysteine, though we have used each of these with some success in those with thick and/or copious secretions. Clot removal with cryotherapy for pulmonary hemorrhage has been successful for multiple patients with COVID-19 with restoration of ventilation or oxygenation as well as radiographic improvement [13, 15]. Using extensive cryotherapy without exposing the room to aerosols from the ventilator is more

challenging than simple bronchoscopy with lavage. Similarly, bronchoscopy in those with tracheostomy tubes instead of oral or nasal endotracheal tubes are unable to have a fully closed circuit throughout due to the inability to clamp the tube. Complete neuromuscular blockade and disconnection at end expiration can be considered as a substitute.

Teams should be prepared with a plan for when there is a breach of PPE during a bronchoscopy or other aerosol generating procedure. The procedure should be immediately terminated if possible; if not possible another proceduralist should be prepared to immediately take over. Prior statements recommend isolation of the exposed providers, but have not been updated since vaccinations became available [7]. Post-exposure symptom monitoring is a must and testing should be deferred to institutional policies and the infection control team at the institution.

There is limited data around bronchoscopy outside of the ICU in patients on mechanical ventilation for COVID-19, but similar precautions should be taken. If using an operating room or procedure suite, ideally negative airflow should be maintained and everyone in contact with the patient should wear appropriate PPE. Appropriate post-procedure time should be allowed to diminish any residual droplets to remain before another case. The use of open ventilation circuits, such as those used with rigid bronchoscopy or jet ventilation, should not be used unless no alternative procedural or ventilation strategy exists.

---

### **Bronchoscopy in the Non-intubated COVID-19 Patient**

The same precautions should be taken in regard to PPE around bronchoscopy in the non-intubated patient with COVID-19. Triage strategies as noted above should be utilized, notably the SAB recommends bronchoscopy be performed within 2 weeks for those with lung nodules suspicious for early-stage cancer, a nodule or mass with adenopathy needing staging, or known lung cancer with possible progression of disease when bronchoscopy would alter the treatment

course [7]. Optimization of the ventilation and oxygenation strategy have to be more carefully weighed in non-intubated patients positive for COVID-19: avoiding exposure of additional staff such as an anesthesiologist and anesthesia team can be beneficial overall but the bronchoscopist also has to balance the risk of respiratory failure and the need for emergency staff entrance, putting those staff at risk of inadequate time to don PPE. Given the increase in aerosol generation in the non-intubated patient with COVID-19 and the decreased life-threatening nature of specifically identified co-infections, we in general defer bronchoscopy for suspected usual typical or atypical organisms, especially in the immuno-intact host. The role of bronchoscopy in those non-intubated patients with COVID-19 who are immunosuppressed, such as those status post solid organ or stem cell transplant or those with severe neutropenia, the benefit of targeted therapy has to be weighed again the risk of patient decompensation and staff exposure. Depending on currently circulating strains and population vaccination status, this risk: benefit ratio is situationally dependent for both inpatients and outpatients.

### **Bronchoscopy in Patients with Persistent Radiographic Abnormalities After COVID-19**

CT abnormalities in survivors of COVID-19 are common. Seventy percent of CT scans were abnormal in COVID-19 ARDS survivors at 3 months post-hospitalization, with reticular findings in 49% and fibrotic patterns in 21% [35]. This appears to still be within a convalescence period, with only approximately a third of similar patients demonstrating changes at 6 months with findings including consolidation, opacification, reticulation, and fibrotic-like changes including traction bronchiectasis and honeycombing. Age and illness severity metrics during acute illness appear to correlate with presence and severity of radiographic findings [36]. Those with fibrotic findings have been shown to be persistent and correlate with pulmonary function test abnormalities at 12 months post-recovery [37]. There are cur-

rently no guidelines for the utility of bronchoscopy in these patients, especially given the lack of available treatment for fibrotic post-COVID ARDS. Other radiographic findings include that of organizing pneumonia (OP), with one study showing approximately 5% of hospitalized survivors with this finding on CT done 6 weeks after hospitalization with higher variability than the fibrotic patients in the initial level of illness. It has also been demonstrated that OP treated with corticosteroids can result in a robust symptom and radiographic response [38]. Given the potential for treatment and the overlap of OP with infectious pneumonia such as post-viral bacterial pneumonia, there may be a role for bronchoscopy in select patients. Indeed, if co-existing infection, such as post-viral bacterial or fungal infection, is suspected, it may be reasonable to pursue bronchoscopy after sufficient time has passed per the guidelines noted above, or sooner if clinical benefits warrant [6–12].

---

### **Specimen Handling, Equipment Processing, and Room Turnover**

Specimens sent for SARS-CoV-2 testing should include at least 2–3 mL of fluid and placed in a labeled sterile, dry container. They must be processed in an appropriate laboratory: routine viral testing/staining/examination for SARS-CoV-2 can be assessed in a biosafety level 2 facility [39]. Disposable equipment, including bronchoscopes, should be used whenever possible [6, 7]. Reusable bronchoscopy equipment can be processed with standard cleaning followed by high-level disinfection. There are no current recommendations supporting the use of additional cleaning maneuvers, though staff should wear full PPE and be appropriately trained and experienced [6, 40]. According to one study SARS-CoV-2 can remain aerosolized for up to 3 h and is viable on plastic and stainless-steel surfaces for up to 72 h [41]. Therefore, prior to bronchoscopy, the turnover of the procedure room and patient recovery process should follow pre-establish protocol. Institutional infection control teams should dictate this process, which is dependent on the ventilation capa-

bilities of the procedure room and the air turnover time. Alterations in procedural time and recovery areas should be accounted for as compared to non-COVID-positive bronchoscopy procedures. All horizontal and work surfaces, monitors, and hardware should be disinfected with approved cleaners after bronchoscopy.

---

### **COVID Clearance: A Role for Bronchoscopy**

As previously discussed, SARS-CoV-2 virus can be detected in patients post the initial infectious period for variable amounts of time. Both test-based strategies, requiring one or more negative respiratory RT-PCR tests, or symptom-based strategies, maintaining infectious precautions for a set amount of time post symptoms, have been employed in variable populations. In both patients and healthcare workers with symptomatic COVID-19, data show the average time to transition from RT-PCR positive to negative is 24 days after symptom onset, with up to 10% of patients having a positive test even 33 days after symptoms started [42]. Reinfection, given the duration of the pandemic, and variable immunity with new variants is also possible, warranting retesting in those with recurrence of symptoms or known exposures despite former status as resolved. Institutional guidelines on clearance should be followed; for example, in one of our institutions, two BAL specimens negative for SARS-CoV-2 have to be done more than 24 h apart for clearance to be established. Obviously, this errs on the side of caution.

---

### **Long COVID: A Role for Bronchoscopy**

As the pandemic continues, there are reports of long-lasting COVID-19 symptoms in many patients, including those asymptomatic or with minor symptoms in the acute phase. Symptoms are widely variable, but most commonly include fatigue, headache, dyspnea, and anosmia. This so-called “long COVID” is reported to affect up

to 13% of patients for more than 28 days post infections and at least 12 weeks in more than 2% and there is now evidence to suggest age, body mass index, and female sex as well as experiencing more symptoms during acute illness increase the likelihood of prolonged symptoms [43]. There is currently scant evidence-based treatment available for long COVID, with rehabilitation and physical therapy thought to be helpful in certain populations and no pharmaceutical has yet been proven helpful [44]. In the absence of known beneficial therapies, there is not yet a role for bronchoscopy in long COVID. However, the identification of radiographic findings consistent with another disease pattern, such as sarcoidosis, other interstitial lung diseases, indolent infections such as non-tuberculous mycobacteria should be appropriately investigated.

### **Bronchoscopy and COVID: The Questions that Remain**

The roles for bronchoscopy in different populations of COVID 19 patients has yet to be fully scrutinized. It will be complex to evaluate if those undergoing bronchoscopy in the intensive care unit had improved outcomes: ventilator free days, organ failure, antimicrobial usage, extubation, or mortality differences. The differences between institutional, regional, and national practices will make this difficult to assess post-pandemic. We the authors certainly witnessed intubated ICU patients with improvements post-bronchoscopy from moribund states to eventual discharge from the hospital in the setting of therapeutic aspiration bronchoscopy for asphyxiation from mucus plugging or hemoptysis with blood clots in the airways. Similarly, the identification of co-existing bacterial and fungal pathogens has led to changes in antimicrobials leading to clinical improvement in both ICU patients as well as those hospitalized on the floor, especially those with immunocompromise and/or co-morbidities. Finally, the next few years will be revealing the effect of the COVID-19 pandemic had on those without COVID-19 who rely on bronchoscopy



for diagnosis and treatment decisions, including those with lung cancer.

The societal and association guidelines have yet to undergo revisions, with the majority having been written in the first 6 months of a now 2-year pandemic. How healthcare providers need to account for the difference in circulating strains; duration of the pandemic; and the availability, effectiveness, and utilization of, by both patients and providers, vaccines when making judgments about bronchoscopy triage and timing.

---

## Preparing for the Next Pandemic

The COVID-19 pandemic has highlighted the need to have up-to-date and accurate information for healthcare providers to provide optimal care for those with, without, and recovering from severe respiratory viruses such as SARS-CoV-2. As the first droplet-transmitted viral pandemic in the modern age of rapid global communication, epidemiology, and healthcare, as well as advanced bronchoscopy; information and resources influenced all aspects of patient care. Regional, national and global differences in practice and resources also lead to differences in practices in provided care, including bronchoscopy. Initial studies about the safety and role of bronchoscopy during the COVID-19 pandemic, as well as the rapid development of effective vaccines, led to additional changes in practice. As additional data in the post-pandemic years to come is gathered and more studies complete, guidelines around bronchoscopy in airborne viral pandemics will no doubt be updated. We hope this will lead to improved outcomes, recommendations, and preparedness for the role of bronchoscopy in the next pandemic arises.

---

## References

- Richardson S, Hirsch J, Narasimhan M, Crawford J, McGinn T, Davidson K, et al. Presenting characteristics, comorbidities, and outcomes among 5700 patients hospitalized with COVID-19 in the New York City area. *JAMA*. 2020;323(20):2052.
- Wang D, Hu B, Hu C, Zhu F, Liu X, Zhang J, et al. Clinical characteristics of 138 hospitalized patients with 2019 novel coronavirus-infected pneumonia in Wuhan, China. *JAMA*. 2020;323(11):1061–9.
- Lai CC, Wang CY, Wang YH, Hsueh SC, Ko WC, Hsueh PR. Global epidemiology of coronavirus disease 2019 (COVID-19): disease incidence, daily cumulative index, mortality, and their association with country healthcare resources and economic status. *Int J Antimicrob Agents*. 2020;55(4):105946.
- WHO coronavirus (COVID-19) dashboard. <https://covid19.who.int/>
- Esai SM. Risk factors for death from COVID-19. *Nat Rev Immunol*. 2020;20(7):407.
- Wahidi MM, Shojaee S, Lamb CR, Ost D, Maldonado F, Eapen G, Caroff DA, Stevens MP, Ouellette DR, Lilly C, Gardner DD. The use of bronchoscopy during the coronavirus disease 2019 pandemic: CHEST/AABIP guideline and expert panel report. *Chest*. 2020;158(3):1268–81.
- Pritchett MA, Oberg CL, Belanger A, De Cardenas J, Cheng G, Nacheli GC, Franco-Paredes C, Singh J, Toth J, Zgoda M, Folch E. Society for Advanced Bronchoscopy Consensus Statement and Guidelines for bronchoscopy and airway management amid the COVID-19 pandemic. *J Thorac Dis*. 2020;12(5):1781.
- Houston SA, McDonald CM, Tyan CC, Fortin M, Sakr L, Gillson AM, Myers R, Bendiak GN, Dumoulin E, Gonzalez AV, Hergott CA. Bronchoscopy during the COVID-19 pandemic: a Canadian Thoracic Society position statement. *Can J Respir Crit Care Sleep Med*. 2021;5(4):246–52.
- Thoracic S. Expert consensus for bronchoscopy during the epidemic of 2019 novel coronavirus infection (Trial version). *Zhonghua Jie He He Hu Xi Za Zhi*. 2020;43(3):199–202.
- Darwiche K, Ross B, Gesierich W, Petermann C, Huebner RH, Grah C, Gompelmann D, Hetzel J, Holland A, Eisenmann S, Stanzel F. Empfehlungen zur Durchführung einer Bronchoskopie in Zeiten der COVID-19-pandemie. *Pneumologie*. 2020;74(05):260–2.
- Cordovilla R, Alvarez S, Llanos L, Cases E, Ares AN, Perez DD, Flandes J. Recomendaciones separ de consenso sobre el uso de la broncoscopia y la toma de muestras de la vía respiratoria en pacientes con sospecha o con infección confirmada por COVID-19 [Internet]. 2020.
- de Broncoesofagología AA. RECOMENDACIONES Asociación Argentina de Broncoesofagología (AABE) basados en la Wold Association for Bronchology and Interventional Pulmonary WABIP para el manejo de pacientes con COVID 19 en situación de pandemia [Internet]. 2020. Accessed 26 Mar 2020.
- Chang SH, Jiang J, Kon ZN, Williams DM, Geraci TC, Smith DE, Cerfolio RJ, Zervos M, Bizakis C. Safety and efficacy of bronchoscopy in critically ill patients with coronavirus disease 2019. *Chest*. 2021;159(2):870–2.

14. Bruyneel M, Gabrovská M, Rummens P, Roman A, Claus M, Stevens E, Dechamps P, Demey L, Truffaut L, Ninane V. Bronchoscopy in COVID-19 intensive care unit patients. *Respirology*. 2020;25(12):1313–5.
15. Mondoni M, Papa GF, Rinaldo R, Faverio P, Marruchella A, D’Arcangelo F, Pesci A, Pasini S, Henchi S, Cipolla G, Tarantini F. Utility and safety of bronchoscopy during the SARS-CoV-2 outbreak in Italy: a retrospective, multicentre study. *Eur Respir J*. 2020;56(4):2002767.
16. Cumbo-Nacheli G, Colt H, Agrawal A, Cicienia J, Corbetta L, Goel AD, Goga A, Lee HJ, Murgu S, Pannu J, Senitko M. Bronchoscopy in patients with known or suspected covid-19: results from the global pandemic sars-cov-2 bronchoscopy database (GPS-bd). *J Bronchol Interv Pulmonol*. 2022;29(2):146–54.
17. COVIDSurg Collaborative, GlobalSurg Collaborative, Nepogodiev D, Simoes JF, Li E, Picciochi M, Glasbey JC, Baiocchi G, Blanco-Colino R, Chaudhry D, AlAmeer E. Timing of surgery following SARS-CoV-2 infection: an international prospective cohort study. *Anaesthesia*. 2021;76(6):748–58.
18. Gao CA, Bailey JI, Walter JM, Coleman JM, Malsin ES, Argento AC, Prickett MH, Wunderink RG, Smith SB. Bronchoscopy on intubated patients with COVID-19 is associated with low infectious risk to operators. *Ann Am Thorac Soc*. 2021;18(7):1243–6.
19. Ofner-Agostini M, Gravel D, McDonald LC, Lem M, Sarwal S, McGeer A, Green K, Vearncombe M, Roth V, Paton S, Loeb M. Cluster of cases of severe acute respiratory syndrome among Toronto health-care workers after implementation of infection control precautions: a case series. *Infect Control Hosp Epidemiol*. 2006;27(5):473–8.
20. Jazieh AR, Chan SL, Curigliano G, Dickson N, Eaton V, Garcia-Foncillas J, Gilmore T, Horn L, Kerr DJ, Lee J, Mathias C. Delivering cancer care during the COVID-19 pandemic: recommendations and lessons learned from ASCO global webinars. *JCO Global Oncol*. 2020;6:1461–71.
21. Passaro A, Addeo A, Von Garnier C, Blackhall F, Planchard D, Felip E, Dziadziuszko R, De Marinis F, Reck M, Bouchaab H, Peters S. ESMO management and treatment adapted recommendations in the COVID-19 era: lung cancer. *ESMO Open*. 2020;5:e000820.
22. Diaz A, Sarac BA, Schoenbrunner AR, Janis JE, Pawlik TM. Elective surgery in the time of COVID-19. *Am J Surg*. 2020;219(6):900–2.
23. Garassino MC, Whisenant JG, Huang LC, Trama A, Torri V, Agustoni F, Baena J, Banna G, Berardi R, Bettini AC, Bria E. COVID-19 in patients with thoracic malignancies (TERAVOLT): first results of an international, registry-based, cohort study. *Lancet Oncol*. 2020;21(7):914–22.
24. Wang W, Xu Y, Gao R, Lu R, Han K, Wu G, Tan W. Detection of SARS-CoV-2 in different types of clinical specimens. *JAMA*. 2020;323(18):1843–4.
25. Johansson MA, Quandelacy TM, Kada S, Prasad PV, Steele M, Brooks JT, Slayton RB, Biggerstaff M, Butler JC. SARS-CoV-2 transmission from people without COVID-19 symptoms. *JAMA Netw Open*. 2021;4(1):e2035057.
26. Storino CB, Watson JC, Sanchez W, Brown MJ, Tande AJ, Loftus CG. Revamping outpatient care for patients without COVID-19. *Mayo Clinic Proc*. 2020;95(9):S44–6.
27. Tande AJ, Pollock BD, Shah ND, Farrugia G, Virk A, Swift M, Breeher L, Binnicker M, Berbari EF. Impact of the coronavirus disease 2019 (COVID-19) vaccine on asymptomatic infection among patients undergoing preprocedural COVID-19 molecular screening. *Clin Infect Dis*. 2022;74(1):59–65.
28. American Society of Anesthesiologists. ASA and APSF joint statement on elective surgery and anesthesia for patients after COVID-19 infection. Schaumburg, IL: American Society of Anesthesiologists; 2021.
29. Llorca K, Álvarez A, Felipe Montiel A, Ferrer R, Roca O, García-de-Aciliu M, Clofent D, Landivar JC, Polverino E, Culebras Amigo M. Safety, diagnostic, and therapeutic value of flexible bronchoscopy in critically ill COVID-19 patients. *Can J Anesth*. 2021;68(3):434–5.
30. Torrego A, Pajares V, Fernández-Arias C, Vera P, Mancebo J. Bronchoscopy in patients with COVID-19 with invasive mechanical ventilation: a single-center experience. *Am J Respir Crit Care Med*. 2020;202(2):284–7.
31. Yin W, Cao W, Zhou G, Wang L, Sun J, Zhu A, Wang Z, Zhou Y, Liu X, Li Y, Zhong N. Analysis of pathological changes in the epithelium in COVID-19 patient airways. *ERJ Open Res*. 2021;7(2):00690–2020.
32. Kreitmann L, Monard C, Dauwalder O, Simon M, Argaud L. Early bacterial co-infection in ARDS related to COVID-19. *Intensive Care Med*. 2020;46(9):1787–9.
33. Dudoignon E, Caméléna F, Deniau B, Habay A, Coutrot M, Ressaire Q, Plaud B, Berçot B, Dépret F. Bacterial pneumonia in COVID-19 critically ill patients: a case series. *Clin Infect Dis*. 2021;72(5):905–6.
34. Koehler P, Cornely OA, Böttiger BW, Dusse F, Eichenauer DA, Fuchs F, Hallek M, Jung N, Klein F, Persigehl T, Rybniker J. COVID-19 associated pulmonary aspergillosis. *Mycoses*. 2020;63(6):528–34.
35. González J, Benítez ID, Carmona P, Santistevé S, Monge A, Moncusí-Moix A, Gort-Paniello C, Pinilla L, Carratalá A, Zuñil M, Ferrer R. Pulmonary function and radiologic features in survivors of critical COVID-19: a 3-month prospective cohort. *Chest*. 2021;160(1):187–98.
36. Han X, Fan Y, Alwalid O, Li N, Jia X, Yuan M, Li Y, Cao Y, Gu J, Wu H, Shi H. Six-month follow-up chest CT findings after severe COVID-19 pneumonia. *Radiology*. 2021;299(1):E177–86.

37. Han X, Fan Y, Alwalid O, Zhang X, Jia X, Zheng Y, Shi H. Fibrotic interstitial lung abnormalities at 1-year follow-up CT after severe COVID-19. *Radiology*. 2021;301(3):E438–40.
38. Myall KJ, Mukherjee B, Castanheira AM, Lam JL, Benedetti G, Mak SM, Preston R, Thillai M, Dewar A, Molyneaux PL, West AG. Persistent post-COVID-19 interstitial lung disease. An observational study of corticosteroid treatment. *Ann Am Thorac Soc*. 2021;18(5):799–806.
39. McFee RB. COVID-19 laboratory testing/CDC guidelines. *Dis Mon*. 2020;66(9):101067.
40. SAGES management of endoscopes, endoscope reprocessing, and storage areas during the COVID-19 pandemic. Los Angeles, CA: SAGES.
41. Van Doremalen N, Bushmaker T, Morris DH, Holbrook MG, Gamble A, Williamson BN, Tamin A, Harcourt JL, Thornburg NJ, Gerber SI, Lloyd-Smith JO. Aerosol and surface stability of SARS-CoV-2 as compared with SARS-CoV-1. *N Engl J Med*. 2020;382(16):1564–7.
42. Gombar S, Chang M, Hogan CA, Zehnder J, Boyd S, Pinsky BA, Shah NH. Persistent detection of SARS-CoV-2 RNA in patients and healthcare workers with COVID-19. *J Clin Virol*. 2020;129:104477.
43. Sudre CH, Murray B, Varsavsky T, Graham MS, Penfold RS, Bowyer RC, Pujol JC, Klaser K, Antonelli M, Canas LS, Molteni E. Attributes and predictors of long COVID. *Nat Med*. 2021;27(4):626–31.
44. Yong SJ. Long COVID or post-COVID-19 syndrome: putative pathophysiology, risk factors, and treatments. *Infect Dis*. 2021;53(10):737–54.



# Tracheostomy in COVID-19 Patients

# 10

Laura K. Frye

## Historical Perspective

Mechanical ventilation is lifesaving in severe respiratory failure, and few medical therapies have the same potential to rapidly stabilize critically ill patients. Mechanical ventilation may be provided via non-invasive or invasive methods, with invasive positive pressure ventilation requiring the placement of an artificial airway. Tracheostomy is commonly performed when patients are predicted to require prolonged mechanical ventilation. The use of this procedure has increased, especially following the introduction of a bedside percutaneous tracheostomy technique in 1985 [1], such that up to one-third of patients requiring prolonged mechanical ventilation now receive a tracheostomy [2, 3]. Transitioning from orotracheal intubation to percutaneous tracheostomy provides many potential benefits. Tracheostomy improves airway security, lessens airway resistance (even for tubes of identical inner diameter), facilitates oral care and speech, provides more effective bronchopulmonary toilet, and increases patient comfort and potentially allows reduced sedation [4]. Extensive evidence exists which guides the practice of tracheostomy placement though some of the data on timing is conflicting and as such timing is also guided by institutional

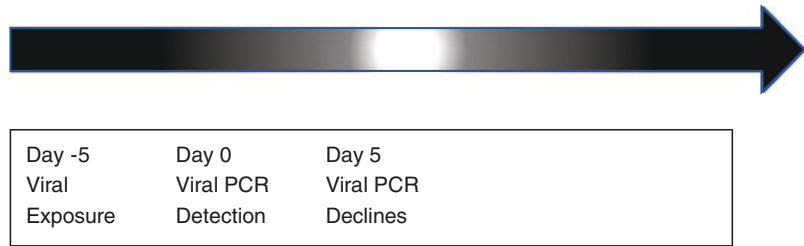
practices. Tracheostomy is commonly performed 7–21 days following the initiation of mechanical ventilation.

For many years, the evidence to guide the timing of tracheostomy was based on small, single center randomized controlled trials. In 2010, Terragni et al. reported the results of an Italian study, which was the first large multicenter randomized trial of early vs. late tracheostomy [5]. Early was defined as 6–8 days after initiation of ventilation and late was defined as 13–15 days after intubation. Conducted in 12 intensive care units, the trial enrolled 600 patients who had undergone 24 h of mechanical ventilation. The 600 patients were followed up for another 48 h and the 419 patients (70%) who were deemed eligible for a potential tracheostomy were randomized to early or late tracheostomy. In the early group, 145 patients (69%) underwent tracheostomy, and 119 patients (57%) underwent tracheostomy in the late group. The primary end point of ventilator associated pneumonia was not different between the 2 groups. Nearly half of the late treatment group never required a tracheostomy and therefore favored the late wait-and-see strategy.

In 2013, Young et al. reported the results of a larger trial examining early vs. late tracheostomy [6]. This trial was conducted at 72 centers in the United Kingdom and randomized 909 patients who had been mechanically ventilated for less than 5 days and with the expectation to require at

L. K. Frye (✉)  
Division of Pulmonary and Critical Care, University  
of Wisconsin, Madison, WI, USA

**Fig. 10.1** COVID infectivity



least one more week of ventilation. Patients randomized to the early group were scheduled immediately for tracheostomy. The late group was scheduled after 10 days of mechanical ventilation. Of the 455 patients assigned to early tracheostomy, 91.9% received a tracheostomy and of the 454 assigned to late tracheostomy, 44.9% received a tracheostomy. There were no differences in the primary end point of 30-day all-cause mortality or other outcomes including critical care unit length of stay or 2-year mortality.

In the early stages of the pandemic, the timing and techniques for tracheostomy were based on the evidence from prior viral pandemics including Middle East Respiratory Syndrome MERS, H1N1, and the severe acute respiratory syndrome (SARS) pandemic of 2003. In the SARS pandemic of 2003, 14–20% of patients required endotracheal intubation and mechanical ventilation [7]. Early case report in the 2003 SARS pandemic demonstrated that tracheostomy could be performed safely with appropriate personal protective equipment, including a water impermeable cap, goggles with an anti-mist screen, N95 mask, plastic transparent full-face shield worn outside goggles and N95 masks, disposable water-impermeable surgical gown, and double surgical gloves and plastic shoe covers. These procedures were performed under apnea and with neuromuscular blockade to prevent coughing or other movement [8].

Previous experience with the SARS outbreak in 2003 led proceduralists to develop tracheostomy protocols that take into account the infectivity of virus-infected patients. Surgical tracheostomy was favored over a percutaneous approach given the potential for aerosolization with disconnections from the ventilator. Early

tracheostomy was recommended against during the SARS outbreak, due to significant infectivity during the early acute period, the high mortality in patients who were mechanically ventilated, and the lack of compelling data regarding tracheostomy-facilitated weaning efficacy. Despite the lower mortality rate in coronavirus disease 2019 (COVID-19) compared with SARS (2.3% vs. 11%), a similarly high percentage of patients (9.8–15.2%) require invasive mechanical ventilation or extracorporeal membrane oxygenation and thereby placement of tracheostomy [8, 9]. The lessons learned in prior viral pandemics can be used to guide current practice taking into consideration the unique challenges of resource and staffing allocation as well as the risk of exposure to healthcare workers. In COVID-19, the viral load falls from a peak associated with the onset of symptoms at around day 5 (Fig. 10.1).

## Indications and Contraindications

Patient selection and timing of tracheostomy is based on expert guidance and varies based on society. Early in the COVID-19 pandemic, multiple organizations published consensus statements in academic journals to provide direction to their membership. While there was not significant variation in patient selection, there was variation in the recommended timing. Organizations did not support proceeding with tracheostomy in patients with multiorgan failure, tenuous respiratory status (such as requiring prone ventilation), the need for cardiovascular support beyond low dose vasopressors, or when the performance of a tracheostomy or the post-tracheostomy care put healthcare workers or



other patients at risk of infection. The Airway and Swallowing Committee of the American Academy of Otolaryngology-Head and Neck Surgery published recommendations in 2020 [10]. They recommended that tracheostomy could be considered in patients with stable pulmonary status but should not take place sooner than 2–3 weeks from intubation and, preferably, with negative COVID-19 testing. They noted that patients who show no clinical or radiological remission within 10 days may be more likely to require ongoing ventilation and many physicians adopted a 21-day policy prior to open surgical tracheostomy based on the mean time from onset to death of 23.7 days in the SARS-1 pandemic [11].

The American Association of Bronchology and Interventional Pulmonology and American College of Chest Physicians recommended tracheostomy in patients with COVID-19 when prolonged ventilator support is anticipated, defined as anticipated duration of mechanical ventilation of >10–15 days [12]. The lack of COVID-19 tracheostomy-related evidence, the conflicting published data on early vs. late tracheostomy in general, and the general resource allocation issues of COVID led the group to not provide specific guidance on timing. The AABIP/CHEST does not suggest routine COVID-19 testing prior to the procedure.

The contraindications to tracheostomy noted were largely related to patient risk of death and risk of infectivity. As the procedures are recommended to be performed under apnea, an apneal trial is performed prior to the procedure and as such patients with high requirements for oxygenation or ventilation are not ideal candidates. The usual relative and absolute contraindications also apply. These include high fractional inspired oxygen and positive end expiratory pressure, hemodynamic instability, local controlled infection, proximity to burns/wounds, coagulopathy, difficult anatomy, prior neck radiation, and elevated intracranial pressure as relative contraindications. Absolute contraindications include an unstable cervical spine, uncontrolled coagulopathy, and severe local infections of the anterior neck.

## Equipment Needed and Modifications in a Viral Pandemic

Equipment for surgical and percutaneous tracheostomy includes the usual procedure trays or kits as well as additional equipment which functions to reduce aerosolization and protect members of the healthcare team. Personal protective equipment should include a powered air purifying respiratory or water impermeable cap, goggles with an anti-mist screen, N95 mask, and plastic transparent full-face shield worn outside goggles and N95 mask, as well as a disposable water-impermeable surgical gown, surgical gloves, and plastic shoe cover. The most experienced and smallest team, ideally the proceduralist, bronchoscopist, and a respiratory therapist, is recommended and medication considerations include the use of neuromuscular blockade to minimize the cough reflex and aerosol generation.

For elective surgical tracheostomy, a tracheostomy set of instruments is required. For emergency tracheostomy, a cricothyrotomy and a separate tracheostomy set are required. There is a recommendation to rely on cold instrumentation and avoid monopolar electrocautery as able. A cuffed, non-fenestrated tracheostomy tube should be placed and a heat moisture exchanger (HME) with viral filter or a ventilator filter should be placed in the ventilator circuit.

The consensus statement of the AABIP/CHEST recommended additional supplies for percutaneous tracheostomy beyond the usual percutaneous tracheostomy kit. This kit generally includes a surgical scalpel blade, an introducer needle, a guidewire, a small tracheal dilator, a single-stage progressive tracheal dilator, a tracheal loading dilator, and a small slip-tip syringe (Fig. 10.2). They recommend consideration of packing of the oropharynx such as with kerlix and the use gauze or a sponge at the stoma site to further reduce aerosols. The use of a disposable video bronchoscope was also recommended. Ultrasound could also be used as an adjunct to identify anatomic landmarks and to evaluate vascular structures prior to the procedure.



**Fig. 10.2** Cook punch dilator, single-step dilator, and loading dilators

## Procedural Technique and Modifications

A tracheostomy can be created with an open surgical or a percutaneous dilation technique and can take place in an operating room or at the patient's bedside, with a percutaneous approach having the benefit of being performed at the bedside and minimizing transportation of the patient. The open technique involves dissection of the anterior pretracheal tissue and insertion of a tracheostomy tube under direct visualization. The percutaneous technique is performed with the use of a modified Seldinger technique and bronchoscopic guidance.

For percutaneous tracheostomy, the team should perform the standard time out to verify the patient details and procedure to be performed. Modifications to the technique should be addressed at this time if members of the team are unfamiliar. This should be performed outside the room, if possible, to minimize personnel in the room. The nurse should administer additional sedation if needed after the time out is performed and once the desired sedation level is reached, administer a short-acting neuromuscular blocker. The nurse should remain immediately available outside the patient's room for the duration of the procedure.

After patient positioning and identification of anatomic landmarks, the anterior neck is prepped and draped [13]. At this time, the respiratory therapist induces apnea and the ventilator circuit is disconnected from the endotracheal tube to insert a bronchoscope adapter and allow insertion of the

flexible bronchoscope. Ventilation can now be resumed and an inspection of the airways performed. If packing of the oropharynx is pursued, it can be performed with moist kerlix at this time. The bronchoscope is then positioned at the distal aspect of the endotracheal tube. Apnea is again induced, the cuff is deflated, and the bronchoscopist and respiratory therapist withdraw the endotracheal tube to the subglottic level under direct visualization and the cuff is inflated. Local anesthesia is performed in the field using 1% lidocaine with epinephrine.

The proceduralist can now proceed with the tracheostomy using a Seldinger technique. The introducer needle is inserted between the second and third tracheal ring at the midline. With the bevel of the needle directed downward, the guidewire is now inserted via the needle into the distal trachea and advanced just beyond the main carina. The introducer needle is withdrawn and a 2–3 cm incision (vertical or horizontal) is made. The small tracheal punch dilator is now inserted over the guidewire and withdrawn leaving the guidewire in place. The single-stage dilator with the protective sheath is now loaded over the wire and the dilation is performed. The progressive dilator is removed and the tracheostomy tube with the loading dilator is advanced over the guidewire and protective sheath. Once the tracheostomy tube is positioned within the airway, the loading dilator, protective sheath, and guidewire can be removed. To minimize aerosolization, apnea can be induced from the time the punch dilation is performed until inflation of the tracheostomy cuff and wet gauze can be placed over the stoma to minimize any potential leak. The tracheostomy tube can be connected to the ventilator circuit, the cuff inflated, and ventilation resumed if a period of apnea was used. The tracheostomy tube can now be secured with sutures and a tracheostomy collar.

A modified approach to the percutaneous technique was described early in the pandemic by faculty at New York University [14]. They utilized a side-by-side technique whereby they placed the bronchoscope alongside the endotracheal tube, not inside it. This allowed visualization during the procedure as well as continued

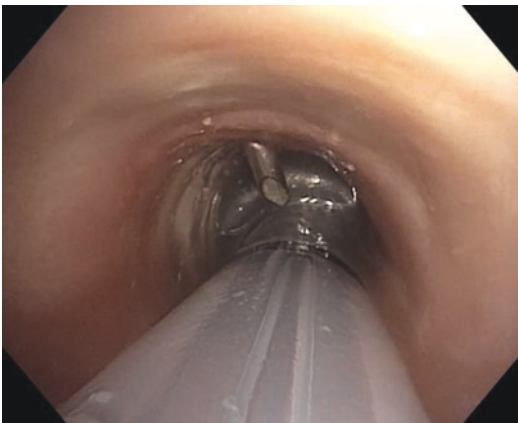
standard mechanical ventilation with the cuff inflated after positioning the endotracheal tube cuff in the distal trachea (Figs. 10.3 and 10.4). This technique mitigates the risk of virus aerosolization during the procedure.

For open surgical tracheostomy, anatomic landmarks are palpated and marked. The surgical field is then prepped and draped. Under a period of apnea, the existing endotracheal tube is advanced distal to the desired surgical site and the cuff is inflated. Apnea is maintained as tolerated while incising the trachea. A 1–2 cm vertical or horizontal incision is made inferior to the cricoid cartilage. The incision is extended through the platysma muscle to expose the strap muscles

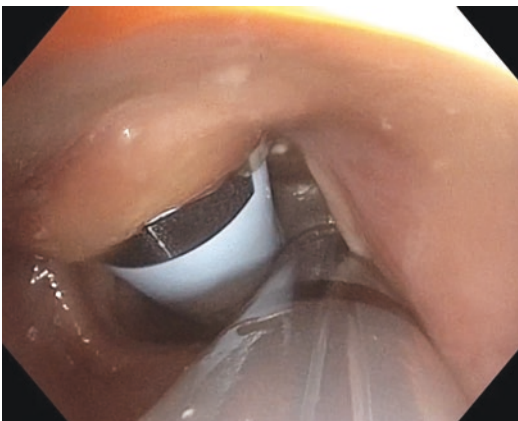
(sternohyoid and sternothyroid), identifying the median raphe. The strap muscles are then retracted laterally, exposing the cricoid cartilage and thyroid gland. The thyroid isthmus is identified and ligated, if necessary, depending on its location along the trachea. Hemostats can be utilized to cross-clamp the isthmus, subsequently oversewing each stump with a silk suture to ensure hemostasis of thyroid tissue. A cricoid hook is then placed under the cricoid cartilage to elevate the larynx and trachea into the operative field. The second and third tracheal rings are identified. An incision is made between the second and third rings, and the tracheostomy tube is placed. The tracheostomy tube is then connected to the circuit and the cricoid hook is released. The tracheostomy tube is now secured to the anterior neck and a soft or hard tracheostomy collar is placed.

A group of otolaryngologists in the United Kingdom described additional techniques to minimize aerosolization [15]. They describe clamping the endotracheal tube at two to three points in the procedure, with the tube clamped when advancing into the distal trachea beyond the proposed tracheal window, when the tube is withdrawn proximal to the tracheal window to allow insertion of the tracheostomy tube, and with the endotracheal tube remaining clamped as tolerated until the conclusion of the procedure. Various modifications in the standard surgical technique may also be performed including stay suture placement laterally to provide traction for tube placement and additional post-operative security, removal of an anterior cartilage window, or the creation of a Bjork flap (an inferiorly based cartilage flap is created and secured to the subcutaneous tissues) [16].

In the post-operative period, cuff leak and cuff pressures should be assessed regularly and the cuff should be maintained appropriately inflated. Circuit disconnections should be avoided and suctioning should be performed via a closed circuit. Deflation of the cuff, replacement of the tracheostomy tube, and initiation of a plan for decannulation should be deferred until the patient is known to be COVID-19 negative.



**Fig. 10.3** Exploratory tracheocentesis with modified technique



**Fig. 10.4** Single-step dilator with modified technique

## Evidence-Based Review

Early in the COVID-19 pandemic, small case series and retrospective reviews were published demonstrating the safety of tracheostomy in patients requiring >5–10 days of mechanical ventilation and anticipated to require prolonged ventilatory support. These publications yielded the dissemination of new techniques as noted above. The Summer of 2020 yielded studies sharing short-term outcomes of patients who had undergone tracheostomy for COVID-19 related illness. In a study by Murphy et al. [17], they shared their experience with percutaneous tracheostomy using intermittent apnea. In their patient population, roughly one-third of patients required an ICU level of care. The mortality rate for mechanically ventilated patients was 29%. They assessed 18 patients for percutaneous dilational tracheostomy and performed tracheostomy on 11. No personnel had infections related to the procedure. In the short follow-up (average of 20 days), 1 patient died from multiorgan failure, 2 were discharged from the hospital on mechanical ventilation, and the remaining 8 patients were liberated from the ventilator. A study from the University of Pennsylvania Health System published around the same time shared their experience with percutaneous and open surgical tracheostomy using techniques to mitigate aerosol exposures and demonstrated similarly successful implementation of new practices with no healthcare worker exposures [18].

Having documented safety, the question of impact on weaning and liberation from the ventilator and sedation requirements remained. This question was answered by Carmichael et al. [19], who performed a retrospective review of the outcomes of patients requiring mechanical ventilation for COVID-19 between March 1 and June 30, 2020. In their cohort, 206 patients required mechanical ventilation and 26 underwent tracheostomy tube placement at a mean of  $25 \pm 5$  days after initial intubation. 81% of tracheostomy patients were liberated from the ventilator at a mean of  $9 \pm 6$  days post-procedure, and 54% were decannulated prior to hospital discharge at a mean of  $21 \pm 10$  days post-procedure. Sedation

and pain medication requirements decreased significantly in the week after the procedure with daily morning assessments using the Richmond Agitation and Sedation Scale (RASS) and the Critical Care Pain Observation Tool (CPOT) recorded, and patients considered to be adequately sedated with a RASS  $\leq 1$  and CPOT of 0.

Early in the pandemic, a COVID-19 diagnosis was a reason to categorically delay or avoid tracheostomy tube placement. This practice was challenged when faculty managing the initial surge in New York City published their data supporting early tracheostomy [20]. In their study, they defined early tracheostomy as those procedures performed prior to day 10 of intubation and late as those occurring at day 10 or later. Timing of tracheostomy was significantly associated with length of stay with median length of stay of 40 days in those who underwent early tracheostomy and 49 days in those who underwent late tracheostomy. In a competing risks model with death as the competing risk, the late tracheostomy group was 16% less likely to discontinue mechanical ventilation. While safety was not an outcome of this study, 0/3 interventional pulmonologists performing percutaneous tracheostomies contracted COVID-19. The department of otolaryngology consisted of 35 faculty and 6 contracted COVID-19. Of these 6 cases, 5 were not involved in performing tracheostomies before they became ill.

Further support for early tracheostomy came via a propensity matched cohort study from Hernandez et al. which aimed to answer whether early tracheostomy could benefit overstrained intensive care units [21]. In their retrospective cohort study, which included consecutive patients with COVID-19 pneumonia who had undergone tracheostomy in 15 Spanish ICUs during the surge, they evaluated the outcomes of patients undergoing the procedure at three time intervals. The timing was <8 days, 8–10 days, and 11–14 days after intubation. Earlier tracheostomy was associated with more ventilator-free days at 28 days. ICU bed-free days at day 28 also favored earlier tracheostomy though there was no difference in hospital bed-free days between the groups. This study suggested that earlier trache-

ostomy has the potential to provide relief to overstained ICUs.

A small proportion of patients with COVID-19 will exceed the support provided by mechanical ventilation and be considered for extracorporeal membrane oxygenation (ECMO). Performing a tracheostomy on ECMO carries similar risk of aerosol generation but also carries a higher bleeding risk given the use of systemic anticoagulation. To answer the question of safety, one of the five UK ECMO centers created a prospective tracheostomy database at the beginning of the COVID-19 surge [22]. They shared their experience with percutaneous tracheostomy placement in 38 patients mechanically ventilated in the ICU between March 27 and May 15, 2020. The average time of intubation before tracheostomy was 11.66 days. Complications were minimal with 2 patients requiring skin sutures for cessation of bleeding. No patient required the transfusion of blood products for tracheostomy-related bleeding. Given the hypercoagulable state of COVID-19 patients, they safely performed the procedure without an anticoagulation hold in 15 patients.

More recently a systematic review and meta-analysis was conducted to determine the cumulative incidence of complications, mortality, time to decannulation, and ventilatory weaning in patients undergoing tracheostomy for COVID-19 [23]. Additional outcomes related to surgical versus percutaneous and outcomes relative to tracheostomy timing were analyzed. From 1016 unique studies, 39 articles reporting outcomes for a total of 3929 patients were included for meta-analysis. The cumulative incidence of complications was 14.24% with bleeding the predominant complication, accounting for 52% of those complications reported. There was no difference in incidence of mortality, decannulation, complications, and time to decannulation between percutaneous and surgical tracheostomy. In this meta-analysis, no difference was found in mortality between early and late tracheostomy and timing of tracheostomy did not predict time to decannulation. Given the small number of studies and subsequent sample size, linear regression

was used to confirm that time to tracheostomy did not significantly predict time to decannulation. Time from tracheostomy to weaning was only reported in 8 studies.

---

## Summary and Recommendations

Tracheostomy guidelines during the COVID-19 pandemic vary by physician group and specialty, hospital system, and resource/staffing allocation. Society-based guidelines published in academic journals must be balanced against institutional policies and unique staffing or resource issues. The current literature suggests that with appropriate precautions, tracheostomy can be performed safely with the benefit of a bedside procedure minimizing transportation of COVID positive patients. The timing of the procedure should be guided by the patient's clinical trajectory as well as institutional resources and policies related to the management of tracheostomy in patients who may have evidence of viral shedding. This summary is provided as a point-in-time current state of in November 2021 and is anticipated to change in coming weeks and months as the pandemic, vaccination status, and antibody testing evolves.

---

## References

1. Ciaglia P, Firsching R, Syniec C. Elective percutaneous dilatational tracheostomy: a new simple bedside procedure; preliminary report. *Chest*. 1985;87(6):715–9.
2. Combes A, Luyt CE, Nieszkowska A, et al. Is tracheostomy associated with better outcomes for patients requiring long-term mechanical ventilation? *Crit Care Med*. 2007;35(3):802–7.
3. Cox CE, Carson SS, Holmes GM, et al. Increase in tracheostomy for prolonged mechanical ventilation in North Carolina, 1993–2002. *Crit Care Med*. 2004;32(11):2219–26.
4. Nieszkowska A, Combes A, Luyt CE, et al. Impact of tracheotomy on sedative administration, sedation level, and comfort of mechanically ventilated intensive care unit patients. *Crit Care Med*. 2005;33(11):2527–33.
5. Terragni PP, Antonelli M, Fumagalli R, et al. Early vs late tracheotomy for prevention of pneumonia in mechanically ventilated adult ICU patients: a randomized controlled trial. *JAMA*. 2010;303(15):1483–9.



6. Young D, Harrison DA, Cuthbertson BH, Rowan K. For the TracMan collaborators. Effect of early vs late tracheostomy placement on survival in patients receiving mechanical ventilation: the TracMan randomized trial. *JAMA*. 2013;309(20):2121–9.
7. Wei WI, Tuen HH, Ng RWM, Lam LK. Safe tracheostomy for patients with severe acute respiratory syndrome. *Laryngoscope*. 2003;113:1777–9.
8. Tay JK, Khoo ML, Loh WS. Surgical considerations for tracheostomy during the COVID-19 pandemic: lessons learned from the severe acute respiratory syndrome outbreak. *JAMA Otolaryngol Head Neck Surg*. 2020;146(6):517–8.
9. Wu Z, McGoogan JM. Characteristics of and important lessons from the coronavirus disease 2019 (COVID-19) outbreak in China: summary of a report of 72,314 cases from the Chinese center for disease control and prevention. *JAMA*. 2020;323(13):1239–42.
10. Parker NP, Schiff BA, Fritz MA, Airway and Swallowing Committee of the American Academy of Otolaryngology-Head and Neck Surgery, et al. Tracheotomy recommendations during the COVID-19 pandemic. 2020. <https://www.evhc.net/coronavirus/covid-19/hm-intensivist-resources/tracheostomy-recommendations.pdf>.
11. Leung GM, Hedley AJ, Ho L-M, et al. The epidemiology of severe acute respiratory syndrome in the 2003 Hong Kong epidemic: an analysis of all 1755 patients. *Ann Intern Med*. 2004;141:662–73.
12. Lamb CR, Desai NR, Angel L, et al. Use of tracheostomy during the COVID-19 pandemic: American college of chest physicians/American association for bronchology and interventional pulmonology/association of interventional pulmonology program directors expert panel report. *Chest*. 2020;158(4):1499–514.
13. Hashimoto DA, Axtell AL, Auchincloss HG. Percutaneous tracheostomy. *N Engl J Med*. 2020;383:e112.
14. Angel L, Kon ZN, Chang SH, et al. Novel percutaneous tracheostomy for critically ill patients with COVID-19. *Ann Thorac Surg*. 2020;110:1006–11.
15. Takhar A, Walker A, Tricklebank S, et al. Recommendation of a practical guideline for safe tracheostomy during the COVID-19 pandemic. *Eur Arch Otorhinolaryngol*. 2020;277:2173–84.
16. Raimonde AJ, Westhoven N, Winters R. Tracheostomy. In: StatPearls. Treasure Island, FL: StatPearls; 2021. <https://www.ncbi.nlm.nih.gov/books/NBK559124/>. Accessed 31 Jul 2021.
17. Murphy P, Holler E, Lindroth H, et al. Short-term outcomes for patients and providers after elective tracheostomy in COVID-19 positive patients. *J Surg Res*. 2021;260:38–45.
18. Chao TN, Harbison SP, Braslow BM, et al. Outcomes after tracheostomy in COVID-19 patients. *Ann Surg*. 2020;272:e181–6.
19. Carmichael H, Wright FL, McIntyre RC, et al. Early ventilator liberation and decreased sedation needs after tracheostomy in patients with COVID-19 infection. *Trauma Surg Acute Care Open*. 2021;6:e000591.
20. Kwak PE, Connors JR, Benedict PA, et al. Early outcomes from early tracheostomy for patients with COVID-19. *JAMA Otolaryngol Head Neck Surg*. 2021;147(3):239–44.
21. Hernandez G, Ramos FJ, Añon JM, et al. Early tracheostomy for managing ICU capacity during the COVID-19 outbreak: a propensity-matched cohort study. *Chest*. 2021;S0012-3692(21):01125–9.
22. Valchanov K, Salaunkey K, Parmar J. Percutaneous dilatational tracheostomy in coronavirus disease 2019 extracorporeal membrane oxygenation patients: a case series. *J Cardiothorac Vasc Anesth*. 2021;35:348–50.
23. Ferro A, Kotecha S, Auzinger G, et al. Systematic review and meta-analysis of tracheostomy outcomes in COVID-19 patients. *Br J Oral Maxillofac Surg*. 2021;59:1013. <https://doi.org/10.1016/j.bjoms.2021.05.011>.
24. WHO. COVID-19 dashboard. Geneva: World Health Organization; 2020. <https://covid19.who.int/>.

---

## Part III

# Tracheobronchial Obstructions



# Laser Bronchoscopy in Tracheobronchial Obstructions

# 11

## Laser Bronchoscopy

Michela Bezzi

### Introduction

Central airway obstruction is a problem that faces both medical and surgical physicians treating chest diseases and requires a comprehensive multidisciplinary approach.

Central airway obstruction can occur secondary to a variety of lung primary, adjacent, or metastatic malignancies and benign processes. It can be either intrinsic or extrinsic [1, 2].

Considering the epidemiology of lung cancer, an increasing number of patients will develop complications related to proximal bronchial involvement. Moreover, considering the efficacy of cancer treatment, the number of long-term cancer survivors is increasing. Furthermore, with increased use of artificial airways such as endotracheal intubation in the aging population and in patients with severe acute respiratory syndrome coronavirus-2 (SARS-CoV-2) infection, the incidence of both benign and iatrogenic complications is also likely going to increase.

The most common cause of malignant central airway obstruction is direct extension from an adjacent lung tumor (most commonly bronchogenic carcinoma) followed by esophageal and thyroid carcinoma. Primary tumors of the airway are not common and mainly represented by squa-

mous cell carcinoma and adenoid cystic carcinoma for trachea, and carcinoid tumors distal to the carina. Metastases may also localize to the airways, most frequently from renal cell, breast, and thyroid carcinoma.

Benign disease can be congenital or acquired. The most common histologically benign strictures are postintubation tracheal stenosis and post-tracheostomy tracheal stenosis, followed by idiopathic and autoimmune causes (granulomatosis with polyangiitis, sarcoidosis, ulcerative colitis), airway foreign bodies, tracheal, or bronchomalacia. Strictures can also occur as a fibrotic evolution of endobronchial tuberculosis or lung transplantation. All these conditions must be excluded before considering the stricture as idiopathic. This is relevant for treatment, as idiopathic laryngotracheal stenosis is characterized by hypertrophy of the mucosa and submucosa with intact cartilaginous structures, for which stent insertion should not be used [1–3].

Interventional options for central airway obstruction require experienced personnel and equipment. The choice of intervention is based on the degree of obstruction and severity of symptoms, the nature of the underlying problem, and the patient's overall prognosis and quality of life. In case of airway tumors, surgical resection is the treatment of choice. However, most patients with an endobronchial mass have an advanced stage of disease, poor performance status, com-

---

M. Bezzi (✉)  
SC Pneumologia - SS Pneumologia Interventistica  
ASST Spedali Civili di Brescia, Brescia, Italy

plete or partial atelectasis of the affected lung, and thus are not suitable for surgery [1–7].

Thirty percent of patients with lung cancer will develop obstruction of trachea and main bronchi [8] with consequent dyspnea, bleeding, and infection. The technique of endobronchial coagulation and disobstruction plays a pivotal role in all these situations, since conventional treatment with chemo- and radiotherapy is often performed with unsatisfactory results with regard to the endobronchial component of the tumor [9, 10]. Endoscopic coagulation and debulking allow restoring of airway patency, palliation of symptoms, and improvement of quality of life. However, palliation with endoscopic techniques should be reserved to inoperable obstructive central tumors in symptomatic patients.

Airway obstruction due to a benign lesion may also be amenable to laser resection. If exclusively endoluminal, endoscopic laser resection should be the first therapeutic choice for central benign tumors. Surgery should be limited to those cases with partial or exclusive extra bronchial growth or in case of recurrence.

The advent of endoscopic therapy has also deeply modified the approach to the management of inflammatory tracheo-bronchial strictures. Candidates for bronchoscopic laser resection include those who are not eligible for open resection (because of age, overall medical status, fear of surgery, severity of other underlying disease, or the extent, location and degree of the stricture), but also severe, dreadfully symptomatic stenosis. Interestingly, most simple stenosis (e.g., web-like stenosis or stenosis without cartilage involvement) can be successfully dilated through laser-assisted mechanical dilation and surgery may no longer be necessary [11].

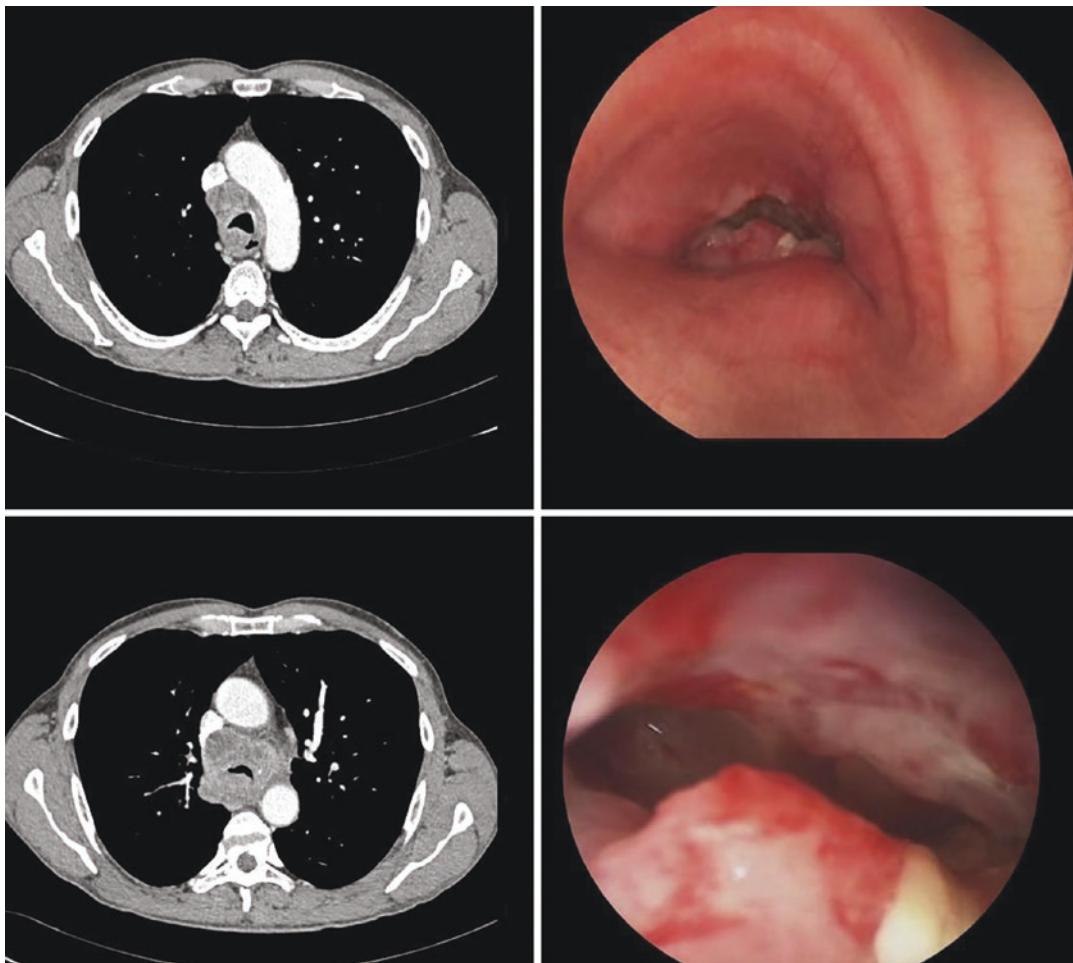
## Clinical Presentation

CAO may cause a variety of symptoms, from shortness of breath to respiratory failure and death. The entity of symptoms does not only rely on the etiology but is mainly affected by the location (tracheal vs. bronchial) and the rate of progression of the obstruction: patients may develop symptoms

suddenly, as can happen with foreign body aspiration, or more gradually, as is often the case with slowly growing malignant obstructions. Symptoms and signs develop when airflow impairment reaches a critical threshold. Patients complain of shortness of breath, which is often constant and unresponsive to bronchodilators. Monophonic wheezing may be present, and can be unilateral if the lesion is distal to the carina. Stridor is a sign of severe subglottic or tracheal obstruction. Breathing becomes labored in advanced phases and heralds impending respiratory failure. In the decompensated patient, immediate restoration of ventilation and oxygenation is of vital importance. Patients with minor obstruction are often asymptomatic or may present with other nonspecific symptoms such as exertional dyspnea and positional wheezing, since airflow limitation is mild. However, rapid deterioration may occur if swelling or secretions increase the degree of luminal impingement during a respiratory tract infection. It is not uncommon for patients with subcritical lesions to be misdiagnosed as suffering from an exacerbation of asthma or chronic obstructive pulmonary disease unresponsive to bronchodilators. Patients with airway obstruction also frequently present with pneumonia [1–3].

## Diagnosis

A number of studies are employed to confirm the presence of central airway obstruction and estimate its magnitude. Conventional chest radiographs are rarely diagnostic, yet are often obtained as the initial radiologic test. Obvious pathology, such as tracheal deviation, can be identified; however, chest X-ray is unable to determine airway invasion or aid in procedure planning. If an airway lesion is suspected and time permits, a high-resolution chest computed tomography (CT) should be performed. CT scans give better characterization as to whether the lesion is intraluminal or extrinsic to the airway and whether the airway distal to the obstruction is patent. In addition, it allows us to define its relationship to other structures such as vessels [1–3] (Fig. 11.1).



**Fig. 11.1** CT scan showing tracheobronchial stenosis. Bronchoscopy allows direct visualization to determine the nature, length, diameter of the obstruction. This information is crucial for treatment planning

In a stable patient spirometry can show the characteristic flattening of the curve on flow-volume loops, frequently before abnormalities in the spirometric volumes are noted.

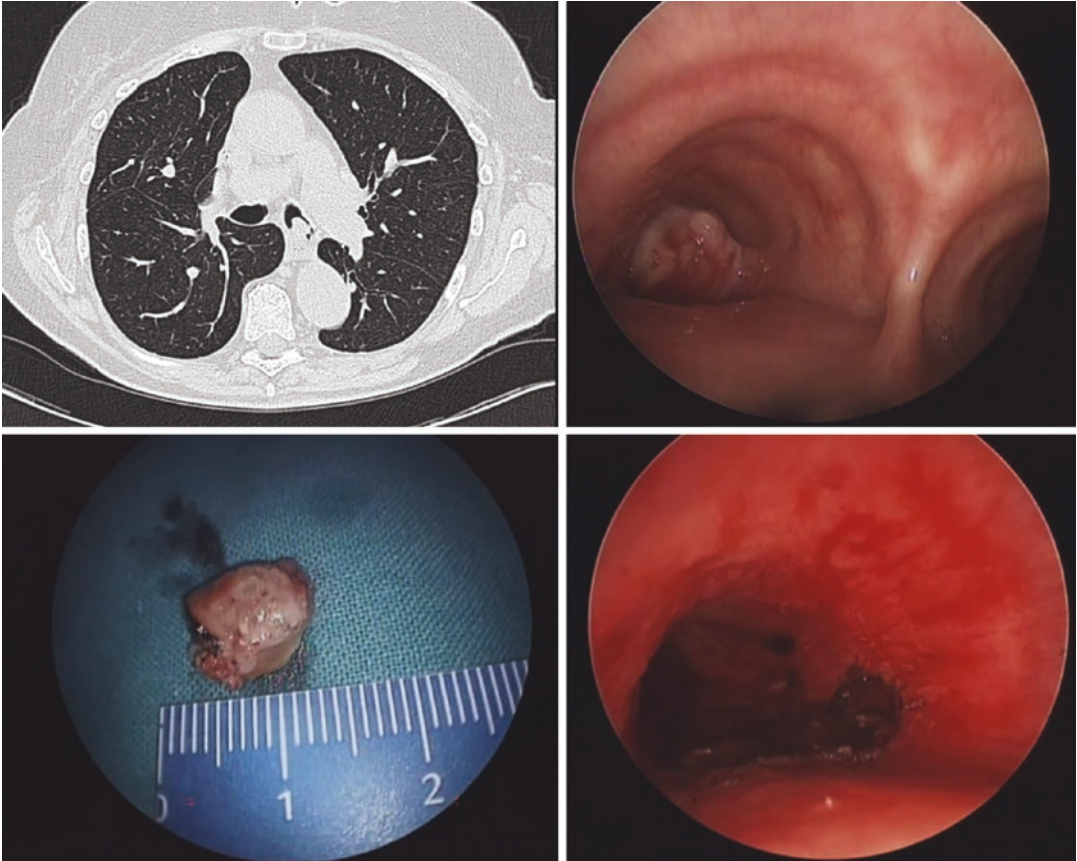
Bronchoscopy is always necessary in assessing airway obstructions. Direct visualization allows to determine the nature, length, diameter of the obstruction and precise location in relation to the vocal cords and main carina, and provides useful information for treatment planning, such as the relative amount of intraluminal and extraluminal disease and patency of distal airways (Fig. 11.2) [1–3].

## Treatment

Several techniques are available to manage central airway obstruction and include airway dilatation, ablation techniques, tracheo-bronchial stenting, and surgery [12]. In each case, management requires initial stabilization of the patient with secure access to the airways to guarantee ventilation.

In a stable patient, imaging studies and pulmonary function tests should be obtained as mentioned above. A patient with severe tracheal or bronchial obstruction and marginal lung function





**Fig. 11.2** CT scan shows left main bronchus stenosis due to vegetation. Flexible bronchoscopy shows neoplastic vegetation with a small implant base and a patent distal lumen. These conditions are an optimal indication for

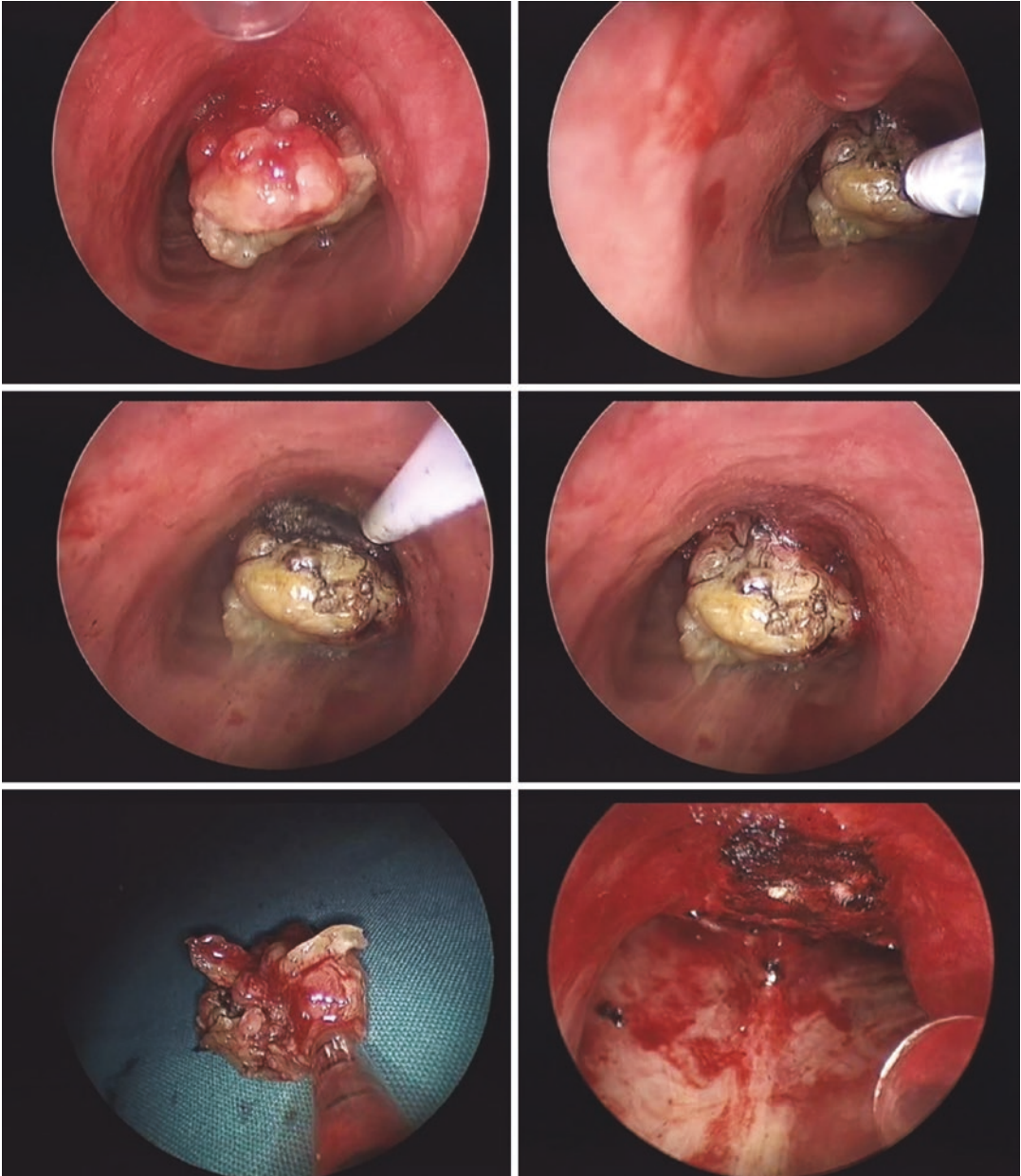
laser-assisted mechanical resection. The procedure restored the left main bronchus lumen. Low power laser allowed implant base treatment to postpone endobronchial recurrence

requires initial stabilization to secure ventilation and oxygenation. Flexible bronchoscopy can be performed after the airway has been secured (orotracheal tube/deep sedation or general anesthesia) and appropriate gas exchange documented. During the bronchoscopic examination, the airway is inspected, lesions are assessed, distal secretions are suctioned, and diagnostic tissue is obtained if needed. This information is used to plan further interventions aimed at opening an airway and maintaining patency. After the patient has been stabilized, he should be transferred to a specialized center where a dedicated airway team is available. In case of severe tracheal obstruction, use of the open ventilating rigid bronchoscope is the preferred method of airway control.

The rigid bronchoscope not only provides a secure airway during visualization, but is also a therapeutic tool. In emergent cases, the rigid bronchoscope is the preferred instrument for unstable patients and when significant bleeding is expected. The airway can be dilated with the barrel of the scope [4]. During this procedure, the patient is intubated with the instrument under general anesthesia. The optical telescope is advanced through the stenotic airway opening and the barrel then pushed through the obstruction in a rotating motion. Bleeding is usually minimal due to compression of the lesion by the rigid instrument. In one session, using the rigid bronchoscope under general anesthesia, immediate good results can be achieved: bronchial

recanalization with improvement of ventilation and/or drainage of post-stenotic secretions (Fig. 11.3). Dilation is immediately effective for intrinsic and extrinsic lesions, but the results are usually not sustained. For this reason, multimodality approaches featuring a combination of sev-

eral interventions are preferred for their mucosal sparing effects and long-term success over dilation alone [4, 5]. The number and scope of therapeutic options has increased dramatically, and a given intervention must be chosen carefully in the context of an individual patient's situation.



**Fig. 11.3** Endoluminal obstruction caused by malignant vegetation. Laser-assisted mechanical resection allowed safe removal, avoiding bleeding, and restoring airway

patency. Implant base photocoagulation will delay potential recurrence

They can be divided into “slow methods” such as photodynamic therapy, cryotherapy and brachytherapy or fast methods: laser, argon plasma coagulation, and electrocautery. Differences relate to their mechanisms of action, onset of effect (immediate vs. delayed), depth of tissue penetration and complication profile [12]. Fast methods will be the topic of this chapter.

Laser therapy normally integrates rigid bronchoscopic resection. This procedure is known worldwide as Laser Assisted Mechanical Resection (LAMR) and represents the safest and more effective way to obtain all potential effects of laser in bronchoscopy. Some authors use laser with the flexible bronchoscope with limited safety and efficacy if compared to LAMR. The tissue–light interaction leads to thermal tissue damage with vaporization, coagulation, resection, or incision of obstructing lesions [13, 14].

Laser therapy was originally indicated for short endobronchial central airway lesions with a visible distal lumen. Bronchoscopists who become familiar with the technique will use it even in complete stenoses where the distal bronchial tree can only be reached using the suction tube and the rigid bronchoscope basing upon precise knowledge of the anatomy and preferably with support from CT scan images. In these cases, the combination of rigid bronchoscopy and laser firing is crucial. The technique is most commonly applied in cases of malignant intrinsic airway obstruction or in postintubation tracheal stenosis. The effects upon airway lumen size are usually immediate and accompanied by excellent control of bleeding. Laser is not useful for central airway obstruction caused by extrinsic airway compression.

Electrocautery and argon plasma coagulation also rely on thermal tissue destruction. With electrocautery, a high-frequency current is applied to the lesion with bipolar probes. When the current is directly applied to the tissue, heat develops and leads to tissue necrosis. Electrocautery is traditionally defined as “the poor man’s laser” since it can mimic the effects of laser firing when vaporization or resection are needed with a less expensive equipment.

Argon plasma coagulation is a related therapeutic intervention. Argon gas is emitted through a flexible Teflon tube. This gas is ionized because of exposure to high-frequency current and an electrical arc is formed which allows for desiccation and tissue destruction. It is a valuable tool in treating superficial bleeding and debulking granulation tissue and tumors.

Electrocautery and Argon plasma coagulation are cheaper than Laser and may be performed using flexible bronchoscopy in patients under conscious sedation. Both penetrate tissue less than laser and while this reduces the extent of large tumor debulking, it also limits the risk of airway damage and perforation [12].

Indications, equipment, application, and outcomes of these techniques will be extensively discussed hereafter.

---

## History and Historical Perspectives

Gustav Kilian, the so-called father of bronchoscopy, was the first who introduced a tube into the trachea, in order to extract a small piece of pork bone from the right main bronchus of a German farmer in 1897 [15]. Few years later, in 1907 Chevalier Jackson realized a bronchoscope based on the instruments used for esophagoscopy [16].

However, the development of flexible bronchoscopy and the improvement of its use in the 1970s made the rigid bronchoscope less used and until the early 80s the endoscopic treatment of central airway obstructions was hazardous and often inadequate because of the high risk of bleeding and the short-term results provided. The introduction of endoscopic electrosurgery and cryotherapy partially succeeded in reducing the risk of bleeding, even though these techniques gave an unpredictable risk of damaging the adjacent healthy tissues. Cryotherapy was initially used in the 1970s in the treatment of inoperable endobronchial cancers, but in the following years it was more and more used with good results in effectiveness and safety [17].

The introduction of the endobronchial Nd-YAG laser in 1982 by Dumon [18] and the



following improvements allowed the reduction of hemorrhages and the prolonged palliation in central airway obstruction due to lung cancer. So, bronchoscopic mechanical resection turned into Laser Assisted Mechanical Resection (LAMR).

### Indications and Contraindications

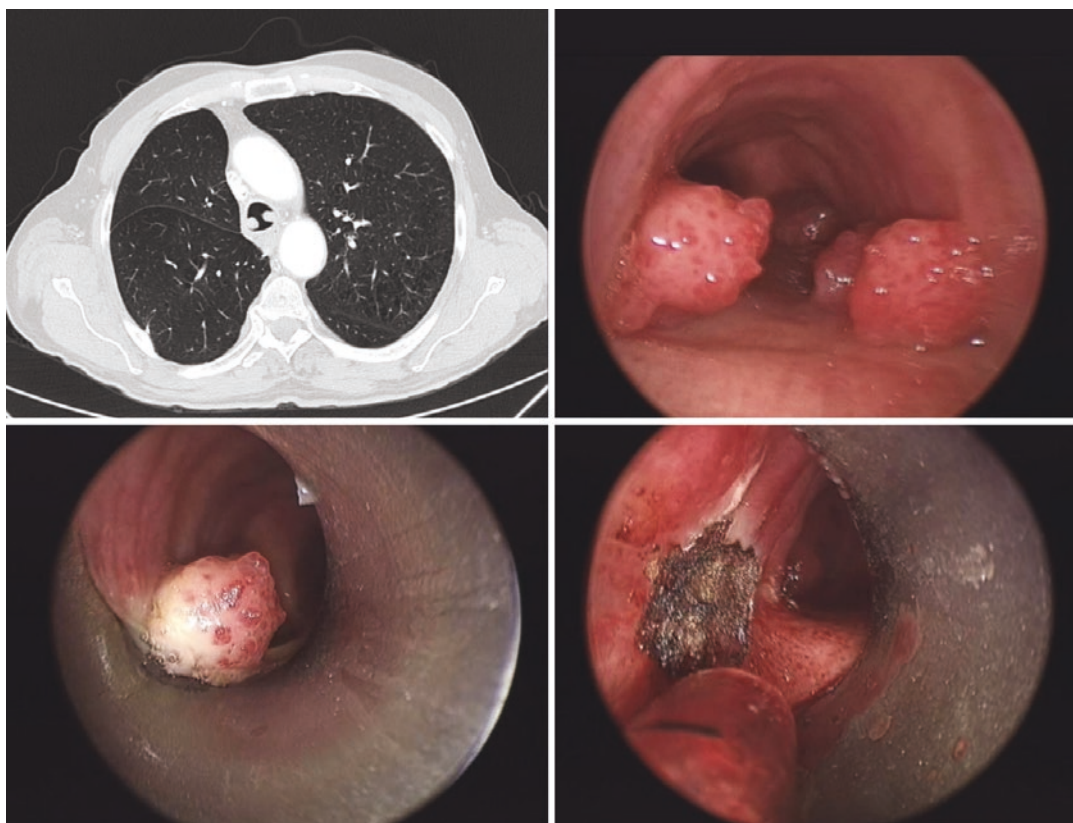
While bronchoscopic laser resection (LAMR) finds its application as a malignant and benign intraluminal tumors treatment, with relevant effectiveness especially when dealing with exophytic proximal airway lesions, it has no role when the obstruction is caused by extrinsic compression [19, 20]. Laser-assisted bronchoscopy can also be used to treat tracheo-bronchial stenosis of different etiology, such as idiopathic, vasculitis-related (i.e., granulomatosis with poly-

angiitis subglottic localizations), pseudo-glottic, or due to either prolonged orotracheal intubation or tracheostomy.

### Benign and Malignant Tumors

Although rare, benign tumors are the best indication for laser therapy due to its radicality and relative invasivity. In fact, since endoluminal benign tumors are usually polypoid with a definite base on bronchial mucosa, laser resection should be considered a as first-option treatment because of its ability to remove the lesion in toto; moreover, implant base photocoagulation can be carried out to reduce to minimal levels the chance of tumor recurrence (Fig. 11.4).

While laser therapy is indicated when dealing with endoluminal tumors or cases with partial



**Fig. 11.4** Multiple papillomatous lesions. Laser-assisted mechanical resection is effective in benign lesions to restore airway patency and prevent recurrence

extraluminal growth, lesions with exclusive extraluminal development should be reserved for a surgical approach.

As for malignant lesions, airway obstruction from bronchogenic carcinoma is the most frequent indication for laser resection. It is typically employed in patients who have exhausted their therapeutic options, although some may be eligible for salvage chemotherapy, brachytherapy, or surgical resection [4, 5, 21]: although a risky maneuver due to the often-declining condition of these types of patients, the benefits of bronchial reopening and prevention of irreversible respiratory failure (or, worse, asphyxia) are too obvious to be overlooked.

The same principle is applied when dealing with endobronchial metastases, the most frequent cases arising from gastrointestinal, kidney, melanoma, or lymphoproliferative disorders progression. Basically, every malignancy with bronchial tropism, including the group classified as low-grade malignancy (as adenoid cystic carcinoma, mucoepidermoid carcinoma, bronchial carcinoids) can be addressed by laser resection, provided it is demonstrated in previous evaluation with a flexible bronchoscope that the stenosis can be overcome and that there is patency of the downstream airway [22, 23].

In fact, while the histology of the lesion is certainly relevant in determining the prognosis of the patient, the main objective of laser-assisted resection is to restore airway patency by recanalizing the tracheobronchial tree (thus guaranteeing an adequate ventilation); therefore, the site of the lesion is the main factor to be considered in the preoperative evaluation. Moreover, it is necessary to consider the macroscopic aspect of the lesion in order to have clear relations with contiguous structures, the possible vascular pedicle, as well as a preliminary indication of the possibility of bleeding once the coring out process begins.

The greatest respiratory distress occurs when the occlusion involves large caliber airways, such as the trachea and main bronchi, since the proportion of ventilation that is lost is greater. Access to this type of lesions is easier than in the more distal airways, and intubation can be carried out

with tubes of larger diameter providing the operator not only a more comfortable route to perform the procedure, but also an easier way to manage any complication. Just think of bleeding: if the tumor is located in the more proximal airway, it is possible to localize the source of the leak, the removal of blood can occur at higher flows and the possibility of cauterizing the site is exponentially greater.

On the contrary, tumors obstructing segmental bronchi do not impair ventilation to such a degree to produce severe impairment, usually. Furthermore, the risk of perforation is also significantly augmented since bronchial walls begin to be thinner and laser delivery lacks direction due to reduced accessibility provided by smaller, longer tubes. Procedures on lesions localized at segmental level or further downstream are therefore reserved for conditions in which the benefit far outweighs the risk, as in the case of progressively growing benign obstructive lesions or post-obstructive pneumonia with the need for cleansing of purulent secretions (otherwise untreatable given the poor effectiveness of antibiotic therapy in cases of impeded drainage).

It is critical for the endoscopist to identify the base of the obstructing endobronchial tumor. Polypoid tumors can be easy to remove and often completely resectable (Fig. 11.3). Bronchial wall infiltration means the lesion cannot be radically treated, so the indication relies on whether ventilation is significantly reduced and the patient's quality of life is impaired. If the airway lumen is not quite as compromised, laser resection may be delayed or not be necessary.

When occluding endobronchial growth tumors consist of a significant extraluminal or parenchymal component, or if there is mediastinal invasion (frequently with rapid growth) that results in dysventilation-related symptoms, laser-assisted resection under rigid bronchoscopy is often unsuccessful beyond the very short term. In fact, although the endoluminal growing component may be initially successfully removed, the natural progression involves recurrence of the occlusion due to continued growth of the part that cannot be treated endoscopically, to such a degree to result in compression from the outside or even



representation at the endoluminal level. Usually, the way to control this type of evolution is to place an endotracheal or endobronchial stent, safeguarding the patency of the airway for a longer period of time than a simple resection allows. Thus, laser treatment should be considered as a means to gain the minimal patency preservable by stenting or, if the extra-luminal component is merely and immediately outside the bronchi, to reduce the lesion as much as possible before approaching it by brachytherapy. Pure extrinsic compression, instead, is a major contraindication for endoscopic laser treatment.

One of the major indications for laser treatment is the development of hemoptysis due to bleeding from particularly vascularized endoluminal lesions, regardless of their histological type, location, or impact on ventilation. Resectability is not a determining factor in these cases, nor is it often possible due to the nature of the lesion and its anatomical relationships, but laser-assisted coagulation allows to control the hemoptysis leading not only to an improvement from a clinical standpoint, but also from the patient's emotional point of view given the burden it often represents.

Furthermore, at the very least in every of the aforementioned conditions endoscopic resection allows a precise assessment of the extent of the tumor, thereby widening the treatment possibilities of previously ill-defined lesions and possibly allowing lung-spare resections or shifting to surgery patients originally considered to be inoperable [24].

When treatments only have a palliative role, laser-assisted endoscopic resection plays a fundamental role in preparing the patient for radiotherapy or chemotherapy: in fact, it has been shown that these approaches have little effect on the endoluminal growth of a tumor, especially after airway patency has been completely compromised [9, 10]. Combining endobronchial laser therapy with other palliative therapies is therefore recommended and can be extremely advantageous. The addition of radiotherapy is particularly useful either by external beam radiation or endobronchial brachytherapy. If indicated, laser resection should be performed before radiother-

apy in order to improve the patient's functional status by restoring and adequate airflow throughout at least the main airways. Similar therapeutic algorithms for the management of central airway neoplastic obstructions have been described by different authors [25–27].

### **Tumors with Uncertain Prognosis**

Lung tumors of uncertain prognosis consist of numerous histologic types characterized by slow growth and rare tendency to metastasize; the most common and well-known lesions among this group include carcinoid tumors, adenoid-cystic carcinomas, and mucoepidermoid. Within each histological definition tumors with different degrees of malignancy are represented, as in the case of typical and atypical carcinoids. The higher the proliferation index and therefore the degree of malignancy of the lesion, the less effective may be the endoscopic laser-assisted resection for the reasons described above. Consequently, the indications in these cases of major evolution are comparable to those of malignant tumors, including regarding combined therapies for palliative purposes or better definition before surgical procedures.

On the contrary, tumors with a low degree of malignancy and especially lesions with well-defined implantation base as target of laser therapy constitute a group comparable to benign lesions, often allowing radicality of the local treatment: in these cases laser-assisted mechanical resection may be totally curative [28, 29]. The main examples are typical carcinoid tumors, lung neoplasms with low biological aggressiveness that originate from neoplastic degeneration of Kultschitzky cells of the bronchoalveolar Amine Precursor Uptake and Decarboxylation system (APUD) and are part of the differentiation spectrum of thoracic neuroendocrine tumors together with the faster proliferating atypical lung carcinoid, large cell carcinoma and small cell carcinoma or microcitoma. Typical carcinoid tumors can be considered somewhat benign lesions: they usually have an exclusively endoluminal growth with a narrow, well targetable base, with polyp-

oid evolution. Attention must be paid, however, to the possibility that a typical carcinoid produces serotonin or cortisol, and that its treatment can trigger symptoms such as skin flushing, watery diarrhea, heart palp, cognitive disorders (serotonergic syndrome).

Not to be confused are atypical carcinoids, which deeply infiltrate the bronchial wall and produce an appearance similar to the bronchogenic carcinoma: radicality should not be expected when resecting this kind of neoplasm, as reoccurrence is often an issue to deal with in the following months leading to the need for close endoscopic monitoring and possibly repeated resections.

## Inflammatory Disease

Finally, airway obstruction due to inhaled foreign bodies or inflammatory diseases may also be an indication to endoscopic treatment with laser resection. This vast group includes airway narrowing due to granulation tissue, intubation injuries or post-radiation-, lung-transplantation-, post-resection and tracheal resection anastomosis, benign exophytic disease with either mucosal infiltration or circumferential narrowing due to granulomatosis with polyangiitis (formerly called Wegener's granulomatosis), amyloidosis, tuberculosis, or endometriosis [30].

While patients carrying inflammatory airway strictures due to causes other than infection should always be considered for open surgical resection [4, 5], the development of endobronchial treatments has changed the way we approach patients who develop dyspnea due to inflammation-based airway lumen restrictions [18, 31]. Immediate laser-assisted recanalization should always be considered the first-choice option in painfully symptomatic and progressive close stenosis which pose a risk of death to the patient: the objective is not only to restore an adequate flow within the airways, but also to avoid the execution of urgent tracheostomies with all the risks related to the surgical procedure, its management and its possible future weaning. The emergency condition therefore represents a major indication for rigid laser-assisted

bronchoscopy, regardless of the etiology of the stenosis that determines it as the endoscopic procedure constitutes the most quickly performed, symptom-relieving option. Once the emergency has been handled, then, the best therapeutic strategy can be found electively.

Oftentimes, when dealing with slow developing stenosis without acute ventilation threats, endoscopic therapy should be considered as an alternative to open surgery when the latter is contraindicated. Anyway, at the very least an endoscopic assessment of every surgically treatable stenosis should be carried out in order to identify its entity, allowing for better handling of the pre-operative symptoms and for better identification of the surgical edges. Once surgery has been performed, complications may arise determining long-term restenosis such as granulomas or structural failure due to phlogosis of the anastomosis site, but also short-term complications such as fibrin formation. Where there is no indication to repeat surgery, restenosis can be effectively treated endoscopically: in some selected simple stenoses like fibrin formation, web-like stenosis or stenosis without cartilage involvement stable good results can be achieved after laser-assisted mechanical resection and surgery could no longer be necessary [31–33].

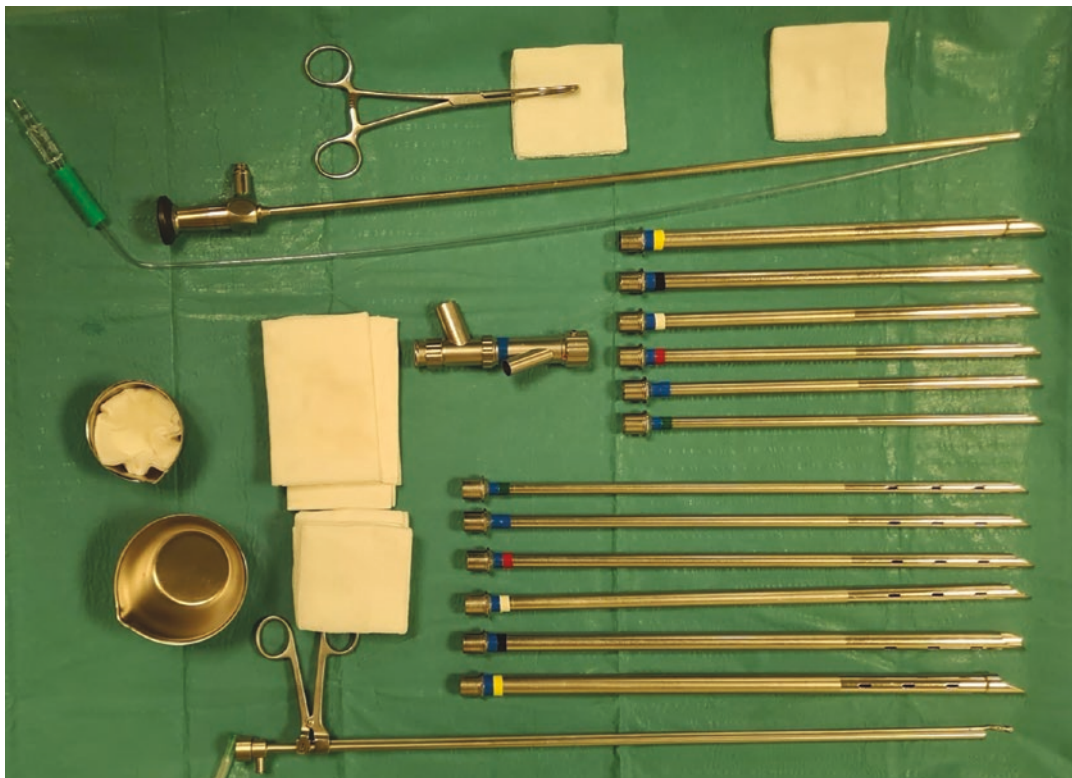
---

## Description of the Equipment Needed

The instrumentation required to set up an endoscopy room for interventional pneumology is relatively simple. It consists of rigid tracheoscope and bronchoscope, rigid optics, forceps to mount on the optics, rigid suction tubes, laser fibers, accessories for loading, and releasing endobronchial stents.

The rigid bronchoscope consists of a metal tube, the proximal end of which allows the insertion of the necessary instrumentation and the distal end of which is flute beak shaped to facilitate debulking maneuvers (Fig. 11.5).

Bronchoscopes and tracheoscopes differ mainly in length and their choice depends on the site to be treated and the type of lesion



**Fig. 11.5** Rigid bronchoscopy equipment. This set consists of tracheoscopes and bronchoscopes in a range of calibers to allow mechanical resection and progressive dilatation, rigid forceps, rigid suction tubes

(debulking vs. dilatation vs. prosthesis placement). Bronchoscope instruments of different calibers allow progressive dilatation. The forceps mounted on the optics, the suction probe, and the laser fiber can be used in all instruments of the appropriate caliber.

The rigid optics encapsulate the light source. This made it possible to remove the light rod from the bronchoscope and improve its caliber.

The clamps load onto the optics allowing direct vision of the instrument and the site of use.

Another fundamental instrument is the rigid aspirator which, in addition to aspirating, is a true exploration and recanalization tool.

The word LASER is the acronym of Light Amplification of Stimulated Emission of Radiation. The main components of a laser are the laser cavity, the pumped material and the pumping system. The cavity is a reflecting cylin-

dric camera with mirrors at each extremity, one of which is partially reflective. When, inside the camera, an active substance is electrically or optically stimulated, it spontaneously emits photons which are reflected by the mirrors through the active substance itself producing new photons with the same wavelength (and energy) and direction. The result of this stimulated radiation is a laser beam. The wavelength depends on the nature of the active material that is stimulated. For example, Nd:YAG laser emits in the infrared range at 1.064 nm.

The main characteristics of a laser beam are:

- coherence (the waves emitted are in phase),
- collimation (the waves are parallel to each other) and,
- monochromatic (the waves are all of the same length).

These properties allow concentration, without loss of power, of the laser beam on a small target. When using laser, one should always have a precise knowledge of a few physical aspects:

- Laser Power is the power released by the laser machine and can be exclusively regulated through the laser equipment. It is measured in Watts (W).
- Laser Power = Watts (W)
- Laser Energy is affected by the time of exposition in a physically determined manner:
- Laser Energy (Joule) = Power (Watts) × time (sec)
- Laser Power Density is strongly dependent on the extension of the impact surface.
- Power Density (Watts/cm<sup>2</sup>) = Laser Power (Watts)/surface (cm<sup>2</sup>).

Releasing high power density can cut and vaporize living tissue. A lower power density laser can rather coagulate tissue determining necrosis or hemostasis without loss of substance. The interaction between laser and living tissues also depends on many other factors, such as wavelength, distance from fiber to target, angle of incidence, color of impact surface, exposure time, absorption and penetration in depth of the radiation. The thermal effects are the best known and the most used.

With regard to temperature, below 50 °C we obtain tissue necrosis and inflammation, at a higher temperature vaporization is observed. Power density is inversely proportional to square distance. Penetration, which is inversely proportional to absorption, depends on the frequency of the radiation, tissue color and its vascularization. There are many types of biomedical lasers, including the carbon dioxide (CO<sub>2</sub>) laser, the neodymium-yttrium-aluminum-garnet (Nd:YAG) laser, neodymium-yttrium-aluminum-perovskite (Nd:YAP) laser, argon ion laser, excimer laser, potassium titanyl phosphate (KTP) laser, alexandrite laser, diode lasers, pulsed dye lasers, and the most recent Thulium laser.

CO<sub>2</sub> laser was the first laser used in bronchoscopy. It is invisible (10.600 nm in infrared range) and is transmitted to the tissue through an articu-

late arm composed of mirrors. These characteristics limit its application in bronchial endoscopy. Biologically, tissue vaporization is precise and efficient because of low penetration in depth; yet low penetration determines poor hemostasis.

The laser that is most commonly used for bronchoscopic laser resection is the Nd:YAG laser. Its energy is delivered through flexible quartz fibers that are inserted through either a rigid or flexible bronchoscope. The wavelength of this laser (1064 nm) is invisible; thus, a red helium-neon beam is used to indicate where the laser energy will be applied. It delivers sufficient power to vaporize tissue, also producing a good coagulating effect. The active substance is a crystal of Yttrium-Aluminum-Garnet doped with Neodyme. A 1320 nm Nd:YAG laser is also available with greater cutting and vaporization effects, especially in low vascularized tissues with high water content.

Coagulation and vaporization are produced by a thermal effect which is not limited to the tissue surface: the laser beam can be transmitted as deep as 1 cm. This radiation is differently absorbed by tissues, depending on the color of the surface and laser power density. The beam can pass through a pale and low vascularized tissue without a visible effect but it will be absorbed by a dark surface limiting penetration in depth.

Diode laser is a newly conceived laser exploiting a semiconductor diode technology. When electrical current passes through a diode, it emits a laser radiation. Diode technology reduces problems related to the laser cavity complexity, allowing the design of portable, compact and high-power air-cooled lasers. It is available in different wavelengths (808, 940, 980, and 1470 nm). The 808 and 940 nm are exclusively absorbed by hemoglobin. This laser is very useful for treating highly vascularized tissues, but absolutely indolent if fired on a white surface. The 980 and 1470 nm are also well absorbed by water, so very effective when treating white tissues too.

Nd:YAP laser: the active substance is Yttrium-Aluminum-Perovskite, with a wavelength of 1.340 nm, which is absorbed by water 20 times more than the 1.064 nm of the Nd:YAG, thus

providing a better effectiveness/power ratio. Coagulation is particularly good.

Thulium laser has recently been considered for endobronchial application. The 2  $\mu\text{m}$  wavelength emitted by Cyber TM (Thulium) laser is strongly absorbed by water resulting in an outstanding coagulation and aero-hemostatic effects with preservation of the surrounding tissue. Since 2- $\mu\text{m}$  laser wavelength is strongly absorbed by water which is ubiquitous in all tissues, the speed of cutting and vaporizing will remain relatively constant regardless of tissue vascularization. Energy from the Thulium Laser penetrates only a fraction of millimeter in the tissue, with a high degree of control and substantially reduced risk of inadvertent injury.

In practice, the ideal laser in bronchoscopy should be transmissible by fiber, safe, easy to set-up and use, cheap, and portable. It should produce many and sometimes opposite specific effects: excellent coagulation so as to control bleeding and different resecting modes according to clinical occurrence. For cicatricial stenosis, mainly post-intubation tracheal stenosis, lasers should be as precise as a scalpel to spare the surrounding tissues; on the contrary, for endoluminal neoplastic masses, a vaporizing effect on large volumes is needed. More important, high penetration of energy without loss of substance, producing deep thermal damage and consequently a cytotoxic effect, is required to treat the tumor base in depth and delay (malignant tumors) or even prevent recurrences. This is the principle for cure in benign, strictly endoluminal tumors, typical carcinoids, carcinoma in situ, and early cancers. All these characteristics do not perfectly coexist in the same laser, so the interventional pulmonologist has to choose the best compromise or use more than one tool.

---

## Application of the Technique

Mechanical resection with a biopsy forceps or the distal tip of a rigid bronchoscope entails a high risk of bleeding and usually, if successful, provides only short-lasting results. Bronchoscopic laser therapy, more than cryotherapy or electro-

surgery, is the most useful technique for treating tracheobronchial obstruction [28].

Despite some authors using laser with the flexible bronchoscope with limited safety and efficacy, most bronchoscopic laser resections will be performed via rigid bronchoscopy in the operating room or endoscopy suite equipped for general anesthesia [28–30]. In fact, laser therapy normally integrates rigid bronchoscopic mechanical resection; this procedure is known worldwide as Laser Assisted Mechanical Resection (LAMR) and represents the safest and more effective way to obtain all potential effects of laser in bronchoscopy. LAMR is performed using general anesthesia, the patient's oxygenation and ventilation are supported through the rigid bronchoscope by spontaneous-assisted ventilation or jet ventilation [14, 24, 34]. Intermittent Negative Pressure Ventilation applied to the chest wall through a poncho or cuirass has shown to prevent intraoperative apneas and respiratory acidosis in non-paralyzed patients. In paralyzed patients it allows opioid sparing, shortened recovery time, prevents respiratory acidosis, reduces the need for manually assisted ventilation and the amount of  $\text{O}_2$  required, while maintaining optimal surgical condition [35]. Also, muscle relaxants and paralytic agents can be helpful during general anesthesia because they prevent cough during resection and they facilitate insertion of the rigid bronchoscope.

Laser treatment requires well trained teamwork with a bronchoscopist, an anesthesiologist experienced with interventional pulmonology techniques and airway management, an endoscopy nurse familiar with the equipment, and a second endoscopy nurse who assists the bronchoscopist and controls the laser settings. General anesthesia is comfortable for both the patient and the operator, it allows maximal control of ventilation, optimal visualization of the lesions, and immediate management of complications. Ideal anesthetic agents allow spontaneous ventilation with maximum suppression of the cough reflex. They should be rapidly eliminated or readily reversible so that the patient can be rapidly awakened at the end of the procedure and postoperative mechanical ventilation or Non-Invasive



Ventilation (NIV) can be avoided. Regardless of the type of anesthesia, the interventional pulmonologist and the anesthesiologist need to work in close agreement throughout the procedure, adapting to mutual needs.

For endobronchial tumors, which represent the most common indication for laser treatments, the use of a rigid bronchoscope is crucial since tumor mass removal is mechanically performed. Rigid suction tubes and the laser fiber are simultaneously passed through the rigid bronchoscope as its working channel is wide enough to ensure ventilation. In this setting Laser is more efficiently used to coagulate the endoluminal mass before the mechanical resection to avoid or reduce bleeding. Simultaneous coagulation of a bleeding site with laser and suction of blood and clots is most important when dealing with an airway hemorrhage. The flexible bronchoscope can be passed through a rigid bronchoscope for treating cancer in the upper lobe bronchi or to reach a distal implantation base of the tumor in order to treat it in depth and delay recurrences or to achieve cure in case of benign tumors, selected typical carcinoids, early cancers, and carcinoma in situ [36].

The four main effect laser can produce are Coagulation, Resection, Vaporization, and Incision (Table 11.1).

Laser Resection is generally facilitated by the use of the rigid scope in the so-called Laser Assisted Mechanical Resection already mentioned before. It follows Laser Coagulation which involves directing the laser at the target lesion, devitalizing the lesion via photocoagulation of the feeding blood vessels, so that the devitalized tissue can be more easily removed with the beveled edge of the bronchoscope, forceps, or suction minimizing the risk of bleeding. Coagulation is possible because the laser penetrates tissue to a depth of up to 10 mm in an inverted cone fashion and provides reliable photocoagulation at this depth. Its power density can be altered by moving the laser closer to or farther from the target tissue. Laser Vaporization is possible because energy from the laser is relatively well absorbed by water. It involves aligning the laser parallel to the bronchial wall and aiming at the edge of the

**Table 11.1** Laser Techniques

Techniques		
Laser vaporization	Flexible bronchoscope	Up to 90% of cases. Time consuming but can be effective
	Rigid bronchoscope	Rare; for control of bleeding and vaporization of tumor remnants after mechanical resection
Laser resection	Rigid bronchoscope (LAMR)	To reduce risk of bleeding during tumor debulking
Laser coagulation	Rigid bronchoscope	To prevent bleeding before mechanical resection
		To treat implant base in depth (up to 5 mm) and delay recurrence
Radial incision	Flexible/rigid	Performed to reduce tension of cicatricial stenoses (before dilation if rigid scope is used)

intraluminal lesion (the laser should never be discharged perpendicular to the airway wall because of an increased risk of perforation). It can also be performed through the flexible scope; in this setting laser pulses of only 1 s or less are used to vaporize the tissue to prevent thermal injury to the scope and airways. On the contrary, when performed in rigid bronchoscopy, laser can be used for longer periods of time reaching higher temperatures with higher power densities. This is possible because laser debris and smokes can be effectively suctioned by the suction tube inserted through the scope minimizing the risk of injury. Laser vaporization applied using a fiberoptic bronchoscope should be limited to small non-bleeding lesions, to refine and complete treatments previously performed with the rigid scope and, through a tracheal tube, for treating neoplasms in the upper lobe bronchi, in distal locations and for distal tracheobronchial toilette.

The channel of the rigid bronchoscope is wide enough to ensure ventilation and passage of telescopes, suction tubes, and the laser fiber. Simultaneous laser coagulation of a bleeding site and suction of blood and clots is very important

when dealing with airway hemorrhage. In addition, the rigid bronchoscope allows mechanical resection of polypoid tumors, previously coagulated with laser, which saves considerable time over laser vaporization. For all these reasons most bronchoscopists prefer rigid bronchoscopy, although a flexible bronchoscope is to be available if the airway abnormality is within a distal segmental bronchus and also to remove blood and debris from the distal airways. In the treatment of cicatricial tracheal stenosis (e.g., post-intubation web-like stenosis), laser is used in contact mode to perform radial incisions before a mechanical dilatation is obtained with rigid bronchoscopes of progressive caliber. The radial incisions permit to reduce tension with minimum heating of the adjoining tissue thus limiting recurrence [37–39]. Other authors described a different technique with repeated small radial incisions in contact mode through the flexible bronchoscope [40].

Several types of lasers have been used in the airway, including CO<sub>2</sub> and argon but the commonest in use today is neodymium: yttrium, aluminum, garnet (Nd:YAG).

Nd:YAG via a flexible quartz fiber is currently the laser best suited for use in bronchology because it has sufficient power to vaporize tissue while also producing an excellent coagulating effect. It penetrates deeper into tissues than CO<sub>2</sub> and argon and its wavelength is less absorbed by hemoglobin. Nd:YAG effects on living tissues are significantly higher than those visible: power setting and pulse duration determine the volume of ablation [12]. A proposed technique for laser treatment of endobronchial tumors consists in initial low power Nd:YAG laser firing (<30 W) to coagulate the tumor followed by removal of the endoluminal portion of the lesion with the tip of the rigid bronchoscope, the biopsy forceps and the suction tube. High power settings (50–60 W) are then employed to vaporize the residual endoluminal tumor. Vaporization is easily performed on dark tissue with high power density and using fiber close to pathological tissue. When destruction effects begin tissue became dark and vaporization local effect increase. At the end of the procedure, the base of the lesion is exposed to

low power settings with long pulses (20–30 W for 4–5 s; 2000 J/cm<sup>2</sup>) to obtain a cytotoxic effect in depth within the airway wall. Dark colored tissues (e.g., charred or hemorrhagic tissue) and large lesions require special consideration. With respect to dark tissues, laser coagulation in depth is limited because the dark color enhances tissue absorption, limits deep tissue penetration, and reduces deep photocoagulation. To avoid charring and vaporization due to radiation absorption on the surface and to obtain coagulation in depth, the laser fiber must be kept at a sufficient distance from the tumor surface and directed a little bit more tangentially to the bronchial wall, thus obtaining, because of the divergence of the beam, an increase of the diameter of the spot and therefore a reduction of the power density. Not only distance and laser position are aspects to consider: tissue radiation for 10–15 s in the same position could determine a “popcorn like effect” with tissue explosion. For this reason, it’s important to use laser discontinuously, especially if not experienced, reducing risk of excessive heating.

Firing with laser in full tumor is not advisable. It is time-consuming and uselessly risky to reduce the whole endoluminal mass by charring and vaporizing it with laser. Bronchoscopic laser resection should only be performed by bronchoscopists who have advanced training and experience. Bronchoscopists and team members should remain familiar with techniques, potential complications, and necessary precautions [41]. To minimize the risk of combustion fraction of inspired oxygen should be kept below 40% during laser firing [42]. Power settings should not exceed the maximum recommended for the laser being used (60 Watts for the Nd:YAG laser), flammable materials (including silicone stents) should be kept far away from the operating field. Adequate suction must be available to remove the combustible laser plume (the smoke caused by vaporization of tissues) [43]. If a flexible bronchoscope is employed, the laser must be kept at a sufficient distance beyond the tip of the bronchoscope.

Video systems allow all personnel to observe the procedure, which makes it easier for assistants to anticipate the needs of the bronchoscopi-

pist and the patient. Many bronchoscopic laser resection procedures are performed in less than 1 h [44].

---

## Evidence Based Review

Bronchoscopic laser resection appears to be a quick and safe method to relieve airway obstruction due to invasive lung cancer; this applies to both primary and secondary lung cancer [45]. In fact, in literature multiple studies have been carried out in order to investigate the safety and feasibility of this procedure.

A large case series including more than 2000 laser resections in 1838 patients with malignant airway obstruction showed that airway patency improved and symptoms were palliated in over 90% of patients [24]; rigid bronchoscope was used in 92% of the treatments, almost always performed under general anesthesia, whereas the fiberoptic bronchoscope alone was used in less than 10% of the cases. In 93% of the patients affected by endobronchial malignant obstruction, Nd:YAG laser therapy allowed to obtain the patency of the central airways, avoiding the most distressing and invalidating symptoms of the disease (such as dyspnea and respiratory failure), therefore enhancing the patient's quality of life.

The location and macroscopic appearance of the lesion play a crucial role in determining the success of the procedure: when the trachea and/or the main bronchi were invaded and obstructed by the tumor, almost every patient reported immediate results (>95%). The median time between the first and second palliative treatment was 102 days, whereas mortality was <1% within 7 days of the procedure, making it a safe procedure.

In literature smaller studies have reported similar results [14], whereas in a larger series of patients death occurred in only 15 out of 5049 procedures (0.3%), whereas severe complications occurred in 119 out of 5049 patients (2.4%) [46].

In another series, including 38 typical carcinoids and more than 150 benign tumors, laser therapy was considered curative; in all these

lesions, the base of the tumor could be easily reached by the bronchoscope, especially in endoluminal polypoid tumors, when coagulation of the tumor and mechanical resection was possible. These procedures were followed by a systematic treatment of the base of the tumor with low power setting and long exposure time, in order to avoid tissue loss, yet obtaining a deep cytotoxic effect on the mucosa. Overall mortality rate was 0.25% [47].

In benign stenosis and particularly in post-intubation tracheal stenosis, it has been observed that laser-assisted mechanical dilation can guarantee cure in up to two-thirds of the cases; this value raised to 100% when only cicatricial web-like stenosis are considered [11].

Complications of bronchoscopic laser resection are infrequent, and include a wide range of clinical manifestations: hypoxia, hemorrhage, airway wall perforation, airway wall necrosis, and fistula formation. Hypoxia, whether due to the use of general anesthetics or to major bleeding, can lead to irreversible cardiovascular complications and thus must be corrected promptly by bleeding suction and ventilation control. Adequate control of hemorrhage and ventilation, which are fundamental, can only be assured with the rigid bronchoscope. Other possible complications include perforation of the airway: in these cases, due to the air leak, it is possible to observe mediastinal emphysema, pneumothorax, and infection. Luckily, perforation of the airway is unlikely if the procedure is performed by experienced endoscopists who are familiar with rigid bronchoscopy. Airway fires, although extremely rare, have been reported, particularly when flexible fiberoptic instruments are used. Furthermore, arterial air embolism has been rarely reported as a complication of bronchoscopic laser resection. Studies of continuous transesophageal echocardiographic monitoring during rigid bronchoscopy laser treatment suggest that air emboli may be caused by coolant gas (this gas exits the bronchoscope under high flow and pressure conditions in order to cool the laser probe), entering the pulmonary venules and gaining access to the systemic circulation [48]. The incidence of this complication may be reduced by maintaining the

laser fiber coolant airflow at the minimum level and avoiding direct contact between the laser probe and the airway tissue.

## Summary and Recommendations

- Bronchoscopic laser resection has to be considered as a part of a more complete treatment called “Laser Assisted Mechanical Resection/Dilation—LAMR/LAMD). It is rapid, effective, repeatable, and may be complementary to other therapies.
- Bronchoscopic LAMR/D is used to relieve malignant or benign intraluminal airway obstruction. It has no role when the obstruction is caused by sole extrinsic compression.
- In malignant stenosis LAMR consists of—firstly laser coagulation, then mechanical resection, finally low power laser treatment in depth of the implantation base.
- The type of laser that is most commonly used for LAMR is the neodymium-yttrium-aluminum-garnet (Nd:YAG) laser. It relieves airway obstruction by either resecting or vaporizing the obstructing lesion.
- Bronchoscopic laser resection should only be performed by bronchoscopists who have advanced training and experience.
- Complications are infrequent but they include hemorrhage, airway wall perforation, airway wall necrosis, fistula formation, and air embolism.

## References

1. Gorden JA, Ernst A. Endoscopic management of central airway obstruction. *Semin Thorac Cardiovasc Surg.* 2009;21(3):263–73.
2. Ernst A, Feller-Kopman D, Becker HD, Mehta AC. Central airway obstruction. *Am J Respir Crit Care Med.* 2004;169:1278.
3. Murgu SD, Egressy K, Laxmanan B, et al. Central airway obstruction: benign strictures, tracheobronchomalacia, and malignancy-related obstruction. *Chest.* 2016;150(2):426–41.
4. Ernst A, Silvestri GA, Johnstone D, American College of Chest Physicians. *Interventional pulmonary proce-*

*dures: guidelines from the American College of Chest Physicians.* *Chest.* 2003;123:1693.

5. Bolliger CT, Mathur PN, Beamis JF, et al. ERS/ATS statement on interventional pulmonology. *European Respiratory Society/American Thoracic Society.* *Eur Respir J.* 2002;19:356.
6. Stephens KE Jr, Wood DE. Bronchoscopic management of central airway obstruction. *J Thorac Cardiovasc Surg.* 2000;119:289.
7. Seijo LM, Serman DH. *Interventional pulmonology.* *N Engl J Med.* 2001;344:740.
8. Minna JD, Higgins GA, Glaistein EJ. Cancer of the lung. In: De Vita VT, Hellman S, Rosenberg SA, editors. *Cancer principles and practice of oncology.* Philadelphia: JB Lippincott; 1989. p. 591–705.
9. Chetty KG, Moran EM, Sassoon CSF, et al. Effect of radiation therapy on bronchial obstruction due to bronchogenic carcinoma. *Chest.* 1989;95:582–4.
10. Hazuca MB, Bunn PA. Controversies in the treatment of stage III non small cell cancer (state of the art). *Am Rev Respir Dis.* 1992;145:967–77.
11. Cavaliere S, Bezzi M, Toninelli C. Management of post-intubation tracheal stenoses using the endoscopic approach. *Monaldi Arch Chest Dis.* 2007 Jun;67(2):73–80.
12. Williamson JP, Phillips MJ, Hillman DR, Eastwood PR. Managing obstruction of the central airways. *Intern Med J.* 2010;40(6):399–410.
13. Duhamel DR, Harrell JH 2nd. Laser bronchoscopy. *Chest Surg Clin N Am.* 2001;11:769.
14. Ramser ER, Beamis JF Jr. Laser bronchoscopy. *Clin Chest Med.* 1995;16:415.
15. Zollner F. Gustav Killian: father of bronchoscopy. *Arch Otolaryngol.* 1965;82:656–9.
16. Jackson C. *The life of chevalier Jackson—an autobiography,* vol. 106. New York: Macmillan; 1938.
17. Marasso A, Gallo E, Massaglia GM, et al. Cryosurgery in bronchoscopic treatment of tracheobronchial stenosis. Indications, limits, personal experience. *Chest.* 1993;103:472–4.
18. Dumon JF, Reboud E, Garbe L, et al. Treatment of tracheobronchial lesions by laser photoresection. *Chest.* 1982;81:278–84.
19. Kvale PA, Selecky PA, Prakash UB, American College of Chest Physicians. *Palliative care in lung cancer: ACCP evidence-based clinical practice guidelines* (2nd edition). *Chest.* 2007;132:368S.
20. Wahidi MM, Herth FJ, Ernst A. State of the art: interventional pulmonology. *Chest.* 2007;131:261.
21. Daddi G, Puma F, Avenia N, et al. Resection with curative intent after endoscopic treatment of airway obstruction. *Ann Thorac Surg.* 1998;65:203.
22. Mehta AC, Golish JA, Ahmad M, et al. Palliative treatment of malignant airway obstruction by Nd-YAG laser. *Cleve Clin Q.* 1985;52:513.
23. Carlin BW, Harrell JH, Olsen LK, Moser KM. Endobronchial metastases due to colorectal carcinoma. *Chest.* 1989;96:1110.

24. Cavaliere S, Venuta F, Foccoli P, et al. Endoscopic treatment of malignant airway obstruction in 2,008 patients. *Chest*. 1996;110:1536–42.
25. Bolliger CT. Combined treatment modalities in lung cancer. In: Rigid bronchoscopy meeting, Marseille; 1994. p. 177–87.
26. Vergnon JM. Which treatment for inoperable obstructive lung cancer?. In: Transatlantic interventional pulmonology course. Marseille; 1996. p. 109–21.
27. Casalini A, Cavaliere S, Consigli GF, et al. Standard operativi e linee guida in endoscopia toracica. *Rass Pat App Resp*. 1997;12:314–29.
28. Cavaliere S, Beamis J. Endoscopic views-laser. In: Cavaliere S, Beamis J, editors. Atlas of therapeutic bronchoscopy, laser–stents. Brescia: RIBeL; 1991. p. 45.
29. Sutedja TG, Schreurs AJ, Vanderschueren RG, et al. Bronchoscopic therapy in patients with intraluminal typical bronchial carcinoid. *Chest*. 1995;107:556–8.
30. Puma F, Carloni A, Casucci G, et al. Successful endoscopic Nd-YAG laser treatment of endobronchial endometriosis. *Chest*. 2003;124:1168.
31. Grillo HC, Donahue DM. Post intubation tracheal stenosis. *Semin Thorac Cardiovasc Surg*. 1996;8:370–80.
32. Foccoli P, Scappaticci E, Rea F. Monaldi Arch Chest Dis. 2011;75(1):82–5. Management of post-intubation and/or tracheotomy tracheal stenoses.
33. Strausz J. Management of postintubation tracheal stenosis with stent implantation. *J Bronchol Interv*. 1997;4:294–6.
34. Morice RC, Ece T, Ece F, Keus L. Endobronchial argon plasma coagulation for treatment of hemoptysis and neoplastic airway obstruction. *Chest*. 2001;119:781.
35. Natalini G, Cavaliere S, Seramondi V, Foccoli P, Vitacca M, Ambrosino N, Candiani A. Negative pressure ventilation vs external high-frequency oscillation during rigid bronchoscopy. A controlled randomized trial. *Chest*. 2000;118(1):18–23.
36. Dumon JF, Cavaliere S. Manuale di laserterapia endotracheobronchiale. Edizioni Clas International s.r.l.
37. Shapshay SM, et al. Endoscopic treatment of subglottic and tracheal stenosis by radial laser incision and dilatation. *Ann Otol Rhinol Laryngol*. 1987;96:661–4.
38. Metha AC, Fyw L, Cordasco EM, Eliachar I, De Boer G. Concentric tracheal and subglottic stenosis: management using the Nd-YAG laser for mucosal sparing followed by gentle dilatation. *Chest*. 1993;104:673–7.
39. Baugnee PE, Marquette CH, Ramon P, et al. Endoscopic treatment of post-intubation tracheal stenosis. A review of 58 cases. *Rev Mal Respir*. 1995;12:585–92.
40. Perrone R. Treatment of post intubation stenosis with neodymium-YAG contact laser by flexible endoscopy and topical anesthesia: instrumentation and results. *J Bronchol Interv*. 1996;3:252.
41. Dumon JF. Technique of safe laser surgery. *Lasers Med Sci*. 1990;5:171.
42. Scherer TA. Nd-YAG laser ignition of silicone endobronchial stents. *Chest*. 2000;117:1449.
43. Ossoff RH, Duncavage JA, Eisenman TS, Karlan MS. Comparison of tracheal damage from laser-ignited endotracheal tube fires. *Ann Otol Rhinol Laryngol*. 1983;92:333.
44. Personne C, Colchen A, Bonnette P, et al. Laser in bronchology: methods of application. *Lung*. 1990;168(Suppl):1085.
45. Uğur Chousein EG, Turan D, Özgül MA, Çetinkaya E. Secondary pulmonary malignancies requiring interventional bronchoscopic procedures. *Turk Gogus Kalp Damar Cerrahisi Derg*. 2021;29(3):360–9. <https://doi.org/10.5606/tgkdc.dergisi.2021.19927>.
46. Cavaliere F, Dumon JF. Laser bronchoscopy. In: Bollinger CT, Mathur PN, editors. Interventional bronchoscopy. Basel: Karger AG; 2000. p. 108.
47. Cavaliere S, Foccoli P, Farina PL. Nd:YAG laser bronchoscopy. A five-year experience with 1,396 applications in 1,000 patients. *Chest*. 1988;94(1):15–21.
48. Tellides G, Ugurlu BS, Kim RW, Hammond GL. Pathogenesis of systemic air embolism during bronchoscopic Nd:YAG laser operations. *Ann Thorac Surg*. 1998;65:930.





## Introduction

Endobronchial cryotherapy refers to the use of freezing temperatures inside the airway, with the help of flexible cryoprobe or cryospray. While using cryoprobe, the cryogen is recirculated in the probe catheter and never released endobronchially. Spray cryotherapy (SCT), however, involves direct application of cryogen and hence its release inside the tracheobronchial tree. There are several uses for cryoprobes such as diagnostic biopsies and therapeutic interventions that work on two primary principles, that is, cryoadhesion and cryoablation.

Cryoablation refers to adherence of target tissue to the tip of cryoprobe due to rapid freezing of fluid in the interface and inside the tissue. This principle is used for retrieving endobronchial tissue including tumor and granulation tissue for diagnostic purposes as well as for intent of mechanical debulking. Some foreign bodies are also retrieved by using cryoadhesion and can lead

to avoidance of rigid bronchoscopy. Finally, pulmonary parenchyma can also be adhered to tip of cryoprobe for a transbronchial cryobiopsy and has diagnostic applications for diffuse parenchymal lung disease and peripheral lung nodules.

Cryoablation refers to the tissue destruction induced by crystallization of intracellular water content and disruption of cell membrane upon freezing. A chain of events ensue, eventually leading to cell death and necrosis with resultant “slow” debulking of endobronchial tumors [1]. This effect of cryotherapy is also referred to as “Cold ablation” or cryodevitalization.

## Historical Perspective

The word “Cryo” originates from the Greek word “kruos” and when translated to English means “ice cold” or “frost.” The cryoprobe was initially devised for neurosurgical application [2]. The first use of cryotherapy in an endobronchial application was described in 1968 by Gage in the form of a rigid cryoprobe applicator on an endobronchial tumor [3]. It worked on the principle of using extreme cold in a rapid “freeze and thaw cycle” to incite cell death and cause tumor destruction [3, 4]. The advent of flexible cryotherapy probes in 1994 (ERBE Elektromedizin GmbH, Tübingen, Germany) led to widespread utilization of this technology, which now constitutes as the most common method of endobron-

---

E. Josan  
The Ohio State University Hospital,  
Columbus, OH, USA

The University of Tennessee Medical Center,  
Knoxville, TN, USA  
e-mail: [ejosan@utmck.edu](mailto:ejosan@utmck.edu)

J. Pannu  
The Ohio State University Hospital,  
Columbus, OH, USA  
e-mail: [jasleen.pannu@osumc.edu](mailto:jasleen.pannu@osumc.edu)

chial application [5]. This is in part due to the ease of application via either the flexible or rigid bronchoscope.

Spray cryotherapy was first described for endoscopic use in the esophagus in 1999 [6]. Several endobronchial applications have been explored since then for cryoablation for airway stenosis and an investigational utility in chronic bronchitis.

## Equipment

The two essential components of cryotherapy include the cryogen and the delivery device.

The cryogen or the cooling agent is a liquified gas stored in a tank under pressure. The cryogen when applied in the form of cryoprobe or

cryospray incites the freezing of tissue for the desired effect. The gases used for probe cryotherapy include nitrous oxide ( $N_2O$ ), carbon dioxide ( $CO_2$ ) and for spray cryotherapy include liquid nitrogen ( $N_2$ ) [1, 7].

The delivery device includes three things:

1. The tank in which the cryogen is saved.
2. The console and the foot paddle for a controlled release of the cryogen by the proceduralist.
3. The probe or catheter delivers the cryogen to the desired target.

There are two vastly used ERBE probe cryotherapy systems. The previous generation console ERBOKRYO® CA (ERBE Elektromedizin GmbH, Tübingen, Germany) has an analogue

**Fig. 12.1** Title: Cryotherapy Equipment. Description: (a) shows the old generation ERBOKRYO® CA unit. (b) Shows the Erbe pulmonology workstation that includes the newer generation ERBECRYO® 2 console. (Image© Erbe Elektromedizin GmbH)



switch and basic controls. It uses a foot paddle with a light indicator for when the device is activated. It also has an analog manometer that shows the pressure of gas, usually 45–50 bar (Fig. 12.1a). This machine uses N<sub>2</sub>O or CO<sub>2</sub> with reusable cryoprobes and is not in production anymore.




**Fig. 12.2** Title: ERBECRYO® 2 console. Description: The newer generation cryotherapy console has a digital display. It has a broader functionality and the ability to select effect level and presets for application. (Image© Erbe Elektromedizin GmbH)

The newer generation ERBECRYO® 2 (ERBE Elektromedizin GmbH, Tübingen, Germany) uses CO<sub>2</sub> gas and has a digital display with a broader functionality (Fig. 12.2). Although it has similar clinical functionality, it has different presets for the user, including cryoablation, cryobiopsy, and free freeze option. It also shows the timer, effect level, and information on cryoprobe which is automatically detected by the console. This equipment is available as a stand-alone device or as a part of the Erbe pulmonology workstation (Erbe Elektromedizin GmbH, Tübingen, Germany) which combines units for electrosurgery, Argon plasma coagulation, and cryosurgery (Fig. 12.1b).

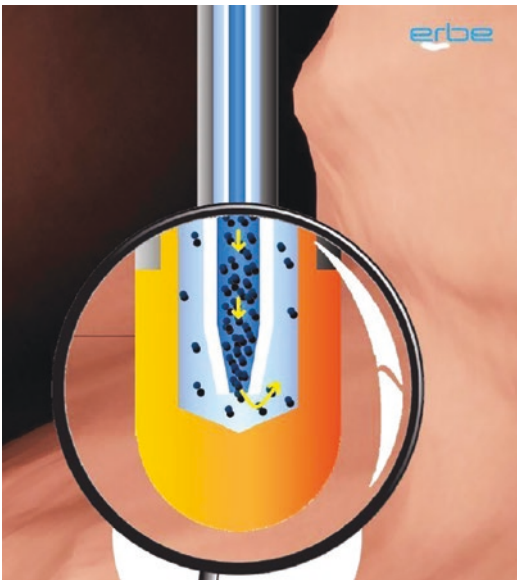
Flexible cryoprobes consist of a long-insulated catheter with a blunt metal tip and can be passed through a flexible bronchoscope for endobronchial utilization. The reusable cryoprobes are not in production anymore but still in use at some centers with the previous generation ERBOKRYO® CA console. They are 78–90 cm in length and

**Fig. 12.3** Title: Cryoprobes. Description: (a) shows the reusable cryoprobe that is compatible with ERBOKRYO® CA console and is available in 1.9 mm and 2.4 mm size. (b) Shows the single use cryoprobes that are compatible with ERBECRYO® 2 and available in 1.1 mm, 1.7 mm and 2.4 mm size. (Image© Erbe Elektromedizin GmbH)



are available in 1.9 and 2.4 mm size (Fig. 12.3a), for use with a minimum working channel of 2.0 and 2.8 mm, respectively [1]. The tip of the reusable cryoprobe is approximately 6 mm in length [7, 8]. The single use cryoprobes are exclusively used with ERBECRYO® 2 console and are developed to overcome technical limitations with miniaturization as well as to better ensure reproducibility. These disposable cryoprobes also overcome the risk of cross-contamination that can be an area of concern with reusable probes [9]. They are 115 cm in length and available in 1.1 mm, 1.7 mm and 2.4 mm (Fig. 12.3b), for use with a minimum working channel of 1.2, 2.0, and 2.8 mm, respectively [7].

Rigid cryoprobes are also available as straight or right-angled tip and may have a reheating system to allow rapid thawing. They are 60 cm in length with a 3 mm diameter and 9.2 mm cooling tip [1]. The equipment for spray cryotherapy is described in a separate section in the later part of this chapter.



**Fig. 12.4** Title: Joule-Thompson Effect. Description: Cryogen is released from the tank in a controlled fashion. It travels through the inner channel and is forced to pass through the nozzle at tip of the cryoprobe. The relaxation gather energy and cools down the surrounding region leading to a freezing effect. (Image© Erbe Elektromedizin GmbH)

## Mechanism of Action

The freezing effect of probe cryotherapy is based on the Joule-Thompson effect (Fig. 12.4). The pressurized cryogen gas from the cylinder (either carbon dioxide or nitrous oxide) is forced through the narrow inner channel of the flexible cryoprobe to the tip of the probe. After passing the internal nozzle, the pressurized gas suddenly decompresses and cools. The relaxation of cryogen gathers energy from the surrounding area and cools down to the freezing temperature of the gas ( $-78.5^{\circ}\text{C}$  for  $\text{CO}_2$  and  $-89^{\circ}\text{C}$  for  $\text{N}_2\text{O}$ ) to incite freezing of tissue in contact with the tip of the probe [4]. Since it is a closed system, the cryogen does not come in direct contact with the tissue. The decompressed gas is then returned to the console via the external channel of cryoprobe which then dissipates into the surrounding atmosphere. In contrast, spray cryotherapy directly applies the liquid nitrogen to endobronchial tissue leading to a flash freeze. While the freezing temperature of  $\text{CO}_2$  is  $-78.5^{\circ}\text{C}$  [4], the value can be reduced via the cryotherapy system to achieve temperatures between  $-35^{\circ}\text{C}$  and  $-50^{\circ}\text{C}$  at the tip of the probe which is required for an effective cell death in neoplastic tissue [7, 10].

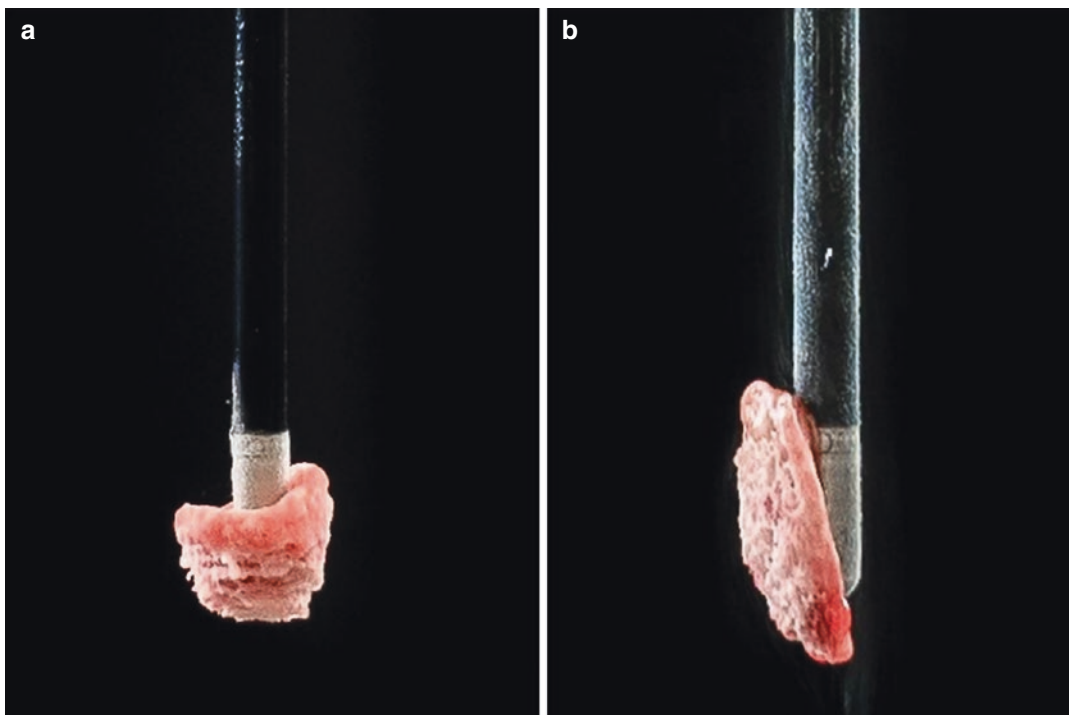
## Techniques and Application

The tissue effects of cryotherapy can be broadly classified into two categories based upon the underlying principle.

1. Cryoadhesion uses the strong adherence of cryoprobe and target tissue.
2. Cryoablation uses intracellular cell death from rapid freezing.

## Cryoaddhesion

Cryoaddhesion works on the principle of freezing the fluid between the tip of the cryoprobe and the target as well as the fluid within the target. This leads to the formation of ice crystals and adheres



**Fig. 12.5** Title: Cryoadhesion. Description: The target tissue can be adhered to the cryoprobe with either a “frontal” approach that leads to circumferential application (a)

or the “lateral” approach that can adhere a longer segment (b). (Image© Erbe Elektromedizin GmbH)

the two surfaces together. This effect can be used with either a frontal or tangential approach (Fig. 12.5) to remove blood clots, extract foreign bodies, obtain endobronchial or transbronchial tissue biopsies, and recanalize the airway by extracting endobronchial tumors [7].

This cryoadhesive effect is dependent on the size of the frozen area which is in turn affected by the freeze time, contact area, moisture level, tissue/foreign body properties, the cylinder pressure, and ambient temperature of the environment [7]. Freeze time is the easiest to control by the operator. There is rapid freezing in the first 5 seconds following which the effect is gradually weaned due to freezing around the probe tip and thermal equilibrium which dissipates the surrounding heat to the frozen probe tip [7]. The freeze time can be controlled by allocating a preset or by pressing the pedal for longer period in the “free freeze” preset. The contact area is determined by the diameter of the probe tip with larger freezing effect exerted by the larger probe. The

1.7, 1.9, and 2.4 mm probes are adequate for both endobronchial and transbronchial use.

Moisture between the tip and target as well within the target plays a vital role for cryoadhesion. An organic material with good water content such as lung tissue, tumor, or a porous foreign body is more likely to freeze on contact with cryoprobe in comparison to an inorganic object such as metallic or plastic foreign body. Different body tissues respond differently to cryotherapy with some tissues being sensitive due to their water content (e.g., tumor, granulation tissue, mucus membrane). On the other hand, some tissues are resistant to effect of cryotherapy (e.g., cartilage, fat, connective tissue and fat). Therefore, the tracheobronchial wall which is mainly composed of fibrocartilaginous structure is less likely to be damaged from the effects of repeated application of cryotherapy, while a tumor attached to this wall will be affected significantly [1]. The ambient temperature of the working environment has a direct effect on the



pressure in the cryogen cylinder which can affect the performance of the machine. High environmental temperature can lead to high cylinder pressure which affects the evaporation pressure of liquid CO<sub>2</sub>. While a high pressure can be compensated by the machine, the low pressure can lead to poor freezing. Newer devices can alert the user of such issues [7].

### Indications

The flexible cryotherapy probes are widely used upon the principle of cryoadhesion. The effect is useful for recanalization of central airway obstruction (whether malignant or benign); a tangential biopsy of infiltrating tumors, devitalizing tissue; removal of blood clots or foreign body; and for transbronchial biopsy in interstitial lung disease or peripheral lung nodules [9, 11]. The use of cryotherapy for these purposes of tumor debulking, endobronchial cryobiopsy, and cryorecanalization is endorsed by British thoracic society [12] and American College of Chest Physicians [13].

Cryotherapy is often used in conjunction with thermal therapies such as electrocautery, laser, argon plasma coagulation, balloon dilation, and airway stenting to restore and maintain airway patency. Unlike thermal therapy, it is safe to use with higher oxygen concentration and the preferred therapy when low fraction of inspired oxygen (FiO<sub>2</sub>) cannot be tolerated by the patient. It is also safer to use around combustible substances such as stents and endotracheal tubes. Moreover, it does not interfere with cardiac pacemakers or implanted defibrillators unlike electrical therapy [1].

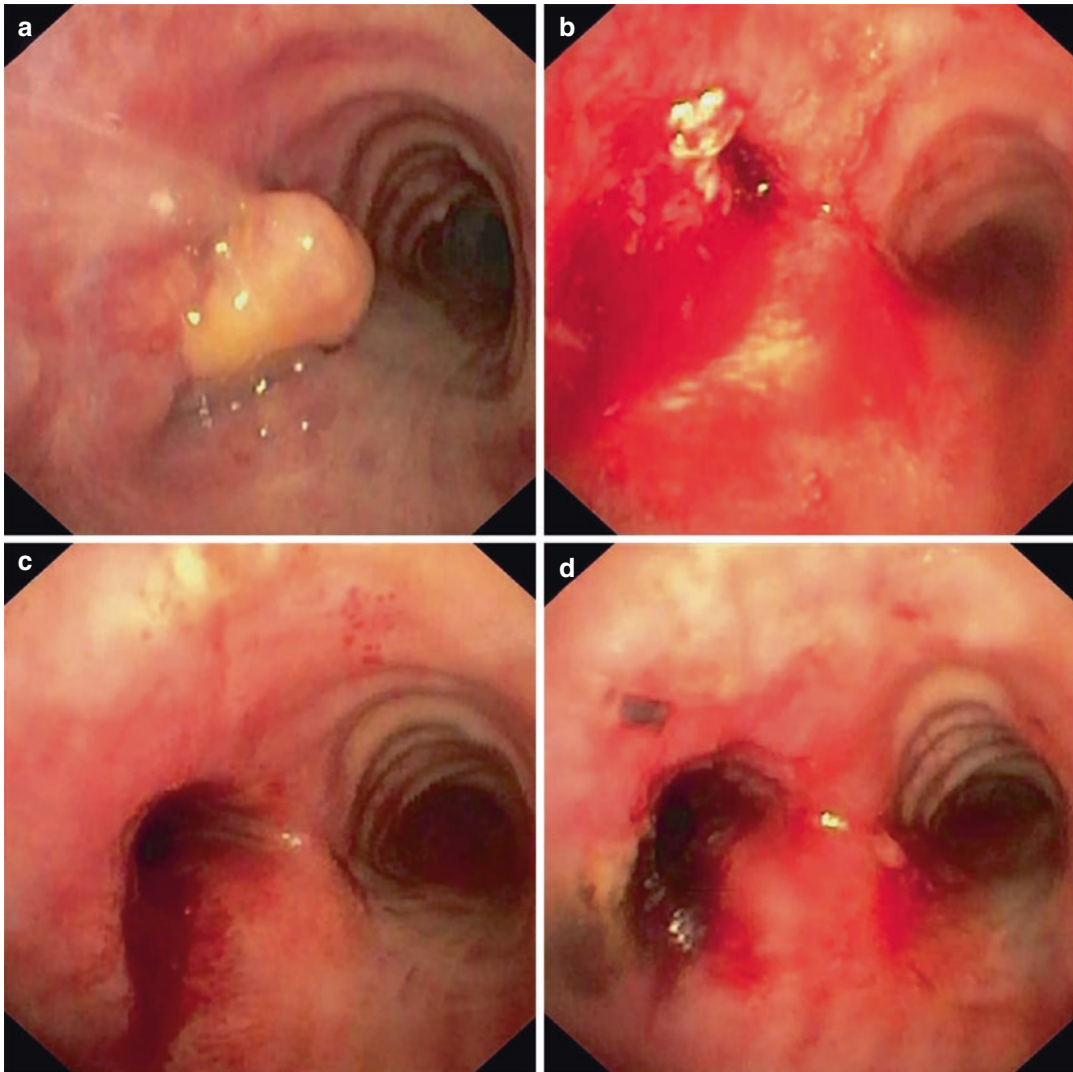
### Cryorecanalization

Patient with endobronchial tumor and airway obstruction can benefit from endoscopic debulking if the airway and parenchyma distal to this obstruction are salvageable. The principle of cryoadhesion can be used to remove exophytic endoluminal tumor or granulation tissue for an immediate effect on airway patency. The cryoprobe is activated on contact with target tissue for 3–15 seconds to incite cryoadhesion followed by a rapid pull with the intent of removing large

pieces of tissue (Fig. 12.6). Since the debulked tissue is too large for working channel of bronchoscope, the probe is removed en-bloc and thawed in saline [14]. The bronchoscope should be quickly reinserted to assess any bleeding from the site. For a central tumor, any size cryoprobe can be used depending on the intended size of tissue fragments. Typically, the larger probes (1.7, 1.9, and 2.4 mm) are utilized for central cryodebulking due to larger size effects which lead to more efficient tumor removal and recanalization and yield larger tissue fragments for pathological testing [7]. This method is safe and effective for rapid debulking of endobronchial tumor and restores airway patency more rapidly than its counterpart cryodevitalization.

The goal of cryorecanalization (also referred to as cryodebulking) is to improve the patient's performance status and survival even if they are not eligible for surgical treatment [12]. The overall efficacy of cryorecanalization in symptom palliation is reported in 70–90% patients [14]. The largest analysis on cryorecanalization by Maiwand et al. ( $n = 476$ ) reported a mean of 2.4 cryosurgical treatments in malignant endobronchial tumors. The study reported that 86% had improvement in  $\geq 1$  symptoms (hemoptysis, cough, dyspnea, and chest pain). The mean Karnofsky score improved from 59.6 to 75.2 and the average increase in Forced expiratory volume in the first second (FEV1) and Forced Vital Capacity (FVC) was 90 and 130 mL, respectively [14, 15].

In addition, Schumann et al. ( $n = 225$ ) described the use of cryorecanalization in symptomatic airway stenosis and noted a 91.1% success rate. In this retrospective analysis, length of lesion more than 2 cm was associated with unsuccessful intervention. Adjunctive modalities such as stent (4.9%) or APC (16.4%) were used infrequently [16]. Another retrospective analysis by Inaty et al. ( $n = 156$ ) reported restoration of airway patency in 95% patients with improvement in respiratory symptoms noted in 82% of symptomatic patients. Adjunctive modalities such as mechanical debridement (51%) and thermal therapy (EC 30%, APC 17%) were used much more frequently in this study. They noted cryotherapy



**Fig. 12.6** Title: Cryorecanalization. Description: (a) shows a necrotic tumor in left mainstem orifice resulting in complete obstruction. (b) Shows the effect of partial removal of this tumor using cryodebulking technique. (c) Shows the result of complete cryorecanalization with res-

toration of patency of left mainstem bronchus. (d) Shows a follow up bronchoscopy at 4 weeks. (Images courtesy of Dr. Nicholas Pastis, The Ohio State University Hospital, Columbus, Ohio)

was most efficacious in treating central airway lesion [17]. A smaller prospective study by Hetzel et al. ( $n = 60$ ) reported successful recanalization in 83% out of which 61% had complete and 22% had partial improvement in patency [5]. Another small study by Yilmaz et al. ( $n = 40$ ) reported successful cryorecanalization in 72.5% patients. They also reported that the success rate was related to the presence of the distal involvement and the older age of obstruction [18].

### Cryoadhesion and Foreign Body Removal

Foreign body aspiration is common in children younger than 3 years old and in adults after sixth decade of life. Flexible bronchoscopy has gained significant experience with various apparatuses available for endobronchial use. It has therefore replaced rigid bronchoscopy as a less invasive alternative [19]. When flexible bronchoscopy

fails to perform, a cryoprobe can be used by adhering the aspirated object to the tip of the cryoprobe [1]. There are several case reports that describe the use of cryotherapy for this particular application for removal of chewing gums, mucus plugs, aspirated food material, etc. [1].

In a small in vitro study, it was noted that most organic objects (such as aspirated food, clots, and mucus plugs) are retrievable, while some nonporous objects (such as teeth or bones) and inorganic objects (such as metallic paper clips) are not easily adherent to the cryoprobe. The study highlights the ease of use as well as the variability in the application of cryotherapy for foreign body removal and recommends an external test to confirm the target object will be adherent to the tip of the probe [20]. The use, however, can be limited by lack of equipment and absence of experience in using the technology [21]. The use of cryotherapy for retrieval of foreign bodies can therefore be reserved as a second-line interventions or to avoid rigid bronchoscopy depending upon the nature of the foreign body.

### **Cryo-adhesion and Mucus Plugs/Blood Clot Retrieval**

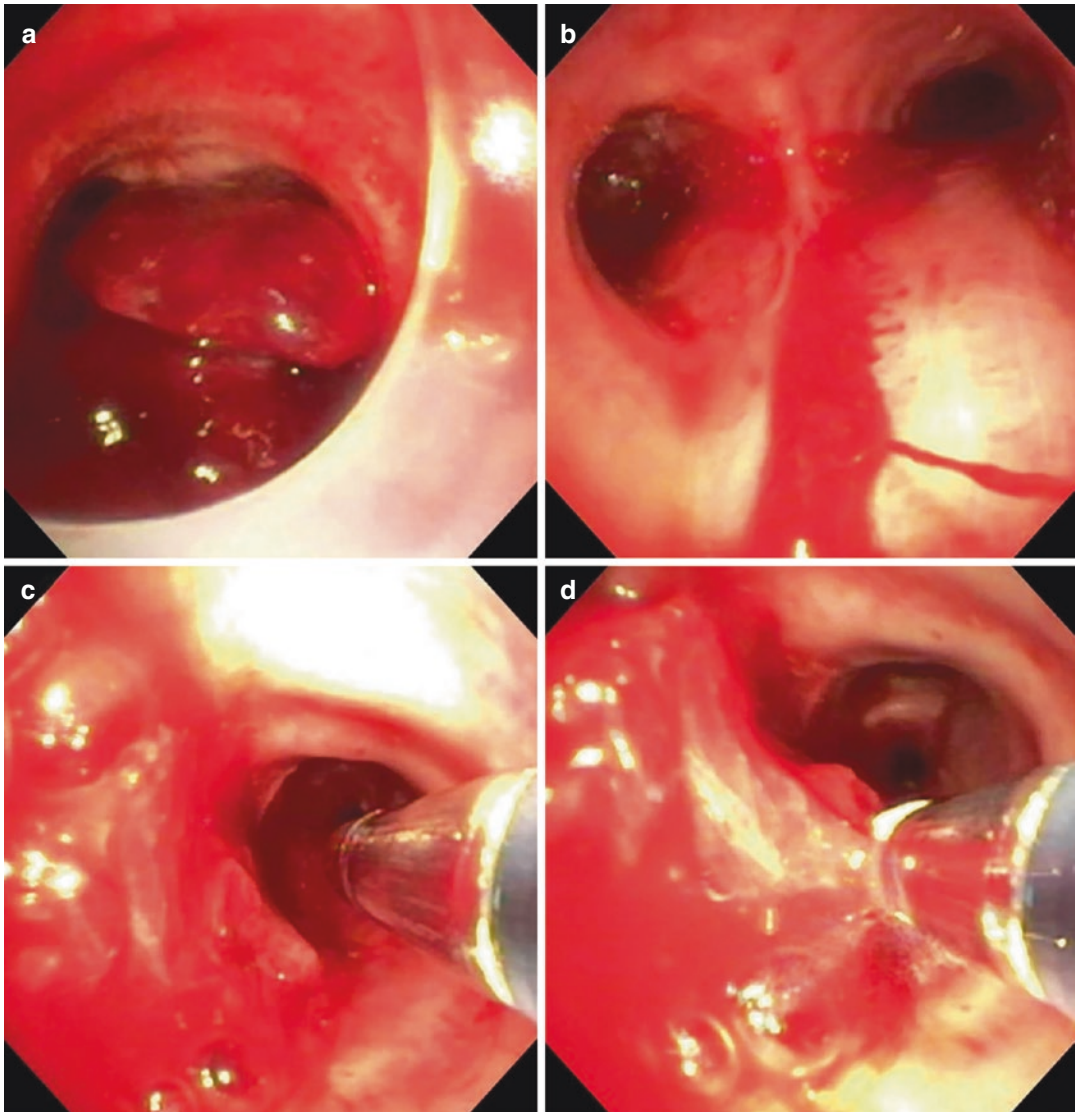
Massive airway bleeding and subsequent blood clot formation can lead to life-threatening airway obstruction. The ensuing loss of ventilation and oxygenation calls for immediate recanalization. Several conditions can predispose a critically ill patient to massive hemoptysis, e.g., bronchiectasis, cystic fibrosis, tuberculosis, malignancy, post-biopsy, and pathologic or iatrogenic coagulopathy (e.g., during extracorporeal membrane oxygenation). Traditionally rigid bronchoscopy has been recommended as it permits use of larger instruments for suction. However, it requires technical equipment and adequate training. Flexible bronchoscopy has emerged as a less complicated alternative and has almost replaced rigid bronchoscopy for this indication. A large bore “therapeutic” bronchoscope can effectively remove large blood clots by using powerful suctioning. In addition, flexible forceps can be used for large adherent clots.

Cryotherapy has been well described for the removal of extensive clot burden in tracheobronchial tree. It is especially helpful to remove fragile clots that would otherwise break into smaller fragments while using forceps. In addition, large clots that are adherent to the bronchial wall can be difficult to remove with the suction force of the bronchoscope alone. Cryoextraction is very successful in these cases as either an en-bloc or piecemeal removal (Fig. 12.7). A single-center retrospective review by Narin et al. ( $n = 38$ ) reviewed efficacy of cryoprobe extraction and reported 92% overall success in the subgroup of blood clots [22]. Another review by Schmidt et al. ( $n = 16$ ) evaluated the efficacy of cryoextraction in critically ill patients with 68.8% patients on ECMO (extracorporeal membrane oxygenation). They noted successful application in 56.2%; however, repeat cryoextraction was needed in 56% [23].

### **Endobronchial Cryobiopsy**

A frozen tissue sample from a central or peripheral tumor and even the pathological lung parenchyma can be removed with the intent for further histopathological sampling. The underlying principle uses cryoadhesion to extract the targeted specimen, wherein the removed fragment is frozen in contact with the tip of the cryoprobe [7].

To obtain a cryobiopsy, the probe is advanced through the working channel of flexible bronchoscope into the bronchus. A short freezing cycle of 3–5 seconds is activated to freeze the target tissue surrounding the probe tip. The duration of freeze is variable and depends on the cryosurgical unit, the cryogen, and the probe size. A pre-biopsy freeze ball test is helpful to determine the freeze duration. It is performed by dipping the tip of cryoprobe in water and observing the time needed to form the desired ice ball which correlates with the size of harvested specimen. After the desired time of freezing, both the flexible bronchoscope and cryoprobe are swiftly removed as a unit since the harvested specimens are too large for working channel of the bronchoscope (Fig. 12.8). This maneuver also prevents any damage to the working channel from the frozen tip of the cryoprobe [24]. After removal, the biopsy specimen at tip of



**Fig. 12.7** Title: Cryotherapy for blood clot removal. Description: Fig. A shows a large saddle clot in distal trachea extending into bilateral mainstem. Fig. B shows the restoration of central airway patency after removal of this clot with cryotherapy. Fig. C and D shows the technique

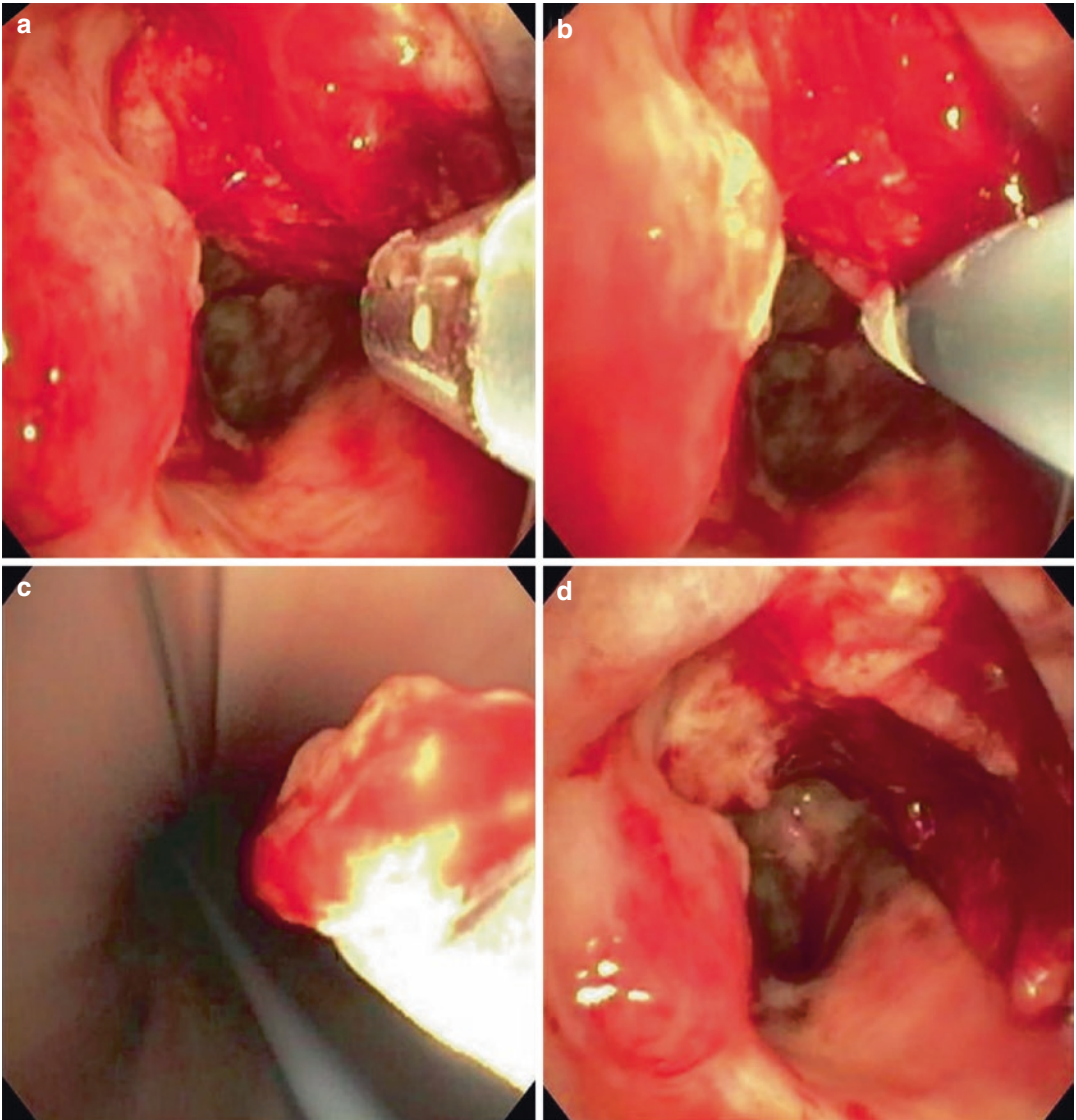
with application of cryoprobe tip to large clot in left mainstem and subsequent adherence on freezing that facilitates its removal. (Images courtesy of Dr. Christian Ghattas, The Ohio State University Hospital, Columbus, Ohio)

cryoprobe is thawed in normal saline and collected in an appropriate medium such as neutral 10% buffered formalin. The bronchoscope is quickly reinserted to the site of biopsy to monitor for any post-biopsy bleeding.

Endobronchial cryobiopsy can be deemed superior to traditional forceps biopsy due to larger sample size and low biopsy-related tis-

sue alterations including crush artifact [24]. Conventional forceps-mediated endobronchial biopsy has a diagnostic yield of 72–88% [9]. A cryoprobe also allows wider angle of positioning including an almost tangential approach which can otherwise be a limiting factor with forceps. In addition, the size can be regulated by duration of freeze in contrast to using a different size for





**Fig. 12.8** Title: Endobronchial cryobiopsy. Description: Fig. A show an exophytic tumor in distal trachea. Fig. B shows the cryoprobe with lateral application to the tumor followed by rapid freeze. Fig. C shows the en-bloc removal and the retrieved tissue in endotracheal tube. Fig.

D shows the target site without signs of major bleeding and the defect in the tumor at the site of cryobiopsy. (Images courtesy of Dr. Alberto Revelo, The Ohio State University Hospital, Columbus, Ohio)

forceps [24]. Endobronchial cryobiopsy can be obtained in a wide array of lung cancers (either primary bronchogenic or metastatic), sarcoma, lymphoma, leiomyoma, chondroma, and carcinoid. Moreover, higher quality detection of both cytoplasmic and nuclear antigens has been noted in cryobiopsy specimens [4, 25]. It can also be

used for benign indications such as granuloma and endobronchial tuberculosis.

Hetzel et al. ( $n = 600$ ) coordinated a prospective randomized multicenter trial at 8 centers. Endobronchial cryobiopsy was noted to have 95% rate of diagnosis in comparison to 85.1% in conventional forceps biopsy ( $p < 0.001$ ) whilst having no difference in the incidence of significant



bleeding [24]. Schumann et al. ( $n = 296$ ) compared endobronchial cryobiopsy and forceps biopsy in the same patient in the first 55 patients and reported a higher diagnostic yield (89.1% vs. 65.5%,  $p < 0.05$ ) as well as significantly larger sized biopsies and artifact-free tissue sections for cryobiopsy compared with forceps biopsy ( $p < 0.0001$ ) [26]. In another study, El-Dahdouh et al. compared cryobiopsy to traditional forceps biopsy in the same patient; the former was noted to have lesser crushing and loss of architecture ( $p < 0.001$ ), larger diameter of sample (1.4 cm vs. 0.5 cm,  $p < 0.001$ ), and better diagnosis rate (100% vs. 80%). The rate of hemorrhage was not significantly different by either technique [27]. Similar results were noted in other studies comparing these two interventions [28]. The utility for obtaining a biopsy of flat mucosal lesions has been explored with improvement in mean volume and diagnostic yield [29]. The optimal number of endobronchial cryobiopsy has also been evaluated by Segmen et al. ( $n = 50$ ) with a significant difference noted till the second biopsy ( $p = 0.031$ ) and no additional value noted with third or fourth biopsy specimen [30]. Finally, Jabari et al. ( $n = 60$ ) reported that a 5 second freeze times yields a larger specimen in comparison to a 3 second freeze or forceps biopsy ( $p < 0.001$ ) [31].

The safety and efficacy of endobronchial cryobiopsy have been described in multiple studies. In the Schumann paper, the overall bleeding has been reported to 5.1% with mild bleeding in 11 cases (3.7%), moderate bleeding in 3 cases (1.0%), and severe bleeding in only 1 case (0.3%) [26]. The risk of bleeding doesn't appear to differ significantly between cryotherapy and mechanical forceps [24]. Although a longer freeze time is noted to procure larger specimens, it doesn't appear to have an impact on the bleeding frequency either [31].

### Transbronchial Cryobiopsy for Lung Cancer

Transbronchial lung cryobiopsy (TBLC) is commonly utilized for diagnosis of diffuse parenchymal lung disease. It may also offer a viable option for diagnosis of peripheral lung nodule where a complete characterization of tumor is required

(including molecular alterations). Forceps biopsy have a similar drawback with small sample size, crush artifact, and hemorrhage that can lower the quality of specimen and influence the histopathological analysis [9]. TBLC for diagnosis of lung cancer is at an early investigational phase and additional evidence is required to assess safety and efficacy.

A pilot study described the use of thin cryoprobe for peripheral ground glass opacities and noted diagnostic yield of 82.6–91.6% [9, 32]. In comparison, the radial endobronchial ultrasound (EBUS)-guided transbronchial needle aspiration (TBNA) has a yield between 46 and 86.7% [9]. The advantage of cryobiopsy arises from the large sample size and preserved lung architecture with surrounding areas of healthy tissue. This could lead to improved molecular targeted therapy and have a potential impact on management of non-small cell lung cancer.

The use of thin cryoprobe has also been described for sampling mediastinal lesions under the guidance of EBUS. A dual-center clinical trial compared transbronchial needle aspiration and mediastinal cryobiopsy guided by EBUS in the same patient. Prior to the mediastinal cryobiopsy, the airway wall was opened with an electrocautery needle knife. The study noted a significantly higher diagnostic yield with cryobiopsy (91.8 vs. 79.9%), although it was nonsignificant for common malignancies. A higher percentage of samples were noted to be adequate for molecular testing in cryobiopsy group (93.3% vs. 73.5%;  $p < 0.001$ ) [33].

### Safety Concerns and Contraindications

The contraindications of cryotherapy include general contraindication for bronchoscopy such as the inability to tolerate general anesthesia. A basic rule of safety while using cryoprobe for any endobronchial intervention is to monitor the site of application visually and control the movement of the cryoprobe tip whilst using the freeze function. It is not uncommon for a bystander airway wall to get accidentally adhered at the frozen tip leading to an inadvertent fixation. The best course of action here is to stop further freezing and let the tip thaw passively until the wall is released

from the tip. If a release is attempted at normal mucosal site before the tip is thawed, airway mucosal or wall injury and tear can happen with consequent bleeding or ulceration.

The risk of bleeding should be kept in consideration while pursuing cryorecanalization for it can lead to moderate bleeding with a risk as high as 4–25% [14]. Although the application of cryotherapy leads to vasoconstriction, its hemostatic effect is limited to the immediately adjacent area. The tumor-tissue interface is farther away from the cryoprobe tip and is more prone to bleeding due to neovascularization. Finally, cryotherapy has limited efficacy for removal of inorganic or metallic foreign bodies [20].

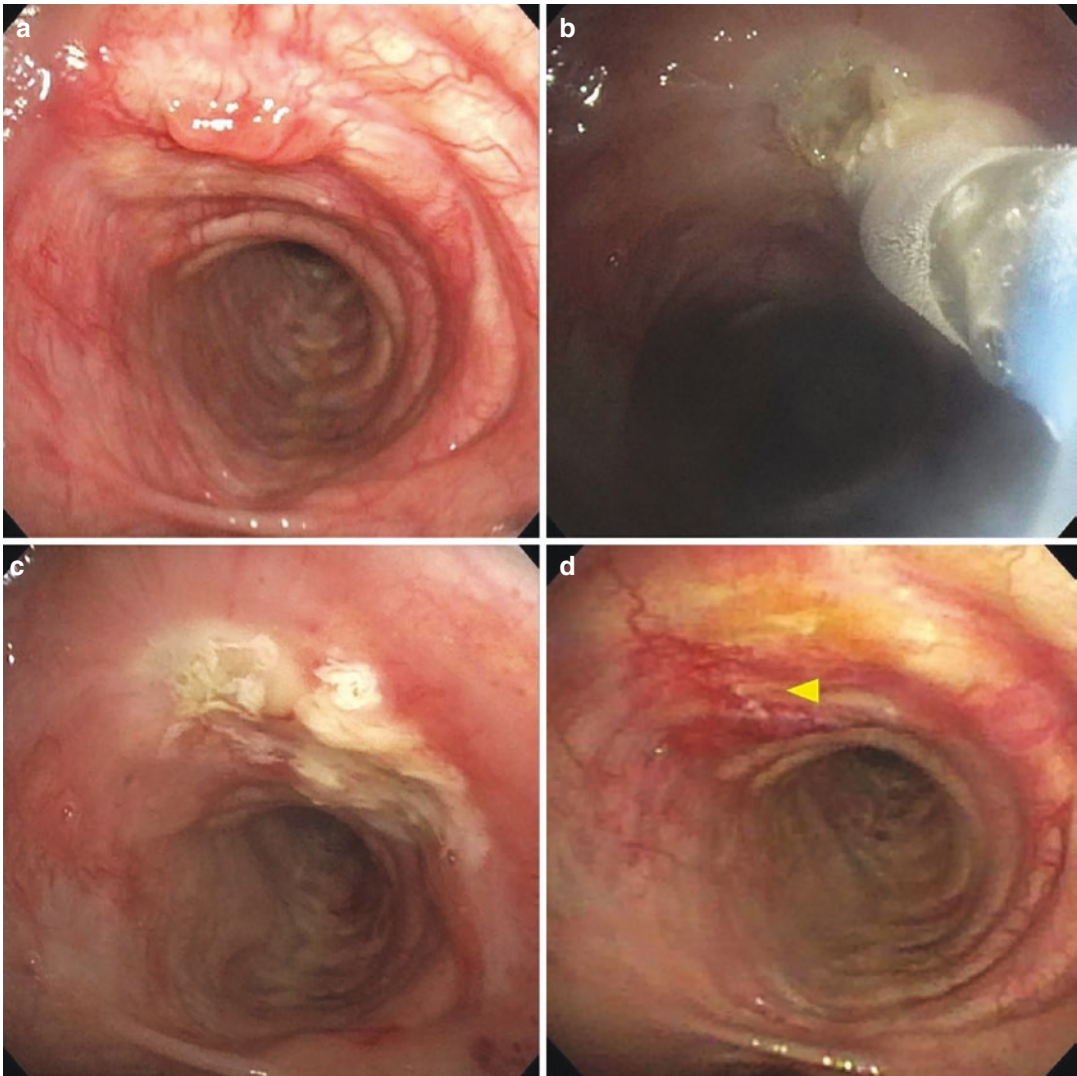
## Cryoablation

Cryoablation (also referred to as cryodevitalization) works by using the freezing temperatures to induce intracellular and extracellular ice crystal formation with repeated freeze-thaw cycles. This leads to cell death and enables tissue devitalization and necrosis [1]. This method of devitalization is also referred to as slow ablation and is not suitable for patients with critical airway stenosis and acute symptoms. Tissue destruction using cryoadhesion, mechanical measures (using rigid bronchoscope), or thermal therapy (laser, electrocautery, argon plasma coagulation, etc.) is more suited in those situations and can be combined with cryoablation for a tailored approach to central airway obstruction.

The technique for cryoablation is simple. The tip of cryoprobe is applied on the tumor for 10–30 seconds followed by a period of passive thawing (Fig. 12.9). Adjacent zones that are three to 5 mm apart are treated with slight overlap. A freeze-thaw cycle is usually repeated at least two–three times for effective tissue devitalization [14]. Although the freeze time is usually 10–30 seconds, longer times (up to 3 minutes) have been described in literature. However, some studies suggest that a shorter freeze time is just as effective for devitalization and a freeze time over 2 minutes is not necessary [7, 34].

The effect of cryotherapy on tissue can be subdivided into immediate (within an hour) and delayed (over hours to days). The immediate effect is due to the formation of ice crystals in both intracellular and extracellular compartments. This leads to direct cell injury from cell membrane damage and indirect cell death from intracellular organelle damage which further leads to intracellular hyperosmolarity, influx of water, and swelling of nucleus and cell itself leading to rupture [1, 10]. In addition, rapid cooling leads to vasoconstriction and loss of circulation. This is coupled with a vascular injury in thawing phase when the temperature rises back to baseline and restores circulation. This leads to an initial hyperemic response with increased capillary permeability, endothelial injury, and tissue edema. Subsequently, it leads to platelet and micro-thrombi formation and hyper-viscosity leading to loss of circulation in about an hour [1, 14]. The delayed effect of cryotherapy stems from further cell apoptosis promoted by ischemic injury and resultant cytokine release and immune-mediated mechanisms. This effect continues for oncoming hours to days and corresponds to the extent of frozen tissue. The most significant effect is at center of the freezing point and it blunts towards the periphery which contains a mixture of live and dead tissue. It is therefore important to pursue cryoablation at multiple sites on the target tissue for a more homogenous effect.

Cryoablation is affected by the tissue water content, coldest temperature, freeze time, the rate of cooling and thawing as well as the number of times the cycle is repeated. While a temperature of  $-10^{\circ}\text{C}$  initiates tissue death, a target lower than  $-35$ – $-50^{\circ}\text{C}$  is often required for effective devitalization [7, 10]. A fast rate of cooling and slow thawing is the prime destructive factor and leads to the most effective cell death [10]. The cooling rate of flexible cryoprobes is often over  $-1500^{\circ}\text{C}/\text{min}$  which is far more than the  $-10$  to  $-50^{\circ}\text{C}/\text{min}$  cooling rate necessary for ice crystallization in tissue. While thawing cannot be controlled directly, a slower (passive) thawing contributes to osmotic cell lysis by intracellular concentration of water [7].



**Fig. 12.9** Title: Cryoablation. Description: Fig. **a** shows a left mainstem endobronchial carcinoid tumor. Figure **b** shows the application of cryoablation therapy in repeated

freeze-thaw cycles. Figure **c** shows the mucosal changes at the site of lesion after cryoablation. Figure **d** shows the follow up bronchoscopy with resultant necrosis of lesion site

### Indications

Cryoablation can be used as an adjunctive therapy for endobronchial disease and is commonly used for both benign and malignant conditions. As mentioned earlier, it is a form of slow ablation and induces delayed tumor necrosis of endoluminal tissue into sloughed necrotic debris that may require a follow-up bronchoscopy for removal in 1–2 weeks [14]. Therefore, it is more suited for subacute airway stenosis where additional time can be afforded. Cryoablation is less commonly

used for non-malignant conditions or for inoperable microinvasive lung carcinoma. There is potentially a positive effect on bleeding due to vasoconstriction and hemostatic effect following cryoablation [23]. Application prior to mechanical debulking may benefit in minimizing the risk of bleeding.

### Evidence

The efficacy of contact probe cryotherapy with the intent of cryoablation has been evaluated in

multiple studies that have reported a successful restoration of airway patency and performance status in 60–90% cases with a synergistic effect from radiation and chemotherapy [14]. The early work from 1993 by Marasso et al. ( $n = 234$ ) using a 3.2 mm probe for a freeze time of 1–2 min repeated 2–3 times via a rigid bronchoscopy reported outcomes in 170 patients with malignant lesions. The use of cryotherapy led to improvement in dyspnea in 81% and reduction or resolution of hemoptysis in 93% in patients with malignant tumors [34]. Maiwand et al. ( $n = 153$ ) in a prospective study used temperatures of  $-70^{\circ}\text{C}$  to tumor site using a 2.2 or 5 mm cryoprobe via a rigid bronchoscope for two sessions of 3-min periods followed by a cleanup bronchoscopy (usually at 2 weeks). He reported a subjective symptomatic improvement for cough (68.3%), dyspnea (63.9%), hemoptysis (92.7%), and chest pain (55.5%). He also reported a mean increase in FEV1 by 110 cc, FVC by 90 cc, and Karnofsky performance status by 54.6% [35]. Another smaller study by Walsh et al. ( $n = 33$ ) reported improvement in overall symptoms, stridor, dyspnea, and hemoptysis. They also reported relief of obstruction in 77% by bronchoscopic assessment [36]. Mathur et al. ( $n = 20$ ) also reported complete removal of endobronchial component in 90% patients [37].

For benign disease, Mu et al. ( $n = 76$ ) reported the efficacy and safety of endobronchial cryotherapy as freeze-thaw cycles every 2 weeks for granular endobronchial tuberculosis. This retrospective study noted a complete removal of endobronchial lesions in 100% patient when endobronchial cryotherapy was used alongside anti-tuberculosis therapy in comparison to 78.9% in patients with anti-tuberculosis therapy alone. The study also noted a faster rate of disappearance in combined therapy [38].

### Safety Concerns and Contraindications

Contact probe cryotherapy is a relatively safe modality with minimal risks. It doesn't impose the fire risk of thermal therapy and is relatively easier to learn. In addition, it has almost no risk of airway perforation [39]. Still, the proceduralist must exercise care while activating cryoprobe

inside the airway. Any inadvertent contact to the tracheobronchial wall with an accidental tug can lead to significant mural injury. This requires caution, especially in pediatric patients due to smaller cross-section of the airways and softer cartilage.

Cryoablation is a slow form of ablation and not ideal for the management of acute airway obstruction. Cryodebulking if applicable can be pursued for a more rapid effect. Moreover, it is not helpful for extrinsic airway compression and is less effective for management of pauci-cellular lesions such as lipomas, fibrotic stenosis, postintubation strictures, and cartilaginous or bony lesion [1]. Airway edema is common after the application of cryotherapy due to resultant immune response from cell death [14]. Application to critical airway stenosis can initially lead to worsening symptoms due to narrowing from edema. In addition, necrotic sloughed up tissue can also cause airway obstruction.

### Cryospray

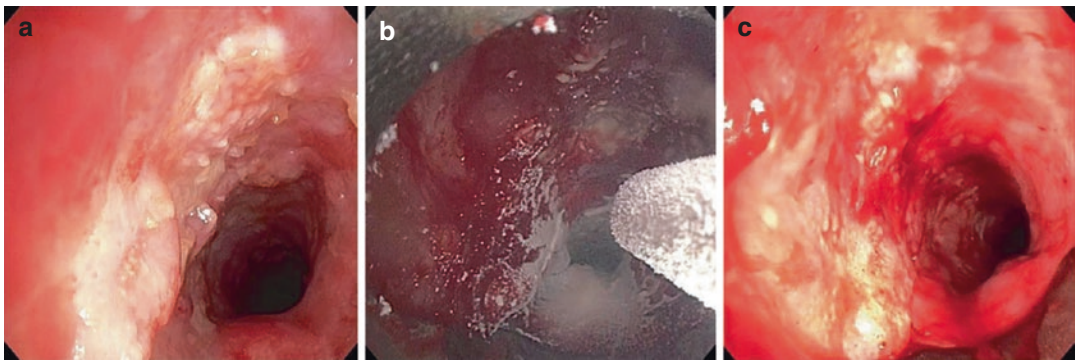
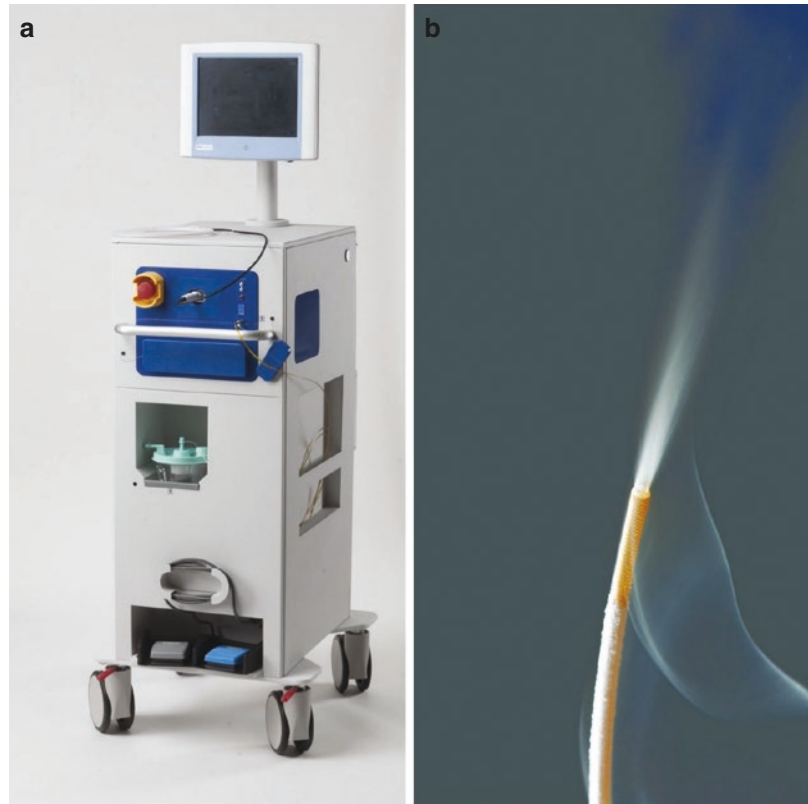
Spray cryotherapy (SCT) pertains to endobronchial application of medical-grade liquid nitrogen ( $\text{N}_2$ ) via a radial head catheter in a small, accurately directed, uniform spray in multiple locations inside the tracheobronchial tree. This allows for treating a relatively large area of irregular surface encountered in endobronchial disease. This direct application can yield temperatures as low as  $-196^{\circ}\text{C}$  by phase transformation of nitrogen from liquid to gas [1, 40]. It was initially developed for endoscopic use in esophagus and its utility in tracheobronchial tree was later explored in an animal study by Au et al. [40].

### Indications

The TruFreeze<sup>®</sup> system (Steris Endoscopy, Dublin, Ireland) received FDA approval in 2012 and is available for a multitude of benign and malignant etiologies such as tracheal stenosis, tumor destruction, hemostasis, post-lung transplant anastomotic strictures, and stent management. It can generate adjustable flow rates (12.5 and 25 watts) from the console and is delivered



**Fig. 12.10** Title: TruFreeze<sup>®</sup> system. Description: Fig. **a** shows the TruFreeze<sup>®</sup> system console. Figure **b** shows the Air PV<sup>™</sup> catheter for endobronchial application of spray cryotherapy. (Images courtesy of STERIS Endoscopy. Unauthorized use not permitted)



**Fig. 12.11** Title: Spray cryotherapy for cryoablation. Description: Fig. **a** shows a mid-tracheal stenosis and endobronchial mucosal changes in setting of radiation therapy. Figure **b** shows direct application of liquid Nitrogen to target site with flash freeze effect.

Figure **c** shows post treatment changes after passive thawing is allowed and blanching of mucosa. (Image: Courtesy of Dr. See Wei Low and Dr. Otis Rickman, Vanderbilt University Medical Center, Nashville, Tennessee)

to the site of application via the 7-French Air PV<sup>™</sup> catheter for the passive venting method (Fig. 12.10). The direct endobronchial application of nitrogen for an approximately 5 s freeze cycle incites flash freeze with intracellular crystal formation while sparing the cryoresistant

extracellular matrix (Fig. 12.11). The intact extracellular matrix is suggested to heal with reduced fibrosis. Therefore, the use of SCT alongside balloon bronchoplasty in benign bronchial lesions facilitates easier dilation by two mechanisms; a softer scar that prevents lac-



eration and reduced incidence of laceration which prevent further scarring and stricture formation [40]. In malignant lesions, after debulking the superficial tissue with faster thermal ablation, SCT can be preferentially used at the base of the lesion which is composed of normal and abnormal tissue. The underlying tissue matrix is preserved with SCT and regrows with minimal fibrosis in contrast to thermal ablation [41]. In addition, SCT leads to vascular stasis and can be used prior to mechanical debulking for hemostatic control. For bulky lesions and critical airway stenosis, complementary therapies such as balloon bronchoplasty, mechanical debridement, and endobronchial stenting are often necessary since SCT does not produce immediately visible effects.

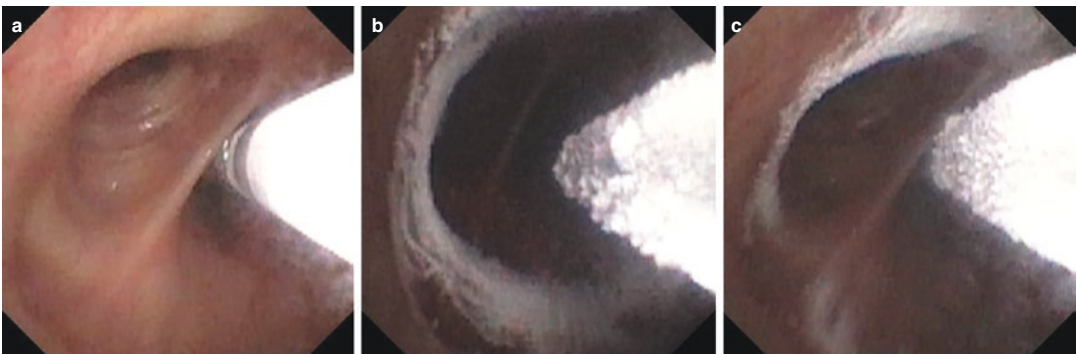
In recent years, spray cryotherapy has been investigated for chronic bronchitis as well. RejuvenAir® System (CSA Medical, Inc., Lexington, MA) is currently under investigation for this application and uses a radial spray catheter and an algorithm to deliver a nominal metered cryospray in a protocolized dosing pattern in two sessions (Fig. 12.12). The study hypothesizes that the cryospray application leads to destruction of abnormal surface epithelium and promotes regrowth with normal ciliated epithelium. Consequently, there is a reduction in chronic inflammation and mucosal swelling [42]. This application of spray cryotherapy is currently under investigation.

## Evidence

Spray cryotherapy has been evaluated in multiple studies and has noted promising results. A large multi-institutional registry by Finley et al. ( $n = 80$ ) reported restoration of airway patency in 98.8% of patients. In addition, the number of airway stenosis with grade  $>75\%$  reduced from 74% pre-treatment to 10% post-treatment [43]. In another single-center, retrospective review by Janke et al. ( $n = 22$ ), use of SCT was associated with a 86.4% of the patients experiencing an improvement in grade of stenosis [44]. The utility of SCT in benign strictures has also been demonstrated by Fernando et al. ( $n = 35$ ) with 85% improvement in symptoms when it was used alongside balloon bronchoplasty and highlights the role of adjunctive modalities when using SCT [45]. Similarly, Browning et al. ( $n = 27$ ) utilized additional modalities in 39% of their procedures [41].

## Safety Concerns and Contraindications

The most common side effect reported with use of SCT is the risk of pneumothorax. The direct endobronchial application of nitrogen leads to phase transformation of liquid nitrogen to gas which expands the lung volume to higher threshold of capacity leading to barotrauma. In addition, it can displace oxygen leading to hypoxia. These effects were significantly highlighted by the early data including Finley registry noting a 19% rate of complication supposedly due to barotrauma [43]. The lack of experience in using SCT in airway



**Fig. 12.12** Title: Spray cryotherapy in RejuvenAir® System. Description: Fig. **a** shows the tip of radial spray catheter positioned at the site of application. Figure **b** shows the direct endobronchial application of liquid nitro-

gen resulting in flash freezing. Figure **c** shows the passive thawing of the targeted region. (Images courtesy of Dr. Christian Ghattas, The Ohio State University Hospital, Columbus, Ohio)

likely led to high incidence rate during its early adoption. Subsequent studies reported routine egress of nitrogen during “passive venting” which relies on the principle that the nitrogen gas formed during SCT application will egress through path of least resistance, that is, via endotracheal tube to the atmosphere [40]. The protocol for passive venting was later developed and uses the following steps during SCT application (1) Deflate endotracheal tube cuff (2) Disconnect tube from ventilator circuit (3) Visualize passive egress (misting of gas through endotracheal tube or rigid bronchoscope, by a designated person (4) Confirm lack of chest wall rise during spray (5) Remove bronchoscope between treatments (6) Monitor hemodynamic data—Heart rate, blood pressure, oxygen saturation and telemetry (7) Treat proximal lesion first (8) Abort procedure if passive venting is compromised. In addition, the manufacturer recommends a minimum vent area of  $\geq 20$  mm<sup>2</sup> between the outer diameter of bronchoscope and inner diameter of endotracheal tube for the nitrogen gas to passively egress. It is important to avoid deploying SCT beyond anatomical obstructions such as severe airway stenosis (>90%) or while the bronchoscope is wedged within the lumen. While using rigid bronchoscope, jet ventilation should be halted during the spray to avoid pushing the gas downstream. While the development of passive venting protocol has reduced the risk of pneumothorax, the necessary apnea while holding ventilation can potentiate to risk of hypoxia, hypercarbia, respiratory acidosis, and bradycardia.

SCT is most often used with endotracheal tube or rigid bronchoscope. While use with laryngeal mask airway (LMA) is reported, there is concern of laryngospasm which can prevent the passive egress. In addition, accidental dislodgment can allow nitrogen to vent down into the stomach [41]. Overall, SCT is a relatively safe modality with low complication rate of approximately 3% in both benign and malignant airway disease and is noted to be safe for application near a silicone, hybrid, or metal stent [41, 45]. A case series by Bhora et al. reported SCT as a safe adjunct modality for the management of benign tracheal stenosis suggesting value in patients who have failed conventional therapies [46].

## Advantages of Cryotherapy

Cryotherapy offers many advantages over thermal therapies. It takes away the risk of airway fire, especially if the targeted area is near a combustible substance such as airway stent or endotracheal tube. It doesn't require lowering the inspired fraction of oxygen (FiO<sub>2</sub>) to less than 40% in contrast to thermal therapies which pose a risk of airway fire at higher FiO<sub>2</sub>. Finally, it avoids the risk of injury to extracellular matrix (e.g., cartilage) due to its low water content and allows regeneration with minimal fibrosis which can be an unintended side effect of thermal ablation.

The addition of endobronchial cryotherapy to chemoradiation therapy was compared in a prospective cohort study by Rashad et al. ( $n = 60$ ) in malignant endobronchial obstruction. Combined therapy led to significant improvement in respiratory symptoms, respiratory function tests, mean Karnofsky score as well as median survival [47]. Cryotherapy is also hypothesized to have a synergistic effect to immunotherapy that can potentiate the treatment response to anti-programmed death-ligand 1 (PDL-1) monotherapy, that is, PD-L1  $\geq 50\%$  or tumor expressing EGFR (epidermal growth factor receptor) mutations ([Clinicaltrials.gov](https://clinicaltrials.gov) Identifier: NCT04793815, NCT02759835). The mechanism of action involves the abscopal effect wherein local radiation therapy to primary tumor site releases the tumor antigens into circulation and triggers a systemic immune response to metastatic lesions. The cell necrosis from local cryoprobe application is hypothesized to mimic the effect of local radiation.

---

## Limitations

Cryotherapy has an extensive array of clinical applications. However, its widespread use has been limited due to significant practice variations amongst institutions. It is considered a slow form of ablation that often requires a follow-up bronchoscopy and has a variable utility for acute or critical airway stenosis. It is relatively easier to

learn cryotherapy techniques in comparison to other more invasive interventions such as thermal therapies or mechanical debulking. However, most pulmonary and critical care training programs do not have the ability or protocols to train their fellows in cryosurgery with a goal for proficiency. In the United States, the use of cryotherapy is often limited to interventional pulmonology. These overall limitations are reflected in the reported use of cryotherapy in Acquire registry. Despite a low overall complication rate of 3.8%, cryotherapy was only used in 8% of the cases (out of 1115 therapeutic procedures in 15 institutions) [48].

---

## Summary and Recommendations

Application of cryotherapy as a local ablative modality has demonstrated efficacy and safety in a wide array of trachea-bronchial pathologies. It can augment the efficacy of other systemic therapeutic agents such as chemotherapy, radiation therapy, and immunotherapy. It is also an effective tool for recanalization of critical airway stenosis and allows retrieval of tissue for diagnosis. Unlike thermal ablation therapies, cryotherapy leads to tumor destruction without heat-related denaturation and can have a similar effect by releasing intracellular contents into circulation.

---

## Future Research Directions

The efficacy and safety of percutaneous cryoablation for management of non-operable stage 1 tumors have been evaluated for many years now. It has demonstrated local control and survival rate comparable to radiofrequency ablation and sublobar resection. Several studies have reported great success with an overall 3 and 5 year survival rate of approximately 80 and 68%, respectively [14, 49–51]. While efficacious, it is associated with significant adverse effects including a high risk of pneumothorax (12–62%), hemoptysis (0–62%), fever (3–42%), and pleural effusions (14–70%) [14]. Endobronchial approach for peripheral ablation has been suggested by some with the hope of reducing some of these adverse

events. In addition, it can also lead to a “one-stop shop” tactic for diagnosis, staging, and treatment of early-stage lung cancer.

However, up until recently, there has been a lack of stable and accurate navigation platforms as well as cryoprobes that are thin enough to be advanced to the periphery. The advent of “Robot Assisted Navigation Bronchoscopy” (RANB) has demonstrated a stable navigation system that can provide a channel to peripheral lung regions. In addition, the targeted application can be confirmed with real time, in-suite cone-beam computed tomography imaging. This allows for delivery of ablative therapies such as microwave, radiofrequency, and photodynamic therapy with precision [52]. The widespread utilization of RANB and the development of thinner cryoprobes have paved the path for cryotherapy to be used for diagnostic modality in the targeted periphery. The utility for targeted cryobiopsy of peripheral lung nodules has been already described [32]. However, the therapeutic applications for endobronchial cryoablation to peripheral lung nodule are currently lacking. The major limitation for this application is the limited depth of penetration of cold via thin cryoprobes. For a successful ablation using cryotherapy, the ideal zone of freezing would extend approximately 1 cm beyond the radiographically designated tumor region. Unfortunately, cryotherapy suffers from heat/cold sink effect. If the target tumor is closely related to a vessel >3 mm in diameter, the efficacy of cryotherapy to extract the heat and incite a strong freeze may be limited due to heat convection from adjacent circulation [53]. Regardless, it could be lucrative for application to centrally located parenchymal tumors due to relative preservation of surrounding collagenous architecture and minimal damage to the important structures.

---

## References

1. Díaz-Jimenez JP, Rodriguez AN. Interventions in pulmonary medicine. Cham: Springer; 2017. <https://doi.org/10.1007/978-3-319-58036-4>.
2. Cooper IS, Lee ASJ. Cryostatic congelation: a system for producing a limited, controlled region of cooling

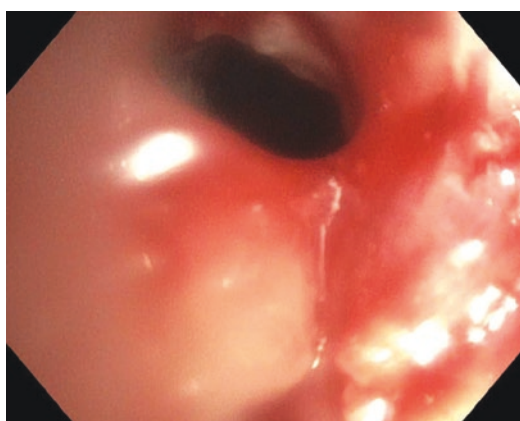
- or freezing of biologic tissues. *J. Nerv. Ment. Dis.* 1961;133(3):259–63.
3. Gage AA. Cryotherapy for cancer. Springfield, IL: Charles C. Thomas; 1968.
  4. Lentz RJ, Christine Argento A, Colby TV, Rickman OB, Maldonado F. Transbronchial cryobiopsy for diffuse parenchymal lung disease: a state-of-the-art review of procedural techniques, current evidence, and future challenges. *J Thorac Dis.* 2017;9:2186–203.
  5. Hetzel M, Hetzel J, Schumann C, Marx N, Babiak A. Cryorecanalization: a new approach for the immediate management of acute airway obstruction. *J Thorac Cardiovasc Surg.* 2004;127:1427–31.
  6. Pasricha PJ, Hill S, Wadwa KS, Gislason GT, Okolo PI, Magee CA, Canto MI, Kuo WH, Baust JG, Kalloo AN. Endoscopic cryotherapy: experimental results and first clinical use. *Gastrointest Endosc.* 1999;49:627–31.
  7. Flexible single-use cryoprobes development file: D144191. *Med Clin North Am.* 2011;95:1095–114.
  8. Avasarala SK, Wells AU, Colby TV, Maldonado F. Transbronchial cryobiopsy in interstitial lung diseases: state-of-the-art review for the interventional pulmonologist. *J Bronchol Interv Pulmonol.* 2021;28:81–92.
  9. Simon M, Simon I, Tent PA, Todea DA, Haranguş A. Cryobiopsy in lung cancer diagnosis—a literature review. *J Med.* 2021;57(4):393. <https://doi.org/10.3390/medicina57040393>.
  10. Gage AA, Baust J. Mechanisms of tissue injury in cryosurgery. *Cryobiology.* 1998;37:171–86.
  11. DiBardino DM, Lanfranco AR, Haas AR. Bronchoscopic cryotherapy: clinical applications of the cryoprobe, cryospray, and cryoadhesion. *Ann Am Thorac Soc.* 2016;13:1405–15.
  12. Du Rand IA, Barber PV, Goldring J, et al. British thoracic society guideline for advanced diagnostic and therapeutic flexible bronchoscopy in adults. *Thorax.* 2011;66:iii1. <https://doi.org/10.1136/thoraxjnl-2011-200713>.
  13. Maldonado F, Danoff SK, Wells AU, et al. Transbronchial cryobiopsy for the diagnosis of interstitial lung diseases: CHEST guideline and expert panel report. *Chest.* 2020;157:1030–42.
  14. Chaddha U, Kyle Hogarth D, Murgu S. Bronchoscopic ablative therapies for malignant central airway obstruction and peripheral lung tumors. *Ann Am Thorac Soc.* 2019;16:1220–9.
  15. Maiwand MO, Evans JM, Beeson JE. The application of cryosurgery in the treatment of lung cancer. *Cryobiology.* 2004;48:55–61.
  16. Schumann C, Hetzel M, Babiak AJ, Hetzel J, Merk T, Wibmer T, Lepper PM, Krüger S. Endobronchial tumor debulking with a flexible cryoprobe for immediate treatment of malignant stenosis. *J Thorac Cardiovasc Surg.* 2010;139:997–1000.
  17. Inaty H, Folch E, Berger R, Fernandez-Bussy S, Chatterji S, Alape D, Majid A. Unimodality and multimodality cryodebridement for airway obstruction: a single-center experience with safety and efficacy. *Ann Am Thorac Soc.* 2016;13:856–61.
  18. Yilmaz A, Aktaş Z, Alici IO, Çağlar A, Sazak H, Ulus F. Cryorecanalization: keys to success. *Surg Endosc.* 2012;26:2969–74.
  19. Mehta AC, Rafanan AL. Extraction of airway foreign body in adults. *J Bronchol.* 2001;8:123–31.
  20. Fruchter O, Kramer MR. Retrieval of various aspirated foreign bodies by flexible cryoprobe: in vitro feasibility study. *Clin Respir J.* 2015;9:176–9.
  21. Sehgal IS, Dhooria S, Ram B, Singh N, Aggarwal AN, Gupta D, Behera D, Agarwal R. Foreign body inhalation in the adult population: experience of 25, 998 bronchoscopies and systematic review of the literature. *Respir Care.* 2015;60:1438–48.
  22. Sriratanaviriyakul N, Lam F, Morrissey BM, Stollenwerk N, Schivo M, Yoneda KY. Safety and clinical utility of flexible bronchoscopic cryoextraction in patients with non-neoplasm tracheobronchial obstruction. *J Bronchol Interv Pulmonol.* 2015;22:288–93.
  23. Schmidt LH, Schulze AB, Goerlich D, et al. Blood clot removal by cryoextraction in critically ill patients with pulmonary hemorrhage. *J Thorac Dis.* 2019;11:4319–27.
  24. Hetzel J, Eberhardt R, Herth FJF, et al. Cryobiopsy increases the diagnostic yield of endobronchial biopsy: a multicentre trial. *Eur Respir J.* 2012;39:685–90.
  25. Pajares V, Puzo C, Castillo D, et al. Diagnostic yield of transbronchial cryobiopsy in interstitial lung disease: a randomized trial. *Respirology.* 2014;19:900–6.
  26. Schumann C, Hetzel J, Babiak AJ, Merk T, Wibmer T, Möller P, Lepper PM, Hetzel M. Cryoprobe biopsy increases the diagnostic yield in endobronchial tumor lesions. *J Thorac Cardiovasc Surg.* 2010;140:417–21.
  27. El-Dahdouh S, Elaali GAA, El-kady N. Comparison between endobronchial forceps-biopsy and cryobiopsy by flexible bronchoscopy. *Egypt J Chest Dis Tuberc.* 2016;65:325–9.
  28. Aktas Z, Gunay E, Hoca NT, Yilmaz A, Demirag F, Gunay S, Sipit T, Kurt EB. Endobronchial cryobiopsy or forceps biopsy for lung cancer diagnosis. *Ann Thorac Med.* 2010;5:242–6.
  29. Rubio ER, Le SR, Whatley RE, Boyd MB. Cryobiopsy: should this be used in place of endobronchial forceps biopsies? *Biomed Res Int.* 2013;2013:1. <https://doi.org/10.1155/2013/730574>.
  30. Segmen F, Aktaş Z, Öztürk A, Kızılgöz D, Yılmaz A, Alici IO, Demirağ F, Pehlivanoğlu P. How many samples would be optimal for endobronchial cryobiopsy? *Surg Endosc.* 2017;31:1219–24.
  31. Jabari H, Sami R, Fakhri M, Kiani A. Different protocols for cryobiopsy versus forceps biopsy in diagnosis of patients with endobronchial tumors. *Pneumologia.* 2012;61:230–3.
  32. Jiang S, Liu X, Chen J, Ma H, Xie F, Sun J. A pilot study of the ultrathin cryoprobe in the diagnosis of peripheral pulmonary ground-glass opacity lesions. *Transl Lung Cancer Res.* 2020;9:1963–73.
  33. Zhang J, Guo J-R, Huang Z-S, Fu W-L, Wu X-L, Wu N, Kuebler WM, Herth FJF, Fan Y. Transbronchial

- mediastinal cryobiopsy in the diagnosis of mediastinal lesions: a randomised trial. *Eur Respir J*. 2021;58:2100055.
34. Marasso A, Gallo E, Massaglia GM, Onoscuri M, Bernardi V. Cryosurgery in bronchoscopic treatment of tracheobronchial stenosis; indications, limits, personal experience. *Chest*. 1993;103:472–4.
  35. Maiwand MO. The role of cryosurgery in palliation of tracheo-bronchial carcinoma. *Eur J Cardiothoracic Surg*. 1999;15:764–8.
  36. Walsh DA, Maiwand MO, Nath AR, Lockwood O, Lloyd MH, Saab M. Bronchoscopic cryotherapy for advanced bronchial carcinoma. *Thorax*. 1990;45:509–13.
  37. Mathur PN, Wolf KM, Busk MF, Briete WM, Datzman M. Fiberoptic bronchoscopic cryotherapy in the management of tracheobronchial obstruction. *Chest*. 1996;110:718–23.
  38. Mu D, Nan D, Li W, Fu E, Xie Y, Liu T, Jin F. Efficacy and safety of bronchoscopic cryotherapy for granular endobronchial tuberculosis. *Respiration*. 2011;82:268–72.
  39. Vergnon JM, Huber RM, Moghissi K. Place of cryotherapy, brachytherapy and photodynamic therapy in therapeutic bronchoscopy of lung cancers. *Eur Respir J*. 2006;28:200–18.
  40. Moore RF, Lile DJ, Abbas AE. Current status of spray cryotherapy for airway disease. *J Thorac Dis*. 2017;9:S122–9.
  41. Browning R, Turner JF, Parrish S. Spray cryotherapy (SCT): institutional evolution of techniques and clinical practice from early experience in the treatment of malignant airway disease. *J Thorac Dis*. 2015;7:S405–14.
  42. Slebos DJ, Breen D, Coad J, Klooster K, Hartman J, Browning R, Shah PL, McNulty WH, Al-Abdul Mohsin M, Irshad K. Safety and histological effect of liquid nitrogen metered spray cryotherapy in the lung. *Am J Respir Crit Care Med*. 2017;196:1351–2.
  43. Finley DJ, Dycoco J, Sarkar S, Krinsky WS, Sherwood JT, Dekeraty D, Downie G, Atwood J, Fernando HC, Rusch VW. Airway spray cryotherapy: initial outcomes from a multiinstitutional registry. *Ann Thorac Surg*. 2012;94:199–204.
  44. Janke KJ, El-Sayed Abbas A, Ambur V, Yu D. The application of liquid nitrogen spray cryotherapy in treatment of bronchial stenosis. *Innovations*. 2016;11(5):349–54.
  45. Fernando HC, Dekeraty D, Downie G, Finley D, Sullivan V, Sarkar S, Rivas R, dos RS S. Feasibility of spray cryotherapy and balloon dilation for non-malignant strictures of the airway. *Eur J Cardiothoracic Surg*. 2011;40:1177–80.
  46. Bhora FY, Ayub A, Forleiter CM, Huang CY, Alshehri K, Rehmani S, Al-Ayoubi AM, Raad W, Lebovics RS. Treatment of benign tracheal stenosis using endoluminal spray cryotherapy. *JAMA Otolaryngol Head Neck Surg*. 2016;142:1082–7.
  47. Rashad A, Badawy MS, Ali MM, Mansour H, Abdel-Bary M. The value of endobronchial cryotherapy in the management of malignant endobronchial obstruction in patients with inoperable NSCLC: a prospective analysis of clinical and survival outcomes. *Egypt J Bronchol*. 2021;15:1–8.
  48. Ost DE, Ernst A, Grosu HB, et al. Complications following therapeutic bronchoscopy for malignant central airway obstruction: results of the AQUIRE registry. *Chest*. 2015;148:450–71.
  49. Moore W, Talati R, Bhattacharji P, Bilfinger T. Five-year survival after cryoablation of stage I non-small cell lung cancer in medically inoperable patients. *J Vasc Interv Radiol*. 2015;26:312–9.
  50. Yamauchi Y, Izumi Y, Hashimoto K, et al. Percutaneous cryoablation for the treatment of medically inoperable stage I non-small cell lung cancer. *PLoS One*. 2012;7:e33223. <https://doi.org/10.1371/journal.pone.0033223>.
  51. Zemlyak A, Moore WH, Bilfinger TV. Comparison of survival after sublobar resections and ablative therapies for stage I non-small cell lung cancer. *J Am Coll Surg*. 2010;211:68–72.
  52. Agrawal A, Hogarth DK, Murgu S. Robotic bronchoscopy for pulmonary lesions: a review of existing technologies and clinical data. *J Thorac Dis*. 2020;12:3279–86.
  53. Zhao ZR, Lau RWH, Ng CSH. Catheter-based alternative treatment for early-stage lung cancer with a high-risk for morbidity. *J Thorac Dis*. 2018;10:S1864–70.

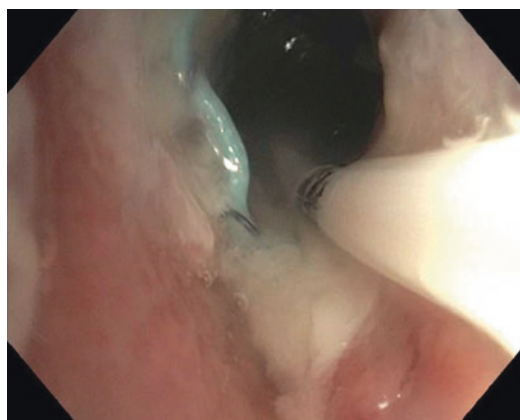


## Introduction and Definition of the Procedure

Patients with advanced stage lung cancer with endoluminal disease have limited treatment options for relief of dyspnea, or cough resulting from obstructing tumor. Advanced therapeutic bronchoscopy utilizing a combination of rigid and flexible bronchoscopic techniques allows for local tumor destruction using hot modalities (i.e., electrocautery, argon plasma, or laser) or cold modalities such as cryotherapy (Fig. 13.1). Aforementioned techniques which have been discussed fully in other chapters can be used in combination with stenting if appropriate to maintain airway patency. Endobronchial brachytherapy (EBBT) is a localized form of radiation which, in combination with above techniques, can help restore airway patency over a longer period of time. It involves the placement of an afterloading catheter under direct visualization using the flexible bronchoscope (Fig. 13.2). Once the catheter is in place, the bronchoscope is then removed, and the catheter is secured (Fig. 13.3a,



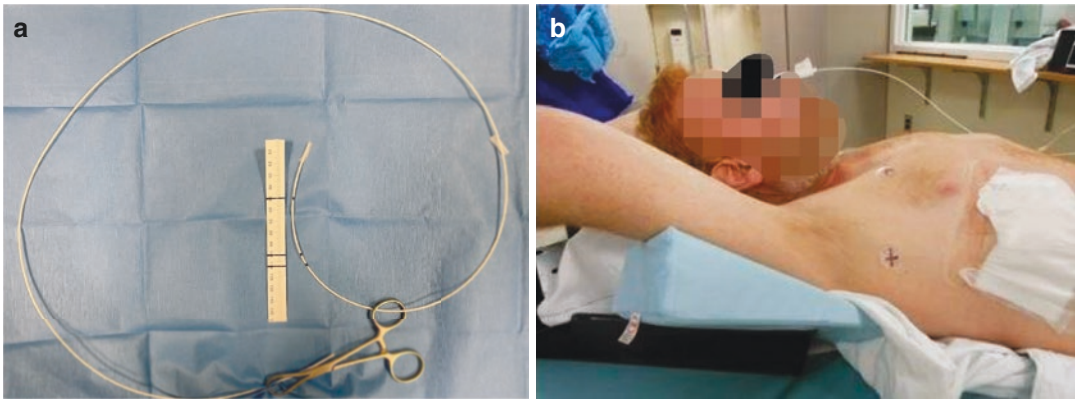
**Fig. 13.1** Restoration of airway patency after tumor debulking



**Fig. 13.2** Airway after multimodality treatment (stent and brachytherapy catheter shown)

S. Shadchehr (✉)  
Interventional Pulmonology, TUSM, Lahey Hospital  
and Medical Center, Burlington, MA, USA  
e-mail: [Sara.shadchehr@lahey.org](mailto:Sara.shadchehr@lahey.org)

I. Iftimia  
Radiation Oncology, TUSM, Lahey Hospital and  
Medical Center, Burlington, MA, USA  
e-mail: [ileana.n.iftimia@lahey.org](mailto:ileana.n.iftimia@lahey.org)



**Fig. 13.3** (a) Pre-bronchoscopy preparation of brachytherapy catheter with tip marked at 5, 10, and 11 cm. (b) Patient after bronchoscopic placement of brachytherapy catheter

b). Marker seeds are inserted into the catheter for tumor localization and treatment planning, which will subsequently be replaced by the radioactive source when the patient undergoes local radiation. The EBBT treatment is usually repeated several times in sequence based on a predetermined plan set in place by the radiation oncologist.

---

### History and Historical Perspective

Since the discovery of X-ray by Wilhelm Roentgen and Radium by Marie Curie, both modalities have since been extensively investigated and utilized by the medical field to treat malignancies. The delivery of X-ray to the target sites through machines like linear accelerators is called teletherapy (or External Beam Radiation Therapy—EBRT), meaning to treat at a long distance. On the other hand, the delivery of radiation by applying radio-isotopes to the tumor site is known as brachytherapy (BT), meaning to treat at a short distance. In 1922, Yankauer described two cases of lung tumors treated endoscopically with radium [1]. Since then there have been innumerable publications on the application of various radio-isotopes in the treatment of malignancies in the form of brachytherapy which further advanced the use of this technique in treating intraluminal lung cancer.

The mainstay of treatment for intrathoracic malignancies usually involves the combination

of EBRT with systemic treatment such as chemotherapy or immunotherapy. However, with the help of significant advancement in technology such as computerized tomography (CT), 3D treatment planning, and high dose rate (HDR) afterloading delivery system, the use of EBBT plays a more important role in the treatment of lung cancer. It has been utilized as adjuvant treatment postoperatively for positive margins in the stump, boost dose to the endobronchial disease site to enhance local control when combined with EBRT, and symptomatic relief in patients with symptoms such as bleeding or bronchial obstructions [2, 3]. Though EBBT is not routinely recommended as the first line definitive treatment for early stage lung cancer, it remains a useful alternative treatment in a highly selected group of surgically inoperable patients with limited or occult endobronchial cancer less than 1 cm without metastatic lymphadenopathy or disease [2, 4].

---

### Description of the Equipment Needed

EBBT is the procedure of bringing the radioactive source intraluminally to the target site by a multidisciplinary team consisting of the pulmonologist, radiation oncologist, anesthesiologist, medical physicist, dosimetrist, radiation therapist, and nurses. It requires meticulous communi-

cation between all specialties. CT scanning and simulation for planning and treatment is highly recommended.

The advantage of brachytherapy is that it can deliver a higher relative dose to the tumor site as compared to the surrounding normal structures because of the physical phenomenon known as the “inverse square law.” The radiation dose rate falls off rapidly, inversely as a function of the square of the distance from the radioactive source, so that the contacting tumor can be treated to a higher relative dose while sparing the further distant normal tissues. Historically, brachytherapy was done by manual application of low dose rate (LDR) radio-isotopes such as Iodine 125 seeds to the tumor. Because the dose rate is less than 2 Gray (Gy) per hour, it will take a longer time to treat, which in turn can cause patient discomfort, seed migration, and unnecessary radiation exposure to personnel [5, 6]. Nowadays, nearly all EBBT is delivered by high dose rate (HDR) radio-isotopes such as Iridium 192 with a dose rate of over 2 Gy per minute through an afterloading machine. When not in use, the HDR Ir192 source located at the tip of a flexible wire is housed by the remote afterloader lead shielded unit. The unit has a system to deliver the source from the storage location to the patient via a catheter and to return it back to the storage at the end of the treatment and during power failure or emergencies. During treatment the radioactive source is maintained in various planned positions (called dwell positions) for a planned amount of time (called dwell time), so as to provide optimal dose coverage to the target. The delivery of radiation is performed with only the patient in a radiation bunker while a physicist can remotely control the afterloader safely outside. After treatment planning and dose calculation are performed, the computer within the machine will control the movement of the source and the wire, the dwell time and position of the source along the length of the active treatment, so as to deliver the designed cylindrical-like dose volume to the target. Figure 13.4 shows a photo of the Varian GammaMediX remote afterloader. The GammaMediX unit has 24 channels and can



**Fig. 13.4** Varian GMEDiX HDR remote afterloader

extend the radioactive source to a fixed distance of 130 cm.

The afterloader uses an HDR Ir192 source with a nominal activity of 10 Ci. The source radioactivity is decaying in time. Consequently, the source needs to be replaced at least quarterly to ensure the treatment time does not become excessively long.

The HDR afterloading technique has the advantage of:

- (a) Providing 3D customized dose plan to the specific target volume with maximal tumor dose and minimal normal tissue dose
- (b) Shortening treatment time per session and reducing patient discomfort
- (c) Reducing unnecessary radiation exposure to caregivers and personnel since there is no direct handling of the radioactive source

**Table 13.1** The ABS dose recommendations for endobronchial brachytherapy

<i>Brachytherapy alone</i>	
Pulsed dose rate	30 Gy in one insertion (using pulses that offer biological equivalence to low dose rate)
High dose rate	10 Gy in one fraction
	15 Gy in one fraction
	14.2–20 Gy in two fractions
	22.5 Gy in three fractions
	24 Gy in four fractions
	30 Gy in six fractions (high dose palliation)
<i>Brachytherapy as a boost following EBRT</i>	
Pulsed dose rate	15–20 Gy in one insertion (using pulses that offer biological equivalence to low dose rate)
High dose rate (HDR)	10–15 Gy in two to three fractions (following up to 60 Gy in 30 fractions)

There is no consensus on the optimal dose fractionation for EBBT and it depends on the intention of treatment, condition of the patient, and institutional experience. Frequently it is given in two or three fractions of 5–10 Gy requiring repeated bronchoscopies [2]. The American Brachytherapy Society (ABS) published a list of guidelines on dose fractionation as listed in Table 13.1.

## Indications and Contraindications

EBBT is considered an adjunctive procedure for palliative management of endobronchial tumor burden. Patient selection is essential as the patient must be able to tolerate several bronchoscopy procedures in sequence (i.e., 1 week apart) for the therapy to be effective. ABS Consensus guidelines recommend suitable patients who have the following characteristics:

- Significant intraluminal disease
- Predicted survival over 2 months to allow time for treatment response
- Patient who are unable to undergo EBRT or who have already received EBRT

Contraindications to bronchoscopy such as severe hypoxic respiratory failure, irreversible

coagulopathy, or recent MI exclude the possibility of EBBT.

## Application of the Technique

The ABS recommends flexible bronchoscopy via the transnasal approach to evaluate the anatomic location and length of the lesion with the patient comfortable. The treatment area should be photographed for documentation and comparison on follow-up examination. The majority of procedures can be performed under moderate sedation; however, general anesthesia may be required to keep patients from coughing excessively and dislodging the catheter. A pre-marked flexible polyethylene catheter is inserted via the working channel. Graduated markings on the catheter help determine its location relative to the tumor (Fig. 13.3a). If pre-marked catheters are not available, marking the distal portion of the catheter at 5-cm intervals before insertion provides these visual reference points for catheter placement and treatment planning. Although the exact length to be treated depends on the extent of bronchial or tracheal involvement, lengths of 5–7 cm are commonly irradiated. The catheter may need to be introduced over a guidewire in stenotic areas too tight for the bronchoscope. The catheter tip should be at least 2 cm beyond the most distal aspect of the tumor when possible. Localizing the tip in a segmental bronchus can help hold the catheter in place [7]. It should be noted that the endobronchial lesion is usually well visualized under bronchoscopy but not under fluoroscopy. Conversely, the catheter tip with the guidewire in place can usually be clearly seen under fluoroscopy, but the tip's position in relation to the distal end of the tumor is harder to verify on bronchoscopy. Therefore, both methods should be used to ensure accurate position of the catheter. The catheter is then secured to the patient's nose and the catheter exit (at the nostrils) is marked (Fig. 13.3b).

High-dose-rate endobronchial brachytherapy (HDR-EBBT) is a multi-disciplinary procedure. After the catheter is placed by the pulmonologist, the patient is transferred to the Radiation



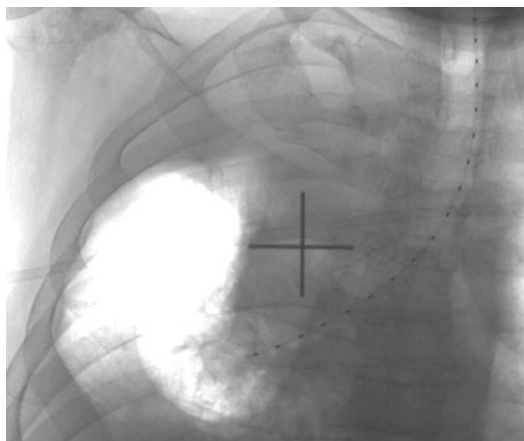
Oncology Department, where a team (radiation oncologist, nurse, radiation therapist, physicist, and dosimetrist) is involved in the patient care. The HDR-EBBT procedure consisting of imaging, treatment planning, and treatment should be competently and efficiently performed in order to minimize the amount of time the patient has the bronchial catheter(s) in place. Before imaging, the catheter length is checked using a gauge wire and assessed for kinks or obstruction along its pathway. The physicist should check the catheter exit marking to ensure that the catheter has maintained its proper position (i.e., not shifted out). Then, a dummy wire (i.e., a thin plastic wire with 1 cm apart small metal markers) is placed inside the catheter. The metal markers having a high atomic number are clearly visible on the X-ray and CT images, which in turn may help with catheter digitization during the treatment planning process. The images used for treatment planning are acquired using a breath hold technique to reduce blurriness and to help with digitizing the catheter(s).

Based on the tumor location, two or more catheters may be needed to achieve good dosimetric coverage. There are various ways to generate the treatment plans, such as using CT or orthogonal X-ray images to identify the catheter(s), or using pre-calculated treatment plans (for single catheter cases). This last approach is less accurate for curved catheters [8].

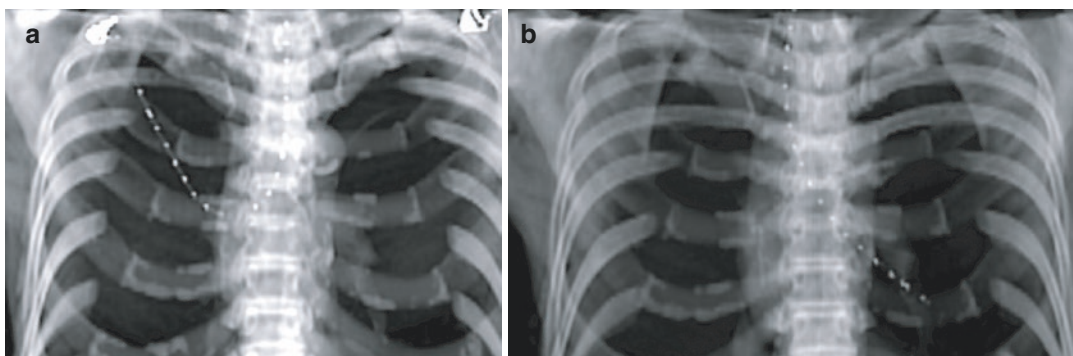
Based on the current ABS guidelines [3], the orthogonal X-ray imaging approach can be used,

but whenever possible CT scan of the patient to identify the catheter(s) should be performed. Figure 13.5 shows an anterior-posterior X-ray fluoroscopic image with the catheter and dummy wire in place. Figure 13.6a, b show anterior-posterior digitally reconstructed radiographs from CT images, with the applicator and dummy wire in place, for a right and a left bronchial tumor, respectively.

Images are then imported to the Treatment Planning System (TPS) and used to generate a treatment plan. The catheter(s) are digitized, and based on the information received from the Interventional pulmonologist, the distal and proximal extents of the tumor are marked on the digitized catheter(s). If necessary, the radiation



**Fig. 13.5** Anterior-posterior X-ray fluoroscopic image with the catheter and dummy wire in place



**Fig. 13.6** (a) Anterior-posterior digitally reconstructed radiograph from CT images (R side tumor), showing the applicator and dummy wire. (b) Anterior-posterior digi-

tally reconstructed radiograph from CT images (L side tumor), showing the applicator and dummy wire



oncologist will contour the tumor. A 1–2 cm margin should be added to each end of the tumor, in order to account for microscopic extension, as well as placement and dosimetric uncertainties [7]. Subsequently, the catheter(s) are after-loaded with radioactive sources (i.e., HDR dwell positions) to cover the tumor plus margins.

If the tumor is located in close proximity to organs at risk, the areas of concern can also be contoured as avoidance areas on the CT images and dose adjusted to ensure the organ at risk dose is within limits. This may help to avoid subsequent complications, such as major hemoptysis [7, 9].

There is some variation on how lung brachytherapy is performed, but practitioners should follow the current guidelines [3, 10]. The HDR-EBBT treatment often consists of multiple fractions. The treatment can be performed in a same day single insertion with the fractions spaced at least 6 h apart or consecutive weekly insertion usually over 2–3 weeks. For a single insertion approach, a single plan can be generated and used for all fractions, but X-ray or CT images should be performed before each fraction to ensure the catheter is in the same position as used for the treatment plan (no displacements or kinks). For the multi-insertion approach, imaging should be acquired and a new treatment plan should be generated for each fraction. There are two methods to prescribe the dose for the HDR-EBBT: (a) to a fixed depth from the center of the catheter throughout (typically 10 mm) or (b) to 10 mm from the center of the catheter in the area of trachea/main bronchus, and gradually to a smaller depth distally, ranging from 5 to 10 mm, depending on the bronchus position [3, 10]. For CT-based planning and curved catheters, the dose at 10 mm should be averaged over 4 points (located in 2 orthogonal directions). If the tumor extent is known and contoured, the CT-based plan can be designed to adequately cover the tumor with the prescribed dose. When using a 5F catheter the distance to the airway walls may not be symmetric, unless a centering device is used. This may increase the dose to normal tissue, or could be a benefit for tumor coverage [3].

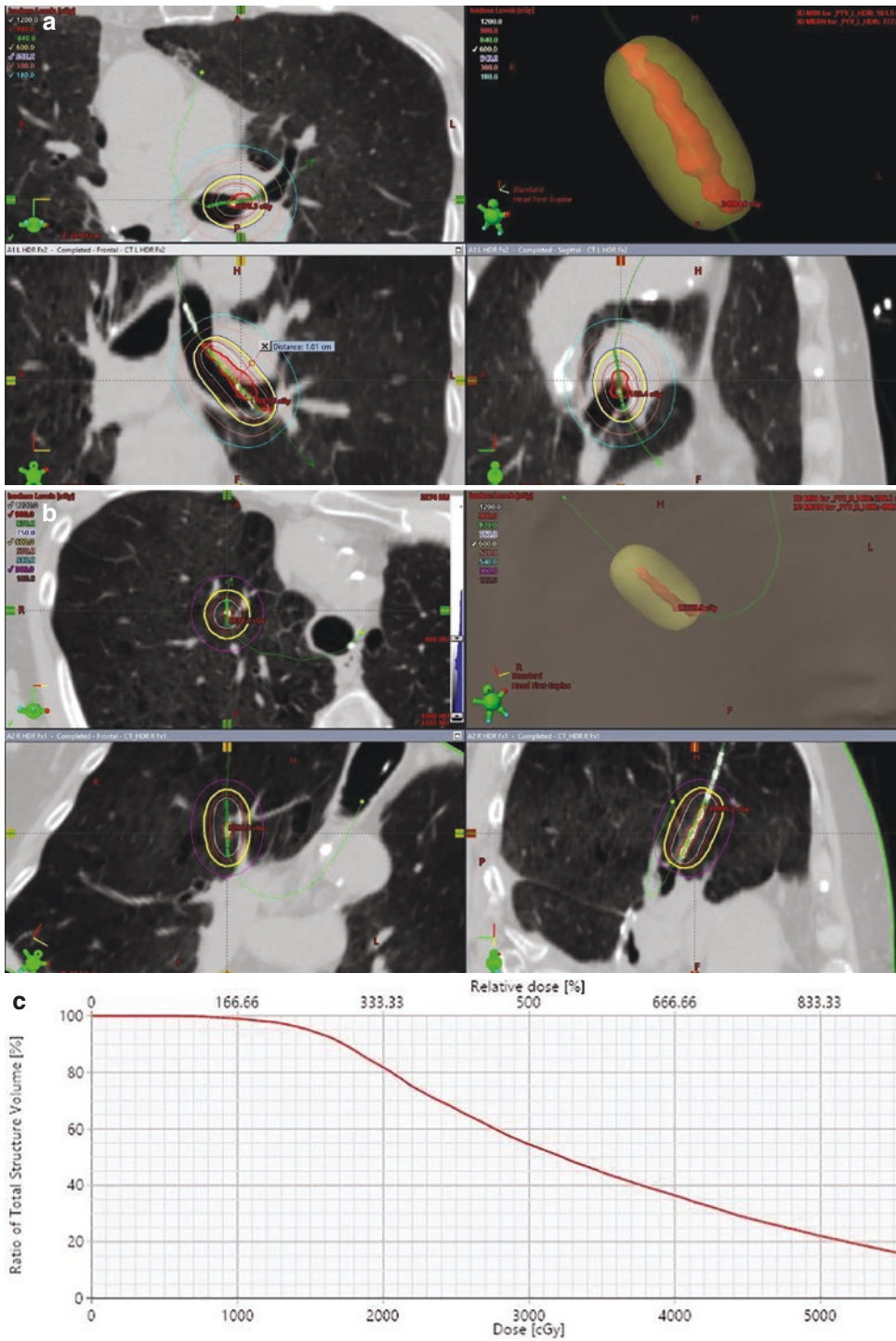
For palliative cases, the HDR-EBBT can be used as monotherapy or as a boost treatment, in combination with EBRT. The common prescription doses recommended by the ABS are 7.5 Gy\*3 and 10 Gy\*2 fractions for HDR-EBBT monotherapy, and 7.5 Gy\*2 and 5 Gy\*3 fractions for boost HDR-EBBT treatments (see Table 13.1), at 10 mm from the center of the catheter [3, 7]. The fractions are usually weekly. These dose/fractionations regimes have similar biological effects [7]. The prescription dose for the HDR-EBBT will be reduced if patients are treated concurrently with chemotherapy. If possible, concomitant HDR-EBBT-chemotherapy should be avoided.

For selected patients (with predominantly endobronchial tumor) the HDR-EBBT (monotherapy or boost) can be used as a curative approach, with similar doses as listed above for the palliative cases. This approach is still under exploration [11–13].

Figure 13.7a, b show the dose cloud around the catheter for an HDR-EBBT CT-based boost plan, for a left and a right bronchial tumor, respectively. Yellow line is the prescription dose of 6 Gy per fraction. Tumor with margins is shown in red. Figure 13.7c shows the Dose Volume Histogram (DVH) plot for the left bronchial tumor, 100% covered with the prescribed dose of 6 Gy. The tumor is surrounding the catheter in close proximity to the HDR source dwell positions. This results in a high dose to some parts of the tumor, reflected in the long tail of the DVH plot. Prior to the HDR treatment, this patient was treated bilaterally using an EBRT approach. The dose cloud for this bilateral bronchus EBRT plan is shown in Fig. 13.8. Yellow line is the prescribed dose of 45 Gy, delivered in 25 fractions. The tumor is shown in color wash.

Dose cloud around a catheter for an HDR-EBBT monotherapy CT-based plan is shown in Fig. 13.9. Yellow line is the prescription dose of 7 Gy per fraction.

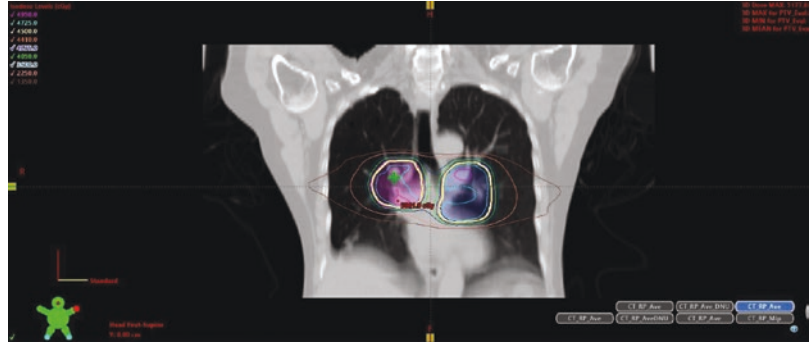
The HDR-EBBT procedure is performed in a very compressed time and the entire treatment is delivered in only a few fractions. After the plan generated by the planner (dosimetrist or physi-



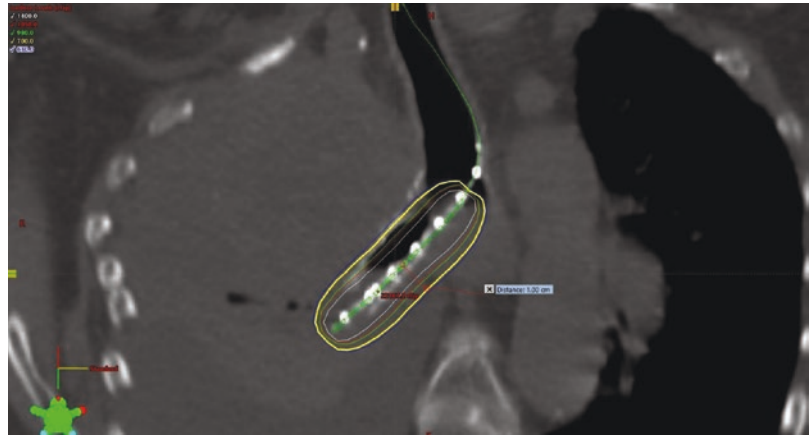**Fig. 13.7** (a) L side tumor: dose cloud around the catheter showed on CT images for an HDR-EBBT boost plan. Yellow line is the prescribed dose. Tumor with margins is shown in red. Prescription depth is 10 mm from the center of the catheter. (b) R side tumor: dose cloud around the

catheter showed on CT images for an HDR-EBBT boost plan. Yellow line is the prescribed dose. Tumor with margins is shown in red. (c) Dose Volume Histogram plot for a left bronchial tumor showing 100% coverage at the prescribed dose of 6 Gy

**Fig. 13.8** Dose cloud for a bilateral bronchus EBRT plan. Yellow line is the prescribed dose. The tumor is shown in color wash



**Fig. 13.9** R side tumor: dose cloud around the catheter shown on CT images for an HDR-EBBT monotherapy plan. Yellow line is the prescribed dose. Prescription depth is 10 mm from the center of the catheter



cist) is ready and approved by the radiation oncologist, a physicist performs a second check before the treatment commences. The purpose for this is to find and eliminate potential errors. The treatment plan is then transferred to the HDR remote afterloader computer, in order to deliver the prescribed dose.

The computer used for the treatment will receive from the TPS the information regarding the HDR source, dwell positions, and corresponding dwell times along the catheter(s). The patient is identified by two means, then a patient-specific quality assurance checklist is filled out by the radiation oncologist and physicist before the treatment starts. Both the radiation oncologist and physicist must be present at the HDR console area during treatment and should be available if any emergency occurs. It is a good practice to acquire the images and treat the patient in the same position. If the patient cannot lie down during treatment, he/she can be treated while sitting in a chair. The catheter is checked again using a

gauge wire to ensure there is no obstruction, the catheter exit marking is verified, and then the catheter is connected to the HDR remote afterloader. There is no need for respiratory motion management during treatment, since the bronchial catheter moves with the anatomy. For the multi-insertion approach, the catheter is removed by the radiation oncologist after each HDR-EBBT treatment. After treatment completion and catheter removal, the patient and room should be surveyed to ensure that the radioactive source was returned to its storage location. The patient should be observed after the procedure and discharged when stable.

## Evidence-Based Review

The 2001 ABS guidelines recommended the use of EBBT for palliation, particularly for endobronchial lesions not amenable to laser therapy or stenting.

Patient selection is based on the typical symptoms of malignant airway obstruction including dyspnea, cough, lobar collapse, or post-obstructive pneumonia. These patients often have not responded or are not candidates for standard chemotherapy or EBRT. The lesion must be amenable to bronchoscopy including placement of a small-bore catheter in the airway. Tumors in the airway that show significant vascular involvement or ulceration should be considered for other options due to higher risk of complications such as hemoptysis and further airway damage. It is important to note that the patients with acute or severe symptoms of airway obstruction should have an alternative ablative technique as first-line treatment due to the delayed effects of EBBT on restoring airway patency. As a general rule, EBBT is typically not selected or recommended as a first-line therapy for obstructing endobronchial malignancy [3, 14]. EBBT can be performed in the vicinity of metal airway stents, but data from esophageal metal stents show that mucosal doses can be increased substantially in the immediate adjacent tissue [15].

EBBT remains a viable option to provide localized radiation in order to reestablish airway patency, reduce symptoms, and enhance performance status with minimal side effects. The radiation oncology database of patients treated with EBBT at Lahey Clinic from 1996 to 2009 was used to perform a retrospective chart review of 88 patients. Each patient record was reviewed for symptoms of cough, dyspnea, chest pain, hemoptysis, pneumothorax, respiratory failure necessitating hospital admission before and after EBBT. A small percentage of procedure-related sided effects were noted in our cohort (4.5%). One patient (1.1%) developed a cough immediately after the procedure. Three patients (3.4%) developed respiratory failure after the procedure, necessitating transfer to a higher level of care for either increased oxygen therapy or closer monitoring (without endotracheal intubation). There were no deaths during treatment. There were no documented symptoms of shortness of breath, chest pain, hemoptysis, or pneumothorax documented related to EBBT. EBBT seemed to result

in improvement in the following symptoms: hemoptysis (90.9%), respiratory failure (85.7%), cough (79.5%), chest pain (76.9%), and shortness of breath (73.2%). Upper lobe position of the brachytherapy catheter can pose technical challenges. The likelihood of catheter malposition was 25% in the right upper lobe (RUL). The survival benefit was documented as days alive after EBBT. Survival was broken down by diagnostic category into small cell carcinoma, non-small cell carcinoma, and metastatic or other (that included carcinoid tumors). The survival benefit was highest in the metastatic/other category (272 days), followed by non-small cell carcinoma (122 days), and small cell carcinoma (112 days) [16].

A Cochran meta-analysis in 2012 reviewed 14 randomized clinical trials involving EBBT either as isolated therapy or in combination with other modalities. There was no clear survival advantage with fewer vs. multiple fractions of EBBT or when added to EBRT or compared to Nd:YAG laser [17]. A large retrospective study of 648 patients showed no difference in efficacy or survival in groups treated with 1 fraction versus multiple fractions [18]. Another larger randomized trial of 142 patients showed improved local tumor response in 2 fractions versus 4 fractions with similar overall survival but a trend toward reduced fatal hemoptysis with fewer fractions [19].

---

## Adjuvant Treatment

The combination of brachytherapy and EBRT is not commonly used for palliative purposes. However, combined therapy can be used in cases where it is felt that prolonged palliation is achievable [7].

The ABS suggests 2 fractions of 7.5 Gy each, 3 fractions of 5 Gy each, or 4 fractions of 4 Gy each (prescribed at 1.0 cm) should be given when HDR therapy is used as a planned boost to supplement palliative EBRT of 30 Gy in 10–12 fractions, when patients have no previous history of radiation treatment to the chest. The interval between fractions is generally weekly [7].



---

## Palliative Treatment

Patients with endobronchial malignant lesions can present with airway obstruction, dyspnea, hemoptysis, and pain. Intraluminal brachytherapy can provide symptomatic relief if they are not amenable to other treatment modality. This is more common in non-small cell carcinoma since it is quite unusual for small cell carcinoma to have luminal mucosal involvement [2]. Chella et al. reported a small randomized study of 29 patients with NSCLC who were treated with Nd-YAG laser combined with HDR-EBBT or laser only. It was found that the combination of Nd-YAG laser and HDR-EBBT for central airway malignant lesions is superior to laser alone in terms of symptoms free survival (8.5 vs. 2.8 months  $p < 0.05$ ) and progression free survival (7.5 vs. 2.2 months  $p < 0.05$ ). There were no treatment-associated morbidities or mortalities reported [20]. Also, HDR-EBBT can be safely combined with photodynamic therapy achieving complete endoscopic response in 87.5% of the patients at 24 months [21]. In a retrospective analysis consisting of 226 patients treated with EBBT with or without EBRT, the complete endoscopic response rate was 93.6% at 3 months [22].

---

## Definitive Treatment

Standard definitive therapy for unresectable lung cancer is a combination of chemotherapy and EBRT. Selected patients (those with predominantly endobronchial tumor) may benefit from EBBT, either alone or as a boost to EBRT. The ideal patients for curative EBBT alone are those with occult carcinomas of the lung confined to a bronchus or trachea. Moreover, EBBT can be used as a boost treatment for selected patients with inoperable non-small cell carcinoma, in combination with EBRT. Brachytherapy boost is especially advantageous in cases of post-obstructive pneumonia or lung collapse to overcome bronchial obstruction, so that the lung is aerated and

the tumor volume is better defined. This allows sparing of the normal lung from external beam radiation. Brachytherapy with curative intent can be an option in early-stage patients who are medically inoperable. Additionally, EBBT can be used as adjuvant treatment after surgical resection with minimal residual disease [7].

---

## Complications

EBBT is generally considered to be a safe procedure with minimal side effects. Nevertheless, complications occur in around 3–30% of patients, including fistula formation, radiation bronchitis, tracheal perforation, ulcers, hemorrhage, bronchial stenosis or necrosis with some complications being fatal [23]. Catheter dislodgement when attempting to treat upper lobe bronchi is a common procedure-related complication which was noted in our Lahey cohort [16].

Post-treatment bronchoscopy may be needed to diagnose and treat urgent complications (i.e., to address hemoptysis, or to clear airway from radiation induced mucosal debris).

---

## Summary and Recommendations

EBBT is a safe procedure with relatively low complication rate. Careful patient selection and modification of the number of intended treatments in cases where there is evidence of radiation-induced damage to the airway epithelium seems to avert significant procedural complications. Patients with endobronchial ulceration, fistula formation, or severe airway tumor obstruction are typically not recommended for EBBT [14]. Patients may require monitoring for transient worsening airway obstruction from sloughing tissue or edema, and may require repeat bronchoscopy in the first few days following treatment [14].

EBBT in conjunction with other invasive interventional procedures can be used for palliating respiratory symptoms caused by endoluminal tumor burden in carefully selected patients.



**Acknowledgment** The authors are indebted to Professor Gene Wong, MD, for his major contributions to this chapter and for his patient guidance throughout the project. We are grateful to Joan Gabriel, RN, and Nicole Walker for the photographs in this chapter.

## References

1. Yankauer S. Two cases of lung tumor treated bronchoscopically. *NY Med J.* 1922;21:741.
2. Gaspar L. Brachytherapy in lung cancer. *J Surg Oncol.* 1998;67:60–70.
3. Stewart A, Parashar B, Patel M, et al. American Brachytherapy Society consensus guidelines for thoracic brachytherapy for lung cancer. *Brachytherapy.* 2016;15:1–11.
4. Hennequin C, Bleichner O, Tredaniel J, et al. Long-term results of endobronchial brachytherapy: a curative treatment? *Int J Radiat Oncol Phys.* 2007;67(2):425–30.
5. Qui B, Jiang P, Ji Z, et al. Brachytherapy for lung cancer. *Brachytherapy.* 2021;20:454–66.
6. Chargari C, Deutsch E, Blanchard P, et al. Brachytherapy: an overview for clinicians. *CA Cancer J Clin.* 2019;69:386–401.
7. Nag S, Kelly JF, Horton JL, et al. Brachytherapy for carcinoma of the lung. *Oncology.* 2001;15(3):371–81.
8. Ezzell GA. Limitations of the straight-line assumption for endobronchial HDR brachytherapy treatments. *MedPhys.* 2000;27:151–3.
9. Perol M, Caliandro R, Pommier P, et al. Curative irradiation of limited endobronchial carcinomas with high dose rate brachytherapy. Results of a pilot study. *Chest.* 1997;111(5):1417–23.
10. Nag S, Abitbol AA, Anderson LL, et al. Consensus guidelines for high-dose-rate remote brachytherapy in cervical, endometrial, and endobronchial tumors. *Int J Radiat Oncol Biol Phys.* 1993;27:1241–4.
11. Nomoto Y, Ii N, Murashima S, et al. Endobronchial brachytherapy with curative intent: the impact of reference points setting according to the bronchial diameter. *J Radiat Res.* 2017;58(6):849–53.
12. Hosni A, Bezjak A, Rink A, et al. High dose rate brachytherapy as a treatment option in endobronchial tumors. *Lung Cancer Int.* 2016;2016:3086148.
13. Kawamura H, Ebra T, Katoh H, et al. Long-term results of curative intraluminal high dose rate brachytherapy for endobronchial carcinoma. *Radiat Oncol.* 2012;7:112–8.
14. Shepherd R, Radchenko C. Bronchoscopic ablation techniques in the management of lung cancer. *Ann Transl Med.* 2019;7(15):362.
15. Li XA, Chibani O, Greenwald B, et al. Radiotherapy dose perturbation of metallic esophageal stents. *Int J Radiat Oncol Biol Phys.* 2002;54:1276–85.
16. Shadchehr S, Pantano J, Lamb C. Endobronchial brachytherapy treatment: a treatment option with minimal side effects. *Chest.* 2010;138(4):721A. <https://doi.org/10.1378/chest.10650>.
17. Reveiz L, Rueda J-R, Cardona AF. Palliative endobronchial brachytherapy for non-small cell lung cancer. *Cochrane Database Syst Rev.* 2012;12:CD004284. <https://doi.org/10.1002/14651858.CD004284.pub3>.
18. Skowronek J, Kubaszewska M, Kanikowski M, et al. HDR endobronchial brachytherapy (HDRBT) in the management of advanced lung cancer-comparison of two different dose schedules. *Radiother Oncol.* 2009;93:436–40.
19. Niemoeller OM, Pollinger R, Niyazi M, et al. Mature results of a randomized trial comparing two fraction schedules of high dose rate endobronchial brachytherapy for the treatment of endobronchial tumors. *Radiat Oncol.* 2013;8:8.
20. Chella A, Ambroggi MC, Ribechini A, et al. Combined Nd-YAG laser/HDR brachytherapy versus Nd-YAG laser only in malignant central airway involvement: a prospective randomized study. *Lung Cancer.* 2000;27:169–75.
21. Freitag L, Ernst A, Thomas M, et al. Sequential photodynamic therapy (PDT) and high dose brachytherapy for endobronchial tumour control in patients with limited bronchogenic carcinoma. *Thorax.* 2004;59:790–3.
22. Maud A, Bernard P, Sunyach M, et al. High-dose-rate brachytherapy for non-small cell lung carcinoma: a retrospective study of 226 patients. *Int J Radiat Oncol Biol Phys.* 2011;79:1112–6.
23. Qiu B, Jiang P, Ji Z, et al. Brachytherapy for lung cancer. *Brachytherapy.* 2021;20:454–66.



## Introduction

Photodynamic therapy (PDT) is an approved treatment for several types of tumors and certain benign diseases, based on the use of a light-absorbing compound (photosensitizer) and light irradiation. Light-activation of the photosensitizer accumulated in cancer tissues leads to local production of reactive oxygen species that kill the tumor cells, in the presence of molecular oxygen.

PDT may also be called photoradiation therapy, phototherapy, or photochemotherapy. In respiratory care, it is used as a minimally invasive modality for treatment of premalignant and malignant lung tumors as a proven antitumor modality well tolerated and with few negative effects. The U.S. Food and Drug Administration approved PDT for the treatment of microinvasive endobronchial non-small cell lung cancer in early 1998 and for advanced partially obstructing endobronchial lung cancer in late 1998 [1]. The FDA also has approved photodynamic therapy to treat: [actinic keratosis](#) advanced, [cutaneous T-cell](#)

[lymphoma](#), [Barrett esophagus](#), [basal cell skin cancer](#), [esophageal](#) (throat) cancer, [non-small cell lung cancer](#), [squamous cell skin cancer](#) (Stage 0).

Despite their known drawbacks, conventional interventions including surgery, radiation therapy, and chemotherapy remain the first options in the oncologist's toolbox for the treatment of patients. Photodynamic therapy (PDT) has been proven to be an interesting alternative to the three described treatment modalities in several indications [2, 3].

PDT can be used as solo therapy or in combination with surgery, chemotherapy, or standard radiation therapy. The primary indications are for obstructive disease and symptom palliation in patients with tumors that are not eligible for standard surgery and radiation therapy.

Photodynamic therapy is also used to relieve symptoms of some cancers, including [esophageal cancer](#) when it blocks the throat and non-small cell lung cancer when it blocks the airways [4].

## Photosensitizers

Photosensitizer agents are natural or synthetic structures that transfer light energy. Although there are thousands of them that participate in nature processes such as photosynthesis, or derived from porphyrins or chlorophyll from plants and bacteria, only a few meet the necessary characteristics for PDT and only a few have been approved by the FDA for clinical use (Table 14.1). PDT has been studied for decades

---

J. P. Díaz-Jiménez (✉)  
Interventional Pulmonary Department, Hospital  
Universitari de Bellvitge, Hospitalet de Llobregat,  
Barcelona, Spain  
e-mail: [pablodiaz@pablodiaz.org](mailto:pablodiaz@pablodiaz.org)

A. N. Rodríguez  
School of Medicine, National University of Mar del  
Plata, Buenos Aires, Argentina

**Table 14.1** Summary of main photosensitizers

Photosensitizer/generic name	Commercial name	Administration formulation	Approved indications/clinical trials	Skin photosensitivity
Hematoporphyrin derivatives (HpD)/porfimer sodium	Photofrin®	IV/topic/powder for solution	Esophageal cancer, high grade dysplasia in Barrett's esophagus, gastric, cervical dysplasia, bronchial, bladder and lung cancer	1–3 months
		Wavelength: 630 nm		
Benzoporphyrin derivate monoacid ring A (BPD–MA)/Verteporfin	Visudyne®	IV/liposomes	Age-related macular degeneration	3–5 days
MesoTetraHydroxy-Phenilcnlorin (m THPC)/Temoporfin	Foscan®	IV/solution in ethanol and propylene glycol	Palliative advanced head and neck cancer/squamous cell carcinoma	Up to 6 weeks
		Wavelength: 652 nm		
Tinethyletiopurpurin (SnET2)/Rostaporfin	Purlytin®	IV/lipid emulsion	<i>Clinical trials:</i> skin, prostate and metastatic breast cancer, Kaposi's sarcoma and aged related macular degeneration	2–3 weeks
Lutetium Texaphyrin/Motexafin Lutetium	Lutrin®	IV/powder for solution	<i>Clinical trials:</i> skin and breast cancer	1–2 days
5 Aminolevulinic acid (5 ALA)	Levulan®	Topical/oral/IV/powder for solution/cream	Active keratosis. <i>Clinical trials:</i> basal cell carcinoma, esophageal, gastrointestinal, lung and non-melanoma skin cancer	1–2 days
Methylamino levulinate	Metvix®	Topical/cream	Active keratosis, basal cell carcinoma, Bowen's disease. <i>Clinical trials:</i> acne	Uncommon
Hexylaminolevulinate (HAL)	Hexvix®	Topical powder for solution/gel	Bladder cancer diagnosis. <i>Clinical trials:</i> rectal adenoma and cancer diagnosis, cervical dysplasia	Uncommon

and its usefulness has been recognized for a large variety of malignant tumors, but the photosensitivity phenomenon was already known in the early twentieth century.

Most of the early photosensitizers were derivatives of hematoporphyrins. Hematoporphyrins are tetrapyrrolic pigments, whose base is porphyrin, formed by four pyrrolic units linked by four methyl bridges, configuring a cyclic molecule.

In 1961, a group of physicians at Mayo Clinic reported that tumor fluorescence was enhanced when a derivative of hematoporphyrin was employed. Lipson, Baldes, and Olsen obtained "Hematoporphyrin Derivative" (HpD), a purer compound suitable for use in humans [5, 6]. In 1968 Gregory et al. published a recipe along with a report that this agent could be used to localize

neoplasia by the resulting tumor fluorescence. They administered intravenously hematoporphyrin derivative to 226 patients to study fluorescence of various lesions utilizing a Baldes activating blue violet light. One hundred seventy-three patients of them had malignant neoplasms and 53 patients had benign lesions. Result was that 132 (76.3%) of the malignant lesions showed tumor fluorescence, while only 12 of the benign had fluorescence (22.6%) [7].

In the mid-1970s, the first successful treatment of animal tumors was performed at the Roswell Park Memorial Institute, using a xenon lamp as the light source. The introduction of laser equipment resulted in much faster progress in PDT. In the early 1980s, PDT was used to treat early stages of squamous cell lung cancer.

In 1983 Dougherty found a new component in HpD: bis-1,3 (1 hydroxyethyl) deuteroporphin 8 ethyl ether or dihematoporphyrin (DHE), which seemed to be responsible, among the mix of components of HpD, for the ability to sensitize tumors [8].

Another known sensitizer is tetraphenylsulfonate (TPPS), capable of being as active as HpD. Its neurotoxicity and its slow elimination from the serum mean that it cannot be applied clinically [9].

The correct choice of the photosensitizer is important for a successful response to PDT's treatment. PS must be non-toxic for the cells in absence of light exposure and should be selectively retained by the target (malignant) cells. Also, PS should be able to induce an immunogenic response over treated cells as changes of surface glycoproteins receptors and consequently activate a cascade of immunologic cells response and malignant cells death [10].

An ideal photosensitizer should have the following qualities: significant chemical purity, effective absorption affinity at an appropriate wavelength between 400 and 800 nm, with high quantum yield singulate oxygen production, minimal toxicity in the dark, and delayed phototoxicity, easy dissolution in injectable solvents, good stability and selective tumor localization.

Based on their specific characteristics and the time of development, PSs have been classified in generations.

---

### First-Generation Photosensitizers

Porfimer Sodium (Photofrin®). It is the most extensively studied photosensitizer. In January 1998, the Food and Drug Administration approved in the United States the use of Photofrin® (porfimer sodium) for PDT in patients with microinvasive lung tumor who are ineligible for surgery or radiotherapy [11].

The palliation use of certain tumors was approved in 1997.

Photofrin® and its predecessor, hematoporphyrin derivative are obtained by a complex mixture of esters from hematoporphyrin. The cytotoxic effect for PDT is limited by the maxi-

imum penetration capacity of the laser light at 630 nm wavelength. This wavelength has the highest power to penetrate tissue from 3 to 5 mm.

Following the administration of Photofrin, there is a systemic photosensitivity period that can last up to 6 weeks.

However, its low light absorption within the therapeutic window (from 600 to 700 nm) and prolonged photosensitivity made that second-generation photosensitizers with better absorption features and fewer adverse reactions were developed.

Photofrin®-PDT proves to be effective as a palliative treatment in lung cancer, but is associated with prolonged photosensitivity of the skin. In addition, it is less effective with lesions larger than 1 cm.

Although the majority of photosensitizers at the preclinical stage are porphyrin derivatives, a diverse number of nonporphyrin photosensitizers also exist.

---

### Second-Generation Photosensitizers

Despite the fact that PDT has slowly progressed in its oncological therapeutic applications due to the low sensitivity and phototoxicity produced by first-generation sensitizers, research into second-generation photosensitizers has meant that in recent years PDT, once again, has the place that it deserves as an effective and well-tolerated modality with fewer adverse effects than chemotherapy or radiotherapy in the treatment of cancer.

In order to improve the efficacy of PDT, and specially to ensure that the photosensitizer reaches the malignant cell and destroys it avoiding secondary effects on healthy cells as much as possible, researchers also are trying to find new photosensitizers that make it more selective and effective and with fewer adverse effects.

Several studies have recently been conducted to better characterize the efficacy and selectivity of PSs. New photosensitizers of the second generation present advantages due to their characteristics of better penetration, developing agents with longer absorption wavelengths that allow

better penetration in the target tissues. The goal of using these second-generation PSs was to achieve better tumor selectivity and reduce the total drug dose. The advantage of using lower doses is that the product is eliminated faster and the photosensitivity of the skin can be reduced from weeks to days [12].

***Benzoporphyrin Derivate (BPD)*** It is a second-generation of PS, which is a hydrophobic molecule with a maximum absorbing peak at 690 nm, higher than the absorption of the hemoglobin. So it is not attenuated by the blood and has a maximum tissue penetration. Furthermore, BPD is quickly accumulated in the target tissue allowing a PDT treatment from 30 to 150 min after intravenous injection. It is also rapidly cleared from the body. Photosensitivity of the skin does not extend more than a few days [13].

***Aminolevulinic Acid (ALA)*** Endogenous photosensitization induced by ALA is a new approach for photodynamic therapy and tumor detection. It consists in a biosynthetic reaction to produce endogenous porphyrins Hem, particularly photoporphyrin IX, which is a very effective photosensitizer that accumulates in mucosal surfaces, such as skin, conjunctiva, oral, rectal, vaginal, endometrial, and ureteral mucosa [14].

It has been used with acceptable results to treat superficial tumors of the skin, such as the basal cell carcinoma, squamous cell carcinoma, and adenocarcinoma. Residual photosensitivity after treatment lasts about 48 h.

ALA has been also applied orally and by aerosol inhalation via jet nebulizer, showing that both modalities were well tolerated, allowing tumor visualization and after oral administration it was possible to perform photodynamic therapy. At 5 and 12 weeks after PDT, marked reduction in tumor volume and recanalization of the bronchus was observed bronchoscopically, with no associated adverse effects [15].

ALA fluorescence can be used in the detection of bladder lesions, early stage “in situ” lung carcinoma, and malignant glioma.

Chlorins have been extensively investigated for their potential to treat oral cancer. Extensive cellular damage and complete tumor regression within a week treatment have been reported [16].

Although chlorine exhibits good water solubility and stability, aqueous solutions did not represent the best delivery system in many tumors such as oral cavity or endobronchial tumors. A combination to a mucoadhesive delivery system shows to increase the absorption in the target tissue and improves the overall outcomes [17].

### **N-Aspartyl Chlorin e6 (NPE6) (Talaporfin Sodium, Laserphyrin®), Meiji Seika, Tokyo, Japan**

NPE6 is a second-generation, water-soluble photosensitizer with a molecular weight of 799.69 and a chlorine annulus. Its maximum absorption peak is at a wavelength of 407 nm, and there is a second peak at 664 nm.

It belongs to the second generation of PS that stands out for its excellent antitumor effects and rapid skin clearance in laboratory animals. The Npe6 has a longer absorption band (664 nm) than Photofrin®, so it has a slight advantage in deep tumor treatment. The administered dose is 40 mg/m<sup>2</sup> and the laser power density is 100 J/cm<sup>2</sup>. Adverse effects are minimal and cutaneous photosensitivity disappears within 2 weeks after administration. It has been approved by the Japanese authorities (Japan Ministry of Health, Labor and Welfare) since 2004 for lung cancer treatment, and from early 2010 for advanced lung cancer treatment.

### **M-Tetrahidroxofenil Cloro (mTHPC) (Foscan®)**

It is a synthetically pure chlorine derivative whose best quality is to produce a rapid photodynamic reaction. It is very effective at treating primary and recurrent head and neck cancers. The drug is so active that after administration, patients must stay in a dark room for 24 h, as room light will activate the drug and cause severe burns. The



treatment times are very short and the lighting is very painful for this reason the treatments are recommended under anesthesia [18].

Due to their submicron size, nanoparticles as PS delivery system have numerous advantages such as the protection against enzymatic PS degradation, the control of PS release allowing a constant and uniform concentration into target cells, and the ability to penetrate target cells [19].

---

### Third Generation of Photosensitizers

The low specificity of current photosensitizers to localize and reach tumor tissue is one of the most important problems of PDT to achieve greater efficacy.

Second-generation photosensitizers bound to carriers such as antibodies and liposomes for selective accumulation within tumor tissue are referred to as third-generation photosensitizers and currently represent an active research area in the field [20].

A third generation of PSs results by modification of the second generation with biologic conjugates such as carriers, antibodies, or liposomes to improve their physical, chemical, and therapeutic properties. Recently, significant efforts have employed in the synthesis of pure chemical derivatives in order to create new sensitizers with improved activity and minimal side effects.

In this sense, the transport of photosensitizers by means of nanoparticles is increasingly being investigated to improve permeability and retention [21]. The incorporation of PS into nanostructured drug delivery systems, such as polymeric nanoparticles (PNPs), solid lipid nanoparticles (SLNs), nanostructured lipid carriers (NLCs), gold nanoparticles (AuNPs), hydrogels, liposomes, liquid crystals, dendrimers, and Cyclodextrin is a potential strategy to overcome this difficulty [22].

This type of nanoparticles is synthesized biomolecules for drug delivery, which are used in PDT to enhance transcytosis across epithelial and endothelial barriers and optimize delivery of poorly water-soluble PS and co-delivery of PS

into cells. Also, due to their submicron size, nanoparticles as a PS delivery system have other advantages such as protection against PS enzymatic degradation, the control of PS release that allows a constant and uniform concentration in target cells, and the ability to penetrate target cells [19].

PS incorporation of nanoparticles opens new perspectives and challenges to this field.

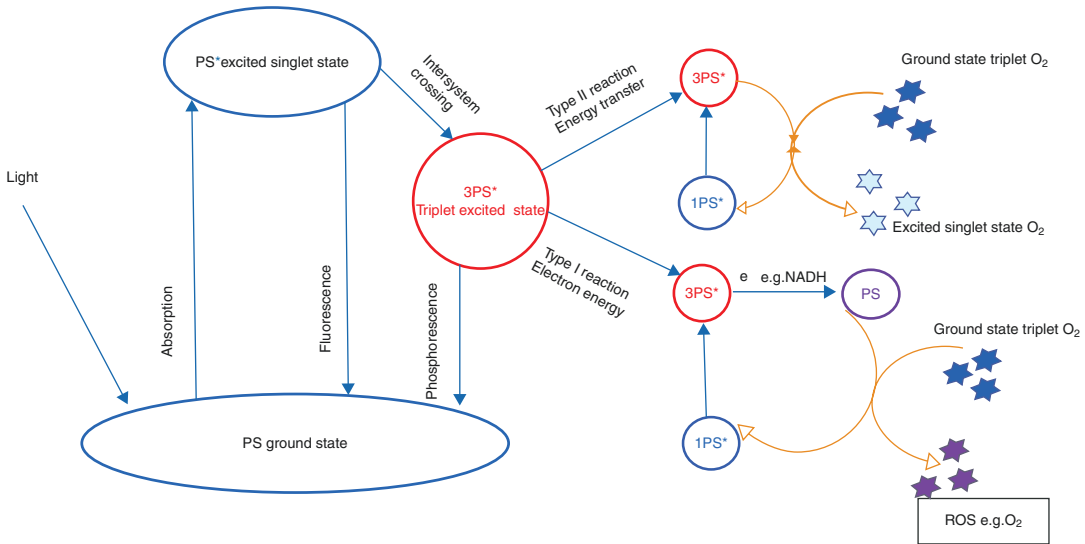
---

### PDT Reaction

Figure 14.1 involves administration of a photosensitizing agent followed by light irradiation of the previously sensitized tissue, at a wavelength corresponding to an absorbance band of the PS. In the presence of oxygen, a series of events lead to direct tumoral cell death, damage to the microvasculature, and induction of a local inflammatory reaction [23].

The photochemical reaction requires three fundamental components: a sensitizer, photons, and oxygen. The mechanism of action of PDT is determined by the uptake of a photosensitizer (PS) molecule which, upon being excited by light in a determined wavelength, reacts with oxygen and generates oxidant species: singlet oxygen, radicals that produce peroxidative reactions in cell membranes, cytoplasm, or organelles that cause cell damage and death by apoptosis or necrosis of tumor cells, closes the vasculature of the tumor, and further affects the immune system [23, 24].

This photodynamic reaction is activated when an appropriate wavelength of light is emitted on a previously sensitized tissue. When the light arrives at the target tissue, it is absorbed by the photosensitizer (Ps) who has two electrons with opposite spin in their ground state that makes that one of them jumps to an excited energy singlet state, generating an unstable excited photosensitizer. This unstable excited photosensitizer can emit excess energy as heat and/or fluorescence (a feature which can be used for the purposes of diagnostics and optical monitoring). Alternatively, the electron may have its spin inverted (parallel to its counterpart) creating a new excited triplet



**Fig. 14.1** Type I and Type II reactions in PDT (“photodynamic reaction”) Schematic Jablonski’s diagram showing PDT’s mechanism of action. Following light absorption, the PS reaches an excited singlet state ( $PS^*$ ). After an intersystem crossing, photosensitizer in a triplet excited state ( $^3PS^*$ ), can react in two ways: (1) it reacts with biomolecules

through a *hydrogen atom transfer* to form radicals, which react with molecular oxygen to generate ROS (Type I reaction); (2)  $^3PS^*$  can react directly with oxygen through *energy transfer*, generating singlet oxygen ( $^1O_2$ ) (Type II reaction). *PS* photosensitizer,  $PS^*$  excited singlet,  $^3PS^*$  excited triplet singlet, *ROS* reactive oxygen species,  $^1O_2$  singlet oxygen

state in a process called intersystem crossing. From here, one of two things can happen: The particle reacts directly with the surrounding tissue (substrate) forming a radical anion or cation which then reacts with oxygen in the air to produce reactive oxygen species (ROS) (Type I reaction); or all of the electron’s energy is transferred to oxygen from the air forming singlet oxygen (Type II reaction) [2].

The balance between these two processes (type I and II reaction) depends on the nature of PS being used, the concentrations of oxygen and substrate, and affinity of the PS with the substrate. Both types of reactions reach cell death but in general, under hypoxic conditions primarily occurs a type I photodynamic reaction, while in oxygenated conditions prevail the generation of type II photochemical reactions which is the most important pathway for PDT clinical use, because the PS interacts with oxygen to generate singlet oxygen, which is considered to be the basis of PDT’s tumor and vascular ablation ability. This oxygen-dependent type II PDR is essential for PDT [25–28].

## Tumor Damage Process

Tumor destruction is based on the following facts: After the administration, the photosensitizer is distributed in all cells and can be found in the liver, spleen, kidney, bone marrow, and tumor tissue. Normal organs quickly clear this substance, but in tumor cells it remains inside for more than 48 h. Due to differences in the vasculature and lymphatic drainage of tumors and its uptake, the photosensitizer is selectively retained by the tumor, its cells, and its interstitial tissue, so that after 2 days its concentration will be higher in the tumor than in the rest of the tissues. Finally, the photosensitizer is activated at the target tissue by an appropriate wavelength light. The photosensitizing substance will absorb the light energy and oxygen derivatives (singlet oxygen) will be produced, with the consequent destruction acting on the different cell structures from the membrane to the nucleus. PDT also causes a cessation of vascular tumor circulation with tissue hypoxia and secondary tumor necrosis, while nearby tissues are not affected. This reaction is the main cause for tumor destruction.

Events related to the reaction have drawn attention lately, such as the antitumor activity of inflammatory cells and the triggered immune reaction by the tumor sensitized with a photodynamic substance. These two reactions are initiated by photodynamic damage and contribute to a more complete tumor destruction.

Some factors can limit tumor cell death, such as an inhomogeneous distribution of the photosensitizing substance within the tumor, and also the availability of oxygen. These factors have been largely avoided with the appearance of new third-generation photosensitizers, as we will see later.

PDT reaches the cytotoxic effects on tumor cells by indirect and direct mechanisms. Indirect mechanisms lead to changes in the tumor micro-environment as anti-vascular effect (vasoconstriction, thrombosis or vessel leakage) and anti-tumor immune response (release pro-inflammatory cytokines and tumor associated antigens or fixation of complement). Direct mechanisms produce cell killing due to macromolecule damage with apoptosis and necrosis process. The reactive oxygen species (ROS) that are produced during PDT have been shown to destroy tumors by multifactorial mechanisms [29, 30].

ROS (reactive oxygen species) and singlet oxygen have a high reactivity but a short half-life (40 ns). Due to this, PDT directly affects only those biological substrates that are close to the region where these species are generated, usually within a 20 nm radius [25].

Apoptotic cell death tends to predominate in the most PDT sensitive cell lines at lower light/photosensitizer doses [31, 32], while the necrotic mechanism tends to predominate at higher light/photosensitizer doses [33]. Activation of an autophagic mode of cell death following irradiation of certain photosensitizers have been also described by changes in the cellular morphology, chromatin condensation, loss of mitochondrial membrane potential and formation of vacuoles containing cytosolic components [34].

The damage of a specific subcellular target depends on the location of the photosensitizer, due to the reduced capacity of migration of oxy-

gen. Photofrin<sup>®</sup>, one of the most used photosensitizers, is accumulated in the mitochondria and once activated causes apoptosis. Other PSs have empathy for determinate organelles, like lysyl chlorin p6 for lysosomes. The initial damages that PDT produces in cells membranes can be observed after light exposure: edema, blistering, ruptured vesicles containing enzymes, reduction of active cell transport, plasmatic membrane depolarization producing more photosensitizer income, increased chromate permeability and ATPase inhibition [35].

The administration of some medications will also affect the final result of the photodynamic effects. The two best known are Adriamycin and glucocorticoids. Both improve the effects of therapy increasing the area of tumor necrosis when administered 24 h after photoradiation [36–39].

Additionally, other animal studies have shown that the photodynamic reaction is time-dependent, even when it starts almost immediately after exposure to light, the process of tumor cell destruction continues to act slowly over a rather long time. “In vivo” models showed that tumor cells transplanted immediately after treatment were able to be implanted and to reproduce, while those transplanted 24 h after treatment were not [40].

---

## Procedure


For PDT treatment of malignant tumors in the tracheobronchial tree, bronchoscopy is performed under topical anesthesia or conscious sedation 48 h. After a slow intravenous injection of the photosensitizer, doses and window period until bronchoscopy are variable depending on the chosen photosensitizer. Photofrin<sup>®</sup> is used at a dose of 2 mg/kg 48 h before bronchoscopy while Npe6 is administered at doses of 40 mg/m<sup>2</sup> 4 h before. The PS should be preferably excited by light of a wavelength included in the therapeutic range between 600 and 800 nm, which has greater capacity for tissue penetration. The period of time between the drug is given and the light is applied, called the drug-to-light interval, can be anywhere from a couple of hours to a couple of days, depending on the chosen agent [41].

Tumors should be irradiated (630 nm light) through a flexible fiberoptic bronchoscope  $40 \pm 50$  h after oral or intravenous administration of PS. The tumor area is illuminated for 500 s with a 630 nm wavelength of a with non-thermal effect laser light, such as Argon-Dye laser or Diode laser (Fig. 14.2). In case of using Photofrin® as a photosensitizer, the residual tumor could receive additional illumination within 6–7 days since the photosensitizer concentration is still in the therapeutic range.

Two different radiation fibers are used depending on the type and the size of the tumor: front light microlens fibers (Fig. 14.3) or 360° diffusing light cylindrical fibers (Fig. 14.4). Microlens fibers are used for small and superficial tumors such as “in situ” lesions. When a radical treatment is intended, it is necessary to carry out an exhaustive inspection of the entire bronchial tree, especially at the peripheral areas. The extent of the tumor should be mapped and any synchronous airway lesion should be confirmed or excluded before the procedure.



**Fig. 14.2** Diodes laser



**Fig. 14.3** Microlens fiber

The use of the ultrafine fiberscope and EBUS can be very useful for diagnosing small peripheral lesions inaccessible to the conventional fiberscope. The procedure has to be performed in an appropriate suite following the laser safety rules (Fig. 14.5).

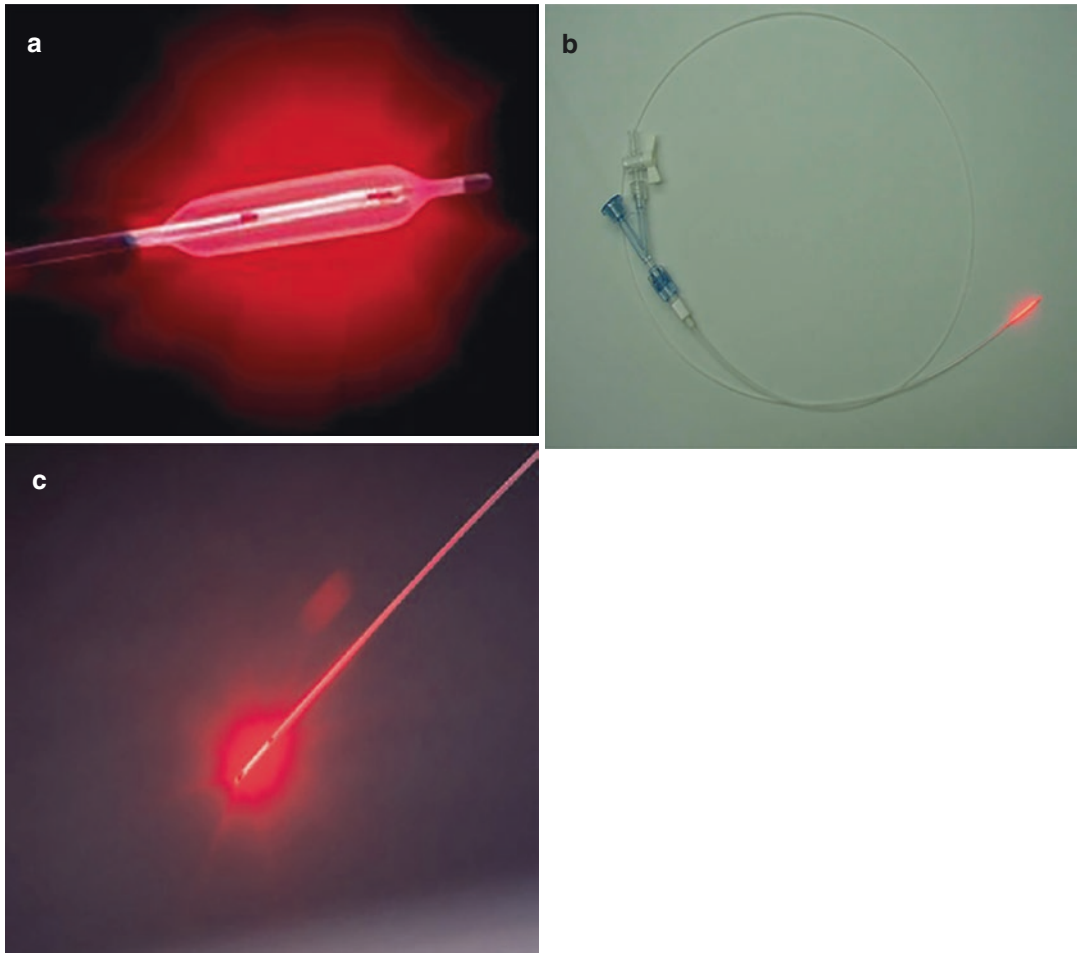
For exophytic tumors more than 0.5 cm and for parallel bronchial lumen tumors or those that involve small branches of the bronchial tree, the cylindrical fiber or 360° diffusing light cylindrical fiber inserted directly inside the tumor is appropriate.

Between 2 and 5 days after treatment, a new bronchoscopy is performed to clean out debris. A second illumination is advisable if parts of the tumor show no signs of necrosis  $96 \pm 120$  h after the first illumination.

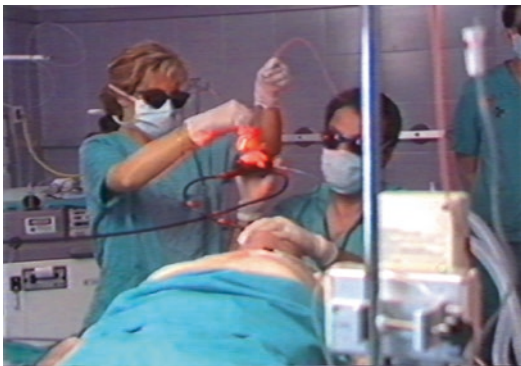PDT clinical efficacy is dependent on complex dosimetry of total light dose, light exposure time, and light delivery mode [42]. Current protocols use a power of 200–400 mW/cm<sup>2</sup> to apply a total light dose of 100–200 J/cm<sup>2</sup> in a treatment time of 500 s [43].

In addition to Argon-Dye and Diode lasers, other laser types have been used, such as gold vapor laser, copper-dye laser, laser-dye excimer, yttrium laser, aluminum and garnet (YAG) with a crystal of potassium titanyl phosphate laser and an optical parametric oscillator. The therapeutic window for the majority of PDT applications lies in the red region of the spectrum between 620 and 850 nm achieving optimal tissue penetration and PS activation. For the delivery of light, both lasers and incandescent light have proven to be effective [43, 44].





**Fig. 14.4** (a–c) Cylindrical and interstitial diffuse fibers



**Fig. 14.5** PDT room

Photosensitivity is the most common secondary effect of PDT. It usually lasts for 4–6 weeks. During all this time patients are

advised to cover their skin completely when exposed to direct or indirect sunlight, and to avoid bright indoor light. The patient must also wear sunglasses and should not use hair dryers or other devices that give direct heat to the skin. The new generations of photosensitizers have less photosensitivity, reducing this period from weeks to days.

As we mentioned, one or several clean-up bronchoscopy should be performed 2 or 3 days after tumor illumination, in order to remove viscous debris and detritus from the tumor process destruction to avoid complications such as atelectasia, infections, respiratory distress, or respiratory failure. A new follow-up bronchoscopy should be done if the patient persists or develops bronchial obstruction symptoms.



In case of obstructive tumors, when symptoms recur within 30 days after the first treatment or if additional bronchoscopy reveals local recurrence, patients could receive a second PDT session. The same dose of photosensitizer followed by laser photoradiation can be repeated. Patients could receive a maximum of three photosensitizer doses at 1-month intervals and up to 6 laser photo-irradiations, with a maximum of 2 photo-irradiations per session. If toxic effects occur, treatment must be withheld until they resolve.

**Indications**

Summary of curative and palliative indications of photodynamic therapy in the management of patients with non-small cell carcinoma is depicted below [45–47] (Table 14.2).

**Curative PDT Indications**

1. In situ Carcinoma (first-line indication)
2. Microinvasive and limited to the bronchial wall non-small cell lung cancer:
  - (a) Early-stage intraluminal and central tumors following definitive surgery or radiation therapy

- (b) Roentgenographically occult central tumors
- (c) Synchronous primary carcinomas
3. Recurrence of operated non-small cell lung carcinoma (stump area) or treated by radiotherapy
4. Severe dysplasia

Patient’s selection should be cautious taking into account area and depth of tumoral extent. The Japanese Lung Cancer Society in 2010 defined the criteria of early central lung tumor selection [48]:

- distal limit at subsegmental bronchus location,
- bronchoscopically identifiably tumor margins,
- tumor size less than 2 cm in its greatest dimension, and
- squamous cell carcinoma is proven histologically.<sup>1</sup>
- It also defines three types of lesions according to the endoscopic appearance: flat lesions, nodular lesions, and early polypoid lesions. It has been shown that lesions protruding (nodular or polypoid) tend to invade the bronchial wall deeper than the flat-type lesions. Flat lesions <1 mm in diameter and visible distal margins are in situ carcinoma more than 90%

**Table 14.2** PDT summary indications

Summary of curative and palliative indications of photodynamic therapy in the management of patients with non-small cell carcinoma
Definitive therapy for early-stage central endobronchial tumors
Definitive therapy for early-stage locally recurrent central tumors following definitive surgery or radiation therapy
Definitive therapy for roentgenographically occult central tumors
Definitive therapy for synchronous primary carcinomas
Palliation to reduce endobronchial luminal obstruction and tumor stenosis, improve performance status and respiratory function, and resolve acute hemoptysis and poststenotic pneumonia
Neoadjuvant therapy to reduce the extent of surgical resection (pneumonectomy → lobectomy)
Neoadjuvant therapy to convert originally inoperable patients to surgical candidates
Treatment of locally advanced disease as part of multi-modality therapy
Treatment of disease with pleural spread as part of multi-modality therapy

**Published Clinical Indications of PDT to Treat Patients with Non-Small Cell Lung Cancer Thoracic Malignancies.** Modified from: Simone CB, et al. Photodynamic therapy for the treatment of non-small cell lung cancer. *J Thorac Dis.* 2012 Feb;4(1):63-75. [28]

<sup>1</sup>Both squamous and adenocarcinoma can be currently treated by PDT.

of the time, suggesting this to be the ideal indication [49, 50].

**Palliative PDT Indications**

1. Endobronchial obstruction caused by any type of tumor: all histological types, primary and/or metastatic, have responded to treatment [51–53].  
 Small cell carcinoma is not included among the histologic types that can benefit from this treatment mainly because it is known that these tumors respond well to chemotherapy and because they present more as infiltrative tumors than obstructive masses.
2. Slow down tumor progression.
3. Improve symptoms such as bleeding, secretions, and dyspnea [51, 54].
4. Some authors have suggested to use PDT for inoperable patients making them candidates for surgical treatment [55–57].

Review of available data on this indication, published by four authors [58–61] shows results of 106 responses on 111 patients treated.

Recently, PDT has been used at the Tokyo Medical University Hospital as pre-operative therapy in 26 patients, reducing the extension of non-small cell tumor and/or converting patients into operable candidates. Four of the 5 patients originally inoperable became operable, and 18 of the 21 patients originally can-

- didates for pneumonectomy were eligible for less invasive surgery such as lobectomy [57].
5. Recurrence at the surgical stump. Historically, survival of these patients is around 9 months. McCaughan and Williams have observed 5-year survivals of similar cases treated repeatedly with PDT [54].
  6. Bleeding control, through PDT ability to cause thrombosis of small vessels. In a study, the amount of bleeding was recorded before, during, and after treatment with PDT, and there was statistically a significant reduction of bleeding during and after PDT treatment. PDT has also been described as effective in the palliative treatment of patients with uncontrollable life-threatening hemoptysis [62].
  7. Malignant pleural dissemination: patients can be treated by PDT following a complete surgical resection. As with malignant pleural mesothelioma, PDT may be utilized as part of multimodality management. In fact, PDT can be used for non-small cell lung cancer with pleural spread. In a phase II trial with pleural spread and clinical T4 non-small cell lung cancer, 20 patients underwent surgery that was followed by pleural PDT, and in only 2 patients, PDT was practiced alone. After 6 months of control, the rate of survival was 73.3%, and median overall survival was 21.7 months, compared with 6–9 months for similar patients based on historical controls [63].  
 See Table 14.3.

**Table 14.3** PDT advantages, disadvantages, and complications

Advantages	Disadvantages	Complications
– Selectivity and affinity for tumor tissue	– Photosensitivity	– Fever (20%)
– Minimally invasive	– Efficacy depends on adequate patient and photosensitizer selection and accurate light delivery to tumor	– Skin and eye photosensitivity (from 4 to 6 weeks)
– Short treatment time		– Allergic reactions to photosensitizers
– Outpatient treatment		– Worsening dyspnea due to airway edema and accumulated secretions
– Repeatable		– Atelectasis or respiratory failure
– No long term side effects		– Infections: bronchitis and post-obstructive pneumonia
– Low systemic toxicity		– Massive hemoptysis

(continued)

**Table 14.3** (continued)

Advantages	Disadvantages	Complications
– Fewer adverse effects		
– Lower treatment cost		
– Does not interfere with simultaneous of future treatments		
– Not mutagenic		
– High rate of success		

## Contraindications

1. Porphyria or porphyrins allergy
2. Main vessel infiltration (high risk of bleeding)
3. Tracheoesophageal or bronchopleural fistula
4. In situ carcinoma with lymph node involvement
5. Extrinsic compression or submucosal infiltration
6. Severe airway obstruction (more than 50%), compromise of the main carina or patients with pneumonectomy, acute airway obstruction. PDT causes inflammatory reactions, and airway edema worsening the airway obstruction that can go from partial to complete, risking respiratory failure and death, so a fast-acting treatment, such as laser therapy, should be employed instead.
7. Leukocyte count less than 2000/mm<sup>3</sup>, thrombocyte count less than 100,000/mm<sup>3</sup>, or prothrombin time upper than 1.5 normal limit.

## Applications of PDT

### Rationale for Use in Early-Stage Lung Cancer

The average survival of patients with lung cancer is about 13% [64]. One third of these tumors are non-small cell carcinomas. At the moment of diagnosis, approximately one third of patients are stage I or II. Surgery is the standard treatment for patients in stage I, II, or IIIA. Survival for stage I patients has been established from 55 to 75%. For the subgroup of patients with T1N0 disease, survival at 5 years is around 60–82% [65, 66].

In one series, recurrences were about 27%, 60% of them during the first 2 years after resection. Recurrence in the same lung or in the stump area was more common in squamous cell carcinoma. The incidence of a second primary was 34% and was constituted by synchronous (12%) and metachronous (88%) tumors. Therefore, despite surgery, patients with early stage lung cancer have a high rate of tumor recurrence and a high probability of developing a second tumor [67].

Radiation therapy is the standard second-line treatment for patients who are inoperable, with a range of complete response from 50 to 70% and a median survival of 22–48 months for stage I disease [68]. The 5-year survival for patients with T1 tumors who are treated with external radiation varies from 10 to 40% [69]. The best results observed in surgical patients may be due to the fact that patients are less compromised and the extent of the condition is more carefully staged. Patients who are inoperable due to a poor pulmonary reserve will suffer further deterioration after radiation, due to secondary radiation pneumonitis and/or fibrosis. Patients who received surgery or maximum radiation doses cannot be retreated in most cases, which is a great disadvantage in a disease with a high recurrence rate.

Therefore, there is a need for therapeutic modalities that can be applied at multiple occasions, if necessary, and do not exclude the use of other methods in case of need. So far, treatment modalities that produce local damage to the tumor include brachytherapy, cryotherapy, electrocoagulation, laser, and photodynamic therapy. They all, however, are limited to centrally located tumors within the endoscopic view and have a penetration power of millime-

ters. While most of these treatments cause non-specific tumor damage, PDT causes selective death of cancer cells with subsequent necrosis of the tumor, without injury of the adjacent healthy tissue.

The curative effect of PDT in early stage and superficial tumors has been studied extensively and has been documented in several studies in phase II and III. Since 1980, more than 800 patients have been treated. Success rate oscillates from 80 to 100% in short-term follow-up and between 50 and 60% in long-term follow-up. The main and influencing factors for survival are tumor size and penetration in depth. It also depends on the ability to visualize the full extent of the tumor during bronchoscopy, and its complete irradiation with laser light. Evaluating the location and tumor size is therefore very important. The use of bronchoscopy and high-resolution computed tomography may improve staging and response assessment. Ultrasound has also been used to estimate the depth of the tumor in patients with roentgenographically occult cancer and determine the presence of nodal compromise.

One of the reasons for long-term photodynamic therapy failure is the high incidence of a second primary tumor. Therefore, patients must be followed with regular bronchoscopies, to control local recurrence and to exclude the presence of metachronous lesions, which can be treated with PDT if present.

Complete and prolonged remissions that have been published are promising, but they do not reach the success of surgery (more than 80%). However, it is essential to consider that the term “early cancer” is generic and includes different histological types, with different biological properties and prognosis.

Carcinoma “in situ” is an indication of PDT first-line treatment. Microinvasive carcinoma, however, is an optional indication to be only used in high risk or inoperable patients. Invasive carcinoma is an indication only in a highly selected group of inoperable patients. Severe dysplasia is not a formal indication of this treatment so far.

## **PDT Results in Early-Stage Lung Cancer**

The most useful application of PDT is the management of early-stage lung cancer (ESLC) for a curative intent minimizing the loss of lung tissue. Conventional treatment for patients with ESLC is surgery, and regardless of lesion size, approximately 70% of them require lobectomy. The remaining 30% will require bi-lobectomy or pneumonectomy [70]. Furthermore, a majority of these patients with lung cancer had a diminished pulmonary function. In addition, the cumulative risk of a second primary cancer in patients with non-small cell lung cancer ranges from 20 to 30% within 6–8 years after initial treatment. Patients successfully treated for small cell lung cancer develop a second primary cancer at an average rate of approximately 6% per year, which increases from 2 to more than 10% per patient per year 10 years after the initial treatment [71, 72].

In Japan, Hayata and colleagues have studied extensively PDT in ESLC, showing that approximately 90% of superficial tumors less than 1 cm of diameter can be completely eradicated with PDT. Patients with nodular tumors less than 0.5 cm diameter showed the same results [73].

Of 81 patients who had complete response to treatment, only 2 died of primary disease during the follow-up period. Fifteen patients were alive and free from disease at 5 years, and three showed similar results at 10 years of follow-up. Complete response (CR) rate was 71%.

PDT is not useful if there is nodal involvement, so that it is very important to verify absence of nodular compromise before starting treatment. Endobronchial ultrasound has been presented as a useful and complementary method to determine the depth of invasion of small tumors and to detect nodular invasion.

Cortese and colleagues reported a group of 21 patients with ESLC treated with PDT. Fifty-two percent of them had a CR over 1 year. A total of nine patients, who were followed for an average of 68 months, were able to avoid surgery. Ten patients treated with PDT required a second time

surgery, and in 30% of them, N1 nodal staging was found. It is difficult to know if nodal involvement in that series was due to a surgery delay while they were treated with PDT, or it was present before treatment. In any case, it shows the need to aggressively search for nodal involvement before PDT indication.

Authors concluded that 43% of patients (range 22–66.6%) who are candidates for treatment with PDT could be treated without surgery [74].

Therefore, PDT offers a better quality of life particularly in patients with multiple tumors or elderly ones [75].

Table 14.4 modified by Sutedja et al. summarizes the results of early lung cancer treated by PDT with curative intent [71].

Regarding tumor extension, several studies demonstrated that tumor length on the bronchial surface is strongly related to outcome. Kato and colleagues reported complete remission (CR) in 84.8% of patients using Photofrin® for central early-stage lung cancer. Outcome varied according to size of the treated lesions. Four groups were defined as follows: <0.5; 0.5–0.9; 1.0–2.0; and >2.0 cm. The CR rates of the first two groups were 94.6% and 93.5%, respectively, while 80 and 44.1% were reported for lesions from 1.0 to 2.0 cm, and for lesions >2.0 cm, respectively [72].

Usuda et al. reported results of 91 consecutive central early-stage lung cancer (CELC) lesions treated with NPe6 at Tokyo Medical University between June 2004 and December 2008. CR was obtained in 93.4% of patients. Of the 91 lesions examined in this study, 70 had a diameter of ≤1.0 cm and the rest of the 21 cancer lesions were >1.0 cm in size. The CR rate of CELC ≤1.0 cm in diameter was 94% and for those >1.0 cm in diameter 90.4%, respectively [81].

Those studies suggest that central early-stage lung cancer lesions less than 1 cm in diameter showed a favorable cure rate using PDT.

Regarding treatment of patients with roentgenographically occult carcinoma, surgical resection is the historical indication, but it has significant morbidity. PDT is a minimally invasive option associated with less side effects and morbidity than surgery. Most often, those patients with roentgenographically occult carcinoma present a centrally located early-stage squamous cell carcinoma. Endo et al. [82] treated 48 patients with a follow-up of 12 years. They were all surgical candidates presenting with occult bronchogenic squamous cell tumors of less than 10 mm in length. Ninety-four percent of them have a complete response with a survival rate of 81% at 5 years and 71% at 10 years.

Fujimura and colleagues consider PDT as a first-line treatment modality for patients with roentgenographically occult carcinoma of the lung, bronchoscopically visible and less than 1 cm in length, without extra cartilaginous invasion or lymphatic node involvement [83].

Finally, in treating patients, careful monitoring is necessary. Recurrences following PDT can be treated with surgery or radiation therapy.

About synchronous bronchogenic tumors, they present mainly in a central location and they are more often squamous cell tumors [84].

In these cases, PDT should be considered for those patients who are medically or surgically inoperable. Also, it proved benefits in properly selected patients who can be surgical candidates with a tumor less than 1 cm in diameter. Sokolov and colleagues reported 104 patients with synchronous lung primary tumors treated with PDT that had a significant correlation between tumor size and regression. A complete regression was observed in tumors less than 1 cm in diameter [85].

**Table 14.4** PDT in early stage lung cancer

Reference	Pathology (n)	Response	Surviving (months)
Edell et al. [76]	14	CR 14/17 (71%)	7–49 (10 pat.)
Furuse et al. [77]	59	CR 45/59 (83%)	14–32
Imamura et al. [78]	39	CR 25/39 (64%)	4–169 (17 pat.)
Okunaka et al. [79]	10 (sync)	CR 10/10 (100%)	38 (media)
	17 (met)	CR 16/17 (94%)	
Sutedja et al. [80]	39	CR 28/39 (72%)	2–95

CR complete response, *Sync* synchronic, *Met*. metachronic, *Pat*. patients



## Application of PDT in Advanced Lung Cancer

### Rationale

A review of lung cancer death showed that 57% of patients with nonsurgical disease die of local complications such as asphyxia, hemoptysis, pneumonia, and empyema [86–88].

Other studies show that 36% die from the same causes, whether or not they had surgery. Similar causes of death were found in 58% of patients with surgery versus 83% without surgery [89]. Considering that at most, 20–30% of patients with bronchogenic carcinoma are surgical candidates at the time of diagnosis, it can be assumed that the majority of inoperable patients will require palliative treatment at some point during the course of their disease.

However, the use of PDT as palliation in inoperable obstructive cancer patients should be evaluated in the context of what can be obtained with conventional treatment. By applying Nd-YAG laser, coagulation and vaporization of the tumor tissue is achieved. Laser therapy is usually performed under general anesthesia and is highly effective for debulking airways, especially in centrally located tumors. Massive hemorrhage, respiratory failure, or cardiac arrests are possible severe complications of laser photoresection, but their incidence is quite low (1.5%). Patients can also experience a minor complication in the order of 0.5% of cases.

PDT has proven to be an effective palliative treatment. The first treatment with PDT was performed in the 1980s, and since then the number of patients who have benefited from it is increasing day by day. The best results are obtained when the tumor is in early stage (carcinoma “in situ”) as shown by several publications and discussed previously [90–94]. When results are depicted according to the stage, tumors in stage I responded with complete response in 80% of cases. Patients who presented in stages II, III, and IV did not obtain complete response except in one patient in 24 cases. Some studies have reported a longer duration response and lower risk of local recurrence when PDT is applied.

Photosensitivity is still a problem. However, it is expected that the second generation of photosensitizers will decrease it significantly. The photosensitizing agent used in most clinical trials is Photofrin®, which produces photosensitivity for approximately 6 weeks since the skin, liver, kidneys, and spleen retain the photosensitizer longer than the rest of the organs. As a consequence, skin protection is essential, and patients must avoid sunlight for a period of 4–6 weeks; otherwise severe retinal and skin damage can occur [95, 96]. No benefit was found in sunscreen creams for the skin, so its use is not recommended.

### PDT vs. Nd-YAG Laser Therapy for Advanced-Stage Non-small Cell Lung Cancer

PDT as a palliation method was compared to Nd-YAG laser, which has been used for palliation since 1970s. Photoresection using Nd-YAG laser is considered, by many experts, as the “gold standard” for central airway partial or complete tumor obstruction which is due to nonsurgical malignant primary or metastatic disease. There are enough publications supporting this statement [97, 98].

However, PDT is a useful palliative method with some advantages over laser therapy, particularly in peripheral tumor localization. In fact, PDT produces more complete tumor destruction, and a better survival rate has been objectified as shown in many studies comparing laser versus photodynamic therapy.

In a 1998 prospective randomized study comparing PDT versus Nd-YAG laser in partial obstruction of lung cancer, data of 16 centers in Europe and 20 in the USA and Canada were compared. In the European study, only 40% of patients had prior treatment, while in the American group, all patients had some type of treatment. Results showed that tumor response was similar for the 2 therapies in the first week, but within a month, 61% and 42% of patients treated with PDT in Europe and the USA/Canada, respectively, had a response, while patients treated with Nd-YAG, 36% and 19%, respectively, were responding in the 2 work groups

(Europe and USA/Canada). Twelve percent and 6% of patients treated with PDT versus 3% and 5% of patients treated with Nd-YAG experienced complete response, with biopsy proven in Europe and the USA/Canada, respectively. The improvement in dyspnea and cough was higher in patients treated with PDT in Europe and was similar in both treatments in the USA/Canada group. The study conclusion was that PDT is superior to the Nd-YAG laser to improve dyspnea, cough, and hemoptysis. The incidence of adverse events was similar in both groups, and 20% of patients treated with PDT showed photosensitivity reactions. Those events were due to failure to comply with the precautions suggested [99].

Our group participated in that study, and the above results were confirmed in a most recent publication (Table 14.5). We found patients had variable degrees of central airway obstruction due to inoperable non-small cell lung cancer and were prospectively randomized to PDT or Nd-YAG laser. Fourteen of these patients received Photofrin® therapy, 17 conventional laser therapy with Nd:YAG laser. The success of recanalization was verified by control bronchoscopy 1 week and

4 weeks after treatment. After 1 week, success rates were 43% in the PDT group and 53% in the Nd:YAG laser group. However, the endoscopic control after 1 month showed that in the PDT group, 38.5% of the open bronchi were still patent, while in the Nd:YAG group the first positive result was reduced from 53% to 23.5%. Survival time was also significantly longer in the PDT arm. Palliation of symptoms as for Karnofsky index was similar in both groups. PDT group had a higher incidence of adverse effects, and these were more severe than in the group treated with Nd-YAG laser. Photosensitivity was the most important one [100].

In a series of 258 patients with symptomatic advanced lung cancer 81 patients with PDT and 177 with Nd-Yag laser were treated at Tokyo Medical College. The overall treatment effectiveness was 75% with PDT and 81% with Laser. Nd:YAG laser was more effective for tumors in the trachea or main bronchi (93% vs. 73%); however, PDT was a little bit better for tumors in lobar or segmental bronchi (73% vs. 76%) [52].

Another study from 1997 shows a 14-year prospective experience in 175 patients treated with PDT for squamous cell tumor, endobronchial adenocarcinoma, and tracheal adenocarcinoma [54]. It included patients that had failed or refused conventional treatment or were ineligible for it. Results showed that survival was affected mainly by the stage of cancer, are presented in Table 14.6 (modified from McCaughan and Williams) [54]. Analysis of the period of time after treatment until re-obstruction in patients treated by Nd-YAG laser or PDT showed that immediate results were better in patients treated by Nd-YAG laser bronchoscopy. Airway re-obstruction was faster in patients treated by Nd-YAG laser than PDT (2 weeks with Nd-YAG vs. 4 weeks with PDT).

A randomized study conducted in the USA, which compared the efficacy and safety of PDT versus Nd-YAG laser, showed that both treatments are equally effective in relieving tumor endobronchial obstruction. The time to treatment failure was slightly longer in the group treated with PDT, and the risk of local recurrence after PDT was lower than after Nd-YAG laser treat-

**Table 14.5** PDT versus Nd-Yag laser in advanced NSCLC

Type of response	Group			
	PDT		Nd-YAG laser resection	
N	14		17	
Partial response	6	3	8	4
Stable disease	6	2	4	
Progressive disease	1	3		5
Complete Response 1 <sup>a</sup>		1	1	
Complete Response 2 <sup>b</sup>		1	4	
Unclassified <sup>c</sup>		3		8
Death	1			

Tumor response at 1 week and 1 month. Treatment response was similar in both groups. At 1-week follow-up examination, response rate was 43% in the PDT group versus 53% in the Nd-YAG laser resection group; the corresponding figures at 1 month were 38.5% versus 23.5% [100], Diaz-Jimenez et al. Eur Respir J 1999; 14 :800-5

<sup>a</sup> No tumor on bronchoscopy and biopsy

<sup>b</sup> No tumor on bronchoscopy, evidence of malignancy in biopsy samples

<sup>c</sup> Unable to undergo bronchoscopy or loss of follow-up. PDT photodynamic therapy, Nd-YAG Neodymium Yttrium Aluminium Garnet

**Table 14.6** PDT Treatment, comparative analysis of survival by stage in lung cancer TNM (6th edition TNM classification) (modified by McCaughan and Williams) [54]

Stage	I (N = 16) Squamous cell carcinoma	II (N = 9) Squamous cell carcinoma	IIIa (N = 42)3 Adeno Ca.	IIIb (N = 64)7 Adeno Ca	IV (N = 44)7 Adeno Ca
Medium survival (months)	Not reached	22.5	5.7	5.5	5
Average survival	63	39	11	12	8
KPS <sup>a</sup> >50	Not reached	22.5	8.2	7.2	6.5
KPS <50	–	–	2	4	2.6
5-year survival	93%				

<sup>a</sup> Karnosky Performance Status

ment [101]. In a prospective study of 41 patients, a combination of PDT and radiotherapy versus radiotherapy alone were compared. Results showed airway obstruction completely opened in 10% of patients treated with radiation therapy, versus 70% of patients treated with the combination of PDT and radiotherapy. Twenty percent of patients did not have any response to either treatment [102].

A group of ten patients with inoperable non-small cell carcinoma and a different degree of tracheobronchial obstruction ( $86 \pm 2\%$ ) showed a response of 50% or more in 4 patients and 50% or less in 6 patients. However, all patients improved their symptoms, especially cough. Adverse effects included burns in two patients and one moderate edema [58].

### PDT in Combination with Other Techniques for Advanced-Stage Non-small Cell Lung Cancer

Both Nd-YAG laser application and PDT are useful in centrally located, obstructive malignant lesions of the airways. The choice of one method over the other depends upon many factors, such as a patient's preferences, his/her general health status, and physician's experience.

Historically, it had been accepted that the combination of chemotherapy and radiotherapy is the choice for advanced lung cancer treatment [103]. However, new combinations are accepted as a valid therapy in the palliative management of non-small cell carcinoma. PDT treatment associated with external radiotherapy seems less harmful than the combination of radiotherapy and

brachytherapy. It is reasonable to assume that PDT produces less toxicity and it can be a valid option in the multidisciplinary palliative treatment. We compared a group of patients with central airway obstruction due to non-small cell carcinoma treated with only external radiotherapy (30 Gy in ten sessions) with patients treated with radiotherapy and PDT. Results revealed better symptom control with radiological and functional improvement when both methods were combined [104].

Prospective studies of Freitag and colleagues have suggested combining PDT and brachytherapy for palliative control of endobronchial non-small cell carcinomas according to the principle of synergistic action. Control at 24 months was successful and without complications [105].

However, the sequence of the treatment combination is not well defined for PDT and radiotherapy or brachytherapy (PDT before or after the associated treatment).

Endoscopic techniques could be helpful in choosing the best sequence of application. AFB can evaluate superficial tumor extension along the bronchial mucosa and detect early lesions or local recurrence. EBUS can evaluate the real tumor extension in the bronchial wall and allows a better selection of patients.

PDT was deemed well-tolerated and effective as part of a multi-modal treatment for endobronchial non-small cell lung cancer (NSCLC) in another retrospective study with 9 patients, 8 males and 1 female aged 52–73 who received combined PDT and HDR for endobronchial cancers. Intervention was with HDR (500 cGy to

5 mm once weekly for 3 weeks) and PDT (2 mg/kg Photofrin, followed by 200 J/cm<sup>2</sup> illumination 48 h post-infusion). Group one received HDR first and Group two received PDT first. In Group one patients, local tumor control was achieved in 6 of 7 patients for: 3 months (until death), 15 months, 2+ years (until death), 2+ years (ongoing), and 5+years (ongoing,  $N = 2$ ). In Group two, local control was achieved in only one patient, for 84 days. Authors conclude that combined HDR/PDT treatment for endobronchial tumors is well tolerated and can achieve prolonged local control with acceptable morbidity when PDT follows HDR and when the spacing between treatments is 1 month or less [106].

### Commentary

As a palliative treatment, PDT can be used as a single method or in a combined therapy. The excellent work published by McCaughan and Williams is very convincing in the sense that patients with endobronchial obstruction caused by advanced cancer still have a median survival of 7 months and then aggressive palliation seems to be indicated. The correct treatment is something that physicians evaluate considering patient characteristics, availability of the different methods, technique costs, and finally, his or her own personal experience.

Nd-YAG laser and PDT are effective in improving airway obstruction caused by intraluminal tumors. Resection with Nd-YAG laser seems to be the best method in centrally located tumors, which are easily reached with the rigid bronchoscope, coagulated, and then resected. PDT, on the other hand, its application through a flexible bronchoscope can treat more peripheral lesions and does not require mechanical removal after irradiation. However, a cleaning bronchoscopy after PDT to remove debris is needed.

PDT cannot be used in patients with tracheal lesions extended to both main bronchi and extensive carina involvement or in patients with pneumonectomy. The inflammatory reaction following PDT treatment generates edema that can be severe, worsening obstruction and risking patient's life.

When the tumor has infiltrated the tracheobronchial wall or vascular structures, PDT application may cause perforation and/or fatal bleeding. Another disadvantage is that PDT does not relieve the obstruction immediately, and patients who present acute obstructive symptoms are not candidates for this treatment and should be treated with a fast re-opening method.

Photoresection with Nd-YAG laser and PDT are both ineffective when there is submucosal infiltration or extrinsic compression. In this case, patients can benefit from radiation therapy, and if necessary, placement of airway prosthesis. Since most patients have a combination of intraluminal, submucosal, and peri-bronchial tumor involvement, it seems reasonable to use a combination of PDT and external radiation [106]. PDT can also be used as palliation for debulking an obstructed or a stenotic bronchus or to reduce tumor extension in order to perform a less aggressive surgery [55, 107].

PDT is recognized worldwide as a palliative option for advanced non-small cell lung cancer. In fact, many studies report a poor quality of life with a shorted life in patients with metastatic non-small lung cancer [108, 109].

PDT can be a palliative option for patients with locally advanced or metastatic non-small cell lung cancer, decreasing dyspnea, and airway obstruction improving respiratory function and quality of life [110].

### Complementary Endoscopic Methods for PDT Applications

In the evaluation of early-stage lung cancer, EBUS can determine the real depth of "in situ" diseases, because in many cases, the mucosa appears macroscopically intact or has only minimal changes. With EBUS submucosa invasion or peri-bronchial extension can be detected more accurately. The absence of invasion confirmed by the EBUS suggests localized tumor and can be treated endoscopically with curative intent [111].

Other authors also suggest that the absence of tracheobronchial wall invasion assessed by EBUS defines injury as "early disease" and there-

fore should be considered an indication for the successful use of PDT [112].

Kurimoto et al. demonstrated the usefulness of EBUS in evaluating the depth of bronchial tumor and its accuracy. EBUS was in accordance with histopathological findings in 95.8% of the cases. Five layers of the bronchial wall in ultrasound images are defined. From the third to the fifth layer, it corresponds to the cartilage. Phototherapeutic treatment response is complete in lesions whose third (sonographically defined) layer is intact [113].

Takahashi et al. performed EBUS to evaluate the degree of carcinoma invasion into the bronchial wall in 22 lesions suspected of central early lung cancer before treatment. Fourteen lesions were diagnosed to be intracartilaginous lesions, and ten of them were treated by PDT. A complete remission was obtained in nine patients [114].

In fact, the endoscopic view is limited to the surface of the airway. Ultrasound can evaluate structures in depth. Processes located on the wall or outside the lumen can only be suspected by indirect signs such as discoloration, edema of the wall, changes in the vasculature, elevation of the mucosa, and distortion of the bronchial wall. Many abnormalities involving the peribronchial structures have no visible signs. Advanced imaging techniques such as computerized axial tomography or magnetic resonance imaging can be useful, but they are limited in detecting carcinomatous spread in peribronchial areas.

Optical coherence tomography (OCT) examination of the airways provides high-resolution images of the bronchial surface, making possible a detailed examination of intraepithelial lesions. Tissue layers between epithelium and basement membrane are clearly demonstrated, which is helpful to evaluate the depth of invasion of bronchial tumors [115, 116].

EBUS evaluation helps to determine the extent and depth of tumor invasion and to select the optimal treatment modality. In the near future, OCT will be widely applied and may prove to be a better complementary method for PDT treatment.

## Clinical Applications of New Sensitizers

The investigation of the new sensitizers of the second and third generations, presents new perspectives of treatment obtaining similar to better results than those obtained with sensitizers of the first generation.

Clinical experience is available for **non surgical patients**, advanced non-small cell carcinoma, applying NPe6 talaporfin sodium, Laserphyrin®, combined with chemotherapy [117]. At 1 month after PDT, symptoms and QOL were improved in all patients, and there was an objective response to treatment, as indicated by a substantial increase in the openings of the bronchial lumen and the prevention of obstructive pneumonia, with minimum adverse events. Even when the number of patients was small, authors were enthusiastic that, if the results are supported by additional studies, they would recommend that procedures be adopted as standard therapy.

Radachlorine, another second-generation photosensitizer, was applied in ten patients with advanced non-small lung cancer with **central airway obstruction** (Stage IIIA or higher). All patients received 1 mg/kg of Radachlorine®, 4 h before light irradiation. Twenty percent of patients showed successful results, 70% showed partially successful results and 10% showed an unsuccessful result. The 1 year survival rate after PDT was 70% and was significantly improved than that obtained by patients with non-small cell lung carcinoma treated with conventional therapy. Authors conclude that Radachlorine®-based PDT is safe and effective treatment for relieving central airway obstruction in advanced NSCLC[118].

**Neoadjuvant therapy** is often given in an attempt to shrink tumors and improve the chance of successful surgery. In one study 42 patients were randomized to either neoadjuvant chemotherapy and endobronchial PDT or chemotherapy alone followed by surgical resection. Chlorine E6 and laser light at 662 nm were used to perform PDT before each of the three courses of chemotherapy.

After neoadjuvant treatment partial response was obtained in 19 pts (90%) in the PDT arm and



16 pts (76%) in the No-PDT arm, these patients underwent [thoracotomy](#). In the group of PDT, 14 pneumonectomies and 5 lobectomies were performed. In the non-PDT group, patients underwent ten pneumonectomies and three lobectomies, with three patients showing unresectable tumors. Completeness of resection was significantly higher in the PDT group.

The authors concluded that neoadjuvant PDT along with chemotherapy made possible to convert to surgical candidates and to improve resection completeness in [stage III](#) central NSCLC patients, and it is effective and safe. The addition of Radachlorine<sup>®</sup>-PDT to preoperative CT significantly increased the number of patients eligible for radical resection compared to neoadjuvant CT alone [119].

An alternative approach in which light activation enables spatiotemporal specificity and control of the intracellular drug release, called Photo-Chemical Internalization (PCI), is a modified form of PDT with a light-controlled drug-delivery [120]. This novel approach combined with CSPG4-targeting immunotoxin in 225.28-saporin was applied in three cases of TNBC (triple negative breast cancer cells) and two mutated malignant melanoma cells. Results showed that the combination of the drug delivery technology PCI and CSPG4-targeting immunotoxins is an efficient, specific, and light-controlled strategy for the elimination of aggressive cells of TNBC and malignant melanoma origin [121].

---

## New Perspectives

The choice of optimal combinations of photosensitizers, light sources, and treatment parameters are crucial for effective PDT. The efficacy of therapy depends upon type of photosensitizer, oxygen concentration within target tumor cells, dose of light applied, and concentration of photosensitizer with cancer cells [122].

In this sense, research on the transport of photosensitizers by means of nanoparticles, improving permeability and retention, opens up a promising horizon in improving the efficacy of PDT in the treatment of tumors [123–126].

## Other PDT Applications

**Microbacterial Resistance** In the last decade, microbial resistance to antibiotics has increased in a large number of diseases [127]. The treatment of Infectious diseases using PDT is a relatively recent application that does not discriminate between strains that are and are not resistant to antibiotics [128]. Antimicrobial Photodynamic Therapy (aPDT) has become an important component in the treatment of human infections [129].

Multiple and extreme (a lack of susceptibility to four or more drugs) antibiotic resistance has necessitated the use of alternative treatment methods for microbial infection including electroporation; antimicrobial peptides; photothermal therapy; or photodynamic therapy (PDT). Photoactivated porphyrins display a potent cytotoxic activity toward a variety of Gram-positive bacteria, mycoplasma, and yeasts, but not Gram-negative microbial cells, as show Malik et al. in an study where they observed the changes produced by PDT in the structures of gram-positive and gram-negative microorganisms, analyzing the differences between them and their sensitivity to PDT [130].

**Anti-Tumor Immune Response** PDT not only kills the targeted cells and damages the tumor associated vasculature but also activates an anti-tumor immune response through processing of antigens from destroyed tumor cells by dendritic cells, which in turn serve as antigen presenting cells to T cells. However, tumor cells adapt to varying degrees of immune cell evasion. Antitumor effects of PDT derive from three inter-related mechanisms: direct cytotoxic effects on tumor cells, damage to the tumor vasculature and induction of a robust inflammatory reaction, PDT produces the tumor-cell destruction in the context of acute inflammation acts as a ‘danger signal’ to the innate immune system.

The inflammation produced by the PDT photo-reaction produces start-up of T lymphocytes with the ability to recognize and destroy tumor cells at a

distance and develop immune memory to act later against possible tumor recurrences. The escape mechanisms that the tumor has in order to progress and evade the immune attack, can be prevented by PDT in combination with immunomodulatory strategies capable of overcoming or evading those escape mechanisms used by the progressing tumor. In this way, this process leads to development of systemic immunity and makes itself vulnerable to evoke antitumor immune response followed by tumor destruction [131, 132].

The best way to restore an immune system response against tumors is to therapeutically elicit a cancer cell death pathway that is associated with high immunogenicity and possibly capable of inhibiting or reducing the influence of protumorigenic cytokine signaling [133].

Antitumor activity of inflammatory cells and immune reactions are triggered by the sensitized tumor. These reactions contribute to more complete tumor destruction. But there are some factors that limit it, such as the uneven distribution of the PS agent inside the tumor, or oxygen availability. PS should be able to induce an immunogenic response over treated cells such as changes of surface glycoproteins receptors and consequently activate a cascade of immunologic cell response and malignant cell death.

The strong inflammatory process produced by PDT in the form of local edema at the site of the photothermal reaction can lead to the development of a systemic immune response, which is a non-tumor antigen-specific process produced by the immune system itself. Therefore, the development of a novel combination of PDT and immune checkpoint blockade therapy could be beneficial for metastatic lung cancer [134].

Three immune checkpoint agents for melanoma therapy have been approved by the FDA and other drugs will be approved to treat patients with various cancer types including kidney, lung, bladder, and prostate cancer [135].

In 2011, the antibody agent against CTLA-4 (ipilimumab) was approved and 3 years later, other two antibody agents against PD-1 (pembrolizumab and nivolumab) were approved [136, 137].

Photothermal therapy is based on the conversion of light energy (usually in the near-infrared

region) into heat energy to induce subsequent cellular necrosis or apoptosis [138]. The combination of photodynamic therapy (PDT) and photothermal therapy (PTT) was used in order to test the immune responses stimulated for the treatment of advanced cancer.

In one animal lab study, Yang et al. engineered a multitask theranostic platform Gd-Ce6@SWNHs Gd<sup>3+</sup> and chlorin e6 loaded single-walled carbon nanohorns(Gd-Ce6@SWNHs), to study the synergistic immunologic responses triggered by sequential PDT and PTT on the primary tumor and they have demonstrated that they are a strong immune adjuvant, and have high tumor targeting and penetration efficiency.

Sequential photodynamic and photothermal therapy ablates the primary tumors and triggers synergistic, complementary and long-lasting host immune response, inhibiting the spontaneous pulmonary metastases and tolerating cancer rechallenge.

The authors conclude that the study has demonstrated the great potency of combined immune-stimulating therapies of PDT + PTT using Gd-Ce6@SWNHs and provided a potential way toward tumor synergistic immunotherapy, which is promising for the elimination of tumor metastases and inhibition of recurrence in the clinic. However, the antitumor efficacy by PDT or PTT alone is less potent and unsustainable against cancer metastasis and relapse [139].

**Near Infrared-Photoimmunotherapy (NIR-PIT)** is a new, highly selective tumor treatment that employs an antibody-photon absorber conjugate (APC). When the APC attaches to its target cell and is exposed to NIR light, highly selective cell killing is observed.

Nagaya et al. show the efficacy of NIR-PIT, using hYP218 as the antibody within the APC to target a mesothelin expressing A431/H9 cell.

They conclude that the new anti-mesothelin antibody, hYP218, is suitable as an antibody-drug conjugate for NIR-PIT. Furthermore, NIR-PIT with hYP218-IR700 is a promising candidate for the treatment of mesothelin-expressing tumors that could be readily translated to humans [140].

## Conclusions

PDT represents a promising but currently under-used alternative treatment modality for lung cancer treatment. For patients with early-stage non-small cell lung cancer, PDT is primarily employed as an endobronchial therapy for a definite treatment of endobronchial, roentgenographically occult, or synchronous primary carcinomas. PDT appears to be effective as definitive monotherapy in treating bronchoscopically visible lung cancers  $\leq 1$  cm extension and without extra cartilaginous invasion.

Finally, for patients with locally advanced-stage non-small cell lung cancer, PDT can be used to palliate obstructing endo-bronchial lesions as a neoadjuvant component of multimodality therapy, to reduce the extent of surgery, to palliate symptoms, and to increase operability.

Finally, ongoing research on the many aspects and applications of PDT makes this therapy a promising tool whose applications keep expanding to newer indications.

## References

1. Federal Drug Administration "Medical Devices," 19 July 2011. <http://www.fda.gov/MedicalDevices/default.htm>. Accessed 9 Sep 2011.
2. Robertson CA, Evans DH, Abrahamse H. Photodynamic therapy (PDT): a short review on cellular mechanisms and cancer research applications for PDT. *J Photochem Photobiol B Biol*. 2009;96(1):1–8.
3. Moan J, Peng Q. An outline of the hundred-year history of PDT. *Anticancer Res*. 2003;23(5A):3591–600.
4. Photodynamic therapy to treat cancer. National Cancer Institute NCI Updated: June 21, 2021.
5. Lipson RL, Baldes EJ, Olsen AM. Hematoporphyrin derivative: a new aid for endoscopic detection of malignant disease. *J Thorac Cardiovasc Surg*. 1961;42:623–9.
6. Lipson RL, Baldes EJ, Olsen AM. The use of a derivative of hematoporphyrin in tumor detection. *J Natl Cancer Inst*. 1961;26:1–11.
7. Gregorie HB Jr, Horger EO, Ward JL, Green JF, Richards T, Robertson HC Jr, Stevenson TB. Hematoporphyrin-derivative fluorescence in malignant neoplasms. *Ann Surg*. 1968;167(6):820–8.
8. Dougherty TJ, Boyle DG, Weishaup KR, et al. Photoradiation therapy. Clinical and drug advances. *Adv Exp Med Biol*. 1983;160:3.
9. Bellnier D, Linn C. In vivo photoradiation-hematoporphyrin derivative accumulation and interaction with ionizing radiation. PhD. thesis. State University of New York at Buffalo; 1982.
10. Mroz P, Hashmi JT, Huang Y-Y, Lange N, Hamblin MR. Stimulation of anti-tumor immunity by photodynamic therapy. *Expert Rev Clin Immunol*. 2011;7:75–91.
11. Reynolds T. Using lasers and light-activated drugs, researchers home in on early lung cancers. *J Natl Cancer Inst*. 1998;90:417–8.
12. O'Connor AE, Gallagher WM, Byrne AT. Porphyrin and non porphyrin photosensitizers in oncology: preclinical and clinical advances in photodynamic therapy. *Photochem Photobiol*. 2009;85:1053–74.
13. Levy JG. Photosensitizers in photodynamic therapy. *Semin Oncol*. 1994;21:4–10.
14. Dougherty TJ, Gomer CJ, Henderson BW, et al. Photodynamic therapy. *J Natl Cancer Inst*. 1998;90:889–905.
15. Gamarra F, Baumgartner R, Stepp Herbert G, Kai R, Leberig A, Huber RM. 5-aminolaevulinic acid for fluorescence diagnosis and photodynamic therapy of bronchial cancer: a case report. *Proc SPIE*. 1994;2371:398–402.
16. Kato H, Furukawa K, Sato M, Okunaka T, Kusunoki Y, Kawahara M, Fukuoka M, Miyazawa T, Yana T, Matsui K, Shiraishi T, Horinouchi H. Phase II clinical study of photodynamic therapy using mono-L-aspartyl chlorin e6 and diode laser for early superficial squamous cell carcinoma of the lung. *Lung Cancer*. 2003;42:103–11.
17. Boddupalli BM, Mohammed ZNK, Nath RA, Banji D. Mucoadhesive drug delivery system: an overview. *J Adv Pharm Technol Res*. 2010;1:381–7.
18. Allison RR, Moghissi K. Photodynamic therapy (PDT): PDT mechanisms. *Clin Endosc*. 2013;46(1):24–9.
19. Calixto G, Bernegossi J, Fonseca-Santos B, Chorilli M. Nanotechnology-based drug delivery systems for treatment of oral cancer: a review. *Int J Nanomedicine*. 2014;9:3719–35.
20. Juzeniene A, Peng Q, J. Moan milestones in the development of photodynamic therapy and fluorescence diagnosis. *Photochem Photobiol Sci*. 2007;6:1234–45.
21. Hamblin MR, Newman EL. On the mechanism of tumor localizing effect in photodynamic therapy. *J Photochem Photobiol B*. 1994;23:3–8.
22. Calixto GM, Bernegossi J, de Freitas LM, Fontana CR, Chorilli M. Nanotechnology-based drug delivery systems for photodynamic cancer therapy: a review. *Molecules*. 2016;21(3):342.
23. Agostinis P, Berg K, Cengel KA, Foster TH, Girotti AW, Gollnick SO, Hahn SM, Hamblin MR, Juzeniene A, Kessel D, Korbelik M, Moan J, Mroz P, Nowis D, Piette J, Wilson BC, Golab J. Photodynamic therapy of cancer: an update. *CA Cancer J Clin*. 2011;61(4):250–81.

24. Krammer B. Vascular effects of photodynamic therapy. *Anticancer Res.* 2001;21:4271–7.
25. Henderson BW, Dougherty TJ. How does photodynamic therapy work? *Photochem Photobiol.* 1992;55:145–57.
26. Macdonald IJ, Dougherty TJ. Basic principles of photodynamic therapy. *J Porphyrins Phthalocyanines.* 2001;5:105–29.
27. Dolmans DE, Fukumura D, Jain RK. Photodynamic therapy for cancer. *Nat Rev Cancer.* 2003;3:380–7.
28. Simone CB, Friedberg JS, Glatstein E, Stevenson JP, Serman DH, Hahn SM, Cengel KA. Photodynamic therapy for the treatment of non-small cell lung cancer. *J Thorac Dis.* 2012;4(1):63–75.
29. Castano AP, Demidova TN, Hamblin MR. Mechanisms in photodynamic therapy: part two, cellular signaling, cell metabolism and modes of cell death. *Photodiagn Photodyn Ther.* 2005;2:1–23.
30. Castano AP, Demidova TN, Hamblin MR. Mechanisms in photodynamic therapy: part three, photosensitizer pharmacokinetics, biodistribution, tumor localization and modes of tumor destruction. *Photodiagn Photodyn Ther.* 2005;2:91–106.
31. Oleinick NL, Morris RL, Belichenko I. The role of apoptosis in response to photodynamic therapy: what, where, why, and how. *Photochem Photobiol Sci.* 2002;1(1):1–21.
32. Kepp O, Tesniere A, Schlemmer F, et al. Immunogenic cell death modalities and their impact on cancer treatment. *Apoptosis.* 2009;14(4):364–75.
33. Bellnier DA. Potentiation of photodynamic therapy in mice with recombinant human tumor necrosis factor- $\alpha$ . *J Photochem Photobiol B Biol.* 1991;8(2):203–10.
34. Kessel D, Vicente MG, Reiners JJ Jr. Initiation of apoptosis and autophagy by photodynamic therapy. *Autophagy.* 2006;2:289–90.
35. Shafirstein G, Battoo A, Harris K, Baumann H, Gollnick SO, Lindenmann J, Nwogu CE. Photodynamic therapy of non-small cell lung cancer. narrative review and future directions. *Ann Am Thorac Soc.* 2016;13(2):265–75.
36. EdellES, Cortese DA. Potentiation of hematoporphyrin derivative phototherapy with adriamycin. Porphyrin photosensitization workshop. Abstract form; IPA Los Angeles, July 1986. p. 15.
37. EdellES, CorteseDA. Interaction between glucocorticosteroids and hematoporphyrin derivative phototherapy. Porphyrin photosensitization workshop. Abstract form; IPA Los Angeles July 1986. p. 15. 1986. p. 16.
38. Cowled PA, Mackenzie L, Forbes IJ. Potentiation of photodynamic therapy with hematoporphyrin derivatives by glucocorticoids. *Cancer Lett.* 1985;29(1):107–14.
39. Tong ZS, Miao PT, Liu TT, Jia YS, Liu XD. Enhanced antitumor effects of BPD-MA-mediated photodynamic therapy combined with adriamycin on breast cancer in mice. *Acta Pharmacol Sin.* 2012;33(10):1319–24.
40. Díaz-JiménezJP, EdellES, CorteseDA. Time dependence on cell survival after HpD - PDT. IPA Los Angeles: Porphyrin Photosensitization Workshop; 1986.
41. American Cancer Society getting photodynamic therapy. Last revised: November 19, 2021.
42. Kim MM, Darafsheh A. Light sources and dosimetry techniques for photodynamic therapy. *Photochem Photobiol.* 2020;96:280–94.
43. Yoon I, Li JZ, Shim YK. Advance in photosensitizers and light delivery for photodynamic therapy. *Clin Endosc.* 2013;46:7–23.
44. Straten D, Mashayekhi V, de Bruijn H, Oliveira S, Robinson DJ. Oncologic photodynamic therapy: basic principles, current clinical status and future directions. *Cancers.* 2017;9:19.
45. Moghissi K, Dixon K, Thorpe JA, Stringer M, Oxtoby C. Photodynamic therapy (PDT) in early central lung cancer: a treatment option for patients ineligible for surgical resection. *Thorax.* 2007;62(5):391–5.
46. Moghissi K, Dixon K, Freeman T, Thorpe A, Brown S. The place of bronchoscopy photodynamic therapy in advanced unresectable lung cancer: experience of 100 cases. *Eur J Cardiothorac Surg.* 1999;15(1):1–6.
47. Corti L, Toniolo L, Boso C, Colaut F, Fiore D, Muzzio PC, Koukourakis MI, Mazarotto R, Pignataro M, Loreggian L, et al. Long-term survival of patients treated with photodynamic therapy for carcinoma *in situ* and early non-small-cell lung carcinoma. *Lasers Surg Med.* 2007;39:394–402.
48. The Japan Lung Cancer Society Classification of Lung Cancer Kanehara, Tokyo; 2010.
49. Konaka C, Hirano T, Kato H, Furuse K, Takada M, Saito Y, Monden Y, Matsui E, Watanabe Y. Comparison of endoscopic features of early-stage squamous cell lung cancer and histological findings. *Br J Cancer.* 1999;80:1435–9.
50. Akaogi E, Ogawa I, Mitsui K, Onizuka M, Ishikawa S, Yamamoto T, Inage Y, Ogata T. Endoscopic criteria of early squamous cell carcinoma of the bronchus. *Cancer.* 1994;74:3113–7.
51. Jones BU, Helmy M, Brenner M, Serna DL, Williams J, Chen JC, Milliken JC. Photodynamic therapy for patients with advanced non-small-cell carcinoma of the lung. *Clin Lung Cancer.* 2001;3:37–41.
52. Furukawa K, Okunaka T, Yamamoto H, Tsuchida T, Usuda J, Kumasaka H, et al. Effectiveness of photodynamic therapy and Nd-YAG laser treatment of tructed tracheobronchial malignancies. *Diagn Ther Endosc.* 1999;5:161–6.
53. Cai XJ, Li WM, Zhang LY, Wang XW, Luo RC, Li LB. Photodynamic therapy for intractable bronchial lung cancer. *Photodiagn Photodyn Ther.* 2013;10:672–6.
54. McCaughan JS Jr, Williams TE. Photodynamic therapy for endobronchial malignant disease: a prospective fourteen-year study. *J Thorac Cardiovasc Surg.* 1997;114:940–6; discussion 946–7.
55. Hayata Y, Kato H, Konaka C, Ono J, Takizawa N. Hematoporphyrin derivative and laser photoradiation in the treatment of lung cancer. *Chest.* 1982;81:269–77.

56. Konaka C, Usuda J, Kato H. Preoperative photodynamic therapy for lung cancer. *Nihon Geka Gakkai Zasshi*. 2000;101:486–9.
57. Okunaka T, Hiyoshi T, Furukawa K, Yamamoto H, Tsuchida T, Usuda J, et al. Lung cancers treated with photodynamic therapy and surgery. *Diagn Ther Endosc*. 1999;5:155–60.
58. LoCicero J, Metzdorff M, Almgren C. Photodynamic therapy in the palliation of late stage obstructing non-small cell lung cancer. *Chest*. 1990;98:97–100.
59. Kato H, Konaka C, Kawate N, et al. Five-year disease-free survival of a lung cancer patient treated only by photodynamic therapy. *Chest*. 1986;90:768–70.
60. McCaughan JS Jr, Williams TE Jr, Bethel BH. Photodynamic therapy of endobronchial tumors. *Lasers Surg Med*. 1986;6:336–45.
61. Balchum OJ, Doiron DR. Photoradiation therapy of endobronchial lung cancer: large obstructing tumors, non-obstructing tumors, and early stage bronchial cancer lesions. *Clin Chest Med*. 1985;6:255–75.
62. McCaughan JS Jr, Hawley PC, LaRosa JC, Thomas JH, Hicks WJ. Photodynamic therapy to control life-threatening hemorrhage from hereditary hemorrhagic telangiectasia. *Lasers Surg Med*. 1996;19(4):492.
63. Friedberg JS, Mick R, Stevenson JP, Zhu T, Busch TM, Shin D, et al. Phase II trial of pleural photodynamic therapy and surgery for patients with nonsmall-cell lung cancer with pleural spread. *J Clin Oncol*. 2004;22:2192–201.
64. Ginsberg RJ, Kris MG, Armstrong JG. Cancer of the lung. In: DeVita VT, Hellmann S, Rosenberg SA, editors. *Cancer: principles and practices of oncology*. Philadelphia: JB Lippincott; 1993.
65. Mountain CF. Revisions in the international system for staging lung cancer. *Chest*. 1997;111:1710–7.
66. Mountain CF. A new international staging system. *E. for lung cancer*. *Chest*. 1986;89:225.
67. Martini N, Manjit S, Bains MS, Burt ME, et al. Incidence of local recurrence and second primary tumors in resected stage I lung cancer. *J Thorac Cardiovasc Surg*. 1995;109(1):120–9.
68. Parashar B, Arora S, Wernicke AG. Radiation therapy for early stage lung cancer. *Semin Interv Radiol*. 2013;30(2):185–90.
69. Bunn P. The treatment of non-small cell lung cancer: current perspectives and controversies, future directions. *Semin Oncol*. 1994;21:49–59.
70. Cortese DA, Pairolero PC, Bergstrahl EJ, et al. Roentgenographically occult lung cancer. A ten-year experience. *J Thorac Cardiovasc Surg*. 1983;86:373–80.
71. Sutedja G, Postmus PE. Photodynamic therapy in lung cancer. A review. *J Photochem Photobiol*. 1996;36(2):199–204.
72. Kato H, Usuda J, Okunaka T, Furukawa K, Honda H, Sakaniwa N, Suga Y, Hirata T, Ohtani K, Inoue T, Maehara S, Kubota M, Yamada K, Tsutsui H. Basic and clinical research on photodynamic therapy at Tokyo Medical University Hospital. *Lasers Surg Med*. 2006;38:371–5.
73. Hayata Y, Kato H, Konaka C, et al. Photodynamic therapy (PDT) in early stage lung cancer. *Lung Cancer*. 1993;9:287–94.
74. Cortese DA, Edell ES, Kinsey JH. Photodynamic therapy for early stage squamous cell carcinoma of the lung. *Mayo Clinic Proc*. 1997;72:595–602.
75. Kato H. Photodynamic therapy for early stage central type of lung cancer [editorial]. *Mayo Clinic Proc*. 1997;72:688–90.
76. Edell ES, D.A. C. Photodynamic therapy in the management of early superficial squamous cell carcinoma as an alternative to surgical resection. *Chest*. 1992;102:1319–22.
77. Furuse K, Fukuoka M, Kato H, et al. A prospective phase II study on photodynamic therapy with Photofrin II for centrally located early-stage lung cancer. *J Clin Oncol*. 1993;10:1844–5.
78. Imamura S, Kusunoki Y, Takifuji N, et al. Photodynamic therapy and/or external beam radiation therapy for roentgenologically occult lung cancer. *Cancer*. 1994;73:1608–14.
79. Okunaka T, Kato H, Konaka C, et al. Photodynamic therapy for multiple primary bronchogenic carcinoma. *Cancer*. 1991;68:253–8.
80. Sutedja G, Postmus PE. Photodynamic therapy in lung cancer. A review. *Photochem Photobiol*. 1996;36(2):199–204.
81. Usuda J, Ichinose S, Ishizumi T, Hayashi H, Ohtani K, Maehara S, Ono S, Honda H, Kajiwara N, Uchida O, Tsutsui H, Ohira T, Kato H, Ikeda H. Outcome of photodynamic therapy with NPe6 for bronchogenic carcinomas in central airways more than 1.0 cm in diameter. *Clin Cancer Res*. 2010;16:2198–204.
82. Endo C, Miyamoto A, Sakurada A, Aikawa H, Sagawa M, Sato M, et al. Results of long-term follow-up of photodynamic therapy for roentgenographically occult bronchogenic squamous cell carcinoma. *Chest*. 2009;136:369–75.
83. Fujimura S, Sakurada A, Sagawa M, Saito Y, Takahashi H, Tanita T, et al. A therapeutic approach to roentgenographically occult squamous cell carcinoma of the lung. *Cancer*. 2000;89:2445–8.
84. Usuda J, Ichinose S, Ishizumi T, Hayashi H, Ohtani K, Maehara S, et al. Management of multiple primary lung cancer in patients with centrally located early cancer lesions. *J Thorac Oncol*. 2010;5:62–8.
85. SokolovVV, TeleginaLV, TrakhtenbergAKh, KolbanovKI, PikinOV, Frank sokolo GA. [Endobronchial surgery and photodynamic therapy for the treatment of multiple primary lung cancer]. *Khirurgiia (Mosk)*. 2010;(7):28–31.
86. Poinso R, Charpin J, Zafiropoulo A. Quand et comment meurt-on dans le cancer primitif des bronches? *Bull Acad Nat Med*. 1960;144:434.
87. DepierreA, GarnierG, DubiezA. Étude informatique des causes de décès dans les cancers bronchiques épidermoïques traités en unité cancérologique. *Société de Médecine*; 1983.



88. Bariety M, Delaure J, Paillass J, Rullieri R. Les carcinomes bronchiques primitifs, vol. I. Paris: Mason; 1967. p. 367–77.
89. Carrol M, Morgan S, Yarnold JA, Hill JM, Wright NM. Prospective evaluation of a watch policy in patients with inoperable non-small cell cancer. *Eur J Cancer Clin Oncol.* 1986;22:1352–6.
90. Cortese DA, Kinsey JH. Hematoporphyrin derivative phototherapy for local treatment of the bronchogenic carcinoma. *Chest.* 1984;86:8–13.
91. Hayata Y, Kato H, Konaka C, et al. Photoradiation therapy with hematoporphyrin derivative in early stage I lung cancer. *Chest.* 1984;86:169–77.
92. Keller GS, Doiron DR, Fisher GU. Photodynamic therapy in otolaryngology--head and neck surgery. *Arch Otolaryngol.* 1985;111:758–61.
93. Li JH, Chen YP, Zhao SD, Zhang LT, Song SZ. Application of hematoporphyrin derivative and laser induced photochemical reaction in the treatment of lung cancer. *Lasers Surg Med.* 1984;4:31–7.
94. Lam S. Photodynamic therapy in lung cancer. *Semin Oncol.* 1994;21:15–9.
95. Sperduto PW, DeLaney PF, Thomas G, et al. Photodynamic therapy for chest wall recurrence of breast cancer. *Int J Radiat Oncol Biol.* 1991;21:441–6.
96. Dachowski LJ, DeLaney TF. Photodynamic therapy: the NCI experience and its nursing implications. *Oncol Nurs Forum.* 1992;19:63–7.
97. Personne C, Colchen A, Leroy M, Vourc'h G, Toty L. Indications and technique for endoscopic laser resections in bronchology. A critical analysis based upon 2,284 resections. *J Thorac Cardiovasc Surg.* 1986;91:710–5.
98. Diaz Jimenez JP, Martinez Ballarin JJ, Farrero E, Kovitz K, Castro MJ. Video endoscopy for laser photoresection in tracheobronchial pathology: some considerations after 9 years experience with 2105 treatments. *Diagn Ther Endosc.* 1995;2:79–87.
99. Wieman TJ, Diaz-Jiménez JP, Moghissi K, Leroy M, McCaughan J, Spinelli P, Lang N, Diaz-Agero P, York E. The Photodynamic Therapy Lung Cancer Study Group Louisville, KY, USA/Barcelona, Spain. Photodynamic therapy (PDT) with Photofrin is effective in the palliation of obstructive endobronchial lung cancer. Results of two clinical trials (abstract). XXXIV ASCO. Los Angeles CA, 1998.
100. Diaz-Jiménez JP, Martínez-Ballarín JE, Lluñell A, Farrero E, Rodríguez A, Castro MJ. Efficacy and safety of photodynamic therapy versus Nd-YAG laser resection in NSCLC with airway obstruction. *Eur Respir J.* 1999;14:800–5.
101. McCaughan JSJ. Photodynamic therapy versus Nd-YAG laser treatment of endobronchial or esophageal malignancies. In: P S, editor. *Photodynamic therapy and medical laser applications*. Milan – Italy; 1992. p. 23–36.
102. Lam S, Crofton C, Cory P. Combined photodynamic therapy (PDT) using photofrin and radiotherapy (XRT) versus radiotherapy alone in patients with inoperable distribution non-small cell bronchogenic cancer. In *Proc SPIE Proc* 1991. p. 20–28.
103. Scheff RJ, Schneider BJ. Non small cell lung cancer: treatment late stage disease: chemotherapeutics and new frontiers. *Semin Interv Radiol.* 2013;30:191–8.
104. Lam S, Kostashuk EC, Coy EP, Laukkanen E, LeRiche JC, Mueller HA, et al. A randomized comparative study of the safety and efficacy of photodynamic therapy using Photofrin II combined with palliative radiotherapy versus palliative radiotherapy alone in patients with inoperable obstructive non-small cell bronchogenic carcinoma. *Photochem Photobiol.* 1987;46:893–7.
105. Freitag L, Ernst A, Thomas M, Prenzel R, Wahlers B, Macha HN. Sequential photodynamic therapy (PDT) and high dose brachytherapy for endobronchial tumor control in patients with limited bronchogenic carcinoma. *Thorax.* 2004;59:790–3.
106. Weinberg BD, Allison RR, Sibata C, Parent T, Downie G. Results of combined photodynamic therapy (PDT) and high dose rate brachytherapy (HDR) in treatment of obstructive endobronchial non-small cell lung cancer (NSCLC). *Photodiagn Photodyn Ther.* 2010;7:50–8.
107. Kato H. History of photodynamic therapy--past, present and future. *Gan To Kagaku Ryoho.* 1996;23:8–15.
108. Maione P, Perrone F, Gallo C, Manzione L, Piantedosi F, Barbera S, et al. Pretreatment quality of life and functional status assessment significantly predict survival of elderly patients with advanced non-small-cell lung cancer receiving chemotherapy: a prognostic analysis of the multicentre Italian lung cancer in the elderly study. *J Clin Oncol.* 2005;23:6865–72.
109. Movsas B, Moughan J, Sarna L, Langer C, Werner-Wasik M, Nicolaou N, et al. Quality of life supersedes the classic prognosticators for long-term survival in locally advanced non-small-cell lung cancer: an analysis of RTOG 9801. *J Clin Oncol.* 27(34):5816–22.
110. Jones BU, Helmy M, Brenner M, Serna DL, Williams J, Chen JC, et al. Photodynamic therapy for patients with advanced non-small-cell carcinoma of the lung. *Clin Lung Cancer.* 2001;3:37–41.
111. Becker HD. Photodynamische therapie. In: Hermann H, editor. *Medikamentöse Therapie Maligner*, vol. 3. New York: Gustav Fischer Verlag, Stuttgart-Jena; 1995. p. S75–80.
112. Harris K, Oakley E, Bellnier D, Shafirstein G. Endobronchial ultrasound guidance for interstitial photodynamic therapy of locally advanced lung cancer, a new interventional concept. *J Thorac Dis.* 2017;9:8.
113. Kurimoto N, Murayama M, Yoshioka S, Nishisaka T, Inai K, Dohi K. Assessment of usefulness of endobronchial ultrasonography in determination of depth of tracheobronchial tumor invasion. *Chest.* 1999;115:1500–6.

114. Takahashi H, Sagawa M, Sato M, Sakurada A, Endo C, Ishida I, Oyaizu T, Nakamura Y, Kondo T. A prospective evaluation of transbronchial ultrasonography for assessment of depth of invasion in early bronchogenic squamous cell carcinoma. *Lung Cancer*. 2003;42:43–9.
115. Tsuboi M, Hayashi A, Ikeda N, Honda H, Kato Y, Ichinose S, Kato H. Optical coherence tomography in the diagnosis of bronchial lesions. *Lung Cancer*. 2005;49:387–94.
116. Lam S, Standish B, Baldwin C, McWilliams A, LeRiche J, Gazdar A, Vitkin AI, Yang V, Ikeda N, MacAulay C. In vivo optical coherence tomography imaging of preinvasive bronchial lesions. *Clin Cancer Res*. 2008;14:2006–11.
117. Kimura M, Miyajima K, Kojika M, Kono T, Kato H. Photodynamic therapy (PDT) with chemotherapy for advanced lung cancer with airway stenosis. *Int J Mol Sci*. 2015;16:25466–75.
118. Ji W, Yoo JW, Bae EK, Lee JH, Choi CM. The effect of Radachlorin@PDT in advanced NSCLC: a pilot study. *Photodiagn Photodyn Ther*. 2013;10:120–6.
119. Akopov A, Rusanov A, Gerasin A, Kazakov N, Urtenova M, Chistyakov I. Preoperative endobronchial photodynamic therapy improves resectability in initially irresectable (inoperable) locally advanced non small cell lung cancer. *Photodiagn Photodyn Ther*. 2014;11(3):259–64.
120. Norum O, Kristian P, Weyergang A, Giercksky K, Berg K. Photochemical internalization (PCI) in cancer therapy: from bench towards bedside medicine. *J Photochem Photobiol B Biol*. 2009;96:83–92.
121. Eng MS, Kaur J, Prasmickaite L, Engesæter BØ, Weyergang A, et al. Enhanced targeting of triple-negative breast carcinoma and malignant melanoma by photochemical internalization of CSPG4-targeting immunotoxins. *Photochem Photobiol Sci*. 2018;17:539–51.
122. Dandler J, Scheer H. Inhibition of aggregation of [Pd]-bacteriochlorophylls on mesoporous silica. *Langmuir*. 2009;25:11988–92.
123. Chen CH, Lu TK. Development and challenges of antimicrobial peptides for therapeutic applications. *Antibiotics*. 2020;9(1):24.
124. Klausen M, Ucuncu M, Bradley M. Design of photosensitizing agents for targeted antimicrobial photodynamic therapy. *Molecules*. 2020;25(22):523.
125. Bullous AJ. Photosensitizers–antibody conjugates for photodynamic therapy. *Photochem Photobiol Sci*. 2011;10:721–50. Gold nanoparticles conjugated with antibodies or antimicrobial peptides (AMPs) then introduced into the bloodstream and irradiated externally achieve both photodynamic and photothermal effects.
126. Choi SK. Photo activation strategies for therapeutic release in nanodelivery systems. *Adv Ther*. 2020;3(10):2000117.
127. Davies J, Davies D. Origins and evolution of antibiotic resistance. *Microbiol Mol Biol Rev*. 2010;74(3):417–33.
128. Hamblin MR. Antimicrobial photodynamic inactivation: a bright new technique to kill resistant microbes. *Curr Opin Microbiol*. 2016;33:67–73.
129. Alison M. Mackay The evolution of clinical guidelines for antimicrobial photodynamic therapy of skin. *Photochem Photobiol Sci*. 2022;7:1–11.
130. Malik Z, Hanania J, Nitzan Y. New trends in photobiology bactericidal effects of photoactivated porphyrins—an alternative approach to antimicrobial drugs. *J Photochem Photobiol B Biol*. 1990;5(3–4):281–93.
131. Brackett CM, Gollnick SO. Photodynamic therapy enhancement of anti-tumor immunity. *Photochem Photobiol Sci*. 2011;10:649–52.
132. Reginato E, Wolf P, Hamblin MR. Immune response after photodynamic therapy increases anti-cancer and anti-bacterial effects. *World J Immunol*. 2014;4:1–11.
133. Dos Santos AF, deAlmeida DRQ, Terra LF, Baptista MS, Labriola L. Photodynamic therapy in cancer treatment, an update review. *J Cancer Metastasis Treat*. 2019;5:25.
134. Rizvi NA, Mazieres J, Planchard D, Stinchcombe TE, Dy GK, Antonia SJ, et al. Activity and safety of nivolumab, an anti-PD-1 immune checkpoint inhibitor, for patients with advanced, refractory squamous non-small-cell lung cancer (CheckMate 063): a phase 2, single-arm trial. *Lancet Oncol*. 2015;16:257–65.
135. Sharma P, Allison JP. The future of immune checkpoint therapy. *Science*. 2015;348(6230):56–61.
136. Min Y, Roche KC, Tian S, Eblan MJ, Mckinnon KP, Caster JM, Chai S, Herring LE, Zhang L, Zhang T. Antigen-capturing nanoparticles improve the abscopal effect and cancer immunotherapy. *Nat Nanotechnol*. 2017;12(9):113.
137. Hwang HS, Shin H, Han J, Na K. Combination of photodynamic therapy (PDT) and anti-tumor immunity in cancer therapy. *J Pharm Investig*. 2018;48:143–51.
138. Ray PC, Khan SA, Singh AK, Senapati D, Fan Z. Nanomaterials for targeted detection and photothermal killing of bacteria. *Chem Soc Rev*. 2012;41:3193–209.
139. Yang J, Hou M, Sun W, Wu Q, Xu J, Xiong L, et al. Sequential PDT and PTT using dual-modal single-walled carbon nanohorns synergistically promote systemic immune responses against tumor metastasis and relapse. *Adv Sci (Weinh)*. 2020;7:2001088.
140. Nagaya T, Nakamura Y, Sato K, Zhang YF, Ni M, Choyke PL, Ho M, Kobayashi H. Near infrared photoimmunotherapy with an anti-mesothelin antibody. *Oncotarget*. 2016;7(17):23361–9.



## Introduction and Definition

Tracheal or laryngotracheal stenosis and bronchial stenosis are non-specific terms implying the presence of airway compromise involving the larynx, trachea, laryngotracheal, or bronchi. It is the consequence of progressive reduction in the tracheal lumen, with multiple mechanisms depending on their etiology.

In general, there is an alteration of normal epithelium after an attack leading to an abnormal repair and a structural problem.

Scar formation is associated with different degrees of morbidity depending upon the location, extent, and degree of airway obstruction. The sequence of events that leads to tracheal stenosis in adults involves inflammatory reactions with associated granulation tissue, ulceration of the mucosa and the cartilage, fibrous tissue formation, and contraction of fibrous scar tissue.

The principal etiology of tracheobronchial stenosis is postintubation and post-tracheostomy.

Other causes are idiopathic, infectious, chemical damage (such as gastroesophageal reflux or toxic inhalation), radiotherapy and systemic diseases (e.g., Wegener's granulomatosis, amyloidosis).

Clinically, tracheal or bronchial stenosis results in shortness of breath and is characterized by the progressive reduction in the airway diameter. Patients can present with variable symptoms, depending upon the severity of the stenosis and to his/her cardiorespiratory reserve: from no symptoms at all to dyspnea on exertion, progressive dyspnea, dyspnea at rest, wheezing, stridor, and a life-threatening situation such as respiratory failure or respiratory arrest.

Management of this condition is still not standardized or unified around the world, but it is well established that treatment of benign tracheal stenosis requires a multidisciplinary approach by a team of dedicated and experienced physicians.

Acute clinical situations can be handled by endoscopic treatment as tracheal dilatation or laser treatment, which solves the immediate problem in almost all cases. Although relapses are frequent, a percentage between 70% and 80% of non-surgical benign tracheal stenosis presents definitive cure with the support of endotracheal stents [1]. In our opinion, surgery must be addressed when cartilage destruction is diagnosed with rigid bronchoscopy inspection. Such compromise will not benefit from an endoscopic approach.

---

J. P. Díaz-Jiménez (✉)  
Interventional Pulmonary Department, Hospital  
Universitari de Bellvitge, Hospitalet de Llobregat,  
Barcelona, Spain  
e-mail: [pablodiaz@pablodiaz.org](mailto:pablodiaz@pablodiaz.org)

R. López Lisbona  
Bronchoscopy and Interventional Pulmonology Unit,  
Respiratory Department, Hospital Universitari de  
Bellvitge, Hospitalet de Llobregat, Barcelona, Spain  
e-mail: [rl@bellvitgehospital.cat](mailto:rl@bellvitgehospital.cat)

The initial intervention and the type of treatment depend upon location of the stenosis, wall integrity, length, and severity, as well as to the presence of comorbidities and overall health status of the patient.

Traditionally, surgery has been the mainstay of treatment, with excellent results in 90% of cases [2–4]. However, surgery is not always definitive and there is a percentage of recurrence that can reach 10% in some series [5]. Surgery involves some risks, and associated complications have been reported to be greater than 8–12% with a mortality rate of 5% [6, 7]. Although in recent years, complications and mortality rates have decreased due to an improvement in surgical techniques, intraoperative and postoperative care [8]. Moreover, many patients are unable to undergo a surgical procedure because of underlying cardiopulmonary limitations and there is a non-depreciable number of patients that refuse the surgery. Endoscopic management of tracheal stenosis provides a safe and efficient therapeutic option and is often the first-line therapy in patients who are not appropriate surgical candidates or who have failure after airway resection. Several modalities have been used to relieve endoluminal obstructions, including mechanical approaches such as dilatation with a rigid bronchoscope or with balloon; heat-related modalities such as laser, electrocautery, and argon plasma coagulation; contact probe cryotherapy; and a variety of airway stents [9, 10].

Drug therapy combined with endoscopic treatment, as systemic steroids [11], intralesional injection of corticosteroids [12], topical application of mitomycin-C [13, 14], or other drugs as paclitaxel [15], is another option in the treatment of this pathology but experience is very limited and results are variable. So far none of these last treatments are curative.

---

## Etiology

### Congenital Tracheal Stenosis

Congenital tracheal stenosis is a rare but underdiagnosed anomaly which can present as life-threatening respiratory insufficiency in neonates

and infants. Congenital anomalies are the most common cause of airway narrowing in the pediatric population. They are rare malformation, produced by the absence of most of the membranous portion of the trachea in the affected segment, and the cartilaginous rings extend along the entire circumference of the tracheal wall. Three anatomical types have been described which are as follows:

- (a) Generalized stenosis, from the cricoid to the carina with possible bronchial involvement;
- (b) Infundibular stenosis, where part of the trachea, proximal or distal, has a normal caliber.
- (c) Segmental stenosis, with involvement of a short portion of the trachea.

These malformations can appear alone or, very often, associated with other abnormalities of the bronchovascular tree and other organ malformations, of which the most frequently seen is esophageal atresia [16].

Cardiac anomalies are frequently associated and may be addressed at the time of tracheal surgery.

Management of congenital stenosis is very challenging. Children can present stridor, recurrent pneumonia, cyanosis, wheezing, and sometimes respiratory failure.

Corrective surgery is the treatment of choice; in short stenosis, resection of the compromised segment and anastomosis is the best option. When the stenosis affects long segments of the trachea, anastomosis becomes difficult for excessive pressure on the suture line and the endoscopic approach can be an effective alternative to help these patients.

### Iatrogenic

The causes of postintubation and post-tracheostomy tracheal stenosis are well established. Endotracheal tube (ETT) causes pressure injury to the glottis, subglottis, and tracheal mucosa and may result in severe scarring.

Physiologically, the healing of the ulcer formed by the cuff pressure in the mucosa

involves regenerating epithelium (primary healing) and repair (secondary recovery), but sometimes the regeneration of the epithelium does not occur and leads to an overgrowth of granulation tissue. Eventually, the tissue subsequently becomes avascular resulting in a fibrous scar stricture.

Postintubation tracheal stenosis was recognized for the first time as an entity in 1880, after MacEwen instituted prolonged endotracheal intubation as a therapy in four patients with main airway obstruction [17].

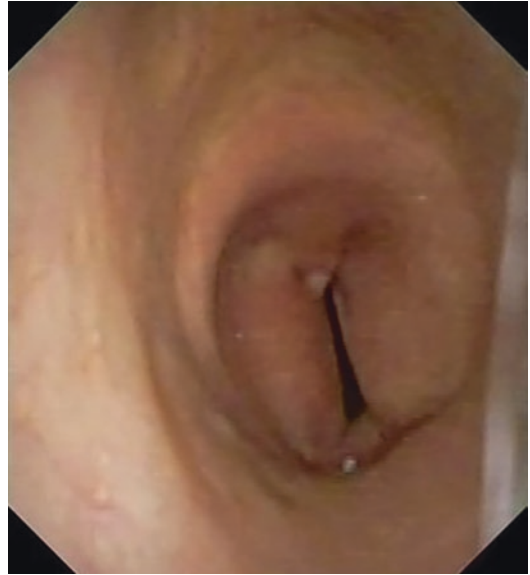Since then, many reports have been published on serious complications resulting from postintubation stenosis (PIS) or post-tracheostomy stenosis (PTS). The rate of presentation varies: among all intubated patients, 0.6–21% will develop tracheal stenosis. PTS in turn can present from 6 to 21% of all patients that have undergone tracheostomy [7, 17, 18]. Only a minority of them (1–2%) will present with symptoms or severe stenosis [19].

Currently, the calculated incidence of moderate or severe stenosis resulting from endotracheal intubation or tracheostomy is estimated at 4.9 cases per million per year in the general population [20].

Prolonged tracheal intubation can produce tracheal stenosis at many tracheal levels [21] from the tip of the endotracheal tube to the glottic and subglottic area, but the most affected places are the level of the endotracheal tube (ETT) cuff and around the stoma in tracheostomized patients.

The development of the stenosis has many stages; at the beginning there is mucosal ulceration due to decreased blood flow at the level of contact with the ETT cuff. Then, cartilage exposure and perichondritis develop, followed by granulation tissue formation, which over time becomes an established fibrous stenosis, which can be more or less fixed. In the worst cases, cartilage destruction occurs and the airway wall loses its support.

PTS usually affects the area of the stoma, where the tracheostomy tube curves down, following the same sequence mentioned above. Sometimes granulation tissue is formed above



**Fig. 15.1** Post-tracheostomy tracheal stenosis

the bend of the tube and progresses toward fibrosis [22, 23].

The presence of infection, very common in ventilated patients (tracheitis, mucositis), is a contributing factor for the development of airway stenosis [24]. A common finding in post-tracheostomy patients is retraction of the tracheal cartilage at the area of the tracheostomy, producing different degrees of stenosis (Fig. 15.1). Surgery is the treatment of choice in these situations. When the patient is not a surgical candidate, an airway stent may be beneficial.

Percutaneous tracheostomy is a procedure that is increasingly indicated in the critically ill patient, and although the long-term complications of this procedure are infrequently mentioned in the literature, some published data suggests that the rate of tracheal stenosis is significantly higher than reported [25].

A publication on 100 patients that underwent percutaneous tracheostomy revealed that major postoperative complications presented in 2.4% of cases, and these included death, cardiac arrest, loss of the airway, pneumothorax, tracheoesophageal fistula, and injury to the posterior wall of the trachea (mucosal tear). Tracheal stenosis was reported in 31% of patients, 20% of which were symptomatic [26].



Other studies showed better results. Van Heurn et al. [27] found an index of stenosis greater than 10% in 26% of 80 decannulated patients after percutaneous tracheostomy, being moderate in 4% of the cases, and severe in 2%. Hill et al. [28] revealed that 8 of 214 (3.7%) patients with percutaneous tracheostomies developed symptomatic tracheal stenosis.

Therefore, iatrogenic airway injury after endotracheal intubation and tracheostomy continues to be a serious clinical problem.

In fact, nowadays because of the coronavirus disease (severe acute respiratory syndrome **coronavirus-2** [SARS-CoV-2]) pandemic with an increase in intensive care unit (ICU) admission of patients with bilateral pneumonia (11% of all cases of pneumonia) [29], requiring prolonged intubation and tracheostomy, it is feared that an increase in cases of iatrogenic tracheal stenosis could be happened [30].

In addition to the most frequent causes of post-coronavirus disease 2019 (COVID-19) dyspnea such as interstitial or vascular alterations [31], this entity should be considered in patients with persistent dyspnea after prolonged admission in the ICU due to bilateral COVID-19 pneumonia. Some case reports with a few cases have been published since the end of the first wave [32–34].

In these patients, endoscopic treatments may be more relevant, because they can be in a poor physical situation or in a recovery phase.

## Infectious

Many airway infections can cause damage to the tracheal mucosa, resulting in stenosis. Tuberculosis (TB), fungal infections, bacterial tracheitis, histoplasmosis, and diphtheria are some of them, being TB the most frequently seen.

TB is the most common infectious cause of airway stenosis. It usually produces distal stenosis (at the level of the bronchi), but central airway stenosis can also occur. This complication can present at the time of the active infection or long after that, up to 30 years [35]. The most important risk factor for developing airway stenosis is the presence of TB bronchitis, which

is found in 10–37% of patients with pulmonary TB when bronchoscopy is performed [35, 36] In those cases, over 90% of patients will develop tracheobronchial stenosis in spite of correct TB treatment [37].

Infectious stenosis is more prevalent in underdeveloped countries, particularly in Asia and Africa. Active infection produces necrosis and ulceration of the bronchial mucosa, giving rise to granulation tissue and subsequent fibrous stenosis.

During fibrous, established stenosis, dilatation of the lesion is an option. When the stenosis occurs at bronchial level, balloon dilatation can be offered. At tracheal level, rigid bronchoscope dilatation is useful as well. Repeated dilatations or stent placement are often required, since recurrence rate is very high.

## Idiopathic Tracheal Stenosis

The term idiopathic tracheal stenosis (ITS) is used to include patients with tracheal stenosis when all other etiologies have been investigated and ruled out.

ITS is a rare condition, characterized by circumferential fibrous stenosis beginning at the subglottic area and compromising the proximal segment of the trachea [38]. Typically, it affects women in their third to fifth decade, so it is thought that estrogens could play an important role [39]. Another hypothesis is that it is related to gastroesophageal reflux [40]. Clinically ITS is presented with months to years of symptoms such as progressive dyspnea, wheezing, stridor, or a combination of all of them. In many cases, patients are misdiagnosed as difficult to treat asthmatics [41].

Grillo et al. [41] presented 49 patients with tracheal stenosis where no etiology was found after extensive evaluation. They highlighted the need to pay special attention to the airway in chest radiographs or computerized tomographies when evaluating a patient with a history of prolonged dyspnea and wheezing. Also, the flow-volume curve and the bronchoscopy are essential for diagnosis.

Surgery remains the treatment of choice [42]. Some authors have shown that endoscopic treatment with mechanical dilation or associated with laser or electrocoagulation and stent placement could be efficient, but with recurrences during the follow-up, that also can be treated with endoscopic procedures [43].

### Bronchial Stenosis Post-lung Transplantation

Since the first lung transplant in 1963, technical advances in thoracic surgery along with new immunosuppressive agents have made lung transplantation a more common indication for those patients with terminal lung disease. However, one of the main problems of this surgical procedure is the development of stenosis at the level of the suture.

Perianastomotic stenosis occurs in 12–40% of patients and nonanastomotic distal bronchial stenosis in 2–4% of all lung transplants [44, 45].

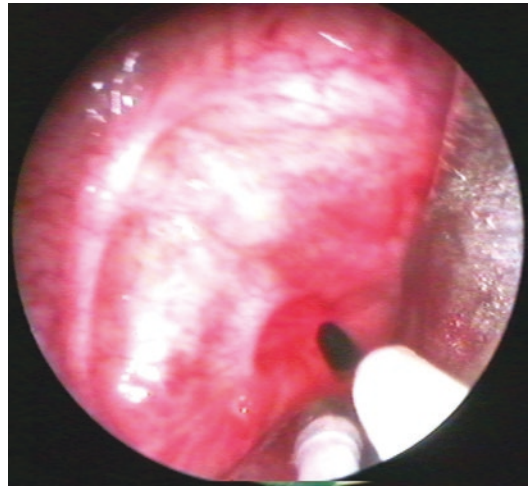
Bronchial stenosis is related to airway inflammation, with mononuclear cell injury to the epithelium and mesenchyme that is further complicated by endothelial injury on a poorly vascularized area. The severe blood-flow impairment may lead to bronchial cartilage ossification, calcification, or fragmentation, leading to stenosis [46].

Other factors increase the risk for suture stenosis, such as the use of a simple suture and prolonged mechanical ventilation. There is a very high risk of suture infection also due to low blood flow and the presence of inflammation. Infection should be looked for and appropriately treated before performing any endobronchial manipulation, particularly if a stent placement is considered.

Success depends primarily on the experience of the interventional pulmonology team and the medical resources available.

### Distal Bronchial Stenosis

As mentioned previously, bronchial stenosis secondary to pulmonary tuberculosis is quite



**Fig. 15.2** Bronchial stenosis of the right upper lobe

common. Approximately 43% of patients with pulmonary tuberculosis will develop stenosis at the distal bronchi [47, 48] (Fig. 15.2). This number corresponds to approximately 4.1% of all bronchoscopies performed in a hospital.

Another cause for distal stenosis is bronchial anthracosis (called anthracostenosis) [49, 50].

As a result of bronchial stenosis, there exists difficult drainage of secretions and recurrent infections distal to the obstruction, with the development of bronchiectasis. In these situations, it is indicated to offer a dilatational therapy that can be performed via balloon dilatation with or without laser application. This treatment is simple to apply, and can be easily performed during a short procedure. It has good results, improving secretions clearance which in turn prevents repeated infections. In addition to bronchoscopy, three-dimensional helical tomography of the tracheo-bronchial tree can be very useful in the evaluation of this condition, since it allows a better distal inspection than bronchoscopy [51].

Another less common cause of airway stenosis is radiation therapy. The incidence of bronchial stenosis has increased following treatment with brachytherapy or external beam radiotherapy of malignant lesions of the airways, with an estimated incidence of 9–12% [52].

Bronchial stenosis is established within an average of 40 weeks after initiation of radiother-

apy. Bronchoscopy can show the presence of a whitish-colored membrane covering the mucosa, with an important inflammatory response that ultimately results in fibrous stenosis [52]. Radiation therapy rarely compromises the tracheal mucosa.

---

## Diagnosis Methods

### Patient History

Due to the broad range of etiologies and the non-specific nature of presentation, the diagnosis of airway stenosis may be delayed in time. A careful medical history should be obtained in patients suspected of airway stenosis, since background data is very important. Prior infectious diseases, history of airway intubation, prolonged mechanical ventilation, timing and severity of dyspnea, presence of dysphonia, etc., should be recorded and evaluated.

Symptoms develop gradually as progressive dyspnea until tracheal stridor appears; this could happen in most of the cases, when the diameter is affected around the 70% (diameter around 5 mm).

When patients present emergently, it is important to offer a therapeutic procedure to reopen the airway to avoid worsening of symptoms and serious complications such as respiratory failure or respiratory arrest. The goal of treatment is to restore and maintain patency of the airway as soon as possible and then a multidisciplinary team can decide which is the best long-term solution for a given patient.

In clinical practice, most of the patients present with symptoms of stenosis when they are in the fibrous phase of the stenosis, with minimal evidence of inflammation. They frequently have a history of a prior airway intubation or prolonged mechanical ventilation in the past. Many patients have been diagnosed and treated like asthma with difficult control and with minimal or no response to asthma therapy.

A significantly smaller number of patients will present within days or weeks from extubation,

and in those cases an important airway inflammation can be seen.

Onset of symptoms is very variable. Baugnée et al. [53] described 58 patients with airway stenosis, 5 of them developed symptoms within 5 days, and 23 patients presented symptoms from 5 to 30 days of extubation, 19 patients from 30 to 90 days, and 8 patients took more than 90 days in presenting symptoms. Half of them went to the emergency room with acute respiratory failure.

Auscultation of wheezes, especially a fixed one, indicates that the passage of airflow through the airway is reduced, but its location does not always correlate with the site of airflow obstruction. When a fixed wheeze is heard over the trachea, it does not necessarily indicate that the source of the obstruction is the trachea [53, 54]. When wheezing is unilateral, it often suggests an obstruction of the airway distal to the carina.

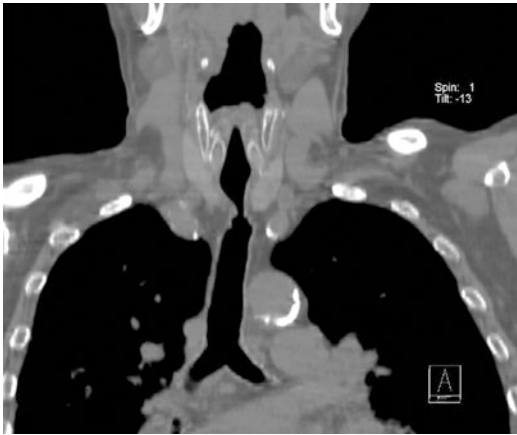
The persistence of a fixed unilateral wheezing should always warrant bronchoscopy examination, paying special attention to the distal airway (segmental or subsegmental bronchi). Stridor is always a sign of severe laryngeal or tracheal obstruction and occasionally main bronchial obstruction.

### Imaging Techniques

In the study of tracheobronchial stenosis of the airway, noninvasive imaging techniques have an important role. They help not only in the diagnosis but also in deciding the most appropriate treatment and assessing response to therapy during the follow-up period. These techniques were developed significantly in the past years [55] allowing a better approach to airway stenosis.

Simple chest-X ray is rarely diagnostic of central airway obstruction.

Computed tomography (CT) has been the most commonly used imaging test for diagnosis and evaluation of airway stenosis in order to have better information of the length and size of the stricture, degree of destruction of the airway wall, surrounding organ injury and also to have images controlled after treatments (Fig. 15.3).



**Fig. 15.3** Coronal CT image of benign tracheal stenosis

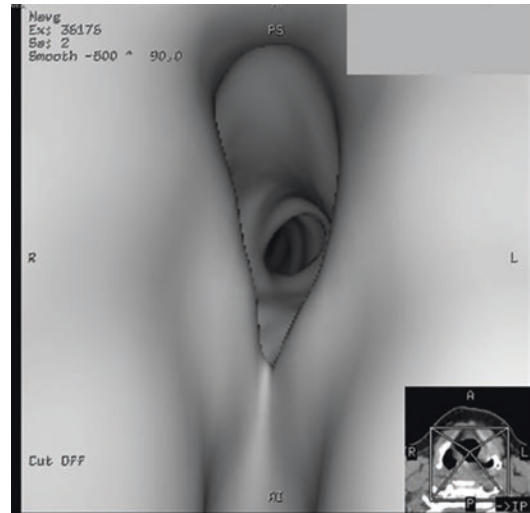
Although very useful, CT has some limitations particularly in the evaluation of subtle airway stenosis in axial images, underestimation of the craniocaudal extent of the disease, and generation of a large number of images for review [56].

The introduction of multiplanar reformatting (MPR) CT scans with option to generate three-dimensional (3D) images and virtual endoscopy (VE) provides additional information regarding airway pathology [57] bringing visual data that closely resemble the images obtained from flexible bronchoscopy [58].

MPR CT scan allows the acquisition of thin-slice axial sections of entire body volumes during a single breath-hold, thus eliminating respiratory artifacts [59].

This technique provides information on the length and caliber of the stenosis and the degree of compromise of the laryngotracheal wall. It allows visualizing lesions in depth, showing thickening or thinning of the tracheal wall, fibrous involvement of the submucosa, or disappearance of the tracheal rings. Also, the relationship of the injury to adjacent organs can be better evaluated.

Virtual endoscopy (VE) is a reconstruction technique that exploits the natural contrast between endoluminal air and the surrounding tissue [60], allowing navigation through the tracheobronchial tree with the same endoluminal perspective as an endoscopy [58] (Fig. 15.4).



**Fig. 15.4** Virtual bronchoscopy

Several authors have demonstrated the high diagnostic accuracy, sensitivity, and specificity of noninvasive, multirow detector CT virtual endoscopy in detecting and grading central and segmental airway stenosis and its close correlation with flexible bronchoscopy [57, 60–62]. However, it is slightly more accurate at assessing central airway stenosis than segmental airway stenosis [60].

The combination of axial imaging, multiplanar reformatting, and three-dimensional rendering is useful prior to tracheal intervention, especially when there is significant anatomical distortion or airway narrowing [61].

Recently, some authors advocate the use of MRI for diagnosis localization and extension of tracheal stenosis. MRI is a noninvasive procedure without ionizing radiation and can be used to identify the relationship of the trachea to adjacent vascular structures and to determine the degree and length of tracheal stenosis in high-resolution imaging with excellent soft-tissue contrast and without applying ionizing radiation or intravenous contrast medium.

Unfortunately, standard MRI has a limited ability to show dynamic organs.

The use of real-time, dynamic, cine MRI (CMRI) can achieve better results showing the mobility of the organs identified [63].

## Bronchoscopy

Flexible bronchoscopy remains the primary diagnostic technique in the study of tracheal stenosis and is considered the gold standard procedure for this pathology, allowing direct visualization of the airway lumen and sampling, with possibility to perform biopsies and microbiological studies. However, when the patient is in acute severe symptoms, flexible bronchoscopy is best avoided due to the risk of precipitating acute or complete airway obstruction. In these cases, the best approach has to be rigid bronchoscopy [64].

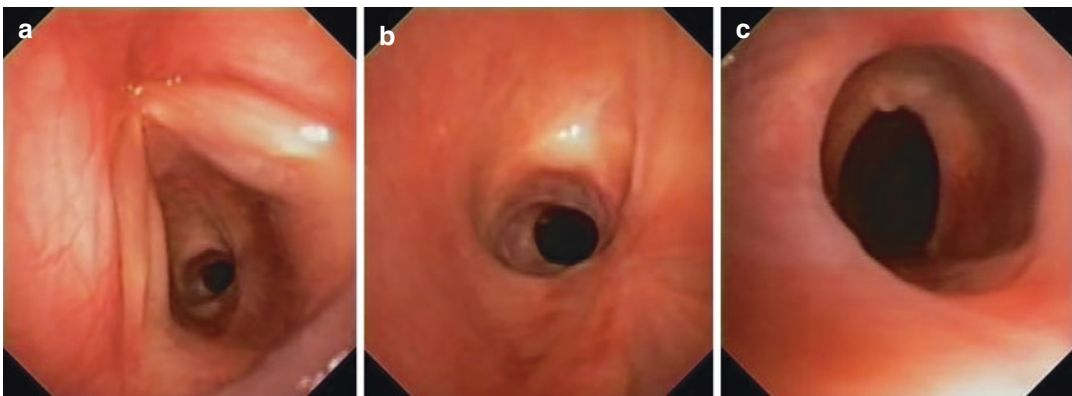
Moreover, bronchoscopy offers information at different levels and can assess the mobility and morphology of the vocal cords and arytenoids in subglottic laryngeal stenosis. In tracheal stenosis, it allows location of the lesion and evaluation of the degree and length of the stenosis and notes characteristics such as the presence or absence of malacia, mucosal involvement in inflammatory disorders, granulomas, ulcerations, or established fibrosis (Fig. 15.5a–c). It also enables obtaining biopsies, a procedure that should always be performed in tracheal stenosis, to rule out other inflammatory conditions. Bronchoscopy is a minimally invasive procedure, with the additional advantage of not exposing the patient to ionizing radiation. One limitation of this technique is the inability to evaluate the distal airways in severe stenosis, since the bronchoscope cannot be further advanced from the stenotic area. In these

cases, sedation during the procedure and the use of an ultrathin bronchoscope with external diameter of 2.1–3.2 mm can help interventional pulmonologists to explore tracheobronchial trees beyond the stenosis since the bronchoscopy is better tolerated.

New bronchoscopic technologies, however, permit a more accurate assessment of the airway wall structure and characterization of the stricture before, during and after treatment, since the correct evaluation of tracheal wall structures is necessary for optimal management of tracheal stenosis.

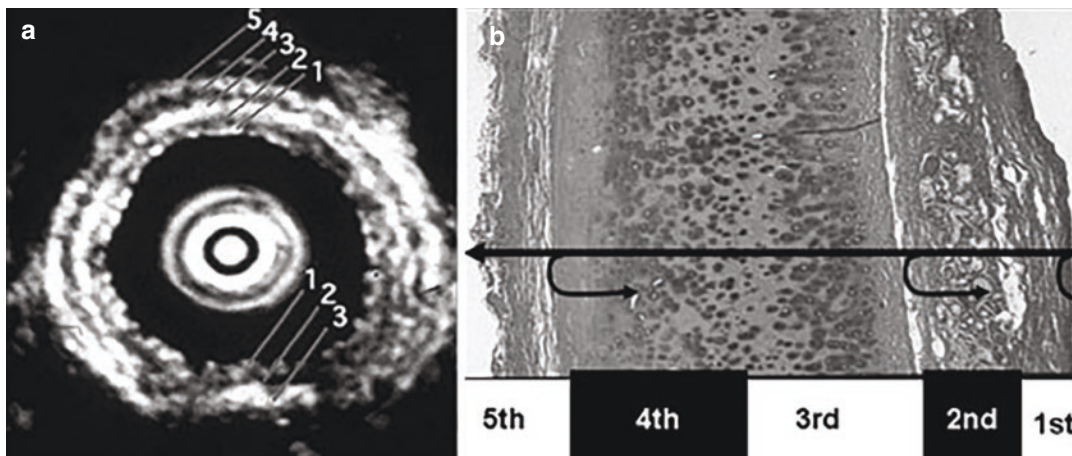
Endobronchial ultrasound (EBUS) has been introduced as an adjunct to diagnostic bronchoscopy. Radial EBUS helps evaluate the different tracheal and bronchial wall layers, as well as peribronchial structures. Cartilage damage can be better assessed, influencing the type of treatment that will be offered [65]. Also, EBUS could assess differences in central airway wall structure in patients with various forms of expiratory central airway collapse who can be identified by endobronchial ultrasound using a 20 MHz radial probe [66] (Fig. 15.6a and b).

Optical coherence tomography (OCT) is another bronchoscopic imaging technique that generated considerable interest since it has a much better space resolution than computed tomography. It is capable of generating high-resolution cross-sectional images of complex tissue in real time.



**Fig. 15.5** Bronchoscopy allows the correct evaluation of the distance from vocal cords to stricture (a), the degree of compromise of the cricoid cartilage (b), the length of the stricture (c) and the distance from stenosis to main carina





**Fig. 15.6** Radial EBUS shows the different tracheal (a) and bronchial wall layers (b) [65]. (With permission)

Similar to ultrasound, OCT measures back-scattered light intensity using coherence interferometry to construct topographical images of complex tissue. It can provide a micron level, real-time image of the airway wall structure with a resolution approaching histology [67]. It offers a unique combination of high resolution (1–15  $\mu\text{m}$ ) and in-depth penetration of 2–3 mm that is adequate for imaging superficial airway anatomy and pathology. OCT has the potential to increase the sensitivity and specificity of biopsies, create 3D images of the airway to guide diagnostic procedures, and may have a future role in different areas such as the study of tracheal stenosis. Some authors hypothesize that this technology may in the future provide a noninvasive “optical biopsy” [68], helping, as we said, in diagnosis and treatment of a number of conditions (Fig. 15.7).

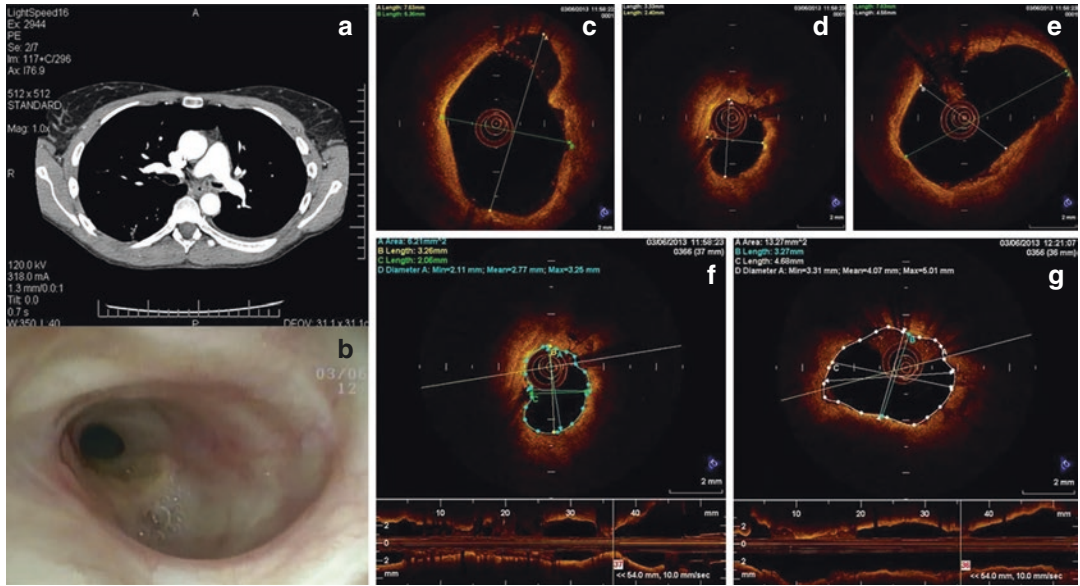
Anatomic optical coherence tomography (aOCT), a modification of conventional OCT, is a light-based imaging tool with the capacity to measure the diameter and lumen area of the central airways accurately during bronchoscopy. This technique can measure tracheal stenosis dimensions, having good correlation with chest CT scan findings and guiding the selection of a proper sized airway stent [69]. Standard OCT also could obtain accurate measures of stenosis.

All these technologies are very promising and they are currently under active research to define their proper role in the study of airway conditions.

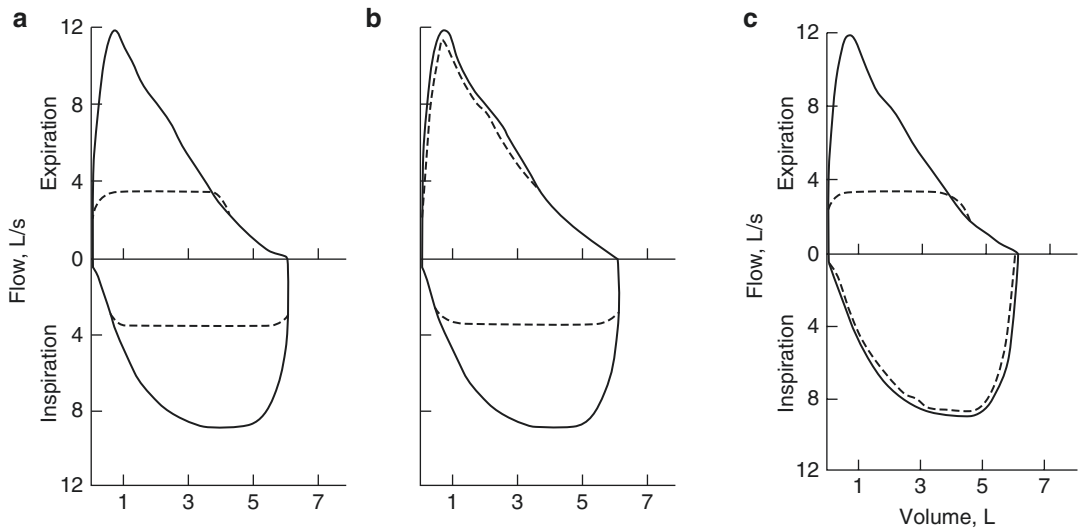
Though flexible bronchoscopy and the different imaging techniques have shown to be useful and reliable in the diagnosis of tracheobronchial strictures, they all have technical limitations that can lead to an inaccurate characterization of airway stenosis [70]. The best way to evaluate these conditions is to combine different diagnostic approaches in order to correctly define the injury and then plan the best procedure, case by case, based on clinical, endoscopic, and radiological findings.

### Pulmonary Function Test

Regardless of the cause, tracheal stenosis causes increased airway resistance and decreased flows. A simple test such as spirometry can help diagnosing and characterizing a central airway stenosis. The shape of the flow-volume curve (F/V) obtained by spirometry and flow resistance (raw) calculated by plethysmography can give important information. For instance, flattening of the inspiratory loop with preservation of expiratory flow represents variable extrathoracic obstruction of the central airway. In turn, compromise of the expiratory loop with a normal inspiratory limb



**Fig. 15.7** Application of OCT image for measurement of tracheobronchial stenosis. CT scan (a) and bronchoscopic (b) image of left main bronchus stenosis. OCT images of normal bronchial lumen before (c) and after (e) of the bronchial stenosis (d). OCT allows accurate measurements pre (f) and post (g) treatment with balloon dilatation. (Courtesy from Dr. Shaipanich and Dr. Lam)



**Fig. 15.8** Pulmonary function test. (a) Fixed obstruction. (b) Intrathoracic obstruction. (c) Extrathoracic obstruction

indicates variable intrathoracic obstruction. In a fixed obstruction (intra- or extrathoracic), both inspiratory and expiratory curves are affected, presenting with a classic flattening in the F/V loop [71] (Fig. 15.8). Other important informa-

tion that can be obtained by spirometry concerns the functional status, and helps deciding whether or not the patient is a surgical candidate.

Spirometry can also be very useful in the follow-up of these patients after treatment [72].

## Classification of Benign Tracheal Stenosis

Airway narrowing may result from intrinsic stenosis or extrinsic compression or for both. It has been classified following different parameters, in an attempt to design a useful algorithm for treatment.

Cotton et al. [73] in one of the first classifications of tracheal stenosis in 1984 used the cross-sectional area of the stenosis in a group of pediatric patients, and divided this condition into four grades:

1. 50% obstruction.
2. 51–70% obstruction.
3. 71–99% obstruction.
4. Complete obstruction.

In this classification, location and length are noted but without affecting the grading of the stenosis.

In 1992, McCaffrey [74] retrospectively reviewed the treatment of 72 cases of laryngotracheal stenosis. Although diameter and length were factors, the predominant predictor of outcome was location. Locations were confined to the glottis, subglottic area, and upper trachea.

Four stages were defined as follows.

1. Stage 1 in the subglottis or trachea, 1 cm in length.
2. Stage 2 in the subglottis, 1 cm in length.
3. Stage 3 in the subglottis and upper trachea.
4. Stage 4 in the glottis with vocal cord fixation and paralysis.

In 1999, Bricchet and coworkers [10] proposed a classification based on three categories depending on bronchoscopic findings:

- Pseudo Glottic stenosis: defined as typically “A”-shaped stenosis due to lateral impacted fracture of cartilages in patients with a history of tracheostomy.
- Web-like stenosis: when it involves a short segment (<1 cm), membranous concentric stenosis without damage to the cartilages.
- Complex stenosis: all other stenosis were defined as such, including those with an extensive scar ( $\geq 1$  cm), circumferential hourglass-like contraction scarring, or malacia.

Amoros Moya et al. [75] reviewed 54 patients that underwent surgery for laryngotracheal stenosis, and defined findings according to topographic and lesion criteria, incorporating three independent variables: stage of development (S), caliber (C), and length (L). Later, this classification was adapted and modified [76]. It is presented in Table 15.1.

In 2007, Freitag et al. [77] proposed a standardized scheme, presenting descriptive images and diagrams for rapid and uniform classification of central airway stenosis. Classification was based on the type of lesion, degree, and location. They divided airway stenosis into structural and dynamic, and they included malignant causes as well.

The structural group has four major types.

- Type 1: includes exophytic intraluminal malignant or benign tumors and granulation tissue.

**Table 15.1** Classification criteria for inflammatory stenosis of the trachea. Adapted from Moya et al. [58]

Structure (S)		Caliber (C)		Length (L)	
Structure of the tracheal wall		Internal diameter (at the point of smaller diameter)		Axis of the larynx-trachea	
S1	Acute-sub acute inflammation	C1	>10 mm (area >25 $\mu$ )	L1	Stenosis $\leq 2$ cm
S2	Organized scar fibrosis	C2	8–10 mm (area 16–25 $\mu$ )	L2	2–4 cm stenosis
S3	Malacia	C3	$\leq 8$ mm (area $\leq 6$ $\mu$ )	L3	>4 cm stenosis
S4	Tracheoesophageal fistula				

- Type 2: stenosis is due to extrinsic compression of all causes, including non-pulmonary tumors.
- Type 3: stenosis is due to distortion, kinking, bending, or buckling of the airway wall.
- Type 4: shrinking and scarring are the predominant features.

Stenoses were further classified in dynamic if a malacic condition was found. Malacia causes changes in the shape of the airway with the respiratory cycle. They included two different types:

- Type 1: triangular (tent-shaped) benign stenosis in which the cartilage is damaged.
- Type 2: it is the inward bulging of a floppy posterior membrane.

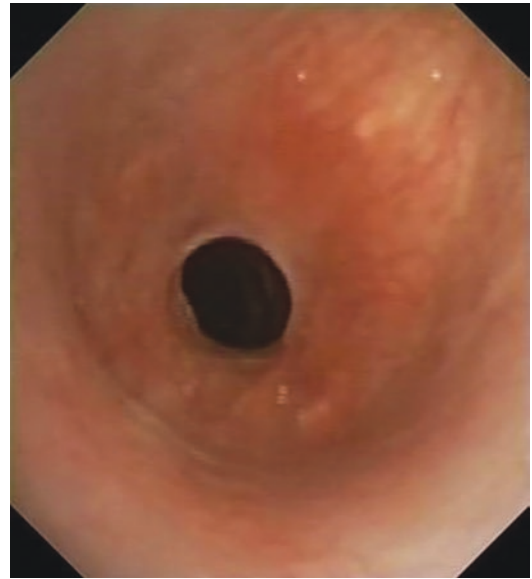In turn, the degree of stenosis was assigned a numerical code that could be applied to any site:

- Code 0: no stenosis
- Codes 1: 25% decrease in cross-sectional area
- Code 2: 50% decrease
- Code 3: 75% decrease
- Code 4: 90% decrease

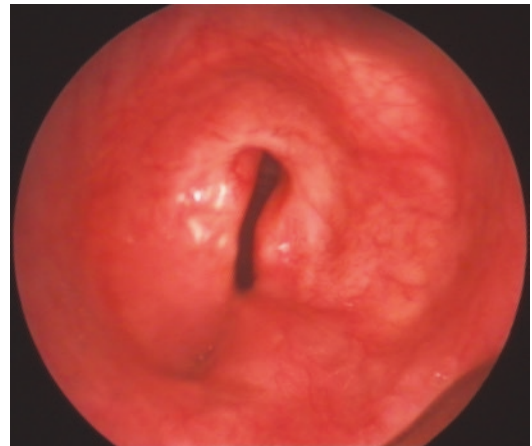They defined five locations within the central airways:

- Location I: upper third of the trachea
- Location II: middle third of the trachea
- Location III: lower third of the trachea
- Location IV: right main bronchus
- Location V: left main bronchus.

In 2009, other authors [2, 78] classified airway stenosis into two groups, according to their morphological aspect in simple and complex, similar to the Brichet's classification [10]. Simple stenosis included granulomas, weblike, and concentrically scarring stenosis. All these lesions were characterized by endoluminal occlusion of a short segment (<1 cm), absence of tracheomalacia, or loss of cartilaginous support (Fig. 15.9). Complex stenoses were represented by a longer lesion (greater than 1 cm) with tracheal wall



**Fig. 15.9** Simple tracheal stenosis



**Fig. 15.10** Complex tracheal stenosis

involvement and subsequent scarring contraction of the latter, in some cases also associated with malacia (Fig. 15.10).

Almost all of these classifications quantify the degree of the stenosis as a percentage, which is a subjective observation during bronchoscopy. Sometimes we can have an approximation with images such as a CT scan, but this method is not exact either since measurements vary according to the respiratory timing of image acquisition (inspiration, expiration).



Murgu and Colt [79] published a study on subjective assessment using still bronchoscopic images of benign stenosis, containing normal and abnormal airway cross-sectional areas, that were objectively analyzed using morphometric bronchoscopy. This method allowed to classify the stenosis as mild (<50%), moderate (50–70%), or severe (>70%). These images were then subjectively assessed by 42 experienced interventional pulmonologists participating in an interventional bronchoscopy course. Only 47% of strictures were correctly classified by study participants (mean  $16.48 \pm 2.8$ ). Of the 1447 responses included in this analysis, 755 were incorrect: 71 (9%) were over-classifications of strictures' severity and 684 (91%) were under-classifications.

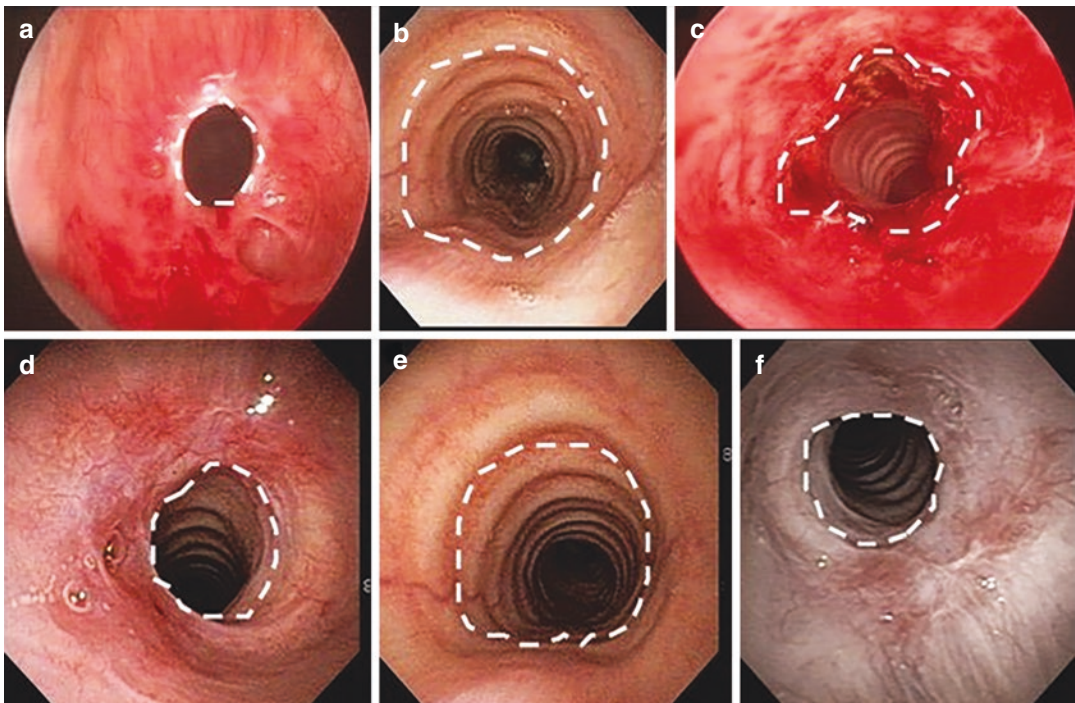
In another paper, a similar survey of 123 members of the American Association for Bronchology (AAB) shows that the assessment in central airways obstruction (CAO) is currently performed in a visual manner (91% of the con-

sulted clinicians). Eighty-six percent of the clinicians consulted agreed that there is an urgent need to avoid subjective visual evaluation and standardize calculations during in vivo explorations [80].

This demonstrates the importance of using systems that allow us to make a more objective measurement for conducting exploration.

Murgu and Colt propose the morphometric bronchoscopy [81]. They use an imaging system called Image J. During the bronchoscopy procedure, different captures are taken, in the center of the proximal airway, distal and directly into the lesion. Then after the procedure, with this manual method, it is possible to calculate the stenosis index (SI) (Fig. 15.11).

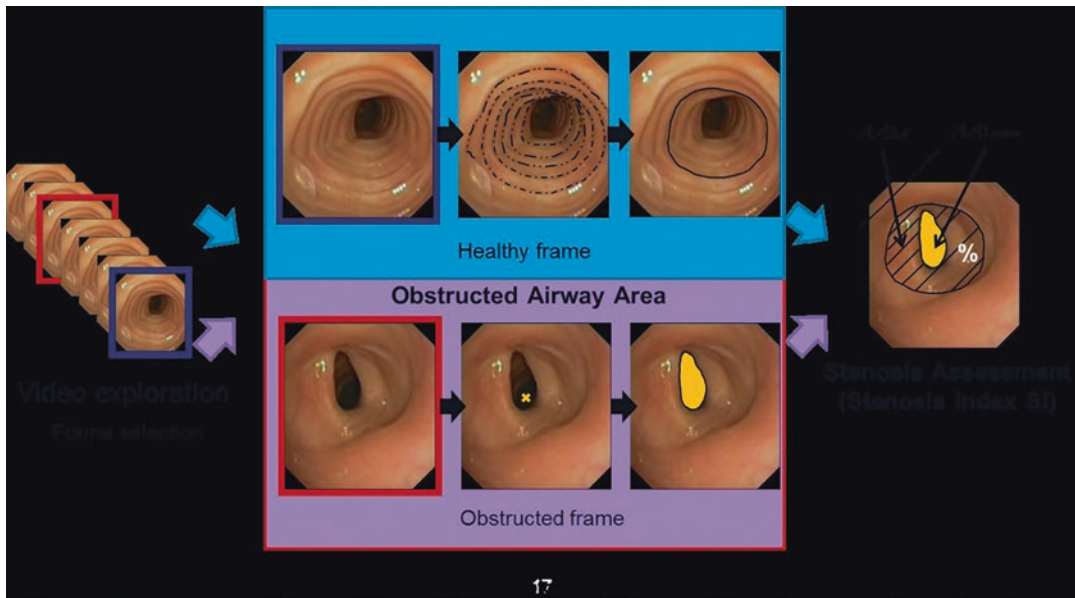
Other methods to calculate the stenosis index have been proposed as the one from the Computer Vision Center of Autonomous University of Barcelona (UAB) [82]. Recording a video during bronchoscopy procedure, this imaging system ana-



**Fig. 15.11** Bronchoscopic images of idiopathic subglottic stenosis (a) and the normal distal tracheal lumen (b). The calculated stenosis index (SI) was 80%. SI improved to 30% after laser and rigid bronchoscopic dilation (c).

The stenosis (d) and the normal distal tracheal lumen (e) at 12 months follow-up. The calculated SI was 50%. At 18 months follow-up the stenosis was stable with an SI of 50% (f). (Murgu [81] with permission)





**Fig. 15.12** Stenosis index using the Computer Vision Center of UAB method [82]. (With permission)

lyzes different cuts at the stenotic area level as well as at the normal tracheal level and subsequently, through a mathematical algorithm, calculates the area at the level of normal and stenotic trachea. Then it compares the caliber of stenosis with normal trachea giving us the real degree of stenosis (Fig. 15.12). This system was later validated in a pilot study, showing an objective SI measurement with a precision up to 99.5% and improving at least 15% from visual estimation [83].

The ultimate aim of the various proposed classification is to define a treatment algorithm accepted and followed by all physicians dealing with these complex conditions. It is also very important to use the same definitions in order to carry out research projects designed to identify the best, type-specific, therapeutic option.

In 2015, the European Laryngological Society published a consensus paper proposing a five-step endoscopic airway assessment and a standardized reporting system to better differentiate fresh, incipient from mature, cicatricial laryngotracheal stenosis, simple one-level from complex multilevel laryngotracheal stenosis and finally “healthy” from “severely morbid” patients [84].

Authors believe that, from the surgery point of view, this is an excellent article in order to choose

the best treatment modality for each individual patient and assess distinct post-treatment outcomes accordingly.

## Treatment

Most significant tracheal stenosis needs interventional bronchoscopy or surgical resection.

Effective management of tracheal stenosis requires a multidisciplinary assessment of a patient’s overall clinical status and medical history in addition to etiology and morphology of the stricture. When deciding the approach, the dedicated physician has to consider whether or not the patient is a surgical candidate, determine precise intraoperative technique, the extent of the resection, and an estimation of the risk for recurrence. Other treatments to consider are repeated dilatations or the placement of airway stents. Symptoms of patients with an airway obstruction are variable and depend not only on location, severity of the stricture, and the speed of progression but also on underlying medical conditions.

We cannot overemphasize that when an obstruction of the tracheobronchial tree is suspected, a careful review of medical history, patient examina-

tion and review of complementary methods such as pulmonary function testing and imaging studies (chest RX, CT scan) should be performed thoroughly. Virtual bronchoscopy can be used to have a preview of the airway, but it does not replace conventional flexible bronchoscopy as the most useful diagnostic tool to assess the extent of the stenosis as well as its severity, and to determine its cause by direct inspection and biopsies. Patient clinical status is the main parameter in deciding the next step, since it will determine how urgent the treatment is needed and which is the most appropriate instrument to perform the procedure.

## Endoscopic Treatment

Rigid bronchoscopy under general anesthesia is an essential method in the treatment of severe symptomatic laryngotracheal stenosis. It allows a secure airway and the application of different interventional tools such as tracheal or bronchial dilatation with different sizes of tracheal or bronchial tubes or with occlusive and nonocclusive balloon dilatation, laser resection, electrocautery, placement of an airway stent, etc. It is an expeditious procedure to reopen the airway, very safe and effective when applied by a well-trained team. The flexible bronchoscope also has an important role, complementary to the rigid bronchoscope during the first approach.

Our recommendation when treating a patient with severe central airway obstruction is to provide appropriate oxygenation and ventilation by intubation with the rigid bronchoscope. The rigid tube serves two purposes: first, it secures the airway, and second, it can be used to dilate the airway. Once successful intubation is achieved, the flexible bronchoscope can be used through the rigid scope to inspect the stenosis and the distal airway, and to aspirate retained secretions.

The immediate therapeutic approach depends on the type and severity of the stenosis found. Many times, rigid bronchoscopy will resolve the acute situation by dilating the stricture, and will represent a bridge to definitive treatment to be performed electively.

According to the endoscopic findings, several steps can be followed. For instance, simple severe stenosis (concentric membrane) can be immediately resolved with laser resection and dilatation with the rigid bronchoscope. In this particular situation, that may be the only procedure that the patient will need. A close endoscopic follow-up is indicated to detect and treat recurrences.

Complex stenoses represent a different situation. They may be addressed initially with endoscopic therapy to overcome the acute respiratory failure, but the definitive solution is always surgery providing that the patient has a good clinical status.

Patients that present with progressive symptoms can be inspected with both the rigid or the flexible bronchoscope and a definitive procedure can be planned after discussing the case in a multidisciplinary team, once all information has been collected.

As we commented at the classification section, treatment algorithms based on different classifications have been recommended, to follow in benign tracheal stenosis, according to several defined criteria [2, 10, 76] (Fig. 15.13 and Table 15.2).

## Dilatation

As we discussed above, in urgent cases the sole use of a rigid bronchoscope causes dilatation and enlargement of the airway, improving both extrinsic and intrinsic obstruction (Fig. 15.14a–c) shows the result of the dilatation of original tracheal stenosis (a), first time treatment dilatation with rigid bronchoscopy and two more dilatations after 2 and 3 months (b). Bronchoscopy control: stability after 24 months (c). No more recurrence at the present.

When a rigid bronchoscope is not available, dilatation can be performed by using progressive diameter balloons that are introduced sequentially, thus achieving a greater diameter of the tracheal (Fig. 15.15a–c) or bronchial lumen (Fig. 15.16a–c).

SC = surgical candidate  
 NSC = non-surgical candidate

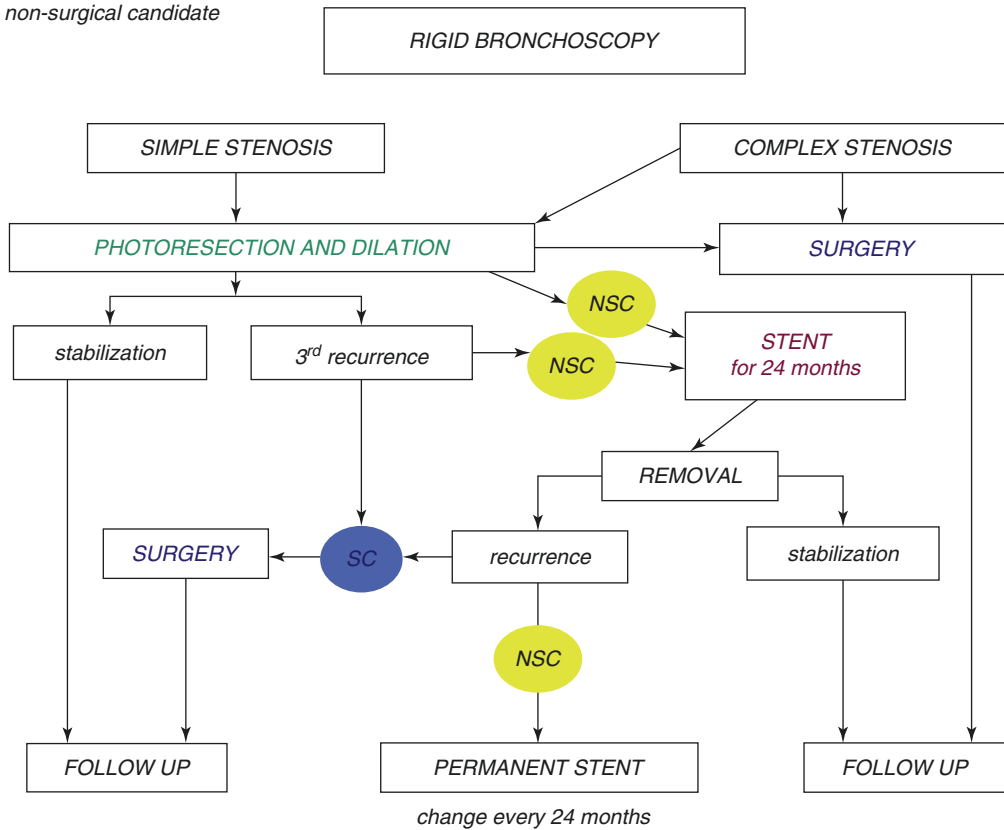


Fig. 15.13 Tracheal Stenosis Treatment Algorithm. (Modified from [2])

Table 15.2 Endoscopic treatment according to morphological criteria. Moya and cols.

Category	First option	Second option
S1/C1-2-3/ L1-2	ET ± Laser ± Prosthesis	Surgery
S1/C2-C3/ L3	ET ± Laser ± Prosthesis	-----
S2/C2-3/ L1-2	ET ± Laser	Surgery
S2/C2-3/L3	ET ± Laser ± Prosthesis	-----
S3/C2-3/ L1-2	Surgery	-----
S3/C1-2-3/ L3	Prosthesis	-----
S4/C1-2-3/ L1-2-3	Surgical correction of fistula + myoplasty	

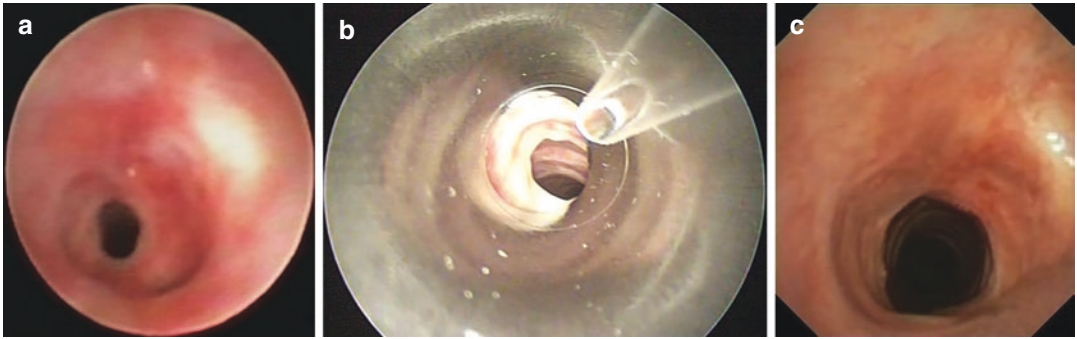
S stage, C caliber, L length

Balloon dilatation does not have long lasting effects, and it is indicated to relieve the obstruction until a more definitive treatment can be offered.

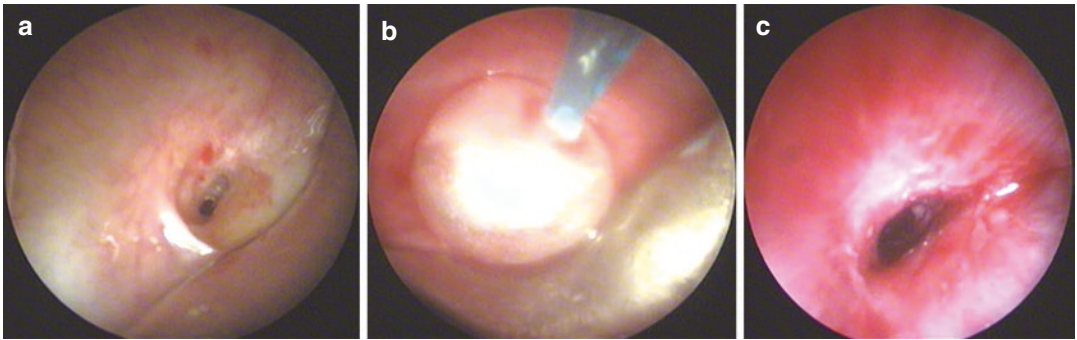
Two types of balloon dilatation could be used, the occlusive and nonocclusive balloon dilatation. The second one has the advantage of allowing ventilation by anesthesia while performing the dilatation procedure, being more secure for the patient.

### Laser Therapy

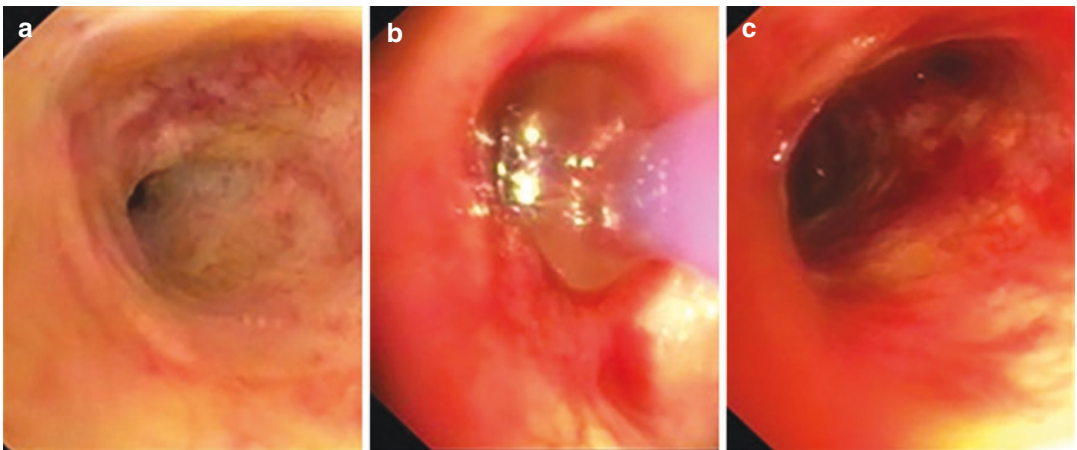
Laser treatment involves application of a laser light to the lesion. The effects of laser are deter-



**Fig. 15.14** (a–c) Dilatation with rigid bronchoscope



**Fig. 15.15** (a–c) Occlusive Balloon Dilatation of iatrogenic tracheal stenosis (before, during and after treatment)



**Fig. 15.16** (a–c) Occlusive Balloon Dilatation of bronchial stenosis cause by radiation injury

mined by many factors: type of laser applied, distance and surface of application, and target tissue. Some authors published their first experience with Nd YAG laser (neodymium, yttrium, aluminum and garnet) laser combined by tracheal dilatation [85, 86], in patients with benign tracheal stenosis. Our group also published the results of 400 cases of benign and malignant disease treated with laser [87]. Ninety-two patients were treated for benign tracheal stenosis, and received 113 laser applications. Laser resection was successful in obtaining a 50% increment on the tracheal diameter in most cases.

In another publication, we report our experience with laser resection followed by airway stents placement in 63 patients with no surgical benign tracheal stenosis [1]. About 79% of patients obtained a definitive cure.

In order to improve the opening of the airway and make easier the dilatation of the stenosis, some authors recommend to apply three or four radial cuts by laser (Fig. 15.17a–c) at the cardinal points of the stenotic circumference of the trachea and then to perform a careful dilatation with the rigid bronchoscope [88]. Other options to perform the radial cuts can be using other instruments as a rigid scissor, or a combination of a hand drill and rigid scissor [89, 90].

Vaporization of cartilaginous structures is strictly contraindicated because it results in weakening of the tracheal wall and potentially induces restenosis to a more severe grade.

The flexible bronchoscope can be used to apply a laser as well, and then use the rigid instrument to take advantage of simultaneous dilatation.

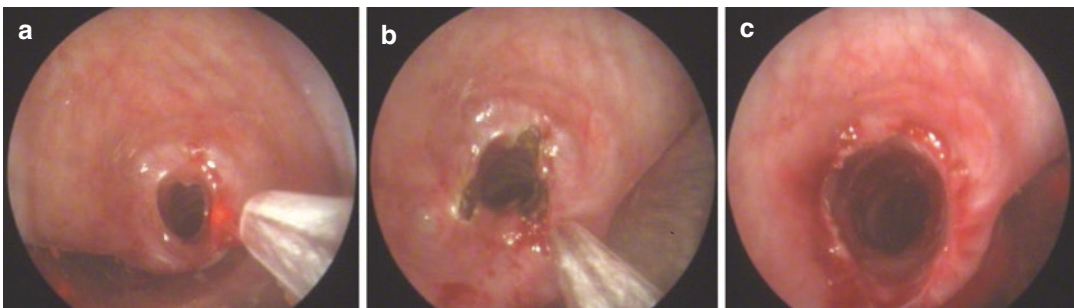
In case of severe subglottic stenosis, we recommend the use of a CO<sub>2</sub> laser to take advantage of its cutting capacities avoiding inflammation, or only dilation with the rigid bronchoscopy. Instead, Nd YAG laser can increase the stenotic area due to inflammation and put the patient at higher risk (Fig. 15.18a–c), where a worsening of stenosis can be seen, due to an increase in granulomatous tissue (Fig. 15.18a–c). In those cases, if there are no other options of treatment, tracheostomy is necessary as a first procedure of choice.

### Cryotherapy, Electrocautery, and Argon Plasma Coagulation

Cryotherapy, electrocautery (EC), and argon plasma coagulation (APC) are methods that obtain variable results in tracheal stenosis treatment.

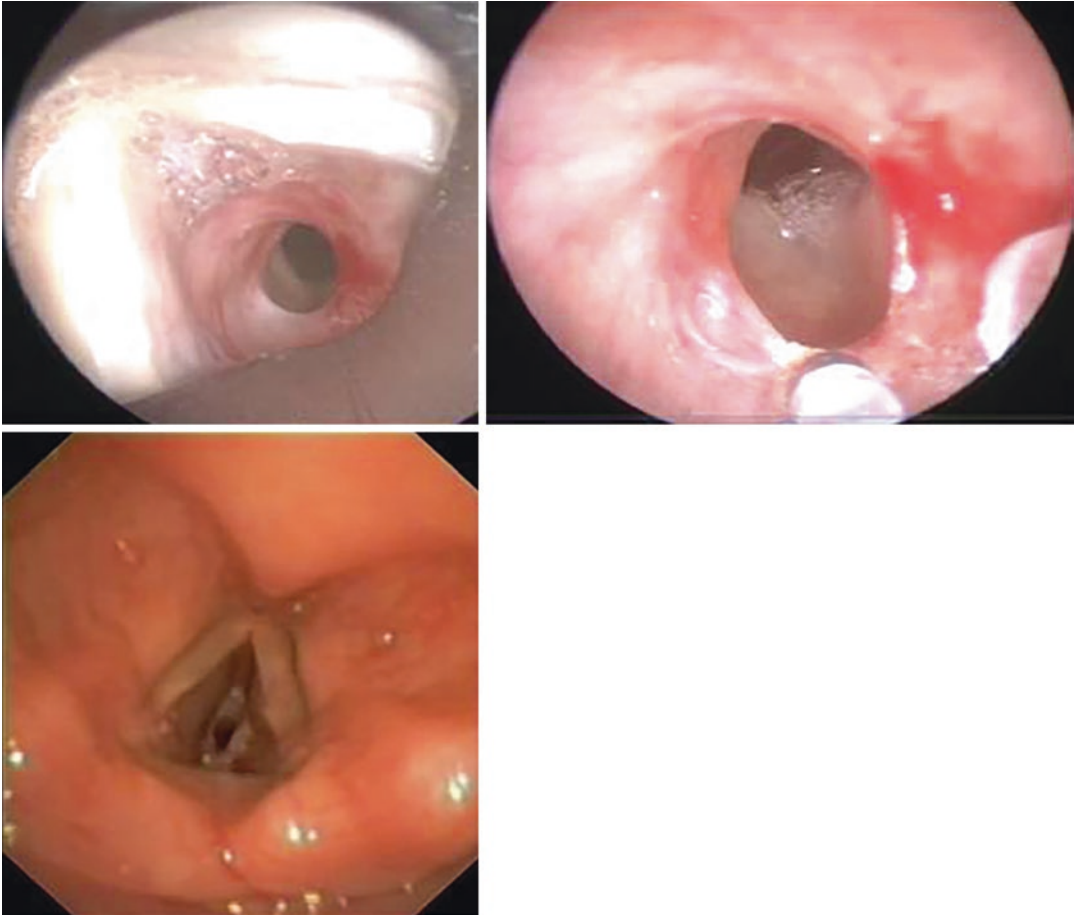
Results on the application of these techniques in tracheobronchial stenosis of different etiology are available. Fernando et al. [91] treated 35 patients with postintubation, post-tracheostomy, radiation induced, prior surgery, other causes, or unknown etiology of tracheal or bronchial stenosis with spray cryotherapy (SC). Seventeen patients (49%) required additional SC therapy. Only two complications occurred (3.2%) and these included pneumothorax and intraoperative tracheostomy. Twelve patients were asymptomatic, 16 improved, 4 had no improvement or were worse, and 1 patient died from an unrelated cancer.

They concluded that initial experience with SC for benign airway stenosis suggested that



**Fig. 15.17** (a–c) Laser application in tracheal stenosis





**Fig. 15.18** Complication after laser YAG treatment in subglottic stenosis. Stenosis is worse, due to granulomatous tissue growing after laser therapy

this could be used safely, and could be effective in improving symptoms and reducing the severity of airway narrowing, but almost half of the patients required re-intervention.

Some authors agree that when applied to post-intubation tracheal stenosis EC and APC can be fibrogenetic, causing more damage and scarring of the mucosa. Cryotherapy is almost ineffective given the paucity of blood vessels in the stenotic area.


These three methods, however, are very useful in granulomas, especially APC [92–94]. Laser therapy still has many advantages over all of them; since it is fast, it has high coagulation power and a minimal impact on surrounding tissues.

## Stents

Airway stents are tubes of different shapes, sizes, and materials designed to stabilize or reconstruct the lumen of the airways.

In benign tracheal stenosis, tracheal stents placement may be considered when surgical treatment is not an option in the following situations:

- (a) Treatment failure after dilatation of a simple stenosis.
- (b) First option in cases of complex stenosis as a bridge to surgical treatment or as a definitive treatment when it is not possible.
- (c) As the only option in unresectable disease (length >50% of the trachea).



**Fig. 15.19** Montgomery T-tube

Silicone stents are the stents of choice in benign tracheal stenosis, because despite the complications associated such as obstruction due to accumulation of secretions, colonization, granuloma formation, or stent migration [95, 96], they are easy to remove. Silicone stents are safe, well tolerated, and effective in the maintenance or airway patency [1, 97].

When the subglottic area is involved, a Montgomery T tube [98] should be used to avoid caudal migration (Fig. 15.19). A transcordal silicone stent [99] or a LT-Mold™ should be another option in severe glotto-subglottic stenosis [100]. Uncovered or partially covered self-expandable metallic stents (SEMS) are not recommended because of the difficulty in removal because of the granulation tissue formation and other complications associated such airway perforation and fatal hemoptysis [101]. In fact, the Food and Drug Administration (FDA) advised against metallic stent application in benign conditions in the year 2005 [102].

Since the development of the totally covered SEMS, different studies have been published showing good results in long-term follow-up. SEMS are easy to place and remove, but they are not free of potential complications [103–105].

New devices, currently under study, such as biodegradable stents or drug-coated stents may have a role in benign tracheal stenosis in the future [106–108].

## How to Proceed

Rigid bronchoscopy and laser resection have been used for decades, showing excellent results on the treatment of endotracheal or endobronchial growing tissue.

Concerning treatment of benign stenosis, rigid bronchoscopy, and laser resection has virtually no morbidity/mortality when the technique is appropriately applied in carefully selected patients.

When implementing this treatment, we recommend to proceed as follows:

1. Careful intubation with the rigid bronchoscope, maintaining the rigid optic lens slightly behind the tip of the bronchoscope in order to have a broad view of the airway during the procedure. It is important to perform a planned intubation, and to take every possible precaution during the procedure, since these patients often have a history of difficult intubation and rush maneuvers can easily damage the upper airway, especially at the arytenoids and vocal cords area.
2. Once the lesion is on view, careful inspection of the area should be performed. Anatomic characteristics, extent, degree of compromise of the airway wall, and presence of inflammation should be recorded. It is important to touch the lesion with the tip of the suction catheter in order to test the nature of the stenosis, inflammation, fibrosis, cartilage affectation, etc.
3. When the tracheal caliber is equal or greater than half the diameter of the rigid tube in use, the stenosis can be dilated by placing the bevel of the bronchoscope at the beginning of the stenosis and then surpassing the stricture dilating. During the maneuver, a slight rotation movement is applied to the scope as it is advanced through the stenotic area. In case of bleeding, use the bronchoscope to compress the bleeding area for a few minutes. If the lumen diameter obtained after dilatation is not appropriate, it will be necessary to move on to a larger diameter bronchoscope.

4. When the stenosis has a caliber of less than half the diameter of the bronchoscope, a laser in cutting mode can be applied, performing three or four cuts at 12, 3, 6, and 9 o'clock of the stenotic circumference. Laser should always be applied parallel to the tracheal lumen, avoiding damage to the posterior tracheal wall and the esophagus that could result in a tracheoesophageal fistula. The anterior tracheal wall can also be accidentally damaged, injuring large vessels placed beyond the wall, such as the innominate artery.

After several cuts, the stenotic tissue tends to open or is easily removed by the rigid bronchoscope, applying again a rotation pressure and resecting the stenotic membranes. Bleeding rarely occurs, or is minimal. Another option is to cut the membrane stenosing the airway with endoscopic scissors, minimizing laser application to avoid burn damage to the mucosa. After the incisions, the rigid bronchoscope is used to dilate the stenotic area.

5. Once the stenosis is surpassed, the flexible bronchoscope is passed through the rigid tube, to carefully inspect the distal airways and to aspirate retained secretions or detritus.
6. Finally, the rigid bronchoscope is withdrawn above the stenotic area, to check that the tracheal caliber remains appropriate. Given the case the lumen remains stenotic, one can assume that there is a complex damage to the tracheal wall such as cartilage disruption or malacia. Placement of an airway stent is then the safer recommendation, since it will allow solving the situation avoiding immediate recurrence of the stenosis. Also, it will give time to collect other important information and to discuss the case in a multidisciplinary fashion in order to offer a more definitive solution.

## Stent Placement

When placing an airway stent, the first consideration to evaluate is whether or not the stent will really improve the clinical situation or make it worse.

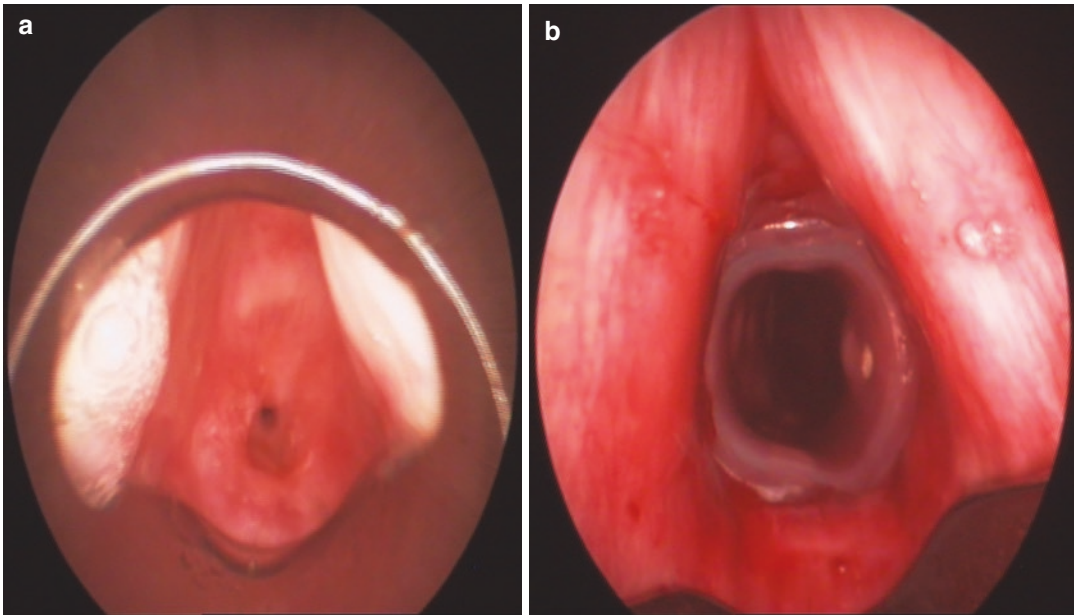
Once risks and benefits have been evaluated and the assessment favored a stent placement, the dedicated physician should inspect the lesion again, noting carefully the size and length of the stenotic area and the characteristics of the surrounding healthy tissue. Two distances are particularly important: vocal cords to the beginning of the stenosis and end of stenosis to the main carina.

A stent positioned too close to the vocal cords will bring speech problems, and will be prone to granuloma formation leading to more stenosis. When the distance to the vocal cords is less than 2 cm, the best results are obtained proceeding directly to tracheostomy and placing a Montgomery T tube (Fig. 15.20a, b). In turn, when a low stent has to be placed, less than 2 cm from the carina, it is better to offer a Y stent, since a tubular stent will contact and irritate carinal mucosa leading also to granuloma formation and subsequent stenosis.

### Placing a Montgomery T Tube

For the placement of a Montgomery tube in a high tracheal stenosis, it is advisable to treat the stenosis first and obtain a good caliber. Then measure the caliber of the trachea in that area as well as the distance between the vocal cords and the tracheostoma and between the tracheostoma and the carina to choose the most suitable Montgomery. The Montgomery tube insertion procedure should always be done with a rigid bronchoscope since all the movements of the insertion and the correct location of the tube can be ensured, with direct vision, by following the next steps in a simple technique:

1. Intubation with a rigid bronchoscope
2. Introduction of the distal portion of the Montgomery tube through the tracheostoma
3. Grasp it with the forceps and push it towards the distal portion of the trachea until the proximal portion enters into the tracheal lumen, then
4. Grab the proximal portion of the Montgomery and pull it towards the vocal cords
5. Check endoscopically if the proximal and distal positions are correctly placed



**Fig. 15.20** (a, b) Tracheal stenosis less than 2 cm from the vocal cords (a) before and (b) after a Montgomery tube placement

During the entire procedure, the outer part of the Montgomery tube must always be firmly held with grasping forceps by an assistant (Fig. 15.21a–d).

Bronchoscopic follow-up: The Montgomery tube must always be closed to preserve the humidity of the respiratory system and avoid the formation of dry secretions that could cause obstruction of the prosthesis. Instillations of 2 cm of saline should be made twice a day, depending on the case. In case of acute obstruction, it should be removed urgently.

Bronchoscopic reviews should be done according to protocol and clinical criteria, in order to inspect the correct placement of the Montgomery, and to check the presence of secretions or granulomas. The bronchoscope must be introduced through the external branch of the Montgomery, and directed towards the vocal cords after tilting it downwards, to favor the view of the vocal cords from below. In the case of the inspection of the carina, which is easier, the external branch of the Montgomery should tilt slightly upwards (Fig. 15.22a–d).

### The Rule of Twos for Benign Tracheal Stenosis (Fig. 15.23)

For a more effective and accurate tracheal stent placement and in order to avoid complications in relation to the vocal cords and main carina, we have designed a scheme that may obtain better results when a stent has to be placed near these areas.

With regard to the vocal cords:

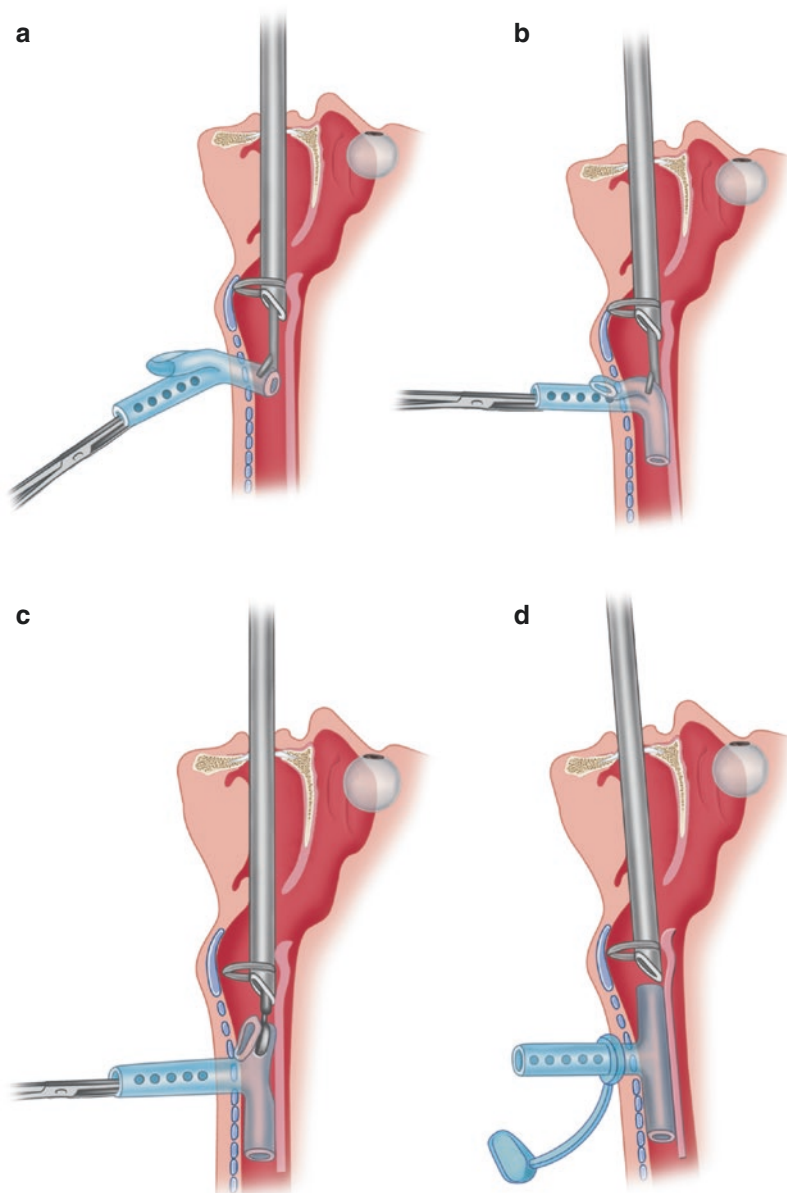
In strictures close to the vocal cords, a placement of the stent can lead to the production of granuloma due to stent movement during breathing or to frequent coughing. The continuous rubbing of the stent with the vocal cords will generate granulomas that almost inevitably will cause new subglottic stenosis.

With regard to the carina:

The same scenario is possible when a stent has to be placed close to the main carina. Due to cough or breathing movements, continuous mucosal irritation will produce granuloma formation.

**Fig. 15.21 (a-d)**

Placing of Montgomery T-Tube. After intubation with the rigid bronchoscope and the introduction of the caudal portion of the Montgomery T-tube we will procedure to grasp it with the forceps and push it towards the distal portion of the trachea until the proximal portion enters into the tracheal lumen, then grab the proximal portion of the Montgomery and pull it towards the vocal cords and check endoscopically if the proximal and distal positions are correctly placed. During the entire procedure, the outer part of the Montgomery tube must always be firmly held with grasping forceps by an assistant



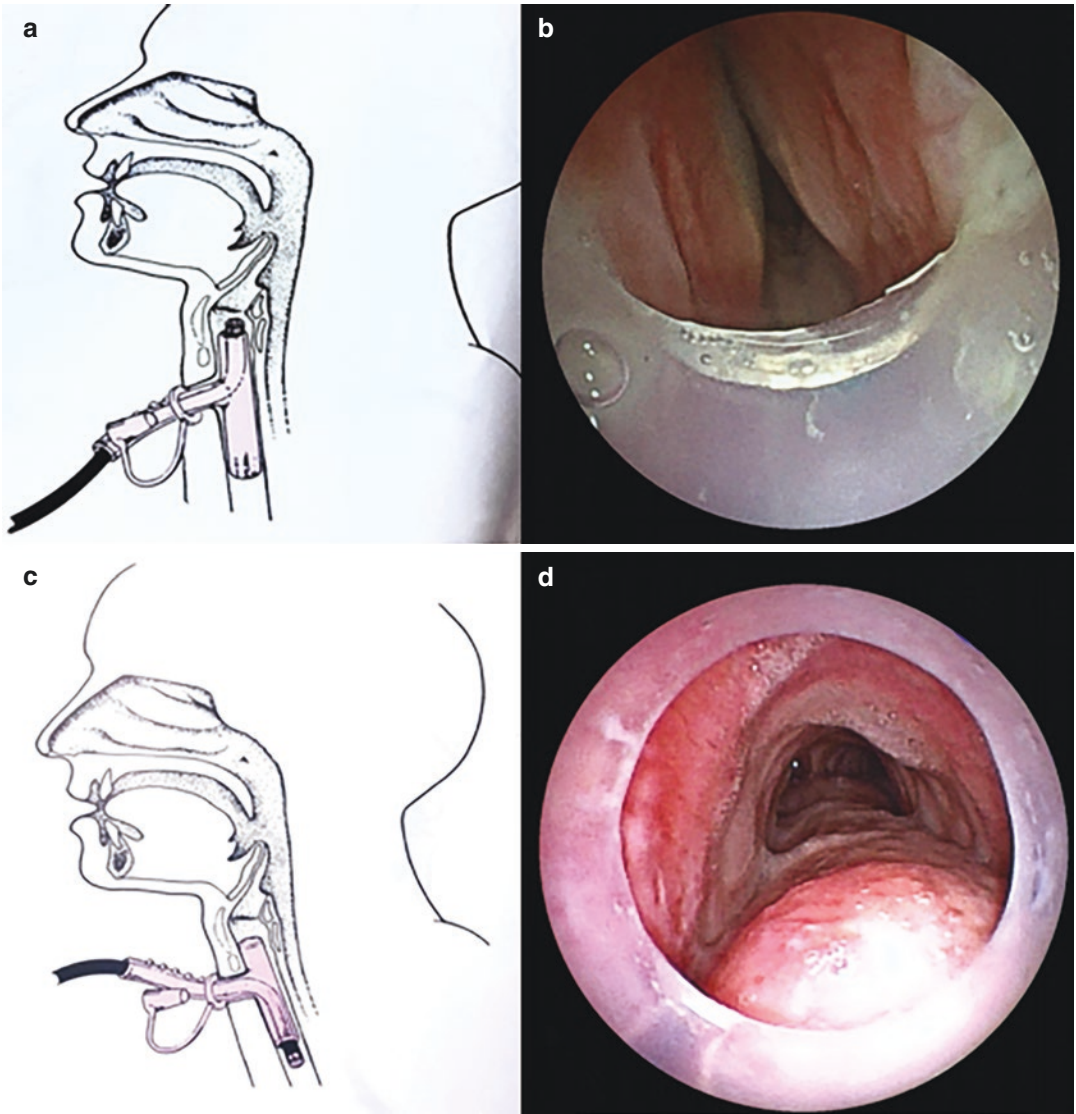
After 35 years of experience in the placement of stents, we advocate that a 2 cm distance between the vocal cords and the proximal edge of the stent can prevent the production of granulomas on the vocal cords.

Same with the stenosis near the main carina: we advocate that a 2 cm distance between the carina and the distal end of the stent will prevent the production of granulomas at this level.

So, we suggest for approaching stenting:  
When considering the vocal cords, stents should

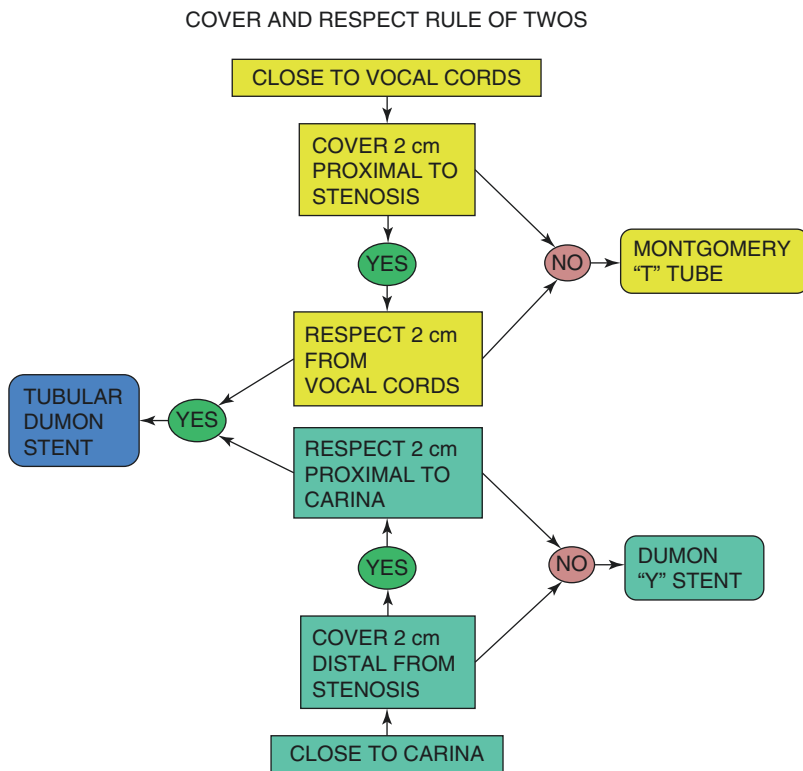
1. Cover the affected area of stenosis and two additional centimeters above and below that area.
2. Respect the 2 cm of healthy mucosa, proximal to the vocal cords.





**Fig. 15.22** (a–d) Montgomery T-Tube. Flexible ronchosopic inspection from the external branch: vision towards vocal cords (a, b) and vision towards carina (c, d)

**Fig. 15.23** Algorithm of stenting tracheal stenosis



If (1) and (2) are not possible, then a Montgomery T tube should be placed.

Related to the carina, stents should:

1. Cover the affected area of stenosis and two additional centimeters above and below that area.
2. Respect the 2 cm of healthy tissue proximal to the carina.

If (1) and (2) are not possible, then a Y stent should be placed.

### Surgery

Surgical treatment of tracheal stenosis comprises a wide range of techniques such as tracheal resection and anastomosis or tracheal reconstruction.

It is necessary to perform an accurate selection of the patient. The choice of ideal treatment should be individualized, based on the characteristics of each patient after evaluating all the advantages and disadvantages of the procedures by an experienced surgical team to improve the success of the surgical procedures and to minimize complications.

In patients with more than 1 cm long stenosis and chondritis with malacia, dilation and laser are not effective enough to achieve a permanent good result, then surgery as a first option or stenting become necessary.

Complex tracheal stenosis affecting multiple rings with involvement at various levels and a large inflammatory component is usually an indication for surgery as a first step. Inoperable patients may benefit from a permanent airway stent.

*Primary tracheal sleeve resection* is considered the treatment of choice in patients who are oper-

able. Other complex laryngotracheal techniques are necessary when the subglottic is involved. The Spanish Society of Thoracic Surgeons (SECT) [109] drafted a consensus document about tracheal and laryngotracheal surgery. They performed a surgical classification of the stenosis into five types depending on the affected area and the extent of the lesion, and they proposed different surgical techniques depending on the stenosis type: tracheal resection and anastomosis, Pearson surgery [110], Grillo surgery [111], Maddaus surgery [112], or Couraud surgery [113].

Some surgeons recommend avoiding endoscopic procedures in all patients who are potentially candidates for surgery, stating that laser treatment or stent placement can worsen the situation. However, there is no evidence to support that. In fact, most patients are immediately relieved of their symptoms after dilatation, laser resection, or stenting of the airway. Reevaluation of these patients after the acute distress is resolved will determine the next step.

Before the surgery, it is important to have control of the inflammation or infection or the airways to avoid complications. Antibiotic treatment should be administered in these cases. The principal complications related to surgical procedures are restenosis, granuloma formation on the anastomotic suture, infections, bleeding, and subcutaneous emphysema [4, 114]

---

## Summary and Recommendations

Dealing with airway stenosis can be difficult. A variety of methods can be applied in order to relieve the situation. In fact, almost any technique discussed above is useful, and can be applied alone or in combination with other methods. A multidisciplinary approach will always bring the best results for patients; important considerations should be thoroughly discussed with the team:

- General status of the patient and his/her wishes.
- Type of injury (acute versus chronic, extrinsic or intrinsic obstruction, fixed or dynamic stenosis, benign or malignant stenosis).

- Equipment availability.
- Personal experience and expertise on a given method.

After that, the “best” approach for a given patient can be offered.

As we said, frequently best results are obtained with a combination of treatments, and better outcomes for the patient are achieved in multidisciplinary, referral centers that have both extensive experience and sufficient equipment to deal with these complex clinical situations. We believe that all the team implicated in the management of tracheal stenosis: interventional pulmonologists, thoracic surgeons, and otorhinolaryngologists must discuss thoroughly the indications, contraindications, and possible complications that can arise, case by case.

We favor that the interventional team should be well trained, able to apply both the rigid and flexible bronchoscope, and has to be also knowledgeable on handling airway stents. The American College of Chest Physicians (ACCP) guidelines to interventional procedures provide useful recommendations including training requirements and number of suggested procedures to become competent and maintain proficiency in all the procedures described in this chapter [115].

---

## References

1. Martinez-Ballarín JJ, Díaz-Jiménez JP, Castro MJ, Moya JA. Silicone stents in the management of benign tracheobronchial stenoses. Tolerance and early results in 63 patients. *Chest*. 1996;109:626–9.
2. Galluccio G, Lucantoni G, Battistoni P, Paone G, Batzella S, Lucifora V, et al. Interventional endoscopy in the management of benign tracheal stenoses: definitive treatment at long-term follow-up. *Eur J Cardiothorac Surg*. 2009;35:429–33; discussion 933–4.
3. Lorenz RR. Adult laryngotracheal stenosis: etiology and surgical management. *Curr Opin Otolaryngol Head Neck Surg*. 2003;11:467–72.
4. Rea F, Callegaro D, Loy M, Zuin A, Narne S, Gobbi T, et al. Benign tracheal and laryngotracheal stenosis: surgical treatment and results. *Eur J Cardiothorac Surg*. 2002;22:352–6.
5. Ashiku SK, Kuzucu A, Grillo HC, Wright CD, Wain JC, Lo B, et al. Idiopathic laryngotracheal stenosis: effective definitive treatment with laryn-

- gotracheal resection. *J Thorac Cardiovasc Surg.* 2004;127:99–107.
6. Abbasidezfouli A, Akbarian E, Shadmehr MB, Arab M, Javaherzadeh M, Pejhan S, et al. The etiological factors of recurrence after tracheal resection and reconstruction in post-intubation stenosis. *Interact Cardiovasc Thorac Surg.* 2009;9(3):446–9. <https://doi.org/10.1510/icvts.2009.202978>.
  7. Marulli G, Rizzardi G, Bortolotti L, Loy M, Breda C, Hamad A-M, et al. Single-staged laryngotracheal resection and reconstruction for benign strictures in adults. *Interact Cardiovasc Thorac Surg.* 2008;7:227–30; discussion 230.
  8. Maurizi G, Vanni C, Rendina EA, Ciccone AM, Ibrahim M, Andreetti C, et al. Surgery for laryngotracheal stenosis: improved results. *J Thorac Cardiovasc Surg.* 2021;161(3):845–52. <https://doi.org/10.1016/j.jtcvs.2020.12.023>.
  9. Grillo HC, Donahue DM, Mathisen DJ, Wain JC, Wright CD. Postintubation tracheal stenosis. Treatment and results. *J Thorac Cardiovasc Surg.* 1995;109:486–92; discussion 492–3.
  10. Brichet A, Verkindre C, Dupont J, Carlier ML, Darras J, Wurtz A, et al. Multidisciplinary approach to management of postintubation tracheal stenoses. *Eur Respir J.* 1999;13:888–93.
  11. Shadmehr MB, Abbasidezfouli A, Farzanegan R, Pejhan S, Daneshvar Kakhaki A, Sheikhy K, et al. The role of systemic steroids in postintubation tracheal stenosis: a randomized clinical trial. *Ann Thorac Surg.* 2017;103:246–53.
  12. Hoffman MR, Coughlin AR, Dailey SH. Serial office-based steroid injections for treatment of idiopathic subglottic stenosis. *Laryngoscope.* 2017;127:2475–81.
  13. Hartnick CJ, Hartley BE, Lacy PD, Liu J, Bean JA, Willging JP, et al. Topical mitomycin application after laryngotracheal reconstruction: a randomized, double-blind, placebo-controlled trial. *Arch Otolaryngol Head Neck Surg.* 2001;127:1260–4.
  14. Smith ME, Elstad M. Mitomycin C and the endoscopic treatment of laryngotracheal stenosis: are two applications better than one? *Laryngoscope.* 2009;119:272–83.
  15. Qiu X-J, Zhang J, Wang J, Wang Y-L, Xu M. Application of paclitaxel as adjuvant treatment for benign cicatricial airway stenosis. *J Huazhong Univ Sci Technolog Med Sci.* 2016;36:817–22.
  16. Cantrell JR, Guild HG. Congenital stenosis of the trachea. *Am J Surg.* 1964;108:297–305.
  17. Macewen W. Clinical observations on the introduction of tracheal tubes by the mouth, instead of performing tracheotomy or laryngotomy. *Br Med J.* 1880;2:163–5.
  18. Stauffer JL, Olson DE, Petty TL. Complications and consequences of endotracheal intubation and tracheotomy. A prospective study of 150 critically ill adult patients. *Am J Med.* 1981;70:65–76.
  19. Dutau H. Tracheal stenoses endoscopic treatment. In: *Proceedings of the 12th world congress for bronchology*; 2002. Boston: Monduzzi Editore; 2002. p. 83–8.
  20. Nouraei SAR, Ma E, Patel A, Howard DJ, Sandhu GS. Estimating the population incidence of adult post-intubation laryngotracheal stenosis. *Clin Otolaryngol.* 2007;32:411–2.
  21. Poetker DM, Ettema SL, Blumin JH, Toohill RJ, Merati AL. Association of airway abnormalities and risk factors in 37 subglottic stenosis patients. *Otolaryngol Head Neck Surg.* 2006;135:434–7.
  22. Grillo HC. Management of neoplastic diseases of the trachea. In: Shields TW, LoCicero III J, Ponn RB, editors. *General thoracic survey*, vol. 1. 5th ed. Philadelphia: Lippincott Williams & Wilkins; 2000. p. 885–97.
  23. Anand VK, Alemar G, Warren ET. Surgical considerations in tracheal stenosis. *Laryngoscope.* 1992;102:237–43.
  24. Sarper A, Ayten A, Eser I, Ozbudak O, Demircan A. Tracheal stenosis after tracheostomy or intubation: review with special regard to cause and management. *Tex Heart Inst J.* 2005;32:154–8.
  25. Walz MK, Peitgen K, Thürauf N, Trost HA, Wolfhard U, Sander A, et al. Percutaneous dilatational tracheostomy—early results and long-term outcome of 326 critically ill patients. *Intensive Care Med.* 1998;24:685–90.
  26. Norwood S, Vallina VL, Short K, Saigusa M, Fernandez LG, McLarty JW. Incidence of tracheal stenosis and other late complications after percutaneous tracheostomy. *Ann Surg.* 2000;232:233–41.
  27. van Heurn LW, Goei R, de Ploeg I, Ramsay G, Brink PR. Late complications of percutaneous dilatational tracheostomy. *Chest.* 1996;110:1572–6.
  28. Hill BB, Zweng TN, Maley RH, Charash WE, Toursarkissian B, Kearney PA. Percutaneous dilatational tracheostomy: report of 356 cases. *J Trauma.* 1996;41:238–43; discussion 243–4.
  29. Zhang JJY, Lee KS, Ang LW, Leo YS, Young BE. Risk factors for severe disease and efficacy of treatment in patients infected with COVID-19: a systematic review, meta-analysis, and meta-regression analysis. *Clin Infect Dis.* 2020;71:2199–206.
  30. Piazza C, Filauro M, Dikkers FG, Nouraei SAR, Sandu K, Sittel C, et al. Long-term intubation and high rate of tracheostomy in COVID-19 patients might determine an unprecedented increase of airway stenoses: a call to action from the European Laryngological Society. *Eur Arch Otorhinolaryngol.* 2021;278:1–7.
  31. Sibila O, Molina-Molina M, Valenzuela C, Ríos-Cortés A, Arbilla-Etxarri A, Torralba García Y, et al. Documento de consenso de la Sociedad Española de Neumología y Cirugía Torácica (SEPAR) para el seguimiento clínico post-COVID-19. *Open Respir Arch.* 2020;2:278–83.
  32. Mattioli F, Marchioni A, Andreani A, Cappiello G, Fermi M, Presutti L. Post-intubation tracheal stenosis in COVID-19 patients. *Eur Arch Otorhinolaryngol.* 2021;278:847–8.

33. Giordano D, Botti C, Castellucci A, Piro R, Ghidini A. Tracheal stenosis after tracheotomy for COVID-19. *Ear Nose Throat J*. 2021; 1455613211045539.
34. Gervasio CF, Averono G, Robiolio L, Bertoletti M, Colageo U, De Col L, et al. Tracheal stenosis after tracheostomy for mechanical ventilation in COVID-19 pneumonia—a report of 2 cases from Northern Italy. *Am J Case Rep*. 2020;21:e926731.
35. Kim YH, Kim HT, Lee KS, Uh ST, Cung YT, Park CS. Serial fiberoptic bronchoscopic observations of endobronchial tuberculosis before and early after antituberculosis chemotherapy. *Chest*. 1993;103:673–7.
36. McIndoe RB, Steele JD, Samsom PC, et al. Routine bronchoscopy in patients with active pulmonary tuberculosis. *Am Rev Tuberc*. 1939;39:617–28.
37. Han JK, Im JG, Park JH, Han MC, Kim YW, Shim YS. Bronchial stenosis due to endobronchial tuberculosis: successful treatment with self-expanding metallic stent. *AJR Am J Roentgenol*. 1992;159:971–2.
38. Valdez TA, Shapshay SM. Idiopathic subglottic stenosis revisited. *Ann Otol Rhinol Laryngol*. 2002;111:690–5.
39. Damrose EJ. On the development of idiopathic subglottic stenosis. *Med Hypotheses*. 2008;71:122–5.
40. Terra RM, de Medeiros IL, Minamoto H, Nasi A, Pego-Fernandes PM, Jatene FB. Idiopathic tracheal stenosis: successful outcome with antigastroesophageal reflux disease therapy. *Ann Thorac Surg*. 2008;85:1438–9.
41. Grillo HC, Mark EJ, Mathisen DJ, Wain JC. Idiopathic laryngotracheal stenosis and its management. *Ann Thorac Surg*. 1993;56:80–7.
42. Liberman M, Mathisen DJ. Treatment of idiopathic laryngotracheal stenosis. *Semin Thorac Cardiovasc Surg*. 2009;21:278–83.
43. Perotin J-M, Jeanfaivre T, Thibout Y, Jouneau S, Lena H, Dutau H, et al. Endoscopic management of idiopathic tracheal stenosis. *Ann Thorac Surg*. 2011;92:297–301.
44. Sonett JR, Conte JV, Orens J, Krasna M. Removal and repositioning of “permanent” expandable wire stents in bronchial airway stenosis after lung transplantation. *J Heart Lung Transplant*. 1998;17:328–30.
45. Alvarez A, Algar J, Santos F, Lama R, Aranda JL, Baamonde C, et al. Airway complications after lung transplantation: a review of 151 anastomoses. *Eur J Cardiothorac Surg*. 2001;19:381–7.
46. Santacruz JF, Mehta AC. Airway complications and management after lung transplantation: ischemia, dehiscence, and stenosis. *Proc Am Thorac Soc*. 2009;6:79–93.
47. Lee JH, Park SS, Lee DH, Shin DH, Yang SC, Yoo BM. Endobronchial tuberculosis. Clinical and bronchoscopic features in 121 cases. *Chest*. 1992;102:990–4.
48. Chung HS, Lee JH. Bronchoscopic assessment of the evolution of endobronchial tuberculosis. *Chest*. 2000;117:385–92.
49. Chung MP, Lee KS, Han J, Kim H, Rhee CH, Han YC, et al. Bronchial stenosis due to anthracofibrosis. *Chest*. 1998;113:344–50.
50. Gómez-Seco J, Pérez-Boal I, Guerrero-González J, Sáez-Noguero F, Fernández-Navamuel I, Rodríguez-Nieto MJ. Anthracofibrosis or anthracostenosis. *Arch Bronconeumol*. 2012;48:133–6.
51. Kauczor HU, Wolcke B, Fischer B, Mildenerger P, Lorenz J, Thelen M. Three-dimensional helical CT of the tracheobronchial tree: evaluation of imaging protocols and assessment of suspected stenoses with bronchoscopic correlation. *AJR Am J Roentgenol*. 1996;167:419–24.
52. Speiser BL, Spratling L. Radiation bronchitis and stenosis secondary to high dose rate endobronchial irradiation. *Int J Radiat Oncol Biol Phys*. 1993;25:589–97.
53. Bagnée PE, Marquette CH, Ramon P, Darras J, Wurtz A. [Endoscopic treatment of post-intubation tracheal stenosis. Apropos of 58 cases]. *Rev Mal Respir* 1995;12: 585–92.
54. Hollingsworth HM. Wheezing and stridor. *Clin Chest Med*. 1987;8:231–40.
55. Boiselle PM, Ernst A. Recent advances in central airway imaging. *Chest*. 2002;121:1651–60.
56. Naidich DP, Gruden JF, McGuinness G, McCauley DI, Bhalla M. Volumetric (helical/spiral) CT (VCT) of the airways. *J Thorac Imaging*. 1997;12:11–28.
57. Amorico MG, Drago A, Vetrucchio E, Bollino F, Pizzuti G, Gallo E. Tracheobronchial stenosis: role of virtual endoscopy in diagnosis and follow-up after therapy. *Radiol Med*. 2006;111:1064–77.
58. Vining DJ, Liu K, Choplin RH, Haponik EF. Virtual bronchoscopy. Relationships of virtual reality endobronchial simulations to actual bronchoscopic findings. *Chest*. 1996;109:549–53.
59. Grenier PA, Beigelman-Aubry C, Fétita C, Prêteux F, Brauner MW, Lenoir S. New frontiers in CT imaging of airway disease. *Eur Radiol*. 2002;12:1022–44.
60. Hoppe H, Dinkel H-P, Walder B, von Allmen G, Gugger M, Vock P. Grading airway stenosis down to the segmental level using virtual bronchoscopy. *Chest*. 2004;125:704–11.
61. Van Rompaey V, De Foer B, Casselman J, Offeciens E. Response to: Prognostic indicators of hearing after complete resection of cholesteatoma causing a labyrinthine fistula by Stephenson MF and Saliba I. *Eur Arch Otorhinolaryngol* 2011 Mar 9 [epub ahead of print]. *Eur Arch Otorhinolaryngol*. 2011;268:1697–8. <https://doi.org/10.1007/s00405-011-1767-8>.
62. Polverosi R, Vigo M, Baron S, Rossi G. [Evaluation of tracheobronchial lesions with spiral CT: comparison between virtual endoscopy and bronchoscopy]. *Radiol Med*. 2001;102:313–9.
63. Faust RA, Remley KB, Rimell FL. Real-time, cine magnetic resonance imaging for evaluation of the pediatric airway. *Laryngoscope*. 2001;111:2187–90.
64. Carretta A, Melloni G, Ciriaco P, Libretti L, Casiraghi M, Bandiera A, et al. Preoperative assessment in patients with postintubation tracheal stenosis: rigid and flexible bronchoscopy versus spiral CT scan



- with multiplanar reconstructions. *Surg Endosc.* 2006;20:905–8.
65. Herth F, Becker HD, LoCicero J, Ernst A. Endobronchial ultrasound in therapeutic bronchoscopy. *Eur Respir J.* 2002;20(1):118–21. <https://doi.org/10.1183/09031936.02.01642001>.
  66. Murgu S, Kurimoto N, Colt H. Endobronchial ultrasound morphology of expiratory central airway collapse. *Respirology.* 2008;13:315–9.
  67. Hou R, Le T, Murgu SD, Chen Z, Brenner M. Recent advances in optical coherence tomography for the diagnoses of lung disorders. *Expert Rev Respir Med.* 2011;5:711–24.
  68. Michel RG, Kinasewitz GT, Fung K-M, Keddissi JI. Optical coherence tomography as an adjunct to flexible bronchoscopy in the diagnosis of lung cancer. *Chest.* 2010;138(4):984–8. <https://doi.org/10.1378/chest.10-0753>.
  69. Williamson JP, McLaughlin RA, Phillips MJ, Armstrong JJ, Becker S, Walsh JH, et al. Using optical coherence tomography to improve diagnostic and therapeutic bronchoscopy. *Chest.* 2009;136:272–6.
  70. Finkelstein SE, Schrupp DS, Nguyen DM, Hewitt SM, Kunst TF, Summers RM. Comparative evaluation of super high-resolution CT scan and virtual bronchoscopy for the detection of tracheobronchial malignancies. *Chest.* 2003;124(5):1834–40. <https://doi.org/10.1378/chest.124.5.1834>.
  71. Acres JC, Kryger MH. Clinical significance of pulmonary function tests: upper airway obstruction. *Chest.* 1981;80:207–11.
  72. Alrabiah A, Almohanna S, Aljasser A, Zakzouk A, Habib SS, Almohizea M, et al. Utility of spirometry values for evaluating tracheal stenosis patients before and after balloon dilation. *Ear Nose Throat J.* 2022;101:NP62–7.
  73. Cotton RT. Pediatric laryngotracheal stenosis. *J Pediatr Surg.* 1984;19(6):699–704. [https://doi.org/10.1016/s0022-3468\(84\)80355-3](https://doi.org/10.1016/s0022-3468(84)80355-3).
  74. McCaffrey TV. Classification of laryngotracheal stenosis. *Laryngoscope.* 1992;102:1335–40.
  75. Amorós JM, Ramos R, Villalonga R, Morera R, Ferrer G, Díaz P. Tracheal and cricotracheal resection for laryngotracheal stenosis: experience in 54 consecutive cases. *Eur J Cardiothorac Surg.* 2006;29(1):35–9. <https://doi.org/10.1016/j.ejcts.2005.10.023>.
  76. López-Lisbona R, Rosell Gratacós A, Cubero de Frutos N. Capítulo 5: Procedimientos endoscópicos (27-34). En Moya Amorós J, Rosell Gratacós A, Díaz Martos I. *Manual Separ de Procedimientos 23.* ISBN Módulo 23: 978-84-938706-8-3. Patología inflamatoria de la vía aérea principal. Barcelona. Editorial Respira, 2012. ISBN Obra completa: 84-7989-152-1.
  77. Freitag L, Ernst A, Unger M, Kovitz K, Marquette CH. A proposed classification system of central airway stenosis. *Eur Respir J.* 2007;30:7–12.
  78. Grillo HC, Donahue DM, Mathisen DJ, Wain JC, Wright CD. Postintubation tracheal stenosis. *J Thorac Cardiovasc Surg.* 1995;109(3):486–93. [https://doi.org/10.1016/s0022-5223\(95\)70279-2](https://doi.org/10.1016/s0022-5223(95)70279-2).
  79. Murgu S, Colt H. Subjective assessment using still bronchoscopic images misclassifies airway narrowing in laryngotracheal stenosis. *Interact Cardiovasc Thorac Surg.* 2013;16:655–60.
  80. Begnaud A, Connett JE, Harwood EM, Jantz MA, Mehta HJ. Measuring central airway obstruction. What do bronchoscopists do? *Ann Am Thorac Soc.* 2015;12(1):85–90. <https://doi.org/10.1513/annalsats.201406-268oc>.
  81. Murgu S, Colt HG. Morphometric bronchoscopy in adults with central airway obstruction: case illustrations and review of the literature. *Laryngoscope.* 2009;119(7):1318–24. <https://doi.org/10.1002/lary.20478>.
  82. Sánchez C, Bernal J, Javier Sánchez F, Diez M, Rosell A, Gil D. Toward online quantification of tracheal stenosis from videobronchoscopy. *Int J Comput Assist Radiol Surg.* 2015;10(6):935–45. <https://doi.org/10.1007/s11548-015-1196-z>.
  83. Gil D, Ortiz RM, Sánchez C, Rosell A, SENSEA team. Objective endoscopic measurements of central airway stenosis: a pilot study. *Respiration.* 2018;95:63–9.
  84. Monnier P, Dikkers FG, Eckel H, Sittel C, Piazza C, Campos G, et al. Preoperative assessment and classification of benign laryngotracheal stenosis: a consensus paper of the European Laryngological Society. *Eur Arch Otorhinolaryngol.* 2015;272(10):2885–96. <https://doi.org/10.1007/s00405-015-3635-4>.
  85. Dumon JF, Reboud E, Garbe L, Aucomte F, Meric B. Treatment of tracheobronchial lesions by laser photoresection. *Chest.* 1982;81:278–84.
  86. Cavaliere S, Foccoli P, Farina PL. Nd:YAG laser bronchoscopy. A five-year experience with 1,396 applications in 1,000 patients. *Chest.* 1988;94:15–21.
  87. Díaz Jiménez JP, Canela Cardona M, Maestre Alcacer J, Balust Vidal M, Fontanals Tortra J, Balust Vidal J. [Treatment of obstructive tracheobronchial disease with the Yag-Nd laser: 400 procedures in a 4-year experience]. *Med Clin.* 1989;93:244–8.
  88. Mehta AC, Lee FY, Cordasco EM, Kirby T, Eliachar I, De Boer G. Concentric tracheal and subglottic stenosis. Management using the Nd-YAG laser for mucosal sparing followed by gentle dilatation. *Chest.* 1993;104:673–7.
  89. Batzella S, Lucantoni G, Fiorelli A, Iacono RD, Battistoni P, Caterino U, et al. A new endoscopic hand drill for management of tracheal stenosis. *Interact Cardiovasc Thorac Surg.* 2016;23:168–70.
  90. Amat B, Esselmann A, Reichle G, Rohde H-J, Westhoff M, Freitag L. The electrosurgical knife in an optimized intermittent cutting mode for the endoscopic treatment of benign web-like tracheobronchial stenosis. *Arch Bronconeumol.* 2012;48:14–21.
  91. Fernando HC, Dekeraty D, Downie G, Finley D, Sullivan V, Sarkar S, et al. Feasibility of spray cryotherapy and balloon dilation for non-malignant strictures of the airway. *Eur J Cardiothorac Surg.* 2011;40:1177–80.

92. Tremblay A, Marquette C-H. Endobronchial electrocautery and argon plasma coagulation: a practical approach. *Can Respir J*. 2004;11:305–10.
93. Grund KE, Zidel C, Farin G. Argon plasma coagulation (APC) in flexible endoscopy: experience with 2,193 applications in 1,062 patients. *Gastroenterology*. 1998;A603. [https://doi.org/10.1016/s0016-5085\(98\)82460-8](https://doi.org/10.1016/s0016-5085(98)82460-8).
94. Maiwand MO, Zehr KJ, Dyke CM, Peralta M, Tadjkarimi S, Khagani A, et al. The role of cryotherapy for airway complications after lung and heart-lung transplantation. *Eur J Cardiothorac Surg*. 1997;12:549–54.
95. Wood DE, Liu Y-H, Vallières E, Karmy-Jones R, Mulligan MS. Airway stenting for malignant and benign tracheobronchial stenosis. *Ann Thorac Surg*. 2003;76:167–74. [https://doi.org/10.1016/s0003-4975\(03\)00033-x](https://doi.org/10.1016/s0003-4975(03)00033-x).
96. Murgu SD, Egressy K, Laxmanan B, Doblare G, Ortiz-Comino R, Kyle Hogarth D. Central airway obstruction. *Chest*. 2016;426–41. <https://doi.org/10.1016/j.chest.2016.02.001>.
97. Tsakiridis K, Darwiche K, Visouli AN, Zarogoulidis P, Machairiotis N, Christofis C, et al. Management of complex benign post-tracheostomy tracheal stenosis with bronchoscopic insertion of silicon tracheal stents, in patients with failed or contraindicated surgical reconstruction of trachea. *J Thorac Dis*. 2012;4(Suppl 1):32–40.
98. Montgomery WW. T-tube tracheal stent. *Arch Otolaryngol*. 1965;82:320–1.
99. Bourinet V, Raguin T, Fortin M, Chetrit E, Guinde J, Laroumagne S, et al. Experience with transcordal silicone stents in adult laryngotracheal stenosis: a bicentric retrospective study. *Respiration*. 2018;95(6):441–8. <https://doi.org/10.1159/000487242>.
100. Alshammari J, Monnier P. Airway stenting with the LT-Mold™ for severe glotto-subglottic stenosis or intractable aspiration: experience in 65 cases. *Eur Arch Otorhinolaryngol*. 2012;269:2531–8.
101. Rodriguez AN, Díaz-Jiménez JP, Edell ES. Silicone stents versus metal stents for management of benign tracheobronchial disease con: metal stents. *J Bronchol*. 2000;7(2):184–7. <https://doi.org/10.1097/00128594-200007020-00017>.
102. FDA Public Health Notification: Complications from metallic tracheal stents in patients with benign airway disorders. 2005. [www.fda.org](http://www.fda.org).
103. Xiong X-F, Xu L, Fan L-L, Cheng D-Y, Zheng B-X. Long-term follow-up of self-expandable metallic stents in benign tracheobronchial stenosis: a retrospective study. *BMC Pulm Med*. 2019;19:33.
104. Dahlqvist C, Ocak S, Gourdin M, Dincq AS, Putz L, d'Odémont J-P. Fully covered metallic stents for the treatment of benign airway stenosis. *Can Respir J*. 2016;2016:8085216.
105. Fortin M, MacEachern P, Hergott CA, Chee A, Dumoulin E, Tremblay A. Self-expandable metallic stents in nonmalignant large airway disease. *Can Respir J*. 2015;22:235–6.
106. Stehlik L, Hytych V, Letackova J, Kubena P, Vasakova M. Biodegradable polydioxanone stents in the treatment of adult patients with tracheal narrowing. *BMC Pulm Med*. 2015;15:164.
107. Wang T, Zhang J, Wang J, Pei Y-H, Qiu X-J, Wang Y-L. Paclitaxel drug-eluting tracheal stent could reduce granulation tissue formation in a canine model. *Chin Med J*. 2016;129:2708–13.
108. Zarogoulidis P, Darwiche K, Walter R, Li Q, Teschler H, Freitag L, et al. Research spotlight: sirolimus-coated stents for airway tracheal stenosis: a future 3D model concept with today's knowledge. *Ther Deliv*. 2013;4:1093–7.
109. En Martínez Hernández N, López Villalobos JL, Tarrazona Hervás V. Documento de consenso SECT sobre cirugía traqueal y laringotraqueal. ISBN: 978-84-9110-159-8 (ebook) 2016, EDITORIAL MÉDICA PANAMERICANA, S. A.
110. Pearson FG, Cooper JD, Nelems JM, Van Nostrand AW. Primary tracheal anastomosis after resection of the cricoid cartilage with preservation of recurrent laryngeal nerves. *J Thorac Cardiovasc Surg*. 1975;70: 806–16.
111. Grillo HC. Primary reconstruction of airway after resection of subglottic laryngeal and upper tracheal stenosis. *Ann Thorac Surg*. 1982;33:3–18.
112. Maddaus MA, Toth JL, Gullane PJ, Pearson FG. Subglottic tracheal resection and synchronous laryngeal reconstruction. *J Thorac Cardiovasc Surg*. 1992;104:1443–50.
113. Couraud L, Jougon JB, Ballester M. Techniques of management of subglottic stenoses with glottic and supraglottic problems. *Chest Surg Clin N Am*. 1996;6:791–809.
114. Wright CD, Grillo HC, Wain JC, Wong DR, Donahue DM, Gaisser HA, et al. Anastomotic complications after tracheal resection: prognostic factors and management. *J Thorac Cardiovasc Surg*. 2004;128:731–9.
115. Emst A, Silvestri GA, Johnstone D, American College of Chest Physicians. Interventional pulmonary procedures: Guidelines from the American College of Chest Physicians. *Chest*. 2003;123:1693–717.



# Endobronchial Prosthesis

# 16

Claudia Freitas, Sean Stoy,  
and Septimiu Dan Murgu

## Abbreviations

6MWT	Six-minute walk test
BAO	Benign airway obstruction
BPF	Bronchopleural fistula
CAO	Central airway obstruction
CPAP	Continuous positive airway pressure
CT	Computed tomography
DATS	Dynamic A-shape Tracheal Stenosis
EBUS	Endobronchial ultrasound
ECAC	Expiratory central airway collapse
EDAC	Excessive dynamic airway collapse
EPP	Equal pressure point
ERF	Esophagorespiratory fistulas
ETT	Endotracheal tube
FLS	Flow limiting segment
HRQOL	Health related quality of life
IOS	Impulse oscillometry
MAO	Malignant airway obstruction
MRC	Medical Research Council
PL	Intraluminal pressure
Plat	Lateral airway pressure
POTS	Postoperative tracheal stenosis

Ppl	Pleural pressure
QOL	Quality of life
R	Resistance
RP	Relapsing polychondritis
RRP	Recurrent respiratory papillomatosis
SEMS	Self expandable metallic stents
TBM	Tracheobronchomalacia
TLC	Total lung capacity

C. Freitas  
Pulmonology Department, Centro Hospitalar e  
Universitário de São João and Faculty of Medicine,  
University of Porto, Porto, Portugal

S. Stoy  
North Memorial Health, Robbinsdale, MN, USA

S. D. Murgu (✉)  
The University of Chicago Medicine,  
Chicago, IL, USA  
e-mail: [smurgu@medicine.bsd.uchicago.edu](mailto:smurgu@medicine.bsd.uchicago.edu)

## Introduction

This chapter is focused on the indications, physiologic basis, and complications of airway stent insertion. Airway stents have been consistently shown to help patients suffering from benign and malignant central airway obstruction (CAO)<sup>1</sup> and esophagorespiratory fistulas, by improving their airflow, quality of life, and potentially survival. The incidence rate of adverse events depends on patient and stent-related factors. Prior to inserting such a device, the bronchoscopist should determine the need and expected benefits of this procedure. A first step is to objectively classify the obstruction based on histology, mechanism of obstruction, and dynamic features (Fig. 16.1). An objective assessment of the extent and severity of

<sup>1</sup>Central airway obstruction is defined in this chapter as any clinically significant narrowing of the airway from the subglottis to the lobar bronchi.

<b>Classification of Central Airway Obstruction</b>	
<b>Qualitative Criteria</b>	<b>Quantitative Criteria</b>
<p><b>I. Histology</b> Benign Malignant</p> <p><b>II. Mechanism of obstruction</b> Extrinsic compression Intraluminal     exophytic; infiltrative; stricture Mixed</p> <p><b>III. Dynamic features</b> Fixed Dynamic</p>	<p><b>I. Severity of airway narrowing</b> Normal; Mild: Moderate; Severe</p> <p><b>II. Extent of airway narrowing</b> Normal; Mild: Moderate; Severe</p> <p><b>III. Functional Impairment</b> Normal; Mild: Moderate; Severe</p>

**Fig. 16.1** Classification of central airway obstruction based on qualitative and quantitative criteria. Dynamic features refer to the phase of respiration during which there is flow limitation. In a fixed obstruction, there is limitation to flow both during inspiration and expiration, while in dynamic obstruction, only during a respiratory phase, as is the case with tracheomalacia. The quantitative criteria could be objectively assessed. For instance, based on physiologic data, for tracheal stenosis, the

severity of airway narrowing can be quantified as mild (<50% narrowing), moderate (50–70%) and severe (>70%); the extent is the vertical length of the stenosis, and based on outcomes from bronchoscopic and open surgical interventions, can be quantified as mild (<1 cm), moderate (1–4 cm) and severe (>4 cm). Functional impairment can be objectively assessed using a variety of validated tools such as MRC dyspnea scale or WHO functional class

airway narrowing is necessary, as well as an accurate assessment of the impact of the airway narrowing on functional status (Fig. 16.1).

### Historical Perspective and Emerging Concepts in Airway Stenting

Since the beginning of documented airway stent insertion at the end of nineteenth century, tracheobronchial prostheses have been generally made of two types of materials: metal or rubber. As the understanding of airway physiology and airway interaction with the prosthetic materials has advanced, the manufacturers take into consideration the biomechanical and biocompatibility characteristics, even though this information is not always available to the practicing bronchoscopist. Clinically used airway stents are currently made of polymers, alloy metallic mesh, or a combination of the two (aka hybrid stents). In

general, the pure metallic stents have been abandoned because of severe complications.

The future may see the incorporation of treatment agents such as chemotherapeutic (e.g., mitomycin C, paclitaxel), radioactive agents, three-dimensional (3D) printed, or bioabsorbable stents [1]. In vitro studies demonstrated that paclitaxel incorporated into silicone was efficiently released and reduced interleukin-8 (IL-8) levels in cancer cells, with no cytotoxic effect being observed in other cells [2].

In theory, stents made of bioabsorbable polymers may be ideal, especially in pediatric population, as they can support the airway wall and dissolve after the remodeling process is completed, thus providing temporary airway stiffness, sometimes necessary in infants with tracheobronchomalacia (TBM). Such stents have the advantage of potentially avoiding the need for repeated interventions under general anesthesia for removal or revision [3–5]. Only pilot human studies of bioabsorbable stents have been published to date [6,

7]. Bioabsorbable drug-eluting stents have the potential advantage of reducing the risk of stent-related complications, but they have only been studied in animal models of benign tracheal stenosis [1]. In animal models, novel bioabsorbable stents (made of polycaprolactone) with cisplatin elution have been developed to overcome some of the problems associated with chronic indwelling stents (tumor ingrowth, fracture, migration) [8]. The mechanical strength of these stents was shown to be comparable to the strength of Ultraflex self-expandable metallic stents (SEMS) and provided a steady release of cisplatin for >4 weeks in vitro. The in vivo study showed sustained cisplatin levels in rabbit trachea for >5 weeks with a minimum drug level in blood. Histologic examination showed an intact ciliated epithelium and marked leukocyte infiltration in the submucosa of the stented area, findings suggesting potential use in malignant CAO. In a human study, six biodegradable polydioxanone tracheal stents were safely implanted in four patients with benign inoperable tracheal stenosis. The authors report that all patients had “some” benefit from treatment and suggested that further research is needed to fully assess the outcomes of this therapy [9]. Biodegradable stents have been used in airway compression caused by vascular compression in pediatric population [10]. However, their safety remains of concern since degradation fragments can lead to airway obstruction [11]. Despite the limited clinical experience, 3D printed stents can represent a more patient-focused alternative to manage CAO. These stents consist in patient-specific silicone airway stents generated using computed tomography (CT) imaging and 3D printing technology. Gildea et al. reported improved durability, improvement in patient-reported symptoms leading to a reduced need for stent changes, and modifications in two patients with granulomatosis with polyangiitis (GPA) at 1 year follow-up [12]. Whether these stents will be incorporated into clinical practice remains to be determined. One concern is the lack of their availability at the time of the procedure. This makes them impractical as additional procedures are necessary since the CT scanning is performed post-debulking/dilation.

Airway bioengineering using stented aortic matrices implantation is a novel concept and was

shown to be clinically feasible. In a study of 13 patients, 8 had normal breathing through newly formed airways after stent removal at 3-year follow-up. More studies are needed to assess the efficacy and safety of this technique [13].

As of this writing, the original described problems of migration, granulation, mucus plugging, infection, and even airway perforation and fatal hemoptysis are still present after stent insertion [14]. Therefore, operators have to carefully review the indications and expected results before inserting airway stents.

---

## Indications

Airway stents are most commonly used for symptomatic extrinsic airway compression with or without associated airway mucosal infiltration. Stents can also be used if there is still significant (generally considered more than 50%) narrowing after the endoluminal component of a purely exophytic or mixed type of obstruction has been treated using one or more bronchoscopic techniques<sup>2</sup> [15]. Various stents have been used as well for sealing malignant, inoperable benign esophagorespiratory, and bronchial stump fistulas. Stents are occasionally used to improve symptoms of severe crescent type tracheobronchomalacia and excessive dynamic airway collapse, in patients who are refractory to more conservative measures (i.e., continuous positive airway pressure [CPAP], gastroesophageal reflux disease [GERD] management) and are not candidates for an open surgical procedure (i.e., tracheobronchoplasty for diffuse disease or sleeve resection for focal disease) [16, 17]. Studies performed within the last 25 years have shown that airway stents improve lung function in patients with central airway obstruction and may improve survival in patients whose CAO is due to malignant disease. In this section, we will describe the indications of stent insertion based on the mechanism of obstruction.

---

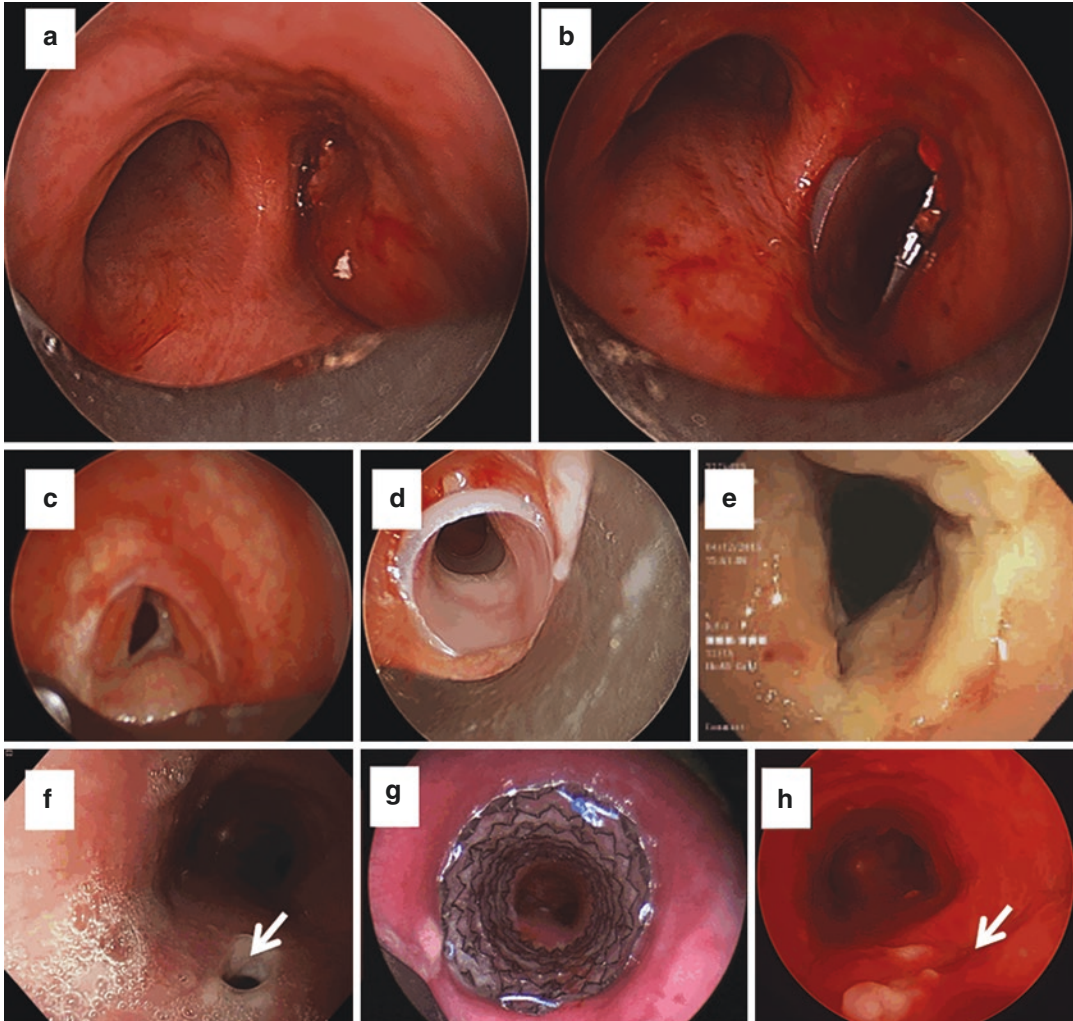
<sup>2</sup>These include rigid or flexible bronchoscopic resection, laser, electrocautery, cryotherapy, photodynamic therapy, or brachytherapy and are described in detail in other chapters in this book.



## Extrinsic Compression

Extrinsic compression from benign or malignant thyroid disease, primary lung tumors (Fig. 16.2), mediastinal masses, or massive intrathoracic lymphadenopathy is the most common indication

for airway stent insertion. Rarely, vascular abnormalities such as aortic aneurysm, vascular sling, and double aortic arch may cause symptomatic extrinsic airway obstruction and may require stent insertion for patients who do not undergo corrective surgery.



**Fig. 16.2** Indications for airway stent insertion. Severe extrinsic compression of the right mainstem bronchus due to primary lung cancer, before (a) and after (b) silicone stent insertion. Severe, complex post tracheostomy, triangular or A-shaped stenosis with malacia in a non-surgical candidate before (c) and after (d) a 16 × 40 mm straight silicone stent was inserted. Follow up bronchoscopy triggered by excessive coughing and inability to raise secretions dem-

onstrated restored tracheal patency but the stent migrated down to the main carina (e) and required removal. Benign gastro-tracheal fistula (f) after esophagectomy and gastric pull up procedure. As repeat surgery was unsuccessful at closing the fistula, a fully covered SEMS was used (g). Four weeks later the stent was removed and fortunately, the airway wall completely healed (h) without recurrence of the fistula during the follow up

## Intraluminal Obstruction

Stent insertion may be useful in selected cases of endoluminal exophytic benign central airway obstruction (CAO); this is the case of refractory endobronchial recurrent respiratory papillomatosis (RRP) when medical and other endobronchial therapies fail to restore airway patency. Case reports show that papilloma debulking and silicone stents can offer adequate control of symptoms [18]. However, histologically benign intraluminal obstruction necessitating stent insertion is mostly caused by strictures, either idiopathic or related to other disorders. The most common cause of benign strictures is post-intubation and post-tracheostomy stenosis (Fig. 16.2), but it is important to note that a variety of other conditions associated with strictures should be ruled out before making the diagnosis of idiopathic stenosis. This is relevant as the management strategies need to be individualized. Examples include granulomatosis with polyangiitis (GPA), amyloidosis, sarcoidosis, ulcerative colitis, post-tuberculosis, or due to *Klebsiella rhinoscleromatis* infection. For example, 12 to 23% of patients with GPA develop tracheobronchial stenosis. A multicenter retrospective study of 47 patients with GPA-associated tracheobronchial stenosis found that these patients benefit from a delay in any interventional procedures following the diagnosis, allowing for a “cooling off” period from the associated inflammation. It is also advisable to have patients on an increased dose of corticosteroids to >30 mg/day during the peri-procedural period [19]. Studies suggest that subglottic stenosis (SGS) can prove refractory to pharmacologic therapy alone with up to 62% patient experiencing a relapse on conventional GPA therapy [19]. Laryngotracheal resection with reconstruction in patients with GPA has been associated with disease relapse even in a highly selective group with 55 to 75% patients requiring additional tracheal dilation and 9 to 13% patients requiring a permanent tracheostomy [20, 21]. Therefore, stent insertion should be considered for patients with pharmacologically refractory GPA who require multiple dilations,

The remainder of this section will focus on the role of stent insertion for benign stenoses associated with intubation (PITS) and tracheostomy (PTTS). The incidence rate of benign tracheal stenosis following intubation has historically ranged from 0.6 to 19% and following tracheostomy from 6 to 65%. Fortunately the advent of low-pressure cuffs has substantially decreased these rates (by up to tenfold), yet still 1–5% of patients suffer from traumatic symptomatic PITS or PTTS, typically occurring 2–3 months following the event [22]. It remains to be determined whether the introduction of new mechanical ventilators with continuous endotracheal cuff pressure monitoring or the low pressure, low volume tracheostomy tubes could further reduce the incidence of PITS.

The true incidence of PITS in patients requiring mechanical intubation due to coronavirus disease 2019 (COVID-19) is unknown. However, prolonged intubations frequently followed by tracheostomy, prone mechanical ventilation, and possible endotracheal tube (ETT) cuff overinflation due to lack of proper surveillance in overwhelmed healthcare facilities might contribute to a higher incidence of PITS in COVID-19 patients [23]. Furthermore, shared risk factors between PITS and severe COVID-19 pneumonia, such as obesity and diabetes, may also justify this association. More investigation is needed to understand the exact pathophysiology of PITS in patients who underwent mechanical intubation for severe COVID-19, specifically the role of inflammation in the development of scarring within airway mucosa [24].

For post-intubation or post-tracheostomy strictures, stent placement should be considered only in inoperable patients; in addition, patients need to be symptomatic and the lumen of the airway below half of its normal after other interventional endoscopic techniques have been applied. We believe these patients are better served by a multidisciplinary airway team consisting of interventional pulmonologists, thoracic surgeons and otolaryngologists [25].

Benign airway obstruction can be classified in a variety of ways, and management techniques and success rates vary based on the type of steno-

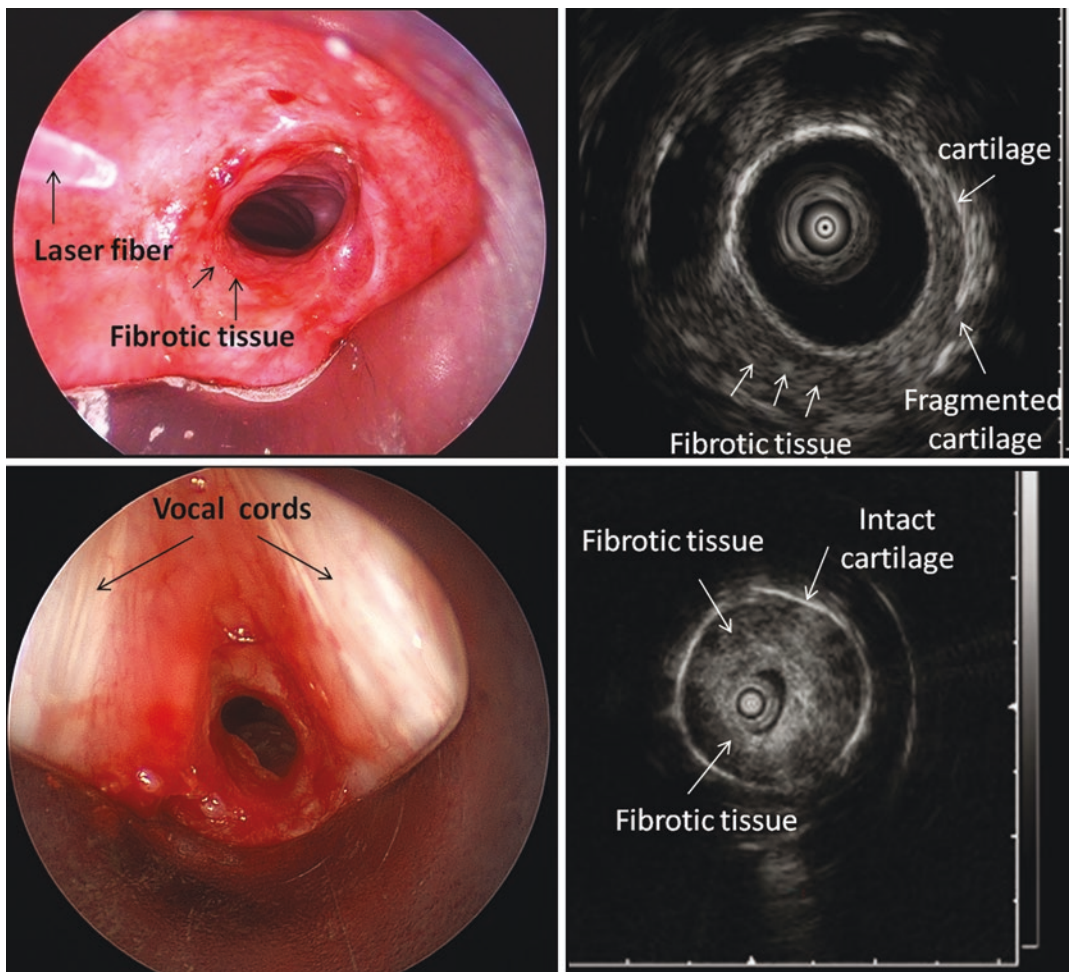
sis. For example, a simple web-like stricture (vertical extent less than 1 cm), which is dilated and does not recur, will not require a stent [26, 27]; a complex stricture, however, often has associated chondritis, and dilation alone (with or without laser assistance) is not usually successful and a stent would be required to maintain airway patency [28]. Another way of classifying strictures uses the terms “structural” and “dynamic”: a structural stenosis is a result of scarring and fixed constriction of the airway, which is the most common form. A dynamic stenosis is a form of focal, localized malacia with degree of obstruction dependent on the variability of transthoracic pressures during respiration. Another classification has been proposed: that of a dynamic A-shape tracheal stenosis (DATS) which is an amalgamated variation that combines both a structural stenosis from a fractured anterior cartilage ring with a dynamic stenosis from posterior malacia (Fig. 16.2). This results in a triangular “A-shaped” trachea on imaging. This is an important finding as the structural component is not the result of scarring/shrinkage of the trachea and as such the management of DATS differs significantly from that of other structural forms of benign airway strictures. Specifically, patients with DATS do not benefit from dilation alone. At the same time, due to the dynamic component to the stenosis, patient experiences higher rates of stent migration than typical structural stenosis patients (Fig. 16.2) [22].

Silicone stent insertion performed using rigid bronchoscopy under general anesthesia is considered an acceptable alternative to surgery for inoperable patients with complex tracheal strictures. A 2016 retrospective study of 90 patients undergoing stenting for histologically benign airway obstruction showed that in patients with simple stenosis undergoing stenting there was a 100% success rate with a single stent placed and mean stent duration of 5.6 months. On the other hand, patients with complex stenoses did not fare as well: 45% required multiple re-stenting procedures, 60% required stent repositioning, the stents remained in place for 12 months, and despite this the success rate was 70% at 1 year [27]. In an older study of 42 patients with complex stenoses, only 9 were surgi-

cal candidates and 33 were treated with silicone stent insertion, with a success rate of 69% [29]. The success rate of bronchoscopic treatment once stents are removed (usually after at least 6 months) in cases of complex stenosis is reportedly low (17.6%) suggesting the need for long-term indwelling airway stent. A higher rate of airway stability after stent removal (46.8%, in 22 out of 47 patients) was described after stents remained in place for a longer period of time (mean of 11.6 months) [30], with almost 50% of patients (12/22) having their stents for more than 12 months. We thus propose a trial of stent removal at 1-year post-insertion understanding that patients with recurrence may need to be reconsidered for open surgical intervention or need long-term indwelling airway silicone stents.

Predictors of success of bronchoscopic treatments are stenoses shorter than 1 cm in vertical extent and without associated malacia (i.e., chondritis). Lesion extent (i.e., height) and intubation-to-treatment latency have also been reported to independently predict the success of bronchoscopic intervention. In one study, 96% of patients with lesions <3 cm in height were successfully treated bronchoscopically, but the success rate decreased to 20% for lesions longer than 3 cm. Patients with stenosis present for more than 6 months since the original injury were also less likely to be successfully treated bronchoscopically [31], suggesting that the established fibrotic tissue counteracts the expansile force of the remaining cartilage [32]. In fact, knowing the integrity of the cartilage in post-intubation or post-tracheostomy stenoses is important in the treatment decision-making process. In complex post-intubation/tracheostomy stenosis, cartilage integrity or lack thereof is not always easily assessed on white light bronchoscopy, mainly because of the overlying stenotic hypertrophic tissues [33] (Fig. 16.3). To assess the integrity of the cartilage, one may use high frequency endobronchial ultrasound (20 MHz balloon based radial probe) during the bronchoscopic intervention. The EBUS image using this system has a high resolution and allows visualization of the stenotic tissue and the cartilaginous structures and may be a surrogate of gross





**Fig. 16.3** Rigid bronchoscopic and sonographic view of laryngotracheal stenosis. In the upper panel, the circumferential post intubation tracheal stenosis is noted but on white light imaging, the cartilage cannot be assessed. High frequency endobronchial ultrasound (20 MHz probe) can identify the cartilage and its disruption. The knowledge that the cartilage is affected could impact man-

agement since simple laser assisted mechanical dilation without stent insertion is unlikely to be maintain airway patency in the long term. In the lower panel, idiopathic subglottic stenosis at the level of the cricoid is seen on white light imaging, but the intact cricoid cartilage itself is only identified on high frequency endobronchial ultrasound

histology for tracheal stenosis; for instance, in idiopathic tracheal stenosis, the cartilage is known to be normal, but there is clear hypertrophy of the mucosa and submucosa as visualized by EBUS as well. On the other hand, in complex stenoses, there is partial or total destruction of cartilage histologically which can be identified by EBUS [33] (Fig. 16.3). Since the balloon-based radial EBUS probe is not available on all markets, proceduralists could consider using the linear EBUS, but there is no data about its abil-

ity to define tracheal stenosis complexity or guiding management in this disease.

When used for benign stenosis, silicone stents are preferable and can be helpful for splinting post-intubation/tracheostomy stenoses and are considered appropriate to palliate airway narrowing in nonsurgical candidates<sup>3</sup> [28, 34, 35]. Stent-

<sup>3</sup>Coexistent diseases: coronary heart disease, severe cardiac or respiratory insufficiency, or poor general condition or stenosis length >4 cm.

related complications, however, are not uncommon in this disease and include migration, obstruction from secretions, infection, and significant granulation tissue formation at the proximal or distal extremities of the stent [14, 36].

Silicone T-tubes (Montgomery T tubes) or tracheostomy tubes are sometimes used for benign tracheal strictures, especially when they involve the cricoid cartilage; they should be inserted through the area of stenosis, if possible, to conserve airway not involved by the stenotic lesion. For most patients who do not require mechanical ventilatory support, a silicone T-tube could provide symptomatic improvement [37]. These therapies are warranted in the few patients with critical stenoses who are neither candidates for surgery nor for indwelling airway stent insertion or for who develop recurrence after such interventions [28]. T-tubes can also be used when tracheal resection and reconstruction or dilation techniques are either not available or have failed, or as a solution for patients who had silicone stent placement complicated by frequent migrations [36]. In a large case series including 53 patients with complex tracheal stenoses (24 post-tracheostomy), silicone T-tube insertion was effective in 70% of patients with limited complications [38]. The sharper edge of the proximal aspect of the T-tube, in cases when it has to be cut, suboptimal tracheostomy tract (i.e., non-midline stoma), as well as its placement within 0.5 cm from the vocal cords are known risk factors for granulation tissue development<sup>4</sup> [38]. In addition, airway secretions may become dry and cause obstruction. Patients, families, and referring physicians benefit from instruction on how to care for and monitor T-tubes. Frequent bronchoscopies may be necessary to remove mucus plugs, with some investigators performing three to four biweekly bronchoscopies, followed by once every 4 weeks once stent patency has been documented [38].

<sup>4</sup>Granulation tissue formation at the proximal end of the T-tube has also been described and it is believed that chronic airway irritation incites infection and promotes or aggravates granulation tissue formation.

The inherent disadvantage of a T-tube is the need for a tracheostomy. It also requires patient compliance with pulmonary hygiene measures including but not limited to saline nebulization, deep breathing exercises, and self-suctioning. In our opinion, T-tubes should be used for patients who are not surgical candidates for open resection and when endoluminal stent placement is associated with frequent stent-related complications.

Self-expandable metallic stents (SEMS) have been associated with significant complications and are to be avoided, if possible, in benign disorders. Immediate symptomatic improvement is reported and expected, but the long-term complications are common and may be life threatening [39]. In one study of 30 patients who underwent SEMS for benign tracheal stenosis, half of the patients required stent removal due to complications, with migration being the most frequent one. However, if there are no other options available, this report suggests that it is safe to proceed with SEMS and remove the stent after 4 months [40].

Self-expandable silicone stents, contrary to metal stents, have the advantage of being easily removable. They are, however, placed under rigid bronchoscopy or suspension laryngoscopy. Some of these silicone stents have been studied in benign airway obstruction including tracheal stenosis and malacia [30]. While immediate symptom palliation was established in most cases, the incidence of complications was high (75%) with stent migration occurring in 69% of cases [41, 42]. One such particular device, the Polyflex Stent (Boston Scientific) is no longer manufactured or available on the market.

### **Postoperative Tracheobronchial Stenosis (POTS)**

A variant of histologically benign tracheal stenosis, postoperative tracheal stenosis (POTS) is a challenging problem following tracheal resection. Despite improved recognition and surgical techniques, the rate of POTS is 2–9% following tracheal resection. The majority of patients with POTS are not candidates for further surgical man-



agement due to a combination of high general surgical risk, poor lung function, and technical difficulties associated with previously resected tracheal segments. As such, bronchoscopic intervention is considered a therapeutic option. In a single-center retrospective review, 30 patients with POTS managed by bronchoscopic intervention were studied and included dilations (balloon or bouginage), YAG laser, and stenting (63% underwent silicone stents, no metallic stents were used). The majority (97%) achieved improvement in dyspnea within 24-h post-procedure. Stents were successfully removed in 37% of patients. Average stent duration in those amenable to removal was 7 months; 16% of those with stents removed developed tracheomalacia [43].

### **Mixed Obstruction: Malignant Central Airway Obstruction**

Malignant central airway obstruction (CAO) is a frequent complication of primary lung cancer and other tumors that metastasize to the chest (especially breast, colon, melanoma, and renal cell cancers). Malignant CAO can be intrinsic (endobronchial/intraluminal), extrinsic, or mixed, which has features of both intrinsic and extrinsic compromise. The most common form of malignant CAO is a mixed obstruction [44]. In a series of 172 patients who underwent stent insertion for malignant CAO at a cancer institution, 62.5% of the stents were placed for mixed disease, while only 16.4% and 14.8% were placed for extrinsic compression and intraluminal obstruction, respectively [14]. In general, the management principles for malignant intraluminal obstruction are the same as those for benign disease: if there is still obstruction after recanalization with various ablative techniques, if extrinsic compromise is present, or if there is a loss of airway structure (i.e., severe malacia due to cartilage invasion and destruction by tumor), a stent is placed to maintain airway patency. The impact of silicone stent placement in endoluminal lesions due to lung cancer was recently investigated in a prospective, randomized trial (SPOC). In this trial, 78 patients after therapeutic bronchoscopy

were randomized to a stent arm ( $n = 40$ ) or control ( $n = 38$ ). The study demonstrated that local recurrences and subsequent bronchoscopies were less frequent in the stent group comparing with controls, leading to longer lasting symptom relief. Moreover, stenting was showed to be beneficial only after the failure of the first-line anti-cancer treatment [45].

Management of malignant CAO often requires a combination of multiple different management modalities. The choice of techniques is operator dependent and is contingent not only on the etiology of the obstruction, but also availability of various technologies. To study the impact of procedural volume and choice of technique in bronchoscopic management of malignant CAO, a large multicenter retrospective review of bronchoscopic management of patients with malignant CAO was undertaken from the American College of Chest Physicians (CHEST) Quality Improvement Registry, Evaluation, and Education (AQuIRE) registry. Overall, the study found that despite significant inter-institutional differences in procedural preferences and volumes, there was no impactful difference in technical success and that one specific therapeutic modality could not be recommended over another [44]. More recently, in a study including 301 procedures for malignant CAO, factors associated with technical success of therapeutic bronchoscopy included smoking status (never smokers having better results than smokers), patent distal airway on CT and during bronchoscopy and time from radiographic finding to therapeutic bronchoscopy [46].

Interventional treatment of malignant CAO is considered to be primarily palliative as once cancer progresses to the point of CAO it is almost invariably incurable. As such, endoscopic interventions focus predominantly on attempting to improve quality of life. Relieving the CAO due to malignant disease has been proposed to prevent post-obstructive pneumonia, sepsis and septic shock; allow extubation, change in level of care, permit initiation of systemic therapy; and improve survival. There is evidence that bronchoscopic therapies often provide acute relief of the obstruction, improve quality of life, and serve as a therapeutic bridge until systemic treatments become

effective [47–49]. Prospective studies show that bronchoscopic intervention for malignant CAO is associated with improvement in the six-minute walk test (6MWT), spirometry, and dyspnea [50]. In addition, studies show that airway stent insertion resulted in significant palliation of symptoms in patients with malignant CAO as evaluated by Medical Research Council (MRC) dyspnea scale and performance status [51].

In the AQUIRE registry mentioned above, bronchoscopic interventions were associated with a significant decrease in dyspnea (decrease in Borg score by  $0.9 \pm 2.2$ ). Specifically, 48% reported clinically significant improvement in dyspnea, 43% reported no change, and 9% had worsened dyspnea. Of particular relevance, dyspnea improved proportionally to the pre-procedure severity of dyspnea. Another notable finding was that those with lobar (as opposed to more central) obstruction were less likely to have much improvement in dyspnea. Bronchoscopic interventions were also associated with a significant increase in health-related quality of life (HRQOL). Overall, 42% had a significant improvement of HRQOL, 33% remained unchanged, and 25% reported worsened HRQOL. Again, as with the predictors of dyspnea relief, a higher baseline Borg (i.e., worse baseline dyspnea) predicted a more pronounced improvement in HRQOL, while those with lobar obstruction were found to have less improvement in HRQOL [44]. While airway patency was improved in >90% of patients, less than half improved their HRQOL scores. These findings suggest that we need better prediction models for whom dyspnea and HRQOL improves after such interventions. Despite the focus on palliation and improved quality of life with these procedures, a significant post-procedural survival advantage was also apparent in those without severe performance limitations prior to their procedures when compared with historical controls [51].

The presence of stridor (reflecting critical CAO) prior to intervention was found to be a poor prognostic indicator for survival in patients undergoing bronchoscopic intervention for malignant CAO: those without stridor had a 1 year and 2-year survival of 35.5% and 31%,

respectively, while those with stridor had a 1 year and 2 year survival of 12.5% and 0%, respectively. Patients requiring stent placement for malignant CAO as opposed to dilation +/- other non-stenting interventions had significantly lower 1- and 2-year survivals [52]. In another study of 74 patients with malignant CAO, extrinsic compression from esophageal cancer and stent placement correlated with poor survival [53]. It is not clear whether lower survival rates are because of the stenting or just because patients requiring stents had more severe/extensive airway obstruction.

Subsequent chemotherapy and/or radiotherapy have been shown to increase disease free survival during the first year after restoration of airway patency [47, 54]. A retrospective single-center study of 48 patients with malignant CAO who underwent bronchoscopic intervention reviewed the effects of chemotherapy following bronchoscopic interventions. The patients who received post-procedural palliative chemotherapy had a median survival of 6 months with a 1 year and 2-year survival of 35% and 31%, respectively. Those patients who received no post-procedural chemotherapy had a median survival of 2.5 months with a 1 year and 2-year survival of 18% and 14%, respectively [52]. In addition, it appears that airway stent insertion followed by adjuvant therapy may improve survival even in treatment-naïve patients with severe symptomatic airway obstruction caused by advanced lung cancer. In one study, while the performance status and dyspnea scales improved in both treatment-naïve and terminal-stage lung cancer, the median survival time and 1-year survival rate after stent insertion were 1.6 months and 5.1%, respectively, in the terminal stage group, and 5.6 months and 25.0%, respectively, in the treatment-naïve group [55].

Lung cancer patients who develop respiratory failure due to CAO have particularly poor prognoses: only 25% are successfully liberated from the ventilator and 40–70% die in the hospital. In addition to the quality-of-life issues, ventilated patients are often not considered candidates for additional oncologic treatment. Furthermore, patients with malignant CAO may be given low

priority for ICU level admission [56], as they are considered to have low probability of reversibility and survival. A small single-center retrospective study addressed this assumption of lack of reversibility. Twelve patients with non-small cell lung cancer with associated CAO resulting in respiratory failure requiring mechanical ventilation who were not candidates for surgical procedures were managed with bronchoscopic intervention and various combinations of mechanical debulking, laser resection, and airway stenting: 66% underwent stenting. The majority (83%) were successfully liberated from mechanical ventilation and the post-procedural median survival was 313 days. As such, bronchoscopic intervention should be considered for lung cancer patients with respiratory failure due to CAO [57]. Survival after bronchoscopic intervention was investigated in another study including 224 patients with airway obstruction due to primary lung cancer. Factors related with poor survival comprised chronic obstructive pulmonary disease (COPD), poor performance status, extended lesions, extrinsic compression or mixed lesions, disease progression, and absence of adjuvant treatment after bronchoscopic intervention [58].

### Stump Fistulas

A less common indication for stent insertion is to cover large stump fistulas after lobectomy or more commonly, after pneumonectomy [59]. In general, management strategies for central bronchopleural fistula (BPF) depend on the underlying histology (malignant versus benign), size, time to fistula formation post-surgery, and health status of the patient. Surgery is the treatment of choice of this condition, but bronchoscopic techniques have been advocated as an option when surgery is not possible or has to be postponed [60]. Surgical repair is not a good option for patients requiring mechanical ventilatory support because postoperative mechanical ventilation is associated with a high failure rate due to persistent barotrauma on the repaired stump [60]. As a general rule, when stents are used for this indication, a large stent must be used to seal the stump

fistula as tight as possible in order to prevent aspiration pneumonia, empyema, and allow satisfactory single lung ventilation when the patient requires mechanical ventilation. Stent selection would depend on the size and location of the fistula, as well as on the physical properties of the stent and the operator's ability to manage potential stent-related complications. Several case reports and case series of endobronchial stent insertion for isolated fistulas have been published [61]. The effect of case-selection bias is difficult to assess from the limited literature on this topic.

### Esophago-respiratory Fistulas (ERF)

Tracheoesophageal or broncho-esophageal fistulas can be covered by airway stents. While these fistulas can be congenital, the vast majority are acquired either after esophagectomy, after intubation or in the setting of malignancy. A multi-center retrospective US study addressed the endoscopic management of 25 patients with esophago-respiratory fistulas (11 benign and 14 malignant). An overall technical success of 97% (94% in benign, 100% in malignant) and clinical success of 80% (90% in benign, 71% in malignant) were reported. Regarding adverse events, all were reportedly minor and were seen in 40% of the patients (36% in benign, 43% in malignant). Notably, there was no significant differences between esophageal stenting alone and esophageal and airway stenting combined [62].

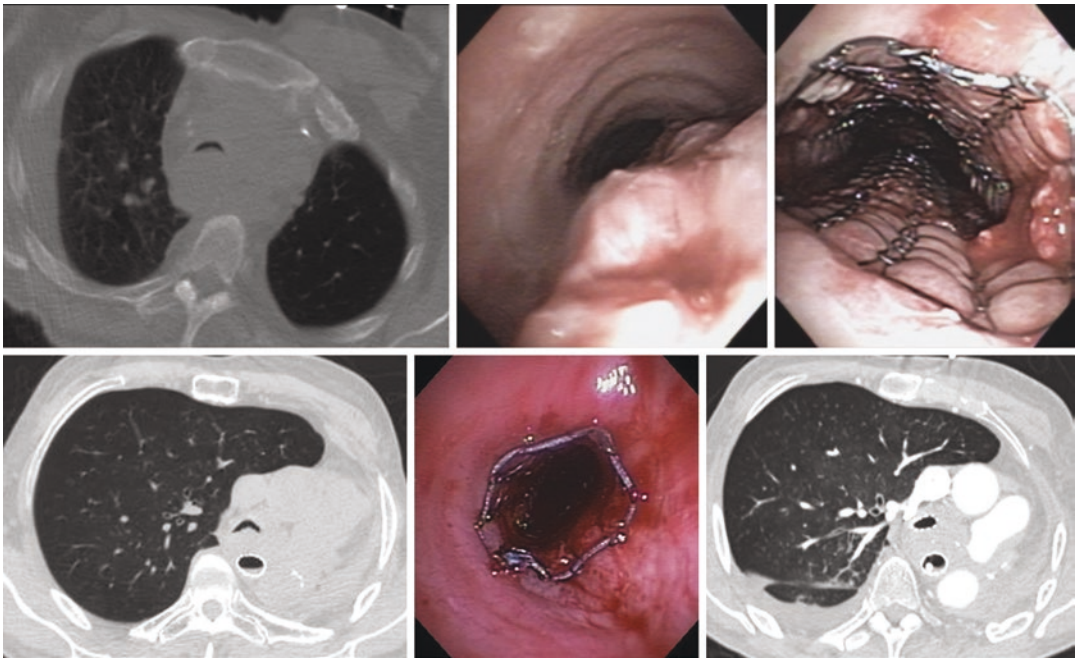
Benign esophago-respiratory fistulas (ERF) is not expected to improve after stent insertion and in fact, stenting should only be considered as a palliative intervention if there are no operative modalities (Fig. 16.2) [63]. Debourdeau et al. classified 22 non-malignant esophagorespiratory fistulas into three categories: I—punctiform, diameter less than the diameter of a closed biopsy forceps; II—medium, larger size but without visibility of tracheobronchial tree; and III—large, bronchial tree seen throughout the fistula's orifice with the endoscope. The authors demonstrated that the size of the orifice was associated with mortality and based on this finding, proposed an algorithm to manage this condition: type I and II

fistulas undergo esophageal stenting with covered SEMS; type I–II fistulas in which esophageal stenting failed or type III should receive surgical treatment as first-line and, if not possible, definitive esophageal stenting and enteral feeding should be considered [64].

Malignant ERF is common in esophageal cancer, having a 5–15% occurrence, and occurs rarely in bronchogenic carcinoma (~1%). Once developed, the prognosis is poor, with a poor QOL and 3- to 4-months survival. Although surgical resection and reconstruction has the greatest potential benefit, it comes at a high-risk complications and prolonged hospitalized recovery. Alternatively, gastro/jejunostomy tube feeding is a strategy utilized to minimize effect of malignant ERF, but this may not be accepted by patients and has the potential to further reduce quality of remaining life [65]. Palliation for

malignant ERF is usually achieved with endoscopic placement of esophageal, airway or parallel (dual) stent insertion (in the esophagus and airway). As mentioned above, there is no clear evidence that dual stent insertion works better than a single prosthesis. However, the prognosis remains poor with a median of 3 months survival after dual stent placement for obstructive or fistulous lesions near the carina [66]. Particular attention should be paid to airway compression or erosion caused by placement of esophageal stents, and if there is concern for significant tracheobronchial obstruction operators should consider placement of an airway stent prior to the esophageal one (Fig. 16.4).

The choice of tracheal stent used for ERF closure should take into consideration the size and location of the fistula. The Freitag classification system [67] was developed to systemati-



**Fig. 16.4** Airway stents in obstruction caused by esophageal tumors. In the upper panel, chest computed tomography (CT) shows severe tracheal narrowing from a mediastinal mass, known to be esophageal carcinoma. Bronchoscopy confirmed the CT findings and a partially covered metallic stent was placed to palliate the airway obstruction prior to esophageal stent insertion for dyspha-

gia. In the lower panel, severe tracheal and right mainstem obstruction occurred after the insertion of an esophageal stent and resulted in respiratory failure in this patient with poor lung function from his previous pneumonectomy. A partially covered metallic stent was inserted from the lower trachea to the mainstem bronchus, palliating the obstruction and allowing liberation from mechanical ventilation



cally define the location and severity of central airway stenosis, but this system can be used to define the location of an ERF. Location I: upper third of trachea; II: middle third of trachea; III: Lower third of Trachea; IV: Carina; V: Right mainstem; VI: Bronchus intermedius; VII: Left mainstem; VIII: Left distal bronchus. Using this system and by defining a small fistula as one that is <1 cm in size, a single center developed an algorithm for stent choice in ERF stenting: an I-shaped stent for small fistulas in locations I, II, and VIII; an L-shaped stent for small fistula in locations V, VI, VII; and a Y-stent for any fistulas in locations III or IV, or large fistulas in locations II, V, and VII. This approach resulted in complete fistula closure in 72% of patients and clinically beneficial partial closure in the remaining patients [65].

A dedicated fistula stent, The DJ cufflink-shaped prosthesis, was designed exclusively for closure of malignant ERF secondary to esophageal or lung cancer. It can be sized to the fistula diameter to occlude the abnormal communication [68, 69]. Insertion of silicone Y stents was shown to improve symptoms, reduce infections, and improve the quality of life in patients with malignant ERF. Mean survival of these patients, however, remains poor and is in the range of 2 months [70]. A conservative palliative approach including only symptomatic control but no interventions (i.e., stent insertion) is not unreasonable especially since interventions in this frail population could be harmful. Without treatment, however, survival may be limited to only a few days [71]. On the other hand, in a prospective study of 112 patients with malignant ERF, airway stents were inserted in 65 (58%) patients, esophageal stents in 37 (33%) patients, and both airway and esophageal stents in 10 (9%) patients. Contrary to previous data, the authors found an overall mean survival was 236.6 days (airway stent 219.1 days, esophageal stent 262.8 days, and combined airway-esophageal stent 252.9 days). Since a few patients are operable, currently airway and/or esophageal stent insertion is mainly used with a palliative intent to improve the quality of life (QOL) in patients with malignant ERF [72].

## Expiratory Central Airway Collapse

Airway stent insertion has been used to improve cough, secretions, and QOL in patients with expiratory central airway collapse (ECAC) [16, 17]. There are, however, different morphologic types of ECAC, for some of which stent insertion is not physiologically justifiable in regard to flow limitation and dyspnea. Excessive dynamic airway collapse (EDAC) is due to bulging of the posterior membrane within the airway lumen during exhalation that significantly narrows the lumen by 50% or more and the cartilage is intact in this process. Tracheobronchomalacia (TBM), on the other hand, refers to softening of the airway cartilaginous structures [73]. The decision to insert an airway stent in these processes is complicated by at least two factors: (1) the lack of standardized definitions and cutoff values to define abnormal airway narrowing; and (2) the lack of clear understanding if these entities are truly responsible for airflow limitation. In fact, the limit between normal and abnormal narrowing of the central airways during exhalation has not been physiologically established and different investigators propose different cutoff values. In addition, there is no standardized way to measure the narrowing in terms of location or respiratory maneuver (Table 16.1) [73]. To illustrate this lack of consensus, a study found that almost 80% of normal individuals met the currently accepted 50% narrowing during forced exhalation criterion [74]. In an attempt to provide a common language for these patients with ECAC, a classification system was proposed based on objective quantifiable criteria, which can be applied before and after stent insertion (Table 16.1) [73].

Studies show that in the short term (up to 10–14 days), airway stabilization with silicone stents in patients with expiratory central airway collapse (malacia and EDAC) improves symptoms, quality of life, and functional status [16, 17]. QOL and functional status scores improved in 70% of patients and dyspnea scores improved in 91% of patients after stent insertion [17]. Stent-related complications in this case series



**Table 16.1** Summary of classification systems for expiratory airway collapse

First author/year	Parameters	Comments
Rayl/1965	<i>Extent</i> : Proximal, mediastinal and intrapulmonary airways	Collapse during cough on cine-bronchography
Johnson/1973	<i>Severity</i> : Four degrees and focal type	TM: >50% collapse during coughing on fluoroscopy
Feist/1975	<i>Etiology</i> : Congenital and acquired	TM: >50% collapse during coughing on fluoroscopy
Jokinen/1977	<i>Severity</i> : Mild, moderate, severe <i>Extent</i> : TM, TBM, BM	First classification <sup>1</sup> based on bronchoscopic findings
Mair/1992	<i>Etiology</i> : Congenital, extrinsic compression, acquired <i>Severity</i> : Mild, moderate, severe	Described for pediatric TBM Empirical severity score
Masaoka/1996	<i>Etiology and extent criteria</i> Pediatric, adult and secondary	TBM: >80% collapse during expiration
Murgu/2007	<i>Functional class</i> <i>Extent</i> <i>Morphology</i> <i>Origin (Etiology)</i> <i>Severity</i>	Stratification criteria (functional class, extent and severity are objectively assessed) Morphology: includes EDAC and three forms of TBM (there are three morphologic types of TBM: crescent type, when the anterior wall is collapsing; saber-sheath type, when the lateral walls are collapsing and the circumferential or mixed type, when the anterior and the lateral walls are collapsing, as is seen with relapsing polychondritis) Origin: idiopathic or secondary

TM tracheomalacia, TBM tracheobronchomalacia, BM bronchomalacia, EDAC excessive dynamic airway collapse

included obstruction from mucus plugging and migration, and almost 10% of patients (5/52 patients) had complications related to the bronchoscopic procedure itself. Although SEMs are able to relieve symptoms among ECAC patients, complications do develop rapidly (almost 70% of the patients with granulation tissue after a 10–14 day stent trial) [75]. In our opinion, the findings of this study support the concept that SEMs should be avoided in this condition and the decision to perform tracheobronchoplasty (TBP), when indicated, should not be based on temporary SEMs insertion. In fact, several tracheal surgeons have abandoned the practice of stent trial prior to TBP [76].

Because expiratory central airway collapse continuously alters the shape of the central airways as well as the surface contact between a stent and the airway wall, stent-related complications may occur more frequently in dynamic forms of airway obstruction than in fixed benign obstruction. Although not life-threatening, these stent-related adverse events require multiple repeat bronchoscopies [16]. In one series of patients with mostly TBM, adverse effects from silicone stent insertion were very common, with

a total of 26 stent-related adverse events noted in 10 of 12 patients (83%), a median of 29 days after intervention [16]. TBM due to relapsing polychondritis (RP) is one disease for which stent insertion is often necessary due to a diffuse lack of airway cartilaginous support. Both self-expandable metallic stents and silicone stents have been used in patients with malacia from RP [77, 78]. Sometimes, more than one stent may be required if symptoms persist after stent insertion, presumably because of distally migrated choke points [78]. Because airway stents are not the best solution for this disease, a more conservative approach such as continuous positive airway pressure (CPAP) may be safer. CPAP may indeed be considered a “pneumatic stent.” The excessive airway narrowing in ECAC and the resulting turbulent flow result in increased airway resistance. This requires greater trans-pulmonary pressures to maintain expiratory airflow, which will increase the work of breathing and result in dyspnea. Thus, noninvasive positive pressure ventilation such as CPAP decreases pulmonary resistance and can be used to maintain airway patency, facilitate secretion drainage, and improve expiratory flow. Small studies showed

that nasal CPAP improves spirometry values, sputum production, atelectasis, and exercise tolerance, but its long-term efficiency has not been clearly demonstrated [79]. As of this writing, however, the limited published evidence suggests that QOL and functional status are improved in patients with ECAC undergoing stent insertion, but the lung function as measured by FEV<sub>1</sub> has not been consistently reported to improve after stent insertion. The FEV<sub>1</sub> improvement after central airway stabilization (i.e., membranous tracheoplasty) has been variable, suggesting that proper patient selection is critical [17, 76]. These facts raise questions about the physiologic basis for stent insertion for both fixed and dynamic forms of CAO.

---

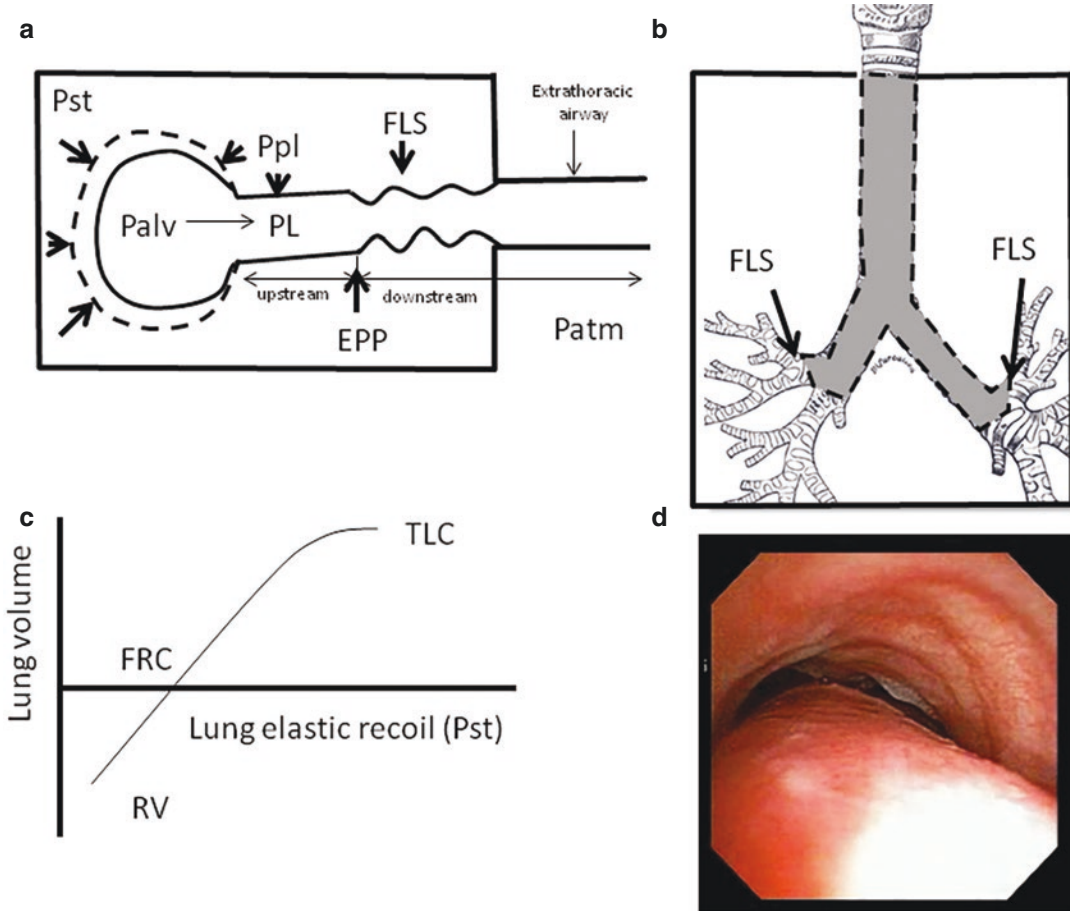
### Physiologic Rationale for Airway Stent Insertion

In general, for symptomatic patients with fixed tracheal obstruction, a stent is inserted to improve the lumen to less than 50% obstruction; for symptomatic patients with dynamic obstruction, stents are meant to stabilize the airway at the collapsible segment responsible for flow limitation (aka choke point).

*For tracheal stenosis*, symptoms relate to the amount of pressure drop along the stenosis; this depends on the degree of the obstruction, but also on the flow velocity through the airway narrowing. This flow dependence of symptoms explains why different patients with similar degree of airway narrowing have different clinical presentations, depending on their level of activity. These facts highlight the need to individualize treatment based not just on degree of narrowing as assessed by radiographic or bronchoscopic imaging but also on the stenosis impact on functional status. In fact, functional status and dyspnea scales may be more relevant than static lung function measurements, which were shown to weakly correlate with the MRC dyspnea scales in laryngotracheal stenosis [80]. In addition to functional status, a classification system for tracheal stenosis should include the vertical extent, morphology (shape of the lumen), and the severity of

airway narrowing, factors that impact the decision to insert an airway stent. To quantify the severity of airway narrowing, the cutoff values used in the available systems are 50% and 70% to define moderate and severe stenosis, respectively [81]. These values seem to be justified by physiologic studies in which the investigators found that the effect of the glottis narrowing was noted to be of the same order as that of the 50% stenosis; these data suggests that a 50% or less narrowing may not even be clinically detected or require treatment; however, a significant pressure drop is seen at 75, 85, and 90% stenosis, pressure drop which correlates with significant work of breathing [82]. Based on these physiologic data, therefore, one could classify stenosis as mild, with less the 50% narrowing, moderate, from 50% to 70%, and severely narrowed when more than 70% of the lumen is occluded, justifying the practice of improving the airway lumen to less than 50% narrowing, with stent insertion, if necessary.

*For expiratory central airway collapse*, it is still not clear what degree of airway collapse is physiologically significant; furthermore, as of this writing, there are no accepted non-invasive physiologic tests to predict response to stent insertion. However, when patients have clear inability to raise secretions and recurrent pneumonia or even respiratory failure, then a stent is inserted regardless of the cause of collapse. From flow dynamics standpoint, the clinically relevant question in this process is whether stent insertion improves the expiratory flow. Physiologists proposed a theory to explain expiratory flow limitation, theory which is useful to understand the role of stent insertion in patients with dynamic CAO such as malacia or EDAC. Physiologic studies showed that once expiratory flow becomes limited at a given lung volume, there would be a region within the intrathoracic airway where intra-bronchial and extra-bronchial pressures become equal (equal pressure point, EPP) (Fig. 16.5) [83]. At a given lung volume, driving pressure upstream (alveoloward) from the EPP would be equal to lung elastic recoil, because pleural pressure (Ppl) equals the intraluminal pressure (PL); downstream from the EPP (mouthward), airways would be compressed during



**Fig. 16.5** Choke point physiology based on Starling resistor. **(a)** The alveolar pressure ( $P_{alv}$ ) is the driving pressure that causes gas to flow through airways during expiration and is approximately equal to the recoil pressure of the lungs ( $P_{st}$ ) plus the pleural pressure ( $P_{pl}$ ):  $P_{alv} = P_{pl} + P_{st}$ . Normally, a pressure drop is required to accelerate a gas as it moves from an upstream (alveolarward) region of low velocity to a downstream (towards the mouth) region of high velocity. Because of this pressure drop, the intraluminal pressure ( $P_L$ ) eventually becomes equal to pleural pressure ( $P_{pl}$ ). The point within the airway at which this occurs is called the equal pressure point (EPP). This equal pressure point (EPP) divides the airways into upstream segments (alveolarward from the EPP) at which transmural pressure is positive, and downstream segments (mouthward from the EPP) at which the transmural pressure is positive within the extrathoracic airways and negative within the intrathoracic airways. At a given lung volume, driving pressure upstream from the EPP would be equal to lung elastic recoil, while downstream from the EPP, airways would be compressed during expiration. This region of compression of intraluminal caliber is referred to as a flow-limiting segment (FLS) or

“choke point”. **(b)** As lung volume decreases from TLC towards RV the elastic recoil ( $P_{st}$ ) decreases as well, and pleural pressure ( $P_{pl}$ ) increases during forced expiration. **(c)** Thus, the EPP migrate upstream, resulting in a lengthening of the increasingly narrow downstream segment. This increases airway resistance and prevents further increases in expiratory airflow, causing the EPP to become fixed when airflow becomes constant. FLS have tracheal location at high lung volumes, (i.e., TLC), whereas others found FLS in lobar and segmental airways over a range in volume approximating TLC to functional residual capacity (FRC). As lung volume decreases during exhalation, the FLS move peripherally to the lobar/ segmental and at most subsegmental bronchi. **(d)** Therefore, if the choke points (FLS) in humans are often located in the lobar bronchi, a mainstem bronchial or tracheal collapsibility should not result in any pressure drop between the mouth and the choke point and should not affect flow. Thus, bronchoscopic or radiologic detection of expiratory tracheal or mainstem bronchial compression (excessive dynamic airway collapse) should trigger a search for causes of airflow obstruction within the lung, not the central airways

expiration. This region of compression of intraluminal caliber is referred to as a flow-limiting segment (FLS) or “choke point.” As lung volume decreases and pleural pressure (Ppl) increases during forced expiration, the EPP migrates upstream, resulting in a lengthening of the increasingly narrow downstream segment. This increases airway resistance and prevents further increases in expiratory airflow, causing the EPP to become fixed when airflow becomes constant. EPP and therefore the FLS have tracheal location at high lung volumes (TLC), but as lung volume decreases during exhalation, the FLS move peripherally, but they still stay in the central airways, in the lobar/segmental, the farthest in subsegmental bronchi [84]. Therefore, if the choke points in humans are often located in the lobar bronchi, a mainstem bronchial or tracheal collapsibility in the form of EDAC, often seen on CT or bronchoscopy, should not result in any pressure drop between the mouth and the choke point and should not affect flow. In fact, physiologists suggest bronchoscopic or radiologic detection of expiratory tracheal or mainstem bronchial compression (EDAC) should trigger a search for causes of airflow obstruction within the lung, not the central airways [85]. Loss of pressure in the abnormally narrowed peripheral airways in patients with asthma, COPD, or bronchiolitis, will lead to decreased intraluminal pressure by the time that airflow reaches central airways, so that these airways (trachea and mainstem bronchi) will collapse at the weakest point, which is the posterior membrane. Thus, EDAC is most often a reflection of peripheral airway disease, but it can also be seen with morbid obesity due to increased pleural pressure and possible flow limitation at rest. A study of patients with obesity and COPD and normal volunteer controls found that EDAC was significantly associated with BMI (69% tracheal collapse among morbidly obese patients with BMI  $\geq 35$  compared to 57% in others,  $p = 0.002$ ) [86] EDAC has been documented in 22% of patients with COPD assessed by dynamic chest CT and in morbidly obese patients under general anesthesia likely due to positive pressures throughout the chest [87]. This does

not mean that EDAC is responsible for flow limitation. In fact, even when defined as forced expiratory collapse of  $>80\%$ , according to some reports, EDAC is not flow limiting as there is no significant correlation between end-expiratory or dynamic expiratory collapse and percent predicted FEV<sub>1</sub> [88]. Another strong argument that EDAC is a reflection of peripheral airway disease and emphysema and not a central airway problem is the fact that EDAC was shown to resolve after lung transplantation [89]. In this study, EDAC was seen in 4.8% (8/165) of patients referred for bilateral lung transplantation. All eight patients had resolution of EDAC after transplantation documented by bronchoscopy or dynamic CT.

On the other hand, epidemiologic studies show that EDAC is responsible for worse QOL in smokers [90]. A total of 8820 patients from 21 clinical centers were enrolled in the COPD gene study. On paired inspiratory-expiratory dynamic CT (measurements at aortic arch, carina and bronchus intermedius), EDAC was found in 443/8820 patients (5%). The primary outcome variable, quality of life (QOL) as measured by SGRQ, was worse in EDAC, which was also responsible for increased frequency and severity of exacerbations. In addition, some patients may improve their functional status after stent placement in the central airways not only for malacia but also for EDAC; one explanation is that improved central airway stability, regardless of which wall is collapsing, makes the flow less turbulent, similar to heliox, which was shown to improve exercise capacity in patients with moderate-to-severe COPD, even though these patients typically have choke points in the small airways (of 2 mm or less) [91]. It is possible than in the future, in addition to bronchoscopic and imaging methods, new physiologic or imaging studies may have a role in identifying the choke point physiology in CAO. For instance, using impulse oscillometry (IOS), increased resistance I at a low oscillation frequency (5 Hz) reflects an increase in total respiratory resistance suggestive of airway obstruction such as that found in patients with COPD, while increased R at a higher frequency (20 Hz) reflects more specifi-

cally increased central airway resistance such as that found in patients with malacia [92]. Until these methods are validated in large studies, a trial-and-error approach is still clinically used by some operators: temporarily place a stent and test whether the patient improves clinically; if they do, a surgeon may perform an external splinting procedure; if not, the stent is removed [93]. Another assessment method, more accurate but minimally invasive, is the intraluminal pressure monitoring using a small pressure catheter. As pointed above, dynamic airway compression causes the formation of FLS in the central airways during forced expiration. Both in animal and human studies, these FLS could be located with the use of intraluminal airway catheters by measuring lateral airway pressure (Plat) during induced flow limitation generated by either an increase in pleural pressure or a decrease in downstream pressure. The measurements of lateral pressure in malacia before and after stent insertion show that before stenting, a large pressure difference is seen between the upper trachea and right lower bronchus and carina. After stenting, the pressure difference could vanish for both inspiration and expiration and a regular respiratory cycle is seen [94]. By measuring lateral airway pressure on each aspect of the airway narrowing (proximal and distal) and plotting the two pressures against each other (pressure-pressure curves) during quiet breathing intra-operatively, the site of maximum obstruction and the degree of airway narrowing can be determined quantitatively [95]. Analysis of the pressure difference and the angle of pressure-pressure curve allow intra-operative estimation of the outcomes of a particular interventional bronchoscopic procedure. However, stents may improve flow but the choke points migrate distally. This process can be addressed either by additional stent insertion or by the use of non-invasive positive pressure ventilation. Detection of choke point migration can be demonstrated bronchoscopically or by dynamic computed tomography (CT) in the form of airway wall collapse distal to the stent.

## Stent Selection Criteria

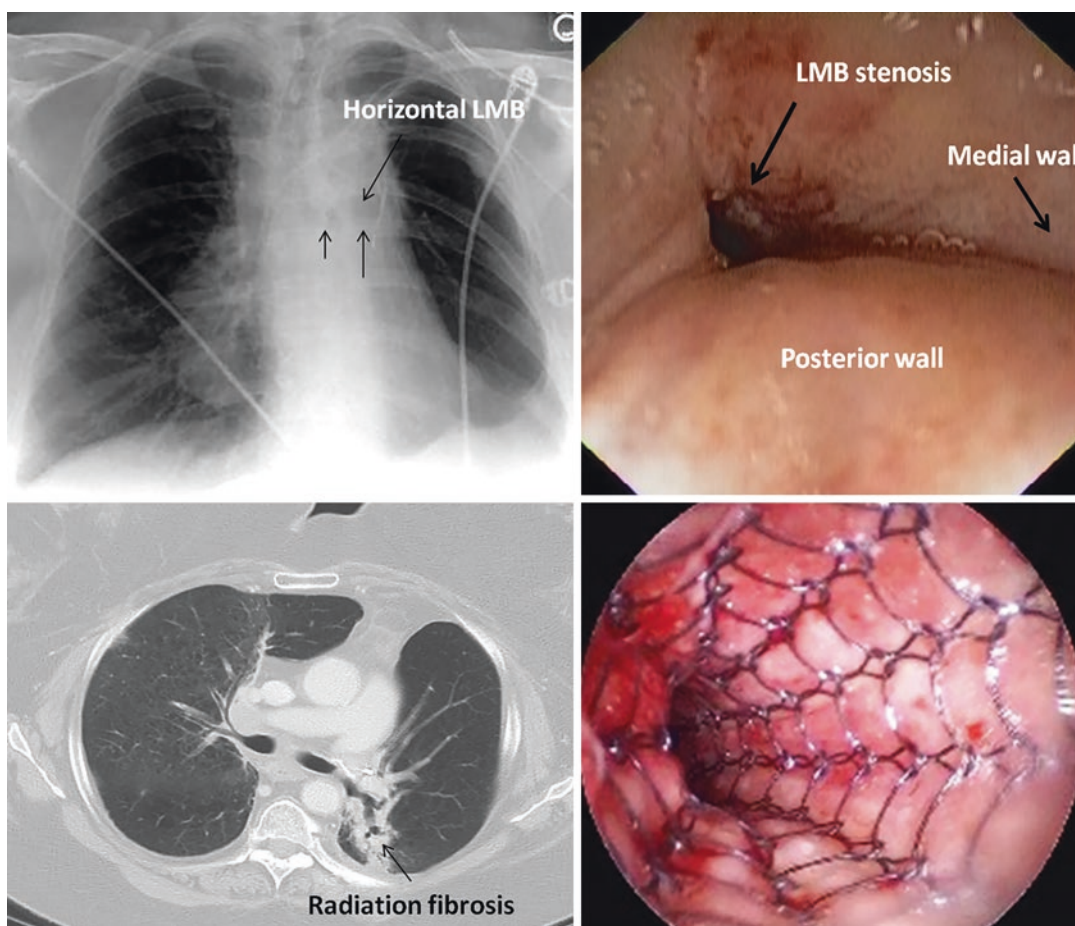
*Stent retrievability* is an important criterion to consider before stenting patients with benign disease or with malignancy for which a temporary stent placement is expected. For example, for patients with malignant CAO who will undergo further systemic chemotherapy and/or radiation therapy, and respond to treatment, the stent may become loose, migrate, and require removal [96]. Inserting a stent is not always the biggest challenge encountered in practice. It is advisable to select a stent that can be removed, if necessary, without causing further tissue damage. Another selection criterion is based on the stent's *morphology and positioning*: for instance, T-tubes require a tracheostomy, straight indwelling stents splint open the trachea and the mainstem bronchi while bifurcated stents are placed at the main carina and sometimes at secondary carinas. One other factor to consider prior to insertion is the *stent material*. In fact, the traditional way to classify stents was based on material type: metal, polymers, and hybrid stents partially covered or fully covered. Recently, Lachkar et al. analyzed the results of silicone and SEMS Y stenting among 78 patients with main carina malignant lesions and demonstrated that although placement failures and procedure duration were increased in the silicone stent group, no significant differences in terms of early or late complications, symptom relief, stenting time, or stent removal were noticed between the two groups [97].

In another recent study of SEMS versus silicone stenting in malignant CAO, the cumulative incidence of complications increased between 1 and 6 months. Overall, SEMS showed a higher probability of developing a complication but when adjusted for mortality, age, sex, smoking status, histology, and stage, this difference was lost [98]. These recent data support our clinical observations that the type of stent may not matter in patients with malignant CAO as long as the airway is open, but the duration of stenting is directly related to complication rates.



The type of stent inserted should also be decided based on the *biomechanical characteristics* (dependent on the material but also on design and thickness) because stents differ greatly in their elasticity and resistance to angulation [99, 100]. The expansile force (strength) and ability to withhold angulation (buckling) vary among different types of stents. In this regard, the silicone stents have a high expansile force [80] and may be preferred in obstruction due to severe and extensive airway compression. However, for a distorted, curved airway, angulation properties

become important because they determine whether the stent can conform to an acutely angulated airway and still remain patent, such as is often the case in patients with left main bronchial obstruction due to extrinsic compression (Fig. 16.6). In these cases, the Ultraflex stent may be a better choice than a straight silicone stent because of the Ultraflex stent's known resistance to angulation. A study evaluating the role of interventional bronchoscopy for malignant CAO showed that the most common stent used in the trachea and right mainstem bronchi (relatively



**Fig. 16.6** Example of how airway anatomy impacts stent selection. Chest radiograph reveals nearly horizontal left main bronchus (upper left). Chest computed tomography shows that this was in part caused by volume loss from radiation fibrosis (lower left).

Bronchoscopy revealed significant torsion of the left main bronchus and mid-distal left main bronchial stenosis (upper right). Due to its resistance to angulation, a partially covered self-expandable metallic stent was inserted to restore airway patency

straight airways) was the Dumon stent, while the most common one for the left mainstem bronchus (curved, tapered airway, often distorted in the setting of malignancy) was the Ultraflex stent, likely because of its better ability to withhold angulation<sup>5</sup> [101]. Therefore, stent biomechanics bench testing data such as the crush (expansile) force, infolding (angulation) properties and fatigue life, which are for the most part considered confidential and proprietary information, may be very useful to the interventional bronchoscopist. For instance, fatigue life may become important in patients with benign etiology of CAO, especially malacia, in which cycled compression of the stent with each exhalation may lead to stent fracture and its associated complications.

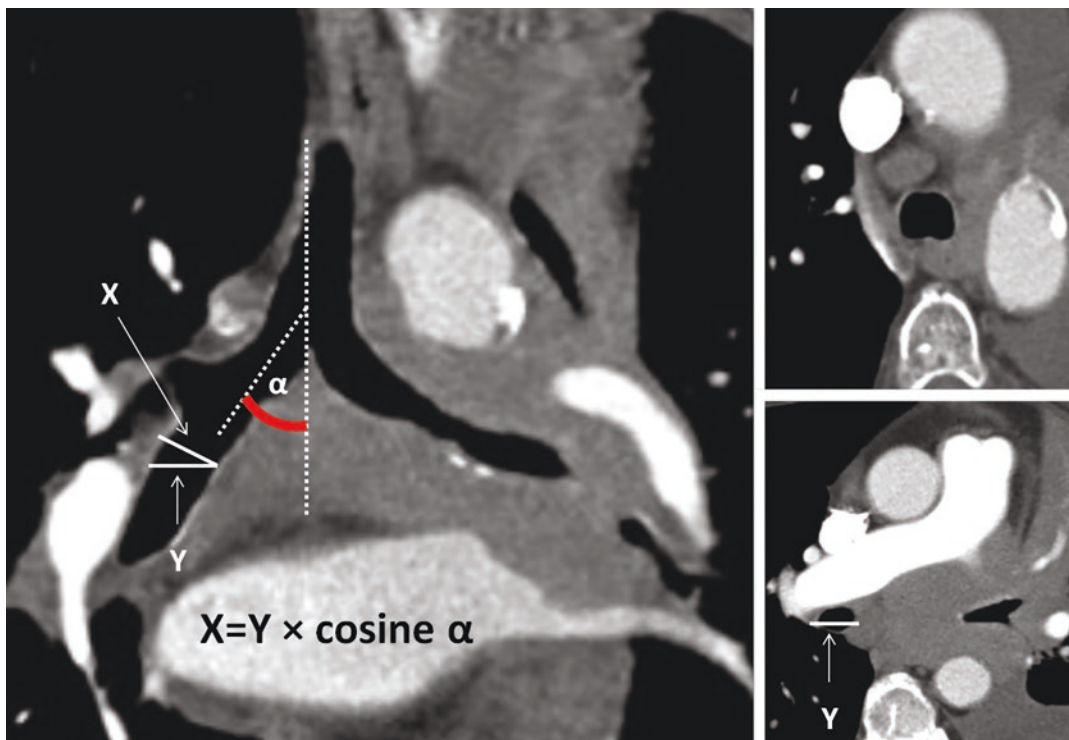
In regard to *size*, following dilation, usually a stent with a diameter that is bigger than the remaining stenosis should be inserted. The actual size of the stent could be objectively determined by carefully evaluating the airway diameter using CT, measuring devices or even radial probe EBUS, or long range, anatomical optical coherence tomography. Many experienced rigid bronchoscopists, however, do not need or use these technologies and often choose the size of the stent based on the “tactile feedback” resulting from the viscoelasticity property of the airway; in general, the stent is slightly larger (1–2 mm) than the size of the dilating bronchoscope or the balloon used for dilating the stricture. However, if CT scanning is used to determine the stent size, one should remember that for mainstem bronchi, contrary to trachea, the diameter of the airway on the CT is different than the actual airway diameter and corrections are necessary (Fig. 16.7) [102].

Contrary to *size*, the *length* of the stent does not have an important impact on flow dynamics [82]. That is simply because the resistance to flow is linearly and directly proportional to the length of stenosis, and inversely proportional to the radius of the airway narrowing at the power of at 4 (for laminar flow). In simulation studies,

for instance, long stenoses show a modest difference in pressure profile with a slightly bigger magnitude of total pressure drop than the web-like stenosis of comparable airway narrowing (90%) [82]. The extent of the narrowing is important, however, for surgical decisions and for stent’s length selection. In general, the length of the stent should be longer than the actual stenosis, to avoid migration and obviously to properly palliate the airway narrowing. In general, the stent should exceed the stenosis by 0.5–1 cm on both sides. This principle may be difficult to apply in short airway such as right main bronchus, when the stent may need to be customized on site in order to provide ventilation to the right upper lobe. The exact length can be measured based on previously performed chest CT scanning for a different indication. Given the risk of radiation and alternative methods, ordering a CT scan for the sole purpose to determine stent size or length may not be warranted or cost-effective. The operator can use the scope itself, the telescope or accessory instruments (available sizing devices) to measure the extent of stenosis during bronchoscopy.

All these stent factors (*size*, *length*, *morphology*, *material*, and *biomechanics*) become important in selecting a particular stent for a specific type of obstruction. For instance, the dynamic features of TBM can make the selection of the type and size of the stent being inserted problematic. Sometimes very large stents (20–22 mm diameter) are required for those patients with tracheobronchomegaly. In addition, the expansile force has to be high enough to prevent significant collapse during expiration. Even though they rarely migrate, we use Y-shaped stents infrequently because we try to preserve as much normal mucosa as possible, and thus decrease the likelihood of stent obstruction by tenacious mucous secretions, a common complication, especially in patients with chronically inflamed airways. In addition, Y stent insertion in a patient with complete airway collapse and inflamed and friable airway mucosa is not always straightforward and could be complicated by lack of unfolding, airway perforation and subsequent ventilation, oxygenation, and hemodynamic disturbances.

<sup>5</sup>In this study, patients with esophageal carcinoma involving the airway mostly required only stent placement without laser assisted debulking, probably because the main problem was extrinsic compression.



**Fig. 16.7** Chest computed tomography use for stent size selection. Contrary to trachea (upper right), for mainstem bronchi and bronchus intermedius (lower right), the diameter of the airway on the CT ( $Y$ ) is different than the actual airway diameter and corrections are necessary (right

panel).  $Y$  represents the measured transverse diameter of the bronchus on chest tomography and  $X$  represents the corrected transverse bronchial diameter.  $\alpha$  denotes the angle between the central axis of the trachea and bronchus, which equals the angle between  $Y$  and  $X$

## Technique and Equipment

Airway stents can be placed via flexible (for SEMS) or rigid bronchoscopy (SEMS or silicone). The principles are the same; first, the operator will dilate the stenotic lesion (extrinsic compression, stricture or significant residual obstruction after other endobronchial therapy); second, a stent large enough is deployed inside the airway to prevent migration and properly restore airway patency.

In case of *rigid bronchoscopy*, the scope is introduced through the mouth and then between the vocal cords under direct visualization to assure a secure airway at all times. We usually choose large rigid bronchoscopes (12–13 mm diameter) to allow deployment of a large tracheal/bronchial stents and facilitate easy passage of accessory instruments (large grasping forceps

or large suction tubing that may become necessary in case of severe airway bleeding post-debulking). The beveled tip of the scope facilitates lifting of the epiglottis, and atraumatic passage of the scope through the vocal cords, but also assists for dilation and removal of exophytic endoluminal lesions (i.e., rigid bronchoscopic debulking). Operators should be familiar with the length of their scope and be able to decide how much the stent introducer should be inserted inside the scope in order to avoid deployment of the stent too distally (beyond the stenosis) or too proximally (inside the rigid bronchoscope). There are two techniques of straight silicone stent insertion, as one can expulse the stent either partially beyond the stricture and then pull it back or to directly deploy it within the stricture itself. There are also two techniques to deploy a Y stent and the operators can choose the one they are most

familiar with: the “push” technique, in which the stent is ejected from the bronchoscope above the carina and then is pushed down with an open rigid grasping forceps placed at stent bifurcation; and the “pullback” technique, in which both bronchial limbs are placed within one bronchus (usually the one involved with most disease), then the stent is pulled back slowly until the shorter limb pops out in the contralateral bronchus. While this has not been studied, the “pullback” technique may be safer in patients with abnormal airway wall (friable, infiltrated mucosa, pre-existent fistula) because of potential reduced risk of pushing the stent into the mediastinum. Accessory instruments such as grasping forceps may be needed post-deployment to assist with stent unfolding and positioning in the desired location. If the operator works through an open system, he or she may occasionally need to use Vaseline petroleum gauze packing strip or Kerlex gauze roll to pack the nose and the mouth, respectively, in case of significant air leak and subsequent impaired ventilation and oxygenation.

*Flexible bronchoscopy* is used by many operators to insert SEMS. This procedure can even be performed while the patient is on the ventilator in the intensive care unit. The technique of placing these stents under fluoroscopic guidance is well described [103], but fluoroscopy in the intensive care unit is cumbersome and often unavailable. There are techniques for placing these stents without fluoroscopy, one of which will be described here. First, the bronchoscope is inserted in the mouth through a bite block alongside the endotracheal tube (ETT), after deflating the ETT cuff, and advanced into the space between the tracheal wall and the ETT. The scope is then positioned proximal to the stenosis. A guide wire is inserted through the bronchoscope and passed alongside the lesion, after which the bronchoscope is withdrawn, leaving the guide wire in place. The scope is reinserted into the ETT to confirm guide wire location. A stent delivery catheter is advanced over the guide wire, and the stent is deployed under bronchoscopic visualization. The delivery catheter and guide wire are withdrawn together, leaving the stent in position. If necessary, the stent can be repositioned by grasping its proximal loop with a flexible alligator forceps.

## Stent-Related Complications

Complications following stent placement can be divided into procedure-related complication and long-term sequelae of the physical presence of an airway stent. While rarely reported, procedure-related complications can occur during stent insertion and as a result of their deployment and include: perforation of the airway wall resulting in broncho-mediastinal fistula, massive hemorrhage (from large vessel laceration) and potentially mediastinal misplacement of the stent; hypoventilation and hypoxemic respiratory failure caused by the large stent not unfolding satisfactorily or by occlusion of the stent with mucus or blood immediately following deployment.

The AQuIRE registry found that in patients undergoing any type of bronchoscopic intervention (including stenting) for malignant CAO, the overall severe 30-day complication rate was 4%. Overall complication risk was increased by moderate sedation (as opposed to general anesthesia), urgent or emergent procedures, American Society of Anesthesiologists (ASA) score >3, and redo therapeutic bronchoscopy. The rate of significant bleeding necessitating intervention was 0.5%. The risk for significant bleeding was increased in patients undergoing urgent and emergent procedures, APC use, redo therapeutic bronchoscopy. The rate of procedurally related death was 0.5%. Risk of death as a result of procedural complication was increased in urgent or emergent procedure. In the patients with malignant CAO, the post-procedure 30 day overall mortality was 15%. Risk of death within 30 days increased with the use of stents, and Y-stents had a significantly higher risk of 30-day mortality compared to straight “tube” stents: it is unclear if this is a result of the stent itself or, more likely, the increased severity and extent of disease which necessitate a stent and more-so a Y-stent. In addition, the risk of 30-day mortality was increased in patients with a Zubrod performance status score >1, ASA score >3, or any intrinsic or mixed obstructive disease. Overall, the rate of immediate procedurally related complications is rare. Of the modifiable risk factors, the two most pertinent risk factors are utilizing general anesthesia



instead of moderate sedation, a judicious decision for the use of stenting and the type of stent employed [44].

The remainder of this section will address long-term adverse events related to the presence of indwelling airway stent. In this regard, stents are indeed foreign objects inside the airway and adverse events are therefore expected. Several complications have been identified and reported as incidence proportion<sup>6</sup> [14] in case series but only recently this issue has been systematically approached using clear definitions and statistics using incidence rate<sup>7</sup> rather than proportions to report these adverse events [14]. Because of different biomechanics, significant differences exist between airway stent types in terms of long-term complications related to stent infection, granulation tissue, mucus plugging, stent migration, and stent fracture which could injure the airway wall or the adjacent mediastinal vessels [104]. While perioperative complications are rare and the immediate effects of stent insertion could be gratifying, both bronchoscopists and patients should be aware that long-term complications are common and potentially life threatening [105].

## Granulation Tissue

This stent-related complication may also promote the development of secondary stenoses [106]. The exact prevalence of stent obstruction by granulation tissue versus tumor overgrowth or ingrowth in patients with malignant obstruction is somewhat confounded by the fact that studies tend to report them together rather than separately but when it occurs may be clinically significant in approximately 25% of patients [107]. The estimated incidence proportion of recurrent obstruction from either granulation tissue or tumor is 9–67% in patients with metal stents and 6–15% in patients with silicone stents [108]. The

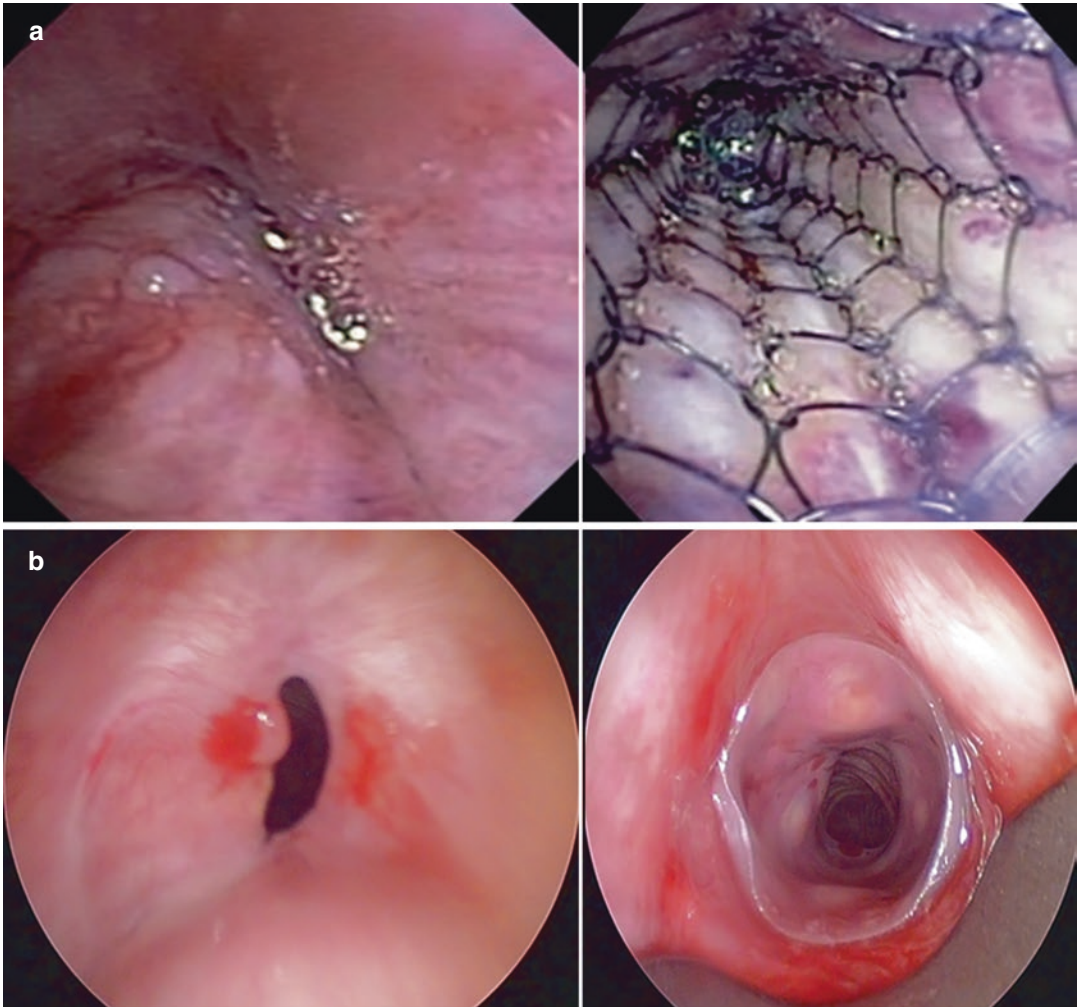
likely mechanism for granulation tissue formation consists of excessive pressure on the airway wall, which may lead to ischemic necrosis due to capillary closure. From physics standpoint, if the expansion force of a stent would be distributed equally over its complete outer surface, this would result in a relatively small contact pressure on the airway wall. However, if the stent wall touches a small portion of the inner tracheal wall (as may be the case with cylindrical stents for stomal, triangular stenoses), then the local pressure at that contact zone would be much higher and would result in considerable impairment of mucosal blood flow promoting further tissue ischemia and damage. This process is also seen when SEMS is used even though such a stent may have the same or lower overall expansion force compared with a silicone stent, that is because SEMS can shut down the mucosal blood flow at spots where the thin wires come in contact with the tissue (Fig. 16.8). Thus, the ciliated epithelium is replaced by fibroblasts and granulation tissue. Over-sizing the stent has been suspected as a risk factor especially when stents are placed in the upper trachea or subglottis. In one study, Dumon stent insertion for benign tracheobronchial stenoses showed an incidence proportion of 28% for granulation tissue after a mean period of follow-up of 303 days. The stent-to-airway diameter ratio of 90% was found to be the critical cut-off point for predicting granulation tissue formation (odds ratio [OR]: 47.5285) [102]. The optimal ratio between the stent and the airway diameter that could reduce granulation tissue formation has yet to be determined. Friction between the sharp edges of the stent and airway mucosa and the formation of galvanic currents (with SEMS) may cause granulation tissue formation; this is especially true if electrocautery is used in the vicinity of the stent, and these currents are generated<sup>8</sup> around the metal wires [107]. This granulation tissue ingrowth can make removal

<sup>6</sup>An incidence proportion is defined as the number of cases with complications divided by the number of cases overall and is an appropriate measure for analyzing immediate perioperative complications [6].

<sup>7</sup>It measures events per person-time at risk [6].

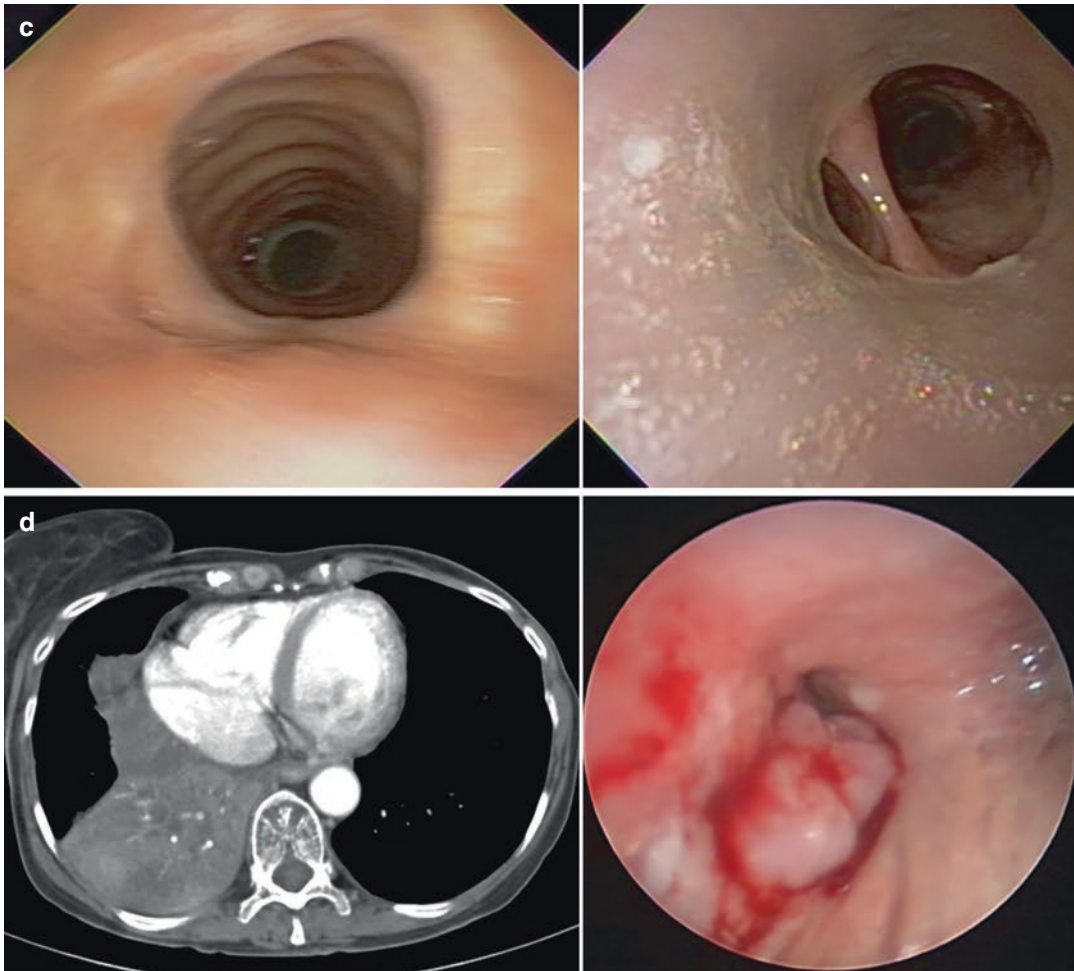
<sup>8</sup>An electrical current in which the electron flow is in only one direction; galvanic currents cause fibroblasts proliferation resultant increase in collagen synthesis, property used for wound healing and also implicated in keloid formation.





**Fig. 16.8** (a) Severe, complete left main bronchial obstruction due to extrinsic compression and mucosal infiltration (left panel); A partially covered self expandable metallic stent was inserted which caused at blanching spots where the thin wires come in contact with the tissue, suggesting mucosal ischemia from mucosal blood flow compromise (right panel). (b) Post tracheostomy related tracheal stenosis with chondritis and hypertrophic tissues (left panel); post dilation, a straight silicone stent was placed which was well compressed after deployment (right panel); (c) In the same

patient, several months later, bronchoscopy showed that the stent migrated downwards to the main carina (left panel); this resulted in significant obstruction of the left main bronchus and inability to clear secretions (right panel). (d) Computed tomography performed 3 months prior to bronchoscopy showed complete absence of aeration in the right lower lobe, thus precluding bronchoscopic intervention to restore airway patency (left panel); bronchoscopy in this case, showed mucosal infiltration and friability and no evidence of airway patency distal to the obstruction (right panel)



**Fig. 16.8** (continued)

difficult and result in substantial airway wall trauma [109]. Other factors such as stent kinking or fracture also contribute to granulation tissue formation. Overall, however, granulation tissue formation is not easily predictable but seems to be more common in patients with keloids and in those with chronic airway infection [110]. Management of this problem is complicated by the difficulty of removing metal stents [110, 111]. Interestingly, one study addressing malignant CAO, when compared with Ultraflex stents, both silicone stents and Aero stents seem to be more likely to lead to granulation tissue forma-

tion [14]. In the multivariate model, however, only silicone stents (hazard ratio [HR] = 3.32) and lower respiratory tract infection (HR = 5.69) were associated with increased risk for granulation. It is likely that the observed differences in granulation tissue may be related to repetitive motion trauma and infection. Coated stent models such as polyurethane-coated metallic stent may reduce the histobiological reaction to foreign bodies in animal experiments (i.e., granulation tissue formation) and still maintain sufficient expansion force [112]. In vivo human studies are warranted.

## Stent Fracture

This is a rare complication seen with metal stent insertion, but it may result in airway wall perforation and hemoptysis, potentially fatal events [14, 39, 113]. United States Food and Drug Administration warned that metallic tracheal stents in patients with benign airway disorders should be used only after thoroughly exploring all other treatment options (such as surgical procedures or placement of silicone stents) [39]. The use of these stents as a bridging therapy to surgery is also not recommended, because the removal of these stents is associated with significant complications.

## Stent Associated Lower Respiratory Infection and Mucus Obstruction

When a definition of respiratory infection is based on the presence of clinical findings (fever, increased volume and purulence of sputum, and worsening cough), with or without radiographic evidence of pneumonia but requiring the managing physician to prescribe antibiotics, the incidence proportion of lower respiratory tract infections was 36–39% in patients suffering from cancer [14]. The authors of this study found that respiratory infections led to significant morbidity and mortality: over half the patients were hospitalized, and 23% of patients with respiratory infections died within 14 days of their infection. Respiratory infections were more frequent in patients with Aero stents compared with silicone or Ultraflex. Various degrees of obstruction by mucus are not uncommon. This tends to be more common in patients with ineffective cough and in smokers. In patients with malignant CAO, having a left-sided stent (HR = 3.07), age (HR = 0.97), having a silicone stent (HR = 2.72) versus Ultraflex stents, and having chemotherapy post-stent placement (HR = 0.32) had significant impact on time to mucus impaction. The higher risk with left sided stents makes sense; because of the sharper angle<sup>9</sup> between the left main bron-

chus and trachea, the patient may have difficulty in raising secretions and also because the left mainstem bronchial stents are longer than the right sided ones, for simple anatomical reasons. In addition to obstructing the airway, in time this could also lead to halitosis because the stent becomes covered chronically with a biofilm (Fig. 16.8). Recent in vitro studies evaluated a new methodology to create highly hydrophobic micro-/nanostructured silver antibacterial surfaces against Gram-positive and Gram-negative bacteria, using low-pressure plasma. This micro-/nanostructured silver coating demonstrated antibacterial properties causing a reduction in Gram-positive and Gram-negative bacteria viability on airway stents [114].

## Migration

While an oversized stent could cause granulation tissue formation, an undersized stent would likely migrate. In one study, stent migration was 5.26%, 6.06%, and 15.38% in patients in whom the stent-to airway diameter was between 90% and 100%, 80% and 90%, and <80%, respectively [102]. The migrated stent, in addition to not palliating the airway narrowing for which was initially placed, could result in inability to clear secretions, in continuous friction between the wall of the stent and the airway mucosa, and cause granulation as well. Ideally, a stent is well compressed once is deployed, but even if it is sized appropriately and placed properly and sitting tightly at the end of the procedure, it can still migrate later because of the viscoelastic properties of the tracheal tissues (Fig. 16.8). This complication is seen more commonly in benign disease or in patients with cancer undergoing therapy, likely because patients with benign disease survive longer and because of the changes in airway viscoelastic properties (in time the airway stenosis progressively dilates). This probably explains why about 20% of patients with strictures may have their stent removed after ~18 months. For patients with ECAC, silicone stent insertion improves functional status immediately post-intervention, but is associated with a high rate of

<sup>9</sup>Especially in patients with tumors who might have a nearly horizontal left main bronchus due to large subcarinal adenopathy.

adverse effects with frequent stent migration. In fact, in one study of malignant CAO, among various stents (Ultraflex, Aero and silicone) only silicone tube stents had a significant effect on migration risk with a HR of 3.52 [14]. Stent migration requires a revision procedure to maintain satisfactory airway patency and prevent further complications.

Bronchoscopy is currently the standard for the detection and treatment of stent-related complications and, in non-urgent situations, usually involves a two-step procedure. Initially, diagnostic flexible bronchoscopy is performed to detect and characterize a stent complication; if a treatable complication is detected, rigid bronchoscopy may be required for therapeutic intervention. In this regard, from regulatory perspective, the stent insertion package should probably contain information about stent's biomechanics, sterilization (although this may not affect the infection rate) [14] in addition to reporting indications, expected results, incidence rates of long-term complications as well as potential contraindications to stent insertion.

---

## Contraindications

There are certain circumstances when stent insertion should not be offered. For instance, in idiopathic or secondary benign subglottic stenosis (within 2 cm from the vocal cords), stents may extend the length of the stenotic segment [93]. This is particularly true for metallic stents. In one study, all patients with laryngotracheal stenosis who had undergone covered or uncovered metallic stent placement developed new strictures or granulation tissue that precluded definitive surgical treatment or required more extensive resections [93]. In fact, some tracheal surgeons believe that SEMS should never be used in patients who are potential candidates for resection because these are likely to cause additional airway injury and possibly make a potentially resectable disease, unresectable<sup>10</sup> [115].

---

<sup>10</sup>In this regard, histologically benign CAO should be treated surgically or for non surgical candidates, with silicone stents whenever possible.

The absence of a functional “distal airway” such is the case with significant and chronic (usually >1 month) distal parenchymal tumor infiltration or confirmed lack of perfusion of underlying lung are also contraindications to stent insertion and, for the same reasons, for any endoluminal therapy aimed at restoring airway patency. In patients with CAO (lobar or mainstem bronchi), assessing the functionality of the lung parenchyma distal to the obstruction is useful when considering interventions meant to establish airway patency. Functionality of the lung distal to the obstruction may not be restored in patients who have had chronic complete obstruction and lack of ventilation (Fig. 16.8). Determining whether there is functional airway and lung parenchyma beyond an obstruction is essential to any successful bronchoscopic intervention,<sup>11</sup> in part because significant friability of bleeding from infiltrated bronchial mucosa, or lack of lung perfusion<sup>12</sup> despite restored airway patency, might preclude intervention. In one study, 71% of patients who initiated radiation therapy within 2 weeks after radiological evidence of atelectasis had complete re-expansion of their lungs, compared with only 23% of those irradiated after 2 weeks [116]. Studies pertaining to successful bronchoscopic treatment and time to treatment are lacking. In addition, significant mucosal friability and bleeding of bronchial mucosa might also preclude interventions because stent insertion may result in broncho-mediastinal fistula, loss of the stent within the mediastinum, or hemorrhage (Fig. 16.8).

---

<sup>11</sup>Other conditions include experienced bronchoscopist and team, experienced anesthesiologist, control of patient's overall performance status, additional systemic or local therapy still possible, and control of comorbidities.

<sup>12</sup>One way to assess the perfusion status of lung parenchyma distal to an airway obstruction is to attempt bypassing the stenosis using a high-resolution EBUS radial probe.



## Follow-Up and Patient Education

Immediately after stent insertion, a chest radiograph is performed to confirm its location. Because stents are associated with significant adverse events, a stent alert card should be given to the patient upon discharge from the hospital; this provides information both for patients and for the doctors that may encounter patients with airway stents. They are informed that even though some stents (i.e., silicone) are not radio-opaque, one can still identify them on the chest radiographs as straight lines. In addition, the card includes the patient's name, indication for stent insertion, type, location and size of stent inserted, contact information, and instructions for both patients and physicians in case of stent-related complications. Also, if intubation is necessary for whatever reason, bronchoscopic intubation using a cuffless # 6 ETT to avoid stent dislodgement or mucosal trauma is advisable.

Granulation tissue, secretions, migration, tumor progression, and fistula formation are usually detected during follow-up bronchoscopy or on chest CT. Studies show that the extent of air pockets around the stent on follow-up chest CT correlate with the success of stent removal, and indicates regression of stenosis, and may help guide the optimal time for stent removal [117]. Stent-related complications, however, are usually detected by the onset of new respiratory symptoms and may not necessitate systematic (scheduled) routine flexible bronchoscopy. In those patients suspected of having stent-related adverse effects, however, bronchoscopy should be performed for diagnosis and potentially for therapy. While routine follow-up bronchoscopy in the lack of symptoms may not be warranted in all patients after stent insertion, given that most complications occur within 6 weeks post-stent insertion [14, 16, 17], one could choose to perform surveillance bronchoscopy in patients at high risk for complications after stent insertion. A recent retrospective study enrolling 70 patients who underwent to either silicone stent or SEMS for malignant CAO showed an increase in cumulative incidence of complications between 1 and 6 months after stent placement, which highlights

the need for close clinical and bronchoscopic surveillance among these patients [98].

In a study of 134 patients with 147 stents, 94 patients ( $n = 100$  stents) had follow-up bronchoscopy at a mean of 42 days. The authors showed that stent-related complications were seen in 69% of stents inserted, with the majority requiring an intervention such as aspiration of secretions, stent removal, and stent replacement [118].

There are reports suggesting that time to granulation tissue detection after SEMS insertion is longer in patients with dynamic airway obstruction than in those with structural airway obstruction (396 vs. 95 days  $p = 0.02$ ) [106], so a need for prolonged follow-up in these patients may be warranted. Some physicians perform routine bronchoscopy every couple of months, while others only do it when patients complain of new symptoms [119]. We perform follow-up bronchoscopy 30 days after stent insertion and then based on clinical judgment depending on concurrent systemic therapy as well as the status of the airway and the stent at the time of first follow-up bronchoscopy. Preventive measures for obstruction by mucus such as aerosol therapy, respiratory physiotherapy, and clinical visits are advocated. Also, while not a universal practice, saline nebulization is offered by many bronchoscopists to keep the stent humidified in order to avoid excessive mucus plugging. In fact, severely disabled patients such as those who are bedridden and with poor cough or impaired mental status are unlikely to benefit from indwelling airway stents since the risk of obstruction by mucus may outweigh the benefit gained by placing the stent and only temporarily restore airway patency.

---

## Summary and Recommendations

Airway stents improve symptoms of selected patients with malignant and benign central airway obstruction, esophago-respiratory, and bronchial stump fistulas but in general, their insertion should be reserved to patients for whom curative open surgical interventions are not feasible or contraindicated. Metallic stents should be avoided in benign disease unless surgery or sili-



cone stent placement is not possible or feasible and there are no other alternatives for maintaining airway patency. For malignant disease, stents are placed with a palliative intent. They should therefore be inserted by operators able to handle intraoperative, short-term, and long-term complications. Long-term complications after placing such prostheses are not uncommon and can occasionally be fatal. Airway stents are not equal in terms of biomechanics and stent-tissue interactions and currently, these data are considered confidential, proprietary, and regulatory bodies do not mandate their reporting. However, in our opinion, manufactures should describe some key biomechanical properties including the resistance to angulation, expansile force, and time to mechanical failure (cough cycles) to help physicians better predict successful airway patency restoration, as well as immediate- and long-term stent-related complications.

## References

- Zhu GH, Ng AHC, Venkatraman SS, Boey FYC, Wee ALY, Trasti SL, et al. A novel bioabsorbable drug-eluting tracheal stent. *Laryngoscope*. 2011;121:2234–9.
- Xu J, Ong HX, Traini D, Williamson J, Byrom M, Gomes Dos Reis L, et al. Paclitaxel-eluting silicone airway stent for preventing granulation tissue growth and lung cancer relapse in central airway pathologies. *Expert Opin Drug Deliv*. 2020;17:1631–45.
- Korpela A, Aarnio P, Sariola H, Törmälä P, Harjula A. Comparison of tissue reactions in the tracheal mucosa surrounding a bioabsorbable and silicone airway stents. *Ann Thorac Surg*. 1998;66:1772–6.
- Saito Y, Minami K, Kobayashi M, Nakao Y, Omiya H, Imamura H, et al. New tubular bioabsorbable knitted airway stent: biocompatibility and mechanical strength. *J Thorac Cardiovasc Surg*. 2002;123:161–7.
- Robey TC, Välimaa T, Murphy HS, Törmälä P, Mooney DJ, Weatherly RA. Use of internal bioabsorbable PLGA “finger-type” stents in a rabbit tracheal reconstruction model. *Arch Otolaryngol Head Neck Surg*. 2000;126:985–91.
- Vondryš D, Elliott MJ, McLaren CA, Noctor C, Roebuck DJ. First experience with biodegradable airway stents in children. *Ann Thorac Surg*. 2011;92:1870–4.
- Antón-Pacheco JL, Luna C, García E, López M, Morante R, Tordable C, et al. Initial experience with a new biodegradable airway stent in children: is this the stent we were waiting for? *Pediatr Pulmonol*. 2016;51:607–12.
- Chao Y-K, Liu K-S, Wang Y-C, Huang Y-L, Liu S-J. Biodegradable cisplatin-eluting tracheal stent for malignant airway obstruction: in vivo and in vitro studies. *Chest*. 2013;144:193–9.
- Stehlik L, Hytych V, Letackova J, Kubena P, Vasakova M. Biodegradable polydioxanone stents in the treatment of adult patients with tracheal narrowing. *BMC Pulm Med*. 2015;15:164.
- Griffiths BT, James P, Morgan G, Diamantopoulos A, Durward A, Nyman A. Biodegradable stents for the relief of vascular bronchial compression in children with left atrial enlargement. *J Bronchol Interv Pulmonol*. 2020;27:200–4.
- Sztanó B, Kiss G, Márai K, Rác G, Szegedi I, Rác K, et al. Biodegradable airway stents in infants—potential life-threatening pitfalls. *Int J Pediatr Otorhinolaryngol*. 2016;91:86–9.
- Gildea TR, Young BP, Machuzak MS. Application of 3D printing for patient-specific silicone stents: 1-year follow-up on 2 patients. *Respir Int Rev Thorac Dis*. 2018;96:488–94.
- Martinod E, Chouahnia K, Radu DM, Joudiou P, Uzunhan Y, Bensidhoum M, et al. Feasibility of bioengineered tracheal and bronchial reconstruction using stented aortic matrices. *JAMA*. 2018;319:2212–22.
- Ost DE, Shah AM, Lei X, Godoy MCB, Jimenez CA, Eapen GA, et al. Respiratory infections increase the risk of granulation tissue formation following airway stenting in patients with malignant airway obstruction. *Chest*. 2012;141:1473–81.
- Bolliger CT. Multimodality treatment of advanced pulmonary malignancies. In: Bolliger CT, Mathur PN, editors. *Interventions bronchoscopy*, vol. 30. Basel: Karger Publishers; 2000. p. 187–96.
- Murgu SD, Colt HG. Complications of silicone stent insertion in patients with expiratory central airway collapse. *Ann Thorac Surg*. 2007;84:1870–7.
- Ernst A, Majid A, Feller-Kopman D, Guerrero J, Boiselle P, Loring SH, et al. Airway stabilization with silicone stents for treating adult tracheobronchomalacia: a prospective observational study. *Chest*. 2007;132:609–16.
- Bondaryev A, Makris D, Breen DP, Dutau H. Airway stenting for severe endobronchial papillomatosis. *Respir Int Rev Thorac Dis*. 2009;77:455–8.
- Terrier B, Dechartres A, Girard C, Jouneau S, Kahn J-E, Dhote R, et al. Granulomatosis with polyangiitis: endoscopic management of tracheobronchial stenosis: results from a multicentre experience. *Rheumatology (Oxford)*. 2015;54:1852–7.
- Wester JL, Clayburgh DR, Stott WJ, Schindler JS, Andersen PE, Gross ND. Airway reconstruction in Wegener’s granulomatosis-associated laryngotracheal stenosis. *Laryngoscope*. 2011;121:2566–71.
- Costantino CL, Niles JL, Wright CD, Mathisen DJ, Muniappan A. Subglottic stenosis in granulomatosis with polyangiitis: the role of laryngotracheal resection. *Ann Thorac Surg*. 2018;105:249–53.

22. Plojoux J, Laroumagne S, Vandemoortele T, Astoul PJ, Thomas PA, Dutau H. Management of benign dynamic “A-shape” tracheal stenosis: a retrospective study of 60 patients. *Ann Thorac Surg.* 2015;99:447–53.
23. Mattioli F, Marchioni A, Andreani A, Cappiello G, Fermi M, Presutti L. Post-intubation tracheal stenosis in COVID-19 patients. *Eur Arch Otorhinolaryngol.* 2020;1–2.
24. Alturk A, Bara A, Darwish B. Post-intubation tracheal stenosis after severe COVID-19 infection: a report of two cases. *Ann Med Surg.* 2012;2021(67):102468.
25. Agrawal A, Baird BJ, Madariaga MLL, Blair EA, Murgu S. Multi-disciplinary management of patients with benign airway strictures: a review. *Respir Med.* 2021;187:106582.
26. Mehta AC, Lee FY, Cordasco EM, Kirby T, Eliachar I, De Boer G. Concentric tracheal and subglottic stenosis. Management using the Nd-YAG laser for mucosal sparing followed by gentle dilatation. *Chest.* 1993;104:673–7.
27. Dalar L, Karasulu L, Abul Y, Özdemir C, Sökücü SN, Tarhan M, et al. Bronchoscopic treatment in the management of benign tracheal stenosis: choices for simple and complex tracheal stenosis. *Ann Thorac Surg.* 2016;101:1310–7.
28. Bricchet A, Verkindre C, Dupont J, Carlier ML, Darras J, Wurtz A, et al. Multidisciplinary approach to management of postintubation tracheal stenoses. *Eur Respir J.* 1999;13:888–93.
29. Galluccio G, Lucantoni G, Battistoni P, Paone G, Batzella S, Lucifora V, et al. Interventional endoscopy in the management of benign tracheal stenoses: definitive treatment at long-term follow-up. *Eur J Cardiothorac Surg.* 2009;35:429–33; discussion 933–934.
30. Cavaliere S, Bezzi M, Toninelli C, Foccoli P. Management of post-intubation tracheal stenoses using the endoscopic approach. *Monaldi Arch Chest Dis.* 2007;67:73–80.
31. Nouraei SAR, Ghufour K, Patel A, Ferguson T, Howard DJ, Sandhu GS. Outcome of endoscopic treatment of adult postintubation tracheal stenosis. *Laryngoscope.* 2007;117:1073–9.
32. Cooper JD, Grillo HC. The evolution of tracheal injury due to ventilatory assistance through cuffed tubes: a pathologic study. *Ann Surg.* 1969;169:334–48.
33. Murgu SD, Colt HG, Mukai D, Brenner M. Multimodal imaging guidance for laser ablation in tracheal stenosis. *Laryngoscope.* 2010;120:1840–6.
34. Patelli M, Gasparini S. Post-intubation tracheal stenoses: what is the curative yield of the interventional pulmonology procedures? *Monaldi Arch Chest Dis.* 2007;67:71–2.
35. Zias N, Chroniou A, Tabba MK, Gonzalez AV, Gray AW, Lamb CR, et al. Post tracheostomy and post intubation tracheal stenosis: report of 31 cases and review of the literature. *BMC Pulm Med.* 2008;8:18.
36. Martinez-Ballarín JI, Diaz-Jimenez JP, Castro MJ, Moya JA. Silicone stents in the management of benign tracheobronchial stenoses. Tolerance and early results in 63 patients. *Chest.* 1996;109:626–9.
37. Wain JC. Postintubation tracheal stenosis. *Semin Thorac Cardiovasc Surg.* 2009;21:284–9.
38. Liu H-C, Lee K-S, Huang C-J, Cheng C-R, Hsu W-H, Huang M-H. Silicone T-tube for complex laryngotracheal problems. *Eur J Cardiothorac Surg.* 2002;21:326–30.
39. U.S. Food and Drug Administration. Metallic tracheal stents in patients with benign airway disorders. Silver Spring, MD: FDA; 2016. <http://www.fda.gov/Safety/MedWatch/SafetyInformation/SafetyAlertsforHumanMedicalProducts/ucm153009.htm>; Accessed 08 July 2016.
40. Fortin M, Lacasse Y, Elharrar X, Tazi-Mezalek R, Laroumagne S, Guinde J, et al. Safety and efficacy of a fully covered self-expandable metallic stent in benign airway stenosis. *Respir Int Rev Thorac Dis.* 2017;93:430–5.
41. Gildea TR, Murthy SC, Sahoo D, Mason DP, Mehta AC. Performance of a self-expanding silicone stent in palliation of benign airway conditions. *Chest.* 2006;130:1419–23.
42. Jog M, Anderson DE, McGarry GW. Polyflex stent: is it radiopaque enough? *J Laryngol Otol.* 2003;117:83–4.
43. Jeong B-H, Um S-W, Suh GY, Chung MP, Kwon OJ, Kim H, et al. Results of interventional bronchoscopy in the management of postoperative tracheobronchial stenosis. *J Thorac Cardiovasc Surg.* 2012;144:217–22.
44. Ost DE, Ernst A, Grosu HB, Lei X, Diaz-Mendoza J, Slade M, et al. Complications following therapeutic bronchoscopy for malignant central airway obstruction: results of the AQuIRE registry. *Chest.* 2015;148:450–71.
45. Dutau H, Di Palma F, Thibout Y, Febvre M, Cellerin L, Naudin F, et al. Impact of silicone stent placement in symptomatic airway obstruction due to non-small cell lung cancer—a French multicenter randomized controlled study: the SPOC trial. *Respir Int Rev Thorac Dis.* 2020;99:344–52.
46. Giovacchini CX, Kessler ER, Merrick CM, Gao J, Wang X, Wahidi MM, et al. Clinical and radiographic predictors of successful therapeutic bronchoscopy for the relief of malignant central airway obstruction. *BMC Pulm Med.* 2019;19:219.
47. Stanopoulos IT, Beamis JF, Martinez FJ, Vergos K, Shapshay SM. Laser bronchoscopy in respiratory failure from malignant airway obstruction. *Crit Care Med.* 1993;21:386–91.
48. Lo CP, Hsu AA, Eng P. Endobronchial stenting in patients requiring mechanical ventilation for major airway obstruction. *Ann Acad Med Singap.* 2000;29:66–70.
49. Jeon K, Kim H, Yu C-M, Koh W-J, Suh GY, Chung MP, et al. Rigid bronchoscopic intervention in patients with respiratory failure caused by malig-

- nant central airway obstruction. *J Thorac Oncol.* 2006;1:319–23.
50. Oviatt PL, Stather DR, Michaud G, MacEachern P, Tremblay A. Exercise capacity, lung function, and quality of life after interventional bronchoscopy. *J Thorac Oncol.* 2011;6(1):38–42.
  51. Razi SS, Lebovics RS, Schwartz G, Sancheti M, Belsley S, Connery CP, et al. Timely airway stenting improves survival in patients with malignant central airway obstruction. *Ann Thorac Surg.* 2010;90(4):1088–93.
  52. Okiror L, Jiang L, Oswald N, Bille A, Rajesh P, Bishay E, et al. Bronchoscopic management of patients with symptomatic airway stenosis and prognostic factors for survival. *Ann Thorac Surg.* 2015;99:1725–30.
  53. Verma A, Goh SK, Tai DYH, Kor AC, Abisheganaden J, Sein ZNN, et al. Outcome differences between recanalized malignant central airway obstruction from endoluminal disease versus extrinsic compression. *Lasers Med Sci.* 2019;34:955–62.
  54. Lemaire A, Burfeind WR, Toloza E, Balderson S, Petersen RP, Harpole DH, et al. Outcomes of tracheobronchial stents in patients with malignant airway disease. *Ann Thorac Surg.* 2005;80:434–7; discussion 437–438.
  55. Furukawa K, Ishida J, Yamaguchi G, Usuda J, Tsutsui H, Saito M, et al. The role of airway stent placement in the management of tracheobronchial stenosis caused by inoperable advanced lung cancer. *Surg Today.* 2010;40:315–20.
  56. Guidelines for intensive care unit admission, discharge, and triage. Task force of the American College of Critical Care Medicine, Society of Critical Care Medicine. *Crit Care Med.* 1999;27:633–8.
  57. Murgu S, Langer S, Colt H. Bronchoscopic intervention obviates the need for continued mechanical ventilation in patients with airway obstruction and respiratory failure from inoperable non-small-cell lung cancer. *Respir Int Rev Thorac Dis.* 2012;84:55–61.
  58. Kim BG, Shin B, Chang B, Kim H, Jeong BH. Prognostic factors for survival after bronchoscopic intervention in patients with airway obstruction due to primary pulmonary malignancy. *BMC Pulm Med.* 2020;20(1):54.
  59. Deschamps C, Bernard A, Nichols FC, Allen MS, Miller DL, Trastek VF, et al. Empyema and bronchopleural fistula after pneumonectomy: factors affecting incidence. *Ann Thorac Surg.* 2001;72:243–7; discussion 248.
  60. Lois M, Noppen M. Bronchopleural fistulas: an overview of the problem with special focus on endoscopic management. *Chest.* 2005;128:3955–65.
  61. Han X, Wu G, Li Y, Li M. A novel approach: treatment of bronchial stump fistula with a plugged, bullet-shaped, angled stent. *Ann Thorac Surg.* 2006;81:1867–71.
  62. Silon B, Siddiqui AA, Taylor LJ, Arastu S, Soomro A, Adler DG. Endoscopic management of esophagorespiratory fistulas: a multicenter retrospective study of techniques and outcomes. *Dig Dis Sci.* 2017;62:424–31.
  63. Shen KR, Allen MS, Cassivi SD, Nichols FC, Wigle DA, Harmsen WS, et al. Surgical management of acquired nonmalignant tracheoesophageal and bronchoesophageal fistulae. *Ann Thorac Surg.* 2010;90:914–8; discussion 919.
  64. Debourdeau A, Gonzalez J-M, Dutau H, Benezech A, Barthet M. Endoscopic treatment of nonmalignant tracheoesophageal and bronchoesophageal fistula: results and prognostic factors for its success. *Surg Endosc.* 2019;33:549–56.
  65. Wang H, Tao M, Zhang N, Li D, Zou H, Zhang J, et al. Airway covered metallic stent based on different fistula location and size in malignant tracheoesophageal fistula. *Am J Med Sci.* 2015;350:364–8.
  66. Khan A, Hashim Z, Neyaz Z, Agarwal A, Mohindra S, Nath A. Dual airway and esophageal stenting in advanced esophageal cancer with lesions near carina. *J Bronchol Interv Pulmonol.* 2020;27:286–93.
  67. Freitag L, Ernst A, Unger M, Kovitz K, Marquette CH. A proposed classification system of central airway stenosis. *Eur Respir J.* 2007;30:7–12.
  68. Rodriguez AN, Diaz-Jimenez JP. Malignant respiratory-digestive fistulas. *Curr Opin Pulm Med.* 2010;16:329–33.
  69. Diaz-Jimenez JP. New cufflink-shaped silicon prosthesis for the palliation of malignant tracheobronchial-esophageal fistula. *J Bronchol Interv Pulmonol.* 2005;12:207–9.
  70. Dumon J-F, Dumon MC. Dumon-Novatech Y-stents: a four-year experience with 50 tracheobronchial tumors involving the carina. *J Bronchol Interv Pulmonol.* 2000;7:26–32.
  71. Burt M, Diehl W, Martini N, Bains MS, Ginsberg RJ, McCormack PM, et al. Malignant esophagorespiratory fistula: management options and survival. *Ann Thorac Surg.* 1991;52:1222–8; discussion 1228–1229.
  72. Herth FJF, Peter S, Baty F, Eberhardt R, Leuppi JD, Chhajed PN. Combined airway and oesophageal stenting in malignant airway-oesophageal fistulas: a prospective study. *Eur Respir J.* 2010;36:1370–4.
  73. Murgu SD, Colt HG. Description of a multidimensional classification system for patients with expiratory central airway collapse. *Respirology.* 2007;12:543–50.
  74. Boiselle PM, O'Donnell CR, Bankier AA, Ernst A, Millet ME, Potemkin A, et al. Tracheal collapsibility in healthy volunteers during forced expiration: assessment with multidetector CT. *Radiology.* 2009;252:255–62.
  75. Majid A, Alape D, Kheir F, Folch E, Ochoa S, Folch A, et al. Short-term use of uncovered self-expanding metallic airway stents for severe expiratory central airway collapse. *Respir Int Rev Thorac Dis.* 2016;92:389–96.
  76. Lazzaro R, Patton B, Lee P, Karp J, Mihelis E, Vatsia S, et al. First series of minimally invasive, robot-

- assisted tracheobronchoplasty with mesh for severe tracheobronchomalacia. *J Thorac Cardiovasc Surg.* 2019;157:791–800.
77. Sarodia BD, Dasgupta A, Mehta AC. Management of airway manifestations of relapsing polychondritis: case reports and review of literature. *Chest.* 1999;116:1669–75.
  78. Miyazawa T, Nishine H, Handa H, Nobuyama S, Ishida A, Kida H, et al. Migration of the choke point in relapsing polychondritis after stenting. *Chest.* 2009;136:81S.
  79. Adliff M, Ngato D, Keshavjee S, Brenaman S, Granton JT. Treatment of diffuse tracheomalacia secondary to relapsing polychondritis with continuous positive airway pressure. *Chest.* 1997;112:1701–4.
  80. Nouraei SAR, Nouraei SM, Randhawa PS, Butler CR, Magill JC, Howard DJ, et al. Sensitivity and responsiveness of the Medical Research Council dyspnoea scale to the presence and treatment of adult laryngotracheal stenosis. *Clin Otolaryngol.* 2008;33:575–80.
  81. Myer CM, O'Connor DM, Cotton RT. Proposed grading system for subglottic stenosis based on endotracheal tube sizes. *Ann Otol Rhinol Laryngol.* 1994;103:319–23.
  82. Brouns M, Jayaraju ST, Lacor C, De Mey J, Noppen M, Vincken W, et al. Tracheal stenosis: a flow dynamics study. *J Appl Physiol.* 1985;2007(102):1178–84.
  83. Mead J, Turner JM, Macklem PT, Little JB. Significance of the relationship between lung recoil and maximum expiratory flow. *J Appl Physiol.* 1967;22:95–108.
  84. Smaldone GC, Smith PL. Location of flow-limiting segments via airway catheters near residual volume in humans. *J Appl Physiol.* 1985;1985(59):502–8.
  85. Baram D, Smaldone G. Tracheal collapse versus tracheobronchomalacia: normal function versus disease. *Am J Respir Crit Care Med.* 2006;174:724; author reply 724–725.
  86. Boiselle PM, Litmanovich DE, Michaud G, Roberts DH, Loring SH, Womble HM, et al. Dynamic expiratory tracheal collapse in morbidly obese COPD patients. *COPD.* 2013;10:604–10.
  87. Behazin N, Jones SB, Cohen RI, Loring SH. Respiratory restriction and elevated pleural and esophageal pressures in morbid obesity. *J Appl Physiol* (1985). 2010;108:212–8.
  88. O'Donnell CR, Bankier AA, O'Donnell DH, Loring SH, Boiselle PM. Static end-expiratory and dynamic forced expiratory tracheal collapse in COPD. *Clin Radiol.* 2014;69:357–62.
  89. Singh J, Sese D, Lehr CJ, Pichurko B, McCurry K, Mehta AC. Effect of bilateral lung transplantation on excessive dynamic airway collapse. *Clin Transpl.* 2019;33:e13578.
  90. Bhatt SP, Terry NLJ, Nath H, Zach JA, Tschirren J, Bolding MS, et al. Association between expiratory central airway collapse and respiratory outcomes among smokers. *JAMA.* 2016;315:498–505.
  91. Hogg JC, Macklem PT, Thurlbeck WM. Site and nature of airway obstruction in chronic obstructive lung disease. *N Engl J Med.* 1968;278:1355–60.
  92. Pomsuriyasak P, Ploysongsang Y. Impulse oscillometry system in diagnosis of central airway obstruction in adults: comparison with spirometry and body plethysmography. *Chest.* 2009;136:123S.
  93. Murgu SD, Colt HG. Tracheobronchomalacia and excessive dynamic airway collapse. *Respirology.* 2006;11:388–406.
  94. Handa H, Miyazawa T, Murgu SD, Nishine H, Kurimoto N, Huang J, et al. Novel multimodality imaging and physiologic assessments clarify choke-point physiology and airway wall structure in expiratory central airway collapse. *Respir Care.* 2012;57:634–41.
  95. Nishine H, Hiramoto T, Kida H, Matsuoka S, Mineshita M, Kurimoto N, et al. Assessing the site of maximal obstruction in the trachea using lateral pressure measurement during bronchoscopy. *Am J Respir Crit Care Med.* 2012;185:24–33.
  96. Witt C, Dinges S, Schmidt B, Ewert R, Budach V, Baumann G. Temporary tracheobronchial stenting in malignant stenoses. *Eur J Cancer.* 1997;33:204–8.
  97. Lachkar S, Couraud S, Salaün M, Roger M, Bota S, Guisier F, et al. Self-expanding metallic Y-stent compared to silicone Y-stent for malignant lesions of the main carina: a single center retrospective study. *Respir Med Res.* 2020;78:100767.
  98. Ortiz-Comino RM, Morales A, López-Lisbona R, Cubero N, Diez-Ferrer M, Tebé C, et al. Silicone stent versus fully covered metallic stent in malignant central airway stenosis. *Ann Thorac Surg.* 2021;111:283–9.
  99. Chan AC, Shin FG, Lam YH, Ng EK, Sung JJ, Lau JY, et al. A comparison study on physical properties of self-expandable esophageal metal stents. *Gastrointest Endosc.* 1999;49:462–5.
  100. Freitag L, Eicker K, Donovan TJ, Dimov D. Mechanical properties of airway stents. *J Bronchol Interv Pulmonol.* 1995;2:270–8.
  101. Chhajed PN, Somandin S, Baty F, Mehta AJ, Azzola A, Leuppi J, et al. Therapeutic bronchoscopy for malignant airway stenoses: choice of modality and survival. *J Cancer Res Ther.* 2010;6:204–9.
  102. Hu H-C, Liu Y-H, Wu Y-C, Hsieh M-J, Chao Y-K, Wu C-Y, et al. Granulation tissue formation following Dumon airway stenting: the influence of stent diameter. *Thorac Cardiovasc Surg.* 2011;59:163–8.
  103. Saad CP, Murthy S, Krizmanich G, Mehta AC. Self-expandable metallic airway stents and flexible bronchoscopy: long-term outcomes analysis. *Chest.* 2003;124:1993–9.
  104. Agrafiotis M, Siempos II, Falagas ME. Infections related to airway stenting: a systematic review. *Respir Int Rev Thorac Dis.* 2009;78:69–74.
  105. Ernst A, Feller-Kopman D, Becker HD, Mehta AC. Central airway obstruction. *Am J Respir Crit Care Med.* 2004;169:1278–97.

106. Chung F-T, Lin S-M, Chou C-L, Chen H-C, Liu C-Y, Yu C-T, et al. Factors leading to obstructive granulation tissue formation after ultraflex stenting in benign tracheal narrowing. *Thorac Cardiovasc Surg.* 2010;58:102–7.
107. Freitag L. Airway stents. In: Strausz J, Bolliger CT, editors. *Interventional pulmonology.* Lausanne: European Respiratory Society Journals Ltd; 2010. p. 190–217. <https://doi.org/10.1183/1025448x.00991409>. Accessed 27 Dec 2021.
108. Dalupang JJ, Shanks TG, Colt HG. Nd-YAG laser damage to metal and silicone endobronchial stents: delineation of margins of safety using an in vitro experimental model. *Chest.* 2001;120:934–40.
109. Alazemi S, Lunn W, Majid A, Berkowitz D, Michaud G, Feller-Kopman D, et al. Outcomes, health-care resources use, and costs of endoscopic removal of metallic airway stents. *Chest.* 2010;138:350–6.
110. Matt BH, Myer CM, Harrison CJ, Reising SF, Cotton RT. Tracheal granulation tissue. A study of bacteriology. *Arch Otolaryngol Head Neck Surg.* 1991;117:538–41.
111. Lunn W, Feller-Kopman D, Wahidi M, Ashiku S, Thurer R, Ernst A. Endoscopic removal of metallic airway stents. *Chest.* 2005;127:2106–12.
112. Matsui H, Hiroma T, Hasegawa H, Ogiso Y. Decreased granulomatous reaction by polyurethane-coated stent in the trachea. *Pediatr Int.* 2014;56:817–21.
113. Bolot G, Poupard M, Pignat JC, Bertocchi M, Wiesendanger T, Thevenet F, et al. Self-expanding metal stents for the management of bronchial stenosis and bronchomalacia after lung transplantation. *Laryngoscope.* 1998;108:1230–3.
114. Gilibert-Porres J, Martí S, Calatayud L, Ramos V, Rosell A, Borrós S. Design of a nanostructured active surface against gram-positive and gram-negative bacteria through plasma activation and in situ silver reduction. *ACS Appl Mater Interfaces.* 2016;8:64–73.
115. Gaissert HA, Grillo HC, Wright CD, Donahue DM, Wain JC, Mathisen DJ. Complication of benign tracheobronchial strictures by self-expanding metal stents. *J Thorac Cardiovasc Surg.* 2003;126:744–7.
116. Reddy SP, Marks JE. Total atelectasis of the lung secondary to malignant airway obstruction. Response to radiation therapy. *Am J Clin Oncol.* 1990;13:394–400.
117. Verma A, Park HY, Lim SY, Um S-W, Koh W-J, Suh GY, et al. Posttuberculosis tracheobronchial stenosis: use of CT to optimize the time of silicone stent removal. *Radiology.* 2012;263:562–8.
118. Lee HJ, Labaki W, Yu DH, Salwen B, Gilbert C, Schneider ALC, et al. Airway stent complications: the role of follow-up bronchoscopy as a surveillance method. *J Thorac Dis.* 2017;9:4651–9.
119. Matsuo T, Colt HG. Evidence against routine scheduling of surveillance bronchoscopy after stent insertion. *Chest.* 2000;118:1455–9.



---

## **Part IV**

# **Lung Cancer, General Considerations**



# Lung Cancer Screening and Incidental Lung Nodules

# 17

Javier J. Zulueta and Marta Marín

## Introduction

With more than 10 million deaths in 2019, cancer was the second cause of mortality worldwide, preceded by cardiovascular diseases, which caused 18.56 million deaths [1]. Tracheal, bronchus, and lung cancer led all cancers in mortality with a rate of 25 deaths per 100,000 individuals, more than the next two categories (i.e., colon and stomach) combined [1]. In some parts of the world, lung cancer incidence is decreasing, but in others, it is still increasing, especially in women [2]. In the United States, between the years 2000 and 2018, the incidence of lung cancer per 100,000 in men has decreased by 36%, from 87.6 (95% confidence interval [CI], 86.7–88.5) to 56.3 (95% CI, 46.2–47.2) [3]. In women, the incidence over the same period has only dropped by 13%, from 53.7 (95% CI, 53.1–54.3) to 46.7 (95% CI, 46.2–47.2). In some countries in central and eastern Europe, and in South America (i.e., Brazil), the incidence in women continues to increase [4]. Regional differences in lung cancer incidence by sex reflect geographic trends in tobacco consumption, except

for women in some Asian countries where the incidence of lung cancer in never smokers is higher [4, 5]. In China and Brunei, the prevalence of smoking among women is as low as 2%, significantly lower than in most western countries, but the incidence rates of lung cancer are similar, between 22 and 27 per 100,000 [5].

Lung cancer remains the deadliest cancer mainly because it is predominantly diagnosed in advanced stages, even after numerous studies have shown that screening individuals at high risk for the disease results in early detection and in significant reductions in mortality. In the United States, between the years 2011 and 2017, the 5-year relative survival rate of patients diagnosed with lung cancer was 21.7% [6]. This is an improvement when compared to just a few years earlier but is still much lower than the survival rates of other common cancers. The small improvement may be attributed to multiple factors, including the emergence of new targeted therapies and immunotherapies that achieve better survival rates in a large proportion of patients. A recent analysis of the surveillance, epidemiology, and end results (SEER) database suggests that the awareness of lung cancer screening using low-dose computed tomography (LDCT) has resulted in slightly increased rates of early detection although, according to the national cancer institute (NCI), only 5.9% of adults who were eligible in 2015 underwent lung cancer screening [7].

J. J. Zulueta (✉)

Pulmonary, Critical Care, and Sleep Medicine, Icahn School of Medicine, Mount Sinai Morningside Hospital, New York, NY, USA  
e-mail: [Javier.zulueta@mountsinai.org](mailto:Javier.zulueta@mountsinai.org)

M. Marín

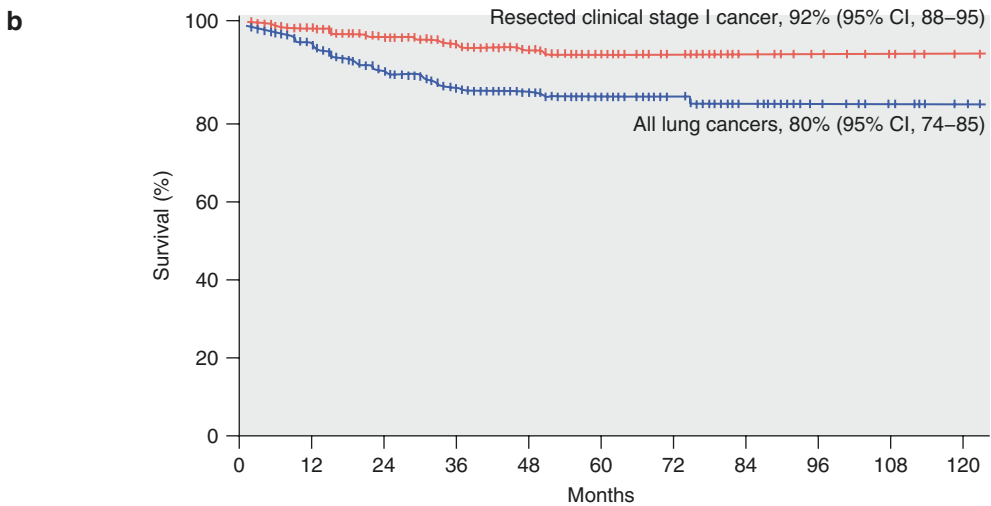
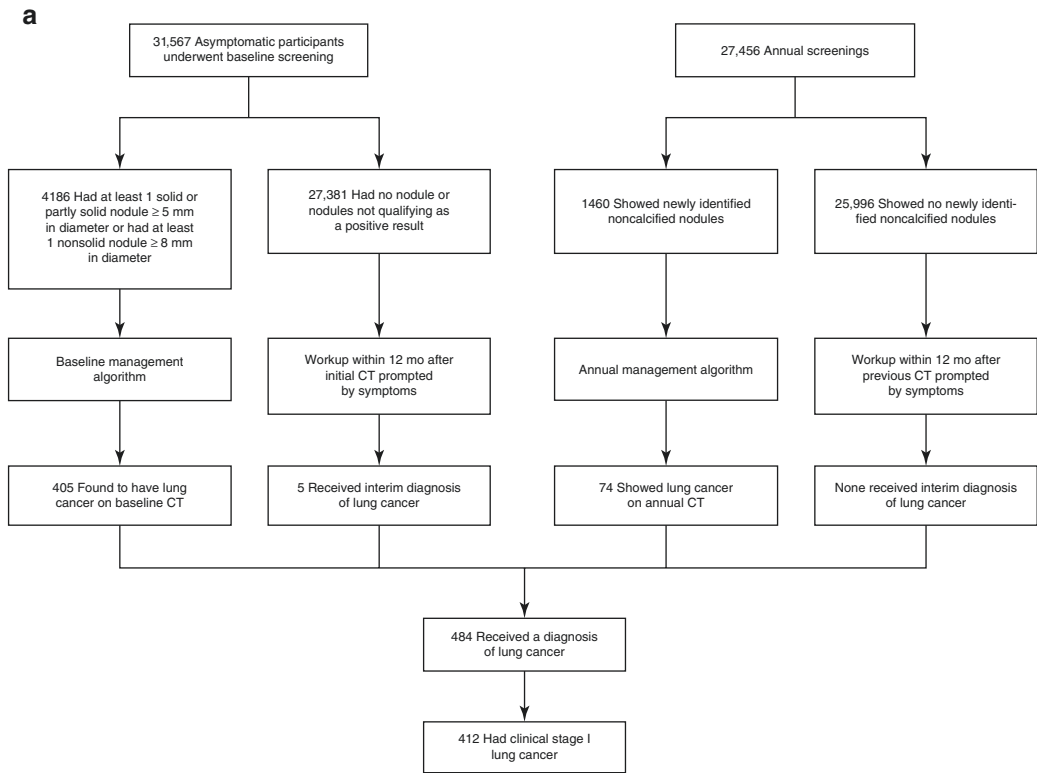
Pulmonary Medicine Service, Hospital Clínico-Universitario Lozano Blesa, Zaragoza, Spain

## Lung Cancer Screening: Historical Review

Randomized controlled trials of lung cancer screening of individuals at high risk for lung cancer with chest-X-rays (CXRs) and/or sputum cytology conducted in the 1970s failed to show any benefit in lung cancer mortality [8–11]. Subsequently, studies conducted in Japan showed promising results, but it wasn't until 1999, with the publication of a study conducted by the Early Lung Cancer Action Program (ELCAP), that a new era in lung cancer screening using low-radiation dose computed tomography (LDCT) commenced [12]. The authors of this study performed a LDCT of the thorax on 1000 asymptomatic individuals at high risk for lung cancer due to their smoking history. The LDCT was done at the time of recruitment (baseline) and repeated 1 year later (annual). The study used a novel lung cancer screening protocol based on detection of non-calcified nodules and tracking of their potential growth using periodic follow-up LDCTs at predetermined intervals. The results of the initial baseline screening showed that 23% of the participants had between one and six non-calcified nodules of at least 5 mm in diameter on LDCT, of which only a fraction was detected on a simultaneous chest radiograph (CXR). Of these nodules, 27 were diagnosed as lung cancer for a prevalence of 2.7%, and 85% of them were diagnosed in stage I according to the seventh Edition of the TNM staging system for lung cancer [13]. Only 7 of the 27 cancers were visualized on CXR. This publication generated great interest in lung cancer screening. The same authors expanded the research group creating an international consortium of investigators named international ELCAP, or I-ELCAP. This group included over 60 centers around the world in which lung cancer screening using LDCT was conducted using a similar protocol and a central database [14]. The most important results of this study were published in a landmark publication in 2006 (Fig. 17.1). After 59,023 screenings (31,567 baseline screenings and 27,456 annual screenings) with LDCT, 484 lung cancers were diagnosed, 85% of which were in stage I at the time

of diagnosis. The overall 10-year survival of these patients with cancer was 80% (95% CI: 74%–85%). Of those patients diagnosed in stage I, and in whom surgery was performed within 1 month since the moment of diagnosis, the 10-year survival reached 92% (95% CI: 88%–95%) (Fig. 17.1).

In 2011, results of the National Lung Screening Trial (NLST), the first randomized, controlled trial of lung cancer screening using LDCT, were published. In a trial sponsored by the NCI Division of Cancer Treatment and Diagnosis, Cancer Imaging Program, 53,454 individuals were recruited and randomized to undergo lung cancer screening with LDCT or CXR in 33 participating medical institutions. Participants were men and women between 55 and 74 years of age, with a history of smoking of at least 30 pack-years, and who currently smoked or had quit within the last 15 years prior to enrollment [15]. Exclusion criteria included a previous diagnosis of cancer, a chest CT done within 18 months before enrollment, hemoptysis, or an unexplained weight loss of more than 6.8 kg in the preceding year. Screenings occurred at 3 time-points: time of recruitment (initial screening), and after 12 and 24 months (annual screenings) [15]. Based on concepts established previously by IELCAP investigators but with slight differences, a screening in NLST was considered positive if a LDCT had a non-calcified nodule of 4 mm in diameter or more in any diameter. Positive LDCTs were notified to the participants or their health care providers, but no specific evaluation approach was recommended. The main outcome of the study, a 20% reduction in lung cancer-specific mortality in the arm in which screening was done with LDCT, was reached ahead of the expected end of the follow-up period and the study had to be stopped prematurely (Fig. 17.2). One-third of the cancers diagnosed in this trial were detected during the follow-up period following the first three cycles of screening that occurred in years 0, 1, and 2 (Fig. 17.2). When compared to the distribution of lung cancers diagnosed in one of the screening cycles, the proportion of lung cancers diagnosed in early stages was smaller during the subsequent follow-up years. Although impossi-

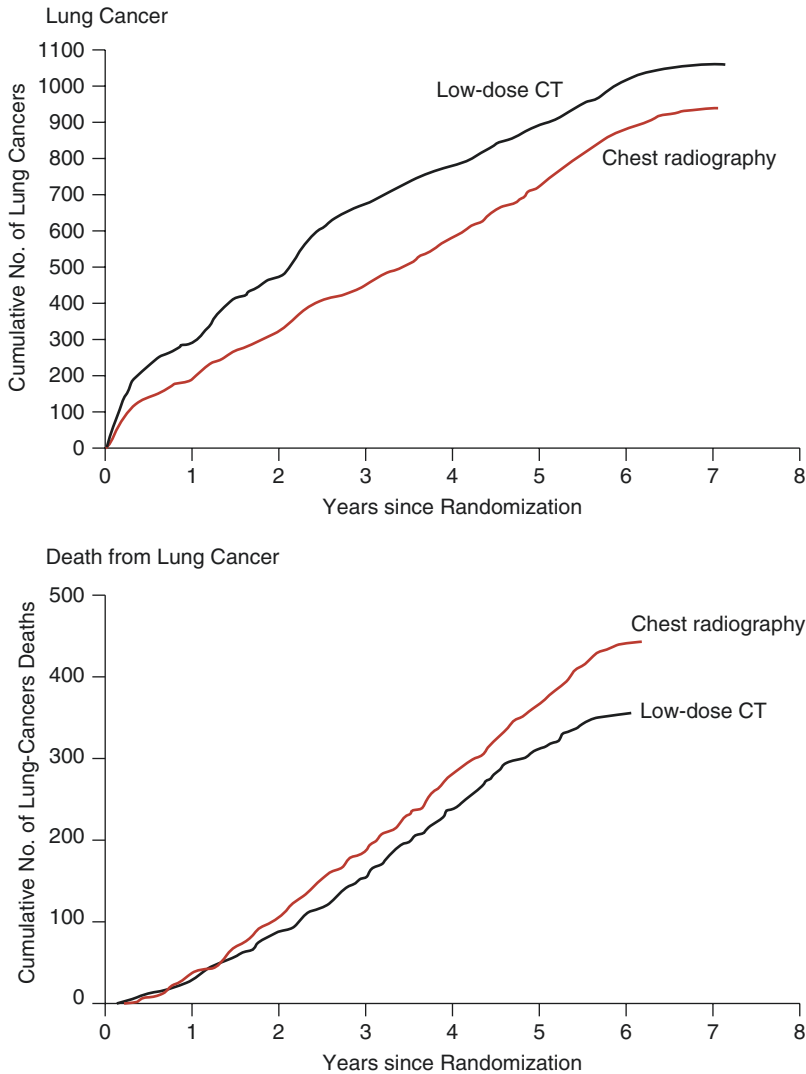


**No. at Risk**

All participants	484	433	356	280	183	90	50	28	16	9	2
Participants undergoing resection	302	280	242	191	120	59	34	18	12	7	1

**Fig. 17.1** Panel **a**: diagnosis of Lung Cancer in the IECALP study resulting from baseline screening and annual screening with LDCT. Panel **b**: Kaplan-Meier sur-

vival curves for 484 participants with lung cancer and 302 participants with stage I cancer resected within a month after diagnosis. (*N Engl J Med.* 2006; 355 (17): 1763–71)



**Fig. 17.2** Cumulative numbers of lung cancers and of deaths from lung cancer in the NLST. (*N Engl J Med.* 2011 Aug 4;365 (5):395–409)

ble to know retrospectively, if lung cancer screening would have been performed yearly over the entire trial period, it is possible that the differences in mortality between the groups might have been greater.

Two additional studies from Europe have confirmed the effectiveness of lung cancer screening using LDCT in reducing lung cancer-specific mortality, the NELSON trial, and the MILD trial [16, 17]. The Dutch-Belgian lung cancer screening trial, known as the NELSON, was a population-based, randomized, controlled

trial that recruited 15,792 current or former smokers between 50 and 74 years of age (84% men), who had smoked more than 15 cigarettes a day for more than 25 years, or more than 10 cigarettes a day for more than 30 years. Former smokers had to have quit within 10 years of recruitment. One of the novelties of this trial with respect to previous studies was the use of volumetric analysis of nodules to determine growth. Individuals were randomized to undergo four rounds of screening with LDCT with intervals of 1, 2, and 2.5 years (screening group), or



to continue standard of care that did not include any form of screening (control group). After 10 years of follow-up, screening with LDCT resulted in a 24% reduction in lung cancer mortality. Whether volumetric analysis of lung nodules is a superior method of nodule management requires validation in future studies [16]. The MILD trial, an Italian randomized controlled trial comparing LDCT screening with no intervention, reported a 39% reduction in lung cancer mortality at 10 years in the LDCT arm [17]. This trial also compared annual to biannual screening and found no differences, suggesting a less intensive regimen of screening may be as effective. However, this trial was smaller than the other randomized controlled trials and its results will have to be validated in further studies.

## Benefits and Risks of Lung Cancer Screening

The benefits and risks of lung cancer screening using annual LDCT have been summarized by the National Comprehensive Cancer Network (NCCN) guidelines and are shown in Table 17.1 [18]. The major benefit of screening is to reduce mortality by detecting the disease in early stages when curative surgery is still feasible. The main risks include overdiagnosis, false positives, false negatives, radiation, and risk of complications [18].

## Overdiagnosis

The large IELCAP study published in 2006 consisted of a single arm, observational study in which all participants underwent screening. Four hundred eighty four out of 59,023 participants were diagnosed with lung cancer, and 85% of them were diagnosed in stage 1. The estimated 10-year survival rate regardless of treatment was 88% (95% CI, 84–91). Critics argued that such positive results were likely due to overdiagnosis, that is, the diagnosis of cancers that would not result in the death of an individual if not detected, and that without a control group to show reduction in mortality it was not possible to accept the effectiveness of lung cancer screening. As previously mentioned, three randomized controlled trials comparing screening with LDCT with a control arm have reported similar results showing significant reductions in mortality with the use of LDCT. Although there might be some degree of overdiagnosis, the reduction in lung cancer-specific mortality confirms that lung cancer screening with LDCT is beneficial and that the very significant improvements seen in long-term survival rates in observational studies are not due to overdiagnosis.

Furthermore, more than 25 years of research have advanced the understanding of lung nodule subtypes to a point where the radiologic characteristics on LDCT allow for a better distinction

**Table 17.1** Risks and benefits of lung cancer screening

Risks	Benefits
• Futile detection of small aggressive tumors or indolent disease	• Decreased lung cancer mortality
• Quality of life	• Quality of life
Anxiety of test findings	Reduction in disease-related morbidity
• Physical complications from diagnostic workup	Reduction in treatment-related morbidity
• False-positive results	Improvement in healthy lifestyles
• False-negative results	Reduction in anxiety/psychosocial burden
• Unnecessary testing and procedures	• Discovery of other significant occult health risks (e.g. thyroid nodule, severe but silent coronary artery disease, early renal cancer in upper pole of kidney, aortic aneurysm, breast cancer)
• Radiation exposure	
• Cost	
• Incidental lesions	

National comprehensive cancer network (NCCN). *J Natl Compr Canc Netw* 2018;16 (4):412–441

between nodules that are more likely to be cancer from those that are more likely benign. And among those that are likely to be cancer, certain radiologic characteristics such as a ground glass appearance on CT are generally indicative of a more indolent type of tumor that can be managed mostly by close observation (see non-solid nodules below) [19].

Traditionally, the consensus among lung cancer specialists has been that untreated lung cancer is universally fatal [18]. However, recent advances in knowledge of the biological behavior of the different subtypes of adenocarcinomas have been translated into different management recommendations of suspicious lung nodules. Low-grade lung cancers known as adenocarcinoma in situ (AIS), formerly known as bronchoalveolar carcinoma, and minimally invasive adenocarcinoma (MIA), are easily identifiable on LDCT as they typically present as non-solid nodules. After complete resection, patients with these types of tumors have 100% 5-year disease-free survival rates [18, 20, 21]. Most guidelines now recommend follow-up of non-solid nodules even if they are growing. The appearance in follow-up LDCTs of a new solid component in a previously detected non-solid nodule, or the growth of a previously known solid component, should alert to the possibility of invasive adenocarcinoma and prompt a different management strategy.

### False Positives

LDCT detects nodules in a high proportion of individuals. In NLST, 27% of participants had non-calcified nodules of 4 mm or more in diameter [15]. In the IELCAP study, 13% of participants had a positive LDCT, defined by the presence of one or more non-calcified nodules of at least 5 mm in diameter [14]. The great majority of nodules detected by LDCT in participants in lung cancer screening programs are considered false positives because they are benign, raising the concern of unnecessary invasive procedures, including surgery. However, after screening numerous participants, the pro-

cedures for the management of nodules used in these studies have resulted in few unnecessary procedures. In the IELCAP study, more than 90% of all invasive diagnostic procedures done resulted in a diagnosis of cancer [12]. In a recent analysis of surgeries performed on participants of the IELCAP cohort, 89% of patients who underwent surgery had a histologic diagnosis of cancer. These low figures of surgical interventions for benign disease have been confirmed by other studies [22].

The American Cancer Society has developed Lung-RADS to standardize LDCT lung examinations (Fig. 17.3). This reporting system has been shown to increase the detection rate of lung cancer while decreasing the rate of false positives to approximately 10% and 5% in baseline and subsequent annual screening rounds, respectively [15, 18]. To expand on this concept and to minimize risks, the NCCN guidelines incorporate recommendations from three of the major protocols: I-ELCAP, NLST, and Lung-RADS [18].

### Radiation

In the LDCT studies conducted between 2000 and 2011, the dose of radiation patients received with each screening ranged between 0.8 and 1.5 mSv, about 7 times less than common doses for conventional diagnostic chest CTs at that time, and approximately 10 times that of chest radiography [23]. A study published shortly after the initial lung cancer screening trial results were known, estimated that in the US population, lung cancer screening with LDCT of 50% of the population at risk between the ages of 50 and 75, could result in an increase in the number of cancers induced by radiation by 1.8% [24]. The modeling in this study assumed higher doses of radiation than those currently used with LDCT, and estimated risks of cancer from radiation by extrapolating data from exposures to radiation in survivors of the atomic bombs. Studies that are more recent have suggested that lower doses of radiation result in favorable benefit to risk ratios with greater effects on mortality reduction than on risk of radiation exposure [25, 26].



Lung-RADS® v2022

Release Date: November 2022

Lung-RADS	Category Descriptor	Findings	Management
0	Incomplete Estimated Population Prevalence: ~1%	Prior chest CT examination being located for comparison (see note 9)	Comparison to prior chest CT;
		Part or all of lungs cannot be evaluated	Additional lung cancer screening CT imaging needed;
		Findings suggestive of an inflammatory or infectious process (see note 10)	1-3 month LDCT
1	Negative Estimated Population Prevalence: 39%	No lung nodules OR Nodule with benign features: • Complete, central, popcorn, or concentric ring calcifications OR • Fat-containing	12-month screening LDCT
2	Benign - Based on imaging features or indolent behavior Estimated Population Prevalence: 45%	Juxtapleural nodule: • < 10 mm (524 mm <sup>3</sup> ) mean diameter at baseline or new AND • Solid; smooth margins; and oval, lentiform, or triangular shape	
		Solid nodule: • < 6 mm (< 113 mm <sup>3</sup> ) at baseline OR • New < 4 mm (< 34 mm <sup>3</sup> )	
		Part solid nodule: • < 6 mm total mean diameter (< 113 mm <sup>3</sup> ) at baseline	
		Non solid nodule (GGN): • < 30 mm (< 14,137 mm <sup>3</sup> ) at baseline, new, or growing OR • ≥ 30 mm (≥ 14,137 mm <sup>3</sup> ) stable or slowly growing (see note 7)	
Airway nodule, subsegmental - at baseline, new, or stable (see note 11)			
Category 3 lesion that is stable or decreased in size at 6-month follow-up CT OR Category 4B lesion proven to be benign in etiology following appropriate diagnostic workup			
3	Probably Benign - Based on imaging features or behavior Estimated Population Prevalence: 9%	Solid nodule: • ≥ 6 to < 8 mm (≥ 113 to < 268 mm <sup>3</sup> ) at baseline OR • New 4 mm to < 6 mm (34 to < 113 mm <sup>3</sup> )	6-month LDCT
4A	Suspicious Estimated Population Prevalence: 4%	Part solid nodule: • ≥ 6 mm total mean diameter (≥ 113 mm <sup>3</sup> ) with solid component < 6 mm (< 113 mm <sup>3</sup> ) at baseline OR • New < 6 mm total mean diameter (< 113 mm <sup>3</sup> )	
		Non solid nodule (GGN): • ≥ 30 mm (≥ 14,137 mm <sup>3</sup> ) at baseline or new	
		Atypical pulmonary cyst: (see note 12) • Growing cystic component (mean diameter) of a thick-walled cyst	
Category 4A lesion that is stable or decreased in size at 3-month follow-up CT (excluding airway nodules)			
4B	Very Suspicious Estimated Population Prevalence: 2%	Solid nodule: • ≥ 8 to < 15 mm (≥ 268 to < 1,767 mm <sup>3</sup> ) at baseline OR • Growing < 8 mm (< 268 mm <sup>3</sup> ) OR • New 6 to < 8 mm (113 to < 268 mm <sup>3</sup> )	3-month LDCT; PET/CT may be considered if there is a ≥ 8 mm (≥ 268 mm <sup>3</sup> ) solid nodule or solid component
4B	Very Suspicious Estimated Population Prevalence: 2%	Part solid nodule: • ≥ 6 mm total mean diameter (≥ 113 mm <sup>3</sup> ) with solid component ≥ 6 mm to < 8 mm (≥ 113 to < 268 mm <sup>3</sup> ) at baseline OR • New or growing < 4 mm (< 34 mm <sup>3</sup> ) solid component	
		Airway nodule, segmental or more proximal - at baseline (see note 11)	
4B	Very Suspicious Estimated Population Prevalence: 2%	Atypical pulmonary cyst: (see note 12) • Thick-walled cyst OR • Multilocular cyst at baseline OR • Thin- or thick-walled cyst that becomes multilocular	
4B	Very Suspicious Estimated Population Prevalence: 2%	Airway nodule, segmental or more proximal - stable or growing (see note 11)	Referral for further clinical evaluation
		Solid nodule: • ≥ 15 mm (≥ 1,767 mm <sup>3</sup> ) at baseline OR • New or growing ≥ 8 mm (≥ 268 mm <sup>3</sup> )	Diagnostic chest CT with or without contrast;
		Part solid nodule: • Solid component ≥ 8 mm (≥ 268 mm <sup>3</sup> ) at baseline OR • New or growing ≥ 4 mm (≥ 34 mm <sup>3</sup> ) solid component	PET/CT may be considered if there is a ≥ 8 mm (≥ 268 mm <sup>3</sup> ) solid nodule or solid component;
		Atypical pulmonary cyst: (see note 12) • Thick-walled cyst with growing wall thickness/nodularity OR • Growing multilocular cyst (mean diameter) OR • Multilocular cyst with increased loculation or new/increased opacity (nodular, ground glass, or consolidation)	tissue sampling; and/or referral for further clinical evaluation
4B	Very Suspicious Estimated Population Prevalence: 2%	Slow growing solid or part solid nodule that demonstrates growth over multiple screening exams (see note 8)	Management depends on clinical evaluation, patient preference, and the probability of malignancy (see note 13)
4X	Estimated Population Prevalence: < 1%	Category 3 or 4 nodules with additional features or imaging findings that increase suspicion for lung cancer (see note 14)	
S	Significant or Potentially Significant Estimated Population Prevalence: 10%	Modifier: May add to category 0-4 for clinically significant or potentially clinically significant findings unrelated to lung cancer (see note 15)	As appropriate to the specific finding

Fig. 17.3 Lung-RADS to standardize LDCT lung examinations

**NOTES**

1. **Lung-RADS Category:** Each exam should be coded 0-4 based on the nodule with the highest degree of suspicion.
2. **Lung-RADS Management:** The timing of follow-up imaging is from the date of the exam being interpreted. For example, 12-month screening LDCT for Lung-RADS 2 is from the date of the current exam. Also note that management of 4A lesions follows a stepped approach based upon follow-up stability or decrease in size.
3. **Practice Audit Definitions:** A negative screen is defined as categories 1 and 2; a positive screen is defined as categories 3 and 4. A negative screen does not mean that an individual does not have lung cancer.
4. **Nodule Measurement:** To calculate nodule mean diameter, measure both the long and short axis to one decimal point in mm, and report mean nodule diameter to one decimal point. The long and short axis measurements may be in any plane to reflect the true size of the nodule. Volumes, if obtained, should be reported to the nearest whole number in mm<sup>3</sup>.
5. **Size Thresholds:** Apply to nodules at first detection and that enlarge, reaching a higher size category. When a nodule crosses a new size threshold for other Lung-RADS categories, even if not meeting the definition of growth, the nodule should be reclassified based on size and managed accordingly.
6. **Growth:** An increase in mean diameter size of > 1.5 mm (> 2 mm<sup>3</sup>) within a 12-month interval.
7. **Slow Growing Non Solid (Ground Glass) Nodules:** A ground glass nodule (GGN) that demonstrates growth over multiple screening exams but does not meet the > 1.5 mm threshold increase in size for any 12-month interval may be classified as a Lung-RADS 2 until the nodule meets findings criteria of another category, such as developing a solid component (then manage per part solid nodule criteria).
8. **Slow Growing Solid or Part Solid Nodules:** A solid or part-solid nodule that demonstrates growth over multiple screening exams but does not meet the > 1.5 mm threshold increase in size for any 12-month interval is suspicious and may be classified as a Lung-RADS 4B. Slow growing nodules may not have increased metabolic activity on PET/CT; therefore, biopsy, if feasible, or surgical evaluation may be the most appropriate management recommendation.
9. **Prior Exams:** If waiting on prior exams (either a prior screening or diagnostic CT), the Lung-RADS 0 category is temporary until the comparison study is available and a new Lung-RADS category is assigned.
10. **Suspected Infectious or Inflammatory Findings:**
  - a. Lung-RADS 0 with 1-3 month follow-up LDCT may be recommended for pulmonary findings suggesting an indeterminate infectious or inflammatory process. Such findings may include segmental or lobar consolidation, multiple new nodules (more than six), large solid nodules (≥ 8 mm) appearing in a short interval, and new nodules in certain clinical contexts (e.g. immunocompromised patient). At 1-3 month follow-up, a new Lung-RADS classification and management recommendation should be provided based on the most suspicious nodule.
  - b. New solid or part solid nodules with imaging features more concerning for malignancy than an infectious or inflammatory process meeting Lung-RADS 4B size criteria may be classified as such with appropriate diagnostic and/or clinical evaluation.
  - c. Some findings indicative of an infectious or infectious process may not warrant short-term follow-up (e.g. tree-in-bud nodules or new < 3 cm ground glass nodules). These nodules may be evaluated using existing size criteria with a Lung-RADS classification and management recommendation based on the most suspicious finding.
11. **Airway Nodules:**
  - a. Endotracheal or endobronchial abnormalities that are segmental or more proximal are classified as Lung-RADS 4A.
  - b. Subsegmental and/or multiple tubular endobronchial abnormalities favor an infectious process; if no underlying obstructive nodule is identified, these lesions may be classified as Lung-RADS 0 (likely infectious or inflammatory) or 2 (benign).
  - c. The presence of air in segmental or more proximal airway abnormalities often favors secretions; if no underlying soft tissue nodule is identified, these findings may be classified as Lung-RADS 2.
  - d. Segmental or more proximal airway nodules that persist on 3-month follow-up CT are upgraded to Lung-RADS 4B with management recommendation for further clinical evaluation (typically bronchoscopy).
12. **Atypical Pulmonary Cysts:**
  - a. Thin-walled Cyst: Unilocular with uniform wall thickness < 2 mm. Thin-walled cysts are considered benign and are not classified or managed in Lung-RADS.
  - b. Thick-walled Cyst: Unilocular with uniform wall thickness, asymmetric wall thickening, or nodular wall thickening ≥ 2 mm (cystic component is the dominant feature); manage as an atypical pulmonary cyst.
  - c. Multilocular Cyst: Thick or thin-walled cyst with internal septations. Manage as an atypical pulmonary cyst.
  - d. Cavitary Nodule: Wall thickening is the dominant feature; manage as a solid nodule (total mean diameter).
  - e. Cyst with an Associated Nodule: Any cyst with adjacent internal (endophytic) or external (exophytic) nodule (solid, part-solid, or ground glass). Management is based upon Lung-RADS criteria for the most concerning feature.
  - f. Growth: > 1.5 mm increase in nodule size (mean diameter), wall thickness, and/or size of the cystic component (mean diameter) occurring within a 12-month interval.
  - g. Fluid-containing cysts may represent an infectious process and are not classified in Lung-RADS unless other concerning features are identified.
  - h. Multiple cysts may indicate an alternative diagnosis such as Langerhans cell histiocytosis (LCH) or lymphangioleiomyomatosis (LAM) and are not classified in Lung-RADS unless other concerning features are identified. (Reference: [Seaman DM, Meyer CA, Gilman MD, McCormack FX. Diffuse Cystic Lung Disease at High-Resolution CT. AJR 2011;196: 1305-1311](#))
13. **Category 4B:** Management is predicated on clinical evaluation (comorbidities), patient preference, and risk of malignancy. Radiologists are encouraged to use the McWilliams, et al Assessment Tool when making recommendations (<https://brocku.ca/lung-cancer-screening-and-risk-prediction/risk-calculators/>).
14. **Category 4X:** Category 3 or 4 nodules with additional imaging findings that increase the suspicion of lung cancer, such as spiculation, lymphadenopathy, frank metastatic disease, a GGN that doubles in size in 1 year, etc. 4X is a distinct Lung-RADS category; X should not be used as a modifier.
15. **Exam Modifier:** An S modifier may be added to Lung-RADS categories 0-4 for clinically significant or potentially clinically significant findings unrelated to lung cancer.
  - a. Management should adhere to available ACR Incidental Findings management recommendations (<https://www.acr.org/Clinical-Resources/Incidental-Findings>). The ACR Lung Cancer Screening CT Incidental Findings Quick Reference Guide summarizes common findings and management (<https://www.acr.org/-/media/ACR/Files/Lung-Cancer-Screening-Resources/LCS-Incidental-Findings-Quick-Guide.pdf>).
  - b. Findings that are already known, and have been or are in the process of clinical evaluation DO NOT require an S-modifier. Any evidence of a concerning change in a known significant or potentially significant finding that is unexpected warrants renewed use of the S-modifier.
16. **Lung Cancer Diagnosis:** Once a patient is diagnosed with lung cancer, further management (including additional imaging such as PET/CT) may be performed for purposes of lung cancer staging; this is no longer considered screening.

**Abbreviations:** LDCT: low dose chest CT; GGN: ground glass nodule

Additional resources available at: <https://www.acr.org/Clinical-Resources/Reporting-and-Data-Systems/Lung-Rads>

**Fig. 17.3** (continued)

## Risk of Complications

Lung cancer screening results in a significant proportion of invasive procedures including surgery. These are done for both diagnosis and for treatment. In the IELCAP study, the rate of perioperative mortality was 0.5% [14]. However, the surgical mortality rate for major lung surgery across the US is 5% [19]. Major complications after a diagnostic procedure in the NLST occurred in 0.06% of patients with a positive LDCT that did not result in cancer, and 11.2% of those that did result in the diagnosis of cancer [15].

There is consensus among the different guidelines that lung cancer screening should be performed in centers with multidisciplinary lung cancer groups with expertise in minimally invasive diagnostic techniques (endobronchial ultrasound and navigational bronchoscopy), and in treatments with less morbidity, such as VATS, robotic surgery, or SBRT.

---

## Lung Cancer Screening: Eligibility Criteria

In December of 2013, the United States Preventive Services Task Force (USPSTF) published its first recommendation in favor of annual lung cancer screening in the US for adults aged 55–80 years who have a 30 pack-year smoking history and currently smoke or have quit within the past 15 years [27]. These selection criteria based on age and smoking history are similar to the entry criteria to the NLST, except that in the latter, the age range was between 55 and 74 years [15]. In an updated version in 2021, the USPSTF changed the age range and pack-year eligibility, recommending screening with LDCT in adults aged 50–80 years who have a 20 pack-year history of smoking and currently smoke or have quit within 15 years [28].

Retrospective studies have shown that applying the NLST entry criteria to other lung cancer screening cohorts would have rendered up to 40% of patients who were diagnosed with lung cancer ineligible for screening [29]. Retrospective analyses of lung cancer screening cohorts suggest that

other risk factors for lung cancer may play a role in selecting the right candidates for screening. For example, the presence of emphysema on the baseline LDCT in a screening program is associated with a two to threefold increased risk of a lung cancer diagnosis [29, 30]. Some suggest that entry criteria should be different for the initial screenings than for subsequent annual screenings. More flexible entry criteria in the first screening may allow for better risk prediction for subsequent annual screening using data obtained on the baseline LDCT (e.g., radiologic emphysema) [29]. The USPSTF acknowledges that other risk factors for lung cancer may play an important role in identifying high risk individuals who can benefit from lung cancer screening but recommends determining risk by age and smoking history because of lack of evidence that risk prediction models would improve outcomes [28].

---

## Lung Cancer Screening Around the World

Almost 10 years after the publication of the initial favorable recommendations, less than 10% of eligible individuals each year in the US undergo lung cancer screening. In Europe, no official recommendation for screening had been made up until 2022 when the EU published an official report in which it recommends, “extending population-based screening programs to lung and prostate cancer and ensure preparedness for the introduction of new methods” [31]. Croatia is the only European country that has implemented a nation-wide lung cancer screening program [32]. Other countries in the EU are currently analyzing benefits and risks associated with the implementation of nationwide programs or are designing pilot studies to determine the feasibility of nationwide population-based lung cancer screening programs [33].

Japan was one of the first countries in the world to conduct research on the use of LDCT for lung cancer screening. In 1993, the Anti-lung Cancer Association, a for profit organization supported by a government grant, conducted the first trial exploring LDCT as an alternative to chest-



X-ray (CXR) for lung cancer screening [34]. Results showed that screening with LDCT is superior to CXR and can detect stage I lung cancer in more than 90% of high-risk individuals diagnosed with the disease [34]. Since, there have been numerous studies confirming the benefits of lung cancer screening using LDCT [5]. By 2009, more than 125,000 individuals had been screened in Japan, with cancer detection rates between 0.15% and 0.33% and stage I diagnoses between 70% and 79% [5]. By 2015, there were 1347 physicians, and 854 centers, certified by the Japanese Accreditation Council for Lung Cancer CT Screening to do screening using LDCT [5]. Despite Japan's pioneering efforts in conducting research and in implementing lung cancer screening, few studies from this country, if any, are included in the discussions about implementation of lung cancer screening programs in Western countries.

Screening with LDCT also started in China many years before the rest of the world. Initial efforts in the early 90s were followed by international collaborations with the groups from I-ELCAP and NELSON [5]. There are currently large ongoing trials exploring LDCT for screening not only lung cancer, but also COPD and cardiovascular diseases [27]. One of these studies, the China National Cancer Early Screening Trial (CHANCES), will randomize 78,500 individuals to explore different aspects of lung and colorectal cancer screening: biomarkers, screening intervals, and mortality rates [5].

South Korea has ongoing pilot programs to assess the feasibility to implement population-based lung cancer screening with LDCT [5]. Australia's government is engaging and consulting key stakeholders to seek input on key design elements of a potential population based, nationwide, lung cancer screening program [35].

---

## Incidental Lung Nodules

Since the publication of the first studies on lung cancer screening using LDCT, the number of lung nodules on CT reports has increased notably. One study suggests that most of the increase

is due to more awareness of radiologists, and perhaps also due to improvements in technology [36]. Using natural language processing algorithms to scan free text on radiology reports, researchers analyzed trends in lung nodule detection over a period of 7 years. The study was conducted in a large integrated healthcare system prior to the implementation of lung cancer screening programs, but more than a decade after positive results of several lung cancer screening studies were published. Extrapolating data to the census of the United States, 1.57 million new lung nodules were reported in 2010 [36], more than ten times prior estimates of the prevalence of incidental lung nodules, previously referred to as solitary pulmonary nodules [37]. Furthermore, the incidence of lung nodules detected increased steadily throughout the study duration, from 2006 to 2012 [12]. Approximately 5% of individuals with a new lung nodule were diagnosed with lung cancer [36]. Despite the increase in the number of nodules detected, the incidence of lung cancer diagnosis did not increase in this group of individuals, suggesting the main reasons for the increases in lung nodule incidence are greater awareness of the radiologists and improvements in CT technology. This translates into a higher risk of unnecessary invasive diagnostic and therapeutic procedures. Another concern raised by several studies is an exceedingly high proportion (up to 60%) of patients with lung nodules detected outside of lung cancer screening programs that are lost to follow-up [38]. For this reason, some centers are developing programs aimed at tracking incidental lung nodules and other findings. In a large healthcare system in southern United States, researchers analyzed the diagnosis of lung cancer through three different pathways: a lung cancer screening program (5659 participants between 2015 and 2021), an incidental lung nodule program (15,461 patients between 2015 and 2021), and a multidisciplinary thoracic oncology program (1766 patients not belonging to any of the other two groups, between 2015 and 2020) [39]. The number of lung cancers diagnosed in each pathway was 156 (3%), 772 (5%), and 1139 (65%), respectively. Moreover, the proportion of patients diagnosed in stage I or II was

61%, 61%, and 44%, respectively. In comparison to the lung cancer screening pathway, there were more underserved patients belonging to minorities or uninsured in the lung nodule program. Several reports suggest that lung cancer screening using LDCT is being implemented more widely among more affluent and predominantly white individuals. Thus, a program that detects nodules incidentally may be an opportunity, not only to identify more individuals with lung cancer in early stages, but also to overcome the racial and economic inequalities seen with screening.

---

## Management of Lung Nodules

Guidelines for the management of nodules published by several professional societies based on expert consensus have been evolving over the last decade and are being updated frequently. Some have been developed specifically for nodules detected in the course lung cancer screening (Lung-RADS<sup>+</sup>, NCCN), others for nodules detected incidentally (Fleischner Society), and some independent of the detection pathway (American College of Chest Physicians and British Thoracic Society) [18, 40–43]. In general, most recommendations are based on expert reviews and are evolving so quickly that a comprehensive analysis is beyond the scope of this text. The main objectives of guidelines must be to reduce unnecessary invasive procedures and to minimize risks for patients while optimizing the chances of diagnosing the disease in early stages when cure is still feasible with surgery. As mentioned previously, in the IELCAP trial, 11% of surgical procedures were performed on nodules that had benign histology. In NLST, 25% of surgical procedures were performed on benign nodules [44].

Recommendations of all guidelines are based on the pretest probability a nodule has of being cancer, with minor differences in thresholds of risk chosen for immediate diagnostic procedures or observation. In an analysis of two Canadian cohorts of individuals with lung nodules, one from a lung cancer screening study (PanCan), and the other from a chemoprevention study (British Columbia Cancer Agency or BCCA),

researchers tested and validated parameters potentially associated with lung cancer [44]. Over 1800 individuals from the PanCan study, and 1090 from the BCCA study were included with prevalence rates of lung cancer of 5.5% and 3.7%, respectively. In a univariate analysis, size, type (non-solid, part-solid, or solid), location, and the number of nodules were significant predictors of lung cancer. In a parsimonious model, the diagnosis of cancer was associated with female sex, increasing size of the nodule, location of the nodule in the upper lobes, and spiculation of the borders. Additional parameters associated with lung cancer in a full model were older age, family history of cancer, emphysema, lower nodule count, and part solid as compared with solid nodules. Non-solid nodules (ground glass opacities) had a reduced risk when compared to solid nodules [44].

---

## Lung Cancer Screening and Incidental Findings

A high proportion of LDCTs done in the lung cancer screening setting detect incidental findings [45]. The most common are cardiovascular (coronary calcifications and aortic disorders) and respiratory (emphysema and reticular opacities) [45, 46]. Other less common findings that may have an impact on patients undergoing lung cancer screening include lymphadenopathy, thyroid nodules, and extrapulmonary malignancies [45, 47]. Some incidental findings have been found to have a major impact on lung cancer screening itself, especially emphysema, and lymphadenopathy [45, 47, 48]. Although the prevalence of mediastinal lymphadenopathy is low (<2%), in a retrospective analysis of NLST, individuals with enlarged lymph nodes had a significantly higher incidence of lung cancer as compared to those without enlarged nodes (17.1% vs. 3.9%). Furthermore, the presence of enlarged lymph nodes was associated with a later stage at diagnosis, increased number of deaths, and reduced survival times [45].

The prevalence of emphysema observed on LDCT in the context of lung cancer screening has been reported to range between 28% and 44%

[47–49]. For decades it has been known that patients with chronic obstructive pulmonary disease (COPD) have a higher risk of lung cancer [50, 51]. In 2006, an analysis of a lung cancer screening cohort was first to show that emphysema detected qualitatively on the LDCT was significantly associated with a 2.5-fold greater risk of lung cancer [48]. When both emphysemas, detected on LDCT, and COPD, diagnosed by spirometry, were included in a multivariate analysis adjusted for age, sex, and smoking history, only emphysema remained as an independent predictor of risk of lung cancer. These findings have been confirmed by other studies [30, 52–55]. Most retrospective analyses of lung cancer screening cohorts have found a significant association between emphysema and the risk of diagnosis of lung cancer, with one study also reporting an increased risk of death from lung cancer [52].

How incidental findings may impact outcomes in lung cancer screening is yet to be determined. There is the risk of harm caused by detecting abnormalities that may lead to unnecessary invasive diagnostic procedures or treatments, but there are potential benefits beyond early treatment of potentially severe diseases. For example, as mentioned previously, one study has suggested that the presence of emphysema on a baseline lung cancer screening LDCT may have a beneficial impact on the selection of high-risk individuals who should undergo subsequent annual screening [29]. Other possible benefits include early diagnosis of diseases other than lung cancer, such as coronary artery diseases or other malignancies.

## References

1. <https://ourworldindata.org/causes-of-death>. Accessed 30 Jan 2022.
2. <https://ourworldindata.org/grapher/lung-cancer-deaths-per-100000-by-sex-1950-2002>. Accessed 30 Jan 2022.
3. [https://seer.cancer.gov/explorer/application.html?site=47&data\\_type=1&graph\\_type=2&compare\\_By=sex&chk\\_sex\\_3=3&chk\\_sex\\_2=2&rate\\_type=2&race=1&age\\_range=1&stage=101&advopt\\_precision=1&advopt\\_show\\_ci=on&advopt\\_display=2](https://seer.cancer.gov/explorer/application.html?site=47&data_type=1&graph_type=2&compare_By=sex&chk_sex_3=3&chk_sex_2=2&rate_type=2&race=1&age_range=1&stage=101&advopt_precision=1&advopt_show_ci=on&advopt_display=2). Accessed 30 Jan 2022.
4. Barta JA, Powell CA, Wisnivesky JP. Global epidemiology of lung cancer. *Ann Glob Health*. 2019;85:8.
5. Triphuridat N, Henschke C. Landscape on CT screening for lung cancer in Asia. *Lung Cancer Targets Ther*. 2019;10:107–24.
6. <https://seer.cancer.gov/statfacts/html/lungb.html>. Accessed 30 Jan 2022.
7. Flores R, Patel P, Alpert N, Pyenson B, Taioli E. Association of stage shift and population mortality among patients with non-small cell lung cancer. *JAMA Netw Open*. 2021;4(12):e2137508. <https://doi.org/10.1001/jamanetworkopen.2021.37508>.
8. Berlin NI, Buncher CR, Fontana RS, Frost JK, Melamed MR. The National cancer institute cooperative early lung cancer detection program. Results of the initial screen (prevalence). Early lung cancer detection: introduction. *Am Rev Respir Dis*. 1984;130:545–9.
9. Flehinger BJ, Kimmel M, Polyak T, Melamed MR. Screening for lung cancer. The Mayo Lung Project revisited. *Cancer*. 1993;72:1573–80.
10. Strauss GM, Gleason RE, Sugarbaker DJ, Caro JJ. Screening for lung cancer. Another look; a different view. *Chest*. 1997;111:754–68.
11. Marcus PM, Bergstrahl EJ, Zweig MH, et al. Extended lung cancer incidence follow-up in the mayo lung project and overdiagnosis. *J Natl Cancer Inst*. 2006;98:748.
12. Henschke CI, McCauley DI, Yankelevitz DF, Naidich DP, McGuinness G, Miettinen OS, et al. Early lung cancer action project: overall design and findings from baseline screening. *Lancet*. 1999;354(9173):99–105.
13. Edge SB, Compton CC. The American joint committee on cancer: the 7th edition of the AJCC cancer staging manual and the future of TNM. *Ann Surg Oncol*. 2010;17(6):1471–4. <https://doi.org/10.1245/s10434-010-0985-4>.
14. International Early Lung Cancer Action Program Investigators, Henschke CI, Yankelevitz DF, Libby DM, Pasmantier MW, Smith JP, Miettinen OS. Survival of patients with stage I lung cancer detected on CT screening. *N Engl J Med*. 2006;355(17):1763–71.
15. Aberle DR, Adams AM, Berg CD, Black WC, Clapp JD, Fagerstrom RM, Gareen IF, Gatsonis C, Marcus PM, Sicks JD. Reduced lung-cancer mortality with low-dose computed tomographic screening. *N Engl J Med*. 2011;365(5):395–409.
16. de Koning HJ, van der Aalst CM, de Jong PA, Scholten ET, Nackaerts K, Heuvelmans MA, Lammers J-WJ, Weenink C, Yousaf-Khan U, Horeweg N, van't Westeinde S, Prokop M, Mali WP, Hoesein FAAM, van Ooijen PMA, Aerts JGJV, den Bakker MA, Thunnissen E, Verschakelen J, Vliegenthart R, Walter JE, ten Haaf K, Groen HJM, Oudkerk M. Reduced lung-cancer mortality with volume CT screening in a randomized trial. *N Engl J Med*. 2020;382(6):503–13.
17. Pastorino U, Silva M, Sestini S, Sabia F, Boeri M, Cantarutti A, Sverzellati N, Sozzi G, Corrao G, Marchiano A. Prolonged lung cancer screening

- reduced 10-year mortality in the MILD trial: new confirmation of lung cancer screening efficacy. *Ann Oncol.* 2019;30:1–8.
18. Kazerooni EA, Baum S, Eapen G, Ettinger D, Hou L, Jackman D. Lung cancer screening, version 32018: clinical practice guidelines in oncology. *J Natl Compr Canc Netw.* 2018;16(4):412–41. <https://doi.org/10.6004/jnccn.2018.0020>.
  19. Hammer MM, Hatabu H. Subsolid pulmonary nodules: controversy and perspective. *Eur J Radiol Open.* 2020;7:100267. <https://doi.org/10.1016/j.ejro.2020.100267>.
  20. Travis WD, Brambilla E, Noguchi M, et al. International association for the study of lung cancer/American thoracic society/European respiratory society international multidisciplinary classification of lung adenocarcinoma. *J Thorac Oncol.* 2011;6:244–85.
  21. Yoshizawa A, Motoi N, Riely GJ, Sima CS, Gerald WL, Kris MG, Park BJ, Rusch VW, Travis WD. Impact of proposed IASLC/ATS/ERS classification of lung adenocarcinoma: prognostic subgroups and implications for further revision of staging based on analysis of 514 stage I cases. *Mod Pathol.* 2011;24:653–64.
  22. Mesa-Guzman M, Gonzalez J, Alcaide AB, Berto J, de -Torres JP, Campo A, Seijoc LM, Ocon MM, Pueyo JC, Bastarrika G, Lozano MD, Pío R, Montuenga LM, García-Granero M, Zulueta J. Surgical outcomes in a lung cancer-screening program using low dose computed tomography. *Arch Bronconeumol.* 2021;57(2):101–6.
  23. Vonder M, Dorrius MD, Vliegenthart R. Latest CT technologies in lung cancer screening: protocols and radiation dose reduction. *Transl Lung Cancer Res.* 2021;10(2):1154–64. <https://doi.org/10.21037/tlcr-20-808>.
  24. Brenner DJ. Radiation risks potentially associated with low-dose CT screening of adult smokers for lung cancer. *Radiology.* 2004;231:440–5.
  25. Mascalchi M, Belli G, Zappa M, et al. Risk-benefit analysis of X-ray exposure associated with lung cancer screening in the Italung-CT trial. *AJR Am J Roentgenol.* 2006;187:421–9.
  26. Rampinelli C, De Marco P, Origgi D, et al. Exposure to low dose computed tomography for lung cancer screening and risk of cancer: secondary analysis of trial data and risk-benefit analysis. *BMJ.* 2017;356:j347.
  27. Moyer VA, U.S. preventive services task force. Screening for lung cancer: U.S. preventive services task force recommendation statement. *Ann Intern Med.* 2014;160:330–8.
  28. Krist AH, Davidson KW, Mangione CM, Barry MJ, Cabana M, Caughey AB, Davis EM, Donahue KE, Doubeni CA, Kubik M, Landefeld CS. Screening for lung cancer: US preventive services task force recommendation statement. *JAMA.* 2021;325(10):962–70. <https://doi.org/10.1001/jama.2021.1117>.
  29. Sanchez-Salcedo P, Wilson DO, de Torres JP, Weissfeld JL, Berto J, Campo A, Alcaide AB, Pueyo J, Bastarrika G, Seijo LM, Pajares MJ, Pio R, Montuenga LM, Zulueta JJ. Improving selection criteria for lung cancer screening. The potential role of emphysema. *Am J Respir Crit Care Med.* 2015;191(8):924–31. <https://doi.org/10.1164/rccm.201410-1848OC>.
  30. Wilson DO, Weissfeld JL, Balkan A, Schragin JG, Fuhrman CR, Fisher SN, Wilson J, Leader JK, Siegfried JM, Shapiro SD, Sciruba FC. Association of radiographic emphysema and airflow obstruction with lung cancer. *Am J Respir Crit Care Med.* 2008;178(7):738–44. Epub 2008 Jun 19. PMID: 18565949; PMCID: PMC2556456. <https://doi.org/10.1164/rccm.200803-435OC>.
  31. [https://ec.europa.eu/info/news/improving-citizens-participation-cancer-screening-programmes-and-extending-them-more-types-cancer-will-help-saving-lives-eu-chief-scientific-advisor-recommend-2022-mar-02\\_en](https://ec.europa.eu/info/news/improving-citizens-participation-cancer-screening-programmes-and-extending-them-more-types-cancer-will-help-saving-lives-eu-chief-scientific-advisor-recommend-2022-mar-02_en). Accessed 20 Feb 2022.
  32. <https://echalliance.com/croatia-first-to-introduce-early-screening-for-lung-cancer/#:~:text=The%20Croatian%20Health%20Ministry%20has,for%20early%20lung%20cancer%20detection>. Accessed 22 Feb 2022.
  33. van Meerbeeck JP, Franck C. Lung cancer screening in Europe: where are we in 2021? *Transl Lung Cancer Res.* 2021;10(5):2407–17.
  34. Kaneko M, Eguchi K, Ohmatsu H, et al. Peripheral lung cancer: screening and detection with low-dose spiral CT versus radiography. *Radiology.* 1996;201(3):798–802.
  35. <https://www.canceraustralia.gov.au/about-us/lung-cancer-screening>.
  36. Gould MK, Tang T, Liu I-LA, Lee J, Zheng C, Danforth KN, Kosco AE, Di Fiore JL, Suh DE. Recent trends in the identification of incidental pulmonary nodules. *Am J Respir Crit Care Med.* 2015;192:1208–14.
  37. Ost D, Fein AM, Feinsilver SH. Clinical practice. The solitary pulmonary nodule. *N Engl J Med.* 2003;348(25):2535–42.
  38. Pyenson BS, Bazell CM, Bellanich MJ, Caplen MA, Zulueta JJ. No apparent workup for most new indeterminate pulmonary nodules in US commercially-insured patients. *J Health Econ.* 2019;6(3):118–29.
  39. Osarogiagbon RU, Liao W, Faris NR, Meadows-Taylor M, Fehnel C. Lung cancer diagnosed through screening, lung nodule, and neither program: a prospective observational study of the detecting early lung cancer (DELUGE) in the Mississippi Delta Cohort. *J Clin Oncol.* 2022;40(19):2094–105. <https://doi.org/10.1200/JCO.21.02496>.
  40. American College of Radiology Committee on Lung-RADS®. Lung-RADS Assessment Categories version 1.1. <https://www.acr.org/-/media/ACR/Files/RADS/Lung-RADS/LungRADSAssessmentCategoriesv1-1.pdf>. Accessed 30 Apr 2022.
  41. Gould MK, Donington J, Lynch WR, Mazzone PJ, Midthun DE, Naidich DP, Wiener RS. Evaluation of individuals with pulmonary nodules: when is it lung cancer? *Chest.* 2013;143(5 Suppl):e93S–e120S.
  42. MacMahon H, Naidich DP, Goo JM, Lee KS, Leung ANC, Mayo JR, Mehta AC, Ohno Y, Powell CA, Prokop M, Rubin GD, Schaefer-Prokop CM, Travis

- WD, van Schil PE, Bankier AA. Guidelines for management of incidental pulmonary nodules detected on CT images: from the Fleischner Society 2017. *Radiology*. 2017;284:228–43.
43. Baldwin DR, Callister MEJ, Guideline Development Group. The British Thoracic Society guidelines on the investigation and management of pulmonary nodules. *Thorax*. 2015;70:794–8. <https://doi.org/10.1136/thoraxjnl-2015-207221>.
  44. McWilliams A, Tammemagi MC, Mayo JR, Roberts H, Liu G, Soghrati K, Yasufuku K, Martel S, Laberge F, Gingras M, Atkar-Khattra S, Berg CD, Evans K, Finley R, Yee J, English J, Nasute P, Goffin J, Puksa S, Stewart L, Tsai S, Johnston MR, Manos D, Nicholas G, Goss GD, Seely JM, Amjadi K, Tremblay A, Burrows P, MacEachern P, Bhatia R, Tsao M-S, Lam S. Probability of cancer in pulmonary nodules detected on first screening CT. *N Engl J Med*. 2013;369(10):910–9.
  45. McLoud TC. Incidental lymphadenopathy at CT lung cancer screening. *Radiology*. 2022;302:693–4.
  46. Pinsky PF, Lynch DA, Gierada DS. Incidental findings on low-dose CT scan lung cancer screenings and deaths from respiratory diseases. *Chest*. 2022;161(4):1092–110.
  47. Chalian H, McAdams HP, Lee Y, et al. Mediastinal lymphadenopathy in the National Lung Screening Trial (NLST) is associated with interval lung cancer. *Radiology*. 2022;302(3):684–92.
  48. de Torres JP, Bastarrika G, Wisnivesky JP, Alcaide AB, Campo A, Seijo LM, Pueyo JC, Villanueva A, Lozano MD, Montes U, Montuenga L, Zulueta JJ. Assessing the relationship between lung cancer risk and emphysema detected on low-dose CT of the chest. *Chest*. 2007;132(6):1932–8. <https://doi.org/10.1378/chest.07-1490>. PMID: 18079226.
  49. Wilson DO, Weissfeld JL, Balkan A, Schragin JG, Fuhrman CR, Fisher SN, Wilson J, Leader JK, Siegfried JM, Shapiro SD, Sciurba FC. Association of Radiographic Emphysema and Airflow Obstruction with Lung Cancer. *Am J Respir Crit Care Med*. 2008;178:738–44.
  50. Skillrud DM, Offord KP, Miller RD. Higher risk of lung cancer in chronic obstructive pulmonary disease. A prospective, matched, controlled study. *Ann Intern Med*. 1986;105:503–7.
  51. Tockman MS, Anthonisen NR, Wright EC, Donithan MG. Airways obstruction and the risk for lung cancer. *Ann Intern Med*. 1987;106:512–8.
  52. Zulueta JJ, Wisnivesky JP, Henschke CI, et al. Emphysema scores predict death from COPD and lung cancer. *Chest*. 2012;141(5):1216–23. <https://doi.org/10.1378/chest.11-0101>.
  53. Maldonado F, Bartholmai BJ, Swensen SJ, et al. Are airflow obstruction and radiographic evidence of emphysema risk factors for lung cancer? A nested case-control study using quantitative emphysema analysis. *Chest*. 2010;138:1295–302.
  54. Kishi K, Gurney JW, Schroeder DR, et al. The correlation of emphysema or airway obstruction with the risk of lung cancer: a matched case-controlled study. *Eur Respir J*. 2002;19:1093–8.
  55. Labaki WW, et al. Quantitative emphysema on low-dose CT imaging of the chest and risk of lung cancer and airflow obstruction: an analysis of the national lung screening trial. *Chest*. 2021;159:1812–20, ISSN 0012-3692. <https://doi.org/10.1016/j.chest.2020.12.004>.





# Tissue Acquisition in Patients with Suspected Lung Cancer: Techniques Available and Sampling Adequacy for Molecular Testing

Semra Bilaceroglu

## Introduction

Conventional bronchoscopic methods used in the diagnosis and/or staging of lung cancer are endobronchial biopsy, transbronchial biopsy (TBB), brushing, bronchoalveolar lavage (BAL) and bronchial washing. Besides these conventional bronchoscopic methods mediastinoscopy, endobronchial ultrasound-guided transbronchial needle aspiration (EBUS-TBNA), endoscopic ultrasound-guided fine needle aspiration (EUS-FNA), conventional TBNA, radial-probe EBUS (r-EBUS)-guided procedures, navigational bronchoscopy-guided procedures, imaging-guided fine needle aspiration (FNA) or core needle biopsy (CNB), pleural procedures such as thoracentesis, pleural biopsy and medical thoracoscopy, and sputum cytology have also been used for diagnosing and/or staging lung cancer. Of the above-mentioned modalities mediastinoscopy, EBUS-TBNA, EUS-FNA, conventional TBNA, r-EBUS-guided procedures, navigational bronchoscopy-guided procedures, imaging-guided FNA or CNB, and medical thoracoscopy have been increasingly used minimally invasive tissue sampling modalities in the clinical practice for the last two decades. Furthermore, they can obtain adequate cellular material for pathologic diagnosis and molecu-

lar testing besides having low complication rates. Within the multidisciplinary team approach to identify the best evidence-based treatment plan for lung cancer care, these minimally invasive procedures have provided rapid and safe acquisition of tissue used for the diagnosis, staging, and molecular testing. The continuous evolution in diagnosis, staging and treatment has led to improved survival and quality of life in lung cancer. Education, training and technological advancements will narrow the gap in the pertinent clinical practice that still exists between academic and community hospitals [1–4].

Diagnosis and staging of lung cancer should be managed promptly and accurately by an efficient process minimizing procedures before treatment. The possibility of the ideal tissue acquisition for simultaneous diagnosis, tumor classification, molecular testing and staging by the initial procedure depends on the individual patient and the need for sufficient and appropriate tissue for current and future cytological, immunohistochemical, and molecular studies [2–4].

## History and Historical Perspective

The most frequently encountered histologic subtypes of lung cancer -*the leading cause of cancer deaths worldwide*- are adenocarcinoma and squamous cell carcinoma as the main epithelial-derived non-small cell lung cancer (NSCLC), and small cell lung cancer (SCLC) as the major

S. Bilaceroglu (✉)

Izmir Faculty of Medicine, Dr. Suat Seren Training and Research Hospital for Thoracic Medicine and Surgery, University of Health Sciences, Izmir, Turkey  
e-mail: [semra.bilaceroglu@sbu.edu.tr](mailto:semra.bilaceroglu@sbu.edu.tr)

high-grade neuroendocrine carcinoma. As most lung cancers are diagnosed at advanced stages, the differentiation of NSCLC and SCLC led to palliative management of lung cancer until the early 2000s. Thus, the diagnostic approach was focused on tissue acquisition by obtaining small samples to determine histopathological character of the tumor combined with imaging studies to perform a thorough tumor, node, metastasis (TNM) staging. From 1980s to early 2000s, the development in anti-cancer management (mainly the introduction of platinum-doublets as the main palliative modality for stage IV NSCLC) was driven by *NSCLC histology not otherwise specified* (NOS) and advanced TNM staging [5].

With the introduction of new cytotoxic (pemetrexed) and biological agents (bevacizumab) having increasing efficacy or toxicity depending on histology, respectively, significance of defining NSCLC subtypes and insufficiency of NSCLC NOS was recognized in the early 2000s [6, 7]. To this end, histochemical and immunohistochemical studies were used more widely to differentiate adenocarcinoma and squamous cell carcinoma in cytologic and small biopsy specimens more consistently. To define the minimally required immunohistochemical markers for differentiating squamous cell carcinoma and adenocarcinoma in previously NSCLC NOS-classified small samples, an international group of experts in medical oncology, pulmonology, pathology, and thoracic surgery developed the International Association for the Study of Lung Cancer/American Thoracic Society/European Respiratory Society (IASLC/ATS/ERS) lung adenocarcinoma classification in 2011 [8].

This change in goals and requirements for the acquisition of tumor tissue continues to reflect on lung cancer care and drug development (e.g. immune-checkpoint inhibitors of programmed death-ligand-1 for advanced squamous cell lung cancer) [9]. In parallel with the novel anti-cancer therapies targeting weaknesses in genomic basis of cancer, the importance of adequate tissue in diagnosing and treating NSCLC has increased considerably in the last 10 years.

Among the heterogeneous consequences of cancers (invasion and metastasis, induction angiogenesis, replicative immortality, resistance to cell

death, reprogramming of energy metabolism, evasion of immune surveillance, circumvention of growth suppressors, and sustained proliferative signaling), particularly sustained proliferative signaling is frequent in some NSCLC subgroups as it generally originates from genomic mutations in key oncogenes which encode for activated tyrosine kinases [2, 10]. Three major genomic events leading to the direct activation of tyrosine kinases in NSCLC are overexpression or amplification, mutation, and rearrangement with partner genes. The most prevalent oncogenes that are amplified, mutated, or rearranged in NSCLCs are KRAS, EGFR, ALK, ROS1, MET, ERBB2, BRAF in adenocarcinomas, and FGFR1, FGFR2/3/4, PI3KCA and DDR2 in squamous cell carcinomas [11–13]. The most prevalent and clinically applicable driver oncogenes in NSCLC care are EGFR mutations, and ALK mutations occurring through gene rearrangements [14–19].

The requirement for sufficient and high-quality tissue sample for diagnosis, staging and treatment selection has increased in parallel with the growing minimally-invasive procedures for tissue acquisition. With the aim of standardizing the use of tissue for molecular diagnosis in lung cancer, molecular testing guidelines was published by the IASLC, Association for Molecular Pathology (AMP), and College of American Pathologists (CAP) in 2013 for selecting lung cancer patients to be treated with EGFR and ALK tyrosine kinase inhibitors [20]. Although rapid single gene assays are used currently as their use is prioritized in the guidelines, owing to the technological advances, comprehensive molecular profiling by next generation sequencing (NGS) can be possible in routine clinical practice [21, 22].

---

## Minimally Invasive Procedures

### Mediastinoscopy

Mediastinoscopy is a surgical procedure performed under general anesthesia for exploring the superior mediastinum between the sternal notch and subcarinal area but can occasionally access the level of main bronchi [23].

As performed during EBUS-TBNA or EUS-FNA, the contralateral lymph nodes are explored first to rule out N3 disease and then exploration proceeds in a systematic way. Usually, the last to sample is the subcarinal lymph nodes as controlling bronchial artery and perinodal bleeding can be problematic. Cervical mediastinoscopy is conventionally considered to have a specificity and a positive predictive value of 100% as all lymph nodes are resected for histologic examination. However, the positive results are not corroborated by other methods. The median sensitivity and negative predictive value of conventional mediastinoscopy are reported as 78% and 91%, respectively [1–3] while video-mediastinoscopy has a median sensitivity and negative predictive value of 89% and 92%, respectively. Complications are rarely encountered (3%); serious bleeding requiring mediastinotomy occurs occasionally (0.4%) [24, 25], and mortality is low (0.5%) [26, 27].

*Video-assisted mediastoscopic lymphadenectomy* (VAMLA) and *transcervical extended mediastinal lymphadenectomy* (TEMLA) –two technical variations of mediastinoscopy for systematic resection of mediastinal lymph nodes—are not widely used although they have exceptional diagnostic performances. Both are performed through an incision similar to that used for mediastinoscopy to remove the lymph nodes systematically. In VAMLA, first the subcarinal and right inferior paratracheal lymph nodes are removed en bloc, and then the left inferior paratracheal lymph nodes [28]. In TEMLA, mediastinal lymphadenectomy from the supraclavicular to the paraesophageal lymph nodes is performed using a sternal retractor to elevate the sternum. For removing the subaortic and para-aortic lymph nodes, a thoracoscope is used [29]. The sensitivity of VAMLA is about 100% while the sensitivity of TEMLA is higher than mediastinoscopy and EBUS-TBNA [30, 31]. However, VAMLA and TEMLA currently are not performed in the routine mediastinal staging of lung cancer owing to their invasiveness and high complication risks when compared with EBUS-TBNA and EUS-FNA that have comparable accuracy but less invasiveness [32]. These two

mediastinoscopic techniques are not included in the American College of Chest Physicians (ACCP) and European Society of Thoracic Surgeons (ESTS) Guidelines for staging lung cancer [1] but their use in clinical trials is encouraged [33].

### **Convex-Probe Endobronchial Ultrasound-Guided Transbronchial Needle Aspiration (EBUS-TBNA)**

EBUS-TBNA –with lower morbidity and mortality, and higher cost-effectiveness than mediastinoscopy—have become the procedure of choice for diagnosis and staging of lung cancer [1, 34, 35]. Complications occur rarely; the rate of pneumothorax is 0.07–0.2% [36]. EBUS-TBNA is performed usually as an outpatient procedure by pulmonologists, interventional pulmonologists, or thoracic surgeons in a procedure or operating room, under moderate sedation or general anesthesia depending on the local practices, and by using a dedicated flexible bronchoscope with an ultrasound at the distal end. EBUS bronchoscope is advanced from the mouth, a laryngeal mask or an endotracheal tube to the distal trachea and then the US probe is apposed to the airway wall to reveal contiguous structures. The lymph node station is identified based on anatomic landmarks and a 21- or 22-gauge needle is pushed through the airway wall into the target lesion under real-time visualization on US [2].

There is no consensus on the number of needle passes into each lesion but three passes and 15 excursions for each pass can usually obtain diagnostic material in more than 95% of cases [37]. The needle is withdrawn after each pass and some of the obtained sample can be placed and smeared on slides, and the rest of the sample can be placed in a preservative solution for cytologic analysis and cell block preparation, or the whole sample can be placed in the preservative solution.

2R and 2L (upper paratracheal), 4R and 4L (lower paratracheal), 7 (subcarinal), 10R and 10L (hilar), 11R and 11L (interlobar) and occasionally 12R and 12L (lobar) lymph node stations as

well as paratracheal and parabronchial masses next to the airway can be accessed by EBUS-TBNA [2]. Access to station 5 (subaortic) through a transpulmonary artery route [38] has been reported however it is not performed routinely and widely.

### **Endoscopic Ultrasound Guided Fine Needle Aspiration (EUS-FNA)**

EUS is used to guide transesophageal needle aspiration, another real-time ultrasound procedure. Posterior mediastinal sampling through the esophageal wall can be performed by EUS-FNA. The inferior pulmonary ligament (level 9), paraesophageal (level 8), subcarinal (level 7), and left paratracheal (level 4L) lymph nodes can be accessed and sampled by EUS-FNA whereas anterolateral paratracheal (levels 2R, 2L, and 4R) lymph nodes are difficult to access and sample by EUS-FNA. As with EBUS-TBNA, EUS-FNA has a very low complication rate [39, 40]. EUS-FNA is unique in that it can access extramediastinal locations: the left lobe and a significant part of the right lobe of the liver as well as the left adrenal gland [2, 41].

With its above-mentioned strengths and weaknesses, EUS-FNA is complementary to EBUS-TBNA in diagnosing and staging lung cancer. The combination of EUS-FNA and EBUS-TBNA has a higher diagnostic performance (pooled sensitivity: 91%, pooled specificity: 100%) than each technique alone [1–3, 42].

### **Conventional Transbronchial Needle Aspiration (TBNA)**

The diagnosis and involvement of hilar and mediastinal lymph nodes in lung cancer can be determined cytologically or histologically by conventional transbronchial needle aspiration which is a safe and economical bronchoscopic method. However, as a “blind” method with no imaging guidance used during bronchoscopy, it can be adequate in staging if there are 1.5–2-cm or larger lymph nodes close to carina (paratra-

cheal and subcarinal) in the presence of a high pretest clinical probability of malignancy. Furthermore, as the performance of conventional TBNA in staging depends considerably on the prevalence of mediastinal involvement and operator skills, its accuracy varies widely. This method has a high false-negative rate and thus, cannot be considered as a definitive mediastinal staging technique in routine practice [43, 44].

### **Radial-Probe EBUS-Guided Procedures**

There are two types of r-EBUS: miniaturized and ultraminiaturized versions for the assessment of central airway wall and contiguous structures [45], and for the detection of peripheral pulmonary nodules/masses [46], respectively.

In the central airways, miniaturized r-EBUS is used to guide conventional TBNA. However, it is not a real-time guidance as in EBUS-TBNA. Indications of r-EBUS in the central airways are early lung cancer diagnosis, lung cancer diagnosis and staging, evaluation of mediastinal invasion, diagnosis of a mediastinal or intrapulmonary lesion abutting airway wall, and guiding decisions regarding interventional bronchoscopic therapy, surgery or radiotherapy [45, 47–49]. The diagnostic yield of r-EBUS-TBNA for central lesions is 86% [47] while the accuracy of r-EBUS in showing airway involvement is 93% [48], and its utility in guiding interventional bronchoscopic therapy is 43% [49].

The ultraminiature r-EBUS is used to detect peripheral pulmonary nodules and masses or infiltrative lesions and to diagnose them by guiding procedures: TBB or cryo-TBB, TBNA, brushing and bronchoalveolar lavage. However, this is not real-time guidance. First, the guide sheath covered r-EBUS probe is advanced and the lesion is localized, then the probe is removed and biopsy procedures are performed through the guide sheath that is left in place and held in a fixed position [46, 50]. The diagnostic yield of r-EBUS-guided procedures in peripheral pulmonary lesions (70%; range: 46–92%) is higher than the yield of conventional bronchoscopic proce-

dures (40–62%) and comparable to those guided by navigational bronchoscopy techniques such as electromagnetic navigation bronchoscopy (ENB) (74%) or virtual bronchoscopy (67%). Using a multimodality approach can increase the diagnostic yield of r-EBUS: to 77% by combining r-EBUS, ultrathin bronchoscope and virtual bronchoscopy particularly in lesions located in the middle and outer 1/3 of the lung, up to 92% by combining guide sheath, fluoroscopy and virtual bronchoscopy, and from 67% to 88% by combining r-EBUS with ENB [46, 51].

Highest diagnostic yields are obtained by r-EBUS-guided TBNA (55–85%) or TBB (69–72%) while r-EBUS-guided brushing or bronchoalveolar lavage has a yield of about 30–40%. Combining diagnostic procedures during r-EBUS, particularly TBNA and transbronchial biopsy increases the diagnostic yield [50–53]. A lesion size of greater than 2 cm, malignant nature, presence of bronchus sign, probe position within the lesion, and visibility by r-EBUS are the factors positively impacting the diagnostic yield of r-EBUS-guided bronchoscopic procedures [51]. However, using cryo-TBB instead of TBB does not increase the yield significantly (77% vs. 72%, respectively) [54].

### **Navigational Bronchoscopy-Guided Procedures**

As with the r-EBUS, navigational bronchoscopy can also be used to access pulmonary parenchymal lesions that are hard to reach. The term -initially used synonymously with ENB- currently involves peripheral bronchoscopy augmented by a computer-aided system using ENB-based guidance or non-ENB-based guidance. ENB depends upon the generation of an electromagnetic field around the patient's body, which allows a sensor to track within this field. The volume within this electromagnetic field is mapped to correspond with a three dimensional reconstruction of the patient's anatomy using CT imaging. The sensor, then, can navigate through this volume while its position is shown on a virtual three dimensional map of the lung. Non-ENB-based platforms uti-

lize virtual bronchoscopy by using only chest CT to generate a rendering of the airway, fluoroscopy guidance for transparenchymal nodule access, or augmented fluoroscopic tomography and C-arm based tomography for navigating to and localizing nodules, respectively [55].

Navigational bronchoscopy has a significantly higher diagnostic yield (74%) than conventional bronchoscopy but comparable yield to r-EBUS as mentioned above. The lung cancer screening programs as well as increased use of cardiac and abdominal CT scans have increased the detection and thus, the importance of the management of pulmonary nodules, over 90% of which are found to be benign in nature after further assessment. Currently, various navigational bronchoscopy platforms are present to deal with the issue of managing these nodules. The main purpose of these systems is to assist with the acquisition of diagnostic tissue by a safe and minimally invasive method. However, the cost of navigational bronchoscopy is high, at least 5 times that of r-EBUS [46, 51, 55].

Besides the traditional navigational technologies mentioned above, there are several novel navigational technologies: fluoroscopic navigation, robotic-assisted bronchoscopy, and cone beam computed tomography.

In fluoroscopic navigation, digital tomosynthesis is incorporated to re-register the target during the procedure to lessen divergence between the location of the nodule on the pre-procedural CT and its actual location during the procedure.

Two currently available platforms of robotic bronchoscopy -the latest wave of navigational bronchoscopy- enable the bronchoscopist to direct a bronchoscope via a controller apparatus that provides precision control [55].

Cone beam tomography provides reconstruction of the detailed and isotropic images of a specified anatomical area in the body. It uses a high-resolution two-dimensional detector for obtaining images. The C-arm in the system has to be rotated to obtain a three dimensional data set. The use of this technique in peripheral bronchoscopy is quite novel, the first publication being in 2014. As it is rather an adjunctive imaging tool to assist in localizing lesions more precisely by



making adjustments to redirect and confirm “tool-in-lesion” prior to biopsy procedures, it is hard to classify this technique under navigation systems but better to consider as a static and refreshable map. Cone beam tomography can be performed by itself or with adjunct navigation systems in peripheral bronchoscopy. Its combination with thin and ultrathin bronchoscopy has a diagnostic yield of 70% [56].

In summary, traditional or novel navigational bronchoscopy-guided procedures generally have a yield of 66–79% (range: 33–96%). There is a gap of high-quality evidence regarding the diagnostic performance of these systems in pulmonary medicine and thoracic oncology [46, 51, 55]. Besides obtaining a diagnosis, precise navigation and localization of a parenchymal lung lesion has an impact on the treatment of the lesion by enabling dye marking for thoracic surgery, fiducial placement for stereotactic body radiation therapy, and marking for bronchoscopic ablative therapies that are currently being studied [55].

### Image-Guided Transthoracic Needle Biopsy

Transthoracic needle biopsy is generally used to diagnose peripherally located lung lesions, usually nodules or masses. It can be performed CT-guided, fluoroscopy-guided or US-guided.

### CT-Guided Transthoracic Biopsy

The details of anatomic location, margins, shape and attenuation of the lesion, invasion of the chest wall, presence of mediastinal, hilar and segmental lymph nodes, and distance to surrounding structures can be provided by CT. The pooled sensitivity (82–99%) and specificity (94–100%) of transthoracic CT-guided FNA are comparable to those of transthoracic CT-guided CNB. The diagnostic performances of both needle methods are higher in malignancy -particularly lung cancer- than in benign diseases. Although they have high diagnostic performances, their complication risks are high: 18.8% and 25.3% risks of pneumothorax with transthoracic CT-guided FNA and CT-guided CNB, respectively, and a 5–15%

risk of bleeding (major hemorrhage: 1%) with both methods. Emphysema, smaller lesion, deeper needle penetration, and multiple passes of needle are the risk factors for complications during transthoracic needle biopsy [2, 3, 57, 58].

### Fluoroscopy-Guided Transthoracic Biopsies

Uni- or bi-planar fluoroscopy -the first technique used to guide transthoracic FNA and CNB- is widely available, familiar to most operators and provides real-time control of the procedure. The sensitivities (72–98%) and specificities (93–100%) of fluoroscopy-guided transthoracic FNA and CNB are high and comparable in malignancy, particularly in lung cancer. However, they also have high complication rates. Most frequent complication is pneumothorax (11–28%) [3, 59, 60], and more than half of the pneumothoraces may require chest tube drainage [3, 59].

### US-Guided Transthoracic Biopsy

As a safe procedure with a low risk of complications and cost-effective alternative to CT-guided transthoracic biopsy, US-guided transthoracic biopsy is preferred especially if the alternative is diagnostic surgery. In many centers, the procedure is integrated into the overall invasive program performed by pulmonologists. US-guided transthoracic needle biopsy has an acceptable sensitivity (62–95%) and specificity (95–100%) in lung cancer. The complication rate (2.5% pneumothorax, 0.5% hemoptysis) is generally lower than that for CT-guided transthoracic biopsies, and chest tube placement is required in only about 50% of pneumothoraces. US-guided transthoracic biopsies should be preferred when a lesion can be visualized by US. However, a central lesion in the lungs or a lesion peripheral but not next to visceral pleura, can not be visualized by ultrasound owing to the reflection of ultrasound waves in air between the lesion and visceral pleura [3, 58].

Compared with transthoracic FNA, transthoracic CNB has similar sensitivity for malignancy (86–98% and 92–98%, respectively) whether CT, fluoroscopy or US guidance is used. However, transthoracic CNB has a significantly higher performance in determining a specific diagnosis for

benign disease (100% vs. 45–50%) and is more likely to obtain sufficient tissue for mutation analysis in lung cancer [2, 3].

## Thoracentesis and Pleural Biopsy

Pleural involvement in lung cancer can be by direct extension of the primary tumor into visceral (T2) or parietal pleura (T3), or by metastasis as pleural-based nodules and/or malignant cells in a pleural effusion (M1a). When there is a suspicion of pleural metastasis, sampling of pleural space is performed by thoracentesis and/or pleural biopsy.

### Thoracentesis

In patients with pleural effusions, thoracentesis is performed to obtain at least 50–60 mL of pleural fluid sample for pleural fluid cytology and cell block preparation. Blind thoracentesis can be performed in cases with moderate-large and free-flowing effusions but image-guidance usually with US is recommended, particularly in small, loculated and/or hard-to-localize effusions. The mean sensitivity of thoracentesis for malignancy is 72% (49–91%). If cytology is negative or indeterminate for cancer, sampling should be repeated before considering pleural biopsy by medical or surgical thoracoscopy, image-guided pleural biopsy, or closed pleural biopsy. Repeated thoracentesis increases sensitivity. Positivity for malignancy is 30% in the second, and 5–25% in the third thoracentesis. Molecular tumor markers on pleural fluid can be evaluated although its sensitivity is low and assay methodology is variable [61].

### Pleural Biopsy

If pleural fluid cytology is negative, or if there are pleural masses or thickening, pleural biopsy is indicated. Pleural biopsy options are surgical or medical thoracoscopy, US- or CT-guided pleural biopsy, and closed pleural biopsy.

### Surgical or Medical Thoracoscopy

Surgical thoracoscopy is generally performed under general anesthesia and video assistance in the operating room. Medical thoracoscopy (pleu-

roscopy) is an endoscopic procedure performed usually under conscious sedation in the endoscopy unit. By using either procedure, biopsy samples can be obtained randomly or from macroscopically visible lesions on the parietal and visceral pleura under direct visualization. Among the three options for pleural biopsy, the highest diagnostic performance can be achieved by thoracoscopy (sensitivity: 80–99%, negative predictive value: 93–96%). Furthermore, thoracoscopy provides therapeutic options to prevent recurrent effusion (pleurodesis, insertion of an in-dwelling catheter) [61–63].

### Image-Guided Pleural Biopsy

CT- or US-guidance is used for image-guided pleural biopsy that can be performed with or without sedation in the interventional radiology suite. Focal pleural lesions/abnormalities with or without associated pleural effusions are the main indications for this modality. Its sensitivity and negative predictive value are 76–88% 75–80%, respectively. Image-guided CNB of pleura can have a sensitivity comparable to thoracoscopy in identifying lung cancer (93% vs. 100%, respectively), and CT-guided CNB can be more sensitive than US-guided CNB (82% versus 67%) [61, 62].

### Closed Pleural Biopsy

In current practice, blind closed pleural biopsy is rarely performed for diagnosing and staging lung cancer. It can only be performed if pleural fluid is present and can obtain samples only from the parietal pleura. Low sensitivity and consequent limited utility of closed pleural biopsy may be due to the occurrence of pleural metastases more commonly on the visceral pleura as well as decreasing utilization and expertise in this method [61].

### Image-Guided Biopsies for Extrathoracic Metastases

Histologic confirmation of extrathoracic metastases of lung cancer is necessary to determine isolated (M1b) and multiple metastases (M1c) in sites such as liver, adrenal gland, brain, bone, and

in supraclavicular lymph nodes (N3). A positive sample means stage IV disease to be managed with systemic treatment while a negative biopsy will lower the stage designation and may direct the patient to potentially curative surgery.

As low volume tissue and cytologic material are provided by the techniques used in sampling distant metastases, obtaining sufficient material for diagnosis, immunohistochemistry, and mutational analysis should be the aim. Suspected metastatic sites should be sampled first rather than the suspected primary lesion. If there are multiple sites of metastases (M1c), the site that can be sampled by the safest or easiest approach is preferred for pathologic confirmation [61].

Depending on the local expertise, CT- or US-guided percutaneous FNA/CNB, or EUS-FNA can be used to sample suspected metastatic lesions in liver, or adrenal gland. Brain biopsy for suspected metastatic lesions is rarely performed when there are neurological symptoms/signs and a focal abnormality on imaging. As it is a high-risk procedure, potential benefits and harms of the procedure in the individual patient should be weighed by neurosurgical consultation. For suspected bone metastasis, CT-guided percutaneous CNB can be performed but practices may show differences according to the institution and physician. Owing to the need for decalcification, molecular analysis of bone biopsy specimens are usually suboptimal. Thus, if present, biopsy of another metastatic site is preferred. Supraclavicular or scalene lymph node metastasis should be the first to sample among other metastases. Percutaneous FNA or CNB is used to identify lung cancer involvement of these lymph nodes. US- or CT-guidance can be used during FNA or CNB if required [64].

---

### **Sputum Cytology: A Noninvasive Method**

As a noninvasive method, sputum cytology can be used in patients with suspected lung cancer but not able or willing to go under other diagnostic procedures. However, it does not provide staging information and ideal specimens for

immunohistochemical or molecular studies. It has a pooled sensitivity of 66% (42–97%) in the diagnosis of NSCLC. The sensitivity is higher in central and large tumors than in peripheral and small tumors. Its utility is quite limited as every patient cannot produce sputum, a negative test does not exclude lung cancer and a second diagnostic procedure will be required, and additional testing for staging will be needed even if sputum cytology is positive in the presence of suspected mediastinal or distant metastasis. Thus, sputum cytology can be useful in patients with multiple comorbidities, contraindications to invasive procedures, and metastatic disease and can permit palliative or other treatment avoiding the risk of biopsy. If sputum cytology is positive, chest CT to search for the tumor, and further diagnostic and staging procedures targeted at the primary or metastatic lesions will be required. In cases with negative chest imaging, white light bronchoscopy with or without autofluorescence bronchoscopy will be indicated [61].

---

## **Tissue Acquisition, Handling and Processing**

### **Implications of Tissue Acquisition**

The above-mentioned techniques for tissue acquisition can help the clinician in diagnosing and choosing the appropriate treatment for the lung cancer patient: primary resection, neoadjuvant chemotherapy and/or radiation, or palliative chemotherapy and/or radiotherapy. Combining diagnostic or staging techniques strategically provides more successful yields and better outcomes in the management, and may possibly be more cost-effective (e.g. combination of EBUS-TBNA and EUS-FNA, and if negative, followed by mediastinoscopy) [65]. However, there had been significant underuse of multimodality diagnosis and/or staging but it has been increasing since 1998. Using a multimodality approach improves survival irrespective of the lung cancer stage. Furthermore, approximately 15–40% of the patients will not be chosen for a therapy given with curative intent if only imaging

techniques are used for staging. Therefore, in a case with suspected lung cancer, findings of primary and metastatic tumor on imaging should be corroborated by cytological or histological studies. Unfortunately, it is not uncommon to see inadequate pathological evaluation particularly for staging (e.g. not identifying nodal disease). The most important consequence of such an approach will most probably be reduction in survival related to lung cancer [2, 66].

### **Guideline Recommendations for Tissue Acquisition in Mediastinal Staging**

The guidelines of the several major international societies such as ACCP and ESTS share similar recommendations regarding indications and procedures for diagnosing and staging lung cancer [1, 33].

Sampling a single enlarged lymph node or random sampling is considered inadequate in surgical staging. This approach against random sampling can be extrapolated to staging by minimally invasive procedures [2]. Although recommendations for appropriate staging include stations 2R, 2L, 4R, 4L and 7, sampling of nodes smaller than 5 mm is not easy and will more likely provide insufficient amounts of tissue for diagnosis and staging. Sampling should also be performed from the clinically suspicious lymph nodes (with a short axis diameter of 1 cm or larger, or FDG-avid). ESTS guidelines and two other guidelines from the UK and Canada recommend a systematic assessment of at least three mediastinal node stations including station 7 (subcarinal) [33, 67, 68].

### **Differences in Sample Acquisition and Processing: Cytology Versus Histology**

Having an appreciation of cytological/histological processing and evaluation of small biopsies obtained by minimally invasive procedures is required. For establishing a diagnosis of malignancy,

subclassifying cancer reliably by using immunohistochemical stains, and for molecular analysis to determine targetable driver mutations, the obtained cytologic or histologic (small biopsy) specimens should be sufficient in quality and amount. Over the past 2 decades, the information obtained from these small specimens has increased significantly.

Specimens obtained by minimally invasive means provide limited cellular material. Endobronchial biopsy, TBB, and transthoracic CNB can obtain samples with tissue architecture that is useful in differentiating invasive carcinoma from in-situ or lepidic patterns. However, limitations in sampling can be a problem for these specimens. Cytological aspirates obtained by procedures such as EBUS-TBNA or EUS-FNA usually do not have tissue architecture but fragments of tissue can occasionally be obtained and recognized on smears or cell block preparations. As cytological features of malignancy are usually not difficult to recognize, diagnosing malignancy on cytological specimens is rarely an issue. Whereas biopsy specimens are almost always formalin-fixed and paraffin-embedded, processing and evaluation of cytologic specimens can be performed through several ways: cell block preparations, alcohol-fixed or air-dried direct smears or touch prints of tissue biopsies, and alcohol-fixed liquid-based concentration methods. Cell block preparation collects the cellular material into a pellet which is formalin-fixed and paraffin-embedded and thus, creates a specimen similar to a tissue biopsy. From this tissue-biopsy-like specimen, multiple serial slides can be cut and used for immunohistochemical stains and molecular testing. Indeed, the difference between a small biopsy specimen and a cytology specimen, *particularly a cell block preparation*, is not so clear anymore as both types of specimens can provide specific histologic diagnosis and can be used for molecular testing [2].

According to the 2015 WHO classification of lung tumors [69] and the 2011 IASLC/ATS/ERS classification of lung carcinomas on small biopsy/cytology specimens [70], a panel of immunostains should be performed judiciously and in a focused manner to preserve cellular material for down-

stream molecular testing during the diagnostic work-up of a suspected NSCLC if histology or cytology by itself cannot distinguish squamous cell carcinoma from adenocarcinoma. First, one marker for lung adenocarcinoma (transcription factor TTF-1) and one marker for squamous cell carcinoma (usually p63 or p40- an isoform of p63) are employed [71]. If conclusive results are not obtained by these markers, second-line markers for lung adenocarcinoma (aspartic proteinase Napsin-A) and for squamous cell carcinoma (cytokeratin 5/6) can be used. To reveal glandular differentiation, a mucicarmine histochemical stain can also be utilized. In cases with carcinoma metastatic to the lungs, clinical and radiologic correlation should always be used to adjust the immunohistochemical work-up, particularly if more lung-specific markers are negative [2].

### Different Techniques in Genotyping

As recommended by the current guidelines from IASLC and two international pathology societies: AMP and CAP, molecular analysis of all lung adenocarcinomas (including mixed tumors having adenocarcinoma component) in advanced stage should be performed for EGFR mutations by PCR-based techniques, and for ALK gene rearrangements by FISH assay or screening immunohistochemistry [20]. Another commonly used molecular analysis for lung cancer is testing for KRAS mutations which show resistance to tyrosine kinase inhibitors. Besides these main genomic targets, there is a growing list of less common driver mutations in lung adenocarcinoma such as ROS1 rearrangements, ERBB2 and BRAF mutations, MET amplification, etc. The increasing number of genomic targets for lung cancer and one-off testing approach in molecular analysis will result in the depletion of the cellular specimen although the cytopathologist can maximize cellularity of cell block and minimize loss from the specimen in the initial work-up. Consequently, multiplexed panels will be a must in the near future.

High success rates of molecular testing on small biopsy and cytology specimens have been

reported in many pertinent publications. Small biopsy specimens (including TBB or transthoracic CNB) and cell block specimens generally have comparable success in molecular analysis. Depending on the study parameters, success rate of molecular testing is 55–100% on small biopsy specimens, and 46–95% on transthoracic FNA or EBUS-TBNA cell block specimens [72–74]. Owing to the limited tumor cellularity in small biopsy or cytology specimens, failure rate of molecular testing on them is higher than that on larger surgical specimens [75]. As reported in a publication by the Lung Cancer Mutation Consortium, using an 8-gene panel testing, about 35% of cytology specimens and 26% of small biopsies can be inadequate for molecular analysis compared to only 5% of surgical resection specimens. However, if a specimen is adequate (sufficient tumor cellularity) for molecular analysis, using cytology, small biopsy or surgical resection specimen has no effect on the performance of the subsequent molecular testing [76]. Thus, cytology or small biopsy specimens with adequate tumor cells are shown to be appropriate for molecular analysis as long as there is optimal pathologic work-up that minimizes tumor cell loss.

### Methods to Overcome Challenges in Tissue Acquisition and Genotyping

Targeted treatment that is personalized based on molecular profiling of advanced NSCLC can provide an objective response rate exceeding 50%, a progression-free survival of about 3 years and a median overall survival exceeding 6 years for patients with ALK rearrangements. Therefore, identifying molecular biomarkers is a requisite in advanced-stage NSCLC to tailorize the treatment aimed at optimal outcomes [77, 78]. However, there are several challenges in tissue acquisition, handling and processing for pathological diagnosis and genotyping:

1. *Inadequate lung cancer tissue* (10–20%) may be obtained by minimally invasive procedures and these procedures may need to be repeated,



2. *Histological and biological heterogeneity of the tumor* not captured in small biopsies or cytological specimens may negatively impact detection of specific molecular targets. Different molecular profiles in primary tumor and metastatic lesion (*intertumor heterogeneity*), and alterations in the tumor biology due to treatment may require serial biopsies to track tumor evolution.
3. *Resistance mechanisms may be heterogeneous* in multiple metastases. Thus, re-biopsy of the progressive tumor site to clarify the resistance mechanism may not be representative. It may also not show the genetic heterogeneity of the whole tumor owing to *intratumor heterogeneity*.
4. *Poor performance status* of most lung cancer patients with advanced and/or recurring disease, and *complication risks* due to biopsy procedures reduce the feasibility of tissue acquisition and genotyping.

These challenges can be potentially overcome with several approaches: rapid onsite evaluation, combination of minimally invasive procedures with sensitive genotyping assays, and/or liquid biopsy (analysis of tumor cell genomic contents in body fluids) [78–80].

### Rapid on-Site Evaluation (ROSE)

ROSE, combined with cell block preparation, can optimize diagnostic performance of cytological specimens obtained by EBUS-TBNA and other procedures. It increases the diagnostic sensitivity by about 8% with no increase in procedure time. Furthermore, ROSE allows for repeating aspirations from sites giving diagnostic specimens. In an approach to triage small specimens appropriately, these additional specimens are separated for processing by priority to increase yields in histologic and molecular analysis. ROSE is recommended for procedures obtaining cytological specimens (e.g. EBUS-TBNA, FNA, touch imprints of CNB) but it may not be available in every institution owing to time, cost, and personnel limitations [4, 81, 82].

Diff-Quik smears for ROSE may be better than cell blocks in identifying genomic altera-

tions by NGS in lung cancer, and DNA can be extracted directly from ROSE cytology smears [78, 83]. Communication among interventionists, physician assistants, nurses, cytotechnologists and cytopathologists is critical. Furthermore, the whole team should use the same terminology for differentiating morphological adequacy from molecular adequacy [4, 82].

### Sensitive Genotyping Assays

In scaling traditional single biomarker assays, tissue reduction in small biopsy or cytological samples is an increasingly encountered issue. Furthermore, the list of therapeutically relevant biomarkers have been expanding for NSCLC. Consequently, there has been a need for feasible and cost-effective assays characterizing a wider genomic profile that may have prognostic and therapeutic implications.

Recently, there has been a strong tendency to use multiplexed genetic sequencing panels. NGS is at the forefront of this changing practice. Significantly higher sensitivity and specificity of NGS compared with single-gene targeted assays has been shown previously. The optimal approach to molecular analysis in non-squamous NSCLC is still under debate. Sequential, small-panel, or larger-panel NGS testing is suggested within potential strategies. Sequential testing is cost-effective if employed only for *EGFR*, *ALK* and *ROS1*. However, upfront NGS becomes the optimal and cost-effective strategy for an expanded panel beyond these three biomarkers [84, 85].

Besides *EGFR*, *BRAF* and *MET* mutations and *ALK*, *ROS1*, *RET* and *NTRK* translocations that have already been included in the NSCLC diagnostic standards in parallel with the entrance of their inhibitors into clinical treatment, there are emerging biomarkers such as *KRAS* G12C substitutions and *HER2* activating alterations that are likely to be included in NSCLC guidelines after the approval of the corresponding drugs. In addition to the genetic analyses, analysis of PD-L1 protein expression is also performed in NSCLC to direct the use of immune checkpoint inhibitors. The integration of multiple molecular assays into a single diagnostic pipeline is the aim of ongoing studies. For com-

prehensive multiple biomarker testing in NSCLC, the analysis of distinct biological molecules (DNA, RNA, proteins) and the use of appropriate analytical platforms (PCR, DNA sequencing, immunohistochemistry, FISH) are required [86].

### Liquid Biopsy

Liquid biopsy is performed by using minimally invasive technologies to detect circulating biomarkers (circulating tumor cells and nucleic acids including cell-free RNA, micro-RNA, and circulating cell-free DNA that includes cell-free circulating tumor DNA, exosomes, tumor-associated antigens and tumor-educated platelets) in blood and other body fluids (pleural fluid, BAL fluid, saliva, cerebrospinal fluid, urine, etc.). Intact and often viable circulating tumor cells released into the bloodstream from the primary tumor or metastatic site can be used for DNA-, RNA- and protein-based analysis and may reveal the heterogeneity that cannot be shown by indirect molecular approaches. Despite advances in cell detection technologies, these fragile circulating tumor cells are quite rare. Thus, their detection rate in NSCLC is usually low. However, recently circulating tumor cells have been identified in pulmonary venous blood in 48% of resected lung cancers. This finding suggests that it can be a clinically useful test in the future with improvements in technology. Somatic mutations in primary tumors can be more easily detected in circulating tumor DNA than in circulating tumor cells. Highly sensitive blood-based assays can identify molecular alterations at very low concentrations of circulating tumor DNA by either a narrow approach using PCR to target short sequences of DNA or a broad approach using NGS to target broader regions of DNA and multiple genes [78, 87].

Although small non-coding RNA (including miRNA) is stabilized by processing circulatory proteins, cell-free RNA is degraded fast in the circulation. The miRNA can be used as a biomarker in diagnosis, screening and determining prognosis as it can be quantified by using quantitative reverse transcription-polymerase chain reaction. However, miRNA is not in clinical use yet because there are no standard set of markers and thresholds for positivity used in the related studies [78].

Improvements in the diagnostic performances of the assays have led to the entrance of liquid biopsies into routine clinical practice for non-invasive genotyping and monitoring the disease course. NGS is increasingly used for cell-free DNA testing as it can sequence multiple targeted genomic regions simultaneously in shorter turnaround time and with reduced sample requirements [87].

Nonetheless, in advanced NSCLC tissue still remains as the issue for personalized medicine which depends on sufficient tissue for biomarker testing. Liquid biopsy is complementary to tissue biopsy in determining driver and resistance mutations but it cannot replace tissue biopsy currently. The major challenges in using liquid biopsy are lack of standardization in tests, low sensitivity in early lung cancer, posttreatment or in detecting minimal residual disease, and clonal hematopoiesis of uncertain clinical significance causing false positive results. In the right clinical context, liquid biopsy can be beneficial regarding risk stratification, diagnosis, prognostication, monitoring, and decreasing the number of invasive procedures [78, 87].

---

### Summary, Recommendations and Highlights

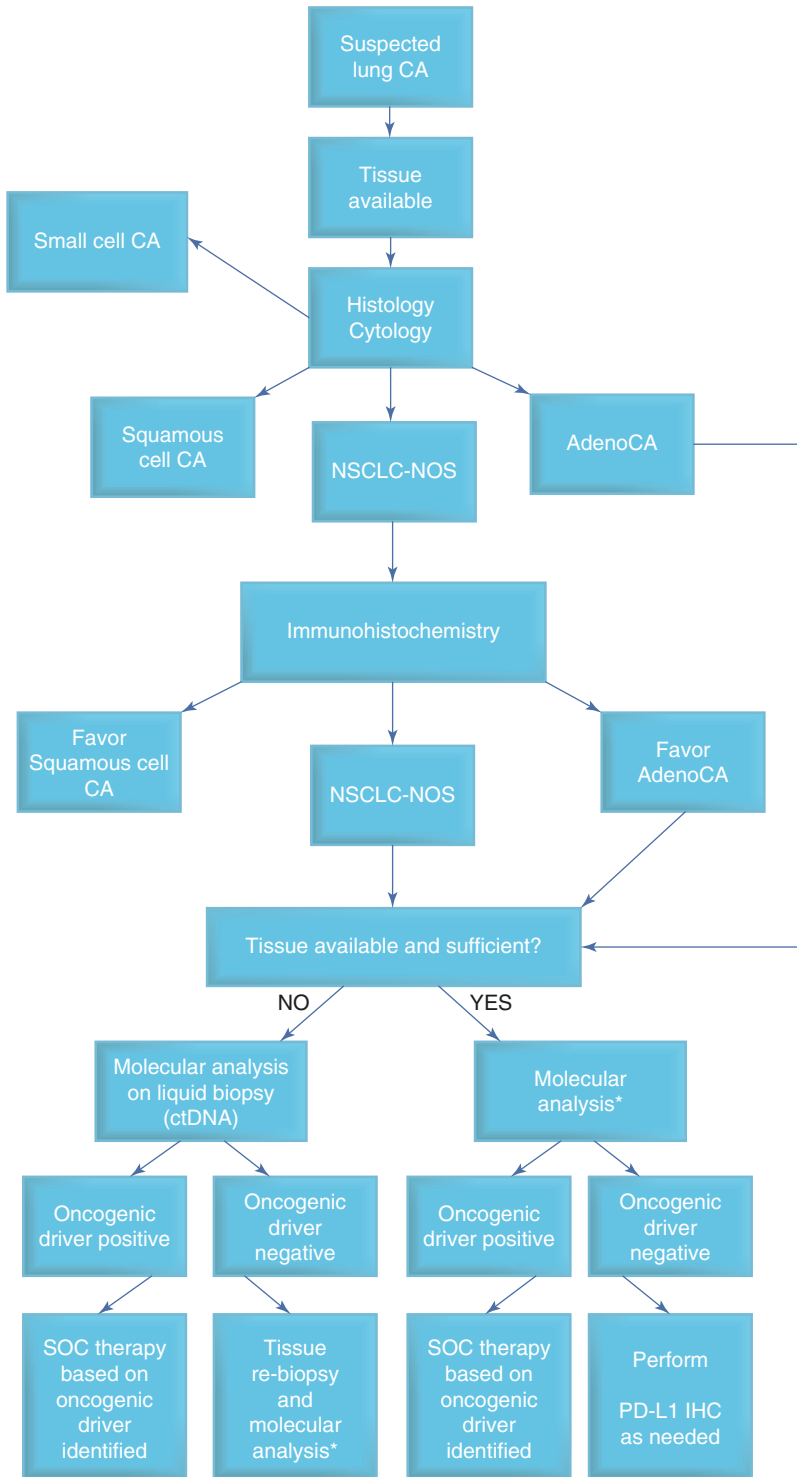
1. Diagnosis and staging of lung cancer should be managed promptly and accurately by an efficient process minimizing procedures before treatment.
2. Within the multidisciplinary team approach to identify the best evidence-based treatment plan for lung cancer care, minimally invasive procedures provide rapid and safe acquisition of tissue for the diagnosis, staging, and molecular testing (Table 18.1).
3. The possibility of the ideal tissue acquisition for simultaneous diagnosis, tumor classification, molecular testing and staging by the initial procedure depends on the individual patient and the need for sufficient and appropriate tissue for current and future cytological, immunohistochemical, and molecular studies.

**Table 18.1** Pathologic yields and molecular adequacies of the specimens obtained by various diagnostic procedures in lung cancer [1–3, 61, 78, 87–89]

Procedure	Diagnostic yield	Molecular adequacy
<i>Mediastinoscopy</i>	78–89% (32–97%)	76–100%
<i>EBUS-TBNA</i>	86–92% (57–97%)	46–95%
<i>EUS-FNA</i>	84–94% (50–100%)	46–95%
<i>EBUS-TBNA + EUS-FNA</i>	87–95% (68–100%)	70–98%
<i>R-EBUS-guided procedures (for peripheral lesions)</i>	63–77% (46–92%)	50–75%
<i>Navigational bronchoscopy-guided procedures</i>	66–78% (33–96%)	53–74%
<i>TBNA</i>	56–78% (23–90%)	42–70%
<i>TBB</i>	51–63% (17–80%)	45–84%
<i>EBB</i>	70–74% (48–97%)	55–100%
<i>Brushing</i>	54–61% (16–93%)	45–60%
<i>BAL</i>	30–43% (12–65%)	40–66%
<i>Bronchial washing</i>	35–47% (31–78%)	35–60%
<i>Image-guided transthoracic FNA</i>	87–93% (71–99%)	46–95%
<i>Image-guided transthoracic CNB</i>	92–97% (70–100%)	55–100%
<i>Medical thoracoscopy</i>	91–98% (80–100%)	78–100%
<i>Image-guided pleural biopsy</i>	79–85% (70–88%)	55–100%
<i>Closed pleural biopsy</i>	46–54% (43–77%)	45–72%
<i>Thoracentesis</i>	44–55% (40–91%)	20–85%
<i>Image-guided FNA (extrathoracic)</i>	89–96% (82–99%)	46–98%
<i>Image-guided CNB (extrathoracic)</i>	90–98% (85–100%)	55–100%
<i>Sputum cytology</i>	54–60% (42–97%)	50–80%
<i>Liquid biopsy (ctDNA)</i>	55–67% (47–100%)	30–85%

*EBUS-TBNA* endobronchial ultrasound-guided transbronchial needle aspiration, *EUS-FNA* endoscopic ultrasound-guided fine needle aspiration, *R-EBUS* radial-probe endobronchial ultrasound, *TBNA* transbronchial needle aspiration, *TBB* transbronchial biopsy, *EBB* endobronchial biopsy, *BAL* bronchoalveolar lavage, *FNA* fine needle aspiration, *CNB* core-needle biopsy, *ctDNA* cell-free circulating tumor DNA

4. A systematic assessment of at least three mediastinal node stations including station 7 (subcarinal) is recommended as random or single-node sampling can be inadequate.
5. A multimodality approach by combining diagnostic or staging techniques strategically provides more successful yields and better outcomes in the management, and may possibly be more cost-effective.
6. For establishing a diagnosis of malignancy, subclassifying cancer reliably by using immunohistochemical stains, and for molecular analysis to determine targetable driver mutations, the obtained cytologic or histologic (small biopsy) specimens should be sufficient in quality and quantity. Thus, tissue with sufficient number of lung cancer cells is the issue.
7. Whenever cytological samples are obtained, smears should be combined with cell block preparations to increase the diagnostic yield and molecular adequacy.
8. A panel of immunostains should be performed judiciously and in a focused manner to preserve cellular material for downstream molecular testing during the diagnostic work-up of a suspected NSCLC if histology or cytology by itself cannot distinguish squamous cell carcinoma from adenocarcinoma (Fig. 18.1).
9. Molecular analysis of all lung adenocarcinomas (including mixed tumors having adenocarcinoma component) in advanced stage may be performed for EGFR mutations by PCR-based techniques, and for ALK gene rearrangements by FISH assay or screening immunohistochemistry.
10. However, the increasing number of genomic targets for lung cancer and one-off testing approach in molecular analysis will result in



**Fig. 18.1** A diagnostic algorithm for histologic subtyping and molecular analysis in treatment-naive NSCLC patients [2, 4, 78, 82]. (\*): next generation sequencing (NGS) preferred if available, CA cancer, NSCLC-NOS

non-small cell lung cancer histology not otherwise specified, *ctDNA* cell-free circulating tumor DNA, *SOC* standard of care, *PD-L1* programmed death ligand 1, *IHC* immunohistochemistry

the depletion of the cellular specimen although the cytopathologist can maximize cellularity of the cell block and minimize loss from the specimen in the initial work-up.

11. Consequently, multiplexed panels for genomic analysis will be a must in the near future. Upfront NGS becomes the optimal and cost-effective strategy for an expanded panel beyond three biomarkers.
12. ROSE, sensitive genotyping assays (NGS) and/or liquid biopsy can be used to overcome challenges such as inadequate lung cancer tissue in the sample, histological and biological heterogeneity of the tumor, heterogeneous resistance mechanisms in the progressive tumor, and poor performance status of the patient.

## References

1. Silvestri GA, Gonzalez AV, Jantz MA, Margolis ML, Gould MK, Tanoue LT, et al. Methods for staging non-small cell lung cancer: diagnosis and management of lung cancer, 3rd ed: American College of Chest Physicians evidence-based clinical practice guidelines. *Chest*. 2013;143:e211S–50S. <https://doi.org/10.1378/chest.12-2355>.
2. Folch E, Costa DB, Wright J, VanderLaan PA. Lung cancer diagnosis and staging in the minimally invasive age with increasing demands for tissue analysis. *Transl Lung Cancer Res*. 2015;4:392–403. <https://doi.org/10.3978/j.issn.2218-6751.2015.08.02>.
3. Rivera MP, Mehta AC, Wahidi MM. Establishing the diagnosis of lung cancer: diagnosis and management of lung cancer, 3rd ed: American College of Chest Physicians evidence-based clinical practice guidelines. *Chest*. 2013;143(5 Suppl):e142S–65S. <https://doi.org/10.1378/chest.12-2353>.
4. Sung S, Heymann JJ, Crapanzano JP, Moreira AL, Shu C, Bulman WA, et al. Lung cancer cytology and small biopsy specimens: diagnosis, predictive biomarker testing, acquisition, triage, and management. *J Am Soc Cytopathol*. 2020;9:332–45. <https://doi.org/10.1016/j.jasc.2020.04.014>.
5. Schiller JH, Harrington D, Belani CP, Langer C, Sandler A, Krook J, et al. Comparison of four chemotherapy regimens for advanced non-small cell lung cancer. *N Engl J Med*. 2002;346:92–8. <https://doi.org/10.1056/NEJMoa011954>.
6. Sandler A, Gray R, Perry MC, Brahmer J, Schiller JH, Dowlati A, et al. Paclitaxel-carboplatin alone or with bevacizumab for non-small-cell lung cancer. *N Engl J Med*. 2006;355:2542–50. <https://doi.org/10.1056/NEJMoa061884>.
7. Scagliotti GV, Parikh P, von Pawel J, Biesma B, Vansteenkiste J, Manegold C, et al. Phase III study comparing cisplatin plus gemcitabine with cisplatin plus pemetrexed in chemotherapy-naive patients with advanced-stage non-small-cell lung cancer. *J Clin Oncol*. 2008;26:3543–51. <https://doi.org/10.1200/JCO.2007.15.0375>.
8. Travis WD, Brambilla E, Noguchi M, Nicholson AG, Geisinger KR, Yatabe Y, et al. International Association for the Study of Lung Cancer/American Thoracic Society/European Respiratory Society International Multidisciplinary Classification of Lung Adenocarcinoma. *J Thorac Oncol*. 2011;6:244–85. <https://doi.org/10.1097/JTO.0b013e318206a221>.
9. Brahmer J, Reckamp KL, Baas P, Crinò L, Eberhardt WE, Poddubskaya E, et al. Nivolumab versus docetaxel in advanced squamous-cell non-small-cell lung cancer. *N Engl J Med*. 2015;373:123–35. <https://doi.org/10.1056/NEJMoa1504627>.
10. Hanahan D, Weinberg RA. Hallmarks of cancer: the next generation. *Cell*. 2011;144:646–74. <https://doi.org/10.1016/j.cell.2011.02.013>.
11. Ettinger DS, Wood DE, Akerley W, Bazhenova LA, Borghaei H, Camidge DR, et al. Non-small cell lung cancer, version 6.2015. *J Natl Compr Canc Netw*. 2015;13:515–24. <https://doi.org/10.6004/jncn.2015.0071>.
12. Gerber DE, Gandhi L, Costa DB. Management and future directions in non-small cell lung cancer with known activating mutations. *Am Soc Clin Oncol Educ Book*. 2014;34(1):e353–65. [https://doi.org/10.14694/EdBook\\_AM.2014.34.e353](https://doi.org/10.14694/EdBook_AM.2014.34.e353).
13. Kris MG, Johnson BE, Berry LD, Kwiatkowski DJ, Iafrate AJ, Wistuba II, et al. Using multiplexed assays of oncogenic drivers in lung cancers to select targeted drugs. *JAMA*. 2014;311:1998–2006. <https://doi.org/10.1001/jama.2014.3741>.
14. Jorge SE, Kobayashi SS, Costa DB. Epidermal growth factor receptor (EGFR) mutations in lung cancer: preclinical and clinical data. *Braz J Med Biol Res*. 2014;47:929–39. <https://doi.org/10.1590/1414-431X20144099>.
15. Mok TS, Wu YL, Thongprasert S, Yang CH, Chu DT, Saijo N, et al. Gefitinib or carboplatin-paclitaxel in pulmonary adenocarcinoma. *N Engl J Med*. 2009;361:947–57. <https://doi.org/10.1056/NEJMoa0810699>.
16. Rosell R, Carcereny E, Gervais R, Vergnenegre A, Massuti B, Felip E, et al. Erlotinib versus standard chemotherapy as first-line treatment for European patients with advanced EGFR mutation-positive non-small-cell lung cancer (EURTAC): a multicentre, open-label, randomised phase 3 trial. *Lancet Oncol*. 2012;13:239–46. [https://doi.org/10.1016/S1470-2045\(11\)70393-X](https://doi.org/10.1016/S1470-2045(11)70393-X).
17. Sequist LV, Yang JC, Yamamoto N, O'Byrne K, Hirsh V, Mok T, et al. Phase III study of afatinib or



- cisplatin plus pemetrexed in patients with metastatic lung adenocarcinoma with EGFR mutations. *J Clin Oncol.* 2013;31:3327–34. <https://doi.org/10.1200/JCO.2012.44.2806>.
18. Kwak EL, Bang YJ, Camidge DR, Shaw AT, Solomon B, Maki RG, et al. Anaplastic lymphoma kinase inhibition in non-small-cell lung cancer. *N Engl J Med.* 2010;363:1693–703. <https://doi.org/10.1056/NEJMoa1006448>.
  19. Costa DB, Shaw AT, Ou SH, Solomon BJ, Riely GJ, Ahn MJ, et al. Clinical experience with crizotinib in patients with advanced ALK-rearranged non-small cell lung cancer and brain metastases. *J Clin Oncol.* 2015;33:1881–8. <https://doi.org/10.1200/JCO.2014.59.0539>.
  20. Lindeman NI, Cagle PT, Beasley MB, Chitale DA, Dacic S, Giaccone G, et al. Molecular testing guideline for selection of lung cancer patients for EGFR and ALK tyrosine kinase inhibitors: guideline from the college of American pathologists, international association for the study of lung cancer, and association for molecular pathology. *Arch Pathol Lab Med.* 2013;137:828–60. <https://doi.org/10.5858/arpa.2012-0720-OA>.
  21. Frampton GM, Fichtenholtz A, Otto GA, Wang K, Downing SR, He J, et al. Development and validation of a clinical cancer genomic profiling test based on massively parallel DNA sequencing. *Nat Biotechnol.* 2013;31:1023–31. <https://doi.org/10.1038/nbt.2696>.
  22. Zheng Z, Liebers M, Zhelyazkova B, Cao Y, Panditi D, Lynch KD, et al. Anchored multiplex PCR for targeted next-generation sequencing. *Nat Med.* 2014;20:1479–84. <https://doi.org/10.1038/nm.3729>.
  23. Weeden D, Tsang VT. Cardiothoracic surgery. In: Johnson CD, Cumming J, editors. *Essential surgical technique*. New York: Springer; 1997. p. 197–232.
  24. Kramer H, Groen HJ. Current concepts in the mediastinal lymph node staging of nonsmall cell lung cancer. *Ann Surg.* 2003;238:180–8. <https://doi.org/10.1097/01.SLA.0000081086.37779.1a>.
  25. Park BJ, Flores R, Downey RJ, Bains MS, Rusch VW. Management of major hemorrhage during mediastinoscopy. *J Thorac Cardiovasc Surg.* 2003;126:726–31. [https://doi.org/10.1016/s0022-5223\(03\)00748-7](https://doi.org/10.1016/s0022-5223(03)00748-7).
  26. Kirschner PA. Cervical mediastinoscopy. *Chest Surg Clin N Am.* 1996;6:1–20. PMID: 8646496.
  27. Urschel JD. Conservative management (packing) of hemorrhage complicating mediastinoscopy. *Ann Thorac Cardiovasc Surg.* 2000;6:9–12. PMID: 10748353.
  28. Hürtgen M, Friedel G, Toomes H, Fritz P. Radical videoassisted mediastinoscopic lymphadenectomy (VAMLA)—technique and first results. *Eur J Cardiothorac Surg.* 2002;21:348–51. [https://doi.org/10.1016/s1010-7940\(01\)01125-3](https://doi.org/10.1016/s1010-7940(01)01125-3).
  29. Kuzdzał J, Zieliński M, Papla B, Szlubowski A, Hauer Ł, Nabiałek T, et al. Transcervical extended mediastinal lymphadenectomy—the new operative technique and early results in lung cancer staging. *Eur J Cardiothorac Surg.* 2005;27:384–90. <https://doi.org/10.1016/j.ejcts.2004.12.008>; discussion 390.
  30. Zielinski M, Szlubowski A, Kołodziej M, Orzechowski S, Laczynska E, Pankowski J, et al. Comparison of endobronchial ultrasound and/or endoesophageal ultrasound with transcervical extended mediastinal lymphadenectomy for staging and restaging of non-small cell lung cancer. *J Thorac Oncol.* 2013;8:630–6. <https://doi.org/10.1097/JTO.0b013e318287c0ce>.
  31. Kuzdzał J, Zieliński M, Papla B, Szlubowski A, Hauer Ł, Nabiałek T, et al. The transcervical extended mediastinal lymphadenectomy versus cervical mediastinoscopy in non-small cell lung cancer staging. *Eur J Cardiothorac Surg.* 2007;31:88–94. <https://doi.org/10.1016/j.ejcts.2004.12.008>.
  32. Kuzdzał J, Warmus J, Grochowski Z. Optimal mediastinal staging in non-small cell lung cancer: what is the role of TEMPLA and VAMLA? *Lung Cancer.* 2014;86:1–4. <https://doi.org/10.1016/j.lungcan.2014.07.015>.
  33. De Leyn P, Doooms C, Kuzdzał J, Lardinois D, Passlick B, Rami-Porta R, et al. Revised ESTS guidelines for preoperative mediastinal lymph node staging for non-small-cell lung cancer. *Eur J Cardiothorac Surg.* 2014;45:787–98. <https://doi.org/10.1093/ejcts/ezu028>.
  34. Steinfort DP, Liew D, Conron M, Hutchinson AF, Irving LB. Cost-benefit of minimally invasive staging of non-small cell lung cancer: a decision tree sensitivity analysis. *J Thorac Oncol.* 2010;5:1564–70. <https://doi.org/10.1097/JTO.0b013e3181e8b2e6>.
  35. Varela-Lema L, Fernández-Villar A, Ruano-Ravina A. Effectiveness and safety of endobronchial ultrasound-transbronchial needle aspiration: a systematic review. *Eur Respir J.* 2009;33:1156–64. <https://doi.org/10.1183/09031936.00097908>.
  36. Eapen GA, Shah AM, Lei X, Jimenez CA, Morice RC, Yarmus L, et al. Complications, consequences, and practice patterns of endobronchial ultrasound-guided transbronchial needle aspiration: results of the AQUIRE registry. *Chest.* 2013;143:1044–53. <https://doi.org/10.1378/chest.12-0350>.
  37. VanderLaan PA, Wang HH, Majid A, Folch E. Endobronchial ultrasound-guided transbronchial needle aspiration (EBUS-TBNA): an overview and update for the cytopathologist. *Cancer Cytopathol.* 2014;122:561–76. <https://doi.org/10.1002/cncy.21431>.
  38. Folch E, Santacruz J, Machuzak M, Gildea T, Majid A. Safety and efficacy of EBUS-guided TBNA through the pulmonary artery: a preliminary report. *Chest.* 2011;140(4):p600A. <https://doi.org/10.1378/chest.1119000>.
  39. Dettlerbeck FC, Jantz MA, Wallace M, Vansteenkiste J, Silvestri GA. American college of chest physicians. Invasive mediastinal staging of lung cancer: ACCP evidence-based clinical practice guidelines (2nd edition). *Chest.* 2007;132:202S–20S. <https://doi.org/10.1378/chest.07-1362>.

40. Micames CG, McCrory DC, Pavey DA, Jowell PS, Gress FG. Endoscopic ultrasound-guided fine-needle aspiration for non-small cell lung cancer staging: a systematic review and metaanalysis. *Chest*. 2007;131:539–48. <https://doi.org/10.1378/chest.06-1437>.
41. Chang KJ, Erickson RA, Nguyen P. Endoscopic ultrasound (EUS) and EUS-guided fine-needle aspiration of the left adrenal gland. *Gastrointest Endosc*. 1996;44:568–72. [https://doi.org/10.1016/s0016-5107\(96\)70010-x](https://doi.org/10.1016/s0016-5107(96)70010-x).
42. Wallace MB, Pascual JM, Raimondo M, Woodward TA, McComb BL, Crook JE, et al. Minimally invasive endoscopic staging of suspected lung cancer. *JAMA*. 2008;299:540–6. <https://doi.org/10.1001/jama.299.5.540>.
43. Fiorelli A, Santoriello C, Di Natale D, Cascone R, Musella V, Mastromarino R, et al. In the era of ultrasound technology, could conventional transbronchial needle aspiration still play a role in lung cancer mediastinal staging? *J Thorac Dis*. 2017;9(Suppl 5):S386–94. <https://doi.org/10.21037/jtd.2017.04.13>.
44. Medford ARL, Bennett JA, Free CM, Agrawal S. Mediastinal staging procedures in lung cancer: EBUS, TBNA and mediastinoscopy. *Curr Opin Pulm Med*. 2009;15:334–42. <https://doi.org/10.1097/MCP.0b013e32832b8a45>.
45. Yasufuku K, Nakajima T, Chiyo M, Sekine Y, Shibuya K, Fujisawa T. Endobronchial ultrasonography: current status and future directions. *J Thorac Oncol*. 2007;2:970–9. <https://doi.org/10.1097/JTO.0b013e318153fd8d>.
46. Schuhmann M, Eberhardt R, Herth FJ. Endobronchial ultrasound for peripheral lesions: a review. *Endosc Ultrasound*. 2013;2:3–6. <https://doi.org/10.7178/eus.04.002>.
47. Herth F, Becker HD, Ernst A. Conventional vs endobronchial ultrasound-guided transbronchial needle aspiration: a randomized trial. *Chest*. 2004;125:322–5. <https://doi.org/10.1378/chest.125.1.322>.
48. Tanaka F, Muro K, Yamasaki S, Watanabe G, Shimada Y, Imamura M, et al. Evaluation of tracheo-bronchial wall invasion using transbronchial ultrasonography (TBUS). *Eur J Cardiothorac Surg*. 2000;17:570–4. [https://doi.org/10.1016/s1010-7940\(00\)00372-9](https://doi.org/10.1016/s1010-7940(00)00372-9).
49. Herth F, Becker HD, LoCicero J 3rd, Ernst A. Endobronchial ultrasound in therapeutic bronchoscopy. *Eur Respir J*. 2002;20:118–21. <https://doi.org/10.1183/09031936.02.01642001>.
50. Chen A, Chenna P, Loissele A, Massoni J, Mayse M, Misselhorn D. Radial probe endobronchial ultrasound for peripheral pulmonary lesions. A 5-year institutional experience. *Ann Am Thorac Soc*. 2014;11:578–82. <https://doi.org/10.1513/AnnalsATS.201311-384OC>.
51. Ali MS, Trick W, Mba BI, Mohananeey D, Sethi J, Musani AI. Radial endobronchial ultrasound for the diagnosis of peripheral pulmonary lesions: a systematic review and meta-analysis. *Respiology*. 2017;22:443–53. <https://doi.org/10.1111/resp.12980>.
52. Boonsamsuk V, Kanoksil W, Laungdamrongchai S. Diagnosis of peripheral pulmonary lesions with radial probe endobronchial ultrasound-guided bronchoscopy. *Arch Bronconeumol*. 2014;50(9):379–83. <https://doi.org/10.1016/j.arbres.2014.02.018>.
53. Takai M, Izumo T, Chavez C, Tsuchida T, Sasada S. Transbronchial needle aspiration through a guide sheath with endobronchial ultrasonography (GS-TBNA) for peripheral pulmonary lesions. *Ann Thorac Cardiovasc Surg*. 2014;20:19–25. <https://doi.org/10.5761/atcs.0a.13-00261>.
54. Sryma PB, Mittal S, Madan NK, Tiwari P, Hadda V, Mohan A, et al. Efficacy of radial endobronchial ultrasound (R-EBUS) guided transbronchial cryobiopsy for peripheral pulmonary lesions (PPL's): a systematic review and meta-analysis. *Pulmonology*. 2021. <https://doi.org/10.1016/j.pulmoe.2020.12.006>.
55. Cicienia J, Avasarala SK, Gildea TR. Navigational bronchoscopy: a guide through history, current use, and developing technology. *J Thorac Dis*. 2020;12:3263–71. <https://doi.org/10.21037/jtd-2019-ndt-11>.
56. Casal RF, Sarkiss M, Jones AK, Stewart J, Tam A, Grosu HB, et al. Cone beam computed tomography-guided thin/ultrathin bronchoscopy for diagnosis of peripheral lung nodules: a prospective pilot study. *J Thorac Dis*. 2018;10:6950–9. <https://doi.org/10.21037/jtd.2018.11.21>.
57. Wiener RS, Schwartz LM, Woloshin S, Welch HG. Population-based risk for complications after transthoracic needle lung biopsy of a pulmonary nodule: an analysis of discharge records. *Ann Intern Med*. 2011;155:137–44. <https://doi.org/10.7326/0003-4819-155-3-201108020-00003>.
58. Christiansen IS, Clementsen PF, Bodtger U, Naur TMH, Pietersen PI, Laursen CB. Transthoracic ultrasound-guided biopsy in the hands of chest physicians—a stepwise approach. *Eur Clin Respir J*. 2019;6:1579632. <https://doi.org/10.1080/20018525.2019.1579632>.
59. Sidhu JS, Salte G, Christiansen IS, Naur TMH, Høegholm A, Clementsen PF, et al. Fluoroscopy guided percutaneous biopsy in combination with bronchoscopy and endobronchial ultrasound in the diagnosis of suspicious lung lesions—the triple approach. *Eur Clin Respir J*. 2020;7:1723303. <https://doi.org/10.1080/20018525.2020.1723303>.
60. Gasparini S, Ferretti M, Secchi EB, Baldelli S, Zuccatosta L, Gusella P. Integration of transbronchial and percutaneous approach in the diagnosis of peripheral pulmonary nodules or masses. Experience with 1,027 consecutive cases. *Chest*. 1995;108:131–7. <https://doi.org/10.1378/chest.108.1.131>.
61. Thomas KW, Gould MK. In: Colt HG, Finlay G, editors. Procedures for tissue biopsy in patients with suspected non-small cell lung cancer. Waltham, MA: UpToDate; 2021. <https://www.uptodate.com/contents/procedures-for-tissue-biopsy-in-patients-with-suspected-non-small-cell-lung-cancer>. Accessed 2 Feb 2022.

62. Metintas M, Ak G, Dundar E, Yildirim H, Ozkan R, Kurt E, et al. Medical thoracoscopy vs CT scan-guided Abrams pleural needle biopsy for diagnosis of patients with pleural effusions: a randomized, controlled trial. *Chest*. 2010;137:1362. <https://doi.org/10.1378/chest.09-0884>.
63. Page RD, Jeffrey RR, Donnelly RJ. Thoracoscopy: a review of 121 consecutive surgical procedures. *Ann Thorac Surg*. 1989;48:66. [https://doi.org/10.1016/0003-4975\(89\)90179-3](https://doi.org/10.1016/0003-4975(89)90179-3).
64. Thomas KW, Gould MK. In: Midthun DE, Finlay G, editors. Selection of modality for diagnosis and staging of patients with suspected non-small cell lung cancer. Waltham, MA: UpToDate; 2020. <https://www.uptodate.com/contents/selection-of-modality-for-diagnosis-and-staging-of-patients-with-suspected-non-small-cell-lung-cancer>. Accessed 3 Feb 2022.
65. Annema JT, van Meerbeeck JP, Rintoul RC, Dooms C, Deschepper E, Dekkers OM, et al. Mediastinoscopy vs endosonography for mediastinal nodal staging of lung cancer: a randomized trial. *JAMA*. 2010;304:2245–52. <https://doi.org/10.1001/jama.2010.1705>.
66. Osarogiagbon RU, Allen JW, Farooq A, Wu JT. Objective review of mediastinal lymph node examination in a lung cancer resection cohort. *J Thorac Oncol*. 2012;7:390–6. <https://doi.org/10.1097/JTO.0b013e31823e5e2d>.
67. Darling GE, Dickie AJ, Malthaner RA, Kennedy EB, Tey R. Invasive mediastinal staging of non-small-cell lung cancer: a clinical practice guideline. *Curr Oncol*. 2011;18:e304–10. <https://doi.org/10.3747/co.v18i6.820>.
68. National Collaborating Centre for Cancer (Great Britain), National Institute for Health and Clinical Excellence (Great Britain). The diagnosis and treatment of lung cancer (update). NICE clinical guidelines no 121. Cardiff: National Collaborating Centre for Cancer (UK); 2011. p. 34–5. PMID: 22855970.
69. Travis WD, Brambilla E, Burke AP, Marx A, Nicholson AG. Introduction to the 2015 World health organization classification of tumors of the lung, pleura, thymus, and heart. *J Thorac Oncol*. 2015;10:1240–2. <https://doi.org/10.1097/JTO.0000000000000663>.
70. Travis WD, Brambilla E, Noguchi M, Nicholson AG, Geisinger K, Yatabe Y, et al. Diagnosis of lung cancer in small biopsies and cytology: implications of the 2011 International Association for the Study of Lung Cancer/American Thoracic Society/European Respiratory Society classification. *Arch Pathol Lab Med*. 2013;137:668–84. <https://doi.org/10.5858/arpa.2012-0263-RA>.
71. Bishop JA, Teruya-Feldstein J, Westra WH, Pelosi G, Travis WD, Rekhtman N. p40 ( $\Delta$ Np63) is superior to p63 for the diagnosis of pulmonary squamous cell carcinoma. *Mod Pathol*. 2012;25:405–15. <https://doi.org/10.1038/modpathol.2011.173>.
72. Folch E, Yamaguchi N, VanderLaan PA, Kocher ON, Boucher DH, Goldstein MA, et al. Adequacy of lymph node transbronchial needle aspirates using convex probe endobronchial ultrasound for multiple tumor genotyping techniques in non-small-cell lung cancer. *J Thorac Oncol*. 2013;8:1438–44. <https://doi.org/10.1097/JTO.0b013e3182a471a9>.
73. Coley SM, Crapanzano JP, Saqi A. FNA, core biopsy, or both for the diagnosis of lung carcinoma: obtaining sufficient tissue for a specific diagnosis and molecular testing. *Cancer Cytopathol*. 2015;123:318–26. <https://doi.org/10.1002/ency.21527>.
74. Wang S, Yu B, Ng CC, Mercorella B, Selinger CI, O'Toole SA, et al. The suitability of small biopsy and cytology specimens for EGFR and other mutation testing in non-small cell lung cancer. *Transl Lung Cancer Res*. 2015;4:119–25. <https://doi.org/10.3978/j.issn.2218-6751.2015.01.05>.
75. Vanderlaan PA, Yamaguchi N, Folch E, Boucher DH, Kent MS, Gangadharan SP, et al. Success and failure rates of tumor genotyping techniques in routine pathological samples with non-small-cell lung cancer. *Lung Cancer*. 2014;84:39–44. <https://doi.org/10.1016/j.lungcan.2014.01.013>.
76. Sholl LM, Aisner DL, Varella-Garcia M, Berry LD, Dias-Santagata D, Wistuba II, et al. Multi-institutional oncogenic driver mutation analysis in lung adenocarcinoma: the lung cancer mutation consortium experience. *J Thorac Oncol*. 2015;10:768–77. <https://doi.org/10.1097/JTO.0000000000000516>.
77. Solomon BJ, Kim DW, Wu YL, Nakagawa K, Mekhail T, Felip E, et al. Final overall survival analysis from a study comparing first-line crizotinib versus chemotherapy in ALK-mutation-positive non-small-cell lung cancer. *J Clin Oncol*. 2018;36:2251–8. <https://doi.org/10.1200/JCO.2017.77.4794>.
78. Liam CK, Mallawathantri S, Fong KM. Is tissue still the issue in detecting molecular alterations in lung cancer? *Respirology*. 2020;25:933–43. <https://doi.org/10.1111/resp.13823>.
79. Vogelstein B, Papadopoulos N, Velculescu VE, Zhou S, Diaz LA Jr, Kinzler KW. Cancer genome landscapes. *Science*. 2013;339:1546–58. <https://doi.org/10.1126/science.1235122>.
80. de Bruin EC, McGranahan N, Swanton C. Analysis of intratumor heterogeneity unravels lung cancer evolution. *Mol Cell Oncol*. 2015;2:e985549. <https://doi.org/10.4161/23723556.2014.985549>.
81. Bilaceroglu S. Molecular markers in lung cancer: role of EBUS. *Curr Opin Pulm Med*. 2017;23:247–53. <https://doi.org/10.1097/MCP.0000000000000376>.
82. Jung CY. Biopsy and mutation detection strategies in non-small cell lung cancer. *Tuberc Respir Dis (Seoul)*. 2013;75:181–7. <https://doi.org/10.4046/trd.2013.75.5.181>.
83. Fielding D, Dalley AJ, Bashirzadeh F, Singh M, Nandakumar L, McCart Reed AE, et al. Diff-Quik cytology smears from endobronchial ultrasound transbronchial needle aspiration lymph node specimens as a source of DNA for next-generation sequencing instead of cell blocks. *Respiration*. 2019;97:525–39. <https://doi.org/10.1159/000495661>.
84. Tan AC, Lai GGY, Tan GS, Poon SY, Doble B, Lim TH, et al. Utility of incorporating next-generation

- sequencing (NGS) in an Asian non-small cell lung cancer (NSCLC) population: incremental yield of actionable alterations and cost-effectiveness analysis. *Lung Cancer*. 2020;139:207–15. <https://doi.org/10.1016/j.lungcan.2019.11.022>.
85. Smeltzer MP, Wynes MW, Lantuejoul S, Soo R, Ramalingam SS, Varella-Garcia M, et al. The International association for the study of lung cancer global survey on molecular testing in lung cancer. *J Thorac Oncol*. 2020;15:1434–48. <https://doi.org/10.1016/j.jtho.2020.05.002>.
86. Imyanitov EN, Iyevleva AG, Levchenko EV. Molecular testing and targeted therapy for non-small cell lung cancer: current status and perspectives. *Crit Rev Oncol Hematol*. 2021;157:103194. <https://doi.org/10.1016/j.critrevonc.2020.103194>.
87. Di Capua D, Bracken-Clarke D, Ronan K, Baird AM, Finn S. The liquid biopsy for lung cancer: state of the art, limitations and future developments. *Cancers (Basel)*. 2021;13:3923. <https://doi.org/10.3390/cancers13163923>.
88. Ofiara LM, Navasakulpong A, Beaudoin S, Gonzalez AV. Optimizing tissue sampling for the diagnosis, subtyping, and molecular analysis of lung cancer. *Front Oncol*. 2014;4:253. <https://doi.org/10.3389/fonc.2014.00253>.
89. Albanna AS, Kasymjanova G, Robitaille C, Cohen V, Brandao G, Pepe C, et al. Comparison of the yield of different diagnostic procedures for cellular differentiation and genetic profiling of non-small-cell lung cancer. *J Thorac Oncol*. 2014;9:1120–5. <https://doi.org/10.1097/JTO.0000000000000230>.



# The Newly Proposed Lung Cancer TNM Classification: Review and Clinical Implications

# 19

Roberto F. Casal and Rodolfo F. Morice

## History

The tumor-node-metastases (TNM) staging system currently applied to almost all solid malignancies was coined by Dr. Pierre Denoix in the 1940s [1]. As chair of the Union Internationale Contre Le Cancer (UICC) staging committee, he coordinated the standardization of TNM staging for 23 solid organ cancers [2]. The first proposal for lung cancer TNM staging was developed by Dr. Clifton Mountain, and adopted by the American joint Committee on Cancer (AJCC) and the UICC in 1973 and 1974, respectively [3]. This original system was based on outcome data from a single institution (M.D. Anderson Cancer Center, Houston, TX, USA) and a limited number of patients (2155, 1712 with non-small cell lung cancer-NSCLC). Three subsequent revisions occurred in the following 25 years, all based on Dr. Mountain's database continued to grow up to 5319 cases by the time of the last revision in 1997 [4]. Some of the limitations of this system such as the small number of patients—particularly for subgroup analysis—the single institution origin, and lack of external validation, prompted the IASLC to create the IASLC Staging Committee. This group,

composed of international members of all disciplines involved in lung cancer, was set to develop and analyze a more powerful, current, and universal database of patients with lung cancer in order to review its staging. An unrestricted grant from Eli Lilly helped establish the database (the company had no role in data collection or analysis), which was created in collaboration with the CRAB (Cancer research and Biostatistics Office, Seattle, Washington). Sub-committees were formed to retrieve and analyze data on T, N, and M descriptors, prognostic factors, nodal mapping, broncho-pulmonary carcinoid tumor, and small-cell lung cancer (SCLC) [5]. The IASLC recommendations for the seventh TNM staging system were published in a series of articles in the *Journal of Thoracic Oncology* in 2007–2009 [6–16]. While the sixth edition of the AJCC and UICC lung cancer TNM staging system published in 2002 was mainly a review of Dr. Mountain's work, the seventh edition, adopted in January 2010, was based on a truly international database of patients treated by all modalities, with rigorous analysis and validation [11]. Despite the vastness of this database, not all T, N, and M descriptors could be thoroughly analyzed, and this prompted the IASLC Staging and Prognostic Factors Committee to launch a second phase of its Lung Cancer Staging Project with the objective to overcome the limitations of the initial project [17].

R. F. Casal (✉) · R. F. Morice  
Department of Pulmonary Medicine, The University  
of Texas M.D. Anderson Cancer Center,  
Houston, TX, USA  
e-mail: [casal@bcm.edu](mailto:casal@bcm.edu); [rucasal@mdanderson.org](mailto:rucasal@mdanderson.org)



## Data Source and Methodology

A new database was utilized to inform the eighth edition of the TNM classification of lung cancer [17]. This new database consists of 94,708 patients diagnosed from 1999 to 2010. Their data originated from established databases (90,041 patients) or were submitted via the electronic data capture (EDC) system set by Cancer Research and Biostatistics (4667 patients). The inclusion criteria were: new lung cancer diagnosis (not recurrent cancer), adequate follow-up for survival analysis, histological subtyping, and complete clinical (cTNM) and/or pathological (pTNM) staging. Europe contributed 46,560 patients, Asia: 41,705, North America: 4660, Australia: 1593, and South America: 190. This new data came from 35 sources in 16 countries. After excluding 17,552 patients, mainly because of unknown or different histology and incomplete stage information, 77,156 patients (70,967 with NSCLC and 6189 with SCLC) remained for analyses. The majority of these patients (99%) had been collected by consortia or registries, with no patients coming from clinical trials. Nearly 85% of the patients underwent surgical treatment either alone or in combination with chemotherapy or radiotherapy. In this new database, the TNM descriptors were collected according to the seventh edition. In addition, a total of 23 non-anatomical elements were collected to aid with prognostic calculations. These included, among others, patient-related elements (i.e., demographics, lung function tests, performance status, smoking history), tumor-related elements (i.e., T and N SUV max, histology and degree of differentiation, vascular invasion), and environment-related elements (i.e., method of detection, treatment, geographic area of origin). This was done with the idea of combining anatomical and non-anatomical elements for a more accurate prognosis. Although this database includes a smaller number of patients, it is richer than the prior one in details allowing for refinement in the analysis of the different descriptors.

## Proposal for the Revision of T Descriptors

In the NSCLC group, 33,115 patients met the T descriptors subcommittee's initial analytic requirements of M0 NSCLC, a complete set of either clinical (c) TNM or pathological (p) TNM, known tumor size, and sufficiently detailed T descriptors to support the assigned T category [18]. Survival was measured from the date of diagnosis for clinically staged patients and date of surgery for pathologically staged patients and overall survival was assessed with Kaplan–Meier method. Log-rank statistics were derived from hypothetical size cut points, and the highest log-rank statistic was used to select the optimum cut point.

### Tumor Size

The size cut-point of 3 cm was confirmed and retained to differentiate T1 from T2 tumors, and it continues to be the best cut-point for all sizes over all T categories. Five-year survival was analyzed at 1-cm increment in tumor size:  $\leq 1$  cm (92%),  $>1$ –2 cm (83%),  $>2$ –3 cm (76%),  $>3$ –4 cm (67%),  $>4$ –5 cm (60%),  $>5$ –6 cm (56%),  $>6$ –7 cm (46%), and  $> 7$  cm (38%). This analysis showing a progressive decrease in survival for each 1-cm cut-point, led to a new proposal for the T status according to tumor size (see summary of proposed changes in Table 19.1).

### Involvement of the Main Bronchus

Involvement of the main bronchus less than 2 cm from the main carina, without invasion of the carina (currently a T3 descriptor), was found to have better prognosis than other T3 descriptors. The distance from the carina (up to 2 cm or  $>2$  cm) does not seem to increase risk of death after adjusting for tumor size. Hence, it was proposed to group all tumors invading the main bronchi regardless of the distance to the carina—as long as the carina is not invaded—as T2.

**Table 19.1** Proposed descriptors for the eighth TNM classification of lung cancer

Descriptor	Subgroup	Definition
T (tumor)		
T0		No evidence of primary tumor
T1		Tumor $\leq 3$ cm, surrounded by lung or visceral pleura, not more central than the lobar bronchus
	<b>T1a (mi)</b>	<b>Minimally invasive adenocarcinoma</b> (solitary adenocarcinoma $< 3$ cm, with predominant lepidic pattern and $< 5$ mm invasion)
	<b>T1a</b>	$\leq 1$ cm
	<b>T1b</b>	$> 1$ cm and $\leq 2$ cm
	<b>T1c</b>	$> 2$ cm and $\leq 3$ cm
T2		Tumors $> 3$ cm and $\leq 5$ cm or with any of the following features: – <b>Involves main bronchus without invading main carina, regardless distance to main carina</b> – Involves visceral pleura – <b>Associated atelectasis or pneumonitis of part or all lung</b>
	<b>T2a</b>	$> 3$ cm and $\leq 4$ cm
	<b>T2b</b>	$> 4$ cm and $\leq 5$ cm
T3		<b>Tumors <math>&gt; 5</math> cm and <math>\leq 7</math> cm</b> (prior T2b), or with separate nodule(s) in same lobe, invading chest wall, phrenic nerve or parietal pericardium
T4		<b>Tumors <math>&gt; 7</math> cm</b> (prior T3), or with separate nodule(s) in a different ipsilateral lobe, <b>invading diaphragm</b> (prior T3), mediastinum, heart, great vessels, trachea, carina, recurrent laryngeal nerve, esophagus, or vertebral body
N (regional LN)		
N0		No regional metastases
N1		Metastases to ipsilateral peribronchial, perihilar, or intrapulmonary LN
N2		Metastases to subcarinal or ipsilateral mediastinal LN
N3		Metastases to contralateral hilar or mediastinal LN, or involvement of any scalene or supraclavicular LN
M (metastasis)		
M0		No metastasis
M1		Metastasis present
	<b>M1a</b>	Separate nodule(s) in contralateral lung, malignant pleural/pericardial effusion, or pleural/pericardial nodule
	<b>M1b</b>	<b>Single extrathoracic metastasis</b>
	<b>M1c</b>	<b>Multiple extrathoracic metastases in one or more organs</b>

**Note:** changes to the seventh edition of TNM are in bold. LN lymph node. Adapted from Goldstraw et al. [19]

## Involvement of the Diaphragm

Involvement of the diaphragm, a current T3 descriptor, was found to confer a worse prognosis than other T3 descriptors both in clinical and pathological settings. Hence, it is proposed to re-classify involvement of the diaphragm as T4.

## Atelectasis/Pneumonitis

This new analysis showed that complete atelectasis/pneumonitis may have a better prognosis than other T3 descriptors, and besides the small num-

ber of patients with these characteristics, it is proposed to re-classify these patients from T3 to T2. The new proposal is to include in T2 category patients with any degree of atelectasis or pneumonitis.

## Ground Glass/Lepidic Features and Pneumonic Type Tumors

Tumors presenting with ground glass/lepidic pattern (GG/L) and “pneumonic” type infiltrates, are typically multifocal, have different biologic behavior, and they are difficult to classify with

our current TNM. A subcommittee of the IASLC was created to provide a consistent nomenclature for these particular presentations of lung cancer [20]. Since the IASLC database did not capture information on GG/L and pneumonic type tumors, an evidence-based approach was taken, systematically reviewing the literature from 1995 to 2015. Multifocal GG/L lung adenocarcinoma should be classified by the T category of the lesion with the highest T, with the number (#) of lesions or simply (m) for multiple indicated in parentheses. The size is determined by the largest diameter of the solid component (by CT) or the invasive component under the microscope. The designation of Tis should be used for adenocarcinomas in situ (AIS) and T1a (mi) for minimally invasive adenocarcinomas MIA (e.g., T1a (mi) (m) N0 M0). The (#) or (m) is applied regardless of location (e.g., same lobe, different lobe or lung). The T component should include all tumors whether resected or not that are thought to be malignant (either suspected or proved), as well as to those that are only discovered on pathological examination [18]. A single N and M category is applied to all GG/L tumors. Pneumonic-type lung cancer has a worse prognosis than GG/L type, yet nodal or extrathoracic metastases are rare. In cases of pneumonic-type cancers with a single area of tumor, the current TNM is easily applied. Unlike with GG/L tumors, in cases of multiple areas of involvement, the T or M category will be applied: T3 within the same lobe, T4 within different lobe of same lung, M1a in contralateral lung. This classification applies to both grossly and microscopically found tumors. If a tumor crosses a boundary between 2 lobes, a T4 classification should be applied. If a tumor is confined to one lobe but hard to measure, a T3 classification is given.

### Summary of “Proposed” T Changes for the Eighth Edition of the TNM Classification of Lung Cancer

1. The sub-classification of T1 into:
  - (a) T1a: tumor 1 cm or less in greatest dimension.

- (b) T1b: tumor more than 1 cm but not more than 2 cm in greatest dimension.
  - (c) T1c: tumor more than 2 cm but not more than 3 cm in greatest dimension.
2. The sub-classification of T2 into:
  - (a) T2a: tumor more than 3 cm but not more than 4 cm in greatest dimension.
  - (b) T2b: tumor more than 4 cm but not more than 5 cm in greatest dimension.
3. The re-classification of tumors more than 5 cm but not more than 7 cm in greatest dimension as T3.
4. The re-classification of tumors more than 7 cm in greatest dimension as T4.
5. The grouping of the involvement of the main bronchus as a T2 descriptor, regardless of distance from the carina, but without invasion of the carina.
6. The grouping of partial and total atelectasis or pneumonitis as a T2 descriptor.
7. The re-classification of diaphragm invasion as T4.
8. Multiple GG/L tumors should be given the T category of the largest lesion with the number of lesions between parenthesis or simply (m) next to the T category, with bilateral lesions not considered as M1a.
9. Both clinical and pathological information (when available) should be applied to GG/L tumors when describing the TNM.
10. Pneumonic-type tumors are classified according to the size of the involved area, and they follow the standard definitions of T3, T4, and M1a for lesions in different lobes.

---

### Proposal for the Revision of N Descriptors

Nodal status continues to be one of the most reliable indicators of prognosis in lung cancer, and it is a major determinant of the optimal therapeutic option. The seventh edition of the TNM staging categorized the N status based on the location of the involved lymph nodes (LN) as N0 (no LN involved), N1 (ipsilateral hilar LN involvement), N2 (ipsilateral mediastinal LN involvement), and

N3 (contralateral hilar or mediastinal, or ipsilateral/contralateral supraclavicular LN involvement), regardless the number of LN involved. This seventh edition of the TNM also accepted the IASLC Nodal Map as the standard of care to describe LN involvement in lung cancer [9, 11]. The new database was analyzed to corroborate the prognostic ability of the current N categorization and to explore if there is a more sophisticated method for describing LN involvement [21]. Among 70,976 patients with NSCLC, data on the “N component” were available in 38,910 (54.8%) patients for “clinical” nodal (cN) status and in 31,426 (44.3%) patients for pathological nodal (pN) status. Of note, Japan submitted the most data, which consisted of 23,012 (59.1%) patients for cN status and 23,463 (74.7%) patients for pN status, in which the “Naruke-Japanese map” was exclusively used to designate the location of metastatic lymph nodes and to determine the nodal status [22]. Despite the fact that in 2009 the new international lymph node map (IASLC map) was promulgated by the IASLC and recommended by the seventh edition of the TNM, this map was rarely utilized. With the collected data it was not possible to reconcile the discrepancies between the 2 maps.

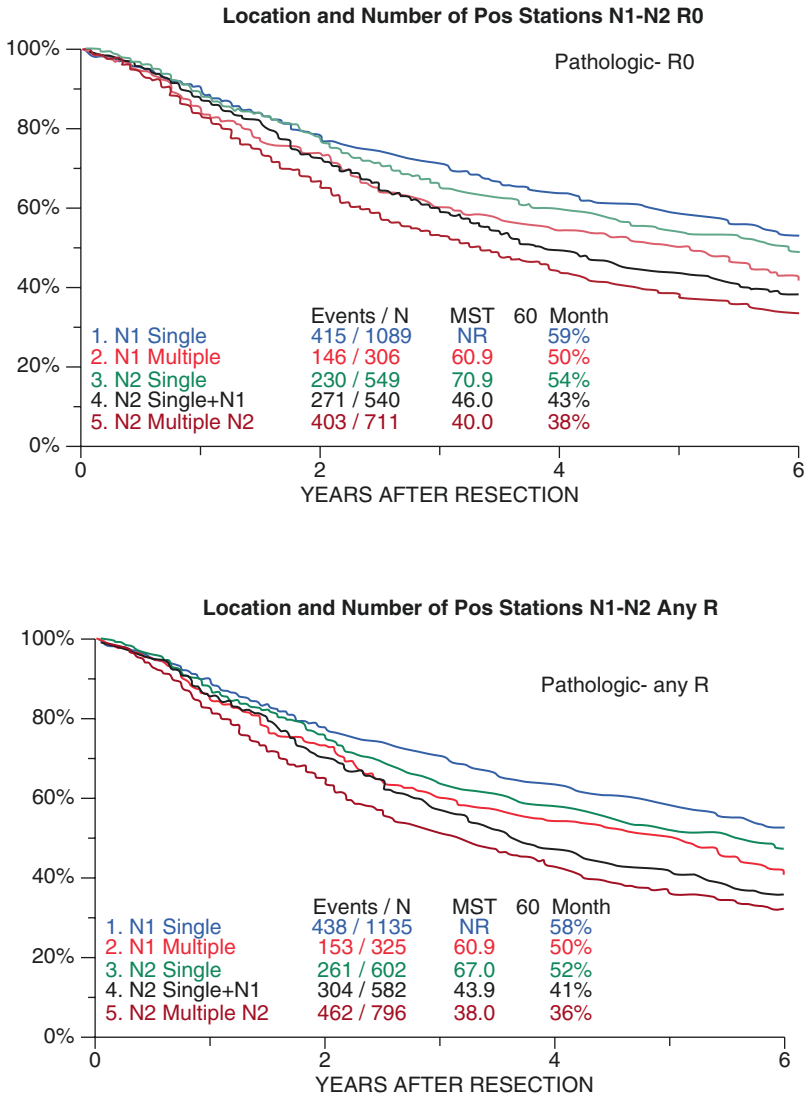
## Nodal Staging

Clear differences in overall survival were evidenced again in the new database for both clinically and pathologically staged cases, supporting the traditional classification of N0, N1, N2, and N3, without changes from the seventh TNM (new 5-year survival rates were 60%/75% for cN0/pN0; 37%/49% for cN1/pN1; 23%/36% for cN2/pN2; and 9%/20% for cN3/pN3). For T1 and T2 tumors, cN status continued to show a difference in prognosis for each category. For T3 and T4 tumors there was no statistically significant difference between cN0 and cN1, but there was a difference between cN1 and cN2, and cN2 and cN3. Further analyses were performed to explore the prognostic impact of combining the number of involved LN stations with the current nodal

categories in T-any M0 patients. Unfortunately, this specific data on the number of involved stations was only available on pathological data, and not clinical. Pathological N categories were further subdivided: pN1 was divided into pN1 single (pN1a) and pN1 multiple (pN1b) and pN2 was divided into pN2 single (pN2a) and pN2 multiple (pN2b). The survival curves for pN1b and pN2a overlapped, with 5-year survival rates of 50% and 49% for R0 resections, respectively (Fig. 19.1). The presence of skip metastasis was further taken into consideration: pN2a was divided into pN2 single with skip (no pN1 involvement, pN2a1), pN2 single without skip (pN1 involvement as well, pN2a2), and pN2b. There was a statistically significant difference in 5-year survival between pN2a1 (skip) and pN2a2 (no skip) (54% vs. 43%, respectively). However, there was no significant difference in prognosis between pN1b and pN2a1 (50% vs. 52%, respectively). These results indicated that the prognosis of pN2a1 (skip metastasis) was close to that of pN1b (multiple N1 stations). Since these interesting findings derived from pathological data and could not be corroborated in clinical staging, they could not be utilized to propose modifications in the N descriptors. Moreover, the analysis on the N descriptor was thought to be partly hampered by differences between the Naruke and the MD-ATS nodal maps.

## Summary of “Proposed” N Changes for the Eighth Edition of the TNM Classification of Lung Cancer

- No changes were made in N descriptors, retaining the traditional N0, N1, N2, and N3.
- Further N category classification based on single vs. multiple involved stations and presence or absence of skip metastases needs further prospective evaluation before it can be applied to our TNM system.
- The IASLC nodal map recommended by the seventh edition of TNM continues to be recommended to provide precise anatomic definitions for all LN stations.



**Fig. 19.1** Analysis of survival in patients with pN1 and pN2 disease with single and multiple station involvement, both for R0 and any R resections. R0 = complete resection. Any R = complete and incomplete resections. (Copyright IASCL 2015)



## Proposal for the Revision of M Descriptors

Since the database generated for the seventh edition of the TNM, there have been multiple advances in diagnosis, staging, and management of lung cancer. The widespread use of PET-CT and MRI, the more precise local radiation therapies, the advent of minimally invasive surgery, and the individualized molecular-targeted oncologic treatments has changed our approach to patients with advanced disease. With the new and prospectively collected database being much richer than the prior one, the IASLC Staging and Prognostic Factors Committee has revised the M descriptors focusing on the burden of metastatic disease [23]. While data from 2411 non-resected M1 patients was available for analysis, only 1059 patients submitted through EDC had the specific data required to assess the objectives set out by IASLC, and the analysis was restricted to this group of patients. Median follow-up for M1a and M1b cases in the EDC was 29.3 months. Overall survival was measured since the day of diagnosis for clinically staged patients and survival was estimated with Kaplan–Meier method. The analysis corroborated the difference in prognosis between the seventh edition TNM M1a (pleural/pericardial effusions, contralateral/bilateral tumor nodules, pleural/pericardial nodules) and M1b patients (extrathoracic metastases). The former category showed a median survival of 11.5 months and the latter 7.5 months. In addition, the new database showed that patients with a single extrathoracic metastatic site had a similar survival to patients with M1a disease (median survival of 11.4 months), and much better survival than those patients with multiple extrathoracic metastases (median of 6.3 months). This prompted the reclassification of extrathoracic

disease into M1b (single metastasis) and M1c (multiple metastatic disease in one organ or metastasis in multiple organs).

## Summary of “Proposed” M Changes for the Eighth Edition of the TNM Classification of Lung Cancer

- Maintain M1a category (pleural/pericardial effusions, contralateral/bilateral tumor nodules, pleural/pericardial nodules).
- Reclassify current M1b category for patients with a single extrathoracic metastatic lesion.
- Introduce the new category M1c for patients with extrathoracic metastatic disease characterized by either multiple lesions in a single organ or lesions in multiple organs.

---

## Proposal for the Revision of Stage Groupings

Based on the previously described proposed changes to T and M descriptors (Table 19.1), new subsets of group stages were also developed [19]. Proposed TNM stage groupings were evaluated for survival based on clinical, pathologic, and best-stage. Survival was calculated with Kaplan–Meier method, and it was measured from date of diagnosis for clinically staged tumors and from date of surgery for pathologically staged tumors. The newly proposed stage groupings are summarized in Table 19.2. The proposed changes in T or M categories are translated into multiple migrations between stage groups. These migrations are highlighted with up or down arrows in Table 19.2. The overall survival for clinical and pathological stage in the proposed stage grouping of the eighth edition of TNM is summarized in Table 19.3.

**Table 19.2** Proposed stage groupings for the eighth TNM classification of lung cancer

Seventh TNM descriptor	Proposed eighth TNM descriptor	N0	N1	N2	N3
T1 ≤1 cm	T1a	<b>IA1</b> (IA)	<b>IIB</b> (IIA) ▲	IIIA	IIIB
T1 >1–2 cm	T1b	<b>IA2</b> (IA)	<b>IIB</b> (IIA) ▲	IIIA	IIIB
T1 >2–3 cm	T1c	<b>IA3</b> (IA)	<b>IIB</b> (IIA) ▲	IIIA	IIIB
T2 >3–4 cm	T2a	IB	<b>IIB</b> (IIA) ▲	IIIA	IIIB
T2 >4–5 cm	T2b	<b>IIA</b> (IB) ▲	<b>IIB</b> (IIA) ▲	IIIA	IIIB
T2 >5–7 cm	T3	<b>IIB</b> (IIA) ▲	<b>IIIA</b> (IIB) ▲	<b>IIIB</b> (IIIA) ▲	<b>IIIC</b> (IIIB) ▲
T3 >7 cm	T4	<b>IIIA</b> (IIB) ▲	IIIA	<b>IIIB</b> (IIIA) ▲	<b>IIIC</b> (IIIB) ▲
T3 endobronchial 3–4 cm (location/atelectasis)	T2a	<b>IB</b> (IIB) ▼	<b>IIB</b> (IIIA) ▼	IIIA	IIIB
T3 endobronchial 4–5 cm (location/atelectasis)	T2b	<b>IIA</b> (IIB) ▼	<b>IIB</b> (IIIA) ▼	IIIA	IIIB
T3 invasion	T3	IIB	IIIA	<b>IIIB</b> (IIIA) ▲	<b>IIIC</b> (IIIB) ▲
T3 diaphragm invasion	T4	<b>IIIA</b> (IIB) ▲	IIIA	<b>IIIB</b> (IIIA) ▲	<b>IIIC</b> (IIIB) ▲
T4	T4	IIIA	IIIA	IIIB	<b>IIIC</b> (IIIB) ▲
M1a	M1a	<b>IVA</b> (IV)	<b>IVA</b> (IV)	<b>IVA</b> (IV)	<b>IVA</b> (IV)
M1b single metastasis	M1b	<b>IVA</b> (IV)	<b>IVA</b> (IV)	<b>IVA</b> (IV)	<b>IVA</b> (IV)
M1b multiple metastases	M1c	<b>IVB</b> (IV) ▲	<b>IVB</b> (IV) ▲	<b>IVB</b> (IV) ▲	<b>IVB</b> (IV) ▲

**Note:** Stage migrations are bolded, prior stage is within parenthesis, arrows indicate up or down-staging  
 Adapted from Goldstraw et al [19]

**Table 19.3** Overall survival by clinical and pathological stage according to the proposed eighth TNM stage groupings

Proposed stage	MST (months) (clinical/pathological)	24 month survival rate (%) (clinical/pathological)	60 month survival rate (%) (clinical/pathological)
<b>IA1</b>	NA/NA	97/97	92/90
<b>IA2</b>	NA/NA	94/94	83/85
<b>IA3</b>	NA/NA	90/92	77/80
<b>IB</b>	NA/NA	87/89	68/73
<b>IIA</b>	NA/NA	79/82	60/65
<b>IIB</b>	66/NA	72/76	53/56
<b>IIIA</b>	29.3/41.9	55/65	36/41
<b>IIIB</b>	19/22	44/47	26/24
<b>IIIC</b>	12.6/11	24/30	13/12
<b>IVA</b>	11.5/NA	23/NA	10/NA
<b>IVB</b>	6/NA	10/NA	0/NA

MST median survival time, NA not available

### Small Cell Lung Cancer (SCLC)

SCLC represents approximately 15% of all lung cancers. Since SCLC is rarely amenable for surgery, the use of TNM staging for SCLC is seldom utilized, and for simplicity, disease is either referred to as “limited” (LD) or “extensive” (ED). The former corresponds to disease confined to one hemithorax with or without ipsilateral LN or

pleural effusion, and the latter to all other cases. This broad classification can potentially hide patients who would benefit from more aggressive therapies [5, 8]. The results of the analyses performed by this IASLC subcommittee confirmed that TNM staging closely correlates with survival of SCLC by stage, identifies patients with different prognosis, and can be applied to surgically managed patients [5, 8]. Hence, the seventh edi-

tion of TNM recommended applying the TNM criteria, particularly to early SCLC. The proposed revision for the eighth edition of TNM classification discussed above was applied to SCLC [24]. A total of 5002 patients, of which 4848 were clinically staged, 582 pathologically staged and 428 both clinically and pathologically staged were included. The proposed changes to T and M descriptors were able to discriminate as well as the prior ones (seventh edition). The revision of the TNM stages was also evaluated in this new database; however, some stage categories were underrepresented. Statistically significant differences in prognosis were only seen between stages IIB and IIIA, and between stages IIIC and IV. The IASLC committee continues to recommend the use of TNM classification for patients with SCLC who have limited disease.

---

## Discussion

The seventh TNM staging system represented a major step forward in lung cancer care with a clear progression from previous versions of the staging system. Despite its large size, the database utilized for this seventh edition of TNM was purely retrospective and not all descriptors could be validated. This prompted the creation of a new database that gathered both prospective and retrospective data and that were utilized to inform the eighth revision of the TNM. Multiple changes in T descriptors, M descriptors, and group stages are being proposed for the eighth edition, and, of course, with these changes the new TNM system has inevitably gained higher complexity. We will briefly discuss some limitations and clinical implications of the methodology and different descriptors.

## Methodology

Though the IASLC Staging and Prognostic Factors Committee is devoted to prospectively collecting data that is specifically designed to revise the TNM, the added complexity of such data has led to the continuous utilization of retro-

spective sources of data that was collected for other purposes. Of note, although the new database continues to be international in nature, it has a higher proportion of patients from Asia (mostly from Japan, contributing to 41%), which has increased the proportion of patients receiving surgery as part of their treatment from 53% to 85%. In addition, there was an increase in the number of cases coming from registries and a lack of cases from clinical trials. These variations resulted in an increased stage-for-stage survival in all stages and a decrease in survival for advanced stages. The migration of descriptors and stages has sacrificed backwards compatibility with previous TNM staging. This backward incompatibility makes it difficult to extrapolate established treatment algorithms to the new stage groupings. However, it is important to remember that stage alone does not dictate treatment. Changes to treatment algorithms based on new stages should be assessed in clinical trials [11]. Although many people might expect a staging system to be able to allocate patients to different treatment strategies, this would only be an oversimplification of lung cancer management. The TNM staging system has a limited capacity to define prognosis with a particular treatment and it was not intended to do so. Optimal treatment can only be defined with clinical trials. Suitability for a particular therapy is based on the interaction of different factors: patient-related (i.e., performance status), tumor-related, and therapy-related.

## T Descriptors

The proposal for the eighth TNM has clearly reinforced the crucial impact that tumor size has on prognosis, with well-defined and validated new cut-points. The survival analyses according to 1-cm cut points showed that from 1 to 5 cm, every cm counts, the larger the tumor the worse the prognosis. In lung cancer screening programs, where 60–70% of lung cancers are detected in stage I, recognizing the difference in prognosis of these smaller tumors is highly relevant [25]. While data regarding the involvement of the main bronchus that informed the seventh edition of

TNM was not reliable, a distinction was made based on the distance to the carina (T3 if <2 cm, T2 if 2 cm or more). The new database has proven that the prognosis is the same, regardless of the distance from the carina (as long as the carina is not involved), hence simplifying this descriptor to a single T2. Though invasion of the diaphragm has been grouped in T3 invasion by the seventh TNM, it has been shown to confer worse prognosis and it has been up-staged to T4 in the proposed revision. Complete atelectasis was now shown to have a similar prognosis as partial atelectasis, and they were grouped together as T2. It is important to notice that there is a paucity of patients in this new database that underwent chemotherapy or radiation therapy as the sole treatment modality. Since the prognostic implications of these different T descriptors may differ when different therapies are applied, the generalizability of the new database findings is reduced.

## N Descriptors

No major changes resulted from the analyses of the N descriptors and it was proposed that the current N0, N1, N2, N3 definitions were carried to the eighth edition of TNM without modifications [21]. While the number of involved LN (tumor burden) is relevant in the nodal categorization of most tumors, for lung cancer the N category is solely based on the location of the involved LN. Unfortunately, this new database did not have information regarding the exact number of LN involved. However, data on the number of LN “stations” was available from a few institutions and further analysis was performed, evaluating the prognosis of single vs. multiple LN stations at N1 and N2 levels, and the prognosis of skip metastasis (N2 without N1). Patients with multiple N1 stations were found to have a similar prognosis as those with a single N2 station and patients with skip N2 metastases were found to have a better prognosis than those without skip metastases (who had N1 in addition to N2 disease). A major limitation of the new database with regard to the N descriptors is that roughly two-thirds of the cases originated in Japan, where, despite the rec-

ommendations of the seventh TNM of adopting the IASLC lymph node map, the Naruke map was utilized [22]. One of the major discrepancies between the Naruke map and the IASLC map is that the Naruke map considers LN in the subcarinal space along the inferior border of the main stem bronchus to be station 10 (hence, N1), whereas these are considered as station 7 (and, therefore, N2) in the well-established IASLC nodal map. Thus, the above findings based on single vs. multiple stations or skip metastases were not proposed as changes for the eighth edition TNM. The IASLC staging manual requires that 3 mediastinal and three N1 lymph nodes or stations be sampled. What remains unclear is whether they refer to the number of individual nodes or stations, which can create a significant difference in staging. Unfortunately, to date, there is no validated data to support a specific number of LN or stations to be sampled, and systematic intraoperative node assessment is recommended by clinical guidelines [9, 11].

## M Descriptors

The new database was able to specifically analyze the prognostic impact of the burden of metastatic disease [23]. Single metastatic disease (M1b) was found to have a prognosis similar to that of M1a (pleural/pericardial effusion or nodules, or contralateral lung nodule). Though metastatic disease to the adrenals seemed to confer a worse prognosis (in comparison to other organs), this could not be confirmed in all patient groups. Multiple metastases in one or multiple organs (M1c) were found to confer a worse survival in comparison to single metastatic disease. While retrospective data had already suggested this difference in prognosis between single and multiple metastases in lung cancer, this is the first time the concept is validated prospectively [26–28]. Future collection of the exact number of metastatic sites, size of metastatic lesions, pathological confirmation of lesions, and number of involved organs may help us discriminate subsets of patients with more favorable prognosis that may benefit from potentially curative therapies within clinical trials [23].

## Summary

The UICC seventh edition of the TNM Classification System was undoubtedly a major improvement in our scientific basis for the staging of lung cancer, supported by a large international database and subject to thorough internal and external validation process. The much richer and prospectively collected database that supports the recommendations for the eighth edition TNM has allowed the IASLC committees to propose multiple key modifications to the T and M descriptors as well as to the stage groupings. As these proposals are accepted and placed in practice, more ambiguities will come up to light, and it is paramount to gather, scrutinize, and share this data to better comprehend the limitations of this TNM system and to rise above them.

## References

1. Denoix P. The TNM staging system. *Bull Inst Natl Hyg.* 1952;7:743.
2. Carson J, Finley DJ. Lung cancer staging: an overview of the new staging system and implications for radiographic clinical staging. *Semin Roentgenol.* 2011;46(3):187–93.
3. Mountain CF, Carr DT, Anderson WA. A system for the clinical staging of lung cancer. *Am J Roentgenol Radium Ther Nucl Med.* 1974;120(1):130–8.
4. Mountain CF. Revisions in the international system for staging lung cancer. *Chest.* 1997;111(6):1710–7.
5. Deterbeck FC, Boffa DJ, Tanoue LT. The new lung cancer staging system. *Chest.* 2009;136(1):260–71.
6. Groome PA, Bolejack V, Crowley JJ, Kennedy C, Krasnik M, Sobin LH, et al. The IASLC lung cancer staging project: validation of the proposals for revision of the T, N, and M descriptors and consequent stage groupings in the forthcoming (seventh) edition of the TNM classification of malignant tumours. *J Thorac Oncol.* 2007;2(8):694–705.
7. Postmus PE, Brambilla E, Chansky K, Crowley J, Goldstraw P, Patz EF Jr, et al. The IASLC lung cancer staging project: proposals for revision of the M descriptors in the forthcoming (seventh) edition of the TNM classification of lung cancer. *J Thorac Oncol.* 2007;2(8):686–93.
8. Rami-Porta R, Ball D, Crowley J, Giroux DJ, Jett J, Travis WD, et al. The IASLC lung cancer staging project: proposals for the revision of the T descriptors in the forthcoming (seventh) edition of the TNM classification for lung cancer. *J Thorac Oncol.* 2007;2(7):593–602.
9. Rusch VW, Crowley J, Giroux DJ, Goldstraw P, Im JG, Tsuboi M, et al. The IASLC lung cancer staging project: proposals for the revision of the N descriptors in the forthcoming seventh edition of the TNM classification for lung cancer. *J Thorac Oncol.* 2007;2(7):603–12.
10. Chansky K, Sculier JP, Crowley JJ, Giroux D, Van Meerbeeck J, Goldstraw P. The International association for the study of lung cancer staging project: prognostic factors and pathologic TNM stage in surgically managed non-small cell lung cancer. *J Thorac Oncol.* 2009;4(7):792–801.
11. Rusch VW, Asamura H, Watanabe H, Giroux DJ, Rami-Porta R, Goldstraw P. The IASLC lung cancer staging project: a proposal for a new international lymph node map in the forthcoming seventh edition of the TNM classification for lung cancer. *J Thorac Oncol.* 2009;4(5):568–77.
12. Travis WD, Brambilla E, Rami-Porta R, Vallieres E, Tsuboi M, Rusch V, et al. Visceral pleural invasion: pathologic criteria and use of elastic stains: proposal for the 7th edition of the TNM classification for lung cancer. *J Thorac Oncol.* 2008;3(12):1384–90.
13. Travis WD, Giroux DJ, Chansky K, Crowley J, Asamura H, Brambilla E, et al. The IASLC lung cancer staging project: proposals for the inclusion of broncho-pulmonary carcinoid tumors in the forthcoming (seventh) edition of the TNM classification for lung cancer. *J Thorac Oncol.* 2008;3(11):1213–23.
14. Vallieres E, Shepherd FA, Crowley J, Van Houtte P, Postmus PE, Carney D, et al. The IASLC lung cancer staging project: proposals regarding the relevance of TNM in the pathologic staging of small cell lung cancer in the forthcoming (seventh) edition of the TNM classification for lung cancer. *J Thorac Oncol.* 2009;4(9):1049–59.
15. Goldstraw P, Crowley J, Chansky K, Giroux DJ, Groome PA, Rami-Porta R, et al. The IASLC lung cancer staging project: proposals for the revision of the TNM stage groupings in the forthcoming (seventh) edition of the TNM classification of malignant tumours. *J Thorac Oncol.* 2007;2(8):706–14.
16. Shepherd FA, Crowley J, Van Houtte P, Postmus PE, Carney D, Chansky K, et al. The International association for the study of lung cancer lung cancer staging project: proposals regarding the clinical staging of small cell lung cancer in the forthcoming (seventh) edition of the tumor, node, metastasis classification for lung cancer. *J Thorac Oncol.* 2007;2(12):1067–77.
17. Rami-Porta R, Bolejack V, Giroux DJ, Chansky K, Crowley J, Asamura H, et al. The IASLC lung cancer staging project: the new database to inform the eighth edition of the TNM classification of lung cancer. *J Thorac Oncol.* 2014;9(11):1618–24.
18. Rami-Porta R, Bolejack V, Crowley J, Ball D, Kim J, Lyons G, et al. The IASLC lung cancer staging project: proposals for the revisions of the T descriptors in the forthcoming eighth edition of the TNM classification for lung cancer. *J Thorac Oncol.* 2015;10(7):990–1003.



19. Goldstraw P, Chansky K, Crowley J, Rami-Porta R, Asamura H, Eberhardt WE, et al. The IASLC lung cancer staging project: proposals for revision of the TNM stage groupings in the forthcoming (eighth) edition of the TNM classification for lung cancer. *J Thorac Oncol.* 2016;11(1):39–51.
20. Detterbeck FC, Marom EM, Arenberg DA, Franklin WA, Nicholson AG, Travis WD, et al. The IASLC lung cancer staging project: background data and proposals for the application of TNM staging rules to lung cancer presenting as multiple nodules with ground glass or lepidic features or a pneumonic-type of involvement in the forthcoming eighth edition of the TNM classification. *J Thorac Oncol.* 2016;11(5):666–80.
21. Asamura H, Chansky K, Crowley J, Goldstraw P, Rusch VW, Vansteenkiste JF, et al. The International association for the study of lung cancer lung cancer staging project: proposals for the revision of the N descriptors in the forthcoming 8th edition of the TNM classification for lung cancer. *J Thorac Oncol.* 2015;10(12):1675–84.
22. Naruke T, Suemasu K, Ishikawa S. Lymph node mapping and curability at various levels of metastasis in resected lung cancer. *J Thorac Cardiovasc Surg.* 1978;76(6):832–9.
23. Eberhardt WE, Mitchell A, Crowley J, Kondo H, Kim YT, Turrisi A 3rd, et al. The IASLC lung cancer staging project: proposals for the revision of the M descriptors in the forthcoming eighth edition of the TNM classification of lung cancer. *J Thorac Oncol.* 2015;10(11):1515–22.
24. Nicholson AG, Chansky K, Crowley J, Beyruti R, Kubota K, Turrisi A, et al. The International association for the study of lung cancer lung cancer staging project: proposals for the revision of the clinical and pathologic staging of small cell lung cancer in the forthcoming eighth edition of the TNM classification for lung cancer. *J Thorac Oncol.* 2016;11(3):300–11.
25. National Lung Screening Trial Research T, Aberle DR, Adams AM, Berg CD, Black WC, Clapp JD, et al. Reduced lung-cancer mortality with low-dose computed tomographic screening. *N Engl J Med.* 2011;365(5):395–409.
26. Bonnette P, Puyo P, Gabriel C, Giudicelli R, Regnard JF, Riquet M, et al. Surgical management of non-small cell lung cancer with synchronous brain metastases. *Chest.* 2001;119(5):1469–75.
27. Gray PJ, Mak RH, Yeap BY, Cryer SK, Pinnell NE, Christianson LW, et al. Aggressive therapy for patients with non-small cell lung carcinoma and synchronous brain-only oligometastatic disease is associated with long-term survival. *Lung Cancer.* 2014;85(2):239–44.
28. Congedo MT, Cesario A, Lococo F, De Waure C, Apolone G, Meacci E, et al. Surgery for oligometastatic non-small cell lung cancer: long-term results from a single center experience. *J Thorac Cardiovasc Surg.* 2012;144(2):444–52.

---

**Part V**

**Diagnosing and Staging of Lung Cancer**



# Bronchoscopy Role in the Evaluation of Peripheral Pulmonary Lesions: An Overview

Stefano Gasparini and Lina Zuccatosta

## Introduction

The definition of peripheral pulmonary lesion (PPL) is generally used to indicate an area of consolidation (nodule, mass, infiltrates, or ground glass opacity) located in the peripheral one-third of the lung. Since a well precise radiological landmark that is able to distinguish central from peripheral lesions has not yet been defined, from the bronchoscopic point of view a PPL implies a lesion that originates outside the visible range of a standard flexible bronchoscope.

The widespread use of chest CT scan and the advent of lung cancer screening programs with low-dose CT, have greatly increased the detection of PPLs allowing to identify even small sub-centimeter lesions. The results of lung cancer screening projects show that the discovery of noncalcified PPLs is very common in asymptomatic smokers or ex-smokers (20–50%). Even if in patients without any previous history of cancer less than 1% of PPLs <5 mm are malignant, the

likelihood of malignancy increases with lesion size, being 18% for lesions between 8 and 20 mm and reaching value of about 80% for PPLs greater than 20 mm [1].

Although some guidelines on diagnosis and management of lung cancer suggest an immediate surgical resection when a PPL has a moderate or high probability of malignancy by imaging features and/or by PET positivity, most of the patients have an indeterminate pattern of the lesion and/or are poor candidate for surgery due to age or comorbidities. Consequently, in clinical practice, a bioptic approach with cytohistological definition of a PPL is often required.

A PPL may be approached for bioptic purposes both percutaneously and transbronchially.

The percutaneous or transthoracic biopsy, generally performed under CT guidance, will be the topic of a dedicated chapter in this book. It is well known that the percutaneous approach of PPLs has a better diagnostic sensitivity in comparison to the transbronchial approach, but it does not provide any information about staging (central airways involvement and/or simultaneous central endobronchial lesions) and it is burdened by a higher incidence of complications, especially pneumothorax [1].

The role of bronchoscopy with exploration of central airways in the diagnostic pathway of PPLs is still debated.

In an old retrospective study performed on 91 patients with a PPL less than 6 cm in size,

---

S. Gasparini (✉)

Department of Public Health and Biomedical Sciences, Polytechnic University of Marche Region, Ancona, Italy

Pulmonary Diseases Unit, Department of Internal Medicine, Azienda “Ospedali Riuniti”, Ancona, Italy  
e-mail: [s.gasparini@fastnet.it](mailto:s.gasparini@fastnet.it)

L. Zuccatosta

Pulmonary Diseases Unit, Department of Internal Medicine, Azienda “Ospedali Riuniti”, Ancona, Italy

Torrington et al. [2] did not find by preoperative bronchoscopy any relevant information that changed the stage of the diseases and that obviate the need for surgery. On the contrary, in a study on 64 patients with peripheral bronchogenic carcinoma, Arsitizabal et al. [3] detected by bronchoscopy unsuspected endobronchial lesions on CT in 17% of patients and three of these patients had a nodule less than 3 cm in size. Chhaged et al., retrospectively, assessed the role of bronchoscopy in nodules less than 3 cm and they observed additional endobronchial tumors manifestations in 8% of cases [4]. In another study, Schwarz et al. [5] detected unsuspected endobronchial involvement in 5.5% of 181 patients with peripheral lung cancer, and flexible bronchoscopy changed the planned surgical approach in five cases. Furthermore, the authors found during bronchoscopy anatomic variant of the bronchial tree in 15 cases, and this might be of interest for the surgical strategy.

These studies provide some evidence that bronchoscopy still plays an important role in the preoperative workup of PPLs and in the clinical practice the endoscopic evaluation is generally routinely performed before surgery for peripheral pulmonary lesions. Considering also the lower incidence of complications of the transbronchial approach in comparison to the percutaneous biopsy, any effort must be made to use bronchoscopy to obtain a cytohistological diagnosis of a PPL, avoiding further and more risky procedures.

---

## Historical Perspective

It is well known that, although a PPL is not visible by bronchoscopy, sampling instruments can be inserted through the working channel of the scope and pushed in the peripheral airways, making possible biopsy of lesions localized even at subpleural level. In patients with localized PPL the use of a guidance technique is mandatory, since blind samples or bronchoalveolar lavage have a very low diagnostic yield [1].

The transbronchial approach to PPLs was first described in 1959, before the advent of the flexi-

ble bronchoscope. Tsuboi et al. [6], using “Metras” catheters with various bended shape to be inserted in all the lobar bronchi, were able to introduce a curette in the lung periphery under fluoroscopic guidance, providing diagnosis of lung cancer in 81.6% of 158 cases of peripheral lung carcinoma. In the 1970s, after the advent of the flexible bronchoscope, the technique became easier, it spread widely around the world, and a large number of studies were published, always using fluoroscopy as a guidance system.

In the first studies the sampling instruments used were mainly brushing and forceps biopsy, while in the 1980s and 1990s also the use of flexible transbronchial needles (TBNA) was introduced [7].

Based on a large number of studies carried out with fluoroscopic guidance, it became evident that the diagnostic sensitivity with this technique was not optimal, due to the difficulty or the inability of fluoroscopy to visualize small lesions or soft attenuations like ground glass opacity or PPLs located in areas fluoroscopically hidden by mediastinal structures.

To overcome such limits, to improve the diagnostic yield of the transbronchial approach to PPLs, and to reduce radiation exposure to patients and staff, in the last decades technological developments led to the introduction of new and innovative guidance systems.

In 2002 the use of virtual bronchoscopy navigation to identify the route to the lesion was described [8].

In the same year, Herth et al. [9] introduced the use of ultrasound flexible mini probes adequate to be inserted in the working channel of the scope and to be pushed in the periphery of the bronchial tree. The radial echo mini probes (rEBUS) are able to recognize the hypoechogenic signal of a solid lesion. To facilitate the bioptic approach with the use of ultrasound mini probe, in 2004 Kurimoto et al. [10] introduced the use of a guide sheath inserted together with the probe in the working channel of the bronchoscope. Once the location of the lesion is identified, the probe is withdrawn leaving the sheath in site, in this way providing guidance for the introduction of biopsy forceps.

In 2005 the use of the electromagnetic navigation system (EMN) was introduced [11]. This technology uses low frequency electromagnetic waves that are able to localize a sensor probe introduced through the bronchoscope in the airways; the dynamic position of the probe is then superimposed, using a dedicated software, on previously acquired CT images.

In recent years, further and new modalities of guidance have been proposed.

Cone-beam computed tomography (CBCT) is a radiographic imaging method that allows three-dimensional images, with the use of a cone-shaped X-ray beam produced by a C-arm rotating around the patient and able to acquire a complete data volume set in a single rotation. This technology, already used in other fields of medicine, has been introduced in interventional pulmonology as a guidance system for the bronchoscopic approach to PPLs [12, 13].

More recently, a novel navigation and guidance system that utilizes multimodal image fusion of preoperative CT and intraoperative fluoroscopy to enable real-time augmented fluoroscopic images has been proposed (LungVision system, Body Vision Medical Ltd) [14, 15]. This system may be used with a standard C-arm fluoroscopy, without the need of an expensive cone beam CT.

Some authors utilized together two or more of the above-mentioned guidance systems, in this way integrating the advantages of each technique (rEBUS plus virtual navigation bronchoscopy, rEBUS plus EMN, rEBUS plus fluoroscopy, EMN plus CBCT, EMN plus, and rEBUS plus CBCT), trying to demonstrate that the combination of multiple guidance modalities can increase the diagnostic yield [16].

One of the last techniques proposed in the history of the transbronchial approach to PPLs is the so-called “trans-parenchymal nodule access,” that was developed with the aim of allowing lesion centering, independently from its relationship with bronchial tree. This method is based on a hole done in the bronchial wall with a coring needle, allowing to create a tunnel into the parenchyma, from the bronchus to the lesion. A dedicated virtual navigation system is required, to

create a 3D model of airways and to calculate the best vessel free point where the hole may safely be performed [17].

Regardless of introduction of different guidance systems, progress in the transbronchial approach to PPLs is related also to development of new bronchoscopes, such as ultrathin instruments that can be pushed more peripherally in the airways. The first publication regarding the usefulness of a thin bronchoscope for PPLs in adult patients was reported by Prakash in 1985 [18].

The first generation of ultrathin bronchoscopes with a 2.7 mm outer diameter had the limit of a small working channel (0.8 mm), which was not wide enough for allowing the introduction of standard sampling instruments, and were proposed mainly for pediatric use. In the following years, ultrathin bronchoscopes with an outer diameter of 2.8 mm and a working channel of 1.2 mm and, more recently, a 3 mm bronchoscope with a 1.7 working channel were realized [19]. A 1.7 mm working channel allows inserting dedicated flexible transbronchial needles and these instruments have been more extensively used with many of the guidance systems described above, to improve the outcome of the transbronchial approach to PPL.

At the end of this historical review, it must be mentioned the last innovation for the transbronchial diagnosis of PPLs: robotic bronchoscopy (RB). RB may be used with different guidance systems (fluoroscopy, rEBUS, EMN). The advantages are the possibility to more precisely maneuver the scope and instruments into the periphery of the lungs under direct visualization while also ensuring stability during sampling of the target lesions. Specific chapters of this book are dedicated to ultrathin bronchoscopes and to robotic bronchoscopy and they will provide more detailed data about these fascinating techniques.

---

## Systems of Guidance: Methods and Results

In this paragraph the technique of fluoroscopic-guided approach to PPLs will be described in detail.



Since in the last years a huge number of studies have been published with the new guidance systems (rEBUS, EBUS-TBNA, EMN, CBCT, LungVision) and dedicated chapters of this book describe most of these methods, we will provide for each of these techniques a short overview on some technical aspects and on the diagnostic yields, as obtained by meta-analyses if available.

## Fluoroscopy

Despite the advent of more advanced methods, fluoroscopy, due to low cost and to the availability in the majority of hospitals, still remains worldwide the most widely used guidance system for the transbronchial approach to PPLs.

A rotating C-arm or a biplane fluoroscope must be available (Fig. 20.1) to visualize the position of the sampling instrument both, in the posterior–anterior and lateral view (Fig. 20.2). Bi-plan control is mandatory, otherwise the instrument can be misplaced in front or behind the lesion.

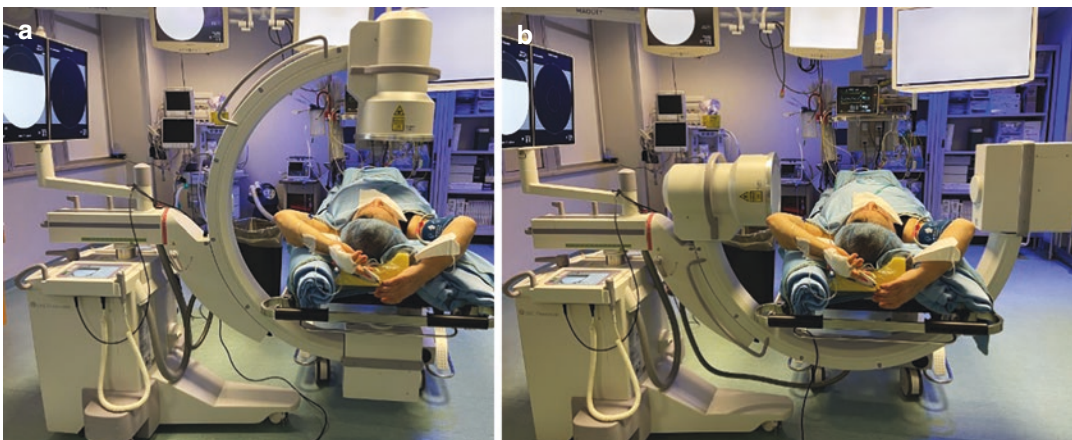
A careful evaluation of CT scan is necessary to precisely identify the bronchus that is leading or that comes closest to the target, before performing bronchoscopy. It is possible to visualize on different adjacent CT slides this bronchus during its pathway. We suggest, starting from the lesion and progressing toward the central air-

ways, to create a “mental navigation” that allows us to figure out the bronchial route to follow (Fig. 20.3).

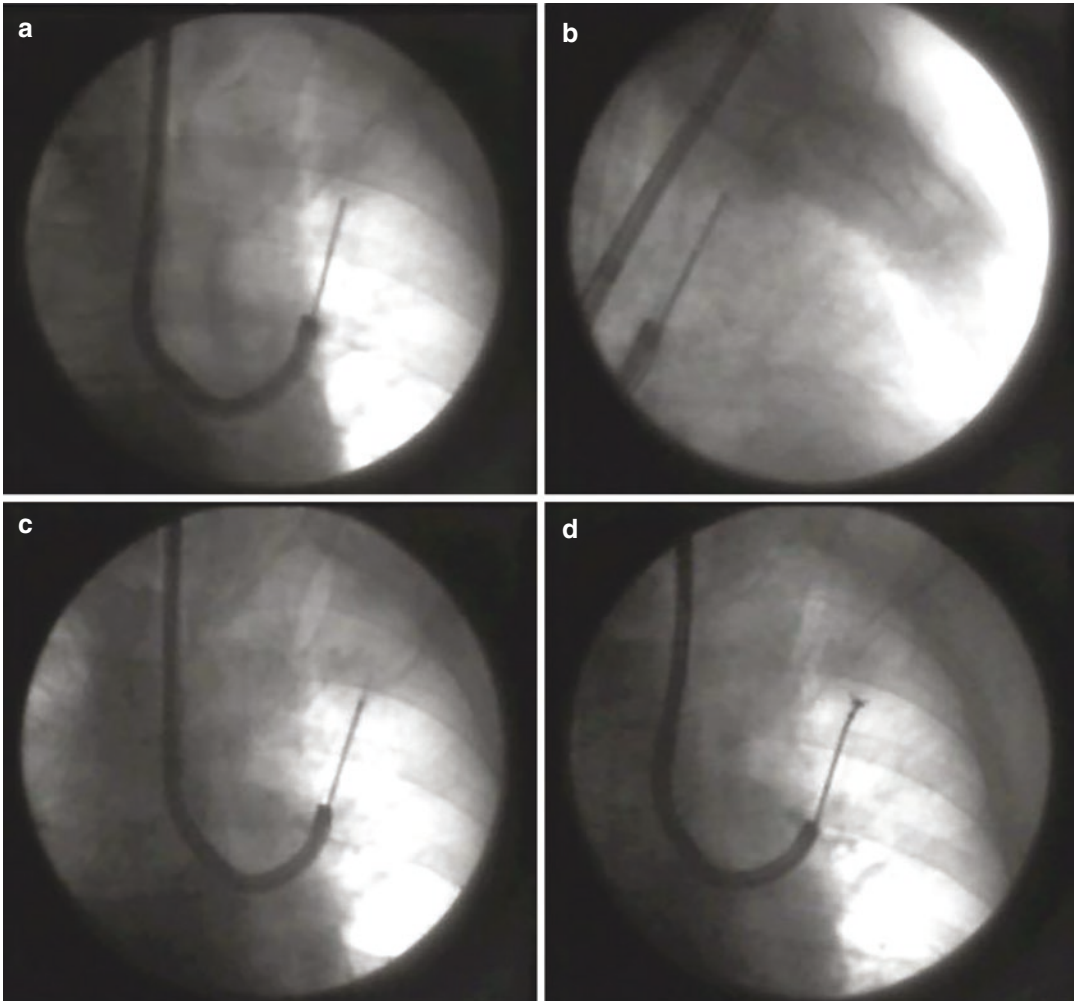
At this point, bronchoscopic procedures can start. After exploration of the tracheobronchial tree, the tip of the bronchoscope must be wedged into the segmental or subsegmental bronchus that is leading into the lesion. Then, the sampling instrument must be inserted, following its progression at the fluoroscopic screen and trying to direct it toward the lesion. The tip of the bronchoscope should be bended or rotated to find the most appropriate way to reach the target [20]. After obtaining the centering of the lesion in posterior–anterior view, the C-arm must be rotated 90° to verify the correct position in lateral view. For this purpose, it is useful to place the patient’s arms high, above the head, to prevent the humeri from reducing the clarity of fluoroscopic vision (Fig. 20.1).

The results of the published studies using fluoroscopy as a guidance system led to some considerations. Diagnostic yield evaluated by meta-analysis showed an average sensitivity of 78%, but a great heterogeneity of results is reported, ranging from 33% to 88% [21]. The reasons for these different results are linked to several factors.

All the studies demonstrated that the lesion size plays a major role in affecting the outcome. For PPLs less than 2 cm the diagnostic yield can



**Fig. 20.1** Rotating C-arm fluoroscope. Postero-anterior (a) and latero-lateral (b) position. The patient’s arms are high, above the head, to prevent the humeri from reducing the clarity of fluoroscopic vision



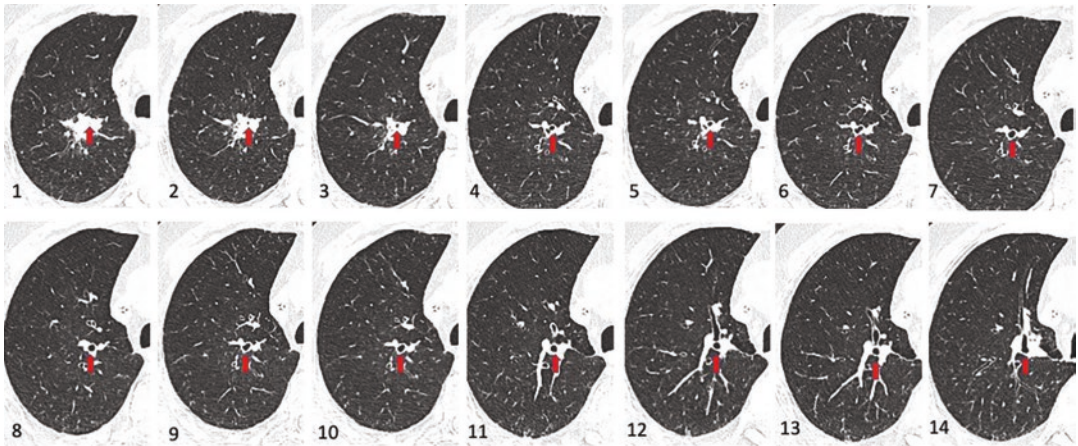
**Fig. 20.2** Sampling under fluoroscopic guidance of a peripheral pulmonary nodule located in the left upper lobe. The correct position of the sampling instrument is

verified in postero-anterior (a) and in lateral view (b). TBNA (c) and biopsy (d) of the nodule

be estimated between 5% and 64%, while for lesions greater than 2 cm values ranging from 30% to 75% are reported [1, 22]. The diagnostic sensitivity may increase to over 80% for masses with a diameter greater than 4 cm [1].

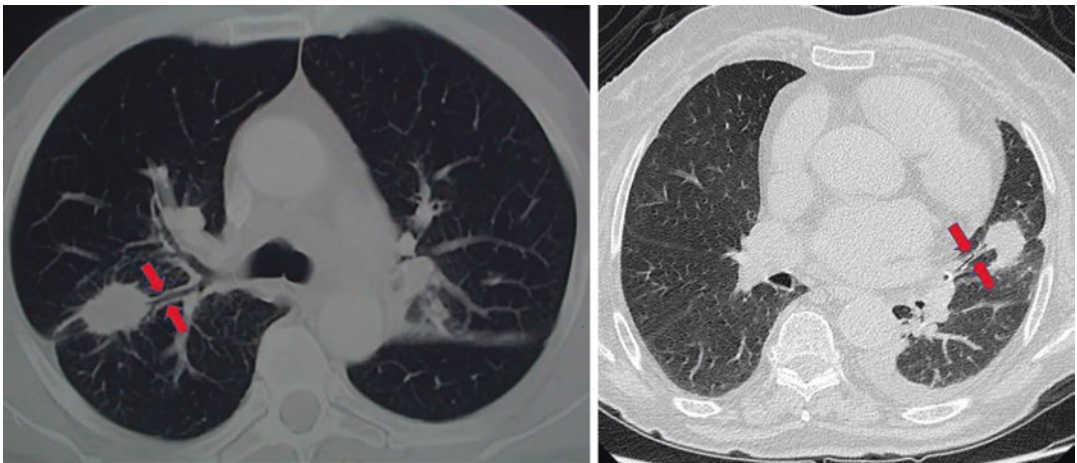
Other factors that may influence the results are the sampling instruments used, as discussed later in this chapter, and the operator experience. The location of the lesion may also have a role in affecting results. In a study on 177 patients, Baaklini et al. [23] grouped lesions according to distance from the hilum and yields of bronchos-

copy in central, intermediate, and peripherally located PPLs were 82%, 61%, and 53%, respectively. In the same study the authors found a trend toward higher diagnostic yield when the lesion was located in the right middle lobe and lingula, when compared to all other segments. On the contrary, Radke et al. [24] were unable to find any correlation between diagnostic yield and the distance between the nearest edge of the lesion and the carina on either the postero-anterior or lateral roentgenogram, nor statistical differences according to the segmental location. In the same



**Fig. 20.3** Mental navigation. It is possible to identify the bronchus leading into the lesion and follow its pathway (red arrows), to create a “mental navigation” that allows to figure out the bronchial route: starting from the lesion

(1–3), following the bronchus in the adjacent CT slides (4–11) up to arriving in a recognizable segmental bronchus (in this case left n.1) (12–14)



**Fig. 20.4** Two peripheral lesions with a positive bronchus sign. A bronchus leading into the lesion is well recognizable (red arrows)

study, a precise diagnosis was more likely for malignant than for benign lesions, but in this paper benign PPLs were significantly smaller and size may have affected results.

A further element which strongly affects results of the transbronchial approach to PPL is the relationship of the lesion with the bronchial tree. If there is not a bronchus leading into the lesion, it will be difficult or impossible to insert the sampling instrument into the target. This concept was demonstrated by Naidich et al. [25] that

introduced the definition of “bronchus sign,” i.e., a bronchus leading to or contained into the lesion visualized by CT scan (Fig. 20.4). In a study on 65 patients, Naidich et al. showed a sensitivity of transbronchial biopsy of 55% if the bronchus sign was present and of only 32% in absence of bronchus sign [25]. The relevance of the bronchus sign, evaluated in several studies also using others and more advanced guidance systems, was confirmed in a meta-analysis by Ali et al. [26], aimed to determining the association between



computed tomography bronchus sign and the diagnostic yield of different guided bronchoscopy modalities. In this meta-analysis the results of 23 studies were evaluated, including 2199 lesions with bronchus sign and 971 lesions without bronchus sign. The overall weighted diagnostic yield was respectively 74.1% and 49.6% when the bronchus sign was present or not.

Table 20.1 shows the results of different studies using fluoroscopic guidance for the diagnostic approach to PPLs (only trials with more than 50 patients are considered).

The complications of the transbronchial approach to PPLs using fluoroscopy as a guidance system are not frequent. The risk of major bleeding is reported with an incidence of 1–4% and its rate may further increase in immunocompromised patients, subjects with uremia, ventilated patients, pulmonary hypertension, and in coagulation disorders [20]. The incidence of pneumothorax in transbronchial biopsy under fluoroscopic guidance of PPLs is low and reported as less than 1% on large series of cases [28].

In conclusion, advantages of fluoroscopic guidance are the possibility to perform the sampling under real-time vision and the low-cost of the procedure, if a biplane or rotating C-arm fluoroscope is available, such as in most hospitals. Disadvantages are radiation exposure, both for the patients and the operators, and the difficulties to visualize small lesions, radiologically faint opacity or fluoroscopically hardly visible PPLs due their position superimposed on the mediastinal structures.

### Radial EBUS Mini Probe (rEBUS)

Endobronchial ultrasound technology, applied to the diagnostic workup of PPLs, utilizes a rotating ultrasound transducer located at the end of a mini probe that can be introduced through the working channel of a flexible bronchoscope and pushed in the peripheral airways, until a characteristic ultrasound signal of a solid lesion is visualized, different from “snowstorm-like” whitish image of air-containing lung tissue. Thinner mini probes

**Table 20.1** Diagnostic yield of transbronchial approach under fluoroscopic guidance in PPLs (only studies with more than 50 patients are reported)

Author	Patients <i>n</i>	Lesion size (cm)	Sampling instrument	Diagnostic yield (%)
Radke et al. [24]	97	All	FB+B	63
		<2.0		28
		≥2.0		64
Mori et al. [27]	85	<1.5	Curette	83.5
				66.7
		1.5–2.0		88.5
Gasparini et al. [28]	570	All (0.8–8)	TBNA+FB	75
Lai et al. [29]	170	All	FB+B	62.4
		<2.0		35.3
		2.1–4.0		64.5
		>4		68.8
Bilaceroglu et al. [30]	92	2–5	TBNA+FB+B	68
Reichenberger et al. [31]	152	All	TBNA	35
		≤3		27.5
		>3		65.5
Baaklini et al. [23]	177	All	FB + B	60.0
		≤2.0		23.0
		2.1–2.5		40.0
		2.6–4		62.0
		>4		83.0

*FB* forceps biopsy, *B* brushing, *TBNA* transbronchial needle aspiration

(1.4 mm) are also available, and they can be used through ultrathin bronchoscopes with a 1.7 working channel.

The main advantages of rEBUS are real time visualization of the lesion and the possibility to identify small PPLs not detectable by fluoroscopy. However, there is no direct control when the sampling instrument is inserted into the target and for this reason rEBUS was employed together with fluoroscopy or other guidance systems in most of the studies.

Various meta-analyses and systematic reviews were published on rEBUS sensitivity [32–35], the first in 2011 and the latest in 2020. The results of these meta-analyses are reported in Table 20.2 and the diagnostic yield is quite similar (from 69% to 73%). However, all the meta-analyses highlight the great heterogeneity of the results, with a sensitivity ranging from 36% to 96%. The reasons for this heterogeneity may be consequent to several factors. In the meta-analyses by Steinfert et al. [32] and by Ali et al. [33], lesion size and prevalence of malignancy were identified as possible cause of different results, while Sainz Zuniga et al. [35] failed to demonstrate an association between sensitivity and average nodule size or cancer prevalence. Other factors that may influence sensitivity are the different additional guidance systems that in many studies are utilized with rEBUS (fluoroscopy, virtual bronchoscopy, EMN), making it difficult to assess the single value of this technique [36].

However, in the majority of the studies on rEBUS, the presence of concentric lesions (rEBUS probe within the lesion), rather than eccentric (rEBUS probe adjacent to the lesion), and PPLs with a prevalent ground glass component are associated with a lower diagnostic yield.

Overall complication rate reported with rEBUS is very low, with an incidence of pneumothorax of 0.7% [35].

Only a few studies directly compared rEBUS and fluoroscopy.

In a prospective study on 50 patients with PPLs (mean diameter = 3.31 cm, range 2–6 cm), fluoroscopy-guided and rEBUS-guided transbronchial biopsies were performed in a random order [9]. Diagnostic material was obtained in 80% of patients with EBUS and in 76% with fluoroscopy. Even if there was a trend for EBUS to have a higher yield than fluoroscopy for lesions <3 cm in diameter, the authors did not find a significant difference between the two techniques. Tanner et al., in a multicenter randomized study [37], compared the diagnostic yield of a thin bronchoscope and rEBUS with standard bronchoscopy and fluoroscopy in 197 patients affected by PPL (lesion size = 31.2 mm). Although the diagnostic yield was higher in rEBUS arm (49% vs. 37%), this difference was not statistically significant. The largest trial comparing rEBUS-guided and fluoroscopic-guided transbronchial lung biopsy for PPLs was performed by Triller et al. [38] on 304 consecutive patients. 116 patients underwent rEBUS (mean diameter of the lesions = 31.5 mm) and 188 fluoroscopic guidance with conventional bronchoscopes (mean diameter of the lesions = 34.5 mm). Diagnostic biopsy samples were obtained in 77% using rEBUS and in 74% using fluoroscopy, without any statistically significant difference. Even if the diagnostic yield was not different, the authors conclude that rEBUS procedure is safer because it does not involve exposure to radiation for the patients and the medical staff.

**Table 20.2** Diagnostic yield of transbronchial approach to PPLs under rEBUS guidance evaluated by meta-analyses

Author	Studies <i>n</i>	Patients <i>n</i>	Lesion size (cm)	Diagnostic yield (%)
Steinfert et al. [32]	16	1420	All	73
Ali et al. [33]	57	7872	All	70.6
Zhan et al. [34]	31	2329	All	69
Sainz Zuniga et al. [35]	51	7601	All	72



## Ultrasound Bronchoscope (EBUS)

Transbronchial needle aspiration under echo endoscopic guidance, with the use of a bronchoscope with a linear ultrasound probe at its tip, is widely reported for the transbronchial (EBUS-TBNA) or transesophageal approach (EUS-B-FNA) to hilar-mediastinal lymph nodes for diagnosis and staging of lung cancer. This instrument is generally not mentioned among the techniques for the diagnosis of PPL. However, in selected cases, where the lung lesion is adjacent to the trachea or the major bronchi or to the esophagus, this technique can also be used to sampling pulmonary nodules or masses that originate peripherally and that are not visible on bronchoscopy, due to their location outside the bronchial tree. The sensitivity of EBUS-TBNA in the diagnosis of pulmonary lesions is very high and reported with a value greater than 90% [39]. Furthermore, it is possible to wedge the tip of the echo bronchoscope in smaller bronchi up to 5 mm in size, making possible the ultrasound visualization even of small PPLs if they are adjacent or in close proximity with the airway. Even if the lesion is not closely adjacent to the airway and there is a distance of few millimeters between the tracheobronchial wall and the PPL, it is possible to bend the tip of the echoscope in this way pushing the bronchus toward the target and making possible the visualization and the sampling of the lesion.

Figure 20.5 shows two cases of PPLs diagnosed using EBUS-TBNA.

A major limit of this technique is the impossibility to insert the eco-bronchoscope in the upper lobes segmental bronchi and this approach is mainly feasible in PPLs located in the lower lobes.

Pulmonologists should be aware of the possibility that, in selected cases of PPLs, EBUS-TBNA may be an alternative for a safe and effective technique of sampling.

## Virtual Bronchoscopy

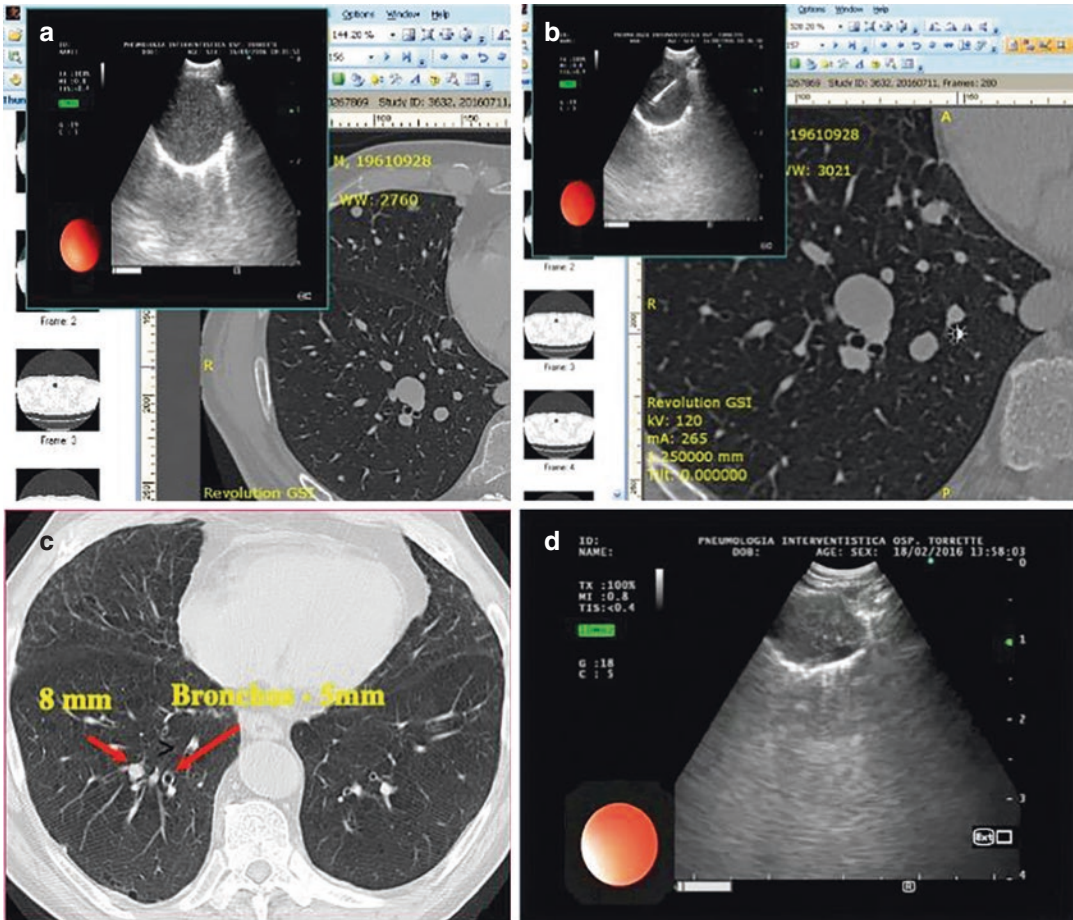
Virtual bronchoscopy (VB) is a software which allows, based on CT scan, the development of 3D high-resolution images of the tracheobronchial tree and endobronchial view that simulate the findings of a conventional bronchoscopy. In case of PPL, VB shows the bronchial pathway that must be followed for reaching the target. Several VB systems are currently available.

Generally, virtual bronchoscopy is utilized together with other navigation systems, such as fluoroscopy and rEBUS.

Ishida et al. published the results of a multicenter randomized trial on 199 PPLs  $\leq 30$  mm in which VB was associated with rEBUS [40]. The sensitivity of VB-assisted procedure was 80.8% compared to 67.0% when VB was not employed. In this study the difference between two groups was even greater for PPLs  $< 20$  mm, in which the diagnostic yield for the VB group was 75.9% vs. 59.3% in the non-VB group. In another randomized trial on 334 patients, where fluoroscopy and ultrathin bronchoscope were used with or without VB to approach PPLs less than 30 mm, the overall diagnostic yield of two groups was similar (67.1% with VB and 59.9% without VB), but it was significantly higher when VB was utilized in PPLs located in the right upper lobe (81.3% vs. 53.2%), in the peripheral third of the lung field (64.7% vs. 52.1%) and for lesions not visible on fluoroscopy (63.2% vs. 40.5%) [41].

In a meta-analysis evaluating 12 studies performed with VB [42], the overall diagnostic yield was 73.8% and 67.4% for lesions  $\leq 2$  cm. The diagnostic yield ranged from 65.4% to 81.6% in the studies where VB was associated to computed tomography and ultrathin bronchoscope, 63.3–84.4% using rEBUS with a guide sheath, and from 62.5% to 78.7% using fluoroscopy.

The major limit of VB is that it just provides a bronchial route for approaching the lesion, but it requires other systems for confirming the arrival to the target.



**Fig. 20.5** Examples of PPLs approached using EBUS-TBNA. Upper: nodule located in the right lower lobe, adjacent to a subsegmental bronchus. The echo bronchoscope wedged in the bronchus allows to visualize the nodule (a) and to perform EBUS-TBNA (b) (diagnosis:

carcinoid). Lower: 8 mm nodule located in the right lower lobe, close to a small bronchus (5 mm) (arrows) (c); the echo bronchoscope wedged in this bronchus allows to visualize the nodule (d) (diagnosis: metastasis from urothelial cancer)

### Electromagnetic Navigation Bronchoscopy (EMN)

EMN is a method that uses a pre-procedure CT scan-derived virtual 3D reconstruction of the lung and of the tracheobronchial tree and superimposes the real-time position of the bronchoscope instruments using an electromagnetic sensor, inserted into the working channel of the bronchoscope. An electromagnetic field generator, located outside the patient's body, tracks the position of the sensor. To overcome the limit of PPLs located tangentially to the bronchus, catheters with the possibility to bend the tip were developed. At the current time the two

ENB systems available on the market in Europe and the United States are: superDimension (Medtronic, Minneapolis, MN) and SPiN Thoracic Navigation System (Veran Medical Technologies, Inc, St. Louis, MO, now acquired and distributed by Olympus Corporation, Tokyo, Japan). There are no clinical trials that compare the two systems.

The overall diagnostic yield of EMN is ranging from 64% to 82%, as reported by four meta-analyses (Table 20.3). As we have seen for fluoroscopic guidance and for rEBUS, also for EMN a significant heterogeneity of results is observed. The reasons for this heterogeneity are the size and location of the lesions, the use of dif-

**Table 20.3** Diagnostic yield of electromagnetic navigation bronchoscopy evaluated by meta-analyses

Author	Studies <i>n</i>	Patients <i>n</i>	Lesion size (cm)	Diagnostic yield (%)
Gex et al. [43]	15	1033	All	64.9
Zhang et al. [44]	17	1106	All	82.0
Folk et al. [45]	40	3342	All	77.0
Qian et al. [46]	32	1981	All	80.0

ferent sampling instruments, the presence of a bronchus sign, the procedure performance under general anesthesia, the use of ROSE, the prevalence of malignancy [43]. Furthermore, the frequent additional use of other guidance systems may have a role, as demonstrated by Eberhardt et al. [16], that compared three different guidance modalities (EMN alone, EMN +rEBUS, rEBUS alone) in a randomized trial on 120 patients. The best diagnostic yield (88%) was obtained when EMN was combined with rEBUS, in comparison to rEBUS alone (69%) or EMN alone (59%).

The discrepancy in results between studies is well evident comparing the data of the AQUIRE registry (data from fifteen Centers in the United States on 581 patients), where the EMN diagnostic yield was very low (38.5%) [47] with the data of a large prospective multicenter study (NAVIGATE) [48] that involved 29 centers and 1215 patients, with a diagnostic yield of 73%. However, it must be observed that in the NAVIGATE trial, fluoroscopy was used with EMN in 91% and rEBUS in 57% of cases.

The major limit of EMN is that it is not a real time guided procedure and that a mismatch between the lesion location on pre-procedural CT scan and its real position during procedure (the so-called “CT-to-body” divergence) may occur, due to movement of the lung with respiratory variation during bronchoscopy. The CT-to-body divergence may explain the difference between the very high reported navigation success (97.4%) and the lower diagnostic yield. Recently, to overcome this limit, a novel technology that use digital tomosynthesis via a conventional fluoroscopy C-arm has been introduced (fluoroscopic EMN, Medtronic, Minneapolis, MN). This system allows visualization of the target nodule on near real-time imaging. In a retrospective study on 67 lesions (mean diameter = 16 mm, range 12–24)

approached by fluoroscopic EMN, diagnostic yield was 79.1% [49].

### Trans-Parenchymal Access

To overcome the limit due to the position of the PPL outside the bronchial tree (no bronchus sign), the technique called bronchoscopic trans-parenchymal nodule access (BTPNA) was proposed [17]. This method is based on the creation of a direct pathway from the bronchial wall to the lesion. Underlying the procedure, it is necessary to have a 3D model of airway realized by a virtual navigation system (Archimedes Bronchus Medical, Mountain View, CA) based on CT scan, that visualizes the lesion, the airways and the vascular structures. This system is able to identify the optimal airway point of entry and an avascular path through lung tissue from the point of entry and the PPL. After this pre-procedure evaluation, a coring needle is introduced at the defined point of entry and a balloon dilator is used to enlarge the hole. Then, a radiopaque sheath with a blunt dissection stylet is inserted through the hole and pushed in the lung parenchyma toward the lesion under fluoroscopic guidance. Once the lesion is reached, the stylet is removed and biopsy forceps are inserted through the sheath.

In the first feasibility study [17], 12 patients were recruited (average size of PPL= 25 mm, range 17–40), tunnel pathway was created in ten and diagnostic yield was 83%, without complications. Another study was performed using this system on a small number of patients (6 subjects) [50], confirming a high diagnostic yield (83%). The major limitation of the technique is the impossibility of realizing a tunnel pathway in some patients, due to the position of the PPL and

to the presence of vascular structures. This limit is particularly evident in PPL located in the apex of the left upper lobe, for the presence of aorta and pulmonary artery [17].

Another trans-parenchymal access system (Bronchoscopic Transbronchial Access Tool—TBAT) was evaluated in a pilot study on 22 patients [13], using EMN and cone beam CT. Seven patients without a definitive airway leading to the lesion underwent TBAT. The overall diagnostic yield was 77.2% (17/22) and 100% (7/7) when TBAT was used.

Further studies on a larger number of patients are needed to define the real advantage of the trans-parenchymal approach in terms of safety and cost/benefit ratio.

**Cone Beam CT (CBCT)**

Cone beam CT is a variant of computed tomography that uses a cone-shaped X-ray beam instead of a fan-shaped X-ray beam. CBCT uses a rotating C-arm acquiring 2D images that are then reconstructed with a dedicated algorithm to provide 3D images analogous to conventional multislice CT. The lesion and the bronchial path visualized by CBCT can be overlaid on live fluoroscopy (augmented fluoroscopy), providing

real-time intra-procedural images and allowing also the simultaneous visualization of the lesion and of the position of the sampling instrument in a full 3D view, with the accuracy and the quality of CT view.

CBCT was used first in other fields of medicine (dentistry, interventional radiology, interventional cardiology, neurosurgery, vascular surgery), but in the recent years several papers demonstrated the possibility to use it as guidance system for the transbronchial approach to PPLs. In the largest study performed with CBCT used with EMN on 93 PPLs (median nodule size = 20 mm), overall diagnostic yield was 83% [51]. Other studies on a smaller number of patients reported a diagnostic yield ranging from 70% to 90% [12, 29]. However, in all the studies CBCT was used in combination with EMN and/or rEBUS and/or ultrathin bronchoscopy.

Diagnostic yields reported using CBCT are summarized in Table 20.4.

**Lung Vision**

The LungVision system (Body Vision Medical Inc., New York, NY) is a novel method of navigation that provides image fusion of preoperative CT and intraoperative fluoroscopy to create

**Table 20.4** Diagnostic yield of CBCT and LungVision system (only studies with more than 20 patients are reported)

Author	Lesions <i>n</i>	Lesion size (mm)	Additional guidance systems	Diagnostic yield (%)
<b>CBCT</b>				
Prichett et al. [51]	93	All (median: 16.0)	EMN	83.7
Sobieszczyk et al. [13]	22	All (median: 21.0)	EMN, rEBUS with TBAT	77.2 100
Casal et al. [12]	20	All (median: 21.0)	rEBUS	70.0
Ali et al. [29]	40	All (<3 cm)	Virtual bronchoscopy; ultrathin bronchoscope	90
<b>LungVision</b>				
Pertzov et al. [14]	63	All (median: 25.0)	rEBUS	81.8
		<20		72.2
Prichett et al. [15]	51	All (median: 18.0)	CBCT	78.4

EMN electromagnetic navigation system; rEBUS radial endobronchial ultrasound mini probe, CBCT cone beam computed tomography

real-time augmented fluoroscopic guidance, utilizing artificial intelligence techniques and dedicated algorithms [15]. The CT scan of the patient is imported into the LungVision planning software and during the procedure an augmented fluoroscopic view of the instrument and of the lesion is displayed on the screen together with the navigation pathway. A study that assessed the distance between lesion location as shown by LungVision augmented fluoroscopy and actual location measured by cone beam CT (CBCT) reported an average distance of only 5.9 mm, demonstrating the reliability of the system [15]. In this trial, performed on 51 patients with a PPL (median size = 18 mm, range 7–48 mm), the diagnostic yield was

78.4%. In another study on 63 patients (median lesion size = 25.0 mm, range: 18–28 mm), using LungVision and rEBUS to confirm the correct location, the overall diagnostic yield was 81.8% and 72.2% for lesions smaller than 2 cm [14] (Table 20.4).

The major advantage of LungVision system is to provide an almost real time vision and an augmented fluoroscopy using a standard fluoroscopy C-arm, in this way allowing visualization of fluoroscopically invisible lesions and reducing the cost in comparison to the more expensive cone beam CT.

Table 20.5 summarizes the advantages and disadvantages of all the above-described guidance systems.

**Table 20.5** Advantages and disadvantages of the guidance systems available for the transbronchial approach to PPLs

Guidance system	Advantages	Disadvantages
Fluoroscopy	<ul style="list-style-type: none"> <li>• Wide availability</li> <li>• Cheap</li> <li>• Time sparing</li> <li>• Real time biopsy</li> </ul>	<ul style="list-style-type: none"> <li>• Poor vision of small and/or low-density lesions</li> <li>• Radiation exposure</li> </ul>
rEBUS	<ul style="list-style-type: none"> <li>• Real time visualization of the lesion</li> <li>• Possibility to visualize small lesions</li> <li>• No radiation exposure</li> </ul>	<ul style="list-style-type: none"> <li>• Poor view of ground glass opacity</li> <li>• Biopsy is not real-time</li> </ul>
EBUS-TBNA	<ul style="list-style-type: none"> <li>• Very high sensitivity</li> <li>• Real-time biopsy</li> <li>• No radiation exposure</li> </ul>	<ul style="list-style-type: none"> <li>• Only PPLs adjacent to the bronchi &gt;5 mm or adjacent to the esophagus</li> <li>• Impossibility to access PPLs in the upper lobes</li> </ul>
Virtual bronchoscopy	<ul style="list-style-type: none"> <li>• No radiation exposure</li> <li>• Visualization of the bronchial pathway to reach the lesion</li> </ul>	<ul style="list-style-type: none"> <li>• Inability to visualize the target lesion and the biopsy site</li> <li>• Need for another guidance system</li> </ul>
EMN	<ul style="list-style-type: none"> <li>• No radiation exposure</li> <li>• 3D reconstruction pathway</li> </ul>	<ul style="list-style-type: none"> <li>• Expensive</li> <li>• No real time visualization</li> <li>• “CT to body” divergence</li> </ul>
Transparenchymal access	<ul style="list-style-type: none"> <li>• Possibility to sample PPLs without relationship with the airways</li> </ul>	<ul style="list-style-type: none"> <li>• Complex procedure</li> <li>• Need navigation system</li> <li>• Impossibility to reach some PPLs when a vascular structure is interposed</li> </ul>
CBCT	<ul style="list-style-type: none"> <li>• Real time 3D high fidelity visualization of PPLs</li> <li>• Possibility to visualize small and/or low-density lesions</li> <li>• Augmented fluoroscopy</li> <li>• Possibility to define a pathway to the lesion</li> <li>• Real time biopsy</li> </ul>	<ul style="list-style-type: none"> <li>• Expensive</li> <li>• Radiation exposure</li> </ul>
LungVision	<ul style="list-style-type: none"> <li>• Augmented fluoroscopy</li> <li>• Possibility to visualize small lesions</li> <li>• Almost real-time biopsy</li> <li>• Possibility to use a conventional C-arm fluoroscope</li> </ul>	<ul style="list-style-type: none"> <li>• Radiation exposure</li> </ul>



## Sampling Instruments

Whatever guidance system is used, several sampling instruments can be employed for the transbronchial approach to PPLs, alone or in association, to obtain diagnostic cells or tissue (Table 20.6). It must be emphasized that there are no standardized guidelines on the type of sampling tool or tools to be used. The use of one or more sampling instruments is linked to the operator habits or to the availability in each institution. This is one of the reasons that may explain the heterogeneity of results between studies reported in the literature with most of the guidance systems.

Furthermore, in the era of tailored therapy of lung cancer, the evaluation of diagnostic yield, as reported in many studies, should be associated with the assessment of tool-specific adequacy for histotype definition and for complete molecular testing for tumor genotyping. It would be desirable that all future studies on the value of diagnostic techniques in the field of PPLs take this aspect into consideration when analyzing the results.

Bronchoalveolar lavage (BAL) or bronchial washing is a diffuse technique in the transbronchial approach to PPLs, especially in centers that are not provided by a guidance system. It is performed by introducing an amount of fluid (150 mL in case of BAL) through the segmental bronchus leading to the lesion and using the recovered liquid for a cytological evaluation.

In a study on 55 patients with peripheral lung cancer, BAL was diagnostic in only 28% of

patients with nodular lesions. Diagnostic yield was higher (40%) in cancer with an infiltrative pattern, like bronchoalveolar carcinoma or carcinomatosis lymphangitis. On the contrary, BAL provided a high diagnostic yield in diseases other than lung cancer (e.g., tuberculosis of other infectious diseases) [52]. The low diagnostic accuracy of BAL and/or washing in case of localized peripheral lesions does not support their routine use as the only means of sampling, except cases where there is a suspicion of infectious disease.

There are few randomized studies comparing the diagnostic yield of different sampling instruments.

In a prospective randomized trial on 218 patients affected by PPL, Trisolini et al. [53] compared the diagnostic value of forceps biopsy (FB), transbronchial needle and bronchial washing. TBNA was more sensitive (65%) than either FB (45%) and bronchial washing (22%). Furthermore, TBNA was the only diagnostic procedure in 21% of patients with malignant lesions, and 27% of PPLs without bronchus sign.

In a systematic review and meta-analysis evaluating the accuracy of TBNA under fluoroscopic guidance in the diagnosis of PPL and comparing its diagnostic yield with FB, Mondoni et al. [54] included 18 studies. The overall diagnostic yield of TBNA was statistically higher when compared to FB (60% vs. 45%). The subgroup analyses documented a higher TBNA yield when the bronchus sign was present (70% vs. 51%), in the case of malignant lesions (55% vs. 17%) and for lesions >3 cm (81% vs. 55%).

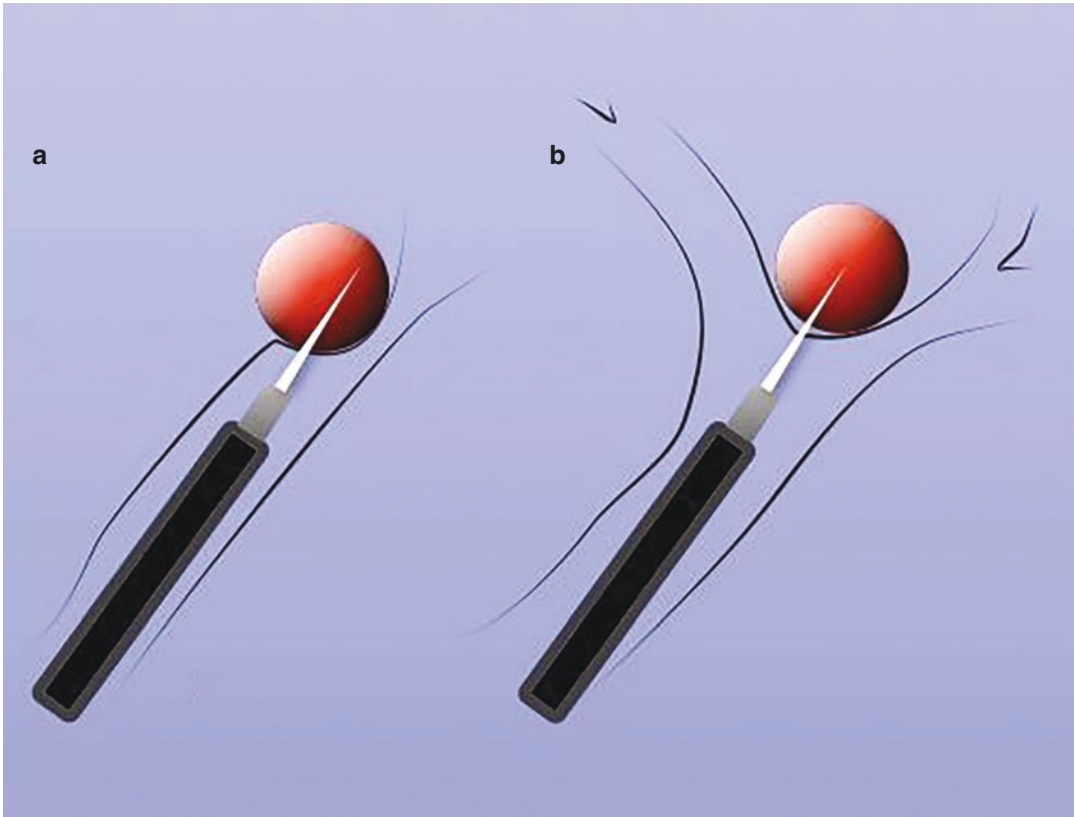
The better results obtained by TBNA are due to the ability of the needle to penetrate the lesion even if it does not involve the mucosal surface or it is located in the peri-bronchial area (Fig. 20.6).

Despite this evidence, the employment of TBNA in the transbronchial approach to PPLs is still underutilized.

From the practical point of view, there are some tricks that must be considered to optimize the results of TBNA in this clinical setting. First of all, if the needle is used in association with

**Table 20.6** Sampling instrument utilized in the transbronchial approach to PPLs

Bronchoalveolar lavage (BAL)
Curette
Brushing
Catheter
Forceps biopsy
Flexible transbronchial needles (TBNA)
Triple needle cytology brush
GenCut core biopsy system
Criobiopsy

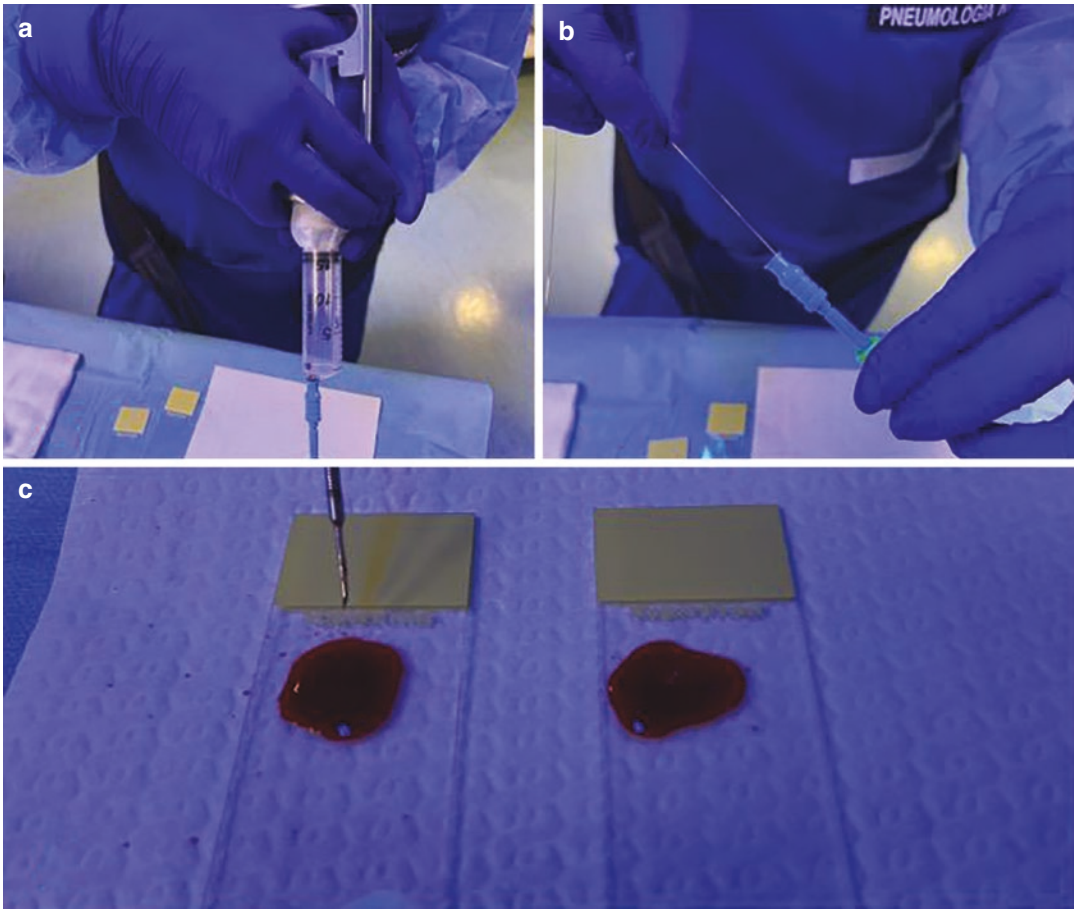


**Fig. 20.6** Possible relationship between the nodule and the airways in which the needle may be the only sampling instrument able to penetrate the lesion. In (a) the lesion

compresses but not involves the mucosal surface. In (b) the lesion is located adjacent to a bronchial spur

forceps or brushing, it should be employed first, since the previously performed samplings could induce perilesional bleeding that may allow to aspirate an increased amount of blood, thus reducing the diagnostic value of TBNA. The second trick is to choose a kind of needle with a great flexibility, allowing the insertion into the most angulated bronchi, like the peripheral airways of the upper lobes. In our experience, the most appropriate needles for peripheral lesions are those with a metallic sheath, that are very flexible and that remain straight after insertion, allowing to maintain their direction during progression in the periphery [20]. However, new very flexible plastic sheath needles that can be used also with ultrathin bronchoscopes, have been recently introduced into the market [55].

Another important point that must be emphasized is the way to manage the TBNA samples. The material obtained by TBNA is expelled using a syringe filled by air onto one or more slides (Fig. 20.7a). Sometimes it is not possible to expel the sample by pushing with the syringe, because the material coagulates inside the needle. In such cases, the needle stylet can be used to push out the content of the needle (Fig. 20.7b). While specimens retrieved with forceps biopsy are managed in a standard way (formalin fixing, paraffin embedding), samples obtained with needle aspiration procedures provide material which can be processed in different ways. In our routine practice, the material obtained with the first needle pass is expelled on a slide and smeared. If there is an abundant sample, it is possible to obtain two



**Fig. 20.7** TBNA samples expelled on slides by a syringe filled by air (a) or with the help of a stylet (b). If tissue core or clots are present on the slide (c), these can be retrieved and put into a formalin vial for cell block evaluation

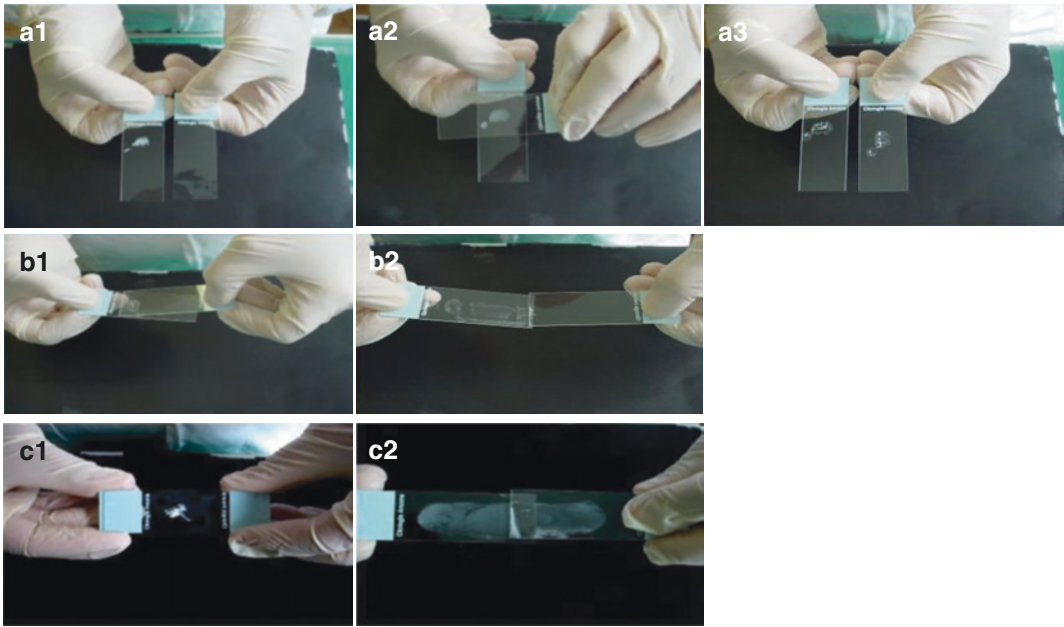
or more slides with the same material, just imprinting one slide on another (Fig. 20.8a). The technique for smearing slides is shown in Fig. 20.8b, c. One slide is immediately stained for rapid on-site evaluation. If some tissue cores or clots are present on the slide, these are retrieved with a syringe needle and put in formalin.

Advantages to having smear cytology is that it is suitable for ROSE and it can also provide good material for immunocytochemistry (histological definition) and also for next-generation sequencing (genotyping of the tumor). If ROSE is positive showing that the target has been centered, other TBNA passes are performed and the material is directly flushed into a formalin vial for cell block or tissue core evaluation (Fig. 20.9). This material is useful for some tumor markers,

like PDL1, and it could be treated as a histological sample, facilitating pathologists that are more confident with tissue evaluation than with smeared cytology.

In the majority of studies on the transbronchial approach to PPLs, whatever guidance method was used, a higher diagnostic yield was obtained with the association of more than one sampling instrument.

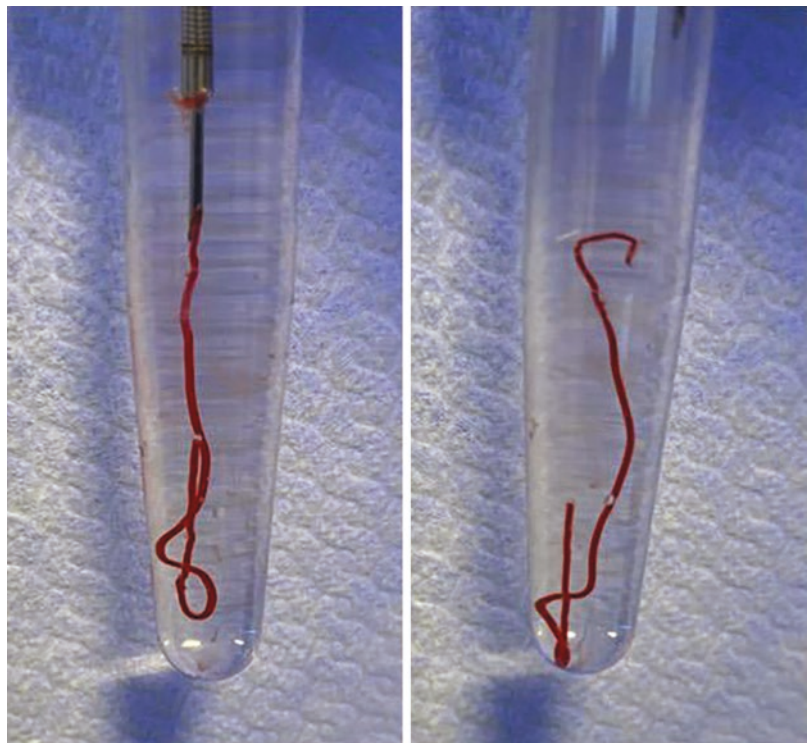
In post-hoc analysis of patients included in the NAVIGATE trial [48] (1215 enrolled subjects that underwent EMN bronchoscopy for diagnosis of PPL), Gildea et al. compared the results obtained using a restricted number of tools (only biopsy forceps, standard cytology brush, and/or BAL) with an extensive multimodal strategy (biopsy forceps, cytology brush, TBNA, triple



**Fig. 20.8** Methods to prepare cytological slides. (a) The material can be passed on other slides, just imprinting one slide on another (A2), in this way obtaining two slides with similar material (A3). (b) The material is smeared using a second slide placed over and gently swiped. Note

that the second slide is held slightly inclined and parallel to the other. (c) In this “flat” technique, the second slide is placed on top of the other and the two slides are gently pulled in opposite direction

**Fig. 20.9** Material obtained by TBNA, flushed directly into a formalin vial for cell block evaluation. A tissue core for histological evaluation is obtained by a 21 G needle





needle cytology, core biopsy system, BAL). 86.8% of true positive diagnoses were obtained using multimodal strategies and, among the different instruments used, positive rates were highest for biopsy forceps and TBNA [56].

Since it is not feasible to use all the sampling instruments, based on the above-mentioned considerations, the most appropriate association is the employment of TBNA with forceps biopsy. TBNA provides a better sensitivity for malignant lesions, while biopsy is reported to provide a better yield in cases of benign lesions [28].

Among the sampling instruments that can be used for the transbronchial diagnosis of PPLs, it must be mentioned also cryobiopsy, that in the last decade has gained large diffusion as a commonly used tool in the diagnostic pathway of infiltrative lung diseases. Recently, several studies have been performed, using cryobiopsy for the diagnosis of PPLs. The aim of these studies was to verify if cryoprobes can provide a better sensitivity and a greater amount of histological material in comparison to conventional forceps biopsy.

Even if cryoprobe can be used with different guidance systems, the majority of the studies employed rEBUS to localize the lesion. A meta-analysis recently published by Sryma et al. [57] identified nine studies performed on 300 patients using cryobiopsy and rEBUS. Most of the studies used a 1.9 mm cryoprobe and a freezing time between 3 and 5 s. Even if some studies included in this meta-analysis showed a better diagnostic yield with cryobiopsy in eccentrically and adjacently orientated lesions, the overall pooled sensitivities of cryobiopsy and of forced biopsy were similar (77% vs. 72%) and not statistically different. One severe bleeding and three pneumothorax requiring tube placement were reported with cryobiopsy (major complication rate = 1.8%).

Further multicenter randomized studies are needed to establish the utility of cryobiopsy for PPLs in a real-life setting, and if such tool could provide advantages in terms of sample adequacy for tumor genotyping.

## Rapid On-Site Cytological Evaluation (ROSE)

Rapid on-site evaluation of the samples (ROSE) is a cytological diagnostic procedure that allows assessment of the adequacy of the material obtained during bronchoscopy. ROSE can be performed during transbronchial approach to PPLs, whatever guidance system is used.

Usually, ROSE is done when cytological sampling instruments like TBNA are employed, but it is possible to perform ROSE even with material obtained by forceps biopsy, using the so-called “squashing” (the biopsy fragment is squeezed onto a glass slide) or “rolling” (the biopsy fragment is rolled repeatedly over the slide, on which cellular material will be deposited) techniques.

Slides are immediately fixed (95% alcohol or air dried, according to the type of stain used) and one is stained for ROSE. A variety of quick stain systems can be utilized, depending on the pathologist preference (Diff-Quick, Haemacolor Merk, rapid Papanicolaou, hematoxylin and eosin).

While there are several prospective randomized studies that evaluate the role of ROSE during transbronchial needle aspiration for mediastinal lesions, both with conventional TBNA or EBUS-guided TBNA, there are few reports to assess the value of ROSE in the transbronchial approach to PPLs.

In 1995 our group published a study on 1027 patients affected by PPL that were approached first by fluoroscopic-guided transbronchial needle aspiration and biopsy. ROSE was performed in all cases and, if negative, immediately after patients underwent a percutaneous needle aspiration [28]. In this study, which showed the possibility to integrate transbronchial and percutaneous approaches during the same session, ROSE played a crucial role to indicate if the bronchoscopic samplings were diagnostic, avoiding in this way the unnecessary transthoracic puncture.

More recently, a randomized trial was performed to evaluate the role of ROSE during rEBUS [58]. 84 patients received rEBUS-guided biopsy with ROSE and 74 without



ROSE. Diagnostic yield was higher in the ROSE group, both for lesions >20 mm (88.0% vs. 77.6%) and for PPLs ≤20 mm (88.0% vs. 77.6%). Furthermore, in the non-ROSE group, the number of biopsies, the hemorrhage rate and the operation times were all higher than that of the ROSE group [58].

In the meta-analysis by Mondoni et al. [54], evaluating the yield of fluoroscopic-guided TBNA on 18 studies, a significant improvement of diagnostic yield is reported when ROSE was performed. Furthermore, the authors underline the possible role of a positive and adequate material on ROSE in stopping additional sampling, thus potentially avoiding the use of useless forceps biopsy and reducing risk.

The meta-analysis by Sainz Zuniga et al. [35], evaluating 51 studies performed with rEBUS, reports that the use of ROSE was associated with a higher sensitivity, even if only a small number of studies ( $n = 4$ ) used ROSE in this review, leading the author to conclude that this finding requires further consideration.

From the above mentioned data, there is some evidence that ROSE may be useful in the transbronchial approach to PPLs, while it would be desirable to have more large randomized trials to definitely assess the real advantage of rapid on-site evaluation with the different guidance systems and with different sampling techniques employed.

---

## Conclusions

Even though many years have passed and great progress has been made since the first papers on the possibility of bronchoscopy to diagnose pulmonary peripheral lesions, the transbronchial approach to PPLs still remains a challenging task for bronchoscopists.

The aim is to diagnose smaller and smaller lesions and to improve the diagnostic yield, making the bronchoscopic sampling equivalent in terms of sensitivity to the percutaneous biopsy, which is burdened by a higher risk of complications. The major obstacle that limits the diagnos-

tic yield of the transbronchial sampling, whatever guidance system is used, is represented by the location of some PPLs that have no relationship with the airways.

In this chapter, we have provided an overview of all the techniques at this moment available.

The accuracy of all the guidance systems mentioned could be further increased with the use of ultrathin bronchoscopes and of robotic bronchoscopy, which we have not considered, since there are specific dedicated chapters in this book.

Although, from comparison of different papers and from meta-analyses it seems that the new guidance systems may provide better results, especially for small lesions, there are no large randomized trials that compare the various technologies. The heterogeneity of results makes difficult the comparison between different studies, since several variables play a role in determining the diagnostic yield of the transbronchial approach to PPLs (size and nature of the lesions, their location, their relationships with the bronchial tree, the type and the number of sampling instruments, operator experience, multiple guidance system used at the same time, time employed, availability of ROSE).

Furthermore, the problem of costs should also be considered. The new technologies are burdened by high costs, for both the equipment and the disposable material, and cannot be available everywhere. The identification of Centers of excellence, where high technologies must be concentrated, should be part of health policy programs of each Country.

Due to these reasons, the use of one or more guidance systems and of one or more sampling instruments is still linked to the operator's experience and/or to the local availability of facilities and resources.

The interventional pulmonologist community would deserve more scientific evidence and more well conducted randomized trials, that could allow a standardization of the transbronchial approach to PPLs and to define the best strategy to be followed.

## References

- Gasparini S. Diagnostic management of solitary pulmonary nodule. *Eur Respir Mon.* 2010;48:90–108. <https://doi.org/10.1183/1025448x.00990709>.
- Torrington KG, Kern JD. The utility of fiberoptic bronchoscopy in the evaluation of the solitary pulmonary nodule. *Chest.* 1993;104:1021–4. <https://doi.org/10.1378/chest.104.4.1021>.
- Arsitizabal JF, Young R, Nath H. Can chest CT decrease the use of preoperative bronchoscopy in the evaluation of suspected bronchogenic carcinoma? *Chest.* 1998;113:1244–9. <https://doi.org/10.1378/chest.113.5.1244>.
- Chhajed PN, Bernasconi M, Gambazzi F, et al. Combining bronchoscopy and positron emission tomography for the diagnosis of the small pulmonary nodule  $\leq 3$  cm. *Chest.* 2005;128:3558–64. <https://doi.org/10.1378/chest.128.5.3558>.
- Schwarz C, Schonfeld N, Bittner RC, et al. Value of flexible bronchoscopy in the preoperative work-up of solitary pulmonary nodules. *Eur Respir J.* 2013;41:177–82. <https://doi.org/10.1183/09031936.00018612>.
- Tsuboi E. Studies on an early diagnosis of lung cancer-especially cytological diagnosis of bronchial cells obtained by a direct scrape-off method. *Nipp Act Radiol.* 1959;19:133–51.
- Wang KP, Haponik EF, Britt EJ, et al. Transbronchial needle aspiration of peripheral pulmonary nodules. *Chest.* 1984;86:819–23. <https://doi.org/10.1378/chest.86.6.819>.
- Asano F, Matsuno Y, Matsushita T, et al. Transbronchial diagnosis of a pulmonary peripheral small lesion using an ultrathin bronchoscope with virtual bronchoscopic navigation. *J Bronchol.* 2002;9:108–11.
- Herth FJF, Ernst A, Becker H. Endobronchial ultrasound-guided transbronchial lung biopsy in solitary pulmonary nodules and peripheral lesions. *Eur Respir J.* 2002;20:972–4. <https://doi.org/10.1183/09031936.02.00032001>.
- Kurimoto N, Miyazawa T, Okimasa S, et al. Endobronchial ultrasonography using a guide sheath increases the ability to diagnose peripheral pulmonary lesions endoscopically. *Chest.* 2004;126:959–65. <https://doi.org/10.1378/chest.126.3.959>.
- Becker HD, Herth FJ, Ernst A. Bronchoscopic biopsy of peripheral lung lesions under electromagnetic guidance. *J Bronchol.* 2005;12:9–13. <https://doi.org/10.1097/01.laboratory.0000147032.67754.22>.
- Casal RF, Sarkiss M, Jones AK, et al. Cone beam computed tomography-guided thin/ultrathin bronchoscopy for diagnosis of peripheral lung nodules: a prospective pilot study. *J Thorac Dis.* 2018;10(12):6950–9. <https://doi.org/10.21037/jtd.2018.11.21>.
- Sobieszczyk MJ, Yuan Z, Li W, et al. Biopsy of peripheral lung nodules utilizing cone beam computer tomography with and without trans bronchial access tool: a retrospective analysis. *J Thorac Dis.* 2018;10:5953–9. <https://doi.org/10.21037/jtd.2018.09.16>.
- Pertzov B, Gershman E, Kassirer M, Heching M, Rosengarten D, Kramer M. Use of LUNGVISION navigational system to improve diagnostic yield of peripheral lung nodule biopsy. *Chest.* 2019;156:A385.
- Pritchett MA. Prospective analysis of a novel endobronchial augmented fluoroscopic navigation system for diagnosis of peripheral pulmonary lesions. *J Bronchology Interv Pulmonol.* 2021;28:107–15. <https://doi.org/10.1097/LBR.0000000000000700>.
- Eberhardt R, Anantham D, Ernst A, et al. Multimodality bronchoscopic diagnosis of peripheral lung lesions: a randomized controlled trial. *Am J Respir Crit Care Med.* 2007;176:36–41. <https://doi.org/10.1164/rccm.200612-1866OC>.
- Herth FJ, Eberhardt R, Sternman D, et al. Bronchoscopic transparenchymal nodule access (BTPNA): first in human trial of a novel procedure for sampling solitary pulmonary nodules. *Thorax.* 2015;70:326–32. <https://doi.org/10.1136/thoraxjnl-2014-206211>.
- Prakash UB. The use of the pediatric fiberoptic bronchoscope in adults. *Am Rev Respir Dis.* 1985;132:715–7. <https://doi.org/10.1164/arrd.1985.132.3.715>.
- Oki M, Saka H, Kitagawa C, et al. Novel thin bronchoscope with a 1.7-mm working channel for peripheral pulmonary lesions. *Eur Respir J.* 2008;32:465–71. <https://doi.org/10.1183/09031936.00169107>.
- Gasparini S. Conventional biopsy techniques. In: Ernst A, Herth F, editors. *Principles and practice of interventional pulmonology.* New York: Springer; 2013. [https://doi.org/10.1007/978-1-4614-4292-9\\_15](https://doi.org/10.1007/978-1-4614-4292-9_15).
- Rivera MP, Mehta AC, Wahidi MM. Establishing the diagnosis of lung cancer. diagnosis and management of lung cancer, 3rd ed: American College of Chest Physicians evidence-based clinical practice guidelines. *Chest.* 2013;143:142–65. <https://doi.org/10.1378/chest.12-2353>.
- Dasgupta A, Mehta AC. Transbronchial needle aspiration: an underused diagnostic technique. *Clin Chest Med.* 1999;20:39–51. [https://doi.org/10.1016/S0272-5231\(05\)70125-8](https://doi.org/10.1016/S0272-5231(05)70125-8).
- Baaklini WA, Reinoso MA, Gorin AB, et al. Diagnostic yield of fiberoptic bronchoscopy in evaluating solitary pulmonary nodules. *Chest.* 2000;117:1049–54. <https://doi.org/10.1378/chest.117.4.1049>.
- Radke JR, Conway WA, Eyler WR, et al. Diagnostic accuracy in peripheral lung lesions: factors predicting success with flexible fiberoptic bronchoscopy. *Chest.* 1979;76:176–9. <https://doi.org/10.1378/chest.76.2.176>.
- Naidich DP, Sussman R, Kutcher WL, et al. Solitary pulmonary nodules: CT-bronchoscopic correlation. *Chest.* 1988;93:595–8. <https://doi.org/10.1378/chest.93.3.595>.

26. Ali MS, Sethi J, Taneja A, et al. Computed tomography bronchus sign and the diagnostic yield of guided bronchoscopy for peripheral pulmonary lesions. A systematic review and meta-analysis. *Ann Am Thorac Soc.* 2018;15:978–87. <https://doi.org/10.1513/AnnalsATS.201711-856OC>.
27. Mori K, Yanase N, Kaneko M, et al. Diagnosis of peripheral lung cancer in cases of tumors 2 cm or less in size. *Chest.* 1989;95:304–8. <https://doi.org/10.1378/chest.95.2.304>.
28. Gasparini S, Ferretti M, Bichi Secchi E, et al. Integration of transbronchial and percutaneous approach in the diagnosis of peripheral pulmonary nodules or masses: experience with 1,027 consecutive cases. *Chest.* 1995;108:131–7. <https://doi.org/10.1378/chest.108.1.131>.
29. Ali EAA, Takizawa H, Kawakita N, et al. Transbronchial biopsy using an ultrathin bronchoscope guided by cone-beam computed tomography and virtual bronchoscopic navigation in the diagnosis of pulmonary nodules. *Respiration.* 2019;98:321–8. <https://doi.org/10.1159/000500228>.
30. Bilaceroglu S, Kumcuoglu Z, Alper H, et al. CT bronchus sign-guided bronchoscopic multiple diagnostic procedures in carcinomatous solitary pulmonary nodules and masses. *Respiration.* 1998;65:49–55. <https://doi.org/10.1159/000029237>.
31. Reichenberger F, Weber J, Tamm M, et al. The value of transbronchial needle aspiration in the diagnosis of peripheral pulmonary lesions. *Chest.* 1999;116:704–8. <https://doi.org/10.1378/chest.116.3.704>.
32. Steinfurt DP, Khor YH, Manser RL, Irving LB. Radial probe endobronchial ultrasound for the diagnosis of peripheral lung cancer: systematic review and meta-analysis. *Eur Respir J.* 2011;37(4):902–10. <https://doi.org/10.1183/09031936.00075310>.
33. Ali MS, Trik W, Mba I, et al. Radial endobronchial ultrasound for the diagnosis of peripheral pulmonary lesions: a systematic review and meta-analysis. *Respirology.* 2017;22:443–53. <https://doi.org/10.1111/resp.12980>.
34. Zhan P, Zhu QQ, Miu YY, et al. Comparison between endobronchial ultrasound-guided transbronchial biopsy and CT-guided transthoracic lung biopsy for the diagnosis of peripheral lung cancer: a systematic review and meta-analysis. *Transl Lung Cancer Res.* 2017;6:23–34. <https://doi.org/10.21037/tlcr.2017.01.01>.
35. Sainz Zuniga PV, Vakil E, Molina S, et al. Sensitivity of radial endobronchial ultrasound-guided bronchoscopy for lung cancer in patients with peripheral pulmonary lesions. An updated meta-analysis. *Chest.* 2020;157:994–1011. <https://doi.org/10.1016/j.chest.2019.10.042>.
36. Gasparini S, Mei F, Bonifazi M, et al. Bronchoscopic diagnosis of peripheral pulmonary lesions. *Curr Opin Pulm Med.* 2022;28:31–6. <https://doi.org/10.1097/MCP.0000000000000842>.
37. Tanner NT, Yarmus L, Chen A, et al. Standard bronchoscopy with fluoroscopy vs thin bronchoscopy and radial endobronchial ultrasound for biopsy of pulmonary lesions: a multicenter, prospective, randomized trial. *Chest.* 2018;154:1035–43. <https://doi.org/10.1016/j.chest.2018.08.1026>.
38. Triller N, Dimitrijevic J, Rozman A. A comparative study on endobronchial ultrasound-guided and fluoroscopic-guided transbronchial lung biopsy of peripheral pulmonary lesions. *Respir Med.* 2011;105:S74–7. [https://doi.org/10.1016/S0954-6111\(11\)70015-4](https://doi.org/10.1016/S0954-6111(11)70015-4).
39. Nakajima T, Yasufuku K, Fujiwara T, et al. Endobronchial ultrasound-guided transbronchial needle aspiration for the diagnosis of intrapulmonary lesions. *J Thorac Oncol.* 2008;3:985–8. <https://doi.org/10.1097/JTO.0b013e31818396b9>.
40. Ishida T, Asano F, Yamazaki K, et al. Virtual bronchoscopic navigation combined with endobronchial ultrasound to diagnose small peripheral pulmonary lesions: a randomized trial. *Thorax.* 2011;66:1072–7. <https://doi.org/10.1136/thx.2010.145490>.
41. Asano F, Shinigawa N, Ishida T, et al. Virtual bronchoscopic navigation combined with ultrathin bronchoscopy. A randomized clinical trial. *Am J Respir Crit Care Med.* 2013;188:327–33. <https://doi.org/10.1164/rccm.201211-2104OC>.
42. Asano F, Eberhardt R, Herth FJF. Virtual bronchoscopy navigation for peripheral pulmonary lesions. *Respiration.* 2014;88:430–40. <https://doi.org/10.1159/000367900>.
43. Gex G, Pralong JA, Combesure C, et al. Diagnostic yield and safety of electromagnetic navigation bronchoscopy for lung nodules: a systematic review and meta-analysis. *Respiration.* 2014;87:165–76. <https://doi.org/10.1159/000355710>.
44. Zhang W, Chen S, Dong X, et al. Meta-analysis of the diagnostic yield and safety of electromagnetic navigation bronchoscopy for lung nodules. *J Thorac Dis.* 2015;7:799–809. <https://doi.org/10.3988/j.ssn.2072-1439.2015.04.46>.
45. Folch EE, Labarca G, Ospina-Delgado D. Sensitivity and safety of electromagnetic navigation bronchoscopy for lung cancer diagnosis. Systematic review and meta-analysis. *Chest.* 2020;158:1753–69. <https://doi.org/10.1016/j.chest.2020.05.534>.
46. Qian K, Krinsky WS, Sarkar SA, et al. Efficiency of electromagnetic navigation bronchoscopy and virtual bronchoscopic navigation. *Ann Thorac Surg.* 2020;109:1731–40. <https://doi.org/10.1016/j.athoracsur.2020.01.019>.
47. Ost DE, Ernst A, Lei X, et al. Diagnostic yield and complications of bronchoscopy for peripheral lung lesions. Results of the AQUIRE registry. *Am J Respir Crit Care Med.* 2016;193:68–77. <https://doi.org/10.1164/rccm.201507-1332OC>.
48. Folch EE, Pritchett MA, Nead MA, et al. Electromagnetic navigation bronchoscopy for peripheral pulmonary lesions: one-year results of the prospective, multicenter NAVIGATE study. *J Thorac Oncol.* 2019;14:445–8. <https://doi.org/10.1016/j.jtho.2018.11.013>.

49. Aboudara M, Roller L, Rickman O, et al. Improved diagnostic yield for lung nodules with digital tomosynthesis-corrected navigational bronchoscopy: initial experience with a novel adjunct. *Respirology*. 2020;25:206–13. <https://doi.org/10.1111/resp.13609>.
50. Harzheim D, Sterman D, Shah PL, et al. Bronchoscopic transparenchymal nodule access: feasibility and safety in an endoscopic unit. *Respiration*. 2016;91:302–6. <https://doi.org/10.1159/000445032>.
51. Pritchett MA, Schampaert S, de Groot JAH, et al. Cone-beam CT with augmented fluoroscopy combined with electromagnetic navigation bronchoscopy for biopsy of pulmonary nodules. *J Bronchol Interv Pulmonol*. 2018;25:274–82. <https://doi.org/10.1097/LBR.0000000000000536>.
52. De Gracia J, Bravo C, Miravittles M, et al. Diagnostic value of bronchoalveolar lavage in peripheral lung cancer. *Am Rev Respir Dis*. 1993;147:649–52. <https://doi.org/10.1164/ajrccm/147.3.649>.
53. Trisolini R, Cancellieri A, Tinelli C, et al. Performance characteristics and predictors of yield from transbronchial needle aspiration in the diagnosis of peripheral pulmonary lesions. *Respirology*. 2011;16:1144–9. <https://doi.org/10.1111/j.1440-1843-2011-02026x>.
54. Mondoni M, Sotgiu G, Bonifazi M, et al. Transbronchial needle aspiration in peripheral pulmonary lesions: a systematic review and meta-analysis. *Eur Respir J*. 2016;48:196–204. <https://doi.org/10.1183/13993003.00051-2016>.
55. Tremblay A, Myers R, Beaudoin EL, et al. Initial clinical experience with a flexible peripheral 21-G needle device. *J Bronchol Interv Pulmonol*. 2018;25:346–8. <https://doi.org/10.1097/LBR.0000000000000505>.
56. Gildea TR, Folch EE, Khandhar SJ, et al. The impact of biopsy tool choice and rapid on-site evaluation on diagnostic accuracy for malignant lesions in the prospective: multicenter NAVIGATE study. *J Bronchol Interv Pulmonol*. 2021;28:174–83. <https://doi.org/10.1097/LBR.0000000000000740>.
57. Sryma PB, Mittal S, Madan NK, et al. Efficacy of radial endobronchial ultrasound (R-EBUS) guided transbronchial cryobiopsy for peripheral pulmonary lesions (PPL's): a systematic review and meta-analysis. *Respirology*. 2021. <https://doi.org/10.1016/j.pulmoe.2020.12.006>.
58. Chunhua X, Wang W, Yuan Q, et al. Rapid on-site evaluation during radial endobronchial ultrasound-guided transbronchial lung biopsy for the diagnosis of peripheral pulmonary lesions. *Technol Cancer Res Treat*. 2020;19:1533033820947482. <https://doi.org/10.1177/1533033820947482>.



# Early Lung Cancer: Methods for Detection

# 21

Takahiro Nakajima and Kazuhiro Yasufuku

## Introduction and Definition of the Procedure

Lung cancer is the leading cause of cancer mortality worldwide [1]. Despite evolving knowledge of lung cancer molecular genetics and improved lung cancer detection technology, the overall lung cancer survival is still quite poor (18–21%-5-year survival) [1]. National Lung Cancer Screening Trial showed a dramatic, 20% relative decrease in lung cancer mortality with low dose CT chest screening in high-risk groups [2], proving the concept that early lung cancer detection which allows prompt surgical intervention, offers survival benefit. However, screening CT thorax detects smaller peripheral lung lesions, but is insensitive for detection of microscopic tumors arising from the central airways [3]. Microscopic tumors arising in the central airways require other techniques for early detection [4].

Squamous cell carcinomas, accounting for approximately 25–30% of all lung cancers, arise in central airways. Pathobiologically, progression

from normal bronchial epithelium to squamous metaplasia followed by dysplasia, carcinoma in situ (CIS), and finally invasive carcinoma has been well described [5, 6]. Studies have shown that patients with preinvasive bronchial lesions progress to develop CIS/invasive carcinoma over the median time of 24 months (range: 6–54 months) [7]. Approximately 11% of patients with moderate dysplasia and 19% to as high as 50% with severe dysplasia develop invasive carcinoma [8, 9]. The existence of COPD or heavy smoking history are at high risk of developing lung cancer [7]. Therefore, prompt detection through screening of high-risk patients (heavy smokers especially) could potentially offer early diagnosis of early preinvasive or early invasive lesions and allow for prompt therapeutic intervention and improved survival. However, conventional airway imaging modality, white light bronchoscopy (WLB) has been shown to be relatively insensitive in inspection of bronchial mucosa with only 30% sensitivity to detect early-stage carcinoma in the central airways [10].

New bronchoscopic modalities with higher spatial resolution are able to take advantage of intrinsic properties of healthy and abnormal tissues to change appearance when illuminated with different wavelengths of light, have been developed to serve the purpose of more advanced central airway imaging for the purpose of abnormal airway diagnosis [11]. Currently available in clinical practice modalities for detecting bron-

---

T. Nakajima  
Department of General Thoracic Surgery, Dokkyo  
Medical University, Mibu, Tochigi, Japan  
e-mail: [takahiro\\_nakajima@med.miyazaki-u.ac.jp](mailto:takahiro_nakajima@med.miyazaki-u.ac.jp)

K. Yasufuku (✉)  
Division of Thoracic Surgery, Toronto General  
Hospital, University Health Network, University of  
Toronto, Toronto, Canada  
e-mail: [kazuhiro.yasufuku@uhn.ca](mailto:kazuhiro.yasufuku@uhn.ca)



chial epithelial abnormalities include: autofluorescence bronchoscopy (AFB) and narrow band imaging (NBI). More precise airway inspection especially for the depth of tumor invasion to the bronchial layer can be obtained with radial probe endobronchial ultrasound (EBUS) and optical coherence tomography (OCT) [4]. Confocal laser endomicroscopy (CLE) using flexible probe-based system is another useful technique, allowing in vivo microscopic assessment of the airway basement membrane and alveolar components [12]. Endocytoscopy bronchoscopy system has allowed in vivo microscopic imaging of bronchial mucosa [13]. However, confocal laser endomicroscopy and endocytoscopy system are still under investigational use.

In this chapter, the advanced bronchoscopic imaging techniques of the airway will be reviewed and their roles in the early diagnosis of lung cancer will be shown.

---

## History and Historical Perspective

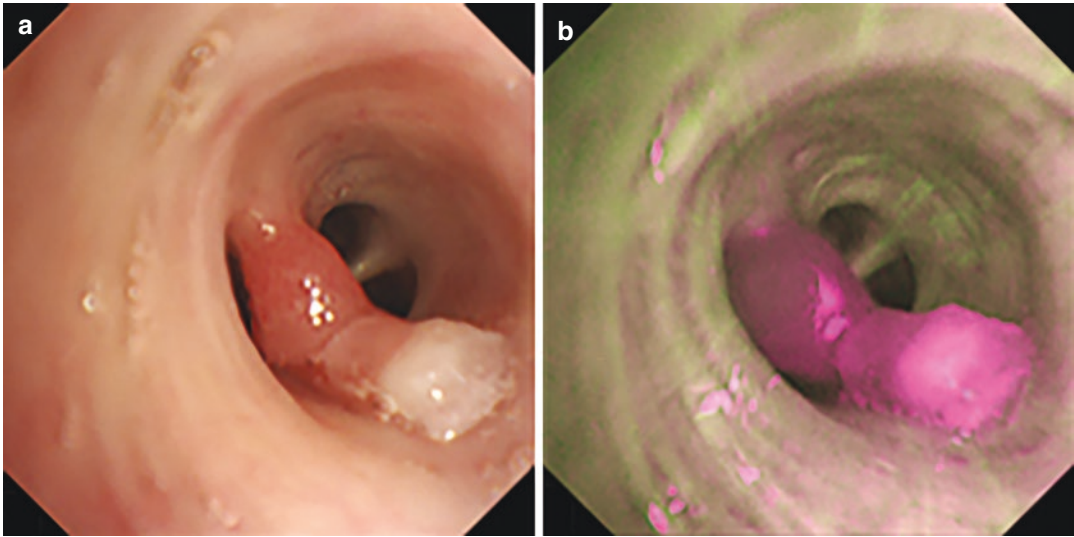
### Autofluorescence Bronchoscopy (AFB)

AFB combined with white light observation improves sensitivity for detection of preinvasive lesions in the central airways [10]. It is a technique of advanced mucosal airway examination taking advantage of the property of the normal, pre-neoplastic and neoplastic tissues to change appearance when illuminated with different wavelengths of light depending on differential epithelial thickness, tissue blood flow, and fluorophore concentration. Preinvasive and neoplastic tissues express diminished red and subsequently green autofluorescence compared with normal tissues when illuminated with blue-light (440–480 nm wavelength) [14]. Natural tissue chromophores (elastin, collagen, flavins, nicotinamide adenine dinucleotide, nicotinamide adenine dinucleotide hydrogen [NADH]) emit light when their electrons return to ground level after being excited with light of specific wavelength. The low level of tissue autofluorescence cannot be

picked up with WLB given the “noise” from high degree background reflected and backscattered light. However, AFB selectively picks up the subtle changes in natural tissue autofluorescence patterns. Tissue metaplasia, dysplasia, and neoplasia reduce natural concentration of airway chromophores (diminished expression of riboflavin, flavin, and NADH due to increased anaerobic metabolism and lactic acid production) [15]. Higher neoplastic tissue blood flow increases light absorption by the hemoglobin. Malignant tissue proliferation even if only microscopic at first results in higher degree of light scattering by tissue hyperplasia. These changes overall result in diminished tissue green autofluorescence with the abnormal tissue assuming a red-brown color [16]. These initially subtle mucosal changes are identifiable by WBL in only less than 30% of cases, even by experienced bronchoscopists. Different AFB imaging systems have been developed all with slightly different sensitivity for detection of the mucosal abnormalities. Continuous improvement of AFB devices allows for increased specificity. In the SAFE 1000 system (Pentax, Asahi Optical, Tokyo, Japan), xenon lamp replaced used in the light-induced fluorescence endoscopy (LIFE) device laser light. AFB is highly sensitive for detection of pre-neoplastic and neoplastic lesions, however, lacks specificity for detection of pre-invasive lesions. It often cannot differentiate between the areas of high blood flow and metabolism occurring in chronic inflammatory states like bronchitis. To overcome this limitation, video-autofluorescence systems such as SAFE-3000 and AFI has been developed [17] (Fig. 21.1).

### Narrow Band Imaging (NBI)

Narrow band imaging (NBI) is an optical image technology classified as an image enhancement endoscopy using special blue and green light wavelengths allowing for enhanced visualization of microvascular structures in the mucosal and submucosal layers [18–20]. NBI utilizes wavelengths at 415 nm (blue light) and 540 nm (green



**Fig. 21.1** Autofluorescence bronchoscopy (AFB) image using AFI system. Representative case of carcinoma in situ. (a) White light bronchoscopy showed thickening of the bifurcation and partially covered with white coat. (b)

Corresponding AFB image using AFI system (Olympus). The cancerous area was visualized as a magenta lesion with a clear border to normal mucosa

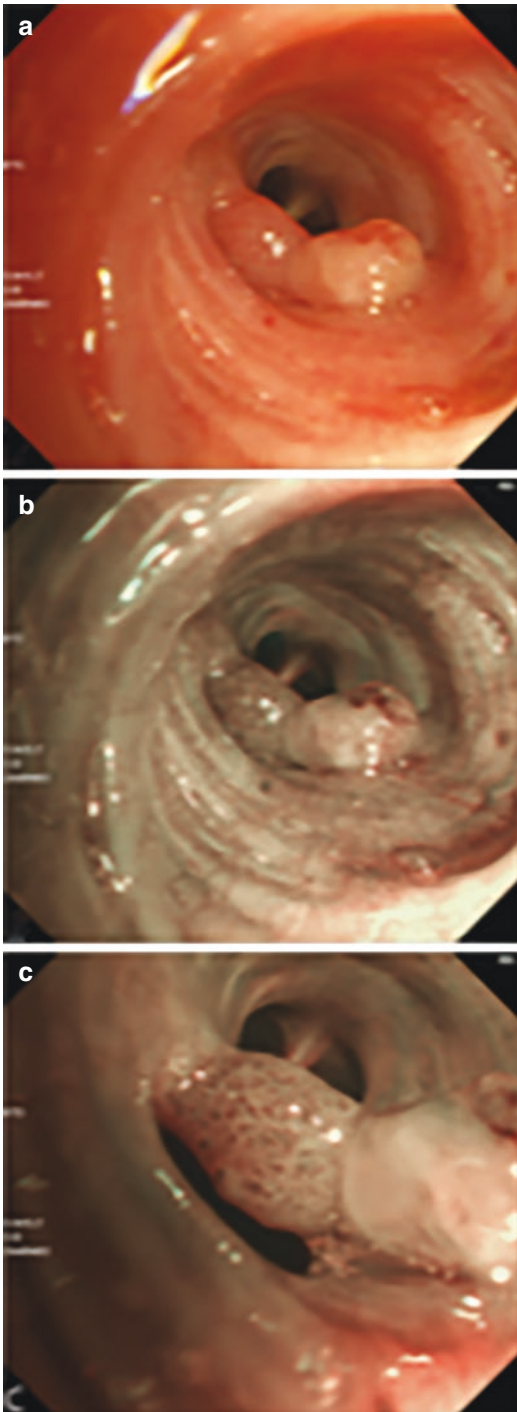
light). Narrow bandwidths reduce the mucosal light scattering and enable enhanced visualization of endobronchial microvasculature structure. The 415 nm blue light is absorbed by the superficial capillary vessels whereas the 540 nm wavelength is absorbed by the hemoglobin in the deeper, submucosal vessels. Fine blood vessels appear brown and the deeper vessels cyan.

Beside molecular changes allowing autonomous progression of cell cycle that imparts metastatic potential, cancer cells must also develop extended angiogenic capabilities allowing for rapid growth and invasion. Multi-step angiogenesis process has been described in epithelial tumors [21, 22]. To fulfill high metabolic demands of rapidly dividing tumor, neoplastic cells have to develop enhanced angiogenic capabilities. Animal and human invasive neoplasia pathogenesis studies suggest that so-called “angiogenic switch” is thought to occur in pre-invasive lesions prior to invasive tumor formation [23, 24]. Since squamous cell cancer is thought to progress through developmental staged from

squamous cell metaplasia to dysplasia and CIS, detection of each of these stages could have a significant impact on therapeutic interventions and prognosis (Fig. 21.2).

### High Magnification Bronchovideoscope (HMB)

High magnification bronchovideoscope (HMB) is a system that was developed to enhance detailed white light observation of bronchial dysplasia. Increased thickening of the bronchial epithelium and increased vessel growth are thought to be related to the appearance of areas of abnormal fluorescence, suggesting roles for neovascularization or increased mucosal microvascular growth in bronchial dysplasia. However, the only abnormality seen on WLB in dysplasia is swelling and redness at the bronchial bifurcations. HMB is a direct viewing WLB system that has an outer diameter of 6 mm and can easily be inserted into the tracheobronchial tree. HMB combines



**Fig. 21.2** Narrow band imaging (NBI). Representative case of carcinoma in situ (same as Fig. 21.1). (a) White light bronchoscopy using high definition bronchovideoscope. (b) Narrow band imaging (NBI) of the same area. (c) Close view of NBI identified dotted vessel and spiral/screw type vessels which was typically observed for carcinoma in situ

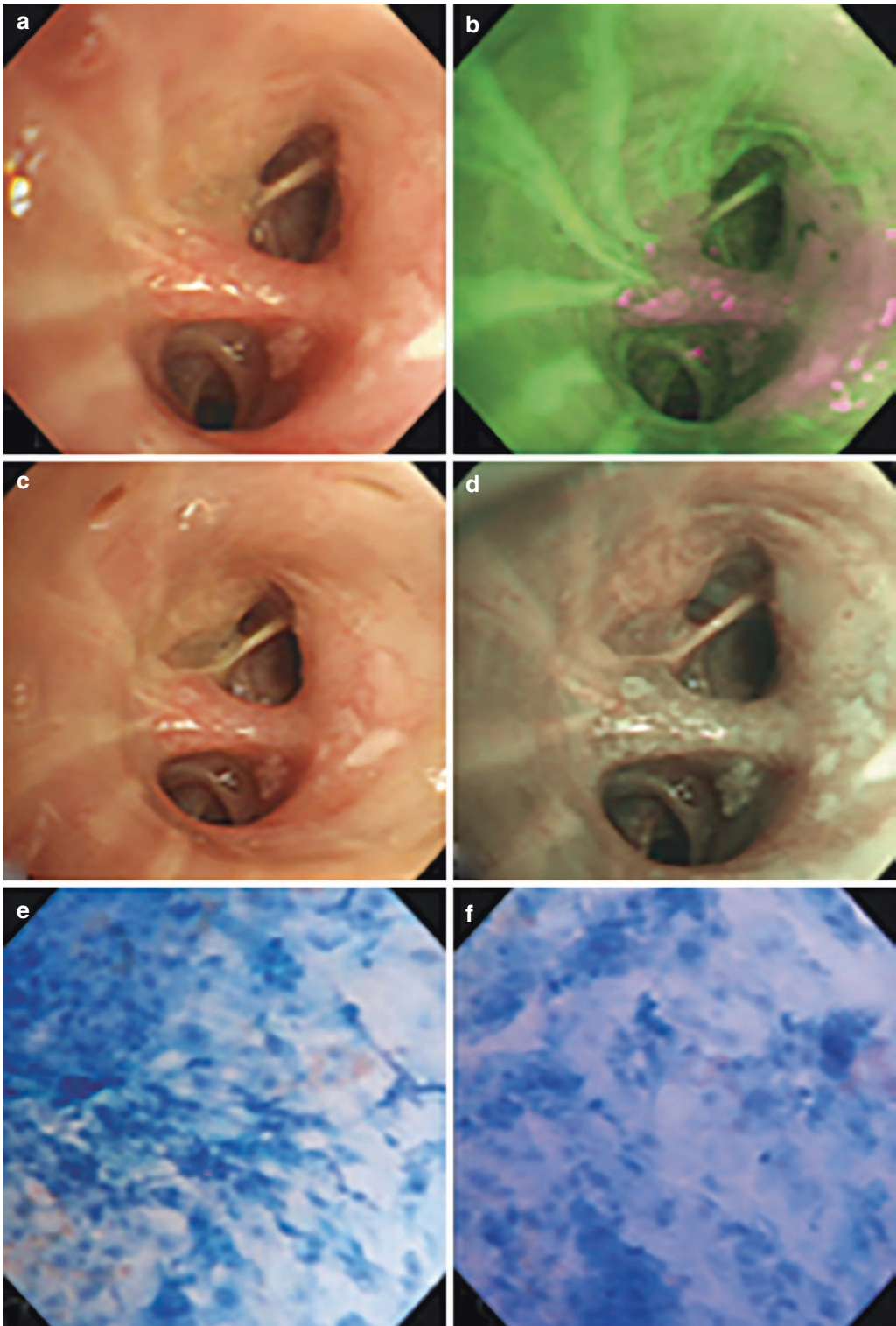
two systems—a video observation system for high magnification observation and a fiber observation system for orientation of the bronchoscope tip. For the video observation system an objective optical system, in fixed focus mode rather than zoom mode, was used to give an outer diameter of about 6 mm to allow for the bronchoscope and the observation depth of 1–3 mm. Magnification is about fourfold higher than that of the regular bronchovideoscope. The bronchial mucosa is observed minutely on a 14-inch TV monitor at a high magnification of 110 times at the nearest point [25].

HMB has enabled observation of vascular networks within the bronchial mucosa in patients with respiratory disease such as asthma, chronic bronchitis, sarcoidosis, and lung cancer. Areas of increased vessel growth and complex networks of tortuous vessels in the bronchial mucosa that are detected using HMB at sites of abnormal fluorescence may allow clinicians to differentiate between bronchitis and dysplasia. In areas of abnormal fluorescence on AFB, HMB can detect dysplasia more accurately than AFB alone with a sensitivity of 70% and specificity of 90% [25]. HMB observation in patients with asthma showed that the vessel area density and vessel length density are significantly increased compared to control subjects [26] (Fig. 21.3).

### Dual Red Imaging (DRI)

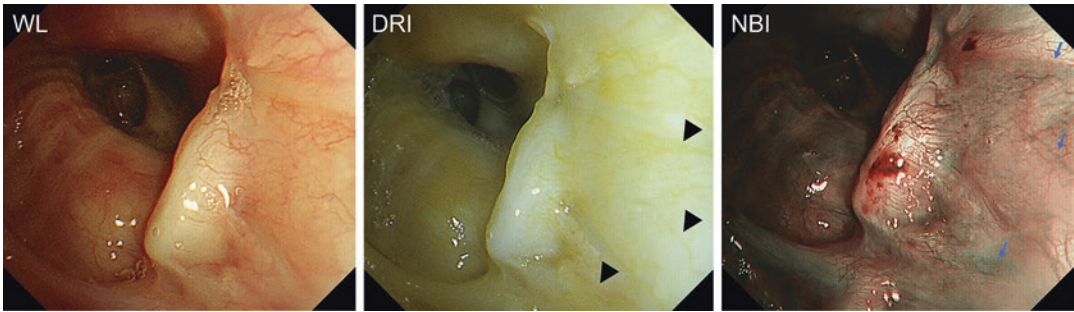
DRI is a novel image enhanced endoscopy technology that enables to visualization of relatively deeper blood vessels in the tissue by using two different wavelength lights, 600 nm and 630 nm, in the red band [27]. This technology is used primarily in the gastrointestinal field because RDI images easily find the blood vessels in deeper tissue. DRI increased the visibility of esophageal varices [28] and was applied to evaluate the severity of ulcerative colitis [29]. DRI is also valid for endoscopic treatment in the gastrointestinal field, such as endoscopic mucosal resection. DRI quickly detects the blood vessels in the deeper mucosal layer and the bleeding point during the procedure [27]. The utility of





**Fig. 21.3** Several bronchoscopic imaging techniques of the airway. Representative case of micro-invasive squamous cell carcinoma. (a) White light bronchoscopy. (b) AFB using AFI system. (c) White-light bronchoscopy

using high definition bronchovideoscope. (d) Narrow band imaging. (e, f) Endocytoscopy images using methylene blue staining of the mucosa



**Fig. 21.4** Comparison of white light, dual red imaging, and narrow band imaging for endobronchial vasculature. Representative image of endobronchial vasculature by white light, dual red imaging, and narrow band imaging at

the bronchial anastomosis of lung cancer surgery. Dual red imaging visualizes the blood vessels in deeper tissue as dark yellow (arrow). (Referenced vessels were shown in NBI by thinner arrow)

DRI during bronchoscopic observation is unclear, and further clinical information would be required (Fig. 21.4).

### Endobronchial Ultrasound (EBUS)

Two types of endobronchial ultrasound (EBUS) are currently available for clinical use. The radial probe EBUS first described in 1992 is used for the evaluation of bronchial wall structure, visualization of detailed images of the surrounding structures for assisting TBNA as well as detection of peripheral intrapulmonary nodules [30]. On the other hand, the convex-probe EBUS first described in 2004 has a built-in ultrasound probe on a flexible bronchoscope which enables bronchoscopists to perform real-time TBNA of mediastinal and hilar lesions [31].

Pre-malignant lesions or small intrabronchial radiologically invisible tumors are being detected more frequently as a result of new advanced mucosal imaging technologies. The decision to use endoscopic therapeutic intervention depends on the extent of tumor within the different layers of the bronchial wall. Conventional radiological imaging alone is not capable of distinguishing the tumor extent. The radial probe EBUS is a sensitive method for detection of alterations of the multi-layer structure of the bronchial wall even in small tumors [32].

### Optical Coherence Tomography (OCT)

OCT is an optical imaging method that uses properties of light waves instead of sound waves [33]. OCT can generate high-resolution cross-sectional images of complex, living tissues in real time. Lam and colleagues investigated the ability of OCT to discern the pathology of lung lesions identified by AFB in a group of high-risk smokers and reported that normal or hyperplastic mucosa is characterized by 1 or 2 cell layers above a highly scattering basement membrane and upper submucosa [34]. As the epithelium changes from normal/hyperplasia to metaplasia, various grades of dysplasia, and CIS, the thickness of the epithelial layer increases. The basement membrane was still intact in CIS but became discontinuous or no longer visible with invasive cancer. Michel and colleagues examined 5 patients with endobronchial masses on chest imaging with OCT [35]. OCT images showed differences between neoplasms and normal bronchial mucosa, and neoplastic lesions displayed irregular, ragged, dark lines between 2 light areas, which had the appearance of a fracture in the subepithelium.

### Indications and Contraindications

By the use of its' high sensitivity for detecting lung cancer as well as preinvasive lesions, third ACCP guideline recommended AFB may be used

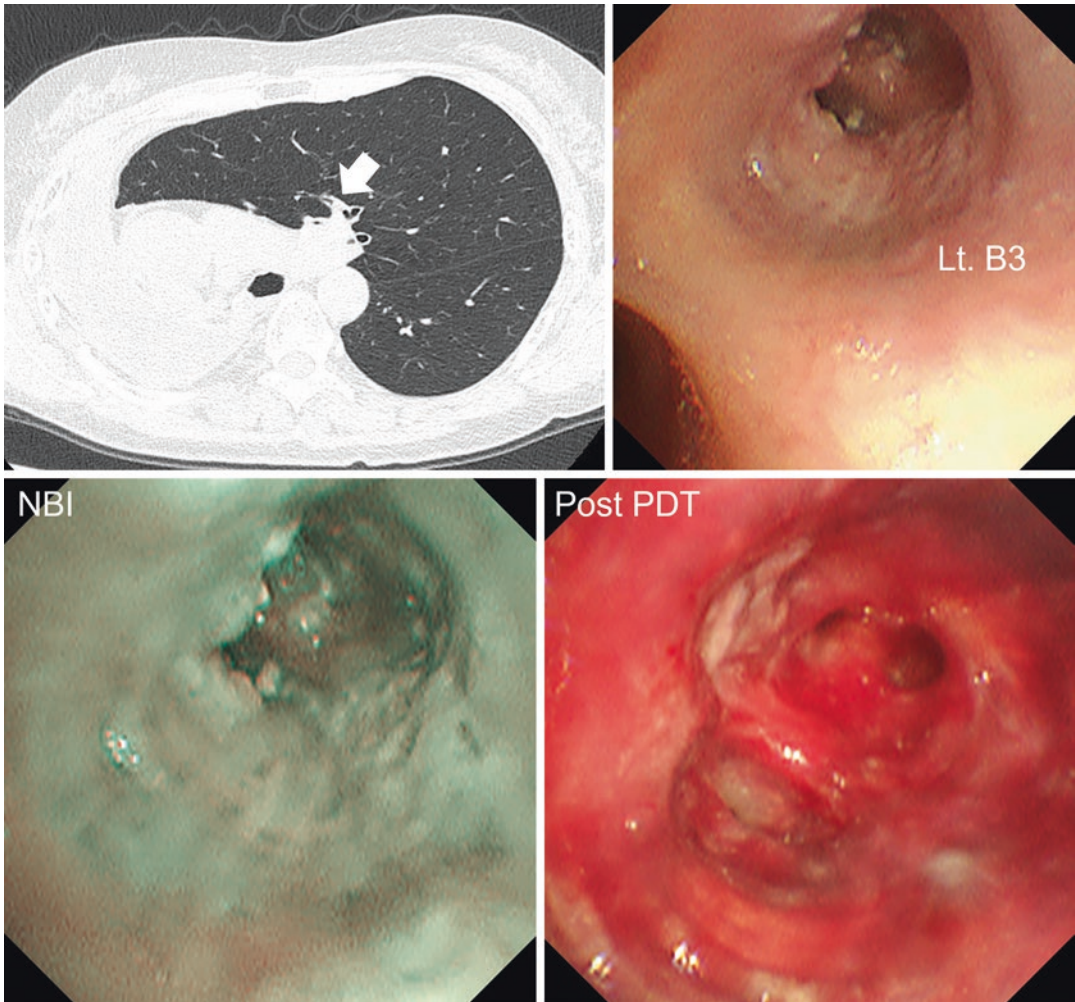


as an adjunct modality when available in patients with severe dysplasia or CIS in sputum cytology who have chest imaging studies showing no localizing abnormality. In addition, patients with known severe dysplasia or CIS of central airways should be followed with WLB or AFB, when available [36]. AFB has also been shown to increase detection sensitivity of recurrent or new intraepithelial neoplasias and invasive carcinomas when added to WLB (from 25% for WLB alone to 75% when AFB is used in conjunction with WLB) in postoperative surveillance of patients who underwent curative resection for NSCLC [37]. AFB is also suggested for patients with early lung cancer who will undergo resection for delineation of tumor margins and assessment of synchronous lesions [36]. AFB combined with CT of the thorax in patients with radiographically suspicious and occult lung cancer has shown to be an effective lung cancer staging and tumor extension assessment modality with impact on therapeutic strategy choice [38, 39].

The Lung SEARCH clinical trial of surveillance for the early detection of lung cancer in high-risk group was conducted [40]. The study targeted on 1568 high-risk individuals and the patients who showed abnormal sputum receive annual CT and AFB screening to identify early lung cancer. The results of this trial were opened and published in 2019 [41]. In this study, the sensitivity of sputum-positive individuals who had AFB, sensitivity was 45.5%, and the cumulative false-positive rate was 39.5%. Unfortunately, this study strategy, using sputum cytology/cytometry to select high-risk individuals for AFB and LDCT, did not lead to a clear stage shift and did not improve the efficiency of lung cancer screening [41].

However, before AFB and NBI can be incorporated into lung cancer screening, few issues need to be addressed. First, natural history of the squamous cell carcinoma (SCC) and bronchial dysplasia must be better characterized. SCC represents a third of all lung cancers diagnosed in the United States [1]. It is thought that pathologically, invasive cancer results from a stepwise

process that begins with metaplasia then dysplasia followed by CIS and finally invasive cancer. Previous studies showed development of invasive carcinoma in 40–83% of patients with severely dysplastic lesions [42, 43]. However, animal models and human studies show spontaneous regression of some of the lesions [44, 45]. Breuer et al. documented a 9–32% rate of malignant transformation for all dysplastic lesions in 52 patients followed over an 8-year period. Fifty-four percent spontaneous regression of all preinvasive lesions as well as non-stepwise transformation with development of invasive carcinoma at sites previously characterized as normal in appearance, has also been described. These findings suggest that development of SCC may not always follow classic stepwise transformation pattern [45]. Also, population of patients at risk must be clearly identified and those with highest risk lesions (most likely to progress to invasive cancer) should be screened. Finally, appropriate therapeutic options and follow-up surveillance schedule must be developed based on evidence in order to decrease overall cancer mortality and recurrence [46]. Unfortunately, the recent data from the Pan-Canadian Lung Cancer Screening Study showed that the additional AFB only found one typical carcinoid tumor and one CIS lesion that were CT occult cancers. They concluded that additional AFB to LDCT in a high lung cancer risk cohort detected too few CT occult cancers (0.15%) to justify its incorporation into a lung cancer screening program [47]. Until all these issues have been addressed, the use of AFB and NBI will be predominantly in the research setting. The incidence of metachronous lung cancer in hilar early lung cancer has been reported to be 10–30% [48]; hence, we need to pay attention to second primary lung cancer after initial treatment. CT follow-up and enhanced bronchoscopy may contribute to detecting the second lung cancer in the early stage and enable treating the lesion by less invasive, respiratory function preservative treatment modality such as photodynamic therapy (Fig. 21.5).



**Fig. 21.5** Second lung cancer treated by photodynamic therapy. Representative case of micro-invasive squamous cell carcinoma as second lung cancer arising in the patients with post-pneumectomy for right lung cancer.

A small nodular shadow was detected in the left B3 bronchus during follow-up. Bronchoscopy showed micro-invasive squamous cell carcinoma, and the patient was successfully treated by photodynamic therapy

## Description of the Equipment Needed

### Autofluorescence Bronchoscopy (AFB)

Autofluorescence imaging (AFI) (Olympus, Tokyo, Japan) is a currently commercially available AFB system. The AFI system transmitted 3 wavelengths: excitation blue light (395–445 nm, to induce autofluorescence), 550 nm (red reflected light), and 610 nm (blue reflected light) [49].

Improved discriminatory nature of AFI system results from its ability to integrate three signals: autofluorescence signal with reflected green and red-light signals [50]. Composite image displayed depicts normal epithelium as light green, areas of abundant blood flow seen not only in malignant epithelium, but also in areas of chronic benign inflammation as dark green and magenta color for malignant tissue due to mixed red/blue reflected signals and lack the green autofluorescence signal [51] (Fig. 21.1). AFI demonstrated improved specificity over the LIFE AFB system

(83% vs. 36.6%) but slightly lower sensitivity (80% vs. 96.7%) in detection of pre-malignant and malignant bronchial lesions [51].

### **Confocal Laser Endomicroscopy and Endocytoscopy**

The confocal laser endomicroscopy (CLE) system is a new *in vivo* microscopic imaging device allowing the endoscopist to obtain real-time *in vivo* optical biopsies during ongoing endoscopy. The probe-based confocal laser endomicroscopy system (Cellvizio; Mauna Kea Technologies, Paris, France), which is capable of passage through the accessory channel of a standard endoscope, is available. Thiberville and colleagues observed 27 preinvasive lesions (metaplasia and dysplasia) and 2 invasive lesions and reported some specific basement membrane alterations within preinvasive lesions [52]. Methylene blue is a potent fluorophore, and its application to the target makes it possible to reproducibly image the epithelial layer of the main bronchi as well as cellular patterns of peripheral solid lung nodules [53]. Wellikoff et al. compared the images obtained by the probe-based confocal laser endomicroscopy and histological findings of biopsied malignant specimen in the same area [54]. They found an irregular connective tissue architecture with disorganization and fragmentation as well as mottling or 'black holes' that represent nests of cells interrupting the fluorescence of the underlying connective tissue was correlated with a malignant diagnosis [54]. However, whether confocal laser endomicroscopy can discriminate among diseases requires additional studies. Shah et al. examined 25 patients with endobronchial abnormalities by CLE. CLE provides adequate visual information for all patients; however, it was hard to distinguish between dysplasia and carcinoma [55].

The endocytoscopy system (ECS; Olympus Medical System Corp) is another recently introduced, emerging endoscopic imaging technique enabling real-time *in vivo* diagnosis of cellular patterns at extremely high magnification [56].

The tip of the instrument contains an optical magnifying lens system and CCD. This endoscope can be inserted through the 4.2-mm biopsy channel and Olympus mother bronchoscope to become an "endocytoscope." The ECS has a 570-fold magnification and provides an observation field of  $300 \times 300 \mu\text{m}$ , an observation depth of 0–30  $\mu\text{m}$ , and spatial resolution of 4.2 mm for bronchial imaging. Shibuya and colleagues examined 22 patients with endobronchial abnormalities and reported that ECS was useful to discriminate between normal bronchial epithelial cells, dysplastic cells, and malignant cells during ongoing bronchoscopy [13]. Another group used ECS in 4 patients for the immediate *in vivo* diagnosis of small cell lung cancer during ongoing bronchoscopy [57]. ECS was able to reliably identify numerous small blue cells with hyperchromatic nuclei, which were confirmed in an *in vivo* diagnosis of small cell lung cancer by corresponding histopathologic diagnosis [57]. Although the utility of ECS was reported, it is technically more difficult than CLE to obtain an adequate image to evaluate [55].

### **Raman Spectrophotometry**

Use of Raman spectrophotometry system in addition to AFB and WLB may offer improved specificity (91%) in detection of preinvasive lesions, with only minor compromise in sensitivity (96%) as documented by a recent pilot study [58]. Laser Raman Spectroscopy (LRS), currently used only in experimental setting, involves exposing the tissue to low-power laser light and collecting the scattered light for spectroscopic analyses [59]. This technology collects spectra non-destructively and light scattered from tissues with different molecular composition can be easily differentiated. Using this technology can potentially reduce the number of false-positive biopsies for detection of preneoplastic lesions. Use of Raman spectra with AFB and WLB can offer a more objective airway mucosal assessment and detect more preneoplastic lesions. Also, Raman may be able to identify biomolecular changes in histologically pre-neoplastic and non-preneoplastic

lesions that could be markers for development into late-stage malignancy. McGregor et al. examined 280 sites including 72 high grade dysplasia/malignant lesions and 208 normal sites in 80 patients using real-time endoscopy Raman spectroscopy system. They could detect high grade dysplasia/malignant lesions with a sensitivity of 90% and specificity of 65% [60]. More studies are needed to assess addition of this technology to armamentarium of tools for endobronchial neoplasia detection.

---

## Application of the Technique

### Autofluorescence Imaging and Optical Coherent Tomography

As previously described, autofluorescence imaging provides biochemical information about tissue by visualizing fluorescent tissue components such as collagen and elastin and OCT provides high resolution detailed information about tissue morphology. By combination of these two modalities, more precise observation of airway structure with emission of autofluorescence could be performed using *ex vivo* human lung [61]. This novel technology can apply for the peripheral pulmonary lesions and the more precise observation on tumor tissue structure with vasculature information can be provided [62].

### Supplemental Technology for Diagnostic Bronchoscopy

For the improvement of diagnostic rate of cytopathological material obtained by diagnostic bronchoscopy, several approaches have been attempted. By adding multitarget fluorescence *in situ* hybridization to conventional cytological smear, the sensitivity for detecting malignant cells was improved for bronchial brushing and washing specimens [63]. The immunohistochemistry for six protein expression including TP53, Ki67, MCM6, MCM7, KIAA1522, and KIAA0317 for bronchial brushing specimen improved the detection rate of lung cancer with sensitivity of 81.1% for non-small cell lung cancer

and 83.3% for small cell lung cancer [64]. Recently a bronchial genomic classifier for the diagnostic evaluation of lung cancer has been reported [65]. In this study, epithelial cells were collected from the normal appearing mainstem bronchus in current or former smokers undergoing bronchoscopy for suspected lung cancer. By evaluating 23 gene expressions, the diagnostic yield of bronchoscopy for the detection of lung cancer was improved with high negative predictive value of 91% [65]. These advanced multidirectional analysis technologies will be the powerful support for detecting early lung cancer in combination with diagnostic bronchoscopy [66] (Fig. 21.3).

---

## Evidence-Based Review

Multiple studies demonstrated that AFB improves detection of preinvasive central airway lesions and when combined with WLB also of squamous dysplasia, CIS, and early lung carcinoma. The meta-analysis of 21 studies comparing WLB used with AFB versus WLB alone in diagnosis of intraepithelial neoplasia and invasive lung cancer, involving 3266 patients, reported a pooled relative sensitivity of 2.04 (95% CI 1.72–2.42) on a per-lesion basis in favor of combined AFB and WLB approach [50]. Another meta-analysis showed that the pooled sensitivity of AFI and WLB was 0.89 (95% confidence interval [CI] 0.81–0.94) and 0.67 (95% CI 0.46–0.83) and the pooled specificity of AFI and WLB was 0.64 (95% CI 0.37–0.84) and 0.84 (95% CI 0.74–0.91), respectively [67]. However, the superiority of AFI in comparison with WLB has been controversial, as documented in previous individual studies, the sensitivity for detection of CIS and early invasive carcinomas was not superior to WLB alone (the RR of 1.15 at 95% CI 1.05–1.26) [50]. This suggests that while screening for invasive cancer WLB may be sufficient and more cost effective. Recently, a meta-analysis data of autofluorescence imaging video bronchoscopy (AFI) performed with the Evis Lucera Spectrum (Olympus) was published [68] and both sensitivity and specificity of AFI was superior to WLB (sensitivity: AFI of 0.92 (95% CI, 0.88–0.95)



over WLB's 0.70 (95% CI, 0.58–0.80) with  $P < 0.01$ , specificity: AFI of 0.67 (95% CI, 0.51–0.80) compared with WLB's 0.78 (95% CI, 0.68–0.86) with  $P = 0.056$  [68].

AFB can become a useful tool in endobronchial pre-malignant and malignant lesion detection screening, especially in high-risk groups (patients with head and neck cancers, chronic obstructive pulmonary disease [COPD], and smokers) knowing that the incidence of synchronous lesions ranges from 0.7% to 15% and metachronous lesions might occur in as many as 5% high risk patients annually [69, 70]. However, more studies are needed to determine how the AFB can best be incorporated into clinical practice in an economically efficient way and with reasonable reduction in lung cancer mortality.

NBI shows higher sensitivity compared to AFB in detection of metaplastic and moderately dysplastic bronchial mucosal squamous lesions. It has equivalent sensitivity as AFB in detection of early preinvasive malignant lesions (CIS) and invasive cancer (ranging between 90–100% for NBI and 83–89.2% for AFB). However, NBI has a higher than AFB specificity for detection of early lung cancer [71]. The recently published meta-analysis data from eight studies on NBI showed a pooled sensitivity of 0.80 [95% confidence interval (CI): 0.77–0.83] and a pooled specificity of 0.84 (95% CI: 0.81–0.86) [72].

Combining AFB and NBI increases both the sensitivity (93.7%) and specificity (86.9%) of early lung cancer detection. But the improvement is small as compared to each technique alone. Therefore, combining the two technologies in cancerous and pre-cancerous lesion detection does not have significant impact on diagnostic accuracy and may result in unnecessary cost without significant clinical benefit. Judging by the results of the studies, NBI can be used alternatively to AFB in cancerous and pre-cancerous lesion screening of the endobronchial epithelium without compromising sensitivity and with significantly improvement in specificity [73].

Using NBI and HMB, previous studies have shown angiogenesis and microvascular structure alteration of bronchial dysplastic lesions at sites detected as abnormal autofluorescence [74]. Using NBI combined with high magnification

bronchovideoscopy, Shibuya et al. showed statistically significant increase in capillary blood vessel diameter occurring as tissue progresses from angiogenic squamous dysplasia (ASD) to CIS, microinvasive cancer, and invasive squamous cell carcinoma [75]. Architectural organization of the vessels also differed between the pre-malignant and malignant lesions. Classification system was proposed based on vascular appearance of endobronchial lesions of varying invasiveness. It showed high correlation with lesions' histopathologic features [75, 76]. However, more studies using the classification are needed to further validate it.

A comparison between the ultrasound and the histologic findings in 24 lung cancer cases revealed that the depth diagnosis was the same in 23 lesions (95.8%) [32]. In another study in a series of 15 patients, EBUS showed a high diagnostic yield of 93% for predicting tumor invasion into the tracheo-bronchial wall [77]. EBUS also improves the specificity (from 50% to 90%) for predicting malignancy in small AFB-positive lesions that were negative on white light bronchoscopy [78].

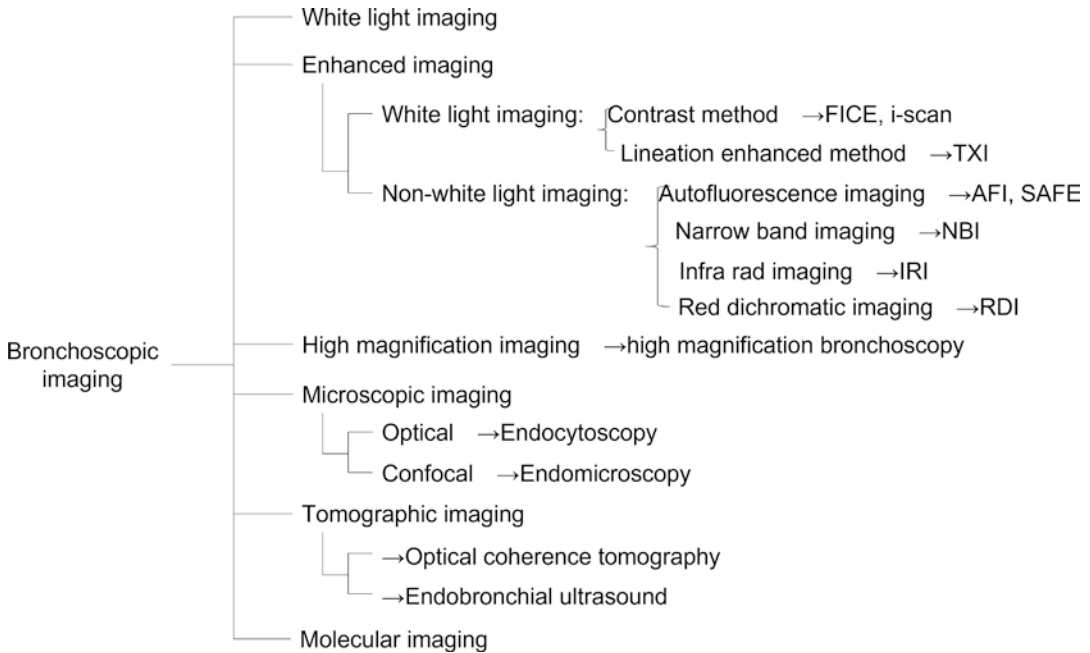
Photodynamic therapy (PDT) is an alternative treatment for selected patients with central type early-stage lung cancer. EBUS was performed to evaluate tumor extent in 18 biopsy-proven early-stage squamous cell carcinomas (including three CIS) [79]. Nine lesions were diagnosed as intracartilaginous by EBUS and PDT was subsequently performed. The other nine patients had extracartilaginous tumors unsuspected by computed tomographic scanning and were considered candidates for other therapies such as surgical resection, chemotherapy, and radiotherapy. Using EBUS, 100% complete remission rate was achieved in the endoluminal-treated group.

---

### **Summary and Recommendations, Highlight of the Developments During the Last Three Years (2013 on)**

Recent advances in the field of bronchology have allowed bronchoscopists to evaluate the airway with advanced high-resolution imaging





**Fig. 21.6** Classification of advanced bronchoscopic imaging techniques and representative modalities

modalities discussed in this chapter (Fig. 21.6) [80]. Centrally arising squamous cell carcinoma of the airway, especially in heavy smokers, is thought to develop through multiple stages from squamous metaplasia to dysplasia, followed by carcinoma in situ, progressing to invasive cancer. Early detection is key for improved survival. It would be ideal if we can detect and treat preinvasive bronchial lesions defined as dysplasia and carcinoma in situ before progressing to invasive cancer. Bronchoscopic imaging techniques capable of detecting preinvasive lesions currently available in clinical practice including AFB, NBI, HMB, and EBUS were discussed in this chapter.

AFB increases the diagnostic accuracy for squamous dysplasia, carcinoma in situ, and early lung carcinoma when used simultaneously with conventional white light bronchoscopy. However, the specificity of AFB for detecting preinvasive lesions is moderate. AFB displays areas of epithelial thickness and hypervascularity as abnormal fluorescence which suggests a role for neovascularization or increased mucosal microvascular growth in bronchial dysplasia. HMB

enables visualization of these vascular networks. HMB can detect increased vessel growth and complex networks of tortuous vessels of various sizes in the bronchial mucosa. To further evaluate the vascular network in the bronchial mucosa, a new imaging technology NBI was developed and is now commercially available.

AFB and NBI are complimentary for the evaluation of preinvasive bronchial lesions. The strength of AFB is its high sensitivity acting as a monitor to pick up potentially neoplastic lesions. However, the potential limitation is its moderate specificity. NBI on the other hand enhances the mucosal and vascular patterns which is best suited for detailed inspection of the mucosa. A combination of autofluorescence and NBI into a single bronchovideoscope system would decrease the time for the procedure as well as unnecessary biopsies. For a bronchoscopist, AFB, NBI, and HMB are just the same as performing a routine WLB without any complicated procedures necessary. Interpretation of the results seems to be fairly straight forward. The radial probe EBUS is an excellent tool for the evaluation of the airway structure which is use-

ful for the determination of the depth of tumor invasion. Minimally invasive treatment may be suitable for selected patients with central type early-stage lung cancer.

**Acknowledgments** TN received honoraria and lecture fees from Olympus Corporation, and KY received unrestricted educational and research grant from Olympus Corporation.

## References

1. Siegel RL, Miller KD, Fuchs HE, Jemal A. Cancer Statistics, 2021. *CA Cancer J Clin.* 2021;71(1):7–33.
2. The National Lung Screening Trial Research Team. Reduced lung cancer mortality with low-dose computed tomographic screening. *NEJM.* 2011;365:395–409.
3. Yasufuku K. Early diagnosis of lung cancer. *Interv Pulmonol.* 2010;31:40–7.
4. Nakajima T, Yasufuku K. Early lung cancer: methods for detection. *Clin Chest Med.* 2013;34:373–83.
5. Niklinski J, Niklinski W, Chyczewskis L, et al. Molecular genetic abnormalities in premalignant lung lesions: biological and clinical implications. *Eur J Cancer Prev.* 2001;10:213–26.
6. Thiberville L, Payne P, Vielkinds J, et al. Evidence of cumulative gene losses with progression of the premalignant epithelial lesions to carcinoma of the bronchus. *Cancer Res.* 1995;155:5133–9.
7. Alaa M, Shibuya K, Fujiwara T, et al. Risk of lung cancer in patients with preinvasive bronchial lesions followed by autofluorescence bronchoscopy and chest computed tomography. *Lung Cancer.* 2011;72:303–8.
8. Venmans BJ, van Boxem TJ, Smith EF, et al. Outcome of bronchial carcinoma in situ. *Chest.* 2000;117:1572–6.
9. Ikeda N, Hayashi A, Iwasaki K, et al. Comprehensive diagnostic bronchoscopy of central type early stage lung cancer. *Lung Cancer.* 2007;56:295–302.
10. Lam S, Kennedy T, Unger M, et al. Localization of bronchial intraepithelial neoplastic lesions by fluorescence bronchoscopy. *Chest.* 1998;113:696–702.
11. van der Heijden EH, Hoefsloot W, van Hees HW, et al. High definition bronchoscopy: a randomized exploratory study of diagnostic value compared to standard white light bronchoscopy and autofluorescence bronchoscopy. *Respir Res.* 2015;16:33.
12. ASGE Technology Committee. Confocal laser endomicroscopy. *Gastrointest Endosc.* 2014;80:928–38.
13. Shibuya K, Fujiwara T, Yasufuku K, et al. In vivo microscopic imaging of the bronchial mucosa using an endo-cytoscopy system. *Lung Cancer.* 2011;72:184–90.
14. Keith RL, Miller YE, Gemmill RM, et al. Angiogenic squamous dysplasia in bronchi of individuals at high risk for lung cancer. *Clin Cancer Res.* 2000;6:1616–25.
15. Bolliger CT, Mathur PN. Interventional bronchoscopy. *Progress in respiratory research*, vol. 30. Cham: Kaarger; 2000. p. 243.
16. Colt H, Murgu S. Interventional bronchoscopy form bench to bedside: new techniques for early lung cancer detection. *Interv Pulmonol.* 2010;31:29–37.
17. He Q, Wang Q, Wu Q, et al. Value of autofluorescence imaging videobronchoscopy in detecting lung cancers and precancerous lesions: a review. *Respir Care.* 2013;58:2150–9.
18. Gono K, Obi T, Yamaguchi M, Ohyama N, Machida H, Sano Y, et al. Appearance of enhanced tissue features in narrow-band endoscopic imaging. *J Biomed Opt.* 2004;9:568–77.
19. Tajiri H, Niwa H. proposal for a consensus terminology in endoscopy: how should different endoscopic imaging techniques be grouped and defined? *Endoscopy.* 2008;40:775–8.
20. Kaltenbach T, Sano Y, Friedland S, Soetikno R. American Gastroenterological Association (AGA) institute technology assessment on image-enhanced endoscopy. *Gastroenterology.* 2008;134:27–40.
21. Hirsch FR, Franklin WA, Gazdar AF, Bunn PA Jr. Early detection of lung cancer: clinical perspectives of recent advances in biology and radiology. *Clin Cancer Res.* 2001;7:5–22.
22. Shibuya K, Nakajima T, Fujiwara T, et al. Narrow band imaging with high-resolution bronchovideoscopy: a new approach for visualizing angiogenesis in squamous cell carcinoma of the lung. *Lung Cancer.* 2010;69:194–202.
23. Hanahan D, Folkman J. Patterns and emerging mechanisms of the angiogenic switch during tumorigenesis. *Cell.* 1996;86:353–64.
24. Hanahan D, Inoue H, Nagai K, Kawano T, et al. The hallmarks of cancer. *Cell.* 2000;100:57–70.
25. Shibuya K, Hoshino H, Chiyo M, et al. Subepithelial vascular patterns in bronchial dysplasias using a high magnification bronchovideoscope. *Thorax.* 2002;57:902–7.
26. Tanaka H, Yamada G, Sakai T, et al. Increased airway vascularity in newly diagnosed asthma using a high-magnification bronchovideoscope. *Am J Respir Crit Care Med.* 2003;168:1495–9.
27. Yahagi N, Fujimoto A, Horii J, et al. Dual red imaging: a novel endoscopic imaging technology visualizing thick blood vessels in the gastrointestinal wall. *Endosc Int Open.* 2019;7:E1632–5.
28. Furuichi Y, Gotoda T, Moriyasu F, et al. Dual red imaging (novel advanced endoscopy) can increase visibility and can predict the depth in diagnosing esophageal varices. *J Gastroenterol.* 2017;52:568–76.
29. Naganuma M, Yahagi N, Bessho R, et al. Evaluation of the severity of ulcerative colitis using endoscopic dual red imaging targeting deep vessels. *Endosc Int Open.* 2017;5:E76–82.
30. Hürter T, Hanrath P. Endobronchial sonography: feasibility and preliminary results. *Thorax.* 1992;47:565–7.
31. Yasufuku K. Current clinical applications of endobronchial ultrasound. *Expert Rev Respir Med.* 2010;4:491–8.

32. Kurimoto N, Murayama M, Yoshioka S, Nishisaka T. Assessment of usefulness of endobronchial ultrasonography in determination of depth of tracheobronchial tumor invasion. *Chest*. 1999;115:1500–6.
33. Ohtani K, Lee AM, Lam S. Frontiers in bronchoscopic imaging. *Respirology*. 2012;17:261–9.
34. Lam S, Standish B, Baldwin C, et al. In vivo optical coherence tomography imaging of preinvasive bronchial lesions. *Clin Cancer Res*. 2008;14:2006–11.
35. Michel RG, Kinasewitz GT, Fung KM, et al. Optical coherence tomography as an adjunct to flexible bronchoscopy in the diagnosis of lung cancer: a pilot study. *Chest*. 2010;138:984–8.
36. Wisnivesky JP, Yung RC, Mathur PN, et al. Diagnosis and treatment of bronchial intraepithelial neoplasia and early lung cancer of the central airways: diagnosis and management of lung cancer, 3rd ed: American College of Chest Physicians evidence-based clinical practice guidelines. *Chest*. 2013;143(5):e263S–77S.
37. Weigel TL, Yousem S, Dacic S, et al. Fluorescence bronchoscopic surveillance after curative surgical resection for non-small-cell lung cancer. *Ann Surg Oncol*. 2000;7:176–80.
38. Sutedja TG, Codrington H, Risse EK, et al. Autofluorescence bronchoscopy improves staging of radiographically occult lung cancer and has an impact on therapeutic strategy. *Chest*. 2001;120:1327–32.
39. Zaric B, Becker HD, Perin B, et al. Autofluorescence imaging videobronchoscopy improves assessment of tumor margins and affects therapeutic strategy in central lung cancer. *Jpn J Clin Oncol*. 2010;40:139–45.
40. Spiro SG, Hackshaw A, LungSEARCH Collaborative Group. Research in progress—LungSEARCH: a randomised controlled trial of surveillance for the early detection of lung cancer in a high-risk group. *Thorax*. 2016;71:91–3.
41. Spiro SG, Shah PL, Rintoul RC, et al. Sequential screening for lung cancer in a high-risk group: randomised controlled trial: LungSEARCH: a randomised controlled trial of Surveillance using sputum and imaging for the EARLY detection of lung Cancer in a High-risk group. *Eur Respir J*. 2019;54:1900581.
42. Risse EK, Voojts GP, van't Hoff MA. Diagnostic significance of 'severe dysplasia' in sputum cytology. *Acta Cytol*. 1988;32:629–34.
43. Band PR, Feldstein M, Saccomanno G. Reversibility of bronchial marked atypia: implication for chemoprevention. *Cancer Detect Prev*. 1986;9:157–60.
44. Sawyer RW, Hammond WG, Teplitz RL, et al. Regression of bronchial epithelial cancer in hamsters. *Ann Thorac Surg*. 1993;56:74–8.
45. Breuer RH, Pasic A, Smith EF, et al. The natural course of preneoplastic lesions in bronchial epithelium. *Clin Cancer Res*. 2005;11:537–43.
46. Vincent B, Fraig M, Silvestri G. A pilot study of narrow-band imaging compared to white light bronchoscopy for evaluation of normal airways and pre-malignant and malignant airways disease. *Chest*. 2007;131:1794–9.
47. Tremblay A, Taghizadeh N, McWilliams AM, et al. Low prevalence of high grade lesions detected with autofluorescence bronchoscopy in the setting of lung cancer screening in the pan-Canadian lung cancer screening study. *Chest*. 2016;150:1015–22.
48. Ikeda N, Usuda J, Maehara S. Photodynamic therapy for central-type early-stage lung cancer. *Gen Thorac Cardiovasc Surg*. 2020;68:679–83.
49. Van Rens M, Schramel F, Elbers J, et al. The clinical value of lung imaging autofluorescence endoscope for detecting synchronous lung cancer. *Lung*. 2001;32:13–8.
50. Sun J, Garfield D, Lam B. The role of autofluorescence bronchoscopy combined with white light bronchoscopy compared with white light alone in diagnosis of intraepithelial neoplasia and invasive lung cancer. *J Thorac Oncol*. 2011;6:1336–44.
51. Chiyo M, Shibuya K, Hoshino H, et al. Effective detection of bronchial preinvasive lesions by a new autofluorescence imaging bronchovideoscope system. *Lung*. 2005;48:307–13.
52. Thiberville L, Moreno-Swiric S, Vercauteren T, et al. In vivo imaging of the bronchial wall microstructure using fibered confocal fluorescence microscopy. *Am J Respir Crit Care Med*. 2007;175:22–31.
53. Thiberville L, Salaun M, Lachkar S, et al. Confocal fluorescence endomicroscopy of the human airways. *Proc Am Thorac Soc*. 2009;6:444–9.
54. Wellikoff AS, Holladay RC, Downie GH, et al. Comparison of in vivo probe-based confocal laser endomicroscopy with histopathology in lung cancer: a move toward optical biopsy. *Respirology*. 2015;20:967–74.
55. Shah PL, Kemp SV, Newton RC, et al. Clinical correlation between real-time endocytoscopy, confocal endomicroscopy, and histopathology in the central airways. *Respiration*. 2017;93(1):51–7.
56. Neumann H, Fuchs FS, Vieth M, et al. Review article: in vivo imaging by endocytoscopy. *Aliment Pharmacol Ther*. 2011;33:1183–93.
57. Neumann H, Vieth M, Neurath MF, et al. In vivo diagnosis of small-cell lung cancer by endocytoscopy. *J Clin Oncol*. 2011;29:e131–2.
58. Short MA, Lam S, McWilliams AM, et al. Using laser Raman spectroscopy to reduce false positive of autofluorescence bronchoscopy. A pilot study. *J Thorac Oncol*. 2011;6:1206–14.
59. Tu AT. *Raman spectroscopy in biology: principles and applications*. New York: Wiley; 1982.
60. McGregor HC, Short MA, McWilliams A, et al. Real-time endoscopic Raman spectroscopy for in vivo early lung cancer detection. *J Biophotonics*. 2016;10(1):98–110.
61. Pahlevaninezhad H, Lee AM, Lam S, et al. Coregistered autofluorescence-optical coherence tomography imaging of human lung sections. *J Biomed Opt*. 2014;19:36022.
62. Pahlevaninezhad H, Lee AM, Ritchie A, et al. Endoscopic Doppler optical coherence tomography and autofluorescence imaging of peripheral pulmo-

- nary nodules and vasculature. *Biomed Opt Express*. 2015;6:4191–9.
63. Zhai J. Multitarget fluorescence in situ hybridization assay for the detection of lung cancer in bronchial cytology specimens: a comparison with routine cytology. *Diagn Cytopathol*. 2015;43:819–24.
  64. Liu YZ, Jiang YY, Wang BS, et al. A panel of protein markers for the early detection of lung cancer with bronchial brushing specimens. *Cancer Cytopathol*. 2014;122:833–41.
  65. Silvestri GA, Vachani A, Whitney D, et al. A bronchial genomic classifier for the diagnostic evaluation of lung cancer. *N Engl J Med*. 2015;373:243–51.
  66. Billatos E, Vick JL, Lenburg ME, et al. The airway transcriptome as a biomarker for early lung cancer detection. *Clin Cancer Res*. 2018;24(13):2984–92.
  67. Wang Y, Wang Q, Feng J, et al. Comparison of autofluorescence imaging bronchoscopy and white light bronchoscopy for detection of lung cancers and precancerous lesions. *Patient Prefer Adherence*. 2013;7:621–31.
  68. Sun S, Yang Y, Chen M, et al. Comparison of autofluorescence and white-light bronchoscopies performed with the Evis Lucera Spectrum for the detection of bronchial cancers: a meta-analysis. *Transl Lung Cancer Res*. 2020;9(1):23–32.
  69. Furukawa K, Ikeda N, Miura T, et al. Is autofluorescence bronchoscopy needed to diagnose early bronchogenic carcinoma? Pro: autofluorescence bronchoscopy. *J Bronchol*. 2003;10:64–9.
  70. Pierard P, Vermylen P, Bosschaerts T, et al. Synchronous roentgenographically occult lung carcinoma in patients with resectable primary lung cancer. *Chest*. 2000;7:176–80.
  71. Herth FJ, Eberhardt R, Anantham D, et al. Narrow-band imaging bronchoscopy increases the specificity of bronchoscopic early lung cancer detection. *J Thorac Oncol*. 2009;4:1060–5.
  72. Iftikhar IH, Musani AI. Narrow-band imaging bronchoscopy in the detection of premalignant airway lesions: a meta-analysis of diagnostic test accuracy. *Ther Adv Respir Dis*. 2015;9:207–16.
  73. Zaric B, Perin B, Becker HD, et al. Combination of narrow band imaging (NBI) and autofluorescence imaging (AFI) videobronchoscopy in endoscopic assessment of lung cancer extension. *Med Oncol*. 2012;29:1638–42.
  74. Kumaji Y, Inoue H, Nagai H, et al. Magnifying endoscopy, stereoscopic microscopy, and the microvascular architecture of superficial esophageal carcinoma. *Endoscopy*. 2002;34:369–75.
  75. Shibuya K, Nakajima T, Fujiwara A, et al. Narrow band imaging with high-resolution bronchovideoscopy: a new approach for visualizing angiogenesis in squamous cell carcinoma of the lung. *Lung*. 2010;69:194–202.
  76. Shibuya K, Nakajima T, Yasufuku K, et al. Narrow band imaging with high resolution bronchovideoscopy: a new approach to visualize angiogenesis in squamous cell carcinoma of the lung. *Eur Respir J*. 2006;28(Suppl 50):601.
  77. Tanaka F, Muro K, Yamasaki S, et al. Evaluation of tracheo-bronchial wall invasion using transbronchial ultrasonography (TBUS). *Eur J Cardiothorac Surg*. 2000;17:570–4.
  78. Herth FJ, Becker HD. EBUS for early lung cancer detection. *J Bronchol*. 2003;10:249.
  79. Miyazu Y, Miyazawa T, Kurimoto N, et al. Endobronchial ultrasonography in the assessment of centrally located early-stage lung cancer before photodynamic therapy. *Am J Respir Crit Care Med*. 2002;165:832–7.
  80. Tajiri H, Niwa H. A new classification and precise definitions of endoscopic imaging. *Gastroenterol Endosc*. 2009;51(8):1677–85.



# Optical Coherence Tomography: A Review

# 22

Hamid Pahlevaninezhad and Stephen Lam

## Introduction

Globally, lung cancer is the most common cause of cancer deaths with over 1.6 million deaths per year [1]. Adenocarcinoma is the predominant cell type among women. In men, aside from a few European countries, such as France, Spain, and the Netherlands, adenocarcinoma has surpassed squamous cell carcinoma as the predominant cell type [2]. The shift in lung cancer cell types from the more centrally located squamous cell and small cell carcinomas to the more peripherally located adenocarcinomas, as well as smaller lesions detected by thoracic CT, necessitate a change in the approach to bronchoscopic diagnosis of peripheral lung lesions that are generally beyond the range of a standard flexible bronchoscope  $\geq 3$  cm in outer diameter. Radial probe endobronchial ultrasound with or without an electromagnetic navigation or virtual bronchoscopy navigation system improves the diagnostic yield from an average of 34–69% [3–7]. This is lower than CT-guided transtho-

racic lung biopsy with a diagnostic yield  $\geq 80\%$  even for lesions  $\leq 2$  cm [8, 9]. In the context of a CT lung cancer screening program, only 20–34% of the screening CT detected lung cancers are diagnosed by bronchoscopy (Table 22.1) [10, 11, and unpublished data]. Although endoscopic biopsy has a lower complication rate in pneumothorax and bleeding than CT-guided transthoracic lung biopsy [8, 9, 12, 13], improvement in the accuracy of endoscopic biopsy for small peripheral lung lesions is needed if bronchoscopy is going to play a major role in lung cancer diagnosis. For centrally located bronchial cancers that are not visible by CT, it is often difficult to differentiate between in situ carcinoma versus invasive carcinoma. The ability to diagnose the depth of tumor invasion can guide therapy. In this chapter, the role of Optical Coherence Tomography (OCT), Doppler-OCT, Polarization-sensitive OCT (PS-OCT), and autofluorescence-OCT in the diagnosis of lung cancer and the potential application in non-malignant lung diseases are discussed.

---

H. Pahlevaninezhad · S. Lam (✉)  
Cancer Imaging Unit, Integrative Oncology  
Department, British Columbia Cancer Agency  
Research Centre and the University of British  
Columbia, Vancouver, BC, Canada  
e-mail: [slam2@bccancer.bc.ca](mailto:slam2@bccancer.bc.ca)



**Table 22.1** Mode of diagnosis and accuracy for screening CT detected lung cancers

Modality	NLST		PanCan	
	Diagnostic method (%)	Positive rate (%)	Diagnostic method (%)	Positive rate (%)
Bronchoscopy	34	55.5	20	55.6
CT-FNA/core	19	66.5	38	81.1
Surgery	47	73.9	42	77.6

CT computed tomography, *FNA* fine needle transthoracic lung biopsy, *NLST* National Lung Screening Trial. *Pan-Can* Pan-Canadian Early Detection of Lung Cancer Study

## History and Historical Perspective

Optical coherence tomography (OCT) was originally developed for non-invasive cross-sectional imaging of biological systems [14, 15]. This optical imaging method offers near histologic resolution for visualizing cellular and extracellular structures at and below the tissue surface up to 2–3 mm. The utility of this imaging modality was first demonstrated in ophthalmology and cardiology [16, 17]. It was later developed as an optical imaging and biopsy tool in other organs such as the esophagus and lung [18–21].

OCT is similar to B-mode ultrasound. Instead of sound waves, light waves are used for imaging. Optical interferometry is used to detect the light that is scattered or reflected by the tissue to generate a one-dimensional tissue profile along the light direction. By scanning the light beam over the tissue, two-dimensional images or three-dimensional volumetric images can be recorded. For bronchoscopic application, the imaging procedure is performed using fiberoptic probes that can be miniaturized to enable imaging of airways down to the terminal bronchiole. These probes can be inserted down the instrument channel during standard bronchoscopic examination under conscious sedation. The axial and lateral resolutions of OCT range from approximately 5–30  $\mu\text{m}$  and the imaging depth is 2–3 mm depending on the imaging conditions. This combination of resolution and imaging depth is ideal for examining changes originating in epithelial tissues such as airways. Unlike ultrasound, light does not require a liquid coupling medium and thus is more compatible with airway imaging. There are no associated risks from the weak near-infrared light sources that are used for OCT.

In time domain OCT, a depth-resolved line profile of tissue is obtained by measuring the auto-cor-

relation function [14, 22] using a low-coherence-time light source and an interferometer comprised of a variable-length reflective reference arm and a sample arm where the tissue is illuminated. A signal is generated when the path length of light scattered from a particular tissue depth matches that from the reference arm. In frequency domain OCT, the spectral density function is measured to obtain a depth-resolved optical scattering of the tissue through Fourier transformation. The spectral density function can be measured with interferometers using either a broadband light source and a spectrometer or a wavelength-swept light source and a square-law detector. This approach was shown to provide orders of magnitude enhancement in detection sensitivity compared to time-domain OCT [23–27].

In Doppler OCT, the energy of photons from a moving system is transformed according to the four-vector momentum and the Lorentz transformation. According to the special theory of relativity, the energy of photons emitted from an object moving relative to an observer is transformed the same way leading to different energies compared to those seen by an observer that is stationary relative to the photon source. These different energies that correlate with different frequencies are called Doppler effect that can be used to detect moving sources by measuring a change in the frequency of the optical field emitted from the source. The OCT signal contains the information about the phase of the optical field scattered from a tissue sample. Therefore, moving objects can be detected by evaluating frequency shifts in their OCT signals [28, 29]. This technique can be used to visualize pulmonary vasculature in vivo during endoscopic imaging [30]. Doppler signals are created by analyzing the OCT data stream using the Kasai velocity estimator to evaluate the Doppler phase shift between A-scans in each frame. Endoscopic Doppler OCT can be difficult due to the motion

artifacts such as from cardiac pulsations and breathing movement. Bulk tissue motion correction algorithms are used to reduce artifacts.

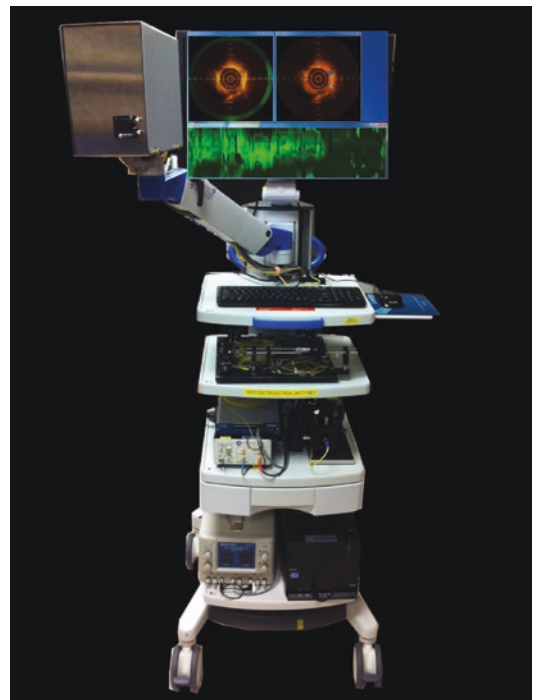
Polarization-sensitive OCT (PS-OCT) is another extension to OCT to improve detailed tissue differentiation. By analyzing the polarization state of back-scattered light, PS-OCT can provide information about tissue birefringence, diattenuation, optical axis orientation, and depolarization. Using PS-OCT, highly organized, anisotropic tissue layers such as muscles, bones, and blood vessel walls can be identified by their innate birefringence. Clinical applications of PS-OCT have been demonstrated in the determination of burn depth *in vivo* [31], the measurement of collagen and smooth muscle cell content in atherosclerotic plaques [32], the differentiation of benign lesions from malignant lesions in the larynx [33], and the detection of nerve fiber bundle loss in glaucoma [34, 35]. Obtaining polarization-dependent optical properties of tissue with PS-OCT entails two essential requirements. First, the incident light on the tissue needs to have known polarization states (commonly circular polarization) [36, 37] or multiple sequential polarization states (not necessarily known) with defined polarization relation between them [38, 39]. Second, the polarization state of light scattered from tissue needs to be detected using a polarization diversity detection scheme. Polarization sensitive detection can also be used to reduce the effects of polarization in structural OCT imaging that uses rotary probes. As the spinning fiber optic probe is continuously flexing and in motion, the polarization state of the light exiting the tip of the probe is constantly varying, creating artificial intensity variations during OCT imaging. These variations can be significantly reduced using polarization diversity detection [40].

A recent advance in OCT imaging is co-registered autofluorescence OCT (AF-OCT) [41]. Autofluorescence imaging makes use of fluorescence and absorption properties to provide information about the biochemical composition and metabolic state of endogenous fluorophores in tissues [42, 43]. Most endogenous fluorophores are associated with the tissue matrix or are involved in cellular metabolism. The most important fluorophores are structural proteins such as collagen and elastin and those involved in cellular metabolism such as nicotinamide adenine dinucleotide

(NADH) and flavins [43]. Upon illumination by violet or blue light (380–460nm), normal tissues fluoresce strongly in the green (480–520 nm). Malignant tissues have a markedly reduced and red-shifted autofluorescence signal due to the breakdown of extracellular matrix components as well as increased absorption by blood. These differences have been exploited to detect pre-invasive and invasive bronchial cancers in central airways [44]. AF-OCT overcomes the limitation of autofluorescence bronchoscopy because the OCT imaging probes are much smaller than flexible videobronchoscopes allowing access to small peripheral airways beyond bronchoscopic view. AF-OCT allows rapid scanning of airway vasculature less prone to motion artifacts compared to Doppler-OCT [45].

## Endoscopic AF-OCT System

The schematic diagram for the equipment required for an endoscopic AF-OCT system is shown in Fig. 22.1 and an AF-OCT prototype is shown in Fig. 22.1. A Mach-Zehnder interferom-

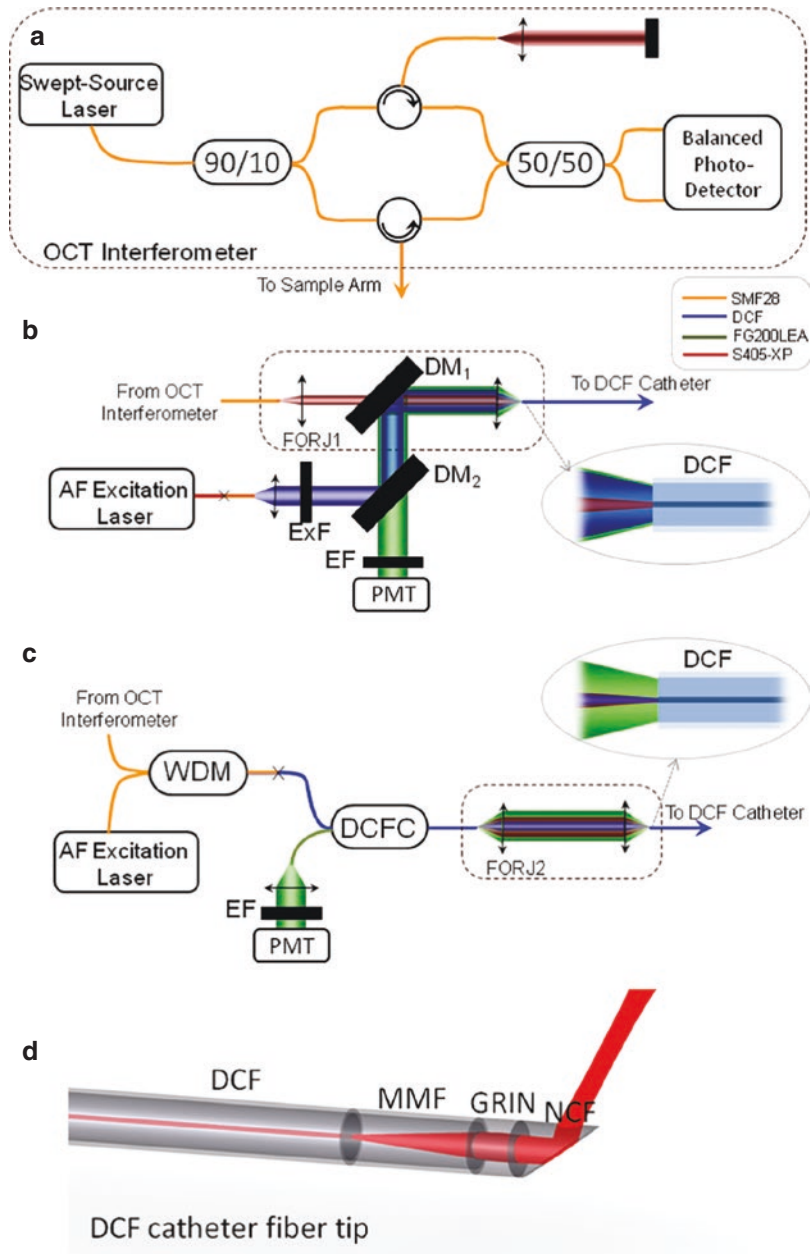


**Fig. 22.1** AF-OCT prototype

eter driven by a wavelength-swept source comprises the OCT subsystem (Fig. 22.2a). The AF subsystem uses a 445 nm excitation laser and a photo-multiplier tube for the detection of auto-fluorescence emission. Endoscopic imaging of airways is implemented using fiberoptic catheters that scan in a rotational manner using proximal motors. A large-scale motor actuates the rotor of

a fiberoptic rotary joint (FORJ) that is connected to an imaging catheter, enabling proximally driven rotational scans of the catheter’s fiber assembly. The imaging catheter consists of a double-clad fiber (DCF) catheter. This fiber assembly is fixed inside a torque cable that transfers rotational and pullback motions from the proximal end to the distal end (Fig. 22.2b). The

**Fig. 22.2** Schematic diagram of OCT and AF-OCT. (a) OCT, (b) inner-cladding AFI excitation, (c) core AFI excitation subsystems, and (d) optical elements at the tip of the DCF catheter. *DM* dichroic mirror, *ExF* excitation filter, *EF* emission filter, *PMT* photomultiplier, *WDM* wavelength division multiplexer, *DCFC* double-clad fiber coupler, *FORJ* fiber optic rotary joint, *DCF* double-clad fiber, *MMF* (step-index) multimode fiber, *GRIN* graded index fiber, *NCF* no-core fiber

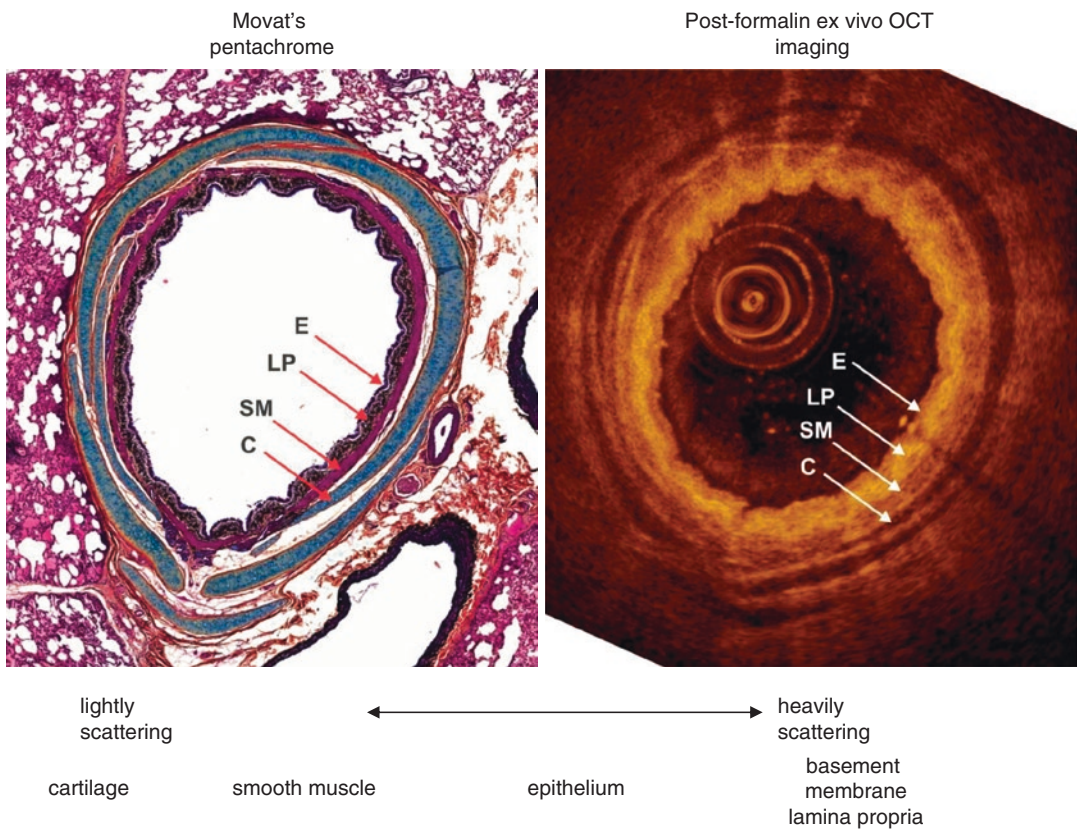


rotating assembly is placed inside a close-ended 900 μm diameter stationary plastic tube if the catheter is going to be reused.

In one configuration (Fig. 22.2b), the AF light excitation light is coupled to the DCF inner-cladding [41] and in another system configuration (Fig. 22.2c) the AF excitation light is coupled to the DCF core using fused fiber components [46–48] and a custom designed FORJ [49]. The latter allows a tightly focused AF excitation light exits the catheter, enabling higher resolution AF imaging.

### Preclinical Studies

Ex vivo studies have shown that OCT can visualize structural features in airways, adjacent alveoli, and pulmonary nodules that correspond closely to the histopathology (Fig. 22.3) [20, 50–54]. The basement membrane can be clearly seen between the epithelial and submucosal layer. Cartilage usually appears as darker signal-poor regions due to its low scattering properties. OCT measurements of mean luminal diameter, inner luminal area, airway wall area, and percent air-



**Fig. 22.3** Correlation of OCT image with histopathology in porcine airway. Black = nuclei, elastic fibers; Yellow = collagen, reticular fibers; Blue = ground substance, mucin; Bright red = fibrin; Red = muscle



way wall thickness prior to surgical resection were found to correlate significantly with the histology down to the ninth-generation bronchi in the resected specimens [55].

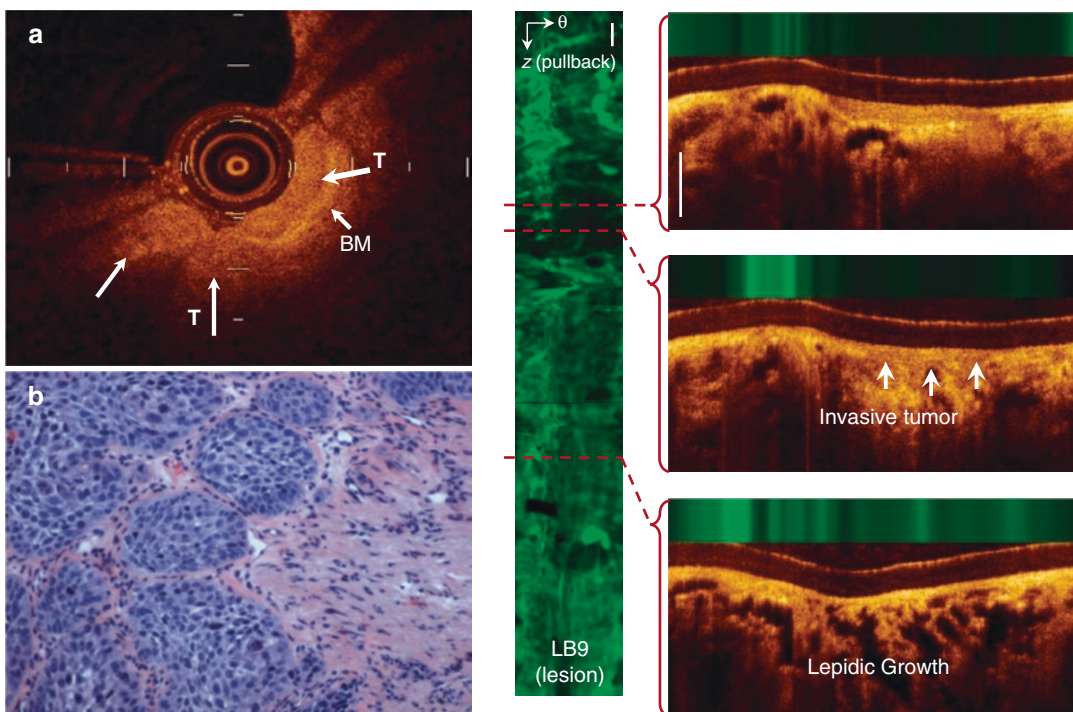
## Clinical Studies

Endoscopic OCT imaging is performed during flexible bronchoscopy under local anesthesia applied to the upper airways and conscious sedation [21, 56]. The OCT probe can be inserted inside a guide sheath similar to radial endobronchial ultrasound through the working channel of the bronchoscope into the targeted airways. When clinically indicated, following removal of the catheter, histological and/or cytological samples are collected. OCT imaging adds about 5–10 min to the standard procedure time. It is usually well tolerated by patients. Repeat OCT measurements of airways were found to be reproducible and hence can be used for longitudinal assessment of changes in airway morphology [57].

## Lung Cancer

The ability of OCT to discern invasive cancer versus CIS or dysplasia was investigated [21]. Normal or hyperplasia is characterized by one or two cell layers above a highly scattering basement membrane and upper submucosa. As the epithelium changes from normal/hyperplasia to metaplasia, various grades of dysplasia and CIS, the thickness of the epithelial layer increases. Quantitative measurement of the epithelial thickness showed that invasive carcinoma is significantly thicker than carcinoma in situ ( $p = 0.004$ ) and dysplasia is significantly thicker than metaplasia or hyperplasia ( $p = 0.002$ ). The nuclei become more readily visible in high-grade dysplasia or CIS. The basement membrane is still intact in CIS but became discontinuous or no longer visible with invasive cancer [21]. Squamous cell carcinoma has different OCT features than adenocarcinoma [52, 53] (Fig. 22.4).

The morphology of the peripheral lung nodules has been characterized. Lung parenchyma can be identified by the presence of signal-void alveolar



**Fig. 22.4** (a) OCT and histological image of a squamous cell carcinoma showing the in situ component and invasion through the basement membrane (arrows). (b)

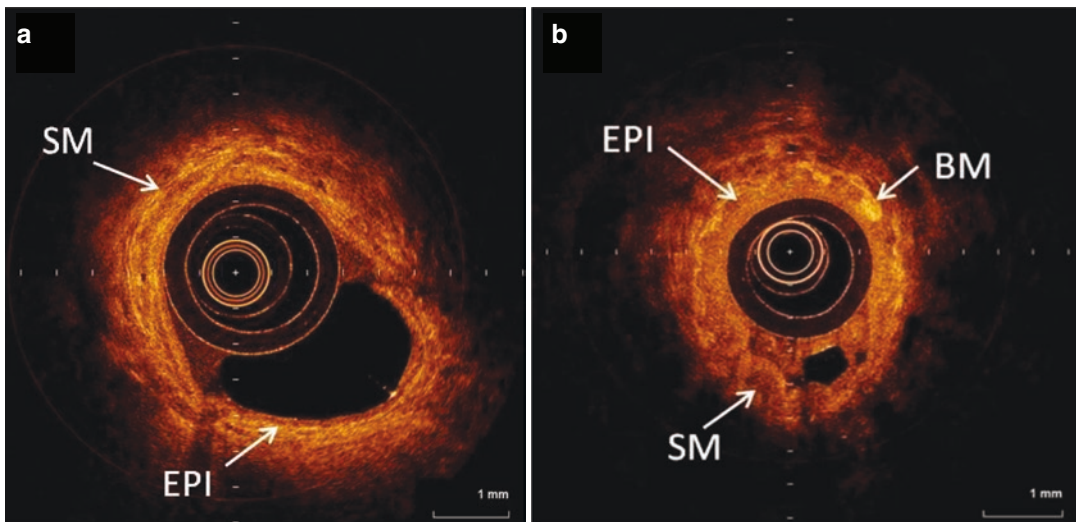
AF-OCT of an adenocarcinoma with lepidic growth. In the AF image, there is a loss of green autofluorescence



spaces that appears as a honeycomb like structure. Pulmonary nodule is identified by replacement of alveoli with solid tissue [45, 58, 59]. Adenocarcinomas with lepidic growth pattern are recognized by their thickened alveolar walls [45] (Fig. 22.4). After OCT interpretation training sessions, clinicians can diagnose common primary lung cancers (adenocarcinoma, squamous cell carcinoma, and poorly differentiated carcinoma) with an average accuracy of 82.6% (range 73.7–94.7%) [60]. Although OCT cannot replace histology in the diagnosis of lung carcinoma, it has the potential to aid in diagnosing lung carcinomas as a complement to tissue biopsy, particularly when insufficient tissue is available for pathology assessment. OCT may be useful for confirming the nature of the lesion before taking a biopsy. Since OCT probes can be miniaturized, they can be inserted inside biopsy needles/catheters to guide biopsy under real time without removing the imaging probe from a guide sheath and re-insert the biopsy forceps or needle with the possibility of displacement or migration to a different airway [56].

## Asthma

It is known that asthma phenotypes are heterogeneous and influence the response to treatment. Bronchial thermoplasty (BT) is a non-pharmacologic method to treat patients with chronic persistent asthma [61]. Currently, there is no method to select patients who will benefit from BT. OCT imaging was performed in two patients with chronic persistent steroid-dependent asthma prior to and immediately after bronchial thermoplasty as well as at 3 weeks, 6 weeks, 6 months, and 2 years after bronchial thermoplasty. Prior to BT, distinct asthma phenotypes were observed between the patient (Patient A) who had sustained benefit from BT for over 2 years versus the one who did not (Patient B) (Fig. 22.5) [62]. PS-OCT [36, 63, 64] that can define highly organized tissue layers such as smooth muscle and collagen may be a useful non-biopsy tool to study the effect of pharmacologic and non-pharmacologic therapies.



**Fig. 22.5** OCT images of two patients before bronchial thermoplasty (BT) illustrating different phenotypic features. (a) Long-term responder following BT; (b) Non-

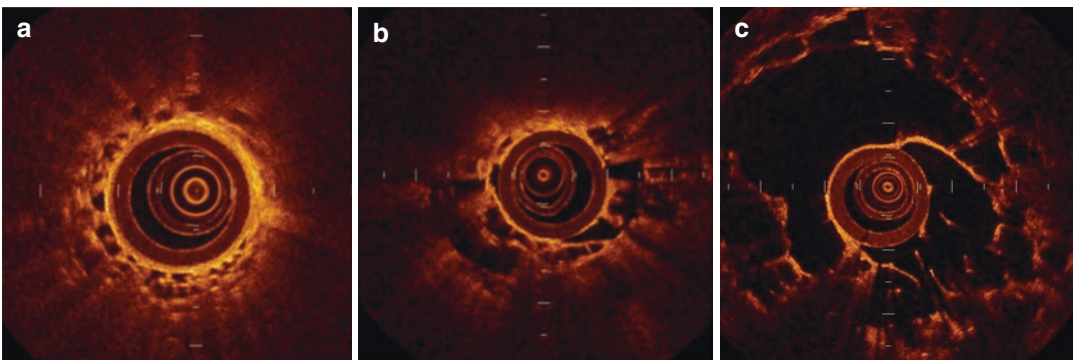
responder with BT. *EPI* epithelium, *BM* basement membrane, *SM* smooth muscle

## Chronic Obstructive Pulmonary Disease

Chronic obstructive pulmonary disease (COPD) is a heterogeneous disease characterized by both small airway and parenchymal abnormalities. There is increasing evidence to suggest that these two morphologic phenotypes, although related, may have different clinical presentations, prognosis, and therapeutic responses to medications. A recent *ex vivo* study using micro-CT showed that narrowing and disappearance of small conducting airways occurs prior to the onset of emphysematous destruction and that these changes can explain the increased peripheral airways resistance reported in COPD [65]. Clinical CT using an acceptable dose of radiation provides airway images up to the fifth generation. Unfortunately, the resolution of CT is not adequate to image critical events that begin at the seventh branching generation nor can it measure morphological changes in different layers of the airway wall. OCT can overcome this limitation with small optical probes that can image airways as small as terminal bronchioles with high resolution [55, 65, 66]. Coxson et al. compared OCT measurements with CT scans and lung function in COPD patients [67]. In 44 current and former smokers, OCT imaging was used to measure the airway dimensions in specific bronchial segments. These data were compared with CT mea-

surements of the exact same airway using a three-dimensional reconstruction of the airway tree (Pulmonary Workstation 2.0; VIDA Diagnostics, Inc., Iowa City, IA). A strong correlation between CT and OCT measurements of lumen and wall area was observed. The correlation between FEV<sub>1</sub>% predicted and CT- and OCT-measured wall area (as percentage of the total area) of fifth-generation airways was good for both imaging modalities, but the slope of the relationship was much steeper using OCT than using CT, indicating greater sensitivity of OCT in detecting changes in wall measurements that relate to FEV<sub>1</sub>. They concluded that OCT is more sensitive for discriminating the changes in the more distal airways of subjects with a range of expiratory airflow obstruction compared with CT. In addition to airway wall remodeling, alveolar wall destruction in COPD can also be clearly visualized using OCT with the emphysematous alveoli appearing as large voids compared with the small alveoli seen in those with normal lung function [53] (Fig. 22.6).

Sex differences in airway remodeling in COPD have also been investigated using OCT to help understand why women have a 50% increased risk of COPD compared with men after adjustment for the amount of smoking. Female human smokers have significantly thicker airway walls compared to male human smokers similar to the changes in a mouse model of COPD [68].



**Fig. 22.6** OCT image of terminal bronchiole and adjacent alveoli. (a) Normal bronchiole; (b) Patient with moderate emphysema; (c) Patient with severe dysplasia showing progressive destruction of alveolar walls

## Airway and Lumen Calibration

Airway diameter measurement via bronchoscopy is not reliable due to optical distortion of the bronchoscope lens that varies among bronchoscopes and limited ability to gauge depth. Respiratory motions interfere with airway measurement. Airway measurement can be performed using CT scans. However, real-time examination is not always available and radiation exposure is a concern. Using phantoms, excised pig airways, and in vivo human airways during bronchoscopy, Williamson et al. demonstrated that airway measurements using anatomic OCT are accurate, reliable, and compare favorably with CT imaging [69]. OCT was used to measure airway diameter in patients with subglottic tracheal stenosis, main bronchial stenosis, and tracheomalacia. The real-time OCT information was found to be helpful for determining the length of the stenosis, extent of tumor involvement beyond the bronchoscopic view, severity of the tracheomalacia, or guide the choice of airway stent. The investigators conclude anatomic OCT with conventional bronchoscopy allows accurate real-time airway measurements and may assist bronchoscopic assessment [70].

## Obstructive Sleep Apnea

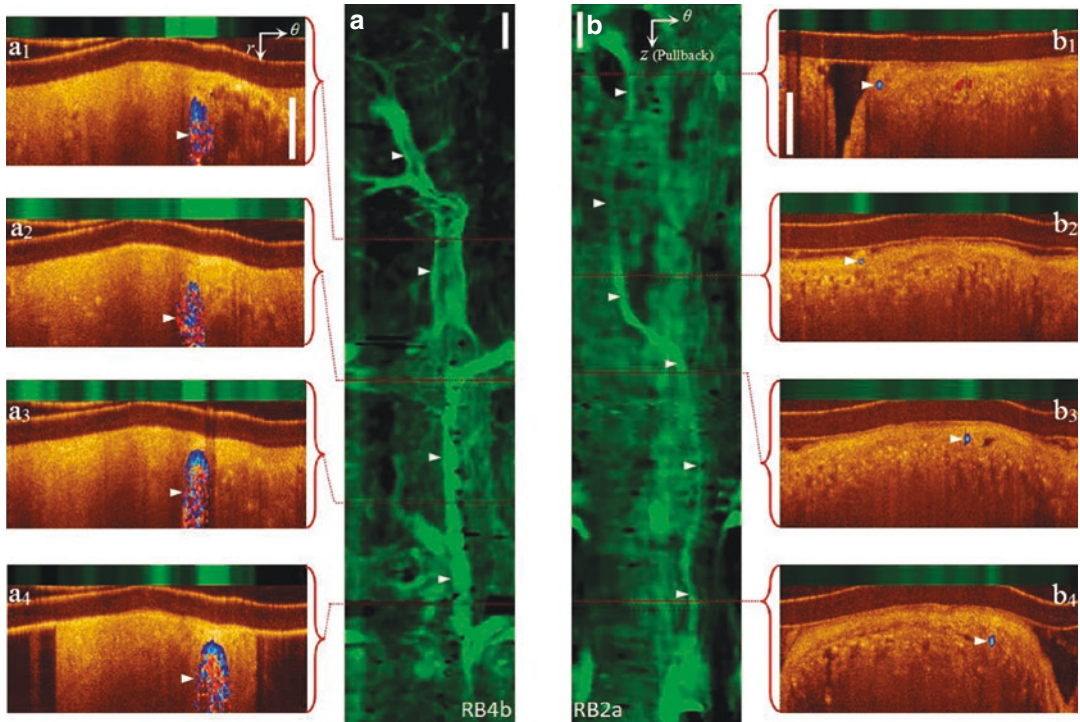
Changing of the upper airway sizes during sleep is the key pathophysiologic change in patient with obstructive sleep apnea (OSA). Reduction in pharyngeal size correlates with increased sleep disorder breathing and degree of nocturnal desat-

uration [71]. CT scan has been used to measure the upper airway size. However, measuring upper airway dimension during sleep and awake with CT is not practical plus concern with radiation exposure. Anatomic OCT offers a real-time quantitative measurement of the upper airway shape and size during sleep or awake comparable to CT scan [72]. Individuals with OSA were found to have a smaller velopharyngeal cross-sectional area than BMI-, gender-, and age-matched control volunteers, but comparable shape suggesting it is an abnormality in size rather than shape that is the more important anatomical predictor of OSA [73].

---

## Future Applications

The ability to image the bronchial vasculature down to 12  $\mu\text{m}$  diameter in 5–7 cm airway segments during bronchoscopy along with structural information using AF-OCT (Fig. 22.7) [49] enables comparison of vasculature in normal and abnormal airways. The ability to visualize detailed vascular networks could provide opportunities to study angiogenesis to differentiate benign from malignant lung nodules, characterize biological aggressiveness of lung cancer, study vascular remodeling in different lung diseases such as COPD and asthma [74–76], and improve safety of cryobiopsy by avoiding biopsy of larger blood vessels. AF-OCT may provide the means to monitor rejection following lung transplantation. The effect of therapy in patients with pulmonary fibrosis can be studied by PS-OCT that can characterize collagen and elastin [59].



**Fig. 22.7** Bronchial vasculature detection by AF-OCT with validation by Doppler OCT. **(a)** A large blood vessel running parallel to the airway (RB4b) with several smaller branching vessels is clearly visualized in the AF image. Doppler OCT ( $a_1$ – $a_4$ ) confirms these structures as blood

vessels. **(b)** Another example of smaller airway blood vessels identified by AF-OCT confirmed by Doppler-OCT. ( $b_1$  to  $b_4$ ). Small vessels down to 12  $\mu\text{m}$  in diameter are visualized by dark lumen in the magnified image. White scale bars are 1 mm

## Summary

OCT, PS-OCT, Doppler-OCT, and AF-OCT provide unprecedented opportunity to provide high-resolution structural and functional information on airway and lung tissue that cannot be otherwise obtained by other imaging modalities such as CT or MRI. In the central airways, it can differentiate in situ from invasive squamous cell carcinoma to guide therapy. In the peripheral lung, it has the potential to diagnose peripheral lung nodules, guide biopsy in real time with improve accuracy and safety as well as to study the effect of pharmacologic and non-pharmacologic therapies. It is a minimally invasive procedure that can be performed in conjunction with standard flexible bronchoscopy under conscious sedation. It has tremendous potential to be integrated into pulmonary medicine as a standard diagnostic procedure.

## References

1. Fitzmaurice C, Dicker D, Pain A, Hamavid H, Moradi-Lakeh M, MacIntyre MF, et al. The global burden of cancer 2013. *JAMA Oncol.* 2015;1(4):505–27.
2. Lortet-Tieulent J, Soerjomataram I, Ferlay J, Rutherford M, Weiderpass E, Bray F. International trends in lung cancer incidence by histological subtype: adenocarcinoma stabilizing in men but still increasing in women. *Lung Cancer.* 2014;84(1):13–22.
3. Schreiber G, McCrory DC. Performance characteristics of different modalities for diagnosis of suspected lung cancer: summary of published evidence. *Chest.* 2003;123(1 Suppl):115S–28S.
4. Wang Memoli JS, Nietert PJ, Silvestri GA. Meta-analysis of guided bronchoscopy for the evaluation of the pulmonary nodule. *Chest.* 2012;142(2):385–93.
5. Chen A, Chenna P, Loiselle A, Massoni J, Mayse M, Misselhorn D. Radial probe endobronchial ultrasound for peripheral pulmonary lesions. A 5-year institutional experience. *Ann Am Thorac Soc.* 2014;11(4):578–82.
6. Eberhardt R, Kahn N, Gompelmann D, Schumann M, Heussel CP, Herth FJ. LungPoint—a new



- approach to peripheral lesions. *J Thorac Oncol*. 2010;5(10):1559–63.
7. Ost DE, Ernst A, Lei X, Kovitz KL, Benzaquen S, Diaz-Mendoza J, et al. Diagnostic yield and complications of bronchoscopy for peripheral lung lesions. Results of the AQuIRE registry. *Am J Respir Crit Care Med*. 2016;193(1):68–77.
  8. Kothary N, Lock L, Sze DY, Hofmann LV. Computed tomography-guided percutaneous needle biopsy of pulmonary nodules: impact of nodule size on diagnostic accuracy. *Clin Lung Cancer*. 2009;10(5):360–3.
  9. Heyer CM, Reichelt S, Peters SA, Walther JW, Muller KM, Nicolas V. Computed tomography-navigated transthoracic core biopsy of pulmonary lesions: which factors affect diagnostic yield and complication rates? *AcadRadiol*. 2008;15(8):1017–26.
  10. Church TR, Black WC, Aberle DR, Berg CD, Clingan KL, Duan F, et al. Results of initial low-dose computed tomographic screening for lung cancer. *N Engl J Med*. 2013;368(21):1980–91.
  11. Aberle DR, DeMello S, Berg CD, Black WC, Brewer B, Church TR, et al. Results of the two incidence screenings in the National Lung Screening Trial. *N Engl J Med*. 2013;369(10):920–31.
  12. Wiener RS, Schwartz LM, Woloshin S, Welch HG. Population-based risk for complications after transthoracic needle lung biopsy of a pulmonary nodule: an analysis of discharge records. *Ann Intern Med*. 2011;155(3):137–44.
  13. Steinfurt DP, Khor YH, Manser RL, Irving LB. Radial probe endobronchial ultrasound for the diagnosis of peripheral lung cancer: systematic review and meta-analysis. *Eur Respir J*. 2011;37(4):902–10.
  14. Fujimoto JG, De Silvestri S, Ippen EP, Puliafito CA, Margolis R, Oseroff A. Femtosecond optical ranging in biological systems. *Opt Lett*. 1986;11(3):150.
  15. Youngquist RC, Carr S, Davies DE. Optical coherence-domain reflectometry: a new optical evaluation technique. *Opt Lett*. 1987;12(3):158–60.
  16. Huang D, Swanson EA, Lin CP, Schuman JS, Stinson WG, Chang W, et al. Optical coherence tomography. *Science*. 1991;254(5035):1178–81.
  17. Tearney GJ, Brezinski ME, Boppart SA, Bouma BE, Weissman N, Southern JF, et al. Images in cardiovascular medicine. Catheter-based optical imaging of a human coronary artery. *Circulation*. 1996;94(11):3013.
  18. Fujimoto JG, Brezinski ME, Tearney GJ, Boppart SA, Bouma B, Hee MR, et al. Optical biopsy and imaging using optical coherence tomography. *Nat Med*. 1995;1(9):970–2.
  19. Tearney GJ, Brezinski ME, Bouma BE, Boppart SA, Pitris C, Southern JF, et al. In vivo endoscopic optical biopsy with optical coherence tomography. *Science*. 1997;276(5321):2037–9.
  20. Tsuboi M, Hayashi A, Ikeda N, Honda H, Kato Y, Ichinose S, et al. Optical coherence tomography in the diagnosis of bronchial lesions. *Lung Cancer*. 2005;49(3):387–94.
  21. Lam S, Standish B, Baldwin C, McWilliams A, leRiche J, Gazdar A, et al. In vivo optical coherence tomography imaging of preinvasive bronchial lesions. *Clin Cancer Res*. 2008;14(7):2006–11.
  22. Fercher AF, Mengedoh K, Werner W. Eye-length measurement by interferometry with partially coherent light. *Opt Lett*. 1988;13(3):186–8.
  23. Choma M, Sarunic M, Yang C, Izatt J. Sensitivity advantage of swept source and Fourier domain optical coherence tomography. *Opt Express*. 2003;11(18):2183–9.
  24. de Boer JF, Cense B, Park BH, Pierce MC, Tearney GJ, Bouma BE. Improved signal-to-noise ratio in spectral-domain compared with time-domain optical coherence tomography. *Opt Lett*. 2003;28(21):2067–9.
  25. Leitgeb R, Hitzinger C, Fercher A. Performance of Fourier domain vs. time domain optical coherence tomography. *Opt Express*. 2003;11(8):889–94.
  26. Wojtkowski M, Bajraszewski T, Targowski P, Kowalczyk A. Real-time in vivo imaging by high-speed spectral optical coherence tomography. *Opt Lett*. 2003;28(19):1745–7.
  27. Yun SH, Tearney GJ, de Boer JF, Iftimia N, Bouma BE. High-speed optical frequency-domain imaging. *Opt Express*. 2003;11(22):2953–63.
  28. Izatt JA, Kulkarni MD, Yazdanfar S, Barton JK, Welch AJ. In vivo bidirectional color Doppler flow imaging of picoliter blood volumes using optical coherence tomography. *Opt Lett*. 1997;22(18):1439–41.
  29. Yang V, Gordon M, Qi B, Pekar J, Lo S, Seng-Yue E, et al. High speed, wide velocity dynamic range Doppler optical coherence tomography (part I): system design, signal processing, and performance. *Opt Express*. 2003;11(7):794–809.
  30. Lee AMD, Ohtani K, MacAulay C, McWilliams A, Shaipanich T, Yang VXD, et al. In vivo lung microvasculature visualized in three dimensions using fiber-optic color Doppler optical coherence tomography. *J Biomed Opt*. 2013;18(5):50501.
  31. Park BH, Saxer C, Srinivas SM, Nelson JS, de Boer JF. In vivo burn depth determination by high-speed fiber-based polarization sensitive optical coherence tomography. *J Biomed Opt*. 2001;6(4):474–9.
  32. Nadkarni SK, Pierce MC, Park BH, de Boer JF, Whittaker P, Bouma BE, et al. Measurement of collagen and smooth muscle cell content in atherosclerotic plaques using polarization-sensitive optical coherence tomography. *J Am Coll Cardiol*. 2007;49(13):1474–81.
  33. Burns JA, Kim KH, deBoer JF, Anderson RR, Zeitels SM. Polarization-sensitive optical coherence tomography imaging of benign and malignant laryngeal lesions: an in vivo study. *Otolaryngol Head Neck Surg*. 2011;145(1):91–9.
  34. Braaf B, Vermeer KA, de Groot M, Vienola KV, de Boer JF. Fiber-based polarization-sensitive OCT of the human retina with correction of system polarization distortions. *Biomed Opt Express*. 2014;5(8):2736–58.
  35. Zotter S, Pircher M, Torzicky T, Baumann B, Yoshida H, Hirose F, et al. Large-field high-speed polariza-



- tion sensitive spectral domain OCT and its applications in ophthalmology. *Biomed Opt Express*. 2012;3(11):2720–32.
36. Hee MR, Huang D, Swanson EA, Fujimoto JG. Polarization-sensitive low-coherence reflectometer for birefringence characterization and ranging. *J Opt Soc Am B*. 1992;9(6):903–8.
  37. deBoer JF, Milner TE, vanGemert MJC, Nelson JS. Two-dimensional birefringence imaging in biological tissue by polarization-sensitive optical coherence tomography. *Opt Lett*. 1997;22(12):934–6.
  38. Kim KH, Park BH, Tu YP, Hasan T, Lee B, Li JA, et al. Polarization-sensitive optical frequency domain imaging based on unpolarized light. *Opt Express*. 2011;19(2):552–61.
  39. Baumann B, Choi W, Potsaid B, Huang D, Duker JS, Fujimoto JG. Swept source/Fourier domain polarization sensitive optical coherence tomography with a passive polarization delay unit. *Opt Express*. 2012;20(9):10229.
  40. Lee AM, Pahlevaninezhad H, Yang VX, Lam S, MacAulay C, Lane P. Fiber-optic polarization diversity detection for rotary probe optical coherence tomography. *Opt Lett*. 2014;39(12):3638–41.
  41. Pahlevaninezhad H, Lee AMD, Shaipanich T, Raizada R, Cahill L, Hohert G, et al. A high-efficiency fiber-based imaging system for co-registered autofluorescence and optical coherence tomography. *Biomed Opt Express*. 2014;5(9):2978–87.
  42. Lam S. The role of autofluorescence bronchoscopy in diagnosis of early lung cancer. In: Hirsch FR, Kato H, et al., editors. *IASLC textbook for prevention and detection of early lung cancer*. London: Taylor & Francis; 2006. p. 149–58.
  43. Wagnieres G, McWilliams A. Lung cancer imaging with fluorescence endoscopy. In: Mycek M, editor. *Handbook of biomedical fluorescence*. New York: Springer; 2003. p. 361–96.
  44. McWilliams A, Shaipanich T, Lam S. Fluorescence and navigational bronchoscopy. *Thorac Surg Clin*. 2013;23(2):153–61.
  45. Pahlevaninezhad H, Lee AM, Shaipanich T, Zhang W, Ionescu DN, et al. Endoscopic Doppler optical coherence tomography and autofluorescence imaging of peripheral pulmonary nodules and vasculature. *Biomed Opt Express*. 2015;6(10):4191–9.
  46. Madore WJ, De Montigny E, Ouellette O, Lemire-Renaud S, Leduc M, Daxhelet X, et al. Asymmetric double-clad fiber couplers for endoscopy. *Opt Lett*. 2013;38(21):4514–7.
  47. Lorensen D, Yang X, Kirk RW, Quirk BC, McLaughlin RA, Sampson DD. Ultrathin side-viewing needle probe for optical coherence tomography. *Opt Lett*. 2011;36(19):3894–6.
  48. Scolaro L, Lorensen D, Madore WJ, Kirk RW, Kramer AS, Yeoh GC, et al. Molecular imaging needle: dual-modality optical coherence tomography and fluorescence imaging of labeled antibodies deep in tissue. *Biomed Opt Express*. 2015;6(5):1767–81.
  49. Pahlevaninezhad H, Lee AM, Hohert G, Lam S, Shaipanich T, Beaudoin E, et al. Endoscopic high-resolution autofluorescence imaging and OCT of pulmonary vascular networks. *Opt Lett*. 2016;41(14):3209–12.
  50. Lee AM, Kirby M, Ohtani K, Candido T, Shalansky R, MacAulay C, et al. Validation of airway wall measurements by optical coherence tomography in porcine airways. *PLoS One*. 2014;9(6):e100145.
  51. Hariri LP, Applegate MB, Mino-Kenudson M, Mark EJ, Bouma BE, Tearney GJ, et al. Optical frequency domain imaging of ex vivo pulmonary resection specimens: obtaining one to one image to histopathology correlation. *JoVE*. 2013;71:3855.
  52. Hariri LP, Applegate MB, Mino-Kenudson M, Mark EJ, Medoff BD, Luster AD, et al. Volumetric optical frequency domain imaging of pulmonary pathology with precise correlation to histopathology. *Chest*. 2013;143(1):64–74.
  53. Ohtani K, Lee AM, Lam S. Frontiers in bronchoscopic imaging. *Respirology*. 2012;17(2):261–9.
  54. Pahlevaninezhad H, Lee AM, Lam S, MacAulay C, Lane PM. Coregistered autofluorescence-optical coherence tomography imaging of human lung sections. *J Biomed Opt*. 2014;19(3):36022.
  55. Chen Y, Ding M, Guan WJ, Wang W, Luo WZ, Zhong CH, et al. Validation of human small airway measurements using endobronchial optical coherence tomography. *Respir Med*. 2015;109(11):1446–53.
  56. Tan KM, Shishkov M, Chee A, Applegate MB, Bouma BE, Suter MJ. Flexible transbronchial optical frequency domain imaging smart needle for biopsy guidance. *Biomed Opt Express*. 2012;3(8):1947–54.
  57. Kirby M, Ohtani K, Nickens T, Lisbona RM, Lee AM, Shaipanich T, et al. Reproducibility of optical coherence tomography airway imaging. *Biomed Opt Express*. 2015;6(11):4365–77.
  58. Hariri LP, Mino-Kenudson M, Applegate MB, Mark EJ, Tearney GJ, Lanuti M, et al. Toward the guidance of transbronchial biopsy: identifying pulmonary nodules with optical coherence tomography. *Chest*. 2013;144(4):1261–8.
  59. Hariri LP, Villiger M, Applegate MB, Mino-Kenudson M, Mark EJ, Bouma BE, et al. Seeing beyond the bronchoscope to increase the diagnostic yield of bronchoscopic biopsy. *Am J Respir Crit Care Med*. 2013;187(2):125–9.
  60. Hariri LP, Mino-Kenudson M, Lanuti M, Miller AJ, Mark EJ, Suter MJ. Diagnosing lung carcinomas with optical coherence tomography. *Ann Am Thorac Soc*. 2015;12(2):193–201.
  61. Trivedi A, Pavord ID, Castro M. Bronchial thermoplasty and biological therapy as targeted treatments for severe uncontrolled asthma. *Lancet Respir Med*. 2016;4(7):585–92.
  62. Kirby M, Ohtani K, Lopez Lisbona RM, Lee AM, Zhang W, Lane P, et al. Bronchial thermoplasty in asthma: 2-year follow-up using optical coherence tomography. *Eur Respir J*. 2015;46(3):859–62.

63. De Boer J, Srinivas S, Malekafzali A, Chen Z, Nelson J. Imaging thermally damaged tissue by polarization sensitive optical coherence tomography. *Opt Express*. 1998;3(6):212–8.
64. Everett MJ, Schoenenberger K, Colston BW Jr, Da Silva LB. Birefringence characterization of biological tissue by use of optical coherence tomography. *Opt Lett*. 1998;23(3):228–30.
65. McDonough JE, Yuan R, Suzuki M, Seyednejad N, Elliott WM, Sanchez PG, et al. Small-airway obstruction and emphysema in chronic obstructive pulmonary disease. *N Engl J Med*. 2011;365(17):1567–75.
66. Coxson HO, Mayo J, Lam S, Santyr G, Parraga G, Sin DD. New and current clinical imaging techniques to study chronic obstructive pulmonary disease. *Am J Respir Crit Care Med*. 2009;180(7):588–97.
67. Coxson HO, Lam S. Quantitative assessment of the airway wall using computed tomography and optical coherence tomography. *Proc Am Thorac Soc*. 2009;6(5):439–43.
68. Tam A, Churg A, Wright JL, Zhou S, Kirby M, Coxson HO, et al. Sex differences in airway remodeling in a mouse model of chronic obstructive pulmonary disease. *Am J Respir Crit Care Med*. 2016;193(8):825–34.
69. Williamson JP, Armstrong JJ, McLaughlin RA, Noble PB, West AR, Becker S, et al. Measuring airway dimensions during bronchoscopy using anatomical optical coherence tomography. *Eur Respir J*. 2010;35(1):34–41.
70. Williamson JP, McLaughlin RA, Phillips MJ, Armstrong JJ, Becker S, Walsh JH, et al. Using optical coherence tomography to improve diagnostic and therapeutic bronchoscopy. *Chest*. 2009;136(1):272–6.
71. Haponik EF, Smith PL, Bohlman ME, Allen RP, Goldman SM, Bleecker ER. Computerized tomography in obstructive sleep apnea. Correlation of airway size with physiology during sleep and wakefulness. *Am Rev Respir Dis*. 1983;127(2):221–6.
72. Armstrong JJ, Leigh MS, Sampson DD, Walsh JH, Hillman DR, Eastwood PR. Quantitative upper airway imaging with anatomic optical coherence tomography. *Am J Respir Crit Care Med*. 2006;173(2):226–33.
73. Walsh JH, Leigh MS, Paduch A, Maddison KJ, Philippe DL, Armstrong JJ, et al. Evaluation of pharyngeal shape and size using anatomical optical coherence tomography in individuals with and without obstructive sleep apnoea. *J Sleep Res*. 2008;17(2):230–8.
74. Carmeliet P, Jain RK. Angiogenesis in cancer and other diseases. *Nature*. 2000;407(6801):249–57.
75. McDonald DM. Angiogenesis and remodeling of airway vasculature in chronic inflammation. *Am J Respir Crit Care Med*. 2001;164(10 Pt 2):39–45.
76. Jeffery PK. Structural and inflammatory changes in COPD: a comparison with asthma. *Thorax*. 1998;53(2):129–36.



Alberto A. Goizueta and George A. Eapen

## History and Historical Perspective

Ultrasound has long been used to visualize intrathoracic structures, but prior to the introduction of endoscopic ultrasound, the bronchoscopist's view was limited to those structures seen within the airways or with fluoroscopy. In 1980, the use of ultrasound to visualize intrathoracic structures was first described in the field of gastroenterology for staging esophageal and gastric malignancies [1]. It wasn't until the early 1990s when ultrasound technology was introduced within the airway. Small ultrasound probes, also known as "miniproboscopes," were the first version of radial probe ultrasound endobronchial ultrasound (RP-EBUS) and became the first endobronchial ultrasound to visualize structures surrounding the airway wall [2]. In 2002, Herth et al. published the first report of RP-EBUS-guided transbronchial lung biopsy (RP-EBUS-TBBx) for solitary pulmonary nodules and peripheral lesions [3]. At this point, the endobronchial ultrasound could provide confirmation that the target was reached but the biopsy was still performed without imaging guidance. This led to the development of the convex probe EBUS (CP-EBUS) in 2002 which provided both target confirmation and real-time

guidance during the biopsy [4]. The wide acceptance of CP-EBUS-guided transbronchial needle aspiration (CP-EBUS-TBNA) as a safe and effective tool for mediastinal and hilar lymphadenopathy resulted in a rapid decline in the use of mediastinoscopy from 21.6 to 10.0% from 2006 to 2010 [5, 6]. While RP-EBUS continues to be a tool used for the confirmation of peripherally located lesions, its use has been limited by the fact it does not provide real-time biopsy imaging.

## The Basics of Endobronchial Ultrasound

Ultrasound is an imaging modality that utilizes the mechanical properties of high-frequency sound waves passing through different densities of tissue to produce images of internal body structures. The ultrasound waves are created by applying an electrical current to crystals with unique piezoelectric properties within the ultrasound probe, resulting in the vibration of the crystals to generate sound waves. The sound waves then penetrate the tissue and are reflected as an echo onto the crystals causing them to vibrate and generate electrical current that is analyzed by the ultrasound machine and reconstructed into an image. Sound waves are measured by their wavelength and frequency. Wavelength is the distance sound travels in one cycle and fre-

A. A. Goizueta · G. A. Eapen (✉)  
Department of Pulmonary Medicine, The University  
of Texas MD Anderson Cancer Center,  
Houston, TX, USA  
e-mail: [geapen@mdanderson.org](mailto:geapen@mdanderson.org)

quency refers to the number of cycles of rarefaction in a sound wave per second. Wavelength is an important factor in the axial resolution of the ultrasound image and is inversely proportional to frequency. This means that the shorter the wavelength, the higher the frequency and resolution, but less depth of penetration, making higher frequency probes better for visualizing superficial structures and lower frequency probes better for deeper structures. The production of an ultrasound image is also dependent on the density of tissue penetrated and propagation speed which is collectively known as acoustic impedance. If two materials have no difference in acoustic impedance, an echo will not be produced (e.g., pleural effusion, simple cysts) and when there is a large difference, the echo is completely reflected resulting in total acoustic shadowing (e.g., bone). The direction from where the sound wave is reflected, and the time taken to reach and return from the tissue gives information on the location and distance of the target from the probe, respectively. These properties of ultrasound provide the ability to accurately and clearly visualize structures not visible to the naked eye.

## Radial Probe Endobronchial Ultrasound

### Description of the Equipment and Technique

#### Equipment

The RP-EBUS is a catheter-based probe that is introduced through the working channel of the bronchoscope into the airways to provide a 360° view of the adjacent structures (Fig. 23.1). The outer diameter of the radial probes currently available are 1.4 mm and 1.7 mm which are compatible with the working channel of most bronchoscopes. The most commonly used frequency of RP-EBUS is 20 MHz which can provide a depth of penetration up to 5 cm and a resolution of less than 1 mm [2]. The high-resolution probe can easily differentiate structures with different echogenicities within millimeters of each other. In order to use the RP-EBUS, additional equip-



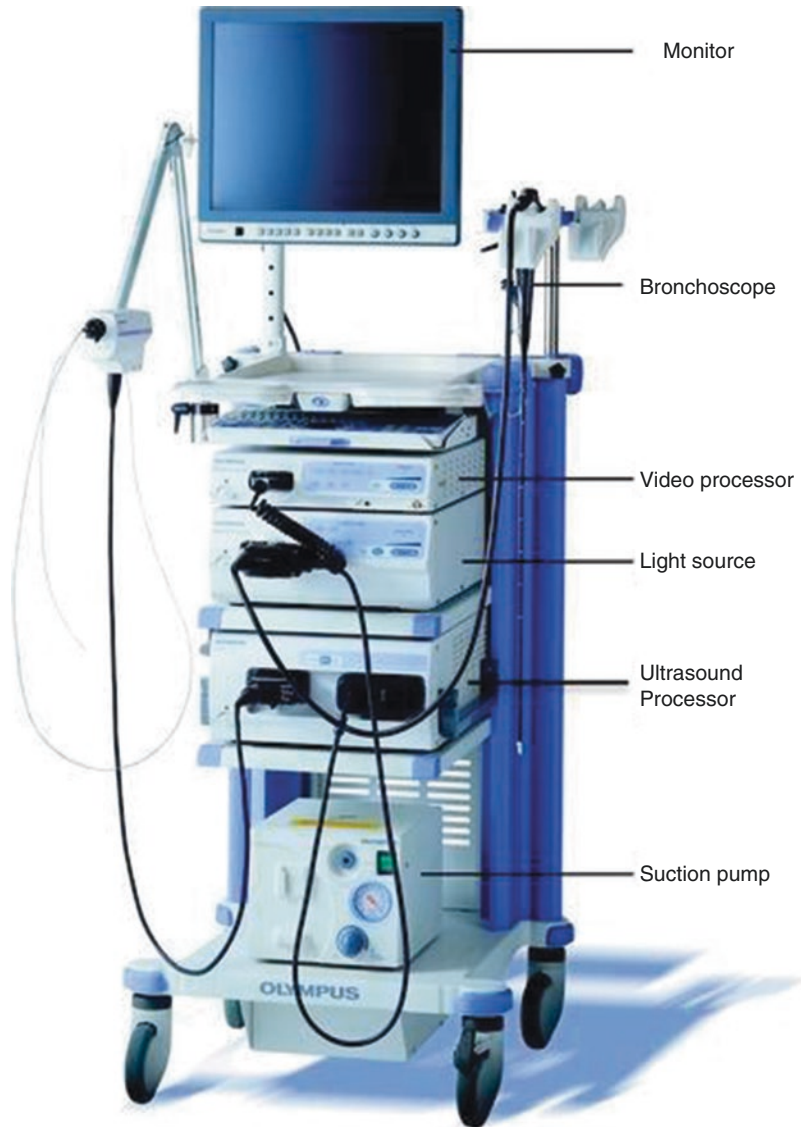
**Fig. 23.1** RP-EBUS (UM-S20-17S, Olympus, Tokyo, Japan) advanced through the working channel of a flexible bronchoscope (Reprinted with permission from Olympus)

ment is required including a bronchoscope, light source, video processor, ultrasound processor, and a monitor (Fig. 23.2). The radial probe is connected to an ultrasound processor with the ability to process the image and project it on to a monitor with outstanding image quality. There are different ultrasound processors on the market which are compact and have capabilities to process both RP-EBUS and CP-EBUS ultrasound images. Although the RP-EBUS cannot provide Doppler imaging, like CP-EBUS, the images can be captured, and the size of the target can be measured.

#### Technique

Once the bronchoscope has been advanced into the appropriate location and is determined to be near the target, a scanning technique is used to locate the target by advancing the radial probe outside of the bronchoscope toward where the lesion is suspected. Normal aerated lung tissue will typically appear as a “snowstorm like” whitish image due to the difference in impedance (Fig. 23.3). If the ultrasound probe is not in direct contact with the wall, the image will not be visible due to the lack of ultrasound penetrance and complete reflection of the ultrasound waves. Solid tumors can usually be differentiated from normal lung by a homogeneously gray area with a well-demarcated white echogenic border that commonly lacks a discrete air bronchogram [7] (Fig. 23.4). Necrotic areas will appear darker and

**Fig. 23.2** Endobronchial ultrasound system that includes a radial probe endobronchial ultrasound, bronchoscope, light source, video processor, ultrasound processor, and a monitor (Reprinted with permission from Olympus)



blood vessels will appear as black well demarcated circular or tubular structures. Benign lesions and atelectasis will usually have an inhomogeneous pattern with air bronchograms and white spots caused by varying structures within the lung. The RP-EBUS lacks the capability of Doppler ultrasonography requiring full evaluation of the length and presence of pulsatility to confidently differentiate between necrotic tissue and blood vessels.


When using RP-EBUS to biopsy a lesion within the lung, fluoroscopy is commonly used to

assist in directing not only the bronchoscope but the radial probe and the biopsy tool of choice toward the target lesion. This combination of tools has been proven to increase diagnostic yield compared to fluoroscopy alone. The use of forceps to perform TBBx remains one of the most frequently used tools to biopsy peripheral lesions allowing for histological and immunohistological examination. In addition to the standard forceps biopsies, brushings, TBNA, and cryobiopsy can be performed. In certain situations, the use of a guide sheath to extend the working channel of the





**Fig. 23.3** RP-EBUS image of normal aerated lung tissue with a “snowstorm like” whitish appearance



**Fig. 23.4** A typical RP-EBUS image of a malignant tumor showing a concentric homogeneous structure with clear borders

bronchoscope provides a more reliable conduit to pass biopsy tools and obtain samples. When using a standard bronchoscope, with a 2.0 mm working channel and a 1.4 mm RP-EBUS probe, a 1.9 mm guide sheath should be used and when using the 1.7 mm RP-EBUS probe, a 2.7 mm guide sheath and 2.8 mm working channel bronchoscope should be used.

## Indication, Application, and Evidence

While previous indications for the use of RP-EBUS included diagnostic evaluation of endobronchial lesions, staging of non-small cell lung cancer (NSCLC), diagnosis of mediastinal lesions, and the diagnostic evaluation of lung nodules it now has evolved into a tool used mainly for the evaluation of peripherally located pulmonary nodules. This transition followed the development and widespread use of the CP-EBUS. As a result, the balloon catheter used to evaluate endobronchial lesions and mediastinal structures has recently been discontinued in the United States. Currently, RP-EBUS is used to assist in verifying the target lesion's location, provide ultrasound characteristics of the lesion, and improve diagnostic yield when used in combination with other guided bronchoscopy modalities.

In combination with other clinical and radiographic modalities, the RP-EBUS has the ability to provide sonographic characteristics of peripherally located pulmonary nodules that can assist in determining the probability a lung nodule may be malignant [8]. This was first attempted in 2002 by Kurimoto et al. who analyzed 124 patients with peripheral pulmonary lesions who had both a confirmed histologic diagnosis and a preoperative RP-EBUS. The major characteristics identified were a homogenous pattern (Type I), hyperechoic dots and linear arcs pattern (Type II), and a heterogeneous pattern (Type III). The nodules with a Type I pattern were found to be benign in 23/25 (92.0%) of the cases and the Type II and III lesions were malignant in 98/99 (99.0%) of the cases [9]. In 2006, Chao et al. applied a similar concept by identifying four RP-EBUS characteristics in 20 patients with known histologic diagnoses of the pulmonary nodules. These characteristics included continuous hyperechoic margin, homogenous or heterogenous internal echoes, hyperechoic dots in the lesion, and concentric circles along the echo probe. They subsequently enrolled 126 patients who were found to have the specified ultrasound characteristic, but only 93 had a definitive diagnosis and were included in the

analysis. After multivariate analysis, only the presence of concentric circles on RP-EBUS was statistically significant for predicting benign etiology (odds ratio [OR] 46.07,  $p = 0.03$ , 95% confidence interval [CI] 3.546–598.802) [7]. Additionally, in 2007 Kuo et al. assessed 224 patients with peripheral lung lesions who underwent RP-EBUS and had a definitive diagnosis at time of analysis. The ultrasound images were reviewed, and three characteristics were selected to describe the pulmonary nodules including a continuous or noncontinuous margin between the lesion and adjacent lung, presence or absence of air bronchogram within the lesion, and homogenous or heterogenous echogenicity of the lesion. The presence of a continuous lung margin, absence of a discrete air bronchogram within the lesion, and a heterogeneous echogenicity of the lesion were all found to be predictive of malignancy. A lesion with none of the three features had a negative predictive value of 93.7% for malignancy and a lesion with two of the three features carried a positive predictive value for malignancy of 89.2% [10].

The ability of RP-EBUS to confirm localization of a peripheral lung lesion has provided an additional tool to improve diagnostic yield and safety when compared to lung biopsy performed percutaneously or by conventional bronchoscopy. Although image-guided percutaneous core biopsies and fine needle aspirations (FNA) have reported sensitivities of 95% and 90%, respectively, they come with significant complications [11]. Pneumothoraces secondary to percutaneous biopsy of peripheral lung lesions are reported to be between 15–43% with 4–18% of those patients requiring chest tube drainage [12]. Regarding conventional bronchoscopy, a systematic review of centrally and peripherally located pulmonary lesions biopsied reported a pooled sensitivity of 88% and 78%, respectively, but this was largely dependent on the size of the lesion. For example, peripheral lesions  $>2$  cm had a sensitivity of 63% and 34% for lesions  $\leq 2$  cm [13]. In 2002, Herth et al. performed a crossover study on 50 patients with peripheral lung lesions who were randomized to undergo either TBBx using RP-EBUS followed by TBBx with fluoroscopy or vice versa.

The group reported no significant difference in diagnostic yield between the two methods and a diagnostic accuracy using RP-EBUS of 80% [3]. A similar study published by Paone et al. reported improved sensitivity (79% vs. 69%) and diagnostic accuracy (85% vs. 69%) when performing RP-EBUS-guided TBBx versus TBBx without RP-EBUS [14]. The introduction of a guide sheath has also shown improvement in the diagnostic yield of TBBx when used with RP-EBUS. The technique involves placing the radial probe within a guide sheath which is advanced through the working channel of the bronchoscope and into the periphery of the lung toward the lung lesion. Once the lesion is confirmed on ultrasound, the radial probe is removed leaving the sheath as an extended working channel for biopsy tools to be inserted [15]. Kurimoto et al. were the first to introduce this technique and reported a diagnostic yield of 76% in lesions 10 mm or less [16]. TBNA is another biopsy tool that has been reported to increase the diagnostic yield when used in combination with RP-EBUS to biopsy peripheral lung lesions. Chao et al. reported a randomized study where they used RP-EBUS with a guide sheath or fluoroscopy on 182 patients to locate peripheral lung lesions. The patients were randomized to undergo conventional biopsy sampling (e.g., TBBx and bronchial washing) or conventional biopsy with the addition of TBNA. The addition of TBNA to conventional sampling increased the overall diagnostic yield from 60% to 78% [17]. Many other factors have been described that increase diagnostic yield when using RP-EBUS to biopsy peripheral lung lesions including lesions  $>2$  cm in size, lesions closer to the hilum, visualization on fluoroscopy, malignant disease (as compared to benign), having the probe within the lesion rather than adjacent to it, and taking at least 5 biopsy specimens [18–20]. Overall, the use of RP-EBUS has been shown to improve diagnostic outcomes when compared to conventional bronchoscopic techniques, and despite the significant heterogeneity among studies it can provide a sensitivity of over 70% [21, 22].

Over time advancements in bronchoscopic technology and platforms have provided new

and better ways to approach peripheral lung lesions. The development of thin and ultrathin bronchoscopes has improved the ability to maneuver distally through the bronchial tree. Additionally, virtual bronchoscopy and electromagnetic navigation have given us a three-dimensional road map to the target lesion with bronchoscopic tracking. The synergistic combination of these bronchoscopic modalities with RP-EBUS has shown to improve diagnostic outcomes for peripheral lung lesions. Asashina et al. combined virtual bronchoscopy with RP-EBUS and guide sheath to perform biopsies of small peripheral lung lesions in 29 patients. They reported a sensitivity of 92% for lesions between 20 and 30 mm in size but only 44% for lesions less than 20 mm [23]. Ishida and colleagues constructed a similar study of 199 patients with small peripherally located lung lesions who were randomized to either RP-EBUS with virtual bronchoscopy or RP-EBUS alone and reported a diagnostic yield of 80% and 67%, respectively [24]. Eberhardt et al. randomized 120 patients with peripherally located lung lesions to undergo biopsy using either electromagnetic navigational bronchoscopy (ENB), RP-EBUS, or a combination of both techniques. The reported diagnostic yield was 88% with combined ENB/RP-EBUS, 69% with RP-EBUS, and 59% with ENB alone [25]. The current literature suggests that there is synergy when using multimodal approaches to biopsy peripherally located lung lesions.

As discussed, once CP-EBUS became the tool of choice for mediastinal staging and the balloon catheter for the RP-EBUS to evaluate airway walls was discontinued, the RP-EBUS had become primarily a tool used for peripheral lung nodule localization. In addition to peripheral lung lesion biopsies, it can be used during placement of fiducial markers to guide stereotactic radiation [26]. In areas where the balloon catheter is available, it has been used to visualize airway walls in the setting of tumor infiltration, lung transplantation, and asthma [27–29].

## Convex Probe Ultrasound

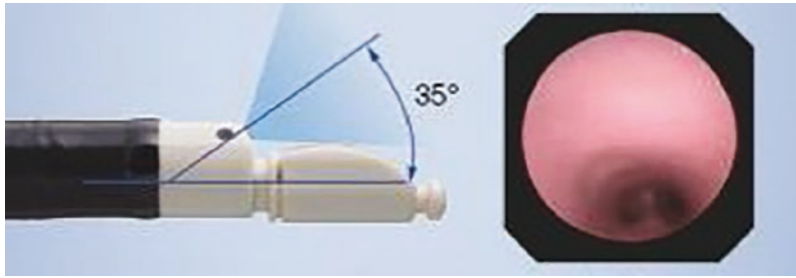
### Description of the Equipment and Technique

#### Equipment

CP-EBUS, also known as linear EBUS, is a bronchoscope with the addition of an integrated curvilinear ultrasound transducer at the distal end. At the tip of the bronchoscope, you will find a 10 mm long curved linear array electronic transducer in front of a 30° oblique facing fiber-optic lens with 80° angle view (Fig. 23.5). In order to obtain an ultrasound image, the transducer must be in contact with the airway wall. To assist in obtaining contact, a balloon attached to the tip of the bronchoscope can be inflated with saline. The bronchoscope has an additional angulation range of 160° anteflexed and 90° retroflexed to assist with maneuverability and wall contact. The outer diameter of the insertion tube is 6.3 mm and the distal end outer diameter is 6.9 mm with a working channel of 2.2 mm. The ultrasound frequency ranges from 7.5 to 12.5 MHz with a penetration depth of about 5 cm and has a scanning view of 70–90° with respect to the longitudinal axis of the bronchoscope. This provides a real-time high-resolution ultrasound image of the surrounding tissue and enables direct visualization of the echogenic needle as it penetrates the target. The CP-EBUS scope also has the ability to perform a real-time Doppler examination prior to penetrating the tissue in order to avoid any unwanted puncture of nearby vessels (Fig. 23.6).

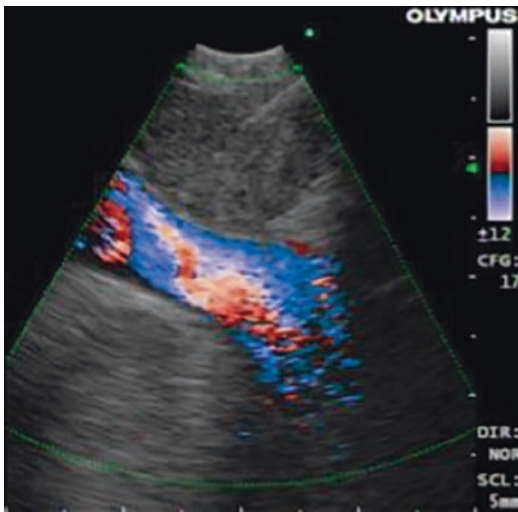
During CP-EBUS-TBNA, two monitors are required to visualize both the bronchoscopic image and the ultrasound image. The CP-EBUS is connected to a central ultrasound scanner where the images are processed (Fig. 23.2). Ultrasound scanners are commonly equipped with color Doppler and even power Doppler modes. The ultrasound scanner can also capture images and take two-dimensional size measurements.

While multiple needle gauges are available, 21-gauge and 22-gauge needles are most com-



**Fig. 23.5** On the left, illustration of the 35° oblique facing fiber-optic lens with an 80° angle of view at the tip of the CP-EBUS. On the right, the image demonstrates the

oblique angle of view bronchoscopically (Reprinted with permission from Olympus)



**Fig. 23.6** The use of color Doppler while performing CP-EBUS to assist in avoiding biopsy of nearby vessels

monly used to perform EBUS-TBNA and will fit through the 2.2 mm working channel of the bronchoscope. The needle has adjustable settings that act as safety mechanisms to prevent damage to the bronchoscope as well as harm to the patient. The needle will exit the bronchoscope at a 20° angle with respect to the longitudinal axis of the bronchoscope and will extend to a maximum of 40 mm (Fig. 23.7). As the needle is passed outside of the bronchoscope, it can be visualized by the optic and the ultrasound as it passes through the tissue.

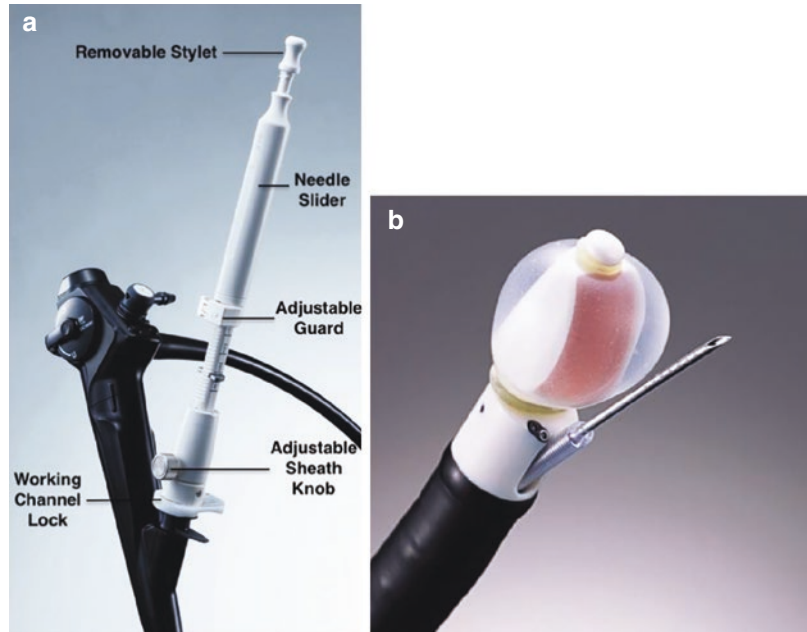
### Technique

CP-EBUS-TBNA can be performed under conscious sedation or general anesthesia as an outpatient procedure. Under conscious sedation, the bronchoscope is inserted orally due to inability to pass the large distal tip of the scope easily through the nose. Additionally, under conscious sedation the cough reflex is still active which is significantly reduced with general anesthesia. An endotracheal tube or laryngeal mask airway (LMA) is used with general anesthesia with both having their advantages and disadvantages [30].

The CP-EBUS is initially inserted orally or through a LMA passed the vocal cords unless an endotracheal tube was used. The bronchoscope is then advanced to the area of interest and the balloon is inflated with normal saline to obtain optimal wall contact. A technical aspect to be aware of is that due to the 30° oblique angle of the optic, to obtain an en face view of the airway, the bronchoscope must be slightly retroflexed. This technique can decrease contact between the ultrasound transducer and the wall requiring adjustment to either bronchoscopic position or balloon inflation. Locating the target, whether it be a lymph node or a parenchymal lesion, is done by using both airway and ultrasound landmarks. The bronchoscopic image provides a general starting point to allow a more precise and detailed scan with the ultrasound image. Vascular landmarks are the key to identifying the



**Fig. 23.7** (a) Identifies the adjustable sheath and guard to prevent unwanted damage to the bronchoscope or harm to the patient. (b) The balloon attached to the tip of the CP-EBUS inflated with saline and the needle advanced outside of the bronchoscope through the working channel (Reprinted with permission from Olympus)



specific lymph node stations according to the International Lymph Node Map by the International Association for the Study of Lung Cancer (Table 23.1) [31]. The Doppler on the CP-EBUS can also help recognize the surrounding blood vessels to assist in determining the borders of the lymph node stations and prevent unwanted vessel punctures. Sonographic lymph node features associated with an increased risk of malignancy, which include size greater than 1 cm, heterogeneous echogenicity, sharp border, round or oval shape, and the presence coagulation necrosis, can help guide the decision to biopsy the lymph node [32].

After the lesion to be biopsied has been identified, the point of entry is determined by using the bronchoscopic view to visualize landmarks on the airway wall. This may require relaxation of the flexion on the bronchoscope. The TBNA needle is then passed through the working channel of the bronchoscope while in the neutral position and locked into place. The needle has a sheath adjuster knob so that the sheath can be placed just outside the bronchoscope tip, which can be visualized on the bronchoscopic image, to prevent damage to the scope. Bronchoscopic flexion is then used to reinitiate contact with the airway

wall to visualize the target on ultrasound and the needle is advanced in real-time under ultrasound to the appropriate depth (Fig. 23.8). The needle also has an internal stylet that is agitated within the needle to clear out the internal lumen of any unwanted bronchial tissue or debris. The stylet is then removed, and a syringe is attached that provides negative pressure while within the target prior to any passes taking place. Negative pressure is not required and in instances of hypervascular lesions it is not recommended as it may cause bloody samples. The needle can then be moved back and forth with a smooth motion traversing from the most proximal to most distal portion of the target if possible. Important tips to improve the sample quality while taking passes through the target include assuring the ultrasound image is in the same axis as the needle to allow visualization of each pass and not coming out or passing through the lesion. Lastly, the needle is retracted back into the sheath and unattached from the bronchoscope. The processing of the specimen from the TBNA is also key to achieve optimal results. To prepare the specimen for processing, the inner stylet is usually placed back into the needle to push out the first few drops of the specimen onto a glass slide for rapid onsite



**Table 23.1** Lymph node stations

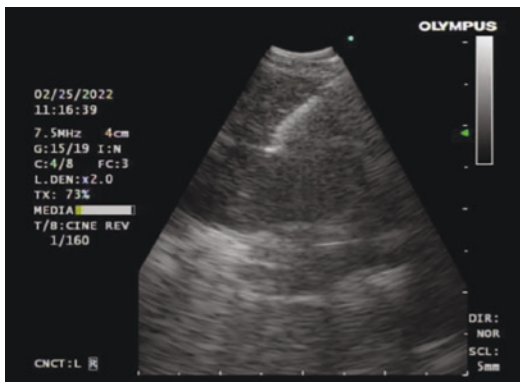Lymph node	Definition	Bronchoscopic landmark	CP-EBUS landmark
Station 11Ri	– Right interlobar lymph node that lies between the RML and RLL bronchi	– RLL superior segment laterally, RML medially, proximal to the RLL medial basal bronchi – Transducer placed in the RLL bronchus and scan between 8 and 11 o'clock	– Descending interlobar artery anteriorly
Station 11Rs	– Right interlobar lymph node that lies between the RUL and RML bronchus	– RUL and RC1 laterally – Transducer placed in the RBI and scan between 1 and 4 o'clock	– Truncus anterior and descending interlobar anteriorly
Station 10R	– Right hilar lymph node that lies along the RMS distal to the azygos and proximal to the RUL	– Right tracheobronchial angle proximally and the RUL bronchus distally – Transducer placed in the RMS and scan between 11 and 3 o'clock	– Azygos vein proximally and the right pulmonary artery distally
Station 4R	– Right lower paratracheal lymph node that lies along the right mid/lower trachea proximal to the azygos vein and distal to the brachiocephalic vein	– Main carina distal and medial, RMS distal and lateral, mid to upper trachea proximally – Transducer placed in the lower trachea and scan between 11 and 3 o'clock	– Lower border of the azygos veins distally, SVC anteriorly, brachiocephalic vein anterior and proximally
Station 2R	– Right upper paratracheal lymph node that lies along the right mid/upper trachea proximal to the brachiocephalic vein	– Upper trachea looking to the right lateral aspect – Transducer placed in the upper trachea and scan between 11 and 3 o'clock	– Proximal to the right lateral aspect of the brachiocephalic vein anteriorly
Station 7	– Subcarinal lymph node that lies between the mainstem bronchi	– Main carina medially, proximal to the RML bronchus – Transducer can be placed in the RMS and scan between 9 and 12 o'clock or placed in the LMS and scan between 12 and 3 o'clock	– Right pulmonary artery anteriorly when in the RMS and the main pulmonary artery anteriorly when in the LMS
Station 2L	– Left upper paratracheal lymph node that lies along the left upper/mid trachea proximal to the superior border of the aortic arch	– Upper trachea looking to the left lateral aspect – Transducer can be placed in the upper trachea and scan between 8 and 11 o'clock	– Proximal to the superior border of the aortic arch laterally
Station 4L	– Left lower paratracheal lymph node that lies along the left mid/lower trachea proximal to the LMS, proximal to the superior border of the left main pulmonary artery, and distal to the inferior border of the aortic arch	– Mid/lower trachea, main carina medially, proximal to the left secondary carina – Transducer placed in the LMS and scan between 9 and 12 o'clock or in the lower trachea scan between 9 and 11 o'clock	– Proximal to the superior border of the left main pulmonary artery, distal to the superior border of the aortic arch

(continued)

**Table 23.1** (continued)

Lymph node	Definition	Bronchoscopic landmark	CP-EBUS landmark
Station 10L	– Left hilar lymph node that lies along the distal left mainstem, LUL upper division, and left main pulmonary artery	– Distal LMS, medial and proximal to LC2 – Transducer placed in the distal LMS or LUL upper division and scan between 10 and 12 o'clock	– Distal to the left main pulmonary artery
Station 11L	– Left interlobar lymph node that lies between the LUL and the LLL bronchi	– LLL bronchus, medial to the LLL superior segment, and inferior to the LC2 – Transducer placed in the LLL bronchus and scan between 8 and 12 o'clock	– Medial to the left descending interlobar pulmonary artery

*RUL* right upper lobe, *RML* right middle lobe, *RLL* right lower lobe, *LUL* left upper lobe, *LLL* left lower lobe, *RMS* right mainstem, *LMS* left mainstem, *RC1* right carina 1, *LC2* left carina 2



**Fig. 23.8** Real-time visualization of needle passing into a lymph node during CP-EBUS-TBNA

cytological evaluation (ROSE) using Diff-Quik staining. The remaining portion of the sample is placed in a 50 mL conical tube filled with a cell growth medium for cell block preparation.

**Indication, Application, and Evidence**

Prior to bronchoscopic ultrasound, conventional TBNA was once used as a minimally invasive technique to obtain a tissue diagnosis for intrathoracic adenopathy. Due to the variable yield with conventional TBNA, the radial probe ultrasound was used as a potential replacement with improved diagnostic yield. A study by Herth et al. reported the diagnostic yield of conventional TBNA compared to RP-EBUS for lymph

nodes other than in the subcarinal area to be higher with the RP-EBUS (84%) than conventional TBNA (58%) [33]. The major issue with both techniques was the inability to perform needle aspiration under direct real-time visualization which ultimately led to the development of the CP-EBUS [6]. Since the development of the CP-EBUS, it has become the gold standard for mediastinal staging of non-small cell lung cancer and indicated for the use in sampling mediastinal and central lung parenchymal lesions.

**CP-EBUS for Non-malignant Mediastinal or Hilar Adenopathy**

The presence of mediastinal adenopathy and other abnormalities is common incidental imaging finding. Malignancy remains high in the differential in this setting, but there are a variety of benign diseases that can present with intrathoracic adenopathy.

Sarcoidosis is a multisystemic inflammatory disease of unknown etiology that can result in intrathoracic adenopathy, commonly confused radiographically for malignancy. The use of CP-EBUS-TBNA has outperformed the yield of conventional TBNA for the diagnosis of sarcoidosis and demonstrated improved diagnostic yield when performed in combination with conventional bronchoscopic biopsies (TBBx or endobronchial biopsy). A large multicentered randomized control study was published in 2013 by von Bartheld et al. comparing transbronchial

and endobronchial biopsies to endosonographic fine needle aspiration (EUS or CP-EBUS) of lymph nodes to detect non-caseating granulomas in patients with clinical or radiographic suspicion of stage I or II sarcoidosis. The diagnostic yield in the endosonographic group was 74% compared to only 48% in the other group [34]. Tremblay et al. conducted a prospective randomized control study comparing conventional TBNA with a 19-gauge needle and a CP-EBUS with a 22-gauge needle in 50 patients with intrathoracic adenopathy and a clinical suspicion for sarcoidosis. They reported an 83% diagnostic yield for CP-EBUS-TBNA compared to 54% for the conventional TBNA group [35, 36]. A meta-analysis reviewing the efficacy of CP-EBUS-TBNA for the diagnosis of sarcoidosis in 533 patients with the disease from 15 studies reported the diagnostic yield ranged from 54% to 93% with a pooled diagnostic yield of 79% [36]. These findings have led to the recommendation of performing CP-EBUS-TBNA in patients suspected of having sarcoidosis with intrathoracic adenopathy [37].

Intrathoracic adenopathy can also occur as a consequence of bacterial, fungal, and mycobacterial infections. A study by Madan et al. evaluated 102 patients from an endemic population for tuberculosis who underwent CP-EBUS-TBNA for diagnosis. They sampled 216 lymph nodes and the diagnostic yield, defined as positive acid-fast bacilli stain or positive necrotizing granulomas with supportive clinical investigation, was 84.8% [38]. The use of CP-EBUS-TBNA to diagnose a wide variety of infectious diseases causing mediastinal masses and intrathoracic adenopathy have been reported and shown to be effective [39, 40].

CP-EBUS has also been used for the diagnosis of bronchogenic cyst, thyroid nodules, intrathoracic goiters, parathyroid adenomas, and many other nonmalignant intrathoracic abnormalities [41, 42]. While most bronchogenic cyst can be diagnosed by CT imaging alone, some can mimic the appearance of soft tissue making it a difficult diagnosis and require biopsy. In these cases, CP-EBUS can be used to perform TBNA to obtain tissue and make the diagnosis [43, 44].

### **CP-EBUS for Malignant Mediastinal or Hilar Adenopathy**

The importance of CP-EBUS in the diagnosis and staging of lung cancer is well established in the literature and its application has been extended to other malignant diseases of the mediastinum such as lymphoma, thymoma, and metastatic diseases with positive results [45–51].

Lymphoma has been reported to present with intrathoracic adenopathy in up to 75% of patients with Hodgkin's Lymphoma making it a disease of interest for the use of CP-EBUS-TBNA for some time [52]. Previously, it was thought that fine needle aspiration of intrathoracic lymph nodes could not provide a diagnosis of lymphoma due to reported discordance between cytologic and histologic samples. This ultimately led to more invasive techniques to obtain adequate tissue including mediastinoscopy, thoracoscopy, and even thoracotomy [53]. Although still a valid concern, since the implementation of CP-EBUS as a platform to perform TBNA of the lymph nodes, many studies have shown success in diagnosing and subtyping lymphoma bronchoscopically, suggesting that prior results may have been due to technical issues and cytopathologic expertise. Kennedy et al. in 2008 published a study evaluating 25 patients with intrathoracic adenopathy suggestive of lymphoma who underwent CP-EBUS-TBNA lymph node biopsy with a 22-gauge needle. All samples were sent to on-site cytology and 24 of the 25 samples had adequate lymphoid tissue present with 10 patients positive for lymphoma and 14 patients labeled as benign. Of those 14 patients, 1 patient had a false negative result and contributed to the sensitivity of 91%, a specificity of 100%, and a negative predictive value of 93% for diagnosis of lymphoma, but the ability to subtype these patients from the tissue obtained was not reported [54]. Another study published in 2010 by Steinfort et al. retrospectively reviewed a prospectively collected database to determine the utility of CP-EBUS-TBNA in the diagnosis of lymphoma. They evaluated 98 patients with isolated intrathoracic adenopathy and excluded all patients with clinical radiographic features of sarcoidosis leaving a total of 55 patients for evaluation. Of the 55

patients, 42 patients received a definitive diagnosis and 21 of those patients were diagnosed with lymphoma. Of the patients diagnosed with lymphoma 16 were by CP-EBUS-TBNA but 4 of those patients required surgical biopsy to subtype the lymphoma due to low volume samples. Although the sensitivity and specificity for a definitive diagnosis was 57% and 100%, respectively, 76% of the patients with lymphoma were able to avoid a surgical biopsy for diagnosis [53]. A subsequent larger study published in 2015 evaluated 181 patients with clinical symptoms of lymphoma or a history of lymphoma with intrathoracic adenopathy to determine the value of CP-EBUS-TBNA to exclude the presence of lymphoma. Overall, 41.5% of the patients were diagnosed with lymphoma and the sensitivity of CP-EBUS-TBNA to diagnose and subtype lymphoma, de novo lymphoma, relapsed lymphoma, and Hodgkin's lymphoma was 77%, 67%, 81%, and 57%, respectively. Additionally, the likelihood ratio for a patient to have lymphoma when the cytology results showed granulomatous inflammation to be 0.00 and when there was adequate/inadequate lymphoid tissue present to be 0.31 [50]. The current literature therefore supports the use of CP-EBUS-TBNA as the initial procedure to evaluate patients with intrathoracic adenopathy suggestive of lymphoma and it may prevent the use of more invasive procedures to obtain a definitive diagnosis [37].

### **CP-EBUS for the Staging of Non-small Cell Lung Cancer**

Lung cancer is the leading cause of cancer deaths among men and women in the world and non-small cell lung cancer (NSCLC) accounts for approximately 85% of all lung cancer [55, 56]. The implementation of lung cancer screening programs has led to an increase in the number of people diagnosed with lung cancer. This has resulted in an increase in the number of patients diagnosed with early-stage lung cancer which could potentially be treated with curative therapy [57, 58]. The American College of Chest Physicians' evidence-based clinical practice guideline for the staging of NSCLC recommends invasive mediastinal staging in the absence of

known distant metastasis when there is discrete enlargement of mediastinal or hilar lymph nodes, a central tumor, a tumor >3 cm in diameter, or when mediastinal or hilar lymph nodes demonstrate increased uptake on PET scan [59]. The use of CP-EBUS for lung cancer diagnosis and staging greatly impacts the prognosis and management of lung cancer. In 2016, a new edition for TNM classification and staging was published with many changes that better defined the differences between NSCLC based on prognosis and treatment outcomes (Tables 23.2 and 23.3) [60]. CP-EBUS is considered the modality of choice for staging non-small cell lung cancer due to its overall superiority in accurate staging and the ability to be minimally invasive compared to other imaging and procedural techniques [59].

Once it has been determined mediastinal and hilar lymph node assessment for staging NSCLC is required, understanding which lymph nodes will need a biopsy is key. Two groups assessed the ability of ultrasonographic lymph nodes features to predict nodal metastasis using CP-EBUS. Fujiwara et al. performed a retrospective analysis of 1061 lymph nodes from 461 patients who underwent CP-EBUS-TBNA staging for NSCLC at a single center. Images of all lymph nodes were evaluated by 3 expert reviewers who were blinded to the results of the CP-EBUS-TBNA. The ultrasonographic appearance was classified into six characteristics which were compared to the final pathologic diagnosis for each lymph node. Of the six features, round shape, distinct margin, heterogeneous echogenicity, and presence of coagulation necrosis sign were found to be independently predictive of lymph node metastasis. The presence of any one of the four features increased the risk of lymph node metastasis and the absence of all 4 characteristics had a negative predictive value of 96% for malignancy within the node [32]. An additional study published in 2011 by Memoli et al. prospectively assessed 227 lymph nodes in 100 patients who had suspected or confirmed NSCLC and underwent CP-EBUS-TBNA at a single center. Five ultrasound characteristics were recorded which included size, shape, echogenicity, border definition, and number of lymph nodes at each

**Table 23.2** TNM lung cancer classification

T, N, and M classification for lung cancer (8th edition)	
T: primary tumor	
Tx	Primary tumor cannot be assessed, or tumor proven by presence of malignant cells in sputum or bronchial washings but not visualized by imaging or bronchoscopy
T0	No evidence of primary tumor
Tis	Carcinoma in situ
T1	Tumor $\leq 3$ cm in greatest dimension surrounded by lung or visceral pleura without bronchoscopic evidence of invasion more proximal than the lobar bronchus (i.e., not in the main bronchus)
T1a (mi)	Minimally invasive adenocarcinoma
T1a	Tumor $\leq 1$ cm in greatest dimension
T1b	Tumor $>1$ cm but $\leq 2$ cm in greatest dimension
T1c	Tumor $>2$ cm but $\leq 3$ cm in greatest dimension
T2	Tumor $>3$ cm but $\leq 5$ cm or tumor with any of the following features: <ul style="list-style-type: none"> <li>• Involves main bronchus regardless of distance from the carina but without involvement of the carina</li> <li>• Invades visceral pleura</li> <li>• Associated with atelectasis or obstructive pneumonitis that extends to the hilar region, involving part or all of the lung</li> </ul>
T2a	Tumor $>3$ cm but $\leq 4$ cm in greatest dimension
T2b	Tumor $>4$ cm but $\leq 5$ cm in greatest dimension
T3	Tumor $>5$ cm but $\leq 7$ cm in greatest dimension or associated with separate tumor nodule(s) in the same lobe as the primary tumor or directly invades any of the following structures: chest wall (including the parietal pleura and superior sulcus tumors), phrenic nerve, parietal pericardium
T4	Tumor $>7$ cm in greatest dimension or associated with separate tumor nodule(s) in a different ipsilateral lobe than that of the primary tumor or invades any of the following structures: diaphragm, mediastinum, heart, great vessels, trachea, recurrent laryngeal nerve, esophagus, vertebral body, and carina
N: regional lymph node involvement	
Nx	Regional lymph nodes cannot be assessed
N0	No regional lymph node metastasis
N1	Metastasis in ipsilateral peribronchial and/or ipsilateral hilar lymph nodes and intrapulmonary nodes, including involvement by direct extension
N2	Metastasis in ipsilateral mediastinal and/or subcarinal lymph node(s)
N3	Metastasis in contralateral mediastinal, contralateral hilar, ipsilateral or contralateral scalene, or supraclavicular lymph node(s)
M: distant metastasis	
M0	No distant metastasis
M1	Distant metastasis present
M1a	Separate tumor nodule(s) in a contralateral lobe; tumor with pleural or pericardial nodule(s) or malignant pleural or pericardial effusion
M1b	Single extrathoracic metastasis
M1c	Multiple extrathoracic metastases in one or more organs

T tumor, N node, M metastasis, Tis carcinoma in situ, T1a(mi) minimally invasive adenocarcinoma

Table reproduced from: Goldstraw P, Chansky K, Crowley J, Rami-Porta R, Asamura H, Eberhardt WE, et al. The IASLC Lung Cancer Staging Project: Proposals for Revision of the TNM Stage Groupings in the Forthcoming (Eighth) Edition of the TNM Classification for Lung Cancer. *J Thorac Oncol.* 2016;11(1):39–51

station. Size greater than 10 mm and oval or round shape were the only two ultrasonographic features that increased the probability of lymph node malignancy. Of note, 10% of lymph nodes less than 10 mm in size were confirmed to have

malignancy which supports the widely used  $>5$  mm cut off to perform a needle biopsy [61]. These findings show that although ultrasonographic characteristics may be able to predict lymph node metastasis the low sensitivity and



**Table 23.3** TNM lung cancer staging

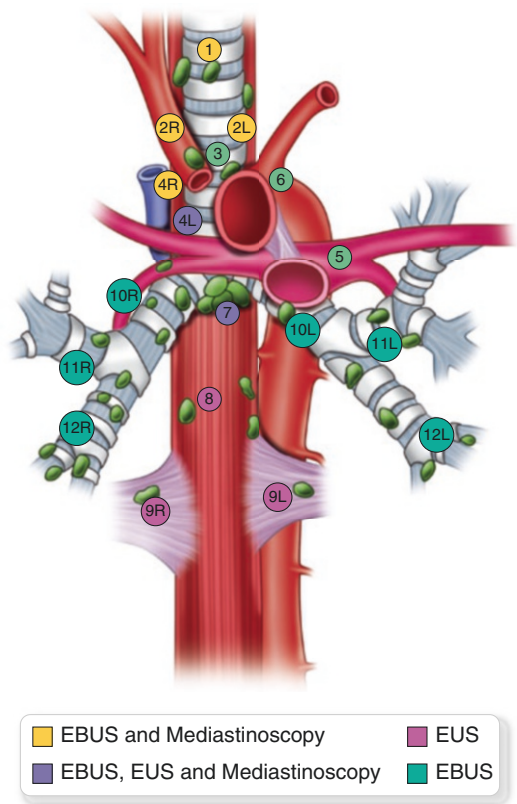
T, N, and M staging (8th edition)					
Category	Subcategory	N0	N1	N2	N3
T1	T1a	IA1	IIB	IIIA	IIIB
	T1b	IA2	IIB	IIIA	IIIB
	T1c	IA3	IIB	IIIA	IIIB
T2	T2a	IB	IIB	IIIA	IIIB
	T2b	IIA	IIB	IIIA	IIIB
T3		IIB	IIIA	IIIB	IIIC
T4		IIIA	IIIA	IIIB	IIIC
M1	M1a	IVA	IVA	IVA	IVA
	M1b	IVA	IVA	IVA	IVA
	M1c	IVB	IVB	IVB	IVB

T tumor, N node, M metastasis, *Tis* carcinoma in situ, *T1a(mi)* minimally invasive adenocarcinoma  
 Table reproduced from: Goldstraw P, Chansky K, Crowley J, Rami-Porta R, Asamura H, Eberhardt WE, et al. The IASLC Lung Cancer Staging Project: Proposals for Revision of the TNM Stage Groupings in the Forthcoming (Eighth) Edition of the TNM Classification for Lung Cancer. J Thorac Oncol. 2016;11(1):39–51

negative predictive value do not support the ability to rule out malignancy without a biopsy.

Additional concerns to be considered include the ability to reach the lymph node and which modality will provide that access. Of the current modalities to perform biopsies of intrathoracic lymph nodes CP-EBUS provides the best accessibility (Fig. 23.9). CP-EBUS can provide access to the upper and lower paratracheal, hilar, and interlobar lymph nodes bilaterally. It also has the capability of reaching the paraesophageal lymph nodes if introduced through the esophagus, but generally cannot reach the sub or para-aortic lymph nodes. In comparison, mediastinoscopy is limited to the mediastinum and has difficulty effectively accessing more posteriorly located station 7 lymph node, while endoscopic ultrasound (EUS) is limited only to left paratracheal, paraesophageal, and pulmonary ligament lymph nodes. The concept of performing EBUS and EUS in one setting to obtain a complete mediastinal lymph node evaluation has been raised, but the clinical utility and resource constraints are debatable and will be discussed later.

The ability of CP-EBUS to guide real-time TBNA of mediastinal and hilar lymph nodes has led to its widespread use in staging NSCLC, replacing previous modalities. In 2005, Yasufuku et al. first described the use of CP-EBUS for mediastinal staging in 105 patients who had confirmed or suspected NSCLC with suspicious



**Fig. 23.9** Nodal stations and the modalities able to access the indicated lymph nodes

mediastinal lymph nodes in the node (N) 2 or N3 station. They sampled 163 lymph nodes which resulted in 64 patients diagnosed with cancer. Of

the remaining patients with negative CP-EBUS-TBNA, 7 were followed clinically for 12 months which resulted in a benign course and 37 underwent thoracotomy for further sampling with 33 of the 37 patients showing no evidence of N2 or N3 metastasis. This study yielded a diagnostic accuracy of 96%, sensitivity of 94.6%, specificity of 100%, negative predictive value of 89%, and positive predictive value of 100% [62]. Since this study, many other studies supporting this data and comparing other modalities for mediastinal staging to CP-EBUS have been published.

Imaging modalities such as chest computed tomography (CT) and positron emission tomography have shown to be helpful but suboptimal for determining a definitive nodal stage in NSCLC. A pooled analysis of the use of CT scans and PET scans for staging of the mediastinal and hilar lymph nodes yielded a sensitivity of 55% for CT scans and 77% for PET scans [59]. In 2006, Yasufuku et al. prospectively compared the performance of CP-EBUS-TBNA to CT scan and PET scan for mediastinal staging in 102 patients with confirmed or suspected lung cancer who were thought to be candidates for surgical resection. The entire group underwent CT and PET scan followed by CP-EBUS-TBNA prior to surgery. The patients who underwent CP-EBUS-TBNA and confirmed to have stage I, II, IIIA with only a single positive N2 station were considered operable and underwent thoracotomy with lymph node dissection. Of the 26 patients confirmed to have mediastinal metastasis, CP-EBUS-TBNA correctly staged 24 patients resulting in a sensitivity of 92%, specificity of 100%, negative predictive value of 97%, and overall diagnostic accuracy of 98%. This was considerably better than CT scan (sensitivity 77%, specificity 55%, negative predictive value 88%, diagnostic accuracy 61%) and PET scan (sensitivity 80%, specificity 70%, negative predictive value 92%, diagnostic accuracy 73%) [63]. A similar study in 2008 published by Herth et al. evaluated 100 patients with suspected NSCLC that had CT scans negative for enlarged intrathoracic adenopathy and PET scans negative for any intrathoracic lymph node uptake. All the patients underwent CP-EBUS-TBNA with biop-

sies of any lymph node  $\geq 5$  mm and subsequently underwent either a mediastinoscopy or thoracotomy with lymph node dissection which was used as the standard of reference for comparison. 8 patients with no intrathoracic adenopathy on CT and PET scan were found to have positive results for lung cancer on CP-EBUS-TBNA and only 1 patient negative for lung cancer with CP-EBUS-EB was found to have a lymph node metastasis at the time of surgery. The overall results in this study reported a sensitivity of 89%, specificity 100%, and negative predictive value of 99% for CP-EBUS-TBNA [64]. A third study compared the use of CP-EBUS-TBNA to integrated PET/CT for the diagnosis of intrathoracic lymph node metastasis in 129 patients with suspected or confirmed operable NSCLC. A total of 117 patients underwent analysis and 27 patients were found to have lymph nodes positive for lung cancer on CP-EBUS-TBNA. Of the 90 patients that were found to have negative lymph nodes on CP-EBUS-TBNA 3 patients had malignancy found at surgery. The sensitivity (90%), specificity (100%), negative predictive value (97%), and diagnostic accuracy (97%) of CP-EBUS-TBNA compared to integrated PET/CT (70%, 60%, 85%, 62%, respectively) was again superior [65].

Mediastinoscopy was traditionally considered the gold standard modality for invasive staging of the mediastinal lymph nodes. Despite this longstanding title, mediastinoscopy has limited access to the paratracheal and subcarinal lymph nodes and no ability to sample the hilar lymph nodes. These sampling limitations resulted in reported sensitivities ranging from 40 to 92%, making CP-EBUS a more optimal tool for completely sampling lymph nodes for lung cancer staging. Supporting evidence by Ernst et al. reported 66 patients who were surgical candidates with lesions suspicious for NSCLC and intrathoracic adenopathy limited to the paratracheal and subcarinal lymph nodes. All patients underwent mediastinoscopy and a CP-EBUS-TBNA within a week of the mediastinoscopy with a definitive diagnosis found in 49 or the 66 (76%) patients. Patients with limited IIIA disease or better were offered surgical resection which resulted in 61 patients undergoing surgery. In the per-patient

analysis there was no statistically significant difference in diagnostic yield when comparing CP-EBUS-TBNA to mediastinoscopy (89% vs. 79%;  $p = 0.1$ ). But in the per-lymph node analysis, there was a statistically significant difference for CP-EBUS-TBNA diagnostic yield compared to mediastinoscopy (91% vs. 78%;  $p = 0.007$ ), which was due entirely to the difference in yield at station 7 with CP-EBUS [66]. Annema et al. also randomized 241 patients with potentially resectable NSCLC to compare mediastinoscopy with endosonographic staging which consisted of EUS-FNA and CP-EBUS-TBNA. All patients with no evidence of nodal metastasis on CP-EBUS-TBNA also underwent mediastinoscopy. Endosonographic staging with mediastinoscopy showed a greater sensitivity compared to mediastinoscopy alone (94% vs. 79%;  $p = 0.02$ ) and a 11% (7% vs. 18%) absolute reduction in thoracotomies [67]. An additional study published by Yasufuku et al. illustrated that CP-EBUS-TBNA is equivalent to mediastinoscopy for staging NSCLC and is associated with fewer complications. They evaluated 153 patients with NSCLC who required mediastinal staging. All patients underwent CP-EBUS-TBNA immediately followed by cervical mediastinoscopy and any patient who was found without evidence of N2/N3 disease during staging underwent surgical lung and lymph node resection. The results were similar between CP-EBUS-TBNA and mediastinoscopy sensitivities (81% vs. 79%), negative predictive values (91% vs. 90%), and diagnostic accuracy (93% vs. 93%) [68].

Several years prior to the development of CP-EBUS the endoscopic ultrasound (EUS) was commonly used by gastroenterologists. Like CP-EBUS, EUS has a camera for visualization while inside the gastrointestinal tract and an ultrasound transducer for real-time sonographic visualization during fine needle aspiration. EUS-FNA has also been used to diagnose mediastinal masses and assist in mediastinal staging of lung cancer but has limited application due to its inability to sample lymph nodes to the right or anterior to the trachea and any hilar lymph nodes. CP-EBUS-TBNA has the advantage of sampling the paratracheal and hilar lymph node stations

but has its own limitation in accessing lymph nodes at the aortopulmonary window, lower esophagus, and inferior pulmonary ligament [31, 62] (Fig. 23.9). The combination of the two modalities to sample the mediastinum for lung cancer staging are complementary and can easily access all intrathoracic lymph nodes except the nodes in the aortopulmonary window and upper prevascular stations. Several published studies have assessed the combination of the two modalities for lung cancer staging with promising results [69, 70]. In 2010, Herth et al. assessed 150 patients suspected to have NSCLC and no evidence of extrathoracic metastasis which resulted in 139 patients who were confirmed to have NSCLC that were included in the analysis. The patients underwent CP-EBUS-TBNA and EUS-FNA by a single operator using only a CP-EBUS scope resulting in 619 lymph node biopsies. Additionally, all patients underwent either thoracotomy, thoracoscopy, or 6–12 months follow-up to confirm the endosonographic results. They found the prevalence of mediastinal lymph node metastasis was 52% (71/139 patients) with 65/71 (91%) of the positive lymph nodes detected by CP-EBUS-TBNA, 63/71 (89%) by EUS-FNA, and 68/71 (96%) with combined modalities. The sensitivity (96%) of the combined approach was superior to either CP-EBUS-TBNA (92%) or EUS-FNA (82%) alone [71]. Hwango et al. also assessed the efficacy of combined CP-EBUS-TBNA and EUS-FNA to stage NSCLC. They enrolled 150 patients with suspected or confirmed NSCLC and performed both CP-EBUS-TBNA and EUS-FNA which resulted in 38 patients with mediastinal lymph node metastasis diagnosed by CP-EBUS and an additional 3 patients by EUS. Of the 109 patients not found to have metastatic lymph nodes, 7 patients were excluded from the analysis and 4 patients were found to have metastatic disease during surgical dissection. The sensitivity, negative predictive value, and diagnostic accuracy for CP-EBUS-TBNA were 84.4%, 93.3%, and 95.1%, respectively, which was improved with EUS-FNA in the combined analysis to 91.1%, 96.1%, and 97.2%, but not to a statistical significance. One outcome that showed statistical significance was the higher

proportion of accessible lymph node stations with the combined approach compared to CP-EBUS-TBNA alone (85% vs. 79%;  $p = 0.015$ ) [72]. The current literature supports the combined use of combined CP-EBUS-TBNA and EUS-FNA, and is likely beneficial in situations when it will change the outcome provided by CP-EBUS-TBNA alone, but limitations in operator experience, credentialing, and equipment restrict generalizability.

### **CP-EBUS for Restaging NSCLC After Neoadjuvant Chemotherapy**

Advancements in chemoimmunotherapy have changed the management approach to patients with stage IIIA-N2 NSCLC. Previously this group of patients was labeled to have unresectable lung cancer and definitive chemoradiation was the treatment of choice. Now the use of induction chemotherapy and neoadjuvant therapy has expanded the options for certain patients in this group to include surgery pending the results of a mediastinal restaging [73]. This management approach continues to be controversial, but the literature supports that induction chemotherapy and neoadjuvant chemotherapy prior to surgery may improve overall survival in this group of patients [74, 75]. The optimal method for mediastinal restaging is yet to be determined, but CP-EBUS-TBNA remains an acceptable option due to the low sensitivity and negative predictive value of PET/CT, and the technical difficulty encountered when performing mediastinoscopy following recent chemoradiation. To assess adequacy of CP-EBUS-TBNA for restaging, Herth et al. in 2008 enrolled 124 patients with stage IIIA-N2 NSCLC who had shown a positive response or stable disease on CT after undergoing neoadjuvant chemotherapy prior to undergoing surgical resection with lymph node dissection. All patients underwent CP-EBUS-TBNA restaging with 89 patients (72%) found to have residual N2 disease and 35 patients (28%) with no residual disease. Thoracotomy confirmed the 89 patients with residual N2 disease but discovered

an additional 28 of the 35 patients with no residual disease on CP-EBUS-TBNA had residual N2 disease present. CP-EBUS-TBNA for residual N2 disease after neoadjuvant chemotherapy for NSCLC demonstrated a sensitivity of 76%, specificity of 100%, negative predictive value of 20%, and an overall diagnostic accuracy of 77%. Of the 28 false negative N2 lymph nodes, 91% were sampled by CP-EBUS and the failure to diagnose residual malignancy was attributed to sampling error and changes induced within the lymph following neoadjuvant therapy [76]. Although these results do not support the use of CP-EBUS-TBNA to rule out residual N2 disease following neoadjuvant therapy, the ability to identify residual N2 disease and therefore potentially prevent a patient from undergoing an unnecessary surgery makes it an important part of the management approach.

### **CP-EBUS for Biomarker Testing**

Since the advent of immunotherapy and targeted therapy for NSCLC, the type of tissue and optimal modality to obtain that tissue has been vigorously discussed. CP-EBUS-TBNA has been instrumental in the diagnosis and staging of NSCLC, but its ability to provide adequate samples for full molecular testing has been debated. Currently, clinical guidelines support obtaining malignant tissue for the identification of several targetable biomarkers which can optimally direct treatment plans in patients with NSCLC [77, 78]. A recent study published by Martin-Deleon evaluated 72 patients with suspected stage III or IV lung cancer who underwent CP-EBUS-TBNA for mediastinal staging resulting in 42 patients diagnosed with NSCLC. Among the cytological samples provided by CP-EBUS-TBNA, next-generation sequencing (NGS) genotyped 92.9%, nCounter genotyped 95.2%, and 100% of the samples were adequate for immunohistochemistry testing [79]. These findings and previous studies support the use of CP-EBUS-TBNA as a reasonable modality to obtain material for NSCLC biomarker testing [80–82].

## Complications

While CP-EBUS and RP-EBUS are associated with the same procedural and sedation complications as flexible bronchoscopy, they add a few specific complications but remain an extremely safe procedure overall. In a systematic review of 20 publications including 14 original research studies, performing CP-EBUS-TBNA of regional lymph nodes was reported to only cause minor complications including cough, agitation, and puncture site bleeding without any serious complications [83]. Similarly, RP-EBUS does not directly contribute to any significant complications, but the coupling of TBBx of peripheral pulmonary lesions to the procedure as a whole increases the risk for complications. Serious complications of RP-EBUS-guided TBBx include bleeding (<1%) and pneumothorax (<4%) [16, 84, 85]. Overall, the use of EBUS is safe with low morbidity.

## Summary

Since the introduction of EBUS, it has become one of the most versatile and powerful tools available to the bronchoscopist. The application of EBUS for sampling peripheral lung nodules, diagnosing diseases of the mediastinum, and its most widespread use in staging NSCLC has reshaped the field by ultimately outperforming the previous technically difficult and ineffective approaches. As the role of EBUS continues to grow, additional applications are likely to emerge and play an influential role in pulmonology.

## References

1. DiMugno EP, Buxton JL, Regan PT, Hattery RR, Wilson DA, Suarez JR, et al. Ultrasonic endoscope. *Lancet*. 1980;1(8169):629–31.
2. Hurter T, Hanrath P. Endobronchial sonography: feasibility and preliminary results. *Thorax*. 1992;47(7):565–7.
3. Herth FJ, Ernst A, Becker HD. Endobronchial ultrasound-guided transbronchial lung biopsy in solitary pulmonary nodules and peripheral lesions. *Eur Respir J*. 2002;20(4):972–4.

4. Yang H, Zhang Y, Wang KP, Ma Y. Transbronchial needle aspiration: development history, current status and future perspective. *J Thorac Dis*. 2015;7(Suppl 4):S279–86.
5. Vyas KS, Davenport DL, Ferraris VA, Saha SP. Mediastinoscopy: trends and practice patterns in the United States. *South Med J*. 2013;106(10):539–44.
6. Yasufuku K, Chiyo M, Sekine Y, Chhajed PN, Shibuya K, Iizasa T, et al. Real-time endobronchial ultrasound-guided transbronchial needle aspiration of mediastinal and hilar lymph nodes. *Chest*. 2004;126(1):122–8.
7. Chao TY, Lie CH, Chung YH, Wang JL, Wang YH, Lin MC. Differentiating peripheral pulmonary lesions based on images of endobronchial ultrasonography. *Chest*. 2006;130(4):1191–7.
8. Yasufuku K, T. F. Endobronchial ultrasound: indications, advantages, and complications. Waltham: UpToDate; 2012.
9. Kurimoto N, Murayama M, Yoshioka S, Nishisaka T. Analysis of the internal structure of peripheral pulmonary lesions using endobronchial ultrasonography. *Chest*. 2002;122(6):1887–94.
10. Kuo CH, Lin SM, Chen HC, Chou CL, Yu CT, Kuo HP. Diagnosis of peripheral lung cancer with three echoic features via endobronchial ultrasound. *Chest*. 2007;132(3):922–9.
11. Zhang HF, Zeng XT, Xing F, Fan N, Liao MY. The diagnostic accuracy of CT-guided percutaneous core needle biopsy and fine needle aspiration in pulmonary lesions: a meta-analysis. *Clin Radiol*. 2016;71(1):1–10.
12. Wiener RS, Schwartz LM, Woloshin S, Welch HG. Population-based risk for complications after transthoracic needle lung biopsy of a pulmonary nodule: an analysis of discharge records. *Ann Intern Med*. 2011;155(3):137–44.
13. Rivera MP, Mehta AC, Wahidi MM. Establishing the diagnosis of lung cancer: diagnosis and management of lung cancer, 3rd ed: American College of Chest Physicians evidence-based clinical practice guidelines. *Chest*. 2013;143(5 Suppl):142S–65S.
14. Paone G, Nicastrì E, Lucantoni G, Dello Iacono R, Battistoni P, D'Angeli AL, et al. Endobronchial ultrasound-driven biopsy in the diagnosis of peripheral lung lesions. *Chest*. 2005;128(5):3551–7.
15. Kikuchi E, Yamazaki K, Sukoh N, Kikuchi J, Asahina H, Imura M, et al. Endobronchial ultrasonography with guide-sheath for peripheral pulmonary lesions. *Eur Respir J*. 2004;24(4):533–7.
16. Kurimoto N, Miyazawa T, Okimasa S, Maeda A, Oiwa H, Miyazu Y, et al. Endobronchial ultrasonography using a guide sheath increases the ability to diagnose peripheral pulmonary lesions endoscopically. *Chest*. 2004;126(3):959–65.
17. Chao TY, Chien MT, Lie CH, Chung YH, Wang JL, Lin MC. Endobronchial ultrasonography-guided transbronchial needle aspiration increases the diagnostic yield of peripheral pulmonary lesions: a randomized trial. *Chest*. 2009;136(1):229–36.



18. Yamada N, Yamazaki K, Kurimoto N, Asahina H, Kikuchi E, Shinagawa N, et al. Factors related to diagnostic yield of transbronchial biopsy using endobronchial ultrasonography with a guide sheath in small peripheral pulmonary lesions. *Chest*. 2007;132(2):603–8.
19. Huang CT, Ho CC, Tsai YJ, Yu CJ, Yang PC. Factors influencing visibility and diagnostic yield of transbronchial biopsy using endobronchial ultrasound in peripheral pulmonary lesions. *Respirology*. 2009;14(6):859–64.
20. Tay JH, Irving L, Antippa P, Steinfors DP. Radial probe endobronchial ultrasound: factors influencing visualization yield of peripheral pulmonary lesions. *Respirology*. 2013;18(1):185–90.
21. Steinfors DP, Khor YH, Manser RL, Irving LB. Radial probe endobronchial ultrasound for the diagnosis of peripheral lung cancer: systematic review and meta-analysis. *Eur Respir J*. 2011;37(4):902–10.
22. Wang Memoli JS, Nietert PJ, Silvestri GA. Meta-analysis of guided bronchoscopy for the evaluation of the pulmonary nodule. *Chest*. 2012;142(2):385–93.
23. Asahina H, Yamazaki K, Onodera Y, Kikuchi E, Shinagawa N, Asano F, et al. Transbronchial biopsy using endobronchial ultrasonography with a guide sheath and virtual bronchoscopic navigation. *Chest*. 2005;128(3):1761–5.
24. Ishida T, Asano F, Yamazaki K, Shinagawa N, Oizumi S, Moriya H, et al. Virtual bronchoscopic navigation combined with endobronchial ultrasound to diagnose small peripheral pulmonary lesions: a randomised trial. *Thorax*. 2011;66(12):1072–7.
25. Eberhardt R, Anantham D, Ernst A, Feller-Kopman D, Herth F. Multimodality bronchoscopic diagnosis of peripheral lung lesions: a randomized controlled trial. *Am J Respir Crit Care Med*. 2007;176(1):36–41.
26. Harley DP, Krinsky WS, Sarkar S, Highfield D, Aygun C, Gurses B. Fiducial marker placement using endobronchial ultrasound and navigational bronchoscopy for stereotactic radiosurgery: an alternative strategy. *Ann Thorac Surg*. 2010;89(2):368–73; discussion 73–4.
27. Herth F, Ernst A, Schulz M, Becker H. Endobronchial ultrasound reliably differentiates between airway infiltration and compression by tumor. *Chest*. 2003;123(2):458–62.
28. Irani S, Hess T, Hofer M, Gaspert A, Bachmann LM, Russi EW, et al. Endobronchial ultrasonography for the quantitative assessment of bronchial mural structures in lung transplant recipients. *Chest*. 2006;129(2):349–55.
29. Soja J, Grzanka P, Sladek K, Okon K, Cmiel A, Mikos M, et al. The use of endobronchial ultrasonography in assessment of bronchial wall remodeling in patients with asthma. *Chest*. 2009;136(3):797–804.
30. Sarkiss M. Anesthesia for bronchoscopy and interventional pulmonology: from moderate sedation to jet ventilation. *Curr Opin Pulm Med*. 2011;17(4):274–8.
31. Rusch VW, Asamura H, Watanabe H, Giroux DJ, Rami-Porta R, Goldstraw P, et al. The IASLC lung cancer staging project: a proposal for a new international lymph node map in the forthcoming seventh edition of the TNM classification for lung cancer. *J Thorac Oncol*. 2009;4(5):568–77.
32. Fujiwara T, Yasufuku K, Nakajima T, Chiyo M, Yoshida S, Suzuki M, et al. The utility of sonographic features during endobronchial ultrasound-guided transbronchial needle aspiration for lymph node staging in patients with lung cancer: a standard endobronchial ultrasound image classification system. *Chest*. 2010;138(3):641–7.
33. Herth F, Becker HD, Ernst A. Conventional vs endobronchial ultrasound-guided transbronchial needle aspiration: a randomized trial. *Chest*. 2004;125(1):322–5.
34. von Bartheld MB, Dekkers OM, Szlubowski A, Eberhardt R, Herth FJ, in't Veen JC, et al. Endosonography vs conventional bronchoscopy for the diagnosis of sarcoidosis: the GRANULOMA randomized clinical trial. *JAMA*. 2013;309(23):2457–64.
35. Tremblay A, Sather DR, Maceachern P, Khalil M, Field SK. A randomized controlled trial of standard vs endobronchial ultrasonography-guided transbronchial needle aspiration in patients with suspected sarcoidosis. *Chest*. 2009;136(2):340–6.
36. Agarwal R, Srinivasan A, Aggarwal AN, Gupta D. Efficacy and safety of convex probe EBUS-TBNA in sarcoidosis: a systematic review and meta-analysis. *Respir Med*. 2012;106(6):883–92.
37. Wahidi MM, Herth F, Yasufuku K, Shepherd RW, Yarmus L, Chawla M, et al. Technical aspects of endobronchial ultrasound-guided transbronchial needle aspiration: CHEST guideline and expert panel report. *Chest*. 2016;149(3):816–35.
38. Madan K, Mohan A, Ayub II, Jain D, Hadda V, Khilnani GC, et al. Initial experience with endobronchial ultrasound-guided transbronchial needle aspiration (EBUS-TBNA) from a tuberculosis endemic population. *J Bronchol Interv Pulmonol*. 2014;21(3):208–14.
39. Steinfors DP, Johnson DF, Connell TG, Irving LB. Endobronchial ultrasound-guided biopsy in the evaluation of intrathoracic lymphadenopathy in suspected tuberculosis: a minimally invasive technique with a high diagnostic yield. *J Infect*. 2009;58(4):309–11.
40. Casal RF, Adachi R, Jimenez CA, Sarkiss M, Morice RC, Eapen GA. Diagnosis of invasive aspergillus tracheobronchitis facilitated by endobronchial ultrasound-guided transbronchial needle aspiration: a case report. *J Med Case Rep*. 2009;3:9290.
41. Steinfors DP, Irving LB. Endobronchial ultrasound staging of thyroid lesion in small cell lung carcinoma. *Thorac Cardiovasc Surg*. 2010;58(2):128–9.
42. Casal RF, Phan MN, Keshava K, Garcia JM, Grosu H, Lazarus DR, et al. The use of endobronchial ultrasound-guided transbronchial needle aspiration in the diagnosis of thyroid lesions. *BMC Endocr Disord*. 2014;14:88.

43. Casal RF, Jimenez CA, Mehran RJ, Eapen GA, Ost D, Sarkiss M, et al. Infected mediastinal bronchogenic cyst successfully treated by endobronchial ultrasound-guided fine-needle aspiration. *Ann Thorac Surg.* 2010;90(4):52–3.
44. Anantham D, Phua GC, Low SY, Koh MS. Role of endobronchial ultrasound in the diagnosis of bronchogenic cysts. *Diagn Ther Endosc.* 2011;2011:468237.
45. Moonim MT, Breen R, Gill-Barman B, Santis G. Diagnosis and subclassification of thymoma by minimally invasive fine needle aspiration directed by endobronchial ultrasound: a review and discussion of four cases. *Cytopathology.* 2012;23(4):220–8.
46. Yoshida Y, Singyoji M, Ashinuma H, Itakura M, Iizasa T, Tatsumi K. Successful diagnosis of a thymoma by endobronchial ultrasound-guided transbronchial needle aspiration: a report of two cases. *Intern Med.* 2015;54(21):2735–9.
47. Sanz-Santos J, Cirauqui B, Sanchez E, Andreo F, Serra P, Monso E, et al. Endobronchial ultrasound-guided transbronchial needle aspiration in the diagnosis of intrathoracic lymph node metastases from extrathoracic malignancies. *Clin Exp Metastasis.* 2013;30(4):521–8.
48. Navani N, Nankivell M, Woolhouse I, Harrison RN, Munavvar M, Oltmanns U, et al. Endobronchial ultrasound-guided transbronchial needle aspiration for the diagnosis of intrathoracic lymphadenopathy in patients with extrathoracic malignancy: a multicenter study. *J Thorac Oncol.* 2011;6(9):1505–9.
49. Tournoy KG, Govaerts E, Malfait T, Dooms C. Endobronchial ultrasound-guided transbronchial needle biopsy for M1 staging of extrathoracic malignancies. *Ann Oncol.* 2011;22(1):127–31.
50. Grosu HB, Iliesiu M, Caraway NP, Medeiros LJ, Lei X, Jimenez CA, et al. Endobronchial ultrasound-guided transbronchial needle aspiration for the diagnosis and subtyping of lymphoma. *Ann Am Thorac Soc.* 2015;12(9):1336–44.
51. Detterbeck FC, Lewis SZ, Diekemper R, Addrizzo-Harris D, Alberts WM. Executive Summary: Diagnosis and management of lung cancer, 3rd ed: American College of Chest Physicians evidence-based clinical practice guidelines. *Chest.* 2013;143(5):7–37.
52. Romano M, Libshitz HI. Hodgkin disease and non-Hodgkin lymphoma: plain chest radiographs and chest computed tomography of thoracic involvement in previously untreated patients. *Radiol Med.* 1998;95(1-2):49–53.
53. Steinfert DP, Conron M, Tsui A, Pasricha SR, Renwick WE, Antippa P, et al. Endobronchial ultrasound-guided transbronchial needle aspiration for the evaluation of suspected lymphoma. *J Thorac Oncol.* 2010;5(6):804–9.
54. Kennedy MP, Jimenez CA, Bruzzi JF, Mhatre AD, Lei X, Giles FJ, et al. Endobronchial ultrasound-guided transbronchial needle aspiration in the diagnosis of lymphoma. *Thorax.* 2008;63(4):360–5.
55. Torre LA, Bray F, Siegel RL, Ferlay J, Lortet-Tieulent J, Jemal A. Global cancer statistics, 2012. *CA Cancer J Clin.* 2015;65(2):87–108.
56. Barta JA, Powell CA, Wisnivesky JP. Global epidemiology of lung cancer. *Ann Glob Health.* 2019;85(1):8.
57. Aberle DR, Adams AM, Berg CD, Black WC, Clapp JD, Fagerstrom RM, et al. Reduced lung-cancer mortality with low-dose computed tomographic screening. *N Engl J Med.* 2011;365(5):395–409.
58. Horeweg N, Scholten ET, de Jong PA, van der Aalst CM, Weenink C, Lammers JW, et al. Detection of lung cancer through low-dose CT screening (NELSON): a prespecified analysis of screening test performance and interval cancers. *Lancet Oncol.* 2014;15(12):1342–50.
59. Silvestri GA, Gonzalez AV, Jantz MA, Margolis ML, Gould MK, Tanoue LT, et al. Methods for staging non-small cell lung cancer: diagnosis and management of lung cancer, 3rd ed: American College of Chest Physicians evidence-based clinical practice guidelines. *Chest.* 2013;143(5 Suppl):e211S–e50S.
60. Goldstraw P, Chansky R, Crowley J, Rami-Porta R, Asamura H, Eberhardt WE, et al. The IASLC lung cancer staging project: proposals for revision of the TNM stage groupings in the forthcoming (eighth) edition of the TNM classification for lung cancer. *J Thorac Oncol.* 2016;11(1):39–51.
61. Memoli JS, El-Bayoumi E, Pastis NJ, Tanner NT, Gomez M, Huggins JT, et al. Using endobronchial ultrasound features to predict lymph node metastasis in patients with lung cancer. *Chest.* 2011;140(6):1550–6.
62. Yasufuku K, Chiyo M, Koh E, Moriya Y, Iyoda A, Sekine Y, et al. Endobronchial ultrasound guided transbronchial needle aspiration for staging of lung cancer. *Lung Cancer.* 2005;50(3):347–54.
63. Yasufuku K, Nakajima T, Motoori K, Sekine Y, Shibuya K, Hiroshima K, et al. Comparison of endobronchial ultrasound, positron emission tomography, and CT for lymph node staging of lung cancer. *Chest.* 2006;130(3):710–8.
64. Herth FJ, Eberhardt R, Krasnik M, Ernst A. Endobronchial ultrasound-guided transbronchial needle aspiration of lymph nodes in the radiologically and positron emission tomography-normal mediastinum in patients with lung cancer. *Chest.* 2008;133(4):887–91.
65. Hwangbo B, Kim SK, Lee HS, Lee HS, Kim MS, Lee JM, et al. Application of endobronchial ultrasound-guided transbronchial needle aspiration following integrated PET/CT in mediastinal staging of potentially operable non-small cell lung cancer. *Chest.* 2009;135(5):1280–7.
66. Ernst A, Anantham D, Eberhardt R, Krasnik M, Herth FJ. Diagnosis of mediastinal adenopathy-real-time endobronchial ultrasound guided needle aspiration versus mediastinoscopy. *J Thorac Oncol.* 2008;3(6):577–82.

67. Annema JT, van Meerbeeck JP, Rintoul RC, Dooms C, Descheppe E, Dekkers OM, et al. Mediastinoscopy vs endosonography for mediastinal nodal staging of lung cancer: a randomized trial. *JAMA*. 2010;304(20):2245–52.
68. Yasufuku K, Pierre A, Darling G, de Perrot M, Waddell T, Johnston M, et al. A prospective controlled trial of endobronchial ultrasound-guided transbronchial needle aspiration compared with mediastinoscopy for mediastinal lymph node staging of lung cancer. *J Thorac Cardiovasc Surg*. 2011;142(6):1393–400.
69. Rintoul RC, Skwarski KM, Murchison JT, Wallace WA, Walker WS, Penman ID. Endobronchial and endoscopic ultrasound-guided real-time fine-needle aspiration for mediastinal staging. *Eur Respir J*. 2005;25(3):416–21.
70. Vilmann P, Krasnik M, Larsen SS, Jacobsen GK, Clementsen P. Transesophageal endoscopic ultrasound-guided fine-needle aspiration (EUS-FNA) and endobronchial ultrasound-guided transbronchial needle aspiration (EBUS-TBNA) biopsy: a combined approach in the evaluation of mediastinal lesions. *Endoscopy*. 2005;37(9):833–9.
71. Herth FJ, Krasnik M, Kahn N, Eberhardt R, Ernst A. Combined endoscopic-endobronchial ultrasound-guided fine-needle aspiration of mediastinal lymph nodes through a single bronchoscope in 150 patients with suspected lung cancer. *Chest*. 2010;138(4):790–4.
72. Hwangbo B, Lee GK, Lee HS, Lim KY, Lee SH, Kim HY, et al. Transbronchial and transesophageal fine-needle aspiration using an ultrasound bronchoscope in mediastinal staging of potentially operable lung cancer. *Chest*. 2010;138(4):795–802.
73. Daly ME, Singh N, Ismaila N, Antonoff MB, Arenberg DA, Bradley J, et al. Management of stage III non-small-cell lung cancer: ASCO guideline. *J Clin Oncol*. 2021;40(12):1356–84.
74. Koshy M, Fedewa SA, Malik R, Ferguson MK, Vigneswaran WT, Feldman L, et al. Improved survival associated with neoadjuvant chemoradiation in patients with clinical stage IIIA(N2) non-small-cell lung cancer. *J Thorac Oncol*. 2013;8(7):915–22.
75. Eberhardt WE, Pöttgen C, Gauler TC, Friedel G, Veit S, Heinrich V, et al. Phase III study of surgery versus definitive concurrent chemoradiotherapy boost in patients with resectable stage IIIA(N2) and selected IIIB non-small-cell lung cancer after induction chemotherapy and concurrent chemoradiotherapy (ESPATUE). *J Clin Oncol*. 2015;33(35):4194–201.
76. Herth FJ, Annema JT, Eberhardt R, Yasufuku K, Ernst A, Krasnik M, et al. Endobronchial ultrasound with transbronchial needle aspiration for restaging the mediastinum in lung cancer. *J Clin Oncol*. 2008;26(20):3346–50.
77. Lindeman NI, Cagle PT, Aisner DL, Arcila ME, Beasley MB, Bernicker EH, et al. Updated molecular testing guideline for the selection of lung cancer patients for treatment with targeted tyrosine kinase inhibitors: guideline from the College of American Pathologists, the International Association for the Study of Lung Cancer, and the Association for Molecular Pathology. *J Mol Diagn*. 2018;20(2):129–59.
78. Kalemkerian GP, Narula N, Kennedy EB. Molecular testing guideline for the selection of lung cancer patients for treatment with targeted tyrosine kinase inhibitors: American Society of Clinical Oncology Endorsement Summary of the College of American Pathologists/International Association for the Study of Lung Cancer/Association for Molecular Pathology clinical practice guideline update. *J Oncol Pract*. 2018;14(5):323–7.
79. Martin-Deleon R, Teixido C, Lucena CM, Martinez D, Fontana A, Reyes R, et al. EBUS-TBNA cytological samples for comprehensive molecular testing in non-small cell lung cancer. *Cancer*. 2021;13(9):2084.
80. Righi L, Franzi F, Montarolo F, Gatti G, Bongiovanni M, Sessa F, et al. Endobronchial ultrasound-guided transbronchial needle aspiration (EBUS-TBNA)-from morphology to molecular testing. *J Thorac Dis*. 2017;9(5):395–404.
81. Casadio C, Guarize J, Donghi S, Di Tonno C, Fumagalli C, Vacirca D, et al. Molecular testing for targeted therapy in advanced non-small cell lung cancer: suitability of endobronchial ultrasound transbronchial needle aspiration. *Am J Clin Pathol*. 2015;144(4):629–34.
82. Faber E, Grosu H, Sabir S, San Lucas FA, Barkoh BA, Bassett RL, et al. Adequacy of small biopsy and cytology specimens for comprehensive genomic profiling of patients with non-small-cell lung cancer to determine eligibility for immune checkpoint inhibitor and targeted therapy. *J Clin Pathol*. 2021;75(9):612–9.
83. Varela-Lema L, Fernández-Villar A, Ruano-Ravina A. Effectiveness and safety of endobronchial ultrasound-transbronchial needle aspiration: a systematic review. *Eur Respir J*. 2009;33(5):1156–64.
84. Hayama M, Izumo T, Matsumoto Y, Chavez C, Tsuchida T, Sasada S. Complications with endobronchial ultrasound with a guide sheath for the diagnosis of peripheral pulmonary lesions. *Respiration*. 2015;90(2):129–35.
85. Chen A, Chenna P, Loiselle A, Massoni J, Mayse M, Misselhorn D. Radial probe endobronchial ultrasound for peripheral pulmonary lesions. A 5-year institutional experience. *Ann Am Thorac Soc*. 2014;11(4):578–82.



# Electromagnetic Navigation: A Review

# 24

Danai Khemasuwan and Atul C. Mehta

## Introduction

Lung cancer is the second most common cancer worldwide [1]. Lung cancer screening with low dose CT (LDCT) scans demonstrated a survival benefit in high-risk groups [2]. Among other routine cancer screening modalities, the numbers needed to screen (NNS) to prevent one death for LDCT is 320 [2]. However, a high proportion of false-positive nodules on LDCT scans necessitates a carefully implemented follow-up plan based on the patient's probability of malignancy. As the number of lung nodule detection on LDCT increases, there is an increasing demand to perform tissue biopsy of lung nodules. Generally, there are three options for tissue biopsy of the lung nodule: surgical resection, CT-guided trans-thoracic needle biopsy (CT-TTNB), and trans-bronchial biopsy (TBBx). In lung cancer patients, there is a high proportion of patients with poor lung function are also at risk for complications following surgical or percutaneous biopsy. CT-TTNB, through meta-analyses, has been

shown to have excellent diagnostic yield up to 92% [3]; however, it is frequently complicated by pneumothorax requiring chest tube placement and hospitalization in half of the subjects [4, 5].

TBBx is one of the minimally invasive procedures which is frequently used to determine the etiology of solitary pulmonary nodules (SPN). However, when it comes to the nodules located in the peripheral one-third of the lung and less than 2 cm in diameter, the procedure is of limited value and establishing the diagnosis remains challenging. TBBx has historically had a low diagnostic yield, with diagnostic rates for nodules under 2 cm estimated to be 34% and still only 63% for lesions over 2 cm [6]. In addition, TBBx has reached its plateau in terms of its diagnostic yield for the SPN. In most instances the diagnostic yield is limited by an inability to steer biopsy tools directly to the lesion. The sensitivity of bronchoscopy for diagnosing etiology of a SPN depends on several factors including (1) the size of the nodule; (2) the proximity of the nodule to the central airway; and (3) the prevalence of cancer in the study population. If the CT reveals a positive “bronchus sign” the diagnostic yield of TBBx increases up to 72%; unfortunately, not a common occurrence for smaller lesions [7].

Although the addition of radial probe endobronchial ultrasound (rp-EBUS) to the traditional bronchoscopy has improved the diagnostic yield, its usefulness is technically limited as the ultrasound probes cannot be easily steered beyond the

---

D. Khemasuwan (✉)  
Pulmonary and Critical Care Division, Virginia  
Commonwealth University, Richmond, VA, USA  
e-mail: [danai.khemasuwan@vcuhealth.org](mailto:danai.khemasuwan@vcuhealth.org)

A. C. Mehta  
Lerner College of Medicine, Buoncore Family  
Endowed Chair in Lung Transplantation, Respiratory  
Institute, Cleveland Clinic, Cleveland, OH, USA  
e-mail: [Mehtaa1@ccf.org](mailto:Mehtaa1@ccf.org)

visible portions of the airways. The next step in guiding the bronchoscopic biopsy tools through the lung periphery has been electromagnetic navigation (EMN). Real-time guidance and the ability to steer biopsy instruments to the pre-selected virtual peripheral lesion is critical for a successful bronchoscopic biopsy procedure. EMN is a novel technology that facilitates approaching peripheral lung lesions which are difficult to biopsy with conventional TBbx. In this review, we describe existing electromagnetic navigation technologies with particular focus on available clinical data, procedural maneuver, and limitations. To date, there are two major platforms for EMN are available in the US; (1) superDimension Navigation System (Medtronic, Minneapolis, MN) and (2) SPiN System (Veran Medical Technologies, Inc., St. Louis, MO).

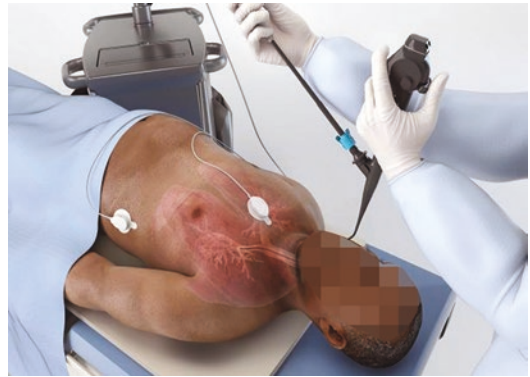### What Is Electromagnetic Navigation?

The navigation system involves creating an electromagnetic (EM) field around the patient's chest and then directing bronchoscopic biopsy tools using a micro-sensor placed upon previously acquired CT images. In other words, EMN is an image-guided localization device which assists in placing bronchoscopic biopsy tools in the targeted areas of the lung. The principles, the components, and procedural maneuvers of the EMN are provided below [8–13].

#### SuperDimension Navigation System (EMN-SD)

EMN-SD operates on the principles of electromagnetism. Electromagnetic Location Board emits low frequency electromagnetic (EM) waves. The patient is in supine position and their torso is placed within the electromagnetic field created by the board (Fig. 24.1).

A retractable micro-sensor probe is mounted on the tip of a flexible cable Locatable Guide (LG) (Fig. 24.2). This micro-sensor is the cardinal feature of the system. Once placed within the EM field, its position in  $x$ ,  $y$ ,  $z$  axes as well as in-motion (rotate, forward and backward) is captured by the EMN system and displayed on the



**Fig. 24.1** Electromagnetic location board placed at the cephalic end of the bronchoscopy table

monitor in real-time. These images are superimposed upon previously acquired CT images (Fig. 24.3).

#### Computerized Tomography

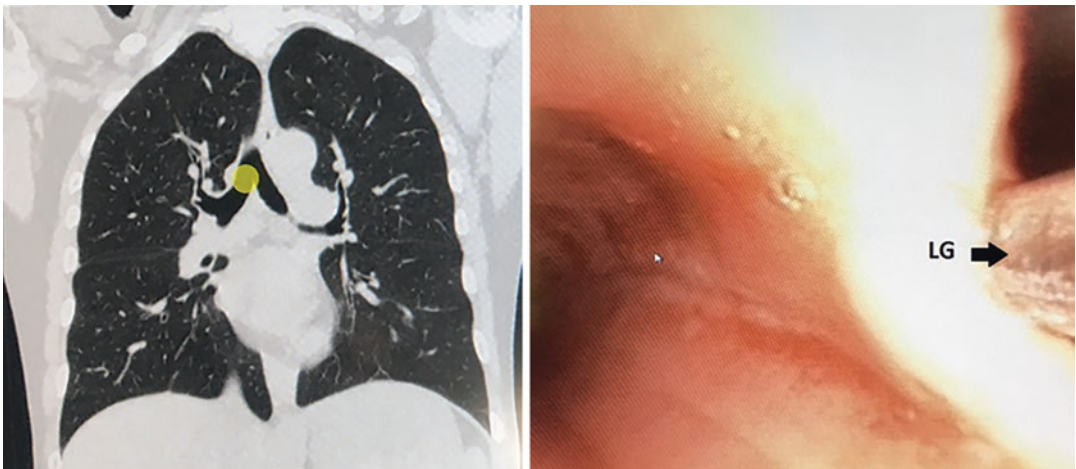
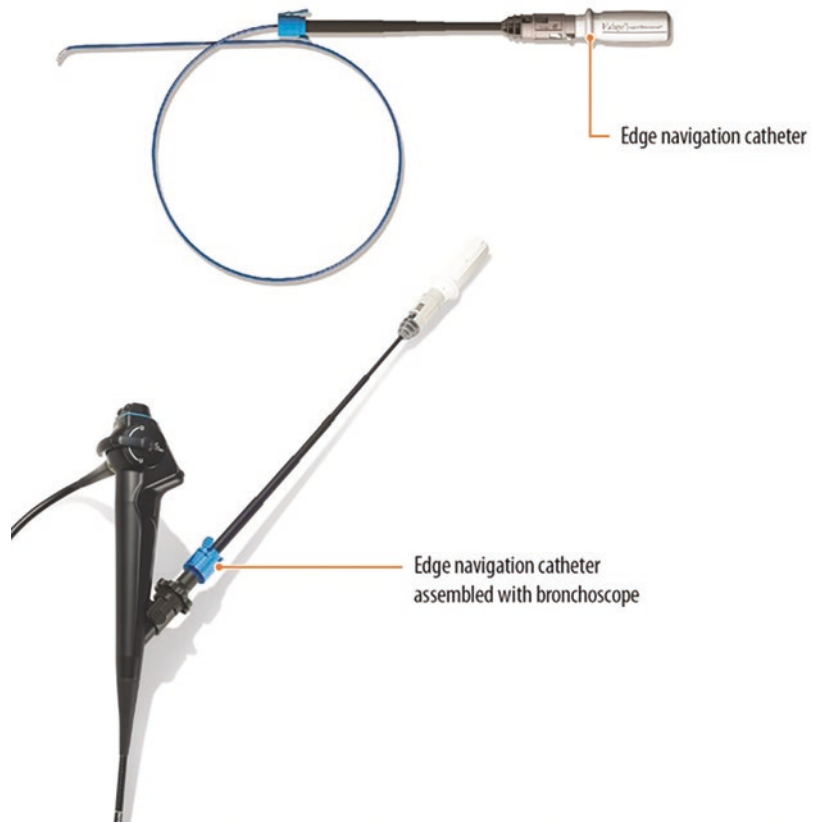
To overlay the patient's radiographic information on the patient's anatomy in the electromagnetic field, a high-resolution spiral CT scan of the chest is performed (with or without the contrast) and reconstructed with a protocol specific to the scanner manufacturer. The recommended reconstruction protocols optimize CT images suitable for planning and navigation with slice thickness between 1.0 and 1.25 mm; a slice interval range between 0.8 and 1.0 mm; and image overlap between 20 and 50% [14]. DICOM (Digital Imaging Communication in Medicine) images from a low dose CT scan can be accepted and viewed in the planning module; however, the detail and quality of the images produced may not be suitable to enable the advanced features of the EMN system. The information is gathered in the DICOM format and placed either on a compact disc or directly down-loaded on the system's laptop from the picture archiving and communication system (PACS).

#### Computer Interphase

The SuperDimension system provides dedicated software for "Planning" and "Navigation procedure." The CT chest images can be transferred from PACS into DICOM CD and the images can be uploaded directly into the planning software.



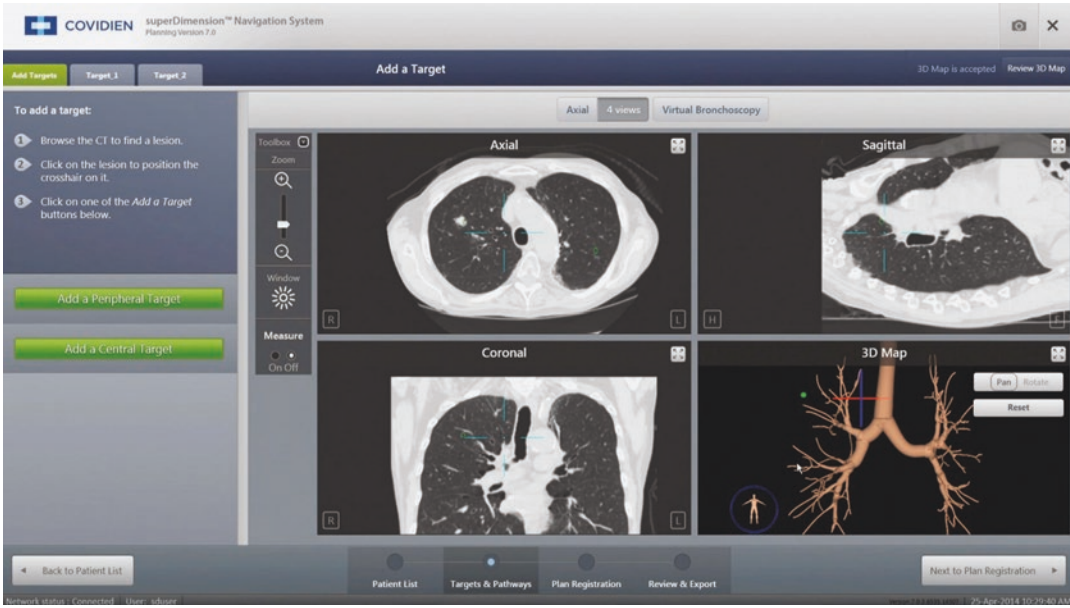**Fig. 24.2** (Top) The edge navigation catheter with sensor at the distal tip. (Bottom) Edge navigation catheter assembled with a working channel of bronchoscope



**Fig. 24.3** (Left) The position of locatable guide (LG) at the main carina in coronal view CT scan and (Right) real-time superimposed bronchoscopic image of LG at the main carina

The planning software program provides images of the chest in coronal, sagittal, and axial fashion as well as a virtual bronchoscopic image and a three-dimensional representation of the patient's

tracheobronchial tree and pleura. These images are used to plan all aspects of the procedure. The main computer software and the monitor allow the bronchoscopist to view the reconstructed



**Fig. 24.4** Computer interphase: dedicated program on the laptop provides coronal, axial, and sagittal views of the chest along with virtual bronchoscopy

images of the patient's anatomy together with superimposed graphic information depicting the position of the LG as well as position of the target lesion.

The virtual 3D bronchial tree made possible with the technology extends deep into the lung parenchyma and enables several automated features such as automatic registration, automated pathway planning, and airway sync. Further, the customized high-definition views offer bronchoscopist multiple navigation perspectives to improve detection and diagnosis. A high definition widescreen allows six viewports to be displayed simultaneously, including one video input, enabling the physician to evaluate positional data and optimize central and peripheral guidance within the lung (Fig. 24.4).

### The Edge Catheter: Extended Working Channel (EWC)

Since the adult size flexible bronchoscope cannot be advanced beyond the fourth or fifth generation bronchus the iLogic system provides an extended working channel with the distal end angulated at different degrees to facilitate approaching the

PPL (Edge). The Edge catheter is a 130-cm-long, 1.9-mm-diameter flexible catheter, serving as a EWC for the FB. It is available with its distal end curved at 45°, 90°, 180°, and medial angles. The distal tip of this catheter could be soft or hard and based on the bronchoscopists preference. These options are to facilitate navigation between the SPN and the adjacent bronchus, as judged by the bronchoscopist. The Edge navigation catheter can be steered to the SPN in 360-degree fashion. The proximal white steering knob has a socket for connecting a wire, which relays the information from the sensor to the main computer (Fig. 24.5).

Once the tip of the bronchoscope is wedged into the segmental bronchus of interest, the LG is advanced along with the EWC under the guidance provided by the navigation system. Upon reaching the desired target, the LG is withdrawn leaving the EWC in place. The biopsy tools (needle, cytology brush, and forceps) then are inserted through the EWC to sample the target. In 2015, the GenCut biopsy device is one of the most recent biopsy tools in the EMN-SD navigation system. It is activated with aspiration to create



**Fig. 24.5** The main processor of the SuperDimension navigation system

shearing force and collect multiple tissue samples with a single pass. In a recent study, the GenCut TBNA alone had a diagnostic yield of 37.3%, lower than the average of TBBx. However, the GenCut increased the diagnostic yield by 7.4% from 43.2% with TBBx alone to 50.6% when both biopsy tools were used [15].

#### Procedural Steps

The procedure of EMN is performed in the following steps:

#### Planning

Planning involves identifying the target, selecting anatomical landmarks, and identifying a virtual approach to the target using digital software provided by the system.

#### Identification of the Target

Target(s) are identified by scrolling through the CT cross sections in axial, coronal, and sagittal axes. Once identified, the location of the target(s) is marked using a cursor and highlighted. The dimensions of the target are also measured.

#### Detecting Anatomical Landmarks

A virtual bronchoscopy image extending to the 4th generation of tracheobronchial tree is required to enable automatic superimposition of the CT images on the patient's body. If a 3D map is not available, anatomical landmarks (primary and secondary carinas) can be identified using the CT cross sections. Five or more easily recognizable endobronchial locations (landmarks) are selected for the purpose; more specifically main carina as well as two points in each lung, one in the upper lobe and one in its middle or lower lobe. These radiographic landmarks are matched with the actual anatomic landmarks of the patient during the bronchoscopic procedure either automatically or manually.

#### Pathway Planning

If a 3D map is available, one or more automatic pathways to each target can be constructed to assist in navigation. The automatic pathway is constructed using the 3D map as a reference. A review of the automatic pathway should be completed utilizing the CT cross sections and the 3D map. Additionally, a virtual navigation of the pathway can be performed using the pathway preview feature. The suggested pathway can be modified, extended with waypoints or it can be accepted for guidance as it is.

#### Saving the Plan and Exiting

When the procedure plan is complete, it is exported to a CD, a removable disk (USB), or to a network storage location for transfer to the procedure system.

#### Registration

The information gathered during the planning stage is uploaded into the system's main computer using the external memory device. The

electromagnetic sensors are placed on the patient's chest wall to accommodate for respiratory motion, coughing, and nominal patient movements. Flexible bronchoscopy is performed in a usual fashion to clear any excess airway secretions. The Edge catheter is inserted via the working channel of the scope.

During the automatic registration process (Fig. 24.6), the system records the location of the LG while the bronchoscopist performs a bronchoscopic airway examination, creating a virtual cloud of navigation points that approximates the tracheobronchial tree. The system completes the registration process by matching the navigation cloud to the 3D map. The virtual bronchoscopy (VB) will appear during the bronchoscopic survey when the system has collected the minimal amount of data needed to match to the 3D tree. After completing the balanced survey, visual verification and image rotation the registration is accepted and the navigation phase of the procedure begins.

In a small percentage of procedures, the CT images will not support generation of a 3D tree. In this case, manual registration will be required. The radiological landmarks (registration points) selected on the virtual bronchoscopy images in planning are identified *in vivo* and touched with the tip of the LG to register their location in the

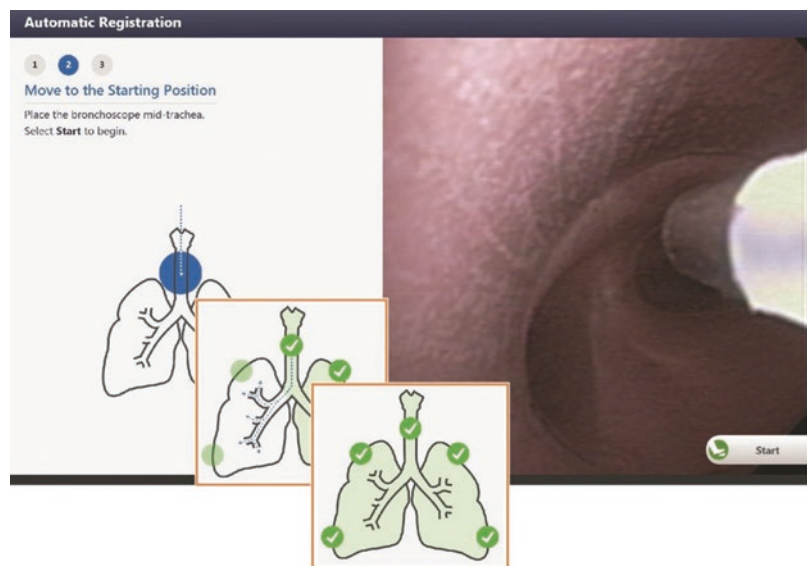
system's main computer to establish radiographic–anatomic alignment. Registration of all the above information into the computer software automatically synthesized a navigation scheme to approach the lesion with precision. Accuracy of the navigation depends upon this Radiographic–Anatomic alignment also referred as “average fiducial target registration error” (AFTRE); which defines registration quality. The AFTRE can be improved or corrected by repositioning the misplaced landmarks or by eliminating that with a greatest deviation. The registration error of 5 mm or less can be considered acceptable [16].

### Real-Time Navigation

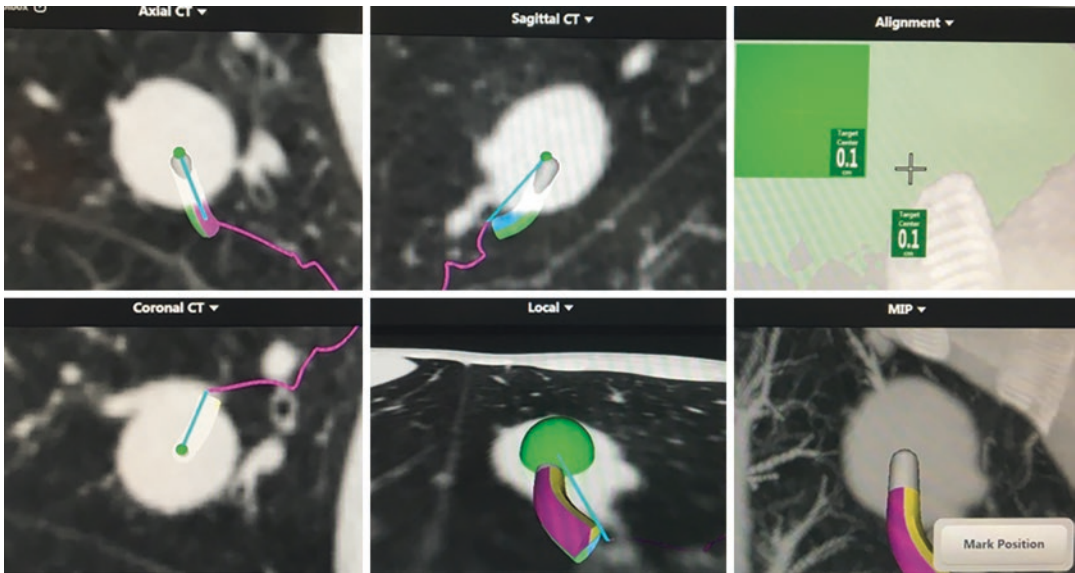
Following a successful registration, the scope with the LG in place is advanced toward the segmental bronchus of interest. The navigation screen consists of six different viewports. The configuration of viewports is customizable with 11 different viewports available. Each viewport provides information that is meaningful at different points in the navigation procedure. The targets and pathways defined during planning will be available for selection during Navigation. Once a target and pathway have been selected, the available views are used to guide the LG to the target.

Following are the viewports available to aid navigation (Fig. 24.7):

**Fig. 24.6** Automatic pathway. Automatic registration with LG catheter







**Fig. 24.7** Target alignment view

- Planar CT axial, coronal, and sagittal image (3 views). The views show the selected target and optionally, the selected pathway and waypoints.
- Static 3D map. A view of the 3D map showing the selected target, selected pathway, waypoints, and real-time location of the LG tip.
- Dynamic 3D map. A view of the 3D map showing the selected target, selected pathway, waypoints, and real-time location of the LG tip. The 3D map is automatically rotated, panned, and zoomed during navigation.
- Tip view. A graphical representation of the steering wheel on the LG handle. This view shows the direction to rotate the steering wheel to turn the LG toward the selected navigation object (target, pathway, or waypoint).
- 3D CT. A planar projection of the CT volume located directly in front of the LG tip.
- Video bronchoscope. Live display of the video input feed, typically used to show the bronchoscope video.
- Virtual bronchoscopy. A live display of the virtual bronchoscopy showing the real-time location of the LG tip. The selected pathway, waypoints, and 3D map centerlines can be overlaid on the view.
- Local view. A planar CT image located at and aligned with the LG tip. The view shows the selected target, selected pathway, waypoints, and 3D map branches.
- Alignment view. A view of target alignment with the LG tip.
- MIP (Maximum intensity projection). A pseudo three-dimensional projection of the CT volume below the LG tip. MIP shows high intensity structures, such as blood vessels and lesions.

Navigation guidance to the target is primarily given through the selected Pathway. The pathway is displayed in the 3D map, local view, virtual bronchoscopy, and CT cross sections. The objective during navigation is to steer and advance the LG along the pathway. In addition to pathway guidance, steering directions are provided to specific navigation objects using the tip view. Navigation objects include targets, the automatic pathway, and waypoints, and are represented by spheres in all views.

The lesion is represented as a green sphere on all of the system viewports. As the LG gets closer to the lesion, the green dot continues to get larger in a relative fashion. The screen also shows the



distance between the LG and the targeted lesion in millimeters (mm). Once the LG reaches the desired target location, the EWC is fixed at the proximal end of the biopsy channel of the bronchoscope by a special locking mechanism and the LG is withdrawn. Bronchoscopic biopsy tools such as biopsy forceps, transbronchial aspiration needle and endobronchial brush can be inserted via the EWC to obtain a tissue specimen. The bronchoscopists may then biopsy at this location. However, there is no further guidance from the navigation system once LG is withdrawn. In addition, the biopsy tools may miss the target due to catheter-to-nodule deflection as EWC curve returns after removal of LG [17]. To compensate with this shortcoming, other imaging modalities are useful to guide the biopsy tools to maintain a precision during the biopsy.

Fluoroscopy can be performed to confirm the biopsy tools in the desired location before performing biopsy. Cone-beam CT (CBCT) is another novel tool to be used to confirm the location of biopsy tool. The fluoroscopy unit uses a flexible C-arm, which is lower in power and radiation exposure to the bronchoscopists and the patients. CBCT scans images in a cone shape rather than fan shape as in traditional CT [18]. Lastly, an rp-EBUS probe can also be inserted for additional location confirmation. Rp-EBUS is a thin, flexible catheter with a rotating ultrasound transducer that creates a 360-degree “radial” image. This device allows for a real-time localization of lesions that are located distally to the tip of the bronchoscope.

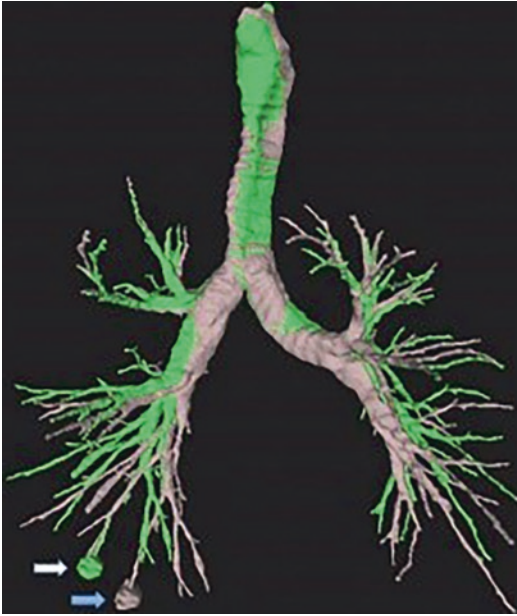### SPiN System Veran Medical Technologies (EMN-VM)

The SPiN System uses an always-on tipped track technology. The sensor tracking is built into the biopsy instruments allowing for real time navigation of the biopsy tools (Fig. 24.8). There are two additional features of the SPiNView system: (1) it incorporates a transthoracic needle system to biopsy lesions similar to CT-guided transthoracic needle aspiration (TTNA); (2) The SPiNView offers the respiratory tracking technology that monitors patient respiration during the procedure. Respiratory motion can be a problem dur-



**Fig. 24.8** The main processor of the SPiN System® Veran Medical Technologies

ing TBBx because an average motion of pulmonary lesions has shown to be approximately 17.6 mm. With this much respiratory motion it may affect the diagnostic yield of EMN-guided TBBX or any other lung biopsy procedures [19]. Therefore, SPiN system develops pre-procedural virtual maps built off a CT scan closer to physiological lung volumes based on both inspiration and expiration CT scan (Fig. 24.9). During the airway inspection, SPiN system tracks the sensor probe to collect 3D points that are reconstructed into the lumen registration map. It predicts SPN location on a virtual inspiration and expiration map which is compared with lumen registration. A study found that predicted SPN location with expiration CT scan is significantly closer to actual nodule location (4.5 mm for expiration vs. 14.9 mm for inspiration) [20].



**Fig. 24.9** Planning procedure with inspiration and expiration CT scan

### Procedure

The procedure of SPiNView is performed in the following steps

#### Planning

This phase is similar to the iLogic(R) system. vPads tracker is placed on the patient chest prior to the CT scan. It contains electromagnetic sensors which enable automatic registration and respiratory motion tracking. The system uses both inspiration and expiration CT images of the patients' airways to plan the route to the lesion. The targeted SPN is marked and the software then creates a 3D roadmap of targeted lesions. The SPiNView software uses an expiration CT scan to match a patient's respiration state. Then, the pathway is transferred and is uploaded for the navigation phase.

#### Navigation

A SPiNView bronchoscopy catheter is available with steerability. The SPiNView system can automatically perform registration without bronchoscopist effort. During this phase, the electromagnetic generator tracks the Always-On Tip Tracked instrument as it advances toward the

lesion in the lung. The view peripheral catheter provides digital laser optics which has built in electromagnetic sensors. It provides guidance throughout the procedure.

#### Biopsy

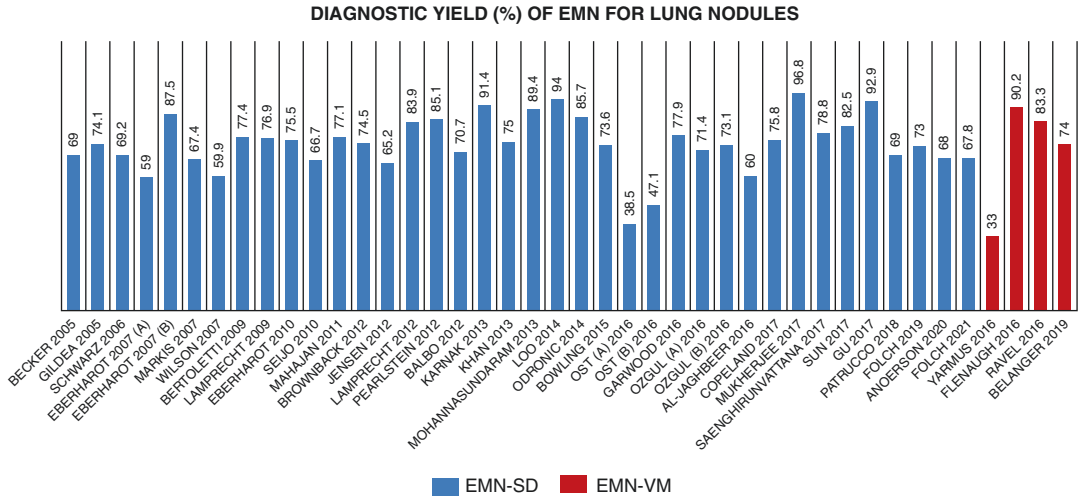
The targeted lesion is reached by a tip tracked instrument. The bronchoscopist performs biopsies of the lesion while the instrument is left in place. The tip tracked steerable working channels, tip tracked aspiration needles and navigation guide wires that enable ultrathin bronchoscopes to be navigated to the peripheral regions of the lung all with clear virtual visualization. The SPinFlex needle is made with nitinol, making it possible to turn 180° and get to difficult lesions in the lungs. The bronchoscopist always knows where the sensor is within the body while sampling. The confirmation by fluoroscopic image is optional.

### Diagnostic Yield and Results of EMN-Guided TBBx

Early studies were primarily retrospective, single-center case series which varied significantly in their study designs and outcomes (Fig. 24.10).

In 2003, Schwarz et al. [21] performed the first animal trial to determine the practicality, accuracy and safety of the real time EMN in locating peripheral lung lesions in a swine model. The study proved that EMN was accurate when added to the standard bronchoscopy to assist in reaching peripheral lung lesions. The average procedure time was 2 min for the mapping component and 5 min for the navigation component. Artificially created lung lesions were sampled without difficulty or complications, using conventional biopsy tools.

Becker et al. [11] published results of a pilot study in humans. They obtained biopsies of the peripheral lesions under the guidance of EMN in 30 adults. Evaluation was possible in 29 patients; definitive diagnosis was established in 20 patients (69%). EMN added a mean of 7.3 min of time to the bronchoscopy procedure. There was one



**Fig. 24.10** Diagnostic yield for EMN-guided biopsy of lung lesions. Diagnostic yield is defined as the percentage of peripheral lung lesions with a definitive diagnosis (Blue - the studies on EMN-SD; Red - the study on EMN-VM)

pneumothorax requiring chest tube insertion. They concluded that EMN is feasible and safe as an aid to obtaining biopsies of peripheral lung lesions.

In 2005, a second electromagnetic navigation system, the Aurora electromagnetic tracking device (Northern Digital, Waterloo, ON, Canada) was described by Hautmann et al. [22]. The prospective evaluation of an EMN system for the diagnosis of peripheral infiltrates or solitary lesions was conducted in 16 patients. In all of the pulmonary infiltrates and solitary lesions, the navigation system was able to guide the sensor tip to the center of the lesion, despite some being undetectable by fluoroscopy. All the lesions were reached by EMN and tissue was sampled successfully for the histological examination. Overall, EMN was well-tolerated and proved to be safe and useful in localizing small and fluoroscopically invisible lung lesions with an acceptable level of accuracy.

The first large-scale prospective clinical study was conducted by Gildea et al. [13] to determine the ability of EMN to sample peripheral lung lesions and mediastinal lymph nodes. Sixty subjects were enrolled and the diagnostic yield was 74% for the peripheral lesions and 100% for mediastinal lymph nodes. A diagnosis was obtained in 80.3% of bronchoscopic procedures

with EMN. The lesions were accessed in all subjects. Two patients developed pneumothorax (3.5%). There was no significant relationship between diagnosis and size or the location of the peripheral lesions or lymph nodes.

The other prospective studies were undertaken by Makris et al. and Eberhardt et al. [23–27] to determine the yield of EMN without using fluoroscopy in the diagnosis of peripheral lung lesions. The diagnostic yield in these studies ranged from 59% to 87.5%. In this study, the diagnostic yield was lower for the upper lobe lesions probably due to the acute angle of the corresponding bronchus having a sharper angle in the bronchial tree and it may be challenging to navigate [26]. These studies concluded that EMN can be used as a stand-alone procedure (without fluoroscopy) without compromising diagnostic yield or increasing the risk of pneumothorax.

It has also been established by a prospective, randomized trial that combination of EBUS (Endobronchial Ultrasound) and EMN improves the diagnostic yield of FB in peripheral lung lesions without compromising safety [25]. In this particular study, 72% of all 118 patients recruited had a positive diagnostic yield via FB. Combined EBUS/EMN had a significantly higher diagnostic yield of 88% compared to that of EBUS (69%) and EMN (59%) alone. In this study, the diagnos-

tic yield from the lower lobes was significantly lower which could be attributed to navigation error. Navigation in lower lobes may be more challenging due to diaphragmatic movement during breathing. The planning data are based on CT images acquired in a single breath hold and cannot compensate for breathing movements. The improved yield of the joint procedure ascribed to combining the ability of EBUS to directly visualize the peripheral lung lesions with the precise navigation capabilities of EMN. The overall pneumothorax rate was 6% (7 patients) and 6.3% (5 patients) when EMN was used. Four of the 7 patients required a chest tube placement. Although this combination provides a higher diagnostic yield compared to either one of them alone, the issues of cost and training need to be addressed.

The utility of Rapid On-Site Evaluation (ROSE) along with EMN has been demonstrated in a retrospective, single-center study was carried out to evaluate the diagnostic yield of bronchoscopy, guided by EMN plus the ROSE of the cytology specimens [28]. Of 248 subjects, 65% received a definitive malignant or non-malignant diagnosis on the day of the procedure. During the follow-up 12 patients (5%) were confirmed to be free of malignancy and 8 patients (3%) were confirmed as having malignant disease. Sixty-seven patients (27%) were lost for follow-up. The diagnostic yield probably ranged between 70% and 97% based upon the assumptions made regarding the outcome of the cases that had an inconclusive diagnosis on the day of the procedure. In this particular study, pneumothorax was encountered in three patients and a few other minor complications yet none of the latter were related to the use of EMN. It was concluded that combination of EMN and ROSE can provide a better diagnostic yield in patients with a peripheral lung lesion.

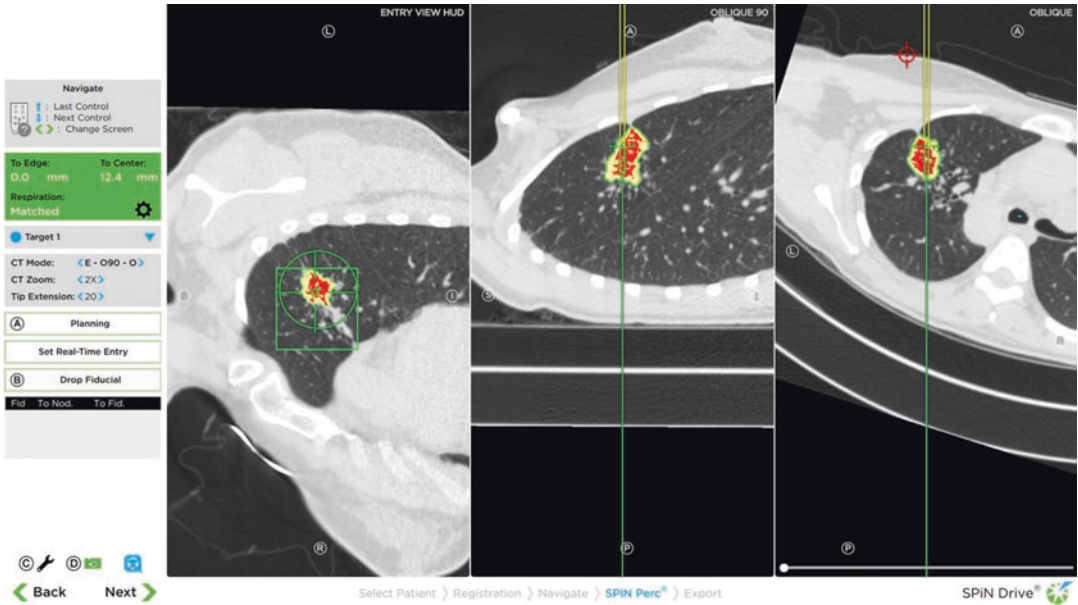
The combination of EMN, PET-CT, and ROSE were further studied for the routine diagnostic workup of peripheral lung lesions [29]. EMN was performed in 13 subjects, where the PET-CT scans were the part of the diagnostic workup. In 76.9% of the patients EMN resulted with a definitive diagnosis. No pneumothorax or any other complications related to the procedure were encountered. Patients with peripheral lung lesions, EMN in

combination with ROSE and prior PET-CT, were shown to be safe and highly effective.

Catheter aspiration was compared to the traditional forceps biopsy technique of small pulmonary nodules suspicious for malignancy using EMN [27]. Both tools were used to sample suspicious malignant lesions in 53 patients. EBUS was used to verify the accuracy of target lesions as well. Diagnosis was obtained in 75.5%. Sampling by catheter aspiration was associated with a higher diagnostic yield than sampling by forceps biopsy alone ( $p = 0.035$ ). When rp-EBUS verified the lesion location after navigation, the diagnostic yield was 93% compared to only 48% when lesion location was not confirmed [28]. There was 1 pneumothorax, treated conservatively.

In meta-analysis, including 11 ENB studies, the weight diagnostic yield of ENB was at 67% [30]. Nine of these studies utilized ENB alone without other diagnostic modalities such as radial probe EBUS. Another meta-analysis and systematic review of ENB included 1033 lung nodules which showed the overall definite diagnostic yield of 64.9%. Several variables included size of the nodule, location in lower lobe, bronchus sign, average fiducial target registration error (AFTRE), visualization of nodule with radial-probe EBUS, and catheter suction technique were reported to be significant predictors in univariate analysis. However, only bronchus sign was reported as a significant predicting factor in multivariate analysis [31]. Meanwhile, the use of General anesthesia and rapid onsite cytologic evaluation were associated with better diagnostic yield. However, there were only four trials using these techniques, precluding final conclusions. The large AQUIRE registry included 581 patients and showed diagnostic yield of 38.5% when the use of EMN as single modality, 57% with rp-EBUS alone. The combination of EMN and rp-EBUS provides a diagnostic yield of 47.1% [32]. Recently, the EMN-SD platform was studied in a large, prospective, multicenter study (NAVIGATE). This study included over 1000 patients from 29 centers in the United States. Almost half of all lesions (49.1%) were less than 20 mm in size. Successful navigation and tissue acquisition





**Fig. 24.11** Electromagnetic guidance transthoracic needle aspiration (ETTNA) with SPiNView system

rate was 94.4%, the 12-month diagnostic yield was 72.9%, and the 12-month sensitivity for malignancy was 68.8% [33]. Overall complication rates were low: pneumothorax rate of 4.3%, serious bleeding rate of 1.5%, and respiratory failure rate of 0.4%. Recently, NAVIGATE study reported prospective 24-month follow-up from the same cohort. The 24-month diagnostic yield was 67.8% and the pneumothorax rate was 4.7% [34]. To date, NAVIGATE study is the largest published EMN-SD study. The combination of staging EBUS along with EMN-guided biopsy of peripheral lesions is considered as standard of care for minimally invasive staging of lung cancer. The ongoing study is designed to evaluate the diagnostic yield of a staged procedure using EBUS, ENB, and EMN-TTNA for the diagnosis of SPN [35].

### Electromagnetic Guidance Transthoracic Needle Aspiration (ETTNA)

There are only two reports related to the experience of using SPiNView system for electromagnetic guidance transthoracic needle aspiration

[36]. The pilot study in 24 patients underwent both EMN-guided TBBx and ETTNA. The diagnostic yield for ETTNA alone was 83% and increased to 87% when ETTNA was combined with navigational bronchoscopy. With the combination with EBUS for complete staging, ETTNA and NB had a diagnostic yield of 92%. There was no major bleeding. However, there was 21% risk of pneumothorax of which only two (from five) patients required drainage. The second study enrolled 102 patients into the study. Twenty cases, 22% (20/92) were converted to the percutaneous transthoracic core needle biopsy. The diagnostic yield rate was raised approximately 20% by concurrent percutaneous transthoracic needle biopsy. There is 10% risk of pneumothorax with the need for chest tube drainage (Fig. 24.11) [37].

### Therapeutic Interventions of EMN System

EMN is a promising technology not only in diagnosing the peripheral lung lesions and mediastinal lymph nodes, but also may provide a means for treating patients with possible lung cancer.



Localizing non-visible and non-palpable peripheral lung nodules during thoroscopic resection can be challenging. A variety of techniques have been described to mark the pleural surface in the vicinity of these nodules to guide the surgeon. The use of EMN-guided pleural tattoo injection with methylene blue or indigo carmine to assist video-assisted thoroscopic surgical (VATS) wedge resection of pulmonary nodules has been reported in a few studies [38–40].

The use of EMN for subpleural fiducial markers placement was reported in a few studies. This was followed by successful VATS wedge resection during the same procedure. Fiducial placement of an average of three markers led to an adequate retention rate to allow for successful treatment of lung cancer in patients undergoing stereotactic radiation. There are several brands of fiducial markers available in the market which have different retention rates. The VortX coil fiducial had a retention rate of 96.7% [41, 42].

In external beam radiation of lung cancer, the metallic fiducials are usually implanted transcutaneously under CT or fluoroscopic guidance. Kupelian et al. compared this method to transbronchial placement of metallic fiducials using EMN [43]. Eight of the 15 patients who had the implantation transcutaneously developed pneumothorax and 6 of them required a chest tube. No pneumothorax was observed in the 8 patients who underwent the placement using EMN bronchoscopy. The implanted markers were stable within the tumors throughout the treatment duration regardless of implantation method.

Stereotactic body radiation therapy (SBRT) is a treatment option for patients who are medically suitable to undergo surgical lung tumor resection [44]. This technology has been complemented by more targeted chemotherapeutic regimens, novel methods of administering more accurate and more concentrated doses of radiation therapy, and innovative local excisional methods. For a precise tumor ablation, SBRT requires fiducial marker placement in or near the tumor. In the past it was being carried out via transthoracic route under CT guidance with an obviously high risk of pneumothorax. In a single study a total of 39

fiducial markers were successfully deployed in 8 of 9 patients using EMN guidance without any complication [45]. This finding supports the notion that EMN can be used to deploy fiducial markers for SBRT, safely and accurately.

A recent study described the use of coil-spring fiducial markers in inoperable patients with isolated lung tumors planned for CyberKnife treatment [46]. A total of 52 consecutive patients underwent fiducial markers placement using EMN bronchoscopy. Of these, 4 patients received 17 linear fiducial markers and 49 patients with 56 tumors received 217 coil-spring fiducial markers. A total of 234 fiducial markers were successfully deployed in 52 patients with 60 tumors. At CyberKnife planning, 8 (47%) of 17 linear fiducial markers and 215 (99%) of 217 coil-spring fiducial markers were still in place ( $p = 0.0001$ ). Of the 4 patients with linear fiducial markers, 2 required additional fiducial placements while none of the patients with coil fiducial markers required additional procedures. Three pneumothoraces (5.8%) were encountered (2 of them needed a chest tube). The bronchoscopy procedures were performed under moderate sedation in an outpatient bronchoscopy suite.

A novel EMN system that provides tracking for percutaneous procedures has been introduced to aid radiologists in their different pulmonary interventions [47, 48]. The tracking is performed percutaneously without using bronchoscopy. This system did not show any benefit in terms of reducing CT fluoroscopy time or radiation dose when compared to the traditional percutaneous CT fluoroscopy-guided-biopsy of small lung lesions [49]. This EMN system was also evaluated to determine its potential to reduce the number of skin punctures and instrument adjustments during CT-guided percutaneous ablation and biopsy of lung nodules [47]. This early experience suggested a low number of skin-puncture and instrument adjustments when using the system.

In terms of Radiofrequency-induced Tissue ablation (RFA), this approach offers a minimally invasive modality [48, 49]. A small prospective trial for RFA demonstrated the early histopathological changes following RFA in a surgical set-

ting. There was near-complete ablation (>90%) in 9 of 18 patients. ENB-guided RFA was considered as an alternative method for local tumor control in inoperable candidates with SPN [46]. However, several complications could be encountered in 16–35% of patients (pain, hemothorax, pneumothorax, and pleural effusion) [50–52]. In addition, one limitation of endoscopic RFA is that coagulated necrotic tissue can be formed around the tip. It can lead to inadequate tissue ablation. ENB-guided RFA seems to be a good alternative for treatment of lung cancer in inoperable candidates. In addition to RFA, other therapeutic modalities have been in development for bronchoscopic ablation of peripheral lung tumors which includes photodynamic therapy, and microwave ablation [53–55]. EMN-guided bronchoscopy provides an ability to navigate to the targeted lesions; however, the confirmation remains suboptimal [56]. EMN-guided biopsy and intraprocedural cone-beam CT (CBCT) provide an ability to demonstrate presence of intralésional bronchoscopic catheters/probes [57]. The clinical data on bronchoscopic ablation for peripheral lung nodules remains to be established. Lastly, the EMN bronchoscopy can also be used to draw a path to locate a distally located foreign body. Such an approach can preclude the need for lobectomy [58].

## Complications

Pneumothorax is the most common complication encountered with the use of EMN-guided biopsy and occurs in the range of 0–7.5% [13, 22–34]. In the published studies related to EMN effectiveness in the diagnosis of peripheral lung lesions, 18 patients have developed pneumothorax. Four of these patients needed chest tube drainage while in the remaining 14, it resolved spontaneously. Theoretically the rate of pneumothorax could be affected by AFTRE, as an error of even a few millimeters could be crucial in these small peripheral lesions, especially if the fluoroscopic guidance is not utilized.

Self-limiting bleeding may be encountered in some cases [11, 28]. It is believed that the EWC

also facilitates to tamponade the bleeding by allowing the scope to remain wedged at the subsegmental bronchus throughout the procedure [23, 29].

## Limitations

We believe that a major obstacle to the widespread use of the EMN is its cost and the need for expensive disposable LG and EWC. Medical economics can certainly limit its use in developing and third world countries. In addition, there was a concern of using magnetic fields and EMN has been considered relatively contraindicated in patients with pacemakers and implantable cardioverter-defibrillators (ICDs). Khan et al. have shown that the magnetic field in EMN-guided biopsy is less than 0.001 T and the procedure is safe to perform in patients with pacemakers and ICDs [59].

In recent years, several studies have reported a difference between the static pre-procedural CT reconstructions and the dynamic, breathing lung during the bronchoscopic procedure. This term is called “CT-to-body divergence [60].” For EMN-SD, the CT images used in planning the virtual navigation pathway are obtained at full inspiration or inspiration reserve in an awake patient, often several days prior to the procedure. The anatomical difference occurs primarily due to changes in lung volumes in sedated and sometimes mechanically ventilated patients. In addition, intra-procedural atelectasis can cause inaccurate virtual maps, and cause visual impairment on image modalities. Intra-procedural atelectasis has been well-documented; however, it is often an underappreciated issue [61, 62]. In one study, CBCT identified atelectasis in 40% of the cases overall and resulted in a decreased diagnostic yield [63]. Optimizing ventilation protocols with using higher tidal volume (10–12 mL/kg) and positive end expiratory pressure (8–15 cmH<sub>2</sub>O) may mitigate atelectasis. Furthermore, minimizing unnecessary suctioning, and avoiding overwedging of the airway may significantly minimize atelectasis.

Recently, EMN-SD system launched a real-time guidance system with Tomosynthesis-based fluoroscopic navigation (Illumisite) which has been available since July 2020. Fluoroscopic navigation uses advanced software algorithms and digital tomosynthesis reconstruction [64, 65] to provide accurate 3D modeling. The retrospective study of this new EMN-SD system has showed to improve diagnostic yield compared to standard navigation (79.1% vs. 54.4%) [66].

## Summary

Electromagnetic navigation is a novel tool which aids diagnostic yield of flexible bronchoscopy for the peripheral lung lesions. The procedure is safe, effective, and easy and can be performed with or without the use of fluoroscopy. It plays a complementary role with endobronchial ultrasound for mediastinal staging. It has a potential to be an important tool in improving accuracy and outcomes from thoracoscopic resections, external beam radiotherapy, stereotactic body radiation therapy, CyberKnife treatment, and other bronchoscopic ablation techniques. A high initial capital investment and variable costs for disposable LG/biopsy tools could hinder the adoption of this technology in the healthcare system. Furthermore, the diagnostic utility of EMN could suffer from technical challenges, especially CT-to-body divergence. Several imaging techniques provide a real-time confirmation of biopsy tools in the lesions which can be used as an adjunct to EMN-guided biopsy. Novel robotic technologies, such as the Monarch (Auris Health) and ION (Intuitive Surgical) robotic endoscopy platforms, have emerged as the latest wave of navigational bronchoscopy. The Monarch system uses electromagnetic navigation and robotic kinematic data to locate the tip of a bronchoscope in a patient's airways. Although these two systems are in an early adoptive phase, several publications have supported the systems safely navigating to the peripheral lesion through enhanced dexterity, and stability.

## References

1. CDC. NPCR and SEER—U.S. cancer statistics: public use database. Available [www.cdc.gov/uscs](http://www.cdc.gov/uscs). Accessed 12 December 2021.
2. Aberle DR, Adams AM, Berg CD, et al. Reduced lung-cancer mortality with low-dose computed tomographic screening. *N Engl J Med*. 2011;365(5):395–409.
3. DiBardino DM, Yarmus LB, Semaan RW. Transthoracic needle biopsy of the lung. *J Thorac Dis*. 2015;7(Suppl 4):304–16.
4. Geraghty PR, Kee ST, McFarlane G, et al. CT-guided transthoracic needle aspiration biopsy of pulmonary nodules: needle size and pneumothorax rate. *Radiology*. 2003;229(2):475–81.
5. Yeow KM, Su IH, Pan KT, et al. Risk factors of pneumothorax and bleeding: multivariate analysis of 660 CT-guided coaxial cutting needle lung biopsies. *Chest*. 2004;126(3):748–54.
6. Rivera MP, Mehta AC, Wahidi MM. Establishing the diagnosis of lung cancer: Diagnosis and management of lung cancer, 3rd ed: American College of Chest Physicians evidence-based clinical practice guidelines. *Chest*. 2013;143(5 Suppl):e142S–65S.
7. Minezawa T, Okamura T, Yatsuya H, et al. Bronchus sign on thin-section computed tomography is a powerful predictive factor for successful transbronchial biopsy using endobronchial ultrasound with a guide sheath for small peripheral lung lesions: a retrospective observational study. *BMC Med Imaging*. 2015;15:21.
8. Mehta AC, Hood KL, Schwarz Y, Solomon SB. The evolutionary history of electromagnetic navigation bronchoscopy: state of the art. *Chest*. 2018;154(4):935–47.
9. Cicienia J, Avasarala SK, Gildea TR. Navigational bronchoscopy: a guide through history, current use, and developing technology. *J Thorac Dis*. 2020;12(6):3263–71.
10. Shepherd RW. Bronchoscopic pursuit of the peripheral pulmonary lesion: navigational bronchoscopy, radial endobronchial ultrasound, and ultrathin bronchoscopy. *Curr Opin Pulm Med*. 2016;22(3):257–64.
11. Becker HD, Herth F, Ernst A, Schwarz Y. Bronchoscopic biopsy of peripheral lung lesions under electromagnetic guidance: a pilot study. *J Bronchol*. 2005;12:9–13.
12. Schwarz Y, Greif J, Becker HD, et al. Real-time electromagnetic navigation bronchoscopy to peripheral lung lesions using overlaid CT images: the first human study. *Chest*. 2006;129(4):988–94.
13. Gildea TR, Mazzone PJ, Karnak D, et al. Electromagnetic navigation diagnostic bronchoscopy: a prospective study. *Am J Respir Crit Care Med*. 2006;174(9):982–9.
14. Illumisite Platform. Recommended CT scan and reconstruction parameters. Illumisite. 2020. Available <https://www.medtronic.com/content/dam/covidien/>

- [library/us/en/product/interventional-lung-solutions/illumisite-platform-scan-parameters-information-sheet.pdf](#). Accessed 29 December 2021.
15. Orr L, Krochmal R, Sonti RM, et al. Comparison of the GenCut core biopsy system to transbronchial biopsy forceps for flexible bronchoscopic lung biopsy. *J Bronchol Interv Pulmonol*. 2021;29(2):140–5.
  16. Karnak D, Ciledağ A, Ceyhan K, et al. Rapid on-site evaluation and low registration error enhance the success of electromagnetic navigation bronchoscopy. *Ann Thorac Med*. 2013;8(1):28–32. <https://doi.org/10.4103/1817-1737.105716>.
  17. Pickering EM, Kalchiem-Dekel O, Sachdeva A. Electromagnetic navigation bronchoscopy: a comprehensive review. *AME Med J*. 2018;3:117.
  18. Verhoeven RLJ, Vos S, van der Heijden EHF. Multimodal tissue sampling in cone beam CT guided navigation bronchoscopy: comparative accuracy of different sampling tools and rapid on-site evaluation of cytopathology. *J Thorac Dis*. 2021;13(7):4396–406.
  19. Chen A, Pastis N, Furukawa B, et al. The effect of respiratory motion on pulmonary nodule location during electromagnetic navigation bronchoscopy. *Chest*. 2015;147(5):1275–81.
  20. Furukawa BS, Pastis NJ, Tanner NT, et al. Comparing pulmonary nodule location during electromagnetic bronchoscopy with predicted location on the basis of two virtual airway maps at different phases of respiration. *Chest*. 2018;153(1):181–6.
  21. Schwarz Y, Mehta AC, Ernst A, et al. Electromagnetic navigation during flexible bronchoscopy. *Respiration*. 2003;70(5):516–22.
  22. Hautmann H, Schneider A, Pinkau T, et al. Electromagnetic catheter navigation during bronchoscopy: validation of a novel method by conventional fluoroscopy. *Chest*. 2005;128(1):382–7.
  23. Makris D, Scherpereel A, Leroy S, et al. Electromagnetic navigation diagnostic bronchoscopy for small peripheral lung lesions. *Eur Respir J*. 2007;29(6):1187–92.
  24. Makris D, Gourgoulis KI. Electromagnetic navigation diagnostic bronchoscopy and transbronchial biopsy. *Chest*. 2008;133(3):829–30.
  25. Eberhardt R, Anantham D, Ernst A, et al. Multimodality bronchoscopic diagnosis of peripheral lung lesions: a randomized controlled trial. *J Respir Crit Care Med*. 2007;176:36–41.
  26. Eberhardt R, Anantham D, Herth F, et al. Electromagnetic navigation diagnostic bronchoscopy in peripheral lung lesions. *Chest*. 2007;131(6):1800–5.
  27. Eberhardt R, Morgan RK, Ernst A, et al. Comparison of suction catheter versus forceps biopsy for sampling of solitary pulmonary nodules guided by electromagnetic navigational bronchoscopy. *Respiration*. 2010;79(1):54–60.
  28. Wilson DS, Barlett RJ. Improved diagnostic yield of bronchoscopy in a community practice: a combination of electromagnetic navigation system and rapid on-site evaluation. *J Bronchol*. 2007;14(4):227–32.
  29. Lamprecht B, Porsch P, Pirich C, Studnicka M. Electromagnetic navigation bronchoscopy in combination with PET-CT and rapid on-site cytopathologic examination for diagnosis of peripheral lung lesions. *Lung*. 2009;187(1):55–9.
  30. Wang-Memoli JS, Nietert PJ, Silvestri GA. Meta-analysis of guided bronchoscopy for the evaluation of the pulmonary nodule. *Chest*. 2012;142(2):385–93.
  31. Gex G, Pralong JA, Combesure C, et al. Diagnostic yield and safety of electromagnetic navigation bronchoscopy for lung nodules: a systematic review and meta-analysis. *Respiration*. 2014;87(2):165–76.
  32. Ost DE, Ernst A, Lei X, et al. Diagnostic yield and complications of bronchoscopy for peripheral lung lesions. results of the AQUIRE registry. *Am J Respir Crit Care Med*. 2016;193(1):68–77.
  33. Folch EE, Pritchett MA, Nead MA, et al. Electromagnetic navigation bronchoscopy for peripheral pulmonary lesions: one-year results of the prospective, multicenter NAVIGATE study. *J Thorac Oncol*. 2018;14:445–58.
  34. Folch EE, Bowling MR, Pritchett MA, et al. NAVIGATE 24-month results: electromagnetic navigation bronchoscopy for pulmonary lesions at 37 centers in Europe and the United States. *J Thorac Oncol*. 2021;29:S1556.
  35. Thiboutot J, Lee HJ, Silvestri GA, Chen A, et al. Study design and rationale: a multicenter, prospective trial of electromagnetic bronchoscopic and electromagnetic transthoracic navigational approaches for the biopsy of peripheral pulmonary nodules (ALL IN ONE trial). *Contemp Clin Trials*. 2018;71:88–95.
  36. Yarmus LB, Arias S, Feller-Kopman D, et al. Electromagnetic navigation transthoracic needle aspiration for the diagnosis of pulmonary nodules: a safety and feasibility pilot study. *J Thorac Dis*. 2016;8(1):186–94.
  37. Moore C, Whang B, Wiener D, et al. Electromagnetic navigational bronchoscopy and EMN percutaneous transthoracic needle biopsy of the chest lesion: the first 102 consecutive early experience cases. *Chest*. 2019;156(4):1678.
  38. Tay JH, Wallbridge PD, Larobina M, et al. Electromagnetic navigation bronchoscopy-directed pleural tattoo to aid surgical resection of peripheral pulmonary lesions. *J Bronchol Interv Pulmonol*. 2015;23(3):245–50.
  39. Sun J, Mao X, Xie F, et al. Electromagnetic navigation bronchoscopy guided injection of methylene blue combined with hookwire for preoperative localization of small pulmonary lesions in thorascopic surgery. *J Thorac Dis*. 2015;7(12):E652–6.
  40. Speicher JE, Bowling MR, Anciano CJ. Bronchoscopically placed dye marking for minimally invasive thoracic surgery: a surgeon's perspective. *Clin Pulm Med*. 2017;24(6):239–49.
  41. Andrade RS. Electromagnetic navigation bronchoscopy-guided thorascopic wedge resection of small pulmonary nodules. *Semin Thorac Cardiovasc Surg*. 2010;22(3):262–5.

42. Minnich DJ, Bryant AS, Wei B, et al. Retention rate of electromagnetic navigation bronchoscopic placed fiducial markers for lung radiosurgery. *Ann Thorac Surg.* 2015;100(4):1163–5.
43. Kupelian PA, Forbes A, Willoughby TR. Implantation and stability of metallic fiducials within pulmonary lesions. *Int J Radiat Oncol Biol Phys.* 2007;69(3):777–85.
44. Sherwood JT, Brock MV. Lung cancer: new surgical approaches. *Respirology.* 2007;12(3):326–32.
45. Anantham D, Feller-Kopman D, Shanmugham LN, et al. Electromagnetic navigation bronchoscopy-guided fiducial placement for robotic stereotactic radiosurgery of lung tumors: a feasibility study. *Chest.* 2007;132(3):930–5.
46. Schroeder C, Hejal R, Linden PA. Coil spring fiducial markers placed safely using navigation bronchoscopy in inoperable patients allows accurate delivery of CyberKnife stereotactic radiosurgery. *J Thorac Cardiovasc Surg.* 2010;140:1137–42.
47. Santos RS, Gupta A, Ebright MI, DeSimone M, Steiner G, Estrada MJ, Daly B, Fernando HC. Electromagnetic navigation to aid radiofrequency ablation and biopsy of lung tumors. *Ann Thorac Surg.* 2010;89:265–8.
48. Eberhardt R, Kahn N, Herth FJ. ‘Heat and destroy’: bronchoscopic-guided therapy of peripheral lung lesions. *Respiration.* 2010;79(4):265–73.
49. Grand DJ, Atalay MA, Cronan JJ, Mayo-Smith WW, Dupuy DE. CT-guided percutaneous lung biopsy: comparison of conventional CT fluoroscopy to CT fluoroscopy with electromagnetic navigation system in 60 consecutive patients. *Eur J Radiol.* 2011;79:e133–6.
50. Ahmed M, Liu Z, Afzal KS, et al. Radiofrequency ablation: effect of surrounding tissue composition on coagulation necrosis in a canine tumor model. *Radiology.* 2004;230:761–7.
51. Dupuy DE, Goldberg SN. Image-guided radiofrequency tumor ablation: challenges and opportunities – part II. *J Vasc Interv Radiol.* 2001;12:1135–48.
52. Dupuy DE, Mayo-Smith WW, Abbott GF, DiPetrillo T. Clinical applications of radiofrequency tumor ablation in the thorax. *Radiographics.* 2002;22:S259–69.
53. Sabath BF, Casal RF. Bronchoscopic ablation of peripheral lung tumors. *J Thorac Dis.* 2019;11(6):2628–38. <https://doi.org/10.21037/jtd.2019.01.65>.
54. Xie F, Zheng X, Xiao B, et al. Navigation bronchoscopy-guided radiofrequency ablation for nonsurgical peripheral pulmonary tumors. *Respiration.* 2017;94(3):293–8.
55. Tsushima K, Koizumi T, Tanabe T, et al. Bronchoscopy-guided radiofrequency ablation as a potential novel therapeutic tool. *Eur Respir J.* 2007;29(6):1193–200.
56. Mudambi L, Ost DE. Advanced bronchoscopic techniques for the diagnosis of peripheral pulmonary lesions. *Curr Opin Pulm Med.* 2016;22(4):309–18.
57. Pritchett MA, Schampaert S, de Groot JAH, et al. Cone-beam CT with augmented fluoroscopy combined with electromagnetic navigation bronchoscopy for biopsy of pulmonary nodules. *J Bronchol Interv Pulmonol.* 2018;25(4):274–82.
58. Karpman C, Midthun DE, Mullan JJ. A distal airway foreign body removed with electromagnetic navigation bronchoscopy. *J Bronchol Interv Pulmonol.* 2014;21(2):170–2.
59. Khan AY, Berkowitz D, Krinsky KS, et al. Safety of pacemakers and defibrillators in electromagnetic navigation bronchoscopy. *Chest.* 2013;143(1):75–81.
60. Pritchett MA, Bhadra K, Calcutt M, Folch E. Virtual or reality: divergence between preprocedural computed tomography scans and lung anatomy during guided bronchoscopy. *J Thorac Dis.* 2020;12(8):4593–5.
61. Strandberg A, Tokics L, Brismar B, et al. Atelectasis during anaesthesia and in the postoperative period. *Acta Anaesthesiol Scand.* 1986;30:154–8.
62. Brismar B, Hedenstierna G, Lundquist H, et al. Pulmonary densities during anesthesia with muscular relaxation—a proposal of atelectasis. *Anesthesiology.* 1985;62:422–8.
63. Casal RF, Sarkiss M, Jones AK, et al. Cone beam computed tomography-guided thin/ultrathin bronchoscopy for diagnosis of peripheral lung nodules: a prospective pilot study. *J Thorac Dis.* 2018;10:6950–9.
64. Ferrari A, Bertolaccini L, Solli P, et al. Digital chest tomosynthesis: the 2017 updated review of an emerging application. *Ann Transl Med.* 2018;6:91.
65. Nelson G, Wu M, Hinkel C, et al. Improved targeting accuracy of lung tumor biopsies with scanning-beam digital X-ray tomosynthesis image guidance. *Med Phys.* 2016;43:6282.
66. Aboudara M, Roller L, Rickman O, et al. Improved diagnostic yield for lung nodules with digital tomosynthesis corrected navigational bronchoscopy: Initial experience with a novel adjunct. *Respirology.* 2020;25:206–13.





# Cone Beam Computed Tomography-Guided Bronchoscopy

# 25

Bruce F. Sabath and Roberto F. Casal

## Introduction

Cone-beam computed tomography (CBCT) is a type of computed tomography (CT) that has emerged over the last several years as a potent and versatile tool that can be used intra-operatively, garnering much attention from a number of procedural subspecialties. It allows real-time, three-dimensional imaging for surgeries and procedures that have traditionally relied on two-dimensional imaging techniques such as standard fluoroscopy. Initially developed for orthodontics, it has since found application in interventional radiology, vascular surgery, brain radiosurgery, breast imaging, and orthopedics, among others [1–6]. In the last number of years, CBCT has also attracted the attention of bronchoscopists faced with the task of diagnosing peripheral pulmonary lesions. Heretofore, despite the development of various technologies meant to reach these pulmonary lesions, diagnostic yield has essentially plateaued and pulmonologists have been unable to consistently make much progress in this endeavor.

The need for technology like CBCT stems from several challenges related to the diagnosis of peripheral pulmonary nodules. First, early

stage lung cancers are small and challenging to reach. The majority of nodules detected by lung cancer screening, for example, are located in the outer one-third of the lung where they cannot be directly visualized by bronchoscopy, where airway diameter becomes progressively small in the sub-centimeter range, and often dangerously close to the pleura [7]. Not only that, but the specific location in the periphery can be difficult to reach due to branching patterns of the airways leading to these sites. Sites such as the upper lobes and the superior segments of the lower lobes (the latter being fairly cephalad as well despite being part of the lower lobes) have leading airways that require fairly tortuous and tight turns at acute angles in order to reach them, making attempts at reaching and sampling lesions therein all the more difficult.

To address these challenges, technology has slowly developed over the last two to three decades but has itself faced some barriers. Radial probe endobronchial ultrasound (EBUS) was first introduced in the early 1990s [8]. This underwent multiple iterations through collaborations between investigators from different countries and industry over many years and the history of its development has been well documented [9]. Ultimately, among other applications, this allowed for the real-time detection and confirmation of nodules but not real-time sampling and acquisition as the probe and biopsy tool cannot both be passed through a bronchoscope simultaneously

---

B. F. Sabath (✉) · R. F. Casal  
The University of Texas MD Anderson Cancer  
Center, Houston, TX, USA  
e-mail: [bsabath@mdanderson.org](mailto:bsabath@mdanderson.org)

(though more recent attempts have been made to design a hybrid system allowing concurrent use of radial probe and biopsy tool) [10].

While radial probe EBUS allowed for confirmation of having reached a lesion of interest, navigation bronchoscopy was developed to aid in the complementary task of driving to the lesion in the first place. Navigational systems have been termed “virtual” and “electromagnetic” [11]. The former engages CT-derived images with proprietary software in order to reconstruct a virtual rendering of the bronchial tree and, thereby, a path to a given nodule or mass. The goal is to help guide one’s bronchoscope to the lesion but, as the name implies, the guidance is virtual and not actual. Electromagnetic navigation also uses CT data but links this to an electromagnetic field to provide dynamic feedback regarding the location of the bronchoscope as one is moving through the airways. The bronchoscope is followed in real time but, again, this airway map is also virtual and not necessarily reflective of true anatomy.

Despite these advancements, diagnostic yield for peripheral bronchoscopy has generally been limited to approximately 70%, nearly regardless of the study or the technology used [12–24]. The hypothesized reasons for this “ceiling” are varied. Navigation guided by virtual methods are, by design, not real and are prone to any limitations in the ability of software to accurately convert CT data into an accurate virtual bronchoscopic tree. Navigation guided by direct vision and fluoroscopy depends on the bronchoscopist’s ability to correlate CT anatomy to bronchoscopic anatomy and is limited by the two-dimensional view that fluoroscopy offers. The concept of “pseudo-confirmation” must be considered as well. When using radial probe ultrasound, for example, atelectatic lung can have a very similar sonographic appearance to solid tissue, misleading the proceduralist into believing that the target has been reached. The development of intra-procedural atelectasis recently was proven to be a very common occurrence during bronchoscopy and this could explain non-diagnostic results if biopsies are taken from such erroneous locations [25]. CT-to-body divergence is another phenomenon that has received much attention and discussion

[26]. CT scans that identify lesions of interest are performed often with arms extended over the head and during an inspiratory breath hold under negative inspiratory pressure by an awake patient—often days or weeks before the procedure. Bronchoscopy is performed under positive pressure with the arms down by the side of the patient who is sedated or even paralyzed. All of these can create a discrepancy between what is expected based on the preprocedural CT and what is encountered during the procedure. Finally, even when a target can be clearly and accurately identified by some modality, the relative position of the biopsy tool can be less clear. When attempting to sample a lesion using fluoroscopy—heretofore the standard and staple of peripheral bronchoscopy—it may occur that a tool appears to have reached a target but, in reality, the tool is simply in the same two-dimensional plane as the target but not within it at all (e.g., it may be anterior or posterior to it). Thus, taken together, the gap between navigation (to a lesion), confirmation (of having arrived at it), and acquisition (of a representative sample) versus achieving accurate diagnosis has been a singular challenge within pulmonary medicine.

Cone-beam computed tomography, however, stands positioned as a promising innovation within this realm and may be able to bridge this space. Allowing for three-dimensional images while bronchoscopy tools are in place, many of the aforesaid pitfalls can be avoided. Accurate visualization of a target can be accomplished as the lesion can be seen on the CT image and distinguished from atelectasis or another false-positive finding that might lead to an invalid biopsy. There is no CT-to-body divergence, essentially, because CT is being used intraoperatively, in real time. And the relationship of the biopsy tool and the target can be precisely noted with subsequent adjustments made and tool-in-lesion being confirmed. Moreover, the advantages of other technologies such as the ones mentioned above (e.g., radial EBUS, navigation software) can be used concurrently. Indeed, all these tools are complimentary.

The need for progress in the challenge of the peripheral pulmonary nodule is pressing and

urgent as pulmonologists are seeing an increasing number of these cases, likely due to a variety of factors including the support of lung cancer screening by several professional organizations as well as the prevalent use of chest CT scans [27–33]. Indeed, the peripheral nodule burden will continue to grow heavier on our specialty as populations age. To that point, as more early lung cancers are detected in elderly patients who may not be surgical or even radiation candidates, bronchoscopic ablation has been gaining research interest and may be yet another forthcoming application of cone-beam technology [34].

Here we will provide a technical review of cone-beam computed tomography followed by a review of the current medical literature. We will conclude by discussing future directions that this technology may take. Our aim is to provide a thorough understanding of CBCT so that pulmonologists may be equipped to decide how and whether they might incorporate this into their patient care.

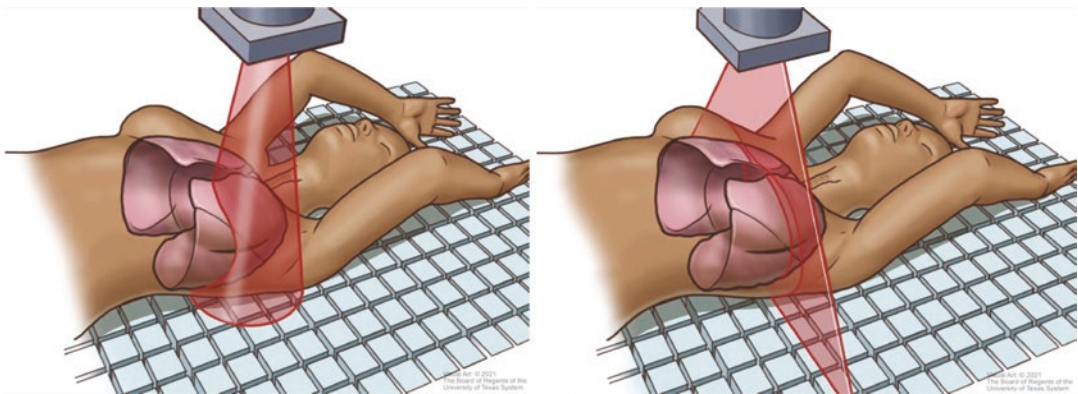
### Technical Review: The Practice of the Art

CBCT images are obtained by the rotation of a C-arm approximately  $200^\circ$  around the patient with a series of two-dimensional images being acquired at precise angles and intervals. Several hundred projection images are obtained with

the exact number depending on the specific system and protocol being used. Smaller intervals yield higher quality images albeit necessarily with a higher cumulative radiation dose as well. These images are then reconstructed in a manner similar to that with conventional CT and can be formatted into axial, sagittal, and coronal renderings [35].

### Cone-Beam CT Versus Multidetector CT

There are several differences between CBCT and conventional multislice, or multidetector CT (MDCT). The X-rays are produced by the source in CBCT in a cone-shaped distribution and collected by a high-resolution two-dimensional detector (Fig. 25.1). The C-arm does this in a single rotation as it moves around the patient who is immobile. As such, the Z-axis (craniocaudal dimension) of the acquisition is a function of the detector size. By comparison, MDCT is performed with X-rays being emitted in a thin, fan-shaped configuration. This output is then collected by a series of one-dimensional detector element rows (e.g., typical scanners are equipped with 64 though some with 256 and even 320 exist) as the patient table moves through the radiation field [1]. The X-ray rotation combined with patient movement produces a helical, or “spiral,” pattern of radiation and leads to a Z-axis that is



**Fig. 25.1** Schematic of X-ray emission by cone beam computed tomography in a cone-shape distribution (left) compared to multislice detector computed tomography in

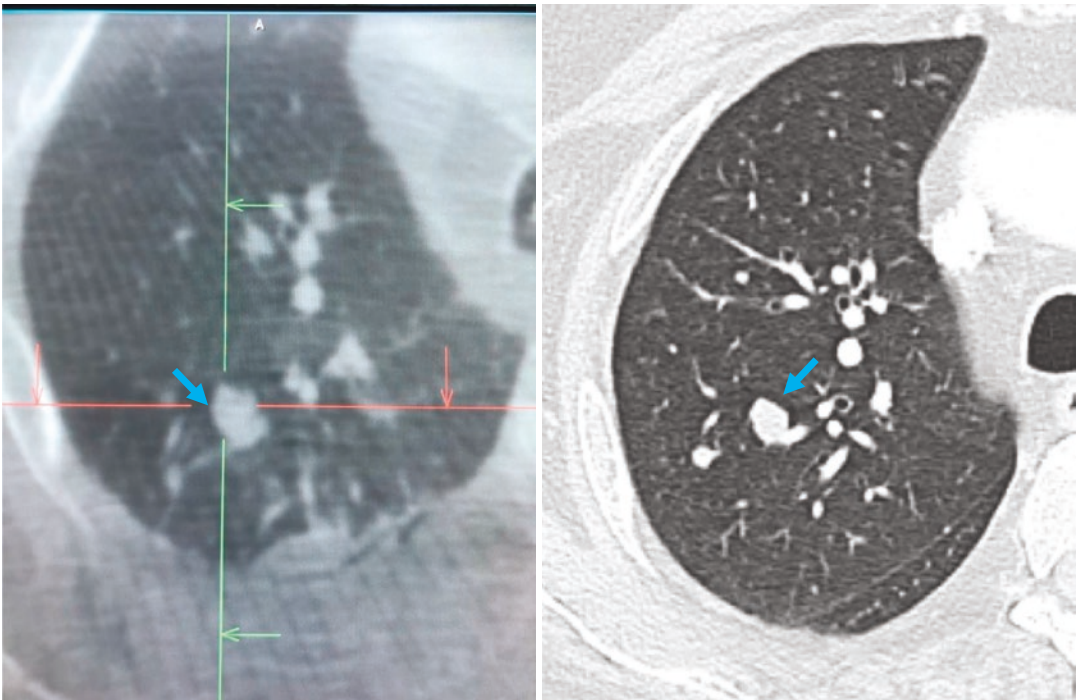
a fan-beam shape distribution (right). (Image courtesy of the University of Texas MD Anderson Cancer Center)

dependent on the degree of table movement. The MDCT gantry takes approximately 0.4 s for a full rotation so even a fairly large section of a patient's anatomy can be scanned in several seconds. CBCT takes upward of 20 s or more to acquire an image even though images are captured using a single rotation of the C-arm. Thus, even though MDCT requires multiple gantry rotations for a given body region, it is in actuality faster than CBCT. Moreover, the reconstruction algorithm is mathematically more complex for CBCT, leading to nearly 1 min of reconstruction time compared to what is effectively real-time reconstruction offered by MDCT [1]. Nevertheless, from a practical perspective, CBCT has an advantage specific to bronchoscopy in that the C-arm remains positioned over the chest and does not have the patient's head within it as with MDCT. This avoids any potential physical obstructions or collisions between the scanner and bronchoscope

and any other tools inserted through the airway. Moreover, while the patient moves in MDCT, the C-arm of the CBCT rotates around the patient who remains immobile, preventing dislodgement of bronchoscopic equipment.

### Image Acquisition

CBCT and MDCT have somewhat similar spatial resolution. However, CBCT has decreased contrast capability by comparison, making the distinction between soft tissue structures less clear (Fig. 25.2). In fact, the image intensity of CBCT is not with calibrated Hounsfield units as in MDCT but, rather, non-calibrated gray-scale units [35]. As a result, typical lung or soft tissue windows that are customary with MDCT are not possible with CBCT. Yet, images can be improved by increasing both the number of acquired images



**Fig. 25.2** Representative axial plane image of right lung with target nodule (blue arrow) as seen by cone beam CT reconstruction (left) versus multidetector CT reconstruction (right). Notice how the CBCT image is truncated, not

capturing the entire right lung due to smaller imaging field. Nevertheless, the area of interest and surrounding structures are adequately apprehended

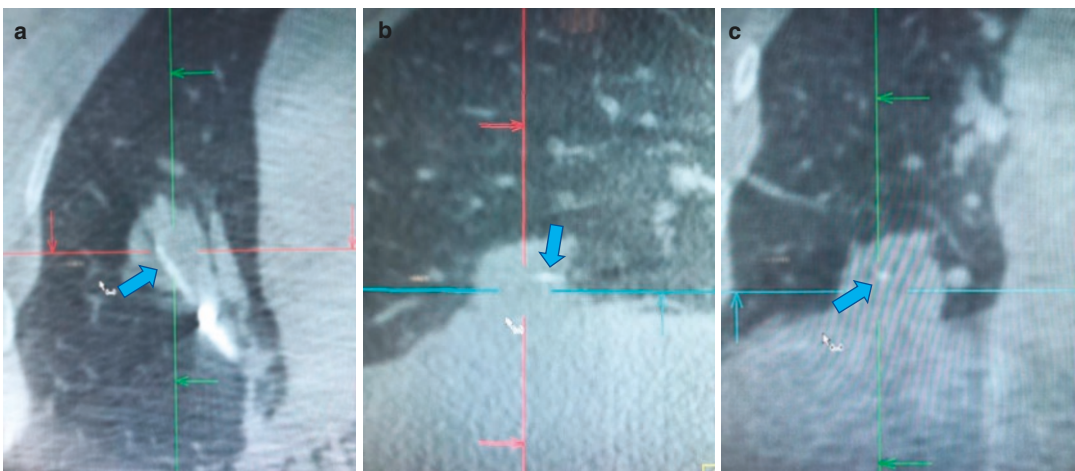


and the dose per image. This provides more data that can be reconstructed while also decreasing “noise,” leading to a more detailed image.

CBCT is nevertheless susceptible to different artifacts that can negatively affect image quality. CBCT can particularly be affected by scattered radiation compared to MDCT. With regard to bronchoscopy, this can be caused by the presence of the bronchoscope or biopsy tools that cause streak artifact. MDCT scanners are equipped with anti-scatter septae between their detector channels but these cannot be used with the flat panel detectors of CBCT [1]. The collimation that is meant to filter and focus X-rays is wider in CBCT and, thus, image quality is reduced. Multiple techniques can be employed to attempt to reduce scatter but most are beyond the scope of this chapter. More applicable to the bronchoscopist using CBCT, interventions such as increasing the number of images or the dose per image can be attempted. Additionally, viewing the reconstructed images as either a multi-planar reconstruction or thin maximum intensity projection may reduce noise [35]. Artifact distortion can also occur due to the presence of nearby metallic objects (e.g., electrocardiographic monitoring leads) and these should be moved out of the field of view as much as possible, at least during image acquisition.

Motion artifact is another concern that can affect image quality. Lesions near the heart (or great vessels) and diaphragm are particularly susceptible to motion from the cardiac and respiratory cycles, respectively. Motion during the capture of the two-dimensional images will correspondingly lead to a blurred three-dimensional image. A breath-hold on the ventilator in a paralyzed patient can be performed to minimize or eliminate respiratory motion. There is no way to circumvent cardiac motion but software algorithms (currently in the research and development phase) may be able to make adjustments for this in the future [35]. A representative image of an intraoperative CT identifying the biopsy tool in the lesion is shown in Fig. 25.3.

There are also a few practical points to heed that can ensure optimal image acquisition and quality. First, the target lesion should be at the isocenter of the CBCT scanning field. This is, essentially, the geometrical center point of the image field. This will safeguard that not only the lesion but any other relevant anatomy (e.g., adjacent airways or nearby structures to avoid) is included within the captured image. CBCT systems each have a method of identifying the isocenter, such as light lasers in the anterior-posterior and medial-lateral planes that form a crosshair that are placed (from an external perspective) as near to the estimated location of the lesion as



**Fig. 25.3** Multiplanar reconstruction of intraoperative CT image demonstrating needle (blue arrow) within the lesion in axial (a), sagittal (b), and coronal (c) planes



possible. Second, once this has been accomplished, one must ensure that the C-arm can complete its rotation around the patient and table given the location of the isocenter. If the isocenter is in somewhat of an extreme location, the C-arm may run into the patient or table as it attempts to rotate around the isocenter. In such a case, the patient may need to be moved such that the isocenter is closer to the center of the table, making it more likely that the C-arm will be able to clear its rotation around both sides of the table. Raising the patient's arms above the head may also help ensure C-arm clearance around the chest, particularly in larger patients. This may have the added benefit of reducing X-ray interference from the arms, especially with posterior lung lesions that may lay in the same plane as the arms when at the patient's side. If the arms are raised, care must be taken to minimize both the degree of manipulation (flexion/extension of joints) and the length of time during which the arms are manipulated in order to reduce the risk of injury.

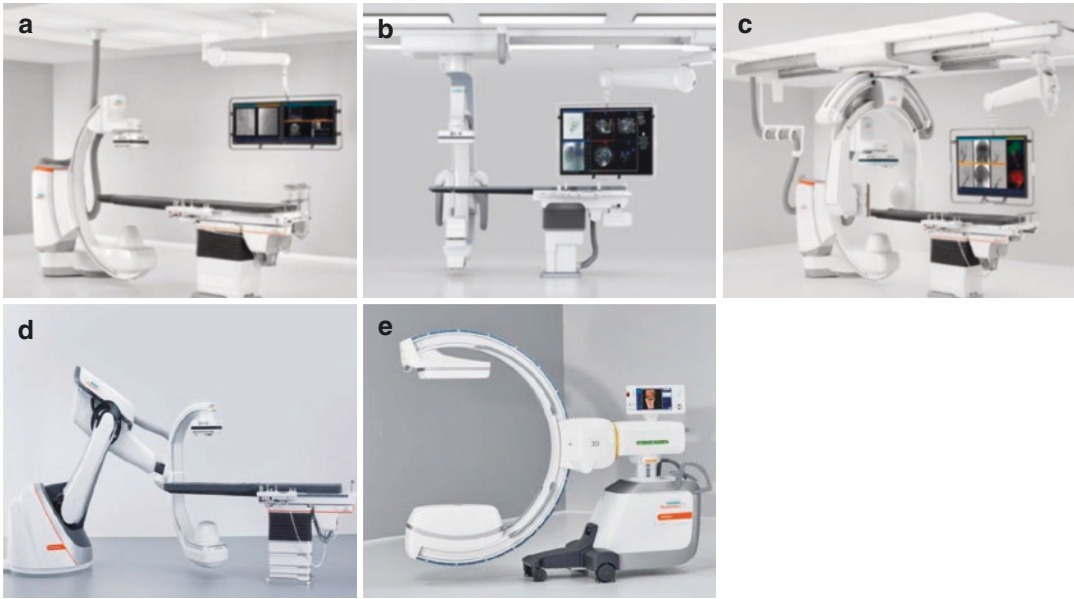
The probability of intra-operative atelectasis is another matter of which to be aware. Atelectasis has been demonstrated in up to 90% of anesthetized patients undergoing various procedures [36, 37]. This can obscure the visualization of a given target by CBCT if the lesion becomes buried within collapsed lung parenchyma. Indeed, the authors recently published a prospective, observational study of peripheral bronchoscopy to determine the incidence of atelectasis developed during bronchoscopy as detected by radial probe EBUS [25]. The posterior segments of the upper lobes as well as the superior, lateral, and posterior segments of the lower lobes were evaluated. Of 57 patients examined, 89% developed atelectasis in at least one of these segments and 1 in 3 developed atelectasis in 6 of the 8 examined segments. To attempt to minimize such effects, different ventilatory interventions have been advocated including the use of higher tidal volumes (e.g., 8–12 mL/kg of ideal body weight), higher levels of positive end-expiratory pressure (e.g., 10–15 cm H<sub>2</sub>O), the use of an endotracheal tube rather than a laryngeal mask airway (in order to better preserve intrathoracic pressures), avoiding

hyperoxia, and the use of recruitment maneuvers [26, 35, 38–40]. A clinical trial is currently underway comparing two specific ventilatory strategies and hopefully will provide higher quality data in this regard specific to peripheral bronchoscopy[41]. Finally, placing the patient in a lateral decubitus position with the target side up can also be considered, particularly for very posterior lesions that are at high risk of being obscured by atelectasis.

## Hardware

Fixed (i.e., non-portable) CBCT systems exist in various designs: floor-mounted, ceiling-mounted, biplane (both ceiling- and floor-mounted components), and robotic (Fig. 25.4). Floor-mounted and biplane systems are attached to the floor at the head of the patient table so this may interfere with procedural workflow for bronchoscopy, specifically. They also scan near the level of the head of the patient and so may be unable to capture images in the more caudal lung fields. Ceiling-mounted and robotic systems are a bit more versatile in their ability to be moved away from the patient and associated tools in use (this may be particularly useful when using electromagnetic navigation as the presence of the X-ray detector may interfere with the magnetic field generated by the EMN equipment). Nevertheless, all of these systems can be used for bronchoscopy at the discretion of the physician.

Mobile C-arm-based systems have been designed as well and are newer on the market compared to conventional CBCT. The scan area provided by these devices is somewhat smaller than CBCT with a slightly lesser image quality but both are nevertheless adequate for the purposes of bronchoscopy and guiding the biopsy of lung lesions. They do offer certain advantages over usual CBCT, however. The footprint of these devices is only slightly larger than the typical C-arms currently used for fluoroscopy, obviating any need to make adjustments to the setup of the room in order to incorporate cone-beam technology (as with fixed systems, discussed below). Moreover, they are fully mobile, mounted on



**Fig. 25.4** Types of available CBCT systems: floor-mounted (a), ceiling-mounted (b), biplane (c), robotic (d), mobile (e)

wheels. As such, they can be brought in and out of any bronchoscopy suite that presently uses fluoroscopy. This can be particularly useful to pulmonary procedural programs that run more than one procedure room at the same time and may need to share equipment concurrently. Mobile C-arm-based systems are also lower cost compared to conventional CBCT.

Finally, a radiolucent patient table (most often a carbon-fiber table) is required for CBCT, regardless of whether a fixed or mobile system is used. If a metallic or otherwise radio-opaque table is used, this will generate significant degrees of artifact as the X-rays are absorbed by the table [35].

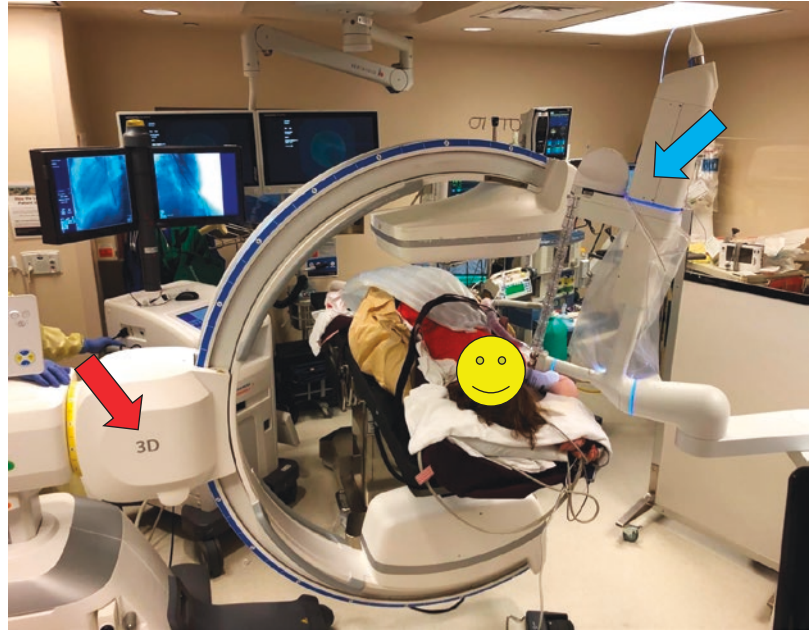
### Practical Considerations

Multiple personnel are often required for diagnostic bronchoscopy using cone-beam technology including: the bronchoscopist, anesthesia, bronchoscopy technicians to aid with the procedure, a radiology technician to manipulate the scanner, and often cytology staff as well. Members of the team need to coordinate their

efforts and adapt their roles to this new technology in order to obtain a better outcome. Aside from lead aprons and other personal protective equipment, CT rooms are equipped with a control room that is both impervious to radiation and also can serve as an area to review the acquired images and to plan subsequent steps as needed. In the case of bronchoscopy suites whose prior design may not have been mindful of the future addition of CT technology, portable radiation shields can be wheeled into the room to protect staff that must remain during the scan while other staff can temporarily exit the room.

Planning room setup and workflow is important as well. The main concept requiring careful attention is that interference with the C-arm does not occur by ancillary equipment. Anesthesia equipment often is sizeable but longer tubing and/or wires may allow for creative ways to keep the ventilator and other larger machines in an accommodating location (to that end, the authors use Velcro straps to keep these together and out of the way of the rotating C-arm). The bronchoscope and its tower/cart and any other necessary technology (e.g., navigation equipment) must be close enough to the head of the patient to allow

**Fig. 25.5** Typical room setup during peripheral bronchoscopy guided by intraoperative CT: CBCT (red arrow) to left of patient with robotic bronchoscopy platform (blue arrow) to the right of the patient. In this particular case, the patient is in right lateral decubitus position to biopsy a nodule in the posterior left lower lobe



proper use yet located or angled far enough away to not hinder the C-arm. Video monitor(s) must also be situated in a location visible to the bronchoscopist. Finally, consideration must be given to how the bronchoscope (and any tools within its working channel) will be maintained in a secure and stationary position during the scan when the bronchoscopist has moved to a radiation-safe location. Any number of creative methods can be employed with some previously described and/or commercially available [42–44]. This is obviously not needed when robotic bronchoscopy is being utilized. A typical room setup used by the authors is illustrated in Fig. 25.5.

## Radiation Dose

The total dose of radiation to which a patient is exposed is directly related to the number of CT acquisitions as well as the number of images captured within a given acquisition and the radiation dose per image. The total dose increases linearly with each acquisition [35].

When comparing exposure dosages between studies in the medical literature, one must be aware that these have been reported dissimilarly

at times, making comparisons difficult. For example, the most appropriate metrics for radiation dose with CBCT are the air Kerma ( $K_{ar}$ ) but most studies report the effective dose ( $E$ ). The problem with the latter is that  $E$  carries with it a conversion factor and this is specific not only to the system being used but also is a factor of anatomic location. This has been dealt with extensively previously [42]. Nevertheless, the effective radiation dose with CBCT acquisitions of 248, 312, and 419 projection images has been translated into levels of 0.98 mSv, 1.33 mSv, and 3.32 mSv, respectively [45–47]. These levels of radiation are the same as or slightly above those associated with low-dose CT for lung cancer screening.

## Limitations and Challenges

One of the main limitations in the use of cone-beam technology is that of access. An individual CBCT system costs in the millions of dollars. Moreover, outfitting a bronchoscopy suite for CBCT will typically require a complete redesign of the room—if not creation of a new lab altogether—in order to allow sufficient space and

infrastructure, particularly for ceiling-mounted devices [48]. Space and budget limitations could make this prohibitive for many pulmonary services. An alternative, then, could be the aforementioned mobile CT systems. These provide adequate imaging quality and can be used in any current procedure suite that can accommodate a traditional C-arm—and at lower cost.

Added procedure time is another consideration. Of course, using an additional technology/tool consumes time that would not have been used otherwise. However, it may be that CBCT ultimately can save time as a bronchoscopist can know with certainty if the desired target has been reached or not and only obtain biopsies when “on target,” avoiding multiple non-diagnostic samples.

---

## Literature Review: The State of the Art

Over the last few years, original investigation of CBCT has been growing at an accelerated pace, not only in the form of case reports and series but predominantly in much more sophisticated studies [43, 49]. These studies lay the foundation and generate the hypotheses for future research that will more definitively identify the role of true real time, three-dimensional image guidance in the diagnosis of pulmonary lesions. We will provide a review of the salient points herein. The studies are summarized in Table 25.1.

The earliest study of CBCT in the evaluation of pulmonary nodules was by Hohenforst-Schmidt et al., published in 2014 [50]. This prospective, feasibility study included 33 nodules in as many patients. Mean diameter was 25 mm. A steering catheter was allowed to be used at the bronchoscopist’s discretion. The only biopsy tool used was forceps. Navigational yield, defined as the forceps being located within the nodule, was 91% overall. However, diagnostic yield (not explicitly defined) was lower at 70%. Regarding complications, two patients developed pneumothorax. The radiation dose was not specifically reported but was referred to as <2 mSv. The same group reported levels between 0.98 and 1.15 mSv

in an earlier phantom study of the same technology and referenced that paper as a precursor to the current study [45]. Overall, this study made the first case for the utility of real-time intraoperative imaging.

Subsequent studies of CBCT did not appear until three years later in 2017. Park and colleagues retrospectively reviewed data on 59 patients who underwent peripheral bronchoscopy in their institution in South Korea [51]. Again, the only biopsy tool used was forceps. The bronchoscope was advanced to the segmental bronchus in question after which forceps were further advanced under fluoroscopic guidance. A CT was then performed and the forceps adjusted as needed. A maximum of two CT scans were allowed in order to limit radiation exposure. Average lesion size was 33 mm. Overall, diagnostic yield was 71.2% with a sensitivity for malignancy of 85.7%. Multivariate regression analysis was performed to identify factors associated with diagnostic yield; unsurprisingly, the only factor found to have a significant association was when forceps were identified by CT to be located within the target lesion compared to not having reached the lesion. This same year, Bowling et al. also reported a smaller cohort of patients ( $n = 14$ ) who underwent EMN-guided peripheral bronchoscopy with CBCT but with the added use of a transparenchymal access tool designed to reach lesions without a bronchus sign [44]. A steerable, extended working channel (Edge catheter, Medtronic, Inc) was also used in all cases. Overall diagnostic yield was 71%. Of note, the investigators made a change to their procedural protocol at the midpoint of patient recruitment. Initially, they would deploy the transparenchymal access tool and/or the biopsy tool and then obtain the CBCT. However, they noted that this could lead to distortion of the image of the target lesion due to bleeding that had been incited by the intervention. This made it difficult to know how to redirect the tools to better attempt to reach the lesion. As a result, they changed their approach by first obtaining a CBCT in order to determine the location of the extended working channel relative to the target before deploying the transparenchymal access tool.

**Table 25.1** Summary of cone beam CT studies in peripheral bronchoscopy

Study (type)	N	Target size (mm)	CBCT	Bronchoscopic technique	Sampling tools	DY (%)	Radiation dose (mean)
Hohenforst-Schmidt et al. (prospective)	33	25 (mean)	DynaCT (Siemens)	Standard bronchoscopy Guide sheath	Forceps	70	$E < 2$ mSV
Park et al. (retrospective)	59	33 (mean)	Artis Zee (Siemens)	Standard	Forceps	71.2	NR
Bowling et al. (retrospective)	14	23.8 (mean)	Artis Zeego (Siemens)	EMN EWC TPAT	Needle Forceps	71	$E = 4.3$ mSV
Pritchett et al. (retrospective)	93	16 (median)	Allura Xper FD20, AF (Philips)	EMN EWC	Needle Brush Forceps Core tool BAL	83.7	$E = 3.0$ mSV DAP = 31 Gycm <sup>2</sup>
Sobieszcyk et al. (retrospective)	22	21 (mean)	NR	EMN EWC RP-EBUS TPAT	Needle Brush Forceps Core tool	77.2	NR
Casal et al. (prospective)	20	21 (median)	Artis dTA (Siemens)	Thin/ultra-thin scope Guide sheath RP-EBUS	Needle Brush Forceps BAL	70	$P_{KA} = 64.6$ Gycm <sup>2</sup>
Ali et al. (prospective)	40	20 (median)	Artis Zeego (Siemens)	Ultra-thin scope VBN	Brush Forceps BAL	90	NR
Kheir et al. (retrospective) <sup>a</sup>	31	16 (median)	Artis Zeego (Siemens)	EMN EWC RP-EBUS	Needle Brush Forceps BAL	74.2	NR
Benn et al. (prospective)	59	21.9 (mean)	NR	Robotic	Needle Forceps	86	$E = 1.69$ mSV
Verhoeven et al. (prospective, randomized, cross-over) <sup>b</sup>	87	16.6 (mean)	Allura Clarity FD 20 (Philips); Artis Zeego (Siemens), AF	RP-EBUS/EMN vs RP-EBUS alone TPAT EWC Steerable curette	Needle Brush Forceps Cryoprobe	70.2 (diagnostic accuracy)	NR



Yu et al. (retrospective, propensity-matched) <sup>c</sup>	53	28 mm (mean)	Artis Zee (Siemens) AF	AF/RP-EBUS vs. RP-EBUS	Brush Forceps BAL	75.5	$P_{KA} = 19.6$ Gycm <sup>2</sup>
Verhoeven et al. (prospective) <sup>d</sup>	248	13 (median)	Allura Clarity FD 20 (Philips) Azurion (Philips) Artis Zeego (Siemens), AF	RP-EBUS/EMN vs RP-EBUS alone TPAT EWC Steerable curette	Needle Brush Forceps Cryoprobe BAL	90 (diagnostic accuracy)	DAP = 25.4 Gycm <sup>2</sup>

N number of nodules sampled, *DY* diagnostic yield. See text for definition, if described, *NR* not reported, *TPAT* transparenchymal access tool, *EWC* extended working channel, *EMN* electromagnetic navigation, *AF* augmented fluoroscopy, *BAL* bronchoalveolar lavage, *RP-EBUS* radial probe endobronchial ultrasound, *VBN* virtual bronchoscopic navigation

<sup>a</sup> Values are only for EMN + CBCT group as the comparison group did not use CT

<sup>b</sup> Value for target size is for the primarily-CBCT group

<sup>c</sup> Values are for the AF group as the comparison group did not use CT

<sup>d</sup> Values represent the latter part of the study as the design was to evaluate how outcomes changed over time

Interestingly, the remaining 7 patients managed under this new protocol had a 100% diagnostic yield.

The year 2018 saw the publication of three separate studies on cone-beam CT for peripheral bronchoscopy. Pritchett et al. described their retrospective experience with 93 nodules biopsied in 75 consecutive patients [52]. All nodules were sampled in a single sitting, guided by electromagnetic navigation with augmented fluoroscopy. The aforementioned curved, steerable catheter was also used. After intubation, an initial CT was obtained. The data were uploaded into software through which the nodule underwent three-dimensional segmentation. This segmentation then could be overlaid on live fluoroscopic imaging that guided the advancement of biopsy tools once the bronchoscope was steered to the appropriate location using EMN guidance. The tools used included standard cytology brush, fine needle for aspiration, forceps, GenCut core biopsy tool (Medtronic), cytology brushes, and bronchoalveolar lavage (BAL). Median lesion size was 16 mm with less than half being visible by standard fluoroscopy. Diagnostic yield was 83.7% with diagnostic accuracy of 93.5%. The former was defined as the bronchoscopy procedure providing a specific malignant or benign diagnosis, excluding non-specific findings such as inflammation; the definition for the latter included those lesions that were subsequently confirmed as benign by clinical and radiographic follow-up. Most cases required only a single CT scan which the authors attribute to the fact that they used augmented fluoroscopy as an additional guidance tool. Of note, in this study CBCT was mostly used for navigation rather than for confirmation. Soon after this report, Sobieszczyk and colleagues also described their retrospective review of 22 patients with 22 nodules [53]. Electromagnetic navigation was used to reach the lesions with subsequent radial EBUS and CBCT to confirm the location they had attained. Only a single CT scan was performed in each case. A transparenchymal sampling tool was used as needed. In addition to the Edge catheter, a variety of tools were used at the discretion of the bronchoscopist, including either forceps, fine needle,

brush, or GenCut. Mean nodule size was 21 mm. Overall diagnostic yield was 77.2% with a statistical trend toward increased yield with increasing size of the lesion, and there were no complications. The definition of diagnostic yield was not described. When used, the transparenchymal tool led to a diagnosis in all 7 cases in which it was used. Finally in 2018, Casal et al. published the first study of CBCT combined with thin/ultrathin bronchoscopy and radial EBUS [42]. Entry criteria limited nodules to 10–30 mm in size and only if located within the outer 2/3 of the lung field. Diagnostic yield was defined as the proportion of patients in whom a malignant or benign process was identified, the latter including pathology that was confirmed benign either surgically or clinico-radiographically at six-month follow-up. Additionally—and distinct from previous studies—these investigators specified the added benefit of CBCT. Termed “post-CBCT yields,” these were defined as the proportion of cases in which CBCT allowed the operator to reach the lesion when it had not been reached prior to the scan (“post-CBCT navigational yield”) and, thereby, to obtain a diagnosis that would not have been made prior to the scan (“post-CBCT diagnostic yield”). When the CT demonstrated that initial navigation to the nodule was unsuccessful, additional maneuvers were employed such as re-navigation, changing to an ultrathin bronchoscope, or using additional tools. A second CBCT would then be performed to evaluate the result of the adjustments made. Median nodule size was 21 mm. Sixty percent of targets were not visible by fluoroscopy. Pre-CBCT navigation and diagnostic yields were both 50%; additional post-CBCT maneuvers increased the navigation yield to 75% and diagnostic yield to 70%. The additional nodules that were reached and diagnosed with the use of CBCT were all smaller than the average of the other cases and 75% were not visible by fluoroscopy. Interestingly, an additional benefit of CBCT described in this study was that it allowed for the incidental discovery of the development of intra-procedural atelectasis, obscuring the target in 20% of cases. This observation led to the subsequent study described above that specifically investigated and further

unfolded how atelectasis can develop during bronchoscopy [25]. One pneumothorax occurred but otherwise no adverse events were observed.

The following year also saw the publication of a study combining CBCT with ultrathin bronchoscopy, but with the use of virtual navigation (VBN) technology [54]. Patients were included with solid or subsolid nodules  $\leq 30$  mm but nodules without a bronchus sign were excluded. VNB software was used to guide bronchoscopy as close as deemed possible to the target bronchus of interest and forceps were introduced. Thereafter, CBCT was performed to demonstrate the location reached; CBCT was repeated as needed after adjustments were made to approximate the biopsy tool to the lesion as closely as possible. Forceps biopsies, brushings, and/or bronchoalveolar lavage were performed depending on how closely the nodule was reached (if CT confirmed that the nodule was not reached at all, only bronchoalveolar lavage was performed). In all, 40 patients were enrolled with a median tumor size of 20 mm. Eighty percent of nodules had a bronchus leading to the center of the lesion. An average of 1.8 scans were performed after forceps insertion (range 1–5). Overall diagnostic yield was 90%, subdivided into lesions with an airway leading to their center (diagnostic yield 96.9%) and those with an airway leading to the nodule periphery (diagnostic yield 62.5%). However, diagnostic yield was not clearly defined. Nevertheless, this higher yield compared to other studies was postulated by the authors to be likely related to patient selection as those without a bronchus sign were excluded. One patient developed a pneumothorax and lung abscess.

With the background of these initial studies showing promise, investigation into CBCT continued to accelerate, with 2021 producing the most publications to date on this technology. Kheir et al. in the United States reported an interesting retrospective study design in which the diagnostic yield for EMN-guided bronchoscopy with augmented fluoroscopy was determined before and after the introduction of CBCT into their practice [55]. Sixty-two patients (31 with EMN alone before CBCT, and 31 with EMN plus

CBCT) were evaluated. The aforementioned steerable Edge catheter was also used in all cases. Patients underwent usual EMN-guided bronchoscopy with the use of radial probe EBUS for confirmation of having reached the nodule in both groups. In the EMN-only group, at that point, sampling was obtained under conventional C-arm fluoroscopy. In the EMN plus CBCT group, however, after radial probe confirmation, the aspirating needle was deployed and a CBCT was performed. Based on the location of the needle tip as revealed by the CT, adjustments were made under fluoroscopic guidance. Repeat CBCT was performed as needed. Once satisfactory needle position was obtained, samples were taken. Tools used included cytology brush, fine needle, forceps, and BAL. Diagnostic yield was calculated as the number of true positive malignant or specific benign diagnoses divided by the total number of procedures for that study arm; non-specific inflammation, atypical cells, or normal lung parenchyma were considered non-diagnostic. The median size of target nodules was 16 mm in the EMN-CBCT group but 21.5 mm in the EMN-only group. Diagnostic yield was 74.2% in the EMN-CBCT group compared to 51.6% in the other. Procedures were also a median of 16 min shorter when CBCT was used. When multivariate regression analysis was performed adjusting for nodule size, presence of a bronchus sign, and distance from the pleura, EMN-CBCT was found to yield a diagnosis 3.4-fold more often than EMN alone (i.e., odds ratio 3.4; 95% CI 1.03–11.26,  $p = 0.04$ ). Two patients in each arm developed a pneumothorax.

Benn et al. then published the first study of CBCT combined with robotic bronchoscopy [56]. Performed at a single center, fifty-nine nodules in 52 patients (seven patients had two nodules) underwent bronchoscopy with navigation initially guided by the robotic platform followed by CBCT for secondary confirmation. Mean largest diameter in any dimension was 21.9 mm. Biopsy tools were 21-gauge needle and forceps. Overall diagnostic yield was not explicitly defined but was based on all available biopsy and imaging data, including two nodules which had resolved or regressed on follow-up CT. As such,

diagnostic yield was reported as 86% with a sensitivity for malignancy of 84%. Overall radiation exposure was reported as 1.69 mGy with a dose-length product of 750 mGycm. Two pneumothoraces were observed.

Verhoeven and colleagues in the Netherlands then reported their comparison of two approaches to peripheral nodules, in a cross-over design: a primarily CBCT-guided approach and a primarily EMN-guided approach [57]. In the former, CBCT with augmented fluoroscopy was used to reach the lesion with radial EBUS for initial confirmation. CBCT was used as needed to definitively confirm location after which sampling was done. If this approach was unsuccessful in reaching the lesion, the case crossed over to the other study arm and EMN guidance was added. Of note, straight catheters with a steerable curette or a catheter with a preformed curvature were also used. For the primarily EMN-guided approach, usual electromagnetic navigation was used to attempt to reach the lesion. Once the lesion appeared to have been attained, radial EBUS was used for confirmation. If radial EBUS also was favorable, CBCT was performed for additional confirmation. If CBCT was needed for subsequent navigation readjustments, the case was considered to have crossed over into the CBCT arm. Biopsy tools included a cytology brush, needle, forceps, and even cryobiopsy on a case-by-case basis if considered safe. Navigation was deemed successful if CBCT confirmed that a tool was within a lesion or in contact with its outer boundary. Ultimately, in the primarily-CBCT-guided arm, 47 patients with 59 lesions were included with an average size of 16.6 mm. In the primarily-EMN-guided group, 40 patients with 48 lesions were included with an average size of 14.2 mm. Navigation was successful in 76.3% of lesions in the primarily-CBCT group but only 52.2% in the primarily-EMN group ( $p = 0.016$ ). When EMN was added to CBCT group cases, navigation success increased by 13.6–89.9%; when CBCT was added to EMN group cases, navigation success increased by 35.3–87.5%. Despite high navigation success, diagnostic

accuracy was 70.2% for the primarily-CBCT group and 75% for the primarily-EMN group ( $p = 0.797$ ).

The next CBCT study of 2021 was published by Yu et al. out of Taiwan [58]. This study focused on the augmented fluoroscopy technology that can CBCT provide. In a propensity-matched analysis, they retrospectively evaluated patients that underwent bronchoscopy for peripheral pulmonary nodules that underwent transbronchial biopsy either with a combination of CBCT-derived augmented fluoroscopy (AF) with radial EBUS or transbronchial biopsy with radial EBUS alone. In the AF group, a CBCT scan was performed at the beginning of the procedure. This allowed the physicians to highlight the area of interest using annotation software which then transferred and projected the annotated markers to live fluoroscopy. This augmented fluoroscopy, along with radial EBUS, was then used to guide bronchoscopy until a satisfactory position was attained. At that point, biopsy forceps, brushings, or bronchial washings were used at the discretion of the bronchoscopist. In the radial-EBUS-only group, radial probe EBUS was used without augmented fluoroscopy, though presumably conventional two-dimensional fluoroscopy was used to visualize probe positioning within the lung (however, this was not explicitly stated in the report). Diagnostic yield was based on whether a specific malignant or benign process was identified. Final diagnoses were based on pathologic evidence from biopsies (bronchoscopic or otherwise) as well as microbiological results or clinical follow-up of at least one year post-bronchoscopy. In an attempt to minimize confounding in the analysis, propensity scores were generated using the following factors: age, gender, smoking, lesion size, lesion location relative to the hilum (i.e., central, middle, peripheral), and presence of bronchus sign. Ultimately, 53 pairs were matched between the two groups. Median nodule size was 28 mm in the AF group and 29 mm in the radial EBUS-only group. Diagnostic yield was 75.5% in the AF group compared to 52.8% in the radial EBUS-only group ( $p = 0.015$ ). There was a statistically significant difference favoring the AF group in terms of diagnosis of malignancy but no differ-

ence for benign lesions. In terms of complications, there was 1 pneumothorax in the radial EBUS group. Moderate bleeding was encountered in 2 cases in the AF group and 1 case in the radial EBUS group.

Finally, in 2021, Verhoeven and colleagues published a follow-up to their earlier study described above [59]. The goal of this investigation was to evaluate how radiation dosages and diagnostic accuracy changed over time as they gained more experience with cone-beam technology. The investigators changed how they administered radiation over the course of their experience. Initially, their imaging protocols sought to obtain the highest quality images possible. However, later realizing that lesser quality images could suffice depending on the indication, they eventually changed to an imaging protocol with three different radiation dosages: low dose when they needed only to know the relative positioning of tools and lesions; medium dose to evaluate when a ground glass nodule was accessed; high (original) dose to be able to visualize individual bronchi for navigation purposes. Regarding diagnostic accuracy, malignant and benign findings on bronchoscopy were considered to be true if not negated by later findings. Non-specific benign results were considered true negatives if confirmed by subsequent biopsies (e.g., percutaneous or surgical) or clinical follow-up of at least six months. Patients were included from the beginning of the investigators' CBCT-AF program. One hundred patients were included for the radiation analysis. Two hundred forty-eight lesions in 208 patients were included in the diagnostic accuracy analysis; median diameter was 13 mm. At the start of the program, the mean dose area product (DAP) was 47.5 Gy-cm<sup>2</sup> (effective dose 14.3 mSv). Over time, as more experience was gained and the above-mentioned imaging protocols were instituted, procedural DAP decreased to 25.4 Gy-cm<sup>2</sup> (5.8 mSv) by the end of the study period, largely attributable to a reduction in fluoroscopic DAP. Diagnostic accuracy increased from 72% to 90% over the study period, despite the fact that lesion size did not change over time but fewer lesions had a bronchus sign.

## Mobile CT Studies

Though not necessarily the focus of this chapter on conventional CBCT, the mobile CT technology that offers similar imaging with similar advantages is certainly worth citing. As alluded to above, these devices may, in fact, be more widely accessible to bronchoscopists than conventional CBCT. A few reports currently exist in the literature as to their application for peripheral lung nodules, but further research is already underway [60, 61].

Avasarala and colleagues were the first to report the use of this technology in diagnostic bronchoscopy [62]. They employed the Cios-Spin (Siemens Healthineers, Malvern, PA), a mobile 2D/3D C-arm with a 30 cm<sup>2</sup> imaging field capable of 1952-pixel resolution, originally designed for orthopedic and spinal surgery. Eight patients underwent bronchoscopy. All cases used radial EBUS; two additionally used EMN. "Tool-in-lesion" was confirmed in all cases. Interestingly, intraoperative atelectasis was noticed in the same lung as the target in 75% of cases and in the same segment (partially obscuring the lesion) in over one-third of cases. Diagnostic yield was not determined as patients were not followed longitudinally. Nevertheless, safety and feasibility were shown.

Subsequently, Sadoughi and colleagues reported a series of four patients evaluated with ultrathin bronchoscopy combined with radial EBUS and mobile CT [63]. Interestingly, while none of the cases had a bronchus sign on preoperative CT, the radial probe was nevertheless found to be within the target in three of the cases and adjacent to it in the remaining case. This was confirmed by intraoperative CT in all cases. A diagnosis was obtained in all as well.

Finally, Chen and colleagues similarly reported a series of two patients [64]. One patient had a peripheral nodule reached and diagnosed with the aid of mobile CT and, interestingly, another had a previously-diagnosed lung adenocarcinoma treated with microwave ablation after mobile CT confirmed that the ablation tool had reached the center of the lesion. CT imaging



was then repeated to confirm that the ablation zone covered the entire tumor as well as to evaluate for any immediate complications. Follow-up as far as nine months confirmed that the lesion had been successfully treated. Indeed, as will be discussed in the following section, intraoperative CT is a powerful tool that can make the bronchoscopic treatment of peripheral cancers a more common and effective practice in the future.

### Limitations of the Literature

With any emerging technology in a challenging field, the medical literature—while informative—will necessarily have some pitfalls and confines. In the case of cone-beam CT for the peripheral pulmonary lesion, studies have often been retrospective, single-center, and even single operator. This limits the quality and generalizability of the data. Prospective trials have been relatively small.

There is also the issue of heterogeneity between the studies. As was detailed above, different studies utilized different navigational or imaging modalities and different combinations thereof. Different-sized bronchoscopes have been used (which is particularly germane to the issue of reaching peripheral lesions) and different biopsy tools employed. Different definitions of diagnostic yield have been applied as well and only a few report sensitivity for malignancy. Importantly, data on radiation exposure and the interpretation thereof have been variable. For all of these reasons, comparisons between studies are difficult.

Last, the effect of experience must be taken into account. Many of the aforementioned studies reflect the somewhat initial experiences of the different centers with this technology. As demonstrated by the recent Verhoeven study described above, further exercise over time can improve one's skill in the use of a given technology. It can possibly be anticipated that improved outcomes would result from these same investigators as they gained more experience and subsequent studies performed.

### Future Directions

The future holds many opportunities for progress in this area of investigation. The research described in this chapter needs to be replicated in larger, well-designed, and prospective studies. Dedicated attention needs to be given to radiation exposure with investigation into how to minimize it in particular. Advancements in software, hardware, and the algorithms that link these together will hopefully lead to better images with less radiation.

Additionally, a new era in pulmonary medicine has been entered with the introduction of robotic bronchoscopy. The versatility in steering and ability for minute changes in any direction provide maneuverability that has not been seen in bronchoscopy before. Initial studies have been promising [65–69]. Combined with the real-time imaging that cone-beam CT provides, along with existing navigational technologies, we may finally witness diagnostic yield breach the 70% ceiling as was observed in the robotic study by Benn described above. Another study specifically combining robotic bronchoscopy with intraoperative CT is currently underway with surely more to come [60].

Finally, CBCT may prove to be an ideal platform for bronchoscopic ablation of peripheral tumors. The minimally invasive treatment of peripheral tumors is an area of active research which could solidify bronchoscopy as a “one-stop shop” of diagnosis, nodal staging, and treatment of early-stage cancers—all in one setting [34]. Precise localization of tumors for ablation is critical because ablation zones are larger than the lesions within them. As such, nearby structures may be affected and, thus, real-time, three-dimensional imaging would be quite helpful. In-room imaging has the added benefit of immediate evaluation for complications as well.

---

### Conclusion

Intraoperative CT imaging is an area of active research in peripheral bronchoscopy but still in its relatively early stages. As technology contin-

ues to innovate and further investigation continues, we will hopefully see continued advancement in our ability to diagnose peripheral lesions—ones that are increasingly difficult to reach and progressively smaller, enabling us to detect lung cancer at ever earlier junctures. Cone-beam CT is currently at the forefront of this endeavor, having an established place in our armamentarium and holding much promise for the future.

**Acknowledgments** We thank Mr. David Aten, MA, CMI for invaluable help with medical illustration.

## References

- Orth RC, Wallace MJ, Kuo MD. C-arm cone-beam CT: general principles and technical considerations for use in interventional radiology. *J Vasc Interv Radiol.* 2008;19(6):814–20. <https://doi.org/10.1016/j.jvir.2008.02.002>.
- O'Connell A, Conover DL, Zhang Y, Seifert P, Logan-Young W, Lin CF, et al. Cone-beam CT for breast imaging: radiation dose, breast coverage, and image quality. *AJR Am J Roentgenol.* 2010;195(2):496–509. <https://doi.org/10.2214/AJR.08.1017>.
- Lerisson E, Patterson BO, Hertault A, Klein C, Pontana F, Sediri I, et al. Intraoperative cone beam computed tomography to improve outcomes after infra-renal endovascular aortic repair. *J Vasc Surg.* 2021;75(3):1021–9. <https://doi.org/10.1016/j.jvs.2021.08.057>.
- El Nihum LI, Zubair MM, Chinnadurai P, Peden EK. Cone-beam CT and image fusion-guided percutaneous recanalization of occluded central venous stent. *JACC Case Rep.* 2021;3(17):1816–21. <https://doi.org/10.1016/j.jaccas.2021.09.016>.
- Bertin E, Meyer C, Louvrier A, Weber E, Barrabé A, Pons M. Intraoperative cone-beam computed tomography for open reduction and internal fixation of condylar head fractures. *J Stomatol Oral Maxillofac Surg.* 2021;123(5):593–7. <https://doi.org/10.1016/j.jormas.2021.12.003>.
- Régis J, Merly L, Balossier A, Baumstarck K, Hamdi H, Mariani S, et al. Mask-based versus frame-based gamma knife ICON radiosurgery in brain metastases: a prospective randomized trial. *Stereotact Funct Neurosurg.* 2021;100(2):86–94. <https://doi.org/10.1159/000519280>.
- Horeweg N, van der Aalst CM, Thunnissen E, Nackaerts K, Weenink C, Groen HJ, et al. Characteristics of lung cancers detected by computer tomography screening in the randomized NELSON trial. *Am J Respir Crit Care Med.* 2013;187(8):848–54. <https://doi.org/10.1164/rccm.201209-1651OC>.
- Hürter T, Hanrath P. Endobronchial sonography: feasibility and preliminary results. *Thorax.* 1992;47(7):565–7. <https://doi.org/10.1136/thx.47.7.565>.
- Becker H. Short history of the development of endobronchial ultrasound – a story of success. In: Bolliger CTHF, Mayo PH, Miyazawa T, Beamis JF, editors. *Clinical chest ultrasound: from the ICU to the bronchoscopy suite.* Basel: Karger; 2009. p. 129–39.
- Yarmus LB, Mallow C, Pastis N, Thiboutot J, Lee H, Feller-Kopman D, et al. First-in-human use of a hybrid real-time ultrasound-guided fine-needle acquisition system for peripheral pulmonary lesions: a multicenter pilot study. *Respiration.* 2019;98(6):527–33. <https://doi.org/10.1159/000504025>.
- Chandrika S, Yarmus L. Recent developments in advanced diagnostic bronchoscopy. *Eur Respir Rev.* 2020;29(157):190184. <https://doi.org/10.1183/16000617.0184-2019>.
- Steinfort DP, Khor YH, Manser RL, Irving LB. Radial probe endobronchial ultrasound for the diagnosis of peripheral lung cancer: systematic review and meta-analysis. *Eur Respir J.* 2011;37(4):902–10. <https://doi.org/10.1183/09031936.00075310>.
- Wang Memoli JS, Nietert PJ, Silvestri GA. Meta-analysis of guided bronchoscopy for the evaluation of the pulmonary nodule. *Chest.* 2012;142(2):385–93. <https://doi.org/10.1378/chest.11-1764>.
- Chen A, Chenna P, Loïselle A, Massoni J, Mayse M, Misselhorn D. Radial probe endobronchial ultrasound for peripheral pulmonary lesions. A 5-year institutional experience. *Ann Am Thorac Soc.* 2014;11(4):578–82. <https://doi.org/10.1513/AnnalsATS.201311-384OC>.
- Gex G, Pralong JA, Combesure C, Seijo L, Rochat T, Soccal PM. Diagnostic yield and safety of electromagnetic navigation bronchoscopy for lung nodules: a systematic review and meta-analysis. *Respiration.* 2014;87(2):165–76. <https://doi.org/10.1159/000355710>.
- Ost DE, Ernst A, Lei X, Kovitz KL, Benzaquen S, Diaz-Mendoza J, et al. Diagnostic yield and complications of bronchoscopy for peripheral lung lesions. results of the AQuIRE registry. *Am J Respir Crit Care Med.* 2016;193(1):68–77. <https://doi.org/10.1164/rccm.201507-1332OC>.
- Tanner NT, Yarmus L, Chen A, Wang Memoli J, Mehta HJ, Pastis NJ, et al. Standard bronchoscopy with fluoroscopy vs thin bronchoscopy and radial endobronchial ultrasound for biopsy of pulmonary lesions: a multicenter, prospective, randomized trial. *Chest.* 2018;154(5):1035–43. <https://doi.org/10.1016/j.chest.2018.08.1026>.
- Patrucco F, Gavelli F, Daverio M, Antonini C, Boldorini R, Casadio C, et al. Electromagnetic navigation bronchoscopy: where are we now? Five years of a single-center experience. *Lung.* 2018;196(6):721–7. <https://doi.org/10.1007/s00408-018-0161-3>.
- Oki M, Saka H, Asano F, Kitagawa C, Kogure Y, Tsuzuku A, et al. Use of an ultrathin vs thin bronchoscope for peripheral pulmonary lesions: a random-

- ized trial. *Chest*. 2019;156(5):954–64. <https://doi.org/10.1016/j.chest.2019.06.038>.
20. Folch EE, Pritchett MA, Nead MA, Bowling MR, Murgu SD, Krimsky WS, et al. Electromagnetic navigation bronchoscopy for peripheral pulmonary lesions: one-year results of the prospective, multicenter NAVIGATE study. *J Thorac Oncol*. 2019;14(3):445–58. <https://doi.org/10.1016/j.jtho.2018.11.013>.
  21. Jiang S, Xie F, Mao X, Ma H, Sun J. The value of navigation bronchoscopy in the diagnosis of peripheral pulmonary lesions: a meta-analysis. *Thorac Cancer*. 2020;11(5):1191–201. <https://doi.org/10.1111/1759-7714.13373>.
  22. Silvestri GA, Bevil BT, Huang J, Brooks M, Choi Y, Kennedy G, et al. An evaluation of diagnostic yield from bronchoscopy: the impact of clinical/radiographic factors, procedure type, and degree of suspicion for cancer. *Chest*. 2020;157(6):1656–64. <https://doi.org/10.1016/j.chest.2019.12.024>.
  23. Giri M, Puri A, Wang T, Huang G, Guo S. Virtual bronchoscopic navigation. *Thor Adv Respir Dis*. 2021;15:17534666211017048. <https://doi.org/10.1177/17534666211017048>.
  24. Kitamura A, Okafuji K, Imai R, Murakami M, Ro S, Tomishima Y, et al. Reproducibility of peripheral branches in virtual bronchoscopic navigation using VINCENT and LungPoint software for peripheral lung lesions. *Respir Investig*. 2021;59(6):772–6. <https://doi.org/10.1016/j.resinv.2021.04.006>.
  25. Sagar AS, Sabath BF, Eapen GA, Song J, Marcoux M, Sarkiss M, et al. Incidence and location of atelectasis developed during bronchoscopy under general anesthesia: the I-LOCATE trial. *Chest*. 2020;158(6):2658–66. <https://doi.org/10.1016/j.chest.2020.05.565>.
  26. Pritchett MA, Bhadra K, Calcutt M, Folch E. Virtual or reality: divergence between preprocedural computed tomography scans and lung anatomy during guided bronchoscopy. *J Thorac Dis*. 2020;12(4):1595–611. <https://doi.org/10.21037/jtd.2020.01.35>.
  27. Moyer VA. Screening for lung cancer: U.S. Preventive Services Task Force recommendation statement. *Ann Intern Med*. 2014;160(5):330–8. <https://doi.org/10.7326/m13-2771>.
  28. Detterbeck FC, Mazzone PJ, Naidich DP, Bach PB. Screening for lung cancer: diagnosis and management of lung cancer, 3rd ed: American College of Chest Physicians evidence-based clinical practice guidelines. *Chest*. 2013;143(5 Suppl):e78S–92S. <https://doi.org/10.1378/chest.12-2350>.
  29. Jaklitsch MT, Jacobson FL, Austin JH, Field JK, Jett JR, Keshavjee S, et al. The American Association for Thoracic Surgery guidelines for lung cancer screening using low-dose computed tomography scans for lung cancer survivors and other high-risk groups. *J Thorac Cardiovasc Surg*. 2012;144(1):33–8. <https://doi.org/10.1016/j.jtcvs.2012.05.060>.
  30. Wender R, Fontham ET, Barrera E Jr, Colditz GA, Church TR, Ettinger DS, et al. American Cancer Society lung cancer screening guidelines. *CA Cancer J Clin*. 2013;63(2):107–17. <https://doi.org/10.3322/caac.21172>.
  31. Wiener RS, Gould MK, Arenberg DA, Au DH, Fennig K, Lamb CR, et al. An official American Thoracic Society/American College of Chest Physicians policy statement: implementation of low-dose computed tomography lung cancer screening programs in clinical practice. *Am J Respir Crit Care Med*. 2015;192(7):881–91. <https://doi.org/10.1164/rccm.201508-1671ST>.
  32. Wood DE, Eapen GA, Ettinger DS, Hou L, Jackman D, Kazerooni E, et al. Lung cancer screening. *J Natl Compr Cancer Netw*. 2012;10(2):240–65.
  33. Gould MK, Tang T, Liu JL, Lee J, Zheng C, Danforth KN, et al. Recent trends in the identification of incidental pulmonary nodules. *Am J Respir Crit Care Med*. 2015;192(10):1208–14. <https://doi.org/10.1164/rccm.201505-0990OC>.
  34. Sabath BF, Casal RF. Bronchoscopic ablation of peripheral lung tumors. *J Thorac Dis*. 2019;11(6):2628–38. <https://doi.org/10.21037/jtd.2019.01.65>.
  35. Setser R, Chintalapani G, Bhadra K, Casal RF. Cone beam CT imaging for bronchoscopy: a technical review. *J Thorac Dis*. 2020;12(12):7416–28. <https://doi.org/10.21037/jtd-20-2382>.
  36. Tusman G, Böhm SH, Warner DO, Sprung J. Atelectasis and perioperative pulmonary complications in high-risk patients. *Curr Opin Anaesthesiol*. 2012;25(1):1–10. <https://doi.org/10.1097/ACO.0b013e32834dd1eb>.
  37. Lundquist H, Hedenstierna G, Strandberg A, Tokics L, Brismar B. CT-assessment of dependent lung densities in man during general anaesthesia. *Acta Radiol*. 1995;36(6):626–32.
  38. Neumann P, Rothen HU, Berglund JE, Valtysson J, Magnusson A, Hedenstierna G. Positive end-expiratory pressure prevents atelectasis during general anaesthesia even in the presence of a high inspired oxygen concentration. *Acta Anaesthesiol Scand*. 1999;43(3):295–301. <https://doi.org/10.1034/j.1399-6576.1999.430309.x>.
  39. Rusca M, Proietti S, Schnyder P, Frascarolo P, Hedenstierna G, Spahn DR, et al. Prevention of atelectasis formation during induction of general anesthesia. *Anesth Analg*. 2003;97(6):1835–9. <https://doi.org/10.1213/01.ANE.0000087042.02266.F6>.
  40. Coussa M, Proietti S, Schnyder P, Frascarolo P, Suter M, Spahn DR, et al. Prevention of atelectasis formation during the induction of general anesthesia in morbidly obese patients. *Anesth Analg*. 2004;98(5):1491–5. <https://doi.org/10.1213/01.ane.0000111743.61132.99>.
  41. Ventilatory strategy for the prevention of atelectasis during bronchoscopy under general anesthesia, VESPA trial. <https://clinicaltrials.gov/ct2/show/NCT04311723>. Accessed 2 January 2022.
  42. Casal RF, Sarkiss M, Jones AK, Stewart J, Tam A, Grosu HB, et al. Cone beam computed tomography-

- guided thin/ultrathin bronchoscopy for diagnosis of peripheral lung nodules: a prospective pilot study. *J Thorac Dis.* 2018;10(12):6950–9. <https://doi.org/10.21037/jtd.2018.11.21>.
43. Ng CS, Yu SC, Lau RW, Yim AP. Hybrid DynaCT-guided electromagnetic navigational bronchoscopic biopsy. *Eur J Cardiothorac Surg.* 2016;49(Suppl 1):87–8. <https://doi.org/10.1093/ejcts/ezv405>.
  44. Bowling MR, Brown C, Anciano CJ. Feasibility and safety of the transbronchial access tool for peripheral pulmonary nodule and mass. *Ann Thorac Surg.* 2017;104(2):443–9. <https://doi.org/10.1016/j.athoracsur.2017.02.035>.
  45. Hohenforst-Schmidt W, Banckwitz R, Zarogoulidis P, Vogl T, Darwiche K, Goldberg E, et al. Radiation exposure of patients by cone beam CT during endobronchial navigation - a phantom study. *J Cancer.* 2014;5(3):192–202. <https://doi.org/10.7150/jca.8395>.
  46. Choi JW, Park CM, Goo JM, Park YK, Sung W, Lee HJ, et al. C-arm cone-beam CT-guided percutaneous transthoracic needle biopsy of small ( $\leq 20$  mm) lung nodules: diagnostic accuracy and complications in 161 patients. *AJR Am J Roentgenol.* 2012;199(3):322–30. <https://doi.org/10.2214/AJR.11.7576>.
  47. Choo JY, Park CM, Lee NK, Lee SM, Lee HJ, Goo JM. Percutaneous transthoracic needle biopsy of small ( $\leq 1$  cm) lung nodules under C-arm cone-beam CT virtual navigation guidance. *Eur Radiol.* 2013;23(3):712–9. <https://doi.org/10.1007/s00330-012-2644-6>.
  48. Kpodonu J. Hybrid cardiovascular suite: the operating room of the future. *J Card Surg.* 2010;25(6):704–9. <https://doi.org/10.1111/j.1540-8191.2010.01111.x>.
  49. Piro R, Fontana M, Casalini E, Taddei S, Bertolini M, Iori M, et al. Cone beam CT augmented fluoroscopy allows safe and efficient diagnosis of a difficult lung nodule. *BMC Pulm Med.* 2021;21(1):327. <https://doi.org/10.1186/s12890-021-01697-y>.
  50. Hohenforst-Schmidt W, Zarogoulidis P, Vogl T, Turner JF, Browning R, Linsmeier B, et al. Cone beam computed tomography (CBCT) in interventional chest medicine - high feasibility for endobronchial realtime navigation. *J Cancer.* 2014;5(3):231–41. <https://doi.org/10.7150/jca.8834>.
  51. Park SC, Kim CJ, Han CH, Lee SM. Factors associated with the diagnostic yield of computed tomography-guided transbronchial lung biopsy. *Thorac Cancer.* 2017;8(3):153–8. <https://doi.org/10.1111/1759-7714.12417>.
  52. Pritchett MA, Schampaert S, de Groot JAH, Schirmer CC, van der Bom I. Cone-beam CT with augmented fluoroscopy combined with electromagnetic navigation bronchoscopy for biopsy of pulmonary nodules. *J Bronchol Interv Pulmonol.* 2018;25(4):274–82. <https://doi.org/10.1097/LBR.0000000000000536>.
  53. Sobieszczyk MJ, Yuan Z, Li W, Krinsky W. Biopsy of peripheral lung nodules utilizing cone beam computer tomography with and without trans bronchial access tool: a retrospective analysis. *J Thorac Dis.* 2018;10(10):5953–9. <https://doi.org/10.21037/jtd.2018.09.16>.
  54. Ali EAA, Takizawa H, Kawakita N, Sawada T, Tsuboi M, Toba H, et al. Transbronchial biopsy using an ultrathin bronchoscope guided by cone-beam computed tomography and virtual bronchoscopic navigation in the diagnosis of pulmonary nodules. *Respiration.* 2019;98(4):321–8. <https://doi.org/10.1159/000500228>.
  55. Kheir F, Thakore SR, Uribe Becerra JP, Tahboub M, Kamat R, Abdelghani R, et al. Cone-beam computed tomography-guided electromagnetic navigation for peripheral lung nodules. *Respiration.* 2021;100(1):44–51. <https://doi.org/10.1159/000510763>.
  56. Benn BS, Romero AO, Lum M, Krishna G. Robotic-assisted navigation bronchoscopy as a paradigm shift in peripheral lung access. *Lung.* 2021;199(2):177–86. <https://doi.org/10.1007/s00408-021-00421-1>.
  57. Verhoeven RLJ, Fütterer JJ, Hoefsloot W, van der Heijden EHF. Cone-beam CT image guidance with and without electromagnetic navigation bronchoscopy for biopsy of peripheral pulmonary lesions. *J Bronchol Interv Pulmonol.* 2021;28(1):60–9. <https://doi.org/10.1097/LBR.0000000000000697>.
  58. Yu KL, Yang SM, Ko HJ, Tsai HY, Ko JC, Lin CK, et al. Efficacy and safety of cone-beam computed tomography-derived augmented fluoroscopy combined with endobronchial ultrasound in peripheral pulmonary lesions. *Respiration.* 2021;100(6):538–46. <https://doi.org/10.1159/000515181>.
  59. Verhoeven RLJ, van der Sterren W, Kong W, Langereis S, van der Tol P, van der Heijden EHF. Cone-beam CT and Augmented fluoroscopy-guided navigation bronchoscopy: radiation exposure and diagnostic accuracy learning curves. *J Bronchol Interv Pulmonol.* 2021;28(4):262–71. <https://doi.org/10.1097/LBR.0000000000000783>.
  60. Cios Mobile 3D spin for robotic bronchoscopy. <https://clinicaltrials.gov/ct2/show/NCT04740047>. Accessed 2 January 2022.
  61. Robotic bronchoscopy with cone CT and indocyanine green to aid removal of lung lesions in patients with stage I non-small cell lung cancer or lung metastases, REPLACING study. <https://clinicaltrials.gov/ct2/show/NCT04987281>. Accessed 2 January 2022.
  62. Avasarala SK, Machuzak MS, Gildea TR. Multidimensional precision: hybrid mobile 2D/3D C-arm assisted biopsy of peripheral lung nodules. *J Bronchol Interv Pulmonol.* 2020;27(2):153–5. <https://doi.org/10.1097/LBR.0000000000000650>.
  63. Sadoughi A, Virdi S. Mobile 3D intraprocedural fluoroscopy in combination with ultrathin bronchoscopy for biopsy of peripheral lung nodules. *J Bronchol Interv Pulmonol.* 2021;28(1):76–80. <https://doi.org/10.1097/LBR.0000000000000711>.
  64. Chen J, Xie F, Zheng X, Li Y, Liu S, Ma KC, et al. Mobile 3-dimensional (3D) C-arm system-assisted transbronchial biopsy and ablation for ground-glass opacity pulmonary nodules: a case report. *Transl*

- Lung Cancer Res. 2021;10(7):3312–9. <https://doi.org/10.21037/tlcr-21-561>.
65. Fielding DIK, Bashirzadeh F, Son JH, Todman M, Chin A, Tan L, et al. First human use of a new robotic-assisted fiber optic sensing navigation system for small peripheral pulmonary nodules. *Respiration*. 2019;98(2):142–50. <https://doi.org/10.1159/000498951>.
66. Chaddha U, Kovacs SP, Manley C, Hogarth DK, Cumbo-Nacheli G, Bhavani SV, et al. Robot-assisted bronchoscopy for pulmonary lesion diagnosis: results from the initial multicenter experience. *BMC Pulm Med*. 2019;19(1):243. <https://doi.org/10.1186/s12890-019-1010-8>.
67. Simoff MJ, Pritchett MA, Reisenauer JS, Ost DE, Majid A, Keyes C, et al. Shape-sensing robotic-assisted bronchoscopy for pulmonary nodules: initial multicenter experience using the Ion™ Endoluminal System. *BMC Pulm Med*. 2021;21(1):322. <https://doi.org/10.1186/s12890-021-01693-2>.
68. Chen AC, Pastis NJ, Mahajan AK, Khandhar SJ, Simoff MJ, Machuzak MS, et al. Robotic bronchoscopy for peripheral pulmonary lesions: a multicenter pilot and feasibility study (BENEFIT). *Chest*. 2021;159(2):845–52. <https://doi.org/10.1016/j.chest.2020.08.2047>.
69. Kalchiem-DekeIO, ConnollyJG, LinIH, HustaBC, AdusumilliPS, BeattieJA, et al. Shape-sensing robotic-assisted bronchoscopy in the diagnosis of pulmonary parenchymal lesions. *Chest*. 2021. <https://doi.org/10.1016/j.chest.2021.07.2169>.





Tarek Dammad and Bilal A. Jalil

## Historical Perspective

The word robot comes from the Czech word “robota” meaning laborer. In 1921, the term robot was first introduced by Karel Capek in his play Rossom’s Universal Robots. He described the creation and evolution of robots and eventually their revolt against humans. In 1942, writer Isaac Asimov defined the three rules of robotics in his science fiction books “Runaround” and “I, Robot”: robots must not harm humans, must follow instructions, and protect their existence [1].

Before the term “robot” came to life, autonomously operated machines could be dated to 400 BC when Archytas developed a steam-powered, self-propelling wooden pigeon capable of flying 200 meters [2]. However, Leonardo da Vinci in 1495 designed the “Metal-Plated Warrior”, the first robot that imitated human movements of the jaw, arms, and neck (Fig. 26.1). This invention inspired Gianello Torriano, who created a robotic mandolin-playing lady in 1540 [1].

It was not until 1985 that robotics entered the field of medicine. Robot-assisted surgeries have

been an ongoing development in the last five decades. The first robot to be used in surgical procedures was the PUMA 560, introduced in 1985 and assisted in performing computed tomography (CT)-guided biopsies of the brain. Almost a decade after the introduction of the PUMA 560, an endoscopic surgical robot called the AESOP (Automated Endoscopic System for Optimal Positioning) was developed. A decade after introducing the AESOP, Intuitive Surgical, in 1997, introduced the Da Vinci Surgery System for laparoscopic surgery, where the first laparoscopic cholecystectomy was performed in Belgium [3]. The Da Vinci system has seen an immense expansion in its utility from general surgery, gynecologic surgery, and cardiac and thoracic surgical procedures.

The limitations in conventional bronchoscopy led the path of innovations over the years to attempt tissue sampling in peripheral airways, beyond the visualization of a bronchoscope. One of these innovations is electromagnetic navigational bronchoscopy (ENB), which is the most common modality used to approach peripheral nodules that are beyond the visualization of the subsegmental anatomy and relies on using a combination of a virtual map of the tracheobronchial tree generated from reconstructed CT images and electromagnetically-mapped images to navigate more peripheral airways and lesions. The other modality is radial-endobronchial ultrasound (R-EBUS) which allows for sonographic visualization of peripheral lung lesions combined with

---

T. Dammad (✉)  
AdventHealth Orlando, Orlando, FL, USA

Houston Methodist, Houston, TX, USA

B. A. Jalil  
Heart and Vascular Institute, West Virginia University,  
Morgantown, WV, USA

**Fig. 26.1** The “Metal-Plated Warrior” designed by Leonardo da Vinci in 1495, the first robot that imitated human movements of the jaw, arms, and neck



guidance sheath, with or without fluoroscopy or ENB. Although prior data suggested diagnostic yields as high as 70%, more recent data suggests the diagnostic yield to be inconsistent and closer to 40–60% [4–6]. There are a multitude of technical concerns with the stability and extension beyond the bronchoscope during sampling of peripheral lung tissue, which may explain the lower diagnostic yield. Robotic-assisted bronchoscopy (RAB) is an attempt to improve on the problems experienced during ENB.

The first robotic-assisted bronchoscopy (RAB) platform is the Monarch (Auris Health), utilizing electromagnetic (EM) Guidance that attained Food and Drug Administration (FDA) approval in March 2018. In February 2019, the FDA approved a second RAB platform, the Ion Robotic Endoluminal platform (Intuitive Surgical), utilizing Shape Sensing Technology. Both platforms comprise similar equipment, including a bronchoscope, a robotic interface, and a controller; however, they have a few operational differences.


## Description and Design

### The Monarch Platform (Auris Health, Inc. Redwood City, CA)

The Monarch RAB platform (Fig. 26.2) consists of four main components: The bronchoscope, cart (robotic arms), tower, and the electromagnetic generator.

The bronchoscope (Fig. 26.3a–c) consists of an inner bronchoscope with an outside diameter of 4.2 mm, a working channel of 2.1 mm, a camera, and an integrated light source that enable direct visualization during the procedure. The outer sheath has a 6 mm outer diameter.

The inner bronchoscope is made to telescope through the outer sheath, and its movement can be coupled or uncoupled when advanced in the bronchial tree. Usually, their movement is uncoupled past the three-fourth generation of the bronchial tree. The outer sheath and inner bronchoscope both offer four-way steering control



**Fig. 26.2** The Monarch RAB platform with its 4 main components: the bronchoscope, cart (robotic arms), tower, and the electromagnetic generator

and articulate up to 180 degrees. This configuration enhances the stability of the bronchoscope and maneuverability of the scope to access lesions further into the lung. The proximal end of the bronchoscope (Fig. 26.3d) is equipped with a valve that accesses the 2.1 mm working channel and enables irrigation, suction, and the insertion of various ancillary tools, such as radial ultrasound probe, needle, brush, or biopsy forceps.

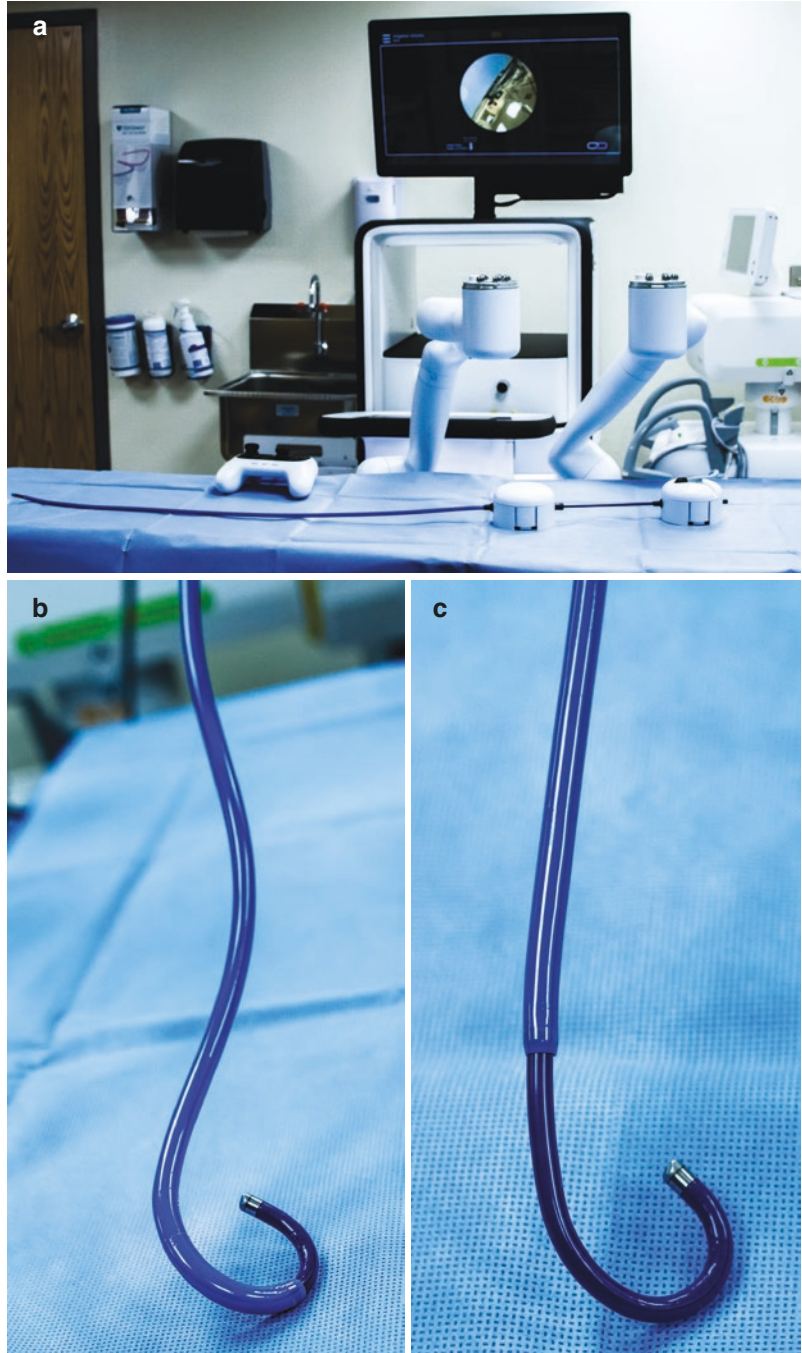The cart (Fig. 26.4) comprises two robotic arms with rotary pulleys (Fig. 26.5) that connect to the bronchoscope cables and exert proper tension to drive the inner bronchoscope and the outer sheath in coupled or uncoupled modes. The bronchoscopist uses a video game-type controller to move the robotic arms to drive and navigate the bronchoscope. The cart contains the electronic systems required to operate the platform and adjust its height and level the robotic arms and the bronchoscope with the entry point of the outer tip of the endotracheal tube.

The tower (Fig. 26.6) connects to the bronchoscope, controller, and the electromagnetic gener-

ator. The controller (Fig. 26.7), with its two joysticks and other control buttons, is used to drive, articulate the bronchoscope, and navigate the screen of the tower to reach the target lesion. The tower has two computers that operate the system, a non-real-time computer and a real-time computer that communicate with each other during the procedure. The non-real-time computer receives input from the pendant, keyboard, mouse, camera, electromagnetic localizer, and power distribution unit. It also contains an interface to the camera at the bronchoscope's tip that performs the necessary image processing and generates video output streams. On the other hand, the real-time computer receives inputs from the non-real-time computer. Real-time video captured from the bronchoscope's tip and overlaid with other information from the robotic system is displayed on the tower monitor.

The electromagnetic field generator is placed close to the patient's chest with the attached reference electromagnetic sensors, and it is an essential tool for navigation guidance [7].

**Fig. 26.3** (a) The Monarch Bronchoscope. Photograph by Leslie Kumpf RRT, CPFT. (b) The Monarch Bronchoscope in articulation. Photograph by Leslie Kumpf RRT, CPFT. (c) The inner bronchoscope of the Monarch platform with the bronchoscope extending beyond the outer sheath. Photograph by Leslie Kumpf RRT, CPFT








**Fig. 26.4** The robotic arms of the Monarch platform



**Fig. 26.6** The bronchoscope tower of the Monarch platform



**Fig. 26.5** A close-up view of the robotic arm of the Monarch platform



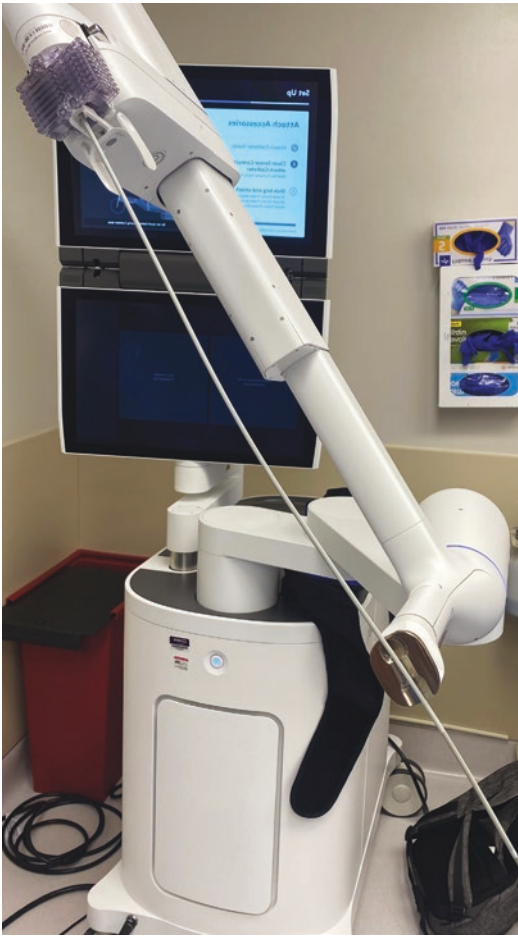**Fig. 26.7** The video-game based controller of the Monarch platform



## The Ion Robotic Endoluminal System (Intuitive Surgical, Sunnyvale, CA, USA)

The Ion Endoluminal System uses shape-sensing technology rather than electromagnetic navigation. It consists of three main components: the flexible robotic catheter (bronchoscope), the robotic cart with display screens, and a controller (Fig. 26.8).

The flexible robotic catheter (bronchoscope) has an outer diameter 3.5 mm and a working channel of 2.0 mm. Within the catheter sits the removable vision probe. The robotic catheter articulates 180 degrees in all directions



**Fig. 26.8** The Ion platform with its components



**Fig. 26.9** The shape-sensing catheter of the Ion platform

(Fig. 26.9). It contains shape-sensing fibers through its entire length that communicates in real-time to the robotic software and system, enabling positional and shape feedback, precise location of the bronchoscope, and its distance to the target and nearest pleural surface, all to ensure smooth maneuverability and precise reach and sampling of the target lesion. The robot cart has display screens that can project the bronchoscopic and radial ultrasound views. Finally, there is a controller cart with a trackball and scroll wheel.

Once the target lesion is reached or approached, the robotic catheter/bronchoscope is locked in position, and the vision probe is removed to enable insertion of diagnostic tools like radial US probe, needles, forceps, or brush. The bronchoscopist receives real-time feedback through the displayed catheter shape, confirming non-slippage.

## Procedure and Technique

Pre-procedure planning is essential for the success of the procedure. It starts with thin-cut chest computed tomography images with a slice thickness of 0.5–1 mm and slice interval of 0.5–0.8 mm.

Three-dimensional virtual lung reconstruction is generated via the software. The target lesion is marked and sized. Then, the robotic system software generates and maps the pathway. Manual planning or segmentation of the airway is possible, especially in the absence of a bronchus sign. The computed tomography scan should preferably be done within 27 days of the procedure.

Metallic objects should be removed from the immediate EM field during the setup, registration, and electromagnetic navigation part of the procedure in the case of the Monarch Robotic System to prevent signal interference. There is no need to this when using the Ion Endoluminal Robotic system.

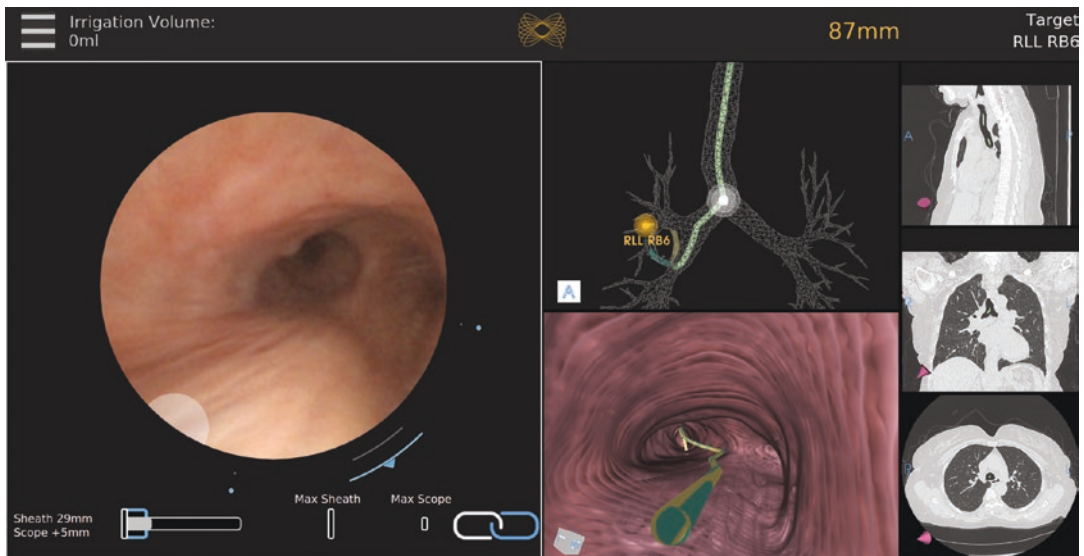
After consent is obtained and time-out is done, the patient undergoes general anesthesia by the anesthesia team. Paralytics are not mandatory but deep sedation is important. Patient is usually intubated with an endotracheal tube no smaller than 7.5 mm. A tidal volume of 8 mL/kg of predicted body weight and positive end expiratory pressure

(PEEP) of 8 to 10 cmH<sub>2</sub>O is recommended to prevent atelectasis in the anesthetized patients.

Conventional flexible bronchoscopy is first done with a flexible bronchoscope to inspect the tracheobronchial tree thoroughly and identify other abnormalities in addition to clearing secretions. Once completed, the flexible bronchoscope is removed and the robotic bronchoscope is advanced to the patient's airways. Next, registration is done to couple virtual anatomy with the patient's real-time airway anatomy. The bronchoscopist thereafter navigates to the target lesion.

In the case of the Monarch Robotic Bronchoscope, the outer sheath and the inner bronchoscope are advanced in coupled mode. Once the segmental airway is reached or around the 3-4th bronchial generation, the outer sheath is locked in place, and the inner bronchoscope is uncoupled and advanced further to navigate to the target lesion. The Monarch platform preserves real-time white light vision, while ancillary tools are utilized at the target lesion (Fig. 26.10).

On the other hand, the robotic catheter of the Ion Endoluminal System with the bronchoscope will reach the target lesion, and it will be locked in position; at that point, the vision probe must be removed



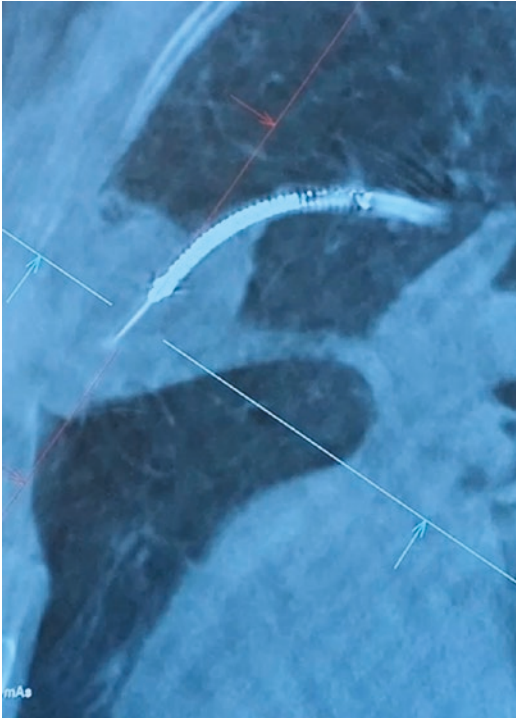
**Fig. 26.10** The view screen of the Monarch platform with a live view, virtual map, and CT images

to enable the utility and insertion of the ancillary tools, losing the white light real-time vision but preserving location by the continuous, real-time feedback of the shape-sensing technology.

Both systems will provide distance from the catheter tip to the lesion, allowing for controlled transbronchial needle aspiration and setting the extension distance of biopsy needle, forceps, or brush.

In patients with implantable cardiac pacemakers or defibrillators, using electromagnetic navigation with the Monarch Robotic System is not advisable. Considering its excellent reach and stability, a recent publication proposed that the Monarch Robotic Bronchoscopy System be used without using electromagnetic guidance in this patient population [8].

Ancillary imaging like fluoroscopy, cone-beam CT (Fig. 26.11), or radial US can be utilized during the procedure. Real-time feedback of tissue/cells acquisition through Rapid-on-site cytological Evaluation (ROSE) is recommended.



**Fig. 26.11** The Ion bronchoscope showing a needle within the lesion on cone-beam CT

## Evidence-Based Review

### Safety and Feasibility

Both current robotic systems are safe with low complication rates, and in general are very comparable to conventional flexible bronchoscopy safety's profile. The first feasibility and safety study were performed by Rojas-Solano et al., in 2018 using the Monarch RAB system in 15 patients with suspicious Pulmonary nodules and bronchus sign. The average nodule size was 26 mm (10–63 mm). Biopsies were obtained in 93% of patients with no occurrence of pneumothorax nor significant bleeding [9].

Fielding et al., in 2019, reported the first use of shape-sensing technology of the Ion Endoluminal Robotic System in the diagnosis of peripheral lung nodules in humans. He included 29 subjects with a mean lesion size of around 12 mm. The CT bronchus sign was absent in 41.4% of cases. In 96.6% of cases, the target was reached, and samples were obtained. No complications were noted in the study. The overall diagnostic yield was 79.3%, and a diagnostic yield for malignancy was 88%. This first Ion study concluded that the system is safe and able to navigate to the very periphery of the lung, reaching small pulmonary nodules and, due to its stability, provided excellent diagnostic yield [10].

Chaddha et al., in 2019 (165 patients) study of the Monarch system, reported 3.6% overall pneumothorax incidence (2.4% required intervention) [11], and Chen et al., in a 2021 study of 54 patients, reported a 3.7% overall pneumothorax rate and only 1.9% required intervention [7].

In the case of the Ion Endoluminal Robotic System, Kalchier-Dekel et al. in 2021 reported a 1.5% pneumothorax rate in a study that included 131 patients [12] and a 3.3% rate (0.4% requiring intervention for pneumothorax in a larger study that included 241 patients by Reisenauer et al. in 2022 [13]. There was no reported mortality in any of the studies.

## Diagnostic Yield

### Monarch RAB

Chaddha et al. [11], in a multi-center retrospective study of 167 lesions (71% were in the outer third of the lung), 165 patients were included in the analysis, with an average follow-up of  $185 \pm 55$  days. The average size of target lesions was  $25.0 \pm 15.0$  mm. An excellent safety profile was demonstrated where pneumothorax and airway bleeding occurred in 3.6 and 2.4% cases, respectively. Reaching the target was successful in 88.6% of cases, and biopsies were successfully obtained in 98.8%. The diagnostic yield estimates ranged between 69.1% and 77%, assuming the cases of biopsy-proven inflammation without any follow-up information ( $N = 13$ ) were non-diagnostic and diagnostic, respectively. The yield was 81.5, 71.7, and 26.9% for concentric, eccentric, and absent r-EBUS views, respectively. Diagnostic yield was not affected by lesion size, density, lobar location, or centrality.

The study concluded that RAB implementation in community and academic centers is safe and feasible, with an initial diagnostic yield of 69.1–77% in patients with lung lesions that require diagnostic bronchoscopy. It is important to mention that diagnostic yield in this study was defined as the percentage of procedures yielding a diagnosis based on final pathology.

In the first prospective, multi-center study (The BENEFIT study) of total 54 patients, Chen et al. [7] demonstrated a very high lesion localization rate of 96.2% of peripheral lesions with a median diameter of 23 mm. Bronchus sign was present in 59.3%, R-EBUS was utilized, and diagnostic yield was 74.1%. Pneumothorax was reported in 2 of 54 cases (3.7%); tube thoracotomy was required in 1 of the cases (1.9%). No additional adverse events occurred.

### Ion Endoluminal Robotic System

Feilding et al. were the first to use it in humans, as mentioned earlier in 29 patients with a mean lesion size of 14 mm diameter roughly and bron-

chus sign present in 58.6%. The diagnostic yield in his study was 88%. The same diagnostic yield was re-demonstrated in three other studies. Benn et al. [14] combined robotic bronchoscopy with cone-beam CT for secondary confirmation in 52 patients with predominantly upper lobe solid nodules with diameter less than 2 cm. The main objective was to determine the overall diagnostic accuracy of the technique and sensitivity of malignancy. Bronchus sign was present in 46% of the patients. An 84% procedural sensitivity for malignancy and an overall 86% diagnostic yield were achieved when all biopsy results and follow-up imaging were included in the analysis. The study concluded that combining RAB with cone beam CT increases sensitivity for malignancy and diagnostic accuracy of lung nodule biopsies.

Another publication of the shape-sensing technology of RAB in 2021 by Kalchier-Dekel et al. [12] evaluated the feasibility, diagnostic yield, and determinants and found an overall diagnostic yield of 81.7%. A total of 159 pulmonary lesions were targeted with a median lesion size of 1.8 cm (1.3–2.7 cm) and bronchus sign present in 62.9%. Two-thirds of the lesion were located beyond the sixth-generation airway. Lesions at or larger than 1.8 cm had a much higher diagnostic yield, concluding that lesion size remains a major predictor of the diagnostic procedure. The overall complication rate was 3.0%, and the pneumothorax rate was 1.5%.

Ost et al. in a prospective multi-center analysis of shape-sensing robotic-assisted bronchoscopy for the biopsy of pulmonary nodules (The PRECISE study) published preliminary results of 155 enrolled patients with a mean nodule diameter of 17 mm where 69% located in the upper lobes and bronchus sign only present in 25% of cases. Diagnostic yield was 82% for nodules at or less than 20 mm and 85% for nodules >20 mm. One asymptomatic pneumothorax was reported, and no chest tube placement was needed (Table 26.1).



**Table 26.1** A summary of available literature of the feasibility, diagnostic outcomes and safety of RAB

Study	Robotic platform	Patients number (N)	Lesion size mm (Mean/range)	Bronchus sign	Diagnostic outcome/yield	Pneumothorax (Chest tube rate)
2018 Rojas-Solano	Monarch	15	26 (10–63)	100%	NR	0%
2019 Fielding	Ion	29	14.8 (10–26.4)	58.6%	88.0%	0%
2019 Chaddha	Monarch	165	25	63.5%	69.1%	3.6% (2.4%)
2020 Chen	Monarch	54	23 (10–50)	59.3%	74.1%	3.7% (1.9%)
2021 Kalchiem	Ion	131	18 (13–27)	62.9%	81.7%	1.5% (1.5%)
2021 Benn	Ion/ CBCT	52	21.9 (7–60)	46%	86%	3.8% (1.4%)
2021 Reisenauer	Ion	241	18.8 (10–27)	NR	NR	3.3 (0.4%)
2021 (preliminary) Ost	Ion	155	17 (10–27)	25%	83%	(0.0%)

## Therapeutic Robotic-Assisted Bronchoscopy

The current literature is encouraging that RAB can reach further in the lung periphery with a steady, stable scope position. In real-time, combined with 3D fluoroscopy or cone-beam CT, a diagnosis of the target lesion can be made. This approach opens the door for ablative therapies like microwave probes, LASER, photodynamic therapy, and cryoablation and to the delivery of certain therapeutics in non-operable patients when appropriate. Studies are still needed to ensure feasibility, safety, and document outcomes.

## Summary

Despite the advances in innovation and early data suggesting a role for the use of robotic bronchoscopy in peripheral lesions, the adoption of this platform is still in its infancy. As with any new technology, many logistical limitations prevent the widespread adaptation of robotic bronchoscopy in current times. First and foremost, the equipment cost may be prohibitive in early adap-

tation until a clear advantage in yield, a decreased need for additional procedures, or a shorter procedure time is apparent. The complexity of equipment set-up in operating rooms and bronchoscopy suites, as well as training of clinicians as well as ancillary staff all follow a steep learning curve, which further slows down the adoption process. Larger prospective studies are needed to explore the utility and efficacy of RB for peripheral lesions in the future.

These platforms may also guide the way to peripheral lesions with superior stability to deliver ablative therapies for inoperable peripheral lung tumors, such as photodynamic therapy, LASER, radiofrequency ablation, cryoablation, and microwave ablation. Further combination of RAB with cone-beam CT may increase the already higher precision offered by RAB, although this is still to be studied and applied in routine clinical practice.

## References

1. Valero R, et al. Robotic surgery: history and teaching impact. *Actas Urol Esp.* 2011;35(9):540–5.
2. Patel RP, Casale P. Robotic pediatric urology. *Minerva Urol Nefrol.* 2007;59(4):425–7.



3. Ballantyne GH. Robotic surgery, telerobotic surgery, telepresence, and telementoring. Review of early clinical results. *Surg Endosc.* 2002;16(10):1389–402.
4. Eberhardt R, et al. Multimodality bronchoscopic diagnosis of peripheral lung lesions: a randomized controlled trial. *Am J Respir Crit Care Med.* 2007;176(1):36–41.
5. Wang Memoli JS, Nietert PJ, Silvestri GA. Meta-analysis of guided bronchoscopy for the evaluation of the pulmonary nodule. *Chest.* 2012;142(2):385–93.
6. Folch EE, et al. Electromagnetic navigation bronchoscopy for peripheral pulmonary lesions: one-year results of the prospective, Multicenter NAVIGATE Study. *J Thorac Oncol.* 2019;14(3):445–58.
7. Chen AC, et al. Robotic bronchoscopy for peripheral pulmonary lesions: a multicenter pilot and feasibility study (BENEFIT). *Chest.* 2021;159(2):845–52.
8. Murgu SD. Robotic assisted-bronchoscopy: technical tips and lessons learned from the initial experience with sampling peripheral lung lesions. *BMC Pulm Med.* 2019;19(1):89.
9. Rojas-Solano JR, Ugalde-Gamboa L, Machuzak M. Robotic bronchoscopy for diagnosis of suspected lung cancer: a feasibility study. *J Bronchology Interv Pulmonol.* 2018;25(3):168–75.
10. Fielding DIK, et al. First human use of a new robotic-assisted fiber optic sensing navigation system for small peripheral pulmonary nodules. *Respiration.* 2019;98(2):142–50.
11. Chaddha U, et al. Robot-assisted bronchoscopy for pulmonary lesion diagnosis: results from the initial multicenter experience. *BMC Pulm Med.* 2019;19(1):243.
12. Kalchier-Dekel O, et al. Shape-sensing robotic-assisted bronchoscopy in the diagnosis of pulmonary parenchymal lesions. *Chest.* 2021;161(2):572–82.
13. Reisenauer J, et al. Ion: technology and techniques for shape-sensing robotic-assisted bronchoscopy. *Ann Thorac Surg.* 2022;113(1):278–315.
14. Benn BS, et al. Robotic-assisted navigation bronchoscopy as a paradigm shift in peripheral lung access. *Lung.* 2021;199(2):177–86.



# Mediastinoscopy, Its Variants and Transcervical Mediastinal Lymphadenectomy

# 27

Ramón Rami-Porta and Sergi Call

## Introduction and Definition of the Procedure

Mediastinoscopy is a surgical procedure that allows the inspection and the palpation of the upper mediastinum as well as the taking of biopsies of lymph nodes, tumours or any other tissue within the range of the exploration. For lung cancer staging, the range of exploration includes the cervical lymph nodes of the sternal notch; the lymph nodes along the trachea and both main bronchi, that is, the superior and inferior, left and right, paratracheal lymph nodes; the subcarinal nodes and the right and left hilar lymph nodes, according to the International Association for the Study of Lung Cancer (IASLC) lymph node map [1]. Inspection and palpation of the upper mediastinum are essential to identify the lymph nodes,

see their aspect and feel their consistency and degree of attachment to mediastinal structures, as well as to differentiate between mere contact and tumour invasion of the mediastinum. The removal or the taking of biopsies of lymph nodes is performed under direct vision, and these specimens allow the pathologist to examine the status of the nodal capsule and the involvement of the extranodal tissues that are criteria of incomplete resection [2].

## History and Historical Perspective

When Eric Carlens described the technical details of mediastinoscopy and reported six exemplary cases in 1959, he had already performed more than 100 procedures without complications [3]. Mediastinoscopy was the culmination of a series of procedures developed to diagnose intrathoracic diseases without relying on thoracotomy. As early as 1942, Albanese, from Buenos Aires, Argentina, described an incision over the sternocleidomastoid muscle to explore and biopsy the paratracheal and the para-oesophageal lymph nodes [4]. Seven years later, in 1949, Daniels described the biopsy of the scalene fat pad through a small supraclavicular incision. This biopsy allowed the diagnosis and staging of lung, digestive and gynaecological cancers and the diagnosis of intrathoracic inflammations and infections, such as sarcoidosis and tuberculosis,

R. Rami-Porta (✉)  
Thoracic Surgery Service, Hospital Universitari Mútua Terrassa, University of Barcelona, Terrassa, Spain

Network of Centres for Biomedical Research in Respiratory Diseases (CIBERES), Lung Cancer Group, Terrassa, Spain

S. Call  
Thoracic Surgery Service, Hospital Universitari Mútua Terrassa, University of Barcelona, Terrassa, Spain

Department of Morphological Sciences, Medical School, Autonomous University of Barcelona, Bellaterra, Spain

respectively [5]. A step forward was the insertion of a laryngoscope through the cervical incision performed to reach the scalene fat pad. This exploration was a limited unilateral mediastinoscopy and was published in 1954 by Harken et al. [6] One year later, Radner used an incision over the cervical midline to explore the paratracheal lymph nodes [7].

Mediastinoscopy was quickly spread in Europe as the books by Otto Jepsen [8] and by Tauno Palva [9] show. The main advantage of mediastinoscopy was that it allowed the diagnosis of intrathoracic diseases with no need to open the chest cavity. For lung cancer, diagnosis and staging were simultaneous in many cases. Tuberculosis, sarcoidosis, silicosis, vascular anomalies, mediastinal tumours and inflammation could also be diagnosed via this transcervical approach. Its systematic indication in the clinical staging before lung resection showed that those lung cancers with involved mediastinal lymph nodes identified at mediastinoscopy had worse prognosis than those with nodal disease identified at thoracotomy [10]. This gave a prognostic perspective to the procedure in addition to diagnosis and staging. With the introduction of computed tomography (CT) in clinical practice, the most common trend was to indicate mediastinoscopy when there were abnormal lymph nodes [11]. However, some authors favoured its systematic use, regardless of the size of the lymph nodes on CT, even for early stages [12].

The design of the video-mediastinoscope by Lerut in 1989 and of the two-bladed video-mediastinoscope by Linder and Dahan in 1992 increased the possibilities of the exploration for staging and therapeutic indications, leading to mediastinal lymphadenectomy and complex therapeutic procedures, such as closure of bronchopleural fistula and lobectomy through the transcervical approach [13–17].

## Indications and Contraindications

For lung cancer staging, the guidelines of the American College of Chest Physicians (ACCP) revised in 2013 recommend invasive nodal staging in the following situations: (a) discrete medi-

astinal lymph node enlargement with or without positron emission tomography (PET) uptake in mediastinal lymph nodes; (b) PET activity in mediastinal lymph nodes and abnormal lymph nodes on CT; (c) high suspicion of N2 or N3 disease either by lymph node enlargement on CT or PET uptake and (d) intermediate suspicion of N2 or N3 disease by CT and PET, a central tumour or N1 disease. According to these guidelines, invasive mediastinal staging would not be indicated in patients with massive mediastinal infiltration or in those with stage IA tumours without any mediastinal nodal abnormality on CT and PET [18].

In a similar way, the recommendations for invasive mediastinal staging of the revised European Society of Thoracic Surgeons (ESTS) guidelines are (a) positive mediastinal nodes on CT, PET or PET-CT; and (b) when there is no evidence of N2–N3, but there is suspicion of N1 disease, in central tumours larger than 3 cm and in adenocarcinomas with high PET uptake. Invasive staging could be spared in patients with no enlarged lymph nodes on CT or abnormal uptake on PET and tumours less than 3 cm in greatest dimension located peripherally in the outer one-third of the lung [19].

The ACCP and the ESTS favour the use of endoscopic procedures for initial invasive staging, such as transbronchial needle aspiration (TBNA), endobronchial ultrasound-guided fine-needle aspiration (EBUS-FNA) or oesophageal ultrasound-guided FNA (EUS-FNA). If these explorations are positive for cancer, the information may be adequate to start a multidisciplinary treatment protocol. However, if they are unavailable or negative, a surgical technique is recommended, instead, to confirm their negative results, because their negative predictive value is too low to make further therapeutic decisions [18, 19]. Regarding the indication of a surgical technique to confirm a negative result of an ultrasound-guided endoscopic needle aspiration or biopsy, the North American guidelines state that a surgical technique should be performed when there is high suspicion of nodal involvement [18]. On the other hand, the European guidelines recommend either EBUS-TBNA/EUS-FNA or video-assisted mediastinoscopy for tumours with an intermedi-

ate risk of nodal disease (central tumours, suspicion of N1 by CT and/or PET, tumours larger than 3 cm and adenocarcinomas with a high PET uptake) depending on the local expertise and adherence to the minimal requirements for staging [19]. The ambiguity of both guidelines regarding what has to be done after a negative endoscopy may be responsible for the fact that not all negative results of EBUS-TBNA/EUS-FNA are confirmed by a surgical technique. When the latter are performed, mediastinoscopy usually is the procedure of choice, but mediastinotomy or thoracoscopy could be performed if the target lesion is within the range of these explorations.

The ESTS guidelines also recommend to pathologically confirm tumour response after induction therapy. As at initial staging, this can be done by endoscopic techniques, but if their results are negative, then a surgical procedure is recommended. Over the years, remediastinoscopy has proved to be a safe and reliable restaging method [20–22]. It is important to confirm or rule out persistent nodal disease and tumour progression after induction therapy. Persistent nodal involvement and progressive disease are unfavourable prognostic factors and lung resection should be avoided because it does not add any survival benefit [20, 23, 24]. With the increased use of EBUS-TBNA and EUS-FNA for initial staging, the sequence ‘staging mediastinoscopy–restaging remediastinoscopy’ is not so common now. If nodal disease has been diagnosed at staging endoscopy, then the same endoscopy can be used for restaging. If this is negative, mediastinoscopy can be indicated to confirm the results. This restaging mediastinoscopy will not be a reoperation and will be performed without having to negotiate the adhesions caused by the initial exploration. Alternatively, thoracoscopy can be used for restaging after a staging mediastinoscopy with results similar to those of remediastinoscopy [25].

There are very few contraindications. Severe neck rigidity and large goitres are anatomic abnormalities that can prevent the correct insertion of the mediastinoscope, but they are extremely rare in lung cancer patients. Aortic aneurism is a contraindication, because the aortic

arch is compressed by the mediastinoscope when it is inserted in front of the trachea and may be injured. Abnormal coagulation tests are a relative contraindication. As in any other intervention, they should be corrected before the operation and the operation rescheduled when they are normalized. In the past, superior vena cava obstruction, a previous mediastinoscopy or a previous mediastinal operation by median sternotomy, tracheostomy or total laryngectomy were considered contraindications, but experience has proved that mediastinoscopy can be performed safely when other less invasive procedures have not established a diagnosis [26, 27].

---

## Description of the Equipment Needed

### General

For the incision and initial dissection, the following instruments are needed: standard surgical knife, dissection forceps, Mayo and Metzenbaum scissors and a right-angle dissector. Silk 2-0 sutures may be necessary to ligate small anterior jugular veins. Absorbable 2-0 and 3-0 sutures are used to close the incision in two layers: platysma and subcutaneous tissue together and skin, respectively.

### Specific

There are two types of scopes: the conventional ones and the video-mediastinoscopes that, since the late 1980s, are progressively replacing the former. Mediastinoscopes are in the right-angle shape, with the vertical arm as handle and the horizontal arm, in the shape of a truncated cone, as the scope proper. The conventional mediastinoscopes are in a single piece and the video-mediastinoscopes are made either in a single piece or in two spreadable blades to widen the operative field. Video-mediastinoscopes are connected to a camera and the exploration is seen on a television monitor. The equipment is completed with a light source and a recorder to register the operations.

The dissection-suction-coagulation device is fundamental to dissect and identify the lymph nodes from the peritracheal fatty tissue. Suction keeps the operative field clean at all times and coagulation controls bleeding from small veins, lymph nodes or fatty tissue.

A glass tube connected to a needle on one end and to suction on the other is used for puncture test when the nature of the structure to be biopsied is not clear. This is more useful when the conventional mediastinoscope is used. Mediastinal structures are much better seen with the video-mediastinoscope and this makes the puncture test rarely necessary.

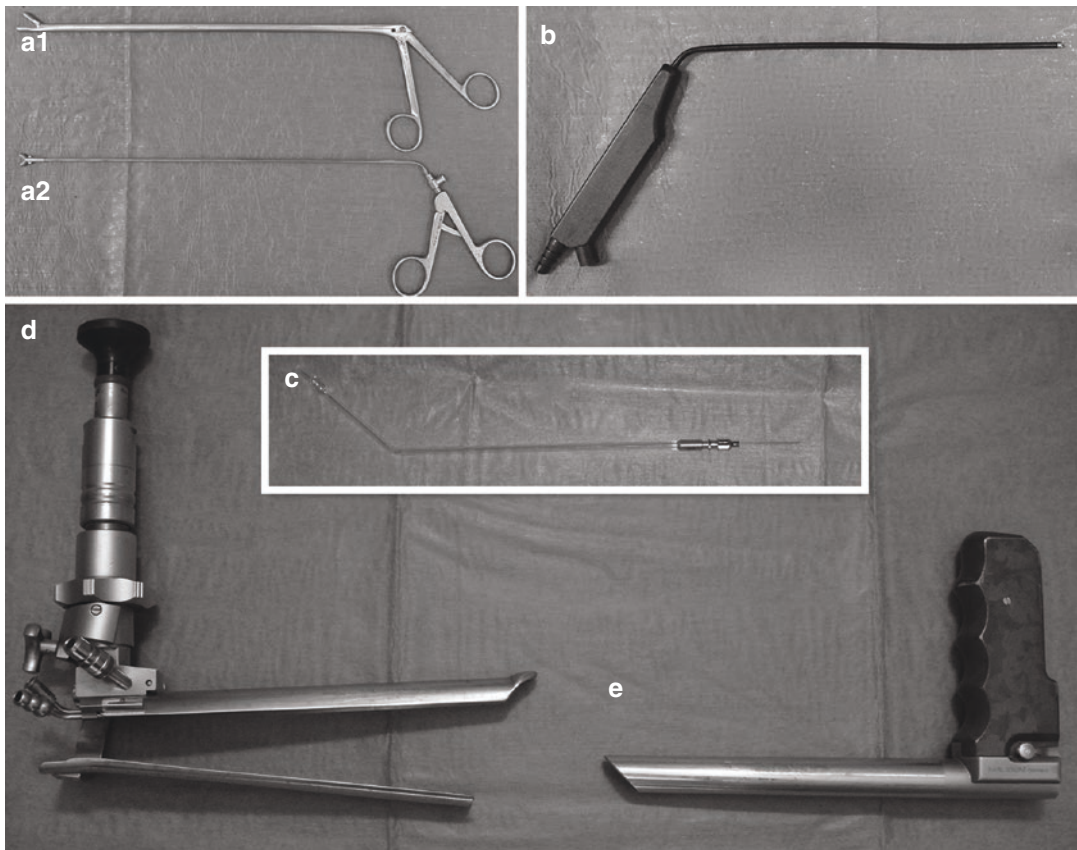
There are several types of biopsy forceps. Some are spherical and others, oval, and they come in different sizes.

There also are several types of graspers and ring forceps that allow the surgeon to hold the tis-

sue with one hand and dissect with the other, while the assistant holds the mediastinoscope in place.

Endoscopic clips should be available in case clipping of the bronchial arteries is necessary. The new energy devices for haemostasis and cutting may reduce the risk of bleeding and are easy to use especially with the two-bladed video-mediastinoscope that allows a larger operative field for the insertion of these devices. They are especially valuable at the beginning of the learning curve to reduce the risk of bleeding and of injury of the left recurrent laryngeal nerve, because the heat does not spread to the tissues close to the blades of the device. These devices can safely coagulate vessels of up to 8 mm in diameter.

Figure 27.1 shows the basic instruments for mediastinoscopy; and Fig. 27.2, the general view of the operative field. Figure 27.3 shows the use of an energy device in the subcarinal space.

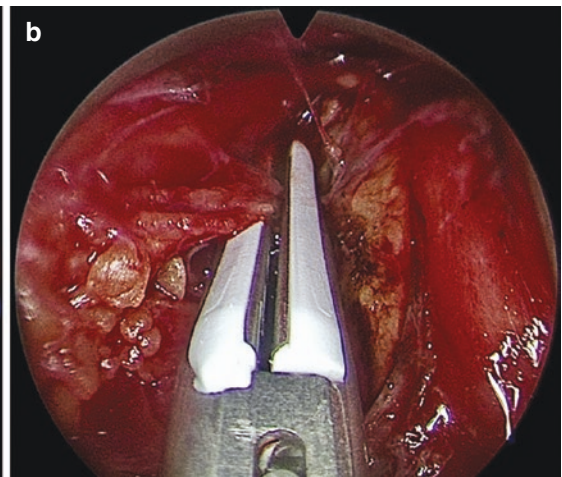
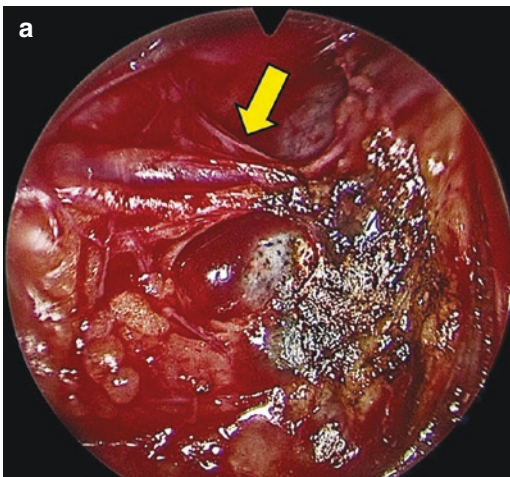
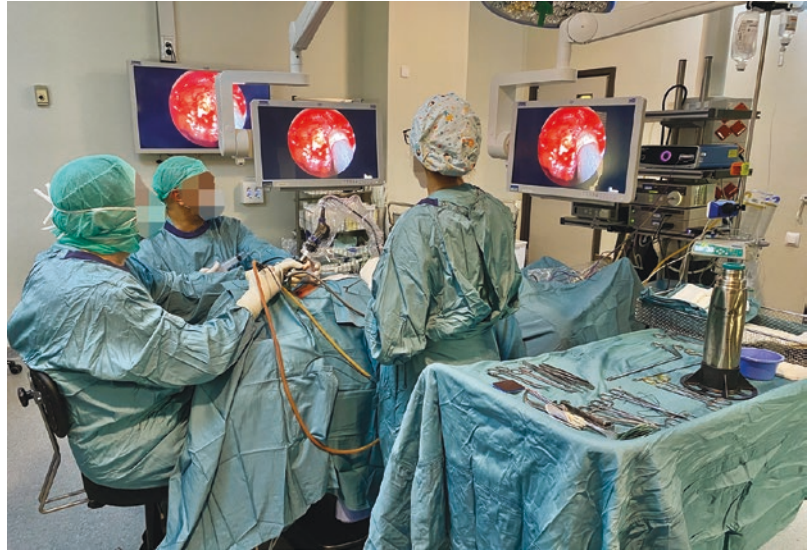

**Fig. 27.1** Basic instruments set: (a1) Biopsy forceps with oval jaws, size 8 mm × 16 mm. (a2) Biopsy forceps with spherical jaws, size 5 mm. (b) Dissection-suction-coagulation

cannula. (c) Glass tube connected to a needle for puncture test. (d) Linder-Dahan two-bladed spreadable video-mediastinoscope. (e) Lerut video-mediastinoscope



**Fig. 27.2** View of an integrated operating room. This operating room has two room-mounted displays and a 40" plasma monitor on the wall with the aim to avoid trip-hazards caused by cabling and allowing easy access and visibility to the surgical video. For the different surgical exploration of the mediastinum, one of the monitors is located in front of the surgeon at the patient's feet. The surgeon sits comfortably on a chair at the patient's head



**Fig. 27.3** Use of an energy device in the subcarinal space: (a) endoscopic view of a small bronchial artery (yellow arrow); (b) coagulation and cutting of the artery using an energy device

### Application of the Technique

The surgical technique is essentially the same Carlens described in 1959, [3] but several variants have been developed to widen the range of the exploration and to increase its sensitivity.

### Preoperative Care

Patients planned to undergo mediastinoscopy should have a complete history and physical examination. It is important to know if the patient had previous interventions in the neck

and in the mediastinum, i.e. cervicotomy for goitre or neck tumours, tracheostomy, laryngectomy or median sternotomy for mediastinal or heart diseases. These rarely contraindicate mediastinoscopy, but the surgeon should be aware of them. Neck flexibility should be checked, too, because it is important to properly insert the mediastinoscope. Complete blood count and biochemistry, as well as coagulation tests, should be available before the operation. For those patients with high or moderate risk for thromboembolism (patients with a mechanical heart valve, atrial fibrillation or venous thrombosis) bridging anticoagulation is recommended with therapeutic doses of subcutaneous low-molecular-weight heparin five days before the operation. Regarding the perioperative antiplatelet therapy, it is recommended to stop aspirin and clopidogrel 5–7 days prior to surgery and restart within 24 h after surgery, except for doses of 100 mg of aspirin, that do not need to be stopped [28]. In any case, the discontinuation of anticoagulation and antiplatelet therapy should be assessed individually depending on the indication of the drugs and the risk of bleeding associated with the procedures [29].

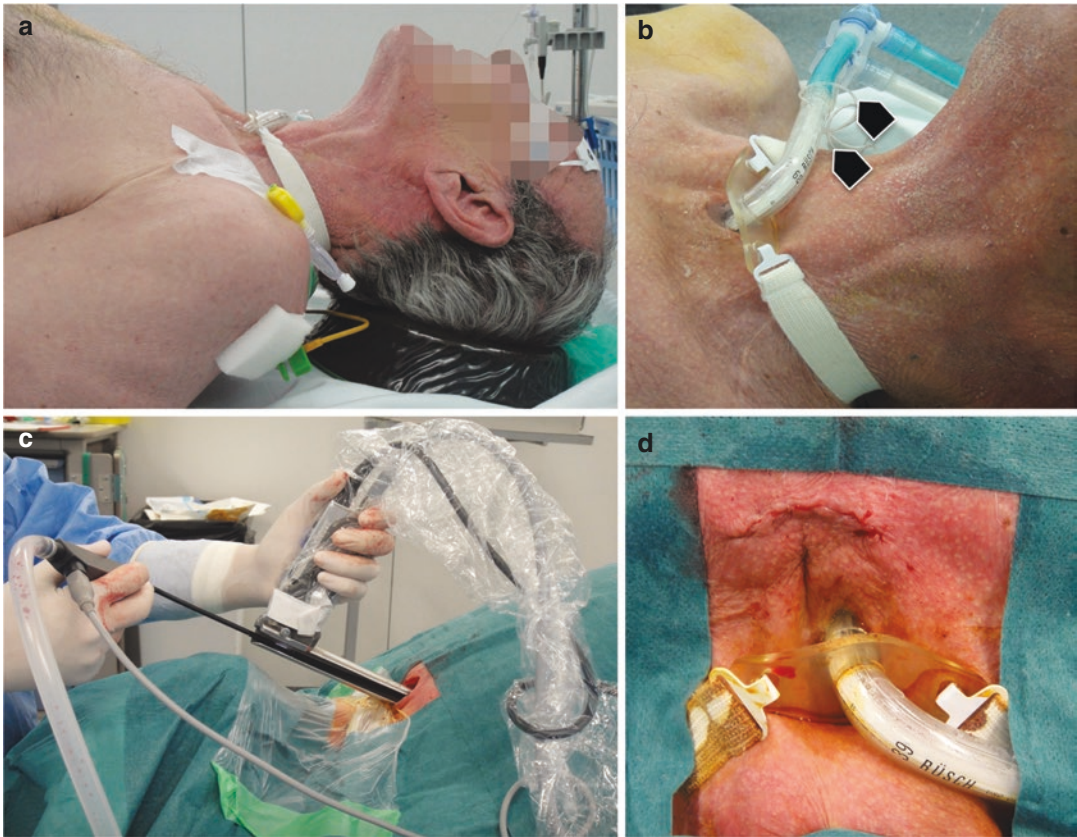
Chest x-rays, CT of the chest and PET are necessary to identify the target areas in the mediastinum and should be available at the time of the operation. Although mediastinoscopy should be as complete as possible in all cases, if the surgeon knows the location of the abnormal lymph nodes or the site where the tumour contacts the mediastinum, these areas are not likely to be missed. The patient should be seen by an anaesthesiologist to assess the risk associated with general anaesthesia, and should be informed of the most frequent complications (left recurrent laryngeal nerve palsy, pneumothorax) and of the rare but potentially fatal ones (bleeding, tracheo-bronchial and oesophageal perforation), as well as of the potential need for blood transfusion. The patient is required to sign an informed consent form.

## Patient's Position and Operative Field

Under general anaesthesia and oro-tracheal intubation, the patient is positioned in the supine decubitus. A double-lumen oro-tracheo-bronchial tube may be necessary if additional procedures are planned. For standard intercostal thoracoscopy or for mediastino-thoracoscopy, for which opening of the mediastinal pleura to reach the pleural space is required during mediastinoscopy, selective single-lung ventilation is needed to inspect the pleural space properly. The patient's shoulders are raised with a long sand cushion. This allows some hyperextension of the neck and exposure of a long segment of the intrathoracic trachea, especially in young patients. The patient's head is allowed to rest on a circular rubber pillow to prevent displacement during the operation. In addition to the EKG leads and the blood pressure cuff, a pulse metre is fixed in one right-hand finger to control the occlusion of the innominate artery that may occur during mediastinoscopy, when excessive pressure is exercised on the artery with the mediastinoscope against the anterior chest wall. Repositioning the mediastinoscope will easily relieve this pressure (Fig. 27.4).

An operative field is prepared and draped from the mandible, cranially, to the xiphoid, caudally, and from nipple to nipple, laterally. An extra drape is positioned caudal to the sternal notch to cover the sternum. In case median sternotomy is needed during mediastinoscopy, this drape can be quickly removed.

The surgeon either stands or sits at the head of the patient, depending on the moment of the operation. The assistant is besides the surgeon, on the right or on the left, and the scrub nurse stands on the right. The television monitors, if the procedure is performed with a video-mediastinoscope, are positioned at the patient's feet and in front of the scrub nurse (Fig. 27.2).



**Fig. 27.4** Patient with tracheostomy, a classic contraindication of mediastinoscopy. The patient had a centrally located tumour and mediastinoscopy was indicated to rule out mediastinal nodal disease. (a) Position of the patient for videomediastinoscopy. The neck is hyperextended and

the head rests on a circular pillow. (b) A double-lumen oro-tracheo-bronchial tube (black arrows) is inserted because a pleural inspection was planned. (c) Insertion of the videomediastinoscope. (d) View of the wound after closing the incision with absorbable intradermal suture

### Incision and Initial Dissection

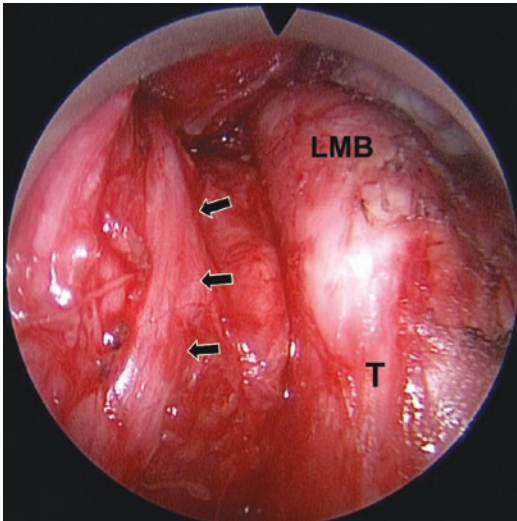
A 5-cm collar incision is performed as close to the sternal notch as possible. After incising the skin, subcutaneous tissue and platysma, the avascular midline is incised and the paratracheal muscles are dissected and separated laterally. Although this is a low-neck incision, sometimes the thyroid gland can be found covering the trachea. By blunt dissection and finger retraction, the thyroid gland can be pulled cranially to allow the insertion of the mediastinoscope. The pretracheal fascia is intimately attached to the trachea. It is held with dissection forceps and incised with scissors. The fascia is further separated from the trachea by finger dissection: the index finger is

inserted into the fascial opening and the finger is carried caudally tearing most of the length of the pretracheal fascia.

### Palpation

Contrary to other endoscopies performed in virtual cavities, i.e. the pleural cavity (pleuroscopy), the peritoneum (laparoscopy) or a joint (arthroscopy), there is no mediastinal space as such. A space must be created in the upper mediastinum by finger dissection. In addition to creating an adequate mediastinal space, palpation allows the surgeon to feel the size, consistency and degree of attachment of mediastinal lymph nodes, medi-





**Fig. 27.5** Endoscopic view of left paratracheal space. Black arrows show left recurrent laryngeal nerve. *LMB* left main bronchus; *T* trachea

astinal tumours or bronchogenic carcinomas with direct mediastinal contact or invasion.

Palpation must be systematic and the anatomical landmarks must be recognized. In the typical case, after inserting the distal phalange of the index finger, the pulsation of the innominate artery can be felt. In young patients, when the neck is hyperextended, the innominate artery may become cervical and may be seen after completing the cervical incision. In older patients, the innominate artery may be located more caudally, if the neck cannot be hyperextended, or more cranial if the aortic arch is elongated. In all these circumstances, care must be taken not to injure it in these initial manoeuvres. Following the course of the innominate artery on the left, the aortic arch can be felt. Then, the finger is passed more distally behind the aortic arch. By palpation, the tracheal cartilages can be felt. Close to the carina, they are disrupted, as the trachea separates into the two main bronchi.

### Insertion of the Mediastinoscope and Mediastinal Inspection

After creating a peritracheal space by finger palpation, the mediastinoscope is inserted into the upper mediastinum. At this point, the exploration

is performed more comfortably if the surgeon sits on a chair. The heights of the operating table and of the chair have to be regulated to relieve tension at the surgeon's shoulders and elbows (Fig. 27.2).

From top to bottom, the pulsation of the innominate artery is seen first. The pulsation of the ascending aorta is seen on the left. More caudally, at the level of the right tracheo-bronchial angle, the azygos vein can be identified. The fatty tissue of the right paratracheal space has to be dissected to find the azygos vein. This landmark is important because, according to the new regional lymph node map, nodes caudal to the inferior rim of the azygos vein are coded as right hilar nodes, or 10R, although they are anatomically located in the mediastinum [1]. If the dissection is carried out more distally on the right, the whole length of the right main bronchus can be seen and, in some patients, even the origin of the right upper lobe bronchus. Over the right main bronchus the right pulmonary artery is found, usually the distal end of the exploration on the right. Over the subcarinal space, the prolongation of the pretracheal fascia has to be torn to reach the subcarinal nodes. The right pulmonary artery crosses in front of them and the oesophagus is behind. Care must be taken not to injure these structures. If the integrity of the oesophagus is questionable, a naso-oesophageal tube can be inserted and air injected into it. With the subcarinal space flooded with saline, an air leak will be evident if there is an oesophageal perforation. In more than three thousand mediastinoscopies, we have inserted a naso-oesophageal tube once, only, to rule out oesophageal perforation. On the left, it is important not to injure the recurrent laryngeal nerve that runs along the left paratracheal margin (Fig. 27.5). The left tracheo-bronchial angle can be identified and, distal to it, the left pulmonary artery, marking the end of the exploration on the left. Nodes caudal to its upper rim are now coded as left hilar nodes, or 10 L [1].

### Biopsy

Lymph node biopsies for lung cancer staging must be systematically taken to obtain the maximal benefit from the exploration. Ideally, the tak-

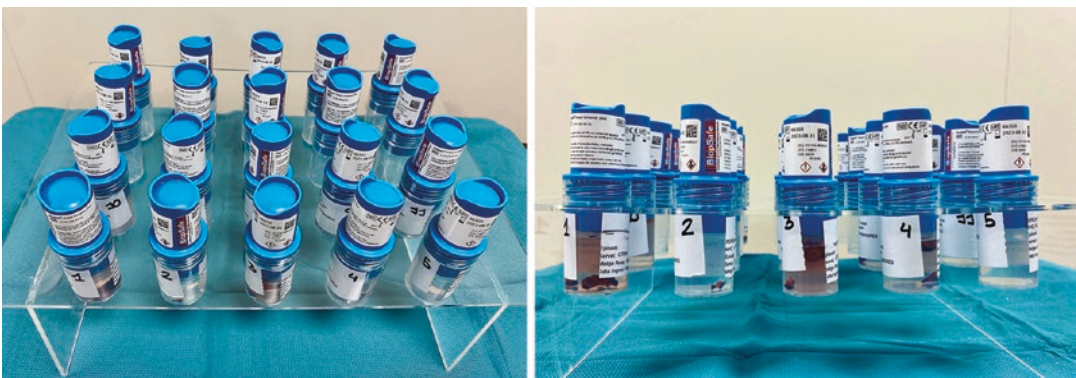ing of biopsies should start on the contralateral side to the tumour to rule out N3 disease. Macroscopically abnormal nodes should be sent for frozen section examination and, if nodal involvement is identified, mediastinoscopy may be terminated unless the patient is in a protocol that requires more information on the extent of nodal disease. Then, the subcarinal and the ipsilateral paratracheal nodes are biopsied. If the nodes are not removed entirely, the initial biopsies of each lymph node are ideal to examine the involvement of the nodal capsule and the extranodal tumour invasion. Each complete node or all the biopsies from one node are kept in a container and properly labelled according to the present nodal nomenclature [1]. This makes the counting of the removed and involved nodes much easier and reliable (Fig. 27.6). Whenever possible, it is better to remove the entire nodes to avoid missing micrometastases and increase the sensitivity of the exploration. Mediastinal lymph nodes are embedded in the peritracheal fatty tissue. Exploration of this fatty tissue with the dissection-suction-coagulation device allows the surgeon to identify them and free them from their surroundings. Sometimes, fragments of lymph nodes or whole small lymph nodes are suctioned during dissection. In this case, it is recommendable to filter the contents of the suction container to retrieve the suctioned lymph nodes or their fragments for pathological examination.

Mediastinoscopy allows the surgeon to reach the cervical nodes at the sternal notch, the supe-

rior and inferior paratracheal nodes on both sides, the subcarinal nodes and the right and left hilar nodes. However, the superior paratracheal nodes are hidden by the mediastinoscope when it is inserted and are not easy to identify. They are better explored and biopsied in the open fashion at the time of cervicotomy. The European Society of Thoracic Surgeons (ESTS) guidelines require biopsies from, at least, one right and one left inferior paratracheal nodes, and one subcarinal node for an acceptable mediastinoscopy in clinical practice. In addition, the superior paratracheal and hilar stations should be explored, if there is imaging suspicion of nodal involvement. For cancers of the left lung, exploration of the subaortic and para-aortic nodes is also required, either by left parasternal mediastinotomy, extended cervical mediastinoscopy or left thoracoscopy [19] (Fig. 27.7).

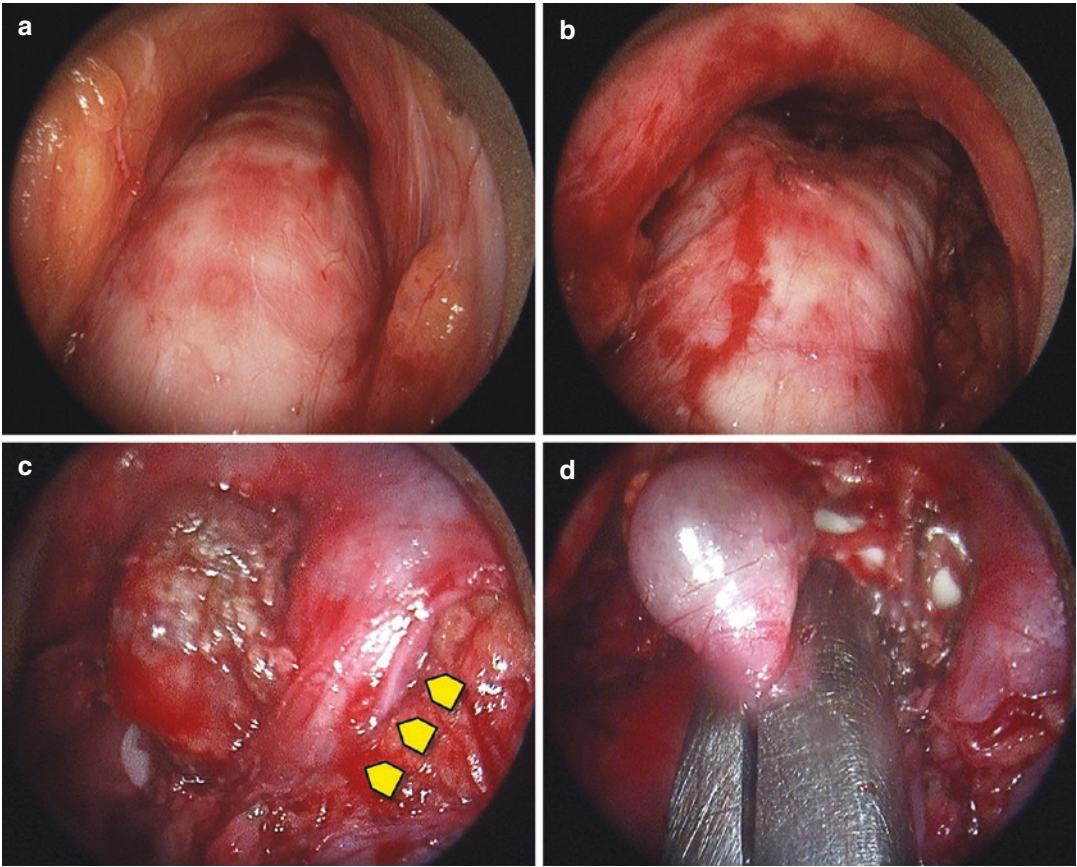
### Control of Haemostasis and Closure

The use of the dissection-suction-coagulation cannula minimizes bleeding during dissection of peritracheal tissue. Mediastinal lymph nodes usually are dark blue or black because of their anthracotic content. The azygos vein or a partially visualized superior vena cava may resemble lymph nodes. In case of doubt, especially if the standard mediastinoscope is used, a puncture test should be performed. If blood is seen along the glass suction tube, the needle should be



**Fig. 27.6** Formalin filled containers. Each container has one complete lymph node or fragments of the same lymph node





**Fig. 27.7** Endoscopic images of video-mediastinoscopy. (a) Proximal trachea. (b) Distal trachea, right and left main bronchi. (c) Right hilar lymph node. This lymph

node is located caudal to the inferior rim of the azygos vein (yellow arrows). (d) Hilar lymph node biopsy

removed and the bleeding site gently pressed with gauze for haemostasis. During this manoeuvre, care must be taken not to puncture through the trachea, because perforation of the endotracheal cuff is possible and already has been described [30]. All biopsy sites should be checked before closure. Coagulation of biopsied lymph nodes or peritracheal fatty tissue is enough to control bleeding. Control of bleeding from the bronchial arteries in the subcarinal space, especially those running in front of the left main bronchus, should be tried first with gauze packing and coagulation. If bleeding persists, clipping or coagulation with energy devices of the bronchial artery may be necessary. The gauze used for packing must be removed through the mediastinoscope to minimize tumour seeding in the cervi-

cal incision. Tumour cell dissemination during mediastinoscopy is possible. Cytological analyses of mediastinal lavage fluid have shown that tumour cells can be identified before and after taking biopsies, although long follow-up periods are needed to understand their prognostic value [31]. Major bleeding is an uncommon complication that may occur in 0.4% of procedures and may come from the azygos vein, the pulmonary arteries, the innominate artery - the most common sites of serious bleeding -, the superior vena cava and the aorta. Packing and median sternotomy or thoracotomy, depending on the location of bleeding, is the usual procedure of haemorrhage control [32]. The choice of access to the chest is important because each provides a different exposure to the intrathoracic vessels. The

glass cannula for puncture test may be connected to a syringe to puncture and aspirate lymph nodes. This is especially useful when the nodes are fixed to vessels. In this case, pulling or taking biopsies from the nodes may injure the attached vessel. The aspirate is then sent for cytological examination.

The paratracheal muscles are not sutured to the midline. This facilitates remediastinoscopy, if it is needed. The incision is closed in two layers: platysma and subcutaneous tissue together with 2-0 continuous absorbable suture, and skin with 3-0 absorbable intradermal suture. Drainage is not necessary. The wound is dressed with gauze that can be removed in 24 h.

### Postoperative Care

The patient is awakened and extubated in the operating room, and sent to recovery room till the patient is fully conscious and the vital constants are normal and stable. Then the patient is transferred to the normal ward or to the outpatient surgery room. Oral intake is started 6 h after the operation. The patient can be discharged on the same day, if an outpatient surgery programme is active in the hospital, or next day. The admission rate after outpatient mediastinoscopy for all indications ranges from 1 to 4%, and the main reasons are supraventricular arrhythmias, pneumothorax, bleeding from bronchial artery, or late end of the operation [33]. Postoperative chest x-rays are not necessary unless something unusual has occurred during (opening of the mediastinal pleura or bleeding) or after surgery (fever, dyspnoea or chest pain).

### Complications

Intraoperative complications are infrequent, ranging from 0.6% to 3.7% [34, 35]. The occlusion of the innominate artery and bleeding from the most common sites have been described above. Other complications are wound infection, pneumothorax, mediastinitis, left recurrent laryngeal nerve palsy, oesophageal perforation, bron-

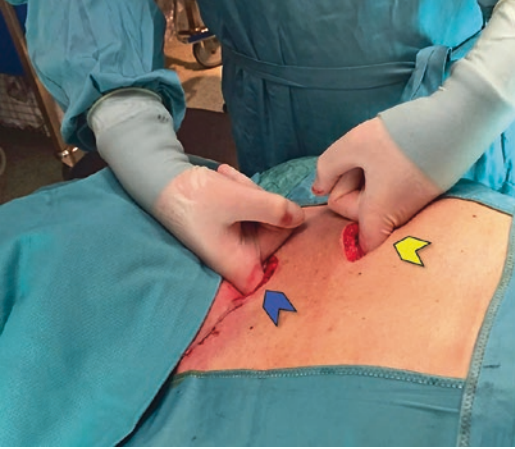chial injury, chylomediastinum, haemothorax and incisional metastasis [36–41]. Mortality is below 0.5% [4, 42, 43].

### Technical Variants

Technical variants of mediastinoscopy have been devised over the years to reach mediastinal locations beyond the range of the standard exploration and to expand the possibilities of this transcervical approach.

### Extended Cervical Mediastinoscopy

Subaortic and para-aortic nodal stations cannot be reached with mediastinoscopy. Left parasternal mediastinotomy, performed over the second or third intercostal space, facilitates the exploration of this area, but requires an additional incision and very often the removal of a costal cartilage [44, 45]. In 1987, Ginsberg et al. [46] reported their experience in extended cervical mediastinoscopy as a staging procedure for cancers of the left upper lobe, using the approach first described by Specht in 1965 [47]. To stage cancers of the left lung, after mediastinoscopy has been completed and from the same cervical incision, a passage is created by finger dissection over the aortic arch, between the innominate artery and the left carotid artery, either in front or behind the left innominate vein. Once the fascia between these two vessels is torn with the finger, the finger can be advanced easily over the aortic arch. Then, the mediastinoscope is inserted and the lymph nodes in the subaortic station can be explored and biopsied. By moving the mediastinoscope medially, the para-aortic nodes also can be explored, although differentiating between subaortic and para-aortic nodes is not easy because mobilization of the mediastinoscope is limited by the bony structures of the chest wall. Extended cervical mediastinoscopy does not allow the surgeon to palpate the subaortic space well. If palpation is needed to differentiate between mere contact and tumour invasion in this area, then parasternal mediastinotomy is a much better approach. The para-



**Fig. 27.8** Bimanual palpation from the collar incision of mediastinoscopy (blue arrow) and the left parasternal mediastinotomy (yellow arrow)

sternal incision allows the surgeon to inspect the subaortic space directly, but the mediastinoscope can also be used to facilitate the exploration. Additionally, a small rib spreader can be inserted to widen the operative field. Bimanual palpation from the collar incision and from the parasternal incision is useful to explore the integrity of the aortic arch (Fig. 27.8). Access to the pericardium, pleural space and lung is also possible from this incision. Right parasternal mediastinotomy is useful to assess the superior vena cava, the azygos vein, the right pulmonary artery, the right superior pulmonary vein and the right anterior mediastinal nodes [48].

The European Society of Thoracic Surgeons guidelines recommend the exploration of the subaortic and para-aortic lymph nodes in left-lung cancers [19]. The extended cervical mediastinoscopy can be performed with no additional incisions, does not require a chest tube and is not limited by pleural adhesions, which are advantages over parasternal mediastinotomy and thoracoscopy. Its yield is highest when there are abnormal nodes by CT and/or PET in the subaortic space: sensitivities of 0.44 and 0.76 for routine (all cases regardless of the CT and/or PET findings) and selective (abnormal CT and/or PET) indications, respectively, have been reported [49].

### Mediastinoscopic Biopsy of Scalene Lymph Nodes

From the cervical incision of mediastinoscopy, the mediastinoscope can be passed under the insertions of the sternocleidomastoid muscle on one or both sides of the neck to reach the scalene lymph nodes. There is one publication on this technique, only, but the reported results are clinically relevant: 15% of patients with N2 disease and 63% of those with mediastinal N3 diagnosed at mediastinoscopy had subclinical N3 disease in the scalene lymph nodes [50]. These results have to be taken into account when selecting patients for clinical trials on N2 disease.

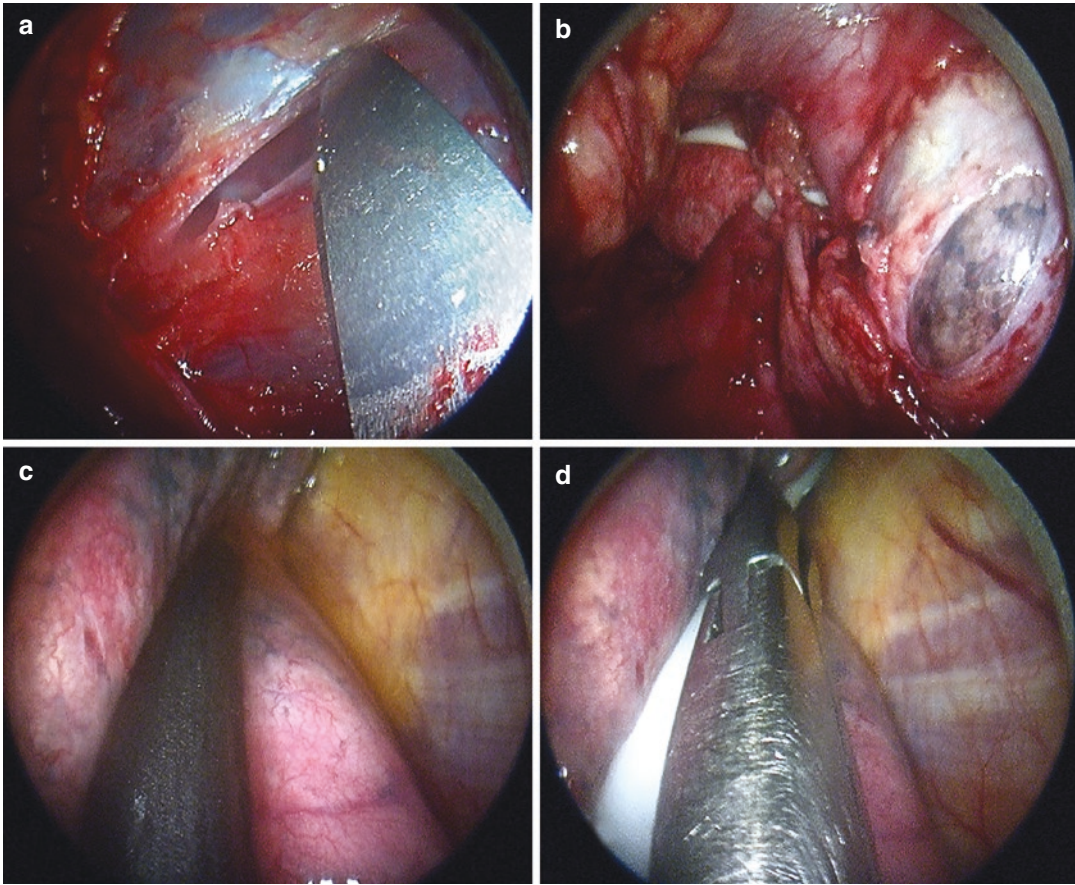
### Inferior Mediastinoscopy

The mediastinoscope is inserted into the antero-inferior mediastinum from a subxiphoid approach. Although this is rarely needed, inferior mediastinoscopy is useful to explore mediastinal lesions beyond the reach of mediastinoscopy [51, 52]. The opening of the pericardium and the insertion of the mediastinoscope into the pericardial space allow the surgeon to perform a subxiphoid pericardioscopy, which is useful to diagnose pericardial effusions and establish the anatomic extent of locally advanced cancers [53].

### Mediastino-Thoracoscopy

From the superior mediastinum, at the time of mediastinoscopy, the mediastinal pleura can be opened and the pleural space, explored. On the right side, this can be performed either between the trachea and the superior vena cava or between the superior vena cava and the anterior chest wall. On the left, the supra-aortic approach is the most direct one, as used for extended cervical mediastinoscopy. Single-lung ventilation facilitates the exploration of the pleural space in patients with pleural effusion, lung nodules, parietal pleura nodules and diaphragmatic and pericardial lesions. If the target lesions cannot be reached with the mediastinoscope, a thoracoscope can be passed through it; by doing so, even the diaphragm can be reached. Pleurodesis also can be performed through this approach [54, 55]. The two-bladed video-mediastinoscopes also allow the insertion of endoscopic staplers to perform





**Fig. 27.9** Mediastino-thoracoscopy. (a) The mediastinal pleura is opened by endoscopic scissors. (b) View of the right lung through the incision of the mediastinal pleura. (c) Exploration of the pleural space with single-lung ven-

tilation. Pleural effusion of clear fluid is identified and it is suctioned with suction cannula. (d) Small bore chest tube is inserted with endoscopic forceps

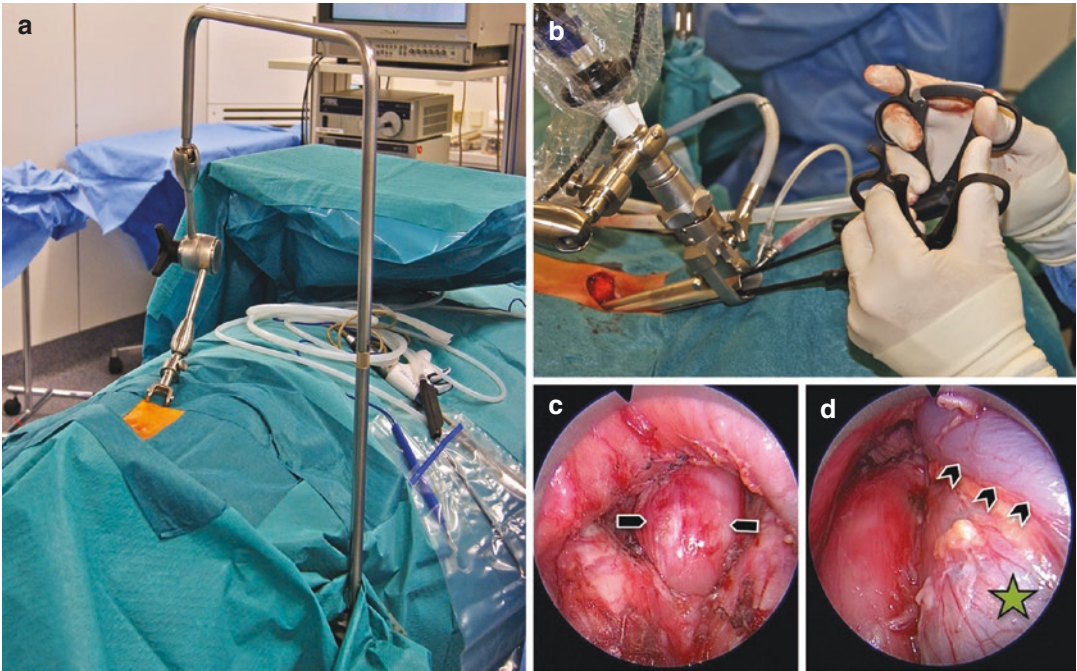
wedge resections of the lung in case of lung cancer and additional peripheral lung nodules [56] (Fig. 27.9).

## Transcervical Mediastinal Lymphadenectomies

### Video-Assisted Mediastinoscopic Lymphadenectomy

Video-assisted mediastinoscopic lymphadenectomy (VAMLA) is a very thorough mediastinoscopy with the objective to remove the upper mediastinal lymph nodes. It is performed with the two-bladed video-mediastinoscope through

the standard collar incision for mediastinoscopy. A holder can be used to fix the video-mediastinoscope so that the surgeon can work with two hands, holding the specimen with a forceps with one hand and the dissector with the other. The subcarinal and the right inferior paratracheal lymph nodes are removed en bloc with the mediastinal fatty tissue. Those located in the left inferior paratracheal station are removed one by one to prevent injury of the left recurrent laryngeal nerve [10, 11]. VAMLA can be combined with video-thoracoscopy to improve the radicality of lymphadenectomy [57] (Fig. 27.10). As with mediastinoscopy, it can also be combined with transcervical thoracos-



**Fig. 27.10** Video-assisted mediastinoscopic lymphadenectomy (VAMLA). (a and b) The surgeon can work with two hands because the video-mediastinoscope is fixed by an articulated holder. (c) View of the subcarinal space after removing all subcarinal lymph nodes. Black arrows

show the oesophagus completely dissected. (d) View of the right mediastinal pleura after removing the right inferior paratracheal lymph nodes en bloc with the mediastinal fatty tissue. Black arrows show the superior vena cava. Green star shows the mediastinal pleura

copy to explore the mediastinum and the pleural space in the same procedure and through the same incision [58].

Adhesion to the standardized technique and anatomic limits is important in VAMLA to avoid complications. The subcarinal space is explored first. The fatty tissue containing nodes is dissected off the margins of the main bronchi and the carinal angle. Once this is done, the bloc is grasped with forceps on one side and its dissection is continued towards the other using the dissection-suction-coagulation cannula, endoscopic scissors or energy devices. The bloc has to be freed from the adhesions that keep it attached to both main bronchi, laterally, to the pulmonary arteries, anteriorly, and to the oesophagus, posteriorly. During this manoeuvre, clipping of the bronchial artery that usually runs anterior to the left main bronchus may be necessary, if coagulation is not enough to control bleeding around this bloc of fatty tissue and lymph nodes. Once the bloc is removed, the oesophagus protrudes ante-

riorly. A wet gauze is left in the subcarinal space for haemostasis while the procedure is continued in other nodal stations.

On the right paratracheal nodal station, dissection is started from the inferior margin of the innominate artery. The bloc of fatty tissue and lymph nodes is detached from the mediastinal pleura and the superior vena cava and moved medially and caudally towards the azygos vein. This manoeuvre can be facilitated by finger dissection or by inserting a gauze and pushing it caudally. Finally, the bloc is detached from the ascending aorta with coagulation, scissors or energy devices. It is important to remove the nodes that are located anterior to the trachea between the ascending aorta and the superior vena cava. They can pass unnoticed, hidden by the mediastinoscope. On this side, the procedure can be completed with the exploration of the right hilar nodes, that is, those caudal to the inferior margin of the azygos vein around the right main bronchus.



On the left paratracheal nodal station, it is important to identify the left recurrent laryngeal nerve to prevent its injury. (Fig. 27.5) Once this is done, the left inferior paratracheal lymph nodes are either biopsied or removed one by one (not en bloc as in the subcarinal and right inferior paratracheal nodal stations). Coagulation should be restricted to the minimum necessary; a warm wet gauze is usually enough to control bleeding from the nodes or the fatty tissue. As on the right side, the procedure can be completed with the exploration of the left hilar nodes, those caudal to the upper rim of the left pulmonary artery.

Once the dissection is finished, the gauzes are removed and a final inspection is performed to check for bleeding. Drainage is not needed and the incision is closed as for mediastinoscopy.

### **Transcervical Extended Mediastinal Lymphadenectomy**

In comparison with VAMLA, transcervical extended mediastinal lymphadenectomy (TEMLA) is a more extensive procedure. The objective of TEMLA is to remove all the mediastinal nodes from the cervical station to the paraoesophageal station. A cervical incision slightly longer than that for mediastinoscopy is performed, and the sternum is elevated with a hook fixed to a metal frame mounted on the operating table. The procedure is almost exclusively performed in an open fashion, but a two-bladed mediastinoscope is used to dissect the subcarinal and the para-oesophageal lymph nodes, and a videothoracoscope is inserted to have a better vision at the time of dissection of the subaortic space [12].

---

## **Evidence-Based Review**

### **Conventional Mediastinoscopy Versus Video-Mediastinoscopy**

There are evident advantages of video-mediastinoscopy over conventional mediastinoscopy. The view of the operative field is much larger and can be seen simultaneously by all personnel in the operating theatre. The whole

procedure or parts of it can be recorded for future use in clinical sessions, medical meetings and educational materials. However, because there are no prospective randomized trials comparing both procedures, there is no clear evidence indicating that video-mediastinoscopy is safer or more effective than conventional mediastinoscopy. Video-mediastinoscopy seems to be a more thorough exploration, because of an increased number of biopsied lymph nodes and explored lymph node stations compared with conventional mediastinoscopy, as well as a better tool for training [59].

### **Staging Values of the Different Techniques**

A review of 26 reports published between 1983 and 2011, including a total of 9267 patients who had undergone conventional mediastinoscopy, showed a median sensitivity of 0.78 and a median negative predictive value of 0.91. An additional series of 995 patients who had undergone video-assisted mediastinoscopy and were reported in seven papers published from 2003 to 2011 showed a median sensitivity of 0.89 and a median negative predictive value of 0.92. By convention, specificity and positive predictive value of mediastinoscopy is 1, although positive results are not confirmed by other tests [18].

The combined analyses of 456 patients who underwent extended cervical mediastinoscopy reported in five articles published between 1987 and 2012 revealed a median sensitivity of 0.71 and a median negative predictive value of 0.91 [18].

The initial reports from the two groups who developed VAMLA in 2002 and 2003, describing their results with 40 and 25 patients, respectively, showed sensitivities, negative predictive values and diagnostic accuracies of 1 [10, 11] An updated publication from one of the groups, with 144 patients, reported a sensitivity of 0.88 and a negative predictive value of 0.98 [60]. The largest series published to date, with 160 procedures for lung cancer staging, reported the following staging values: sensitivity 0.96, negative predictive

value 0.99 and diagnostic accuracy 0.99 [61]. VAMLA is a safe procedure and requires a short learning curve of 16 to 17 cases to overcome the initial complication rate [62].

Sensitivity and negative predictive value of TEMPLA are high: 0.9 and 0.95, respectively, in the first report including 83 patients, [12], and 0.94 and 0.97, respectively, in an updated reports with 256 patients [63]. With the increasing number of procedures (698 TEMPLAs), sensitivity and negative predictive values are still maintained at 0.96 and 0.98 respectively [64]. TEMPLA has proved to be highly reliable as a restaging method in those patients with lung cancer initially staged by endoscopic techniques and fine-needle aspiration. In these cases, sensitivity, negative predictive value and accuracy were 0.95, 0.97 and 0.98, respectively [65]. In addition, TEMPLA can be combined with uniportal transcervical lobectomy, if imprint cytology examination proves all the removed lymph nodes are negative. This was attempted in nine patients, and the procedure had to be converted to uniportal videothoroscopic approach in only one case because of extensive adhesions [66].

## Summary and Recommendations

Mediastinoscopy explores the upper mediastinum and is useful in the assessment of nodal disease, direct tumour invasion and diagnosis of mediastinal diseases. To expand the range of the exploration, procedures such as parasternal mediastinotomy, extended cervical mediastinoscopy, mediastino-thoracoscopy and inferior mediastinoscopy have been devised during the past decades. VAMLA and TEMPLA have the objective to perform a mediastinal lymphadenectomy as thorough as that performed at the time of lung cancer resection. They are indicated when the mediastinum is normal on CT and PET, and their sensitivity and negative predictive values are higher than those for mediastinoscopy. Therefore, they should be incorporated in future staging algorithms. At the present time, the ESTS guidelines are valuable, have been validated in two studies, with sensitivity and negative predictive

values of 0.84 and 0.94, respectively, [67] and of 0.95 and 0.94, respectively [68]. Therefore, they should be applied in the management of patients with lung cancer.

## References

1. Rusch VW, Asamura H, Watanabe H, Giroux DJ, Rami-Porta R, Goldstraw P. The IASLC lung cancer staging project. A proposal for a new international lymph node map in the forthcoming seventh edition of the TNM classification for lung cancer. *J Thorac Oncol.* 2009;4:568–77.
2. Rami-Porta R, Wittekind C, Goldstraw P. Complete resection in lung cancer surgery: proposed definitions. *Lung Cancer.* 2005;49:25–33.
3. Carlens E. Mediastinoscopy: a method for inspection and tissue biopsy in the superior mediastinum. *Dis Chest.* 1959;4:343–52.
4. Albanese AR. Biopsia por vía cervical, de ganglio o tumor del mediastino superior. *Dia Med.* 1942;23:1226.
5. Daniels AC. A method of biopsy useful in diagnosing certain intrathoracic diseases. *Dis Chest.* 1949;16:360–7.
6. Harken DE, Black H, Clauss R, Farrand RE. A simple cervicomediastinal exploration for tissue diagnosis of intrathoracic disease. *N Engl J Med.* 1954;251:1041–4.
7. Radner S. Suprasternal node biopsy in lymph-spreading intrathoracic disease. *Acta Med Scandinav.* 1955;152:413–5.
8. Jepsen O. Mediastinoscopy. Copenhagen (Denmark): Munksgaard; 1966.
9. Palva T. Mediastinoscopy. Basel (Switzerland): S Karger; 1974.
10. Pearson FG, Nelems JM, Henderson RD, Delarue NC. The role of mediastinoscopy in the selection of treatment for bronchial carcinoma with involvement of superior mediastinal lymph nodes. *J Thorac Cardiovasc Surg.* 1972;64:382–90.
11. Maggi G, Casadio C, Giobbe R, et al. The value of selective mediastinoscopy in predicting resectability of patients with bronchogenic carcinoma. *Int Surg.* 1992;77:280–3.
12. Choi YS, Shim YM, Kim J, Kim K. Mediastinoscopy in patients with clinically stage I non-small cell lung cancer. *Ann Thorac Surg.* 2003;75:364–6.
13. Coosemans W, Lerut T, Van Raemdonck D. Thoracoscopic surgery: the Belgian experience. *Ann Thorac Surg.* 1993;56:721–30.
14. Hürtgen M, Friedel G, Toomes H, Fritz P. Radical video-assisted mediastinoscopic lymphadenectomy (VAMLA) – technique and first results. *Eur J Cardiothorac Surg.* 2002;21:348–51.
15. Leschber G, Holinka G, Linder A. Video-assisted mediastinoscopic lymphadenectomy (VAMLA)—a

- method for systematic mediastinal lymph node dissection. *Eur J Cardiothorac Surg.* 2003;24:192–5.
16. Kuzdzal J, Zielinski M, Papla B, Szlubowski A, Hauer L, Nabialek T, et al. Transcervical extended mediastinal lymphadenectomy—the new operative technique and early results in lung cancer staging. *Eur J Cardiothorac Surg.* 2005;27:384–90.
  17. Zielinski M, Rami-Porta R. The transcervical approach in thoracic surgery. Heidelberg: Springer; 2014.
  18. Silvestri GA, Gonzalez AV, Jantz MA, Margolis ML, Gould MK, Tanoue LT, et al. Methods for staging non-small cell lung cancer. Diagnosis and management of lung cancer, 3<sup>rd</sup> edition: American College of Chest Physicians evidence-based clinical practice guidelines. *Chest.* 2013;143(Suppl):e211S–50S.
  19. De Leyn P, Doomes C, Kuzdzal J, Lardinois D, Passlick B, Rami-Porta R, et al. Revised ESTS guidelines for preoperative mediastinal lymph node staging for non-small cell lung cancer. *Eur J Cardiothorac Surg.* 2014;45:787–98.
  20. Marra A, Hillejan L, Fechner S, Stamatis G. Remediastinoscopy in restaging of lung cancer after induction therapy. *J Thorac Cardiovasc Surg.* 2008;135:843–9.
  21. De Waele M, Hendriks J, Lauwers P, Van Schil P. Different indications for repeat mediastinoscopy: single institution experience of 79 cases. *Minerva Chir.* 2009;64:415–8.
  22. Call S, Rami-Porta R, Obiols C, Serra-Mitjans M, Gonzalez-Pont G, Bastis-Piulats R, et al. Repeat mediastinoscopy in all its indications: experience with 96 patients and 101 procedures. *Eur J Cardiothorac Surg.* 2011;39:1022–7.
  23. De Waele M, Hendriks J, Lauwers P, Ortmanns P, Vanroelen W, Morel AM, et al. Nodal status at repeat mediastinoscopy determines survival in non-small cell lung cancer with mediastinal nodal involvement treated by induction therapy. *Eur J Cardiothorac Surg.* 2006;29:240–3.
  24. De Waele M, Serra-Mitjans M, Hendriks J, Lauwers P, Belda-Sanchis J, Van Schil P, et al. Accuracy and survival of repeat mediastinoscopy after induction therapy for non-small cell lung cancer in a combined series of 104 patients. *Eur J Cardiothorac Surg.* 2008;33:824–32.
  25. Jaklitsch MT, Gu L, Demmy T, et al. Prospective phase II trial of pre-resection thoracoscopic mediastinal restaging after neoadjuvant therapy for IIIA (N2) non-small cell lung cancer: results of CALGB protocol 39803. *J Thorac Cardiovasc Surg.* 2013;146:9–16.
  26. Yamada K, Kumar P, Goldstraw P. Cervical mediastinoscopy after total laryngectomy and radiotherapy: its feasibility. *Eur J Cardiothorac Surg.* 2002;21:71–3.
  27. Dosios T, Theakos N, Chatziantoniou C. Cervical mediastinoscopy and anterior mediastinotomy in superior vena cava obstruction. *Chest.* 2005;128:1551–6.
  28. Douketis JD, Berger PB, Dunn AS, Jaffer AK, Spyropoulos AC, Becker RC, et al. American College of Chest Physicians evidence-based clinical practice guidelines (8<sup>th</sup> edition). *Chest.* 2008;133(6 suppl):299s–339s.
  29. Vivas D, Roldán I, Ferrandis R, et al. Perioperative and periprocedural management of antithrombotic therapy: consensus document of SEC, SEDAR, SEACV, SECTCV, AEC, SECPRE, SEPD, SEGO, SEHH, SETH, SEMERGEN, SEMFYC, SEMG, SEMICYUC, SEMI, SEMES, SEPAR, SENEC, SEO, SEPA, SERVEI, SECOT and AEU. *Rev Esp Cardiol (Engl Ed).* 2018;71:553–64.
  30. Mavridou P, Papadopoulou M, Igropolou O, Manataki A. Unexpeted endotracheal tub cuff perforation during video mediastinoscopy. *J Cardiothorac Vasc Anesth.* 2007;21:723.
  31. Büyükkarabacak YB, Sengül AT, Maeydan BC, et al. The risk of tumor cell dissemination in mediastinoscopy: a cytological study. *Turk J Med Sci.* 2015;45:872–6.
  32. Park BJ, Flores R, Downey RJ, Bains MS, Rusch VW. Management of major hemorrhage during mediastinoscopy. *J Thorac Cardiovasc Surg.* 2003;126:726–31.
  33. Molins L, Fibla JJ, Pérez J, Sierra A, Vidal G, Simón C. Outpatient thoracic surgical programme in 300 patients: clinical results and economic impact. *Eur J Cardiothorac Surg.* 2006;29:271–5.
  34. Hammoud ZT, Anderson RC, Meyers BF, Guthrie TJ, Roper CL, Cooper JD, et al. The current role of mediastinoscopy in the evaluation of thoracic diseases. *J Thorac Cardiovasc Surg.* 1999;118:894–9.
  35. Kliems G, Savic B. Complications of mediastinoscopy. *Endoscopy.* 1979;1:9–12.
  36. Hoyer ER, Leonard CE, Hazuka MB, Wechsler-Jentzsch K. Mediastinoscopy incisional metastasis: a radiotherapeutic approach. *Cancer.* 1992;70:1612–5.
  37. Le Pimpec BF, D'Attellis N, Assouad J, Badia A, Souilamas R, Riquet M. Chylous leak after cervical mediastinoscopy. *J Thorac Cardiovasc Surg.* 2003;126:1199–200.
  38. Saumench-Perramon R, Rami-Porta R, Call-Caja S, Iglesias-Sentis M, Serra-Mitjans M, Bidegain-Pavón C, et al. Mediastinoscopic injuries to the right main bronchus and their mediastinoscopic repair. *J Bronchol.* 2008;15:191–3.
  39. Benouaich V, Marcheix B, Carfagna L, Brouchet L, Guitard J. Anatomical bases of left recurrent nerve lesions during mediastinoscopy. *Surg Radiol Anat.* 2009;31:295–9.
  40. Pop D, Nadeemy AS, Venissac N, Guiraudet P, Mouroux J. Late mediastinal hematoma followed by incisional metastasis after video-assisted mediastinoscopy. *J Thorac Oncol.* 2010;5:919–20.
  41. Elsayed H. Haemothorax after mediastinoscopy: a word of caution. *Eur J Cardiothorac Surg.* 2012;41:138–9.
  42. Kirschner PA. Cervical mediastinoscopy. *Chest Surg Clin North Am.* 1996;6:1–20.
  43. Urschel JD. Conservative management (packing) of hemorrhage complicating mediastinoscopy. *Ann Thorac Cardiovasc Surg.* 2000;6:9–12.

44. Stemmer EA, Calvin JW, Chandor SB, Connolly E. Mediastinal biopsy for indeterminate pulmonary and mediastinal lesions. *J Thorac Cardiovasc Surg.* 1965;49:405–11.
45. McNeil TM, Chamberlain JM. Diagnostic anterior mediastinoscopy. *Ann Thorac Surg.* 1966;2:532–9.
46. Ginsberg RJ, Rice TW, Goldberg M, Waters PF, Schmocker BJ. Extended cervical mediastinoscopy: a single staging procedure for bronchogenic carcinoma of the left upper lobe. *J Thorac Cardiovasc Surg.* 1987;94:673–8.
47. Specht G. Erweiterte Mediastinoskopie. *Thoraxchir Vask Chir.* 1965;13:401–7.
48. Motus IY. Surgical diagnostic procedure in assessing resectability of lung carcinoma. Experience from the Urals region. *Lung Cancer.* 2003;40:103–5.
49. Obiols C, Call S, Rami-Porta R, et al. Extended cervical mediastinoscopy: mature results of a clinical protocol for staging bronchogenic carcinoma of the left lung. *Eur J Cardiothorac Surg.* 2012;41:1043–6.
50. Lee JD, Ginsberg RJ. Lung cancer staging: the value of ipsilateral scalene lymph node biopsy performed at mediastinoscopy. *Ann Thorac Surg.* 1996;62:338–41.
51. Arom KV, Franz JL, Grover FL, Trinkle JK. Subxiphoid anterior mediastinal exploration. *Ann Thorac Surg.* 1977;24:289–90.
52. Hutter J, Junger W, Miller K, Moritz E. Sunxiphoidal videomediastinoscopy for diagnostic access to the anterior mediastinum. *Ann Thorac Surg.* 1998;66:1427–8.
53. Trujillo-Reyes JC, Rami-Porta R, Call-Caja S, Belda-Sánchez J. Subxiphoid videopericardioscopy. *Multimed Man Cardiothorac Surg.* 2015;2015:mmv009. <https://doi.org/10.1093/mmcts/mmv009>.
54. Chamberlain MH, Fareed K, Nakas A, Martin-Ucar AE, Waller DA. Video-assisted cervical thoracoscopy: a novel approach for diagnosis, staging and pleurodesis of malignant pleural mesothelioma. *Eur J Cardiothorac Surg.* 2008;34:200–3.
55. Fowkes L, Lau KK, Shah N, Black E. A cervical approach to investigate pleural disease. *Ann Thorac Surg.* 2009;88:315–7.
56. Obiols C, Call S, Rami-Porta R, Trujillo-Reyes JC. Utility of the transcervical approach in bilateral synchronous lung cancer. *Asian Cardiovasc Thorac Ann.* 2015;23:991–4.
57. Witte B, Messerschmidt A, Hillebrand H, Gross S, Wolf M, Kriegel E, et al. Combined videothoracoscopic and videomediastinoscopic approach improves radicality of minimally invasive mediastinal lymphadenectomy for early stage lung carcinoma. *Eur J Cardiothorac Surg.* 2009;35:343–7.
58. Trujillo-Reyes JC, Martínez-Téllez E, Rami-Porta R, Obiols C, Call S, Belda-Sánchez J. Combination video-assisted mediastinoscopic lymphadenectomy and transcervical thoracoscopy. *Multimed Man Cardiothorac Surg.* 2018;2018 <https://doi.org/10.1510/mmcts.2018.004>.
59. Zakkar M, Tan C, Hunt I. Is video mediastinoscopy a safer and more effective procedure than conventional mediastinoscopy? *Inter Cardiovasc Thoracic Surg.* 2012;14:81–4.
60. Witte B, Wolf M, Huertgen M, Toomes H. Video-assisted mediastinoscopic surgery: clinical feasibility and accuracy of mediastinal lymph node staging. *Ann Thorac Surg.* 2006;82:1821–7.
61. Call S, Obiols C, Rami-Porta R, Trujillo-Reyes JC, Iglesias M, Saumench-Pont G, et al. Video-assisted mediastinoscopic lymphadenectomy for staging non-small cell lung cancer. *Ann Thorac Surg.* 2016;101:1326–33.
62. Daemen JHT, van den Broek RAM, Lozekoot PWJ, Maessen JG, Hulsewé KWE, Vissers YLJ, de Loos ER. The learning curve of video-assisted mediastinoscopic lymphadenectomy for staging of non-small-cell lung carcinoma. *Interact Cardiovasc Thorac Surg.* 2020;31:527–35.
63. Zielinski M. Transcervical extended mediastinal lymphadenectomy: results of staging in two hundred fifty-six patients with non-small cell lung cancer. *J Thorac Oncol.* 2007;2:370–2.
64. Zielinski M, Hauer L, Hauer J, Pankowski J, Szlubowski A, Nabiałek T. Transcervical extended mediastinal lymphadenectomy (TEMLA) for staging of non-small-cell lung cancer (NSCLC). *Pneumonol Alergol Pol.* 2011;79:196–206.
65. Zielinski M, Hauer L, Hauer J, Nabiałek T, Szlubowski A, Pankowski J. Non-small-cell lung cancer restaging with transcervical extended mediastinal lymphadenectomy. *Eur J Cardiothorac Surg.* 2010;37:776–80.
66. Zieliński M, Rybak M, Solarczyk-Bombik K, et al. Uniportal transcervical video-assisted thoracoscopic surgery (VATS) approach for pulmonary lobectomy combined with transcervical extended mediastinal lymphadenectomy (TEMLA). *J Thorac Dis.* 2017;9:878–84.
67. Gunluoglu MZ, Melek H, Medetoglu B, Demir A, Kara HV, Dincer SI. The validity of preoperative lymph node staging guidelines of European Society of Thoracic Surgeons in non-small-cell lung cancer patients. *Eur J Cardiothorac Surg.* 2011;40:287–90.
68. Turna A, Melek H, Kara HV, Kılıç B, Erşen E, Kaynak K. Validity of the updated European Society of Thoracic Surgeons staging guideline in lung cancer patients. *J Thorac Cardiovasc Surg.* 2018;155:789–95.



# Lung Cancer Staging Methods: A Practical Approach

# 28

Travis L. Ferguson, Tejaswi R. Nadig,  
and Gerard A. Silvestri

## Abbreviations

ACCP	American College of Chest Physicians	LDCT	Low dose computed tomography
ALK	Anaplastic lymphoma kinase	MET	Mesenchymal epithelial transition
BRAF	B-Raf proto-oncogene serine/threonine kinase	MPE	Malignant pleural effusion
CP-EBUS	curvilinear probe endobronchial ultrasound	MRI	Magnetic resonance imaging
CT	Computed tomography	NTRK	Neurotrophic tyrosine receptor kinase
CXR	Chest x-ray	NCCN	National comprehensive cancer network
EBUS-FNA	Endobronchial ultrasound fine needle aspiration	NLST	National lung cancer screening trial
EBUS-TBNA	Endobronchial ultrasound with transbronchial needle aspiration	NPV	Negative predictive value
ECM	Extended cervical mediastinoscopy	NSCLC	Non-small cell lung cancer
EGFR	Epidermal growth factor receptor	PD-L1	Programmed death ligand 1
ENB	Electromagnetic navigation bronchoscopy	PE	Pulmonary embolism
EUS-FNA	Endoscopic ultrasound fine needle aspiration	PET-CT	Positron emission tomography-computed tomography
FDG	18F-Fluorodeoxyglucose	PPL	Peripheral pulmonary lesions
HHM	Humoral hypercalcemia of malignancy	PPV	Positive predictive value
		RB	Robotic bronchoscopy
		RCT	Randomized controlled trials
		RET	Rearranged during transfection
		ROS1	c-Ros oncogene 1
		ROSE	Rapid onsite evaluation
		RP-EBUS	Radial probe endobronchial ultrasound
		SCC	Squamous cell carcinoma
		SCM	Standard cervical mediastinoscopy
		SIADH	Syndrome of inappropriate antidiuretic hormone secretion

T. L. Ferguson · T. R. Nadig · G. A. Silvestri (✉)  
Department of Medicine, Division of Pulmonary and  
Critical Care, Allergy and Sleep Medicine, Medical  
University of South Carolina, Charleston, SC, USA  
e-mail: [fergustr@musc.edu](mailto:fergustr@musc.edu); [nadigt@musc.edu](mailto:nadigt@musc.edu);  
[silvestri@musc.edu](mailto:silvestri@musc.edu)



SUV	Standardized uptake value
TBNA	Transbronchial needle aspiration
TNM	Tumor node metastasis
TTNA	Transthoracic needle aspiration
USPSTF	United States preventive services task force
VATS	Video-assisted thoracoscopic surgery
VBN	Virtual bronchoscopic navigation

men and 112,350 for women with a total of 234,030 new cases for the year. Lung cancer is the second most common cancer in both men and women, but accounts for the most cancer deaths in the United States [3]. With the NELSON trial demonstrating reduced lung cancer mortality in high-risk individuals who underwent low radiation dose computed tomography (CT) screening and the update to the United States Preventative Services Task Force (USPSTF) 2021 [4, 5], the incidence of imaging detected lung nodules/lung cancer will undoubtedly increase [5]. Accurate staging of lung cancer is crucial as this will guide treatment. The eighth edition of tumor node metastasis (TNM) staging for non-small cell lung cancer (NSCLC) helps categorize tumors on the basis of primary tumor characteristics (T), the presence or absence of regional lymph node involvement (N), and the presence or absence of distant metastases (M) [6]. The eighth edition of the TNM staging system had major changes to T and M classifications and was adopted as of January 1, 2018 (Fig. 28.1). If disease is isolated within the thorax, mediastinal and hilar lymph node staging becomes critical for determining the best approach for curative intent treatment. In addition to accurate staging, samples should be

### Introduction

Lung cancer incidence and mortality continue to increase worldwide. It is estimated that there are 2.2 million new lung cancer cases worldwide and 1.8 million deaths from lung cancer [1]. In Europe, there are estimated to be four million new cases of cancer and 1.9 million cancer-related deaths as of 2020. Lung cancer accounted for 11.8% of new cancer diagnoses and 380,000 deaths, or approximately one-fifth of all cancer-related deaths [2]. As of 2018, the incidence of lung cancer in the United States was 121,680 for

**Fig. 28.1** TNM lung cancer staging 8th edition

T/M	Label	N0	N1	N2	N3
T1	T1a ≤1	IA1	IIB	IIIA	IIIB
	T1b >1-2	IA2	IIB	IIIA	IIIB
	T1c >2-3	IA3	IIB	IIIA	IIIB
T2	T2a Cent, Yise Pt	IB	IIB	IIIA	IIIB
	T2b >3-4	IB	IIB	IIIA	IIIB
	T2b >4-5	IIA	IIB	IIIA	IIIB
T3	T3 >5-7	IIB	IIIA	IIIB	IIIC
	T3 Inv	IIB	IIIA	IIIB	IIIC
	T3 Sasell	IIB	IIIA	IIIB	IIIC
T4	T4 >7	IIIA	IIIA	IIIB	IIIC
	T4 Inv	IIIA	IIIA	IIIB	IIIC
	T4 Ipsi Nod	IIIA	IIIA	IIIB	IIIC
M1	M1a Conir Nod	IVA	IVA	IVA	IVA
	M1a PI Dissem	IVA	IVA	IVA	IVA
	M1b Single	IVA	IVA	IVA	IVA
	M1c Multi	IVB	IVB	IVB	IVB

evaluated for molecular biomarkers as more and more therapies are being developed to treat cancers which harbor these specific mutations. The National Comprehensive Cancer Network (NCCN) guidelines on NSCLC recommends testing for ALK rearrangements, BRAF mutations, epidermal growth factor receptor (EGFR) mutations, METex14 skipping mutations, neurotrophic tyrosine receptor kinase 1/2/3 (NTRK1/2/3) gene fusions, rearranged during transfection (RET) rearrangements, and c-ros oncogene 1 (ROS1) rearrangements along with immunohistochemical testing for programmed death ligand 1 (PD-L1) [7]. This list will likely increase quickly over the next decade as new therapeutic targets are identified.

Initial evaluation of a patient with suspected lung cancer begins with a thorough history and physical examination. Asymptomatic patients will commonly present after an incidental finding on chest imaging or dedicated lung cancer screening. Every effort should be made to review prior images to help determine the age and growth pattern of said abnormalities. Intra-thoracic effects of lung cancer include a wide range of symptoms including cough, dyspnea, and weight loss [8]. When evaluating for extra thoracic metastasis, the most common sites in descending order of frequency are nervous system, bone, liver, lung, and adrenal glands [9]. Extra-thoracic effects of metastatic disease depend on the organ/system involved. For example, a patient with suspected lung cancer who is experiencing new onset headaches may warrant a brain computerized tomography (CT) or magnetic resonance imaging

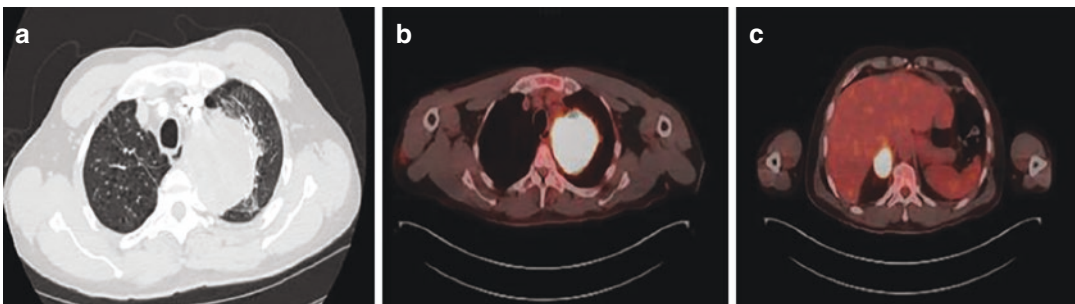
(MRI) to search for metastatic disease. Paraneoplastic syndromes can involve various systems that include dermatologic, rheumatologic, neurologic, endocrine, hematologic, renal, and ophthalmologic systems [10]. Paraneoplastic syndromes can occur in up to 10% of patients with lung cancer; the two most common being humoral hypercalcemia of malignancy (HHM) in squamous cell carcinoma (SCC) and the syndrome of inappropriate antidiuretic hormone secretion (SIADH) in small cell lung cancer [11].

This chapter will be presented in a case-based format that highlights the proper initial evaluation, diagnosis, and staging of lung cancer. The cases will highlight the important clinical aspects for clinicians to consider when evaluating these patients.

## Case 1

*A 55-year-old man with a 40 pack-year smoking history came to clinic with complaints of shoulder pain. During evaluation he underwent a CT chest (Fig. 28.2a) which revealed a large solid appearing mass in the left upper lobe abutting the mediastinum and chest wall. There were enlarged left hilar and mediastinal lymph nodes with 4 L measuring 1.2 cm. Lung parenchyma revealed widespread multilobular emphysema. Skeletal exam was unremarkable.*

The purpose of searching for extrathoracic disease in NSCLC is to detect metastatic disease at common metastatic sites, such as the adrenal



**Fig. 28.2** (a) Large  $8.5 \times 7.9$  cm left upper lobe mass abutting and invading the superior mediastinum. (b) Large hypermetabolic left apical mass with a max SUV of 28.9.

(c) Hypermetabolic right adrenal mass measuring 3.6 cm with a max SUV of 17.5

glands, liver, brain, and skeletal system. A biopsy of a distant site of metastasis would both diagnose and stage, thereby sparing the patient futile surgical interventions. The current practice is based on clinical evaluation of organ-specific symptoms, constitutional signs and symptoms, along with simple laboratory tests to aid in workup of extrathoracic disease. If patients have abnormal symptoms, physical exam, or blood tests, there is a high likelihood of metastasis [12]. One study found that distant metastases may become evident as early as 4 weeks in 3% of untreated patients and may increase to 13% as early as 8 weeks. This leads the authors to propose complete restaging after a 4 to 8 weeks delay in therapy [12]. It is also known that patients with an oligometastatic lesion in a single organ such as brain, liver, bone, distant lymph node, skin, peritoneum, or adrenal gland have better survival than those with multiple extrathoracic lesions. These patients may be candidates for surgical resection or local ablative therapy with curative intent [13]. Five-year relative survival rate of patient with distant spread of lung cancer is around 7% as compared to 60% in localized disease [14]. The median overall survival of patients with stage IV lung cancer ranges between 7.0 and 12.2 months depending on treatment, histologic type, and other associated factors such as patient co-morbidities [14]. One study found that survival for those with advanced stage disease, those who have a targetable mutation or are responsive to immunotherapy, can be significantly longer, 20 months vs. 12.2 months [15]. Given the impact of extrathoracic disease on patient prognosis, it is crucial to choose the most appropriate imaging and biopsy modalities. Histopathologic confirmation of the extrathoracic disease is necessary to confer the highest and most accurate stage to the patient. In addition, it is incumbent on the pulmonologist to provide a “molecular stage” which may provide significantly better treatment options for patients.

Computerized tomography of the chest, CT or MRI with contrast of the brain, and  $^{99m}\text{Tc}$  nuclear imaging of the skeletal system are the conventional staging studies; however, data over the last decade confirm the superiority of the per-

formance characteristics of positron emission tomography (PET) and PET-CT scans, compared with conventional scans, in the evaluation of metastatic disease in key specific distant sites. Specifically, PET scan reveals unsuspected metastases in 6–37% of patients [12]. In the results of a 2013 meta-analysis of nine studies, fluorodeoxyglucose (FDG) PET-CT had a sensitivity of 93%, a specificity of 96%, a positive likelihood ratio of 28.4%, and a negative likelihood ratio of 0.08% for detection of distant metastases [16]. Additionally, PET is cost-effective compared with CT. Søggaard et al. reported that PET-CT increased the cost by 3927 Euros and that 5 PET-CT scans are needed to prevent one noncurative surgical resection [17]. The American College of Chest Physicians (ACCP) guidelines recommends PET to evaluate for extrathoracic metastasis, except for brain metastasis (where PET is not useful), in patients with a normal clinical evaluation and no suspicious extrathoracic abnormalities on chest CT being considered for curative-intent treatment [12]. Advanced thoracic lesions and mediastinal lymphadenopathy, particularly N2 disease, are associated with higher rates of asymptomatic metastases and in those cases PET should be performed [18].

Important limitations relating to false positive and false negative scans exist within extrathoracic disease imaging and a positive PET scan requires careful clinical correlation with biopsy confirmation to accurately stage the patient [12]. Clinicians must have pathologic evidence of metastatic disease that was suggested by PET unless there are overwhelming findings on the scan such as multiple bilateral nodules or multiple sites of uptake in the bony skeleton.

## **Pleura and Pleural Effusion**

There are limited data to suggest that CT and PET scan are useful in identifying malignant pleural effusion (MPE); although, much of the data pertain to non-pulmonary malignancies [12]. Certain CT features such as pleural thickening, pleural nodularity, or lung parenchymal

lesions in close proximity to the pleura heighten suspicion for pleural metastases. One study found the sensitivity of CT for MPE can be increased by its integration with FDG-PET, reaching 93% in comparison to 70% with CT alone [19]. No radiological study can substitute for cytohistological confirmation if pleural malignancy is a consideration.

### Adrenal and Hepatic Metastases

Incidental adrenal nodules are found in 20% of patients with NSCLC [20]. Although it is common to encounter adrenal masses in a routine CT scan, unilateral adrenal masses measuring greater than 3 cm in a patient with suspected lung cancer is more likely to be a metastasis rather than a benign lesion [20].

Computerized tomography, MRI, PET, percutaneous biopsy, and even adrenalectomy can be used to help distinguish benign from malignant disease [12]. Delayed contrast-enhanced CT can help aid the differentiation of benign and malignant lesions, but is rarely performed. MRI has not shown superiority when compared to CT because of the considerable overlap of signal intensity in benign and malignant lesions. PET scan outperforms both CT and MRI in identifying malignant lesions of the adrenal gland. A recent meta-analysis of nine studies evaluating the diagnostic accuracy of PET-CT for the detection of adrenal metastasis noted a pooled sensitivity of 89% and a specificity of 90%. False-negative results can occur in metastases with hemorrhage, necrosis, and in lesions measuring less than 1 cm. Adrenal hyperplasia, adrenal adenoma, and infections can result in false-positive results [21].

Most liver lesions are benign cysts or hemangiomas, but a contrast CT scan or ultrasound is often required to establish a likely diagnosis. Although there are limited data with NSCLC, PET-CT and MRI have been used to detect liver metastases. The PET scan has an accuracy of 92–100% with rare false positives results [12]. A recent meta-analysis showed that MRI has a higher sensitivity and specificity when compared

to CT scan in detecting liver lesions (93.1% vs. 82.1% for sensitivity, 87.3% vs. 73.5% for specificity) [22].

### Brain

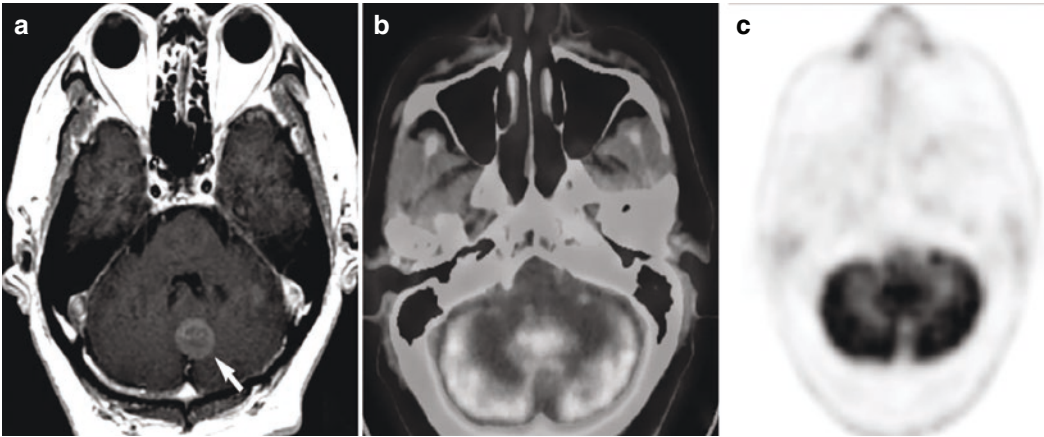
Magnetic resonance imaging is the gold standard to evaluate for brain metastases. ACCP guidelines suggest routine MRI brain for clinical stage III or IV NSCLC, but not for asymptomatic stage I or II disease [23]. CT scans are also used to evaluate metastasis to the brain. Because of brain abscesses, gliomas, and other lesions, CT scans under perform in detecting brain metastasis. The false negative and false positive rates of cranial CT are reported to be 3% and 11%, respectively [12]. Detection of brain metastases is a problem for PET-CT because the high background brain FDG uptake can mask the small size of most brain metastases. Lesions can be either hypermetabolic or hypometabolic (Fig. 28.3) [24]. The results of a meta-analysis showed pooled sensitivities of 21% and 77% and specificities of 100% and 99% for PET and MRI, respectively [25].

### Bone

Radionucleotide bone scintigraphy can be used to detect bone metastases but is troubled with a high false positive rate owing to the frequency of degenerative and traumatic skeletal damage. PET appears to have excellent performance characteristics in assessing bone metastases. One meta-analysis of patients with lung cancer revealed that FDG PET-CT was more accurate for the diagnosis of bone metastases when compared to MRI or bone scintigraphy. In addition, combined PET-CT has better performance characteristics than any other method for detecting bony metastases [26].

### Case 1 Continued

*The patient underwent a PET-CT which demonstrated a hypermetabolic 8.5 cm left apical mass along with increased uptake in left hilum, medi-*



**Fig. 28.3** Contrast-enhanced T1-weighted brain MR image. (a) Demonstrates the presence of a cerebellar metastasis (white arrow). (b and c), PET/CT and PET images show decreased FDG uptake

*astinum, and thoracic vertebrae. There was a hypermetabolic left pleural nodule and a 3.6 cm right adrenal lesion (Fig. 28.2b, c).*

Once imaging is suspicious for extrathoracic spread, the next step is tissue acquisition. The goal of any biopsy is to provide adequate samples for the pathologist to arrive at a definitive histopathologic diagnosis and have adequate tissue for molecular analysis to help dictate therapy.

Although bone biopsy has a high rate of success for diagnosing metastatic disease, it often has inadequate tissue for molecular analysis. VanderLaan et al. showed that of the 207 patients with concurrent testing, the failure rate for bone-derived specimens were 23.1% for EGFR, 15.4% for KRAS, and 23.1% for ALK. This is attributed to the decalcification process of the tumor tissue which alters the DNA leading to failure of molecular analysis [27]. Adrenal lesions with radiographic features suspicious for malignancy can be sampled by percutaneous fine needle aspiration/biopsy or, less commonly, by endoscopic ultrasound-fine needle aspiration (EUS-FNA) [12]. Brain biopsy is not routinely performed but should be considered when the diagnosis of brain metastases is in doubt. This is particularly important in patients with a concern for oligometastatic disease. Tissue sampling of a distant metastatic site is not necessary if there is overwhelming radiographic evidence of metastatic disease in multiple sites [12]. Patients with suspected lung cancer who present with a pleural

effusion should undergo ultrasound-guided thoracentesis with a goal of drawing at least 50 mL of pleural fluid. The diagnostic yield for pleural fluid cytology has a reported mean sensitivity of 72%, with a range of 49–91%. The sensitivity of pleural fluid cytology increases a further 27% with a second thoracentesis, but only a 5% yield from a third. If cytology after two subsequent thoracentesis is negative for cancer, one should consider imaging guided biopsy, surgical biopsy or thoracoscopy [28].

## Biomarkers

Historically, patients with advanced NSCLC received cytotoxic chemotherapy regimens, including platinum-based chemotherapies. The 5-year relative survival for metastatic disease is approximately 7% in these individuals [14]. Sensitizing mutations in EGFR, with regard to NSCLC, were first described in 2004 [29]. Nearly two decades later, there have been incredible advancements in detecting and treating lung cancer patients with approved treatments for which there are specific mutations found on the tumor. Why is this important? We know that patients who receive matched targeted therapy have superior overall survival compared with patients who receive cytotoxic chemotherapy or no therapy at all. Gutierrez et al. reported survival data for 805 patients with advanced NSCLC. The 131 patients



who received targeted therapy at some time during their treatment had a median overall survival of 31.8 months compared to 12.7 months for cytotoxic chemotherapy and 5.1 months for supportive care only [30]. Biomarkers are classified as actionable or prognostic. Actionable biomarkers are the mutations for which treatments have been developed compared to prognostic biomarkers which are indicative of a patient's survival independent of the treatment received. The NCCN guidelines recommend testing for ALK rearrangements, BRAF mutations, EGFR mutations, METex14 skipping mutations, NTRK1/2/3 gene fusions, RET rearrangements, and ROS1 rearrangements for individuals with advanced NSCLC [7]. Biomarker status should be documented prior to initiation of therapy as patients may be able to receive targeted therapy or immunotherapy with or without chemotherapy. If mutational analysis cannot be performed on a biopsy sample, the patient may need to a repeat procedure/biopsy to obtain tissue solely for molecular analysis. Some patients may not be able to undergo another procedure for molecular analysis. In these instances, a liquid biopsy drawn from a blood sample searching for circulating tumor cell free DNA can be obtained to assess for actionable mutations. If a patient has both a

molecular biomarker and high PD-L1 expression, targeted therapy is usually recommended first prior to consideration of immunotherapy [7].

### Case 1 Concluded

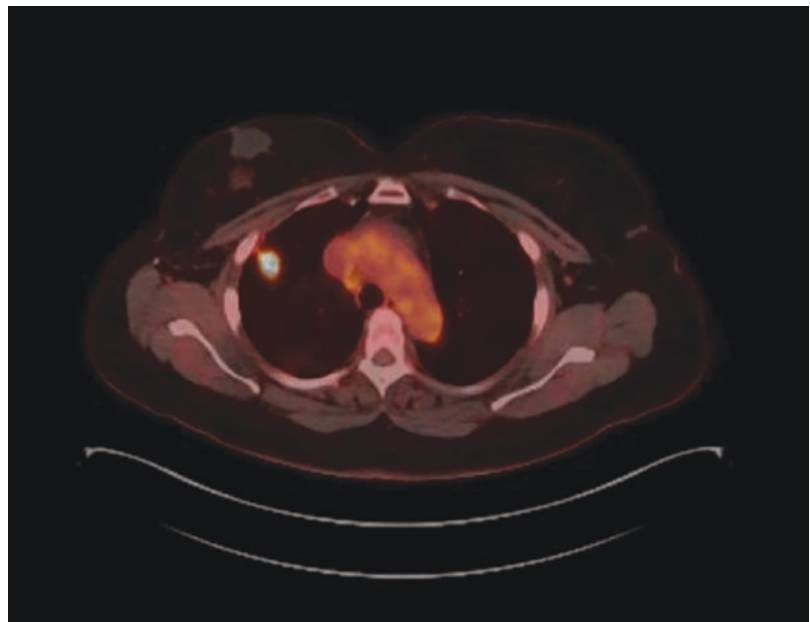
*Patient underwent CT-guided biopsy of the adrenal lesion which was diagnostic for adenocarcinoma of the lung and Stage IVB was confirmed. Molecular analysis documented an EGFR mutation and he was referred to Oncology for targeted therapy.*

### Case 2

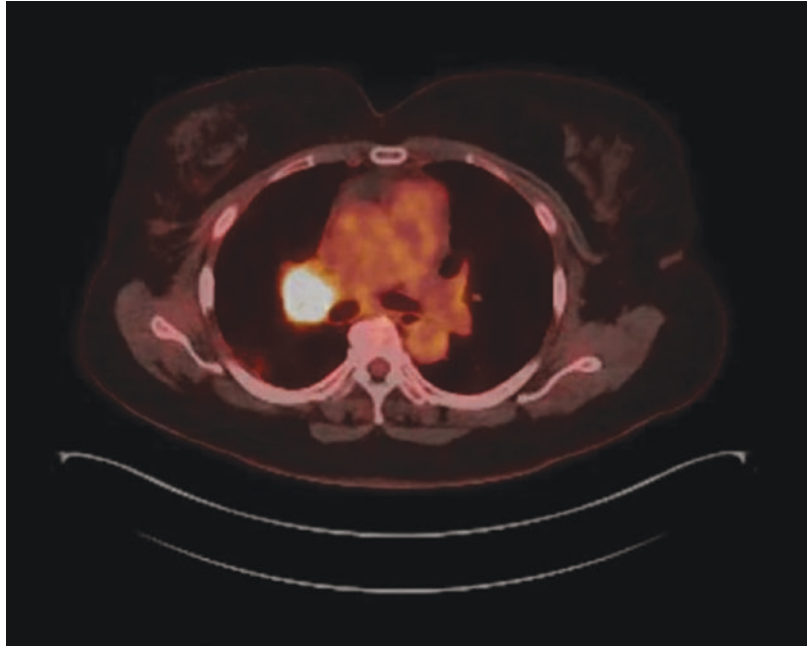
*A 64-year-old female with a previous smoking history is evaluated in clinic with a 1.8 cm RUL nodule. Due to patient preference, a follow-up CT scan obtained 6 months later showed that the nodule had grown in size. PET-CT was performed (Figs. 28.4 and 28.5) and revealed the nodule was hypermetabolic along with a hypermetabolic right hilar lymph node.*

The first step in deciding which invasive approach to stage the mediastinum is to perform initial radiographic staging (Table 28.1).

**Fig. 28.4** PET-CT showing a RUL 2.4 cm hypermetabolic nodule with an SUV of 10.1



**Fig. 28.5** PET-CT showed a hypermetabolic right hilar lymph node measuring 2.1 cm with an SUV of 10



**Table 28.1** Definition of intrathoracic radiographic categories of lung cancer

Group	Description	Definition (by chest CT scan)
A	Mediastinal infiltration	Tumor mass within the mediastinum such that discrete lymph nodes cannot be distinguished or measured
B	Enlarged discrete mediastinal nodes	Discrete mediastinal nodes $\geq 1$ cm in short axis diameter on a transverse CT image
C	Clinical stage II or central stage I tumor	Normal mediastinal nodes ( $< 1$ cm) but enlarged N1 nodes ( $> 1$ cm) or a central tumor (within proximal one-third of the hemithorax)
D	Peripheral clinical stage I tumor	Normal mediastinal and N1 nodes ( $< 1$ cm) and a peripheral tumor (within outer two-thirds of hemithorax)

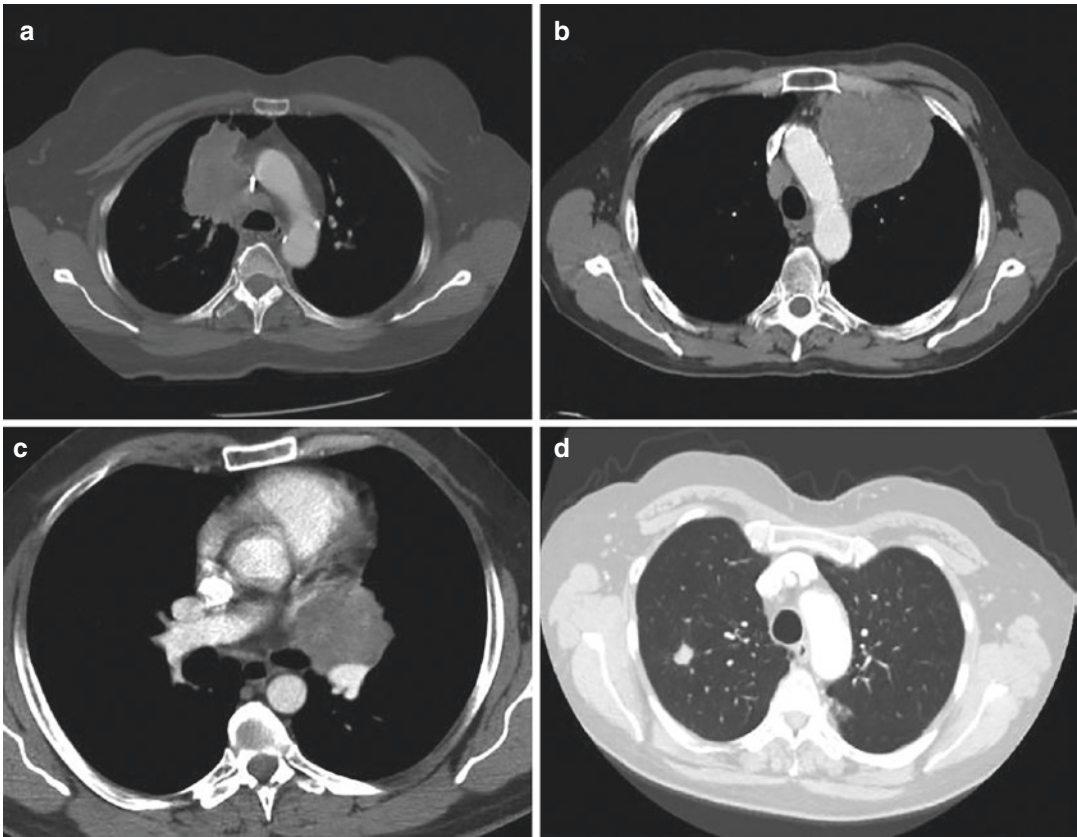
### Chest X-Ray

Although CXR is a good tool in providing preliminary information such as obvious chest wall and mediastinal invasion in large tumors, it has limited sensitivity to predict T3/T4 disease or metastases to the mediastinum. The patient will

need further imaging for better delineation of the extent of disease prior to consideration of treatment options.

### Computerized Tomography

Computerized tomography scan of the chest is the cornerstone of lung cancer imaging on which further management is decided. Ideally, it should be extended to include the liver and adrenal glands to assess for metastatic disease. Based on the intra-thoracic radiographic characteristics (including both the primary tumor and the mediastinum), patients with lung cancer can be separated into four groups, A to D (Table 28.1 and Fig. 28.6). Radiographic group A involves patients with mediastinal infiltration that encircles the vessels and airways, so that the discrete lymph nodes can no longer be discerned or measured. Group B involves patients with enlarged mediastinal node ( $\geq 1$  cm in short axis diameter) in whom the size of the discrete nodes can be measured. The last two groups involve patients with normal mediastinal nodes. In radiographic group C, the presence of a central tumor or sus-



**Fig. 28.6** American College of Chest Physicians intra-thoracic radiographic (CT) categories for lung cancer. (a) Mediastinal infiltration by tumor. (b) Enlarged discrete

N2,3 nodes. (c) A central tumor or a tumor with enlarged N1 nodes, but a normal mediastinum. (d) A peripheral small tumor with normal sized lymph nodes

pected N1 disease makes the chance of N2 or N3 nodal involvement relatively high, 20–25%. Despite normal-sized mediastinal lymph nodes, further confirmation is needed. In group D, those with a clinical stage I tumor, the chance of either distant metastases or mediastinal involvement is quite low [12]. The advantage of CT is that it provides accurate anatomic definition of the tumor within the thorax. For example, it helps us accurately identify T3 or T4 lesions and enlarged lymph nodes which directs tissue biopsy for histopathologic diagnosis and staging.

The major limitation of CT is its low accuracy in the identification of mediastinal metastases. The ACCP guidelines published the performance characteristics of CT for staging the mediastinum which involved 35 studies in a meta-analysis. The analysis showed a pooled sensitivity of 51%

(95% CI 47–54%) and a pooled specificity of 86% (95% CI 84–88%) [31]. This limitation is more evident in 5–15% of patients with clinical T1N0 lesions that will be found to have positive lymph node involvement by surgical sampling [32]. It is usually inappropriate to rely solely on chest CT to determine the mediastinal lymph node status; regardless, CT continues to play an important role in the evaluation of patients with either a known or suspected lung cancer who are eligible for treatment [12].

### Positive Emission Tomography

The advent of the PET scan has been the single most notable addition to lung cancer staging in recent history. Cancer cells demonstrate increased

cellular uptake of glucose when compared with normal cells. PET scan uses 18-FDG, a radio-labeled glucose analogue which undergoes the same cellular uptake as glucose. After phosphorylation, is not further metabolized and becomes trapped in cells. This accumulation of isotope is identified by a PET detector [33]. There are no standardized criteria defining what constitutes a positive PET result and no ideal cutoff point for the standardized uptake value (SUV). However, lymph nodes with FDG uptake greater than that observed in the mediastinal blood pool are highly suspicious for metastatic disease [34].

Whole body PET imaging in preoperative staging of lung cancer has been shown to increase identification of patients with mediastinal and extrathoracic disease compared to conventional staging by 20% [35–38]. In addition, PET improves discrimination between N0-1 and N2-3 disease [39]. One systematic review of 45 studies which included 4105 patients reported sensitivity, specificity, positive predictive value (PPV) and negative predictive value (NPV) of 80%, 88%, 75%, and 91%, respectively for mediastinal staging [12]. One limitation of PET scan is the poor anatomic definition of suspicious lesions. Integrated PET-CT enables the direct correlation of FDG-accumulating lesions with morphological structures. There is an improvement in the number of patients correctly staged with this modality over CT or PET alone, but that has not been shown to improve mortality [40, 41].

There have been 5 randomized controlled trials (RCTs) evaluating the role of PET scan in lung cancer patients all with varying results. While two studies suggest a reduction in the rate of futile thoracotomies with the use of PET as a staging modality [36, 38], three studies suggest no difference in a similar population [35, 37, 42]. This variation was likely due to the significant differences among the patients enrolled, their evaluation prior to PET, and the risk for advanced disease. Population-based studies suggest that the use of PET has had increased stage migration from stage III to stage IV, but adds little to the staging of patients with clinical stage I cancer [43]. One of the downsides to increasing sensitivity in detecting occult metastases is incorrectly

upstaging patients and potentially withholding possible curative management [12].

When staging the mediastinum with PET or PET-CT, benign FDG-avid lesions such as infections, inflammation, and granulomatous disease can present as false positives. Additionally, lymph nodes <10 mm have a lower chance of detection from PET scan compared to enlarged lymph nodes [44]. In patients without mediastinal lymphadenopathy, a negative PET-CT is highly valid and patients may proceed to surgery unless they have a central tumor. However, the false negative rate is considerable in enlarged lymph nodes without FDG uptake (30%) [39].

Despite its widespread use, there is no consensus regarding the routine use of PET as a staging modality for patients with suspected NSCLC. Confirmation of PET findings is essential because it also carries a significant rate of incorrect upstaging. Needle techniques to assess the mediastinum are the most rational next step. Nevertheless, there are enough data (including RCTs, prospective studies, and population studies) which suggest that the PET-CT is of more benefit than harm [12].

## Magnetic Resonance Imaging

Historically, MRI of lung was thought not to be ideal due to low signal-to-noise ratio, which includes susceptibility artifacts caused by multiple air-tissue interfaces and motion artifacts [45]. Currently, MRI is indicated for superior sulcus tumors, such as a Pancoast tumor, and assessment of possible invasion of the spinal cord [46]. Recent improvements in MRI techniques such as short echo times, ultrafast turbo-spin-echo acquisitions, projection reconstruction technique, breath-hold imaging, electrocardiogram triggering, and oxygen enhancement have widened the potential for investigations of pulmonary parenchymal disease [45]. Once radiographic staging has been completed, the physician can select the proper invasive test depending on the location of the target and the performance characteristics of the test selected (Table 28.2) [12].

**Table 28.2** Accuracy of staging tests in lung cancer patients: meta-analysis ACCP guidelines

Procedure	Number of studies	N	Sensitivity	Specificity
Mediastinoscopy	33	9267	78	100
EUS	26	2443	88	100
EBUS	31	2756	89	100
EBUS/EUS	7	811	91	100

### Endobronchial Ultrasound with Transbronchial Needle Aspiration

Endobronchial ultrasound with transbronchial needle aspiration (EBUS-TBNA) utilizes real-time ultrasound to visualize the target lesion within the airway wall/mediastinum and to visualize the biopsy needle itself during biopsy [47]. Not only is EBUS-TBNA used to diagnose and stage advanced lung cancer, but can also provide enough material for molecular analysis for treatable driver mutations [48]. There are two types of EBUS, the radial probe EBUS (RP-EBUS) and the curvilinear probe EBUS (CP-EBUS). RP-EBUS is utilized by passing the probe through the working channel of a bronchoscope and advanced into the airway to obtain a 360-degree grey scale image of the airway and surrounding structures. Unfortunately, the RP-EBUS does not allow for ultrasound guidance biopsy in real time. In comparison, the CP-EBUS has a 35 degrees forward oblique view. The scope is passed directly into the airway and the probe balloon is inflated with water to allow contact with the airway wall and conduction of ultrasound waves. This provides a higher resolution image with the ability to perform real-time ultrasound guided biopsies. Color flow and Doppler can also be utilized for identification of vascular and cystic structures [49].

The EBUS scope can access a wide range of mediastinal and hilar lymph nodes that include 2R, 2L, 3P, 4R, 4L, 7, 10R, 10L, 11R, 11L (Fig. 28.7). The overall median sensitivity of EBUS-TBNA is reported to be 89% in a systematic review of 2756 patients, with values ranging from 46% to 97%. The median NPV was 91% ([12], Table 28.2). Most of the studies in the review included patients with bulky lymphadenopathy, mostly radiographic group B and some

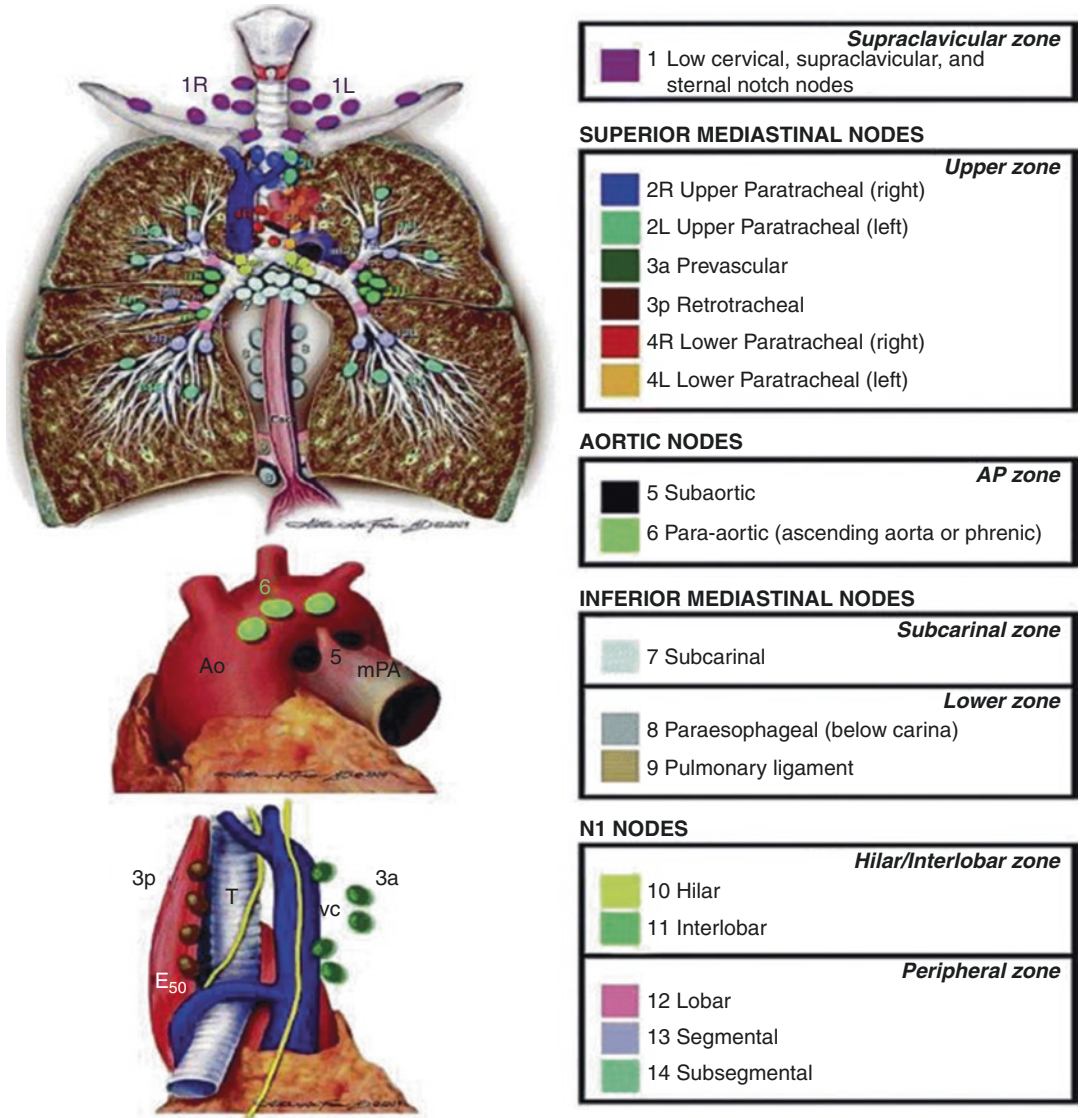
A and C. However, two studies evaluated the performance of EBUS-TBNA in patients with a normal mediastinum by CT scan and PET-CT, respectively. The prevalence of mediastinal disease was lower in the negative PET-CT group, likely due to the higher sensitivity of PET-CT to detect disease. Despite this, the negative predictive value was comparable in both groups at around 96% [50, 51].

### Navigational and Robotic Bronchoscopy

Peripheral pulmonary lesions (PPL) frequently pose a dilemma for patients and physicians trying to establish the best strategy for workup. Historically, RP-EBUS and standard bronchoscopy with fluoroscopy have been used to try to biopsy these peripheral lesions. Tanner et al. in a RTC in 2018 compared thin bronchoscopy with radial EBUS (R-EBUS) with standard bronchoscopy and fluoroscopy (SB-F) and found a diagnostic yield of 49% for the R-EBUS arm and 37% for the SB-F arm. This was not statistically significant [52]. Newer technologies such as virtual bronchoscopic navigation (VBN), electromagnetic navigational bronchoscopy (ENB) and robotic bronchoscopy (RB), facilitates PPL diagnosis by directing a bronchoscope to its intended target via visualized three-dimensional lung models [53].

Virtual bronchoscopy involves two phases, planning phase which uses a CT scan to construct a virtual bronchial tree and the actual bronchoscopy [53]. A prospective, multicenter trial randomized 199 patients to a procedure with or without VBN resulting in a diagnostic yield of 80% for VBN vs. 67% without VBN [54]. Recently, there have been controversies involving utility and yield of VBN. Bo et al. randomized





**Fig. 28.7** Regional lymph node stations

subjects to a standard bronchoscopy, RP-EBUS-guided bronchoscopy, or bronchoscopy combining both RP-EBUS and VBN. While both guided bronchoscopy groups were superior to standard bronchoscopy, there was again no difference in diagnostic yield between groups with and without VBN [55].

Electromagnetic navigational bronchoscopy involves generation of an electromagnetic field around the patient in which devices equipped with small transponders can be tracked [53]. One

RTC looked at three arms, either RP-EBUS, ENB, or a combination of the two. The diagnostic yields were 88% for the combined procedure, 69% for RP-EBUS alone, and 59% for ENB alone [56]. Similar to VBN, there have been conflicting data regarding yield of ENB. The results from the AQUIRE registry showed a much lower diagnostic yield of 38.5% with ENB alone and 47.1% with EBN combined with RP-EBUS [57].

Robotic bronchoscopy shows the ability to hold the endoscope in a locked curved position,

favoring the placement of biopsy tools within the target without straightening during sampling [58]. A recent prospective, multicenter study involving 54 patients from Chen and colleagues showed a diagnostic yield of 74% [59]. Ideally, a prospective, randomized trial or a robust comparison of diagnostic yield will need to be performed before robotic bronchoscopy can become mainstream in diagnosis and staging of lung cancer.

### Transthoracic Needle Aspiration

Transthoracic needle aspiration has been utilized by clinicians for decades to biopsy lung lesions and rarely stage the mediastinum. Advances in histopathology and imaging, specifically the switch between fluoroscopy to CT, have increased the accuracy and efficacy of TTNA [60]. The procedure involves marking the patient's skin with radio-opaque markers and then undergoing a short spiral CT for planning of needle trajectory. Once the site and trajectory are selected, the needle passes percutaneously under image guidance to aspirate or biopsy (TTNB) tissue [61]. The pooled sensitivity for TTNA is reported to be 90% in a meta-analysis of 19 studies with a trend toward a lower sensitivity involving lesions <2 cm [62]. Given the proximity of lymph nodes to major thoracic vessels and to heart, TTNA is mostly limited to the superior mediastinal lymph nodes. The most common complication of TTNA is iatrogenic pneumothorax. The incidence of pneumothorax averages approximately 15% and 6.6% requiring chest tube placement for evacuation [63]. These factors limit the use of TTNA in staging the mediastinum and clinicians may have to rely on other biopsy modalities to obtain tissue.

### Transbronchial Needle Aspiration

Transbronchial needle aspiration (TBNA) has been utilized for decades to biopsy the mediastinum, but this was initially done through a rigid bronchoscope. The first use of TBNA through a flexible bronchoscope was introduced in 1983,

but it wasn't until a year later that Wang and colleagues described the procedure in detail [64]. The procedure involves passing the needle catheter, which comes in different sizes, through the working channel of the bronchoscope and then directed to the target lesion. The needle is then passed through the bronchial wall and material is aspirated for tissue sampling. It can be performed as an unguided procedure during bronchoscopy or under image-guidance using a bronchoscope with endobronchial ultrasound or electromagnetic navigational capability. It is used most commonly to assess subcarinal lymph nodes and less frequently with paratracheal lymph nodes due to difficulty with directing the bronchoscope and the needle toward these lymph nodes. The overall median sensitivity was 78% (range 14%–100%) and the negative predictive value was 77% in a systematic review evaluating 2408 patients [12]. The patients included in the studies mainly had N2/N3 disease. As such, these results can be reliably applied to patients with bulky mediastinal disease; however, the high false negative rates make TBNA less useful for staging the mediastinum in patients with normal sized lymph nodes. A negative TBNA therefore cannot effectively rule out mediastinal nodal involvement and additional staging procedures should be performed. In a comparative study directly evaluating the accuracy of TBNA against the endobronchial ultrasound fine needle aspiration (EBUS-FNA) and endoscopic ultrasound fine needle aspiration (EUS-FNA), TBNA was less sensitive when individually compared to EBUS-FNA and EUS-FNA in identifying mediastinal involvement (36% vs. 69%). Ultrasound guided techniques, such as EBUS-TBNA and EUS-FNA, have largely replaced TBNA and this is due to TBNA having a lower sensitivity than ultrasound guided biopsy techniques [65].

### Endoscopic Ultrasound with Needle Aspiration

Endoscopic ultrasound with fine needle aspiration for cytologic diagnosis of pancreatic cancer was first performed by Peter Vilmann in 1991

[66]. In the following decade, EUS-FNA has aided in the diagnosis and staging of mediastinal disease [67]. EUS is performed using an endoscope with an ultrasound transducer at the tip. There are two types of echoendoscopes, radial and curvilinear. The radial echoendoscope provides a 360-degree view while the curvilinear echoendoscope provides a 180-degree view. Through the esophageal wall, EUS can visualize stations 2L, 4L, 5, 7, 8, and 9. EUS can visualize and sample the left adrenal gland and liver lesions which aids in both diagnosis and complete staging [68]. The reported sensitivity, specificity, and accuracy were 81%, 100%, and 97%, respectively [69].

A meta-analysis was done in 2021 looking at EUS-FNA's accuracy at diagnosing benign and malignant mediastinal and abdominal lymphadenopathy. The meta-analysis included twenty-six studies with 2753 patients with 2833 lymph nodes. EUS-FNA had a pooled sensitivity of 87% and a pooled specificity of 100% [70].

### Combined EUS-FNA and EBUS-TBNA

EUS-FNA and EBUS-TBNA have a complementary diagnostic yield and can allow for complete access to all nodal stations with EUS providing access to the posterior and inferior mediastinum (Stations 2L, 4L, 5, 7, 8, 9) and EBUS-TBNA providing access to the anterior/superior mediastinum in conjunction with hilar lymph nodes (Stations 2R, 2L, 3P, 4R, 4L, 7, 10R, 10L, 11R, 11L). EUS can also provide sampling of the left adrenal gland and liver lesions. In a systematic review of seven studies including 811 patients, the pooled median sensitivity and specificity were 91% and 100%, respectively [12].

### Case 2 Concluded

*Patient underwent EBUS-TBNA with sampling of the hypermetabolic 10R lymph node that showed adenocarcinoma documenting Stage IIB. She*

*was referred to cardiothoracic surgery for consideration of surgical resection followed by adjuvant chemotherapy.*

### Case 3

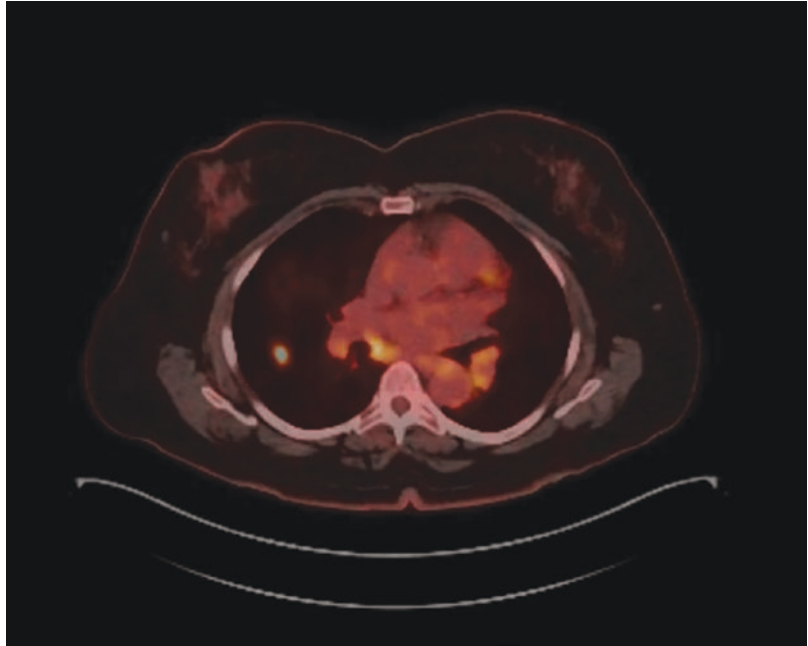
*A 63-year-old female with a past medical history of smoking in her 20s presented to clinic with an incidentally discovered RLL nodule. PET-CT showed uptake within the nodule and scattered hypermetabolic mediastinal and hilar lymph nodes (Fig. 28.8). She underwent a staged EBUS-TBNA and Robotic Navigational Bronchoscopy for diagnosis and staging. Biopsies were negative and she was referred to Cardiothoracic Surgery.*

Tissue confirmation can be done endoscopically or surgically. When both modalities are available, current recommendations are to start with endoscopic techniques. If biopsy results are negative, the patient should undergo surgical staging of the mediastinum to confirm the diagnosis [71]. Available techniques include standard cervical mediastinoscopy (SCM), extended cervical mediastinoscopy (ECM), video-assisted thoracoscopic surgery (VATS) and anterior mediastinotomy (Chamberlain Procedure).

### Standard Cervical Mediastinoscopy

The first reported mediastinoscopy was done in 1959 by Carlens and was considered the gold standard for mediastinal nodal assessment for more than half a century. Cervical mediastinoscopy is the preferred technique for sampling stations 3, 2R, 2L, 4R, 4L, 7, 10R, 10L [71]. Nodal stations that cannot be reached using this modality include posterior 7, 8, 9, 5, and stations 11–14. During the procedure, a midline transverse incision is made immediately above the sternal notch. A mediastinoscope is inserted and follows the whole length of the trachea and bronchi allowing the exploration of the superior and middle mediastinum. The advantage of mediastinoscopy over minimally invasive needling techniques is direct visualization of the lymph node and the ability to

**Fig. 28.8** PET-CT showing a hypermetabolic right lower lobe nodule measuring 1.5 cm with a hypermetabolic hilar lymph node



take large biopsies. This allows for more adequate samples for immunohistochemical staining, molecular analysis, and culture. The use of video techniques, videomediastinoscopy, has improved visualization, allows for the concurrent use of multiple surgical instruments, and allows for true mediastinal lymphadenectomy [72]. In a review of 9, 257 patients, the overall median sensitivity of standard cervical mediastinoscopy as compared to videomediastinoscopy and mediastinal lymphadenectomy was reported to be 78%, 89%, and 94%, respectively. The negative predictive value was 91%. The false negative cases were predominantly nodal stations that were not accessible by traditional mediastinoscopy and possibly affected by operator diligence in node dissection and sampling [12].

### Extended Cervical Mediastinoscopy

Extended cervical mediastinoscopy was first described by Specht in 1965 and allows for access to the sub aortic and para-aortic lymph nodes. It also allows for access to the same nodal stations as a standard cervical mediastinoscopy, stations 1, 2, 3, 4, 7, 10 ( [73], Fig. 28.7).

Historically, mediastinal staging would be accomplished by performing a standard cervical mediastinoscopy and a Chamberlain procedure, but ECM allows for access to the aortopulmonary window through the same incision made for the standard cervical mediastinoscopy without the surgical risk associated with a Chamberlain procedure.

### Anterior Mediastinoscopy

Historically, the aortopulmonary window (station 5) and prevascular (station 6) have been difficult to gain access to and cannot be reached by minimally invasive techniques or standard cervical mediastinoscopy (Fig. 28.7). Lymphatic drainage to these lymph nodes usually involves the left upper lobe. McNeill and Chamberlain described the technique for gaining access to these lymph nodes in 1966. The procedure is performed by creating a left parasternal incision at the level of the second or third intercostal space and dissecting down to the lymph nodes for biopsy. It also allows for access to the left upper lobe tumors for simultaneous resection when there is no evidence of

nodal involvement [71]. In a systematic review from 2013 of 238 patients, the reported median sensitivity of the Chamberlain procedure was 71% and the NPV was 91% [12]. With the invention of video-assisted thoracic surgery (VATS), this has largely replaced the Chamberlain procedure for accessing the aorto-pulmonary window (station 5) and para-aortic (station 6) lymph nodes. A retrospective cohort study was done in 2007 which included 112 patients with clinically suspected N2 disease in lymph node stations 5 and 6. Thirty-nine patients underwent VATS which concluded in the correct diagnosis in 100% [74].

### Video-Assisted Thoracic Surgery

The first practical use of thoracoscopy was reported in 1910 by Dr. Jacobaeus when he used a thoracoscope to investigate and treat pleural effusions. The first thoroscopes were similar to the first endoscopes. There were several limitations which included a lack of magnification, only the operator can see the structures clearly, and the function of the assisted instruments were lacking. With the invention of the video-assisted imaging system, surgeons were able to magnify the image but also share the image with other surgeons simultaneously. The minimal requirements to perform a VATS include a rigid telescope, a light source with cable, a camera, and an imaging processor [75].

VATS for mediastinal staging is usually performed when needle techniques fail or are unable to access the lymph nodes in question. One major advantage of VATS over needle techniques is the direct visualization of the lung and mediastinal structures, including lymph node stations. It can provide a complete staging including TNM (Fig. 28.1). The major disadvantage of VATS is increased morbidity and mortality associated with surgery. In a 2013 meta-analysis of 4 studies, the reported median sensitivity was 99% (range 58–100%) and the negative predictive value was 96% (range 88–100%) for staging the mediastinum [12].

### Surgical vs Minimally Invasive Techniques

When evaluating a patient with lung cancer, accurate staging is what dictates treatment and management. Invasive biopsy is still the main modality for diagnosis and staging, which can be done surgically or with minimally invasive techniques. The guidelines recommend that minimally invasive needle techniques are the first modality of choice to confirm mediastinal involvement in accessible lymph nodes stations. This recommendation is based on the availability of these technologies (EBUS-TBNA, EUS-FNA, etc.) and the appropriate skill of the operator. If minimally invasive techniques are negative and there is still a high clinical suspicion of disease, surgical biopsy is then recommended ( [12], Table 28.2).

### Case 3 Concluded

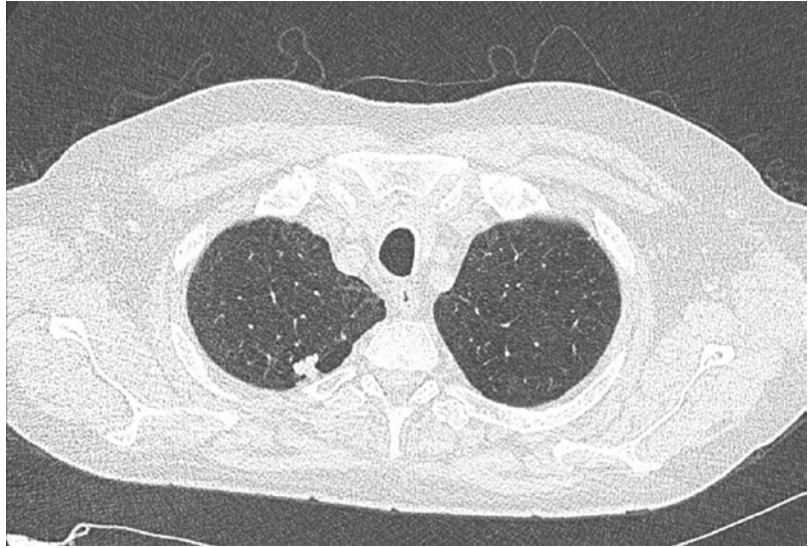*Patient was evaluated by Cardiothoracic Surgery and underwent PFTs which were favorable for surgery. She underwent wedge resection that showed squamous cell carcinoma and subsequently underwent lobectomy with mediastinal lymph node dissection with curative intent.*

### Case 4

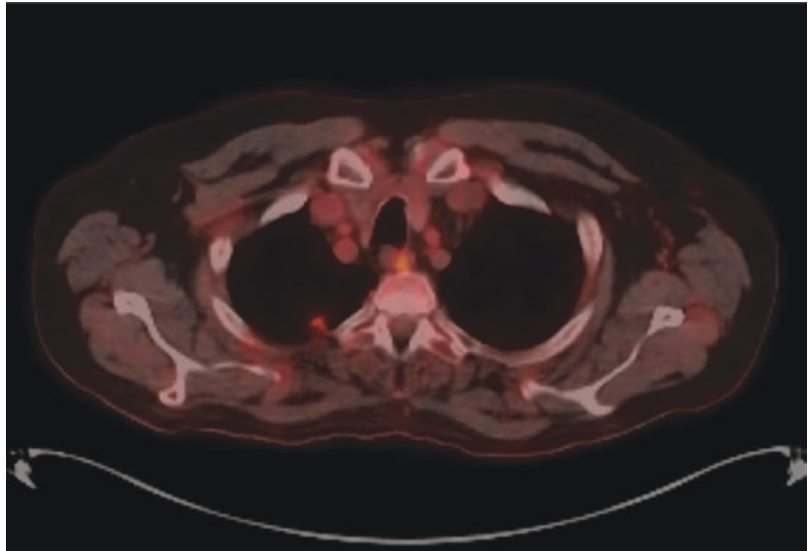
*A 64-year-old man, former smoker with a 45-pack year smoking history, presented with a productive cough, dyspnea, and tachycardia. A chest CT showed a 1.4 cm right upper lobe nodule without lymphadenopathy along with centrilobular emphysema. A subsequent PET-CT revealed increased uptake in with an SUV of 3.3 from the right upper lobe nodule with no mediastinal or hilar uptake (Figs. 28.9 and 28.10). Patient had a clinical stage IA tumor. Pulmonary function tests showed moderate obstruction with FEV1 of 60%. Given his high-risk nature; A referral to cardiothoracic surgery was placed. After evaluation, patient underwent a right upper lobectomy in the*



**Fig. 28.9** CT chest showing 1.4 cm right upper lobe nodule with surrounding emphysema



**Fig. 28.10** PET CT showing slightly increased uptake in right upper lobe nodule with SUV 3.3



operating room for curative intent. Pathology showed *aT1bN0M0 squamous cell carcinoma*.

When there is a high probability that the lesion in question is lung cancer with a normal clinical examination and no suspicious extrathoracic abnormalities on chest CT, the patient should be considered for curative intent treatment. The next step is to obtain a PET-CT to evaluate for mediastinal uptake and distant metastasis. If the PET shows negative nodal involvement, invasive perioperative evaluation of the mediastinal nodes is not required [12]. Ideally, the patient should be

evaluated by a thoracic surgeon or a multidisciplinary team for consideration of surgical resection.

---

## Summary

When evaluating patients suspected of having lung cancer, the first step is to acquire a thorough history, complete exam, and radiologic data to guide further treatment. Once imaging is obtained, further diagnostic workup is usually

warranted with tissue sampling to acquire a histological diagnosis and accurate stage. CT scan of the chest is usually the first imaging test of choice, followed usually by PET-CT if further information is required. PET-CT has proven to be invaluable in aiding physicians by providing information about the tumor, mediastinum, and metastases, both within the chest and beyond. Brain MRI has proven to be superior to CT in identifying metastases to the brain and can be utilized to search for metastatic disease. Once imaging is completed, the next step in diagnosis is usually tissue acquisition by needle techniques and these include EBUS-TBNA, EUS-FNA, TTNA, TBNA, and navigational bronchoscopy with use of RP-EBUS. When patients have stage I or II disease, surgery is usually the best option and patients may undergo surgical staging of the mediastinum. Surgical staging includes standard cervical mediastinoscopy, extended cervical mediastinoscopy, anterior mediastinoscopy (Chamberlain Procedure), and VATS. Regardless of technique, molecular analysis and immunohistochemical staining have become crucial in the treatment for NSCLC and should be evaluated.

## References

1. Sung H, Ferlay J, Siegel RL, et al. Global cancer statistics 2020: GLOBOCAN estimates of incidence and mortality worldwide for 36 cancers in 185 countries. *CA Cancer J Clin.* 2021;71(3):209–49. <https://onlinelibrary.wiley.com/doi/abs/10.3322/caac.21660>. <https://doi.org/10.3322/caac.21660>.
2. Dyba T, Randi G, Bray F, et al. The European cancer burden in 2020: incidence and mortality estimates for 40 countries and 25 major cancers. *Eur J Cancer.* 1990;2021(157):308–47. <https://doi.org/10.1016/j.ejca.2021.07.039>.
3. Siegel RL, Miller KD, Jemal A. Cancer statistics, 2018. *CA Cancer J Clin.* 2018;68:7–30. <https://doi.org/10.3322/caac.21442>.
4. de Koning HJ, van der Aalst, Carlijn M, de Jong PA, et al. Reduced lung-cancer mortality with volume CT screening in a randomized trial. *N Engl J Med.* 2020;382(6):503–13. <https://doi.org/10.1056/NEJMoa1911793>.
5. US Preventive Services Task Force, Krist AH, Davidson KW, et al. Screening for lung cancer: US preventive services task force recommendation statement. *JAMA.* 2021;325(10):962–70. <https://escholarship.org/uc/item/4d08218t>
6. Goldstraw P, Chansky K, Crowley J, et al. The IASLC lung cancer staging project: proposals for revision of the TNM stage groupings in the forthcoming (eighth) edition of the TNM classification for lung cancer. *J Thorac Oncol.* 2016;11(1):39–51. <https://doi.org/10.1016/j.jtho.2015.09.009>.
7. Ettinger DS, Wood DE, Aisner DL, et al. NCCN guidelines insights: Non–Small cell lung cancer, version 2.2021. *J Natl Compr Cancer Netw.* 2021;19(3):254–66. <https://doi.org/10.6004/jnccn.2021.0013>.
8. Kocher F, Hilbe W, Seeber A, et al. Longitudinal analysis of 2293 NSCLC patients: A comprehensive study from the TYROL registry. *Lung Cancer.* 2015;87(2):193–200. <https://www.sciencedirect.com/science/article/pii/S0169500214005169>. <https://doi.org/10.1016/j.lungcan.2014.12.006>.
9. Riihimäki M, Hemminki A, Fallah M, et al. Metastatic sites and survival in lung cancer. *Lung Cancer.* 2014;86(1):78–84. <https://www.sciencedirect.com/science/article/pii/S0169500214003201>. <https://doi.org/10.1016/j.lungcan.2014.07.020>.
10. Kanaji N, Watanabe N, Kita N, et al. Paraneoplastic syndromes associated with lung cancer. *World J Clin Oncol.* 2014;5(3):197–223. <https://doi.org/10.5306/wjco.v5.i3.197>.
11. Spiro SG, Gould MK, Colice GL. Initial evaluation of the patient with lung cancer: symptoms, signs, laboratory tests, and paraneoplastic syndromes: ACCP evidenced-based clinical practice guidelines (2nd edition). *Chest.* 2007;132:149S–60S.
12. Silvestri GA, Gonzalez AV, Jantz MA, et al. Methods for staging non-small cell lung cancer: diagnosis and management of lung cancer, 3rd ed: American college of chest physicians evidence-based clinical practice guidelines. *Chest.* 2013;143(5 Suppl):e211S–50S. <https://www.ncbi.nlm.nih.gov/pubmed/23649440>. <https://doi.org/10.1378/chest.12-2355>.
13. Varela G, Thomas PA. Surgical management of advanced non-small cell lung cancer. *J Thorac Dis.* 2014;6(Suppl 2):S217–23. <https://www.ncbi.nlm.nih.gov/pubmed/24868439>. <https://doi.org/10.3978/j.issn.2072-1439.2014.04.34>.
14. Surveillance Research Program, National Cancer Institute SEER\*Stat software (seer.cancer.gov/seerstat) SEER 18 2011–2017.
15. Kowalski DM, Cho BC, Lubiniecki GM, et al. Pembrolizumab versus chemotherapy for previously untreated, PD-L1-expressing, locally advanced or metastatic non-small-cell lung cancer (KEYNOTE-042): A randomised, open-label, controlled, phase 3 trial. *Lancet.* 2019;393(10183):1819–30. [https://doi.org/10.1016/S0140-6736\(18\)32409-7](https://doi.org/10.1016/S0140-6736(18)32409-7).
16. Li J, Xu W, Kong F, Sun X, Zuo X. Meta-analysis: accuracy of 18FDG PET-CT for distant metastasis staging in lung cancer patients. *Surg Oncol.* 2013;22(3):151–5. <https://doi.org/10.1016/j.suronc.2013.04.001>.

17. Sogaard R, Fischer BMB, Mortensen J, Højgaard L, Lassen U. Preoperative staging of lung cancer with PET/CT: cost-effectiveness evaluation alongside a randomized controlled trial. *Eur J Nucl Med Mol Imaging*. 2011;38(5):802–9. <https://doi.org/10.1007/s00259-010-1703-y>.
18. Silvestri GA, Littenberg B, Colice GL. The clinical evaluation for detecting metastatic lung cancer : A meta-analysis. *Am J Respir Crit Care Med*. 1995;152(1):225–30.
19. Sun Y, Yu H, Ma J, Lu P. The role of 18F-FDG PET/CT integrated imaging in distinguishing malignant from benign pleural effusion. *PLoS One*. 2016;11(8):e0161764. <https://www.ncbi.nlm.nih.gov/pubmed/27560933>. <https://doi.org/10.1371/journal.pone.0161764>.
20. Brady MJ, Thomas J, Wong TZ, Franklin KM, Ho LM, Paulson EK. Adrenal nodules at FDG PET/CT in patients known to have or suspected of having lung cancer: A proposal for an efficient diagnostic algorithm. *Radiology*. 2009;250(2):523–30. <https://www.ncbi.nlm.nih.gov/pubmed/19188319>. <https://doi.org/10.1148/radiol.2502080219>.
21. Wu Q, Luo W, Zhao Y, Xu F, Zhou Q. The utility of 18F-FDG PET/CT for the diagnosis of adrenal metastasis in lung cancer: A PRISMA-compliant meta-analysis. *Nucl Med Commun*. 2017;38(12):1117–24. <https://www.ncbi.nlm.nih.gov/pubmed/28953208>. <https://doi.org/10.1097/MNM.0000000000000757>.
22. Choi SH, Kim SY, Park SH, Kim KW, Lee JY, Lee SS, Lee MG. Diagnostic performance of CT, gadoxetate disodium-enhanced MRI, and PET/CT for the diagnosis of colorectal liver metastasis: systematic review and meta-analysis. *J Magn Reson Imaging*. 2018;47(5):1237–50. <https://doi.org/10.1002/jmri.25852>. Epub 2017 Sep 13
23. Detterbeck FC, Mazzone PJ, Naidich DP, Bach PB. Screening for lung cancer: diagnosis and management of lung cancer, 3rd ed: American college of chest physicians evidence-based clinical practice guidelines. *Chest*. 2013;143(5 Suppl):e78S–92S. <https://www.ncbi.nlm.nih.gov/pubmed/23649455>. <https://doi.org/10.1378/chest.12-2350>.
24. Lee HY, Lee KS, Kim B, et al. Diagnostic efficacy of PET/CT plus brain MR imaging for detection of extrathoracic metastases in patients with lung adenocarcinoma. *J Korean Med Sci*. 2009;24(6):1132–8. <https://www.ncbi.nlm.nih.gov/pubmed/19949671>. <https://doi.org/10.3346/jkms.2009.24.6.1132>.
25. Li Y, Jin G, Su D. Comparison of gadolinium-enhanced MRI and 18FDG PET/PET-CT for the diagnosis of brain metastases in lung cancer patients: A meta-analysis of 5 prospective studies. *Oncotarget*. 2017;8(22):35743–9. <https://www.ncbi.nlm.nih.gov/pubmed/28415747>. <https://doi.org/10.18632/oncotarget.16182>.
26. Qu X, Huang X, Yan W, Wu L, Dai K. A meta-analysis of 18FDG-PET–CT, 18FDG-PET, MRI and bone scintigraphy for diagnosis of bone metastases in patients with lung cancer. *Eur J Radiol*. 2012;81(5):1007–15. 10.1016/j.ejrad.2011.01.126
27. VanderLaan PA, Yamaguchi N, Folch E, et al. Success and failure rates of tumor genotyping techniques in routine pathological samples with non-small-cell lung cancer. *Lung Cancer*. 2014;84(1):39–44. <https://www.clinicalkey.es/playcontent/1-s2.0-S016950021400049X>. <https://doi.org/10.1016/j.lungcan.2014.01.013>.
28. Rivera MP, Mehta AC, Wahidi MM. Establishing the diagnosis of lung cancer: diagnosis and management of lung cancer, 3rd ed: American college of chest physicians evidence-based clinical practice guidelines. *Chest*. 2013;143(5 Suppl):e142S–65S. . <https://www.ncbi.nlm.nih.gov/pubmed/23649436>. <https://doi.org/10.1378/chest.12-2353>.
29. Lynch TJ, Bell DW, Sordella R, et al. Activating mutations in the epidermal growth factor receptor underlying responsiveness of non-small-cell lung cancer to gefitinib. *N Engl J Med*. 2004;350(21):2129–39. <http://content.nejm.org/cgi/content/abstract/350/21/2129>. <https://doi.org/10.1056/NEJMoa040938>.
30. Gutierrez ME, Choi K, Lanman RB, et al. Genomic profiling of advanced non-small cell lung cancer in community settings: gaps and opportunities. *Clin Lung Cancer*. 2017;18(6):651–9. <https://www.clinicalkey.es/playcontent/1-s2.0-S1525730417301092>. <https://doi.org/10.1016/j.clcc.2017.04.004>.
31. Silvestri GA, Gould MK, Margolis ML, et al. Noninvasive staging of non-small cell lung cancer: ACCP evidenced-based clinical practice guidelines (2nd edition). *Chest*. 2007;132(3 Suppl):178S–201S. <https://www.ncbi.nlm.nih.gov/pubmed/17873168>
32. Pretreatment evaluation of non-small-cell lung cancer. The American Thoracic Society and The European Respiratory Society. *Am J Respir Crit Care Med*. 1997;156(1):320–32. <https://doi.org/10.1164/ajrccm.156.1.ats156.1>.
33. Wahl RL, Hutchins GD, Buchsbaum DJ, Liebert M, Grossman HB, Fisher S. 18F-2-deoxy-2-fluoro-D-glucose uptake into human tumor xenografts. feasibility studies for cancer imaging with positron-emission tomography. *Cancer*. 1991;67(6):1544–50. [https://doi.org/10.1002/1097-0142\(19910315\)67:6<1544::AID-CNCR2820670614>3.0.CO;2-0](https://doi.org/10.1002/1097-0142(19910315)67:6<1544::AID-CNCR2820670614>3.0.CO;2-0).
34. Paesmans M, Garcia C, Wong CO, et al. Primary tumour standardised uptake value is prognostic in nonsmall cell lung cancer: A multivariate pooled analysis of individual data. *Eur Respir J*. 2015;46(6):1751–61. <https://www.narcis.nl/publication/RecordID/oi:cris.maas-trichtuniversity.nl:publications%2F2c3174a7-5568-45e4-b08f-d2aa911cc6b0>. <https://doi.org/10.1183/13993003.00099-2015>.
35. Maziak DE, Darling GE, Levine MN, et al. Positron emission tomography in staging early lung cancer: A randomized trial. *Ann Intern Med*. 2009;151(4):221–8. <https://www.ncbi.nlm.nih.gov/pubmed/19581636>. <https://doi.org/10.7326/0003-4819-151-4-200908180-00132>.

36. van Tinteren H, Hoekstra OS, Smit EF, et al. Effectiveness of positron emission tomography in the preoperative assessment of patients with suspected non-small-cell lung cancer: the PLUS multicentre randomised trial. *Lancet*. 2002;359(9315):1388–92. [https://doi.org/10.1016/S0140-6736\(02\)08352-6](https://doi.org/10.1016/S0140-6736(02)08352-6).
37. Viney RC, Boyer MJ, King MT, et al. Randomized controlled trial of the role of positron emission tomography in the management of stage I and II non-small-cell lung cancer. *J Clin Oncol*. 2004;22(12):2357–62. <http://jco.ascopubs.org/content/22/12/2357.abstract>. <https://doi.org/10.1200/JCO.2004.04.126>.
38. Fischer B, Lassen U, Mortensen J, et al. Preoperative staging of lung cancer with combined PET-CT. *N Engl J Med*. 2009;361(1):32–9. <http://content.nejm.org/cgi/content/abstract/361/1/32>. <https://doi.org/10.1056/NEJMoa0900043>.
39. Fischer BM, Mortensen J, Hansen H, et al. Multimodality approach to mediastinal staging in non-small cell lung cancer. Faults and benefits of PET-CT: A randomised trial. *Thorax*. 2011;66(4):294–300. <https://doi.org/10.1136/thx.2010.154476>.
40. De Wever W, Vankan Y, Stroobants S, Verschakelen J. Detection of extrapulmonary lesions with integrated PET/CT in the staging of lung cancer. *Eur Respir J*. 2007;29(5):995–1002. <http://erj.ersjournals.com/cgi/content/abstract/29/5/995>. <https://doi.org/10.1183/09031936.00119106>.
41. De Wever W, Ceyssens S, Mortelmans L, et al. Additional value of PET-CT in the staging of lung cancer: comparison with CT alone, PET alone and visual correlation of PET and CT. *Eur Radiol*. 2007;17(1):23–32. <https://www.ncbi.nlm.nih.gov/pubmed/16683115>. <https://doi.org/10.1007/s00330-006-0284-4>.
42. Herder G, Kramer H, Hoekstra OS, et al. Traditional versus up-front [18F] Fluorodeoxyglucose–Positron emission tomography staging of Non–Small-cell lung cancer: A dutch cooperative randomized study. *J Clin Oncol*. 2006;24(12):1800–6. <http://jco.ascopubs.org/content/24/12/1800.abstract>. <https://doi.org/10.1200/JCO.2005.02.4695>.
43. Morgensztern D, Goodgame B, Baggstrom MQ, Gao F, Govindan R. The effect of FDG-PET on the stage distribution of non-small cell lung cancer. *J Thorac Oncol*. 2008;3(2):135–9. <https://doi.org/10.1097/JTO.0b013e3181622e2c>.
44. Gupta NC, Graeber GM, Bishop HA. Comparative efficacy of positron emission tomography with fluorodeoxyglucose in evaluation of small (<1 cm), intermediate (1 to 3 cm), and large (>3 cm) lymph node lesions. *Chest*. 2000;117(3):773–8. <https://doi.org/10.1378/chest.117.3.773>.
45. Kauczor H, Kreitner K. MRI of the pulmonary parenchyma. *Eur Radiol*. 1999;9(9):1755–64. <https://www.ncbi.nlm.nih.gov/pubmed/10602947>. <https://doi.org/10.1007/s003300050919>.
46. Webb WR, Gatsonis C, Zerhouni EA, et al. CT and MR imaging in staging non-small cell bronchogenic carcinoma: report of the radiologic diagnostic oncology group. *Radiology*. 1991;178(3):705–13. <http://radiology.rsn.org/content/178/3/705.abstract>. <https://doi.org/10.1148/radiology.178.3.1847239>.
47. Wahidi MM, Herth F, Yasufuku K, et al. Technical aspects of endobronchial ultrasound-guided transbronchial needle aspiration: CHEST guideline and expert panel report. *Chest*. 2016;149(3):816–35. <https://www.ncbi.nlm.nih.gov/pubmed/26402427>. <https://doi.org/10.1378/chest.15-1216>.
48. Grosu HB. EBUS-TBNA for the diagnosis of lymphoma: time to give in? *J Bronchology Interv Pulmonol*. 2018;25(3):165–6. <https://www.ncbi.nlm.nih.gov/pubmed/29944587>. <https://doi.org/10.1097/LBR.0000000000000524>.
49. Avasarala SK, Aravena C, Almeida FA. Convex probe endobronchial ultrasound: historical, contemporary, and cutting-edge applications. *J Thorac Dis*. 2020;12(3):1085–99. <https://www.ncbi.nlm.nih.gov/pubmed/32274177>. <https://doi.org/10.21037/jtd.2019.10.76>.
50. Herth FJF, Ernst A, Eberhardt R, Vilmann P, Dienemann H, Krasnik M. Endobronchial ultrasound-guided transbronchial needle aspiration of lymph nodes in the radiologically normal mediastinum. *Eur Respir J*. 2006;28(5):910–4. <http://erj.ersjournals.com/cgi/content/abstract/28/5/910>. <https://doi.org/10.1183/09031936.06.00124905>.
51. Herth FJF, Eberhardt R, Krasnik M, Ernst A. Endobronchial ultrasound-guided transbronchial needle aspiration of lymph nodes in the radiologically and positron emission tomography-normal mediastinum in patients with lung cancer. *Chest*. 2008;133(4):887–91. <https://doi.org/10.1378/chest.07-2535>.
52. Tanner NT, Yarmus L, Chen A, et al. Standard bronchoscopy with fluoroscopy vs thin bronchoscopy and radial endobronchial ultrasound for biopsy of pulmonary lesions: A multicenter, prospective, randomized trial. *Chest*. 2018;154(5):1035–43. <https://www.ncbi.nlm.nih.gov/pubmed/30144421>. <https://doi.org/10.1016/j.chest.2018.08.1026>.
53. Silvestri GA, Feller-Kopman D, Chen A, Wahidi M, Yasufuku K, Ernst A. Latest advances in advanced diagnostic and therapeutic pulmonary procedures. *Chest*. 2012;142(6):1636–44. <https://www.clinicalkey.es/playcontent/1-s2.0-S0012369212607004>. <https://doi.org/10.1378/chest.12-2326>.
54. Ishida T, Asano F, Yamazaki K, et al. Virtual bronchoscopic navigation combined with endobronchial ultrasound to diagnose small peripheral pulmonary lesions: A randomised trial. *Thorax*. 2011;66(12):1072–7. <https://doi.org/10.1136/thx.2010.145490>.
55. Bo L, Li C, Pan L, et al. Diagnosing a solitary pulmonary nodule using multiple bronchoscopic guided technologies: A prospective randomized study. *Lung Cancer*. 2019;129:48–54. <https://doi.org/10.1016/j.lungcan.2019.01.006>.
56. Berhardt R, Anantham D, Ernst A, Feller-Kopman D, Herth F. Multimodality bronchoscopic diagnosis of peripheral lung lesions: A randomized controlled trial.



- Am J Respir Crit Care Med. 2007;176(1):36–41. <http://ajrccm.atsjournals.org/cgi/content/abstract/176/1/36>. <https://doi.org/10.1164/rccm.200612-1866OC>.
57. Ost DE, Ernst A, Lei X, et al. Diagnostic yield and complications of bronchoscopy for peripheral lung lesions. Results of the AQUIRE registry. *Am J Respir Crit Care Med*. 2016;193(1):68–77. <https://www.ncbi.nlm.nih.gov/pubmed/26367186>. <https://doi.org/10.1164/rccm.201507-1332OC>.
  58. Murgu SD. Robotic assisted-bronchoscopy: technical tips and lessons learned from the initial experience with sampling peripheral lung lesions. *BMC Pulm Med*. 2019;19(1):89. <https://www.ncbi.nlm.nih.gov/pubmed/31072355>. <https://doi.org/10.1186/s12890-019-0857-z>.
  59. Chen AC, Pastis J, Nicholas J, Mahajan AK, et al. Robotic bronchoscopy for peripheral pulmonary lesions: A multicenter pilot and feasibility study (BENEFIT). *Chest*. 2021;159(2):845–52. <https://www.ncbi.nlm.nih.gov/pubmed/32822675>. <https://doi.org/10.1016/j.chest.2020.08.2047>.
  60. Chockalingam A, Hong K. Transthoracic needle aspiration: the past, present and future. *J Thorac Dis*. 2015;7(Suppl 4):S292–9. <https://www.ncbi.nlm.nih.gov/pubmed/26807277>. <https://doi.org/10.3978/j.issn.2072-1439.2015.12.01>.
  61. Birchard KR. Transthoracic needle biopsy semin intervent radiol. 2011;28(1):87–97. <https://doi.org/10.1055/s-0031-1273943>.
  62. Schreiber G, Mccrory DC. Performance characteristics of different modalities for diagnosis of suspected lung cancer: summary of published evidence. *Chest*. 2003;123(1):115S–28S. <https://www.ncbi.nlm.nih.gov/pubmed/12527571>
  63. Wiener RS, Schwartz LM, Woloshin S, Welch HG. Population-based risk for complications after transthoracic needle lung biopsy of a pulmonary nodule: an analysis of discharge records. *Ann Intern Med*. 2011;155(3):137–44. <https://www.ncbi.nlm.nih.gov/pubmed/21810706>. <https://doi.org/10.7326/0003-4819-155-3-201108020-00003>.
  64. Liu Q, Ben S, Xia Y, Wang K, Huang H. Evolution of transbronchial needle aspiration technique. *J Thorac Dis*. 2015;7(Suppl 4):S224–30. <https://www.ncbi.nlm.nih.gov/pubmed/26807269>. <https://doi.org/10.3978/j.issn.2072-1439.2015.11.31>.
  65. Wallace MB, Pascual JMS, Raimondo M, et al. Minimally invasive endoscopic staging of suspected lung cancer. *JAMA*. 2008;299(5):540–6. <https://doi.org/10.1001/jama.299.5.540>.
  66. Yamao K, Sawaki A, Mizuno N, Shimizu Y, Yatabe Y, Koshikawa T. Endoscopic ultrasound-guided fine-needle aspiration biopsy (EUS-FNAB): past, present, and future. *J Gastroenterol*. 2005;40(11):1013–23. <https://www.ncbi.nlm.nih.gov/pubmed/16322944>. <https://doi.org/10.1007/s00535-005-1717-6>.
  67. Wang Z, Jiang C. Endoscopic ultrasound in the diagnosis of mediastinal diseases. *Open Med*. 2015;10(1):560–5. <http://www.degruyter.com/doi/10.1515/med-2015-0095>. <https://doi.org/10.1515/med-2015-0095>.
  68. Colella S, Vilmann P, Konge L, Clementsen PF. Endoscopic ultrasound in the diagnosis and staging of lung cancer. *Endosc Ultrasound*. 2014;3(4):205–12. <https://www.ncbi.nlm.nih.gov/pubmed/25485267>. <https://doi.org/10.4103/2303-9027.144510>.
  69. Vazquez-Sequeiros E, Levy MJ, Van Domselaar M, et al. Diagnostic yield and safety of endoscopic ultrasound guided fine needle aspiration of central mediastinal lung masses. *Diagnostic and therapeutic endoscopy*. 2013;2013:150492–6. <https://www.airitilibrary.com/Publication/aIDetailedMesh?DocID=P20151216003-201312-201703090034-201703090034-8-13>. <https://doi.org/10.1155/2013/150492>.
  70. Chen L, Li Y, Gao X, et al. High diagnostic accuracy and safety of endoscopic ultrasound-guided fine-needle aspiration in malignant lymph nodes: A systematic review and meta-analysis. *Dig Dis Sci*. 2021;66(8):2763–75. <https://search.proquest.com/docview/2446671513>. <https://doi.org/10.1007/s10620-020-06554-2>.
  71. Call S, Obiols C, Rami-Porta R. Present indications of surgical exploration of the mediastinum. *J Thorac Dis*. 2018;10(Suppl 22):S2601–10. <https://www.ncbi.nlm.nih.gov/pubmed/30345097>. <https://doi.org/10.21037/jtd.2018.03.183>.
  72. D'Andrilli A, Maurizi G, Venuta F, Rendina EA. Mediastinal staging: When and how? *Gen Thorac Cardiovasc Surg*. 2020;68(7):725–32. <https://www.ncbi.nlm.nih.gov/pubmed/31797211>. <https://doi.org/10.1007/s11748-019-01263-8>.
  73. Witte B, Wolf M, Hillebrand H, Kriegel E, Huertgen M. Extended cervical mediastinoscopy revisited. *Eur J Cardiothorac Surg*. 2014;45(1):114–9. <https://www.ncbi.nlm.nih.gov/pubmed/23803515>. <https://doi.org/10.1093/ejcts/ezt313>.
  74. Cerfolio RJ, Bryant AS, Eloubeidi MA. Accessing the aortopulmonary window (#5) and the paraaortic (#6) lymph nodes in patients with non-small cell lung cancer. *Ann Thorac Surg*. 2007;84(3):940–5. <https://www.clinicalkey.es/playcontent/1-s2.0-S0003497507009289>. <https://doi.org/10.1016/j.athoracsur.2007.04.078>.
  75. Luh S, Liu H. Video-assisted thoracic surgery—the past, present status and the future. *J Zhejiang Univ Sci B*. 2006;7(2):118–28. <https://www.airitilibrary.com/Publication/aIDetailedMesh?DocID=16731581-200602-7B-2-118-128-a>. <https://doi.org/10.1631/jzus.2006.B0118>.



---

## Part VI

# Pleural Conditions



Juan Antonio Moya Amorós

## Pleural Embryonic Development

Once the embryonic disc has been formed in the trilaminar phase, which contains three germ layers, namely, ectoderm, mesoderm, and endoderm, the embryo will experience morphological changes following a basic body structuring plan, based on:

- (a) Craniocaudal differentiation gradient with the formation of the notochord, and the neural plate.
- (b) Body regular and transversal segmentation pattern, which evokes the evolutionary phases of the phylogenetic past (fish, reptiles, etc.).
- (c) Body lateral folding, approaching the midline, converting its flat, trilaminar shape into a cylindrical structure with the ectoderm on the outside, the endoderm on the inside, and the mesoderm between the two.

It is precisely from the mesoderm that the pleura derives, among other embryo intermediate structures, forming a serous membrane that along with the peritoneum, internally covers the future coelomic cavity (parietal serosa), as well as

externally covers the organs and viscera contained inside that cavity (visceral serosa).

The first pleural vestige appears in the 22–23-day embryo, when it has already acquired three blastoderm sheets: ectoderm, mesoderm, and endoderm [1]. From this moment on, in the flat embryo thickness, the mesoderm (hereinafter mesenchyme) in turn undergoes fragmentation changes in three territories:

1. Medial territory or chordamesoderm, from which the notochord will derive.
2. Two lateral masses or lateral mesoderms, on each side of the embryo, from which they derive:
  - (a) The somites, precursors of muscles, and bones.
  - (b) The gononephrotome, precursor of the kidney, and the gonads.
  - (c) The somatic mesoderm or somatopleura (future parietal pleura), and the splanchnic mesoderm or splanchnopleura (visceral pleura precursor) (Fig. 29.1).

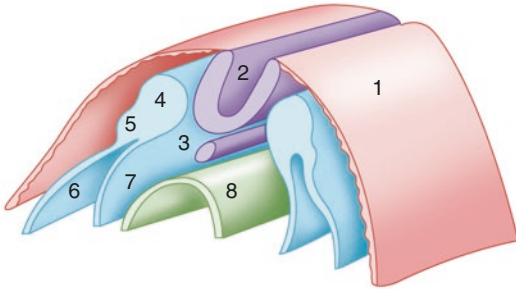
The somatopleura is configured by the somatic mesoderm fusion with the ectoderm internal part, so that the “coalescence” of both structures will end up forming the parietal pleura, which will internally cover the ribs and the intercostal space elements (costal pleura), with which it is kept separated by the endothoracic fascia.

---

J. A. Moya Amorós (✉)  
Thoracic Surgery Department, Bellvitge University  
Hospital, Barcelona, Spain  
e-mail: [juan.moya@bellvitgehospital.cat](mailto:juan.moya@bellvitgehospital.cat)

The splanchnopleura, however, is produced by the fusion of the splanchnic mesoderm with the endoderm external part, so that the serosa resulting from this fusion will be the visceral pleura that will intimately surround the lung mesenchyme (lung parenchyma).

Approximately at the fourth week [2], the embryo has already evolved from having a flat shape to progressively acquiring a tubular-



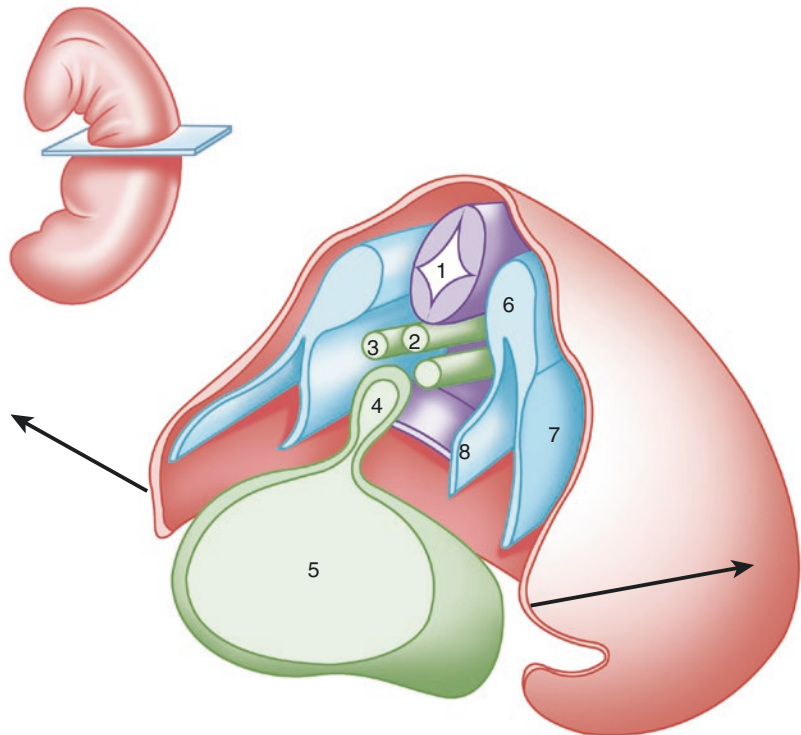
**Fig. 29.1** Diagram of a 23-day embryo with 8 somites, at the neural canal stage in the lateral and ventral folding phases. (1) Ectoderm, (2) Neural canal, (3) Notochord, (4) Somite, (5) Gononephrotome, (6) Somatopleura, (7) Splanchnopleura, (8) Endoderm

cylindrical shape due to a folding process of its lateral walls, both in the cranial-caudal and lateral-medial directions. The cause still does not have a coherent explanation, although as a consequence of it, there is an approximation and fusion in all the embryonic leaves midline, except at the point where the omphalo-mesenteric duct or future umbilical cord emerges.

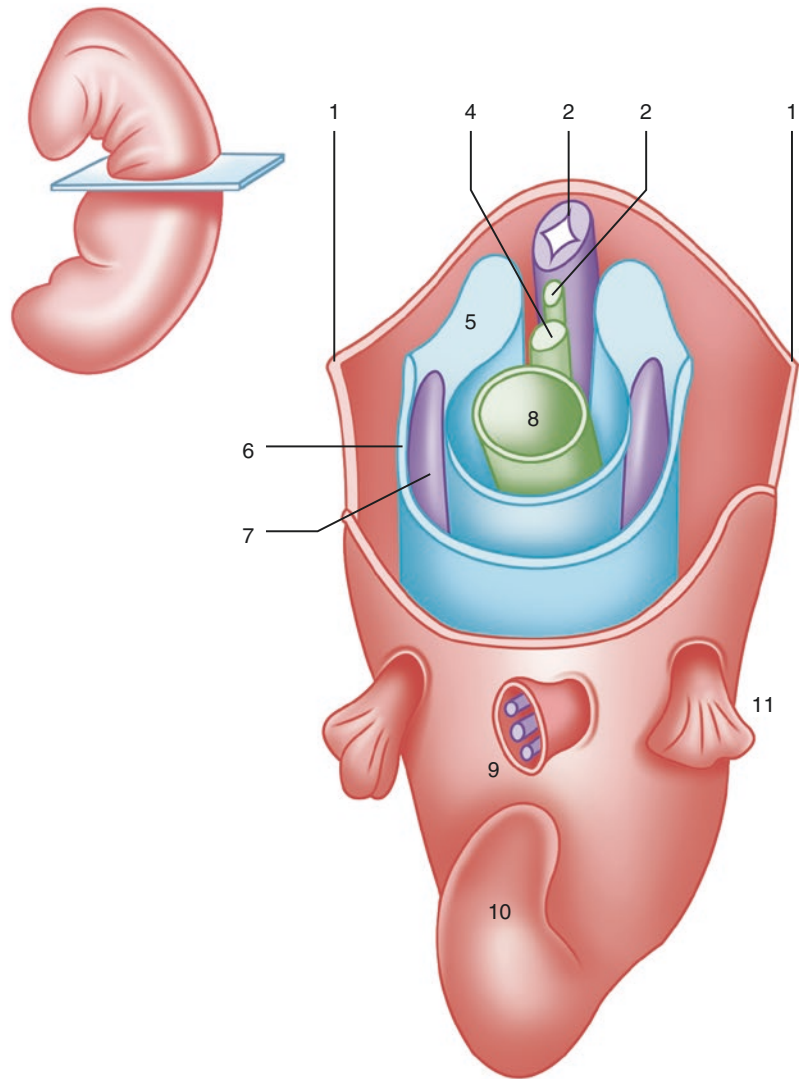
From this development moment, the embryo will have a closed body or trunk with a single cavity inside or coelomic cavity, which contains the future viscera (Fig. 29.2).

In parallel, embryonic changes have also been taking place at the level of the endoderm foregut anterior face. Immediately below the III to IV pharyngeal pouch, an endodermal cells outgrowth appears in the form of a laryngo-tracheo-bronchial bud [3] that progressively and after 24 divisions comes to constitute both adult lungs tracheobronchial tree. In this sense, the lung can be considered as an enormous gland that, from the endodermal duct, invaginates towards the mesenchyme depth, maintaining communication with the outside through the embryo primitive mouth (stomodeum).

**Fig. 29.2** Embryo of 25 days with 8–10 somites in the initial stage of tubular closure. (1) Closed neural tube, (2) Notochord, (3) Dorsal aorta, (4) Endoderm connected toon (5) Extraembryonic coelom (yolk vesicle), (6) Somite, (7) Somatopleura, (8) Splanchnopleura



**Fig. 29.3** A 28-day embryo with 12 somites, in the single cavitation stage of the coelom. (1) Ectoderm, (2) Neural tube, (3) Notochord, (4) Aorta, (5) Somite, (6) Somatopleura, (7) Splanchnopleura, (8) Endoderm, (9) Omphalo-mesenteric duct, (10) Caudal Tubercle, (11) Left caudal appendage (outline of the lower limb)



Between the fourth and ninth weeks, inside the coelomic cavity, a new transverse septation process is outlined at the expense of a mesoderm septum internal growth (transverse septum), which will form the future diaphragm. As a consequence of this septation the coelomic cavity, (until now the only one) it is divided into two interconnected cavities, one cranial or thoracic and caudal or abdominal.

Parallel to these embryonic movements, in the paraxial regions inside the thoracic cavity, some cardinal folds emerge that protrude towards the cavity interior, pushing the somatopleura [4] in a dorso-ventral and cranio-caudal direction, in

relation to vascular structures formation contained within. As a consequence of these folds progressive growth, the definitive septation of the thoracic cavity results in three cavities: a central one or pericardial cavity and two lateral ones or pleural cavities [4, 5] (Fig. 29.3).

### Pleural Molecular Biology During Embryogenesis

Since 1990, molecular biology techniques application has made it possible to understand the correlation between the fundamental embryologic

morphological changes, and the molecular aspects involved in genes maintenance and conservation that direct or guide the body's normal development.

Currently, molecular families that direct embryonic development are already recognized, and in this sense, genetic sequencing studies have shown a phylogenetic conservatism from the rudimentary species of worms to humans, so that there are very few changes in the developmental regulatory genes nucleotide bases. It is also known that the same gene can express different functions in the different ontogenesis phases, and can even act in different organs.

There is the possibility that the same specific gene acts even differently both in the embryonic phase and after birth. To all this molecular complexity is added the fact that mutated genes presence can induce changes even to the point of converting a normal cell into tumoral cells (proto oncogenes). The fundamental molecular processes during this body structuring period are grouped into categories that act as:

1. Transcription factors, which are proteins with domains that bind specific genes DNA, or even act on RNA polymerase II and, consequently, regulate the amount of RNA-messenger that the gene produces. Specifically in humans the 38 homologous genes are called Hox genes, POU genes, and Pax genes.

They belong to this group that are collectively called Homeobox:

- Basic protein helix-loop-helix.
  - Zinc finger proteins.
  - Homeodomain proteins.
2. Activation or signal factors, most of which are proteins that act as peptide growth factors. The first one obtained in the 1950s was neural growth factor, later on TGF- $\beta$  (transforming growth factor  $\beta$ ), and FGF (fibroblast growth factor), involved in mesenchymal cells fibroblastic proliferation capacity. Another important family of activation molecules are the

hedgehog proteins, of which the sonic hedgehog is the most peculiar in that it undergoes autoprolysis that allows obtaining a peptide capable of stimulating the target cell to directly or indirectly produce new differentiation pathways.

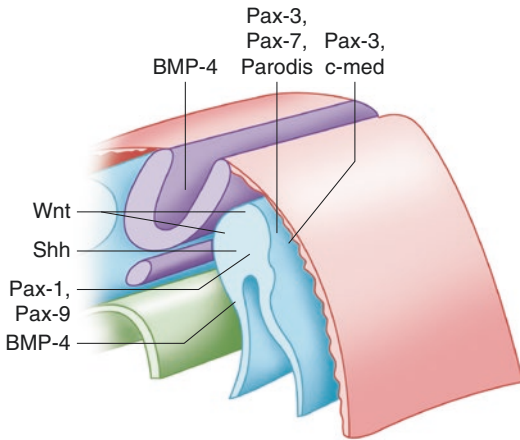
Specifically, the pleura, as a mesoderm derivative, is constituted as a morphogenetic field that remains at the mercy of molecular signals influenced from the ectoderm, neural tube, and notochord (Speman's induction theory, 1938) [5]. These molecular signals cause very curious but necessary events such as the transformation of mesenchymal cells into epithelial cells, and vice versa.

Once the epithelial somites have formed, their ventromedial cells undergo the inductive stimulus of activation by sonic hedgehog [6] (which originates in the notochord and neural tube). The response to this induction is Pax-1 and Pax-91 expression inside the somite, and as a final consequence, there is a cell adhesion molecule loss, specifically N-cadherin6, which again favors the "transformation of epithelial cells into mesenchymal cells," thus acquiring the ability to migrate towards the embryo midline after forming the secondary mesoderm.

Contrary to these events, the somite is exposed to the influence of products secreted by neural tube Wnt gene [6], which establish a sonic hedgehog inhibitory action, and the somatic cells remain under Pax-3, Pax-7 and paraxis expression, obtaining dermatome and myotome morphogenesis.

On the other hand, under BMP-4 influence from the ectoderm [6], lateral mesoderm cells also begin to produce it. This molecule has the ability to influence the paraxial or lateral mesoderm to assume lateral mesoderm properties. All these biological facts together allow to establish a balance between the medializing forces coming from the neural tube and the notochord, against the lateralizing forces coming from the ectoderm (Fig. 29.4).





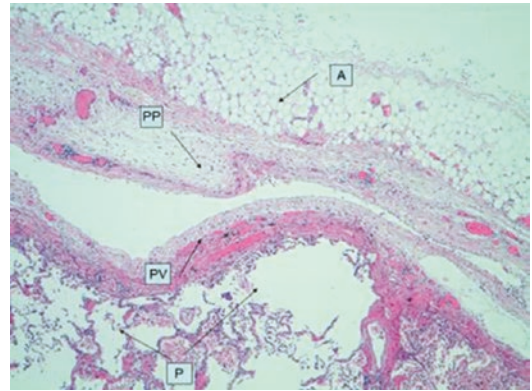
**Fig. 29.4** Ectodermal **BMP-4** induces the lateral mesoderm to also produce **BMP-4**. The *sonic hedgehog* produced in the neural tube and notochord stimulates expression of *Pax-1* and *Pax-9* inside the somite, and as a consequence there is a loss of cell adhesion molecules (**N-cadherina**), favoring cell emigration typical of monostratified pleural mesothelium

### Pleural Histology

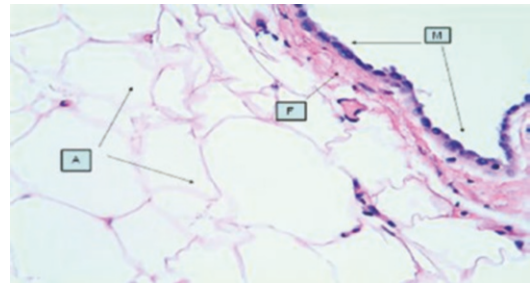
Both the parietal and visceral pleura are characterized by their thinness and transparency. It is firmly attached by elastic fibers to the underlying endothoracic fascia elastic layer (costal pleura) or to the underlying alveolar wall [7] (visceral pleural), respectively.

The visceral pleura structure is made up of five thin layers distinguishable by light microscopy (Figs. 29.5, 29.6, 29.7) which are from superficial to deep:

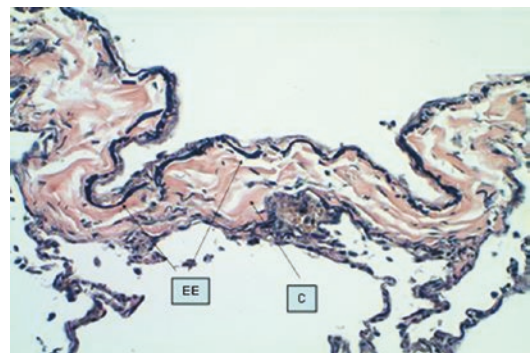
- Mesothelial layer, which is the outermost layer, formed by mesothelial cells.
- Submesothelial connective tissue layer.
- Superficial elastic layer, whose thickness varies during the respiratory cycle.
- Subpleural connective tissue layer, which constitutes the pulmonary decortication cleavage plane. It contains the blood and lymphatic vessels.
- Deep fibroelastic layer is attached to the alveolar elastic membrane.



**Fig. 29.5** Relationship between parietal pleura (**PP**) and visceral pleura (**PV**) stained with hematoxylin-eosin. Below the parietal pleura, adipose tissue is observed (**A**) and below the visceral pleura, the lung parenchyma (**P**)



**Fig. 29.6** Hematoxylin-eosin stained parietal pleura showing the mesothelial cell layer (**M**), submesothelial fibrous tissue (**F**) and subpleural adipose tissue (**A**)



**Fig. 29.7** Visceral Pleura. Vong Gieson stain for elastin, that stains black the external elastic layer (**EE**), and brown the collagen fibers (**C**)

The parietal pleura structure is arranged in three layers, which are, in order from superficial to deep:

- Mesothelial layer, which is the outermost layer, formed by mesothelial cells.
- Superficial elastic layer.
- Connective tissue layer, thick, where the blood vessels are located. It constitutes the cleavage plane between the parietal pleura and the endothoracic fascia [7].

Parietal pleura thickness varies, reaching the maximum thickness at the level of the costal arches, and the minimum thickness at the level of the sternum and pericardium [8]. At the cervicothoracic straight height, it thickens in the form of a septum or fibrous septum described by Bourgeroy.

## Mesothelial Cells, Characteristics, and Function

### Cytological Characteristics

They are the cells that cover the pleural cavity inside, and they have the ability to stretch, varying in shape and size depending on the location, and can have a flattened, cubic, columnar, or cylindrical shape.

- Flattened: They are quiescent cells on the visceral surface or on the parietal surface on rigid structures such as the costal arches. They will be observed more flattened the greater the lung expansion, at the visceral pleura level [5].
- Cubic or columnar: They are cells associated with a fatty substructure.

From the ultrastructural point of view, mesothelial cells are characterized by being covered by an abundant and dense layer of microvilli 0.1  $\mu\text{m}$  in length, which facilitates identification in mesothelioma microscopic study.

Mesothelial cells have abundant endoplasmic reticulum indicating a certain secretory

capacity and significant metabolic activity, so they are responsible, to a certain extent, for pleural fluid composition and quantity. The cytoplasm is also rich in pinocytotic vesicles and mitochondria, which, in turn, are connected by a rich network of intercellular desmosomes.

Fine threads 150 nm in diameter emanate from the superficial glycocalyx between the microvilli, creating compartments between these threads and the last ones, trapping liquid intended to protect the pleural surface [8].

They have phospholipids similar to those of pulmonary surfactant, produced by mesothelial cells, which act by lubricating the pleural surfaces to facilitate movement during the respiratory cycle [9].

### Mesothelial Cells Functions

Mesothelial cells functions are as follows:

- Increase the effective surface favoring phagocytosis and transcytosis (liquid absorption).
- Trap hyaluronic acid, which acts as a lubricant to decrease friction between the lung surface and the chest wall.

Regarding its possible diagnostic utility, a small mesothelial cell number can be found in normal pleural fluid. They can also be found in pleural effusions in both transudate and exudate.

### Pleural Space Defense Mechanism

Inside the pleural cavity, Kampmeier foci are located, which are macrophages, lymphocytes, histiocytes, mast cells, and undifferentiated mesenchymal cells aggregates that are found surrounding thick blood capillaries and lymphatic channels [10]. They are strategically located in the mediastinal pleura lower portion and are similar to the lymphoid tissue found in the tonsils. Among its functions, pleural space defense stands out through the following actions [11–16]:

- Leukocytes production under inflammatory stimulus.
- Phagocytosis.
- Trapping particles and macrophages.

## Pleura Macroscopic Anatomy

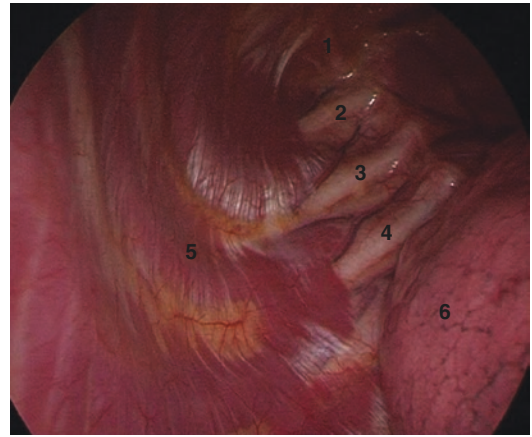
After birth, the pleural space is a cavity in continuous movement with a 10–20  $\mu\text{m}$  separation between the parietal and visceral serosa [11]. It is known that, to favor the movement of the lungs located inside this space, small amounts of pleural fluid rich in hyaluronic acid (0.1–0.2 mL/kg) are contained, which is essential for lubrication between the pleural serosa and maintain surface tension between them.

The pleura, being arranged as a covering sheet, does not have its own shape, rather it adapts by covering the intra-thoracic elements that protrude and make relief towards the pleural cavity interior. Its 20–40  $\mu\text{m}$  thickness [6] explains its transparency, which allows the elements it covers to be seen through it (bones, vessels, muscles, fat, nerves, lung, pericardium...). The pleural free surface is smooth, polished, and shiny to the point that it reflects light from the thoracoscope.

In the pleura, we distinguish two parts or territories that recall its embryonic origin: visceral pleura (splanchnopleura) and parietal pleura (somatopleura) in which three zones are considered: costal, mediastinal, and diaphragmatic pleura (Fig. 29.8).

### Visceral Pleura (Pleura Visceralis or Pulmonalis)

It is 20  $\mu\text{m}$  thick [12–15], intimately attached to the lung external surface, without a detachment or cleavage plane with parenchyma periphery, so it cannot be dissected without injuring the organ. The visceral serosa runs through all lung reliefs, penetrating to the depth of the fissures. Through it, the subpleural lymphatic canaliculi are visualized and identified, adopting a reticular distribution with a dark blue color due to inhaled foreign



**Fig. 29.8** References (1, 2, 3 and 4) for ribs I<sup>a</sup>, II<sup>a</sup>, III<sup>a</sup>, y IV<sup>a</sup>; (5) Intercostal spaces; (6) Visceral pleura for the right upper lobe

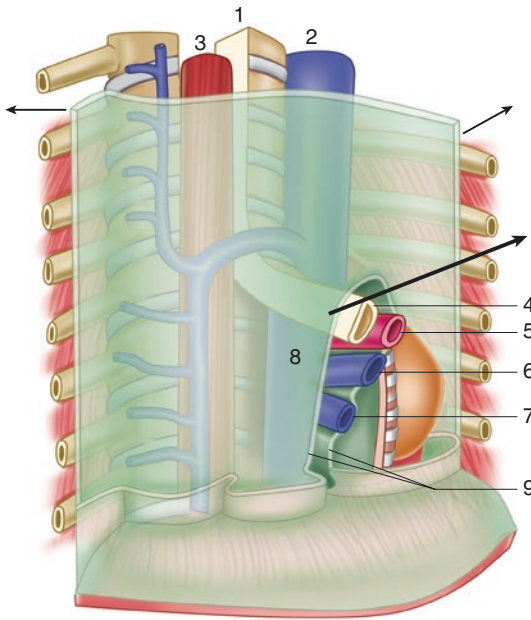
particles accumulation (physiological anthracosis), which in turn delimit small areas of polygonal appearance or pulmonary lobules [12–15].

The visceral serosa is arranged as a mesothelial cells monocellular layer, which externally lines the lung surface. Immediately below, it extends a fibrous and elastic connective tissue layer that externally surrounds the peripheral pulmonary alveoli, emitting radially directed expansions or connective septa, which go deep towards the lobar pulmonary hilum.

On the lung medial side, and at the pulmonary hilum level, the pulmonary serosa reflects on itself without loss of continuity, to continue imperceptibly with the mediastinal parietal pleura, forming the reflection of the mediastinal pleura (Fig. 29.9).

### Parietal Pleura (Pleura Parietalis)

It is 30–40  $\mu\text{m}$  thick [12–15]. It covers and lines the pleural cavity internally, it remains loosely adhered to the endothoracic fascia from which it is easily dissected for surgical convenience, while there is no dissection plane at the level of the diaphragm muscle tendinous center, where the pleura is practically inseparable from the arcuate fibers. According to the topographical zone that it covers, 3 portions are distinguished: costal, diaphragmatic and mediastinal:



**Fig. 29.9** Right posterolateral view of the mediastinal and diaphragmatic pleura. (1) tráchea, (2) superior vena cava, (3) esophagus, (4) right main bronchus, (5) right pulmonary artery, (6) right superior pulmonary vein, (7) right inferior pulmonary vein, (8) Reflection of the mediastinal pleura, (9) pulmonary ligament

### Mediastinal Parietal Pleura (Mediastinalis)

It extends as a parasagittal septum on each side of all mediastinum organs, reflecting posteriorly at the level of the costovertebral canal, and anteriorly in the costosternal angle. The mediastinal serosa is not a continuous septum, but is interrupted by the pulmonary hilum bronchovascular and nervous elements, which it surrounds (Fig. 29.9).

The mediastinal pleura, when reflected at the pulmonary hilum level, forms the mesonneum, which, in a racket form, surrounds the pulmonary pedicle elements in its most cranial part, while caudally it forms the pulmonary ligament that extends in the form of a triangular sheet towards the mediastinum and diaphragm, fixing the lower lobe.

The presence of the mesonneum allows the mediastinal pleura to be divided into 3 portions:

anterior, superior, and posterior. The serosa adapts to mediastinum prominences, sometimes forming recesses or cul-de-sacs: inter-azygoesophageal recess in the right hemithorax, and inter-aortic-esophageal recess in the left hemithorax, which can even be configured as an orifice that communicates the right pleural cavity with the left (Von Morosof foramen) (Fig. 29.9).

### Costal Parietal Pleura (Costalis)

Internally covers the musculoskeletal elements, membranes, nerves, vessels, lymph nodes and adipose tissue inside the costal wall. It extends over the ribs, the intercostal muscles, cartilage, and a small portion of the sternum (pectus sternum costalis).

Costal pleura upper limit (pleural dome), ascends cranially to the first rib level, reaching the cervical region base. The pleural dome is held in suspension by 3 extrapleural ligaments: transverse pleural, vertebropleural, and costopleural.

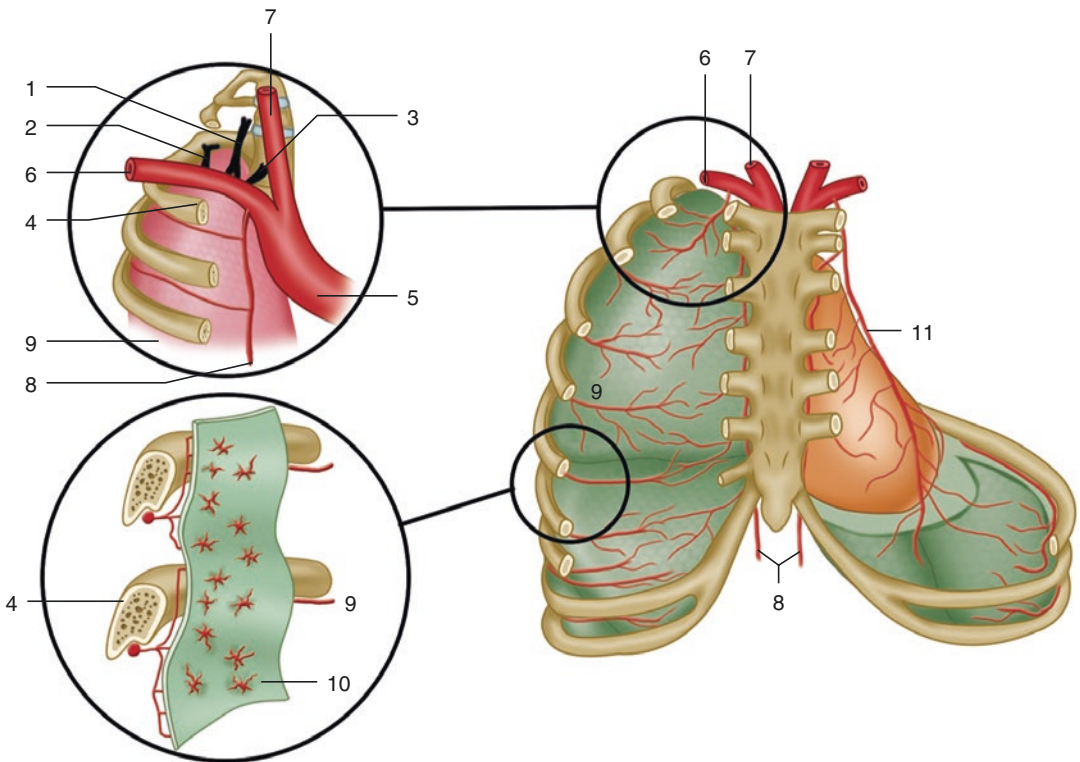
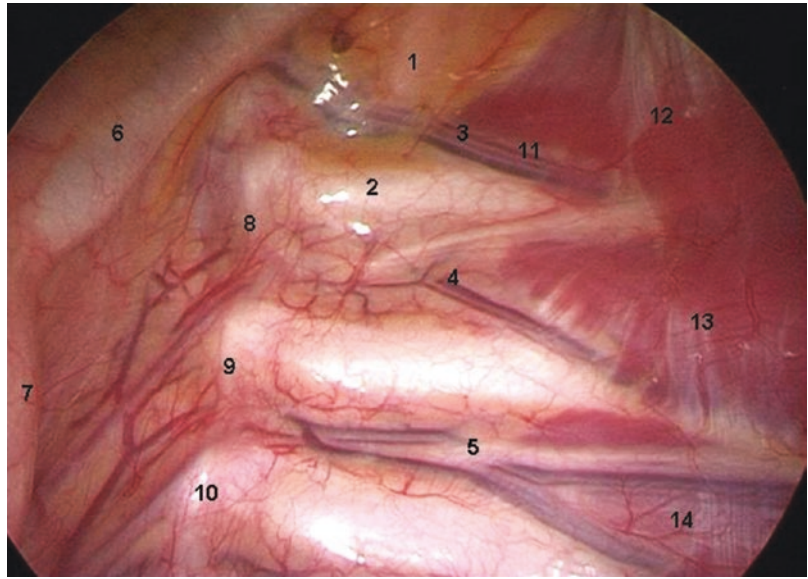
Costal pleura lower limits are the pleural sinuses, which in the form of a dihedral angle are established laterally between the costal wall and the diaphragm muscle (lateral costophrenic sinus). Subsequently, the posterior costal-phrenic recess or sinus is formed as a trihedral angle, where the costal plane, the vertebral bodies and the diaphragm muscle coincide. Anteriorly, the cardio-phrenic sinus is formed when the costal plane, the mediastinal-pericardial plane and the diaphragm muscle coincide at a trihedral angle (Fig. 29.10).

### Diaphragmatic Parietal Pleura (Diaphragmatic)

Cranially it covers the corresponding hemidiaaphragm, to which it joins very firmly at the His tendinous center level (where it does not allow its dissection), and with a looser union in the diaphragm muscular portion. The serosa transparent thickness makes it possible to see through its diaphragm muscle fleshy fibers, arranged in the anterior, lateral and posterior areas (Fig. 29.11).



**Fig. 29.10** Costal pleura view, left pleural apex. (1) Costal pleural dome, (2) II<sup>a</sup> left rib, (3, 4, 5) left intercostal neurovascular bundles, (6) Left subclavian artery, (7) aortic arch, (8, 9, 10) sympathetic chain, (11, 12, 13, 14) intercostal muscles



**Fig. 29.11** Right apex parietal pleura view, (1, 2) y (3) suspensory ligaments of the right pleural dome, (4) second rib, (5) brachiocephalic arterial trunk, (6) right sub-

clavian artery, (7) right carotid artery, (8) internal thoracic artery, (9) intercostal artery, (10) costal pleura, (11) left pericardium phrenic artery



## Pleural Cavity (Cavitas Thoracis)

It is a virtual slit-like space located between the parietal and visceral pleura that is 10–20  $\mu\text{m}$  in size and contains few milliliters of serous fluid. The pleural serosa, by adapting to the anatomical elements that stand out inside the pleural cavity, forms depressions that are called sinuses or pleural recesses (*recessus pleuralis*). The most prominent and constant are as follows:

### Pleural Apex or Superior Pleural Sinus [12–15]

It is a pleural cleft formed by the costal and mediastinal pleurae confluence. It occupies a cervical position forming the superior cone or dome, which is located above the clavicle, at the neck base.

To keep the pleural apex fixed to the neck base, there are 3 ligaments that act as fibrous straps inserted through the external pleural face towards the neighboring bony structures, and which are collectively called the Sebileau suspensory apparatus (Fig. 29.11):

- Transverse-pleural ligament: It extends from the C7 vertebra transverse process to the pleural apex, and also emits an expansion towards the 1st rib. If it contains muscle fibers it is called *scalenus minimus* muscle.
- Costo-pleural ligament: It extends from the neck and the 1st rib posteromedial border to the pleural apex.
- Vertebro-pleural ligament: It extends from the C7 vertebral body to the pleural apex.

Section of the three ligaments causes the pleural dome descent. This surgical maneuver called *apicolysis* was used in the past to carry out tuberculous cavern collapse therapy, when located in the upper lobe.

### Anterior Costal-Phrenic Sinus or Cardio-Phrenic Sinus

Cleft that forms at the retrosternal level by the confluence or intersection between the costal, diaphragmatic and mediastinal pleurae. It has a trihedral angle appearance with some adipose content, with abundant lymphoid tissue from the thoracic and abdominal walls, as well as from the supramesocolic compartment. On the left side, it is located lateral to the heart up to 4 cm from the midsagittal line (Fig. 29.12).

### Posterior Costal-Phrenic Sinus

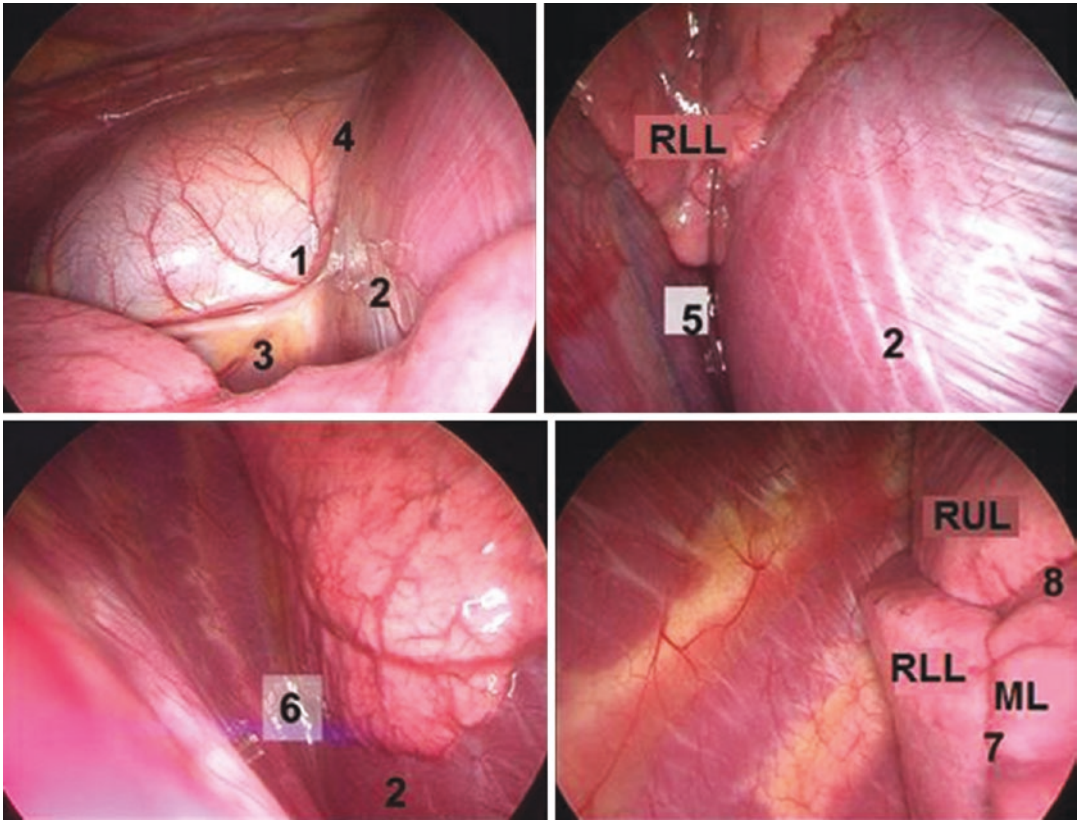
Cleft is formed by the intersection of the diaphragmatic, costal and mediastinal pleurae, on the D11 vertebral body. It is the pleural cavity lowest point, and therefore the place where the fluid accumulated in the pleural cavity is deposited in pathological processes (Fig. 29.12).

### Cost-Diaphragmatic Sinus or Lateral Cost-Phrenic Sinus

Pleural cleft is located between the diaphragm descending flanks and the chest wall. It is formed by the costal and diaphragmatic pleurae reflection, adopting the appearance of a dihedral angle. It runs over the diaphragm costal insertions, surpassing them behind the arcuate ligament, with which it can go beyond the 12th rib lower border (Fig. 29.12).

### Fissures<sup>18</sup>

They are depressions on the lung surface covered with visceral pleura, in the form of visceral pleura invaginations towards the lung parenchyma. They divide each lung into different lobes: three



**Fig. 29.12** Thoracoscopic view of the right pleural cavity, (1) Pericardium, (2) diaphragm, (3) phrenic nerve and pericardiophrenic vein, (4) cardiophrenic sinus, (5) poste-

rior costophrenic sinus, (6) lateral costophrenic sinus, (7) major fissure, (8) minor fissure, *RUL* right upper lobe, *RLL* right lower lobe, *ML* middle lobe

in the right lung and two in the left. There may be anomalies in the number of cracks, both due to excess and defect (Fig. 29.12).

- Major fissure, oblique: Presents an oblique trajectory, from the fourth dorsal vertebra level to the end of the fifth intercostal space. In the right lung, it begins at fourth rib neck levels, follows an oblique path downwards and forwards to reach the fifth intercostal space diaphragmatic face. In depth, it crosses from lateral to medial and reaches the pulmonary hilum anterior and inferior part.

At the posterior and superior part, it separates the superior lobe from the inferior lobe, while in the anterior and inferior part, it separates the inferior lobe from the middle lobe.

In the left lung, there is only a major fissure, and it has a slightly different path as it descends in the form of an italic j from its uppermost part to the anterior and lower part.

- Minor fissure, horizontal: It only exists on the right side, begins at the fourth intercostal space level, and ascends slightly until it ends at the third intercostal space level. It runs forward in depth and medially reaches the hilum anterior part, separating the upper lobe from the middle lobe.
- Superior and inferior accessory fissures: the superior or azygos fissure originates from the azygos vein arch, which, during its embryonic development, splits the upper lobe mesenchyme into two parts: a medial or Wrisberg azygos lobe and a lateral or superior lobe. This fissural anomaly is often associated with the

right upper lobar bronchus anomalous origin at tracheal lower third level [17, 18].

- Lower accessory fissure: It was described by Nelson and is located in the lower lobe, separating segment 6 from the rest of the lobe (basal pyramid). When this occurs, the lung portion associated with this segment is called Fowler's lobule.

## Pleural Vascularization

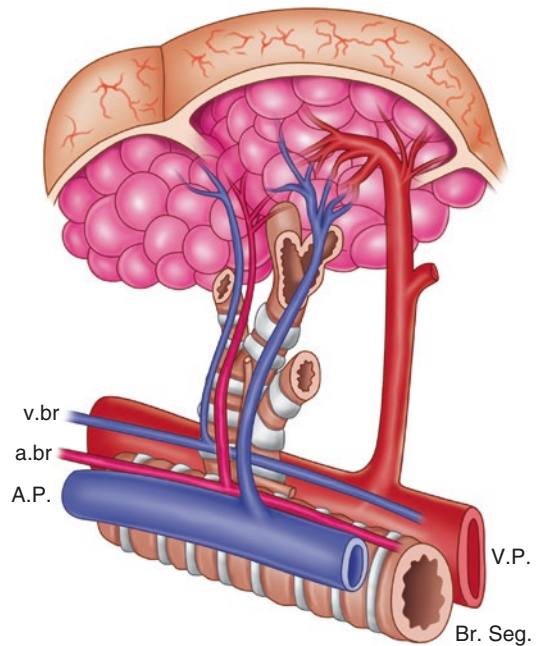
### Arterial and Venous Irrigation [19, 20]

Parietal pleura arterial circulation comes from the aortic artery systemic territory, through small arterioles from intercostal arteries that irrigate the costal pleura and the diaphragmatic pleura most peripheral part; by internal thoracic and pericardial-phrenic arteries branches that supply the mediastinal pleura, and by cranial phrenic arteries branches that supply the diaphragmatic pleura central part.

However, the visceral pleura arterial blood supply comes primarily from the pulmonary or functional circulation, via pulmonary capillaries. This pulmonary territory peripheral circulation receives systemic pulmonary communications from bronchial artery branches, through Leford's precapillary anastomosis or Von Hayeck's post-capillary anastomosis (Figs. 29.12, 29.13 and 29.14).

### Parietal Pleura Lymphatic Drainage

The lymphatic system begins with tiny stomata, 8–10  $\mu\text{m}$  in diameter, that are scattered on the pleural endocavitary surface, and that communicate in a dense lymphatic collectors network, equipped with endoluminal valves, (with negative pressures inside), draining into submesothelial lymphatic lacunae or cisterns. These lacunae have a collagen fibers layer and mesothelial cells on the pleural side, and endothelial cells on the lacuna side. They can remove up to 20 times the volume of fluid formed under normal conditions, approximately up to 0.2 mL/kg/h.



**Fig. 29.13** Subpleural pulmonary microcirculation. **A.P.:** peripheral pulmonary artery **V.P.:** peripheral pulmonary vein, **a.br.:** subsegmentary bronchial artery, **v.br.:** subsegmentary bronchial vein, **Br.Seg.:** subsegmentary bronchus

Following the general outline of the body, the parietal pleura lymphatic vessels form a dense subpleural network that drains most of the fluid, accompanying the intercostal, internal thoracic, pericardiophrenic, and superior phrenic veins along its course.

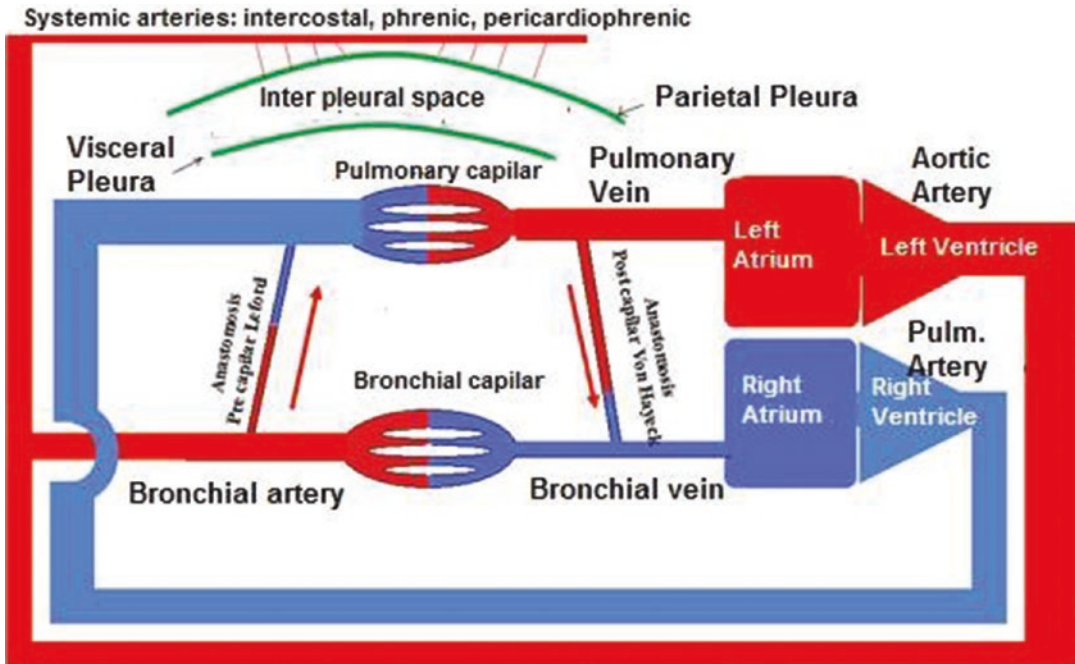
At the costal pleura, lymph collects in the intercostal lymph nodes on the posterior side, and by the internal thoracic vein lymph nodes on the anterior side.

The diaphragmatic pleura drains the lymph towards ganglion chains located in the mediastinum, and in the vicinity of the celiac trunk [21].

### Visceral Pleura Lymphatic Drainage

Visceral pleura lymphatic circulation is more complex, draining through two systems:

- (a) A superficial subpleural network that circulates on the lung surface directly towards the pulmonary hilum.



**Fig. 29.14** Functional and systemic pulmonary circulation relationship. Both circuits are interconnected before and after the pulmonary capillary through Leford and Von Hayeck anastomoses

(b) A deep network that, from the aforementioned subpleural network, penetrates radially into the lung parenchyma thickness, forming lymph node relays, known as: intra-segmental (without capsule) or level 13, inter-segmental (with rudimentary capsule) or level 12, interlobar (with capsule) or level 11, and hilar or level 10.

Both parietal and visceral pleura lymphatic circulations communicate with each other through the exchange zones or anastomoses located in the mediastinum, where in turn the lymph from more caudal territories also drains, especially from the abdomen supramesocolic compartment.

## Pleural Innervation

Somatic sensory or proprioceptive nerve endings are present in the costal and diaphragmatic parietal pleura. Intercostal nerves D1 to D12 innervate the costal pleura and the diaphragmatic

pleura peripheral part, transmitting the serosa general sensitivity.

Stimulation of these areas is perceived as pain that is referred or projected segmentally, according to the corresponding metamere, towards the adjacent chest wall. In contrast, the diaphragmatic pleura central part is innervated by the phrenic nerve (C3), and stimulation of this pleural part causes pain referred to the supraclavicular fossa, the ipsilateral shoulder, and even radiating to the jaw angle.

The visceral pleura is only innervated by vegetative endings from the pulmonary plexus (sympathetic) and the vagus nerves; however, the sensitivity is deep and unconscious, in relation to pulmonary distension reflexes described by Hering Breuer [22].

## References

1. Dietrich S, Schubert FR, Lumsden A. Control of dorsoventral pattern in the chick paraxial mesoderm. *Development*. 1997;124:3895–908.

2. Carlson BM. *Embriología Humana y Biología del Desarrollo*. 6th ed. Amsterdam: Elsevier; 2019. eBook ISBN: 9788491135838
3. Sobonya RE. Normal anatomy and development of the lung. In: Baum GL, Wolinsky E, editors. *Textbook of pulmonary diseases*. 4th ed. Boston: Little Brown; 1989. p. 3–20.
4. Jacobson AG. Somitomeres: mesodermal segments of the head and trunk. In: Hanken J, Hall BK, editors. *The skull*, vol. 1, Development, Chicago. Chicago: University of Chicago Press; 1993.
5. Spemann H. *Embryonic development and induction*. Nueva York: Hafner; 1938.
6. Tonegawa A, et al. Mesodermal subdivision along the mediolateral axis in chicken controlled by different concentrations of BMP-4. *Development*. 1997;124:1975–84.
7. Lemos M, Pozo RM, Mantes GS, Saldiva PH. Organization of collagen and elastic fibers studied in stretch preparations of whole mounts of human visceral pleura. *Anat Anz*. 1997;179:447.
8. Andrews PM, Poner KR. The ultrastructural morphology and possible functional significance of mesothelial microvilli. *Anat Rec*. 1973;177:409.
9. Hills BA. Graphite-like lubrication of mesothelium by oligolamellar pleural surfactant. *J Appl Physiol*. 1992;73:1034.
10. Wang QX, Ohtani O, Saitoh M, Ohtani Y. Distribution and ultrastructure of the stomata connecting the pleural cavity with lymphatics in the rat costal pleura. *Acta Anat*. 1997;158:255.
11. Chrétien J, Huchon GJ. Anatomy and physiology of the pleural space. New contributions to the understanding of pleural space structure and function. In: *International Trends in General Thoracic Surgery*, vol. 6. 1st ed. St. Louis, Missouri: The C.V. Mosby Company; 1990. p. 4–9.
12. Wang S. Anatomy. In: Dail DH, Sp H, editors. *Pulmonary pathology*. 2nd ed. New York: Springer-Verlag; 1993. p. 21–44.
13. Lee KF, Olak J. Anatomy and physiology of the pleural space. *Chest Surg Clin N Am*. 1994;4(3):391–403.
14. Mehran RJ, Deslauriers J. Anatomy and physiology of the pleural space. In: Patterson GA, Cooper JD, Deslauriers J, Lerut A, Luketich JD, Rice TW, editors. *Pearson's thoracic and esophageal surgery*. 3rd ed. Philadelphia: Churchill Livingstone Elsevier; 2008. p. 1001–7.
15. Charalampidis C, et al. Physiology of the pleural space. *J Thorac Dis*. 2015;7(Suppl 1):S33–7.
16. Bouchet A, Cuilleret J. *Anatomie topographique*. France, Simep: Le thorax. Villurbanne; 1974.
17. Testut L, Latarjet A. *Anatomía Humana*. Barcelona: Salvat Editores reimpression; 1979. Tomo III. p. 1003–1021
18. Godwin JD, Tarver RD. Accessory fissures of the lung. *AJR*. 1985;144:39–47.
19. Mackinnon P, Morris J. *Oxford. Anatomía Funcional. Tórax y abdomen*, vol. II. Madrid Editorial Médica Panamericana; 1993. p. 24–67.
20. Rouviere H, Delmas A. *Anatomía Humana*. 11th ed. Barcelona: Masson; 2005. p. 308–32.
21. Moya J, Ureña A. *Pleural Anatomy*, vol. 23. New York: Springer capítulo; 2013. p. 337–41.
22. Feneis H. *Nomenclatura anatómica ilustrada*. 5th ed. Masson: continuada por Wolfgang Dauber; 2014.





## Introduction

In the last decades, technology advances have greatly improved the imaging capacity of chest ultrasound (CUS). Major advantages of chest sonography include the lack of ionization radiation, low cost, flexibility, reproducibility, short time examination, and bedside availability for reduced mobilization of patients. CUS is notably helpful for critically ill patients [1] because of its portability, simplicity, and for the follow-up of the diseases [1]. Transthoracic scanning has proved to be a reliable imaging tool for the evaluation of thoracic pathologies. Studies have proven ultrasonography's superiority to chest radiography [2] and computed tomography (CT) scan [3] for detecting pleural effusion, pneumothorax, lung consolidation, or interstitial syndrome. Furthermore, sonography offers the possibility to

guide needle aspiration or biopsy with an increased success rate and reduced risk of complications [4, 5]. Certainly, ultrasounds did not provide a complete overview of the chest but only a section of it for a specific problem under investigation. Intrapulmonary processes can be detected by sonography only when they extend up to the chest wall or through a sound-conducting medium such as fluid or consolidated lung. Most ultrasound emitted by the transducer are repelled at the interface between the pleura and the lung due to the large difference of acoustic impedance between the soft tissue and the air. Ribs also act as a natural barrier to the ultrasound beam.

## The Technique

Thoracic sonography can easily be performed by chest physicians with several modality systems as B mode, M mode, color Doppler, and spectral analysis curve. Brightness mode or B mode imaging is the traditional two-dimensional gray-scale cross-sectional imaging mode. Motion mode or M mode ultrasound studies the velocity of a specific organ or structure relative to the probe position and it is displayed in one dimension. Both B and M modes are often complementary for chest disease characterization. Color Doppler is useful for a qualitative study of parenchymal vascularization and distinction between artifacts from respiratory and cardiac move-

---

R. Tazi Mezalek (✉)  
Bronchoscopy Unit and Interventional Pulmonology,  
Hospital Universitari Germans Trias i Pujol,  
Barcelona, Spain

Gerència Metropolitana Nord, Institut Català de la  
Salut, Barcelona, Spain  
e-mail: [rtazi.germanstrias@gencat.cat](mailto:rtazi.germanstrias@gencat.cat)

P. Trias Sabrià  
Bronchoscopy and Interventional Pulmonology Unit,  
Department of Respiratory Medicine, Hospital  
Universitari de Bellvitge, Hospitalet de Llobregat,  
Barcelona, Spain  
e-mail: [ptrias@bellvitgehospital.cat](mailto:ptrias@bellvitgehospital.cat)

ments. Finally, spectral curve analysis studies the arterial flow signal patterns in the specific area of investigation, very helpful to discern pathologies [6–8].

Physicians who practice with ultrasounds should be familiar with the basic controls, including the freeze, depth, gain functions, and focus... Freeze function creates still images allowing measurements of the structures and printing images for the clinical report. Depth function is a digital zoom that defines what portion of the scanned image is displayed on the monitor at a certain magnification (close or far from the probe), and it is adjusted in function of operator's interest with a scale in the vertical axis. Gain function allows an adjustment of the amplification of echoes and determines the brightness of the image, very useful for an optimal contrast between adjacent tissues. Focus function should be positioned at the pleural line in order to enhance the quality of the image; but it should be moved deeper when the main target is less superficial.

The choice of transducer depends largely on the area to study and the depth of the pathology in question. Low-frequency probes (2 to 5 MHz) with a curvilinear shape are suitable for scanning deeper structures, while high-frequency linear shape probes (5–10 MHz) are used for chest wall diseases, diagnosis of pneumothorax, and for a refined assessment. In fact, higher frequency allows a superior resolution close to the probe but at the cost of reduced penetration [6, 9]. Small sector scanners with a reduced footprint may on occasion be useful for visualizing lesions through a small acoustic window, for example in the case of a narrow intercostal space. For daily practice, the best combination is one curved probe of 3.5–5 MHz with a 5–8 MHz small linear probe.

Patient position for scanning is important to obtain the best images possible, and it depends on the location of the diseases under investigation [9, 10]. Chest physicians often use available imagery (chest X-rays or CT scans) to identify the area of interest and determine the patient's position for an optimal examination [6, 9]. Scanning the posterior chest is better to do it with the patient sitting upright, while the anterior part

of the chest is in the decubitus position. Lateral exploration can be done in both positions depending on each patient and on the extension of the disease. The caudal parts of the lung may be accessed more easily via a subcostal approach, using the liver or spleen as an acoustic window. Parasternal and supraclavicular approaches may be used for the assessment of the mediastinum and lung apices [11, 12, 13]. Raising the arm above the patient's head increases the rib space distance, and facilitates a wider ultrasound window. It also elevates the scapula for a better posterior chest exploration. Scanning along the intercostal spaces and avoiding the shadow of the ribs make possible a maximum visualization of lung and pleura. A quiet or suspended respiration of the patient can help to exanimate in more detail some structures. The probe should be held by the sonographer as a pen with generous application of gel in contact with the skin. Physicians should be trained to use both hands to scan with and reserve the dominant hand for interventional procedures guided by ultrasounds. Contralateral side should be always being explored and used as a control. Ultrasound exploration is better done in a reduced lighting environment and the operator should be able to describe echogenicity (compared with that of the liver) and to characterize all the findings in a specific ultrasound report. Saving images and short clips of exploration in a database are highly recommended.

---

## The Normal Thorax

The different layers of the chest wall are easy to identify with a high-frequency ultrasound probe. The intercostal muscles appear as hypoechoic linear structures containing echogenic fascial layers. On a vertical (or longitudinal) scanning, ribs appear as convex structures with a typical posterior acoustic shadowing and on a horizontal (or oblique) view, the anterior cortex appears as an uninterrupted echogenic line. Both visceral and parietal pleura usually appear as a single highly echogenic line no more than 2 mm wide representing the pleuropulmonary interface [6, 9, 10], but they can be seen as two distinct echo-

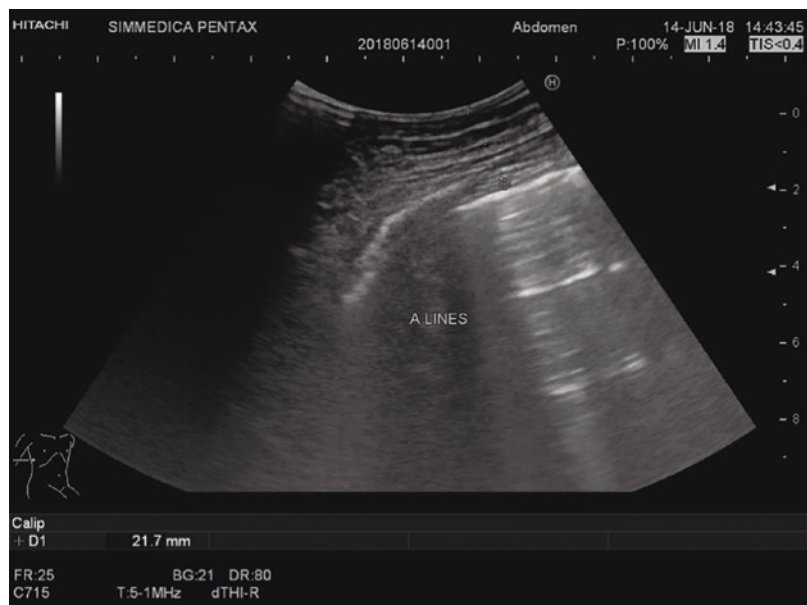genic lines on high-resolution scanning. In B mode, sliding of the two layers of pleura during respiration gives rise to the “gliding pleura” or “sliding lung sign.” The amplitude of sliding is greatest at the lung bases and minimal at the lung apices [14], and it is best appreciated on horizontal scanning and its presence has a high negative predictive value for the diagnosis of a pneumothorax [15–17]. Normal lung parenchyma cannot be visualized on transthoracic ultrasonography because the ultrasound beam undergoes complete reflection at the interface between the pleura and the aerated lung. However, this large acoustic difference impedance creates hyperechoic reverberations artifacts, easy to identify, and essential to know for the physician.

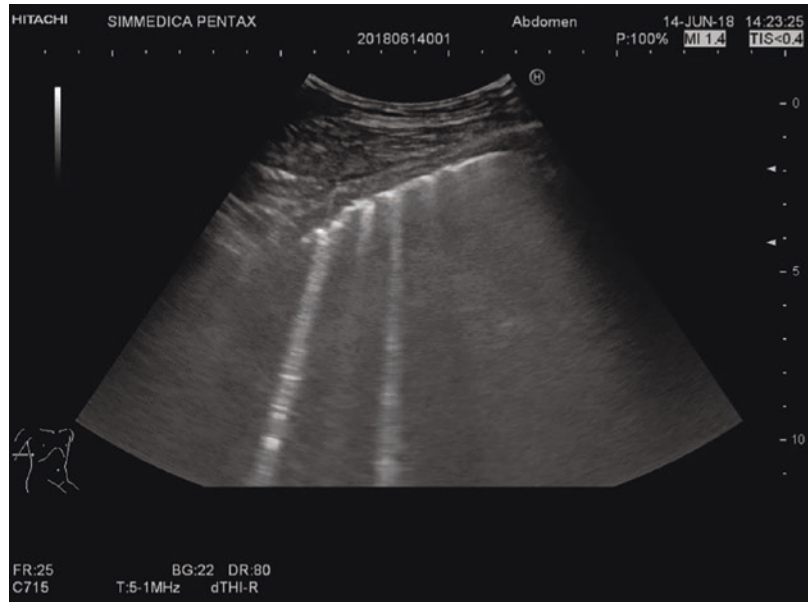
“A lines” are brightly and static echogenic horizontal artifacts which run parallel to the pleural surface (Fig. 30.1). They represent reverberation signals between the pleural surface and the outer surface of the chest wall. They are visualized in a multiplicative distance between the skin surface and the pleural line.

“B lines” are vertical lines that arise from pleural line and spread uninterrupted up to the edge of the screen, also known as “lung rockets” or “comet tail sign,” and can be seen at the lung bases in healthy volunteers representing fluid-

filled subpleural interlobular septa (Fig. 30.2). They are usually hyperechoic and multiple in one longitudinal scan. Less than three B lines may be normal in the lower and lateral part of the lung [18, 19]. They are dynamic artifacts and move synchronously with the lung sliding and tend to erase A lines at the point of intersection. In fact, distribution of B lines is helpful in assessing alveolar and interstitial lung diseases [18]. Thickening of the interlobular septa due to interstitial edema results in multiple and regular 7 mm spaced B lines. More closely (3 mm) spaced B lines and confluent to the pleural line are seen in case of alveolar edema, and have been correlated with elevated pulmonary capillary wedge pressure [22]. An absence of B lines is typically seen in the pneumothorax. Thus, the presence of a single B line is enough to rule out the diagnosis of pneumothorax [20, 21]. Occasionally, ultrasound parasites appear as vertical lines which should never be confused with B lines. They are called “Z line” and have no known meaning. They arise from the pleural line but they are ill-defined and fade after a few centimeters. They are not hyperechoic as B lines but gray at their onset with respect to the pleural line and they don’t erase A lines. Finally, they don’t move with lung sliding [23].

**Fig. 30.1** A-lines



**Fig. 30.2** B-lines

“Acoustic shadow” and “tadpole tail sign” are other signs that one should recognize. They are artifacts due to the attenuation of ultrasound beams. Ultrasound waves propagating through a low impedance structure within a higher impedance tissue are less attenuated than others which propagated through the surrounding area. Thus, they are displayed as a brighter signal, known as a “tadpole tail sign.” When the ultrasound beam is almost completely reflected by the high impedance structure (as bone or calculus), the posterior area does not receive ultrasound waves or only at a very low energy level and, finally, they are displayed as an “acoustic shadow.”

Another basic sign to consider is the “bat sign” obtained in a longitudinal scanning. The bat sign is formed by the superior and inferior ribs and the pleural line between them. The periosteum of the ribs represents the wings and the bright hyperechoic pleural line represents the bats’ body. By rotating the probe until an oblique position, one can visualize a larger part of the pleural line which is not interrupted by the rib shadows. The pleural line appears as a horizontal line.

## Chest Wall Pathology

Ultrasound represents often the first-line radiological investigation for a palpable chest wall lump whatever inflammatory or neoplastic. Masses generally are easy to detect but have variable echogenicity and the sonographic findings are too nonspecific to determine precisely the etiology. In addition, CUS detects the tumoral necrosis area to avoid during the puncture for an optimal diagnosis Table 30.1.

Lymph nodes can be detected in the palpation by the examiner and which are the most clinically relevant finding. In B mode and with a high-frequency probe, sonography helps to differentiate between malignant and benign lymph nodes. The vascularization pattern on color Doppler provides more information about the type of the node. Changes in size, shape, margins, echogenicity in conjunction with clinical information help to make a correct diagnosis. US characteristics of lymph nodes are similar to those established during endobronchial ultrasound (EBUS) examination. But the final assessment is made by the histological sample which can be guided by US as well.

**Table 30.1** Chest ultrasound signs and artifacts

Signs and artifacts	Definition and ultrasound findings
1. A lines	Brightly and static echogenic horizontal artifacts which run parallel to the pleural surface, and represent a reverberation signal between the pleural surface and the outer surface of the chest wall. They are visualized in B mode in a multiplicative distance between the skin surface and the pleural line, and represent physiologic air or free gas
2. B lines	Vertical and equidistant lines that arise from the pleural line and spread uninterrupted up to the edge of the screen, and can be seen at the lung bases in Normal individuals and represent fluid-filled subpleural interlobular septa. Normal in a number less than three. Known as lung rockets or comet tails artifacts
3. Z lines	They are ultrasound parasites with no known meaning and which should not be confused with B lines. Common points with the B-lines are: Vertical comet-tail artifacts and arising from the pleural line. Five opposed points with B lines could define Z lines: Not well defined, fade after a few centimeters, do not erase A lines, are not hyperechoic but gray at their onset with the pleural line and do not move with lung sliding
4. A line sign	Represent a pattern of exclusive A-lines plus a complete absence of B-line. Typical pneumothorax
5. E lines	Similar to B lines but they arise from the chest wall above the pleural line, and are generated by subcutaneous emphysema. E lines are aligned vertical lines
6. W lines	Similar to E lines but are not aligned. The resulting image of several lines is similar to letter W
7. Gliding sign or sliding sign	Sliding of the two layers of pleura during respiration in B mode
8. Tadpole tail sign	It is due to an attenuation of the ultrasound beams through a low impedance structure surrounded by a higher impedance tissue. Less attenuated US are displayed as a brighter signal coming out from the corresponding structure
9. Acoustic shadow	It is the reverse sign of the tadpole tail sign. US energy is almost attenuated by a high impedance tissue. The US beams are displayed as a shadow behind the structure
10. Bat sign	It is only visible using a longitudinal scan of an intercostal space. It is formed by the superior and inferior ribs and the pleural line. The periosteum of the ribs represents the wings and the bright hyperechoic pleural line in between them represents the bats' body
11. Seashore sign	It is the equivalent of lung sliding in the M-mode. The straight motionless aspect represents the chest wall ("waves") that lies above the granular layer ("beach") which is indicative of the respire-phasic movement of the lung. It is present in normal exploration
12. Stratosphere sign or bar code sign	It is the equivalent of absent lung sliding in M-mode (typical in pneumothorax). Monitor displays a straight and motionless image representing the chest wall only ("waves"). It suggests a pneumothorax
13. Quad sign	It is a static sign identified on B mode as a quadrangular image limited laterally by the acoustic shadows of the ribs, superiorly by the pleural line and inferiorly by lung surface. Central anechoic image corresponds to a pleural effusion
14. Sinusoid sign	It is the dynamic equivalence of quad sign on M mode. It detects the variation of the interpleural distance in a fluid collection. The cyclic motion of the underlying lung confirms the presence of pleural collection
15. Fluid color sign	It is a color signal that appears with a fluid collection in the pleural space during respiration or cardiac cycles on doppler mode
16. Swirling pattern or plankton sign	It is a free-floating echogenic particle due to protein and tissue debris in an echogenic fluid collection (= suggestive of exudate)
17. Whirlpool sign or snowstorm sign	It corresponds to free echogenic particles due to tissue debris and air bubbles inside a highly echogenic collection (=suggestive of empyema)
18. Lung flapping or jellyfish sign	It represents an oscillating movement of an atelectatic lung (seen as tongue-like) within a large pleural effusion in rhythm with respiration and heart beats like a jellyfish
19. Lung point	It is seen at the point where the lung edge reaches the chest wall in an incomplete lung collapse or partial pneumothorax
20. Double lung point	It is seen in the separation of visceral and parietal pleura in case of small and localized pneumothorax

(continued)



**Table 30.1** (continued)

Signs and artifacts	Definition and ultrasound findings
21. Lung pulse sign	It is produced by the transmission of cardiac pulse to pleural line, given that the visceral and parietal pleura contact with each other
22. Shred sign	It represents the deep and irregular border of a pneumonic consolidation
23. C line	C for centimetric cupuliform consolidation. It represents a pleural based small lung consolidation, and it is seen abutting a hyperechoic dotted and irregular pleural line
24. Air bronchogram or bronchoaerogram	It is a hyperechoic punctiform or branched linear artifact within the lung consolidation. It is a specific sign of lung consolidations
25. Dynamic air bronchogram	It is defined as inspiratory centrifugal movement of air bronchogram in B mode and highlighted on M mode of at least 1 mm, demonstrating a non-retractile consolidation like pneumonia
26. Fluid bronchogram	It is an anechoic or hypoechoic branched linear structure with hyperechoic walls on B mode and color doppler negative inside, differentiating it from vessels. It is a typical sign of post-obstructive atelectasis
27. Chimney sign or light-house phenomenon	It is a repetitive reverberation artifact under a subtle rib fracture
28. Hilar fat sign	Marked echogenic central zone representing fat and connective tissue in the center of the lymph node. It is seen particularly during the healing phase of inflammatory processes

Rib fractures can be identified two to six times more frequently by sonography than with chest radiography [24, 25]. They are visualized as a clear disruption of the anterior echogenic margin of the rib with associated step or overlying hematoma. Subtle rib fractures give rise to a reverberation artifact, also known as the “chimney sign” or “light-house phenomenon.” Fracture healing may be demonstrated by the evidence of an echogenic callus with a marked cortical reflex and fine acoustic shadow [26].

Metastatic lesions within the ribs have variety sonography appearances: disruption of the bony cortex, hypoechoic rounded, and well-demarcated space occupying lesions or expansive lesion with rib destruction. Paik et al. (2005) found that sonography helps to distinguish metastasis from traumatic rib lesions in cases of hot-uptake lesions on bone scintigraphy, by demonstrating mass effect and irregular bony destruction [27]. Color Doppler reveals a corkscrew-like neofornation of vessels [28].

Chest extension of lung tumor can be access by ultrasound with a high-frequency scanning probes (7.5–10 MHz) useful for a clear discrimination between chest wall tissue layers. Thoracic US is significantly helpful for diagnosing chest wall extent of lung cancer. Direct evidence on US

of infiltration of wall structures and rib destruction are reliable criteria [29]. Sugama et al. have defined three US pattern of chest wall invasion: UP1 (Ultrasound Pattern) indicates that the tumor is in contact with the visceral pleura, but on US the visceral pleura line is intact and the movement of the tumor with respiration is unaltered. UP2 indicates that the tumor has extended beyond the visceral pleura and is in contact with the parietal pleura. On US, the visceral pleura line is invaded or interrupted and the movement of the tumor is disturbed. Finally, UP3 means that the tumor has extended to the chest wall through both visceral and parietal pleura. The visceral pleura line is invaded or interrupted and the movement of the tumor is not present on US [30].

Parietal subcutaneous emphysema can be detected as well by US with typical findings. Characteristic “E lines” are present on the scanning. E lines (E for emphysema) are known as well as “stripe of emphysema.” They are hyperechoic, vertical, and aligned artifacts spreading to the edge of the screen like B lines. The difference is that they arise not from the pleural line but from a hyperechoic line horizontally located just above it. Keep in mind that no bat sign is visible because we are not in a lung ultrasonography but just above in the soft tissue.

When E lines are not aligned, they are called “W lines” showing an image similar to the W letter. It is due to a random disposition of air bubbles in the soft tissue [31].

## Pleural Pathology

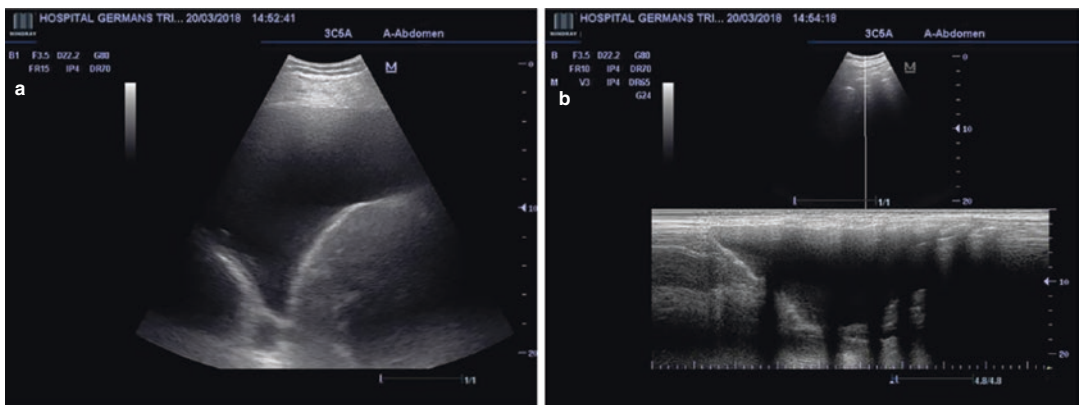
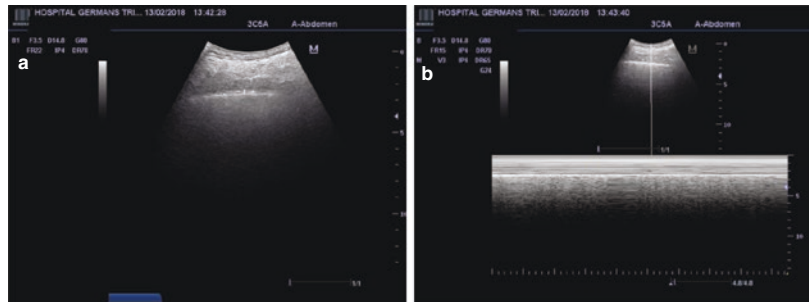
### Pleural Effusions

Chest ultrasound is a great tool for the study of pleural effusion and the detection of underlying diseases (Figs. 30.3a, b and 30.4a, b). It takes part of the pulmonologist guidelines for unilateral pleural effusion investigation [32]. The effusion is an echo-free zone between visceral and parietal pleural which displays changes of form during breathing. One can recognize dynamic findings, such as the oscillation of the adjacent lung with respiration, cardiac pulsation and diaphragmatic movement, floating, and moving of echogenic particles or septations.

In large pleural effusion, the collapsed lung adopts a tongue-like shape and its oscillating movement is known as “lung flapping” or “jellyfish sign” [33] (Fig. 30.5). Ultrasounds are able to detect five milliliters effusion in sitting position [34] and small amounts of liquid even located between the chest wall and diaphragm or close to a hypoechoic pleural thickening [35], but with the exception of fluid captured in the interlobar space of aerated lung. In fact, sonography is more sensitive and specific than conventional chest X-ray for pleural effusion identification in a standing position (100% against 71% and 99.7% against 98.5%, respectively [33]).

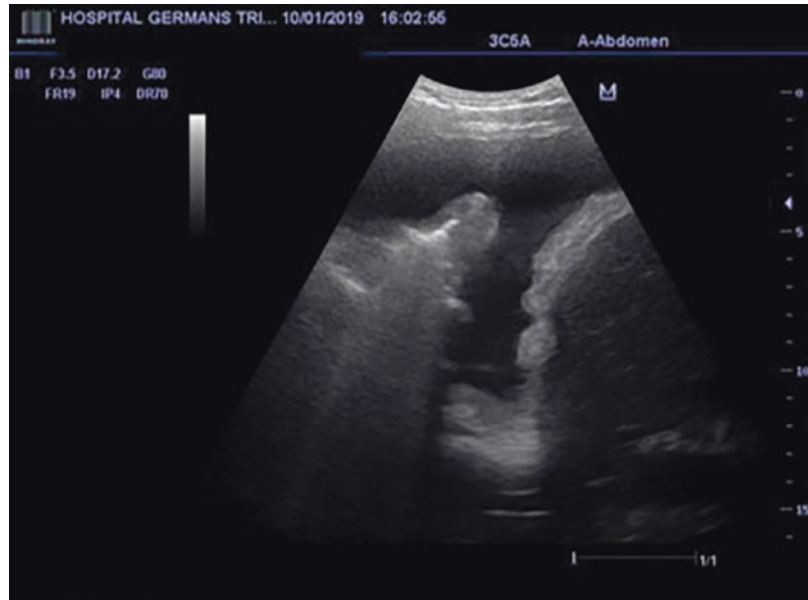Color Doppler mode differentiates small amounts of fluid from pleural thickening. The “fluid color sign” is a color signal that appears with a fluid collection in the pleural space during respiration or cardiac cycles and is absent in case of pleural thickening [34]. The “quad sign” and “sinusoid sign” are others signs valid for located pleural effusion detection with a specificity of

**Fig. 30.3** (a) Pleural thickening. (b) Pleural thickening



**Fig. 30.4** (a) Large pleural effusion. (b) “Sonographic Ellis-Damoiseau line”

**Fig. 30.5** Diaphragmatic metastatic nodules



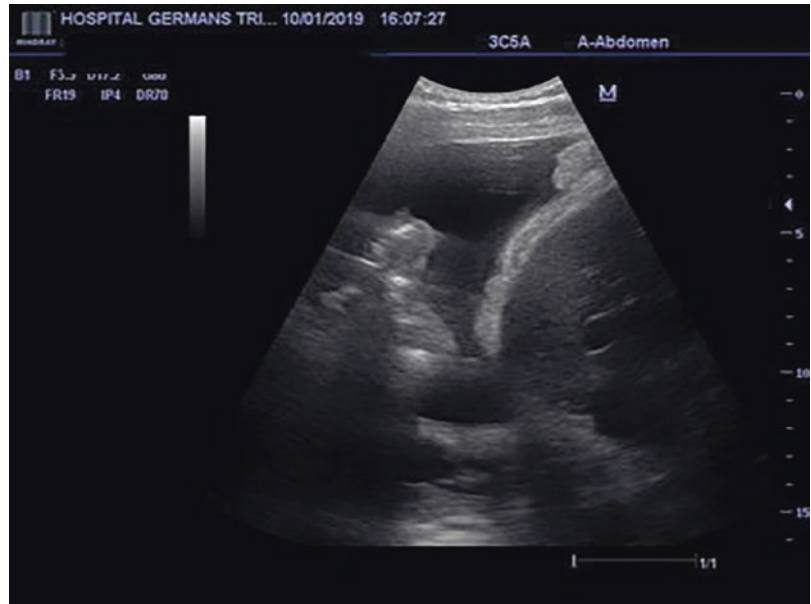97% [36–38]. The “quad sign” is a static sign on B mode, defined as a quadrangular image limited laterally by the acoustic shadows of the ribs, the “pleural line” and inferiorly by the regular surface of the lung which is always regular and roughly parallel to the pleural line [38]. The central anechoic image corresponds to a pleural collection.

The “sinusoid sign” is the equivalent of the “quad sign” on the motion mode. Based on the cyclic motion of the respiration, the lung within a pleural effusion gets closer to parietal pleura describing a sinusoidal pattern or “sinusoid sign” [38].

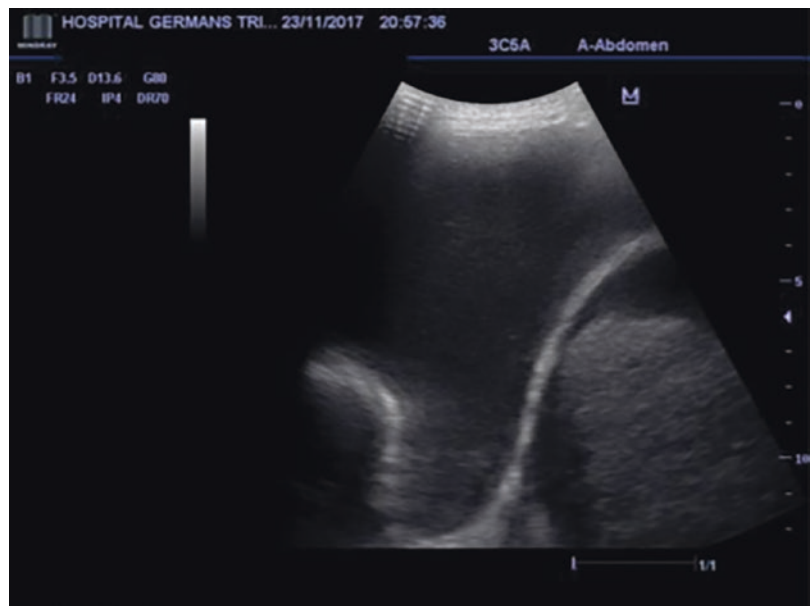
Four US pattern are recognized based on the internal echogenicity and characteristic of pleural effusion: anechoic pattern, homogeneously echogenic pattern, complex non-septated pattern (complex = with internal echoes), and complex septated pattern (septation = thick or thin and mobile) [10]. An echo-free fluid collection is suggestive of transudate which contain no components whereas exudate appears as echogenic. In an exudative pleural collection, free echoes represent floating particles due to protein, cell-containing, and tissue debris, known as “swirling sign” or “plankton sign,” which is not pathogno-

monic. Post-inflammatory effusion can present “Honeycomb-like appearance” due to fibrin organization. In such cases, ultrasound avoids frustrating attempts of thoracentesis with the potential risk of injury. Empyema are seen highly echogenic with “snowstorm sign” or “whirlpool floating sign” inside suggesting tissue debris and air bubbles, and generally accompanied by pleural thickening depending on the stage of the disease. Malignant pleural effusion is usually anechoic with possible metastatic pleural nodules and thickening (Figs. 30.6, 30.7 and 30.8). Underlying tumoral processes can be detected through the fluid. The effusion presents as well the “swirling sign” on B mode induced by echoes floating and making circular movement [39]. It may become septated in case of repeated diagnosis thoracentesis. Finally, hemothorax appearances vary regarding the time of the trauma: hypoechoic in fresh blood collection or echogenic occasionally with large layering structures representing clots [40]. In a clinical context of inflammation or infection, identification of septa in the pleural collection is suggestive of complicated pleural effusion and has clinical implications. Several studies have shown that patients with septated effusions needed longer chest tube drainage, longer hospi-

**Fig. 30.6** Costodiaphragmatic metastatic lesion



**Fig. 30.7** Pleural effusion due to ascites

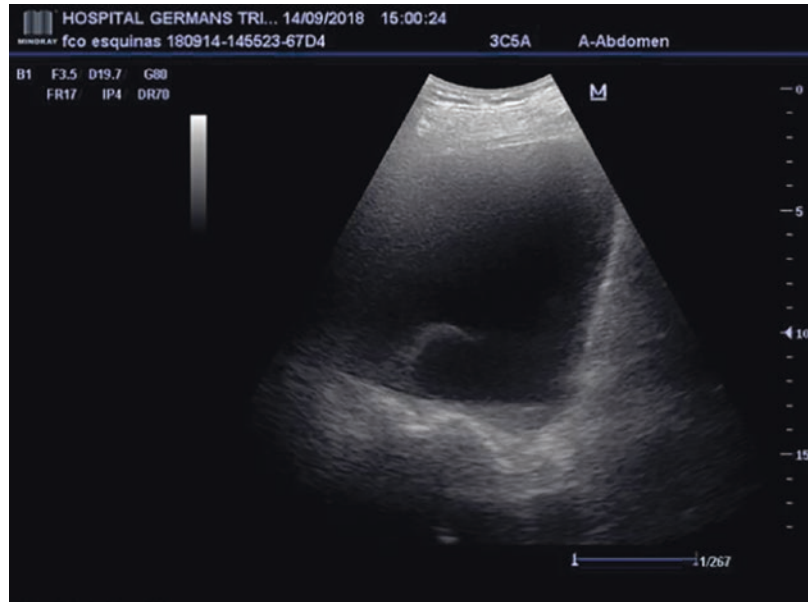

tal care and were more likely to require fibrinolytic therapy or surgery compared to those with non-septated effusions [41, 42].

Volume quantification with chest US is possible. Many studies demonstrate the correlation between the depth of pleural effusion and the volume of removed pleural liquid. More than 5 cm between the pleura and lung at the base predicted a drained volume > 500 mL with a sensitivity of

83%, specificity of 90%, positive predictive value of 91%, and negative predictive value of 82% in patients receiving mechanical ventilation [43]. Balik et al. established the relationship between volume of pleural fluid and maximum separation of pleural layers with a simplified formula:  $V \text{ (mL)} = 20 \times \text{Sep (mm)}$ . Significant correlation was found between separation and volume of pleural fluid ( $r = 0.72$ ;  $p < 0.001$ ) [44]. Remerand

**Fig. 30.8** Flattening of the diaphragmatic curvature



et al. use a multiplanar ultrasound approach increasing the accuracy of measuring pleural effusions in critically ill patients. Ultrasound evaluation was tightly correlated with drained volume ( $r = 0.84$ ,  $p < 0.001$ ) and with pleural effusion measure with CT scan ( $r = 0.90$ ,  $p < 0.001$ ). This new method seems to be more accurate than previous methods [45]. A practical way to classify the pleural effusion is: minimal or none if the echo-free space is confined to the costophrenic angle, small if pleural effusion occupied 1 or less than 1 rib space, moderate if it extended to 2 or 3 rib spaces and finally large if it is more than 4 rib spaces. More than an exact measurement, what is desirable in clinical practice is an estimation of pleural effusion to correlate with a patient's symptomatology, in order to indicate a possible therapeutic aspiration. The added table gives us an approximation of the fluid volume [46]. Finally, quantification of the pleural effusion is useful for follow-ups.

### Pleural Thickening

Pleural thickening is often defined as a focal lesion greater than 3 mm in width, arising from the visceral or parietal pleura with or without

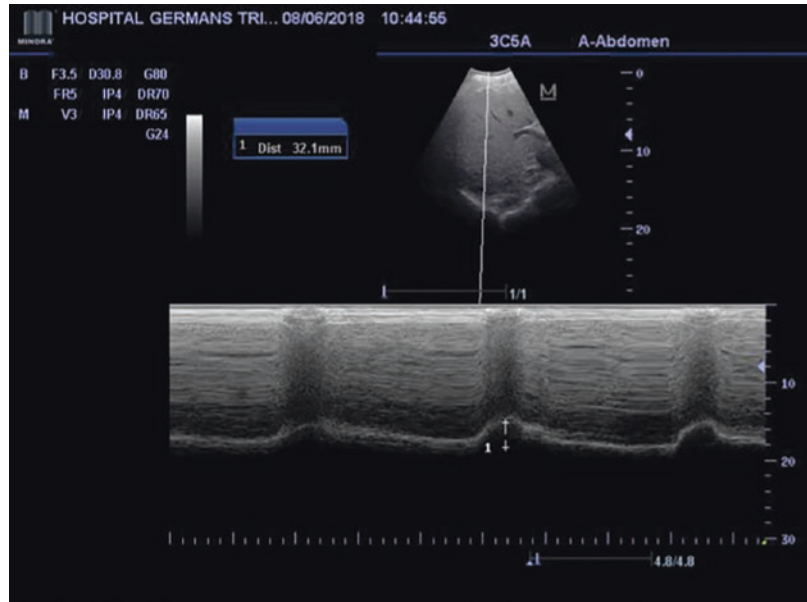
irregular margin [6, 9, 10] (Fig. 30.9). Distinction between pleural thickening and small effusion is done on color Doppler mode (positive “fluid color sign” in pleural effusion with 89.2% of sensitivity and 100% of specificity) [47] or on M-Mode (presence of “sinusoid sign” in pleural effusion) [36–38]. Diffuse pleural thickening is described in long-term exudative pleural effusion, asbestosis related effusion, empyema, and mesothelioma (see below). It is hypoechoic but often presents several echogenicities and accompanying pleural effusion. Calcification suggests chronicity and it is also present in empyema and tuberculosis [10].

Pleural plaques are descriptive in asbestos exposure, trauma, pneumonia, and chemical pleurodesis. They appear as a circumscribed, smooth border, hypoechoic lesion, and sometimes calcified with adjacent non-calcified pleural thickening [35].

Pleuritis should be diagnosed based on ultrasound findings and clinical correlation by an exclusion of other chest pain diseases. US shows a rough appearance and interruption of the normally smooth pleura (89.4%) with a small subpleural consolidation from 0.2 to 2 cm (63.8%) and localized parietal and basal pleural effusion (63.8%) [48]. Typical missing



**Fig. 30.9** Subcostal examination of the excursion of the diaphragm



“gliding sign” with a focal interstitial disease and multiple B lines accompanied those anterior characteristics [49].

Malignant pleural mesothelioma appears sonographically as nodular, planar or irregular and diffuse pleural thickening. It is often associated with pleural effusion [34, 35]. Invasion of the chest wall or the diaphragm can be detected by ultrasound [50]. The definitive diagnosis can be done by thoracoscopy established in more than 90% of cases or by percutaneous biopsies under ultrasound guidance achieving nearly the same accuracy [51, 52].

Pleural metastases are usually seen as hypoechoic nodular, round-shaped, or brand-based polyp at the lower part of the pleura or over the diaphragmatic pleura with or without pleural effusion. Presence of pleural effusion sonographically as malignant pleural effusion increases the probability to have a malignant spread disease. Breast cancer or bronchial carcinomas are mostly the causes. Chest ultrasound can help to guide a biopsy or to avoid pleural masses choosing the ideal port of entry for diagnostic thoracoscopy procedures [35].

## Pneumothorax

The diagnosis of a pneumothorax by ultrasonography is not equivalent to the detection of pleural fluid and requires more experience. What we expect to see in a fluid pleural effusion is not applicable to the presence of air between visceral and parietal pleura.

While CT is the gold standard for diagnosis of pneumothorax, ultrasound has the advantage of being rapidly available at the bedside, and therefore useful particularly in the intensive care unit (ICU) or emergency department. A meta-analysis found ultrasound to be both more sensitive and specific in the diagnosis of pneumothorax than plain chest radiography, with an estimated sensitivity of 88% and specificity of 100%, as compared to 52% and 99%, respectively, with chest x-ray [53]. Furthermore, Galbois et al. show that ultrasound is more accurate at assessment of residual pneumothorax post drainage, with 39% of ultrasound detected and subsequently proven residual pneumothoraces missed by chest x-ray [54].

Because the air in the pleural space tends to redistribute anteriorly in a decubitus position, the third to fourth intercostal space in the midclavicular line is generally the most appropriate starting point for assessment.

A major criterion for the diagnosis of pneumothorax is the absence of “lung sliding” in B mode (sensitivity of 95% and negative predictive value of 100%) [55]. The “seashore sign” is the equivalent of lung sliding on the M mode, normally seen in healthy person (straight motionless aspect representing chest wall = “sea” above a granular layer = “shore”) which is indicative of the phasic movement of the lung. In the presence of pneumothorax, the “seashore sign” is typically absent and replaced by the “stratosphere sign” or “bar code sign” (only straight motionless layer).

Another typical ultrasound sign of pneumothorax is the “A line sign” which is represented by an exaggerated A lines artifact and the absence of vertical B lines. This association increases the specificity and it rounds 96% for the diagnosis of complete pneumothorax. Keep in mind that the presence of a single B line is enough to rule out a pneumothorax [21].

In case of incomplete lung collapse (partial pneumothorax), the “lung point” is seen at the point where the lung edge reaches the chest wall. It is a 100% specific sign for pneumothorax. Another ultrasonic sign is the “double lung point,” which represents the separation of visceral and parietal pleura in case of localized pneumothorax [56]. Between these two points there is no lung sliding neither B-lines, but laterally to the points, normal pleural signs are evident [57–59].

Contrary to pleural effusion, sonography is not useful to quantify the volume of pneumothorax. It is a binary system to rule out (or not) the pneumothorax but not to precise its degree. Although, many authors consider the hypothesis that the more laterally the lung point locates, the larger size of pneumothorax would be [60, 61]. In the animal model, Oveland et al. demonstrated the linear relation between the pneumothorax size and the lateral position of the lung point [62]. However, the differentiation between small and large pneumothorax using the lung point by bed-

side ultrasound is still considered as a grade C in the 2012 international evidence-based recommendations [16].

The “lung pulse” is an ultimate sonographic sign useful in the diagnosis of pneumothorax and consists in the transmission of cardiac pulse to pleural line, given that the visceral and parietal pleura contact with each other. Volpicelli and colleagues give an important value to the lung pulse sign, when lung point cannot be detected, by stating that “even in the absence of lung sliding and B lines, visualization of a lung pulse rules out pneumothorax” [63].

Keep in mind that, the presence of lung sliding in all parts of the pleura rules out the pneumothorax with 100% cases [55]. However, the absence of lung sliding is not specific to pneumothorax. Potential false positives may occur with ARDS, a history of pleurodesis, massive fibrosis, extensive pneumonia, and pleural adhesions, asbestos-related diffuse pleural thickening, giving to this sign an approximate specificity of 91% [55]. False positive diagnosis of pneumothorax may also arise in severe acute asthma and emphysematous patients, particularly with anterior bullous disease, due to absent lung sliding. Slater et al. (2006) affirm that chronic obstructive pulmonary disease (COPD) patients can mimic the appearance of pneumothorax on US; therefore, they recommend confirmation with other imaging modalities [64].

Ultrasonography may be used routinely to screen for postprocedural pneumothorax after transthoracic interventions and may obviate the need for routine post-procedural chest radiographs. However, a disadvantage of ultrasound is the lack of quantification of a pneumothorax and the assessment of the indication for chest tube drainage [65].

---

## Pulmonary Pathology

Pathological process in the lung parenchyma can be detected with ultrasonography when it's located in the peripheral part of the lung with a pleural contact, or when aerated lung is replaced by consolidated lung tissue or finally when a

pleural effusion exists which allows US beams transmission. “Consolidation” can be identified by ultrasound including pneumonia, pulmonary embolism, lung tumors, atelectasis or pulmonary contusion [16].

A correct diagnosis should be always done by ultrasound based on clinical correlations.

1. *Pneumonia*: It is visible sonographically if the consolidated lung directly opposes the pleura, or if there is an adjacent pleural effusion which acts as an acoustic window. Pneumonic consolidation tends to appear as irregular echogenic area with serrated and somewhat blurred margins, isoechoic to the liver and containing multiple echogenic foci which correspond to air filled bronchi called “broncho-aerogram,” “bronchopneumogram” or “air bronchogram.” Air bronchogram is a branched linear hyperechoic image with millimetric lenticular shape echoes (Fig. 30.10). It represents a specific sign for lung consolidation. “Dynamic air bronchogram” is another specific sign and it is defined as an inspiratory centrifugal movement of bronchogram on B mode and highlighted on M mode. It has 94% specificity and 97% positive predictive value for diagnosing pneumonia and distinguishing

it from obstructive atelectasis [66]. The deepest part of the pneumonic process often has an irregular border described in the literature as the “shred sign” [67].

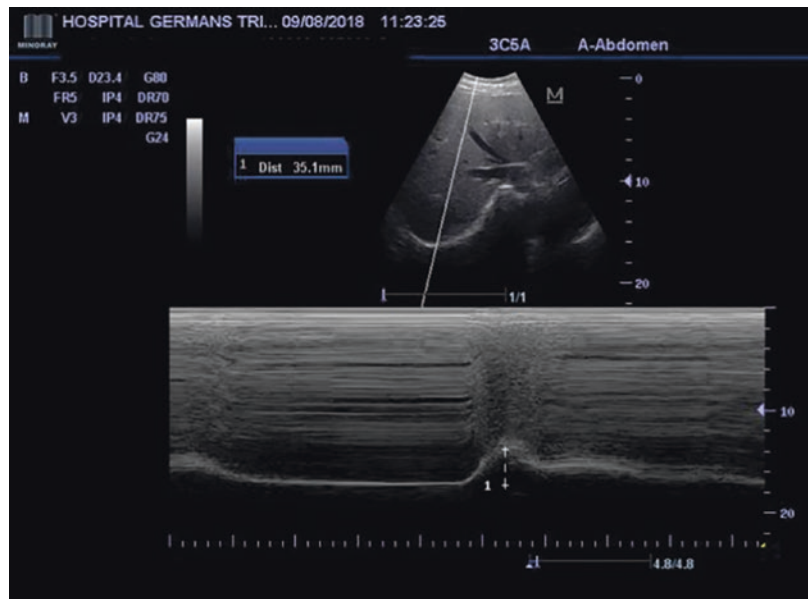
Sonography assessment may be of particular benefit in critical care, in order to avoid transportation of unstable patients [68] and in pediatric patients avoiding excessive radiation [69, 70].

Peripheral lung abscesses may also be detected by ultrasound. These appear as rounded, hypoechoic, or anechoic lesions surrounded by echodense tissue. Deep abscesses and those surrounded by air are not detectable by ultrasound.

In general, the size of pneumonia appears smaller on ultrasound than on radiographs because of the presence of artifacts, surrounding air of ventilated lung parenchyma and because of the narrow acoustic window.

Another detail regarding centimetric and peripheral pneumonia is the “C line.” C is coming from centimetric cupuliform consolidation. C line is a sonographic image of small lung consolidation. It represents somehow the shred sign for the small and very distal alveolar syndrome [71].

**Fig. 30.10** Sniff respiration



2. *Passive atelectasis.* Passive or compression lung atelectasis is due to a moderate or large pleural effusion compression. The typical sonographic image is a homogeneous and echogenic tongue-like lung with sharp and smooth borders. Limit border with ventilated parenchyma is blurred. There is a typical capacity of reexpansion during/after pleural volume evacuation. During inspiration, because of the increase of air in the atelectatic area, air bronchogram can appear.
3. *Post-obstructive atelectasis.* It is important to differentiate it from a pneumonic consolidation or passive lung atelectasis. Central tumor is the origin of the distal and obstructive atelectasis and it is identified as a homogenous and hypoechoic area. In general, the amount of the pleural effusion is moderate or small, even absent in some cases. And contrary to passive atelectasis, there is an absence of reventilation with inspiration or with the evacuation of the pleural effusion. Depending on the duration of the obstruction, evidence of “fluid bronchogram” is typically present. This sign is visualized as a branching pattern of anechoic structures with hyperechoic walls, without perfusion signs inside on color Doppler differentiating it from vessels. Special attention should be paid in a persistent fluid bronchogram during follow up. That should raise suspicion of poststenotic etiology and will require additional studies such as a CT scan and eventually bronchoscopy.  
Another ultrasound characteristic is the absence of both “lung sliding” and “lung pulse” [72].
4. *Neoplastic consolidation.* Tumor process is identified as a hypoechoic structure with infiltrating borders known as “finger-shaped ramifications” [73]. It is mainly non-homogeneous with sometimes necrosis areas. Contrarily to inflammatory diseases, tumoral processes are not ventilated and are well demarcated from the surrounding lung tissue. Tumor consolidation may still contain residual ventilated areas with some bronchial branches. Lung metastasis can be seen when they reach the edge of the lung, in contact with the pleura.  
Progression to the chest wall of peripheral tumor is possible to be detected by ultrasound (see extrathoracic pathology). Targeted investigation with a correct transducer allows the physician to make a correct extension diagnosis and staging of the tumor.
5. *The white hemithorax.* It’s a challenge for the physician to determine the exact cause between potential number etiology of unilateral lung opacity. The hemithorax can be potentially occupied by massive lung consolidations and complete obstructive or by large pleural effusion or a combination of these. Chest ultrasound plays a crucial role for the assessment and to determine what is the next step in the study of such disease (tap the pleura, pleural biopsies, chest drain insertion, bronchoscopy...). Using B mode and Doppler mode, the physician can be more confident to differentiate a “conventional pneumonia” from a post-obstructive pneumonia which require a different therapeutic approach. The same thing is true for loculated pleural effusions, that will not resolve by a simple pleural tap [74].
6. *Interstitial lung diseases.* They are characterized by multiple comet tails artifacts distributed over the entire lung associated with pleural thickening, irregular and fragmented pleural line, and subpleural consolidation in some cases. Minimal amount of pleural fluid can be present [75]. The typical ultrasound pattern in a longitudinal scan is constituted by 7 mm regularly spaced comet tails which correspond to thickened interlobar septae (7 mm corresponds roughly to the average size of a lobule), coming from the pleural line and spreading up without fading to the edge of the screen. It is known as the “septal rockets pattern” in opposition to the “ground-glass pattern” present in the alveolar edema, where B lines are regularly spaced in 3 mm and confluent to the pleural line [18, 76]. Presence of isolated B lines in a panel is not considered diagnostic of interstitial syndrome. Ultrasound interstitial syndrome examination is considered positive when three or more B lines are simultaneously visible between two ribs [76].

### 7. Pulmonary embolism or lung infarction.

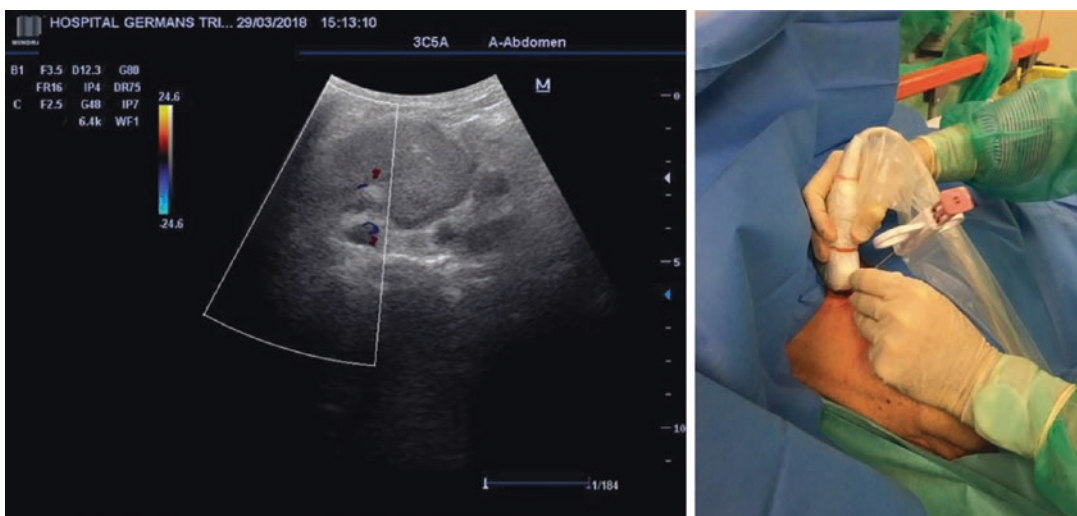
Acute pulmonary infarcts are most frequently visualized as a hypoechogenic pleural-based wedge shaped area, usually in the lower lobes and often associated with a localized pleural effusion [77]. Other typically sonographic features include within the wedge-shaped area of parenchymal abnormality, the absence of arterial flow [78]. Lung infarction has been described as “consolidation with little perfusion” [79, 80]. The overlapping sonographic appearances of pulmonary embolism with other subpleural pathologies such as pneumonia, subpleural tumors, and pleurisy limit its use as a primary diagnostic tool. Small studies have shown ultrasound to have a specificity ranging from 66 to 87% [77, 81, 82].

during expiration (moves upwards). Both hemidiaphragm move together. In healthy subjects, 1–2.5 cm of excursion in quiet breathing and 3.6–9.2 cm during deep breathing are considered normal [83] (Figs. 30.11 and 30.12). Up to 9 cm can be seen in young or athletic individuals in deep inspiration. Excursion in women is slightly less than men [83].

Diaphragmatic paralysis is suggested by an absence of movement or paradoxical movement during respiration which can be accentuated with forced inspiration (“sniff test”) (Fig. 30.13). Paradoxical movement is easily detectable in case of large pleural effusion with an inverted shape form of the dome. In general, those patients will present severe dyspnea after a while until they present a diaphragmatic fatigue. Thoracentesis is mandatory to improve the symptomatology and to relieve muscle function. Remember that the puncture should be done at least at two intercostal rib spaces from the inverted dome. The restitution of the normal shape of the diaphragm during evacuation of the fluid can occlude the trocar and consequently produces pain in the homolateral shoulder and neck (innervation of the central part of the diaphragm by cervical nerve C3 and C4). While fluoroscopic evaluation of the diaphragm is the most commonly used technique to assess paraly-

## Evaluation of the Diaphragm

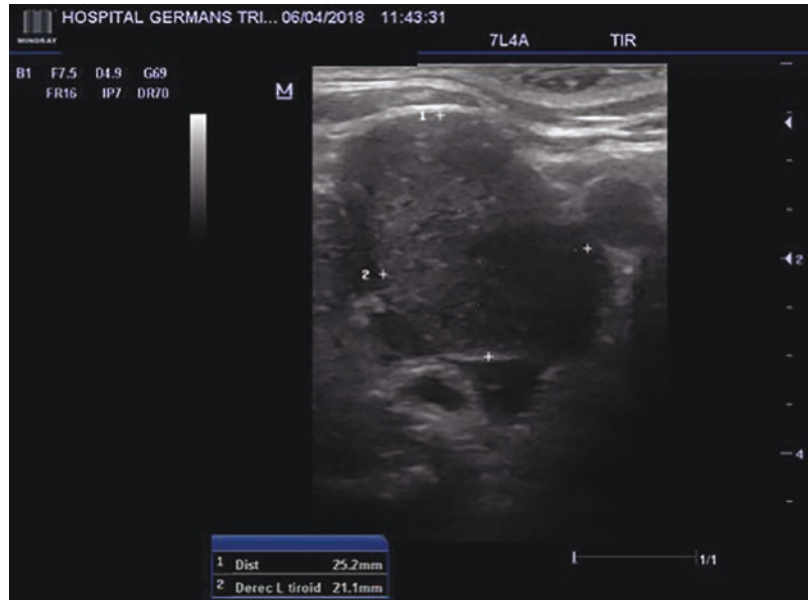
The diaphragm is visualized sonographically as a three-layered structure: a central hypoechoic muscular layer bounded by two echogenic lines representing the diaphragmatic pleura and peritoneal membrane. It is best examined in the lower intercostal spaces through an organ window (liver and spleen). The diaphragm contracts during inspiration (moves downwards) and relaxes



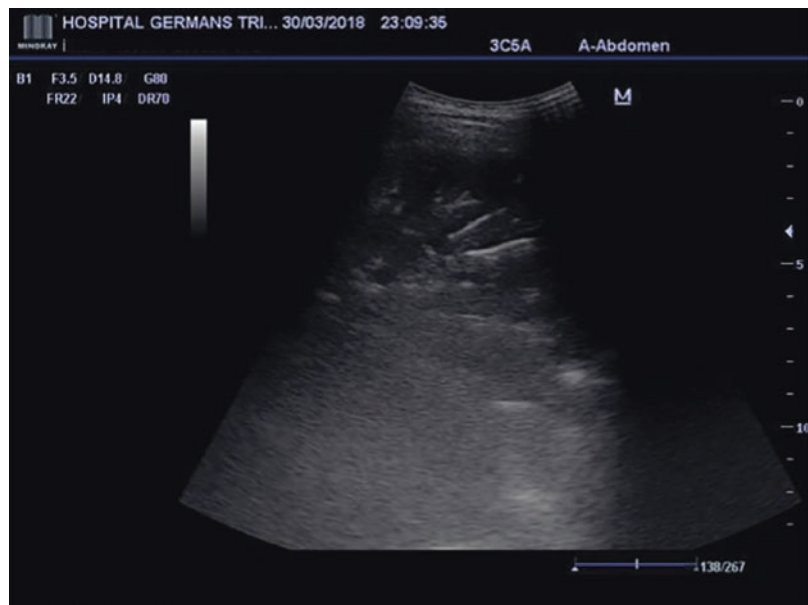**Fig. 30.11** Supraclavicular lymph node puncture guided by ultrasound



**Fig. 30.12** Significant supraclavicular lymph node



**Fig. 30.13** Lobar pneumonia with fluid bronchogram



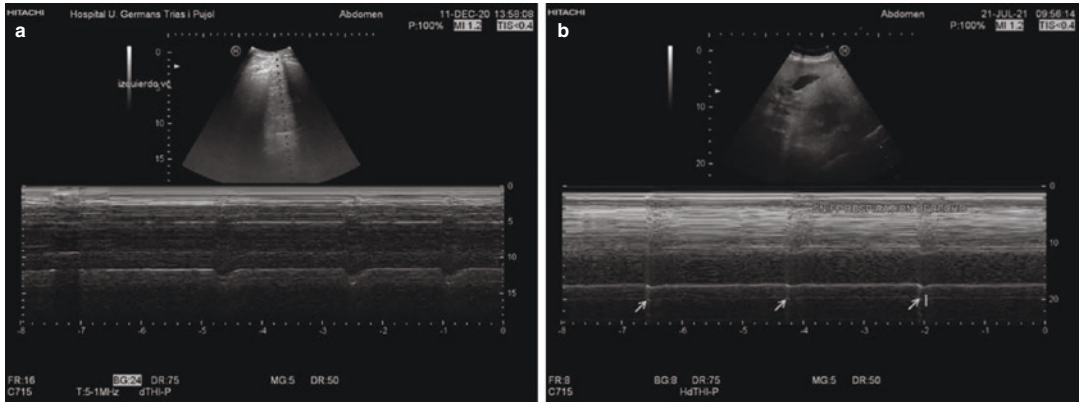
sis, ultrasound can be useful in the ICU and has also been used to monitor recovery from diaphragmatic paralysis [84].

### Extrathoracic Lymph Nodes

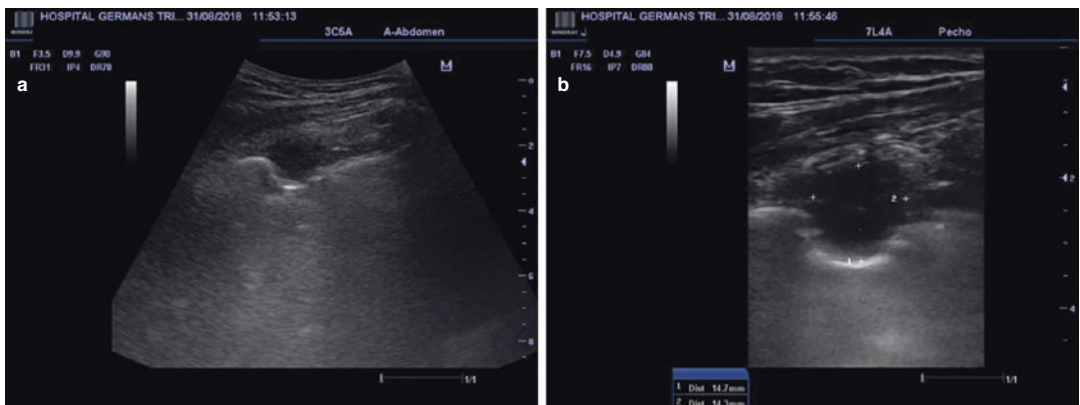
Sonography using a high-frequency linear probe is a practice tool for the assessment of benign and malignant lymph nodes in conjunction with clinical

data. Lymph nodes appear on ultrasound as ovoid form structures with a relatively hypoechoic cortex and hyperechoic medulla because of the presence of hilum (Fig. 30.14a, b). Similar characteristics of lymph nodes are seen during the endobronchial ultrasound bronchoscopy (EBUS).

Some are long and thin and their center becomes larger during the healing reaction of an inflammatory process. The definitive assessment should be done by histological



**Fig. 30.14** (a) Diaphragmatic paralysis. (b) Diaphragmatic paralysis



**Fig. 30.15** (a) Lung tumor metastasis in the internal mammary lymph node chain. (b) Lung tumor metastasis in the internal mammary lymph node chain

confirmation; however, the existence of sonomorphological criteria can assist the physician in the study. A rounded shape, loss of the echogenic hilum, asymmetrical or nodular thickening of the cortex, and cystic necrosis are signs of malignant involvement [28] (Fig. 30.15a, b). Changes in size are seen in inflammatory processes (seldom exceed 20 mm) and malignant diseases. Extracapsular spread in a malignant node is characterized by a loss of clarity or irregularity of the node capsule. Microcalcifications may be seen within metastatic nodes from papillary and medullary thyroid carcinomas, breast cancer and in tuberculous infection. In tuberculosis, lymph

nodes may be enlarged and hypoechoic. Marked echogenic central zone, known as “hilar fat sign” represent fat and connective tissue in the center of an active lymph node. This sign is seen during the healing phase of inflammatory processes [28]. Age-related changes include cortical atrophy and fatty replacement [75, 85]. Ultrasound has a well-established role in the evaluation of extra-thoracic lymph nodes, and reveals suspicious lymph nodes in a high number of patients with lung cancer. Guided biopsy in non-palpable nodes increases the possibility to prove malignant extension, that is N3/M1 stage, avoiding more invasive diagnostic procedures [86].

## Intervention and Therapeutics Guided by Chest Ultrasound

There is little doubt that concerns about patient safety in pleural interventions have been a major driving force behind the increased uptake of CUS by clinicians other than radiologists over the past decade. Basic use of CUS allows the safe and accurate identification of pleural fluid and other relevant anatomical structures, such as the underlying lung, heart, diaphragm, and abdominal viscera. The global evidence that supports the use of CUS as an adjunct to pleural intervention and the associated reduction in risk to patients is overwhelming (Fig. 30.16). CUS assessment should be considered an essential “gold standard” before any pleural intervention for suspected fluid [86].

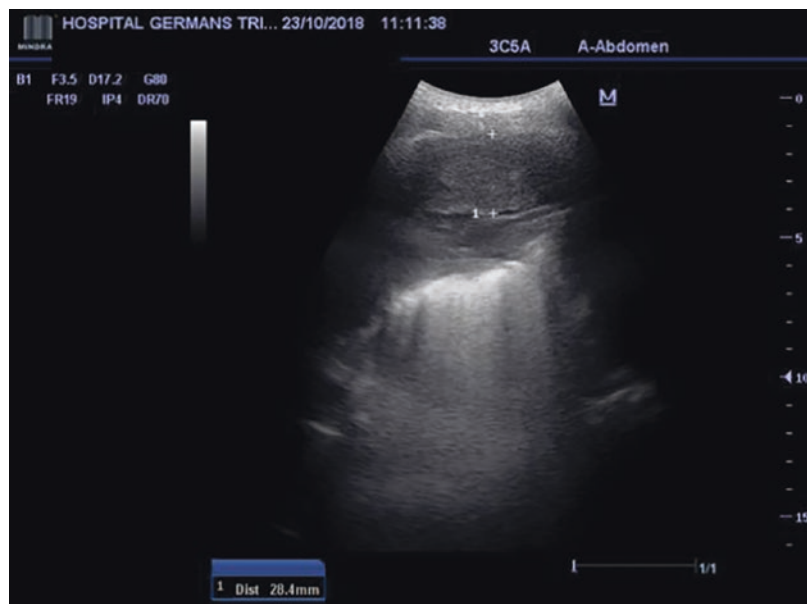However, CUS does not guarantee appropriate site selection for intervention and might encourage clinicians to venture outside the anatomical safe triangle, since fluid is often most easily seen

posteriorly where the costodiaphragmatic recess permits the greatest accumulation with the patient sitting upright.

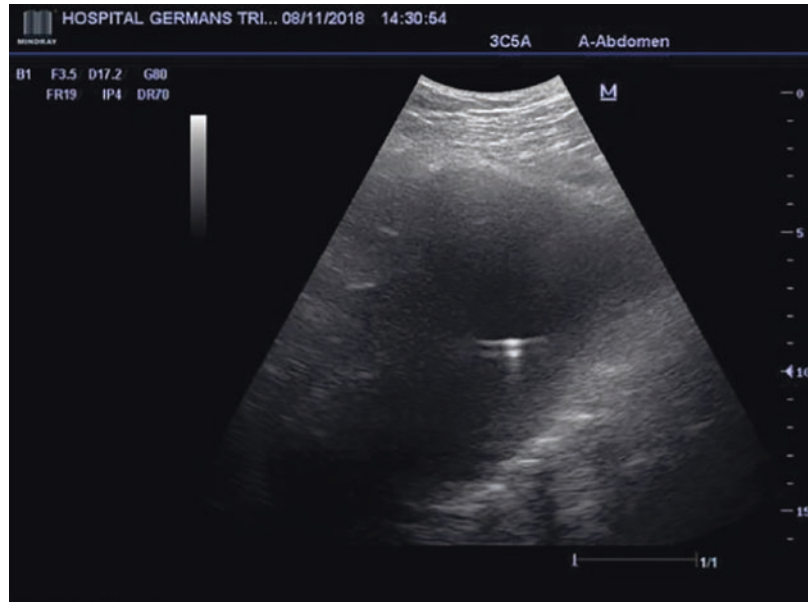
The role played by CUS in improving patient safety does not end when the procedure begins. Other than providing the ability to allow real-time guidance of any pleural intervention, CUS also offers the operator an opportunity to identify any iatrogenic complications as early as possible. Postprocedural ultrasound screening at the site of intervention can identify either active bleeding from the parietal pleural surface or the rapid accumulation of highly echogenic fluid within the pleural space, demonstrating a swirling or gradient effect as heavier cellular material is deposited in the more dependent part of the collection (Fig. 30.17).

CUS can be used to recognize iatrogenic pneumothorax following procedures such as thoracentesis, transbronchial lung biopsy or image-guided lung biopsy, using key ultrasonographic features such as the presence of a lung point, or absence of B-lines and lung sliding.

**Fig. 30.16** Lung carcinoma stage IV with pleural effusion and metastatic implants over the parietal pleura



**Fig. 30.17** Tip of intrathoracic chest tube visible by US

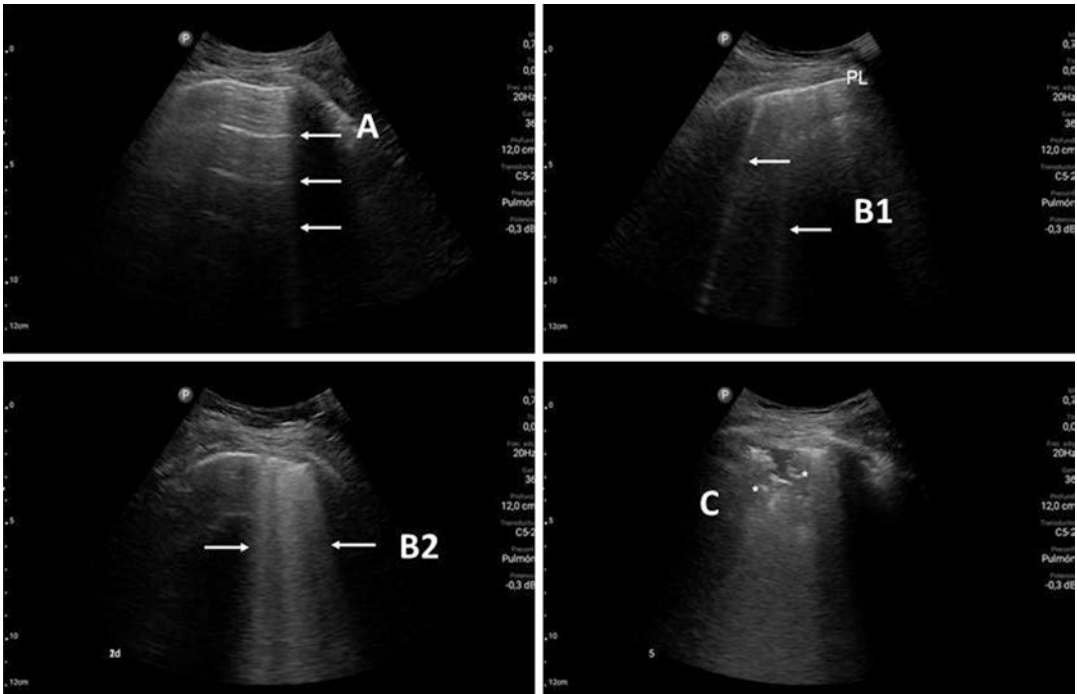
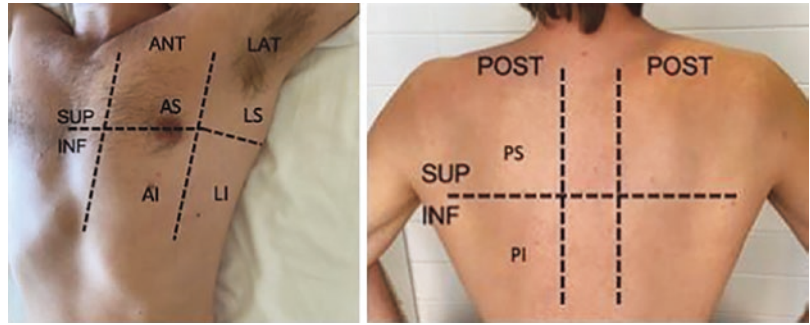


## COVID and Chest Ultrasound

CUS use has increased as a diagnostic and monitoring tool in critically-ill patients [87]. Ultrasonographic patterns mentioned previously have been useful for assessing pneumonia, atelectasis, pleural effusion, pulmonary edema, pneumothorax, and acute respiratory distress syndrome (ARDS) [88, 89], as well as for monitoring respiratory response in patients with invasive ventilation [90, 91]. In this regard, lung ultrasound score (LUS) is a semiquantitative index for assessing lung aeration loss and prediction of clinical outcomes in acute severe coronavirus disease 2019 (COVID-19) patients [92]. LUS evaluates lung parenchyma following a twelve-zone examination of the thorax [93]. Anterior (midclavicular line), lateral (midaxillary line), and posterior (paravertebral line) chest regions are divided in two (superior and inferior) (Fig. 30.18a, b). Posterior exploration is performed when a patient is able to sit or tilt sideways. When this is not possible, it was substituted

with posterior axillary line exploration. Both high or low-frequency transducers can be used, though linear high-frequency probe is preferred because of the definition of pleural line. The transducer is placed longitudinal to the ribs to enhance the acoustic window. Each region is then scored following recommendations for point-of-care CUS [94]: lung sliding with A-lines or fewer than three isolated B-lines score 0; multiple well-defined B-lines (B1) score 1; multiple coalescent B-Lines (B2) or white lung score 2; and subpleural consolidation (C-profile) scores 3 (Fig. 30.19). The sum of the scores defined the LUS, ranging from 0 to 36 points [93]. A LUS  $\geq$  24 points is associated with a poor outcome at 30 days (ICU admission and mortality). The presence of B2-lines and C-profile is related to different thoracic CT-scan features such as consolidation and ground glass opacity; and are also related to lung fibrosis and diffuse alveolar damage in lung parenchyma [92]. LUS can be used in the follow-up in COVID-19 patients, in addition to diaphragmatic examination.

**Fig. 30.18** 12 regions of exploration



**Fig. 30.19** CUS findings in COVID

**Conclusions**

Thoracic ultrasound is a well-established diagnostic tool for the chest physician. It is quick, portable, and available providing real-time dynamic imaging and does not expose patients to ionizing radiation. It has a particular advantage to be a rapid bedside test. The investigation of chest wall abnormality, pleural effusion, and lung consolidation remains the major indications. The role played by CUS in improving patient safety does not end when the procedure begins. Other than providing the ability to allow

real-time guidance of any pleural intervention, CUS also offers the operator an opportunity to identify any iatrogenic complications as early as possible.

Furthermore, it allows morphological and dynamic study of each hemidiaphragms in case of raised hemidiaphragm, dyspnea following a surgical procedure (thoracic or abdominal), or road accident trauma and many other diseases.

Sonography is not a complicated technique to put in place, but the appropriate knowledge and the identification of basic ultrasound signs are fundamental to ensure an accurate diagnosis.



## References

1. Yu CJ, Yang PC, Chang DB, et al. Diagnostic and therapeutic use of chest sonography: value in critically ill patients. *AJR Am J Roentgenol.* 1992;159:695–701.
2. Lichtenstein D, Goldstein I, Mourgeon E, et al. Comparative diagnostic performances of auscultation, chest radiography and lung ultrasonography in acute respiratory distress syndrome. *Anesthesiology.* 2004;100:9–15.
3. Lichtenstein D, Peyrouset O. Lung ultrasound superior to CT? The example of a CT-occult necrotizing pneumonia. *Intensive Care Med.* 2006;32:334–5.
4. Yang PC, Kuo SH, Luh KT. Ultrasonography and ultrasound-guided needle biopsy of chest diseases: indications, techniques, diagnostic yields and complications. *J Med Ultrasound.* 1993;2:53–63.
5. Beckh S, Bolcskei PL, Lessnau KD. Real-time chest ultrasonography: a comprehensive review for the pulmonologist. *Chest.* 2001;122:759–73.
6. Koh DM, Burke S, Davies N, et al. Transthoracic US of the chest: clinical uses and applications. *Radiographics.* 2002;22:e1.
7. Tsai TH, Yang PC. Ultrasound in the diagnosis and management of pleural disease. *Curr Opin Pulm Med.* 2003;9:282–90.
8. Görg C. *Vascularization in chest sonography.* 3rd ed. New York: Springer; 2011. <https://doi.org/10.1007/978-3-642-21247-5>. ISBN 978-3-642-21246-8
9. Koegelenberg CFN, Bolliger CT, Diacon AH. Pleural Ultrasound. In: Light RW, Lee YC, editors. *Textbook of pleural disease.* 2nd ed. London: Hodder & Stoughton; 2008. p. 275–83.
10. Koegelenberg CFN, Diacon AH, Bolliger CT. Transthoracic ultrasound of the chest wall, pleura, and the peripheral lung. In: Bolliger CT, FJF H, Mayo PH, et al., editors. *Progress in respiratory research. Clinical chest ultrasound, vol. 37.* Basel: Karger; 2009. p. 22–33.
11. Tsai T-H, Jerng J-S, Yang P-C. Clinical applications of transthoracic ultrasound in chest medicine. *J Med Ultrasound.* 2008;16(1):7–25.
12. Beckh S, Bölskei PL, Lessnau KD. Real-time chest ultrasonography: a comprehensive review for the pulmonologist. *Chest.* 2002;122(5):1759–73.
13. Bouhemad B, Zhang M, Lu Q, Rouby JJ. Clinical review: bedside lung ultrasound in critical care practice. *Crit Care.* 2007;11(1):205.
14. Lichtenstein D, Menu Y. A bed-side ultrasound sign ruling out pneumothorax in the critically ill: lung sliding. *Chest.* 1995;108:1345–8.
15. Koenig SJ, Narasimhan M, Mayo PH. Thoracic ultrasonography for the pulmonary specialist. *Chest.* 2011;140:1332–41.
16. Volpicelli G, Elbarbary M, Blaivas M, et al. International evidence-based recommendations for point-of-care lung ultrasound. *Intensive Care Med.* 2012;38:577–91.
17. Tsai TH, Jemg J-S, Yang P-C. Clinical applications of transthoracic ultrasound in chest medicine. *J Med Ultrasound.* 2008;16:7–25.
18. Lichtenstein D, Meziere G, Biderman P, Gepner A, Barre O. The comet-tail artifact. An ultrasound sign of alveolar-interstitial syndrome. *Am J Respir Crit Care Med.* 1997;156:1640–6.
19. Volpicelli G, Caramello V, Cardinale L, Mussa A, Bar F, Frascisco MF. Detection of sonographic B-lines in patients with normal lung or radiographic alveolar consolidation. *Med Sci Monit.* 2008;14(3):CR122–8.
20. Agricola E, Bove T, Oppizzi M, Marino G, Zangrillo. Ultrasound comet-tail images: a marker of pulmonary edema. A comparative study with wedge pressure and extra vascular lung water. *Chest.* 2005;127:1690–5.
21. Lichtenstein DA, Meziere G, Lascols N, Biderman P, Courret JP, Gepner A. Ultrasound diagnosis of occult pneumothorax. *Crit Care Med.* 2005;33:1231–8.
22. Lichtenstein D, Meziere G, Biderman P, Gepner A. The comet tail artifact: an ultrasound sign ruling out pneumothorax. *Intensive Care Med.* 1999;25:383–8.
23. Lichtenstein DA. Interstitial syndrome and the BLUE-protocol. In: *Lung ultrasound in the critically ill: the BLUE protocol.* Switzerland: Springer International Publishing; 2016. [https://doi.org/10.1007/978-3-319-15371-1\\_11](https://doi.org/10.1007/978-3-319-15371-1_11).
24. Bischnau R, Gehmacher O, Kopf A, Scheier M, Mathis G. Ultrasonography in the diagnosis of rib and sternal fracture. *Eur J Ultrasound.* 1996;3(2):197.
25. Griffith JF, Rainer TH, Ching AS, Law KL, Cocks RA, Metreweli C. Sonography compared with radiography in revealing acute rib fracture. *AJR Am J Roentgenol.* 1999;173(6):1603–9.
26. Turk F, Kurt AB, Saglam S. Evaluation by ultrasound of traumatic rib fractures missed by radiography. *Emerg Radiol.* 2010;17(6):473–7.
27. Paik SH, Chung MJ, Park JS, Goo JM, Im JG. High-resolution sonography of the rib: can fracture and metastasis be differentiated? *AJR Am J Roentgenol.* 2005;184(3):969–74.
28. Mathis G, Blank W. The chest wall. In: *Chest sonography.* 3rd ed. Berlin Heidelberg: Springer-Verlag; 2011. <https://doi.org/10.1007/978-3-642-21247-5>. ISBN 978-3-642-21246-8.
29. Prosch H, Mathis G, Mostbeck G. Percutaneous ultrasound in diagnosis and staging of lung cancer. *Ultraschall Med.* 2008;29:466–84.
30. Sugama Y, Tamaki S, Kitamura S, et al. Ultrasonographic evaluation of pleural and chest wall invasion of lung cancer. *Chest.* 1988;93:275–9.
31. Lichtenstein DA. Interstitial syndrome and the BLUE-protocol. In: *Lung ultrasound in the critically ill: the BLUE protocol.* Springer International Publishing Switzerland; 2016. <https://doi.org/10.1007/978-3-319-15371-1>. ISBN 978-3-319-15370-4.
32. Hooper C, Lee YC, Maskell N, BTS Pleural Guideline Group. Investigation of a unilateral pleural effusion in adults: British Thoracic Society pleural disease guideline 2010. *Thorax.* 2010;65 (Suppl 2):ii4 eii17 <https://doi.org/10.1136/thx.2010.136978>.

33. Goecke W, Schwerk WB. Die Real-Time-Sonographie in der Diagnostik von Pleuraergüssen. In: Gebhardt J, Hackelöer BJ, Klinggräff G, Seitz K, editors. *Ultraschalldiagnostik '89*. Berlin/Heidelberg/New York/Tokio: Springer; 1990.
34. Grymnski J, et al. The diagnosis of pleural effusion by ultrasonic and radiologic techniques. *Chest*. 1976;70(1):33–7.
35. Reuss J. The pleura. In: Mathis G, editor. *Chest sonography*. 2nd ed. New York: Springer Verlag Berlin-Heidelberg; 2008.
36. Lichtenstein D, Hulot JS, Rabiller A, Tostivint I, Mezière G. Feasibility and safety of ultrasound-aided thoracentesis in mechanically ventilated patients. *Intensive Care Med*. 1999;25:955–8.
37. Lichtenstein D. Should lung ultrasonography be more widely used in the assessment of acute respiratory disease? *Expert rev. Respir Med*. 2010;4(5):533–8. <https://doi.org/10.1586/ers.10.51>.
38. Lichtenstein DA. LUCI and the concept of the “PLAPS”. In: *Lung Ultrasound in the Critically Ill: The BLUE Protocol*. <https://doi.org/10.1007/978-3-319-15371-1>. ISBN 978-3-319-15370-4.
39. Chian CF, Su WL, Soh LH, et al. Echogenic swirling pattern as a predictor of malignant pleural effusions in patients with malignancies. *Chest*. 2004;126:129–34.
40. Islam S, Tonn H. Thoracic ultrasound overview. In: Bolliger CT, Herth FJF, Mayo PH, Miyazawa T, Beamis JF, editors. *Clinical chest ultrasound: from the ICU to the bronchoscopy suite*. Prog Respir res, vol. 37. Basel: Karger; 2009. p. 11–20.
41. Chen KY, Liaw YS, Wang HC, et al. Sonographic septation: a useful prognostic indicator of acute thoracic empyema. *J Ultrasound Med*. 2000;19:837–43.
42. Tu CY, Hsu WH, Hsia TC, et al. Pleural effusions in febrile medical ICU patients: chest ultrasound study. *Chest*. 2004;126:1274–80.
43. Roch A, Bojan M, Michelet P, Romain F, Bregeon F, Papazian L, Auffray JP. Usefulness of ultrasonography in predicting pleural effusions >500 mL in patients receiving mechanical ventilation. *Chest*. 2005 Jan;127(1):224–32.
44. Balik M, Plasil P, Waldauf P, Pazout J, Fric M, Otahal M, Pacht J. Ultrasound estimation of volume of pleural fluid in mechanically ventilated patients. *Intensive Care Med*. 2006;32(2):318–21. Epub 2006 Jan 24
45. Remérand F, Dellamonica J, Mao Z, Ferrari F, Bouhemad B, Jianxin Y, Arbelot C, Lu Q, Ichai C, Rouby JJ. Multiplane ultrasound approach to quantify pleural effusion at the bedside. *Intensive Care Med*. 2010;36(4):656–64. <https://doi.org/10.1007/s00134-010-1769-9>. Epub 2010 Feb 6
46. Light RW. *Pleural diseases*. 4th ed. Philadelphia: Lippincott Williams&Willkins; 2001. p. 21–41.
47. Wu RG, Yang PC, Kuo SH, Luh KT. “Fluid color” sign: a useful indicator for discrimination between pleural thickening and pleural effusion. *J Ultrasound Med*. 1995;14:767–9.
48. Gehmacher O, Kopf A, Scheier M, et al. Ist eine Pleuritis sonographisch darstellbar? *Ultraschall Med*. 1997;18:214–9.
49. Volpicelli G, Caramello V, Cardinale L, Cravino M. Diagnosis of radio-occult pulmonary conditions by real-time chest ultrasonography in patients with pleuritic pain. *Ultrasound Med Biol*. 2008;34:1717–23.
50. Geiger D, Düll T, von Pawel J, et al. Thoraxwandinfiltration und Stichkanalinvasion beim malignen Pleuramesotheliom. *Ultraschall Med*. 2003;24:34, abstract)
51. Adams RF, Gray W, Davies RJ, Gleeson FV. Percutaneous image-guided cutting needle biopsy of the pleura in the diagnosis of malignant mesothelioma. *Chest*. 2001;120:1798–802.
52. Heilo A, Stenwig AE, Solheim P. Malignant pleural mesothelioma: US-guided histologic core-needle biopsy. *Radiology*. 1999;211:657–9.
53. Ding W, Shen Y, Yang J, He X, Zhang M. Diagnosis of pneumothorax by radiography and ultrasonography: a meta-analysis. *Chest*. 2011;140(4):859–66.
54. Galbois A, Ait-Oufella H, Baudel JL, Kofman T, Bottero J, Viennot S, Rabate C, Jabbouri S, Bouzeman A, Guidet B, Offenstadt G, Maury E. Pleural ultrasound compared with chest radiographic detection of pneumothorax resolution after drainage. *Chest*. 2010;138(3):648–55.
55. Lichtenstein D, Menu Y. A bedside ultrasound sign ruling out pneumothorax in the critically ill: lung sliding. *Chest*. 1995;108:1345–8.
56. Copetti R, Cattarossi L. The “double lung point”: an ultrasound sign diagnostic of transient tachypnea of the newborn. *Neonatology*. 2007;91(3):203–9.
57. Aspler A, Pivetta E, Stone MB. Double-lung point sign in traumatic pneumothorax. *Am J Emerg Med*. 2014;32(819):e1–2.
58. Volpicelli G, Audino B. The double lung point: an unusual sonographic sign of juvenile spontaneous pneumothorax. *Am J Emerg Med*. 2011;29(355):e1–2.
59. Zhang Z. Double lung point in an 18-month-old child: a case report and literature review. *J Thorac Dis*. 2015;7(3):E50–3. <https://doi.org/10.3978/j.issn.2072-1439.2015.01.14>.
60. Lichtenstein DA. Ultrasound in the management of thoracic disease. *Crit Care Med*. 2007;35(5 Suppl):S250–61.
61. Volpicelli G, Boero E, Sverzellati N, Cardinale L, Busso M, Boccuzzi F, Tullio M, Lamorte A, Stefanone V, Ferrari G, Veltri A, Frascisco MF. Semi-quantification of pneumothorax volume by lung ultrasound. *Intensive Care Med*. 2014;40(10):1460–7. <https://doi.org/10.1007/s00134-014-3402-9>. Epub 2014 Jul 24
62. Oveland NP, Lossius HM, Wemmelund K, Stokkeland PJ, Knudsen L, Sloth E. Using thoracic ultrasonography to accurately assess pneumothorax progression during positive pressure ventilation: a comparison with CT scanning. *Chest*. 2013;143(2):415–22.

63. Volpicelli G, et al. Unusual new signs of pneumothorax at lung ultrasound. *Crit Ultrasound J.* 2013;5:10.
64. Slater A, Goodwin M, Anderson KE, Gleeson FV. COPD can mimic the appearance of pneumothorax on thoracic ultrasound. *Chest.* 2006;129(3):545–50.
65. Kreuter M, Eberhardt R, Wenz H, et al. The correct one is: diagnostic value of transthoracic ultrasound compared to chest radiography in the detection of a post-interventional pneumothorax. *Ultraschall Med.* 2011;32:E20–3.
66. Lichtenstein D, Mezière G, Seitz J. The dynamic air bronchogram. A lung ultrasound sign of alveolar consolidation ruling out atelectasis. *Chest.* 2009;135(6):1421–5.
67. Lichtenstein DA. The extended-BLUE-protocol. In: Lung ultrasound in the critically ill: the BLUE protocol. Switzerland: Springer International Publishing; 2016. [https://doi.org/10.1007/978-3-319-15371-1\\_11](https://doi.org/10.1007/978-3-319-15371-1_11).
68. Lichtenstein DA, Lascols N, Mezière G, Gepner A. Ultrasound diagnosis of alveolar consolidation in the critically ill. *Intensive Care Med.* 2004;30(2):276–81.
69. Barillari A, De Franco F, Colonna F. Chest ultrasound helps to diagnose pulmonary consolidations in paediatric patients. *J Med Ultrasound.* 2011;19:27–31.
70. Caiulo VA, Gargani L, Caiulo S, Fiscaro A, Moramarco F, Latini G, Picano E, Mele G. Lung ultrasound characteristics of community acquired pneumonia in hospitalized children. *Pediatric Pulmonol.* 2012;48(3):280–7.
71. Lichtenstein DA. PLAPS and lung consolidation (usually alveolar syndrome) and the C-profile. In: Lung Ultrasound in the Critically Ill: The BLUE Protocol. New York: Springer; 2016. [https://doi.org/10.1007/978-3-319-15371-1\\_17](https://doi.org/10.1007/978-3-319-15371-1_17).
72. Lichtenstein DA, Lascols N, Prin S, Mezière G. The “lung pulse”: an early ultrasound sign of complete atelectasis. *Intensive Care Med.* 2003;29(12):2187–92. Epub 2003 Oct 14
73. Mathis G, Beckh S, Görg C. Lung consolidations. In: Chest sonography. 3rd ed. Berlin Heidelberg: Springer-Verlag; 2011. <https://doi.org/10.1007/978-3-642-21247-5>. ISBN 978–3–642-21246-8.
74. Görg C. The white hemithorax in chest sonography. 3rd ed. Springer; 2011. <https://doi.org/10.1007/978-3-642-21247-5>. ISBN 978–3–642-21246-8
75. Mathis G. Thorax sonography--Part I: Chest wall and pleura. *Ultrasound Med Biol.* 1997;23(8):1131–9.
76. Lichtenstein DA. Lung rockets: the ultrasound sign of interstitial syndrome. In: Lung Ultrasound in the Critically Ill: The BLUE Protocol. New York: Springer; 2016. [https://doi.org/10.1007/978-3-319-15371-1\\_17](https://doi.org/10.1007/978-3-319-15371-1_17).
77. Reissig A, Heynes JP, Kroegel C. Sonography of lung and pleura in pulmonary embolism: sonomorphologic characterization and comparison with spiral CT scanning. *Chest.* 2001;120:1977–83.
78. Mathis G, Bitschnau R, Gehmacher O, Scheier M, Kopf A, Schwarzler B, Amann T, Doring W, Hergan K. Chest ultrasound in diagnosis of pulmonary embolism in comparison to helical CT. *Ultraschall Med.* 1999;20:54–9.
79. Reissig A, Kroegel C. Transthoracic ultrasound of lung and pleura in the diagnosis of pulmonary embolism: a novel non-invasive bedside approach. *Respiration.* 2003;70(5):441–52.
80. Mathis G. Vascular lung consolidations: pulmonary embolism and pulmonary infarction. In: Chest Sonography. 3rd ed. New York: Springer; 2011. <https://doi.org/10.1007/978-3-642-21247-5>. ISBN 978-3-642-21246-8.
81. Mathis G, Metzler J, Fussenegger D, Sutterlütli G, Feurstein M, Fritzsche H. Sonographic observation of pulmonary infarction and early infarctions by pulmonary embolism. *Eur Heart J.* 1993;14(6):804–8.
82. Pfeil A, Reissig A, Heyne JP, Wolf G, Kaiser WA, Kroegel C, Hansch A. Transthoracic sonography in comparison to multislice computed tomography in detection of peripheral pulmonary embolism. *Lung.* 2010;188(1):43–50.
83. Boussuges A, Gole Y, Blanc P. Diaphragmatic motion studied by M mode ultrasonography: methods, reproducibility and normal values. *Chest.* 2009;135:391–400.
84. Summerhill EM, El-Sameed YA, Glidden TJ, McCool FD. Monitoring recovery from diaphragm paralysis with ultrasound. *Chest.* 2008;133(3):737–43.
85. Esen G. Ultrasound of superficial lymph nodes. *Eur J Radiol.* 2006;58(3):345–59.
86. Prosch H, Strasser C, Sonka C, et al. Cervical ultrasound (US) and US-guided lymph node biopsy as a routine procedure for staging of lung cancer. *Ultraschall Med.* 2007;28:598–603.
87. Lichtenstein DA. BLUE-protocol and FALLS-protocol: two applications of lung ultrasound in the critically ill. *Chest.* 2015;147(6):1659–70.
88. Lichtenstein D, van Hooland S, Elbers P, Malbrain MLNG. Ten good reasons to practice ultrasound in critical care. *Anaesthesiol Intensive Ther.* 2014;46(5):323–35.
89. Mojoli F, Bouhemad B, Mongodi S, Lichtenstein D. Lung ultrasound for critically ill patients. *Am J Respir Crit Care Med.* 2019;199(6):701–14.
90. Yin W, Zou T, Qin Y, Yang J, Li Y, Zeng X, et al. Poor lung ultrasound score in shock patients admitted to the ICU is associated with worse outcome. *BMC Pulm Med.* 2019;19(1):1.
91. Pérez Pallarés J, Flandes Aldeyturriaga J, Cases Viedma E, Cordovilla PR. SEPAR-AEER consensus recommendations on the usefulness of the thoracic ultrasound in the Management of the Patient with suspected or confirmed infection with COVID-19. *Arch Bronconeumol.* 2020;56:27–30.
92. Trias-Sabrià P, Molina-Molina M, Aso S, Argudo MH, Diez-Ferrer M, Sabater J, et al. Lung ultrasound

- score to predict outcomes in COVID-19. *Respir Care*. 2021;66(8):1263–70.
93. Soldati G, Smargiassi A, Inchingolo R, Buonsenso D, Perrone T, Briganti DF, et al. Proposal for international standardization of the use of lung ultrasound for patients with COVID-19: a simple, quantitative, reproducible method. *J Ultrasound Med*. 2020;39(7):1413–9.
94. Buonsenso D, Piano A, Raffaelli F, Bonadia N, de Gaetano DK, Franceschi F. Point-of-care lung ultrasound findings in novel coronavirus disease-19 pneumoniae: a case report and potential applications during COVID-19 outbreak. *Eur Rev Med Pharmacol Sci*. 2020;24(5):2776–80.



# Overview of the Spectrum of Chest Tubes with a Focus on Indwelling Pleural Catheters: Disease-Specific Selection

Audra J. Schwalk and Anastasiia Rudkovskaia

## Introduction

Diagnostic and therapeutic aspiration of air and fluid via thoracentesis or chest tube placement is one of the most basic and commonly performed pleural procedures. It is primarily performed by interventional pulmonologists, interventional radiologists, and thoracic surgeons; however, due to increasing service demands, there is a need for physicians from other backgrounds to develop competency in performing these procedures. This chapter will focus on the indications, contraindications, necessary equipment and preparation, basic procedural techniques and complications of chest tube, and indwelling pleural catheter (IPC) placement. Literature pertaining to post-procedure management and complications will be reviewed with a primary focus on IPCs. Training tools and methods of determining procedural competency for pleural procedures will also be discussed.

## History of Chest Tubes

The first recorded evidence of chest tube use belongs to Hippocrates. He described irrigation of the pleural cavity with warm wine and oil followed

by the intrapleural insertion of a hollow drainage tube in a patient recovering from empyema [1]. Almost 2000 years after Hippocrates, Dominique Anel described the use of a silver tube with suction generated by a piston syringe to aspirate the contents of a pleural cavity [2]. The first “water-seal” drainage system was described by Playfair which he used to manage empyema in a 7-year-old child [3]. It was not until the late 1950s that closed chest tube drainage systems became commonplace and the standard of care for managing intrathoracic trauma during the Vietnam War [4].

## Overview of Chest Tubes

Chest tubes and IPCs are indicated in the treatment of multiple conditions, namely pneumothorax and pleural effusion from hemothorax, empyema, and malignancy. Various chest tubes and pigtail catheters in a range of sizes are commercially available. Chest tube and pigtail catheter sizes are measured in French gauge (Fr), where 1 Fr equals 1/3 mm. There is significant variability in the definition of small and large bore chest tubes but generally 8–14 Fr is considered small bore and 28–40 Fr large bore. The choice of a chest tube size should be guided by the disease process and is discussed in detail later in the chapter. Larger chest tubes may be necessary to successfully drain air out of the pleural cavity and prevent tension pneumothorax in patients with large air leaks requiring continuous positive airway pressure. In addition,

A. J. Schwalk (✉) · A. Rudkovskaia  
Internal Medicine, Pulmonary and Critical Care  
Division, The University of Texas Southwestern  
Medical Center, Dallas, TX, USA  
e-mail: [audra.schwalk@utsouthwestern.edu](mailto:audra.schwalk@utsouthwestern.edu)



blood and fibrin clots may occlude a small diameter tube and lead to tension physiology, lung collapse, or re-accumulation of pleural fluid, especially when managing traumatic injuries and postoperative complications. Poiseuille's law states that volume and flow are proportional to the radius to the fourth power ( $Q \propto r^4$ ), which explains why larger tubes are more effective in certain clinical scenarios. Larger chest tubes are associated with more pain and discomfort for patients; therefore, clinical judgment should be used when deciding on a specific chest tube to balance maximal effectiveness and patient comfort.

### Contraindications for Chest Tube Placement

Pleural drainage procedures are relatively simple but can result in high morbidity and mortality in the hands of an inexperienced operator. It is imperative to master the technique and understand the indications and contraindications of these procedures to prevent unnecessary interventions and complications (Table 31.1).

The only absolute contraindications to chest tube placement are lack of informed consent or operator and equipment availability, pleural fusion, and entry site infection. Computed tomography (CT)-guided placement of chest tubes is

preferred in the setting of multiple loculations, pleural adhesions, and scarring. Relative contraindications include increased risk of bleeding due to thrombocytopenia, uncorrected coagulopathy (INR > 1.7), or therapeutic anticoagulation, all of which should be reversed when feasible [5]. It is important to note that the relative contraindications do not apply to emergencies, like tension pneumothorax or massive hemothorax, when timely intervention is of utmost importance.

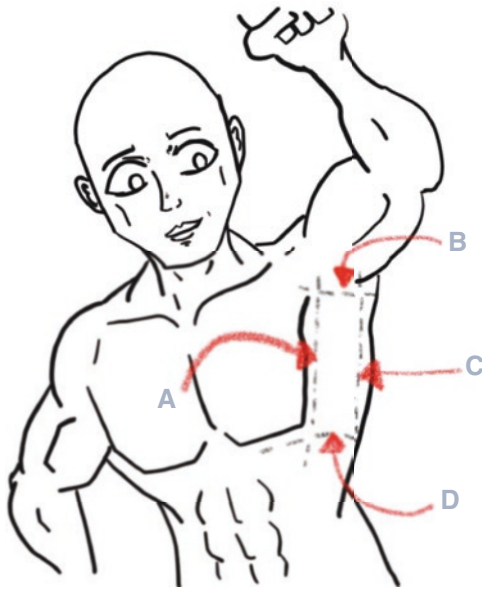
### Chest Tube Procedural Technique

A thorough pre-procedural evaluation is the key to any successful intervention. History of prior procedures and complications, hemodynamic, and coagulation parameters and active medications should all be carefully reviewed and optimized prior to chest tube placement. Chest tube placement for non-traumatic conditions does not routinely require pre-procedural antibiotic prophylaxis [6]. Relevant images should always be reviewed prior to the procedure. The chest tube insertion site is ideally chosen based on an ultrasonographic image, but the "triangle of safety" is the best insertion site in emergencies or when ultrasound is unavailable. The "triangle of safety" is an anatomic area on the chest identified by the lateral border of the pectoralis major muscle, the lateral border of the latissimus dorsi, and the nipple line inferiorly (Fig. 31.1). The patient can remain upright while leaning forward on a table during thoracentesis or may be placed in a lateral decubitus or semi-recumbent position for chest tube insertion for pleural effusion drainage. The supine position for tube placement in the second intercostal space in the mid-clavicular line or lateral decubitus position is best for chest tube placement for the treatment of pneumothorax. Of note, inserting a chest tube in the second intercostal space in patients with post-procedural pneumothorax related to pacemaker placement is not recommended due to an increased risk of infection.

The initial steps in chest tube placement are to identify and mark the site of insertion, clean the site with chlorhexidine or other sterilization solution, and place a sterile drape over the area. Next, inject 1% lidocaine (5–7 mg/kg) to anesthetize the subcutaneous, intercostal, and

**Table 31.1** Indications for chest tube insertion in adults

<b>Pleural effusion:</b>
Large malignant or non-malignant pleural effusion requiring slow drainage for symptom relief
Non-malignant or malignant pleural effusion as part of a pleurodesis procedure
Infectious pleural effusion (parapneumonic, empyema)
Chylothorax
Pleural effusion related to post-operative complications
Hemothorax
<b>Pneumothorax:</b>
Large or symptomatic primary spontaneous pneumothorax
Secondary spontaneous pneumothorax
Pneumothorax in patients on positive pressure ventilation
Tension pneumothorax
Large or symptomatic traumatic or iatrogenic pneumothorax



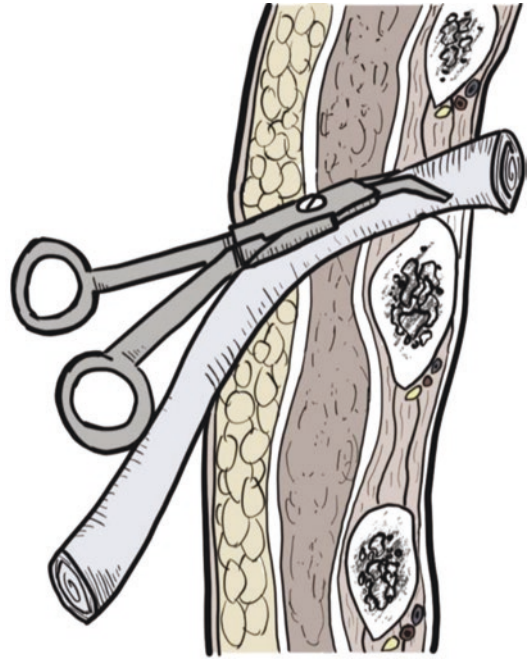
A: Lateral edge of pectoris major; B: base of axilla  
C: Lateral edge of latissimus dorsi; D: fifth intercostal space

**Fig. 31.1** Illustration outlining the anatomical borders of the “triangle of safety” utilized during chest tube placement to avoid damage to the chest wall and breasts. The “triangle of safety” is bounded anteromedially by the lateral edge of the pectoralis major, inferiorly by a horizontal line at the level of the nipple and posteriorly by the lateral edge of the latissimus dorsi. *Illustration by Faris Kudrath*

parietal pleural spaces in the intended placement tract. The needle entrance point should be above the rib to minimize risk of injury to the neurovascular bundle. The appearance of fluid or air within the syringe signifies entrance into the pleural space in the case of pleural effusion or pneumothorax, respectively. The two most used techniques for chest tube placement are the blunt operative dissection and the percutaneous Seldinger technique, both described below.

The blunt operative dissection technique for placement of larger chest tubes involves the following:

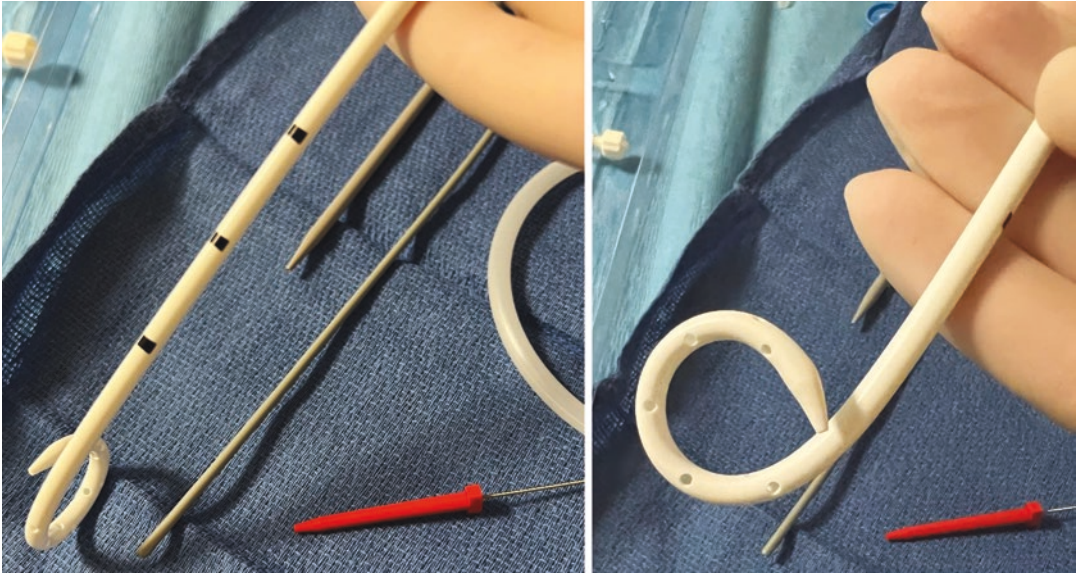
1. Make a 2–3 cm skin incision parallel to the rib.
2. Dissect through the subcutaneous tissue and intercostal space using a curved clamp (hemostat or Kelly) until you enter the pleural space on the superior border of the rib. The sensation of a “pleural pop” may be felt as the pleural space is entered.



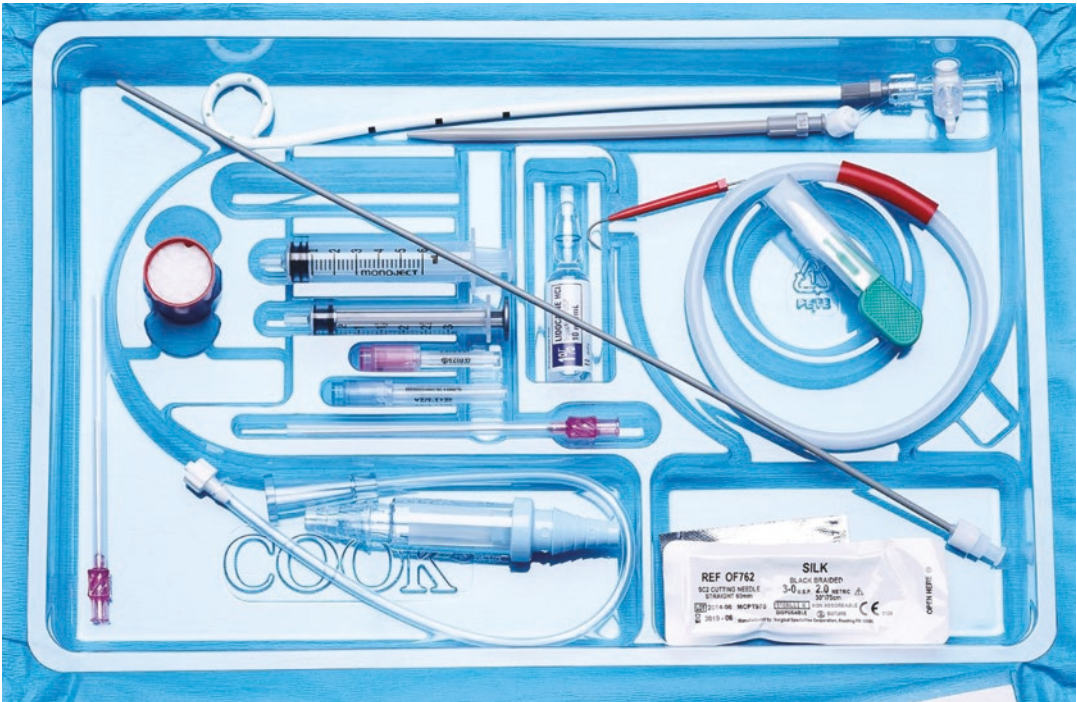
**Fig. 31.2** Illustration of blunt operative chest tube insertion technique using a curved hemostat to place a large bore chest tube over the superior aspect of the rib to minimize risk of damage to the neurovascular bundle. *Illustration by Faris Kudrath*

3. Use the clamp to dilate the pleural insertion site to a size large enough to accommodate insertion of finger.
4. Insert a sterile gloved finger into the pleural space and perform a finger sweep to confirm intrapleural position, remove thin adhesions, and ensure sufficient space for chest tube placement.
5. Grasp the large bore chest tube with the clamp and direct the chest tube through the insertion site into the pleural space. Aim apically and anteriorly for the treatment of pneumothorax and inferiorly in the setting of pleural effusion (Fig. 31.2).
6. Secure the chest tube to the skin with a suture to prevent migration or premature removal.

The percutaneous Seldinger technique is typically used for the placement of small-bore pigtail catheters (Fig. 31.3). The technique involves placement of the catheter over a guidewire after appropriate dilation. A Cook® Wayne Pneumothorax catheter is one of the commercially available sets (Fig. 31.4). There are also




**Fig. 31.3** Photo of a small-bore pigtail catheter (Cook® Wayne Pneumothorax) showing curved tip with multiple fenestrations to allow for drainage of pleural fluid or air. Distinct marks are present on the catheter to indicate depth of placement



**Fig. 31.4** Cook® Wayne Pneumothorax catheter insertion kit. Courtesy of Cook Medical





**Fig. 31.5** Cook® Thal-Quick chest tube. Courtesy of Cook Medical

commercially available large, straight (up to 32 Fr) chest tubes (Cook® Thal-Quick) that can be inserted through the percutaneous approach (Fig. 31.5); however, larger tubes (above 16–18 Fr) are usually more challenging to place via this technique because of the significant number of dilations needed for insertion.

### Complications of Chest Tube Placement

The most reported complications of chest tube placement include bleeding, skin and pleural infections, pneumothorax, organ injury (lung, heart, liver, spleen, etc.), tube malposition and dislodgement, re-expansion pulmonary edema, pain requiring chest tube removal, and tumor seeding of the tract. The development of complications depends on operator training level, whether it is an emergent or elective procedure, and the complexity of the pleural space, but are reported to occur in 1% to 6% of cases [7].

### Special Considerations

#### Pneumothorax

CT scan of the chest is the gold standard for estimating the size of pneumothorax and differentiating this from large bullae and emphysema

in patients with underlying lung disease. The cutoff of >2 cm between the lung edge and the chest wall at the level of the hilum is used to define a large pneumothorax based on the 2010 British Thoracic Society (BTS) guidelines, [5] whereas the American College of Chest Physicians (ACCP) uses 3 cm from the apex to the thoracic cupola for this definition [8]. The Light's index utilizes the length of the lung (L) and the length of the hemithorax (H) at the hilum to calculate the percentage of pneumothorax based on the formula  $(1 - L3/H3) \times 100$  (Fig. 31.6) [9]. While recent evidence suggests that patients with a moderate to large primary spontaneous pneumothorax can be effectively managed at home, [10, 11] patients with secondary spontaneous pneumothorax require close medical attention. Unstable patients, regardless of the size of the pneumothorax, require chest tube placement.

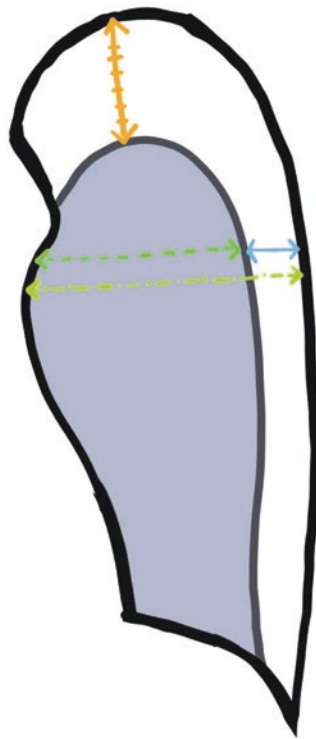
#### Empyema

Pleural fluid should be sampled when there is suspicion of a pleural infection and a chest tube should be inserted in cases of complicated effusions and empyema, with the goal being prompt evacuation and complete drainage of infected pleural fluid. If imaging suggests residual pleural fluid without sufficient drainage from the chest tube, fibrinolytics are often administered to facilitate drainage. Thoracic surgery should be consulted for consideration of surgical intervention in cases of incomplete drainage of the pleural space despite fibrinolytics. There is also evidence that medical thoracoscopy is safe and may shorten the length of the hospital stay in a select group of patients with empyema [12].

#### Hemothorax

Hemothorax is the presence of blood in the pleural space defined by a pleural fluid hematocrit of at least 50% blood hematocrit. It is usually secondary to trauma or iatrogenic causes. A chest tube is placed to evacuate the pleural space and

**Fig. 31.6** British Thoracic Society, American College of Chest Physicians and Light Index for measurement of pneumothorax. Illustration by Faris Kudrath



American college of chest physicians:

←+++→ Apex-cupola distance

British thoracic society:

↔ Interpleural distance at hilum

Light index:

←- - -> L: Diameter of collapsed lung

← · · · > H: Diameter of inner hemithorax at hilum

Estimated pneumothorax size =  $(1-L^3/H^3) \times 100$

estimate the rate of bleeding to determine the need for additional interventions such as surgery or arterial embolization. Historically, larger chest tubes were recommended for hemothorax given concern for clogging of smaller tubes with blood clots. More recent literature suggests that there is no significant difference [13, 14] in chest tube failure rates between smaller pigtail catheters and larger bore chest tubes in the management of hemothorax, but the decision should still be made on a case-by-case basis.

## Malignant Pleural Effusion

Malignant pleural effusion (MPE) is a common clinical problem and can complicate almost any malignancy. Definitive management for a symptomatic MPE is recommended for recurrence after initial drainage [15–17]. Chest tubes are frequently part of the management plan and are placed during thoracoscopic and non-thoracoscopic pleurodesis procedures. IPCs are another option for definitive

MPE management and will be discussed in further detail later in the chapter.

## Chest Tube Size Considerations

The TIME-1 (First Therapeutic Intervention in Malignant pleural Effusion) trial evaluated the effect of chest tube size on pleurodesis success and pleural pain in patients with MPE undergoing both thoracoscopic and non-thoracoscopic pleurodesis procedures. One-third of the patients (114 out of 320) were randomized to 12 versus 24 Fr tube placement for non-thoracoscopic pleurodesis. The trial showed that smaller bore chest tubes may be inferior to larger chest tubes for pleurodesis, although the study was underpowered for this outcome with a 15% non-inferiority margin. There was a statistically significant difference in pain between the two groups with less pain experienced by those with smaller chest tubes. This difference, however, may not correlate with actual clinical benefit given the small absolute difference in pain



between the two groups [18]. A more recent 2018 meta-analysis of randomized controlled trials evaluating the impact of chest tube size on pleurodesis efficacy in MPE showed no significant difference between large (>14 Fr) and small ( $\leq$ 14 Fr) bore chest tubes [11].

A systematic review and meta-analysis of 11 studies by Chang and colleagues demonstrated small-bore chest tubes were as efficacious as large-bore chest tubes for the management of spontaneous pneumothorax with significantly lower complication rates (for secondary spontaneous pneumothorax), shorter duration of drainage, and hospital stay with small bore chest tube use [19]. Bauman et al. published their 7-year experience with 14 Fr pigtail catheters versus 32–40 Fr chest tubes in patients with traumatic hemothorax and hemopneumothorax in 2018, which showed no difference in chest tube failure rates [14]. This study was followed by a randomized controlled trial by the same group, published in 2021, which confirmed no significant difference in the failure rates between 14-Fr and 28–32 Fr chest tubes. Patients also reported a better experience during placement of smaller chest tubes [13]. The MIST-1 (Multi-center Intrapleural Streptokinase) trial compared intrapleural streptokinase to placebo for the treatment of pleural infection. Other measured outcomes included change in lung function at three months, chest radiograph improvement, hospital length of stay, and difference in pain between groups with various sized chest tubes. Smaller, guidewire-inserted chest tubes were found to cause less pain and discomfort than blunt-dissection-inserted larger tubes and there was no difference in therapeutic outcomes [20]. Based on current literature, there is no solid evidence to demonstrate the superiority of larger bore chest tubes over small-bore chest tubes in the routine treatment of empyema, pneumothorax, or hemothorax.

### Complications and Troubleshooting Chest Tubes

Small-bore chest tubes have a greater tendency to become occluded and saline flushes every 6–12 h

to ensure patency is recommended [7]. The absence of respiratory variation suggests kinking or chest tube occlusion. If a persistent air leak is present, it is important to remove the entire dressing and examine the chest tube insertion site to ensure that one of the side holes is not located outside of the pleural cavity, giving a false impression of a continued bronchopleural or alveolar-pleural fistula. A simple test includes clamping the chest tube close to the skin to ensure that the air leak is not coming from the drainage system. If it continues after clamping, then it does not originate in the pleural cavity.

Assessment of the readiness for chest tube removal depends on the etiology, either pneumothorax or pleural effusion. There should be evidence of clinical and radiographic improvement in pneumothorax with the absence of a visible air leak. Once these criteria are met, the tube can be transitioned from suction to “water seal” for 4 to 24 h. If no significant change in clinical status or chest imaging occurs, the tube can be clamped for an additional 4 to 24 h (based on clinical judgment) and then removed after repeat chest imaging. Complete pleural apposition is the desired outcome, but this is not always possible, especially in patients with significant underlying lung disease. A small residual pneumothorax may be accepted if stability is achieved. In general, chest tubes are maintained for the duration of mechanical ventilation in patients receiving positive pressure ventilation. Clinical and radiographic improvement (chest x-ray and bedside ultrasound) with chest tube output of <150 mL in a 24-h period signifies readiness for chest tube removal when placed for pleural effusion.

### Pleural Drainage Systems

Pleural drainage systems are connected to chest tubes to prevent air entry into the pleural space while allowing for the drainage of air or pleural fluid during the treatment of pneumothorax or pleural effusion, respectively. There are an increasing number of pleural drainage systems, but all serve this same basic function.

When excessive pleural fluid drainage is not a consideration, the Heimlich valve can be used. It is a one-way valve used to treat pneumothorax that closes upon inspiration to prevent unwanted air entry into the pleural space and opens on expiration to allow for the escape of air. The Rocket® Pleural Vent™ is another pneumothorax device allowing for improved patient mobility during treatment. Both devices can be used while in the hospital or implemented upon discharge to minimize hospital length of stay in patients that do not require continuous pleural suction. These devices are then removed once a pneumothorax and alveolar-pleural fistula have resolved.

The three-chamber drainage systems are commonly used for both pleural effusions and pneumothorax and consist of three basic parts: (1) a water-seal chamber that has a one-way valve allowing air or fluid to exit the pleural space while inhibiting air entry into the pleural space, (2) a collection chamber that collects and measures drainage from the pleural space, and (3) a wet or dry suction control chamber to regulate the amount of suction applied to the pleural space. The level of suction is controlled by the amount of sterile water in the system for wet-suction setups (typically  $-20$  cmH<sub>2</sub>O), whereas there is a self-controlled dial that regulates the amount of suction applied in dry-suction systems. Not all patients require suction on the pleural drainage system so this is determined on an individual basis.

More advanced digital drainage systems have now been developed that function similarly to the three-chamber drainage system described above. They also have the capability to collect data about pleural fluid volume, variations in pleural pressure, and severity of air leak in patients with alveolar- or broncho-pleural fistulas while providing precise levels of suction. The commercially available digital drainage systems are the Thopaz™ (Medela, Switzerland) and Atmos® (Atmosmed, Allentown, PA, USA).

AIRFIX® was the first digital chest tube air-flometry device used to quantify air leak after lung resection [21]. Measurements are made based on a “mass airflow sensor” that collects and transmits data to a specialized software sys-

tem. The AIRFIX® device is attached in-line to the chest tube and drainage system and displays airflow as mL per breath (mL/b) and mL/minute (mL/min). This device was first validated in patients undergoing lung resection or lymph node dissection for non-small cell lung cancer. Air leak values obtained via intra-operative spirometry and leak tests were compared to the AIRFIX® values and were found to be very similar [21]. The DigiVent™ system was the first commercially available digital pleural drainage system that allowed for measurements and recordings of airflow and pressure [22].

A 2019 systematic review and meta-analysis by Wang et al. compared the efficacy of digital drainage systems with traditional drainage systems after pulmonary resection [23]. Digital drainage systems were not only found to reduce the incidence of prolonged air leak but the ability to objectively review data trends also reduced intra-observer variability leading to shorter duration of chest drainage and hospital lengths of stay [23]. It has also been shown that there is a reduced need for chest tube re-insertion after removal when digital drainage systems are used [23].

---

## History of and Introduction to Indwelling Pleural Catheters

As already discussed, there are multiple potential causes of pleural effusions that require intervention both for patient safety and palliation of symptoms. Pleural effusion is a common clinical problem estimated to affect 1.5 million people in the United States each year and an even larger portion of patients across the world [24]. Many pleural effusions are related to infection or non-malignant conditions, but malignant pleural effusions are also quite common. Many cancer patients will develop a pleural effusion at some point during their disease, either malignant or paramalignant. Approximately 50% of all cancer-related pleural effusions are due to lung cancer and up to 15% of these patients will have an MPE at diagnosis [25]. Almost any malignancy can be complicated by a MPE with breast cancer, lymphoma and leukemia being the next most com-

mon types [15]. Paramalignant effusions have negative pleural fluid cytology but develop as a result of tumor effects on the pleural space, primarily bronchial obstruction, infiltration of mediastinal lymph nodes and vascular structures, non-expandable lung or pulmonary embolus from hypercoagulability of malignancy. Regardless of the underlying etiology, pleural effusions may cause significant dyspnea, cough, and chest discomfort, resulting in a poor quality of life for patients. After identification of a pleural effusion, particularly in symptomatic patients, a thoracentesis is performed to analyze pleural fluid and assess improvement in patient symptoms to guide further management. The majority of MPEs will recur within 90 days of initial drainage [26] and additional interventions are often required.

Definitive management is recommended for most patients with a recurrent, symptomatic MPE [15–17] and the primary goals of treatment are palliation of symptoms while minimizing complications. Historically, chemical pleurodesis, either thoroscopic or via chest tube, was the treatment of choice in these patients, but these procedures require hospitalization and potentially general anesthesia. IPCs are being placed with increasing frequency since their introduction over 30 years ago, [27] largely because of the ease of outpatient placement and lack of need for general anesthesia and hospitalization. Repeat thoracentesis procedures may be the best management in patients with limited life expectancy. A thorough discussion about treatment options, patient preferences and goals should occur prior to any intervention to determine the best treatment approach. This chapter will focus on summarizing the latest, high-quality evidence, and recommendations for IPC use in patients with recurrent, symptomatic pleural effusions.

---

## Indications and Contraindications for IPC Placement

IPCs are traditionally placed in patients with a recurrent, symptomatic MPE, but as discussed in more detail in this chapter, they may also be uti-

lized for the management of non-malignant pleural effusions that are refractory to optimal medical management. IPCs are typically placed in patients with a poor performance status but may also be utilized in those with a good performance status that wish to minimize hospitalization as compared to thoracoscopy and pleurodesis.

Contraindications for IPC placement are similar to any chest tube or other invasive procedure and are already described in this chapter. Regarding pleural catheters, it is important to determine if a patient has symptomatic improvement after initial pleural fluid drainage. If the patient does not experience symptomatic improvement, then IPC placement would expose the patient to unnecessary risks with minimal benefit and should not be pursued. Active pleural infection, multiple pleural loculations, inadequate pleural space for safe implantation and lack of an area for IPC tunneling are additional contraindications to IPC placement. IPCs require maintenance to minimize complications. If a patient is incapable of caring for the catheter themselves or if an adequate support system is unavailable, then alternatives for the treatment of a recurrent, symptomatic pleural effusion should be investigated.

---

## IPC Procedural Technique and Necessary Equipment


Several IPC options are available and the decision to use one catheter over another depends on local availability and provider preference. Each catheter has slight differences, but all are made of soft silicone material and have multiple fenestrations to allow for drainage of pleural fluid. The Merit Medical Aspira<sup>®</sup> drainage system is designed to drain with low pressure via gravity, [28] whereas the PleurX<sup>®</sup> and Rocket<sup>®</sup> systems drain fluid via vacuum bottle [29, 30]. IPC procedural technique may vary slightly between providers and depending on which IPC is placed but are generally quite similar.

The procedure should be performed in an area capable of continuous telemetry and pulse oximetry monitoring. A peripheral IV should be placed



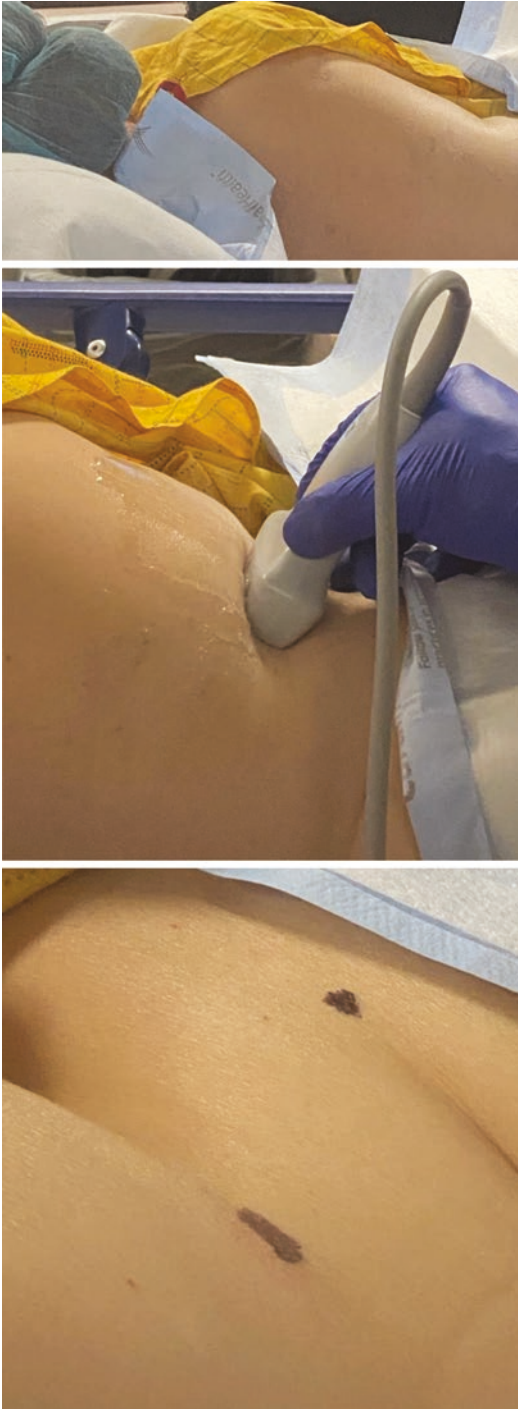in the event intravenous fluids or emergency medications need to be administered. A procedure nurse and a technician are typically required, in addition to the proceduralist placing the IPC. A time out procedure should be performed prior to IPC insertion. The patient's name, medical record

number and date of birth should be read aloud while all procedural participants are present. This allows for confirmation of the correct patient, procedure, and intended IPC insertion site. One approach to IPC placement is listed here (Figs. 31.7, 31.8, 31.9, 31.10, 31.11 and 31.12).



**Fig. 31.7** PleurX® catheter insertion kit contents: (a) insertion kit just after opening, (b) syringes with lidocaine and needle, (c) guidewire introducer needle and j-tipped wire, (d) dilator and peel away catheter insertion sheath,

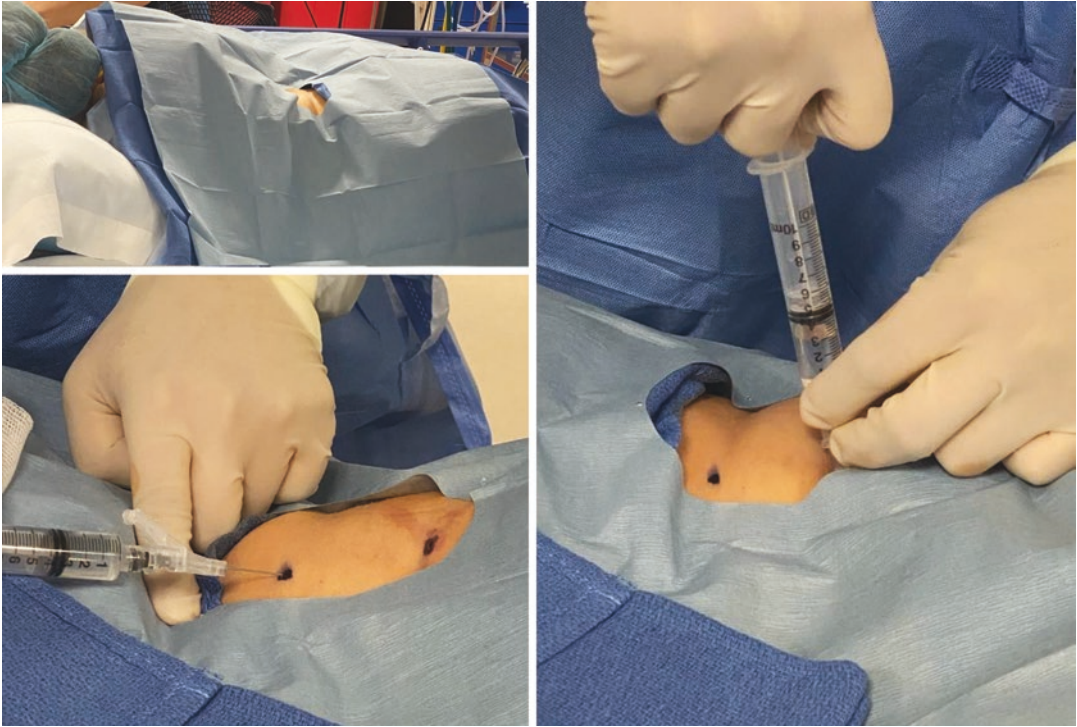
(e) silicone catheter with multiple fenestrations and attached metal tunneler, (f) suture for anchoring catheter and dressing contents



**Fig. 31.8** Patient positioning (lateral decubitus or supine), ultrasound of the pleural space and marking of appropriate IPC insertion sites

1. Place the patient in a semi-recumbent position. Other positions are acceptable, such as lateral decubitus, depending on patient tolerance, and expected insertion site.
2. Secure the patient's ipsilateral arm above the head or across the chest to fully expose the potential pleural entry site.
3. Identify the optimal site for IPC insertion and exit with the use of an ultrasound and mark these sites. Ideally, the largest collection of fluid is chosen as the insertion site. When possible, avoid areas of skin with evidence of active infection or malignant skin infiltration.
4. Clean the pleural entry and exit sites as well as the surrounding chest wall. An alcohol-based solution such as chlorhexidine is most used.
5. Don sterile personal protective equipment and prepare the IPC insertion kit.
6. Cover the chest with a sterile drape, leaving only the intended catheter insertion site exposed. Additional cleaning of the skin is typically performed.
7. Use the filter straw to prepare syringes with 1% lidocaine and then anesthetize the skin, subcutaneous tissue, and parietal pleura with the 22G or 25G needle. Ensure aspiration of pleural fluid and adequate anesthetization of the pleura.
8. Advance the guidewire introducer with needle in the anesthetized area, while applying suction, until pleural fluid is aspirated.
9. Hold the needle and syringe stable and advance the guidewire introducer into the pleural space until it is flush against the patient's skin. Remove the needle. Pleural fluid may drain out of the guidewire introducer at this point.
10. Insert the J-tip wire through the guidewire introducer and into the pleural space.
11. Remove the guidewire introducer, leaving the guidewire in place.
12. Use a scalpel to make an approximate 1 cm incision around the wire in the patient's skin and subcutaneous tissue. This is the pleural

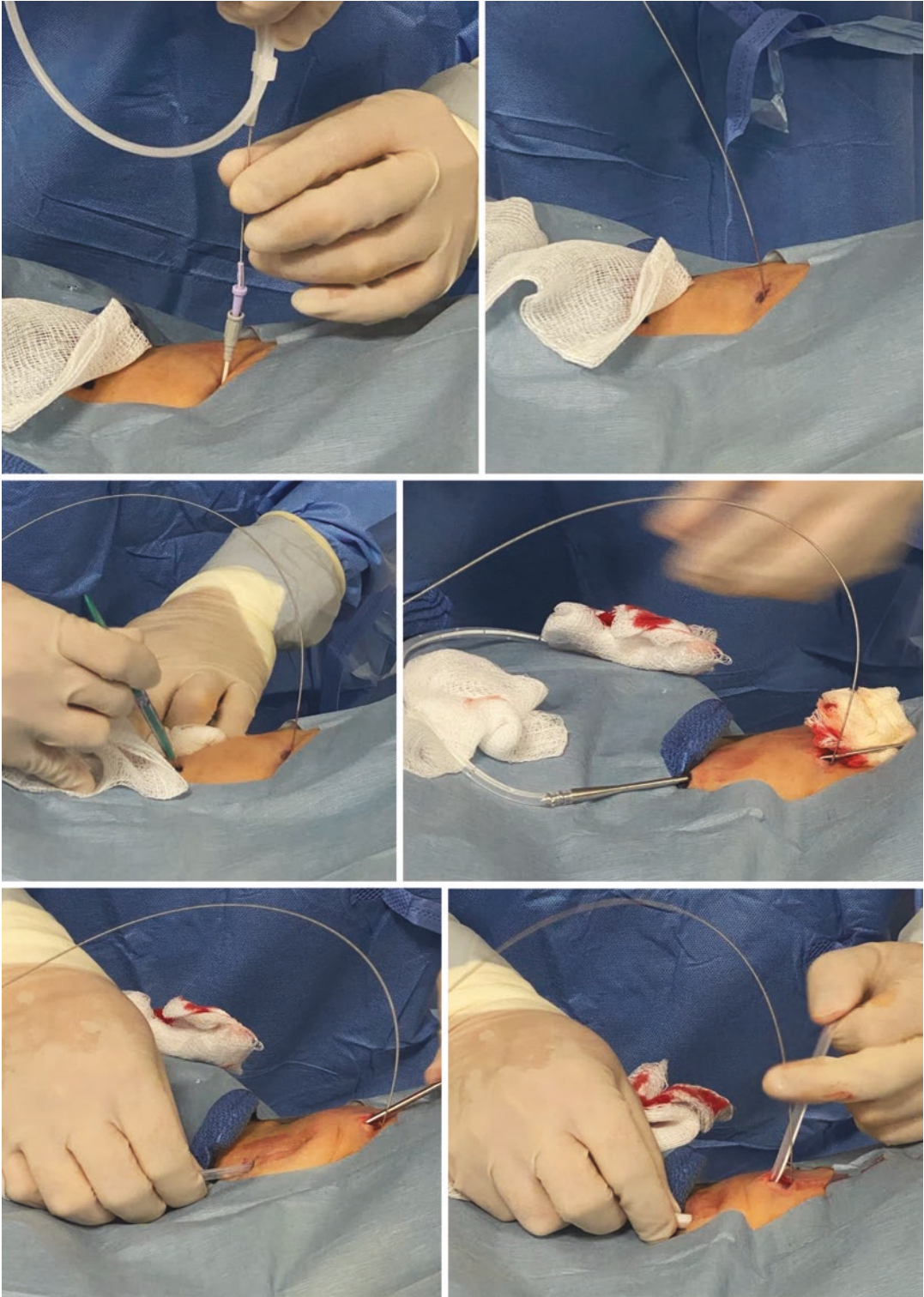




**Fig. 31.9** Sterilized and draped patient and injection of lidocaine to anesthetize the IPC insertion site and tunnel tract

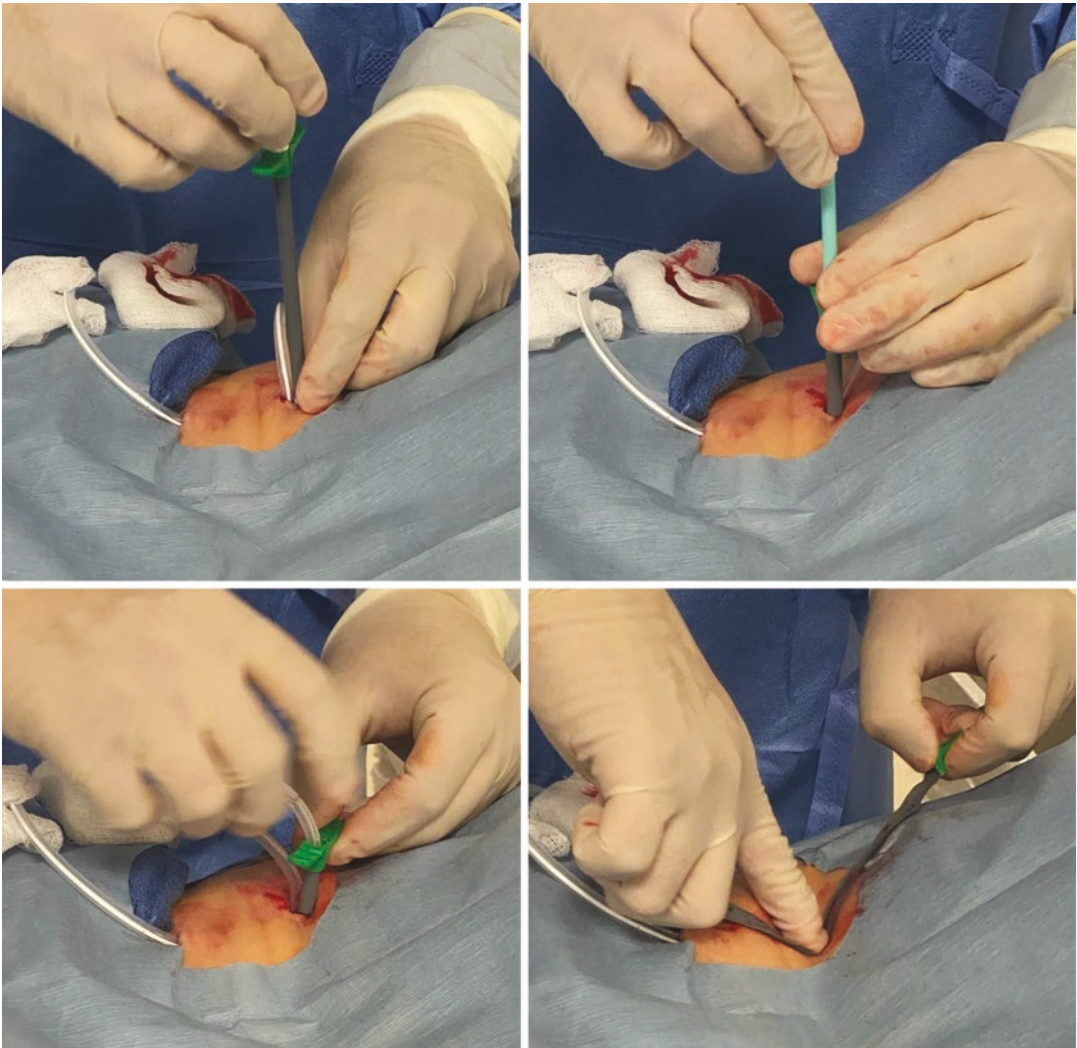
entry site. Make a second incision approximately 5 cm from the pleural entry site. This will serve as the catheter exit site.

13. Attach the metal tunneler to the fenestrated end of the pleural catheter and tunnel the catheter under the skin and subcutaneous tissue, entering at the catheter exit site, and directing the tunneler toward the pleural entry site. Pass the tunneler out through the pleural entry site where the guidewire is located. Pull the tunneler through the pleural entry site until the catheter cuff is just under the skin at the catheter exit site. Once in position, remove the metal tunneler from the catheter. Note: tunnelling the catheter too superficially can lead to excessive granulation tissue formation and difficulty with future removal.
14. Advance the peel-away introducer and dilator over the wire and into the pleural space.
15. Remove the central dilator and the wire while leaving the peel away sheath in place. Pleural fluid may drain out of the peel away sheath at this point.
16. Insert the fenestrated end of the catheter through the peel away sheath and into the pleural space.
17. Peel away the sheath while advancing the catheter into the pleural space using a thumb.
18. Ensure the catheter is inserted fully into the pleural space and feel for any evidence of a kinked catheter.
19. Attach the catheter tip to the specialized drainage bottle or suction using the appropriate adapter with access tip. Drain the pleural space. This ensures the catheter is functioning well after placement and allows for any necessary troubleshooting while the patient is in the procedure area.



**Fig. 31.10** Guidewire insertion followed by tunneling of the catheter

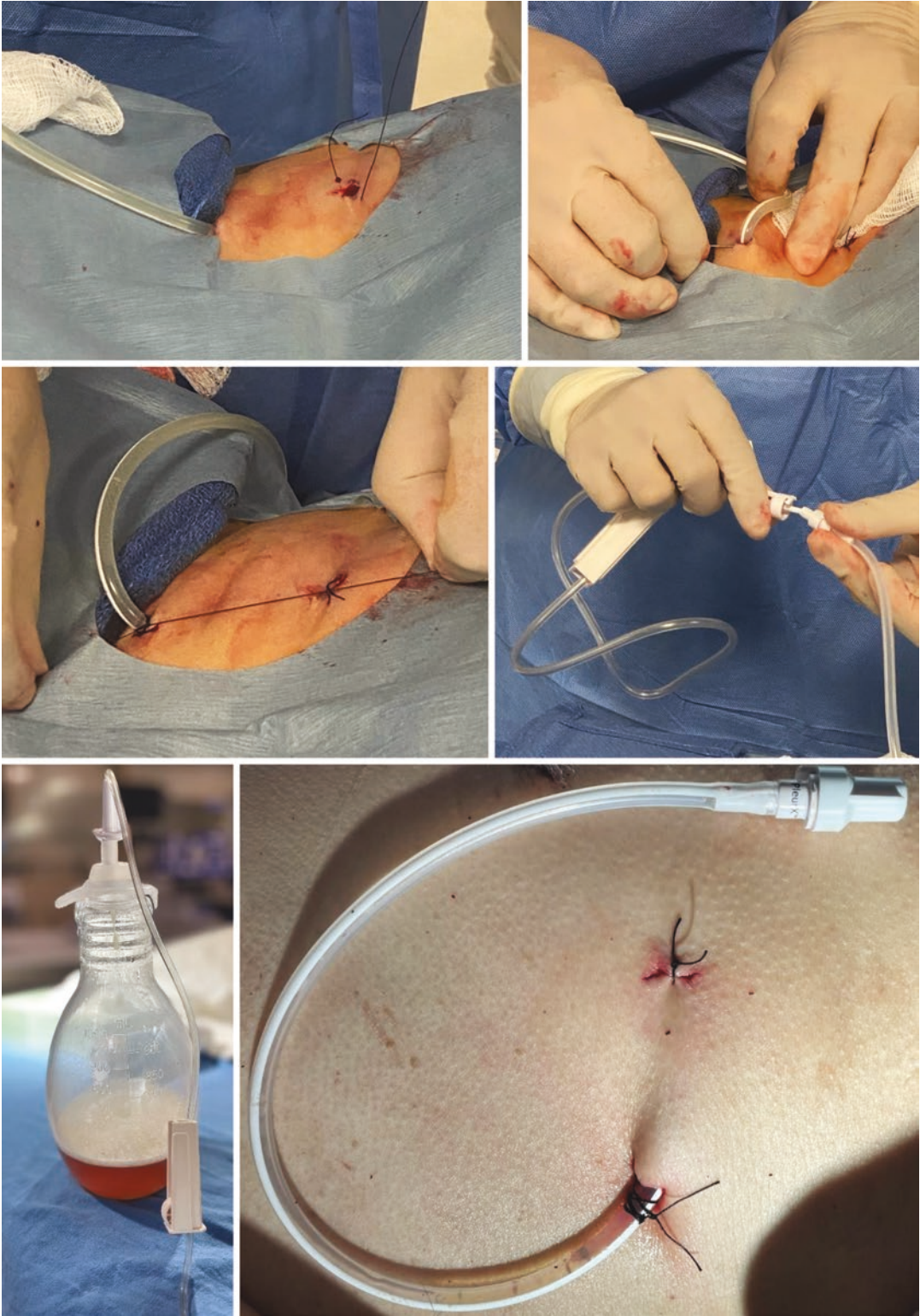



**Fig. 31.11** Dilator and peel away sheath insertion into the pleural space over the guidewire, feeding of IPC through the sheath and peeling of the sheath while holding the catheter in place

20. Remove the access tip and drainage line and place the specialized cap on the end of the catheter.
21. Use the 2-0 silk, straight needle suture to secure the IPC to the skin.
22. Use the 4-0 absorbable, curved needle suture to close the insertion site incision.
23. Place the foam catheter pad on the skin and coil the catheter on top of it, then cover with gauze.
24. Use the provided self-adhesive dressing for optimal coverage and catheter protection.

A post-procedure chest radiography is obtained to document proper IPC placement and the patient can often be discharged home the day of the procedure. It is customary to provide repeat IPC education prior to discharge to maximize the benefits of IPC placement while minimizing the risk of IPC-related complications. Instructional



**Fig. 31.12** Suture placement, IPC drainage and sterile dressing application





**Fig. 31.12** (continued)

videos and handbooks are available from the IPC manufacturers and can complement hands-on training.

---

### **Complications of IPC Placement Procedure**

Complications during IPC placement are rare but should be discussed during the informed consent process as they can occur in up to 6% of procedures. Procedural complications are similar to those encountered with any pleural procedure and include bleeding, pain, subcutaneous emphysema, unintended malpositioning of the catheter, unsuccessful IPC placement, and pneumothorax

[31]. Pneumothorax during IPC placement is rarely secondary to visceral pleural injury and is usually related to aspiration of air into the pleural space. Specialized adapters allow for IPC connection to a pleural drainage device in the event a clinically significant pneumothorax is present.

---

### **Special Considerations**

#### **Malignant Pleural Effusion**

Recurrent MPE is the most common indication for IPC placement and IPCs are well established as a means to provide significant symptom improvement in these patients [32–34]. Chemical



pleurodesis, either thoracoscopic or via chest tube, was the primary treatment modality for recurrent MPE prior to the development of IPCs and therefore many studies have compared the two in regard to pleurodesis rates, symptom improvement, and other clinical end points. The TIME2 (Second Therapeutic Intervention in Malignant Effusion) study was one of the largest randomized controlled trials to evaluate differences in dyspnea relief between the two groups [35]. Patients in both the IPC and talc pleurodesis group experienced an improvement in dyspnea and there was no significant difference between the two groups until 6 months when patients with an IPC had less dyspnea than the talc pleurodesis group [35]. Several other randomized controlled trials (RCTs) have compared the improvements in dyspnea or quality of life experienced by patients with IPCs versus chemical pleurodesis, either talc or doxycycline, and no significant difference has been identified [36–38].

IPCs and chemical pleurodesis do, however, differ significantly in hospitalization rates, lengths of stay and need for repeat pleural procedures as evaluated in several studies. All studies clearly show there is a significant decrease in total hospitalization days and initial length of stay when an IPC is placed for the treatment of a recurrent, MPE compared to chemical pleurodesis [35–38]. IPCs are also associated with a decreased need for repeat ipsilateral interventions [36, 37].

### **Non-expandable Lung**

Non-expandable lung, often referred to as “trapped,” does not fully expand after pleural fluid drainage and can develop because of a variety of malignant and non-malignant conditions that cause significant visceral pleural thickening. As seen with other pleural effusions, patients with non-expandable lung are often symptomatic and require interventions. Guidelines recommend placement of an IPC over chemical pleurodesis in patients with non-expandable lung owing to the fact that adequate apposition of the parietal and visceral pleura is not achieved, mak-

ing chemical pleurodesis less effective [15, 17, 26]. Approximately 50% of patients with non-expandable lung achieved pleurodesis after IPC placement at 6 months in the AMPLE-2 (Australasian Malignant PLeural Effusion-2) trial; therefore, pleurodesis is still achievable in this patient population [33]. As with patients with fully expandable lung, daily IPC drainage is associated with higher pleurodesis rates compared to symptom-guided drainage in this patient population [33].

Pien et al. were the first group to report on the use of IPCs for non-expandable lung in 11 patients with MPE. All patients experienced symptomatic benefit after IPC placement [39]. Several infectious complications were reported but only one was thought to result in patient death. Larger studies on this topic are now available with most reporting improvement in patient symptoms such as dyspnea and quality of life that are comparable to that achieved in patients with fully expandable lung after chemical pleurodesis [35]. In addition to patients with non-expandable lung, IPC placement may be the best treatment strategy for those with interconnected pleural loculations [26].

### **Non-malignant Pleural Effusion**

Non-malignant pleural effusions (NMPE) are common and can contribute to significant morbidity in affected patients. Congestive heart failure (CHF), hepatic hydrothorax, and end-stage renal disease (ESRD) are the most common non-infectious causes and treatment is typically aimed at the underlying disease process [40]. Despite optimal medical management many pleural effusions are refractory and alternatives for symptom palliation must be pursued. As described earlier in the chapter, IPCs were initially designed for the management of recurrent, symptomatic MPEs but their use has now been expanded to the treatment of refractory NMPEs not responding to optimal medical management. This is a patient population with a high mortality rate and need for optimal symptom control [40, 41]. Available data pertaining to the use of IPCs for NMPEs is not as

robust as that for MPEs and has traditionally been composed of low-quality non-RCTs describing NMPE from a variety of etiologies. More recent studies have focused on the safety and efficacy of IPCs for NMPEs from specific etiologies, primarily hepatic hydrothorax, and will be described here.

Hepatic hydrothorax is a complication of liver cirrhosis that can develop in the presence or absence of abdominal ascites. Medical management with diuretics, salt and fluid restriction, repeated thoracentesis, transjugular intrahepatic portosystemic shunt, and liver transplantation are the mainstays of treatment but when unsuccessful or unavailable, IPCs may be used for symptom control. Shojaee et al. published a multicenter retrospective evaluation of IPC use in 79 patients with refractory hepatic hydrothorax [42]. The pleurodesis rate was lower than that observed in patients with MPE, but catheter removal was achievable and occurred in 28% of patients [42]. The observed infection rate in this population was 10% with an associated 2.5% mortality rate [42]. This infection rate is much higher than that observed with MPEs but lower than previously published rates.

Congestive heart failure is the most common cause of NMPE and is managed similarly to hepatic hydrothorax with fluid and sodium restriction, diuretics, and afterload reduction [40, 41]. Available data suggests IPC-related infectious complications are much lower in patients with CHF compared to hepatic hydrothorax with most reported empyema rates ranging between 0% and 4% [43]. Pleurodesis rates may also be higher compared to those with hepatic hydrothorax and range from 25% to 44% with IPC alone to even higher when combined with talc administration [43–45]. Other important considerations that require monitoring when placing an IPC for the management of refractory NMPEs are electrolyte disorders, renal failure and protein loss, which seem to be more of an issue for hepatic hydrothorax compared to congestive heart failure.

Whereas available data specific to IPC use for hepatic hydrothorax and congestive heart

failure is slowly increasing, only small case series are available for IPC use in patients with ESRD-related pleural effusions. Potechin et al. reported outcomes of eight patients with IPCs placed for refractory ESRD-related effusions [46]. All patients experienced a significant improvement in dyspnea and 37.5% of patients achieved pleurodesis allowing for IPC removal after a median time of 45.5 days. No cases of empyema or other serious complications were reported [46].

IPC placement for the management of refractory, symptomatic NMPEs may be a good option in select patients as a bridge to transplant or in those where transplant or other advanced therapies are unavailable. Well-designed randomized controlled trials are necessary to determine how appropriate they are for long term use in these patient populations.

## Chylothorax

Chylothorax is defined as a pleural effusion with a triglyceride level of >110 mg/dL or identification of chylomicrons within the pleural fluid. It can develop after trauma to the thoracic duct or in association with specific malignant and non-malignant conditions. Approximately 50% of patients with chylothorax have cancer with lymphoma being the primary cause in most patients [47]. Chylothoraces can be large volume and may rapidly reaccumulate after drainage causing debilitating symptoms for affected patients. Management often proves challenging and is complicated by protein and electrolyte loss and immunologic compromise secondary to the nature of this fluid. Treatment is aimed at the specific underlying cause and in non-traumatic cases, traditionally includes repeat thoracentesis procedures, medications such as octreotide, dietary restriction of fat and possible total parenteral nutrition. Other procedural interventions include thoracic duct ligation, pleuroperitoneal shunting, pleurectomy, thoracoscopic pleurodesis or more recently, consideration of IPC placement. Frequent large

volume drainage of a chylothorax has historically not been recommended given the aforementioned reasons and patients with an IPC were thought to be exposed to increased infectious complications, thus limiting their use. Small retrospective case series describing the use of IPC for refractory chylothorax are published but no large studies are available for this patient population [47, 48].

Jimenez et al. published their experience with 19 patients with refractory chylothorax related to malignancy [47]. Ten patients were managed with IPC placement and the other nine underwent repeat thoracentesis procedures, talc pleurodesis or pleuroperitoneal shunt for symptom management. Patients receiving an IPC were older, but the two groups were otherwise similarly matched in patient and pleural fluid characteristics. Patients with an IPC drained daily until they experienced chest pain or persistent cough or there was no more fluid to drain. Changes in weight, absolute lymphocytes counts and albumin levels in addition to pleurodesis and complication rates and time to second pleural intervention were compared. A significant decrease in albumin was seen following IPC placement but recovered to baseline at a median time of 46 days after IPC removal. Patients with an IPC underwent significantly fewer repeat pleural procedures as compared to the control group during the 500 days of follow-up. No significant differences in pleurodesis rates, symptom improvement or complications was seen between the groups [47].

De Pew et al. described a cohort of 11 patients with refractory non-malignant chylothorax managed with IPCs [48]. Pleurodesis was defined as the absence of a recurrent pleural effusion after IPC removal and was achieved in 64% of patients with a median time of 176 days. Reductions in total protein, albumin, and lymphocyte counts were observed but none resulted in significant infectious or nutritional adverse outcomes [48].

IPC placement for the management of a refractory, symptomatic chylothorax may be a reasonable and safe option based on available data, but larger prospective studies are needed prior to routine use.

## Pleurodesis

Pleurodesis rates have historically been the focus of many studies, although patient-centered outcomes of quality of life and improvement in dyspnea are increasingly being evaluated. Pleurodesis, usually defined by radiographic absence of a residual pleural effusion and no recurrence within a pre-specific amount of time, occurs at higher rates for patients with IPCs placed for MPE compared to other conditions as detailed above, but reported rates remain less than 50% [32–34]. IPC-related pleurodesis rates may also vary depending on drainage regimen and are important from a cost perspective. This has been evaluated in one study by Shafiq et al. that determined daily IPC drainage was not cost-effective in any clinical scenario and symptom-guided drainage was cost-effective for patients with a life expectancy less than four months or an expected probability of pleurodesis greater than 20% [49].

The IPC-plus trial randomized patients to IPC plus placebo or talc slurry and found those treated with IPC plus talc slurry achieved pleurodesis at a significantly higher rate during the initial follow-up period [50]. The safety of silver nitrate coated IPCs have also been evaluated in a small study which reported high pleurodesis rates [51]. IPC plus pleural sclerosant may be a good treatment option for some patients to maximize symptom relief while minimizing cost and risk of IPC-related complications.

## Follow-Up and IPC Removal

A standardized follow-up schedule for patients with an IPC has not been established owing to a lack of formal studies, but regular follow-up is recommended even in the absence of catheter-related concerns. The frequency of follow-up should be individualized and considerations for determining a schedule include patient understanding of proper IPC care, reliability of caregivers to identify and communicate concerns, distance from healthcare providers and the financial, emotional and time burdens of treatment and

follow-up appointments [52]. At least one in-person visit for suture removal is typically required with a healthcare provider within 2 to 4 weeks after initial placement.

Drainage protocols and algorithms for IPC removal will vary between providers and institutions. The most commonly prescribed IPC drainage regimens include daily, every other day, and symptom-guided drainage. Evaluating patient symptoms and priorities is important when determining an IPC drainage regimen. Based on available information, IPC drainage regimen does not seem to affect patient breathlessness but there is conflicting data regarding its impact on quality of life [33, 34]. Daily IPC drainage is associated with shorter catheter-days in many patients, so if IPC removal is a priority, then an aggressive drainage strategy should be used [33, 34, 52].

General recommendations are to decrease drainage frequency when output decreases below a certain volume, often 50–100 mL [53]. If drainage is less than 50–100 mL for at least three consecutive drainage sessions, the next step is to decrease drainage frequency and assess readiness for catheter removal [53]. Review of patient symptoms and chest imaging are recommended prior to IPC removal to differentiate a non-draining catheter from successful pleurodesis, especially if an abrupt decrease in pleural fluid drainage occurred. Symptomatic pleural effusions may recur in up to 10% of patients after IPC removal requiring future pleural interventions, so this should be discussed with patients prior to removal [32, 54].

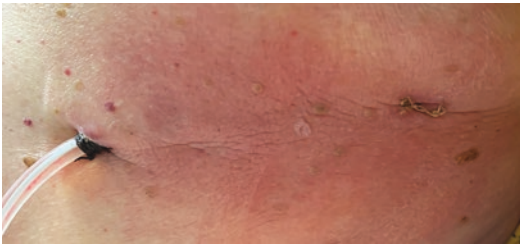
### **IPC-Related Complications and Management**

IPC-related complications are rare but can occur as long as the catheter is in situ. A thorough discussion regarding potential complications should be performed with each patient prior to placement so any issues can be promptly identified in order to minimize associated morbidity and mortality. The most common long-term complications include a non-draining catheter, tract

metastasis and infection [52, 53]. Other complications include catheter fracture, migration out of the pleural space, chest pain, and development of pleural loculations. Contrary to previous beliefs, IPC removal is not always necessary in the setting of a complication and is typically required in less than 10% of patients [54]. Expert-panel recommendations and guidelines for the management of IPCs and associated complications are now available and will be highlighted in the following discussion [52, 53].

When a non-draining catheter is encountered, further investigation should be performed to distinguish between successful pleurodesis and catheter malfunction. A review of drainage trends, patient symptoms, and chest imaging (typically thoracic ultrasound or chest radiography) should be obtained. Chest radiography is easy to obtain, but thoracic ultrasound may be more sensitive at identifying a persistent pleural effusion. Catheter malfunction is the most likely culprit in the setting of abrupt cessation of drainage and persistent respiratory symptoms, especially if chest imaging reveals a persistent pleural effusion. Catheter malfunction has been reported to occur in 5–14% of patients and is typically the result of IPC occlusion with a fibrin clot or the development of pleural loculations [52]. The first step for the treatment of catheter malfunction is to flush the IPC with sterile saline. If pleural fluid drainage does not improve after flushing with saline, then administration of intra-pleural fibrinolytics may be considered, barring any contraindications. Several studies have evaluated the use of various intra-pleural fibrinolytics for the treatment of symptomatic pleural loculations, but alteplase at a dose of 2 to 10 mg is the most reported medication. Most studies show fibrinolytic administration may be successful after a dwell time of 60–120 min, but many patients will require repeat administration. Bleeding is the most common complication of intra-pleural fibrinolysis, albeit rarely (<3%), but individual bleeding risk should be evaluated prior to use [52, 55, 56].

Tunnel tract metastasis is thought to occur from migration of tumor cells from the pleural



**Fig. 31.13** Tunnel tract infection

space through the subcutaneous tissue and is an uncommon occurrence seen in less than 5% of patients with IPC [31]. Tract metastasis is most common in patients with mesothelioma but can occur with other malignancies. Diagnosis can be obtained with a biopsy and localized radiation is typically the treatment [31].

Cellulitis and exit-site infections are the most common IPC-related infections, but infections in the pleural space are the most worrisome (Fig. 31.13). Pleural space infections are reported to occur in less than 5% of patients and although outcomes are much better than previously reported, they are associated with a mortality rate of 6% and therefore every effort should be made to prevent this complication [57]. Specific management recommendations depend on the underlying infection and patient-related factors, but removal of an IPC is often not required [52, 53]. Outpatient antibiotics adequately targeting skin pathogens are generally sufficient to treat cellulitis, exit site, and tunnel tract infections. The suggested duration of treatment ranges from seven to ten days, but longer courses of treatment may be necessary for tunnel tract infections [53]. Fluid cultures should be obtained when a pleural space infection is suspected [52], but further research is necessary to determine the optimal method for obtaining the fluid, either from the IPC or a separate thoracentesis procedure. Broad spectrum antimicrobial therapy that includes coverage of anaerobes, *Staphylococcus aureus*, and gram-negative organisms should be started initially and then narrowed based on culture results and patient clinical status. As with any pleural space infection, continuous pleural drainage is optimal, and intra-pleural fibrinolyt-

ics and DNase can be used in patients with sub-optimal drainage or significant loculations [52, 53]. Lung decortication or other surgical intervention is typically reserved for those patients not improving with more conservative measures and is not recommended as first-line therapy [53]. IPC removal and placement of a chest tube may be necessary when a tunnel tract infection is complicating a pleural space infection, if pleural drainage is poor despite fibrinolytic administration and if there is no significant clinical improvement despite antibiotics and continuous IPC drainage [52, 53].

Patients treated with chemotherapy do not have a significantly increased risk of IPC-related infectious complications based on current evidence; therefore, IPC placement is recommended for palliation of symptoms in this patient population [52, 58].

---

## Competency and Training

Competency with chest tube insertion is important in maximizing procedural success and patient outcomes while minimizing potential complications. According to the BTS guidelines published in 2010, required preprocedural training for chest tube insertion involves a “combination of didactic lectures, simulated practice, and supervised practice” until the achievement of competency [5]. The ACCP suggests 10 procedures are required to achieve basic competency with an additional five procedures each year to maintain [59]. Despite the small number of required procedures recommended to achieve competency, only 30% of pulmonary medicine fellowship programs in the US and Canada meet all the necessary procedural requirements [60, 61]. An interventional pulmonary (IP) fellowship may help to fill training gaps and provide additional advanced skills not required by the European Respiratory Society, American College of Chest Physicians and American Thoracic Society guidelines for general pulmonary training. According to guidelines published by the multi-society interventional pulmonology fel-



lowship accreditation committee, a minimum of 20 image-guided thoracoscopy tubes and 20 IPC placement procedures must be performed to successfully complete an IP fellowship [62]. The number of procedures is used as a general outline to standardize training across various IP fellowship training programs; however, it is not the sole criterion that guarantees competency achievement.

Trainees enter fellowship with various skillsets and learning styles, which requires an individualized approach to training and competency assessment. Due to the need for a personalized approach, the traditional apprenticeship training, where trainees are expected to imitate skills of experienced operators on live patients, is no longer acceptable in the early stages of training. Studies have shown that the participation of trainees in procedures not only increases procedure time and the number of sedative medications used, but may also result in a higher rate of complications [63]. One proposed methodology for advanced procedural training recommends organization into five stages: (1) theoretical lectures, recorded videos, and manuals with an emphasis on problem-based learning, (2) practical application using low and high-fidelity simulators, cadavers, and animal models, (3) supervised sessions on patients, (4) assessment of competency using various assessment tools, and (5) continuous professional development and maintenance of skills [64].

There are various approaches to qualitative competency assessment, including case-based questionnaires, evaluation of appropriate decision-making, management of complications, and assessment of maneuvers on mannequins and patients under direct supervision. TUBE-iCOMPT and UGSTAT have been developed in line with BTS guidelines and international consensus. TUBE-iCOMPT (Chest Tube Insertion Competency Test) is a validated chest tube insertion procedural assessment tool consisting of five assessment domains, four of which are applicable to evaluate Seldinger technique and four to assess knowledge of blunt dissection method, with a final score of 100 points [65, 66]. UGSTAT is the

Ultrasound-Guided Thoracentesis Skills and Tasks Assessment Test, which consists of 11-domains with a 100-point scoring system and serves as a validated tool for assessing the adequacy of thoracic ultrasound [67]. Finally, the Tool for Assessing Chest Tube Insertion Competency (TACTIC) was developed and validated to assess pediatric emergency medicine practitioner's skills and consists of 20 items with a 40-point scoring system.

We recommend an individualized and multifaceted approach to procedural training and competency assessment first utilizing all available study and simulation materials followed by supervised practice. It is recommended that trainees progress from observing to assisting and later to placing chest tubes under supervision. Continued assessment of procedural skills and outcome analyses during fellowship is essential to ensure trainee competency and confidence prior to graduation and the start of independent practice.

---

## Summary

Chest tubes are utilized for the treatment of a multitude of pleural diseases with increasing data to support the use of small-bore chest tubes over larger ones for many of these conditions. Indwelling pleural catheters are being placed with increasing frequency for both malignant and non-malignant pleural effusions and can contribute to significant improvement in patient symptoms. An ever-expanding amount of research pertaining to IPC use is now available including guidelines and expert panel recommendations for post-insertion management and treatment of complications. Available data is expected to increase over time and remaining educated regarding this new information is crucial for optimal patient outcomes. Patient safety is of utmost importance when performing any procedure, including chest tube and IPC placement; therefore, validated tools and guidelines have been established to standardize training and competency in pleural procedures.

## References

- Hippocrates. Potter P t. Hippocrates, vol. VI. Cambridge (MA): Harvard University Press; 1988. p. 39–43.
- Churchill ED. Wound surgery encounters dilemma. *J Thorac Surg.* 1958;35:279–90.
- Playfair GE. Case of empyema treated by aspiration and subsequently by drainage: recovery. *Br Med J.* 1875;1:45.
- Maloney JVJ. The conservative management of traumatic hemothorax. *Am J Surg.* 1957;93:533–9.
- Havelock T, Teoh R, Laws D, Gleeson F, Group BTSPDG. Pleural procedures and thoracic ultrasound: British Thoracic Society pleural disease guideline 2010. *Thorax.* 2010;65 Suppl 2:61–76.
- Corcoran JP, Psallidas I, Wrightson JM, Hallifax RJ, Rahman NM. Pleural procedural complications: prevention and management. *J Thorac Dis.* 2015;7(6):1058–67.
- Collop NA, Kim S, Sahn SA. Analysis of tube thoracostomy performed by pulmonologists at a teaching hospital. *Chest.* 1997;112(3):709–13.
- Baumann MH, Strange C, Heffner JE, Light RW, Kirby TJ, Klein J, et al. Management of spontaneous pneumothorax: an American College of Chest Physicians Delphi Consensus Statement. *Chest.* 2001;119(2):590–602.
- Light RW. Pneumothorax. In: Light RW, editor. *Pleural diseases.* 6th ed. Philadelphia; 2013.
- Hallifax RJ, McKeown E, Sivakumar P, Fairbairn I, Peter C, Leitch A, et al. Ambulatory management of primary spontaneous pneumothorax: an open-label, randomised controlled trial. *Lancet.* 2020;396(10243):39–49.
- Thethi I, Ramirez S, Shen W, Zhang D, Mohamad M, Kaphle U, et al. Effect of chest tube size on pleurodesis efficacy in malignant pleural effusion: a meta-analysis of randomized controlled trials. *J Thorac Dis.* 2018;10(1):355–62.
- Kheir F, Thakore S, Mehta H, Jantz M, Parikh M, Chee A, et al. Intrapleural fibrinolytic therapy versus early Medical thoracoscopy for treatment of pleural infection. Randomized controlled clinical trial. *Ann Am Thorac Soc.* 2020;17(8):958–64.
- Bauman ZM, Kulvatunyou N, Joseph B, Gries L, O’Keeffe T, Tang AL, et al. Randomized clinical trial of 14-French (14F) pigtail catheters versus 28-32F chest tubes in the Management of Patients with traumatic hemothorax and hemopneumothorax. *World J Surg.* 2021;45(3):880–6.
- Bauman ZM, Kulvatunyou N, Joseph B, Jain A, Friese RS, Gries L, et al. A prospective study of 7-year experience using percutaneous 14-French pigtail catheters for traumatic hemothorax/hemopneumothorax at a Level-1 trauma center: size still does not matter. *World J Surg.* 2018;42(1):107–13.
- Roberts ME, Neville E, Berrisford RG, Antunes G, Ali NJ, Group BTSPDG. Management of a malignant pleural effusion: British Thoracic Society pleural disease guideline 2010. *Thorax.* 2010;65 Suppl 2:32–40.
- Antony V, Loddenkemper R, Astoul P, Boutin C, Goldstraw P, Hott J, et al. Management of Malignant Pleural Effusions. *Am J Respir Crit Care Med.* 2000;162:1987–2001.
- Bibby AC, Dorn P, Psallidas I, Porcel JM, Janssen J, Froudarakis M, et al. ERS/EACTS statement on the management of malignant pleural effusions. *Eur Respir J.* 2018;52(1):1800349.
- Rahman NM, Pepperell J, Rehal S, Saba T, Tang A, Ali N, et al. Effect of opioids vs NSAIDs and larger vs smaller chest tube size on pain control and pleurodesis efficacy among patients with malignant pleural effusion: the TIME1 randomized clinical trial. *JAMA.* 2015;314(24):2641–53.
- Chang SH, Kang YN, Chiu HY, Chiu YH. A systematic review and meta-analysis comparing pigtail catheter and chest tube as the initial treatment for pneumothorax. *Chest.* 2018;153(5):1201–12.
- Rahman NM, Maskell NA, Davies CW, Hedley EL, Nunn AJ, Gleeson FV, et al. The relationship between chest tube size and clinical outcome in pleural infection. *Chest.* 2010;137(3):536–43.
- Anegg U, Lindenmann J, Matzi V, Mujkic D, Maier A, Fritz L, et al. AIRFIX: the first digital postoperative chest tube airflowmetry--a novel method to quantify air leakage after lung resection. *Eur J Cardiothorac Surg.* 2006;29(6):867–72.
- Dernevik L, Belboul A, Radberg G. Initial experience with the world’s first digital drainage system. The benefits of recording air leaks with graphic representation. *Eur J Cardiothorac Surg.* 2007;31(2):209–13.
- Wang H, Hu W, Ma L, Zhang Y. Digital chest drainage system versus traditional chest drainage system after pulmonary resection: a systematic review and meta-analysis. *J Cardiothorac Surg.* 2019;14(1):13.
- Light RW. Pleural effusions. *Med Clin North Am.* 2011;95(6):1055–70.
- Koegelenberg CFN, Shaw JA, Irusen EM, Lee YCG. Contemporary best practice in the management of malignant pleural effusion. *Ther Adv Respir Dis.* 2018;12:1753466618785098.
- Feller-Kopman DJ, Reddy CB, DeCamp MM, Diekemper RL, Gould MK, Henry T, et al. Management of Malignant Pleural Effusions. An official ATS/STS/STR clinical practice guideline. *Am J Respir Crit Care Med.* 2018;198(7):839–49.
- Ost DE, Niu J, Zhao H, Grosu HB, Giordano SH. Quality gaps and comparative effectiveness of management strategies for recurrent malignant pleural effusions. *Chest.* 2018;153(2):438–52.
- Medical M Aspira drainage system clinician product brochure. 2019. Available from: <https://www.merit.com/products/home/documents/>.
- Patient Information - PleurX System: BD; 2021. Available from: <https://www.bd.com/en-us/offerings/capabilities/interventional-specialties/peritoneal-and->

- [pleural-drainage/about-the-pleurx-drainage-system/patient-information-pleurx-system](#)
30. plc. RM. IPC Indwelling Drainage Catheters - Pleural & Peritoneal 2011–2019. Available from: <https://sales.rocketmedical.com/products/indwelling-drainage-catheters>
  31. Chalhoub M, Saqib A, Castellano M. Indwelling pleural catheters: complications and management strategies. *J Thorac Dis.* 2018;10(7):4659–66.
  32. Ost DE, Jimenez CA, Lei X, Cantor SB, Grosu HB, Lazarus DR, et al. Quality-adjusted survival following treatment of malignant pleural effusions with indwelling pleural catheters. *Chest.* 2014;145(6):1347–56.
  33. Muruganandan S, Azzopardi M, Fitzgerald DB, Shrestha R, Kwan BCH, Lam DCL, et al. Aggressive versus symptom-guided drainage of malignant pleural effusion via indwelling pleural catheters (AMPLE-2): an open-label randomised trial. *Lancet Respir Med.* 2018;6(9):671–80.
  34. Wahidi MM, Reddy C, Yarmus L, Feller-Kopman D, Musani A, Shepherd RW, et al. Randomized trial of pleural fluid drainage frequency in patients with malignant pleural effusions. The ASAP trial. *Am J Respir Crit Care Med.* 2017;195(8):1050–7.
  35. Davies HE, Mishra EK, Kahan BC, Wrightson JM, Stanton AE, Guhan A, et al. Effect of an indwelling pleural catheter vs chest tube and talc pleurodesis for relieving dyspnea in patients with malignant pleural effusion: the TIME2 randomized controlled trial. *JAMA.* 2012;307(22):2383–9.
  36. Thomas R, Fysh ETH, Smith NA, Lee P, Kwan BCH, Yap E, et al. Effect of an indwelling pleural catheter vs talc pleurodesis on hospitalization days in patients with malignant pleural effusion: the AMPLE randomized clinical trial. *JAMA.* 2017;318(19):1903–12.
  37. Boshuizen RC, Vd Noort V, Burgers JA, Herder GJM, Hashemi SMS, Hiltermann TJN, et al. A randomized controlled trial comparing indwelling pleural catheters with talc pleurodesis (NVALT-14). *Lung Cancer.* 2017;108:9–14.
  38. Putnam JB, Light RW, Rodriguez RM, Ponn R, Olak J, Pollak JS, et al. A randomized comparison of indwelling pleural catheter and doxycycline pleurodesis in the management of malignant pleural effusions. *Cancer.* 1999;86:1992–9.
  39. Pien GW, Gant MJ, Washam CL, Sterman DH. Use of an implantable pleural catheter for trapped lung syndrome in patients with malignant pleural effusion. *Chest.* 2001;119(6):1641–6.
  40. DeBiasi EM, Pisani MA, Murphy TE, Araujo K, Kookoolis A, Argento AC, et al. Mortality among patients with pleural effusion undergoing thoracentesis. *Eur Respir J.* 2015;46(2):495–502.
  41. Walker SP, Morley AJ, Staddon L, De Fonseca D, Arnold DT, Medford ARL, et al. Nonmalignant pleural effusions: a prospective study of 356 consecutive unselected patients. *Chest.* 2017;151(5):1099–105.
  42. Shojaaee S, Rahman N, Haas K, Kern R, Leise M, Alnijoumi M, et al. Indwelling tunneled pleural catheters for refractory hepatic hydrothorax in patients with cirrhosis: a multicenter study. *Chest.* 2019;155(3):546–53.
  43. Bramley K, DeBiasi E, Puchalski J. Indwelling pleural catheter placement for nonmalignant pleural effusions. *Semin Respir Crit Care Med.* 2018;39(6):713–9.
  44. Aboudara M, Maldonado F. Indwelling pleural catheters for benign pleural effusions: what is the evidence? *Curr Opin Pulm Med.* 2019;25(4):369–73.
  45. Majid A, Kheir F, Fashjian M, Chatterji S, Fernandez-Bussy S, Ochoa S, et al. Tunneled pleural catheter placement with and without talc Poudrage for treatment of pleural effusions due to congestive heart failure. *Ann Am Thorac Soc.* 2016;13(2):212–6.
  46. Potechin R, Amjadi K, Srour N. Indwelling pleural catheters for pleural effusions associated with end-stage renal disease: a case series. *Ther Adv Respir Dis.* 2015;9(1):22–7.
  47. Jimenez CA, Mhatre AD, Martinez CH, Eapen GA, Onn A, Morice RC. Use of an indwelling pleural catheter for the management of recurrent chylothorax in patients with cancer. *Chest.* 2007;132(5):1584–90.
  48. DePew ZS, Iqbal S, Mullon JJ, Nichols FC, Maldonado F. The role for tunneled indwelling pleural catheters in patients with persistent benign chylothorax. *Am J Med Sci.* 2013;346(5):349–52.
  49. Shafiq M, Simkovich S, Hossen S, Feller-Kopman DJ. Indwelling pleural catheter drainage strategy for malignant effusion: a cost-effectiveness analysis. *Ann Am Thorac Soc.* 2020;17(6):746–53.
  50. Bhatnagar R, Keenan EK, Morley AJ, Kahan BC, Stanton AE, Haris M, et al. Outpatient talc administration by indwelling pleural catheter for malignant effusion. *N Engl J Med.* 2018;378(14):1313–22.
  51. Bhatnagar R, Zahan-Evans N, Kearney C, Edey AJ, Staddon LJ, Tremblay A, et al. A novel drug-eluting indwelling pleural catheter for the management of malignant effusions. *Am J Respir Crit Care Med.* 2018;197(1):136–8.
  52. Miller RJ, Chrissian AA, Lee YCG, Rahman NM, Wahidi MM, Tremblay A, et al. AABIP evidence-informed guidelines and expert panel report for the Management of Indwelling Pleural Catheters. *J Bronchology Interv Pulmonol.* 2020;27(4):229–45.
  53. Gilbert CR, Wahidi MM, Light RW, Rivera MP, Sterman DH, Thomas R, et al. Management of Indwelling Tunneled Pleural Catheters: a modified Delphi consensus statement. *Chest.* 2020;158(5):2221–8.
  54. Fortin M, Tremblay A. Pleural controversies: indwelling pleural catheter vs. pleurodesis for malignant pleural effusions. *J Thorac Dis.* 2015;7(6):1052–7.
  55. Thomas R, Piccolo F, Miller D, MacEachern PR, Chee AC, Huseini T, et al. Intrapleural fibrinolysis for the treatment of indwelling pleural catheter-related symptomatic loculations: a multicenter observational study. *Chest.* 2015;148(3):746–51.
  56. Vial MR, Ost DE, Eapen GA, Jimenez CA, Morice RC, O'Connell O, et al. Intrapleural fibrinolytic therapy in patients with nondraining indwelling

- pleural catheters. *J Bronchology Interv Pulmonol*. 2016;23(2):98–105.
57. Fysh ETH, Tremblay A, Feller-Kopman D, Mishra EK, Slade M, Garske L, et al. Clinical outcomes of indwelling pleural catheter-related pleural infections: an international multicenter study. *Chest*. 2013;144(5):1597–602.
  58. Mekhaieel E, Kashyap R, Mullon J, Maldonado F. Infections associated with Tunnelled indwelling pleural catheters in patients undergoing chemotherapy. *J Bronchology Interv Pulmonol*. 2013;20:299–303.
  59. Ernst A, Silvestri GA, Johnstone D. American College of Chest P. Interventional pulmonary procedures: guidelines from the American College of Chest Physicians. *Chest*. 2003;123(5):1693–717.
  60. Pastis N, Nietert P, Silvestri G. Variation in training for interventional pulmonary procedures among US pulmonary/critical care fellowships: a survey of fellowship directors. *Chest*. 2005;127:1614–21.
  61. Stather D, Jarand J, Silvestri G. An evaluation of procedural training in Canadian respirology fellowship programs: program directors' and fellows' perspectives. *Can Respir J*. 2009;16:55–9.
  62. Mullon JJ, Burkart KM, Silvestri G, Hogarth DK, Almeida F, Berkowitz D, et al. Interventional pulmonology fellowship accreditation standards: executive summary of the multisociety interventional pulmonology fellowship accreditation committee. *Chest*. 2017;151(5):1114–21.
  63. Stather DR, MacEachern P, Chee A, Dumoulin E, Tremblay A. Trainee impact on procedural complications: an analysis of 967 consecutive flexible bronchoscopy procedures in an interventional pulmonology practice. *Respiration*. 2013;85(5):422–8.
  64. Fielding DI, Maldonado F, Murgu S. Achieving competency in bronchoscopy: challenges and opportunities. *Respirology*. 2014;19(4):472–82.
  65. Salamonsen M, McGrath D, Steiler G, Ware R, Colt H, Fielding D. A new instrument to assess physician skill at thoracic ultrasound, including pleural effusion markup. *Chest*. 2013;144(3):930–4.
  66. Salamonsen MR, Bashirzadeh F, Ritchie AJ, Ward HE, Fielding DI. A new instrument to assess physician skill at chest tube insertion: the TUBE-iCOMPT. *Thorax*. 2015;70(2):186–8.
  67. Williamson JP, Twaddell SH, Lee YC, Salamonsen M, Hew M, Fielding D, et al. Thoracic ultrasound recognition of competence: a position paper of the Thoracic Society of Australia and new Zealand. *Respirology*. 2017;22(2):405–8.



## Introduction and Classification

Parapneumonic effusions can be classified as either uncomplicated or complicated. Uncomplicated, or simple, parapneumonic effusions represent effusions devoid of infection, derangements of fluid chemistry, or loculation that typically resolve with appropriate antibiotic care. Complicated parapneumonic effusions, however, are characterized by often identifiable infection, derangements in pleural chemistry, and the development of loculations with persistent clinical or biochemical signs of sepsis [1]. Finally, empyema is defined by the presence of purulence in the pleural space.

While the primary cause of empyema remains parapneumonic effusions, other etiologies include bronchogenic carcinoma, esophageal rupture, infected congenital cysts of the airway and esophagus, mediastinitis, and blunt or penetrating trauma [2]. Post-operative empyema is a distinct entity, with frequency decreasing to 1% after 2000, with a progressively decreasing mortality currently estimated at 11.6% [3]. Primary empyema, defined as a direct invasion

of the pleural space with bacteria, often manifests as bacterial translocation from the oropharynx or via hematogenous spread [4]. Similar to the incidence of parapneumonic effusions, the incidence of primary empyema seems to be increasing [5].

In addition to its substantial mortality, upwards of 20–30% of patients with empyema will require surgical drainage of the pleural space [2]. Citing the significant burden surgery can represent, Steven Sahn and Richard Light in 1989 popularized the now well-known phrase, “The sun should never set on a parapneumonic effusion.” [6] They argued an aggressive posture with regard to pleural fluid sampling and drainage, preferring, “Too many chest tubes placed than obtain a result requiring thoracotomy, embryectomy, and decortication if drainage had not been done or was delayed.” [6] Recognition of failure antibiotic therapy in patients with pneumonia and persistent septic signs should prompt the investigation for a parapneumonic effusion. Delays in pleural drainage, misdiagnosis, inappropriate antibiotic selection, and chest tube mispositioning are all known risk factors for treatment failure [1]. As such, The British Thoracic Society in 2010 published guidelines codifying the need for early consultation by a chest physician or thoracic surgeon in all patients undergoing evaluation for and drainage of a pleural infection [1].

To aid in the appropriate selection of patients requiring pleural drainage, the American College

---

D. Shore (✉) · J. W. Toth  
Division of Pulmonary, Allergy, and Critical Care  
Medicine, Department of Medicine, Penn State  
Milton S. Hershey Medical Center,  
Hershey, PA, USA  
e-mail: [dshore@pennstatehealth.psu.edu](mailto:dshore@pennstatehealth.psu.edu);  
[jtoth@pennstatehealth.psu.edu](mailto:jtoth@pennstatehealth.psu.edu)



of Chest Physicians published a consensus statement in 2000 classifying patients with parapneumonic effusions into categories based off risk for poor outcomes. Referred to as the A, B, C classification, parapneumonic effusions were characterized based on three variables: anatomic characteristics, bacteriology, and chemistry [7]. The anatomy is based on the size of the effusion, whether it is free flowing, and whether the parietal pleural is thickened. Bacteriology is based off positive or negative gram stain and culture, or frank purulence seen on sampling. Finally, chemistry relies primarily on pH measurement greater or less than 7.2 (alternatively, a pleural fluid glucose greater or less than 60 mg/dL). Based on these three characteristics, a parapneumonic effusion can be characterized into one of four categories: very low (category 1), low (category 2), moderate (category 3), and high (category 4, with categories 3 and 4 requiring drainage).

---

## Historical Perspectives

From around 3000 BCCE, empyema was first described in the Edwin Smith Surgical Papyrus, a collection of trauma and medical cases classified by a physician who is thought to be Imhotep, the chief vizier of Pharaoh Zoser [1, 8, 9]. Later, Hippocrates described “peripneumonia,” or empyema, in much greater detail. In addition to suggesting an etiology where, “Affluent pus runs from the head to the lung,” [10], he is often quoted describing its morbidity, where if, “Persons who become affected with empyema after pleurisy, if they get clear of it in 14 days from the breaking of it, escape the disease; but if not, it passes into phthisis.” [11] Hippocrates even goes as far as describing methodology for enteral feedings, thoracotomy, and pleural irrigation with instillation of antiseptics, a combination of water and olive oil, for 12 h in pursuit of empyema resolution [10].

Prior to 1918, the treatment for empyema was remarkably similar to what was first described by Hippocrates thousands of years prior. Updates in management focused on early surgical treatment

via thoracotomy, extensive decortication, and marsupialization of the pleural space to allow continued external drainage (Eloesser flap) [12]. Mortality for this approach was unacceptably high, ranging from 30.2% to 84%, and after facing an epidemic Group A streptococcus pneumonia and resultant empyema in 1917, The United States Army formed The Empyema Commission [12, 13]. Under Major Evans Graham, the Commission standardized several interventions, including early drainage via tube thoracostomy, repeated sterilizing lavage of the pleural space, and a heavy emphasis on nutrition and physical therapy, dropping mortality at Camp Lee from 40% to 4.3% [12, 13]. These interventions, first widely implemented during the Spanish Influenza of 1918, remain the framework of modern treatment of empyema.

---

## Incidence

In 2010, the British Thoracic Society described a combined incidence of parapneumonic effusion and empyema of 80,000 in the United States and United Kingdom [1]. This represents a progressive increase in the incidence of empyema over the past 20 years. In 2008, Carlos Grijalva et al. used national hospitalization data to compare incidence of parapneumonic effusion and empyema admissions between 1996 and 2008. He found a start increase, with parapneumonic empyema incidence increasing to 5.98 per 100,000 peoples in 2008 compared to 3.04 in 1996, nearly a twofold increase [14]. The greatest burden was seen in adults greater than 65 years of age, with an annual incidence of 9.94 per 100,000. This increase in parapneumonic empyema hospitalizations was seen in across all age groups, with a 1.9-fold increase seen in children <18 years of age, 1.8-fold increase in the age group 18–39, and 1.7-fold increase in adults  $\geq$  than 65 years of age. While the in-hospital case fatality ratio for empyema hospitalization did decrease from 8.0% to 7.2%, the overall rate of fatal empyema-associated hospitalizations increased by 1.8-fold from 0.24 per 100,000 to 0.43 per 100,000.

## Epidemiology

Empyema has been described as a disease with a bimodal age distribution, with peaks in both childhood and in older adults [4]. Per Grijalva, however the greatest burden of disease was seen in ages 40–64 years of age, followed by those  $\geq$  than 65 years of age [14]. Men are affected twice as often as women [14–16]. Risk factors associated with empyema include cardiac disease, chronic lung disease, diabetes, immunosuppression including corticosteroid use, gastro-esophageal reflux, excessive alcohol intake, and intravenous (IV) drug use [1, 16].

Parapneumonic effusion and empyema increase the mortality compared to that just pneumonia. Compared to patients presenting to the emergency department with pneumonia, patients with pneumonia and concomitant simple parapneumonic effusion were more likely to be admitted, have twice the length of stay, and a higher 30-day mortality with an odds ratio of 2.6. Furthermore, typical pneumonia severity guidelines tend to underestimate mortality seen in patients with pneumonia and simple effusions, with eCURB65 in one study predicting 7% mortality compared to 14% actual mortality. Morbidity in patients with empyema is also high, with the average length of stay ranging from 15 to 30 days [14, 15].

Overall mortality associated with empyema is high, with Rahman et al. in MIST-2 finding a 3-month mortality of 8.3%, and a 12-month mortality of 12.4% [15]. Mortality can be influenced by a variety of factors, including infective etiology, age, and nutritional status [14, 17]. Grijalva et al. found patients with staphylococcal-related empyema had both longer hospitalization and the highest in-hospital case fatality ratio [14]. In a secondary analysis of First Multicenter Intrapleural Sepsis Trial (MIST-1), Maskell et al. confirmed this finding, further elucidating a significant difference in mortality in empyema associated with community acquired pneumonia (CAP) versus hospital acquired pneumonia (HAP), with a 1-year mortality of 17% in CAP and 47% in HAP (relative risk 4.24) [18]. This was largely influenced, just as Grijalva described,

by bacteriology; HAP-related empyema was associated with *S. aureus* and gram-negative bacteria (largely Enterobacteriaceae), with a 44% and 45% 1-year mortality, respectively [18]. Maskell et al. further elucidated that patients with streptococcal infection generally have the best prognosis, with 83% 1-year survival, while those with staphylococcal, enterobacterial, and mixed aerobic infections had the worst, with a 1-year survival of only 45% [18].

Age is also strongly associated with mortality. While identifying risk factors for poor outcome, Rahman et al. identified that patients older than 70, compared to those <50 years of age, had an odds ratio of 25.63 for mortality [17]. When compounded with like staphylococcal empyema for example, being older than 65 cause a precipitous increase in in-hospital case fatality from an average 7.2 across all age groups and causes of infection of to 21.8% [14].

---

## Pathogenesis

Parapneumonic effusions and empyema are exudative with a predominance of neutrophils [19]. Thus, initial sampling, usually by thoracentesis, will determine the exudative or transudative nature of the effusion. In the 1970s, Light established differential criteria based on levels of lactate dehydrogenase (LDH) and protein found in pleural fluid compared with the patient's serum. Light's criteria define an exudate as having any one of the following characteristics: (1) pleural fluid protein to serum protein ratio greater than 0.5; (2) pleural fluid LDH to serum LDH ratio greater than 0.6; (3) pleural fluid LDH greater than two thirds of the upper limit of normal serum LDH [20].

Parapneumonic effusions progress through three stages within a continuous spectrum. The first, or *exudative*, stage is characterized by fluid with a relatively low LDH, normal glucose, and normal pH. The pleural fluid at this stage is sterile, and microbiologic studies are negative. This accumulation of sterile fluid is caused by a rapid outpouring of fluid into the pleural space due to both increased pulmonary interstitial fluid and

increased permeability of the capillaries in the pleural space [1]. Proinflammatory cytokines including tumor necrosis alpha (TNF- $\alpha$ ) and interleukin 8 (IL-8) drive this increased capillary vascular permeability [1]. This stage is ideally treated by antibiotics, drainage, and observation since the prognosis is favorable at this point. When untreated or inappropriately treated, the second, or *fibrinopurulent*, stage occurs. Characterized by bacterial invasion, formation of loculations, and derangements of pleural chemistry because of an inflammatory milieu, positive bacterial studies, glucose level below 60 mg/dL, pH less than 7.2, and high LDH characterize the fluid in this stage. There is progressive loculation due to increased fibrin deposition, cellular debris, and white blood cells with the ultimate formation of limiting fibrin membranes. At this stage, drainage is indicated, and will become more difficult as more loculations form. If the effusion is allowed to persist, the third, or *organization*, stage occurs as fibroblasts grow into the exudative fibrin sheet coating the visceral and parietal pleura. This process results in the formation of an inelastic membrane or pleural “peel” which encases the lung and renders it functionless. At this point, surgery with decortication is indicated. While the rate of progression through these stages can be variable, it has been estimated that it can take 2–3 weeks to progress from the fibrinopurulent to the organizing stage [21]. While most parapneumonic effusions progress through all three stages, primary empyema can proceed straight to the fibrinopurulent stage.

---

## Clinical Presentation

The clinical features of parapneumonic effusion and empyema are poorly distinct from that of pneumonia. As initially described by Hippocrates, patients typically present as, “The fever was acute, and there were pains on either side, or in both, and if cough was present, and the sputa expectorated had a blood or vivid colour, or likewise was thin, frothy, and florid.” [10] As such, pneumonia both with or without a parapneumonic effusion present as a constellation of fever,

dyspnea, pleuritic pain, productive cough, and leukocytosis. Persistent clinical and biochemical signs of sepsis despite several days of antibiotics, however, should prompt the investigation of a parapneumonic effusion. The median duration of symptoms prior to presentation is 2 weeks; however, anaerobic infections can present more insidiously [2]. Symptoms can be acute or chronic, with both elderly patients and those with anaerobic infections presenting with anemia, fatigue, and failure to thrive [2, 22].

---

## Radiologic Evaluation

The initial radiologic assessment should include the standard posterior-anterior and lateral projections of a chest radiograph. When free-flowing, pleural fluid collects in the most dependent area of the involved hemithorax: initially the costophrenic angle, then laterally, anteriorly, and finally apically. As much as 100 mL of pleural fluid may be undetectable via plain chest radiography. Between 175 to 500 mL is needed to blunt the lateral costophrenic angle. The lateral decubitus views can better define pleural effusions. The well-performed decubitus view can detect small volumes of fluid, reveal sub-pulmonic collections or pseudotumors, and identify loculations. The ubiquitous posterior-anterior and lateral chest radiograph can separate the broad air-fluid level of an empyema from the more spherical fluid collection surrounded by lung parenchyma characteristic of lung abscess.

Ultrasonography is widely available and frequently employed after a suspicious chest radiograph. Ultrasound is rapid and portable, but is operator dependent. This technique can localize small volume of fluid and define loculations; identify and characterize pleural peels; and define solid lesions such as pleural or parenchymal tumors. Using a 3.5 MHz or 5.0 MHz transducer and an intercostal acoustic window, an empyema is characterized as having acoustic homogeneity. Complex or advanced empyema has debris and floating fronds. An organized empyema has an echogenic pleural peel, and the lung appears immobile or entrapped. Diagnostic thoracentesis,

catheter drainage, or tube thoracostomy can be guided by ultrasound.

Computed tomography (CT) has become the most reliable radiographic technique used to characterize pleural effusions. Intravenous contrast material can define pulmonary vascular anatomy and enhance the parietal pleura. Parapneumonic effusions and empyema have abnormally high Hounsfield units (−20 HU) compared to transudative effusions (−100 HU). Differentiating empyema, lung abscess, transudative pleural fluid, and subdiaphragmatic fluid (ascites) is often difficult without CT. Lung abscesses generally appear as air-fluid spherical lesions forming acute angles with the lung parenchyma. The lung appears destroyed rather than compressed. There is an abrupt cutoff of vessels and bronchi. Empyema appears laterally, pushing or compressing adjacent lung parenchyma, vessels, and bronchi. The shape is not uniform, and angles with the pleura are acute. Lateral lung abscesses or abscesses in the basilar segments of the lung near the diaphragm may be difficult to distinguish from empyema.

---

## Biochemical Analysis

In health, pleural fluid is typically low in volume (<1 mL), consisting of a small number of cells including mesothelial cells, macrophages, and lymphocytes [1]. Pleural fluid tends to contain more bicarbonate compared to serum, typically with a pH of 7.6, with lower levels of sodium than the serum, and similar levels of glucose [1]. As described in the section on pathophysiology, the first changes seen in simple, uncomplicated parapneumonic effusions reflect the pathophysiologic changes seen in the exudative phase. The fluid rapidly increases in volume and develops a neutrophilic exudate. Ancillary testing at this stage can, for the patient with recent retching and rapidly progressing pleural fluid, also include fluid amylase to evaluate for potential esophageal rupture [1].

The typical biochemical evaluation to distinguish simple, uncomplicated parapneumonic effusion with sterile pleural fluid from compli-

cated parapneumonic effusion include pleural pH, pleural glucose, and pleural LDH. The most sensitive pleural fluid measurement that indicates a parapneumonic effusion is complicated and should be drained is the pH, which drops to 7.20 before the glucose drops or LDH rises to greater than three times the upper limit of normal [19, 23]. Neutrophil phagocytosis and bacterial death fuel an inflammatory milieu which results in increased production of pleural lactic acid and carbon dioxide production, accompanied later with increased glucose metabolism, and as these leukocytes die, a production in pleural LDH. Per both British Thoracic Society and American Association for Thoracic Surgery guidelines, therefore, complicated parapneumonic effusions are defined by a pleural pH < 7.20, glucose <40 mg/dL (or 2.2 mmol/L), and LDH > 1000 IU/L [1, 2].

Despite being the earliest and most sensitive indication for complicated pleural effusion, pH measurement can also be fraught with error. Besides needing to be evaluated in a blood-gas analyzer as opposed to pH paper or a pH indicator strip, pleural loculations, residual lidocaine or heparin in the pleural space, residual air, and delays in time to analysis have all been found to affect the diagnostic accuracy of pleural pH [24, 25]. Pleural glucose, the second most-sensitive biochemical measure (receiver operating characteristic with area under the curve (AUC) of 0.84 compared to 0.92 of pleural pH), is not affected by measurement technique and represents a reasonable alternative for pleural fluid testing.

To eliminate some of this measurement bias and time to results, several studies have measured the efficacy of point-of-care (POC) pleural fluid testing at the bedside. In 2000, Kohn et al. demonstrated agreement between tabletop blood-gas analyzers with laboratory evaluation, with an absolute difference of 0.024 U [26]. In a similar vein, to evaluate other POC-systems, Abdo et al. evaluated the use of bedside POC pleural glucose via ACCU-CHEK glucometers, finding agreement between lab-measured and POC pleural glucose, particularly for values <80 mg/dL, and earlier diagnosis by nearly 2 h, however, with a

mean difference between lab-measured and POC glucose of 14.8 mg/dL [27].

Besides pleural pH, glucose, and LDH, other biomarkers have been evaluated or potential diagnostic utility. Inflammatory cytokines (TNF- $\alpha$ , IL-8, IL-16, and IL-1B), enzymes (neutrophil elastase, myeloperoxidase, metalloproteinases, lipopolysaccharide binding protein, soluble triggering receptor expressed on myeloid cells-1, STREM-1, and CRP) have all been evaluated, and have yet to outperform traditional criteria [5]. Zou et al. performed a meta-analysis for pleural procalcitonin and CRP, finding while CRP was slightly more specific compared to procalcitonin (77% compared to 70%, respectively), both performed poorly with poor sensitivity (54% and 67%, respectively) [28]. High-throughput proteomics may represent the next phase for identifying pleural fluid biomarkers, with one study using i-TRAQ-based mass spectrometry finding four new potential biomarkers (BP1, NGAL, AZU1, and calprotectin) with excellent sensitivity and specificity [29]. BP1, a neutrophil granule protein with antimicrobial properties, had the best sensitivity and specificity of the four (AUC 0.966, sensitivity 97%, specificity 91.4%), and when combined with LDH, an even higher sensitivity of 100%, and may even represent disease severity, with levels in empyema found to be two-fold compared to those in parapneumonic effusions, although prospective validation is still pending.

---

## Microbiology

The standard bacteriology of parapneumonic effusions and empyema were, classically, those reflected in the etiologies of pneumonia. CAP-associated pleural infections were traditionally caused by streptococcal species, most common *S. pneumoniae*, while HAP-associated parapneumonic effusions and empyema were more closely related with staphylococcal and gram-negative bacteria. After all, the pathogen that led to the empyema outbreak of 1917 that led to the original formation of the Empyema Commission was Group A *Streptococcus* [13]. Over time, however,

through the development of pneumococcal vaccines, the bacteriology has started to evolve. When Grijalva reviewed causes of pleural infection from 1996 to 2008, he found stable rates of pneumococcal empyema, but an increase in both streptococcal and staphylococcal related empyema (1.9 and 3.3-fold, respectively) [14]. This has had profound effects on hospitalization and mortality, as staphylococcal-related empyema is associated with longer hospitalization and the highest in-hospital case fatality ratio [14]. Of these causes of empyema, however, 62.4% of empyema in the period from 1996 to 2008 had after routine microbiologic evaluation to have no identified infectious cause [14].

Through better detection techniques and changing patterns of infection and vaccination, the MIST-1 study group also found a shift away from pneumococcal causes of parapneumonic effusion and empyema, shifting instead to the *Streptococcus milleri* group (encompassing *S. constellatus*, *S. intermedius*, and *S. mits*), seen in 23% of community-acquired isolates [16, 18]. In this same community acquired group, they also found anaerobic infection to be remarkably common, found in 20% of the identified causes of pleural infection. Furthermore, with the use of bacterial identification via nucleic acid amplification in addition to routine gram stain and culture reduced unknown causes for infection from 42% to 26% of their total population. Of those patients initially found to be culture negative, 16% had an identified etiology via nucleic acid amplification [18]. Of note, they did find that patients who received antibiotics prior to pleural fluid sampling were more likely to be culture negative (61%). Finally, they found that parapneumonic effusion and empyema infection were microbiologically distinct from that of pneumonia, postulating that bacteria that thrive in the low pH and  $P_{O_2}$  environment of the pleura, like the *S. milleri* group, are more likely to cause pleural infection.

In addition to nucleic acid amplification, several other methodologies have been proven and proposed for better identification of the infective cause. One small study of 57 patients found that inoculation of pleural fluid into blood aerobic and anaerobic BacTec culture bottles in addition



to standard culture increased bacterial isolation from 37.7% to 58.5% [30]. Interestingly, this study also evaluated the incidence of bacteremia in these patients, finding only 11.8% of patients with blood cultures had bacteremia. Another small study, the AUDIO study, evaluated the feasibility of pleural biopsy at the time of tube thoracostomy to increase microbiologic diagnostic yield. Using a 18-gauge Temno cutting needle with a throw of 2 cm, they performed six to eight biopsies at the site with >3 cm of pleural fluid, and found it increased diagnostic yield by 25% [31]. Furthermore, in patients who had previously received antibiotics, they found that pleural biopsy increased diagnostic yield from by 27%. Finally, they trialed nucleic acid amplification of pleural biopsy samples, finding that 16S rRNA amplification and qPCR-based pathogen detection feasible and a potential method for rapid, sensitive microbiological detection, but yet requiring broader investigation.

Finally, uncommon causes of parapneumonic effusion and empyema can be influenced by geography and severe immunocompromised status. Throughout Thailand, for example, up to 22% of patients present with pulmonary melioidosis caused by *Burkholderia pseudomallei*, and places with high infection of *Entamoeba histolytica* can present with pleuropulmonary amoebiasis following rupture of a hepatic collection with transdiaphragmatic spread [1]. Fungal empyema can also be seen, albeit <1% of cases, and is typically from *Candida* species with resultant mortality up to 73% [1].

---

## Non-operative Management

The mainstay of non-operative management of parapneumonic effusions and empyema is the selection of appropriate antibiotics based on local microbiology and antibiotic resistance patterns. The appropriate selection of antibiotics, however, should include broad spectrum antibiotics, as the secondary analysis of MIST-1 demonstrated pleural bacteriology is distinct compared to pneumonia. While 50% of community acquired parapneumonic effusion isolates

were penicillin-sensitive streptococci, the other 50% of isolates were typically penicillin resistant species, including penicillin-resistant staphylococci, Enterobacteriaceae, and anaerobes [18]. Antibiotic selection for hospital acquired parapneumonic effusion and empyema should include consideration for multi-drug resistant organisms as gram negative bacteria are much more common than in community-acquired infection. The length of antibiotic therapy has never been studied in comparative trials, with guidelines recommending anywhere from 2 to 6 weeks pending drainage, clinical improvement (i.e., defervescence), radiological, and laboratory (i.e., CRP) improvement [1, 2].

Appropriate supportive care is also recommended in all patients with parapneumonic effusion and empyema. This traditionally includes nutritional support, as malnutrition is known to correlate with poor outcomes, and deep vein thrombosis prophylaxis [1, 17].

In addition to appropriate selection of antibiotics, there are several options for the management of pleural infection, namely, observation, therapeutic thoracentesis, tube thoracostomy with or without intrapleural instillation of fibrinolytics, pleuroscopy, video-assisted thoracoscopic surgery (VATS) with decortication, thoracotomy with decortication, and open drainage. Non-interventional therapy is rarely effective, and often contraindicated for management of parapneumonic effusions and empyema, particularly those with continued signs of sepsis.

Thoracentesis can be both diagnostic and therapeutic. For simple, *exudative* parapneumonic effusions, thoracentesis, observation, and culture-sensitivity-based antibiotic therapy are appropriate and generally successful. Knowing when to perform diagnostic thoracentesis can be subtle, although most argue for thoracentesis in patients with pleural effusions and persistent signs of sepsis [1]. More objective indications have included patients with free-flowing fluid greater than 1 cm from the inside of the chest wall to the pleural line on a lateral decubitus view, but with the advent of thoracic computed tomography and ultrasound, the recognition of the effusion may be earlier [6]. When the parapneumonic effusion is moderate

and free flowing, the initial “diagnostic” thoracentesis using a vacuum bottle or other drainage system can evacuate the pleural space completely, thereby permitting pulmonary re-expansion. If the lung expands sufficiently and the fluid does not reaccumulate, no further intervention beyond clinical observation is required. If the fluid reaccumulates, repeat thoracentesis can aid diagnostically, but serial therapeutic thoracentesis is less desirable due to patient discomfort from repeated procedures and the possibility of incomplete drainage leading to lung entrapment and the need for surgical intervention, and is no longer recommended in the American Association for Thoracic Surgery consensus guidelines [2]. Finally, for patients with complicated, *fibrinopurulent* or *organized* parapneumonic effusions, however, therapeutic thoracentesis is rarely successful, and it is crucial not to delay drainage, as the fluid will become more difficult to drain as loculations form.

Historically, tube thoracostomy using a large-bore chest tube (32 Fr to 38 Fr) was the initial intervention when the diagnosis of empyema was established. These chest tubes were later converted to an “empyema tube” at 14–21 days when pleural symphysis had occurred, to be slowly withdrawn slowly over several weeks. Patients often were discharged with the tube connected to a drainage bag. When the initial drainage by chest tube was unsuccessful at eliminating all loculations or lung entrapment was present, open surgical drainage with decortication was performed. An empyema tube is less frequently used today due to earlier use of antibiotics, improved diagnosis by CT, image-guided drainage, and earlier use of VATS.

Today, tube thoracostomy is performed by image-guided catheter placement via Seldinger technique with a smaller (8–20 Fr), more flexible catheter. The theory for large-bore chest tubes was that fibrin or the viscosity of pus would impede drainage via small-bore chest tubes, inhibiting timely drainage and increasing treatment failure [32]. While there are no randomized, prospective, comparative trials of small versus large-bore chest tubes, a secondary analysis of MIST-1 dichotomized chest tube size into “small” (<14 Fr) and

“large” (>14 Fr), and analyzed both clinical outcomes and perceived pain. Small-bore chest tubes were found to have no difference in the combined outcome of death or surgery at 1 year, individual outcomes of death or surgery, length of stay, or 3-month forced vital capacity (FVC), forced expiratory volume (FEV1), and chest radiography [33]. Patients with large-bore chest tubes, however, had increased perception of pain during placement and while in-situ. Most guidelines thus recommend tube thoracostomy with small (10–14 Fr)-bore chest tubes, with the BTS Pleural Infection guidelines specifically recommending routine flushing of small-bore chest tubes with 20–30 mL of saline every 6 hours via 3-way stopcock to ensure continued patency [1]. Chronic indwelling pleural catheters have even been suggested, with one small study even describes placement of 15.5 Fr indwelling pleural catheters for the management of patients with chronic pleural infection who are poor surgical candidates [34].

If drainage is incomplete or lung entrapment has occurred, intrapleural fibrinolytic therapy should be considered. This strategy relies on cleavage of intrapleural fibrinous septations to better facilitate chest tube drainage. Observational data had initially suggested that intrapleural administration of fibrinolytic drugs reduced the frequency of failed drainage and subsequent surgery. The debate between which fibrinolytic agent continues, with initial efforts studying streptokinase, and subsequent studies suggesting urokinase was more efficacious and less likely to cause a febrile or allergic reaction. The first large, multi-center trial, prospectively randomized, placebo-controlled trial evaluating the clinical effectiveness of streptokinase, MIST-1, however, demonstrated no difference in death or surgical drainage at 3 months, nor any clinical benefit in length of stay, residual pleural thickness (RPT), or post-recovery spirometry [16]. Later case series supported the use of a different direct-acting fibrinolytic agent, recombinant tissue plasminogen activator (t-PA). Based on a theory that the presence of extracellular DNA and other bacterial components in the pleural space may increase viscosity and permit biofilm formation, a second multi-center, prospective, double-

dummy, factorially randomized trial MIST-2 evaluated the effectiveness of t-PA and the DNase. They found the combination of t-PA 10 mg twice daily and DNase 5 mg instilled for 1 h via clamping the thoracostomy tube twice daily, for 3 days improved their primary outcome of improved pleural drainage as measured by changes in pleural opacification as a percentage of hemithorax via chest X-ray (CXR) on day 7 [15]. They also found a reduction in their secondary outcomes of surgical referral at 3 months (4% vs. 16% in placebo), reduced hospital length of stay (mean difference of 6.7 fewer days in t-PA + DNase group compared to placebo), and reduced fever on day 7, but no change in mortality at 3 or 12 months. The question of when to consider thrombolytics versus proceed with operative management is still a topic of considerable debate, which MIST-3, comparing thrombolytics to early video-assisted thoracoscopic surgery (VATS) will attempt to address [5].

---

## Prognostication

Multiple studies have attempted to identify prognostic factors associated with empyema. In 1999, Davies et al. sought to identify clinical predictors for failure of medical treatment. They found an absence of frank purulence on sampling of the pleura to be useful for predicting success for medical therapy (positive predictive value 93%). While the presence of purulence was seen more often in treatment failure (77% vs. 40%), it had a poor positive predictive value of 26% for predicting failure [35]. Bacteremia seemed, with a non-significant trend toward predicting medical failure. Interestingly, they found no difference in medical treatment successes or failures for delays in antibiotics, delays for chest drainage, pleural fluid biochemistry or bacteriology, or pleural fluid collection size.

Later, Rahman. et al. continued this work, but instead of identifying risk factors for medical treatment failure, they evaluated 22 baseline characteristics from the patient in the MIST-1 cohort to see which were associated with a high-risk of death. From these 23 characteristics, they

derived the RAPID (renal, age, purulence, infection, and dietary) score [17]. Patients were given an aggregate score from 0–78 based on renal function (BUN in mg/dL, 0 points for <14, 1 point 14–23, or 2 points >23), age (0 for <50, 1 50–70, 2 for >70), purulence (0 for present, 1 absent), infective source (0 for CAP, 1 for HAP), and dietary evaluation (1 points for albumin <2.7, 1 for albumin >2.7). Of these 5 risk factors, hypoalbuminemia and elevations in urea were the only statistically significant predictors for mortality at 3 months (odds ratio of 2.8 and 3.96, respectively), while the others demonstrating strong effects but not significance. Compared to the 1999 Davies et al. retrospective analysis, Rahman et al. found the absence of purulence to be risk factor for worse outcomes.

Based on their aggregate score, patients were then grouped into risk low (0–2), medium (3–4), and high (5–7) risk categories. These risk categories were then prospectively applied to the Second Multicenter Intrapleural Sepsis Trial (MIST-2) patient cohort. They found the RAPID score predicted mortality well, with an area under the curve (AUC) of 0.88 but did not predict requiring surgery at 3 months (AUC 0.36). When evaluating the individual risk groups, the RAPID score described a significant difference in mortality, with 3-month mortality in the low-risk group of 1–3%, compared to the medium risk 3-month mortality of 9%, and the high-risk group mortality of 31%. Interestingly, this importance of nutrition reflects the 1918 U.S. Army Empyema Commission findings, where nutritional needs, estimated via 24-hour urine and chest tube aspiration nitrogen quantification, were estimated between 3300 and 3500 calories [12].

---

## Surgical Management

The two essential goals when managing parapneumonic effusions and empyema are *draining the pleural fluid* and *achieving pulmonary re-expansion*, thereby resolving the infection and restoring pulmonary function. *Exudative* effusions are best managed with thoracentesis and antibiotic therapy. The majority of those with

*fibrinopurulent* effusions can be successfully treated with pleural drains and intrapleural fibrinolytic therapy with t-PA—DNase. Yet a significant proportion of those with *fibrinopurulent* effusions, and most with effusions in the *organization* stage, will have suboptimal results with intrapleural fibrinolytic, manifested as incomplete drainage, inadequate pulmonary re-expansion, or clinical deterioration. These patients require a surgical drainage procedure. Such individuals often can be identified early in their clinical course by suggestive findings on chest CT, including multiple loculations and contrast enhancement of the parietal pleura suggesting a “peel” or “rind,” indicative of the *organization* stage.

Video-assisted thoracoscopic surgery (VATS) should be the therapeutic maneuver after unsuccessful intrapleural fibrinolytic therapy, or when fibrinolytic therapy is unlikely to be successful. Thoracoscopy has been used for endoscopic examination of the pleural space since the middle of the nineteenth century. Progress in video technology led to its expanded use in the 1980s. The indications for VATS have broadened considerably in the past three decades. VATS was initially utilized for minor pleural procedures such as pleural biopsy, drainage of effusions or hemothoraces, pleurodesis, and limited pulmonary procedures including bullectomy and wedge resection. Increasing application to major thoracic procedures has emerged and VATS is employed for a host of operations such as: anatomic pulmonary resections including segmentectomy, lobectomy, and pneumonectomy; esophageal procedures such as myotomy and minimally invasive esophagectomy; and mediastinal surgery. VATS has several advantages over thoracotomy, for example, decreased pain, fewer perioperative complications, shorter chest tube duration, decreased length of stay, faster return to functional status, and improved oncologic outcomes.

VATS affords the ability to visualize the infected pleural space and determine when complete drainage of all empyema fluid and disruption of all adhesions and loculations have been accomplished. If lung entrapment is present, decortication is indicated. Performed early before

collagen deposition on the visceral pleura and entrapment of the lung, VATS can be used to disrupt fibrinous adhesions, completely drain all infected fluid, debride the parietal and visceral pleura, and precisely locate chest tubes. As with all interventions for parapneumonic effusions and empyema, VATS must accomplish the two key therapeutic goals of establishing a unified pleural space via thorough fluid drainage and ensuring total re-expansion of the lung with obliteration of the pleural cavity. When VATS provides inadequate visualization due to the complexity of loculations, if debridement is insufficient, or if the time required to adequately perform the operation is excessive, thoracotomy is indicated. The earlier that VATS is employed, the more likely it is to be successful, thus avoiding thoracotomy. Hence, VATS should occur promptly if intrapleural fibrinolytic therapy is unlikely to be successful or if it has failed to clear the pleural space effectively and re-expand the lung.

On VATS examination of the pleural space, a determination is made as to whether all fluid can be drained and the extent of lung entrapment. When the lung is not entrapped, debridement, irrigation, and disruption of all adhesions and loculations can be accomplished in a straightforward manner. Two or three large-bore (24 Fr to 28 Fr) chest tubes are placed using video assistance and left to suction drainage until outputs diminish, sometimes within 2 days. When the output is sufficiently low and the drained fluid is clear, rather than purulent, chest tubes can be removed. Success using VATS usually depends on whether the lung is entrapped by a thick visceral peel (*organized* phase of empyema). The *fibrinopurulent*, multiloculated stage of empyema is particularly amenable to thoracoscopic management. If the lung is found to be entrapped, conversion to thoracotomy for decortication is more often required. Decortication using VATS can result in parenchymal lung injury and bleeding, may inadequately remove the peel, and is frequently time-consuming.

Decortication via a thoracotomy should be performed when the *organization* stage of empyema is suggested by a CT scan that reveals vis-

eral pleural enhancement without fibrin septation in multiple areas of loculation. It should also be considered if the lung does not re-expand after thorough fluid drainage. Entrapment should be suspected when this has occurred, particularly when the pleural process is known to have been ongoing for greater than 2 weeks. After creating a thoracotomy, a complete decortication can be performed with wider exposure. The videoscope can still be used through the incision, or through planned chest tube sites, to better access the hard-to-reach areas. The first objective of the operation is to remove all purulent fluid, fibrinous debris, and thickened parietal pleura. Hemostasis is critical or a resulting hemothorax may occur, defeating the initial purpose. The second objective, more technically challenging but most critical task, is to resect the visceral pleural peel. A plane of separation between the peel and visceral pleura must be established. This is accomplished with scissors, knife, and curettes. Blunt dissection can result in parenchymal injury, and should be utilized cautiously. When the proper plane is established, the peel is stripped completely from the entire lung. The lung must be freed entirely from the chest wall, mediastinum, and diaphragm. All of the fibrotic visceral peel should be removed, even within the lung fissures. The costophrenic angle should be re-established. Complete re-expansion of all lung parenchyma is the goal. Decortication is achieved most easily through the fifth or sixth intercostal space, which allows access from the diaphragm and costophrenic angle to the apex. This is a major operation and results in significant morbidity and mortality rates, especially among debilitated patients and those with significant medical co-morbidities.

When the operative risk of thoracotomy with decortication is prohibitive, a lesser open drainage procedure may be considered. The Eloesser flap originally was described as a drainage procedure for tuberculous empyema. A U-shaped flap of skin and subcutaneous tissue is formed and then sewn into the most dependent portion of the empyema cavity after resecting a portion of the underlying two or three ribs and attached intercostal muscles. With the flap acting as a tubeless,

one-way valve, air is allowed to egress against less resistance than air entering. The lung may then gradually re-expand and obliterate the cavity. Alternatively, when a smaller window is sufficient to achieve drainage, a short segment single rib resection can be performed. A silicone salivary bypass drain is inserted with the flange secured to the skin with sutures and a colostomy apparatus used to collect the drainage. These lesser open drainage procedures are more effective when a unilocular empyema is present and located inferiorly or laterally. The procedure can be accomplished under local anesthesia with intravenous sedation in a high-risk surgical patient.

---

## Survivorship

For those patients who survive treatment, many have been found to have residual pleural defects. In 2003, Castro et al. evaluated the prevalence of persistent pleural thickening 6 months after infection, and risk factors associated with its development. They defined persistent pleural thickening as pleural thickness  $\geq 10$  mm, measured at the lateral chest wall at the level of an imaginary line tangential to the dome of the diaphragm on a posterior-anterior film. Of 348 patients with parapneumonic effusion or empyema, 13.79% had residual pleural thickening (RPT) at 6 months [21]. Patients with RPT had significantly larger effusions, lower pleural fluid pH levels, and higher pleural fluid LDH and leukocyte levels. Pleural leukocyte counts had the highest diagnostic accuracy for RPT, with patients with pleural fluid leukocytes  $>1000$  per  $\text{mm}^3$  having an AUC of 0.78 (compared to volume effusion AUC 0.63, pleural fluid glucose 0.47, and pleural fluid pH 0.61). Despite this, when comparing patients with and without RPT, there was no statistically significant differences in forced vital capacity values at 6 months, nor in the Borg dyspnea index. Patients without RPT, however, did experience significantly higher improvement in FVC between discharge and 6 months compared to those with RPT, suggesting that RPT has limited functional impact.



## Summary and Recommendations

With increasing incidence, evolving bacteriology, and persistently high morbidity and mortality, the early involvement of an interventional pulmonologist or thoracic surgeon is recommended. Early evaluation by ultrasound or chest CT can better evaluate potential effusions, and imaging-guided tube thoracostomy with thoracentesis or small-bore chest tube is the diagnostic and initial therapeutic procedure of choice. Evaluation by pleural chemistry combined with fluid culture with gram stain coupled with inoculation of blood culture bottles currently offers the best diagnostic yield, with next-generation biomarkers and microbiological analysis providing future hope for better pathogenic identification. For complicated parapneumonic effusion, current best practice favors appropriate antibiotics and intrapleural thrombolytics with t-PA and DNase, with further studies are pending to identify which patients would benefit with earlier surgical intervention via VATS with decortication. In patients with evidence of an organized parapneumonic effusion, the early involvement of thoracic surgery allows for expedient pulmonary re-expansion.

## References

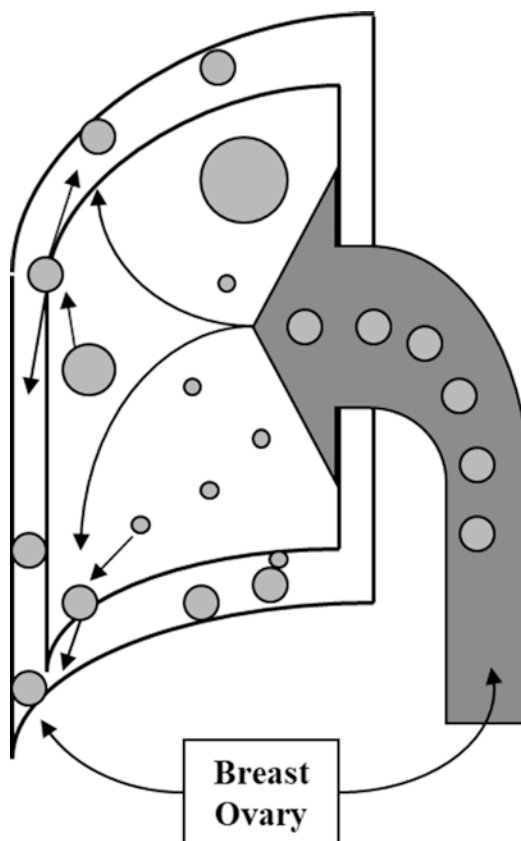
- Davies HE, Davies RJO, Davies CWH. Management of pleural infection in adults: British Thoracic Society pleural disease guideline 2010. *Thorax*. 2010;65(Suppl 2):ii41–53.
- Shen KR, et al. The American Association for Thoracic Surgery consensus guidelines for the management of empyema. *J Thorac Cardiovasc Surg*. 2017;153(6):e129–46.
- Kanai E, Matsutani N. Management of empyema: a comprehensive review. *Curr Challenges Thorac Surg*. 2020;2:38.
- Broaddus VC, et al. Murray & Nadel's textbook of respiratory medicine e-book. Philadelphia, PA: Elsevier Health Sciences; 2021.
- Bedawi EO, et al. Advances in pleural infection and malignancy. *Eur Respir Rev*. 2021;30(159):200002.
- Sahn SA, Light RW. The sun should never set on a parapneumonic effusion. *Chest*. 1989;95(5):945–7.
- Colice GL, et al. Medical and surgical treatment of parapneumonic effusions: an evidence-based guideline. *Chest*. 2000;118(4):1158–71.
- Breen DP, Daneshvar C. Role of interventional pulmonology in the management of complicated parapneumonic pleural effusions and empyema. *Respirology*. 2014;19(7):970–8.
- Breasted JH. The Edwin Smith surgical papyrus: published in facsimile and hieroglyphic transliteration with translation and commentary in two volumes. Chicago, IL: University of Chicago Press; 1930.
- Tsoucalas G, Sgantzios M. Hippocrates (ca 460–375 bc), introducing thoracotomy combined with a tracheal intubation for the parapneumonic pleural effusions and empyema thoracis. *Surg Innov*. 2016;23(6):642–3.
- The Internet Classics Archive. Aphorisms by Hippocrates. November 20, 2021; <http://classics.mit.edu/Hippocrates/aphorisms.5.v.html>.
- Tung J, Carter D, Rappold J. Empyema commission of 1918—impact on acute care surgery 100 years later. *J Trauma Acute Care Surg*. 2019;86(2):321–5.
- Moizingo AE. The surgical treatment of empyema by a closed method. *JAMA*. 1918;71(25):2062.
- Grijalva CG, et al. Emergence of parapneumonic empyema in the USA. *Thorax*. 2011;66(8):663–8.
- Rahman NM, et al. Intrapleural use of tissue plasminogen activator and DNase in pleural infection. *N Engl J Med*. 2011;365(6):518–26.
- Maskell NA, et al. U.K. controlled trial of intrapleural streptokinase for pleural infection. *N Engl J Med*. 2005;352(9):865–74.
- Rahman NM, et al. A clinical score (RAPID) to identify those at risk for poor outcome at presentation in patients with pleural infection. *Chest*. 2014;145(4):848–55.
- Maskell NA, et al. The bacteriology of pleural infection by genetic and standard methods and its mortality significance. *Am J Respir Crit Care Med*. 2006;174(7):817–23.
- Light RW. Parapneumonic effusions and empyema. *Proc Am Thorac Soc*. 2006;3(1):75–80.
- Light RW, et al. Pleural effusions: the diagnostic separation of transudates and exudates. *Ann Intern Med*. 1972;77(4):507–13.
- Jiménez Castro D, et al. Prognostic features of residual pleural thickening in parapneumonic pleural effusions. *Eur Respir J*. 2003;21(6):952–5.
- Feller-Kopman D, Light R. Pleural disease. *N Engl J Med*. 2018;378(8):740–51.
- Heffner JE, et al. Pleural fluid chemical analysis in parapneumonic effusions. A meta-analysis. *Am J Respir Crit Care Med*. 1995;151(6):1700–8.
- Rahman NM, et al. Clinically important factors influencing the diagnostic measurement of pleural fluid pH and glucose. *Am J Respir Crit Care Med*. 2008;178(5):483–90.
- Maskell NA, et al. Diagnostically significant variations in pleural fluid pH in loculated parapneumonic effusions. *Chest*. 2004;126(6):2022–4.
- Kohn GL, Hardie WD. Measuring pleural fluid pH: high correlation of a handheld unit to a tra-

- ditional tabletop blood gas analyzer. *Chest*. 2000;118(6):1626–9.
27. Abdo TF, et al. Pleural fluid glucose testing using a finger stick glucometer: a novel bedside test. *J Thorac Dis*. 2019;11(11):4904–8.
  28. Zou MX, et al. The use of pleural fluid procalcitonin and C-reactive protein in the diagnosis of parapneumonic pleural effusions: a systemic review and meta-analysis. *Am J Emerg Med*. 2012;30(9):1907–14.
  29. Wu K-A, et al. Proteome profiling reveals novel biomarkers to identify complicated parapneumonic effusions. *Sci Rep*. 2017;7(1):4026.
  30. Menzies SM, et al. Blood culture bottle culture of pleural fluid in pleural infection. *Thorax*. 2011;66(8):658–62.
  31. Psallidas I, et al. A pilot feasibility study in establishing the role of ultrasound-guided pleural biopsies in pleural infection (the AUDIO study). *Chest*. 2018;154(4):766–72.
  32. Light RW. Pleural controversy: optimal chest tube size for drainage. *Respirology*. 2011;16(2):244–8.
  33. Rahman NM, et al. The relationship between chest tube size and clinical outcome in pleural infection. *Chest*. 2010;137(3):536–43.
  34. Davies HE, et al. Use of indwelling pleural catheters for chronic pleural infection. *Chest*. 2008;133(2):546–9.
  35. Davies CWH, et al. Predictors of outcome and long-term survival in patients with pleural infection. *Am J Respir Crit Care Med*. 1999;160(5):1682–7.

Carlos A. Jiménez and Vickie R. Shannon

## Definition and Pathogenesis

Malignant pleural effusion (MPE) is the accumulation of pleural fluid (PF) caused by malignant involvement of the pleural cavity. It is an ominous finding that usually signifies widespread metastases [1]. Most pleural metastases arise from tumor emboli to the visceral pleura, with secondary seeding to the parietal pleura [2, 3]. Direct extension of tumor from the lung, chest wall, mediastinal structures, or diaphragm and hematogenous metastasis to the parietal pleura are other mechanisms of malignant pleural involvement (Fig. 33.1) [2, 4]. In addition to direct tumor involvement of the pleura, MPEs can result from lymphatic blockage anywhere between the parietal pleura and the mediastinal lymph nodes [3, 5]. Increased pleural permeability caused by tumor involvement and over production of local factors, such as vascular endothelial growth factor (VEGF), play a significant role in the formation of MPE [6–8]. Among VEGF homologs, VEGF-D showed a 92.6% rate of positive expression in a study of MPE [9]. The unbalance created by the

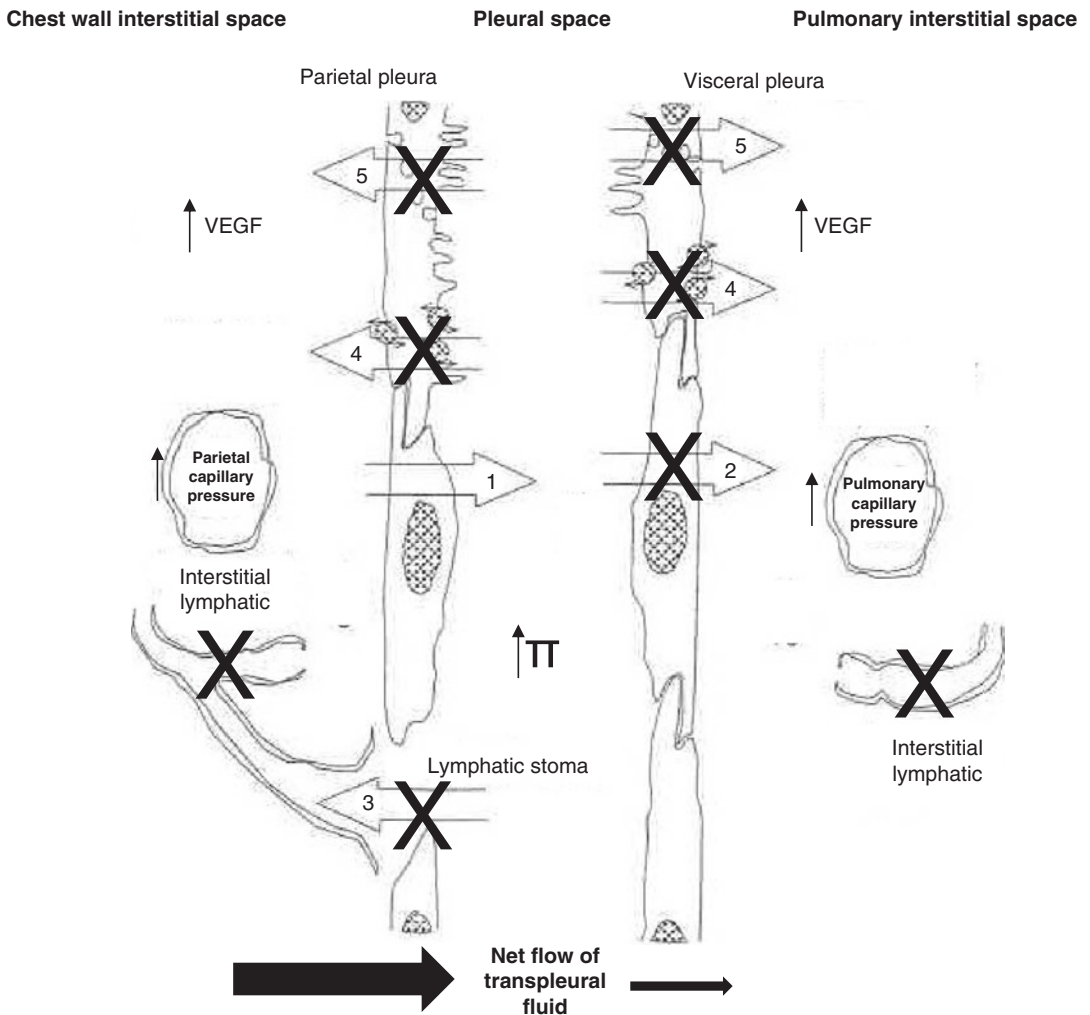


**Fig. 33.1** Pathogenesis of pleural metastases. Modified from Rodriguez-Panadero F [4]. Visceral pleural is seeded via tumor embolization or direct invasion. The parietal pleura is affected by neoplastic spread across the pleural cavity from the visceral pleura along areas with pleural adhesions, and by exfoliated malignant visceral pleural cells attaching to the parietal pleural. Hematogenous metastases to the parietal pleural occur with some malignancies (i.e., ovarian or breast origin)

C. A. Jiménez (✉) · V. R. Shannon  
 Department of Pulmonary Medicine, The University  
 of Texas MD Anderson Cancer Center,  
 Houston, TX, USA  
 e-mail: [cajimenez@mdanderson.org](mailto:cajimenez@mdanderson.org);  
[vshannon@mdanderson.org](mailto:vshannon@mdanderson.org)

abnormal excess production and decreased absorption of PF results in a surplus accumulation of PF (Fig. 33.2) [10]. Seventeen percent of all pleural effusions in patients with cancer are “paramalignant,” a term used for effusions that occur in the setting of cancer that is not caused by direct malignant involvement of the pleural space [11]. These effusions develop as a result

of local or systemic effects of the tumor, complications of cancer therapy, or concurrent non-malignant disease [12]. Lymphatic obstruction is associated with both malignant and paramalignant effusions and is the most common cause of paramalignant effusions. Other common causes include bronchial obstruction, trapped lung, and pulmonary embolism.



**Fig. 33.2** Pathophysiology of malignant pleural effusion. (Modified from Zocchi L. [10]). *VEGF* vascular endothelial growth factor (elevated).  $\pi$  = pleural space oncotic pressure (increased). (1) Elevated parietal pleural starling

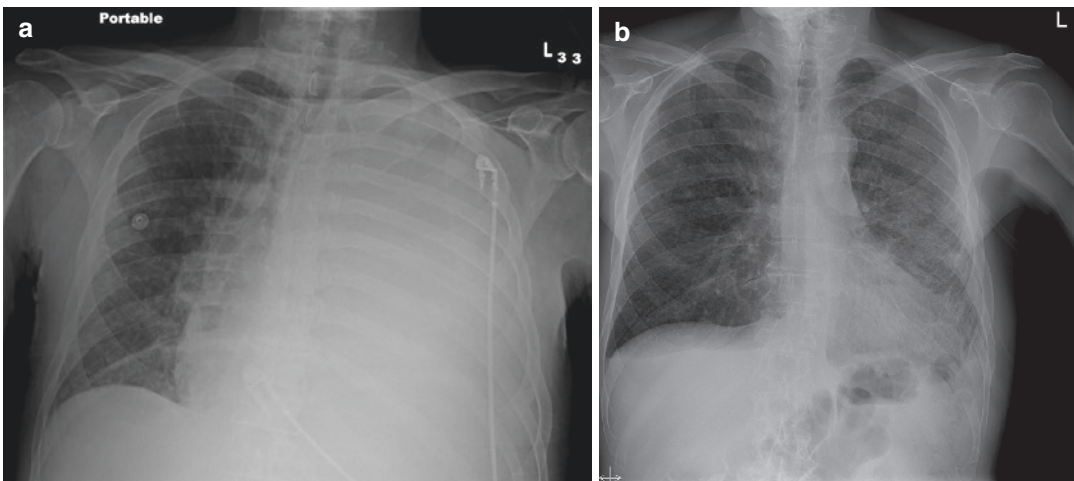
filtration. (2) Impaired starling absorption. (3) Obstruction of lymphatic stoma. (4) Hampered electrolyte-coupled liquid outflow. (5) Disturbed vesicular flow of liquid accompanying protein transcytosis

## Clinical Manifestation, Imaging Studies, and Diagnosis

Between 20% and 40% of patients with a malignant pleural effusion claim to be symptom free [13, 14]. Most of them have very small amounts of PF. Unsurprisingly, the commonest symptom is progressive exertional dyspnea. The physiopathology of breathlessness associated with a pleural effusion continues to be a subject of debate. Recent evidence supports prior findings suggesting dyspnea is related to increased breathing effort due to impaired respiratory mechanics. Compromised diaphragmatic function associated with a caudal displacement of the dome of the diaphragm, rather than compression of the lung parenchyma or hypoxemia, is the pathophysiologic mechanism responsible for impaired respiratory mechanics and dyspnea [15, 16]. In fact, patients presenting with hypoxemia and pleural effusion should undergo further workup to determine an alternative cause to explain the hypoxemia, even if the pleural effusion is large [15].

Cough or chest discomfort is reported in approximately 50% of the patients [17]. Associated symptoms of hemoptysis and chest wall pain suggest malignant endobronchial disease and tumoral invasion of the chest wall [18]. Constitutional symptoms are common signals of advanced malignant disease, and thus malaise, weight loss, and poor appetite will become more frequent complaints as the patient's overall condition worsens [18].

Standard chest X-rays and ultrasonography of the chest provide critical information in the initial evaluation of pleural effusions, including effusion size, position of the mediastinum and diaphragms, presence of loculations, or air fluid levels within the pleural space and characteristics of the underlying lung parenchyma. Knowledge regarding the position of the mediastinum is imperative in therapeutic decision-making. Large pleural effusions with contralateral mediastinal shift typically require prompt therapeutic thoracentesis (Fig. 33.3a, b) [4, 18]. When a centered or ipsilateral shift of the mediastinum is seen



**Fig. 33.3** (a) 66-year-old man with pancreatic adenocarcinoma. Anteroposterior view of the chest with complete opacification of the left hemithorax and contralateral mediastinal shift caused by a large pleural effusion. (b) Posteroanterior chest view after drainage of 5350 cc of

pleural fluid. There is complete lung expansion with a small apical left pneumothorax and small residual right and left pleural effusions. There are bilateral opacities more prominent on the left hemithorax and bilateral nodular lesions



with a large pleural effusion, other disease processes need to be considered, including a frozen or fixed mediastinum associated with malignant mesothelioma or lymphoma, atelectasis related to occlusion of the ipsilateral central airway, or extensive tumoral infiltration of the ipsilateral lung simulating a large effusion [4, 18, 19].

Computer tomography (CT) is helpful in identifying loculated effusions; it offers more detailed anatomical information of the chest wall, parietal and visceral pleurae, mediastinal structures, and lung parenchyma, and is especially valuable in delineating alternate diagnoses. CT findings that suggest malignancy include pleural nodularity, pleural rind, mediastinal pleura involvement, parietal pleura thickening of more than 1 cm, and invasion of adjacent structures [18, 20].

Ultrasonography is more sensitive than chest radiographs detecting PF and discerning pleural effusions from lung consolidation, solid pleural abnormalities or diaphragmatic displacement (Fig. 33.4a–e) [21, 22]. It provides guidance in locating the optimal site for thoracentesis and is particularly helpful in the setting of loculated pleural effusions [22]. In addition, utilizing ultrasound with M mode and strain analysis could be useful in identifying entrapped lung prior to PF drainage, facilitating the selection of those patients suited for pleurodesis [23].

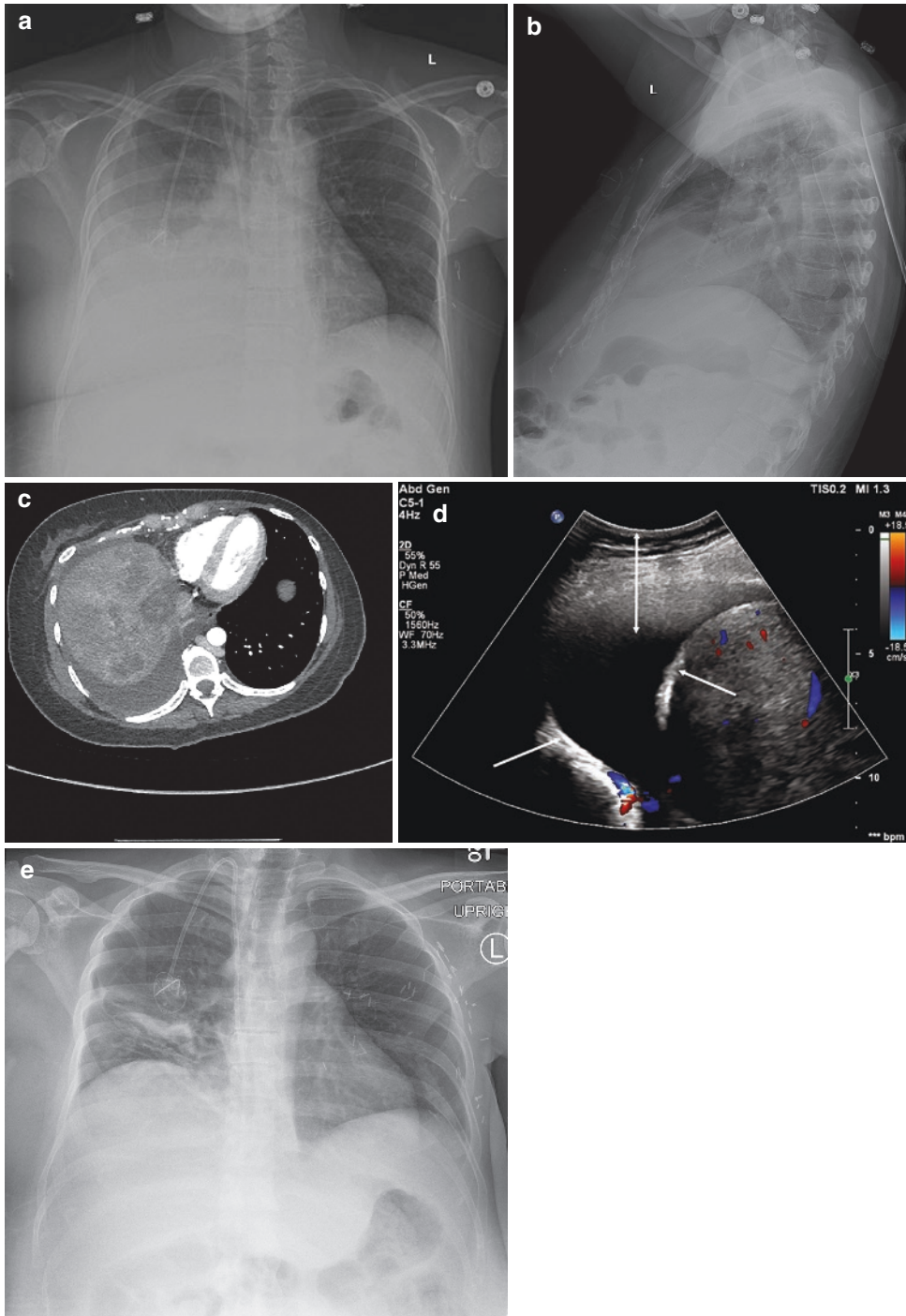
Positron emission tomography (PET) with 18F- fluorodeoxyglucose (FDG) and magnetic resonance imaging (MRI) are both helpful in highlighting extra-pleural extension of disease [18]. PET imaging provides valuable information associated with malignant mesothelioma; however, its utility in the evaluation of other malignant pleural diseases has not been established [18].

PF analysis reveals an exudative effusion in most cases, with only 5% of MPE effusions being

transudates [12]. Positive PF cytology, noted in 62–67% of cases, represents the diagnostic cornerstone of MPE [24–26]. However, the yield of PF cytology varies according to tumor type [4, 26]. It is higher in those patients with pleural effusion caused by endometrial cancer (75%), thyroid cancer (77%), adenocarcinoma of the lung (78%), urothelial carcinoma (83%), ovarian cancer (84%), breast cancer (85%), and pancreatic cancer (86%). PF cytology yield is lower on patients with sarcoma (20%), head and neck malignancies other than thyroid cancer (21%), renal cancer (37%), and squamous cell carcinoma of the lung (39%).

The presence of elevated tumor markers in pleural effusions should not be used alone to diagnose malignancy, but should prompt additional invasive procedures to determine a more accurate diagnosis [27, 28]. The diagnostic approach to pleural effusions of patients with suspected or established hematopoietic or lymphoid malignancies requires an excellent clinical evaluation and a prompt PF analysis to detect infection, fluid overload, thrombosis, or therapy-related causes [29–33]. If malignant involvement is suspected, it is recommend to use a stepwise approach, implementing increasingly complex techniques such as immunohistochemistry, flowcytometry, and electron microscopy in order to increase the diagnostic yield [30, 34].

Pleuroscopic pleural biopsies have a 95% sensitivity in the diagnosis of pleural malignancies, and diagnostic yield increases only incrementally (1%) when combined with PF cytology [24]. Image-guided pleural biopsies have a slightly lower sensitivity (87%) [35]. By contrast, closed pleural biopsy has a diagnostic yield of only 44–47% but improves to 77% when combined with an analysis of PF cytology [24, 35].



**Fig. 33.4** (a) 37-year-old woman with breast cancer and extensive metastases. Posteroanterior chest view with opacification of the lower half of the right hemithorax. (b) Lateral view of the chest. The right hemidiaphragm cannot be delineated. (c) CT chest axial cut. Enlarged liver with metastatic disease with cephalad displacement of the

right hemidiaphragm. (d) Ultrasound image of the right hemithorax with a moderate size pleural effusion. Starting from the top in a clockwise direction, arrows show the chest wall and parietal pleura, the right hemidiaphragm and the collapsed right lower lobe. (e) Anteroposterior chest view after draining 800 cc of pleural fluid

## Management of Malignant Pleural Effusions

### Evaluation

Because MPE often signals advanced disease and incurability, the goals of care are usually aimed at symptom palliation. A complete history and physical evaluation are key in determining individual palliative treatment goals. Selecting the best therapeutic option is based on the patient's exercise tolerance and ability to perform certain activities of daily living (performance status), tumor histology, and estimated life expectancy. Information regarding prior thoracenteses, including the volume of fluid evacuated, whether lung re-expansion and symptom palliation were obtained, and the time interval between repeated taps, is a key component of the initial evaluation. Predicting the life span of individual patients is challenging. Certain prognostic tools (i.e., LENT and PROMISE) are seldom used in clinical practice and often the prediction is made using the performance status and clinical information [36–38]. Chest wall abnormalities, cancer treatment plans, the patient's beliefs and expectations, and the availability of family support should be pondered before proposing a strategy. Figure 33.5a, b shows the algorithms for management of MPE at our institution [39].

### Initial Intervention

Since most of the individuals with a suspected or established MPE will most likely require a thoracentesis, we recommend performing an ultrasound-guided symptom-limited maximal drainage of fluid using any of the commercially available custom-fit safety thoracentesis needles with small-bore catheters. This approach may be applied even on to those patients with ipsilateral deviation of the mediastinum (Fig. 33.6a–e) [40]. Patients can safely tolerate

more than 1.5 L of fluid drainage in one sitting as long as there are no procedure-related symptoms of chest pain/discomfort or persistent cough. It is desirable to have a diagnostic image of the chest within 2–3 days prior to the intervention to compare it with a post-procedure one. Evidence for the use of pleural manometry during large volume thoracentesis is limited and its implementation is cumbersome, time consuming, and potentially costly. Additionally, poor implementation and interpretation of the data can lead to unexpected harm as already observed with the adoption of other technologies in the medical field. We do not ordinarily use pleural manometry [40].

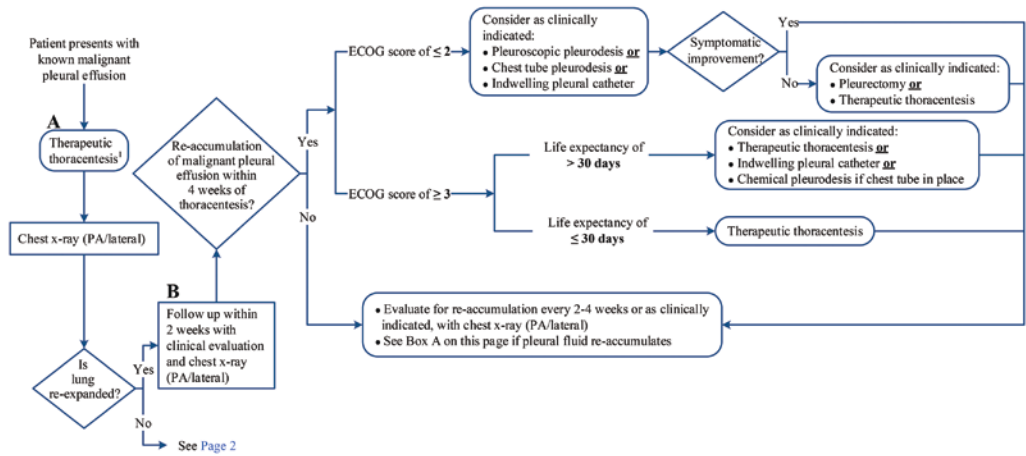
Thoracenteses are routinely performed on ambulatory patients under local anesthesia. From our standpoint of view, the use of moderate/deep sedation or general anesthesia should be limited, as feedback provided by the patient during the procedure is fundamental in knowing when to stop drainage. Fluid drainage could be accomplished either by gravity, manual aspiration using a syringe, or active aspiration with vacuum bottles or wall suction [40]. The use of aspiration decreases the procedure time when compared to gravity drainage [41].

The procedure is safe and there are no absolute contraindications other than patient's refusal and absence of PF. It has a low incidence of complications including pneumothorax requiring intervention (0.3%), re-expansion pulmonary edema (0.1%), and serious bleeding events requiring additional intervention (0.05%) [40, 42]. We regularly perform the procedure on patients with platelet counts as low as 30 K/ $\mu$ L. In patients with platelets below 30 K/ $\mu$ L and even those who are refractory to platelet transfusions, thoracentesis may be considered on a case-to-case basis with transfusion of platelets prior to or during the procedure [29]. In patients with coagulopathy or treated with anticoagulant/antiplatelet therapy, it is desirable to perform the thoracentesis once the abnormalities are corrected or the medications are stopped. However,

**a** **Management of Malignant Pleural Effusion - Adult** **Page 1 of 4**

THE UNIVERSITY OF TEXAS MDAnderson Cancer Center Making Cancer History<sup>®</sup>

Disclaimer: This algorithm has been developed for MD Anderson using a multidisciplinary approach considering circumstances particular to MD Anderson's specific patient population, services and structure, and clinical information. This is not intended to replace the independent medical or professional judgment of physicians or other health care providers in the context of individual clinical circumstances to determine a patient's care.



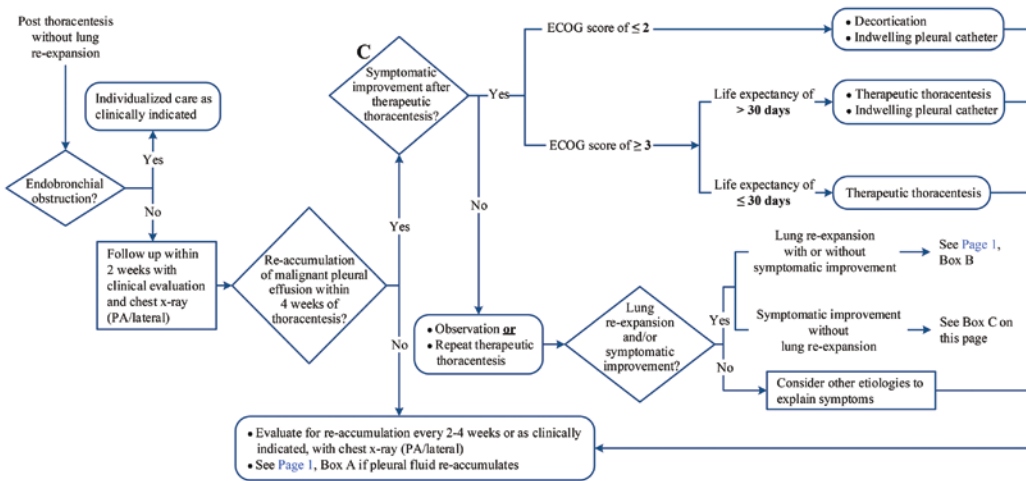
ECOG = Eastern Cooperative Oncology Group  
 1 Patients with chemo-radiosensitive tumors on initial treatment (lymphoma, breast cancer, and small cell lung cancer) could obtain palliation with therapeutic thoracentesis while waiting on systemic treatment results

Copyright 2021 The University of Texas MD Anderson Cancer Center Department of Clinical Effectiveness V2  
 Approved by The Executive Committee of the Medical Staff on 04/20/2021

**b** **Management of Malignant Pleural Effusion - Adult** **Page 2 of 4**

THE UNIVERSITY OF TEXAS MDAnderson Cancer Center Making Cancer History<sup>®</sup>

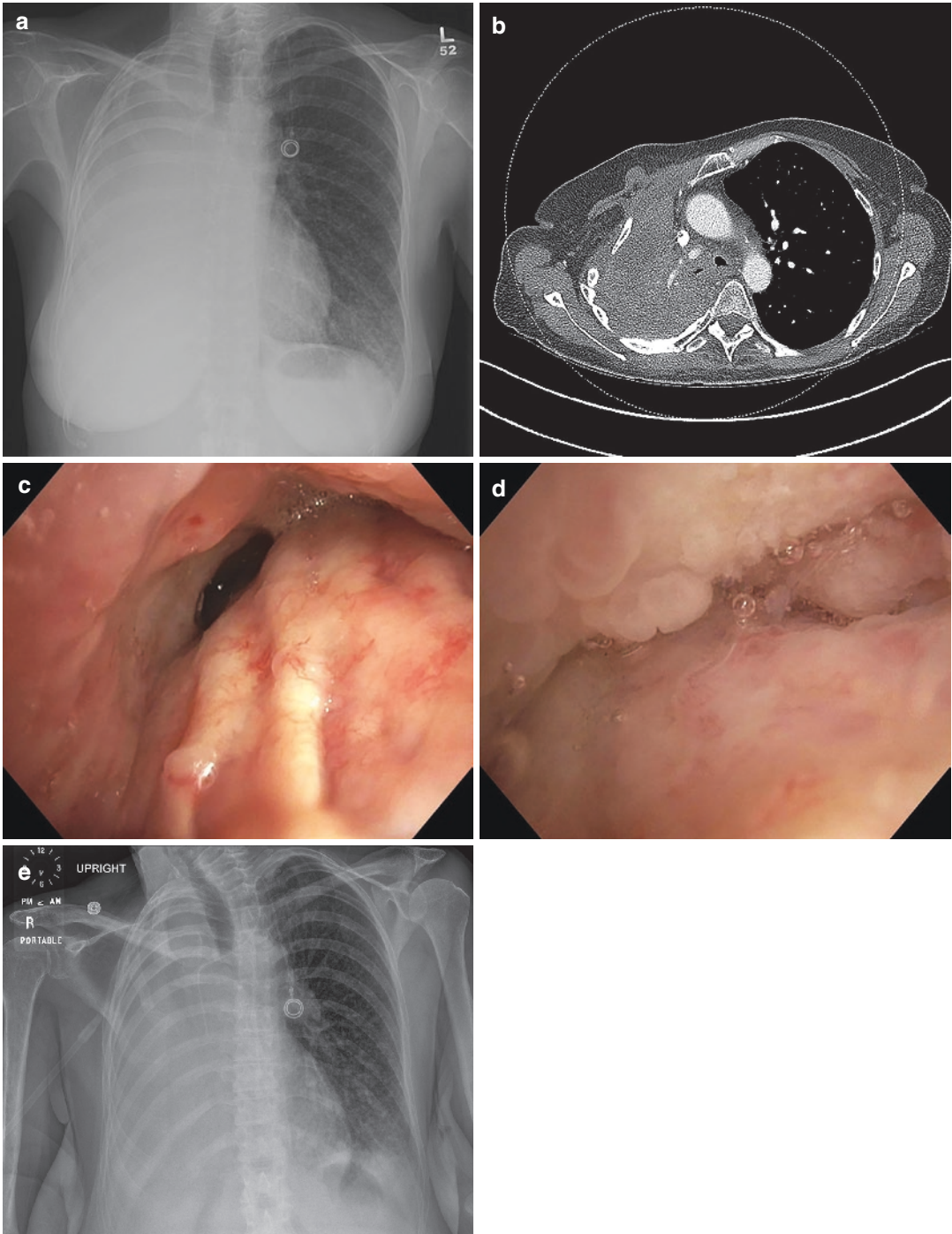
Disclaimer: This algorithm has been developed for MD Anderson using a multidisciplinary approach considering circumstances particular to MD Anderson's specific patient population, services and structure, and clinical information. This is not intended to replace the independent medical or professional judgment of physicians or other health care providers in the context of individual clinical circumstances to determine a patient's care.



Copyright 2021 The University of Texas MD Anderson Cancer Center Department of Clinical Effectiveness V2  
 Approved by The Executive Committee of the Medical Staff on 04/20/2021

**Fig. 33.5** (a) Management of malignant pleural effusions on patients with lung re-expansion after thoracentesis. (Copyright 2021. The University of Texas MD Anderson Cancer Center (with permission)). (b) Management of malignant pleural effusions on patients without lung re-expansion after thoracentesis. (Copyright 2021. The University of Texas MD Anderson Cancer Center (with permission))





**Fig. 33.6** (a) 52-year-old woman with adenocarcinoma of the lung previously treated with chemotherapy and radiation. Posteroanterior chest view with complete opacification of the right hemithorax and ipsilateral mediastinal shift. (b) CT chest with contrast. Axial cut just below the main carina showing a right main stem obstruction, atelectasis and pleural effusion. (c) Bronchoscopy

image of the right main stem bronchus. The proximal right upper bronchus is completely obstructed. The proximal bronchus intermedius is partially obstructed. (d) Bronchoscopy image of the distal bronchus intermedius with a complete obstruction. (e) Anteroposterior chest view after draining 1250 cc of pleural fluid



when an urgent thoracentesis is needed or anti-coagulation/antiplatelet therapy cannot be discontinued, the incidence of serious bleeding events is still low and the procedure should be offered [42, 43].

After a therapeutic thoracentesis, lung re-expansion, time to PF re-accumulation, performance status, life expectancy, and patient preference guide our subsequent recommendations.

Approximately 97% of MPEs will recur within 1 month after drainage, with most fluid re-accumulations occurring within 1–3 days [25]. Patients with sizable pleural effusions on diagnostic imaging, larger volumes of PF drained, and higher lactate dehydrogenase (LDH) levels on PF are at an increased hazard of having a pleural effusion recurrence that requires a pleural intervention. On the other hand, those patients without malignant cells on PF cytology have a decreased hazard of PF recurrence [44].

Anti-cancer treatment may mitigate the risk of MPE recurrence avoiding then additional pleural interventions. Those malignancies that potentially respond well to anti-tumoral treatment include breast cancer, lymphoma, small cell lung cancer, germ cell tumors, prostate, ovarian and thyroid neoplasms. An initial therapeutic thoracentesis followed by a reasonable observation period to evaluate the response to treatment is acceptable in these cases [18].

Several studies have explored the potential benefits of vascular endothelial growth factor/epidermal growth factor receptor (VEGF/EGF) signaling inhibition on patients with MPE caused by non-small cell lung cancer [45, 46]. Although some patients with EGFR mutations could initially respond to these treatments, acquired resistance to these medications and recurrence of the MPE occur frequently [47]. There is not evidence at this time supporting the use of intrapleural agents to treat MPE.

Radiation therapy directed to the mediastinum could be effective in controlling MPE particularly in patients with lymphoma [48].

## **Pleural Interventions for Recurrent Symptomatic MPE**

After the initial evaluation and therapeutic thoracentesis, the most important step is to refer patients to a skilled team that will effectively implement a longitudinal management of MPEs. Implementation of guideline consistent care will improve patient's quality of life by reducing the number of procedures needed, procedure-related complications, and inpatient days [49, 50]. However, there is no consensus about an optimal guideline or best procedure to date, and in addition to the previously mentioned patient-related factors (lung re-expansion, time to PF re-accumulation, performance status, life expectancy, expected response to antitumoral therapy and patient preferences), local resources, expertise, and social conditions are also important variables to consider. In most of the situations, more than one management option may be available.

*Repeated therapeutic thoracenteses* are our preferred alternative for MPEs that re-accumulate slowly and for those patients with limited life expectancy (<30 days) and poor performance status. Implementation of comfort measures, including oxygen supplementation and opioids, and briefing the patient and care givers with truthful information and reasonable expectations, will help providing optimal end of life care and minimizing the number of unnecessary invasive and painful procedures that could even lead to undesirable trips to the emergency department or hospital admissions. Repeated thoracenteses are also a logical approach for patients with malignancies that are expected to respond to anti-tumoral therapy; however, frequent thoracentesis may trigger the production of local cytokines and fibrin, resulting in PF loculation, which not only complicates further thoracenteses but also limits future modes of palliation [51].

*Patients with good functional status and lung expansion* are suited to have either an indwelling pleural catheter (IPC), pleurodesis (using chest tube thoracostomy or thoracoscopy), or a combination of both.

*An indwelling tunneled pleural catheter (IPC)* is considered one of the first-line management alternatives for patients with dyspnea related to recurrent malignant pleural effusion. IPCs are placed mainly in an outpatient setting using a Seldinger wire technique [52]. Following IPC placement, the patient and caregivers follow simple instructions to drain the fluid intermittently at home. When evaluated in prospective fashion daily drainage of PF via an IPC led to a higher rate of autopleurodesis and faster time to liberation from the IPC than every other day drainage [53]. Our group encourages to continue the drainage of fluid, even above 1 L, until the patient develops cough or chest discomfort, or flow stops spontaneously. The incidence of autopleurodesis up to 12 weeks after IPC placement ranges from 30–70% in various reports, with most of experts agreeing that it occurs in about 40% of the cases [53–55].

When compared with patients undergoing pleurodesis using talc slurry, patients receiving IPCs had a shorter hospital stay, without differences in quality of life, pain or dyspnea improvement for up to 6 months after the procedure [56, 57]. It is also well documented that it is safe to continue with systemic anti-tumoral treatment, as the risk of IPC-related infectious complications does not increase [58, 59]. In fact, patients receiving anti-tumoral treatment after IPC placement experienced a greater improvement in quality adjusted life days as well as those patients that were more dyspneic at baseline [60].

As is true for all medical devices, IPCs are subject to post-implantation failures and complications. Timely recognition and treatment of most of these complications might prevent hospital admissions, additional interventions, and worsening quality of life.

The safety profile of IPC is acceptable and life-threatening complications are rare. Incidence of complications varies from 8% to 20% depending on the definitions used by investigators, and most of complications seem to occur within 1 month of IPC placement [60–65].

*During IPC placement, bleeding* causing hemodynamic instability, is a rare complication and its true incidence is unknown, but likely less

than 1 in 1000 IPC placements. Significant bleeding occurs in 0.4% of the cases. Bleeding during IPC placement is generally mild and subsides with application of local pressure. Significant bleeding can be prevented identifying patients with risk factors before procedure, including thrombocytopenia (especially if platelet count is less than 30 K), use of anticoagulant or antiplatelet agents, and coagulation disorders (including severe liver and renal impairment). It is our practice to stop antiplatelet agents, except for aspirin that is usually continued, at least 5 days prior to intervention, re-starting them the next day after catheter insertion. Platelet counts are maintained at 30 K or higher during catheter placement and for 48 h after procedure. Anticoagulation is stopped, waiting enough time to allow for a normal coagulation function. Anticoagulants will be also re-started next day after IPC placement [29, 66]. Bleeding during chronic PF (PF) drainage using IPC is also unusual and it seldom requires additional intervention. It might be caused by local trauma on the pleura or malignant pleural implants during the evacuation maneuver using negative pressure. In the rare event a hemothorax occurs, IPC can successfully be used to drain it, while establishing all needed supportive management.

*The incidence of pneumothorax* during IPC placement is 5–10%. Most of the pneumothoraces are identified immediately after IPC placement and could be the result of a non-expandable lung or room air entering the pleural cavity during IPC placement. Additional interventions are rarely needed, and patients are instructed to start drainage the following day. If there is concern a pneumothorax can worsen and/or cause deterioration of patient's respiratory function, overnight hospital observation is warranted and repeat chest x-rays at 4 and 12 h after intervention are recommended. Pneumothorax caused by local damage of the visceral pleural during chronic PF drainage using negative pressure is rare, and generally does not require additional intervention, but only continuation of regular PF drainage. IPC can be connected preferably to a close chest tube drainage system to relieve a symptomatic or tension pneumothorax and to evaluate the air leak in the subse-

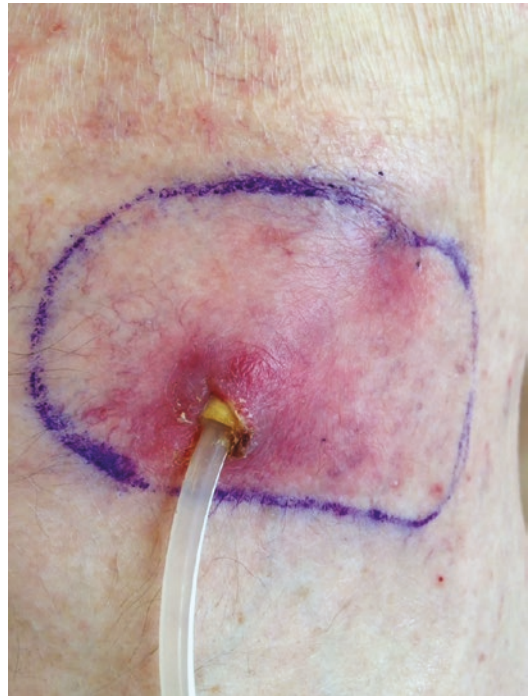quent days. Application of suction to a close drainage system is in general discouraged unless symptoms are not relief, since it could perpetuate the air leak. Additional interventions (chest tubes, placement of intrabronchial valves or thoracotomy) are very seldom needed.

*Kinked IPC* is reported in 0.4% of the cases. Attention to proper catheter insertion technique is the only way to avoid this problem. It generally occurs when IPC is not properly sitting on the tunnel tract or if a suture is accidentally placed around the catheter.

*Catheter-related infections* are the most common complication after IPC placement and most of the studies report an incidence below 10%. Our group divides this complication in *exit site infection*, *tunnel infection* and *pleural space infection*. Patients with *exit site infection* present without fever or symptoms of systemic infection. Purulent secretion at the catheter exit site can be observed, and samples should be obtained for gram stain and culture if that is the case. Empiric oral antibiotic treatment (10 days) for methicillin-resistant *Staphylococcus aureus* (MRSA) should be started and adjusted according to clinical response and culture results. Patients are closely followed up during the subsequent 2 weeks. Progression of infection is unusual, and removal of IPC is rarely needed.

Patients with *tunnel infection* have erythema, tenderness and induration overlying the tunnel tract or extending greater than 2 cm from the IPC exit site (Fig. 33.7). Removal of IPC after drainage of PF is recommended in addition to empiric oral antibiotic treatment. In this situation, the removal of the IPC is fundamental to allow for proper drainage of the infection that is impeded by the catheter's polyester cuff.

Patients with *empyema* might present with fever, rigors or other clinical evidence of a systemic inflammatory response. Drained PF might be purulent, but on occasions it is clear, and a diagnostic thoracentesis is recommended to prove infection of the pleural space in these situations. PF drained using the IPC should not be submitted for microbiology studies, since false positive results are common due to intraluminal catheter bacterial colonization. Drainage of fluid



**Fig. 33.7** Tunnel infection. Skin erythema and induration of more than 2 cm from the indwelling pleural catheter exit site, also affecting the tunnel track. Culture of exit site secretion grew *S. aureus*

is paramount, and it can be accomplished using the IPC. Evaluation of residual fluid with CT chest and thoracic ultrasound is needed, and drainage of residual PF should be accomplished either with chest tubes or thoracentesis. Thoracoscopy or thoracotomy are seldom required, and risk and benefits of these interventions should be carefully considered in patients with advanced malignant disease. In patients with empyemata and malignant pleural disease, the use of intrapleural fibrinolytic agents with or without mucolytic agents should be considered with caution, due to the increased risk of pleural hemorrhage. Empiric intravenous antibiotics to cover MRSA should be started and modified according to culture results and clinical response. Antibiotic treatment needs to continue for 2–4 weeks following defervescence. IPC can often be removed after completing antibiotic treatment, and pleurodesis is achieved frequently. Figure 33.8a, b display our algorithm for management of IPC-related infections [67].

a



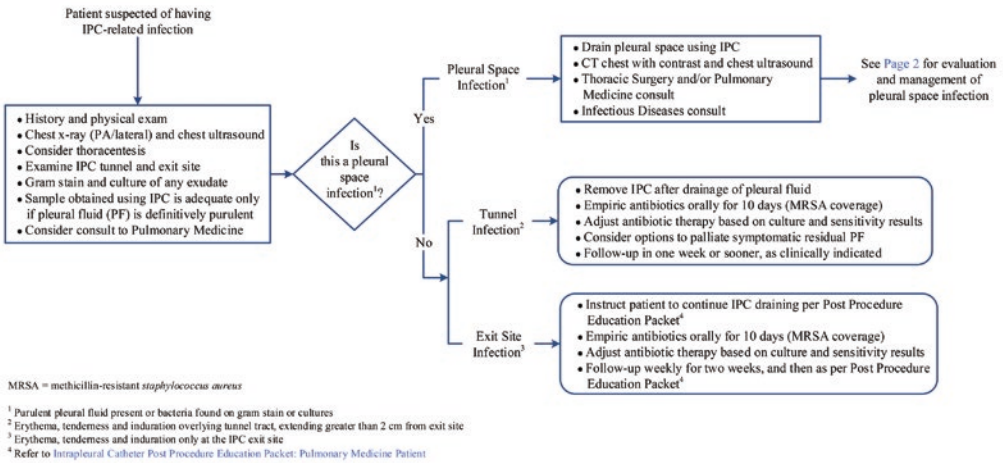
# Intrapleural Catheter (IPC) Related Infections

Page 1 of 4

Disclaimer: This algorithm has been developed for MD Anderson using a multidisciplinary approach considering circumstances particular to MD Anderson's specific patient population, services and structure, and clinical information. This is not intended to replace the independent medical or professional judgment of physicians or other health care providers in the context of individual clinical circumstances to determine a patient's care.

## INITIAL ASSESSMENT

## EVALUATION AND MANAGEMENT



Copyright 2021 The University of Texas MD Anderson Cancer Center

Department of Clinical Effectiveness V3  
Approved by the Executive Committee of the Medical Staff on 11/16/2021

b



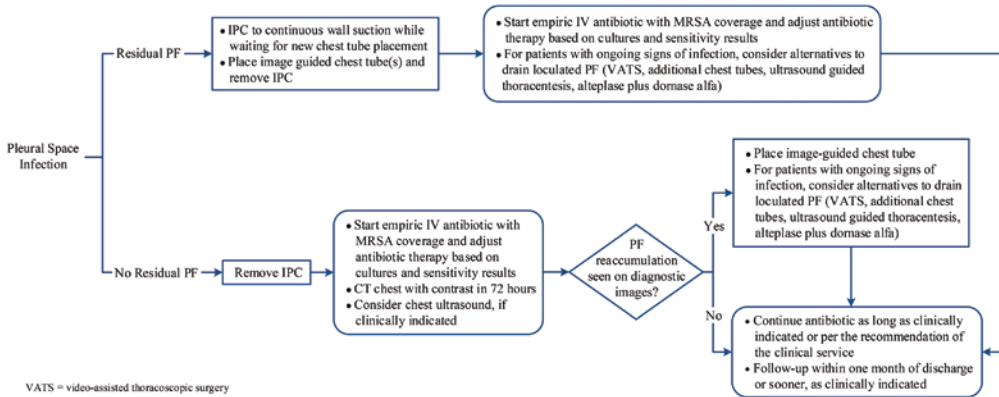
# Intrapleural Catheter (IPC) Related Infections

Page 2 of 4

Disclaimer: This algorithm has been developed for MD Anderson using a multidisciplinary approach considering circumstances particular to MD Anderson's specific patient population, services and structure, and clinical information. This is not intended to replace the independent medical or professional judgment of physicians or other health care providers in the context of individual clinical circumstances to determine a patient's care.

## EVALUATION

## MANAGEMENT AND FOLLOW-UP



Copyright 2021 The University of Texas MD Anderson Cancer Center

Department of Clinical Effectiveness V3  
Approved by the Executive Committee of the Medical Staff on 11/16/2021

**Fig. 33.8 (a)** Management of intrapleural catheter related infections. (Copyright 2021. The University of Texas MD Anderson Cancer Center (with permission)).

**(b)** Management of intrapleural catheter related infections. (Copyright 2021. The University of Texas MD Anderson Cancer Center (with permission))



*Mechanical complications including obstruction or clogging of IPC* have been reported in 3–9.1% of patients. It is important to correctly identify patients with this complication. Patients presenting with sudden reduction of PF drainage, having significant residual fluid identified by ultrasound or computed tomography on areas expected to be drained by a properly placed IPC, are very likely to have an obstructed catheter. We recommend to initially flush the IPC with 20 cc of saline solution. If drainage of PF following this maneuver remains below 150 cc, then we proceed with instillation of 4 mg of tissue plasminogen activator (tPA) diluted on 20 cc of saline solution with a dwell time of 1 h. A second 4 mg tPA dose with a dwell time of 12–24 h is used if PF drainage after the first dose remains below 150 cc. Chest x-ray PA and lateral is requested at any time more than a 150 cc of PF are obtained, to evaluate and document successful removal of residual PF. If drainage of PF remains below 150 cc after a second tPA dose, treatment is considered a failure, and additional procedures to remove PF should be considered to alleviate patient's dyspnea. Restoration of IPC flow with tPA is reported in about 80% of patients, with a re-occlusion incidence of 30% [68].

*Leakage* around the IPC is also rare (less than 2% incidence) occurring most often immediately after insertion and persisting for a few days. Increasing frequency of drainage using IPC generally resolves the problem. Leakage presenting several days after IPC placement should prompt an evaluation for a catheter-related infection.

*Dislodged catheter* occurs in up to 6% of patients after catheter insertion. Making small exit site incisions (0.5 cm), intentionally forcing the catheter polyester cuff into the tunnel and leaving an anchoring suture for 2 weeks, are our recommendations to prevent this complication. Patients presenting with dislodge catheters after fibrous adhesions have formed around the polyester cuff should prompt an evaluation for a catheter-related infection. All dislodge IPCs should be removed. If clinically indicated, a new IPC can be placed in a different location.

Some degree of *pain* related to catheter insertion is expected during the first 48 h after IPC placement. If needed, acetaminophen or nonsteroidal anti-inflammatory drugs (NSAIDs) can be prescribed to alleviate discomfort. Also, some mild-to-moderate pleurisy is expected at the end of the drainage procedure. Its cause is not well established but might be related to shearing forces over the parietal pleura caused by PF drainage. Pleurisy improves rapidly after drainage is stopped, lasting less than 30 min. On rare occasion, pleuritic pain might be intense. Premedication 20–30 min before PF drainage with acetaminophen, NSAID, or oral narcotics is recommended in these situations. Additional maneuvers that could help decreasing pleurisy include pinching or kinking the tubing system to decrease PF flow and/or stopping drainage after reaching certain amount of fluid before pain occurs. Persistent pain caused by nerve or periosteum damage and requiring removal of IPC has been reported in 0.4% of patients.

*Tumor seeding of insertion tract* might occur with any tumor type, but over 90% of the cases are patients with mesothelioma. The reported incidence of this complication is as low as 0.4% but was 10% in one case series. This complication develops 2 months or more after IPC insertion. Some groups advocated for prophylactic radiation therapy within 2 weeks after procedure, but there is not enough evidence to support this approach. Once catheter tract metastases developed, palliative radiation is safe and effective controlling pain and local disease progression.

Dedicated outpatient clinics to follow up patients after IPC insertion might help to promptly identify and treat complications related to catheter placement and use. Additionally, systematic data collection from these encounters will help implementing institutional quality assessment/quality improvement programs to improve patient care. Our group follows up patients 2 weeks after IPC insertion (suture removal is done at this time), and then every month for as long as the catheter is in place. Patients are evaluated clinically and radiographi-



cally with a posteroanterior and lateral chest x-ray. Patients are also encouraged to contact our clinic if they have questions or concerns related to the IPC. Clear guidelines are needed to know when IPC can be removed due to pleurodesis to avoid unnecessary additional days with IPC in place. Once daily catheter drainage is 150 cc or less for 3 consecutive days, our patients are instructed to drain PF every other day. While draining every other day, if PF is  $\leq 150$  cc in three consecutive occasions, patients are instructed to contact our clinic for evaluation of IPC removal.

Finally, placement of IPC using maximal sterile barrier precautions, on a standardized location, and with the assistance of ancillary personnel familiarized with catheter placement techniques, might decrease the incidence of catheter-related infections [65, 66].

Traditionally, *pleurodesis* has been the most widely used method to control recurrent MPE, and palliation might be obtained in a shorter time without the need for daily drainage of fluid as it occurs with IPCs. In general, the availability of sclerosing agents and local expertise will determine what will be offered to patients. The results from available literature suggest that chemical pleurodesis using large particle, sterilized asbestos-free talc is safe, efficacious, and cost-effective [69–72]. Both, thoracoscopic talc insufflation and talc slurry via chest tube seem to be equally effective as a method of administration, with reported success rates of  $>70\%$ , without significant differences in the rate of overall complications [73, 74]. The administration of talc slurry seems to be more effective using a large-bore chest tube (24 French) rather than a small-bore one (12 French), while large-bore chest tube might cause more discomfort to patients [70, 75].

Multiple complications are reported after talc pleurodesis including wound infection, empyema, persistent air leaks, pneumonia, pulmonary embolism, and acute respiratory failure [74]. However, the use of calibrated French large-particle talc has reduced the majority of the most

serious complications observed. Fever and pain are the most common post-procedure complications, but their actual incidence is unknown. Pain occurs almost invariably, and its management should be planned before the procedure is started. As expected, local practices and patient preferences affect the strategy selected to control pain, and more high-quality evidence-based information is required to properly address this aspect of pleurodesis, as there is a global desire to reduce the use of opioids. Results from a one randomized study suggest that when compared to opioids, using nonsteroidal anti-inflammatory drugs (NSAIDs) to control pain after talc slurry required more frequent rescue analgesia. However, the anti-inflammatory effect of the NSAIDs did not seem to affect pleurodesis rates [75]. New strategies using regional anesthetic blocks or epidural catheters for pain control, coupled with shorter duration of chest tube drainage and involvement of specialized pain control services, could result in higher patient satisfaction and less use of opioids [76].

Table 33.1 compares the advantages and disadvantages of IPCs and talc pleurodesis.

*Inpatient and outpatient strategies combining talc pleurodesis with IPCs* have been also studied, aiming at reducing the number of inpatient days and days with IPC in place.

One approach used thoracoscopic talc insufflation with a chest tube placed using the thoracoscopy port and a separate IPC. Although the quality of the evidence describing this technique is not ideal, it suggests that there is a reduction in inpatient days without affecting the pleurodesis rates or increasing the number of complications [77–79].

Outpatient administration of talc slurry using a previously placed IPC has also been employed in the management of recurrent pleural effusions. A randomized trial evaluating this strategy reported a higher rate of pleurodesis when compared with standard IPC drainage (43% vs. 23% at 35 days). However, the results need to be inter-

**Table 33.1** Compared advantages and disadvantages of IPC and talc pleurodesis

	IPC	Talc pleurodesis
Symptom palliation	Yes	Yes
Pleurodesis	≈35–45%	≈70%
Does palliation depend on pleurodesis success?	No	Yes
Outpatient procedure	Yes	No
Interruption of anti-cancer treatment	No	Yes (1–3 weeks)
Lung expansion required	No	Yes
Performance status	Any (better ≤2)	≤2
Life expectancy	Any (better >30 days)	>30 days (better >90 days)
Pleural fluid drainage after intervention?	Yes, daily or 3–4 times a week	No
Social support/care giver needed after intervention?	Likely	Unlikely
Incidence of infection	≈5%	≈1%
Overall morbidity	Low	Low
Mortality	Low	Low
Percentage of patients with MPE that could be eligible for the intervention	≈80–90%	≈20–30%

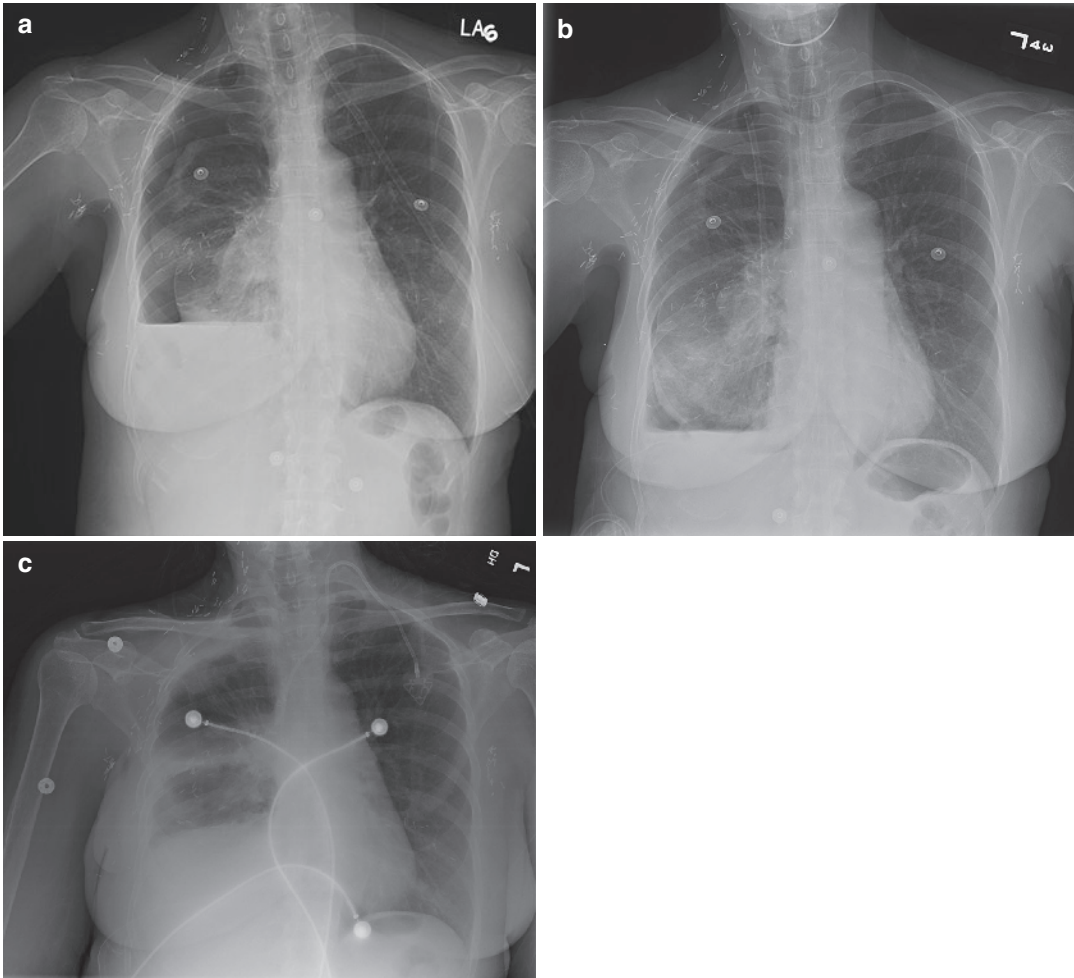
preted cautiously, considering that a large number of patients enrolled were excluded from the trial and nearly 10% of the patients assigned to a treatment arm were not included in the final analysis [80].

*Patients with suspected non-expandable lung* require further assessment to exclude the possibility of an airway obstruction amenable to endobronchial intervention before considering a pleural intervention.

An additional advantage of IPCs in the management of MPE is that their placement is appropriate whether there is an expandable lung, an important factor to ponder since nonexpandable lung might be highly prevalent (50%) among patients with MPEs [81]. Attempts at pleurodesis using any sclerosing agent or surgical technique in this group of patients is in general discouraged as it is futile and it can cause unnecessary harm. Therefore, the best alternative for patients with MPE and nonexpandable lung is an IPC.

IPCs are also a suitable alternative on those patients with pleural effusions and endobronchial obstructions that are not candidates for endobronchial interventions, patients with loculated effusions and after chemical or surgical pleurodesis failures.

The frequency of pleural fluid drainage using IPCs on patients with nonexpandable lung can be adjusted according to patient's needs and symptoms. Patient with ex-vacuo hydropneumothoraces without radiographic improvement after 1 or 2 weeks of daily drainage might prefer to drain pleural fluid only every several days to relieve symptoms. On the other hand, some patients might benefit from aggressive daily drainage of pleural fluid and air, as some of them might have autopleurodesis (Fig. 33.9a–c). The incidence of autopleurodesis in these situations is unknown.



**Fig. 33.9** (a) Ex-vacuo hydropneumothorax on a breast cancer patient after thoracentesis with drainage of 1800 cc of pleural fluid. Patient had improvement of dyspnea post-procedure. There were no clinical or radiographic evidence of tension pneumothorax. (b) Decreased

hydropneumothorax after IPC placement and drainage of 650 cc of fluid and air. Drainage was stopped due to chest pressure. Catheter was placed 24 h after thoracentesis. (c) Autopleurodesis four weeks after IPC insertion with daily drainage

### Especial Circumstances

Rarely, alternative modalities such as pleuroperitoneal shunts and parietal pleurectomy are used in the management of recurrent symptomatic effusions following pleurodesis failures or effusions associated with trapped lung.

Parietal pleurectomy, decortication, and pleuro-pneumonectomy are seldom feasible alternatives as these procedures are associated with more than 10% mortality rates and hardly

provide better symptom control than other palliative options. Candidates that might be considered for one of these procedures need to be in great physical condition and should have excellent disease control elsewhere and a life expectancy of more than a year [48, 82, 83].

Chylous effusions associated with malignancy are best controlled by treating the primary malignancy and implementing serial therapeutic thoracenteses while waiting on the results of the anti-cancer therapy. Prolonged loss of chyle, a

protein-rich, fat-laden, and lymphocyte-predominant fluid, may result in lymphopenia, severe nutritional depletion, and water and electrolyte unbalances. Mortality due to chylothorax can be as high as 50%. Among those patients with recurrent symptomatic chylothorax and cancer relapse or progressive disease despite adequate treatment, using dietary modifications, somatostatin, octreotide, midodrine, lymphatic embolization or thoracic duct ligation will be rarely successful. Case series assessing chemical pleurodesis on this population show mixed results and IPCs are a reasonable palliative option. Pleuroperitoneal shunt placement appears to be an attractive alternative; however, its mechanism displaces only 1.5–2.5 mL at a time, making its use cumbersome. Additionally, the incidence of device obstruction and infection is high [84–87]. On those patients presenting with malignant chylothorax and chylous ascites, chemical pleurodesis fails frequently. A strategy combining either therapeutic thoracentesis, paracentesis, IPC, or peritoneal drainage along with anti-tumoral treatment is a sensible choice that could control symptoms using less invasive interventions.

In summary, in patients with limited life expectancies, modalities that offer the best chance for palliation of symptoms, the lowest procedure-related morbidity and mortality, and the shortest hospital stay represent a reasonable approach to the management of recurrent malignant effusions. A multidisciplinary approach, involving oncology, pulmonary medicine, interventional radiology, and thoracic surgery, offers optimal opportunities to achieve these goals.

## References

1. Chernow B, Sahn SA. Carcinomatous involvement of the pleura: an analysis of 96 patients. *Am J Med.* 1977;63(5):695–702.
2. Rodríguez-Panadero F, Borderas Naranjo F, López MJ. Pleural metastatic tumours and effusions. Frequency and pathogenic mechanisms in a post-mortem series. *Eur Respir J.* 1989;2(4):366–9.
3. Meyer PC. Metastatic carcinoma of the pleura. *Thorax.* 1966;21(5):437–43.
4. Rodríguez-Panadero F. Effusions from malignancy. *Textbook of pleural diseases.* 2nd ed. London: Hodder and Arnold; 2008. p. 323–37.
5. Rodríguez-Panadero F, Borderas Naranjo F, López MJ. Neoplastic lymphatic block as a cause of pleural effusion. Incidence in a necropsy series. *Med Clin (Barc).* 1987;89(17):725–7.
6. Zebrowski BK, Yano S, Liu W, et al. Vascular endothelial growth factor levels and induction of permeability in malignant pleural effusions. *Clin Cancer Res.* 1999;5(11):3364–8.
7. Yeh HH, Lai WW, Chen HHW, Liu HS, Su WC. Autocrine IL-6-induced Stat3 activation contributes to the pathogenesis of lung adenocarcinoma and malignant pleural effusion. *Oncogene.* 2006;25(31):4300–9.
8. Yano S, Herbst RS, Shinohara H, et al. Treatment for malignant pleural effusion of human lung adenocarcinoma by inhibition of vascular endothelial growth factor receptor tyrosine kinase phosphorylation 1. *Clin Cancer Res.* 2000;6(3):957–65.
9. Maa H-C, Chao T-T, Wang C-Y, Pei D, Liang Y-J, Chen Y-L. VEGF-D as a marker in the aid of malignant metastatic pleural effusion diagnosis. *Appl Immunohistochem Mol Morphol.* 2015;23(3):209–14.
10. Zocchi L. Physiology and pathophysiology of pleural fluid turnover. *Eur Respir J.* 2002;20(6):1545–58.
11. Rodríguez-Panadero F, Borderas Naranjo F, López MJ. Benign pleural effusions in cancer patients. Frequency and etiopathogenic mechanism in a series of autopsy cases. *Rev Clin Esp.* 1988;183(6):311–2.
12. Sahn S. Pleural diseases related to metastatic malignancies. *Eur Respir J.* 1997;10(8):1907–13.
13. Porcel JM, Gasol A, Bielsa S, Civit C, Light RW, Salud A. Clinical features and survival of lung cancer patients with pleural effusions. *Respirology.* 2015;20(4):654–9.
14. Tremblay A, Robbins S, Berthiaume L, Michaud G. Natural history of asymptomatic pleural effusions in lung cancer patients. *J Bronchology Interv Pulmonol.* 2007;14(2):98–100.
15. Muruganandan S, Azzopardi M, Thomas R, et al. The pleural effusion and symptom evaluation (PLEASE) study of breathlessness in patients with a symptomatic pleural effusion. *Eur Respir J.* 2020;55(5):1900980.
16. Estenne M, Yernault J-C, De Troyer A. Mechanism of relief of dyspnea after thoracocentesis in patients with large pleural effusions. *Am J Med.* 1983;74(5):813–9.
17. Martínez-Moragón E, Aparicio J, Sanchis J, Menéndez R, Rogado MC, Sanchis F. Malignant pleural effusion: prognostic factors for survival and response to chemical Pleurodesis in a series of 120 cases. *Respiration.* 1998;65(2):108–13.
18. Shannon VR, Eapen GA, Jimenez CA, et al. Respiratory complications. *Holland-Frei Cancer Med.* 2016;1–29.
19. Sahn SA. Malignancy metastatic to the pleura. *Clin Chest Med.* 1998;19(2):351–61.

20. Evans AL, Gleeson FV. Radiology in pleural disease: state of the art. *Respirology*. 2004;9(3):300–12.
21. Lichtenstein D, Goldstein I, Mourgeon E, Cluzel P, Grenier P, Rouby JJ. Comparative diagnostic performances of auscultation, chest radiography, and lung ultrasonography in acute respiratory distress syndrome. *Anesthesiology*. 2004;100(1):9–15.
22. Mayo PH, Doelken P. Pleural ultrasonography. *Clin Chest Med*. 2006;27(2):215–27.
23. Salamonsen MR, Lo AK, Ng AC, Bashirzadeh F, Wang WY, Fielding DI. Novel use of pleural ultrasound can identify malignant entrapped lung prior to effusion drainage. *Chest*. 2014;146(5):1286–93.
24. Loddenkemper R. Thoracoscopy--state of the art. *Eur Respir J*. 1998;11(1):213–21.
25. Anderson CB, Philpott GW, Ferguson TB. The treatment of malignant pleural effusions. *Cancer*. 1974;33(4):916–22.
26. Grosu HB, Kazzaz F, Vakil E, Molina S, Ost D. Sensitivity of initial thoracentesis for malignant pleural effusion stratified by tumor type in patients with strong evidence of metastatic disease. *Respiration*. 2018;96(4):363–9.
27. Light RW. Tumor markers in undiagnosed pleural effusions. *Chest*. 2004;126(6):1721–2.
28. Porcel JM, Vives M, Esquerda A, Salud A, Pérez B, Rodríguez-Panadero F. Use of a panel of tumor markers (carcinoembryonic antigen, cancer antigen 125, carbohydrate antigen 15–3, and cytokeratin 19 fragments) in pleural fluid for the differential diagnosis of benign and malignant effusions. *Chest*. 2004;126(6):1757–63.
29. Faiz SA, Bashoura L, Lei X, et al. Pleural effusions in patients with acute leukemia and myelodysplastic syndrome. *Leuk Lymphoma*. 2013;54(2):329–35.
30. Faiz SA, Sahay S, Jimenez CA. Pleural effusions in acute and chronic leukemia and myelodysplastic syndrome. *Curr Opin Pulm Med*. 2014;20(4):340–6.
31. Nguyen A, Bashoura L, Jimenez CA, et al. Characteristics of pleural effusions in patients after hematopoietic stem cell transplantation. *Chest*. 2010;138(4):812A.
32. Vakil E, Jimenez CA, Faiz SA. Pleural effusions in hematologic malignancies and their management with indwelling pleural catheters. *Curr Opin Pulm Med*. 2018;24(4):384.
33. Styskel BA, Lopez-Mattei J, Jimenez CA, Stewart J, Hagemester FB, Faiz SA. Ibrutinib-associated serositis in mantle cell lymphoma. *Am J Respir Crit Care Med*. 2019;199(12):e43–4.
34. O'hara MF, Cousar JB, Glick AD, Collins RD. Multiparameter approach to the diagnosis of hematopoietic-lymphoid neoplasms in body fluids. *Diagn Cytopathol*. 1985;1(1):33–8.
35. Maskell N, Gleeson F, Davies R. Standard pleural biopsy versus CT-guided cutting-needle biopsy for diagnosis of malignant disease in pleural effusions: a randomised controlled trial. *Lancet*. 2003;361(9366):1326–30.
36. Clive AO, Kahan BC, Hooper CE, et al. Predicting survival in malignant pleural effusion: development and validation of the LENT prognostic score. *Thorax*. 2014;69(12):1098–104.
37. Psallidas I, Kanellakis NI, Gerry S, et al. Development and validation of response markers to predict survival and pleurodesis success in patients with malignant pleural effusion (PROMISE): a multicohort analysis. *Lancet Oncol*. 2018;19(7):930–9.
38. Burrows CM, Mathews WC, Colt HG. Predicting survival in patients with recurrent symptomatic malignant pleural effusions: an assessment of the prognostic values of physiologic, morphologic, and quality of life measures of extent of disease. *Chest*. 2000;117(1):73–8.
39. The University of Texas MD Anderson Cancer Center. Management of malignant pleural effusion - Adult. 2021.; <https://www.mdanderson.org/content/dam/mdanderson/documents/for-physicians/algorithms/clinical-management/clin-management-pleural-effusion-diag-web-algorithm.pdf>. Accessed 18 Mar 2022.
40. Sagar AES, Landaeta MF, Adrianza AM, et al. Complications following symptom-limited thoracentesis using suction. *Eur Respir J*. 2020;56(5):1902356.
41. Lentz RJ, Shojaee S, Grosu HB, et al. The impact of gravity vs suction-driven therapeutic thoracentesis on pressure-related complications: the GRAVITAS multicenter randomized controlled trial. *Chest*. 2020;157(3):702–11.
42. Sundaralingam A, Bedawi EO, Harriss EK, Munnavar M, Rahman NM. The frequency, risk factors and management of complications from pleural procedures. *Chest*. 2022;161(5):1407–25.
43. Fong C, Tan CWC, Tan DKY, See KC. Safety of thoracentesis and tube thoracostomy in patients with uncorrected coagulopathy: a systematic review and meta-analysis. *Chest*. 2021;160(5):1875–89.
44. Grosu HB, Molina S, Casal R, et al. Risk factors for pleural effusion recurrence in patients with malignancy. *Respirology*. 2019;24(1):76–82.
45. Massarelli E, Onn A, Marom EM, et al. Vandetanib and indwelling pleural catheter for non-small-cell lung cancer with recurrent malignant pleural effusion. *Clin Lung Cancer*. 2014;15(5):379–86.
46. Verma A, Chopra A, Lee YW, et al. Can EGFR-tyrosine kinase inhibitors (TKI) alone without talc pleurodesis prevent recurrence of malignant pleural effusion (MPE) in lung adenocarcinoma. *Curr Drug Discov Technol*. 2016;13(2):68–76.
47. Jänne PA, Yang JC-H, Kim D-W, et al. AZD9291 in EGFR inhibitor-resistant non-small-cell lung cancer. *N Engl J Med*. 2015;372(18):1689–99.
48. Heffner JE. Management of malignant pleural effusions. *Up to Date*. 2008;1–7.
49. Ost DE, Niu J, Zhao H, Grosu HB, Giordano SH. Quality gaps and comparative effectiveness of management strategies for recurrent malignant pleural effusions. *Chest*. 2018;153(2):438–52.



50. Mitchell MA, Dhaliwal I, Mulpuru S, Amjadi K, Chee A. Early readmission to hospital in patients with cancer with malignant pleural effusions: analysis of the nationwide readmissions database. *Chest*. 2020;157(2):435–45.
51. Chung C-L, Chen Y-C, Chang S-C. Effect of repeated thoracenteses on fluid characteristics, cytokines, and fibrinolytic activity in malignant pleural effusion. *Chest*. 2003;123(4):1188–95.
52. Uzbeck MH, Almeida FA, Sarkiss MG, et al. Management of malignant pleural effusions. *Adv Ther*. 2010;27(6):334–47.
53. Wahidi MM, Reddy C, Yarmus L, et al. Randomized trial of pleural fluid drainage frequency in patients with malignant pleural effusions. The ASAP trial. *Am J Respir Crit Care Med*. 2017;195(8):1050–7.
54. Muruganandan S, Azzopardi M, Fitzgerald DB, et al. Aggressive versus symptom-guided drainage of malignant pleural effusion via indwelling pleural catheters (AMPLE-2): an open-label randomised trial. *Lancet Respir Med*. 2018;6(9):671–80.
55. Kapp CM, Lee HJ. Malignant pleural effusions. *Clin Chest Med*. 2021;42(4):687–96.
56. Davies HE, Mishra EK, Kahan BC, et al. Effect of an indwelling pleural catheter vs chest tube and talc pleurodesis for relieving dyspnea in patients with malignant pleural effusion: the TIME2 randomized controlled trial. *JAMA*. 2012;307(22):2383–9.
57. Thomas R, Fysh ET, Smith NA, et al. Effect of an indwelling pleural catheter vs talc pleurodesis on hospitalization days in patients with malignant pleural effusion: the AMPLE randomized clinical trial. *JAMA*. 2017;318(19):1903–12.
58. Mekhaieel E, Kashyap R, Mullon JJ, Maldonado F. Infections associated with tunnelled indwelling pleural catheters in patients undergoing chemotherapy. *J Bronchology Interv Pulmonol*. 2013;20(4):299–303.
59. Chan Wah Hak C, Sivakumar P, Ahmed L. Safety of indwelling pleural catheter use in patients undergoing chemotherapy: a five-year retrospective evaluation. *BMC Pulm Med*. 2016;16(1):1–6.
60. Ost DE, Jimenez CA, Lei X, et al. Quality-adjusted survival following treatment of malignant pleural effusions with indwelling pleural catheters. *Chest*. 2014;145(6):1347–56.
61. Casal RF, Bashoura L, Ost D, et al. Detecting medical device complications: lessons from an indwelling pleural catheter clinic. *Am J Med Qual*. 2013;28(1):69–75.
62. Tremblay A, Michaud G. Single-center experience with 250 tunnelled pleural catheter insertions for malignant pleural effusion. *Chest*. 2006;129(2):362–8.
63. Van Meter ME, McKee KY, Kohlwes RJ. Efficacy and safety of tunneled pleural catheters in adults with malignant pleural effusions: a systematic review. *J Gen Intern Med*. 2011;26(1):70–6.
64. Iyer NP, Reddy CB, Wahidi MM, et al. Indwelling pleural catheter versus pleurodesis for malignant pleural effusions. A systematic review and meta-analysis. *Ann Am Thorac Soc*. 2019;16(1):124–31.
65. Gilbert CR, Lee HJ, Akulian JA, et al. A quality improvement intervention to reduce indwelling tunneled pleural catheter infection rates. *Ann Am Thorac Soc*. 2015;12(6):847–53.
66. Faiz SA, Pathania P, Song J, et al. Indwelling pleural catheters for patients with hematologic malignancies. A 14-year, single-center experience. *Ann Am Thorac Soc*. 2017;14(6):976–85.
67. The University of Texas MD Anderson Cancer Center. Intrapleural catheters (IPC) related infections. 2021. <https://www.mdanderson.org/content/dam/mdanderson/documents/for-physicians/algorithms/clinical-management/clin-management-intrapleural-catheters-web-algorithm.pdf>. Accessed 18 Mar 2022.
68. Vial MR, Ost DE, Eapen GA, et al. Intrapleural fibrinolytic therapy in patients with nondraining indwelling pleural catheters. *J Bronchology Interv Pulmonol*. 2016;23(2):98–105.
69. Janssen JP, Collier G, Astoul P, et al. Safety of pleurodesis with talc poudrage in malignant pleural effusion: a prospective cohort study. *Lancet*. 2007;369(9572):1535–9.
70. Clive AO, Jones HE, Bhatnagar R, Preston NJ, Maskell N. Interventions for the management of malignant pleural effusions: a network meta-analysis. *Cochrane Database Syst Rev*. 2016;2016(5):CD010529.
71. Shaw PH, Agarwal R. Pleurodesis for malignant pleural effusions. *Cochrane Database Syst Rev*. 2004(1):CD002916.
72. Walker-Renard PB, Vaughan LM, Sahn SA. Chemical pleurodesis for malignant pleural effusions. *Ann Intern Med*. 1994;120(1):56–64.
73. Bhatnagar R, Piotrowska HE, Laskawiec-Szkonter M, et al. Effect of thorascopic talc poudrage vs talc slurry via chest tube on pleurodesis failure rate among patients with malignant pleural effusions: a randomized clinical trial. *JAMA*. 2020;323(1):60–9.
74. Dresler CM, Olak J, Herndon JE, et al. Phase III intergroup study of talc poudrage vs talc slurry sclerosis for malignant pleural effusion. *Chest*. 2005;127(3):909–15.
75. Rahman NM, Pepperell J, Rehal S, et al. Effect of opioids vs NSAIDs and larger vs smaller chest tube size on pain control and pleurodesis efficacy among patients with malignant pleural effusion: the TIME1 randomized clinical trial. *JAMA*. 2015;314(24):2641–53.
76. Cujíño IF, Velásquez M, Ariza F, Loaiza JH. Awake epidural anesthesia for thorascopic pleurodesis: a prospective cohort study. *Colomb J Anesthesiol*. 2013;41(1):10–5.
77. Reddy C, Ernst A, Lamb C, Feller-Kopman D. Rapid pleurodesis for malignant pleural effusions: a pilot study. *Chest*. 2011;139(6):1419–23.

78. Boujaoude Z, Bartter T, Abboud M, Pratter M, Abouzgheib W. Pleuroscopic Pleurodesis combined with tunneled pleural catheter for management of malignant pleural effusion. *J Bronchology Interv Pulmonol*. 2015;22(3):237–43.
79. Krochmal R, Reddy C, Yarmus L, Desai NR, Feller-Kopman D, Lee HJ. Patient evaluation for rapid pleurodesis of malignant pleural effusions. *J Thorac Dis*. 2016;8(9):2538.
80. Bhatnagar R, Keenan EK, Morley AJ, et al. Outpatient talc administration by indwelling pleural catheter for malignant effusion. *N Engl J Med*. 2018;378(14):1313–22.
81. Chopra A, Judson MA, Doelken P, Maldonado F, Rahman NM, Huggins JT. The relationship of pleural manometry with postthoracocentesis chest radiographic findings in malignant pleural effusion. *Chest*. 2020;157(2):421–6.
82. Antony VB, Loddenkemper R, Astoul P, et al. Management of malignant pleural effusions. *Eur Respir J*. 2001;18(2):402–19.
83. Fry WA, Khandekar JD. Parietal pleurectomy for malignant pleural effusion. *Ann Surg Oncol*. 1995;2(2):160–4.
84. Maldonado F, Cartin-Ceba R, Hawkins FJ, Ryu JH. Medical and surgical management of chylothorax and associated outcomes. *Am J Med Sci*. 2010;339(4):314–8.
85. Mares DC, Mathur PN. Medical thoracoscopic talc pleurodesis for chylothorax due to lymphoma: a case series. *Chest*. 1998;114(3):731–5.
86. Heffner JE. Management of chylothorax. In: Post GF, BVC, editors. *UpToDate*. Waltham: UpToDate; 2016. Accessed 2014.
87. Jimenez CA, Mhatre AD, Martinez CH, Eapen GA, Onn A, Morice RC. Use of an indwelling pleural catheter for the management of recurrent chylothorax in patients with cancer. *Chest*. 2007;132(5):1584–90.



Melissa Tukey, KeriAnn Van Nostrand,  
and Gaëtane C. Michaud

## Introduction

Medical thoracoscopy is both a diagnostic and therapeutic pleural procedure to visualize the pleural space, obtain biopsies, and in certain cases perform localized interventions. It may be performed safely in either an inpatient or outpatient setting, requiring only moderate sedation, local anesthesia, and a small amount of analgesia. It offers a minimally invasive alternative to video-assisted thoracoscopic surgery (VATS). Medical thoracoscopy is sometimes referred to as pleuroscopy and is most often performed in the setting of undiagnosed exudative effusions, malignant pleural effusions, or recurrent pneumothorax. It is frequently considered when pleural fluid analysis and cytology from thoracentesis fail to identify the etiology of a recurrent, exudative pleural effusion. Worldwide, medical thoracoscopy is considered the gold standard for the diagnosis of tuberculous pleural effusions with a high degree of safety and efficacy. It is also highly sensitive and specific for the diagnosis of malignant pleural effusions, while also achieving a high rate of pleurodesis when chemical pleurodesis is performed.

The very first case report of medical thoracoscopy dates back to 1866 when Richard

Cruise described his single patient experience. Hans Christian Jacobeus further developed the technique in the early 1900s and is considered the “father” of medical thoracoscopy. In the pre-antibiotic era, medical thoracoscopy was primarily used in the management of infectious pleural effusions, particularly tuberculous effusions, but its use declined with the discovery and optimization of antibiotic regimens. Interest in the procedure was renewed when Roche and his colleagues first described the use of medical thoracoscopy to achieve pleurodesis by instilling talc into the pleural space in 1963. Interestingly, these procedures were mainly performed by pulmonary physicians until the early 1990s when thoracic surgeons adapted these techniques along with advances in abdominal laparoscopic surgery to the thorax [1]. No data exists regarding the exact prevalence of the use of medical thoracoscopy around the world, although variation may mirror the prevalence of diseases for which it is commonly performed, such as malignancy and tuberculosis (TB), and with the availability of other expertise such as video-assisted or robotic-thoracic surgery. According to a survey of US pulmonology training programs published in 2005, only 12% of programs offered training in medical thoracoscopy [2]. The availability of the procedure is thought to be much more widespread in Europe, as many of the pioneers and champions of this procedure are European.

---

M. Tukey (✉) · K. Van Nostrand · G. C. Michaud  
Pulmonary, Critical Care and Sleep Medicine,  
University of South Florida, Tampa, FL, USA  
e-mail: [melissatukey@usf.edu](mailto:melissatukey@usf.edu); [keriannv@usf.edu](mailto:keriannv@usf.edu)

## Diagnostic Approach to Pleural Effusions

The initial step in the management of nearly all pleural effusions is diagnostic and/or therapeutic thoracentesis. Light and his colleagues classified pleural effusions into the diagnostic categories of exudates and transudates based on the pleural fluid composition obtained via thoracentesis [3]. Transudative effusions are defined as having low pleural to serum ratios of protein and lactate dehydrogenase (LDH) and are often associated with conditions leading to increased hydrostatic pressure such as heart failure, liver or renal disease. On the other hand, exudative effusions are defined by the presence of elevated pleural to serum ratios of total protein ( $>0.5$ ) and/or LDH ( $>0.6$  or pleural LDH  $>2/3$  the upper limit of the normal serum value). The differential diagnosis of exudative effusions remains broad. Worldwide the most common causes are infections, including tuberculosis, and malignancy. Light's classification system, developed nearly 50 years ago, has been widely criticized as the results may be influenced by manipulation of the pleural space either mechanically or chemically. Disruption of the pleural space results in localized inflammation which may change the cellular and biochemical makeup of the pleural fluid. In addition, diuretic therapy may alter the pleural fluid composition resulting in the misclassification of a transudate as an exudate. Although the purpose of classifying pleural effusions as transudative and exudative is to limit the differential diagnosis and mitigate patient risk from futile diagnostic testing, it must also be noted that approximately 10% of transudative effusions may be malignant and necessitate appropriate evaluation [4]. There are a few plausible explanations as to how a malignant effusion could be meet diagnostic criteria of a transudate. Early malignant effusions may simply be the result of the tumor causing obstruction of the lymphatics as opposed to frank invasion or tumor emboli to the pleura. The other consideration is that the cancer patient may have a concomitant medical issue leading to a transudative pleural effusion such as pulmonary edema. In the setting where there is a high pre-test prob-

ability of malignancy, further evaluation of the pleural space with medical thoracoscopy in transudative effusions should be considered.

Medical thoracoscopy is a powerful tool in the diagnostic evaluation of undiagnosed or what are commonly called "unclear" exudative effusions. An unclear exudate is defined as an effusion meeting Light's Criteria for an exudate, but the etiology remains unidentified after initial routine evaluation including imaging, thoracentesis for cytology, microbiology and biochemistries, as well as special tests for certain populations. Approximately 15% of exudative effusions are categorized as unclear exudates [5]. These effusions require additional diagnostic testing, particularly to exclude malignancy. Although it is commonly believed that pleural fluid appearance predicts malignancy, a recent study has demonstrated that bloody appearance is not necessarily indicative of malignancy [6]. The sensitivity of thoracentesis for malignancy is unfortunately only 40% for the initial specimen, rising to around 70% with 3 consecutive thoracenteses [7]. The procedures with high sensitivity and specificity for diagnosing malignancy include closed pleural biopsy, medical thoracoscopy, and VATS. Computed tomography (CT)-guided biopsy is also a consideration; however, this procedure is often limited by access to the procedure, risk of pneumothorax, bleeding, and technical aspects related to movement particularly when lesions are near or on the hemidiaphragm. With respect to closed pleural biopsy, it can readily be done at the bedside; however, relatively few practicing pulmonologists or even newer generation interventional pulmonologists have much experience with this procedure. In a 2005 survey of pulmonary and critical care program directors, only 48% of programs stated that their fellows performed the requisite five procedures considered the minimal standard for competence [2]. Interestingly, in a similar survey of interventional pulmonology fellowships nearly a decade later, closed pleural biopsy is not mentioned as a core competence [8]. In a systematic review and meta-analysis of studies comparing the sensitivity and specificity of closed pleural biopsy compared with medical thoracoscopy,

closed pleural biopsy had pooled sensitivity and specificities of 77% and 99%, respectively, compared with 93% and 100% for medical thoracoscopy [9]. Medical thoracoscopy allows for directed biopsies of abnormalities identified by direct inspection of the pleura, at least partially explaining the increased sensitivity of the procedure. Both procedures are quite safe with pooled complication rates of 8% for medical thoracoscopy and 5% for closed pleural biopsy. Although the complication rate appears significantly higher for medical thoracoscopy, the most common complication documented is subcutaneous emphysema which for the most part is of little clinical significance [10].

---

## Diagnostic Indications for Medical Thoracoscopy

### Lung Cancer

As stated above, medical thoracoscopy has an important clinical role in the diagnostic algorithm for unclear exudates and in some cases transudative effusions. Staging of cancers is one of the most common indications for medical thoracoscopy with a pooled sensitivity of 92% (range 88–95%). A major advantage of medical thoracoscopy is the ability to visually assess the pleura. Sanchez-Armengol first described a simple, semi-quantitative method to assess disease involvement of the pleura at time of thoracoscopy in 1993. Essentially it assigns a score of 0–3 depending on whether there is no, isolated, diffuse or massive tumor involvement of the costoparietal, visceral, and diaphragmatic pleural surfaces [11]. This method has subsequently been modified to add a grade for adhesions (0–4) and whether or not the effusion is bloody. The adhesions are graded as follows: 0 none, 1 localized and non-obstructive, 2 obstructing 1/3 of thoracic cavity from visualization, 3 obstructing 2/3 pleural surface from view, and 4 fused pleural space unable to perform procedure. Extent of pleural carcinomatosis (EPC) and grade of adhe-

sion are both associated with prognosis on multivariate analysis ( $p = 0.007$  and  $p = 0.019$ , respectively). Of note, these findings predict a median survival difference for non-small cell lung cancer of 3 months for EPC and 6 months for grade of adhesions [12].

### Mesothelioma

Mesothelioma can often portend a more complex diagnostic dilemma as disease extent is directly correlated with prognosis which in turn impacts on treatment. The extent of tumor invasion, cellular subtype, and molecular profile may impact prognosis and treatment. Literature is sparse comparing the diagnostic techniques for malignant mesothelioma. Pleural fluid cytology alone for the diagnosis and prognostication of malignant mesothelioma is limited with reported low sensitivity. Reactive mesothelial cells may have a similar appearance in cytology specimens. Newer techniques including an increasing array of biomarkers will most assuredly increase the utility of pleural fluid analysis for mesothelioma in the future but at present these remain experimental due to small sample sizes and variability in methods of analysis [13]. Computed tomography or ultrasound-guided biopsy do have the advantage in that they may be safely performed in patients with overall poor performance status including those with small or no effusion or those unable to tolerate sedation due to comorbid illness. Recently published guidelines by the American Society for Clinical Oncology suggest that thoracoscopy with pleural biopsy be performed as it may assist with staging, elucidate pathologic cell type, confirm or establish the diagnosis, as well as provide material for additional testing such as molecular profiling [14]. Medical thoracoscopy provides an advantage over other surgical options such as video-assisted thoracoscopic surgery or robotic surgery in that it is generally performed using a single, small access port that may be readily resected or radiated to avoid tumor spread along the procedural tract.



## Other Tumors

Medical thoracoscopy may be beneficial in other tumor cell types such as hematologic malignancy, and breast cancer. The literature regarding the utility of the procedure in the management of pleural involvement from hematologic malignancies is limited. Effusions in patients with hematologic malignancy may be either malignant or benign. Pleural involvement does portend a poorer prognosis for patients with hematologic malignancies [15].

Diagnosis of hematologic malignancies via pleural fluid analysis may be limited by lack of cellularity and ambiguous morphology. Flow cytometry and immunohistochemistry may be performed on tissue samples when pleural fluid studies are non-diagnostic. In these cases, medical thoracoscopy with directed biopsy of the pleura may assist with diagnosis, prognostication, and treatment.

With respect to breast cancer, many patients with advanced-stage breast cancer will develop a pleural effusion over the course of their illness. The effusion may be secondary to drug toxicity, radiation injury, volume overload, or metastatic disease. The ability to determine the cause of the effusion may markedly alter therapy. Pleural fluid may be used for tumor markers including estrogen and progesterone receptors, HER2/neu, and even check point inhibitors such as PD-L1 (programmed death-ligand 1). This does require preparation of a cell block. Biopsies performed via thoracoscopy are large, generally have a high tumor tissue burden when taken from areas of obvious malignancy, and may reliably provide tissue for the detection of hormone receptors [16]. Our unpublished experience is that thoracoscopic biopsies from grossly abnormal areas of the pleura also provides ample tissue for molecular analysis including next-generation sequencing. In the era of personalized medicine, the pleura represents a rich source of tissue that may be obtained at the same time

as performing palliative procedures such as pleurodesis or tunneled pleural catheter placement.

## Tuberculosis

Worldwide tuberculosis (TB) represents one of the predominant causes of pleural effusion; however, in developed countries the prevalence is much lower. Although pleural fluid is often sent for acid fast bacilli (AFB), it is believed that fluid accumulation is primarily the result of an inflammatory response to the pathogen, as evidenced by granulomatous inflammation of the pleura, as opposed to a heavy burden of organisms. As such it is not surprising that the diagnostic yield of pleural fluid AFB alone is low. When combined with an adenosine deaminase (ADA)  $>40 \mu\text{L}$  and LDH  $>200 \mu\text{L}$ , the sensitivity of pleural fluid analysis increases to 74% with a specificity of 80%. False positives may occur in patients with empyema or lymphoma related-effusions which may also have elevated ADA and LDH levels [17]. Medical thoracoscopy provides the opportunity to inspect the pleural space. Kong and colleagues described the classic visual findings seen at thoracoscopy for pleural TB. These include necrosis, diffuse miliary nodules, pleural nodularity, and thickened pleura with or without loculation [18]. The classic appearance alone carries a diagnostic accuracy of 93%. When biopsies are performed, the sensitivity of thoracoscopy nears 100% with granulomatous inflammation as the defining feature. Closed pleural biopsy in the setting of a lymphocytic effusion with an ADA  $>40 \mu\text{L}$  and LDH  $>200 \mu\text{L}$  approaches the diagnostic yield of medical thoracoscopy when both histopathology and culture results are considered; however, for the subset of patients with culture positivity alone it may take longer to obtain a diagnosis considering the high sensitivity and specificity of the simple appearance of the pleura in pleural TB. Closed pleural biopsy cultures are diagnostic in approximately 60% of cases, but these results are often delayed several weeks [18, 19].

## Therapeutic Indications

### Pleurodesis for Malignant Pleural Effusion

The term pleurodesis is used to describe pleural symphysis achieved by mechanical or chemical means. There exists a large volume of literature comparing pleurodesis agents and efficacy. The more commonly described chemical pleurodesis agents are talc, bleomycin, doxycycline, and betadine. A Cochrane review published in 2020 comparing chemical pleurodesis agents showed that talc results in fewer pleurodesis failures compared to bleomycin or doxycycline [20]. Pleurodesis via chest tube (talc slurry) is essentially as efficacious as talc insufflation via medical thoracoscopy (talc poudrage). Indwelling pleural catheters offer an alternative to either talc slurry or talc poudrage and in many patients will result in auto-pleurodesis. Daily drainage may increase pleurodesis rates and allow for earlier catheter removal [21]. Reddy and colleagues described a technique that combined talc poudrage via medical thoracoscopy followed by insertion of an indwelling pleural catheter [22]. This combined procedure reduced the length of hospital stay from 3.5 days to 1.8 days and the time to pleural catheter removal to a median of 7.5 days. A small study only published in abstract form described a similar technique combining medical thoracoscopy with parietal pleural biopsy followed by tunneled pleural catheter placement without talc poudrage. Similar to the rapid pleurodesis protocol described by Reddy, tunneled pleural catheters could be removed at the 2 week follow-up visit in 92% of patients and 96% of patients were discharged the day of the procedure [22]. Although less invasive means of palliation of malignant pleural effusions are available, thoracoscopy has the advantage of being able to inspect the pleural space, perform directed biopsies and achieve effective pleurodesis safely and expeditiously.

### Pleurodesis of Pneumothorax

Little has been written in recent years about the role of medical thoracoscopy for pneumothorax. The most recent guidelines come from the European Respiratory Society Task Force in 2015 [23]. The task force performed a comprehensive review of the literature on which it based its recommendations. Talc pleurodesis for the prevention of recurrence of spontaneous pneumothorax has a long history and has been associated with an efficacy rate of >90%. Recurrence rate following talc poudrage was 5% compared to 27% following chest tube drainage without pleurodesis [24]. The safety of talc has been raised due to concern for the systemic absorption of the particles and the subsequent development of adult respiratory distress syndrome. This may be particularly true for small particle size talc which may lead to greater systemic absorption and more intense pleural inflammation [25]. As the talc supply in Europe does appear to be safe, European pulmonologists have developed treatment algorithms including talc poudrage for pleurodesis after pneumothorax and there is a drive to include medical pleuroscopy with talc poudrage even earlier in the algorithm, at the index collapse rather than awaiting relapse [26]. The rationale is to minimize recurrence of the pneumothorax considering the high relapse rate described above. The role of medical thoracoscopy with talc poudrage in secondary pneumothorax is poorly studied as these patients often have complex medical histories that impact on their ability to tolerate even moderate sedation.

### Thoracoscopic Drainage

Medical thoracoscopy can be a valuable tool in the management of both parapneumonic effusions and empyemas. Infectious pleural effusions may rapidly become more complex as fibrin deposition occurs. Over time the thin fibrinous bands become thicker and more complex, with

the development of loculations. Penetration of antibiotics into the pleural space may be limited, particularly in loculated pleural effusions; therefore, intervention to release the infected fluid from the loculations and free the pleural space may be necessary. Thoracoscopic drainage may be considered following a failure of antibiotics and chest tube drainage alone. Alternatively, it may be considered when ultrasound or other imaging identifies a complex pleural space. Ravaglia et al. evaluated the use of medical thoracoscopy in addition to antibiotics for the management of infectious effusions. They reported an efficacy of 85% overall: 100% for free-flowing effusions, 92% for effusions with simple loculations and 50% for effusions with complex or multifocal loculations [27]. Intrapleural fibrinolytic therapy as an alternative to thoracoscopic management has been studied extensively. The MIST2 (Multicenter Intrapleural Sepsis Trial) trial evaluated the intrapleural instillation of t-PA (tissue plasminogen activator) and DNase (deoxyribonuclease) into the pleural space to reduce pleural fluid viscosity and breakdown fibrin. Compared to placebo or either agent alone, the use of t-PA and DNAase demonstrated a favorable safety profile and resulted in a reduction in length of stay and need for surgical intervention [28]. That said, it is associated with a high cost of care [29]. A small, multicenter study presented some preliminary data suggesting that medical thoracoscopic drainage in addition to antifibrinolytics may further reduce length of stay and positively impact the cost of care [30]. This strategy needs to be validated in a larger study. In centers with expertise in medical thoracoscopy, the role of formal decortication in the management of infectious pleural effusions may be limited to patients with non-expansile lungs despite less invasive strategies.

## Drug Delivery

Due to the vascular nature of the pleura, it is a prime site for drug and vaccine delivery. Although this has been studied for many years, there remains little high-level data. Systemic response

to local treatment in the pleura has the potential to add significantly to current therapies for multiple cancer types including primary pleural malignancies such as mesothelioma, lung cancer, or metastatic non-pulmonary malignancies.

---

## Procedural Safety and Contraindications

Medical thoracoscopy is a very safe procedure that can be performed in most patients. A large retrospective study evaluating the safety of medical thoracoscopy included 1926 patients over 25 years [10]. Mortality was 0.1% and was attributable to one patient not tolerating the induction of a pneumothorax. Seven patients experienced bleeding complications (0.4%), one of whom required surgical intervention. Lung injury occurred in six patients (0.3%) and nine (0.5%) patients developed prolonged air leaks. Air leaks were most frequent in patients undergoing bullectomy. Of the minor complications described, localized skin infection, subcutaneous emphysema, pain, and fever were the most common (7.1%, 3.4%, 38.9%, and 20.8%, respectively). It should be noted that complication rates (pain, fever and infection) for diagnostic thoracoscopy are significantly lower compared to those for therapeutic thorascopies.

Medical thoracoscopy does require the patient to tolerate moderate sedation, local anesthesia, and lateral decubitus positioning for the duration of the procedure. Contraindications therefore include uncorrectable bleeding diathesis, coagulopathies, or the inability to tolerate holding anti-coagulation for the procedure, tenuous cardiopulmonary status, inability to position the patient to allow access to the pleural space, and a completely fused pleural space.

---

## Equipment

Medical thoracoscopy may be performed using either rigid or semi-rigid thorascopes. The semi-rigid thoracoscope is quite similar to the flexible bronchoscope. It is rigid down to the last

inch of the scope and then it articulates similar to the flexible bronchoscope. It is a 0 degree optic with 160 degrees of flexion and 130 degrees of extension. The scope has an outer diameter of 6.9 mm and fits through a dedicated 7 mm port. There is a 2.8 mm working channel that is safe for thermal modalities such as electrocautery or laser.

There are several commercially available rigid thoroscopes on the market. In general, the instruments include a 4 mm optic with a 30-degree angle to be able to fully inspect the pleural space. Many also include an over-tube suction and optical forceps for single port procedures. In some cases, a second port is necessary for pleural intervention and non-optical forceps are available to biopsy the pleura. Dedicated re-useable ports measuring 5–10 mm are available. A dedicated apparatus for pleurodesis consisting of a powder dispenser and a bulb to aerosolize into the pleural space is also available.

A comprehensive list of equipment to perform the procedure is listed in Table 34.1.

A prospective, randomized, pilot study designed to compare the diagnostic yield between the rigid and semi-rigid thoroscopes determined that there was equipoise between the two instruments with diagnostic accuracies of 100%

and 97.6%, respectively. The main difference between the two instruments was the size of biopsy specimens derived from the procedure. The average specimen obtained by the rigid thoracoscope was 25 mm versus 12 mm for the semi-rigid scope [31].

## Procedure

### Pre-procedural Preparations and Considerations

The importance of appropriate patient selection cannot be overstated. A comprehensive history and physical detailing the patient's medical comorbidities, medications including anticoagulants, cancer history both personal and family, occupational and social histories to determine risk factors for malignancy should be performed. Radiology with a focus on obtaining prior imaging for comparison is very important and should be supplemented with bedside ultrasound to determine optimal site of entry into the thorax. Pertinent, pre-procedural lab investigations are dependent on the patient's underlying medical comorbidities, that said many centers require a baseline complete blood count (CBC), international normalized ratio (INR), basic metabolic panel, and electrocardiogram (EKG). Informed consent should be obtained with explanation of the reason for the procedure and expected outcomes and a balanced discussion of risks, potential benefits, and common complications.

### Procedural Technique [32]

Medical thoracoscopy should be performed in sterile fashion. Proper positioning of the patient is essential to avoid post-procedural neuropathies. The patient is positioned with the unaffected side down in the lateral decubitus position with the arms outstretched and knees bent. An axillary roll may be inserted along with support for the knees (pillow between them), arms, and head. Cardiac, blood pressure, and oxygen saturation monitoring should be performed through-

**Table 34.1** Medical thoracoscopy equipment

<i>Medical Thoracoscopy equipment</i>
Thoracoscope (rigid or semi-rigid)
Biopsy forceps
Biopsy and suction valves if semi-rigid
Suction over-tube if rigid
Suction tubing
Light source
HD camera if rigid
Port
Kelly clamp or scissors for blunt dissection
Scalpel
Multiple 10 ml sterile syringes, hypodermic needles and 1% lidocaine
Talc poudrage apparatus if pleurodesis being performed
Suture material
Chest tube
Pleurovac
Chest tube dressing materials

out the procedure and until the patient is fully recovered from sedation. Our group performs the time out with site and side verification immediately after positioning to allow the patient to participate. Transthoracic ultrasound is performed to re-evaluate the pleural space in the procedural position. The hemidiaphragm, lung, liver/spleen, and any pleural-based abnormalities are identified. In the case of a loculated or complex effusion, the largest pocket of free-flowing fluid is usually selected for entry into the thorax and the site marked on the skin surface. For pleural effusions, the preferred entry site for uncomplicated effusions is the anterior axillary line in the fifth intercostal space. This allows for ease of visual inspection of the pleural space. On the other hand, the preferred entry site for the management of pneumothorax is the third interspace in the anterior axillary line such that the operator has a comprehensive view of the apex of the lung, particularly if considering thoracoscopic management of blebs.

Once positioned, the patient is draped in sterile fashion and then moderate sedation administered. The patient should continue to breathe spontaneously and caution should be taken to avoid over-sedation. Next, an intercostal block is performed using 1% lidocaine. Generous local anesthesia will minimize the sedation required for patient comfort. A 1-inch superficial wheel of lidocaine is injected along the entry site just above the lower rib, then extended down along the tract to the pleura. If malignancy is suspected, caution should be taken to not inoculate the tract after breaching the pleura and aspirating pleural fluid. Using a clean needle, the periosteum of the upper and lower ribs is anesthetized. The intercostal space is then also infiltrated with lidocaine. A 1-inch incision is made into the skin and blunt dissection with forceps is used to form a tract for the port. Stylistic differences exist, but some physicians prefer to penetrate the pleura with their digit as opposed to with the forceps to avoid accidental injury to the lung and intercostal vessels. Once the pleura is breached, the index finger is used to perform a sweep of the pleural space to ensure that the lung is not adherent to the pleura. The port is then advanced into the thoracic cavity

and the trocar removed. The thoracoscope is advanced through the port and into the pleural space. Fluid is aspirated to allow for complete inspection of the surfaces of the lung, hemidiaphragm, and chest wall. Once the pleural space has been evaluated and key landmarks identified, then biopsies may be performed if appropriate. In order to minimize the risk of injury to vascular structures, the tip of the forceps is used to identify the rib. Then the forceps are used to peel off the parietal pleura. It is prudent to biopsy away from vascular structures. In addition, fissures should be avoided whenever possible to limit accidental injury to the vessels or airways.

Simple thin loculations may either be aspirated using the suction or gently broken down using the tip of the thoracoscope. Extreme caution must be taken as thicker bands may be vascularized and bleeding may occur if interrupted accidentally. Cautery may be employed to address potential bleeding from an adhesion. Both rigid and flexible cautery probes are available for this purpose. With respect to pleurodesis, specifically talc poudrage, the procedure depends upon whether there is an integrated channel for pleurodesis. If so (which is the case for many rigid scopes), the scope is advanced into the pleural space and talc insufflated under direct visualization. A thin layer of talc is applied to all surfaces including the visceral and parietal pleura. It is important to slowly move the thoracoscope anteriorly, posteriorly, apically, and along the hemidiaphragm. Once complete, a chest tube is inserted through the thoracoscopy incision and oriented either basally along the hemidiaphragm or apico-posteriorly depending on the indication (fluid or pneumothorax, respectively). A pressure dressing with Vaseline gauze around the tube is applied and the chest tube connected to suction at  $-20$  cm  $H_2O$  until the lung is re-inflated. The duration of ongoing chest tube drainage is dependent on the indication and physician preference. For pleural effusions, it is preferable to leave the chest tube on suction when attempting pleurodesis until such time as the volume is minimal to minimize the risk of incomplete symphysis and formation of symptomatic loculations. With respect to pneumothorax, the



tube may be removed once there is no further air leak.

As mentioned above, procedure modifications have been implemented to decrease hospital stay. A tunneled pleural catheter may be placed at the time of the thoracoscopy either in addition to the surgical chest tube or alternatively in lieu of the chest tube. If a tunneled pleural catheter is placed in lieu of a chest tube, then the drainage line and chest tube adapter are attached to the one-way valve and the tube connected to the pleurovac. For diagnostic procedures, that is, without any manipulation of the visceral pleura and no air leak at the end of the case, the chest tube may be removed or the tunneled catheter capped once the lung has fully re-inflated.

As the patient receives minimal sedation, they are generally sent to the recovery room to emerge from any sedation and to have a chest X ray performed to verify the chest tube position and determine whether the lung has fully re-inflated. If diagnostic, it may not be necessary for the patient to be admitted to the hospital for further monitoring unless complications arise. On the other hand, suction may be necessary for at least 24 hours if attempting pleurodesis.

Most North American pulmonologists do not perform visceral pleural or parenchymal biopsies via medical thoracoscopy. When performed by pulmonologists, they are mostly done using dedicated cautery to seal the air leak simultaneously. Thoracoscopic rigid cautery probes exist to assist with cauterization of localized bleeding to achieve hemostasis. They are also useful for interruption of the sympathetic chain. Additional thoracoscopic procedures not routinely performed in North America will not be addressed in this chapter.

---

## Medical Thoracoscopy Versus VATS

Medical Thoracoscopy and VATS (Video-Assisted Thoracoscopic Surgery) differ technically although there exists overlap in their indications particularly in the setting of malignant and infectious effusions as well as pneumothorax management [33]. Both allow for a

comprehensive pleural evaluation. Medical thoracoscopy may be performed in a procedure space such as an endoscopy suite in some hospitals whereas VATS is performed in a surgical suite under general anesthesia and single lung ventilation. In medical thoracoscopy either a pneumothorax is induced in advance of the procedure or as a part of the procedure allowing the lung to passively deflate. Patients undergoing medical thoracoscopy breathe spontaneously throughout the procedure while a dual lumen endotracheal tube is usually placed for VATS to isolate the lungs and achieve collapse of the surgical side.

Although there is overlap between these two procedures, VATS has a wide array of additional applications including lung resection. As such it also has a higher overall complication rate that may be attributable at least in part to the need for general anesthesia and intubation as well as the technical aspects of the additional procedures performed. Both procedures can readily be employed for diagnosis and staging cancer in malignant effusions. The advantage of medical thoracoscopy in this setting is that it can be performed without the need/risk of general anesthesia in stage IV cancer patients. Also, with newer technical modifications, patients may be discharged several days sooner even in the case of interventions such as pleurodesis.

There have been many technical advances in VATS, particularly with the development of articulating instruments and stapling devices to mitigate post procedure air leak. This procedure not only allows for pleural intervention but also other lung and esophageal procedures. The most appropriate procedure for the patient should be selected and this decision should take into account patient factors such as comorbid illness, patient preference if there is procedural equipoise, and cost.

---

## Conclusion

Medical thoracoscopy is both safe and effective in the management of pleural disease. It has both diagnostic and therapeutic indications including diagnosis of unclear exudates, management of

malignant pleural disease, and infectious effusions. It is minimally invasive and may be performed in a procedural area under moderate sedation allowing for a potentially broader spectrum of patients than VATS including less clinically robust patients. It may be considered an alternative to VATS for procedural indications that overlap. The role of medical thoracoscopy is expanding and future research in the potential use of the pleura for drug delivery and stimulation of the immune system are exciting. Finally procedural innovations are allowing for very early discharge and lower costs of care in these patients.

## References

- Loddenkemper R, Mathur P, Lee P, Noppen M. History and clinical use of thoracoscopy/pleuroscopy in respiratory medicine. *Breathe*. 2001;8:145–55.
- Pastis N, Nietert P, Silvestri G. Variation in training for interventional pulmonary procedures among US pulmonary/critical care fellowships. *Chest*. 2005;127:1614–21.
- Light R, MacGregor M, Luchsinger P, Nall W. Pleural effusions: the diagnostic separation of transudates and exudates. *Ann Intern Med*. 1972;77:507–13.
- Ferreiro L, Gude F, Toubes M, Lama A, Suárez-Antelo J, San-José E, González-Barcala F, Golpe A, Álvarez-Dobaño J, Rábade C, Rodríguez-Núñez N, Díaz-Louzao C, Valdés L. Predictive models of malignant transudative pleural effusions. *J Thorac Dis*. 2017;9:106–16.
- Michaud G. Approach to unclear exudates. Principles and practice of interventional pulmonology. New York: Springer Science and Business Media; 2013.
- Ozcarar B, Martinez C, Morice R, Eapen G, Ost D, Sarkiss M, Chiu H, Jimenez C. Does pleural fluid appearance really matter? The relationship between fluid appearance and cytology, cell counts, and chemical laboratory measurements in pleural effusions of patients with cancer. *J Cardiothorac Surg*. 2010;5:63.
- Hooper C, Lee YC, Maskell N. Investigation of a unilateral pleural effusion in adults: British Thoracic Society pleural disease guideline 2010. *Thorax*. 2010;65 Suppl 2:ii4–17.
- Yarmus L, Feller-Kopman D, Imad M, Kim S, Lee HJ. Procedural volume and structure of interventional pulmonary fellowships: a survey of fellows and fellowship program directors. *Chest*. 2013;144:935–9.
- Wei Y, Shen K, Lv T, Liu H, Wang Z, Wu J, Zhang H, Colella S, Wu F, Milano M, Zhan P, Song Y, Lu Z. Comparison between closed pleural biopsy and medical thoracoscopy for the diagnosis of undiagnosed exudative pleural effusions: a systematic review and meta-analysis. *Transl Lung Cancer Res*. 2020;9:446–58.
- Wan Y, Zhai C, Lin X, Yao Z, Liu Q, Zhu L, Li D, Li X, Wang N, Lin D. Safety and complications of medical thoracoscopy in the management of pleural diseases. *BMC Pulm Med*. 2019;19:125.
- Sanchez-Armengol A, Rodriguez-Panadero F. Survival and talc pleurodesis in metastatic pleural carcinoma, revisited. Report of 125 cases. *Chest*. 1993;104:1482–5.
- Xie L, Wang X, You W, Ma X, Wang Y, Liu T, Jian S. Predictors of survival in non-small cell lung cancer patients with pleural effusion undergoing thoracoscopy. *Thoracic Cancer*. 2019;10:1412–8.
- Sun H, Vaynblat A, Pass H. Diagnosis and prognosis-review of biomarkers for mesothelioma. *Ann Transl Med*. 2017;5:244.
- Kindler H, Ismaila N, Armato A, Bueno R, Hesdorffer M, Jahan T, Jones C, Miettinen M, Pass H, Rimmer A, Rusch V, Sterman D, Thomas A, Hassan R. Treatment of malignant pleural mesothelioma: American Society of Clinical Oncology clinical practice guideline. *J Clin Oncol*. 2018;36:1343–73.
- Chen YP, Huang HY, Lin KP, Medeiros LJ, Chen TY, Chang KC. Malignant pleural effusions correlate with poorer prognosis in patients with diffuse large B-cell lymphoma. *Am J Clin Pathol*. 2015;143:707–15.
- Schwarz C, Lubbert H, Rahn W, Schonfeld N, Serke M, Loddenkemper R. Medical thoracoscopy: hormone receptor content in pleural metastases due to breast cancer. *Eur Respir J*. 2004;24:728–30.
- Bays AM, Pierson DJ. Tuberculous pleural effusion. *Respir Care*. 2012;57(10):1682–4.
- Kong X, Zeng H, Chen Y, Liu T, Shi Z, Zheng D, Zhou R, Cai S, Chen P, Luo H. The visual diagnosis of tuberculous pleuritis under medical thoracoscopy: a retrospective series of 91 cases. *Eur Rev Med Pharmacol Sci*. 2014;18:1487–95.
- Kirsch C, Kroe D, Azzi R, Jensen W, Kagawa F, Wehner J. The optimal number of pleural biopsy specimens for a diagnosis of tuberculous pleurisy. *Chest*. 1997;112:702–6.
- Dipper A, Jones H, Bhatnagar R, Preston N, Maskell N, Clive A. Interventions for the management of malignant pleural effusions: a network meta-analysis. *Cochrane Database Syst Rev*. 2020;4(4):CD010529.
- Wahidi M, Reddy C, Yarmus L, Feller-Kopman D, Musani A, Shepard RW, Lee H, Bechara R, Lamb C, Shofer S, Mahmood K, Michaud G, Puchalski J, Rafeq S, Cattaneo S, Mullan J, Leh S, Mayse M, Thomas S, Peterson B, Light R. Randomized trial of pleural fluid drainage frequency in patients with malignant pleural effusions. The ASAP trial. *Am J Respir Crit Care Med*. 2017;195:1050–7.
- Reddy C, Ernst A, Lamb C, Feller-Kopman D. Rapid pleurodesis for malignant pleural effusions: a pilot study. *Chest*. 2011;139:1419–23.

23. Tschopp JM, Bintcliffe O, Astoul P, Canalis E, Driesen P, Janssen J, Krasnik M, Maskell N, Van Schil P, Tonia T, Waller D, Marquette CH, Cardillo G. ERS task force statement: diagnosis and treatment of primary spontaneous pneumothorax. *Eur Respir J*. 2015;46:321–35.
24. Hallifax R, Yousef A, Jones H, Corcoran J, Psallidas I, Rahman N. Effectiveness of chemical pleurodesis in spontaneous pneumothorax recurrence prevention: a systematic review. *Thorax*. 2017;72:1121–31.
25. Ferrer J, Montes J, Villarino M, Light R, Garcia-Valero J. Influence of particle size on extrapleural talc dissemination after talc slurry pleurodesis. *Chest*. 2002;122:1018–27.
26. Plojoux J, Foudrarakis M, Janssens JP, Soccia P, Tschopp JM. New insights and improved strategies for the management of primary spontaneous pneumothorax. *Clin Respir J*. 2019;13:195–201.
27. Ravaglia C, Gurioli C, Tomassetti S, Casoni G, Romagnoli M, Guriolo C, Agnoletti V, Poletti V. Is medical thoracoscopy efficient in the management of multiloculated and organized thoracic empyema? *Respiration*. 2012;84:219–24.
28. Rahman N, Maskell N, West A, Teoh R, Arnold A, Mackinlay C, Peckham D, Davies AN, Kinnear W, Bentley A, Kahan B, Wrightson J, Davies H, Hooper C, Lee YCG, Hedley E, Crosthwaite N, Choo L, Helm E, Gleeson F, Nunn A, Davies R. Intrapleural use of tissue plasminogen activator and DNase in pleural infection. *N Engl J Med*. 2011;365:518–26.
29. Luengo-Fernandez R, Penz E, Dobson M, Psallidas I, Nunn A, Maskell N, Rahman N. Cost-effectiveness of intrapleural use of tissue plasminogen activator and DNase in pleural infection: evidence from the MIST2 randomized controlled trial. *Eur Respir J*. 2019;54:1801550.
30. Kheir F, Thakore S, Mehta H, Jantz M, Parikh M, Chee A, Kaphle U, Sisnega C, Fernandez-Bussy S, Majid A. Intrapleural fibrinolytic therapy versus early medical Thoracoscopy for treatment of pleural infection: randomized controlled clinical trial. *Ann Am Thorac Soc*. 2020;17:958–64.
31. Rozman A, Camlek L, Marc-Malovrh M, Triller N, Kern I. Rigid versus semi-rigid thoracoscopy for the diagnosis of pleural disease: a randomized pilot study. *Respiration*. 2013;18:704–10.
32. Michaud G, Berkowitz D, Ernst A. Pleuroscopy for diagnosis and therapy for pleural effusions. *Chest*. 2010;138:1242–6.
33. Shojaee S, Lee H. Thoracoscopy: medical versus surgical-in the management of pleural disease. *J Thorac Dis*. 2015;7:S339–51.

---

## **Part VII**

# **Interventional Bronchoscopy for Specific Conditions**



# Endoscopic Methods for Lung Volume Reduction

# 35

Luis M. Seijo Maceiras

## Introduction and Definition of the Procedure

Pulmonary emphysema is a chronic, debilitating, often fatal disease, characterized by progressive destruction of the lung parenchyma, hyperinflation, reduced lung elasticity, and impaired gas exchange. Patients with severe emphysema complain of progressive dyspnea as the hyperinflated lung becomes entrapped in a rigid chest wall. Medical treatment of emphysema offers limited symptomatic relief, but has failed thus far to improve survival. Lung volume reduction surgery, a therapeutic option in advanced emphysema, while successful in a selected group of patients, is associated with considerable morbidity and mortality [1]. The landmark National Emphysema Treatment Trial (NETT) found a striking improvement in survival in patients undergoing surgery with upper lobe predominant emphysema and poor exercise tolerance [1]. Despite such promising findings, the NETT may be credited with a widespread reluctance to refer patients for the procedure because of the reported 5% mortality, which was alarmingly high in some high-risk patients [2]. Furthermore, 50% of the patients in the surgical arm suffered from pro-

longed hospitalizations, air leaks, and/or infection. Consequently, only 538 procedures were reported in the US in an 8.5 year time period between 2003 and 2011 [3]. Since then, expert centers have continued to perform a steadily increasing number of procedures in a highly selected minority of patients with severe emphysema [4]. Reported 6-month operative mortality has been low in this setting with limited median lengths of intensive care unit (ICU) and hospital stay and sustained improvement at 5 years [5].

Pulmonologists have been investigating a variety of minimally invasive alternatives to lung volume reduction surgery for years. The promise of a technique or device capable of reproducing the benefits of the surgical procedure without incurring the side effects, mortality, and morbidity of surgical lung volume reduction is appealing for obvious reasons. Not surprisingly, interest in endoscopic lung volume reduction (ELVR) continues to expand to this day. In general, ELVR can be defined as a minimally invasive bronchoscopic procedure devoted to the reduction in total or regional lung volumes in patients with severe emphysema and significant exertional dyspnea [6]. Some procedures rely on device insertion, including endobronchial valves, coils, and bypass stents, while others instill bioactive substances such as a polymer, water vapor, or even autologous blood, with identical therapeutic intentions. The methods are diverse, but rely for the most part on the flexible bronchoscope using deep

---

L. M. Seijo Maceiras (✉)  
Pulmonary Department, University Clinic, Navarra,  
Pamplona, Spain  
e-mail: [lseijo@unav.es](mailto:lseijo@unav.es)



sedation or general anesthesia. Most procedures last less than 1 h and may target one or both lungs. Patients may undergo pulmonary rehabilitation prior to treatment, and must be on standard medical therapy for chronic obstructive pulmonary disease (COPD), including bronchodilators and occasionally low dose steroids. In general, patients with frequent exacerbations are excluded as they may be at greater risk of complications following device implantation. Endoscopic lung volume reduction has also been postulated as a bridge to lung transplantation.

### Historical Perspective

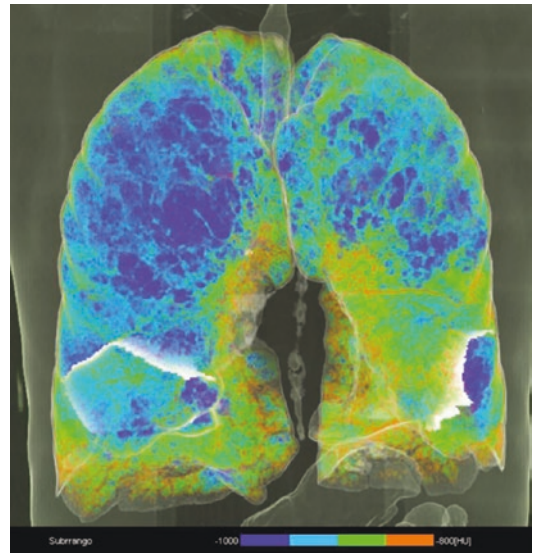
Pioneers of ELVR focused on obtaining improvements in lung function and seeking measurable lung volume reduction, essentially attempting to reproduce surgical results [7]. However, the paradigm has shifted back and forth as failure to obtain comparable lung volume reduction despite improvements in quality of life made many investigators weary of attempting to match surgical outcomes. Also, while ELVR was initially reserved for ideal surgical candidates with upper lobe predominant emphysema, subsequent studies have included patients with homogeneous emphysema as well as patients with heterogeneous emphysema not necessarily upper lobe predominant. Endoscopic lung volume reduction may also be an alternative for selected patients who are not candidates for lung volume reduction surgery because of their extremely poor lung function.

The role of computed tomography (CT) has also widened. It was originally limited to patient selection, but has become a useful tool for follow-up since it can quantify regional lung volume changes in the absence of overall lung volume reduction. Collateral ventilation, a major limitation of many ELVR approaches, has also been studied with CT [8]. A multicenter European study demonstrated that fissure analysis by CT correlates well with endoscopic collateral ventilation measurements [9]. If fissure integrity on

CT analysis is >95%, collateral ventilation can be considered negligible [10]. Such analysis may improve patient selection for a given procedure since valve treatment success is highly dependent on the absence of collateral ventilation while other methods of ELVR are not.

### Indications and Contraindications

Endoscopic lung volume reduction is indicated for a highly selected group of patients with advanced emphysema. Originally, ELVR was reserved for patients with upper lobe predominant disease (Fig. 35.1). However, indications for ELVR have widened to include a more diverse population of patients suffering from emphysema in response to the ongoing proliferation in techniques and devices, including patients with homogeneous emphysema, alpha-1 antitrypsin deficiency, or lower lobe predominant disease.



**Fig. 35.1** CT reconstruction of a patient with upper lobe predominant emphysema. (Diseased lung is represented in blue). This patient with an forced expiratory volume in 1 second (FEV1) of 0.73 L (24% of predicted) was a candidate for endoscopic lung volume reduction, but a hereditary cardiomyopathy, frequent exacerbations, and pulmonary hypertension were considered contraindications to the procedure

In general, candidates for ELVR must suffer from severe emphysema and moderate-to-severe dyspnea despite optimal medical therapy. Patients with alpha-1 antitrypsin deficiency have been historically excluded from clinical trials, although limited evidence from recent trials investigating the role of ELVR for those patients and at least one small series showed significant benefit from ELVR in that setting [11, 12].

Ideal candidates for ELVR must be ambulatory and capable of walking at least 100–150 m with or without supplemental oxygen during a 6 min walk test. They must abstain from smoking and demonstrate severe obstruction on spirometry as well as air trapping and hyperinflation on plethysmography. ELVR should probably not be attempted in patients with residual volumes <175% of predicted. Patients with extremely low diffusing capacities (<20%), as well as those with severe gas exchange abnormalities, especially hypercapnic patients, and frequent exacerbations are not considered good candidates for ELVR. However, a recent retrospective analysis of data collected from the German Lung Emphysema Registry showed no difference in outcomes in individuals with very low diffusing capacity for carbon monoxide (DLCO) (<20%) treated with ELVR. The technique improved lung function and quality of life in those patients, while adverse effects were similar to those seen in patients with higher DLCOs [13].

Giant bullous or reactive airways disease and severe pulmonary hypertension are also considered important contraindications to ELVR, especially coil placement, while major medical comorbidities may be an issue for some individuals. Patients with coexisting bronchiectasis, especially those colonized by *P. aeruginosa*, should not be treated, while patients with FEV1s less than 20–25% of the age-adjusted predicted value are generally not treated. That notwithstanding, at least one retrospective analysis has found ELVR to be feasible and safe in individuals with extremely low FEV1s improving lung function at the expense of a 25% risk of pneumothorax [14].

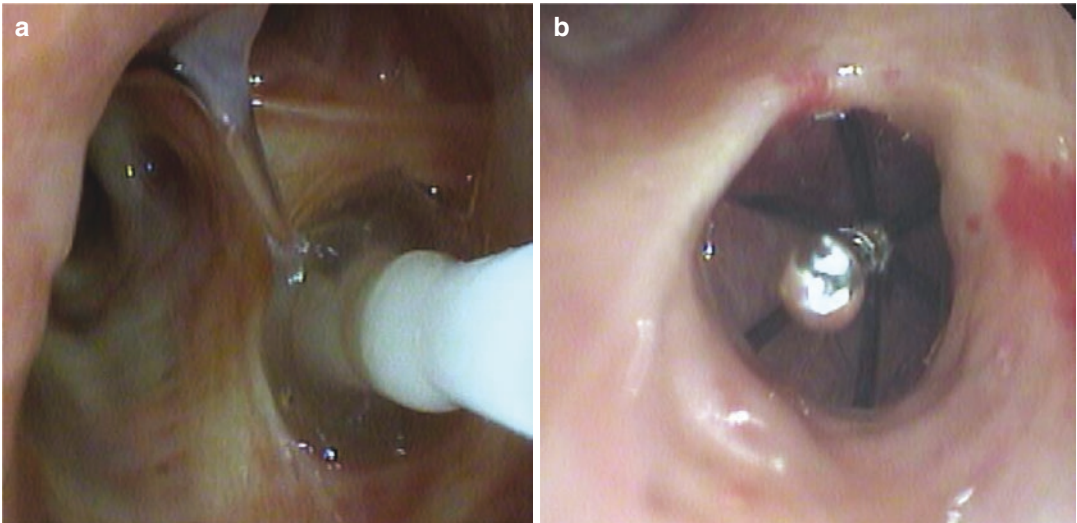
Elderly patients have generally been excluded from clinical trials, so outcomes of ELVR in patients older than 75 are uncertain. Most procedures are performed under general anesthesia or deep sedation, so patients unable to tolerate either cannot be treated. One should keep in mind that each device or technique designed to achieve ELVR is unique, so indications, patient selection, and/or treatment strategy (i.e., unilateral vs. bilateral treatment) may vary or are liable to change based on incoming evidence.

---

## Description of the Equipment Needed

ELVR can be performed in a variety of hospital settings. Many procedures are performed in the bronchoscopy suite and do not require special equipment beyond that which can generally be found in a well-stocked unit. A diagnostic or therapeutic flexible bronchoscope may be used, depending on the method chosen. Devices tend to require the larger 2.8 mm channel of the therapeutic bronchoscope. Vapor-induced ELVR requires special equipment unique to this procedure.

In general, deployment of most devices, including valves, is straightforward for an experienced bronchoscopist and requires little additional training (Fig. 35.2). However, valve removal can be quite challenging if not impossible in some cases. Coil therapy is best performed under fluoroscopic guidance, a technique familiar to many bronchoscopists who perform trans-bronchial biopsies or stent implantation. Some bronchoscopists use the Chartis™ system in order to assess fissure integrity and collateral ventilation, but others rely on CT scan data. Finally, some bronchoscopists prefer to treat patients under general anesthesia using the rigid bronchoscope or an endotracheal tube. Anesthesia support is mandatory in such cases, while others prefer conscious sedation which may be administered by the endoscopic team.



**Fig. 35.2** Balloon calibration (a) and placement (b) of an Intrabronchial valve (IBV) device in a patient with severe upper lobe predominant emphysema

## Evidence-Based Review

### Endobronchial Valves

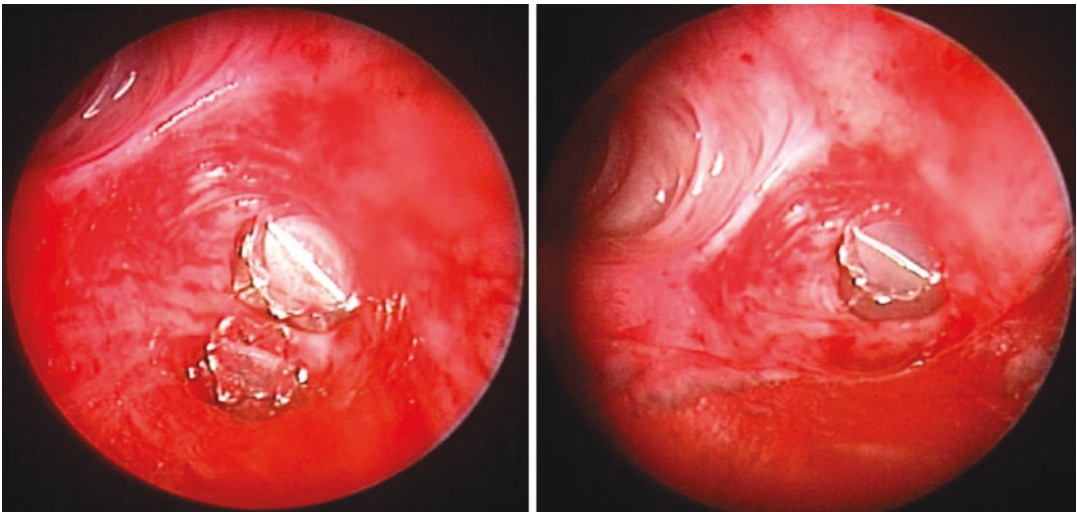
Endobronchial valves were among the first devices to be developed for ELVR. They have been widely studied and results from well-designed randomized trials are available and continue to enrich our understanding of how ELVR might benefit selected patients with severe emphysema. The landmark endobronchial valve for emphysema palliation trial (VENT), a multicenter randomized controlled trial, demonstrated that endobronchial valves can achieve modest statistically significant improvements in a variety of endpoints, including lung function, exercise capacity, and quality of life [15]. The study was completed in 2007 and enrolled 321 patients. It compared the safety and efficacy of endobronchial valve therapy employing a unilateral lobar approach in patients with heterogeneous emphysema with optimal medical care. Despite achieving statistical significance, the results were considered by many, including the U.S. Food and Drug Administration (FDA), underwhelming [16]. Improvements in FEV1 (60 mL), the 6 min walk distance (19 m), and reductions in the St. George's respiratory questionnaire (SGRQ) scores with treatment (3.4 points) have been considered by some clinically insignificant.

Careful scrutiny of VENT results, however, left much room for optimism. Improvements in the body mass index, obstruction, dyspnea, exercise, index (BODE) index, more common among valve treated patients, are provocative since this index correlates well with prognosis in COPD [17]. In addition, patients with complete fissures who achieved a greater than 50% reduction in lobar volume demonstrated clinically relevant improvements in FEV1 (23%) which may have survival implications as demonstrated in a subsequent report from a group of investigators using the same valves as the VENT [18]. These authors found a survival benefit in a small cohort of patients among those who achieved atelectasis at the expense of more pneumothoraces, suggesting that ELVR may match surgical results in some patients with heterogeneous emphysema. The BeLieVeR HIFi single-center study confirmed the hypothesis that patients with intact interlobar fissures benefit from ELVR using endobronchial valves [19]. In that randomized, sham bronchoscopy-controlled trial, unilateral lobar occlusion with endobronchial valves placed in patients with heterogeneous emphysema and intact interlobar fissures as measured by CT was associated with significant improvements in lung function and quality of life. Results of the STELVIO randomized trial which assessed collateral ventilation

using the Chartis™ system provided further evidence supporting this strategy [20]. In that study, patients treated with endobronchial valves showed a statistically significant benefit with improvements in FEV1, FVC, and 6MWT distance that were clinically relevant. The overall responder rate was 75% when the interlobar fissure was largely intact precluding significant collateral ventilation. Two subsequent multicenter studies known as TRANSFORM and LIBERATE demonstrated the benefit of ELVR with endobronchial valves with 55% and 47%, respectively, of treated patients benefiting from valve placement [21, 22].

In its original ruling denying approval for the Zephyr device (Fig. 35.3) employed in the VENT (a self-expanding nitinol stent with a silicon one-way duckbill valve), the FDA expressed concern regarding the complications of ELVR, including a major increase in the number of hospitalizations for COPD exacerbations in the treatment arm (17 vs 1) and other complications such as hemoptysis [16]. Fear of the risks undermined the modest benefits of the trial. As a result, more research was requested. Evidence is now available regarding patient selection and the role of collateral ventilation and fissure integrity in pneumothorax susceptibility. Furthermore, three studies, including long term follow-up of patients treated with endobronchial valves, have shown a significant survival benefit in ELVR responders [18, 23, 24].

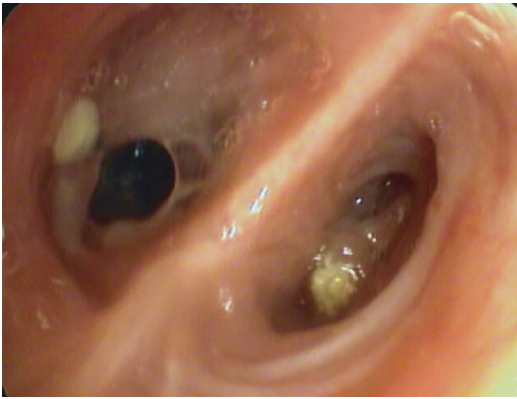
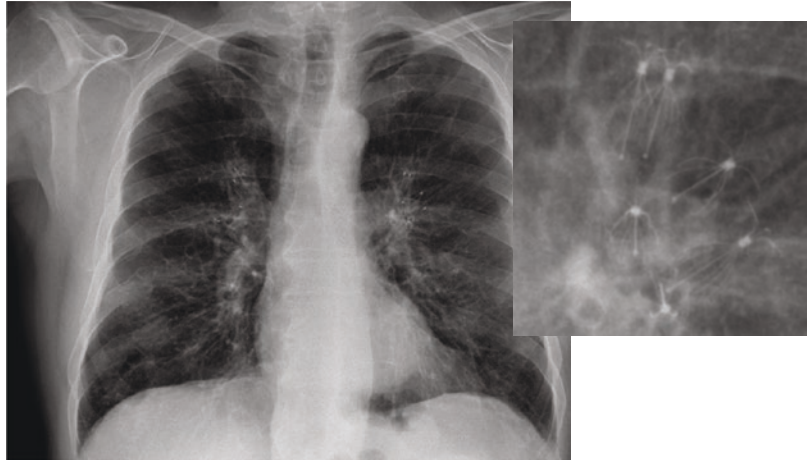Results from a randomized sham bronchoscopy controlled trial using the Spiration IBV system (an umbrella-shaped, self-expanding device) were reported some years ago (Fig. 35.4). This smaller trial kept patients blinded for 3 months [25]. The treatment strategy differed significantly from the VENT, since it focused on a bilateral approach purposefully avoiding lobar occlusion by sparing a segmental or subsegmental bronchus in the right upper lobe as well as the lingula on the left side. The trial failed to achieve clinically relevant improvements in hard outcomes such as FEV1, gas exchange, or exercise capacity, but demonstrated statistically significant improvements in a combined endpoint including quality of life and regional lung volume changes as measured by CT. At the conclusion of the Spiration trial, 31% of the treated patients demonstrated an improvement of eight points in the SGRQ score, and a significant regional lung volume reduction in the treated upper lobes. The companion and larger US trial using the IBV system but prolonging blinded follow-up to 6 months was also underwhelming [26]. In that trial, only 6 out of 121 patients in the treatment arm were considered responders. Although lobar volume changes were significantly better in the treated arm vs control (−224 mL vs −17 mL), there were no significant differences in quality of life as measured by the St. George's Respiratory Questionnaire. As



**Fig. 35.3** Duck-billed shaped endobronchial valves (Zephyr) (Courtesy Dr. Dutau)



**Fig. 35.4** Chest radiograph of a patient with upper lobe predominant severe emphysema treated with 10 endobronchial valves (IBV). The characteristic umbrella shaped valves can be seen in both upper lobes. Lobar occlusion was avoided in this patient



**Fig. 35.5** Endobronchial valves (IBV) in the right upper lobe 3 years after deployment

expected, serious adverse events were more common in the treatment group (14.1%) compared with the control group (3.7%), although most were neither procedure nor device related (Fig. 35.5). The disappointing results of the bilateral approach avoiding lobar collapse coupled with demonstrable improvements by responders with intact fissures treated with the lobar occlusion method have rendered the strategy used in the Spiration trials obsolete. Interestingly, a pilot trial seeking lobar occlusion found significant improvements in lung function and more impressive reductions in SGRQ scores in patients who achieved atelectasis with the IBV system [27]. The risks associated with this complication motivated the subsequent change

in treatment strategy. However, it is clear from the available evidence that while avoiding atelectasis improves safety, it does so at the expense of efficacy. The randomized EMPROVE study explored the efficacy of the IBV system using the unilateral complete occlusion approach in 172 patients with severe heterogeneous emphysema, intact fissures, and hyperinflation. Nearly 37% of those treated were considered responders with an improvement in FEV1  $\geq$  15%. Six deaths were reported in the treatment arm, but only one in the standard care arm, and a 12.4% incidence of pneumothorax was also reported after valve treatment [28].

One of the most striking findings of the initial Spiration trials was the impressive magnitude of the placebo effect. Many patients undergoing sham bronchoscopy reported significant benefits in quality of life. Such findings match results from a bronchial thermoplasty trial employing sham bronchoscopy [29]. Clearly, the placebo effect has a significant impact in device-related interventions and should be taken into account in trials using soft endpoints such as quality of life as the primary outcome.

### Airway Bypass Tracts

While most ELVR techniques are designed to promote lung volume reduction by limiting flow to the most affected region of lung parenchyma,



Broncus (Mountain View, CA) developed a technique which reduces air trapping by promoting non-anatomic collateral flow. This method of ELVR known as the Exhale™ emphysema treatment system shunned atelectasis, currently an essential goal of valve treatment, striving instead to create airway fenestrations in order to facilitate exhalation of trapped air. A Doppler system was used in order to avoid damaging major vessels and select the appropriate site for stent deployment using a needle. This approach reduced end-expiratory volume without altering lung recoil and could be tested in patients with both homogeneous and heterogeneous emphysema.

Preliminary evidence treating explanted lungs was quite encouraging. Improvements in FEV1 following deployment of multiple stents in one small study of 12 explanted lungs were dramatic [30]. Outcomes in vivo, however, were frustrating, mostly as a consequence of stent occlusion by granulation tissue. Drug-eluting stents have been created to avoid this complication and seem to work in animal studies, prolonging patency [31]. An open label study of the drug-eluting stents showed that the Exhale™ system can reduce hyperinflation for a limited time in a selected group of patients with severe emphysema [32]. Unfortunately, while results at 1 month were impressive including improvements in FEV1, quality of life, and total lung capacity in more than 30 treated patients, results at 6 months were less encouraging. Post-procedure complications including COPD exacerbations were relatively frequent, and one patient died as a consequence of massive hemoptysis induced by stent implantation.

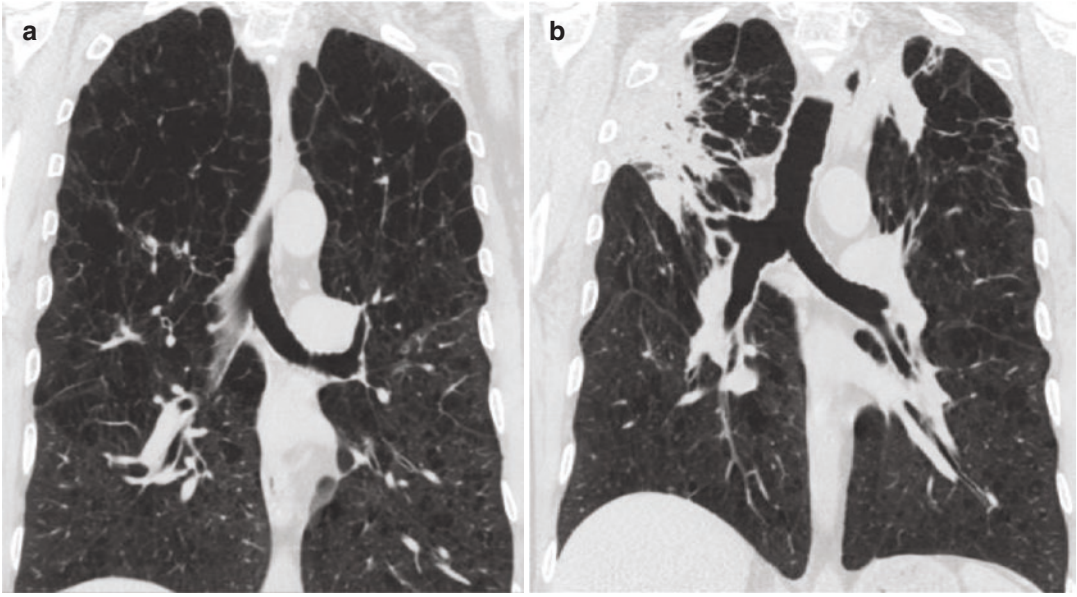
The Exhale™ system was used in a multicenter randomized, sham-bronchoscopy controlled trial known as EASE (Exhale Airway Stents for Emphysema) [33]. Three hundred and fifteen patients with severe hyperinflation defined as a ratio of residual volume to total lung capacity of  $\geq 0.65$  from 38 centers worldwide were enrolled. Patients were followed for 12 months. Treated patients did not achieve the co-primary endpoints of a 12% improvement in FVC and 1 point improvement in the mMRC dyspnea score when compared to controls, though the latter did

show a statistically significant improvement. Only 30 out of 208 treated patients met the co-primary endpoint, although a considerable mean reduction in residual volume averaging 0.5 L was achieved in 40% of the treated patients. This finding predicted clinical success. The 6-month composite primary safety endpoint combining 5 severe adverse events was 14.4% for the treatment arm which compared favorably with 11.2% for the control group and was judged non-inferior. This ELVR technique is currently not available in the US or Europe [34].

---

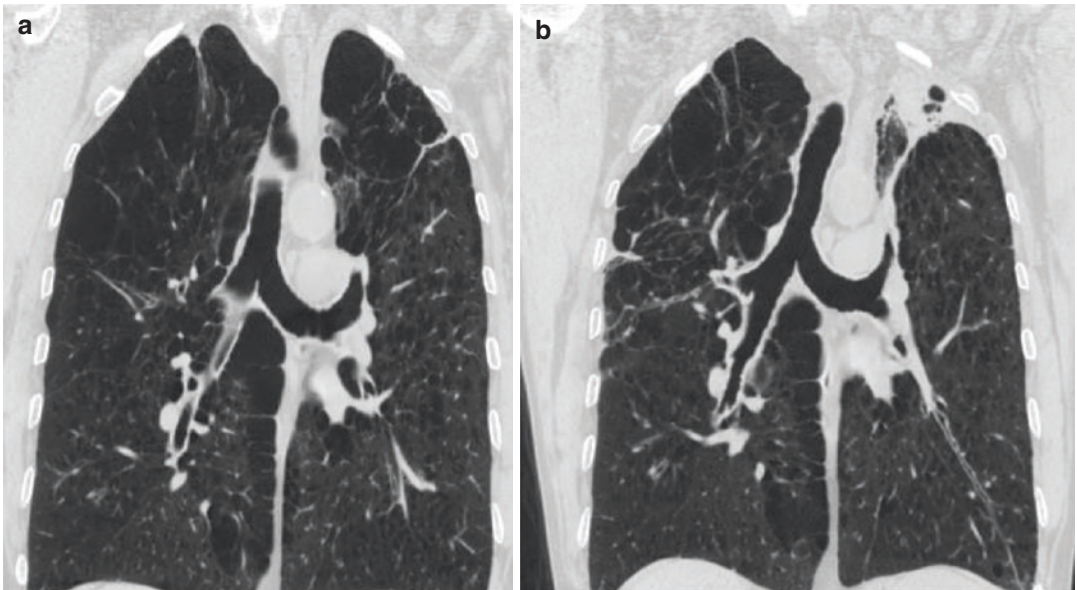
### Biologic/Polymer Lung Volume Reduction

Biologic lung volume reduction, unlike its predecessors, was not device based. This method of ELVR, developed by Aeris Therapeutics (Woburn, MA), sought to achieve its goals employing tissue engineering principles [35]. Remodeling of damaged lung parenchyma by the next generation polymer-based treatment created progressive atelectasis in treated subsegments of the upper lobes thus promoting true lung volume reduction (Figs. 35.6 and 35.7). The ability of the polymer to spread through the airway limited the impact of collateral ventilation, a major concern with endobronchial valves. Treatment was found to be irreversible and frequently associated with considerable, though relatively brief, inflammation which mandated prophylactic treatment with steroids and antibiotics, akin to a COPD exacerbation in most treated patients. A preliminary small open label phase I trial showed the treatment to be safe and moderately effective in a small group of patients [36]. Results from a phase 2 clinical trial enrolling 50 patients were subsequently reported [37]. High dose therapy was effective in that trial and yielded sustained benefits, but COPD exacerbations were frequent, occurring in 28% of treated patients. A subsequent trial enrolling patients with homogeneous emphysema also showed benefit with high dose treatment and had a similar safety profile [38]. Evidence from three separate clinical trials demonstrated the benefit of polymer treatment inde-



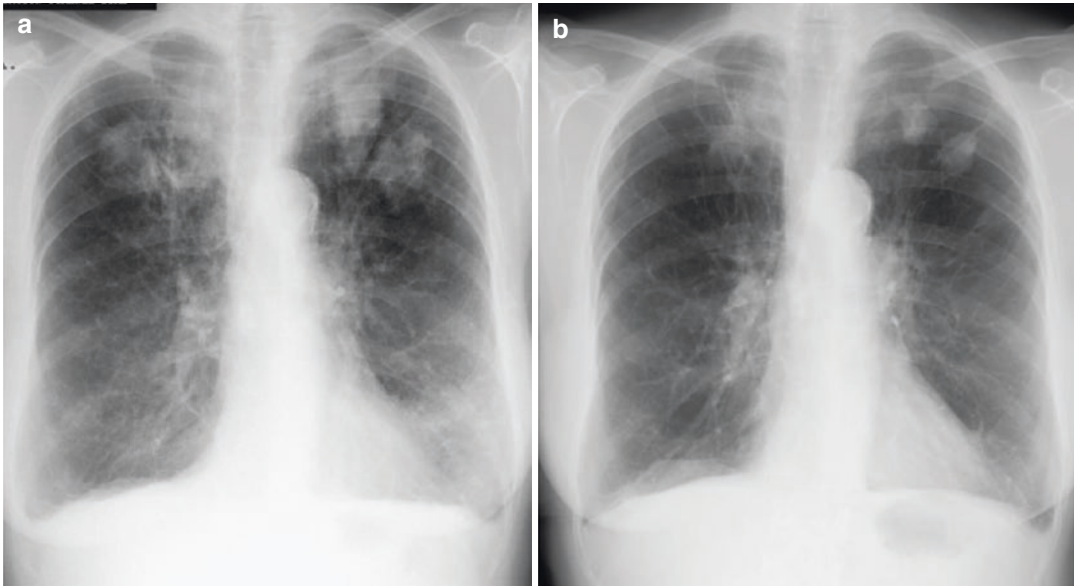
**Fig. 35.6** Before (a) and after (b) coronal CT images of a patient with heterogenous upper-lobe predominant emphysema treated with AeriSeal. The patient's FEV1

improved by 69%, his SGRQ score diminished by 8.3 units, and the RV/TLC ratio dropped by 9% (courtesy of Dr. Ingenito)



**Fig. 35.7** Before (a) and after (b) coronal CT images of a patient with homogenous emphysema treated with AeriSeal. The patient's FEV1 improved by 29%, his

SGRQ score diminished by 8.5 units, and the RV/TLC ratio dropped by 8% (courtesy of Dr. Ingenito)



**Fig. 35.8** Chest x rays of a patient with upper lobe predominant emphysema and collateral ventilation treated with AeriSeal, immediately following ELVR (a) and after

3 years of follow up (b). Radiographic changes persist and evolve over time complicating radiographic surveillance

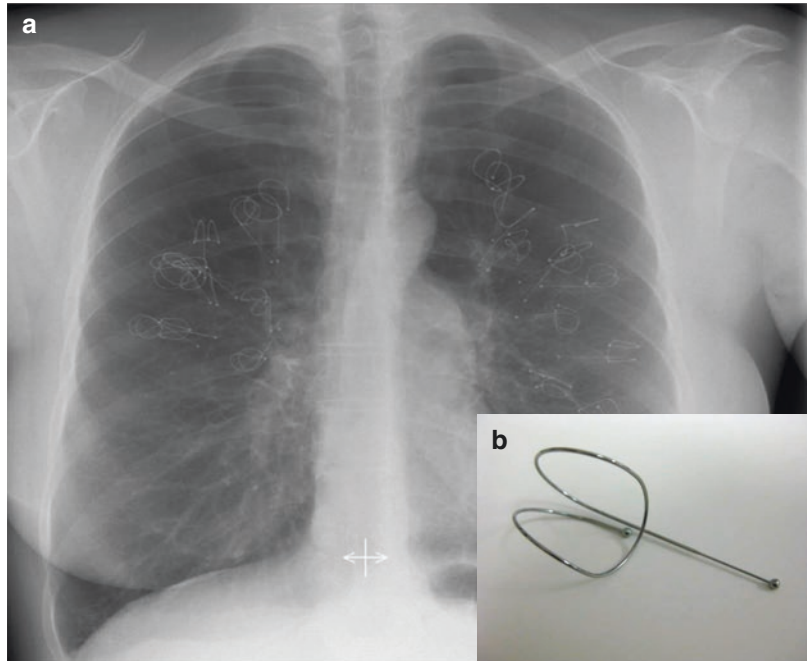
pendent of fissure integrity, rendering it a promising option for ELVR in patients with significant collateral ventilation [39]. A prospective multicenter randomized trial of polymer induced lung volume reduction known as the ASPIRE trial was initiated, but terminated prematurely for lack of funding. Ninety-five patients had been randomized prior to study termination. FEV1, dyspnea scores, and quality of life showed improvements at 3 months following treatment. The benefit was sustained at 6 months, but unfortunately 44% of treated patients required hospitalization and 2 deaths were reported ( $p = 0.01$ ) [40]. The premature termination of the study was a blow to the technique, but following the acquisition of Aeris Therapeutics by Pulmonx, AeriSeal® received CE Mark approval at the end of 2015 (Fig. 35.8). A subsequent trial known as the AeriSeal-STAGE Trial demonstrated significant volume reduction on computed tomography, but a lack of clinical benefit of administering a much lower dose and staged delivery of AeriSeal (NCT02877459). Future-intended uses of the AeriSeal system include sequential treatment for patients with collateral ventilation using the

AeriSeal system to eliminate collateral ventilation prior to valve treatment in the aptly named CONVERT prospective trial.

## Coils

Nitinol self-actuating reduction coils (PneumRx Inc.; Mountain View, CA) have been developed as an alternative method of ELVR. Nitinol's shape memory is ideally suited for this application since it facilitates deployment of the coils using a small caliber catheter (Fig. 35.9). Once deployed, the coils recover their pre-formed shape, retracting the surrounding lung tissue and therefore reducing lung volumes. Initial reports demonstrated the feasibility and relative safety of the procedure [41, 42]. The RESET trial, a randomized controlled trial enrolling 47 patients, reported coil-related statistically significant improvements in quality of life [43]. A subsequent multicenter trial enrolling 60 patients confirmed sustained benefit at 1 year following ELVR with coils [44]. The treatment strategy was bilateral in most patients deploying

**Fig. 35.9** Chest radiograph of a patient treated with the PneumRx coils (a). The coil in more detail (b)



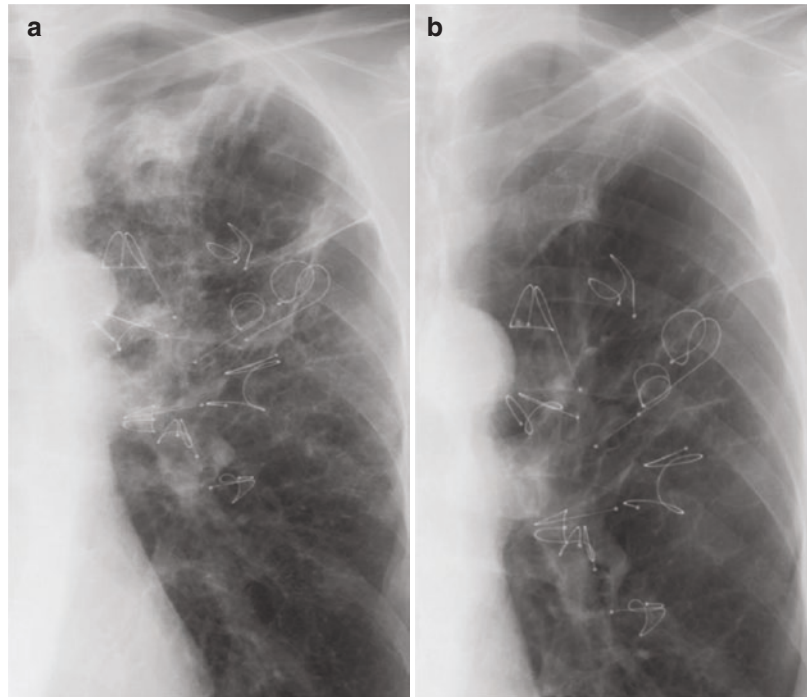
a median of 10 coils per treated lobe. Serious adverse events were common, however, occurring in 18 patients (30%) including COPD exacerbations, pneumonia, pneumothorax, and hemoptysis (Fig. 35.10). Clinically relevant improvements in SGRQ scores ( $-11.1 \pm 13.3$  points) and 6 min walk tests ( $+51.4 \pm 76$  m) were observed at 12 months. Lung function improvement was not as impressive with FEV1 improving marginally at 1 year ( $+0.11 \pm 0.30$  L) despite an impressive reduction in residual volumes ( $-0.71 \pm 0.81$  L).

Evidence from two randomized controlled trials is available. The REVOLENS trial reported a 36% responder rate for patients treated with coils based on changes in 6 min walk distance as compared to an 18% responder rate in the usual care group ( $P = 0.03$ ) [45]. However, no difference in FEV1 was found comparing both groups and only a slight difference in quality of life, which accounted for a disappointing cost-effectiveness

assessment of \$782,598 per additional quality-adjusted life-year. The RENEW trial enrolled 315 volunteers, including two-thirds of patients with homogeneous emphysema [46]. Those treated with coils showed a statistically significant though clinically underwhelming improvement of 10 m in the 6 min walk test (6MWT) at 12 months when compared to a control group. Clinically meaningful improvements in SGRQ scores and lung function were reported. The authors concluded that the use of endobronchial coils compared with usual care achieved only a modest improvement in median exercise tolerance with a higher likelihood of major complications. A post-hoc analysis of the RENEW data found that a residual volume  $\geq 200\%$  predicted and CT analysis are critical for successful endobronchial coil therapy. CT analysis can exclude patients who are unlikely to benefit with less severe emphysema, while identifying those with worse outcomes [47].



**Fig. 35.10** Chest radiographs of a patient treated with coils. Symptomatic pneumonia developed in the treated right upper lobe (a). The infection subsided after appropriate antibiotic treatment (b)



### Other Methods of ELVR

Bronchoscopic Thermal Vapor Ablation (Update Medical Inc.; Seattle, WA) has been studied as yet another method of ELVR. Conceptually akin to the polymer treatment, thermal ablation seeks to create inflammation and subsequent atelectasis of a treated diseased lobe thereby promoting lung volume reduction. A small multicenter trial enrolling 44 patients with upper lobe predominant emphysema reported sustained benefits in quality of life, lung function, and exercise tolerance at 1 year [48]. However, serious adverse events occurred in 53% of patients, chief among them COPD exacerbations. The STEP-UP trial which enrolled 70 patients reported a mean relative improvement in FEV1 favoring the treatment group was +14.7% [49]. Mean SGRQ scores were also improved in the treatment arm by 9.7 points. COPD exacerbations were once again common in the treatment arm occurring in 24% as compared with 4% of the control group, accounting for one death possibly related to treatment. The study investigators claimed that targeted thermal vapor ablation offers clinically

meaningful and statistically significant improvements in lung function and quality of life at 6 months, with an acceptable safety profile.

A few small clinical series or trials have reported a benefit from autologous blood instillation as a method of ELVR in bullous disease [50]. This low-cost technique requires adequately powered randomized trials to find its place as a novel ELVR alternative.

### Summary and Recommendations

A growing body of evidence suggests that ELVR is reasonably safe and can offer modest regional or total lung volume reduction and significant improvements in quality of life in carefully selected patients with severe emphysema. Unfortunately, clinically relevant efficacy is underwhelming for most procedures and as a general rule randomized trial data show marginal benefits in key outcomes, while highlighting the risks associated with some methods of ELVR, including serious adverse events. We are currently optimizing patient selection and refining



treatment strategies. I believe we should continue to strive for improvements in lung function and survival. Only then will device-related complications or significant increases in morbidity become acceptable in this patient population.

## References

- National Emphysema Treatment Trial Research Group. A randomized trial comparing lung-volume-reduction surgery with medical therapy for severe emphysema. *N Engl J Med.* 2003;348(21):2059–73.
- National Emphysema Treatment Trial Research Group. Patients at high risk of death after lung-volume-reduction surgery. *N Engl J Med.* 2001;345(15):1075–83.
- Decker MR, Levenson GE, Jaoude WA, Maloney JD. Lung volume reduction surgery since the National Emphysema Treatment Trial: study of Society of Thoracic Surgeons Database. *J Thorac Cardiovasc Surg.* 2014;148(6):2651–8.
- Attaway AH, Hatipoglu U, Murthy S, Zein J. Lung volume reduction surgery in the United States from 2007 to 2013 increasing volumes and reason for caution. *Chest.* 2019;155(5):1080–1.
- Stanifer BP, Ginsburg ME. Lung volume reduction surgery in the post-National Emphysema Treatment Trial era. *J Thorac Dis.* 2018;10(Suppl 23):S2744–7.
- Maxfield RA. New and emerging minimally invasive techniques for lung volume reduction. *Chest.* 2004;125:777–83.
- Toma TP. The flexible bronchoscopic approach to lung volume reduction. *Pneumologia.* 2001;50:97–100.
- Mantri S, Macaraeg C, Shetty S, et al. Technical advances: measurement of collateral flow in the lung with a dedicated endobronchial catheter system. *J Bronchology Interv Pulmonol.* 2009;16(2):141–4.
- Herth FJ, Eberhardt R, Gompelman D, et al. Radiological and clinical outcomes of using Chartis to plan endobronchial valve treatment. *Eur Respir J.* 2013;41:302–8.
- Schuhmann M, Raffy P, Yin Y, et al. Computed tomography predictors of response to endobronchial valve lung reduction treatment. Comparison with Chartis. *Am J Respir Crit Care Med.* 2015;191:767–74.
- Hillerdal G, Mindus S. One- to four-year follow-up of endobronchial lung volume reduction in alpha-1-antitrypsin deficiency patients: a case series. *Respiration.* 2014;88(4):320–8.
- Perotin JM, Leroy S, Marquette CH, et al. Endobronchial coil treatment in severe emphysema patients with alpha-1 antitrypsin deficiency. *Int J COPD.* 2018;13:3645–9.
- Lenga P, Ruwwe-Glösenkamp C, Grah C, et al. Endoscopic lung volume reduction with endobronchial valves in very low DLCO patients: results from the German Registry. *ERJ Open Res.* 2021;7:00449–2020.
- Trudzinski FC, Höink AJ, Leppert D, et al. Endoscopic lung volume reduction using endobronchial valves in patients with severe emphysema and very low FEV1. *Respiration.* 2016;92(4):258–65.
- Sciurba F, Ernst A, Herth F, et al. For the VENT study research group a randomized study of endobronchial valves for advanced emphysema. *N Engl J Med.* 2010;363:1233–44.
- <http://www.fda.gov/ohrms/dockets/ac/08/transcripts/2008-4404-t001.pdf>.
- Sciurba F, Goldin J, Criner GJ, et al. Endobronchial valves for emphysema. *N Engl J Med.* 2011;364:381–4.
- Hopkinson NS, Kemp SV, Toma TP, et al. Atelectasis and survival after bronchoscopic lung volume reduction for COPD. *Eur Respir J.* 2011;37:1346–51.
- Davey C, Zoumot Z, Jordan S, et al. Bronchoscopic lung volume reduction with endobronchial valves for patients with heterogeneous emphysema and intact interlobar fissures (the BeLieVeR-HiFi study): a randomised controlled trial. *Lancet.* 2015;386:1066–73.
- Klooster K, ten Hacken NH, Hartman JE, Kerstjens HAM, van Rikxoort EM, Slebos DJ. Endobronchial valves for emphysema without interlobar collateral ventilation. *N Engl J Med.* 2015;373:2325–35.
- Kemp SV, Slebos DJ, Kirk A, et al. A multicenter RCT of Zephyr® endobronchial valve treatment in heterogeneous emphysema (TRANSFORM). *Am J Respir Crit Care Med.* 2017;196:1535–43.
- Criner GJ, Sue R, Wright S, et al. A multicenter RCT of Zephyr® endobronchial valve treatment in heterogeneous emphysema (LIBERATE). *Am J Respir Crit Care Med.* 2018;198:1151–64.
- Venuta F, Anile M, Diso D, et al. Long-term follow-up after bronchoscopic lung volume reduction in patients with emphysema. *Eur Respir J.* 2012;39:1084–9.
- Garner J, Kemp SV, Toma TP, Hansell DM, Polkey MI, Shah PL, Hopkinson NS. Survival after endobronchial valve placement for emphysema: a 10-year follow-up study. *Am J Respir Crit Care Med.* 2016;194:519–21.
- Ninane V, Geltner C, Bezzi M, et al. Multicentre European study for the treatment of advanced emphysema with bronchial valves. *Eur Respir J.* 2012;39:1319–25.
- Wood DE, Nader DA, Springmeyer SC, et al. IBV Valve Trial Research Team. The IBV valve trial: a multicenter, randomized, double-blind trial of endobronchial therapy for severe emphysema. *J Bronchology Interv Pulmonol.* 2014;21(4):288–97.
- Springmeyer SC, Bolliger CT, Waddell TK, et al. Treatment of heterogeneous emphysema using the spiration IBV valves. *Thorac Surg Clin.* 2009;19:247–53.
- Criner GJ, Delage A, Voelker K, et al. Improving lung function in severe heterogeneous emphysema with the Spiration valve system (EMPROVE). A multicenter, open-label randomized controlled clinical trial. *Am J Respir Crit Care Med.* 2019;200:1354–62.

29. Castro M, Rubin AS, Laviolette M, Fiterman J, De Andrade M, Shah PL. Effectiveness and safety of bronchial thermoplasty in the treatment of severe asthma. A multicenter, randomized, double-blind, sham-controlled clinical trial. *Am J Respir Crit Care Med.* 2010;181:116–24.
30. Lausberg HF, Chino K, Patterson GA, et al. Bronchial fenestration improves expiratory flow in emphysematous human lungs. *Ann Thorac Surg.* 2003;75:393–7.
31. Chong CK, Phan L, Massetti P, et al. Prolongation of patency of airway bypass stents with use of drug-eluting stents. *J Thorac Cardiovasc Surg.* 2006;131:60–4.
32. Cardoso PF, Snell GI, Hopkins P, et al. Clinical application of airway bypass stents with paclitaxel eluting stents: early results. *J Thorac Cardiovasc Surg.* 2007;134:974–81.
33. Shah PL, Slebos J, Cardoso PFG, et al. Bronchoscopic lung-volume reduction with exhale airway stents for emphysema (EASE trial): randomised, sham-controlled, multicentre trial. *Lancet.* 2011;378:997–1005.
34. Gompelmann D, Eberhardt R, Herth F. Endoscopic lung volume reduction: a European perspective. *Ann Am Thorac Soc.* 2013;10(6):657–66.
35. Ingenito EP, Berger RL, Henderson AC, et al. Bronchoscopic lung volume reduction using tissue engineering principles. *Am J Respir Crit Care Med.* 2003;167:771–8.
36. Reilly J, Washko G, Pinto-Plata V, et al. Biological lung volume reduction: a new bronchoscopic therapy for advanced emphysema. *Chest.* 2007;131:1108–13.
37. Criner GJ, Pinto-Plata V, Strange C, et al. Biologic lung volume reduction in advanced upper lobe emphysema: phase 2 results. *Am J Respir Crit Care Med.* 2009;179:791–8.
38. Refaely Y, Dransfield M, Krameer MR, et al. Biologic lung volume reduction therapy for advanced homogeneous emphysema. *Eur Respir J.* 2010;36:20–7.
39. Magnussen H, Kramer MR, Kirsten AM, et al. Effect of fissure integrity on lung volume reduction using a polymer sealant in advanced emphysema. *Thorax.* 2012;67:302–8.
40. Come CE, Kramer MR, Dransfield MT, et al. A randomised trial of lung sealant versus medical therapy for advanced emphysema. *Eur Respir J.* 2015;46:651–62.
41. Herth FJ, Eberhardt R, Gompelmann D, Slebos DJ, Ernst A. Bronchoscopic lung volume reduction with a dedicated coil: a clinical pilot study. *Thorax.* 2010;4:225–31.
42. Slebos DJ, Klooster K, Ernst A, Herth F, Kerstjens H. Bronchoscopic lung volume reduction coil treatment of patients with severe heterogeneous emphysema. *Chest.* 2012;142:574–82.
43. Shah PL, Zoumot Z, Singh S, et al. Endobronchial coils for the treatment of severe emphysema with hyperinflation (RESET): a randomised controlled trial. *Lancet Respir Med.* 2013;1:233–40.
44. Deslee G, Klooster K, Hetzel M, et al. Lung volume reduction coil treatment for patients with severe emphysema: a European multicentre trial. *Thorax.* 2014;69:980–6.
45. Deslée G, Mal H, Dutau H, et al. Lung volume reduction coil treatment vs usual care in patients with severe emphysema: the REVOLENS randomized clinical trial. *JAMA.* 2016;315(2):175–84.
46. Sciruba FC, Criner GJ, Strange C, et al. Effect of endobronchial coils vs usual care on exercise tolerance in patients with severe emphysema. *JAMA.* 2016;315(20):2178–89.
47. Slebos DJ, Cicienia J, Sciruba FC, et al. RENEW StudyGroup. Predictors of response to endobronchial coil therapy in patients with advanced emphysema. *Chest.* 2019;155:928–37.
48. Herth FJ, Ernst A, Baker KM, et al. Characterization of outcomes 1 year after endoscopic thermal vapor ablation for patients with heterogeneous emphysema. *Int J Chron Obstruct Pulmon Dis.* 2012;7:397–405.
49. Herth FJ, Valipour A, Shah PL, et al. Segmental volume reduction using thermal vapour ablation in patients with severe emphysema: 6-month results of the multicentre, parallel-group, open-label, randomised controlled STEP-UP trial. *Lancet Respir Med.* 2016;4(3):185–93.
50. Joglekar MM, Slebos DJ, Leijten J, Burgess JK, Pouwels SD. Crosslink bio-adhesives for bronchoscopic lung volume reduction: current status and future directions. *Eur Respir Rev.* 2021;30:210142.



Ekaterina Yavarovich

## Introduction

Bronchial thermoplasty (BT) is a non-pharmacological endoscopic procedure that decreases airway smooth muscle (ASM) by applying thermal energy [1]. Multiple randomized controlled trials (RCTs) including Asthma Intervention Research (AIR), Research in Severe Asthma (RISA), and AIR2 demonstrated that BT reduced exacerbations and improved quality of life while maintaining a good safety profile [2]. The initial improvement in quality of life and decrease in the rate of severe exacerbations at 1-year post-BT have been shown to be persistent with long-term data extending out to 10 years of post-BT treatment [3, 4]. Careful patient selection is the key. BT therapy is performed in three separate bronchoscopic sessions 3 weeks apart [2].

## Mechanism of Action

In subsets of severe asthmatics, airway remodeling driven by increased airway smooth muscle (ASM) mass in the absence of inflammation may be the underlying pathophysiology explaining the refractoriness to anti-inflammatory therapies in these

patients [1]. In addition, ASM function normally aids in mucus clearance, augmentation of lymphatic and venous flow, and structure protection, and plays a role in the effectiveness of cough and dead space. In patients with severe asthma, ASM mass can increase significantly. Bronchial thermoplasty directly reduces the amount of ASM in patients with asthma [5, 6]. However, this improvement in airway remodeling is not consistently associated with improvement in clinical outcomes. Small imaging studies demonstrate objective improvement in computed tomography (CT) airway volume after BT compared to not-treated airways at 4 weeks [7]. CT imaging showed persistently reduced airway wall thickness and decreased air trapping 2 years after BT [7, 8].

Beyond direct reduction in ASM, potential mechanisms of ASM include reduced inflammatory mediators and lasting changes in the histopathology of airways. The ASMATHERM study examined the correlation between clinical and histopathological changes in patients who underwent BT comparing pre- and 3 months post-BT [6]. The study found BT at 1 year results in reductions in ASM area, neuroendocrine epithelial cells, and nerve endings, while there was no change in hypertrophy or hyperplasia of mucous glands and goblet cells [1, 6]. Other studies suggest BT may decrease the expression of airway inflammatory markers and production of protein-like interleukin (IL)-13, which is responsible for mucus secretions and goblet cell hyperplasia [1, 9].

E. Yavarovich (✉)  
Lahey Hospital & Medical Center, Pulmonary &  
Critical Care Medicine, Burlington, MA, USA  
e-mail: [ekaterina.yavarovich@lahey.org](mailto:ekaterina.yavarovich@lahey.org)

## Efficacy and Safety

### Trials

The first randomized control trial for BT was the Asthma Intervention Research (AIR) trial [10, 11]. AIR was an unblinded, prospective, randomized controlled trial (RCT) that enrolled 112 patients with moderate to severe asthma comparing BT to standard of care (forced expiratory volume in one second (FEV1) 72.7% in the BT group vs. 76.1% in the control group) [10]. Patients were followed for 12 months and the study met the primary endpoint showing a reduction in exacerbation rates at 12 months (change in frequency per subject per week:  $-0.16 \pm 0.37$  vs.  $0.04 \pm 0.29$ ;  $p = 0.005$ ) [10]. Additionally, there was an improvement in secondary endpoints in BT-treated patients in the Asthma Control Questionnaire (ACQ) and Asthma Quality of Life Questionnaire (AQLQ) [2, 10, 11].

The second trial was Research in Severe Asthma (RISA), which evaluated BT in severe asthmatics alone (prebronchodilator FEV1: 62.9% in BT group vs. 66.4% in control group) [12]. RISA trial was also unblinded, RCT of 32 patients. The primary endpoint was safety and efficacy. BT group had short-term increase in hospitalizations due to asthma symptoms in 4 of 15 BT-treated patients. Two patients developed lobar collapse and one needing bronchoscopic aspiration. Despite this, at one-year follow-up, there was a persistent improvement in asthma symptoms ACQ ( $-1.04$  to  $\pm 1.03$  vs.  $-0.13$  to  $\pm 1.00$ ;  $p = 0.02$ ) and a decrease in rescue medications in the BT group ( $-25.6$  to  $\pm 31.2$  vs.  $-6.1$  to  $\pm 12.4$  puffs/7 d;  $p < 0.05$ ) [3, 12].

The criticism of both AIR and RISA trials is they were unblinded. AIR2 trial was the first BT study to utilize sham bronchoscopy study, which was a multicenter, double-blinded RCT that enrolled 288 patients with severe persistent asthma (FEV1: 77.8% in the BT group and 79.7% in the control group) [2, 13]. AIR2 trial's primary endpoint was an improvement in AQLQ by 0.5 or greater, with secondary endpoint reduction in severe exacerbations, emergency depart-

ment (ER) visits, and days missed from school/work at 12 months post-BT [2]. Due to results from the AIR2 trial, BT was approved by Food and Drug Administration (FDA) for treatment of uncontrolled severe persistent asthma despite long-acting beta blocker (LABA) and inhaled corticosteroid (ICS) [11], although this approval was contingent based on the post-FDA approval study (PAS2) three-year post-marketing research. See Table 36.1 for summary of BT studies.

### Short Term: Three- to Five-Year Studies

PAS2 study followed the 190 patients treated with BT from AIR2 trials for 3 years. The results of the PAS2 trial confirmed results from AIR2 with a 45% decrease in severe exacerbations, a 55% decrease in emergency room visits, and a 40% decrease in hospitalizations [14].

AIR, RISA, and AIR2 all had long-term follow-up five-year study. All studies found stable FEV1 and long-term safety, and persistent reduction in hospitalizations and emergency department visits at 5 years [15–17].

### Long Term: Ten-Year Study

Recent data have been published on safety and effectiveness of BT after 10 years (10.8–15.6 years; median 12.1 years) post-treatment, from AIR, RISA, and AIR2 trials, which is demonstrated in the BT10+ study [4]. About half of the AIR, RISA, and AIR2 trial participants were enrolled: 192/429 or 45% [4]. Of these, 136 subjects received bronchial thermoplasty, and 56 were sham or control patients who did not undergo BT. The proportion of severe exacerbations were similar at 1 year (24%), 5 years (22%), and 10 years (25%) in BT group. Additional sustained effect was observed in quality of life measures and spirometry at 1, 5, and 10 years. After the trial concluded, the results were similar for 18/56 control/sham patients treated with BT [4]. See Table 36.1 for summary of studies.

**Table 36.1** Bronchial thermoplasty trial I

Study	Study design	Patients, <i>N</i>	Outcomes
AIR [10]	Prospective RCT	112	<p><i>Primary end point:</i></p> <ul style="list-style-type: none"> <li>• Reduction in exacerbation rates</li> </ul> <p><i>Secondary end points:</i></p> <ul style="list-style-type: none"> <li>• Improvement in ACQ and AQLQ</li> <li>• Five-year follow-up: Stable FEV1; stable long-term safety profile</li> </ul>
RISA [12]	Prospective RCT	32	<p><i>Primary end point:</i></p> <ul style="list-style-type: none"> <li>• Safety and efficacy: short-term increase in hospitalizations due to asthma symptoms post-procedure</li> </ul> <p><i>Secondary end points:</i></p> <ul style="list-style-type: none"> <li>• ACQ and decrease in rescue medication use</li> <li>• Five-year follow-up: Stable FEV1; reduction in hospitalizations and ER visits</li> </ul>
AIR2 [13]	Randomized, double-blind, sham controlled	288	<p><i>Primary end point:</i></p> <ul style="list-style-type: none"> <li>• Improvement in AQLQ</li> </ul> <p><i>Secondary endpoint:</i></p> <ul style="list-style-type: none"> <li>• Reduction in severe exacerbations, ER visits, and days missed from school/work in 12 months</li> <li>• Five-year follow-up: Stable FEV1; persistent reduction in severe exacerbation and ER visits</li> </ul>
PAS2 [14]	Post-FDA approval study; three-year follow-up of patients from AIR2 trial	190	Stable FEV1; persistent decrease in severe exacerbations, ER visits, and hospitalization due to asthma
BT10+ study [4]	Ten-year follow-up from AIR, RISA, AIR2	192	FEV1 stable; similar quality of life measures; similar proportions of severe exacerbations at one, five, and ten years (24%, 22%, and 25%, respectively)

ACQ Asthma Control Questionnaire, AIR Asthma Intervention Research, AQLQ Asthma Quality of Life Questionnaire, ER, FDA, FEV1, PAS2 post-FDA approval study, RISA Research in Severe Asthma, RCT randomized controlled trial

## Patient Selection

Eligibility guidelines are based on the inclusion criteria used in the AIR2 and RISA trials [12, 13]. All patients should be rigorously screened. BT is used for patients with severe refractory asthma despite optimal medical maintenance therapy, including biologics [2]. First and foremost, confirmation of the correct diagnosis/criteria of severe asthma as defined by American Thoracic Society/European Respiratory Society (ATS/ERS) guidelines should be done despite adher-

ence to high-dose ICS and LABA and possible biologics. All patients should be evaluated and treated for contributing factors like environmental triggers (occupational exposures, allergens) and comorbidities (gastroesophageal reflux, post-nasal drip, obstructive sleep apnea (OSA), vocal cord dysfunction) [2, 11]. Contraindications to BT should be assessed before the procedure (implantable electronic devices such as a pacemaker and/or defibrillator, prior BT treatment, tracheal stenosis). See Table 36.2 for inclusion and exclusion criteria.



**Table 36.2** Inclusion and exclusion criteria for BT

Criteria	Inclusion	Exclusion
Age	18–65 years of age	
Asthma controller medications	High-dose inhaled corticosteroids (ICS) Long-acting B2 agonist ±Prednisone oral <10 mg per day AIR2 and <30 mg RISA	
Pulmonary function	FEV1 > 50% (RISA), >60% (AIR 2)	Post-bronchodilator FEV1 <55% (RISA) Diffusion capacity <70% (RISA)
Smoking	<10 pack year history (h) No smoking for ≥1 year	Ten pack year (h) Current smoker
Medical history		Chronic or uncontrolled sinus disease Inability to discontinue anticoagulation before the procedure
Hospitalization		≥3 in 12 months
Respiratory infections		More than 3 in 12 months
Corticosteroid pulses		≥4 in 12 months
Intubation for asthma		In the past 24 months
Bronchoscopy	Ability to undergo the procedure under moderate sedation or monitored anesthesia care	

AIR Asthma Intervention Research, BT bronchial thermoplasty, FEV1, h history, RISA Research in Severe Asthma

## Bronchial Thermoplasty Procedure

### Equipment

“Alair” BT system delivers radiofrequency energy (electromagnetic energy) at approximately 65°C through the Alair RF controller/generator and the Flexible Alair Catheter (Figs. 36.1 and 36.2) [2]. The Flexible Alair Catheter is a disposable single-use device with a basket-like expandable electrode array with a deployment handle that requires a grounding gel-pad attached to the patient to provide a complete circuit [11]. A flexible bronchoscope with a minimum 2.0 working channel is used.

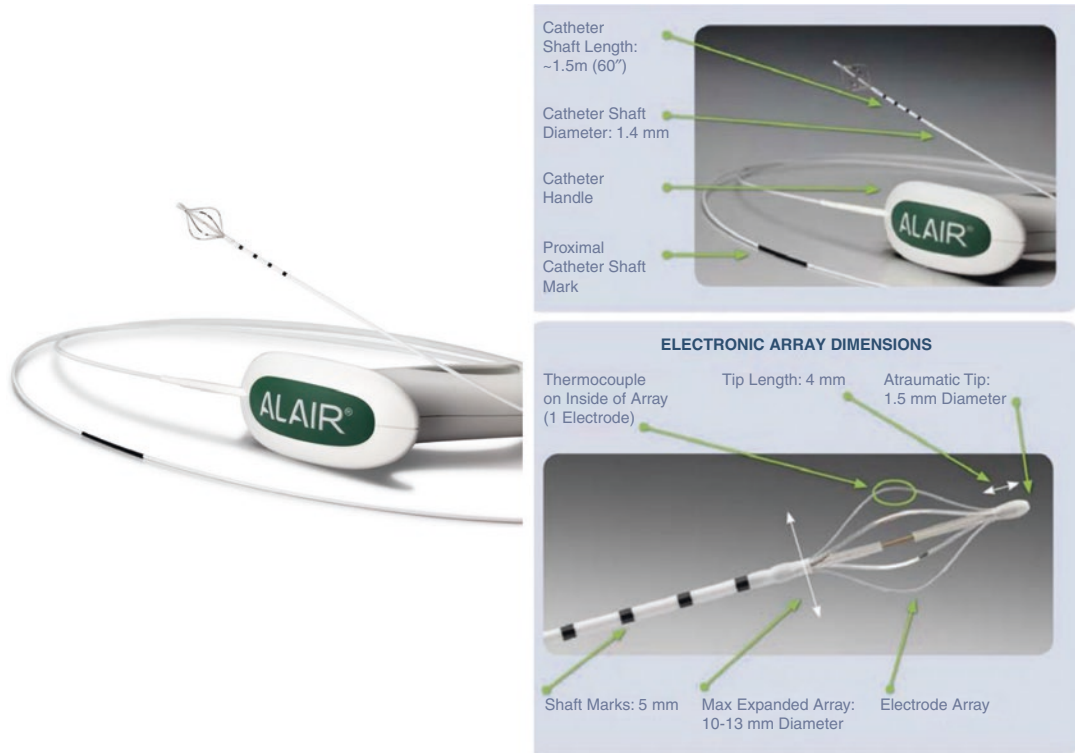
BT is performed in three bronchoscopy treatment sessions at three- to six-week intervals, with separate systematic sessions for each lower lobe and the last session for combined upper lobes. The right middle lobe is typically not treated to prevent right middle lobe syndrome [1, 2]. Treatments are divided to minimize asthma exacerbation that can occur from post-procedural airway edema and inflammation [11].

## Pre-procedure

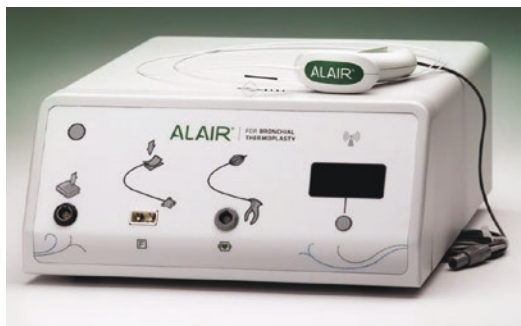
Patients should be in stable condition prior to BT procedure without a recent asthma exacerbation or pulmonary infection for at least 14 days before the procedure. Patients should be pre-treated with prednisone 50 mg daily for a total of 5 days—3 days before procedure, on the day of procedure, and on the day post-procedure—in addition to their baseline asthma therapy [2]. Additionally, patients undergo spirometry with measurement of FEV1 on the day of or day prior to the procedure, with goals of post-bronchodilator FEV1 > 80% before the procedure.

### Bronchoscopy

Bronchoscopy treatment sessions can be performed under moderate sedation or general anesthesia. The choice is based on local expertise and availability to achieve adequate sedation for the duration of the procedure, which lasts 40–60 min (approximately 44 min for each lower lobe and



**Fig. 36.1** The Alair bronchial thermoplasty catheter. (Courtesy of Boston Scientific)

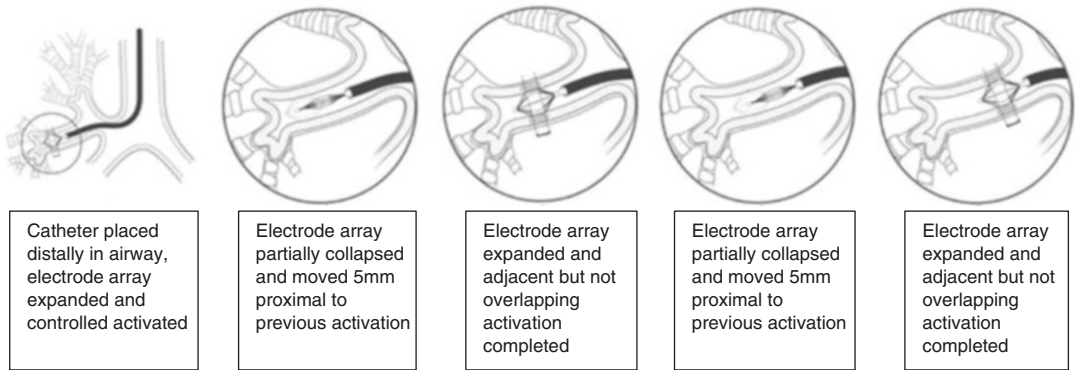


**Fig. 36.2** The Alair BT radiofrequency controller and catheter. (Courtesy of Boston Scientific)

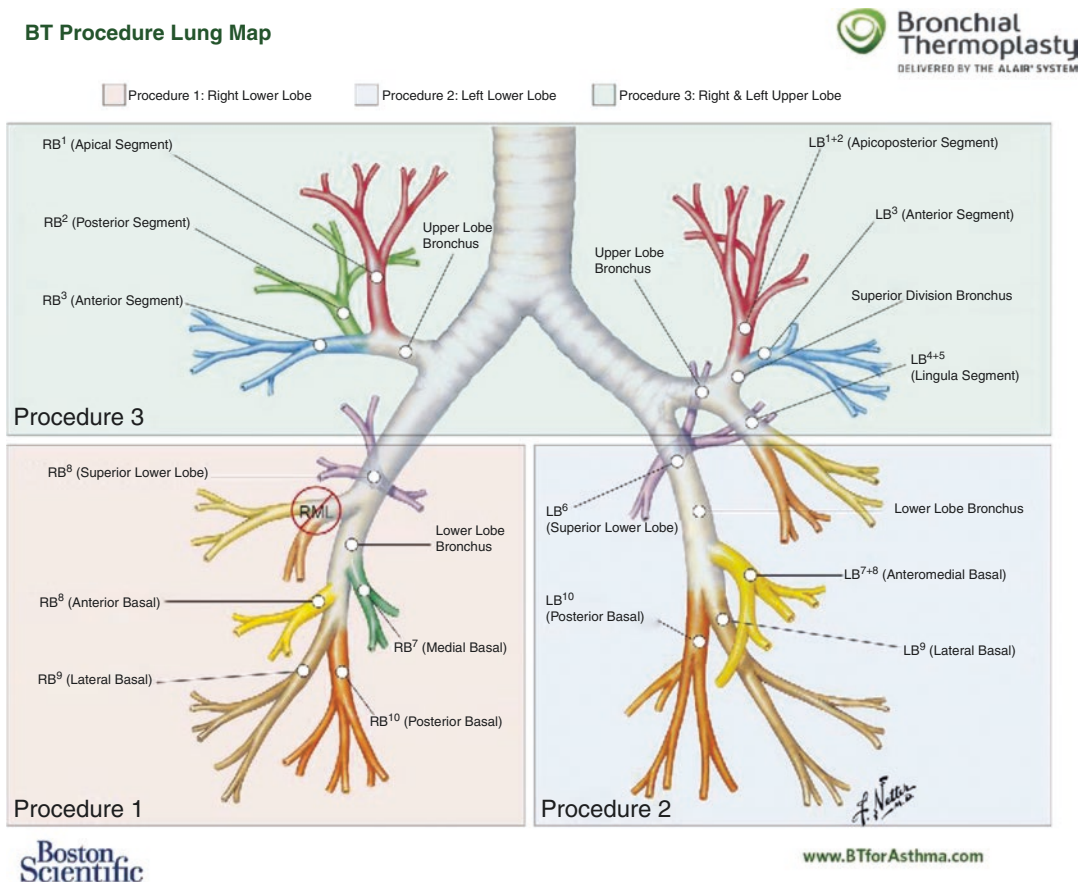
58 min for both upper lobes) [2]. Some of the frequently encountered symptoms during the BT procedure are cough, pain, and dyspnea.

Having an organized treatment plan is essential. Working from distal to proximal airways assures that all airways are treated and minimizes the chance of the same airway being treated twice [11]. First, airway inspection is performed with attention to any airway abnormalities. During

bronchoscopy, the Alair Flexible Catheter is introduced through the working channel of the flexible bronchoscope until four black catheter markings are visible with a catheter in position at the most distal subsegmental airways [11]. The deployment handle is used to open/expand the catheter electrode array until contact with the airway wall [2, 11]. Next, the “activations” are delivered by pressing and releasing the controller footswitch at ten-second intervals [1, 2, 11]. If the footswitch is released prematurely before completion of the treatment cycle, an error sound with the cancelation of treatment will be observed [11]. Additionally, if one of the four electrodes is not in contact with the airway wall, the cycle error will also sound with cessation of treatment [2]. After activation is delivered successfully, the catheter is closed and retracted to the following 5-mm black marking; subsequently, it is opened again with the next activation delivered [2]. The above steps are repeated for each black marking (total four) in each subsegmental airway of the



**Fig. 36.3** Schematic views of the Alair catheter during activation. (Courtesy of Boston Scientific)



**Fig. 36.4** BT procedure airway map. (Courtesy of Boston Scientific )

treatment lobe (Fig. 36.3). The BT activation map is used to document the number of activations per activation site (Fig. 36.4) [2]. Approximately 40–70 activations are delivered in the lower

lobes, and 50–100 in the upper lobes combined [2]. The typical sequence of treatment sessions is: right lower lobe at first session, left lower lobe at second session, and the bilateral right upper

and left upper lobes at a third and final treatment session [11]. All three treatments are done approximately 3 weeks apart to minimize asthma exacerbation.

## Post-procedure

Patients are observed post-procedure as per local treatment protocols, experience, and routine post-bronchoscopy care. Nebulized bronchodilators are administered post-procedure every 15 min on as needed basis. Based on the AIR, RISA, and AIR2 trials, the most common adverse events are severe asthma exacerbation, cough, wheezing, and respiratory tract infections [11]. Spirometry with post-treatment FEV1 < 80% compared to pre-BT FEV1 on the day of procedure warrants an admission. Chest X-ray is not typically performed post-procedure. Asthma exacerbation was seen most commonly within one-week post-procedure. Due to this, routine check-in is recommended with the patient at 24 h, 48 h, and at 7 days post-procedure [11]. Most importantly, post-educational material should be provided to patients and families.

## Conclusion

BT is FDA-approved non-pharmacological endoscopic treatment that should be considered for severe refractory asthma that is otherwise not controlled despite maximal therapy. BT reduced exacerbations and improved quality of life while maintaining a good safety profile that is persistent at 1, 5, and 10 years.

**Acknowledgments** Boston Scientific is acknowledged for allowing to present Figs. 36.1, 36.2, 36.3, and 36.4 in this text.

## References

1. Thomson NC. Recent developments in bronchial thermoplasty for severe asthma. *J Asthma Allergy*. 2019;12:375–87.

2. Bonta PI, et al. Bronchial thermoplasty in severe asthma: best practice recommendations from an expert panel. *Respiration*. 2018;95(5):289–300.
3. Wahidi MM, Kraft M. Bronchial thermoplasty for severe asthma. *Am J Respir Crit Care Med*. 2012;185(7):709–14.
4. Chaudhuri R, et al. Safety and effectiveness of bronchial thermoplasty after 10 years in patients with persistent asthma (BT10+): a follow-up of three randomised controlled trials. *Lancet Respir Med*. 2021;9(5):457–66.
5. d'Hooghe JNS, et al. Airway smooth muscle reduction after bronchial thermoplasty in severe asthma correlates with FEV1. *Clin Exp Allergy*. 2019;49(4):541–4.
6. Pretolani M, et al. Effectiveness of bronchial thermoplasty in patients with severe refractory asthma: clinical and histopathologic correlations. *J Allergy Clin Immunol*. 2017;139(4):1176–85.
7. Langton D, et al. Bronchial thermoplasty increases airway volume measured by functional respiratory imaging. *Respir Res*. 2019;20(1):157.
8. Konietzke P, et al. Quantitative CT detects changes in airway dimensions and air-trapping after bronchial thermoplasty for severe asthma. *Eur J Radiol*. 2018;107:33–8.
9. Haj Salem I, et al. Persistent reduction of mucin production after bronchial thermoplasty in severe asthma. *Am J Respir Crit Care Med*. 2019;199(4):536–8.
10. Cox G, et al. Asthma control during the year after bronchial thermoplasty. *N Engl J Med*. 2007;356(13):1327–37.
11. Tan LD, et al. Bronchial thermoplasty: a decade of experience: state of the art. *J Allergy Clin Immunol Pract*. 2019;7(1):71–80.
12. Pavord ID, et al. Safety and efficacy of bronchial thermoplasty in symptomatic, severe asthma. *Am J Respir Crit Care Med*. 2007;176(12):1185–91.
13. Castro M, et al. Effectiveness and safety of bronchial thermoplasty in the treatment of severe asthma: a multicenter, randomized, double-blind, sham-controlled clinical trial. *Am J Respir Crit Care Med*. 2010;181(2):116–24.
14. Chupp G, et al. Long-term outcomes of bronchial thermoplasty in subjects with severe asthma: a comparison of 3-year follow-up results from two prospective multicentre studies. *Eur Respir J*. 2017;50(2):1700017.
15. Thomson NC, et al. Long-term (5 year) safety of bronchial thermoplasty: asthma intervention research (AIR) trial. *BMC Pulm Med*. 2011;11:8.
16. Pavord ID, et al. Safety of bronchial thermoplasty in patients with severe refractory asthma. *Ann Allergy Asthma Immunol*. 2013;111(5):402–7.
17. Wechsler ME, et al. Bronchial thermoplasty: long-term safety and effectiveness in patients with severe persistent asthma. *J Allergy Clin Immunol*. 2013;132(6):1295–302.



# Bronchoscopy Role in Interstitial Lung Disease

# 37

Ana Gruss and María Molina-Molina

## Introduction

Interstitial lung diseases (ILDs) involve a group of respiratory entities in which the main pathological alteration affects the interstitial alveolar structures, but also can affect the small airways and the pulmonary vasculature [1]. Clinical, radiologic, and lung function presentations may be common in several ILDs [1]. Cytological evaluation and/or histological study are usually crucial to achieve the confident diagnosis and to rule out other causes of interstitial lung pathology such as infections or cancer [1]. Surgical lung biopsy (SLB) may be too risky in some cases given the clinical, lung function, or cardiovascular status and it is performed in only 20–40% of patients [2]. Therefore, bronchoscopy with bronchoalveolar lavage (BAL) and transbronchial lung biopsy (TLB) is often the initial procedure [2–4]. BAL and TLB, specially the transbronchial lung cryobiopsy (TLB-C), may provide sufficient evidence to diagnose sarcoidosis, amyloidosis, hypersensitivity pneumonitis (HP), eosinophilic pneumonias, organizing pneumonia, pulmonary Langerhans cell disease (histiocytosis X), Goodpasture's syndrome, lymphocytic interstitial pneumonia, some pneumoconiosis, pulmonary lymphangioleiomyomatosis, and pulmonary

alveolar proteinosis (PAP), as well as infections and neoplastic processes presenting with interstitial lung infiltrates [3, 4]. The introduction of TLB-C achieves better preserved and bigger histological samples, allowing the identification of the whole spectrum of histological patterns. Therefore, this new tool increases the diagnostic yield of bronchoscopy in ILDs. When clinical information and high-resolution computed tomography (HRCT) findings are combined with BAL fluid analysis and TLB-C, a confident diagnosis frequently emerges that obviates the need for SLB [4]. However, some considerations should be made to take advantage of both procedures in ILD evaluation.

## Bronchoalveolar Lavage (BAL)

BAL has gained wide acceptance as a safe method to obtain respiratory secretions for the examination of cellular and acellular components for both diagnostic and research purposes [5, 6]. Certainly, much data have been published over the past decades that demonstrate the utility of BAL to identify agents of respiratory infections and changes in the composition of the airspace environment associated with the presence of non-infectious parenchymal lung diseases. The introduction of HRCT at the end of the last century represented a revolutionary improvement in the diagnosis of specific forms of ILD and a useful

A. Gruss · M. Molina-Molina (✉)  
ILD Unit, Respiratory Department, Hospital  
Universitari de Bellvitge, Hospitalet de Llobregat,  
Barcelona, Spain



tool to decide the best place to obtain respiratory samples [6]. BAL is now routinely used as a tool to diagnose respiratory infections, study diffuse parenchymal lung diseases, and monitor the status of transplanted lung allografts [7]. Despite the widespread use of BAL by pulmonologists, BAL cellular analysis, especially nucleated immune cell differential counts, may be underused in ILD diagnosis since its results differ from center to center and depends on multiple factors [8, 9]. BAL appearance and differential cell count should be interpreted appropriately and evaluated with an updated awareness of the potential diagnoses associated with each cellular pattern to provide useful diagnostic clues [7–9].

---

### Technical Aspects of BAL Procedure

The usefulness of the BAL in ILD is only possible if: (a) the bronchoscopist uses an appropriate technique to obtain the fluid; (b) the differential cell count is performed according to good clinical laboratory practice, by experienced personnel; and (c) cell count and evaluation is interpreted by an expert pathologist in ILDs [6–8].

BAL technique through the fiberoptic bronchoscope is not difficult to perform but it could reach best results if certain advice is followed [10–12]. To retrieve alveolar cells or cells from distal airspaces, enough isotonic saline should be instilled [12]. Proximal large airway secretion contamination should be avoided by maintaining the distal end of the bronchoscope in a wedged position in a segmental or subsegmental bronchus throughout the period required for the instillation and retrieval of saline aliquots [12]. Furthermore, aliquots should be aspirated immediately once the entire aliquot volume has been instilled. Many different BAL protocols have been published and consist of multiple aliquots: five or six aliquots of 20 mL each, three of 50 mL, or four of 60 mL [12, 13]. The first aliquot frequently represents bronchial airway cells and secretions, so it is recommended to keep it separate and just use it for microbiological analysis. The other aliquots should be pooled and used for cellular analysis [12, 13].

The right middle lobe and lingula of the left upper lobe have traditionally been used for lavage since they are easily accessible areas and allow good return of BAL fluid [10]. However, nowadays patients with ILD are routinely evaluated with chest HRCT images that are used to target areas of the lung that may be more representative of the disease process (ground glass attenuation, prominent nodularity, or fine reticulation) and that could increase the possibility to obtain relevant information (abnormal areas located proximal and peribronchial) [6].

If possible, the percentage of BAL fluid that is retrieved should be  $\geq 30\%$  of the instillation for a reliable cellular analysis [13]. An accurate cell count and evaluation of BAL requires examination of at least more than 300 nucleated cells [6]. The presence of squamous epithelial cells suggests that oropharyngeal secretions have contaminated the BAL fluid. More than 5% of squamous or bronchial epithelial cells mean that the BAL sample is unsuitable for cell analysis. It is of key importance that the technicians handling the samples, analyzing the BAL slide preparations, and performing differential counts are adequately trained in proper identification of BAL cells [6]. Afterward, expert pulmonologists in ILD, familiar with BAL cell patterns, should interpret the BAL analysis results [8, 9].

BAL fluid obtained from healthy, never-smoking individuals contains most alveolar macrophages (80–95%), some lymphocytes (5–12%), and very few neutrophils (<5%) or eosinophils (<1%) [4]. BAL cell count from smokers has a significantly increased total BAL cell amount, but the BAL differential cell count is similar than never-smokers or ex-smokers, except for a lower percentage of lymphocytes [4, 14]. Age can modify the total and differential BAL cell account. It seems that elderly subjects present more lymphocytes and neutrophils in their differential cell count, and that the volume of retrieved fluid declines with advanced age [15]. Regarding the total volume instilled of saline solution, a range from 100 to 250 mL appears to give similar cell differentials in individual patients with ILD [12]. When a bacterial infection is suspected during the study of diffuse lung infiltrates or co-exists

with non-infectious ILD, the first non-centrifuged aliquot of BAL should be examined for quantitative bacterial culture, including mycobacterial and fungal screening. If viral infection or intracellular bacteria (*Pneumocystis jirovecii*) are suspected, centrifuged BAL fluid enhances their detection through stains or viral nucleic acid probes [10].

### ILD Cell Patterns and Diagnosis from BAL

A confident BAL cell evaluation, including differential cell count and other macro or microscopic characteristics, in combination with clinical and imaging data, provides relevant information that contributes significantly to the diagnosis of specific ILD (Table 37.1) [1, 5, 17–19]. Furthermore, cytopathological examination may rule out other causes of parenchymal lung diseases with a similar radiological pattern such as malignancies (bronchoalveolar and lymphangitic carcinoma) or infection (*P. jirovecii*) [20]. In the appropriate clinical and radiological setting, certain gross and cellular findings in BAL may help in the differential diagnosis for a specific ILD. Recent data suggest that predictive value of BAL for ILD diagnosis is very useful for some entities such as sarcoidosis (frequent and predominant peribronchial disorder), in contrast to rare forms of ILD or common forms that predominantly affect subpleural space or do not associate a specific differential cell count (such as idiopathic pulmonary fibrosis [IPF]) [21].

BAL macroscopic appearance is very important. Retrieved BAL fluid that has milky or light brown appearance, with protein content that settles to the bottom of its container, clearly suggests pulmonary alveolar proteinosis (PAP) [22]. The diagnosis requires confirmation through the positive staining with Schiff periodic acid (PAS+). In this case, whole-lung lavage is still considered the treatment for PAP, although there is no scientific evidence that supports the best protocol to perform it. On the other hand, a grossly bloody lavage fluid is suggestive of diffuse alveolar hemorrhage (DAH) when it

**Table 37.1** Histopathological patterns and MDD diagnosis for specimens obtained by TLB-C and SLB

	TLB-C	SLB
<i>Histopathological patterns</i>		
UIP pattern	41 (63%)	39 (60%)
Hypersensitivity pneumonitis	10 (15%)	15 (23%)
Sarcoidosis	3 (5%)	2 (3%)
Respiratory bronchiolitis-ILD or desquamative interstitial pneumonia	2 (3%)	2 (3%)
Non-specific interstitial pneumonia overlapping with organizing pneumonia pattern	2 (3%)	2 (3%)
UIP pattern consistent with connective tissue disease-ILD	0	2 (3%)
Unclassifiable	3 (5%)	1 (2%)
Non-diagnostic tissue	3 (5%)	1 (2%)
Non-ILD diagnosis	1 (2%)	1 (2%)
<i>MDD final diagnoses<sup>a</sup></i>		
Idiopathic pulmonary fibrosis	38 (58%)	35 (54%)
Hypersensitivity pneumonitis	15 (23%)	18 (28%)
Sarcoidosis	2 (3%)	2 (3%)
Smoking-related ILD	1 (2%)	2 (3%)
Connective tissue disease-ILD	1 (2%)	2 (3%)
Lymphangioleiomyomatosis	1 (2%)	1 (2%)
Unclassifiable ILD	6 (9%)	3 (5%)
Non-ILD diagnosis	1 (2%)	1 (2%)

*n* = 65; *ILD* interstitial lung diseases, *MDD* multidisciplinary discussion, *SLB* surgical lung biopsy, *TBL-C* transbronchial lung cryobiopsy, *UIP* usual interstitial pneumonia

Modified from: “Diagnostic accuracy of transbronchial lung cryobiopsy for interstitial lung disease diagnosis (COLDICE): a prospective, comparative study.” *The Lancet Respiratory Medicine* 2020;8:171–181 [16]

<sup>a</sup>For the MDD final diagnoses, raw agreement between TBL-C and SLB was 76.9% with a  $\kappa$  of 0.62 (0.47–0.78)

increases in the sequentially retrieved BAL fluid aliquots [21]. Furthermore, alveolar macrophages can stain positively for hemosiderin if the BAL is performed 24–48 h after the onset of hemorrhage.

BAL lymphocytosis can be found in cryptogenic organizing pneumonia (COP), cellular non-specific interstitial pneumonia (NSIP), hypersensitivity pneumonitis (HP), sarcoidosis,

drug toxicity, and lymphoid interstitial pneumonia (LIP) [21]. When mast cells or plasma cells are also increased, the diagnosis of HP is more probable, although mast cells can be observed in sarcoidosis, drug reactions, and ILD associated with collagen vascular disease or COP [21]. A percentage of eosinophils higher than 25% is usually associated with eosinophilic lung disease, mainly acute eosinophilic pneumonia [23]. Neutrophil's predominance is usually due to infection or acute lung injury, although some IPF patients also present increased neutrophil count, but to a lesser degree.

Some morphological changes in alveolar macrophages are also important: cytoplasmic inclusions are suggestive of viral infection, vacuolated cytoplasm with positive staining for fat can be observed in chronic aspiration pneumonitis, asbestos bodies in asbestos disease, dust particles in other pneumoconiosis, and phagocytosed red blood cells in DAH [21].

BAL differential cell count utility in a patient with ILD that presents a usual interstitial pneumonia (UIP) pattern in the thoracic HRCT is limited. It mainly helps identify other non-IPF entities that can also present the same radiological findings. An increased lymphocyte cell count in BAL would suggest the possibility of chronic HP, fibrotic NSIP, or other diagnoses associated with BAL lymphocytosis [2, 3, 24, 25]. However, if clinical or epidemiological data suggest other non-IPF UIP entity, BAL could help in the differential diagnosis, and it may help to identify some chronic HP [24, 25].

Flow cytometric analysis can improve the performance of BAL in some instances, mainly when the ILD differential diagnosis includes sarcoidosis, pulmonary Langerhans cells histiocytosis, and lymphoid malignancy [1, 21, 26]. However, due to the high cost of this procedure, flow cytometry is only used for the evaluation of CD4+/CD8+ cell ratio [21].

Alterations in BAL lymphocyte subsets have been widely examined, especially for sarcoidosis [1, 27]. Conventionally, a high CD4+/CD8+ T-lymphocyte ratio associated with BAL lymphocytosis is suggestive of sarcoidosis. However, elderly subjects can also present elevated CD4+/

CD8+ ratio, so age is a variable to consider for appropriate interpretation [17]. Recent data have demonstrated that the presence of a CD4+/CD8+ ratio of  $\geq 3.5$  is relatively specific for sarcoidosis [21, 27]. However, the sensitivity of this ratio is low since many patients do not have an elevated ratio or may even have a low one [21]. On the other hand, a decreased CD4+/CD8+ ratio has been observed in HP, drug toxicity, COP, and eosinophilic diseases [4, 21]. Therefore, the efficacy of this ratio is low for other ILDs different from sarcoidosis.

The diagnosis of pulmonary Langerhans cell histiocytosis can be supported by the presence of more than 4% CD1+ cells in BAL, which is more frequent in early stages of the disease [28]. These cells can be seen by means of immunohistochemistry or flow cytometry. Both techniques are also useful to identify monoclonal lymphocyte populations in the differential diagnosis of lymphoid diseases.

Finally, BAL cell analysis early in the study of an acute ILD, such as acute interstitial pneumonia, eosinophilic pneumonia, DAH, acute HP, acute COP, drug toxicity, or acute exacerbation of an underlying ILD, may help in their diagnosis [4, 21]. The study of BAL fluid can reveal infection or hemorrhage, large numbers of eosinophils (eosinophilic pneumonia), and an increase in lymphocytes (acute HP and drug toxicity) or plasma cells (acute HP). Careful consideration of the respiratory and clinical status should be evaluated before performing BAL, since worsening in those parameters is not unusual and has been reported after this procedure [3, 5].

Some centers use less amount of instillation while performing BAL in acute disease, with good results. A risk–benefit analysis is in order, in a patient-to-patient basis [3].

---

## Transbronchial Lung Biopsy: A New Era Introducing the Cryobiopsy

Some ILDs are associated with typical histopathologic features that can be distinctive even in small lung biopsy specimens. Whereas in most granulomatous pneumonias conventional trans-

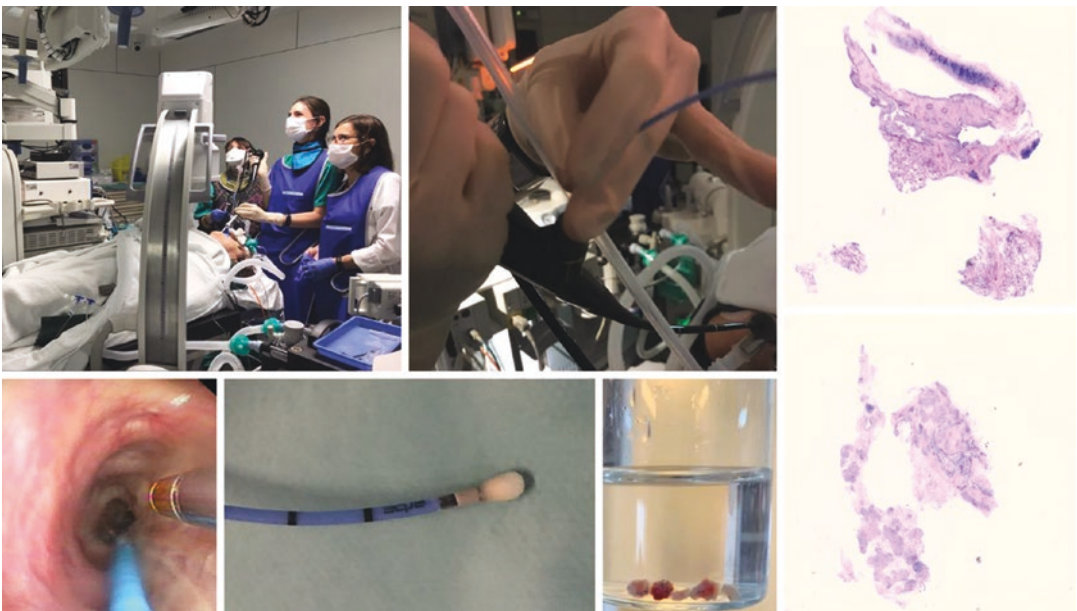
bronchial biopsies with forceps may be enough to achieve a confident diagnosis, for many other ILDs only the possibility of bigger and better transbronchial samples using cryoprobes has brought new possibilities for the diagnostic yield of bronchoscopy.

The main utility of the TLB-C in ILD is based on the possibility of making a specific diagnosis, which avoids the need of an SLB in several cases. Bronchoscopy can be done as an outpatient procedure, usually with minimal morbidity and mortality [29, 30]. A new tool for obtaining samples through fiberoptic bronchoscopy was developed at the beginning of this century: the cryoprobe. It is a device with a distal fast frozen probe that removes tissue samples. This new technique was initially used for the diagnosis of lung cancer, but during the last decades, it has been found to be a safe method to study diffuse lung diseases (Fig. 37.1).

Classically, conventional TLB by forceps has been an appropriate first biopsy procedure in patients with broncho-centric ILD, especially sarcoidosis, lymphangitis, organizing pneumonia, hemosiderosis, and infection [31–35]. Currently, with the introduction of cryoprobes

and the progressive improvement in the procedure of TLB-C, with better samples and protocols to decrease the incidence of adverse events (bleeding and pneumothorax), almost all ILDs can be diagnosed in the appropriate multidisciplinary expert approach [16, 36–43].

The efficacy of TLB in the diagnosis of ILD depends in part on the differential diagnosis that is done after careful evaluation of clinical and radiological findings [31–35]. UIP cannot be accurately diagnosed by conventional TLB, since its histological pattern cannot be determined by this technique due to two main reasons: (a) the “subpleural” space is quite impossible to be evaluated, and (b) the size of the tissue sample obtained with forceps is not enough to appreciate all the changes required to define this condition [31, 36]. However, Tomassetti et al. described the possibility of finding a UIP pattern through TLB-C [16, 41], and many other groups further validated this observation. With cryoprobes, subpleural lung samples may be obtained in which UIP histological criteria could be achieved, which represented a change in the diagnostic approach of fibrotic and non-fibrotic ILDs [16].



**Fig. 37.1** Clinical utility of TLB-C in ILDs diagnosis

The flexible bronchoscope is the main source of diagnosis in sarcoidosis, even by using conventional forceps for the biopsy. A high degree of diagnostic accuracy is achieved if more than four samples are taken. The distribution of granulomas along pulmonary lymphatic routes is frequent and bronchial lesions can be sampled directly with the cupped forceps. It has been shown that TLB samples can detect granulomas even when radiological findings fail to reveal lung parenchymal disease [37]. Some cystic interstitial lung diseases can also be diagnosed by either TLB or TLB-C. Langerhans cell histiocytosis is an airway-centered disease, and TLB can identify the typical histological lesion. The performance of immunohistochemical stains for Langerhans cells (S100 protein and CD1a) is not required when histological findings are characteristic. On the other hand, in lymphangioleiomyomatosis (LAM), immunohistochemical staining may be useful even if definite lesions are not seen [33, 38]. LAM cells are eosinophilic on hematoxylin-eosin-stained sections and HMB-45 immunohistochemical stains confirm the diagnosis.

Some studies that evaluate the diagnostic yield of TLB-C in ILDs show a range of 50–100% (depending on the cohort), with an excellent agreement in the context of a multidisciplinary team evaluation [16, 36, 40–47]. So, the probability to achieve an accurate diagnosis for ILDs is clearly higher by using transbronchial cryoprobes than by conventional forceps [36]. Furthermore, a prospective, multicenter study investigating diagnostic agreement between TLB-C and SLB showed high levels of concordance for both histopathological interpretation and multidisciplinary discussion (MDD) diagnoses supporting the clinical utility of TLB-C in ILDs' diagnostic algorithms (Table 37.1) [16]. Consequently, in most expert centers for transbronchial cryobiopsy, this new tool has replaced the conventional TLB. Complications of TLB-C include pneumothorax in 0–26% and bleeding in 0–42% with a very low mortality rate of 0.3% [16, 36, 40–47]. Severe bleeding, exacerbations, respiratory infections, and persistent air leak are rare [16, 40–47].

## Technical Advises for Conventional TLB and TLB-C in ILD

Another determinant for the utility of TLB in ILD is the technical procedure [31]. Biopsies from two different segments from the same lung can be obtained, but biopsy specimens from both lungs are contraindicated. After introducing the bronchoscope until a segmental bronchus, the forceps or cryoprobe is distally introduced.

In conventional TLB, the patient is asked to inhale, and the forceps are opened. The patient is then asked to exhale, and, at end-expiration, the forceps' jaws are closed. If the patient experiences pain at this point, the forceps is opened and withdrawn because the only pain-sensitive structure in the area is the visceral pleura. Approximately four to six biopsies are the ideal number for pathologists, although this number of samples is not always possible due to many reasons.

In TLB-C, the patient requires deep sedation to avoid cough, an endotracheal tube is required to protect the upper airway (rigid or semi-rigid), three to five biopsies should be obtained with fluoroscopic guidance to place the probe 1 cm from the visceral pleura, and an endobronchial blocker or a Fogarty balloon is required for selective bronchial blockade in case of bleeding [42]. Ideally, the procedure requires two bronchoscopists and nurses, anesthesiologist, and the adequate installations to perform the procedure in a safe manner. Safety considerations and contraindications regarding how to perform TLB-C have been described (Table 37.2) [42].

The main complication of conventional TLB and TLB-C is bleeding, which is the primary limiting factor in obtaining more or larger biopsy samples. Less frequent complications are pneumothorax, hypoxemia, or cardiac arrhythmias during the procedure. Although less common, pneumothorax may induce significant deterioration in lung fibrosis. The risk of pneumothorax is influenced by functional impairment, fibrotic HRCT score, and UIP pattern [47]. It frequently occurs if the evaluation of the pleural–subpleural area is the objective (as for UIP) [16]. Usually,



**Table 37.2** Contraindications, safety, and technical issues regarding TLB-C

<i>Contraindications and safety considerations</i>
1. Major risks after TLB-C are pneumothorax and bleeding
2. Bleeding diathesis and anticoagulant therapy, treatment with thienopyridines or other new antiplatelet drugs, and thrombocytopenia with platelets $<50 \times 10^9/L$ should be considered as contraindications
3. Pulmonary hypertension may increase the bleeding risk and is therefore considered as a relative contraindication
4. No age limits are suggested
5. b forced vital capacity (FVC) $<50\%$ and lung capacity for diffusion of carbon monoxid (DLCO) $<35\%$ of the predicted values are regarded as relative contraindications
<i>How should TLB-C be performed?</i>
1. TLB-C should be performed in patients under deep sedation or general anesthesia, with a proper airway control (laryngeal mask airway, endotracheal tube, or rigid bronchoscope)
2. If a flexible endotracheal tube is used for airway management, an endobronchial blocker or a Fogarty balloon should be used prophylactically to control bleeding and prevent central airway blood flooding. In case of intubation with a rigid bronchoscope, prophylactic balloon placement may be helpful, but is not felt to be mandatory
3. It is suggested to obtain three to five biopsies, 1 cm from the visceral pleura, and fluoroscopic guidance be used
4. TLB-C should be performed by interventional bronchoscopists trained at a center with experience in the management of potential complications like bleeding, pneumothorax, or respiratory failure
5. TLB-C should be performed in the operating room with full anesthesia support or in a dedicated bronchoscopy suite with emergency equipment immediately available with possibility to admit the patient to the intensive care unit and escalate care if needed

DLCO, FVC, *TBL-C* transbronchial lung cryobiopsy

fluoroscopic guidance for a correct placement of the forceps or cryoprobe is effectively used to reduce the rate of pneumothorax.

Conventional TLB is a safe procedure that does not require general anesthesia, with an overall mortality of 0.1%, and can be performed as an outpatient procedure. Bleeding occurs to some degree in virtually all TLB procedures, and in some cases can be substantial. Bleeding is a

major concern because of the limited options available to manage excessive bleeding through the flexible bronchoscope. The suction channel is millimetric and the volume of blood that can be suctioned is limited; also, visibility is impaired as blood obscures the lens. Moreover, because the entire tracheobronchial tree is only about 150 mL in volume, a relatively small amount of blood can produce major problems with oxygenation [31].

TLB-C presents a variable probability of pneumothorax (mean of 12%) and bleeding (mean of 39%), with higher severity (grades 2–4) [40]. However, the fact of performing this procedure under an endotracheal tube and the possibility of controlling bleeding through angioplasty balloons selectively located in the distal bronchi allow decreasing morbidity–mortality if this complication arises.

TLB is contraindicated in the presence of bleeding abnormalities. An international normalized ratio (INR) greater than 1.5 is an absolute contraindication. When oral anticoagulation therapy is taken, it should be withheld for at least four days or until INR is  $<1.5$  [31]. Fresh-frozen plasma can be administered to reverse oral anticoagulant therapy more quickly. TLB is also contraindicated if the platelet count is less than 50,000/ $\mu L$ . The platelet count can improve quickly with platelet transfusions prior to the procedure. There are insufficient data on antiplatelet agents such as clopidogrel, but some bronchoscopists require withholding treatment with this agent at least 1 week before the procedure. Finally, arterial pulmonary hypertension, which is quite usual in advanced stages of some fibrotic ILDs, may increase the risk of fatal bleeding.

Functional respiratory test and oxygen saturation should be evaluated prior to TLB or TLB-C, since it is not recommended in severe hypoxemia ( $PaO_2 < 55$  mmHg), DLCO  $< 35\%$ , or FVC  $< 50\%$  [3, 42]. There are some contraindications inherent to fiberoptic endoscopic procedures that of course also apply, such as uncontrolled cardiac arrhythmias, unstable angina, or high intracranial pressure. There is little information about TLB performed in patients on mechanical ventilation, but it is known that there is a higher risk for pneumothorax [31].

## Future Directions

The pathogenesis of different ILDs has been better understood thanks to continuous research on transbronchial samples [48–56]. Recently, it has been known that gene and protein expression patterns could identify key molecules involved in different ILDs [48–56]. These specific protein findings could provide relevant information for clinical diagnosis of ILDs and targets for effective therapies. Protein synthesis is determined by genetic and metabolic factors that may be the clue to some ILD development. Different technologies such as DNA and protein microarrays are useful to identify gene and protein expression patterns. The improvement in the world of genomic–proteomic approach may increase the utility of BAL for ILD diagnosis and management, monitoring disease activity, and assessing the effect of therapeutic interventions [54]. Recent investigations based on protein profile examination in BAL have demonstrated differences between IPF and other fibrotic lung diseases such as HP or fibrosis associated with connective tissue disease or other ILDs such as sarcoidosis [52–56]. More recently, the BRAVE clinical trials with Envisia genomic classifier have demonstrated to identify the UIP pattern from lung samples obtained through conventional means and from cryobiopsy transbronchial lung samples [57, 58]. Therefore, the future clinical use of arrays that will help in identifying the histological pattern could increase the requirement of transbronchial lung samples.

## Summary and Recommendations

The number of recognizable cyto-histopathologic reaction patterns in ILDs is limited, and their morphological specificity in the diagnosis of ILDs is variable.

BAL should be considered in all patients with suspected infection, malignancy, and some ILDs in which it may be diagnostic. The utility of BAL in ILD diagnosis depends on different factors: expertise obtaining, analyzing, and interpreting the results are the main ones. When diagnosis is

uncertain after clinical assessment and HRCT scanning, typical BAL cellular profiles may provide important clues in some ILDs such as sarcoidosis or HP. However, BAL is not a diagnostic tool in patients with clinical features and HRCT pattern typical of IPF (consistent UIP pattern). In this situation, BAL mainly helps to support other entities with similar presentation, such as HP or NSIP, and it is only recommended in a clinical context not appropriate for IPF.

Some biopsy specimens may provide specific clues that are diagnostic of the underlying disease, whereas others reveal only non-specific abnormalities. TLB-C is a powerful tool for diagnosis of specific ILD when matched with appropriate expectations on the part of clinicians, radiologists, and pathologists, and may avoid the need of SLB.

HRCT images are essential for choosing the best place to biopsy and to help in the final diagnosis. TLB is the initial procedure of choice in those patients in whom small samples may be diagnostic, particularly if the disease has a tendency for broncho-centric involvement, and, when possible, BAL and TLB should be performed before the initiation of any treatment. Conventional TLB is not recommended in IPF or other ILDs with UIP radiological pattern; however, TLB-C may be useful for diagnostic yield of the MDD in these cases.

## References

1. Costabel U, Guzman J. Bronchoalveolar lavage in interstitial lung disease. *Curr Opin Pulm Med.* 2001;7:255–61.
2. Travis WD, King TE, Bateman ED, et al. ATS/ERS international multidisciplinary consensus classification of idiopathic interstitial pneumonias. General principles and recommendations. *Am J Respir Crit Care Med.* 2002;165:277–304.
3. Bradley B, Branley HM, Egan JJ, Greaves MS, Hansell DM, Harrison NK, et al. British Thoracic Society Interstitial Lung Disease Guideline Group. British Thoracic Society Standards of Care Committee; Thoracic Society of Australia; New Zealand Thoracic Society; Irish Thoracic Society. Interstitial lung disease guideline: the British Thoracic Society in collaboration with the Thoracic Society of Australia and New Zealand and the Irish Thoracic Society. *Thorax.* 2008;63 Suppl 5:v1–58.

4. Xaubet A, Ancochea J, Blanquer R, Montero C, Morell F, Rodríguez Becerra E, Sueiro A, Villena V. Grupo de Investigación en Enfermedades Pulmonares Intersticiales Difusas. Area de Técnicas y Transplante. SEPAR. Diagnosis and treatment of diffuse interstitial lung diseases. *Arch Bronconeumol*. 2003;39(12):580–600.
5. Drent M, Meyer KC, Baughman RP. Bronchoalveolar lavage. *Prog. Respir Res*. 2007;36:58–67.
6. Kanne JP. Interstitial lung diseases (ILD): imaging finding, and the role of imaging in the evaluation of the patient with known or suspected ILD. *Semin Soentgenol*. 2010;45:3.
7. Meyer KC. Bronchoalveolar lavage as a diagnostic tool. *Semin Respir Crit Care Med*. 2007;28:546–60.
8. Meyer KC. The role of bronchoalveolar lavage in interstitial lung disease. *Clin Chest Med*. 2004;25(4):v637–49.
9. Ryu JH, Daniels CE, Hartman TE, Yi ES. Diagnosis of interstitial lung diseases. *Mayo Clin Proc*. 2007;82(8):976–86.
10. Baughman RP. Technical aspects of bronchoalveolar lavage: recommendations for a standard procedure. *Semin Respir Crit Care Med*. 2007;28:475–85.
11. Dhillon DP, Haslam PL, Townsend PJ, et al. Bronchoalveolar lavage in patients with interstitial lung diseases: side effects and factors affecting fluid recovery. *Eur J Respir Dis*. 1986;68:341–50.
12. Dohn MN, Baughman RP. Effect of changing instilled volume for bronchoalveolar lavage in patients with interstitial lung disease. *Am Rev Respir Dis*. 1985;132:390–2.
13. Rosell A, Xaubet A, Agustí C, Castella J, Puzo C, Curull V, de Gracia J, RASTA study group. A new BAL fluid instillation and aspiration technique: a multicenter randomized study. *Respir Med*. 2006;100(3):529–35.
14. Costabel U, Guzman J. Effect of smoking on bronchoalveolar lavage constituents. *Eur Respir J*. 1992;5:776–9.
15. Meyer KC, Soergel P. Bronchoalveolar lymphocyte phenotypes change in the normal aging human lung. *Thorax*. 1999;54:697–700.
16. Troy LK, Grainge C, Corte TJ, Williamson JP, Vallely MP, Cooper WA, Mahar A, Myers JL, Lai S, Mulyadi E. Diagnostic accuracy of transbronchial lung cryobiopsy for interstitial lung disease diagnosis (COLDICE): a prospective, comparative study. *Lancet Respir Med*. 2020;8:171–81.
17. Haslam PL, Baughman RP. Guidelines for the measurement of acellular components and recommendations for standardization of bronchoalveolar lavage (BAL). *Eur Respir Rev*. 1999;9:25–157.
18. Baughman RP, Drent M. Role of bronchoalveolar lavage in interstitial lung disease. *Clin Chest Med*. 2001;22:331–41.
19. Meyer KC. The role of bronchoalveolar lavage in interstitial lung disease. *Clin Chest Med*. 2004;25:637–49.
20. Raghu G. Is bronchoalveolar lavage clinically useful for everyday practice in interstitial lung disease? Con: bronchoalveolar lavage. *J Bronchol*. 1999;6:217–21.
21. Meyer KC, Raghu G. Bronchoalveolar lavage for the evaluation of interstitial lung disease: is it clinically useful? *Eur Respir J*. 2011;38(4):761–9.
22. Martin RJ, Coalson JJ, Roger RM, et al. Pulmonary alveolar proteinosis: the diagnosis by segmental lavage. *Am Rev Respir Dis*. 1980;121:819–25.
23. Allen JN, Davis WB. Eosinophilic lung diseases. *Am J Respir Crit Care Med*. 1994;150:1423–38.
24. Raghu G, Collard HR, Egan JJ, et al. An official ATS/ERS/JRS/ALAT statement: idiopathic pulmonary fibrosis: evidence-based guidelines for diagnosis and management. *Am J Respir Crit Care Med*. 2011;183:788–824.
25. Raghu G. Idiopathic pulmonary fibrosis: guidelines for diagnosis and clinical management have advanced from consensus-based in 2000 to evidence-based in 2011. *Eur Respir J*. 2011;37:743–6.
26. Welker L, Jörres RA, Costabel U, et al. Predictive value of BAL cell differentials in the diagnosis of interstitial lung diseases. *Eur Respir J*. 2004;24:1000–6.
27. Drent M, Mansour K, Linssen C. Bronchoalveolar lavage in sarcoidosis. *Semin Respir Crit Care Med*. 2007;28:486–95.
28. Costabel U, Guzman J, Bonella F, et al. Bronchoalveolar lavage in other interstitial lung diseases. *Semin Respir Crit Care Med*. 2007;28:514–24.
29. Hernandez Blasco L, Sanchez Hernandez IM, Villena Garrido V, de Miguel PE, Delgado Nuñez M, Alfaro AJ. Safety of the transbronchial biopsy in outpatients. *Chest*. 1991;99:562–5.
30. Churg A. Transbronchial biopsy: nothing to fear. *Am J Surg Pathol*. 2001;25:820–2.
31. Margaritopoulos GA, Wells AU. The role of transbronchial biopsy in the diagnosis of diffuse parenchymal lung diseases: con. *Rev Port Pneumol*. 2012. Epub ahead of print;18:61.
32. Poletti V, Casoni GL, Cancellieri A, Piciucchi S, Dubini A, Zompatori M. Diffuse alveolar damage. *Pathologica*. 2012;102:453–63.
33. Leslie KO, Gruden JF, Parish JM, Scholand MB. Transbronchial biopsy interpretation in the patient with diffuse parenchymal lung disease. *Arch Pathol Lab Med*. 2007;131(3):407–23.
34. Colby TV, Fukuoka J, Ewaskow SP, Helmers R, Leslie KO. Pathologic approach to pulmonary hemorrhage. *Ann Diagn Pathol*. 2001;5:309–19.
35. Oliveira CC, Fabro AT, Ribeiro SM, Defaveri J, Capelozzi VL, Queluz TH, Yoo HH. Evaluation of the use of transbronchial biopsy in patients with clinical suspicion of interstitial lung disease. *J Bras Pneumol*. 2011;37(2):168–75.

36. Pajares V, Torrego A, Puzo C, Lerma E, Gil De Bernabé MA, Franquet T. Transbronchial lung biopsy using cryoprobes. *Arch Bronconeumol*. 2010;46:111–5.
37. Babiak A, Hetzel J, Krishna G, et al. Transbronchial cryobiopsy: a new tool for lung biopsies. *Respiration*. 2009;78:203–8.
38. Franke KJ, Theegarten D, Hann von Weyhern C, et al. Prospective controlled animal study on biopsy sampling with new flexible cryoprobes versus forceps: evaluation of biopsy size, histological quality and bleeding risk. *Respiration*. 2010;80(2):127–32.
39. Griff S, Ammenwerth W, Schönfeld N, et al. Morphometrical analysis of transbronchial cryobiopsies. *Diagn Pathol*. 2011;16(6):53.
40. Johannson KA, Marcoux VS, Ronksley PE, Ryerson CJ. Diagnostic yield and complications of transbronchial lung cryobiopsy for interstitial lung disease: a systematic review and meta-analysis. *Ann Am Thorac Soc*. 2016;13:1828–38.
41. Tomassetti S, Wells AU, Costabel U, et al. Bronchoscopic lung cryobiopsy increases diagnostic confidence in the multidisciplinary diagnosis of idiopathic pulmonary fibrosis. *Am J Respir Crit Care Med*. 2016;193(7):745–52.
42. Hetzel J, Maldonado F, Ravaglia C, Wells AU, Colby TV, Tomassetti S, Ryu JH, Fruchter O, Piciucchi S, Dubini A, Cavazza A, Chilosi M, Sverzellati N, Valeyre D, Leduc D, SLF W, Gasparini S, Hetzel M, Hagemeyer L, Haentschel M, Eberhardt R, Darwiche K, Yarmus LB, Torrego A, Krishna G, Shah PL, Annema JT, FJF H, Poletti V. Transbronchial cryobiopsies for the diagnosis of diffuse parenchymal lung diseases: expert statement from the Cryobiopsy Working Group on safety and utility and a call for standardization of the procedure. *Respiration*. 2018;95:188–200.
43. Maldonado F, Danoff SK, Wells AU, Colby TV, Ryu JH, Liberman M, Wahidi MM, Frazer L, Hetzel J, Rickman O, Herth FJF, Poletti V, Yarmus L. CHEST Guideline and Expert Panel Report CHEST: Transbronchial Cryobiopsy for the Diagnosis of Interstitial Lung Diseases; 2019.
44. Cooper WA, Mahar A, Myers JL, Grainge C, Corte TJ, Williamson JP, Vallely MP, Lai S, Mulyadi E, Torzillo PJ. Cryobiopsy for identification of usual interstitial pneumonia and other interstitial lung disease features: further lessons from COLDICE, a prospective multi-center study. *Am J Respir Crit Care Med*. 2021;203(10):1306–13.
45. Echevarria-Uraga JJ, Pérez-Izquierdo J, García-Garai N, Gómez-Jiménez E, Aramburu-Ojearrena A, Tena-Tudanca L, Miguélez-Vidales JL, Capelastegui-Saiz A. Usefulness of an angioplasty balloon as selective bronchial blockade device after transbronchial cryobiopsy. *Respirology*. 2016;21:1094–9.
46. Inomata M, Kuse N, Awano N, Tone M, Yoshimura H, Jo T, Minami J, Takada K, Yuan B, Kumasaka T. Prospective multicentre study on the safety and utility of transbronchial lung cryobiopsy with endobronchial balloon. *ERJ Open Res*. 2020;6:00008–2020.
47. Tomassetti S, Ravaglia C, Wells AU, Cavazza A, Colby TV, Rossi G, Ley B, Ryu JH, Puglisi S, Arcadu A. Prognostic value of transbronchial lung cryobiopsy for the multidisciplinary diagnosis of idiopathic pulmonary fibrosis: a retrospective validation study. *Lancet Respir Med*. 2020;8:786–94.
48. Martin WJ, Iannuzzi MC, Gail DB, Peavy HH. Future directions in sarcoidosis research: summary of an NHLBI working group. *Am J Respir Crit Care Med*. 2004;170:567–71.
49. Costello LC, Hartman TE, Ryu JH. High frequency of pulmonary lymphangioliomyomatosis in women with tuberosus sclerosis complex. *Mayo Clin Proc*. 2000;75:591–4.
50. Agostini C, Miorin M, Semenzato G. Gene expression profile analysis by DNA microarrays: a new approach to assess functional genomics in diseases. *Sarcoidosis Vasc Diffuse Lung Dis*. 2002;19:5–9.
51. Thornhofer R, Maercker C, Popper HH. Expression of sarcoidosis related genes in lung lavage cells. *Sarcoidosis Vasc Diffuse Lung Dis*. 2002;19:59–65.
52. Selman M, Pardo A, Barrera L, et al. Gene expression profiles distinguish idiopathic pulmonary fibrosis from hypersensitivity pneumonitis. *Am J Respir Crit Care Med*. 2006;173:188–98.
53. Magi B, Bini L, Perari MG, et al. Bronchoalveolar lavage fluid protein composition in patients with sarcoidosis and idiopathic pulmonary fibrosis: a two-dimensional electrophoretic study. *Electrophoresis*. 2002;23:3434–44.
54. Rottoli P, Magi B, Perari MG, et al. Cytokine profile and proteome analysis in bronchoalveolar lavage of patients with sarcoidosis, pulmonary fibrosis associated with systemic sclerosis and idiopathic pulmonary fibrosis. *Proteomics*. 2005;5:1423–30.
55. De Torre C, Ying S, Munson PJ, et al. Proteomic analysis of inflammatory biomarkers in bronchoalveolar lavage. *Proteomics*. 2006;6:3949–57.
56. Bowler RP, Ellison MC, Reisdorph N. Proteomics in pulmonary medicine. *Chest*. 2006;130(567–574):77.
57. Kheir F, Alkhatib A, Berry GJ, Daroca P, Diethelm L, Rampolla R, Saito S, Smith DL, Weill D, Bateman M. Using bronchoscopic lung cryobiopsy and a genomic classifier in the multidisciplinary diagnosis of diffuse interstitial lung diseases. *Chest*. 2020;158:2015–25.
58. Raghu G, Flaherty KR, Lederer DJ, Lynch DA, Colby TV, Myers JL, Groshong SD, Larsen BT, Chung JH, Steele MP. Use of a molecular classifier to identify usual interstitial pneumonia in conventional transbronchial lung biopsy samples: a prospective validation study. *Lancet Respir Med*. 2019;7:487–96.



# Interventional Pulmonology in the Pediatric Population

# 38

Nathaniel Silvestri, Lonny B. Yarmus,  
and Christopher R. Gilbert

## Introduction

Interventional pulmonology (IP) is an exciting field that has continued to evolve and innovate since its introduction [1]. IP has been defined as the art and science of medicine related to the performance of diagnostic and invasive therapeutic procedures that require additional training and expertise beyond that required in standard pulmonary medicine training programs [2]. Over the years, IP has continued to grow both in regard to practitioners and the literature base.

The question of IP in pediatrics, or a pediatric population, remains an interesting one. Since the majority of the standard IP's practice is largely based in advanced malignancy, the interaction or "need" for interaction is generally less, mainly related to pediatric cancers involving the airways and thorax, fortunately not as common as

in adults. Additionally, the standard IP's training program remains in adult medicine (internal medicine residency, pulmonary and critical care fellowship, interventional pulmonology fellowship). The need and/or potential of exposure to the pediatric population can vary widely in this type of training including the potential for never seeing a patient less than 18 years of age in the entire training timeframe. A somewhat different issue may arise during pediatric pulmonology fellowship training. Pediatric pulmonology fellowships remain limited to those completing pediatric residencies. During fellowship training, pediatric pulmonologists are taught bronchoscopy; however, data suggest that the training is variable and there remain no objective requirements for their procedural training [3, 4]. Current requirements expect trainees to "demonstrate competence in performing bronchoscopy," but there are no clear standards in place per current American College of Graduate Medical Education Requirements. A recent survey of pediatric pulmonology training programs reported the average graduating fellow had completed 89 flexible bronchoscopies with a range of 10–200, illustrating the variation in exposure for pediatric practitioners [5].

While the difference in exposure between the training programs is likely directly related to the lower "demand" in the pediatric population, recent innovations have been made to increase the "supply" of training exposures for both cohorts to gain competency in pediatric interven-

---

N. Silvestri  
Department of Pediatrics, The Johns Hopkins  
Hospital, Baltimore, MD, USA

L. B. Yarmus  
Interventional Pulmonology, Division of Pulmonary  
Disease and Critical Care Medicine, The Johns  
Hopkins Hospital, Baltimore, MD, USA

C. R. Gilbert (✉)  
Thoracic Surgery and Interventional Pulmonology,  
Swedish Cancer Institute, Seattle, WA, USA

Center for Lung Research in Honor of Wayne  
Gittinger, Seattle, WA, USA  
e-mail: [christopher.gilbert@swedish.org](mailto:christopher.gilbert@swedish.org)



tional procedures. Some researchers and educators have begun replicating the pediatric airway with three-dimensional (3D) reconstruction of computed tomography (CT) scans of the airway of infants and children for trainee bronchoscopy practice [6]. Others have been able to replicate the respiratory cycle using four-dimensional (4D) dynamic CT airway protocols and have constructed tracheobronchial trees that represent pediatric airways. This technology may offer the ability to introduce pathologies to the simulations such as tracheobronchomalacia and subsequent stent placement training [7]. With models, some training programs have been able to educate both pediatric and adult providers in pediatric IP and could close the experience gap between clinicians [8].

---

### **Complex Problems and Multidisciplinary Approaches**

Similar to many issues in medicine, patients with complex problems often require complex solutions—which are likely better served within a multidisciplinary evaluation. Since many issues encountered by IP are complex (airway and pleural disease), IP commonly works with other physicians from anesthesia, intensive care medicine, otolaryngology, pulmonology, and thoracic surgery on a daily basis. This type of model is often in place at many institutions, and many IP physicians are familiar with the processes of multidisciplinary evaluation and management of patients. Additionally, review of the available literature appears to describe that multidisciplinary care of pediatric patients with central airway obstruction (CAO) already occurs [3], however is often reported within the surgical literature (otolaryngology, thoracic, or pediatric surgery). There appears to be limited data on pulmonologists (pediatric or adult) performing therapeutic airway interventions within the pediatric population [9], except perhaps the plethora of data during foreign body removal.

### **The Pediatric Airway**

While many general principles related to airway management are the same regardless of age and size, there are some distinct differences physicians must be aware of for both patient safety and procedural feasibility. Preoperative airway evaluations including a patient history and physical examination, as well as a review of any previous history of airway difficulties from the medical record and from parents/guardians are required. When evaluating newborns and infants, a maternal and perinatal history is often appropriate. When encountering children with congenital or malformation syndromes, a thorough understanding of their defined and potentially unrecognized manifestations remains essential for appropriate procedural and anesthetic planning [10]. The utilization of a multidisciplinary approach and open dialogue between all team members, especially pediatric anesthesiologists, intensivists, surgeons, and pulmonologists, have often been helpful in pre-, intra-, and post-procedural planning.

Significant head and neck changes occur during normal child growth that affect airway anatomy and access. Initially, children have large heads with small, immobile mandibles. However, over time, head size proportions decrease and the mandible becomes larger and mobile. Additionally, the tongue becomes smaller in proportion to the airway, the epiglottis decreases, and the location of the glottic opening changes. In smaller children, the cricoid cartilage remains the smallest diameter of the airway (as opposed to adults in which the glottic opening is the smallest); therefore an instrument that passes through the glottic opening may not pass further into the trachea [11].

Airway diameter remains an extremely important consideration for procedural planning and selection of appropriate equipment. Utilization of the ventilating rigid bronchoscope for safe airway control and numerous interventions is relatively common in adults. However, despite the

**Table 38.1** Pediatric airway equipment and sizes: suggested size of endotracheal tube and laryngeal mask airway based on child's age and weight

Age	Weight	Endotracheal tube size	Laryngeal mask airway size
0–6 months	0–4 kg	2.5–3.5	1
6–12 months	5–10 kg	3.5–4.0	1.5
1–3 years	10–15 kg	4.0–4.5	2
4–7 years	15–20 kg	5.0–5.5	2–2.5
8–10 years	20–30 kg	5.5–6.0	2.5
>10 years	>30 kg	>6.0	>3

Adapted from Anesthesiology [10], Basics of Anesthesia [13], and from American Trauma Life Support for Doctors Manual [14]

same ability to use these same types of ventilating rigid bronchoscopes in pediatrics, numerous differences need to be recognized. The presence of a smaller airway diameter limits the size of endotracheal appliances (rigid bronchoscope or endotracheal tube) that can be introduced, affects the ability to utilize many instruments, and increases potential risk of complications from excessive airway pressures [12]. Endotracheal tube size is often estimated by age or weight in pediatrics (Table 38.1), but can also be done by selecting an outer diameter similar in size to the child's fifth finger [15].

## Advanced Diagnostic Procedures

### Endobronchial Ultrasound

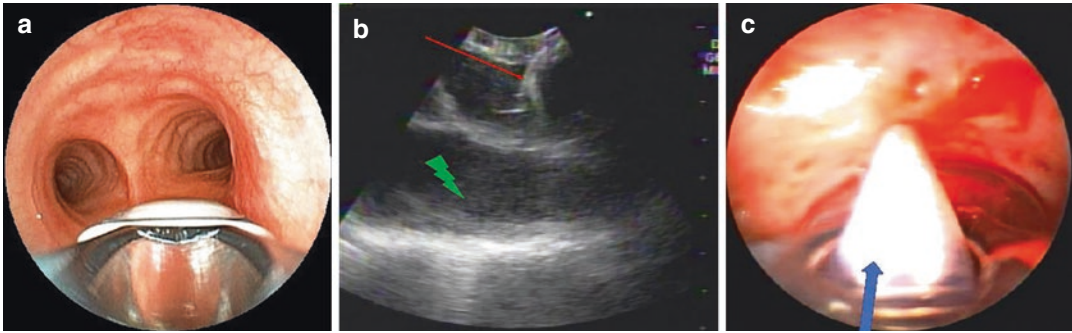
Endobronchial ultrasound-guided transbronchial needle aspiration (EBUS-TBNA) was initially introduced to the adult pulmonology community as a way to increase diagnostic yield in lung cancer. It has since experienced widespread acceptance and popularity, with a recent PubMed search of over 4000 articles. However, there remains a paucity of literature related to utilization in pediatrics.

The convex probe endobronchial ultrasound (EBUS) puncturescope (Fig. 38.1) was introduced in early 2000 [16] and since has revolutionized the care of adult patients with mediastinal and hilar lymphadenopathy, especially regarding the care of patients with suspected lung cancer. These bronchoscopes are generally designed for examination of the more central structures, often medi-

astinal and hilar lymphadenopathy, but can also access centrally located lesions [17]. Currently, the main limitation for use of the EBUS puncturescope within the pediatric population remains the large scope diameter, with all possessing an outer diameter of greater than 6 mm. However, there is ongoing development of a smaller diameter EBUS scope that may lead to greater usability within the pediatric population [18, 19].

The adult literature suggests widespread adoption of Endobronchial Ultrasound - Transbronchial Needle Aspiration (EBUS-TBNA) and in most high-volume institutions that provide multidisciplinary care to patients with thoracic malignancies, EBUS-TBNA has often replaced mediastinoscopy as an initial diagnostic test [20–22]. Attractive features to EBUS-guided procedures include the potential for decreased cost, complications, and hospital resource utilization.

The pediatric literature remains scant; however, over time, there have been more publications, and the data suggest the procedure remains feasible, even in small children and infants. Initial case reports described EBUS in children 6 [23] and 13 [24] years of age. Following this, a multicenter study identified 21 pediatric patients safely undergoing EBUS with ages ranging from 18 months to 18 years [25]. Additional larger cohorts have also demonstrated that both EBUS-TBNA (bronchoscope) and endoscopic ultrasound guided fine-needle aspiration using the EBUS scope (EUS-B-FNA) (gastroscope) are safe with good diagnostic yield [26, 27]. Additionally, a larger systematic review of 173 patients suggested both major and minor complications were minimal at 0.3% and 3.5%, respectively [28].



**Fig. 38.1** Convex probe endobronchial ultrasound (CP-EBUS) puncturescope. (a) Photograph of CP-EBUS puncturescope tip from within the trachea. The ultrasound probe is located at the distal tip of the scope, whereas the working channel is in the immediate near field view. (b) Ultrasound image of a transbronchial needle aspiration

(TBNA) needle (red arrow) within a lymph node. The superior vena cava is also identified (green lightning bolt). (c) View of EBUS puncturescope during TBNA, with needle (blue arrow) coming through working channel and buried in 4R lymph node

## Virtual Navigational Bronchoscopy

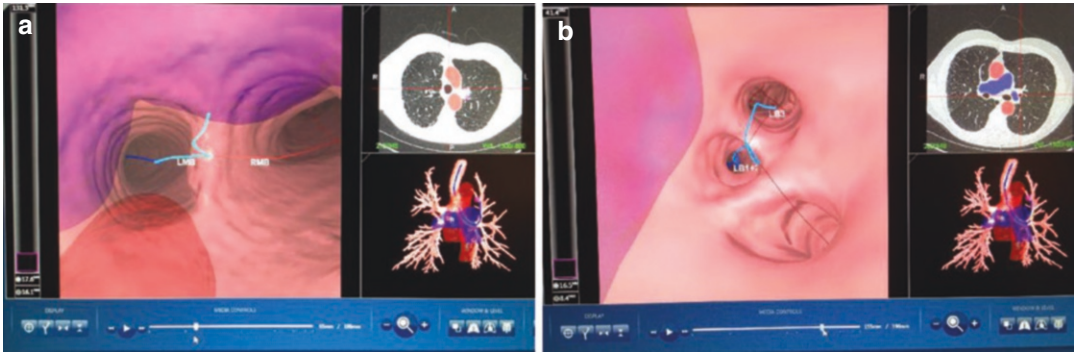
Navigational bronchoscopy is a rapidly expanding tool within the adult population. This technology remains feasible for use in pediatrics as it often has no specific requirements or needs that would limit use to the adult population only. However, the use of these technologies does require the use of specially formatted computed tomography scans (Fig. 38.2). One small study using intraoperative electromagnetic navigational bronchoscopy in the pediatric population demonstrated high diagnostic yield (seven of eight biopsies changing disease management) [29]. Virtual bronchoscopy has also been utilized as a comparison to flexible bronchoscopy (FB) in the diagnosis of pediatric tracheobronchomalacia. It remains unclear if virtual bronchoscopy would replace flexible bronchoscopy; however, it appears that virtual bronchoscopy might be a viable option with a specificity of greater than 87% and 95% for tracheomalacia and bronchomalacia detection, respectively [30].

## Cryobiopsy

Flexible bronchoscopic cryobiopsy is a recent innovation that has been used in the diagnosis of

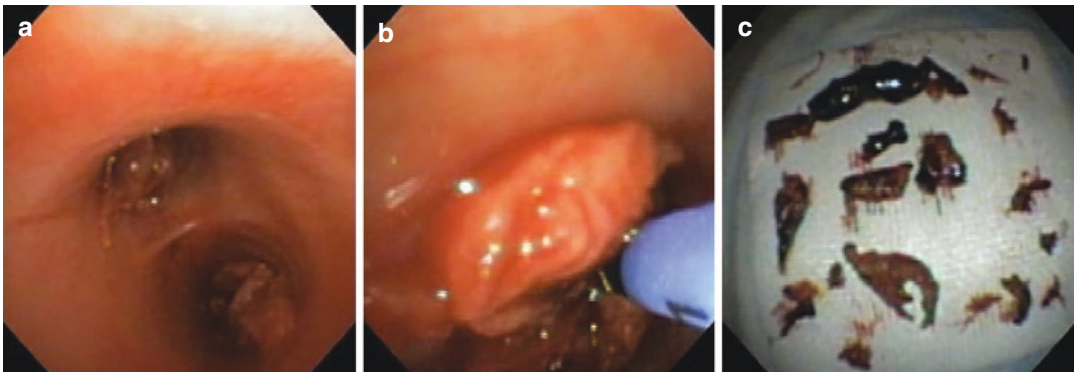
interstitial lung disease and endobronchial tumors in the adult population. Cryobiopsy allows for larger biopsy sample collection when compared to conventional techniques, and without the crush artifact that comes with forceps biopsy [31, 32]. Much like other IP advances made in the adult population, cryobiopsy has slowly been introduced to pediatric populations. Due to recent improvements in size of available bronchoscopes and cryoprobes, cryobiopsy has now been used in the diagnosis of an endobronchial tumor [33] and interstitial lung disease in the pediatric population [34]. As this technology and technique continues to become more widespread in the IP community, we can only imagine similar advances will continue in the pediatric population.

Additionally, a common indication for bronchoscopy in children remains foreign body aspiration (Fig. 38.3). The cryoprobe can provide an additional tool in the armamentarium of foreign body retrieval tools. Some proposed benefits of foreign body cryoprobe extraction techniques include removal of the original object and any broken off portions en masse, as well as fragmenting or slipping through a traditional forceps [35]. More recent studies have been performed with larger cohorts and with similar success (over 85% of FB in the first pass, with over 90% in two passes) [36].



**Fig. 38.2** Navigational bronchoscopy techniques. Screen views of LungPoint (Bronchus Technology, Redmond, WA, USA) Navigational Bronchoscopy software. (a) Screenshot of view from main carina, with subsequent axial planning image highlighting aorta in red and three-

dimensional image of airway tree and major vessels. (b) Virtual image of left upper lobe entrance with corresponding axial images and three-dimensional airway images. The software pre-labels major airways with segmental anatomy identified from computed tomography scans



**Fig. 38.3** Cryoprobe via flexible bronchoscopy for use during foreign body removal. A 13-year-old girl developed respiratory failure from viral pneumonia and was placed on extracorporeal membrane oxygenation (ECMO). During this course she developed recurrent hemoptysis, eventually

leading to airway obstruction (a). The use of the flexible cryoprobe in multiple freeze/thaw cycles (b) enabled to remove large amounts of blood clot casts that had been occluding the central airways (c)

## Therapeutic Procedures

Multiple publications are currently available regarding the use of rigid bronchoscopy within pediatrics, with many authors' training originating in otolaryngology, thoracic surgery, and/or pediatric surgery. Within this review we have elected to exclude foreign body retrieval, as this remains the most commonly reported use of rigid bronchoscopy in children and many other reviews are currently available for such purposes [37–39]. We instead elected to focus on other less described therapeutic bronchoscopic interventions in pediatrics.

Within the pediatric population, central airway obstruction (CAO) related to non-malignant causes remains more common than malignant disease. This distinction remains quite important and is the central challenge in long-term management of pediatric CAO. Another challenging factor is the future ability of airway size changes as the child ages, providing predictable increase in airway dimension. This fact can provide both advantages (improvement in airway stenosis and malacia as the obstruction may represent a smaller fraction of the overall airway diameter) and disadvantages (growth can result in in situ stent migration from airway diameter changes). While surgical treatment



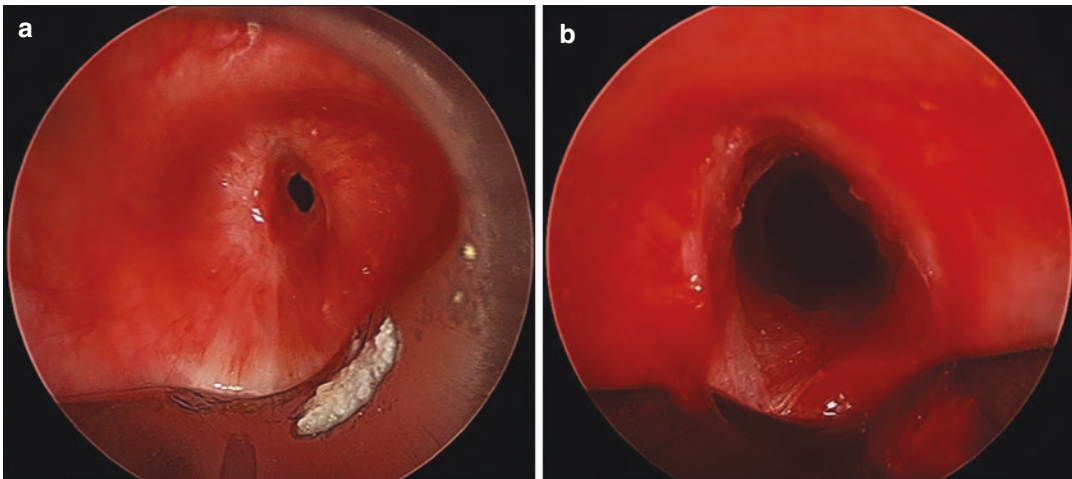
remains the optimal therapy for airway obstruction in non-malignant disease, airway stenting and other endoscopic interventions may provide a viable solution for non-surgical candidates or as a bridge to surgery. Endobronchial airway stenting for malacia warrants ongoing multidisciplinary discussion, as treatment alternatives including aortopexy, non-invasive ventilation, and tracheostomy tube placement have been well reported also. The above interventions in the setting of future airway growth and improving structural integrity have also been met with success [40]. In some cases, airway obstruction may occur after surgical correction of airway reconstruction, congenital vascular anomalies (vascular sling, extrinsic compression, enlarged vasculature), Kommerell's diverticulum, or bronchogenic cyst [41]. Herein, we will describe common endoscopic interventions with a focus on the pediatric population. As some of the literature in pediatric CAO is limited, we will present data regarding adult use as needed.

## Dilation Procedures

Airway dilation procedures can be performed for central airway obstruction (CAO) related to stenosis, often intraluminal and non-malignant. Dilation is often accomplished with balloon equipment or the barrel of a rigid tracheoscope/bronchoscope (Fig. 38.4).

Balloon dilation can be performed utilizing specially designed controlled radial expansion balloons, which are inflated under pressure to a corresponding size. These non-conformal balloons can be filled with radiopaque fluid or with saline depending on preference and planned use of fluoroscopic guidance. Other balloon techniques are reported, often utilizing conformal balloons (vascular embolectomy catheters [42], urinary catheters [43], etc.). The authors do not routinely recommend their use in adults (due to their inability to deliver a standard and uniform balloon size and distribution), however suspect their use in pediatrics may relate to difficulty obtaining non-conformal balloons that will accommodate pediatric airways.

The likely most common indication for dilation procedures in children remains subglottic stenosis, potentially from intubation and tracheostomy complications. Data exist for balloon dilation as small retrospective series in children ranging from 1 month of age to young adults [44, 45] with success rates ranging from 57–98%. Despite the general reported success of the procedure, it is also reported that many require repeat dilation procedures [46]. Less commonly reported uses include palliation of pediatric malignant CAO [9], and airway clearance adjuncts. Reports of using balloon dilation to improve airway patency exist in both obstruct-



**Fig. 38.4** Airway dilation under direct visualization. (a) Bronchoscopic image of severe tracheal stenosis. (b) Post-procedure bronchoscopic image with significant improvement in airway caliber

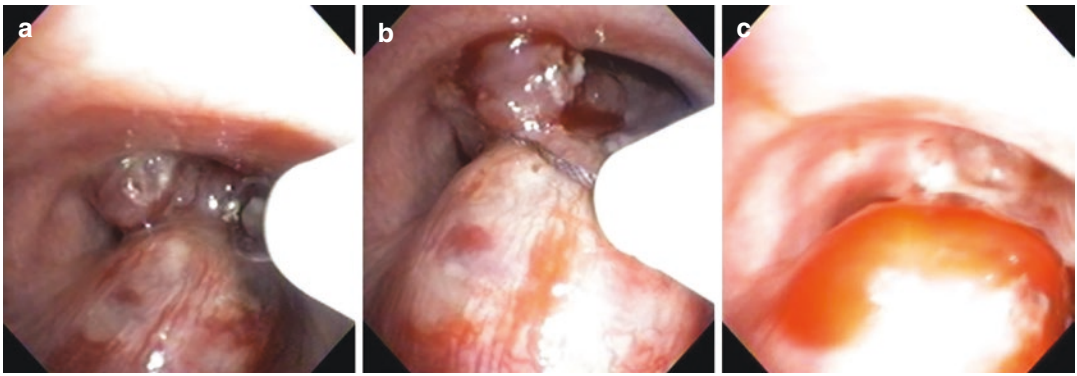


ing fibrinous tracheal pseudomembrane [29] and foreign body aspiration [47].

### Thermal Techniques

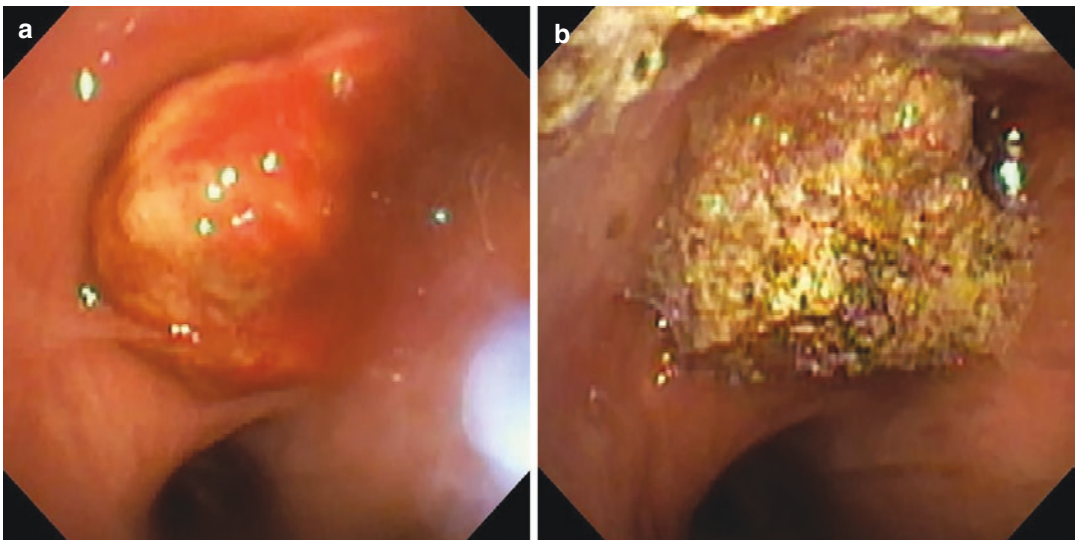
Thermal techniques utilize energy to cause tissue destruction via vaporization, cauterization, and/or coagulation (Figs. 38.5 and 38.6). One of the most

commonly used thermal energy techniques utilized for airway obstruction is the endobronchial laser. Laser therapies are currently available in different wavelengths and sizes, and are commonly reported as Neodymium: Yttrium-Aluminum-Garnet, Carbon Dioxide, and Potassium-Titanium-Phosphate. Other options for thermal destruction include direct contact electrocautery, as well as argon plasma coagulation (APC).



**Fig. 38.5** Thermal destruction technique for endobronchial disease utilizing electrocautery. (a) Endoscopic view of endobronchial lesion within the right mainstem causing airway obstruction in an 18-year-old boy with persistent cough and sarcoma. Endobronchial use of electrocautery

snare as it is being deployed within the airway. (b) Snare is fully deployed, encircling exophytic portion of lesion. (c) Endoscopic view immediately after removal. Patency is significantly improved after debulking/removal of intrinsic disease has been done, with minimal bleeding



**Fig. 38.6** Thermal destruction technique for endobronchial disease utilizing argon plasma coagulation (APC). (a) Bleeding tumor emanating from right upper lobe ori-

fice. (b) Improvement in hemostasis after generous application of APC to tumor

The majority of children undergo thermal destruction of airway lesions related to non-malignant etiologies. Laser use is well represented in case series and observational cohorts, but no randomized studies are available for direct comparison or the lasers themselves or of alternative treatments. Laser destruction/resection of lesions is reported in granulation tissue [48–50], subglottic cysts [51–53], and hemangiomas [54, 55]. Most reports offer successful conclusions, although some report recurrent disease and unsuccessful tracheostomy tube decannulation [48].

Complications have also been reported, but retrospective trial design and lack of follow-up likely lead to selection bias in reporting. Major complications such as death and airway fire have been reported, however appear rare. Mild granulation tissue and subglottic stenosis have been reported in some series [51, 55].

Successful palliation of malignancy-related CAO has been reported with both the laser and APC, with no reported complications during the procedure [9, 56]. There was one reported intraoperative death, thought to occur during an inadvertent tissue flap created during repeat flexible bronchoscopy for recurrent tumor, leading to airway obstruction and asphyxiation. The authors

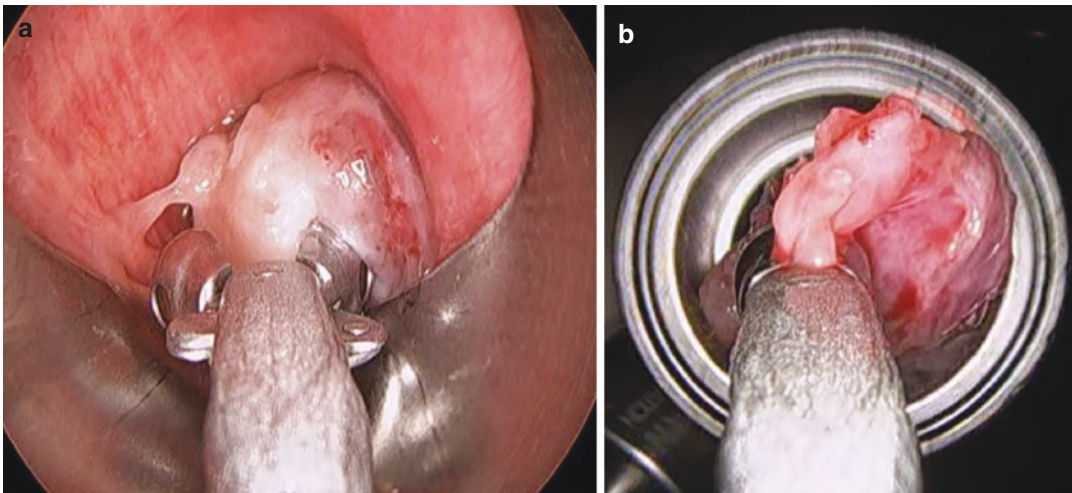
comment on their early use of flexible bronchoscopy, noting that since all procedures are performed with rigid bronchoscopy [56].

## Mechanical Debridement

Mechanical debridement techniques involve removing tissue with forceps (Fig. 38.7) or other steel instruments to improve airway patency. The main limitation to performing mechanical debridement is that it requires the presence of intrinsic airway obstruction, whereas the presence of pure extrinsic (i.e., endoluminal compression from mass) disease is a contraindication. The instruments utilized for mechanical debridement can range from fairly straightforward (tip and barrel of rigid bronchoscope) to the more complex (automated microdebrider instrument).

The use of mechanical debridement appears successfully reported in pediatric non-malignant CAO, including descriptions of use in suprastomal granulation tissue management [48] as well as tuberculosis granulomata [57]. Additionally, it can also play a role in malignant obstruction [9, 48].

Complications overall for mechanical debridement do exist, and can be major, such as bleeding,



**Fig. 38.7** Mechanical debridement of endobronchial tumor. (a) Rigid bronchoscopic view of an endobronchial mass obstructing the right mainstem bronchus. Optical cup forceps are open on the tumor. (b) After some initial

mechanical debridement, grasping of the mass allowed for removal. Endoscopic view of large mass being withdrawn through the barrel of the rigid bronchoscope

cardiac arrest, and death. A report of forceps debulking of granulation tissue led to subsequent loss of tissue into distal trachea, further airway obstruction, subsequent hospital complications, and eventually the child's death [48]. Other reports exist of excessive bleeding after granuloma debridement leading to uncontrollable airway hemorrhage and subsequent asphyxiation [57].

## Endobronchial Airway Stents

Endobronchial airway stents are commonly utilized for palliation of CAO and come in multiple different formulations, configurations, and sizes. Similar to the adults, CAO improvement is commonly reported in pediatric series. While stents can often make immediate impacts to respiratory status, this potential benefit must still be considered in the long-term management plan of the patient's underlying problem. There are also well-documented long-term complications associated with stent placement; therefore it remains paramount that one should never sacrifice long-term options such as a potential curative surgical resection over short-term gains. Patients should be evaluated and managed in a multidisciplinary fashion with experts in CAO and pediatric airway disease.

The indications for airway stents in pediatric patients are quite different from their adult counterparts. Most cases requiring stenting of the airway in children are related to congenital or iatrogenic airway malacia or stenosis, and more rarely can be related to neoplasms of the thorax [58]. The ideal pediatric airway stent would be easy to place in relatively small airways, provide structure to the airway, have minimal adverse effects, and be removable at any time or unnecessary to remove (grow with the patient as the airway diameters increase). Currently, there is no such stent. Therefore, the placement of these endobronchial stents should not be taken lightly as serious long-term complications can arise, especially in patients with non-malignant CAO. Additionally, while rare, stent-related morbidity/mortality has been reported for almost all airway stents [59, 60].

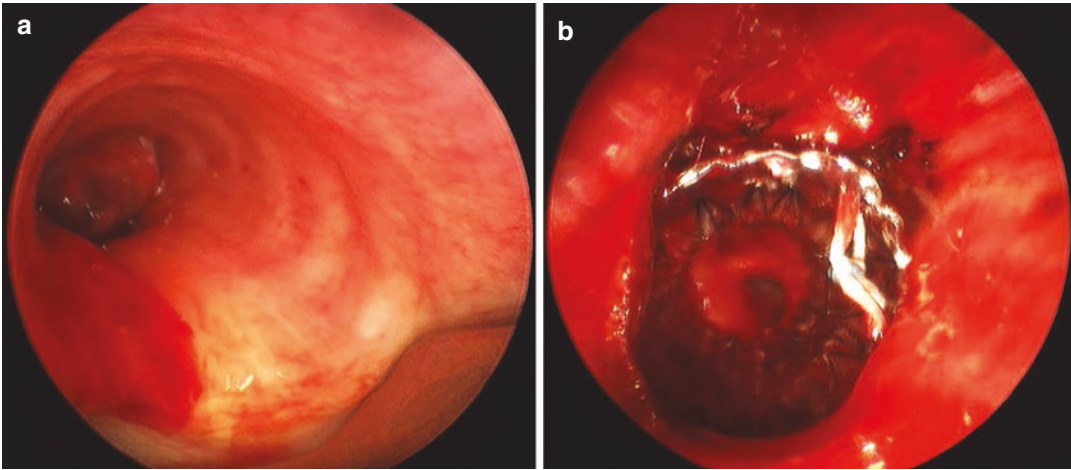
Airway stents can be divided into different categories based on the material content of the stent. We have therefore divided this topic into three different categories: metallic, silastic, and novel stents.

### Metallic Stents

Metallic stents can be easier to place, including with the use of flexible bronchoscopy and/or fluoroscopy (Fig. 38.8). As airway caliber can be a significant limitation in infants and young children, the ability to place a small stent over a guidewire under fluoroscopy is potentially attractive [61].

Two types of metallic stents are available: balloon-expandable and self-expanding; however, no metallic stents are currently approved by the Food and Drug Administration (FDA) for pediatric use. The only FDA-approved metallic airway stent is the Merit Aero (Merit Medical Systems, South Jordan, UT, USA). They are self-expandable metal stents (SEMS) with a polyurethane coating and constructed from nickel-titanium (Nitinol). Current stent size diameters range from 6 mm to 20 mm. Over the years, Aero SEMS have been modified and many are able to be placed over a wire or over a bronchoscope, or the new smaller stents (6 × 10 mm and 6 × 15 mm) are able to be placed through the bronchoscope. The currently available balloon-expandable metallic stents are often designed for vascular or cardiac purposes but have been reported for airway use in the literature. The best described balloon-expandable stent in pediatrics appears to be the Palmaz (Cordis Corporation, Miami Lakes, FL, USA). Designed as a vascular stent made of stainless steel, it is likely popular due to the available small dimensions and ease of placement. Palmaz stent sizes range from 5 mm to 10 mm in outer diameter [50]. Intrastent (IntraTherapeuticsInc, MN, USA) additionally offers similar-sized stents and has the advantage of magnetic resonance imaging (MRI) compatibility and retrievability [62].

Complications of stent placement are well described, with granulation tissue and migration being described as the most common. Recurrent granulation tissue can be managed with serial dilation procedures and/or debulking of excess



**Fig. 38.8** Placement of self-expandable metal stent (SEMS) into left mainstem bronchus. **(a)** Bronchoscopic view of left mainstem obstruction. **(b)** After partial debulking of left mainstem lesion, significant extrinsic compression remained, therefore a 10 × 30 mm SEMS was placed with excellent restoration of airway patency

tissue [60, 63]. Excessive granulation tissue may also be colonized with pathogenic organisms, potentially increasing bacterial overgrowth concerns, especially in smaller airways (i.e., infants) [41, 64].

The re-epithelialization of metal stents within the airway has remained a concern, including a black box warning by the Federal Drug Administration in 2005 [65]. Some patients have experienced airway growth within stents, preventing endoscopic removal, leading to fracture with retained metal, then requiring surgical intervention/resection [63]. The largest concern related to the SEMS placement remains the documented episodes wherein patients who likely had surgical correctable disease (i.e., subglottic stenosis curable by short-segment tracheal resection), however, subsequently became inoperable due to metallic stent-related complications [66]. Despite these potential complications, some believe that in appropriate situations, given the potential size options, SEMS remains appropriate [67].

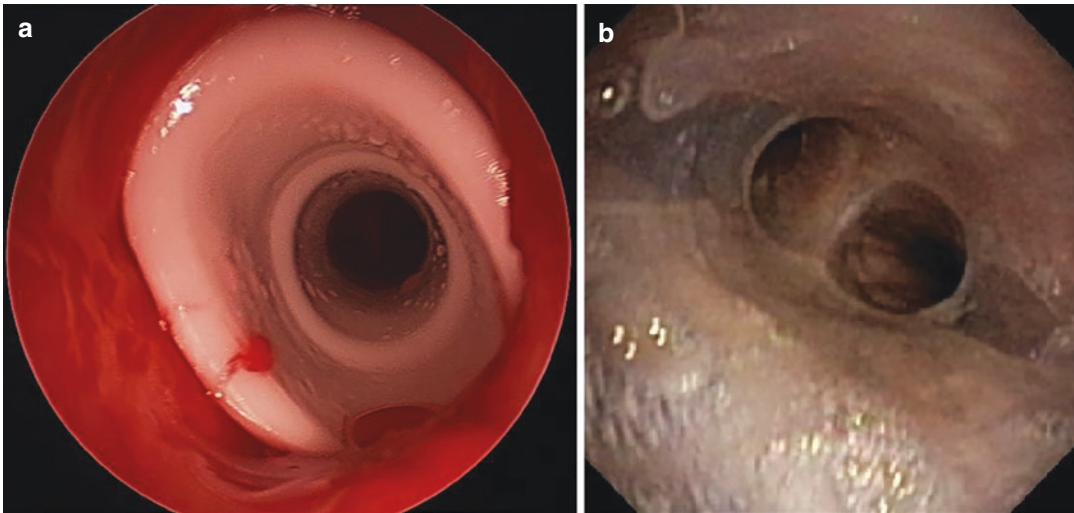
As time has allowed some longitudinal follow-up, studies have described the longer-term out-

comes of SEMS in pediatrics. One study of 146 SEMS placed in 87 children with  $9.4 \pm 6.7$  years of follow-up demonstrated clinical improvement in all but two of the patients [62]. Another study of 41 SEMS in 24 infants showed gradual and significant expansion of stents after placement, illustrating the potential advantage of expandable metallic stents in the pediatric airway—the ability to be further expanded in the still growing lumen [68].

### Silastic Stents

Silicone stents are currently available in multiple sizes and configurations. Silicone stents require rigid bronchoscopy for placement (Figs. 38.9 and 38.10), which may be more challenging in smaller airways. The smallest commercially available silicone stent in the United States is of 6 mm. Potential advantages of silicone stent placement include the inert properties of silicone. As a result, they have the potential for removal after long in situ durations. However, complications (similar to stents in general) include granulation, stent migration, and mucus impaction.





**Fig. 38.9** Silicone stent placement for non-malignant disease. **(a)** Recurrent tracheal stenosis after surgical resection/reconstruction for tracheal stenosis prompted placement of endotracheal silicone stent. Endoscopic view of proximal end of tracheal silicone stent placement dem-

onstrating preserved airway caliber. **(b)** Bronchoscopic view from within a Y-stent placed for tracheobronchomalacia. The left mainstem entrance is at the 10 o'clock position and the right mainstem entrance is at the 4 o'clock position

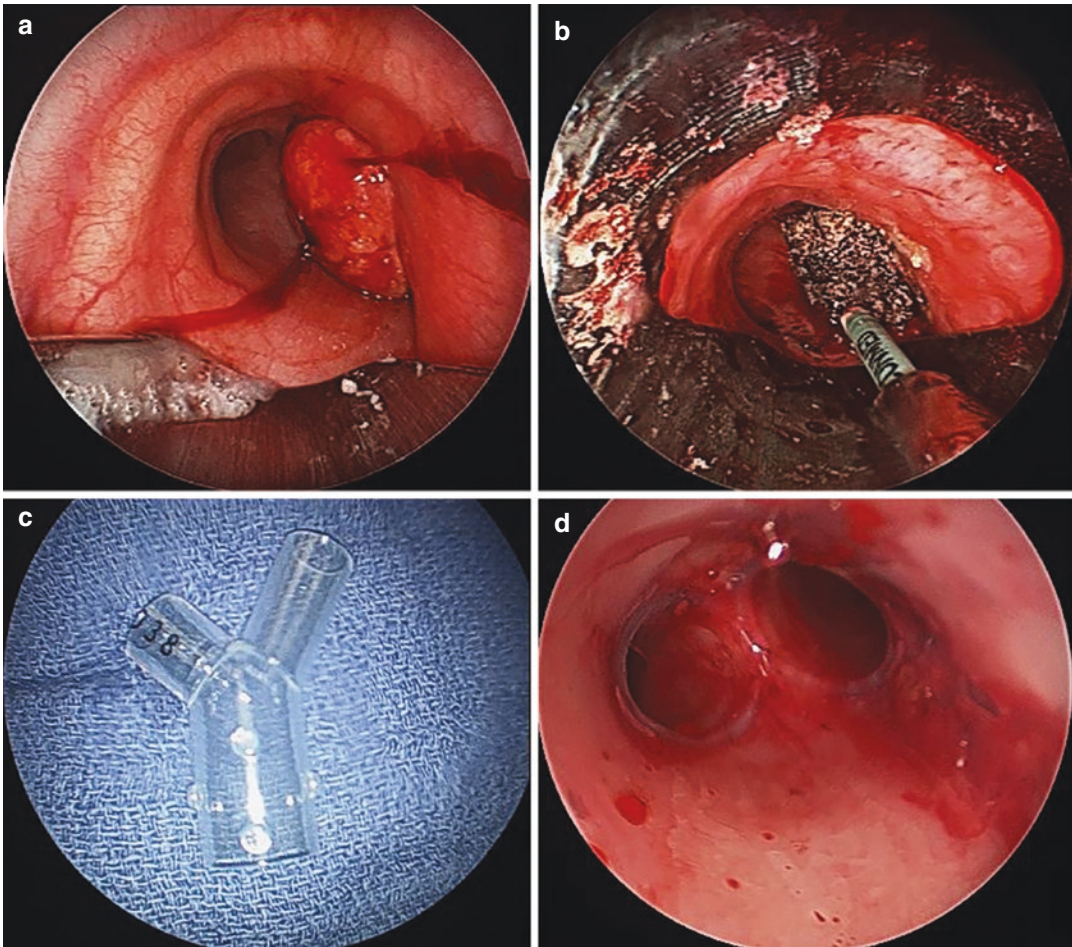
Another potential drawback is that the inner to outer diameter ratio is greater than metallic stents and therefore may occupy more diameter of the airway. A long-term advantage of silastic stents is that they are non-expanding and will not develop fatigue fracture of the stent wires. Reports of successful cases are feasible in infants; however, poor results have been associated with high-pressure vascular compression [69].

### Novel Stents

Absorbable or biodegradable stents remain attractive within the realm of pediatric airways; however, they are unavailable for use within the United States. Biodegradable stents could remain within the airway for a finite time without the need for additional removal procedures. Similar stents are being utilized in some disciplines: urethral, biliary, and vascular; however, data within the airway could dramatically modify airway

plans for children as they continue to grow. One promising technology appears to be Polydioxanone stents, which are composed of semi-crystalline, biodegradable polymers. They have initial shape memory, but later will degrade by random hydrolysis of its ester bonds. Small case series suggest 15 weeks for complete absorption while in an animal model 10 weeks were needed for degradation [70]. European data suggest that polydioxanone stents are likely both safe and efficacious in infants with severe tracheobronchial obstruction. They also describe fewer complications than traditional stents and the biocompatibility remains a great advantage. Longer-term durability and cost issues remain unclear as admittedly rapid stent degradation may necessitate repeat stenting. Therefore, additional consideration of cost-benefit in absorbable vs traditional stenting will likely be needed keeping patient age, pathology, and provider experience in mind [58].





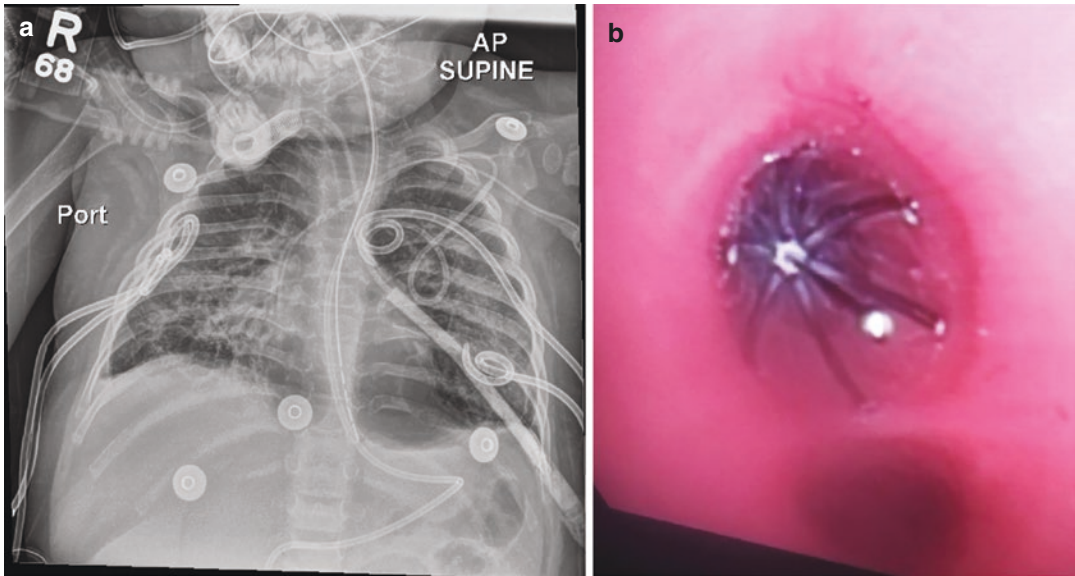
**Fig. 38.10** Silicone Y-stent placement for malignant disease. (a) Endoscopic view of mass located in the distal trachea and proximal right mainstem. (b) Initial attempts at

tumor destruction with APC probe coating tumor surface. (c) Back table preparation of Y-stent prior to placement. (d) Endoscopic view from within tracheal limb of Y-stent

## Endobronchial Valves

Alveolar-pleural fistula and persistent air leak remains a serious clinical problem with increased morbidity and mortality [71]. Air leaks appear commonly related to underlying parenchymal lung disease and thoracic surgery. Adult data suggest endobronchial valve (EBV) placement has utility in the treatment of prolonged air leak [71–73] and emphysema [74, 75]; however, the data in pediatrics remain limited (Fig. 38.11). A case

report describes successful EBV use in an 18-year-old patient with cystic fibrosis and recurrent pneumothorax to avoid pleurodesis while awaiting lung transplantation [76]. Additionally, a case series of four pediatric patients (age range: 16 months to 16 years) described successful EBV use in the setting of bronchopleural fistula related to empyema and recurrent pneumothorax related to barotrauma [77]. No significant complications related to valve placement were identified within these reports.



**Fig. 38.11** Endobronchial valve. A 16-month-old male with persistent air leak after ventilator barotrauma. (a) Chest radiograph demonstrating multiple chest tubes in

place. (b) Bronchoscopic view post-placement of a unidirectional endobronchial valve

## Bronchial Thermoplasty

Bronchial thermoplasty (BT) is an endoscopic treatment available to adults with severe persistent asthma undergoing maximal medical therapy but still suffering from persistent symptoms [78]. BT attempts to alter smooth muscle mass of lobar and segmental bronchi by delivering heat energy to these airways via a radiofrequency generator. Initial data support the global reduction in smooth muscle mass [79], as well as further clinical studies demonstrating quality of life improvements [80] and decrease in mean hospital days at one year post treatment [81]. However, all the current data remain in adults, and these authors are currently unaware of any literature within the pediatric population. The evaluation of BT with the pediatric population appears to be mainly retarded by a self-imposed manufacturer moratorium and remains unclear if and when this will move forward. As of 2021, FDA approval for BT remains in patients 18 years of age and older.

## Pediatric IP and the COVID-19 Pandemic

We would be remiss if we did not comment on the pandemic that has caused some of the most widespread interruptions to the modern health care system. While the morbidity and mortality of Coronavirus Disease-2019 (COVID-19) in the pediatric population is astronomically less than their adult counterparts, many children have contracted the virus and its severity and clinical course can be wide ranging [82]. Bronchoscopy has no role in the diagnosis, and, in children, it has a very limited role in the management of acute disease [83]. Unfortunately, given the widespread nature of the disease it is safe to say that some patients may come to require intervention during an acute infection or after infection resolution. Recent recommendations for bronchoscopy in pediatric patients follow many of the same tenets as what guide us in the adult population. First, all patients undergoing bronchoscopy

should undergo risk stratification for the procedure, i.e., if the case is urgent (obstruction, foreign body), semi-urgent (mucous plug removal or respiratory sample collection), or elective (chronic cough evaluation, etc.) [84]. Second, it is recommended that any patient undergoing bronchoscopy be screened for illness. Third, if the procedure must go forward, the team performing the procedure must wear proper personal protective equipment with proper training on donning and doffing the personal protective equipment [85]. Finally, the procedure should be performed in a well-ventilated or negative pressure suite. Flexible bronchoscopy is preferred to rigid bronchoscopy if possible, and, if possible, single-use flexible bronchoscopes would be optimal. Techniques such as use of non-invasive ventilation masks with an opening for a bronchoscope or having patients wear masks for as much as allowed have been suggested to minimize aerosolizing virus [84]. Minimizing cough reflex has also been suggested to minimize exposure to health care workers. While performing procedures in actively infected patients is suboptimal and will pose some risk to health care workers, as the pandemic has dragged on it is becoming more likely that we will have to continue to adapt care for infected patients. Risk mitigation strategies should continue to be utilized and developed in order to continue to care for our patients and protect ourselves as health care workers.

## Discussion

Our review suggests that there is literature to support increasing utilization of IP expertise within the pediatric population for complex thoracic and airway management problems. The current use of IP expertise within pediatrics appears relatively underutilized, likely the result of inertia in the medical fields and the current satisfaction and/or acceptance of management paradigms. It remains unclear regarding the clinical impact of additional support by mainly adult trained IP within the pediatric world of medicine; however, initial reports from the literature appear encouraging. Additionally, as the care of many complex pedi-

atric patients is multidisciplinary, the potential collaboration remains exciting and likely vital to the advancement of the field and care of these patients.

**Conflicts of Interest** NS, LBY, and CRG have no conflicts of interest related to this article.

## References

1. Seijo LM, Sterman DH. Interventional pulmonology. *N Engl J Med.* 2001;344(10):740–9.
2. Beamis JF, Becker HD, Cavaliere S, Colt H, Diaz-Jimenez JP, Dumon JF, et al. ERS/ATS statement on interventional pulmonology. *Eur Respir J.* 2002;19(2):356–73.
3. McLaren CA, Elliott MJ, Roebuck DJ. Tracheobronchial intervention in children. *Eur J Radiol.* 2005;53:22–34.
4. Masters IB, Cooper P. Paediatric flexible bronchoscopy. *J Paediatr Child Health.* 2002;38:555–9.
5. Leong AB, Green CG, Kurland G, Wood RE. A survey of training in pediatric flexible bronchoscopy. *Pediatr Pulmonol.* 2014;49(6):605–10.
6. Byrne T, Yong SA, Steinfors DP. Development and assessment of a low-cost 3D-printed airway model for bronchoscopy simulation training. *J Bronchology Interv Pulmonol.* 2016;23(3):251–4.
7. Maier P, Silvestro E, Goldfarb SB, Piccione J, Phinzy PA, Andronikou S. Three-dimensional printed realistic pediatric static and dynamic airway models for bronchoscopy and foreign body removal training. *Pediatr Pulmonol.* 2021;56(8):2654–9.
8. Leong A, Benschoter D, Brewington J, Torres-Silva C, Wood RE. Pediatric flexible airway endoscopy training during a pandemic and beyond: bending the curve. *Pediatr Pulmonol.* 2021;56(6):1386–8.
9. Gilbert CR, Feller-Kopman D, Akulian J, Hayes M, Yarmus L. Interventional pulmonology procedures in the pediatric population. *Pediatr Pulmonol.* 2014;49(6):597–604.
10. Yastor M, Elliot R. Preoperative assessment of the newborn. New York: McGraw Hill Medical; 2008.
11. Wetzel R. Evaluation of children. New York: McGraw Hill; 2008.
12. Lockhart CH, Elliot JL. Potential hazards of pediatric rigid bronchoscopy. *J Pediatr Surg.* 1984;19(3):239–42.
13. Stackhouse R, Infosino A. Airway management. In: Stoeltin RK, Miller RD, editors. *Basics of Anesthesia.* 5th ed. Philadelphia: Churchill Livingstone; 2007. p. 207–39.
14. Surgeons ACo. American trauma life support for doctors. Student course manual. 7th ed. Chicago: First Impression; 2004. p. 262.
15. Everett L. Anesthesia for children. New York: McGraw Hill; 2008.



16. Yasufuku K, Chiyo M, Sekine Y, Chhahjed PN, Shibuya K, Iizasa T, et al. Real-time endobronchial ultrasound-guided transbronchial needle aspiration of mediastinal and hilar lymph nodes. *Chest*. 2004;126(1):122–8.
17. Nakajima T, Yasufuku K, Fujiwara T, Chiyo M, Sekine Y, Shibuya K, et al. Endobronchial ultrasound-guided transbronchial needle aspiration for the diagnosis of intrapulmonary lesions. *J Thorac Oncol*. 2008;3(9):985–8.
18. Fujino K, Ujiie H, Kinoshita T, Lee CY, Igai H, Inage T, et al. First evaluation of the next-generation endobronchial ultrasound system in preclinical models. *Ann Thorac Surg*. 2019;107(5):1464–71.
19. Patel P, Wada H, Hu HP, Hirohashi K, Kato T, Ujiie H, et al. First evaluation of the new thin convex probe endobronchial ultrasound scope: A human ex vivo lung study. *Ann Thorac Surg*. 2017;103(4):1158–64.
20. Yasufuku K, Nakajima T, Fujiwara T, Chiyo M, Iyoda A, Yoshida S, et al. Role of endobronchial ultrasound-guided transbronchial needle aspiration in the management of lung cancer. *Gen Thorac Cardiovasc Surg*. 2008;56(6):268–76.
21. Gilbert C, Yarmus L, Feller-Kopman D. Use of endobronchial ultrasound and endoscopic ultrasound to stage the mediastinum in early-stage lung cancer. *J Natl Compr Cancer Netw*. 2012;10(10):1277–82.
22. Yasufuku K, Pierre A, Darling G, de Perrot M, Waddell T, Johnston M, et al. A prospective controlled trial of endobronchial ultrasound-guided transbronchial needle aspiration compared with mediastinoscopy for mediastinal lymph node staging of lung cancer. *J Thorac Cardiovasc Surg*. 2011;142(6):1393–400 e1.
23. Siemsen M, Anderson NEO, Nielsen KG. EBUS in a 6-year-old boy with enlarged hilar lymph nodes. *J Bronchology Interv Pulmonol*. 2011;18(2):204–5.
24. Wurzel DF, Steinfurt DP, Massie J, Ryan MM, Irving LB, Ranganathan SC. Paralysis and a perihilar protuberance: an unusual presentation of sarcoidosis in a child. *Pediatr Pulmonol*. 2009;44(4):410–4.
25. Gilbert CR, Chen A, Akulian JA, Lee HJ, Wahidi M, Argento AC, et al. The use of convex probe endobronchial ultrasound-guided transbronchial needle aspiration in a pediatric population: A multicenter study. *Pediatr Pulmonol*. 2014;49(8):807–15.
26. Dhooria S, Madan K, Pattabhiraman V, Sehgal IS, Mehta R, Vishwanath G, et al. A multicenter study on the utility and safety of EBUS-TBNA and EUS-B-FNA in children. *Pediatr Pulmonol*. 2016;51(10):1031–9.
27. Gulla KM, Gunathilaka G, Jat KR, Sankar J, Karan M, Lodha R, et al. Utility and safety of endobronchial ultrasound-guided transbronchial needle aspiration and endoscopic ultrasound with an echo bronchoscopy-guided fine needle aspiration in children with mediastinal pathology. *Pediatr Pulmonol*. 2019;54(6):881–5.
28. Madan K, Iyer H, Madan NK, Mittal S, Tiwari P, Hadda V, et al. Efficacy and safety of EBUS-TBNA and EUS-B-FNA in children: A systematic review and meta-analysis. *Pediatr Pulmonol*. 2021;56(1):23–33.
29. Harris K, Schaefer E, Rosenblum J, Stewart FD, Arkovitz MS. Intraoperative electromagnetic navigation bronchoscopy (IENB) to localize peripheral lung lesions: A new technique in the pediatric oncology population. *J Pediatr Surg*. 2022;57(9):179–82.
30. Su SC, Masters IB, Buntain H, Frawley K, Sarikwal A, Watson D, et al. A comparison of virtual bronchoscopy versus flexible bronchoscopy in the diagnosis of tracheobronchomalacia in children. *Pediatr Pulmonol*. 2017;52(4):480–6.
31. Babiak A, Hetzel J, Krishna G, Fritz P, Moeller P, Balli T, et al. Transbronchial cryobiopsy: a new tool for lung biopsies. *Respiration*. 2009;78(2):203–8.
32. Lentz RJ, Argento AC, Colby TV, Rickman OB, Maldonado F. Transbronchial cryobiopsy for diffuse parenchymal lung disease: a state-of-the-art review of procedural techniques, current evidence, and future challenges. *J Thorac Dis*. 2017;9(7):2186–203.
33. Dhochak N, Mittal S, Jain D, Jat KR, Singh V, Jana M, et al. The first report of pediatric endobronchial cryobiopsy: expanding horizon of bronchoscopic cryotherapy for airway tumors. *Pediatr Pulmonol*. 2021;56(9):3051–3.
34. Srikanta J, Swarna S, Shylendra D, Mehta R. Transbronchial lung cryobiopsy for diagnosis of pediatric interstitial lung disease. *Indian Pediatr*. 2018;55:519–20.
35. Kazachkov M, Vicencio A. Foreign body removal is getting “cooler”. *Pediatr Pulmonol*. 2016;51(9):886–8.
36. Moslehi M. Foreign body retrieval by using flexible cryoprobe in children. *J Bronchology Interv Pulmonol*. 2021;28(2):103–6.
37. Boufersaoui A, Smati L, Benhalla KN, Boukari R, Smail S, Anik K, et al. Foreign body aspiration in children: experience from 2624 patients. *Int J Pediatr Otorhinolaryngol*. 2013;77:1683–8.
38. Foltran F, Ballali S, Passali FM, Kern E, Morra B, Passali GC, et al. Foreign bodies in the airways: A meta-analysis of published papers. *Int J Pediatr Otorhinolaryngol*. 2012;76 Suppl 1:S12–S9.
39. Swanson KL, Prakash UB, Midthun DE, Edell ES, Utz JP, McDougall JC, et al. Flexible bronchoscopic management of airway foreign bodies in children. *Chest*. 2002;121(5):1695–700.
40. Pillai JB, Smith J, Hasan A, Spencer D. Review of pediatric airway malacia and its management, with emphasis on stenting. *Eur J Cardiothorac Surg*. 2005;27(1):35–44.
41. Jacobs JP, Quintessenza JA, Botero LM, van Gelder HM, Giroud JM, Elliott MJ, et al. The role of airway stents in the management of pediatric tracheal, carinal, and bronchial disease. *Eur J Cardiothorac Surg*. 2000;18:505–12.
42. Fouty BW, Pomeranz M, Thigpen TP, Martin RJ. Dilation of bronchial stenosis due to sarcoidosis using a flexible fiberoptic bronchoscope. *Chest*. 1994;106(3):677–80.
43. Malik AM, Ahmed Z, Durgham N, Stockmann PT, Belenky WM, Zestos M. Airway and ventilation management during repair of a large acquired tracheo-

- esophageal fistula: the novel use of a readily available tool. *J Clin Anesth.* 2012;24(2):133–6.
44. Maksoud-Filho JG, Gonçalves MEP, Cardoso SR, Tannuri U. Early diagnostic and endoscopic dilatation for the treatment of acquired upper airway stenosis after intubation in children. *J Pediatr Surg.* 2008;43(7):1254–8.
  45. Whigham AS, Howell R, Choi S, Pena M, Zalzal G, Preciado D. Outcomes of balloon dilation in pediatric subglottic stenosis. *Ann Otol Rhinol Laryngol.* 2012;121:442–8.
  46. Goussard P, Morrison J, Bekker A, Fourie B. Acquired neonatal bronchial stenosis after selective intubation: successful managed with balloon dilatation. *Clin Case Rep.* 2019;7(5):917–9.
  47. Thornton CS, Yunker WK. Rigid bronchoscopy and balloon dilation for removal of aspirated thumbtacks: case series and literature review. *Int J Pediatr Otorhinolaryngol.* 2015;79(9):1541–3.
  48. Yellon RF. Totally obstructing tracheotomy-associated suprastomal granulation tissue. *Int J Pediatr Otorhinolaryngol.* 2000;53:49–55.
  49. Mandell DL, Yellon RF. Endoscopic KTP laser excision of severe tracheotomy-associated suprastomal collapse. *Int J Pediatr Otorhinolaryngol.* 2004;68:1423–8.
  50. Sharp HR, Hartley BEJ. KTP laser treatment of suprastomal obstruction prior to decannulation in paediatric tracheostomy. *Int J Pediatr Otorhinolaryngol.* 2002;66:125–30.
  51. Madgy D, Ahsan SF, Kest D, Stein I. The application of the potassium-titanyl-phosphate (KTP) laser in the management of subglottic hemangioma. *Arch Otolaryngol Head Neck Surg.* 2001;127:47–50.
  52. Aksoy EA, Elsurer C, Serin GM, Unal OF. Evaluation of pediatric subglottic cysts. *Int J Pediatr Otorhinolaryngol.* 2012;76:240–3.
  53. Lim J, Hellier W, Harcourt J, Leighton S, Albert D. Subglottic cysts: The Great Ormond Street experience. *Int J Pediatr Otorhinolaryngol.* 2003;67:461–5.
  54. Cholewa D, Waldschmidt J. Laser treatment of hemangiomas of the larynx and trachea. *Lasers Surg Med.* 1998;23:221–32.
  55. Nicolai T, Fischer-Truestedt C, Reiter K, Grantzow R. Subglottic hemangioma: a comparison of CO<sub>2</sub> laser, Neodym-Yag laser, and tracheostomy. *Pediatr Pulmonol.* 2005;39(3):233–7.
  56. Wang H, Zhang N, Tao M, Li D, Zhou Y, et al. Application of interventional bronchoscopic therapy in eight pediatric patients with malignant airway tumors. *Tumori.* 2012;98:581–7.
  57. Hewitson JP, Von Oppell UO. Role of thoracic surgery for childhood tuberculosis. *World J Surg.* 1997;21:468–74.
  58. Anton-Pacheco JL, Luna C, Garcia E, Lopez M, Morante R, Tordable C, et al. Initial experience with a new biodegradable airway stent in children: is this the stent we were waiting for? *Pediatr Pulmonol.* 2016;51(6):607–12.
  59. Filler RM, Forte V, Chait P. Tracheobronchial stenting for the treatment of airway obstruction. *J Pediatr Surg.* 1998;33(2):304–11.
  60. Anton-Pacheco JL, Cabezali D, Tejedor R, Lopez M, Luna C, Comas JV, et al. The role of airway stenting in pediatric tracheobronchial obstruction. *Eur J Cardiothorac Surg.* 2008;33(6):1069–75.
  61. Santoro G, Picardo S, Testa G, Formigari R, Marianeschi S, Catena G, et al. Ballon-expandable metallic stents in the management of tracheomalacia in neonates. *J Thorac Cardiovasc Surg.* 1995;110(4):1145–8.
  62. Soong WJ, Tsao PC, Lee YS, Yang CF. Flexible endoscopy for pediatric tracheobronchial metallic stent placement, maintenance and long-term outcomes. *PLoS One.* 2018;13(2):e0192557.
  63. Maeda K, Ono S, Tazuke Y, Baba K. Long-term outcomes of congenital tracheal stenosis treated by metallic airway stenting. *J Pediatr Surg.* 2013;48:293–6.
  64. Shin JH, Hong S-J, Song H-Y, Park SJ, Ko G-Y, Lee S-Y, et al. Placement of covered retrievable expandable metallic stents for pediatric tracheobronchial obstruction. *J Vasc Interv Radiol.* 2006;17(2, Part 1):309–17.
  65. Administration USFaD. FDA public health notification: complications from metallic tracheal stents in patients with benign airway disorders 2005. <http://www.fda.gov/MedicalDevices/Safety/AlertsandNotices/PublicHealthNotifications/ucm062115.htm>.
  66. Gaissert HA, Grillo HC, Wright CD, Donahue DM, Wain JC, Mathisen DJ. Complication of benign tracheobronchial strictures by self-expanding metal stents. *J Thorac Cardiovasc Surg.* 2003;126(3):744–7.
  67. Nicolai T, Huber RM, Reiter K, Merkschlagler A, Hautmann H, Mantel K. Metal airway stent implantation in children: follow-up of seven children. *Pediatr Pulmonol.* 2001;31:289–96.
  68. Hsieh KH, Chou YL, Soong WJ, Lee YS, Tsao PC. Long-term management and outcomes of tracheobronchial stent by flexible bronchoscopy in infants <5 kg: A 13-year single-center experience. *J Chin Med Assoc.* 2019;82(9):727–31.
  69. Fayon M, Donato L, De Blic J, Labbe A, Becmeur F, Mely L, et al. French experience of silicone tracheobronchial stenting in children. *Pediatr Pulmonol.* 2005;39:21–7.
  70. Novotny L, Crha M, Rauser P, Hep A, Misik J, Necas A, et al. Novel biodegradable polydioxanone stents in a rabbit airway model. *J Thorac Cardiovasc Surg.* 2012;143(2):437–44.
  71. Wood DE, Cerfolio RJ, Gonzalez X, Springmeyer SC. Bronchoscopic management of prolonged air leak. *Clin Chest Med.* 2010;31(1):127–33.
  72. Gillespie CT, Serman DH, Cerfolio RJ, Nader D, Mulligan MS, Mularski RA, et al. Endobronchial valve treatment for prolonged air leaks of the lung: a case series. *Ann Thorac Surg.* 2011;91(1):270–3.
  73. Travaline JM, McKenna RJ Jr, De Giacomo T, Venuta F, Hazelrigg SR, Boomer M, et al. Treatment of



- persistent pulmonary air leaks using endobronchial valves. *Chest*. 2009;136(2):355–60.
74. Lee HJ, Shojaae S, Sterman DH. Endoscopic lung volume reduction. An American perspective. *Ann Am Thorac Soc*. 2013;10(6):667–79.
  75. Gompelmann D, Eberhardt R, Herth FJ. Endoscopic lung volume reduction. A European perspective. *Ann Am Thorac Soc*. 2013;10(6):657–66.
  76. Yarmus L, Akulian J, Gilbert C, Illei P, Shah P, Merlo C, et al. Cryoprobe transbronchial lung biopsy in patients after lung transplantation: a pilot safety study. *Chest*. 2013;143(3):621–6.
  77. Toth JW, Podany AB, Reed MF, Rocourt DV, Gilbert CR, Santos MC, et al. Endobronchial occlusion with one-way endobronchial valves: A novel technique for persistent air leaks in children. *J Pediatr Surg*. 2015;50:82–5.
  78. Silvestri GA, Feller-Kopman D, Chen A, Wahidi M, Yasufuku K, Ernst A. Latest advances in advanced diagnostic and therapeutic pulmonary procedures. *Chest J*. 2012;142(6):1636–44.
  79. Cox PG, Miller J, Mitzner W, Leff AR. Radiofrequency ablation of airway smooth muscle for sustained treatment of asthma: preliminary investigations. *Eur Respir J*. 2004;24(4):659–63.
  80. Castro M, Rubin AS, Laviolette M, Fiterman J, De Andrade LM, Shah PL, et al. Effectiveness and safety of bronchial thermoplasty in the treatment of severe asthma. *Am J Respir Crit Care Med*. 2010;181(2):116–24.
  81. O'Reilly A, Browne I, Watchorn D, Egan JJ, Lane S. The efficacy and safety of bronchial thermoplasty in severe persistent asthma on extended follow-up. *QJM*. 2018;111(3):155–9.
  82. Alsohime F, Temsah MH, Al-Nemri AM, Somily AM, Al-Subaie S. COVID-19 infection prevalence in pediatric population: etiology, clinical presentation, and outcome. *J Infect Public Health*. 2020;13(12):1791–6.
  83. Eber E, Goussard P. Bronchoscopy precautions and recommendations in the COVID-19 pandemic. *Paediatr Respir Rev*. 2021;37:68–73.
  84. La Regina DP, Nenna R, Schramm D, Freitag N, Goussard P, Eber E, et al. The use of pediatric flexible bronchoscopy in the COVID-19 pandemic era. *Pediatr Pulmonol*. 2021;56(7):1957–66.
  85. Wahidi MM, Shojaae S, Lamb CR, Ost D, Maldonado F, Eapen G, et al. The use of bronchoscopy during the coronavirus disease 2019 pandemic: CHEST/AABIP guideline and expert panel report. *Chest*. 2020;158(3):1268–81.



# Aero-Digestive Fistulas: Endoscopic Approach

# 39

Alicia N. Rodríguez and José Pablo Díaz-Jiménez

## Introduction

Aero-digestive fistulas (ADF) are pathological communications between any part of the digestive system (more commonly the esophagus) and the respiratory tract, congenital or acquired, resulting from various causes but mainly from tumor invasion through the esophagus and the tracheal or bronchial walls. They are often called tracheo-esophageal, bronchoesophageal, or esophageal-pulmonary fistulas, and they can be benign or malignant in origin. In the last case, they represent serious complications of neoplasms that arise in the esophagus, lung, or mediastinum.

Most of the malignant ADF arise from digestive tumors and only a small proportion is due to lung tumors. Other tumors such as thyroid, larynx, or mediastinal metastatic nodes represent only a very low percentage of causes of ADF. Ninety percent of patients with malignant ADF have advanced or metastatic disease with high Eastern Cooperative Oncology Group (ECOG) scores.

---

Authors have no conflict of interest to declare.

---

A. N. Rodríguez  
School of Medicine, National University of Mar del Plata, Buenos Aires, Argentina

J. P. Díaz-Jiménez (✉)  
Interventional Pulmonary Department, Hospital Universitari de Bellvitge, Hospitalet de Llobregat, Barcelona, Spain  
e-mail: [pablodiaz@pablodiaz.org](mailto:pablodiaz@pablodiaz.org)

Spontaneous closure of the fistula is rare. The evolution is usually morbid due to the dramatic clinical implications and subsequent infections. Once symptoms of respiratory infection begin, in most cases, these complications cause aspiration pneumonia leading to sepsis, mediastinitis, acute respiratory distress syndrome (ARDS), and a fatal outcome. The prognosis is serious and the patient usually dies within a few weeks.

The main goals of management of a patient with ADF should be to treat recurrent infections with antibiotics and seal the communication between the esophagus and the airway, and ensure proper enteral feeding.

Non-malignant causes can occur as a consequence of treatments such as surgery, radiotherapy, chemotherapy, or radiotherapy associated with some angiogenic drugs, resections with laser, manipulations with esophageal or tracheobronchial prostheses, infectious diseases, granulomatous processes, chest trauma, necrosis caused by pressure from the cuff of the endotracheal intubation or tracheostomy tube, foreign bodies, and/or ingestion of caustics. Surgical repair, when possible, is the best option for non-malignant ADF.

---

## Etiology

### Congenital ADF

They are due to failure of the embryonic organs to fully form and are usually associated with other

congenital abnormalities, vertebral, esophageal, or anal atresias, and especially cardiac abnormalities as part of the vertebral defects, anal atresia, cardiac defects, tracheo-esophageal fistula, renal anomalies, and limb abnormalities, vertebral defects, anal atresia, tracheo-esophageal fistula with esophageal atresia, and radial and renal dysplasia (VACTERL/VATER) Association [1] and are usually diagnosed on all in early childhood. They arise when there are abnormalities in the formation of the laryngotracheal tubes (which divide into trachea and esophagus) in the fourth week of embryonic development [2].

Congenital fistulas are rare and usually occur in 0.04% of all births. Their discussion is out of the scope of the present chapter.

## Malignant ADF

Most acquired aero-digestive fistulas result from cancer, and emerge due to tumor invasion or from a complication of oncological treatments such as surgery, radiotherapy/chemotherapy, laser resections, necrosis caused by the pressures produced by intubation, or direct pressure coming from esophageal or tracheobronchial prostheses.

The pathogenesis of the fistulas is favored by the proximity of both neighboring organs. On the one hand, the trachea and the left main bronchus are closely linked to the esophagus, so tumors originating in any of these adjoining parts can invade the thin layer that separates them and end up communicating both organs.

On the other hand, the mediastinal nodes, especially in the subcarinal area, can also invade and communicate with the airway and the digestive tract, since they are part of the lymphatic drainage on both systems.

From the anatomical point of view, both benign and malignant ADF are located in 57% of cases between the esophagus and the trachea and 37% between the esophagus and one or both of the main bronchi. Fistulas between the esophagus and the lung parenchyma are usually the least frequent, close to 10% [3]. Quite less frequent are bronchopleural, bronchovascular, and broncho-peritoneal fistulas.

Martini et al. [4] reported the largest study on ADF and showed that it occurred in 5% of 1943

esophageal cancer patients, 0.16% of 5714 lung cancer patients, and 15% of 41 tracheal cancer patients.

Burt et al. [5], in an excellent retrospective study including 207 patients with ADF, showed that for most of the aero-digestive fistulas, primary tumor site was esophagus in 161 (77%), lung in 33 (16%), trachea in 5 (2%), metastatic nodes in 4 (2%), larynx in 3 (1%), and thyroid in 1. The risk of developing malignant ADF was also higher in patients with esophageal carcinoma. The incidence of ADF in patients with esophageal cancer was 4.5%, and 0.3% in patients with primary lung cancer.

Balazs et al. [6], in a series of 264 patients with malignant fistulas, found that 243 had esophageal cancer, 19 had lung tumors, and 2 had mediastinal tumors.

Of all malignant esophageal-pulmonary fistulas, 92% have esophageal cancer and 7% have lung cancer. Other neoplasms of different origin, such as thyroid carcinoma, larynx, lymphomas, or malignant mediastinal nodules, correspond to only a small percentage of these fistulas [7].

## Cancer Treatment-Related ADF

Some therapies used for cancer can result in ADF. Bevacizumab is a monoclonal antibody directed at vascular endothelial growth factor (VEGF). In combination with paclitaxel and carboplatin, it is indicated for the treatment of advanced non-small cell lung carcinoma (NSCLC). This angiogenic agent has been shown to cause the formation of tracheal or broncho-esophageal fistulas when administered in combination with radiochemotherapy [8].

Some publications warn of the danger of causing esophageal respiratory fistulas due to the combination of bevacizumab and radiochemotherapy for treating both non-small and small cell lung cancer. In a report on small cell carcinoma treated patients, 2/29 developed tracheo-esophageal fistula and another patient died of aero-digestive hemorrhage. Of the group of five patients with advanced non-small cell carcinoma, treated with a combination of bevacizumab and radiochemotherapy, two developed tracheoesophageal fistula. With these findings, both trials were closed to additional enrollment.

All patients and treating physicians were notified of these potential safety issues and protocol-based treatment was stopped. Genentech and appropriate regulatory authorities including the U.S. Food and Drug Administration and National Cancer Institute were notified. Consequently, a black box warning was issued in the bevacizumab label [9].

As suggested by this and many other reports [9–12], the use of antiangiogenic therapies such as bevacizumab, and especially when associated with concomitant radiotherapy in patients with thoracic malignant neoplasms, can lead to the formation of fistulas (which in most cases tend to be fatal), even months after completion of radiotherapy treatment. This complication may be common to all VEGF pathway inhibitors, advising that the safety of bevacizumab treatments in patients previously treated with radiotherapy should be studied with extreme caution, suggesting that these cases should only be included in carefully designed clinical trials [13].

Regarding safety of endoscopic procedures in patients who have been treated with antiangiogenic agents (AAs), Kachaami et al. [14] reported a retrospective multicenter study of a consecutive case series of 445 cancer patients, from 5 oncology hospitals, who underwent endoscopy within 31 days of antiangiogenic agents' administration.

The most common types of cancer were colorectal, lung, and breast, and most patients had stage III or IV disease at the time of diagnosis.

Among the 445 patients who received a total of 545 endoscopies, 3 procedure-related adverse events (0.7%) occurred within 30 days of the procedure. Two of them were minor, and a third patient developed pancreatitis. The authors concluded that, in this study, the rate of adverse events related to endoscopy procedures in patients with antiangiogenic agents (AAs) seemed to be low, only 0.7% when performed in a specialized cancer center.

The use of immunotherapy agents for advanced lung adenocarcinoma has been associated with rapid development of ADF in a report. In this particular case, after mechanical debulking and stent placement, the patient received nivolumab and 12 days after that, a tracheoesophageal fistula was diagnosed related to a metastatic

lymph node [14]. As lung cancer treatments become more complex, special attention should be paid on possible unusual complications.

## Benign ADF

Benign non-tumoral acquired ADF can result from different conditions:

- Traumatic: blunt or penetrating chest trauma [15]
- Inflammatory diseases/Infectious diseases (tuberculosis, histoplasmosis)
- Iatrogenic: postoperative, post radiotherapy, post intubation, post tracheostomy (particularly percutaneous), post stent placement (esophageal or airways)
- Esophageal diverticula
- Caustic ingestion
- Foreign body
- Other conditions

*Infectious conditions* such as granulomatosis processes (i.e., tuberculosis [16], actinomycosis, Wegener's) can result in ADF as well. Other infections can also be responsible: herpetic esophagitis, acquired immunodeficiency syndrome (AIDS)-related esophageal candidiasis, cytomegalovirus, or *Staphylococcus aureus* [17].

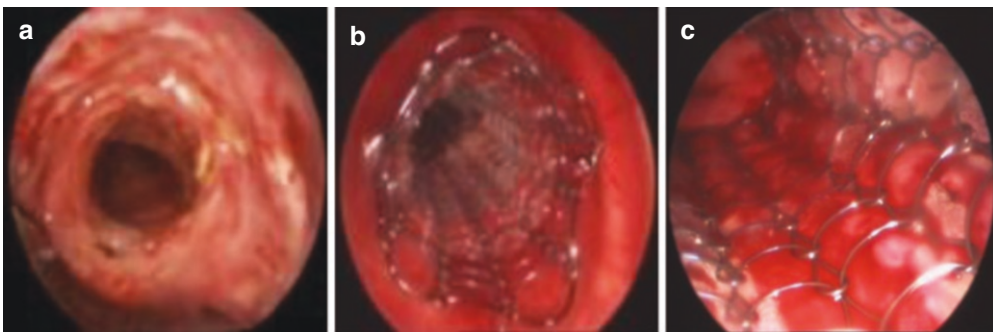
*Inflammatory processes* resulting from ingestion of foreign bodies or corrosive agents [18] or patients with Zenker's diverticulum can also be the cause of aero-digestive fistulas [19, 20].

Lenz et al. [21] published a retrospective review between 2001 and 2012, of 123 tracheo-bronchial esophageal fistulas: 53% were malignant and 47% were of benign etiology, 60% of which were postoperative. The rest of the benign etiologies were: mediastinal inflammation, radiotherapy, esophageal diverticula, caustic ingestion, broncholithiasis, tracheal stenosis, and actinomycosis. However, Shen et al. [22] found in a retrospective study from 1978 to 2007 that 14% of the 35 benign fistulas found were due to granulomatous infections. According to Bixby et al. [23], this discrepancy in ADF etiologies between the two studies can be explained by the decline in granulomatous diseases and better

treatments for those conditions in the United States in recent years compared to the 1970s.

### Iatrogenic ADF

- Injuries resulting from manipulations (especially during thoracic surgical procedures) [24, 25] or traumatic tracheal intubations [26] that can injure the posterior wall of the trachea can result in iatrogenic ADF.
- Prolonged mechanical ventilation after tracheal surgical reconstruction is also a reported iatrogenic cause for ADF [27].
- Mediastinoscopy and lymph node biopsies: After these procedures, ADF can arise following the formation of granulomas as a consequence of mediastinitis [28]. Special care must be taken in the lower left paratracheal station 4 L and in station 7.
- Treatments of esophageal strictures: Placement of prostheses after dilation or resection is sometimes the cause of ADF, especially at the level of the proximal edge or at the distal edge of the prosthesis or also at the level of the previously treated stenosis [29].
- Treatment of tracheal stenosis: The use of uncovered metal prostheses in the respiratory tract for the treatment of tracheal stenosis can be the cause of tracheoesophageal fistulas (Fig. 39.1a, b), due to posterior tracheal wall perforation secondary to stent wire fractures during extraction maneuvers [30].
- Tracheostomies or percutaneous tracheostomies could also be a cause of ADF. Louis et al. [31] published a case of ADF diagnosed after removal of the endotracheal tube. Three weeks before, a percutaneous tracheostomy had been performed. The authors enforced the perioperative use of bronchoscopy as a guide for this procedure and the need for rigorous learning, since insertion of different-sized cannulas can be difficult.
- Endotracheal tube balloon is the most frequent cause of tracheoesophageal fistula, noted already by Flege in 1967 [32]. In 1976, Grillo et al. described the involvement of both the trachea and the esophagus in the formation of tracheoesophageal fistulas, suggesting that the main component would be the compression due to the high-pressure cuff on one side and the nasogastric tube on the other [33]. After the high-volume, low-pressure cuffs became standard, its incidence has decreased but still remains as one of the most important causes, particularly after prolonged intubation.



**Fig. 39.1** (a, b, and c) Posterior tracheal wall perforation secondary to stent wire fractures during extraction maneuvers



## Diagnosis

Diagnosis of ADF should be suspected by clinical symptoms and should be corroborated by respiratory or digestive endoscopy or both. Exploration with radiological images can help in the case of small fistulas.

Because the initial symptoms are quite non-specific, diagnosis of esophageal respiratory fistulas can be delayed in time. In some cases the diagnosis of benign fistulas can be delayed even up to 18 months after symptoms have started [6].

If patients have a predisposing condition (i.e., a known esophageal tumor) once symptoms ensued, suspicious and clinical diagnoses are relatively easy. Patients complain of coughing, especially when swallowing liquids or solids, due to the passage of these to the respiratory system through the fistula (*Ono's sign*). Cough can be productive with sputum mixed with secretions and in the case of large fistulas, with food debris. These patients often also have episodes of bronchitis, dysphagia, recurrent pneumonia that are difficult to treat, and signs of malnutrition [34, 35]. Symptoms of cough, stridor, or hemoptysis are usually more frequent if the tumor is originally from trachea or bronchi, and rare when the primary tumor is originally from esophagus.

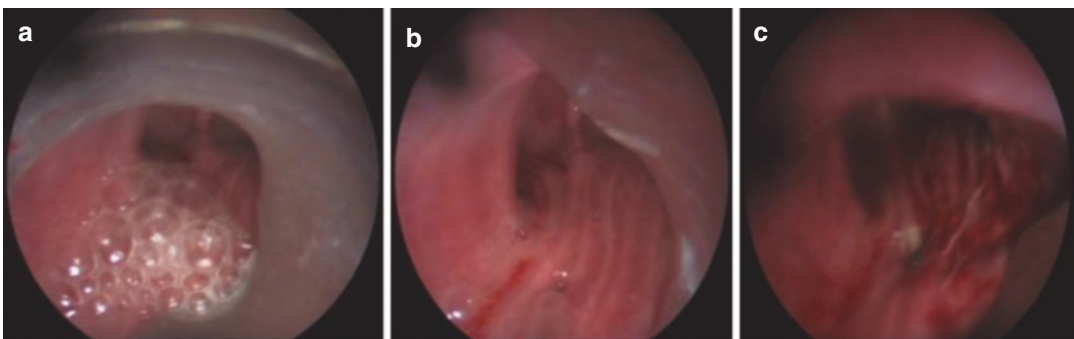
In the series of Burt et al. [5] that include 207 patients, the main symptoms were cough (56%), aspiration (37%), fever (25%), dysphagia (19%), pneumonia (5%), hemoptysis (5%), and chest pain (5%).

In patients with assisted mechanical ventilation, the appearance of sudden abdominal distention should make us think about the presence of a fistula.

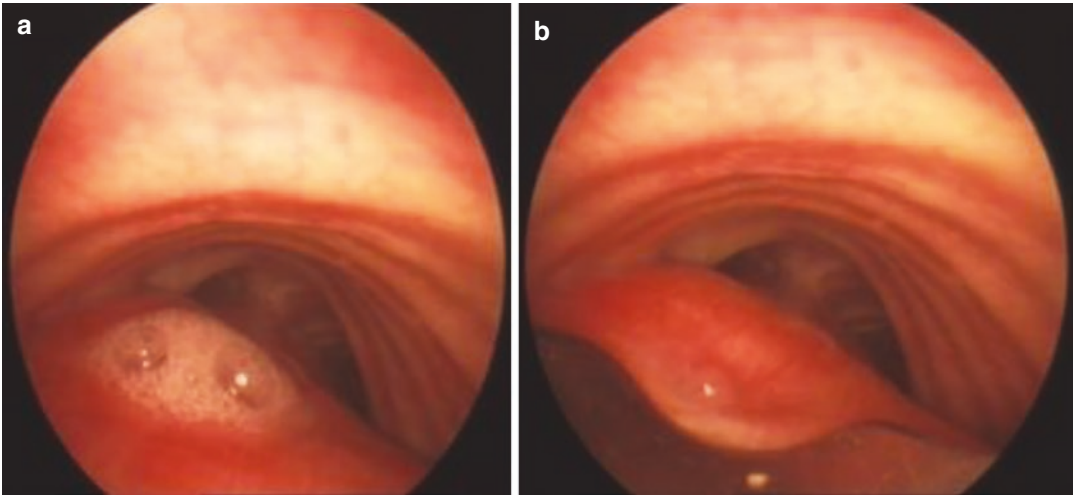
The diagnosis of tracheal or bronchoesophageal fistulas by respiratory or digestive endoscopy or by both [36] is usually successful. However, when the fistula orifice is small and surrounded by inflammatory tissue, diagnosis is more difficult and may require the use of swallowed contrast [37] for dynamic endoscopic inspection. Air bubbles or foamy secretions of biliary aspect during exploration can appear and help in locating the fistula (Figs. 39.2a, b and 39.3). When the orifice is larger, the endoscopic diagnosis is much easier. A chest X-ray or chest computed tomography (CT) scan can help with small fistulas but are rarely essential. However, radiological control is essential in monitoring the evolution of the disease.

After the development of a malignant fistula, the prognosis is dire, with most patients dying within 1 or 2 months due to respiratory infections and malnutrition. Therapy is aimed at alleviating symptoms and maintaining quality of life (QoL).

Ninety percent of patients with malignant ADF have advanced or metastatic disease with high ECOG scores (Eastern Cooperative Oncology Group). Most patients present with frequent lung contamination, bronchial obstructions and aspiration, and lung superinfections, which are difficult to treat. In most cases, these complications



**Fig. 39.2** (a and b) Air bubbles and foamy secretions arising from ADF. (c) Closure with laser application



**Fig. 39.3** (a) Endoscopic view of a posterior tracheal wall fistula with foamy secretions. (b) Closure by granulomatous tissue after laser treatment

cause aspiration pneumonia leading to sepsis, mediastinitis, ARDS, and a fatal outcome.

### Treatment Options

Managing patients with ADF is always challenging. The first thing to consider is the etiology, since benign conditions are approached differently than those of malignant origin. Table 39.1 suggests an algorithm for management.

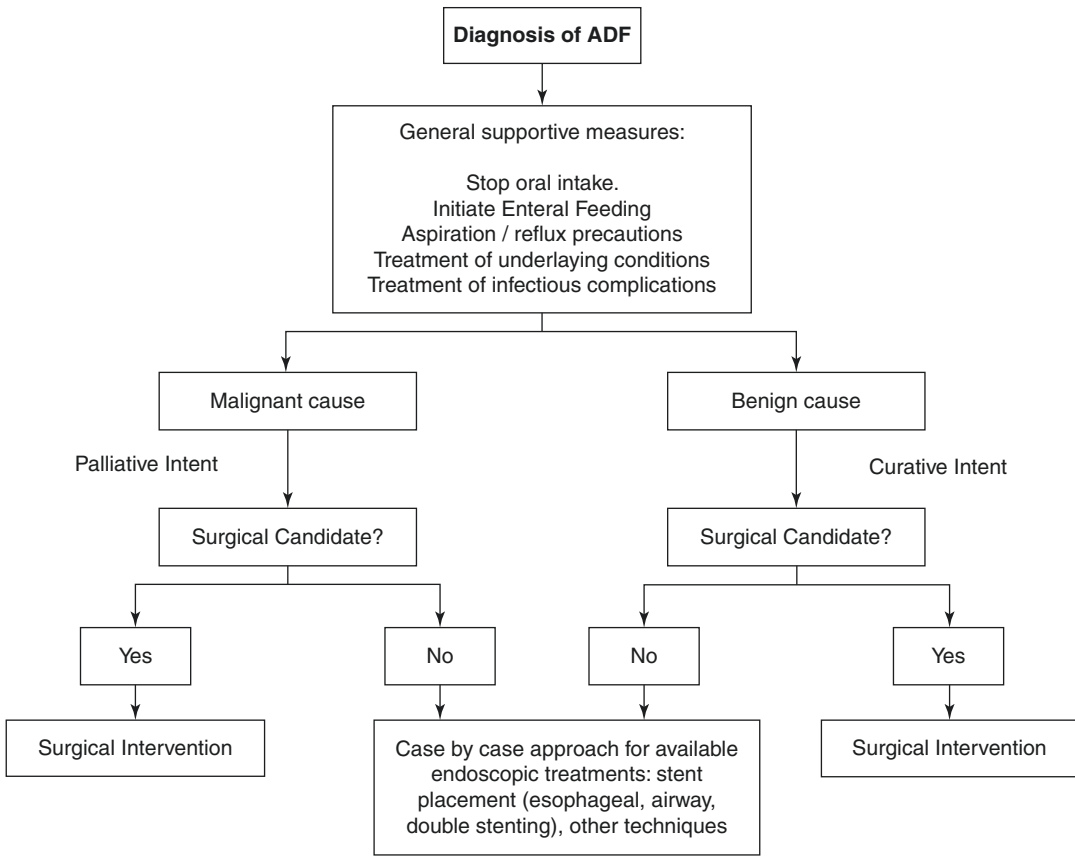
In malignant ADF, the main goals of the management are: to treat recurrent infections with antibiotics, seal the communication between the esophagus and the airway if possible, and ensure proper enteral feeding. We have to consider that usually patients are in an advanced cancer condition; they present malnutrition, and recurrent infections; and they have received chemotherapy or radiotherapy that impact also on their physical conditions.

Surgical procedures such as the occasional esophageal exclusion, esophageal bypass, and fistula resection and repair, which in benign pathology can have good results, in the presence of a malignant fistula carry a high morbidity/mortality rate, with poor results [5].

Endoscopic procedures should be aimed at closing the communication and preventing esophageal fluid from passing into the bronchial tree in order to alleviate the symptoms and improve the quality of life of a patient with an unfortunate prognosis. The simultaneity of these procedures with the appropriate oncological treatment must be taken into account, especially considering the repercussion and incompatibilities between them.

Endoscopic treatment should be individualized and may include esophageal stenting, tracheobronchial stenting, or dual stenting (stenting of both sides).

**Table 39.1** ADF algorithm (Modified from Bixby et al. [23])



In fistulas with a small orifice, less than 3 mm, locally applied treatments can be tried and can be relatively safe and easy.

## Endoscopic Techniques

### Stents

There are two types of stents that we can consider to use for the treatment of ADF: silicone stents and self-expanding metallic stents (SEMS).

Silicone stents were first invented and placed by J.F. Dumon for the treatment of benign and malignant tracheobronchial stenosis as well as ADF. They are available in different configurations: straight and Y-shaped stents, with studs on the outer surface designed to avoid migration. In the case of the treatment of long aero-digestive

fistulas, Dumon prostheses have the drawback that they can prevent complete closure of the fistula if the studs further injure in the fistulous tract; for this reason SEMS prostheses increasingly replaced Dumon prostheses in the airway for the treatment of ADF.

First generation of metallic stents, Gianturco stainless steel wire stents or Strecker stents, made of tantalum were early abandoned due to poor flexibility and adaptability, and high complication rate.

The so-called second generation of SEMS include the Wallstent—self-expandable with internal silicone-based covering with flared ends, made of a stainless steel alloy woven into a tubular mesh—and the Schneider prosthesis—a cobalt-based superalloy—both inserted using a flexible fiberoptic bronchoscope.

Subsequently, these prostheses were improved giving place to self-expanding metal stents, cov-

ered with silicone (third generation) to avoid the important problems of the non-covered self-expanding metal prostheses (such as granulomatous or tumor growth through the metal mesh, generating obstructions and re-epithelialization of the mucosa involving the metallic wires that make extraction almost impossible).

Examples of third-generation airway stents are: Ultraflex Stent, made of nitinol (nickel–titanium alloy) uncovered or covered by silicone, Aero Stent made of nitinol and covered by polyurethane, and Micro-Tech Stent and Aerostent made of nitinol and completely covered by silicone. Also, the Bona Stent (made of nitinol and covered by silicone) and the NiTi Stent (made of nitinol and covered by polytetrafluoroethylene) are currently the most frequently chosen last-generation stents.

Nitinol alloys give the stent two important characteristics: *pseudoelasticity* effect, that is, an elastic response to an applied stress, and *shape-memory* effect, that is, maintaining a deformed shape at body temperature. These two effects are due to the thermodynamic and crystallographic structure of the elements conforming the stent.

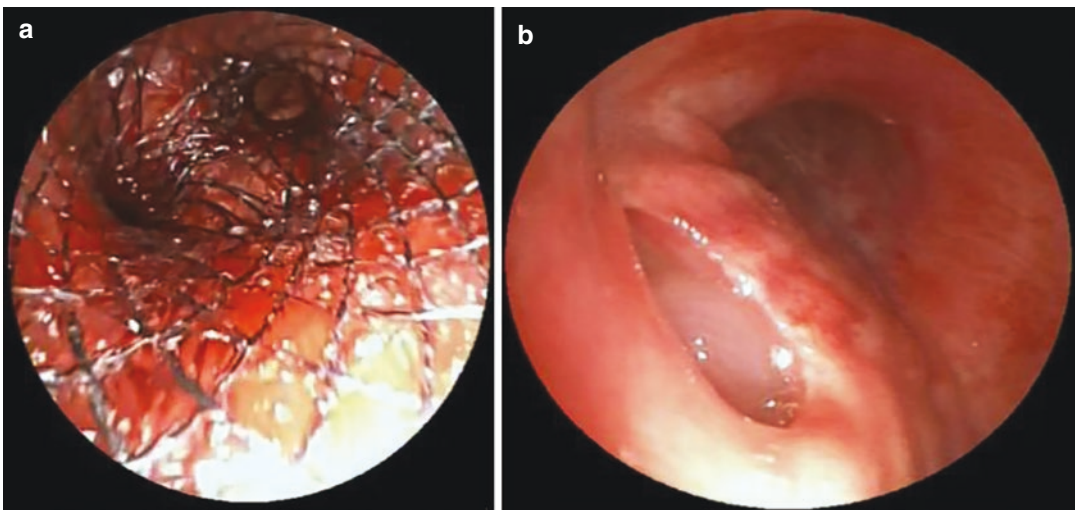
Easy deployment and the ability to achieve better apposition to the airway mucosa are the two most important qualities of SEMS. These stents can be inserted and deployed with a fiber-

optic bronchoscope and they are very adaptable to changes in both the direction and caliber of the airway. The advantage of these stents is that they adapt much better to the tracheal wall deformities, but also have the inconvenience of generating inflammatory and granulomatous tissue growing in the mucosa. The lifespan of these stents is short, so metal fatigue and stent fracture can occur.

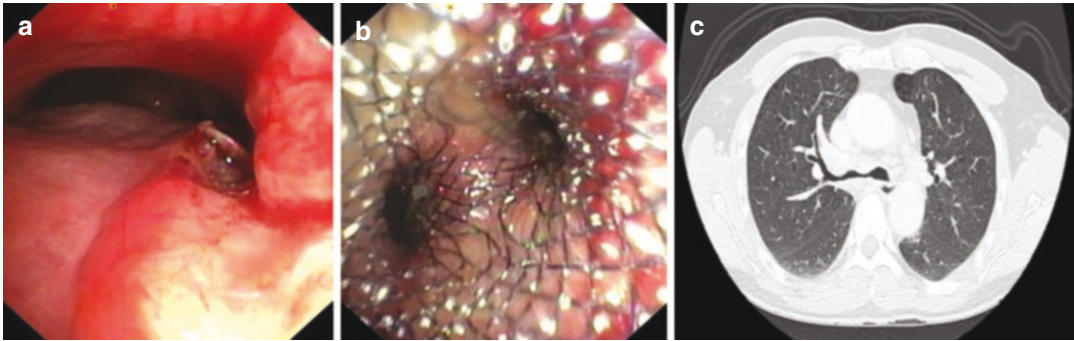
As we mentioned before, both silicone and self-expanding metal covered stents have been used for treatment of ADF (Figs. 39.4, 39.5, 39.6, and 39.7).

The first approach to seal ADF should be esophageal stent [38]. Placement of the esophageal prosthesis is not difficult, except when the fistulae are located near the ends of the esophagus or there is an esophageal stenosis. In those cases, the procedure could be more complicated or sometimes impossible.

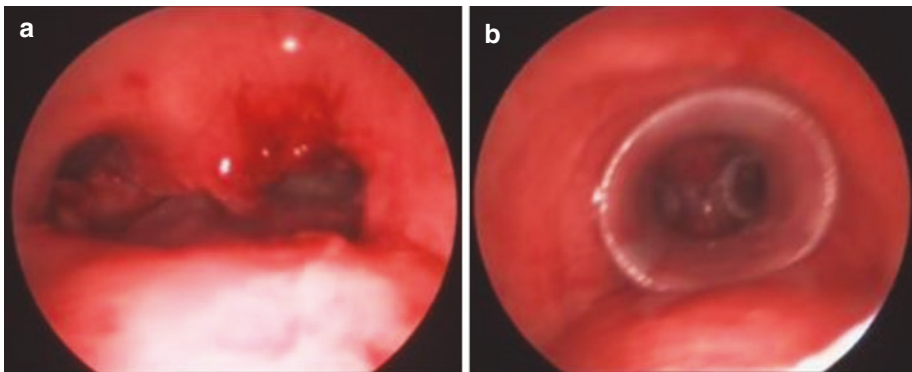
Self-expanding stents are more widely accepted for use in the esophagus since it manages to seal the fistulous orifice more efficiently. However, there are two important drawbacks for those stents: one is due to their self-expanding property—if the size is not carefully selected, an oversized stent can stretch the lumen with its expansible radial forces, and can increase the fistula due to excessive expansion of the esophageal



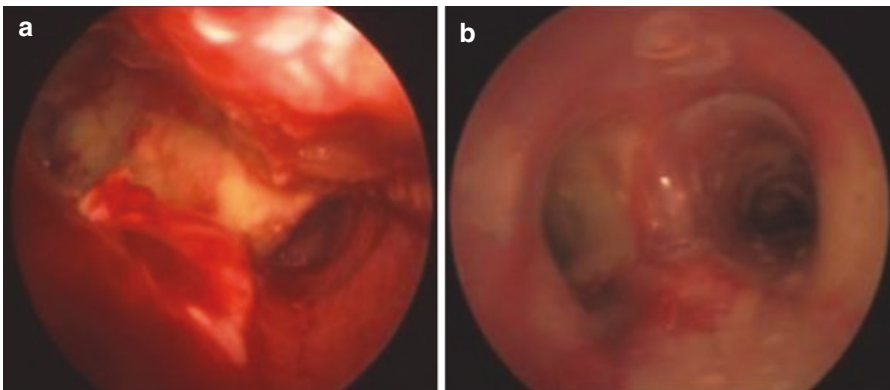
**Fig. 39.4** (a and b) Tracheoesophageal fistula covered with a metallic stent



**Fig. 39.5** (a, b, and c) Tracheal-mediastinal fistula (right paratracheal) treated with metallic stent. Chest CT shows tumor infiltration with compromised tracheal rings



**Fig. 39.6** (a and b) Silicone Dumon Y-stent covering an ADF affecting the lower trachea and both mainstem bronchi. An additional stent was added within the right main bronchus for better coverage



**Fig. 39.7** (a and b) Silicone Dumon Y-stent covering an ADF resulting from radiotherapy

wall. There is also the additional risk of penetration through the airway wall. SEMS can also migrate more frequently than silicone stents since they have a smooth outer surface (36 Eliminar).

When silicone stents are chosen, we have to take into account that the studs (covering the external wall of Dumon stents) can prevent a good sealing and more than that, they can further



injure the compromised mucosa and worsen the output through the fistula. To avoid this problem, it is very important to try to place the stent avoiding the coincidence of the studs with the fistulous orifice. Assisted rigid bronchoscopy with forceps is essential for the insertion and placement of silicone prostheses. It is important to choose a relatively long stent in order to cover the fistulae and to have both ends of the stent with a safe distance from the fistula to avoid complications.

The indications for placing a prosthesis in the airway will be conditioned by the effectiveness of the esophageal prosthesis. Sometimes the airway prosthesis placement is essential to achieve good palliation of symptoms, when the esophageal prosthesis does not completely cover the fistula and cannot be replaced by another one or in cases that esophageal stenting is not possible due to location, as well as when the lesion has affected a large portion of the esophageal wall or when there is a degree of esophageal stenosis that makes progression of the stent difficult or impossible. Of course if there is evidence of airway obstruction, it may be another indication for airway stent placement.

When dual stenting (both esophageal and airway) is considered, it has to be carefully planned and discussed in a multidisciplinary fashion, given the risks involved, since double stenting can enlarge the fistula and worsen clinical situation [39]. In case it is considered appropriate, it is recommended to place the respiratory prosthesis first followed by the esophageal one, to avoid extrinsic compression or collapse of the airway secondary to the digestive prosthesis pressing on the tracheal or bronchial wall.

Although there seems to be a general consensus on the use of dual stents for ADF, its application is still controversial with authors preferring to place only one prosthesis. As mentioned, a case by case multidisciplinary discussion is in order to make the best decision for the patient [39].

Regarding airway stent choice, it will depend mainly on location, and size of the fistulous orifice, as well as the characteristics of the wall abnormalities [38]. Straight and hourglass-shaped stents are commonly used in the trachea while Y-shaped or L-shaped stents are usually

used in lower airway fistula, near the carina, or affecting both carina and mainstem bronchi. When the esophageal fistula orifice is located in middle and distal esophagus without main airway stenosis, an esophageal covered stent is adequate, and there is no need for an airway stent [40].

Chaddha et al. [41] suggested that the ideal stent should meet the following requirements: (i) cover the fistula orifice completely and fit perfectly to the tracheal wall; (ii) press firmly against the tracheal wall to prevent dislocation; (iii) the membrane of the metallic stent has to be secure and durable; (iv) the stent has to be able to keep a certain tension for a long period; and (v) it can be placed and withdrawn easily.

A careful clinical, radiological, and endoscopic examination is mandatory in order to decide the kind, size, shape, diameter, and length of the prosthesis. After placement, endoscopic follow-up will help determine status of the stent, presence of obstruction or migration, granulation or tumor tissue growing, or retention of secretions.

We recommend using a rigid bronchoscope for all these procedures, since it is easier, more effective, and safer than the fiberoptic bronchoscope, especially when silicone stents are involved. With SEMS, after deployment through the fiber bronchoscope, we also recommend always having a rigid bronchoscope at hand, and the necessary accessories to use them, in case there is need to treat complications during the procedure.

---

## Clinical Results

Many articles have been published evaluating the efficacy and safety of stent placement in malignant digestive-respiratory fistulas (DRF).

Herth et al. published the efficacy of dual stenting versus single stenting regarding quality of life (QoL) in a group of cancer patients suffering from malignant DRF. Some patients received a single prosthesis in the airway, while the other two groups received either only in the esophagus or dual stenting. The overall QoL scores of the patients improved significantly after placement of stents. The improvement in QoL 10 days post

stent insertion was quite evident in most of the patients. There was no significant difference between the groups, demonstrating that airway and/or esophageal stent insertion was appropriate in improving the overall QoL. The authors concluded that airway and/or esophageal stent insertion provides an effective approach to improve QoL in patients with malignant ADF [42].

In order to assess the efficacy of the stent treatment in patients with ADF and based on an existing classification for central airway stenosis (the Freitag Classification System [43]), Wang et al. [44] developed a thorough system that could be useful in the choice of one stent for the treatment of ADF, depending on the location. They included 63 patients with malignant ADF, 12 patients with lung cancer, and 46 patients with esophageal cancers.

They differentiate eight different zones according to location:

- 1) Zone I, upper trachea
- 2) Zone II, middle trachea
- 3) Zone III, lower trachea
- 4) Zone IV, carina
- 5) Zone V, right main bronchus
- 6) Zone VI, middle lobar bronchus
- 7) Zone VII, proximal mainstem bronchus
- 8) Zone VIII, distal left mainstem bronchus

A total of 63 malignant tracheo-esophageal fistula (MTEF) patients were included: 12 patients with lung cancer and 46 patients with esophageal cancers. Most fistulas were located in Zone II.

Different stents were placed based on different locations and sizes of fistulas.

Airway stents were successfully inserted in all patients, and both airway and esophageal stents in eight patients. The stents included 10 "I" shaped, 8 "L" shaped, and 45 "Y" shaped.

Complete closure was achieved in 45 patients (71.4%), and incomplete closure and leakage in 18 patients. Most of the patients improved their quality of life after the placement of stents for relieving symptoms. Mean survival time was 163 days.

The authors concluded that airway stent insertion provides an effective approach to improve

symptoms and quality of life and suggested that a stent choice according to location and size of the fistula can be of use in clinical practice.

In benign ADF, some retrospective studies have shown that the degree of success (defined as complete closure after 6 months) was mainly related with the size of the fistula. Debourdeau et al. [45] in a retrospective study describe the endoscopic management of 22 patients with benign ADF. In this group of patients, fistulas were postoperative, secondary to esophageal dilation, post radiotherapy, mechanical ventilation, and post tracheotomy. They all received endoscopic procedures, including stent placement or clips, and sometimes a combination of both. Endoscopic success rate was 45.5%, with the highest percentage in pinpointed fistulas, followed by medium-sized ones. Large fistulas had only a 14% response rate. Fistula persistence after 6 months of endoscopic treatment was associated with failure. Large-sized fistulas were also associated with a high mortality rate, 71% in this group of patients.

Another publication [46] reports good results in closure when esophageal fistulas were located distally, with worse rates of clinical and technical success being in proximal fistulas.

In conclusion, it seems to be a good response rate for endoscopic treatment in benign ADF when they are small and distally located. Endoscopic treatment allows advancement of diet and has minor adverse events. As suggested, these patients have to be carefully selected and discussed in multidisciplinary teams, to personalize the best approach.

---

## Stent Complications

When applied to ADF, stents can result in various complications ranging from minor to lethal. The most common ones include pain, stent migration, restenosis, mucosa erosion, aspiration, tracheal obstruction, tumor overgrowth, food impaction, fistula neof ormation, stent fracture, gastroesophageal reflux, massive bleeding, and early unexpected deaths. Most of these complications occurred in malignant fistulas [6, 47–52].

Some rare complications have been published exceptionally, such as superior vena cava occlusion 24 h after implantation of dual prosthesis due to a tracheoesophageal fistula [53]. Migration and perforation of the airway, with subsequent airway obstruction, has also been reported [54].

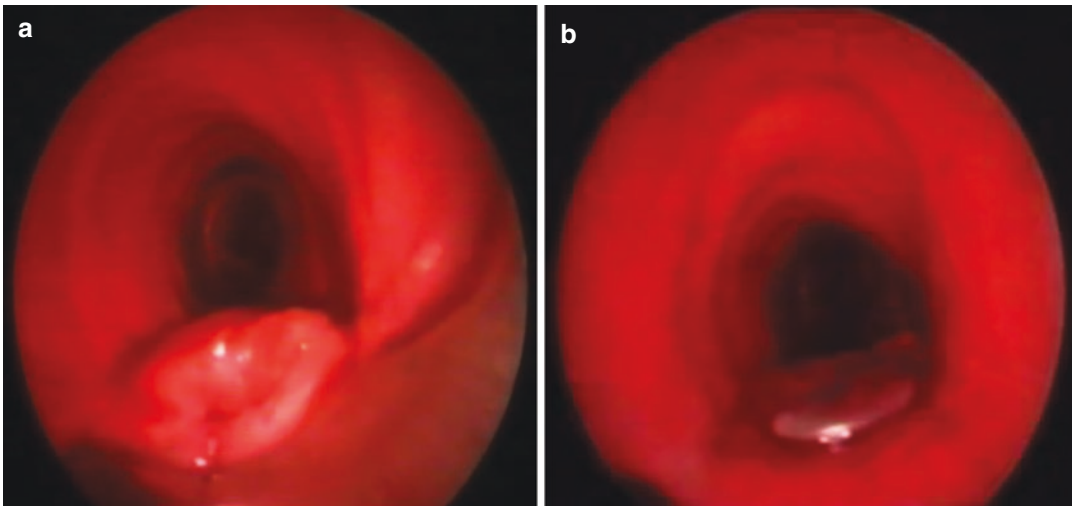
Many of the minor complications, such as retention of secretions, aspiration, granulomas at the distal ends of the prostheses, or food impaction, can be avoided preventively with good follow-up, carrying out protocolized endoscopic controls according to location, type of prosthesis, and patient's condition in terms of symptoms and prognosis. An early endoscopic intervention can easily eliminate secretions, food impaction, granuloma, or incipient tumor growth. Unfortunately, many of these patients are unable to tolerate procedures to resolve serious complications related to the prosthesis, such as perforation, tumor obstruction, or displacement.

### Other Available Stents

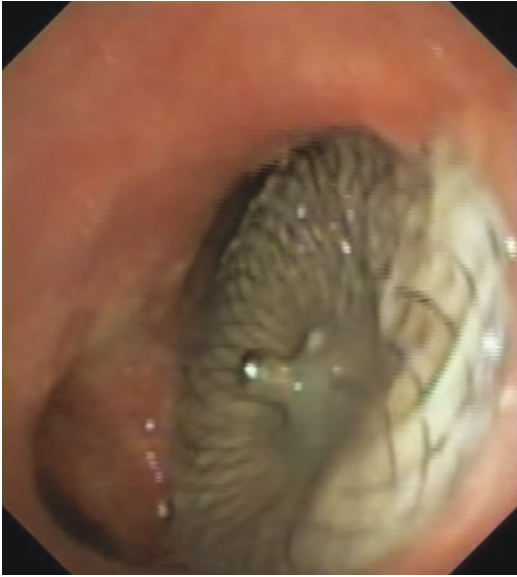- *Cufflink-shaped prosthesis (DJ-Fistula stent)*<sup>®</sup> made in silicone was designed exclusively for closure of malignant aero-digestive fistulas. The DJ<sup>®</sup> stent presents some advantages over the prosthesis used for palliation of malignant tracheoesophageal and bronchoesophageal

fistulas (Fig. 39.8a, b). It is soft and easy to place, sized exactly to the fistula diameter, and occluding completely the abnormal communication in both sides [55]. Some articles reported a combination of the DJ<sup>®</sup> stent with a Y tracheobronchial silicone stent in order to avoid dislodgement of the DJ<sup>®</sup> prosthesis secondary to cough, with good results [56]. A similarly designed prosthesis called septal button (Micromedics, St Paul, Minnesota, USA) has been also used successfully to treat post-laryngectomy tracheoesophageal fistulas [57].

- *Cardiac septal defect occluder* devices were originally designed for transcatheter closure of cardiac defects with the goal of inducing an endothelial response and closure of the defect. Amplatzer<sup>®</sup> is a shape-memory, self-expanding, double-disk device composed of nitinol and interwoven polyester that promotes occlusion and tissue in-growth. Amplatzer device has been used for other non-cardiological pathologies such as gastrointestinal fistulas [58], gastrotracheal fistula [59], bronchopleural fistulas [60–63] (Fig. 39.9), and ADF [48, 63, 64] with success. Some related complications, such as migration of the device with secondary airway obstruction [64], have raised concerns on safety discouraging its use on ADF, due to the risk of airway



**Fig. 39.8** (a and b) Posterior tracheal wall ADF treated with a DJ<sup>®</sup> stent



**Fig. 39.9** Amplatzer device occluding a bronchoesophageal fistula (mediastinal wall)

obstruction and the possibility of increasing the size of the fistula, mucostasis, granulation tissue formation, migration and respiratory mucosa erosion, and hemoptysis. A new similar device has been proposed for tracheoesophageal fistula [48]. It is dumbbell-shaped and made of laminated nitinol mesh with two self-expanding disks connected by a thin waist allowing mechanical closure of both ends of the fistula, giving a potential substrate for subsequent organized in-growth. According to the authors, this new model device reduces tracheal mucosal erosion and obstruction due to its size, as well as facilitates its endoscopic extraction if necessary. This new device was recently successfully used in a 69-year-old patient with a chronic tracheoesophageal fistula [65].

## Other Endoscopic Methods

- *Submucosal fibrin injections:* In fistulas with a small orifice, punch and glue has been recommended in a recent publication [66]. Small bronchopleural fistulas resulting from suture failure after pneumonectomy can be solved

with endoscopic submucosal injection of polidocanol (sclerotherapy) and application of cyanoacrylate with good results [67]. Combining a covered stent and fibrin sealant has been reported as well [68]. Placement of metallic coils plus fibrin also has been used for small fistulas [69].

- *Endoscopic chemocauterization* of congenital and recurrent fistulas, using trichloroacetic acid 50%, could be an effective, simple, and safe technique in pediatric patients and avoids the morbidity of open surgery [70, 71].
- *Laser application or argon plasma coagulation* can be a good remedy if applied superficially at low power and only with the intention of creating granulation tissue surrounding the fistula orifice that leads to closure (Figs. 39.2c and 39.3b). The procedure must be done very carefully to avoid increasing the size of the fistula orifice [34, 72].
- *Autologous corticocancellous bone grafts* have been applied with good results. In an excellent study and with good results, Chittithavorn et al. implanted in post-pneumonectomy bronchopleural fistulas, at the bronchial stump, an autologous corticocancellous bone graft from the adjacent rib in order to create a completely air- and water-tight sealing. Autologous corticocancellous bone grafts were sewn to the inner wall of the bronchial lumen in a spiral pattern from below to close the fistula and induce rapid healing [73].
- *OTSC system<sup>®</sup>* (Ovesco Endoscopy GmbH, Tübingen, Germany) is a new endoscopic tool for compression of large tissue areas, which was originally introduced for the closure of gastrointestinal defects and also indicated for difficult-to-control non-varicose bleeding. It consists of a nitinol clip, attached to an applicator integrated onto the tip of an endoscope. Good outcomes have been reported with its use in the management of ADF [74–76].
- *Size-adjusted sponge* placed endoscopically, combined with continuous suction has resolved post-esophagectomy ADF [48]. This system creates negative pressure by placing a sponge within the fistula lumen. The sponge is

connected to a nasogastric tube that continuously removes secretions. Complete closure is achieved by inducing granulation tissue at the fistula. The authors suggested that endoscopic vacuum-assisted closure with a sponge might be an adequate alternative treatment option for esophageal stenting for esophagoatracheal fistula after esophagectomy.

- *AlloDerm*, an acellular dermal matrix derived from donated human skin tissue, used for tissue reconstruction, has been used to treat a 4 cm fistulous tract developed after a lower right lobectomy. *AlloDerm* was used during the surgical procedure to reconstruct the membranous trachea, close the esophageal defect primarily, and interpose a muscle flap. The procedure was successful in completely closing the fistula, suggesting that *AlloDerm* can be a useful tool for complex airway reconstructions when options are limited [77].

## Summary and Recommendations

Aero-digestive fistulas represent complex clinical situations. When they are congenital or result from benign conditions, surgical treatment with curative intent is the procedure of choice. Some other procedures can be applied as well, but they have to be evaluated personalized to the patient, taking into consideration his/her desires, clinical status, comorbidities, and possibilities for success (risk/benefit assessment), and discussed in a multidisciplinary team.

In malignant ADF, chances for long-term success are almost null, and the main focus should be palliation of symptoms and quality of life. In that respect, preserving nutrition status and avoiding aspiration and respiratory infections are priorities. To achieve the best palliation goals, many methods are available.

We cannot overemphasize the need of a multidisciplinary approach, where a careful risk/benefit assessment is considered. Patient's wishes should be respected and included in any therapeutic decision.

## References

1. Solomon BD. VACTERL/VATER association. *Orphanet J Rare Dis.* 2011;6:56.
2. Polin RA, Abman SH, Rowitch D, et al. *Fetal and neonatal physiology.* 5th ed. Amsterdam: Elsevier; 2017.
3. Freitag L, Tekolf E, Steveling H, et al. Management of malignant esophagoatracheal fistulas with airway stenting and double stenting. *Chest.* 1996;110:1155–60.
4. Martini N, Goodner JT, D'Angio GJ, Beattie EJ Jr. Tracheoesophageal fistula due to cancer. *J Thorac Cardiovasc Surg.* 1970;59:319–24.
5. Burt M, Diehl W, Martini N, et al. Malignant esophagorespiratory fistula: management options and survival. *Ann Thorac Surg.* 1991;52:1222–9.
6. Balazs A, Kupcsulik PK, Galambos Z. Esophagorespiratory fistulas of tumorous origin. Non-operative management of 264 cases in a 20-year period. *Eur J Cardiothorac Surg.* 2008;34:1103–7.
7. Reed MF, Mathisen DJ. Tracheoesophageal fistula. *Chest Surg Clin N Am.* 2003;13:271–89.
8. Sandler A, Gray R, Perry MC, et al. Paclitaxel-carboplatin alone or with bevacizumab for non-small-cell lung cancer. *N Engl J Med.* 2006;355:2542–50.
9. Spigel DR, Hainsworth JD, Yardley DA, et al. Tracheoesophageal fistula formation in patients with lung cancer treated with chemoradiation and bevacizumab. *J Clin Oncol.* 2009;28:43–8.
10. Gore E, Currey A, Choong N. Tracheoesophageal fistula associated with bevacizumab 21 months after completion of radiation therapy. *J Thorac Oncol.* 2009;4:1590–1.
11. Goodgame B, Veeramachaneni N, Patterson A, Govindan R. Tracheo-esophageal fistula with bevacizumab after mediastinal radiation. *J Thorac Oncol.* 2008;3:1080–1.
12. Seiwert TY, Haraf DJ, Cohen EE, et al. Phase I study of bevacizumab added to fluorouracil- and hydroxyurea-based concomitant chemoradiotherapy for poor prognosis head and neck cancer. *J Clin Oncol.* 2008;26:1732–41.
13. Kachaamy T, Gupta D, Edwin P, Vashi P. Safety of endoscopy in cancer patients on antiangiogenic agents: a retrospective multicenter outcomes study. *PLoS One.* 2017;12(5):e0176899. <https://doi.org/10.1371/journal.pone.0176899>.
14. Mizuguchi S, Takahama M, Nakajima R, Inoue H, Ito R, Yamamoto R. Rapid progression of tracheoesophageal fistula caused by immunotherapy administered after tracheal stent placement. *Biomed Hub.* 2019;4(2):1–5.
15. Antkowiak JG, Cohen ML, Kyllonen AS. Tracheoesophageal fistula following blunt trauma. *Arch Surg.* 1974;109:529–31.
16. Tautz E, Wagner D, Wiesemann S, Jonaszik A, Bode C, Wengenmayer T, Staudacher D, Biever P, Hoepfner J, Duerschmied D. Treatment of a broncho-



- esophageal fistula complicated by severe ARDS. 2019;47(3):483–7.
17. Wong TRT, Davis RS, M., et al. Esophago-airway fistula in AIDS. *Ann Thorac Surg.* 1995;60:440–2.
  18. Santra G, Pandi N. Tracheoesophageal fistula. *J Assoc Physicians India.* 2009 Apr;57:310.
  19. Senders CW, Babin RW. Management of benign fistulae between Zenker's diverticulum and the trachea. *Ann Otol Rhinol Laryngol.* 1983;92(4 Pt 1):349–52.
  20. Avella DM, Bernal C, Wiesemann SD, Kaifi JT. Benign tracheoenteric fistula to a Zenker's diverticulum with complete esophageal obstruction. *Ann Thorac Surg.* 2021;111(4):e257–8.
  21. Lenz CJ, Bick BL, Katzka D, et al. Esophagorespiratory fistulas: survival and outcomes of treatment. *J Clin Gastroenterol.* 2018;52:131–6.
  22. Shen KR, Allen MS, Cassivi SD, et al. Surgical management of acquired nonmalignant tracheoesophageal and bronchoesophageal fistulae. *Ann Thorac Surg.* 2010;90:914–8.
  23. Bixby BA, Maddock SD, Reddy CB, Iravani A, Ansari SA. Acquired esophago-respiratory fistulae in adults. *Shanghai Chest.* 2020;4:4.
  24. Manoj K, Sanwal PG, Tandom MSJ. Posttracheostomy tracheoesophageal fistula. *J Anaesthesiol Clin Pharmacol.* 2012;28(1):140–1.
  25. Trotter SJ, Hazard PB, Sakabu SA, et al. Posterior tracheal wall perforation during percutaneous dilational tracheostomy: an investigation into its mechanism and prevention. *Chest.* 1999;115:1383–9.
  26. Mooty RC, Rath P, Self M, et al. Review of tracheoesophageal fistula associated with endotracheal intubation. *J Surg Educ.* 2007;64:237–40.
  27. Grillo HC, Zannini P, Michelassi F. Complications of tracheal reconstruction. Incidence, treatment, and prevention. *J Thorac Cardiovasc Surg.* 1986;91:322–8.
  28. Bertolaccini L, Rizzardi G, Luzzi L, Terzi A. Treatment of late tracheomediastinal fistula following diagnostic mediastinoscopy treated by multiple pedicled muscle flaps. *Thorac Cardiovasc Surg.* 2011;59(6):364–6.
  29. Shamji FM, Inculet R. Management of malignant tracheoesophageal fistula. *Thorac Surg Clin.* 2018;28:393–402.
  30. Gaissert HA, Grillo HC, et al. Benign tracheobronchial strictures treated by self expanding metal stents. *J Thorac Cardiovasc Surg.* 2003;126:744–7.
  31. Louis JS, Antok E, Charretier PA, Winer A, Ocquidant P. Tracheo-oesophageal fistula. A rare complication of percutaneous tracheostomy. *Ann Fr Anesth Reanim.* 2003;22:349–52.
  32. Flege JB Jr. Tracheoesophageal fistula caused by cuffed tracheostomy tube. *Ann Surg.* 1967;166:153–6.
  33. Grillo HC, Moncure AC, McEnany MT. Repair of inflammatory tracheoesophageal fistula. *Ann Thorac Surg.* 1976;22:112–9.
  34. Rodriguez AN, Diaz-Jimenez JP. Malignant respiratory-digestive fistulas. *Curr Opin Pulm Med.* 2010;16:329–33.
  35. Zhou C, Hu Y, Xiao Y, Yin W. Current treatment of tracheoesophageal fistula. *Ther Adv Respir Dis.* 2017;11:173–80.
  36. Zori AG, Jantz MA, Forsmark CE, Wagh MS. Simultaneous dual scope endotherapy of esophago-airway fistulas and obstructions. *Dis Esophagus.* 2014;27(5):428–34.
  37. Shah A, Ost D, Eapen GA, Morice RC, Jimenez CA. Diagnostic methylene blue test for stent covered tracheoesophageal fistula. *Am J Respir Crit Care Med.* 2012;185:e9.
  38. Kakuturu J, Dhamija A, Toker A. Malignant tracheoesophageal fistula: diagnosis and management. *Curr Chall Thorac Surg.* 2021.
  39. Colt HG, Meric B, Dumon JF. Double stents for carcinoma of the esophagus invading the tracheo-bronchial tree. *Gastrointest Endosc.* 1992;38:485–9. [https://doi.org/10.1016/S0016-5107\(92\)70482-9](https://doi.org/10.1016/S0016-5107(92)70482-9).
  40. Ke M, Wu X, Zeng J. The treatment strategy for tracheoesophageal fistula. *J Thorac Dis.* 2015;7:S389–97.
  41. Chaddha U, Hogarth DK, Murgu S. Perspective on airway stenting in inoperable patients with tracheoesophageal fistula after curative-intent treatment for esophageal cancer. *J Thorac Dis.* 2019;11(5):2165–74.
  42. Herth FJ, Peter S, Baty F, et al. Combined airway and oesophageal stenting in malignant airway – oesophageal fistulas: a prospective study. *Eur Respir J.* 2010;36:1370–1374.
  43. Freitag L, Ernst A, Unger M, et al. A proposed classification system of central airway stenosis. *Eur Respir J.* 2007;30:7–12.
  44. Wang H, Tao M, Zhang N, et al. Airway covered metallic stent based on different fistula location and size in malignant tracheoesophageal fistula. *Am J Med Sci.* 2015;350:364–8.
  45. Debourdeau A, Gonzalez JM, Dutau H, Benezech A, Barthet M. Endoscopic treatment of nonmalignant tracheoesophageal and bronchoesophageal fistula: results and prognostic factors for its success. *Surg Endosc.* 2019;33(2):549–56.
  46. Silon B, Siddiqui AA, Taylor LJ, et al. Endoscopic Management of Esophagorespiratory Fistulas: a multicenter retrospective study of techniques and outcomes. *Dig Dis Sci.* 2017;62:424–31.
  47. Miller PE, Arias S, Lee H, et al. Complications associated with the use of the amplatzer device for the management of tracheoesophageal fistula. *Ann Am Thorac Soc.* 2014;11:1507–9.
  48. Lee HJ, Lee H. Endoscopic Vacuum-assisted closure with sponge for Esophagotracheal Fistula after esophagectomy. *Surg Laparosc Endosc Percutan Tech.* 2015;25(2):e76–7.
  49. Buitrago DH, Pinto D, Berkowitz SJ, et al. Fatal hemoptysis after closure of gastrobronchial fistula using an Amplatzer vascular device. *Ann Thorac Surg.* 2018;105:e71–3.
  50. Fruchter O, El Raouf BA, Abdel-Rahman N, Saute M, Bruckheimer E, Kramer MR. Efficacy of bronchoscopic closure of a bronchopleural fistula with

- amplazter devices: long-term follow-up. *Respiration*. 2014;87:227–33.
51. Belle A, Lorut C, Lefebvre A, et al. Amplatzer occluders for refractory esophago-respiratory fistulas: a case series. *Endosc Int Open*. 2021;09:E1350–4.
  52. Elsharkawy A, El-Geidie A. Self-expanding metal stents in palliation of malignant dysphagia: outcome of 124 Egyptian patients. *Eur Arch Otorhinolaryngol*. 2010;267(7):1123–7.
  53. Kapadia MR, de Hoyos AL, Blum MG. Acute superior vena cava occlusion after stenting of tracheoesophageal fistula. *Ann Thorac Surg*. 2009;87:1260–2.
  54. Alazemi S, Chatterji S, Ernst A, et al. Mediastinal migration of self-expanding bronchial stents in the management of malignant bronchoesophageal fistula. *Chest*. 2009;135:1353–5.
  55. Diaz-Jimenez JP. New cufflink-shaped silicon prosthesis for the palliation of malignant tracheobronchial – esophageal fistula. *J Bronchol*. 2005;12:207–9.
  56. Mattingley JS, Edell ES, Rickman OB. Difficult to manage bronchogastric fistula palliated with DJ (Diaz-Jimenez) fistula prosthesis and tracheal Y-stent. *Chest*. 2009;136:25S-d.
  57. Schmitz S, Van Damme JP, Hamoir M. A simple technique for closure of persistent tracheoesophageal fistula after total laryngectomy. *Otolaryngol Head Neck Surg*. 2009;140:601–3.
  58. De Moura DTH, Baptista A, Jirapinyo P, De Moura EGH, Thompson C. Role of cardiac septal occluders in the treatment of gastrointestinal fistulas: a systematic review. *Clin Endosc*. 2020;53(1):37–48.
  59. Lee HJ, Jung ES, Park MS, et al. Closure of a gastro-tracheal fistula using a cardiac septal occluder device. *Endoscopy*. 2011;43 Suppl 2 UCTN:E53–4.
  60. Kramer MR, Peled N, Shitrit D, Atar E, Saute M, Shlomi D, Amital A, Bruckheimer E. Use of Amplatzer device for endobronchial closure of bronchopleural fistulas. *Chest*. 2008;133:1481–4.
  61. Marwah V, Rajput AK, Madan H, Garg Y. Closure of chronic bronchopleural fistula using atrial septal occluder device. *J Bronchology Interv Pulmonol*. 2014;21:82–4.
  62. Bai Y, Li Y, Chi J, et al. Endobronchial closure of the bronchopleural fistula with the ventricular septal defect occluder: a case series. *BMC Pulm Med*. 2021;21:313.
  63. Gómez López A, García Luján R, De Pablo GA, et al. First use of Amplatzer device for bronchopleural fistula after lung transplantation. *Thorax*. 2017;72:668–70.
  64. Sang H, Peng L, Zhang G. Tracheoesophageal fistula closed by a new gastrointestinal occluder device. *Endoscopy*. 2020;53:E203–4.
  65. Zhu C, Li L, Wang Y, Zhang W, Li W, Li X, Zhang G. Endoscopic closure of tracheoesophageal fistula with a novel dumbbell-shaped occluder. *Endoscopy*. 2021;54:E334. <https://doi.org/10.1055/a-1524-0761>.
  66. Scappaticci E, et al. Closure of an iatrogenic tracheoesophageal fistula with bronchoscopic gluing in a mechanically ventilated adult patient. *Ann Thorac Surg*. 2004;77:328–9.
  67. Kanno R, Suzuki H, Fujii K, et al. Endoscopic closure of bronchopleural fistula after pneumonectomy by submucosal injection of polidocanol. *Jpn J Thorac Cardiovasc Surg*. 2002;50:30–3.
  68. Wong A, McDonald A, Jones B, Berkowitz D. Novel technique in bronchoesophageal fistula repair and broncholith removal with stent and fibrin glue. *J Bronchology Interv Pulmonol*. 2021;28(3):e45–9.
  69. Sivrikoz CM, Kaya T, Tulay CM, Ak I, Bilir A, Döner E. Effective approach for the treatment of bronchopleural fistula: application of endovascular metallic ring-shaped coil in combination with fibrin glue. *Ann Thorac Surg*. 2007;83(6):2199–201.
  70. Lelonge Y, Varlet F, Varela P, Saitúa F, Fourcade L, Gutierrez R, Vermesch S, Prades JM, Lopez M. Chemocauterization with trichloroacetic acid in congenital and recurrent tracheoesophageal fistula: a minimally invasive treatment. *Surg Endosc*. 2016;30(4):1662–6.
  71. Sung MW, Chang H, Hah JH, Kim KH. Endoscopic management of recurrent tracheoesophageal fistula with trichloroacetic acid chemocauterization: a preliminary report. *J Pediatr Surg*. 2008;43(11):2124–7.
  72. Aynacı E, Kocatürk CI, Yıldız P, Bedirhan MA. Argon plasma coagulation as an alternative treatment for bronchopleural fistulas developed after sleeve pneumonectomy. *Interact Cardiovasc Thorac Surg*. 2012;14(6):912–4.
  73. Chittithavorn V, Duangpakdee P, Rergkliang C, Preukprasert N. A novel approach for the treatment of post-pneumonectomy bronchopleural fistula by using an autologous corticocancellous bone graft. *J Thorac Dis*. 2018;10(7):4453–63.
  74. Zhou C, Hu Y, Xiao Y, et al. Current treatment of tracheoesophageal fistula. *Ther Adv Respir Dis*. 2017;11:173–80.
  75. Traina M, Curcio G, Tarantino I, et al. New endoscopic over-the-scope clip system for closure of a chronic tracheoesophageal fistula. *Endoscopy*. 2010;42(Suppl 2):E54–5.
  76. Vinnamala S, Murthy B, Parmar J, et al. Rendezvous technique using bronchoscopy and gastroscopy to close a tracheoesophageal fistula by placement of an over-the-scope clip. *Endoscopy*. 2014;46 Suppl 1 UCTN:E301.
  77. Su JW, Mason DP, Murthy SC, Rice TW. Closure of a large tracheoesophageal fistula using AlloDerm. *J Thorac Cardiovasc Surg*. 2008;135(3):706–7.



# Foreign Bodies in the Airway: Endoscopic Methods

# 40

Michael Simoff, Harmeet Bedi,  
and Bianka Eperjesiova

## Abbreviations

APC	Argon plasma coagulation
ARDS	Acute respiratory distress syndrome
CT	Computed tomography
ED	Emergency department
EGCR	Esophagoglottal closure reflex
FB	Foreign body
GPA	Granulomatosis with polyangiitis
LES	Lower esophageal sphincter
Nd:YAG	Neodymium-doped yttrium aluminum garnet
NSC	National Safety Council
PDT	Photodynamic therapy
PGCR	Pharyngoglottal closure reflex
TEP	Tracheo-esophageal prosthesis
UES	Upper esophageal sphincter

## Introduction

Airway foreign body (FB) aspiration is defined by the presence of foreign material anywhere in the glottis and/or tracheobronchial tree, with or without airflow obstruction. One cannot discuss FB retrieval without mentioning the birth of interventional pulmonology (IP) and its pioneers. On March 30, 1897, using illuminated rigid esophagoscope with a mirror and rigid forceps, Dr. Gustav Killian performed the first documented FB retrieval from the right mainstem bronchus of a German farmer who had aspirated a small piece of pork bone while eating a soup [1]. This event marks the beginning of bronchoscopy and IP with Dr. Killian identified as the “Father of Bronchoscopy.”

The first FB retrieval performed in the USA was at Massachusetts General Hospital by Algernon Coolidge in 1898. Dr. Chevalier Jackson, following in Dr. Killian’s footsteps, continued to advance the technique of bronchoesophagoscopy and developed various instruments, including the first illuminating bronchoscope. For his work, he is credited as “Father of American Bronchoesophagology.” Like Gustav Killian, he was a renowned otolaryngologist. His collection of over 2000 foreign bodies that he retrieved over his career is still on display at the Mütter Museum in Philadelphia, Pennsylvania (USA).

---

M. Simoff (✉)  
Department of Pulmonary & Critical Care Medicine,  
Bronchoscopy and Interventional Pulmonology,  
Henry Ford Hospital, Wayne State University,  
Detroit, MI, USA  
e-mail: [Msimoff1@hfhs.org](mailto:Msimoff1@hfhs.org)

H. Bedi  
Stanford University, Stanford, CA, USA  
e-mail: [hbedi@stanford.edu](mailto:hbedi@stanford.edu)

B. Eperjesiova  
University of Florida, Health Shands Hospital System  
and VA, Gainesville, FL, USA

In this chapter, we will review various clinical aspects of airway FB aspiration and retrieval, including diagnostic and therapeutic techniques and considerations.

---

## **Anatomy and Physiology of Swallowing**

### **Upper Airway Embryological Development and Anatomy**

The development of the aerodigestive organs begins with the primitive foregut [2–5]. From onset, the glottal folds are present which represent the future vocal cords. Around the 6th–7th weeks during gestation, development of the epiglottis, aryepiglottic folds, false vocal cords, and laryngeal ventricles begins. The epiglottis arises from the hypobranchial eminence, which is also the precursor for the development of the tongue. The separation of these structures occurs around the seventh week. Eventually the larynx is formed as a result of the primitive foregut folding upon itself to create the laryngotracheal bud, which divides, and is responsible for the creation of the bronchopulmonary segments in the future. The fourth and sixth pharyngeal arches are responsible for the development of the laryngeal muscles and are innervated by branches of cranial nerve X. The intrinsic muscles of the larynx are supplied by the recurrent laryngeal nerve, while the superior laryngeal nerve supplies constrictors of the pharynx, cricothyroid, and levator palatini. Other supraglottic structures such as the pharyngeal walls, posterior one-third of the tongue, stylopharyngeus muscle are all supplied by the glossopharyngeal nerve. This nerve also provides sensory fibers to the mucosa of the oropharynx and palatine tonsils.

The esophagus is a muscular tubular structure that consists of two muscle layers: an inner circular layer and a longitudinal outer layer [6, 7]. The proximal esophagus is striated muscle, while the distal esophagus consists of smooth muscle. The upper esophageal sphincter (UES) forms the anatomic boundary where a zone of high pressure is generated between the pharynx and esophagus.

Pressure in this zone is generated primarily by the cricopharyngeal muscle, as well as the cervical esophagus and inferior pharyngeal constrictor. The UES receives innervation from the vagus nerve branches (pharyngoesophageal, superior laryngeal, and recurrent laryngeal nerves), the glossopharyngeal nerve, and sympathetic branches of the cervical cranial ganglion.

### **Functional Physiology of Swallowing**

The pharyngoesophageal interface is responsible for facilitating airway protection, deglutition with safe transport of proximal esophageal contents, and clearance of volume during swallowing and emesis. The laryngeal structures are responsible for accommodating the following three functions: phonation, ventilation, and airway protection. Swallowing is a complex series of motions that requires very coordinated voluntary and involuntary movements of the oropharynx, larynx, and esophagus. Swallowing can be divided into three different phases based on the relationship between the food bolus and anatomical structure: oral, pharyngeal, and esophageal [8–10].

*Oral Phase:* The oral phase can further be divided into the preparatory and early transfer phases. The preparatory phase consists of various oral movements such as chewing, suckling, and masticating. The aim of this phase is to break down food and mix it with saliva with the eventual goal of making a food bolus that can easily and safely be transported. The transfer phase initiates once a decision to swallow has been made. At this point, the tongue contracts against the hard palate which leads to a squeezing motion that moves the bolus toward the oropharynx through a chute created by the posterior tongue. Subsequently, the soft palate contracts superiorly to protect the nasopharynx from nasal regurgitation. Finally, the posterior tongue contracts against the palate and there is contraction of the posterior pharyngeal wall which allows the food bolus to pass in a one-way direction toward the pharynx [11–13].

*Pharyngeal Phase:* At the start of this phase, the nasopharynx is sealed off by the soft palate

and the oropharynx is sealed off by the tongue pressing against the palate. Pharyngeal constrictor muscles contract in a top to down motion to propel the bolus distally. Airway protection mechanisms are of the utmost importance during this phase as this is the time where airway aspiration is most likely to occur. The opening to the trachea is protected by vocal cord closure, which is supplemented by arytenoid closure. Additionally, the epiglottis then swings down to cover and protect the laryngeal vestibule. During the pharyngeal phase, the hyoid bone moves the larynx superiorly and anteriorly. The suprahyoid and thyrohyoid muscle contractions facilitate the movement of the hyoid bone. This mechanism helps move the larynx to a position that is distant from the path of the bolus. Finally, the UES is moved upwards by facilitation of the widening and shortening of the pharynx. This motion decreases the distance the bolus has to transfer and allows the esophagus to be an open position to accept the bolus. The estimated time for transfer of a bolus through the pharynx is 1 s, with an approximate speed of 40 cm/s [14, 15].

*Esophageal Phase:* Once the bolus enters the esophagus through an open and relaxed UES, a series of peristaltic waves occur to transport the bolus down the esophagus. There is an initial wave of relaxation that occurs at the location of the bolus, which is followed by a wave of contraction that propels the bolus distally. When in an upright position, gravity can assist in this movement. While a liquid bolus can move distally with just gravity, a solid requires peristaltic motion to advance it toward the stomach. As the bolus is propelled, the lower esophageal sphincter (LES) relaxes and allows for passage into the stomach. The estimated travel time through the esophagus is approximately five to 6 s.

## Upper Airway Protective Reflexes

Through the entire complex and well-coordinated process of swallowing, the human body has incorporated many involuntary mechanisms to protect the lungs from aspiration from birth until the end of life. The neuromuscular interface of

these reflexes is so robust that its protective nature works within the space shared by laryngeal and esophageal structures [5, 16].

*Laryngeal Adductor Reflex:* This reflex represents the best line of defense against pulmonary aspiration. Contraction of the lateral cricoarytenoid and interarytenoid muscle leads to adduction of the anterior and posterior aspects of the vocal cords, respectively. The vocalis and thyroarytenoid muscles, which make up the laryngeal tensors, assist with vocal cord closure during various physical activities. As already mentioned, additional protection is provided by descent of the epiglottis, arytenoid adduction, and laryngeal elevation.

*Esophagoglottal Closure Reflex (EGCR):* It is important to recognize that aspiration does not have to necessarily occur with anterograde movement of contents. Retrograde movement of gastric contents is a major cause of aspiration, especially in the elderly population. There are various causes of retrograde movement such as reflux, belching, regurgitation, and vomiting. The major stimulus for the EGCR is dilation and distention of the esophagus. The vagus nerve is responsible for the afferent innervation and impulse resultant from stretch of the esophagus. Impulses from this reflex result in efferent output to the glottal structures via the recurrent laryngeal nerve. Stimulation leads to vocal cord adduction.

*Pharyngoglottal Closure Reflex (PGCR):* It has been demonstrated that exposure of the pharynx to different quantities of instilled water leads to vocal cord adduction [17]. This adduction has a linear relationship to the amount of water instilled. There is also evidence that the elderly patients require significantly larger amounts of fluid volume to obtain PGCR in comparison to younger individuals. Similarly, larger volumes are required for stimulation in smokers compared to non-smokers [18].

*Upper Esophageal Sphincter (UES):* As mentioned above, the UES is the zone of pressure generated at the junction of the pharynx and esophagus, primarily influenced by the cricopharyngeal muscle. The pharyngeal constrictors and proximal esophagus also act as adjunct muscles



in generating tone. The UES is an additional safety measure in preventing retrograde movement of gastric and esophageal contents. It is mainly stimulated during esophageal distention and gastric reflux, especially when gastric contents reach the distal esophagus.

---

## Epidemiology and Risk Factors

Bronchoscopic FB retrieval accounts for 0.16–0.33% of all bronchoscopies [19]. Aspiration can occur at any age, but is most commonly found in young children and in the elderly. There tends to be a bimodal distribution for airway FB-associated death with peak incidences at less than 1 year of age and greater than 75 years of age. According to the National Safety Council (NSC) 2019 data, 2500 people died from choking; most, older than 75 years of age. The odds of dying from aspiration of food in the USA is approximately 1 in 3408 [20]. Choking and suffocation related to FB aspiration account for a great proportion of pediatric emergency department (ED) visits on an annual basis. According to the Centers for Disease Control and Prevention, ED visits for nonfatal injuries related to foreign bodies accounted for 371,000 visits in 2018 [21]. Overall, FB aspiration was the fourth leading cause of ED visits for children less than 5 years of age.

There does appear to be a gender bias for aspiration, with males being affected approximately twice as much as females [22–24]. While data is sparse in regard to the impact of geographical and cultural factors on FB aspiration in children, there does appear to be some relationship between the primary language spoken at home and the incidence of aspiration events [25]. In one study, children from non-English speaking households had a significantly higher incidence of foreign body aspiration, especially with nuts, compared to English speaking households. As the language spoken in a household is a surrogate marker for cultural background differences, this relationship can be more indicative of dietary-related variances (i.e. promotion of culture-specific diets with increased presence of nuts), but also cloth-

ing and cultural practice-related differences that exist among different ethnic groups. One example of such cultural risk factors is aspirated scarf pins in Iraqi females, also known as “Hijab syndrome,” retrieved mostly from left tracheobronchial tree [26].

Additional risk factors associated with FB aspiration are advanced age, sedative medications and illicit drug use, neurological disorders, cognitive impairment, trauma with loss of consciousness, dental care, alcohol use, tracheostomy [27].

---

## Types of Foreign Bodies

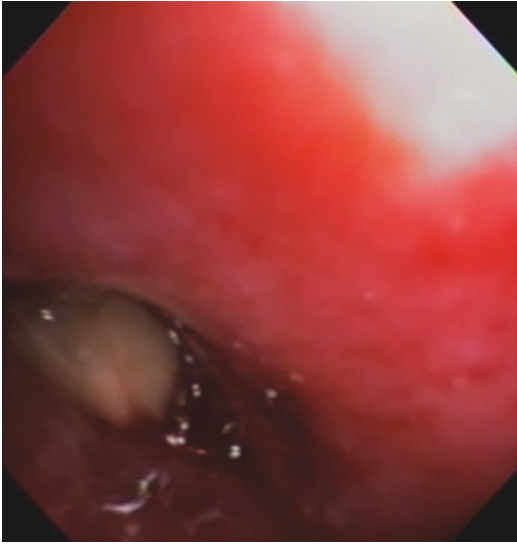
Any object or material that can fit in the oral cavity has the potential to cause airway obstruction. The most commonly aspirated foreign bodies are nuts, seeds, bones, and dental-related objects [22, 24, 28]. Foreign bodies can be divided into the following categories: organic, inorganic, mineral, and miscellaneous.

### Organic

As airway aspiration is usually a byproduct of malfunction of airway reflex mechanisms, one can expect aspiration of edibles to be the most likely offender. Organic material is responsible for the majority of airway FB aspiration cases. The most frequent types of organic aspirations result from nuts and seeds. The most common type of nut aspirated are usually peanuts (Fig. 40.1), but other varieties including: walnuts, almonds, and pistachios can also be seen. The most common seeds aspirated are sunflower seeds. Other types of aspirated organic material include popcorn, fruits, vegetables, and cereals.

### Inorganic

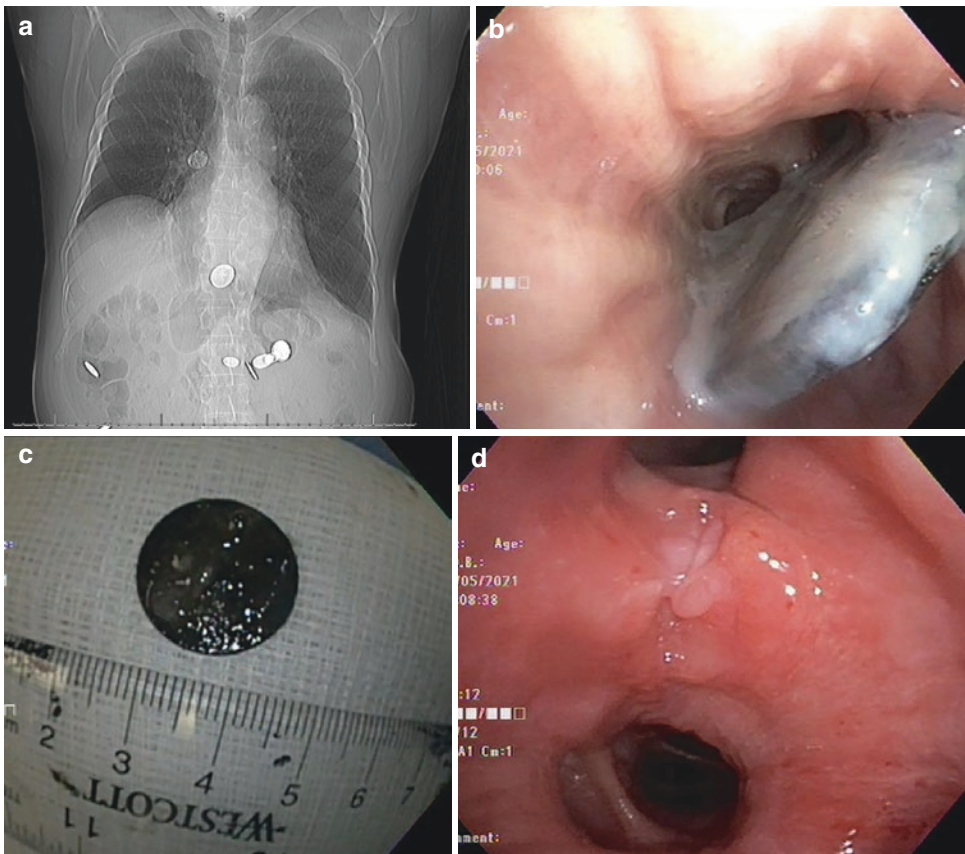
Inorganic material can be divided into metallic and plastic materials. Most often implicated metallic foreign bodies are different types of pins and coins (Fig. 40.2a–d). Other aspirated metallic foreign bodies include nails (Fig. 40.3a–c), jew-



**Fig. 40.1** Peanut identified in the left mainstem bronchus

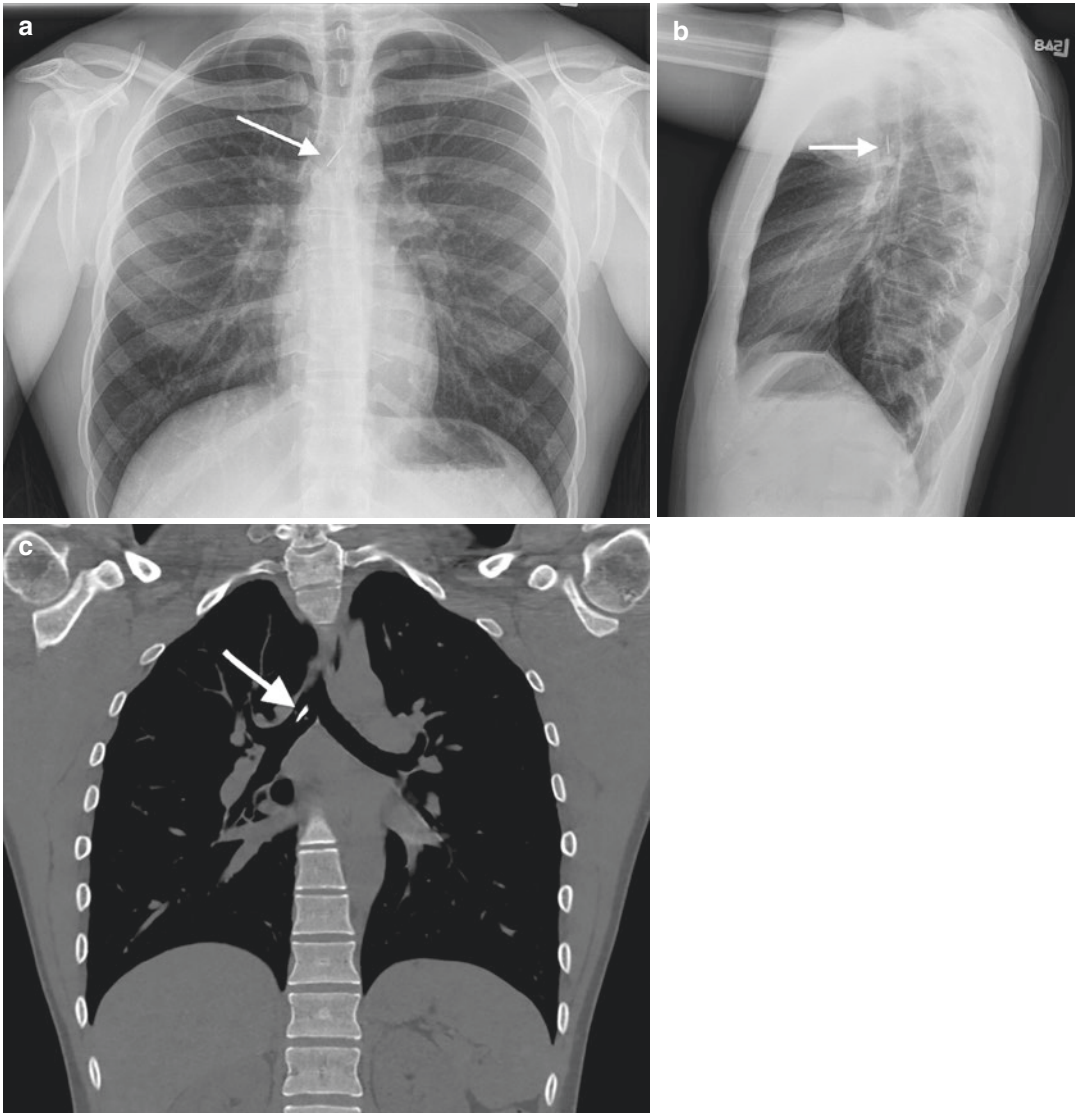
elery, and even wiring from undergarments (Fig. 40.4a–c). Plastic foreign bodies include medical-related devices such as broken endotracheal and tracheostomy tubes and their respective supplies (Fig. 40.5a, b), nasopharyngeal airways, intubating introducers, tracheoesophageal prosthesis (Fig. 40.6a, b), pill bottle caps (Fig. 40.7a–c), and drug delivery devices such as inhalers and inhaler caps. Thumbtacks (Fig. 40.8a, b), plastic toys, and pen caps are also relatively common [25, 28].

Dental-related appliances usually account for the most frequently aspirated objects after organic matter. Examples of dental-related appliances include bridges, porcelain or metal crowns (Fig. 40.9a–e), dentures, mouth guards, and fillings. There have been reports of aspiration of dentistry tools during procedures (Fig. 40.10) [29].



**Fig. 40.2** Aspirated coin. (a) Low dose CT/chest X-ray with multiple coins in right mainstem bronchus, distal esophagus, and intestine. (b) Coin in right mainstem bron-

chus, lodged against proximal right upper lobe. (c) Retrieved coin. (d) Endobronchial mucosa after coin retrieval



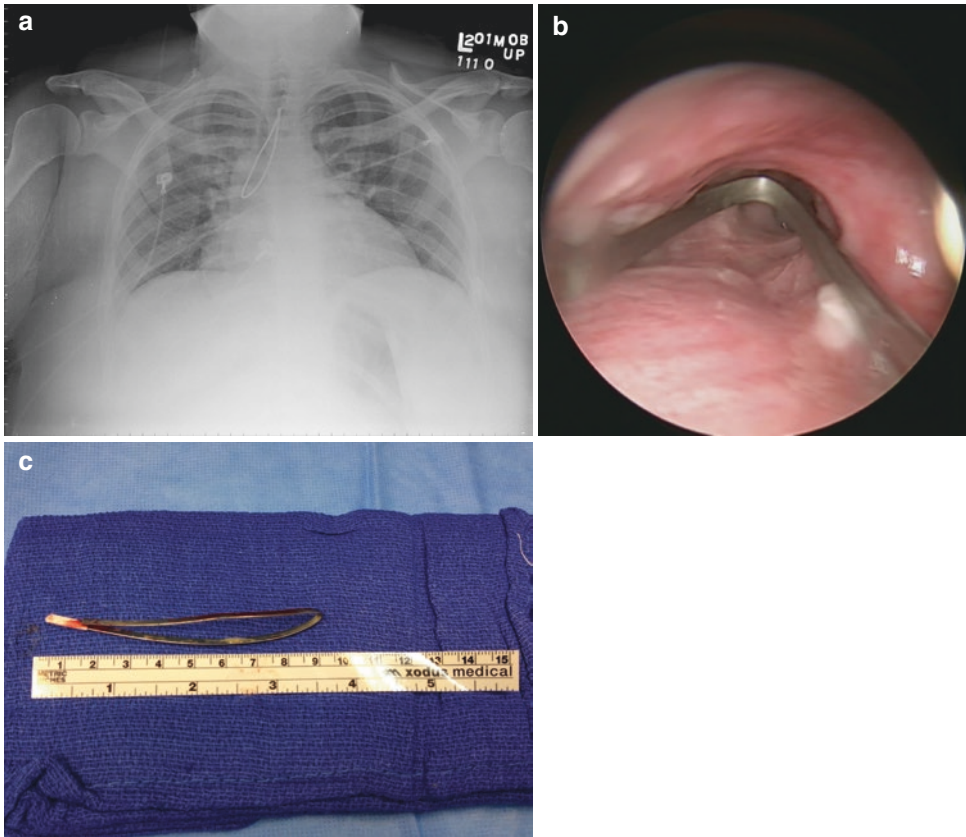
**Fig. 40.3** Metal nail aspirated into the distal trachea. White arrow points to the nail in each radiologic study. (a) Posterior–anterior chest plain film. (b) Lateral chest plain film. (c) Coronal CT chest

## Mineral

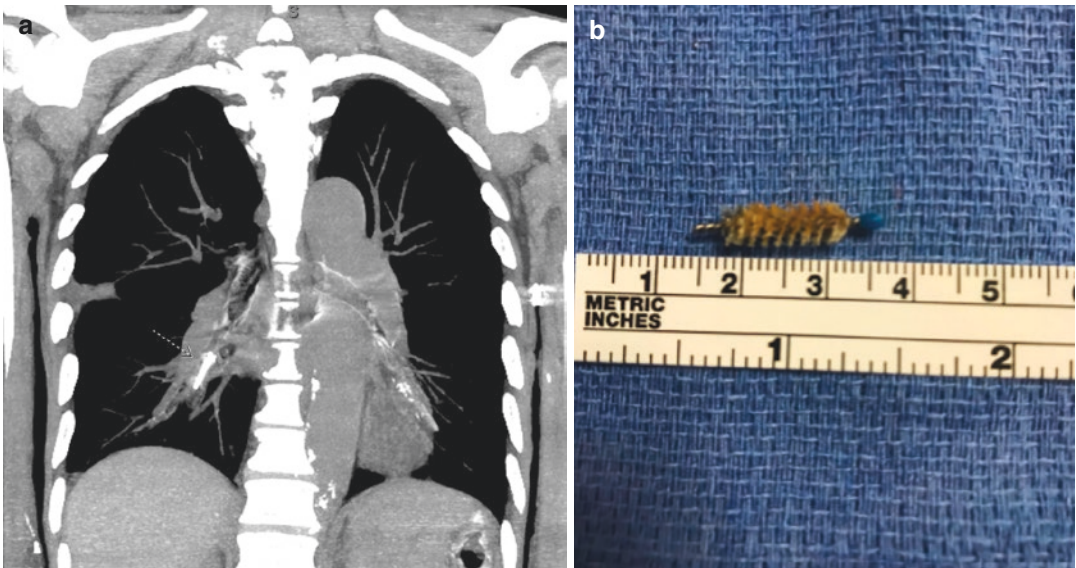
Aspiration of teeth comprises the majority of cases under mineral-related foreign bodies (Fig. 40.11). This can occur in relation to trauma, impaired airway reflexes (i.e. neurological disease), and during impaired states of consciousness (i.e. sleep, alcohol/drug intoxication, anesthesia, etc.). Bones from meats and fish are also reported to be aspirated. Another mineral

is glass, which can be from broken glass pipe fragments (used for inhalation of illicit drugs) and from motor vehicle accidents with shattered glass. It is important to understand that even endogenous substances can act as foreign bodies when they produce airflow obstruction with or without gas exchange abnormalities. As an example, broncholiths that have eroded into the intraluminal can act as foreign bodies (Fig. 40.12).

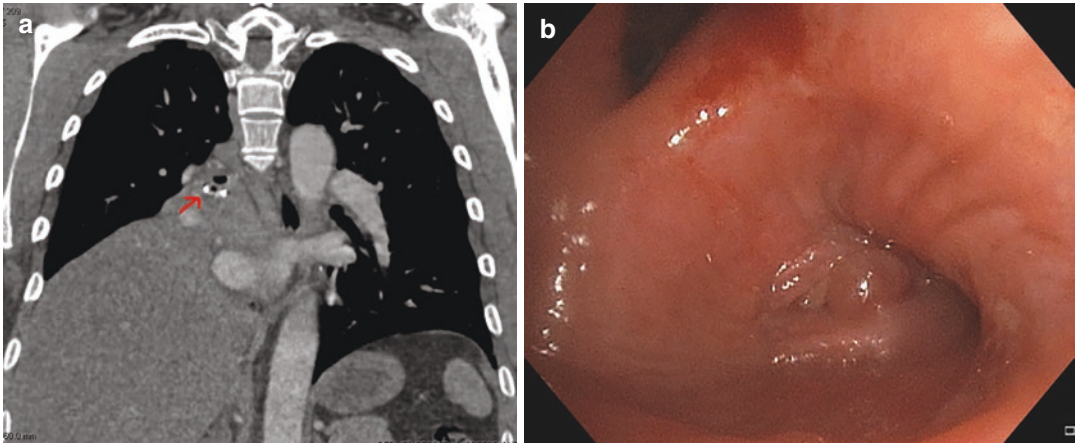




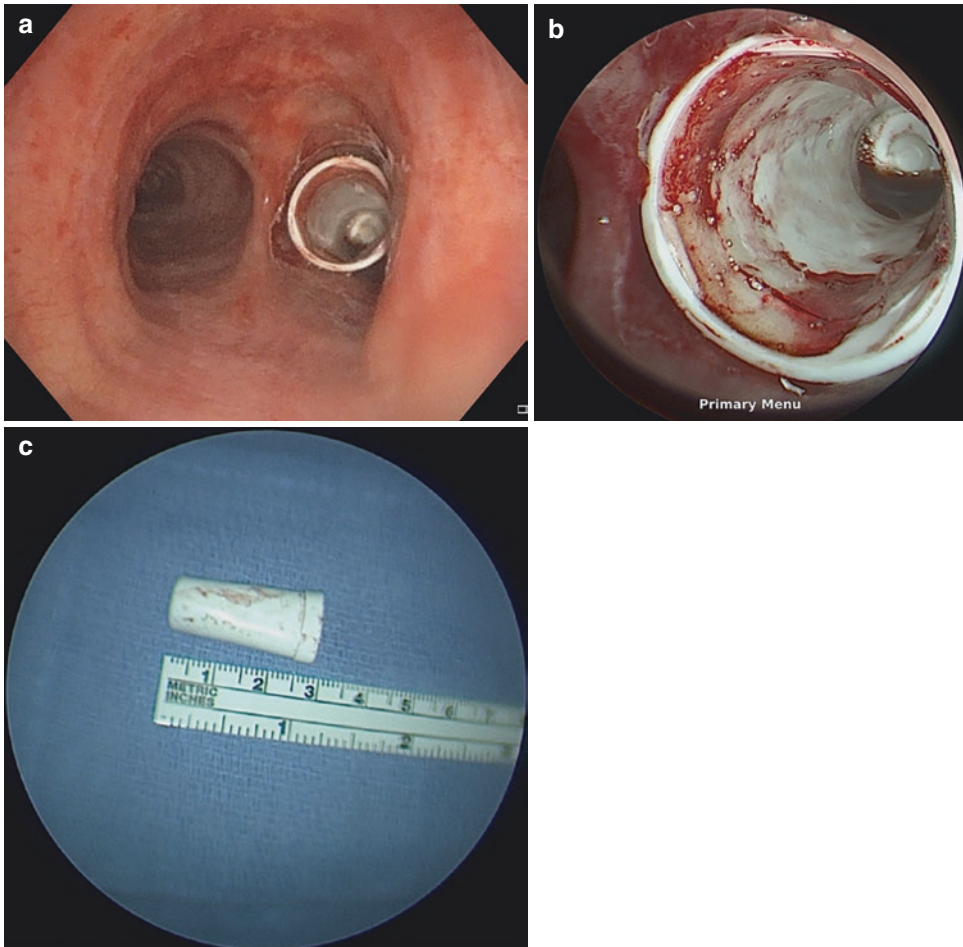
**Fig. 40.4** Wire from women’s bra aspirated into the trachea and right mainstem bronchus. (a) Posterior–anterior chest plain film. (b) Bra wiring seen in right mainstem bronchus and bronchus intermedius. (c) Bra wiring visualized after bronchoscopic removal



**Fig. 40.5** Tracheostomy cleaning brush. (a) CT chest with retained brush in right lower lobe. (b) Retrieved brush

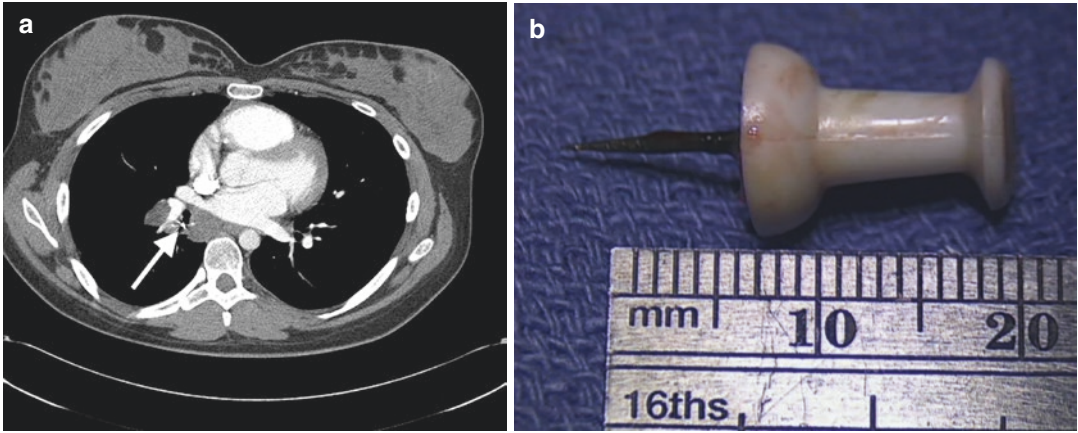


**Fig. 40.6** Tracheo-esophageal prosthesis (TEP). (a) CT chest with TEP device in bronchus intermedius causing collapse of right middle and lower lobes. (b) Granulation tissue chronically formed around TEP

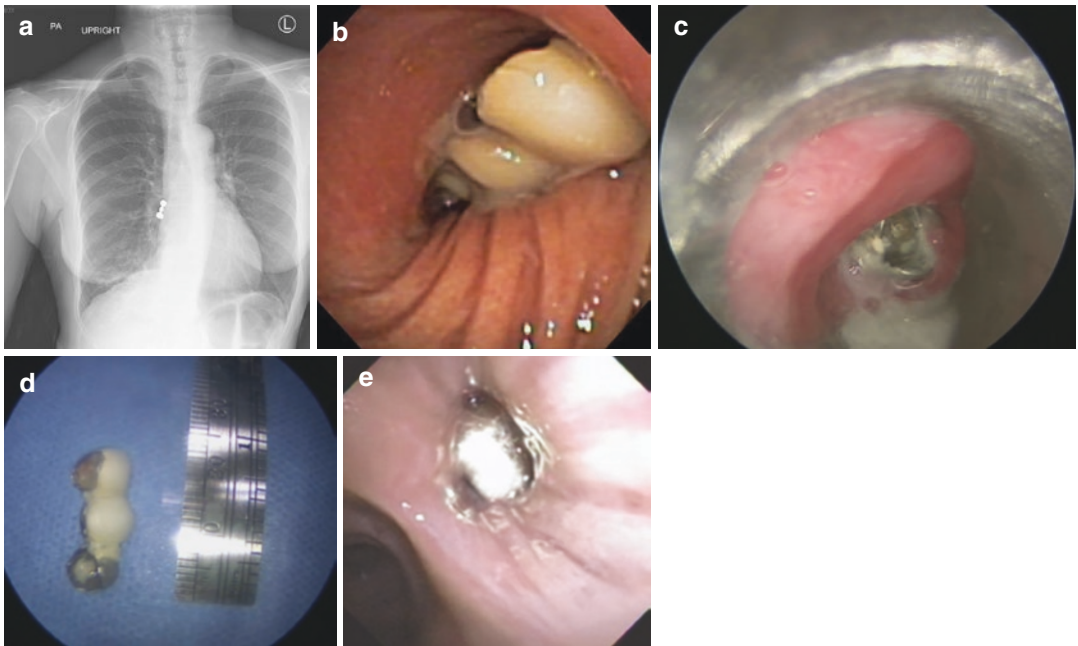


**Fig. 40.7** Azelastine bottle cap. (a) Bottle cap in right mainstem bronchus. (b) Close-up image of wedged bottle cap. (c) Bottle cap after retrieval





**Fig. 40.8** A thumbtack aspirated by a patient. (a) Axial CT scan with white arrow pointing to thumbtack in the right lower lobe bronchus. (b) Thumbtack after bronchoscopic retrieval

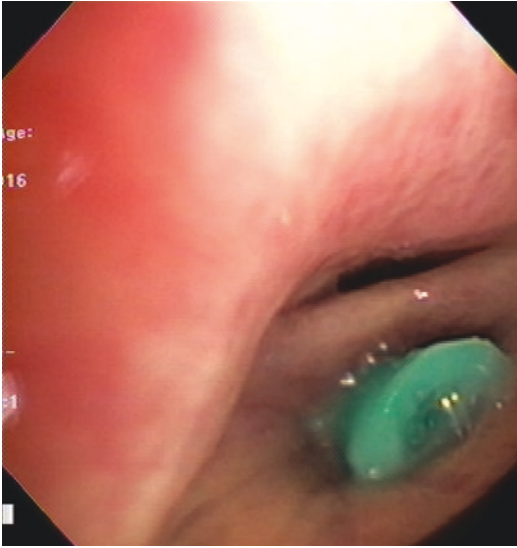


**Fig. 40.9** Types of dental appliances aspirated into the airway. (a) Chest X-ray of dentures in bronchus intermedius. (b) Dental bridge. (c) Dental bridge removal with rigid bronchoscope. (d) Retrieved dental bridge. (e) Gold dental crown

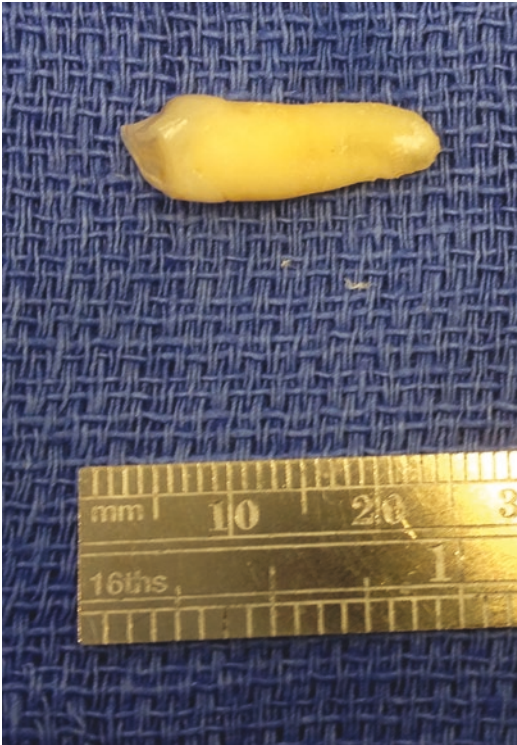**Miscellaneous**

*Pills and Capsules:* There are various factors that promote the aspiration of pills and capsules including (but not limited to) the motion of placing them into the oral cavity, the state of airway reflexes in the subject (i.e. neurological disease,

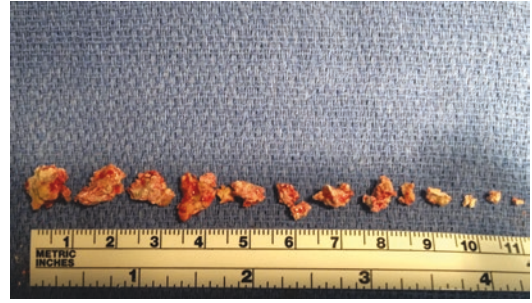
age, etc.), as well as the quantity and frequency of medication regimens which tend to be more prevalent in the elderly population. When evaluating pill aspiration, it is important to evaluate its obstructive properties, as well as its early and late inflammatory potential. Technically, any pill has the potential to be aspirated. There are well-



**Fig. 40.10** Right lower lobe obstructed by green plastic cylinder, part of a cleaning tool at a dentist office



**Fig. 40.11** Tooth that was aspirated and bronchoscopically retrieved



**Fig. 40.12** Multiple broncholiths retrieved from a single patient

known sequelae related to aspiration of specific medications such as iron supplementation, potassium preparations, and activated charcoal.

Iron pill aspiration is a well-recognized problem. Any medication containing ferrous sulfate ( $\text{FeSO}_4$ ), when aspirated, has a caustic effect on the bronchial mucosa secondary to its acidic pH (usually  $<3$ ). This leads to a local inflammatory cascade of effects including acute mucosal damage, which can lead to the formation of granulomas and fibrosis and eventually, airway stenosis [30–32]. Further specifics of iron pill aspiration will be discussed in-depth later in this chapter.

Potassium preparations are also very well associated with local inflammatory effects when aspirated. Of the potassium-based formulations, potassium chloride (KCL) is the most commonly aspirated preparation. Due to the hyperosmolar properties of KCL, it leads to mucosal irritation with additional erosive properties to the airway [33]. Similar to ferrous sulfate, late effects can result in airway stenosis. Enteric-coated KCL preparations take time to dissolve and may initially present with airway obstruction.

Activated charcoal is reported to be aspirated in approximately 2.3% of all patients receiving it for gastric emptying indications [34]. Although charcoal is biologically inert and non-absorbable, it is immunogenic, and that can cause a local inflammatory response within the airways. Bronchospasm, airway obstruction (due to inflammatory response), pneumonitis, and acute

respiratory distress syndrome (ARDS) have all been reported with charcoal aspiration [33].

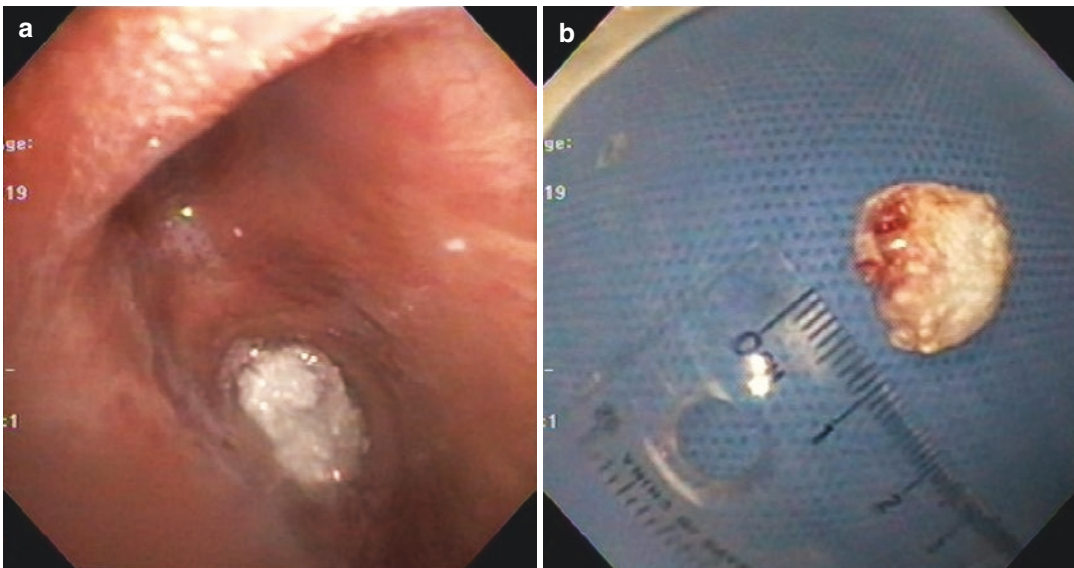
Other medications that are associated with similar inflammatory response include nortriptyline, metformin, pomegranate supplements, barium sulfate, magnesium oxide (Fig. 40.13a, b), and alendronate. While technically not a medication (but are administered similar to oral medications), endoscopic capsules (pill camera) used in diagnostic gastrointestinal evaluation have also been aspirated into the airway [35]. As endoscopic capsules are inorganic, they do not dissolve and act more as obstructive foreign bodies (Fig. 40.14a–d). While extremely rare, aspiration occurs more commonly in elderly patients, who may or may not have a history of swallowing dysfunction.

**Stents:** While airway stents are used in the treatment of airway obstruction, it is well known among bronchoscopists that stents migrate. Airway stent migration rates have been reported between 4.6% and 17% [36, 37]. Migration of airway stents can occur due to inappropriate choice of stent in relation to airway size, but can also be a result of successful treatment of the underlying etiology for stent requirement. For example, stents are deployed for the management of malignant central airway obstruction

and after successful treatment of tumor, there may be shrinkage or resolution of the initial malignant obstruction. The response to therapy may lead to stent migration because of the lack of airway support on the outer surface of the stent. Additionally, stents used for benign disease in conditions such as tracheal and bronchial stenosis, similar response to therapy and/or excessive coughing may lead to inadvertent stent migration. Airway stents are also known to promote bronchial secretions with the risk of developing airway obstruction due to tenacious secretions. While secretions are not foreign bodies, airway stents obstructed with mucus can present in a similar manner.

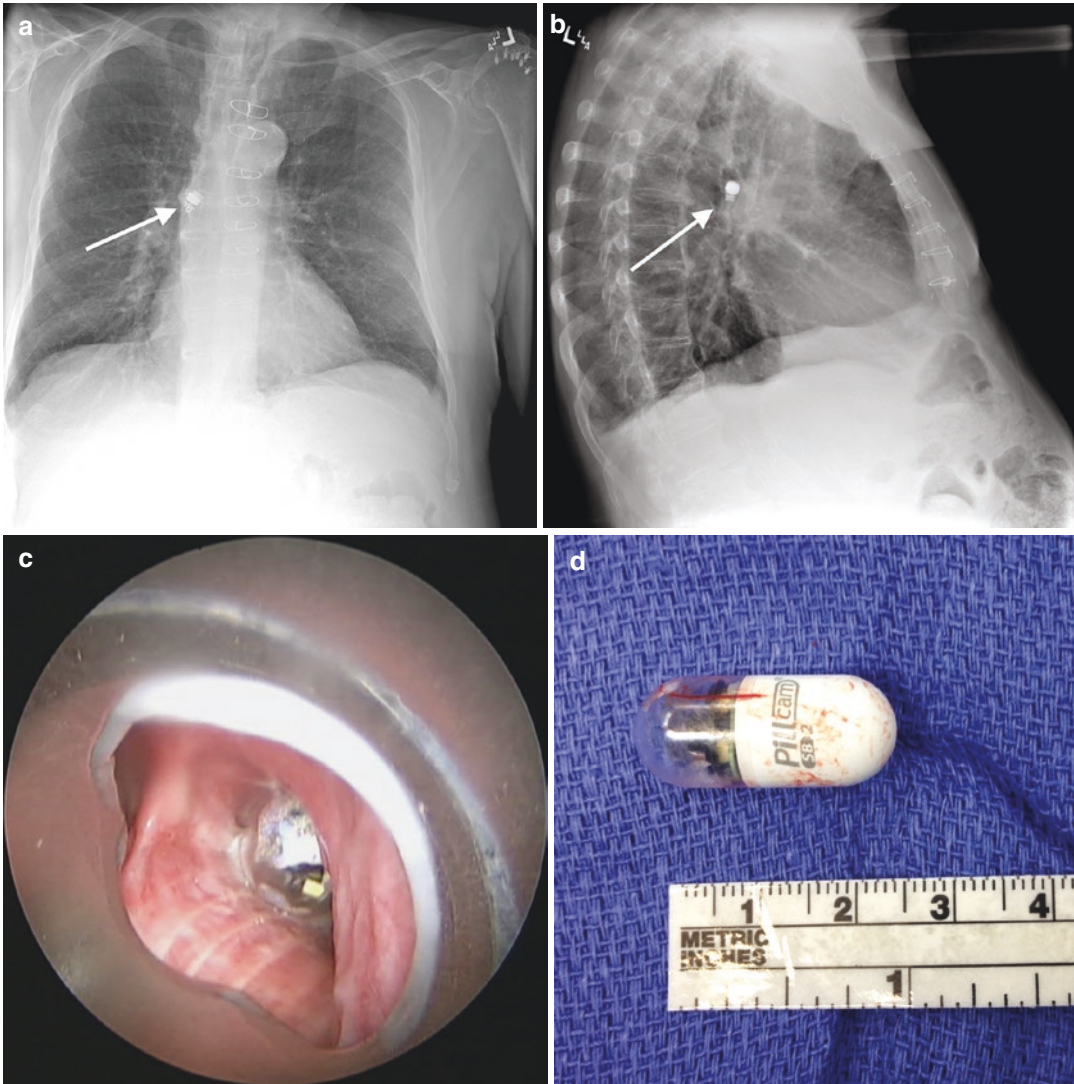
Esophageal stents have also been implicated in FB airway obstruction. Although esophageal stent migrations are associated with distal esophageal/gastric migrations [38], there have been reports of acute airway obstruction from proximal migration of esophageal stents with occlusion of the glottis [39]. There have also been case reports of esophageal stents migrating through the posterior membrane of the trachea leading to severe acute airway obstruction and asphyxiation [40].

**Photodynamic Therapy (PDT):** PDT is a photo-ablative therapy used as an adjunct treat-



**Fig. 40.13** Magnesium oxide pill (a) lodged in right lower lobe. (b) Pill after retrieval





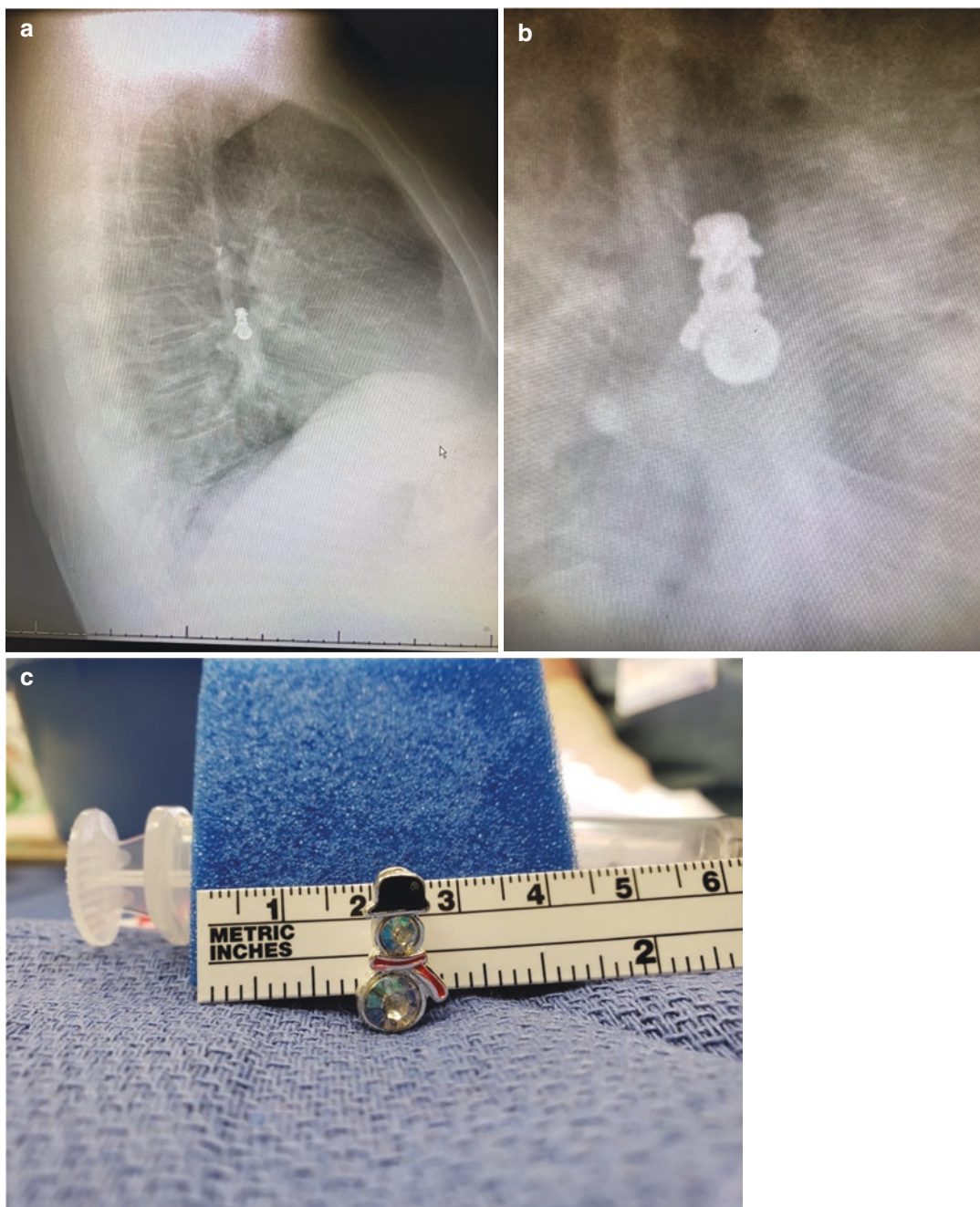
**Fig. 40.14** An aspirated endoscopic capsule (pill camera). White arrows are pointing toward the capsule in the radiologic studies. (a) Posterior–anterior chest plain film.

(b) Lateral chest plain film. (c) Bronchoscopic image of capsule in the right mainstem bronchus. (d) Endoscopic capsule after retrieval

ment of central airway NSCLC malignant disease not amenable to further standard treatment options. Routine practice is to perform a follow-up bronchoscopy 48–72 h post-procedure to clear necrotic debris induced by the therapy. In some instances, this debris can slough off and can obstruct the central airways. There have been reports of acute airway obstruction in the immediate hours after completion of PDT [41]. Similar to other incidences, tumor slough is typically not

thought of as a true FB, yet its clinical presentation mirrors that of other foreign bodies.

*Other Miscellaneous Foreign Bodies:* Other rare causes of FB aspiration include everyday world objects (Fig. 40.15a–c), erosion of grafted rib material during tracheoplasty, endobronchial suture material from bronchial stumps status post-lobectomy/pneumonectomy, Alloderm© patches and migrated gauze packing from nasal and oropharyngeal indications.



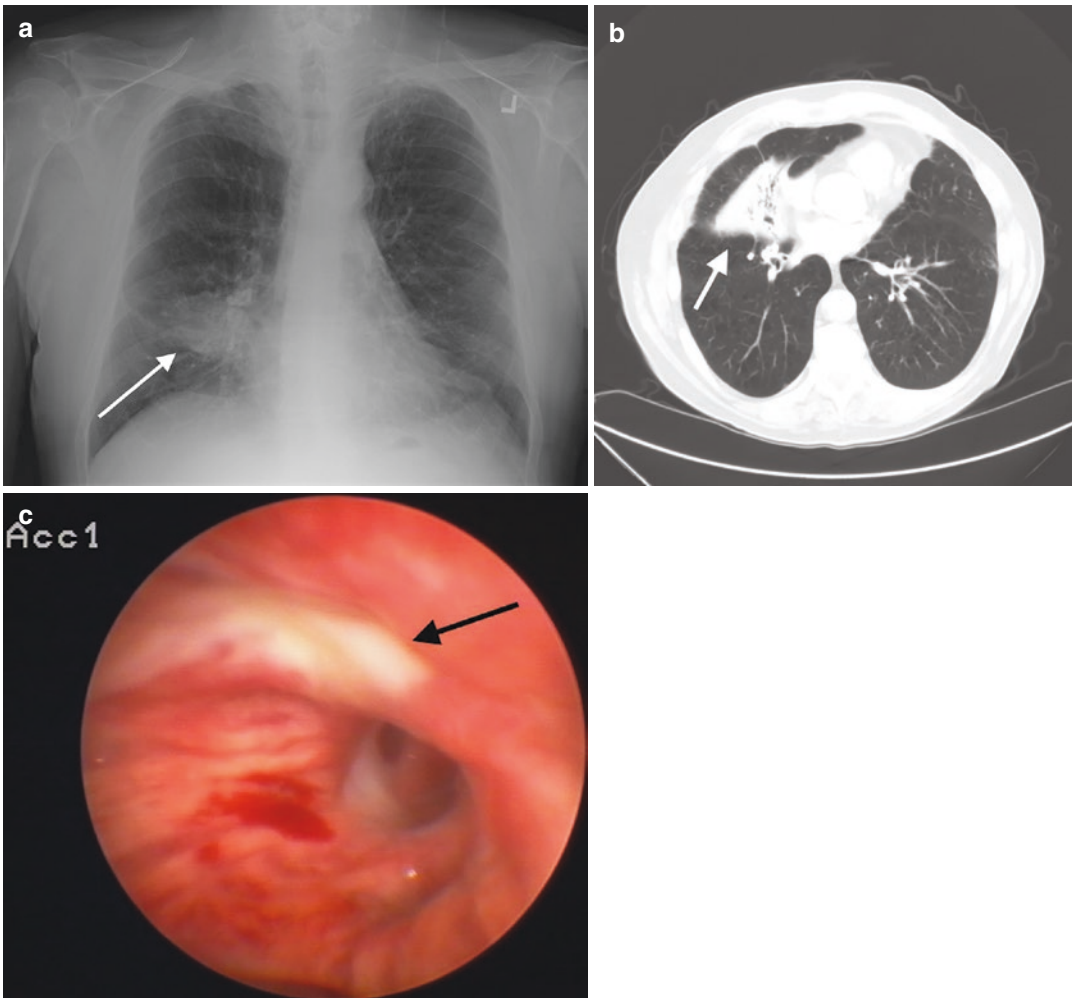
**Fig. 40.15** Snowman figure (a) in CXR lateral projection (b) zoomed in appearance of Snowman on CXR. (c) Snowman post-retrieval



## Clinical Presentation

Patients that aspirate an airway FB can have a wide array of presentations, ranging from being asymptomatic to immediate death. Patients typically present with one of two presentations: acute or symptoms related to a retained FB. Acute FBs are relatively early in the sequence of events, either immediately after the aspiration event or within hours/days often associated with minimal airway inflammation. Retained FBs are those cases where

the FB has initiated a significant airway inflammatory cascade with subsequent complications such as mucosal inflammation, granulation tissue, stenosis, or post-obstructive pneumonia (Fig. 40.16a–c). Patients with such cases tend to have presented in a relatively delayed manner (i.e. weeks, months, or years) or aspirated a FB known to be associated with mucosal inflammatory effects. While children commonly present in the acute time period, adults more commonly seek medical attention in a delayed manner [42].



**Fig. 40.16** Aspiration of vegetative matter leading to a retained foreign body presentation. White arrows are indicating air space consolidation in the right middle lobe. (a) Posterior–anterior chest plain film. (b) Axial CT chest. (c)

Bronchoscopy demonstrating right middle lobe bronchus occluded by a calcified lesion and granulation tissue. Endobronchial biopsy of this lesion revealed retained vegetative debris with surrounding mild inflammation

## Acute FB

Most patients in this population will seek and require medical attention in the immediate post-aspiration time period, often with a relatively inert FB. Patients will usually know exactly when the aspiration event occurred and what type of FB was aspirated. When the patient is unable to provide history, witnesses may provide information regarding the event. Depending on the type of FB, the size, the location of FB impaction, and the time taken to reach medical services, presentation can range from being asymptomatic to death. The most common presentation is cough (66.1%), choking (27%), dyspnea (26.6%), and fever (22.2%) [27]. Acute asphyxiation, also referred to as a *café coronary*, is more commonly found in children compared to adults [43]. Usually in these cases, the laryngotracheal region is obstructed by a relatively large FB.

Correctly identifying the risk factors, potential etiologies, and comorbidities will allow the interventional pulmonologist to plan their intervention carefully and completely to ensure that the best management plan is chosen for each patient. Physical examination findings will vary depending on the location of FB impaction. However, keep in mind, the initial symptoms are heavily reliant upon one's airway reflexes, and patients with blunted reflexes, from any cause, may not demonstrate these symptoms and/or findings.

When the laryngotracheal region is involved, choking, stridor, wheezing, dyspnea, and hoarseness of voice are commonly observed. Generally, inspiratory stridor occurs with obstruction of the larynx, while expiratory stridor occurs when the tracheobronchial tree is involved. As would be expected with an upper airway obstruction, cyanosis and/or cardiopulmonary decompensation can occur with prolonged hypoxia. Approximately one-third of patients with acute asphyxiation will have FB impaction at the level of the supraglottic region [44]. This said, the oral cavity must undergo a thorough evaluation in any presentation of aspiration to ensure that the FB or any remnants of it are not left behind.

With primary bronchial involvement, there is usually an initial choking event that is followed by dyspnea, wheezing, and usually coughing. Although less common, hemoptysis can also be a presenting symptom. More serious findings such as severe hypoxia can occur with complete main-stem bronchial obstruction. With more distal airway involvement, patients will usually have an initial choking event that is followed by a relatively symptom-free period. For such patients, the choking event may or not be followed by respiratory symptoms such as coughing, shortness of breath, or hemoptysis.

## Retained FB

A retained FB presentation is more common in the adult population. Seeking medical attention not uncommonly can be delayed by weeks or even months, and in some cases, years later. The hallmark in this population usually encompasses patients seeking medical attention for persistent respiratory symptoms due to the complications which develop because of retained foreign bodies such as chronic cough, shortness of breath, fever of unknown origin, recurrent hemoptysis, recurrent pulmonary infections, obstructive emphysema, bronchiectasis, bronchial stenosis, pleural effusion, bronchopleural fistula, pneumothorax, and pneumomediastinum [27]. The most common presenting symptom is chronic cough. A subset of patients may have a FB discovered as a consequence of clinical evaluation for suspected lung cancer because of concerning findings during a diagnostic work-up (i.e. radiologic findings, advanced age, constitutional symptoms, etc.).

As patients presenting with the symptoms of prolonged aspiration of a FB is not common in most practices, having a high index of suspicion is key to rapid diagnosis. The literature suggests that most adults with aspirations are unable to recall a choking episode in their history [22, 42]. This may be due to the size difference of foreign bodies in comparison to the adult airway, neurologic disease prevalence in this population, influ-

ence of medications and drugs, as well as adults in iatrogenic circumstances such as intensive care and anesthesia-related. To complicate obtaining a thorough history further, it is not uncommon to experience a transient choking event that is followed by a relatively asymptomatic period due to the distal migration of the FB. In addition to many adults' aversion to seeing a physician, this may lead many patients to delay seeking treatment until respiratory symptoms recur or become significantly bothersome.

## Radiologic Findings

While the sensitivity of plain films for visualizing radiopaque foreign bodies is notoriously low and is approximately 4–21% in the pediatric and adult populations [45–50], it is reasonable to start with plain films of the neck and chest because of their availability, ease of use, and cost. Associated radiographic changes for foreign bodies do tend to improve the sensitivity for plain films to above 70–85% [23, 24, 42, 51]. In evaluating plain films, it is important to evaluate two different aspects: direct visualization of FB (24.6%), and radiographic changes related to foreign body presence/impaction [19]. In acute FB aspiration event, air-trapping, atelectasis, volume loss with mediastinal shift, air-space opacities can be observed. Patients with retained FBs may have additional findings such as persistent or recurrent air space disease, presence of a mass, and/or a pleural effusion. Visualization of foreign bodies is inherently dependent upon size and material. Most foreign bodies tend to be organic material which tends to be radiolucent (Figs. 40.2a, 40.4a, and 40.15a), while inorganic metallic materials are radio-opaque. Once again, it is important to emphasize that one must have high index of suspicion in evaluation of this population and to understand how a FB's size and properties may have effects on plain film appearance. Interestingly, normal chest films may be noted in approximately 9–37% of adults and children [42, 43, 48, 52]. If foreign body aspiration is of high

concern and a normal plain film is encountered, computed tomography (CT) imaging should be obtained.

CT imaging of the chest and neck is considered to be the most sensitive method for imaging in suspected airway FB aspiration. CT imaging has many advantages over plain films such as the superior ability to define location, spatial relationship to important anatomic structures (i.e. vascular structures), and better definition of associated FB effects (Figs. 40.5a and 40.8a). Depending on the size of the FB, CT imaging also has the ability to identify radiolucent materials. Thin slice CT imaging may be preferred for identification of smaller foreign bodies and debris. The detection for airway foreign bodies is much greater with CT imaging than plain films, and CT imaging has been reported to have a sensitivity of 100% in this regard [51–53]. Additionally, in situations like these, CT imaging has the benefit of providing useful information that can assist bronchoscopists in their therapeutic approach to FB retrieval. It is important to note that false positives can occur with CT imaging due to mucus impaction.

## Bronchoscopy

Regardless of symptoms and radiology findings, bronchoscopy remains the gold standard for diagnosing FB aspiration. The decision to start with flexible versus rigid bronchoscopy will be discussed under the "Airway Management" section of this chapter. When performing bronchoscopy, it is of the utmost priority to perform a detailed airway exam of not only the central and segmental airways, but to also thoroughly assess the nasopharynx, oropharynx, and glottal structures. In examining the segmental airways, not only do the bronchopulmonary segments need to be evaluated, but complete examination of the most distal visible sub-segments needs to be performed to ensure that there is no distal impaction or residual debris. This is particularly important in the evaluation of smaller foreign bodies such as nuts, seeds,

and pills. It is unclear what the best approach to minimize tracheobronchial tree stenosis post-FB retrieval is, however, experimental bronchoalveolar lavage with lidocaine, epinephrine, and dexamethasone has been shown to decrease proinflammatory cytokines [54].

---

## Airway Management

### Rigid Vs. Flexible Bronchoscopy

Traditionally, the gold standard method for FB retrieval has been rigid bronchoscopy. This said, the decision to use rigid or flexible bronchoscopy depends significantly on institutional practices, operator experience, equipment availability, stability of the patient, and size of FB and potential injury it can cause to mucosa or vocal cords while being retrieved. The success rates for rigid bronchoscopy in retrieval of foreign bodies are reported between 95 and 100% [22, 23, 43], compared to flexible bronchoscopy which has reported rates of success between 61 and 90% [22, 42, 43, 55]. In our practice, we avoid viewing rigid and flexible bronchoscopy as mutually exclusive techniques, but more as valuable complementary tools. Each patient is unique and their clinical presentation should guide the selection of the best method for FB retrieval. Patient safety should always outweigh the bronchoscopist's personal preference and equipment availability. If rigid bronchoscopy is required for safe retrieval of a FB, then arrangements should be made for this to occur, including the transfer of a patient to a specialized center.

Flexible bronchoscopy has the benefit of not only acting as a diagnostic tool and aid in procedure planning but can also be used for therapeutic FB retrieval with various instruments that can be inserted through the working channel of the bronchoscope. It has the benefit of being able to be performed with moderate sedation. When using flexible bronchoscopy, a therapeutic bronchoscope with a working channel of 2.8–3.2 mm is recommended to allow passage of all available retrieval instruments. The transnasal route should be avoided as the nasal passage may be too nar-

row to allow passage of the retrieved FB with increased risk of losing the FB within these airways. In patients with upper airway/tracheal FBs, stridor, or respiratory failure, rigid bronchoscopy is the preferred tool because of its capability to protect the airway and maintain oxygenation and ventilation. Rigid bronchoscopy also allows the use of various specialty instruments that are designed for FB retrieval. Additionally, rigid bronchoscopy almost always uses a flexible bronchoscope through it, allowing many more options. In children, rigid bronchoscopy is almost always recommended as airway size limits ventilation when a flexible bronchoscope is used.

### Retrieval Procedure

As in any therapeutic procedure, preparation is of the utmost importance prior to onset of procedure. Always ensure that all potential equipment, personnel, and medications are available. Anticipation of complications is the best preventive strategy for such circumstances. Trendelenburg positioning can allow the FB to fall toward main airways if mobilized. When a central airway obstruction (i.e. trachea) is encountered, particularly in an unstable patient, consider distal advancement of the FB to allow for improved ventilation. Many FBs will have induced airway injury or stimulated certain inflammatory pathways. Blood, pus, and other secretions will often cover and/or surround the FB. Clear visualization of the FB is a priority and allows examination of various characteristics of the FB and the airways surrounding it, such as size, proximity to surrounding airways, and whether the FB is free-laying or adherent by granulation tissue and/or adhesions. Also, assess for the presence of surrounding inflammation, blood, and bleeding potential during FB manipulation. Topical epinephrine can be instilled in such circumstances to minimize bleeding.

Retained FBs have a higher potential for the development of associated granulation tissue and may require tissue resection in order to release the FB. Tissue debulking can be achieved mechanically or with ablative therapies (i.e. laser,

argon plasma coagulation, cryotherapy, and electrocautery). Before using laser, argon plasma coagulation (APC), or electrocautery, one must consider if the involved FB has combustible properties and if the patient can tolerate an inspired fraction of oxygen less than 40%.

The choice of which instrument to use for retrieval will depend on whether retrieval is being achieved with rigid and/or flexible bronchoscopy, instrument availability, location of FB (i.e. central or distal), and FB qualities (i.e. hard, soft, smooth, rough, sharp, size, etc.). FB repositioning may introduce different options for retrieval and instrument selection, but this always increases the risk of the FB moving more distally and out of reach or further injuring the airway. Retrieval instruments and their respective advantages and disadvantages are discussed in the next section. After the FB has been secured with the selected instrument(s), care must be taken while pulling out to ensure that the path of least resistance is taken not only in the airways, but also through a rigid scope or artificial airway. Request to hold ventilation from Anesthesia can help the FB to not be displaced distally while retrieving. If the FB is too large for the rigid scope or artificial airway, the FB attached to the retrieval instrument and airway device (i.e. rigid scope or endotracheal tube) may need to be removed in an en bloc fashion. This also applies to cases where the FB was lost in the airway device. Plans to re-establish airway immediately post-FB retrieval should be established prior to retrieval. Mucosal and vocal cord injury can occur during this process and bleeding may occur.

Once the FB is removed, distal airways must be assessed adequately to ensure there are not any additional foreign bodies or remnants that need removal. Also, assess the physical properties of the removed FB to identify if the FB was retrieved in a complete manner or if there is evidence of FB fracture suggesting the presence of retained pieces. In retained FB cases there may be evidence of secretion retention and/or post-obstructive pneumonia, with expulsion of purulent secretions from the distal airways. Our practice is to perform airway washings, using 10 mL aliquots of normal saline instilled sequen-

tially to remove small plugs which might have formed, assist with drainage of secretions, and ensure that no retained debris is left behind.

After completion of FB retrieval, a detailed airway exam in the region of the FB to assess for inflammation, granulation tissue, mucosal tear, and/or airway stenosis should be performed. Some of these injuries may need subsequent follow-up examinations to assess for progression.


## Instruments

### Grasping Forceps

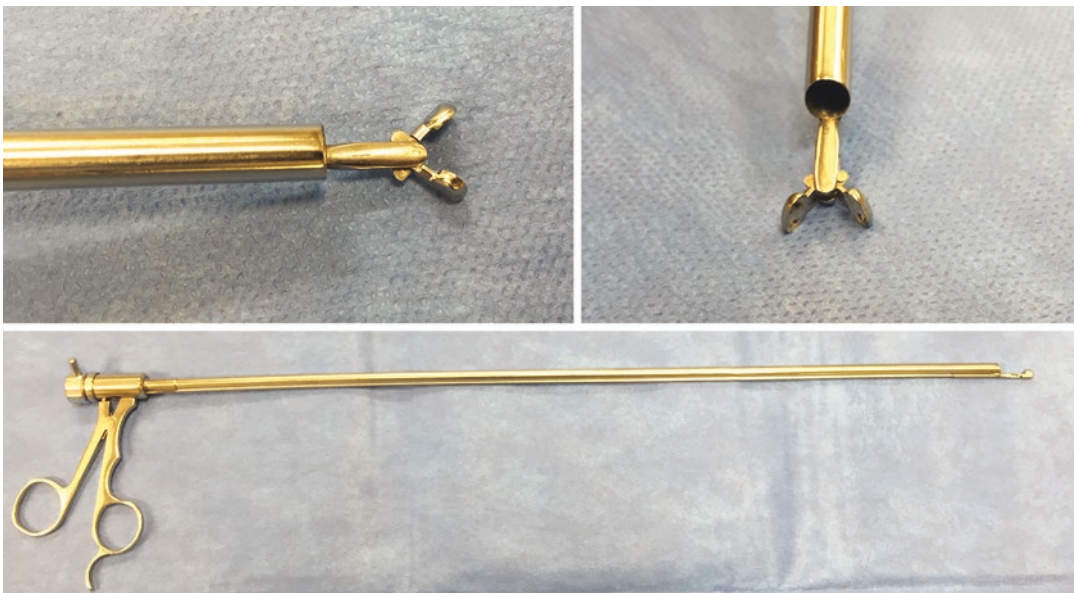
Grasping forceps represent the mainstay of FB retrieval because of their versatility, ease of use, and variety. Forceps are available for both rigid and flexible approaches. There are two primary forceps mechanism designs: single and dual action. In single-action forceps, one jaw of the forceps is stationary and in a fixed position, while the other jaw is movable. In dual-action forceps, there are two movable jaws that open symmetrically away from each other (i.e. alligator jaw forceps). There are a variety of jaw surfaces available with variances in serration size, number, and arrangement. Additionally, there are available variances in surface area, shapes, presence of a needle, and fenestrations. Some examples of different available forceps designs include curved, needle-forceps, rat-tooth, V-shape, and shark-tooth. Forceps can also have different coatings, such as latex and rubber, which can help with enhancing grip of specific FBs. Some rigid forceps have the capability to rotate upon their axis, which can allow for an easier approach (Fig. 40.17a, b). Rigid optical forceps are also available (Fig. 40.18). These forceps can be used in conjunction with a Hopkins telescope, which allows direct visualization when grasping FBs.

FB properties and location should determine the selection of forceps. The use of rigid forceps requires the FB to be directly in the pathway of the rigid tracheoscope/bronchoscope barrel. Distal FBs will often require the addition of a flexible bronchoscope and flexible forceps. When a FB is located in a confined space or is up against an airway wall, single-action forceps are consid-





**Fig. 40.17** Rigid forceps and graspers. (a) Variety of rigid forceps and graspers. (b) Close-up of jaws of different forceps that can be used for removal of foreign bodies



**Fig. 40.18** Rigid optical forceps. These forceps work in conjunction with the Hopkins telescope and allow for direct visualization during use


ered initially because the space required for jaw opening is less than dual-action forceps. Rattooth forceps have a configuration where the teeth of the jaws interlace with each other when closing, which make these useful in retrieval of softer FBs. Objects with flat surfaces such as coins and certain dental appliances are better grasped with V-shape and shark-tooth forceps (known for having a firm grip).

While technically not forceps, multi-pronged graspers serve FB retrieval in a similar manner


(Fig. 40.19). These graspers can have anywhere from three to five arms that open wide apart, usually to accommodate larger FBs. The tips of these arms come in different shapes, such as rings, to avoid mucosal trauma when opening them.

### Baskets

Baskets are essentially complex snares that contain two or more wires that are in a loop formation and can be tightened in order to “capture” a FB (Fig. 40.20). Use of retrieval baskets origi-



**Fig. 40.19** Flexible 3-pronged grasper



**Fig. 40.20** Boston Scientific Zero Tip™ Airway Retrieval Basket (Spencer, Indiana, USA)

nated in the field of gastroenterology, with it being the primary tool for removal of resected polyps. However, the use of baskets has spread to many other endoscopic and laparoscopic specialties for removal of various tissues and materials. While baskets are generally used in conjunction with flexible bronchoscopes, there are rigid varieties available. Baskets come in different sizes, number of wire loops, stiffness, and different tips. Some baskets have nets built into them to assist in retrieval of smaller material. Baskets are especially useful for airway FBs that are round or spherical in shape, as well as those that are smooth. Caution should be used in FBs that are

less solid or soft in nature, as retraction of wire loops can lead to unintended cutting of the FB into multiple smaller pieces.

### Balloons

Balloons used for airway dilation, embolectomies, and bronchial blockage purposes can also be used to assist in the removal of FBs indirectly. For distal FBs that are “wedged” or in a confined space that will not allow for instrumentation, the use of a balloon can be considered. The technique involves passing a balloon distal to the FB and then inflating it. By slowly retracting the balloon proximally, the FB can sometimes be dislodged and/or moved. The purpose of this maneuver is to allow for improved positioning of the FB giving the operator more retrieval options. Another use of a balloon is placing it distal to the FB to prevent migration into smaller airways during instrumentation or to have it available for inflation to facilitate rapid tamponade if removal of FB results in brisk bleeding. This technique usually requires use of rigid bronchoscopy to control multiple tools within the airways. Keep in mind that balloons should be avoided with sharp FBs as the pulling/dislodgement can lead to mucosal injury in addition to balloon rupture. Caution must be maintained when deciding to pass the balloon distal to the airway FB, as this maneuver does pose the risk of pushing the FB further into the airway.

### Suction Instruments

Particularly when a FB is sitting more freely within an airway, there are various methods to utilize suction during FB retrieval. Most simply, this can be accomplished directly with the flexible bronchoscope’s working channel and/or with the plastic or metal suction catheters used with rigid bronchoscopy. It is very important to acknowledge that despite its ease, this method does not allow for secure procurement of the FB during retrieval. Precautions must be taken during retrieval, especially, when the bronchoscope is used trans-orally without an artificial airway. It is possible for the FB to become loose and detached from the bronchoscope at any number of levels (i.e. vocal cords, hypopharynx, pharynx,

etc.). This may lead to the FB becoming obstructive in a more proximal or central location, such as the trachea, glottis, or supraglottic region. To prevent losing a FB during retrieval, a suction catheter can be utilized to retrieve the FB into proximal large airways, where forceps or basket can be used for removal from the airway. If loss of FB occurs in the upper airway and proximal to the vocal cords, direct laryngoscopy can be performed with the use of Magill forceps (Fig. 40.21) for retrieval of the lost FB. Loss of FB in the trachea can lead to cardiopulmonary decompensation and may require endotracheal intubation. In such cases, bronchoscopically advancing the FB distally into a mainstem may allow for improved ventilation and further stabilization of the patient.

Rigid bronchoscopy allows for the use of large caliber suction catheters. These catheters are specifically useful in suction of macerated and/or fragmented FBs such as medication pills and chewed edibles. Also, large-bore catheters are excellent for suctioning large volumes of blood, if massive hemoptysis occurs associated with the FB aspiration or its removal.

### Ablative Therapies

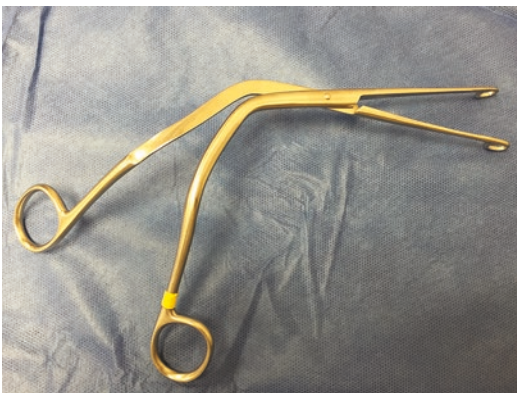While ablative therapies are routinely used for their tissue coagulative and destructive effects, they have a unique role in management of FBs. Granulation tissue is a common consequence of retained FBs and can make retrieval challenging. Ablative therapies such as laser, argon plasma coagulation (APC), and electrocautery are all

effective tools in destroying granulation tissue and allowing easier access to the FB. Cryotherapy is unique in that in addition to its ablative effects, it can directly be used for FB retrieval of organic material. Below, we discuss in-depth aspects of cryotherapy, laser therapy, and electrocautery/APC.

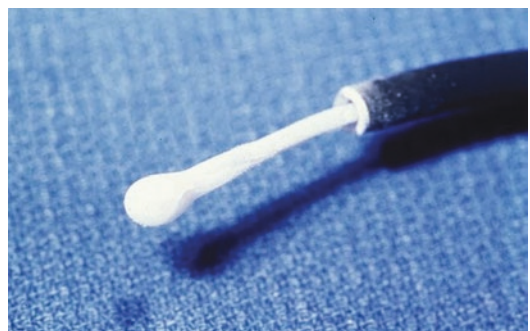### Cryotherapy

Cryotherapy is traditionally used for its destructive properties in the treatment of obstructive airway lesions, but it is also a very useful tool in specific cases of FB retrieval. The extremely cold temperatures produced by cryotherapy allow organic FBs to freeze and attach to the probe. Often these FBs can be removed without much difficulty adhered to the probe. Once the probe is in contact with the FB a freezing cycle is started. Once the ice ball is forming (Fig. 40.22), the FB should be attached to the probe (approximately 10–20). The operator must be very careful not to touch the airway wall while attempting to remove the FB, as the probe will stick to the wall also.

Cryotherapy can also be used to remove blood clots and mucus plugs from obstructed airways. Because of their water content, blood and mucus are excellent candidates for cryotherapy and are efficiently removed by placing the probe into the clot or plug, begin a freezing cycle, and slowly pull out with the bronchoscope. Mucus and blood casts of the tracheobronchial tree can be removed in an en bloc manner. Again, ensure that the probe does not touch the airway wall during this maneuver.



**Fig. 40.21** Magill forceps



**Fig. 40.22** Iron pill aspiration-induced bronchostenosis of the right lower lobe bronchus



Organic FBs such as vegetables, fruits, and meats (without bones) are excellent candidates for removal with cryotherapy. Medication pills are also often retrievable with cryotherapy. Objects without water content (i.e. metals, plastics, etc.) will not attach to the cryotherapy probe. Another technique reported in the literature that has been used in FBs without water content is instilling normal saline around the FB and then applying cryotherapy until ice forms around the object [56]. This allows for solidification of the normal saline and subsequent encasement of the FB. Cryotherapy can also be used in the resection of the associated granulation tissue caused by FBs.

### **Laser Therapy**

Laser therapy has three potential uses in the management of FBs: resection of granulation tissue, photocoagulation to minimize or treat bleeding, and intentional fracturing of FBs. As stated earlier, it is important to ensure that the FB in question is non-combustible and that the inspired fraction of oxygen concentration is less than 40%. Laser therapy can be performed with a variety of different types of lasers. Photodesiccation can be used to destroy granulation tissue obstructing the FB or attached to it when this tissue interferes with the removal of the FB. If mucosa in the vicinity is inflamed or demonstrates a significant bleeding potential during retrieval, photocoagulation techniques can be used to minimize mucosal bleeding prior to instrumentation. Laser has also been used to reduce the size of a FB, referring to a report of neodymium-doped yttrium aluminum garnet (Nd:YAG) being used to fracture a large broncholith into smaller fragments to allow retrieval [57]. In the GI literature, there is a case report of using laser to intentionally fracture a denture impacted in an esophagus to allow for successful retrieval [58].

### **Electrocautery and APC**

Electrocautery and APC are not tools used in FB retrieval; however, they can be used for those situations where granulation tissue has grown

around the FB, impeding retrieval. Before using, the bronchoscopist must know what the FB is and ensure that it is non-combustible. As in any case using thermal energy, the inspired fraction of oxygen concentration must be reduced below 40% during use. Electrocautery and APC can be used to resect granulation tissue with or without the FB attached and provide coagulation effects to the affected mucosa, limiting bleeding, which can negatively affect visualization.

### **Surgical Management**

Surgical intervention should be used as a last resort. Bronchoscopic retrieval is considered to be first-line therapy as it is minimally invasive, safe, and highly effective. However, there are a few indications that may warrant surgical resection for retained FBs. For distally impacted FBs that are not amenable to FB retrieval or were unable to be retrieved successfully, thoracic surgery consultation should be sought for consideration of surgical resection. Another indication is for deeply embedded FBs. These FBs usually represent retained FBs that may have been aspirated months or years earlier and can be associated with intense inflammation, infection, excessive granulation tissue, or fibrosis. If bronchoscopic retrieval is unsuccessful or considered to be high-risk for complications, surgical intervention should be considered.

Sharp foreign bodies may require surgical resection as they can be challenging to retrieve and pose risks such as mucosal tearing, airway perforation, and bleeding. Additionally, sharp FBs can be “wedged” or embedded into tissue, which can make retrieval more high-risk. Surgery may be considered for FBs that have penetrated the airway wall and are in contact with mediastinal or hilar structures/vessels. Bronchoscopic retrieval may lead to undesired communications and/or bleeding. Regardless, a multidisciplinary approach should be used as it is very valuable to provide the best plan of action for each patient with such circumstances.

## Complications

In the hands of experienced bronchoscopists, the complication rate for bronchoscopic intervention in children and adults is reported at less than 5%, with most studies indicating rates of less than 1%. Mortality from bronchoscopic FB retrieval is exceedingly rare and is reported as less than 0.1% [22, 24, 28, 43]. The most common complications associated with FB retrieval include mucosal injury, bleeding, and airway perforation. While extremely rare, post-obstructive pulmonary edema after FB retrieval and perforation which can lead to pneumothorax and/or pneumomediastinum can also occur. Perforations should be managed in a multidisciplinary fashion with interventional pulmonology, thoracic surgery, and/or otolaryngology involved.

## Bleeding and Hemoptysis

When patients present with hemoptysis due to FB aspiration, rigid bronchoscopy should be the modality of choice for retrieval. Rigid bronchoscopy allows for superior visualization, stabilization of airway, and better instrumentation options for bleeding and retrieval simultaneously. Remember, minor hemoptysis associated with FB aspiration may foreshadow more significant bleeding that can occur during retrieval.

Excessive bleeding during retrieval will likely occur in the setting of FB-associated perforation of the pulmonary or bronchial arterial circulation. Massive intraoperative bleeding during flexible bronchoscopic retrieval should lead to aborting the retrieval and stabilizing the patient emergently. In these cases, airway securement is of the utmost importance, whether it is with endotracheal mainstem intubation, balloon blockade of the bleeding airway, or rigid bronchoscopy. Adjunct therapies such as placing the patient in the lateral decubitus position (on side of bleeding) or sedation/paralytics to control coughing can also be utilized. In sub-massive bleeding with relative patient stability, a bronchial blocker balloon may be used in conjunction with securing the airway.

For minor intra-procedure bleeding, topical epinephrine mixed with normal saline (1:10,000 concentration) can be instilled as 2 mL aliquots delivered over the affected area. Keep in mind to avoid topical epinephrine in patients that are elderly or have a history of arrhythmias, carcinoid tumors, and coronary artery disease. Laser therapy, electrocautery, or APC can be used to photocoagulate mucosal irregularities when friable mucosa is observed or bleeding is expected, prior to proceeding with FB retrieval or afterward in the appropriate clinical situations. When bleeding originates from a FB in a distal segmental airway, consider wedging the bronchoscope in the affected airway for 2–5 min to promote clot formation. While technically, clotting time for human blood ranges from 5 to 15 min [59] and bleeding time ranges from 1 to 3 min [60], our recommendations are to first wedge bronchoscope for 2 min and then reassess. If bleeding persists, then to re-wedge for 4 min and then reassess. Another technique that can be utilized is wedging the bronchoscope into the affected airway and instilling iced saline, which promotes vasoconstriction and applies pressure to the airway mucosa to decrease bleeding, but could affect FB position.

## Distal Airway Impaction

Smaller FBs have a tendency to migrate into segmental and subsegmental airways. Impaction of these FBs can occur because of specific FB properties such as their texture and shape. Additionally, impaction may occur as a result of a weak cough reflex or anatomic variations, which may not be conducive to proximal movement of the FB. As always, care must be taken with retrieving sharp FBs. Prior to retrieval, it is important to assess the FB and its relationship to the airway to explain the cause of impaction. Always try to identify the point of maximal resistance and points of contact that may pose risks for airway trauma during retrieval.

Flexible bronchoscopy is best for these situations because of the ability to navigate and enter distal airways. We recommend using flexible



bronchoscopy in combination with a rigid bronchoscope for these situations. Having a secure airway allows for easy exchange of different types of bronchoscopes (pediatric, diagnostic, and therapeutic scopes) and provides a safe environment for unexpected bleeding. Because flexible bronchoscopy is the only modality that can reach distal airways, flexible instruments are used via the working channel of the bronchoscope.

The aim of retrieval in these circumstances is to remove the FB in the path of least resistance with minimal injury to the airway wall and/or displace the FB to a location (i.e. central airway) where retrieval is more feasible. While each FB and patient present with its unique challenges, the following represents general principles that should be considered during retrieval. Topical epinephrine (as previously described) is very useful in minimizing bleeding during the actual removal process. When feasible, the FB should be removed with protection over the sharp aspect of the FB and in a manner to prevent chances of dropping it. This can be achieved by grasping the FB from the sharp edge or by repositioning the FB with the aim of moving the sharp edge to the middle of the lumen. As mentioned earlier, distal positioning of a balloon and inflation can help pull impacted FBs proximally into a more ideal retrieval location when it does not pose the risk of pushing the FB into a worse position during balloon placement. Pulling FBs too proximally is actually undesired, as the FB may move excessively while you are trying to grasp it with forceps. To achieve good control, there must be some resistance to the FB while grasping it. Preferably, you should place it up against a wall which can simplify this process. Remember that for simultaneous use of a balloon and flexible bronchoscope, rigid bronchoscopy is recommended. A distally placed balloon can also act as a safeguard to prevent further distal migration of the FB during manipulation and instrumentation, but you need to get it past the FB without dislodging it. The appropriate size balloon should be used also to minimize risk of over-dilation of such relatively small diameter airways which could lead to inadvertent tearing and bleeding.

A small caliber bronchoscope can also be used as an instrument for retrieval. If the bronchoscope can be passed distally to the impacted FB, flexion of the distal end of the scope can be used to displace or move the FB proximally. This technique should not be used with any FB that may pose danger or damage to the scope. As stated earlier, if granulation tissue is contributing to the impaction, ablative techniques can be utilized to resect the tissue to detach or “loosen” the FB from the airway wall and allow retrieval.

### Iron Pill Aspiration

In this section we will discuss iron pill aspiration, as from our experience and from various case reports, it is well known to be associated with severe airway injury when aspirated. Iron supplementation comes in three different formulations: ferrous sulfate, ferrous gluconate, and ferrous fumarate. Ferrous sulfate is the most common preparation used by patients. Its caustic properties are a direct result of its acidic pH (<3) when dissolved [32] and mixed with bronchial secretions. Consequences of exposure to airway mucosa include intense acute and chronic inflammation, granuloma formation, and eventual fibrosis and bronchostenosis. Radiologically, patients present with findings consistent with sequelae of retained FBs and airway obstruction such as recurrent pneumonias and atelectasis.

Interestingly, on bronchoscopic examination, iron pills are almost never visualized as they are known to rapidly fragment. Endobronchial biopsy of affected mucosa usually will show iron deposition when stained with Prussian blue stain with associated inflammation (acute and/or chronic). These findings have been reported even 1 year after the initial pill aspiration event [30]. Also, bronchial washings may demonstrate reactive epithelial cells and histiocytes which may stain positive for iron also. In the relatively acute period, bronchoscopic exam may yield a green-brown coating over the bronchial mucosa which represents necrotic debris [33]. A history of pill aspiration and intense bronchial inflammation should raise suspicion for iron formulation aspi-

ration. In our experience, iron pill aspiration is notorious for its sequelae of bronchial inflammation and recurrent stenosis which is relatively difficult to manage.

Iron pill aspiration-related bronchostenosis behaves very similarly to severe autoimmune inflammatory disorders such as granulomatosis with polyangiitis (GPA, formerly known as Wegener's disease) and sarcoidosis. Bronchostenosis can be severe to the point where lobar/segmental collapse may develop with/without post-obstructive pneumonia. In our practice, we treat iron pill-associated bronchostenosis with balloon bronchoplasty and resection of necrotic tissue. These cases always require surveillance bronchoscopies to assess for recurrent bronchostenosis, which is common, and need for repeat therapeutic interventions. There are case reports of topical mitomycin C, a chemotherapeutic agent, used in conjunction with balloon bronchoplasty and treatment of such bronchostenosis cases [30, 31]. Mitomycin can be applied with a concentration of 0.2 mg/mL to the affected area for a total duration of 5 min. In severe cases of recurrent airway obstruction, an airway stent may be considered. From our experience, iron pill-induced bronchostenosis does resolve, but usually requires three to five interventions.

---

## Follow-Up and Sequelae

Historically, the mortality related to foreign bodies in the nineteenth century was estimated to be 23%; however, this changed profoundly with the advent of bronchoscopy with literature now suggesting mortality in FB aspiration cases seeking medical help to be less than 1% [24, 27, 61, 62]. Over the past century, further advances in medicine, diagnostic and therapeutic bronchoscopy have drastically improved the morbidity and mortality attributed to this condition.

The majority of acute FB retrieval cases with minimal signs of airway injury do not require any subsequent diagnostic interventions (i.e. bronchoscopy, imaging, etc.). Associated mucosal inflammation from FB aspiration is common and is expected to resolve in a majority of cases.

While literature is lacking, we recommend follow-up bronchoscopy in certain circumstances for acute FB cases. When severe airway inflammation, endobronchial obstruction from associated granulation tissue, or stenosis is encountered, it is our practice to perform a follow-up bronchoscopy 4–6 weeks later to assess for resolution or progression of findings. It is important to recognize that severe inflammation from a relatively acute FB may foreshadow undesired sequelae to occur, similar to other benign inflammatory airway disorders.

Unlike acute FBs, chronic/retained FBs are almost always associated with inflammation, infection, granulation tissue, fibrosis, or some degree of stenosis. For these cases, our practice is to routinely perform a follow-up bronchoscopy 4–6 weeks after retrieval. Some of these cases may require further interventions similar to other benign airway disorders (i.e. balloon dilation, tissue resection, etc.). Subsequent follow-up bronchoscopies should be determined on a case-to-case basis. Patients with retained FBs in segmental or subsegmental airways may have associated atelectasis and/or chronic regional changes (i.e. fibrosis, bronchiectasis, scarring, etc.). These changes do not require routine follow-up and should be assessed on a case-to-case basis.

Iatrogenic airway injury from retrieval should be followed up with a follow-up bronchoscopy on a case-to-case basis. Small mucosal injury/tears can occur during retrieval and may not require any further escalation. As mentioned above, larger tears and/or perforations may require intervention and should be followed up with a bronchoscopic exam and preferably in a multidisciplinary manner with thoracic surgery and/or otolaryngology consultation. If after FB retrieval, the patient fails to improve as expected from a symptom standpoint or an infection occurs in the previous FB-involved region, one must consider if there is a retained FB that was not visualized during bronchoscopic retrieval. If there is any doubt, repeat CT imaging (preferably thin cut, high-resolution) with a follow-up bronchoscopy to assess for retained fragments, additional FB presence, or subsequent unexpected changes in the airway from the initial FB.

## Conclusion

While airway FB aspiration and retrieval are less commonly encountered and vary from center to center, it does, however, represent the origins of interventional pulmonology and bronchoscopy. In the hands of well-trained bronchoscopists, bronchoscopic FB retrieval represents the gold standard treatment for airway FBs. Rigid and/or flexible bronchoscopy combined with a vast arsenal of available instruments allows for various approaches and therapeutics not only for retrieval but for its associated complications.

Retained FBs are a very important subset of patients, as this population commonly presents with nonspecific respiratory complaints secondary to the FB-associated inflammatory cascade and its sequelae such as airway inflammation, granulation tissue, airway stenosis, and/or post-obstructive pneumonia. A high level of suspicion must be maintained to avoid misdiagnosis and/or delay in treatment. Clinical presentation, FB location, and/or presence of inflammatory sequelae should guide the bronchoscopist on the selection of the bronchoscopic approach (rigid and/or flexible bronchoscopy). Regardless, adequate training and knowledge are required not only to successfully perform bronchoscopic retrieval but also to competently manage all possible complications. When encountering a high-risk patient or a complication from retrieval, a multidisciplinary approach involving interventional pulmonology, otolaryngology, and/or thoracic surgery should be applied to formulate the best plan of action for each patient.

## References

- Zollner F, Gustav Killian. *Arch Otolaryngol*. 1965;82(6):656–9.
- Sadler T. *Special embryology, respiratory system*. 7th ed. Baltimore: Williams and Wilkins; 1995. p. 232–71.
- Mansfield L. Embryonic origins of the relation of gastro-esophageal reflux disease and airway disease. *Am J Med*. 2001;111(Suppl 8A):3S–7S.
- Miller J, Sonies B, Macedonia C. Emergence of oropharyngeal, laryngeal and swallowing activity in the developing fetal upper aerodigestive tract: an ultrasound evaluation. *Early Hum Dev*. 2003;71:61–87.
- Jadcherla S, Hogan W, Shaker R. Physiology and pathophysiology of glottic reflexes and pulmonary aspiration: from neonates to adults. *Semin Respir Crit Care Med*. 2010;31(05):554–60.
- Lang I, Shaker R. Anatomy and physiology of the upper esophageal sphincter. *Am J Med*. 1997;103(5A):50–5.
- Goyal R, Sivarao D. *The esophagus*. 3rd ed; 1999. p. 1–31.
- Matsuo K, Palmer JB. Anatomy and physiology of feeding and swallowing: normal and abnormal. *Phys Med Rehabil Clin N Am*. 2008;19(4):691–707.
- Dodds W, Steward E, Logemann J. Physiology and radiology of the normal oral and pharyngeal phases of swallowing. *Am J Roentgenol*. 1990;154(5):953–63.
- Logemann J. *Evaluation and treatment of swallowing disorders*. 2nd ed. Austin, TX: Pro-Ed; 1998.
- Palmer J, Rudin N, Lara G, Crompton A. Coordination of mastication and swallowing. *Dysphagia*. 1992;7(4):187–200.
- Hiiemae K, Palmer J. Food transport and bolus formation during complete feeding sequences on foods of different initial consistency. *Dysphagia*. 1999;14(1):31–42.
- Dua K, Ren J, Bardan E, Xie P, Shaker R. Coordination of deglutitive glottal function and pharyngeal bolus transit during normal eating. *Gastroenterology*. 1997;112(1):73–83.
- Shaker R, Dodds W, Dantas R, Hogan W, Arnodorfer R. Coordination of deglutitive glottic closure with oropharyngeal swallowing. *Gastroenterology*. 1990;98(6):1478–84.
- Ohmae Y, Logemann J, Kaiser P, Hanson D, Kahrilas P. Timing of glottic closure during normal swallow. *Head Neck*. 1995;17(5):394–402.
- Shaker R, Dodds W, Ren J, Hogan W. Esophagoglottal closure reflex: a mechanism of airway protection. *Gastroenterology*. 1992;102:857–61.
- Shaker R, Ren J, Bardan E, Easterling C. Pharyngoglottal closure reflex: characterization in healthy young, elderly and dysphagic patients with predeglutitive aspiration. *Gerontology*. 2003;49:12–20.
- Dua K, Bardan E, Ren J, Sui Z, Shaker R. Effect of chronic and acute cigarette smoking on the pharyngoglottal closure reflex. *Gut*. 2002;51:771–5.
- Sehgal IS, Dhooira S, Ram B, Singh N, Aggarwal AN, Gupta D, et al. Foreign body inhalation in the adult population: experience of 25,998 bronchoscopies and systematic review of the literature. *Respir Care*. 2015;60(10):1438–48.
- Council NS. *Principal types of public preventable-injury-related deaths, United States 2019*. 2020.
- Prevention CfDca. *National Hospital Ambulatory Medical Care Survey: 2018 Emergency Department Summary Tables*. 2019.
- Limper AH, Prakash UB. Tracheobronchial foreign bodies in adults. *Ann Intern Med*. 1990;112(8):604–9.

23. Debeljak A, Sorli J, Music E, Kecelj P. Bronchoscopic removal of foreign bodies in adults: experience with 62 patients from 1974-1998. *Eur Respir J*. 1999;14(4):792-5.
24. Fidkowski CW, Zheng H, Firth PG. The anesthetic considerations of tracheobronchial foreign bodies in children: a literature review of 12,979 cases. *Anesth Analg*. 2010;111:1016-25.
25. Choroomi S, Curotta J. Foreign body aspiration and language spoken at home: 10-year review. *J Laryngol Otol*. 2011;125(07):719-23.
26. Abduljabbar MA, Jabir SN, Ahmed OF, Kakamad FH, Salih AM, Mikael TM, et al. Scarf pin inhalation; presentation and management; a case series. *Ann Med Surg (Lond)*. 2021;62:73-5.
27. Blanco Ramos M, Botana-Rial M, Garcia-Fontan E, Fernandez-Villar A, Gallas TM. Update in the extraction of airway foreign bodies in adults. *J Thorac Dis*. 2016;8(11):3452-6.
28. Hsu W c, Sheen T, Lin C d, Tan C t, Yeh T, Lee S y. Clinical experiences of removing foreign bodies in the airway and esophagus with a rigid endoscope: a series of 3217 cases from 1970 to 1996. *Otolaryngol Head Neck Surg*. 2000;122(3):450-4.
29. Cossellu G, Farronato G, Carrassi A, Angiero F. Accidental aspiration of foreign bodies in dental practice: clinical management and prevention. *Gerodontology*. 2015;32(3):229-33.
30. Lee P, Culver DA, Farver C, Mehta AC. Syndrome of iron pill aspiration. *Chest*. 2002;121(4):1355-7.
31. Jimenez Rodriguez BM, de Jesús SC, Merinas López CM, González de Vega San Román JM, Romero Ortiz AD. Bronchial stenosis after iron pill aspiration. *J Bronchology Interv Pulmonol*. 2013;20(1):96-7.
32. Carlborg B, Densert O. Esophageal lesions caused by orally administered drugs. An experimental study in the cat. *Eur Surg Res*. 1980;12(4):270-82.
33. Küpeli E, Khemasuwan D, Lee P, Mehta AC. "Pills" and the air passages. *Chest*. 2013;144(2):651-60.
34. Bond GR. The role of activated charcoal and gastric emptying in gastrointestinal decontamination: a state-of-the-art review. *Ann Emerg Med*. 2002;39(3):273-86.
35. Choi HS, Kim JO, Kim HG, Lee TH, Kim WJ, Cho WY, et al. A case of asymptomatic aspiration of a capsule endoscope with a successful resolution. *Gut Liver*. 2010;4(1):114-6.
36. Ernst A. Airway stabilization with silicone stents for treating adult tracheobronchomalacia. *Chest*. 2007;132(2):609-8.
37. Cavaliere S. Endoscopic treatment of malignant airway obstructions in 2,008 patients. *Chest*. 1996;110:1536-42.
38. Ko H-K, Song H-Y, Shin JH, Lee GH, Jung H-Y, Park S-I. Fate of migrated esophageal and gastroduodenal stents: experience in 70 patients. *J Vasc Interv Radiol*. 2007;18(6):725-32.
39. Sloan PAHW. Esophageal stent migration as a cause of severe upper airway obstruction. *Emerg Med Open Access*. 2014;04(04):1-3.
40. Katsanos K, Sabharwal T, Koletsis E, Fotiadis N, Roy-Choudhury S, Dougenis D, et al. Direct erosion and prolapse of esophageal stents into the tracheobronchial tree leading to life-threatening airway compromise. *J Vasc Interv Radiol*. 2009;20(11):1491-5.
41. Khan AM, Pipkin M, Mozayyan S, Hwang D, Yasufuku K. Severe acute airway obstruction and respiratory failure with fibrous plug following photodynamic therapy (PDT): indication for early bronchoscopy and debridement. *Photodiagn Photodyn Ther*. 2014;11(2):254-8.
42. Lan RS. Non-asphyxiating tracheobronchial foreign bodies in adults. *Eur Respir J*. 1994;7(3):510-4.
43. Casalini AG, Majori M, Anghinolfi M, Burlone E, D'Ippolito R, Toschi M, et al. Foreign body aspiration in adults and in children: advantages and consequences of a dedicated protocol in our 30-year experience. *J Bronchol Interven Pulmonol*. 2013;20(4):313-21.
44. Mittleman RE, Wetli CV. The fatal cafe coronary. Foreign-body airway obstruction. *JAMA*. 1982;247(9):1285-8.
45. Cataneo AJM, Cataneo DC, Ruiz RL. Management of tracheobronchial foreign body in children. *Pediatr Surg Int*. 2008;24(2):151-6.
46. Sersar SI, Rizk WH, Bilal M, El Diasty MM, Eltantawy TA, Abdelhakam BB, et al. Inhaled foreign bodies: presentation, management and value of history and plain chest radiography in delayed presentation. *Otolaryngol Head Neck Surg*. 2006;134(1):92-9.
47. Zaupa P, Saxena AK, Barounig A, Höllwarth ME. Management strategies in foreign-body aspiration. *Indian J Pediatr*. 2009;76(2):157-61.
48. Viot A, Babin E, Bequignon A, Moreau S, Vadillo M, Valdazo A. Bronchial foreign bodies in children. *Ann Otolaryngol Chir Cervicofac*. 2002;119(3):174-80.
49. Tokar B, Ozkan R, Ilhan H. Tracheobronchial foreign bodies in children: importance of accurate history and plain chest radiography in delayed presentation. *Clin Radiol*. 2004;59(7):609-15.
50. Heyer CM, Bollmeier ME, Rossler L, Nuesslein TG, Stephan V, Bauer TT, et al. Evaluation of clinical, radiologic, and laboratory prebronchoscopy findings in children with suspected foreign body aspiration. *J Pediatr Surg*. 2006;41(11):1882-8.
51. Haliloglu M, Ciftci AO, Oto A, Gumus B, Tanyel FC, Senocak ME, et al. CT virtual bronchoscopy in the evaluation of children with suspected foreign body aspiration. *Eur J Radiol*. 2003;48(2):188-92.
52. Sattar A, Ahmad I, Javed AM, Anjum S. Diagnostic accuracy of chest x-ray in tracheobronchial foreign body aspiration in paediatric patients. *J Ayub Med Coll Abbottabad*. 2011;23(4):103-5.
53. Hong S-J, Goo HW, Roh J-L. Utility of spiral and cine CT scans in pediatric patients suspected of aspirating radiolucent foreign bodies. *Otolaryngol Head Neck Surg*. 2008;138(5):576-80.
54. Luo HN, Ma SJ, Guo HL, Wang ZH, Ren XY. Effects of different bronchoalveolar lavage methods on tracheobronchial foreign body patients. *Laryngoscope*. 2016;126(4):1000-5.

55. Ma W, Hu J, Yang M, Yang Y, Xu M. Application of flexible fiberoptic bronchoscopy in the removal of adult airway foreign bodies. *BMC Surg.* 2020;20(1):165.
56. Schumann C, Kropf C, Rudiger S, Wibmer T, Stoiber KM, Lepper PM. Removal of an aspirated foreign body with a flexible cryoprobe. *Respir Care.* 2010;55(8):1097–9.
57. Miks VM, Kvale PA, Riddle JM, Lewis JW Jr. Broncholith removal using the YAG laser. *Chest.* 1986;90(2):295–7.
58. Lam YH, Ng EK, Chung SC, Li AK. Laser-assisted removal of a foreign body impacted in the esophagus. *Lasers Surg Med.* 1997;20(4):480–2.
59. Mosby's medical dictionary. 9th ed. Elsevier; 2009.
60. Stedman's medical dictionary for the health professionals and nursing. Farlex; 2012.
61. Clerf LH. Historical aspects of foreign bodies in the air and food passages. *South Med J.* 1975;68(11):1449–54.
62. Chouhan M, Sharma S. Tracheobronchial foreign bodies: the importance of timely intervention and appropriate collaboration. *Indian J Otolaryngol Head Neck Surg.* 2019;71(Suppl 1):972–5.





# Hemoptysis, Endoscopic Management

# 41

Rosa Cordovilla and Juan Alejandro Cascón

## Definition

Hemoptysis is defined as the expectoration of blood from the lower respiratory tract. Bleeding from the upper airway is excluded from this definition.

In most cases the amount of bleeding is slight, the patient has hemoptoic expectoration (blood-streaked sputum), and hemoptysis is self-limited. In other cases the amount is higher (evident hemoptysis) or may even present massive hemoptysis (expectoration of fresh blood in important quantities).

Massive hemoptysis usually refers to the expectoration of large amounts of blood and/or the rapidity of this bleeding and accounts for 20% of hemoptysis [1]. The amount of expectorated blood in 24 h is usually used to differentiate between massive and non-massive hemoptysis. However, this definition varies widely in the literature, with values ranging from an expectorated blood volume of 100–1000 mL during a period of time that is also variable. Difficulty is even higher considering that hemoptysis is difficult to quan-

tify: it could be both overestimated and underestimated by patients. Underestimation may occur when part of the blood is retained in the tracheobronchial tree.

It is therefore preferable to use the term life-threatening hemoptysis, defined as that having clinical consequences, potentially fatal. This risk is determined by the total volume of bleeding, its velocity, and the patient's cardiopulmonary reserve [2]. As risk indicators, the amount of hemoptysis (greater than 100 mL), the presence of airway obstruction, respiratory failure, and hemodynamic instability should be considered [3]. Since 150 mL is the total volume of conduction airways, asphyxia due to clot formation along with cardiocirculatory collapse is usually the cause of death, not exsanguination. Mortality of untreated threatening hemoptysis is high, up to 80% with adequate management [4], so it is very important to have immediate assessment of the patient and identification of the causes of bleeding in order to start an appropriate treatment and avoid a fatal outcome.

R. Cordovilla (✉)

Interventional Pulmonology Unit, University Hospital of Salamanca, Salamanca, Spain  
e-mail: [rcordovilla@usal.es](mailto:rcordovilla@usal.es)

J. A. Cascón

Interventional Pulmonology Unit, Hospital Central de Asturias, Oviedo, Spain  
e-mail: [jcasconh@huca.es](mailto:jcasconh@huca.es)

## Etiology of Hemoptysis

The causes of hemoptysis are multiple and varied.

Before detailing, it is important to know the system of vascularization of the lung.

## Vascular Origin of Hemoptysis

There are two systems by which blood reaches the lungs: pulmonary arteries and bronchial arteries. The pulmonary arteries conform to a low-pressure system that contains all cardiac output, and are responsible for gas exchange. The bronchial arteries (greater pressure and much lower flow) are part of the systemic circulation and the irrigation of the bronchi and the visceral pleura depends on them. Despite its lower contribution to pulmonary blood supply, the bronchial arteries are the source of most hemoptysis. Sometimes other systemic non-bronchial arteries may be the source of hemoptysis. In a much lower percentage, the bleeding comes from the pulmonary arteries or from the pulmonary microcirculation [5].

The vessels of the bronchial network causing bleeding are usually neofomed. Inflammation (bronchiectasis, sarcoidosis, lung abscess, tuberculosis, etc.), hypoxia, and neoplasia can induce proliferation of bronchial vasculature via pro-angiogenic factors (vascular endothelial growth factor, angiopoietin-1). Although new vessels are thin-walled and fragile, they are surrounded by smooth muscle fibers capable of contracting, both physically and pharmacologically. Arterial embolization is also an effective method to treat this neovascularization. However, the pulmonary artery network is not capable of generating a vasospasm as potent as the bronchial vessels, since its walls are thin and do not contract. Therefore, the physical and pharmacological means have only a slight effect on them. The most frequent cause of hemorrhage is ulceration of the vessel wall caused by a destructive process of the lung parenchyma (pulmonary neoplasia, bacterial necrotizing pneumonia, mycetoma). In these cases, the cessation of bleeding is usually due to the temporary sealing by a clot whose dissolution or progression of the tear can lead to a relapse with greater hemorrhage [6]. Unfortunately, it is not always feasible to differentiate the vascular network originating the hemorrhage (Table 41.1).

Multiple conditions may produce hemoptysis by affecting the airway, lung parenchyma, or pulmonary vessels. Although they vary according to

**Table 41.1** Etiology of hemoptysis: Description of the most frequent causes of hemoptysis worldwide (the most important ones are underlined>

1. Pulmonary	
(a) Airways	<ul style="list-style-type: none"> <li>• <u>Bronchiectasis</u></li> <li>• <u>Bronchitis</u></li> <li>• Fistula</li> <li>• Foreign body</li> <li>• <u>Neoplasm</u></li> <li>• Trauma</li> </ul>
(b) Parenchyma	<ul style="list-style-type: none"> <li>• Infection               <ul style="list-style-type: none"> <li>– Abscess</li> <li>– <u>Mycetoma</u></li> <li>– <u>Pneumonia</u></li> <li>– <u>Tuberculosis</u></li> </ul> </li> <li>• Inflammatory or immunologic               <ul style="list-style-type: none"> <li>– Behçet's disease</li> <li>– Goodpasture syndrome</li> <li>– Granulomatosis with polyangiitis</li> <li>– Microscopic polyangiitis</li> <li>– Systemic lupus erythematosus</li> </ul> </li> </ul>
(c) Vascular	<ul style="list-style-type: none"> <li>• Arteriovenous malformation</li> <li>• Dieulafoy's disease</li> <li>• Pulmonary artery pseudoaneurysm</li> <li>• <u>Pulmonary embolism</u></li> <li>• Pulmonary veno-occlusive disease</li> </ul>
2. Cardiovascular	<ul style="list-style-type: none"> <li>• Congenital heart disease</li> <li>• <u>Heart failure</u></li> <li>• Mitral stenosis</li> </ul>
3. Iatrogenic	<ul style="list-style-type: none"> <li>• Drugs               <ul style="list-style-type: none"> <li>– Antithrombotic drugs</li> <li>– Vascular endothelial derived growth factor inhibitor</li> </ul> </li> <li>• Procedures               <ul style="list-style-type: none"> <li>– Transbronchial biopsy</li> <li>– Fine needle aspiration</li> <li>– Swan-Ganz catheter placement</li> </ul> </li> </ul>
4. Miscellaneous	<ul style="list-style-type: none"> <li>• Coagulation disorders</li> <li>• Cocaine abuse</li> <li>• Endometriosis (catamenial hemoptysis)</li> </ul>
5. Idiopathic	

Adapted from Cordovilla et al. (2016) [7]. Copyright © 2016 SEPAR. Published by Elsevier España, S.L.U. All rights reserved

the population studied, the most frequent causes are: tuberculosis (the leading cause of massive hemoptysis worldwide, [8] bronchiectasis,

chronic bronchitis, and bronchogenic carcinoma [9]. A score has been developed to stratify the risk of mortality.

### 1. Pulmonary

(a) Airways: Pathology of the airway is the most frequent cause of hemoptysis and includes:

- Inflammatory diseases: bronchiectasis—frequently associated with moderate and severe bleeding—and chronic bronchitis.
- Neoplasms: bronchogenic carcinoma, carcinoid tumor, and endobronchial metastasis. A European observational study showed that malignancy was the most frequent cause. Although up to 20% of bronchogenic cancer patients have some degree of hemoptysis, only 3% develop massive hemoptysis. [10]
- Fistulas between the tracheobronchial tree and blood vessels, especially in the case of thoracic aorta aneurysms.
- Foreign bodies and trauma.

(b) Pulmonary parenchyma: Bleeding originating from the lung parenchyma is usually due to:

- Infections: pneumonia (associated with mild expectoration), tuberculosis, lung abscess, and fungal infections, mainly aspergilloma.
- Inflammatory or immunological diseases leading to diffuse alveolar hemorrhage: Goodpasture syndrome, systemic lupus erythematosus (SLE), granulomatous polyangiitis (Wegener), and microscopic polyarteritis.

(c) Pulmonary vascular: Hemoptysis caused by diseases of the pulmonary arteries [9] may appear due to the same causes as those originating in the pulmonary parenchyma—intrinsic to the pulmonary vasculature conditions (pulmonary embolism, arteriovenous malformations).

- Dieulafoy's disease of the bronchi (presence of an abnormal bronchial artery, contiguous to the bronchial mucosa) [11, 12].

### 2. Cardiovascular

(a) Increased pulmonary capillary pressure (mitral stenosis).

### 3. Iatrogenic

- (a) Complications of procedure: transbronchial biopsy, pulmonary fine needle aspiration, artery perforation originated by a Swan-Ganz catheter placement [13].
- (b) Treatment with antithrombotic (antiplatelet or anticoagulant) drugs or bevacizumab (vascular endothelial derived growth factor inhibitor).

### 4. Miscellaneous

- (a) Coagulopathies: thrombocytopenia.
- (b) Cocaine inhalation.
- (c) Endometriosis: catamenial hemoptysis.

### 5. Idiopathic

In up to 10–30% of cases it is not possible to establish an etiological diagnosis of hemoptysis following bronchoscopy and chest computed tomography (CT) [9, 14] and the patient is considered to have idiopathic or cryptogenic hemoptysis. Most of these patients are smokers and hemoptysis is usually due to inflammation of the bronchial wall produced by tobacco, rather than to an unspecified cause, known as tobacco-related hemoptysis [15]. Idiopathic hemoptysis is also related to chronic or acute bronchial inflammation, occult bronchiectasis, inactive tuberculosis, vascular pulmonary malformations, and coagulation disorders.

It is likely that with the use of multidetector CT, the proportion of cryptogenic hemoptysis will be reduced [15].

---

## History and Historical Perspective

Given its potentially fatal outcome, hemoptysis has been a challenge for physicians throughout the ages.

The first modern publications of cases of hemoptysis date back to the nineteenth century, in which the rupture of pulmonary artery aneurysms was described as a possible cause in patients with chronic pulmonary phthisis [16].

The predominant etiology has varied over the centuries, conditioned by toxic inhalation and environmental exposure, as well as by hygienic conditions and access to health care, which even today produce large regional variations.

Over time, treatments have changed from an initial systemic treatment (Gallic acid in the oldest publications) to the incorporation of both rigid and flexible bronchoscopy and the endobronchial use of different substances and devices, many of them without strong scientific evidence.

On the other hand, the generalization of CT and arteriography has significantly modified diagnostic and therapeutic management.

Recently in the context of the pandemic caused by Severe Acute Respiratory Syndrome Coronavirus-2 (SARS-CoV-2) infection, few cases have been described in which hemoptysis was one of the initial manifestations [17].

---

### Indications of Bronchoscopy in Hemoptysis

Bronchoscopy plays a key role in the diagnosis and management of hemoptysis, especially in those cases where the patient is too unstable for radiological tests and requires rapid intubation and in those cases where the origin of the bleeding is not identified by CT or arteriography. It allows confirmation in doubtful cases, location of the bleeding point or, at least, location of the affected lung, and the determination of the cause if the lesion is visible or accessible to endoscopic examination. It also allows the isolation of the hemorrhagic segment or lobe to avoid the spreading of blood to the bronchial tree and reduce the risk of suffocation. In this sense, performing rigid bronchoscopy complemented by flexible bronchoscopy carries a great advantage. In cases where a rigid bronchoscope is not at hand, flexible bronchoscopy as the only endoscopic procedure can also be very useful. It can be performed at the bedside and allows selective intubation or bronchial balloon blockade, as well as the application of local therapies. It can contribute, even temporarily, to control bleeding and the application of more definitive treatments such as embolization of bronchial arteries or even, in selected cases, surgical treatment.

### Diagnostic Bronchoscopy

In the event of severe hemoptysis, diagnostic bronchoscopy can help in many ways:

1. Confirmation of hemoptysis and exclusion of pseudohemoptysis.

Although the clinical history, the characteristics of the episode, and the initial physical examination may suggest the digestive or respiratory origin of the bleeding, sometimes the aspiration of at least part of digestive bleeding content causes cough and can simulate a true hemoptysis (pseudohemoptysis), which requires an ears, nose and throat (ENT) examination, a high digestive endoscopy, or bronchoscopy to differentiate.

2. Diagnostic of at least the side of bleeding, in anticipation of specific treatment.

Although imaging studies (chest CT) can identify the origin of bleeding and its cause sometimes with a superior performance than bronchoscopy [7, 18], this is still necessary. It should be indicated early, especially in massive or life-threatening hemoptysis. Bronchoscopy reveals or confirms the origin of bleeding, especially if it is performed within 48 h of the onset of the episode and in cases of significant bleeding in 73–93% of cases of massive hemoptysis [7, 19]. A study comparing early bronchoscopy (active bleeding or within 48 h after bleeding stopped) to delayed bronchoscopy showed that an early procedure helps detect bleeding sources, especially in cases of moderate to severe hemoptysis without increasing diagnostic yield. [8]

In the case of threatening hemoptysis, it is advisable to perform bronchoscopy as soon as possible if the patient is unstable and once the patient has been intubated [20, 21]. Endoscopy through the endotracheal (ET) tube is safer since the airway is secure and the endoscope can be withdrawn every time oxygenation worsens or the working channel is occluded by clots.

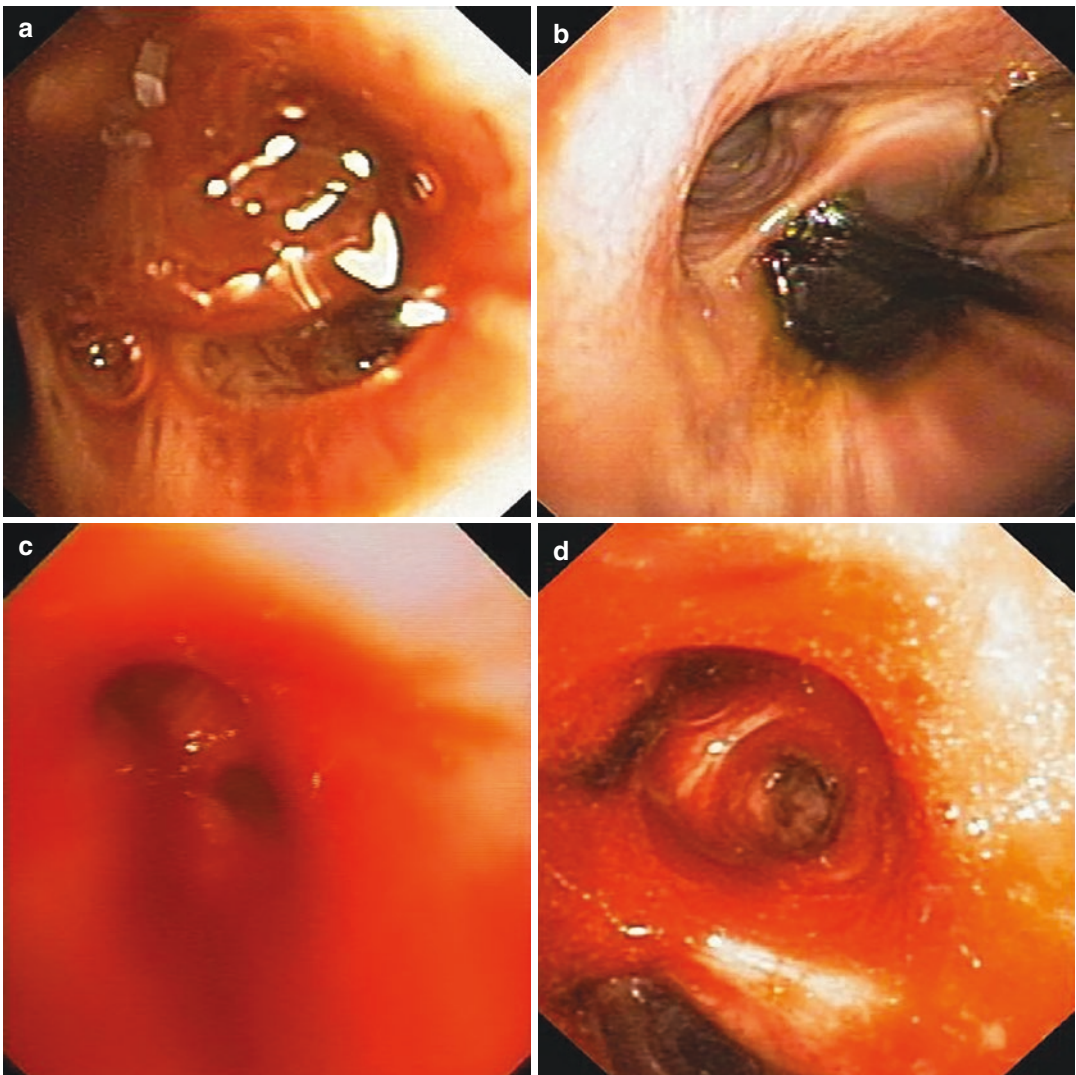
Rigid bronchoscopy can be used for the diagnosis and initial evaluation of threatening hemoptysis, but the flexible bronchoscope has some advantages to it such as the ability to reach the distal airway more easily. It can be

used in the setting more suitable for the patient—intensive care unit (ICU), shock room, bronchoscopy room, etc.—without the additional delays of having to transfer the patient to the operating room (OR) to undergo rigid bronchoscopy, or the radiology room to perform angiotomography.

Bronchoscopy also proves its value in those cases of non-revealing radiological studies or those that show bilateral or non-localizing abnormalities. In any case, even in those non-threatening episodes, it provides useful information in the event that bleeding

increases dangerously in a sudden and unpredictable manner.

Location of the bleeding site requires direct visualization of active bleeding, which determines with certainty one bronchus or the responsible bronchial area. The most frequent endoscopic finding is hematic remains and clots (Fig. 41.1). Locating blood clots does not guarantee the origin of the bleeding. However, a combination of findings such as a great number of clots adhering to a particular bronchus can suggest, together with the imaging techniques, the responsible area. Blood



**Fig. 41.1** (a) Blood clot in the right upper lobe bronchus. (b) Blood clot in the right lower lobe bronchus. (c and d) Active bleeding



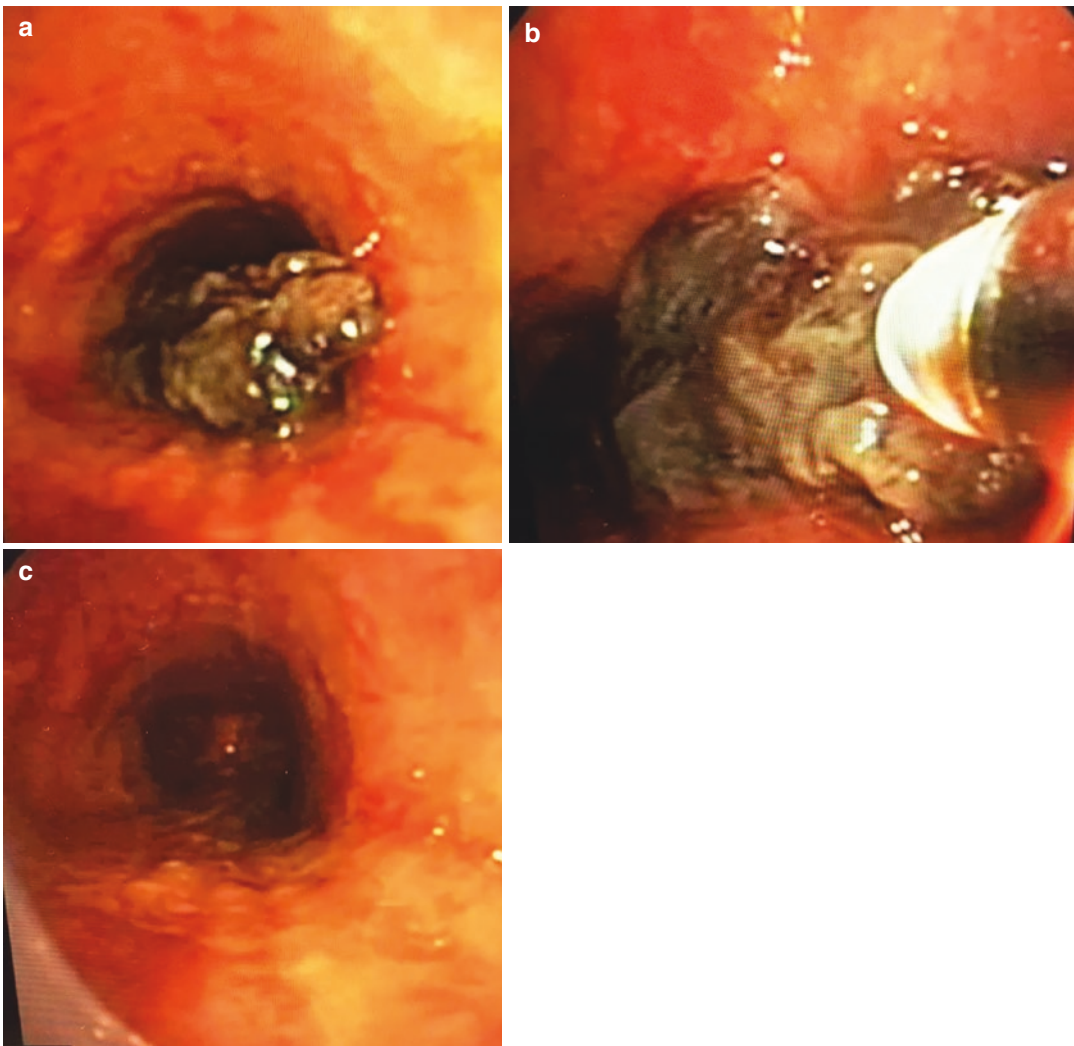
remains should be aspirated through repeated small bronchial washes, in order to improve permeability and allow diagnostic examination of the underlying territory. However, in the presence of fresh clots adhering, it is not advisable to aspirate them given the risk of further bleeding. Subsequently, bronchoscopy can be repeated to evaluate whether they can be removed with a smaller risk of rebleeding.

A cryoprobe can be used for the removal of an adherent clot. In order to do that, a cryoprobe is placed in the center of the clot and

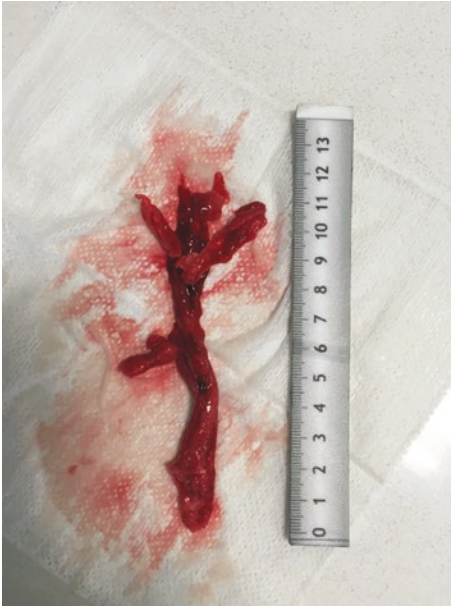freezing activated in 3–4 s. The clot will adhere to the end of the probe and be extracted en bloc with the bronchoscope just like a foreign body would do. This procedure should be done through an ET tube or through a rigid bronchoscope in order to have complete control of the airway in the event of bleeding (Figs. 41.2 and 41.3).

3. Causal diagnosis, in case of accessible bronchial lesions.

Bronchoscopy allows us to perform an endobronchial inspection and evaluate muco-



**Fig. 41.2** (a) Blood clot in trachea. (b) Blood clot removal by cryoextraction. (c) Trachea after cryoextraction



**Fig. 41.3** Right bronchial tree clot

sal changes: hypertrophic or malformed capillary vascular network, areas of inflammatory or infiltrative mucosal thickening, bronchial stenosis, endobronchial tumors, antracosis or antracol stenosis, broncholiths, etc. (Fig. 41.4). In many cases, the changes are non-specific and, therefore, non-diagnostic [22].

In addition to the visual examination, flexible bronchoscopy allows collection of samples for cytological and microbiological studies: bronchial lavage, bronchoalveolar lavage in the presence of suspected alveolar hemorrhage, biopsies, and/or bronchial brushing in the presence of lesions suspected of malignancy. In the case of highly vascular lesions, some authors recommend local instillation of 1–2 mL of adrenaline with 1:20,000 dilution, to reduce the risk of further bleeding, although clinical evidence is low [23].

Bronchoscopy also plays a very important role in non-threatening hemoptysis with no apparent radiological alteration.

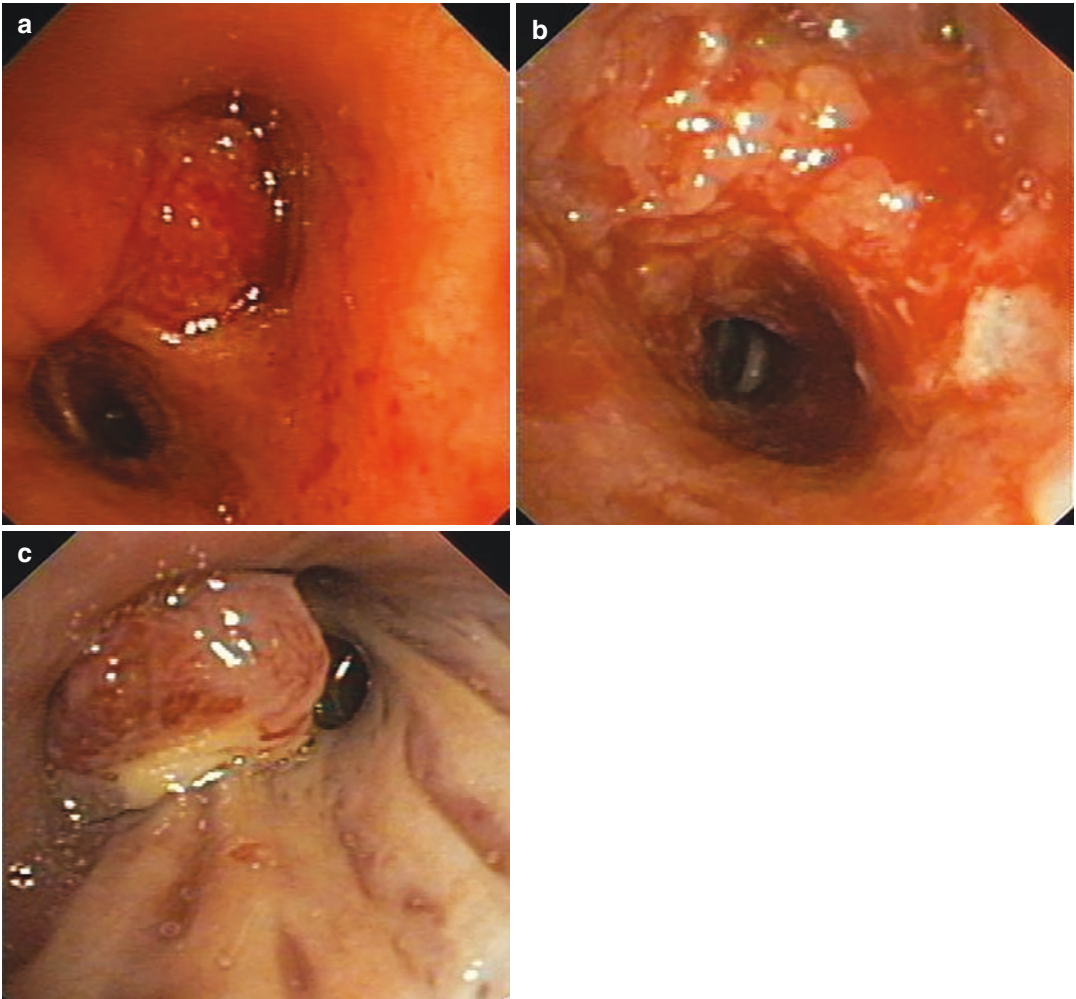
The existence of a normal chest X-ray in the context of hemoptysis does not exclude the pos-

sibility of malignancy or other underlying pathology [5, 24–26]. The probability of malignancy in patients with hemoptysis and normal chest X-ray is low but may reach up to 10% in patients over the age of 40, with a history of smoking [27], and even in patients with mild hemoptysis [28].

Bronchoscopy can detect an endobronchial lesion in 5% of patients with mild hemoptysis and normal chest X-ray [29], and high-resolution computed tomography (HRCT) detects bronchiectasis in up to 70% of cases with severe hemoptysis and normal chest X-rays [7]. Therefore, depending on the type of hemoptysis, bronchoscopy can be performed before or after the complementary radiological tests:

1. Hemoptoic expectoration: If there are no risk factors for cancer, bronchoscopy is indicated when these episodes are recurrent, or when the amount of bleeding increases [29]. In the case of patients with recurrent hemoptysis, the first step is to perform a chest CT scan (HRCT or multidetector computed tomography [MDCT]) as it may be useful to select the most cost-effective endoscopic technique for diagnosis (flexible bronchoscopy or echo bronchoscopy) [7, 11, 30, 31].
2. Evident hemoptysis: If there is no known cause, a bronchoscopy is necessary, especially in patients with risk factors for malignancy. However, depending on the stability of the patient, it may be advisable to perform a chest CT scan first. The combined use of bronchoscopy and MDCT increases the diagnostic yield for locating the bleeding site [7].

If the patient has a normal CT scan, bronchoscopy can diagnose the cause of bleeding in up to 16% of the cases. This percentage increases up to 37% when clinical history is also taken into account [27]. If bronchoscopy does not reveal changes, the patient is considered to have cryptogenic hemoptysis. A combination of CT and negative bronchoscopy has a very low probability of malignancy (1%) after a 6-month follow-up [32].



**Fig. 41.4** (a) Vascular lesion in right upper lobe bronchus. (b) Tumoral infiltration at right B6. (c) Endobronchial mass in right upper lobe bronchus

### Therapeutic Bronchoscopy

Therapeutic bronchoscopy is specifically indicated to eliminate, at least transiently, a risk situation generally in the context of massive or threatening hemoptysis. Therefore, it is an urgent action applied in combination with other life support measures, which seek to recover and keep the patient clinically stable. Diagnosis can then be completed with imaging

techniques if the status of the patient allows, and definitive treatment applied. Bronchial, systemic, and/or pulmonary embolization or surgical embolization can be used according to the situation.

### Description of the Equipment

See Table 41.2.

**Table 41.2** Equipment: Material list frequently used in the management of hemoptysis

1. Bronchial block with flexible bronchoscope and sustained aspiration	
2. Instillation of cold saline	
3. Instillation of hemostatic drugs	
• Vasoconstrictors	• Adrenaline • Antidiuretic hormone derivatives
• Tranexamic acid	
• Fibrinogen-thrombin	
• Biocompatible glue	
4. Other bronchial blockade systems used in case series:	
• Endobronchial stents	• Ultraflex® (Boston Scientific)
• Silicone spigots	• EWS® (Novatech)
• Endobronchial valves	• IBV® (Olympus)
• Oxidized regenerated cellulose	• Surgicel® (Ethicon)
5. Coagulative therapies in endoscopically visible bleeding tumors	
• Argon plasma coagulation	• APC® (Erbe)
• Photocoagulation	
6. Orotracheal tube	
7. Specific oro tracheal tubes	
• Selective bronchial intubation	• TCB Univent® (Fuji)
8. Bronchial blockers	
• Embolectomy catheter	• Edwards Fogarty® Catheter
• Bronchial blockers	• Arndt® (Cook) • Cohen® (Cook) • Uniblocker® (Fuji) • EZ-Blocker® (Rüsch)

Adapted from Cordovilla et al. (2016) [7]. Copyright © 2016 SEPAR. Published by Elsevier España, S.L.U. All rights reserved

## Application of the Technique

### General Measures

First evaluation of the patient should be oriented to estimate the severity of the condition and decide which treatment is most convenient, and where will it take place.

Generally, hemoptoic sputum does not require hospitalization, but evident and life-threatening hemoptysis does. In the latter case, admission to the ICU is warranted.

Next, a quick and accurate diagnosis should be performed in order to locate the place of bleeding and determine its cause simultaneously.

The objectives of treatment are:

- To secure the airway
- To maintain adequate oxygenation
- To achieve hemodynamic stability
- To locate and stop bleeding
- To identify and treat the cause of hemoptysis

Management of the patient during hospital admission includes a series of general measures:

1. Strict bed rest in lateral decubitus position, the affected side down, in order to protect the airway and prevent aspiration of blood into the unaffected lung.
2. Monitoring of clinical parameters (blood pressure, heart and respiratory rate, oxygen saturation) and quantification of hemoptysis.
3. Supplemental oxygen supply if necessary.
4. Suppression of cough by administering anti-tussives, avoiding respiratory physiotherapy techniques.
5. Empirical antibiotic treatment, useful in hemoptysis associated with respiratory infections and, in general, to prevent further complications.
6. Nothing by mouth, to avoid aspiration to the airway, and to allow the performance of urgent tests such as bronchoscopy, CT, or arteriography.
7. Establishment of large-bore venous access for fluid administration, availability of a blood reserve, and, if necessary, transfusion of packed red blood cells.
8. Administration of antifibrinolytic agents such as aminocaproic acid and tranexamic acid (TA); they act by inhibiting the clot dissolution process with the consequent reduction in bleeding. There are two clinical trials evaluating the use of TA (Amchafibrin®), both inhaled and intravenously. Although patients with massive hemoptysis were not included, the results indicate that they may reduce the duration of bleeding and the need for interventional procedures [33, 34]. A review of



published patient series concludes that the reduction in bleeding was associated to a low risk of short-term thromboembolic disease [35]. The recommended dose is 500 mg to 1 g intravenously two or three times per day.

Aminocaproic acid (Caproamin<sup>®</sup>) has been used in case series, as intracavitary instillation in aspergillomas [36, 37].

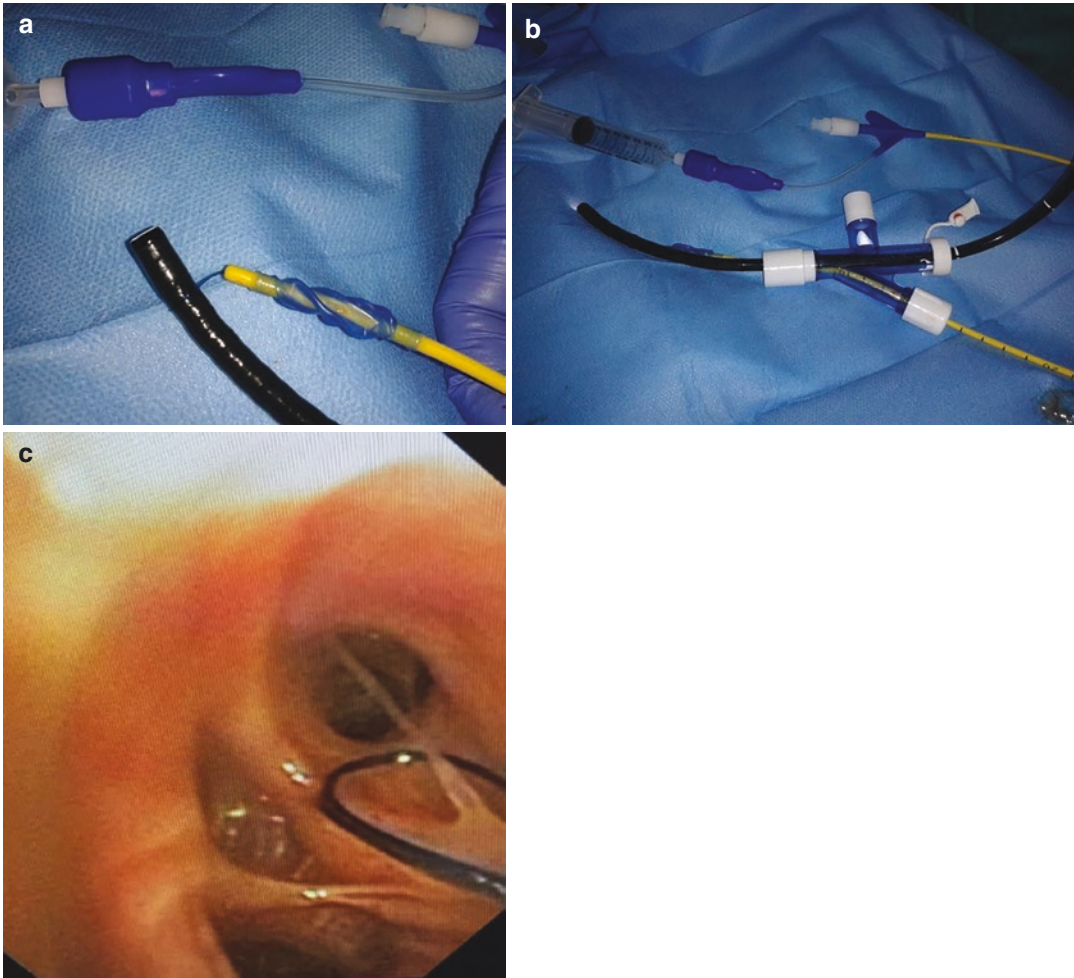
## Protection of the Airway

If there is severe respiratory failure or risk of suffocation (large and rapid bleeding), orotracheal intubation is required, preferably with a thick tube (8–9 mm) to facilitate diagnostic and interventional bronchoscopy [38].

In addition, bronchial blockade may be necessary to control bleeding in order to preserve ventilation of the healthy lung [18, 39]. There are several options to accomplish this:

1. Perform the blockage with the orotracheal tube itself. This is possible in bleeding from the right bronchial tree, since the left main bronchus can be selectively intubated with the aid of the bronchoscope, so that the pneumatic balloon of the tube completely isolates the left lung. It should be taken into account that in tall patients the tube may not be long enough to adequately reach the main bronchus.
2. Use independent bronchial blockers that are placed through a conventional tube:
  - (a) Edwards Fogarty<sup>®</sup> Catheter (n° 7 or higher). This inflatable balloon is introduced parallel to the bronchoscope and it is placed at the selected location under direct vision. This maneuver can be facilitated by rotating the head to the opposite side, in a similar way as the left main bronchus intubation with the rigid bronchoscope, and bringing the end of the tube closer to the tracheal carina. This device cannot be securely anchored during long periods of time, but it may allow blocking completely the bleeding site enough time for a clot to form and adhere. The introduction of the catheter independently of the bronchoscope instead of through its working channel allows continuous suctioning and improved vision.
  - (b) Arndt<sup>®</sup> Endobronchial Blocker (Fig. 41.5). It can be inserted transiently attached to the end of the bronchoscope to be transported to its location [11–13]. It has a transparent head with three ports: one to fix the catheter of the blocking balloon, another for the introduction of the bronchoscope, and the third one for the connection to the ventilator.
  - (c) Cohen<sup>®</sup> Endobronchial Blocker. It is a balloon catheter curved at its distal end to facilitate placement.
  - (d) EZ-Blocker<sup>®</sup>. This catheter has a Y-shaped distal end, to facilitate anchoring in the tracheal carina, and two balloons that can be inflated separately.
3. Perform intubation and blockage with a special orotracheal tube:
  - (a) Torque Control Blocker Univent Tube<sup>®</sup>: This has a bronchial blocker that prolongs the tube itself, designed to occlude any major bronchi with the tube located inside the trachea (Fig. 41.6).
  - (b) Bronchoflex<sup>®</sup>: This particular tube has a catheter on the outside, through which a Fogarty or similar tool can be inserted, and also provides an external fixation system. Its advantage is that it fully preserves the internal gauge of the tube and facilitates the location of the balloon in any of the main bronchi by rotating the orotracheal tube on its major axis.
  - (c) Double-lumen tube: This particular tube allows the blockade of the bleeding site performing selective intubation. Given its reduced caliber, it is not possible to introduce the standard bronchoscope through it, and it is also difficult to anchor since the bleeding site is not directly visible.





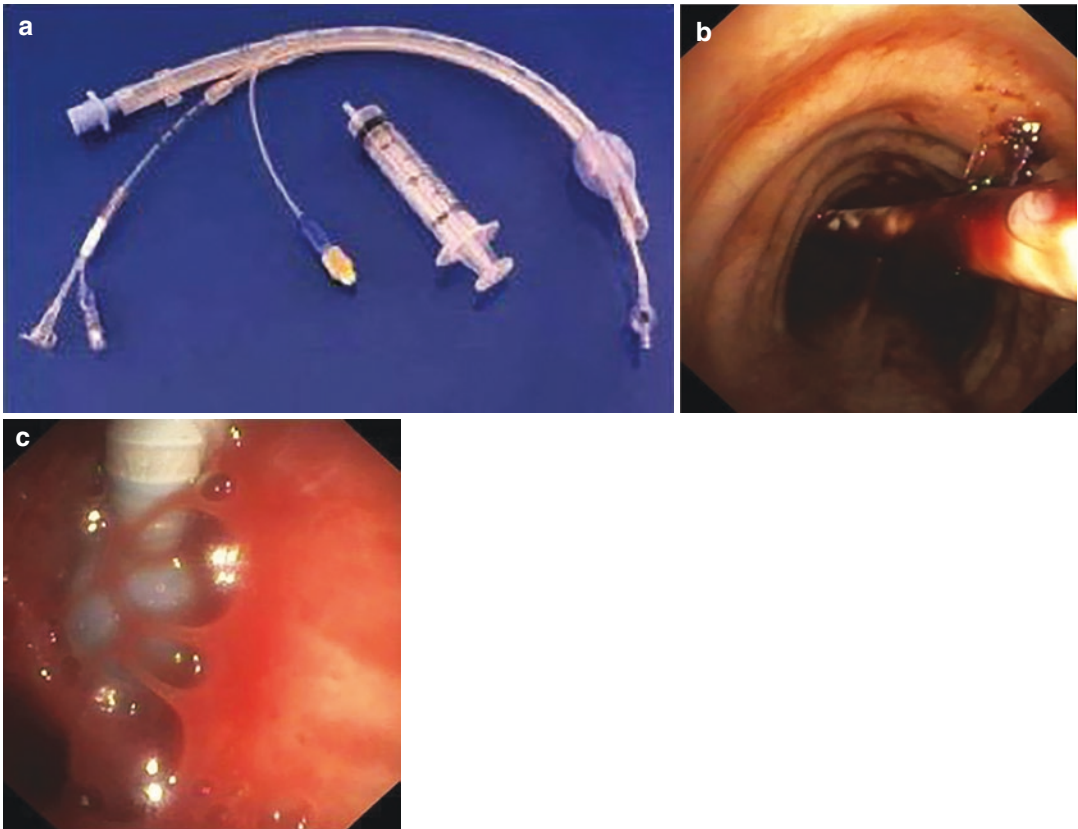
**Fig. 41.5** Arndt catheter. (a) Catheter fixed at the distal end of the flexible bronchoscope. (b) Flexible bronchoscope introduced through the three-headed piece. (c) Catheter placed at the selected site

### Therapeutic Bronchoscopy

In our experience, flexible bronchoscopy is the first procedure indicated when a patient presents with life-threatening hemoptysis, and hemodynamic instability. It can be performed in the intensive care setting or any other critical area. When a rigid bronchoscope is available, it is advisable to intubate with the rigid tube and through it introduce the flexible endoscope. They can complement each other taking advantage of both instruments:

- Ventilate the patient properly.
- Ensure airway permeability by aspiration of blood and clots with large-caliber probes.
- Perform direct hemostasis on bleeding areas, pressing with the external wall of the distal end of the rigid bronchoscope or by the application of vasoconstrictors or endobronchial coagulant therapies.
- Access the distal bronchial tree.

Therefore, the rigid bronchoscope supplemented with the flexible bronchoscope is the



**Fig. 41.6** (a) Univent tube. (b) Univent tube at the trachea, after hemoptysis. (c) Inflated balloon at the level of the bleeding bronchus

most complete and safe procedure in life-threatening hemoptysis [39, 40]. However, flexible bronchoscopy remains the most used procedure in these cases, given its broad availability. Rigid bronchoscopy is less available, it requires a special training that not many pulmonary physicians have, and it has to be used in the operating room under general anesthesia or conscious sedation. That implies moving an unstable patient, a risk that may not be affordable in a life-threatening situation.

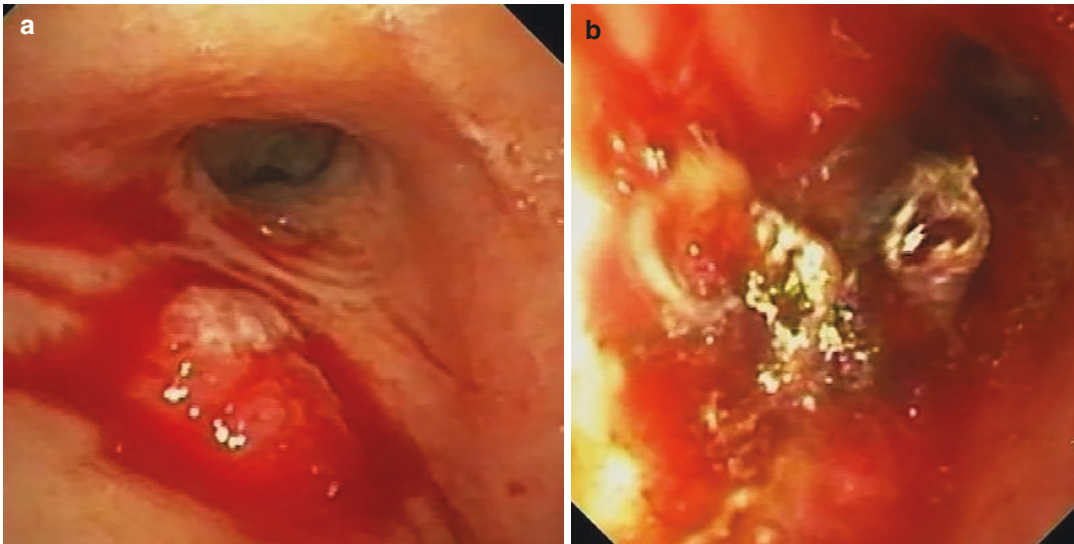
Once the origin of the bleeding has been identified, if a lung blockade is not necessary, local measures can be applied. Their clinical efficacy is limited, as well as the published evidence.

In addition to the methods described above, other interventional procedures can be performed:

1. Bronchial blockade with the flexible bronchoscope and sustained aspiration in order to cause segmental collapse and stop the bleeding.
2. Selective bronchial blockage through the working channel of the bronchoscope:
  - (a) Fogarty n° 5 (5 Fr.) or a similar type of balloon catheter (Olympus B5-2C® and B7-2C® balloon).
  - (b) Longer catheters such as the Olympus Multi-3 V Plus B-V232P-A® balloon catheter. This one is a 190-cm catheter that can be inserted through a working channel of 2.8 mm, and insufflated up to 15 mm in diameter. Without deflating the balloon, it can be clamped and cut to stay in place and finally remove the bronchoscope.

3. Selective bronchial blockade using a guide wire: A guide is inserted through the working channel to the chosen bronchus and after removal of the bronchoscope a balloon catheter is placed through the guide. Although this procedure is technically more complicated, it allows the balloon catheter to be located and the bronchoscope removed [41].

The balloon can be inflated for up to 24–48 h to allow clot formation, although it can be maintained in the airway for up to several days. To prevent mucosal ischemia, it is necessary to deflate it periodically, at least three times a day [42], always under endoscopic vision in order to re-inflate immediately if bleeding persists. If the patient does not bleed again after several hours, the catheter-balloon is withdrawn.
4. Washing of the bronchus with cold saline serum (4°C) using aliquots of 50 mL until bleeding is suppressed, without exceeding 500 mL total volume [43]. The mechanism of action is local vasoconstriction although there are no controlled studies that demonstrate its effectiveness [44].
5. Instillation of hemostatic drugs:
  - (a) Vasoconstrictors: Adrenaline diluted to 1:20,000 and applied through the working channel in 1 mL aliquots. Its effect has not been compared in controlled trials and only clinical experience supports its use. In order to minimize its cardiovascular effects in patients at risk, it has been suggested to substitute it for some antidiuretic hormone derivatives such as terlipressin or ornipressin, although reports are anecdotic [45, 46].
  - (b) Tranexamic acid can be instilled undiluted on the bleeding site, with an initial dose of 500 mg [47, 48].
  - (c) Fibrinogen-thrombin (Tissucol®): It has been used in two case series in hemoptysis cases that could not be controlled with other endoscopic procedures. [49]
  - (d) Thrombin slurry: A series of 13 patients showed that hemostasis was achieved in 77% of patients [50].
  - (e) Recombinant activated factor VII: Topical hemostatics are not useful in fast and severe hemoptysis, since the blood washes out the hemostatic agent diminishing or abolishing its efficacy. Described in a small series of cases.
6. Other bronchial blockade systems that have been used successfully in series of cases:
  - (a) Oxidized regenerated cellulose (Surgicel®): A report by Valipour et al. [49] describes how fragments of this hemostatic and resorbable mesh were introduced into the segmental or subsegmental bronchi causing the hemorrhage to stop. They were previously introduced through the working channel of a standard bronchoscope by pulling them with a flat blade forceps. Once the bleeding site was located, they were pushed into the segmental bronchus with the same forceps. In total, four to ten fragments of 3 × 4 cm were introduced, until hemostasis was achieved. As it was a resorbable material, it was not necessary to extract it later, and the absence of bronchial sequelae was later verified.
  - (b) Endobronchial valves: Designed for endoscopic volume reduction, these are used for other purposes such as persistent air leakage or bronchopleural fistula. Isolated cases of their application in the treatment of hemoptysis have also been described [51].
  - (c) Silicone plugs (Watanabe spigots) [52, 53]: Initially introduced by Watanabe for endoscopic treatment of bronchopleural fistulas, they have demonstrated their efficacy in the transient tamponade of hemorrhagic segmental bronchi. The insertion and removal are performed by apprehending them with a biopsy forceps, and transporting them at the end of the bronchofiberscope. A series of cases reported by Bylicki accounted for a success rate of 78% [9].
  - (d) Stents: In a series of eight patients with cancer-related hemoptysis, bleeding ceased in 75% after stent placement [54].



**Fig. 41.7** (a) Endobronchial lesion in left main bronchus. (b) After argon plasma coagulation application

- (e) Biocompatible glue: Chawla described its use in 168 patients with an immediate control of bleeding in 90% of patients. After the second application, 7.7% additional patients responded.
7. Laser coagulation: The following are used in cases of accessible, endoscopically visible tumor causing bleeding:
- (a) Laser photocoagulation (Neodymium-Yttrium-Aluminum-Garnet [Nd:YAG], Neodymium-Yttrium-Aluminum-Phosphate [Nd:YAP], diode laser): The efficacy in stopping bleeding ranges from 60 to 74%, although a reduction is achieved in up to 94% of cases [55, 56]. If the bleeding is significant, results are not so favorable [57]. Laser can be effective causing photocoagulation in depth. Very good results have been reported when applied on bleeding endobronchial tumors [55], but little is achieved on severe hemoptysis caused by laser application itself. In this context, the results have not been so favorable [57]. In fact, in highly vascular tumors causing severe hemoptysis, there is a tendency to avoid laser treatments unless an obstruction can be solved with the treatment, and the risks are justified.
- (b) Electrocoagulation with argon plasma: Argon plasma is an electrocoagulation method that does not require tissue contact and acts rapidly superficially. It is less effective than laser in coagulating in depth, and mechanical debridement is more difficult. But it can be very effective, at least transiently, in mucosal lesions whenever cough can be effectively inhibited and there is no significant active bleeding at the time of application. In that case, free blood is coagulated and the treatment does not reach the actual site of bleeding. Increasing the argon flow can facilitate its effect, risking the possibility of gas embolism. In a series of patients with endobronchial lesions responsible for active bleeding, argon plasma coagulation immediately stopped bleeding in 100% of cases [58] (Fig. 41.7).

---

### Evidence-Based Review

See Table 41.3.

**Table 41.3** Evidence-based review: List of the most important publications on devices and substances used in endoscopic management of hemoptysis

Thrombin slurry [50]	2018	Peralta et al.	United States	13 patients	Hemostasis was achieved in ten cases (77%) by using standard measures in addition to thrombin slurry
Stents [54]	2017	Barisone et al.	Italy	8 patients	In six cases (75%), the stent placement resulted in bleeding cessation; in one case (12.5%), the bleeding was only briefly reduced
Biocompatible glue [59]	2016	Chawla et al.	India	168 patients	Immediate control of hemoptysis in 151 patients (89.9%); 17 patients had a transient response; a second application of glue was repeated in all of them, out of whom 13 (7.7%) responded to the second procedure; four (2.4%) failed to show any response despite the repeated procedure
Balloon tamponade [60]	2014	Correia et al.	Portugal	3 patients	The balloon was kept inflated for 72 h in the bleeding airway in the first 2 cases with complete resolution of the hemoptysis; in the last case, the balloon was kept inflated for 9 h, until surgery
Silicone Spigot [53]	2012	Bylicki et al.	France	9 patients	Thirteen spigots were inserted; the success rate was 78%
Nd:YAG Laser [55]	2007	Han et al.	Australia	110 patients	76% of patients reported improvement in dyspnea, 94% in hemoptysis, and 75% in cough
Recombinant activated factor VII [61]	2006	Heslet et al.	Denmark	6 patients	A complete and sustained hemostasis after a single dose of rFVIIa was seen in three patients (50%); a sustained hemostasis was achieved by a repeated rFVIIa administration, in the remaining three patients (50%)
Oxidized regenerated cellulose (ORC) [62]	2005	Valipour et al.	Austria	57 patients	Hemostatic tamponed with ORC was successfully performed on 56 of 57 patients (98%) with an immediate arrest of hemoptysis; all patients remained free of hemoptysis for the first 48 h
Argon plasma coagulation (APC) [58]	2001	Morice et al.	United States	60 patients	All patients with hemoptysis experienced a resolution of bleeding immediately after APC

## Summary

Hemoptysis is defined as the expectoration of blood from the lower respiratory tract. In most cases, the amount of bleeding is slight, the patient has hemoptoic sputum (sputum staining with blood streaks), and hemoptysis is self-limited. In other cases, the amount is more significant (evident hemoptysis) or may even present as massive hemoptysis (expectoration of fresh blood in significant quantities). However, it is preferable to use the term life-threatening hemoptysis, defined as the one that poses a risk to life for the patient.

The causes of hemoptysis are multiple and varied. The disease causing hemoptysis can affect the airway, lung parenchyma, or pulmonary ves-

sels. Although they vary according to the population studied, the most frequent causes of hemoptysis are bronchiectasis, chronic bronchitis, and bronchogenic carcinoma. On most occasions, bleeding comes from the bronchial arteries; sometimes other systemic non-bronchial arteries may be the source of hemoptysis. In a much lower percentage, the bleeding comes from the pulmonary arteries or from the pulmonary microcirculation.

Bronchoscopy plays a key role in the diagnosis and management of hemoptysis. It allows confirmation in doubtful cases, location of the bleeding point or, at least, location of the affected lung, and the determination of the cause in lesions accessible to it. It can allow the isolation of the



hemorrhagic segment or lobe to avoid flooding the non-affecting bronchial tree and reduce the risk of suffocation, by selective intubation or bronchial blockade with balloon, as well as the application of local therapies that contribute to controlling the bleeding.

In the last 3 years, there have been no significant changes in endoscopic management, except the introduction of the use of thrombin gel, although additional studies will be needed.

## Recommendations

1. In all patients with hemoptysis, a bronchoscopy is indicated unless the patient no longer has active bleeding and the cause of hemoptysis is known, or when hemoptoic expectoration is self-limited in a patient without risk factors for lung cancer.
2. The first objective of bronchoscopy is to confirm hemoptysis and assess its severity and location.
3. Bronchoscopy should be performed during active bleeding within the first 24–48 h.
4. In life-threatening hemoptysis, bronchoscopy should be performed immediately in order to control bleeding.
5. Location of the source of bleeding requires visualization to determine the bronchus or responsible bronchial area with certainty.
6. In the presence of a fresh clot, its immediate withdrawal should not be performed. It is preferable to have a subsequent examination to reduce the risk of rebleeding.
7. The use of tranexamic acid is recommended to reduce the duration and volume of bleeding in threatening hemoptysis.
8. Intubation in patients with threatening hemoptysis should be performed with endotracheal tubes of 8 mm or larger.
9. Once intubation has been performed, placement of an endobronchial blocker can protect the rest of the airway from the bleeding area.

## References

1. Gagnon S, Quigley N, Dutau H, Delage A, Fortin M. Approach to hemoptysis in the modern era. *Can Respir J*. 2017;2017:1565030.
2. Roig Cutillas J, Llorente Fernández JL, Ortega Morales FJ, Orriols Martínez R, Segarra MA. Manejo de la hemoptisis amenazante. *Arch Bronconeumol*. 1997;33:31–40.
3. Ibrahim WH. Massive haemoptysis: the definition should be revised. *Eur Respir J*. 2008;32:1131.
4. Chun JY, Morgan R, Belli AM. Radiological management of hemoptysis: a comprehensive review of diagnostic imaging and bronchial arterial embolization. *Cardiovasc Intervent Radiol*. 2010;33:240–50.
5. Bruzzi JF, Rémy-Jardin M, Delhay D, Teisseire A, Khalil C, Rémy J. Multidetector row CT of hemoptysis. *Radiographics*. 2006;26:3–22.
6. Jougon J, Ballester M, Delcambre F, Bride TM, Valat P, Gómez F, et al. Massive hemoptysis what place for medical and surgical treatment. *Eur J Cardiothorac Surg*. 2002;22:345–51.
7. Cordovilla R, Bollo de Miguel E, Nuñez A, Cosano JF, Herráez I, Jiménez MR. Diagnosis and treatment of hemoptysis. *Arch Bronconeumol*. 2016;52:368–77.
8. Mondoni M, Carlucci P, Cipolla G, Fois A, Gasparini S, Marani S, et al. Bronchoscopy to assess patients with hemoptysis: which is the optimal timing? *BMC Pulm Med*. 2019;19:36.
9. Ketai LH, Mohammed TL, Kirsch J, Kanne JP, Chung JH, Donnelly EF, et al. ACR appropriateness criteria hemoptysis. *J Thorac Imaging*. 2014;29:W19–22.
10. Mondoni M, Carlucci P, Job S, Parazzini EM, Cipolla G, Pagani M, et al. Observational, multicentre study on the epidemiology of haemoptysis. *Eur Respir J*. 2018;51:1701813.
11. Kolb T, Gilbert C, Fishman EK, Terry P, Pearse D, Feller-Kopman D, et al. Dieulafoy's disease of the bronchus. *Am J Respir Crit Care Med*. 2012;186:1191.
12. Khalil A, Parrot A, Nedelcu C, Fartoukh M, Marsault C, Carette MF. Severe hemoptysis of pulmonary arterial origin: signs and role of multidetector row CT angiography. *Chest*. 2008;133:212–9.
13. Nellaiyappan M, Omar HR, Justiz R, Sprenker C, Camporesi EM, Mangar D. Pulmonary artery pseudoaneurysm after Swan-Ganz catheterization: a case presentation and review of literature. *Eur Heart J Acute Cardiovasc Care*. 2014;3:281–8.
14. Savale L, Parrot A, Khalil A, Antoine M, Théodore J, Carette MF, et al. Cryptogenic hemoptysis: from a benign to a life-threatening pathologic vascular condition. *Am J Respir Crit Care Med*. 2007;175:1181–5.
15. Menchini L, Remy-Jardin M, Faivre JB, et al. Cryptogenic haemoptysis in smokers: angiography and results of embolization in 35 patients. *Eur Respir J*. 2009;34:1031–9.

16. Rasmussen V, Moore WD. Continued observations on Hæmoptysis. *Edinb Med J.* 1869;15:97–104.
17. Peys E, Stevens D, Weygaerde YV, Malfait T, Hermie L, Rogiers P, et al. Haemoptysis as the first presentation of COVID-19: a case report. *BMC Pulm Med.* 2020;20:275.
18. Müller NL. Hemoptysis: high-resolution CT vs bronchoscopy. *Chest.* 1994;105:982–3.
19. Hsiao EI, Kirsch CM, Kagawa FT, Wehner JH, Jensen WA, Baxter RB. Utility of fiberoptic bronchoscopy before bronchial artery embolization for massive hemoptysis. *Am J Roentgenol.* 2001;177:861–7.
20. Jean-Baptiste E. Clinical assessment and management of massive hemoptysis. *Crit Care Med.* 2000;28:1642–7.
21. Dweik R, Stoller JK. Role of bronchoscopy in massive hemoptysis. *Clin Chest.* 1999;20:89–105.
22. Patel SR, Stoller JK. The role of bronchoscopy in hemoptysis. In: Wang KP, Mehta AC, editors. *Flexible bronchoscopy.* Cambridge, MA: Blackwell Science; 1995. p. 298–321.
23. Prakash UBS, Freitag L. Hemoptysis and bronchoscopy-induced hemorrhage. In: Prakash UBS, editor. *Bronchoscopy.* New York: Raven Press; 1994. p. 227–49.
24. Herth F, Ernst A, Becker HD. Long-term outcome and lung cancer incidence in patients with hemoptysis of unknown origin. *Chest.* 2001;120:1592–4.
25. Khalil A, Soussan M, Mangiapan G, Fartoukh M, Parrot A, Carette MF. Utility of high-resolution chest CT scan in the emergency management of haemoptysis in the intensive care unit: severity, localization and aetiology. *Br J Radiol.* 2007;80:21–5.
26. Lee YJ, Lee SM, Park JS, Yim JJ, Yang SC, Kim YW, et al. The clinical implications of bronchoscopy in hemoptysis patients with no explainable lesions in computed tomography. *Respir Med.* 2012;106:413–9.
27. Thirumaran M, Sundar R, Sutcliffe IM, Currie DC. Is investigation of patients with haemoptysis and normal chest radiograph justified? *Thorax.* 2009;64:854–6.
28. O'Neil KM, Lazarus AA. Hemoptysis. Indications for bronchoscopy. *Arch Intern Med.* 1991;151:171–4.
29. Pramanik B. Hemoptysis with diagnostic dilemma. *Expert Rev Respir Med.* 2013;7:91–7.
30. Tak S, Ahluwalia G, Sharma SK, Mukhopadhy S, Guleria R, Pande JN. Haemoptysis in patients with a normal chest radiograph: bronchoscopy-CT correlation. *Australas Radiol.* 1999;43:451–5.
31. McGuinness G, Beacher JR, Harkin TJ, Garay SM, Rom WM, Naidich DP. Hemoptysis: prospective high-resolution CT/bronchoscopic correlation. *Chest.* 1994;105:1155–62.
32. Colice GL. Detecting lung cancer as a causa of hemoptysis in patients with a normal chest radiograph: bronchoscopy vs CT. *Chest.* 1997;111:877–84.
33. Wand O, Guber E, Guber A, Epstein Shochet G, Israeli-Shani L, Shitrit D. Inhaled tranexamic acid for hemoptysis treatment: a randomized controlled trial. *Chest.* 2018;154:1379–84.
34. Bellam BL, Dhibar DP, Suri V, Sharma N, Varma SC, Malhotra S, et al. Efficacy of tranexamic acid in haemoptysis: a randomized, controlled pilot study. *Pulm Pharmacol Ther.* 2016;40:80–3.
35. Moen CA, Burrell A, Dunning J. Does tranexamic acid stop haemoptysis? *Interact Cardiovasc Thorac Surg.* 2013;17:991–4.
36. Shapiro MJ, Albelda SM, Mayock RL, McLean GK. Severe hemoptysis associated with pulmonary aspergilloma. Percutaneous intracavitary treatment. *Chest.* 1988;94:1225–31.
37. Ortiz de Saracho J, Pérez-Rodríguez E, Zapatero J, Sánchez J, Navío P, Flores J. Therapeutic alternatives in complicated nonsurgical pulmonary aspergillomas. *Arch Bronconeumol.* 1995;31:83–5.
38. Haas AR. Management of massive hemoptysis. In: Ernst A, Herth FJF, editors. *Principles and practice of interventional pulmonology.* New York: Springer Science + Business Media; 2013. p. 455–62.
39. Ji L, Gascoigne A, Corris PA. The pulmonary physician in critical care. Illustrative case 7: assessment and management of massive hemoptysis. *Thorax.* 2003;58:814–9.
40. Sakr L, Dutau H. Massive hemoptysis: an update on the role of bronchoscopy in diagnosis and management. *Respiration.* 2010;80:38–58.
41. Freitag L, Tekolf E, Stamatis G, Montag M, Greschuchna D. Three years experience with a new balloon catheter for the management of haemoptysis. *Eur Respir J.* 1994;7:2033–7.
42. Kato R, Sawafuji M, Kawamura M, Kikuchi K, Kobayashi K. Massive hemoptysis successfully treated by modified bronchoscopic balloon tamponade technique. *Chest.* 1996;109:842–3.
43. Conlan AA, Hurwitz SS, Krige L, Nicolaou N, Pool R. Massive hemoptysis. Review of 123 cases. *J Thorac Cardiovasc Surg.* 1983;85:120–4.
44. Cahill BC, Ingbar DH. Massive hemoptysis. Assessment and management. *Clin Chest Med.* 1994;15:147–67.
45. Sharkey AJ, Brennan MD, O'Neill MP, et al. A comparative study of the haemostatic properties and cardiovascular effects of adrenaline and ornipressin in children using enflurane anaesthesia. *Acta Anaesthesiol Scand.* 1982;26:368–70.
46. Tuller C, Tuller D, Tamm M, Brutsche MH. Hemodynamic effects of endobronchial application of ornipressin versus terlipressin. *Respiration.* 2004;71:397–401.
47. Solomonov A, Fruchter O, Zuckerman T, Brenner B, Yigla M. Pulmonary hemorrhage: a novel mode of therapy. *Respir Med.* 2009;103:1196–200.
48. Márquez-Martín E, González Vergara D, Martín-Juan J, Romero Flacón A, López-Campos JL, Rodríguez-Panadero F. Endobronchial administration of tranexamic acid for controlling pulmonary bleeding. A pilot study. *J Bronchology Interv Pulmonol.* 2010;17:122–5.

49. de Gracia J, de la Rosa D, Catalán E, Álvarez A, Bravo C, Morell F. Use of endoscopic fibrinogen-thrombin in the treatment of severe hemoptysis. *Respir Med.* 2003;97:790–5.
50. Peralta AR, Chawla M, Lee RP. Novel bronchoscopic management of airway bleeding with absorbable gelatin and thrombin slurry. *J Bronchology Interv Pulmonol.* 2018;25:204–11.
51. Koegelenberg C, Bruwer JW, Bolliger CT. Endobronchial valves in the management of recurrent haemoptysis. *Respiration.* 2014;87:84–8.
52. Dutau H, Palot A, Haas A, Decamps I, Durieux D. Endobronchial embolization with a silicone spigot as temporary treatment for massive hemoptysis: a new bronchoscopic approach of the disease. *Respiration.* 2006;73:830–2.
53. Bylicki O, Vandemoortele T, Laroumagne S, Astoul P, Dutou H. Temporary endobronchial with silicone spigots for moderate hemoptysis: a retrospective study. *Respiration.* 2012;84:225–30.
54. Barisione E, Genova C, Grosso M, Pasquali M, Blanco A, Felletti R, et al. Palliative treatment of life-threatening hemoptysis with silicone stent insertion in advanced lung cancer. *Monaldi Arch Chest Dis.* 2017;87:781.
55. Han CC, Prasetyo D, Wright GM. Endobronchial palliation using Nd:YAG laser in associated with improved survival when combined with multimodal adjuvant treatments. *J Thorac Oncol.* 2007;2:59–64.
56. Hetzel MR, Smith SG. Endoscopic palliation of tracheobronchial malignancies. *Thorax.* 1991;46:325–33.
57. Shankar S, George PJ, Hetzel MR, Goldstraw P. Elective resection of tumours of the trachea and main carina after endoscopic laser therapy. *Thorax.* 1990;45:493–5.
58. Morice RC, Ece T, Ece F, Keus L. Endobronchial argon plasma coagulation for treatment of hemoptysis and neoplastic airway obstruction. *Chest.* 2001;119:781–7.
59. Chawla RK, Madan A, Aditya C. Glue in hemoptysis. *J Bronchology Interv Pulmonol.* 2016 Oct;23(4):e40–2.
60. Correia S, Dionísio J, Duro da Costa JJ. Modified technique of endobronchial balloon tamponade for persistent hemoptysis. *J Bronchology Interv Pulmonol.* 2014 Oct;21(4):361–5.
61. Heslet L, Nielsen JD, Levi M, Sengeløv H, Johansson PI. Successful pulmonary administration of activated recombinant factor VII in diffuse alveolar hemorrhage. *Crit Care.* 2006;10(6):R177.
62. Valipour A, Kreuzer A, Koller H, Loessler W, Burghuber OC. Bronchoscopy-guided topical hemostatic tamponade therapy for the management of life-threatening hemoptysis. *Chest.* 2005;127:2113–8.

---

**Part VIII**

**Interventional Pulmonary Medicine –  
History And Future Perspective**



# History of Bronchoscopy – The Evolution of Interventional Pulmonology

Tanmay S. Panchabhai, Michael Ghobrial,  
and Atul C. Mehta

## History

### “The Glottiscope” (1807)

The honor of being the Father of “Endoscopy” belongs to Philipp Bozzini [1, 2], who revealed the precursor of all endoscopes in 1807. He managed to deliver candle light into the bodily cavities through his invention of “light conductor” [Lichtleiter]. Speculums of various sizes and designs were created based on the cavities to be examined, embarking in the era of endoscopy. The “glottiscope,” invented in 1828 by Benjamin Guy Babington, for the first time allowed inspection and ability to visualize the laryngeal areas that were earlier not amenable to direct examination [2]. He carried this out by attaching a mirror to a tube to allow the reflection of light and images.

---

T. S. Panchabhai  
Norton Thoracic Institute, St. Joseph’s Hospital and  
Medical Center, Phoenix, AZ, USA  
e-mail: [Tanmay.panchabhai@dignityhealth.org](mailto:Tanmay.panchabhai@dignityhealth.org)

M. Ghobrial · A. C. Mehta (✉)  
Department of Pulmonary Medicine, Respiratory  
Institute, Cleveland Clinic, Cleveland, OH, USA  
e-mail: [mehtaal@ccf.org](mailto:mehtaal@ccf.org)

### “The Esophagoscope” (1895)

A Spanish music teacher and singer, Manuel Garcia, took it upon himself to try to look at the “voice box” of his students in an attempt to see how voice is produced. This indeed was the first known attempt to visualize the larynx, which he accomplished by using a dental mirror [3]. However, Alfred Kirstein (1895, Germany) was the first to report direct visualization of the vocal cords and proximal large airways, using an esophagoscope. He called this process autoscopia (i.e., examining the airways without a mirror) [4, 5].

### “Rigid Bronkoscopy”: From the Era of Gustav Killian (1876–) and Chevalier Jackson (1904–)

Gustav Killian is regarded as the Father of Modern Day Bronchoscopy (Fig. 42.1). He was born in Freiberg, Germany, and was an otolaryngologist. He examined the trachea and the main bronchi of a volunteer, using a laryngoscope, and was later able to remove a pork bone and three other foreign bodies from the main bronchi (Fig. 42.2). This incident was described later by his assistant O. Kollofrath as follows: “On March 30th of this year I had the honor to assist my admired principal, Prof. Killian, in extraction of a piece of bone from the right bronchus. This case is of such peculiarity with respect to its diagnos-

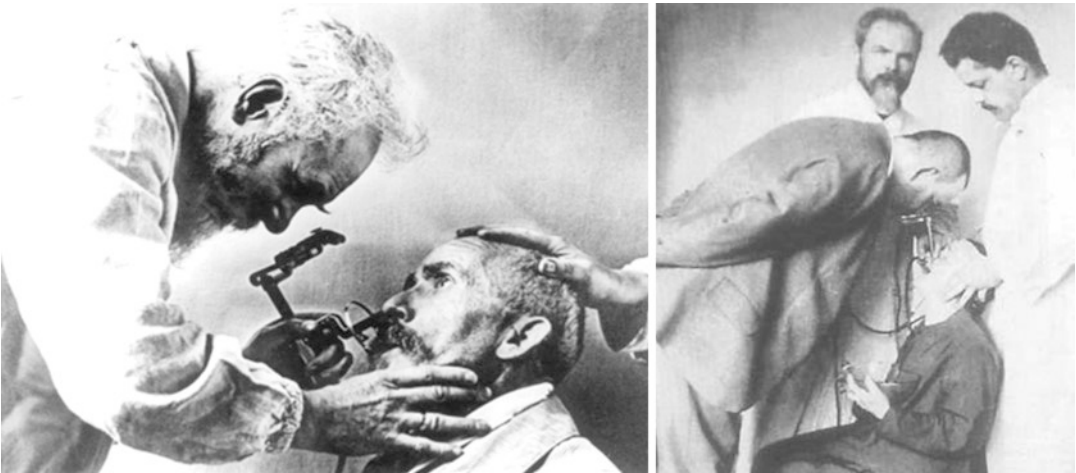




**Fig. 42.1** Gustav Killian—the Father of Bronchoscopy

tic and therapeutic importance that a more extensive description seems justified.” [5, 6] This memorable experience led Killian to coin the term “directe bronkoscopie.”


A direct ocular mechanism consisting of an illumination and suction tubing attached to a rigid bronchoscope was developed by a Philadelphia-based otolaryngologist, Chevalier Jackson (1904) (Figs. 42.3, 42.4, and 42.5). This is considered to be the precursor of the modern day rigid bronchoscopes. Dr. Jackson became renowned in his time for extracting aspirated or swallowed foreign bodies from children and adults. He kept meticulous records of every object he removed to help other doctors learn his techniques. The Mütter Museum in Philadelphia displays 2374 objects recovered by Dr. Jackson during his 75-year-long career. He conducted numerous hands-on training courses that were instrumental in increasing the acceptance of bronchoscopy. The Pan-American Association of Otolaryngology and the International Bronchoesophagology Society were founded by Dr. Jackson. In 1907, he published the first systematic textbook on bronchoesophagology and dedicated it to Killian, the “Father of Bronchoscopy.” [7] Notable men-



**Fig. 42.2** Gustav Killian performing bronchoscopy



**Fig. 42.3** Chevalier Jackson—the Father of American Bronchoesophagology



**Fig. 42.5** Chevalier Jackson working in a watermill to construct rigid bronchoscope

the trachea in 1976, and Hooper and Jackson for endobronchial electrocautery in 1985 [8].

### The Rigid Bronchoscope (1897–)

Killian's descriptions regarding bronchoscopic examination of the proximal airways were critical in providing inspiration to his coworkers Von Eiken, Brunings, Seiffert, and Albrecht, who worked on further development of the rigid bronchoscope. Storz and Wolf became the two pivotal companies that introduced newer technologies and newer versions of the rigid bronchoscope. On the other hand, the development of rigid bronchoscopy in the United States was brought about by Chevalier Jackson with his instrument maker, George Pilling. The next task at hand was the development of telescopic optics for bronchoscopy. This was accomplished by E. Broyles, who had trained under the mentorship of Dr. Jackson (1940). He then also went on to introduce the optical forceps in 1948 followed by fiber illumination techniques in 1962. The use of rigid bronchoscopy had declined since creation of the flexible bronchoscope until special tools for stent placement and neodymium-doped yttrium aluminum garnet (Nd:YAG) laser application were invented by J.-F. Dumon. The use of rigid bronchoscopy has since



**Fig. 42.4** The first illuminated rigid bronchoscope introduced by Chevalier Jackson

tion for other contributors who provided their valuable service in developing the field of bronchoscopy were: Edwin Broyles who developed an optical telescope with forward viewing, Paul H. Holinger for bronchoscopic photography, Neel and Sanderson for endobronchial cryotherapy, Laforet for the use of a CO<sub>2</sub> laser on

regained prominence, particularly for advanced therapeutic bronchoscopy [8].

### The Flexible Bronchoscope (1968–)

The potential of fiberoptic imaging in bronchoscopy was first recognized by Shigeto Ikeda (1962), a thoracic surgeon at the National Cancer Center in Japan (Fig. 42.6). He approached the Machida Corporation to develop a flexible bronchoscope with a diameter of less than 6 mm. In 1964, the prototype device was developed, which since then has undergone numerous revisions. In 1966, the first useful device was presented at Copenhagen in 1966. This device, comprised of over 15,000 glass fibers, was the first modern day fiberoptic bronchoscope [9].

After the optical technology was incorporated, the next round of modifications involved the

adoption of a working channel. This Machida flexible bronchoscope became available in 1968, which is known as the year of the “second revolution” in bronchoscopy. Researchers further revised the bronchoscope to make it more maneuverable at the tip that allows U-turn angulation for entry into the upper lobes. Olympus first came out with its model in 1970 with better imaging capabilities as well as ease of handling [9].

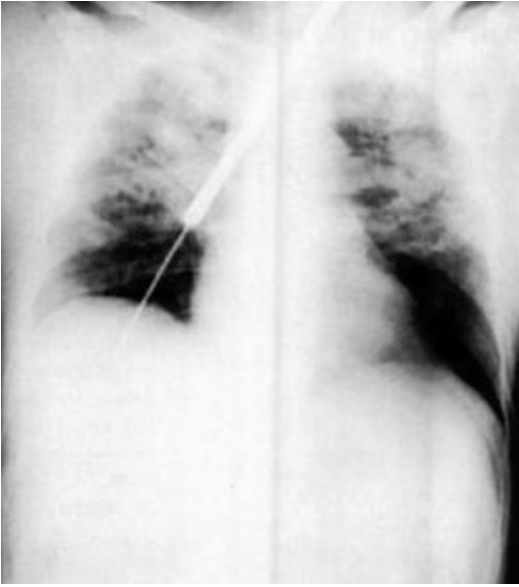
The first videobronchoscope developed by Asahi Pentax Corporation (1967) also involved significant contributions from Shigeto Ikeda [9]. Today, video bronchoscopy is an integral part of the practice of chest medicine as most ailments of the airways can be diagnosed, palliated, or sometimes cured by use of the flexible bronchoscope. Although removal of foreign bodies from the endobronchial tree was the initial application for the rigid bronchoscope, currently the majority of foreign bodies, even in the pediatric age group, are successfully removed with the flexible bronchoscope in a relatively noninvasive fashion [10].

### Transbronchial Lung Biopsy (1972) (Fig. 42.7)

Howard Anderson recognized the potential of accessing and sampling the lung parenchyma through the bronchoscope for histological analysis. After gaining some animal data with initial experiments, they reported their experience in obtaining bronchoscopic biopsies using a flexible forceps in 13 patients [11]. A subsequent larger series was published by Anderson and Fontana reporting data on 450 patients [12]. All biopsies performed by Anderson and colleagues were done using a flexible forceps passed through a rigid bronchoscope. These forceps were 60 cm in length and 7F in circumference. They also explained how they would engage a tiny peripheral bronchial carina with moderate pressure to obtain a small biopsy of the lung without causing a pneumothorax from pleural rupture. The rate of pneumothorax was 19% in the first 150 patients



**Fig. 42.6** Shigeto Ikeda with flexible bronchoscope



**Fig. 42.7** Transbronchial lung biopsy

and 11% in the next 300 patients [12]. Though this technique of lung biopsy was developed and utilized through the rigid bronchoscope, it is now standard of care to use a flexible bronchoscope for this sampling procedure. Transbronchial lung biopsies are standard of care in the diagnostic work-up of a variety of lung diseases and an inherent part of caring for lung transplant recipients [13, 14].

### **Flexible Transbronchial Needle Aspiration (1978–)**

The idea of transbronchial needle aspiration (TBNA) through the rigid bronchoscope was first proposed by Eduardo Schieppati (1958). He proposed that this technique can be accomplished by passing a needle through a rigid bronchoscope to puncture the main carina and sample mediastinal lymph nodes [15]. This concept was furthered by the work of Oho and colleagues [16]. The first report of sampling paratracheal tumors and masses was published in 1978 by Ko-Pen Wang



**Fig. 42.8** Ko-Pen Wang—inventor of the flexible TBNA

(Fig. 42.8) [17]. He successfully accomplished this technique via flexible bronchoscopy. He then further refined the technique by introducing a needle for histological specimen collection to help in diagnosing benign pathologies [18, 19]. Conventional TBNA (C-TBNA), which was commonly used in the 1980s and 1990s, has paved the way for the development of endobronchial ultrasound (EBUS)-guided transbronchial needle aspiration (EBUS-TBNA), which uses ultrasound technology via a probe at the apex of the scope to perform TBNA under direct visualization with ultrasonic images.

### **Laser Therapy (1981–)**

The technique of delivering laser light with a wavelength of 1064 nm via a flexible quartz filament was reported by Lucien Toty and colleagues in 1981. They first reported the use of this Nd:YAG laser in the airways through a rigid bronchoscope [20]. This laser beam had the



potential to coagulate or vaporize endobronchial lesions and abnormalities. The technique of using laser photoresection in patients with either malignant or benign lesions of the airway was further refined by J.-F. Dumon who also played a vital role in developing the techniques of airway stenting. He is considered the Father of Interventional Pulmonology and he propagated the use of endobronchial use of laser to bronchoscopists worldwide.

### **Endobronchial Argon Plasma Coagulation (APC) (1994–)**

The year 1994 saw a newer mode of electro-surgical, noncontact, thermal ablation technique by using ionized argon gas (argon plasma). This pioneering modality was introduced by Grund and colleagues [21]. With this technique, 102 patients were treated endoscopically in 189 sessions with APC in the upper and lower gastrointestinal tracts as well as in the respiratory system. Lesions treated were mainly malignant and benign tumors, diffuse hemorrhages of various origins and sites, tissue overgrowth after stent implantation, tissue remnants after endoscopic resections, and the conditioning of fistulas prior to fibrin sealing. APC was easy and effective in all cases via flexible bronchoscopy with minimal technical or other complications over standard electrocoagulation. Endobronchial APC currently offers the simplicity and low cost of an electrocoagulator with the noncontact approach of an Nd:YAG laser. The noncontact feature of APC allows rapid coagulation with minimal manipulation and mechanical trauma to the target tissue [22].

### **Endobronchial Stents (1990–)**

The very first stent implantation was accomplished by Trendelenburg and Bond for the treatment of central airway strictures [23, 24]. This technique has made rapid progress since 1965.

Montgomery designed the first T-tube with an external side limb made of silicone for tracheal stenosis [25]. J.-F. Dumon achieved a major breakthrough in airway stenting when he introduced a dedicated tracheobronchial prosthesis. This stent has a unique external surface with studs to preserve mucociliary action [26]. Since most pulmonologists in the United States are not trained in rigid bronchoscopy for stent placement, the utility of such stents has been limited. On the other hand, flexible bronchoscopy to place metallic stents is relatively easy but results in a significant amount of granulation tissue. This tissue reaction makes removal of these stents very challenging including possibility of airway laceration. Thus, their role is limited mainly to malignant processes, and they are the treatment of choice for bronchial dehiscence, especially after lung transplantation [27]. *The ideal stent* is one that is “easy to insert and remove, can be customized to fit the dimensions and shape of a stricture, reestablishes luminal patency by resisting compressive forces but is sufficiently elastic to conform to airway contours without causing ischemia or erosion into adjacent structures, is not prone to migration, biocompatible, non irritating, and does not precipitate infection, promote granulation tissue, nor interferes with airway ciliary action necessary to clear secretions, and that is affordable” [28].

That ideal stent does not yet exist [28]. At present, highly specialized technology including three-dimensional printing with advanced radiographics is being employed to device stents specific for each patient’s individual airway anatomy [29].

### **Bronchoscopy in Lung Transplantation (1992–)**

Since 1986 when the first lung transplant was performed, about 50,000 transplants have been performed in the United States for end-stage lung diseases. The most common complications post



lung transplant are: infection and rejection. Both these broad diagnostic categories cannot be narrowed upon without flexible bronchoscopy. Hence, the success of lung transplantation, however, cannot be imagined without the use of the flexible bronchoscope. This argument is supported by the study by Trulock and colleagues where they found a surprisingly high incidence of acute rejection in asymptomatic lung transplant recipients undergoing transbronchial biopsy [30]. The sensitivity of transbronchial lung biopsy was estimated at 72% for the diagnosis of acute rejection and 91% for the diagnosis of cytomegalovirus pneumonia. Surveillance bronchoscopy is performed in the first year after transplant in many lung transplant programs because the incidence of acute rejection resulting in graft dysfunction is highest in this period. Some others perform flexible bronchoscopy with transbronchial biopsies only when clinically indicated (i.e., drop in lung function or new radiographic abnormalities). Nevertheless, both approaches aim to detect subclinical, clinical acute cellular rejection and antibody-mediated rejection. Flexible bronchoscopy is also crucial in the diagnosis and management of airway complications after lung transplantation [31].



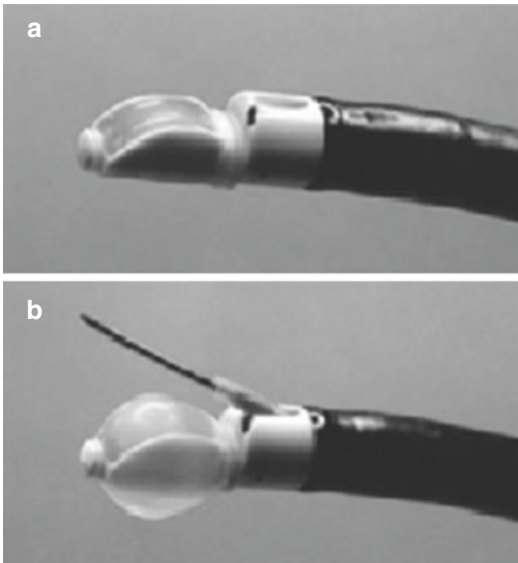
**Fig. 42.9** Heinrich Becker—promoter of the radial probe EBUS

### Radial Probe Ultrasound (1992–) (Fig. 42.9)

C-TBNA demonstrated the ability to access and sample mediastinal lymph nodes. However, the anatomy of the bronchial tree and associated vasculature make direct visualization of structures quite important, especially in the paratracheal regions and the hila. Ultrasound technology has made it possible to noninvasively assess most regions of the body. This concept led investigators to pursue real-time target visualization at the time of sampling. It was the pioneering work of Heinrich Becker that brought to fore the immense potential of applying ultrasound technology to the endobronchial region. This led to the development of EBUS or endobronchial ultrasound to guide sampling of mediastinal lymph nodes and parenchymal lesions [32]. Hurter and Hanrath first reported the usefulness of radial probe EBUS (RP-EBUS) in 74 patients with central lesions and 26 patients with parenchymal lesions in consecutive procedures [33]. Although radial probe endobronchial ultrasound (RP-EBUS) continues to play a pivotal role in the diagnosis of peripheral pulmonary lesions, a major limitation of RP-EBUS, however, is that after localizing the lesion, sampling is still performed in a blind fashion. Investigators have however worked on other technologies to localize pulmonary masses and use real-time sampling in addition to RP-EBUS. This limitation has paved the way for the development of the convex probe EBUS (CP-EBUS) [34].

### Convex Probe Endobronchial Ultrasound (2004–)

Convex probe ultrasound was developed as an attempt to utilize real-time ultrasound technology to sample mediastinal lymph nodes and lung lesions. The distal end of the EBUS bronchoscope has a larger diameter than a flexible bronchoscope, with an angulated forward view at a 30-degree inclination (Fig. 42.10). This



**Fig. 42.10** Convex probe EBUS. (a) Tip of the Endobronchial Ultrasound Bronchoscope. (b) Tip of the bronchoscope with inflated balloon and a biopsy needle inserted through the working channel



**Fig. 42.11** Kazuhiro Yasafuku

is necessary for imaging the lymph nodes and lung lesions and anchoring the scope to the airway while the needle comes out of a slightly

proximal opening. The field of bronchoscopy imported the concept of linear probe ultrasound endoscopes from gastroenterology, after they were developed to sample paraesophageal lesions under real-time guidance. Pedersen and colleagues first described the usefulness of linear EBUS in sampling mediastinal lesions in 1996 [35]. Kazuhiro Yasufuku and colleagues (Fig. 42.11) first demonstrated the high diagnostic yield of the convex probe EBUS (CP-EBUS) in sampling mediastinal lesions [36]. Both studies reported a sensitivity of 96% and specificity of 100% for distinguishing between malignant and nonmalignant lesions [37]. Currently, CP-EBUS has become standard of care for diagnosis and staging of lung cancer as well as the diagnostic work-up of sarcoidosis and interstitial lung diseases [38, 39]. As shown in the granuloma trial, CP-EBUS-TBNA alone has been shown to have a high diagnostic yield for sarcoidosis. The yield is even higher when transbronchial lung biopsies are performed to complement it [40]. Thus, CP-EBUS has almost replaced surgical mediastinoscopy with a less invasive option.

### Electromagnetic Navigation (2003–)

Although the problem of proximal lymph nodes and lung lesions has been solved by the development of RP-EBUS, accessing peripheral lung parenchymal lesions that are closer to the distal endobronchial tree still poses significant challenges. Electromagnetic navigation (EMN) is a technology that has been in continuous evolution since the late 1990s. This concept of navigating the bronchial tree or “global positioning system (GPS) of the lung” originated in Stephen Solomon’s animal laboratory [41]. The technique was refined and applied for the first time in humans by Yehuda Schwarz and colleagues in 2006 [42]. This technique involves a sensor and a computer-integrated magnetic-field generator, which, when coupled with a three-dimensional map created by computerized tomography, helps to visualize small peripheral nodules. This three-

dimensional map essentially is used to create a pathway all the way from the proximal bronchus to the distal bronchus in <1 cm (10 mm) proximity to the lung mass and nodule to be sampled. EMN has now been widely studied and Gildea and colleagues described their yield of 74% and 100% with navigational bronchoscopy for sampling peripheral lesions and lymph nodes with a mean size of  $22.8 \pm 12.6$  mm and  $28.1 \pm 12.8$  mm, respectively [43]. Other factors and adjunct technologies that increase the yield of EMN are: concomitant RP-EBUS, guided sheath techniques, multidimensional fluoroscopy, and rapid onsite cytology evaluation (ROSE). With the results of the National Lung Screening Trial, navigational bronchoscopy coupled with a staging procedure using CP-EBUS is currently the main procedure adopted for the diagnosis and staging of peripheral lung nodules [44].

### **Bronchial Thermoplasty (2006–)**

Using heat to induce structural changes in the airway wall and hence decrease airway reactivity is the basic principle of bronchial thermoplasty (BT). The Alair system from Boston Scientific uses a radiofrequency controller with a treatment catheter to deliver 18 W of heat at each treatment site. Preliminary investigations in dogs showed that application of thermal energy to the airway decreased airway hyperresponsiveness, and replaced smooth muscle with connective tissue with no evidence of scarring at 3 years [45].

After early investigations testing the usefulness of BT in human subjects, Gerard Cox and colleagues established the safety of BT in 16 human subjects over a 2-year period with improvements in symptom-free days, and morning and evening peak flow rates, and without significant complications [46, 47].

The safety of BT and duration of its effects in patients with asthma in terms of decreased emergency room visits and acute exacerbations have been demonstrated in a large multicenter study [48].

### **Bronchoscopic Lung Volume Reduction (2003)**

The National Emphysema Treatment Trial (NETT) proved the beneficial effects of surgical lung volume reduction in carefully selected patients with emphysema [49]. As lung volume reduction surgery (LVRS) is a major surgery with post-surgical mortality and morbidity, significant interest was generated in the possibility of endobronchial lung volume reduction using minimally invasive techniques. Tudor Toma introduced the concept of endobronchial volume reduction using one-way valves in 2003 [50]. Since then two different types of endobronchial valves (EBVs), Zephyr (Pulmonx Inc.) and IBV (Spiration Inc.), have undergone multiple safety and efficacy trials [51, 52].

The utility of endobronchial valves (EBVs) remains experimental in the United States. However, one major spin-off of the technology has been the application of EBVs to the management of bronchopleural fistula. Researchers have clearly shown that EBVs help heal these fistulas, thereby eliminating the need for surgical thoracic procedures [53]. It is also worth noting that the role of endobronchial coils in reestablishing elastic recoil of the lungs in patients with emphysema is being studied in a large international, multicenter trial [54].

### **Endobronchial Microwave Therapy (2004–)**

Microwave coagulation refers to the electromagnetic wave with wavelengths ranging from 1 m to 1 mm, or with frequencies between 300 MHz and 300 GHz, which fall in between the high-frequency electric-argon plasma and laser coagulation techniques.

It is a fairly safe procedure because it induces no tissue vaporization and requires no oxygen during the operation. In addition, it has an appreciable treatment depth. It has been used to treat the trachea blockage condition caused by benign and malignant tumors within the airway, intima hyperplasia of tuberculosis, polyps, granulomas, and other complications.

Bronchoscopic microwave tissue coagulation (MTC) and microwave diathermy (MD) therapy were performed on 37 patients with severe tracheal stenosis at least two times. The effective rate immediately after treatment was 100% in all cases. After 1 month, the rate remained 100% in patients with benign diseases, but it dropped to 67% in patients with malignant tumors [55].

### **Endoscopic Doppler Optical Coherence Tomography and Autofluorescence Imaging (DOCT-AFI) System (2014–) [56]**

Autofluorescence imaging (AFI) can provide biochemical information of tissue by visualizing fluorescent tissue components such as collagen and elastin. AFI has been implemented in commercial bronchoscopes for wide-field imaging in the central airway. When illuminated by blue light, normal central airway tissue emits green autofluorescence (AF) while cancerous tissue is known to have a markedly reduced and red-shifted AF signal due to the breakdown of extracellular matrix components as well as increased absorption by blood [57].

Owing to this contrast mechanism, AFI is up to six times more sensitive compared to white-light bronchoscopy in detecting intraepithelial neoplastic lesions [58, 59]. This increased sensitivity comes at the cost of reduced specificity as inflammation and chronic bronchitis can also lead to reduced AF.

Optical coherence tomography (OCT) can visualize significantly finer tissue structures compared to RP-EBUS with 1–2 mm imaging depth penetration into tissue.

This imaging technique can offer both structural and functional information for the localization and management of pulmonary nodules.

This technology is relatively safe and feasible for the evaluation of pulmonary nodules.

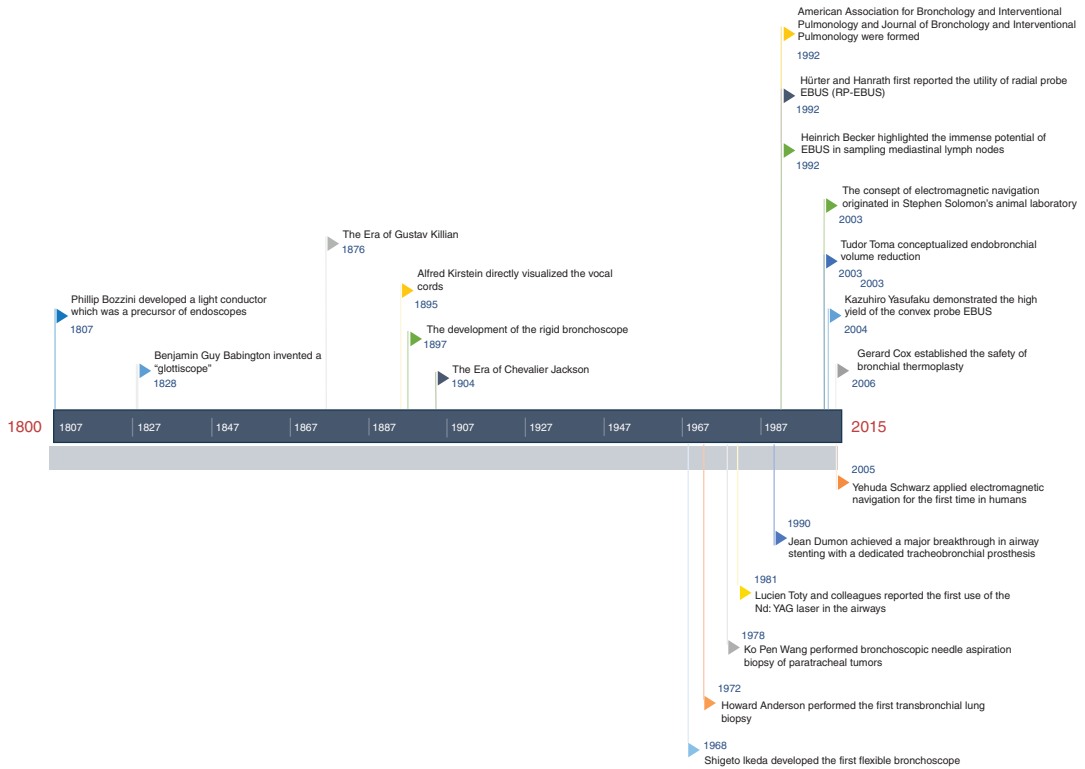
AFI can readily identify the vasculature pattern and suspicious areas along centimeters-long airway segments. Once identified, closer examination of OCT can verify if the site is appropriate for biopsy collection. Thus, DOCT-AFI may increase the ability to identify and locate pulmonary nodules and improve the safety of biopsy collection [60].

### **American Association for Bronchology and Interventional Pulmonology (AABIP) and Journal of Bronchology and Interventional Pulmonology (JOBIP) (1992–)**

AABIP was founded in 1992 by a small group of dedicated bronchoscopists with the goal of advancing the field of bronchoscopy and interventional pulmonology. The AABIP has successfully helped develop training and education programs in interventional pulmonology. The training programs in interventional pulmonology now work with the national residency matching program (NRMP). In addition, board certification has now been established for the specialty of interventional pulmonology that has further strengthened this subspecialty within the domains of pulmonary medicine.

*JOBIP*, the flagship publication of the society, was accepted in *Index Medicus* in 2011. This was a major boost to the research output and recognition of interventional pulmonology around the world [61, 62].

In this chapter and other articles, we have attempted to give the readers a brief glimpse of the development of modern day bronchoscopes and the innovation and creativity that went into building this present day science and technology (Fig. 42.12) [63]. These techniques have revolutionized the diagnosis and management of a variety of lung diseases and advances continue to be made therein [63].



**Fig. 42.12** Timeline of innovation in bronchoscopy (Adapted with permission from Ref. 63)

**References**

1. Engel RM. Philipp Bozzini--the father of endoscopy. *J Endourol.* 2003;17(10):859–62.
2. Reuter HJ, Reuter MA, Loenicker D. Philipp Bozzini und die Endoskopie des 19. Jahrhunderts: Max-Nitze-Museum; 1988.
3. García M. Beobachtungen ober die Menschliche Stimme. Wien: Wilhelm Braumüller; 1878.
4. Hirsch N, Smith G, Hirsch P. Alfred Kirstein. *Anaesthesia.* 1986;41(1):42–5.
5. Becker HD, Marsh BR. Interventional bronchoscopy. In: Anonymous, editor. *History of the rigid bronchoscope.* Basel: Karger Publishers; 2000. p. 2–15.
6. Kollofrath O. Entfernung eines Knochenstücks aus dem rechten Bronchus auf natürlichem Wege und unter Anwendung der directen Laryngoscopie. *MMW.* 1897;38:1038–9.
7. Jackson C. *Tracheo-bronchoscopy, esophagocopy and gastroscopy,* vol. 22. St. Louis, MO: Laryngoscope Company; 1907. p. 613.
8. Beamis Jr JF, Mathur PM. Interventional bronchoscopy. In: Anonymous, editor. *Interventional pulmonology: current status and future direction.* Springer; 2013. p. 3–14.
9. Miyazawa T. Interventional bronchoscopy. In: Anonymous, editor. *History of the flexible bronchoscope.* Basel: Karger Publishers; 2000. p. 16–21.
10. Swanson KL, Prakash UB, Midthun DE, et al. Flexible bronchoscopic management of airway foreign bodies in children. *Chest J.* 2002;121(5):1695–700.
11. Andersen HA, Fontana RS, Harrison EG. Transbronchoscopic lung biopsy in diffuse pulmonary disease. *Chest J.* 1965;48(2):187–92.
12. Andersen HA, Fontana RS. Transbronchoscopia lung biopsy for diffuse pulmonary diseases: technique and results in 450 cases. *Chest J.* 1972;62(2):125–8.
13. Koerner SK, Sakowitz AJ, Appelman RI, Becker NH, Schoenbaum SW. Transbronchial lung biopsy for the diagnosis of sarcoidosis. *N Engl J Med.* 1975;293(6):268–70.
14. Levin DC, Wicks AB, Ellis JH Jr. Transbronchial lung biopsy via the fiberoptic bronchoscope 1, 2. *Am Rev Respir Dis.* 1974;110(1):4–12.



15. Schieppati E. Mediastinal lymph node puncture through the tracheal carina. *Surg Gynecol Obstet.* 1958;107(2):243–6.
16. Oho K, Kato H, Ogawa I, Hayashi N, Hayata Y. A new needle for transfiberoptic bronchoscopic use. *Chest.* 1979;76(4):492.
17. Wang KP, Terry P, Marsh B. Bronchoscopic needle aspiration biopsy of paratracheal tumors I. *Am Rev Respir Dis.* 1978;118(1):17–21.
18. Wang KP, Johns CJ, Fuenning C, Terry PB. Flexible transbronchial needle aspiration for the diagnosis of sarcoidosis. *Ann Otol Rhinol Laryngol.* 1989;98(4):298–300.
19. Mehta AC, Kavuru MS, Meeker DP, Gephardt GN, Nunez C. Transbronchial needle aspiration for histology specimens. *Chest.* 1989;96(6):1228–32.
20. Toty L, Personne C, Colchen A, Vourc'h G. Bronchoscopic management of tracheal lesions using the neodymium yttrium aluminium garnet laser. *Thorax.* 1981;36(3):175–8.
21. Grund KE, Storek D, Farin G. Endoscopic argon plasma coagulation (APC) first clinical experiences in flexible endoscopy. *Endosc Surg Allied Technol.* 1994;2(1):42–6.
22. Morice RC, Ece T, Ece F, Keus L. Endobronchial argon plasma coagulation for treatment of hemoptysis and neoplastic airway obstruction. *Chest J.* 2001;119(3):781–7.
23. Trendelenburg F. Beiträge zu den Operationen an den Luftwegen. Tamponade der Trachea. *Arch Klin Chir.* 1871;12:121–33.
24. Bond CJ. Originally published as volume 1, issue 3523 Note on the treatment of tracheal stenosis by a new T-shaped tracheotomy tube. *Lancet.* 1891;137(3523):539.
25. MONTGOMERY WW. T-tube tracheal stent. *Arch Otolaryngol.* 1965;82(3):320–1.
26. Dumon J. A dedicated tracheobronchial stent. *Chest J.* 1990;97(2):328–32.
27. Mughal MM, Gildea TR, Murthy S, Pettersson G, DeCamp M, Mehta AC. Short-term deployment of self-expanding metallic stents facilitates healing of bronchial dehiscence. *Am J Respir Crit Care Med.* 2005;172(6):768–71.
28. Lee P, Kupeli E, Mehta AC. Airway stents. *Clin Chest Med.* 2010;31(1):141–50.
29. Gildea T. 3D printing: innovation allows customized airway stents. *Respir Exch.* 2014;12–13.
30. Trulock E, Ettlinger N, Brunt EM, Pasque MK, Kaiser LR, Cooper JD. The role of transbronchial lung biopsy in the treatment of lung transplant recipients. An analysis of 200 consecutive procedures. *Chest J.* 1992;102(4):1049–54.
31. Santacruz JF, Mehta AC. Airway complications and management after lung transplantation: ischemia, dehiscence, and stenosis. *Proc Am Thorac Soc.* 2009;6(1):79–93.
32. Becker H. Endobronchial ultrasound—a new perspective in bronchoscopy. *Lung Cancer.* 1996;1(16):112–3.
33. Hurter T, Hanrath P. Endobronchial sonography: feasibility and preliminary results. *Thorax.* 1992;47(7):565–7.
34. Memoli JSW, Nietert PJ, Silvestri GA. Meta-analysis of guided bronchoscopy for the evaluation of the pulmonary nodule. *Chest J.* 2012;142(2):385–93.
35. Pedersen BH, Vilmann P, Folke K, et al. Endoscopic ultrasonography and real-time guided fine-needle aspiration biopsy of solid lesions of the mediastinum suspected of malignancy. *Chest J.* 1996;110(2):539–44.
36. Yasufuku K, Sekine Y, Chhajed P, et al. Direct endobronchial ultrasound guided transbronchial needle aspiration of mediastinal lymph nodes using a new convex probe bronchoscope: a novel approach. *Am J Respir Crit Care Med.* 2003;167:A577.
37. Yasufuku K, Chiyo M, Sekine Y, et al. Real-time endobronchial ultrasound-guided transbronchial needle aspiration of mediastinal and hilar lymph nodes. *Chest J.* 2004;126(1):122–8.
38. von Bartheld MB, Dekkers OM, Szlubowski A, et al. Endosonography vs conventional bronchoscopy for the diagnosis of sarcoidosis: the GRANULOMA randomized clinical trial. *JAMA.* 2013;309(23):2457–64.
39. Silvestri GA, Gonzalez AV, Jantz MA, et al. Methods for staging non-small cell lung cancer: diagnosis and management of lung cancer: American College of Chest Physicians evidence-based clinical practice guidelines. *Chest J.* 2013;143(5\_suppl):e211S–50S.
40. Gupta D, Dadhwal DS, Agarwal R, Gupta N, Bal A, Aggarwal AN. Endobronchial ultrasound-guided transbronchial needle aspiration vs conventional transbronchial needle aspiration in the diagnosis of sarcoidosis. *Chest J.* 2014;146(3):547–56.
41. Solomon SB, White P, Acker DE, Strandberg J, Venbrux AC. Real-time bronchoscope tip localization enables three-dimensional CT image guidance for transbronchial needle aspiration in swine. *Chest J.* 1998;114(5):1405–10.
42. Schwarz Y, Greif J, Becker HD, Ernst A, Mehta A. Real-time electromagnetic navigation bronchoscopy to peripheral lung lesions using overlaid CT images: the first human study. *Chest J.* 2006;129(4):988–94.
43. Gildea TR, Mazzone PJ, Karnak D, Meziame M, Mehta AC. Electromagnetic navigation diagnostic bronchoscopy: a prospective study. *Am J Respir Crit Care Med.* 2006;174(9):982–9.
44. National Lung Screening Trial Research Team. Results of initial low-dose computed tomographic screening for lung cancer. *N Engl J Med.* 2013;368(16):1980–91.
45. Danek CJ, Lombard CM, Dungworth DL, et al. Reduction in airway hyperresponsiveness to methacholine by the application of RF energy in dogs. *J Appl Physiol.* 2004;97(5):1946–53.
46. Cox PG, Miller J, Mitzner W, Leff AR. Radiofrequency ablation of airway smooth muscle for sustained treatment of asthma: preliminary investigations. *Eur Respir J.* 2004;24(4):659–63.

47. Cox G, Miller JD, McWilliams A, FitzGerald JM, Lam S. Bronchial thermoplasty for asthma. *Am J Respir Crit Care Med.* 2006;173(9):965–9.
48. Wechsler M, Laviolette M, Rubin A. Asthma intervention research 2 trial study group bronchial thermoplasty: long-term safety and effectiveness in patients with severe persistent asthma. *J Allergy Clin Immunol.* 2013;132(6):1295–302.
49. National Emphysema Treatment Trial Research Group. A randomized trial comparing lung-volume-reduction surgery with medical therapy for severe emphysema. *N Engl J Med.* 2003;348(26):2059–73.
50. Toma TP, Hopkinson NS, Hillier J, et al. Bronchoscopic volume reduction with valve implants in patients with severe emphysema. *Lancet.* 2003;361(9361):931–3.
51. Wood DE, McKenna RJ, Yusef RD, et al. A multicenter trial of an intrabronchial valve for treatment of severe emphysema. *J Thorac Cardiovasc Surg.* 2007;133(1):65–73. e2
52. Sciruba FC, Ernst A, Herth FJ, et al. A randomized study of endobronchial valves for advanced emphysema. *N Engl J Med.* 2010;363(13):1233–44.
53. Feller-Kopman D, Bechara R, Garland R, Ernst A, Ashiku S. Use of a removable endobronchial valve for the treatment of bronchopleural fistula. *Chest J.* 2006;130(1):273–5.
54. Slebos D, Klooster K, Ernst A, Herth FJ, Kerstjens HA. Bronchoscopic lung volume reduction coil treatment of patients with severe heterogeneous emphysema. *Chest J.* 2012;142(3):574–82.
55. Liu W, Dai L, Lin Y. The efficacy of microwave therapy via bronchofiberscope in the treatment of severe trachea stenosis. *J Innov Opt Health Sci.* 2013;6(01):1350006.
56. Pahlevaninezhad H, Lee AM, Shaipanich T, et al. A high-efficiency fiber-based imaging system for co-registered autofluorescence and optical coherence tomography. *Biomed Opt Express.* 2014;5(9):2978–87.
57. Hung J, Lam S, Leriche JC, Palcic B. Autofluorescence of normal and malignant bronchial tissue. *Lasers Surg Med.* 1991;11(2):99–105.
58. Kennedy TC, Lam S, Hirsch FR. Review of recent advances in fluorescence bronchoscopy in early localization of central airway lung cancer. *Oncologist.* 2001;6(3):257–62.
59. Lam S, Kennedy T, Unger M, et al. Localization of bronchial intraepithelial neoplastic lesions by fluorescence bronchoscopy. *Chest J.* 1998;113(3):696–702.
60. Pahlevaninezhad H, Lee AM, Ritchie A, et al. Endoscopic Doppler optical coherence tomography and autofluorescence imaging of peripheral pulmonary nodules and vasculature. *Biomed Opt Express.* 2015;6(10):4191–9.
61. Prakash UB. The American Association for Bronchology and the Journal of Bronchology. *J Bronchology Interv Pulmonol.* 1994;1(1):1.
62. Serman D. A remarkable time for the American Association for Bronchology and Interventional Pulmonology. *J Bronchology Interv Pulmonol.* 2012;19(4):265–7.
63. Panchabhai TS, Mehta AC. Historical perspectives of bronchoscopy - connecting the dots. *Ann Am Thorac Soc.* 2015;12(5):631–41.

# Index

## A

- ABS consensus guidelines, 192
- Absorbable/biodegradable stents, 661
- Adenocarcinoma, 319, 320
- Advanced diagnostic bronchoscopy, 71
- Aero-digestive fistulas (ADF)
  - diagnosis, 673, 674
  - endoscopic methods, 681, 682
  - etiology
    - benign ADF, 671, 672
    - cancer treatment, 670, 671
    - congenital ADF, 669
    - malignant ADF, 670
  - location, 679
  - pathology, 669
  - prognosis, 669
  - quality of life, 678, 679
  - retrospective studies, 679
  - stents
    - advantage, 676
    - cardiac septal defect occluder, 680, 681
    - characteristics, 676
    - clinical, radiological and endoscopic examination, 678
    - complications, 679, 680
    - DJ-fistula stent, 680
    - esophageal and airway, 678
    - generation, 675, 676
    - history, 675
    - indications, 678
    - requirements, 678
    - silicone and self-expanding metal, 676–678
    - types, 675
    - treatment options, 674, 675
- Aforementioned techniques, 189
- Air bronchogram, 533
- Airway bypass tracts, 624, 625
- Airway devices, 81–82
- Airway foreign body (FB) aspiration
  - causes, 696
  - clinical presentation
    - acute FB, 698, 699
    - bronchoscopy, 700, 701
    - radiologic findings, 700
    - retained FB, 698–700
  - complications
    - bleeding and hemoptysis, 707
    - distal airway impaction, 707, 708
    - follow-up, 709
    - iron pill aspiration, 708, 709
    - mortality, 707
  - definition, 685
  - epidemiology and risk factors, 688
  - history, 685
  - inorganic, 688–694
  - management
    - ablative therapies, 705
    - balloons, 704
    - baskets, 703, 704
    - cryotherapy, 705, 706
    - electrocautery and APC, 706
    - grasping forceps, 702–704
    - laser therapy, 706
    - retrieval procedure, 701, 702
    - rigid vs. flexible bronchoscopy, 701
    - suction instruments, 704, 705
    - surgical management, 706
  - mineral, 690, 694
  - organic, 688, 689
  - PDT, 695, 696
  - pills and capsules, 693–696
  - stents, 695
  - swallowing
    - functional physiology, 686, 687
    - upper airway embryological development and anatomy, 686
    - upper airway protective reflexes, 687, 688
- Airway smooth muscle (ASM), 633
- Airway stent placement, 30–31
- Airway stenting
  - AQuIRE registry, 278
  - CAO, 265–267
  - conservative measurement, 259
  - contraindications, 283
  - deployment, 278
  - ECAC, 269–271

- Airway stenting (*Cont.*)  
 endoluminal component, 259  
 ERF, 267–269  
 for expiratory central airway collapse, 271–273  
 extrinsic compression, 260  
 features, 257, 258  
 follow-up and patient education, 284  
 granulation tissue, 279–281  
 historical perspective, 258, 259  
 incidence proportion, 279  
 intraluminal obstruction, 261–264  
 lower respiratory infection and mucus obstruction, 282  
 migration, 282, 283  
 modifiable risk factors, 278  
 perioperative complications, 279  
 POTS, 264, 265  
 stent fracture, 282  
 stump fistulas, 267  
 technique and equipment, 277, 278  
 for tracheal stenosis, 271
- AlloDerm, 682
- American Association for Bronchology and  
 Interventional Pulmonology (AABIP), 743
- American College of Chest Physicians (ACCP), 73, 466
- Aminolevulinic acid (ALA), 204
- Amplatzer device, 680
- Anderson, Howard, 736, 737
- Anterior-posterior X-ray fluoroscopic image, 193
- Anti-programmed death-ligand 1 (PDL-1)  
 monotherapy, 185
- Anti-tumor immune response, 220, 221
- AQURE registry, 278
- Argentinean Association for Bronchology (AABE), 128
- Argon plasma coagulation (APC), 16, 30, 156, 244,  
 245, 738
- Argon-dye and diode lasers, 208
- Assisted ventilation, 83
- Asthma, OCT, 385
- Augmented fluoroscopy, 84
- Autofluorescence bronchoscopy (AFB), 364, 365,  
 370, 371
- Autofluorescence imaging (AFI), 742
- Autofluorescence-optical coherence tomography  
 (AF-OCT), 387, 388
- Autologous corticocancellous bone grafts, 681
- B**
- Babington, Benjamin Guy, 733
- Basal pyramid, 12
- Basal pyramid bronchus, 12
- Becker, Heinrich, 739, 740
- Benign airway stenosis  
 bronchial stenosis post lung transplantation, 231  
 bronchoscopy, 234, 235  
 classification, 237–240  
 congenital tracheal stenosis, 228  
 cryotherapy, electrocautery and APC, 244, 245  
 dilatation, 241, 242  
 distal bronchial stenosis, 231, 232  
 effective management, 240  
 endoscopic treatment, 241  
 iatrogenic tracheal stenosis, 228–230  
 imaging techniques, 232, 233  
 infectious stenosis, 230  
 ITS, 230, 231  
 laser treatment, 242, 244  
 patient history, 232  
 pulmonary function test, 235, 236  
 results, 248, 249, 251  
 stents placement, 245–248  
 surgical treatment, 251, 252  
 treatment implementation, 246, 247
- Benzodiazepines, 77, 78
- Benzoporphyrin derivate (BPD), 204
- Bleeding diathesis, 19
- Brachytherapy (BT), 190
- BronchAtlas™, 98
- Bronchial arterial supply, 13
- Bronchial arteries, 13
- Bronchial brushings, 23
- Bronchial thermoplasty  
 efficacy and safety  
 long term, 634  
 short term, 634  
 trials, 634, 635  
 equipment, 636, 637  
 mechanism of action, 633  
 patient selection, 635, 636  
 post-procedure, 639  
 pre-procedure, 636  
 randomized controlled trials, 633  
 treatment, 636–639
- Bronchial thermoplasty (BT), 663, 741
- Bronchoalveolar lavage (BAL), 22  
 cell patterns and diagnosis, 643, 644  
 definition, 641, 642  
 technical aspects, 642, 643
- Bronchogenic carcinoma, 151
- Bronchoscopic laser resection (LAMR), 157, 165, 166
- Bronchoscopy, 88, 153
- Bronchoscopy education  
 assessment tools, 96, 101–104  
 bronchoscopy-related consultation, 98  
 digital simulation, 88  
 ethics of teaching, 104–105  
 procedure-related medical instruction, 87  
 technical skills, 98
- Bronchus sign, 346
- Broyles, Edwin, 735
- C**
- Canadian Thoracic Society (CTS), 128
- Cardiac disease, 64
- Cardiovascular function, 71
- Carina, 12, 13
- Carinal stenosis, 109
- Central airway obstruction (CAO), 28, 151, 219, 655, 656
- Central early-stage lung cancer (CELC) lesions, 214

- Central nervous system (CNS) toxicity, 75  
Centres for Disease Control and Prevention (CDC), 121  
Cervical trachea, 11  
Charged coupled device (CCD), 17  
Chartis™ system, 623  
Chest tubes  
  complications, 549, 551  
  contraindications, 546  
  empyema, 549  
  hemothorax, 549, 550  
  history, 545  
  MPE, 550  
  overview of, 545, 546  
  pleural drainage systems, 551, 552  
  pneumothorax, 549, 550  
  procedural technique  
    blunt operative dissection technique, 547  
    Cook® Thal-Quick chest tube, 549  
    Cook® Wayne Pneumothorax catheter, 547, 548  
    small-bore pigtail catheters, 547, 548  
    triangle of safety, 546, 547  
  size considerations, 550, 551  
  troubleshooting, 551  
Chest ultrasound (CUS)  
  advantages, 521  
  brightness mode, 521, 522  
  chest wall pathology, 524–527  
  color Doppler and spectral analysis curve, 521, 522  
  COVID, 539, 540  
  depth function, 522  
  diaphragm evaluation, 535, 536  
  extrathoracic lymph nodes, 536, 537  
  focus function, 522  
  freeze function, 522  
  gain function, 522  
  intervention and therapeutics, 538, 539  
  intrapulmonary processes, 521  
  motion mode, 521, 522  
  normal thorax, 522–524  
  parasternal and supraclavicular approaches, 522  
  patient position, 522  
  pleural pathology  
    effusions, 527–530  
    pneumothorax, 531, 532  
    thickening, 530, 531  
  pulmonary pathology  
    interstitial lung diseases, 534  
    neoplastic consolidation, 534  
    passive/compression lung atelectasis, 534  
    pneumonia, 533  
    post-obstructive atelectasis, 534  
    pulmonary embolism/lung infarction, 535  
    white hemothorax, 534  
Chinese Thoracic Society (CMA), 128  
Chronic obstructive pulmonary disease (COPD), 83, 386  
Chylothorax, 562, 563  
Cisratrium, 80  
CO<sub>2</sub> laser, 162  
Coils, 627, 628  
Cone beam computed tomography (CBCT)  
  accurate visualization, 434  
  diagnostic accuracy, 447  
  diagnostic bronchoscopy, 439  
  EMN-guided bronchoscopy, 445, 446  
  forceps, 441, 444  
  hardware, 438, 439  
  image acquisition, 436–438  
  investigation, 441  
  limitations, 448  
  limitations and challenges, 440, 441  
  mobile CT technology, 447, 448  
  vs. multidetector CT, 435, 436  
  peripheral bronchoscopy, 444, 445  
  planning room setup and workflow, 439, 440  
  propensity-matched analysis, 446, 447  
  pulmonary nodules, 441  
  radiation dosages, 447  
  radiation dose, 440  
  robotic bronchoscopy, 445  
  VBN technology, 445  
Cone-beam computed tomography (CBCT), 27–28, 84  
Confocal laser endomicroscopy (CLE) system, 371  
Congenital tracheal stenosis, 228  
Conventional cryotherapy, 30  
Conventional transbronchial needle aspiration (TBNA), 310  
Convex probe endobronchial ultrasound (CP-EBUS)  
  for biomarker testing, 409  
  complications, 410  
  equipment, 395, 398–400  
  for malignant mediastinal/hilar adenopathy, 403, 404  
  for non-malignant mediastinal/hilar adenopathy, 402, 403  
  NSCLC, 404–409  
  scanning technique, 399–402  
Cook® Thal-Quick chest tube, 549  
Cook® Wayne Pneumothorax catheter, 547, 548  
Coronavirus disease (COVID), 127  
  administrative and organizational measures, 118  
  airway and aerosol-generating procedures, 117  
  bronchoscopy for outpatients, 130  
  clearance, 131–132, 136  
  CUS, 539, 540  
  environmental control, 118–122  
  equipment processing, 135–136  
  foreign body aspiration, 125  
  infectivity, 142  
  inpatients, 131  
  intubated patients, 123–124  
  lung cancer diagnosis and staging, 129–130  
  massive haemoptysis, 125  
  non-intubated COVID-19 patient, 134–135  
  non-intubated patients, 123  
  optimization of circuits, 122  
  pandemic, 49, 663, 664  
  patient safety, 128  
  patient selection, 129–131  
  personal protective equipment, 122  
  preparing for next pandemic, 137  
  provider safety, 128–129



Coronavirus disease (COVID) (*cont.*)  
 recommendations, 125  
 respiratory failure, 132–134  
 room turnover, 135–136  
 SARS-CoV2, 127  
 screening, 129–131  
 severe central airway obstruction, 125  
 specimen handling, 135–136  
 type and prioritization of IP procedures, 121  
 universal screening of asymptomatic patients, 131

Cox, Gerard, 741

Cryoablation, 169, 180–182

Cryoadhesion, 169, 172, 173

Cryoadhesive effect, 173

Cryobiopsy, 21

Cryoextraction, 176

Cryoprobes, 171

Cryorecanalization, 175

Cryotherapy and cryospray, 30, 174, 176, 244, 245  
 advantages of, 185  
 blood clot removal, 177  
 contraindications, 184–185  
 cryoablation, 180–182  
 cryoadhesion  
 contraindications of, 179  
 cryorecanalization, 174–175  
 endobronchial cryobiopsy, 176, 177, 179  
 and foreign body removal, 175–176  
 indications, 174  
 mucus plugs/blood clot retrieval, 176  
 safety concerns, 179–180  
 TBLC, 179  
 endobronchial cryobiopsy, 178  
 equipment, 170–172  
 evidence, 184  
 history, 169–170  
 indications, 182–184  
 limitations, 185–186  
 mechanism of action, 172  
 safety concerns, 184–185  
 thermal ablation therapies, 186

Cryotherapy equipment, 170

Cryptogenic organising pneumonia (COP), 644

Cufflink-shaped prosthesis (DJ-fistula stent), 680

Culmen bronchus, 12

Curvilinear probe EBUS (CP-EBUS), 493

## D

Decortication, 574, 577, 580, 581

Dental prosthesis, 65

Dexmedetomidine, 80

Diffuse alveolar hemorrhage (DAH), 643

Digital simulation, 88

Diode laser, 57, 162

Distal bronchial stenosis, 231, 232

Dumon, J.-F., 738

Dumon-Harrel rigid bronchoscope, 53

Dumon-Harrel system innovation, 53

Dutau-Novatech rigid bronchoscope (DNRB), 54

Dyspnea, 109

## E

Early-stage lung cancer (ESLC), 212–214

Edge™ catheter-extended working channel (EWC), 418, 419

Electrocautery (EC), 30, 60, 156, 244, 245

Electromagnetic guidance transthoracic needle aspiration (ETTNA), 426

Electromagnetic navigation (EMN), 740, 741  
 complications, 428, 429  
 definition, 416  
 diagnostic yield, 423–426  
 EMN-SD (*see* SuperDimension™ Navigation System (EMN-SD))  
 EMN-VM, 422, 423  
 ETTNA, 426  
 therapeutic interventions, 426–428

Electromagnetic navigation (ENB), 84

Electromagnetic navigation bronchoscopy (EMN), 16, 350, 351

Electronic mechanical jet ventilation, 83–84

Empyema, 549

Empyema thoracis  
 biochemical analysis, 575, 576  
 classification, 571, 572  
 clinical presentation, 574  
 epidemiology, 573  
 history, 572  
 incidence, 572  
 microbiology, 576, 577  
 non-operative management  
 antibiotic selection, 577  
 intrapleural fibrinolytic therapy, 578  
 multi-center trial, 578, 579  
 thoracentesis, 577, 578  
 tube thoracostomy, 578  
 pathogenesis, 573, 574  
 prognostication, 579  
 radiologic evaluation, 574, 575  
 surgical management  
 decortication, 580, 581  
 exudative effusions, 579  
 fibrinopurulent effusions, 580  
 survivorship, 581  
 VATS, 580

Endobronchial airway stents  
 absorbable/biodegradable stents, 661  
 CAO, 659  
 indications, 659  
 metallic stents, 659, 660  
 silicone stents, 660–662

Endobronchial approach, 186

Endobronchial brachytherapy (EBBT)  
 adjuvant treatment, 197  
 anterior-posterior digitally reconstructed radiograph, 193  
 application of the technique, 192–196  
 brachytherapy catheter, 190  
 complications, 198  
 contraindications, 192  
 definition, 189–190  
 equipment needed, 190–192  
 evidence-based review, 196–197

- HDRafterloading technique, 191
    - history, 190
    - indications, 192
    - palliative treatment, 198
    - recommendations, 192, 198
    - standard definitive therapy, 198
    - tumor debulking, 189
  - Endobronchial cryobiopsy, 176–179
  - Endobronchial cryotherapy, 169, 182
  - Endobronchial microwave therapy, 742
  - Endobronchial Nd-YAG laser, 156
  - Endobronchial tumors, 164
  - Endobronchial ultrasound (EBUS), 16, 21, 179, 368
    - bronchoscope, 81, 82
    - CP-EBUS (*see* Convex probe endobronchial ultrasound (CP-EBUS))
    - history, 393
    - internal body structures, 393, 394
    - RP-EBUS (*see* Radial probe endobronchial ultrasound (RP-EBUS))
  - Endobronchial ultrasound-guided fine needle aspiration (EBUS-FNA), 466
  - Endobronchial ultrasound guided transbronchial needle aspiration (EBUS-TBNA), 94, 309, 310, 493, 653, 654
  - Endobronchial valve placement, 31
  - Endobronchial valves, 622–624, 662, 663
  - Endocytoscopy system (ECS), 371
  - Endoluminal obstruction, 155
  - Endoluminal polypoid tumors, 166
  - Endoscopic chemocauterization, 681
  - Endoscopic images of video-mediastinoscopy, 474
  - Endoscopic lung volume reduction (ELVR)
    - airway bypass tracts, 624, 625
    - biologic/polymer lung volume reduction, 625, 627
    - bronchoscopic thermal vapor ablation, 629
    - coils, 627, 628
    - COPD, 629
    - definition, 619, 620
    - endobronchial valves, 622–624
    - equipment, 621
    - history, 620
    - indications and contraindications, 620, 621
  - Endoscopic ultrasound with fine needle aspiration (EUS-FNA), 310, 495, 496
  - Endotracheal tube (ETT), 68, 82
  - Enlarged lymph nodes, 3
  - ERBE probe cryotherapy systems, 170
  - ERBECRYO® 2 console, 171
  - Esophagoglottal closure reflex (EGCR), 687
  - Esophago-respiratory fistulas (ERF), 267–269
  - European Respiratory Society (ERS), 128
  - European Respiratory Society and the American Thoracic Society (ERS/ATS), 73
  - European Society for Medical Oncology (ESMO), 129
  - European Society of Thoracic Surgeons (ESTS)
    - guidelines, 466, 473
  - Evident hemoptysis, 719
  - Exophytic tumors, 208
  - Expiratory central airway collapse (ECAC), 269–271
  - Extended cervical mediastinoscopy (ECM), 475–476, 494, 497
  - Extent of pleural carcinomatosis (EPC), 607
  - Extracorporeal membrane oxygenation (ECMO), 147
  - Extrathoracic stenosis, 112
- F**
- Fixed intrathoracic stenosis, 111, 112
  - Flexible Alair catheter, 636, 637
  - Flexible bronchoscopy (FB), 37, 51
    - advanced diagnostic bronchoscopy, 24–28
    - anesthesia and monitoring, 20
    - complications of, 21–22
    - contraindications, 18, 19
    - diagnostic procedures, 22–24
    - equipment, 19
    - flexible bronchoscope, 16
    - history of, 15
    - indications for, 18
    - patient preparation, 19
    - personnel, 19
    - technique of, 21
    - therapeutic procedures, 28–31
    - uses and applications of, 15
  - Flexible cryotherapy probes, 171, 174
  - Flow-limiting segment (FLS), 109
  - Flow–volume curve, 110
  - Fluoroscopy, 42, 44
  - Fowler's lobule, 518
  - Fraction inspired oxygen (FiO<sub>2</sub>), 80
- G**
- GammaMediX, 191
  - General anesthesia, 79
  - German Respiratory Society (DGP), 128
  - GMEDIX HDR remote afterloader, 191
  - Goblet mucous cells, 7
  - Grasping forceps, 702–704
  - Ground glass/lepidic pattern (GG/L), 329, 330
- H**
- Hemoptoic expectoration, 719
  - Hemoptysis
    - airway protection, 722–724
    - bronchoscopy
      - diagnosis, 716–720
      - location, 716
    - definition, 713
    - equipment, 721
    - etiology, 713–715
    - evidence-based review, 727
    - history, 715, 716
    - management, 721, 722
    - therapeutic bronchoscopy, 720
      - advantage, 723
      - bronchial blockade systems, 725, 726
      - instillation of hemostatic drugs, 725
      - laser coagulation, 726
      - rigid bronchoscope, 724
      - selective bronchial blockade, 724, 725
  - Hemothorax, 549, 550

- High magnification bronchovideoscope (HMB), 365, 366, 368
- High-dose-rate endobronchial brachytherapy (HDR-EBBT), 192
- monotherapy CT-based plan, 194
  - procedure, 193, 194
  - treatment, 194
- Holinger, Paul H., 735
- Hypoxemia, 76
- I**
- Iatrogenic tracheal stenosis, 228–230
- Idiopathic tracheal stenosis (ITS), 230, 231
- Ikeda, Shigeto, 736
- Incidental lung nodules
- awareness, 301
  - follow-up, 301
  - incidence, 301
  - management, 302
  - screening pathway, 302
- Indwelling pleural catheters (IPCs)
- chylothorax, 562, 563
  - competency and training, 565, 566
  - complications, 560
  - complications and management, 564, 565
  - follow-up and removal, 563, 564
  - history, 552, 553
  - indications and contraindications, 553
  - MPEs, 560, 561
    - catheter related infections, 595, 596
    - dislodged catheter, 597
    - during placement, bleeding, 594
    - kinked IPC, 595
    - mechanical complications, 597
    - non-expandable lung, 589, 599, 600
    - pain, 597
    - pleurodesis, 598, 599
    - pneumothorax, 594, 595
    - quality of life, 594
    - safety profile, 594
    - tumor seeding of insertion tract, 597, 598
  - NMPE, 561, 562
  - non-expandable lung, 561
  - pleurodesis, 563
  - procedural technique and necessary equipment, 553–560
- Inferior mediastinoscopy, 476
- Inflammatory disease, 160
- Inoperable central airway stenosis, 109
- Intensive care units (ICU), 63
- Intermediate bronchus, 12
- Intermedius bronchus, 10
- International Society for Infectious Disease (ISID), 128
- Interstitial lung diseases (ILD), 534, 641
- BAL
- cell patterns and diagnosis, 643, 644
  - definition, 641, 642
  - technical aspects, 642, 643
- BRAVE clinical trials, 648
- DNA and protein microarrays, 648
- pathogenesis, 648
- sarcoidosis, 646, 648
- TLB-C, 644–647
- Interventional bronchoscopy
- anesthesia of the mouth and oropharynx, 76
  - ASA physical status, 73
  - assessment of flow-volume curve, 109
  - assessment of lateral airway pressure, 110–112
  - benzodiazepines, 77
  - cardiovascular system exam, 74
  - conscious sedation, 77–79
  - contraindications, 73–79
  - dental inspection, 74
  - dexmedetomidine, 80
  - during COVID-19 pandemic, 85
  - dyspnea, 109
  - equipment needed, 81–84
  - FiO<sub>2</sub>, 80
  - flow limitation, 109
  - general anesthesia, 79
  - history, 72
  - indications, 73–79
  - informed consent, 75
  - ketamine, 80
  - laboratory testing, 74
  - MAC, 79
  - medical history, 73
  - modes of ventilation, 82–84
  - monitoring the depth of anesthesia, 80–81
  - muscle relaxants, 80
  - nasal mucosa and nasopharynx, 76
  - opioids, 78
  - peripheral diagnostic and therapeutic bronchoscopy, 84–85
  - pharmacodynamics of, 78
  - physical examination, 73–75
  - positive pressure controlled mechanical ventilation, 83
  - postprocedure care, 84
  - pressure-pressure curve, 112–113
  - procedure-related indications, 75
  - propofol, 79
  - pulmonary function tests, 75
  - radiographic studies, 74
  - recurrent laryngeal nerve block, 77
  - remifentanyl, 80
  - respiratory system assessment, 74
  - side effects of local anesthetics, 75–76
  - superior laryngeal nerve, 76
  - superior Laryngeal nerve block, 77
  - TIVA, 79
  - topical anesthesia, 75
- Interventional pulmonology (IP)
- bronchial thermoplasty, 663
  - bronchoscopy (*see* Bronchoscopy)
  - COVID-19 pandemic, 663, 664
  - definition, 651
  - diagnostic procedures
    - cryobiopsy, 654, 655
    - EBUS-TBNA, 653, 654

- virtual navigational bronchoscopy, 654, 655
- endobronchial valves, 662, 663
- history
  - AABIP, 743
  - AFI, 742
  - bronchial thermoplasty, 741
  - bronchoscopic lung volume reduction, 741, 742
  - convex probe ultrasound, 740, 741
  - EMN, 740, 741
  - endobronchial APC, 738
  - endobronchial microwave therapy, 742
  - endobronchial stents, 738
  - esophagoscope, 733
  - flexible bronchoscope, 736
  - flexible TBNA, 737, 738
  - glottiscope, 733
  - innovation, 743
  - JOBIP, 743
  - laser therapy, 738
  - lung transplantation, 739
  - optical coherence tomography, 742
  - radial probe ultrasound, 739, 740
  - rigid bronchoscope, 733–736
  - transbronchial lung biopsy, 736, 737
- pediatric airway, 652, 653
- therapeutic procedures
  - CAO, 655, 656
  - dilation procedures, 656, 657
  - endobronchial airway stents (*see* Endobronchial airway stents)
  - mechanical debridement, 658, 659
  - thermal techniques, 657, 658
- training programs, 651
- Intrathoracic stenosis, 113
- Inverse square law, 191
- Ion endoluminal system
  - description and design, 458
  - diagnostic yield, 461
- Iron pill aspiration, 708, 709
  
- J**
- Jackson, Chevalier, 734, 735
- Jet ventilation, 83
- Joule-Thompson effect, 172
- Journal of Bronchology and Interventional Pulmonology (JOBIP), 743
  
- K**
- Ketamine, 80
- Killian, Gustav, 733, 734
- Kirstein, Alfred, 733
- Kultschitzky cells, 159
  
- L**
- Laryngeal adductor reflex, 687
- Laryngeal mask airway (LMA), 81–82, 185
- Laser assisted mechanical resection (LAMR), 156, 157, 163
- Laser bronchoscopy
  - adjacent lung tumor, 151
  - airway obstruction, 152
  - application of technique, 163–166
  - benign and malignant tumors, 157–159
  - clinical presentation, 152
  - diagnosis, 152–153
  - endobronchial coagulation and disobstruction, 152
  - endotracheal intubation, 151
  - equipment needed, 160–163
  - evidence based review, 166–167
  - history, 156–157
  - inflammatory disease, 160
  - inflammatory tracheo-bronchial strictures, 152
  - treatment, 153–156
  - tumors with uncertain prognosis, 159–160
- LASER bronchoscopy, 28
- Laser bronchoscopy application, 57, 58
- Laser energy, 162
- Laser power, 162
- Laser resection, 164
- Laser therapy, 16, 156
- Laser vaporization, 164
- Laser-assisted bronchoscopy, 157
- Lateral airway pressure, 111
- Left atrium dilatation, 3
- Left lower lobe bronchus, 10, 12
- Left main bronchus (LMB), 10, 12
- Left parasternal mediastinotomy, 475
- Left pulmonary artery, 13
- Left upper lobe bronchus, 10, 12
- Lidocaine, 65
- Lingular bronchus, 12
- Local anesthesia, 71, 72
- Long-lasting COVID19 symptoms, 136
- Lower lobe bronchus, 10
- Lung cancer
  - adrenal and hepatic metastases, 487
  - anterior mediastinoscopy, 497, 498
  - biomarkers, 488–490
  - bone, 487, 488
  - brain, 487, 488
  - chest x-ray, 490
  - computerized tomography, 490, 491
  - early detection
    - AFB, 364, 365, 370, 371
    - application, 367, 372
    - classification, 373, 374
    - CLE system, 371
    - contraindications, 368–370
    - EBUS, 368
    - endocytoscopy system, 371
    - evidence-based review, 372, 373
    - HMB, 365, 366, 368
    - indications, 368–370
    - NBI, 364–366
    - OCT, 368
    - Raman spectrophotometry, 371, 372
  - EBUS-TBNA, 493
  - ECM, 494, 497

- Lung cancer (*Cont.*)  
 EUS-FNA, 495, 496  
 extrathoracic disease, 486  
 history and physical examination, 307, 308, 485  
 incidence, 484  
 magnetic resonance imaging, 492, 493  
 medical thoracoscopy, 607  
 navigational and robotic bronchoscopy, 493–495  
 NSCLC, 485  
 OCT, 384, 385  
 oligometastatic lesion, 486  
 paraneoplastic syndromes, 485  
 patient history, 485, 487, 489, 490, 496–499  
 PET-CT, 486  
 pleura and pleural effusion, 486, 487  
 positive emission tomography, 491, 492  
 SCM, 496, 497  
 surgical vs. minimally invasive techniques, 498, 499  
 TBNA, 495, 496  
 TNM, 484  
 transthoracic needle aspiration, 495  
 VATS, 498
- Lung cancer screening  
 benefits and risks, 297, 298, 300  
 in China, 301  
 eligibility criteria, 300  
 in Europe, 300  
 historical review, 294–297  
 incidental findings, 302, 303  
 incidental lung nodules, 301, 302  
 in Japan, 300, 301  
 in South Korea, 301  
 in US, 300
- Lung Ultrasound Score (LUS), 539  
 LungPoint®, 42  
 Lymph node biopsies, 472, 473
- M**
- Main bronchi, 10  
 Main left bronchus, 13  
 Main right bronchus, 13  
 Malignant central airway obstruction (CAO), 151, 265–267  
 Malignant pleural effusions (MPEs), 550, 560, 561  
 chylothorax, 600, 601  
 clinical manifestation, imaging studies, and diagnosis, 587–589  
 definition, 585, 586  
 evaluation, 590, 591  
 initial intervention, 590, 592, 593  
 IPC  
 catheter related infections, 595, 596  
 dislodged catheter, 597  
 during placement, bleeding, 594  
 kinked IPC, 595  
 mechanical complications, 597  
 non-expandable lung, 589, 599, 600  
 pain, 597  
 pleurodesis, 598, 599  
 pneumothorax, 594, 595  
 quality of life, 594  
 safety profile, 594  
 tumor seeding of insertion tract, 597, 598  
 longitudinal management, 593  
 parietal pleurectomy, decortication, and pleuro-pneumonectomy, 600  
 pathogenesis, 585, 586  
 repeated thoracenteses, 593  
 Mallampati classification, 73, 74  
 Massive airway bleeding, 176  
 Mechanical ventilation, 141  
 Mediastinal lymphadenopathy, 109  
 Mediastinoscopic biopsy, 476  
 Mediastinoscopy  
 biopsies, 472, 473  
 complications, 475  
 contraindications, 466–467  
 control of haemostasis and closure, 473–475  
 conventional mediastinoscopy versus video-mediastinoscopy, 479  
 definition, 465  
 equipment needed, 467–469  
 extended cervical mediastinoscopy, 475–476  
 history, 465–466  
 incision and initial dissection, 471  
 indications, 466–467  
 inferior mediastinoscopy, 476  
 insertion of mediastinoscope, 472  
 mediastinal inspection, 472  
 mediastinoscopic biopsy, 476  
 mediastino-thoracoscopy, 476–477  
 operative field, 470  
 palpation, 471–472  
 patient's position, 470  
 postoperative care, 475  
 preoperative care, 469–470  
 recommendations, 480  
 staging values, 479–480  
 technical variants of, 475  
 TEMPLA, 479  
 VAMLA, 477–479  
 Mediastino-thoracoscopy, 476–477  
 Medical thoracoscopy  
 definition, 605  
 diagnostic indications  
 hematologic malignancy and breast cancer, 608  
 lung cancer, 607  
 mesothelioma, 607  
 tuberculosis, 608  
 equipment, 610, 611  
 history, 605  
 pleural effusions, 606, 607  
 pre-procedural preparations and considerations, 611  
 prevalence, 605  
 procedural safety and contraindications, 610  
 procedural technique, 611–613  
 therapeutic indications  
 drug delivery, 610  
 pleurodesis for malignant pleural effusion, 609



- pleurodesis of pneumothorax, 609
    - thoracoscopic drainage, 609, 610
  - vs. VATS, 613
  - Medical training, 87
  - Mesothelioma, medical thoracoscopy, 607
  - Metallic stents, 659, 660
  - Methemoglobinemia, 76
  - Microbacterial resistance, 220
  - Middle lobe bronchus, 12
  - Minimally invasive procedures
    - CT-guided transthoracic biopsy, 312
    - EBUS-TBNA, 309, 310
    - EUS-FNA, 310
    - extrathoracic metastases, 313, 314
    - fluoroscopy-guided transthoracic biopsies, 312
    - mediastinoscopy, 308, 309
    - navigational bronchoscopy-guided procedures, 311, 312
    - pleural biopsy, 313
    - radial-probe EBUS-guided procedures, 310, 311
    - TBNA, 310
    - thoracotomy, 313
    - US-guided transthoracic biopsy, 312, 313
  - Mitral stenosis, 3
  - Moderate sedation/analgesia, 71
  - Molecular testing, 318, 319
  - Monarch platform
    - description and design, 454–457
    - diagnostic yield, 461
  - Monitored anesthesia care (MAC), 72, 79–85
  - Monophonic wheezing, 152
  - M-tetrahydroxifenil cloro (mTHPC), 204–205
  - Multidetector CT (MDCT), 435, 436
  - Multiple papillomatous lesions, 157
- N**
- Nanoparticles, 205
  - Nanostructured lipid carriers (NLCs), 205
  - Narrow band imaging (NBI), 21, 364–366
  - N-Aspartyl Chlorin e6 (NPE6), 204
  - National emphysema treatment trial (NETT), 619
  - Navigational bronchoscopy, 21
  - Nd:YAG laser, 161, 166, 197, 215–218
  - Nd:YAP laser, 162
  - Near infrared-photoimmunotherapy (NIR-PIT), 221
  - Neck flexibility, 470
  - Neoadjuvant therapy, 219
  - Neoplastic consolidation, 534
  - New sensitizers, 219, 220
  - Non-invasive ventilation (NIV), 83, 123, 124, 163–164
  - Non-malignant pleural effusions (NMPE), 561, 562
  - Non-small cell lung cancer (NSCLC), 404–409
  - Nothing per os (NPO), 75
- O**
- Obstructive sleep apnea (OSA), 387
  - Oesophageal ultrasound-guided FNA (EUS-FNA), 466
  - Optical coherence tomography (OCT), 219, 368
  - airway and lumen calibration, 387
  - asthma, 385
  - COPD, 386
  - diagnostic bronchoscopy, 379, 380
  - endoscopic AF-OCT system, 381–383, 387, 388
  - history, 380, 381
  - lung cancer, 384, 385
  - OSA, 387
  - preclinical studies, 383
  - PS-OCT, 387
- P**
- Palpation, 472
  - Para-aminobenzoic acid (PABA), 76
  - Parapneumonic effusions, *see* Empyema thoracis
  - Pediatric rigid bronchoscopy, 61–62
  - Percutaneous tracheostomy
    - airway security, 141
    - contraindications, 143
    - equipment needed, 143–144
    - evidence-based review, 146–147
    - lessens airway resistance, 141
    - mechanical ventilation, 142
    - modifications, 144–145
    - patient selection, 142
    - procedural technique, 144–145
    - recommendations, 147
    - tracheostomy-related evidence, 143
  - Peripheral pulmonary lesion (PPL), 493
    - cone beam CT, 352
    - definition, 341
    - EBUS, 349, 350
    - EMN, 350, 351
    - fluoroscopy, 344–347
    - historical perspective, 342, 343
    - LungVision system, 352, 353
    - rEBUS, 347, 348
    - ROSE, 358, 359
    - sampling instruments, 354–358
    - trans-parenchymal access, 351, 352
    - virtual bronchoscopy, 349
  - Personal protection equipment (PPE), 128
  - Pharyngoglottal closure reflex (PGCR), 687
  - Photo-chemical internalization (PCI), 220
  - Photodynamic therapy (PDT), 30, 205, 206, 695, 696
    - advanced lung cancer
      - advanced-stage non-small cell lung cancer, 217, 218
      - commentary, 218
      - complementary endoscopic methods, 219
      - Nd-YAG laser, 215–217
      - rationale, 215
    - anti-tumor immune response, 220, 221
    - complementary endoscopic methods, 218, 219
    - contraindications, 212
    - curative PDT indications, 210
    - early-stage lung cancer, 212–214
    - first generation photosensitizers, 203
    - investigation of new sensitizers, 219, 220

- Photodynamic therapy (PDT) (*Cont.*)  
 microbacterial resistance, 220  
 Nd-Yag Laser, 216  
 NIR-PIT, 221  
 palliative PDT indications, 211  
 photosensitizer agents, 201–203  
 procedure, 207–209  
 second generation photosensitizers  
   ALA, 204  
   BPD, 204  
   mTHPC, 204–205  
   NPE6, 204  
 solo therapy, 201  
 third generation of photosensitizers  
   nanoparticles, 205  
   PDT reaction, 205, 206  
   tumor destruction, 206, 207
- Photofrin®, 203, 207, 216
- Photosensitivity, 209
- Photosensitizer agents, 201–203
- Photothermal therapy, 221
- Pleural anatomy  
 cavity  
   anterior costal-phrenic sinus/cardio-phrenic  
     sinus, 516  
   cost-diaphragmatic sinus/lateral cost-phrenic  
     sinus, 516  
   fissures, 516–518  
   pleural apex/superior pleural sinus, 516  
   posterior costal-phrenic sinus, 516  
 embryonic development, 507–509  
 histology  
   cytological characteristics, 512  
   mesothelial cells functions, 512  
   parietal pleura structure, 512  
   pleural space defense mechanism, 512, 513  
   visceral pleura structure, 511  
 innervation, 519  
 macroscopic anatomy, 513  
   costal parietal pleura, 514, 515  
   diaphragmatic parietal pleura, 514, 515  
   mediastinal parietal pleura, 514  
   visceral pleura, 513, 514  
 molecular biology, 509–511  
 vascularization  
   arterial and venous irrigation, 517–519  
   parietal pleura lymphatic drainage, 518  
   visceral pleura lymphatic drainage, 518, 519
- Pleural drainage systems, 551, 552
- Pleural effusions, 527–530
- Pleural thickening, 530, 531
- Pleurodesis, 563, 598
- Pneumonia, 533
- Pneumothorax, 48, 531, 532, 549, 550, 594, 595
- Polarization-sensitive OCT (PS-OCT), 381, 387
- Polymeric nanoparticles (PNPs), 205
- Porfimer Sodium (Photofrin®), 203
- Positron emission tomography (PET), 466
- Postintubation tracheal stenosis, 151
- Postoperative tracheal stenosis (POTS), 264, 265
- Potassium chloride (KCL), 694
- Problem-oriented BronchAtlas™ video series, 97
- Propofol, 79
- Pulmonary airway, 715
- Pulmonary alveolar proteinosis (PAP), 643
- Pulmonary embolism/lung infarction, 535
- Pulmonary parenchyma, 715
- Pulmonary vascular, 715
- R**
- Radial endobronchial ultrasound (rEBUS), 84, 347, 348
- Radial probe endobronchial ultrasound (RP-EBUS), 21,  
 25–26, 493  
 complications, 410  
 equipment, 394  
 indication, application, and evidence, 396–398  
 scanning technique, 394–396
- Radiation therapy, 212
- Rapid on-site evaluation (ROSE), 317, 358, 359
- Recurrent laryngeal nerve block (RLN), 77
- RejuvenAir® system, 184
- Remifentanyl, 80
- Research in Severe Asthma (RISA), 634
- Residual pleural thickening (RPT), 581
- Right main bronchus, 10, 12
- Right upper lobe bronchus, 10, 12
- Rigid bronchoscope (RB), 51, 64, 72, 82, 154, 160  
 airway obstruction, 52  
 applications and contraindications, 57  
 complications, 63, 64  
 equipment, 161  
 esophagoscope, 51  
 foreign bodies removal, 62–63  
 hemorrhagic accidents, 52  
 ICU, 63  
 indications, 57, 63  
 innovations, 52–56  
 laser bronchoscopy application, 57, 58  
 mechanical debridement, 60–61  
 open tube, 51  
 pediatric rigid bronchoscopy, 61–62  
 procedure, 64, 65  
 suction catheters, 56  
 TBNA, 59–60  
 tracheobronchial dilatation, 62  
 tracheobronchial prosthesis, 58–59  
 treatments for bronchial obstruction, 60
- Rigid cryoprobes, 172
- Risk prediction models, 300
- Robot assisted navigation bronchoscopy (RANB), 186
- Robotic-assisted bronchoscopy (RAB), 84  
 history, 453, 454  
 ion endoluminal system  
   description and design, 458  
   diagnostic yield, 461  
 Monarch platform  
   description and design, 454, 455  
   diagnostic yield, 461  
 procedure and technique, 459, 460

- safety and feasibility, 460
- therapy, 462
- Rocuronium, 80
- S**
- Schieppati, Eduardo, 737
- Schwarz, Yehuda, 741
- Sebileau suspensory apparatus, 516
- Seldinger technique, 144
- Self-expandable metal stent (SEMS), 264, 659, 660, 675
- Self-expandable silicone stents, 264
- Severe acute respiratory syndrome coronavirus 2 (SARS-CoV2), 117, 127, 135
- Silicone stents, 660–662
- Silicone Y stent, 112
- Simbionix bronch mentor (EBUS module), 96
- Simple diagnostic bronchoscopy, 71
- Simultaneous laser coagulation, 164
- Single-step dilator, 145
- Size-adjusted sponge, 681
- Small cell lung cancer (SCLC), 334, 335
- Small subepithelial glands, 7
- Solid lipid nanoparticles (SLNs), 205
- SPiN System® Veran Medical Technologies (EMN-VM), 422, 423
- Spontaneous ventilation, 82
- Spray cryotherapy (SCT), 169, 170, 182–184
- Sputum cytology, 314
- Squamous cell carcinoma, 319, 320
- Stage I disease, 212
- Standard cervical mediastinoscopy (SCM), 496, 497
- Stents airway foreign body aspiration, 695
- Submucosal fibrin injections, 681
- Succinylcholine, 80
- Suction catheters, 56
- SuperDimension™ Navigation System (EMN-SD)
  - computer interphase, 416, 418
  - computerized tomography, 416
  - EWC, 418, 419
  - patient position, 416
  - planning, 419
  - real-time navigation, 420–423
  - registration, 419–421
  - retractable micro-sensor probe, 416, 417
- Superior laryngeal nerve (SLN), 76
- Surgical tracheostomy, 142
- Swallowing
  - functional physiology, 686, 687
  - upper airway embryological development and anatomy, 686
  - upper airway protective reflexes, 687, 688
- T**
- Temporomandibular disorders, 64
- Tetracaine, 65
- Tetraphenylsulfonate (TPPS), 203
- Thoracentesis, 535
- Thoracic trachea, 12
- Thoracoscopy, 125
- Thulium laser, 163
- Tissue acquisition
  - cytology vs. histology, 315, 316
  - genotyping
    - challenges, 316, 317
    - liquid biopsy, 318
    - ROSE, 317
    - sensitive genotyping assays, 317, 318
    - techniques, 316
  - guidelines, 315
  - implications, 314, 315
- Toma, Tudor, 741
- Topical anesthesia, 41, 65, 75
- Total intravenous anesthesia (TIVA), 20, 79
- Toty, Lucien, 738
- Trachea, 12
- Tracheal mucous gland, 8
- Tracheal obstruction, 110, 111
- Tracheobronchial anatomy
  - anatomo-clinical relationships, 7–10
  - blood supply, 7
  - bronchial arterial supply, 13
  - bronchial division, 10–11
  - bronchial tree and anatomical relationships, 11–13
  - external tracheal configuration, 3
  - internal morphology, 6–7
  - main bronchi, 10
- Tracheobronchial bifurcation, 8, 11
- Tracheobronchial dilatation, 62
- Tracheobronchial prosthesis, 58–59
- Tracheobronchial stenosis, 153
- Tracheostomy, 471
- Transbronchial cryobiopsy, 16
- Transbronchial lung biopsy (TLB), 20, 22–23, 644–647
- Transbronchial lung biopsy through cryoprobes (TLB-C), 641, 644–647
- Transbronchial lung cryobiopsy (TLBC), 26–27, 179
- Transbronchial needle aspiration (TBNA), 23, 59–60, 466, 495, 496, 737, 738
- Transcervical extended mediastinal lymphadenectomy (TEMLA), 479
- Trans-parenchymal nodule access, 343
- Transthoracic needle aspiration, 495
- Treatment planning system (TPS), 193
- TruFreeze® system, 182, 183
- TruFreeze® system console, 183
- Tsuboi's classification, 47
- Tube thoracostomy, 577, 578, 582
- Tuberculosis (TB), 608
- Tumor destruction, 206, 207
- Tumor-node-metastases (TNM) staging system
  - data source, 328
  - history, 327
  - M descriptors, 333, 336
  - N descriptors, 336
    - nodal staging, 331, 332
    - overview, 330, 331
    - retrospective sources, 335
  - SCLC, 334, 335

- Tumor-node-metastases (TNM) staging system (*Cont.*)  
 stage groupings, 329, 333, 334  
 T descriptors, 328, 335, 336  
   atelectasis/pneumonitis, 329  
   bronchus involvement, 328  
   diaphragm involvement, 329  
   GG/L, 329, 330  
   pneumonic type infiltrates, 329, 330  
   tumor size, 328  
 treatment algorithms, 335  
 Tunnel tract infection, 565
- U**  
 Ultrasound bronchoscope (EBUS), 349, 350  
 Ultrasound-guided thoracentesis skills and tasks  
   assessment test (UGSTAT), 566  
 Ultrathin bronchoscopy, 26  
   complications, 48  
   contraindications, 39–41  
   conventional bronchoscopes, 37  
   equipment needed, 41–42  
   exploration of cavitated lesions, 39  
   history, 38–39  
   indications, 39–41  
   intra and extrabronchial lesions, 49  
   in peripheral airways, 46  
   peripheral pulmonary nodule, 48  
   position verification, 45–47  
   procedure description, 42–48  
   procedure planification, 43  
   procedure planning, 42–43  
   sampling, 47–48  
   sampling instruments, 48  
   target approximation, 43–45  
 Upper esophageal sphincter (UES), 686–688  
 Usual interstitial pneumonia (UIP), 644
- V**  
 Video-assisted mediastinoscopic lymphadenectomy  
   (VAMLA), 477–479  
 Video-assisted thoracoscopic surgery (VATS), . . . . . ,  
   498, 580  
 Videobronchoscopes, 88  
 Video-mediastinoscopes, 467, 479  
 Virtual bronchoscopic navigation systems, 45  
 Virtual navigation (VBN) technology, 445  
 Vocal cords, 12
- W**  
 Wang, Ko-Pen, 737  
 White hemithorax, 534  
 Wrisberg azygos lobe, 517
- Y**  
 Yasufuku, Kazuhiro, 740, 741
- Z**  
 Zenkel's diverticulum, 671  
 Zephyr device, 623