

Chapter 32

Abdominal Pain



Rosemarie L. Conigliaro and Sreekala Raghavan

Introduction

Abdominal pain is one of the most common presenting complaints in outpatient medicine and one of the most challenging. The etiology of abdominal pain may be related to a structural abnormality of any of the abdominal organs, part of a more systemic process (e.g., vascular or metabolic), or referred pain from a non-abdominal structure (e.g., myocardial ischemia, pleuritis). The initial assessment of abdominal pain involves an assessment of the severity and the timing—acute versus chronic [1]. There is no clear delineation for when abdominal pain is considered chronic; processes which are long-standing yet intermittent, ongoing for months or years, and/or unchanged and not progressive may safely be

R. L. Conigliaro (✉)

Department of Internal Medicine, Northwell Health/Donald and Barbara Zucker School of Medicine at Hofstra/Northwell,
New Hyde Park, NY, USA

e-mail: rconigliaro1@northwell.edu

S. Raghavan

Department of Medicine, Mount Sinai Beth Israel/Icahn School of Medicine at Mount Sinai, New York, NY, USA

e-mail: sreekala.raghavan@mssm.edu

© The Author(s), under exclusive license to Springer Nature Switzerland AG 2022

E. Sydney et al. (eds.), *Handbook of Outpatient Medicine*,

https://doi.org/10.1007/978-3-031-15353-2_32

considered chronic. In the primary care setting, in about one-third of patients with abdominal pain, the underlying cause is not identified [2]. However, any patient with severe abdominal pain and/or pain of recent onset requires an immediate and thorough evaluation.

Key History and Physical Exam

The history is key for the diagnosis of acute abdominal pain; the most important is the chronological sequence of symptoms. Other important information includes a complete description of the pain including localization, characterization, precipitating and relieving factors, and previous episodes [3]. Additional history should include previous surgeries, family history, constitutional symptoms, and extraintestinal manifestations. Finally, a complete medication history, including all over-the-counter medications and supplements, should be obtained, as well as an evaluation for known systemic diseases and risk factors for such (e.g., cardiac or pulmonary).

A careful physical exam is essential to assess the acuity and location of the pain and if the pain is made worse with any pressure changes in the abdomen, such as with palpation, coughing, or movement, which would imply peritoneal irritation. The presence or quality of bowel sounds does not significantly aid in diagnosis, although a completely quiet abdomen is consistent with severe peritonitis. Overall, the sensitivity and specificity of the physical exam is poor for diagnosing a cause of abdominal pain, especially in the setting of chronic abdominal pain [3]. Acute abdominal symptoms may be related to a complete or partial obstruction of a hollow viscus, with pain that comes in waves, referred to as colicky pain. Visceral pain, which may be related to a gastrointestinal, biliary, genitourinary, or gynecologic process, is characteristically dull and may be less well localized than peritoneal pain [3] and thus more difficult to evaluate.

Additional physical examination findings which may be helpful include checking for ascites, vascular bruits, organomegaly or other masses, Murphy's sign (inspiratory arrest due to pain from deep palpation below the right costal margin), Carnett's sign (described below), costovertebral angle tenderness, and palpation of the abdominal wall and muscles. All patients reporting acute abdominal pain should undergo digital rectal examination with testing for occult blood, and pelvic examination should be performed in female patients to assess for pelvic pathology when appropriate.

Laboratory studies which may help determine a specific etiology include urinalysis, serum bilirubin, transaminase and lipase levels, and pregnancy testing. Abnormalities of the leukocyte count, amylase level, electrolytes, and renal function may indicate severity of illness or degree of hydration without elucidating any specific diagnosis. Imaging should be focused and thoughtful and based on clearly delineated differential diagnoses.

For acute abdominal pain, delineating the pain as primarily originating from one of the four abdominal quadrants (right upper, right lower, left upper, left lower) or nonlocalized pain allows for an initial differential diagnosis (see Fig. 32.1). Physical examination in patients with abdominal pain has low specificity and low sensitivity for identifying specific etiologies, and few laboratory tests are diagnostic; thus, the differentiation of causes of acute abdominal pain may require targeted imaging studies [1]. Plain radiography may be useful in cases of suspected bowel obstruction, nephrolithiasis, or foreign body ingestion. More commonly employed are abdominal computerized tomography (CT), usually with contrast, or ultrasound, or no imaging for diagnoses made with alternative testing. CT scan may detect a cause of abdominal pain in approximately half of patients; higher yield of CT occurs in the pediatric setting, in patients with leukocytosis, and with identifying a specified diagnosis prior to obtaining a CT [4]. In the interest of decreasing radiation exposure, magnetic resonance imaging (MRI) and

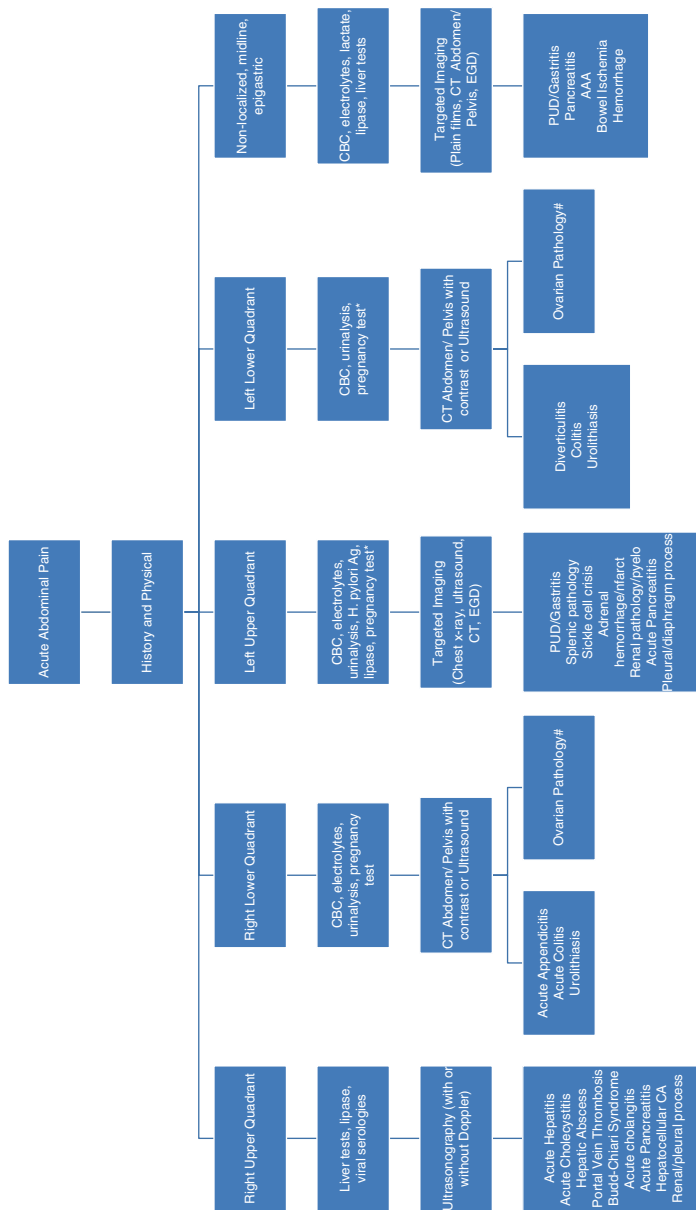


FIGURE 32.1 Acute abdominal pain evaluation. *Substitute ultrasound or MRI for pregnant patients with acute abdominal pain requiring imaging. #Denotes ovarian torsion, ovarian cyst, or ectopic pregnancy. Pelvic inflammatory disease may be diagnosed by pelvic examination and does not require imaging

ultrasound have been utilized more, reserving CT only for nondiagnostic studies in selected cases.

Chronic abdominal pain requires a different approach (see Fig. 32.2). The diagnosis of functional disease relies heavily on the history because there are no characteristic physical or laboratory findings to aid in diagnosis. Functional conditions may be identified by their symptomatology, which is usually vague and insidious, and lack of alarm symptoms (e.g., family history of gastrointestinal cancer, onset after the age of 55 years, weight loss, dysphagia, palpable mass, or evidence of bleeding) [5]. For abdominal wall pain, diagnosis is made by physical exam; a positive Carnett test, where there is an increase of palpable pain with tensing of the abdominal wall muscles, is highly sensitive and specific [6].

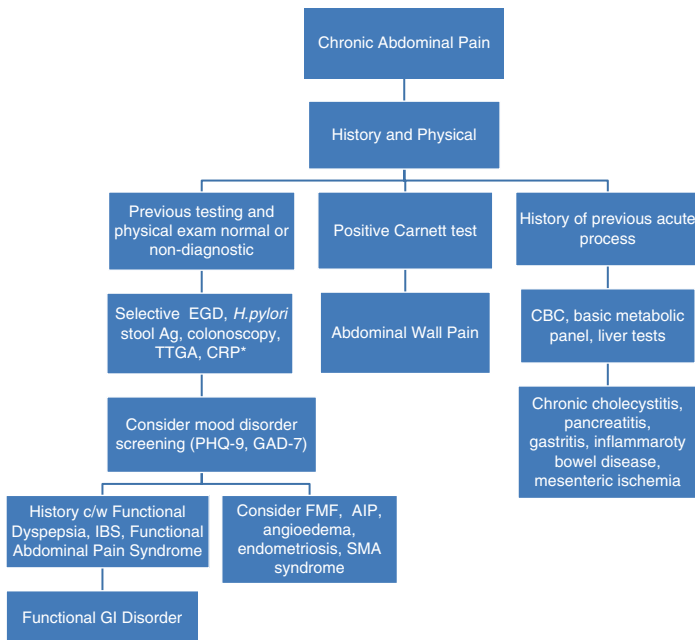


FIGURE 32.2 Chronic abdominal pain evaluation. *Based on symptoms and/or to rule out alternative disorders

Decision-Making/Differential Diagnosis

Patients with acute right upper quadrant (RUQ) pain with an enlarged, tender liver on physical examination, jaundice, and elevated transaminase levels likely have acute hepatitis, either viral or toxin (e.g., drug or alcohol) induced. Pain may be accompanied by nausea, anorexia, and fatigue. These patients do not require further imaging; appropriate serologic tests can discern the underlying etiology, most commonly hepatitis A, B, and C, Epstein-Barr virus, cytomegalovirus, or herpes viruses. Other causes of acute RUQ pain include hepatic infection with abscess formation, which may be of pyogenic, parasitic, or fungal origin [7]. Hepatic tumors may be symptomatic if associated with hemorrhage or rupture. Vascular causes include portal or hepatic vein thrombosis; additional physical exam findings may include hepatomegaly, fever, jaundice, and ascites. Rarely RUQ pain may be caused by peri-hepatic inflammation usually associated with pelvic inflammatory disease [7]. In addition to hepatic causes, right upper quadrant pain may be due to underlying disease of the gallbladder. Biliary colic, which is not colicky but rather a steady and severe ache, usually begins 1–2 h after a meal, usually a fatty meal, lasts 4–6 h, and may be associated with nausea and vomiting. If there is associated fever, persistence of pain, or other symptoms, then the diagnosis is acute cholecystitis, which is a *clinical* diagnosis. Acute cholecystitis is usually caused by gallstones, which may be confirmed via ultrasound. Acute cholangitis caused by bile duct obstruction is also usually caused by stones, although stricture, tumor, parasitic infections, and anatomic abnormalities are other etiologies. Only 70% of patients with acute cholangitis have the classic triage of RUQ pain, fever, and jaundice [5]. Other less common causes include acalculous cholecystitis, biliary sludge, and primary gallbladder or biliary cancers.

The differential diagnosis of acute right lower quadrant (RLQ) pain is significantly narrower, with appendicitis being the most common cause in both adult and pediatric populations. Anatomic variation of location may alter the classic

clinical presentation of acute appendicitis of periumbilical pain with associated anorexia, nausea, and vomiting followed by migration of the pain to the right lower quadrant, which occurs in about 60% of patients [5,8]. Laboratory studies may show a leukocytosis, and patients may exhibit fever later in the course; imaging is undertaken when the diagnosis is in doubt, usually via ultrasound or limited CT [AJS]. Other causes of RLQ pain include mesenteric adenitis, pelvic pathology, Meckel's diverticulum, right-sided diverticulitis, or the initial manifestation of inflammatory bowel disease.

Similarly, the differential diagnosis for left upper quadrant (LUQ) pain is limited. Peptic ulcer disease (PUD) and gastritis are the predominant causes, followed by splenic abnormalities including splenic infarct, infection/abscess, thrombosis, or hemorrhage [9]. PUD pain is usually described as gnawing discomfort or a "hunger" pain. Pain of duodenal ulcer (DU) is usually relieved with food, whereas pain of gastric ulcer (GU) is usually worsened by food and, thus, may be associated with nausea and weight loss. Common etiologies of PUD are *H. pylori* and nonsteroidal anti-inflammatory drug (NSAID) use. Diagnosis is clinical, although endoscopy is indicated for refractory or alarm symptoms (e.g., weight loss, bleeding, or early satiety) [5]. Simple splenomegaly may cause LUQ pain, although less likely as an acute cause, unless associated with one of the entities listed above or in the setting of acute sickle cell crisis. Other less common causes of LUQ pain include pathology of the adrenal glands (e.g., hemorrhage, infarct), genitourinary (GU) system (e.g., abscess, pyelonephritis, stones), pleural or diaphragmatic irritation, and complications of pancreatitis (e.g., pseudocyst, hemorrhage). Because the large bowel can overlies all deeper structures, colitis of the proximal left side can also present as LUQ pain [9].

The most common cause of acute left lower quadrant (LLQ) pain is diverticulitis. Acute diverticulitis classically presents with abdominal pain, fever, and leukocytosis, although the latter two may be absent. Although the prevalence increases with age, 33–50% of patients aged <50 years

have diverticula, thus affecting younger patients as well [4]. CT scan with intravenous (IV) contrast is the preferred diagnostic test, although MRI or ultrasound may be substituted in select populations where limiting radiation exposure is desired. Other causes of LLQ pain include urolithiasis, which usually causes flank pain radiating into the groin with associated nausea, vomiting, and hematuria, either gross or microscopic. Diagnosis is straightforward in patients with a history of previous stones; risk factors for first stones include family history, obesity, diabetes, diet, medications, occupations which predispose to dehydration, and underlying medical conditions related to calcium absorption and excretion. Non-contrast CT approaches 100% sensitivity and specificity and is the diagnostic test of choice [4]. Colitis affecting the left colon may present with left lower quadrant abdominal pain and may be of ischemic, infectious, or inflammatory origin. Colitis will usually be associated with fever, diarrhea, either watery or bloody, and leukocytosis. Other less common causes of LLQ abdominal pain include fecal impaction which is more common in the pediatric and geriatric populations.

Diffuse or nonlocalized abdominal pain may be experienced as periumbilical or epigastric. The most common is pain from PUD or gastritis, which usually presents with vague symptoms such as a gnawing discomfort. Etiologies for PUD are as noted above, and smoking and alcohol use are associated with gastritis. Acute pancreatitis is usually experienced as epigastric pain, which radiates to the back in half of patients. Nausea, vomiting, and anorexia are often present, and patients may have an ileus. Causes include gallstones, alcohol abuse, medications, autoimmune disorders, hypercalcemia, and hypertriglyceridemia. In a quarter of cases, no cause of the pancreatitis is identified [5]. In the setting of a supporting clinical picture and a lipase level > 3 times normal, the diagnosis is made; imaging is not necessary for diagnosis although CT scan is often performed [5]. Ultrasound is recommended once the diagnosis is made to evaluate for stones. Other causes of diffuse abdominal pain include intestinal obstruction, which presents with progressive abdominal pain

and distention, nausea, vomiting, and obstipation. Surgical history is key, as adhesions are the most common cause, followed by masses and hernias. Plain abdominal films may identify dilated bowel loops or air/fluid levels, although CT with oral contrast is needed for specific location and cause. Acute mesenteric ischemia, which may be arterial or venous, produces pain out of proportion to the physical exam. The abdominal exam is usually benign early on with peritoneal signs being a late finding. A high index of suspicion is required and affected patients are usually elderly or have vascular risk factors (e.g., thrombotic, ischemic, or hypoperfusion) or vascular disease. Laboratory studies are generally not helpful; CT angiography is the diagnostic test of choice [5]. Hemorrhage, either retroperitoneal, within the rectus sheath, or within retroperitoneal organs such as the kidney, adrenal, or pancreas, may present as diffuse abdominal pain. Hemorrhage may be traumatic or spontaneous, the latter more associated with anticoagulation. Abdominal aortic aneurysm (AAA) may cause abdominal pain as they expand, whereas ruptured AAA may present with severe abdominal pain and hemodynamic collapse. Rupture may occur in the retroperitoneum, causing back or flank pain, and may be misdiagnosed as renal colic, perforation, or ischemia.

Chronic abdominal pain may be constant or intermittent. Most causes of chronic abdominal pain are functional in origin and include functional dyspepsia, constipation-predominant and diarrhea-predominant irritable bowel syndrome (IBS), and functional abdominal pain syndrome. For these entities, visceral hypersensitivity, altered gut motility and microbiota, and psychosocial factors all play a role [10]. Functional dyspepsia is characterized by epigastric burning and pain, early satiety, postprandial fullness, and nausea, usually lasting months, without weight loss or other alarm symptoms and with no pathology found on workup (if performed). Esophagogastroduodenoscopy (EGD) may be required to exclude other diagnoses; *H. pylori* testing should be done. Response to medications known to be effective for functional disorders also aids in confirming the diagnosis.

Symptoms of functional dyspepsia include postprandial (30–60 min) epigastric pain or burning, bloating, nausea, and early satiety without disordered bowel functions. Patients with IBS may also have meal-associated abdominal pain, associated with altered stool consistency or frequency, and pain improved with defecation. The functional abdominal pain syndrome consists of constant or frequently recurring pain, without associated bowel dysfunction, which impairs daily functioning in patients who do not otherwise meet criteria for IBS or functional dyspepsia. Abdominal wall pain, which is primarily musculoskeletal or neurologic, is usually located in the upper abdomen, more frequently right-sided, localized to a 2–3-cm area, and not related to eating or defecation. It is usually related to impingement of a cutaneous nerve as it courses underneath the rectus muscle [6]. Nonfunctional causes of chronic, intermittent abdominal pain are rare, usually systemic, are more severe during acute episodes, and include entities such as familial Mediterranean fever, acute porphyria, hereditary angioedema, endometriosis, and superior mesenteric artery syndrome. Many causes of acute abdominal pain can also cause chronic pain, such as chronic pancreatitis, which may be associated with evidence of exocrine or endocrine insufficiency, chronic PUD/gastritis, chronic mesenteric ischemia, and chronic cholecystitis.

Treatment

Treatment for most causes of acute abdominal pain consists of intravenous (IV) fluid, bowel rest, pain medications, and treatment for nausea and vomiting. IV antibiotic coverage for gram-negative and anaerobic organisms is indicated for acute cholecystitis and acute pancreatitis only if sepsis is suspected. Patients with suspected peritonitis should be referred immediately to emergency services or a surgeon; further discussion of acute peritoneal processes is beyond the scope of this chapter. For bowel obstruction, decompression via nasogastric tube and correction of electrolyte abnormalities are indi-

cated. Early surgical intervention is recommended for acute cholecystitis for improved outcomes, whereas for bowel obstruction about two-thirds to three-quarters of patients may be managed conservatively without surgery [5]. Treatment for PUD is to discontinue any identified offending agent, test and treat for *H. pylori* if positive, and initiate anti-secretory therapy. Follow-up EGD is warranted for gastric ulcers only [5]. Current guidelines suggest that uncomplicated diverticulitis may not require antibiotic therapy, whereas complicated cases associated with perforation, abscess formation, free air or fluid, or obstruction require hospitalization and IV antibiotics [4].

Principles of therapy for functional disorders include limited testing and referrals, a supportive and validating physician-patient relationship, consideration of adjunct psychotherapy, dietary and lifestyle modification, judicious trials of medications shown to be effective, and avoidance of opioids. Treatment for functional dyspepsia consists of an initial 6–8-week trial of antisecretory therapy, which should be discontinued if ineffective. Tricyclic antidepressants and pro-motility agents are next-line therapies [10]. Specific treatment for diarrhea-predominant IBS includes loperamide, anticholinergics, and tricyclic antidepressants, which slow intestinal transit time. Additionally, alosetron, rifaximin, eluxadoline, and clonidine have been approved for treatment of diarrhea-predominant IBS [10]. For constipation-predominant IBS, increased dietary soluble fiber, selective serotonin reuptake inhibitors (SSRIs) or serotonin and norepinephrine reuptake inhibitors (SNRIs) which increase intestinal transit time, and laxatives are useful. Probiotics may improve bloating and flatus. Treatment for functional abdominal pain syndrome consists of cognitive behavioral therapy (CBT) or other psychological interventions, with behavioral interventions targeted to specific symptoms [10]. Multidisciplinary pain rehabilitation has also been successful [10]. Treatment for abdominal wall pain includes local injection(s) of lidocaine and corticosteroids, neurolysis by phenol injection, or neurec-

tomy [6]. Treatment of other causes of intermittent/chronic abdominal pain is based on etiology.

Clinical Pearls

- The initial assessment of abdominal pain involves an assessment of its severity and timing.
- The differential diagnosis of acute abdominal pain is primarily dictated by the location/quadrant of the pain.
- Physical exam and laboratory findings are useful in helping to focus choice of imaging study.
- A thorough history elucidating the pattern of pain and symptoms is key to making the diagnosis for chronic abdominal pain.

Do Not Miss This!

- Initial evaluation of acute abdominal pain should always include an exam for signs of peritoneal inflammation, which warrants emergent evaluation.
- All patients with a complaint of acute abdominal pain should undergo digital rectal examination with testing for occult blood.
- The evaluation of abdominal pain in women should include a pelvic exam if the differential diagnosis includes ectopic pregnancy, infection, torsion, or other conditions of the female reproductive tract.
- The diagnosis of ischemic bowel requires a high index of suspicion and should always be considered in patients who have risk factors.

References

1. Cartwright SL, Knudson MP. Diagnostic imaging of acute abdominal pain in adults. *Am Fam Physician*. 2015;91(7):452–560.
2. Viniola A, Keuneckea C, Birogaa T, Stadjea R, Katharina Dorniedena K, Bösnera S, Donner-Banzhoffa N, Haasenrittera J, Beckera A. Studies of the symptom abdominal pain—a systematic review and meta-analysis. *Fam Pract*. 2014;31(5):517–29.

3. Pichetshote N, Pimental M. An Approach to the patient with chronic undiagnosed abdominal pain. *Am J Gastrol.* 2019;114:726–32.
4. Bodmer NA, Thakrar KH. Evaluating the patient with left lower quadrant abdominal pain. *Radiol Clin North Am.* 2015;53:1171–88.
5. Marsicano E, Vuong GM, Prather CM. Gastrointestinal causes of abdominal pain. *Obstet Gynecol Clin North Am.* 2014;41:465–89.
6. Kamboy AK, Hoversten P, Oxentenko AS. Chronic abdominal wall pain: a common yet overlooked etiology of chronic abdominal pain. *Mayo Clin Proc.* 2019;94(1):139–44.
7. Bennett GL. Evaluating the patient with right upper quadrant abdominal pain. *Radiol Clin North Am.* 2015;53:1093–130.
8. Patel NB, Wenzke DR. Evaluating the patient with right lower quadrant abdominal pain. *Radiol Clin North Am.* 2015;53:1159–70.
9. Ecanow JS, Gore RM. Evaluating the patient with left upper quadrant abdominal pain. *Radiol Clin North Am.* 2015;53:1131–57.
10. Bharucha AE, Chakraborty S, Sletten CD. Common functional gastroenterological disorders associated with abdominal pain. *Mayo Clin Proc.* 2016;91(8):1118–32.