



Renal Robotic Surgery for Lefties: Left-Handedness in Upper Tract Robotic Surgery

Mylle Toon, Challacombe Ben, Uvin Pieter, and Mottrie Alexandre

8.1 Introduction

Handedness or chirality, is a characteristic of a person defined by the unequal distribution of fine motor skills in both hands. Although right-handedness predominates, an estimated 9.3–18.1% of the global population are left-handed. Recent publications show an increase in the reported rate of left-handedness [8]. A contributing factor may be the easing of cultural pressure against this sinistrality. For centuries, left handers have endured discrimination in a world designed for right hand preference. Literally, ‘right’ means ‘correct’ and ‘sinister’ means ‘left’ or ‘omnious’. Left-handedness is still considered an exception and a physical deviation. It may however be a potential advantage as left-handers are more likely to be better users of their non-dominant hand and many are effectively ambidextrous. This allows more flexibility in complex surgical tasks and the potential to change to the better positioned but non-dominant hand.

M. Toon (✉)

University Hospital of Ghent, Corneel Heymanslaan 10, 9000 Gent, Belgium
e-mail: toon.mylle@ugent.be

C. Ben

Guy’s Hospital, Guy’s and St Thomas’ Trust (GSTT), London, UK
e-mail: benchallacombe@doctors.org.uk

U. Pieter

AZ Sint-Jan, Ruddershove 10, 8000 Brugge, Belgium
e-mail: Pieter.uvin@azsintjan.be

M. Alexandre

O.L.V. Clinic, Moorselbaan 164, 9300 Aalst, Belgium

Every day, left-handed individuals experience difficulties with tools designed for the right-handed persons [4]. These problems extend to instruments as simple as scissors and many other within the operating room. Surgical residents report anxiety about their left-handedness, inconveniences during assisting, and lack of mentorship [9]. For some right-handed senior surgeons, tutoring a left-handed trainee is an uphill task [1]. The default option is to train the left-handed surgeon to perform the operation in a right-handed manner but this is disadvantageous to the leftie. Surgeons and surgical trainees have indicated that difficulties arise in both open and minimally invasive surgery [6].

With a growing rate of left-handedness, there is a need to adapt and expand our surgical training and practice. For the moment, few teaching materials and even less technical reports are available for left-handed surgeons. A more personal approach, adapted for the dominant hand is needed. With a vast majority of laparoscopic and robotic surgeons being right-handed, proper guidelines for left-handed surgeons are in short supply.

The goal of this chapter is to provide tips and tricks to left-handed surgeons. As it rethinks the different possibilities in instrument usage within upper tract robotic surgery, it could be of interest to every upper tract surgeon. To our knowledge, no similar chapter has been written before. This chapter fills a gap that exists in current literature and is therefore based on experience and expert opinions.

8.2 Upper Tract Robotic Surgery

The introduction of the Da Vinci Robotic Surgical System by Intuitive has brought urological surgery into a new era. The engineering feat comes with multiple advances in ‘minimally invasive surgery’, such as seven degrees of freedom, 3-dimensional view, tremor filtration and better instrument precision. The system allows the surgeon to operate in an ergonomic non-sterile manner and -theoretically- at a distant location [2].

The robotic system of Da Vinci got designed to allow as much degrees of freedom as possible. Not only provides the robotic system a better range of motion than a surgeon’s wrist and fingers, recent studies showed that it also can minimize the innate chirality of the surgeon. Novel studies are needed to further distinguish how big the elimination of the chirality is [2, 7].

A second advantage of the Xi system is the possibility of port hopping with the endoscope. Allowing the surgeon to switch positions in the middle of the operation, new possibilities arise. When using the Xi system correctly, being a leftie should not have any impact. Left-handed surgeons can use various unique tips and tricks to use their left-handedness in their advantage. We made them a summary of those tips and tricks.

8.2.1 Instruments

According to a statement Intuitive made for this chapter, all da Vinci Instruments are meant to be used for left-handed and right-handed surgeons. Concerning the da Vinci Instruments with curved tip design (Maryland Bipolar Forceps, Monopolar Curved Scissors, Curved Bipolar Dissector), the designers consider task and approach to tissue regardless of the dominant hand of the surgeon. The curve of the instrument tip can be rotated tip-up or tip-down with the instrument's roll capability to the surgeon's preference by rolling the hand controller. This will move the instrument tip in the direction most comfortable to the surgeon. Intuitive tests the usability of the instrument with both left-handed and right-handed surgeons by evaluations with engineers who observe user interaction to confirm if the device is safe and intuitive to the user. Currently, anno 2021, Intuitive does not sell instruments for left-handed or right-handed surgeons. All the instruments can be used by both.

8.2.2 Renal Robotic Surgery: Positioning and Port Placement

The positioning of the patient during renal robotic surgery is identical as in the right-handed procedure. Secure the patient in a modified lateral position with a 45° angle. Make sure the patient is fitted at the lateral edge of the operative table and the ipsilateral arm is as low as possible to maximize the range motion of the different arms of the robotic system.

Placement of the ports is different with changing handedness. First, the Hasson technique is used to place the assisting port. After pneumoperitoneum is achieved, a first look intra-abdominally must be undertaken to be sure the peritoneum is free of injuries and adhesions. The four remaining ports will be placed in a straight line at the lateral border of the rectus abdominus muscle. For left-handed surgeons, optimal port placement is displayed at Figs. 8.1 and 8.2. At the start of the procedure, scissors will be placed at the most cranial port. The endoscopic camera will be placed at the second most cranial port. In ports number 3 and 4, respectively a ProGrasp and needle holder (or fenestrated bipolar) can be placed.

Note that right-handedness surgery on the right kidney often requires an additional 5 mm port. With the help of this additional port a liver retractor is put in place. With left-handed surgeons, there is no need for a retractor or an extra entry. Using the pitch degree of the robotic instrument in port 4, ProGrasp, the surgeon can easily push aside the liver, gaining view and necessary workspace.

Fig. 8.1 Port placement at start of procedure Da Vinci Xi, left kidney surgery (left-handed). C: Camera / N: Needle holder / S: Bipolar scissors / P: Prograsp / Blue dot: Assisting Port

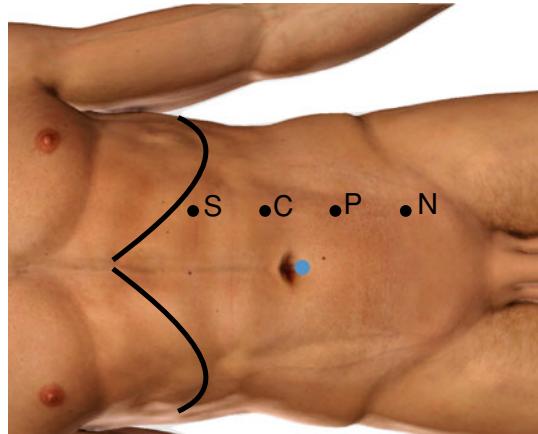
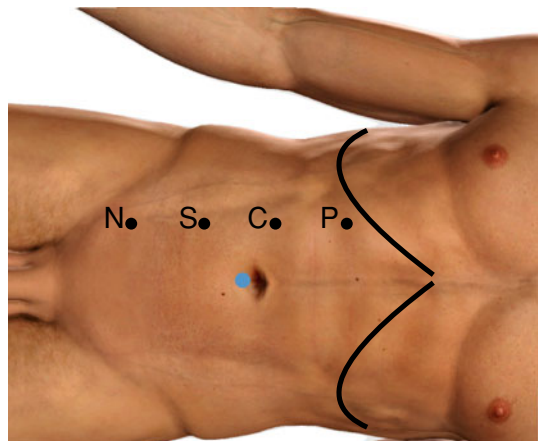


Fig. 8.2 Port placement at start of procedure Da Vinci Xi, right kidney surgery (left-handed). C: Camera / N: Needle holder / S: Bipolar scissors / P: Prograsp / Blue dot: Assisting Port



8.2.3 Port hopping During (Partial) Nephrectomy

During a (partial) nephrectomy, the Xi Da Vinci system allows us to easily switch the camera and the different instruments. Port hopping can provide a better view of the kidney tumor, can facilitate manipulation of the kidney and offers a safe access to cranial, caudal or posterior tumors. Repositioning of the ports displayed on Figs. 8.3 and 8.4 grants the needle holder to grasp adjacent kidney tissue. Now the kidney can be moved around freely around the pedicle.

Fig. 8.3 Port hopping during ischemia time Da Vinci Xi, left kidney surgery (left-handed). **C:** Camera / **N:** Needle holder / **S:** Bipolar scissors / **P:** Prograsp / Blue dot: Assisting Port

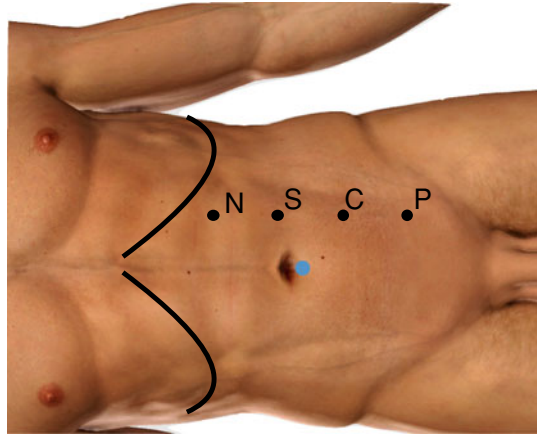
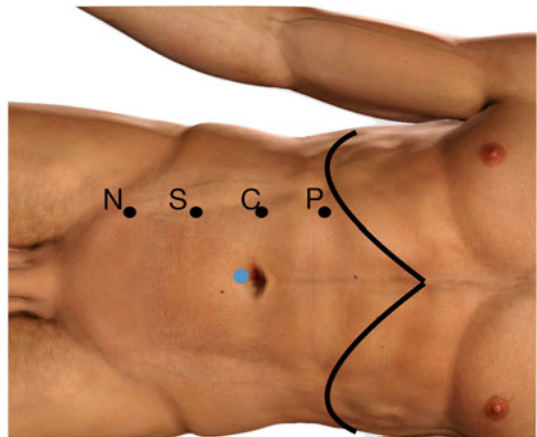


Fig. 8.4 Port hopping during ischemia time Da Vinci Xi, right kidney surgery (left-handed). **C:** Camera / **N:** Needle holder / **S:** Bipolar scissors / **P:** Prograsp / Blue dot: Assisting Port

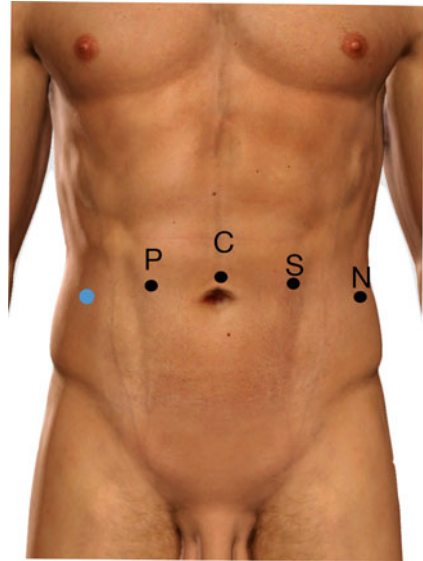


8.2.4 Nephro-Ureterectomy

During the nephrectomy with or without lymphadenectomy, the left-handed console surgeon may use the same setup and starting position as mentioned before (Figs. 8.1 and 8.2).

After the completion of the first portion, ureterectomy may be performed with a different port position. A brief undocking may be helpful for targeting the pelvis. The boom is now rotated and the required angle differences are met. Position the camera port more caudally so the downwards dissection of the ureter can be achieved up to the ureterovesical junction. After the excision of the bladder cuff is finalized, the specimen can be placed in a laparoscopic bag and removed. Repair of cystotomy is performed using either of both hands to suture.

Fig. 8.5 Setup during upper tract surgery in the pelvic region. Da Vinci Xi. Left-handed assisting port. C: Camera / N: Needle holder / S: Bipolar scissors / P: Prograsp / Blue dot: Assisting Port



8.2.5 Cystoureterostomy/Ureterovesical Junction Surgery

Setup for distal ureteral repair and upper tract surgery limited to the pelvis region is similar to other pelvic surgery. Place the ports in a standard ‘prostatectomy’ fashion. Place the 12 mm assistant trocar at the right side if the assistant is left-handed. Favorable placement for left-handed surgeons of the other ports is shown at Fig. 8.5.

Our camera is placed at the umbilical port, between the monopolar scissors at the left and the Prograsp at the right side. At the left lateral port, a needle holder is the preferred choice. With this layout, the surgeon is capable of showing all tissues with the both lateral instruments while operating with the left hand. The endoscope is placed next to the bipolar scissors so that the instruments are as lateral as possible.

8.3 Assisting Upper Tract Robotic Surgery

The success of robot assisted procedures depend on a successful team. However, the literature focuses on the performance of the console surgeons, one study showed that the experience of the bedside assistant is of almost equal interest, shortening the total operation time [3]. Our believe is that adaptation to the right- or left-handedness of the assistant can be helpful, further studies are necessary to review the impact of trocar adjustment.

In case of the upper tract surgery, adaptation of the assisting port can be useful. For a left-handed assistant, the port has to be more cranial or caudal if the targeted region is respectively the right and left kidney. An illustration is added to gain a

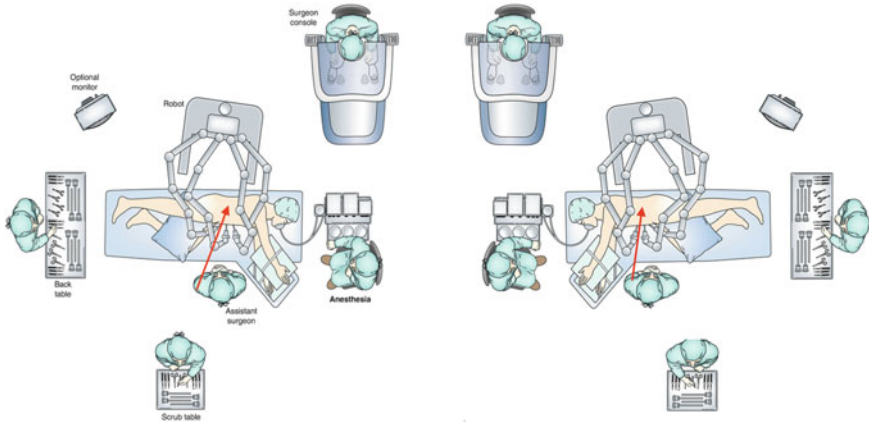


Fig. 8.6 Adaptation of the assisting port following handedness of bedside assistant [5]

better insight in the situation (Fig. 8.6). The scrub table is placed at the right side of the left-handed assistant, so to secure a smooth and elegant transition when changing instruments or loading clip applicators.

8.4 Epilogue

Experienced surgeons often develop their own individualized technique, rather than using the theoretically optimal technique for their dominant hand. When trying the “optimal” technique, it doesn’t always meet the expectations but to apply a different technique or setup, one must leave behind standardized routines, which is not a comfortable process. Every possible setup mentioned above can be adapted to individual preferences. The correct technique, based on the dominant hand, should be educated from the start of training. Therefore, not only literature on specific procedure guidelines is necessary, training should always include the difference between right and left-handedness and their practical consequences. They used to say that left-handers were the only people in their right minds but, it may be that sinister surgeons actually are in a good place for upper tract robotic surgery.

References

1. Adusumilli PS, Kell C, Chang JH, Tuorto S, Leitman IM. Left-handed surgeons: are they left out? *Curr Surg*. 2004;61:587–91.
2. Badalato GM, Shapiro E, Rothberg MB, Bergman A, Roychoudhury A, Korets R, Patel T, Badani KK. The da vinci robot system eliminates multispecialty surgical trainees’ hand dominance in open and robotic surgical settings. *JSL J Soc Laparoendosc Surg*. 2014;18(e2014):00399.

3. Cimen HI, Atik YT, Altinova S, Adsan O, Balbay MD. Does the experience of the bedside assistant effect the results of robotic surgeons in the learning curve of robot assisted radical prostatectomy? *Int Braz J Urol.* 2019;45:54–60.
4. FLATT, A. E. Is being left-handed a handicap? The short and useless answer is “yes and no.” *Proc (Bayl Univ Med Cent).* 2008;21:304–7.
5. Leveillee RJ, Ashouri K. Robot-assisted pyeloplasty. In: SU L-M, editor. *Atlas of robotic urologic surgery.* Cham: Springer International Publishing; 2017. p. 148.
6. LIESKE B. The left handed surgical trainee. *BMJ.* 2008;337:a2883.
7. Mucksavage P, Kerbl DC, Lee JY. The da Vinci(®) Surgical system overcomes innate hand dominance. *J Endourol.* 2011;25:1385–8.
8. Papadatou-Pastou M, Ntolka E, Schmitz J, Martin M, Munafò MR, Ocklenburg S, Paracchini S. Human handedness: a meta-analysis. *Psychol Bull.* 2020;146:481–524.
9. Tchantchaleishvili V, Myers PO. Left-handedness—a handicap for training in surgery? *J Surg Educ.* 2010;67:233–6.