2 Men Behind Principles and Principles Behind Techniques

Ahmed T. Hadidi

Abbreviations

BILAB	Bilateral-based flap
CEDU	Chordee excision and distal urethroplasty
DUG	Distal urethro-glanuloplasty
DYG	Double Y glanulomeatoplasty
LABO	Lateral-based onlay flap
MAGPI	Meatal advancement and glanuloplasty incorporated
MAVIS	Mathieu and V incision sutured
MIP	Megameatus intact prepuce
OIF	Onlay island flap
SLAM	Slit-like adjusted Mathieu
TALE	Tunica albuginea longitudinal excision
TIP	Tubularized incised plate
TPIF	Tubularized preputial island flap
UGPI	Urethral advancement and glanuloplasty procedure

2.1 Short List of Men Behind Principles

The philosopher Santayana (1863–1952) said:

> Those who cannot remember the past are condemned to repeat it.

A. T. Hadidi (✉)
Hypospadias Center and Pediatric Surgery Department, Sana Klinikum Offenbach, Academic Teaching Hospital of the Johann Wolfgang Goethe University, Offenbach, Frankfurt, Germany

In an address to the Royal College of Surgeons, Winston Churchill remarked [1]:

> The longer you look back, the further you can look forward

As Durham Smith mentioned in his forward to the first edition of this book [2]:

> Although the penile repairs can be grouped into five or six major principles, depending on the tissues used, each has been subject to countless variations as one surgeon after another adds yet another modification to an already thrice-modified variation of a procedure adapted from a principle derived from the original!

From Alexandria, Egypt came the first hypospadias pioneers, Heliodorus and Antyllus. Living in the first century, they were the first to describe and define the pathophysiology and treatment of hypospadias [3].

The aim of this chapter is to categorize the enormous variety of techniques in hypospadias into *eight* basic principles and to give credit to the great pioneers who first described these concepts (Table 2.1).

Thus, it is easier for the reader interested in hypospadias to grasp the basic concepts of hypospadias repair. The following account is by no means exhaustive, nor does it include all the techniques described for hypospadias repair.

In dealing with a boy with hypospadias, the surgeon has to correct the following major abnormalities:

A. T. Hadidi (ed.), *Hypospadias Surgery*, https://doi.org/10.1007/978-3-030-94248-9_2

Table 2.1 Short list of men behind principles

Contributor	Date	Contribution
Heliodorus and Antyllus	First century AD	First description of pathophysiology and repair of hypospadias
Galen [4]	130–199 AD	First to use the term "hypospadias" and to emphasize significance of penile curvature
Paré [5]	1510–1590	Extensive discussion of hypospadias and penile curvature and treatment
Dieffenbach [6]	1837	Attempted urethroplasty by piercing the glans to the normal urethra
Mettauer [7]	1842	"Arrest of development" theory for hypospadias etiology; "skin tethering" theory for curvature etiology
Physick [8]	1844	First described chordee correction by dorsal plication
Pancoast [8]	1844	First described chordee correction by transverse incision and longitudinal closure
Bouisson [9]	1861	First to use scrotal skin for urethral reconstruction
Thiersch [10]	1869	U-shaped urethroplasty for epispadias; buttonholing of the prepuce
Wood [11]	1875	Described meatal-based flap with buttonhole of prepuce
Duplay [12]	1880	Acknowledged Thiersch; described incomplete urethroplasty
Van Hook [13]	1896	First description of "preputial vascular island flap" and lateral oblique flap
Beck [14, 15]	1898, 1917	First to describe urethral mobilization; used rotation flap from scrotum for coverage; used a bipedicled preputial flap to resurface ventral penile skin
Nové-Josserand [16]	1897	First description of tubularized free skin graft urethroplasty
Edmunds [17]	1913	Three-stage ventral repositioned prepuce via buttonholed pedicle followed by tubularized urethroplasty
Ombrédanne [18]	1932	Described meatal-based flap and a purse-string suture for urethroplasty and button hole of prepuce for skin coverage
Mathieu [19]	1932	U-shaped flap from proximal skin and two suture lines
Davis [20]	1940	Utilized a tube of skin from the dorsal penile skin for urethral reconstruction
Humby [21]	1941	Tubularized free skin graft urethroplasty; donor sites: inner upper arm, thigh, "mucous membrane from lower lip"
Cecil [22]	1946	Popularized staged scrotal skin incorporation into urethroplasty
Memmelaar [23]	1947	First description of bladder mucosa use for one-stage urethroplasty
Browne [24]	1949	"Buried incomplete urethral plate" urethroplasty
Byars [25]	1955	Popularized midline incision and transposition of the prepuce with second-stage tubularized urethroplasty
DesPrez et al. [26]	1961	Described "island pedicle flap" that circumscribes the meatus and extends along the inner aspect of the prepuce
Devine and Horton [27]	1961	Popularized one-stage free skin graft urethroplasty and V incision of the glans
Broadbent et al. [28]	1961	One-stage urethroplasty with dorsolateral penile skin
Cloutier [29]	1962	Described the two-stage hypospadias repair using preputial graft
Mustarde [30]	1965	Recommended V incision of the glans and large proximal meatal-based flap
Barcat [31]	1969	Described balanic groove technique
Smith [32]	1973	Described de-epithelialization of skin as a second protective layer
Gittes and Maclaughlin [33]	1974	First described artificial erection test
De Sy and Oosterlinck [34]	1980	Introduced silicon foam dressing
Duckett [35]	1981b	Described MAGPI procedure, transverse preputial island flap
Monfort and Lucas [36]	1982	Recommended testosterone stimulation preoperatively
Koyanagi et al. [37]	1983	Described parameatal foreskin flap
Koff and Eakins [38]	1984	Described chordee correction by corporal rotation

Table 2.1 (continued)

Contributor	Date	Contribution
Snow [39, 40]	1986, 1994	Described use of tunica vaginalis wrap, yoke repair
Elder et al. [41]	1987	Described onlay island flap
Retik et al. [42]	1988	Preputial vascular fascia as a second protective layer
Rich et al. [43]	1989	Described hinging of the urethral plate combined with Mathieu repair
Snodgrass [44]	1994	Described tubularized incised plate urethroplasty
Bracka [45, 46]	1995a, b	Popularized two-stage repair with free skin graft
Hadidi [47–56]	1996, 2003, 2004, 2009, 2010, 2012, 2014, 2018	Developed "double Y glanulomeatoplasty" for glanular hypospadias, Y-V glanuloplasty and SLAM for distal hypospadias, LABO for proximal hypospadias without severe chordee, BILAB and CEDU for perineal hypospadias and proximal hypospadias with severe chordee, described the TALE, founded the Hypospadias International Society, developed the Hypospadias International Classification (MCGU) and questioned the role of dressing and stenting
Decter [57]	1999	Described chordee correction by split and roll technique
Boddy and Samuel [58]	2000	Described excision of a triangle from apex of Mathieu flap for distal types
Pippi Salle [59]	2016	Described multiple superficial corporotomies for severe chordee

1. Abnormal ventral curvature or chordee, by orthoplasty
2. Abnormal proximal meatal insertion, by urethroplasty
3. Abnormal-looking glans penis, by glanuloplasty and meatoplasty
4. Abnormal-looking prepuce, either by circumcision or prepuce reconstruction

2.2 Abnormal Ventral Curvature of the Penis (Chordee) and Orthoplasty

The history of chordee is mentioned in detail in the History Chapter (see Chap. 1), and the different approaches are mentioned in detail in the Chordee Chapter (see Chap. 8). Here, we will try to describe the principles behind the different approaches.

Gittes and McLaughlin, writing in 1974, described intraoperative saline inflation of the corpora cavernosa. This guided and ensured successful orthoplasty. This artificial erection test has been refined with saline and transglanular needle placement [33] (Fig. 2.1).

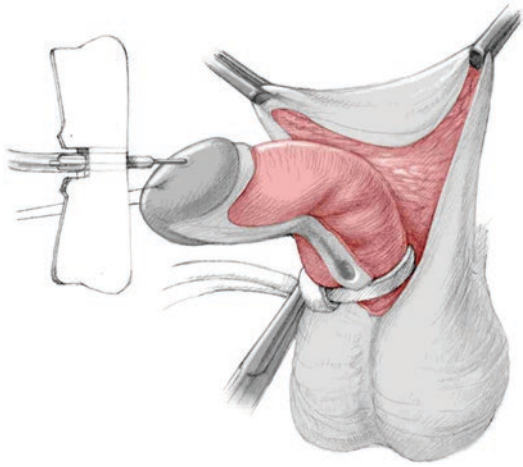

Fig. 2.1 Artificial erection test described by Gittes and MacLaughlin (1974) [33]

There are three types of chordee associated with hypospadias. The first is the chordee that is occasionally present in patients with distal hypospadias (skin chordee). This superficial chordee is subcutaneous, is proximal to the meatus, and is usually corrected by mobilization of the skin proximal to the meatus [60, 61] (Fig. 2.2).

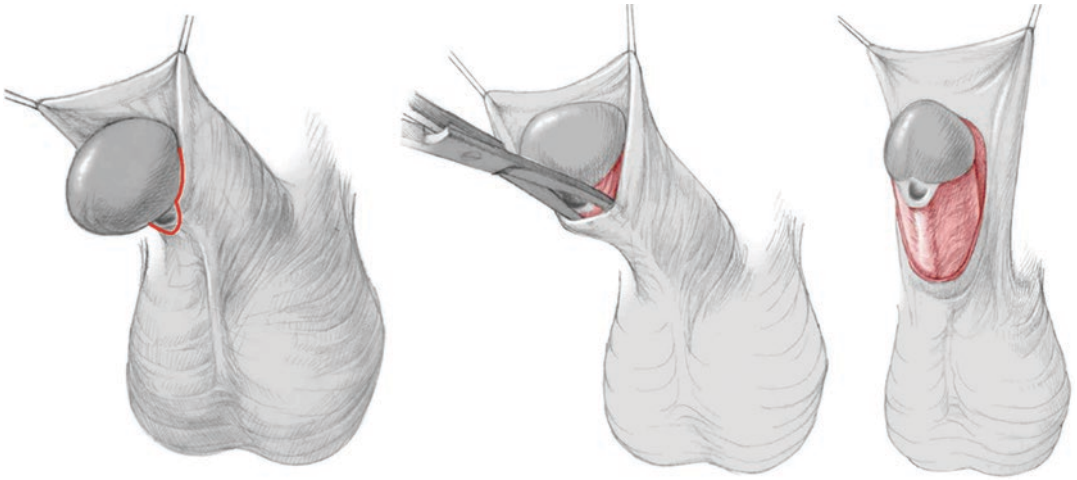

Fig. 2.2 The *superficial chordee* associated with distal hypospadias (uncommon, usually proximal to the meatus, and subcutaneous)

The second type of chordee is commonly associated with proximal hypospadias or deep chordee. It is usually deep, fibrous, and located distal to the meatus. It is due to inadequate or arrested distal migration of the hypoplastic corpus spongiosum. There are three basic techniques to correct this type of deep, hypoplastic chordee (Fig. 2.3).

(a) The abnormal ventral curvature can be corrected by *dorsal plication*, first described by Physick [8] and popularized as the Nesbit procedure [62], but this has the serious disadvantage of shortening the penis. (b) More appropriately, the chordee can be corrected by *excision of the ventral subcutaneous fibrous bands*, usually proximal to the meatus in distal hypospadias (skin chordee). In proximal forms with severe chordee, curvature can be corrected by *excision of the hypoplastic urethral plate* and *the longitudinal layer of tunica albuginea (tunica albuginea longitudinal excision or TALE)* (see Chap. 8). (c) A third method is by incising the corpora ventrally at the point of maximum curvature and putting grafts or flaps. Another way of correcting chordee is by *corporal rotation*, first described by Koff and Eakins [38]. Decter [57] added midline ventral splitting and called it the "split and roll" technique. Various skin and fascial grafts and flaps have been used to cover the resultant defect in multistage repair.

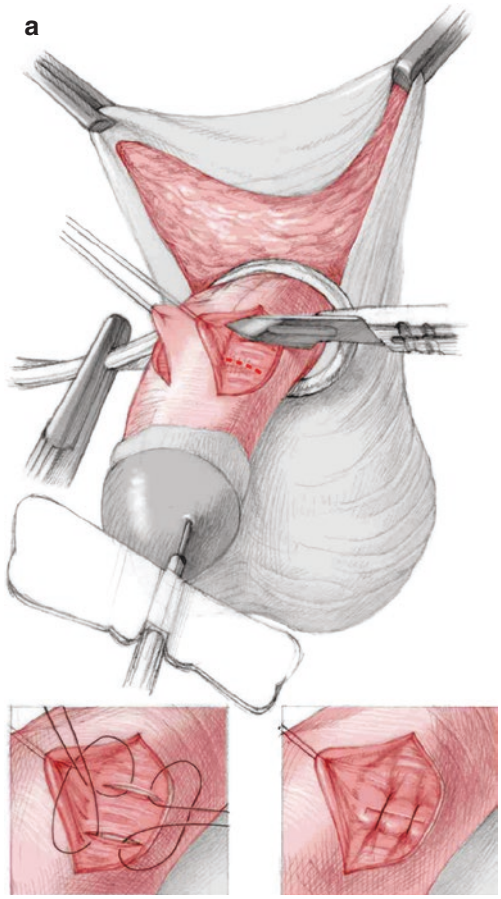

Fig. 2.3 The *deep chordee* associated with proximal hypospadias (common, distal to the meatus, and fibrous). Three different basic principles to correct deep chordee: (**a**) dorsal plication, (**b**) Heineke-Mikulicz technique, (**c**) split and roll technique

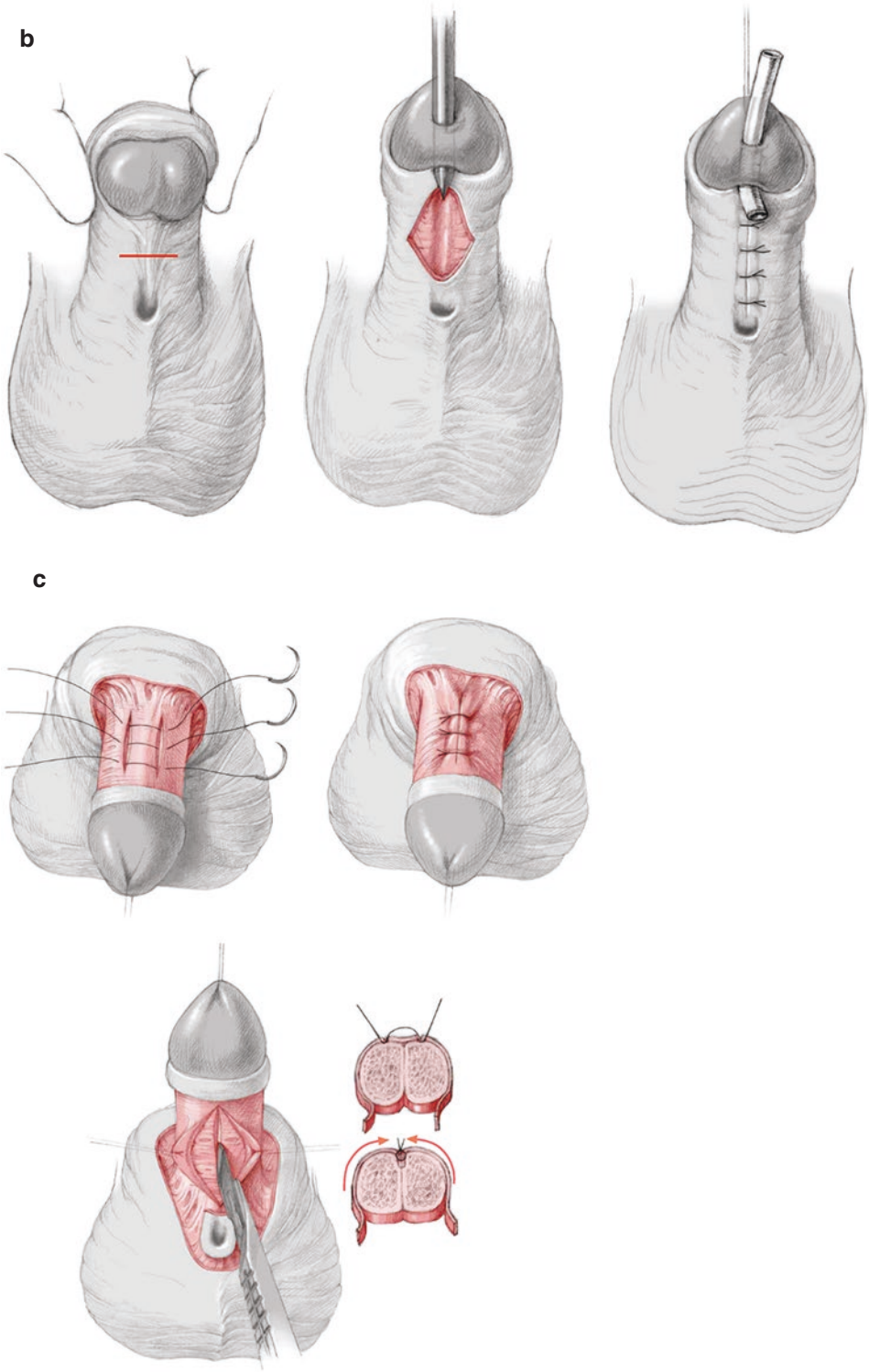

Fig. 2.3 (continued)

2.3 Abnormal Proximal Meatal Insertion and Urethroplasty

To correct hypospadias and achieve a terminal meatus, one may use one of the following basic principles or tissues: (1) distal mobilization of the urethra; (2) skin distal to the meatus; (3) skin proximal to the meatus; (4) preputial skin; (5) combined prepuce and skin proximal to the meatus; (6) scrotal skin; (7) dorsal penile skin; and (8) different grafts; a protective intermediate layer (Fig. 2.4).

2.3.1 Urethral Mobilization

Urethral mobilization and meatal advancement was first described by Beck [63] and Hacker in 1898 [64] (quoted in Horton 1973 [65]) for balanic hypospadias (Fig. 2.5).

The idea is to make use of the elasticity of the urethra. It is easier to understand the principle when one realizes that the adult flaccid penis is about 8 cm long. During erection, the penile length (including the urethra) reaches 15–20 cm long. This means that the normal urethra is flexible and can be stretched. The procedure has the advantage that it is theoretically "risk-free" as the urethra remains completely intact. It has the drawbacks that it can only be applied to very distal forms of hypospadias (grade I or glanular). If the stretched urethra is shorter than the stretched penis, one may risk bringing the glans to the urethra rather than the urethra to the tip of the glans, as the penis is not a rigid structure. Some sur-

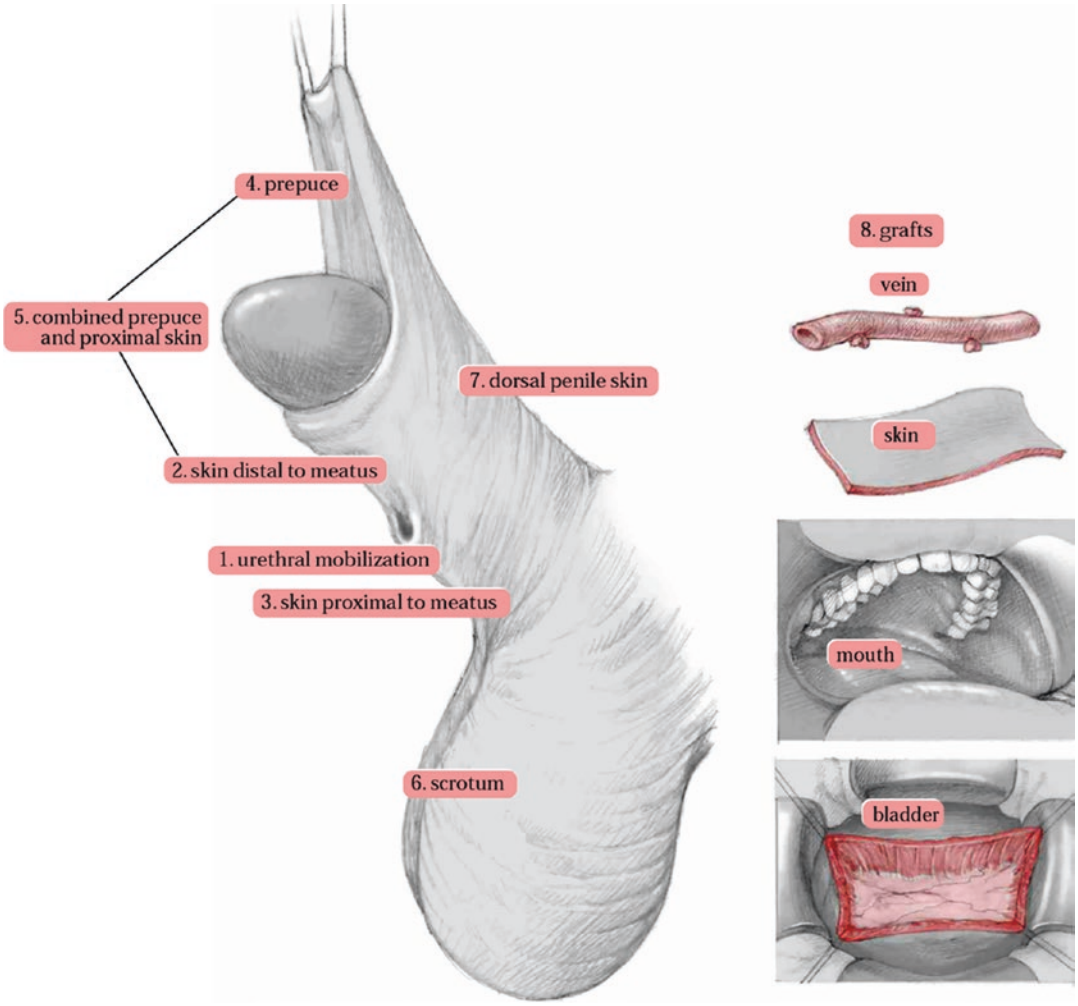

Fig. 2.4 Different tissues used for correction of hypospadias

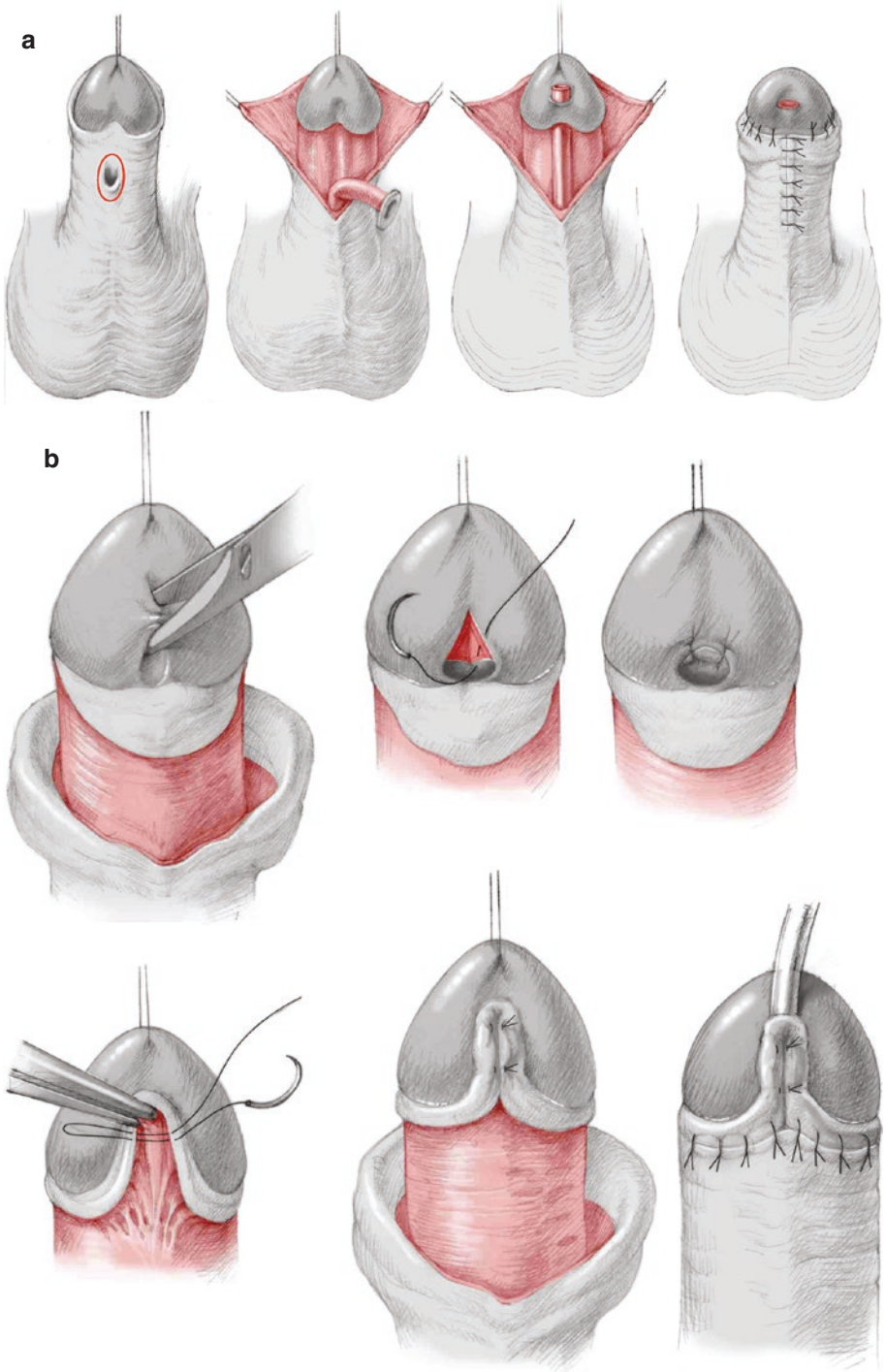

Fig. 2.5 Techniques of urethral mobilization: (**a**) Urethral mobilization first described by Beck [63] and Hacker [64], cited in Horton 1973). (**b**) MAGPI described by Duckett [35] (midline vertical incision closed transversely and mobilization). (**c**) The M configuration by Arap et al. [66], a modification of MAGPI by placing two sutures on the ventral edge. (**d**) UGPI modification of MAGPI by Harrison and Grobbelaar [67], with a V-shaped incision around the original meatus and with deep glanular wings before urethral advancement and upward rotation of the glanular wings. (**e**) DYG (double Y glanuloplasty) after Hadidi [51] ((**e**) ©Ahmed T. Hadidi 2022. All Rights Reserved)

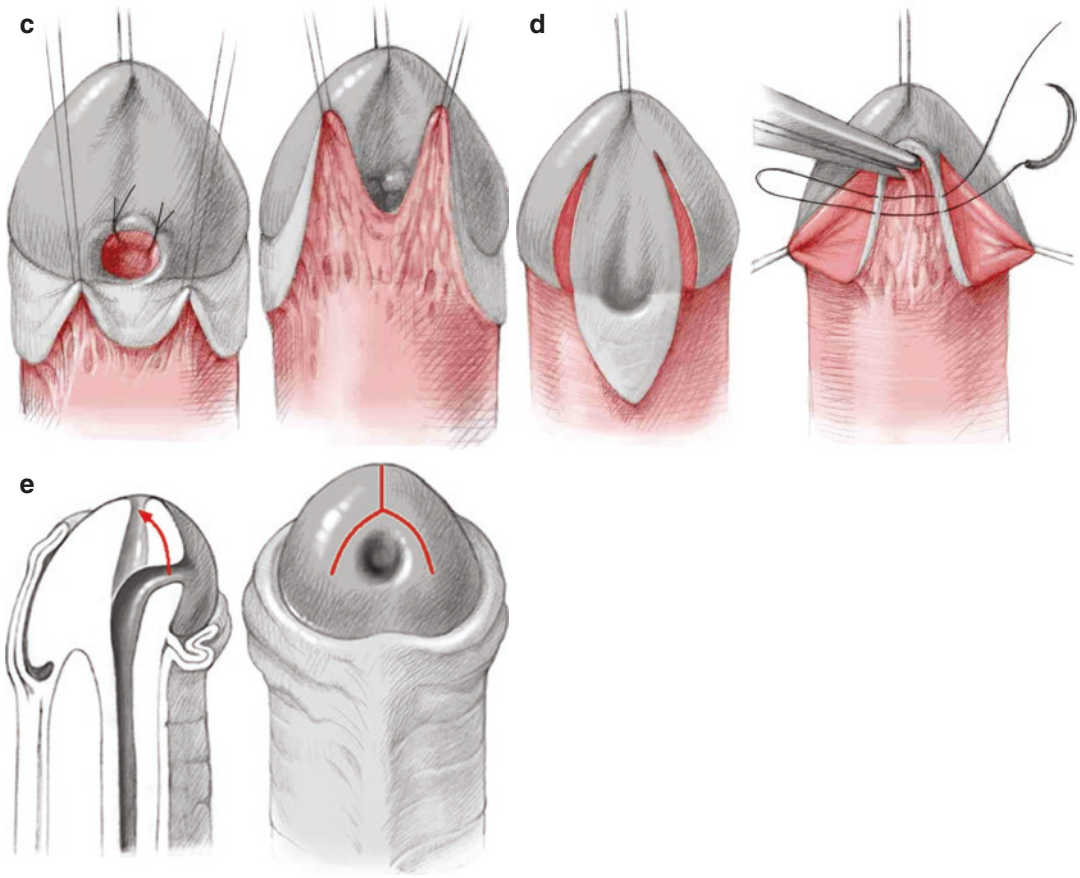

Fig. 2.5 (continued)

geons reported good results with urethral mobilization [68–71]. This technique is still popular in some parts of Europe and America [72, 73].

Duckett [35] described the "meatal advancement and glanuloplasty incorporated" (MAGPI) procedure, which combines the use of the Heineke-Mikulicz technique with urethral mobilization in glanular hypospadias characterized by mobile urethra. Arap and his colleagues, in 1984 [66], modified the MAGPI procedure by placing two sutures on the ventral skin edge and forming an "M" configuration. Harrison and Grobbelaar [67] described the urethral advancement and glanuloplasty procedure (UGPI), which modifies MAGPI by having a V-shaped incision around the original meatus before mobilization and having deep glanular wings. The meatus is advanced to the tip of the glans, and two deep glanular wings are rotated upward and wrapped around the urethra. Hadidi in his double Y glanuloplasty (DYG) applied the Y-V principle to advance the mobile glanular meatus to the tip of the glans and avoid the globular-looking glans associated with MAGPI technique [51].

2.3.2 Use of Ventral Skin Distal to the Meatus

Reconstruction of a completely epithelialized neourethra may make use of the ventral skin distal to the meatus as in the Thiersch technique [10], pyramid repair as described by Duckett and Keating [43] for "megameatus intact prepuce" or MIP, the glans approximation procedure (GAP) by Zaontz [74], distal urethroplasty and glanuloplasty (DUG) by Stock and Hanna [75] (Fig. 2.6), and lateral-based onlay (LABO) by Hadidi [52],

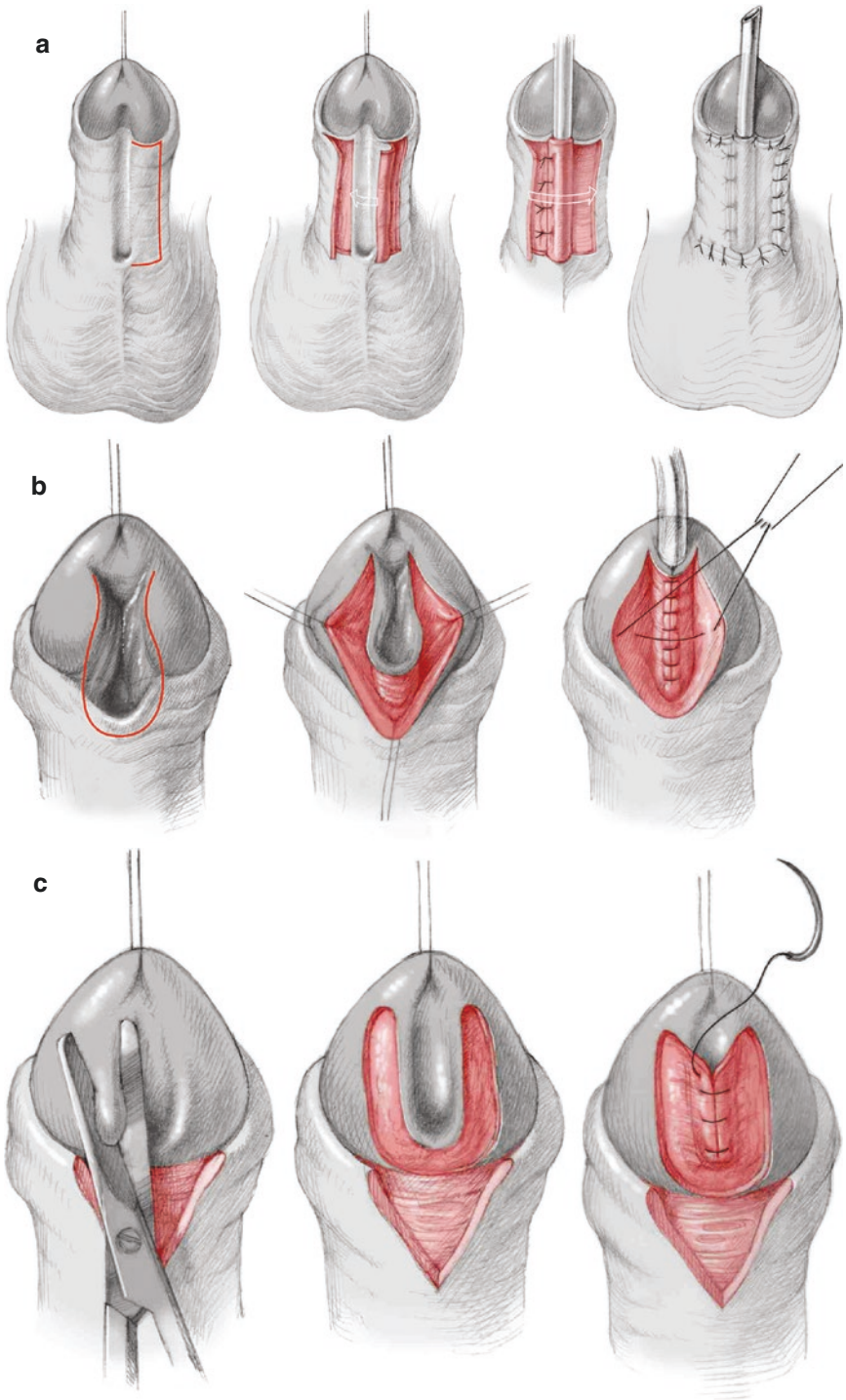

Fig. 2.6 Use of ventral skin distal to the meatus to reconstruct a completely epithelialized neourethra. (**a**) U-shaped incision as first described by Thiersch (1869) [10]. Notice the U incision is not central in order to avoid suture lines on top of each other. (**b**) Pyramid repair by Duckett and Keating (1989) for megameatus intact prepuce (MIP) [76]. (**c**) GAP repair by Zaontz (1989) for glanular hypospadias with cleft glans [74]. (**d**) DUG repair by Stock and Hanna (1997) combining a U-shaped incision with a vertical midline incision closed transversely [75]. (**e**) Lateral-based onlay flap (LABO) after Hadidi [52] ((**e**) ©Ahmed T. Hadidi 2022. All Rights Reserved)

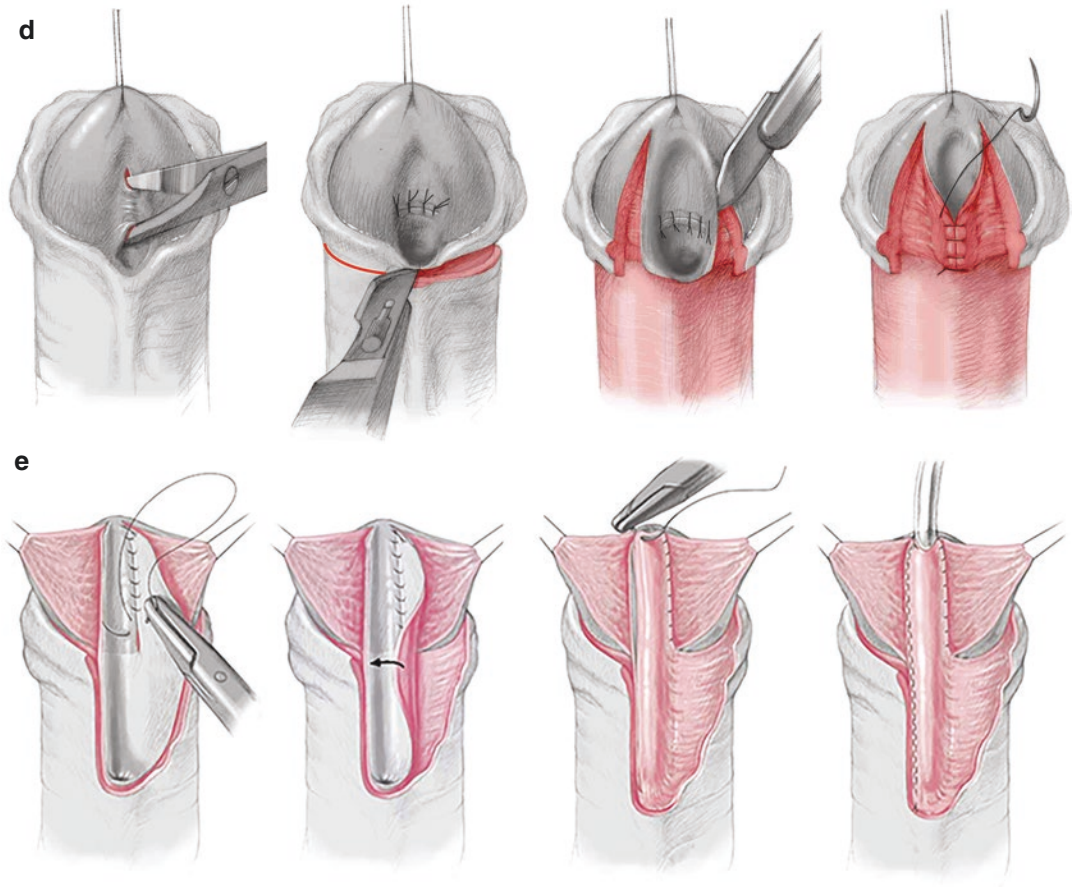

Fig. 2.6 (continued)

where he used the penile skin lateral to the urethral plate to reconstruct the new urethra to the tip of the glans.

Thiersch, 1869, used two parallel vertical incisions to wrap the ventral skin distal to the meatus around a catheter. He originally described this for repair of epispadias [10]. Then Theophile Anger (1874, 1875) [77] applied Thiersch's concepts for epispadias to hypospadias. In the same edition of the *Bulletin of the Surgical Society of Paris* (1874) Duplay of Paris described the three-stage procedure for release of chordee and creation of the ventral tube, which was later joined to the functional meatus [78]. The same principle was adopted by Zaontz (1989) for patients with cleft glans and glanular hypospadias [74]. Also, Duckett and Keating used the same principle to correct the defect known as "megameatus intact prepuce" (MIP), present in about 6% of cases of distal hypospadias, and called it pyramid repair [43]. Stock and Hanna in 1997 [75] combined the Thiersch-Duplay principle with the longitudinal midline incision of MAGPI, closed transversely (Heineke-Mikulicz).

Another principle recommended the use of the ventral skin distal to the meatus to form an incompletely epithelialized neourethra. Techniques adopting this principle include those of Duplay [78], Browne [24], Reddy [79], Orkiszewski [80], Rich et al. [43], and Snodgrass [44].

Duplay was the first to state that it did not matter whether the central tube was incompletely formed [12]. He believed that epithelialization would occur to form a channel if the incomplete tube was buried under the lateral flaps. The same

principle was adopted by Browne in his technique described in 1949 [24]. In both techniques, the defect was ventral. In 1989, Rich et al. described an incision of the urethral plate to obtain a cosmetically acceptable vertical slit meatus for Mathieu repair [43] . This dorsal midline incision was subsequently adopted for the entire length of the urethral plate as a complement to the Thiersch-Duplay urethroplasty for distal hypospadias by Snodgrass in 1994 [44]. The tubularized incised plate (TIP) urethroplasty differs in that the defect is dorsal and the suture line is protected by a preputial subcutaneous fascial flap (Fig. 2.7).

Historically, incision of the urethral plate was first described by Reddy [79], Orkiszewski who called it "the Deadman jacket" [80], and Rich et al. [43], before Snodgrass popularized the principle in 1994 [44].

2.4 Use of Ventral Skin Proximal to the Meatus (Meatal-Based Flaps)

A well-established group of techniques used the ventral skin *proximal* to the meatus as a meatal-based flap. This flap is used to form the ventral part of the neourethra as in the technique first described by Wood [11], Ombrédanne [18, 81], and Bevan [82] and popularized by Mathieu in 1932 [19]. Fevre [83], Mustardé [30], Barcat [84, 85], and Hadidi (Y-V [47] and SLAM [53]) described techniques using the same principle.

Wood [11] described a flap based distally on the meatus to be turned over to form the ventral surface of the neourethra.

Ombrédanne used a perimeatal flap but fashioned the neourethra using a purse-string suture [81]. The repair was too baggy. Mathieu used a perimeatal flap and constructed the neourethra using two lateral suture lines [19]. Mustardé used the same principle but differed in that he used the perimeatal flap to form the whole neourethra, not just the ventral surface [30]. This bore the advantage of having a single suture line deep to the urethra but has the disadvantage of losing the blood supply of the healthy urethral plate. Barcat modified the Mathieu technique by mobilizing the urethral plate and making a midline incision to push the neourethra deeper between the corpora [85]. The goal was always advancement of the neourethra to the glans tip. Stenosis and fistula were frequently the price. Fevre (1961) used a longer meatal-based flap and folded it between the glanular wings [83]. Mustardé included a V incision at the glans to achieve a wider meatus [30]. Hadidi included a Y incision at the tip of the glans closed as a V [47]. He further modified the technique in 2012 to achieve a terminal wide slit-like meatus in his technique slit-like adjusted Mathieu or SLAM technique [53] (Fig. 2.8).

2.4.1 Use of Preputial Skin

The preputial skin plays a very important role in the management of hypospadias (Fig. 2.9). It may be used in different ways:

1. The preputial skin may be mobilized ventrally to cover skin and fascial defects following excision of chordee in two-stage repair. Thiersch did the first buttonhole flap in the prepuce to allow resurfacing of the penis with the prepuce [10].
2. The preputial skin may be divided in the midline to form two flaps to cover the skin deficiency of the penis after chordee resection and after urethroplasty. This was described by Edmunds [17] and popularized by Byars [25].
3. The preputial skin may be used as a free skin graft to cover ventral defect after excision of ventral chordee as the first stage of two-stage repair. This was first described by Cloutier in 1962 [29] and popularized by Bracka [45, 46].
4. The preputial skin may be used as a free skin graft to form the neourethra in single-stage urethroplasty as first described by Devine and Horton in 1961 [27].
5. The preputial skin may be used as a pedicled flap for reconstruction of the neourethral tube. This may be vertical as described by Van Hook [13], Toksu [86], and Hodgson [87] or horizontal and double-faced as described by Asopa et al. [88]. Duckett [89]

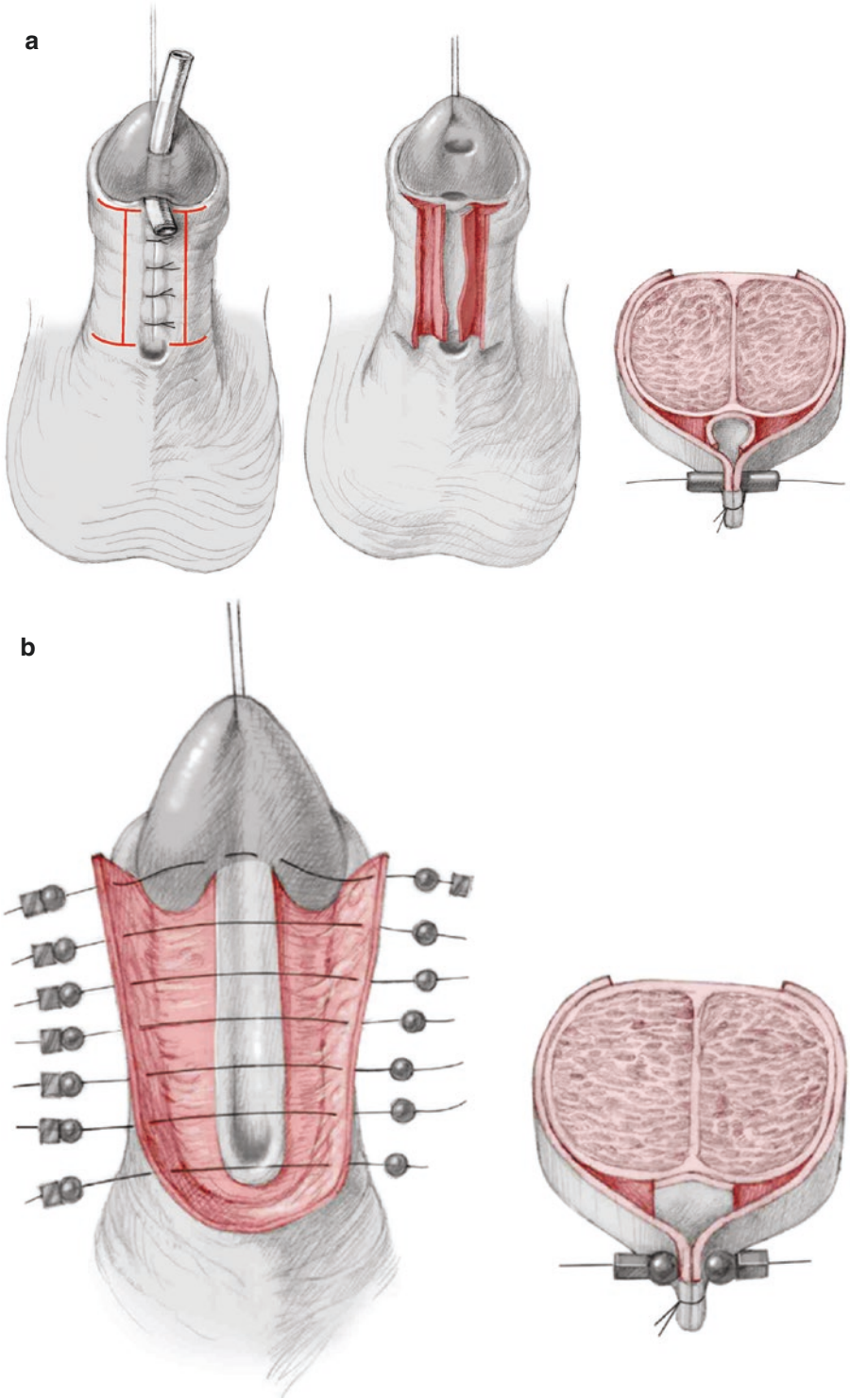

Fig. 2.7 Use of ventral skin distal to the meatus to reconstruct a partially epithelialized neourethra: (**a**) Duplay incomplete urethroplasty (1880) [12]; (**b**) Denis-Browne technique (1949) [24]; (**c**) hinging of the urethral plate (Rich et al. 1989) [43]; (**d**) TIP urethroplasty (1994) [44]

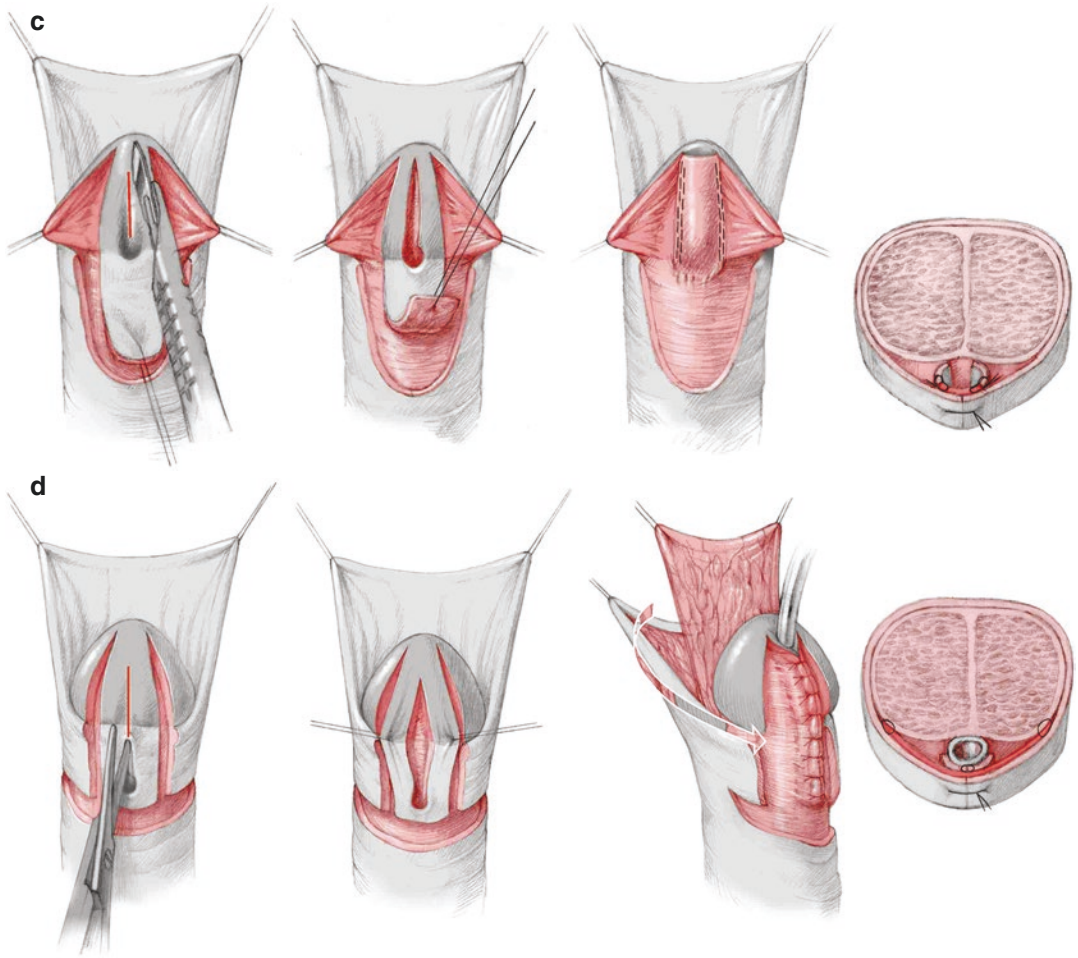

Fig. 2.7 (continued)

adopted this technique using the inner face of the prepuce in a horizontal manner now known as the tubularized preputial island flap technique (TPIF). Standoli described the same technique but used the outer face of the prepuce [90].

6. The preputial skin may be used as a pedicled flap to form the ventral wall of the neourethra (not the whole neourethra), as described by Elder et al. in the technique known as onlay island flap (OIF) in 1987 [41].
7. The preputial vascular fascia without skin may be used as a protective second layer to protect urethroplasty in the same way as after Mathieu and Snodgrass procedures, as first described by Retik et al. in 1988 [42].
8. The preputial skin may be used in continuation with a parameatal skin flap as in Koyanagi et al. [37], yoke repair (Snow) [91], and along with its fascia in the lateral-based flap technique (Hadidi) [50], bilateral-based flap (BILAB, Hadidi) [92], lateral-based onlay (LABO, Hadidi) [52], and chordee excision and distal urethroplasty (CEDU, Hadidi) [55].

2.4.2 Combined Use of Prepuce and Skin Proximal to the Meatus

In proximal hypospadias, one needs to reconstruct a long neourethra. Another principle

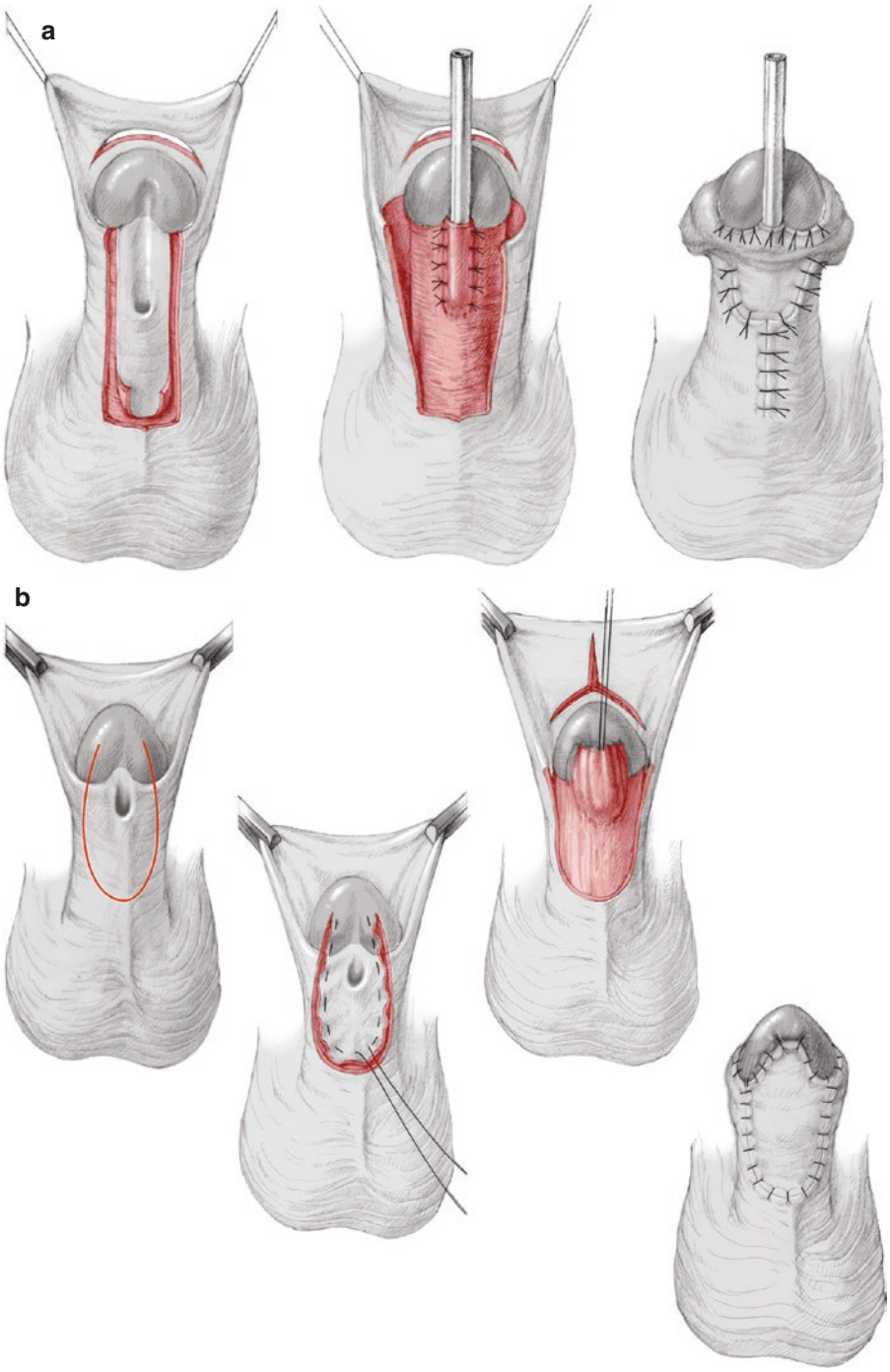

Fig. 2.8 Use of ventral skin proximal to the meatus to reconstruct a fully epithelialized neourethra. (**a**) Wood (1875): meatal-based flap with buttonhole of prepuce. (**b**) Ombrédanne (1911): a large round flap and a purse-string suture. (**c**) Mathieu (1932): a U-shaped incision and two suture lines. (**d**) Mustardé (1965): a rectangular flap and one suture line. (**e**) Barcat (1969): balanic groove technique and a deep midline incision. (**f**) Hadidi (1996): Y-V glanuloplasty, modified Mathieu—a Y incision in the glans, the center at the tip of glans, closed as a V, and dog-ears opened. A small V is excised from the distal end of the flap. (**g**) The slit-like adjusted Mathieu (SLAM) after Hadidi [53] ((**g**) ©Ahmed T. Hadidi 2022. All Rights Reserved)

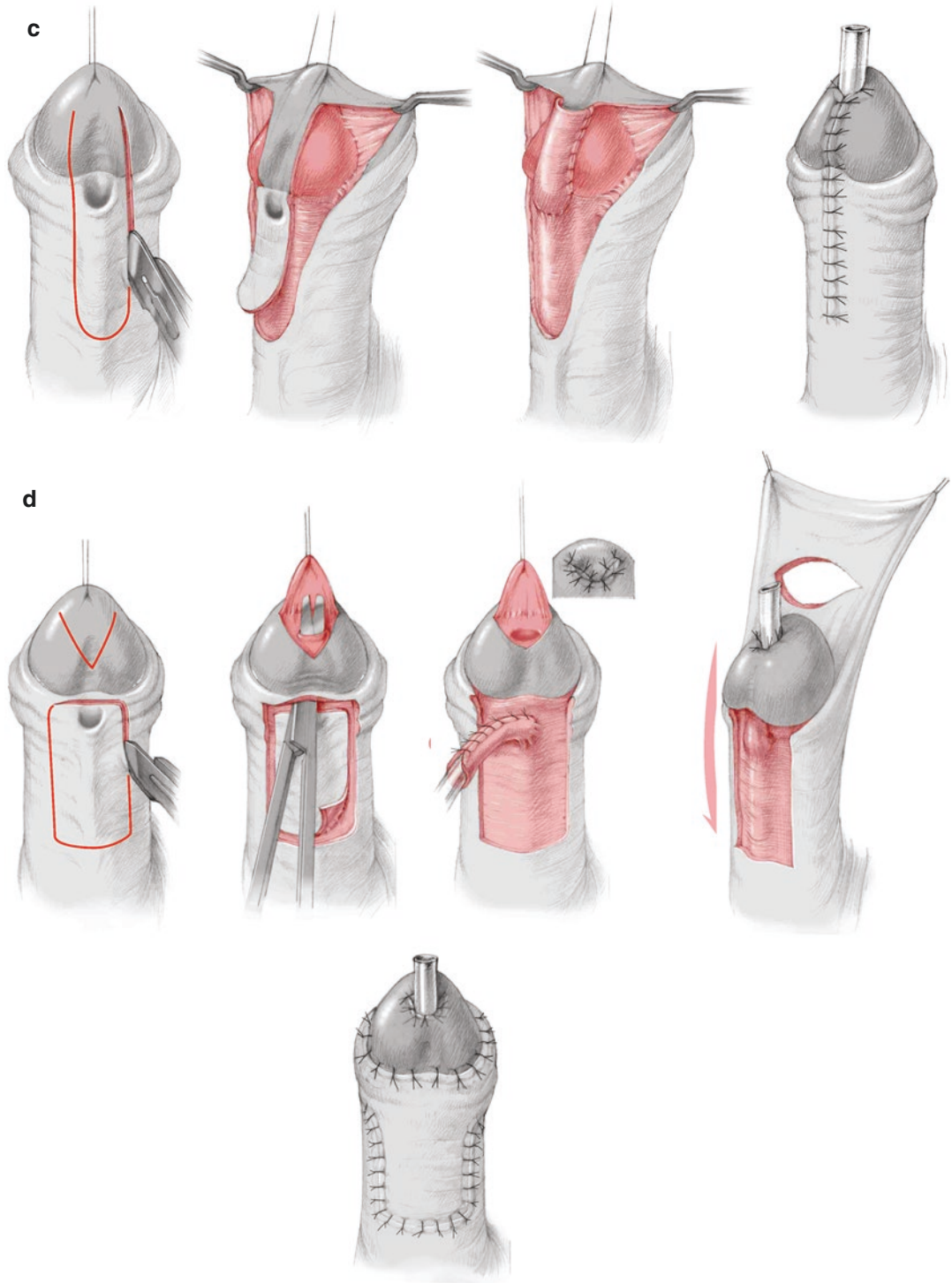

Fig. 2.8 (continued)

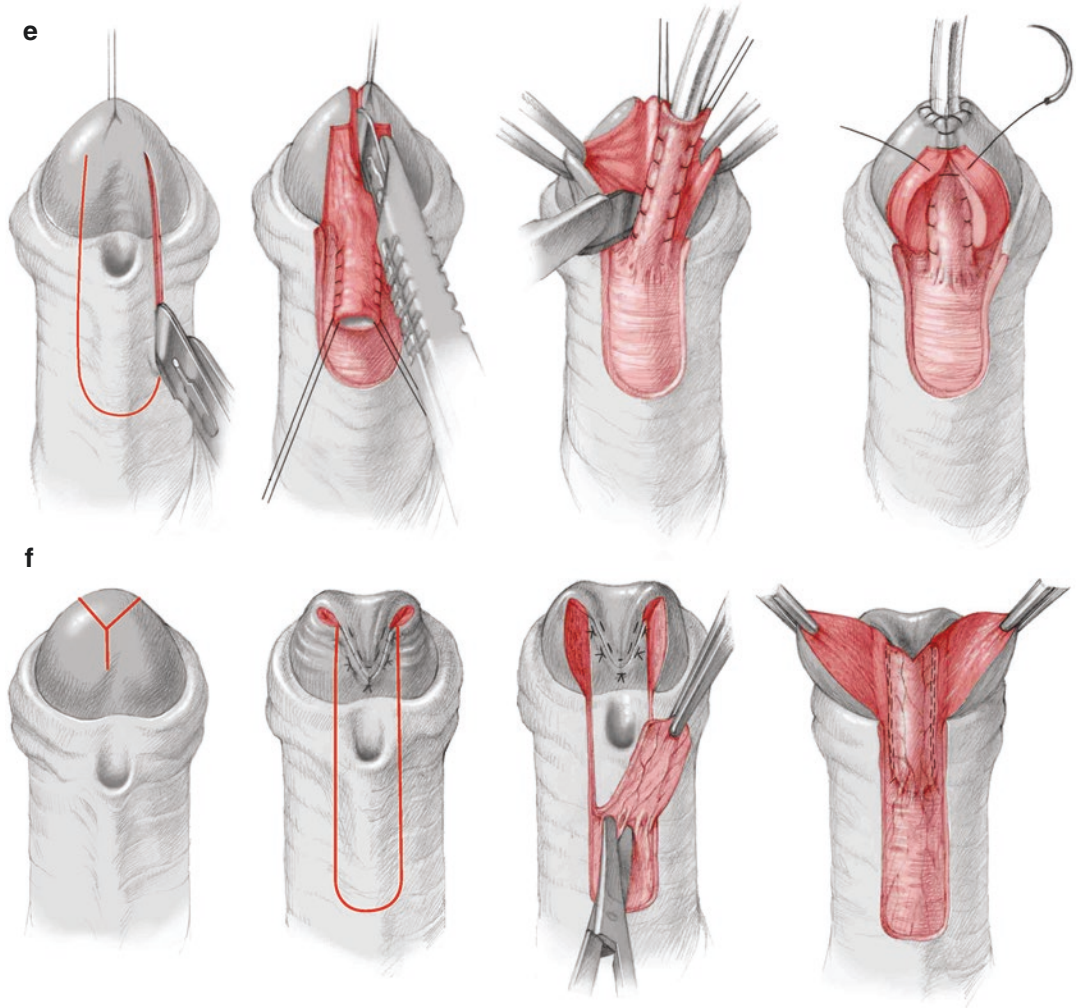

Fig. 2.8 (continued)

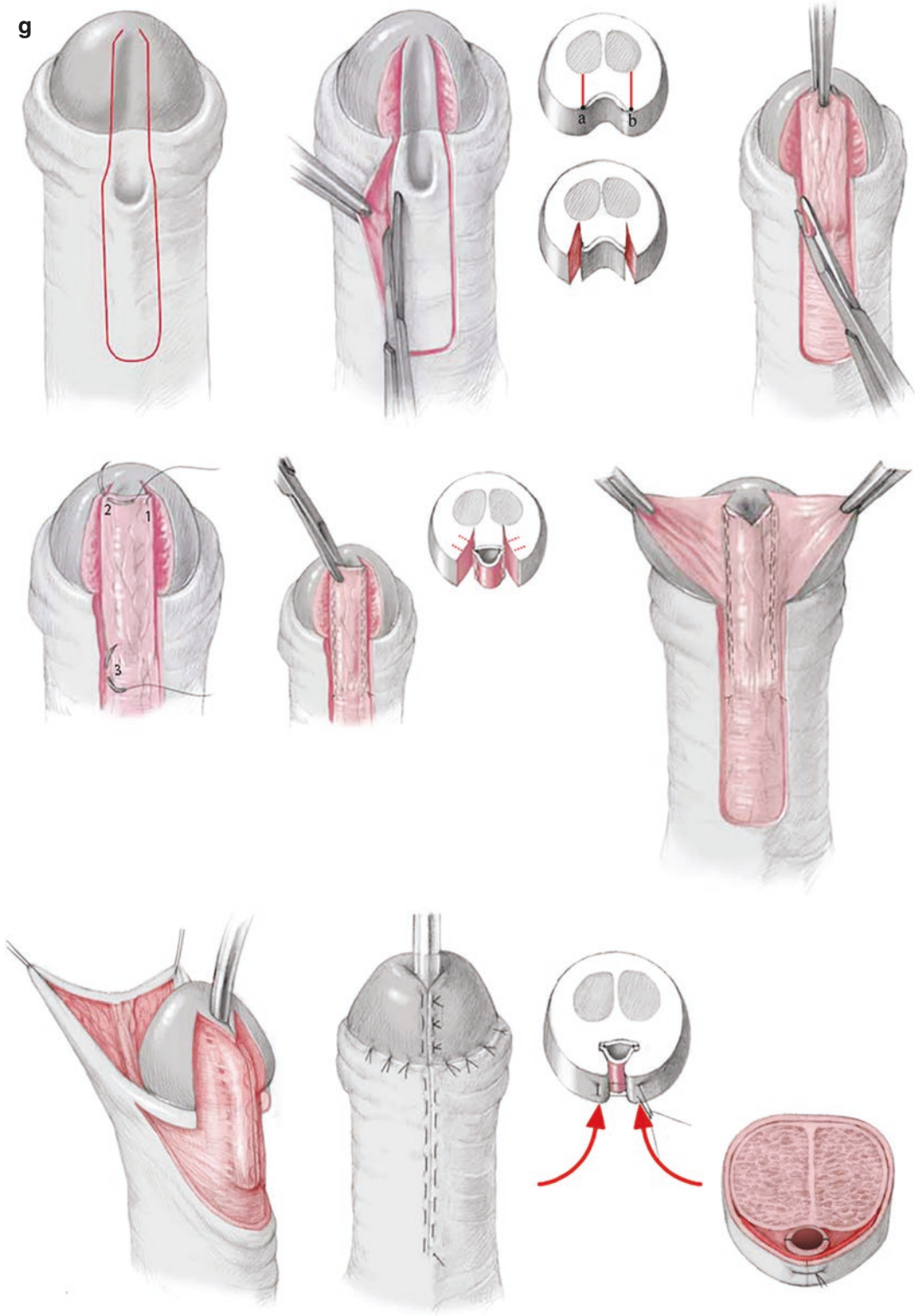

Fig. 2.8 (continued)

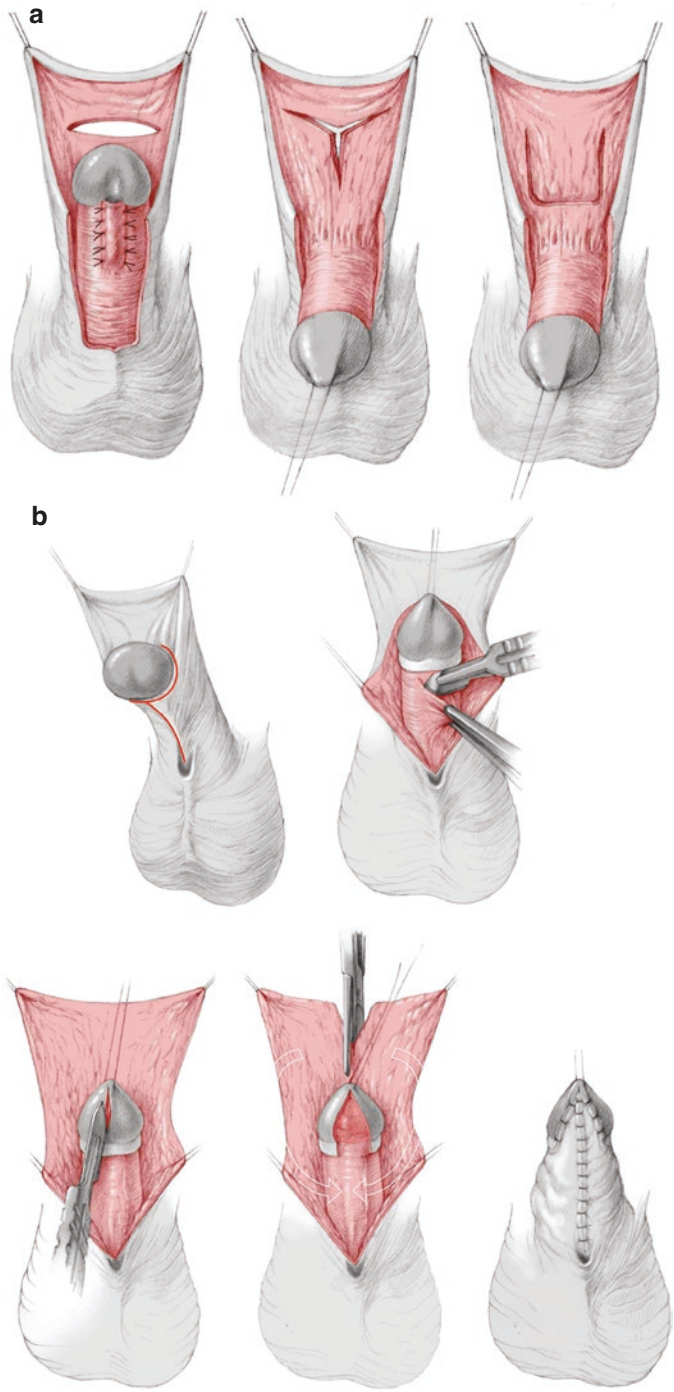

Fig. 2.9 Use of preputial skin for reconstruction of neourethra. (**a**) Buttonholing of the prepuce as described by Thiersch [10]. (**b**) Midline incision of the prepuce as described by Edmunds [17] and Byars [25]. (**c**) Preputial skin as a skin graft to cover the ventral defect of the penis as described by Nové-Josserand [16] and Bracka [45, 46]. (**d**) Preputial skin as a free skin graft to form the neourethra as described by Devine and Horton [27]. (**e**) Preputial island flap as described by Hook [13], Toksu [86], Hodgson [87], Asopa [88], and Duckett et al. [89]. (**f**) Onlay island flap as described by Elder et al. [41]. (**g**) Preputial vascular fascia as a second protective layer as described by Retik et al. [42]

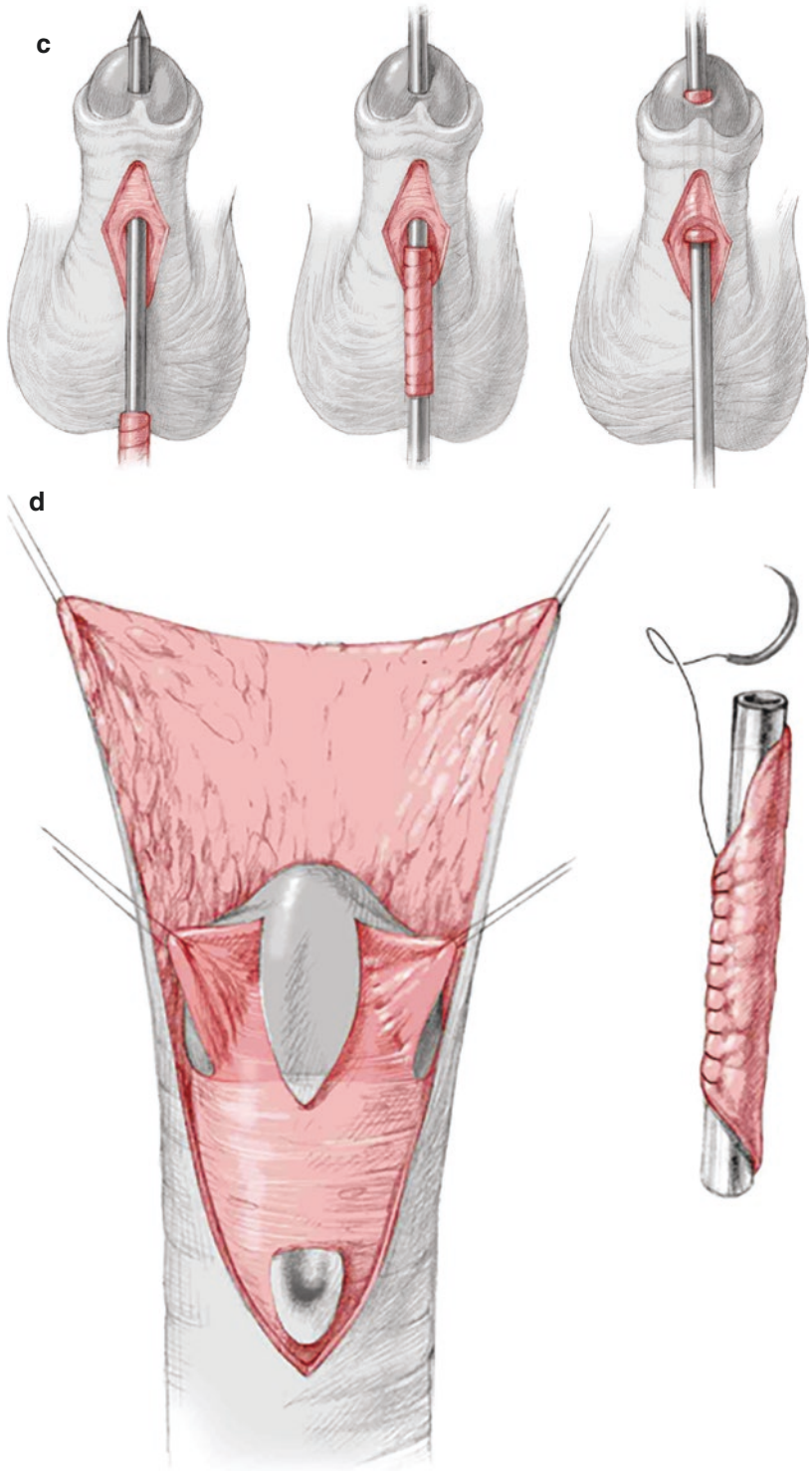

Fig. 2.9 (continued)

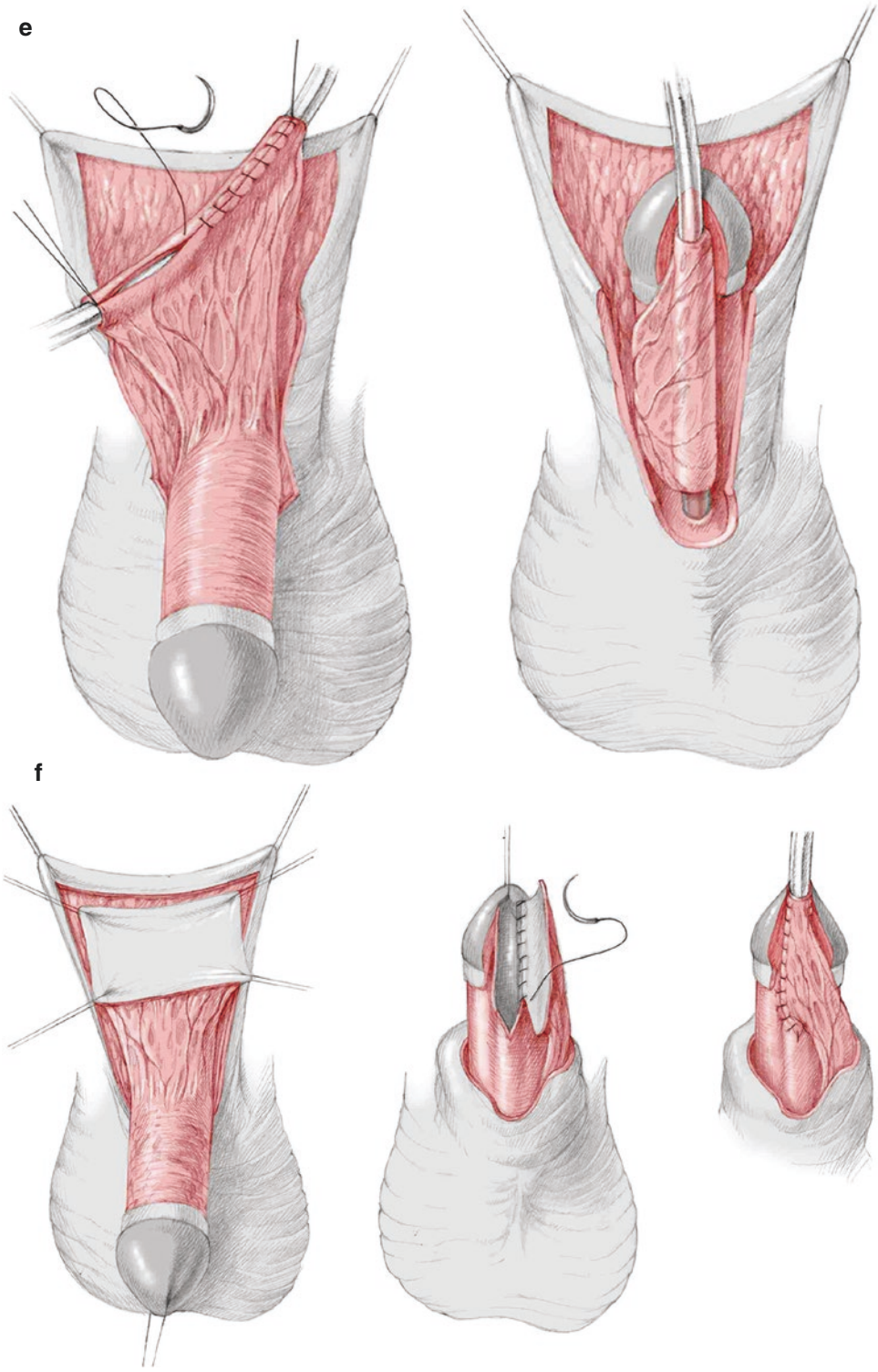

Fig. 2.9 (continued)

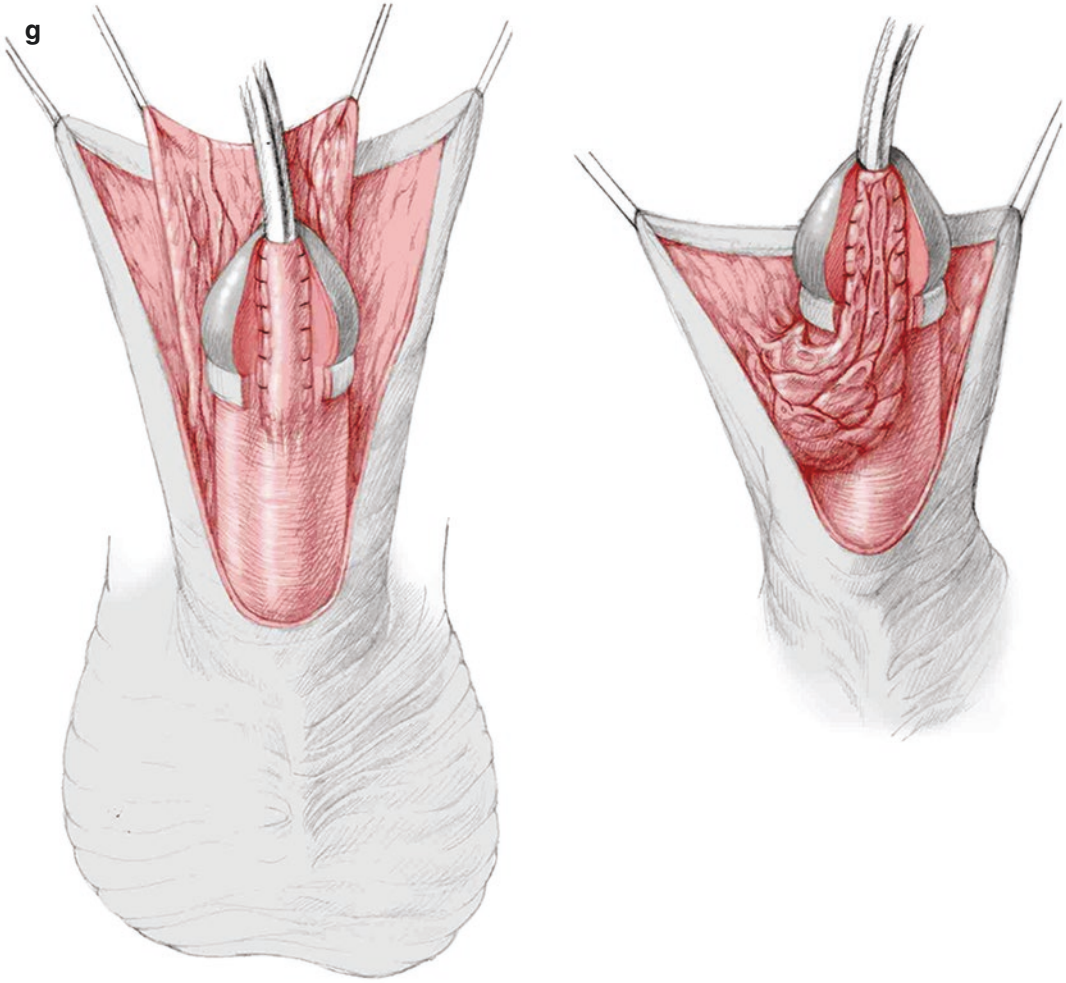

Fig. 2.9 (continued)

employs the combined use of parameatal skin and the prepuce. This was first suggested by van Hook [13]. Many authors, including Broadbent et al. [28], DesPrez et al. [26], Hinderer [93], Koyanagi et al. [37], Snow [91], and Hadidi [50, 52, 54, 55], have described techniques using the same principle.

Van Hook [13] suggested the use of a "lateral oblique flap" from the side of the penis. Broadbent et al. [28], DesPrez et al. [26], and Hinderer [93] adopted the same principle and described a flap extending obliquely from the parameatal skin into the prepuce. Koyanagi et al. [37] modified the technique by using two lateral flaps (from both sides). Snow [91] described the yoke technique, which differed from Koyanagi in buttonholing the prepuce. Hadidi described the lateral-based flap technique using the same principle and combined it with Y-V glanuloplasty [47]. The technique entails adequate mobilization of the preputial vascular fascia with the flap. The lateral-based flap enjoys a double blood supply from the meatal base and the preputial vessels. The Y helps to bring the meatus to the tip, and the V excised from the tube helps to achieve a terminal slit-like meatus (Fig. 2.10).

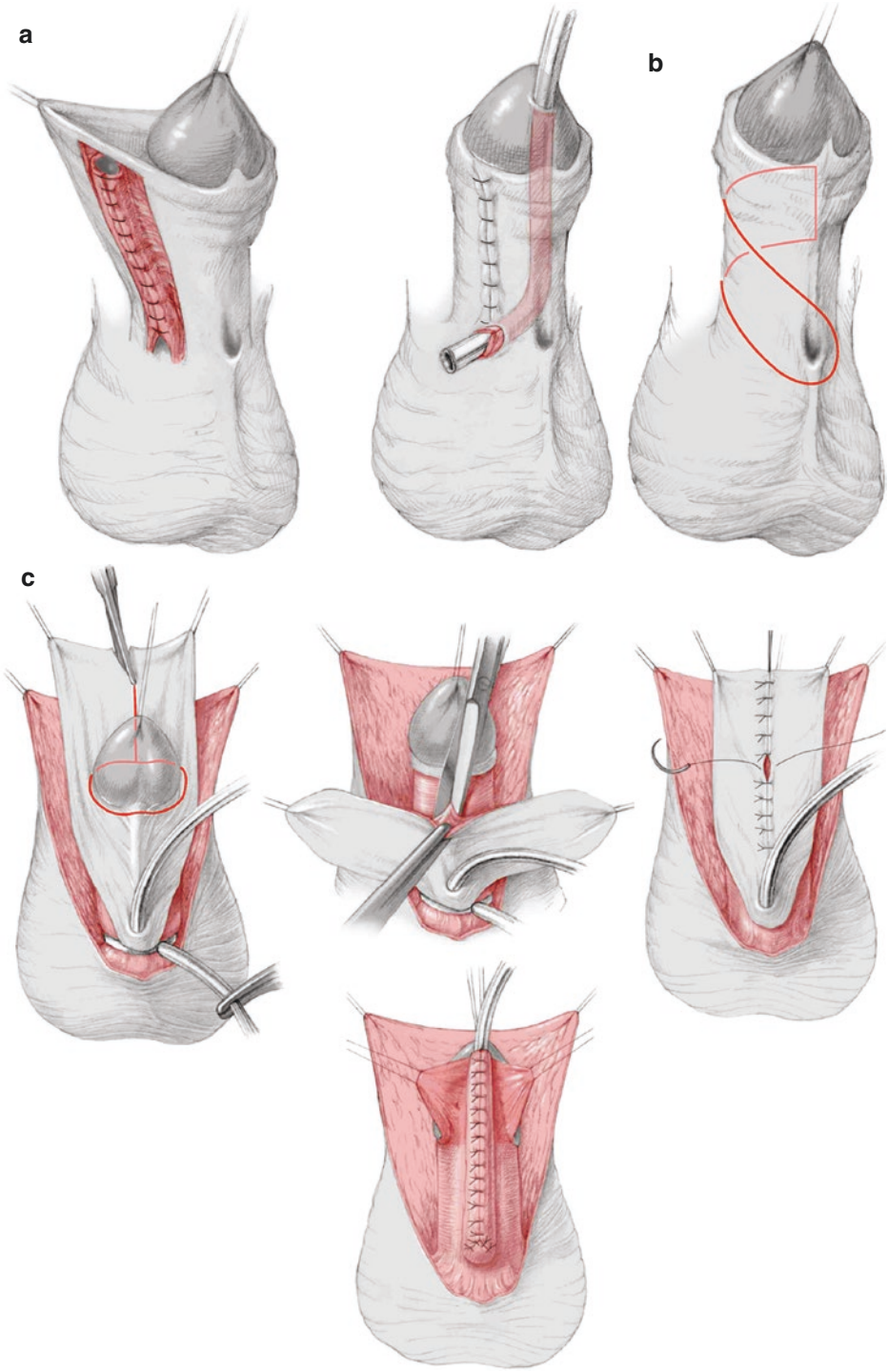

Fig. 2.10 Combined use of prepuce and the skin proximal to the meatus. (**a**) Lateral oblique flap from the side of the penis suggested by Hook [13]. (**b**) One-stage repair for proximal hypospadias described by Broadbent et al. [28]. (**c**) Parameatal foreskin flap described by Koyanagi et al. [37]. (**d**) Yoke repair described by Snow [91]. (**e**) Lateral-based flap combined with Y-V glanuloplasty described by Hadidi [47]. (**f**) Bilateral-based flap (BILAB) after Hadidi [54]. (**g**) Chordee excision and distal urethroplasty (CEDU) after Hadidi [55] ((**f**, **g**) ©Ahmed T. Hadidi 2022. All Rights Reserved)

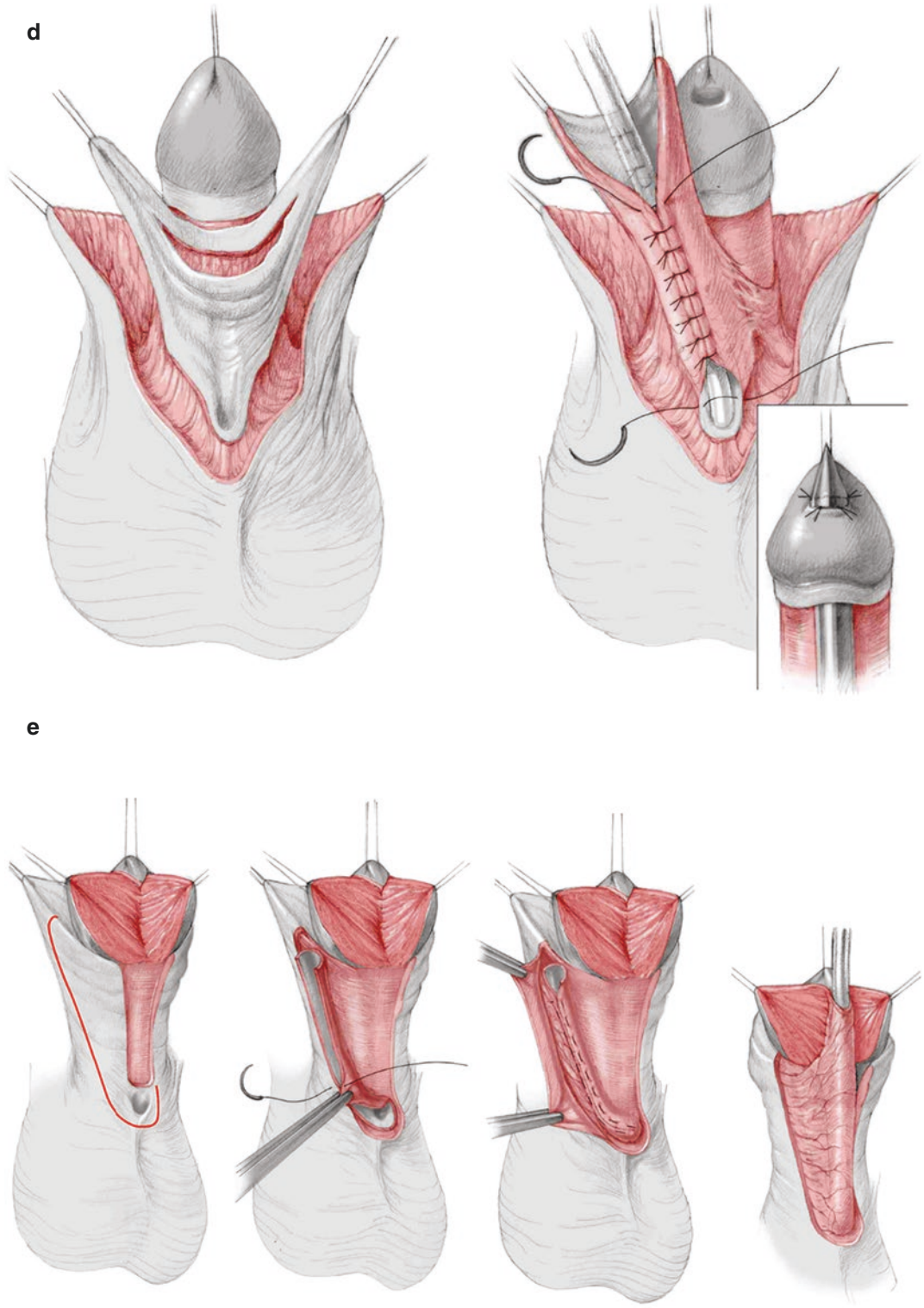

Fig. 2.10 (continued)

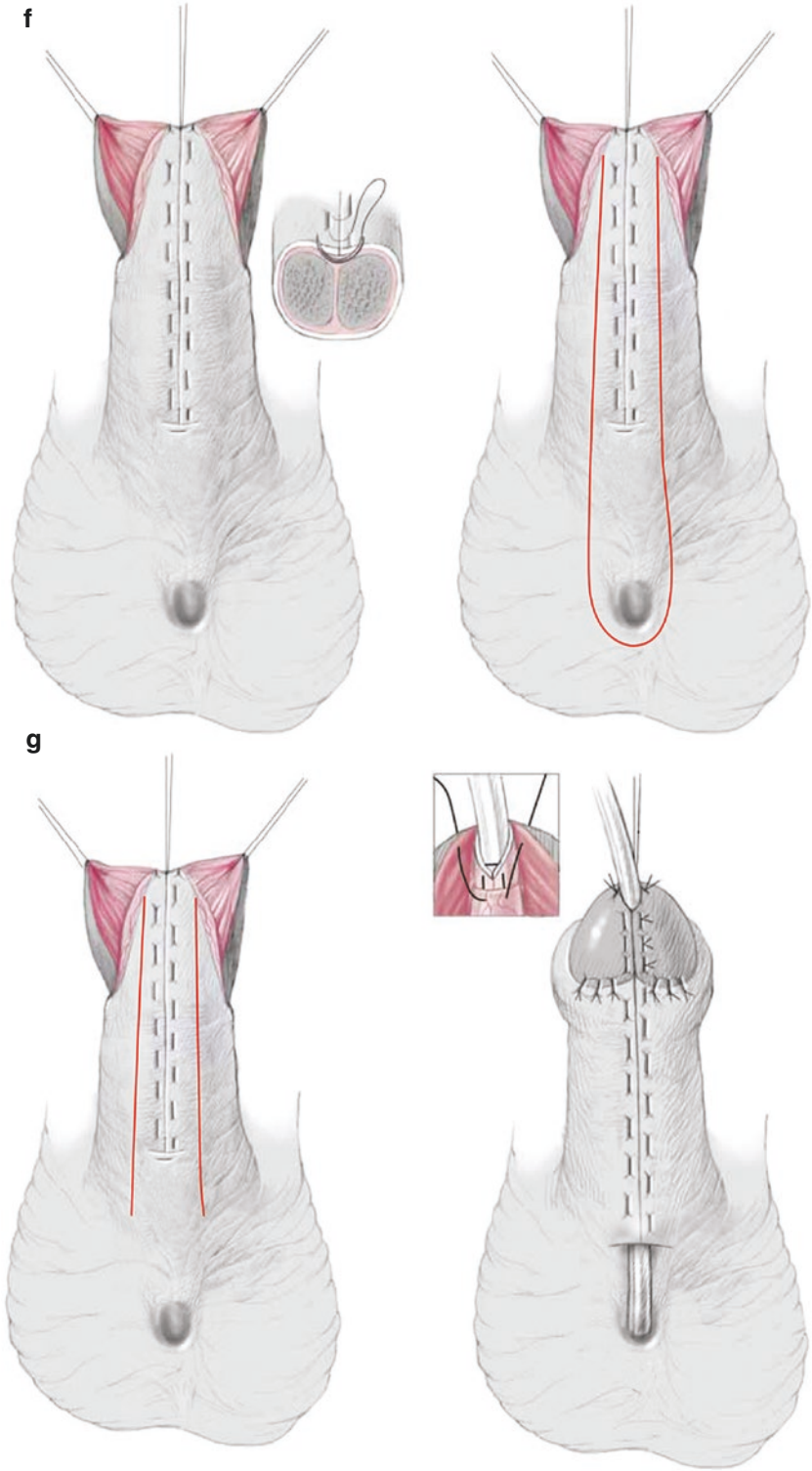

Fig. 2.10 (continued)

2.4.3 Use of the Scrotum

The scrotum may be used in four different ways in hypospadias reconstruction (Fig. 2.11):

1. The scrotal skin may be used to form a completely epithelialized neourethra. Bouisson was apparently the first to report the use of scrotal tissue to reconstruct the ventral wall

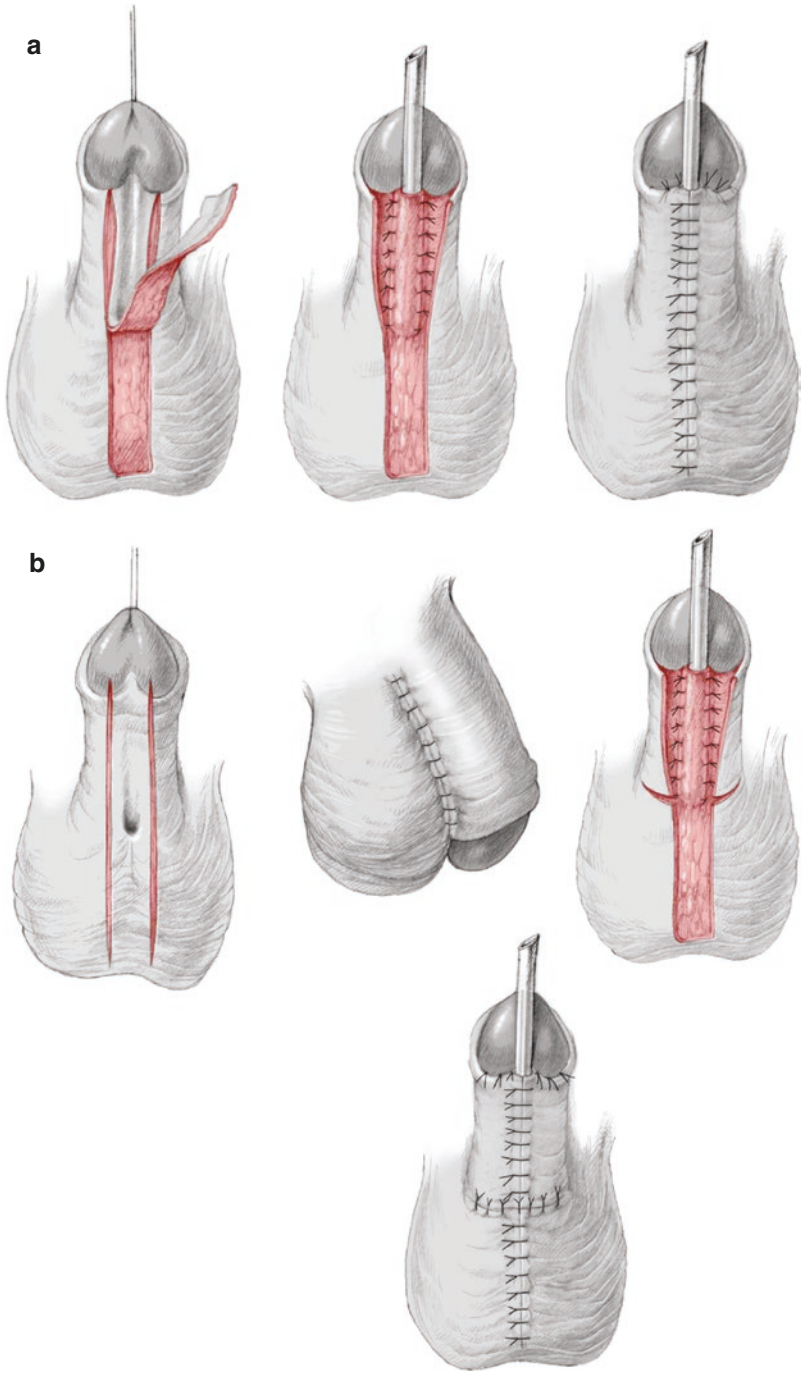

Fig. 2.11 Use of scrotum in hypospadias repair. (**a**) Bouisson was the first to use scrotal skin for urethral reconstruction [9]. (**b**) Rosenberger used scrotal tissue for urethroplasty and buried the penis in the scrotum [97]. (**c**) Rochet used a large scrotal flap for total urethroplasty [94]. (**d**) Lowsley and Begg constructed a long urethral tube from scrotum [95]. (**e**) Beck suggested the Duplay type of urethroplasty and used a rotation flap from the scrotum for coverage [63]. (**f**) Cecil used a modification of the Rosenberger operation following reconstruction of the urethra from ventral penile skin [22]

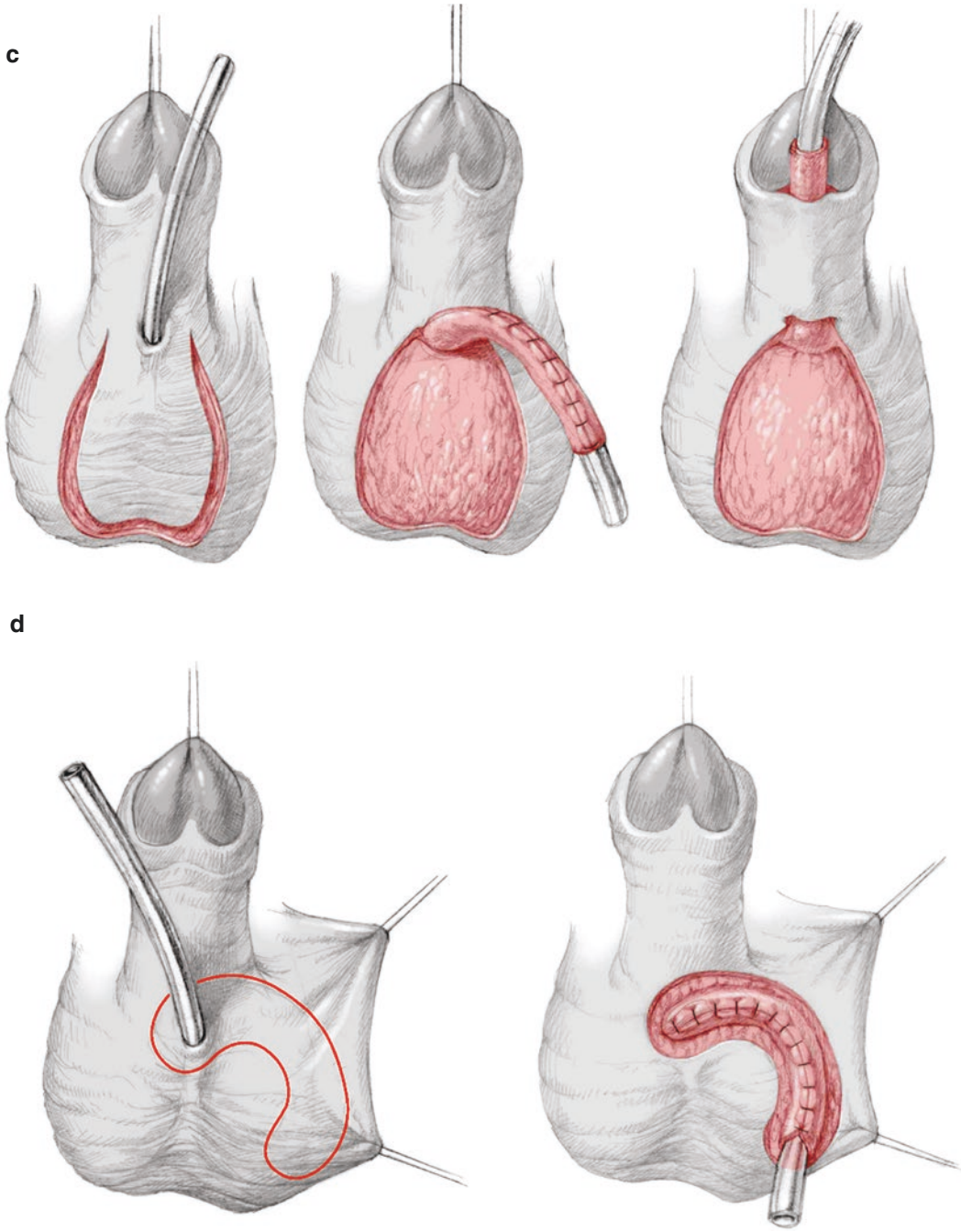

Fig. 2.11 (continued)

Fig. 2.11 (continued)

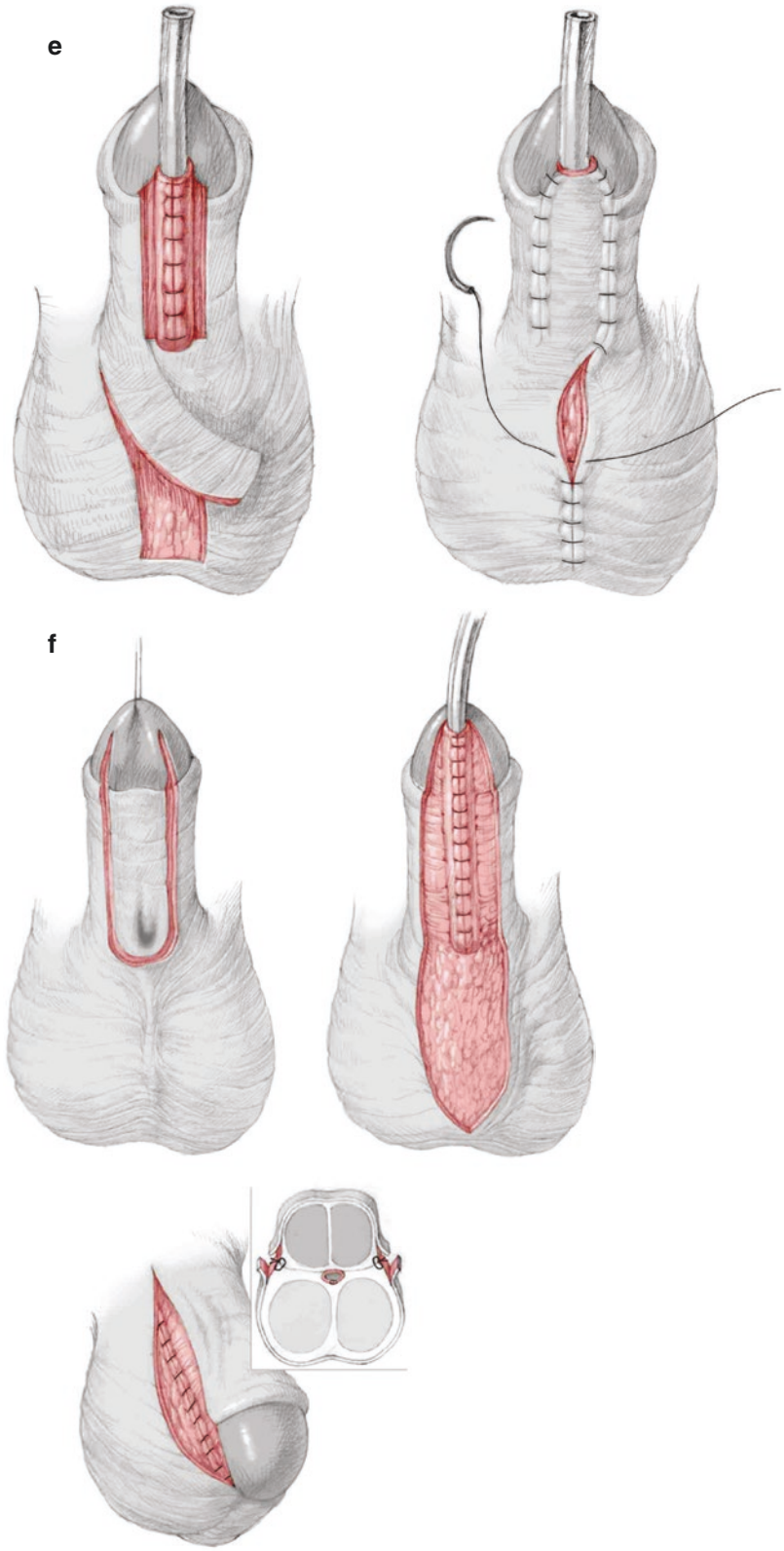

of the neourethra [9]. Rochet used a large scrotal flap for urethroplasty [94]. This flap was buried in a tunnel on the ventral surface of the penis. Lowsley and Begg constructed the neourethra completely from the scrotum [95]. This method fell into disuse because of the problem of hair growth into the neourethra.

2. The scrotal skin may be used to cover the neourethra. This was described by Beck in 1897 [96].
3. The scrotal skin may be used to reconstruct the neourethra and at the same time the scrotum is used to protect the neourethra until healing is complete. Rosenberger [97], Landerer [98], and Bidder [99], used scrotal skin for urethroplasty. They described for the first time burying of the penis in the scrotum to obtain skin coverage. This was modified by Bucknall [100].
4. The scrotum may be used as a bed for the neourethra, a technique that was popularized by Cecil [22] and Culp in 1966 [101] (Cecil-Culp technique).

2.4.4 Use of Dorsal Penile Skin

Davis, in 1940, tubed the dorsal penile skin with the base proximal in the direction of the circulation [20] (Fig. 2.12). The detached distal end of this tube was passed through a channel in the glans and penis by angulating the penis acutely upward and backward. In the second stage, the proximal pedicle was cut and the penis returned to its normal position. The penile gymnastics required for the Davis procedure apparently seemed too demanding for most surgeons. Hodgson [87] and Perovic [102] used longitudinal dorsal skin flaps to reconstruct the new urethra.

2.4.5 Use of Grafts

Nové-Josserand in 1897 started another school of urethroplasty which utilized the free inlay graft [16]. He used a thin split-thickness free graft from the inner thigh and applied the raw surface outward around a metal probe. Sir Archibald McIndoe used a partial-thickness skin graft from the inner upper arm [103]. Young and Benjamin also used a split-thickness skin graft from the medial aspect of the upper arm [104]. From 1909 to 1927, a whole series of homograft including vein, urethra, and appendix were attempted but never with any consistent success. Cloutier used the full thickness prepuce as the graft material after excising the chordee using a T-shaped incision into the glans [29]. He then stitched the graft to the edges of the resulting defect (including the

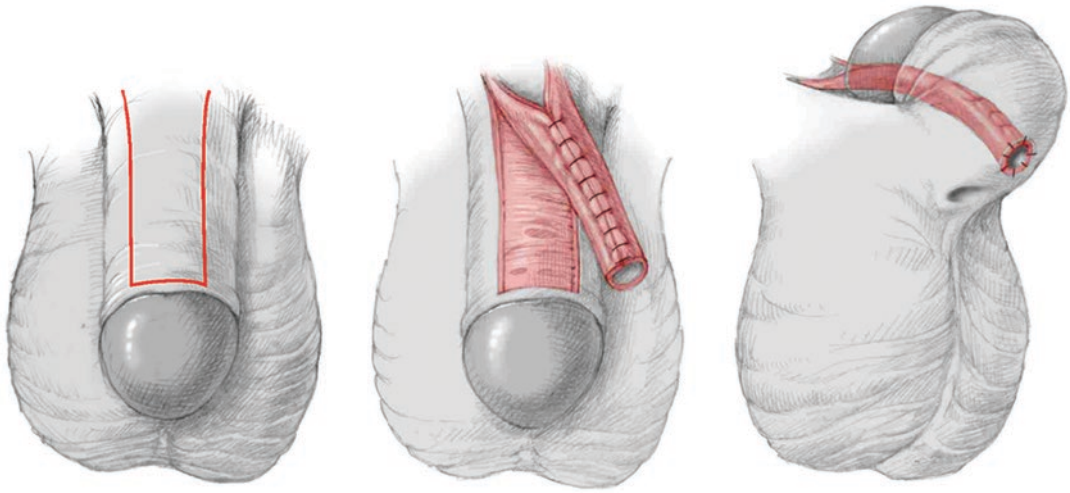

Fig. 2.12 Davis operation (1940) using a dorsal tube pedicle flap to construct the neourethra [20]

glans). In addition, he quilted the graft to the center to ensure better take of the graft. Nicolle [105] and Bracka [45] popularized the use of full-thickness skin graft from the prepuce. Memmelaar, in 1947, was the first to advocate the use of bladder mucosa [23]. Although Humby [21] first proposed and reported the use of buccal mucosa for hypospadias repair, Duckett in 1986 [106] promoted the technique and is credited for the current enthusiasm and widespread acceptance of its use in complex hypospadias repairs (Fig. 2.13). Fine et al. described tunneling of buccal mucosal tube graft for proximal hypospadias [107].

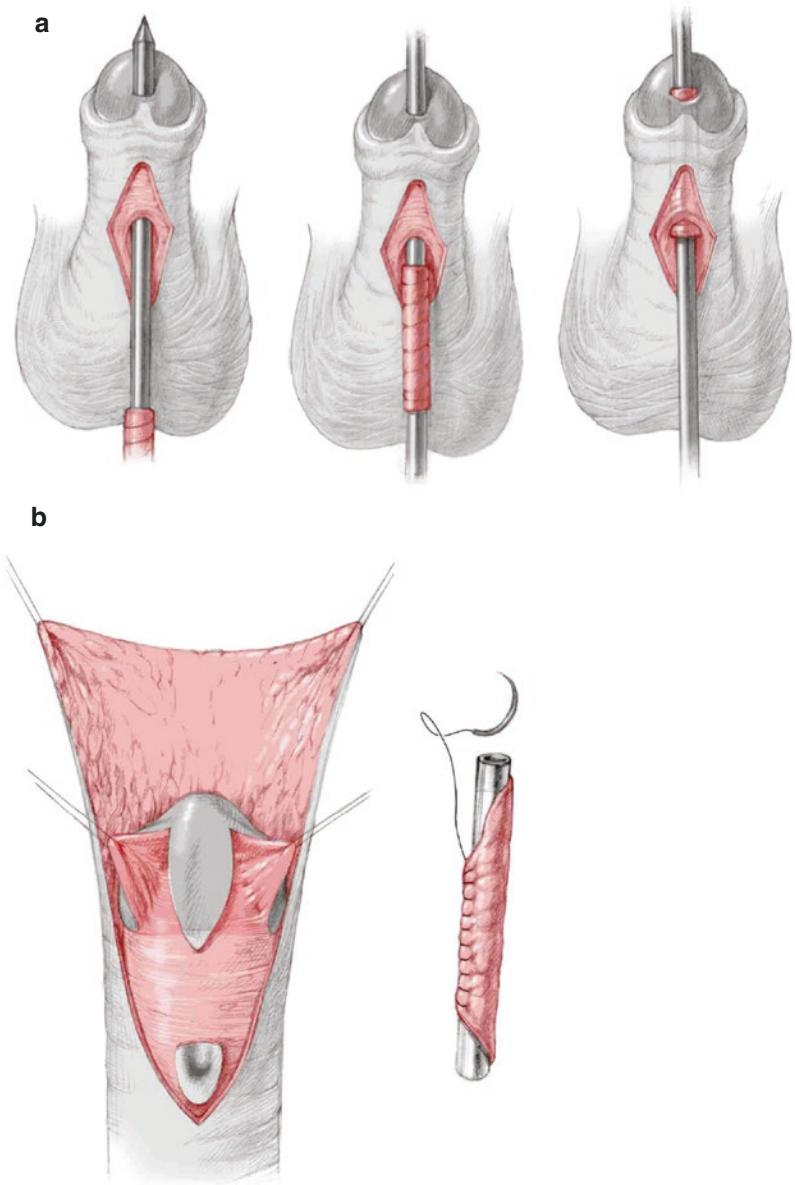

Fig. 2.13 Use of grafts for urethral reconstruction. (**a**) Nové-Josserand used a split-thickness skin graft on a metal probe [16], (**b**) Devine and Horton used preputial full-thickness skin graft in a single-stage repair [27]. (**c**) Bracka used full-thickness skin graft in a two-stage repair [45, 46]. (**d**) Memmelaar used bladder mucosa for urethral reconstruction [23]. (**e**) Humby (1941) first described the use of buccal mucosa for urethral reconstruction [21]

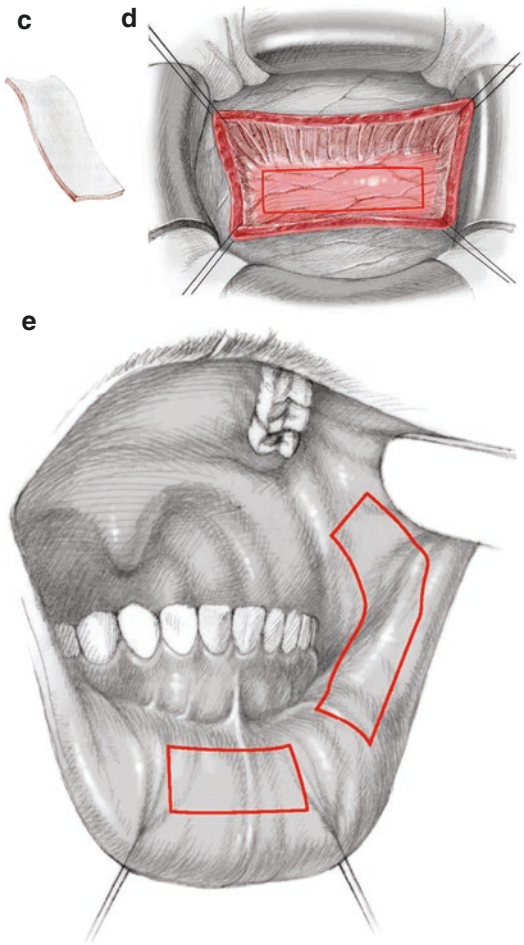

Fig. 2.13 (continued)

2.5 Use of a Protective Intermediate Layer

An important principle in hypospadias repair is to avoid having the skin suture line on top of the urethroplasty suture line. Thiersch as early as 1868 designed his asymmetric U-shaped incision to avoid having the two suture lines on top of each other [10]. Smith was the first to describe the use of an intermediate or interposition layer between the neourethra and the cutaneous suture [32]. Types of interposition waterproofing layer include Smith's de-epithelialized skin [32], Snow's tunica vaginalis wrap from the testicular coverings [39], Retik et al.'s dorsal subcutaneous flap from the foreskin [42], Motiwala's dartos flap from the scrotum [108], and Yamataka et al.'s external spermatic fascia flap [109] (Fig. 2.14).

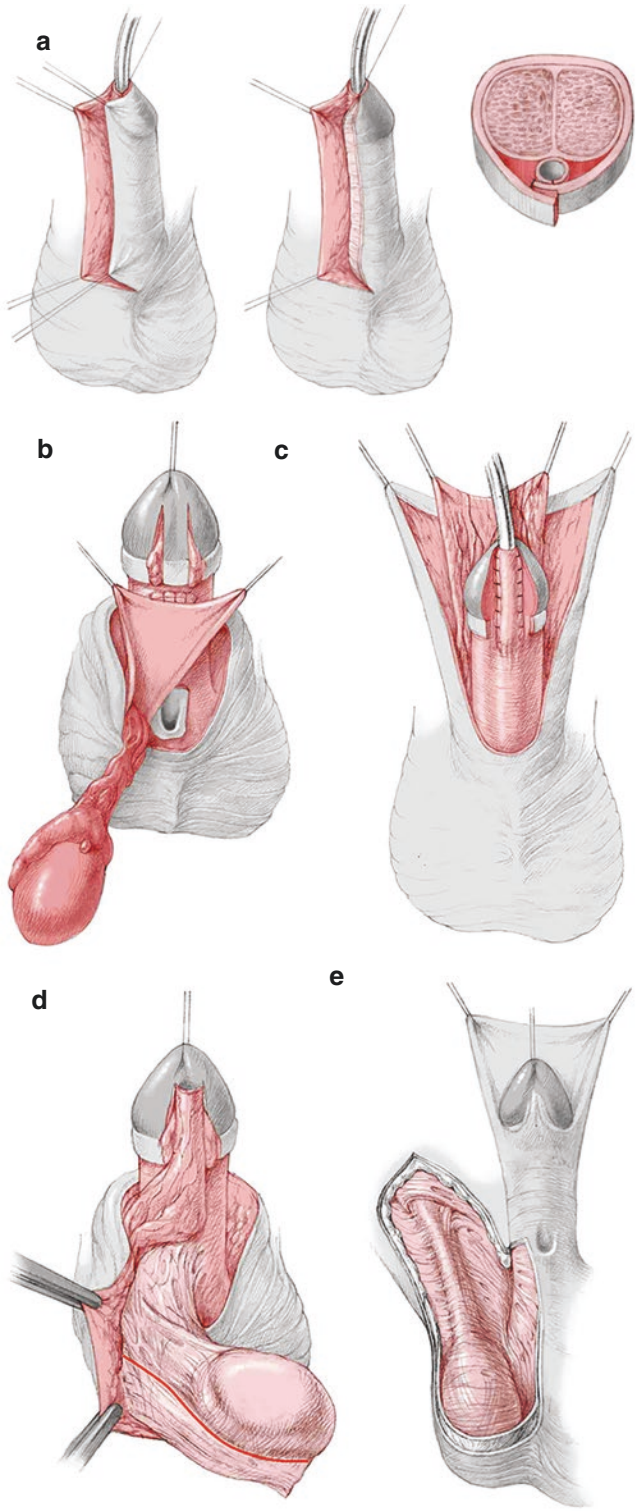

Fig. 2.14 Methods for protective intermediate layer. (**a**) Smith de-epithelialization [32]. (**b**) Snow described the use of a tunica vaginalis wrap [39]. (**c**) Retik et al. was the first to use a dorsal subcutaneous flap from the prepuce [42]. (**d**) Motiwala described the use of a dartos flap from the scrotum [108]. (**e**) Yamataka et al. reported the use of an external spermatic fascia flap [109]

2.6 Abnormal-Looking Glans Penis and Glanuloplasty and Meatoplasty

Thus, various tubes and patches were available to reconstruct the neourethra. The next step was to bring the neourethra to the tip of the glans. The glans had always posed a challenge and had largely not been found amenable to tunneling. Canalization, tunneling, and coring are essentially the same, with progressively larger channels. These are a testimony to glans stenosis.

There are several techniques employed to achieve an apical meatus (Fig. 2.15):

(a) Russell (1900) described the glans channel technique to deliver the urethra to the apex of the glans [110]. Bevan (1917) [82], Davis (1940) [20], Ricketson (1958) [111], Duckett (1980b) [112], and Hendren (1981) [113] used the same principle but different flaps or grafts.
(b) Wing rotation is used in most recent techniques.
(c) Devine and Horton [27] and Mustardé [30] popularized the glans channel procedure and included a dorsal V-flap with the glans channel.
(d) The glans split has been used in various techniques to move the meatus to the apex [15, 21, 85, 114–116].
(e) Duckett, in 1981, described the "meatal advancement and glanuloplasty incorporated" (MAGPI) procedure [35]. Arap et al. modified the MAGPI technique by using two sutures instead of one [66]. Decter, in 1991, described an "M inverted V" technique [117].
(f) Rich et al. described incising the urethral plate in the midline (hinging) [43]. This helped to achieve a slit-like vertical meatus.
(g) Snodgrass extended the concept of urethral plate hinging by incising the whole urethral plate in the midline from the hypospadiac meatus distally [44]. This helps in tubularization of the plate.
(h) Hadidi, in 1996, described the Y-V glanuloplasty [47]. The center of the Y is at the tip of the glans. Each limb is 0.5 cm long and the deep incision is closed as a V. The dog-ears created are widely opened to increase the circumference. A V is excised from the distal end of the neourethra to achieve a slit-like meatus. The Y-V glanuloplasty can be combined with most techniques of hypospadias repair, e.g., Mathieu, Onlay, Duplay, transverse preputial island flap urethroplasty, and lateral-based flap.
(i) Boddy and Samuel described the "Mathieu and V incision sutured" (MAVIS) technique, which results in a vertical slit meatus [58]. In this technique a V incision is made and excised at the apex of the parameatal-based flap. Then each side of the V is sutured to the glanular wings.

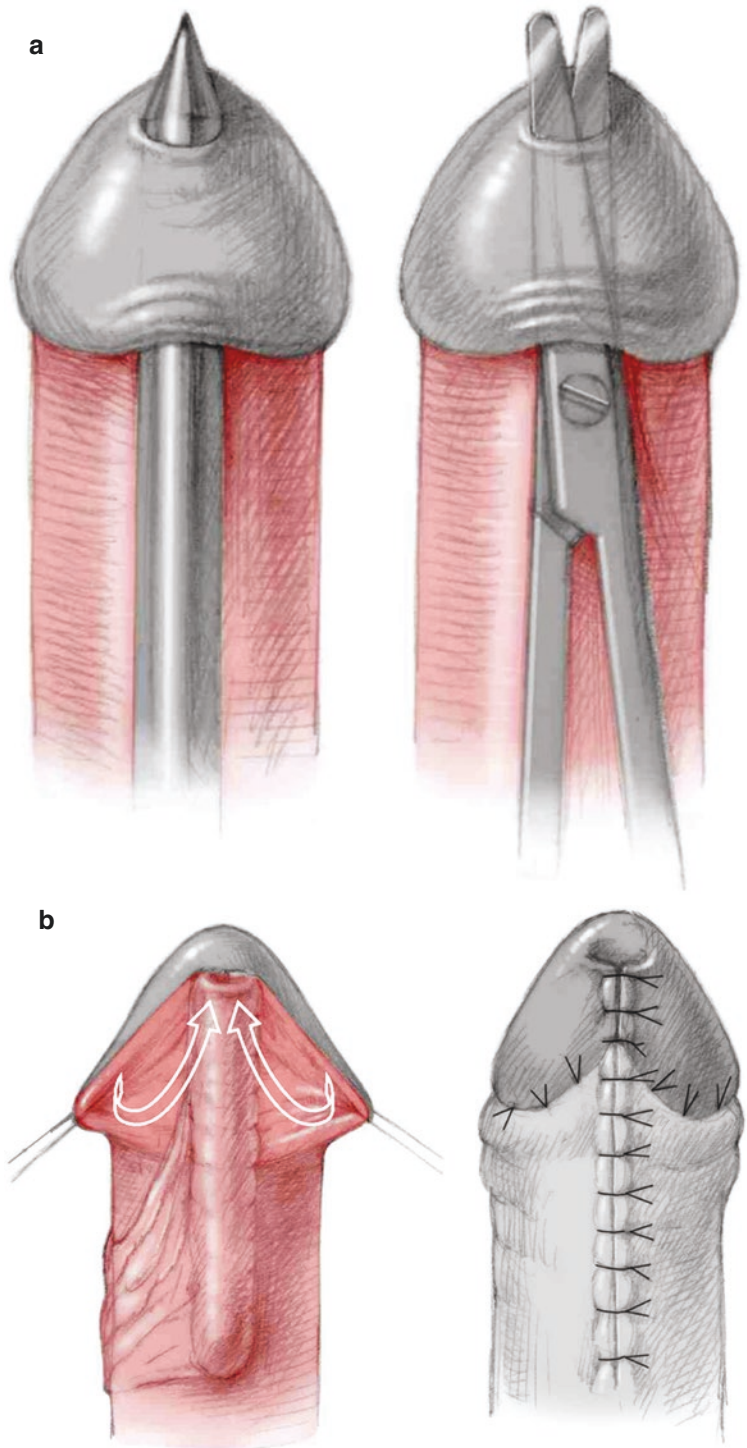

Fig. 2.15 Techniques of glanuloplasty. (**a**) Glans tunneling, canalization, or coring. (**b**) Wing rotation. (**c**) Glans V in the posterior wall by Devine and Horton [27] and Mustardé [30]. (**d**) Glans splitting or kippering has been used for 1000 years. (**e**) MAGPI [35]. (**f**) Y-V glanuloplasty (Hadidi 1996) [47]. (**g**) Hinging of the urethral plate [43]. (**h**) The tubularized incised plate (Snodgrass 1994) follows the same principle [44]. (**i**) MAVIS, a modification of the Mathieu technique, excises a triangle from the apex of the parameatal flap to create a slit-like meatus [58]

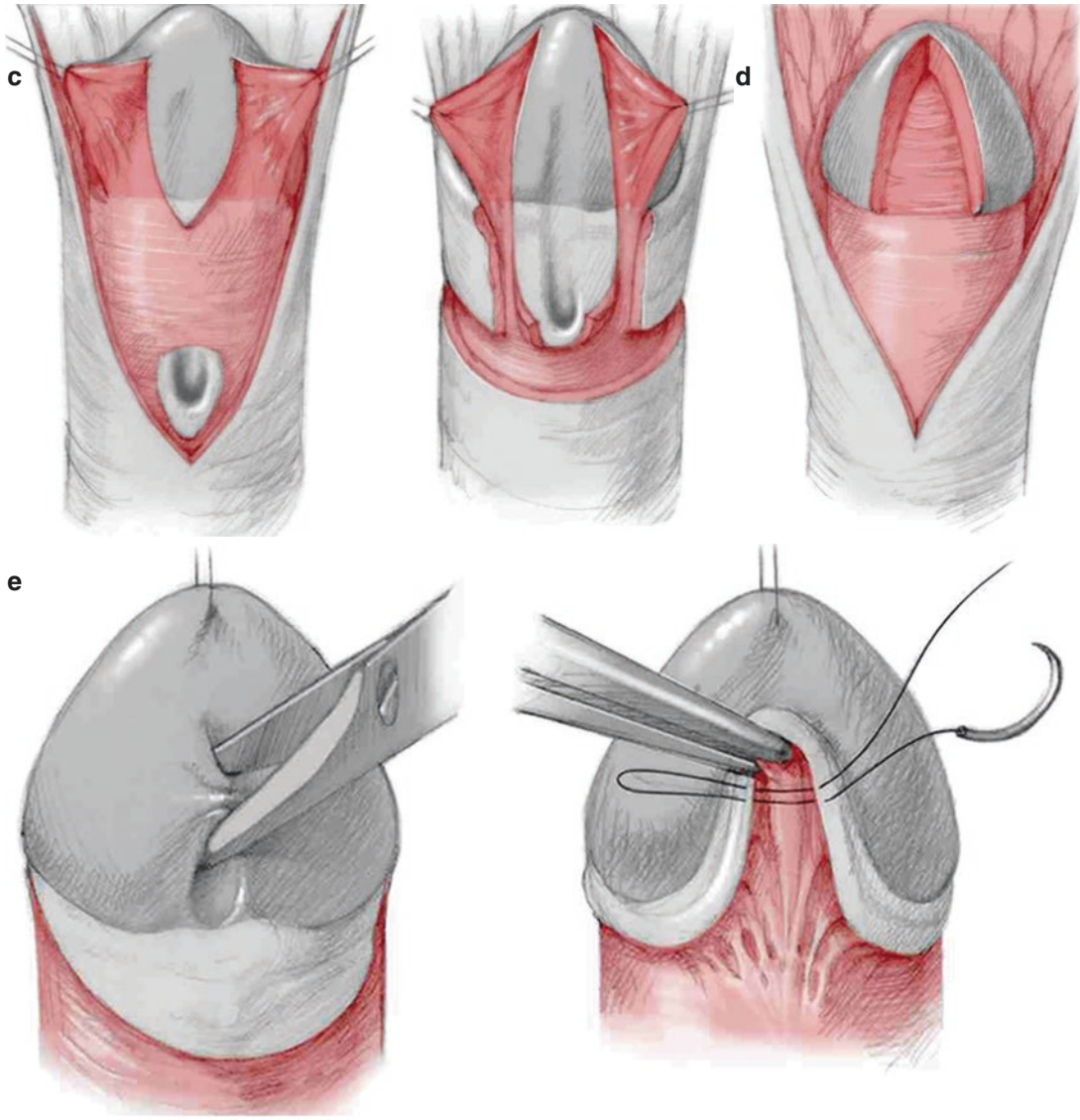

Fig. 2.15 (continued)

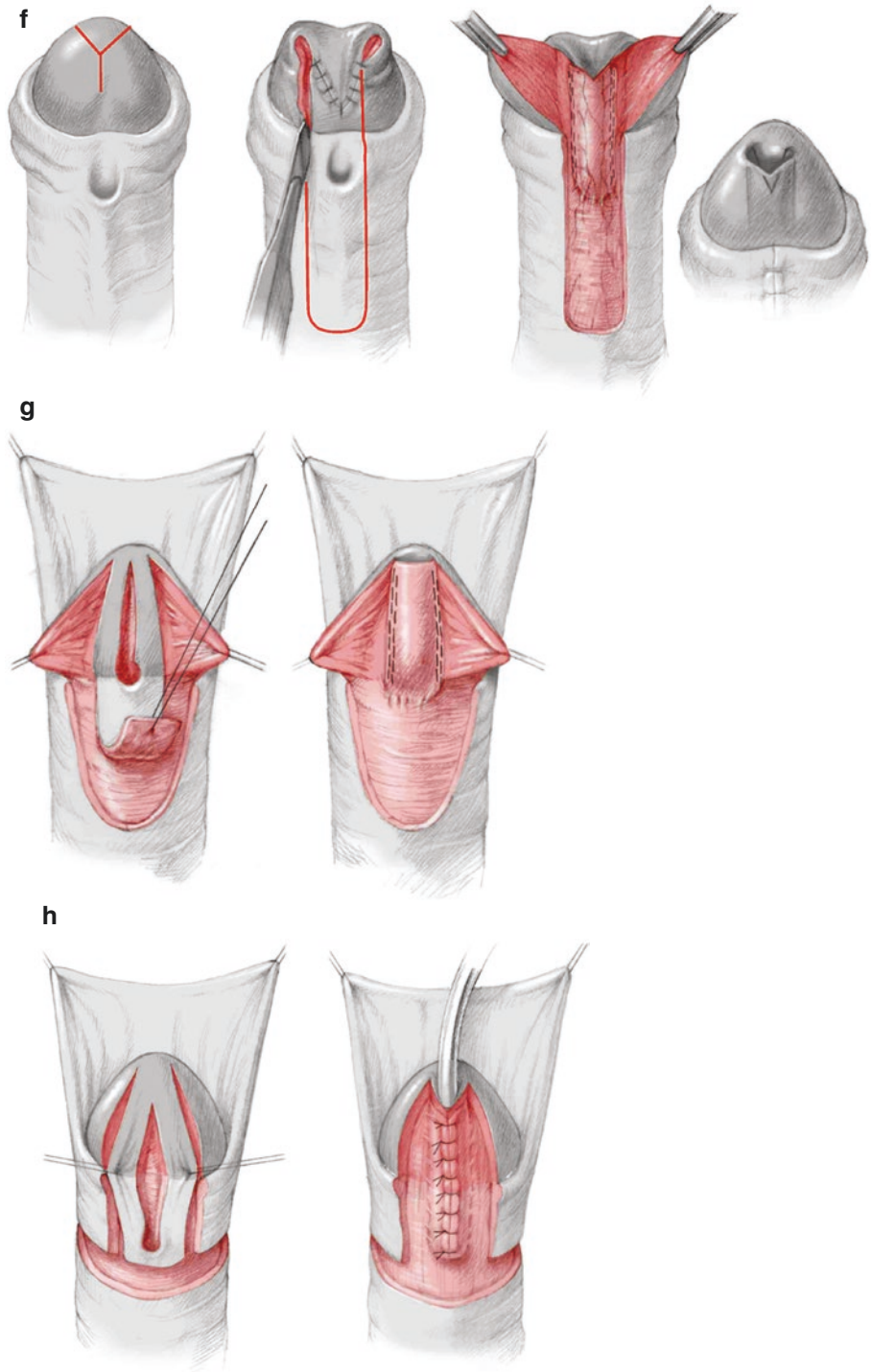

Fig. 2.15 (continued)

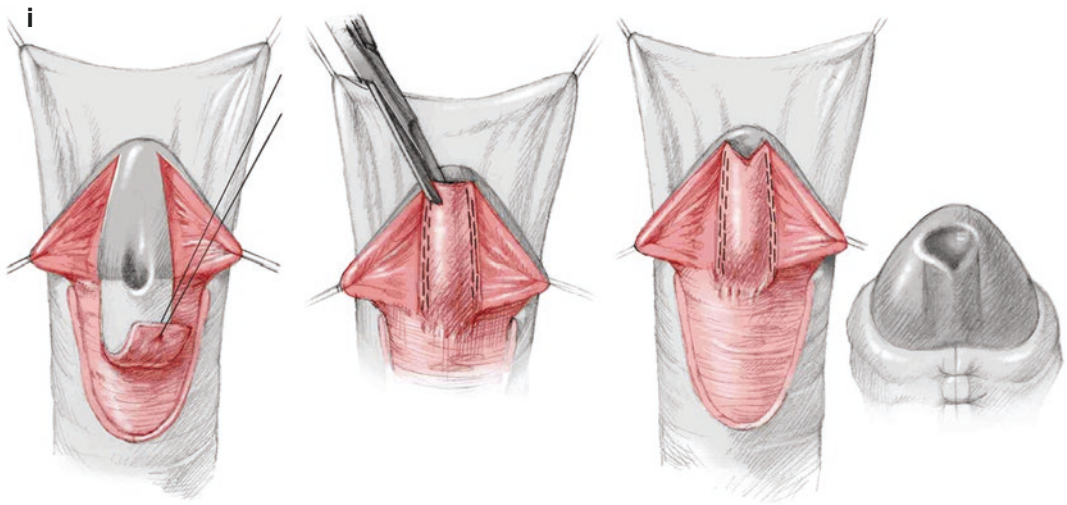

Fig. 2.15 (continued)

References

1. McCarthy JG. Introduction to plastic surgery. In: Plastic surgery. Philadelphia, PA: Saunders; 1990. p. 2.
2. Smith ED. Forward to hypospadias surgery. In: Hadidi AT, Azmy A, editors. Hypospadias surgery: an illustrated guide. 1st ed. Berlin, Heidelberg: Springer Verlag; 2004, p. forward.
3. Bussemaker U, Daremberg C. Oeuvres d'Oribase, texte Gre, en grande partie inedit collationnée sur les manuscrits (6 vols), 1851–1876.
4. Galen K. Opera omnia. In: Kuehn KG, editor. Leipzig: C. Cnobloch; 1826. p. 1001–1003.
5. Paré A. The workes of that famous chirurgion Ambroise Parey. Retrosp Rev. 1825;11:46–65.
6. Dieffenbach J. Guérison des fentes congénitales de la verge, de l'hypospadias. Gaz Hebd Med. 1837:5–156.
7. Mettauer JP. Practical observations on those malformations of the male urethra and penis, termed hypospadias and epispadias, with an anomalous case. Am J Med Sci. 1842; https://doi.org/10.1097/00000441-184207000-00003.
8. Pancoast JA. Treatise on operative surgery. Philadelphia, PA: Carrey and Hart; 1844.
9. Bouisson L. De l'hypospadias et de son traitement chirurgical. Trib Chir. 1861;2:484.
10. Thiersch K. Ueber die Enstehungsweise und operative Behandlung der Epispadie. Arch der Heilkd. 1869:10–20.
11. Wood J. A new operation for the cure of hypospadias. Med Times Gaz I. 1875;114:242.
12. Duplay S. Sur le traitement chirurgical de l'hypospadias et de l'epispadias. Arch Gen Med. 1880:5–257.
13. Van HW. A new operation for hypospadias. Ann Surg. 1896; https://doi.org/10.1097/00000658-189601000-00085.
14. Beck C. A new operation for balanic hypospadias. New York Med J. 1898;67:147–8.
15. Beck C. Hypospadias and its treatment. Surg Gynecol Obstet. 1917;24:511.
16. Nove-Josserand G. Traitement de l'hypospadias; nouvelle method. Lyon Med. 1897;85:198.
17. Edmunds A. An operation for hypospadias. Lancet. 1913; https://doi.org/10.1016/S0140-6736(00)77122-4.
18. Ombrédanne L. Precis clinique et operation de chirurgie infantile. Paris: Masson; 1932.
19. Mathieu P. Traitement en un temps de l'hypospade balanique et juxta-balanique. J Chir. 1932;39:481.
20. Davis DM. The pedicle tube graft in the surgical treatment of hypospadias in the male. Surg Gynecol Obstet. 1940;71:790.
21. Humby G, Higgins TT. A one-stage operation for hypospadias. Br J Surg. 1941; https://doi.org/10.1002/bjs.18002911312.
22. Cecil AB. Repair of hypospadias and urethral fistula. J Urol. 1946; https://doi.org/10.1016/S0022-5347(17)69802-1.
23. Memmelaar J. Use of bladder mucosa in a one-stage repair of hypospadias. J Urol. 1947; https://doi.org/10.1016/S0022-5347(17)69518-1.
24. Browne D. An operation for hypospadias. J R Soc Med. 1949; https://doi.org/10.1177/003591574904200703.
25. Byars LT. A technique for consistently satisfactory repair of hypospadias. Surg Gynecol Obstet. 1955;
26. DesPrez JD, Persky L, Kiehn CL. One-stage repair of hypospadias by island flap technique. Plast Reconstr Surg. 1961; https://doi.org/10.1097/00006534-196110000-00007.

27. Devine CJ, Horton CE. A one stage hypospadias repair. J Urol. 1961; https://doi.org/10.1016/S0022-5347(17)65301-1.
28. Broadbent TR, Woolf RM, Toksu E. Hypospadias: one-stage repair. Plast Reconstr Surg. 1961; https://doi.org/10.1097/00006534-196102000-00002.
29. Cloutier AM. A method for hypospadias repair. Plast Reconstr Surg. 1962; https://doi.org/10.1097/00006534-196209000-00007.
30. Mustardé JC. One-stage correction of distal hypospadias: and other people's fistul┐. Br J Plast Surg. 1965; https://doi.org/10.1016/S0007-1226(65)80068-6.
31. Barcat J. Hypospadias. 3. Les uréthroplasties. Leurs résultats Leurs complications. Ann Chir Infant. 1969.
32. Smith D. A de-epithelialized overlap flap technique in the repair of hypospadias. Br J Plast Surg. 1973;26:106–14.
33. Gittes RF, McLaughlin AP. Injection technique to induce penile erection. Urology. 1974; https://doi.org/10.1016/0090-4295(74)90025-9.
34. De Sy WA, Oosterlinck W. Silicone foam elastomer: a significant improvement in postoperative penile dressing. J Urol. 1982; https://doi.org/10.1016/S0022-5347(17)52744-5.
35. Duckett JW. MAGPI (meatoplasty and glanuloplasty). A procedure for subcoronal hypospadias. Urol Clin North Am. 1981; https://doi.org/10.1097/00005392-200205000-00059.
36. Monfort G, Lucas C. Dihydrotestosterone penile stimulation in hypospadias surgery. Eur Urol. 1982;8:201–3.
37. Koyanagi T, Matsuno T, Nonomura K, Sakakibara N. Complete repair of severe penoscrotal hypospadias in 1 stage: Experience with urethral mobilization, wing flap-flipping urethroplasty and "glanulomeatoplasty". J Urol. 1983; https://doi.org/10.1016/s0022-5347(17)51732-2.
38. Koff SA, Eakins M. The treatment of penile chordee using corporeal rotation. J Urol. 1984; https://doi.org/10.1016/S0022-5347(17)50716-8.
39. Snow BW. Use of tunica vaginalis to prevent fistulas in hypospadias surgery. J Urol. 1986;136:861–3.
40. Snow BW. Use of tunica vaginalis to prevent fistula in hypospadias surgery. J Urol. 1994;151:464–5.
41. Elder JS, Duckett JW, Snyder HM. Onlay island flap in the repair of mid and distal penile hypospadias without chordee. J Urol. 1987; https://doi.org/10.1016/S0022-5347(17)43152-1.
42. Retik AB, Keating M, Mandell J. Complications of hypospadias repair. Urol Clin North Am. 1988;15:223–36.
43. Rich MA, Keating MA, Snyder McC H, Duckett JW. Hinging the urethral plate in hypospadias meatoplasty. J Urol. 1989; https://doi.org/10.1016/S0022-5347(17)39161-9.
44. Snodgrass W. Tubularized, incised plate urethroplasty for distal hypospadias. J Urol. 1994; https://doi.org/10.1016/S0022-5347(17)34991-1.
45. Bracka A. A versatile two-stage hypospadias repair. Br J Plast Surg. 1995; https://doi.org/10.1016/S0007-1226(95)90023-3.
46. Bracka A. Hypospadias repair: the two-stage alternative. Br J Urol. 1995; https://doi.org/10.1111/j.1464-410X.1995.tb07815.x.
47. Hadidi AT. Y-V Glanuloplasty a new modification in the surgery of hypospadias. Kasr El Aini Med J. 1996;2:223–33.
48. Hadidi AT, Abdaal N, Kaddah S. Hypospadias repair: is dressing important? Kasr El Aini J Surg. 2003;4:37–44.
49. Hadidi AT. The Y-V glanuloplasty modified "Mathieu" technique. Hypospadias Surg. 2004; https://doi.org/10.1007/978-3-662-07841-9_19.
50. Hadidi AT. Lateral-based flap: a single stage urethral reconstruction for proximal hypospadias. J Pediatr Surg. 2009; https://doi.org/10.1016/j.jpedsurg.2008.08.012.
51. Hadidi AT. Double Y glanuloplasty for glanular hypospadias. J Pediatr Surg. 2010; https://doi.org/10.1016/j.jpedsurg.2009.11.019.
52. Hadidi AT. Proximal hypospadias with small flat glans: the lateral-based onlay flap technique. J Pediatr Surg. 2012; https://doi.org/10.1016/j.jpedsurg.2012.06.027.
53. Hadidi AT. The slit-like adjusted Mathieu technique for distal hypospadias. J Pediatr Surg. 2012; https://doi.org/10.1016/j.jpedsurg.2011.12.030.
54. Hadidi AT. Perineal hypospadias; The bilateral based (BILAB) skin flap technique. J Pediatr Surg. 2014; https://doi.org/10.1016/j.jpedsurg.2013.09.067.
55. Hadidi AT. Perineal hypospadias: back to the future chordee excision & distal urethroplasty. J Pediatr Urol. 2018; https://doi.org/10.1016/j.jpurol.2018.08.014.
56. Hadidi AT. Hypospadias international classification. 2nd Hypospadias International Society Congress, Frankfurt, Germany; 2018.
57. Decter RM. Chordee correction by corporal rotation: the split and roll technique. J Urol. 1999; https://doi.org/10.1016/S0022-5347(01)68107-2.
58. Boddy SA, Samuel M. A natural glanular meatus after "Mathieu and a V incision sutured": MAVIS. BJU Int. 2000; https://doi.org/10.1046/j.1464-410X.2000.00758.x.
59. Pippi Salle JL, Sayed S, Salle A, Bagli D, Farhat W, Koyle M, Lorenzo AJ. Proximal hypospadias: a persistent challenge. Single institution outcome analysis of three surgical techniques over a 10-year period. J Pediatr Urol. 2016; https://doi.org/10.1016/j.jpurol.2015.06.011.
60. King LR. Hypospadias—a one-stage repair without skin graft based on a new principle: chordee is sometimes produced by the skin alone. J Urol. 1970; https://doi.org/10.1016/S0022-5347(17)62023-8.
61. King LR. Cutaneous chordee and its implications in hypospadias repair. Urol Clin North Am. 1981;

62. Nesbit RM. Congenital curvature of the phallus: report of three cases with description of corrective operation. J Urol. 1965; https://doi.org/10.1016/S0022-5347(17)63751-0.
63. Beck C. Neue Operationsmethode der Eichelhypospadie. N Y Med Monatsschrift. 1897:596–7.
64. Hacker V. Zur operativen Behandlung der Hypospadia Glandis. Bruns Beitr Klin Chir; 1898. p. 271–276.
65. Horton CE, Devine CJJ, Baran N. Pictorial history of hypospadias repair techniques. In: Horton CE, editor. Plastic and reconstructive surgery genital area. Boston, MA: Little Brown; 1973. p. 237–47.
66. Arap S, Mitre AI, De Goes GM. Modified meatal advancement and glanuloplasty repair of distal hypospadias. J Urol. 1984; https://doi.org/10.1016/S0022-5347(17)50846-0.
67. Harrison DH, Grobbelaar AO. Urethral advancement and glanuloplasty (UGPI): a modification of the MAGPI procedure for distal hypospadias. Br J Plast Surg. 1997; https://doi.org/10.1016/S0007-1226(97)91371-0.
68. McGowan AJJ, Waterhouse RK. Mobilization of the anterior urethra. Bull N Y Acad Med. 1964;40:776–82.
69. Waterhouse K, Glassberg KI. Mobilization of the anterior urethra as an aid in the one-stage repair of hypospadias. Urol Clin North Am. 1981;
70. Koff SA. Mobilization of the urethra in the surgical treatment of hypospadias. J Urol. 1981; https://doi.org/10.1016/S0022-5347(17)55048-X.
71. Belman AB. Urethroplasty. Soc Pediatr Urol. 1977:1–2.
72. Keramidas DC, Soutis ME. Urethral advancement, glanduloplasty and preputioplasty in distal hypospadias. Eur J Pediatr Surg. 1995; https://doi.org/10.1055/s-2008-1066240.
73. Haberlik A, Schmidt B, Uray E, Mayr J. Hypospadias repair using a modification of Beck's operation: followup. J Urol. 1997; https://doi.org/10.1016/S0022-5347(01)64771-2.
74. Zaontz MR. The GAP (glans approximation procedure) for glanular/coronal hypospadias. J Urol. 1989; https://doi.org/10.1016/S0022-5347(17)40766-X.
75. Stock JA, Hanna MK. Distal urethroplasty and glanuloplasty procedure: results of 512 repairs. Urology. 1997;49:449–51.
76. Duckett JW, Keating MA. Technical challenge of the megameatus intact prepuce hypospadias variant: the pyramid procedure. J Urol. 1989; https://doi.org/10.1016/S0022-5347(17)41325-5.
77. Anger T. Hypospadias. Paris Bull Soc Chir. 1874.
78. Duplay S. De l'hypospade périnéo-scrotal et de son traitement chirurgical. Arch Gen Med. 1874:1.
79. Reddy LN. One-stage repair of hypospadias. Urology. 1975; https://doi.org/10.1016/0090-4295(75)90070-9.
80. Orkiszewski M. Urethral reconstruction in skin deficit. Urol Pol. 1987;40:12–5.
81. Ombrédanne L. L'hypospadias pénien chez l'enfant. Bull Soc Chir. 1911;1076
82. Bevan AD. A new operation for hypospadias. J Am Med Assoc. 1917;68:1032.
83. Fevre M. Technique for anterior hypospadias. J Chir. 1961;81:562.
84. Barcat J. Symposium Sur l'hypospadias. 16th meeting of the French Society of Children's surgery. Ann Chir Infant. 1969;10:287.
85. Barcat J. Current concepts of treatment. In: Horton CE, editor. Plastic and reconstructive surgery genital area. Boston, MA: Little Brown; 1973. p. 149–263.
86. Toksu E. Hypospadias: one-stage repair. Plast Reconstr Surg. 1970; https://doi.org/10.1097/00006534-197004000-00010.
87. Hodgson NB. A one-stage hypospadias repair. J Urol. 1970; https://doi.org/10.1016/S0022-5347(17)61718-X.
88. Asopa HS, Elhence IP, Atri SP, Bansal NK. One stage correction of penile hypospadias using a foreskin tube. A preliminary report. Int Surg. 1971;
89. Duckett JW. Repair of hypospadias. In: Hendry W, editor. Recent advances in urology. New York: Churchill-Livingstone; 1980. p. 279–90.
90. Standoli L. One-stage repair of hypospadias: preputial island flap technique. Ann Plast Surg. 1982; https://doi.org/10.1097/00000637-198207000-00013.
91. Snow BW, Cartwright PC. Yoke hypospadias repair. J Pediatr Surg. 1994; https://doi.org/10.1016/0022-3468(94)90091-4.
92. Hadidi AT, Roessler J, Coerdt W. Development of the human male urethra: a histochemical study on human embryos. J Pediatr Surg. 2014; https://doi.org/10.1016/j.jpedsurg.2014.01.009.
93. Hinderer U. Hypospadias repair in long-term results. In: Plastic and reconstructive surgery. Boston, MA: Little Brown; 1978. p. 378–410.
94. Rochet V. Nouveau procédé pour réfaire le canal pénien dans l'hypospadias. Gaz Hebd Med. 1899;4:673.
95. Lowsley OS, Begg CL. A three-stage operation for the repair of hypospadias: report of cases. J Am Med Assoc. 1938; https://doi.org/10.1001/jama.1938.02790070011004.
96. Beck C. New Yorker Medicinische Monatsschrift; 1897
97. Rosenberger. Deutsche Medizinische Wochenschrift. Dtsch Med Wochenschr. 1891;9:1250.
98. Landerer. Dtsch Z Chir; 1891. p. 32.
99. Bidder A. Eine Operation der Hypospadie mit Lappenbildung aus dem Scrotum. Dtsch Medizinische Wochenschrift. 1892; https://doi.org/10.1055/s-0029-1198989.
100. Bucknall RTH. A new operation for penile hypospadias. Lancet. 1907; https://doi.org/10.1016/S0140-6736(01)49445-1.

101. Culp OS. Struggles and triumphs with hypospadias and associated anomalies: review of 400 cases. J Urol. 1966; https://doi.org/10.1016/S0022-5347(17)63266-X.
102. Perovic S, Vukadinovic V, Duckett JW. Onlay island flap urethroplasty for severe hypospadias: a variant of the technique. J Urol. 1994; https://doi.org/10.1016/S0022-5347(17)35067-X.
103. McIndoe AH. The treatment of hypospadias. Am J Surg. 1937; https://doi.org/10.1016/S0002-9610(37)90415-X.
104. Young F, Benjamin JA. Repair of hypospadias with free inlay skin graft. Surg Gynecol Obstet. 1948; https://doi.org/10.1097/00006534-194903000-00026.
105. Nicolle FV. Improved repairs in 100 cases of penile hypospadias. Br J Plast Surg. 1976; https://doi.org/10.1016/0007-1226(76)90042-4.
106. Duckett JW. Hypospadias. In: Walsh PC, Gittes RF, Perlmutter AD, editors. Campbell's urology. 5th edit ed. Philadelphia, PA: Saunders; 1986. p. 1969–99.
107. Fine R, Reda EF, Zelkovic P, Gitlin J, Freyle J, Franco I, Palmer LS. Tunneled buccal mucosa tube grafts for repair of proximal hypospadias. J Urol. 2015; https://doi.org/10.1016/j.juro.2014.10.093.
108. Motiwala HG. Dartos flap: an aid to urethral reconstruction. Br J Urol. 1993;72:260.
109. Yamataka A, Ando K, Lane GJ, Miyano T. Pedicled external spermatic fascia flap for urethroplasty in hypospadias and closure of urethrocutaneous fistula. J Pediatr Surg. 1998;33:1788–9.
110. Russell RH. Operation for severe hypospadias. Br Med J. 1900; https://doi.org/10.1136/bmj.2.2081.1432-a.
111. Ricketson G. A method of repair for hypospadias. Am J Surg. 1958;95:287–93.
112. Duckett JW. Hypospadias. Clin Plas Surg. 1980.
113. Hendren WH. The Belt-Fuqua technique for repair of hypospadias. Urol Clin North Am. 1981.
114. May HB. Hypospadias; a concept of treatment. J Urol. 1951; https://doi.org/10.1016/s0022-5347(17)68482-9.
115. Cronin TD, Guthrie TH. Method of Cronin and Guthrie for hypospadias repair. In: Horton CE, editor. Plastic and reconstructive surgery of the genital area. Boston, MA: Little Brown; 1973. p. 304–14.
116. Turner-Warwick R. Observations upon techniques for reconstruction of the urethral meatus, the hypospadiac glans deformity, and the penile urethra. Urol Clin North Am. 1979;
117. Decter RM. M inverted V glansplasty: a procedure for distal hypospadias. J Urol. 1991; https://doi.org/10.1016/s0022-5347(17)37881-3.