



Surgical Procedures. Parathyroidectomy: Indications, Operative Techniques, Management of Complications, Intraoperative PTH Monitoring, Role of Parathyroid Autofluorescence and ICG

Talia Burneikis and Allan E. Siperstein

Contents

- 16.1 Introduction – 410**
- 16.2 Indications for Surgery – 411**
- 16.3 Preoperative Evaluation – 412**
- 16.4 Operative Techniques – 413**
 - 16.4.1 Bilateral Exploration Parathyroidectomy – 413
 - 16.4.2 Focused Parathyroidectomy – 422
- 16.5 Intraoperative PTH Monitoring and Gamma-Probe Localization – 423**
- 16.6 Indocyanine Green and Autofluorescence – 424**

- 16.7 Cryopreservation and Autotransplantation – 425**
- 16.8 Management of Complications – 429**
- 16.9 Outcomes and Prognosis – 430**
- References – 431**

Case Presentation

A 64-year-old woman is referred for hypercalcemia with calcium levels greater than 10.5 mg/dL on multiple occasions, most recently her level was 10.9 mg/dL (normal range 8.8–10.5 mg/dL). Parathyroid hormone (PTH) was 64 pg/mL (normal 15–65 pg/mL). She has no history of kidney stones, or her renal function is normal with a glomerular filtration rate (GFR) of 75 mL/min (normal >60 mL/min). She has no significant cardiac or pulmonary comorbidities. Dual-energy x-ray absorptiometry (DEXA) scan showed osteoporosis at the distal one-third radius with a T-score of -2.1 . On further inquiry, she describes symptoms of constipation, fatigue, depression, and mental fogging.

? Questions

1. Your patient is hesitant about surgery for primary hyperparathyroidism and wants to know the long-term benefit. You counsel her. Which of the following statements regarding parathyroidectomy for hyperparathyroidism is true?
 - (a) Parathyroidectomy can slow the progression of osteoporosis but has not been associated with reversing the disease progression.
 - (b) Bone mineral density significantly improves after parathyroidectomy for primary hyperparathyroidism.
 - (c) Medical management has as good of outcomes as parathyroidectomy in the management of skeletal disease.
 - (d) Medical management is more cost-effective than parathyroidectomy in the management of osteoporosis.
2. Preoperative imaging studies including sestamibi-SPECT CT and neck ultrasound fail to localize a parathyroid adenoma. How should you proceed based on the intraoperative findings?
 - (a) Biopsy the glands as they are identified. Remove the glands that have confirmed hyperplasia. Drawing intraoperative PTH (IOPTH) levels 10 minutes after removal of each gland. Stop when the IOPTH level has dropped by at least 50% even if not all four glands have been identified.
 - (b) Perform a four-gland exploration identifying all four glands before removing any abnormal appearing glands. Remove only the adenomatous appearing glands and stop when IOPTH has dropped by at least 50% and into the normal range.
 - (c) The patient has four-gland hyperplasia. Perform a subtotal, three-and-a-half gland parathyroidectomy,

- regardless of the appearance of the parathyroid glands leaving a normal sized superior remnant, marked with a clip, and perform cryopreservation.
- (d) The patient has four-gland hyperplasia. Use indocyanine green (ICG) intraoperatively given that preoperative imaging failed to localize any abnormal glands. ICG has been shown to aid in the identification of any parathyroid adenomas.
3. During parathyroidectomy for primary hyperparathyroidism, you identify and excise a left upper parathyroid adenoma consistent with preoperative localizing imaging studies. However, the intraoperative PTH drops from 168 preoperatively to 130 pg/mL at 10 minutes after excision. How do you proceed?
- (a) Complete the operation without any further exploration because you excised the only suspicious gland identified on preoperative imaging.
- (b) Wait 5 more minutes and recheck PTH. If the PTH level has dropped by 50% at 15 minutes, close.
- (c) Perform a subtotal three-and-a-half gland parathyroidectomy.
- (d) Perform a comprehensive parathyroidectomy, identifying all four glands and excising any abnormal appearing parathyroid glands, and recheck intraoperative PTH to confirm a PTH drop of >50% from preoperative levels.
4. During four-gland parathyroid exploration for parathyroid hyperplasia you cannot locate the left inferior parathyroid gland. What additional intraoperative maneuver should be performed next?
- (a) Perform a left thyroid lobectomy.
- (b) Perform a median sternotomy in order to find the last gland.
- (c) Perform a cervical thymectomy.
- (d) Complete the surgery, and close and monitor calcium levels postoperatively.
5. Which of the following scenarios would be an indication for bilateral exploration as the primary surgery for a patient with primary hyperparathyroidism?
- (a) A personal history of nephrolithiasis, osteoporosis, and age <45 years.
- (b) A personal history of radiation exposure.
- (c) A family history of hyperparathyroidism, pituitary adenoma, and pancreatic neuroendocrine tumor.
- (d) A drop in PTH from 160 preoperatively to 40 pg/mL 10 min post-excision after removal of a suspected right upper adenoma based on preoperative ultrasound.
6. A middle-aged woman is referred by her Primary Care Physician to your clinic for the evaluation of hyperparathyroidism as detected on routine labs. Which

- of the following would be an indication for parathyroidectomy?
- (a) Calcium of 10.8 mg/dL (normal 8.5–10.5 mg/dL), PTH of 110 pg/mL (normal 10–65 pg/mL), age 45, otherwise asymptomatic.
 - (b) Calcium of 10.1 mg/dL (normal 8.5–10.5 mg/dL), PTH of 50 pg/mL (normal 10–65 pg/mL), age 52, osteopenia.
 - (c) Calcium of 10.6 mg/dL (normal 8.5–10.5 mg/dL), PTH of 80 pg/dL (normal 10–65 pg/mL), age 55, history of kidney stones.
 - (d) A, B, and C.
 - (e) A and C only.
7. Your patient undergoes preoperative neck ultrasound and sestamibi scan. Both demonstrate a right lower parathyroid adenoma. Which of the following surgical strategies would be appropriate?
- (a) Four-gland exploration with excision of the right lower gland and any additional abnormal parathyroid glands found intraoperatively with intraoperative parathyroid hormone measurement.
 - (b) Right-sided neck exploration only. Intraoperative PTH is not needed because two preoperative imaging studies are concordant with a right lower gland.
 - (c) Right-sided neck exploration only, with intraoperative PTH to confirm successful excision of a single adenoma.
 - (d) All of the above.
 - (e) A and C only.
8. A 60-year-old African American male presents with weakness, confusion, and hypertension. Physical exam is significant for a palpable left-sided neck mass. Workup reveals a calcium level of 15.9 mg/dL. A parathyroid hormone level is sent and is 520 pg/mL (10–65 pg/mL). Which of the following is the next best step in management?
- (a) Perform a sestamibi for localization, followed by focused exploration with intraoperative parathyroid hormone assay monitoring.
 - (b) Four-gland exploration and three-and-a-half gland parathyroidectomy.
 - (c) En bloc resection of abnormal parathyroid gland, hemithyroidectomy, and left-sided lymph node dissection.
 - (d) Intravenous hydration for a goal urine output of 100–150 mL/hour.
 - (e) Administration of furosemide, calcitonin, and a bisphosphonate.
9. During parathyroidectomy which of the following is true.
- (a) Dissection should be carried intimately along the thyroid to displace the parathyroid glands laterally and minimizing risk to their vascular pedicles.

- (b) The middle thyroid vein can be isolated, ligated, and divided to provide more exposure with no significant consequences.
 - (c) When preoperative imaging is suggestive of a single adenoma, the suspect adenoma should be removed first before identifying any other parathyroid glands.
 - (d) The middle thyroid vein courses parallel to the inferior thyroid artery, and both travel deep and posteriorly to the carotid artery.
10. During bilateral neck exploration for primary hyperparathyroidism you identify three normal-appearing glands. Which of the following is true regarding the location of missing parathyroid glands?
- (a) The most likely heterotopic location for a missing inferior parathyroid gland is the ipsilateral carotid sheath.
 - (b) The most likely heterotopic location for a missing inferior parathyroid gland is undescended near the angle of the jaw.
 - (c) The most likely heterotopic location for a missing superior parathyroid gland is the cervical thymus.
 - (d) The most likely heterotopic location for a missing superior parathyroid gland is tracheoesophageal groove.

16.1 Introduction

Historically underrecognized and undertreated, primary hyperparathyroidism (PHPT) is the most common cause of hypercalcemia. Most cases of PHPT are diagnosed after hypercalcemia is diagnosed on routine laboratory evaluation but may also be diagnosed in patients undergoing evaluation for nephrolithiasis or symptomatic skeletal disease. After diagnosis, patients are often found to have non-specific symptoms such as mental fatigue, depression, and sleep disturbances. PHPT is more common in postmenopausal women, blacks more than whites, with an incidence of 66 per 100,000 person years in women, and 25 per 100,000 person years in men [1]. PHPT is most commonly due to single parathyroid adenomas, accounting for 80–85% of cases. However, multigland disease including double adenomas occurs in 3–5% of cases and four-gland hyperplasia in the remaining 10–15%. Surgical excision reduces nephrolithiasis and improves symptomatic osteoporosis. Surgical approach varies among practices. Some providers advocate for a routine bilateral exploration examining all four glands given the risk of multigland disease. With the improvement of preoperative localization studies and the advent of IOPTH monitoring, other providers opt for focused parathyroidectomy where only one side is explored as guided by preop-

erative imaging. If IOPTH drops appropriately then the contralateral side is not explored. The argued advantage of a focused approach is avoiding the potential morbidity of a bilateral exploration. However, studies have shown that even with a drop in IOPTH of at least 50% after excision of a parathyroid adenoma, there is still risk of missing an additional pathologic gland [2, 3]. This chapter aims to review the indications for parathyroidectomy and discuss the different approaches and available adjuvants to the procedure.

16.2 Indications for Surgery

Parathyroidectomy offers a surgical cure for hyperparathyroidism. All patients with symptomatic PHPT associated with hypercalcemia and elevated PTH should undergo parathyroidectomy. The latest guidelines from the American Association of Endocrine Surgeons (AAES) recommend parathyroidectomy for the following indications:

- All patients with symptomatic PHPT.
- Serum calcium level is greater than 1 mg/dL above normal reference range regardless of whether objective symptoms are present or absent.
- Objective evidence of renal involvement such as nephrocalcinosis, silent nephrolithiasis, hypercalciuria (24-hour urine calcium level >400 mg/dL), and impaired renal function (GFR <60 mL/min).
- Evidence of osteoporosis, fragility fracture, or vertebral compression fractures.
- Diagnosis of PHPT at age 50 years or younger regardless of whether objective or subjective features are present or absent.
- When clinical or biochemical evidence is consistent with parathyroid carcinoma.
- Patients unable or unwilling to comply with observation protocols.
- Presence of neurocognitive and/or neuropsychiatric symptoms that are attributable to PHPT.
- In patients with cardiovascular disease who might benefit from potential mitigation of cardiovascular sequelae other than hypertension.
- Presence of nontraditional symptoms of muscle weakness, functional capacity, abnormal sleep, gastroesophageal reflux, and fibromyalgia symptoms should be considered for parathyroidectomy [4, 5].

Studies have shown that compared to medical observation, parathyroidectomy improves fracture free survival (10-year fracture-free survival after parathyroidectomy was 94% vs. 81% in observed patients). Patients with osteoporosis demonstrated the largest impact from parathyroidectomy [6].

Additionally, the misnomer of “asymptomatic” hyperparathyroidism is increasingly recognized for neurocognitive symptoms that influence quality of life [7]. Parathyroidectomy for these patients results in objective symptom improvement based on responses to patient reported outcome measures [8–10]. Furthermore, parathyroidectomy has been shown to be more cost-effective for asymptomatic PHPT than observation and medical pharmacologic therapy [11].

When considering bilateral versus focused parathyroidectomy as the initial surgery for PHPT, the surgeon should consider the concordance of preoperative imaging, and specific patient considerations. Indications for bilateral parathyroidectomy as the initial surgery for PHPT include: known or suspected multiple endocrine neoplasia (MEN), failure of the intraoperative PTH to drop after resection of a suspected single adenoma, preoperative imaging sites suggestive of multiple disease sites, coexisting thyroid cancer, or bilateral goiter. Bilateral parathyroidectomy should be strongly considered when preoperative location studies are discordant, if IOPTH monitoring is not available, in cases of lithium-induced PHPT, other cases of familial hyperparathyroidism, or surgeon preference [4]. Focused parathyroidectomy can be considered when preoperative imaging studies suggest single gland disease. IOPTH is used by many surgeons to guide the extent of surgery.

16.3 Preoperative Evaluation

Preoperative evaluation to determine localization of parathyroid pathology is advised. Ideally, the surgeon should have concordant imaging on cervical ultrasonography (US) and ⁹⁹Tc-sestamibi scan with or without four-dimensional single photon emission computed tomography (SPECT). Imaging choice is at the discretion of the surgeon, as there is variability in availability at different institutions and accuracy of localization. Cervical ultrasonography is an inexpensive, widely available tool that additionally permits evaluation for concomitant thyroid pathology, and avoids ionizing radiation [12, 13]. In experienced hands, the sensitivity of US for parathyroid is reported to be 76–79% with a specificity of 96%. These numbers decrease with multigland disease. Parathyroid adenomas will appear either hypoechoic or anechoic near the thyroid gland with an extrathyroidal feeding vessel (see ■ Fig. 16.1). US is limited in its evaluation of retroesophageal and mediastinal glands due to overlying structures such as the esophagus and trachea and may be limited due to patient body habitus. Sestamibi sensitivity varies by institution, ranging from 45 to 92%, and is attributed to variability in institutional protocols. Similar to US, sestamibi sensitivity decreases with multiglandular disease [14–16] (see ■ Fig. 16.2). 4D-CT is a multiphase

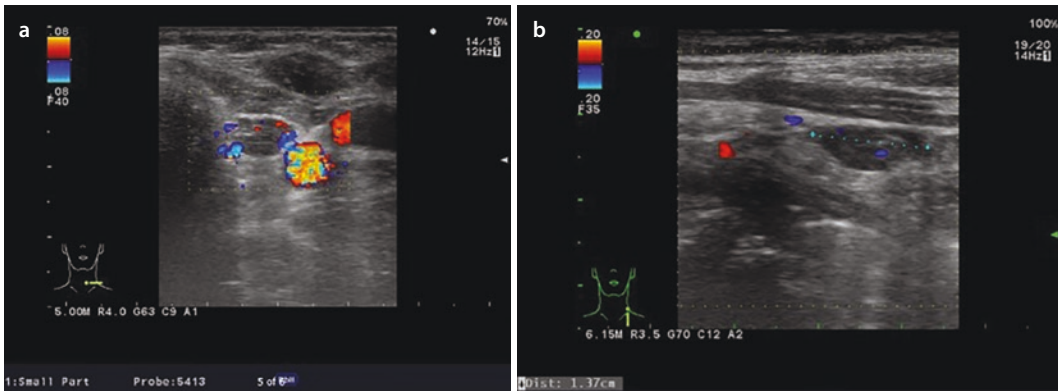


Fig. 16.1 Ultrasound imaging of classic parathyroid adenoma. Ultrasound imaging of a classic left lower parathyroid adenoma lying posterior to the inferior pole of the thyroid. Increased vascularity can be seen in the transverse **a** and sagittal **b** planes

CT technique that uses thin slices (1–3 mm) and offers a fourth dimension of assessing parathyroid gland perfusion changes with contrast attenuation over time. Rapid contrast uptake and washout is characteristic of parathyroid adenomas [17, 18] (see Fig. 16.3). In select cases, such as persistent or recurrent disease, differential jugular venous sampling can be performed for localization, with the side of pathology having at least a 10% greater PTH level than the opposite side.

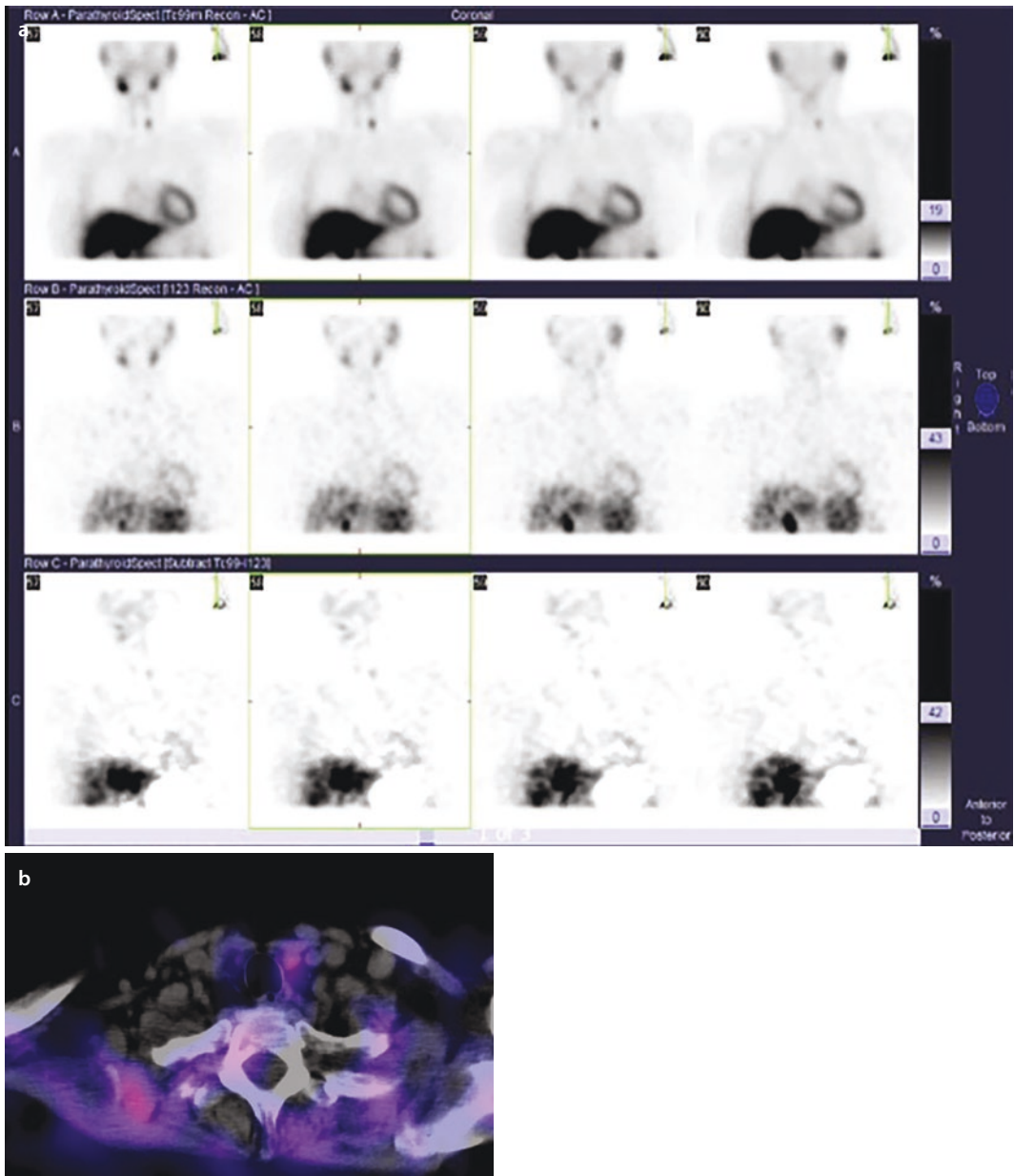
Overall, preoperative imaging assists in localization and operative planning, though which modality of choice is surgeon and institution specific.

16.4 Operative Techniques

Parathyroidectomy can be performed in either a bilateral or focused approach. In contrast, focused parathyroidectomy, also described as “minimally invasive” parathyroidectomy, is often performed when adequate localization of abnormal glands is suggested by preoperative imaging. Although practices vary, intraoperative conversion from a focused parathyroidectomy to a bilateral approach may be performed if intraoperative PTH monitoring fails to confirm unilateral pathology.

16.4.1 Bilateral Exploration Parathyroidectomy

Bilateral neck exploration should be performed for patients who have non-localizing or discordant preoperative imaging studies. Some surgeons routinely use bilateral exploration as the initial approach due to the risk of missing an abnormal gland intraoperatively despite preoperative imaging. Comprehensive parathyroidectomy can be accomplished with



■ Fig. 16.2 Sestamibi subtraction images

a few essential instruments, including appendiceal retractor (lighted if available), spring retractor, peanut on a Kelly clamp, bovie, fine tipped hemostat, and DeBakey forceps (see ■ Fig. 16.4). Parathyroidectomy is most commonly performed under general anesthesia with the addition of local anesthetics, though there are variable practices using deep cervical nerve block and sedation. Antibiotics are typically not needed and sequential compression stockings are sufficient for deep vein thrombosis prophylaxis. The use of intraoperative US is a gen-

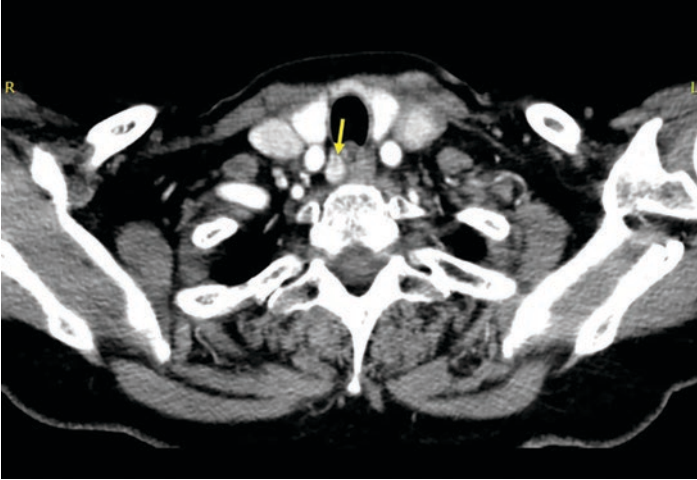

Fig. 16.3 4D CT of parathyroid adenoma. Arterial phase-contrast CT imaging demonstrates an enhancing soft tissue lesion between the right internal carotid artery and esophagus suspicious for a parathyroid adenoma (arrow)

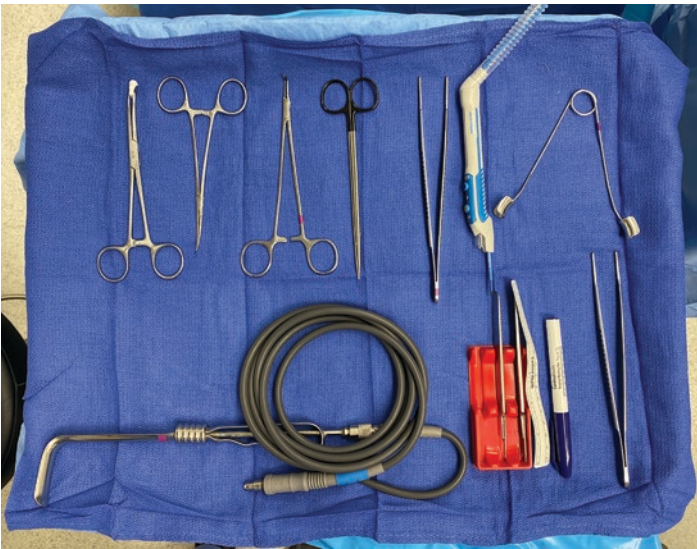
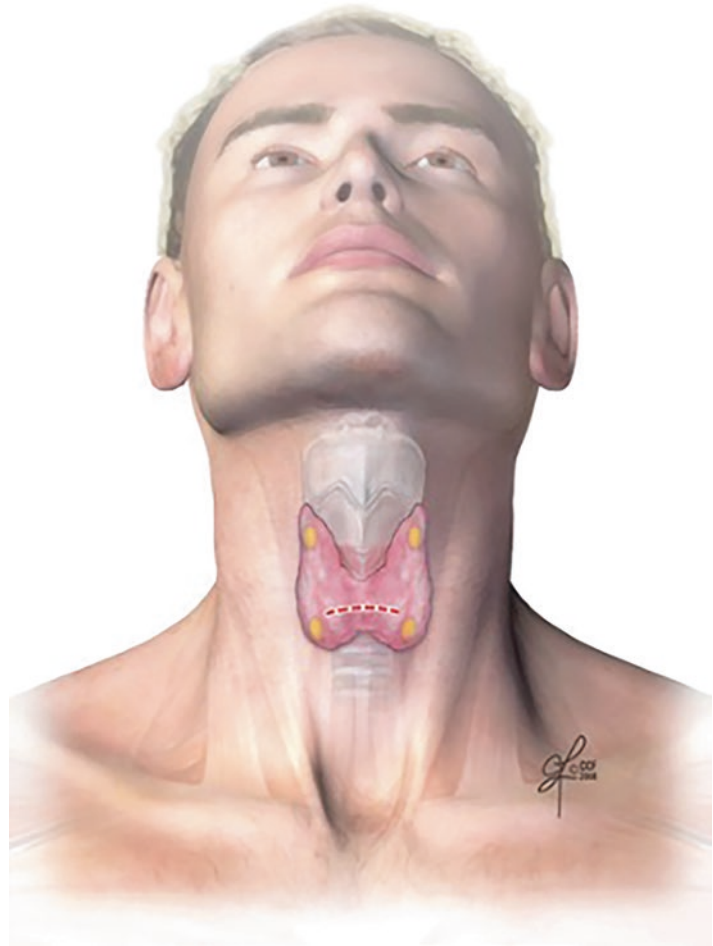


Fig. 16.4 Surgical instruments for parathyroidectomy

eral practice of the authors which allows for incision planning, and quick repeat evaluation of the neck anatomy including concomitant thyroid disease, and adenoma localization. Frozen section histology is most commonly used to confirm parathyroid pathology intraoperatively, but importantly cannot distinguish between adenoma, hyperplasia, or other parathyroid disease states.

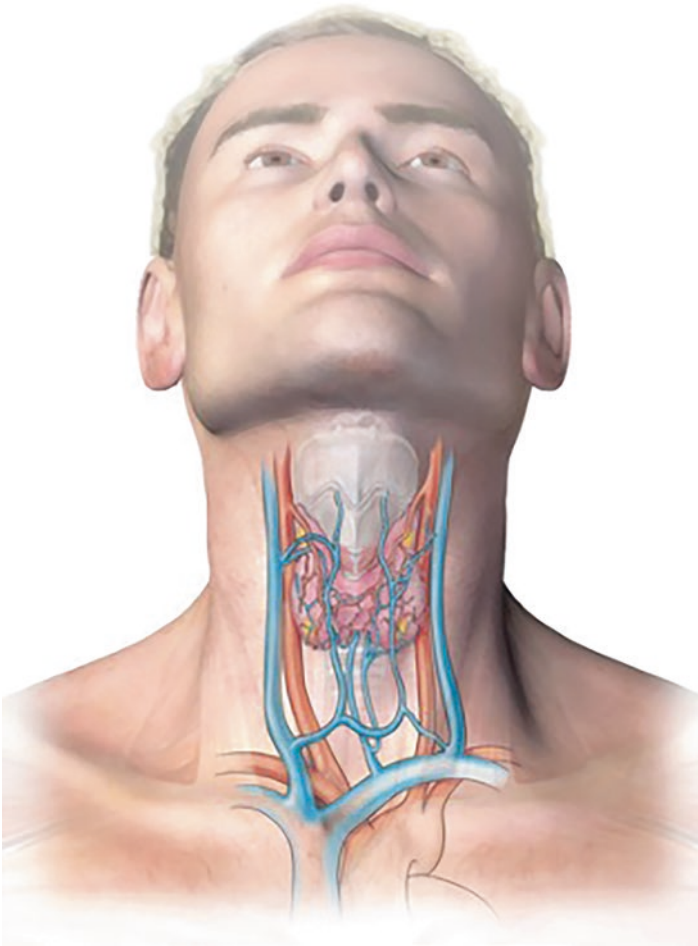
The patient is positioned supine with arms tucked at the side, head slightly hyperextended with a roll, bean bag, or gel cushion between the scapulae. The chin and sternal notch are



■ Fig. 16.5 Cervical incision for parathyroidectomy

positioned to provide symmetrical alignment. Potential incision sites can be marked while the patient is awake and able to flex their head to allow for cosmetic scarring at natural skin creases and is aided with the use of intraoperative ultrasound. Non-flammable chlorhexidine prep avoids skin staining and fire risk. A 4–6 cm transverse incision is made at the optimal site, usually 1.5–2 fingerbreadths above the sternal notch (see ■ Fig. 16.5). The incision is deepened using electrocautery through the platysma. Subplatysmal flaps are dissected until the thyroid cartilage is palpated superiorly and extended to the sternal notch inferiorly. This is an avascular plane superficial to the anterior jugular veins and can be accomplished using a combination of blunt dissection and electrocautery. The anterior jugular veins should be carefully preserved and can be used for IOPTH measurement (see ■ Fig. 16.6).

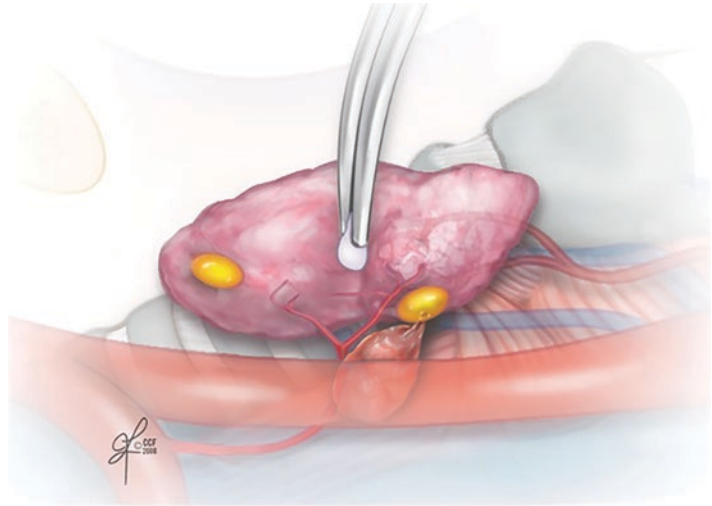
A self-retaining retractor is placed. The strap muscles are separated along the midline raphe exposing the thyroid. The



■ **Fig. 16.6** Vascular anatomy of the neck

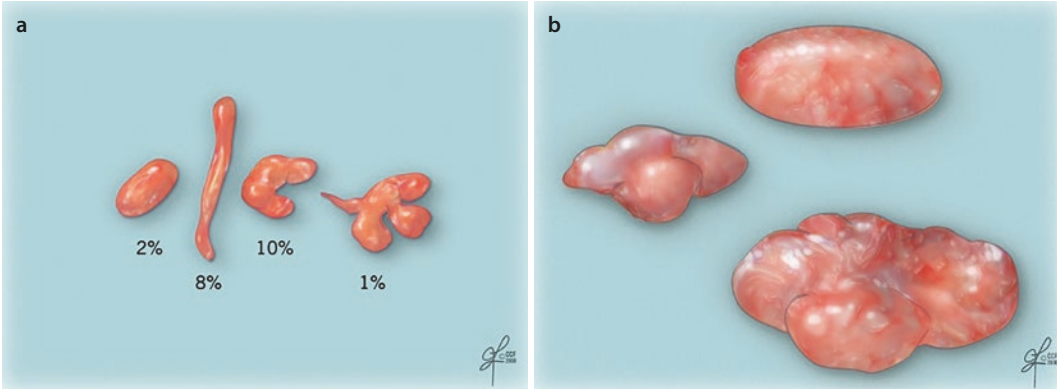
sternothyroid and sternohyoid muscles can be bluntly separated from each other for a short distance to further facilitate exposure. An avascular plane of loose areolar tissue between the sternothyroid muscle and thyroid gland can be separated. In order to avoid displacing parathyroid glands laterally it is important to dissect intimately along the sternothyroid muscle. The thyroid can be medially rotated and elevated using a peanut or 4x4 sponge thereby exposing the lateral and posterior thyroid surface (see ■ Fig. 16.7). The middle thyroid vein will course medial to lateral, similar and often parallel to the inferior thyroid artery. The vein will be above the carotid artery. The inferior thyroid artery will always be situated deep to the carotid artery in its course from the thyrocervical trunk. The middle thyroid vein can be isolated, ligated, and divided to provide more exposure.

Initial dissection should be directed toward any abnormal parathyroid glands suggested by preoperative imaging. Blood

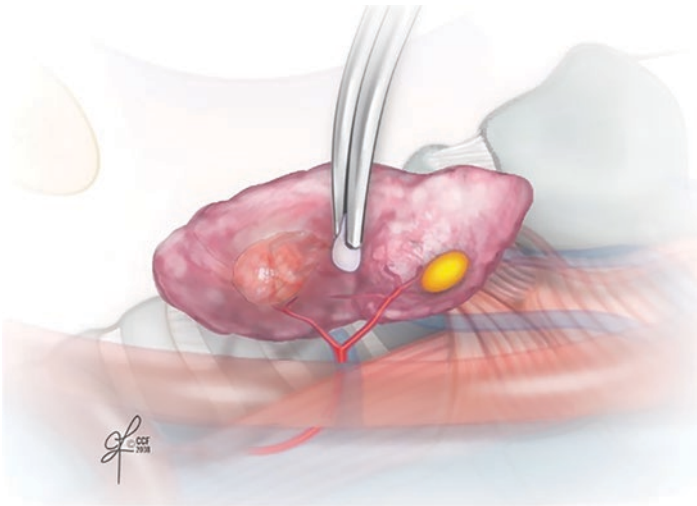


■ **Fig. 16.7** Medial rotation of the thyroid during parathyroidectomy

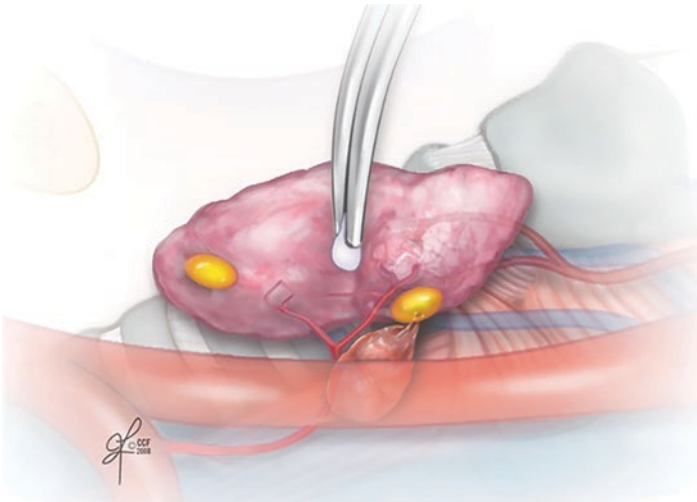
staining during parathyroidectomy discolors the tissue and can make identifying parathyroid glands more difficult. If preoperative imaging is negative, the lower gland can be exposed first as it is more accessible. Purposeful observation for fatty-appearing tissue along the edges of the thyroid or adjacent to the branches of the inferior and superior thyroid artery entering the thyroid gland should be taken. Staying close to the thyroid during this dissection minimizes the risk of recurrent laryngeal nerve injury. The nerve does not need to be routinely exposed, but the direction of its course should be noted and aids in the identification of glands. When a candidate area suspicious for harboring a parathyroid gland is seen, a fine-curved hemostat is used to carefully separate the overlying fatty tissue. Parathyroid tissue appears subtly darker orange to brown in color compared to surrounding tissue. Normal parathyroid glands appear flat with a leaf-like vascular pattern. Abnormal or enlarged glands appear as a bulging mass beneath the surface (see ■ Fig. 16.8). They will appear to slide beneath an overlying layer of tissue, this is known as the “float-sign” (see ■ Fig. 16.9). The gland can be gently coaxed away from surrounding fat and areolar tissues to determine the true size of the gland and be sure an abnormal adenoma is not being hidden under a cap of normal parathyroid gland (see ■ Fig. 16.10). Care should be taken not to disrupt the vascular pedicle arising medially along the thyroid. “Primary parathyroid survey” is performed by assessing the usual anatomic locations for all four glands. Our group advocates a systematic order of exploration until all four glands have been identified, usually working to identify the abnormal gland first, followed by the remaining ipsilateral gland, before exploring the contralateral side.



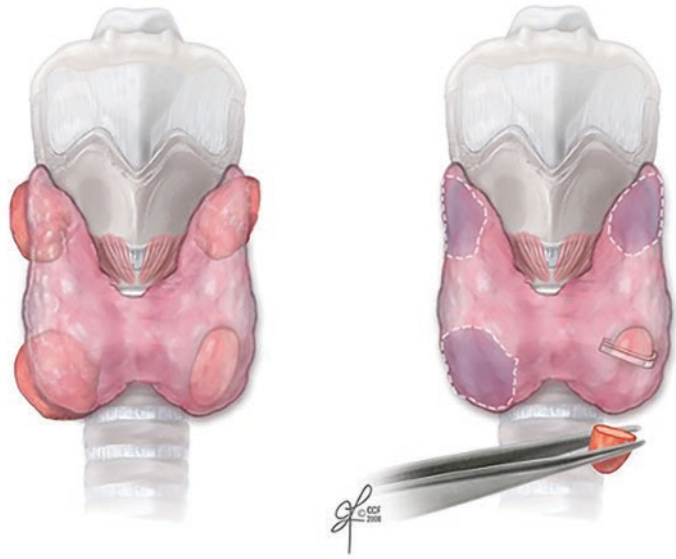
■ Fig. 16.8 Appearance of normal and abnormal parathyroid Glands



■ Fig. 16.9 Inferior parathyroid adenoma



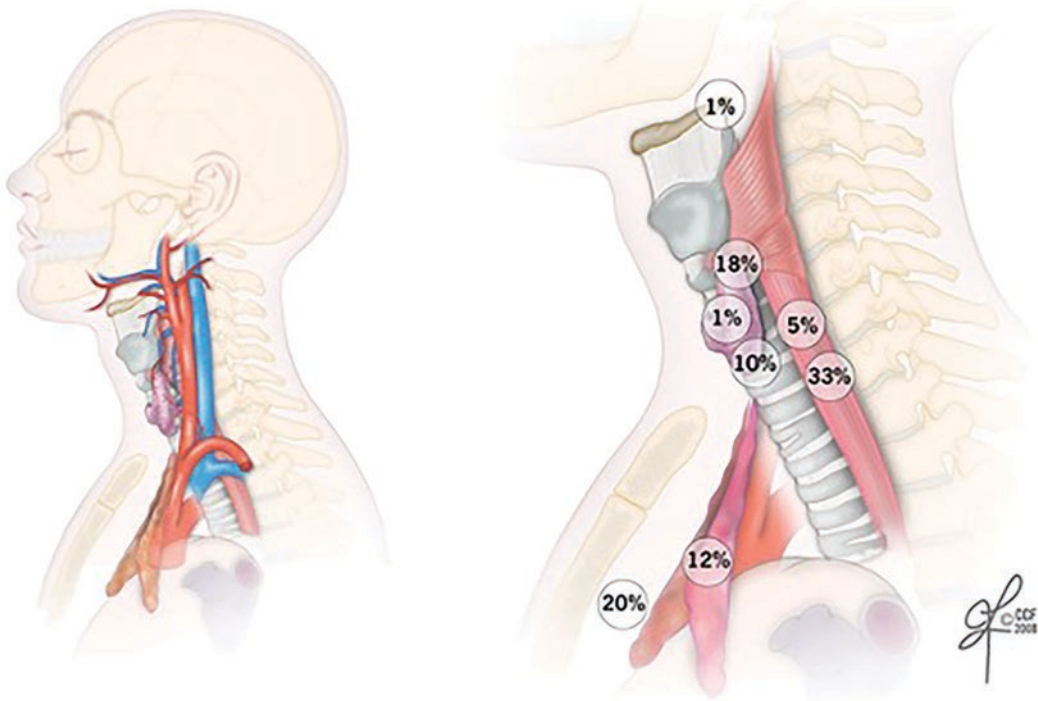
■ Fig. 16.10 Adenoma with cap of normal parathyroid



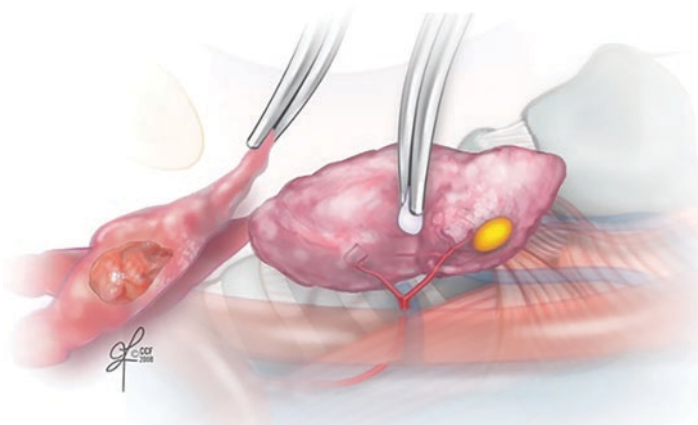
■ Fig. 16.11 Three-and-a-half-gland parathyroidectomy

How to proceed next is determined by the appearance of all four glands. Single or double adenomas are excised, whereas multigland hyperplasia requires subtotal parathyroidectomy and parathyroid cryopreservation. Normal remaining glands are marked with a nearby clip. When performing a subtotal (three-and-a-half gland) parathyroidectomy, the remnant gland should be fashioned first taking care not to disrupt the vascular pedicle. Usually, a more anterior lower gland is chosen in case of future reoperation. The remnant is marked with a clip across the transected surface. Goal size of the remnant is the size of a normal gland, or 6×4 mm, and approximately 25 mg (see ■ Fig. 16.11).

A “secondary parathyroid survey” is performed when all four glands are not readily identified during the “primary parathyroid survey” and thus takes into consideration the possibility of ectopic glands. The most commonly missed gland is a retroesophageal parathyroid. Lying anterior to the spine in the deep posterior space behind the tracheoesophageal groove the inferior thyroid artery often courses anterior to this gland, which is an embryologically upper gland, though it appears more inferior to the actual lower gland (see ■ Fig. 16.12). A search for missing glands is also performed during the secondary parathyroid survey. The thymus can be gently retracted out of the mediastinum without tearing the gland, palpated and excised (see ■ Fig. 16.13). Ligation of the middle thyroid vein can aid in greater exposure. The upper pole of the thyroid can be mobilized as during thyroidectomy without devascularizing it (see ■ Fig. 16.14). Thyroid lobectomy on the side of the missing gland may be considered when no palpable abnormality exists but can be avoided in the absence of any thyroid

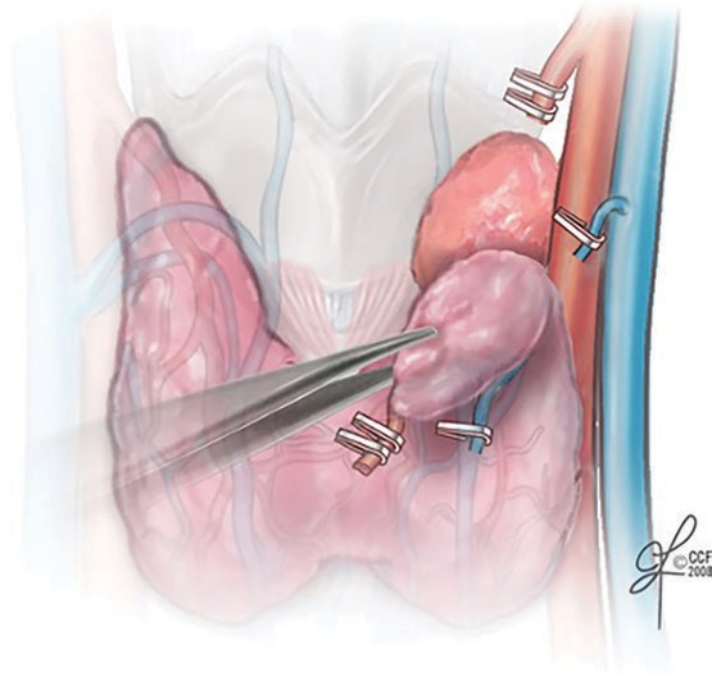


■ Fig. 16.12 Most common locations for ectopic parathyroid glands



■ Fig. 16.13 Thymectomy for intrathyroid parathyroid adenoma

nodules on preoperative ultrasound. Missing glands can also be found along the path of the carotid artery and jugular vein. Parathyroid gland locations are often symmetric on the contralateral side. A gland located in the posterior midpoint of the thyroid can be either a high-riding lower parathyroid gland or a descended superior gland. Both possibilities should be considered when encountered.



■ Fig. 16.14 Ligation of the middle thyroid vein

After exploration and resection are complete the neck is irrigated with sterile water, which lyses red blood cells and provides a clearer view than saline in assessing for hemostasis. Each gland is reevaluated for viability. Mild bruising is generally ok; however if the parathyroid tissue has been devascularized with questionable viability, it can be reimplanted into the ipsilateral sternocleidomastoid muscle. The strap muscles and platysma are re-approximated with absorbable suture and the skin incision closed. Our preferred method of closure, which affords an exceptional cosmetic appearance, is to run a 3–0 prolene subcuticular stitch without knots, leaving long tails on either end. Surgical glue is applied on top of the closure. After extubation, the stitch can be pulled out leaving a sutureless closure [19].

16.4.2 Focused Parathyroidectomy

Focused parathyroidectomy is performed at the discretion of the surgeon and can be considered in cases where parathyroid pathology is well localized on preoperative imaging studies. The positioning, preoperative ultrasound, and initial surgical access to the neck are as described for comprehensive parathyroidectomy above. A preoperative PTH level is obtained

prior to intubation to avoid a PTH spike related to intubation or surgical manipulation prior to excision. The dissection is carried out on the side of anticipated pathology, guided by preoperative imaging. Once the abnormal gland is identified and excised, it should be confirmed to be parathyroid tissue by visual inspection, and IOPTH levels should be sent at 0, 5, and 10 minutes after excision. Conversion to a bilateral exploration is recommended if the IOPTH level fails to drop appropriately, if multigland disease is encountered, or if an abnormal parathyroid gland cannot be found. Adequate hemostasis and closure can be performed as described previously [19].

16.5 Intraoperative PTH Monitoring and Gamma-Probe Localization

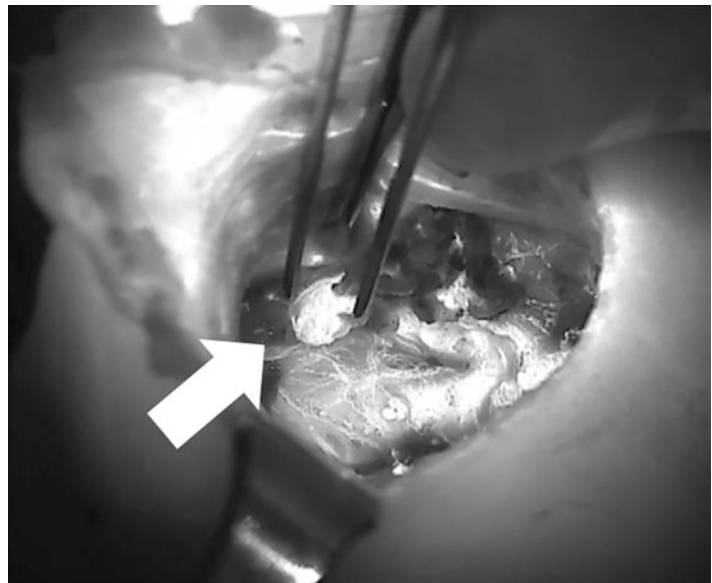
The Miami criterion was first described in the early 1990s by Dr. George Irvin [20–22]. The use of IOPTH monitoring introduced the prospect of performing a focused parathyroid exploration. PTH has a short half-life on the order of 2–4 minutes [23]. Factors that influence lab results include the use of propofol, peripheral sample, dilution, and hemolysis. Using the Miami criterion, successful excision of parathyroid pathology is confirmed by at least a 50% drop in PTH from the highest preoperative or preexcision levels at 10 minutes after excision. Thus, the added potential morbidity of a bilateral exploration could be avoided. However, since its inception, the optimal algorithm for its use has been extensively studied, as there is a possibility of missing multigland disease (only 90% sensitive) [24]. Many surgeons proceed with bilateral exploration in all cases at the initial surgery, citing that parathyroid gland size does not correlate with hypersecretion, and hypercellular pathology can be seen on biopsy of normal appearing glands [25]. *Dual criteria* includes the added criteria that the PTH drop by both 50% and into the normal range and is associated with improved cure rates (97–99%) and sensitivity for multigland disease (97%) [26].

Intraoperative gamma probe comparison of in vivo and ex vivo specimen radiotracer counts has also been described. Technetium 99-m is injected 1–2 hours preoperatively and a handheld gamma probe is used to guide dissection and compare the specimen pre- and post-excision. A 20% drop in gamma emission from the surgical bed is consistent with resection of an abnormal gland. Use of gamma-probe is limited in multigland disease because the probe detects sestamibi uptake as a marker for hyperfunctioning parathyroid tissue. Additionally, thyroid nodules can retain isotope leading to false-positive results [27].

16.6 Indocyanine Green and Autofluorescence

Intraoperative identification of parathyroid glands, both normal and abnormal, has classically been credited, according to the old adage, to the experienced endocrine surgeon [28]. However, indocyanine green fluorescence (ICG) and parathyroid autofluorescence (AF) represent two novel techniques to identify parathyroid glands intraoperatively [29]. Use of these adjuncts decreases the risk of injuring the parathyroid glands and their blood supply, as well as the risk of inadvertently removing normal glands. ICG is an amphiphilic tricarbocyanine dye with near-infrared fluorescent properties at around 820-nm wavelength. ICG is administered intravenously, and fluorescence is detected using near-infrared cameras. Notably, ICG parathyroid fluorescence is limited in part due to interference from background thyroid fluorescence [30] (see **■** Fig. 16.15).

Parathyroid tissues possess a natural fluorophore excited by 785-nm infrared light which in turn emit light at 822-nm [31]. In contrast to ICG, PAF does not require intravenous injection of fluorescent dye, can be detected using a spectrometer or modified near-infrared imaging camera, and persists regardless of gland viability. Thus, PAF can be detected after gland excision to assess for unintended parathyroidectomy. The European trial PARAFUO showed that the use of PAF during thyroidectomy resulted in decreased postoperative hypocalcemia, parathyroid autotransplantation, and inadvertent parathyroid



■ Fig. 16.15 Parathyroid ICG angiography. Image of parathyroid ICG angiography (right superior parathyroid gland after thyroidectomy) showing a well-vascularized parathyroid gland between the forceps (arrows). (Image courtesy of Demarchi et al. [30])

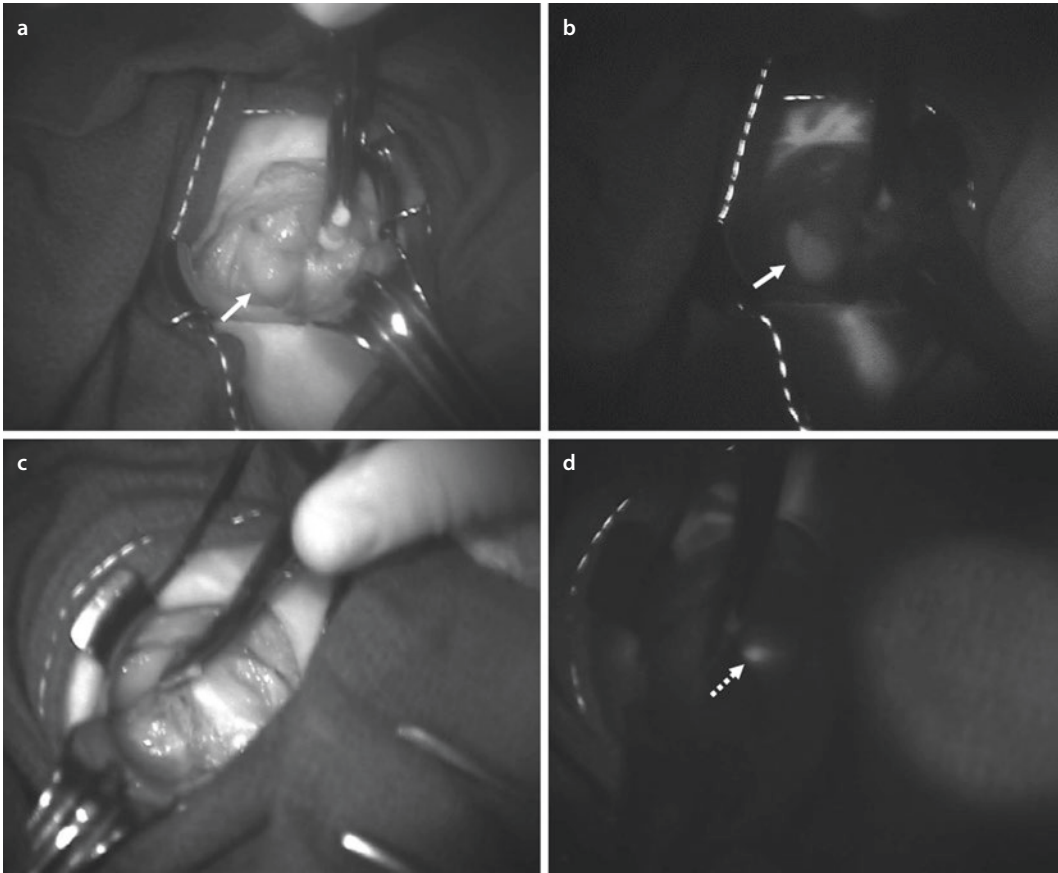


Fig. 16.16 Parathyroid autofluorescence. Four-gland parathyroid exploration demonstrating a left inferior parathyroid adenoma **a**, arrow with intraoperative autofluorescence with near infrared imaging **b**, arrow. Normal right inferior parathyroid not seen on initial visual inspection **c** detected with autofluorescence **d**, dashed arrow. (Images courtesy of Kose et al. [35])

resection [32]. Studies comparing ICG and PAF demonstrate that PAF and ICG had similar detection rates for parathyroid glands [98% (61 of 62) for PAF and 95% (60 of 63) for ICG $P = 0.31$]. When compared to naked eye identification, parathyroid glands are more frequently identified by PAF than ICG. The location of parathyroid glands was suggested before detection by the naked eye more frequently by PAF than ICG [52% (32 of 62) vs. 6% (4 of 63) of PGs; $P < 0.001$] [33–35] (see **Fig. 16.16**). Identification of incidentally resected parathyroid glands by autofluorescence has led to their subsequent reimplantation.

16.7 Cryopreservation and Autotransplantation

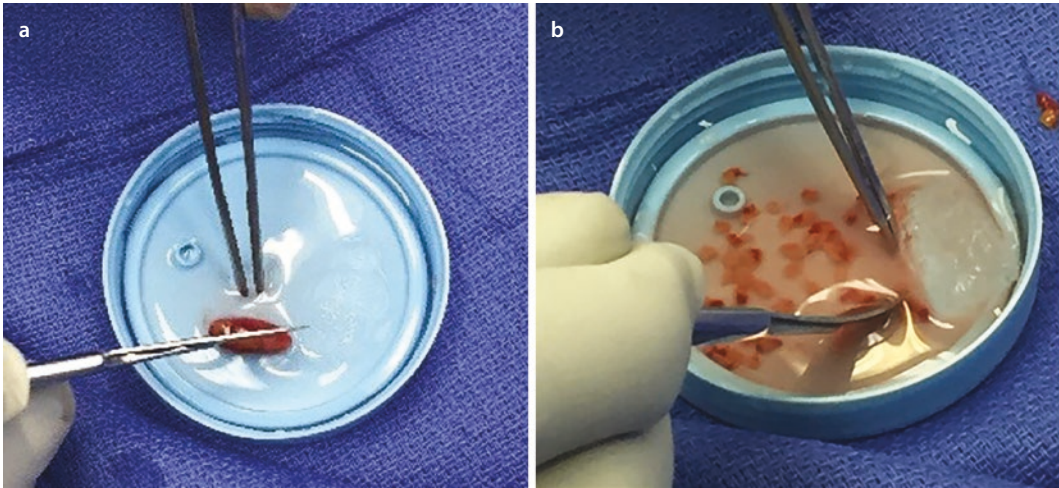
Parathyroid autotransplantation offers rescue from the devastating complication of permanent postoperative hypoparathyroidism. Parathyroid autotransplantation was first described

and performed in humans during a thyroidectomy by Lahey in 1926 [36]. The procedure was largely forgotten for 50 years until Wells et al. reported the first patient series that confirmed functional autografts from the clinical, physiological, and histological perspective [37].

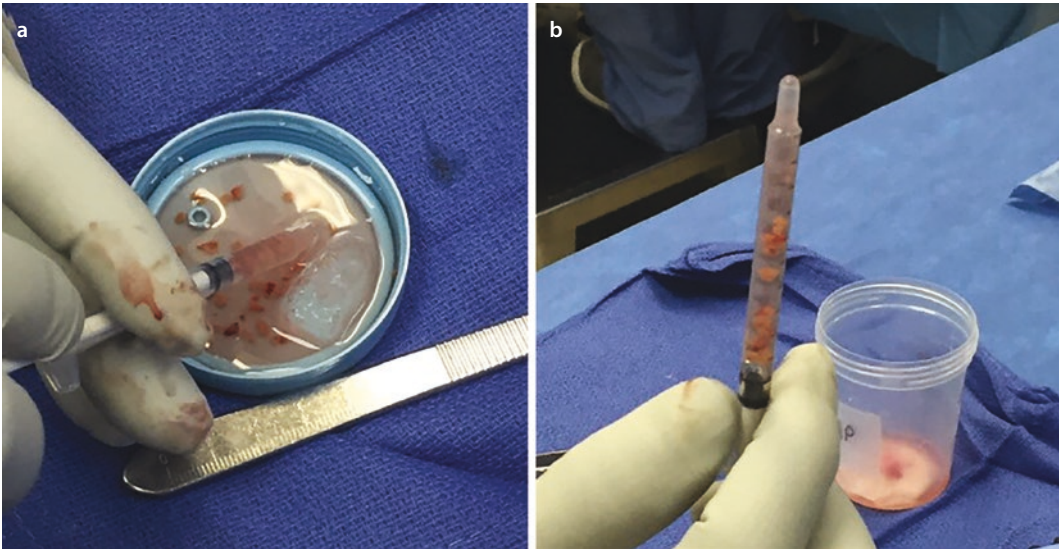
Immediate autotransplantation can be performed if intraoperatively there is concern that no functional parathyroid tissue remains, as may be the devastating case after performing a subtotal parathyroidectomy for hyperplasia with undue trauma to the remnant, or during total thyroidectomy with inadvertent parathyroidectomy. Delayed parathyroid autotransplantation with cryopreservation can be used in patients who develop permanent postoperative hypoparathyroidism. Identification of high-risk patients preoperatively allows the surgeon to anticipate the need for cryopreservation and tissue storage at the time of surgery. Further, it allows assessment of the outcome of the primary surgery prior to transplantation.

Immediate autotransplantation as initially described by Lahey involves the intraoperative transfer of fresh autogenous parathyroid tissue to an alternative site, most commonly the sternocleidomastoid (SCM), pectoralis, or muscle belly of the brachioradialis [36]. Immediate autotransplantation has an 85–99% success rate. The parathyroid gland is minced into 1 mm pieces which can be directly transplanted or aspirated into a syringe of balanced salt solution and then injected into the muscle belly of the SCM, pectoralis, or brachioradialis. Multiple wells within the same muscle can be created for transplantation to minimize the risk that a single site of transplanted tissue fails to take. The implantation sites are marked with either clips or non-absorbable suture [38]. Immediate autotransplantation is associated with a risk of persistent hyperparathyroidism, especially in patients with familial or renal disease who also have an inherently high risk of supernumerary or ectopic glands.

Delayed autotransplantation refers to the transplantation of previously cryopreserved autologous parathyroid tissue. Cryopreservation is done for patients who are high risk for postoperative hypoparathyroidism, including patients undergoing three-and-a-half gland parathyroidectomy for hyperplasia, total thyroidectomy with extensive lymph node dissection, or those undergoing reoperative neck surgery for persistent or recurrent disease [39]. In cases of parathyroid hyperplasia, the least abnormal hyperplastic gland should be used for cryopreservation [40]. Preserving cell viability and tissue integrity is paramount. Intraoperatively, working with chilled reagents and on ice, the harvested tissue is defatted, minced into small (1 × 1 × 1 mm) pieces, and ultimately stored in a cryopreservation medium. At our institution, parathyroid tissue is suspended in saline in the operating room and 15–20 pieces of fragmented



■ **Fig. 16.17** **a** Fragmentation of parathyroid tissue for cryopreservation. **b** Parathyroid tissue is trimmed of fat and minced into 1–2 mm pieces



■ **Fig. 16.18** **a** Parathyroid tissue fragments are aspirated into a tuberculin syringe. **b** Approximately 15–20 pieces per syringe suspended in injectable saline

parathyroid tissue are aspirated into 1 mL tuberculin syringes (see ■ Figs. 16.17, 16.18, and 16.19). A venous blood sample (10–15 mL) is collected in non-additive red top vacutainers and sent to the laboratory with the parathyroid tissue for cryopreservation. Laboratory processing includes decanting the supernatant and transferring approximately ten fragments of tissue into separate sterile cryovials with cryopreservation medium. Cryopreservation medium includes Roswell Park Memorial Institute (RPMI) 1640 solution, a cytoplasmic stabilizer (dimethyl sulfoxide), and autologous serum. Specific

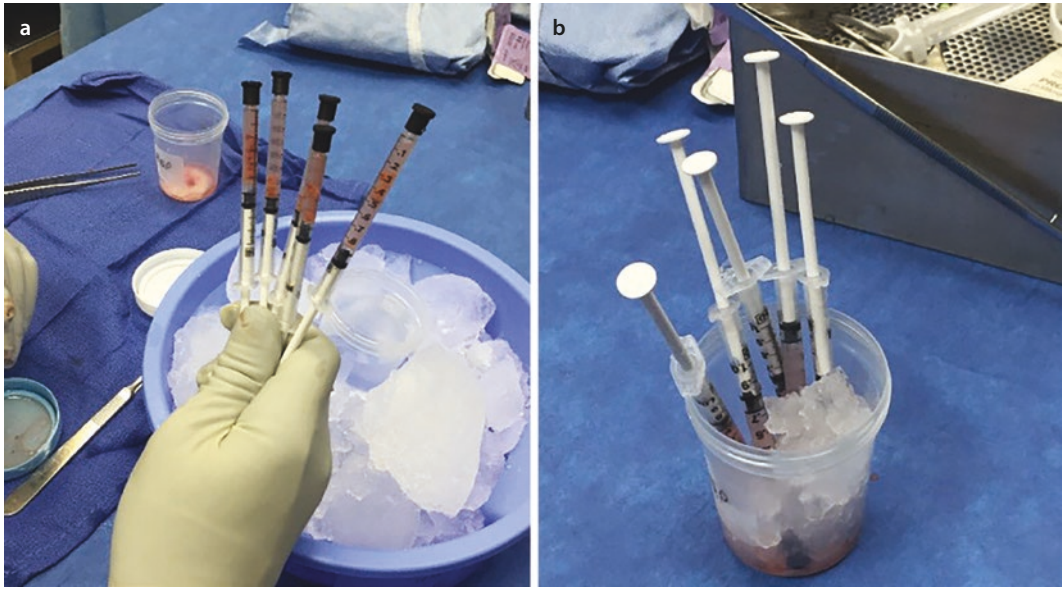


Fig. 16.19 **a** Aspirated parathyroid fragments are collected in one or more syringe per parathyroid gland. **b** Syringes are maintained on ice and transported immediately for cryopreservation (Images courtesy of Moore et al. [42])

proportions for cryopreservation medium ingredients vary by institution [41–43]. The freezing process should be gradual in order to best preserve cellular function, and long-term storage occurs at -196 deg. C. At the time of reimplantation, 20–40 fragments, or the equivalent of two normal parathyroid glands, are transplanted into the non-dominant forearm under local anesthetic (2–3 fragments per pocket), each marked with a clip or non-absorbable suture.

Viability of cryopreserved parathyroid tissue persists up to 2 years (71% <24 months, vs. 1% >24 months) [44, 45]. Routine preservation of parathyroid tissue for all comers is not necessary. We recommend routine cryopreservation generally in patients undergoing reoperative surgery whether for thyroid or parathyroid disease or for patients with a history of other non-endocrine neck surgery. Storage of cryopreserved tissue occurs in approximately 20% of cases, but utilization of stored tissues remains low at only 1–4% [46, 47]. The majority of patients requiring autotransplantation of parathyroid tissue require transplantation within 24 months [47].

Regulatory requirements for cryopreservation or parathyroid tissue are determined by the Food and Drug Administration (FDA) and the Joint Commission on the Accreditation of Healthcare Organizations (JCAHO). Parathyroid cryopreservation, processing, storage, and recall should be performed by an experienced center specializing in long-term tissue storage

such as a given hospital's blood bank, sperm bank, or andrology laboratory.

16.8 Management of Complications

Complications from parathyroidectomy are rare with an overall complication rate of approximately 4% for bilateral neck exploration. Immediate perioperative complications associated with parathyroidectomy include injury to the recurrent laryngeal nerve, hematoma, hypocalcemia, and wound infection. If injury to the recurrent laryngeal nerve, including transection, is identified at the time of surgery, repair should be attempted in order to minimize the risk of vocal cord paralysis. Direct end-to-end neuroorrhaphy should be performed using fine non-absorbable suture. Bilateral recurrent laryngeal nerve injury may require reintubation and possible tracheostomy if the patient is unable to be intubated. Symptomatic postoperative hematoma may cause pain, fullness, dysphagia, or respiratory distress. Life-threatening airway compromise is best treated in the operating room for hematoma evacuation if recognized early. Wound infection after parathyroidectomy is exceedingly rare due to the hypervascular surgical bed, and prophylactic antibiotics are generally not warranted unless performing a reoperative surgery.

Postoperative hypocalcemia can be due to temporary hypoparathyroidism or rarely permanent hypoparathyroidism. Temporary hypoparathyroidism is attributed to suppression of the remaining normal parathyroid glands and resolves within a few days. Permanent hypoparathyroidism occurs when no viable parathyroid tissue remains, which can occur after subtotal parathyroidectomy where the remnant or its blood supply is compromised, or if autotransplantation fails. Permanent hypoparathyroidism is defined as persistent (>6 months) hypocalcemia, secondary to low levels of parathyroid hormone requiring calcium and vitamin D replacement without any period of normal biochemistry [48]. Permanent hypoparathyroidism has been reported to be as high as 30% after reoperative cases [49]. Assessment for postoperative hypocalcemia includes evaluation of parathyroid hormone and calcium levels on postoperative day one. Patients should be counseled to monitor for signs of hypocalcemia, including perioral or acral paresthesias, anxiety, as well as the risk of tetany, seizure, and papilledema. Routine calcium and vitamin D supplementation should be prescribed, especially if not corrected preoperatively. Though practices vary, the authors recommend 500 mg of calcium carbonate three times daily along with at least 1000 IU daily vitamin D depending on the preoperative level. Repeat serum PTH and calcium levels should be assessed at 1 to 2 weeks after surgery, and supplemental calcium may be weaned as indicated.

Hungry bone syndrome occurs when postoperative hypocalcemia is severe and prolonged despite normal or even elevated levels of PTH. It occurs in patients who have bone disease due to chronic bone resorption preoperatively [50]. Relatively decreased levels of PTH postop cause decreased bone resorption, increased bone formation, increased influx of calcium into bone, increased calcium excretion, and decreased intestinal calcium absorption.

Surgical cure after parathyroidectomy is defined as having normal calcium homeostasis 6 months after parathyroidectomy. Blood testing should be repeated at 6 months after surgery, then annually. Long-term follow-up is recommended, and cure should not be assumed based on a single set of normal postop lab values. Recurrent hyperparathyroidism after initially curative surgery occurs in approximately 2% of patients. Prior to embarking on reoperative surgery, prior operative reports should be carefully reviewed, new imaging obtained ideally demonstrating co-localization of residual disease, and direct laryngoscopy to evaluate recurrent laryngeal nerve function performed [4, 51].

16.9 Outcomes and Prognosis

Surgical cure after parathyroidectomy for primary hyperparathyroidism is greater than 95% [52–54]. Recurrent hyperparathyroidism after initially curative surgery is rare, occurring in less than 2% of patients [55]. With respect to osteoporosis, markers of bone resorption normalize rapidly after surgery, and objective improvements in bone mineral density of the lumbar spine, hip, and distal radius are observed as early as 6 months postoperatively [56]. Additionally, parathyroidectomy has been shown to be associated with a 64% reduction in the absolute risk of hip fractures [57, 58]. When compared to long-term observation or pharmacologic therapy, operative management of hyperparathyroidism is more cost-effective [4, 11]. With regard to the renal effects of hyperparathyroidism, the risk of nephrolithiasis decreases following parathyroidectomy; however renal function has not been shown to improve [59, 60]. Additionally, parathyroidectomy is associated with less well proven long-term effects on cardiovascular system including improvement of left ventricular mass index and electrocardiographic abnormalities in patients with PHPT [61, 62].

Patient quality of life improves significantly after parathyroidectomy. Objective improvement in the traditionally mislabeled “asymptomatic” neurocognitive features of PHPT has been demonstrated in numerous studies evaluating patient responses to both general and disease-specific patient reported outcomes measures including the PAS (parathyroid assessment of symptoms), SF-36 quality of life scale, and PROMPT

(Patient-Reported Outcome Measure for Parathyroid and Thyroid Disease). These improvements in depression, fatigue, thirst, and forgetfulness have stable improvement at 10 years after surgery [8–10].

✓ Answers to the Questions

1. (b); 2. (b); 3. (d); 4. (c); 5. (c); 6. (e); 7. (e); 8. (d); 9. (b); 10. (d)

References

1. Yeh MW, Ituarte PHG, Zhou HC, Nishimoto S, Liu I-LA, Harari A, et al. Incidence and prevalence of primary hyperparathyroidism in a racially mixed population. *J Clin Endocrinol Metab.* 2013;98(3):1122–9.
2. Siperstein A, Berber E, Barbosa GF, Tsinberg M, Greene AB, Mitchell J, et al. Predicting the success of limited exploration for primary hyperparathyroidism using ultrasound, sestamibi, and intraoperative parathyroid hormone: analysis of 1158 cases. *Ann Surg.* 2008;248(3):420–6.
3. Norman J, Lopez J, Politz D. Abandoning unilateral parathyroidectomy: why we reversed our position after 15,000 parathyroid operations. *J Am Coll Surg [Internet].* 2012;214(3):260–9. Available from: <https://doi.org/10.1016/j.jamcollsurg.2011.12.007>
4. Wilhelm SM, Wang TS, Ruan DT, Lee JA, Asa SL, Duh QY, et al. The American association of endocrine surgeons guidelines for definitive management of primary hyperparathyroidism. *JAMA Surg.* 2016;151(10):959–68.
5. Bilezikian JP, Brandi ML, Eastell R, Silverberg SJ, Udelsman R, Marcocci C, et al. Guidelines for the management of asymptomatic primary hyperparathyroidism: summary statement from the fourth international workshop. *J Clin Endocrinol Metab.* 2014;99(10):3561–9.
6. VanderWalde LH, Liu ILA, Haigh PI. Effect of bone mineral density and parathyroidectomy on fracture risk in primary hyperparathyroidism. *World J Surg.* 2009;33(3):406–11.
7. Udelsman R, Åkerström G, Biagini C, Duh QY, Miccoli P, Niederle B, et al. The surgical management of asymptomatic primary hyperparathyroidism: proceedings of the Fourth International Workshop. *J Clin Endocrinol Metab.* 2014;99(10):3595–606.
8. Pasiëka JL, Parsons L, Jones J. The long-term benefit of parathyroidectomy in primary hyperparathyroidism: a 10-year prospective surgical outcome study. *Surgery [Internet].* 2009;146(6):1006–13. Available from: <https://doi.org/10.1016/j.surg.2009.10.021>
9. Burneikis T, Colvin J, Jin J, Berber E, Krishnamurthy VD, Shin J, et al. Validation of a novel patient-reported outcome measure for parathyroid and thyroid disease (PROMPT). *Surg (United States) [Internet].* 2019;165(1):232–9. Available from: <https://doi.org/10.1016/j.surg.2018.04.091>.
10. Ejlsmark-Svensson H, Sikjaer T, Webb SM, Rejnmark L, Rolighed L. Health-related quality of life improves 1 year after parathyroidectomy in primary hyperparathyroidism: a prospective cohort study. *Clin Endocrinol.* 2019;90(1):184–91.
11. Zanicco K, Angelos P, Sturgeon C. Cost-effectiveness analysis of parathyroidectomy for asymptomatic primary hyperparathyroidism. *Surgery.* 2006;140(6):874–82.
12. Solorzano CC, Carneiro-Pla D. Minimizing cost and maximizing success in the preoperative localization strategy for primary hyperparathyroidism. *Surg Clin North Am [Internet].* 2014;94(3):587–605. Available from: <https://doi.org/10.1016/j.suc.2014.02.006>

13. Arora S, Balash PR, Yoo J, Smith GS, Prinz RA. Benefits of surgeon-performed ultrasound for primary hyperparathyroidism. *Langenbeck's Arch Surg.* 2009;394(5):861–7.
14. Thier M, Daudi S, Bergenfelz A, Almquist M. Predictors of multiglandular disease in primary hyperparathyroidism. *Langenbeck's Arch Surg.* 2018;403(1):103–9.
15. Wang TS, Cheung K, Farrokhyar F, Roman SA, Sosa JA. Would scan, but which scan? A cost-utility analysis to optimize preoperative imaging for primary hyperparathyroidism. *Surgery* [Internet]. 2011;150(6):1286–94. Available from: <https://doi.org/10.1016/j.surg.2011.09.016>
16. Harari A, Mitmaker E, Grogan RH, Lee J, Shen W, Gosnell J, et al. Primary hyperparathyroidism patients with positive preoperative sestamibi scan and negative ultrasound are more likely to have posteriorly located upper gland adenomas (PLUGs). *Ann Surg Oncol.* 2011;18(6):1717–22.
17. Lubitz CC, Hunter GJ, Hamberg LM, Parangi S, Ruan D, Gawande A, et al. Accuracy of 4-dimensional computed tomography in poorly localized patients with primary hyperparathyroidism. *Surgery* [Internet]. 2010;148(6):1129–38. Available from: <https://doi.org/10.1016/j.surg.2010.09.002>
18. Abbott DE, Cantor SB, Grubbs EG, Santora R, Gomez HF, Evans DB, et al. Outcomes and economic analysis of routine preoperative 4-dimensional ct for surgical intervention in de novo primary hyperparathyroidism: does clinical benefit justify the cost? *J Am Coll Surg.* 2012;214(4):629–37.
19. Siperstein A, Milas M. Comprehensive Parathyroidectomy for the treatment of PHPT. In: Fischer J, editor. *Fischer's mastery of surgery*. 6th ed. Philadelphia: Lippincott Williams & Wilkins; 2012. p. 486–96.
20. Irvin GL, Dembrow VD, Prudhomme DL. Operative monitoring of parathyroid gland hyperfunction. *Am J Surg.* 1991;162(4):299–302.
21. Irvin G 3rd, Dembrow V, Prudhomme D. Clinical usefulness of an intraoperative “quick parathyroid hormone” assay. *Surgery.* 1993;114(6):1019–22.
22. Irvin GL, Prudhomme DL, Deriso GT, Sfakianakis G, Chandarlapaty SKC. A new approach to parathyroidectomy. *Ann Surg.* 1994;219(5):574–81.
23. Maier GW, Kreis ME, Renn W, Pereira PL, Häring HU, Becker HD. Parathyroid hormone after adenectomy for primary hyperparathyroidism. A study of peptide hormone elimination kinetics in humans. *J Clin Endocrinol Metab.* 1998;83(11):3852–6.
24. Lew JI, Irvin GL. Focused parathyroidectomy guided by intra-operative parathormone monitoring does not miss multiglandular disease in patients with sporadic primary hyperparathyroidism: a 10-year outcome. *Surgery.* 2009 Dec;146(6):1021–7.
25. Irvin GL, Carneiro DM, Solorzano CC, Leight GS, Perrier N, Nelson WR, et al. Progress in the operative management of sporadic primary hyperparathyroidism over 34 years. *Ann Surg.* 2004;239(5):704–11.
26. Richards ML, Thompson GB, Farley DR, Grant CS. An optimal algorithm for intraoperative parathyroid hormone monitoring. *Arch Surg.* 2011;146(3):280–5.
27. Chen H, Mack E, Starling JR, Irvin GL, Clark OH, Prinz RA, et al. A comprehensive evaluation of perioperative adjuncts during minimally invasive parathyroidectomy: which is most reliable? *Ann Surg.* 2005;242(3):375–83.
28. Doppman JL, Miller DL. Localization of parathyroid tumors in patients with asymptomatic hyperparathyroidism and no previous surgery. *J Bone Min Res.* 1991;Suppl 2:S153–8; discussion S159.
29. Baj J, Sitarz R, Łokaj M, Forma A, Czezelewski M, Maani A, et al. Preoperative and intraoperative methods of parathyroid gland localization and the diagnosis of parathyroid adenomas. *Molecules.* 2020;25(7):1–22.

30. Demarchi MS, Karenovics W, Bédât B, Triponez F. Intraoperative autofluorescence and Indocyanine green angiography for the detection and preservation of parathyroid glands. *J Clin Med*. 2020;9(3):830.
31. Paras C, Keller M, White L, Phay J, Mahadevan-Jansen A. Near-infrared autofluorescence for the detection of parathyroid glands. *J Biomed Opt*. 2011;16(6):067012.
32. Benmiloud F, Godiris-Petit G, Gras R, Gillot JC, Turrin N, Penaranda G, et al. Association of autofluorescence-based detection of the parathyroid glands during total thyroidectomy with postoperative hypocalcemia risk: results of the PARAFUO multicenter randomized clinical trial. *JAMA Surg*. 2020;155(2):106–12.
33. Kahramangil B, Berber E. The use of near-infrared fluorescence imaging in endocrine surgical procedures. *J Surg Oncol*. 2017;115(7):848–55.
34. Kahramangil B, Berber E. Comparison of indocyanine green fluorescence and parathyroid autofluorescence imaging in the identification of parathyroid glands during thyroidectomy. *Gland Surg*. 2017;6(6):644–8.
35. Kose E, Rudin AV, Kahramangil B, Moore E, Aydin H, Donmez M, Krishnamurthy V, Siperstein A, Berber E. Autofluorescence imaging of parathyroid glands: An assessment of potential indications. *Surgery*. 2020;167(1):173–79. <https://doi.org/10.1016/j.surg.2019.04.072>. Epub 2019 Sep 13. PMID: 31526579.
36. Lahey F. The transplantation of parathyroids in partial thyroidectomy. *Surg Gynecol Obs*. 1926;62:508–9.
37. Wells S Jr, Christiansen C. The transplanted parathyroid gland: evaluation of cryopreservation and other environmental factors which affect its function. *Surgery*. 1974;75(1):49–55.
38. Saxe A, Gibson G. Cryopreservation of parathyroid tissue. In: Clark O, Duh Q, Kebebew E, editors. *Textbook of endocrine surgery*. Philadelphia: Elsevier Saunders; 2005. p. 530–5.
39. Moffett JM, Suliburk J. Parathyroid autotransplantation. *Endocr Pract*. 2011;17(Suppl 1):83–9.
40. Sancho J, Sitges-Serra A. Surgical approach to secondary hyperparathyroidism. In: Clark O, Duh Q, Kebebew E, editors. *Textbook of endocrine surgery*, vol. 1. Philadelphia: Elsevier Saunders; 2005. p. 510–7.
41. Stotler BA, Reich-Slotky R, Schwartz J, Inabnet WB, Lee J, Wu F, et al. Quality monitoring of microbial contamination of cryopreserved parathyroid tissue. *Cell Tissue Bank*. 2011;12(2):111–6.
42. Moore EC, Siperstein A, Gupta S. Cryopreservation of parathyroid tissue: a white paper on establishing a local service. *Endocr Pract*. 2019;25:605–11.
43. Agarwal A, Waghay A, Gupta S, Sharma R, Milas M. Cryopreservation of parathyroid tissue: an illustrated technique using the Cleveland clinic protocol. *J Am Coll Surg [Internet]*. 2013;216(1):e1–9. Available from: <https://doi.org/10.1016/j.jamcollsurg.2012.09.021>
44. Guerrero MA, Evans DB, Lee JE, Bao R, Bereket A, Gantela S, et al. Viability of cryopreserved parathyroid tissue: when is continued storage versus disposal indicated? *World J Surg*. 2008;32(5):836–9.
45. Herrera M, Grant C, van Heerden J, Fitzpatrick L. Parathyroid autotransplantation. *Arch Surg*. 1992;127(7):825–9.
46. Shepet K, Alhefdhi A, Usedom R, Sippel R, Chen H. Parathyroid cryopreservation after parathyroidectomy: a worthwhile practice? *Ann Surg Oncol*. 2013;20(7):2256–60.
47. Borot S, Lapierre V, Carnaille B, Goudet P, Penfornis A. Results of cryopreserved parathyroid autografts: a retrospective multicenter study. *Surgery*. 2010;147(4):529–35.
48. Shoback D. Clinical practice. Hypoparathyroidism. *N Engl J Med*. 2008;359(4):391–403. <https://doi.org/10.1056/NEJMcp0803050>. PMID: 18650515.

49. Rothmund M, Wagner PK. Reoperations for persistent and recurrent secondary hyperparathyroidism. *Ann Surg.* 1988;207(3):310–4.
50. Ho LY, Wong PN, Sin HK, Wong YY, Lo KC, Chan SF, et al. Risk factors and clinical course of hungry bone syndrome after total parathyroidectomy in dialysis patients with secondary hyperparathyroidism. *BMC Nephrol.* 2017;18(1):1–10.
51. Shin JJ, Milas M, Mitchell J, Berber E, Ross L, Siperstein A. Impact of localization studies and clinical scenario in patients with hyperparathyroidism being evaluated for reoperative neck surgery. *Arch Surg.* 2011;146(12):1397–403.
52. Udelsman R. Six hundred fifty-six consecutive explorations for primary hyperparathyroidism. *Ann Surg.* 2002;235(5):665–72.
53. Westerdahl J, Bergenfelz A. Unilateral versus bilateral neck exploration for primary hyperparathyroidism: five-year follow-up of a randomized controlled trial. *Ann Surg.* 2007;246(6):976–80.
54. Powell AC, Alexander HR, Chang R, Marx SJ, Skarulis M, Pingpank JF, et al. Reoperation for parathyroid adenoma: a contemporary experience. *Surgery [Internet].* 2009;146(6):1144–55. Available from: <https://doi.org/10.1016/j.surg.2009.09.015>.
55. Weber C, Sewell C, McGarity W. Persistent and recurrent sporadic primary hyperparathyroidism: histopathology, complications, and results of reoperation. *Surgery.* 1994;116(6):991–8.
56. Silverberg SJ, Clarke BL, Peacock M, Bandeira F, Boutroy S, Cusano NE, et al. Current issues in the presentation of asymptomatic primary hyperparathyroidism: proceedings of the fourth international workshop. *J Clin Endocrinol Metab.* 2014;99(10):3580–94.
57. Lee D, Walker MD, Chen HY, Chabot JA, Lee JA, Kuo JH. Bone mineral density changes after parathyroidectomy are dependent on biochemical profile. *Surg (United States) [Internet].* 2019;165(1):107–13. Available from: <https://doi.org/10.1016/j.surg.2018.04.065>.
58. Cusano NE, Rubin MR, Silva BC, Tay YKD, Williams JM, Agarwal S, et al. Skeletal microstructure and estimated bone strength improve following parathyroidectomy in primary hyperparathyroidism. *J Clin Endocrinol Metab.* 2018;103(1):196–205.
59. Walker MD, Silverberg SJ. Primary hyperparathyroidism. *Nat Rev Endocrinol [Internet].* 2018;14(2):115–25. Available from: <https://doi.org/10.1038/nrendo.2017.104>
60. Khan AA, Hanley DA, Rizzoli R, Bollerslev J, Young JEM, Rejnmark L, et al. Primary hyperparathyroidism: review and recommendations on evaluation, diagnosis, and management. A Canadian and international consensus. *Osteoporos Int [Internet].* 2017;28(1):1–19. Available from: <https://doi.org/10.1007/s00198-016-3716-2>.
61. Pepe J, Cipriani C, Sonato C, Raimo O, Biamonte F, Minisola S. Cardiovascular manifestations of primary hyperparathyroidism: a narrative review. *Eur J Endocrinol.* 2017;177(6):R297–308.
62. Vázquez-Díaz O, Castillo-Martínez L, Orea-Tejeda A, Orozco-Gutiérrez JJ, Asensio-Lafuente E, Reza-Albarrán A, et al. Reversible changes of electrocardiographic abnormalities after parathyroidectomy in patients with primary hyperparathyroidism. *Cardiol J.* 2009;16(3):241–5.