



# Esophageal Atresia

# 14

Debasish Banerjee, Chandrasen K. Sinha,  
and Mark Davenport

*The first successful primary repair of an esophageal atresia was performed in 1941 by Cameron Haight in Michigan, USA, though the infant stayed in hospital for over a year, nonetheless we can probably date this as the effective birth of modern-day neonatal surgery.*

## 14.1 Background

- ~1 per 2500–3000 live births
- M = F
- Isolated (~80%)
- Associated anomalies (20%)
  - These vary in severity and number, but two non-random associations are recognized with esophageal atresia (EA) as a distinct component—VACTERL and CHARGE.

---

D. Banerjee  
Department of Paediatric Surgery, St George's Hospital, Tooting, London, UK  
King's College Hospital, London, UK

C. K. Sinha  
St George's Hospital, London, UK

M. Davenport (✉)  
King's College Hospital, London, UK

### 14.1.1 VACTERL (Previously VATER) Association

This is non-random association of anomalies (not actually a syndrome) and is named for the key components, i.e., **V**ertebral, **A**norectal, **C**ardiac, **T**racheo-**E**sophageal, **R**enal, and **L**imb. EA occurs in about 70% of affected infants with an estimated incidence of about 1 in 10,000 live births.

### 14.1.2 CHARGE Syndrome

Syndrome with genetic basis (*CHD7* mutations on Ch8 in about 70% of affected infants) and includes: **C**oloboma, **H**eart disease, **C**hoanal **A**tresia, **R**etarded growth, **G**enital hypoplasia, **E**ar (deafness).

Among the other recognized associations are:

- Congenital heart disease (~30%) including VSD, PDA, and Tetralogy of Fallot.<sup>1</sup>
- Anorectal malformation (10–15%).
- GI anomalies (10–15%), e.g., duodenal atresia, malrotation.
- GU anomalies (10–15%), e.g., hydronephrosis, renal agenesis, duplex system.
- Tracheo-broncho-pulmonary anomalies, e.g., tracheomalacia, foregut cysts, CCAM, Lung agenesis/hypoplasia.
- Skeletal anomalies, e.g., vertebral anomalies, absent radius, phocomelia,<sup>2</sup> sacral agenesis.

### 14.1.3 Embryology

The trachea arises as the median ventral diverticulum of the primitive foregut at about the 22nd day of gestation. This then invaginates into the ventral mesenchyme. Folds arise from the lateral mesenchyme as tracheaesophageal folds which then fuse to separate the trachea from esophagus at about the 32nd day.

Incomplete fusion of the folds results in a defective tracheaesophageal septum and abnormal connection between the trachea and esophagus.

The etiology is not really known though is clearly multifactorial and may involve genetic factors such as a disturbance in the expression of foregut patterning genes such as Sonic hedgehog and interaction with retinoic acid receptors. There are teratogens (e.g., Adriamycin) described in mouse models where EA is a predictable consequence.

Five anatomical types are described (Table 14.1).

<sup>1</sup>Etienne-Louis Arthur Fallot (1850–1911) French physician described four key features of this cardiac malformation in 1888.

<sup>2</sup>Phocomelia (Greek “seal” + (Latin) “limb”—i.e., absent or shortened limbs, typically followed Thalidomide exposure.

**Table 14.1** Anatomical classification (after Vogt)

Type	Description	Frequency (%)
I	EA alone	7
II	EA and proximal fistula	1
III	EA and distal fistula	87
IV	EA and proximal and distal fistula	1
V	“H” type fistula. No EA	4

## 14.2 Clinical Features

### 14.2.1 Prenatal

Screening maternal US may detect a small or absent stomach accompanied by polyhydramnios. This sign is associated with a positive predictive value of ~50%. Hence, definitive prenatal counselling based on antenatal detection should be guarded. Other features may also be evident (e.g., skeletal anomalies) but there is nothing truly specific.

### 14.2.2 Postnatal Features and Investigation

Excessive salivation and frothing are the classical features of EA. Any attempting to feed such an infant leads to choking and respiratory distress. The diagnosis should be confirmed by passing an 8–10 Fg nasogastric tube or a Replogle<sup>3</sup> tube if possible and taking a chest X-ray. This can help to show the level of the atresia.

- **Chest X-ray**
  - Air in the stomach suggests a distal TEF, while a “gas-less” appearance suggests pure EA and by implication a “long-gap.” Associated duodenal atresia might be suggested with an overlarge stomach and duodenal bubbles.
  - Cardiomegaly might suggest cardiac anomalies and there may be an abnormal silhouette suggestive of a right-sided aortic arch (~2%).
- **Echocardiogram**
  - Define cardiac anatomy and presence of right-sided aortic arch.

The Type V “H-type” TEF has a different set of clinical features and typically presents after the neonatal age with feeding associated respiratory distress. A number of diagnostic options are available including bronchoscopy/esophagoscopy or a tube esophagogram.

#### 14.2.2.1 Management

##### Preoperative

- The upper pouch should be kept empty by continuous low-pressure suction via a Replogle tube.

<sup>3</sup>Robert Replogle—Thoracic surgeon in Chicago described this tube-within-a-tube arrangement.

- Nursed in the horizontal or semi-prone position with frequent change in the infant's position. In those with lung collapse or pneumonia, the child should be placed with the affected side uppermost and gentle physiotherapy instituted.
- Humified air within the incubator may aid suction of pharyngeal secretions.

### **Preoperative Endoscopy**

- Bronchoscopy
  - Although it can help to define the site and size of the fistula, the practice varies considerably between institutions. It can prolong the procedure and the infant can decompensate during this time prior to the ligation of the fistula.
- Esophagoscopy
  - To confirm the diagnosis and to know the length of the proximal pouch.

---

## **14.3 Surgery**

### **14.3.1 Esophageal Atresia and Distal TEF**

Semi-elective operation

- Posterolateral muscle-sparing extrapleural right-sided thoracotomy.
- Expose and ligate the azygous vein.
- Expose proximal pouch (manipulate Replogle tube) and identify TEF (closely related to vagus nerve).
- Divide TEF close to the trachea and then close with non-absorbable sutures (e.g., Prolene®).
- Mobilize upper pouch from the proximal trachea (excluding a further fistula).
- Anastomose with a single layer suture (e.g., 5/0 or 6/0 Prolene® or PDS®).

Most surgeons use a trans-anastomotic tube (6–8 Fr) and feed early. Routine postoperative chest drain is less commonly practiced nowadays. Anastomoses considered to be under tension should be protected by elective paralysis and the infants ventilated for about 4–5 days with their neck flexed.

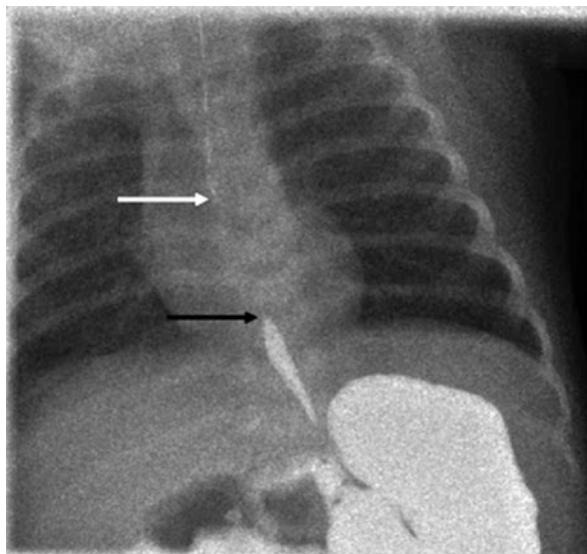
### **14.3.2 “Long-Gap” Esophageal Atresia**

Although there is no universally accepted definition of what constitutes a long gap, the primary determinant is the inability to perform an esophageal anastomosis at the time of initial operation. The gap is usually >4 vertebral bodies. This step is usually avoided for a Type 1 EA but a gastrostomy is needed.

The options thereafter include:

- Cervical esophagostomy
  - The traditional way of managing a blind upper pouch and allows the child to be discharged home to await esophageal replacement.

**Fig. 14.1** Long-gap esophageal atresia. Contrast study of a term infant with Replogle tube in the upper pouch (*white arrow*) and contrast in stomach and distal blind-ending esophagus (*black arrow*) Still 3 vertebral body gap



- Delayed primary anastomosis
  - The commonest approach currently and usually the definitive surgery is at 2–3 months of life.
  - Replogle tube drainage of the proximal pouch and enteral feeding through the gastrostomy continued. A serial assessment of the gap is performed (contrast or probe) to document gap shrinkage with the infant's growth (Fig. 14.1). When this is felt to be small enough (images should almost overlap) then a thoracotomy is performed.
- Lengthening by traction
  - Foker<sup>4</sup> technique—involves placement of traction sutures into the two ends and stretching, could either be open or be thoracoscopic
  - Kimura's extrathoracic advancement<sup>5</sup>—involves initial creation of an esophagostomy and then serial revisions take this progressively down the chest wall to lengthen it.
- **Esophageal replacement** (Indicated if the above maneuvers fail or gap >6 vertebrae.)
  - Gastric transposition. Mobilize stomach and duodenum to allow transit through hiatus into right chest. Also needs pyloroplasty to facilitate gastric drainage.
  - Jejunum conduit. Essentially a long Roux loop is created by the division of 2 or 3 vascular arcades. Could be staged to avoid vascular compromise.
  - Colon interposition. Original replacement technique though not as popular as formerly.

<sup>4</sup> John Foker—American pediatric surgeon working at the University of Minnesota and the Boston Children's Hospital.

<sup>5</sup> Ken Kimura—Retired Japanese American surgeon working at Iowa State University.

### 14.3.3 Surgical Complications

- Anastomotic leak (<5%)
  - Major early (<48 h) leaks should be suspected if pneumothorax develops and re-exploration should be considered. Later leaks can be managed conservatively with thoracostomy tube drainage. Likely formation of stricture.
- *Recurrent fistula* (<5%)
  - Suspected if oral feeding produces coughing and choking. Investigate with contrast esophagogram ± bronchoscopy. Requires revision. A ureteric catheter passed at bronchoscopy may facilitate identification.
- *Stricture* (10–30%)
  - Manifest as early feeding difficulty. Most respond to balloon dilatation(s). The use of prophylactic anti-reflux medication after OA-TOF repair is probably ineffective. Revision is occasionally required.
- *Gastroesophageal reflux* (~40%)
  - Common, but most are amenable to medical therapy. Fundoplication is performed in 10–20% of larger series.
- *Tracheomalacia* (~10%)
  - Although of itself a common finding and part of EA complex, it can be a potent cause of “apparent life-threatening events” (ALTE). Investigated by bronchoscopy to show the airway collapse. Treated by aortopexy, tracheopexy, or even tracheostomy.

#### **Preterm Infants with Respiratory Distress Syndrome and EA/TEF**

Dangerous combination as the necessarily high intratracheal pressures are vented through the fistula and cause gastric distension and even perforation. Consider medical means of reducing airways pressure (e.g., high-frequency oscillation) but surgery should be considered early as an emergency with the prime object of ligation of fistula (by a transpleural thoracotomy—it is quicker).

---

## 14.4 Thoracoscopic Repair

*Thoracoscopic repair* is being practiced in some centers with experts skilled in minimally invasive techniques; the first being reported in 1999 by Thom Lobe and Steve Rothenberg<sup>6</sup> in an 8-month-old infant with a Type 1 EA. There is a theoretical avoidance of chest wall deformity, although this should seldom be a real issue now with muscle-sparing thoracotomies.

---

<sup>6</sup>Thom Lobe and Steven Rothenberg—American pediatric surgeons.

**Table 14.2** Spitz classification

	Birth weight (kg)	Cardiac anomalies	Prognosis (%)
Group 1	>1.5	Absent	>98 <sup>a</sup>
Group 2	either <1.5	or Present	59
Group 3	<1.5	Present	22

<sup>a</sup>Figures taken from reference Spitz et al. [8]

## 14.5 Prognostic Classifications

- *Waterston et al.* [1] classified these patients into three groups based on birth weight, and presence of pneumonia, and other congenital anomalies.
- *Spitz et al.* [8] simplified this but retained birth weight and the presence of major cardiac anomalies (Table 14.2).

Others include *Montreal* (includes ventilator dependence), *Bremen* (includes postoperative complications), and that of *Sinha et al.* (where both weight <1.5 kg and a cardiac anomaly need to be present for a poor prognosis) classifications.

## 14.6 Long-Term Outcomes

- Swallowing
  - Although for most infants there is effective restitution of normal feeding, allowing normal growth and development, it is probably expedient to defer intake of solids for a while in this group. Swallowing is effective but not normal. Peristalsis is impaired or absent and most children learn to chew well and drink with meals.
- Respiratory morbidity
  - Typically, they also have a higher incidence of respiratory-related issues such as recurrent chest infections, intermittent food-related choking, and the characteristic seal-like bark ( “TOF cough” sounds better than “TEF cough”! ) Such problems tend to subside with age presumably due to airway growth and improved luminal stability.
- Barrett’s esophagus
  - There may be a long-term malignancy potential during adulthood, but the risk remains unquantified.

## Further Reading

1. Waterston DJ, Bonham-Carter R, Aberdeen E. Oesophageal atresia: tracheo-oesophageal fistula. A study of survival in 218 infants. *Lancet*. 1962;7234(i):819–22.
2. Davenport M, Rothenberg SS, Crabbe DC, et al. The great debate: open or thoracoscopic repair for oesophageal atresia or diaphragmatic hernia. *J Pediatr Surg*. 2015;50:240–6.

3. Ahmad N, Dobby N, Walker E, et al. A multicentre audit of the use of bronchoscopy during open and thoracoscopic repair of oesophageal atresia with tracheo-oesophageal fistula. *Paediatr Anaesth.* 2019;29:640–7.
4. Sinha CK, Haider N, Marri RR, et al. Modified prognostic criteria for oesophageal atresia and tracheo-oesophageal fistula. *Eur J Pediatr Surg.* 2007;17:153–7.
5. van der Zee DC, Gallo G, Tytgat SHA. Thoracoscopic traction technique in long gap esophageal atresia: entering a new era. *Surg Endosc.* 2015;29:3324–30.
6. Burge DM, Shah K, Spark P, et al. Contemporary management and outcomes for infants born with oesophageal atresia. *Br J Surg.* 2013;100:515–21.
7. Rothenberg SS. Thoracoscopic repair of esophageal atresia and tracheo-oesophageal fistula in neonates: evolution of a technique. *J Laparoendosc Adv Surg Tech.* 2012;22:195–9.
8. Spitz L, Kiely EM, Morecroft JA, et al. Oesophageal atresia: at-risk groups for the 1990s. *J Pediatr Surg.* 1994;29:723–5.