

# Handbook of Pediatric Surgery

Chandrasen K. Sinha  
Mark Davenport  
*Editors*

*Second Edition*

 Springer

---

# Handbook of Pediatric Surgery

---

Chandrasen K. Sinha • Mark Davenport  
Editors

# Handbook of Pediatric Surgery

Second Edition

 Springer

*Editors*

Chandrasen K. Sinha  
Department of Paediatric Surgery  
St George's Hospital  
London, UK

Mark Davenport  
Department of Paediatric Surgery  
King's College Hospital  
London, UK

ISBN 978-3-030-84466-0      ISBN 978-3-030-84467-7 (eBook)  
<https://doi.org/10.1007/978-3-030-84467-7>

© Springer Nature Switzerland AG 2010, 2022

This work is subject to copyright. All rights are reserved by the Publisher, whether the whole or part of the material is concerned, specifically the rights of translation, reprinting, reuse of illustrations, recitation, broadcasting, reproduction on microfilms or in any other physical way, and transmission or information storage and retrieval, electronic adaptation, computer software, or by similar or dissimilar methodology now known or hereafter developed.

The use of general descriptive names, registered names, trademarks, service marks, etc. in this publication does not imply, even in the absence of a specific statement, that such names are exempt from the relevant protective laws and regulations and therefore free for general use.

The publisher, the authors and the editors are safe to assume that the advice and information in this book are believed to be true and accurate at the date of publication. Neither the publisher nor the authors or the editors give a warranty, expressed or implied, with respect to the material contained herein or for any errors or omissions that may have been made. The publisher remains neutral with regard to jurisdictional claims in published maps and institutional affiliations.

This Springer imprint is published by the registered company Springer Nature Switzerland AG  
The registered company address is: Gewerbestrasse 11, 6330 Cham, Switzerland



---

# Contents

|  |  |           |
|--|--|-----------|
| <b>1</b>                                     | <b>Milestones in Pediatric Surgery</b> .....             | <b>1</b>  |
|  | Mark Davenport   |           |
| <b>Part I Principles of Surgical Science</b> |  |           |
| <b>2</b>                                     | <b>Transitional Physiology and Newborn Care</b> .....    | <b>7</b>  |
|  | Vadivelam Murthy and Sandipto Dharr                      |           |
| <b>3</b>                                     | <b>Fluids, Electrolytes, and Dehydration</b> .....       | <b>15</b> |
|  | Ashok Daya Ram and Mark Davenport                        |           |
| <b>4</b>                                     | <b>Metabolic Response to Injury and Sepsis</b> .....     | <b>27</b> |
|  | Ashok Daya Ram and Mark Davenport                        |           |
| <b>5</b>                                     | <b>Shock</b> .....                                       | <b>31</b> |
|  | Ankit Sinha and Mark Davenport                           |           |
| <b>6</b>                                     | <b>Hematology for Surgeons</b> .....                     | <b>37</b> |
|  | Rubina Mallik and Mark Davenport                         |           |
| <b>7</b>                                     | <b>Post-operative Recovery</b> .....                     | <b>47</b> |
|  | Hesham Elagami, Chandrasen K. Sinha, and Mark Davenport  |           |
| <b>8</b>                                     | <b>Parenteral Nutrition</b> .....                        | <b>57</b> |
|  | Rajat Kapoor, Isobel Connolly, and Kerry Moolenschot     |           |
| <b>Part II Trauma and Resuscitation</b>      |  |           |
| <b>9</b>                                     | <b>Trauma Management: General Principles</b> .....       | <b>69</b> |
|  | Apurva More and Shailesh B. Patel                        |           |
| <b>10</b>                                    | <b>Head Injury</b> .....                                 | <b>79</b> |
|  | Bindey Kumar, Anil Kumar, and Arun Prasad                |           |
| <b>11</b>                                    | <b>Thoracic Trauma</b> .....                             | <b>87</b> |
|  | Sunita Singh, Chandrasen K. Sinha, and Mark Davenport    |           |
| <b>12</b>                                    | <b>Abdominal Trauma</b> .....                            | <b>99</b> |
|  | Ramnik V. Patel, Chandrasen K. Sinha, and Mark Davenport |           |

### Part III Neonatal Surgery

|                              |  |     |
|------------------------------|--|-----|
| <b>13</b>                    | <b>Developmental Lung Lesions</b> . . . . .                              | 111 |
|                              | Pablo Laje   |     |
| <b>14</b>                    | <b>Esophageal Atresia</b> . . . . .                                      | 121 |
|                              | Debasish Banerjee, Chandrasen K. Sinha, and Mark Davenport               |     |
| <b>15</b>                    | <b>Congenital Diaphragmatic Hernia</b> . . . . .                         | 129 |
|                              | Saidul Islam, Chandrasen K. Sinha, and Mark Davenport                    |     |
| <b>16</b>                    | <b>Congenital Pyloric Stenosis</b> . . . . .                             | 137 |
|                              | Giorgia Totonelli, Denis A. Cozzi, and Pietro Bagolan                    |     |
| <b>17</b>                    | <b>Intestinal Atresia</b> . . . . .                                      | 143 |
|                              | Chandrasen K. Sinha, A. Saeed, and M. Davenport                          |     |
| <b>18</b>                    | <b>Intestinal Malrotation</b> . . . . .                                  | 151 |
|                              | Ike Njere, Chandrasen K. Sinha, and Mark Davenport                       |     |
| <b>19</b>                    | <b>Necrotizing Enterocolitis</b> . . . . .                               | 159 |
|                              | Eric A. Sparks and Augusto Zani  |     |
| <b>20</b>                    | <b>Meconium Ileus and Surgical Features of Cystic Fibrosis</b> . . . . . | 165 |
|                              | Hesham Elagami, Chandrasen K. Sinha, and Mark Davenport                  |     |
| <b>21</b>                    | <b>Abdominal Wall Defects</b> . . . . .                                  | 173 |
|                              | Chandrasen K. Sinha, Manaswi Upadhyay, and Mark Davenport                |     |
| <b>22</b>                    | <b>Anorectal Malformations</b> . . . . .                                 | 181 |
|                              | Andrea Bischoff, Luis De La Torre, and Alberto Pena                      |     |
| <b>23</b>                    | <b>Hirschsprung's Disease</b> . . . . .                                  | 193 |
|                              | Chandrasen K. Sinha and Atsuyuki Yamataka                                |     |
| <br>                         |  |     |
| <b>Part IV Hepatobiliary</b> |  |     |
| <b>24</b>                    | <b>Investigation of Jaundice</b> . . . . .                               | 203 |
|                              | Mark Davenport   |     |
| <b>25</b>                    | <b>Choledochal Malformation</b> . . . . .                                | 209 |
|                              | Mark Davenport   |     |
| <b>26</b>                    | <b>Biliary Atresia</b> . . . . .   | 215 |
|                              | Mark Davenport   |     |
| <b>27</b>                    | <b>Gallbladder Disease</b> . . . . .                                     | 221 |
|                              | Mark Davenport   |     |
| <b>28</b>                    | <b>Pancreatic Disease</b> . . . . .                                      | 227 |
|                              | Chandrasen K. Sinha and Mark Davenport                                   |     |

- 29 Portal Hypertension** ..... 237  
Mark Davenport
- 30 Liver Transplantation** ..... 243  
Evelyn Geok Peng Ong

## Part V Urology

- 31 Exstrophy-Epispadias Anomaly** ..... 253  
Naser Al Soudan Al Anazi and Imran Mushtaq
- 32 Hypospadias** ..... 261  
Bharat More, Ramnik V. Patel, and Vibhash Mishra
- 33 The Ureter** ..... 269  
Hazem Mosa, Vijai D. Upadhyaya, S. P. Sharma,  
and Pankaj Mishra
- 34 Vesicoureteric Reflux** ..... 281  
Shilpa Sharma and Devendra K. Gupta
- 35 Posterior Urethral Valves** ..... 287  
Ahmed Osama Mohamed and Ashok Rajimwale
- 36 Cryptorchidism** ..... 299  
Feilim Murphy
- 37 Inguinal Hernia Hydrocele and the Acute Scrotum** ..... 305  
Anindya Niyogi and Chandrasen K. Sinha
- 38 Neurogenic Bladder** ..... 317  
Ravindar Anbarasan and Azad Bhushan Mathur
- 39 Urinary Tract Infections** ..... 323  
Anand Pandey, Chandrasen K. Sinha, and Devesh Misra
- 40 Disorders of Sex Development** ..... 331  
Neetu Kumar and Abraham Cherian
- 41 Enuresis** ..... 337  
Ranjit Shail

## Part VI Neurosurgery

- 42 Spina Bifida** ..... 343  
Samantha Hettige, Anan Shtaya, and Ajay N. Gangopadhyay
- 43 Hydrocephalus** ..... 351  
Samantha Hettige, Micaela Uberti, and Ajay N. Gangopadhyay

## Part VII Oncology

- 44 Wilms' Tumor** ..... 363  
Nitinkumar Borkar, Ramnik V. Patel, Chandrasen K. Sinha,  
and Hany Gabra
- 45 Neuroblastoma** ..... 371  
Abid Qazi, Nadeem Haider, and Roly Squire
- 46 Liver Tumors** ..... 381  
Mark Davenport
- 47 Teratomas** ..... 391  
Erica Makin and Mark Davenport
- 48 Other Tumors** ..... 397  
Hany Gabra and Chandrasen K. Sinha

## Part VIII Gastrointestinal

- 49 Gastro-Esophageal Reflux** ..... 413  
Jennifer Billington, Z. Mukhtar, and Chandrasen K. Sinha
- 50 Management of Gastrointestinal Bleeding** ..... 421  
Khizer Mansoor, Ferzine Mohamed, and Ashish Minocha
- 51 Acute Abdomen** ..... 429  
Pablo Laje
- 52 Miscellaneous Causes of Abdominal Pain** ..... 433  
Ankit Sinha and Mark Davenport
- 53 Acute Appendicitis** ..... 441  
Stefano Giuliani
- 54 Intussusception** ..... 449  
Prema Menon and Katragadda L. N. Rao
- 55 Crohn's Disease** ..... 457  
Bruce Jaffray
- 56 Ulcerative Colitis** ..... 465  
Bala Eradi
- 57 Constipation** ..... 471  
Shailinder Jit Singh
- 58 Small Bowel Transplantation** ..... 477  
Evelyn Geok Peng Ong

---

**Part IX Miscellaneous**

|           |  |            |
|-----------|--|------------|
| <b>59</b> | <b>Surgical Neck Pathology</b> . . . . .                                     | <b>489</b> |
|           | Hany O. S. Gabra, Chandrasen K. Sinha, and Mark Davenport                    |            |
| <b>60</b> | <b>Fetal Surgery: General Principles</b> . . . . .                           | <b>499</b> |
|           | Eric Bradley Jelin, Harisa Spahic, and Hanmin Lee                            |            |
| <b>61</b> | <b>Basic Pediatric Laparoscopy and Thoracoscopy</b> . . . . .                | <b>511</b> |
|           | Steven S. Rothenberg   |            |
| <b>62</b> | <b>Vascular Anomalies</b> . . . . .  | <b>523</b> |
|           | Ramnik V. Patel, Joseph I. Curry, Chandrasen K. Sinha,<br>and Mark Davenport |            |
| <b>63</b> | <b>Miscellaneous Surgical Issues</b> . . . . .                               | <b>531</b> |
|           | Chandrasen K. Sinha, A. Saeed, and Mark Davenport                            |            |
| <b>64</b> | <b>Bariatric Surgery</b> . . . . .   | <b>539</b> |
|           | Ashish Desai   |            |
| <b>65</b> | <b>Airway Problems in Newborns and Children</b> . . . . .                    | <b>545</b> |
|           | Ana Bernic and Prince C. Modayil   |            |
| <b>66</b> | <b>Quality and Care Indicators</b> . . . . .                                 | <b>551</b> |
|           | Atif Saeed and Chandrasen K. Sinha   |            |
| <b>67</b> | <b>Pediatric Orthopedics</b> . . . . .                                       | <b>559</b> |
|           | Neel Mohan   |            |
| <b>68</b> | <b>Robotic Pediatric Surgery</b> . . . . .                                   | <b>569</b> |
|           | Anja Matson, Chandrasen K. Sinha, and Munther Haddad                         |            |
| <b>69</b> | <b>Numerical References</b> . . . . .  | <b>577</b> |
|           | Leena Sinha and Mark Davenport   |            |
| <b>70</b> | <b>Anatomical References</b> . . . . .                                       | <b>581</b> |
|           | Ankit Sinha and Mark Davenport   |            |
| <b>71</b> | <b>Human Developmental Milestones</b> . . . . .                              | <b>591</b> |
|           | Apurva More and Mark Davenport   |            |
|           | <b>Index</b> . . . . .   | <b>595</b> |



# Milestones in Pediatric Surgery

# 1

Mark Davenport

The earliest example of elective pediatric surgery has to be the operation of circumcision.<sup>1</sup> Quite why this assumed such importance is not known though it was illustrated among the petroglyphs of the ancient Egyptians in at least the twenty-fourth century BCE. In the Bible, it is recorded as a mark of the covenant between God and Abraham.

## Genesis Chap 17 Verse 10–12. (KJV)

This is my covenant, which ye shall keep, between me and you and thy seed after thee; Every man child among you shall be circumcised.

And ye shall circumcise the flesh of your foreskin; and it shall be a token of the covenant betwixt me and you.

And he that is eight days old shall be circumcised among you, every man child in your generations, he that is born in the house, or bought with money of any stranger, which is not of thy seed.

Classical physicians such as Hippocrates (460–370 BCE) described surgical intervention, including specific treatment for long-bone fractures. The Roman physician Aulus Celsus, in his book “*De Medicina*” (~30 AD), described relatively complex surgery for cleft palate and tonsillectomy as part of a wider manual for surgical and medical therapies (Fig. 1.1).

Western medicine declined with the fall of the Western Roman Empire, but the medical flame was kept alive in the Arab world by Kitab at Tasrif (also known as *Albucasis*), in Cordoba, Spain, who published an encyclopedia of medicine, including diverse subjects such as cleft palate, hydrocephalus, and hypospadias. A version of this widely known text was illustrated by Serafeddin Subuncuoglu, a Turkish

<sup>1</sup>Circumcidere (Latin) “to cut around.”

M. Davenport (✉)  
King’s College Hospital, London, UK

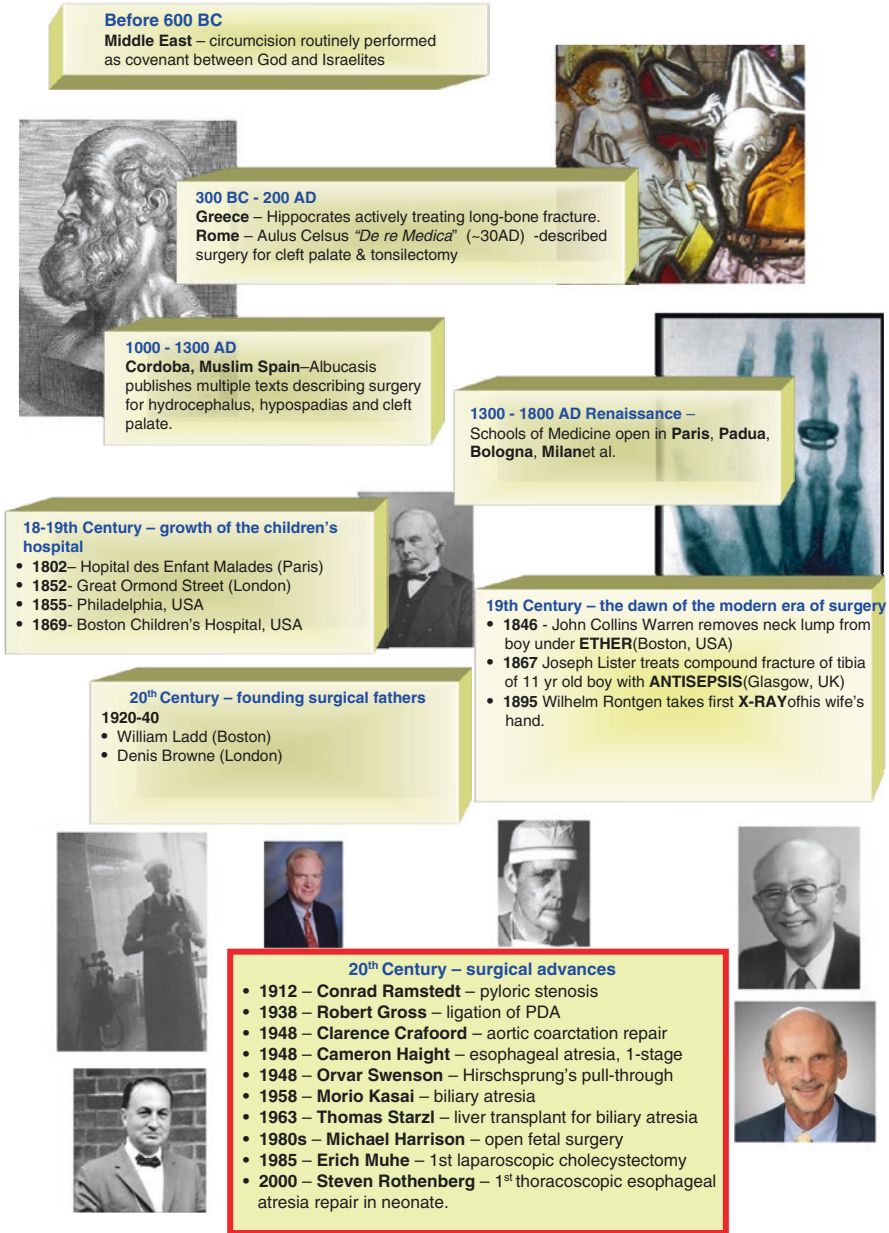


Fig. 1.1 Milestones in surgery



**Fig. 1.2** Founding children's hospitals

physician, in 1465 and circulated widely as an atlas throughout the Middle East and Ottoman empire.

The first detailed textbook dedicated to children's conditions is credited to the Swiss surgeon Felix Wurtz, who published it in 1563.

The medical separation between the young and old was first made clear in the nineteenth century by the establishment of the great children's hospitals across the world, with the first being in Paris (Hôpital des Enfants Malades<sup>2</sup>) in 1802, followed some years later by Great Ormond Street Hospital (London) in 1852, Children's Hospital of Philadelphia in 1855 and Boston Children's Hospital in 1882 (Fig. 1.2).

Some of the first widely-read publications dealing specifically with children's ailments and congenital malformations also appeared in this century. For instance, "A Practical Treatise of Children" by Coley was published in 1846 in London. "The Surgical Diseases of Children" by John Cooper Forester from Guys Hospital, London, published in 1860, described both ether and chloroform anesthesia and the surgical treatment of imperforate anus.

---

<sup>2</sup>Now named the Necker-Enfants Malades hospital after Suzanne Necker, the wife of the Finance Minister of Louis XVI.



Special and separate care of infants probably began in Paris during the 1870s with the introduction of incubators, the concept of sterilization of feeding bottles, and others. Towards the end of this century, continental Europe appeared to be the area where most of the advances were emerging from, and most of the radical physicians were located. Harald Hirschsprung appeared omnipresent, describing not only the disease to bear his name but also the pathology and features of pyloric stenosis and enema reduction of intussusception.

The first half of the twentieth century, while devastated by world war and leaving most continental European cities desolate, bequeathed something like modern-day surgical practice. This was founded on effective, safe anesthesia with basic monitoring of vital signs and the ability to change physiology with intravenous blood and fluids, with operations carried out by trained, competent specialist surgeons experienced in visceral operations or problems of soft-tissue and bone reconstruction. Life-threatening post-operative bacterial infection no longer stalked the wards, limited by antiseptics and treated with antibiotic.

In the interwar period, the “founding fathers” of, at least Western, children’s surgery were practiced. In the USA, William Ladd<sup>3</sup> and his successor Robert Gross were, for the first time, pediatric surgeons rather than interested bystanders. The influential “Abdominal Surgery of Infancy and Childhood” written by Robert Gross was first published in 1941. In England, Denis Browne<sup>4</sup> (Great Ormond Street 1928–1957), an Australian by birth, was the first surgeon to concentrate solely on children, although he clearly did not believe in specialization, publishing innovative techniques in all sorts of fields. He became the first president of the **British Association of Pediatric Surgeons** in 1953—the first real international organization devoted to pediatric surgery. Their equivalents in Europe included Pepe Boix-Ochea in Barcelona, Theodor Ehrenpreis in Stockholm, David Vervat in Rotterdam, Fritz Rehbein in Bremen, Bernard Duhamel in Paris, Mattai Sulumma in Helsinki, and farther afield UC Chakraborty (Calcutta) and Raman Nair (Trivandrum) in India, Douglas Stephens in Australia, and Osamu Wakabayashi and Keijiuro Suruga in Japan.

---

<sup>3</sup>William E. Ladd (1880–1967) Came to prominence as part of the rescue operation following a huge explosion in Halifax, Nova Scotia in 1917.

<sup>4</sup>Sir Denis Wolco Browne (1892–1967)—Came to London during WWI and stayed. Knighted in 1957.

---

**Part I**

**Principles of Surgical Science**



# Transitional Physiology and Newborn Care

# 2

Vadivelam Murthy and Sandipto Dharr

The rapid transition from fetus to neonate is complex but one of the riskiest periods of life. In normal birth this a wellorchestrated process however it is fraught with danger in preterm and complex births.

## 2.1 Fetal Circulation

- The umbilical vein (oxygenated blood) re-enters the fetus and divides within the liver with a minority perfusing the sinusoids but the majority bypassing it via the *ductus venosus*<sup>1</sup> entering the IVC.
- In the right atrium, most bypasses the pulmonary circulation via the *foramen ovale* into the left atrium and the left ventricle. This is then pumped into the aorta to replenish the systemic circulation.
- This shunted portion traveling through the *foramen ovale* to the left heart has the highest oxygen levels and directly perfuses the brain (*via* the carotid arteries) and heart (*via* the coronary arteries).
- Fetal deoxygenated blood returning from the SVC is directed toward the right ventricle and pulmonary trunk. Majority of this blood flow passes through the *ductus arteriosus* into the descending aorta and is returned to the placenta through the two umbilical arteries.

<sup>1</sup>Of Arantius-Julius Caesar Aranzi (1530–1589)—Italian anatomist in Padua and Bologna.

V. Murthy (✉) · S. Dharr  
The Royal London Hospital, Barts Health NHS Trust, London, UK  
e-mail: [v.murthy@nhs.net](mailto:v.murthy@nhs.net); [sandipto.dharr@nhs.net](mailto:sandipto.dharr@nhs.net)

---

## 2.2 Respiratory Adaptation

There is a reduction in pulmonary fluid production during the later weeks of pregnancy, and during normal vaginal birth, any remaining fluid is squeezed out of the lungs. Following the first few breaths, the lungs are inflated, leading to:

- ↑ PaO<sub>2</sub> in the alveoli and arterial circulation (causing vasodilatation)
- ↓ Pulmonary vascular resistance
- ↓ Right-to-left shunting (through ductus arteriosus<sup>2</sup>)
- ↑ Pulmonary venous return to the left atrium
- ↑ Left atrial pressure and cessation of right-to-left shunting (through foramen ovale)
- Establishment of resting functional residual capacity (FRC)
- Functional closure of the ductus arteriosus (*via* ↓ prostaglandin E<sub>2</sub>) to achieve independence of the two circulations (systemic and pulmonary)

---

## 2.3 Newborn Physiology

Changes linking cellular processes to organ function following birth continues to progress at various times ranging from hours to days. The WHO classified the newborn period as a child under 28 days of age, and during this time, a child is at the highest risk of dying. It is thus crucial that appropriate care based on physiological principles is provided during this period, both to improve the child's chances of survival and to lay the foundations for a healthy life.

---

## 2.4 Immediate Management After Birth

- Drying and covering the newborn infant, where necessary taking additional steps to maintain a normal body temperature (i.e., between 36.5 and 37.5 °C).
- Maintaining an open airway and ensure respiration is established.
- If the infant is not breathing, aerating the lungs with inflation breaths.
- Continue ventilating apnoeic infants until respiration is established.

The **Apgar<sup>3</sup> score** is still an acceptable practical method of systemically assessing a newborn infant. However, a low score does not necessarily signify fetal hypoxia/acidosis and does not predict long-term morbidity (Table 2.1).

---

<sup>2</sup>Of Botalli-Leonardo Botallo (1519–1588)—Italian anatomist again in Padua but also Paris.

<sup>3</sup>Virginia Apgar (1909–1974) American anesthesiologist who proposed this method of newborn evaluation in 1953.

**Table 2.1** Apgar score (performed at 1, 5, and 10 min)

| Score | Heart rate (per minute) | Respiration     | Color                        | Muscle tone  | Irritability |
|-------|-------------------------|-----------------|------------------------------|--------------|--------------|
| 0     | Absent                  | Absent          | Blue/pale                    | Limp         | No response  |
| 1     | <100                    | Irregular, slow | Pink torso, blue extremities | Mild flexion | Grimace      |
| 2     | ≥100                    | Crying, active  | Pink                         | Active       | Sneeze       |

### 2.4.1 Thermoregulation

Infants are covered with vernix<sup>4</sup> and amniotic fluid and can lose heat quickly due to their increased surface area. Simple measures of heat preservation include drying the infant after birth, using warm towels, optimizing room temperature, and early skin-to-skin contact with the mother is important to maintain adequate body temperature.

### 2.4.2 Cord Care

Sterile instruments should be used to cut the cord after clamping. The cord should be kept dry and inspected regularly. Any suspicion of infection appropriate antibiotics should be commenced immediately.

### 2.4.3 Feeding

Early skin–skin contact with the mother and breastfeeding is strongly advised. High-risk infants should be monitored closely for hypoglycemia, hypothermia and failure to establish breastfeeding may need intervention to maintain blood glucose levels.

---

## 2.5 Problems of the Premature

In the UK, neonatal stabilization may be considered for babies born from 22 + 0 weeks of gestation following assessment of risk and multi-professional discussion with parents.

In the UK, survival has increased steadily since 2006, and currently, active respiratory care is offered to 88% of babies at 23 weeks and 23% of births at 22 weeks of gestation. Recent estimates suggest that 1 in 3 survivors at 22 weeks have a severe impairment which significantly improves to 1 in 10 at 26 weeks and further improvement with increasing gestation age.

---

<sup>4</sup>Properly *vernix caseosa* (Latin) varnish + cheese-like

### 2.5.1 Respiratory Management

Most preterm infants of <30 weeks need some form of respiratory support, largely due to respiratory distress syndrome (RDS) and lack of surfactant, together with inadequate respiratory muscle strength (diaphragm and intercostals muscle groups) (Fig. 2.1).

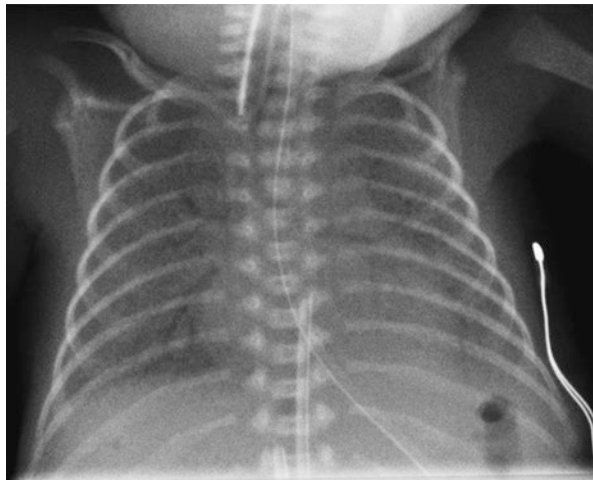
- Pre-natal care
  - Antenatal maternal steroids
- Post-natal care
  - Endo-tracheal administration of surfactant with in the first hour after birth and repeated if indicated
- Ventilation strategies
  - CPAP (Continuous Positive Airway Pressure)
  - Heated humidified high-flow nasal cannula therapy
  - IPPV (Intermittent Positive Pressure Ventilation)
  - HFOV (High-Frequency Oscillatory Ventilation)
- Caffeine therapy to prevent apnoea of prematurity (respiratory drive stimulant)

### 2.5.2 Thermoregulation

Preterm infants are prone to become cold quickly compared to term infants because of:

- A higher ratio of skin surface area-to-weight
- ↓ subcutaneous fat and brown fat
- ↓ caloric intake
- Limited oxygen consumption due to underlying pulmonary problems

**Fig. 2.1** Chest X-ray in respiratory distress syndrome (RDS) showing diffuse fine granular opacities with air trapping



Current incubators can maintain warm environments with high humidity (up to 85%), ensuring a thermal range between 36.4 and 37.5 °C.

### 2.5.3 Jaundice

Most preterm infants need treatment for physiological (unconjugated) jaundice due to:

- Increased bilirubin production (decreased RBC survival)
- Defective conjugation due to ↓ hepatic glucuronyl-transferase activity
- ↓ Hepatic excretion of conjugated bilirubin

Severe jaundice can cause bilirubin encephalopathy (kernicterus<sup>5</sup>) as this can cross the blood-brain barrier. Routine screening and treatment with phototherapy is an essential part of care in preterm and term infants. In the UK, standardized threshold levels for treatment have been established.

The main principles in management are:

- Exclusion of hemolytic causes of jaundice (e.g., ABO incompatibility, Rhesus incompatibility)
- Adequate hydration
- Early phototherapy
- Exchange transfusion for severe jaundice

### 2.5.4 Anemia

Preterm infants are prone to anemia due to decreased production of red blood cells by the immature hematological system. Delayed cord clamping techniques are recommended at preterm birth to reduce the need for blood transfusion.

Blood Volume—Infant  
80–100 mL/kg

---

<sup>5</sup> Kernicterus—(adapted from German—kern meaning central or core (regions of brain) and yellow. Now very rare in UK, perhaps 1 in 100,000 live births.

## 2.6 Neonatal Infections

Preterm infants are prone to infections due to their immature immunological systems and underdeveloped skin barrier. Numerous strategies are undertaken to prevent neonatal infections. These include maternal immunizations, intrapartum antibiotics, handwashing, cord care with antiseptics, promotion of early initiation of exclusive breastfeeding, skin antiseptic preparations, fungal prophylaxis if poor skin integrity and even neonatal immunizations.

### Common transplacental infections include:

- Toxoplasmosis (*T. gondii*)
  - Causes chorioretinitis, mental retardation
- Rubella virus
  - Causes deafness, cataract, PDA, mental retardation, microcephaly
- Cytomegalovirus
  - Causes rash, hepatitis, microcephaly, seizures, low birth weight
- Syphilis
  - Causes hepatic-splenomegaly, anemia, metaphyseal dystrophy

### Common organisms causing neonatal sepsis:

- First 48 h after birth (early onset)
  - *Group B Streptococci* spp., *Escherichia coli*
  - *Listeria monocytogenes*
  - Herpes simplex (HSV-1, HSV-2)
- After 48 h (late-onset)
  - *Staphylococcus epidermidis*, *E. coli*, *Staphylococcus aureus*, *Pseudomonas* spp.

### Clinical Symptoms and Signs of Severe Neonatal Illness Including Sepsis

- Difficulty feeding/non specific abdominal distention
- Lethargic/ irritable, poor response to external stimulus.
- Tachycardia/bradycardia
- Severe chest indrawing (respiratory distress)
- Temperature instability [pyrexia ( $\geq 37.5$  °C) or hypothermia ( $< 35.5$  °C)]
- Hypo- or Hyperglycaemia

### 2.6.1 Investigations

- Blood culture should be performed before the commencement of antibiotics.
- C-reactive protein (CRP), white cell count, platelet count are important in monitoring for infections.



## 2.6.2 Management

Appropriate antibiotics should be commenced as soon as clinical suspicion of sepsis, clinical deterioration is rapid, and the outcome is poor in severe sepsis. Fungal infections should be suspected in extreme prematurity, and aggressive antifungal treatment should be started if proven. In these cases screening for fungal vegetation in the kidneys, brain, and heart to identify the source should be undertaken.

## 2.7 Fluid Management

Strategies to maintain water and electrolyte hemostasis in newborns can be varied based on many factors, including gestation age, birth weight and care environment (e.g., radiant warmers, humidity). Hypoglycemia is common in preterm newborns due to the lack of energy stores, hence the most commonly used maintenance fluid contains variable concentrations of dextrose solution. Sodium, potassium, calcium and phosphate supplementation may be necessary, and close monitoring of blood glucose levels and blood serum electrolyte measurements are necessary during the transition to supplement and maintain hemostasis (Table 2.2).

## 2.8 Neonatal Nutrition

Nutrition and growth in fetal life and early infancy influences long-term health. It is extremely important to optimize nutrition in the early stages to prevent long-term morbidity. Preterm infants are particularly vulnerable to malnutrition and are challenged by immature gut and higher energy demand to maintain their metabolic function. Parenteral nutrition should be provided early and continued until full enteral feeding has been established (Table 2.3).

**Table 2.2** Fluid and requirement in preterm newborn infant

| Day | Type of fluid   | Volume of fluid (mL/kg/day) |
|-----|-----------------|-----------------------------|
| 1   | 5%/10% Dextrose | 50–60                       |
| 2   | 5%/10% Dextrose | 75–90                       |
| 3   | 5%/10% Dextrose | 100–120                     |
| 4   | 5%/10% Dextrose | 125–150                     |
| >5  | 5%/10% Dextrose | 150–175                     |

Electrolyte supplementation should be considered only after completion of the post-natal extracellular volume contraction and establishment of good urine output

**Table 2.3** Nutrition requirement for stable preterm infants

|                   | Units/kg/day   |                |
|-------------------|----------------|----------------|
|                   | VLBW (>1000 g) | ELBW (<1000 g) |
| Water (mL)        | 120–200        | 160–220        |
| Energy (kcal)     | 110–130        | 130–150        |
| Protein (g)       | 3.4–4.2        | 3.8–4.4        |
| Fat (g)           | 1–3            | 1–3            |
| Carbohydrate (g)  | 6–12           | 6–12           |
| Sodium (mmol)     | 2–4            | 2–4            |
| Potassium (mmol)  | 2–3            | 2–3            |
| Chloride (mmol)   | 2–3            | 2–3            |
| Calcium (mmol)    | 2.5–5.5        | 2.5–5.5        |
| Phosphorus (mmol) | 1.9–4.5        | 1.9–4.5        |
| Magnesium (mmol)  | 0.3–0.6        | 0.3–0.6        |
| Iron (mg)         | 2–4            | 2–4            |
| Zinc (µg)         | 1000–3000      | 1000–3000      |
| Copper (µg)       | 120–150        | 120–150        |
| Manganese (µg)    | 0.7–7.5        | 0.7–7.5        |
| Selenium (µg)     | 1.3–4.5        | 1.3–4.5        |

## Further Reading

1. Perinatal management of extreme preterm birth before 27 weeks of gestation—a framework for practice. British Association of Perinatal Medicine; October 2019. <https://www.bapm.org/resources/80-perinatal-management-of-extreme-preterm-birth-before-27-weeks-of-gestation-2019>. Accessed November 2020.
2. Wood NS, Costeloe K, Gibson AT, et al. The EPICure study: growth and associated problems in children born at 25 weeks of gestational age or less. *Arch Dis Child*. 2003;88:F492–500.
3. Field DJ, Dorling JS, Manktelow BN, Draper ES. Survival of extremely premature babies in a geographically defined population: a prospective cohort study of 1994–9 compared with 2000–5. *BMJ*. 2008;336:1221–3.
4. Tsang RC. Nutrition of the preterm infant: scientific basis and practical guidelines. 2nd ed. Cincinnati, OH: Digital Education; 2005.
5. Hay WW Jr. Nutritional support strategies for the preterm infant in the neonatal intensive care unit. *Pediatr Gastroenterol Hepatol Nutr*. 2018;21(4):234–47. <https://doi.org/10.5223/pghn.2018.21.4.234>



# Fluids, Electrolytes, and Dehydration

# 3

Ashok Daya Ram and Mark Davenport

## 3.1 Normal Fluid Physiology

Although most of us are made up predominantly of water, there is considerable variation based on several factors such as gestation, age, sex, weight, underlying pathology, and most importantly, fluid and electrolyte support in a child who is nil by mouth.

The following diagram depicts the distribution of fluid and various compartments in a healthy human body (Fig. 3.1).

Intravascular fluid is maintained by the oncotic pressure exerted by albumin and the permeability of the capillary bed under the influence of Starling's law.<sup>1</sup>

Multiple organ systems are involved in producing blood and regulating blood volume. These systems communicate with one another to control blood volume, which also depends on age, size, and weight of the individual.

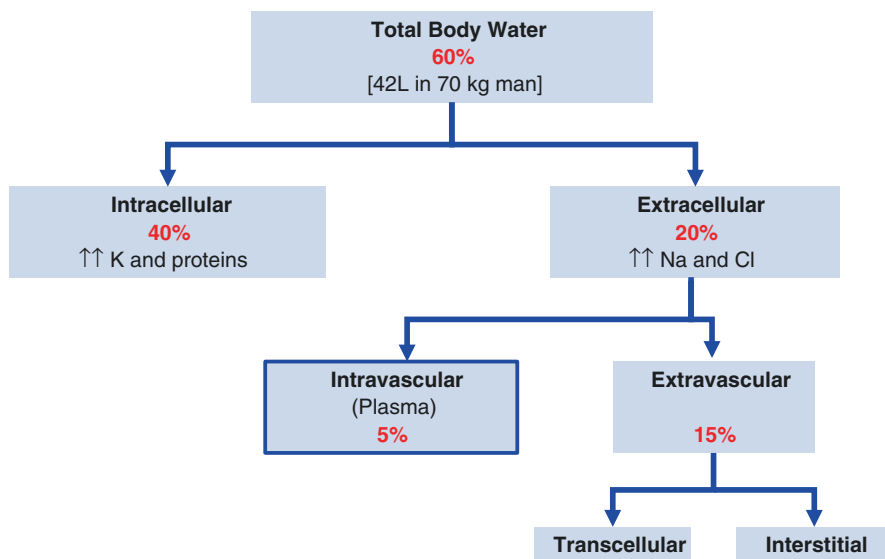
## 3.2 Age-Related Changes

- ↑ Total body water (80% in neonate vs. 60% in adult)
- ↑ ECF → ICF (almost parity in newborn vs. 3:1 in adult)
- ↑ Surface area/body mass ratio

<sup>1</sup>Ernest Starling (1866–1927) English physiologist

A. D. Ram  
Department of Paediatric Surgery, Norfolk & Norwich University Hospital, Norwich, UK  
e-mail: [ashok.ram@nnuh.nhs.uk](mailto:ashok.ram@nnuh.nhs.uk)

M. Davenport (✉)  
King's College Hospital, London, UK



**Fig. 3.1** Body composition

### 3.3 Normal Fluid and Electrolyte Requirements

In general, normal neonatal fluid prescription depends on (a) body weight and (b) day of life (Tables 3.1 and 3.2).

*Basic prescription is:  
100 mL/kg/day (up to 10 kg).  
(Beyond neonatal period.)*

**Table 3.1** Estimated fluid requirements in childhood

|                  | Day of life | mL/kg/day |
|------------------|-------------|-----------|
| Premature infant | 1st         | 60–150    |
|                  | 2nd         | 70–150    |
|                  | 3rd         | 90–180    |
|                  | >3rd        | Up to 200 |

**Table 3.1** (continued)

|                               | Day of life | mL/kg/day                                |
|-------------------------------|-------------|--|
| Term infant                   | 1st         | 60–80                                    |
|                               | 2nd         | 80–100                                   |
|                               | 3rd         | 100–140                                  |
|                               | >3rd        | Up to 160                                |
| Child >4 weeks of age, ≤10 kg |             | 100                                      |
| Child 10–20 kg                |             | 1 L + 50 mL/kg/day for each kg over 10   |
| Child >20 kg                  |             | 1.5 L + 20 mL/kg/day for each kg over 20 |

**Table 3.2** Sample fluid requirements (by body weight)

| Body weight | Calories required (kcal/day) | Maintenance (mL/day) | Maintenance (mL/h) |
|-------------|------------------------------|----------------------|--------------------|
| 3           | 300                          | 300                  | 12                 |
| 5           | 500                          | 500                  | 20                 |
| 10          | 1000                         | 1000                 | 40                 |
| 20          | 1500                         | 1500                 | 60                 |
| 45          | 2000                         | 2000                 | 80                 |
| 70          | 2500                         | 2500                 | 100                |

### 3.4 Insensible Fluid Loss

This is an obligate fluid loss, largely from radiation and evaporation related to body surface area and the work of breathing. Careful consideration is needed to minimize and replace this loss in neonates, especially with those born with anterior abdominal wall defects.

$$\sim 300 \text{ mL} / \text{m}^2 / \text{day}$$

$$\text{Body surface area (m}^2\text{)} = \text{weight (kg)} \times \text{height (cm)}$$

### 3.5 Postoperative Fluid Regimens

A meta-analysis (published in 2014) concluded that isotonic fluids are safer than hypotonic fluids in hospitalized children requiring maintenance IV fluid therapy.

The use of the isotonic saline seldom leads to hypernatremia (although it gives far more than the normal daily requirement of Na Cl (Table 3.3).

Further, because of the metabolic response to surgery (see Chap. 4), there is “inappropriate” secretion of ADH, and many units will prescribe **only two-thirds of the calculated maintenance volume in the first 24–48 h postoperatively**. However, it is contentious, and some units will prescribe full maintenance as long as the kidney function is normal.

**Table 3.3** Sample electrolyte requirements (by body weight)

|                        | Na (mmol/kg) | K (mmol/kg) |
|------------------------|--------------|-------------|
| Neonate (preterm)      | 4–6          | 2–3         |
| Neonate (term) – 10 kg | 3            | 2           |
| 10–20 kg               | 1–2          | 1–2         |
| 20–Adult               | 1–2          | 1           |

**Table 3.4** Electrolyte content of gastrointestinal secretions

| Secretion       | Na <sup>+</sup> (mmol/L) | K <sup>+</sup> (mmol/L) | Cl <sup>-</sup> (mmol/L) | HCO <sub>3</sub> <sup>-</sup> (mmol/L) |
|-----------------|--------------------------|-------------------------|--------------------------|--|
| Saliva          | 44                       | 20                      | 40                       | –                                      |
| Gastric         | 20–120 <sup>a</sup>      | 10                      | 100                      | –                                      |
| Bile            | 140                      | 5                       | 100                      | 40                                     |
| Pancreas        | 140                      | 5                       | 70                       | 70–110                                 |
| Small intestine | 110–120                  | 5–10                    | 90–130                   | 20–40                                  |

<sup>a</sup>Depends on pH and therefore reciprocal with H<sup>+</sup>

**Table 3.5** Composition of commonly available intravenous fluids

|  | Osmolarity (mOsm/L) | Glucose (mmol/L) | Na (mmol/L) | Cl  | K    | HCO <sub>3</sub> | Notes                     |
|--|---------------------|------------------|-------------|-----|------|------------------|---------------------------|
| <i>Intravenous solutions (crystalloid)</i> |                     |                  |             |     |      |                  |                           |
| Lactated Ringer's                          | 273                 | –                | 130         | 110 | 4    | 25               | Lactate Ca <sup>2+</sup>  |
| Hartmann's                                 | 278                 | –                | 131         | 111 | 5    | 29               | Lactate, Ca <sup>2+</sup> |
| 0.9% NaCl "normal saline"                  | 308                 | –                | 154         | 154 | –    | –                |                           |
| Dextrose (5%)                              | 252                 | 300              | –           | –   | –    | –                | 5 g/L = 170 kcal/L        |
| D5 + 0.45% NaCl                            | 454                 | 300              | 77          | 77  | –    | –                |                           |
| D4 + 0.18% NaCl                            | 284                 | 240              | 30          | 30  | –    | –                | Not available in UK       |
| <i>Intravenous solutions (Colloids)</i>    |                     |                  |             |     |      |                  |                           |
| Haemaccel <sup>TM</sup>                    | 293                 | –                | 145         | 145 | 5    | –                | Gelatin (35 g)            |
| Gelofusine <sup>TM</sup>                   | 308                 | –                | 154         | 125 | <0.4 | –                | Gelatin (40 g)            |
| Hetastarch <sup>TM</sup>                   | 310                 | –                | 154         | 154 | –    | –                | Starch (60 g)             |
| Pentastarch <sup>TM</sup>                  | 326                 | –                | 154         | 154 | –    | –                | Starch (100 g)            |
| Albumin (4.5%)                             | 300                 | –                | <160        | 136 | <2   | –                |                           |

N.B. CHO = 3.4 kcal/g, compared with fat 9 kcal/g

Finally, consider ongoing losses from drains, NG tubes, stomas, and fistulas (Table 3.4). In principle, replace *Like with Like*. In most cases, this is an mL for mL replacement with an isotonic (0.9%) saline solution ( $\pm 20$  mmol of K<sup>+</sup>/L). The stoma losses are generally replaced above 20 mL/kg/day, accounting for the natural loss.

The composition of intravenous and oral rehydration fluids is illustrated in Tables 3.5 and 3.6.

**Table 3.6** Oral rehydration solutions

|              | Osmolarity (mOsm/L) | Glucose (mmol/L) | Na (mmol/L) | Cl | K  | HCO <sup>3</sup> | Notes        |
|--------------|---------------------|------------------|-------------|----|----|------------------|--------------|
| WHO-ORS      | 330                 | 110              | 90          | 80 | 20 | 30               |              |
| Pedialyte™   | 270                 | 140              | 45          | 35 | 20 | 30               |              |
| Dioralyte™   |                     | 90               | 60          | 60 | 20 |                  | Common in UK |
| Electrolade™ |                     | 111              | 50          | 40 | 20 |                  |              |

## 3.6 Dehydration

### Dehydration

is a contraction in predominantly the **ECF compartment** because of the relative loss of fluids and sodium.

*It is calculated in terms of % body weight loss*

One key cause of dehydration is excess intestinal losses due to diarrheal illness, and it is a cause of death in >1.5 million children/year. It is important that a pediatric surgeon has a basic working knowledge of the diarrheal illness, as it is so common both in the community (and, therefore on the ward).

### 3.6.1 Infective Causes

- Viruses
  - Rotavirus
  - Calcivirus (incl Norovirus)
  - Astrovirus
  - Adenovirus
  - Coronavirus (COVID-19)
- Bacteria
  - *Campylobacter* spp.
  - *Salmonella* spp.
  - *E. coli*
  - *Clostridium difficile*
  - *Shigella* spp.
- Protozoa
  - *Giardia lamblia*
  - *Cryptosporidium*
  - *Entamoeba histolytica*

### 3.6.2 Surgical Causes

- Intestinal obstruction
- Appendicitis
- Intussusception
- Fistula losses (also stomas)

### 3.6.3 Management

In general, the treatment aims to restore normal fluid and electrolyte balance safely without precipitating complications (e.g., hypernatremic convulsions). The key is to recognize the degree of dehydration (**expressed in terms of % body weight loss—i.e., 5% of a 20-kg child implies a deficit of 1000 mL of fluid**) (Table 3.7) and then the type as defined by the plasma sodium level (Table 3.8).

**Table 3.7** WHO classification of dehydration

|                          | No dehydration                   | Mild/moderate  | Severe                                       |
|--------------------------|----------------------------------|--|--|
| Adult                    | <3%                              | 3–9%   | >9%  |
| Child                    | 5%                               | 10%  | 15%  |
| <i>Clinical features</i> |                                  |  |  |
| Mental status            | Alert                            | Restless, listless                                   | Lethargic, comatose                          |
| Thirst                   | Normal                           | Thirsty  | Unable to drink                              |
| CVS                      | Normal pulse/BP                  | Tachycardia, CRT > 2 s                               | Tachy/brady, CRT >> 2 s                      |
| Respiratory              | Normal                           | Rate   | Inc rate and volume                          |
| Extremities              | Normal                           | Cool   | Cold, mottled                                |
| Mucous membranes         | Moist                            | Dry  | Dry  |
| Skin fold                | Immediate recoil                 | Delayed (>2 s)                                       | >2 s   |
| Urine output             | Normal                           | Diminished   | Absent                                       |
| <i>Management</i>        |                                  |  |  |
|                          | Encourage normal diet and fluids | ORS<br>30–80 mL/h [Consider via NG tube if failing.] | IV initially<br>e.g.<br>20 mL/kg NaCl (0.9%) |

Note: CRT, capillary return time (in seconds); ORS, oral rehydration solution

**Table 3.8** Types of dehydration

|            |                |
|------------|----------------|
| Isotonic   | 130–150 mmol/L |
| Hypotonic  | <130 mmol/L    |
| Hypertonic | >150 mmol/L    |



Aim for rehydration within 12–24 h, *unless* hypernatremia is documented ( $\text{Na} > 150 \text{ mmol/L}$ ), where the period should be lengthened to  $\sim 36\text{--}48 \text{ h}$ . In general, oral rehydration solutions (Table 3.6) should be used whenever possible (may be defined as the presence of a functioning GI tract). Intravenous resuscitation may well be required for more severe episodes of dehydration, particularly where there is a shock-like state and fall in CBV.

---

## 3.7 Specific Electrolyte Problems

### 3.7.1 Potassium

Normal  $3.5\text{--}5.5 \text{ mmol/L}$  –  $\uparrow$  variability in neonates

#### 3.7.1.1 Hyperkalemia ( $< 5.5 \text{ mmol/L}$ )

*NB—beware factitious result due to hemolysis, especially if it is taken from the heel prick.*

- **Surgical causes**

Dehydration, renal failure, post-transfusion, tumor lysis syndrome, rhabdomyolysis.

- **Signs**

ECG: tall “tenting” T waves,  $\uparrow$  PR interval  $\uparrow$  QRS complex duration (Potassium naturally suppresses cardiac function and Calcium is a myocardial stimulant).

- **Treatment**

- *Stopping Potassium in all fluids.*
- Salbutamol (IV or inhaled).
- Intravenous Dextrose with or without Insulin.
- Calcium gluconate ( $100 \text{ mg/kg}$ , IV if  $> 7 \text{ mmol/L}$ )—myocardial membrane stabilization.
- Calcium resonium (oral or rectal)—cation exchange resin.

#### 3.7.1.2 Hypokalemia

- **Surgical causes**

Fistula, dehydration. Aldosterone-secreting tumors.

- **Signs**

ECG: (less obvious changes) flat T waves, U waves, AV conduction defects.

- **Treatment**

Slow  $\uparrow \text{K}$  + replacement (do not exceed  $\text{KCl } 0.51 \text{ mmol/kg/h}$  IV, unless on ECG monitor)

### 3.7.2 Calcium

Normal total 2.0–2.5 mmol / L  $\equiv$  8.5–10.2 mg / dL

Normal ionized 1.0–1.25 mmol / L  $\equiv$  4–5 mg / dL

Most are stored and relatively fixed in the bone. Serum calcium is made up of different components (bound to albumin (~40%) and complexed with bicarbonate (<10%) and free ions (~50%). Ionized calcium is the active part and is <1% of the total. Calcium balance is regulated by parathormone and acid/base balance.

#### 3.7.2.1 Hypocalcemia (Always Check Magnesium Levels Additionally)

Usually neonates

- Surgical causes
  - Chronic renal failure (e.g., PUV), post thyroidectomy, pancreatitis, malabsorption, Di George syndrome, and CHARGE syndrome.
- Signs—tetany, i.e., muscle irritability.
  - **Chvostek**<sup>2</sup>—twitching of facial muscles by tapping facial (VII) nerve.
  - **Trousseau**<sup>3</sup>—inflation of BP cuff causes carpal spasm (*main d'accoucheur*—hand of the obstetrician/deliverer).
- Treatment
  - Calcium (10%) gluconate (IV)
  - Calcium supplements (oral)
  - Vitamin D metabolites

#### 3.7.2.2 Hypercalcemia

Usually children

- Surgical causes
  - MEN (types I, II), Chronic renal failure, parathyroid tumors, hyperthyroidism, rhabdomyosarcoma, neuroblastoma, metastatic disease.
- Signs
  - “*Stones, Bones, Psychic groans, Abdominal moans,*” i.e., renal calculi, osteoporosis, bone cysts, psychiatric manifestations, weakness, confusions, pancreatitis, peptic ulcers.
- *Treatment*
  - Saline rehydration (with furosemide diuresis)
  - Calcitonin
  - Bisphosphonates, etc.

<sup>2</sup>Frantisek Chvostek (1835–1884), Austrian physician.

<sup>3</sup>Armand Trousseau (1801–1867)—French physician.

## 3.8 Acid-Base Imbalance

### 3.8.1 Concepts

#### Definition

- **Acid** H<sup>+</sup> donor
- **Base** – H<sup>+</sup> acceptor
- **Cation** is a +ve ion
- **Anion** is a –ve ion

$$\text{pH} = -\log_{10} [\text{H}^+]$$

- Neutral pH at 37 °C = 6.8
- Normal blood pH = 7.4 ( $\equiv \text{H}^+ = 40 \text{ nmol/L}$ ) (range 7.2–7.6)
- Normal intracellular pH = 7.0 ( $\text{H}^+ = 100 \text{ nmol/L}$ )

**Anion gap**—“difference” between summated anions and cations—there is always more of the latter owing to unmeasured anions (e.g., [protein<sup>–</sup>]). An elevated anion gap is usually due to an increase in [lactate<sup>–</sup>], [butyrate<sup>–</sup>], and others.

Normal is up to 30 mmol/L (but depends on what is being measured).

#### Key Equations

- Henderson<sup>4</sup> equation
 
$$[\text{H}^+] + [\text{HCO}_3^-] \leftrightarrow [\text{H}_2\text{CO}_3] \leftrightarrow [\text{CO}_2] + [\text{H}_2\text{O}] \quad [\text{H}^+] + [\text{HCO}_3^-] \leftrightarrow [\text{H}_2\text{CO}_3] \leftrightarrow [\text{CO}_2] + [\text{H}_2\text{O}]$$
- Henderson–Hasselbalch<sup>5</sup> equation
  - $\text{pH} = \text{pK}_a + \log_{10} \frac{\text{conjugate base}}{\text{conjugate acid}}$
  - i.e.,  $\text{pH} = \text{pK}_a + \log_{10} \frac{\text{HCO}_3^-}{\text{CO}_2}$

### 3.8.2 Base Excess (or Deficit)

**Definition**—“the quantity of base (acid) required to return the plasma in vitro to a normal pH under standard conditions.”

Normal body equilibration is maintained by a series of buffer systems:

- Chemical
  - Bicarbonate, phosphate, protein

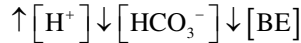<sup>4</sup>Lawrence J. Hendersen (1878–1942) American biochemist.

<sup>5</sup>Karl A. Hasselbalch (1874–1962) Danish chemist.

- Respiratory
  - Elimination of CO<sub>2</sub>
- Renal
  - Elimination or retention of bicarbonate

### 3.8.3 Abnormal Acid-Base States

#### 3.8.3.1 Metabolic Acidosis

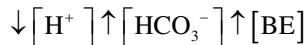

Multiple causes, but can be subdivided on the basis of change in anion gap. Thus, the subdivisions are:

- Normal anion gap
  - Loss of base
  - Renal loss of bicarbonate in renal tubular acidosis
  - Fistula loss of bicarbonate (pancreatic)
- Increased anion gap
  - Tissue hypoxia—anaerobic metabolism  $\uparrow$  [lactate<sup>-</sup>] +  $\uparrow$  [H<sup>+</sup>]
  - Ketoacidosis—diabetic
- **Treatment**
  - Correct the underlying problem
  - Sodium bicarbonate (4.2% IV) infused over 30 min
  - Ensure ventilation adequate to excrete excess CO<sub>2</sub>

*N.B. give half calculated dose—repeat blood gas*

#### 3.8.3.2 Metabolic Alkalosis



This is much less common in pediatric practice. Causes include

- Loss of acid
  - Vomiting of HCl—e.g., pyloric stenosis
  - Loss of acid stools—chronic diarrhea
- Loss of chloride
  - Chronic use of diuretics
  - Renal perfusion impairment with changes in renin/aldosterone axis.
  - Dehydration, cirrhosis
- Hypokalemia
  - Causes  $\uparrow$ hydrogen ion exchange in kidney.

- Contraction alkalosis—as the body fluids are “alkali,” dehydration causes a fall in total body water and ↑concentration of electrolytes, hence ↑pH.

- **Treatment**

- Treat the underlying cause.
- Often simple correction of fluid and saline deficit will allow restoration of homeostasis.

Base deficit (mmol/L)  $\times$  body weight (kg)  $\times$  0.3 = mmol/L of HCO<sub>3</sub>

*Required for full correction*

---

## Further Readings

1. Holliday MA, Ray PE, Friedman AL. Fluid therapy for children: facts, fashions and questions. *Arch Dis Child.* 2007;92:546–50.
2. World Health Organisation. The treatment of diarrhoea: a manual for physicians and other senior health workers. 4th revision. Geneva, Switzerland; 2005.
3. Wang J, Xu E, Xiao Y. Isotonic versus hypotonic maintenance IV fluids in hospitalized children: a meta-analysis. *Pediatrics.* 2014;133(1):105–13. <https://doi.org/10.1542/peds.2013-2041>.



Ashok Daya Ram and Mark Davenport

## 4.1 Metabolic Response to Surgery

It can be subdivided into an early response phase and a late response phase. It is triggered in a region located near the hypothalamus—the paraventricular nucleus and the locus coeruleus<sup>1</sup> and driven by a hypothalamic-pituitary axis and the sympathetic nervous system.

- The **early response** phase is subdivided into:
  - **The Ebb phase**<sup>2</sup> occurs soon after the injury and lasts **24–48 h**. It is characterized by ↓metabolism. It is largely driven by cytokine release and hormones. Lipolysis occurs with the release of free fatty acids.
    - ↓insulin secretion and ↑ catecholamines leading to hyperglycemia.
  - **Flow phase** may last from a **few days to several weeks**, depending on the nature and extent of the injury. It is characterized by increased metabolism. It is largely driven by catecholamines.
    - Proteolysis occurs with the release of amino acids.
- **Late chronic phase**
  - Characterized by efforts at recovery, repair, and restoration.

<sup>1</sup> *Coeruleus* (Latin) dark or even sky blue. Nucleus in the pons which secretes noradrenaline.

<sup>2</sup> David Cuthbertson (1900–89)—British physiologist, introduced this concept in 1942.

A. D. Ram  
Jenny Lind Hospital, Norwich, UK  
King's College Hospital, London, UK  
e-mail: [ashok.ram@nnuh.nhs.uk](mailto:ashok.ram@nnuh.nhs.uk)

M. Davenport (✉)  
King's College Hospital, London, UK

### 4.1.1 Factors Responsible for the Early Phase Response Include

- **Antidiuretic hormone (ADH)**
  - It is produced by the hypothalamus, stored, and released by the posterior pituitary gland.
  - Acts on distal convoluted tubules and collecting ducts in the kidneys to increase water reabsorption, thus conserving water and maintaining blood pressure. In high concentrations, it causes peripheral vasoconstriction, again helping to raise the blood pressure.
- **Renin-angiotensin-aldosterone system**
  - Activation causes salt and water retention in the kidneys, peripheral vasoconstriction and causes the sensation of thirst.
- **Catecholamine release**
  - From adrenal medulla leads to glycogenolysis, proteolysis, and lipolysis.
- **Glucocorticoids**
  - From adrenal cortex causes  $\uparrow$  glucose levels and  $\uparrow$  glycogenolysis, lipolysis and proteolysis.
- **Acute phase reactants**
  - Such as C-reactive protein, fibrinogen, and haptoglobin from the liver also contribute to the inflammatory response.
- **Leucocyte response**
  - $\uparrow$  neutrophil leukocytes  $\uparrow$  lymphocytes.

### 4.1.2 Factors Responsible for the Late Response Phase Include

- Insulin
- Growth hormones
- 17 keto steroids

### 4.1.3 Tissue Response to Injury

The tissues in which the injury occurs also have an innate reaction and response initiated and orchestrated by a variety of cytokines released from monocytes, macrophages, and T cells. They provoke local paracrine and wider systemic effects.

The cytokines are divided into:

- Pro-inflammatory cytokines
  - TNF- $\alpha$  causing  $\uparrow$  temperature and tachycardia
  - Interleukins: IL-1 $\beta$ ; IL-2; IL-6 (regulating liver production of acute-phase reactant proteins); IL-8
  - Interferon- $\gamma$
- Anti-inflammatory cytokines
  - Interleukins: IL-1ra, IL-4, IL-10, IL-12, IL-13
  - TGF- $\beta$

## 4.2 Systemic Inflammatory Response Syndrome (SIRS)

Localized inflammation is a physiological protective response that is generally tightly controlled by the body at the site of injury.

Loss of this local control or an overly activated response results in an exaggerated systemic response which is clinically identified as systemic inflammatory response syndrome (SIRS).

SIRS can be diagnosed (in adults/older children when two or more of the following are present:

- **Heart rate**
  - >90 beats/min
- **Temperature**
  - <36 or >38 °C (>38.5 °C in children)
- **Tachypnea**
  - >20 bpm or, on blood gas, a PaCO<sub>2</sub> < 4.3 kPa (32 mmHg)
- **White blood cell count**
  - <4 or >12 × 10<sup>9</sup>/L

Various modifications have been made with reference to pediatric age groups (Table 4.1).

## 4.3 Multiple Organ Dysfunction Syndrome (MODS)

- Definition
  - “altered organ function (>2 systems) in acute illness such that intervention is needed.”

It is hypothesized by Deitch to be caused by increased intestinal mucosal permeability to the intestinal Gram-negative organisms (mucosal barrier breakdown) secondary to splanchnic hypoperfusion. Additional liver dysfunction leads to the escape of toxins into the circulation, activating widespread immune reactions in tissues resulting in tissue damages and organ dysfunctions.

**Table 4.1** Pediatric definitions of SRS

| Age               | Heart rate |       | Respiratory rate (bpm) | WBC (×10 <sup>9</sup> /L) | BP (systolic) |
|-------------------|------------|-------|------------------------|---------------------------|---------------|
|                   | Brady      | Tachy |                        |                           |               |
| 0–1 week          | <100       | >180  | >50                    | >34                       | <65           |
| 1 week to 1 month | <100       | >180  | >40                    | >19 <5                    | <75           |
| 1 month to 1 year | <90        | >180  | >34                    | >17 <5                    | <100          |
| 2–5 years         | –          | >140  | >22                    | >15 <6                    | <94           |
| 6–12 years        | –          | >130  | >18                    | >13 <4                    | <104          |
| 13–18 years       | –          | >110  | >14                    | >11 <4                    | <117          |



### **Differences with Age**

There are differences in neonates, although much less study has been performed. In principle, the above sequence holds, although in neonates, there is a small increase in oxygen consumption and resting energy expenditure immediately after surgery with a return to normal levels by 12–24 h. Higher endogenous opioids may blunt this response to injury.

Critical illness leading to multiorgan dysfunction syndrome (MODS) and associated acute renal failure is less common in children compared to adult patients.

---

### **Further Reading**

1. Deitch EA. Multiple organ failure. Pathophysiology and potential future therapy. *Ann Surg.* 1992;216:117–34.
2. Pierro A. Metabolism and nutrition in the surgical neonate. *J Pediatr Surg.* 2002;37:811–22.
3. Goldstein B, Giroir BM, Randolph A. International pediatric consensus conference: definitions for sepsis and organ dysfunction in children. *Pediatr Crit Care Med.* 2005;6:2–8.
4. McHoney M, Eaton S, Pierro A. Metabolic response to surgery in infants and children. *Eur J Pediatr Surg.* 2009;19:275–85.



Ankit Sinha and Mark Davenport

## Definition

*“failure to supply the metabolic needs of the tissues,”*

## 5.1 Classification

- **Hypovolemic**
  - E.g. blood loss, dehydration, burns, and fluid loss. This is one of the leading causes of paediatric mortality in the developing world, mainly because of diarrhoea.
- **Cardiogenic**
  - E.g. infarction, arrhythmias, toxins, pump failure, trauma.
- **Distributive,**
  - Inappropriate expansion of vascular bed, ↓ systemic resistance.
- **Anaphylactic**
  - Histamine release → vasodilation.
- **Septic**
  - Endotoxin release → vasodilation “warm shock.”
- **Neurogenic**
  - Spinal injury, leads to ↓ sympathetic vascular tone.
- **Obstructive**
  - E.g. tension pneumothorax, pericardial tamponade, pulmonary embolus.

---

A. Sinha  
University College London Hospitals, London, UK  
e-mail: [ankit.sinha.15@ucl.ac.uk](mailto:ankit.sinha.15@ucl.ac.uk)

M. Davenport (✉)  
King’s College Hospital, London, UK

Shock may be thought of as contraction in predominantly the *intravascular-compartment* due to blood loss, etc. Compare with dehydration which is predominantly a contract of the extracellular compartment.

It is referred to in terms of *% loss of circulating blood volume*.

## 5.2 Degree of Shock

The degree of hypovolemic (only) shock can be estimated from an array of clinical signs and correlated with features of known blood loss (Tables 5.1 and 5.2).

## 5.3 Clinical Features

Any abnormal clinical features will imply that at least 15% of CBV (in adults) will have been lost. A child's physiological compensation is much better, and at least 25% loss of CBV is required to produce even minimal signs of shock. Underestimation is much more likely than overestimation in children (Table 5.3).

**Table 5.1** Modified ATLS (Advanced Trauma and Life Support) classification (adults) for shock

| Degree           | I              | II      | III      | IV                          |
|------------------|----------------|---------|----------|-----------------------------|
| Loss             | <15%           | 15–30%  | 30–40%   | >40%                        |
| Estimate         | 750 mL         | 1000 mL | 2000 mL  |                             |
| Heart rate       | <100           | >100    | >120     | >140                        |
| Blood pressure   | N              | N       | ↓        | ↓↓                          |
| Respiratory rate | 14–20          | 20–30   | 30–40    | >40                         |
| Mental state     | Slight anxiety | Anxious | Confused | Lethargic, comatose if >50% |

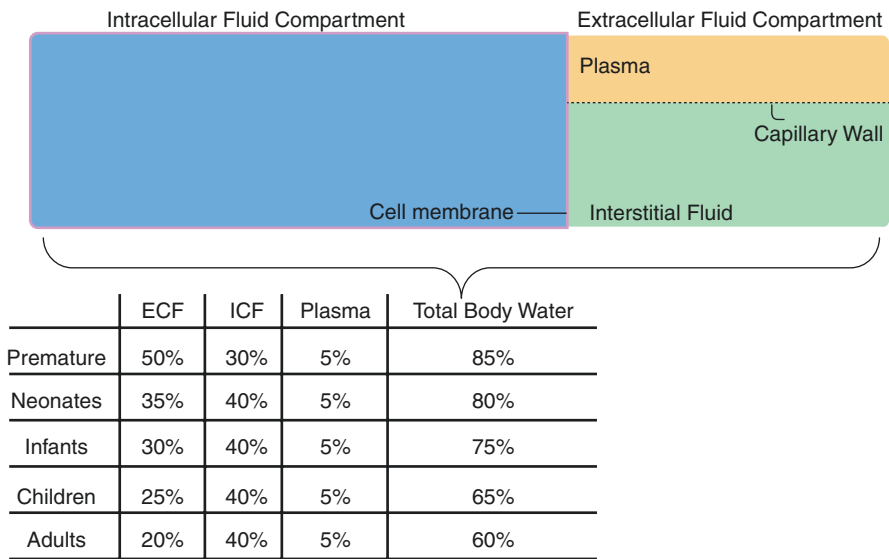
**Table 5.2** Modified ATLS classification (paediatric) for shock

| Loss           | <25%         | 25–45%                                   | >45%          |
|----------------|--------------|--|---------------|
| Heart rate     | N or ↑       | ↑↑                                       | ↓             |
| Blood pressure | N            | N or ↓                                   | ↓↓            |
| Skin           | Cool, clammy | + Cyanosis<br>↓CRT                       | Cold<br>↓↓CRT |
| Mental state   | Anxious      | ↓ Conscious level,<br>↓ Response to pain | Comatose      |

**Table 5.3** Circulating blood volume (CBV)

|         | Blood volume (mL/kg) |
|---------|----------------------|
| Neonate | 90                   |
| Infant  | 85                   |
| Child   | 80                   |
| Adult   | 65–70                |

**Table 5.4** Fluid compartments by age



Tachycardia is the primary response in children to reduced preload, for example from hypovolemic shock, rather than increased contractility. This is due to paediatric myocardium being stiffer than an adult’s, making increasing inotropy less effective, meaning that BP is maintained until late into the disease process. Tachycardia may not be present in a hypothermic patient.

Children are more susceptible to fluid loss due to the higher total body water content, increased metabolism, reduced renal concentration ability as well as lower absolute volumes. The fluid content of the body differs with age (Table 5.4). Therefore, they may need proportionally more fluid than adults to maintain fluid homeostasis. This is shown in the daily fluid requirement for term infants being 100 mL/kg/day, compared to an adult’s 35 mL/kg/day.

### 5.3.1 Differences with Age

- Improved compensation with the onset of shock
- Tachycardia
  - Often normal in young children
- Hypotension
  - Late sign and its criteria vary with age (Table 5.5)
- ↑ Surface area/body weight ratio – ↑ insensible losses, ↑ heat loss

**Table 5.5** Paediatric hypotension by age

|                | Systolic blood pressure (mmHg) |
|----------------|--------------------------------|
| 0–7 days       | <65                            |
| 1 week–1 month | <75                            |
| 1 month–1 year | <100                           |
| 1–10 years     | < (70 + [2 × age in years])    |
| >10 years      | <90                            |

## 5.4 Management

### 5.4.1 Principles

Aggressive fluid resuscitation is usually required, often with an initial 20 mL/kg fluid bolus (40–60 mL/kg used in severe cases). If vascular access is not easily achieved, an intraosseous needle must be used instead.

However, there are caveats to aggressive fluid resuscitation. In cardiogenic shock, trauma, and diabetic ketoacidosis, boluses of 10 mL/kg are advisable.

In **uncontrolled hemorrhagic shock (UCHS)**, where bleeding may have stopped due to ↓BP, rapid infusion to normal pressures leads to ↑bleeding (“popping the clot”), renewed failure to control haemorrhage and a poorer outcome than hypotensive resuscitation. *Stopping the bleeding* is therefore seen to be the primary aim before massive resuscitation.

- **“Scoop and run”**
  - If the journey to the surgical centre is <1 h, then following protection of the Airway and Breathing → immediate transport (with IV resuscitation along the way). If >1 h, then establish IV line and fluids first.
- **“Permissive hypotension”**
  - If UCHS consider small aliquots of fluid based on:
    - Loss of radial pulse
    - Mental awareness
    - Systolic <80 mmHg (adults)
- Empirical observation suggests that the volume of crystalloid required is 3:1, the estimated deficit in CBV.

**(Example: 20% loss in CBV in 10 kg child—assumes 160 mL blood lost, which needs ~480 mL of saline to compensate.)**

Safe practice (neither under nor over) requires bolus administration and then review vital signs and status. The goal is a well-perfused child with warm peripheries (e.g. CRT <2 s), improved mental status (may start complaining and be more aware of pain), and improved vital organ function (e.g. renal—aim for urine output 1–2 mL/kg/h).

If fluid overloaded, stop further fluids and start inotropes. Remember to correct **hypoglycaemia** and **hypocalcaemia** (calcium may be low due to parathyroid hormone impairment, decreased circulating vitamin D hydroxylation, increased end-organ resistance and citrate from blood products binding free calcium). If signs of end-organ dysfunction persist, start peripheral or IO dopamine.

Transfusion of blood may be needed (typically for Class III/IV shock):

- Urgently
  - Uncrossmatched O negative if >40% loss of CBV.
- Emergently
  - Crossmatched, type-specific.
- Electively
  - Following fluid resuscitation and hemodilution—aim for Hb > 80 g/L.

### 5.4.2 Colloids Versus Crystalloids

This is a controversial area with proponents of colloids suggesting that they remain in the intravascular space for longer while crystalloids diffuse across the entire ECF, and therefore having a short-term effect and can exacerbate oedema.

**Three times the volume of crystalloid is required to achieve the same oncotic effects as colloid.**

#### Long-Standing Debate

- **SAFE trial (Saline vs. Albumin Fluid Evaluation,  $n = 7000$ ) trial.**
  - Randomized albumin versus isotonic crystalloid in ill adults (multiple causes).
  - No overall difference in outcome (RR for death with colloid use = 0.99).
  - Two subgroups
    - Trauma—more likely to die with colloids.
    - Severe sepsis—less likely to die with colloids

### 5.4.3 Massive Transfusion

Defined as transfusion of patient's circulating blood volume in <24 h  
(e.g. 5 kg infant (90 mL/kg)  $\equiv$  450 mL)

- Potential issues
  - $\downarrow$  Ca<sup>2+</sup>—citrate tends to bind ionized Ca<sup>2+</sup> (give calcium gluconate)
  - $\uparrow$  K<sup>+</sup>—leakage from red cells
  - Hypothermia—unless deliberately warmed
  - Depletion of 2,3 DPG stores in red cells—shifts O<sub>2</sub> dissociation curve
  - Dilutional coagulopathy

**Typical first bolus—20 mL/kg IV**  
**0.9% saline (or Ringer's lactate, etc.)**  
**May be repeated (×2)**

---

## **Further Reading**

1. Mendelson J. Emergency department management of pediatric shock. *Emerg Med Clin North Am.* 2018;36:427–40.
2. Alam HB, Rhee P. New developments in fluid resuscitation. *Surg Clin North Am.* 2007;87:55–72.
3. Tien H, Nascimento B Jr, Callum J, Rizoli S. An approach to transfusion and hemorrhage in trauma: current perspectives on restrictive transfusion strategies. *Can J Surg.* 2007;50:202–9.
4. Finfer S, Bellomo R, Boyce N, French J, Myburgh J, Norton R, SAFE Study Investigators. A comparison of albumin and saline for fluid resuscitation in the intensive care unit. *N Engl J Med.* 2004;350:2247–56.



Rubina Mallik and Mark Davenport

## 6.1 Coagulation Tests

### 6.1.1 Normal Process of Coagulation

Damaged and exposed endothelium allows:

1. Platelet adherence to collagen, aggregation, and activation (*via* surface glycoprotein and (Von-Willebrand factor—vWF<sup>1</sup>)) with the release of thromboxane A<sub>2</sub>, V, and further vWF.
2. Formation of “**prothrombinase complex**” (*via* VII and exposed (tissue factor—tF) to produce initial **thrombin**).
3. Amplification and activation of XI, IX, and VIII to activate V and produce more thrombin (“**thrombin burst**”).
4. Thrombin polymerizes **fibrinogen** to form insoluble **fibrin**.

#### Inhibition of coagulation

5. Thrombin also activates *protein C and S*, which cleaves V and VIII to inactive components.
6. *Thrombin* binds to *antithrombin*—preventing its action.

<sup>1</sup>Erik Adolf von Willebrand (1870–1949) Finnish physician: described familial bleeding disorder in 1926.

R. Mallik  
Department of Haematology, St George’s University Hospital, London, UK  
Department of Paediatric Surgery, King’s College Hospital, London, UK  
e-mail: [rubina.malik2@nhs.net](mailto:rubina.malik2@nhs.net)

M. Davenport (✉)  
King’s College Hospital, London, UK



**Table 6.1** Possible causes for abnormal coagulation tests

|      | Factors                            |          | Possible cause if isolated                                      |
|------|------------------------------------|----------|---|
| PT   | II, V, VII, X                      | Increase | Liver disease, Vit K deficiency, use of warfarin                |
| APTT | VIII, IX, XI, XII                  | Increase | Hemophilia, Von-Willebrand <sup>1</sup> disease, use of heparin |
| TT   | Reflects fibrinogen to fibrin time |          | Hypofibrinogenaemia   |

Notes:

Vitamin K (fat-soluble) dependent—factors II, VII, IX, and X

vWF, Von Willebrand factor<sup>1</sup>; tPA, tissue plasminogen activator; tF, tissue factor

- Fibrinolysis, by action of *plasmin* (activated by tissue plasminogen activator—tPA) on fibrin into smaller soluble fragments (**fibrin degradation products**, of which D-dimers are one part) (Table 6.1).

Most coagulation screens would include Prothrombin time (PT), activated partial thromboplastin time (APTT), thrombin time (TT), and fibrinogen level, together with a platelet count (and function tests later if all the parameters are normal).

## 6.1.2 Hemophilia

- Hemophilia A, a well-known inherited bleeding disorder, arises due to congenital deficiency of coagulation factor VIII.
- Hemophilia B is due to congenital deficiency of coagulation factor IX.

Both of these are X-linked disorders affecting males, and their mothers and daughters are obligate carriers.

- Von-Willebrand disease is the most common inherited bleeding disorder, which is transmitted in an autosomal dominant fashion and is caused by the qualitative or quantitative defects in VWF (Von-Willebrand Factor).
- Factor concentrates** (Recombinant) are required for replacement therapy immediately before the surgery to minimize the risk of intraoperative bleeding. The factor concentrates should be continued postoperatively to achieve target factor levels according to the type of surgery, aiming to normalize the factor level and maintain the hemostatic level until wound healing is achieved.
- Desmopressin** (DDAVP) can be used for minor surgery in hemophilia and Von-Willebrand disease and can be given 1 h prior to the procedure to raise factor VIII activity levels for a short time. The peak effect of IV desmopressin is achieved in 30–60 min. Common adverse effects are fluid retention with hyponatremia, hypertension, and flushing.

- **Tranexamic acid** (Anti-fibrinolytic agent) can be given intravenously prior to the surgery, and it should be continued orally for a few days postoperatively.

### Platelet Count and Bleeding

The relation of platelet count to bleeding risk is poorly defined because of inadequate clinical studies and also a lack of information about platelet function. In general, there is a risk of spontaneous bleeding with a platelet count  $<20,000/\mu\text{L}$ .

Generally, there is a concept of  $50,000/\mu\text{L}$  for surgical hemostasis and prophylactic platelet transfusion for a count  $<10,000/\mu\text{L}$ . If the count falls  $<10,000/\mu\text{L}$ , then thrombin generation falls proportionately, and it remains maximal if platelets are  $>10,000/\mu\text{L}$ .

### 6.1.3 Blood Transfusion (UK Specific)

The practice of transfusion of whole blood into patients began with the French physician **Jean-Baptiste Denis's** account of a successful (surprisingly) transfusion of 9 oz. of lamb's blood into a 15-year-old boy in 1667.

This was followed by the obstetrician **James Blundell** who successfully transfused donated blood from a husband into his postpartum wife in 1818.

The key discovery of ABO blood groups was made by **Karl Landsteiner**, an Austrian Nobel laureate, in 1901, then later with his discovery of the Rhesus antigen in 1937.

Blood transfusion can be a lifesaving intervention in many surgical conditions. There are hazards of blood transfusion, and blood products are expensive; therefore unnecessary transfusions should be avoided. PBM (Patient Blood Management) is a patient-centered program in UK for good blood management during surgical procedures.

#### 6.1.3.1 ABO System

Two RBC antigens (A and B), with four possible combinations (*AB, A, B, O*). Plasma always contains contrary (IgM) antibodies (i.e., Group A will have anti-B antibody). Individuals with blood group O are considered universal donors as they do not have any antigens, but their plasma contains anti-A and anti-B, which can cause hemolysis, if present in high concentrations.

Marked racial variation—e.g., Norwegian (predominantly Gp A, 42%), Chinese ( $\uparrow$  Gp B, AB, 34%, invariably Rh(D) +ve).

**Table 6.2** Group frequency in UK population

|    | Rhesus +ve (%) | Rhesus -ve (%) |
|----|----------------|----------------|
| O  | 37             | 7              |
| A  | 35             | 7              |
| B  | 8              | 2              |
| AB | 3              | 1              |

### 6.1.3.2 Rhesus (D) System

The Rh antigen is present in 83% of the population. If it is not present, then the anti-D (IgG) antibody is not normally present (unless there has been previous exposure, usually this is a mother from previous Rh (D) +ve fetus) (Table 6.2)

Women and girls of child-bearing age with Rh-negative blood group should not be transfused with Rh-positive blood unless there is an extreme emergency.

### 6.1.3.3 Minor Groups

E.g., Lewis (Le), Kell (K)

## 6.1.4 Need for Blood Transfusion

Any prescription for blood transfusion should include detail of the volume required, any special requirements, e.g., irradiated and rate of infusion.

A Type and Screen takes about 45 min and includes ABO group and a screen for alloantibodies (IAT).

- **Crossmatched blood**
- **Uncrossmatched blood**

#### One Unit: Single Donation

- Whole blood ~500 mL stored in citrate phosphate dextrose (CPD)
  - Life span ~35 days
- Packed red cells ~350 mL

In adults 1 unit should increase Hb by 1 g/dL—and is usually administered over 4 h, and must be infused within 4 h of removal from the fridge.

If a unit of blood is out from the fridge for more than 30 min, it should be returned to the transfusion laboratory.

- I.e., donor O +ve or O -ve (contains no antibodies). Latter preferred for children.

### 6.1.4.1 Platelets

No need for crossmatching

- 1 unit (~50 mL)—administered over 30 min

### 6.1.4.2 Fresh Frozen Plasma

Should be ABO compatible—no need for crossmatching

- 1 unit (150–250 mL), usually single donor—administered over 30 min

### 6.1.4.3 Cryoprecipitate

No need for crossmatching—Administered over 30 min

Fibrinogen and factors VII and VIII

- Unit (~20 mL)

## 6.1.5 Transfusion Reactions

- **Hemolytic reaction (ABO incompatibility)**—invariably arises from a clerical error. The ABO incompatible transfusion occurs in 1:180,000 red cell units transfused. This is rare but causes rapid-onset chest pain, headache, vomiting with signs of shock, rigors, and hemoglobinuria. The patient becomes extremely unwell with shock, DIC, and acute renal failure.
  - **Management:**
    - Stop transfusion.
    - Resuscitation with ABC (Airway-Breathing-Circulation) protocol and maintain venous access using 0.9% sodium chloride.
    - Use BP, pulse, and urine output to guide intravenous fluid management, and the patient can be catheterized if needed.
- **Allergic Reactions (IgE-Mediated to Most Blood Components)**. Common skin reactions due to histamine release. Ranges from mild urticaria to life-threatening angioedema or anaphylaxis (bronchospasm, ↓ BP).
  - **Management:**
    - Stop transfusion.
    - Chlorpheniramine (for mild reaction).
    - Hydrocortisone.
    - If severe reaction or anaphylaxis—give Intramuscular Adrenaline rapidly effective, adult dose 0.5 mL of 1:1000 (500 µg).
- **Febrile reaction (nonhemolytic) (anti-leucocyte antibodies)**—usually with a history of past transfusions, onset after few hours of pyrexia and tachycardia. As part of histamine release. Severe reactions may cause anaphylaxis.
  - **Management:**
    - Stop transfusion
    - Paracetamol,
    - Hydrocortisone/chlorpheniramine (if severe)
    - Blood culture and start broad-spectrum antibiotic
- **Delayed Extravascular Hemolysis (recipient antibody-mediated, e.g., Duffy, Kell)**—manifest as an unexpected fall in Hb at 7–10 days, ↑ jaundice, +ve Coombs' test.

- **TRALI (Transfusion-related acute lung injury):** Occurs when the patient's neutrophils or monocytes react with antibodies in the blood, causing leakage of plasma into alveolar spaces resulting in pulmonary edema. Treatment is supporting with oxygen and ventilator support.
- **TACO (Transfusion-associated circulatory overload):** Occurs in elderly patients with other medical conditions. Treatment is supportive with oxygen therapy and diuretics.
- **TaGVHD (Transfusion-associated Graft-versus-Host disease):** Can occur in immunosuppressed patients due to engraftment of viable T-lymphocytes, which can cause widespread tissue damage. It can be prevented by giving irradiated blood products.

### 6.1.6 Alternatives to Blood Transfusion (Jehovah's Witness)

- Erythropoietin
- Iron supplementation
- Preoperative autologous transfusion
- Intraoperative and postoperative cell salvage

### 6.1.7 Coombs' Test<sup>2</sup>

- **Direct antiglobulin test (DAT)**—detects preformed IgG antibodies (usually) on the red cell. +ve DAT can be
  - Immune-mediated (e.g., transfusion reactions, Rhesus disease, drug-induced hemolytic anemia).
- **Indirect antiglobulin test (IAT)**—detects preformed IgG and IgM antibodies in serum. Is used as a screening test for transfused blood, and during pregnancy. A +ve IAT can be caused by Minor blood group incompatibility (Rh, Lewis, Kell, etc.)

#### 6.1.7.1 Transmissible Hazards of Blood Transfusion

- Hepatitis B (1 in 250,000 in USA) (< 1 in 1.2 million donations in UK).
- Hepatitis C (1 in 13,000 in USA) (< 1 in 28 million in UK).
- HIV (1 in 2 million in USA) (<1 in 7 million in UK).
- Variant Creutzfeldt-Jakob<sup>3,4</sup> disease, (vCJD) (no known cases but export of blood products from UK banned since 1999). Leucodepletion of all blood products in UK since 1999.

<sup>2</sup>Robin Coombs (1921–2006)—British immunologist.

<sup>3</sup>Heinz Gerhard Creutzfeldt (1885–1964) German neuropathologist.

<sup>4</sup>Alfons Maria Jakob (1884–1931) German neurologist.

### 6.1.8 Sickle Cell Disease

- >200,000 new cases worldwide.
- Sickle cell disease (SCD) includes a number of hemoglobinopathies causing chronic hemolytic anemia and painful episodes associated with the sickle cell gene (valine substitution for glutamic acid at position 6 on  $\beta$ -globin chain).
- Homozygous SCD (Hb SS).
- Compound heterozygotes with Hb C (Hb SC) (milder phenotype).
- Heterozygotes with H  $\beta$ -thalassemia (Hb S $\beta$ ).

The abnormal Hb provokes a change in red cell shape (sickle) which tends to cause small vessel occlusion in a wide variety of vascular beds.

#### 6.1.8.1 Sickle Cell Crisis

Not usually seen in the first year but may manifest as

- Dactylitis<sup>5</sup> (i.e., pain/swelling in fingers and toes).
- Long bone pain (younger children).
- Abdominal pain (older children and adolescence).
  - Difficult to differentiate from surgical pathology (e.g., gallstones, appendicitis, intussusception).
  - SCD—↓ incidence of appendicitis.

#### 6.1.8.2 Clinical Features

- Stroke (commonest cause in childhood) (up to 10% of affected children)
- Acute chest syndrome (the commonest cause of death)
- **Sequestration**—causing acute hemolytic anemia and splenomegaly. A similar phenomenon can be seen in the liver in older children
- Orthopedic, e.g., avascular necrosis of hip, osteomyelitis
- Gallstones—causing cholecystitis and choledocholithiasis
- Priapism<sup>6</sup>

### 6.1.9 Surgery in the Child with SCD

Children with SCD may well require surgical intervention either as a result of their pathology or incidentally. The process, whether elective or emergency, needs to be safe, and various areas of best practice are highlighted.

Preoperative planning for transfusion(s) to reduce the incidence of postoperative sickle cell complications.

<sup>5</sup>Daktylos δάκτυλο—Greek for “finger”

<sup>6</sup>Priapus—minor Greek fertility god, always denoted with permanently erect penis.

- Formerly the key component of preparation was to dilute the sickle cells within a more morphologically normal RBC population (typically aiming for a sickle cell percentage of <30%).
- Latterly, a more tolerant attitude has been adopted whereby the aim has been to aspire to a target hematocrit of >30%.
  - If Hb < 80 g/L, a **simple top-up transfusion** can suffice to increase the hematocrit and oxygen-carrying capacity and helps in diluting the HbS percentage. Simple transfusion—for major procedures (e.g., open cholecystectomy).
  - **Exchange transfusion** is usually arranged a week before surgery for those with Hb > 80 g/L needing major surgery and have severe phenotype (ACS, stroke, etc.).
- Hypothermia
  - Use of warming blankets, warmed intraoperative fluids, and temperature monitoring is reasonable standards to avoid peripheral vasoconstriction.
- Tourniquet
  - **Avoid** in operations such as hypospadias, hand surgery, and orthopedic procedures.

### 6.1.10 Acute Chest Syndrome

**Definition**—“the onset of a new lobar infiltration on chest X-ray, excluding atelectasis, accompanied by fever >38.5 °C, respiratory distress or chest pain.”

The cause is multifactorial, including infection, pulmonary sickling and sequestration and fat embolism secondary to bone infarction.

Not uncommon complication (~10%) of invasive surgery (e.g., laparotomy) due to sickling in the pulmonary vasculature. Typically occurs 2–3 days post-surgery with increasing dyspnoea and high temperature. It may be limited by aggressive chest physiotherapy and early mobilization.

#### 6.1.10.1 Management

- Oxygenation and ventilatory support
- Bronchodilators
- Broad-spectrum antibiotics
- Transfusion, possible exchange transfusion in severe cases
- Pain management

### 6.1.11 Leucocytosis or Neutropenia

While leucocytosis can be an indicator of infection, neutropenia can predispose to infection. CRP is a gold standard marker of inflammation.

Antimicrobial therapy might be indicated for treating the infection or for infection prophylaxis in case of neutropenia.

---

## Further Reading

1. Dick MC. Standards for the management of sickle cell disease in children. *Arch Dis Child (Ed Pract)*. 2008;93:169–76.
2. Firth PG. Anaesthesia for peculiar cells—a century of sickle cell disease. *Br J Anaesth*. 2005;95:287–99.
3. Stuart MI, Nagel RL. Sickle-cell disease. *Lancet*. 2004;364:1343–60.





# Post-operative Recovery

# 7

Hesham Elagami, Chandrasen K. Sinha,  
and Mark Davenport

Before undergoing a serious surgical operation, put your affairs in order. You never know you may live!

Victor Hugo (1802–1885)

## 7.1 Analgesia

- Pain is an unpleasant sensory and emotional experience associated with actual or potential tissue damage.
- Relief of pain is a key component of the smooth, uncomplicated post-operative experience—certainly from the patient’s perspective!

Assessment of the severity of pain is often led by experience and what is the norm for a particular operation. In children it is commonly challenging to evaluate the severity of the pain. Facial assessment tools (e.g., Wong and Baker) can help but the cognitive ability of the children and their level of maturity varies (Table 7.1). Therefore experience in assessing the non-speaking preschool child is hence required. Sometimes it is the accouterments (e.g., catheter, IV giving set, etc.) of an operation rather than the wound that causes the most distress.

---

H. Elagami · C. K. Sinha (✉)  
St George’s Hospital, London, UK

M. Davenport  
King’s College Hospital, London, UK

**Table 7.1** Pain assessment by age group

| Age       | Pain assessment tool                               |
|-----------|--|
| <3 years  | Experience and expectancy with the type of surgery |
| 3–8 years | Visual representation tool                         |
| > 8 years | Pain score (0–10)                                  |

**Table 7.2** Common post-operative analgesics

|                         | Mechanism of action  | Dose   | PR                        | Oral                | IV   |
|-------------------------|--|--|---------------------------|---------------------|--|
| Paracetamol             | Prostaglandin inhibition + serotonergic pathway activation (central) | 20 mg/kg <sup>a</sup> qds (max. 1 g)           | 20 mg/kg <sup>a</sup> qds | 250 mg/5 mL (susp.) | 15 mg/kg (if > 10 kg) 7.5 mg/kg (if < 10 kg) |
| Diclofenac              | Inhibition of COX-1 (local)  | 1 mg/kg (50 mg tds) <sup>b</sup>               | 12.5 and 25 mg            | 25 or 50 mg tablets | 1 mg/kg                                      |
| Ibuprofen               | Inhibition of COX-1 (local)  | 10 mg/kg (400 mg tds) <sup>b</sup> (max 2.4 g) |                           | 100 mg/5 mL         | –  |
| Dihydrocodeine tartrate | Opiate   | 1 mg/kg  | Available                 | 25 mg/5 mL          | C/I  |

<sup>a</sup>Quoted dose ranges varies considerably (10–20 mg/kg). Loading dose of 30 mg/kg recommended

<sup>b</sup>Adult and >12 years

### 7.1.1 Concepts: Pre-emptive and Multimodal Analgesia

- **Pre-emptive**

- Administration of the analgesics prior to the incision leads to reduction of the central and peripheral sensitization which consequently reduces the amplification of the nociceptors and accordingly the total requirement of post-operative analgesics.

- **Multimodal analgesia**

- is the concept of using 2 or more drugs simultaneously or cross covering that act by different mechanisms at different receptors leading to better control of pain and total reduction of the single medications albeit opioids thus lower incidence of adverse effects (Table 7.2).

### 7.1.2 Local Anesthesia (LA)

Local anesthetic injection works on the nerve endings located between the epidermal and the dermal layers of the skin hence the injection should be targeting this

**Table 7.3** Commonly used local anesthetics

|                                      | Dose   | Duration | Notes   |
|--------------------------------------|--|----------|---|
| <i>Topical</i>                       |  |          |   |
| 5% EMLA™ <sup>a</sup>                | 1 tube = 5 g                                   | 3 h      | Apply under occlusive dressing—45 min<br>Avoid <3 months      |
| 4% tetracaine Ametop™                | 1 tube = 1 g                                   | 4–6 h    | Apply under occlusive dressing—30 min<br>Avoid <3 months      |
| TAC <sup>b</sup>                     | 2–5 mL applied directly to wound               | 1 h      | Avoid mucus membranes/burns<br>Use probably superseded by LET |
| LET <sup>c</sup>                     | 2–5 mL gel or liquid applied directly to wound | 1 h      | Avoid mucus membranes/burns                                   |
| <i>Infiltration</i>                  |  |          |   |
|                                      | <i>Upper limit</i>                             |          |   |
| Procaine<br>Novocain™                | 7–10 mg/kg                                     |          | Also vasoconstricts,<br>↑ allergic reaction                   |
| Lignocaine (lidocaine)<br>Xylocaine™ | 3 mg/kg<br>(7 mg/kg + adrenaline)              | 1–2 h    | 1%, 2% solutions  |
| Prilocaine<br>Citanest™              | 6 mg/kg  |          |   |
| Mepivacaine<br>Carbocaine™           | 5 mg/kg  |          |   |
| Bupivacaine<br>Marcaine™             | 2 mg/kg  | 3 h      | 0.25% and 0.5% solutions<br>Slow onset                        |

<sup>a</sup>Eutectic Mixture of Local Anesthetic (lignocaine and prilocaine)

<sup>b</sup>Tetracaine (0.5%), Adrenaline (1 in 2,000), Cocaine (11.8%) (used mainly in the USA, although now declining)

<sup>c</sup>Lignocaine, Epinephrine, Tetracaine (used mainly in the USA)

area. They block sodium channels and prevent nerve conduction. Most LAs are tertiary amine bases which require an alkaline tissue pH to be able to diffuse across nerve sheath and membrane to enter the axoplasm—its actual site of action. Hence injecting into an acidic medium such as infected tissue is futile. Commonly used injectable local anesthetic agents are lidocaine,<sup>1</sup> bupivacaine, and mepivacaine, other topical agents such as tetracaine 4% and EMLA 5% (Table 7.3).

LA works variable on different types of nerves.

- Selective—unmyelinated C fibers > A fibers (pain > motor)

### 7.1.2.1 Percentage Solution of Local Anesthetics

- 1% solution implies a concentration of 1 g/100 mL.
  - And thus in mg/ml terms should be multiplied by 10.
  - **1% lidocaine contains 10 mg/mL.**

<sup>1</sup>Lidocaine—formerly known as lignocaine and first amino amide-type local anesthetic. Synthesized by Swedish chemist Nils Löfgren in 1943.

### 7.1.2.2 Adrenaline (Epinephrine)

May be added to increase the duration of action, induce vasoconstriction, and allow a higher dose of LA to be used. The usual dose is 1 in 200,000 (i.e., 5 µg/mL). The dose of lidocaine when mixed with ephedrine can be increased to 7 mg/kg. It is a dogmatic belief that adrenaline should not be used in regions/tissue with end-arteries such as digits and the penis, though there is little real evidence of harm in these sites.

#### Side Effects and Complications

- Toxicity
  - following inadvertent intravascular injection or overdose.
- CNS side effects (usually)
  - include dizziness, tinnitus, circumoral tingling, visual or aural disturbance. Untoward muscle twitching and (rarely) seizures.
- Cardiovascular side effects (rare)
  - sinus bradycardia, decreased myocardial contractility or even arrest.

#### Post-operative Nausea and Vomiting (PONV)

PONV is multifactorial common yet complex complication and one of the main causes of failure to discharge from a day-case ward.

The five main pathways for stimulating vomiting are;

- Chemoreceptor trigger zone
  - Stimulated by nitrous oxide (NO), opioids, and ketamine.
- Vagal mucosa of the GIT
  - Stimulated by NO, opioids, and cytotoxic drugs.
- Reflex pathway of the cerebrum.
- Reflex from the vestibular system
  - Stimulated by NO
- Midbrain afferent.

Acetylcholine, 5-HT, and dopamine are all involved in the reflex arc of vomiting.

- ↑ Incidence in 6–16 year old (low in infants) ~40% risk
- ↑ Incidence in ENT (esp. middle ear procedures and tonsillectomy) and ophthalmic (esp. strabismus correction) procedures and laparoscopy in general (Table 7.4).

#### Management

Can be thought of as prophylactic or as rescue therapy

**Table 7.4** Drugs for PONV

| Receptor  | Drug examples (as per BNF)   |
|---|--|
| 5 Hydroxytryptamine 3 (5-HT <sub>3</sub> ) (i.e., serotonin receptor) | <ul style="list-style-type: none"> <li>• Ondansetron (100–150 µg/kg)</li> <li>• Corticosteroids—dexamethasone</li> </ul>   |
| Histamine (H1)  | <ul style="list-style-type: none"> <li>• Cetirizine</li> <li>• Chlorpromazine</li> </ul>   |
| Dopamine (D2)   | <ul style="list-style-type: none"> <li>• Prochlorperazine</li> <li>• Metoclopramide hydrochloride (5HT<sub>3</sub>, D2 antagonism centrally and 5HT<sub>4</sub> agonism and D2 antagonism peripherally). (N.B. ↑extrapyramidal effects in children—caution)</li> <li>• Chlorpromazine D1 and D2</li> </ul> |
| Neurokinin-1 (NK1)  | <ul style="list-style-type: none"> <li>• Aprepitant</li> </ul>   |

## 7.2 Pyrexia<sup>2</sup>

Normal core body temperature 37 °C ≡ 98.6 °F

Very common problem, with multiple causes.

### 7.2.1 Immediate (<24 h)

- Surgically induced inflammation
  - Maximum temp 38 °C, median time is 11 h, max 24 h
  - Paracetamol, not an indication for antibiotics or cultures unless other cause for suspicion of sepsis.
- Transfusion reactions (see Chap. 6)

### 7.2.2 Early (2–5 Days)

- Persistent stress related inflammation
  - No clinical concern, negative cultures
  - Stop antibiotics if appropriate
- Trauma related
  - Can be persistent with gradual resolution over days or weeks
- Pre-operative infections
  - Worsening of respiratory tract infection post-operatively is common and should not be confused with nosocomial infection.

<sup>2</sup>Pyretos (Greek)—fire. Febrile from *febris* (Latin)—fever

- Lines and drains
  - Urine microscopy and line culture should be part of screening for all persistent post-operative fever.
  - Early removal of the urinary catheter, drains, and lines as well as appropriate antibiotics cover should be started early.
- **Early surgical site infection (SSI)**
  - Wounds should be uncovered and cultured. Deeper infections should be excluded with the appropriate investigations.
  - **Necrotizing fasciitis**, though rare should always be excluded due to its devastating effect.
  - Pharmacological or surgical treatment should be promptly implemented (e.g., drain insertion, change of antibiotics).
- Respiratory causes/infection
  - Routinely examine the chest.
  - CXR as part of the screening.
  - Atelectasis is a common complication and commonly associated with inadequate analgesia.
  - DVT and pulmonary embolism—consider in older children, and patients with comorbidities.

### 7.2.3 Late (>5 Days)

- Wound infection.
  - Culture any discharge.
  - Treatment—drain any subcutaneous collection—open wound—debride wound. Change antibiotic.
- Persisting/related pathology
  - Anastomotic leakage (esophageal, intestinal, biliary).
  - Investigate appropriately CXR/US/CT scan.

---

## 7.3 Wound Infection

- Benchmark ~2–5% (in pediatric general surgical practice)

Wounds may be defined as: (infection rate %)

- **Clean** (e.g., hernia, laparoscopic pyloromyotomy) 2%
- **Clean/contaminated** (e.g., appendectomy) 5%
- **Contaminated** (e.g., resection of bowel for NEC, closure of stoma) 10–22%
- **Dirty** (e.g., drainage of abscess) >20%

SSI above the expected percentages warrants frequent audits and change of practice. Modification of pre-operative antibiotics is highly recommended if the responsible organisms are consistently resistant.

This early cellulitic phase can be abbreviated by systemic antibiotics, but typically once pus develops then this has to be drained (by removal of sutures, etc.) and any necrotic tissue removed (*debridement*). Compared to adults, infection is more often related to duration of surgery and operative events rather than physiology of the patient.

### 7.3.1 Organisms

*Staphylococci* spp. (incl. coagulase negative staphylococci (CONS)), *Streptococcal* spp., *E. coli*, *Klebsiella* spp., anaerobic organisms (e.g., *Bacteroides* spp., *Clostridial* spp.), *Enterobacter* spp., *Pseudomonas aeruginosa*, *Candida* spp.

There are many topical therapies which have shown benefit including:

- Iodine-based (e.g., povidone iodine, Inadine™)
- Silver-based (e.g., silver sulfadiazine)
- Alginate-based<sup>3</sup> (often in combination with above, e.g. Aquacel™)
- Metronidazole

#### Empirical (i.e., “Best Guess”) Antibiotics

- Flucloxacillin (anti-staphylococcal) for Clean and Clean/Contaminated wounds.
- Co-amoxiclav, cefuroxime, cefazolin, and metronidazole (broader spectrum including anaerobes) for Contaminated and Dirty wounds.

#### *Methicillin-Resistant Staphylococcus aureus (MRSA)*

- Topical antibacterial agents
  - Iodine or silver-based.
  - Mupirocin (Bactroban™).

*If systemically unwell*

- Vancomycin or teicoplanin (both glycopeptides and IV only.)
- Second-line antibiotics include linezolid (an oxazolidinone, oral and IV, requires regular FBC—risk of bone marrow suppression)

#### Decolonization

Consider in

- Patients undergoing elective procedures.
- Patients in high risk areas—intensive care, NICU.
- Immunosuppressed patients.

---

<sup>3</sup>Traditionally, alginates are made from acids that are obtained from brown seaweed.

### 7.3.2 Necrotizing Fasciitis

Rare, but devastating (20% mortality in children) complication caused by (typically) mixed organisms (e.g., GpA *Streptococcal* spp., *Pseudomonas aeruginosa*, and anaerobic spp. such as *Clostridial* spp, *Peptostreptococcus*, *Bacteroides* spp.). Rapid spread along deep fascial planes, because of its natural poor blood supply with overlying skin necrosis due to thrombosis.

Can occur primarily—typically scrotal (**Fournier's<sup>4</sup> gangrene**) or as complication of varicella and in the immunosuppressed.

Suspect if excessive pain (becoming anesthetic later) with surrounding skin erythema becoming mottled and pale. **Look for crepitus (gas formation)** within the affected tissue.

Treatment should include high-dose antibiotic (including Penicillin G), wound debridement (early and aggressive), and hyperbaric oxygen and intravenous immune globulin.

---

## 7.4 Clavien–Dindo Classification of Complications

The Clavien–Dindo<sup>5</sup> system is now in wide use internationally and was first proposed in 1992 as a severity-based classification of surgical complications in adult surgical practice. It was revised in 2004 with extra grades and an increased weight given to life-threatening complications requiring intensive care management.

A large UK networked surgical practice reported:

- Incidence of any complication
  - ~4%,
  - Typically wound (SSI) infection.
- Serious complication (defined as  $\geq$ CD III)
  - 2.6%
  - Typically post-appendicectomy collections/abscess.
- Death
  - 0.45%.
  - Usually neonates with NEC (Table 7.5).

---

<sup>4</sup>Jean Alfred Fournier (1832–1915) French dermatologist described a case in 1883.

<sup>5</sup>Pierre Alain Clavien and Daniel Dindo. Contemporary Swiss surgeons introduced concept in 2004.



**Table 7.5** Clavian–Dindo classification

| Grade                  | Definition  |
|------------------------|---|
| I                      | Any deviation from the normal post-operative course not requiring surgical, endoscopic, or radiological intervention<br>Accepted therapeutic regimes include drugs as: anti-emetics, anti-pyretics, analgesics, diuretics, and electrolytes, treatment with physiotherapy and wound infections that are opened at the bedside |
| II                     | Complications requiring pharmacological treatments other than those allowed for Grade I complications; this includes blood transfusion and TPN  |
| IIIA<br>[not under GA] | Complications requiring surgical, endoscopic, or radiological intervention  |
| IIIB<br>[under GA]     |   |
| IV                     | Life-threatening complications; this includes CNS complications which require intensive care<br>Can be divided into (A) Single Organ dysfunction (B) Multi Organ dysfunction.   |
| V                      | Death   |

## Further Reading

1. Rosero EB, Joshi GP. Preemptive, preventive, multimodal analgesia: what do they really mean? *Plast Reconstr Surg.* 2014;134(4S-2):85S–93S. <https://doi.org/10.1097/PRS.0000000000000671>.
2. Shaikh SI, Nagarekha D, Hegade G, Marutheesh M. Postoperative nausea and vomiting: A simple yet complex problem. *Anesth Essays Res.* 2016;10:388–96.
3. Thompson H, Jones C, Pardy C, et al. Application of the Clavian-Dindo classification to a pediatric surgical network. *J Pediatr Surg.* 2020;55:312–5.
4. Ein SH, Sandler A. Wound infection prophylaxis in pediatric acute appendicitis: a 26-year prospective study. *J Pediatr Surg.* 2006;41:538–41.
5. Parks T, Wilson C, Curtis N, et al. Polyspecific intravenous immunoglobulin in clindamycin-treated patients with streptococcal toxic shock syndrome: a systematic review and meta-analysis. *Clin Infect Dis.* 2018;15(67):1434–6.



Rajat Kapoor, Isobel Connolly, and Kerryn Moolenschot

## 8.1 Introduction

Parenteral nutrition refers to the provision of nutrients by the intravenous route. PN should be considered when there is a need to correct, prevent, and/or maintain the patient's fluid and electrolyte homeostasis and nutritional status. The majority of pediatric and neonatal patients are able to tolerate some form of enteral feeding and hence PN is often used as supplement to meet their fluid, electrolytes, and nutritional requirements. The extent to which patients can tolerate enteral nutrition is dependent upon the degree of impairment or immaturity of gastrointestinal function and factors that may influence gut adaptation.

Total parenteral nutrition (TPN) implies that all macronutrients (carbohydrate, nitrogen, and lipid), micronutrients (vitamins, trace elements, and minerals), and fluid requirements are met by an intravenous nutrient solution and no significant nutrition is obtained from other sources.

## 8.2 Indications for Parenteral Nutrition (PN)

Having identified a patient in need of PN, the process of ordering and monitoring is aimed at ensuring safe and effective nutritional support. Nutrition should be delivered via the gastrointestinal tract (GIT) even if only a part of the required nutrition can be given enterally. Enteral nutrition (EN) aids gut adaptation protects the liver and reduces the amount of PN provided. Total parenteral nutrition (TPN), where no EN is given, should only occur where the gut cannot be accessed at all.

---

R. Kapoor (✉) · I. Connolly · K. Moolenschot  
St. George's University Hospital, London, UK  
e-mail: [Rajat.Kapoor@stgeorges.nhs.uk](mailto:Rajat.Kapoor@stgeorges.nhs.uk)

Common indications to start PN in pediatric patients include:

- No EN for >4–5 days
- Unable to meet nutritional requirements after maximizing enteral support
- Short bowel syndrome, e.g. secondary to Necrotizing Enterocolitis (NEC)
- Gastrointestinal surgery, e.g. gastroschisis, atresia, volvulus, malrotation
- Multi-organ failure where enteral feeding is not possible
- Congenital malabsorptive syndromes, e.g. microvillus inclusion disease
- Chronic Intestinal Pseudo-Obstruction (CIPO)
- Severe malnutrition
- Functional immaturity (prematurity) especially if born <29 weeks gestation and/or birth weight <1.2 kg
- Acute severe pancreatitis
- Inflammatory bowel disease
- Mucosal inflammation in Oncology patients

## 8.3 Constituents of PN

### 8.3.1 Energy

Indirect calorimetry, if available, can calculate energy requirements. Alternatively, the Schofield equation (Table 8.1) using actual body weight can be used during acute illness phase. Stress and activity factors can be added when weaned from support, as the patient mobilizes, to promote growth, and for various disease states. A dietitian can calculate energy requirements, especially if bespoke PN required.

From day 1 of life, a premature infant needs at least 45–55 kcal/kg and very low birth weight (VLBW) infants need to be built up to 90–110 kcal/kg in order to gain 15–20 g/day after expected post birth weight loss to prevent a decrease in weight centile. Enteral feed <25 ml/kg/day is negligible and can be excluded from total energy provision.

### 8.3.2 Carbohydrate

Overfeeding carbohydrate, usually supplied as dextrose in PN, should be avoided as it can cause hyperglycemia; increase lipid production and deposition in the liver; enhance hepatic production of very low density lipoprotein (VLDL) triglycerides, and increase carbon dioxide production and respiration rate. The rate of glucose

**Table 8.1** Schofield's equations for calculating resting energy expenditure (REE) (kcal/day)

| Schofield formula | Male                                      | Female                                    |
|-------------------|---|---|
| 0–3 years         | $59.5 \times (\text{weight in kg}) - 30$  | $58.3 \times (\text{weight in kg}) - 31$  |
| 3–10 years        | $22.7 \times (\text{weight in kg}) + 504$ | $20.3 \times (\text{weight in kg}) + 486$ |
| 10–18 years       | $17.7 \times (\text{weight in kg}) + 658$ | $13.4 \times (\text{weight in kg}) + 692$ |

**Table 8.2** Recommended PN glucose supply in pediatrics (not suitable if an underlying metabolic disorder)

| Weight (kg) | Acute phase (mg/kg/min) | Stable phase (mg/kg/min) | Recovery phase (mg/kg/min) |
|-------------|-------------------------|--------------------------|----------------------------|
| <10         | 2–4                     | 4–6                      | 6–10                       |
| 11–30       | 1.5–2.5                 | 2–4                      | 3–6                        |
| 31–45       | 1–1.5                   | 1.5–3                    | 3–4                        |
| >45         | 0.5–1                   | 1–2                      | 2–3                        |

**Table 8.3** Parenteral amino acid supply considered adequate for stable patients (g/kg/day) (ESPGHAN 2018)

|                     |         |
|---------------------|---------|
| Preterm infants     |         |
| First day of life   | 1.5–2.5 |
| From day 2 onwards  | 2.5–3.5 |
| Term infants        | 1.5–3.0 |
| 2nd month–3rd years | –2.5    |
| 3rd–18th years      | –2.0    |

oxidation (RGO) should therefore not be exceeded. Table 8.2 provides guidance on recommended PN glucose supply in pediatrics.

### 8.3.3 Amino Acid

The amino acid (AA) requirement is lower in parenterally fed than in enterally fed infants and children as PN bypasses the intestine. A minimum of 30–40 kcal/1 g AA is recommended to guarantee AA utilization. Neonates have the highest AA requirement with 1.5g/kg needed to prevent negative nitrogen balance. Table 8.3 advises on the parenteral supply in pediatric patients.

### 8.3.4 Lipid

Lipid emulsions are an integral part of PN in order to provide high energy needs without carbohydrate overload and provide essential fatty acids (EFAs). ESPGHAN guidelines (2018) advise that lipids should provide 25–40% of non-protein calories in fully parenterally fed patients.

The choice of lipid emulsions should consider the duration of PN, age, and disease conditions. Commonly used intravenous lipid emulsions are pure soybean oil or a composite of soybean oil, medium chain triglycerides, olive oil, and fish oil (SMOF). ESPGHAN guidelines (2018) advise that the use of pure soybean oil is not appropriate for longer than a few days.

Local practice is to increase lipids by maximum of 0.5–1 g/kg/day. ESPGHAN guidelines (2018) recommend that parenteral lipid intake should not exceed 4 g/kg/day in infants and 3 g/kg/day in children. ESPGHAN guidelines (2018) recommend checking serum triglyceride levels approximately 1–2 days after initiation or adjustment of lipid infusion to assess lipid tolerance. Reduction of the dosage if serum or

plasma triglyceride concentrations during infusion exceed 3 mmol/l (265 mg/dl) in infants or 4.5 mmol/l (400 mg/dl) in older children can be considered. If plasma levels of triglycerides are above the limits, these guidelines recommend lowering, not stopping, the dosage. Omission of lipid emulsions from PN may lead to biochemical evidence of EFA deficiency within a few days in infants.

### **8.3.5 Trace Elements and Vitamins**

All infants and children receiving PN should have vitamins and minerals given daily in PN, e.g. Peditrace<sup>®</sup> solution (contains traces of zinc, copper, manganese, selenium, fluorine, and iodine), Solivito N (contains water-soluble vitamins and usually added to aqueous PN bag), and Vitlipid N (contains fat-soluble vitamins and usually added to lipid PN bag). Consider giving micronutrients to patients where PN is withheld for more than week.

---

## **8.4 Initiation, Adjustment, and Monitoring of PN**

Ensuring that there is reliable venous access is an important consideration when PN is indicated for patient. ESPGHAN guidelines (2018) recommend that a PICC or tunneled CVC should be used for administration of prolonged PN in infants and children.

When commencement of PN is considered, it should be done so as part of an overall nutritional care plan that includes a detailed nutritional assessment.

### **8.4.1 Anthropometry**

Baseline weight and length/height should be measured. Head circumference should be measured in <2 year olds. Weights should be repeated twice weekly as per local guidance. Length and head circumference should be repeated monthly or more frequently in infants. If fluid management is difficult, e.g. edema or high output stoma, then consider daily weights and concentrating PN. Mid-upper arm circumference (>6 months old), tricep skinfold thickness, or dual-energy X-ray absorptiometry (DXA) can assess body composition if available and suitable.

### **8.4.2 Biochemistry**

Baseline biochemical markers are required prior to commencement of PN and at a regular intervals during the time on PN (Table 8.4). Trace elements and vitamins should be checked monthly when the patient has a normal CRP value, as inflammatory state can result in deranged results not accurately reflecting actual body stores.

**Table 8.4** Laboratory monitoring of parenteral nutrition (ESPGHAN 2018)

| Investigation              | Sample | Before starting parenteral nutrition | During parenteral nutrition, before clinical and metabolic stabilization |                      |             | During parenteral nutrition, during clinical and metabolic stabilization |              |             |
|----------------------------|--------|--------------------------------------|--|----------------------|-------------|--|--------------|-------------|
|                            |        |                                      | Once/1–2 days  | At least once a week | As required | Once/1–2 weeks   | Once a month | As required |
| Sodium                     | S      | X                                    | X  |                      |             | X  |              |             |
| Potassium                  | S      | X                                    | X  |                      |             | X  |              |             |
| Chloride                   | S      | X                                    | X  |                      |             |  |              | X           |
| Calcium                    | S      | X                                    | X  |                      |             | X  |              |             |
| Phosphorus                 | S      | X                                    |  | X                    |             | X  |              |             |
| Magnesium                  | S      | X                                    |  |                      | X           | X  |              |             |
| Zinc                       | S      |                                      |  |                      | X           |  |              | X           |
| Blood gasses               | CB     | X                                    |  | X                    |             | X  |              |             |
| Glucose                    | WB, CB | X                                    | X  |                      |             | X  |              |             |
| Total protein              | S      | X                                    |  | X                    |             | X  |              |             |
| Albumins                   | S      | X                                    |  | X                    |             |  | X            |             |
| BUN                        | S      | X                                    |  | X                    |             |  | X            |             |
| Creatinine                 | S      | X                                    |  | X                    |             |  | X            |             |
| Triglycerides              | S      | X                                    |  |                      | X           |  |              | X           |
| Cholesterol                | S      | X                                    |  |                      | X           |  |              | X           |
| Bilirubin                  | S      | X                                    |  |                      | X           |  | X            |             |
| AST                        | S      | X                                    |  |                      | X           |  | X            |             |
| ALT                        | S      | X                                    |  |                      | X           |  | X            |             |
| GGTP                       | S      | X                                    |  |                      | X           |  |              | X           |
| AP                         | S      | X                                    |  |                      | X           |  |              | X           |
| CBC                        | WB     | X                                    |  | X                    |             | X  |              |             |
| INR                        | S      | X                                    |  |                      | X           |  | X            |             |
| CRP                        | S      | X                                    |  |                      | X           |  |              | X           |
| Vit. B12                   | S      |                                      |  |                      | X           |  |              | X           |
| Fe                         | S      |                                      |  |                      | X           |  |              | X           |
| Ferritin                   | S      |                                      |  |                      | X           |  |              | X           |
| PTH                        | S      |                                      |  |                      |             |  |              | X           |
| 25OHD3                     | S      |                                      |  |                      | X           |  |              | X           |
| Trace elements: Se, Zn, Cu |        |                                      |  | X                    |             |  |              | X           |
| Urine                      | US     | X                                    |  | X                    |             |  | X            |             |
| Electrolytes in urine      | US     |                                      |  |                      | X           |  |              | X           |

X, when to perform the test; S, serum, plasma; WB, whole blood; CB, capillary blood; US, urine sample

### 8.4.3 Initiating PN

PN is graded up over a 3–4 day period to reach full nutritional requirements as per local guidance. If the patient has not been fed for >5 days, there may be a risk of refeeding syndrome.

ESPGHAN guidelines (2018) recommend that standard PN solutions should generally be used over individualized PN solutions in most pediatric patients for short periods (up to 2–3 weeks). A bespoke PN solution should be used when the nutritional requirements cannot be met by the available range of standard PN formulations and/or in infants and children requiring PN for prolonged periods, e.g. in short bowel syndrome. PN is generally introduced as a continuous infusion, in neonates the initial duration will be 24 h. Older pediatric patients commence PN over 20 h as per local practice. Reducing hours on PN is recommended for patients requiring longer-term PN in order to protect against intestinal failure related liver disease (IFALD). The infusion rate of glucose, lipids, and potassium need be taken into account when final infusion rate is calculated which is guided by pharmacists.

Children with an acute reason for requiring PN may tolerate rapid introduction of enteral nutrition, orally or via a feeding tube. Patients with more chronic gastrointestinal disease may require a slower introduction which can be tailored to the individual patient under the guidance of a dietitian who can also recommend an appropriate feed. If stoma output <20 ml/kg, then consider starting enteral feeds. Aim for an increase of 10–20 ml/kg/day in enteral feed according to tolerance, e.g. lack of abdominal distention, nausea, vomiting, increased stool/stoma output >20 ml/kg in 24 h.

## 8.5 Complications of PN

Complications of PN can be divided into either catheter-related or metabolic. Metabolic complications may be further classified as short-term and long-term (Table 8.5).

### Line Sepsis (CRBSI: Catheter-Related Blood Stream Infection)

PICC lines may have a lower sepsis incidence, especially if they are single lumen and dedicated to PN administration only. Line sepsis prevention strategies must be maintained by strict adherence to local policies and practices.

**Table 8.5** Complications of PN

| Line complications              | Metabolic                |                          |
|---------------------------------|--------------------------|--------------------------|
|                                 | Acute                    | Chronic                  |
| Line sepsis                     | Refeeding syndrome       | Liver disease (IFALD)    |
| Thrombosis, phlebitis           | Hyper/hypoglycemia       | Cholelithiasis           |
| Occlusion (kinking, clogging)   | Electrolyte disturbances | Metabolic bone disease   |
| Dislodgement, fracture, leaking | Hypertriglyceridemia     | Micronutrient Imbalances |
|                                 | Acute cholestasis        |                          |

Any temperature  $>38^{\circ}\text{C}$  needs to be treated initially as a presumed CVL sepsis. An urgent clinical review must be performed by the medical/surgical team and investigations completed so that treatments (first-line antibiotic therapy as per local microbiology guidance) can be commenced within 1 h of presentation.

---

## 8.6 Concomitant Medications

A variety of medications are used in patients receiving PN. Administration of any medication to a patient with impaired gastrointestinal function requires attention to dosing and route of delivery because absorption and pharmacokinetics are often abnormal. Listed below are some of the commonly used drugs in patients receiving PN:

- *Acid suppression therapy*—Histamine 2 receptor antagonists (e.g., Ranitidine) and Proton Pump Inhibitors (PPIs) (e.g., Omeprazole). Gastric hypersecretion occurs during the early stages following intestinal resection. Acid suppression improves pancreatic enzyme function and nutrient absorption during this phase. These drugs may be particularly helpful in managing gastrointestinal outputs in patients with large resections. Long-term use of PPIs should be avoided due to the risk of complications such as small bowel bacterial overgrowth, Vitamin B12 deficiency, and osteopenia.
- *Bile acid sequestrants*—(e.g., cholestyramine) may be indicated in patients with bile acid diarrhea. Resection of the terminal ileum results in poor reuptake of bile acids and passage of bile acids into the colon.
- *Somatostatin analogs*—(e.g., Octreotide). Octreotide reduces gastrointestinal secretion and motility as well as gallbladder contraction. It is not often used as a first-line drug but may be useful in reducing diarrhea and fluid losses in selected patients, i.e. those with ileostomy diarrhea and large volume jejunostomy losses.
- *Antimotility agents*—(e.g., Loperamide) can be useful in managing chronic diarrhea in infants and children with intestinal failure. Dosages vary from 0.1 mg/kg twice per day to 2 mg/kg daily in divided doses.
- *Adaptive agents*—e.g., Teduglutide, an analog of glucagon-like peptide 2 (GLP-2). This enteroendocrine peptide can be used to facilitate gut adaptation (via mucosal crypt-cell proliferation leading to increased villus height, intestinal length and surface area for fluid and nutrient absorption). Its use in pediatric patients is not well established.
- *Bile acids*—e.g. Ursodeoxycholic acid. Used in various cholestatic disorders by facilitating bile flow through the liver and protecting liver cells.

---

## 8.7 Long-Term Use of PN

ESPGHAN guidelines (2018) recommend that home PN should be considered for any child who is clinically stable, on a stable PN prescription and expected to remain dependent on PN for a minimum of 3 months. The parents require 1–2 week period



to undergo a structured training program to manage PN in their home. Management of home PN by centralized centers with expertise in intestinal failure and with an MDT to support care at home may minimize complications, improve outcome, and allow weaning from PN onto enteral feeds.

---

## 8.8 Intestinal Failure-Associated Liver Disease (IFALD)

Intestinal failure-associated liver disease (IFALD) has now replaced the term parenteral nutrition-associated liver disease (PNALD). IFALD can be defined as liver disease that arises as a consequence of the medical and surgical management strategies for intestinal failure. The diagnosis is a clinical one, provided that other causes of liver damage and cholestasis have been excluded.

Risk factors include:

- Young age
- Short bowel syndrome
- Intercurrent infections (sepsis events)
- Lack of enteral feeding
- Duration of PN
- Lipid emulsions that contain pure soybean oil

Laboratory tests reveal a conjugated hyperbilirubinemia in the presence of abnormal liver enzymes. The risk of developing IFALD can be minimized by administering a balanced PN solution, introducing enteral feeds as soon as possible, cycling PN and preventing and promptly treating sepsis episodes. Treating with a fish oil-based lipid emulsion (e.g., SMOF) rather than a conventional soybean oil-based lipid emulsion also reduces the likelihood of IFALD.

---

## 8.9 Multidisciplinary Team (MDT)

A team approach is essential for the appropriate management of patients who require PN. The MDT should consist of a gastroenterologist, surgeon, nutrition nurse, specialist dietitian, and PN pharmacist. Management of these patients by an MDT is associated with a reduction in catheter-related blood stream infection rates in a number of studies involving adult patients (ESPGHAN 2018). It has been demonstrated that outcomes for patients with PN dependent intestinal failure can be improved following management from a multidisciplinary team.

---

## Further Reading

1. Traeger SM, Williams GB, Milliren G, Young DS, Fisher M, Haug MT 3rd. Total parenteral nutrition by a nutrition support team: improved quality of care. *J Parenteral Enteral Nutr.* 1986;10:408–12.

2. Wales PW, Allen N, Worthington P, George D, Compher C, The American Society for Parenteral and Enteral Nutrition, et al. A.S.P.E.N. clinical guidelines: support of pediatric patients with intestinal failure at risk of parenteral nutrition-associated liver disease. *J Parenteral Enteral Nutr.* 2014;38:538–57.
3. Puntis J, Hojsak I, Ksiazek J. ESPGHAN/ESPEN/ESPR/CSPEN guidelines on pediatric parenteral nutrition: organisational aspects. *Clin Nutr.* 2018;37:2392–400. Copyright Elsevier 2018
4. Josten K, Embleton N, Yan W, Senterre T. ESPGHAN/ESPEN/ESPR/CSPEN guidelines on pediatric parenteral nutrition: energy. *Clin Nutr.* 2018;37:2309–14. Copyright Elsevier 2018
5. Mesotten D, Joosten K, van Kempen A, Verbruggen S. ESPGHAN/ESPEN/ESPR/CSPEN guidelines on pediatric parenteral nutrition: carbohydrates. *Clin Nutr.* 2018;37:2337–43. Copyright Elsevier 2018
6. Lapillonne A, Fidler Mis N, Goulet O. ESPGHAN/ESPEN/ESPR/CSPEN guidelines on pediatric parenteral nutrition: lipids. *Clin Nutr.* 2018;37:2324–36. Copyright Elsevier 2018
7. van Goudoever J, Carnielli V, Darmaun D. ESPGHAN/ESPEN/ESPR/CSPEN guidelines on pediatric parenteral nutrition: amino acids. *Clin Nutr.* 2018;37:2315–23. Copyright Elsevier 2018
8. Hill S, Ksiazek J, Prell C, Tabbers M. ESPGHAN/ESPEN/ESPR/CSPEN guidelines on pediatric parenteral nutrition: home parenteral nutrition. *Clin Nutr.* 2018;37:2401–8. Copyright Elsevier 2018
9. Cernat E, Puntis J. Paediatric parenteral nutrition: current issues. *Frontline Gastroenterol.* 2019;1–7. <https://doi.org/10.1136/flgastro-2018-101127>.
10. BNFc—The British National Formulary for Children 2019–2020.
11. UpToDate—Short bowel syndrome and Intestinal failure-associated liver disease in infants.
12. BAPEN: The British Association for Parenteral and Enteral Nutrition—Resources and Education.

---

## **Part II**

# **Trauma and Resuscitation**



# Trauma Management: General Principles

# 9

Apurva More and Shailesh B. Patel

## 9.1 Basic Approach to Trauma

### 9.1.1 Important Differences Between Children and Adults

- **Airway**
  - In children, a large head and short neck allow neck flexion and airway narrowing. The larger tongue may obstruct the airway, which is also easily obstructed during the chin-lift manoeuvre if inadvertent pressure is placed on the soft tissue of the floor of the mouth. In children, the narrowest part of the airway is the cricoid (it is the larynx in adults).
- **Breathing**
  - The ribs are more horizontal in young children, and a more compliant chest wall means that severe parenchymal damage can occur without the presence of rib fractures. Rib fractures denote massive compression forces. Abdominal organs such as liver and spleen are less protected by the rib cage and more exposed due to a flatter diaphragm.
- **Circulation**
  - Although the circulating blood volume per kilogram of body weight in children is high, the actual volume is low. Therefore, small amounts of blood loss can be critical. Body surface area (BSA)-to-weight ratio falls with increasing age. Smaller children lose heat more rapidly and are prone to hypothermia.

---

A. More  
Nottingham University Hospital, Nottingham, UK

S. B. Patel (✉)  
King's College Hospital, London, UK  
e-mail: [Shailesh.patel@nhs.net](mailto:Shailesh.patel@nhs.net)

- **Psychological**
  - Fear is a common response to trauma. Gentle reassurance, explanation, and honesty are vital to let the child develop trust in the carer and allow repeated assessments. The presence of parents is often helpful.
- **Weight**
  - Drugs and fluids are given as doses per Kg of body weight. Weighing on scales is the most accurate method of measuring weight, but this may have to be estimated before the arrival of the patient.

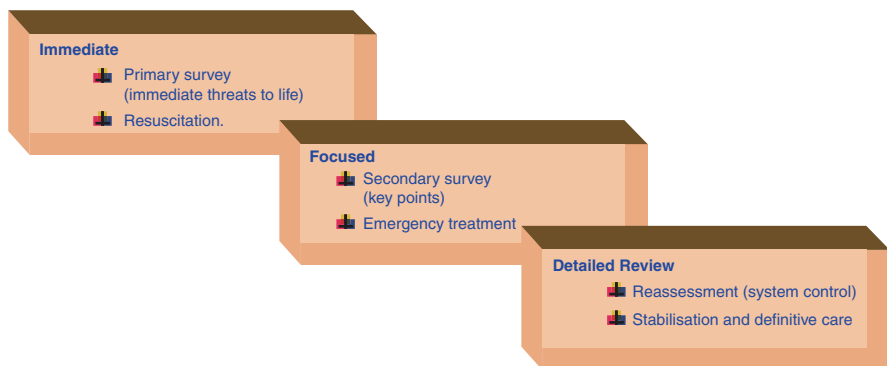
## 9.2 Management Plan

The best outcomes are achieved by establishing Trauma Networks and designated Trauma teams. Adequate training including regular simulation-based practice is vital.

Trauma alert systems enable teams to prepare and brief before the child's arrival. Team Leader and Team Member roles should be pre-assigned during the management of a severely injured child. Team Leader should assimilate the information available in a structured form, e.g., ATMISTER.

- A** Age/sex
- T** Time of injury
- M** Mechanism of injury
- I** Injuries suspected
- S** Signs, vital signs, Glasgow Coma Scale
- T** Treatment already given
- E** Estimated time of arrival to Emergency room
- R** Requirements, e.g., bloods, specialist services, tiered response, ambulance call sign

On the child's arrival a structured handover, e.g., **SBAR** (Situation, Background, Assessment, Recommendation) should take place. Treatment is then based on a structured approach (Fig. 9.1).



**Fig. 9.1** Structured approach

## 9.2.1 Primary Survey and Resuscitation

Assessment begins with **SAFE approach**

- **Shout** for help
- **Approach** with care
- **Free** from danger
- **Evaluate** ABC

The primary survey identifies life-threatening problems and is completed within 1–2 min. Each problem is corrected before moving on to the next step, with reassessment after each intervention. Any deterioration at any stage requires restarting primary survey with appropriate intervention.

Basic life support measures are then initiated (Fig. 9.2).

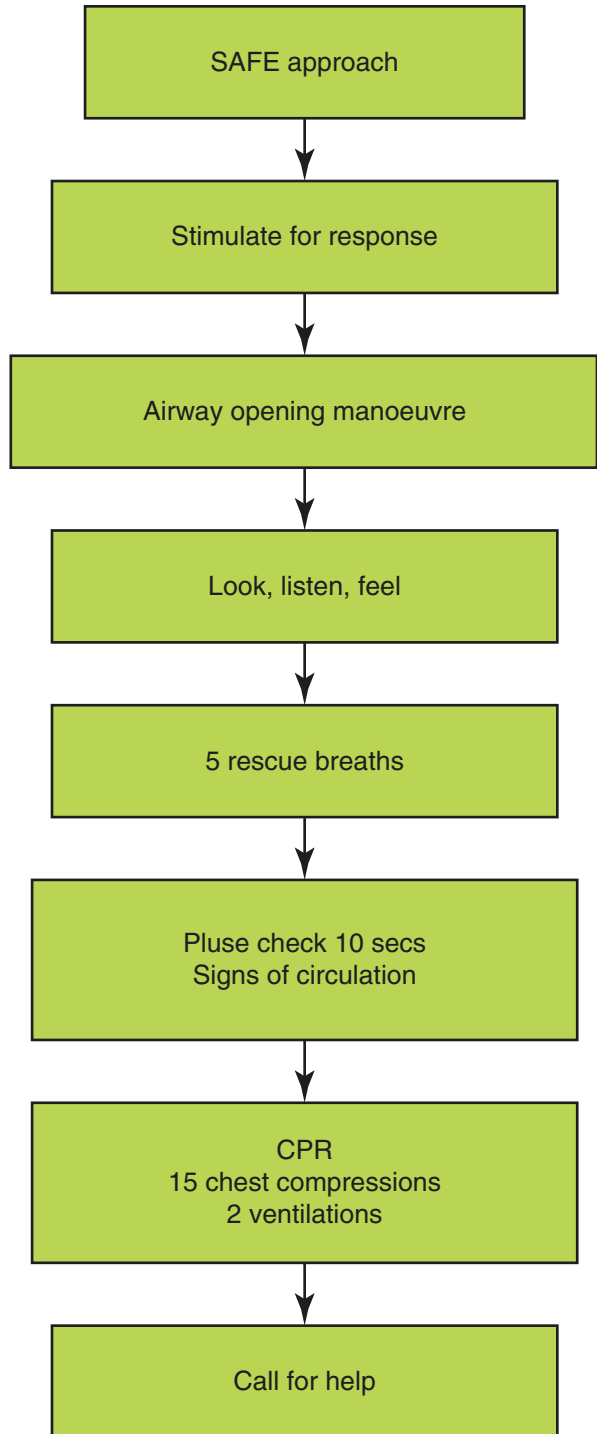
## 9.2.2 <C>ABCDE: Approach

- **Catastrophic external hemorrhage**
  - **Airway** with cervical spine control
  - **Breathing** with ventilatory support
  - **Circulation** with hemorrhage control
  - **Disability** with prevention of secondary insult
  - **Exposure** with temperature control
- 
- **Catastrophic external hemorrhage**
    - Identify and control with direct pressure, hemostatic dressings, or tourniquets immediately in this instance.
    - Give 15 mg/kg tranexamic acid IV/IO as soon as possible.
  - **Airway with cervical spine control**
    - Perform airway opening manoeuvre, jaw thrust only, NO head tilt/chin lift
    - Clear blood/secretions from oropharynx, NO blind finger sweep
    - Looking for Signs of life (chest and/or abdominal movement)
    - Listening for breath sounds
    - Feeling for breath

Give high flow oxygen by face mask. Consider oropharyngeal airway (avoid nasopharyngeal airway if basal skull fracture is suspected), and need for ventilation by supraglottic airway, or endotracheal tube with intubation by skilled personnel. Early surgical airway may need to be considered in facial trauma or burns.

The cervical spine must be stabilized from the beginning with *manual in-line immobilization*, changing to side supports with blocks and straps when convenient. Hard collars are no longer recommended. Precautions should be continued until C-spine is formally cleared, unless the mechanism of trauma excludes the possibility of cervical injury.

**Fig. 9.2** Basic life support:



- **Breathing with ventilatory support**

Assess:

- Effort of breathing
- Efficacy of breathing
- Effects of inadequate respiration on other systems

**Look and Listen**—Check for obvious injuries, sucking chest wounds, asymmetry, flail chest. Auscultate for breath sounds

**Feel**—Check for tracheal deviation, crepitus of surgical emphysema, percuss for hyper-resonance (tension pneumothorax), and dullness (massive hemothorax).

Rescue breaths with bag valve mask should be initiated if there is no or inadequate respiratory effort, and ventilation then continued. Prepare for possible intubation.

- **Circulation with hemorrhage control**

Rapid assessment of heart rate and rhythm, central and peripheral pulse volume, and peripheral perfusion (color, temperature, and capillary refill time) is performed. Capillary refill time is assessed by pressing on a warm area of the body for 5 s and counting the number of seconds for return of capillary flush (normal value is  $\leq 2$  s). Assess for signs of life including movement, coughing, and normal breathing. Failure of circulation is indicated by the absence of a central pulse for 10 s.

A quick check for signs of external hemorrhage is made, and pressure is applied if appropriate. Evidence of internal bleeding (chest, abdomen, pelvis, femurs) is looked for.

**Pulse oximetry, BP cuff, and ECG leads** should be attached at the earliest opportunity.

Systolic pressure is usually raised in injured children, and hypotension is therefore a dangerous sign.

**Two large bore peripheral intravenous cannulae** must be inserted urgently. If any difficulty is encountered, **intraosseous cannulation of the tibia or femur** is the quickest option in the seriously injured child, avoiding limbs with proximal fractures. More secure access can be obtained once stabilized. Bloods must be taken, prioritizing for urgent cross-match, as well as blood gas for hemoglobin and lactate.

If the child is stable with no signs of shock, immediate fluid bolus is not required. **‘The first clot is the best clot’**—overfilling can risk dislodgement of early clots forming at bleeding points.

Fluid resuscitation and blood replacement will be required for severe hemorrhage and shock, following the APLS guidelines:

- Give 15 mg/kg tranexamic acid IV /IO.
- Give 5 ml/kg boluses of *warmed* packed RBC or FFP in 1:1 ratio if blood products are immediately available and reassess.
- Otherwise, give 10 ml/kg of *warm* Normal Saline 0.9% and reassess.



- If shock remains repeat further 10 ml/kg of *warm* Normal Saline 0.9% and reassess.
- After 20 ml/kg blood products, request a major hemorrhage pack containing packed RBC, FFP, and platelets from blood bank.
- Give 10 ml/kg platelets and 0.1 ml/kg 10% Calcium Chloride.
- Monitor Hb on blood gases, keep below 12 g/dl.
- Correct potassium >6 mmol/l with 0.1 units/kg actrapid insulin with 10 ml/kg 10% dextrose.
- Keep platelets above  $100 \times 10^9/l$ .
- If shock persists, have a clear plan with Surgeons/Interventional Radiologists for hemorrhage control.

If rapid transfusion is required, **O-negative or type-specific blood** may be necessary.

Estimated circulating blood volume = 70 – 80 ml / kg

*Chest compressions must be started if:*

- No pulse
  - Slow pulse (<60 beats/min with poor perfusion)
  - No signs of circulation
- **Disability with prevention of secondary insult:**  
Rapid assessment of consciousness level using **AVPU**, pupil size and reactivity, and posture is performed.
    - **A**—Alert
    - **V**—Responds to Voice
    - **P**—Responds only to Pain
    - **U**—Unresponsive to all stimuli

GCS less than 8 or AVPU “P” or “U” requires immediate intervention. Neuroprotective measures must be initiated (see Chap. 10 for further details).

If a serious head injury is suspected, urgent CT brain must be arranged and neurosurgical team alerted. If there is neurological deterioration, urgent transfer to a neurosurgical team may be required even before a CT.

- **Exposure with temperature control**

Proper assessment requires clothes to be removed, but heat loss and embarrassment should be prevented by covering them with a blanket.

### 9.2.3 Life-Threatening Conditions

- Airway obstruction
- Tension pneumothorax
- Open pneumothorax
- Massive hemothorax
- Flail chest
- Cardiac tamponade
- Shock (hemorrhage or otherwise)
- Decompensating head injury

These conditions should be diagnosed on clinical findings alone and treatment started as soon as they are discovered during the primary survey.

### 9.2.4 Other Procedures During Resuscitation

- Chest X-ray and c-spine if an injury cannot be cleared clinically and C-spine CT is not immediately indicated. Routine Pelvis X-ray is not recommended.
- Blood tests (cross-match, full blood count, clotting, amylase, urea and electrolytes, and **Don't Ever Forget Glucose**).
- Nasogastric tube insertion—Acute gastric dilatation is common; use the oral route if basal skull fracture is suspected.
- Urinary catheter—Only if the child is unable to void spontaneously or accurate monitoring is required.
- Analgesia—Morphine (0.1–0.2 mg/kg IV) in small boluses. This dose is reduced if the patient is hypotensive or in case of an altered conscious level.

### 9.2.5 Secondary Survey

A thorough top-to-bottom, front and back examination is performed once all life-threatening conditions have been identified and stabilized. The secondary survey may have to wait until life-saving surgery is performed, but must be subsequently carried out and thoroughly documented.

Relevant investigations, such as cervical spine imaging, head, chest or abdominal CT, or ultrasound, may be indicated at this stage.

- Surface (head to toe, front, and back — will require log roll)
- All orifices (mouth, nose, ears, eyes rectum, and perineum)
- All body cavities (chest, abdomen, pelvis, retroperitoneum)
- All extremities and joints

An **AMPLE** history should be taken from paramedics or carers at the first opportunity:

- Allergies
- Medications
- Past history of any major illness and **Pregnancy**
- Last meal (if the patient needs surgery)
- Environment surrounding injury (e.g., other casualties or fatalities, speed of impact, use of restraints, the height of fall, hot or cold environment, drowning, etc.)

### 9.2.6 Emergency Treatment

Treatment plans for key findings from secondary surveys are started promptly to minimize the risk of deterioration or increased morbidity, e.g., limb-threatening injury.

### 9.2.7 Reassessment and System Control

Detailed attention is now paid to maintaining and normalizing all physiological systems:

- Respiratory
- Circulatory
- Central nervous system
- Metabolism
- Host defenses

### 9.2.8 Continuing Stabilization and Definitive Care

These represent the last stage of trauma resuscitation:

- Note taking
- Referral
- Transfer

#### Useful Formulae During Resuscitation (WETFLAG)

|               |   |
|---------------|---|
| • Weight      | $2 \times (\text{age} + 4) \text{ kg}$                      |
| • Electricity | 2 J/kg DC for defibrillation shock                          |
| • Tube        | $4 + (\text{age}/4)$ mm internal diameter tracheal tube     |
| • Fluids      | 10 ml/s/kg + 10 ml/kg                                       |
| • Adrenaline  | 10 $\mu\text{g}/\text{kg}$ = 0.1 ml/kg of 1:10,000 solution |
| • Glucose     | 5 ml/kg 10% dextrose  |

## 9.3 Important Points About Systemic Injuries

### 9.3.1 Chest Trauma

Thoracic injuries in children can arise from blunt or penetrating trauma. This can present as chest wall, lung, or heart injuries, such as tension pneumothorax, flail chest, and cardiac tamponade.

#### 9.3.1.1 Tension Pneumothorax

Tension pneumothorax is characterized by diminished breath sounds, hyperresonant percussion, and deviation of trachea to the opposite side, which may cause impaired cardiac output and venous return. This is a life-threatening emergency, and immediate needle thoracocentesis in the second intercostal space on the midclavicular line is needed, followed by chest drain insertion into the “**safe triangle**” (intercostal spaces 4–5).

A small asymptomatic pneumothorax is left alone, but a large pneumothorax can cause hypoxia and respiratory distress, and therefore may need a chest drain, particularly if positive pressure ventilation is required.

#### 9.3.1.2 Flail Chest

This is less common in children than adults since children have more compliant chest walls. Flail chest is generally secondary to blunt force trauma and may present alongside pulmonary contusions. “**Paradoxical movement**” (the flail segment appears to collapse with inspiration and bulges out during expiration) is observed, along with respiratory distress and decreased air entry. Treatment involves giving high-flow oxygen therapy, analgesia, and possibly mechanical ventilation to stabilize the thorax. Surgery for rib fixation may be required in some cases.

#### 9.3.1.3 Cardiac Tamponade

This can occur secondary to severe blunt or penetrating injuries. Cardiac tamponade can lead to reduced cardiac output and subsequent cardiogenic shock. Children will present with chest pain, reduced heart sounds, hypotension, and respiratory distress. The preferred treatment is surgical drainage, but needle pericardiocentesis (preferably with ultrasound guidance) should be done in an emergency. Fluid resuscitation and ECG monitoring are necessary.

#### 9.3.1.4 Abdominal Trauma

Children are at higher risk of abdominal injury because of their anatomy. Injuries to the liver, spleen, kidneys, and gastrointestinal tract are frequent while injuries to the great vessels, genitourinary tract, pancreas, and pelvis are less common.

Blunt trauma is the most common mechanism of abdominal injury in children. Contrast CT is the investigation of choice and should be guided by clinical suspicion and the mechanism of injury. Normal abdominal examination and absence of abdominal pain do not reliably exclude serious intra-abdominal injury. FAST scans in the emergency department have NO role to play in the management of injured children, although a detailed US scan by a trained radiologist may be helpful. Diagnostic peritoneal lavage should never be performed.

Blunt liver and spleen injury rarely require surgical intervention. American Pediatric Surgical Association (APSA) guidance published in 2019 suggest hospital admission for observation. Intensive care is needed when vital signs are abnormal after initial volume resuscitation. Duration of hospital admission is based on clinical condition, NOT injury severity (grade). It is advised to restrict activities for injury grade plus 2 weeks.

### **9.3.1.5 Head and Spine Injury**

Head and spine injuries are the leading causes of disability and mortality in children. A thorough neurological assessment is vital in children with suspected spinal injuries. This can be difficult in young children because of age, pain, or altered conscious state. Trauma scales, such as the Glasgow Coma Scale (GCS), are useful to assess the severity of the injury and to predict outcomes. Neurogenic shock can occur as a result of spinal injury above the level of T6. Neurosurgery referral is necessary.

---

## **9.4 Supplemental Data**

### **9.4.1 Physiological**

Respiratory rate, heart rate, and systolic blood pressure all change with age. A chart based on the principles of APLS (Advanced Pediatric Life Support) is available in all resuscitation centers which should be referenced for guidance, when needed.

---

## **Further Reading**

1. Sinha CK, Lander A. Trauma in children: abdomen and thorax. *Surgery* (Oxford). 2013;31(3):123–9.
2. Advanced Life Support Group (2016): *Advanced Paediatric Life Support: The Practical Approach*. 6th edn. Wiley-Blackwell.
3. Acker SN, Ross JT, Partrick DA, Tong S, Bensard DD. Pediatric specific shock index accurately identifies severely injured children. *J Pediatr Surg*. 2015;50(2):331–4.
4. Hirschberg A, Mattox KL, editors. *Top knife: the art and craft of trauma surgery*. North Shrewsbury: TFM; 2005.



Bindey Kumar, Anil Kumar, and Arun Prasad

## 10.1 Introduction

Head injury is one of the leading causes of death in the pediatric population with a mortality rate of 0.5 per 1000 children reporting to emergency rooms according to one Canadian review. However most head injuries are mild in nature and have normal recovery without sequelae with only <1% that requires neurosurgical intervention.

Head injuries in children are perhaps more significant than equivalents in adults because:

- Relative ↑ head size,
- ↓ thickness cranial bones
- Unstable gait and reduced control of neck (toddlers)
- ↓ subarachnoid space, providing less buoyancy.

### Age Variation

- Infants
  - Non-accidental injury

---

B. Kumar (✉)

Department of Paediatric Surgery, All India Institute of Medical Sciences, Patna, Bihar, India

A. Kumar

Trauma and Emergency and General Surgery, All India Institute of Medical Sciences, Patna, Bihar, India

A. Prasad

Trauma and Emergency and Paediatrics, All India Institute of Medical Sciences, Patna, Bihar, India

- Preschool age
  - Falls
- Adolescence
  - Road traffic accident, recreational activities, and violence by assaults and firearms
  - ↑↑ male teenagers

---

## 10.2 Classification and Pathophysiology

- Fractures
  - Linear
  - Stellate
  - Depressed
- Base of skull ± CSF leak
  - Periorbital hematoma (Battle's sign)
  - Retroauricular hematoma (Raccoon eyes)
  - hemotympanum
- Intracranial hemorrhage can be classified as:
  - Extradural (arterial)
    - “talk and die,” classically this is due to laceration of the middle meningeal artery by a temporal bone fracture.
  - Subdural (venous)
    - The hematoma covers the entire hemisphere.
  - Intracerebral
- Diffuse Brain Injury
  - Mild concussion
    - Confusion ± amnesia
  - Classic Concussion
    - Loss of consciousness (LoC)
  - Diffuse Axonal Injury
    - LoC, coma, autonomic dysfunction (e.g., labile blood pressure).

Acceleration–deceleration of the pediatric brain inside the skull leads to mechanical trauma to the brain focally (*coup*) and at the opposite pole (*countercoup*) giving rise to focal injuries.

Following the **primary brain injury** there is release of inflammatory mediators such as the amino acids glutamate and aspartate that can cause neuronal cell death by apoptosis. This is followed by cerebral edema that can be further aggravated by poor cerebral perfusion due to hypoxia, hypotension, and hyperthermia leading to an extensive **secondary brain injury**. Active treatment of primary brain injury (e.g., avoidance of hypoxia, acidosis, and appropriate fluid management) may minimize this **secondary brain injury**.

**Monro–Kellie Doctrine****(Volume of intracranial content is fixed in a rigid box.)**

An expansile mass can only move out the liquid component (e.g., venous blood, CSF).

**Compensated:** → Intracranial pressure (ICP)

**Uncompensated:** ↑↑ ICP

**Cerebral Perfusion Pressure (CPP) = Mean Blood Pressure – ICP**

**Normal ICP ~ 10 mmHg (=13.6 cmH<sub>2</sub>O)**

Hematoma and cerebral edema reduce intracranial content leading to net outflow of blood and CSF and a rising ICP and falling cerebral perfusion. Ultimately, brain herniation occurs through the foramen magnum.

### 10.3 Clinical Assessment

Repeated neurological assessments using the **Glasgow Coma Scale (GCS)** may differentiate traumatic brain injury from clinically important traumatic brain injury (ciTBI) (Table 10.1).

In addition to mode of injury and presence of LoC, it is important to be aware of persistent vomiting, abnormal behavior, headache, and any seizures. Complete neurological examination including assessment of the cervical spine should be repeated frequently to assess changing status. The pupils should be assessed for their reaction to light and whether they match the other side.

**Table 10.1** Glasgow coma scale

|                     | Child                   | Infant                     | Score |
|---------------------|-------------------------|----------------------------|-------|
| Eye(s) opening      | Spontaneous             | Spontaneous                | 4     |
|                     | To Speech               | To speech                  | 3     |
|                     | To Pain                 | To pain                    | 2     |
|                     | No response             | No response                | 1     |
| Verbal response     | Oriented, appropriate   | Coos and babbles           | 5     |
|                     | Confused, inappropriate | Irritable cries            | 4     |
|                     | Inappropriate words     | Cries to pain              | 3     |
|                     | Inappropriate sounds    | Moans to pain              | 2     |
|                     | No response             | No response                | 1     |
| Best motor response | Obeys commands          | Spontaneous, purposeful    | 6     |
|                     | Localizes pain          | Withdrawal from touch      | 5     |
|                     | Withdrawal from pain    | Withdrawal from pain       | 4     |
|                     | Flexion to pain         | Abnormal flexion to pain   | 3     |
|                     | Extension to pain       | Abnormal extension to pain | 2     |
|                     | No response             | No response                | 1     |



### 10.3.1 S-100B Protein

This may be a specific marker of brain parenchymal injury. It is found in glial cells and released into circulation after head injury. Its best use might be to identify those children with mild injury to avoid a CT Scan head. The serum level above which S - 100 B protein becomes pathological is more than 0.105 mg/L.

### 10.3.2 Imaging

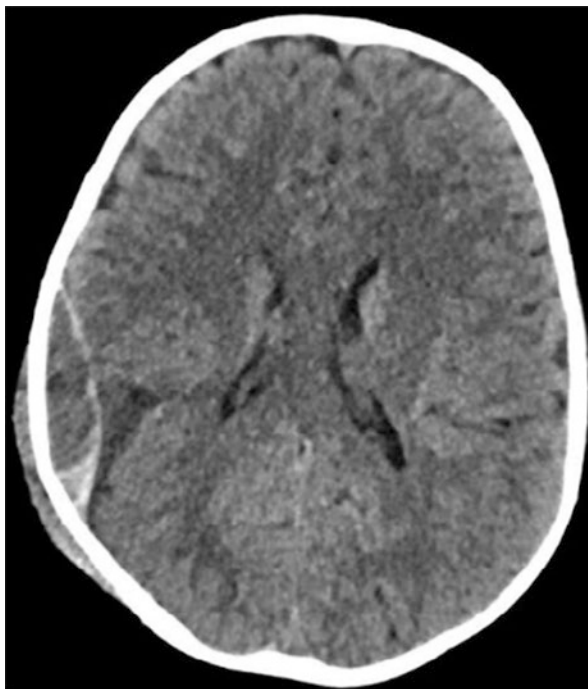
- Plain skull X-rays
  - Have a limited role in evaluating head injury although it may show extent of a skull fracture.
  - Skeletal growth centers in the skull and spine can resemble fractures, hence should be interpreted carefully.
- Cervical spine imaging
  - Both AP and lateral views.
  - Severe head injury may be associated with a neck injury in 10% of cases.
  - **Spinal cord injury without radiographic abnormality (SCIWORA)** may be seen in two-third of children who had spinal cord injury.
- CT scan, may be indicated in:
  - Penetrating or depressed skull fracture.
  - Seizure.
  - Persistent vomiting.
  - Retrograde amnesia of more than half an hour duration.
  - Localized neurological features.
  - Base of skull fracture.
  - GCS scale <13 at any point since the injury.
  - Children under 2 years
    - GCS = 14 with altered level of consciousness or behavior or basilar skull fracture or loss of consciousness for  $\geq 5$  s.
  - Children above 2 years of age
    - GCS = 14 with altered behavior or basilar skull fracture, history of vomiting, severe headache, or severe mechanism of injury (Figs. 10.1 and 10.2).

### Severity Assessment and Management

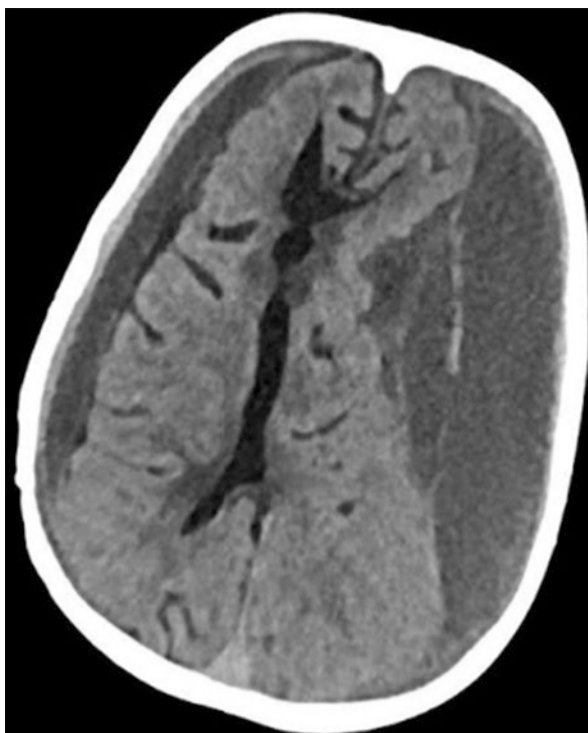- Always begin with an assessment of **Airway, Breathing, and Circulation**.
- After ensuring a clear airway, protect the cervical spine.
- The pediatric **Glasgow Coma Scale (GCS) for under 2 years of age** or **Glasgow Coma Scale Score** still forms the basis for defining the severity of head injury.
  - GCS 13–15: Mild Head Injury.
  - GCS 9–12: Moderate Head Injury
  - GCS 3–8: Severe Head Injury.

*The goal of management is to treat the primary brain injury and prevent or minimize secondary brain injury.*

**Fig. 10.1** A CT scan is showing rt parieto-temporal subacute extradural hematoma after head injury



**Fig. 10.2** A CT scan is showing bilateral subdural hematoma after head injury



The basic principle of management of the head injury is based on measures to ensure adequate cerebral blood flow and perfusion to ensure proper oxygenation of brain tissue, bearing in mind the *Monro–Kellie doctrine*.<sup>1</sup>

Proper oxygenation of the brain may be achieved by giving **assisted ventilation** in those who have severe head injury (GCS score < 8), mid-facial trauma, or with evidence of hypoxia. There is no advantage of endotracheal intubation over bag-mask ventilation.

Hemostasis should be achieved by medical or surgical means and is mostly extracranial. Adequate crystalloid solution should be given to maintain a normal blood pressure and ensure cerebral blood flow. Hypotonic fluids should be avoided for fluid resuscitation or maintenance fluids and normal saline or Ringer's lactate solution should be used instead. Blood products should be transfused to restore intravascular volume, if needed.

Measures to reduce intracranial pressure includes:

- Hyperosmolar therapy
  - 20% mannitol solution
  - Hypertonic saline
- Hyperventilation
  - Aim for a PaCO<sub>2</sub> ~ 35 mm Hg (=4.7 KPa).
  - Hyperventilation should be considered only for a limited period.
- Sedation (barbiturates),
- CSF drainage
  - Lumbar puncture or via a fontanelle.
- **Decompressive surgery**
  - Includes evacuation of expanding hematoma by frontal craniectomy.

Look for physical signs of raised intracranial pressure:

- Cushing<sup>2</sup> reflex
  - ↑systolic blood pressure, ↓ heart rate and ↓ respiratory rate may give warning of impending brain herniation.
- Ipsilateral dilated fixed pupil may show third (Oculomotor) nerve compression especially of the ipsilateral parasympathetic fibers.

Intracranial pressure monitoring plays an important role in management of cerebral edema and prevention of brain herniation.

Seizures should be controlled by anticonvulsant such as phenytoin, but prophylactic anticonvulsants are not recommended.

---

<sup>1</sup>Alexander Monro Secundus (1733–1817) and George Kellie (1770–1829). Both from Edinburgh with the latter a pupil of the former.

<sup>2</sup>Harvey Williams Cushing (1869–1939) Archetypal American neurosurgeon working in Boston and Yale.

---

## 10.4 Prevention of Head Injuries in Children

Head injuries can be prevented in children by the following measures-

- Installing window guards to prevent falls out of open windows
- Using safety gates at the top and bottom of stairs
- Keeping stairs clear of clutter
- Using a nonslip mat in the bathtub or shower floor
- Using playgrounds with shock-absorbing materials on the ground.
- Using a seat belt.

---

### Further Reading

1. Gordon KE. Paediatric minor traumatic brain injury. *Semin Pediatr Neurol.* 2006;13:243–55.
2. Alexiou GA, Sfakianos G, Prodromou N. Pediatric head trauma. *J Emerg Trauma Shock.* 2011;4:403–8.
3. Kelmendi FM, Morina AA, Mekaj AY, et al. Serum S 100 B levels can predict computed tomography findings in pediatric patients with mild head injury. *Biomed Res Int.* 2018;2018:6954045.



Sunita Singh, Chandrasen K. Sinha, and Mark Davenport

## 11.1 Introduction

Injuries involving the chest are one of the most lethal, after the intracranial injuries. However, it is usually the associated injuries that determine the ultimate outcome.

Children <10 years are more likely to develop hypoxia because of lower functional residual capacity to total lung volume ratio, and a higher rate of tissue oxygen consumption.

The mediastinum is more mobile in children allowing rapid development of tension pneumothorax, and the increased mobility of viscera leads to a greater risk of kinking of the great vessels, reducing preload leading to shock.

By 13 years of age, the chest wall responds to trauma more like that of an adult.

## 11.2 Mechanisms of Injury

- Blunt (85%): MVA, Bicycle related, sports related, falls from height, and blast injury.
- Penetrating (15%): Knives, gunshot, impalement on railings, or fence posts.

---

S. Singh (✉)  
AIIMS, Raipur, Chhattisgarh, India

C. K. Sinha  
St George's Hospital, London, UK

M. Davenport  
King's College Hospital, London, UK

## 11.3 Anatomy

Cardiopulmonary structures are protected by the bones and muscle of the chest wall allowing just enough flexibility to breathe but resistance to most severe crushing or penetrating force. The pediatric thoracic wall is more compliant (due to thicker periosteum surrounding immature bone) allowing ribs to bend rather to break, and transfers a greater force to underlying thoracic organs. Visible rib fractures imply a greater degree of trauma in children than adults.

### 11.3.1 Surface Landmarks

|   |              |
|---|--------------|
| • Manubriosternal Angle of Louis <sup>1</sup> —insertion of the 2nd rib | T4/5 level   |
| • Vertebra prominens  | Spine of C7  |
| • Nipple line—Overlies the fourth intercostal space                     |              |
| • Diaphragm—Right dome higher than left                                 | T 9/10 level |

## 11.4 Principles of Management

- **Primary survey** for *immediately* life-threatening injuries: Airway obstruction, tension pneumothorax, open pneumothorax, massive hemothorax, flail chest, and cardiac tamponade.
- **Secondary survey** for *potentially* life-threatening injuries: Pulmonary contusion, myocardial contusion, aortic disruption, traumatic diaphragmatic rupture, tracheobronchial disruption, and esophageal disruption.

## 11.5 Rib Cage Injury

These range from contusion, through actual rib fracture (commonest 4th–9th) to multiple segmental involvements and a flail chest. Such trauma increases the work of breathing, either through inhibition due to pain or by rendering the actual mechanics of breathing impossible. There is a degree of inherent elasticity in the structure (anteroposterior rather than lateral) in children. So, sometimes, this results in severe lung parenchymal crush injury, yet, the shell remains intact.

### 11.5.1 Flail Chest

- $\geq 3$  ribs broken twice, or disarticulation of ribs from sternum.
- Paradoxical movement of the chest wall (i.e., moves inward on inspiration).

<sup>1</sup>Antoine Louis (1723—1792) French surgeon, also key figure in the development of guillotine!

### 11.5.2 Non-accidental Trauma/Child Abuse

Violent squeezing of the chest in non-accidental injury (NAI) can lead to multiple sequential rib fractures with less underlying lung injury. Often rib fractures due to NAI occurs in the posterior aspect of the rib, and may be difficult to diagnose. These can be key observations in the investigation of NAI. As posterior rib fractures are so difficult to diagnose in the acute phase, it is recommended that radiographs are repeated at about 10 days to look for the callus formation.

Note that rib fractures do not follow cardiopulmonary resuscitation (CPR) in children.

### 11.5.3 Investigation

1. CXR (AP and lateral)—are the first line investigations. N.B. cartilaginous ribs may not show injury. Ultrasound can diagnose rib fractures but it is very operator dependent.
2. Whole-body CT:
  - (a) Unenhanced head and cervical spine, and contrast-enhanced chest, abdomen, and pelvis CTs, for severe multi-trauma patients in children is debatable.
3. Extended-Focused Abdominal Sonography for Trauma (eFAST)
  - (a) Aimed to evaluate heart, abdominal organ, pelvis, and chest cavity and allows rapid identification of pneumothorax, hemothorax, and diaphragm rupture.
  - (b) Can be done when access to CT is limited.

### 11.5.4 Caveats and Atypical Injury

- First and second rib fracture—should be well-protected, presence implies significant blunt force. Beware of the injury to underlying subclavian vessels.
- Sternal fracture—seen in association with seat-belt use and steering wheel. Uncommon in children (because of ↑elasticity). Obtain ECG and cardiac enzymes.
- 10–12th rib fracture—suspect underlying liver, spleen, or kidney injury.
- Care is needed in interpretation of the ossification centers (most are fused by adolescence).

### 11.5.5 Management

1. Analgesia—multimodal
  - (a) NSAID, opiate-based regimen (including patient-controlled analgesia (PCA)).

- (b) Local infiltration at the fracture site.
  - (c) Epidural anesthesia.
2. Underlying lung contusional injury (see later).
  3. Treatment of a flail chest depends on its severity and functional impact; but endotracheal intubation and intermittent positive pressure ventilation (IPPV) removes the mechanical element of lung dysfunction, and analgesics. N.B. flail “stabilization” is controversial but ranges from simple “strapping,” to operative fixation.

---

## 11.6 Parenchymal Injury

Wide range of pathology from simple contusion through laceration, and segmental vessel injury to major hilar injury involving bronchus, tracheal, and pulmonary vessels. The effect of injury is manifest in three interrelated ways:

- Contusion—↓ventilation/perfusion (i.e., ↓pO<sub>2</sub>, ↑pCO<sub>2</sub>)
- Air leak (i.e., pneumothorax)
  - Open—penetrating
  - Closed
  - Tension—valve effect leading to accumulation under pressure
- Bleeding (i.e., hemothorax)

### 11.6.1 Clinical Features

Lung contusion is the commonest type of thoracic injury in children and results from blunt force trauma. The injury evolves from simple blood and edema inside alveoli to a widespread inflammatory reaction (*Adult* Respiratory Distress Syndrome—ARDS) over about 24 h. Secondary bacterial pneumonia is possible after 3–5 days.

### 11.6.2 Investigation

1. Chest XR—usually underestimates the degree of parenchymal injury. Alveolar bleeding pushes air out of the lung giving a similar appearance to liver tissue (*hepatization*). Non-segmental consolidation, often sparing the peripheral fields.
  - (a) Serial CXR needed to look for delayed appearing consolidation or the development of ARDS.
2. Chest CT scan—may overestimate the injury as it is able to diagnose small contusions of limited clinical significance.



3. Ultrasound may diagnose pulmonary contusions more rapidly because B lines from edema and alveolar disruption appear rapidly.
4. Arterial blood gas— $\downarrow$  O<sub>2</sub> saturation (<90%),  $\downarrow$ pO<sub>2</sub>,  $\uparrow$ pCO<sub>2</sub> (late).

### 11.6.3 Treatment

- Supportive—supplemental O<sub>2</sub>, CPAP, IPPV
- Avoidance of fluid overload, caution with blood products (exacerbates ARDS)

---

## 11.7 Pneumothorax

A “sucking” wound may be obvious, but a tension pneumothorax needs to be looked for. The key signs are hyperresonance, mediastinal shift (trachea, cardiac impulse), and  $\downarrow$ breath sounds. If untreated, this will cause impairment of venous return, caval kinking, hypotension, and death.

Surgical emphysema and crepitus imply that air is leaking from the pleural space into the subcutaneous tissues via fascial planes.

### 11.7.1 Investigation

1. Chest XR (in expiration if possible) is a better predictor of clinically significant injuries and outcomes. In the ventilated patients signs of a pneumothorax in the supine position are hyperlucency of affected hemithorax, a sharp heart border, a deep costophrenic sulcus with sharp margins, and a double diaphragm sign.
2. Chest CT scan—may overdiagnose clinically insignificant contusion and hemothoraces.
3. e-FAST—“*Lung sliding*” appears if the visceral and parietal pleura are free to slide over each other with respiration. Additionally, “*comet tail artifacts*” require the parietal and visceral pleura to be aligned for visualization. These occur when water under the visceral pleura vibrates. Both “*lung sliding*” and “*comet tails*” will be interrupted and abolished by subcutaneous emphysema, pleural adhesions, or air or blood distending the pleural and suggest the presence of a pneumothorax.

### 11.7.2 Treatment

- Urgent needle thoracostomy (followed by formal tube thoracostomy).
  - Second intercostal space, midclavicular line.

- Tube thoracostomy.
  - “Large-bore” but compatible with rib-space (~32 Fg. in an adolescent).
  - 4/5th intercostal space—anterior/midaxillary line.
  - Incise skin, blunt dissection through rib-space with artery forceps. Enter pleural cavity. N.B. “*Finger sweep*” is usually impossible in a child.
  - Insert tube (**Apex for Air, Base for Blood**).
- Open pneumothorax/ sucking—implies single-lung ventilation only.
  - Close/occlude defect in the chest wall via Vaseline© gauze, three-way occlusion dressing or actual suture closure and insertion of a chest tube at a different site.

---

## 11.8 Hemothorax

One side of chest can hold up to half of a child’s total blood volume. The key signs are dullness to percussion, ↓breath sounds, mediastinal shift (rarely), together with evidence of shock and impaired ventilation.

Retained blood in the pleural space may initiate a fibrotic reaction leading to atelectasis, lung entrapment, pneumonia, empyema, and ventilation/perfusion mismatch.

### 11.8.1 Investigation

1. Chest XR—may show fluid in pleural space (interpret supine and erect films differently).
  - (a) Air/fluid level or a “white-out.”
2. e-FAST

### 11.8.2 Treatment

- Tube thoracostomy (large bore) (as above).
- **Thoracotomy:**
  - Major vascular injury suggested by either massive hemothorax (**15 mL/kg initially after chest tube insertion**) or ongoing bleeding (>7 mL/h in first hour or 3–4 mL/kg/h or >4% of the body blood volume).
  - Possible intervention includes oversewing of lacerations, repair of central bronchovascular injury, etc.
- **Video-assisted thoracoscopy (VATS)**
  - Is indicated in non-critical, and in persistent non-major vessel-bleeding hemothorax for pleural space debridement. VATS is considered to have lower ARDS rates in comparison to an open thoracotomy.

---

## 11.9 Great Vessel Injury

- Rare but still possible.
  - Usually seen in sudden profound deceleration injury causing swinging of heart on great vessels (“*bell clanger*” effect). The ligamentous attachment of the descending aorta to the left pulmonary artery is the most common site. Possible signs include evidence of aortic dissection (e.g., impalpable distal limb pulses).
- CT angiography is indicated for mediastinal or cervical inlet hematoma.
- Intervention remains the province of the cardiothoracic surgeon.

### 11.9.1 Aortic Injury

- MVA is most common, followed by penetrating trauma.
- Thoracic aorta is most commonly injured.
- Chest X-ray may show a widened mediastinum. Angiography is diagnostic.
  - Open repair on cardiopulmonary bypass (gold standard).
  - Endovascular aortic stent graft repair.
- Overall survival ~50%.

---

## 11.10 Tracheobronchial Injury

- Very rare incidence  $\leq 0.05\%$ .
- Due to either penetrating injury or a crush injury of the thorax.
- ~80% occurs within 2 cm of the carina in the trachea or mainstem bronchus.
- Suggested by non-resolving air leak with pneumomediastinum and features of hemopneumothorax.
- Diagnosis by flexible /rigid bronchoscopy or virtual bronchoscopy.
- Most pneumomediastinum resolves spontaneously. But may need:
  - Low flow oxygen supplementation (enhances air absorption), prophylactic antibiotics, and absolute bed rest.
  - For unstable and major air leaks a thoracotomy and primary repair with flap coverage of pleura/ muscle.

---

## 11.11 Cardiac Injury

This is seen either with penetrating injuries (right > left ventricle), or as a result of severe central blunt force trauma ( $\pm$ sternal fracture). Possible injuries ranging from contusion, pericardial effusion, and tamponade to laceration, septal defects, and acute valve dysfunction.

Pericardial tamponade causes muffled heart sounds, impaired venous return (distended neck veins), and diminished cardiac output (Beck's Triad). The pulse pressure narrows as the degree of tamponade increases.

### 11.11.1 Commotio Cordis<sup>2</sup>

A severe direct blow to the precordium triggers ventricular fibrillation or other fatal arrhythmias that quickly deteriorate. Typically seen in sports injury (e.g., cricket, baseball, soccer, lacrosse, and karate) or steering wheel trauma. The treatment is urgent defibrillation within 1–2 min and anti-arrhythmic drugs.

#### 11.11.1.1 Investigations

1. ECG (arrhythmias, ST elevation, etc.)
2. Troponin I
3. Sub-xiphoid view in eFAST
4. Echocardiography if hemodynamic instability and arrhythmia

Specific treatment is outside the remit of this book, but needle pericardiocentesis of the tamponade is an achievable object (ECG controlled, sub-xiphoid approach—aiming for the tip of left scapula).

### 11.11.2 Myocardial contusion

- The most common pediatric cardiac injury.
- Substernal chest pain following blunt chest trauma is indicative of myocardial contusion.
- Dyspnea, hypotension, and cardiac arrhythmias.
- Late complications can be aneurysm formation and possibly cardiac rupture.

#### 11.11.2.1 Investigations

- ↑ troponin (debatable in pediatric patients)
- ECG shows S-T changes, arrhythmias, or heart block
- Echocardiography

### 11.11.3 Treatment

- Treat arrhythmia
- Thoracotomy and repair of structural defect

---

<sup>2</sup>Latin—agitation of the heart.

## 11.12 Diaphragm Injury

Penetrating injury and severe blunt trauma to the abdomen can cause a blow-out injury (left >>right) causing posterolateral tearing. Right-sided injuries are almost inevitably associated with severe liver injury (often caval) and frequently fatal.

Diaphragm injuries are frequently missed during the first 24 h and sometimes only diagnosed intraoperatively.

Delayed presentation is possible as visceral herniation is a secondary phenomenon, and may lead to small bowel obstruction, presenting some weeks after the initial trauma.

### 11.12.1 Investigation

1. Chest XR and abdominal XR—blurring of hemidiaphragm is the first clue, but ~50% appear “normal.” If the stomach is herniated, the nasogastric tube may be deviated in the thorax.
2. US and CT scan—70–100% sensitive to identify visceral herniation, or lack of muscular integrity.

### 11.12.2 Treatment

- Nasogastric decompression.
- Diaphragm repair—abdominal approach if associated visceral injury. If demonstrably an isolated injury then thoracoscopic repair could be considered.
- Indications for VATS in severely injured patients:
  - Penetrating injury with little blood loss in a stable patient.
  - Persistent hemothorax.
  - Delayed developing empyema.
  - Persistent air leakage.
  - Suspicion of diaphragmatic rupture.
- Contraindications to VATS: Hemodynamic unstable patient with severe chest wall or cardiac vessels injuries and need for massive transfusion.

---

## 11.13 Esophageal Rupture

This may be due to a penetrating wound or gunshot injury. Alternatively, a sudden increase in intra-abdominal pressure may cause lower esophageal injury. This usually presents as a left pleural effusion with chest pain, fever, subcutaneous emphysema, dysphagia, tachycardia, and leukocytosis. Mediastinitis can be fatal if ignored.

### 11.13.1 Investigation

1. Chest X-ray—wide mediastinum, subcutaneous emphysema, pneumomediastinum, pneumothorax, and pleural effusion.
2. Neck X-ray—visible air under the pretracheal fascia.
3. Water-soluble contrast esophagogram (dye leak).
4. Diagnostic rigid esophagoscopy or endoscopy.

### 11.13.2 Treatment

- Small contained perforation: IV antibiotics, total parenteral nutrition, pleural drainage. Most children respond to conservative management.
- Mediastinitis: First stabilize the patient with IV fluids and antibiotics. Consider **thoracotomy** to drain the mediastinal contamination.
- Early (<24 h)—primary repair.
- Delayed (>24 h)—an exclusion procedure, i.e., cervical esophagostomy and feeding gastrostomy/ jejunostomy. This mandates a reconstructive second operation.

---

## 11.14 Traumatic Asphyxia (a.k.a. Crush Asphyxia) (Perthes<sup>3</sup> Syndrome)

This is global hypoxia due to inability to expand the chest against external compression by heavy object in conjunction with deep inspiration against a closed glottis. It typically occurs during a crush injury.

- Clinical features include:
  - Facial/ neck/ chest petechiae; facial edema, cyanosis, and subconjunctival hemorrhage.
- Neurologic findings include:
  - Altered mental status, brachial plexus injuries, and even coma.
- Ocular signs:
  - Hemorrhage into retina, vitreous body, or optic nerve, and can result in vision loss.

Immediate removal of the compressive forces allows resumption of breathing and recovery and is the first stage to recovery. Adequate oxygenation and adequate cerebral perfusion needed to promote healing and avoid secondary neurological injury.

---

<sup>3</sup>Georg Clemens Perthes (1869–1927) German surgeon. Also, named for the femoral necrosis seen in young boys.

---

## Further Reading

1. Pearson EG, Fitzgerald CA, Santore MT. Pediatric thoracic trauma: current trends. *Semin Pediatr Surg.* 2017;26:36–42.
2. Reynolds SL. Pediatric thoracic trauma: recognition and management. *Emerg Med Clin N Am.* 2018;36:473–83.
3. Desai N, Harris T. Extended focused assessment with sonography in trauma key points. *BJA Educ* [Internet]. 2018;18:57–62 [cited 2019 Nov 18]. Available from <https://www.rcemlearning.co.uk/references/>
4. Meltzer JA, Stone ME, Reddy SH, Silver EJ. Association of whole-body computed tomography with mortality risk in children with blunt trauma. *JAMA Pediatr.* 2018;172:542–9.
5. Kenefake ME, Swarm M, Walthall J. Nuances in pediatric trauma. *Emerg Med Clin N Am.* 2013;31:627–52.



Ramnik V. Patel, Chandrasen K. Sinha, and Mark Davenport

*Abdominal trauma is present in approximately 25% of pediatric patients with major trauma and is the most common cause of unrecognized fatal injury.*

## 12.1 Epidemiology

- M >> F with ethnic factors
- Bimodal age distribution (toddlers and teenagers), non-accidental injury in infants.
- Summer > winter

## 12.2 Mechanism of Injury

- Blunt (90%)
  - Falls, RTA, bicycle related
  - Kidney (25%), spleen (25%), and liver (15%)

---

R. V. Patel  
Memorial Sloan Kettering Cancer Center, New York, NY, USA

C. K. Sinha  
St George's Hospital, London, UK

M. Davenport (✉)  
King's College Hospital, London, UK



- Penetrating (10%)
  - Knives, gunshot, and impalement injuries
  - Small bowel (20%), colon (15%), and stomach (10%)
- Combined

### 12.2.1 Factors Predisposing to Abdominal Injury in the Child

- Shape—square becoming more rectangular with age.
- Thinner abdominal wall musculature. Lower abdominal fat content.
- Flexible ribs.
- Solid organs are anterior and comparatively larger in the child (more surface area is exposed).
- The bladder is intraabdominal.
- **“Seat Belt injury”**
  - Causes peculiar flexion-distraction injury to the lumbar spine (**Chance fracture<sup>1</sup>**) as it acts as a fulcrum.

---

## 12.3 Clinical Features

The key element in the history is the precise nature and circumstances of the traumatic episode and the degree and type of force that caused it. This should lead to a raised index of suspicion if there is no external evidence of injury.

Various signs of injury include abrasions and contusions, tenderness, seat belt sign, distention, (associated with bleeding or intraperitoneal air), and a scaphoid abdomen (e.g., traumatic diaphragmatic hernia). In addition to abdominal wall bruising, the **“seat belt syndrome”** also includes vertebral fractures and abdominal injuries from compression of intra-abdominal organs between the seat belt and the bony vertebral column. Intraperitoneal blood may be evident after 24 h as bruising in the loins (**Grey-Turner’s sign<sup>2</sup>**) or around the umbilicus (**Cullen’s sign<sup>3</sup>**). Rarely, the scrotum may act as a repository for air, blood, or fluid from intraperitoneal injury.

---

## 12.4 Management (See Also Chap. 9)

- **ABC + Secondary Surgery + Tertiary Survey (usually performed >24 h after admission and aims to identify missed or hidden injuries).**

---

<sup>1</sup>G.Q. Chance—British radiologist who described three cases in 1948, later associated with seat-belt injury in 1965.

<sup>2</sup>George Grey-Turner (1877–1951)—English surgeon, who reported this as late sign of hemorrhagic pancreatitis.

<sup>3</sup>Thomas Stephen Cullen (1868–1953)—Canadian gynecologist, who mentioned sign in connection with ectopic pregnancy.

### 12.4.1 Investigations and Imaging

- FBC, hematocrit, urinalysis, liver function tests, and amylase (occasionally lipase).
- X-ray
  - Commonly performed as a part of secondary survey including spine series, AP chest, and pelvis series. Specific abdominal X-ray may show free air.
- CT scanning (double contrast, i.e., IV for solid organ injury and oral selectively for stomach, duodenum, and proximal bowel).
  - This is currently the standard tool for the assessment of significant abdominal injury in the hemodynamically stable child.
- Ultrasound (**Focused Assessment by Sonography in Trauma—FAST**)
  - FAST is mainly used and evaluated in adults and those who are hemodynamically unstable. Its aim is to detect free fluid, and is highly sensitive in this role. It is also operator dependent, and lacks specificity providing no real information on the grade of organ injury. Currently, it cannot be recommended to replace CT scanning in children.
- Diagnostic peritoneal lavage
  - Limited role in children because positive result does not necessarily require laparotomy. May be considered if:
    - CT scanning is not available.
    - In a hemodynamically unstable child with suspected bleeding from an intraabdominal injury or in the ICU.
    - Other injuries (e.g., head or orthopedic injuries) requiring immediate surgical intervention and with no time for CT scanning.
- Emergent laparoscopy
  - Role is yet to be defined, but should be considered in suitable patients. Should reduce the incidence of negative laparotomies. Indicated in blunt abdominal trauma with suspicious examination findings (e.g., abdominal wall contusions, peritonitis, falling hematocrit with free intraperitoneal fluid but no radiographic solid organ injury). In penetrating injury, accompanied by local wound exploration; then laparoscopic survey may replace the need for formal laparotomy.
- Interventional radiology.
  - Diagnostic angiography and therapeutic embolization may be considered in on-going liver/spleen bleeding.
- ERCP
  - Specific role in the determination of bile and pancreatic duct injury.
- Exploratory laparotomy
  - Indicated as a diagnostic procedure in:
    - Hemodynamically unstable with unequivocal abdominal signs.
    - Penetrating injuries.

### 12.4.2 Hemodynamically “Unstable” vs. “Stable”

This concept underlies a key principle in the management of abdominal trauma but definition tends to be imprecise.

Initial volume resuscitation should begin with a bolus of 10 mL/kg of crystalloid solution, and maybe repeated with a blood transfusion to follow (e.g., 10 mL/kg of packed RBC). The topic of **damage control resuscitation** has become increasingly popular in the recent past. This topic involves several key concepts that include **permissive hypotension** (restrictive fluid resuscitation, balanced resuscitation), which is a strategy that restricts fluid use before any bleeding is controlled to avoid excessive blood loss. American College of Surgeon’s Advanced Trauma Life Support (ATLS) training program emphasizes a “balanced” approach to ensure adequate tissue perfusion and minimize the risk of rebleeding by avoiding inadequate or excessive fluid administration. Moderate fluid resuscitation should be considered to determine patients’ response to the initial fluid resuscitation in trauma patients.

### 12.4.3 Nonoperative Management of Blunt Abdominal Trauma (~95%)

This concept was introduced in the late 1970s, initially for splenic injury, and is currently accepted as the standard for most solid organ injury and is successfully applied in about 95% of the time. It includes:

- Bed rest and hemodynamic monitoring (for at least 24 h)
- Serial hematocrit
- Frequent physical examinations

There should be a restriction on sporting activities after discharge from hospital for up to 4 weeks (depends on the grade of injury).

### 12.4.4 Interventional Radiology

Minimally invasive techniques now play a larger role in stopping bleeding or drainage of collections. Examples would include embolization of hepatic arterial pseudoaneurysms following liver injury and percutaneous drainage of urinomas and pseudocysts following renal and pancreatic injury respectively. Pelviureteric stents may be placed cystoscopically or percutaneously; pancreatic duct stents via an ERCP may be used to improve organ function.

---

## 12.5 Laparotomy for Abdominal Trauma (~5%)

Indications include:

- Unstable/shocked cases
- A transfusion requirement of  $\geq 40$  mL/kg within a 24-h period *probably* mandates laparotomy and intervention.
- Penetrating injuries (see later).
- Specific organ injury (e.g., hollow viscus injury—stomach, small and large bowel, bladder, and diaphragm laceration).

### 12.5.1 Principles

- Midline incision (“Hey diddle diddle, right down the middle”).
- Four quadrant packing and inspection for injury of each in turn.
- **Damage control surgery**
  - Extensive, prolonged surgery in multitrauma patients is associated with a potentially lethal combination of metabolic acidosis, coagulopathy, and hypothermia. A multistage approach is therefore preferable.
  - **Phase I**  
Short primary operation to control bleeding and prevent contamination (stapling/oversew of intestinal lacerations, etc.).  
Phase II—ICU resuscitation.  
Phase III—reoperation (>24 h) and definitive repair of a specific injury.

---

## 12.6 Penetrating Injuries

While exposure to motor vehicles and falls from a height is fairly ubiquitous scenarios for children in the developed world; exposure to guns, knives, etc. is highly variable. Mostly, this is seen as an urban problem and confined to specific areas.

The at-risk population is 10–24 year-old males, and in the USA, gun-related (usually) homicides (~17%) are second only to motor vehicle crashes (~40%) in terms of cause of death.

- Black > white
- Adolescents
- Males >> females

Most penetrating abdominal injuries involve violence, but at least in children, gunshots tend to be accidental while knife injuries are all too deliberate.

The degree of injury with most gunshots is related to the kinetic energy of the missile fired, and therefore, a product of the projectile mass and the square of its velocity. Thus, it can be divided into:

- Low velocity (<250 m/s)
  - Most civilian handguns, shotguns, etc.
- Track injury, little cavitation effect.
- High velocity (750–1000 m/s)
  - Military rifles.
- Track injury and ↑ cavitation
  - Increased potential for massive soft-tissue injury perpendicular to track.

According to the principles above with the addition of mandatory definition of the trajectory of blade or bullet. What starts off in the chest may well end up in the abdomen—transiting the diaphragm in the process.

- Plain radiographic films (radiopaque markers at entry and exit wounds)
  - Pneumoperitoneum
- CT scan (ideally triple contrast) for solid and hollow organ injury
- Poor prognostic features include:
  - Arrival measurements of initial core temperature of <34 °C
  - Systolic blood pressure of <90 mmHg

In general, formal laparotomy is still the usual surgical option in (definitely) penetrating injuries. In certain areas with a high prevalence of such injuries (e.g., South Africa), a policy of “wait and watch” has been adopted for those who are otherwise stable and have no obvious signs of peritonism.

Laparoscopy may be used in selected cases (e.g., diaphragmatic injury, tangential gunshot wound in hemodynamically stable cases).

### 12.6.1 Laparotomy

- Small bowel injury.
  - >50% of circumference involved—aim for resection.
  - <50%—aim for repair.
- Colon injury
  - Depends on the time to laparotomy ( $\geq 24$  h), associated injuries, and degree of fecal contamination. For most cases, primary repair without covering colostomy is practical.
- **Impalement injuries** are uncommon, but the recommendation is to leave them in place until they can be removed in the operating room because of the potential for bleeding.

**Table 12.1** Spleen injury scale

| Grade | Descriptors  |
|-------|--|
| I     | Subcapsular hematoma (<10% surface area)<br>Capsular laceration (<1 cm deep) |
| II    | Subcapsular hematoma (10–50% surface area)<br>Laceration (1–3 cm deep)       |
| III   | Subcapsular hematoma (>50%), ruptured<br>Parenchymal hematoma (>5 cm)        |
| IV    | Hilar or segmental vessel injury ± major (>25%)<br>devascularization         |
| V     | Hilar injury + devascularization<br>Shattered spleen                         |

Notes—If multiple lacerations, advance one grade  
Adapted from American Association for Surgery of Trauma

## 12.7 Specific Organ Injury

### 12.7.1 Splenic Injury

Commonly injured in blunt abdominal trauma. In case of an apparently innocuous injury, suspect the underlying splenic pathology (e.g., malaria). Most injuries can be treated conservatively, but usually the reason for failure is continued bleeding (Table 12.1).

#### 12.7.1.1 Surgical Options

- Splenectomy
  - For example, Grade IV/V) total or partial
- Splenorrhaphy
  - For example, Grades II/III/IV
- Direct suture/Argon Beam coagulator
- Topical agents
  - For example, SURGICEL™ (Ethicon Inc.); CoSeal™ (Baxter) fibrin glue; TachoSil™ (Baxter)
- Absorbable mesh
  - For example, Dexon™ (Davis & Geck), VICRYL™ (Ethicon)
- Splenic autotransplantation
  - Omental pocket, etc.

### 12.7.2 Liver Injury

Common organ (because of size) to be the target of blunt force trauma, and typically involves the posterior segments of the right lobe. CT scans tend to overestimate the degree of injury, and again, most (>90%) can be treated nonoperatively (Table 12.2).

**Table 12.2** Liver injury scale

| Grade | Descriptors  |
|-------|--|
| I     | Subcapsular hematoma (<10% surface area)<br>Capsular laceration (<1 cm deep)                               |
| II    | Subcapsular hematoma (10–50% surface area)<br>Laceration (1–3 cm deep)                                     |
| III   | Subcapsular hematoma (>50%), ruptured parenchymal hematoma (>10 cm)<br>Laceration (>3 cm)                  |
| IV    | Laceration—disruption of <75% of lobe or up to three segments  |
| V     | Laceration—disruption >75% of lobe, or more than three segments<br>Juxta-venous injury (hepatic veins/IVC) |
| VI    | Avulsed liver  |

Notes—If multiple lacerations, advance one grade  
Adapted from American Association for the Surgery of Trauma

### 12.7.2.1 Surgical Options

- Temporary vascular control (Pringle's<sup>4</sup> maneuver).
  - Sling or finger around the portal triad, through the lesser omentum. Stops portal venous and arterial inflow.
  - In case of persisting significant bleeding from injury site, suspect caval or hepatic vein laceration/avulsion.
- Topical agents (as above)/Argon beam coagulator/fibrin glue.
- Perihepatic packing.
  - Large operative gauze packs compressing RUQ. Close abdomen, and remove after 24 h.
- Embolization
  - May complement the above in acute stage, or as definitive treatment for pseudoaneurysm.
- NB—partial hepatectomy, etc. is unwise outside of specialist centers.

Late complications include:

- Biliary leak (5%)
  - Second week postinjury.
- Pseudoaneurysm formation and delayed hemorrhage.
- Hemobilia
  - Bleeding into the biliary tract.
- Bilhemia
  - Bile leaking into the bloodstream.
- Abscess formation.

<sup>4</sup>James Hogarth Pringle (1863–1941) Glasgow surgeon describing this in 8 patients in 1908.

## 12.8 Renal Injury

Relative lack of perirenal fat may predispose to injury in children. This usually involves parenchymal contusions, but injury to the ureteropelvic junction or the vascular pedicle may occur.

- Blunt (90%) >> penetrating—although latter, much more likely to be serious.
- Hematuria (microscopic or frank) and flank mass.

Most (>95%) can be treated conservatively, but the indications for intervention (surgical or radiological) include:

- Expanding retroperitoneal hematoma
- Vascular pedicle injury
  - Nonfunction on contrast CT scan
- Urinoma

Nephrectomy is the usual outcome of surgical exploration for major vascular injury. Partial nephrectomy should be possible for parenchymal lacerations/devascularizations, etc. The retroperitoneal space can be approached by incision and reflection at the paracolic gutters (Cattell-Braasch (right) and Mattox (left) maneuvers), elevating and mobilizing the overlying viscera.

---

## 12.9 Pancreatic Injury

The usual mechanism of injury is a sharp blow to the epigastrium (bicycle, horse kick, etc.) which compresses the neck of the pancreas onto the underlying vertebral column. This splits the parenchyma and lacerates the duct. Presentation is usually delayed, as bleeding is not a problem. Presence of **duct injury is the single most important prognostic feature** (CT scan suggestive, ERCP definitive), and leads to pancreatitis and pseudocyst formation.

Possible interventions include:

- Distal pancreatectomy
  - If duct injury is recognized early enough and is a left-sided injury.
- ERCP and stenting
  - If older child or adolescent.
- Fatalism—allow pseudocyst to form and then intervene.
  - Aspiration (percutaneous ± drain)
  - Endoscopic or open cystogastrostomy



---

## Further Reading

1. Schonfeld D, Lee LK. Blunt abdominal trauma in children. *Curr Opin Pediatr.* 2012;24:1–5.
2. Lynch T, Kilgar J, Al Shibli A. Pediatric abdominal trauma. *Curr Pediatr Rev.* 2018;14(1):59–63.
3. Kim JH, Ko Y, Jung K. Damage control resuscitation in children. *PEMJ.* 2019;6(1):1–10.
4. American College of Surgeons. Pediatric trauma In: American College of Surgeons Committee on Trauma, editor. *Advanced trauma life support for doctors: student course manual.* 9th ed. Chicago: American College of Surgeons; 2012.
5. Hirschberg A, Mattox KL, editors. *Top knife: the art and craft of trauma surgery review.* North Shrewsbury: TFM; 2004.

---

## **Part III**

# **Neonatal Surgery**



# Developmental Lung Lesions

# 13

Pablo Laje

## 13.1 Embryology

The development of the human lung goes through six separate stages to form a mature tracheobronchial progression of each stage highly coordinated process and guided by mesenchymal–epithelial interactions under the influence of a number of regulatory growth factors (Table 13.1).

Most lung lesions appear to develop at different time points during the **pseudoglandular stage**, with the exception of pulmonary agenesis, which occurs during the **embryonal stage**.

**Table 13.1** Development of the lung

| Stage           | Gestational age          | Description   |
|-----------------|--------------------------|---|
| Embryonic       | 26 days to 6 weeks       | From formation of laryngotracheal bud arising from the anterior portion of the aerodigestive tract to division into lobar and segmental bronchi |
| Pseudoglandular | 5–16 weeks               | Development of the preacinar airways and blood vessels, growth of the bronchial tree, and development of all bronchial divisions                |
| Canalicular     | 16–24 weeks              | Capillary growth toward the respiratory epithelium marking the future blood–air interface   |
| Saccular        | 24–36 weeks              | Widening of peripheral air spaces distal to the terminal bronchioles with septa formation   |
| Alveolar        | 36–term                  | Formation of secondary septa and budding alveoli  |
| Microvascular   | Up to 2 years post-natal | Further alveolar development and maturation   |

P. Laje (✉)

Division of General, Thoracic and Fetal Surgery, Children’s Hospital of Philadelphia, Philadelphia, PA, USA

e-mail: [LAJE@email.chop.edu](mailto:LAJE@email.chop.edu)

---

## 13.2 Prenatal Diagnosis

Ultrasonography (US) is usually the first step in the prenatal evaluation of a congenital lung lesion. Serial scans are important to evaluate the prenatal behavior of the lesions, allowing planning of the pre-, peri-, and post-natal management on a case-by-case basis. We routinely perform fetal **ultrafast magnetic resonance imaging (fMRI)** on all cases of prenatally diagnosed lung lesions to define further their anatomy, to evaluate the potential effects that the lesions can exert on surrounding structures, and to search for associated anomalies. That being said, since the quality of the high-resolution U/S images improves constantly, the need for a fMRI in this context is declining.

---

## 13.3 Pulmonary Agenesis

- True pulmonary agenesis is quite rare, but varying degrees of hypoplasia are not that uncommon.
- Spectrum varies from blind-ending main bronchus with no lung tissue to malformed bronchus and poorly developed lung tissue.
- Cardiac, GI, GU, or skeletal anomalies may be present (~50%).
- Prognosis depends (1) degree of hypoplasia, (2) degree of development of contralateral lung, (3) lung volume, and (4) prognosis of their associated anomalies.
- Overall mortality ranges from 70 to 95%.

---

## 13.4 Bronchopulmonary Sequestration (BPS)

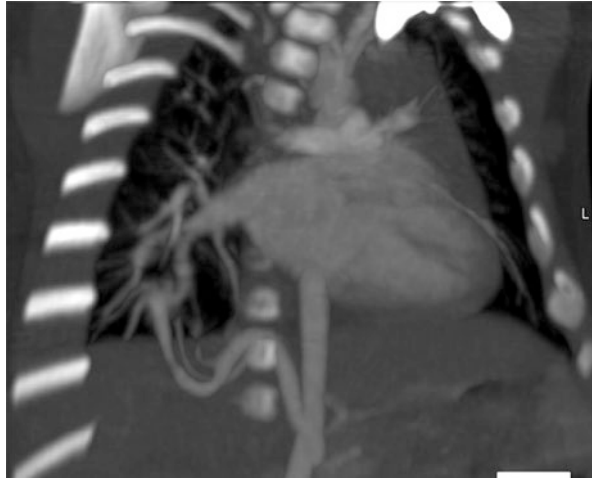### Definition

Nonfunctioning mass of lung parenchyma, isolated from the normal tracheo-bronchial tree, with an independent arterial blood supply arising from systemic circulation.

The venous drainage of a BPS is common to the azygous or hemizygous veins, but can also be to the pulmonary veins (Fig. 13.1). There is an exaggerated yet futile circulation through the BPS, out of proportion to the actual volume of lung tissue supplied.

BPS are subdivided into two types:

**Fig. 13.1** Right lower lobe. Intralobar sequestration showing a large systemic vessel arising from the abdominal aorta, and drainage into the inferior pulmonary vein



- **Extralobar sequestration** (75%)—separate investment of pleura and completely isolated from other lobes.
  - Commonly located in the lower hemithorax.
  - Males >> females.
  - Occasionally are associated with diaphragmatic hernias.
  - Can be located within, or even below the diaphragm.
- **Intralobar sequestration** (25%)—shared pleura with the surrounding lung, and are an integral part of the lobe in which they are located.
  - May have CCAM features, in which case the lesion is called “**hybrid lesion.**”

### 13.4.1 Clinical Features

Most are detected by routine antenatal US. They rarely cause prenatal symptoms such as hydrothorax due to the presence of lymphatic congestion. Postnatally, most are asymptomatic (particularly the extralobar BPS), but a number of complications can develop:

- Infection—despite lack of bronchial connection but more common in intralobar BPS.
- High-output cardiac failure: tachypnoea, tachycardia, cardiomegaly. Occurs as a result of the high-volume shunt caused by the systemic perfusion.

### 13.4.2 Postnatal Investigations

- CXR—typically solid, basal lesion.
- CT (with IV contrast) scan.

### 13.4.3 Postnatal Management

- Symptomatic BPS needs a surgical resection, either by thoracotomy or by thoracoscopy.
- Asymptomatic BPS can be resected surgically or managed expectantly. The approach varies widely around the world, and there is no consensus on what happens in the long-term to lesions that are not resected.

## 13.5 Congenital Cystic Adenomatoid Malformation<sup>1</sup>

### Definition

A multicystic mass of lung parenchyma with an overgrowth of immature bronchioles and a paucity of alveoli.

### 13.5.1 Classification

The original classification of Congenital Cystic Adenomatoid Malformation (CCAM) was based on histological assessment of resected lung tissue and popularized<sup>2</sup> by Col. JT Stocker who divided CCAMs into three types depending on their location, cystic structure, size, and epithelial lining. This was enlarged with the addition of two further categories on either side to retain the original I–III numbering system (Table 13.2).

For those where the first contact was often antenatal and in the absence of a resection a furthermore pragmatic classification emerged (Adzick<sup>3</sup> Classification). This is simply based on the size of the cysts as assessed at prenatal US:

- (i) **Macrocystic lesions** ( $\approx 75\%$  of cases) which contain a dominant cyst or multiple cysts that are  $\geq 5$  mm in diameter.
- (ii) **Microcystic lesions** ( $\approx 25\%$  of cases) presenting as a solid echogenic mass or multiple cysts  $< 5$  mm diameter.

We believe that this classification has a more accurate correlation with the potential clinical presentations and the potential management strategies (Figs. 13.2 and 13.3). As mentioned above, CCAMs can have aberrant systemic vasculature, and these are referred to as hybrid lesions.

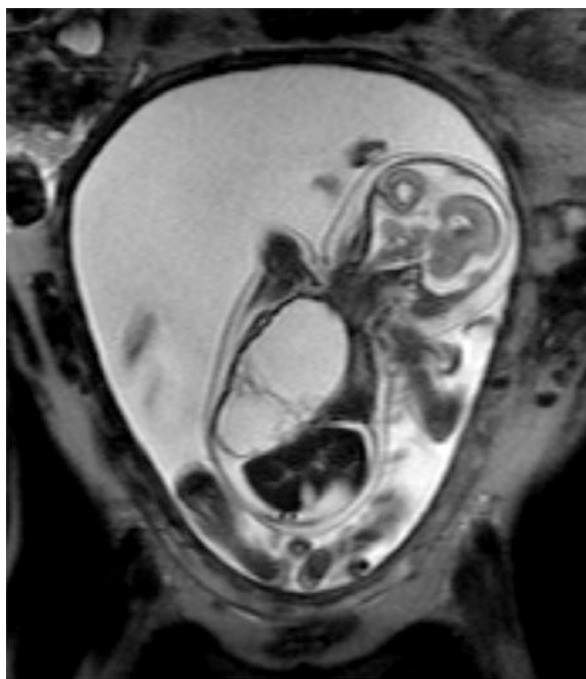
<sup>1</sup> **Terminology:** CPAM is clearly replacing CCAM as the phrase of choice, though originally used an umbrella term for all these developmental lesions it is coming to be a synonym for CCAM.

<sup>2</sup> J. Thomas Stocker—pathologist at Armed Forces Institute of Pathology (to 2011), Washington DC.

<sup>3</sup> N. Scott Adzick—pediatric surgeon at Children’s Hospital of Philadelphia.

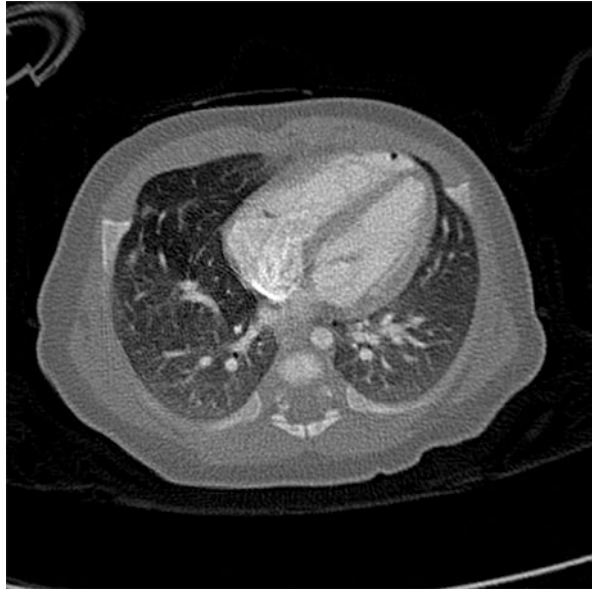
**Table 13.2** Stocker histological classification of CCAM (aka CPAM)

| Type | %  | Histology                                     | Appearance                               | Notes                                      |
|------|----|---|--|--|
| 0    | <2 | Acinar dysplasia                              | Solid                                    | Usually fatal                              |
| I    | 50 | Pseudostratified ciliated columnar epithelium | Single/multiple >2 cm diameter           |  |
| II   | 45 | Ciliated columnar/cuboidal epithelium         | Multiple small cysts <2 cm diameter      |  |
| III  | <5 | Cuboidal epithelium                           | “Solid,” multicystic V small <2 mm cysts |  |
| IV   | <2 | Alveolar epithelium                           | Multiple thin-walled cysts               | Merges into Pleuropulmonary blastoma (PPB) |

**Fig. 13.2** Macrocystic CCAM on the right side, causing hydrops fetalis

*Diagnosis:* Most CCAMs are nowadays detected on prenatal US. Fetal ultrafast magnetic resonance imaging (fMRI) can be used to further define the anatomy, to evaluate the potential effects on surrounding structures, and to search for associated anomalies. Close US surveillance throughout the pregnancy is important to detect early those lesions that can cause fetal distress, allowing a proper perinatal management.

**Fig. 13.3** Microcystic CCAM on the right upper lobe, on a postnatal CT scan



### 13.5.2 Clinical Presentation

- Most CCAMs are asymptomatic during the prenatal life.
- CCAMs that have rapid growth can cause mediastinal shift, hydrops fetalis, and death.
- Postnatally, large lesions can cause severe respiratory distress, requiring immediate postnatal resection. More commonly, CCAMs remain asymptomatic.
- Potential complications that can occur over time are: pneumothorax, infections, rapid expansion with respiratory distress, and malignant transformation.

### 13.5.3 Management

- The prenatal and perinatal behavior of a CCAM can be somewhat predicted by correlating its size to the size of the fetus' head (c.f. congenital diaphragmatic hernia).
  - Formula of the volume of an ellipsoid, and the size of the head is calculated by measuring its maximum circumference. These two measures generate the **“CCAM volume / head circumference ratio,”** or **CVR**. The higher the CVR, the worse the prognosis.
  - Lesions with a CVR > 1.6 are likely to cause hydrops, and need to be evaluated frequently by ultrasound (i.e., 2–3 times per week).
  - Lesions with a CVR < 1.2 can be evaluated once every 2 weeks.



- Hydrops fetalis respond well to the maternal systemic corticosteroids. If there is a dominant large cyst, a percutaneously-placed “thoraco-amniotic” shunt can reverse the hydrops. Fetal resection is an option in very selected cases, but is almost anecdotal nowadays, with the discovery of the remarkable response to steroids.
- Postnatally, any symptomatic CCAM should be resected without delay, either by thoracotomy or by thoracoscopy. The best technique is the one with which the surgeon feels more comfortable with.
- The management of asymptomatic CCAMs is somewhat **controversial** (understatement!). Many centers around the world recommend resecting all lesions within the first 3 months of life, to eliminate all risks, and to provide maximum time for compensatory lung growth. Others advocate for resection around 12 months of age. Finally, many centers recommend observation alone, under the assumption that many cases will never develop symptoms. In our view, the presence of systemic vessels in CCAMs/hybrid lesions is an indication for a resection, since there is no justification to perpetuate the redundant work-load of the heart.
- CCAMs can develop a variety of unusual malignancies, including bronchioalveolar carcinoma, and pleuropulmonary blastoma (DICER 1 +ve) (Table 13.3).

**Table 13.3** Malignancies associated with developmental lung pathology

| Malignancy   | Histology   | Stocker type                                 | Notes   |
|--|---|--|---|
| Pleuropulmonary blastoma<br><i>Former terms—<br/>rhabdomyosarcoma,<br/>embryonal sarcoma</i> | <i>DICER1</i> mutations<br>on Ch14q32.13<br><i>Arises from<br/>mesenchymal<br/>supporting tissues</i> | Histological<br>overlap with Type<br>IV CCAM | < 4 years age<br>I—multicysts<br>Ir (regressed)<br>II—cystic +solid<br>III—solid only |
| Mucinous (mBAC)*<br><i>[invasive mucinous<br/>adenocarcinoma]</i>                            | <i>KRAS</i> mutations<br>on Ch12.21–25<br>Arises from<br>bronchiolar cells                            | Type I CCAM                                  | Predominantly adult<br>onset, though neonates<br>have been reported                   |
| Non-mucinous (nmBAC)<br><i>[lepidic-predominant<br/>adenocarcinoma]</i>                      | Arises from Clara<br>pneumocytes  |  | Adult onset   |
| Mucoepidermoid carcinoma   |   | Type I CCAM                                  | V. rare   |
| Squamous cell carcinoma  |   | Bronchogenic cyst                            | V. rare   |
| BAC  |   |  | V. rare   |
| Leiomyosarcoma   |   |  | V. rare   |

\*Current terminology is confusing and prone to change. Historic terms are given together with current (after 2011 IASLC) nomenclature, e.g., [lepidic-predominant adenocarcinoma]  
BAC—Bronchoalveolar (or Bronchioloalveolar) carcinoma

## 13.6 Congenital Lobar Emphysema

### Definition

Overexpanded lobe (or segment) caused by a valve-like mechanism, either at the level of the bronchioles (due to bronchomalacia), or at the level of larger bronchi (due to intraluminal lesions or external compression).

Congenital or acquired.

### 13.6.1 Clinical Features

- LU lobe > RM lobe > RU lobe (classically).
- M:F 2:1.
- Presents during infancy with tachypnoea, especially during feeding, wheezing. Cyanosis may be seen. Signs include ipsilateral ↓ breath sounds, tracheal and mediastinal displacement. The clinical picture varies widely, from asymptomatic, to severe respiratory distress.
- CXR—hyperlucent with faint bronchovascular markings. Sometimes, there is lung herniation into the mediastinum.
- CT—The involved lobe appears hypodense in comparison with the normal lung.

### 13.6.2 Management

- **Lobectomy**—This is distinctly easier using an open thoracotomy and probably the thoracoscopic option is contraindicated.
- In cases that asymptomatic or mildly symptomatic, Congenital Lobar Emphysema (CLE) can be observed for some time, and operated on an elective basis. Symptomatic cases need, however, prompt resolution.

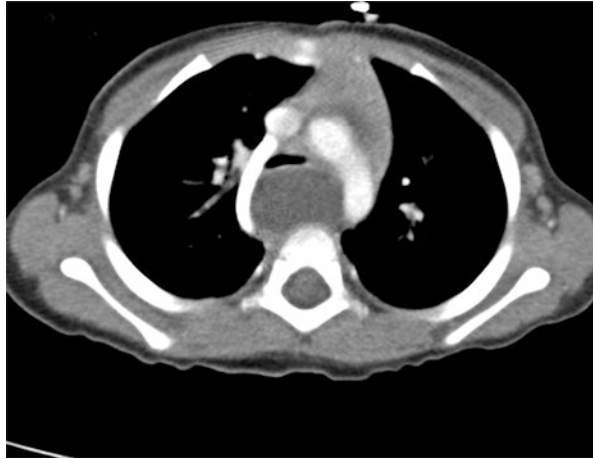
There is also a newly described variant affecting the distal segmental bronchi—here termed *congenital segmental emphysema*. All cases have been detected prenatally with a variety of features and some exhibited postnatal expansion, often after several years. There is often a central mucus-filled cavity termed a bronchocele, which is the result of the accumulation of mucus within an atretic bronchus. Treatment is surgical excision.

## 13.7 Bronchogenic Cyst

### Definition

Bronchogenic cysts are solitary lesions filled with mucous that result from abnormal budding of the foregut primordium.

**Fig. 13.4** Bronchogenic cyst located behind the carina



### 13.7.1 Clinical Features

- M = F.
- Usually there is no communication with the lumen of the normal airway.
- Most are located in the mediastinum, adjacent to a major airway (85%).
- Some are located within the lung parenchyma (15%) (Fig. 13.4).
- Small bronchogenic cysts are not visible by CXR. Large ones may present as a radio-opaque shadow. CT and MRI are excellent studies to delineated the exact anatomy.

Clinically, most bronchogenic cysts remain silent for a long time. In the current era, most are detected incidentally before birth.

Potential complications are: infection, compression of adjacent organs such as the airway or the esophagus), internal bleeding (rare), and malignant transformation (rare).

### 13.7.2 Management

- The treatment is always a surgical resection, via thoracotomy or via thoracoscopy.

---

### Further Reading

1. Zobel M, Gologorsky R, Lee H, et al. Congenital lung lesions. *Semin Pediatr Surg.* 2019;28:150821. <https://doi.org/10.1053/j.sempedsurg.2019.07.004>.
2. Style CC, Cass DL, Verla MA, et al. Early vs late resection of asymptomatic congenital lung malformations. *J Pediatr Surg.* 2019;54:70–4. <https://doi.org/10.1016/j.jpedsurg.2018.10.035>.

3. Pogoriler J, Swarr D, Kreiger P, et al. Congenital cystic lung lesions: redefining the natural distribution of subtypes and assessing the risk of malignancy. *Am J Surg Pathol*. 2019;43:47–55.
4. Laje P, Pearson EG, Simpao AF, et al. The first 100 infant thoroscopic lobectomies: Observations through the learning curve and comparison to open lobectomy. *J Pediatr Surg*. 2015;50:1811–6.
5. Mei-Zahav M, Konen O, Manson D, et al. Is congenital lobar emphysema a surgical disease? *J Pediatr Surg*. 2006;41:1058–61.
6. Paramalingam S, Parkinson E, Sellars M, Diaz-Cano S, Nicolaides KH, Davenport M. Congenital segmental emphysema: an evolving lesion. *Eur J Pediatr Surg*. 2010;20:78–81. <https://doi.org/10.1055/s-0029-1246129>.
7. Peranteau WH, Wilson RD, Liechty KW, et al. Effect of maternal betamethasone administration on prenatal congenital cystic adenomatoid malformation growth and fetal survival. *Fetal Diagn Ther*. 2007;22:365–71. <https://doi.org/10.1159/000103298>.



# Esophageal Atresia

# 14

Debasish Banerjee, Chandrasen K. Sinha,  
and Mark Davenport

*The first successful primary repair of an esophageal atresia was performed in 1941 by Cameron Haight in Michigan, USA, though the infant stayed in hospital for over a year, nonetheless we can probably date this as the effective birth of modern-day neonatal surgery.*

## 14.1 Background

- ~1 per 2500–3000 live births
- M = F
- Isolated (~80%)
- Associated anomalies (20%)
  - These vary in severity and number, but two non-random associations are recognized with esophageal atresia (EA) as a distinct component—VACTERL and CHARGE.

---

D. Banerjee  
Department of Paediatric Surgery, St George's Hospital, Tooting, London, UK  
King's College Hospital, London, UK

C. K. Sinha  
St George's Hospital, London, UK

M. Davenport (✉)  
King's College Hospital, London, UK

### 14.1.1 VACTERL (Previously VATER) Association

This is non-random association of anomalies (not actually a syndrome) and is named for the key components, i.e., **V**ertebral, **A**norectal, **C**ardiac, **T**racheo-**E**sophageal, **R**enal, and **L**imb. EA occurs in about 70% of affected infants with an estimated incidence of about 1 in 10,000 live births.

### 14.1.2 CHARGE Syndrome

Syndrome with genetic basis (*CHD7* mutations on Ch8 in about 70% of affected infants) and includes: **C**oloboma, **H**eart disease, **C**hoanal **A**tresia, **R**etarded growth, **G**enital hypoplasia, **E**ar (deafness).

Among the other recognized associations are:

- Congenital heart disease (~30%) including VSD, PDA, and Tetralogy of Fallot.<sup>1</sup>
- Anorectal malformation (10–15%).
- GI anomalies (10–15%), e.g., duodenal atresia, malrotation.
- GU anomalies (10–15%), e.g., hydronephrosis, renal agenesis, duplex system.
- Tracheo-broncho-pulmonary anomalies, e.g., tracheomalacia, foregut cysts, CCAM, Lung agenesis/hypoplasia.
- Skeletal anomalies, e.g., vertebral anomalies, absent radius, phocomelia,<sup>2</sup> sacral agenesis.

### 14.1.3 Embryology

The trachea arises as the median ventral diverticulum of the primitive foregut at about the 22nd day of gestation. This then invaginates into the ventral mesenchyme. Folds arise from the lateral mesenchyme as tracheaesophageal folds which then fuse to separate the trachea from esophagus at about the 32nd day.

Incomplete fusion of the folds results in a defective tracheaesophageal septum and abnormal connection between the trachea and esophagus.

The etiology is not really known though is clearly multifactorial and may involve genetic factors such as a disturbance in the expression of foregut patterning genes such as Sonic hedgehog and interaction with retinoic acid receptors. There are teratogens (e.g., Adriamycin) described in mouse models where EA is a predictable consequence.

Five anatomical types are described (Table 14.1).

---

<sup>1</sup>Etienne-Louis Arthur Fallot (1850–1911) French physician described four key features of this cardiac malformation in 1888.

<sup>2</sup>Phocomelia (Greek “seal” + (Latin) “limb”—i.e., absent or shortened limbs, typically followed Thalidomide exposure.

**Table 14.1** Anatomical classification (after Vogt)

| Type | Description                        | Frequency (%) |
|------|------------------------------------|---------------|
| I    | EA alone                           | 7             |
| II   | EA and proximal fistula            | 1             |
| III  | EA and distal fistula              | 87            |
| IV   | EA and proximal and distal fistula | 1             |
| V    | “H” type fistula. No EA            | 4             |

## 14.2 Clinical Features

### 14.2.1 Prenatal

Screening maternal US may detect a small or absent stomach accompanied by polyhydramnios. This sign is associated with a positive predictive value of ~50%. Hence, definitive prenatal counselling based on antenatal detection should be guarded. Other features may also be evident (e.g., skeletal anomalies) but there is nothing truly specific.

### 14.2.2 Postnatal Features and Investigation

Excessive salivation and frothing are the classical features of EA. Any attempting to feed such an infant leads to choking and respiratory distress. The diagnosis should be confirmed by passing an 8–10 Fg nasogastric tube or a Replogle<sup>3</sup> tube if possible and taking a chest X-ray. This can help to show the level of the atresia.

- **Chest X-ray**
  - Air in the stomach suggests a distal TEF, while a “gas-less” appearance suggests pure EA and by implication a “long-gap.” Associated duodenal atresia might be suggested with an overlarge stomach and duodenal bubbles.
  - Cardiomegaly might suggest cardiac anomalies and there may be an abnormal silhouette suggestive of a right-sided aortic arch (~2%).
- **Echocardiogram**
  - Define cardiac anatomy and presence of right-sided aortic arch.

The Type V “H-type” TEF has a different set of clinical features and typically presents after the neonatal age with feeding associated respiratory distress. A number of diagnostic options are available including bronchoscopy/esophagoscopy or a tube esophagogram.

#### 14.2.2.1 Management

##### Preoperative

- The upper pouch should be kept empty by continuous low-pressure suction via a Replogle tube.

<sup>3</sup>Robert Replogle—Thoracic surgeon in Chicago described this tube-within-a-tube arrangement.

- Nursed in the horizontal or semi-prone position with frequent change in the infant's position. In those with lung collapse or pneumonia, the child should be placed with the affected side uppermost and gentle physiotherapy instituted.
- Humified air within the incubator may aid suction of pharyngeal secretions.

### **Preoperative Endoscopy**

- Bronchoscopy
  - Although it can help to define the site and size of the fistula, the practice varies considerably between institutions. It can prolong the procedure and the infant can decompensate during this time prior to the ligation of the fistula.
- Esophagoscopy
  - To confirm the diagnosis and to know the length of the proximal pouch.

---

## **14.3 Surgery**

### **14.3.1 Esophageal Atresia and Distal TEF**

Semi-elective operation

- Posterolateral muscle-sparing extrapleural right-sided thoracotomy.
- Expose and ligate the azygous vein.
- Expose proximal pouch (manipulate Replogle tube) and identify TEF (closely related to vagus nerve).
- Divide TEF close to the trachea and then close with non-absorbable sutures (e.g., Prolene®).
- Mobilize upper pouch from the proximal trachea (excluding a further fistula).
- Anastomose with a single layer suture (e.g., 5/0 or 6/0 Prolene® or PDS®).

Most surgeons use a trans-anastomotic tube (6–8 Fr) and feed early. Routine postoperative chest drain is less commonly practiced nowadays. Anastomoses considered to be under tension should be protected by elective paralysis and the infants ventilated for about 4–5 days with their neck flexed.

### **14.3.2 “Long-Gap” Esophageal Atresia**

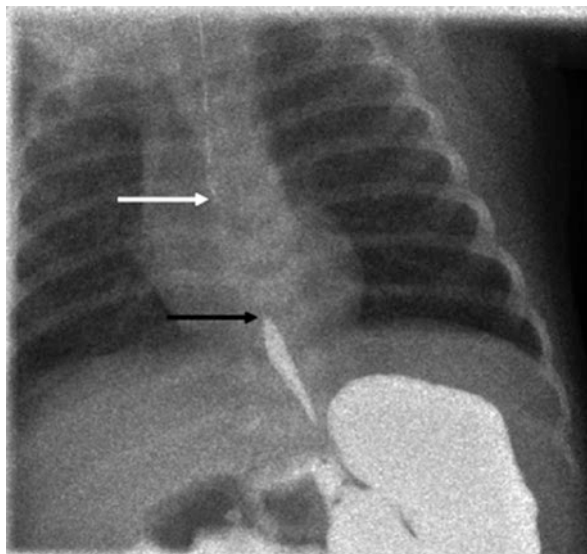
Although there is no universally accepted definition of what constitutes a long gap, the primary determinant is the inability to perform an esophageal anastomosis at the time of initial operation. The gap is usually >4 vertebral bodies. This step is usually avoided for a Type 1 EA but a gastrostomy is needed.

The options thereafter include:

- Cervical esophagostomy
  - The traditional way of managing a blind upper pouch and allows the child to be discharged home to await esophageal replacement.



**Fig. 14.1** Long-gap esophageal atresia. Contrast study of a term infant with Replogle tube in the upper pouch (*white arrow*) and contrast in stomach and distal blind-ending esophagus (*black arrow*) Still 3 vertebral body gap



- Delayed primary anastomosis
  - The commonest approach currently and usually the definitive surgery is at 2–3 months of life.
  - Replogle tube drainage of the proximal pouch and enteral feeding through the gastrostomy continued. A serial assessment of the gap is performed (contrast or probe) to document gap shrinkage with the infant's growth (Fig. 14.1). When this is felt to be small enough (images should almost overlap) then a thoracotomy is performed.
- Lengthening by traction
  - Foker<sup>4</sup> technique—involves placement of traction sutures into the two ends and stretching, could either be open or be thoracoscopic
  - Kimura's extrathoracic advancement<sup>5</sup>—involves initial creation of an esophagostomy and then serial revisions take this progressively down the chest wall to lengthen it.
- **Esophageal replacement** (Indicated if the above maneuvers fail or gap >6 vertebrae.)
  - Gastric transposition. Mobilize stomach and duodenum to allow transit through hiatus into right chest. Also needs pyloroplasty to facilitate gastric drainage.
  - Jejunum conduit. Essentially a long Roux loop is created by the division of 2 or 3 vascular arcades. Could be staged to avoid vascular compromise.
  - Colon interposition. Original replacement technique though not as popular as formerly.

<sup>4</sup> John Foker—American pediatric surgeon working at the University of Minnesota and the Boston Children's Hospital.

<sup>5</sup> Ken Kimura—Retired Japanese American surgeon working at Iowa State University.

### 14.3.3 Surgical Complications

- Anastomotic leak (<5%)
  - Major early (<48 h) leaks should be suspected if pneumothorax develops and re-exploration should be considered. Later leaks can be managed conservatively with thoracostomy tube drainage. Likely formation of stricture.
- *Recurrent fistula* (<5%)
  - Suspected if oral feeding produces coughing and choking. Investigate with contrast esophagogram ± bronchoscopy. Requires revision. A ureteric catheter passed at bronchoscopy may facilitate identification.
- *Stricture* (10–30%)
  - Manifest as early feeding difficulty. Most respond to balloon dilatation(s). The use of prophylactic anti-reflux medication after OA-TOF repair is probably ineffective. Revision is occasionally required.
- *Gastroesophageal reflux* (~40%)
  - Common, but most are amenable to medical therapy. Fundoplication is performed in 10–20% of larger series.
- *Tracheomalacia* (~10%)
  - Although of itself a common finding and part of EA complex, it can be a potent cause of “apparent life-threatening events” (ALTE). Investigated by bronchoscopy to show the airway collapse. Treated by aortopexy, tracheopexy, or even tracheostomy.

#### **Preterm Infants with Respiratory Distress Syndrome and EA/TEF**

Dangerous combination as the necessarily high intratracheal pressures are vented through the fistula and cause gastric distension and even perforation. Consider medical means of reducing airways pressure (e.g., high-frequency oscillation) but surgery should be considered early as an emergency with the prime object of ligation of fistula (by a transpleural thoracotomy—it is quicker).

---

## 14.4 Thoracoscopic Repair

*Thoracoscopic repair* is being practiced in some centers with experts skilled in minimally invasive techniques; the first being reported in 1999 by Thom Lobe and Steve Rothenberg<sup>6</sup> in an 8-month-old infant with a Type 1 EA. There is a theoretical avoidance of chest wall deformity, although this should seldom be a real issue now with muscle-sparing thoracotomies.

---

<sup>6</sup>Thom Lobe and Steven Rothenberg—American pediatric surgeons.

**Table 14.2** Spitz classification

|         | Birth weight (kg) | Cardiac anomalies | Prognosis (%)    |
|---------|-------------------|-------------------|------------------|
| Group 1 | >1.5              | Absent            | >98 <sup>a</sup> |
| Group 2 | either <1.5       | or Present        | 59               |
| Group 3 | <1.5              | Present           | 22               |

<sup>a</sup>Figures taken from reference Spitz et al. [8]

## 14.5 Prognostic Classifications

- *Waterston et al.* [1] classified these patients into three groups based on birth weight, and presence of pneumonia, and other congenital anomalies.
- *Spitz et al.* [8] simplified this but retained birth weight and the presence of major cardiac anomalies (Table 14.2).

Others include *Montreal* (includes ventilator dependence), *Bremen* (includes postoperative complications), and that of *Sinha et al.* (where both weight <1.5 kg and a cardiac anomaly need to be present for a poor prognosis) classifications.

## 14.6 Long-Term Outcomes

- Swallowing
  - Although for most infants there is effective restitution of normal feeding, allowing normal growth and development, it is probably expedient to defer intake of solids for a while in this group. Swallowing is effective but not normal. Peristalsis is impaired or absent and most children learn to chew well and drink with meals.
- Respiratory morbidity
  - Typically, they also have a higher incidence of respiratory-related issues such as recurrent chest infections, intermittent food-related choking, and the characteristic seal-like bark ( “TOF cough” sounds better than “TEF cough”! ) Such problems tend to subside with age presumably due to airway growth and improved luminal stability.
- Barrett’s esophagus
  - There may be a long-term malignancy potential during adulthood, but the risk remains unquantified.

## Further Reading

1. Waterston DJ, Bonham-Carter R, Aberdeen E. Oesophageal atresia: tracheo-oesophageal fistula. A study of survival in 218 infants. *Lancet*. 1962;7234(i):819–22.
2. Davenport M, Rothenberg SS, Crabbe DC, et al. The great debate: open or thoracoscopic repair for oesophageal atresia or diaphragmatic hernia. *J Pediatr Surg*. 2015;50:240–6.

3. Ahmad N, Dobby N, Walker E, et al. A multicentre audit of the use of bronchoscopy during open and thoracoscopic repair of oesophageal atresia with tracheo-oesophageal fistula. *Paediatr Anaesth.* 2019;29:640–7.
4. Sinha CK, Haider N, Marri RR, et al. Modified prognostic criteria for oesophageal atresia and tracheo-oesophageal fistula. *Eur J Pediatr Surg.* 2007;17:153–7.
5. van der Zee DC, Gallo G, Tytgat SHA. Thoracoscopic traction technique in long gap esophageal atresia: entering a new era. *Surg Endosc.* 2015;29:3324–30.
6. Burge DM, Shah K, Spark P, et al. Contemporary management and outcomes for infants born with oesophageal atresia. *Br J Surg.* 2013;100:515–21.
7. Rothenberg SS. Thoracoscopic repair of esophageal atresia and tracheo-oesophageal fistula in neonates: evolution of a technique. *J Laparoendosc Adv Surg Tech.* 2012;22:195–9.
8. Spitz L, Kiely EM, Morecroft JA, et al. Oesophageal atresia: at-risk groups for the 1990s. *J Pediatr Surg.* 1994;29:723–5.



# Congenital Diaphragmatic Hernia

# 15

Saidul Islam, Chandrasen K. Sinha, and Mark Davenport

## 15.1 Epidemiology

There does not appear to be a geographical variation in CDH. Though there is variation depending on when the CDH is appreciated:

- 1 in 3000 live-births
- 1 in 2000 at ~20 weeks gestation. There is increased fetal loss over the pregnancy, and has been referred to as the “hidden mortality” of CDH.
- M = F
- Predominantly left-sided (80%). Bilateral (<2%)
- Isolated (usually) if live-born
- Late-presenters (~10%)—excellent prognosis

## 15.2 Associations

Most infants at term have an isolated CDH. In the Fetal Medicine Clinic, a much higher proportion will have CDH as part of a syndromic association.

- Chromosomal defects
  - For example, Trisomy 13, 18, 21 (rarely survive)

---

S. Islam  
Royal Alexandra Children’s Hospital, Brighton, UK

C. K. Sinha  
St George’s Hospital, London, UK

M. Davenport (✉)  
King’s College Hospital, London, UK

- **Fryns syndrome** (1–2%)
  - “Coarse” facial features, hypertelorism, cloudy corneas, facial clefts, renal, CVS and genital abnormalities
- **Pallister–Killian syndrome** (tetrasomy 12p mosaic)
  - “Coarse” facial features, sparse hair, syndactyly
- **Cantrell syndrome or sequence**
  - Formerly a “Pentalogy” of defects including cardiac, sternal defect, exomphalos and absence of pericardium
- Cardiac defects, e.g. VSD

---

### 15.3 Embryology

Key stage—4–8 weeks of gestation.

The diaphragm is derived from four sources:

- Septum transversum (forming central tendon and some muscle tissue, with innervation by the phrenic nerve)
- Pleuroperitoneal membranous folds
- Thoracic body wall mesoderm
- Oesophageal mesenchyme

All elements contribute to the muscular rim and oesophageal crura.

Prior to this, there is a posterior connection (“canal”) between two cavities—the pericardial and the peritoneal. In-growth of the pleuroperitoneal membranes fill and occlude this canal and failure result in the typical **postero-lateral CDH (of Bochdalek<sup>1</sup>)**. There is a left-sided predominance as this canal is larger and closes later than the right. **Morgagni<sup>2</sup> hernias** occur in the anterior part of the diaphragm on either side (usually right) of the xiphisternum. **Cantrell defects<sup>3</sup>** are typically central and expose the beating heart associated with exomphalos and sternal defects.

The size of the defect varies but complete absence (agenesis) of the hemidiaaphragm is not uncommon. A postero-lateral rim almost always is found covered with pleura contiguous with peritoneum. A hernial sac (10–20%) can also be found together with nonrotation and nonfixation of the mid- and hindgut.

---

<sup>1</sup>Vincent Bockdalek (1801–1883) Czech anatomist. By no means the first to actually describe this but his name has stuck.

<sup>2</sup>Giovanni Battista Morgagni (1682–1761) Italian anatomist, credited with naming many anatomical features.

<sup>3</sup>JR Cantrell. First author on key paper (1958) but clearly the junior and has disappeared from view.

## 15.4 Pulmonary Hypoplasia

Classically, it is said that the visceral herniation into the thoracic cavity inhibits ipsilateral lung development. However, recent studies suggest that the lungs have a primary intrinsic defect before being further impaired by secondary visceral herniation (“dual-hit” hypothesis). Consequently, bronchopulmonary generations are permanently reduced in both lungs, resulting in a reduced number of alveoli. Impaired development of the pulmonary vasculature is almost invariable, resulting in a hypoplastic pulmonary vascular bed with hypertrophied muscular pulmonary arteries with the tendency to pulmonary hypertension and persistence of the fetal circulation with right-to-left shunting.

## 15.5 Clinical Features

### 15.5.1 Antenatal

The fetal lung’s surface area increases 16-fold compared to the 4-fold increase in the head circumference between 22 and 32 weeks of gestational age.

Ultrasonographic measurement of **observed to expected (O/E) lung–head ratio (LHR)** between 22 and 32 weeks of gestational age can be used to predict the severity of pulmonary hypoplasia in isolated CDH. Originally this raw version was used to predict mortality and the need for fetal intervention—the usual level quoted was  $LHR \leq 1.0$  was associated with a >90% survival rate. Increasingly this has been translated into an index of risk based on comparison to normal values and is expressed as a percentage. This is also usually combined with the position of the liver (i.e. Liver UP).

- O/E LHR <25% is considered severe CDH
  - Survival 10% with liver UP and 25% with liver DOWN
- O/E LHR <15%
  - Survival with liver UP—0%

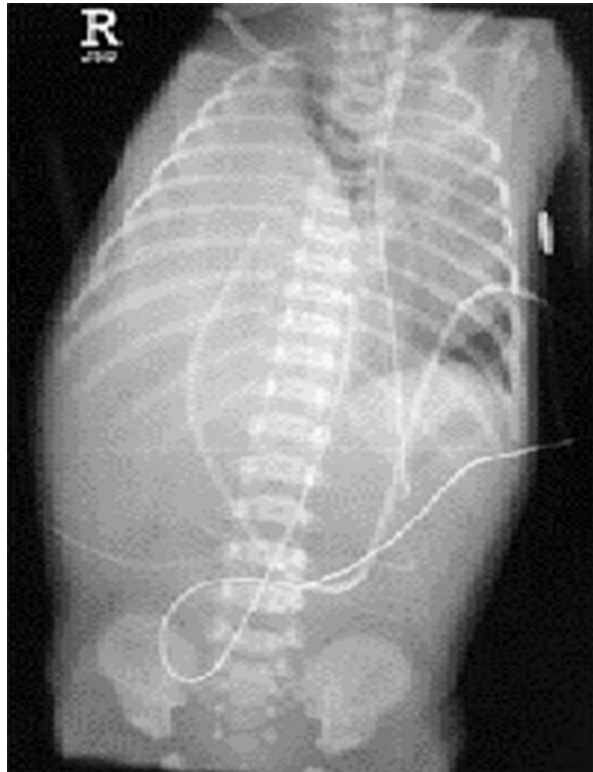
There is a variation of outcome dependent on side. So, in a left-sided CDH, an O/E LHR <25% predicts poor outcome but in a right-side CDH, an O/E LHR <45% predicts poor outcome.

Fetal MRI may be used (where available) for assessment of lung volume and liver herniation in moderate and severe CDH.

The main benefits of early detection are:

1. Detection of associated anomalies
2. Validated prognostic indices, e.g. liver position and lung-to-head ratio (LHR)
3. Antenatal counselling and in utero transfer to paediatric surgical centre

**Fig. 15.1** Right-sided diaphragmatic hernia. Note the severe mediastinal shift and position of the umbilical vein within the liver



### 15.5.2 Postnatal

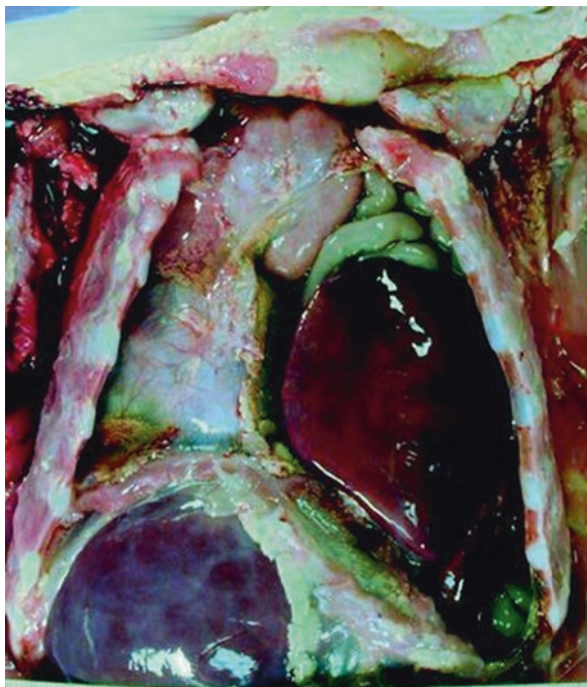
Early respiratory distress and cyanosis after birth together with findings of a scaphoid abdomen, tracheal deviation and mediastinal shift are the typical features of CDH (Figs. 15.1 and 15.2).

Diagnosis is confirmed by:

- CXR
  - Showing herniated intestinal loops and mediastinal shift. If intubated swiftly the loops may remain fluid-filled. The differential of multiple air-filled intra-thoracic loops is a macrocystic CCAM (look at the diaphragm outline).
- US or contrast study
  - If doubt exists, image diaphragm with US or outline viscera with contrast. Right-sided CDH may cause more confusion as the liver is the typical herniated viscus.



**Fig. 15.2** Infant with left-sided CDH who died at 24 h of age. Post-mortem study shows herniation of the left lobe of liver and small bowel into the chest with severe mediastinal shift to the right



## 15.6 Management

The initial strategy should be to maintain near-normal blood gases but without compromising lung injury (by barotrauma). If cardiorespiratory stability is achieved and maintained on acceptable ventilation modes, then consider definitive surgery.

### 15.6.1 Delivery Suite

- Endotracheal intubation and IPPV (not bag/mask as will invariably cause gastric dilatation)
- Naso-gastric tube (to decompress stomach) and venous access
- Sedation should be provided to all mechanically ventilated newborns with CDH. Deep sedation and neuromuscular blockade should be provided selectively to those with greater ventilation or oxygen requirements.

### 15.6.2 In the Intensive Care Unit

- **Arterial blood gas**
  - Preductal (right radial artery) and postductal (left radial, umbilical artery, etc.) to determine the degree of shunting (Aim for preductal  $pO_2 \sim 60$  mmHg, postductal  $\sim 40$  mmHg).

- **Initial ventilation settings**
  - For example, rate 30–60 bpm; peak inspiratory pressure (PIP) = 20–30 cmH<sub>2</sub>O, positive end-expiratory pressure (PEEP) = 3–5 cmH<sub>2</sub>O) to provide adequate tissue oxygenation but avoiding barotrauma at the same time.
  - Concept of “*permissive hypercapnia*” or “*gentilation*” is to limit PIP (ideally <25 cmH<sub>2</sub>O) and FiO<sub>2</sub> to produce preductal saturation >90%, while allowing limited rise (e.g. up to 60–65 mmHg) of pCO<sub>2</sub>.
- Relative fluid restriction (~50 mL/kg/day)
- Consider—inotropic agents
  - For example, dopamine, dobutamine (both 2–20 µg/kg/min) and inhaled nitric oxide (iNO) (1–20 ppm), if signs of significant hypotension or R→L shunting.
- Echocardiography
  - Recommendation: within 48 h of birth and at 2–3 weeks of life
  - To assess pulmonary vascular resistance, as well as left and right ventricular function. Additional studies conducted if indicated.

### 15.6.3 Second-Line Therapy

- **High-frequency oscillatory ventilation (HFOV)**
  - Used to deliver a rate of 100–150 bpm, with gas exchange occurring through bulk diffusion
- **Extracorporeal membrane oxygenation (ECMO)**
  - Indicated in severe refractory hypoxia although most studies have failed to show the real benefit of ECMO in CDH patients. If used, ECMO is indicated if, after maximal therapy, the preductal pO<sub>2</sub> is <50 mmHg, and pCO<sub>2</sub> >50 mmHg, on FiO<sub>2</sub> = 100%. The CDH is usually repaired when the ECMO session is finishing to minimise the risk of bleeding etc.

## 15.7 Surgery

The original target in the timing of CDH surgery was to get the infant to the operating room as quickly as possible. Nowadays that concept has been discredited and preoperative stabilisation has become the norm.

- Subcostal muscle-cutting incision. Divide umbilical vein and falciform ligament (allows rotation of liver to opposite side).
- Remove viscera (caution with left liver and spleen) from the thoracic cavity. Any hernial sac (if present ~20%) should be excised.
- Define anterior and posterior elements of the diaphragm (the latter is frequently flattened on the posterior abdominal wall). Primary apposition and repair if possible using interrupted, non-absorbable sutures (e.g. Prolene™) placed around

ribs if necessary. Avoid tension and inadequate fascia as this will predispose to recurrence.

- Placement of viscera within the abdominal cavity (in Ladd's position  $\pm$  appendectomy). If closure is too tight, consider a temporary prosthetic patch/silo.

*Alternatives if primary closure is not feasible:*

- Prosthetic patch (e.g. Gore-Tex<sup>®</sup>, Permacol<sup>®</sup> (non-absorbable))
- Muscle flap (latissimus dorsi or internal oblique)

A right-sided CDH with an intrathoracic liver presents different problems, as the neonatal liver is friable and the hepatic veins and IVC are at risk during dissection and may kink on return to the abdominal cavity. Division of the falciform and rotation around the hepatic vein axis aids repair. Right-sided CDH required patch repair more often than left-sided CDH.

---

## 15.8 Complications and Outcome

There is a reasonable expectation of survival in up to 80% of all live-born infants with isolated CDH. This would be optimistic if the defect was detected antenatally and certainly in the presence of other anomalies.

- **Chronic lung disease**
  - Due to the combination of underlying hypoplasia, and barotraumas, may be O<sub>2</sub> dependent for long periods. Bronchopulmonary dysplasia and restrictive and obstructive lung dysfunction may all be observed in survivors.
- **Recurrence (10–20%)**
  - Associated with prolonged periods of ventilation, prosthetic patches, ECMO, etc. Assess with CXR and, if doubt, CT/MR scan.
- **Gastro-oesophageal reflux (up to 40%)**
  - Treat medically initially but may need fundoplication.
- **Chylothorax (<5%)**
  - Due to damage of lymphatics overlying posterior abdominal wall. If significant postoperative hydrothorax presents and needs drainage then send fluid for lymphocyte count, albumen, and lipid content.
- **Deformity of spine/chest wall (<5%)**
  - Multifactorial and due to primary body wall anomalies, ipsilateral lung hypoplasia, and perhaps nature of surgical repair (prosthesis, etc.)
- **Neurodevelopmental impairment**
  - These are often infants who have struggled for life, with long periods of ventilator dependence and periods of instability. Hearing loss appears to be particularly common.

## 15.9 Contentious Topics

### 15.9.1 Fetal Surgery

Effective and reliable discrimination of prognosis at the time of antenatal diagnosis has allowed the possibility of in utero intervention in selected cases in some institutions. Lung growth in CDH can be increased by tracheal occlusion (as the lungs expel fluid normally). Initial attempts required open hysterotomy and external tracheal clips, which have now been replaced by **single-port fetoscopy and intratracheal placement of a detachable balloon (at 24–26 weeks gestation) (FETO)**. The balloon is left in situ for 6–8 weeks then removed/punctured to allow the infant a normal delivery. The randomised TOTAL trials have recently been reported showing a significant improvement in survival in poor prognosis fetuses treated with FETO.

### 15.9.2 Minimally Invasive Surgery of CDH

This is an advanced technical procedure but can be done successfully thoracoscopically for Bochdalek hernias, and laparoscopically for Morgagni hernias. The most contentious group for this type of surgery are early-presenting neonates as there is no cardiorespiratory advantage (and it may indeed be associated with a detrimental rise in pCO<sub>2</sub>); it is an intrinsically longer procedure with higher postoperative recurrence rates and the intestinal positioning is left to chance.

---

## Further Reading

1. Lally KP, Lally PA, Van Meurs KP, et al. Congenital Diaphragmatic Hernia Study Group. Treatment evolution in high-risk congenital diaphragmatic hernia: ten years' experience with diaphragmatic agenesis. *Ann Surg.* 2006;244:505–13.
2. Harrison MR, Keller RL, Hawgood SB, et al. A randomized trial of fetal endoscopic tracheal occlusion for severe fetal congenital diaphragmatic hernia. *N Engl J Med.* 2003;349:1916–24.
3. Nguyen TL, Le AD. Thoracoscopic repair for congenital diaphragmatic hernia: lessons from 45 cases. *J Pediatr Surg.* 2006;41:1713–5.
4. Sinha CK, Islam S, Patel S, et al. Congenital diaphragmatic hernia: prognostic indices in the FETO era. *J Pediatr Surg.* 2009;44:312–6.
5. Fryns JP, Moerman F, Goddeeris P, et al. A new lethal syndrome with cloudy corneae, diaphragmatic defects and distal limb deformities. *Hum Genet.* 1979;50:65–70.
6. Cantrell JR, Haller JA, Ravitch MM. A syndrome of congenital defects involving the abdominal wall, sternum, diaphragm, pericardium and heart. *Surg Gynaecol Obstet.* 1958;107:602–14.
7. Partridge EA, Peranteau WH, Herkert L, et al. Right- versus left-sided congenital diaphragmatic hernia : a comparative outcome analysis. *J Pediatr Surg.* 2016;51:900–2.
8. Davenport M, Rothenberg SS, Crabbe DCG, Wulkan ML. The great debate: open or thoracoscopic repair for oesophageal atresia or diaphragmatic hernia. *J Pediatr Surg.* 2015;50:240–6.



# Congenital Pyloric Stenosis

# 16

Giorgia Totonelli, Denis A. Cozzi, and Pietro Bagolan

**Pyloric stenosis is the commonest surgical cause of vomiting during infancy.**

## 16.1 Historical Aspects

The Danish pediatrician, Harald Hirschsprung,<sup>1</sup> first described the key features of pyloric stenosis (PS) based on two infants who had died from it in 1888. This was followed by various rarely successful surgical attempts at bypassing or overcoming the gastric outlet obstruction culminating in Conrad von Ramstedt's<sup>2</sup> classic paper describing two successful cases in 1912 where only the pyloric musculature was divided leaving the mucosa intact.

<sup>1</sup>Harold Hirschsprung (1830–1916)—Danish pediatrician.

<sup>2</sup>Conrad von Ram(m)stedt (1867–1963) either spelling is correct—German military surgeon, later worked in Munster.

G. Totonelli (✉) · P. Bagolan

Department of Medical and Surgical Neonatology, Neonatal Surgery Unit, Bambino Gesù Children's Hospital IRCCS, Rome, Italy  
e-mail: [pietro.bagolan@opbg.net](mailto:pietro.bagolan@opbg.net)

D. A. Cozzi

Pediatric Surgery Unit, Sapienza University of Rome, Azienda Policlinico Umberto I, Rome, Italy  
e-mail: [da.cozzi@uniroma1.it](mailto:da.cozzi@uniroma1.it)

## 16.2 Demographics

- 1–3 per 1000 live births
- M > F 2:1–5:1
- White > Black > Asian

### 16.2.1 Risk Factors

- Firstborn (OR = 1.1).
- Formula > breast fed (OR = 2.5)
- Premature > term (OR = 1.3)
- Caesarean section (OR = 1.6)

### 16.2.2 Genetic Component

- 7% incidence of PS in children of affected parents.
- X4 risk if the mother affected.
- Twin—X200 risk if monozygotic X20 risk if dizygotic.
- ↑ risk if young maternal age.

### 16.2.3 Associations

- Esophageal atresia
- Maternal erythromycin use (via breast milk)

---

## 16.3 Pathophysiology

PS is characterized by hypertrophy of the circular muscle layer so that the pyloric canal is lengthened and narrowed with pronounced thickening of the whole pylorus.

There is some evidence that there is:

- ↓ Non-adrenergic non-cholinergic (NANC) nerves with ↑ collagen deposition.
- ↓ Interstitial cells of Cajal.<sup>3</sup>
- ↓ Expression of neuronal nitric oxide synthase (nNOS).

Gastric outlet obstruction leads to loss of acid (HCl), Na, Cl, K, and water, i.e., *dehydration, metabolic alkalosis, and hypokalemia*. The compensatory response to this is principally renal preservation of Na<sup>+</sup> (initially with loss of further K<sup>+</sup>, and then the later loss of H<sup>+</sup> as a cation exchange, i.e., “paradoxical aciduria”).

---

<sup>3</sup>Santiago Ramon y Cajal (1852–1934)—Spanish pathologist and Nobel laureate.

## 16.4 Clinical Features

Typical postnatal age of onset at 3–6 weeks and is rare beyond 4 months of age.

Symptoms include:

- Progressive, nonbilious, projectile vomiting, occasionally containing “coffee grounds” (due to altered blood and gastritis) in a term infant. This usually takes place immediately after the end of the feeding and rarely after a few hours. Despite the vomiting, the infant will be hungry and eager for more.
- Weight loss or failure to gain weight.
- Dehydration: With infant appearing lethargic with less frequent wet nappies and in some cases developing a sunken anterior fontanelle.
- Persistent jaundice.
- Constipation may also occur because little or no feed will get to the intestine.

The key to clinical diagnosis is palpation of the hypertrophied pylorus in the epigastrium or right hypochondrium. This has the feel and size of an olive. Gastric peristalsis may also be seen. Note that features, symptoms, and signs may well be atypical in the premature infant.

### 16.4.1 Differential Diagnosis

- Gastroenteritis.
  - No projectile vomiting, presence of diarrhea, absence of alkalosis.
- Gastroesophageal reflux.
  - No projectile vomiting. Absence of alkalosis.
- Milk protein allergy.
  - No projectile vomiting, presence of diarrhea.
- Metabolic diseases.
  - No projectile vomiting, no diarrhea, acidosis.

### 16.4.2 Diagnosis

- *Test Feed*: Examine the abdomen from the baby’s left while feeding. The “olive” tumor is usually felt around the lateral margin of the right rectus abdominis muscle below the liver edge. A small feed is best since a greatly distended stomach obscures the tumor. In general, it is easier to feel the tumor at the end of the feed, especially if the infant has just vomited.
- Blood tests including:
  - Urea and electrolytes—↓ Na<sup>+</sup> ↓ K<sup>+</sup> ↓ Cl<sup>-</sup> (↑urea ↑creatinine)
  - Blood gas—↑ pH ↑ HCO<sub>3</sub> (e.g., usually pH >7.45, HCO<sub>3</sub> >26, Base Excess >2) Bicarbonate (HCO<sub>3</sub>) value

- Mild <25 mmol/l
- Moderate 26–35 mmol/l
- Severe >35 mmol/l
- Abdominal US—appearance likened to a “hot dog in a bun”
  - Muscle thickness > 4 mm (normal  $\leq 3$  mm).
  - Pyloric canal length  $\geq 14$  mm (normal  $\leq 12$  mm).
  - Pylorus diameter  $\geq 11$  mm (normal  $\leq 10$  mm)

### 16.4.3 Management

Pyloric stenosis is not a *surgical* emergency—it is a *medical* emergency and initial resuscitation is paramount.

- Nasogastric tube
  - To drain off the stomach content and prevent recurrent vomiting. Keep NG tube on free drainage with hourly aspiration.
  - Replace losses ml for ml with 0.9% NaCl + 10 mmol KCl.
- Intravenous fluids
  - 150 ml/kg/day of 0.9% NaCl + 5% dextrose [+ 10 mmol KCl after confirmation of urine output].
  - Blood glucose concentrations should be monitored.

Most infants come to surgery within 24 h but longstanding vomiting needs careful preparation and stabilization may be over 3–5 days. Surgery will only be performed once the infant’s blood test results are normal.

### 16.4.4 Ramstedt’s Operation

#### 1. Open technique

- (a) Classical incision—vertical or RUQ muscle cutting.
- (b) Circum-umbilical (described by Bianchi in 1986).<sup>4</sup>
  - I. Skin-crease supra-umbilical incision which can be extended outward to resemble the Greek letter omega ( $\Omega$ ). Incise vertically along the linea alba to enter the peritoneal cavity.
  - II. Evert pylorus out of wound.
  - III. Longitudinal incision (2–3 cm) along the anterior, avascular surface of the pyloric “olive.” The back of a scalpel handle or a pyloric “spreader” can be used to split the hypertrophied muscle down to the submucosa.
  - IV. Caution with fornix of the duodenum (most superficial part).

---

<sup>4</sup>Adrian Bianchi—Maltese pediatric surgeon although surgical career entirely in the UK (Manchester).



- V. Test mucosal integrity—inflate stomach via NG tube with ~50 ml air. An unrecognized perforation will lead to peritonitis, sepsis, and even death.
  - (c) “Hybrid” approach.
    - I. Open circum-umbilical incision. Transverse incision into right rectus and through linea alba.
    - II. Placement of 4–6 “stay” sutures in pyloric muscle to allow elevation to wound (but not beyond) and pyloromyotomy under direct vision.
- 2. Laparoscopic technique**
- (a) Developed in the 1990s.
    - I. 5-mm umbilical camera port and two 3 mm working “stab” ports.
    - II. Divide muscle with an (arthroscopic or retractable) blade or hook diathermy. Distract the muscle edges with Tan-pattern spreader or Johann grasping forceps.

Randomized trials suggest marginal improvements in time to full feeds and discharge compared to open pyloromyotomy, with similar intraoperative and postoperative complications. Nonetheless, single-institution series frequently report a higher recurrence incidence compared with the open technique.

### 16.4.5 Postoperative Care

- Remove NG tube on completion of surgery unless mucosa is breached.
- Intravenous fluids.
  - 0.9% saline + 5% Dextrose at 120 ml/kg/day.
- Restoration of oral intake
  - After 4–6 h post-op, start 25% normal feed (milk) 3 hourly and increase as tolerated.
  - Reduce IV fluid as oral intake increases.
- Discharge once tolerated two full feeds (usually 150 ml/kg/day) and no other concerns.
- Minor vomiting can be expected for 1-week post-op.

Complications after surgery may include duodenal perforation, incomplete pyloromyotomy, and wound infection.

If known duodenal perforation, continue NG tube aspiration, add 48 h IV antibiotics, and delay oral feeding for ~48 h.

Persistent postoperative vomiting (defined as prolonged vomiting for >7 days), is usually caused by too rapid advancement of postoperative feeding, or of residual pyloric edema. An incomplete pyloromyotomy is possible but unlikely (need for reoperation <2%). Persistent and frequent daily vomiting in the postoperative period may require an upper GI contrast study. If pyloric stenosis persists, the redo-pyloromyotomy is indicated.

## Further Reading

1. Tan KC, Bianchi A. Circumbilical incision for pyloromyotomy. *Br J Surg.* 1986;73:399.
2. Leclair MD, Plattner V, Mirallie E, et al. Laparoscopic pyloromyotomy for hypertrophic pyloric stenosis: a prospective, randomized controlled trial. *J Pediatr Surg.* 2007;42:692–8.
3. Hall NJ, Pacilli M, Eaton S, et al. Recovery after open versus laparoscopic pyloromyotomy for pyloric stenosis: a double-blind multicentre randomised controlled trial. *Lancet.* 2009;31:390–8.
4. Ceccanti S, Mele E, Frediani S, et al. Moving toward laparoscopic pyloromyotomy: an initial Italian experience and national survey. *Am Surg.* 2013;79:955–8.
5. Taqi E, Boutros J, Emil S, et al. Evaluation of surgical approaches to pyloromyotomy: a single-centre experience. *J Pediatr Surg.* 2007;42:865–8.
6. Zhu J, Zhu T, Lin Z, Qu Y, Mu D. Perinatal risk factors for infantile hypertrophic pyloric stenosis: A meta-analysis. *J Pediatr Surg.* 2017;52(9):1389–97. <https://doi.org/10.1016/j.jpedsurg.2017.02.017>.



Chandrasen K. Sinha, A. Saeed, and M. Davenport

## History Note

Calder first described two infants with **duodenal atresia** in 1733. Other examples followed but no survivors were reported until the twentieth century, when Vidal (1905) described gastrojejunostomy and Ernest (1914) duodeno-jejunosomy for this condition.

## 17.1 Epidemiology

- Pyloric atresia
  - < 1% of all GI atresias
- Duodenal atresia
  - 1 in 5000
  - M>F (slight)
- Jejunioileal atresia
  - 1 in 3000
  - Black > white
- Colonic atresia
  - 1 in 50,000

---

C. K. Sinha  
St George's Hospital, London, UK

A. Saeed  
Department of Paediatric Surgery, St George's Hospital, London, UK

M. Davenport (✉)  
King's College Hospital, London, UK

## 17.2 Embryology

The primitive gut is divided into *fore-, mid-, and hindgut*. Each has its own artery; respectively, the *celiac, superior, and inferior mesenteric* arteries, given off the front of the aorta. Endodermal proliferation is maximal between 30 and 60 days gestation and appears sufficient in some parts to almost completely occlude the lumen. Vacuolation, due to endodermal apoptosis restores the lumen and if this is incomplete it may be responsible for some cases of duodenal atresia (**Tandler<sup>1</sup>—failure of recanalization hypothesis**). This may also be the mechanism for rare causes of atresia such as MIA and epidermolysis), disorders in epithelial proliferation and apoptosis could affect luminal continuity. Differential expression of Sonic Hedgehog (Shh) seems to control key parts of this process.

Alternatively, observations following experimental ligation of the arterial supply to parts of the jejunioileum in the fetal puppy suggested that this could reproduce the appearance of atresia and stenosis (**Vascular hypothesis of Louw and Barnard**).

### Classic Paper

*Louw, J.H.; Barnard, C.N. Congenital Intestinal Atresia Observations on its Origin. Lancet. 1955; 266 (6899): 1065–1067.*

Rapid jejunioileal growth occurs during the late phase of gestation from about 115 cm (at 24 weeks gestation) to about 250 cm (usual length at term). Rotation of the gut is considered in Chap. 18.

## 17.3 Associations

- **Pyloric atresia**
  - Epidermolysis bullosa and (hereditary) multiple intestinal atresias (MIA)
- **Duodenal atresia**
  - Trisomy 21, Down syndrome<sup>2</sup>
    - Up to 30% of unselected series, though frequency currently ↓to 5% currently.
  - Cardiac anomalies
  - Malrotation
  - Esophageal atresia
  - Vertebral anomalies

<sup>1</sup>Julius Tandler (1869–36)—Austrian anatomist.

<sup>2</sup>John Langdon Haydon Down (1828–1896)—English physician. Published “Observations on an Ethnic Classification of Idiots” in 1866.

- **Jejunal-ileo-colic atresia**

- **Abdominal wall defects**—especially gastroschisis
  - Due to localized trauma/ischemia at the entry and exit points
- Maternal glomerulonephritis
- Maternal cocaine use
- Hirschsprung’s disease (colon atresia)
- Vertebral anomalies

---

## 17.4 Classification (After Bland-Sutton<sup>3</sup>, Modified by Grosfeld<sup>4</sup>)

Though this was originally described for duodenal atresia, it is applicable to all parts of the intestine (Fig. 17.1).

- Type I
  - Membrane or web
- Type II
  - Fibrous cord joins two blind ends of the bowel
- Type III
  - Gap between ends with a V-shaped mesenteric defect
  - Type IIIb: large defect in the mesentery, significant intestinal loss, and distal intestine winds round a single, usually tenuous vascular pedicle (“**apple peel**” atresia, “**maypole**” atresia)
- Type IV
  - Multiple atresias—often with the appearance of a “string of sausages”

### 36.4.2 Hereditary Multiple Intestinal Atresia (HMIA)

- **Gene defect *TTC7A* autosomal recessive- on chromosome 2p16**

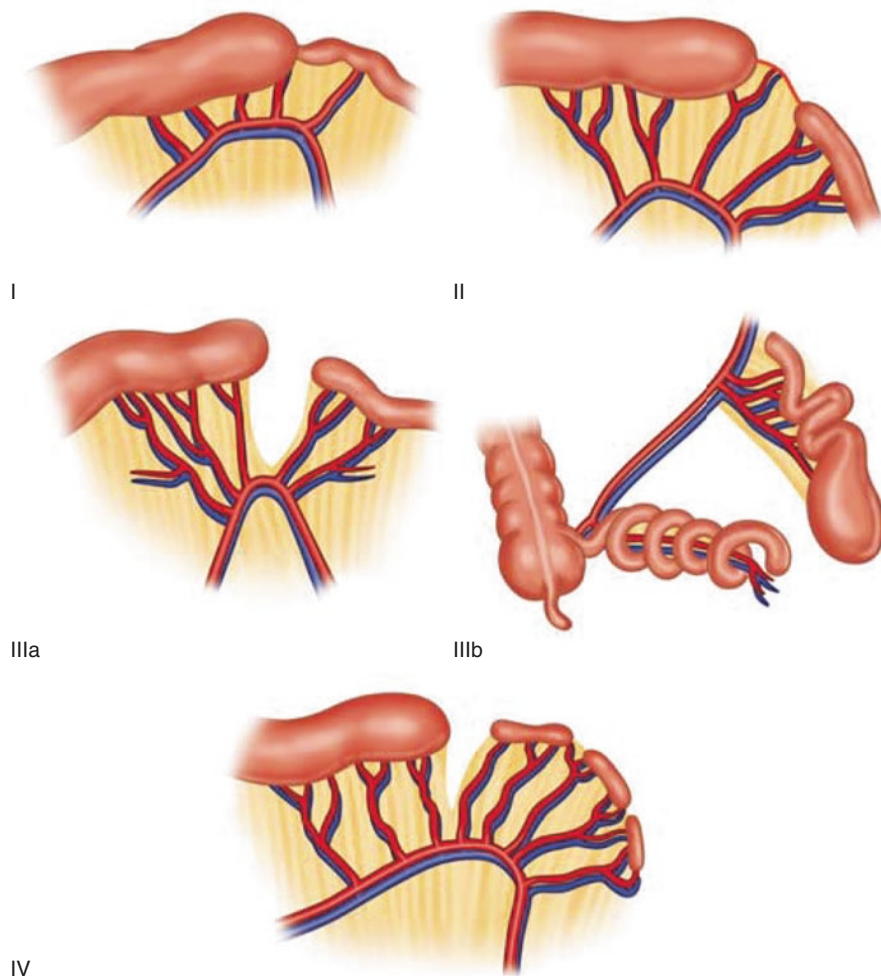
Sporadic or familial condition with multiple atretic segments (from pyloric atresia down, often type 1, and >20). Associated with **Severe Combined immunodeficiency** and a dilated biliary tree. Although there are many possible surgical solutions to retain the native bowel, practically, it is almost uniformly fatal.

Survivors typically require had both small bowel and bone marrow transplants.

---

<sup>3</sup>Sir John Bland-Sutton (1855–1936)—English surgeon.

<sup>4</sup>Jay L Grosfeld (1935–2016)—American surgeon and late lamented Editor of the *Journal of Pediatric Surgery*.



**Fig. 17.1** Intestinal atresia classification—(types 1, 2, 3a, 3b, and 4 (combination or multiple))

## 17.5 Clinical Features

Antenatal US may show polyhydramnios ( $\uparrow$  with the more proximal atresias). A “double bubble,” dilated proximal loops or simply “echogenic” bowel may be seen. Postnatally, infants exhibit bile-vomiting, though some cases of duodenal atresia can have non-bilious vomiting as 15% have pre-ampullary atresia; and varying degrees of distension (depending on the level of obstruction) together with delay in the passage of meconium (not invariable). Stenosis rather than atresia may be tolerated for a period and present later with intermittent vomiting and failure to thrive.

### 17.5.1 Investigations

- AXR will show features of obstruction:
  - “Double bubble” and no distal gas—classical feature in duodenal obstruction
  - Dilated bowel loops and absence of distal gas—more loops will be visible with distal jejunal obstructions.
- Colon atresia
  - Characteristic picture is a single, grossly dilated right-sided loop with a fluid level. This represents the obstructed colon with a competent ileocecal valve—A closed-loop obstruction
- Intrauterine perforation and meconium cyst formation may be suggested by *peritoneal calcification*.
- *Contrast* enema may show a microcolon and is also helpful in ruling out other causes of distal bowel obstruction (e.g., Hirschsprung disease, meconium plug).

### 17.5.2 Differential Diagnosis

- Duodenal atresia/stenosis
  - *Malrotation*. A double bubble appearance implies intrauterine onset and proximal duodenal dilatation. Complete duodenal occlusion can only occur if there is a volvulus in addition to malrotation.
- Jejunoileal atresia/colonic
  - *Meconium ileus*—right iliac fossa “soap-bubble” sign, no fluid levels.
  - *Hirschsprung’s disease* (long segment/total colonic)—↑ dilated bowel loops and transition zone on contrast enema.
  - **Meconium plug syndrome, Left colon syndrome**. Contrast enema should enable diagnostic resolution.

---

## 17.6 Surgery

Mostly a transverse supraumbilical incision is used though the laparoscopic technique can be employed, particularly in duodenal atresia.

### 17.6.1 Duodenal Atresia (Duodenoduodenostomy)

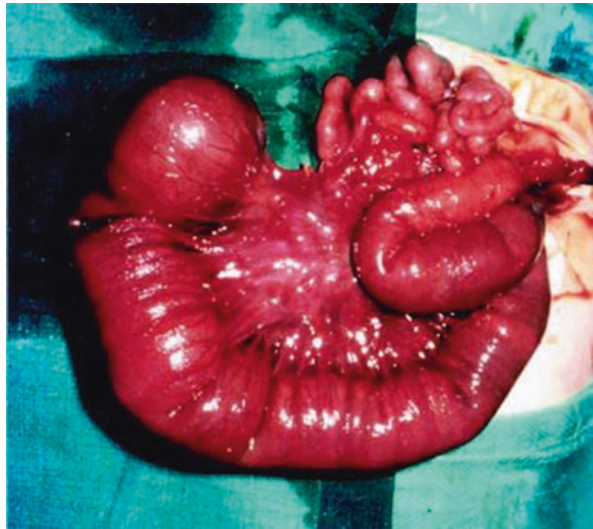
- Recognize and treat any associated *malrotation*.
- Approximate two ends, mobilize to avoid tension (antimesenteric, not mesenteric). Recognize possible “wind-sock” Type 1 anomaly if the bowel is in continuity.

- Transverse incision proximal end. Longitudinal incision distal end **with “diamond-shaped” Kimura anastomosis**. Type 1 membrane may be excised. Caution with the area of ampulla.
- Uncommonly, because of gross proximal dilatation—consider duodenoplasty and tapering as a primary procedure.
- $\pm$  trans-anastomotic tube. Allows early feeding but often “pulled out” early.

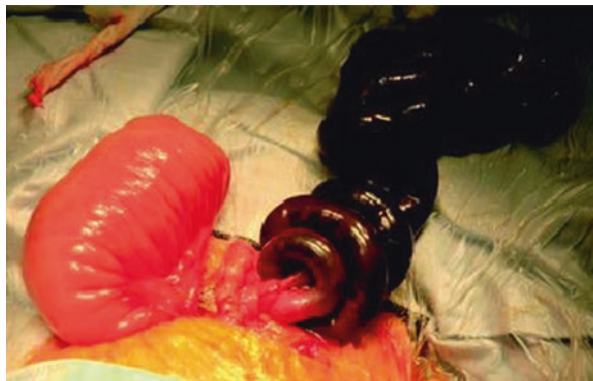### 17.6.2 Jejunal Atresia (Figs. 17.2 and 17.3)

Key observations to make at operation include assessing the: *viability* and *length of residual bowel* together with patency of the distal lumen. Unrecognized distal atresia or stenosis will inevitably cause a proximal anastomotic breakdown.

**Fig. 17.2** Jejunoleal atresia



**Fig. 17.3** Jejunal atresia—type 3a—apple peel atresia (N.B. the volved ileum has infarcted)





- *Bowel Disparity*
  - This will be the main problem in any anastomosis.
    - If there is sufficient residual bowel, then resect back to a more normal caliber.
    - If residual bowel is precious, then either **imbrication** or a **tapering enteroplasty** can be performed.
    - Proximal jejunostomy**—conventional or a tube jejunostomy that allows control over the luminal content and hence protects the skin. This also gives the option of controlled jejunal dilatation. Always ensure with this option that there is a **distal mucous fistula** to allow re-feeding of luminal content.

### 17.6.3 Colon Atresia

Usually, the site of atresia is two-thirds along the transverse colon—the “watershed” between the midgut and the hindgut.

Operative options include:

- *Primary anastomosis*—because of proximal dilatation this may mean a hemicolectomy and ileo-transverse colostomy.
- *Defunctioning colostomy and staged anastomosis*

Postoperatively, parenteral nutrition should be started and continued until enteral feeds are established.

---

## 17.7 Outcome

This is largely dependent on associated anomalies, and the length of the residual small bowel. In general, long-term survival for duodenal and jejunoileal atresia is around >90% and that of colonic atresia should be approaching 100%.

---

## Further Reading

1. Burjonrappa S, Crete E, Bouchard S. Comparative outcomes in intestinal atresia: a clinical outcome and pathophysiology analysis. *Pediatr Surg Int.* 2011;27:437.
2. Festen S, Brevoord JC, Goldhoorn GA, et al. Excellent long-term outcome for survivors of apple peel atresia. *J Pediatr Surg.* 2002;37:61–5.
3. Cox SG, Numanoglu A, Millar AJ, Rode H. Colonic atresia: spectrum of presentation and pitfalls in management. A review of 14 cases. *Pediatr Surg Int.* 2005;21:813–8.
4. Dalla Vecchia LK, Grosfeld JL, West KW, Rescorla FJ, et al. Intestinal atresia and stenosis: a 25-year experience with 277 cases. *Arch Surg.* 1998;133:490–7.



Ike Njere, Chandrasen K. Sinha, and Mark Davenport

## 18.1 Introduction

Malrotation is a term used to describe a spectrum of anomalies of rotation and fixation of the intestines, principally involving the midgut.

- Incidence
  - ~0.2–0.3% of live births and 1% of autopsies
- Males slightly > females
- Symptomatic
  - ~1 in 6000 live births
- Causes
  - ~3–5% of intestinal obstructions in childhood
  - Most (50–70%) are diagnosed in the neonatal period.
- Associated with:
  - Gastroschisis and exomphalos
  - Diaphragmatic hernia
  - Gastrointestinal webs and atresias
  - Intussusception (Waugh's syndrome<sup>1</sup>)
  - Megacystis, Microcolon, Intestinal Hypoperistalsis syndrome (MMIHS)
  - Hirschsprung's disease
  - Dysmotility (Intestinal Neuronal Dysplasia) and pseudo-obstruction

<sup>1</sup>Waugh GEA (1920) The morbid consequences of a mobile ascending colon. *Br J Surg* 7:343.

I. Njere  
Royal Devon & Exeter Hospital, Devon, UK

C. K. Sinha  
St George's Hospital, London, UK

M. Davenport (✉)  
King's College Hospital, London, UK

- Abnormalities of the biliary system and pancreas (Hardikar Syndrome<sup>2</sup>)
- Extraintestinal defects (Congenital heart defects, esophageal atresia)

Malrotation occurs when the normal process of rotation is not complete or is erroneous. The commonest variant being the failure of the final 90° anticlockwise rotation taking the caecum from the right upper quadrant to the right iliac fossa and being fixed in a subhepatic position. Here it tries to fix itself to the retroperitoneum often by discrete peritoneal bands running anteriorly to second part of the duodenum (Ladd's bands).

*The key pathology is the distance between the two ends of the small bowel mesentery (as marked by the DJ flexure and the IC valve). When this is diminished, the risk of volvulus increases.*

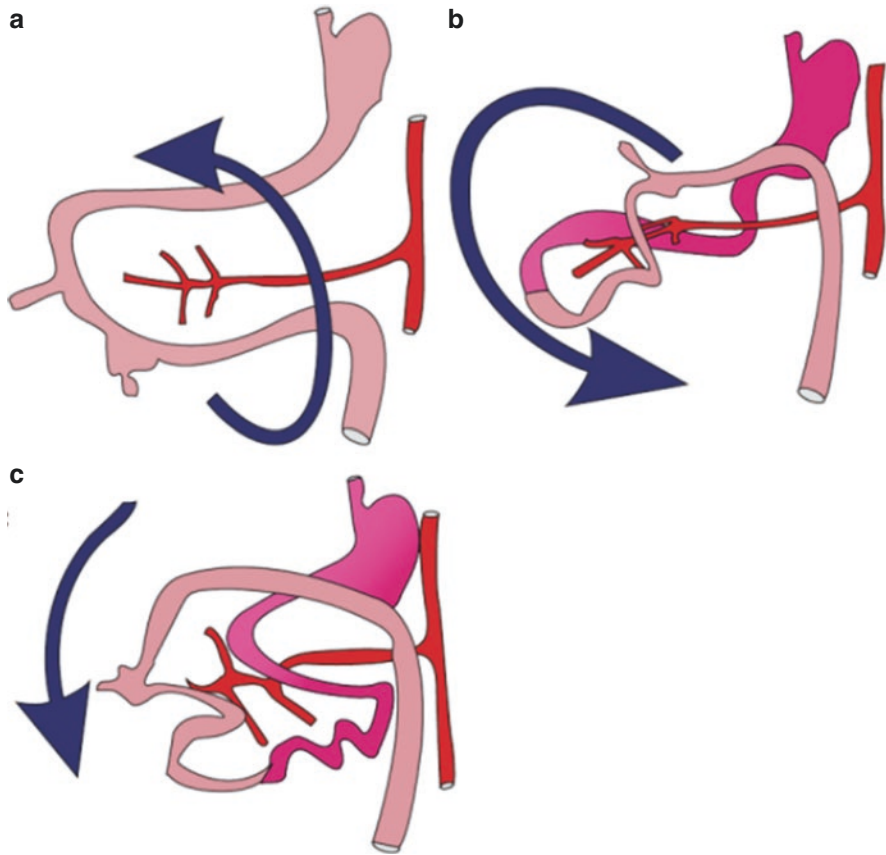
## 18.2 Embryology (After Frazer and Robbins)

The normal embryological development of the intestines takes place between the fifth and twelfth weeks of gestation.

- Stage 1 (5th to 10th week)
  - The midgut herniates into the umbilicus.
- Stage 2 (10th to 11th week)
  - The midgut returns to the abdomen.
- Stage 3 (>11th week)
  - Fixation

The midgut starts as a straight tube in the early embryo. Its blood supply, the superior mesenteric artery (SMA), with the vitelline duct, divides the midgut into a cephalad *prearterial* and a caudal *postarterial* segment. Rapid elongation of the midgut causes it to form a loop along the axis of the SMA and then herniate into the umbilicus. The prearterial segment rotates 180° and the postarterial segment rotates 90° anticlockwise along the axis of the SMA as the midgut herniates into the umbilicus. The prearterial segment reenters the abdomen first undergoing an additional 90° anticlockwise rotation. The postarterial segment then follows, undergoing an additional 180° rotation. This results in the normal C-loop configuration of the duodenum. The distal duodenum passes beneath the SMA and the colon assumes a “picture frame” position with the transverse colon anterior to the SMA and the caecum in the right iliac fossa (Fig. 18.1).

<sup>2</sup>Hardikar et al. Multisystem obstruction with cholestasis, pigmentary retinopathy, and cleft palate: a new syndrome? *Am J Med Genet.* 44: 13–17, 1992.



**Fig. 18.1** Schematic of normal rotation (a) Midline midgut supplied by superior mesenteric artery, initial a/c rotation. (b) Prearterial midgut passing behind SMA to reach LUQ and continuation of a/c rotation of postarterial midgut around the axis of SMA. (c) Final 90° a/c rotation to bring cecum down to RLQ

### 18.3 Etiology

The dorsal mesentery plays a key role in the intestinal rotation and the forkhead box transcription factor *Foxf1* plays a key role in its formation. Ultrastructural changes in the dorsal mesentery initiate intestinal rotation and these are controlled by the transcription factors, paired homeobox gene *Pitx2* and ISL LIM Homeobox *Isl1* that are expressed on the left side of the mesentery.

The cause of malrotation when it occurs in isolation has not been identified; however, there are four etiological groups where a genetic cause can be found.

- Inactivating heterozygous mutations in the *Foxf1*
  - Can also cause congenital short bowel and alveolar capillary dysplasia

- Mutations in genes controlling Left to Right (L-R) patterning
  - Can also cause congenital heart defects, abnormalities of lung lobulation, and situs abnormalities
- Autosomal dominant inheritance in familial non-syndromic intestinal malrotation with midgut volvulus
- Autosomal recessive inheritance in syndromic intestinal malrotation (e.g., Martinez-Frias syndrome<sup>3</sup>, Fryns syndrome<sup>4</sup>, and MMIHS)

---

## 18.4 Clinical Features

Malrotation can present at any age though the classic presentation is a newborn with bile vomiting. Emesis is the presenting symptom in >90% of infants. If delayed then the features are less specific and may include non-bile vomiting, intermittent or acute abdominal pain, diarrhea, constipation, or failure to thrive.

Abdominal pain is the presenting symptom in >80% of older children and adults.

Volvulus is present in a declining proportion. So, in 35% of infants compared to 20% of 1–18-year-olds and 10% of > 18-year-olds.

On physical examination, the abdomen is soft and non-tender to palpation unless volvulus and intestinal strangulation has occurred leading to abdominal distension, tenderness, and blood-stained stools.

### 18.4.1 Investigations

#### 18.4.1.1 Prenatal: Very Unusual

- Ultrasound identification of:
  - A malpositioned stomach, especially a midline stomach
  - Relative positions of SMA and SMV with SMV to the left of SMA
  - Presence of a “Whirlpool sign”
  - Dilated loops with fluid-filled levels

Fetal MRI may confirm the rotational abnormality.

#### 18.4.1.2 Postnatal (Table 18.1)

- AXR may be normal in most cases. But abnormal features may include:
  - Malposition of the bowel (small bowel all to the right and colon all to the left)
  - Lack of distal bowel gas—even a gasless abdomen, a “double bubble” in the duodenum
  - “Whirled” appearance of mid-abdominal bowel

---

<sup>3</sup>Martinez-Frias ML, Frias JL, Galan E, et al. Tracheoesophageal fistula, gastrointestinal abnormalities, hypospadias, and prenatal growth deficiency. *Am J Med Genet* 1992; 3:352–355.

<sup>4</sup>Fryns JP, et al. A new lethal syndrome with cloudy corneae, diaphragmatic defects and distal limb deformities. *Hum Genet* 1979;50:65–70.

**Table 18.1** Contrast studies in malrotation

|                         | Normal features   | Abnormal features  |
|-------------------------|---|--|
| Overall                 | “C”-shaped duodenum   | Redundant duodenum, right-sided jejunal loops                              |
| Lateral appearance      | Overlapping, posterior position of second and fourth parts            | Anterior position of 4th part  |
| Duodeno-jejunal flexure | Left of spinal pedicles; rising to at least level of L1/L2 disk space | Right-sided or centrally placed. Failure of ascent to the level of pylorus |

- Thick-walled, tubular appearing loops with fold thickening or thumbprinting—suggesting chronic volvulus
- **Upper GI Contrast Study**
- Non-ionic water-soluble contrast is usually used and indicated if perforation is a possibility (investigation of choice—if time permits).
- **Lower GI Contrast Study**
  - This is an alternative to identify the position of the cecum but this is less secure and the cecal position may be normal in malrotation (maybe up to 30%). An unfixed cecum may be also found in ~15% of patients with normal rotation.
- Ultrasound and CT scan:
  - Identification of position of the relationship of mesenteric vessels.
  - SMA is to the left of the SMV (normal).
    - If the arrangement is reversed, malrotation should be suspected. The duodenum and jejunum could also be noted in an abnormal position on the CT scan.

## 18.5 Management

Consider if volvulus is likely (or even a possibility), then every minute counts and the child needs urgent laparotomy for intestinal detorsion. Other elements to be considered while this is being prepared are rapid fluid resuscitation, N-G aspiration, correction of acid/base imbalance, IV broad-spectrum antibiotic regimen, and inotropic agents.

The preoperative preparation can be more leisurely if there is no evidence of intestinal ischemia.

### 18.5.1 Surgery: Ladd's Procedure<sup>5</sup>

#### Classic Paper –

Ladd WE. Surgical disease of the alimentary tract in infants. *N Engl J Med* 1936;215:705–708

<sup>5</sup>William E Ladd (1880–1967)—American surgeon working in Boston, MA, regarded as the father of American pediatric surgery and pioneer in many areas.

There are two preludes to this procedure:

- Untwist a volvulus—usually, this means in an anticlockwise direction—but satisfy yourself that this is completely achieved.
  - Assess intestinal damage and prepare for reperfusion syndrome (hypotension,  $\uparrow K^+$ ,  $\uparrow$ lactate).
  - Resection (if unequivocal necrosis)  $\pm$  anastomosis (if safe). If, equivocal and short bowel is likely then consider leaving “ischemic” gut alone and perform second-look laparotomy in 24–36 h.
- Consider the possibility of underlying “windsock” of duodenal/jejunal stenosis/atresia. Look for duodenal/jejunal disparity and pass N-G tube along into jejunum, if doubt.

The aim is to leave the midgut in a position of complete “non-rotation” with duodenum and small bowel on the right, apex of midgut (where a Meckel diverticulum would be) and hence SMA centrally, and cecum and large bowel on left. This achieves the widest possible base to the mesentery thus reducing the propensity to volvulus.

- Division of Ladd’s bands (lying across the duodenum from abnormal caecum in RUQ).
- Widen mesenteric base—divide peritoneum overlying central mesenteric vessels.
- Position bowel—small bowel right and large bowel left.
- $\pm$  Appendectomy.

Laparoscopic treatment of malrotation is also a possibility and may be regarded as the ultimate diagnostic test. It may be difficult to appreciate the relative position of the intestines and for that reason, a conversion to open rate is ~25%.

### 18.5.2 Asymptomatic Patients

In our opinion, it is not necessary to screen asymptomatic patients with congenital heart disease like heterotaxy patients for malrotation. Younger asymptomatic patients with isolated malrotation may be considered for a pre-emptive Ladd’s procedure while observation may be appropriate for the older ones.

---

## 18.6 Outcome and Complications

- Midgut infarction (<5%)
- Recurrence of midgut volvulus post-Ladd’s procedure
  - Laparoscopic ~5%
  - Open ~2%

- Adhesional intestinal obstruction—clearly the aim of Ladd’s procedure is to “fix” the intestines and reduce mobility and this might be an inevitable consequence.
  - Laparoscopic 0%
  - Open 10%

---

## Further Reading

- Frazer JE, Robbins RH. On the factors concerned in causing malrotation of the intestines in man. *J. Anat Physiol.* 1915;51:75–110.
- Miller AJW, Rode H, Cywes S. Malrotation and volvulus in infancy and childhood. *Seminars Pediatr Surg.* 2003;12:229–36.
- Penco JMM, Murillo JC, Hernandez A, et al. Anomalies of intestinal rotation and fixation: consequences of late diagnosis beyond two years of age. *Pediatr Surg Int.* 2007;23:723–30.
- Martin V, Shaw-Smith C. Review of genetic factors in intestinal malrotation. *Pediatr Surg Int.* 2010;26:769–81.
- Bartholmot C, Faure J, Grosjean F, et al. Prenatal diagnosis of antenatal midgut volvulus: specific ultrasound features. *Prenatal Diagnosis.* 2019;39:16–25.
- Catania V, Lauriti G, Pierro A, et al. Open versus laparoscopic approach for intestinal malrotation in infants and children: a systematic review and meta-analysis. *Pediatr Surg Int.* 2016;32:1157–64.
- Graziano K, Islam S, Dasgupta R, et al. Asymptomatic malrotation: diagnosis and surgical management. An American Pediatric Surgical Association outcomes and evidence based practice committee systematic review. *J Pediatr Surg.* 2015;50:1783–90.





# Necrotizing Enterocolitis

# 19

Eric A. Sparks and Augusto Zani

Necrotizing enterocolitis (NEC) is a devastating intestinal disease that affects ~5% of preterm neonates. Despite advancements in neonatal care, mortality remains high (30–50%) and controversy still persists with regards to the most appropriate management of neonates with necrotizing enterocolitis.

## 19.1 Epidemiology

The true incidence of necrotizing enterocolitis is difficult to define due to imprecise diagnosis in early/mild disease:

- Incidence varies inversely with gestational age and birth weight.
- Overall incidence is approximately 5% in infants <32 wks.
- ~90% of cases occur in preterm (<37 weeks of gestation) infants.
- Term infants with NEC are likely to have congenital heart disease (*cardiogenic NEC*).
- Incidence is approximately [3%, 6%, 9%, 12%] for birth weight [500–750 g, 750–1000 g, 1000–1250 g, 1250–1500 g].
- Rates of surgical treatment (35–60%) and mortality rates (20–50%) also vary inversely with birth weight.

---

E. A. Sparks · A. Zani (✉)

Division of General and Thoracic Surgery, The Hospital for Sick Children,  
Toronto, ON, Canada

Department of Surgery, University of Toronto, Toronto, ON, Canada  
e-mail: [eric.sparks@sickkids.ca](mailto:eric.sparks@sickkids.ca); [augusto.zani@sickkids.ca](mailto:augusto.zani@sickkids.ca)

---

## 19.2 Pathogenesis

The exact etiology of NEC remains unclear, but it is likely multifactorial. Recognized factors are:

- **Prematurity**, which predisposes the intestine to several risks:
  - Poor motility.
  - Poor immune function.
  - “Leaky” barrier
  - Microcirculatory insufficiency.
  - Respiratory insufficiency, hypoxia, and hypoxic events.
  - Altered microbiome.
- **Formula feeding**—vs. breast milk.
- **Hyperosmolar fluids**—such as “fortification,” medications, contrast media.
- **Hypoxia**—recurrent episodes of apnea, respiratory distress, assisted ventilation, and umbilical vessel catheterization.
- **Common identified organisms:** *Escherichia Coli*, *Klebsiella pneumoniae*, *Proteus*, *Staphylococcus aureus*, *S. Epidermidis*, *Enterococcus spp.*, *Clostridium perfringens*, and *Pseudomonas aeruginosa*.

**Focal intestinal perforation (FIP) or spontaneous intestinal perforation (SIP)** is a milder disease affecting a short segment of the bowel and typically presents earlier postnatally. The ongoing debate on whether FIP/SIP is a mild form of NEC or a distinct entity.

---

## 19.3 Prevention

Few interventions have strong evidence to prevent the development of NEC. These include:

- Protocols for feeding advancement in VLBW infants.
- Breast milk or donor breast milk nutrition.

Other interventions have been proposed, but with mixed evidence to support:

- Avoidance of early calorie fortification—partially supported, Level 1b.
- Avoidance of umbilical vein catheter malposition—weak support, Level 2b.
- Prophylactic probiotics/prebiotics/synbiotics—partially supported, level 1b.
- Avoidance of indomethacin/ibuprofen/ranitidine—weak supported, Level 2b.
- Prophylactic antibiotics—not supported, Level 1b.
- Peptide immunomodulator supplementation (glutamine, arginine)—not supported, variable data.

**Table 19.1** Modified Bell's stages of NEC

| Stage              | I   | IIA  | IIB   | IIIA   | IIIB                            |
|--------------------|---|--|---|--|---------------------------------|
| Description:       | Suspected NEC   | Mild NEC   | Moderate NEC  | Severe NEC   | Severe NEC                      |
| Systemic signs     | Temperature instability, apnea, bradycardia                                       | Similar to stage I   | Mild acidosis, thrombocytopenia                     | Respiratory and metabolic acidosis, mechanical ventilation, hypotension, oliguria, DIC | Further deterioration and shock |
| Intestinal signs   | Increased gastric residuals, mild abdominal distension, occult blood in the stool | Marked abdominal distension ± tenderness, absent bowel sounds, grossly bloody stools | Abdominal wall edema and tenderness ± palpable mass | Worsening wall edema with erythema and induration                                      | Evidence of perforation         |
| Radiographic signs | Normal or mild ileus  | Ileus, dilated bowel loops, focal pneumatosis  | Extensive pneumatosis, early ascites ± PVG          | Prominent ascites, fixed bowel loop, no free air                                       | Pneumoperitoneum                |

## 19.4 Clinical Features and Diagnosis

“Early” features of NEC include abdominal distension, feed intolerance, and bloody stools. “Late” disease progresses to intestinal perforation and septic shock. The pathognomonic features are pneumatosis intestinalis and portal venous gas and diagnosis is staged according to **modified Bell's criteria** (Table 19.1).

Recommended investigations include:

- Abdominal X-ray.
- Laboratory investigation findings:
  - Leukocytosis or neutropenia.
  - Thrombocytosis or thrombocytopenia.
  - Elevated c-reactive protein, elevated lactate.
  - Coagulopathy ± DIC.

Other investigations may be considered at experienced centers:

- Ultrasonography.
- Near-infrared spectroscopy.
- Diagnostic laparoscopy.
- Novel biomarkers.

## 19.5 Management

The mainstays of management of NEC are bowel rest, antibiotics, and surgical consultation.

- Bell's stage I and II:
  - Antibiotic selection and duration of bowel rest should be chosen according to institutional antibiogram and protocol.
  - No consensus data clearly supports specific coverage or duration of treatment.
- Bell's stage IIIA:

- Same as management above plus conventional critical care/septic shock guidelines.
- Bell’s stage IIIB:
  - Hard indications for surgery:
    - Pneumoperitoneum.
    - Abdominal compartment syndrome.
  - Soft/debated indications for surgery:
    - Refractory septic shock/failure to improve.
    - “Fixed loop” on serial plain films or ischemic/necrotic loop on ultrasound
    - Complex ascites, palpable mass, abdominal wall erythema.
- Many emerging therapies exist but at present are only tested in experimental models (captopril, platelet-activating factor antagonists, heparin-binding epidermal growth factor-like growth factor, granulocyte colony-stimulating factor, and erythropoietin, moderately controlled hypothermia, stem cell derivatives, etc.).

---

## 19.6 Surgical Options

There are many proposed algorithms for surgical management of NEC without clear evidence basis of the best approach.

- Laparotomy.
  - Bowel resection and primary anastomosis.
  - Bowel resection and diversion (debatable if superior to primary anastomosis).
  - “Clip and drop” with second-look laparotomy for evolving/multifocal disease
- Primary peritoneal drain (bedside procedure with insertion of Penrose drain).
  - Peritoneal drain as definitive management.
  - Peritoneal drain as a bridge to laparotomy.
  - Peritoneal drain with subsequent laparotomy if the condition does not improve.

The universal principles of surgery are to achieve source control while preserving bowel length. Temporizing measures (peritoneal drain, “clip and drop,” etc.) are often necessitated by hemodynamic instability, ELBW patients, and available surgical resources.

Surgeons and neonatologists must be prepared to find “**NEC totalis**” (>75% necrotic bowel). This can be managed with:

- Massive enterectomy and attempted rescue with subsequent intestinal failure.
- Diverting jejunostomy.
- Abdominal closure and withdrawal of care.

## 19.7 Outcomes

Mortality rates (20–60%) remain high and are primarily a function of birth weight and disease stage. Perioperative morbidity (anastomosis or enterostomy related complications, sepsis, peritonitis, and wound infections) in up to 70% of infants:

- NEC recurrence (~5%)—usually within a month of initial presentation.
- Intestinal failure/short bowel syndrome—infants with NEC appear to have higher rates of ultimate enteral autonomy than other diagnoses, adjusted for residual bowel length.
- Strictures (5–20%)—typically in the large bowel. Contrast enema is key before stoma closure.
- Neurodevelopmental impairment is reported in 40% of NEC survivors.

---

## Further Reading

1. Bell MJ, Ternberg JL, Feigin RD, et al. Neonatal necrotizing enterocolitis. Therapeutic decisions based upon clinical staging. *Ann Surg.* 1978;187:1–7. [Classic paper, cited now over 2000 times].
2. Siano E, Lauriti G, Ceccanti S, Zani A. Cardiogenic necrotizing enterocolitis: a clinically distinct entity from classical necrotizing enterocolitis. *Eur J Pediatr Surg.* 2019;29:14–22. <https://doi.org/10.1055/s-0038-1668144>.
3. Moss RL, Dimmitt RA, Barnhart DC, et al. Laparotomy versus peritoneal drainage for necrotizing enterocolitis and perforation. *N Engl J Med.* 2006;354:2225–34.
4. Rees CM, Eaton S, Kiely EM, et al. Peritoneal drainage or laparotomy for neonatal bowel perforation? A randomized controlled trial. *Ann Surg.* 2008;248:44–51.
5. Zani A, Eaton S, Puri P, et al. International survey on the management of necrotizing enterocolitis. *Eur J Pediatr Surg.* 2015;25:27–33.
6. Zani A, Pierro A. Necrotizing enterocolitis: controversies and challenges. *F1000Res.* 2015 Nov 30;4. pii: F1000 Faculty Rev-1373.
7. Fitzgibbons SC, Ching Y, Yu D, et al. Mortality of necrotizing enterocolitis expressed by birth weight categories. *J Pediatr Surg.* 2009;44(6):1072–5.
8. Hull MA, Fisher JG, Gutierrez IM, et al. Mortality and management of surgical necrotizing enterocolitis in very low birth weight neonates: a prospective cohort study. *J Am Coll Surg.* 2014;218:1148–55.



# Meconium Ileus and Surgical Features of Cystic Fibrosis

# 20

Hesham Elagami, Chandrasen K. Sinha,  
and Mark Davenport

Meconium ileus may define how an infant enters this world, but it is cystic fibrosis that defines its life thereafter.

## 20.1 Meconium Ileus

### 20.1.1 Definition

Intestinal obstruction is secondary to impaction of inspissated viscid meconium in the terminal ileum in a neonate, typically due to cystic fibrosis (CF).

**Meconium**<sup>1</sup> is the black, thick, viscid substance found in the newborn intestine. It consists of desquamated cells, bile and swallowed amniotic fluid. The abnormal meconium of CF has a higher protein and albumin composition, lower carbohydrate, bicarbonate and reduced fluid content.

<sup>1</sup>Meconium. Greek—μικώμιον. Is related to a diminutive for the poppy and may allude to its use/appearance when producing opium.

H. Elagami  
St George's University Hospital, London, UK

C. K. Sinha  
St George's Hospital, London, UK

M. Davenport (✉)  
King's College Hospital, London, UK

### 20.1.2 History

An infant with small bowel obstruction and histological changes in the pancreas was first described by Karl Landsteiner<sup>2</sup> in 1905. “Fibrocystic disease of the pancreas” was first coined by Dorothy Andersen in 1938. Surgical treatment to both bypass and allow distal access was provided by the Bishop-Koop ileostomy first described in 1957. Non-surgical treatment by use of initially hydrogen peroxide and then later Gastrografin© was pioneered in the 1960s and 1970s by Helen Noblett.

### 20.1.3 Epidemiology

- 10% of neonatal intestinal obstruction
  - 80–90% of infants presenting with MI have CF.
  - ~10% of patients with CF will present with MI.
  - 40% of patients with MI are complicated with perforation or atresia.
- M = F.

---

## 20.2 Cystic Fibrosis

- 1 in 3000 live-births.
- Most common (carrier frequency 1 in 25) recessive disease in Caucasians.

Cystic Fibrosis Transmembrane conductance Regulator is a membrane protein encoded by the **CFTR gene** located on Chromosome 7 (q 31.2) and was identified in 1989 by Francis Collins as a cyclic AMP-dependent chloride channel that regulates ion flow across the apical surface of epithelial cells.

The CFTR2 database recognises more than 2000 genes that can possibly lead to the disease. Phenotypic expression varies according to the specific variant of the pathogenic gene but  $\Delta F508$  is the most common pathogenic variant. Homozygous  $\Delta F508$  is found in about 50% of cases. MI is particularly associated with the  $\Delta F508$  and the G542X genes. Current genetic screening is performed only for a subset of the most commonly encountered genes in the Caucasian population.

### 20.2.1 Pathophysiology

#### 20.2.1.1 Lungs

- Abnormal rheology of airway secretion.
- Viscid secretion and impairment of ciliary mucus clearance together with progressive colonisation particularly with *Ps. aeruginosa*, *H. influenzae* and *St. aureus*.
- Progressive secondary inflammation contributes to pulmonary dysfunctions and bronchiectasis.

---

<sup>2</sup>Karl Landsteiner (1868–1943)—Viennese pathologist perhaps more famous for description of blood groups and eventually a Nobel prize in 1930.

### 20.2.1.2 Gastrointestinal Epithelium

Deranged bile and pancreatic fluids flow lead to malabsorption with the later onset of diabetes.

- Causes  $\uparrow$   $\text{Cl}^-$  in sweat.
- Causes  $\downarrow$   $\text{Cl}^-$  GI tract, pancreas and liver causing  $\uparrow$  viscosity in all secretions.
- Exocrine gland blockage.
- Luminal obstruction—vas deferens.

---

## 20.3 Clinical Features of Meconium Ileus

Definitive diagnosis is based on CFTR function with a sweat chloride test.

### 20.3.1 Antenatal Period

- Antenatal USS scan:
  - Echogenic bowel, which can be dilated and thick-walled.
  - Polyhydramnios.
  - Foetal ascites.
  - Peritoneal wall calcifications.
  - Intra-abdominal cysts.
  - Non-visualisation of the gall bladder on US (also seen in Down syndrome, biliary atresia, intestinal atresia and the normal foetus).
- Genetic testing: Either parental or amniocentesis.

### 20.3.2 Postnatal

Simple (60%) versus Complicated (40%) MI

Typical picture of distal intestinal obstruction with abdominal distension, bile vomiting and absence of passage of meconium. Abdominal examination may show palpable “doughy” or “putty-like” intestinal loops.

### 20.3.3 Complicated MI

- Meconium pseudocyst follows antenatal (sterile) perforation and leakage of content.
- Small intestinal atresia follows antenatal local volvulus.
- Postnatal local volvulus and perforation.

### 20.3.4 Investigations

- Abdominal XR may show non-specific signs of dilated intestinal loops (NO fluid levels) and paucity of distal gas.



- **Neuhauser’s sign** “soap-bubble” or “ground glass” appearance in right lower quadrant due to admixing air into meconium-filled loops.
- Speckled calcification due to *in utero* perforation.
- Contrast enema (water-soluble) may show a micro-colon with progressive filling defects in the terminal ileum.
- Postnatal US—may provide a better definition of a palpable mass (meconium cyst).

#### 20.3.4.1 Laboratory Tests

- **Sweat test** (pilocarpine iontophoresis) Cornerstone of diagnosis, but is operator dependent and needs experience.
- Requirements: >2 weeks of age, >2 kg of weight, > 75 mg of sweat.
- Interpretation:
  - $\leq 29$  mmol/L Normal
  - 30 to 59 mmol/L Inconclusive
  - $\geq 60$  mmol/L Diagnostic
- **Immunoreactive Trypsin (IRT).**
  - In the UK, all newborn babies are screened for cystic fibrosis as part of the newborn blood spot (Guthrie) test IRT.
  - $\uparrow\uparrow$  levels in CF, but not too specific.
- Gene mutation analysis (Diagnosis and screening).

### 20.3.5 Management

Initial stabilisation with IV fluids and NG tube. Start broad-spectrum antibiotics. After excluding complex MI (e.g. perforation, pseudocyst) nonoperative treatment may be attempted.

Classically Gastrografin® was used but seemingly disregarded by paediatric radiologists nowadays. Its physical characteristics include water-solubility, hyperosmolarity (~1900 mOsm/L and a wetting agent (“Tween 80”). Anecdotal reduction in efficacy from ~60% to ~30%, possibly by risk-averse radiologists.

#### 20.3.5.1 Surgery (re-use original figures)

Options include:

1. Enterotomy in proximal healthy bowel with catheter washout (saline, N- acetyl-cysteine, Gastrografin) to break down the impacted meconium then primary closure.
2. Double-barrelled ileostomy and mucous fistula (Mikulicz).
3. Bishop-Koop<sup>3</sup> ileostomy (1961).

<sup>3</sup>Harry Bishop (1921–2009) and “Chick” Everett Koop (1916–2013)—CHOP paediatric surgeons. The latter much more famous later as the Surgeon General of the USA during the Reagan era.

4. Santulli<sup>4</sup> ileostomy.
5. T-tube enterostomy.

*For complicated MI.*

6. Resection of ischemic bowel, cyst or atretic segment often with diverting stoma or rarely primary anastomosis.

### 20.3.5.2 Postoperative care

- Parenteral nutrition.
- N-acetylcysteine (4%) enterally (5–10 mLs) if persisting functional obstruction (anecdotal).
- Enteral pancreatic enzymes replacement therapy which improves faecal fat absorption (e.g. Creon®, Pancrease®, etc.).
- Early involvement of the CF team.

### 20.3.6 Outcome

Many studies show that Meconium ileus in patients with cystic fibrosis does not increase the risk of clinical deterioration and death.

- Current average life expectancy ~35 years.

---

## 20.4 Meconium Plug Syndrome (MPS)

This is a transient disorder of the newborn colon characterised by delayed passage (>24–48 h) of meconium and intestinal dilatation. Typically, a whitish mucus plug is passed followed by thick meconium. It may be associated with:

- Maternal factors (e.g. eclampsia and diabetes).
- Neonatal factors (e.g. sepsis, prematurity, hypothyroidism and neonatal intestinal dysmotility).
- **Small left colon syndrome**—a radiological entity with the transitional zone at the level of the splenic flexure, associated with maternal diabetes.
- Hirschsprung's disease.
- Cystic fibrosis.

---

<sup>4</sup>Thomas V Santulli (1915–1997)—New York-based surgeon.

### 20.4.1 Clinical Features

Features of distal intestinal obstruction, with a differential diagnosis of meconium ileus and Hirschsprung's disease. The key investigation is the diagnostic contrast enema followed by a therapeutic water-soluble contrast enema. Further cot-side rectal washouts may be needed to relieve the obstruction.

Further investigations should include CF genotype and sweat test  $\pm$  rectal suction biopsy, to exclude the underlying conditions referred to above.

---

## 20.5 Distal Intestinal Obstruction Syndrome (DIOS)

**Definition** – acute complete or incomplete obstruction of the distal ileum and colon by inspissated viscid faecal material after the neonatal period in those with CF. It was formerly known as **meconium ileus equivalent**.

- Peak incidence is 6–10 years.
- Affects up to 20% of children and adults with CF at some time.

### 20.5.1 Clinical Features

The aetiology is not known but considered as multifactorial with factors including low fluid intake in the setting of pancreatic exocrine insufficiency. Most children present with colicky abdominal pain and have a palpable mass in the RLQ. An abdominal XR may show faecal loading in both large and small bowel.

### 20.5.2 Management

As for any intestinal obstruction but with a more aggressive regimen to try and clear the intraluminal content. Examples:

- Oral/NG Gastrografin® e.g. 50 mls made up to 400 mls solution.
- Rectal Gastrografin®, e.g. 100 mls.
- Oral N-acetyl-cysteine, e.g. Parvolex®, 30 mls of 20% solution TDS.
- Oral polyethylene glycol, e.g. Movicol® 1 sachet and water TDS.

Failure of medical management mandates surgical intervention which usually entails enterostomy and direct lavage.

---

## 20.6 Fibrosing Colonopathy

In the 1990s, there was a marked increase in the development of peculiar right-sided colon strictures in otherwise healthy CF children. These were diagnosed using a combination of contrast enema and colonoscopy and often required surgery. Histological examination of the strictures was unremarkable. Since that time its prevalence has dropped markedly perhaps due to increasing awareness and the need to moderate high-strength pancreatic supplements.

---

## 20.7 Other Surgical Implications of CF

- **Acute appendicitis.**
  - Tends to present late, with a possible ↑ incidence of abscess due to concurrent antibiotic use.
- **Mucocele of appendix.**
  - Characteristic pathology of CF, and may be asymptomatic.
- **Intussusception.**
  - ~ 1% of CF patients
  - Older children, and not the classical age group. The clinical picture is similar to DIOS.
- **Gallbladder and Biliary Disease.**
  - Neonates.
    - Inspissated bile syndrome – actual viscid mucoid bile much more obstructive than other causes.
  - Adolescence and young adults.
    - Microgallbladder (25–30%).
    - Cholelithiasis (12–15%).
- **Acute and Chronic Pancreatitis.**
  - Adolescence and young adults.
  - Needs some residual degree of function. ERCP is indicated for chronic or relapsing pancreatic pain to exclude duct stricture.
  - Faecal elastase is an accurate measurement of exocrine function.
    - >200 μ/g stool—normal. < 100 μ/g stool—severe deficiency
- **Crohn's disease.**
  - Adolescence and young adults.
  - Up to 17-fold ↑ in prevalence in CF.

---

## 20.8 Malignancy

- Digestive tract cancer (threefold).
- Testicular cancer (twofold).

- Lymphoid leukaemia (twofold).
- ↓ risk of malignant melanoma
- **Inguinal hernia**—↑ incidence.
- **Rectal prolapse**—sometimes a presenting feature.

---

## 20.9 Gene Therapy of Cystic Fibrosis

This has been the goal of CF research for the past 20 years. To date, little practical benefit has been shown.

- **Wave 1**—gene delivery via a liposome.
- **Wave 2**—gene delivery via a nebulised viral vector (modified lentivirus).
  - 136 pts. randomised to CFTR/virus or placebo, every month for 1 year. ~3% improvement in FEV1, and more likely due to the absence of declining function in the placebo group than improvement in the treated group.

---

## Further Reading

1. Carlyle BE, Borowitz DS, Glick PL. A review of pathophysiology and management of fetuses and neonates with meconium ileus for the pediatric surgeon. *J Pediatr Surg.* 2012;47:772–81. <https://doi.org/10.1016/j.jpedsurg.2012.02.019>.
2. Pranke I, Golec A, Hinzpeter A, et al. Emerging therapeutic approaches for cystic fibrosis. From gene editing to personalized medicine. *Front Pharmacol.* 2019; <https://doi.org/10.3389/fphar.2019.00121>.
3. Farrell PM, White TB, Ren CL, et al. Diagnosis of cystic fibrosis: consensus guidelines from the Cystic Fibrosis Foundation. *J Pediatr.* 2017;181S:S4–S15.e1. <https://doi.org/10.1016/j.jpeds.2016.09.064>.
4. Escobar MA, Grosfield JL, Burdick JJ, et al. Surgical considerations in cystic fibrosis: a 32-year evaluation of outcomes. *Surgery.* 2005;138:560–71.
5. Murshed R, Spitz L, Kiely E, et al. Meconium ileus: a ten year review of thirty-six patients. *Eur J Pediatr Surg.* 1997;7:275–7.
6. Burge D, Drewett M. Meconium plug obstruction. *Pediatr Surg Int.* 2004;20:108–10.
7. Keckler SJ, St Peter SD, Spilde TL, et al. Current significance of meconium plug syndrome. *J Pediatr Surg.* 2008;43:896–8.



# Abdominal Wall Defects

# 21

Chandrasen K. Sinha, Manaswi Upadhyay,  
and Mark Davenport

## 21.1 Introduction

There are two distinct types of major anterior abdominal wall defect with distinct behavior and outcome: exomphalos<sup>1</sup> and gastroschisis.<sup>2</sup>

## 21.2 Embryology

At about 8 weeks gestation, the enlarging liver causes temporary displacement of the midgut into the extraembryonic coelom rotating by 90° in an anti-clockwise direction. The midgut rotates a total of 270° as it returns by 10 weeks. Failure to do this results in **exomphalos**. Thus, it should be covered with peritoneum, Wharton's jelly,<sup>3</sup> and amniotic membrane with insertion of the cord at its apex.

The cause of **gastroschisis** is disputed and unclear but appears to culminate in a full-thickness right-sided defect appearing by a normally inserted umbilical cord. Hypotheses proposed include: failure of mesoderm to form abdomen wall; rupture

<sup>1</sup>Exomphalos—Omphalos (Greek)—navel or umbilicus.

<sup>2</sup>Gastroschisis—(Greek)—“Belly cleft.”

<sup>3</sup>Thomas Wharton (1614–73) English physician and anatomist who described a multiplicity of anatomical features including the sub-mandibular duct, and worked at St. Thomas's Hospital, London.

C. K. Sinha (✉)  
St George's Hospital, London, UK

M. Upadhyay  
London Evelina Children Hospital, London, UK  
e-mail: [manasvi.upadhyaya@gstt.nhs.uk](mailto:manasvi.upadhyaya@gstt.nhs.uk)

M. Davenport  
King's College Hospital, London, UK

of amnion around the umbilical ring; abnormal involution of the right umbilical vein and disruption of the right vitelline artery. The timing of this is unclear although most are obvious from about 14 weeks gestation. Prolapse of uncovered viscera occurs thereafter. It is believed that exposure of the exposed intestinal loops to amniotic fluid results in the inflammatory “peel” so evident in this condition.

### 21.3 Exomphalos (Fig. 21.1)

- Hernia of the umbilical cord.
  - Small defect and sac may contain few loops of the intestine.
- Exomphalos minor.
  - Defect <5 cm.
- Exomphalos major.
  - Defect >5 cm, and predominantly contains liver.

#### 21.3.1 Clinical Features

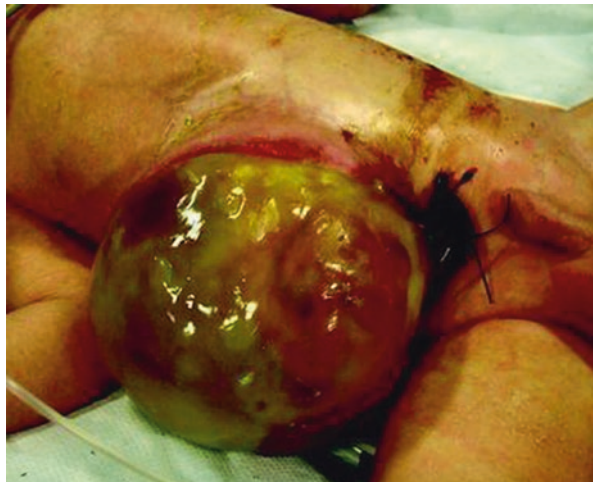##### Upper midline syndrome: Pentalogy of Cantrell

Probably caused by failure of the normal septum transversum, it consists of: an anterior exomphalos in the epigastrium; anterior diaphragmatic hernia, defect in pericardium; sternal cleft, and cardiac anomaly. Rarely this latter is actually an *ectopia cordis*.

##### Lower midline syndrome: OIES

Omphalocele, Imperforate anus, Exstrophy, Spinal anomalies.

**Fig. 21.1** Major exomphalos



- Antenatal (80%) confirmation is possible from ~12 weeks gestation (9 weeks if liver seen outside).
  - At this stage, the key steps are to establish the presence of chromosomal anomalies (by **chorionic villous sampling** (10–12 weeks) or **amniocentesis** (after 15 weeks) and/or other significant anomalies (by fetal echocardiography). There is a high rate of spontaneous intrauterine death, particularly if multiple anomalies.
- Monitor for In Utero Growth Retardation (IUGR) and polyhydramnios (1/3 of cases).
- Third trimester US should evaluate the safest mode of delivery.
  - C-section is indicated for giant exomphalos  $\geq 5$  cm size and 75% of liver outside. This potentially avoids sac rupture, visceral damage and obstructed labor.

Postnatally, it is important to establish if the sac is intact or not. Typically, intrauterine loss of the sac leads to early labor and preterm delivery. Other demographic features are mentioned in Table 21.1.

**Table 21.1** Demographic comparison of gastroschisis and exomphalos

|              | Gastroschisis  | Exomphalos (omphalocele)  |
|--------------|--|---|
| Prevalence   | 1 in 2000 live-births  | 1 in 5000 live-births<br>(1 in 2000 during fetal life)  |
|              | ↑ Incidence in Western world (reasons not known)                                       | Static  |
| Demography   | M = F<br>White > black   | M > F,<br>multiple births   |
| Environment  | Cocaine/recreational drug use<br>↑ professional kitchen users<br>Pesticides (possible) |   |
| Maternal age | Teenagers  | ↑ incidence at extremes of reproductive age   |
| Associations | Intestinal atresia is a complication caused by closing gastroschisis.                  | <b>Structural</b> in 35–70%.<br>E.g., cardiac, genito-urinary; orofacial; neural tube defects; midline diaphragmatic defects; exstrophy.<br><b>Chromosome anomalies</b><br>E.g., Trisomy 13, 18, 21<br>↑ up to 60% if exomphalos minor<br><b>Beckwith–Wiedemann syndrome</b><br>(↑ somatic growth, islet cell hyperplasia (hypoglycemia), macroglossia, and ↑ risk of neoplasia (e.g., Wilms', hepatoblastoma)) |



### 21.3.2 Investigations

It is important to evaluate the whole baby—not just an anterior abdominal wall sac. Look for other anomalies, and particularly if it could be BW syndrome (beware of hypoglycemia). Check for all midline structures.

- Echocardiogram.
- Renal ultrasound.
- Skeletal radiography.

### 21.3.3 Management

- One-third are born preterm.
- Avoid clamping umbilical contents.
- Assess respiratory status.
  - a. Significant pulmonary hypoplasia and hypertension is seen in up to 10%.
- There are a number of surgical options.
  - a. *Elective primary fascial closure.*
    - i. For exomphalos minor and most cases of exomphalos major.
    - ii. Plain AXR to exclude associated atresia.
    - iii. (Possible in exomphalos minor) Upper GI contrast to exclude malrotation and avoid a more formal laparotomy
  - b. *Staged closure (silo).*
    - i. Where primary closure not possible, but a reasonable-sized infant. Multiple surgeries might be necessary.
    - ii. Initial application of custom silo ( $\pm$  removal of sac).
    - iii. Delayed fascial ( $\pm$  prosthetic patch) closure and skin closure (7–10 days).
  - c. *Conservative sac management.*
    - i. For infants with an intact sac who are small, preterm ( $<32/40$ ), or who have other significant anomalies then this is preferred and probably safer. This involves leaving the sac to epithelialize and may be encouraged by various topical agents (e.g., silver sulfadiazine (Flamazine™), Manuka honey).
    - ii. When sac has stabilized, fitting of corset or binder is advised to try and encourage preservation and expansion of the abdominal domain.
    - iii. Fascial closure is performed at some later date (2–3 years), although the problem of viscerο-abdominal disproportion still remains and multiple operations may still be necessary.

## 21.4 Gastroschisis (Fig. 21.2)

Most cases are all too obvious at birth—the only exception is that of a **closed gastroschisis** and “vanishing midgut,” where the prolapsed bowel has died *in utero* and simply fallen off leaving the defect to close spontaneously.

### Closed Gastroschisis

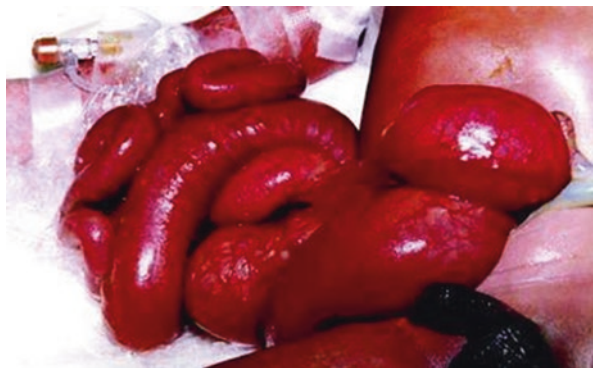This is an extreme scenario where the prolapsed midgut is compromised by a closing fascial ring. Initially this “pinches” the incoming and outgoing intestinal loops leading to stenosis or atresia (i.e., jejunal atresia and colon atresia). If this continues the actual blood vessels in the mesentery are also at risk leading to midgut ischaemia, necrosis and even disappearance.

### 21.4.1 Clinical Features

Antenatal detection is possible from ~14 weeks gestation and most (>90%) are normally picked up at the “fetal anomaly scan” at 18–20 weeks gestation. Elevated maternal serum alpha-fetoprotein (MSAFP) level can be associated. The main risk to the fetus at this stage is the possibility of “closed gastroschisis” (Box 1).

Most cases of gastroschisis can be delivered vaginally without undue harm to the gut. There is no benefit from too early delivery but most fetal medicine centers suggest planned delivery at ~38 weeks. Other demographic features are mentioned in Table 21.1.

**Fig. 21.2** Typical appearance of gastroschisis



## 21.4.2 Management

- *First aid.*
  - Prevent fluid and heat loss. Cover exposed bowel loops with “cling-film.”
  - Ensure no twist in the midgut and consider if ring may be too tight. If so, divide under local anesthesia.
  - IV fluids, antibiotics, nasogastric tube.

## 21.4.3 Surgery

The aim is a safe reduction of the bowel to prevent ischemic bowel damage and/or abdominal compartment syndrome.

There are then a number of surgical options:

- *Primary fascial closure.*
  - This can be accomplished in very favorable cases at the cot-side without anesthesia.
  - Conventional layered closure under GA (still most common option).
- *Staged closure (silo).*
  - **Custom silo and delayed fascial ( $\pm$  prosthetic patch) closure** and skin closure (at 7–10 days).
  - *Spring-loaded preformed silo.*
    - Cot-side application. No anesthesia.
    - Associated with  $\downarrow$  incidence of renal impairment.
    - Possible compartment syndrome/ischemic bowel, and needs early repeated monitoring.
    - Final “sutureless” closure possible without GA, using an intact umbilical cord, Steristrips<sup>TM</sup>, tissue glue, etc.

## 21.4.4 Complications

Abdominal wall integrity is not usually a problem after the first 2 weeks; however, gut dysmotility is prolonged and parenteral nutrition is mandatory.

- Average time to full enteral nutrition  $\sim$ 25 days.
- $\uparrow$  risk of “NEC” ( $\sim$ 5%)
  - This is rarely actually necrotic and usually mild.
- Intestinal atresia.
  - Sometimes occur where the bowel enters and leaves the closing ring. Best option is probably to leave anastomosis until final fascial closure when bowel quality has improved. Avoid stomas.

- Prolonged (>3 months) dysmotility.
  - Decreased transit time from small to the large bowel. Consider distal ileostomy as a solution to chronic pseudo-obstruction.

### 21.4.5 Outcome

- >95% survival in recent series.
- Death usually due to midgut infarction due to closed gastroschisis and prolonged PN-induced liver disease and subsequent liver failure.

---

### Further Reading

1. Lakasing L, Cicero S, Davenport M, et al. Current outcome of antenatally diagnosed exomphalos: an 11 year review. *J Pediatr Surg.* 2006;41:1403–6.
2. Rijhwani A, Davenport M, Dawrant M, et al. Definitive surgical management of antenatally diagnosed exomphalos. *J Pediatr Surg.* 2005;40:516–22.
3. Charlesworth P, Njere I, Allotey J, et al. Postnatal outcome in gastroschisis: effect of birth weight and gestational age. *J Pediatr Surg.* 2007;42:815–8.
4. Houben C, Davenport M, Ade-Ajayi N, et al. Closing gastroschisis: diagnosis, management, and outcomes. *J Pediatr Surg.* 2009;44:343–7.
5. Fullerton BS, Velazco CS, Sparks EA, et al. Contemporary outcomes of infants with gastroschisis in North America: A multicenter cohort study. *J Pediatr.* 2017;188:192–7.
6. Cantrell JR, Haller JA, Ravitch MM. A syndrome of congenital defects involving the abdominal wall, sternum, diaphragm, pericardium, and heart. *Surg Gynecol Obstet.* 1958;107:602–14.



# Anorectal Malformations

# 22

Andrea Bischoff, Luis De La Torre, and Alberto Pena

## 22.1 Introduction

Anorectal malformations (ARM) are congenital defects in which the terminal part of the hindgut is abnormally placed and lies outside (partially or completely) the sphincter mechanism.

### 22.1.1 Epidemiology

- Incidence ~1 in 5000.
- Frequently associated to Down syndrome and Cat Eye syndrome.
- M > F (60:40).
- Second child involvement is rare (<1%).
  - Exception: In those cases of ARM associated with pre-sacral masses second child involvement is extremely high.

About 5% of infants have no fistula (usually associated with Down syndrome) but the vast majority does have a connection between the distal rectum and the adjacent urogenital tract or the perineal skin.

---

A. Bischoff (✉) · L. De La Torre · A. Pena  
International Center for Colorectal and Urogenital Care, Children's Hospital Colorado,  
Denver, CO, USA  
e-mail: [andrea.bischoff@childrenscolorado.org](mailto:andrea.bischoff@childrenscolorado.org); [Luis.deLaTorre@childrenscolorado.org](mailto:Luis.deLaTorre@childrenscolorado.org);  
[Alberto.Pena@cuanschutz.edu](mailto:Alberto.Pena@cuanschutz.edu)

### 22.1.2 Embryology

By 21 days, there is a common chamber (cloaca<sup>1</sup>) occluded by a membrane but visible from the outside as an ectodermal pit—the *proctodeum*. At ~33 days, the posterior hindgut is then separated from the anterior urogenital sinus by mesenchymal ingrowth from the urorectal septum. This cloacal membrane breaks down at about 46 days. The process is regulated by differential expression of the gene Sonic Hedgehog (*SHH*), and other target genes such as *BMP-4* and the *HOX* genes.

### 22.1.3 The Anatomical Classification

| Males   | Females                 |
|---|-------------------------|
| Rectoperineal fistula                                   | Rectoperineal fistula   |
| Rectobulbar fistula                                     | Rectovestibular fistula |
| Rectoprostatic fistula                                  | Cloaca                  |
| Recto bladder neck fistula                              |                         |
| Imperforate anus without fistula (i.e., rectal atresia) |                         |

### 22.1.4 Associated Anomalies

Associated malformations are much more commonly associated with complex defects (e.g., cloacas, recto-bladder neck fistula).

- Urologic— ~50%.
  - Most common: Absent or nonfunctional kidney, hydronephrosis, vesicoureteral reflux.
- Vertebral— ~30%.
  - Mainly hemivertebrae.
- Cardiac— ~30% (only one-third of them require treatment).
- Hydrocolpos in cloaca patients— ~30%.
- Spinal cord— ~25%.
  - Tethered cord.
- Other gastrointestinal.
  - Esophageal atresia ~8%.
  - Duodenal atresia 3–6%.

### 22.1.5 Clinical Features

Perineal examination is the most important part of diagnosis and frequently it allows the diagnosis of the specific type of anomaly to be made.

<sup>1</sup> Cloaca—Latin “sewer.” The Cloaca Magna was the main sewer in Imperial Rome.

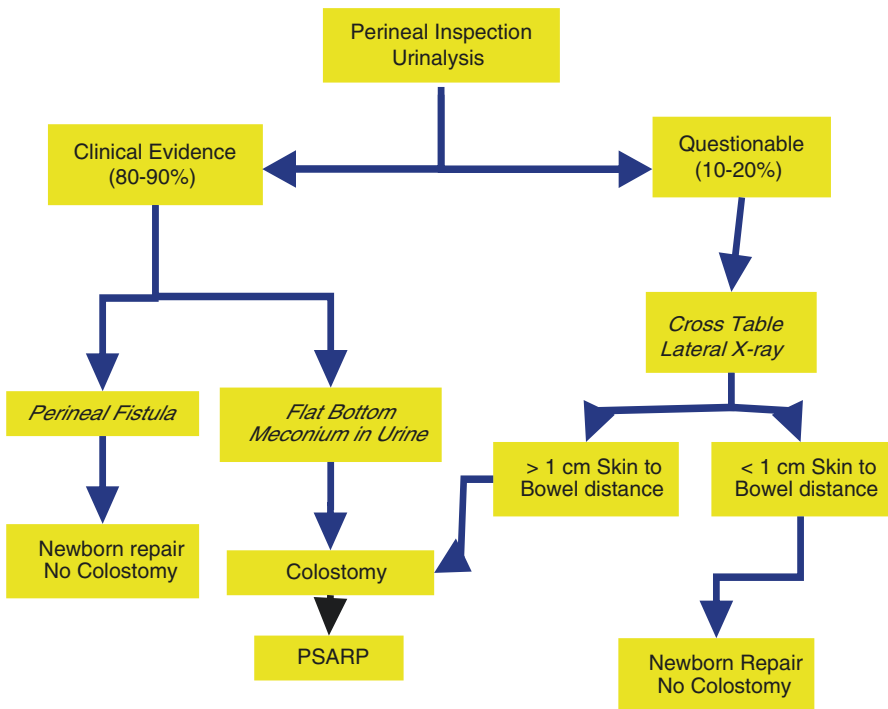
**22.1.5.1 Males** (Fig. 22.1)

- Prominent, well-formed midline groove.
  - Most likely is “benign” and has a good prognosis.
- Anal dimple.
  - Type of malformation is usually a bulbar fistula, or no fistula.
- Bucket handle malformation.
  - Implies that there is a perineal fistula.
- Flat bottom (no midline groove, no anal dimple).
  - Implies that most likely it is a complex malformation.
- Bifid scrotum.
  - Implies that there is a recto-bladder neck or recto-prostatic fistula.
- Meconium in urine.
  - Implies that there is a recto-urinary fistula.

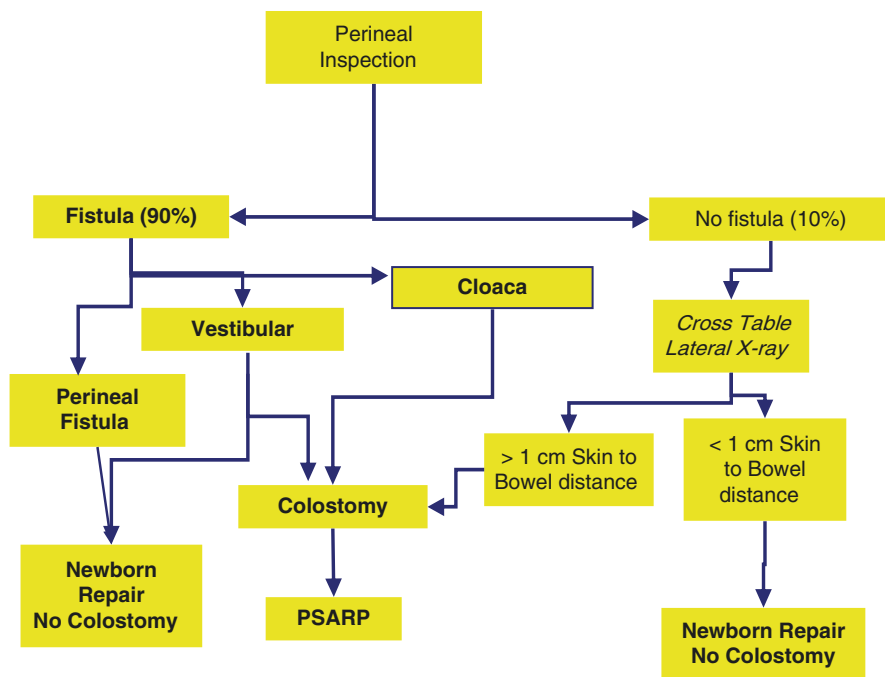
**22.1.5.2 Females** (Fig. 22.2)

The perineal (genital) inspection of female infants allows a precise diagnosis of the specific type of ARM in most cases. It is necessary for the clinician to separate the labia of the genitalia in order to be able to make a precise diagnosis.

- Single perineal orifice.
  - Cloaca.



**Fig. 22.1** Decision algorithm in boys



**Fig. 22.2** Decision algorithm in girls

- Bowel orifice located in the vestibule.
  - Vestibular fistula.
- Bowel orifice located at the perineal body.
  - Recto-perineal fistula.
- Palpable separated pubic bones.
  - Covered cloacal exstrophy.
- Meconium coming from inside the vagina.
  - Recto-vaginal fistula (almost nonexistent).

## 22.2 Neonatal Management

The first 24 hours represents the “window of opportunity” to rule out major associated malformations which may represent a danger to the infant’s life.

- Immediately after birth:
  - Remain fasting.
  - N/G tube must be inserted.
  - IV access must be established.
  - Prophylactic antibiotics.



Once all this is done:

*TWO MAJOR Questions* must be answered:

- Does the infant have a serious malformation that represents a “risk to life” situation?
- Does the infant need a colostomy or a primary repair?

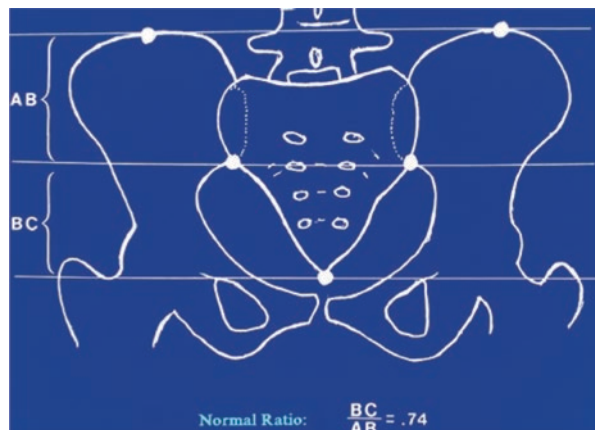
These questions must be answered in the order presented here. In order to do that, the following studies must be performed, **DO NOT PERFORM SURGICAL PROCEDURES BEFORE ANSWERING THESE QUESTIONS.**

- Renal ultrasound in males.
  - Rule out hydronephrosis and/or absent kidney.
- Renal and pelvic ultrasound in females.
  - Rule out hydronephrosis, and/or absent kidney, and presence of hydrocolpos in those with cloacas.
- X-ray film of the sacrum, to estimate the sacral ratio and try to predict the future functional prognosis (See Fig. 22.3).
- Lumbosacral ultrasound to rule out the tethered cord.
- ECHO cardiogram.
- “Babygram”
  - X-ray film of the entire body to rule out hemivertebrae, esophageal, and duodenal atresia.

### 22.2.1 Surgical Management—Colostomy or Primary Repair?

After 24 hours of life, all infants will have abdominal distention. This is a prerequisite to creating a valid image—the “*cross-table lateral film of the pelvis and abdomen.*” This is taken with the infant in prone position, with the pelvis elevated. The

**Fig. 22.3** Sacral ratio



purpose of this film is to determine the location of the most distal part of the rectum, as shown by intraluminal air in the rectum. Most importantly, it will determine the location of the rectum as related to the most distal part of the sacrum and will help the surgeon to determine whether or not the rectum is reachable via the posterior sagittal approach.

This film is mainly valuable when the baby does not have any of the clinical signs described above.

### **22.2.2 Primary Perineal Approach**

Depending on the experience of the surgeon, a primary perineal approach is indicated in cases of full-term infants without any important associated defects, and clearly suffering from:

- Perineal fistula.
- Vestibular fistula.
- Rectal gas is present below the most distal part of the sacrum in the cross-table lateral film.

### **22.2.3 Colostomy**

- This procedure is indicated in all other types of anorectal malformations.

The ideal colostomy is created in the descending colon and is mandatory to separate the stomas enough, to allow the placement of a stoma bag covering only the functional, proximal stoma. The proximal stoma is opened in the center of a triangle formed by the umbilicus, the iliac crest, and the lower rib. The nonfunctional stoma (mucus fistula) is opened medially and lower.

In our opinion, loop colostomies are contraindicated due to the fact that they represent a risk for fecal contamination of the urogenital tract.

In our opinion, transverse colostomies are also contraindicated, because they do not allow removal of meconium from the distal colon; may produce hyperchloremic acidosis due to absorption of urine from the bowel; and, contribute to the formation of a megarectum.

In our opinion, sigmoid colostomies are undesirable, because they sometimes interfere with the performance of the subsequent pull-through.

Following formation of the colostomy, the infant must be checked and followed to be sure that they are growing and developing normally. Once this is demonstrated and depending on the surgeon's experience, the infant can be subjected to the main repair.

### 22.2.4 High-Pressure Distal Colostogram

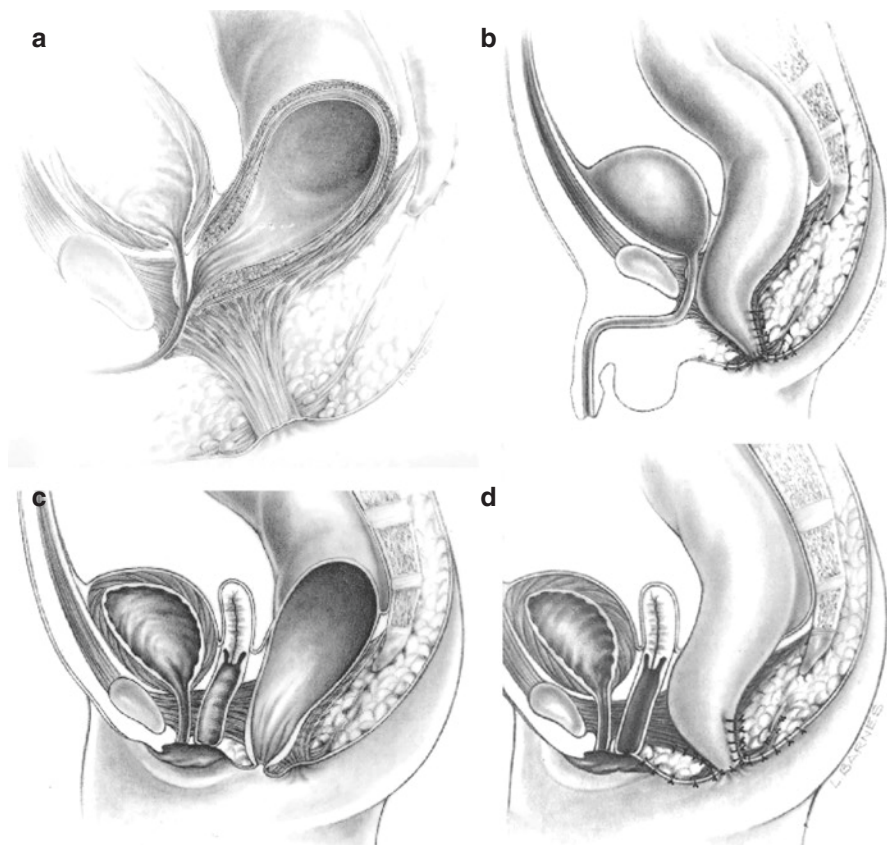
The main repair of an ARM should never be done without a precise anatomic diagnosis done by a high-pressure distal colostogram. The study is done under fluoroscopy, using ONLY water-soluble contrast material. A radio-opaque marker is placed at the anal dimple. A Foley catheter is inserted through the mucous fistula, the balloon of the catheter is inflated with 5 ml of water and the contrast is injected with a syringe by hand. The infant is placed in a supine position and the injection continues until the most distal part of the rectum is reached. Place the infant in a lateral position, being sure that in the fluoroscopy screen one can see the sacrum, the anal marker, and the entire pelvis. This must be a perfect lateral position, as shown by the images of both hips being superimposed. The injection continues until the contrast stops, forming a horizontal line, which may be misinterpreted by an inexperienced radiologist as being the most distal end of the rectum, making the wrong diagnosis of a “high” malformation. That line actually represents the effect of the compression produced by the tone of the funnel-like muscle sphincter mechanism that surrounds the lowest part of the rectum. At that point, the provider must continue injecting the contrast using reasonable hydrostatic pressure, which eventually will show the true most distal part of the rectum. The injection continues in order to demonstrate the fistula location and the passing of contrast through the urethra or back into the bladder. As a bonus, the study will also allow one to rule out the presence of vesicoureteral reflux.

### 22.2.5 Main Repair

The main repair of an ARM should never be a surgical “exploration.” A technically correct pre-op evaluation allows the performance of a planned procedure and avoids technical mistakes.

The type of operation will be determined by the specific anatomic diagnosis:

- Rectourethral bulbar fistula.
  - PSARP (Posterior Sagittal Ano-Recto-Plasty).
- Rectourethral prostatic fistula.
  - Depending on the surgeon’s experience, it can be repaired via PSARP or laparoscopically assisted.
- Recto-bladder neck fistula.
  - Abdominal approach (laparotomy or laparoscopy).
  - N.B. this malformation only occurs in 10% of males.



**Fig. 22.4** PSARP in boys (a, b) – PSARP in girls (c, d)

### 22.2.5.1 PSARP<sup>2</sup>

(Important steps in male patients with rectourethral bulbar or prostatic fistulae (Fig. 22.4a and b))

- Patient in a prone position with the pelvis elevated.
  - ALWAYS put a Foley catheter in the bladder.
- Posterior midline incision running from the coccyx to the perineal body.
  - Preferentially use an electrical stimulator to identify the muscle structures and divide them in the middle.
  - Divide all the sphincter mechanisms in the midline.
- Open the posterior rectal wall and extend the incision all the way down to the fistula.
  - Place multiple fine sutures taking the rectal mucosa cephalad to the fistula.

<sup>2</sup>Classic Paper—deVries PA, Peña A. Posterior sagittal anorectoplasty. *J Pediatr Surg.* 1982; 17: 638–43.

- Create a plane of dissection between the anterior rectal wall and the posterior urethra.
- Close the fistula with three fine absorbable sutures.
- Perform a circumferential dissection of the rectum to bring it down. Remain as close as possible to the rectal wall during the dissection, but do not injure the rectum.
  - Determine the limits of the sphincter mechanism.
  - Place the rectum within the limits of the sphincter.
- Reconstruct the perineal body if necessary.
- Anoplasty to be done with sixteen circumferential stitches of fine absorbable sutures.
- Suture the levator and muscle complex behind the rectum, preferably taking a bite of the posterior rectal wall.

Foley catheter must remain in place for one week. If the catheter accidentally comes out, do not try to replace it, such an attempt may injure the repair and most likely the patient will pass urine uneventfully.

PSARP in cases of recto-prostatic fistula. Same as above, but must look for the rectum higher (in front of the sacrum).

#### **22.2.5.2 Recto-Bladder Neck Fistula**

- Approach the patient via laparotomy or laparoscopy.
- Ligate the fistula.
- Inspect the blood supply of the recto-sigmoid carefully.
- Ligate the necessary vessels to allow the rectum to reach the perineum without tension, being sure to preserve the necessary arcades of the colon's blood supply to guarantee that the rectum receives, a good blood supply.
- Approach the pelvis via a posterior sagittal incision to create the correct space to pull the rectum down.

Pull the bowel down and reconstruct as described for rectourethral *fistulae*.

#### **22.2.5.3 PSARP For Females with Recto-Vestibular Fistula**

(Fig. 22.4b and c)

- Prone position.
  - Make a posterior sagittal incision as previously described.
  - Divide the sphincter mechanism and identify the posterior rectal wall.
  - Apply multiple fine sutures in a circumferential manner at the bowel opening in the vestibule.
- Applying uniform traction on the sutures dissect first the posterior rectal wall, follow by the lateral walls of the rectum.
  - Using a delicate and meticulous technique create a plane of separation between the anterior rectal wall and the posterior vaginal wall (this is the most delicate part of the operation).

- Determine the limits of the sphincter.
- Reconstruct the perineal body.
- Anoplasty and wound closure as previously described.

#### **22.2.5.4 Perineal Fistula in Females**

The technique has been described as a “miniPSARP.” The operation is very similar to the one described for a recto-vestibula fistula. However, the separation of the rectum from the vagina is much easier, because there is a plane of separation between them.

#### **22.2.5.5 Perineal Fistula in Males**

This malformation can be repaired following the same principles described for females. However, the surgeon must keep in mind that the anterior rectal wall is intimately attached to the posterior urethra and there is no real plane of separation. The most common and feared intraoperative complication in this malformation is the urethral injury. Insertion of a Foley catheter is mandatory to perform this procedure.

#### **22.2.5.6 Cloaca**

Rectum, vagina, and urethra are fused together forming a common channel of variable length, and opening at the same location as the normal female urethra. The treatment of these malformations depends on the length of the common channel (distance between the external single perineal orifice and the point of bifurcation or trifurcation of the common channel).

##### **Common Channel <3 cm**

- This malformation is repaired via a posterior sagittal anorectoplasty.
- The rectum is separated from the vagina following the same principles described in other malformations.
- Both urethra and vagina are mobilized using the maneuver called “*Total Urogenital Mobilization.*”
- The limits of the sphincter are determined.
- The perineal body is reconstructed.
- The rectum and anus are reconstructed as previously described.

##### **Common Channel >3 cm**

These malformations require a posterior sagittal approach and a laparotomy. The three structures (urethra, vagina, and rectum) must be separated transabdominally, under direct vision. These complex operations must be done by surgeons fully dedicated to the repair of complex malformation, working in a center with a high volume of cases. The surgeons must have a special training in urology, in addition to pediatric surgery or to work in conjunction with a pediatric urologist with experience in the treatment of these defects.

## Further Reading

1. Brisighelli G, Bischoff A, Levitt M, et al. Coloboma and anorectal malformations: a rare association with important clinical implications. *Pediatr Surg Int.* 2013;29:905–12.
2. Fernandez E, Bischoff A, Dickie BH, et al. Esophageal atresia in patients with anorectal malformations. *Pediatr Surg Int.* 2014;30:767–71.
3. Bischoff A, Bealer J, Wilcox DT, et al. Error traps and culture of safety in anorectal malformations. *Semin Pediatr Surg.* 2019;28:131–4.
4. Bischoff A, Levitt MA, Pena A. Update on the management of anorectal malformations. *Pediatr Surg Int.* 2013;29:899–904.
5. Bischoff A, Martinez-Leo B, Pena A. Laparoscopic approach in the management of anorectal malformations. *Pediatr Surg Int.* 2015;31:431–7.
6. Bischoff A. The surgical treatment of cloaca. *Semin Pediatr Surg.* 2016;25:102–7.
7. Pena A, Bischoff A. Surgical treatment of colorectal problems in children. Springer; 2015. <https://doi.org/10.1007/978-3-319-14989-9>.



# Hirschsprung's Disease

# 23

Chandrasen K. Sinha and Atsuyuki Yamataka

**Harold Hirschsprung** (1830–1916) presented his description of a disease later to bear his name to a pediatric congress in Berlin in 1886. He described two children, who died at 8 and 11 months of age, related to repeated attacks of enterocolitis.

## 23.1 Epidemiology

- 1 in 5000 live births.
- >90% of cases are diagnosed in the neonatal period.
- Approximately 5% of patients with HD are diagnosed after the first year of life.
- Two distinct clinical types with genetic differences (*vide infra*).
- *Short segment* (i.e., recto-sigmoid) 80% (M:F 3:1).
- *Long segment* 20% (M = F).

*Associated anomalies* variable incidence ~10%

- Down's syndrome (~5%).

---

C. K. Sinha (✉)  
St George's Hospital, London, UK

A. Yamataka  
Juntendo University School of Medicine, Tokyo, Japan  
e-mail: [yama@juntendo.ac.jp](mailto:yama@juntendo.ac.jp); [yama@med.jutendo.ac.jp](mailto:yama@med.jutendo.ac.jp)



- Neurocristopathies.
  - Waardenburg–Shah syndrome—white forelock, bicolored iris, deafness.
  - Hypoventilation syndrome (Ondine’s curse<sup>1</sup>)—association with HD termed Haddad syndrome.
- Mental retardation syndromes.
  - Smith-Lemli-Opitz syndrome—mental retardation, polydactyl, defect in cholesterol metabolism.
  - Mowat-Wilson syndrome—mental retardation, characteristic facies.
- Development colon anomalies.
  - Colon atresia, anorectal atresia.
- Miscellaneous.
  - Kaufman-McKusick syndrome—hydrometrocolpos, hypospadias, polydactyl.

N.B. **Multiple Endocrine Neoplasia (MEN) type 2B** (Marfanoid habitus, medullary thyroid cancer, café au lait spots, mucosal neuroma) is associated with *hyperganglionosis* (but functionally similar to HD).

---

## 23.2 Embryology

Migration of neurenteric cells from the neural crest to GI tract—aborally.

1. Esophagus fifth-week gestation.
2. Mid-gut seventh-week gestation.
3. Distal colon by 12th-week gestation.

Some studies suggest that ganglion cells are guided to their destination by neural glycoproteins or fibers (e.g., fibronectin and hyaluronic acid).

---

## 23.3 Anatomy and Neuroanatomy

The normal intestinal wall contains two distinct nerve plexi, between three muscle layers (longitudinal, circular, muscularis mucosae). These are:

- Submucosal plexus (of Meissner<sup>2</sup>).
- Myenteric or intermuscular plexus (of Auerbach<sup>3</sup>).

Each plexi contains a fine meshwork of neurons (ganglion, CD55 + ve) and supporting (glial, CD55 – ve) cells which control motility, absorption, secretion,

---

<sup>1</sup>Ondine—water nymph who cursed her unfaithful husband to breathe only while awake. As he fell asleep he died (German mythology).

<sup>2</sup>Georg Meissner (1829–1905)—German histologist, also described tactile corpuscles of the skin.

<sup>3</sup>Leopold Auerbach (1828–1897)—German neuropathologist.

and blood flow. Ganglion cells (nested in groups of four to six cells) receive extrinsic cholinergic and adrenergic signals.

- **Intrinsic** neuron stimulation causes muscle relaxation.
  - (a) Nitric oxide (NO) is the prime mediator.
  - (b) Other mediators include VIP, Histidine, substance P, Neurokinin A, Enkephalin, Gastrin Release Peptide, isoleucine, and many others.
- **Extrinsic.**
  - (a) Cholinergic neurons (contraction).
  - (b) Adrenergic neurons (relaxation).
- **Nonadrenergic and noncholinergic (NANC) nervous system.**
  - Controlled by interstitial cells of Cajal<sup>4</sup> also seem to play an important role in peristalsis.

---

## 23.4 Genetics

- Strong evidence of genetic predisposition.
  - The average risk of occurrence in siblings is 3–4% (↑ This risk is further increased in siblings of the individuals with long-segment disease involvement).
- **Gene mutations.**
  - The main gene responsible for increased susceptibility has been diagnosed as **RET gene**, which is a proto-oncogene playing a major role in the development of the enteric nervous system on Ch 10q11. Associated with Down's syndrome. Dominant mutations in RET gene have been found (50% familial and 15–35% of isolated cases).
  - Seven other candidate genes have been found to play a role in the pathogenesis of Hirschsprung's disease and these include **SOX10**, **EDNRB** (endothelin receptor type B), **GDNF** (glial cell line neurotrophic factor), **EDN3** (endothelin-3), **ECEL**, **NTN**, **SIPI**.
- Mutations in any of these genes may lead to HD. In 50% of familial and 15–35% of isolated cases, dominant mutations in RET gene have been found.

---

## 23.5 Etiology

A number of hypotheses have been advanced to explain the lack of ganglion cells, including:

- **Failure of migration.**
  - Distal aganglionosis occurs in chick embryos, when the hindgut is transected.
  - Abnormal glycoproteins have been found in the distal aganglionic gut.

---

<sup>4</sup>Santiago Ramon y Cajal (1852–1934)—Spanish pathologist and Nobel laureate.

- **Hostile environment.**
  - Loss of neural cell adhesion molecules (NCAM) leads to inability of normal ganglion cells to adhere to smooth muscle cells.
- **Immunologic attack.**
  - Abnormal immune response mounted by fetus against ganglion cells may lead to the destruction of ganglion cells.

---

## 23.6 Pathology

Lack of progression of peristaltic wave into the aganglionic segment of intestine and absent or abnormal internal anal sphincter relaxation is the hallmark of HD.

The gross appearance of the intestine varies with age of the child. In the neonatal period, the proximal intestine may appear normal but with the passage of time the proximal intestine distends and hypertrophies.

### 23.6.1 Variable Affected Segment

- **Short segment** (commonest).
  - Rectum and variable length of the sigmoid.
- **Long segment.**
  - Typically includes total colonic and a variable length of ileal involvement.
- **Total intestinal aganglionosis** (not compatible with life).
- **Ultra-short segment disease.**
  - Believed to be very rare and some even believe it to be non-existent.
- Similarly, **segmental disease or “skip” lesions** should not be considered in differential diagnosis due to rarity of the condition.

*The affected aganglionic bowel looks normal, the ganglionic bowel looks abnormal.*

---

## 23.7 Clinical Features

Two overlapping scenarios:

- Neonatal bowel obstruction.
  - Delayed passage of meconium, distension, bile vomiting  $\pm$  enterocolitis (variable incidence).

*N.B. 90% of otherwise normal term neonates will pass meconium within the first 24 h of life; and almost 95% will pass this within 48 h.*

- Chronic constipation.
  - Enterocolitis (variable incidence).
  - Failure to thrive.
  - Encopresis (soiling) should be uncommon in HD.

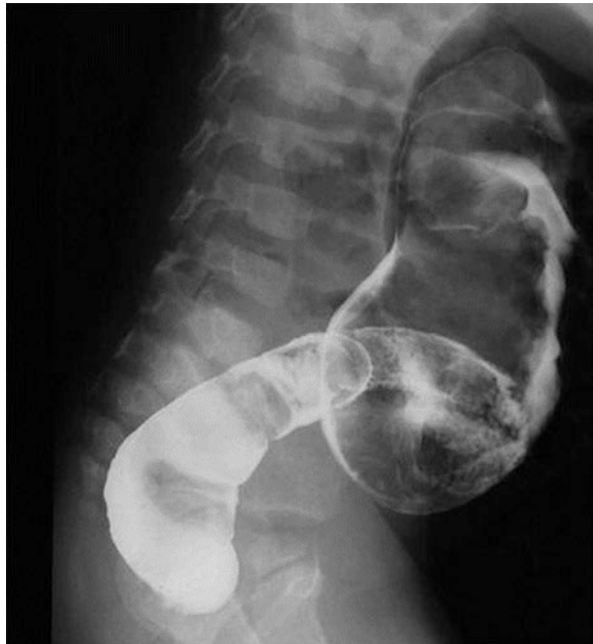**Perforation** may occur (~2%) as a complication of recto-sigmoid HD. Ileal perforation may complicate long-segment HD.

Explosive discharge of fecal matter or meconium may occur after rectal examination and is a valuable diagnostic sign. If this occurs following surgery it may indicate stasis and potentially enterocolitis.

### 23.7.1 Investigations

- *Abdominal XR*—multiple intestinal loops, absence of gas in the rectum.
- *Contrast enema* (Fig. 23.1)—ideally before the rectal examination. Looking for transitional zone. Delayed films may show contrast retention and are suggestive (Fig. 23.1).
- *Submucosal rectal biopsy* (suction or occasionally open under GA).
  - 1 and 2 cm above the dentate line
  - ± Acetylcholinesterase staining (90% accurate, less so in neonates and LS HD)
  - ± Immunohistochemistry (e.g., LDH, S100, SDH, and Calretinin)
  - Pathologist dependent.

**Fig. 23.1** Contrast study showing dilated proximal segment and distal narrow segment



- *Anorectal manometry*—relies on the absence of reflex relaxation of internal anal sphincter in response to rectal dilatation (Not widely available and operator dependent).

### 23.7.2 Differential Diagnosis

- Mechanical causes of neonatal bowel obstruction (e.g., ileal and colon atresia, anorectal malformations, meconium ileus, meconium plug syndrome (10% have HD)).
- Functional hypoperistalsis (e.g., prematurity, sepsis and electrolyte imbalance, small left colon syndrome, and hypothyroidism).

*For the older child*

- Idiopathic constipation, hypothyroidism, intestinal neuronal dysplasia, hyperganglionosis, etc.

---

## 23.8 Management

The aim always in HD is to decompress obstructed bowel and may be attempted even before definitive investigation.

If enterocolitis, a potentially lethal complication, is suspected (sepsis, pyrexia, diarrhea, bloody stool) then further active intervention is required including:

- Rectal washout.
  - 10–20 mL/kg of normal saline is instilled via a rectal tube in small volumes ensuring all fluid inserted is returned. Repeat up to 3× daily.
- Antibiotics (e.g., vancomycin and metronidazole).
- ± **Colostomy/ileostomy**
  - Washouts may not be effective in LS disease and would be the commonest cause of “pathological” failure. Siting of the stoma is crucial and a frozen section should be available.

---

## 23.9 Surgery

Currently, following diagnostic confirmation most infants can be managed (by parents, at home) with daily rectal washouts until they are considered suitable for a single-stage primary pull-through procedure.

- *Colostomy (indications)*.
  - Laparotomy for neonatal intestinal obstruction (in absence of diagnosis).
  - Low birth weight and preterm infants.

- Late diagnosis with hugely distended proximal bowel (especially in older children).
- Repeated episodes of enterocolitis (especially in LS disease).

Colostomy (transverse/sigmoid) or ileostomy (LS disease) should be performed in proximal, ganglionic (ideally confirm by frozen section) bowel. Use access to take serial seromuscular or full-thickness biopsies to confirm the level of disease in remainder of the colon.

### 23.9.1 Pull-Through Procedure

The aim is to resect the aganglionic segment, bringing the ganglionic bowel through the pelvis and anastomosing it near to the anal canal to allow unimpeded voluntary emptying. In historical order the commonest are:

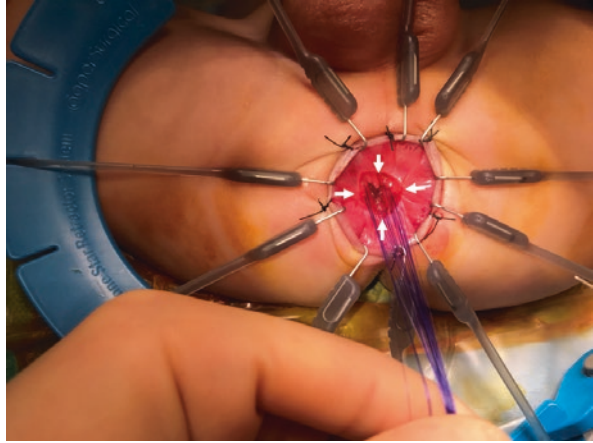
- **Swenson's<sup>5</sup> pull-through (1948).**
  - (a) Removal of all aganglionic bowel up to 1 cm from dentate line posteriorly and 2 cm of dentate line anteriorly. Colo-anal anastomosis from outside.
  - (b) Potential for pelvic nerve (incontinence) and anterior structure (vas, bladder, vagina) damage.
- **Duhamel's<sup>6</sup> pull-through (1956).**
  - (a) Dissection behind rectum (to minimize pelvic nerve damage) to create a tunnel. Ganglionic bowel is brought through ~1 cm above dentate and side-to-side anastomosis is created (with GIA or EndoGIA stapler).
  - (b) Anterior blind pouch may lead to fecaloma and recurrent obstruction.
- **Soave's endorectal pull-through<sup>7</sup> (1964).**
  - (a) At pelvic reflection, the colon dissection continues in the submucosal plane to ~1 cm from dentate line. Ganglionic bowel is pulled through the rectal muscle sleeve and anastomosed to anal mucosa. Avoids potential for nerve damage.
  - (b) Retained aganglionic muscle cuff may cause functional obstruction and constipation or sleeve abscess.
- **Laparoscopy-assisted transanal pull-through.**
  - (a) Any of the above can be performed under laparoscopic vision for the pelvic dissection.
- **Transanal pull-through (Fig. 23.2).**
  - (a) Using a circumferential (e.g., Scott) hook retractor, it is possible to dissect entirely from below (submucosa or full-thickness) into the peritoneal cavity, removing the aganglionic bowel and achieving a safe anastomosis.

<sup>5</sup>Orvar Swenson (1909–2012)—American pediatric surgeon, reached his 102nd birthday!

<sup>6</sup>Bernard Duhamel (1917–1996)—French surgeon, working in Hospital de Saint Denis, Paris.

<sup>7</sup>Franco Soave—Italian pediatric surgeon working in Genoa. As originally described the pull-through bowel was left hanging between the infant's legs and not actually anastomosed.

**Fig. 23.2** Dissection starting on just proximal to the anorectal line as opposed to starting on the dentate line has recently been suggested to improve long-term outcomes. This (arrows) can be identified by hooking the crypts in the dentate line to expose the anal canal with a Scott retractor



## 23.10 Outcome

Early complications include enterocolitis, anastomotic leak and stricture, intestinal adhesion obstruction, and perianal excoriation.

The functional superiority of one of the above over another has not been shown in long-term follow-up series (although these are few). Nonetheless, in general, the Duhamel and Soave procedures seem to have a higher rate of constipation, while Swenson's may have a higher incidence of incontinence. Certainly, all patients need long-term follow-up as minor issues including the need for regular use of laxatives is not uncommon.

## Further Reading

1. Minford JL, Ram A, Turnock RR, et al. Comparison of functional outcomes of Duhamel and transanal endorectal coloanal anastomosis for Hirschsprung's disease. *J Pediatr Surg.* 2004;39:161–5.
2. Conway SJ, Craigie RJ, Cooper LH, et al. Early adult outcome of the Duhamel procedure for left-sided Hirschsprung disease—a prospective serial assessment study. *J Pediatr Surg.* 2007;42:1429–32.
3. De La Torre L, Langer JC. Transanal endorectal pull-through for Hirschsprung disease: technique, controversies, pearls, pitfalls, and an organized approach to the management of postoperative obstructive symptoms. *Semin Pediatr Surg.* 2010;19:96–106.
4. Yamataka A, Miyano G, Azuma T. Laparoscopy assisted pull-through for Hirschsprung's disease. *Atlas of pediatric laparoscopy and thoracoscopy*, 2nd ed., Elsevier; in press.

---

## **Part IV**

# **Hepatobiliary**





# Investigation of Jaundice

# 24

Mark Davenport

In most newborns, jaundice is physiological, fades within 2 weeks, and causes no harm. In a few, it can be the first sign of a deadly disease. The challenge is to find out which infant belongs to which group.

## 24.1 Metabolism of Bilirubin (Fig. 24.1)

Jaundice is clinically detectable (in unpigmented skin) when the bilirubin level is  $>50 \mu\text{mol/L}$  ( $\equiv 3 \text{ mg/dL}$ ).

## 24.2 Scale of Problem

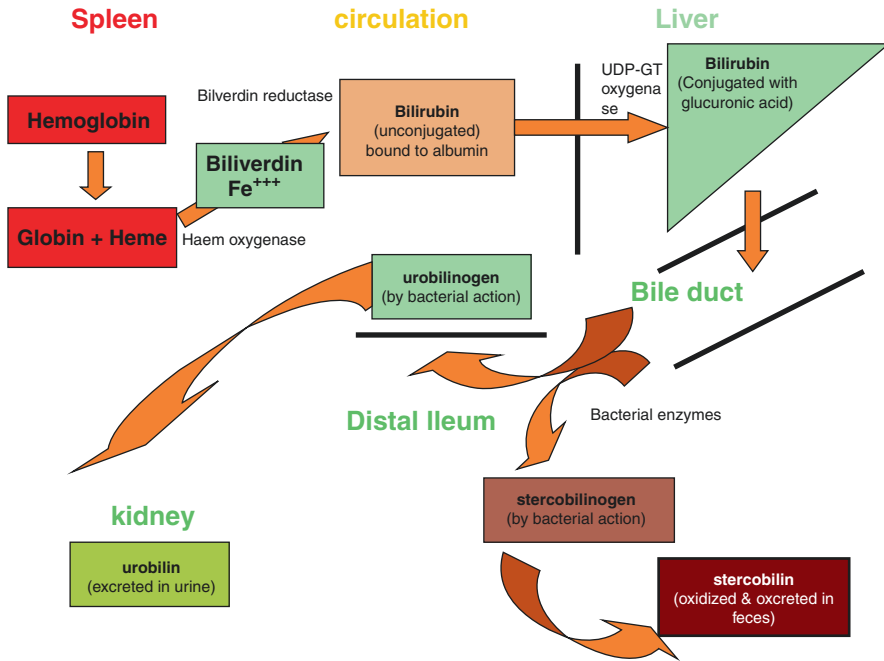
- Up to 60% of infants will be jaundiced in the first week of life.
- 1 in 50–100 infants will have persistence of jaundice at  $>2$  weeks.
- 1–4/1000 infants will have conjugated jaundice.
- 1 in 16,000 (in the UK) infants will have biliary atresia.

## 24.3 Physiological Jaundice

This is always unconjugated and self-limiting with a higher prevalence in the premature. It is caused by:

---

M. Davenport (✉)  
King's College Hospital, London, UK



**Fig. 24.1** Metabolism of bilirubin

1. Immature liver enzymes (specifically glucuronyl transferase).
2. High red cell turnover.
3. Maybe exacerbated by breastfeeding.

## 24.4 Surgical Jaundice in Infants

Surgical jaundice is *always* conjugated and about 80% of such infants will be due to biliary atresia (BA)—see Chap. 26.

The main theme in these infants is the exclusion of possible “medical” causes, which may mimic the much less common “surgical” causes, but for which there may be no specific therapy. These might include Alagille’s syndrome,  $\alpha$ -1-antitrypsin deficiency, and the ubiquitous “neonatal hepatitis.”

Other causes include:

- Inspissated bile syndrome.
- Congenital choledochal malformations (CCM)—aka choledochal cysts.
- Congenital bile duct stenosis (rare).
- Spontaneous biliary perforations (rare).
- Tumors (rare).

## 24.4.1 Investigations

### 24.4.1.1 Ultrasonography (Table 24.1)

Biliary anomalies may already be evident on the antenatal US.

- CCM (80%).
- Cystic BA (20%).

Prenatal differentiation is not necessary but postnatal discrimination is vital. Detection of an abnormality mandates early postnatal investigations (repeat US within 1 week, awareness of stool color, and serial split bilirubin. N.B. an MR scan of the bile duct and cyst may help but the quality is often poor.

The US is also capable of detecting intraluminal stones, debris, and “sludge”; ascites and hepatosplenomegaly, cirrhosis of chronic liver disease, and features of Biliary Atresia Splenic Malformation syndrome (e.g., polysplenia, absence of the inferior vena cava, and situs inversus).

Features suggestive of BA include:

- Triangular cord sign (controversial)—represents fibrous remnants at the porta hepatis.
- Absent or atrophic gall bladder—no feeding-related changes in size.
- Cyst at the porta hepatis.

### 24.4.1.2 Liver Biopsy

This is used in many centers as a definitive investigation for diagnosis of BA (accuracy—85%).

Histological features of BA include:

- Portal tract inflammation—mononuclear cell infiltrate.
- Bile ductal plugging and proliferation.
- Bridging fibrosis with overt features of cirrhosis (late findings).

Such features can also be found in nonsurgical causes of jaundice (e.g.,  $\alpha$ -1-antitrypsin deficiency, giant-cell hepatitis).

Liver biopsy is invasive and carries a risk of bleeding. Interpretation requires considerable experience.

**Table 24.1** Normal biliary dimensions (on ultrasound)

|                | Size  | Gallbladder Length                       |
|----------------|-------|--|
| Neonate        | ~1 mm |  |
| Child < 1 year | ~2 mm | 1.5–3 cm                                 |
| Child > 1 year | ~3 mm | 3–7 cm                                   |
| Adolescents    | 7–10  |  |
|                |       | Gallbladder wall thickness usually <3 mm |

### 24.4.1.3 Duodenal Aspiration

Involves passage of a nasoduodenal tube and 24-h period measurement of aspirates for bile. Objectivity can be improved with Bilitec® 2000 device (Synectics Inc.). This test is typically performed in Japan.

### 24.4.1.4 Radionuclear Isotope

Technetium <sup>99m</sup>Tc-labeled iminodiacetic acid derivatives can be used to assess biliary patency. It is actively taken up by the hepatocyte and excreted in bile.

- Sensitive (for BA) test (>97%), but not specific (40–70%).
- It may be improved by.
  - Delayed imaging (4–6 or 24 h).
  - Phenobarbitol or ursodeoxycholic acid premedication (3–5 days).

### 24.4.1.5 Single Photon Emission Computed Tomography (SPECT)

- Performed in addition to scintigraphy.
- 4–6 h after injection of the isotope
- The test looks for the presence of radioactivity in the gastrointestinal tract.

### 24.4.1.6 Percutaneous Transhepatic Cholangiogram

- Only possible if US shows intrahepatic biliary dilatation (not found in BA).
- Risk of both bleeding and bile leakage.
- Most useful in inspissated bile syndrome where further saline flushing may clear obstruction.

### 24.4.1.7 Endoscopic Retrograde Cholangiopancreatography

Its use is limited in the diagnosis of BA, because of lack of appropriate equipment and experience. Features of BA may include:

- Absence of contrast in the bile duct despite filling of the pancreatic duct.
- Partial filling of the distal CBD and gallbladder only.
- No bile in the duodenum.

### 24.4.1.8 Magnetic Resonance Cholangiopancreatography

- Noninvasive modality but requires “breath-holding” for good quality imaging (GA in infants).
- T2-weighted and single-shot sequences may visualize biliary tree and the absence is regarded as diagnostic of BA (sensitivity 100% and specificity 96%) in one study.
- Key technique in the evaluation of CCM and liver cysts.

### 24.4.1.9 Laparoscopy ± Cholangiography

- Use of 3 mm instruments.
- Insertion of catheter/needle into the gallbladder.

## 24.5 Investigation of Surgical Jaundice in the Older Child

This is virtually always associated with intrahepatic biliary dilatation and causes can be divided according to surgical tradition into cases from within (intramural), from without (extramural) and from the wall itself (mural).

### 24.5.1 Intramural

- Calculi (choledocholithiasis).
  - Primary (uncommon)—arising in intrahepatic, common hepatic, or common bile ducts.
  - Secondary (common)—arising in the gallbladder (in children consider hemolysis, cholesterol, and metabolic (e.g., PFIC)).
- Inspissated bile.
- Parasites.
  - Worms—nematodes (*Ascariasis lumbricoides*—Kashmir and Kenya).
  - Liver flukes—(*Clonorchis sinensis*—China, Korea, and Vietnam).
- Tumors—rhabdomyosarcoma.

### 24.5.2 Extramural

- Tumors—lymphomas, head of pancreas tumors.
- Mirizzi's syndrome<sup>1</sup>—gallbladder pathology causing secondary stenosis of adjacent CHD.
- Chronic pancreatitis.

### 24.5.3 Mural

- Congenital/acquired stenosis (ampulla and above).
- Congenital Choledochal malformation (see Chap. 25).
- Sclerosing cholangitis.
- Cystic fibrosis—cholangiopathy and inspissation of bile.
- AIDS—multiple causes including opportunistic infection.
- Tumors—rhabdomyosarcoma, extensive hepatoblastoma/HCC involving R and L hepatic ducts.

---

<sup>1</sup>Pablo Mirizzi (1893–1964) Argentinian. Mirizzi P (1948) Syndrome del conducto hepatico. J Int de Chir 8:731–777.

## Further Reading

1. Davenport M, et al. The spectrum of surgical jaundice in infancy. *J Pediatr Surg.* 2003;38(10):1471–9.
2. Brumbaugh D, Mack C. Conjugated hyperbilirubinemia. *Pediatr Rev.* 2012;33:291–302.
3. Davis AR, Rosenthal P, Escobar GJ, Newman TB. Interpreting conjugated bilirubin levels in newborns. *J Pediatr.* 2011;158(4):562–565. e1.



# Choledochal Malformation

# 25

Mark Davenport

*Choledochal malformations are typically cystic or fusiform in shape and may be accompanied by intrahepatic bile duct dilatation.*

## 25.1 History

- A choledochal cyst was first recognized by the anatomist Abraham Vater in 1723.
- First surgical operation involving excision and hepaticoduodenostomy reconstruction by McWhorter in 1924.
- First laparoscopic operation involving excision and Roux loop reconstruction by Farelo in 1995.

## 25.2 Epidemiology

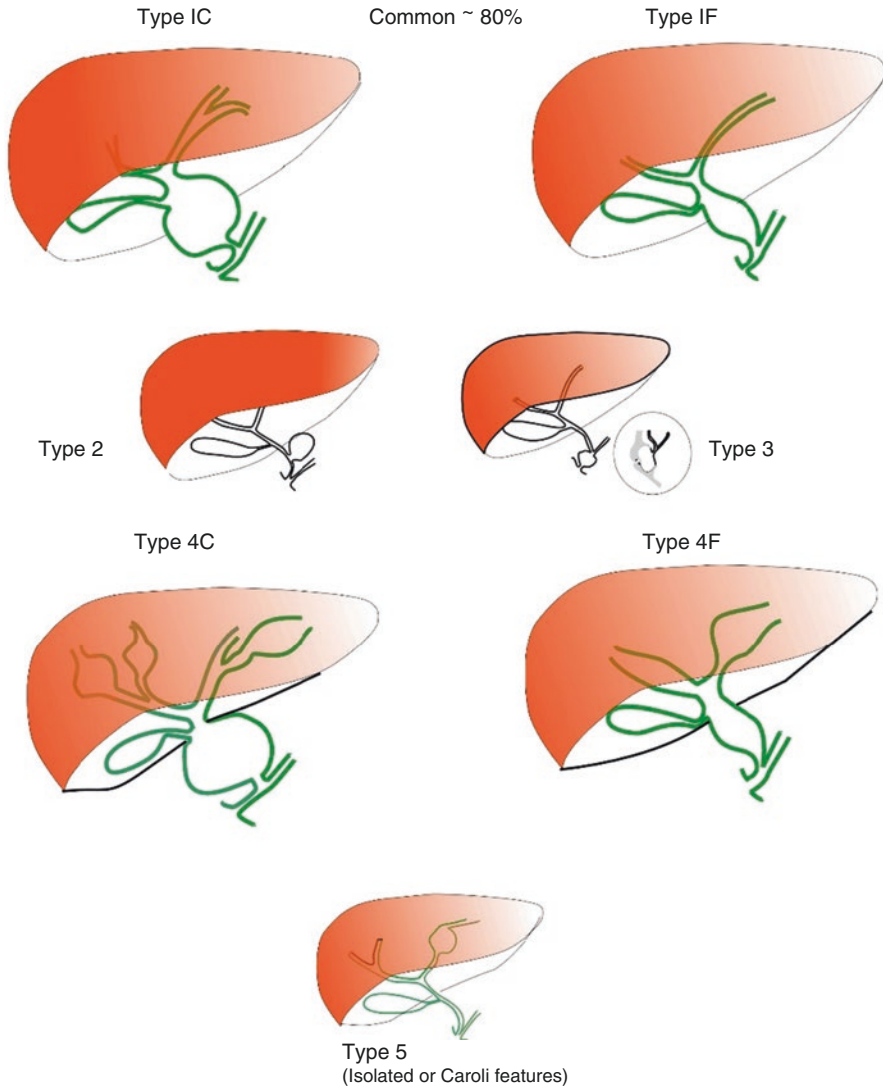
- Essentially unknown prevalence but marked female predominance (4:1).
- Marked racial variation—Chinese and Japanese >> Caucasian.

## 25.3 Classification

The **King's College Hospital Classification** is based on phenotype and is a modification of Alonso-Lej's original and Todani's modification (Fig. 25.1).

---

M. Davenport (✉)  
King's College Hospital, London, UK



**Fig. 25.1** King's College Hospital Classification of choledochal malformation

- **Type 1**—extrahepatic dilatation of CBD and CHD (~80%).
  - Cystic (1C)—classical type.
  - Fusiform (1F)—“spindle-shaped” dilatation, no abrupt change.
- **Type 2**—diverticulum of the common bile duct (<2%).
- **Type 3**—dilatation of the distal intramural portion of the CBD (*synonym* – *choledochocele*) (<2%).



- **Type 4**—intra- and extrahepatic dilatation (~10%).
  - Cystic (4C) extrahepatic dilatation.
  - Fusiform (4F) extrahepatic dilatation
- **Type 5**—dilatation of intrahepatic ducts only (<5%).

N.B. An abnormal configuration of the distal bile and pancreatic duct is commonly observed and may contribute to the pathophysiology. Usually, the term used is “common channel.” This is only seen in Types 1 and 4 CM.

With the possible exception of duodenal atresia, the above are usually found as isolated lesions.

*Caroli's disease*<sup>1</sup>—distinct anomaly with multiple intrahepatic cysts and duct ectasia (left > right) and intrinsic liver fibrosis. Caroli's syndrome (usually autosomal dominant) refers to the association with polycystic kidney disease and usually renal failure. Genetic mutations in *PKHD1* gene.

---

## 25.4 Pathogenesis

The exact etiology is not known. Two hypotheses have been suggested:

1. 2° to congenital bile duct segmental stenosis (can be detected on antenatal US—Type 1c).
2. Reflux of activated pancreatic enzymes via the common channel causes mural weakness and 2° dilatation (Babbitt hypothesis<sup>2</sup>).

Our own work using intraoperative measurement of choledochal pressure and bile amylase levels led us to conclude that there was little evidence for the reflux hypothesis in the actual development of the CM. There was an inverse relationship of pressure with reflux and the greatest dilatation and mucosal destruction were seen with the higher pressures.

The wall of the typical choledochal cyst (Type 1c) is usually thick, vascular, and has an incomplete mucosal lining (this will vary with the age of the child and length of symptoms). Large cystic malformations tend to displace adjacent viscera such as duodenum and colon and expand into head of pancreas.

---

## 25.5 Clinical Features

- Classic triad of presentation.
  - Jaundice, pain, and abdominal mass ~15% of most series.
- Jaundice and acholic stool.
  - Usually in infants—differential with cystic biliary atresia.

---

<sup>1</sup>Jacques Caroli (1902–1979)—French gastroenterologist who worked at Saint Antoine Hospital, Paris.

<sup>2</sup>Donald P. Babbitt (1923–2005)—American radiologist, working at Milwaukee, WI.

- Abdominal pain and pancreatitis.
  - Usually older children  $\pm$  jaundice.
- Cholangitis  $\pm$  stones.
- Intra- or extraperitoneal rupture.
- Biliary cirrhosis—portal hypertension, ascites, and liver failure.
- Malignant epithelial change (e.g., cholangiocarcinoma)—usually during adulthood.

### 25.5.1 Investigations

*Laboratory:* Conjugated jaundice,  $\uparrow$ GGT,  $\uparrow$ alkaline phosphatase, and  $\uparrow$ transaminases. Coagulation profile may be deranged in those with long-standing biliary obstruction due to vitamin K malabsorption.

- US—degree (CBD size); intrahepatic dilatation; intraluminal stones.
- MRCP—excellent anatomical imaging.
- ERCP—currently only indicated if there is doubt about diagnosis (minimal biliary dilatation) or if definitive pancreatic ductal anatomy is required.

## 25.6 Surgery—Type 1c (Cystic Malformation)

*Aim*—excision of the dilated extrahepatic biliary tract together with proximal biliary reconstruction to achieve perfect bile drainage.

**Incision**—RUQ (laparoscopic reconstruction is possible but requires considerable dexterity).

1. Cholangiography—define proximal and distal common channel anatomy.
2. Cholecystectomy and mobilization of the cyst from adjacent viscera, hepatic artery, and portal vein. Proximal division at the level of CHD allows separation of distal cyst from within the head of pancreas. Identify distal, nondilated CBD. Transfix after probing, and clearing common channel. Transduodenal sphincteroplasty may be required for those with dilated common channels.
3. A long Roux loop ( $\sim$ 45 cm) is the recommended reconstruction technique (hepaticoduodenostomy is possible but not widely advocated unless as a shortcut during a laparoscopic approach—long-term issues with bile gastritis).
4. Hepaticojejunostomy (after choledochoscopy, if possible, to define areas of intrahepatic stenosis/stones, etc.). Usually, straightforward anastomosis but may require variation due to local anatomy.

*N.B. If dissection is difficult with marked with infection and inflammation, then removal of the cyst wall can be treacherous—simple removal of mucosa from the inner lining may be a safer pragmatic approach (Lilly's procedure<sup>3</sup>). Also, in sick*

<sup>3</sup>John R. Lilly (1929–1995) American pediatric surgeon, Denver, CO.

*infants with perforated cysts, for instance, a two-stage procedure, i.e., preliminary external drainage using a T-tube may be safer.*

For localized, symptomatic Type V cysts typically containing stones, liver resection should be considered. Alternatively if the cyst occupies the central part of the liver and porta then its extrahepatic portion can be excised leaving the remaining portion with its bilobar draining ducts intact and emptying into a Roux loop.

---

## 25.7 Outcome

It tends to be related to what is left behind!

- Intrahepatic ducts (residual stones/strictures—cholangitis).
- Common channel (residual stones/debris—pancreatitis).
- Biliary mucosa—possible long-term risk of malignancy (limited data available but the outlook seems to be excellent for those undergoing surgery during childhood).

---

## Further Reading

1. Makin E, Davenport M. Understanding choledochal malformation (review). *Arch Dis Child*. 2012;97:69–72.
2. Turowski C, Knisely AS, Davenport M. Role of pressure and pancreatic reflux in the aetiology of choledochal malformation. *Br J Surg*. 2011;98:1319–26.
3. Pergola L, Zen Y, Davenport M. Congenital choledochal malformation: search for a marker of epithelial instability. *J Pediatr Surg*. 2016;51(9):1445–9.
4. Liem NT, Pham HD, Dungle A, et al. Early and intermediate outcomes of laparoscopic surgery for choledochal cysts with 400 patients. *J Laparoendosc Adv Surg Tech A*. 2012;22(6):599–603.
5. Friedmacher F, Ford KE, Davenport M. Choledochal malformations: global research, scientific advances and key controversies. *Pediatr Surg Int*. 2019;35(3):273–82.



Mark Davenport

Biliary atresia is a cholangiodestructive disease affecting all parts of biliary tract. A number of variants can be identified among which the most important are those with other anomalies (e.g., BASM), those with cystic change and those related to CMV infection.

It is invariably fatal if untreated.

## 26.1 Epidemiology

- 1 in 10,000—Japan and China
  - ↓ Incidence of BASM and associated cardiac anomalies
- 1 in 16–20,000—the UK, USA, and Europe
- F > M (slight in isolated BA, marked in BASM and Cystic BA).

## 26.2 Embryology

A primordial bile duct emerges from the distal end of the foregut at about 20 days post-fertilization. This becomes engulfed by the developing liver anlage, which at this stage contains few hepatoblasts and is mainly mesenchyme and a source of blood cell precursors. The critical point of extrahepatic bile duct development is coincident (5–6 weeks gestation) with the determination of abdominal situs, spleen

---

M. Davenport (✉)  
King's College Hospital, London, UK

formation, final development of portal vein, and vena cava (hence the association with BASM).

Biliary epithelial cells differentiate from their hepatoblast precursors to form intrahepatic biliary ductules from about the seventh week of gestation and undergo a process of selection/deletion with progressively fewer but larger remaining ducts. Bile is secreted into the GI tract by 12 weeks emphasizing biliary continuity.

As the etiology of BA is largely unknown, hypotheses abound. Two of them have a degree of evidential support.

- *Developmental—primary failure to form lumen or sufficiently functional intra-hepatic bile ducts.*
  - BASM (polysplenia or asplenia; situs inversus; absence of IVC; pre-duodenal portal vein; cardiac anomalies) ~2% will have gene mutations (*PKD1L1*).
  - Cystic BA— > 60% detected on antenatal US scan.
  - Genetic predisposition—so-called susceptibility genes (e.g., *ADD3*) in Han Chinese.
- *Perinatal acquired—i.e., a normally developed bile duct is damaged later, with secondary loss of luminal continuity. May be due to:*
  - Viral insult—e.g., CMV (N.B. IgM+ BA can be seen in ~10% in the UK). Rotavirus-induced experimental BA in mice.
  - Immunological overreaction.

---

## 26.3 Classification

Figure 26.1 illustrates classification with the most proximal level of obstruction determining the type. About 5% will have cystic change within otherwise obliterated biliary tract (**cystic biliary atresia**). These need to be differentiated from a *choledochal malformation*, which even if obstructed should connect to a smooth, progressively distended intrahepatic duct system.

---

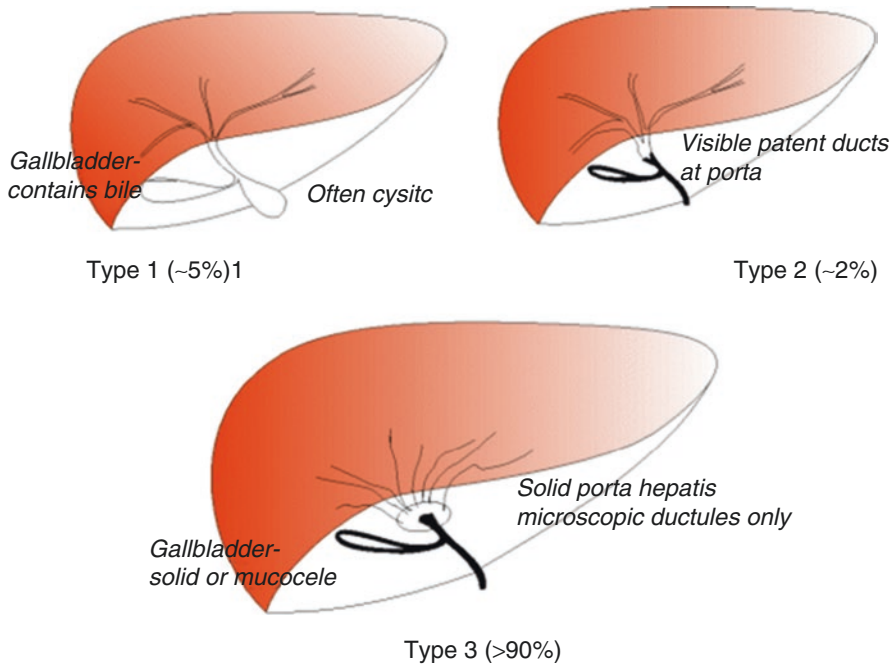
## 26.4 Clinical Features

Conjugated jaundice, pale stools, dark urine, and failure to thrive. Nil specific.

Look for situs, polysplenia, and cardiac anomalies of BASM.

### 26.4.1 Investigations

See Chap. 24 for details.



**Fig. 26.1** Classification of biliary atresia

## 26.5 Surgery

- Correct coagulopathy (vitamin K).
- ~5–10 have associated cardiac anomalies that may need correction *before* KPE.

In most cases, an attempt to preserve native liver using portoenterostomy is a better strategy than primary liver transplantation. However, latter should be considered in “old” infants (>100 days), especially those with obvious cirrhosis (ascites, portal hypertension).

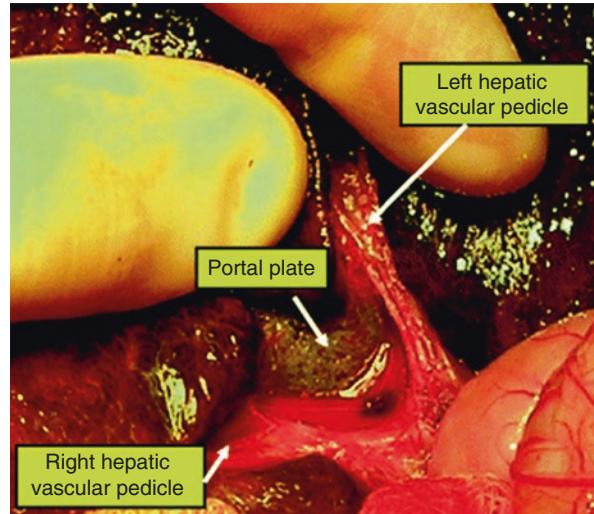
### 26.5.1 Kasai<sup>1</sup> Portoenterostomy (Fig. 26.2)

RUQ—muscle-cutting—extended across midline.

1. Confirm diagnosis ± cholangiogram.
2. Porta hepatis dissection—facilitated by extra-abdominal delivery of liver.

<sup>1</sup>Morio Kasai (1922–2008) Japanese pediatric surgeon who reported initial technique in 1959.

**Fig. 26.2** Kasai portoenterostomy—close up of porta hepatic. Transected bile ductules are visible in this case (unusual)



3. Excision of all extrahepatic remnants to the level of liver capsule, facilitated by retraction of portal vein confluence. Clearance proceeds from bifurcation of right vascular pedicle to insertion of umbilical vein on left portal vein.
4. Roux loop<sup>2</sup> (~40 cm) reconstruction and portoenterostomy (6/0 PDS).

#### Adjuvant Therapy

1. High dose steroids (e.g., prednisolone 4–5 mg/kg/day—tapered for 5 weeks).
2. Ursodeoxycholic acid (5 mg/kg tds).
3. Prophylactic antibiotics (e.g., Septrin™, trimethoprim, cefalexin).

## 26.6 Complications

- Cholangitis (40%).
  - Gram –ve organisms (usually).
  - Treated with IV antibiotics (Tazocin and Gentamicin).
- Portal hypertension.
  - Splenomegaly.
  - Esophageal, gastric, and anorectal varices.
- Hepatopulmonary syndrome.
  - Hypoxia, cyanosis, dyspnea, and clubbing due to the development of pulmonary arteriovenous shunts.
  - ↑ Incidence with BASM, diagnosed with saturation monitoring.
  - Reversed after liver transplantation.

<sup>2</sup>Cesar Roux (1857–1934) Swiss surgeon. Designed “Roux loop” for drainage of the stomach when obstructed but has been used for many indications since.

- Inguinal Hernia.
  - ↑ ascites and intrabdominal pressure.
- Malignancy
  - HCC, hepatoblastoma, and cholangiocarcinoma (rare ~2% native liver survivors).

---

## 26.7 Outcome

Success post-KPE can be gauged by:

1. Proportion to clear jaundice (ideally <20  $\mu\text{mol/L}$ ).
  - (a) 50–60% is achievable.
2. Proportion to survive with own liver.
  - (a) 50% after 5 years is achievable.

Prognosis post-KPE can be affected by:

1. Age at surgery—there are no “cut-off” values however.
2. Experience of surgeon/center.
3. BASM—prognosis reduced by presence of cardiac anomalies.

---

## Further Reading

1. Hartley J, Davenport M, Kelly D. Biliary Atresia – review. *Lancet*. 2009;374:1704–13.
2. Zani A, Davenport M. Inguinal hernias associated with biliary atresia. *Eur J Pediatr Surg*. 2012;22:117–20.
3. Davenport M. Adjuvant therapy in biliary atresia: hopelessly optimistic or potential for change? *Pediatr Surg Int*. 2017;33:1263–73.
4. Davenport M, Petersen C. The aetiology of biliary atresia: what is actually known? *Orphanet J Rare Dis*. 2013 Aug 29;8:128. <https://doi.org/10.1186/1750-1172-8-128>.
5. Parolini F, Hadzic N, Davenport M. Adjuvant therapy of cytomegalovirus IgM +ve associated biliary atresia: Prima facie evidence of effect. *J Pediatr Surg*. 2019;54:1941–5.
6. Davenport M, Puricelli V, Farrant P, et al. The outcome of the older (>100 days) infant with biliary atresia. *J Pediatr Surg*. 2004;39:575–81.





Mark Davenport

## Firsts

- The first cholecystectomy was performed in Berlin by **Carl Langebuch** (1846–1901) in 1882. His patient was a 43-year-old man with a long history of cholecystitis.
- Just over 100 years later, this operation was performed laparoscopically by **Erich Mühe** in Böblingen, West Germany in 1985.

## 27.1 Congenital Anomalies of the Gallbladder

There are a number of true congenital anomalies of the gallbladder, most are rare and usually asymptomatic.

- Duplication
- Agenesis
- Multiseptate
- Multilocular
- Porcelain

## 27.2 Gallstone Disease

*Even children get gallstones!*

---

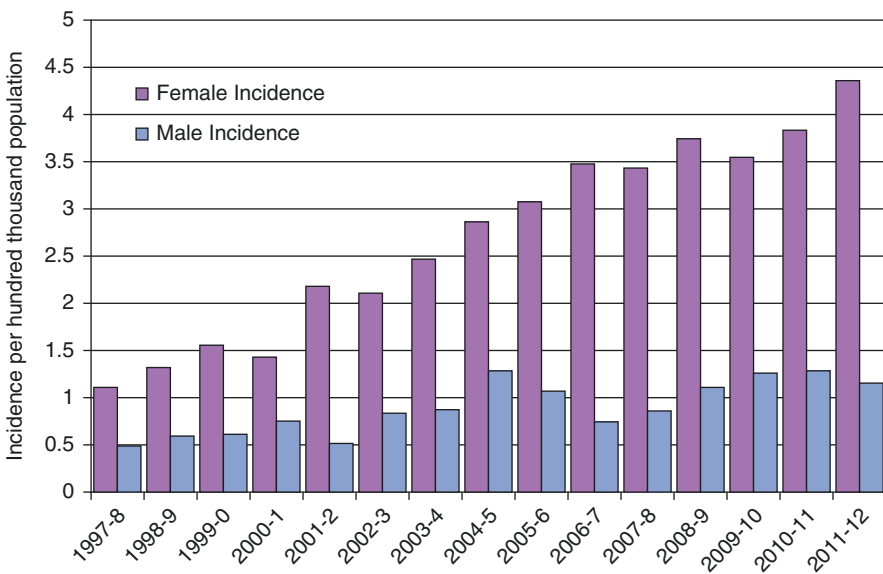
M. Davenport (✉)  
King's College Hospital, London, UK

### 27.2.1 Epidemiology

Gallbladder pathology is increasingly seen in regular pediatric practice due to the increasing prevalence of obesity and widespread use of ultrasound (Fig. 27.1).

### 27.2.2 Predisposition Groups

- Obesity
- Hemolytic disease
  - Sickle cell disease (SCD)
  - Thalassemia
  - Congenital spherocytosis/elliptocytosis
  - Gilbert syndrome
- Parenteral nutrition
- Progressive Familial Intrahepatic Cholestasis (PFIC)—3 types and counting
- Antibiotic usage—ceftriaxone
- Structural issues—e.g., choledochal malformation (see Chap. 26)
- Terminal ileal pathology
  - Surgical resection, e.g., NEC
  - Crohn’s disease



**Fig. 27.1** Incidence of cholecystectomy among English Children ( $\leq 16$  years) (1997–2012) ( $n = 2808$ ). [Reproduced with permission from #2]

### 27.2.3 Chemistry of Gallstones

Gallstones are of four main types in childhood:

- **Cholesterol (50%)**—yellowish, often solitary
  - Usually adolescent girls
- **Bilirubin pigment (40%)**—pigmented, multiple, sludge
- **Mixed (~5%)**
  - Post-infection/dehydration/TPN, etc. in infancy
- **Others**
  - Calcium carbonate (~10%)—↑ in children

**Microlithiasis**—a new concept of gallstones <3 mm in size. May be a cause of symptoms and are difficult to diagnose.

**Inspissated bile (sludge)**—related to gallbladder atony due to sepsis or parenteral nutrition. Can be a cause of jaundice in infants if migrated to the CBD.

### 27.2.4 Clinical Features

Gallstones may cause:

- Biliary colic—postprandial pain, >4 h duration
- Acute and chronic cholecystitis—↑ temp. ↑duration ↑tenderness (+ve Murphy's sign<sup>1</sup>)
- Empyema—palpable RUQ mass and pyrexia
- Choledocholithiasis—↑ conjugated jaundice
  - Cholangitis—pyrexia (~40 °C). Charcot's<sup>2</sup> triad (rigors/tender RUQ/jaundice)
- Acute pancreatitis—↑ amylase

### 27.2.5 Investigations

- US—sensitive, may show thickened wall, sludge, and ↑CBD.
- MRCP—sensitive to CBD stones, choledochal malformation, etc.
- Underlying cause.
  - Evidence of hemolysis (↑reticulocytes).
  - Cholesterol and triglyceride (fasting) level.
- Obstruction of CBD (↑ GGT and ALP, ↑ conjugated bilirubin).

<sup>1</sup> JB Murphy (1857–1916)—New York surgeon, early proponent of surgical treatment of appendicitis. The sign is flinching or gasping on inspiration when palpating in the RUQ due to the inflamed gallbladder impinging on the examiner's hand.

<sup>2</sup> Jean-Martin Charcot (1825–1893): The founder of modern neurology, with many syndromes and signs to his credit. Worked at the Salpêtrière Hospital, Paris.

### 27.2.6 Management

- Asymptomatic stones.
  - Probably best left alone in most children, certainly those detected incidentally without an obvious underlying cause.
  - Advise cholecystectomy in SCD during adolescence (better elective than emergency, ↑complication rate with age).
- Cholangitis/cholecystitis.
  - IV antibiotics (Gram –ve cover predominantly).
- Definitive intervention—2–4 weeks.
- Choledocholithiasis—elective ERCP ± sphincterotomy. Little role for surgical/laparoscopic bile duct exploration in children.

### 27.2.7 Surgery

**Laparoscopic cholecystectomy**—only operation where undoubted benefit compared to open surgery and is truly a gold standard.

- (i) Three working ports (5 mm) and umbilical camera port (10 mm/5 mm).
  - a. French (working between the patient’s legs) or American (surgeon on patient’s left) layout.
- (ii) Calot<sup>3</sup> triangle “of safety”—dissection to define borders and only clipping cystic duct and artery when there is nothing else left.
- (iii) **On-table cholangiogram**—(not routine) indicated in CBD stones, history of jaundice and pancreatitis.
- (iv) Mobilize gallbladder. Remove intact in purse-string bag. Check for bile leak. Check for bleeding.

## 27.3 Acalculous Cholecystitis

Usually associated with generalized sepsis or specific pathogens (e.g., *Salmonella* spp., *Leptospira*, Epstein-Barr virus); trauma, and burn injury. Some may arise in conjunction with autoimmune pathologies such as Henoch-Shonlein purpura and Kawasaki disease. The underlying mechanism appears to be vasculitis in these.

Ultrasound is the usual investigation but signs are often non-specific. The main being ↑wall thickness (>3.5 mm) and pericholecystic fluid.

Treatment is supportive in most cases unless positive evidence of complication (e.g., perforation).

<sup>3</sup>Jean-François Calot (1861–1944): French surgeon, original description is not quite that of current boundaries.

---

## 27.4 Hydrops of the Gallbladder

Features include distended but normal gallbladder and ducts and absence of gall stones. This condition is commonly seen in association with Kawasaki syndrome.

Hydrops may lead to gallbladder necrosis, perforation, and bile peritonitis.

---

## 27.5 Biliary Dyskinesia

This condition is becoming increasingly recognized in North America where it has overtaken gallstones as the indication for cholecystectomy. However, its presence is greeted with some skepticism by European surgeons who remain resistant.

Clinical features are vague but usually included postprandial pain and discomfort. This is usually in the context of an overweight child that is being investigated for chronic abdominal pain.

The pathophysiology is believed to be due to dysmotility disorder of the sphincter of Oddi and asynchrony of the postprandial choleric response.

### 27.5.1 Investigation

- Ultrasound—by definition should be normal.
- Liver biochemistry—by definition should be normal.
- **Radioisotope Biliary Scan**—measurement of Gallbladder Ejection Fraction (GbEF), which is obtained through a cholecystokinin-enhanced hepatobiliary iminodiacetic acid scan (CCK-HIDA).
  - **<35% at 30 mins (adult criterion)**—probable biliary dyskinesia.
  - **>80% at 30 mins**—possible biliary hyperkinesia!

The management is usually cholecystectomy but even so, many children will return with persistent symptoms. An empirical trial of Protein Pump Inhibitors (PPI) or H<sub>2</sub> receptor antagonists may be used prior to surgery or if overweight an active diet.

---

## Further Reading

1. Davenport M, Howard ER, Green DW. Minimally invasive surgery in sickle cell disease. *BMJ*. 1991 Jul 27;303(6796):249.
2. Khoo AK, Cartwright R, Berry S, Davenport M. Cholecystectomy in English children: evidence of an epidemic (1997–2012). *J Pediatr Surg*. 2014;49:284–8.
3. St Peter SD, Keckler SJ, Nair A, et al. Laparoscopic cholecystectomy in the pediatric population. *J Laparoendosc Adv Surg Tech A*. 2008;18:127–30.

4. Durakbasa CU, Balik E, Yamaner S, et al. Diagnostic and therapeutic endoscopic retrograde cholangiopancreatography (ERCP) in children and adolescents: experience in a single institution. *Eur J Pediatr Surg.* 2008;18:241–4.
5. Poddighe D, Sazonov V. Acute acalculous cholecystitis in children. *World J Gastroenterol.* 2018;21(24):4870–79.
6. Coluccio M, Claffey AJ, Rothstein DH. Biliary dyskinesia: fact or fiction? *Semin Pediatr Surg.* 2020;29:150947. <https://doi.org/10.1016/j.sempedsurg.2020.150947>.



Chandrasen K. Sinha and Mark Davenport

### Did You Know?

The pancreas was recognized as separate organ and has a name meaning “*All Flesh*” (Πάγκρεας) in Greek, by Ruphos, a physician working in Ephesus (modern-day Turkey).

## 28.1 Embryology (Fig. 28.1)

- Fifth-week gestation.
  - Ventral anlage<sup>1</sup> arises from biliary diverticulum. Rotates around behind duodenum and sandwiches superior mesenteric vessels.
- Seventh-week gestation.
  - Coalesces with dorsal anlage.
- Eighth-week gestation.
  - Exchange of duct systems—original ventral duct becomes the draining duct for dorsal pancreas (duct of Wirsung<sup>2</sup>). Original dorsal duct becomes more proximal duct of Santorini.<sup>3</sup>

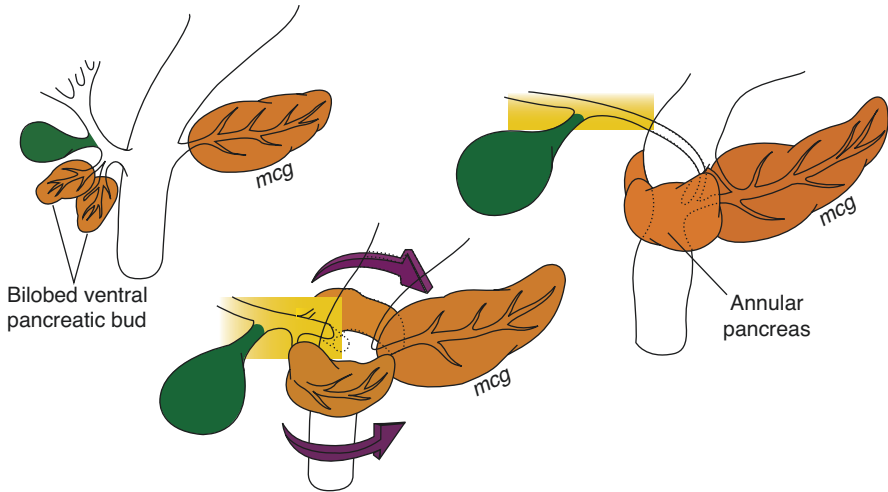
<sup>1</sup>Anlage (sing.) Anlagen (pl.)—Middle German for “plan or arrangement” used in context as cluster of embryonic cells.

<sup>2</sup>Johann Georg Wirsung (1589–1643)—German anatomist working in Padua (Italy), who identified duct in 1642 when dissecting the corpse of a convicted murderer.

<sup>3</sup>Giovanni Domenico Santorini (1681–1737) Italian anatomist.

C. K. Sinha  
St George’s Hospital, London, UK

M. Davenport (✉)  
King’s College Hospital, London, UK



**Fig. 28.1** Embryology of the pancreas [adapted from Shoенwolf et al.—Larsen's Human Embryology]

- Final stage is the absorption of ventral duct (and attached bile duct) into the wall of duodenum.

This complex process results in three key pathologies.

### 28.1.1 Annular Pancreas

Persistence or anterior rotation of the ventral anlage, leading to a ring (*latin annulus*) of normal pancreatic tissue around duodenum.

May cause:

- Duodenal obstruction—probably due to associated anomalies such as malrotation and duodenal atresia/stenosis.
- Susceptibility to acute pancreatitis.

If obstructive features are present, then duodeno-duodenostomy is better option that attempts to divide ring.

### 28.1.2 Pancreas Divisum

Due to failure of duct exchange leaving the dominant dorsal duct to drain via the accessory duct alone. Present in up to 10% of normal population. This is relatively inefficient as a physiological system and predisposes to pancreatitis (acute or chronic). Diagnosed by ERCP (only), MRCP is still relatively insensitive.



Surgical options include:

- (i) Endoscopic sphincterotomy.
- (ii) Transduodenal sphincterotomy.
- (iii) Retrograde duct drainage (e.g., longitudinal pancreato-jejunostomy—Puestow<sup>4</sup> procedure).

### 28.1.3 Common Channel

The ampulla of Vater<sup>5</sup> results from absorption of ventral duct and attached bile duct into the duodenal wall and results in a mechanism keeping bile and pancreatic juices apart. There is an additional sphincter mechanism (of Oddi<sup>6</sup>) controlling the flow. A common channel (defined as >5 mm in child) results from failure of this absorptive process and allows free interchange of secretions.

Associated with

- Choledochal malformation.

Predisposes to

- Acute pancreatitis.

The most effective surgical treatment is biliary diversion (even if bile duct is relatively normal diameter). Consider additional sphincteroplasty if there is marked common channel dilatation.

---

## 28.2 Acute Pancreatitis

It is an acute inflammation of the pancreas with variable severity, which may range from mild inflammation to severe necrotizing pancreatitis.

### 28.2.1 Surgical Etiology

- Choledochal malformation (usually Types 1F and 4F).
- Gallstones (e.g., idiopathic, sickle cell disease, spherocytosis).
- Congenital ductal anomalies (pancreas divisum, common channel, annular pancreas, congenital strictures).
- Cysts (e.g., foregut duplication).
- Blunt abdominal trauma (~25%) (see chapter on pancreatic trauma).

---

<sup>4</sup>Charles Bernard Puestow (1902–1973) American surgeon.

<sup>5</sup>Abraham Vater (1684–1751) German anatomist, described this in 1720.

<sup>6</sup>Ruggero Oddi (1864–1913) Italian anatomist who described this whilst still a medical student.

## 28.2.2 Medical Etiology

- Multisystem disease.
  - Reye’s<sup>7</sup> syndrome—acute onset encephalopathy and fatty liver associated with aspirin use in children.
  - Hemolytic uremic syndrome—severe diarrheal illness (often bloody) usually associated with *Escherichia coli* (serotype O157:H7).
  - Cystic fibrosis (<2% of CF population) and occasionally a presenting feature.
- Viral infections (e.g., mumps, rubella, cytomegalovirus, HIV) (~10%).
- Ascariasis (helminthic infection—India, China) adults>children—although prevalence of infection ↑children.
- Drugs (e.g., sodium valproate, steroids, azathioprine, L-asparaginase (~10%)).
- Metabolic diseases [e.g., hypercalcemia (hyperparathyroidism), familial hypertriglyceridemia] (~2%).

### 28.2.2.1 Hereditary (Aka Familial) Pancreatitis

The active digestive enzyme trypsin is formed as functionally inactive trypsinogen in the pancreatic acinus. Premature conversion leads to premature activation within the parenchyma and “autodigestion.” There are a number of enzymatic inhibitors which are deranged in HP.

Genetic disease (usually autosomal dominant) with a number of different possible mutations.

- *PRSSI* (cationic trypsinogen).
- *SPINK1* (Serine Protease Inhibitor Kazal type 1).
- *CTRC* (*Chymotrypsin C*).
- *CFTR* (Cystic Fibrosis Transmembrane conductance Regulator).

Children present with recurrent abdominal pain, often with several years’ history. Surgical/endoscopic decompression may have a role. The disease is known to be premalignant.

## 28.2.3 Pathology of Pancreatitis

↑ pancreatic duct pressure or premature enzyme activation within acinar cells may lead to autodigestion, inflammatory reaction and initiation of SIRS and even MODS (see Chap. 4). Leakage of secretions (from trauma or duct necrosis) into surrounding tissue may lead to **acute fluid collections** (if early, <4 wks) or with creation of actual non-epithelial lined cavity (>4 wks, **pseudocyst**).

---

<sup>7</sup>R Douglas Reye—Australian pediatrician who published this in 1963.

### 28.2.4 Clinical Features

Often misdiagnosed initially, but usual features are sudden-onset abdominal pain (often radiating to back, relieved by leaning forward) and vomiting. On examination, there may be low-grade fever  $\pm$  signs of shock ( $\uparrow$  pulse  $\downarrow$ BP) depending on severity. There is also tenderness in the upper abdomen.

Late signs include a bruised appearance of umbilicus (Cullen's sign) or in the loins (Grey-Turners sign).

**Acute necrotizing pancreatitis** with a potential for mortality is uncommon in children but will show shock, disseminated intravascular coagulation, GI bleeding, respiratory, and renal failure (i.e., MODS).

### 28.2.5 Investigations

- (i) Laboratory tests:
  - a.  $\uparrow\uparrow$  Amylase and  $\uparrow$  lipase—no correlation of level with severity.
  - b.  $\uparrow$  White cell count
  - c.  $\downarrow$  Calcium,  $\downarrow$  glucose
  - d. Blood gas analysis (evidence of  $\downarrow$ pH) and  $\uparrow$ lactate.
  - e.  $\uparrow$  Bilirubin,  $\uparrow$  GGT
  - f.  $\uparrow$  INR
  - g. Urinary TAP (trypsin activation peptide) level—may predict severity, adult studies cut-off  $>35$  nmol/L.
- (ii) **USS**—showing retroperitoneal and pancreatic edema and looking for evidence of gallstones, biliary dilatation, etc.
- (iii) **CT/MRI**—defines extent of disease process and able to detect pancreatic necrosis.
- (iv) **ERCP** —indicated in acute gallstones pancreatitis.

### 28.2.6 Management

- Supportive—including fluid resuscitation, NG tube (if vomiting) with analgesia and  $H_2$  blockers ( $\downarrow$  gastric acidity). Few need ventilation and blood gas support. Parenteral nutrition important from  $>48$  hrs. Antibiotics if evidence of systemic infection or sepsis.

#### 28.2.6.1 Surgery

- **Early**—consider necrosectomy (open or laparoscopic) ( $<5\%$ ) but only if CT evidence of necrosis and severe systemic illness.
- **Late**:
  - Pseudocyst formation.
    - Supportive ( $\sim 30\%$  will spontaneously diminish).
    - Aspiration—US or CT-guided  $\pm$  pigtail drain.

- Cystgastrostomy.
  - Endoscopic—feasible in children.
  - Open—classical approach.
  - If cyst not near stomach, then a Roux loop will achieve drainage.
- **Pancreatic Ascites**—duct open to peritoneal cavity with free flow.
  - ERCP** (diagnosis), treated by stent.
  - Open**—identify leak and oversew/resect or Roux loop to drain.

---

## 28.3 Chronic Pancreatitis

Characterized by recurrent episodes of symptomatic pancreatic inflammation together with gradual decline of exocrine and endocrine functions.

### 28.3.1 Etiology

Previous list still applies but in addition to congenital duct anomalies, HP and cystic fibrosis are also leading causes.

### 28.3.2 Clinical Features

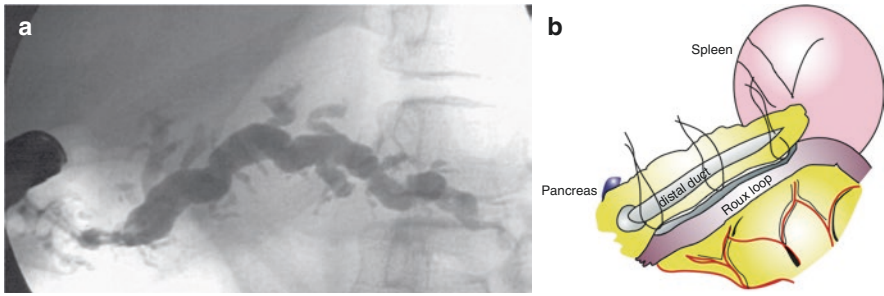
Intermittent epigastric pain (as before), with pain-free intervals (varying duration). Anorexia and weight loss may be features, exacerbated by exocrine failure (e.g., steatorrhea). Endocrine failure (i.e., diabetes) is a late sign, whatever the cause.

### 28.3.3 Investigations

- (i) Fecal elastase (<200  $\mu\text{g/g}$  of stool).
- (ii) AXR—may show calcification, particularly in HP.
- (iii) US—biliary and pancreatic duct dilatation; pseudocysts, calculi, or ascites.
- (iv) CT/MR scan.
- (v) ERCP (Fig. 28.2)—defines ductal anatomy and is key to determine role of surgery.

### 28.3.4 Surgery

Indicated if persistent pain (despite standard therapy of fat restriction enzymes and adequate analgesia), complications (e.g., pseudocyst).



**Fig. 28.2** (a) ERCP showing dilated main pancreatic duct, secondary to chronic pancreatitis; (b) treated by Puestow operation (From Previous Edition)

Options include:

- **ERCP and stent (e.g., Sherman stent)**—only short-term but if successful predicts success of open surgery.
- **Sphincteroplasty (endoscopic or open)**—for localized ampullary stenosis or common channel only.
- **Internal open retrograde duct drainage.**
  - Puestow procedure—longitudinal pancreaticojejunostomy—usually to left of mesenteric vessels.

## 28.4 Persistent Hyperinsulinemic Hypoglycemia of infancy

### 28.4.1 Background

Persistent Hyperinsulinemic Hypoglycemia of Infancy (PHHI) is the most important cause of severe and recurrent hypoglycemia infants. It is characterized by autonomous insulin production requiring intravenous dextrose solutions simply to maintain normal glucose levels. Etiology is unknown and it has a frequency of about 1 in 40,000 live births in the United Kingdom.

### 28.4.2 Associations

- Beckwith–Wiedemann syndrome.
- Perlman syndrome.
- Usher type 1c Soto's syndromes.

### 28.4.3 Pathology

There are two distinct pathological subgroups:

- Diffuse (45%).
- Focal adenomata (55%).

### 28.4.4 Clinical features

Jitteriness, tremors, even convulsions, and a high-pitched cry, typically between feeds. Most infants are macrosomic. Diagnostic criteria:

- Fasting hypoglycemia—plasma glucose  $<3$  mmol/L.
- Hyperinsulinism—plasma insulin  $>3$  mU/L.
- Undetectable or low fatty acids and ketone bodies.

### 28.4.5 Investigations

Focal lesions are typically too small (3–7 mm), for reliable conventional imaging (ultrasound, CT, and MRI). Most large centers have access to a 18F-L-dopa PET scan to differentiate.

### 28.4.6 Management

- Central venous catheter and continuous infusion of IV dextrose  $\pm$  glucagon.
- Oral diazoxide (5–20 mg/kg/day).
- Octreotide (5–35 microgram/kg/day) or long-term depot Lanreotide.

Surgery is indicated for failure of medical management. Near-total pancreatectomy is chosen for diffuse disease with partial resections or even enucleation for adenomata.

---

### Further Reading

1. Dzakovic A, Superina R. Acute and chronic pancreatitis: surgical management. *Semin Pediatr Surg.* 2012;21:266–71.
2. Kandula L, Lowe ME. Etiology and outcome of acute pancreatitis in infants and toddlers. *J Pediatr.* 2008;152:106–10.

3. Ford K, Paul A, Harrison P, Davenport M. Surgical success in chronic pancreatitis: sequential endoscopic retrograde cholangiopancreatography and surgical longitudinal pancreateojejunostomy (Puestow Procedure). *Eur J Pediatr Surg.* 2016;26:232–9.
4. Iqbal CW, Moir CR, Ishitani MB. Management of chronic pancreatitis in the pediatric patient: endoscopic retrograde cholangiopancreatography vs operative therapy. *J Pediatr Surg.* 2009;44:139–43.
5. Laje P, States LJ, Zhuang H, et al. Accuracy of PET/CT Scan in the diagnosis of the focal form of congenital hyperinsulinism. *J Pediatr Surg.* 2013;48:388–93.



Mark Davenport

**Normal Portal Pressure**—not really known in children and rarely measured in any clinical practice.

- Normal (assumed) portal pressure ~5 mmHg.
- Portal hypertension >10 mmHg.
- Size of spleen—surrogate of PHT.

## 29.1 Introduction

Portal hypertension (PHT) is an uncommon state in children, in many, there is an obvious liver disease but the commonest single cause—portal vein thrombosis—may present in the absence of any preceding illness. Significant PHT tends to present with variceal bleeding and/or splenomegaly.

## 29.2 Anatomy

*Anatomy is key to understanding surgical options for PHT.*

The portal vein (PV) is formed by the confluence of the superior mesenteric and splenic vein behind the neck of the pancreas and then ascending as the posterior component of the portal triad (common bile duct and hepatic artery). It then divides

---

M. Davenport (✉)  
King's College Hospital, London, UK



into right and left portal veins at the porta hepatic and these branch within the liver to empty into the liver sinusoids. There is then venous re-formation from this sinusoidal network into the hepatic veins (right, left and middle) which drain into the inferior vena cava at the level of the diaphragm thence almost immediately into the right atrium.

The direction of blood flow in the PV and through the liver is determined entirely by the pressure gradient.

The development of PHT forces portosystemic collaterals to open up around the oesophagus, distal rectum, retroperitoneum, and anterior abdominal wall.

Liver blood flow is from two sources:

- Portal vein ~75% of liver blood flow.
- Hepatic artery ~25% (has the ability to ↑ to compensate).

(As the oxygen saturation is lower in the PV, this implies a 50:50 split into the delivery of O<sub>2</sub>.)

---

## 29.3 Causes of Portal Hypertension

- **Extra-Hepatic** (prehepatic)
  - Portal vein occlusion/thrombosis—often congenital, may be related to neonatal sepsis, use of umbilical vein catheter.
- **Intra-Hepatic**
  - Cirrhosis
    - Post-Kasai biliary atresia (common)
    - Post-hepatitis, autoimmune hepatitis (uncommon)
  - Fibrosis –
    - Congenital liver fibrosis—often related to renal cysts/fibrosis
    - Schistosomiasis (probably commonest cause in the world)
    - Cystic fibrosis
    - Post-pylephlebitis—following portal pyaemia (typically from appendicitis), resulting in small portal venule fibrosis.
- **Post-Hepatic**
  - **Budd–Chiari syndrome**<sup>1</sup>—occlusion of hepatic veins (typically by underlying hypercoagulable state) causes hepatomegaly, ascites, and portal hypertension.
  - Venous-occlusive disease (VOD)—a possible complication of anti-cancer chemotherapy.

---

<sup>1</sup>George Budd (1808–1882) Physician at Kings College Hospital, London who described this in 1845. Hans Chiari (1851–1916) Austrian pathologist later described histological features.

### 29.3.1 Portal Vein Thrombosis

Initial thrombus formation is asymptomatic (and probably occurs in the neonatal period), but gradually collateral veins develop and can be recognised as a “cavernoma” on the US. Overall “portal” blood flow may be maintained but at higher pressure, but the slow flow is the norm. The liver is usually smaller than normal, relatively arterIALIZED but biochemically and histologically normal.

#### 29.3.1.1 Aetiology

- Idiopathic (50%).
- Congenital (20%)—assumed as related to other congenital malformations e.g., radial, craniofacial, and vertebral deformities.
- Neonatal-acquired (30%)—either directly due to umbilical vein catheter abuse, or indirectly related to omphalitis, sepsis, dehydration, etc.

Thrombogenic coagulopathy is an uncommon cause of both hepatic and PVT in children (cf. adults).

#### 29.3.1.2 Clinical Features

Children present with

- Gastrointestinal bleeding.
- Palpable splenomegaly.

Even the initial bleed (haematemesis and/or melaena<sup>2</sup>) can be life-threatening and torrential due to PHT. A history of liver disease (and visible jaundice) makes the diagnosis obvious (although still requiring an endoscopic confirmation), though there is a lag time to develop varices (months). If the only abnormal sign is a palpable spleen, then PVT is the likeliest cause.

Varices develop in a predictable sequence (oesophageal, gastric, and anorectal), again over time, and the latter variants will not be a cause of *de novo* bleeding. A *caput medusae*<sup>3</sup> is the appearance of venous collaterals from a patent umbilical vein draining via the umbilicus into the abdominal wall veins.

Rarely, PHT causes secondary biliary obstruction (bilopathy) and hepatopulmonary syndrome.

#### 29.3.1.3 Investigations

1. Laboratory
  - a. Liver biochemistry (normal in PVT) including Prothrombin Time.

---

<sup>2</sup>Melaena—the word is derived from the Latin for black – but is commonly misspelled as “mal ... aena” implying “bad”.

<sup>3</sup>Caput medusae—Latin for “Head of the Medusa”—mythical winged female creature with venomous snakes for hair and capable of turning men to stone—the definitive “bad hair day”!

- b. Full blood count ( $\downarrow$ Hb,  $\downarrow$  WBC, and  $\downarrow$  platelet count—due to hypersplenism).
  - c. Viral serology, Cu (for Wilson’s disease) and Fe (for haemochromatosis) estimation.
2. Radiology
    - a. Doppler US—looking for cavernoma formation, portal blood flow, and liver parenchymal appearance.
    - b. MRV—to define porto-mesenteric venous anatomy (if a shunt is considered).
    - c. Angiography—typically retrograde hepatic venography (if MesoRex shunt considered).
  3. Endoscopy
    - a. Upper GI endoscopy—diagnostic and therapeutic.

#### 29.3.1.4 Management of Acute Bleeding Episode

If after hemodynamic resuscitation ( $\pm$ blood transfusion), then PHT appears the likeliest cause of the bleeding, use octreotide infusion to reduce PHT, and proceed to urgent endoscopy ( $\pm$ definitive therapy).

- Endoscopic variceal therapy.
- Band ligation (older child) or sclerotherapy (infant).
- Usually requires a course of treatment for eradication (three to four sessions).
- “Superglue” cyanoacrylate injection for gastric varices
- **Sengstaken-Blakemore tube**<sup>4</sup>—a device with gastric and oesophageal balloons (only former is usually needed in children), applied under GA and tension for 24 h.
- Transjugular intrahepatic portosystemic shunt.
  - Rarely used in children—only indicated as short-term “bridge” in cirrhotic livers on way to transplantation.

#### 29.3.1.5 Secondary Prophylaxis

- Few studies in children but possible use of:
- Propranolol.
- Depot somatostatin analogue.

#### 29.3.1.6 Definitive Surgery

- **Shunt surgery**—for PVT (good liver function) and (rarely) cirrhotic liver disease with good liver function. Indications include: Persistent bleeding uncontrolled by endoscopic treatment, and massive splenomegaly.
  - Meso-Rex shunt—only type with no risk of encephalopathy.
    - Native (internal jugular vein) conduit between left portal vein (in Rex fossa) and SMV.

---

<sup>4</sup>Robert Sengstaken & Arthur Blakemore. New York surgeons who described custom-made tube with oesophageal and gastric balloons in 1950. First patient was 15-year-old girl with portal vein thrombosis.

- Portosystemic shunt.
  - Mesocaval shunt—conduit between IVC and SMV.
  - Lienorenal shunt  $\pm$  splenectomy—anastomosis between renal vein and splenic vein.
- **Transplantation**—for cirrhotic disease (poor liver function) [see Chap. 30].

---

## Further Reading

1. Abd El-Hamid N, Taylor RM, Marinello D, et al. Aetiology and management of extrahepatic portal vein obstruction in children: King's College Hospital experience. *J Pediatr Gastroenterol Nutr.* 2008;47:630–4.
2. Zargar SA, Yattoo GN, Javid G, et al. Fifteen-year follow up of endoscopic injection sclerotherapy in children with extrahepatic portal venous obstruction. *J Gastroenterol Hepatol.* 2004;19:139–45.
3. Alberti D, Colusso M, Cheli M, et al. Results of a stepwise approach to extrahepatic portal vein obstruction in children. *J Pediatr Gastroenterol Nutr.* 2013;57:619–26.
4. de Ville de Goyet J, D'Ambrosio G, Grimaldi C. Surgical management of portal hypertension in children. *Semin Pediatr Surg.* 2012;21:219–32.



Evelyn Geok Peng Ong

## 30.1 Indications for Transplantation

### 30.1.1 Acute Liver Failure

Acute fulminant liver failure (i.e., severe coagulopathy, encephalopathy, hypoglycemia, jaundice) is an uncommon indication (<10% of children). Causes may include seronegative hepatitis, neonatal hepatitis, gestational alloimmune liver disease (GALD), drug overdose (e.g., paracetamol), and acute presentation of metabolic disorders, e.g., Wilson's disease.

### 30.1.2 Chronic Liver Failure

The vast majority of LT recipients have end-stage chronic liver disease (CLD). The commonest indication remains extrahepatic biliary atresia (~30%). The onset of liver failure can be insidious and clinicians must be alert to the signs; gastrointestinal bleeding due to portal hypertension, hypersplenism and varices; poor synthetic function with hypoalbuminemia or coagulopathy; failure to thrive; hepatic bone disease and pathological fractures; onset of ascites; recurrent cholangitis; uncontrolled pruritus; hepatopulmonary or hepatorenal disease.

- Extrahepatic biliary atresia (see Chap. 25).
- Alpha-1-antitrypsin deficiency.
  - Caused by mutation in the *SERPINA1* gene.
- Autoimmune hepatitis.

---

E. G. P. Ong (✉)

The Liver Unit, Birmingham Women's and Children's NHS Foundation Trust,  
Birmingham, UK

e-mail: [e.ong@nhs.net](mailto:e.ong@nhs.net)

- Sclerosing cholangitis.
- Caroli's syndrome.
  - May be isolated as multiple intrahepatic duct dilations or associated with renal fibrosis/cysts.
- Wilson's disease.
  - Caused by mutations in the *ATP7B* gene with disruption of copper-transport.
- Cystic fibrosis.
- Progressive familial intrahepatic cholestasis (all types).
- Alagille syndrome.
  - Caused by mutations in the *JAG1* gene on Ch 20p12.
- Glycogen storage disease types 3 and 4.
- Tyrosinaemia type 1.
- Graft *versus* host disease.
- Budd–Chiari syndrome.
- Hepatopulmonary syndrome or portopulmonary hypertension.

### 30.1.3 Inborn Errors of Metabolism (~20%)

- Crigler–Najjar syndrome (Type 1 and 2).
  - Autosomal recessive caused by mutations in the *UGT1A1* gene.
- Urea cycle defects.
- Hypercholesterolemia.
- Organic acidemias.
- Primary hyperoxaluria—often candidates for both renal and liver transplants.
  - Caused by mutations in the *AGXT* gene on Ch 2q37.
- Glycogen storage disease type 1 (aka Von Gierke's disease).
  - Caused by mutations in the *G6PC* gene.
- Inherited disorders of complement causing atypical hemolytic uraemic syndrome.

### 30.1.4 Liver Tumors (~10%)

The commonest malignant indication for LT is hepatoblastoma, followed by hepatocellular carcinoma (HCC). Patients are staged using the PRETEXT classification and are candidates for transplantation only in the absence of extrahepatic disease. The Milan criteria for HCC applied in adults is not applicable in children.

---

## 30.2 Transplant Assessment

Assessment by a multidisciplinary team including:

- Hepatologist—assessment of indications and timing for transplantation. Identifies areas for optimizing medical care prior to transplantation.

- Transplant surgeon—reviews anatomy and surgical approach to transplant including any special requirements such as vascular reconstruction.
- Anesthetist—assessment of the cardiorespiratory resilience and any issues such as poor venous access.
- Specialist nurse—provides structured counseling and checks understanding of the information shared.
- Psychologist—assesses the cognitive ability of patient and family, potential stressors, and mechanisms for coping. Transplant coordinator.

Further, staff may be co-opted into the assessment team depending on the individual child's requirements, e.g., nephrology, cardiology, endocrinology, oncologist, or metabolic disease specialist.

At the end of the assessment, the MDT may make one of three decisions:

1. To add the child to the active waiting list.
2. To recommend further functional assessments, optimization of medical treatment, or establishment of socioeconomic support before reassessing the patient.
3. Decide the child is not a candidate for transplantation.

Transplant should offer the patient a significant improvement in survival and improvement of quality of life. The decline of transplantation may be taken on the grounds that the child is currently well enough to not require it (in which case reassessment at a later date is possible if the disease progresses) or that there is sufficient co-morbidity or anatomical barriers that make transplant or patient survival unlikely or that there will be a significant detriment to the child and family's quality of life.

---

## 30.3 Surgery

### 30.3.1 Donor Allocation

Donor organs are a precious resource and therefore recipients are placed on a waiting list. Different countries take slightly different approaches to organ allocation. Some countries assign a recipient disease severity score which determines recipient priority (e.g., MELD & PELD). However, since 2018, the UK has applied a matching scheme based on the **Transplant Benefit Score (TBS)** is calculated based on 21 recipient criteria and 7 donor criteria (Table 30.1). The algorithm is designed to match the organ with the patient that would derive the most benefit.

Each matching run includes seven tiers:

1. Super-urgent.
2. Hepatoblastoma.
3. Intestinal.
4. Liver and cardiothoracic.
5. Split Liver.

**Table 30.1** Transplant benefit score

| Recipient criteria                | Donor criteria          |
|-----------------------------------|-------------------------|
| Age                               | Age                     |
| Gender                            | Cause of death          |
| Hepatitis C status                | BMI (height and weight) |
| Creatinine                        | Diabetes                |
| Bilirubin                         | Donor type              |
| INR                               | Blood group             |
| Sodium                            | Split liver criteria    |
| Potassium                         |                         |
| Albumin                           |                         |
| Renal Support                     |                         |
| Inpatient status                  |                         |
| Previous abdominal surgery        |                         |
| Encephalopathy                    |                         |
| Ascites                           |                         |
| Time on waiting list              |                         |
| Diabetes                          |                         |
| Maximum AFP level <sup>a</sup>    |                         |
| Maximum tumor size <sup>a</sup>   |                         |
| Two tumors <sup>a</sup>           |                         |
| Three or more tumors <sup>a</sup> |                         |

<sup>a</sup>Malignancy cases

6. Chronic Liver disease according to the TBS.
7. Fast track offer if organ declined by other centers.

### 30.3.2 Organ Donation

The majority of organ donations in the UK are still cadaveric and are organized through a national network.

Donation after brain stem death (DBD) is preferable for pediatric recipients with a lower risk of graft dysfunction following transplant. However, select donations after cardiac death (DCD) are used successfully. The quality of grafts improves with decreased graft ischemia and therefore different strategies are being trialed including liver perfusion machines (both hypothermic and normothermic), *in situ* splittings of the liver during the donor procedure and application of ECMO in the donor.

Living donation is an alternative source of liver grafts and is important in countries that do not have access to a cadaveric donor program (e.g., Japan). Living donation reduces the ischemia time of the graft and allows procedures to be planned. This is particularly important for more complex explant procedures, e.g., tumor resections, recipients who have had multiple previous laparotomies, or require vascular conduits to be constructed. However, the safety of potential living donors is essential, and they must undergo a rigorous physical and psychosocial assessment, performed independently of the team caring for the recipient, before being accepted as a donor. Published data cites a risk of post-operative complications of up to 28%,



mainly due to self-resolving postoperative bile leaks. Only two deaths have been reported worldwide.

Organ allocation systems differ from country to country but are based on ABO blood group compatibility. As we aim for children to thrive and develop into adulthood with their grafts, donors are selected for longevity; ideally, the donor should be less than 40 years old, with a normal BMI, requiring minimal intensive care support (not more than 3 days and minimal use of inotropes) and free from infection or malignancy. Donors are screened for infection and medical and social history are sought from their physician or family members.

---

## 30.4 Surgery

### 30.4.1 Graft Preparation

The number of size-matched pediatric donors is limited. Adult grafts, however, may be reduced for a child recipient or split into two functional grafts, with the left lateral segment (LLS) utilized for a smaller child and the right used for an adult or larger adolescent.

Each functional part must have its own vascular inflow and outflow and biliary drainage and therefore not all livers can be split, particularly those with anomalous arterial supply, without compromising the function of either of the grafts. There is a slightly increased risk of ischemic injury and biliary complications compared with whole grafts but utilization of a split graft program allows the donor pool to be significantly expanded.

Cadaveric grafts are commonly split with the common hepatic artery kept with the left lateral segment and the right hepatic artery is reconstructed using donor artery; the left bile duct cut flush with the cut surface of the liver; the left portal vein and the left hepatic vein is kept with the LLS, repairing their origins on the right graft. Vessels and biliary ducts at the cut surface of the graft are closed either with a thermal device, surgical clips, or by suture.

### 30.4.2 Recipient Surgery

The abdomen is inspected for any pathology and, in particular, the extrahepatic extension of malignant disease. Explant of the liver is undertaken, and any vascular conduits required are formed using donor graft vessels. Unlike in adults, cross-clamping of the IVC can be performed without dramatic impaction of hemodynamic stability and gives good control of the venous outflow. The clamped portal vein similarly does not normally require shunting in children but increased visceral congestion can occur particularly in the absence of pre-existing portal hypertension.

The hepatic venous outflow is reconnected first. The IVC is commonly preserved in the recipient and the graft hepatic outflow is attached in piggy-back fashion with a triangular anastomosis. The portal vein anastomosis is then formed followed by

the arterial anastomosis. The graft may be re-perfused either solely via the portal vein or following the arterial anastomosis.

The majority of bile ducts are drained via a Roux-en-Y loop but older recipients with whole or reduced grafts may have a duct-to-duct anastomosis.

Abdominal closure is performed with attention to preventing compartment syndrome. Any visceral edema or large liver graft in a small abdominal compartment will contribute to a difficult closure and therefore the safest approach would be for staged abdominal closure; the abdomen is temporarily closed with a synthetic fluid impermeable film and the skin edges mobilized to enable closure over the temporary patch. The whole wound has the potential to lose large volumes of ascitic fluid and therefore a suction dressing is applied to control this. Edema usually settles sufficiently to allow complete closure of the abdomen and the temporary patch is removed but a permanent patch (e.g., biological mesh) may be required to bridge any defect in the muscle wall to allow complete closure without tension.

#### **30.4.2.1 Post-Operative Care**

Blood count, lactate, acid-base balance, serum glucose, liver function tests, urea, electrolytes, and clotting are checked every 6 hours and fluids are administered to keep a neutral fluid balance. Maintenance immunosuppression is commenced and serum levels monitored daily. Antibiotic, antifungal, and antiviral prophylaxis are started. Anticoagulation by heparin infusion is initiated as clotting normalizes and the hematocrit is kept intentionally lower than normal to prevent thrombosis in the first week following surgery. Vascular Doppler flows are measured daily to detect any problems with graft perfusion.

### **30.4.3 Complications**

#### **30.4.3.1 Poor Graft Function**

Delayed graft function still occurs, possibly due to reperfusion injury. Some may require inotropic or renal support and management of coagulopathy but function may still normalize with good graft outcomes. Primary non-function is rare (2–5%) and requires urgent retransplant.

#### **30.4.3.2 Vascular**

Doppler surveillance following transplantation is essential to pick up early signs of vascular problems as clinical signs may occur late.

- **Hepatic artery thrombosis (HAT, 2–25%)**—occurs early or late. Early HAT is related to small vessel caliber, technical issues such as kinking of the vessel or anastomotic stenosis, high blood viscosity, or pro-coagulant state. Early detection and treatment are critical to salvaging the graft. Late HAT can occur but the presentation is more subtle with biliary changes, signs of arterial collateralization, derangement of liver function tests, and infection. HAT should prompt investigation for pro-coagulant conditions.

- **Portal vein thrombosis (PVT, 4%)**—usually occurs early post-transplant secondary to portal vein hypoplasia (often associated with biliary atresia) or portal vein stenosis. Early reoperation to clear thrombosis can salvage the graft. Late-onset portal vein thrombosis may present with splenomegaly and signs of portal hypertension. Collateralization may sustain the graft for an indefinite period of time but retransplantation may be necessary.
- **Hepatic venous outflow obstruction**—very rare and usually caused by technical problems. The graft must be carefully positioned to avoid kinking of the hepatic veins and may be secured by the falciform ligament to the abdominal wall at the time of closure to prevent rotation of the graft. Venous outflow obstruction may present with liver dysfunction, bleeding or large volume ascites.

Bleeding is rare and often related to coagulopathy in the post-operative period. Correction of coagulopathy is key to treatment. Reoperation seldom reveals a single bleeding point but may be necessary if not controlled by correcting the clotting.

#### **30.4.3.3 Biliary Complications (up to 30%)**

Leaks commonly manifest a week following transplantation and can occur from orphan ducts at the cut surface of split or reduced liver grafts. Small volume leaks can be controlled with drainage but persistent or larger volume leaks should be managed by stenting the main bile duct to decompress the biliary system. This can be performed either by ERCP (if a duct-to-duct anastomosis was used) or percutaneous transhepatic cholangiography (PTC). Reoperation is rarely required unless there is a ductal stricture in which case a duct-to-duct anastomosis can be converted to a duct to a jejunal Roux loop.

Biliary strictures can occur early or late and should prompt investigation for HAT. This tends to present with cholangitis or derangement of liver function tests. May in up to 10% of transplants and are managed using either PTC or ERCP, with dilatation of the stricture and insertion of a stent. Patients may require several dilations and changes of stent but more recently, absorbable stents have been employed successfully. Recurrence of underlying disease should be considered in some with autoimmune disease. Biliary reconstruction is possible in some patients but in the longer term, patients may require re-transplantation.

#### **30.4.3.4 Rejection**

- **Hyperacute rejection**—exceedingly rare in liver grafts, perhaps due to the dual blood supply and immunoprotective properties of the liver. It is mediated by the presence of pre-existing antibodies to the graft which may have been induced by previous blood transfusions or transplants. It occurs within hours of the transplant and causes widespread graft microvascular thrombosis followed by graft failure.
- **Acute rejection**—can occur by two mechanisms, either alone or in combination. T cell-mediated rejection occurs when donor dendritic cells are activated and behave as antigen-presenting cells thus stimulating T cell maturation and precipitating an inflammatory cascade against the graft. Humoral donor-specific

antibody-mediated rejection can also occur with the initiation of the classic complement cascade. It can be difficult to diagnose in liver grafts; renal grafts may demonstrate vascular deposition of C4d but this is not often detectable in liver grafts.

### 30.4.3.5 Infection

Post-transplant patients have an increased susceptibility to infection as a consequence of immunosuppression. All patients undergo serological screening prior to transplantation and should complete normal childhood immunization courses (including against viral hepatitis and varicella-zoster) prior to activation on the waiting list should time allow. Live vaccines, in particular, should be given prior to listing for transplant.

All patients are commenced on a prophylactic course of antibiotics, antifungals, and antiviral medication following transplant and may be tailored to the recipient depending on pre-existing infection history and donor infection history. As immunosuppression levels are tapered, antiviral prophylaxis can be reduced but physicians should be alert to the infection being a cause for liver dysfunction. CMV and EBV are commonly present in adult donors and may present a de novo infection to seronegative pediatric recipients. Antivirals may help prevent viral replication or reactivation of latent CMV infection. However, a rise in EBV titers should be managed with a reduction of immunosuppression levels and monitoring of the response. Prophylactic co-trimoxazole reduces the risk of *Pneumocystis jirovecii*. Antifungals such as nystatin or fluconazole reduce the risk of candidiasis and aspergillosis though it should be noted that fluconazole will alter the pharmacodynamics of tacrolimus and drug levels should be closely monitored.

---

## 30.5 Outcomes

- Survival—steady improvement ~93% at 1 year and ~70% at 5 years (UK). One of the main problems during the transition to adulthood is compliance with medication. The goal of complete graft tolerance is still some way off.

---

## Further Reading

1. Oishi K, Arnon R, Wasserstein MP, Diaz GA. Liver transplantation for pediatric inherited metabolic disorders: considerations for indications, complications, perioperative management. *Pediatr Transplant*. 2016;20:756–69.
2. Battula NR, Platto M, Anbarasan R, Thamara M, et al. Intention to split policy: a successful strategy in a combined pediatric and adult liver transplant center. *Ann Surg*. 2017;265:1009–15.
3. Del Pilar HM, Martin P, Simkins J. Infectious complications after liver transplantation. *Gastroenterol Hepatol (NY)*. 2015;11:741–53.

---

**Part V**

**Urology**



# Exstrophy-Epispadias Anomaly

# 31

Naser Al Soudan Al Anazi and Imran Mushtaq

**Bladder Exstrophy-Epispadias Complex (BEEC)** is a spectrum of midline anomalies of the anterior abdominal wall, bony pelvis, urinary tract, midgut and spine.

## 31.1 Bladder Exstrophy-Epispadias Complex (BEEC)

### 31.1.1 Classical Bladder Exstrophy (CBE)

- ~2.5 in 100,000 live births
- M: F 2:1.
- Recurrence risk is 1 in 100.

### 31.1.2 Cloacal Exstrophy

- ~1 in 200,000
- M: F 1:1.
- Associated with spinal dysraphism (~66%) and short bowel syndrome (33%).

---

N. A. S. Al Anazi · I. Mushtaq (✉)  
Great Ormond Street Hospital for Children, London, UK  
e-mail: [Imran.Mushtaq@gosh.nhs.uk](mailto:Imran.Mushtaq@gosh.nhs.uk)

---

### 31.1.3 Epispadias

- Isolated 1 in 117,000 males.
- Isolated 1 in 484,000 females.

### 31.1.4 Genetics

- Genetic correlation between **BEEC** and **22q11.2 duplication** has been reported ~ 3.3%.
- **p63** is a member of the p53 tumour suppressor family that is highly expressed in stratified epithelium including the bladder and its overlying skin. Its expression is decreased in CBE patients compared to controls, and p63 knockout mice have CBE-like anomalies.

---

## 31.2 Embryology

**Three hypotheses exist for the embryologic origin of exstrophy:**

1. Premature rupture of the cloacal membrane, mechanical obstruction of the mesodermal migration, and disruption of cellular function resulting in abnormal development (Marshall and Muecke's theory).
2. A mechanical obstruction of the medial migration of the lateral mesodermal layers prevents apposition in the midline (after Männer).
3. Abnormal cell–cell interactions and alteration in cell death have led to ventral mesodermal deficiencies in mouse populations. The resulting mice have a variety of abnormalities, including the BEEC.

---

## 31.3 Clinical Features of BEEC

**Antenatal US findings** suggestive of exstrophy–epispadias complex are:

- Failure to visualize the bladder.
- Lower abdominal wall bulge and low-set umbilicus.
- Abnormal genitalia and abnormal widening of iliac crests.

**Postnatal Appearance**—the bladder is open on the lower abdomen, with the urothelium fully exposed. In males, the penis is short and broad with a dorsal chordee. The urethral plate is short, and the glans penis appears in proximity to the prostatic utricle. In females, the clitoris is bifid, anterior labia are displaced laterally, and the mons pubis is absent. The vagina is anteriorly displaced relative to its usual position.

The pubic symphysis is widely separated in both sexes, with divergent recti muscles. The abdominal wall appears elongated because of a low-set umbilicus and the distance between the umbilicus and anus is also foreshortened.

Inguinal hernias are frequently associated with exstrophy and are typically indirect (80% of males, 10% of females). They are the result of a wide inguinal ring and the lack of an oblique inguinal canal. Laparoscopic inguinal herniotomy is an innovative and effective way to treat inguinal hernias in children with bladder exstrophy.

---

## 31.4 Objectives of Management

- Spontaneous voiding continence.
- Preservation of renal function.
- Reconstruction of functionally and cosmetically acceptable external genitalia.

Immediately after birth the infants do not need to be in a NICU and can be kept with the mother on the postnatal ward. “Clingfilm” should be applied to cover the exposed bladder and the umbilical cord should be ligated to avoid injury to the bladder mucosa by the cord clamp. Infants can be fed orally and there is no need for IV fluids or antibiotics initially.

Ideally, children born with the BEEC should be managed within a limited number of specialized centres, with a multidisciplinary team available to manage this very complex abnormality.

There are now essentially three main approaches to management:

- Modern Staged Repair of Bladder Exstrophy (MSRE).
- The Kelly principle.<sup>1</sup>
- Modified Complete Primary Repair of Exstrophy (CPRE).

### 31.4.1 Modern Staged Repair of Bladder Exstrophy

1. Primary bladder closure at the time of birth:
  - Indwelling ureteric stents, down to bladder neck. The pubic symphysis is recreated but the epispadias is left alone.
  - ± pelvic osteotomies (delayed closure, pubic diastasis >5 cm, and redoclosure). Closure of pelvic ring may be important for the eventual attainment of urinary continence in the functional closure approach.
  - *Postoperative care options:*
    - Traditional – spica cast, modified Buck’s traction, and mermaid bandage.
    - Postoperative paralysis with ventilation for 1 week.
    - No immobilization but good local analgesia with an indwelling epidural infusion.
    - Ureteric stents (removed after 2 weeks), urethral stent (removed at 3 weeks).

---

<sup>1</sup>Justin Kelly—Australian urologist.



2. Repair of epispadias at 12–15 weeks.
  - For example, Cantwell–Ransley<sup>1</sup> technique<sup>2</sup>
3. Urethroplasty at 12–18 months.
  - Allows an increase in bladder outlet resistance in order to increase bladder capacity.
4. Bladder neck reconstruction at about 4 years.
  - This is normally in the form of a modified Young–Dees–Leadbetter repair. The procedure is usually delayed until bladder capacity has approached 60 ml.

### 31.4.2 Kelly Principle (Radical Soft Tissue Reconstruction)

Initial bladder closure is performed as described above in the newborn period without pelvic osteotomy.

The Kelly procedure is ideally performed from 12 months of age and is not dependent on the bladder achieving a predetermined capacity. It comprises the following

1. Reopening the bladder and bilateral ureteric reimplantation.
2. Division of pelvic floor and identification of the pudendal vessels and nerve in Alcock's canal.<sup>3</sup> Complete detachment of penis from the inferior pubic rami with preservation of the pudendal vessels and nerves.
3. Radical reconstruction of the penis and urethra with a muscle wrap in the region of the external sphincter at the base of the urethra distal to the verumontanum.
4. Orthotopic bladder neck construction.

In some cases, a perineal urethrostomy must be fashioned at the time of Kelly procedure to optimize penile length. These boys would then require a two-stage urethral reconstruction.

### 31.4.3 Complete Primary Repair of Exstrophy

The classical Mitchell technique has not attained widespread popularity among surgeons. It comprises primary bladder closure, urethroplasty, and genital reconstruction in a single stage. The more modern CPRE has its origins in the Mitchell technique apart from a less radical penile disassembly and delaying the surgery until 3–6 months of age.

---

<sup>2</sup>FV Cantwell described repair in 1895, updated by Philip Ransley an English urologist at Great Ormond Street Hospital for Children, London.

<sup>3</sup>Benjamin Alcock (1801—not known). Professor of anatomy in Dublin and Cork, Ireland.

### 31.5 Complications

- Bladder dehiscence—partial/complete.
- Bladder prolapse.
- Upper urinary tract dilatation due to high outlet resistance and vesicoureteric reflux (VUR).
- Incomplete bladder emptying.
- Even with successful surgery, patients may have long-term problems with.
- Persistent urinary incontinence and VUR.
- Recurrent urinary tract infections and urolithiasis.
- Sexual dysfunction.
- Malignancy (rare).

### 31.6 Outcome

Even in the best hands, a staged approach to bladder exstrophy means that 60% will be continent only after augmentation cystoplasty—most with bladder neck closure—and only 26% of children with CBE may achieve the holy grail of CBE repair—continence while voiding *per* urethra. Notably, extant series of the complete primary repair of BE, similarly report that ~25% will be continent per urethra, though without additional continence procedures. In our series, continence with spontaneous urethral voiding has been observed after 15 years in about 72%.

The outcome is influenced by factors such as successful initial closure, bladder neck reconstruction, and the experience of the surgeon. The use of iliac osteotomies to reduce the tension and patient immobilization in the postoperative period helps in successful bladder closure and so further continence.

Although sexual function in males with bladder exstrophy is almost normal, fertility is very low owing to retrograde ejaculation or iatrogenic obstruction of the ejaculatory ducts or vas after surgical reconstruction.

Females with exstrophy report both normal sexual function and fertility. The vagina is foreshortened and as the cervix enters the vagina in the anterior wall, they are prone to uterine prolapse. Successful pregnancies have been reported and delivery by caesarean section is generally recommended to avoid injury to the continence mechanism.

Renal scarring due to recurrent UTI has been found bilaterally (6%) and unilaterally (13%) with an overall incidence of (12%).

If continence is not achieved by the above procedures by the age of 10–12 years, the available options for achieving continence are:

- Augmentation cystoplasty with bladder neck reconstruction and Mitrofanoff formation.
- Bulking agents at the bladder neck.
- Bladder neck closure and Mitrofanoff procedure.

In exstrophy patients with multiple failed attempts of functional reconstruction, urinary diversion can be used to provide urinary continence. Ureterosigmoidostomy was the treatment of choice until the 1970s but fell out of favour due to complications such as hyperchloremic metabolic acidosis and risk of colonic adenocarcinoma at the site of ureteral anastomosis. With the advent of intermittent self-catheterization, continent urinary diversions like the Indiana or Mainz pouch are now the preferred options.

---

## 31.7 Primary Epispadias

This is usually detected in the immediate postnatal examination but in some boys may only become evident later. Most patients with epispadias have a good chance of achieving continence with volitional urethral voiding. More than 80% will need additional procedures to achieve socially acceptable continence. The patients have a good erectile and ejaculatory function; however, dissatisfaction with genital appearance is common.

In girls, the diagnosis is usually delayed until after the age of potty training and are often referred to with a history of constant dribbling incontinence. Although the physical findings can be missed on cursory examination, once identified it is usually obvious.

Boys with continent epispadias and good penile length can achieve a good outcome with a Cantwell–Ransley epispadias repair. Those with a short penis and all those with incontinence are probably best managed with the Kelly procedure. As all girls with primary epispadias have a deficient bladder neck mechanism, they also would benefit from a bladder neck repair. The Kelly approach would allow reconstruction of the bladder sphincter and the external genitalia.

Continence outcomes in this group of children are better than their exstrophy counterparts. This is primarily because of having an intact bladder at birth, even though the capacity is often subnormal in most epispadias patients.

---

## 31.8 Cloacal Exstrophy

*Postnatal Appearance*—bladder is open and separated into two halves by an intestinal plate. Each hemi-bladder may have a ureteric orifice. The openings on the intestinal plate are terminal ileum (which may prolapse—and looks like an elephant's trunk), hindgut (with imperforate anus), and one or two appendices. Nearly all patients have an associated exomphalos.

### 31.8.1 Surgical Principles

Closure can be performed as a one-stage procedure but more commonly is staged.

Historically males with cloacal exstrophy underwent gender reassignment in infancy because of small separated hemi-phalluses deemed to be inadequate for

penile reconstruction. The encouraging results of the Kelly procedure now allow for even widely separated corporal bodies to be mobilized and reconstructed into a reasonable midline phallus. For this reason, gender reassignment in male cloacal exstrophy patients is now rarely necessary.

Despite these children having multiple, and sometimes, life-threatening abnormalities, many survive through childhood. Urinary continence can only be achieved with bladder augmentation or urinary diversion.

The sequence of reconstruction is usually as follows:

1. Closure of the omphalocele.
2. Separation of the hindgut plate from the paired separated hemi-bladders.
3. Formation of terminal ileostomy or colostomy incorporating the hindgut plate and reapproximating of hemi-bladders.
4. Bladder closure. Pelvic osteotomies are always required because of the wide pubic diastasis.

---

## Further Reading

1. Burki T, Hamid R, Duffy P, et al. Long-term follow up of patients after redo bladder neck reconstruction for bladder exstrophy complex. *J Urol.* 2006;176:1138–41.
2. Thomas JS, Shenoy M, Mushtaq I, Wood D. Long term outcomes in primary male epispadias. *J Pediatr Urol.* 2020;16:80.e1–80.e6. <https://doi.org/10.1016/j.jpuro.2019.10.027>.
3. Maruf M, Manyevitch R, Michaud J, et al. Urinary continence outcomes in classic bladder exstrophy: a long-term perspective. *J Urol.* 2020;203:200–5.
4. Borer JG, Vasquez E, Canning DA, et al. Short-term outcomes of the multi-institutional bladder exstrophy consortium: successes and complications in the first two years of collaboration. *J Pediatr Urol.* 2017;13:275.e1–275.e6.
5. Mitchell ME, Bägli DJ. Complete penile disassembly for epispadias repair: the Mitchell technique. *J Urol.* 1996;155:300–4.
6. Kelly JH. Vesical exstrophy: repair using radical mobilisation of soft tissues. *Pediatr Surg Int.* 1995;10:298–304.



Bharat More, Ramnik V. Patel, and Vibhash Mishra

## 32.1 Embryology

The development of the male urethra takes place between the eighth and the 15th week of gestation under the influence of testosterone.

1. Formation of the posterior urethra with advancement to the developing phallus as the urethral groove.
2. Ventral fusion of urethral folds—completed distally by the in-growth of ectoderm from the tip of the glans.

Hypospadias result from a failure of male urogenital folds to fuse in various regions, the normal process is described as virilization of the external genitalia. This in turn leads to resulting in a proximally displaced urethral meatus or opening.

### 32.1.1 Etiology

Multifactorial involving genetic, endocrine, and environmental factors.

- *Genetic Factors.*

The exact mode of inheritance is unknown, but is suggested by the following facts:

---

B. More (✉) · R. V. Patel  
Department of Paediatric Surgery and Urology, Nottingham University Hospital, Nottingham, UK  
e-mail: [ramnik@doctors.org.uk](mailto:ramnik@doctors.org.uk)

V. Mishra  
Department of Urology, Royal Free Hospital, London, UK

- Monozygotic twins—eightfold increase in the incidence of hypospadias—may be related to a net deficiency of human chorionic gonadotropin (HCG) caused by the increased demand of two fetuses.
- Familial inheritance: +ve family history—8% of fathers and 14% of brothers.
- Genetic: monogenic and chromosomal abnormalities are present in approximately 30% of hypospadias cases.
- *Endocrine Factors.*
- Deficient androgenic stimulation—which in turn may be the result of defective testosterone production, conversion (to dihydrotestosterone (DHT)), or reduced sensitivity (at target organs). Defects in testosterone biosynthesis, mutations in the 5-alpha reductase (5AR) enzyme, and androgen insensitivity syndromes have been associated with hypospadias.
- Increased maternal progesterone exposure—there is a fivefold increase in the incidence among boys conceived by IVF (progesterone is commonly administered). Progesterone is a substrate for 5AR and causes competitive inhibition of the conversion of testosterone to DHT.
- Low birth weight, assisted reproductive technology, advanced maternal age, paternal subfertility, and endocrine-disrupting chemicals.
- *Environmental Factors.*
- ↑ Incidence of hypospadias and one hypothesis suggests that there is increased maternal exposure to estrogenic substances (contained in pesticides, milk, plastic linings of metal cans, and pharmaceuticals).

---

## 32.2 Clinical Features

### 32.2.1 Classification (Fig. 32.1)

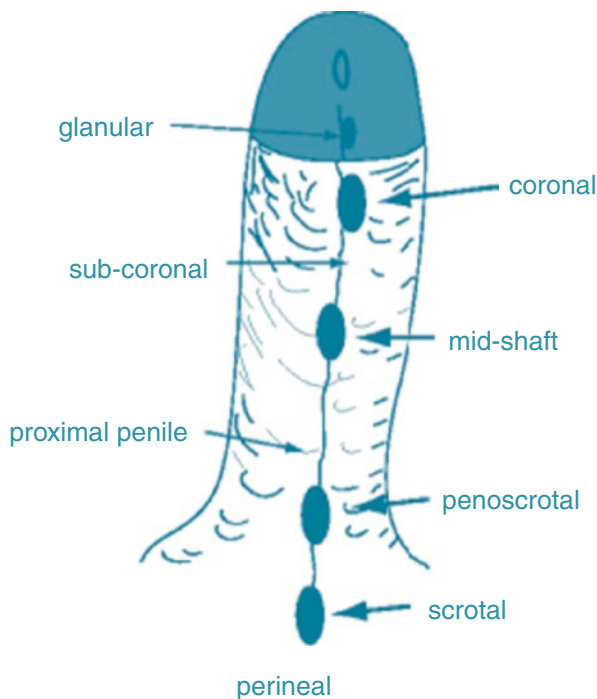
- Distal (glanular, coronal, and subcoronal) (50%).
- Middle (distal penile, midshaft, and proximal penile) (30%).
- Proximal (penoscrotal, scrotal, and perineal) (20%).

Types of hypospadias based on the location of the meatus and include distal (glanular, coronal, and subcoronal), middle (distal penile, midshaft, and proximal penile), and proximal (penoscrotal, scrotal, and perineal) types.

*NB, True location of the meatus should be ascertained after correction of the penile curvature.*

Although usually isolated, it is important to identify a disorder of sexual differentiation (DSD)—suggested by impalpable testes for instance. DSD occurs in ~15% of cases if gonad is palpable but ~50% of cases if impalpable.

A male with hypospadias may suffer from other symptoms including abnormal spraying of urine, having to sit down to urinate, an erectile dysfunction because of the downward curving of the penis and sometimes an inability to fertilize the female partner because of the inability to deliver the semen into her vagina during the sexual intercourse.



**Fig. 32.1** Classification of Hypospadias. Reprinted with permission from Mishra V.C., Motiwala H.G. (2010) Hypospadias. In: Sinha C., Davenport M. (eds) Handbook of Pediatric Surgery. Springer, London. [https://doi.org/10.1007/978-1-84882-132-3\\_44](https://doi.org/10.1007/978-1-84882-132-3_44)

In majority of cases, physical examination is sufficient. In severe cases, evaluation using *US*, *genitography*, *biochemical*, and *chromosomal analysis* is required before making final decisions regarding definitive management (see Chap. 32).

In terms of choice of surgical options, assess hypospadias by (1) location of the meatus, (2) degree of chordee, (3) penile size, (4) quality of ventral and proximal shaft skin, (5) quality of the distal urethral plate, and (vi) the depth of glanular groove.

## 32.3 Surgery

### 32.3.1 Principles

There are several surgical techniques and their modifications have been reported over the years.

The goal of surgery is to create a cosmetically acceptable penis, which allows normal voiding with a forward stream, a straightened penis on erection, and normal ejaculation. Some cases of glanular hypospadias can be left entirely alone for the same reason.

As described by Baskin and Ebbers, there are five basic steps for a successful hypospadias repair which can be applied either sequentially or in various combinations.

1. Orthoplasty (penile straightening).
2. Urethroplasty.
3. Meatoplasty and glanuloplasty.
4. Scrotoplasty.
5. Skin coverage.

### 32.3.2 Preoperative Considerations

- The optimal timing for repair of hypospadias is 6–18 months of age (minimizes the psychological impact of genital surgery).
- Hormone manipulation—The effect of preoperative androgen stimulation on postoperative outcome remains unclear. However, penile size can be increased by three doses of intramuscular injections of testosterone (25 mg/dose or 2 mg/kg) or HCG or topical application of testosterone or DHT for 4–6 weeks before surgery.
- Foreskin Reconstruction—This is possible in most distal and selected proximal hypospadias. The option of foreskin reconstruction should be discussed with the family. There is some evidence that foreskin reconstruction reduces the rate of postoperative complications in distal hypospadias repair.

### 32.3.3 Surgical Techniques

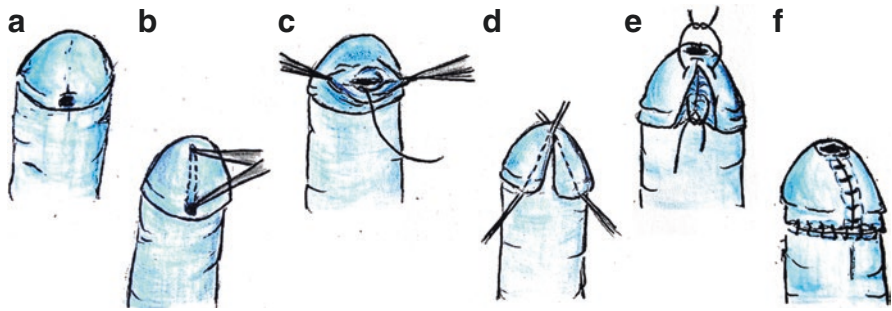
#### 32.3.3.1 Distal Hypospadias

Depends upon the preference of the child's family.

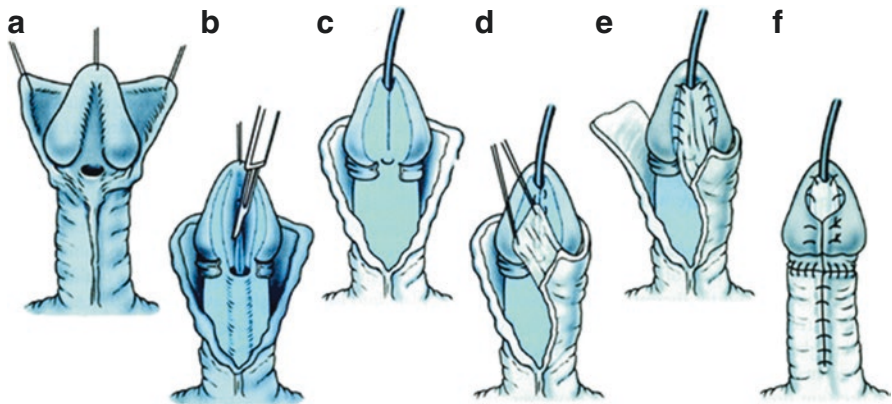
If there is no chordee and if he will be able to void straight in a standing position, the goal of surgery is essentially cosmetic.

1. Advancement techniques—(Fig. 32.2) MAGPI (Meatal Advancement Glanuloplasty) GAP (Glanuloplasty Approximation Procedure).
2. Tubularization techniques—Thiersch-Duplay (for deep urethral groove with a wide urethral plate for both distal and proximal hypospadias) Snodgrass (TIP—Tubularized Incised Plate—Fig. 32.3)—most commonly used procedure for distal hypospadias. Dorsal inlay urethroplasty using preputial skin grafts in tubularized incised-plate has been described for redo repair as well as primary hypospadias repair with poor urethral plate and flat glans.
3. Local tissue flaps—Mathieu procedure (Fig. 32.4).
  - Mathieu (meatal based flap) (Fig. 32.15).

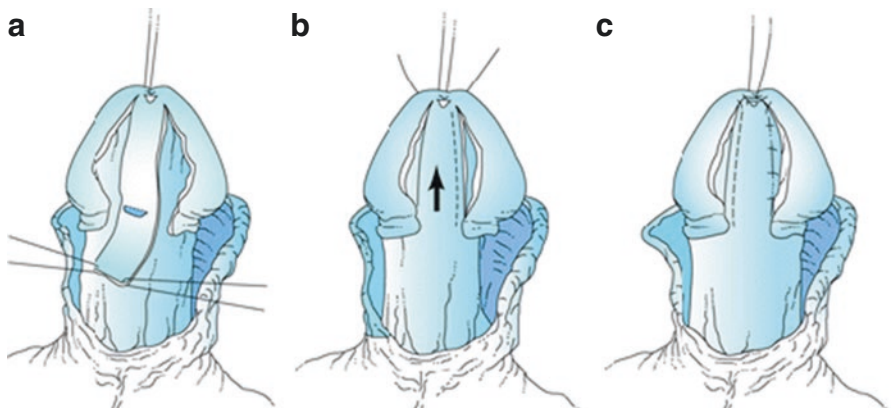




**Fig. 32.2** MAGPI Procedure: (a–c) Meatoplasty, (d–f) Glanuloplasty. Reprinted with permission from Mishra V.C., Motiwala H.G. (2010) Hypospadias. In: Sinha C., Davenport M. (eds) Handbook of Pediatric Surgery. Springer, London. [https://doi.org/10.1007/978-1-84882-132-3\\_44](https://doi.org/10.1007/978-1-84882-132-3_44)



**Fig. 32.3** Common operations for coronal hypospadias. Snodgrass repair (a–f) (Adapted from Belman et al. (Belman AB, King LR, Kramer SA (eds) (2002) Clinical pediatric urology, fourth edn. Martin Dunitz, London, p 1077, Fig. 32.16)). Reprinted with permission from Mishra V.C., Motiwala H.G. (2010) Hypospadias. In: Sinha C., Davenport M. (eds) Handbook of Pediatric Surgery. Springer, London. [https://doi.org/10.1007/978-1-84882-132-3\\_44](https://doi.org/10.1007/978-1-84882-132-3_44)



**Fig. 32.4** Mathieu Procedure : Flip flap

### 32.3.3.2 Proximal Hypospadias

1. Single-stage repair—Island onlay flap (Duckett's) procedure.
2. Two-stage procedure—particularly useful when there is a significant chordee. Bracka technique uses dorsal preputial graft and in some redo cases buccal mucosa or post-auricular skin. The second stage is performed 6 months or more after the first stage.
3. Chordee correction—Artificial erection test is used to decide the extent of chordee. In the majority of cases, complete penile degloving and resection of chordee tissue are sufficient. In minority of cases, a dorsal plication procedure is required.

### 32.3.4 Postoperative Phase

Most hypospadias repairs are done as a day case procedure.

The choice of dressing varies from foam to DuoDERM. The bladder is drained for 1 week with a dripping stent or catheter and double nappies are used. Antimuscarinic agents (e.g., oxybutynin) to reduce bladder spasms and antibiotics are prescribed.

Early complications include bleeding, hematoma, infection, blocked catheter, soaked dressing, and breakdown of repair.

---

## 32.4 Long-Term Outcome

Most series describe a multiplicity of long-term complications such as urethrocutaneous fistula, meatal stenosis, persistent chordee, urethral stricture, and urethral diverticulum. The overall complication rate of hypospadias surgery is around 18% and the rate for individual complications varies according to the type of repair and center.

**Acknowledgments** Apurva More, University of Nottingham Medical School for illustrations.

---

## Further Reading

1. Gundeti MS. Surgical techniques in pediatric and adolescent urology. first ed. London: Jaypee Brothers; 2020.
2. Long CJ, Chu DI, Tenney RW, Morris AR, Weiss DA, Shukla AR, Srinivasan AK, Zderic SA, Kolon TF, Canning DA. Intermediate-term follow up of proximal hypospadias repair reveals high complication rate. *J Urol*. 2017;197(3 Pt 2):852–858. Published online 2016 Nov 10. <https://doi.org/10.1016/j.juro.2016.11.054>.
3. der Horst HJR, de Wall LL. Hypospadias, all there is to know. *Eur J Pediatr*. 2017;176(4):435–441. Published online 2017 Feb 11. <https://doi.org/10.1007/s00431-017-2864-5> Correction in: *Eur J Pediatr*. 176(10):1443.
4. Keays MA, Sumit S. Current hypospadias management: diagnosis, surgical management, and long-term patient-centred outcomes. *Can Urol Assoc J*. 2017;11(1–2Suppl1): S48–S53. <https://doi.org/10.5489/cuaj.4386>.

5. Adams J, Bracka A. Reconstructive surgery for hypospadias: a systematic review of long-term patient satisfaction with cosmetic outcomes. *Indian J Urol.* 2016;32(2):93–102. <https://doi.org/10.4103/0970-1591.179178>
6. Snodgrass W, Bush N. Primary hypospadias repair techniques: a review of the evidence. *Urol Ann.* 2016;8(4):403–8. <https://doi.org/10.4103/0974-7796.192097>.
7. Baskin LS, Ebberts MB. Hypospadias: anatomy, etiology, and technique. *J Pediatr Surg.* 2006;41:463–72.
8. Docimo SG, Canning D, Khoury A, Pippi Salle JL (eds) *The Kelalis–King–Belman textbook of clinical pediatric urology*, sixth edn. CRC Press, London, 2018; pp. 1076–1099.



Hazem Mosa, Vijai D. Upadhyaya, S. P. Sharma,  
and Pankaj Mishra

## 33.1 Anatomy and Embryology

The ureter connects the kidney to the bladder. It lies on psoas major and crosses in front of bifurcating iliac artery to enter the base of the bladder in a short submucosal tunnel. The pelvic ureter is crossed by the vas in males and by the broad ligament and uterine vessels in females. Radiologically, it arises at the level of L1/2, descends on the tip of the transverse process, crossing pelvis at the ischial spine, before veering medially toward the bladder.

Structurally, it is composed of two muscle spirals (inner “longitudinal” and outer “circular”) and is lined by urothelium throughout.

During the fourth and sixth weeks of gestation, the ureteral bud begins to develop from the distal portion of the **mesonephric duct**. The cranial end of the ureteric bud meets the **metanephros** and continues in its cephalic migration. During this process, it forms the pelvis, calyces, and part of the collecting ducts. At the same time, the metanephros differentiates into organized renal parenchyma around the collecting system. The kidneys assume their final position at the eighth week of gestation. During an ascent they rotate 90° on the axial plane, starting with the hilum facing forward and ending with it facing medially. The blood supply changes during the migration, initially the kidneys are supplied by the middle sacral artery, then by the common iliac and finally by the aorta. This should be kept in mind when dealing with ectopic kidneys.

The ureter is believed to be solid at this stage and re-canalizes. Failure of this may explain some UPJ (ureteropelvic junction) obstructions. Caudally, the

---

H. Mosa · P. Mishra (✉)  
Evelina Children’s Hospital, London, UK  
e-mail: [Pankaj.mishra@gstt.nhs.uk](mailto:Pankaj.mishra@gstt.nhs.uk)

V. D. Upadhyaya · S. P. Sharma  
Institute of Medical Sciences, Banaras Hindu University, Varanasi, India

mesonephric duct (along with the ureteral bud) is incorporated into the cloaca as it forms the bladder trigone.

Alterations in bud number, position, or time of development result in ureteral anomalies; early-branching may result in incomplete duplication, with a single ureteral orifice and bifid proximal ureters. An accessory ureteral bud creates a complete duplication, with the upper ureter usually protruding into the bladder more medially and inferiorly than the lower ureter (**Weigert–Meyer<sup>1</sup> rule and Stephen’s hypothesis<sup>2</sup>**). Ectopic termination of a single system or of the ureter of a duplex system is the result of the high (cranial) origin of the ureteral bud from the mesonephric duct. Because of the delayed incorporation of the ureteral bud into the bladder, the resulting position of the ureteral orifice is more caudal and medial.

### 33.2 Ureteropelvic Junction (UPJ) Obstruction

Historically referred to as “pelviureteric junction -PUJ” obstruction.

- Hydronephrosis.
  - ~1% of pregnancies
  - UPJ obstruction in 10–30% of hydronephrosis.
- M:F 2:1; L:R 3:2.
- Bilateral obstruction (10–40%).
- Other system pathology.
  - Uncommon, e.g., VATER association.
- Could be associated with other urological pathology.
  - For example, contralateral UPJ obstruction, VUR.
- Most UPJ obstructions are now detected by antenatal ultrasonography (U/S) (Table 33.1).

**Table 33.1** Differential diagnosis of perinatal hydronephrosis

| Etiology  | Percentage |
|---|------------|
| Transient hydronephrosis  | 40–80      |
| UPJ   | 10–30      |
| VUR   | 10–20      |
| Ureterovesical junction obstruction/megaureter                                      | 5–10       |
| Multicystic dysplastic kidney   | 4–6        |
| Duplex kidney/ureterocele   | 5–7        |
| PUV/urethral atresia  | 1–2        |
| Others: prune belly syndrome, cystic kidney disease, congenital ureteric strictures | Uncommon   |

<sup>1</sup>Carl Weigert (1845–1904) and Robert Meyer (b1864)—German pathologist and physician, respectively.

<sup>2</sup>Frank Douglas Stephens (1913–2011). One of a dynasty of Australian pediatric surgeons who worked at Royal Melbourne Childrens Hospital.

### 33.2.1 Etiology

- Intrinsic.
  - Usually due to the intrinsic narrowing (patent but aperistaltic). Shows ↓ muscle fibers, and replacement by fibrotic tissue with disruption of spiral orientation.
  - Rarely—mucosal valves, polyps, and true ureteric strictures.
- Extrinsic.
  - Aberrant or supernumerary renal vessels. ~30% of UPJ, an artery directly enters the lower pole of the kidney.
- Secondary UPJ obstruction can be from severe vesicoureteral reflux (VUR).

### 33.2.2 Clinical Features

Most infants are usually asymptomatic, having been detected through prenatal screening US.

Older children (and adults) present episodic flank or abdominal pain (~50%), palpable flank mass (~50%), hematuria, or recurrent UTIs (~30%).

### 33.2.3 Investigations

Antenatal ultrasonography (definition of hydronephrosis)

- Renal pelvis AP diameter > 4 mm at a gestational age of <33 weeks.
- Renal pelvis AP diameter of >7 mm at a gestational age of ≥33 weeks.

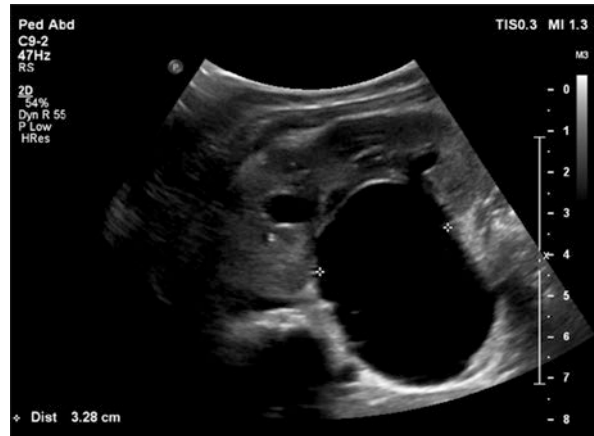Society of Fetal Urology (SFU)<sup>5</sup>

- Grade 0—normal kidney.
- Grade 1—minimal pelvic dilation.
- Grade 2—greater pelvic dilation without caliectasis.
- Grade 3—caliectasis without cortical thinning.
- Grade 4—hydronephrosis with cortical thinning.

#### 33.2.3.1 Postnatal Ultrasonography: Primary Investigations Tool for Hydronephrosis

- Anechoic or hypoechoic cavity that splits the bright, central echo pattern of the renal sinus.
- AP diameter of the renal pelvis correlated with the likelihood of obstruction but not a degree of obstruction. Requires complementary radioisotope scans.
- False-positive, e.g., large extrarenal pelvis, peripelvic renal cyst, nonobstructive hydronephrosis, or VUR.

**Fig. 33.1** Postnatal Ultrasound scan showing UPJ morphology with severe pelvicalyceal dilatation and AP Pelvis of 33 mm



- Renal pyramids may look sonolucent and lead to an erroneous appearance of caliectasis because of medullary immaturity at <3 months of age (Fig. 33.1).

### 33.2.3.2 Radioisotope Scan

- MAG3 is radionuclide of choice, both filtered and secreted by renal tubules.
  - The drainage curve of an obstructed kidney fails to decline even after the administration of diuretics— $t_{1/2}$  is >20 min.
  - Reduction in differential renal function (<40%)—key sign of significant UPJ obstruction needing intervention.

### 33.2.3.3 Treatment

Conservative management in a group with good renal function (>40%) is reasonable.

Pyeloplasty for function deterioration, increasing dilatation or symptoms (pain/uti/calculi).

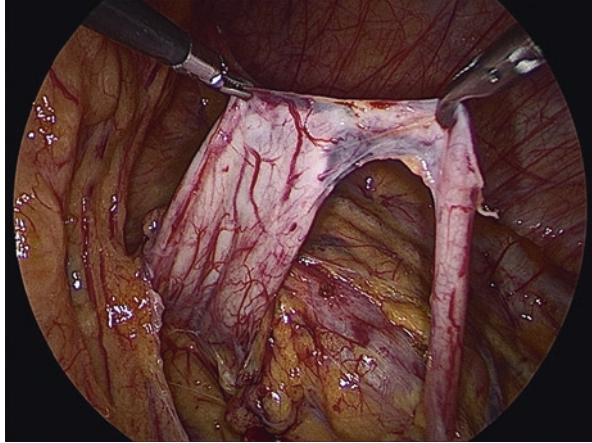
### 33.2.3.4 Surgery

- Anderson–Hynes pyeloplasty.<sup>3</sup>
  - excision of the narrowed segment, spatulation, and anastomosis to the most dependent portion of the renal pelvis.
  - Most commonly done procedure, usually with an internal or external stent.
- Foley<sup>4</sup> YV-plasty.
  - For high ureteral insertion and most cases of horseshoe kidneys.

<sup>3</sup>Jock C. Anderson, Wilfred Hynes—urologist and plastic surgeon, respectively, working in Sheffield, UK.

<sup>4</sup>Frederic E.B. Foley (1891–1966)—American urologist, working in Boston, MA. More famous for his catheter, designed as a medical student in 1929.

**Fig. 33.2** Laparoscopic view of UPJ obstruction



[N.B. Open approach with incisions in lumbotomy, flank, or anterior extraperitoneal incision and muscle cutting or muscle splitting approach.]

- Laparoscopic dismembered pyeloplasty.
  - Yields results that are comparable with those of the open technique (Fig. 33.2).
- Endourological pyeloplasty.
  - Including use of balloon dilatations, percutaneous antegrade endopyelotomy, and retrograde ureteroscopic endopyelotomy.

### 33.3 Duplex Anomalies

Ureteral duplication is one of the commonest anomalies of the urinary tract.

- ~8% in children being evaluated for UTI.
- Single renal unit with two pelvicalyceal systems, which may vary from a single ureter and a duplex collecting system, bifid ureters (*partial or incomplete duplication*), or two ureters all the way that empty separately into the bladder (*complete duplication*).
- Incomplete ureteral duplication ~1 in 25.
- Complete duplication.
  - ~1 in 500
- Ipsilateral complete duplication.
  - ~40% chance of a contralateral complete duplication
- Family history.
  - ~10% of siblings.



The upper ureter is associated with **ectopic insertion**, **ureterocele**, and/or obstruction, whereas the lower ureter is frequently associated with VUR. The upper pole ureter crosses and inserts caudally and more medially in the bladder (**Weigert–Meyer rule**).

### 33.3.1 Clinical Features

Most present with an abnormal finding on routine prenatal US. Otherwise, UTI in the first few months of life is the most common presentation, leading to severe urosepsis. Infants may also exhibit failure to thrive or nonspecific gastrointestinal symptoms. Older children also present with features of UTI, but hematuria or flank pain may also occur.

Clinically, the main difference between ectopic ureter in boys and girls is that for the former the UO of an ectopic ureter is always above the urethral sphincter, providing the maintenance of urinary continence. Whereas, in girls the ectopic ureter can insert below the urethral sphincter, leading to various degrees of incontinence. The ureter draining the lower moiety tends to insert more laterally, with a shorter intramural tunnel, and hence is more prone to reflux.

### 33.3.2 Investigations

#### 33.3.2.1 Ultrasound

- ↑ renal length than those of the contralateral nonduplicated side.
- Disparate hydronephrosis – especially with upper pole dilatation associated with an obstructed or ectopic ureter or with a ureterocele.
- ↑ echogenicity and renal cysts suggest accompanying renal dysplasia.

#### 33.3.2.2 VCUg (Voiding/Micturating Cystourethrogram)

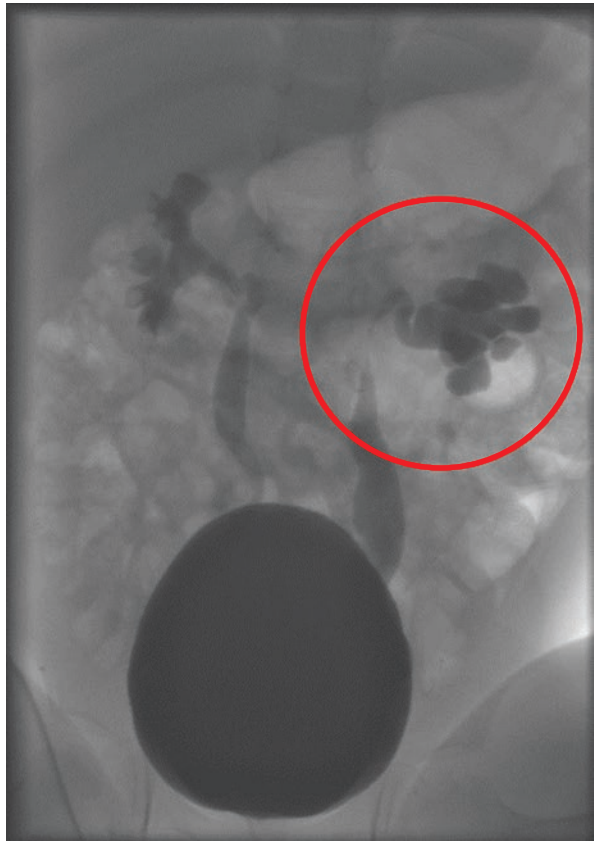
Duplicated collecting systems with lower pole reflux may be visualized.

- Configuration of the kidney lacks opacification of the non-refluxing upper pole, giving it the appearance of a *drooping lily* (Fig. 33.3).
- If the ectopic ureters open outside the bladder neck, the refluxing unit opacifies only during voiding, when the bladder neck is open. Occasionally, the radiologist may inadvertently pass a catheter transurethrally up the ectopic ureter. The initial films then opacify only that collecting system and not the bladder.

#### 33.3.2.3 Radio-Isotope Scan

Usually, MAG3 or DMSA to evaluate relative renal function and drainage including segmental renal function (upper moiety vs. lower moiety).

**Fig. 33.3** MCUG demonstrating bilateral Grade 5 Vesico-Ureteric Reflux in the lower moieties of bilateral duplex kidneys. Drooping Lilly Sign on the left (circled)



#### 33.3.2.4 MR Urography

Helpful in complex duplex, ectopic ureters, and ureterocolic to understand the anatomy.

#### 33.3.2.5 Treatment

Ureteral duplication alone requires no specific intervention. Duplication anomalies with associated pathology (e.g., VUR, obstruction) causing symptoms or drainage problems, however, require appropriate medical therapy and possibly, surgical correction. Treatment depends on symptoms, whether reflux or obstruction is the issue, and simplex or duplex system.

---

### 33.4 Ectopic Ureter

Bilateral single-system ureteral ectopia is rare and usually coexists with a multitude of other urinary tract abnormalities (e.g., VUR, renal dysplasia, rudimentary bladder development, etc.).

- Female predominant M:F 1:6.
- >80% of the ectopic ureters drain duplicated systems (usually the upper pole of duplex kidney).
- Most ectopic ureters in males drain a single system (~10% bilateral).

### 33.4.1 Clinical Features

Girls can present with constant urinary incontinence or vaginal discharge. Boys may present with recurrent epididymitis before puberty, while after puberty there may be chronic prostatitis, with painful intercourse and ejaculation.

Incontinence in males is never due to an ectopic ureter because it never inserts distally to the external urethral sphincter. Single-system ureteral ectopia reveals widespread renal dysplasia in 90% of affected kidneys. Duplicated-system ureteral ectopia reveals renal dysplasia in ~50% of affected renal moieties.

### 33.4.2 Investigations

All of the above but include cystovaginoscopy to determine the site of ectopic orifice; however, the diagnostic yield of cystoscopy is variable (Fig. 33.4).

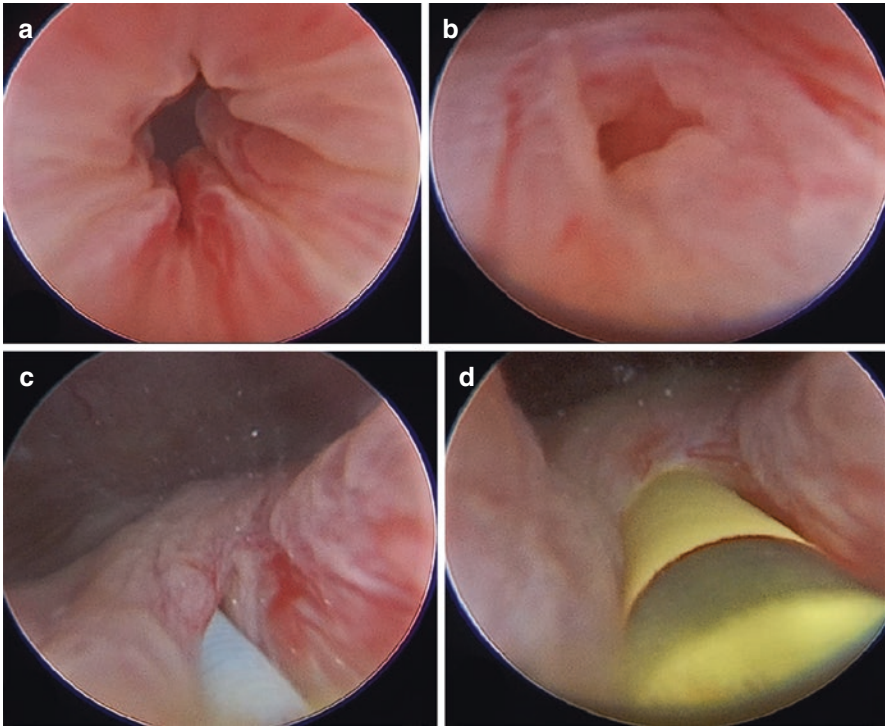
The site of the ectopic orifice in girls could be bladder neck/urethra, vestibule, vagina, and uterus and in boys could be bladder neck/prostatic urethra, seminal vesicle, ejaculatory ducts, vas/epididymis.

---

## 33.5 Surgery

Depends on symptoms, associated duplex system, and functional status of kidneys, options are:

- Nephrectomy.
  - Single system with minimally or non-functioning kidney.
- Hemi-nephrectomy.
  - Duplex kidney with poorly functioning upper moiety.
- Injection of bulking agent STING /HIT.
- Ureteric reimplantation.
  - Single-system good functioning kidney.
- Ureteropyelostomy or ureteroureterostomy.
  - Duplex with salvageable function, also being proposed as a drainage procedure for poorly functioning kidneys.



**Fig. 33.4** Cystoscopic view of an ectopic ureter opening below the bladder neck in a female patient. (a) Bladder neck; (b) Ectopic ureteric opening demonstrated on hydrodistension; (c) Guidewire inserted into the ectopic ureter; (d) Ureteric catheter inserted along the guidewire to allow a retrograde contrast study of the ureter

### 33.6 Megaureter

May be classified as:

- Obstructed.
  - Male predominant M:F 4:1.
  - L > R Bilateral ~20%.
  - **Primary** – due to adynamic juxtavesical segment of the ureter.
  - **Secondary** to ↑vesical pressures, e.g., PUV or a neurogenic bladder.
- Refluxing.
  - Primary—associated with severe VU reflux.
  - **Megacystitis megaureter syndrome.**
- Obstructed/refluxing.
- Nonobstructed/nonrefluxing.

### 33.6.1 Clinical Features

Possible features include increasing hydro-uretero-nephrosis, decrease in renal function of involved kidney, UTI, and recurrent flank pain.

### 33.6.2 Investigations

Including US (hydronephrosis and hydroureter); MAG3 scan (define degree of obstruction and assess differential renal function); and VUCG (will show if there is associated VUR).

### 33.6.3 Management

Depends on the symptoms, loss of function and increasing dilatation and choices are:

- Conservative.
- Injection of bulking agents STING/HIT for pure refluxing.
- Balloon dilatation of vesicoureteric junction for obstructive causes.
- Ureteric reimplantation.
  - Mobilize the megaureter *via* an intravesical, extravesical, or combined approach.
  - Reduce ureteral caliber.
    - Hendren<sup>5</sup> technique—excision of distal redundant ureter.
    - Kalicinski<sup>6</sup> (plication, then folding over) or Starr (invagination) techniques.
  - Anti-reflux reimplant.

Occasionally, the function of the kidney is severely impaired, and if symptomatic nephron-ureterectomy may be necessary.

---

## 33.7 Ureteroceles

Defined as: cystic dilatations of the terminal, intravesical, and usually stenotic ureter. The opening is ectopic in ~60% of cases.

- ~1 in 4000
- Female predominant.
  - M:F 1:4.
- ~10% bilateral
- ~80% cases are associated with duplex system
- Usually upper pole.

---

<sup>5</sup>W. Hardy Hendren III (b1926) American pediatric urologist working in Boston, MA.

<sup>6</sup>Zygmunt H. Kalicinski (1927–1996) Polish pediatric urologist.

### 33.7.1 Types of Ureterocele

- Number.
  - Single-system ureteroceles—single kidney, collecting system, and ureter.
  - Duplex-system ureteroceles.
- Position.

The American Academy of Pediatrics classifies ureteroceles as intravesical (entirely within the bladder) or ectopic (some portion is situated permanently at the bladder neck or in the urethra).

- **Stephens classification**—based on the features of the affected ureteral orifice:
  - Stenotic ureteroceles.
  - Sphincteric ureterocele.
    - Refers to those that lie distal to the internal sphincter. The ureterocele orifice may be normal or patulous, but the distal ureter leading to it becomes obstructed by the activity of the internal sphincter.
  - Sphincterostenotic ureteroceles.
    - Characteristics of both.
  - Cecoureteroceles.
    - Elongated beyond the ureterocele orifice by tunneling under the trigone and the urethra.

### 33.7.2 Clinical Features

May include UTI, urosepsis, obstructive voiding symptoms, retention, failure to thrive, hematuria, cyclic abdominal pain, and stone formation.

#### 33.7.2.1 Investigations

- Ultrasonography.
  - Usually seen as a well-defined cystic intravesical mass that can be proximally followed into a dilated ureter.
- MCUG/VCUG.
- Filling defect in the bladder base. Identifying which side large ureteroceles are associated with can be difficult.
- Reflux of the ipsilateral lower pole is observed in ~50%.
- Contralateral reflux ~25%.
- Reflux into the ureterocele may be observed in ~10%.

#### 33.7.2.2 Surgery

If the conservative management does not work and is aimed at relief of obstruction.

- Endoscopic decompression.
  - If urgent decompression is required (e.g., urosepsis, severe compromise in renal function).

- Better results for single-system intravesical ureterocele than for ectopic ureteroceles (10–40%).
- Upper tract approach.
  - To remove or divert obstructed moiety into the normal moiety.
- Heminephrectomy ± ureterectomy (in duplex system) [Open/Laparoscopic/Robotic].
- Nephrectomy ± ureterectomy (in simplex system).
- Uretero-pyelostomy/uretero-ureterostomy (in duplex system).
- Reimplantation.

---

## Further Reading

1. Nguyen HT, Herndon CD, Cooper C, Gatti J, Kirsch A, Kokorowski P, et al. The Society for Fetal Urology consensus statement on the evaluation and management of antenatal hydronephrosis. *J Pediatr Urol.* 2010;6:212–31.
2. Fernbach SK, Maizels M, Conway JJ. Ultrasound grading of hydronephrosis: introduction to the system used by the Society for Fetal Urology. *Pediatr Radiol.* 1993;23:478–80.
3. Glassberg KI, Braren V, Duckett JW, et al. Suggested terminology for duplex systems, ectopic ureters and ureterocele. *J Urol.* 1984;132:1153–4.
4. Ninan GK, Sinha CK. Dismembered pyeloplasty using double ‘J’ stent in infants and children. *Pediatr Surg Int.* 2009;25:191–4.



Shilpa Sharma and Devendra K. Gupta

---

## 34.1 Introduction

Vesicoureteric reflux (VUR) is abnormal but noted in up to 40% of fetuses. It is:

- Female predominant.
- Peak incidence at 3 years.
- Familial incidence is 2–4% of all cases.
- Unilateral or bilateral (60%).

---

## 34.2 Pathology

- Primary.
  - Presumed to occur as a result of short submucosal tunnel.
  - Intravesical length: width should be about 5:1 to prevent VUR (Paquin’s law).
- Secondary.
  - For example, Posterior urethral valves, anterior urethral valves, neurogenic bladder, ureteroceles, bladder diverticula, and ectopic ureters associated with the duplex system.

---

## 34.3 Clinical Features

- UTI—dysuria, increased frequency, pyuria, and fever.
- Pain in the flank due to pyelonephritis.

---

S. Sharma

Department of Pediatric Surgery, All India Institute of Medical Sciences, New Delhi, India

D. K. Gupta (✉)

Superspeciality Hospital for Children, Noida, India



- Renal scarring.
  - Radiologically demonstrated scarring is almost always due to reflux. Almost 30–60% of children with VUR have scars on initial evaluation. This impairs subsequent renal growth.
- Renal dysfunction.
  - Impairment of renal concentrating ability and a gradual deterioration of GFR.
- Hypertension.
  - Reflux nephropathy may lead to severe hypertension in 10–20% of children with VUR and renal scars.
- Reduced somatic growth.

---

## 34.4 Investigations

- Urine analysis.
  - Routine for pus cells. If pus cells are present then it is followed by urine culture and sensitivity.
- Ultrasound.
- MAG 3 scan.
  - Assess differential renal function.
- DMSA.
  - For renal scars.
- VCUG.
  - Once infection treated, for degree of VUR.
- GFR.
  - For baseline renal function in those likely to be poor.
- Direct radionuclide cystography (DRCG).
  - Usually reserved for follow-up scans.

### 34.4.1 Grading

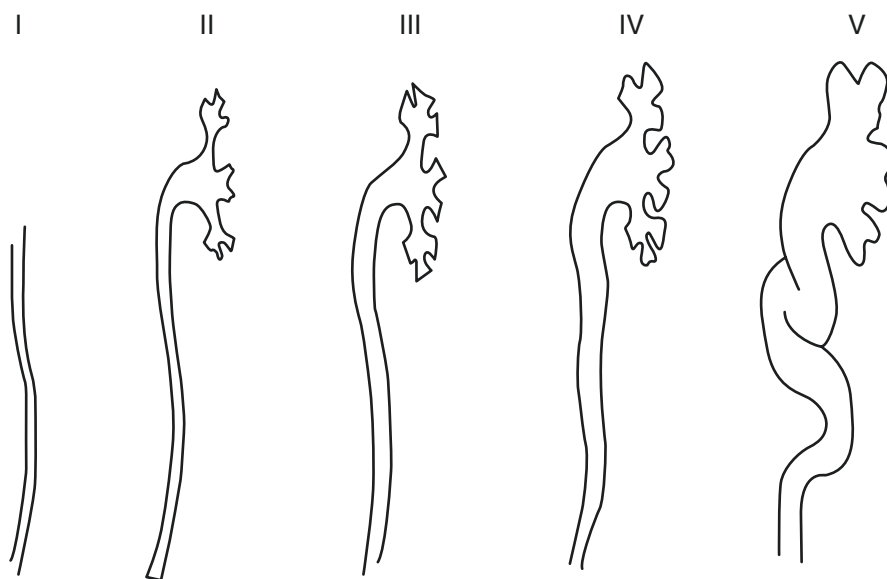
Reflux can be graded from I to V, I being mild and V being most severe with dilatation and tortuosity of ureters (Fig. 34.1, Table 34.1).

---

## 34.5 Management

Low-grade reflux is more likely to resolve spontaneously with age (in the absence of any malformation), but the management options include:

- Antibiotic chemoprophylaxis.
  - Amoxicillin, co-trimoxazole, cephalixin, nitrofurantoin, and quinolones.
  - Long-term prophylactic antibiotics (few months—2 years).
  - Cyclic administration.
  - Ensure compliance.



**Fig. 34.1** Grading of ureteric reflux

**Table 34.1** Classification of VUR

|     | Description                                     |
|-----|---|
| I   | Lower ureter/s (without dilatation)             |
| II  | All ureter (without dilatation)                 |
| III | Dilated pelvicalyceal and ureter. Flat fornices |
| IV  | PLUS convex fornices, dilated ureter            |
| V   | PLUS tortuosity of ureters                      |

Better results are found in unilateral (vs. bilateral); infants (vs. >5 years), nondilated ureters (<1 cm).

• **Submucosal injection therapy.**

- Originally—**Sub-ureteric Teflon Injection (STING) procedure** after Puri and O’Donnell<sup>1</sup>.
- Subureteric injection of Deflux™/Dexell™ (dextranomer microspheres in sodium hyaluronic solution)—is used as the first choice if available. Dexell™ is a new product, which is biochemically similar to Deflux™ but with a different molecular size. Deflux has dextranomer microspheres ranging in size from 80 to 250 microns (an average size of 130 microns) while the size of Dexell dextranomer microsphere is 80–120 microns.
- Results are better for lower grades of reflux up to Grade III (>80% success), may be repeated to improve success rate even in higher grades.
- Less successful in children with bad bladders (i.e., neurogenic bladder, PUV).

<sup>1</sup>Prem Puri, Barry O’Donnell (1926–2019)—Dublin-based pediatric urologists.

- **Surgery.**

- Indications.

- Failed medical management or submucosal injection therapy.
    - Secondary VUR due to anatomical anomalies such as Hutch diverticulum, ureterocele, duplex ureter, primary megaureters, posterior urethral valves, and neurogenic bladder.
    - Failure of conservative management despite prophylaxis therapy given for a maximum period of 2 years.
    - Poor compliance to medical management.
    - Persistent urinary infection or breakthrough infections more than twice in a year despite chemoprophylaxis.
    - Appearance of new scars or enlargement of pre-existing scars during medical management.
    - Deterioration of renal function despite antibiotics.
    - Higher grades (IV, V)—at any age.
    - Documented hypertension due to renal cause.
    - Single kidney with higher grade of VUR.
    - Decrease in renal growth on prophylaxis or lack of somatic growth.

### 34.5.1 Reimplantation of Ureters

- Transtrigonal ureteric (Cohen<sup>2</sup>) reimplantation.
  - Commonest alternative.
- Intravesical technique (Leadbetter–Politano).
  - Usually if a single-sided pathology requiring reimplantation.
- Extravesical detrusorraphy technique (Lich and Gregoir).
  - Considered if the reflux is being treated with another operative procedure in the abdomen.
- ± Ureteric tapering or plication.

### 34.5.2 Complications

- Persistent reflux and ureteric obstruction due to devascularization, kinking, or torsion of the distal ureter.
- Persistent reflux.
  - Usually lower grade and it tends to improve spontaneously on continued antibiotics.
- Retained/broken ureteric stent.
- Ureteral obstruction.
  - Due to angulation, or hiatal obstruction or temporarily due to edema or contraction of the thickened bladder wall during spasm.

---

<sup>2</sup>Samuel Joseph Cohen (1923–2012). South African pediatric urologist working in Manchester, UK.

- Injury to the bowel, Fallopian tubes, and vas deferens, specifically in Leadbetter–Politano technique, since there is inadequate visualization of the retrovesical structures.

---

## 34.6 Outcome

Medical management, though successful in low grades of reflux, takes a long period and the outcome remains unpredictable, as it is dependent on patient compliance.

Surgical repair has a success rate varying from 93 to 98% with improvements in renal catch-up growth, concentration capacity and function.

Dextranomer/hyaluronic acid copolymer injections are the preferred modality, especially in lower grades.

The main factor determining the outcome is the extent of renal scarring or renal parenchymal damage at the onset. Surgery does correct vesicoureteral reflux but does not significantly alter the clinical outcomes in these patients. Thus, on comparing medical vs. surgical treatment, there is no difference in terms of change in GFR, progression of renal scarring, or recurrent UTI in severe grades of VUR.

---

## Further Reading

1. Birmingham Reflux Study Group. Prospective trial of operative versus non-operative treatment of severe vesicoureteric reflux in children: five years' observation. *Br Med J.* 1987;295:237–41.
2. Puri P, O'Donnell B. Treatment of VUR by endoscopic injection of Teflon. *BMJ.* 1984;289:7–8.
3. International Reflux Study Committee. Medical versus surgical treatment of primary vesicoureteral reflux: a prospective international study in children. *J Urol.* 1981;125:272–83.
4. Johnston DL, Qureshi AH, Irvine RW, et al. Contemporary management of vesicoureteral reflux. *Curr Treat Options Pediatr.* 2016;2:82–93. <https://doi.org/10.1007/s40746-016-0045-9>.
5. Williams G, Hodson EM, Craig JC. Interventions for primary vesicoureteric reflux. *Cochrane Database Syst Rev.* 2019;2(2):CD001532. <https://doi.org/10.1002/14651858.CD001532.pub5>.



Ahmed Osama Mohamed and Ashok Rajimwale

## 35.1 Anatomy

The male urethra can be divided into four segments:

- Prostatic urethra.
  - From the bladder neck to the site of the urogenital diaphragm.
- Membranous urethra.
  - Urogenital diaphragm.
- Bulbar urethra.
  - From the distal margin of the urogenital diaphragm to the penoscrotal junction.
- Penile urethra.
  - Urethra that traverses the penile shaft including the glans.

Posterior urethral valves (PUV) results from an anomalous insertion of the mesonephric duct into the urogenital sinus, preventing normal migration of these ducts and their anterior fusion forming the abnormal ridges in the membranous urethra.

## 35.2 Classification

Traditionally, three types of posterior urethral valves have been described as Young's Classification<sup>1</sup> (Table 35.1).

<sup>1</sup>Hugh Hampton Young—Father of American urology, described classification in 1919.

A. O. Mohamed · A. Rajimwale (✉)

Department of Paediatric Surgery, Leicester Royal Infirmary, Leicester, UK

e-mail: [ashok.rajimwale1@nhs.net](mailto:ashok.rajimwale1@nhs.net)

**Table 35.1** Young's<sup>2</sup> classification of posterior urethral valves

| Type        | Description  | Result         |
|-------------|--|----------------|
| I (~95%)    | Bicuspid valve from posterior edge of the verumontanum extending distally and anteriorly and fusing in the midline | Obstructive    |
| II          | Prominent longitudinal folds extending from verumontanum toward the bladder neck                                   | Nonobstructive |
| III (5–10%) | Circumferential ring distal to the verumontanum at the level of the membranous urethra                             | Obstructive    |

- **Congenital Obstructing Posterior Urethral Membrane (COPUM)** is a newer concept whereby the un-instrumented urethra looks more like a circumferential obstructing membrane with a small central or eccentric opening, which following catheterization or instrumentation reverts to the classical “valve” appearance.

### 35.3 Epidemiology

A recent national audit (BAPS-CASS) from the UK and Ireland identified the incidence of PUV to be:

- 1 in 3800 male births.
- 50% of patients with PUV were diagnosed antenatally.
  - 42% within the first year of life and 23% were late diagnosis.

### 35.4 Pathophysiology

The posterior urethral obstruction represents a mechanical obstruction leading to secondary pathological changes to the upper tracts. Severity depends on:

- Degree of obstruction.
- Timing of the obstruction.
- Genotypic factors responsible for ureteral bud anomalies and nephrogenesis predisposing to **end-stage renal disease (ESRD)**.

Experimentally induced fetal bladder outflow obstruction has established the following effects:

- Bladder outlet obstruction (BOO).
  - Causes smooth muscle hypertrophy, hyperplasia of fibroblasts and myoblasts.
  - Due to upregulation of Hypoxia-Inducible factors (HIFs) and ↑expression of profibrotic cytokines which mediates the hypoxic response and ↑in the deposition of type III collagen extracellular matrix in the bladder wall.
  - Progressive stretch injury along with the hypoxia alters the detrusor blood flow resulting in muscular ischemia.
  - Leads to a shift to anaerobic metabolism causing irreversible damage to the nerves of the bladder wall.

This pathological process translates clinically into the following:

- High voiding pressure due to the initial hypertrophy. In early stages, the bladder is able to empty completely.
- ↓ bladder capacity and ↓ compliance caused by the remodeling of the bladder wall.
- Decompensation occurs where the compliance and contractility of the bladder are affected.
  - Leading to incomplete bladder emptying and rise in post-void residual (PVR) urine volume.
  - ↑ intravesical storage pressure.
- Upper tract change.
  - Ureteric dilation, ↓ glomerular filtration rate (GFR), ↑ intra-pelvic pressure causing tubular injury and renal parenchymal fibrosis.

### 35.4.1 Genetics

Angiotensin-converting enzyme (ACE) gene has been found to play an important role in ureteric bud development and nephrogenesis. During nephrogenesis ACE gene dysfunction can lead to ESRD.

Strong links between ACE (DD genotype) gene and progression to ESRD in patients with obstructive uropathies have been established.

---

## 35.5 Clinical Features

- Antenatal diagnosis.
  - Maternal US performed between 16 and 20 weeks gestation.
    - Dilated posterior urethra (Keyhole sign), hydronephrosis and hydroureter.
    - Oligohydramnios (sometimes) due to cystic or echogenic kidneys suggestive of renal dysplasia.
    - Presence of oligohydramnios before 24 weeks of gestation suggests poor prognosis. Oligo or anhydramnios often leads to pulmonary hypoplasia and Potters syndrome.<sup>2</sup>

Apart from PUV, differential diagnosis includes prune-belly syndrome, bilateral vesicoureteral reflux, and urethral atresia.

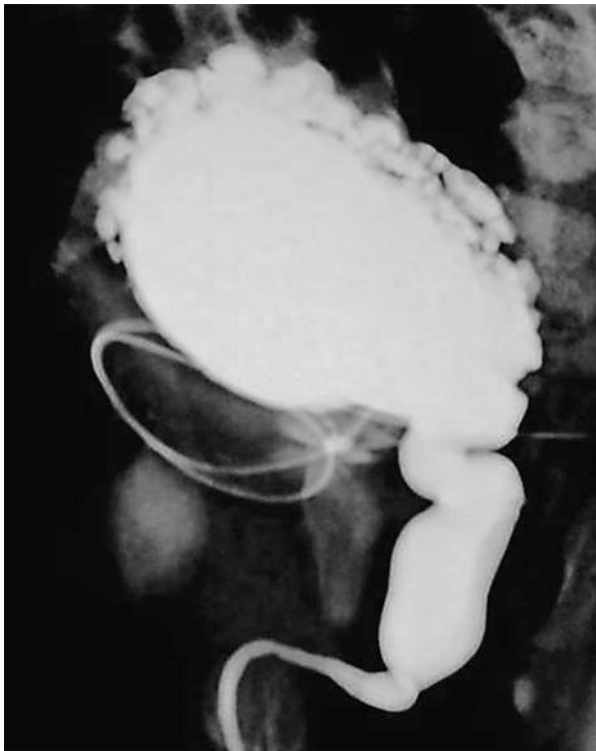- Postnatal.
  - Poor stream ± palpable bladder.
  - UTI.
  - Renal failure with poor somatic growth and lethargy.
  - Diurnal incontinence and/or nocturnal enuresis.

---

<sup>2</sup>Edith Potter (1901–1993) described 20 cases in 1946. Chief of Pathology at the Chicago Lying In Hospital.

### 35.5.1 Investigations

- Ultrasound.
  - Used to confirm and assess the severity of the hydronephrosis and identify a perinephric urinoma, thickening of the bladder wall or urinary ascites.
- **MCUG** is considered the gold standard for the diagnosis of PUV (Fig. 35.1). Features include:
  - Dilated and elongated posterior urethra with a ratio of 5:1 to the anterior urethra.
  - Prominent bladder neck, particularly posterior lip.
  - Partial filling of anterior urethra.
  - Posterior urethral bulging forward over the bulbous urethra.
  - Vesico-ureteric reflux in 40–60% of cases (unilateral in two-third of cases).
  - Valve leaflet lucencies (occasional).
- Radionuclide studies.
  - Can be used to assess baseline differential renal function and degree of renal dysplasia.



**Fig. 35.1** MCUG showing posterior urethral valves with trabeculated bladder with pseudo-diverticuli



## 35.6 Management

- Initial management

Most neonates with posterior urethral obstruction will have a degree of electrolyte imbalance and metabolic acidosis. Initial resuscitation with intravenous hydration and electrolyte replacement should be commenced. Prophylactic antibiotics are started after sending blood and urine samples for testing and cultures.

- Bladder drainage

Temporary drainage of the bladder can be achieved by a transurethral feeding tube as balloon catheters can cause more bladder spasms, obstruct ureteric orifices leading to increased upper tract dilatation and poor emptying of ureters.

At times transurethral catheterization fails due to coiling of catheter/ feeding tube in the dilated posterior urethra and raised bladder neck. In such cases, a **suprapubic catheter** should be inserted to drain the bladder.

In case of premature neonates or poor general condition, bladder drainage is required for prolonged period. In such cases, bladder can be drained either through suprapubic catheter (SPC) or a **vesicostomy**.

- Valve Ablation

After stabilization of the neonate's general condition, **endoscopic transurethral ablation** is the treatment of choice. An endoscopic resectoscope or Bugbee™ electrode can be used to incise the obstructing membrane at the 5, 7, and/or 12 O'clock positions. Nd YAG laser has also been used to ablate PUV.

Repeat Cystoscopy and MCUG are usually performed after 4–6 weeks to confirm satisfactory valve disruption. Circumcision should be offered at the time of cystoscopy to reduce the risk of future UTI.

Complications of valve fulguration include incomplete ablation and urethral stricture. Urethral stricture (5%) can also result from using a bigger resectoscope compare to the size of the urethra. Residual valves are usually seen when ablation is performed using Bugbee™ electrodes.

If ablation is not feasible (small infant or lack of smaller scopes), urinary diversion should be considered. This may include vesicostomy, ureterostomy, or pyelostomy.

- Vesicostomy

The dome of the bladder brought to the skin midway between the umbilicus and the symphysis pubis. This allows drainage but also cycles urine to the bladder and maintains volume. It may be closed once renal function has stabilized, upper tracts have diminished, and the child is large enough for a valve ablation. Valve ablation

should be performed at the time of vesicostomy closure to avoid urethral stricture developing if ablation is performed in a “dry” urethra.

- Upper tract diversion

Higher levels of drainage include the **bilateral ureterostomy or pyelostomy**. Long-term studies have shown that there is no reduction in the incidence of renal failure—which is more likely to be due to intrinsic renal dysplasia. These diversion procedures also result in a small capacity bladder. Therefore, consider only when a vesicostomy is not providing adequate drainage due to poor drainage across VUJ (hypertrophic bladder causing functional obstruction) or in the presence of pyonephrosis.

- Bladder Management

Improving bladder emptying to ↓intravesical storage pressure and take pressure off the upper tracts is crucial in the management of PUV. This can be achieved by the following:

Behavioral modifications:

- Adequate fluid intake.
- Recognizing urge sensation.
- Avoid urine holding manuevres.
- Double voiding.
- Adequate treatment of constipation.

Bio Feedback and Pelvic floor exercises

- Provide significant and durable relief (up to 70%) for persistent lower tract dysfunction.

Drug Treatment

- **Anticholinergics**—Antispasmodic muscarinic effect causing relaxation of bladder smooth muscle.
- **Prophylactic antibiotics.**
- **Onabotulinumtoxin A.**
  - Neurotoxin derived from *Clostridium botulinum*. It prevents Acetylcholine release from the presynaptic membrane preventing detrusor overactivity.
- **Mirabegron.**
  - Is a beta-3 adrenergic receptor agonist that causes relaxation of the detrusor smooth muscle of the urinary bladder and increases bladder capacity.

Intermittent Catheterization and overnight bladder drainage

- Overnight drainage.
  - ↓ upper tract dilatation, ↓ frequency of UTI and improves continence.

- Overnight drainage with **daytime intermittent catheterization (CIC)**.
  - Frequency depends on the degree of dysfunction and is appropriate for poorly compliant bladders.
- SPC or Mitrofanoff channel.
  - Can be used to achieve both CIC and overnight bladder drainage.

---

## 35.7 Long-Term Management

Depends upon renal function (biochemistry, GFR, etc.), bladder urodynamics studies and upper tract changes. Urodynamics is used to assess bladder capacity, compliance, and voiding dysfunction. Types of urodynamic patterns include:

- Instability.
  - Irregular contractions leading to pain and incontinence.
  - Treatment can be with anticholinergics, e.g., oxybutynin and tolterodine.
- Detrusor sphincter dyssynergia.
  - Bladder contracts against an unrelaxed sphincter and hypertrophic bladder neck.
  - Many children used to go on to have bladder neck incisions which improved voiding symptoms and upper tracts dilatation in some, but in others, it also caused incontinence and retrograde ejaculation. Therefore has fallen out of favor and instead alpha-blockers, e.g., doxazosin, are of help in these cases.
- Hypocontractility.
  - Causes incomplete bladder emptying, ↑resting intra-vesicle pressure, hampering upper tract drainage and increased dilatation of the upper tracts. This can also cause overflow incontinence. This so-called “myogenic failure” has been attributed to long-term obstruction and/or prolonged use of anticholinergics.
  - Usually require CIC but poor compliance due to urethral sensitivity or a catheterizable stoma (e.g., Mitrofanoff).

Children with poor compliance/small volume bladders are candidates for bladder augmentation.

### 35.7.1 Bladder Dysfunction and the “Valve Bladder”

Voiding dysfunction is extremely common in children with PUV and is secondary to long-standing obstruction and mural hypertrophy and fibrosis. Urodynamic patterns can change over time from bladder instability during infancy to myogenic failure in older boys.

Bladder dysfunction manifesting as incontinence and persistence of upper tract dilatation is being increasingly recognized as one of the factors responsible for eventual renal deterioration. The underlying mechanisms may be:

- Urine concentrating defects.
  - Long-standing back pressure leads to renal tubular dysfunction causing an acquired form of nephrogenic diabetes insipidus.
  - **Polyuria** exacerbates incontinence and upper tract dilatation.
- Persistent upper tract dilation.
- ↑ urine output and hold up at the VUJ—caused by ureter passing through the thick, noncompliant bladder wall.
- Upper tract pressure studies (Whitaker's<sup>3</sup> test) have shown that the VUJ obstruction is not constant but increases as the bladder fills.
- Treatment with ADH for enuresis is not helpful as it is not due to lower ADH production but due to tubular dysfunction (nephrogenic diabetes insipidus).
- ↑ post-void residual (PVR) urine volume due to poor bladder emptying and increased urine production and the upper tract drainage across VUJ is impaired. This leads to more ureteric dilation and further deterioration of tubular function.
- Vesicoureteric reflux.
  - Bilateral in 50%.
  - Reflux subsides with effective valve ablation (~30%).
  - Persistent reflux (~30%).

Persistent VU reflux (despite adequate treatment to lower intravesical pressure by anticholinergic medication or alpha-blocker to improve bladder emptying) can be successfully treated with **STING procedure** in most cases. Ureteric reimplantation in a trabeculated, noncompliant, high-pressure bladder is not recommended as can be fraught with complications in case of re-implanting in a trabeculated, non-compliant, high-pressure bladder (Failure rate 15–30%).

### 35.7.1.1 VURD Syndrome

In this syndrome, PUV are associated with unilateral **vesicoureteral reflux and renal dysplasia**. The dilated system in these cases acts as a vent for the high-pressure bladder. The pressure “pop-off” mechanism is thought to preserve the function of the contralateral kidney. Nephroureterectomy is usually reserved for cases with recurrent breakthrough UTI with preservation of the dilated ureter to be used for bladder augmentation later on.

### 35.7.1.2 Hydroureteronephrosis (HUN)

- In almost all cases (96%), there is persistent unilateral HUN and bilateral HUN occurs in 70–80%.
- Glassberg classified hydronephrotic upper tracts into three types with upper tracts that:
  - Drain independent of bladder volume.
  - Drains efficiently only with the bladder empty.
  - That are obstructed independent of bladder volume.
- 45–50% resolves after ablation, nearly 25% will have HUN 5–15 years after ablation.

<sup>3</sup>Robert H. Whitaker—British urologist at Cambridge.

## 35.8 Long-Term Outcomes

### 35.8.1 Renal Damage

- Usually Secondary to dysplasia or obstructive uropathy.
- Obstruction and recurrent infections can lead to proteinuria and hyperfiltration.
- Decreased GFR and renal insufficiency occurs.
- Affection of somatic growth and renal development.
- Hypertension.

### 35.8.2 End-Stage Renal disease

- Occurs in 25–30% of cases.
- Can be due to primary renal dysplasia, as a sequel to bladder outflow obstruction, recurrent UTIs or persistent bladder dysfunction.

Poor Prognostic factors of renal outcome are indicated in Table 35.2.

### 35.8.3 Renal Transplantation

Up to 30% of children will ultimately require some form of renal replacement therapy culminating in a transplant. Persistent bladder dysfunction not only increases the risk of developing renal failure but has also been shown to decrease graft survival post-transplant.

**Table 35.2** Poor prognostic factors in prediction of progression to ESRD

| Antenatal factors   | Postnatal factors   |
|---|---|
| Gestation at detection (<24 weeks).   | Nadir (i.e., lowest possible) serum creatinine<br>– >1 mg/dL ( $\equiv$ 88 $\mu$ mol/L) at 1 year of age. |
| US appearance—cystic changes or echogenic kidneys, imply renal dysplasia.   | US appearance: lack of corticomedullary differentiation suggests poor function.                           |
| Oligohydramnios / anhydramnios  | Incontinence—inability to achieve diurnal continence at 5 years of age.                                   |
| Fetal urine analysis<br>– Na >100 mmol/L and Cl >90 mmol/L.<br>– $\beta$ 2 microglobulin >40,<br>– urine osmolality >210 mOsm,<br>– urine output <2 ml/h. | Lack of a protective “pop-off” mechanism such as gross unilateral reflux or urinary ascites.              |
|   | Presence of severe reflux.  |

Note: Cobb’s (Cobb BG, Wolf JA, Ansell JS (1968) Congenital stricture of the proximal urethral bulb. *J Urol*; 99:629–631) collar (or congenital urethral stricture)—distal membrane with a central opening within bulbous urethra

### 35.8.4 Fertility Issues

Diminished fertility possibly due to:

- ↑ posterior urethral pressure *in utero* may affect prostate development.
- ↑ Incidence of undescended testes
- Semen analysis has shown a much thicker ejaculate with decreased sperm motility.
- Voiding dysfunction and retrograde ejaculation.

### 35.8.5 Urinary Incontinence

Thirty-five percent of patients suffer from constant incontinence and an additional 50% with stress incontinence due to additional bladder neck surgery in the past in addition to ablation of valves. Up to 70% have bladder dysfunction and polyuria due to impaired renal function accounting for incontinence.

### 35.8.6 Urinary Ascites (5–10%)

Usually secondary to urine leak from a renal fornix blowout, renal parenchymal rupture, or bladder perforation. Abdominal distension can be marked and cause respiratory compromise. Peritoneal absorption of urine can lead to uremia. Paradoxically, urine leaks actually protect the kidneys from the deleterious effects of constant high back pressure from bladder.

---

## 35.9 Antenatal Intervention

Controversy surrounds the benefit of antenatal intervention in PUV. However, several variables have been used to determine the prognosis. In essence, a high degree of antenatal dysplasia is associated with poor outcome. This can be assessed by US appearances (Increased echogenicity or cystic changes of Parenchyma, early severe oligohydramnios) and characteristics of fetal urine (Na > 100 mmol/L; osmolality >210 mOSm, protein >20 mg/dl and b2-Microglobulin >4 mg/L).

Types of antenatal interventions include:

- Vesicoamniotic shunts

These shunts are passed percutaneously guided by ultrasound and allow the bladder to decompress in the amniotic cavity. Complications include chorioamnionitis and catheter clogging or displacement and fetal morbidity due to pre-term labor.

A randomized trial comparing this intervention to conservative management (**PLUTO trial**)—although stopped early due to poor recruitment—was able to

conclude that shunting may improve neonatal survival after 28 days (probably due to improvement of oligohydramnios) but did not have an effect on renal parenchymal damage.

- Intrauterine valve ablation

This challenging procedure is done in some specialist centers. However, long-term benefits on progression to ESRD remains questionable.

- Elective preterm delivery or termination of pregnancy

This is the most common antenatal intervention, especially in rapidly progressing disease. In case of pre-term delivery, balancing lung growth with the risk of worsening renal damage is crucial.

- Future Therapeutic Strategies

- Intra-detrusor botulinum toxin-A injection was found to improve symptoms of urinary frequency and urgency and decrease bladder fibrosis in animal models with BOO.
- Systemic administration of bone marrow-derived mesenchymal stem cells in animal models with BOO demonstrated short-term urodynamic improvements and significant decrease in inflammatory mediators.
- Experimental anti-fibrotic approaches aim to inhibit cytokines, chemokines, specific matrix metalloproteinases and collagen synthesis.

---

## Further Reading

1. Dewan PA. Congenital obstructing posterior urethral membrane (COPUM): further evidence of a common morphological diagnosis. *Pediatr Surg Int.* 1993;8:45–50.
2. Hoover DL, Duckett JW Jr. Posterior urethral valves, unilateral reflux and renal dysplasia: a syndrome. *J Urol.* 1982;128:994–7.
3. Brownlee E, Wragg R, Robb A, et al. Current epidemiology and antenatal presentation of posterior urethral valves: outcome of BAPS CASS National Audit. *J Pediatr Surg.* 2019;54:318–21.



Feilim Murphy

**Undescended testes** occur in:

- 30–45% of pre-term boys
- 1–5% of full-term infants
- 1% of boys at 6 months.

## 36.1 Anatomy

The testis is a complex structure with a dual role: as the organ of generation and the repository of the spermatozoa together with the production of the defining male hormone, testosterone. Meiosis divides the chromosome content becoming secondary spermatocytes together with a recognizable tail-piece and an acrosome at the head end. These then become spermatids and then the mature spermatozoa which are released into the seminiferous tubules to begin the journey of their life. This process begins from about 10–14 years of age. They empty into the coils of the epididymis which then become the vas deferens. There is a host of supporting cells—**Sertoli<sup>1</sup> cells** and the endocrine **Leydig<sup>2</sup> cells** that secrete testosterone. The whole is covered by dense white tissue—the **tunica albuginea**.

<sup>1</sup>Enrico Sertoli (1842–1910) Italian histologist.

<sup>2</sup>Franz Von Leydig (1821–1908) German zoologist.

F. Murphy (✉)

St George's University Hospital, London, UK



## 36.2 Embryology

Testes develop from the gonadal ridge within the coelomic cavity and below the developing kidneys. At 6 weeks the primordial germ cells migrate to the gonadal ridge from the yolk sac. Sertoli cells develop at 7–8 weeks, producing anti-mullerian<sup>3</sup> hormone (AMH). Leydig cells appear at week 9.

Testicular descent appears to occur in two distinct phases:

- Transabdominal phase (8–15 weeks).
  - Testes descend to the internal ring in a process controlled by the Leydig cell hormone (insulin-like hormone 3).
  - Expansion of gubernaculum.
    - By effect of Mullerian inhibiting substance (MIS) (anti-Mullerian hormone).
- Inguino-scrotal phase (25–35 weeks).
  - Thought to be controlled by androgens and the genitofemoral nerve (via action of calcitonin gene-related peptide (CGRP) (at in rodent models).
  - Together with tongue of peritoneum cavity as the processus vaginalis.

---

## 36.3 Causes

Cryptorchidism is due to a failure in the regulatory or anatomic process of testicular descent. Two main theories exist arguing that it be due to localized affects such as testosterone-related pathways and a central abnormality relating the fetal hypothalamic dysregulation. Two-thirds of neonates born with a UDT will undergo spontaneous testicular descent typically at 3–6 months postnatally, thought to be related to the postnatal testosterone surge.

In undescended testes, there is some evidence that primitive germ cells fail to differentiate into the Adult Dark (AD) spermatogonia at 3–6 months postnatally. These AD spermatogonia are postulated to be the future stem cells for spermatogenesis. The cause for this failure may be related to the high temperature associated with the undescended testes being present in the groin or other intrinsic developmental abnormalities such as genetic irregularities may contribute to cellular arrest.

Impaired fertility associated with cryptorchidism is believed to be due to the lack of AD spermatogonia. Arrested primary germ cells in the cryptorchid that have not differentiated and have not apoptosed are a potential site of mutation hence the development of carcinoma in situ or testicular tumor formation in later life.

Differentiation into AD spermatogonia occurs at 3–6 months and UDT are diagnosed easily at that age. Orchidopexy can occur within 6–18 months and is both acceptable and appropriate.

---

<sup>3</sup>Johannes Peter Müller (1801–1858)—German comparative anatomist.

## 36.4 Clinical Features

- Parental assessment.
- Routine postnatal screening.
  - Postnatal check.
  - 6 week GP check (UK)
- On examination.
  - Asymmetric scrotal appearance.
  - Superficial in the superficial inguinal pouch.
  - Ectopic position—perineum, penile and femoral areas.
  - Impalpable.

### 36.4.1 Associated Abnormalities

UDTs have a high incidence of inguinal hernias, hydroceles, and epididymal abnormalities. In reality, there are a number of conditions that have a higher incidence of UDT; thus, groin examination is mandatory.

- Hypospadias.
- Anterior abdominal defects.
- Prune Belly syndrome.
- Poor abdominal wall tone such as cerebral palsy.

Clinical examination and a detailed history are usually all that is required for the vast majority of cases. Ultrasonography has a possible role in the examination of obese child. Overall cross-sectional imaging is very limited in value and should be avoided.

There are two areas of caution of examination:

- Severe Hypospadias and unilateral impalpable testes.
- Bilateral impalpable testes.

Both of these require urgent investigation for **disorders of sexual development (DSD)** with referral to an appropriate DSD multidisciplinary team. Investigations performed can include LH, FSH, hCG measurements, electrolyte assessment, pelvic ultrasonography, and chromosomal assays. DSD abnormalities are covered in Chap. 31.

---

## 36.5 Management

### 36.5.1 Role of Hormone Therapy

Hormonal therapy has been used in a limited number of units in Europe. It has remained controversial. Both the British Association of Paediatric Urologists and

the Nordic consensus documents recommend either caution or are against their use. Their concerns relate to the variability of outcomes, the potential impact on germ cell function, and limited outcome data.

### 36.5.2 Orchidopexy

The evidence is clear the testicular descent is uncommon after 3–6 months in the full-term male infant; thus, orchidopexy is recommended from 6 to 12 months of age. If diagnosed later then the surgery should occur promptly.

- Palpable UDT.
  - Cosmetic skin incision.
  - Mobilization of the testis needs to occur with or without opening the inguinal canal.
  - The hernia sac should be dissected free while preserving the vas and testicular vessels and ligated at the level of the deep ring (where the vas and vessels divide).
  - The testes can be placed without tension and torsion in a sub-dartos pouch.
- Impalpable UDT.
  - EUA.
  - If the testis is still impalpable a laparoscopic two-stage procedure should be attempted. This is highly successful at both identifying the presence or absence of the testis and facilitating a successful orchidopexy.
  - **Fowler–Stephen’s principle.**<sup>4</sup> The first stage involves ligating the testicular vessels so that collateral blood supply develops enough to allow the vas and testis to survive. The second stage which normally occurs six months later involves mobilizing the vas and what remains of the testicular pedicle enough to reach the scrotum. Often the most direct route is chosen via Hesslebach’s triangle<sup>5</sup> in the inguinal canal. Open staged surgery has nearly disappeared.
  - Shehata Operation.<sup>6</sup>
    - Initial laparoscopic stretching and tethering of the intrabdominal testis to the opposite undersurface of the abdominal wall. Staged orchidopexy as before but with preservation of testicular pedicle.
  - All boys should be followed up at least once at 3–6 months to assess size, location, and potential viability.

Cryptorchidism presenting around puberty is rarely a true cryptorchid but mostly **ascending testes**.

<sup>4</sup>Robert Fowler (b1928)—F Douglas Stephens (1913–2011). Australian pediatric surgeons.

<sup>5</sup>Franz Kaspar Hesslebach (1759–1816) German anatomist and surgeon.

<sup>6</sup>Sameh Shehata. Contemporaneous Egyptian surgeon.

Operative management is based on the belief that damage to the undescended, or now ascended, testes, is a process and not congenital and that by moving the testicle into the correct anatomical position, that process may be minimized.

### 36.5.3 Complications

- Testicular atrophy.
  - Should be <less than 3% in open cases.
  - <30% in staged orchidopexy
- Vas injury.
  - Poor Literature on this topic but <5%.
- Recurrence.
  - ~5%-usually related to excess tension or inadequate mobilization or dissection.

### 36.5.4 Malignancy

- The reported evidence is quite clear that men with a history of cryptorchidism have a 3–7 times relative risk of developing a testicular malignancy as opposed to the normal population.
- There is evidence that orchidopexy under the age of 10–13 years decreases the malignancy risk.

#### 36.5.4.1 Risk Factors

- Intrabdominal position (x5 risk).
- Abnormal external genitalia.
- Abnormal karyotype.
- Bilateral UDT.

The literature also supports that there is an increased risk in the normally descended contralateral testes, and the malignancy risk can be three times the risk of the normally descended testes.

---

## 36.6 Outcome

- The outcome for a single palpable UDT is very good.
- Individual fertility outcomes are very difficult to predict. The literature is based on surgery occurring in much older children undergoing orchidopexy (median age 7). Predicting fertility based on the position of the UDT is problematic.
- Bilateral UDT does not mean absolute infertility. Infertility can be significantly impaired but 25% have adequate sperm counts.
- The outcome for a repaired unilateral UDT is very close to normal.

---

## Further Reading

1. Hutson JM. Treatment of undescended testes – time for a change in European tradition. *Acta Paediatr.* 2007;96:608–10.
2. Martin Ritzén E, Bergh A, et al. Nordic consensus on treatment of undescended testes. *Acta Paediatr.* 2007;96:638–43.
3. Murphy F, SriParan T, Puri P. Orchidopexy and its impact on fertility. *Pediatr Surg Int.* 2007;23:625–32.
4. Hutson J, Balic A, Nation T, Southwell B. Cryptorchidism. *Semin Pediatr Surg.* 2010;19:215–24.



# Inguinal Hernia Hydrocele and the Acute Scrotum

# 37

Anindya Niyogi and Chandrasen K. Sinha

## 37.1 Abdominal Wall Hernia

A hernia is:

“an abnormal protrusion of tissue, or the whole or a part of an organ through the wall of the cavity in which it is enclosed.”

## 37.2 Groin Hernia

- Inguinal.
  - Indirect (most childhood hernia).
  - Direct.
- Femoral.

### 37.2.1 Demography

- 3–5% of full-term infants
- 9–11% of premature newborns
- Most commonly presents during the first year of life.
- Male-to-female ratios 3:1 to 10:1.
- 60% Right, 30% Left, 10% bilateral
- Increased incidence in raised intra-abdominal pressure.

A. Niyogi (✉)

Department of Paediatric Surgery, Kings College Hospital, London, UK

C. K. Sinha

St George's Hospital, London, UK

- Abnormal content.
  - Ascites, ventriculoperitoneal shunt, peritoneal dialysis.
- Abnormal abdominal configuration.
  - Exomphalos, gastroschisis, bladder exstrophy.
- Increased incidence in cystic fibrosis and connective tissue disorders.

### 37.2.2 Embryology

Inguinal hernia and hydrocele are the results of the failure of obliteration of **processus vaginalis**. As the embryonic testis descends from the abdomen to the scrotum through the inguinal canal, it drags the parietal peritoneum with it. The distal part of the peritoneum forms the **tunica vaginalis** in the scrotum, and the proximal part forms the processus vaginalis. Processus vaginalis usually closes after the testicular descent is complete around 35 weeks of gestation. The female equivalent of processus vaginalis is the canal of Nuck containing the round ligament which obliterates around the same time. Failure of closure is common, and the degree of patency determines the likelihood of developing a hernia or hydrocele.

### 37.2.3 Contents of Hernia

- The small and large intestine.
- Omentum.
- Ovary and fallopian tube (in girls).
- Retroperitoneal structures such as the bladder (a “sliding” hernia).
- Appendix (Amyand hernia<sup>1</sup>).
- Meckel’s diverticulum (Littre<sup>2</sup> hernia).
- Antimesenteric bowel wall (Richter<sup>3</sup> hernia).

### 37.2.4 Clinical Findings

#### 37.2.4.1 Reducible Hernia

Children present with a history of intermittent swelling in the groin noted during crying. Demonstration of a groin lump in the clinic that is reducible on gentle

<sup>1</sup>Claudius Amyand (1681–1740)—English surgeon working at St George’s Hospital in London. Reported a case of appendix protrusion in a scrotal hernia which had become infected by ingestion of a pin perforating the appendix. He drained the abscess, ligated the appendix and repaired the hernia.

<sup>2</sup>Alexis Littre (1658–1726)—French surgeon who described a Meckel’s diverticulum in a hernial sac.

<sup>3</sup>August Gottlieb Richter (1742–1812)—German surgeon described the situation where only a part of the intestinal wall becomes trapped within the hernial sac.

pressure confirms the diagnosis. When no hernia is elicited in the clinic despite suggestive history, palpation of a thickened cord (“silk glove sign”) and photographs taken by parents on portable devices are used to reach a diagnosis.

In a female child with bilateral inguinal hernia, **androgen insensitivity syndrome** (AIS) should be considered.

### **37.2.4.2 Incarcerated Hernia**

This is a tender firm groin lump is felt that cannot be reduced by gentle pressure and is due to entrapment of the hernia contents. The testis should be palpable separately. Signs of bowel obstruction such as abdominal distension and vomiting can subsequently develop. If the hernia is left untreated, the blood supply to the content may be compromised, and eventually, it can cause infarction (“strangulation”). Testicular blood supply can also be jeopardized due to pressure on the cord. Incarceration is most common in the first 6 months of life.

### **37.2.4.3 Investigation**

The diagnosis of a hernia is largely clinical, and investigations are usually unnecessary and unhelpful. Ultrasound has been used to diagnose hernia in doubtful cases and to check the contralateral side. The diameter of the inguinal canal at the level of the internal ring if above 5 mm is shown to be associated with patent processus vaginalis. However, this is heavily operator dependent.

## **37.2.5 Management**

Hernia does not spontaneously resolve, and surgery is always necessary, and the conventional approach is open inguinal herniotomy.

### **37.2.5.1 Reducible Hernia**

The repair is performed electively. However, in young infants, performing surgery within two weeks of diagnosis, reduces incarceration rates by half.

- Skin crease groin incision.
- Split the external oblique is split to enter the canal.
- Dissect sac from vas and vessels and ligate at the deep inguinal ring (herniotomy).
  - In some premature infants, a Bassini repair (suture conjoint tendon down to inguinal ligament) may be necessary if there is an associated posterior wall weakness.
  - If there is a sliding component, inversion ligation with a purse-string suture under vision is performed.

### **37.2.5.2 Incarcerated Hernia**

Nonoperative reduction (“taxis”) under monitored conscious sedation is attempted in the absence of obvious peritonitis or septic shock. Reduction of gangrenous



bowel is possible; therefore, children should be admitted for observation after a difficult reduction. After a successful reduction, a delay of 24–48 h is traditionally recommended for edema to settle before open herniotomy is performed. Urgent surgery is necessary if the reduction is unsuccessful. Several open approaches have been described; however, the standard inguinal approach is most used. A lateral incision to extend the internal ring may be necessary for reduction. Resection and anastomosis of the necrotic bowel are possible through the inguinal approach.

### **37.2.5.3 Laparoscopic Repair**

Laparoscopic inguinal hernia repair was introduced in the early 1990s.

Advantages

- Assessment of contralateral internal ring.
- Identification of other (direct, femoral) hernias.
- Less postoperative pain, and better cosmesis.

Disadvantages:

- Longer operative time.
- Higher costs.
- Learning curve, and the need for paralysis and intubation for anesthesia.

The internal ring is closed by either Intracorporeal or extracorporeal/percutaneous techniques. In extracorporeal approach, the ligation is performed percutaneously under laparoscopic vision. Several percutaneous techniques have been described, but none of the approaches have been found to be superior to others. The most common technique used is transperitoneal laparoscopy and intracorporeal nonabsorbable purse-string suture to peritoneum to close the internal inguinal ring.

Laparoscopy has been successful in treating incarcerated hernia where reduction is performed by the combination of external compression and internal traction. Current evidence suggests both open and laparoscopic inguinal hernia repairs have an equivalent outcome.

### **37.2.5.4 Contralateral Exploration**

- A contralateral patent processus is found in a third of patients at laparoscopic evaluation.
- <10% will develop a metachronous hernia if treated conservatively.

Therefore, routine closure of contralateral patent processus is an overtreatment. Contralateral exploration during open herniotomy is not performed to minimize the risk of injury to cord structures on the asymptomatic side. However, during laparoscopic repair, the contralateral side is more frequently repaired as most parents prefer that.

### 37.2.5.5 Hernia in Females

In girls, it is recommended to routinely open the sac as 40% will have adnexa as a sliding component. In this situation, the Bevan repair is performed where a purse-string is applied distal to the sliding element, the sac is then invaginated, and the internal ring is closed with sutures.

During laparoscopic repair in females, as there is no worry about injury to cord structures, an inversion ligation technique can be performed where the sac is invaginated into the abdominal cavity, and Endoloops™ (Ethicon Endo-Surgery) applied to the neck.

Urgent surgery is not necessary for asymptomatic nontender ovarian incarceration as it does not strangulate from vascular compression. However, surgery should be performed promptly, if this becomes tender as there is a high risk of torsion while incarcerated.

### 37.2.5.6 Overnight Admission

Most herniotomies are performed as a day case. Neonates, particularly premature neonates, are at risk of developing postoperative apnoea which requires monitoring. In our center, infants <60 weeks post-conceptual age are kept overnight for observation.

### 37.2.5.7 Outcome

- The overall complication rate for elective herniotomy is <2%.
- Complications such as injury to vas or vessels, recurrence, testicular atrophy, and testicular ascent are rare. However, the complications significantly increase when the surgery is performed as an emergency for incarceration.

---

## 37.3 Hydrocele

A **hydrocele** is:

“a collection of fluid around the testis between the layers of the tunica or in the inguinal canal.”

### 37.3.1 Classification

- Congenital—due to the patent of processus vaginalis (younger children).
  - Communicating hydrocele.
  - Encysted hydrocele of the cord.
- Acquired (adolescent and adults).
  - Idiopathic.
  - Secondary (trauma, malignancy, scrotal filariasis).

### 37.3.2 Clinical Features

- A hydrocele usually presents shortly after since birth and is asymptomatic and painless.
- **Communicating hydrocele** can intermittently change in size.
- The fluid in the hydrocele can increase after a coryzal episode and in some children, hydroceles are first noticed acutely after a viral illness.
- Diagnosis is made clinically based on the finding of nontender cystic swelling with the ability to get above the swelling. Though hydroceles transilluminate, transillumination alone is not confirmatory for hydrocele as in small children, bowel in incarcerated hernia can also transilluminate. The testis is palpable in the posterior part of the hydrocele.
- An **encysted hydrocele** is palpable nontender lump in the groin separate from the testis that moves with traction on the cord.

### 37.3.3 Management

- Hydroceles can spontaneously resolve by obliteration of the PPV. Therefore, expectant management is recommended up to the age of 2 years.
- Persistent communicating hydroceles are treated as hernia with the evacuation of the hydrocele fluid and formal dissection of the processus vaginalis.
- A scrotal approach is used in **non-communicating adolescent hydroceles** to obliterate tunica vaginalis.
  - Either eversion (Jaboulay<sup>4</sup>) or plication (Lord<sup>5</sup>) of the tunica.

---

## 37.4 Abdominoscrotal Hydrocele

An abdominoscrotal hydrocele is a rare type of hydrocele where a large sac extending from scrotum to retroperitoneum with no connection with the peritoneal cavity in a dumbbell configuration is demonstrated. Cross fluctuation can be demonstrated where compression of the abdominal component causes protrusion of the scrotal component and vice versa (“springing back ball sign”).

Ultrasound can be useful in diagnosis. As this is associated with testicular atrophy, early surgery is recommended to excise the sac, which is performed through the inguinal approach with or without an additional abdominal or laparoscopic approach.

---

<sup>4</sup>Mathieu Jaboulay (1860–1913)—French surgeon, also incidentally first person to attempt to graft a animal kidneys onto the circulation of patients dying with renal failure. They did not work!

<sup>5</sup>Peter Herent Lord (1925–2017)—Influential English surgeon working in High Wycombe.

## 37.5 Acute Scrotum

“Testicular torsion—a True Surgical Emergency!”

The acute scrotum is a sudden onset scrotal pain often associated with edema and erythema. All cases of acute scrotum should be considered as testicular torsion until an alternative diagnosis is confirmed. If there is a possibility of testicular torsion or there is any doubt in diagnosis, the scrotum should be urgently explored. The different causes of acute scrotum include:

- Torsion of the testis.
- Torsion of the appendix testis/epididymis.
- Epididymitis/orchitis.
- Inguinal hernia/hydrocele.
- Trauma.
- Tumor.
- Varicocele.
- Idiopathic scrotal edema.
- Cellulitis.
- Vasculitis (Henoch–Schönlein purpura).
- Referred pain.

### 37.5.1 Torsion of the Testis

#### 37.5.1.1 Demography

- Yearly incidence: 3.8 per 100,000 (<18 years old).
- Bimodal age distribution.
  - First peak in the neonatal period and the second peak around puberty (rare in prepubertal boys).

#### 37.5.1.2 Classification

- Intravaginal.
  - Torsion within tunica due to “bell-clapper” deformity, seen in adolescents.
- Extravaginal:
  - Torsion at the level of the spermatic cord due to failure of the fixation of the layers of the scrotum, seen in neonates.

#### 37.5.1.3 Clinical Features

- Diagnosis of torsion is clinical.

Children generally present with acute onset severe unilateral testicular pain which may be associated with nausea and vomiting. Generalized testicular

tenderness is the most consistent finding on examination, usually associated with high-riding with bell-clapper configuration and absent cremasteric reflex. At the time of presentation to hospital, most testes are enlarged and firm in consistency in comparison to the healthy side. Erythema and edema of the scrotum are found based on the duration of symptoms.

#### 37.5.1.4 Investigations

- Urine analysis is performed routinely, and urinary tract infection raises the suspicion of epididymo-orchitis.
- Color Doppler ultrasound scan.
  - Looking for testicular internal Doppler flow signals.
  - 90% sensitivity and 99% specificity for diagnosing testicular torsion. It is not 100% sensitive or specific, it is not lawyer-proof.
  - Still, *an ultrasound scan can delay exploration* and therefore, only recommended when the diagnosis is doubtful or the history is so long as to render a diagnosis of torsion “academic.”
- Sonographic shear wave elastography.
  - To determine the stiffness of the testis and near-infrared spectroscopy to determine the oxygen saturation of testis are newer diagnostic modalities.

#### 37.5.1.5 Surgery

- Note time from onset of symptoms to surgery.
- Median raphe or transverse incision.
- Deliver testis out of tunica.
- Untwist and check the return of perfusion (use warm packs).
- If necrotic with no restoration of perfusion after 15 min—excise; otherwise return. Have low-threshold to retain testis though.
- Perform bilateral 3-point fixation with nonabsorbable sutures.
- Explore and fix the other side.
- Doubtful viability.
  - Theoretically, testicular ischemia damages the blood-testis barrier. Therefore, in pubertal boys, there is a risk of autoimmunization by forming anti-sperm antibodies. Still, human evidence of this is weak and most surgeons try to preserve rather than excise.

#### 37.5.1.6 Manual Detorsion

If there is an unavoidable delay in exploration, manual detorsion may be performed by rotating the testis from medial to lateral (“like opening a book”). Two-third of the twists are lateral to medial. Success is determined by lowering the testis and sudden pain relief. If unsuccessful, rotation in the other direction is attempted. Even if manual detorsion is successful, surgery should not be delayed in order to prevent recurrent torsion and fix the other side.

### 37.5.1.7 Perinatal Testicular Torsion

Perinatal testicular torsion is an extravaginal torsion that can be both a prenatal (75%) or a postnatal event. Prenatal torsion is noticed at birth and usually present with scrotal discoloration and a palpable nontender hard testis and no inflammation. The findings suggest a necrotic testis from a previous torsion. In postnatal torsion, usually, the scrotum is reported to be normal at birth. They present with inflamed edematous scrotum with tender enlarged testis and may warrant emergency exploration. However, the timing of surgery is controversial for prenatal torsion due to low salvage rate.

There are reports of salvage of testis in some cases of perinatal torsion, and there is a theoretical risk of metachronous contralateral torsion. At best, bilateral exploration at the time of diagnosis will salvage ~5% of the ipsilateral testis and prevent asynchronous torsion in <5% of neonates. As the fixation of the scrotal layers can take up to 3 months, contralateral fixation must be performed to prevent asynchronous torsion. Placing the testis in subdartos pouch created by splitting the scrotal layers are equally effective as three-point suture fixation in preventing torsion and is technically easier in neonates.

### 37.5.1.8 Intermittent Testicular Pain

Severe intermittent testicular pain in adolescents may represent testicular torsion with spontaneous resolution. If the child has suffered three or more such episodes, and mainly if there is an associated bell-clapper deformity, elective bilateral testicular fixation is recommended to prevent torsion.

### 37.5.1.9 Outcome

Testicular salvage depends on the duration of ischemia and is timed from the onset of symptoms.

- <6 hours: 85–97%
- 6–12 hours: 55–85%
- 12–24 hours: 20–60%
- >24 hours: <10%.

---

## 37.6 Torsion of Testicular Appendages

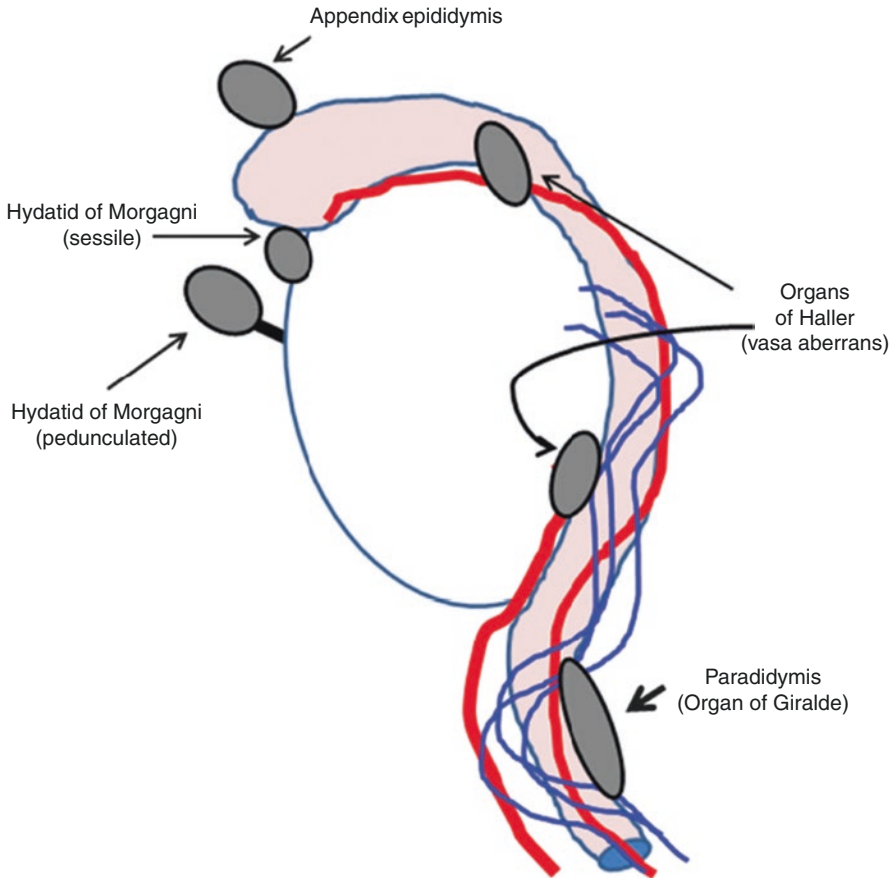
This is one of the most common causes of acute scrotum.

There are five anatomical appendices: (Fig. 37.1)

- Testicular appendages (sessile and pedunculated hydatids of Morgagni<sup>6</sup>).
  - Present in 90% of boys and are Müllerian remnants.
- Epididymal appendage.

---

<sup>6</sup>Giovanni Battista Morgagni (1682–1771)—Italian anatomist who described many anatomical features and curiosities.



**Fig. 37.1** Testicular Appendages [reproduced with permission from Davenport M & Geiger J. *Operative Pediatric Surgery* eighth edition, CRC Press, 2021]

- Paradidymis or organ of Giraldé.<sup>7</sup>
- Superior and inferior vasa aberrans of Haller.<sup>8</sup>
  - Originate from Wolffian duct.

Torsion can happen in prepubertal boys in any of these appendices but is most seen in the hydatid of Morgagni. The onset of pain is insidious. Examination shows a focal polar testicular tenderness and perhaps a “blue or black dot sign.” Torsion of testicular appendages is self-limiting and therefore *if the diagnosis is secure*, can be treated with nonsteroidal anti-inflammatories. Exploration is indicated if the symptoms are prolonged or the diagnosis is doubtful.

<sup>7</sup> Joaquim Giraldé (1808–1875)—Portuguese surgeon and anatomist working mainly in Paris.

<sup>8</sup> Victor Albrecht von Haller (1708–1777)—German anatomist.

---

## Further Reading

1. Erez I, Rathause V, Vacian I, Zohar E, Hoppenstein D, Werner M, et al. Preoperative ultrasound and intraoperative findings of inguinal hernias in children: a prospective study of 642 children. *J Pediatr Surg.* 2002;37:865–8.
2. Montupet P, Esposito C. Laparoscopic treatment of congenital inguinal hernia in children. *J Pediatr Surg.* 1999;34:420–3.
3. Kantor N, Travis N, Wayne C, Nasr A. Laparoscopic versus open inguinal hernia repair in children: which is the true gold-standard? A systematic review and meta-analysis. *Pediatr Surg Int.* 2019;35:1013–26.
4. Kokorowski PJ, Wang HHS, Routh JC, Hubert KC, Nelson CP. Evaluation of the contralateral inguinal ring in clinically unilateral inguinal hernia: a systematic review and meta-analysis. *Hernia.* 2014;18(3):311–24.
5. Monteilh C, Calixte R, Burjonrappa S. Controversies in the management of neonatal testicular torsion: a meta-analysis. *J Pediatr Surg.* 2019;54:815–9.





Ravindar Anbarasan and Azad Bhushan Mathur

- **Function and Ideal**—the bladder should have the ability to fill to capacity while maintaining low pressures; a sensation to void when full and be under voluntary control, and finally to empty at the end of voiding without residual.

---

## 38.1 Anatomy

Table 38.1.

---

## 38.2 Etiology

Table 38.2.

---

## 38.3 Classification

Normally, the detrusor and sphincter complex work in synergy but in the presence of a neurologic deficit, they may either be *overactive* or *underactive*. This leads to the usual functional classification based on *detrusor sphincter dysfunction (DSD)* and is a guide to management.

---

R. Anbarasan (✉) · A. B. Mathur  
Norfolk and Norwich University Hospital NHS Foundation Trust, Norwich, UK

**Table 38.1** Basic Science of Innervation of the bladder and sphincter

|                 |  |
|-----------------|--|
| Parasympathetic | S2–S4 spinal segments (both afferent and efferent).<br>via the pelvic nerves to the detrusor muscle. |
| Sympathetic     | T9–L1 spinal segments<br>via sympathetic chain and hypogastric plexus, mainly to the bladder neck.   |
| Somatic         | S2–S4 segments<br>via pudendal nerve to supply the external sphincter                                |

**Table 38.2** Etiology of Neurogenic Bladder

| Congenital   | Acquired                     |
|--|------------------------------|
| Spinal dysraphism and myelodysplasia (myelomeningocele)        | Traumatic spinal cord injury |
| Spina bifida occulta (including tethered cord, lipoma of cord) | Tumors                       |
| Sacral agenesis  | Transverse myelitis          |
| Imperforate anus   |                              |

- Detrusor overactivity with sphincter overactivity.
- Detrusor overactivity with normal or underactive sphincter.
- Detrusor underactivity with sphincter overactivity.
- Detrusor underactivity with sphincter underactivity.

## 38.4 Clinical Evaluation

Clinical manifestations are varied depending on the age of presentation or diagnosis.

If diagnosed at birth or present in early life, the priority is to secure against renal injury from backpressure and infection by baseline and regular assessments with USS, MCUG, or video-urodynamics and a DMSA for renal function. Around 90% of children born with meningocele have a normal upper urinary tract at birth but without urological monitoring, many develop upper and/or lower urinary tract deterioration.

For children presenting in later life not only renal protection is important but also the management of urinary incontinence.

Clinical assessment includes:

- Examination of back for evidence of spina bifida occulta (e.g., hairy patch, lumbosacral lipoma, etc.) and sacral agenesis.
- Neurological assessment to elicit.
  - Integrity of segments S2–4.
    - Ano-cutaneous reflex (S1–3, pudendal nerve).
    - Bulbocavernous reflex (S1–3).
    - Anal sphincter reflex from glans stimulation.
    - Mapping perianal and lower limb sensation.

- The anus is usually patulous and the child soils continuously with an absent ano-cutaneous reflex and this usually suggests a “safe” bladder that leaks easily under pressure or empties on examination.

---

## 38.5 Basics of Urodynamics

### *Estimated bladder capacity*

- Infants weight (in kg)  $\times$  7 in mL.
- 1–12 years age (in years)  $\times$  30 + 30 in mL
- [example—4-year-old child –  $4 \times 30 + 30 = 150$  mL].

### *Detrusor hyperreflexia*

- Abnormal bladder contractions in a neurogenic bladder and is of significance if the pressure is  $>30$ – $40$  cm H<sub>2</sub>O.

### *Compliance*

- Relationship between volume and pressure. For example, at expected bladder capacity, detrusor pressure should be  $<30$ – $40$  cm H<sub>2</sub>O.

### *Sphincteric incompetence*

- Sphincteric mechanism opens abnormally at low pressures.

### *Leak-point pressure*

- Point at which external sphincter opens.
  - $< 40$  cm H<sub>2</sub>O—bladder regarded as “safe”
  - $> 40$  cm H<sub>2</sub>O—potential for upper tract deterioration

Urodynamics can be performed *via* urethral or suprapubic catheter. A rectal balloon catheter is also used to measure the intraabdominal pressure and is subtracted from the measured pressure to give the **detrusor pressure**. Slow fill occurs at 10–15 mL/min and depends on the estimated bladder capacity. Screening for VUR is done intermittently.

---

## 38.6 Management of Neurogenic Bladder

The main aim is to ensure and maintain an adequately sized reservoir with good compliance that can be emptied completely at low pressures and at regular intervals. Continence is usually addressed when the child reaches school age.

Issues such as elevated detrusor pressure, hydronephrosis and/or reflux and UTIs are treated at any time.

### 38.6.1 Conservative Management

This must be considered prior to surgical intervention and include the use of medical devices, pharmacotherapy, and neuromodulation.

- Medical devices - Clean Intermittent Catheterization (CIC).
- Early institution of CIC using non-latex catheters makes it easier for parents and carers to learn and for children to accept it as they grow older.
- Pharmacotherapy.
  - Antimuscarinics/Anticholinergics (e.g., oxybutynin, tolterodine, solifenacin).
  - Typical first line of treatment for a neurogenic bladder. These act by increasing capacity, decreasing detrusor overactivity, and reducing urinary incontinence. Side effects might include dry mouth, constipation, blurred vision, facial flushing, dizziness, and headache.
  - $\beta_3$  receptor agonists (e.g., mirabegron).
  - These have the advantage of fewer side effects and increased efficacy when used in combination with anticholinergics.
  - $\alpha$  blockers (e.g., doxazosin and tamsulosin).
  - These significantly improve bladder emptying.
- Neuromodulation.
  - Posterior Tibial Nerve Stimulation (PTNS) & Parasacral Transcutaneous Electrical Nerve Stimulation (TENS).
  - These techniques have been successfully used in different studies to overcome overactive bladder in children with varying degrees of success.

### 38.6.2 Surgical Management

Conservative management is usually sufficient in the majority, but surgical procedures should be considered if these measures fail to achieve continence between catheterizations or to preserve upper tracts.

#### 38.6.2.1 Procedures to Augment Storage Capacity of Bladder

- Intravesical injection of BOTOX (Botulinum Toxin A).
- Injected intravesically via cystoscope every 3–6 months to counteract Neurogenic Detrusor Overactivity (NDO).
- Augmentation cystoplasty.
  - Ileocystoplasty (Detubularized ileum).
  - This remains the most common segment used for bladder augmentation as ileum has  $\downarrow$  contractions and  $\downarrow$  mucous. However, it does have a risk of metabolic complications.

- Contraindications include intrinsic bowel disease like Crohn’s disease, congenital anomalies, short bowel syndrome, irradiated bowel, reduced manual dexterity, limited cognitive function with an inability to perform CIC and poor compliance.
- Colocystoplasty.
- Sparingly used these days as it results in ↑contractions, ↑mucous production, and ↑stone formation.
- Gastrocystoplasty.
- Currently abandoned due to significant metabolic disturbances, such as metabolic alkalosis and aciduria.
- Ureterocystoplasty.
- Possible option in those patients with a non-functioning kidney and hydronephrosis where the dilated ureter is used as a segment for augmentation.

### 38.6.2.2 Complications of Cystoplasty

- Mucus production leading to catheter blockage, infection, and bladder stones.
- Metabolic changes—hyperchloremic alkalosis electrolyte disturbance.
- Systemic alkalosis (gastrocystoplasty).
- Spontaneous perforation.
- Metaplasia/malignancy.
- Bowel problems, e.g., diarrhea, vitamin B12 deficiency.
- Dysuria and hematuria (gastrocystoplasty).

### 38.6.2.3 Mitrofanoff<sup>1</sup> and Monti<sup>2</sup> Continent Catheterizable Channels

Creation of a continent catheterizable channel following augmentation cystoplasty serves as a safety mechanism for bladder drainage. Involves creation of a continent catheterizable channel by burying a narrow tube (appendix or tubularized small bowel) within the wall of the bladder or urinary reservoir whose distal end is brought to the abdominal wall as a stoma.

### 38.6.2.4 Procedures to Improve Urinary Continence by Increasing Outlet Resistance

- Bulking agents.
- Injection of bulking agents (collagen, silicone, and Deflux) in the tissues around the urethra and bladder neck to increase outlet resistance in children has been in vogue for the last four decades with varying degrees of success [5].
- Bladder neck suspensions and fascial slings.
  - Marshal–Marchetti bladder neck suspension.
  - Involves suspension of the bladder neck with an autologous fascial strip or artificial material secured to the rectus fascia or the pubic symphysis [6].

<sup>1</sup>Paul Mitrofanoff—French urologist. Technique introduced in 1980.

<sup>2</sup>Paul Ricardo Monti—Brazilian urologist working in Porto Alegre, introduced technique in 1997.

- Bladder neck surgery (closure/reconstruction).
- In “desperate” cases the bladder neck may be closed to overcome persistent leakage despite several attempts to enhance outlet resistance. Long-term results are disappointing due to a reduction in bladder capacity and backpressure changes in the upper urinary tract.
- Artificial urinary sphincter (AUS).
- The ideal patients for AUS implantation are post-pubertal males who can void by volition and empty the bladder completely. A common problem is the development of reduced bladder compliance with time.

### **38.6.2.5 ACE Procedure**

Most neurogenic bladders have associated bowel dysfunction due to neurogenic bowel. An appendix or Monti tube can be implanted between the caecum and the anterior abdominal wall as a catheterizable channel for antegrade continent enemas.

---

## **38.7 Transition to Adult Life**

Lifelong care of continence, monitoring of renal function with a periodic investigation of upper tract changes, renal function, and bladder status is mandatory. Patients with augmentation using intestine should be regularly followed up for complications such as infection, stones, metabolic changes, and neoplasm.

---

## **Further Reading**

1. Dik P, Klijn AJ, van Gool JD, et al. Early start to therapy preserves kidney function in myelomeningocele patients. *Eur Urol.* 2006;49:908–13.
2. Rickwood AMK, Thomas DG, Philp NH, et al. Assessment of congenital neurovesical dysfunction by combined urodynamic and radiological studies. *Br J Urol.* 1982;54:512–8.
3. Dyer L, Franco I, Firlit CF, et al. Endoscopic injection of bulking agents in children with incontinence: Dextranomer/hyaluronic acid copolymer versus polytetrafluoroethylene. *J Urol.* 2007;178:1628–31.
4. Snodgrass W, Keefover-Hicks A, Prieto J, et al. Comparing outcomes of slings with versus without enterocystoplasty for neurogenic urinary incontinence. *J Urol.* 2009;181:2709–14.
5. Ludwikowski BM, Bieda JC, Lingnau A. Surgical Management of Neurogenic Sphincter Incompetence in Children. *Front Pediatr.* 2019;7:97.



# Urinary Tract Infections

# 39

Anand Pandey, Chandrasen K. Sinha, and Devesh Misra

## 39.1 Introduction

Urinary tract infections (UTIs) are one of the most common pediatric infections worldwide.

### Box 39.1

|                     |  |
|---------------------|--|
| <i>All children</i> |  |
| <i>Prevalence</i>   |  |
| 8%                  | <i>All children - 0–19 years</i>   |
| 7%                  | <i>Febrile infants 0–24 months</i>   |
| <i>Girls</i>        |  |
| 11%                 | <i>At least 1 episode up to age 16 years</i>   |
|                     | <i>Highest incidence &gt; 6 months - adolescence</i>                                   |
| <i>Boys</i>         |  |
| 7%                  | <i>At least 1 episode up to age 16 years</i>   |
|                     | <i>Highest incidence in neonatal and early infancy, particularly if uncircumcised.</i> |

A. Pandey (✉)  
King George's Medical University, Lucknow, India

C. K. Sinha  
St George's Hospital, London, UK

D. Misra  
The Royal London Hospital, London, UK  
e-mail: [devesh.misra@nhs.net](mailto:devesh.misra@nhs.net)

**Table 39.1** Bacteria commonly causing urinary tract infection

| Acidic Urine   | Alkaline Urine                |
|--|-------------------------------|
| <i>Gram-negative</i>                                     |                               |
| <i>Klebsiella pneumonia</i>                              | <i>Proteus mirabilis</i>      |
| <i>Proteus mirabilis</i>                                 | <i>Pseudomonas aeruginosa</i> |
| <i>Gram-positive</i>                                     |                               |
| <i>Enterococcus faecalis</i>                             |                               |
| <i>Staphylococcus spp.</i> (e.g., <i>saprophyticus</i> ) |                               |
| <i>Hemophilus spp.</i>                                   |                               |

*Klebsiella* named after the German microbiologist Edwin Klebs (1834–1913).

## 39.2 Microbiology: Table 39.1

*Escherichia coli*<sup>1</sup> (Gram-positive, rod-shaped bacterium) is the commonest bacteria responsible for about 85% of all UTIs. Moreover, its prevalence is consistently related to urinary pH so that it is present in about 80% of UTIs where the pH is acidic (<7) and falls to about 50% where the pH is alkaline (>7).

## 39.3 Risk Factors

An imbalance between the host factors and bacterial virulence can result in UTI. Some bacteria such as *E. coli* have virulence factors such as fimbria to attach, hemolysin, or siderophore to help it in getting nutrients. Some other bacteria, such as *Klebsiella* or *Pseudomonas*, rely on impaired host defense, as they do not have such capabilities.

The host risk factors for UTIs in children are:

- Congenital Anomaly of the Kidneys and Urinary Tract (CAKUT).
- Family history of vesicoureteric reflux (VUR) or renal disease.
- Constipation.
- Dysfunctional voiding.
- Enlarged bladder.
- Evidence of spinal lesion.

## 39.4 Clinical Features

UTIs can be divided into three different categories:

- Acute pyelonephritis (kidney infection).

<sup>1</sup>*Escherichia*—named after its discoverer Theodor Escherich (1857–1911) who was an Austrian pediatrician at Graz and Vienna.



- Acute cystitis (bladder infection).
- Asymptomatic bacteriuria.

The clinical features may vary according to the age of presentation. Overall, fever is the most common presentation. In neonates and infants, other features include irritability, refusal to feeds, abdominal pain (equivalent to flank pain of older children), vomiting, and diarrhea. Sometimes, abdominal distension and jaundice may also result. Failure to thrive may be seen in toddlers.

In older children, symptoms include frequency of micturition, dysuria. Other reported symptoms are vomiting and/or diarrhea, enuresis, suprapubic discomfort, abdominal pain, flank pain, and foul-smelling urine.

The examination may show renal angle, abdominal or suprapubic tenderness, an abdominal mass, or a palpable bladder. Dribbling, poor stream, or straining to void may also be noticed. Hypertension might suggest hydronephrosis or renal parenchyma disease. In severe cases, dehydration and sepsis may be evident.

---

## 39.5 Investigations

Urine analysis is a prerequisite and its collection may be performed by various techniques.

- Mid-Stream Urine (MSU) sample.
  - Continent children who can follow commands may void on request. Cleaning before sample collection may further reduce the chance of sample contamination.
- Spontaneous voiding, “clean catch,” nappy pad or urine bag.
  - Non-toilet trained children. “Clean catch” has the lowest contamination with pads and bags the highest rates of contamination.
- Urethral catheterization or suprapubic needle aspiration (SPA).
  - Least possibility of contamination and more reliable for culture and diagnosis. However, they may be painful and distressing for children.

**Urine Dipstick** Dipstick tests are a group of tests that involve dipping reagent strips into collected urine. It is used for testing *leukocyte esterase* and *nitrite* positivity. A combination of positive leukocyte esterase and nitrite is the most useful test for ruling in UTI. A negative result for both will be most useful in ruling out UTI. The test is preferable in children >2 years of age.

**Microscopy** Evaluation of presence of white cells (WBC), red cells, bacteria, and casts, etc. in urine samples. A negative test for either pyuria (>5 WBC/HPF) or bacteriuria is better at ruling out UTI than dipstick testing. The presence of bacteriuria is better as compared to pyuria for ruling in or ruling out UTI.

*Culture—various standards are in use.*

- The definition of significant bacteriuria includes  $5 \times 10^4$  colony forming units (CFU) per milliliter (CFU/ml) of urine obtained by catheterization or  $> 10^5$  CFU/ml in clean voided urine.
- *European Association of Urology (EAU)/European Society for Paediatric Urology (ESPU)* has varied a bit from these values. According to EAU/ESPU, significant bacteriuria on catheterization is  $>10^3$ – $10^5$  CFU/ml; in clean voided urine:  $>10^4$  CFU/ml with symptoms or  $> 10^5$  without symptoms. If urine cannot be cultured within 4 hours of collection, the sample should be refrigerated or preserved with boric acid immediately.

Dipslide method has not been found to be of much value as compared to standard culture.

**Biomarkers for UTI** There are specific biomarkers that have been evaluated over time for diagnosing UTI.

- Leukocyte esterase and nitrite have been extensively used in the dipstick test.
- Serum Procalcitonin has been found to be very useful (plasma).
- Elastase alpha (1)-proteinase inhibitor (urine and plasma).
- Lactoferrin.
- Secretory immunoglobulin A.
- Heparin-Binding Protein.
- Xanthine Oxidase.
- Myeloperoxidase.
- Neutrophil gelatinase-associated lipocalin.
- A-1 Microglobulin.

[Apart from Procalcitonin and Elastase alpha(1)-proteinase inhibitor, all other markers are assessed in the urine.]

### 39.5.1 Imaging

- *Renal and Bladder Ultrasonography (US)*—for size and shape of kidneys; presence or absence of ureter, etc. Useful in urolithiasis, hydronephrosis, hydroureter, and ureterocele. In toilet-trained children, the scan can give useful information about bladder emptying.
- *Voiding cystourethrogram (VCUG)*—used to diagnose posterior urethral valves or VUR. Bladder anatomy is delineated to show bladder diverticulae or features of neurogenic bladder. In girls, a radio-isotope direct isotope cystogram (DIC) is preferred, as the radiation dose is much smaller.
  - A DIC does not give pictures of the urethra (not required in females!).

- Oral antibiotic prophylaxis should be provided for three days, starting one day before the date of the cystogram.
- *Radio-isotope renal studies-*
  - DMSA scan is the investigation of choice, as it shows the kidney outline and detects renal scars.
  - MAG-3 renogram is preferred (to a DMSA scan) if there is hydronephrosis or if the ureters are dilated. This latter study can pick up VUR in the indirect cystogram phase in toilet-trained children.

As per the UK's *National Institute of Clinical Excellence (NICE)*, the recommended guidelines for investigation of a proven UTI are:

- *Birth to 6 months*
  - US only. (DMSA and VCUG are required if there is abnormality on the US, or if there is evidence of severe, atypical, or recurrent UTI).
- *Six months to 3 years*
  - US and DMSA required if there is severe, atypical, or recurrent UTI.
  - VCUG if there are abnormalities on USG, a family history of VUR, or a poor urinary stream.
- *Three years*
  - US and DMSA as above. No need for VCUG in most cases.

The *American Academy of Pediatrics (AAP)* recommends US for children 2–24 months of age after first febrile UTI. It recommends VCUG for children 2 to 24 months of age after the second febrile UTI, and after the first for patients with abnormalities on US or high-grade VUR. AAP guidelines do not include the use of DMSA in their recommendations.

*EAU/EPISA* recommendations do not include US and do not segregate children into age groups. It recommends either of the two approaches- the bottom-up approach (VCUG and, if positive, DMSA scan) or the top-down (DMSA scan and, if positive, VCUG).

---

## 39.6 Treatment

It has been observed that there is no difference in efficacy between oral and intravenous UTI treatment.

According to NICE recommendations for children 3 months or older with upper UTI, oral antibiotics are recommended for 7 to 10 days. A trial is being conducted by AAP for comparing 5–10 days of treatment for febrile UTI in children. IV antibiotics such as cefotaxime or ceftriaxone may be started at the initiation of treatment if oral intake is not possible. Intramuscular (IM) route may be opted if IV access is not possible.

Antibiotics should be chosen as per the local sensitivity patterns. For lower UTI, oral antibiotics such as trimethoprim, nitrofurantoin, cephalosporin, etc. may be prescribed for 3 days. Further assessment may be needed if patients do not respond within 48 hours. A systematic review of treatments for cystitis in children showed no difference in efficacy with 7–14 days of therapy compared with 2–4 days.

In infants less than 3 months, treatment should start with IV antibiotics according to the feverish illness in children. In the case of pyelonephritis, treatment should continue for approximately 10 days. It may be switched to oral treatment when it is possible.

Routine antibiotic prophylaxis is not recommended anymore after the first UTI but may have a role to play in recurrent infections. Conditions like constipation and dysfunctional voiding are actually more common causes of recurrent UTI than diseases like VUR and must be diligently looked for. Despite the conflicting reports of antimicrobial prophylaxis in VUR, it would be prudent to continue prophylaxis in high-grade VUR. Plenty of water is to be taken by these children.

Asymptomatic bacteriuria in male children does not have any other feature; however, it has also been observed in female children aged 3–10 years in between recurrent UTI episodes. In such situations, some symptoms of functional bladder and bowel dysfunctions have been observed. Hence, a term *covert bacteriuria* has also been suggested. Still, it does not require treatment but needs careful follow-up. If symptoms appear, then urine may need to be tested again, and treatment started.

---

## 39.7 Outcome

Uncomplicated lower UTI resolve without any sequelae. Children having upper UTI (pyelonephritis) need follow-up. They have a possibility of developing complications such as renal scarring, hypertension, and end-stage renal disease. In the case of renal compromise, management by a pediatric nephrologist may be helpful.

---

## Further Reading

- National Institute for Health and Clinical Excellence (NICE) guidelines for Urinary tract infection in children 2007 (Updated October 2018). <https://www.nice.org.uk/guidance/CG54>
- Urinary Tract Infection. Clinical practice guideline for the diagnosis and management of the initial uti in febrile infants and children 2 to 24 months. *Pediatrics*. 2011;128:595–610.
- Subcommittee on Urinary Tract Infection. Reaffirmation of AAP clinical practice guideline: the diagnosis and management of the initial urinary tract infection in febrile infants and young children 2-24 months of age. *Pediatrics*. 2016;138:e20163026.
- Tullus K, Shaikh N. Urinary tract infections in children. *Lancet*. 2020;395:1659–68.
- Stein R, Dogan HS, Hoebeke P, Kočvara R, Nijman RJ, Radmayr C, et al. Urinary tract infections in children: EAU/ESPU guidelines. *Eur Urol*. 2015;67:546–58.
- Matto TK, Carpenter MA, Moxey-Mims M, Chesney RW, Trial Investigators RIVUR. The RIVUR Trial: a factual interpretation of our data. *Pediatr Nephrol*. 2015;30:707–12.

- Downs SM. Technical report: urinary tract infections in febrile infants and young children. The urinary tract subcommittee of the American Academy of Pediatrics Committee on quality improvement. *Pediatrics*. 1999;103:e54.
- Strohmeier Y, Hodson EM, Willis NS, Webster AC, Craig JC. Antibiotics for acute pyelonephritis in children. *Cochrane Database Syst Rev*. 2014:CD003772.
- Michael M, Hodson EM, Craig JC, Martin S, Moyer VA. Short versus standard duration oral antibiotic therapy for acute urinary tract infection in children. *Cochrane Database Syst Rev*. 2003;2003:CD003966.
- Okarska-Napierała M, Wasilewska A, Kuchar E. Urinary tract infection in children: diagnosis, treatment, imaging—comparison of current guidelines. *J Pediatr Urol*. 2017;13:567–73.



# Disorders of Sex Development

# 40

Neetu Kumar and Abraham Cherian

Disorders of Sex Development (DSD) represents a complex congenital condition with atypical development of chromosomes, gonads, or anatomic sex. Much controversy and debate have transpired between professionals and the non-medical community however this exists in a sea of many unknowns, one of them being the long-term consequences of no intervention. The current approach is founded on a multidisciplinary team decision-making process involving the family, supported by psychology. Although the 2006 consensus statement makes an attempt to simplify and be inclusive, the current approach is to individualize care to the patient and family in conjunction with all the psychological, cultural, and social aspects rather than to categorize them.

## 40.1 Embryology

From 6 weeks, early bipotential gonads develop within the genital ridge from primordial germ cells (Fig. 40.1).

## 40.2 Clinical Features

The spectrum broadly and simplistically includes either an undervirilized male or an overvirilized female. However, that is far from complete and the following table makes an attempt to be comprehensive (Table 40.1).

The newborn period raises much anxiety, uncertainty, and social pressures in parents, especially in the presence of ambiguous genitalia. It is critical that

---

N. Kumar · A. Cherian (✉)

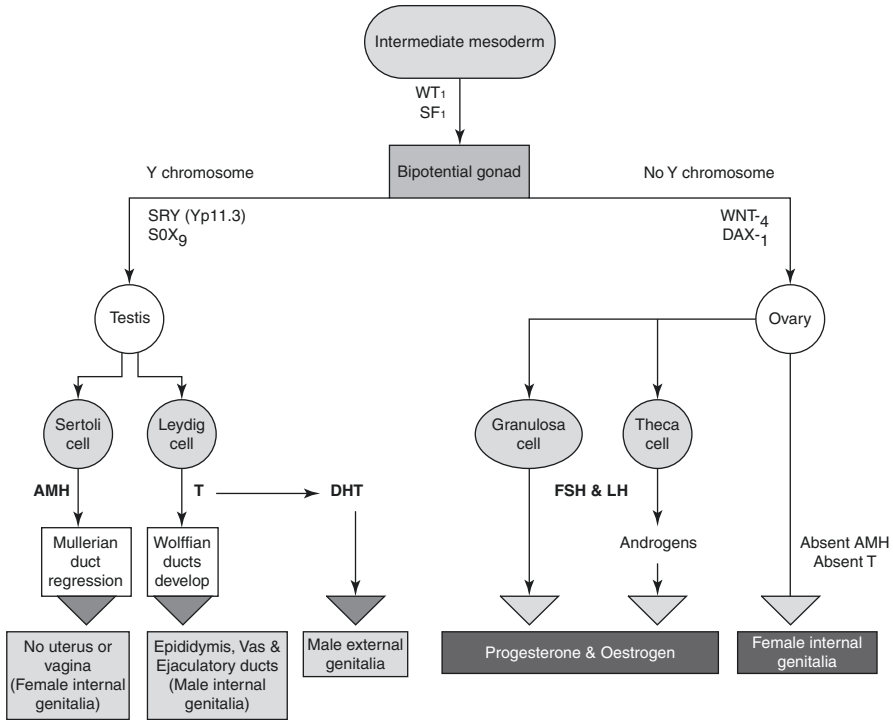
Department of Paediatric Urology, Great Ormond Street Hospital, London, UK

e-mail: [neetu.kumar1@nhs.net](mailto:neetu.kumar1@nhs.net); [cherian@doctors.org.uk](mailto:cherian@doctors.org.uk)

© Springer Nature Switzerland AG 2022

C. K. Sinha, M. Davenport (eds.), *Handbook of Pediatric Surgery*,

[https://doi.org/10.1007/978-3-030-84467-7\\_40](https://doi.org/10.1007/978-3-030-84467-7_40)



**Fig. 40.1** Embryology of sex development

life-threatening conditions like salt-wasting congenital adrenal hyperplasia (CAH) are immediately evaluated and information gathered to facilitate gender assignment. Subsequent management should proceed in a logical and timely manner in a specialized center with multidisciplinary input. Guessing the sex and usage of “he” and “she” should be avoided, with phrases such as “*your baby*” being more appropriate.

A complete clinical history (maternal, fetal, and family) and examination is important. Particular points to be noted when examining include:

- Presence/absence of a palpable gonad on either side- position and size.
- Phallic appearance including length, width, and presence of chordee.
- Appearance of scrotum/labio-scrotal folds, degree of skin rugosity/pigmentation.
- Location of external urethral opening and number of orifices present on the perineum; position of the anal margin.
- Dysmorphic/syndromic features.

Some children will only present later in life such as complete sex reversal (Swyer syndrome) who look unequivocally female (XY, complete gonadal dysgenesis), but who are unable to develop secondary sexual characteristics or menstruate.

**Table 40.1** A classification system for DSD

| Sex chromosome DSD                                 | 46 XY DSD  | 46 XX DSD   |
|--|--|---|
| A: 47 XXY (Klinefelter syndrome & variants)        | A: Disorders of gonadal (testis) development   | A: Disorders of gonadal (ovary) development   |
| B: 45 X (turner syndrome & variants)               | 1. Complete or partial gonadal dysgenesis (e.g., <i>SRY</i> , <i>SOX9</i> , <i>SFI</i> , <i>WT1</i> , <i>DHH</i> etc.)   | 1. Gonadal dysgenesis   |
| C: 45 X/46 XY mosaicism (mixed gonadal dysgenesis) | 2. Ovotesticular DSD   | 2. Ovotesticular DSD  |
| D: 46 XX/46 XY (chimerism)                         | 3. Testis regression   | 3. Testicular DSD (e.g., <i>SRY</i> <sup>+</sup> , <i>dup SOX9</i> , <i>RSPO1</i> ) |
|  | <i>B: Disorders in androgen synthesis or action</i>  | <i>B: Androgen excess</i>   |
|  | 1. Disorders of androgen synthesis   | 1. <i>Fetal</i>   |
|  | LH receptor mutations  | 3β-hydroxysteroid dehydrogenase II  |
|  | Smith–Lemli–Opitz syndrome   | 21-hydroxylase  |
|  | Steroidogenic acute regulatory protein cholesterol side-chain cleavage   | P450 oxidoreductase   |
|  | 3β-hydroxysteroid dehydrogenase II 1   | 11β-hydroxylase   |
|  | 7α-hydroxylase/17,20-lyase   | Glucocorticoid receptor mutations   |
|  | P450 oxidoreductase  | 2. <i>Fetoplaental</i>  |
|  | 17β-hydroxysteroid dehydrogenase III   | Aromatase deficiency  |
|  | 5α-reductase II  | Oxidoreductase deficiency   |
|  | 2. Disorders of androgen action  | 3. <i>Maternal</i>  |
|  | Androgen insensitivity syndrome drugs & environmental modulators   | Maternal virilizing tumors (e.g., luteomas)   |
|  | <i>C: Other</i>  | Androgenic drugs  |
|  | 1. Syndromic associations of male genital development (50+) (e.g., cloacal anomalies, Robinow, Aarskog, hand-foot-genital, popliteal pterygium syndrome, etc.) | <i>C: Other</i>   |
|  | 2. Persistent Mullerian duct syndrome  | 1. Syndromic associations (e.g., cloacal anomalies)                                 |
|  | 3. Vanishing testis syndrome   | 2. Mullerian agenesis/hypoplasia (e.g., MURCS)                                      |
|  | 4. Isolated hypospadias  | 3. Uterine abnormalities (e.g., MODY5)  |
|  | 5. Congenital hypogonadotropic hypogonadism  | 4. Vaginal atresia (e.g., McKusick-Kaufman)   |
|  | 6. Cryptorchidism  | 5. Labial adhesions   |
|  | 7. Environmental influences  |   |

Classification of DSD (after Lee PA, Houk CP, Hughes IA, Ahmed SF, Houk C, et al. Consensus statement on management of intersex disorders. Pediatrics 2006; 118: e488-e500).



In general, *symmetrical* genital appearance suggests a *biochemical* etiology (e.g., congenital adrenal hyperplasia (CAH)), whereas *asymmetrical* appearance implies a *chromosomal* abnormality (e.g., 45X0/46XY).

---

### 40.3 Investigations

The following investigations may be required and each patient should be individualized:

1. Genetic—karyotype and specific gene arrays.
2. Endocrine—blood and urine biochemistry, hormone assays.
3. Imaging—ultrasound (renal/pelvic), contrast studies (cystogram/genitogram), and MRI.
4. Surgical—cystovaginoscopy, laparoscopy, and skin/gonadal biopsies.

---

### 40.4 Principles of Management

The ESPU-SPU Consensus statement 2020 outlines “a one size fits all” approach does not exist for DSD patients. It recommends an individualized non-mandated management taking into account all medical, psychological, social, and cultural considerations of the patient and their parents and caregivers.

#### Medical Management

- Electrolyte balance maintenance (salt losing CAH)
- Hormone replacement or supplementation if needed
- Corticosteroid therapy (CAH)
- Spironolactone for acne/hirsutism
- Oral contraceptive pills (OCP) for menstrual irregularities (CAH)

Medical noncompliance with corticosteroid therapy can cause increasing clitoromegaly, virilization, and short stature due to premature epiphyseal plate closure in 46XX CAH patients.

#### Surgical Management

Currently, there are ongoing contentious debates from various medical and non-medical groups regarding the optimal management of DSD patients particularly regarding surgical intervention. The ethics behind the surgical decision-making, the timing of surgical intervention, and the functional and cosmetic outcomes that can be expected or have been reported are evolving and under discussion. However, the general surgical principles would include:

- Emergency—to create outlets for urine/stool

- Elective
  - Diagnostic investigations: EUA, cystourethroscopy, vaginoscopy, laparoscopy, gonadal biopsy
  - Gonadal Surgery- to reduce the risk of gonadal tumors (streak gonads and Y material)
  - Genital Surgery
    - Masculinizing surgery: Hypospadias repair, chordee correction, orchidopexy, scrotoplasty, excision of Mullerian structures
    - Feminizing Surgery: Vaginoplasty, labioplasty, introitoplasty, clitoroplasty

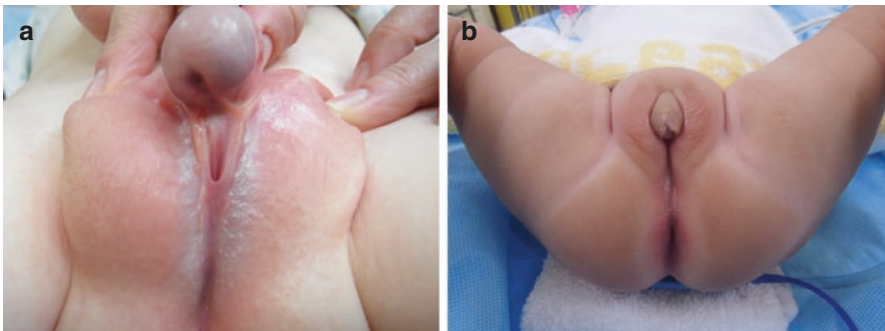### Psycho-Social Management

- Genetic counseling regarding future pregnancies
- Psychological support for family and patient

*Congenital Adrenal Hyperplasia*—Usually 21-Hydroxylase Deficiency.

This is the most common type. Infants present with ambiguous genitalia and bilateral impalpable gonads (Fig. 40.2b). It can be life-threatening due to salt-losing nature (75%) with ↓ aldosterone.

- Urgent karyotype—46XX.(CAH can occur in 46XY but genitalia are usually not ambiguous).
- Steroid profile—↑ 17-hydroxy progesterone ↑ androstenedione levels.
- 46XX CAH babies have clitoromegaly, scrotalization of labio-scrotal folds, and a urogenital sinus. 46XY CAH in most have a normal male phenotype.
- Medical Management with corticosteroid therapy. Feminizing surgery has become more conservative due to better medical management in terms of clitoral size however timing and outcomes of urogenital sinus surgery is still controversial and debated.



**Fig. 40.2** (a) 46, XY DSD (severe hypospadias and impalpable testes). (b) 46, XX DSD (congenital adrenal hyperplasia)

---

## 40.5 Gender Assignment

It is important to avoid guessing the sex and using terms “he” or “she.” Phrases such as “your baby” are more appropriate. Birth is not registered until the final decision has been made, as the reversal process is complex (42 days are allowed to register a birth in the UK except Scotland which is 21 days). Wherever possible, gender is assigned according to *karyotype*, rather than being reassigned to suit the initial appearances of the external genitalia, although this may not always be possible.

An experienced multidisciplinary clinical team should undertake the decision-making of the gender assignment with full involvement of the parents and the child if appropriate. The important factors to be considered during the assignment are: expected gender identity, sexual function, fertility potential, and the psychosocial development of the child.

---

## 40.6 Long-Term Outcomes

- Data on the long-term outcome of surgery for DSD conditions are sparse.
- There are no controlled trials comparing early vs. late surgery and no data exist for the long-term outcome of newer techniques in feminizing genitoplasty, such as total or partial urogenital mobilization and nerve-sparing or corporal-sparing clitoral reduction or clitoroplasty.
- Retrospective reviews suggest that there is much dissatisfaction with the results of surgery performed in the past with regard to cosmetic appearance and function, but this is very difficult to quantify as there is a significant underestimation of the denominator.
- In the current climate of minimal or no intervention what remains to be clarified is the long-term outcome of such an approach. Although there are islands of understanding, it is still in a sea of unknowns. Prospective evaluation over birth to adulthood is recommended for all. Several countries have now started registries to recruit patients and document outcomes which will be invaluable in the future.

---

## Further Reading

- Lee PA, Houk CP, Hughes IA, Ahmed SF, Houk C, et al. Consensus statement on management of intersex disorders. *Pediatrics*. 2006;118:e488–500. <https://doi.org/10.1136/adc.2006.098319>.
- Mouriquand P, Caldamone A, Malone P, Frank J, Hoebcke P. The ESPU/SPU standpoint on the surgical management of sex development (DSD). *J Pediatr Urol*. 2014;10(1):8–10. <https://doi.org/10.1016/j.jpuro.2013.10.023>.
- ESPU-SPU Consensus statement 2020: Management of differences of sex development (DSD) [Online] <https://www.espu.org/members/documents/383-espu-spu-consensus-statement-2020-management-of-differences-of-sex-development-dsd>



Ranjit Shail

### Enuresis Is Very Common!

- 15% to 20% of five-year-old children experience nocturnal enuresis which usually goes away as they grow older
- Still, about 2–5% of young adults experience nocturnal enuresis at times of stress.

## 41.1 Introduction

- Normal variation.
  - Children have daytime bladder control by 2 years with night-time control by 3 years.
  - 85% will be dry by day and night by age 5.
- Nocturnal enuresis<sup>1</sup> is more common than diurnal enuresis.
- *Primary enuresis* (75%) (International Childrens Continence Society—ICCC, definitions).
  - When a child has never had urinary control.
- *Secondary enuresis* (25%).
  - There has been a 6 months preceding period of dryness.

<sup>1</sup>Enuresis (Greek ἐνούρησις) - “to void urine.” The implication is that this is involuntary.

R. Shail (✉)  
St Helier Hospital, London, UK  
e-mail: [ranjitshail@doctors.org.uk](mailto:ranjitshail@doctors.org.uk)

---

## 41.2 Physiology

Urine is stored in the bladder because of sympathetic and pudendal nerve mediated inhibition of detrusor contraction. Voiding occurs with reflex bladder contraction and relaxation of the sphincter.

- *Average bladder capacity is  $(age+2) \times 30$  in mL.*

---

## 41.3 Causes of Enuresis

- Constipation.
  - Most common cause for enuresis especially if nocturnal.
  - Restricts bladder capacity with colonic movement at night triggering uninhibited detrusor contraction.
- Bladder outlet obstruction and overflow incontinence.
  - For example, posterior urethral valves, trauma, infection.
- Urological infection.
  - UTI, cystitis.
- Polyuria.
  - Chronic kidney disease.
  - Diabetes Insipidus.
  - Diabetes Mellitus.
  - Electrolyte imbalance.
  - Reduced ADH at night.
- Bladder capacity issues.
  - Detrusor instability.
  - Neurogenic bladder.
  - Overactive bladder.
- Central nervous system control issues.
  - Developmental delay.
  - Seizures.
  - Sleep disorders, commonly secondary to adenotonsillar hypertrophy.
- Hyperthyroidism.
- Social Issues, major life events.
  - New baby.
  - Moving house, bereavement, parental disharmony, child abuse etc.

---

## 41.4 Clinical Features

- History of birth trauma or cerebral palsy. Failure to pass developmental milestones.
- New-onset frequency and urgency as seen in cystitis and UTI.
- Evidence of sleep disorder or snoring.
- Voiding diary for diurnal variation.

---

### 41.4.1 Examination

- General physical examination including BMI, abdominal and genitourinary examination.
- Neurology and spine examination for possible malformation (sacral abnormalities, spina bifida occulta).
- Rectal examination for constipation and sphincter weakness.
- ENT examination to look for obstructive sleep disorder secondary to adenotonsillar hypertrophy.

### 41.4.2 Investigations

- Blood sugar.
- Electrolytes, including Na, Cl, K, Ca.
- Renal function (urea and creatinine) to look for evidence of acute and chronic renal impairment.
- Serum and urine osmolality.
- Urine for blood, protein, cells and infection.
- Ultrasound and KUB.
  - Bladder capacity, emptying and residual urine.
- Spinal MR scan.
  - For abnormal neurological examination.
- Voiding cystourethrogram.
  - If posterior urethral valves are suspected.
- Urodynamics studies.
  - Will identify urethral obstruction, neurogenic bladder, dysfunctional voiding.

---

## 41.5 Management

- General measures.
  - Children often drink less fluid at the daytime and school, and at the same time, they are very active during this period. They are hungry, thirsty and dehydrated when they are home and drink a large amount of fluid in the evening. They should be encouraged to do the reverse, more fluids during the day and less late evening.
  - Avoid caffeine that has a diuretic effect.
  - Bladder training for regular voiding with alarm warnings.
  - Empty bladder at bedtime.
  - Food with high fiber to avoid constipation, laxatives.
  - Monitor urine output, especially looking for diurnal variation.
- Psychological support.
  - Reassurance and education for under 5 years.
- Behavioral Therapy.
  - Induced waking at night to void, using enuresis alarm.

- *Drugs.*
  - After 7 years of age.
  - *Desmopressin.*

Vasopressin analog that enhances reabsorption of water by distal tubules and collecting ducts of kidney and inhibits the secretion of aldosterone. Oral tablet or sublingual dose is taken at bedtime decreases nocturnal urine output.
  - *Anticholinergics—e.g., Oxybutanin, Tolteridine.*

These bind to choline receptors and produce antagonistic activity against acetylcholine and relieve detrusor overactivity. They are useful in children with bladder spasm, detrusor overactivity, decreased functional bladder capacity, urgency and frequency, which are more common daytime symptoms.
  - *Anticholinergic Tricyclic Antidepressant - e.g., Imipramine.*

Now usually avoided because of side effects (e.g., cardiac).

---

**Part VI**

**Neurosurgery**





Samantha Hettige, Anan Shtaya,  
and Ajay N. Gangopadhyay

## 42.1 Demography

Neural tube defects (NTD) are a group of complex congenital anomalies of the central nervous system (CNS), are the second most common birth defects.

- 2–3/1000 births
- Female predominance (most marked in anencephaly).
- Geographical variation—incidence ↑ Ireland, Scotland; ↓ Japan.
- White > black.

## 42.2 Etiology

- Genetic—the recurrence risk for NTD in siblings is 2–5%.
- Environmental.
- X-irradiation.
- Drugs.
  - Thalidomide, folate antagonists, androgenic hormones, antiepileptics (valproate and carbamazepine), and hypervitaminosis A; substance abuse (e.g., alcohol); chemical agents (e.g., organic mercury, lead).
- Maternal infections.
  - Rubella, cytomegalovirus, *Toxoplasma gondii*, syphilis.

---

S. Hettige (✉) · A. Shtaya  
Department of Neurosurgery, St George's University Hospital, London, UK  
e-mail: [Samantha.Hettige@stgeorges.nhs.uk](mailto:Samantha.Hettige@stgeorges.nhs.uk)

A. N. Gangopadhyay  
Department of Paed Surgery, IMS, BHU, Varanasi, UP, India

- Maternal metabolic conditions.
  - Phenylketonuria, diabetes mellitus.
  - Maternal obesity.
    - Risk increases with increased maternal body mass index.
- Nutritional, e.g., folate deficiency, possibly due to polymorphisms in folate metabolizing enzymes and enhanced likelihood of meiotic nondisjunction.

Periconceptual dietary supplementation of folate can reduce incidence of NTD by 50%.  
(Effect first shown in UK RCT in 1991)

### 42.3 Embryology

NTDs can be classified embryologically as:

- Open NTDs—due to failure of primary neurulation.
- Closed NTDs—from a defect in secondary neurulation.

*Primary neurulation*—formation of neural structures into a tube, thereby forming the brain and spinal cord.

- Thickening of the ectoderm.
  - from primitive node of Hensen<sup>1</sup> caudally to the prochordal plate rostrally,
- Formation of neural plate (days 17–19).
- Neural folding (days 19–21).
- Fusion of the neural folds (days 22–23) (Table 42.1).
- Closure of anterior neuropore (days 24–26).
- Closure of posterior neuropore (days 26–28).

**Table 42.1** Possible neural tube defect malformations

|                                  |  |
|----------------------------------|--|
| Cranial                          |  |
| Anencephaly                      | Failure of closure of anterior neuropore—incompatible with life. F >> M                                  |
| Encephalocele                    | Failure of closure of anterior neuropore—Ranges from occiput (visual impairment) to frontal bones defect |
| Craniorachischisis totalis       | Exposure of entire neural plate. Incompatible with life  |
| Spinal                           |  |
| Spina bifida occulta             | Skin covered defect of the lumbo/sacral spine  |
| Spina bifida cystica (or aperta) | Neural elements can be exposed through skin and dural defect   |

<sup>1</sup>CA Victor Hensen (1835–1924) German zoologist who also coined the term “plankton.”

*Secondary neurulation*—formation of the lower spinal cord and future lumbar and sacral elements starts at day 27.

---

## 42.4 Spina Bifida Occulta (SBO)

- Found in up to 20% of otherwise normal population.

The defect mainly involves the low lumbar and sacral regions and results in closed defects with incomplete vertebral arches with no herniation of meninges. There may be a hairy patch, dermal sinus tract, dimple, hemangioma, or lipoma. Spina bifida occulta is often associated with other skeletal defects including sacral agenesis.

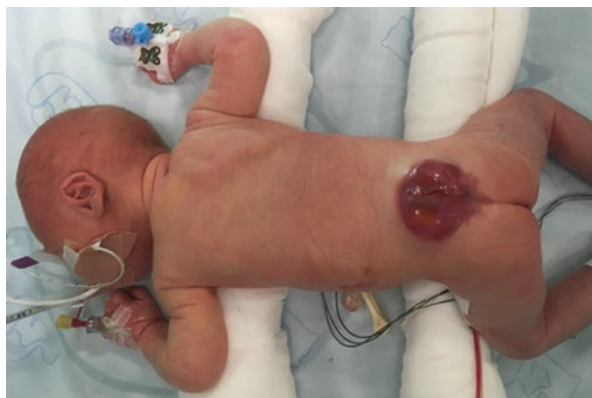*Occult spinal dysraphism*—term used for uncommon (~2%) association with neurological abnormality or symptoms.

---

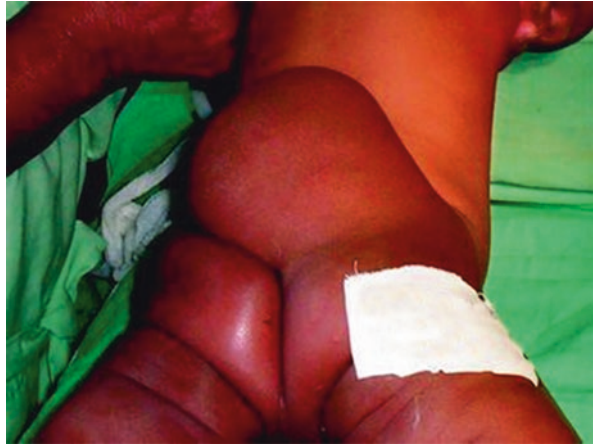## 42.5 Spina Bifida Cystica

- *Myelomeningocele* (75%).
  - Spinal cord and nerve roots herniate into a meningeal sac. The spinal cord often ends in this sac and is splayed open, exposing the central canal. Orthopedic and neurological effects are common (Fig. 42.1).
- *Meningocele* (10%).
  - Herniation of the meninges only through the bony defect. Neurological effects are less common.
- *Lipomeningocele or lipomyelomeningocele* (5%).
  - Skin-covered lipomatous mass that herniates through the bony defect and attaches to the spinal cord, causing tethering of the cord and nerve roots (Fig. 42.2).

**Fig. 42.1** Meningomyelocele (open neural tube defect) in the mid lumbar area



**Fig. 42.2** Large lipomeningocele



- *Myelocystocele* (rare).
  - The spinal cord has a large terminal cystic dilatation resulting from *hydromyelia*. It is associated with other major defects (e.g., cloacal exstrophy, exomphalos).
- *Myelocele* (rare).
  - Most severe form with a complete failure of closure of the neural tube. This is usually fatal.

## 42.6 Management

### 42.6.1 Prenatal

- Maternal serum alpha-fetoprotein (MSAFP)—screening.
- Ultrasound.
- Amniocentesis.

Open NTDs can be detected by measuring alpha-fetoprotein ( $\alpha$ -FP) in the amniotic fluid and maternal serum. The latter one is commonly used as the basis for screening from 15th to 20th week. Fetal US and amniocentesis together with prenatal counseling are then used to complete the diagnosis and plan the next step. Options include termination (if society allows), planned cesarean section delivery (for large defects) or planned induction at 38 weeks for normal vaginal delivery (for smaller defects), at an appropriate neurosurgical center.

The randomized *Management of Myelomeningocele Study* (MOMS) trial looked at the safety and efficacy of fetal surgery for myelomeningocele in three US institutions (2003–2010). Infants were randomized to fetal surgery at 18–25 weeks gestation versus standard repair shortly after birth.

Fetal surgery reduced the risk of death or need for shunt placement during the first year of life and resulted in improvement in a composite score for mental development and motor function at 30 months of age. However, there was a higher risk of preterm delivery and pulmonary edema, and of obstetric complications including placental abruption, dehiscence of the hysterotomy site, and maternal transfusion at delivery.

Because fetal surgery is associated with significant complications, both fetal and maternal, the inclusion criteria are strict, and usually involve only those with low, small defects.

### 42.6.2 Postnatal

Treatment of spina bifida in neonates has evolved over the past half-century from a period of nihilism and allowing nature to take its course through a period of aggressive early (almost emergency) back closure and unrestricted surgery in the 1960s and 1970s to a more selective policy based on the prediction of likely (“acceptable”) outcome.

---

## 42.7 Surgery

Defect closure is indicated mainly to avoid infection and should be done in the first 48 hours of life. It will also protect the compromised neural tissue. It should be sufficiently elective to avoid hypovolemia, hypothermia, and airway compromise.

### Closure of Myelomeningocele

- Measure size of defect and assess whether the lesion is ruptured or unruptured.
  - Ruptured: start antibiotics (e.g., benzylpenicillin and gentamicin, to continue if ventriculoperitoneal shunt anticipated in next 5 or 6 days, or follow local hospital protocol).
  - Ruptured: no antibiotics necessary.
- Cover lesion with a non-adherent absorbent dressing (e.g., Telfa™) then sponges soaked in normal saline and wrap in ClingFilm™ to prevent desiccation.
- Prone or even Trendelenburg position, patient on stomach (keeps pressure off the lesion).
- Perform surgical closure within 48 hrs unless there is a contraindication to surgery.

*Monitor for hydrocephalus and CSF leak (around 70–80% will need a shunt).*

### 42.7.1 Spinal Dysraphism (Lipomyeloceles, Dermal Sinus Tract, Tethered Cord)

The surgical goal in treating these lesions is to detach the lipoma/connective tissue tract of the skin from the lipoma that emerges through the dura, fascia, and bony defect. This can be planned in a delayed fashion, ideally around 8 months of age, and before the child can walk.

Surgical technique: Identify normal anatomy and locate where the lipoma pierces the dura and enters the spinal cord. The lipoma is disconnected from the spinal cord (microsurgical technique). The filum terminale also is divided to further untether the cord.

## 42.8 Long Term Issues

There is a spectrum of disability and deformity in spina bifida because of the varying degree of neurological involvement. It can be difficult to describe the typical child with SB. However, the three main areas that cause most problems are:

- *Central neurological*
  - Typically related to the development of hydrocephalus (usually following back closure) and due to impaired CSF drainage (associated *Arnold–Chiari*<sup>2</sup>*malformation*). About 20% of all infants with myelomeningoceles will have significant hydrocephalus at birth and a further 70–80% develop it after the back is closed requiring a shunt. In some infants, shunt placement may be performed at the same time as back closure.

Management of hydrocephalus and its complication is considered in Chap. 6.2.

- *Orthopedic and peripheral neurological*
  - The degree is related to the level of neural involvement. At birth, there is a flaccid paralysis of the muscle groups affected; however, thereafter various lower limb deformities have the potential to occur depending on the SB level. Usually, this is due to unopposed muscle action across a joint, e.g., fixed flexion deformity of hip occurs with functioning hip flexors (L1) and absent extension (S2). Pressure sores are the principal complication of anesthetic or numb skin.
  - Spinal radiography, CT, and MRI spine will detect relevant bony pathology and evaluate the risk of scoliosis and propensity to secondary neurological pathology (e.g., tethered cord, diastematomyelia, intraspinal division of cord due to bony spur) and syringomyelia (i.e., cystic cavity within the spinal cord,

<sup>2</sup>Julius Arnold (1835–1915) German pathologist. Herniation of the cerebellar tonsils through the foremen magnum.

<sup>3</sup>Hans Chiari (1851–1916) Austrian pathologist.

usually in cervical or thoracic parts, often associated with Arnold–Chiari malformation).

- Management is complex (and outside the limits of this chapter), but a multi-disciplinary approach which may also include operations to centralize joints (tenotomies and casting), and correct scoliosis; together with braces and devices to aid the development of walking, standing, etc.
- *Urology*
  - Related to the level of neural involvement with a potential to develop life-threatening renal failure.
  - The principal problem is the development of a *neuropathic bladder* (small volume, hypercontractile, ↑ intravesical pressure). This may lead to dilatation of upper tracts, hydronephrosis, and ultimately chronic renal failure. Serial US and urodynamics will direct the management strategy with the aim of preserved renal cortical function, an uninfected urinary tract, and a dry child.
  - Crede maneuver—emptying bladder by suprapubic pressure.
  - *Clean intermittent catheterization* (from ~3 weeks old) urethral (usually anesthetic), or via Mitrofanoff<sup>4</sup> conduit (appendix) or Monti<sup>5</sup>(tubularized ileum).
  - *Bladder augmentation* (stomach, ileum, colon)—↑ capacity, ↓ upper tract pressure. Bladder neck reconstruction/closure.
- *Constipation and Incontinence*
  - Sphincter control is often disturbed in SB, leading to incontinence, whereas poor colon motility and reduced activity lead to constipation. Regular laxatives may help timed defecation and a clear colon, so aiding sphincter control. This principle can be taken a step further by the creation of an *ACE* (*ante-grade continent enema*) *stoma* or cecostomy device to allow daily colon lavage.

### 42.8.1 Outcome

- *Intellect*
  - In most series, 60–70% of the children with SB have IQs > 80; others will have IQs in the delayed or severely delayed range.
    - IQ ~ 102—without hydrocephalus.
    - IQ ~ 95—with hydrocephalus.
    - IQ ~ 73—hydrocephalus + CNS infection.
- *Bowel and bladder continence*
  - Only 10–15% of all children with myelomeningoceles are continent of urine.
  - Ambulation.
    - Some children can ambulate in the community, some only in the home, others can only stand but not walk and the rest are wheelchair-bound.
    - Many children with NTDs lose their ability to ambulate as they get older.

<sup>4</sup>Paul Mitrofanoff—French urologist, technique first described in 1980.

<sup>5</sup>Paolo Ricardo Monti—Brazilian urologist, technique described in 1997.

## Further Reading

- Copp AJ, Adzick NS, Chitty LS, et al. Spina Bifida. *Nat Rev. Dis Primers*. 2015;1:15007. <https://doi.org/10.1038/nrdp.2015.7>.
- Adzick NS, Thom EA, Spong CY, et al. A randomized trial of prenatal versus postnatal repair of myelomeningocele. *N Engl J Med*. 2011;364:993–1004. <https://doi.org/10.1056/NEJMoa1014379>.
- Thompson DN. Postnatal management and outcome for neural tube defects including spina bifida and encephaloceles. *Prenat Diagn*. 2009;29:412–9.
- Avagliano L, Massa V, George TM, et al. Overview on neural tube defects: from development to physical characteristics. *Birth Defects Res*. 2019;15(111(19)):1455–67.





Samantha Hettige, Micaela Uberti,  
and Ajay N. Gangopadhyay

Hydrocephalus is an excessive accumulation of cerebrospinal fluid within the ventricles of the brain, secondary to a mismatch between production of CSF and its absorption.

Hydrocephalus can be divided by time into: acute hydrocephalus which occurs over days; subacute over weeks; and chronic over months or years. The prevalence is around 1%.

## 43.1 Physiology

Cerebrospinal fluid (CSF):

- Total volume of CSF in adults is 150 ml and dynamic with 450 ml/day produced daily.
- Total volume is “turned over” 3 times a day.
- Total volume of CSF is 50 ml in a newborn.
- 80% is produced by the choroid plexuses of the lateral (majority) and fourth ventricle.
  - Small amount in the ventricular ependyma.

S. Hettige (✉) · M. Uberti

Department of Neurosurgery, St George’s University Hospital, London, UK  
e-mail: [samantha.hettige@stgeorges.nhs.uk](mailto:samantha.hettige@stgeorges.nhs.uk); [Micaela.uberti@stgeorges.nhs.uk](mailto:Micaela.uberti@stgeorges.nhs.uk)

A. N. Gangopadhyay

Department of Paed Surgery, IMS, BHU, Varanasi, UP, India

- Brain parenchyma (interstitial space).
- The rate of the production is independent of the intracranial pressure (ICP) and is an active process.
- Absorption:
  - Arachnoid granulations in the venous sinuses (mostly).
  - Choroid plexus and lymphatic system (minimal, through the cranial nerve sheaths).
  - Rate of absorption is pressure dependent.
- Normal CSF pressure.
  - ~ 5–12 cmH<sub>2</sub>O in newborns and 7–15 cmH<sub>2</sub>O in adults
- Normal CSF components (per mm<sup>3</sup>):
  - Normal newborn: 7–10 WBC, moderate RBC.
  - Normal child 1–15 yo: 2–3 WBC, 0 RBC.
  - Normal adult: 0–5 WBC (0–5 lymphocytes, no PMN), 0 RBC.

---

## 43.2 Anatomy

CSF flows from the lateral ventricles to the third ventricle through the Foramina of Monro.<sup>1</sup> From the third ventricle it goes to the fourth ventricle through the Aqueduct of Sylvius.<sup>2</sup> From the fourth ventricle, it flows into the subarachnoid space through two lateral Foramina of Luschka<sup>3</sup> and one median Foramen of Magendie.<sup>4</sup> It is absorbed by arachnoid granulations into the dural sinus, and finally into the venous system (Fig. 43.1).

---

## 43.3 Classification

### 43.3.1 Functional

Described by Dandy<sup>5</sup> in 1913.

- *Communicating (non-obstructive)*:
  - Full communication exists between the ventricles and subarachnoid space, so the defect is either in the reabsorption of the CSF by the arachnoid

---

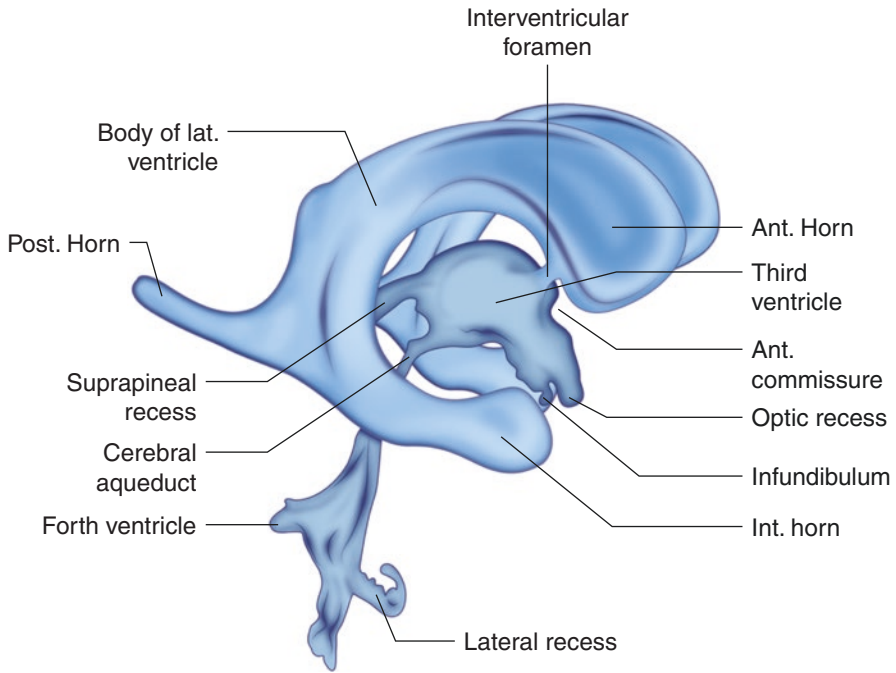
<sup>1</sup>Alexander Monro (1733–1817) Scottish physician.

<sup>2</sup>Franciscus Sylvius (1614–1762) German-born Dutch physician and scientist also credited with invention of gin!

<sup>3</sup>Hubert von Luschka (1820–1875) German anatomist.

<sup>4</sup>Francois Magendie (1783–1855) French physiologist, controversial in his day for practising live vivisection of animals.

<sup>5</sup>Walter Edward Dandy (1886–1946). 1. Pioneer American neurosurgeon, working at Johns Hopkins Hospital, Baltimore, USA.



**Fig. 43.1** Cast of ventricular system (from Gray's anatomy)

granulations, or due to an excess in production). Examples: post-meningitis, post-subarachnoid hemorrhage.

- *Non-communicating (Obstructive):*
  - CSF flow is obstructed within the ventricular system. There is an enlargement of the ventricles proximal to the block, e.g., tumors.

Some pathologies can involve both mechanisms. For example, tumors can lead to obstructive and non-obstructive hydrocephalus, the latter due to protein production from the tumor itself and presumed blockage of the CSF reabsorption.

### 43.3.2 Congenital or Acquired

*Congenital (0.9–1.8/1000 births)*

- Stenosis of the aqueduct of Sylvius (10% neonatal)
  - ↑ lateral and third with normal fourth ventricle
- Aqueduct gliosis due to intrauterine infection
  - For example, congenital toxoplasmosis.

- Dandy–Walker<sup>6</sup> malformation (2–4% neonatal)
  - F >> M, posterior fossa cyst and ↑ fourth ventricle due to atresia of foramina of Luschka and Magendie
- Arnold<sup>7</sup>–Chiari<sup>8</sup> Type 1—cerebellar tonsillar ectopia
- *Arnold–Chiari Type 2—cerebellar vermis displacement associated with spina bifida in 90% of cases*
- Agenesis of the Foramen of Monro
- Bickers–Adams syndrome
  - X-linked recessive, severe mental retardation, spastic paraplegia, adducted thumbs)
- Hydrocephalus associated with stenosis of the aqueduct of Sylvius (HSAS).
  - Due to L1CAM gene mutation > most common heritable form of hydrocephalus

*Acquired (secondary)*

- Meningitis
  - Most common cause of communicating hydrocephalus overall.
- Post hemorrhagic
  - Second most common cause of communicating hydrocephalus.
  - *Intraventricular hemorrhage (IVH)*: It is usually due to prematurity caused by bleeding from the germinal matrix (immature lining of the ventricles).
- 50% of infants <1500 g will develop an IVH.
  - Head injury.
- Mass lesions.
  - Tumors (brain and spinal), cyst, abscess, vascular malformation, hematoma.
- ↑ Venous sinus pressure
  - Secondary to stenosis/thrombosis.
- Iatrogenic.
  - Hypervitaminosis A, isotretinoin.
- Idiopathic, no cause found.

---

## 43.4 Clinical Features

Symptoms are secondary to raised ICP: headaches, nausea, vomiting, gait changes, VI (abducens) nerve palsy (false localizing sign), papilledema, visual disturbance, drop attacks, sudden death.

Other signs in pediatric patients: upward gaze palsy (setting sun sign—Fig. 43.2), irritability, lethargy, poor feed, poor head control, reduced activity, vomiting,

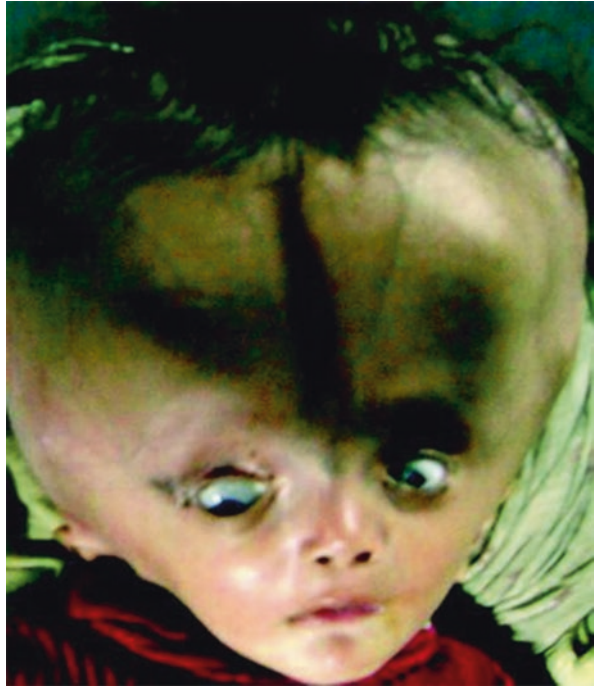---

<sup>6</sup>Arthur Earl Walker (1907–1995) Canadian neurosurgeon, described second case (after Dandy's) in 1942.

<sup>7</sup>Julius Arnold (1835–1915) German pathologist – described after but independently from Chiari's description.

<sup>8</sup>Hans Chiari (1851–1916) Austrian pathologist and also contributed to Budd-Chiari syndrome.

**Fig. 43.2** The “Setting Sun” sign in hydrocephalus



engorgement of scalp veins, hyperactive reflexes, apneic spells and irregular respirations, MacEwan’s sign (cracked pot sound on percussing on the skull on the junction of the frontal, temporal, and parietal bones, over dilated ventricles, hypertonicity (due to stretching of periventricular pyramidal tract fibers).

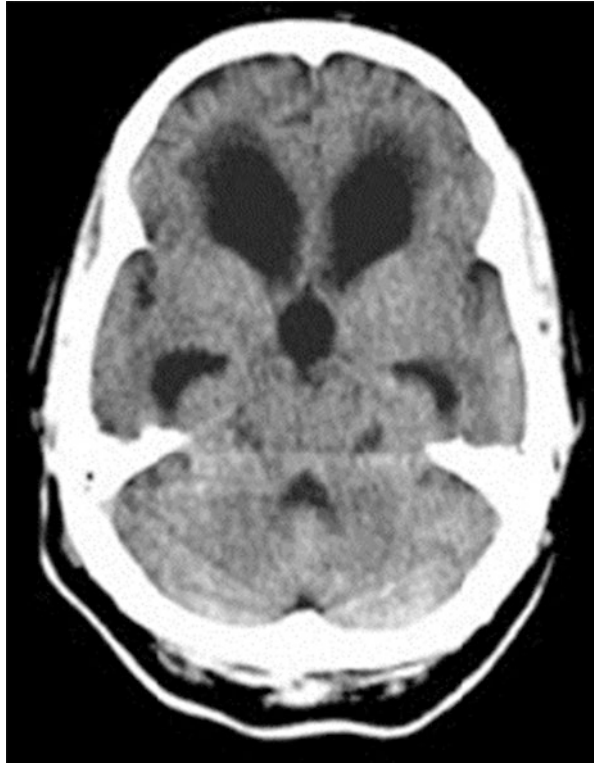Before closure of fontanelles: Increase in Occipito-frontal circumference (OFC), bulging/tense/full fontanelle, engorgement of scalp veins, splaying of cranial sutures.

#### 43.4.1 Imaging

Hydrocephalus may be diagnosed prenatally, but does not develop until the third trimester and may be missed on early US.

- US (in infants) is useful in the evaluation and follow up of subependymal and intraventricular hemorrhage.
- Skull radiographs.
  - Erosion of sella turcica and/or “beaten copper cranium.” The latter can also be seen in craniosynostosis. This is a sign of chronic hydrocephalus.
- *CT/MRI criteria for acute hydrocephalus* include the following (See Fig. 43.3):
  - Temporal horns >2 mm; sylvian and interhemispheric fissures are not visible.

**Fig. 43.3** CT scan showing enlarged temporal horns, dilated frontal horns and third ventricle. The periventricular hypodensity anterior to the frontal horns indicates transependymal flow



- Ratio between the largest width of the frontal horns and the internal diameter from inner table to inner table at this level  $> 0.5$ .
- *Evans ratio:*  
Ratio of the largest width of the frontal horns to maximal biparietal diameter on the same CT slice  $> 0.3$ .
- The classic “transependymal absorption of CSF” (stasis of interstitial fluid on the brain adjacent to the ventricles) is translated on images as periventricular low density on CT, high-intensity signal on T2WI on MRI.
- Ballooning of frontal horns of lateral ventricles (“Mickey Mouse<sup>9</sup>” ventricles) and third ventricle.

Upward bowing of the corpus callosum on sagittal MRI indicates acute hydrocephalus. Thinning of the corpus callosum in a sagittal MRI is compatible with chronic hydrocephalus.

<sup>9</sup>Mickey Mouse–Walt Disney creation, this feature refers to the appearance of his ears!

---

### 43.4.2 Differential Diagnosis

- Hydrocephalus *ex-vacuo*:
  - Due to loss of cerebral tissue, e.g., stroke.
- Hydranencephaly.
  - Congenital absence of the cerebral cortex.
- Agenesis of corpus callosum.
- Septo-optic dysplasia.
- External hydrocephalus.
  - Large subarachnoid space with increasing OFCs, but normal ventricles.

---

## 43.5 Management

### 43.5.1 Medical

Medical treatment is used to delay surgical intervention but may induce metabolic consequences.

- *Acetazolamide (carbonic anhydrase inhibitor) and furosemide.*
  - ↓ CSF secretion by choroid plexus. Side effects from acetazolamide include electrolyte imbalance, lethargy, tachypnoea, diarrhea and paresthesia (tingling in fingertips).
- Serial spinal taps.
  - Only for communicating hydrocephalus until reabsorption of CSF resumes.
- Serial fontanelle taps.
  - For neonates and premature infants who may be at high risk for a definitive procedure.

### 43.5.2 Surgical

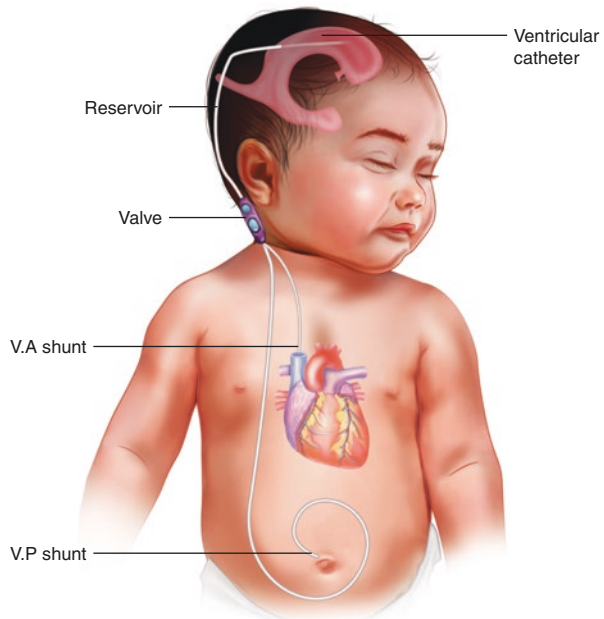
Resection surgery is indicated if the cause is removable (e.g., cyst, tumor, etc.).

#### 43.5.2.1 Insertion of Shunt

The principle is to drain CSF (ventricular or lumbar) to another body cavity where CSF can be absorbed (peritoneum, scalp, right atrium, pleura). The shunt is composed of proximal tubing entering the ventricles or lumbar cistern, which is connected to a valve (this regulates the flow of CSF) and finally drains through a distal tube into the absorbing cavity. Valves can be fixed pressure or variable pressure (the setting of these can be changed using a directed magnet device).

- *Ventriculoperitoneal (VP) shunt.*
  - Most common shunt (Fig. 43.4).

**Fig. 43.4** The shunt consists of 3 parts: a proximal catheter, a valve with a reservoir and a distal catheter



- Ventriculo-subgaleal (VSG) shunt.
  - For neonates that are too small for a lengthier definitive procedure.
- Ventriculo-pleural shunt.
  - For when peritoneum is not an option.
- Ventriculoatrial (VA) shunt.
  - Uses jugular vein to SVC to right atrium.
  - Fallen out of favor but used when abdomen and chest cavity is contraindicated.
- Lumboperitoneal shunt.
  - Only for communicating hydrocephalus. Used in pseudotumor cerebri.
- Torkildsen shunt (rare): shunts the ventricle to cisternal space and is effective only in acquired obstructive hydrocephalus.

#### 43.5.2.2 Shunt Complications

Only about 50% of shunts inserted will be normally functional at 2 years postoperatively. Any of the 3 components of the shunt (proximal tube, valve, or distal tube) can fail/block.

- Proximal catheter obstruction.
  - ↑ risk in the first months following placement, usually due to choroid plexus or blood clot generated from the initial insult.
- Distal shunt malfunction.
  - Most are related to bacterial colonization of the shunt, rather than length problems. Abdominal pseudocyst formation (detected on abdominal US or CT



scan) is presumptive of shunt infection. Length problems (need to lengthen the catheter with growth), tip migration (rare).

- Shunt infections (10–15%).
  - Most of them occurring in the first 3 weeks after surgery. Signs include fever, neck stiffness, light sensitivity, and headaches (Commonest coagulase-negative Staphylococcal spp.). Treatment is by externalization or removal of the shunt and appropriate antibiotics.
- Shunt fracture.
  - Common cause of shunt failure is disconnection or fracture of tubing.
- Over-drainage.
  - This may cause low-pressure headaches, lethargy, and nausea. A change of valve or insertion of an “anti-syphon device” may help but not invariably.
- Slit ventricle syndrome.
  - It occurs after several years and is characterized by chronic or recurring headaches and slit-like ventricles on a CT scan.
- Extrusion of shunt.
  - This has been described as the umbilicus, abdominal wall, anus, vagina, and scrotum.
- Under-drainage:
  - This may occur due to inability to keep up with CSF production and recurrence of hydrocephalus due to blockage or disconnection. Programmable shunts may allow for change in setting, to drain more CSF.
- Seizures:
  - 5% risk of seizures in the first year after shunt placement, drops to 1% after third year (unclear if shunt is the cause)
  - Higher risk with frontal catheters vs parietal ones.
- Conduit for extraneural metastasis.
  - For example, medulloblastoma.
- Silicone allergy.
  - Rare and may resemble shunt infection with skin breakdown.
- Intraventricular hemorrhage.
  - 4% in the absence of coagulopathy.

### 43.5.2.3 Endoscopic Third Ventriculostomy

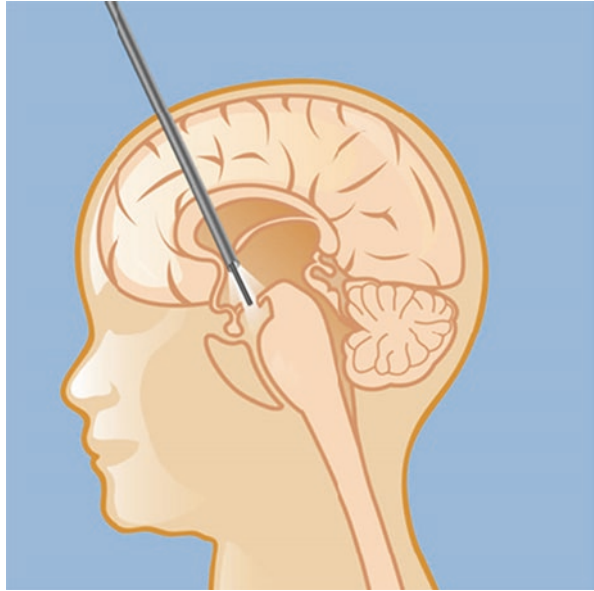
This technique is effective by creating a new channel for the CSF to find its way to the arachnoid granulations and bypassing the obstruction. It is indicated for obstructive hydrocephalus and does not work as well on communicating hydrocephalus, although some studies have shown efficacy (Fig. 43.5).

Tends to be restricted to those <6 months old, because of a high rate of failure/closure. Can close over/fail, causing recurrent raised intracranial pressure and requiring a redo operation.

### 43.5.2.4 Choroid Plexectomy

This reduces the rate of production of CSF but not completely (ventricle ependymal lining and dural sleeves of spinal nerve roots also secrete CSF). Rarely done.

**Fig. 43.5** Endoscopic third ventriculostomy. A hole is made in the floor of the third ventricle to allow CSF to flow into the basal cisterns and around the convexity of the brain to the arachnoid granulations



## 43.6 Outcome

If untreated, the prognosis is poor (>50% mortality within 3 years) and ~25% will survive until adulthood with below-average intelligence.

Hydrocephalus can also lead to blindness due to:

- Due to chronic papilledema.
- Occlusion of posterior cerebral arteries due to downward transtentorial herniation causing ischemia of the occipital lobes.
- Dilatation of third ventricle with compression of the optic chiasm.

With shunt surgery, ~50% will achieve a normal IQ—this is reduced if there is a history of seizures, shunt complications, and with certain underlying causes (e.g., intraventricular hemorrhage and prematurity).

*Arrested hydrocephalus*: balance between production and absorption of the cerebrospinal fluid is restored. Patients have ventriculomegaly in scans, and large heads (if children), but no symptoms of high ICP. Treatment is conservative.

## Further Reading

- Tully HM, Dobyns WB. Infantile hydrocephalus: a review of epidemiology, classification and causes. *Eur J Med Genet.* 2014;57(8):359–68. <https://doi.org/10.1016/j.ejmg.2014.06.002>.
- Sansone JM, Iskandar BJ. Endoscopic cerebral aqueductoplasty: a trans-fourth ventricle approach. *J Neurosurg.* 2005;103:388–92.

---

**Part VII**  
**Oncology**



Nitinkumar Borkar, Ramnik V. Patel, Chandrasen K. Sinha,  
and Hany Gabra

## 44.1 Introduction

Wilms' tumor (WT) or nephroblastoma is the most common primary renal malignancy in pediatric age group. It accounts for 95% of all renal malignancy in children and 6% of all pediatric malignancy.

With use of multimodal treatment, long-term survival of the children with WT now exceeds 85%. This impressive progress in survival is due to multidisciplinary cooperative groups, the International Society of Pediatric Oncology (SIOP), and Children's oncology group (COG—formerly known as National Wilms' tumor study group NWTs).

There is a philosophical difference in the approach of both groups but it has provided evidence-based knowledge to establish the optimal treatment of children with WT.

---

Max Wilms (1867–1918)—German surgeon working in Basel and Heidelberg described cases in 1899. He died on the Western Front of diphtheria.

N. Borkar (✉)  
All India Institute of Medical Sciences, Raipur, India

R. V. Patel  
Nottingham University Hospital, Nottingham, UK  
e-mail: [ramnik@doctors.org.uk](mailto:ramnik@doctors.org.uk)

C. K. Sinha  
St George's Hospital, London, UK

H. Gabra  
The Great North Children Hospital, Newcastle University Hospitals, Newcastle, UK

## 44.2 Epidemiology

- Incidence—10 per million children (~100 cases each year in the UK)
- Median age of onset—3.5 years (unilateral ~36 months; bilateral ~25 months)
- M:F ratio = 0.9:1 (unilateral); 0.6:1 (bilateral)
- Nearly all renal, occasional extra-renal WTs described
- Solitary 88%; multicentric 12%
- Unilateral 93%; bilateral 7% (synchronous 85%; metachronous 15%)
- *Geography*—Africans > Caucasians > East Asians

### 44.2.1 Clinical Patterns

There are four clinical patterns/settings:

- Sporadic (>90%)—no other association, otherwise healthy
- Recognized associations with congenital anomalies (~5%)—GU anomalies
- Familial/hereditary (1–2%)
  - Multiple, bilateral, earlier age of onset
  - AD, specific cytogenetic mutations in one of at least three genes
- Syndromic (rare, <1%)
  - Overgrowth phenotypic syndromes—excessive pre and postnatal somatic growth resulting and hemihypertrophy
  - Beckwith<sup>1</sup>–Wiedemann<sup>2</sup> Syndrome (BWS) (macroglossia, exomphalos, organomegaly)
  - Isolated hemihypertrophy
  - Perlman syndrome (fetal overgrowth, renal hamartomas, nephroblastomatosis)
  - Sotos syndrome (cerebral gigantism)
  - Simpson–Golabi–Behemel Syndrome (similar phenotype to BWS, gene [Xq26] mutations)
- Nonovergrowth phenotypes
  - Wilms' Aniridia GU anomalies (sometimes gonadoblastoma) retardation syndrome (WAGR)—11p deletion syndrome.
  - Denys–Drash syndrome (gonadal dysgenesis, nephropathy, mutation in WT-1 gene). Also, Frasier Syndrome (similar phenotype)
  - Bloom syndrome (AR, short stature, distinct facies, hypogonadism, wide-spread cancer risk)
  - Isolated anorexia, Trisomy 18, etc.

<sup>1</sup>John Bruce Beckwith (1933)—American pathologist, describing key features in abstract format in 1963.

<sup>2</sup>Hans Rudolf Wiedemann (1915)—German pediatrician in Kiel, independent report in 1964.

---

### 44.3 Genetics

- WT1—first gene identified in the development of Wilms' tumor. It is a heterozygous deletion at band 11p13 of chromosome 11. WAGR, Denys-Drash, Frasier (Ambiguous genitalia, streak gonad, focal segmental glomerulosclerosis) are the syndromes associated with WT1.
- WT2—identified on chromosome 11p15 on the observation of loss of heterozygosity. Beckwith–Wiedemann syndrome is associated with this gene.

---

### 44.4 Pathology

WT arises from fetal undifferentiated metanephric blastema tissue via nephrogenic rests (incidence 1%, but only 1% progress to WT).

Approximately 10% are multifocal in a single kidney and 7% are bilateral tumor either synchronous or metachronous.

*Extrarenal* WT are rare and occurs in retroperitoneum, pelvis and thorax thought to arise from displaced metanephric element or mesonephric remnant.

- *Favorable histology (90%)*—classic histologic pattern is *triphasic* (i.e., tubular epithelial, blastemal, and stromal elements). Occasionally, in teratoid WT, foci of cartilaginous, adipose, or muscle tissue may appear.
- *Unfavorable histology (10%)*—anaplasia seen in higher clinical stage and characterized by focal (<10% of specimens) or diffuse (>10% of specimens) nuclear enlargement, nuclear hyperchromasia, and abnormal mitoses.

#### 44.4.1 Pattern of Spread-

It spreads locally and hematogenously. WT also spread to regional lymph nodes in 15–20% of cases. Hematogenous spread involves lung (80%), liver (15%), rarely to bone marrow or brain.

---

### 44.5 Clinical Features

The usual presentation is a small child with an asymptomatic abdominal mass (80%), sometimes abdominal pain (~20%), or hematuria (~20%) may be seen.

Rarer features include

- Urinary tract infection
- Fever from tumor necrosis
- Hypertension and anemia
- Varicocele
- Acute abdomen with tumor hemorrhage or rupture (uncommon)

Differential diagnosis—Xanthogranulomatous pyelonephritis, mesoblastic nephroma, renal cell carcinoma, renal rhabdoid tumor, and neuroblastoma.

#### 44.5.1 Investigations

**Abdominal Ultrasound**—Heterogenous mass, doppler ultrasound to assess intravascular thrombus and its extent.

**Contrast-enhanced computed tomography/MRI** for accurate assessment of the extent of the disease, it helps in staging and finding the vascular extent of tumor. It also establishes the function of contralateral kidney.

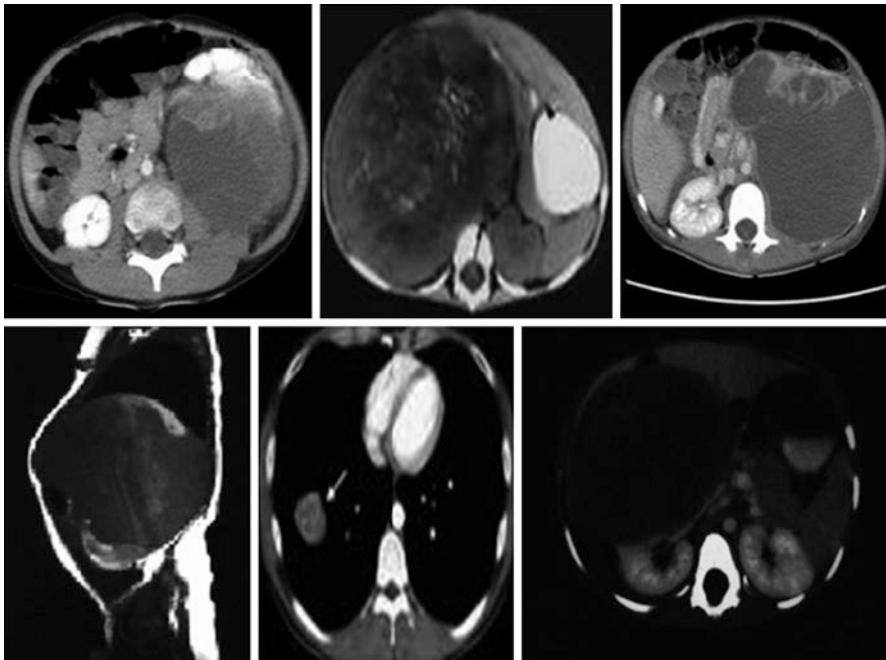
**Echocardiogram**—to rule out intra-atrial extent of tumor thrombus and for a patient receiving doxorubicin.

**DMSA scan** for a bilateral renal tumor or unilateral renal tumor if NSS is planned.

**PET Scan**—for the residual disease at the end of therapy and to find out the extent of disease in relapse.

**Laboratory investigation**—Complete blood count, urine analysis, renal function test, liver function test, electrolyte, serum calcium, and coagulation profile.

**Histology**—US-guided spring-loaded 14–16G cutting-core needle biopsy. *Essential* as 1% have benign disease and 5% have non-WT variants (Fig. 44.1 and Table 44.1).



**Fig. 44.1** Wilms' tumor. *Top row:* Stage I, II, III. *Bottom row:* metastatic WT Stage IV, bilateral WT Stage V

**Table 44.1** Staging of WT (UK): preoperative biopsy and chemotherapy

|   |
|---|
| WT has been divided into five stages (with some national differences)   |
| Stage I—Confined to kidney and completely excised   |
| Stage II—Extending beyond kidney but completely resected  |
| Stage III—Incompletely resected, +ve abdominal lymph nodes, peritoneal spread, rupture (pre or intraoperative), open biopsy |
| Stage IV—Distant metastasis (lungs, liver, bone, or brain)  |
| Stage V—Bilateral synchronous   |

*In COG, the staging is at presentation and stage V can be subdivided into Stage I–III for both sides. SIOP do not advocate a preoperative biopsy.*

## 44.6 Histological Risk Stratification for Prenephrectomy Chemotherapy-Treated WT

Based on these, three groups of tumors have been classified:

- *Low-risk:* Mesoblastic nephromas, cystic partially differentiated WT, and completely necrotic WT.
- *Intermediate-risk:* Nephroblastoma: (epithelial, stromal, mixed type); regressive type with more than two-thirds tumor being necrotic; and focal anaplasia.
- *High-risk:* Nephroblastoma: blastemal type and diffuse anaplasia; clear-cell sarcoma of kidney; and Rhabdoid tumor of kidney.

## 44.7 Management

There are clear differences in the philosophy of treatment across the world. In European centers, the aim has been to give chemotherapy initially to downstage the tumor (advantage—↓ operative morbidity). In North America, surgery is still the preferred initial treatment.

### Preoperative Chemotherapy-

- Vincristine and Actinomycin D for localized tumors—4 wks.
- Vincristine, Actinomycin D and Doxorubicin for metastatic tumors—6 wks.

### 44.7.1 Surgery

- Supraumbilical transverse transabdominal transperitoneal approach.
- Evaluation of abdomen for metastasis and nodal spread.
- Evaluation of opposite kidney prior to nephrectomy of diseased kidney if preoperative imaging suggests any lesion.
- Mobilize the colon toward midline.



- Palpate IVC and renal vein to exclude the intravascular extension of tumor.
- Delicate dissection and handling to avoid tumor rupture.
- Resection of adhered small portion of diaphragm or other non-vital structures can be done to avoid tumor rupture.
- Radical nephroureterectomy is after ligation of ureter, renal artery, and vein.
- Ureter is ligated as low as possible.
- Ipsilateral adrenalectomy is not necessary if the gland is easily getting separated from tumor.
- Lymph node sampling—from hilar, paracaval, paraaortic (depending on tumor side), and aortocaval nodes. Minimum *seven number of lymph node* sampling increases the chances of detecting metastasis.
- *Tumor thrombus*—vascular extension of tumor may occur through renal vein, IVC and right atrium. Incidence of caval extension is around 6–10% with atrial extension in 1%. Vascular extension into IVC below hepatic vein can be removed by venotomy after proximal and distal control. Vascular extension above hepatic vein neoadjuvant chemotherapy is recommended.
- *Partial Nephrectomy*/nephron-sparing surgery.
  - Bilateral WT contralateral pre-existing abnormality of kidney.
  - WT in single kidney.
  - WT with nephroblastomatosis.
- Hepatic or pulmonary resection for persistent metastases (if necessary).

#### 44.7.2 Bilateral Wilms' Tumor (Stage V)

A range of procedures have been used including local enucleation of small tumors, partial nephrectomy and contralateral excision biopsy, bilateral partial nephrectomy, unilateral nephrectomy and contralateral partial nephrectomy, bilateral nephrectomy + dialysis + renal transplant, and finally removal, “bench surgery,” intraoperative radiotherapy + auto-transplant.

#### 44.7.3 Postoperative Chemotherapy Table 44.2

Based on the stage and histological risk group as follows:

Stage IV (Metastatic disease)—Local Stage I/II/III (Low and intermediate-risk histology) and metastatic clearance obtained by chemotherapy or surgery—Vincristine, Actinomycin D, and Doxorubicin—27 wks.

Stage IV (Metastatic disease)—Local stage II/III low and intermediate-risk histology with residual metastatic disease, local stage I/II/III with high-risk histology regardless metastatic status—Cyclophosphamide, Doxorubicin, and Etoposide, Carboplatin alternate courses—34 wks.

(Dose reduction—age < 6 months dose reduced to 50%, weight < 12 kg dose reduced to 66%)

Stage IV and V disease radiotherapy is given according to local stage.

**Table 44.2** Postoperative chemotherapy for Stage I to Stage III

| Disease   | Treatment         |  |  |
|---|-------------------|--|--|
|   | Stage I           | Stage II   | Stage III                                |
| Low risk  | None              | AV (27 weeks)  | AV (27 weeks)                            |
| Intermediate risk<br>(all subtypes, stromal<br>and epithelial type) | AV<br>(4 weeks)   | AV (27 weeks)*   | AV (27 weeks)* + flank<br>radiation      |
| High risk   | AVD<br>(27 weeks) | CDECr (34 weeks) + flank<br>radiation (except blastemal<br>type) | CDECr<br>(34 weeks) + flank<br>radiation |

A Actinomycin D, V Vincristine, D Doxorubicin, CDECr Cyclophosphamide, Doxorubicin and Etoposide, Carboplatin, \* Doxorubicin is added for tumor with non-stromal and non-epithelial type, large volume ( $\geq 500$  ml)

## 44.8 Prognosis

- Long-term survival exceeds 85%.
- Prognosis depends on histology at diagnosis, stage of the tumor, age at diagnosis (older age with adverse prognosis), loss of heterozygosity for 1p and 16 q (increases the risk of relapse).

## Further Reading

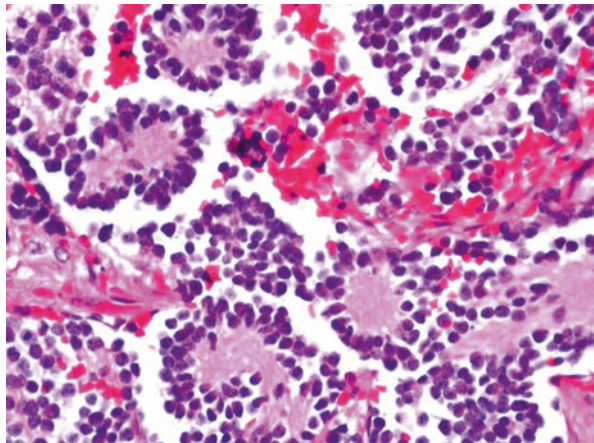
- Breslow N, Olshan A, Beckwith JB, et al. Epidemiology of Wilms tumor. *Med Pediatr Oncol.* 1993;21:172–81.
- Howel L, Messahel B, Powis M, Vujanic G, Saunders D, Alam F, Jones KP. Children Cancer and Leukemia Group. Clinical management guidelines Wilms Tumour. January 2015.
- Irtan S, Ehrlich PF, Pritchard-Jones K. Wilms tumor: “state-of-the-art update”. *Semin Pediatr Surg.* 2016 Oct;25(5):250–6.
- van den Heuvel-Eibrink MM, Hol JA, Pritchard-Jones K, et al. Rationale for the treatment of Wilms tumour in the Umbrella SIOP-RTGS 2016 protocol. *Nat Rev. Urol.* 2017 Dec;14(12):743–52.
- Aldrink JH, Heaton TE, Dasgupta R, et al. Summary article: update on Wilms tumor. *J Pediatr Surg.* 2019 Mar;54(3):390–7.
- Wang J, Li M, Tang D, et al. Current treatment for Wilms tumor: COG and SIOP standards. *World J Ped Surg.* 2019;2:1–4.
- Fernandez C, Geller JI, Ehrlich PF, et al. Renal tumors. In: Pizzo PA, Poplack DG, editors. Principles and practice of pediatric oncology. seventh ed. Philadelphia: Wolters Kluwer; 2016. p. 861–85.

Abid Qazi, Nadeem Haider, and Roly Squire

## 45.1 Introduction

This condition was first described in 1864 by the German physician Rudolf Virchow who called the tumors he found in the abdomens of children *gliomas*. In 1910, James Homer Wright noted that these tumors originated from an immature, primitive form of neural cell and he, therefore, named the tumors *neuroblasts*. He also documented the formation of round clumps of cells in samples of bone marrow and this feature has become the histological characteristic of the disease and is commonly referred to as “*Homer–Wright pseudorosettes*.” Figure 45.1

**Fig. 45.1** Pseudorosette formation in adrenal neuroblastoma [picture courtesy of Ed Uthman, reproduced under Creative Commons]



A. Qazi (✉)  
Al Jalila Children’s Specialty Hospital, PO, Dubai, United Arab Emirates

N. Haider  
Sheikh Khalifa Medical City, Ajman, UAE

R. Squire  
Leeds General Infirmary, Leeds, UK

© Springer Nature Switzerland AG 2022  
C. K. Sinha, M. Davenport (eds.), *Handbook of Pediatric Surgery*,  
[https://doi.org/10.1007/978-3-030-84467-7\\_45](https://doi.org/10.1007/978-3-030-84467-7_45)

- This is the third most common cancer of childhood after leukemia and brain cancer (5–10%) with almost 100 affected children/year in the UK.
- Age of onset Infancy ~30%.
- 1–4 years ~50%
- 10–14 years ~5%
- M > F (slight).
- White > Black > Asian.

---

## 45.2 Sites of Origin

- Adrenal medulla (~50%).
- Abdominal sympathetic ganglia (~25%).
- Posterior mediastinum (~20%).
- Pelvis (~3%).
- Neck (~3%).

---

## 45.3 Pathology

These are soft tumors with areas of hemorrhage and necrosis. More mature areas tend to be firm.

The histological appearance is of sheets of dark blue round cells with scanty cytoplasm, embedded in a delicate vascular stroma and tends to spread with local extension and encasement of major vessels. May metastasize to lymph nodes, bones, bone marrow, liver, and skin. Secondary spread is usually associated with large primaries (except stage MS tumors). There is a characteristic ring of neuroblasts around a neurofibrillary core (*rosette formation*) which differentiate from other blue, round cell tumors (e.g., Ewing's sarcoma, lymphoma, and rhabdomyosarcoma).

### 45.3.1 Shimada<sup>1</sup> System Classification

Based on the

- Mitosis karyorrhexis index (MKI).
- Age of child.
- Degree of differentiation (toward ganglioneuroma).
- Stroma-rich or stroma-poor.

Favorable prognosis includes infants, low MKI, stroma-rich tumors, well-differentiated tumors, or tumors with intermixed degrees of differentiation.

---

<sup>1</sup>Hiroyuki Shimada – Japanese pathologist, latterly working in Los Angeles, USA.

### 45.3.2 Cytogenetics and Prognostic Factors

A large number of molecular abnormalities have been identified in the neuroblastoma cells. These include:

- *MYCN* amplification.
- Gene on Ch 2p leads to activation of angiogenesis pathways and ↑tumor growth.
- Advanced vs. low-stage disease stage (amplification present ~40% vs. ~10%).
- 90% of patients with *MYCN* amplification will die of disease progression irrespective of treatment modality used
- Ch 17q gain, Ch 1p deletion.
- Expression of the *H-ras* oncogene—associated with low-stage disease.
- DNA ploidy and index—diploid DNA associated with *MYCN* amplification.
- CD44 expression—↑expression associated with good prognosis.
- TRKA expression—↑expression associated with good prognosis.
- Multidrug resistance-associated protein (MRP)—↑ levels associated with poor prognosis.

### 45.4 Clinical Features

Usually, there is a palpable abdominal mass and unlike other tumors (e.g., Wilms') children often appear sick, lethargic with fatigue, bone pain, weight loss, fever, sweating, and anemia.

#### *Unusual but Characteristic Features*

- Periorbital ecchymosis or proptosis (raccoon eyes)—retro-orbital secondaries.
- Horner's<sup>2</sup> syndrome—apical thoracic tumors.
- Progressive cerebellar ataxia and trunk opsomyoclonus.
- Dancing eye syndrome—rapid but chaotic, conjugate eye movements.
- Progressive paraplegia—from extradural cord compression.
- Hypertension (~25%) due to catecholamine production or renal artery compression.
- Skin nodules—stage MS disease.
- Diarrhea—due to vasoactive intestinal polypeptide (VIP) release—more typical of ganglioneuromas and ganglioneuroblastomas.

#### 45.4.1 Specific Investigations

- ↑↑*Vanillylmandelic acid (VMA) and homovanillic acid (HVA)*—urinary metabolites of catecholamines
- ↑ferritin, ↑ lactate dehydrogenase (LDH), and ↑ Neuron-specific enolase (NSE)
- AXR—tumor calcification (~50%).
- US—solid vs. cystic, may suggest renal vein and caval involvement.

<sup>2</sup>Johann F. Horner (1831–1886) – Swiss ophthalmologist named triad as meiosis, ptosis and enophthalmos, but can have ↓ facial sweating and iris color change. Described many times before Horner's case in 1869.

- *CT/MRI scans*—anatomy of tumor with IDRF identification and search for metastases. Possible intraspinal extension (“dumb-bell” tumor).
- *MIBG (meta-iodobenzylguanidine) scan*—for abnormal medullary tissue and for primary tumor avidity, is useful for post-treatment assessment.
- Technetium-99 bone scintigraphy in selected cases.
- *Biopsy*—percutaneous or laparoscopic/open.
- Bone marrow aspirate and biopsy (bilateral). *Not required under 6 months.*

## 45.5 Staging: Complex and Evolving

### 45.5.1 International Neuroblastoma Risk Group (INRG) Classification System

The INRG Taskforce introduced a new staging system (*INRGSS*) (Table 45.1) as a pre-treatment staging system based on *Image Defined Risk Factors (IDRF)* (Table 45.2) as opposed to *International Neuroblastoma Staging System (INSS)* which is the post-surgical treatment staging system.

**Table 45.1** INRG task force divided all tumors into 16 pre-treatment groups based on the INRG stage, age, histologic category, grade of tumor differentiation, *MYCN* status, presence/absence of 11q aberrations, and tumor cell ploidy

| INRG Stage | Age (months) | Histologic Category                       | Grade of Tumor Differentiation | <i>MYCN</i>                               | 11q Aberration | Ploidy       | Pretreatment Risk Group |                |
|------------|--------------|---|--------------------------------|---|----------------|--------------|-------------------------|----------------|
| L1/L2      |              | GN maturing; GNB intermixed               |                                |   |                |              | A Very low              |                |
| L1         |              | Any, except GN maturing or GNB intermixed |                                | NA  |                |              | B Very low              |                |
|            |              |   |                                | Amp                                       |                |              | K High                  |                |
| L2         | < 18         | Any, except GN maturing or GNB intermixed | Differentiating                | NA  | No             |              | D Low                   |                |
|            |              |   |                                |   | Yes            |              | G Intermediate          |                |
|            | ≥ 18         |   | GNB nodular; neuroblastoma     | Poorly differentiated or undifferentiated | NA             | No           |                         | E Low          |
|            |              |   |                                |   |                | Yes          |                         | H Intermediate |
|            |              |   |                                | Amp                                       |                | N High       |                         |                |
| M          | < 18         |   |                                | NA  |                | Hyperdiploid | F Low                   |                |
|            | < 12         |   |                                | NA  |                | Diploid      | I Intermediate          |                |
|            | 12 to < 18   |   |                                | NA  |                | Diploid      | J Intermediate          |                |
|            | < 18         |   |                                | Amp                                       |                |              | O High                  |                |
|            | ≥ 18         |   |                                |   |                |              | P High                  |                |
| MS         | < 18         |   |                                |   | No             |              | C Very low              |                |
|            |              |   |                                | NA  | Yes            |              | Q High                  |                |
|            |              |   |                                | Amp                                       |                |              | R High                  |                |

#### INRG consensus pre-treatment classification schema.

Notes: Pre-treatment risk group H has two entries. 12 months = 365 days; 18 months = 547 days; blank field = “any”; diploid (DNA index  $\leq 1.0$ ); hyperdiploid (DNA index  $> 1.0$  and includes near-triploid and near-tetraploid tumors); very low risk (5-year EFS  $> 85\%$ ); low risk (5-year EFS  $> 75\%$  to  $\leq 85\%$ ); intermediate risk (5-year EFS  $\geq 50\%$  to  $\leq 75\%$ ); high risk (5-year EFS  $< 50\%$ ). *GN* ganglioneuroma; *GNB* ganglioneuroblastoma; *amp* amplified; *NA* not amplified; *L1* localized tumor confined to one body compartment and with absence of image-defined risk factors (IDRFs); *L2* locoregional tumor with presence of one or more IDRFs; *M* distant metastatic disease (except stage MS); *MS* metastatic disease confined to skin, liver and/or bone marrow in children  $< 18$  months of age; *EFS* event-free survival.

Reference: Cohn SL et al. The International Neuroblastoma Risk Group (INRG) Classification System: An INRG Task Force Report. *J Clin Oncol.* 2009; 27: 289–297

**Table 45.2** Image Defined Risk Factors in Neuroblastic Tumors**Ipsilateral tumor extension within two body compartments**

Neck-chest, chest-abdomen, abdomen-pelvis

**Neck**

- Tumor encasing carotid and/or vertebral artery and/or internal jugular vein.
- Tumor extending to base of skull.
- Tumor compressing the trachea.

**Cervico-thoracic junction**

Tumor encasing brachial plexus roots

Tumor encasing subclavian vessels and/or vertebral and/or carotid artery

Tumor compressing the trachea

**Thorax**

- Tumor encasing the aorta and/or major branches.
- Tumor compressing the trachea and/or principal bronchi.
- Lower mediastinal tumor, infiltrating the costo-vertebral junction between T9 and T12.

**Thoraco-abdominal**

- Tumor encasing the aorta and/or vena cava.

**Abdomen/pelvis**

- Tumor infiltrating the porta hepatis and/or the hepatoduodenal ligament.
- Tumor encasing branches of the superior mesenteric artery at the mesenteric root
- Tumor encasing the origin of the coeliac axis, and/or of the superior mesenteric artery
- Tumor invading one or both renal pedicles
- Tumor encasing the aorta and/or vena cava
- Tumor encasing the iliac vessels
- Pelvic tumor crossing the sciatic notch.

**Intraspinal tumor extension whatever the location provided that:**

- More than one-third of the spinal canal in the axial plane is invaded and/or the perimedullary leptomeningeal spaces are not visible and/or the spinal cord signal is abnormal.
- Infiltration of adjacent organs/structures. Pericardium, diaphragm, kidney, liver, duodeno-pancreatic block, and mesentery.

**Conditions to be recorded, but *not* considered IDRFs**

Multifocal primary tumors

Pleural effusion, with or without malignant cells

Ascites, with or without malignant cells

**45.5.2 INRGSS: International Neuroblastoma Risk Group Staging System**

- *Stage L1*: Localized tumor not involving vital structures as defined by the list of *Image Defined Risk Factors* and confined to one body compartment.
- *Stage L2*: Locoregional tumor with presence of one or more *Image Defined Risk Factors*.
- *Stage M*: Distant metastatic disease (except Stage MS).
- *Stage MS*: Metastatic disease confined to *skin, liver, and/or bone marrow in children younger than 18 months of age*.

**Table 45.3** International neuroblastoma staging system (INSS) 1989

|          |  |
|----------|--|
| Stage 1  | Localized tumor with complete gross excision, $\pm$ microscopic residual disease; representative I/L nodes –ve for tumor microscopically (nodes attached to and removed with the primary tumor may be +ve)   |
| Stage 2A | Localized tumor with incomplete gross excision; representative I/L no adherent lymph nodes negative for tumor microscopically  |
| Stage 2B | Localized tumor $\pm$ complete gross excision, with I/L nonadherent lymph nodes +ve for tumor. Enlarged contralateral lymph nodes must be negative microscopically   |
| Stage 3  | Unresectable unilateral tumor infiltrating across the midline, $\pm$ regional node involvement; or localized unilateral tumor with C/L regional node involvement; or midline tumor with bilateral extension by infiltration (unresectable) or by node involvement  |
| Stage 4  | Any primary tumor with dissemination to distant lymph nodes, bone, bone marrow, liver, skin, and/or other organs (except as defined for stage 4S)  |
| Stage 4S | Localized primary tumor (as defined for stage 1, 2A, or 2B), with dissemination limited to skin, liver, and/or bone marrow (limited to infants <1 year). Marrow involvement should be minimal (i.e., <10% of total nucleated cells identified as malignant by bone biopsy or by bone marrow aspirate). More extensive bone marrow involvement would be considered to be stage IV disease. The results of the MIBG scan (if performed) should be –ve for disease in the bone marrow |

### 45.5.3 International Neuroblastoma Staging System (INSS)

The Children Oncology Group (USA) introduced the International Neuroblastoma staging system in 1989. This is relevant for the post-surgical staging of tumors (Table 45.3).

## 45.6 Management

- *Immediate resection*
  - current practice suggests that this is reserved for tumors in the absence of *image defined risk factors* (IDRF) i.e. (INRG “L1 TUMORS”).
- *Tumor biopsy*
  - treatment of metastatic and localized tumors with IDRF’s (INRG “L2 Tumors”) can be influenced by their *MYCN* status.

Descriptions of very-low, low-risk, intermediate-risk, or high-risk neuroblastoma according to INRG definitions and pre-treatment groups (Table 45.2) are listed below.

### 45.6.1 Very Low-Risk Neuroblastoma

- Stage L1/L2 with ganglioneuroma maturing or ganglioneuroblastoma inter-mixed histology
- Stage L1 with non-amplified *MYCN*
- Stage MS in children younger than 18 months of age with no 11q aberration



### 45.6.2 Low-Risk Neuroblastoma

- Stage L2 in children younger than 18 months of age with no 11q aberration
- Stage L2 in children older than 18 months of age with ganglioneuroblastoma nodular or neuroblastoma with differentiating histology and no 11q aberration
- Stage M in children younger than 18 months without *MYCN* amplification and hyperdiploidy

Treatment is tailored according to the risk assignment. Most patients with very-low and low-risk disease commonly receive surgery alone. Sometimes, infants with small-localized tumors have been successfully watched closely without any surgery, tumor may mature and regress.

#### 45.6.2.1 Proposed Criteria for Observation

- Age at presentation
- Suprarenal mass measuring <5 cm on US
- No IDRF
- No evidence of metastases on MIBG
- Stable or decreasing size on regular US
- Stable or decreasing catecholamines on regular urinalysis

### 45.6.3 Intermediate-Risk Neuroblastoma

- Stage L2 in children younger than 18 months without *MYCN* amplification with 11q aberration
- Stage L2 in children older than 18 months with ganglioneuroblastoma nodular or neuroblastoma with differentiating histology with 11q aberration
- Stage L2 in children older than 18 months with ganglioneuroblastoma nodular or neuroblastoma with poorly differentiated or undifferentiated histology
- Stage M in children younger than 12 months with diploidy
- Stage M in children 12 months to 18 months with diploidy

Patients with intermediate-risk disease receive surgery and chemotherapy. Number of cycles of chemotherapy is determined by associated risk factors including tumor histology, genetic changes associated with chromosome 1p and 11q, ploidy, and age at presentation.

### 45.6.4 High-Risk Neuroblastoma

- Stage L1 with *MYCN* amplification
- Stage L2 with *MYCN* amplification
- Stage M in children <18 months of age with *MYCN* amplification
- Stage M in children >18 months

- Stage MS in children <18 months with 11q aberration
- Stage MS in children <18 months of age with *MYCN* amplification

*Multi-agent intensive induction chemotherapy* to induce tumor remission, and improve chance of resection. Surgery to excise the tumor is then carried out.

Further high-dose chemotherapy and peripheral stem cell rescue for reconstitution of patient's bone marrow  $\pm$  retinoic acid  $\pm$  radiotherapy.

#### Outcome of Neuroblastoma

- \* 85–90% survival—low /intermediate risk tumors
- \* <50% - high risk tumors

---

## 45.7 Fetal Tumors

Increasingly frequent clinical scenario. Most have favorable biologic markers with no *MYCN* amplification (i.e., Very Low Risk with excellent survival following surgery alone). Some advocate observation only in the early management expecting regression and small (<5 cm) tumors appear to be good candidates for this approach. About 60% of infants can avoid surgery following spontaneous tumor regression.

---

## 45.8 Spinal Cord Compression

Spinal cord compression by dumb-bell type tumors may cause paralysis, paresthesia, or bladder dysfunction. Immediate treatment is mandatory. Treatment options include surgical decompression of the spinal cord, steroids with chemotherapy or radiotherapy. In asymptomatic patients, extraspinal tumor resection is sufficient.

---

## 45.9 Surgery

- Aim of surgery in very low-risk and low-risk tumors is to do a complete resection. No chemotherapy is required once tumor is completely removed.
- Aim of surgery post chemotherapy in intermediate and high-risk tumors is to achieve complete resection. However, this may not always be possible as tumor may be adherent to vital structures.
- Near-complete excision (microscopic residual only) is also associated with a better prognosis in high-risk tumors.
- Aim of second-look procedure is to achieve as complete a debulking as possible without sacrificing major organ function.

Possible role for laparoscopic and thoracoscopic surgery is diagnostic and excision biopsies of smaller tumors. This is evolving in nature as the laparoscopic gadgets are refined and skill level is increasing.

---

## 45.10 New Treatments

- I<sup>131</sup> labeled MIBG.
- New chemotherapy agents—topotecan, irinotecan, etoposide, oral topoisomerase II inhibitor.
- Immunologic therapies include monoclonal antibodies, cytokine therapies, and vaccines.
- Antiangiogenic factors.
- Other experimental agents include tyrosine kinase inhibitors, direct targeting of *MYCN* amplified cells, and creation of chimeric antibodies to deliver cytotoxic drugs.

---

## Further Reading

Neuroblastoma. A neural crest derived embryonal malignancy. Front Mol Neurosci. 2019; <https://doi.org/10.3389/fnmol.2019.00009>.

Iwanaka T, Kawashima H, Uchida H. The laparoscopic approach of neuroblastoma. Semin Pediatr Surg. 2007;16:259–65.

The International Neuroblastoma Risk Group (INRG) classification system: an INRG Task Force report. J Clin Oncol. 2009;27:289–97.

Nuchtern JG, London WB, Barnewolt CE, et al. A prospective study of expectant observation as primary therapy for neuroblastoma in young infants, a COG study. Ann Surg. 2012;256:573–80.



Mark Davenport

*The treatment of hepatoblastoma has been revolutionized by effective chemotherapy and judicious surgery with an overall survival of ~90%.*

## 46.1 Introduction

- Third commonest intra-abdominal malignancy in children
- There are four malignant variants:
  - *Hepatoblastoma* (HB)
    - Typical embryonal tumor
    - M = F
    - 1–3 years
    - White > black ethnicity
    - 10–15 children/year/UK
  - *Hepatocellular Carcinoma* (HCC)
    - End result of chronic liver disease, e.g., biliary atresia
    - ↑ HCC in East Asia, China, Japan (↑ Hepatitis B)
    - 5–16 years
  - *Rhabdomyosarcoma*
    - Botryoid<sup>1</sup> tumor from bile ducts
    - Presents with jaundice due to bile duct obstruction
  - *Undifferentiated Embryonal Sarcoma*
    - 5–10 year

<sup>1</sup> Botryoid (Greek)—grape like.

M. Davenport (✉)  
King's College Hospital, London, UK

- Four benign variants
  - *Hemangiomas*  
ubiquitous, mono, or bilobar,
  - *Mesenchymal Hamartomas*
  - *Focal Nodular Hyperplasia (FNH)*  
Adolescent girls
  - *Adenomas*  
Adolescent girls

---

## 46.2 Associations

- Hepatoblastoma
  - Beckwith–Wiedemann syndrome
  - Hemihypertrophy
  - Low birth weight
  - Fetal alcohol syndrome
  - Familial Adenomatous Polyposis (FAP)
  - Trisomy 18
  - Congenital portosystemic shunts (e.g., Abernethy<sup>2</sup> malformation)
- Hepatocellular carcinoma
  - Cirrhotic liver disease (e.g., biliary atresia, tyrosinemia, and glycogen storage disease)
- Mesenchymal hematoma
  - Placental mesenchymal dysplasia
- Focal nodular hyperplasia
  - Congenital portosystemic shunts (e.g., Abernethy malformation)

---

## 46.3 Pathology

Complex and subject to terminology change.

### 46.3.1 Hepatoblastoma

These are usually unifocal and commoner in the right lobe. Two types recognized:

- Epithelial type
  - Fetal, embryonal, mixed, or small cell undifferentiated (SCU) pattern (↓ differentiation)

---

<sup>2</sup>John Abernethy (1764–1831)—English surgeon working at St. Bartholomew’s hospital in London, described two cases.

- Mixed epithelial and mesenchymal type
  - Teratoid or non-teratoid features

Associated with mutations of the  $\beta$ -catenin gene.

### 46.3.2 Hepatocellular Carcinoma

- Classic features
  - Commoner in the right lobe
- Fibrolamellar (FL-CCC) variant
  - Adolescents and young adults
  - Commoner in left lobe (2/3)

---

## 46.4 Clinical Features

Tumors usually present with a combination of a palpable mass and usually signs of anemia, etc. Metastases at presentation are more common with HCC (~30%). Rarely, the tumor (more characteristic of embryonal sarcoma) may rupture and present acutely.

### 46.4.1 Investigations

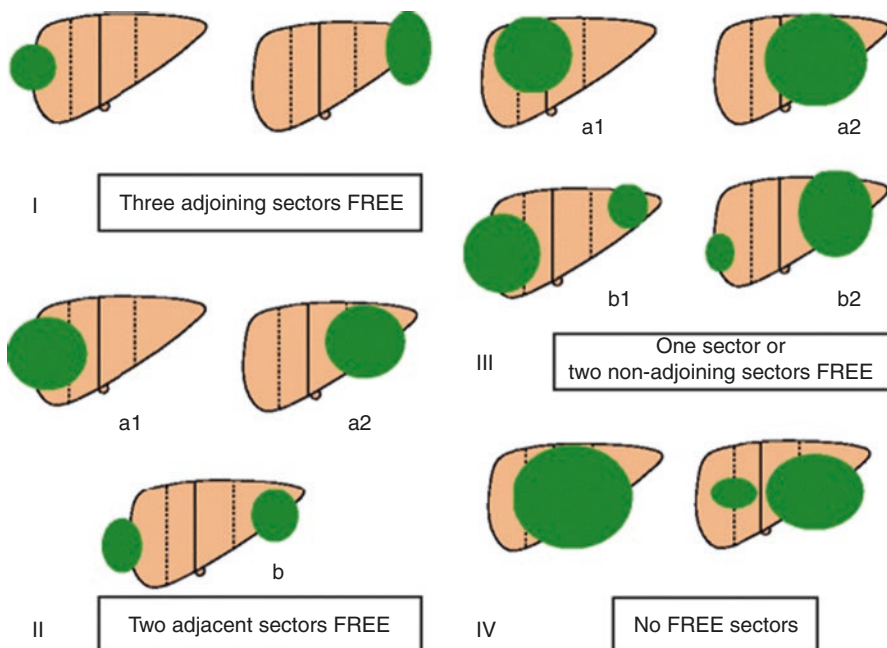
- Specific laboratory studies
  - $\uparrow\uparrow\alpha$ -fetoprotein (AFP)
    - Normal ~10% HB—implies SCU variant.
    - Normal ~40% HCC.
    - Initial level has no prognostic significance, although the degree of fall post-chemotherapy may do.
  - $\uparrow\beta$  human chorionic gonadotropin (hCG) levels.
- US/Doppler
  - Confirms cystic vs. solid; site; multicentric and evidence of portal vein involvement.
- CT/MRI ( $\pm$ angiography) scans
  - Evidence of metastases (other lobe/chest/brain). Resectability and involvement of portal and hepatic veins.
- Percutaneous biopsy.

## 46.5 Staging

Formerly there were two staging systems in use; the older was derived from largely American practice (what was left after the surgeons had had a go at resection) is the *COG classification* (Table 46.1) and the more recent based on the concept of *PRETEXT* (*PRETreatment EXtent of disease*) classification (Fig. 46.1), which originated in Europe. Nowadays, most within the international oncology community have adopted the latter together with its sister: *POST-TEXT* (radiology appearance post-chemotherapy but before surgery).

**Table 46.1** Children's oncology group (COG) staging

| Stage | Features   |     |
|-------|--|-----|
| I     | Complete resection   | 30% |
| II    | Resection with microscopic residual disease  | 30% |
| III   | Resection with gross residual tumor/tumor spillage/positive lymph nodes/<br>incomplete resection | 30% |
| IV    | Distant metastases   | 10% |



**Fig. 46.1** PRETEXT classification of hepatoblastoma

## 46.6 Management

Accurate preoperative staging is important as the current clinical SIOPEL trials adjudicate into *low-risk tumors (PRETEXT I–III)* that are managed quite differently from *high-risk tumors (PRETEXT IV and metastatic disease)*. For the latter group it is important to drive unresectable tumors to become resectable while dealing with metastatic disease through an intensive chemotherapy schedule.

Upfront resection without chemotherapy is possible for a small subgroup of children with completely resected tumors of pure fetal histology and low mitotic index (currently terminology well-differentiated fetal hepatoblastoma (WDF)). These may have been designated as PRETEXT I and II as long as there is sufficient radiological margin from the principal plane of the liver to allow a safe hemihepatectomy.

- Chemotherapy
  - Cisplatin, carboplatin—current trial includes this as monotherapy
  - Doxorubicin
  - Vincristine
  - Cyclophosphamide
  - 5-fluorouracil
  - Paclitaxel and etoposide
  - Irinotecan

Usually six cycles of chemotherapy are administered every 2–4 weeks. AFP levels are used as a guide to determine response to therapy.

- Radiotherapy
  - May be used when microscopic disease is seen at the resection margins and in chemoresistant pulmonary metastases. Dose (usually 1200–2000 centiGray).

### 46.6.1 Surgery

The aim is complete surgical resection of all disease. This may be accomplished by:

- *Liver resection*
  - Segmentectomy
  - R or L hemihepatectomy (V, VI, VII, VIII) or (II, III, IV)
  - R or L extended hemihepatectomy (plus IV) or (plus V, VIII)
  - ± Caudate (I)—unusual to completely resect this
- *Liver transplantation*
  - Indications include unresectable primary, multifocal, or central tumors or when diaphragmatic extension precludes complete resection.
  - Usually living donor to allow appropriate timing.
- Resection of pulmonary metastases may also be needed in some children with long-term disease-free survival, where primary tumor has been already eradicated.



---

## 46.6.2 Outcome

Patients who undergo complete resection of the tumor and adjuvant chemotherapy approach 100% survival. This is dependent on PRETEXT staging.

- Current five-year overall survival (UK)—HB and HCC—73%
  - HB > 80%: HCC < 30%

---

## 46.7 Hepatic Metastases

Possible sites include:

- Neuroblastoma
- Wilms' tumor
- Rhabdomyosarcoma
- Non-Hodgkin's lymphoma
- Osteogenic sarcoma

The criteria for resection of these metastases are reasonable expectations of life with control of the primary tumor and limited number of metastases.

---

## 46.8 Benign Liver Tumors

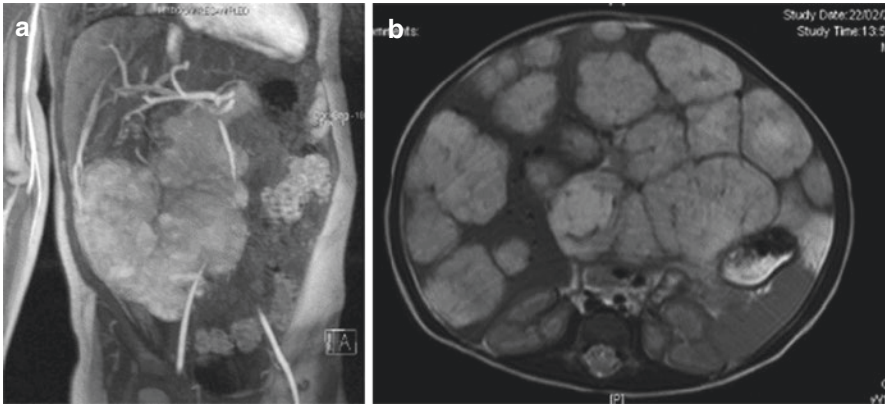
### 46.8.1 Hemangiomas (AKA Hemangioendotheliomas)

Common if looked for, with the majority remaining clinically silent. Some may present in infants with hepatomegaly, high-output cardiac output, and thrombocytopenia.

- Other hemangiomas
  - Usually skin, intestinal, pulmonary (up to 40% of severe examples).
- Female predominant

### 46.8.2 Pathology

Endothelial-lined vascular spaces with variable size. Hemangioendothelioma is used to describe typical lesions of infancy. Some merge with angiosarcoma-like lesions and are best treated as malignant.



**Fig. 46.2** (a) *Hepatoblastoma*: MRI scans showing angiogram phase of a large heterogeneous right lobe tumor (biopsy—hepatoblastoma). (b) *Multifocal Hemangiomas*: T2-weighted—multiple bilobar vascular tumors in a 1-month-old infant

### 46.8.3 Clinical Features

Symptoms may include abdominal distension and hepatomegaly within 1 month of birth. Platelet sequestration and consumptive coagulopathy (Kasabach–Merritt syndrome<sup>3</sup>) may occur (especially if bilobar).

Can be divided radiologically into:

- Solitary (60%)
- Multifocal (35%)
- Diffuse (<5%)

### 46.8.4 Investigations

- Specific laboratory studies
  - FBC (anemia and ↓ platelets)
  - Thyroid function tests (both hypo- and hyperthyroidism have been reported)
- US and Doppler
  - Mono or bilobar high, flow through hepatic artery
- CT/MRI ± angiogram
  - Will delineate anatomy, respectability, and degree of vascular function (Fig. 46.2).

<sup>3</sup> Haig Haigouni Kasabach (1893–1943) and Katharine Krom Merritt (1886–1986) American pediatricians, described this in large cutaneous hemangiomas in 1940.

### 46.8.5 Management

There is a potential for spontaneous regression in the first few years of life. However, active treatment is required for all symptomatic lesions. All those with high-output cardiac failure require support with diuretics and digoxin.

- Chemotherapy
  - Propranolol
    - Effective and in use from 2010
  - Steroids
    - Used now superseded by more efficacious agents.
  - Vincristine
    - Reserved for treatment failures.
- Surgery and Interventional radiology
  - Isolated lesions are best treated with surgical excision.
  - Hepatic artery embolization/ligation (HAE/L)
    - Multifocal or extensive lesions.
  - Liver transplantation
    - Multifocal lesions (typically low-flow) and those with poor responsive to HAE/L.

---

### 46.9 Mesenchymal Hamartomas

These are multicystic heterogeneous lesions, which can be massive. They have been associated with placental pathology and show no evidence of spontaneous regression. It is controversial as to whether they have a malignant potential.

Liver resection is usually preferred.

---

### 46.10 Focal Nodular Hyperplasia and Hepatic Adenomas

FNH and hepatic adenomas are benign tumors seen in children. There is some evidence of a relationship with estrogen exposure (e.g., contraceptive pill), and most do occur in adolescent girls. Sometimes they can be the presenting feature of a congenital portosystemic shunt (Abernethy malformation).

#### 46.10.1 Investigations

- CT/MR scans
  - Appearance of a central scar is a pathognomonic feature of FNH.
- Tc-sulfur colloid radioisotope scan.
- Percutaneous biopsy may be needed for definitive diagnosis.

Indications for resection in both lesions are symptoms and diagnostic doubt.

---

## Further Reading

- Aronson DC, Meyers RL. Malignant tumors of the liver in children. *Semin Pediatr Surg.* 2016;25:265–75.
- Roebuck D, et al. PRETEXT: a revised staging system for primary malignant liver tumours of childhood developed by the SIOPEL group. *Pediatr Radiol.* 2007;37:123–32.
- Macdonald A, Durkin N, Deganello A, et al. Historical and contemporary management of infantile hepatic hemangioma: a 30-year single-center experience. *Ann Surg.* 2020; <https://doi.org/10.1097/SLA.0000000000003881>.
- Martins-Filho SN, Putra J. Hepatic mesenchymal hamartoma and undifferentiated embryonal sarcoma of the liver: a pathologic review. *Hepatic Oncol.* 2020;7 <https://doi.org/10.2217/hep-2020-0002>.



Erica Makin and Mark Davenport

## 47.1 Introduction

Teratomas are germ cell tumors (GCTs) that contain all three embryonic layers (endoderm, mesoderm, and ectoderm) and most of them (~80%) are benign.

They<sup>1</sup> usually arise from the gonads or (usually midline) extragonadal sites. Sacrococcygeal teratoma (SCT) is the commonest variety and the commonest of all solid neonatal tumors. This chapter focuses on extragonadal GCTs.

### 47.1.1 Incidence

- Teratomas (overall)
  - 4 per million children under the age of 15 years
- Sacrococcygeal teratoma
  - 1 in 40,000
  - M:F 2:1

<sup>1</sup>Teratoma is derived from the Greek *teratos* meaning monster and *onkoma* meaning swelling.

E. Makin  
Department of Paediatric Surgery, King's College Hospital, London, UK  
e-mail: [Erica.makin@nhs.net](mailto:Erica.makin@nhs.net)

M. Davenport (✉)  
King's College Hospital, London, UK

### 47.1.2 Embryology

GCTs arise from primordial cells derived from the embryonic yolk sac endoderm at around 24 days of gestation. During the fifth and sixth weeks, these cells migrate along the mesentery of the hindgut toward the genital ridge. Premature migration arrest is thought to result in the formation of extragonadal GCT arising in or near the midline (Table 47.1).

### 47.1.3 Pathology and Classification (Fig. 47.1)

- *Immature teratomas* are not strictly benign and usually contain one or more of the somatic tissues (most commonly neuroepithelial cells). Metastases usually arise from undiagnosed malignant cells within the teratomas at the time of resection.
- *Endodermal sinus tumors (ESTs)* are the commonest malignant GCT.
- *Choriocarcinomas* arise from placental tissue (gestational) or extraplacental tissue in the mediastinum or gonad (nongestational) in an adolescent or via transplacental spread in a newborn.
- *Embryonal carcinomas* are capable of differentiating into embryonic or extraembryonic tumors. They are poorly differentiated, anaplastic, and are highly malignant with the worst prognosis.

### 47.1.4 Staging

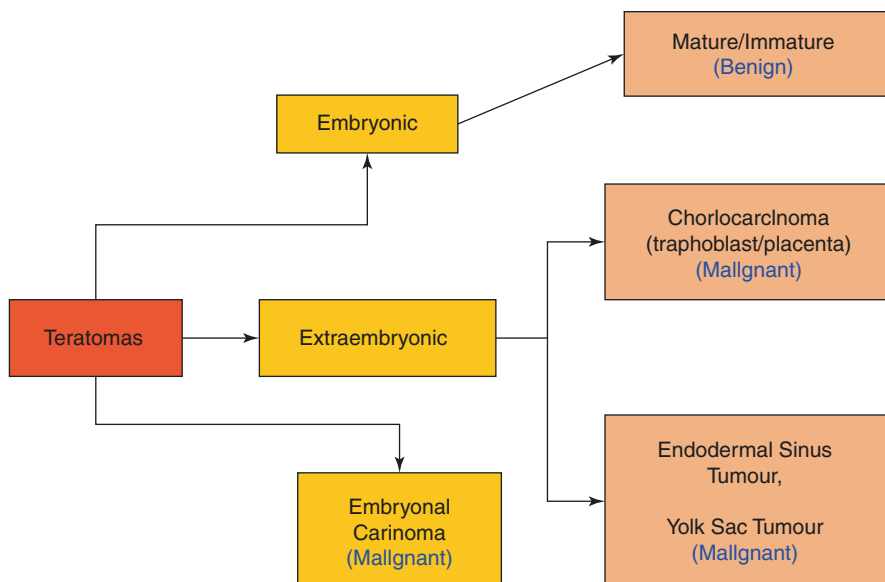
The Pediatric Oncology Group/Children's Cancer Group (POC/CCG) staging system for malignant extragonadal GCTs is outlined in Table 47.2.

### 47.1.5 Tumor Markers

- *$\alpha$ -Feto protein ( $\alpha$ -FP)*—protein produced by embryonic liver, yolk sac, and gastrointestinal tract
  - Very sensitive to the presence of malignant EST.
  - Most commonly elevated with yolk sac tumors, less so with immature teratomas, embryonal carcinoma, and mixed GCT.

**Table 47.1** Distribution of extragonadal GCT

| Site  | %  | Notes   |
|---|----|---|
| Sacrococcygeal  | 70 |   |
| Intracranial  | 10 | Usually pineal gland  |
| Mediastinal   | 5  | Commoner in male adolescents (N.B. Testicular examination essential as mediastinal mass could be a secondary)   |
| Other (cervical, retroperitoneum, omentum, pancreas, stomach, and vagina) | 15 | <ul style="list-style-type: none"> <li>• <i>Retroperitoneum</i>—usually benign</li> <li>• <i>Vaginal</i>—malignant ESTs at presentation</li> <li>• <i>Gastric</i>—benign</li> </ul> |



**Fig. 47.1** Schematic of hierarchy of teratomas

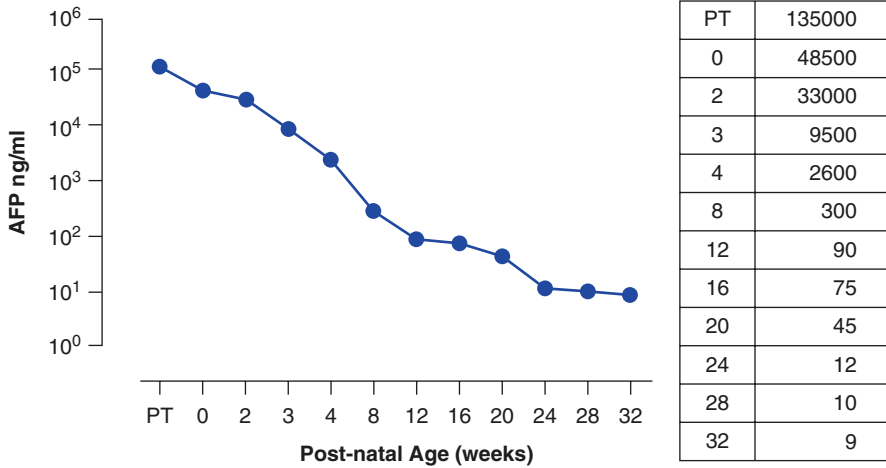
**Table 47.2** Staging of extragonadal GCT

| Stage |  | Overall survival (%) |
|-------|--|----------------------|
| I     | Complete resection. Negative tumor margins. Coccygectomy for sacrococcygeal site                             | 90                   |
| II    | Microscopic residual disease, lymph nodes normal   | 90                   |
| III   | Gross residual disease or biopsy only; retroperitoneal nodes either normal or showing evidence of malignancy | 75                   |
| IV    | Distant metastases, including liver  | 75                   |

- Normally elevated in the neonatal period and reaches normal levels by 9 months of age (Fig. 47.2).
- It is routinely measured postoperatively as screening for recurrence (*NB. Also elevated in benign and malignant liver disease*).
- *Human chorionic gonadotropin ( $\beta$ HCG)*—released by syncytiotrophoblasts.
  - Sensitive marker for choriocarcinoma. May also be elevated in embryonal carcinoma and mixed (GCT).
  - CA-125—most commonly raised with epithelial tumors.

### 47.1.6 Risk Groups

The Children's Oncology Group (COG) and UK Children's Cancer and Leukaemia Group (CCLG) have described categories of patients according to their clinical risk and thus providing guidance for adjuvant therapy, surveillance with the aim to provide prognosis for patients and their families (Table 47.3).



**Fig. 47.2** Serum  $\alpha$ -FP levels in normal infants. (Adapted from Wu JT, Book L, Sudar K (1981) Serum Alpha Fetoprotein (AFP) levels in normal infants. *Pediatr Res* 15:50–52)

**Table 47.3** Risk stratification in extragonadal teratoma (adapted from Frazier et al. *J Clin Oncol* 2015; 33:195–201)

| Risk     | Age(years) | Location     | COG stage | Survival % |
|----------|------------|--------------|-----------|------------|
| Low      | Any age    | Extragonadal | I         | 93         |
| Standard | <11        | Extragonadal | II/III    | 91         |
|          | <11        | Extragonadal | IV        | 79         |
| High     | >11        | Extragonadal | III       | 61         |
|          | >11        | Extragonadal | IV        | 40         |

### 47.1.7 Management

Most GCTs are treated with a combination of surgery and chemotherapy (e.g., UKCCSG GC III protocol (carboplatin, etoposide, and bleomycin—JEB regimen), which has increased the 5-year survival to ~90%. A more toxic regimen (cisplatin, etoposide, and bleomycin—PEB) is reserved for recurrence. The UK P3BEP Trial is due to finish at the end of 2020.

Radiotherapy is the mainstay for intracranial GCTs.

## 47.2 Sacrococcygeal Teratomas

Antenatally diagnosed in >90% cases at 20-week anomaly scan.

Antenatal complications include:

- Polyhydramnios and premature delivery.
- Fetal hydrops (placentomegaly, ascites, pleural effusions) and the development of “maternal mirror” syndrome.



The need for antenatal intervention (exception amnioreduction) is associated with a poor prognosis.

### 47.2.1 Delivery

Ideally should be via C-section (particularly if tumor is >5 cm), to minimize the risks of rupture, hemorrhage, or dystocia during birth. Once stabilized, the extent of the tumor should be ascertained by USS  $\pm$  MRI and classified according to the Altman<sup>2</sup> criteria (Table 47.4).

### 47.2.2 Surgery

Preoperative imaging (MR/US) should define upper extent of the tumor. If upper extent is below sacral promontory, then a sacral-only approach should be possible. Very vascular tumors may benefit from initial laparotomy and preliminary ligation of median sacral vessels.

1. *Position*—“skydiver” with urethral catheter and rectal pack.
2. *Incision*—“chevron,” “Mercedes-Benz,” or “ $\pi$ ” *pi*.
3. Create skin flaps, and dissect from stretched gluteal and anorectal muscle groups.
4. Define plane between rectum and tumor working toward pelvis.
5. Define and divide sacrococcygeal joint (always remove coccyx with tumor). Once tumor is mobile enough, the median vascular pedicle can be defined, trans-fixed, and divided. (NB—although early vascular control via the sacrum is often advocated, this can be difficult with large, bulky tumors within the pelvis.)
6. *Reconstruction*—important stage but often hurried after a long period of dissection. Ensure re-alignment of anorectal and levator muscle complex, adequate buttock volume (consider de-epithelializing excess skin flaps), median sacral cleft, and “normal” distance between anus and sacrum.

**Table 47.4** Altman classification (1974)

| Type | Description  | %  |
|------|--|----|
| I    | Predominantly external   | 45 |
| II   | External with intrapelvic extension                              | 35 |
| III  | Externally visible, mainly pelvic with intra-abdominal extension | 10 |
| IV   | Entirely intrapelvic/intra-abdominal, no external findings       | 10 |

<sup>2</sup>R. Peter Altman—American pediatric surgeon at Columbia University, New York.

*Histology*—presence of yolk sac elements (~5%) or “immature” tumors (50%) has little prognostic significance if tumor is completely resected.

All patients should be followed up for at least 3 years and screening should include a rectal examination and  $\alpha$ FP at regular intervals (e.g., every 2 months for the first 6 months, then every 3 months for 18 months).

Potential long-term morbidity is related largely to neurological involvement (tumor/iatrogenic).

- Urological—↓ sphincter function (incontinence) (5–30%)
- Anorectal—↓ sphincter function (incontinence or constipation) (5–30%)
- Lower limb impairment (rare)
- Cosmetic—leave secondary surgery until primary school years.

### 47.2.3 Outcome

- Antenatally diagnosed SCT—overall survival of ~90%.
- Recurrence occurs in <10% of benign SCTs and in ~30% of malignant stage 1 SCTs (often late presenters).

---

## Further Reading

- Altman RP, Randolph JG, Lilly JR (1974) Sacrococcygeal teratoma: American Academy of Pediatrics Surgical section survey - 1973. *J Pediatr Surg* 9:389–398.
- Derikx JP, De Backer A, van de Schoot L, et al. Long-term functional sequelae of sacrococcygeal teratoma: a national study in The Netherlands. *J Pediatr Surg.* 2007;42:1122–6.
- Frazier AL, Hale JP, Rodriguez-Galindo C, et al. Revised risk classification for pediatric extracranial germ cell tumours based on 25 years of clinical trial data from the United Kingdom and United States. *J Clin Oncol.* 2015;33:195–201.
- Hambraeus M, Al-Mashhadi A, et al. Functional outcome and health related quality of life in patients with sacrococcygeal teratoma – a Swedish multicenter study. *J Pediatr Surg.* 2019;54:1638–43.
- Makin EC, Hyett J, Ade-Ajayi N, et al. Outcome of antenatally diagnosed sacrococcygeal teratomas: single-center experience (1993–2004). *J Pediatr Surg.* 2006;41:388–93.
- Simonini C, Strizek B, Berg C, et al. Fetal teratomas - a retrospective observational single-center study. *Prenat Diagn.* 2020 Nov 26; <https://doi.org/10.1002/pd.5872>.
- Yoon HM, Byeon SJ, Hwang JY. Sacrococcygeal teratomas in newborns: a comprehensive review for the radiologists. *Acta Radiol.* 2018;59:236–46.



Hany Gabra and Chandrasen K. Sinha

### 48.1 Lymphomas

Lymphomas can be divided into:

- *Hodgkin's lymphoma* (HL) (45%)
  - All B cell origin
- *Non-Hodgkin's lymphoma* (NHL) (55%)
  - Both B- and T-cell origin (commonest Burkitt<sup>1</sup> and diffuse large B-cell lymphomas)

#### 48.1.1 Hodgkin's Lymphoma<sup>2</sup>

This is the commonest (~45%) of all childhood lymphomas and can be characterized by the presence of pathognomonic Reed–Sternberg<sup>3</sup> cells.

<sup>1</sup>Denis Parsons Burkitt (1911–1993)—British (N Irish) surgeon, famously one eyed, who identified the tumor in Uganda and showed a marked geographical relationship with endemic malaria.

<sup>2</sup>Thomas Hodgkin (1798–1866), English physician at Guy's Hospital, London described this in 1832.

<sup>3</sup>Dorothy Reed (1874–1964) and Carl Sternberg (1872–1935), American and German pathologists who distinguished these cells independently.

H. Gabra (✉)

Department of Paediatric Surgery, The Great North Children's Hospital, Royal Victoria Infirmary, Newcastle upon Tyne, UK

St George's Hospital, London, UK

e-mail: [hany.gabra@nhs.net](mailto:hany.gabra@nhs.net)

C. K. Sinha

St George's Hospital, London, UK

### 48.1.1.1 Etiology

- Up to 50% are Epstein–Barr<sup>4</sup> virus (EBV) positive.
- HLA-DP alleles are more common in Hodgkin disease.

### 48.1.1.2 Clinical Features

Painless, rubbery, typically fixed lymphadenopathy (usually cervical), often with the involvement of mediastinal lymph nodes which can cause dyspnoea, cough, or stridor. Sometimes, the spread is extra lymphatic, for instance, with lung, bone, and spleen involvement.

*Constitutional (so-called B) symptoms* may also be seen—these are fever (Pel-Ebstein fever, i.e., cyclical over some weeks duration), weight loss (>10%), and drenching night sweats.

### 48.1.1.3 Investigations

- Full blood count, erythrocyte sedimentation rate (ESR), ALAT (GPT), ASAT (GOT), GGT, LDH, AP, creatinine and albumin in the serum, fibrinogen, Immunoglobulin A, G, M.
- Baseline virology recommended to include serologic examinations for antibodies against VZV, EBV, CMV, HSV, HIV, toxoplasmosis, hepatitis A, B, C (HCV-PCR).
- Functional examinations (ECG, Echocardiography).
- ESR measured at presentation as this has been proven to be an important prognostic factor.
  - ↑ESR, ↑ serum copper, and ↑ ferritin (worse prognosis)
  - ↑ Lactate dehydrogenase (LDH) may correlate with tumor bulk.
- USS usually shows abnormal architecture of the lymph nodes.
- CT scan (chest), MRI neck/abdomen/pelvis.
- Positron emission tomography (FDG-PET) ↑ sensitivity (cf. CT scan).
- Biopsy: Either open surgical or radiologically guided Trucut (histology and immunohistochemistry).

Table 48.1 illustrates the commonest staging system for HL—the Ann Arbor Staging Scheme.<sup>5</sup>

*The Rye classification*<sup>6</sup> divides classical HL into four histological subgroups:

1. Nodular sclerosing (70%) best prognosis
2. Mixed cellularity (20%) associated with HIV
3. Lymphocyte predominant (<10%)
4. Lymphocyte depleted (<2%) worst prognosis

<sup>4</sup>Michael Epstein and Yvonne Barr—Virologists (English and Australian), who identified this at Middlesex Hospital, London in 1964.

<sup>5</sup>Ann Arbor—Site of conference in Michigan, USA in 1971.

<sup>6</sup>Rye—After conference held in Rye, New York state in 1966.

**Table 48.1** Ann Arbor classification

| Stage | Definition   |
|-------|--|
| I     | Involvement of a single lymph node region ( <i>I</i> ) or single extralymphatic site ( <i>Ie</i> )   |
| II    | Involvement of two or more lymph node regions on the same side of the diaphragm ( <i>II</i> ) or of one lymph node region and a contiguous extralymphatic site ( <i>IIE</i> )                        |
| III   | Involvement of lymph node regions on both sides of the diaphragm, which may include the spleen ( <i>IIIs</i> ) and/or limited contiguous extralymphatic organ or site ( <i>IIIe</i> , <i>IIIes</i> ) |
| IV    | Disseminated involvement of one or more extralymphatic organs  |

N.B. Spleen is considered as a lymph node area. Involvement of the spleen is denoted with the S suffix (i.e., IIB<sub>S</sub>). A or B designations denote the absence or presence of B symptoms, respectively

*N.B. WHO classification also includes a fifth non-classical type, the nodular lymphocyte-predominant HL.*

#### 48.1.1.4 Management

Combined modality therapy (typically radiation and chemotherapy) is the preferred approach for most patients. The goal is to induce a complete remission, defined as the “disappearance of all evidence of disease” as evaluated by FDG-PET/CT, physical examination, and bone marrow examination (if appropriate).

Currently, the following are used:

- *OEPA* (Prednisone/prednisolone, Vincristine, Doxorubicin, and Etoposide) regimen.
- *COPDAC* (Prednisone/prednisolone, Dacarbazine, vincristine cyclophosphamide).

Treatment is given according to treatment group (TG), which are defined as follows:

- TG-1: patients of stages I A/B and II A without bulk  $\geq 200$  ml and without ESR  $\geq 30$  mm/h
  - 2 cycles of *OEPA*
- TG-2: patients of stages IEA/B, IIEA, II B, or III A and patients of stages I A/B and II A with bulk  $\geq 200$  ml and/or ESR  $\geq 30$  mm/h
  - 2 cycles of *OEPA* + 2 cycles of *COPDAC*
- TG-3: patients of stages IIIEB, IIIEA/B, III B or IV A/B
  - 2 cycles of *OEPA* + 4 cycles of *COPDAC*.

All undergo response assessment including FDG-PET after 2 cycles of *OEPA*.

*In case of inadequate response to two cycles of OEPA chemotherapy modified involved field radiotherapy follows for all treatment groups.*

For disease recurrence after an initial chemotherapy-induced remission, then high-dose chemotherapy and autologous hematopoietic stem cell transplantation may be used.

### Oncological Emergencies: Large Mediastinal Mass

- Involve anesthetist early before biopsy or insertion of central line (careful clinical assessment, chest CT).
- IV prednisolone (pre-phase) 5–10 days prior to anesthesia

### Outcome

- Five-year survival rate ~90%, however, in stage III, IV survival can be as low as 70%.

Most acute and late complications are due to treatment-related toxicities. Patients who survive pediatric HL may develop a secondary malignancy, which includes lung (most common), thyroid, breast, skin, leukemia, and (second) lymphoma, or cardiac toxicity (doxorubicin).

## 48.1.2 Non-Hodgkin's Lymphoma

- NHL accounts for ~4% of all pediatric cancers.

### 48.1.2.1 Etiology

- Most non-Hodgkin lymphomas within the United Kingdom develop sporadically with no clear cause.
- HIV infection/iatrogenic immunodeficiency/primary immunodeficiency.

The most common childhood NHLs are:

- *Lymphoblastic lymphomas (LBL)* (most often T cell, can be B cell)
- *Mature B-cell non-Hodgkin lymphomas*
  - Burkitt's lymphoma lymphomas or Burkitt-like/non-Burkitt lymphomas
  - Diffuse Large Cell B Cell Lymphoma (DLBCL)
- *Anaplastic Large Cell Lymphoma (ALCL)* (T cell)

### 48.1.2.2 Pathology

Many of the molecular alterations that contribute to the malignant phenotype are chromosomal translocations involving genes for immunoglobulin or T-cell receptor (TCR) molecules. Some characteristic chromosomal translocations associated with NHL are highlighted below:

- Burkitt's lymphoma: t(8;14)(q24;q32) translocation → aberrant c-MYC
- LBL: t(11;14)(p13;q11) translocation → enhanced LMO2 expression
- LBL: deletion in a regulatory region of the gene TAL1
- LBL: Inactivation of the multiple tumor suppressor gene 1 (MTS-1/p16INK4 alpha/CDKN2)

- DLBCL: t(8;14)(q24;q32) translocation (same as Burkitt's Lymphoma)
- ALCL (9 T cell): t(2;5)(p23;q35) translocation → nucleophosmin (NPM)/anaplastic lymphoma kinase (ALK) fusion protein p80 (expression may have survival advantage)

### 48.1.2.3 Clinical Features

Typically presents as extra-nodal disease with rapid growth (<1 month history).

- Abdomen (~30%)
  - Especially Burkitt lymphoma which can occur in the Peyer's patches and cause both masses and can act as a lead point for intussusception
- Head and neck (~30%)
- Mediastinum (~25%), especially DLBCL
  - SVC syndrome or airway compromise
- Peripheral nodes or bones, typically LCL

### 48.1.2.4 Investigations

Diagnostic and staging evaluation

- Bloods: Blood count, hepatic and renal function tests, LDH
- Chest X-ray
- CT scan
- Excisional biopsy: histopathology, cytogenetics, molecular genetics
- Diagnosis can also rapidly be made on liquid biopsies such as pleural fluid or ascites
- Bone marrow aspirate
- CSF analysis
- HIV and other viral serology
- Echocardiography
  - To check cardiac function before administering cardiotoxic chemotherapeutic agents.

NHL is staged according to *St. Jude (Murphy) classification* (Table 48.2).

### 48.1.2.5 Management

Childhood NHLs are extremely chemosensitive.

#### Oncological Emergencies: Tumor Lysis Syndrome

- Life-threatening metabolic derangements (hyperkalemia, hyperphosphatemia, hyperuricemia, hypocalcemia) caused by a highly proliferative and/or bulky malignancy.
- Most commonly occurs following chemotherapy, some may present with metabolic derangement or develop it following general anesthetic.
- Treated with intensive hydration, stimulation of diuresis and allopurinol.

**Table 48.2** St. Jude (Murphy) system

| Stage | Definition  |
|-------|---|
| I     | Single extranodal tumor or single anatomic area (nodal), excluding the mediastinum or abdomen   |
| II    | Single extranodal tumor with regional node involvement, or<br>Primary GI tumor ± mesenteric nodes, with gross total resection, or<br>On the same side of diaphragm, 2 or more nodal areas or 2 single (extranodal) tumors ± regional node involvement   |
| III   | Any primary mediastinal, pleural, or thymic intrathoracic tumor, or<br>Any extensive and unresectable abdominal tumor, or<br>Any primary paraspinous or epidural tumor regardless of other sites, or<br>On both sides of the diaphragm, 2 or more nodal areas or 2 single (extranodal) tumors ± regional node involvement |
| IV    | Any of the above with initial central nervous system or marrow (<25%) involvement   |

Lymphoblastic lymphoma is considered analogous to acute lymphoblastic leukemia and most international groups will treat using an ALL or very similar protocol.

Mature B-NHL and ALCL are treated with intensive cyclical chemotherapy, similar to aggressive solid tumors. Modern regimens may involve the use of monoclonal antibody therapies, particularly in higher-stage diseases. Debulking surgery is rarely indicated even for patients with bulky disease. Radiotherapy is avoided in current frontline protocols.

### Outcome

- Complete remission achieved in >90% of patients.
- Survival rate:
  - >90% for stage I, II, and > 80% for stage III, IV for lymphoblastic and Burkitt lymphomas.
  - >90% for stage I, II, and 80–90% for stage III, IV for diffuse large B-cell.
  - 60–70% for advanced anaplastic large cell lymphoma.
- Long-term sequelae include cardiomyopathy from anthracyclines, infertility from alkylating agents, and secondary leukemia due to epipodophyllotoxins used in the treatment of NHL.

### 48.1.3 Rhabdomyosarcoma

Rhabdomyosarcoma (RMS) is the most common soft tissue sarcoma in children (4%) and the third most common extracranial solid tumor of childhood after Wilms' and neuroblastoma and arises from immature mesenchymal cells.

- Bimodal distribution (2–6 years and 10–18) years of age.



### 48.1.3.1 Etiology

- Mainly sporadic
- Familial syndromes:
  - Li Fraumeni (AD, p53 mutation) and Neurofibromatosis type I others: Rubinstein–Taybi syndrome, Gorlin basal cell nevus syndrome, Beckwith–Wiedemann syndrome, Costello syndrome.
  - Family history: other carcinomas including premenopausal breast carcinoma

### 48.1.3.2 Pathology and Genetics

RMS is one of the *small, round blue-cell tumors* of childhood showing variable differentiation along the myogenesis pathway. Desmin, myogenin, and MyoD1 and muscle-specific actin are the commonly used immunohistochemical stains to identify RMS.

Main histological types of RMS:

- *Embryonal RMS (ERMS)*
  - Younger patients (~75%)
  - Sites typically include head and neck and GU tumors.
- *Alveolar RMS (ARMS)*
  - Older patients (~20%) poor prognosis
  - Sites typically include extremities, trunk, and perineum.

### Cytogenetics

Diagnosis is confirmed by cytogenetics or reverse transcriptase polymerase chain reaction (RT-PCR) to identify specific chromosomal abnormalities.

- *ERMS*: Loss of heterozygosity (LOH) at the 11p15 locus in (80%). Within this locus lies the Insulin Growth Factor II (IGF-II) gene.
  - Other genetic aberrations in ERMS: FGFR1 and NRAS mutations
- *ARMS*: MYCN and CDK4, PAX3-FOXO, and PAX7-FOXO fusion and is associated with worse overall survival.
  - N.B. Fusion status will replace tumor histology in the classification and stratification of RMS tumors in future studies and treatment protocols.

### 48.1.3.3 Investigations

- MRI scan—assess the degree of local invasion
- CT scan—predominantly for distal metastasis
- FDG-PET (limited experience in pediatric experience)

The current staging system is the *Lawrence/Gehan Staging System for Intergroup Rhabdomyosarcoma Study (IRS) IV*, which is initiated preoperatively and then completed after resection (Tables 48.3 and 48.4).

**Table 48.3** TNM Lawrence/Gehan pre-treatment staging for IRS IV

| Stage | Site  | Tumor          | Node           | Metastasis |
|-------|---|----------------|----------------|------------|
| I     | Orbit, head, and neck (not parameningeal), genitourinary (not bladder/prostate) | <5 cm or >5 cm | N0, 1, X       | M0         |
| II    | Bladder/prostate, extremity, trunk, parameningeal, others                       | <5 cm          | N0, X          | M0         |
| III   | Bladder/prostate, extremity, trunk, parameningeal, others                       | <5 cm<br>>5 cm | N1<br>N0, 1, X | M0         |
| IV    | All   | <5 cm or >5 cm | N0, 1, X       | M1         |

Notes: N0 no nodal metastasis; N1 regional nodal metastasis; NX unknown nodal status; M0 no distant metastasis; M1 distant metastasis

**Table 48.4** Clinical grouping classification (this is based on the extent of residual disease after the resection—an important prognostic factor in RMS)

| Group | Extent of disease  |
|-------|--|
| I     | Localized tumors, completely resected, no microscopic residual                                       |
| IIa   | As above PLUS microscopically +ve resection margin   |
| IIb   | As above PLUS +ve regional lymph nodes   |
| IIc   | As above PLUS +ve regional lymph nodes and margins of resection                                      |
| III   | Localized or locally invasive tumor, gross residual disease after attempted resection or biopsy only |
| IV    | Distant metastatic tumor   |

#### 48.1.3.4 Clinical Features

Most children with RMS present with a painless swelling, which varies by site of presentation. The most common sites are:

- Head and neck (~30%)
- Extremities (~25%)
- GU tract (~20%)
  - Paratesticular
  - Bladder/prostate
  - Vaginal
- Bile duct (<5%)

#### 48.1.3.5 Management

Risk stratification: Low, intermediate, and high risk based on histology, primary site, initial resection, and distant metastases status.

- *Primary resection* if R0 resection can be achieved (no microscopic residual disease), if feasible, without causing unacceptable disfigurement or loss of function offers the best chance of cure.
- *Primary re-excision* to achieve -ve margins without loss of function or disfigurement can be offered before the initiation of any other form of therapy.

- *Regional LN evaluation* is recommended in extremity and trunk tumors. *Lymphatic mapping and sentinel node biopsy* may allow adequate staging while limiting the operative morbidity.
  - Boys >10 years with paratesticular RMS should undergo sampling of at least 7 retroperitoneal nodes.
- *Delayed primary excision (DPE)*: After completing induction chemotherapy (week 12, R0 or R1), evaluation by CT or MRI to determine response to therapy. Excision of residual tumor via DPE should be considered.
- Debulking has no role in RMS

Medical therapy depends on the staging:

- *ERMS (completely excised)*.
  - Vincristine and dactinomycin (also known as Actinomycin-D) (VA regimen)
- *ARMS and Gp II and III RMS*.
  - *VAC regimen*—addition of cyclophosphamide.
  - Irinotecan or topotecan may be added to this combination for high-grade tumors.
- *Radiation therapy (XRT)*—residual localized disease.
- *Second-look operation* to remove residual tumor after chemotherapy with or without radiotherapy has also been shown to improve survival.

#### 48.1.3.6 Outcome

Overall survival >70%

- Group I (completely resected) low risk (90% survival)
- Group II (microscopic residual disease), alveolar/undifferentiated histology, unfavorable primary sites, and node involvement (85% long-term survival)
- Group III (incomplete resection or biopsy only), tumor size <5 cm, favorable primary sites, and localized tumors with no nodal disease 5-year survival rate > 90% (localized disease).
  - <20% (metastatic disease)
- Group IV (metastases at presentation)
  - 25%—3 years survival.

About 30% of RMS patients will relapse, and between 50% and 95% of these will die of progressive disease.

#### 48.1.4 Malignant Melanoma

Melanoma is the most common tumor to involve the fetus by the transplacental spread. It is a malignancy of primarily skin pigment-producing cells (melanocytes) with a clear relationship to sunlight exposure.

- 0.3–0.4% of melanomas appear in prepubertal children.
- Half of melanomas occur in previous pigmented lesions.
- Melanoma-related conditions with malignant potential.
  - Large/giant congenital melanocytic nevus
  - Spitzoid melanocytic tumors
- Melanoma arising in older adolescents are similar to adult melanoma (conventional melanoma).

#### 48.1.4.1 Clinical Features

##### ABCDE—A Useful Mnemonic

Asymmetry, Border irregularity, Color variegation, Diameter >6 cm, Evolving or changing nevus)

#### 48.1.4.2 Management

- *Wide local excision:*
  - Surgical resection remains the key curative modality with the goal of excising the primary lesion and any micrometastases. Excisional full-thickness skin biopsy with 1–3 mm margins if possible, followed by wide local re-excision of the lesion with margins based on the thickness is part of the definitive treatment once the diagnosis is confirmed.
- *Sentinel lymph node biopsy (SLNB)*
  - Identifies those at risk for recurrence and poorer disease-free survival.
- *Completion Lymph node dissection (CLND)*
  - Children with clinically positive lymph nodes should undergo lymphadenectomy of the involved nodes unless metastatic disease is present.
- *Immune checkpoint inhibitors or BRAF/MEK inhibitors.*

Tumor thickness and skin penetration and sentinel node status are the most important prognostic factors. This is described by:

- *Clark's level* (progressive involvement of skin structures)
- *Breslow's depth* (measured in millimeters)

The narrowest efficacious margins for cutaneous melanoma are yet to be determined. *American Joint Commission on Cancer (AJCC) staging* is most widely accepted.

#### 48.1.4.3 Prognosis

Those with distant metastatic disease have an extremely poor prognosis and chemotherapy is the mainstay of treatment. Biochemotherapy, using standard chemotherapeutic agents with biologic response modifiers such as IL-2, IFN- $\alpha$ , or granulocyte macrophage colony-stimulating factor, has shown some promise.

## 48.1.5 Pancreatic Tumors

### 48.1.5.1 Pancreatoblastoma

This is the embryonal equivalent for this organ although <100 cases have been reported. Associated with Beckwith-Wiedemann syndrome. The majority of these tumors are of an embryonal type, which develops at an early stage of pancreatic differentiation, thus contains both exocrine and endocrine cell types. They are usually present as an asymptomatic mass in the upper abdomen.

- Tumor markers (e.g.,  $\alpha$ -1-fetoprotein, LDH) may be elevated.

Complete excisional surgery is the mainstay of treatment (usually pancreaticoduodenectomy) and is associated with 80% survival. Prognosis is poor in metastatic disease, primarily inoperable disease, or local recurrence.

### 48.1.5.2 Islet Cell Hyperplasia

Diffuse increase of pancreatic islet cell tissue, which may result in hyperinsulinism and hypoglycemia leading to seizures, cerebral damage, and even death. In persistent hypoglycemia, placement of a central venous catheter for 20% glucose infusion is advisable to maintain an adequate blood glucose level. Operative excision is required if it fails to respond to diazoxide. If no localized adenoma is found, a 95% pancreatectomy is recommended.

### 48.1.5.3 Solid Pseudopapillary Epithelial Neoplasm (Better Known as Frantz's Tumor<sup>7</sup>)

Characteristically large cystic tumor arising from the pancreas in teenage girls. Borderline neoplasm with about 50% occurring in those of African ethnicity. Good prognosis with complete resection.

## 48.1.6 Thyroid Tumors

Carcinoma accounts for:

- ~1% of all childhood malignancies.
- F > M 2:1 ↑incidence with age (peak at adolescence).
- ~5% of cancers arising in the head and neck.
- Is identified in ~30% of children, who undergo surgical resection for cold nodules.

### 48.1.6.1 Etiological Factors

- Previous irradiation and chemotherapy for other malignancies (e.g., HL, leukemia, and other head and neck malignancies).

---

<sup>7</sup>VK Frantz—American pathologist described in 1959.

- Iodine deficiency (↑risk of follicular carcinoma).
- Genetic (e.g., mutations in the RET proto-oncogene identified in the *multiple endocrine neoplasia [MEN2] syndromes*).
- ~40% of medullary thyroid carcinomas (MTC) are related to autosomal dominant familial syndromes.

Histologic types include:

- *Papillary* (~75%)
  - Epithelial cells arranged as papillae are disseminated throughout the gland. Lymphocytic infiltrates and psammoma<sup>8</sup> bodies are common.
- *Follicular* (~20%)
  - Malignant cells are adenomatous with follicle formation and are distinguished from benign adenomas only by the presence of nuclear atypia, capsular invasion, or vascular invasion.
- *Medullary* (~5%)
  - Arises from the parafollicular C cells, derived from neural crest cells.
  - Appear as solid islets of regular, undifferentiated cells with abundant granular cytoplasm. The stroma contains fibrotic tissue, amyloid, and calcification.
- *Anaplastic* (rare).

#### 48.1.6.2 Clinical Features

Painless thyroid mass with or without cervical adenopathy. Advanced cases may present with dysphagia, features of tracheal/esophageal compression (e.g., hoarseness), or metastasis.

#### 48.1.6.3 Investigation

- Thyroid function tests (normal in most cases)
- Plasma calcitonin (↑ MTC), thyroglobulin (↑ differentiated TC)
- Genetic testing for MTC (e.g. *RET* proto-oncogene mutations)
- US—differentiate between solid and cystic lesions
- Thyroid scan—Tc 99 m-pertechnetate shows functioning thyroid tissue
- Fine-needle aspiration cytology (FNAC)—role poorly defined in children
  - >13 years → FNAC, <13 years → excision

Benign nodules can be followed safely with serial physical examination and US scans but are resected if growth is shown. Surgical resection is indicated for malignant or suspicious nodules. An aspirated cyst that collapses completely can be observed, but should be removed, if recurs.

#### 48.1.6.4 Surgery

Total or subtotal thyroidectomy is indicated for differentiated carcinoma. Tumor involving the recurrent laryngeal nerve should be shaved off, preserving the nerve

<sup>8</sup>Psammoma (Greek)—sand.

with the parathyroid glands. If viability of the parathyroid glands is questionable, they should be autotransplanted into the sternomastoid muscle of the nondominant forearm.

---

## Further Reading

- Acker SN, Linton J, Tan GM, et al. A multidisciplinary approach to the management of anterior mediastinal masses in children. *J Pediatr Surg.* 2015;50:875–8.
- Crist WM, Anderson JR, Meza JL, et al. Intergroup rhabdomyosarcoma study-IV: results for patients with nonmetastatic disease. *J Clin Oncol.* 2001;19:3091–102.
- Dasgupta R, Fuchs J, Rodeberg D. Rhabdomyosarcoma. *Semin Pediatr Surg.* 2016;25:276–83.
- Rhee DS, Rodeberg DA, Baertschiger RM, et al. Update on pediatric rhabdomyosarcoma: a report from the APSA Cancer Committee. *J Pediatr Surg.* 2020;55:1987–95.
- Tracy ET, Aldrink JH. Pediatric melanoma. *Semin Pediatr Surg.* 2016;25:290–8.

---

## **Part VIII**

# **Gastrointestinal**





Jennifer Billington, Z. Mukhtar, and Chandrasen K. Sinha

- About 85% of infants will vomit during the first week of life and another 10% have symptoms by 6 weeks of age.
- However, 60% of children will be asymptomatic by 2 years (due to upright posture and change to solid foods).

## 49.1 Normal Physiology

There are a number of factors that inhibit reflux of gastric contents, some anatomical, some physiological.

### Anatomical

- Angle of His<sup>1</sup> (between the esophagus and the fundus of stomach) is obtuse in newborns but decreases as infants develop.
- “Pinch-cock” action of right crus of diaphragm.
- Mucosal rosette—Redundant mucosal folds are present at gastro-esophageal junction (GEJ) only when a normal angle of His is present. These folds squeeze together to form a weak anti-reflux valve.

<sup>1</sup>Wilhelm His Sr (1831–1904)—Swiss anatomist, working in Basel and Leipzig, Germany.

J. Billington · Z. Mukhtar  
Department of Paediatric Surgery, St George’s Hospital, London, UK  
e-mail: [jenniferbillington@rcsi.ie](mailto:jenniferbillington@rcsi.ie); [z.mukhtar@nhs.net](mailto:z.mukhtar@nhs.net)

C. K. Sinha (✉)  
St George’s Hospital, London, UK

- Intra-abdominal esophagus
  - >2 cm is regarded as sufficient and <1 cm is regarded as incompetent.
  - An hiatus hernia may cause displacement of distal esophagus into the thorax (negative w.r.t. atmosphere).

### Physiological

- *High-Pressure Zone* (manometric sphincter)
  - An area of increased muscular thickness near the anatomical GEJ. Maturation of and hence ↑ in basal tone continues until ~45 days.

*Gastro-esophageal reflux (GER)* can be divided into:

- Functional GER—common, rarely problematic
- Pathogenic GER (also termed gastro-esophageal reflux disease (GERD))
  - Distinguished from functional GER by the frequency, ↑length of episodes, and the presence of complications such as malnutrition, respiratory problems, erosive esophagitis, bleeding and strictures, and Barrett's<sup>2</sup> esophagus.
- Secondary GER—caused by the presence of a co-existing, underlying condition, e.g., hiatus hernia, esophageal atresia, gastric outlet obstruction, and diaphragmatic hernia.

---

## 49.2 Pathophysiology

The major mechanism in infants and children is *transient LOS relaxation*, which accounts for about 95% of reflux episodes. A supine posture may promote reflux during periods of LOS relaxation phase. The predominantly fluid diet of infants facilitates the process of regurgitation when compared to the solid meals ingested by older children. Finally, ↓ Gastric emptying is commonly seen in premature infants.

---

## 49.3 Associations

- Cerebral palsy, developmental delay.
- Down syndrome<sup>3</sup> and Cornelia de Lange<sup>4</sup> syndrome (genetic mutation, microcephaly, characteristic facies, ↑body hair).

---

<sup>2</sup>Norman Rupert Barrett (1903–1979)—Australian-born, British surgeon described columnar lined esophagus.

<sup>3</sup>John Langdon Down (1828–1926)—English physician, ascribed “racial” characteristics to various types of idiocy.

<sup>4</sup>Cornelia Catherina de Lange (1871–1950)—Dutch pediatrician, eventually professor in Amsterdam.

- Drugs, e.g., benzodiazepines, theophylline.
- Dietary habits (e.g., overeating, nocturnal eating, assuming a supine position shortly after eating), foods with high acid/fat content.
- Food allergies.

---

## 49.4 Clinical Features

There is an array of possible features, which can be dated to the first few months of life, and maybe divided into:

- Regurgitation of food—one of the most common presentations in children, ranges from drooling to projectile vomiting. Most often, regurgitation is post-prandial. May lead to weight loss and failure to thrive.
- Chest or abdominal pain—manifest as atypical crying and irritability in infancy.
- ENT—recurrent sore throat, stridor, hoarseness, and laryngitis.
- Sandifer syndrome<sup>5</sup> (i.e., spasmodic torsional dystonia with back arching and rigid opisthotonus or torticollis due to GER).

### 49.4.1 Relationship with Airway Problems

An infant's proximal airway and esophagus are lined with receptors that are activated by water, acid, or distension. Activation of these receptors by GER can produce laryngospasm, leading to obstructive apnea with resulting hypoxemia, cyanosis, and bradycardia—now termed an *Apparent Life-Threatening Event (ALTE)*.

GOR may be a complicating factor in asthma, possibly due to microaspiration, and reflex bronchoconstriction. Suspect particularly if the history of nocturnal wheezing is found.

### 49.4.2 Investigations

The diagnosis is most commonly a clinical one and conservative measures can be started empirically. However, if the presentation is atypical or if the response to conservative management is inadequate, a number of investigations may be warranted.

- *Upper GI contrast study*—Can identify the presence of hiatus hernia, esophageal strictures, esophagitis, dysmotility, and rotational anomalies. However, as GER is an episodic event, reflux may not be captured, even if it is present.
- *24-h pH study*—quantification of reflux and its relationship to atypical symptoms and events (pathological GER may be defined as acid (<pH 4) exposure  $\geq 4\%$ ).

---

<sup>5</sup>Paul H. Sandifer—English neurologist, worked at Great Ormond Street Hospital, London.

- *Upper GI endoscopy* ( $\pm$  biopsy)—indicated in children, who are unresponsive to medical therapy. Allows for visualization of esophageal mucosa—and diagnosis of peptic esophagitis, peptic ulcer disease, strictures, and *H. pylori* infection.
  - *Histology*—peptic esophagitis is suggested by basal cell hyperplasia, extended papillae, and mucosal eosinophils. (N.B. if  $>20$  per high-powered field may be *allergic (eosinophilic) esophagitis*).
- Gastric scintiscan (not routine)—imaging can assess gastric emptying, observe reflux, and evaluate aspiration. Its disadvantages are the need for immobilization and that it cannot detect late postprandial reflux readily in the brief period it takes for evaluation.
- Esophageal manometry (not routine)—used to assess esophageal motility and LES function.

---

## 49.5 Management

### 49.5.1 Medical

- Functional GOR should only need reassurance
- Conservative measures (although not definitely proven) include: upright positioning after feeding, elevating the head of the bed, providing small frequent thickened feeds, and thickening of formula.
- Nasojejunal or gastrojejunal tube feeding is helpful in some cases.
- Drugs
  - Dopaminergic antagonists (e.g., metoclopramide)— $\uparrow$ LOS tone,  $\uparrow$ gastric emptying.
  - Antacids (e.g., Gaviscon $\text{\textcircled{C}}$ )— $\uparrow$ gastric pH  $> 4$  and inhibits proteolytic activity of pepsin.
  - $H_2$  receptor antagonists (e.g., ranitidine)—similar inhibition of pepsin, together with  $\downarrow$ acid reflux (All medicines are more or less equipotent when used in equivalent doses).
  - Proton pump inhibitors (e.g., omeprazole)—block the gastric H, K-ATPase, and inhibit gastric acid secretion. Recommended in children needing complete acid suppression (e.g., chronic respiratory disease or neurological impairment, ALTE).
  - Surface agents (e.g., sucralfate, sodium alginate in Gaviscon $\text{\textcircled{C}}$ )—adhere to mucosal surfaces, preventing further acid damage and promoting healing. Limited evidence in children, along with the long-term efficacy, and therefore remains a novel, emerging treatment.
  - Complementary and alternative medicine is sought by many families. While no randomized controlled trials are available to guide the use of products, chamomile, slippery elm, and ginger are frequently used by families.

N.B. Therapeutic response may take up to 2 weeks. If successful then  $\uparrow$ weight and  $\downarrow$ vomiting episodes.

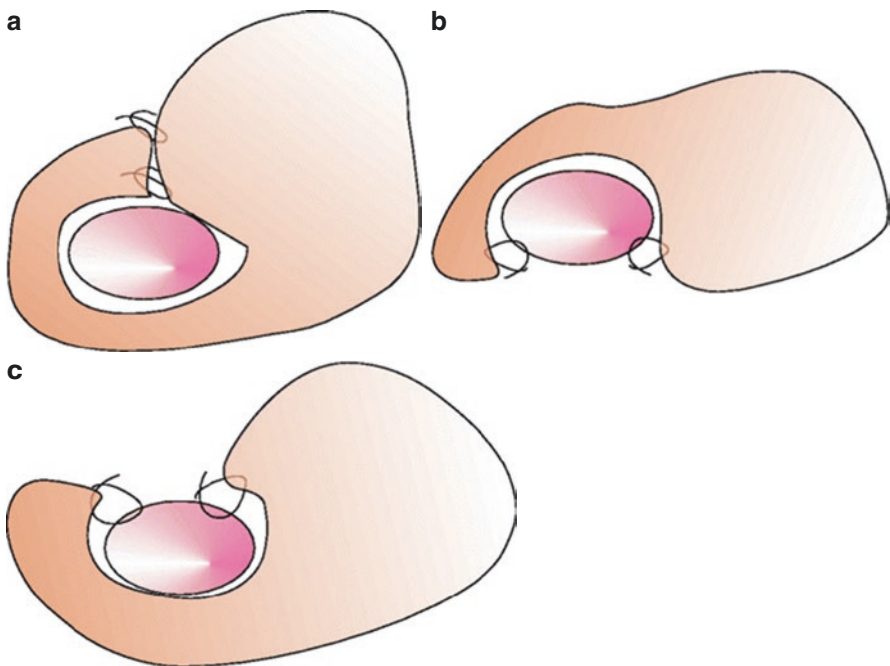
## 49.5.2 Surgery—Fundoplication (Fig. 49.1)

### 49.5.2.1 Indications

- *ALTE* associated with confirmed GER.
- Failure of medical therapy (persisting symptoms, failure to thrive).
- Oropharyngeal and esophageal complications, e.g., peptic stricture, Barrett's esophagus.
- Anatomical GER, e.g., hiatus hernia.
- Severe GER in association with profound medical comorbidities. Such children, are more likely to have intractable GER, and may also benefit from gastrostomy insertion to facilitate gastric or jejunal feeding.

### 49.5.2.2 Relative Contraindications

- Gastrointestinal dysmotility—These children are at higher risk of feed intolerance and intractable retching after fundoplication.
- Neurologic disability—These children have poorer outcomes after fundoplication, due to failure of surgery due to wrap breakdown, retching, and other life-threatening events.
  - One possible cause of higher wrap failure in these children could be gastrointestinal dysmotility (causing impaired gastric compliance) and visceral



**Fig. 49.1** Schematic illustration of different types of fundoplication: (a) Nissen, (b) Thal, and (c) Toupet

hypersensitivity (causing emetic reflex), hence breaking the wrap due to the incoordination between the two. Feeding through percutaneous gastrostomy is gaining popularity among surgeons for treating chronic reflux in these neurological disabled children.

### 49.5.2.3 Pre-Operative Evaluation

- The pre-operative assessment and optimization of patients with severe GER are imperative. Many children have underlying malnutrition and pulmonary dysfunction secondary to chronic aspiration pneumonia which should be optimized before surgery is undertaken.
- For patients with underlying neurological disorders such as cerebral palsy, surgical intervention should be proceeded with caution due to higher complication and procedure failure rates. Identification of delayed gastric emptying and need for pyloroplasty.

### 49.5.2.4 Surgical Principles

- Lengthening of the intra-abdominal esophagus
- Accentuation of the angle of His
- ↑ High-pressure zone at the esophago-gastric junction
- Approximation of the crura

Fundoplication achieves all of the above, although there are many variants. Randomized controlled trials in the pediatric population have been limited and failed to demonstrate superiority of one over another. A partial wrap may be preferred in esophageal dysmotility disorders because these are less likely to cause obstructive symptoms.

There are numerous reported types of fundoplication—each providing different degrees of a circumferential esophageal wrap. A *Nissen's fundoplication*<sup>6</sup> (360° wrap) is the most commonly performed one in children with *Toupet*<sup>7</sup> (270°) and *Thal*<sup>8</sup>(180°) wraps also popular.

All should include a crural repair and may be performed laparoscopically. Laparoscopic fundoplication has been well studied and has become the preferred option as first-line surgical treatment for GER. Open fundoplication still has a role in complex cases, where laparoscopy may not be feasible.

### 49.5.2.5 Procedure (Nissen, Thal, and Toupet) (Fig. 49.1)

1. Mobilization of fundus and distal esophagus—division of short gastric vessels.
2. Definition of hiatal structures—anterior vagus and a separate posterior vagus nerve.

<sup>6</sup>Rudolf Nissen (1896–1981)—German surgeon—posts in Turkey and the USA, before finishing as Professor of Surgery in Basel, Switzerland.

<sup>7</sup>Alan P. Thal—American thoracic surgeon, worked in Minneapolis, MN.

<sup>8</sup>Andre Toupet (b1915)—French surgeon who worked at Hopital Bichat, Paris.

3. Creation of retro-esophageal window—aim to create only enough space to allow fundus through.
4. Repair of crura using non-absorbable suture and  $\pm$  bougie to ensure appropriate esophageal caliber.
5. Formation of wrap (variants as above).
6.  $\pm$  Gastrostomy.

#### 49.5.2.6 Complications

These might include wrap breakdown, small bowel obstruction, *gas bloat syndrome*, atelectasis or pneumonia, esophageal stricture/obstruction. Such complications are more common in those with an underlying neurological disorders, in particular problems with post-operative retching. Increased gastric emptying is also seen in those who have undergone a concurrent antroplasty or pyloroplasty at the time of fundoplication. This is associated with a *dumping syndrome* when large amounts of gastric contents empty into the duodenum/jejunum and cause nausea, vomiting, diarrhea, and sweating.

#### 49.5.2.7 Gastro-Jejunal Feeding

GJ feeding is now considered the least invasive of all surgical options and involves bypassing the stomach and feeding directly into the jejunum, either by naso-jejunal tube or through an existing gastrostomy tract. Under fluoroscopic guidance, the jejunal tube is placed beyond the ligament of Trietz.

Feeding directly into the jejunum usually causes significant resolution of reflux-related symptoms. It is not without its disadvantages, however, with frequent maintenance for tube dislodgement or migration needed and the inability to give bolus feeds. Bowel obstruction and intussusception are also reported, and frequent tube changes every 3–4 months are recommended to minimize these.

This route of feeding has become a common choice for children with neurological impairment or those following failed fundoplication, avoiding the surgical morbidity associated with this procedure. For those requiring long-term jejunal feeding, a Roux-en-Y surgical jejunostomy is often considered.

#### 49.5.2.8 Other Surgical Interventions

In recent years, a number of endoscopic and endoluminal procedures have been developed as alternative therapeutic options for GER. Pediatric experience is still limited and the lack of long-term follow-up means that none of these techniques are recommended as first-line therapy for pediatric GER.

- *Endoluminal gastroplication* (EndoCinch©) tightening of gastro-esophageal junction area by endoscopic suturing and knotting and can be repeated if there is recurrence of symptoms.
- *Stretta procedure* (radio-frequency ablation of LOS to augment lower esophageal sphincter pressure and increase the gastric yield pressure).
- *Endoscopic submucosal injections* (of bovine collagen, Teflon, or nonbiodegradable polymer like ethylene vinyl alcohol at the level of cardia to increase LOS pressure).

- *Total esophagogastric disconnection* may be appropriate as a “rescue” procedure for selective cases of severe GER who have failed fundoplication, though some centers have actually used this as primary surgical therapy. It almost guarantees control of reflux but at the expense of gastrostomy-dependent feeding. It is usually reserved for neurologically impaired children.

---

## 49.6 Outcome

- About 60–80% of GER resolve by 18–24 months (~50% resolve by 12 months). Some infants require lifestyle modifications, and others require medications to control the symptoms of GOR.
- Surgery is required in a minority of cases and it controls reflux in about 90% (95% in neurologically normal/85% in neurologically abnormal).

---

## Further Reading

- Davies I, et al. Guideline Development Group. Gastro-oesophageal reflux disease in children: NICE guidance. *BMJ*. 2015;350:g7703.
- Lansdale N, McNiff M, Morecroft J, Kauffmann L, Morabito A. Long-term and ‘patient-reported’ outcomes of total esophagogastric dissociation versus laparoscopic fundoplication for gastro-oesophageal reflux disease in the severely neurodisabled child. *J Pediatr Surg*. 2015;50:1828–32.
- Michail S. Gastroesophageal reflux. *Pediatr Rev*. 2007;28:101–10.
- Rosen R, Vandenplas Y, Singendonk M, et al. Pediatric gastroesophageal reflux clinical practice guidelines: joint recommendations of the NASPGHAN and ESPGHAN. *J Pediatr Gastroenterol Nutr*. 2018;66:516–54.
- Rossor T, Andradi G, Bhat R, Greenough A. Investigation and management of gastro-oesophageal reflux in United Kingdom neonatal intensive care units. *Acta Paediatr*. 2018;107:48–51.
- Tovar JA, Luis AL, Encinas JL, et al. Pediatric surgeons and gastroesophageal reflux. *J Pediatr Surg*. 2007;42:277–83.





# Management of Gastrointestinal Bleeding

# 50

Khizer Mansoor, Ferzine Mohamed, and Ashish Minocha

## 50.1 Background

Acute gastrointestinal (GI) bleeding is relatively rare in children with an estimated incidence of 1-2/10,000 upper GI bleeding in one French study. By contrast, lower GI bleeding is less well reported and less prevalent. It is true that these events are rarely life threatening as compared to adults. In terms of etiological factors, there is a clear distinction between infants and older children, the latter behaving much more like adults. Conventionally, an upper GI bleed arises proximal to the ligament of Treitz and therefore presents with hematemesis or melena whereas a lower GI bleed arises distally and generally presents with fresh bleeding or altered bleeding per rectum.

### 50.1.1 Initial Presentation and Assessment

Presentation of a child with a GI bleed may be either acute or chronic with fresh rectal bleed, melena, and hematemesis or in any combination. Sometimes gradual development of pallor gives a direction to investigate for GI bleed.

*History should include:*

- Onset, type, and duration of bleeding
- Location, duration, and quantity
- Any underlying medical condition, e.g., bleeding diathesis, sepsis
- Drugs (specifically NSAID's), toxins, exposure to infection, foreign body ingestion

---

K. Mansoor · F. Mohamed · A. Minocha (✉)  
Paediatric & Neonatal Surgery, Jenny Lind Children Hospital, Norfolk and Norwich  
University Hospital NHS Foundation Trust, Norwich, UK  
e-mail: [khizer.mansoor@nnuh.nhs.uk](mailto:khizer.mansoor@nnuh.nhs.uk); [ferzine.mohamed@nnuh.nhs.uk](mailto:ferzine.mohamed@nnuh.nhs.uk);  
[ashish.minocha@nnuh.nhs.uk](mailto:ashish.minocha@nnuh.nhs.uk)

- Associated symptoms: rash, fever, sore throat, retrosternal pain, headache, fever, or diarrhea
- Family history of liver disease/inflammatory bowel disease/bleeding disorders
- History of prolonged TPN administration
- History of umbilical catheterization
- History of prolonged jaundice
- History of blood transfusion

### Physical Examination and Investigations

Massive GI bleeds whether upper or lower should involve the usual ABC's of management. IV access should be gained immediately and blood investigations sent including a cross match. If bleeding is massive, major transfusion protocol may need to be activated. Nasogastric tube should be inserted to assess the severity and rate of bleeding and to prevent aspiration of the vomited blood. Physical examination and secondary assessment may give a clue to potential sources of the bleed like hepatosplenomegaly or other signs of portal hypertension, perianal disease for inflammatory bowel disease, buccal hyperpigmentation for Peutz-Jeghers<sup>1</sup> syndrome etc.

*Physical examination should include:*

- Head, eyes, ears, nose, and throat:
  - Local causes of bleed, e.g., epistaxis, oral trauma, burns to posterior pharynx
- Abdomen: *Caput medusae*, bruising, hepatosplenomegaly, ascites
- Genitourinary: Blood at the urinary meatus, trauma
- Rectal: fissures/fistulae
- Whole-body examination:
  - Skin rash, petechial hemorrhages/ecchymosis, arteriovenous malformations

*Investigations*

- Full blood count
- Clotting profile and fibrinogen levels (when appropriate)
- Liver biochemistry
- Stool cultures
- OGD and colonoscopy and biopsies in suspected inflammatory bowel disease
- X-rays, abdominal ultrasound scan
- (Rarely) scintigraphy/angiography scans for occult bleeding localization
- (Rarely) labelled red blood cell scan

---

<sup>1</sup>Johannes Laurentius Augustinus Peutz (1886–1957) Dutch physician. Harold Joseph Jeghers (1904–1990) American gastroenterologist. Separately described association of familial GI polyposis syndrome with characteristic buccal pigmentation.

### 50.1.2 Management

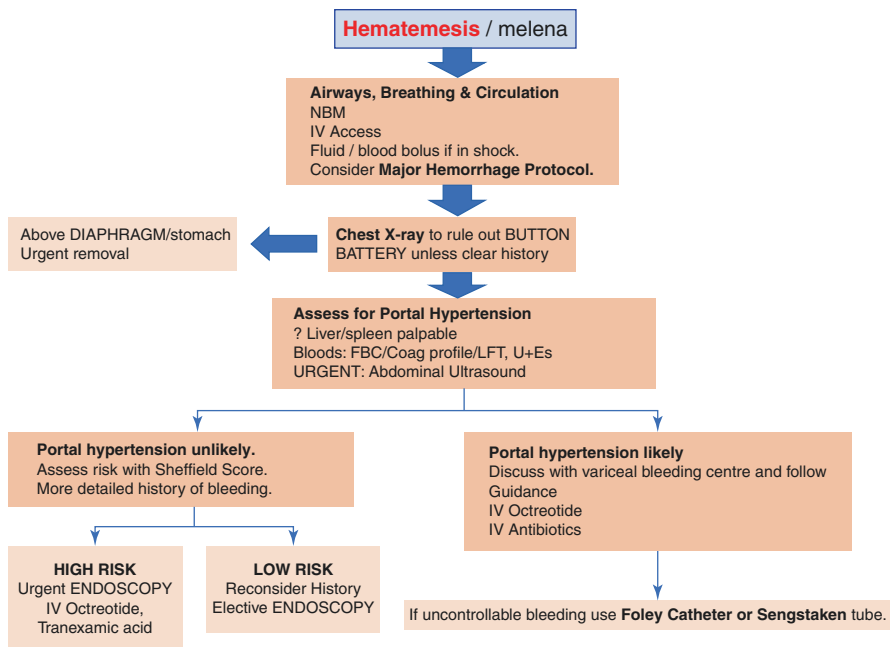
#### 50.1.2.1 Upper GI Bleed (Fig. 50.1)

After stabilization of the child and secondary assessment, definitive treatment should be started. Several scoring systems have been in use for adult patients to predict the need for UGI endoscopy. This has not been translated well to children although the Sheffield score (Fig. 50.2), has gained some acceptance in pediatric practice.

#### Neonates

The most common cause is swallowed maternal blood that may happen during delivery or while breastfeeding from cracked nipples.

- *Apt-Downey test* (alkali denaturation test)
  - A positive test indicates the presence of fetal blood.
- *Kleihauer-Betke test*
  - Quantitative test to detect the presence of fetal blood and is more commonly used.



**Fig. 50.1** Management of Hematemesis (Based on British Society of Paediatric Gastroenterology, Hepatology and Nutrition – BSPGHN guidelines 2020). <https://bspghan.org.uk/wp-content/uploads/2020/02/GIBleedingpathway.pdf>

| <b>Sheffield Scoring Scheme</b>                           |              |
|---|--------------|
| <b>History</b>  |              |
| Significant pre-existing condition                        | 1            |
| Presence of melaena                                       | 1            |
| History of large bloody vomit                             | 1            |
| <b>Clinical examination</b>                               |              |
| HR>20 from mean for age                                   | 1            |
| Prolonged capillary refill                                | 4            |
| <b>Lab tests</b>  |              |
| Hb drop >20g/L  | 3            |
| <b>Management</b>   |              |
| Requirement for IV fluid bolus                            | 3            |
| Requirement for transfusion (Hb<80 g/L)                   | 6            |
| Need for other blood product                              | 4            |
| <b>Maximum score</b>                                      | <b>= 24.</b> |
| <b>High risk of needing endoscopic intervention &gt;8</b> |              |

**Fig. 50.2** Sheffield Scoring Scheme (Adapted from Thomson, M.A.; Leton, N.; Belsha, D. Acute upper gastrointestinal bleeding in childhood: Development of the Sheffield scoring system to predict need for endoscopic therapy. *J. Pediatr. Gastroenterol. Nutr.* 2015; 60: 632–636)

### Pathological Causes

- *Hemorrhagic disease of the newborn—Vitamin K deficiency*
  - Administration of Vitamin K at birth is now universal. Check neonatal records.
  - *Biliary atresia*—lack of bile in intestines causes fat-soluble vitamin deficiency and some present with bleeding.
- *Bleeding disorders and coagulopathy*
  - A careful family history should be taken.
- *Surgically correctable problems*
  - *Duplication cysts*
    - More common in the terminal ileum and may present with GI bleeding.
    - USS typically demonstrates a “gut signature” to the cyst wall.
    - Treatment is surgical excision.
  - *Necrotizing enterocolitis*
    - Typically preterm or “stressed” infants. Exacerbated by thrombocytopenia and gut ischemia
    - Surgical exploration ± intestinal resection.

## Older Infants and Children

- Foreign body ingestion, corrosive injuries, and NSAID-induced ulcerations should be excluded with a careful history and clinical examination.
- Mallory Weiss<sup>2</sup> tear at gastroesophageal junction. Erosive esophagitis/gastritis.
  - Endoscopy
  - Proton pump inhibitors.
- Esophageal varices—commonest cause of de novo bleeding is past *portal vein thrombosis*. Enquire about umbilical vein catheter during neonatal period. Children with chronic liver disease (e.g., biliary atresia and cystic fibrosis) have all got hepatosplenomegaly and a history.
  - Octreotide infusion to lower portal pressure.
  - Endoscopy and variceal ligation/banding/sclerotherapy.
- Child abuse/Munchausen<sup>3</sup> by proxy is possible differential in preschool age group, especially with discrepancies noted in the history and “undiagnosed” repetitive GI bleeding.

Guidelines in children remain vague and based on adult studies as there is a lack of randomized controlled studies. Endoscopy, although an absolute standard in the treatment of adults with GI bleeds, remains controversial in some areas of pediatric practice but should still be considered essential to arriving at an accurate diagnosis.

### 50.1.2.2 Lower Gastrointestinal Bleeding (Fig. 50.3)

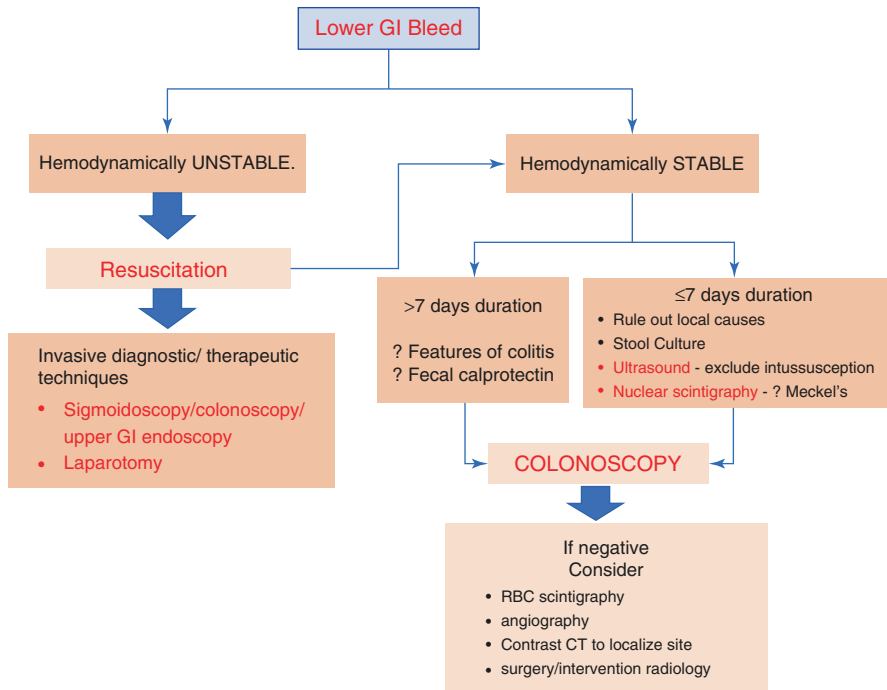
#### Neonates and Infants

Causes of bleeds in neonates that are overlapping with upper GI bleed have been already described.

- *Anal fissures*
  - Commonest cause of lower GI bleed. Managed conservatively.
- *Milk or soy protein allergy*
  - Common cause. Diagnosis can be made on history, infants may have low albumin levels. Exclusion diets.
- *NEC/NEC strictures*
  - Nonoperative management of NEC may resolve initial symptoms. Strictures develop at a later stage (usually 6 weeks and beyond). Operative intervention is usually required.
- *Lymphonodular hyperplasia*
  - Presents as bleeding in an otherwise well infant. Conservatively managed.

<sup>2</sup>George Kenneth Mallory (1900—1986) American. Soma Weiss (1898—1942) Hungarian-born American. Described in 1929.

<sup>3</sup>Baron Münchhausen—Fictitious German nobleman famous for confabulation and made-up stories.



**Fig. 50.3** Management of lower GI bleeding (Adapted from Romano C, Oliva S, Martellosi S, Miele E, Arrigo S, Graziani M et al. Pediatric gastrointestinal bleeding: Perspectives from the Italian Society of Pediatric Gastroenterology. World J Gastroenterol. 2017; 23: 1328)

- *Intussusception and Volvulus*
  - Either may present with intestinal obstruction and/or lower GI bleeding. The best screening tool for intussusception is an ultrasound and pneumatic/hydrostatic reduction remains the current standard of therapy. Surgical reduction or resection may be required. Volvulus requires urgent surgical exploration, detorsion / resection and Ladd's procedure for malrotation of gut.

### Toddlers and Older Children

- *Infectious colitis and Inflammatory Bowel Disease*
  - OGD and colonoscopy are able to evaluate the extent of the disease.
- *Polyps*
  - Commonest is single adenomatous or juvenile polyps in the rectosigmoid colon. Multiple polyps/hamartoma syndromes are rare but include Familial Adenomatous Polyposis; Peutz-Jeghers syndrome.
  - Endoscopic polypectomy/surgical excision of polyps.
- *Meckel's diverticulum*
  - Supposedly present in 2% of the population and due to peptic ulceration in terminal ileum arising from ectopic gastric mucosa at base of diverticulum. May present with altered, sometimes fresh, blood mixed in with feces.

- Technetium-labelled Meckel’s scan (after priming with proton pump inhibitors).
- *Constipation associated with solitary rectal ulcer syndrome, fissures, or rectal prolapse*
  - Common and presumably derived from straining and tearing of anal mucosa.
  - Usually, self-limiting and rarely require any surgical intervention.

### Occult/Obscure GI Bleed

Occult bleeding may be detectable on stool tests or present as anemia. About 75% of the cases are ultimately found to be localized to the small gut but can be difficult to diagnose. *Video capsule endoscopy* or *double-balloon enteroscopy* should be considered if more conventional endoscopy fails. *Surgical on-table enteroscopy* may be considered an option for those cases where the above modalities fail to reveal the origin.

**Table 50.1** Common sources of gastrointestinal bleeding in children (Adapted from Approach to upper gastrointestinal bleeding in children, X Villa, Up to Date, Topic 5857, version 26.0 & Nasher O, Devadason D, Stewart RJ. Upper gastrointestinal bleeding in children: a tertiary UK children’s hospital experience. *Children* (Basel). 2017; 4(11):95. doi: <https://doi.org/10.3390/children4110095>)

| Age group                   | Upper gastrointestinal bleeding  | Lower gastrointestinal bleeding   |
|-----------------------------|--|---|
| Neonates                    | Swallowed maternal blood<br>Hemorrhagic disease of the newborn<br>Stress gastritis<br>Coagulopathy | Cow milk protein allergy<br>Necrotizing enterocolitis<br>Malrotation with volvulus<br>GI duplications   |
| Infants (1 month to 1 year) | Esophagitis<br>Gastritis   | Cow milk protein allergy<br>Anal fissure<br>Intussusception<br>Gangrenous bowel<br>Malrotation with volvulus<br>GI duplications   |
| Preschool child (1–2 years) | Peptic ulcer disease<br>Gastritis  | Anal fissure<br>Intussusception<br>Polyps<br>Meckel’s diverticulum<br>GI duplications   |
| Child (>2 years)            | Peptic ulcer disease<br>Gastritis<br>Esophageal varices<br>Gastric varices                         | Polyps<br>Anal fissure<br>Solitary rectal ulcer syndrome<br>Inflammatory bowel disease<br>Infectious diarrhea<br>Vascular lesions<br>Meckel’s diverticulum<br>GI duplications |

## Further Reading

- Approach to upper gastrointestinal bleeding in children, X Villa, Up to Date, Topic 5857, version 26.0.
- Grimaldi-Bensouda L, Abenheim L, Michaud L, et al. Clinical features and risk factors for upper gastrointestinal bleeding in children: a case-crossover study. *Eur J Clin Pharmacol.* 2010;66:831–7.
- Nasher O, Devadason D, Stewart RJ. Upper gastrointestinal bleeding in children: a tertiary UK children's hospital experience. *Children (Basel).* 2017;4(11):95. <https://doi.org/10.3390/children4110095>.
- Romano C, Oliva S, Martellosi S, Miele E, Arrigo S, Graziani M, et al. Pediatric gastrointestinal bleeding: perspectives from the Italian Society of Pediatric Gastroenterology. *World J Gastroenterol.* 2017;23:1328.
- Thomson MA, Leton N, Belsha D. Acute upper gastrointestinal bleeding in childhood: development of the Sheffield scoring system to predict need for endoscopic therapy. *J Gastroenterol Nutr.* 2015;60:632–6.
- Transfusion Guidelines. [Transfusionguidelines.org](https://www.transfusionguidelines.org). 2020 [Cited 18 February 2020]. Available as PDF under policies from: <https://www.transfusionguidelines.org/uk-transfusion-committees/regional-transfusion-committees/east-of-england/policies>





Pablo Laje

Abdominal pain that develops abruptly without an obvious underlying cause is one of the most common reasons for a visit to a pediatric emergency room. The abrupt nature of the onset can be defined as an “acute abdomen” and these need a prompt evaluation. The critical step in the evaluation is to determine if possible whether the nature of the case is predominantly “surgical” or “medical.” In almost all cases, a thorough history and physical examination, a basic set of blood work, and standard imaging studies are sufficient to find identify the etiology. However, an exploratory laparotomy or laparoscopy can be the only way to make a diagnosis.

The potential causes of an acute abdomen are many and remarkably variable (Fig. 51.1). The best way to approach the list of causes is by age group, which is the way we approach every patient in a real clinical setting (Table 51.1). Alternatively, the many causes of acute abdomen can be divided by its nature in:

- “Obstructive”
  - The pain is accompanied by signs of bowel obstruction such as bilious vomiting and abdominal distension, and includes midgut volvulus, intussusception, and incarcerated hernia.
- “Inflammatory/infectious”
  - The pain is accompanied by systemic signs of inflammation such as fever and an elevated white blood cell count, and includes appendicitis, Crohn’s disease, and cholecystitis.
- “Hemorrhagic”
  - The pain is accompanied by signs of acute hemoglobin loss such as paleness and tachycardia, and include traumas, intraluminal intestinal bleeding from ectopic gastric mucosa, and ruptured ovarian cyst.

---

P. Laje (✉)

Division of General, Thoracic and Fetal Surgery at Children’s Hospital of Philadelphia, Philadelphia, PA, USA

e-mail: [LAJE@email.chop.edu](mailto:LAJE@email.chop.edu)

**Fig. 51.1** Causes of abdominal pain in children



**Table 51.1** Common causes of acute abdomen by age group

| Newborns               | Infants                | 1 to 5 years            | 6 to 12 years           | 13 to 18 years      |
|------------------------|------------------------|-------------------------|-------------------------|---------------------|
| Midgut volvulus        | Intussusception        | Intussusception         | Appendicitis            | Appendicitis        |
| Incarcerated hernia    | Incarcerated hernia    | Meckel's diverticulitis | Cholecystitis           | Cholecystitis       |
| Hirschsprung's disease | Midgut volvulus        | Appendicitis            | Meckel's diverticulitis | Ovarian torsion     |
| NEC                    | Hirschsprung's disease | Mesenteric adenitis     | Mesenteric adenitis     | Mesenteric adenitis |
| Sepsis                 | Infantile colic        | Incarcerated hernia     | Crohn's disease         | PID                 |
|                        | UTI                    | UTI                     |                         | Crohn's disease     |

NEC necrotizing enterocolitis, UTI urinary tract infection, PID pelvic inflammatory disease

## 51.1 Clinical Features

A brief review of the clinical features of some common conditions will follow.

### 51.1.1 Acute Appendicitis (See also Chap. 53)

Acute appendicitis is the most common surgical emergency in children and young people, indeed in people in general and about 250,000 cases can be expected annually in the USA alone.

Most cases present with the typical signs and symptoms, but atypical presentations are also frequent, particularly in the younger patient. The most common initial clinical picture is that of vague abdominal pain that starts in the periumbilical area, and 12–24 h later migrates to the right lower quadrant. Fever, vomiting, and anorexia are typically part of the picture and appear as the hours go by. As the disease progresses and the inflammation reaches the parietal peritoneum, signs of peritonitis start to appear with rebound tenderness and guarding. Generally speaking, children older than about 5 years keep the infection well localized in the right lower quadrant even in cases of appendiceal perforation, developing initially an appendiceal phlegmon,<sup>1</sup> and later an appendiceal abscess. In younger children, the infection is rarely localized and commonly presents in advance stages with generalized peritonitis at the time of the initial hospital visit.

- *Laboratory investigations* may show signs of inflammation including a raised WBC (neutrophilia), ESR, and C-reactive protein.
- *Plain abdominal X-ray*: Fairly nonspecific and rarely diagnostic but a radio-opaque fecalith in the right lower quadrant may be a suggestive finding.
- *Ultrasound*: It is very sensitive and specific for the diagnosis and should always be the first real imaging test to be obtained. An enlarged, non-compressible appendix is almost always diagnostic. The study also allows the evaluation of pelvic organs when the appendix appears normal. And is almost mandatory in adolescent girls.
- *CT scanning*: It is more sensitive and specific than an ultrasound, but the risks of ionizing radiation and the need for IV contrast have made this study obsolete in many areas of the world. Suspicious cases in which ultrasound is non-diagnostic should not undergo a CT, but should undergo a non-contrast, non-sedated MRI, if at all possible.
- *MRI*: Non-contrast, non-sedated MRI has been shown to be as sensitive and specific as a CT scan.

The operation is done laparoscopically almost everywhere in the developed world nowadays. The operative time and the hospital stay are directly related to the status of the appendix (perforated or not perforated) at the time of the operation.

### 51.1.2 Intussusception (See also Chap. 54)

The highest incidence occurs between 6 and 18 months of age, with an ileocecal intussusception being the most common type. Small bowel-to-small bowel intussusception is very common but is self-limited and more often than not an incidental findings in images done for unrelated reasons. The vast majority of cases of ileocolic intussusception in the typical age range are idiopathic. The typical clinical

---

<sup>1</sup>Phlegmon—(Latin) but derived from the Greek (φλέγω—phlégō) meaning “flame or to burn” in the sense of inflammation.

presentation is of colicky abdominal pain, vomiting, and eventually bloody diarrhea. Most infants are lethargic in between the episodes of pain with signs of dehydration if diagnosis is delayed. Bloody diarrhea can also occur if the mucosa of the affected segment becomes ischemic and sloughs off.

Plain radiographs may show signs of a soft-tissue mass in the right upper quadrant or signs suggestive of small bowel obstruction with central, dilated intestinal loops. Ultrasound remains the key investigation in suspected cases and is highly sensitive and specific.

The majority of cases can be successfully treated with an air or other contrast enema, which can be repeated a few times if initially unsuccessful. In cases of failure of the enema, or in cases where the child has peritoneal signs, and perhaps in those in who the imaging studies are suspicious for an abdominal mass as the source of the intussusception should undergo surgery.

### **51.1.3 Incarcerated Inguinal Hernia**

This is a clinical diagnosis, and no tests are required. The younger the patient with an inguinal hernia, the higher the risk of incarceration. Most cases can be safely reduced in the emergency department (with or without sedation), after which the child should be admitted for observation and scheduled for a semi-urgent repair. Ideally, at least 24 h should lapse between the reduction and the repair to allow the tissue edema to settle. On rare occasions, the incarcerated bowel may be suspected to be nonviable or at least severely compromised. This should be suspected if the incarceration has been prolonged for more than a day, if the patient has peritoneal signs, or if free air is visible on radiography (if they were obtained for any reason). External reduction should not be attempted in these cases and they should undergo an emergent exploration.

### **51.1.4 Ovarian Torsion**

Solid and/or cystic masses arising in the ovaries and Fallopian tubes are common in teenage girls, and put the ovaries at risk of torsion, particularly if they have a diameter > 5 cm. Most ovarian lesions are simple follicles that did not regress after the hormonal monthly peak, and continued to develop during several menstrual cycles. Commonly these cysts suffer internal hemorrhages, which can cause a rapid expansion with rupture and spillage of blood in the peritoneal cavity.

Ovarian tumors are infrequent but should always be suspected as an underlying reason for torsion. Epithelial tumors such as cystadenomas are the most common, followed by teratomas. Malignant tumors being really quite rare in pediatric practice. Torsion of the ovary, with or without involvement of the Fallopian tube, causes significant acute abdominal pain that can be intermittent. Ultrasound remains the ideal diagnostic tool and Doppler evaluation can assess the viability of the torqued ovary prior to surgical exploration. When there is any concern for ovarian ischemia, the patient should undergo an immediate exploration.



Ankit Sinha and Mark Davenport

## 52.1 Introduction

Although conditions such as acute appendicitis and intussusception are relatively common causes of acute abdominal pain, neither is as common as the “*nonspecific abdominal pain*” (*NSAP*),<sup>1</sup> which is seen in children of all ages and all places for which no diagnostic test or specific remedy exists. Clinical acumen and experience are the usual diagnostic tools, with reassurance and perhaps temporary relief from food as bedside remedies.

The term, *Functional Abdominal Pain Disorders (FAPDs)*, is a recent umbrella term that can be applied to most forms of chronic abdominal pain. This often overlaps with other terms including functional dyspepsia, abdominal migraine, Irritable Bowel Syndrome (IBS), and functional constipation and are largely diagnoses of exclusion.

Of course, there are still important causes of chronic abdominal pain that have a more classical surgical pathology such as uro-sepsis, uro-calculi, inflammatory bowel disease, and rarely chronic intestinal volvulus. Additionally, girls may suffer from pelvic inflammatory disease, torped ovaries, and mittelschmerz.<sup>2</sup>

Some children may have a more classical metabolic pathology (e.g., diabetic ketoacidosis and hypercalcemia) and hematological disorder (e.g., sickle cell anemia). In all these, abdominal pain will feature and, particularly with de novo cases, confusion can occur as to what is going on.

Apart from the first subject, this chapter is therefore devoted largely to minutiae.

<sup>1</sup>Alternatively “No sweat abdominal pain!”

<sup>2</sup>Mittelschmerz (German) for “middle pain,” i.e., pain felt in middle of period due to ovulation.

A. Sinha  
University College London, London, UK  
e-mail: [ankit.sinha.15@ucl.ac.uk](mailto:ankit.sinha.15@ucl.ac.uk)

M. Davenport (✉)  
King’s College Hospital, London, UK

## 52.2 Functional Abdominal Pain Disorders

Functional Abdominal Pain Disorders (FAPDs) can also be called pain-predominant *Functional Gastro-Intestinal Disorders (FGIDs)*. This is probably the most common cause of chronic abdominal pain in children and adolescents.

- Diagnosed when the pain persists for more than two months with no alarming finding and normal clinical examination.
- Pathological (organic) causes should be ruled out and the focus of diagnosis should also include dyspepsia, constipation, diarrhea, dietary trigger factors (like lactose, gluten, FODMAPs<sup>3</sup>), and anxiety.
- Management plan may also include probiotics, increasing fiber in diet, antispasmodics, and treatment of any associated depression.
- Children with persistent ongoing pain may be referred to a mental health specialist where psychological interventions such as relaxation, distraction, guided imaginary exercises, and cognitive behavioral therapy may help in coping and decreasing anxiety-related functional pain.

### 52.2.1 Functional Dyspepsia

- Pain or discomfort in the epigastric region, characterized by fullness, bloating, nausea, vomiting, or retching, which may be increased by eating. In these children, an acid-based peptic disease should be ruled out.
- The pathophysiology is not clearly known. Possible causes could be delayed gastric emptying, reduced gastric capacity, gastroduodenal dysmotility, and psychosocial causes.

### 52.2.2 Abdominal Migraine

This is characterized by recurrent abdominal pain for more than 6 months associated with at least two of the following features: nausea, vomiting, anorexia, headache, photophobia, and pallor.

- Affects 5–15% of children with chronic abdominal pain.
- Age of presentation is usually 2–10 years.
- Is a clinical diagnosis.
- In about 60% family history of migraines may be found.
- Organic causes should be ruled out in these cases.
- Management is empirical.

---

<sup>3</sup>FODMAPs standing for “fermentable oligo-, di-, mono-saccharides and polyols.”

- Helpful factors in management are: avoidance of foods high in amines or xanthenes, avoidance of stress, good sleep habits, and good hydration. Non-analgesic migraine medicines may be helpful in prophylaxis.
- Acute cases may be responsive to the treatment of migraine (e.g., triptans—serotonin receptor agonists, sodium valproate).
- Long-term prognosis is good as most children stop having attacks of intermittent abdominal pain by early adolescence.

### 52.2.3 Irritable Bowel Syndrome

This is characterized by chronic abdominal pain and altered bowel habit, i.e., constipation or diarrhea without any alarming findings. Such children have a lowered rectal pain threshold and disturbed rectal contractile response to meals, whereas in Functional Dyspepsia the pain is mainly felt in the epigastrium. These children also tend to have associated higher anxiety and depression scores.

## 52.3 Helicobacter Pylori

### Helicobacter Pylori

Is a spiral-shaped Gram –ve bacterium with six or so tails (flagella) first identified living in the stomach in the early 1980s by Australian doctors, Barry Marshall, and Robin Warren.

It escapes the acid by burrowing into the mucus layer of the stomach lining and into the interstices of the cellular (epithelial) layer secreting enzymes which breakdown molecules such as urea into the alkaline ammonia which shields itself, but also induces inflammation in the epithelial layer.

- Usually acquired in childhood (~5% overall), becoming increasingly prevalent with age.
- Associated with large families with poor socioeconomic backgrounds.
- ↑↑ prevalence in North Africans.
- May be ↓ in prevalence (at least in the West and Japan).

### 52.3.1 Clinical Features

- Mostly asymptomatic
- Gastritis, duodenal, and gastric ulceration
- May be associated with malignant change in adults.
  - Gastric (Mucosa Associated Lymphoid Tissue—MALT) lymphoma
  - Gastric carcinoma

### 52.3.2 Investigation

- Serology (anti-*H. pylori* antibodies)
  - Can be nonspecific and not recommended
- Stool Helicobacter Antigen Test - >90% sensitive
- <sup>14</sup>C Urea breath test (e.g., PYtest™)
  - Most reliable noninvasive test
- Mucosal biopsy and “CLOtest®”—rapid urease test for “Campylobacter-like organism”

### 52.3.3 Eradication

- Triple therapy
  - Amoxicillin, clarithromycin (or metronidazole), omeprazole for 1 week
- Bismuth preparations
  - More effective but less palatable
  - Unlicensed in children and may be a cause of Reye’s<sup>4</sup> syndrome

---

## 52.4 Yersinia<sup>5</sup> Infections

*Yersinia enterocolitica*, *Y. pseudotuberculosis* (N.B. *Y. pestis* was the cause of plague)

- Gram –ve cocco-bacillus
- Prevalent in Scandinavia, and may be related to ingestion of undercooked pork, contaminated milk, etc.
- Tends to affect young (<5 years) children.
- Maybe a specific cause of mesenteric adenitis, acute ileitis, appendicitis, and even enterocolitis.
- Sensitive to third-generation cephalosporins; gentamicin; doxycycline; Septrin®(sulfamethoxazole/trimethoprim). Resistant to co-amoxycylav.

---

## 52.5 Pediatric Inflammatory Multisystem Syndrome (PIMS or PIMS-TS)

Emanating from Wuhan in China, *infection with a coronavirus (COVID-19)* quickly became a pandemic with major life-threatening respiratory symptoms principally in adults and particularly the elderly. Children were thought to be relatively protected,

---

<sup>4</sup>Douglas Reye (1912–1977). Australian pathologist who published cases of encephalopathy in 1963.

<sup>5</sup>Alexandre EJ Yersin (1863–1943). Swiss bacteriologist who discovered the cause of bubonic plague (*Y. pestis*) while working in Hong Kong.



not from the virus necessarily but from any pathological consequence. However, a new syndrome was identified, now called PIMS-TS, initially in the United Kingdom where among a list of possible symptoms, abdominal pain featured. At first, this masqueraded with sufficient severity to warrant surgical exploration as possible appendicitis until it was realized that viral infection was the cause. The cause is believed to be an excessive immunological response (“cytokine storm”) to viral infection.

### 52.5.1 Key Clinical Features

- Acute abdominal pain, diarrhea, vomiting, fever, muscle pain, lymphadenopathy, ↓ blood pressure (common)
- Coronary artery aneurysms (Kawasaki disease—like), cardiogenic shock.
- Acute renal failure
- ↑incidence in Afro-Caribbean ethnicity

#### WHO Case Definition: PIMS

Children and adolescents 0–19 years of age with fever >3 days.

**AND**

Two of the following:

- Rash or bilateral non-purulent conjunctivitis or mucocutaneous inflammation signs (oral, hands, or feet)
- Hypotension or shock
- Features of myocardial dysfunction, pericarditis, valvulitis, or coronary abnormalities (including ECHO findings or elevated Troponin/NT-proBNP)
- Evidence of coagulopathy (by PT, PTT, elevated d-Dimers)
- Acute gastrointestinal problems (diarrhea, vomiting, or abdominal pain)

**AND**

- Elevated markers of inflammation such as ESR, C-reactive protein, or procalcitonin

**AND**

- No other obvious microbial cause of inflammation, including bacterial sepsis, staphylococcal, or streptococcal shock syndromes

**AND**

- Evidence of COVID-19 (RT-PCR, antigen test, or serology positive) or likely contact with COVID-19

## 52.6 Lead Poisoning (Painter's Colic)

Chronic exposure, usually ingestion, may lead to poisoning. Found in paint (toys), petrol, plumbing (both pipes and solder)—particularly that of previous centuries, and some herbal preparations. Sometimes due to ingestion of contaminated soil.

### 52.6.1 Clinical Features

- Abdominal colic
- Neurocognitive symptoms
  - Lethargy, hyperactivity, seizures
- ↑ Blood pressure

### 52.6.2 Investigation

- Blood lead level should be <10 µg/L.

---

## 52.7 Porphyrrias<sup>6</sup>

Family of metabolic defects within the synthetic pathway of heme. This leads to tissue accumulation of toxic precursors in the skin, liver, nervous system, etc.

### 52.7.1 Acute Intermittent Porphyrria (AIP): Example

#### 52.7.1.1 Clinical Features

Most present in adolescence, or have +ve family history.

- Recurrent abdominal pain
  - Typical features in AIP, can be triggered by certain drugs (e.g., phenobarbitone), hormones, infection, and fasting. Can be extreme, with minimal abdominal signs, usually lasts for days.
- Discolored urine—red, brown, purple.
- Autonomic neuropathy—↑ heart rate, ↑BP—peripheral neuropathy.
- Anemia.
- Skin sensitivity—sunlight.
- Psychiatric and neurological symptoms (e.g., seizures).

---

<sup>6</sup> Porphyrria (Greek—πορφύρα)—purple. Denoting one of the characteristic features—discoloration of urine.

### 52.7.1.2 Investigations

- ↑↑ porphyrins in urine, feces, and blood.

Treatment is medical and supportive and involves loading with carbohydrate (IV glucose) and hematin supplementation to suppress heme synthesis.

---

## 52.8 Familial Mediterranean Fever

One of the autoinflammatory conditions of childhood, is a hereditary autosomal dominant condition (single gene mutation (*MEFV*) on Ch16) afflicting characteristic groups clustered around the Mediterranean (Armenian, Greeks, Turkey, Sephardi Jews, etc.). There is a deficit in the protein *pyrin*, a key part of the inflammatory cascade.

### 52.8.1 Clinical Features

- Abdominal pain
  - Childhood onset, often prolonged over a period of days. Probably caused by intrinsic peritonitis
- Other inflammatory membranes
  - For example, pleuritis/pericarditis/tunica vaginalis (acute scrotum)
- Joint pain
- Fever (~25%)

### 52.8.2 Investigation

- Nothing specific acutely but ↑↑ CRP and ESR.
- ↑ haptoglobin (indicating red cell breakdown).
- Mutational analysis is possible.

Treatment is supportive but colchicine may have a role in ↓ attacks.

---

## Further Reading

- Blakelock RT, Beasley SW. Infection and the gut. *Semin Pediatr Surg.* 2003;12:265–74.
- Daugule I, Rowland M. *Helicobacter pylori* infection in children. *Helicobacter.* 2008;13(suppl 1):41–6.
- Harwood R, Allin B, Jones CE, et al. A national consensus management pathway for paediatric inflammatory multisystem syndrome temporally associated with COVID-19 (PIMS-TS): results of a national Delphi process. *Lancet Child Adolesc Health.* 2021;5:133–41.
- Henry K, Harris CR. Deadly ingestions. *Pediatr Clin North Am.* 2006;53:293–315.
- Sabbagh P, Javanian M, Koppolu V, Vasigala VR, Ebrahimpour S. *Helicobacter pylori* infection in children: an overview of diagnostic methods. *Eur J Clin Microbiol Infect Dis.* 2019;38:1035–45.



Stefano Giuliani

## 53.1 Epidemiology

*Lifetime risk ~7–8% (in Western populations).*

The incidence of appendicitis has been declining worldwide at least in the last two decades. Current estimates of prevalence are 68/100,000 in the United Kingdom and 100/100,000 in Sweden.

In our age group, the incidence rises with age so for 8–11 year olds it is 122/100,000 and 12–15 year olds it is 163/100,000.

## 53.2 Pathology

Appendicitis is a progressive, inflammatory disease, and may distinct stages:

1. Obstruction of lumen—e.g., fecolith, viral-induced lymphoid hyperplasia, or rarely, foreign body.
2. Catarrhal inflammation and luminal distension. Transmural bacterial migration by resident flora (aerobic and anaerobic; *E. coli* and *Bacteroides* spp., etc.).]
3. Ulceration of mucosa and fibrinopurulent exudates.
4. *Gangrene* eventually occurs as a result of progressive bacterial invasion and vascular impairment.

---

S. Giuliani (✉)

Department of Specialist Neonatal and Paediatric Surgery, Great Ormond Street Hospital for Children, London, UK

e-mail: [Stefano.Giuliani@gosh.nhs.uk](mailto:Stefano.Giuliani@gosh.nhs.uk)

5. *Perforation* (20–40%) causing peritonitis and/or abscess formation.

(a) ↑ Incidence in younger children:

- (i) >80% for <5-year olds
- (ii) ~100% in 1-year olds.

### 53.2.1 Reasons for Increased Perforation in the Young

- Caused by impaired communication and a poorer history than in older children.
- Parents and caregivers assume “gastroenteritis” based on the common features of anorexia, vomiting, diarrhea, and fever.
- Increasing perforation rates may be due to socioeconomic factors such as ethnicity, access to healthcare, insurance status, and patient referral patterns.

## 53.3 Clinical Features

The key features are abdominal pain, non-bile-stained reflex vomiting, and anorexia.

- Pain is initially periumbilical or poorly localized and correlates with luminal distension and early inflammation. Progressive transmural inflammation and serosal exudates cause localized irritation of the overlying parietal peritoneum and a distinct *shift* of the pain to the RLQ (or wherever the appendix is).
- Nausea and vomiting—after the onset of pain and may be short lived.
- Anorexia—almost invariable. If a child is hungry, the diagnosis should be in doubt.

Examination shows a child who appears acutely ill, often with a slight flush of the cheeks.

- Typical maximum point of tenderness—McBurney’s<sup>1</sup> point (*2/3 along a line drawn from umbilicus to anterior iliac spine*). Peritonism limits walking and some children adopt a legs-flexed posture when lying down.
- Hierarchy of abdominal muscle reflex response—from rebound tenderness, through guarding to rigidity—depending on the degree of parietal peritoneal involvement.

### 53.3.1 Named Signs in Appendicitis

- Rovsing’s sign
  - Palpation in the left iliac fossa provokes pain in the RIF.

<sup>1</sup>Charles McBurney (1845–1913)—Surgeon at Roosevelt Hospital, New York City, USA. During the 1880s and 1890s, he was a leading advocate for surgery in appendicitis, describing clinical features and incision.

- Obturator sign
  - Internal rotation of the flexed hip exacerbates RIF pain—due to adjacent retrocecal appendiceal inflammation.
- Psoas sign
  - Leg extension exacerbates pain—due to adjacent retrocecal appendiceal inflammation.
- Hop sign
  - Ask to jump or percussion under the right calcaneus with an extended leg.

Fever is usually moderate (38–39 °C), and indeed if higher it suggests the presence of perforation or another diagnosis (e.g., viral mesenteric adenitis).

Only about half of children show the typical pattern of symptoms described here. In those with an age < 5 years, the most common presenting symptoms are pain, vomiting, fever, anorexia, and diarrhea.

### 53.4 Investigations

Laboratory tests are of limited value in the diagnosis of appendicitis.

- A mild leukocytosis (11,000–15,000) with left-shift is typical but not universal. A high WBC (20,000) in a patient with minimal abdominal findings is suggestive of a different diagnosis.
- Elevated C-reactive protein is typical but does not increase discrimination.

Clinical scoring systems (e.g., Alvarado and Pediatric Appendicitis Score-PAS, see Table 53.1) incorporating elements of the history, examination, and lab studies have been used, but sensitivity and specificity are still modest (70–80%).

**Table 53.1** Most common scores for pediatric appendicitis

| Alvarado Score                                       | Pediatric Appendicitis Score                                 |
|--|--|
| Rebound pain   | 1 Cough or percussion or hop tenderness                      |
| Anorexia   | 1 Anorexia   |
| Pyrexia >37.3 °C                                     | 1 Pyrexia  |
| Nausea/emesis  | 1 Nausea/emesis  |
| Tenderness in RIF                                    | 2 Tenderness in RIF  |
| Leukocytosis >10,000                                 | 2 Leukocytosis >10,000                                       |
| Left shift (neutrophils >75%)                        | 1 Polymorphonuclear neutrophilia                             |
| Migration of pain                                    | 1 Migration of pain  |
| Score of ≥7 is considered diagnostic of appendicitis | Score of 6 or above is considered diagnostic of appendicitis |

Ohle R, O'Reilly F, O'Brien KK, Fahey T, Dimitrov BD. The Alvarado score for predicting acute appendicitis: a systematic review. *BMC Med.* 2011;9:139. Published 2011 Dec 28. doi:10.1186/1741-7015-9-139 and Samuel M. Pediatric appendicitis score. *J Pediatr Surg.* 2002 Jun;37(6):877–81. doi: 10.1053/jpsu.2002.32893. PMID: 12037754

Diagnostic accuracy can be improved by adding the US scan result to these clinical scoring systems.

In addition, clinical pathways have been developed to standardize care, improve outcomes and reduce resource utilization in carrying out a diagnostic or treatment care plan.

In equivocal cases, clinical observation with regular abdominal examinations and lab studies over a period of 12–24 h is the best way to differentiate appendicitis from other nonsurgical conditions. Medical conditions tend to improve with appropriate IV resuscitation.

### 53.4.1 Investigations

Unnecessary if the diagnosis is obvious, and should be reserved for equivocal cases.

- *US scan*—looking for fluid collection, abscess cavity, soft-tissue mass, etc. Excellent specificity (~90%), but variable sensitivity (50–90%) for the disease. Highly operator (and patient) dependent.
- *CT scans*—probably offer no further improvement in accuracy in children but can be useful for those with prolonged or atypical features.

## 53.5 Management

This must include correction of fluid, electrolyte, and acid/base imbalance (due to vomiting, etc.), together with antibiotics (effective against BOTH anaerobes and Gram-negative coliforms) to combat features of systemic bacterial sepsis.

Antibiotic regimen—selected for effect against likely pathogens:

- (a) Non-perforated appendicitis (SIMPLE)—single agent, e.g., second-generation cephalosporins, amoxicillin/clavulanate (Augmentin™) ampicillin/sulbactam, ticarcillin/clavulanate, or piperacillin/tazobactam.
- (b) Perforated appendicitis (COMPLICATED)—“triple” antibiotic regimen (e.g., ampicillin, gentamicin, and clindamicin or metronidazole) or a combination (e.g., ceftriaxone/metronidazole or ticarcillin/clavulanate and gentamicin).

Conservative management of acute and complicated appendicitis is under evaluation with a few clinical trials. At the moment, we would only recommend conservative treatment with antibiotics in case of a localized peri-appendix abscess (“appendix mass”).

### 53.5.1 Timing

- *Short history, nonperforated appendicitis*—prompt appendicectomy. But no real increase in perforation rates or morbidity if delayed to the following morning, etc.

- *Short history, perforated appendicitis*—full IV fluid resuscitation and antibiotic loading with appendectomy after clinical improvement.
- *Longer history, palpable mass*—a continuation of nonoperative management with possible interval appendectomy (>3 months) if clinical resolution. If no clinical improvement (24–72 h), then surgery is indicated.

### 53.5.2 Open Appendectomy

Muscle-splitting RLQ incision centered on McBurney's point (or point of maximum tenderness). Ensure that skin incision follows normal skin crease (Langer's lines) for improved cosmesis.

- Ligation/coagulation of mesoappendix.
- Excision of appendix, suture, and ligature at the base of the appendix with cauterization of the mucosa of the stump.

### 53.5.3 Laparoscopic Appendectomy

- Ensure bladder is empty or place a urinary catheter
- Port Placement (Fig. 53.1)
  - 10 mm open Hasson<sup>2</sup> access supraumbilical
  - 5 mm LLQ and 5 mm pubic region
- Aspirate pus in the peritoneal cavity and send cultures to microbiology.
- Coagulation of mesoappendix as distal as possible using unipolar hook diathermy.
- Ligation/transection of base of appendix using double Endoloops™.
- Excision of appendix (withdrawal through the umbilical port with or without an endo bag).

The choice of approach is variable throughout the world; however, most pediatric studies generally conclude that LA has increased cosmesis with a similar length of stay and postoperative complications.

---

## 53.6 Outcome

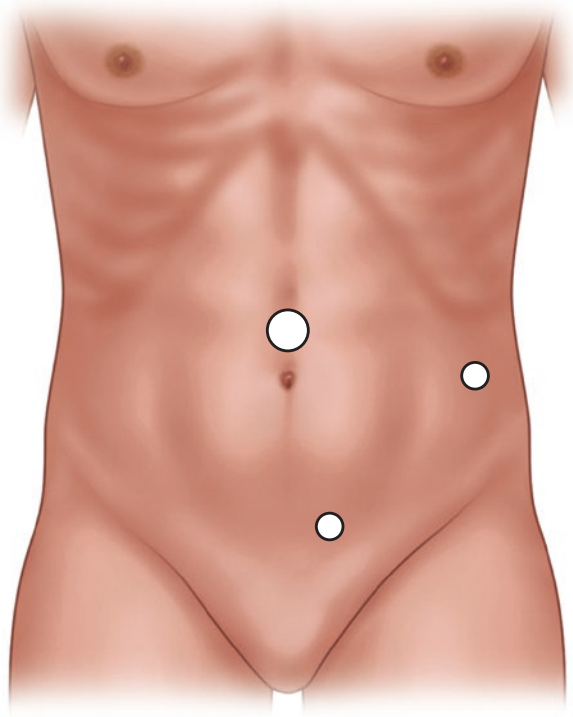
The complication rate in most current series should be <10%, but may consist of:

- *Abscess formation*
  - Interloop, pelvic, rarely subdiaphragmatic, or subhepatic.
- *Intestinal obstruction*
  - Early or late but >90% occur within the first 3 months. It is caused by inflammation and adhesions and may be severe after perforated appendicitis.

---

<sup>2</sup>Harrith Hasson—American gynaecologist—described open access technique in 1971.





**Fig. 53.1** Trocar position in laparoscopic appendectomy

- *Sterility*
  - Due to inflammatory obliteration of the Fallopian tubes in girls with perforated appendicitis. Literature is conflicting and the incidence is controversial.

---

## Further Reading

- Almström M, Svensson JF, Svenningsson A, Hagel E, Wester T. Population-based cohort study on the epidemiology of acute appendicitis in children in Sweden in 1987-2013. *BJS Open*. 2018;2(3):142–50. <https://doi.org/10.1002/bjs5.52>.
- Giuliani S, Cecil EV, Apelt N, et al. Pediatric emergency appendectomy and 30-day postoperative outcomes in district general hospitals and specialist pediatric surgical centers in England, April 2001 to March 2012: retrospective Cohort Study. *Ann Surg*. 2016;263:184–90. <https://doi.org/10.1097/SLA.0000000000001099>.
- Glass CC, Rangel SJ. Overview and diagnosis of acute appendicitis in children. *Semin Pediatr Surg*. 2016 Aug;25(4):198–203. <https://doi.org/10.1053/j.sempedsurg.2016.05.001>.
- Omling E, Salö M, Saluja S, et al. Nationwide study of appendicitis in children. *Br J Surg*. 2019;106(12):1623–31. <https://doi.org/10.1002/bjs.11298>.

- Rautava L, Rautava P, Sipilä J, Kytö V. Occurrence and treatment of pediatric appendicitis in Finland 2004-2014. *J Surg Res.* 2018;232:33-8. <https://doi.org/10.1016/j.jss.2018.06.010>.
- Svensson JF, Patkova B, Almström M, Eaton S, Wester T. Outcome after introduction of laparoscopic appendectomy in children: a cohort study. *J Pediatr Surg.* 2016;51:449-53. <https://doi.org/10.1016/j.jpedsurg.2015.10.002>.



Prema Menon and Katragadda L. N. Rao

Intussusception is a condition largely peculiar to infants with, typically, telescoping of a proximal loop of distal ileum into the adjoining ascending colon.

## 54.1 Epidemiology

- 1–4 cases of intussusception<sup>1</sup> per 1000 live births (in the UK)
- Seasonal variation—suggested to parallel gastroenteritis, i.e., spring/summer
- No racial variation
- Rotavirus vaccine (RotaShield®, but not RotaTeq®)
- M:F ratio is 3:2

## 54.2 Pathogenesis

Can be divided into two types:

- Primary (or idiopathic)—(common)
  - Principally in infants (9–18 months). Unknown underlying but assumed to be hypertrophic Peyer's<sup>2</sup> patch in the distal ileum. Recent viral infections (e.g., adenovirus or rotavirus) may have precipitated hypertrophy.
- Secondary—(~5%)—due to a specific lead point.
  - Meckel's diverticulum

<sup>1</sup> *Intussusception* (Latin)—Intus meaning “within” and suscipere meaning “to receive.”

<sup>2</sup> Johan Conrad Peyer (1653–1712)—Swiss anatomist.

P. Menon · K. L. N. Rao (✉)  
PGIMER, Chandigarh, Chandigarh, India

- Polyps (rarely Peutz<sup>3</sup>–Jeghers<sup>4</sup> syndrome, familial adenomatous polyyps, etc.)
- Duplication cysts
- Lymphoma
- Intramural hematoma (e.g., Henoch–Schonlein purpura, blunt abdominal trauma)

Whatever the cause, there is invagination of the proximal part of the intestine into the distal part. The inner and middle cylinders of the intussuscepted bowel constitute the *intussusceptum*, while the outer cylinder is termed the *intussuscepiens*. The constrained bowel becomes ischemic due to impairment of venous and lymphatic drainage, leading ultimately to necrosis (hence, mucus production and sloughing of mucosa to produce classic “redcurrant jelly stool”).

- Ileocecal region (~80%)
- Ileoileal (~10%)
- Colocolic or ileoileocolic (<10%)

(Very rarely, there is retrograde progression— < 1% in authors’ series over 20 years.)

---

### 54.3 Clinical Features

Typically, a pale, lethargic infant (otherwise well nourished) presents with intermittent attacks of colicky pain associated with pulling up of the legs. Vomiting is almost invariable.

- A sausage-shaped mass is palpable in the RUQ with the RLQ often distinctly empty of palpable bowel loops (Dance’s<sup>5</sup> sign).
- In some environments, there may be diagnostic delay due to a coincident diarrheal illness (especially dysentery). Progression of the condition leads to the mass moving even further along the GI tract. Thus, it may be palpable per rectum or even visible as a prolapse. In this scenario, the gloved finger can pass between the prolapsing bowel and the anus while in a true rectal prolapse this is not possible.
- Mucoïd or bloody stool (“red-currant jelly”).
- Hypovolemia and septic shock may be seen due to the gangrenous bowel ( $\pm$  perforation).

---

<sup>3</sup>Johannes Peutz (1886–1957)—Dutch physician first described features in 1921.

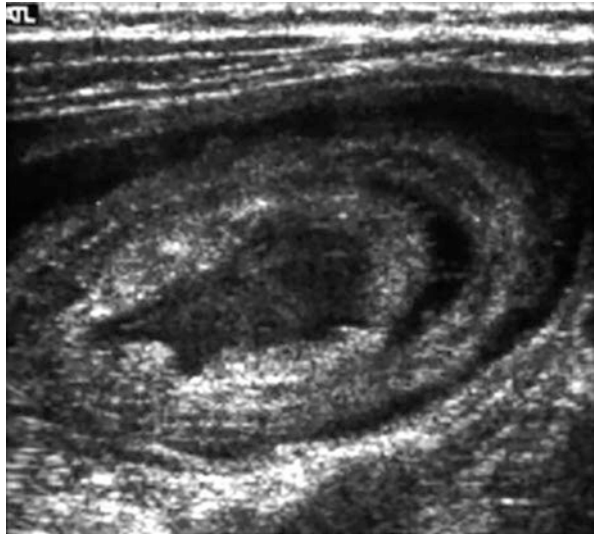
<sup>4</sup>Harold Jeghers (1904–1990)—American physician.

<sup>5</sup>Jean Baptiste Dance (1797–1832)—French pathologist and physician.

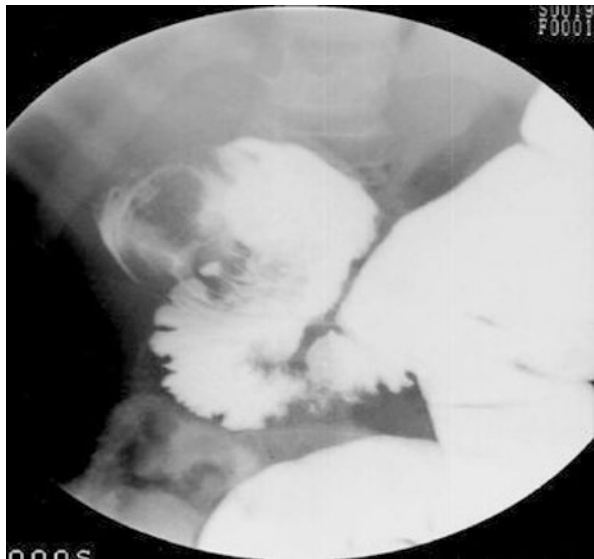### 54.3.1 Investigations

- *AXR*—dilated small bowel loops or a soft-tissue mass.
- *US*—“target” sign, or “pseudokidney” sign (Fig. 54.1). Fluid trapped between the serosal surfaces of the intussuscepted loops and absent blood flow in the outer and inner segment of the intestinal wall on color-Doppler are strong indicators of ischemia, irreducibility, and intestinal necrosis.
- *Contrast enema* still a diagnostic (and therapeutic) option (Fig. 54.2)
- *CT scan*—usually in the older child where there are irregular features and their associated pathology is suspected (e.g., lymphoma) (Fig. 54.3).

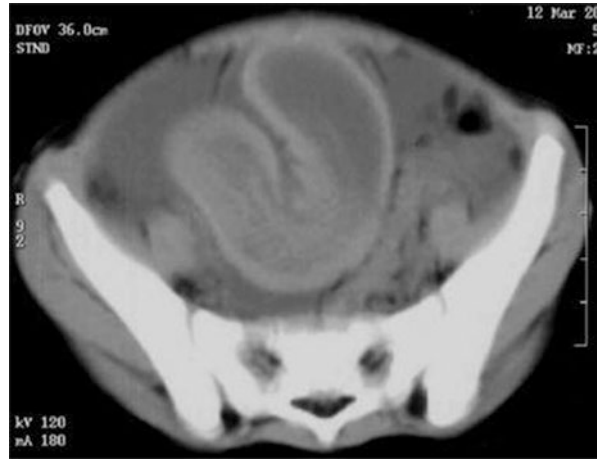**Fig. 54.1** Ultrasound showing a multilayered “target” appearance suggestive of intussusception



**Fig. 54.2** Film taken during barium enema reduction of intussusception in transverse colon



**Fig. 54.3** Non-contrast abdominal CT showing hyperdense bowel in intussuscepted loop suggestive of intramural hematoma



## 54.4 Management

Includes age-appropriate resuscitation and correction of fluid deficits together with NG tube, aspiration, and broad-spectrum antibiotics.

- *Radiology-directed reduction (air, saline, or barium)*—initial method of choice in the absence of perforation, peritonitis
  - Highly variable reported success rate (50–90%).
  - Confirmation of success includes reflux of contrast into the terminal ileum—most units should achieve >60% success rate.
  - Recommended pressures (<120 cm H<sub>2</sub>O for air enema, or 1 m above the level of buttocks for barium or other contrast).
  - If partial reduction—repeat the procedure after 3 h.
  - Perforation is the most important complication (usually due to ischemia of bowel and an inexperienced radiologist)—if obvious pneumoperitoneum—use of needle puncture to decompress.

Therapeutic contrast enema is not useful in ileoileal intussusception and is relatively contraindicated in the older atypical group who tend to have secondary pathology and therefore require surgical management. Occasionally, children with medical conditions (e.g., Henoch–Schonlein purpura) may respond to steroid therapy.

## 54.5 Surgery

Indications

- Peritonitis
- Bowel perforation (during enema reduction)
- Failure of contrast enema

- Secondary pathology suspected
- Ultrasound strongly suggestive of irreducibility and intestinal ischemia

Incision—right transverse close to the umbilicus

1. Deliver mass into wound – cecum is usually mobile in most cases making this easy. Warm saline compresses are applied and the *intussusceptum* gently *pushed* out of the *intussuscepiens* (Fig. 54.4).
2. A segmental resection (and anastomosis) is performed in the presence of perforation, suspected lead point, or if there is persistent ischemia and lack of peristalsis in any part of the bowel (Fig. 54.5).

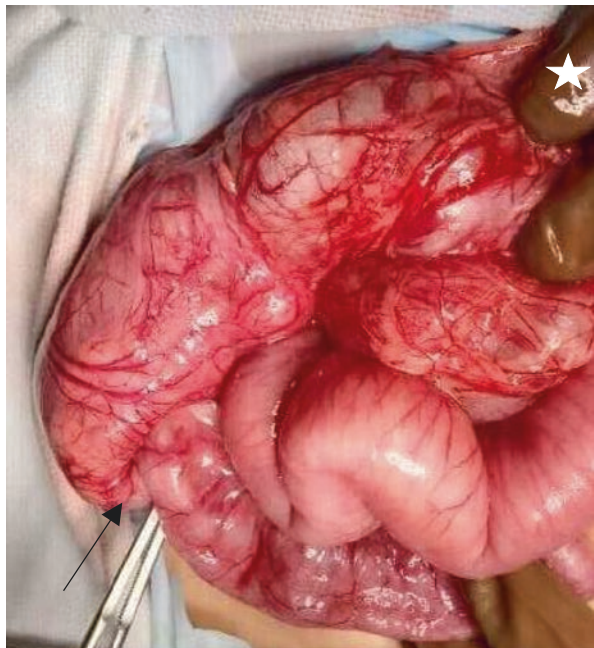
### 54.5.1 Outcome

1. Recurrence—postcontrast enema, 5–10% within the first 72 h
2. Ischemic stricture

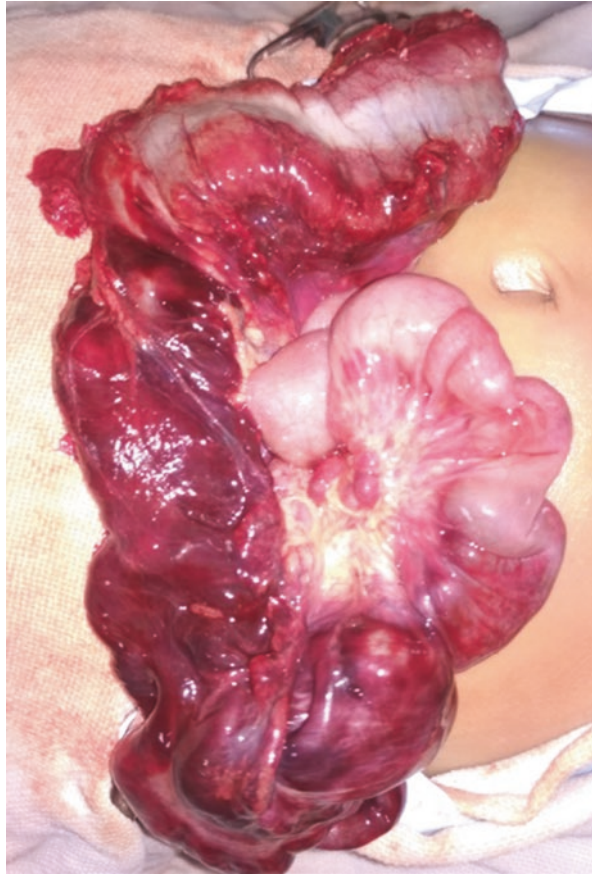### 54.5.2 Laparoscopic Reduction

Reasonable alternative in some centers and can be advantageous if there is doubt about adequacy of reduction postcontrast enema. Nonetheless, safe manipulation of

**Fig. 54.4** Intraoperative picture shows a partially reduced ileocolic intussusception. Further reduction is being carried out by gentle compression over the ascending colon (white star). The black arrow indicates the ileocecal junction



**Fig. 54.5** Intraoperative picture shows a long gangrenous segment involving the distal ileum and proximal colon



ischemic bowel is not easy, and *pulling out* the intussusceptum rather than pushing has been advocated (but is contentious). It is also useful in small bowel intussusception in older children, especially those secondary to polyps. After laparoscopic reduction, the affected segment can be brought out through a small extension of the umbilical camera port and resection anastomosis performed.

**Acknowledgments** The authors thank Dr. Akshay Kumar Saxena, Consultant Pediatric Radiologist, PGI, Chandigarh, India, for the radiology images.

## Further Reading

Daneman A, Navarro O. Intussusception. Part 2: an update on the evolution of management. *Pediatr Radiol.* 2004;34:97–108.

del-Pozo G, Gonzalez-Spinola J, Gomez-Anson B, Serrano C, Miralles M, Gonzalez-deOrbe G, et al. Intussusception: trapped peritoneal fluid detected with US—relationship to reducibility and ischemia. *Radiology.* 1996;201:379–83.



- Fallon SC, Lopez ME, Zhang W, Brandt ML, Wesson DE, Lee TC, et al. Risk factors for surgery in pediatric intussusception in the era of pneumatic reduction. *J Pediatr Surg.* 2013;48:1032. <http://www.who.int/vaccines-documents/DocsPDF02/www640.pdf>
- Kia KF, Momy VK, Drongowski RA. Laparoscopic vs open surgical approach for intussusception requiring operative intervention. *J Pediatr Surg.* 2005;40:281–4.
- Kong MS, Wong HF, Lin SL, Chung JL, Lin JN. Factors related to the detection of blood flow by color Doppler ultrasonography in intussusception. *J Ultrasound Med.* 1997;16:141–4.



Bruce Jaffray

## **Burrill Bernard Crohn (1884–1983)**

BBC was a gastroenterologist working in Mount Sinai Hospital, New York. He published 14 cases of “regional ileitis” in 1932 with Ginzburg and Oppenheimer in the JAMA.

## **55.1 Epidemiology**

The incidence of Crohn's disease (CD) in the West has undergone a steady increase over the past 30 years, with some evidence of a recent plateau. A similar pattern but with a time lag is present in developing countries.

- 6.4/100,000 children per annum—Crohn's disease
  - Prevalence 25/100,000 children
- 2.35/100,000 for ulcerative colitis
- 10–15% of inflammatory bowel disease (IBD) cases present in childhood
  - Tendency for younger children to present with colitis.
- M = F
- Marked racial differences in the incidence of the disease.

Children with presentation <6 years of age are characterized as very early-onset IBD [5], for whom there may be an association with antibiotic exposure during pregnancy.

---

B. Jaffray (✉)

Department of Paediatric Surgery, Great North Children's Hospital, Newcastle, UK

---

## 55.2 Etiology

Crohn's disease results from an interaction between genetic susceptibility, the host's immune system, environmental factors, and the gut microbiota. Chief among causative factors which can be altered is tobacco use; early smoking doubles the odds of developing CD.<sup>1</sup> The importance of environmental factors is illustrated by the increased incidence of CD among the first-generation children of immigrants to Western societies.

---

## 55.3 Pathology

- Macroscopic
  - Ileum—often segmental distribution with cobblestone ulceration, fistulae and bowel wall thickening, fat wrapping, and strictures.
  - Colon but typically with rectal sparing.
- Microscopic
  - Discontinuous chronic inflammation, transmural involvement, serositis, lymphoid aggregates, granulomas, and muscular hypertrophy.

---

## 55.4 Clinical Features

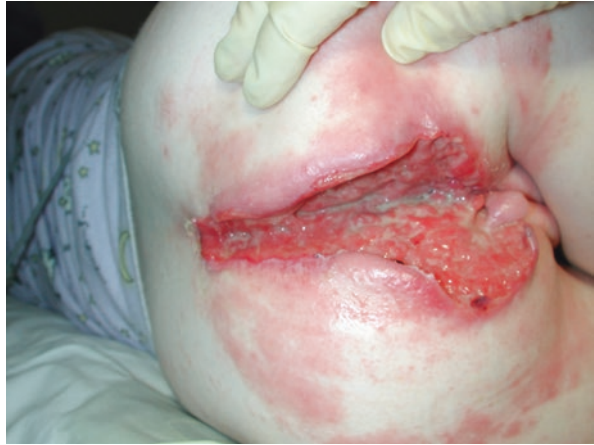There is no typical presentation of CD in children.

- 5% of patients have a first-degree relative with IBD.
- Abdominal pain is common, but the vast majority of children with chronic abdominal pain do not have CD. However, abdominal pain provoked by eating is often seen with ileal CD.
- Cessation of growth
  - A child who was previously growing normally may cease growth as a first manifestation. Inspection of a centile chart with the current weight and the weight 1 year previously can be highly suggestive.
- Perianal pathology (Fig. 55.1)
  - Abscess or fistula. An edematous perianal skin tag is a tell-tale sign.
- Diarrhea and bloody stools
  - May indicate colitis, and are more commonly seen in younger children. It is an error to assume that a child without bloody stools cannot have Crohn's disease.
- Intestinal obstruction, or internal fistulation are late complications of the disease, and would be unusual as presenting features where there is access to advanced healthcare.

---

<sup>1</sup>By contrast—cigarette smoke appears to protect against the development of ulcerative colitis.

**Fig. 55.1** Crohn's disease of perineum



*Extraintestinal manifestations* include:

- Joints
  - Peripheral arthritis, axial arthropathy
- Skin
  - Pyoderma gangrenosum
  - Erythema nodosum
  - Psoriasis
- Eyes
  - Uveitis
- Mouth
  - Aphthous stomatitis

While typically developing years after the gut presentation of the disease, these sites can occasionally be the first manifestation of the disease.

---

## 55.5 Differential Diagnosis

The typical presentation is with terminal ileal disease. In the West, abdominal tuberculosis as a cause of a small bowel stricture or fistula is extremely unlikely, but maybe a valid concern where tuberculosis remains prevalent [11]. Very rarely *Yersinia* infection can be a cause of granulomatous change in the appendix [12].

An issue much discussed, but seldom encountered, is the child operated upon for acute appendicitis in whom CD suspected. The appendix should be removed and subjected to histological examination. The ileal disease should be left alone, unless the cause of a complication such as fistulation, which would mandate surgery. The concept of appendectomy leading to fistulation in the presence of CD has yet to occur in the author's practice.

If the presentation is with colitis, then there may be considerable difficulty in distinguishing CD from UC, even after biopsy. As a practical issue for surgeons, the distinction is immaterial since urgent surgery for both conditions will consist of a subtotal colectomy with ileostomy. Elective surgery will follow diagnostic workup by gastroenterologists, but it is accepted that a proportion of patients thought to have ulcerative colitis will subsequently have their diagnosis revised to Crohn's disease, and vice versa.

---

## 55.6 Investigations

- *Fecal calprotectin.*
  - 90% sensitivity and 75% specificity for the diagnosis of IBD in children [13].
  - It is also useful for the assessment of mucosal healing in response to therapy [14].

Measurement of other surrogates of inflammation such as a full blood count, serum albumin, or C-reactive protein are useful screening adjuncts, but fecal calprotectin outperforms all other tests as a first choice investigation.

Coupled with measurement of fecal calprotectin, abdominal ultrasound should be used as a screening tool for CD in children. The possibility of a child having IBD in the presence of a normal fecal calprotectin and abdominal ultrasound approaches zero.

Other imaging modalities such as MRI enteroscopy, capsule enteroscopy, and CT scanning are used, but the need for these modalities is small once fecal calprotectin is combined with abdominal ultrasound.

If screening assessments suggest the presence of inflammatory bowel disease then combined upper and lower gastrointestinal endoscopy with ileoscopy and biopsy allows determination of disease type and extent. Ileal histology is the gold standard for the diagnosis of Crohn's disease in children.

---

## 55.7 Management

There has been a paradigm shift from the control of symptoms to mucosal healing.

Treatment with *anti-TNF therapy* (e.g., infliximab and adalimumab) based on the objective assessment of mucosal healing is now the accepted modality. However, there is uncertainty whether the use of anti-TNF therapy has led to the hoped-for reductions in surgical resections for CD.

Optimal outcomes result from a multidisciplinary approach with close collaboration between pediatric gastroenterology and specialist pediatric surgeons. Surgery is indicated for the failure of medical therapy to induce remission or where there are complications of the disease such as obstruction or internal fistulation. A more complex issue is whether children with isolated terminal ileal thickening are better served by localized resection or medical therapy as first-line therapy.

*Surgery in Crohn's disease cannot cure the disease—in contrast to ulcerative colitis.*

### 55.7.1 Indications for Surgery

- First-line therapy for isolated ileal disease.
- Failure to achieve mucosal healing with medical therapy Complications, e.g., internal fistulation or perforation.
- Perianal manifestations.

Surgery for childhood CD has changed profoundly as a result of improvements in medical therapy. Severe disease in children rendered Cushingoid by prolonged steroid therapy should no longer be seen. The typical presentation now is with a short ileal segment that is resistant to attempts at mucosal healing; there is often little macroscopic disease to guide the surgeon, and resection is dictated by preoperative imaging. The incidence of colectomy for Crohn's colitis has also markedly declined.

### 55.7.2 Surgical Options

For the typical case, *minimally invasive ileocecal resection* should be the gold standard. The principal advantages are minimization of peritoneal adhesion formation with resulting decrease in risk of adhesional obstruction, reduction in postoperative pain, leading to early mobilization, and improved cosmesis. Practical issues are the siting of the specimen extraction wound. Use of a Pfannenstiel incision leads to excellent cosmesis, but it is difficult to mobilize the colon to reach the incision to allow an extracorporeal anastomosis. The alternative of intracorporeal anastomosis increases the technical difficulty of the procedure considerably. Use of a minilaparotomy midline wound may be a more practical alternative for most surgeons, allowing laparoscopic mobilization and division of the mesentery, with a technically straightforward extracorporeal anastomosis.

There is current research interest in the possibility that wide mesenteric excision may reduce the risk of disease recurrence [22].

There is controversy over the management of *segmental Crohn's colitis*. While segmental resection is possible, there is a significant risk of anastomotic recurrence leading to a need for a further resection. However, it is possible to perform segmental resection with either no further surgery, or further surgery postponed for several years. Many teenagers will want to take the risk of further resection in preference to a permanent ileostomy.

Urgent surgery for colitis consists of *subtotal colectomy with ileostomy*. The rectum should be stapled closed at the peritoneal reflection. Use of a distal mucous fistula in this situation is unnecessary.

If there is rectal sparing and no severe perianal disease, then ileorectal anastomosis is possible. However, in the author's experience the combination of severe left-sided colitis requiring resection coupled with a normal rectum is a rare phenotype.

Complex complications are now rarely seen, since children should be put forward for resection before their development. However, the following may be encountered.

Internal fistulation may be between adjacent loops of small bowel, or between the ileum and the sigmoid colon, or between ileum and bladder or vagina. Management consists of disconnection of the fistula, with resection of bowel back to macroscopically disease-free margins. Adherence of the ileum to the adjacent sigmoid may suggest the need for ileal and sigmoid resection, however, in the author's experience, the sigmoid is "an innocent bystander," and ileal resection alone is enough.

Historically, multifocal small bowel CD was often a cause of short bowel syndrome. The need to avoid excess bowel resection led to the use of stricturoplasty to deal with multiple strictures. The changing phenotype of Crohn's disease has made this a very rare procedure.

### **55.7.2.1 Fistulas**

External fistulation following an anastomosis may be encountered. An apparently successful procedure is complicated by the discharge of bowel content through the wound. In a stable child without signs of peritonitis or sepsis, conservative management can be tried. Such fistulas can follow a surprisingly benign course, closing spontaneously in days or weeks. However, if there are signs of sepsis, or failure to close, the anastomosis will require resection and temporary exteriorization.

### **55.7.2.2 Perianal disease**

Perianal disease is frequent, painful, and distressing. Perianal abscesses should be drained as a matter of urgency. Simple drainage is sufficient; packing is unnecessary and painful. Not all abscesses are clinically evident. Drainage may be dictated by MRI appearances, and the author has encountered abscesses that are neither visible nor palpable, but incision over the site indicated by MRI has led to release of pus.

Laying open of fistula-in-ano should be avoided. Too often this leads to a large indolent ulcer that remains unhealed 6 months later.

Placement of *setons*<sup>2</sup> is a helpful adjunct while awaiting for the effects of anti-TNF therapy. It is frequently the case that the external orifice of the fistula can be cannulated, but the probe cannot be made to reach the lumen of the ano-rectum. With one finger within the rectum, repeated gentle passage of the probe usually lead to a point where there is only thin mucosa separating the probe from the finger. It is a mistake to think that by completing the passage of the probe one is creating a fistula; the internal orifice is already there, but tissue edema prevents the probe from reaching the lumen. The probe should be passed and a seton inserted. These should be left loose and not tightened.

---

<sup>2</sup>Seton—derived from Latin *seta*—a stiff hair or bristle.

**Practice Point**

*Crohn's disease is a pro-thrombotic condition, and all intestinal resections should be performed with deep venous thrombosis prophylaxis, even in children.*

Ano-rectal strictures can be treated by serial dilatation under anesthetic, again while waiting for the effects of medical therapy.

Very rarely, the complex ano-rectal disease may require temporary diversion with a proximal stoma for a period. Reversal of the stoma a year later does not invariably lead to disease flaring again.

---

**55.8 Outcome**

- Early complications include anastomotic leak, hemorrhage, and external fistulation.
- Late complications include disease recurrence, typically peri-anastomotic.

---

**Further Reading**

- Abdelaal K, Jaffray B. Colonic disease site and perioperative complications predict need for later intestinal interventions following intestinal resection in pediatric Crohn's disease. *J Pediatr Surg.* 2016;51:272–6.
- Dilillo D, Zuccotti GV, Galli E, Meneghin F, Dell'Era A, Penagini F, et al. Noninvasive testing in the management of children with suspected inflammatory bowel disease. *Scand J Gastroenterol.* 2019;54:586–91.
- Kapasi R, Glatter J, Lamb CA, Acheson AG, Andrews C, Arnott ID, et al. Consensus standards of healthcare for adults and children with inflammatory bowel disease in the UK. *Frontline Gastroenterol.* 2020;11(3):178–87.
- Murthy SK, Begum J, Benchimol EI, et al. Introduction of anti-TNF therapy has not yielded expected declines in hospitalisation and intestinal resection rates in inflammatory bowel diseases: a population-based interrupted time series study. *Gut.* 2020;69(2):274–82.
- Ng SC, Shi HY, Hamidi N, et al. Worldwide incidence and prevalence of inflammatory bowel disease in the 21st century: a systematic review of population-based studies. *Lancet.* 2017;390(10114):2769–78.
- Rutgeerts P, Vermeire S, Van Assche G. biological therapies for inflammatory bowel diseases. *Gastroenterology.* 2009;136:1182–97.
- van Rheenen PF, Van de Vijver E, Fidler V. Faecal calprotectin for screening of patients with suspected inflammatory bowel disease: diagnostic meta-analysis. *Br Med J.* 2010;341:11.





Bala Eradi

*Ulcerative colitis was first described in 1859 the English physicians, Sir Samuel Wilks who first used this term. While the first pediatric cases were described in 1923 by Helmholz.*

## 56.1 Introduction

There are three diseases within the designation, inflammatory bowel disease (IBD):

- *Crohn's disease (CD)*
- *Ulcerative colitis (UC)*
- *Indeterminate colitis (IC)*

IBD develops at any age and between 10 and 20% are diagnosed in childhood, depending upon the age cut-off used. *Pediatric onset IBD (PIBD)* is more commonly CD while adult IBD is more often UC. However, very early onset IBD (age < 6 years) tends to be more commonly UC again. PIBD tends to be more severe in terms of involvement as well as progression.

---

B. Eradi (✉)  
Leicester Childrens Hospital, Leicester, UK

## 56.2 Epidemiology

There seems a worldwide increase in the incidence of IBD including PIBD and there is also a clear north-south divide with northern states in the USA, Scotland, and northern European countries having a greater incidence than their southern counterparts. The reasons for the increased incidence and pattern of distribution of disease are unclear.

The pathogenesis of IBD is based on a complex interplay of genetics, gut and systemic immune system, the microbiome, and environmental triggers.

## 56.3 Clinical Features

- Considerable overlap between the presenting features of all types of IBD as well as other disorders such as allergic or infectious gastroenteritis and irritable bowel syndrome.
- Abdominal pain and diarrhea are common features in all IBD but visible blood in stools is more common in UC.
- Weight loss is less prominent in UC compared to CD.

There is often a considerable lag in the diagnosis after symptom onset due to the nonspecific nature of the presenting features.

The differences between UC and CD are outlined in Table 56.1.

**Table 56.1** Differences between UC and CD

|                                | Ulcerative colitis  | Crohn's disease  |
|--------------------------------|---|--|
| Disease extent                 | Limited to colon, extends from rectum proximally  | Occurs anywhere from mouth to anus but rectum is relatively spared   |
|                                | Perianal involvement is uncommon  | Perianal involvement is common   |
| Endoscopic features            | Stenosis, abscess, and fistulas are rare  | Stenosis, fistulas, and abscesses are common   |
|                                | Diffuse continuous inflammation extending proximally from the rectum, with friable mucosa, and small superficial ulcers | Patchy inflammation with aphthous or linear ulcers, "cobblestoning" of mucosa, active ileitis  |
| Extraintestinal manifestations | Inflammation limited to mucosa with crypt architectural distortion and crypt abscesses                                  | Transmural inflammation, non-caseating granulomas, rectum sparing, granulomatous inflammation including that of esophagus, stomach, and duodenum |
|                                | Less common, <i>pyoderma gangrenous</i> , and <i>primary sclerosis cholangitis</i>                                      | More common, <i>aphthous stomatitis</i> , <i>erythema nodosum</i>  |
| Surgical treatment             | Maybe curative  | Reserved for treatment of complications, palliation of symptoms  |

### 56.3.1 Investigations

- IBD must be suspected in all children presenting with persistent diarrhea and abdominal pain. Bloody diarrhea is especially a feature of UC.
- Infective causes must be rapidly ruled out by testing stools for common pathogens such as Cytomegalovirus (CMV) and *C. difficile* among others.
- *Fecal calprotectin level* is useful to differentiate between IBD and noninflammatory disease such as irritable bowel syndrome.
- Imaging features are often non-specific. Despite this, initial imaging with US is often used for ease of access and to avoid ionizing radiation. Thickening of the colon with sparing of the small bowel suggests UC and the converse suggest CD.
- *Colonoscopy and biopsies* are the gold standard test for diagnosis (except in acute, severe presentation) and for assessing the extent, and severity of UC. Pediatric-onset UC is more extensive and severe than adult disease, with as many as 90% presenting with pan-colitis.

### 56.4 Management

The mainstay of treatment for UC as with all IBD, is primarily by medical measures.

- *5-Aminosalicylic acid (5-ASA)* compounds such as mesalamine.
  - First-line treatment for induction and maintenance of remission in UC.
  - Orally or in combination with the rectal route. Rectal administration on its own is reserved for isolated proctitis which is very uncommon in children.
- *Corticosteroids*
  - Second-line treatment for mild-to-moderate UC not responding to 5-ASA.
  - Severe UC is treated with intravenous steroids.
  - Second-generation steroids that are poorly absorbed such as *beclomethasone dipropionate (BDP)* and *budesonide-MMX* may be considered in mild disease refractory to 5-ASA.
  - Not used for maintenance of remission.
  - Thiopurines.
    - Used to maintain remission if frequent relapses occur while on 5-ASA.
  - *Infliximab (IFX)*
    - Chronically active or steroid-dependent UC that is uncontrolled by 5-ASA and thiopurines.

Unlike CD, UC is amenable to surgical cure and therefore, surgery should be considered early in children and certainly before medical treatment results in irreversible complications.

#### Indications for Surgery in Children

- Failure of medical treatment.
  - Symptoms despite maximal medical treatment.

- Growth failure.
- Adverse impact on education or ability to participate in sport and social activities.
- Emergency surgery for ongoing, severe bleeding, or toxic megacolon.

### 56.4.1 Surgical Treatment of UC

The primary aim of surgery for ulcerative colitis is removal of the entire colon and rectum. However, simply doing this would result in a *permanent ileostomy* which is not acceptable to most and therefore, various operations have been devised to restore bowel continuity. Restoration of bowel continuity can be done at the same time as the *proctocolectomy* or as a separate procedure, in which case the rectum is initially left in situ as a Hartmann<sup>1</sup> pouch. This type of operation is the procedure of choice in an emergency situation.

As the aim is to retain as little rectal mucosa as possible, an *Ileo-rectal anastomosis* for restoration of bowel continuity is no longer considered acceptable. The rectum is completely excised or a *rectal mucosectomy (Soave-type procedure)* is performed. Rectal mucosectomy has the advantage of a reduced risk of pelvic nerve and urinary tract damage.

- The ileum is anastomosed just above the transitional epithelium of the anal canal.
- A straight ileoanal anastomosis may be performed or the ileum may be folded on itself in various configurations to increase reservoir capacity, the most commonly performed such procedure being an *ileal J-pouch*. This is often considered the procedure of choice for restoration of bowel continuity after total proctocolectomy.
  - The main advantage of a J-pouch over a straight ileoanal anastomosis is that it results in a ↓stool frequency.
  - ↑ complication rate and incidence of pouchitis.
  - The anastomosis may be hand-sewn or stapled, though the use of a circular stapler may be limited by the size of the child.
  - An ileostomy is often created to divert feces and allow the anastomoses to heal though a single-stage operation is also feasible.

Minimally invasive techniques are gaining traction worldwide and a laparoscopic proctocolectomy and ileal pouch anastomosis (IPAA) can be done with good outcomes. A laparoscopy-assisted procedure is also possible in which the colon mobilization is done laparoscopically leaving the removal of the colon and creation of the ileal pouch to be done via a small lower abdominal or Pfannenstiel incision.

---

<sup>1</sup>Henri Albert Hartmann (1860–1952)—French surgeon working in the Hôtel-Dieu in Paris described this in 1923.

## 56.4.2 Complications

Ileal pouch-anal anastomosis is associated with a significant complication rate of 55–75% depending upon the length of follow-up. Up to 50% of patients will require reoperation. The most commonly reported complications are:

- Wound complications
  - Infection, dehiscence (5–20%)
- Anastomotic leak (0–15%)
- Anastomotic stricture (10–25%)
- Fistula, especially pouch vaginal fistula (3–30%)
- Small bowel obstruction (15–30%)
- Pouchitis (30–70%)
- Recurrent pouchitis (5–35%)
- Pouch failure is defined as excision of pouch and permanent ileostomy (up to 10%)
- Afferent limb syndrome (obstruction of the small bowel at the pelvic brim)
- SMA syndrome
- Functional complications
  - Incontinence (up to 15% daytime and 30% at night)
  - Infertility and sexual dysfunction

- *Nonspecific inflammation of the pouch (pouchitis)*

This is the most common complication of Ileal-pouch surgery and manifests as abdominal pain, cramps, urgency, frequency, tenesmus, and hematochezia.<sup>2</sup> Pouchitis is diagnosed based on clinical features. Investigations are not required before treatment. It is treated with a course of antibiotics, usually metronidazole and ciprofloxacin. Endoscopy and biopsy are reserved for recurrent or refractory pouchitis to rule out anatomical problems such as anastomotic stricture. Biopsy is done to look for CD in the pouch. This is an important cause of pouch failure alongside anastomotic leak, prolonged disease, and treatment with biologic agents prior to pouch formation.

- *Acute Severe Ulcerative Colitis (ASUC) and Toxic Megacolon*

Up to a third of pediatric patients with UC will present acutely and require hospitalization within the first 3 years of diagnosis. This acute, severe form of UC is diagnosed based upon clinical criteria including frequency and consistency of stools, blood in stools, abdominal pain, blood in stools, and limitation of activity (*Pediatric UC Activity Index—PUCAI*). Intravenous steroid administration is the mainstay of treatment. Infective causes such as *Clostridium difficile* and CMV should be treated as required. Prophylactic antibiotic therapy is not useful and neither is “gut-rest.” Second-line treatment includes Infliximab.

---

<sup>2</sup>Passage of blood with stools. (Greek) αἷμα—blood and χέζειν—defaecate.

- *Toxic megacolon*

This is a form of acute severe UC in which the colon is dilated (>5.6 cm, or >4 cm if the child is <11 years old) in the absence of mechanical obstruction and there are features of systemic sepsis. The colonic dilation may be segmental or generalized. Colonic perforation is a feared complication, the clinical features of which may be masked by steroid administration. Serial abdominal radiography is therefore used until the patient's clinical condition improves. Treatment is based upon fluid resuscitation and correction of electrolyte imbalance as well as broad-spectrum antibiotic cover.

Failure of ASUC to respond to medical therapy, colonic perforation, sepsis and bleeding are indications for emergency surgery, though it is becoming less likely than, the past. As mentioned previously, subtotal colectomy with Hartmann pouch (blind rectal stump) and end ileostomy is the procedure of choice and this can be safely achieved laparoscopically even in the acute situation.

---

## Further Reading

Goldstein AM, editor. Inflammatory bowel disease in children. *Semin Pediatr Surg.* 2017;26:343–404.



Shailinder Jit Singh

## 57.1 Introduction

Constipation is common with up to 25% of children referred to a pediatric gastroenterologist having some form of defecation disorder. This is divided equally between boys and girls in toddlers, but boys are predominant thereafter. Constipation in children differs significantly from constipation in adults in its prevalence, cause, presentation, and prognosis. Among children presenting with constipation, organic causes are rare, and most suffer from Chronic Idiopathic Constipation (CIC).

## 57.2 Clinical Presentation

- CIC commonly manifests in children between the ages 2 and 4 years. It usually begins with painful passage of stools.
- Constipation in children less than 1 year of age must be evaluated to rule out Hirschsprung's disease (HD) and other organic causes of constipation.
- Medications associated with constipation are oral iron supplements, anticonvulsants, diuretics, and antacids.
- Retention with overflow can be present in children with CIC. Soiling is absent in constipation due to HD. In HD, mostly, there is a history of delayed passage of meconium.
- In CIC, abdominal examination can reveal a mass in the suprapubic area and left lower quadrant. The fecal mass can be indented by digital examination which distinguishes it from any pathological intra-abdominal mass.
- *Late-presenting HD* presents with massive abdominal distention and malnutrition. The digital rectal (PR) examination reveals a tight anal canal with no fecal mass. On the withdrawal of finger there is a gush of fecal matter even where the finger

---

S. J. Singh (✉)  
Nottingham University Hospitals, Nottingham, UK

has failed to reach the dilated segment. CIC is associated with a short and lax anal canal with palpation of hard stool mass a few centimeters above the anal canal.

- Every child with CIC warrants a PR examination once. PR is always performed with parental consent and presence.
  - Begin with perineal examination looking for:
    - Anal fissure (usually in 6 o'clock position) in acute or chronic form (present as skin tag in the perianal region).
    - Anterior anus.
    - Anal fissure in other positions, especially with perianal warts, hematoma, or scars should raise suspicion of non-accidental injury.
    - Stroking of perianal skin with a cotton wool tipped stick helps to elicit reflex where there is “winking” of perianal skin and ascent of anus.
    - PR helps to rule out any mass lesion in the retrorectal space, and elicits closing reflex in the anal canal. Intact reflexes exclude neurological causes.
- Constipation in anorectal malformation is known, especially in anterior and or stenotic anus. Passage of *toothpaste-like stools* is characteristic of anal stenosis.
- Psychological problems are commonly associated with CIC. They are the effects of CIC in majority and the cause of CIC in minority. That is why a behavioral therapy is useful.

---

## 57.3 Laxatives

- Stool softeners such as *lactulose* are useful in children (6 months to 3 years old) in breaking the vicious cycle starting with constipation leading to painful defecation/fissure due to passage of hard stools, prompting withholding behavior and worsening constipation.
- Stimulant laxatives such as *Senokot*<sup>TM</sup> and *Bisacodyl*<sup>TM</sup>, act on colonic muscle and are more useful in constipation with soiling from overflow incontinence. Stool softeners should be avoided in these children as they can make the overflow incontinence worse. They are also useful in the treatment of Slow Transit Constipation (STC).
- Osmotic laxatives such as *Movicol*<sup>TM</sup> sachets and liquid are also used to treat all types of CIC. It is the medicine of choice for treating fecal impaction along with enemas.

---

## 57.4 Investigations

### 57.4.1 X-rays

- Plain X-ray should not be used for the diagnosis of CIC.
  - It can help in informing the extent, and the anatomical location of fecal loading and is useful during the treatment of fecal impaction.
- It can also detect spinal dysraphism in spina bifida occulta and sacral abnormalities.



### 57.4.2 Rectal Biopsy

- Rectal suction biopsies are the gold standard for the diagnosis/exclusion of HD.
- After the age of 3 months, open rectal biopsy under general anesthesia is used as rectal suction biopsy may not provide adequate specimens.

### 57.4.3 Transit Studies

- They can be done by marker studies and plain X-rays or by 3–5 days nuclear transit studies.
- These studies are helpful in the diagnosis of STC.

### 57.4.4 Contrast Enema

- Useful in establishing colon anatomy in older children with mega-sigmoid in whom a surgical management is planned.

### 57.4.5 Pelvic Ultrasound

- *Megarectum (MR)* can be seen, and its dimensions measured, by the pelvic US. This is performed by putting the ultrasound probe above the pubic symphysis and measuring the dimensions of the rectal crescentic shadow seen behind the bladder. In the absence of prospective studies, it is not used as a primary diagnostic modality for the diagnosis of MR.
- It has a great potential for monitoring the shrinkage of MR with laxative treatment. Stoppage of laxatives on attainment of normal rectal dimension rather than clinical improvement can prevent relapses after laxative treatment of CIC.

### 57.4.6 Anorectal Manometry (ARM)

- It is done in an awake state or under ketamine. It is *never* done under GA as anal resting pressure drops.
  - Two useful parameters studied are:
    - Resting anal pressure
    - Length of high-pressure zone.
- It is useful in the diagnosis of HD and internal sphincter achalasia. In both conditions, there is an absent *recto-anal inhibitory reflex (RAIR)*. In normal RAIR the distention of rectum by balloon catheter produces relaxation of the anal sphincter leading to decreased anal resting pressure.

## 57.5 Role of Manual Evacuation

Children in whom a disimpaction regime has failed, those with a massive fecaloma unlikely to respond to medical treatment and those with acute symptoms from fecal impaction should be considered for manual evacuation (with Kleen-Prep™ via nasogastric tube) to lessen the fecal burden and facilitate long-term management.

## 57.6 Role of Rectal Irrigation and Antegrade Continent Enema (ACE)<sup>1</sup>

- Trans-anal irrigation (TAI) is effective in the treatment of children with CIC who fail aggressive medical treatment, especially the ones that are soiling from overflow. If acceptable to child and parent and done diligently, it leads to a high patient and parental satisfaction. It is more acceptable in children above the age of 5–6 years.
- If TAI works but the child does not like the rectal route, there should be very low threshold of converting it to ACE. The reason is that if TAI works in practice, ACE will work too. The advantage of TIA over ACE is avoidance of two operations (i.e., operation and reversal of ACE).
- ACE should only be done when children can demonstrate their ability to sit on toilet for 30 min.

### Antegrade Continent Enema

Originally, it involved isolation of the appendix on its mesentery, reversal, implanting the amputated tip into the caecum and bringing the cecal end to the surface as a small catheterizable stoma. In current practice it is done laparoscopically. A paraumbilical port is inseted to visualize the appendix and another 5 mm port is inserted in right iliac fossa to exteriorize the appendix. It is matured to skin and a Foely's catheter is inserted through the appendix with balloon in caecum. The Foley's catheter can be changed to button after 2–3 months.

<sup>1</sup>Malone PS, Ransley PG, Kiely EM. Preliminary report: the antegrade continence enema. *Lancet*. 1990; 336 (8725): 1217–8. 96 citations.

---

### 57.7 Role of Botox Injection in Anal Sphincter

Injection of Botox is useful in three groups of refractory cases of CIC:

- Those who display *withholding behavior (WB)*
- *Internal sphincter achalasia*
- *Anorectal dyssynergia (ARD)*

WB and ARD are secondary to painful defecation with or without anal fissure. Botox can be counterproductive in children with overflow incontinence.

- It acts by decreasing the anal sphincter tone, leading to increased frequency of bowel movements and decreased pain with defecation in patients with abnormalities of outlet dynamics.
- Botulinum toxin injections retain their efficacy for 3–6 months after injection.

---

### 57.8 Surgical Management with Sigmoid Colectomy with or Without Colostomy

- Resection of a dilated sigmoid is performed in older children and adolescents in some selected cases of mega rectosigmoid that has been refractory to maximal treatment. Resection is usually followed with colostomy and oversew of the distal rectal stump (Hartmann's procedure).<sup>2</sup> Once the bowel has been rested for a year, continuity can then be restored.
- Primary anastomosis can also be done and this can be combined with an ACE.
- These children need active follow-up as the remaining rectum and the colon may still be abnormal and risk of recurrent constipation is high.
- Sigmoid colectomy should not be performed in those with anorectal malformation as the rectal reservoir is needed for eventual bowel function.

---

<sup>2</sup>Henri Albert Charles Antoine Hartmann (1860–1952) French surgeon in the Hôtel-Dieu (Paris)



Evelyn Geok Peng Ong

## 58.1 History

The introduction of parenteral nutrition (PN) in 1969 transformed survival for children with intestinal failure. However, long-term PN has parenteral nutrition is accompanied by significant morbidity such as sepsis, cholestasis, and loss of venous access as well as poor quality of life for the child and their families. Intestinal transplantation (IT) has therefore been pursued as an attractive and potentially curative option.

The development of intestinal transplantation draws parallels from the development of other solid organ transplants. The first attempts at intestinal transplantation in the 1960s were unsuccessful and it was not until the evolution of effective immunosuppressive regimens that intestinal transplant entered clinical practice. In 1988, Deltz and colleagues from Kiel in Germany performed the first successful human IT using cyclosporin albeit with limited patient survival. Later development of tacrolimus-based regimens improved outcome and ensured the worldwide acceptance of its viability as a treatment option. Grant and colleagues from the University of Western Ontario published a case report of a combined intestinal and liver transplant with greater than 1 year survival. A combination of improvement in immunosuppressive drugs, recipient assessment, and surgical technique have led to much-improved graft and patient survival in recent years.

---

E. G. P. Ong (✉)

The Liver Unit, Birmingham Women's and Children's NHS Foundation Trust,  
Birmingham, UK

e-mail: [e.ong@nhs.net](mailto:e.ong@nhs.net)

## 58.2 Indications

Candidates for intestinal transplantation have *irreversible intestinal failure* accompanied by *either failure of parenteral nutrition* (loss of venous access, recurrent life-threatening sepsis, intestinal failure associated with liver disease) or *poor quality of life that could be improved by transplantation*. Common causes of intestinal failure in children include:

- Extensive bowel resection, e.g., following midgut volvulus, necrotizing enterocolitis
- Intestinal atresia
  - For example, Multiple Intestinal Atresia caused by mutations in TTC7A gene on Ch 2p21
- Gastroschisis
  - For example, closed gastroschisis
- Megacystis Microcolon Hypoperistalsis syndrome
  - Mutations in the MYLK gene on Ch 3q21
- Degenerative intestinal leiomyopathy
- Hirschsprung disease—involved small and large bowel
- Chronic Idiopathic Intestinal Pseudo-obstruction (CIIP)
- Microvillus inclusion disease (MVID) (rare)—autosomal recessive
  - Mutations of MYO5B gene on Ch18q21
  - Diagnosed by EM features on mucosal biopsy
- Tufting enteropathy (rare)
  - Mutations in the EPCAM gene on Ch2p21

## 58.3 Assessment

Candidates for IT should still have at least two central veins accessible and be referred before liver dysfunction deteriorates.

- ↑ risk of waiting list mortality is for children with advanced liver disease.

Although the inclusion of the liver in the graft may confer an immune-protective effect on the intestinal graft in the longer term, there is increased mortality in the first year following combined liver and intestinal transplantation.

Multidisciplinary assessment must be made to ensure the patient:

- Fulfils the indications for transplantation.
- There are no contraindications to transplantation.

The team includes a hepatologist, gastroenterologist, surgeon, anesthetist, transplant coordinator, specialist nurses, dietician, social worker, psychologist,

physiotherapist, and pharmacist. Renal review is also important as up to 40% of patients suffer from renal impairment following transplantation.

### **58.3.1 Abdominal Domain Expansion**

Many children are small and may have a reduced abdominal domain due to short bowel syndrome or gastroschisis. Such patients may undergo surgery as an attempt to increase this intra-abdominal domain. Typically, this involves abdominal spacers or subcutaneous tissue expanders inserted to allow at least skin closure over the graft. It may be difficult to tolerate such procedures and the implants can erode through the skin or become infected.

### **58.3.2 Nutritional Preassessment**

- Detailed evaluation of nutritional status and potential for further gut rehabilitation.

Contrast studies may be needed to evaluate the length of residual bowel, and anatomy. Poor gastric emptying is an indication for inclusion of the stomach in the graft. This might also highlight possible non-transplant surgical options such as relief of intestinal obstructions, restoration of bowel continuity, slowing bowel motility, or bowel lengthening procedures.

### **58.3.3 Evaluation of Central Veins**

Usually with Doppler Ultrasound or CT/MR angiogram to define venous anatomy and accessibility. This evaluation may be coupled with recommendations to try to preserve venous access and to decrease risk of sepsis such as line access technique, use of biopatches around the line exit site and antibiotic or anticoagulation line locks.

### **58.3.4 Viral Screening**

Past and present infections and immunity to viral hepatitis, HIV, herpes simplex, varicella zoster, rubella, measles, mumps, EBV, and CMV are established.

The family is seen by a clinical psychologist to assess their ability to understand the process and to identify particular areas for additional psychological support. Practical support may also be needed around the time of transplant and in the longer term and therefore input from a family support worker is essential. It is useful for the family to spend some time on the hospital ward and intensive care unit to familiarize themselves with the environment, staff, and working timetable prior to the transplant admission.

The multidisciplinary team will determine if the patient should be a candidate for transplantation, what intestinal components will be included and whether a liver should be included or not. If the patient is not a candidate, they may be kept under review for reassessment at a future date or rejected if there are clear contraindications to transplant that cannot be improved. It should be noted that due to the discrepancy between the size of pediatric recipients and the availability of size-matched donors, the family needs to be aware of a potentially long wait for transplantation.

---

## 58.4 Surgery

### 58.4.1 Donor Selection

This includes matching of blood group and donor-to-recipient size.

- Approximately half of all pediatric recipients are <10 kg but the majority of potential organ donors are older children and therefore grafts may require reduction in size.
- Screening for risk of infection, malignancy, or potential bowel injury and ideally should have been under intensive care for less than 3 days with minimal inotropic support. HLA matching may be considered particularly if there is a history of previous transplantation or presence of donor-specific antibodies.

The intestine is highly sensitive to ischemic injury and therefore rapid donor surgery and implant are the objective. The ideal cold ischemia time is <8 h and only donations after brain death are currently considered. In order to minimize the cold ischemia time of the graft, recipient surgery may commence as soon as the donor organs are assessed, particularly if there is a prior history of surgery in the recipient which may complicate the explant.

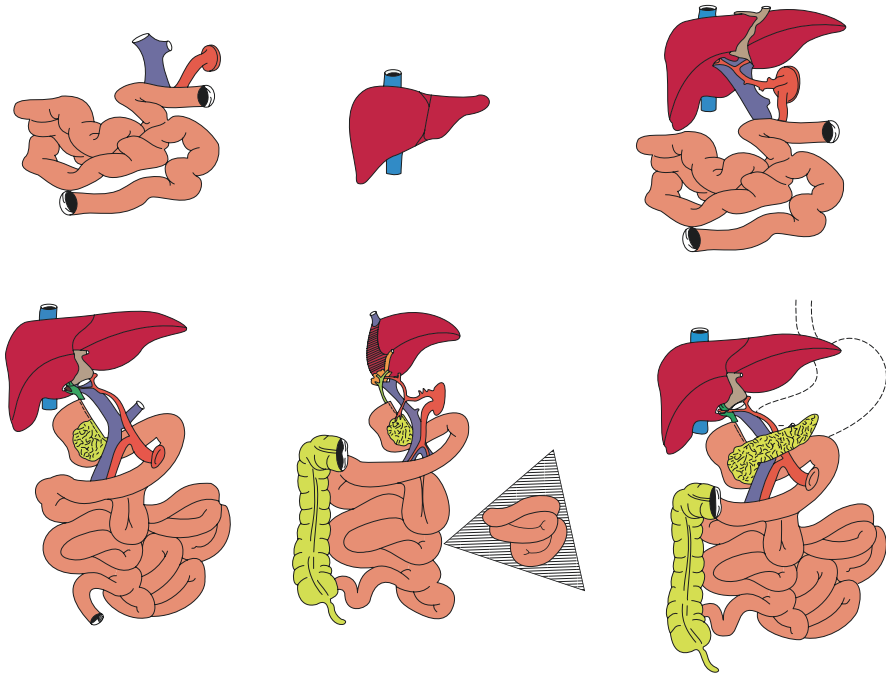
The following intestinal containing grafts may be used (Fig. 58.1):

- *Isolated bowel*—small intestine ± large intestine.
- *Combined liver and bowel*—usually en bloc and including pancreas to preserve vascular supply.
- *Multivisceral*—3 or more organs en bloc, e.g., liver, intestine, and pancreas, ± stomach ± kidney ± spleen.
- *Modified multivisceral*—as in multivisceral, but without liver

### 58.4.2 Donor Surgery

Donor protocols vary between institutions but are essentially divided into three phases:

- 1st phase—dissection of the donor graft while the donor circulation is intact.
- 2nd phase—cold perfusion of the organs with the University of Wisconsin preservation and exsanguination.
- 3rd phase—ex situ preparation of the graft on the back table. The donor bowel may be first decontaminated using an intraluminal antibiotic lavage.



**Fig. 58.1** Types of grafts: isolated intestine, isolated liver for short bowel syndrome, multivisceral grafts including pancreas and stomach with reduced size composite grafts

Cecum, ascending colon, and duodenum are mobilized to expose the aorta and inferior vena cava (IVC). The aorta is isolated and a wide bore infusion catheter is inserted. In all cases, it is important to retrieve good quality lengths of iliac vessels to use for vascular reconstructions in the recipient surgery.

#### 58.4.2.1 Isolated Intestine Retrieval

The colon is further mobilized from the left of the field to expose the root of the mesentery and allowing division of the ligament of Treitz. The spleen is mobilized and with it the tail of the pancreas toward the aorta and the root of the mesenteric vessels. The pylorus is exposed and can be divided with a linear stapler. The right, middle, and left colic vessels are divided and the colon is divided at the pelvic brim. Warm dissection is now complete and cold perfusion is commenced, venting the blood from the supradiaphragmatic vena cava. The intestine is removed en bloc with the pancreas by dividing the portal vein at the confluence with the splenic vein stump kept with the vein to use as a patch and the superior mesenteric artery and coeliac axis are taken with a section of the aorta (Carrel patch). The pancreas can then be removed from the bowel on the back table.



### **58.4.2.2 Combined Liver and Intestine Retrieval**

Donors of combined grafts are usually neonates or infants and the small caliber of the vessels must be considered; procuring the descending aorta provides a good caliber inflow. The procedure commences in the same way as for isolated intestinal retrieval. The gallbladder is dissected and the biliary system is flushed through the cystic duct before being ligated. Dissection proceeds as above to mobilize the spleen, pancreas, and intestine, followed by cold perfusion. The aorta is divided above the renal arteries and the descending aorta may be taken as well by splitting the diaphragm. The descending aorta can then be used as a conduit. The IVC is divided and the liver, intestine, pancreas, and spleen are removed en bloc for further dissection on the back table. The spleen is removed and the splenic artery ligated, preserving the gastroduodenal and inferior pancreaticoduodenal artery supply to the pancreas and duodenum.

### **58.4.2.3 Multivisceral Graft Retrieval**

The procedure is similar to that for combined liver and intestine retrieval, but dissection is extended to include the stomach and/or the kidneys as required. Key to this is the preservation of the gastric arterial supply from the left gastric artery and care to avoid damage during mobilization of the colon. The graft is removed en bloc, transecting at the level of the proximal stomach/distal esophagus.

## **58.4.3 Recipient Surgery**

Commenced in coordination with the donor team to achieve the shortest possible ischemic time. Access is achieved through a midline incision and the abdominal cavity examined. We use basiliximab (IL2 receptor antibodies) as our immunosuppression induction agent but other regimens have employed Campath (Alemtuzumab) or ATG as induction agents.

### **58.4.3.1 Isolated Intestinal Graft**

Recipient bowel is resected and removed. Using donors' vessels, conduits are constructed on the aorta and IVC. Donor intestine is anastomosed to the conduits to provide systemic blood supply and drainage to the graft. The proximal bowel is attached to the recipient jejunum with a wide side to side anastomosis and similarly the distal ileum is anastomosed to the colon in a side-to-side fashion. A distal loop ileostomy is formed. This remains in situ to provide access for serial graft biopsy surveillance and will be reversed once the graft is established.

### **58.4.3.2 Combined Liver and Intestinal Graft**

The implant is largely performed en bloc. The recipient pathological bowel is dissected as above, leaving the bowel attached only by the superior mesenteric vascular pedicle. The recipients' liver is mobilized as in an isolated liver transplant, ligating the hepatic artery and the bile duct. The liver is dissected from the IVC and the portal vein is anastomosed to the IVC to create a portocaval shunt to drain the foregut remaining in situ. The intestinal graft arterial inflow is prepared as an aortic conduit as in an isolated graft but the portal outflow is via the intact portal vein.

Prepared liver/intestinal graft is brought to the table and the liver hepatic venous anastomosis is performed in the usual piggy-back fashion. The SMA is then anastomosed to the aortic conduit to restore perfusion to the graft. Any perfusion fluid may be vented through the splenic vein stump before ligation. Intestinal continuity is restored as described for isolated intestinal transplantation. Note the pancreas is included in the graft to maintain perfusion to the foregut.

### 58.4.3.3 Multivisceral Transplantation

The implantation varies depending on the organs implanted but an en bloc graft maintains the vena cava continuity of the graft. Portocaval shunting is not required as venous drainage is maintained within the graft. The arterial inflow is formed again using an aortic conduit. The proximal intestinal anastomosis is made to a gastric “patch” of fundus. Removal of the SMA may lead to compromise of perfusion of the right and middle colon, requiring removal. The left colonic perfusion is maintained through the preserved inferior mesenteric artery and vein. The distal ileal anastomosis and stoma are formed as above.

Both nasogastric and nasojejunal tubes are left in situ at the end of the procedure for drainage and nutrition respectively. Care must be taken to close the abdomen without increased abdominal pressure; a staged closure may be necessary using a temporary silastic patch for the first few days while edema resolves with planned secondary closure a few days later with or without a biological patch.

### 58.4.4 Postoperative Care

- Aim for neutral fluid balance.
- Abdominal compartment pressure may inhibit formal abdominal wall closure. Abdominal pressure measurements may be performed using a transduced urinary catheter.
- Serial US in the first-week help detect any vascular issues, abdominal collections, and can monitor for peristalsis in the graft.
- Nutrition can be commenced enterally via the jejunal tube as early as the 1st day and PN can be weaned as tolerated.
- Broad spectrum antibiotics, antivirals, and antifungal agents are employed and sepsis is treated aggressively.
- Anticoagulation is initiated to reduce the risk of vessel thrombosis as a heparin infusion and continued longer term with antiplatelet therapy.
- Immunosuppression is a combination of steroid and calcineurin inhibitor.
  - Weekly graft surveillance biopsies are commenced to detect early evidence of rejection but symptoms may include temperature, malaise, increased stoma effluent, or blood in the stoma effluent.
  - Biopsy is required to make the diagnosis but stoma effluent should also be tested for viral infections.
  - Mild rejection can be managed with pulsed high-dose steroids but treatment may be escalated to basiliximab or ATG in moderate to severe rejection.
  - Differentials for acute intestinal bleeds also include CMV enteritis and portal hypertension variceal bleeding and later graft versus host disease.

- Patients should be monitored for hypertension which may be exacerbated by steroids and should be treated along with monitoring of renal function, particularly if a renal graft has been included.
- Preservation of native pancreas and addition of graft pancreas may lead to a period of hypoglycemia in the postoperative period and blood sugar should be monitored regularly.

## 58.4.5 Complications

### 58.4.5.1 Rejection (Common)

Presence of gut lymphocytes may contribute to rejection with the development of antibodies. The inclusion of the liver in the graft may offer an immune-protective effect to the graft as rejection rates are lower than in isolated grafts. However, the role of development of donor-specific antibodies (DSA) is still not completely clear as their presence is not necessarily coincident with rejection. DSA, however, are associated with increased risk of chronic rejection and graft loss.

There are no reliable serum markers for rejection and therefore we are reliant on biopsies and monitoring of intestinal effluent volume and nature to detect rejection. Oral gentamicin administration with serum levels may help give an indication of increased bowel permeability in advance of symptoms. Rejection does not necessarily occur in continuity and therefore a negative biopsy but with persistent symptoms necessitates an endoscopy and biopsy of any suspicious mucosal appearances. The presence of a stoma allows biopsies to be performed on the ward without anesthesia. Biopsy changes seen in early acute rejection include lymphocytic infiltration of the mucosa and increased crypt apoptosis but further advancing rejection may result in villous blunting, confluent crypt apoptosis, and eventually loss of the mucosa. Serial biopsies may be required to monitor progression of disease and response to treatment.

Chronic rejection is histologically distinct with features of vasculitis, focal loss of crypts, and patchy fibrosis of the lamina propria. Clinical features can be subtle with failure to tolerate feeds and chronic pain. The vascular changes cannot be seen on mucosal biopsy samples and therefore a full-thickness biopsy is indicated to confirm the diagnosis.

### 58.4.5.2 Sepsis

EBV and CMV infection as well as rotavirus, norovirus, respiratory syncytial virus, herpes virus, and adenovirus are significant causes of infection and early detection is important.

- CMV—enteritis with inflammation of the crypts leading to decreased enteral absorption.
- EBV may be a prelude to Post-Transplant Lymphoproliferative Disease (PTLD) (see below).

### 58.4.5.3 Post-transplant Lymphoproliferative Disease

Occurs in up to 20% of IT.

- Often associated with (but not exclusively due to) de novo EBV. Surveillance for EBV infection and early treatment with modification of immunosuppression is essential as presentation can be subtle with lymphadenopathy, malaise, and hypoalbuminemia.
- Diagnosis is made by endoscopy and biopsy of any lymphadenopathy. EBER staining will highlight EBV-infected lymphocytes. The majority of cases are of polymorphic PTLD but monomorphic PTLD can occur and has a very malignant course.

As well as reduction of immunosuppression, rituximab can be used to target lymphocytes. Directed cytotoxic T-lymphocytes are a novel approach to eliminating the malignant cell population.

### 58.4.5.4 Graft Versus Host Disease (GVHD)

Occurs in <7% of recipients and usually within the first 2 years with mortality rates of up to 70%.

Onset can be rapid and aggressive compared with other transplant patients. Clinical features include low-grade pyrexia, a flitting skin rash that progresses rapidly, corneal lesions, lung disease, and native bowel. Early skin biopsy of any rash is important to allow rapid initiation of treatment before the disease escalates; and is associated with sepsis following initiation of escalated immunosuppression. Treatment usually involves steroids, thymoglobulins, and Campath (alemtuzumab). Recently, our unit has used extracorporeal photopheresis with some success.

---

## 58.5 Outcomes

- Currently, about six children undergo intestinal transplantation a year in the United Kingdom with a median waiting time of 188 days.
- One year patient survival rates ~85% at 1 year and ~60% at 5 years.
- Patient survival at 5 years is 30% for liver containing grafts versus 72% for intestinal only grafts.
- Between 75 and 90% of patients achieve nutritional autonomy.

It should not be forgotten that due to the need for size-matched grafts, up to 85% of prospective donors are rejected and there is a waiting list mortality. Also, with the improving patient survival rates, we are increasingly addressing longer-term complications such as GVHD, PTLD, and chronic rejection. However, the prospect of improved quality of life for these patients is a strong driver to find solutions to these challenges.

---

## Further Reading

- Chiou FK, Beath SV, Wilkie GM, et al. Cytotoxic T-lymphocyte therapy for post-transplant lymphoproliferative disorder after solid organ transplantation in children. *Pediatr Transplant*. 2018; 22(2) doi: 10.1111/ptr.13133.
- Mazariegos GV, Abu-Elmagd K, Jaffe R, et al. Graft Versus Host Disease in intestinal transplantation. *Am J Transplant*. 2004;4:1459–65.
- Norsa L, Gupte G, Ramos Boluda E, et al. Life of patients 10 years after a successful pediatric intestinal transplantation in Europe. *Am J Transplant*. 2018;18:1489–93.
- Soltys KA, Bond G, Sindhi R, et al. Pediatric intestinal transplantation. *Semin Pediatr Surg*. 2017;26:241–9.

---

**Part IX**

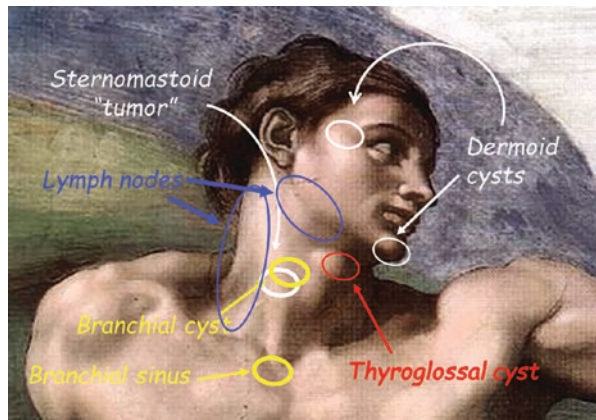
**Miscellaneous**

Hany O. S. Gabra, Chandrasen K. Sinha,  
and Mark Davenport

## 59.1 Introduction

The anatomy of the neck is complex, and the pathology derived from this is myriad. Despite this, consideration of the age of onset, and knowledge of natural history and typical behavior patterns can lead to the correct diagnosis in most cases of unknown swelling, lump, or sepsis (Fig. 59.1).

**Fig. 59.1** Schematic of the differential diagnosis of a lump in the neck



H. O. S. Gabra  
Great North Children's Hospital, Newcastle, UK

C. K. Sinha  
St George's Hospital, London, UK

M. Davenport (✉)  
King's College Hospital, London, UK

Considered here will be:

- Branchial pathology
- Thyroglossal cysts
- Cervical node pathology
- Sternomastoid “tumor”
- Lymphatic malformations
- Dermoid and epidermoid cysts

The anatomy of the neck is a good example of the principle of *recapitulation of ontogeny*<sup>1</sup> as the branchial<sup>2</sup> arches, obvious in the embryo, hark back to the gills of our fishy ancestors.

---

## 59.2 Embryology

### 59.2.1 Branchial<sup>1</sup> Arch Development

There are five pairs of branchial (or pharyngeal) arches evident from day 22, numbered I, II, III, IV, VI (V degenerates and disappears in humans). Each has a cartilaginous center, a nerve, and an aortic arch-associated artery. They are separated externally by ectodermal clefts and internally by endodermal pouches. Derivatives of the first arch cartilage are the malleus and incus of the middle ear; the second arch forms the stapes, stylohyoid, and upper part of the hyoid bone, and the third arch the remainder of the hyoid. Derivatives of the first pouch include the tympanic cavity and Eustachian tube; the second pouch leads to the tonsils, and the third pouch to the thymus gland and inferior parathyroid glands.

### 59.2.2 Thyroid Development

The thyroid originates from two main structures: the primitive pharynx and the neural crest. The thyroid anlage arises on the back of the tongue (*foramen caecum*) and migrates caudally anterior to the hyoid bone to lie in front of the proximal tracheal rings, leaving the potential for a track (should be obliterated by the 5th week) and cyst formation within (*thyroglossal cyst*).

---

## 59.3 Branchial Fistula/Sinus/Cyst (Rare)

Branchial cleft cysts are the most common lateral neck masses and comprising almost one-third of all congenital neck masses and they are bilateral in 2–3%.

---

<sup>1</sup>“ontogeny recapitulates phylogeny” (Haeckel)—Ontogeny is the growth and development of an individual and phylogeny is the evolutionary history of the species. Discarded by current biologists.

<sup>2</sup>Branchial (Greek)—gills.



### 59.3.1 Clinical Features

- Fistula > sinus > cyst
- Branchial cleft cyst
  - No opening in the skin or digestive tract.
- Branchial cleft sinus
  - Single opening to the skin or pharynx.
- Branchial cleft fistula
  - Opening to skin and pharynx.
  - Stratified squamous epithelium lines branchial cleft cysts in 90% of cases.

Although branchial remnants are congenital and therefore present since birth, there is some debate about the etiology of “branchial cysts,” which are usually found in later childhood. Most cysts are located anterior to the sternomastoid muscle, posterior to the submandibular gland, and lateral to the carotid sheath.

Most are usually 2nd arch remnants and their external opening is usually sited near the insertion of the sternomastoid at clavicular level. Sinuses then ascend the neck along the carotid sheath to the level of the hyoid bone turning medially between the internal and external carotid artery, in front of the hypoglossal nerve to end in the region of the tonsillar fossa.

Sometimes, there is mucoid discharge from this opening and occasionally it can become infected.

Cysts occur deep to the middle 1/3 of sternomastoid and can be complicated by sepsis.

### 59.3.2 Investigation

- *Ultrasound*—looking for cystic change.
- *CT or MRI scan*—occasionally in very large cysts when the diagnosis is not clear and lymphatic malformations are suspected.

### 59.3.3 Surgery

Elective excision of the complete tract or cyst. If infected, treat this first before the definitive procedure. Transverse skin incision(s) with methylene blue to outline the sinus.

- Recurrence ~3% after elective operation, ↑ if previous unsuccessful excision.
- *First branchial arch sinus*
  - Rare, with an external opening at the level of the angle of the jaw, and track ascending theoretically toward the middle ear.

Differential diagnosis: Hemangioma, ectopic thyroid or salivary gland tissues, and lymphadenopathy.

---

## 59.4 Thyroglossal Duct Cyst

- Most common congenital cervical anomalies, being about three times as common as branchial cleft cysts.

### 59.4.1 Clinical and Pathological Features

- Most (80%) are related to and in contact with the *hyoid bone*
  - 20–25% suprahyoid
  - 15–20% at hyoid
  - 25–65% at infrahyoid level
- Midline swelling
  - Elevates with swallowing or protrusion of the tongue, is located at or just below the level of the hyoid bone.
- Can track anywhere from the thyroid cartilage up to the base of the tongue.
- Lined by respiratory epithelium, squamous epithelium, or a combination of both.
- In 70% of cases, microscopic foci of ectopic thyroid gland tissue can be found within the cyst wall.
- May be complicated by infection and if allowed to discharge a distal midline fistula often results.

### 59.4.2 Investigation

- Cervical US
  - Shows cystic nature and confirms the presence of a normal thyroid gland.
- Thyroid function tests
  - If ectopic thyroid tissue is expected.

Differential diagnosis includes midline cysts and masses in the neck including nodal pathology, dermoid cyst, thyroid pathology, occasionally 2nd branchial cleft cysts and if suprahyoid, a *ranula*.<sup>3</sup>

---

<sup>3</sup>Ranula—(Latin) Little frog, named for the appearance when in the floor of mouth.

### 59.4.3 Surgery: Sistrunk's Operation<sup>4</sup>

Skin crease incision with the development of skin flaps.

- Mobilize cyst from distal tract (if any).
- Dissect and isolate the body of hyoid in continuity with the cyst (keep the hyoid resection medial to the lesser cornu of the hyoid to avoid hypoglossal nerve injury).
- Identify proximal track to the base of the tongue.
- Repair in layers, approximate hyoid remnants.

If the body of hyoid is removed in continuity with the cyst, then recurrence risk is low (5–10%).

A very small (<1%) risk of cancer has been described in these cysts.

## 59.5 Cervical Node Infections (Common)

Over 75% of lymphatic tissue is found within the head and neck, and this remains the commonest site of manifestation of lymphatic pathology. The ears, nose, mouth, pharynx, and upper airway remain the commonest portal for bacterial and viral entry and this is reflected in the huge incidence of lymphadenitis seen in childhood. Fortunately, most either go without comment and subside spontaneously or is dealt with in general practice by the liberal use of antibiotics. Table 59.1 illustrates the nature of the typical organisms by the age of the child.

### 59.5.1 Clinical Features

Whatever the cause, the usual scenario is to evolve (days) through an active inflammatory *cellulitic phase* with later central *cavitation and pus formation*. The disease process then resolves via discharge to the skin or by surgical intervention (I&D). In both NTM and TB, the process is much more prolonged and “cold,” and because of the inadequacy of the host cellular response, it is often not resolved by discharge or I&D.

**Table 59.1** Common pathogens causing lymphadenitis

| Age group  | Common pathogens   |
|------------|--|
| Neonate    | <i>Staphylococcus aureus</i> , late-onset <i>Group B Streptococcus</i> |
| <5 years   | <i>Group A Streptococcus</i> , <i>St. aureus</i> , NTM                 |
| 5–18 years | EBV, cytomegalovirus, toxoplasmosis, TB, infectious mononucleosis      |

Notes: *NTM* nontuberculous mycobacterium, *EBV* Epstein–Barr virus, *TB* tuberculosis

<sup>4</sup>Walter E. Sistrunk (1880–1933)—American surgeon at Mayo Clinic, MO.

---

## 59.6 Nontuberculous Mycobacterium (NTM) (Aka Atypical *Mycobacterium*)

### 59.6.1 Clinico-Pathology

- *Mycobacterium avium*—*intracellulare* (two species difficult to differentiate), *M. kansasii*, *M. scrofulaceum*.
- Most enter via oropharynx and is a feature in preschool (<5 years) children.
- Typical groups affected include cervical and submandibular nodes.
- Tends to be obvious with overlying skin changes, with ultimate discharge but very often fistula formation.

### 59.6.2 Investigation

- CXR (usually negative)
- Mantoux (i.e., PPD) test (usually negative), now specific NTM antigen skin test
- Ziehl–Neelsen (ZN) stain and culture (takes up to 12 weeks)
- (rapid) PCR (looking for mycobacterial RNA)

### 59.6.3 Management

- Surgical excision (if possible)
  - Beware of proximity to a mandibular branch of Facial (VII) nerve and spinal Accessory (XI) nerve.
- Clarithromycin/azithromycin.

---

## 59.7 Tuberculosis

This is now rare in developed countries but may occur in the Immunosuppressed (e.g., post-transplant).

Surgery is limited to diagnostic biopsy (or fine-needle aspiration cytology), or I&D of abscesses.

---

## 59.8 Cat Scratch Disease or Fever, Felinosis

- *Bartonella henselae*
  - ~40% of cats and kittens carry *B. henselae* at some point in their lives.

---

### 59.8.1 Clinical Features

Usually causes regional lymphadenopathy (typical site is axillary or epitrochlear nodes) but can cause pre-auricular lymphadenopathy (and granulomatous conjunctivitis—Parinaud’s syndrome<sup>5</sup>).

### 59.8.2 Investigations

- ELISA is possible.
- Biopsy—granulomatous reaction. Visible on Warthin–Starry stain.
- PCR on sampled material possible.
- Most are self-limiting in immunocompetent children, but azithromycin for severe symptoms.

---

## 59.9 Kawasaki’s Disease<sup>6</sup>

Known as mucocutaneous lymph node syndrome and is a vasculitic disease of unknown etiology, however, over 40% of children diagnosed with it have tested positive for viral respiratory pathogens. Some of its clinical features overlap with the PIMS-TS seen in COVID-19 pandemic of 2020–21.

### 59.9.1 Clinical Features

It principally affects:

- Heart
  - Coronary artery aneurysm
- Skin and mucous membranes
  - “Strawberry” tongue, red palms, and soles with later desquamation
- Lymph nodes
  - Cervical adenopathy

### 59.9.2 Investigation

No specific test—diagnosed on clinical criteria (5-day fever, erythema of lips, etc.)

---

<sup>5</sup>Henri Parinaud (1844–1905)—French ophthalmologist.

<sup>6</sup>Tomisaku Kawasaki (1925–2020)—Japanese pediatrician who described 50 cases in 1967.

### 59.9.3 Management

- High-dose immunoglobulin and salicylates (aspirin)  $\pm$  steroids.

---

## 59.10 Sternocleidomastoid “Tumor” (Rare)

Also called “fibromatosis colli of infancy,” incidence is rare (0.4% live birth), and is the most common cause of congenital muscular torticollis accounting for 10–20% of the cases.

There has sometimes been a history of birth trauma or breech delivery suggesting that there has been hemorrhage within the muscle, followed by fibrosis and muscle shortening.

### 59.10.1 Clinical Features

Typically presents with a painless lump within the mid or lower part of the sternomastoid muscle at 2–8 weeks of age with or without torticollis (head rotated and tilted away from the affected side). Initially, any abnormal head positioning can be corrected, but with time this becomes fixed. There are then secondary soft tissue changes and facial asymmetry.

### 59.10.2 Investigation

- Ultrasound
  - May show focal or diffuse enlargement of the sternocleidomastoid muscle.
- Cervical radiography
  - Exclude vertebral anomalies (e.g., hemivertebra).
- MRI
  - Precise definition of cervical vertebral anomalies.

### 59.10.3 Management

- *Cervical physiotherapy*—successful in >90% of cases.
  - Early diagnosis and intervention.
  - Passive neck movement and stretching exercises—avoid cot positioning, which exacerbate neck deformity.
- *Surgery*
  - Division of sternomastoid muscle—achieves  $\uparrow$  length.

## 59.11 Lymphatic Malformations

- Benign malformations of the lymphatic system.
- ~50% of these malformations are diagnosed at birth.
- ~90% present before 2 years of age.
- Uncertain incidence—1 in 6000 live births.

### 59.11.1 Associations

- Chromosomal anomalies: Trisomies 13, 18, and 21(Down Syndrome), Noonan syndrome (single gene defect on Ch12q24.1).
- Lymphatic malformations are vascular malformations composed of primitive embryonic lymph sacs of varying sizes. Mostly found in relation to head and neck but can be ubiquitous.

### 59.11.2 Cystic Hygroma

A term used to describe congenital neck lesions. Some are huge and can cause polyhydramnios, obstructed labor, and failure to establish an airway at birth.

They can be divided into three clinical types:

- *Microcystic* (>1 cm)
- *Macrocystic* (<1 cm)
- *Mixed lesions*

They may also be described as *unilocular*, *multilocular*, *focal*, or *diffuse/infiltrative*.

#### 59.11.2.1 Clinical Features

Lymphatic malformations typically increase in size as the child grows, and they may show a rapid increase in size in association with upper respiratory tract infection or intralesional hemorrhage, causing compromise of airway if present in the suprahyoid region.

#### 59.11.2.2 Investigation

- *US*—to determine cyst size and number.
- *MRI*—defines an anatomical relationship between cervical vessels and trachea.

Sometimes, lymphatic malformations may be a part of mixed vascular malformations (typically venous) (see Chap. 62).

#### 59.11.2.3 Management

Contentious, confusing, and contradictory!

- *Sclerotherapy*—percutaneous injection/infiltration.
  - Bleomycin
    - Intralesional injection (total dose of 5 mg/kg).
  - Doxycycline
    - Intralesional injection (maximum dose of 200 mg per injection).
  - Sodium tetradecyl sulfate (1 or 3%)
  - OK-432 (Picibanil™)
    - Lyophilized mixture of *Streptococcus* spp.
    - 2 RCTs showed benefits for macrocystic lesions.
  - Ethibloc™
    - A combination of alcohol, mixed irritant proteins, and a radio-opaque marker.
  - Celecoxib
    - Anti-cyclooxygenase-2 inhibitor (3.5 mg/kg per day)—few case reports in difficult cases.
- *Surgery*
  - Aim for complete excision—but this is often easier said than done! May be difficult owing to nerve proximity, etc.
- *Medical*
  - Sirolimus
    - Also used in vascular malformations
  - Rapamycin (topical 1% applied b.d.)
    - For recurrent, microcystic lesions with skin involvement

---

## 59.12 Dermoid Cysts and Epidermoid Cysts (Common)

Dermoid cysts represent superficial ectodermal elements, which have become trapped beneath the skin and occur at sites of ectodermal fusion. Typical sites include anywhere along the body's midline, or along the line joining upper ear to the upper outer part of the eyebrow (*external angular dermoid*).

- Dermoid cysts contain squamous epithelium and skin appendages such as hair follicles and sebaceous glands.
- Epidermoid cysts contain only squamous epithelium.

---

### Further Reading

- Acierno SP, Waldhausen JH. Congenital cervical cysts, sinuses and fistulae. *Otolaryngol Clin North Am.* 2007;40:161–76.
- Bloom DC, Perkins JA, Manning SC. Management of lymphatic malformations. *Curr Opin Otolaryngol Head Neck Surg.* 2004;12:500–4.
- Lam SC, Yuen HKL. Medical and sclerosing agents in the treatment of orbital lymphatic malformations: what's new? *Curr Opin Ophthalmol.* 2019;30:380–5.
- Schoenwolf GC, Bleyl SB, Brauer PR, Francis-West PH. Development of the pharyngeal apparatus and face. In: Larsen's human embryology. 4th ed. Philadelphia: Churchill Livingstone; 2009. p. 543–80.





# Fetal Surgery: General Principles

# 60

Eric Bradley Jelin, Harisa Spahic, and Hanmin Lee

Fetal surgery has moved from the experimental model to the human condition and even the standard of care for certain diseases. However, despite developments in techniques and imaging, fetal surgery has only been shown to be beneficial in a small subset of patients and still carries significant morbidity risks.

## 60.1 Introduction

The first open surgery on a human fetus was performed for congenital bladder obstruction in 1981 by Michael R Harrison at the University of California, San Francisco (UCSF). Since then, advanced fetal imaging has dramatically improved our understanding of congenital anomalies and has opened the door to new treatments and minimally invasive techniques.

Human fetal surgery is now being performed for diseases such as:

- Congenital diaphragmatic hernia (CDH)
- Twin anomalies
- Mass lesions with hydrops fetalis

---

E. B. Jelin (Deceased) · H. Spahic  
Division of Pediatric Surgery/Fetal Program, Department of Surgery, Johns Hopkins University, Baltimore, MD, USA  
e-mail: [ejelin1@jhmi.edu](mailto:ejelin1@jhmi.edu); [hspahic1@jhmi.edu](mailto:hspahic1@jhmi.edu)

H. Lee (✉)  
Division of Pediatric Surgery/Fetal Treatment Center, Department of Surgery, University of California at San Francisco, San Francisco, CA, USA  
e-mail: [hanmin.lee@ucsf.edu](mailto:hanmin.lee@ucsf.edu)

- Early Pregnancy Renal Anhydramnios
- Spina bifida/Myelomeningocele
- Aortic valve stenosis
- Amniotic Band Syndrome
- Congenital high airway obstruction

---

## 60.2 Ethical Concerns

The welfare of both mother and fetus must be considered within fetal surgery. The treatment of a fetus with a congenital anomaly confers no direct physical benefit to the mother and subjects her to risk. The risk is primarily related to the high incidence of preterm labor and its corresponding morbidity, but as with any operation, fetal surgery also carries a risk of infection, bleeding, and damage to adjacent structures. Fetal surgical procedures should only be considered if the in utero anomaly has been shown to have severe irreversible consequences and the procedure is safe, superior to postnatal options, and beneficial to the fetus with low risk to the mother.

Further considerations must be taken when the fetal intervention addresses one pathophysiological process but necessitates postnatal interventions for another as in congenital renal agenesis. Amnioinfusions in cases of renal agenesis allow for lung development until delivery; however, once born, the child lacks kidneys thus requiring neonatal dialysis and renal transplant.

---

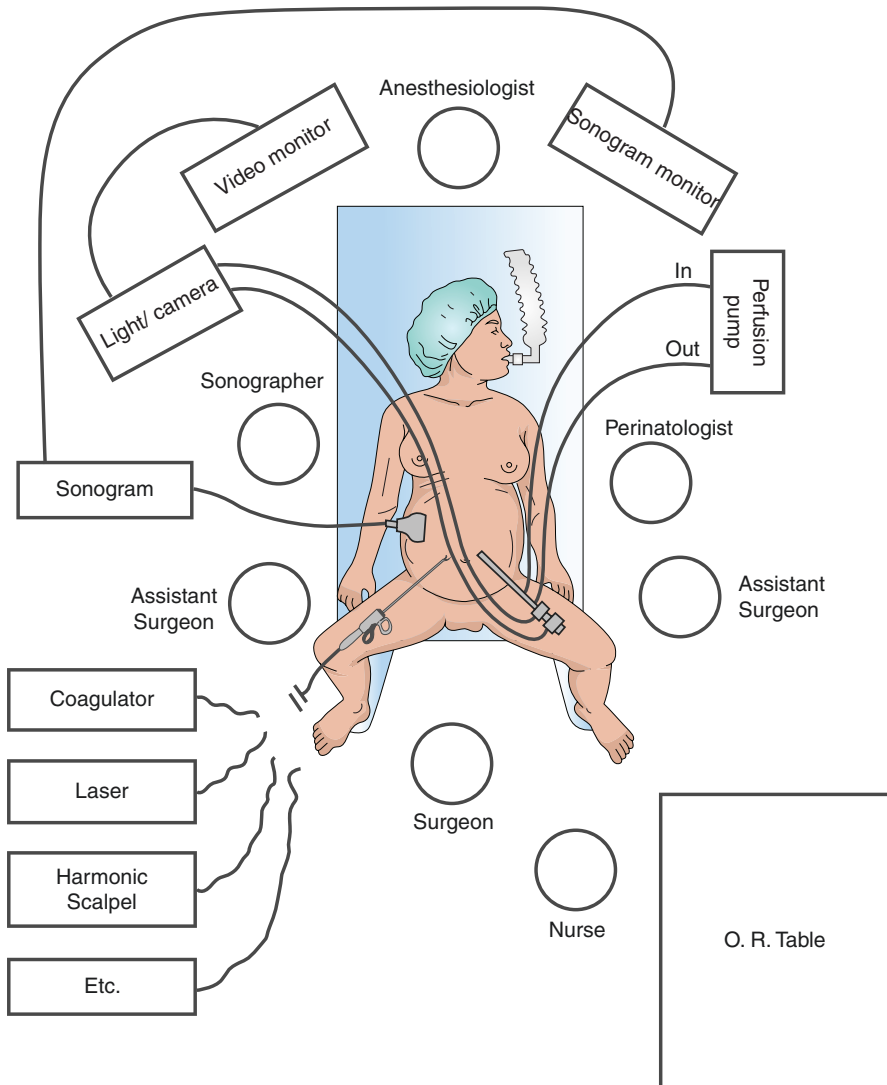
## 60.3 Accessing the Fetus

The gravid uterus can be accessed by open or minimally invasive (fetoscopic and percutaneous) techniques. In both approaches, ultrasound assessment for placental position, uterine anomalies, and fetal position are critical for successful intervention, and a skilled sonologist/ultrasonographer is a mandatory member of the operative team.

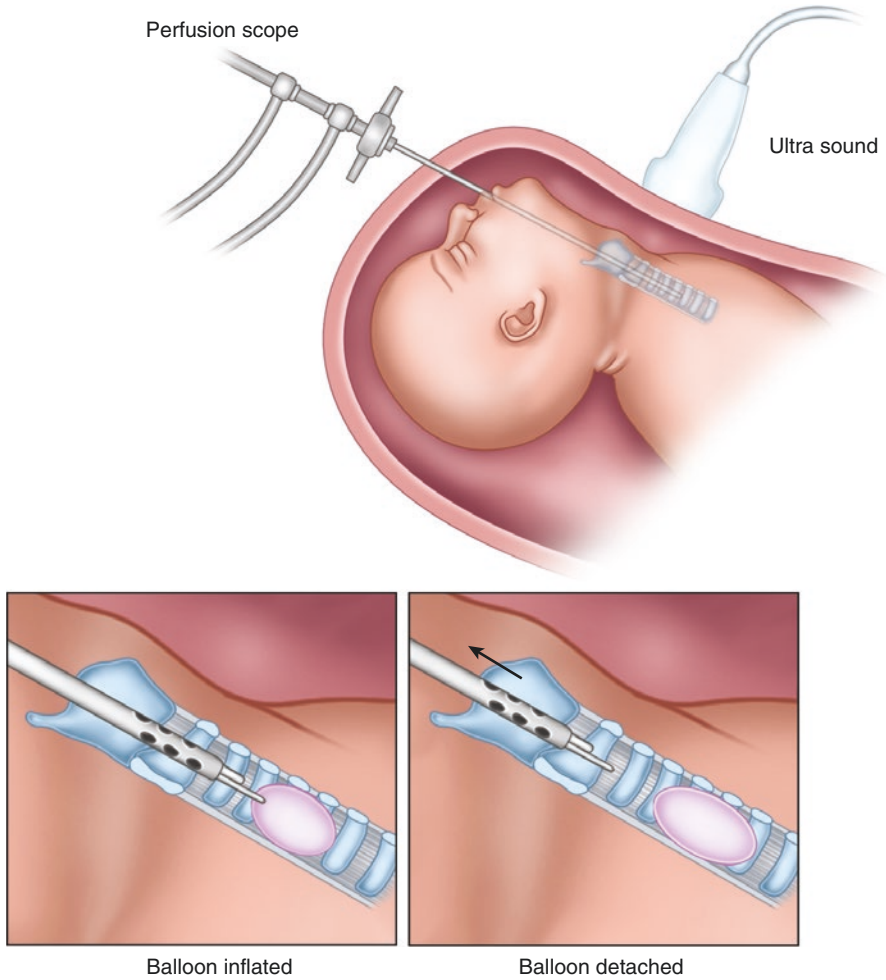
Open fetal surgery requires:

- Maternal low transverse incision.
- Exposure and intraoperative ultrasound of the uterus.
- Analgesia and paralysis of the fetus.
- Hysterotomy opposite placental location using a uterine stapler with absorbable staples thus providing hemostasis, and sealing membranes.
- Exposure of appropriate body part of the fetus.
- Repair of the defect.
- Return of fetus to uterus.
- Closure of hysterotomy with two running layers of absorbable suture and fibrin glue.

Endoscopic techniques for fetal surgery (*FETENDO*), Figs. 60.1 and 60.2 have been adapted from laparoscopic surgery. A minimally invasive approach avoids the maternal morbidity incurred with a large open incision and hysterotomy (e.g., post-operative bleeding, adhesions, and the inability to deliver vaginally). Percutaneous interventions are usually directed at draining fluid-filled fetal structures or radiofrequency ablation of an anomalous twin. “Real-time” continuous ultrasound guides the placement of percutaneous instruments.



**Fig. 60.1** Typical operating room setup for a fetoscopic procedure



**Fig. 60.2** Use of fetoscopy to place an inflatable balloon in the fetal trachea for CDH

## 60.4 Specific Conditions

### 60.4.1 Congenital Diaphragmatic Hernia

#### Principle

Fetal tracheal occlusion (FETO) promotes lung growth and thus improves postnatal lung function.

Fetuses with severe CDH and lung hypoplasia continue to have a dismal prognosis. For these selected patients, fetal surgery may improve survival and reduce post-natal morbidity.

FETO is performed by placing a balloon into the fetal trachea at 26–29 weeks' gestation. An early randomized control trial in 2003 comparing in utero FETO for CDH with standard postnatal care did not show improved survival in the TO group (both groups had a 90-day survival of 75%) (Harrison et al. 2003). However, the study had broad inclusion criteria and did not target the sickest subset of fetuses.

Consequentially, the *Tracheal Occlusion To Accelerate Lung growth (TOTAL)* trial was begun with more stringent selection criteria, randomization to expectant management or FETO, and two study groups consisting of patients with moderate or severe lung hypoplasia. Enrolment has been completed for patients with moderate lung hypoplasia while enrolment for patients with severe lung hypoplasia is near complete. The results have been recently reported (2021) showing significant improvement in survival in the most severely affected fetuses.

## 60.4.2 Twin Anomalies

This is directed at the abnormal circulation during multi-gestational pregnancies putting one or both fetuses at risk for disease and/or death.

### Principle

Fetoscopic laser ablation of abnormal placental connections.

### 60.4.2.1 Twin-Twin Transfusion Syndrome

- Abnormal placental connections cause unequal sharing of blood between fetuses.
- Occurs in up to 15% of monochorionic twin pregnancies.

The condition is fatal in >80% of untreated cases and survivors face a risk of brain damage and morbidity.

A 2004 randomized control trial (Senat et al. 2004) of laser blood vessel ablation showed superiority compared to amnioreduction, the previous therapy of choice, in patients with severe Twin-twin transfusion syndrome (TTTS) ( $\leq 26$  weeks gestation) Survival of at least one twin at 1 month was 76% (laser) vs. 56% (amnioreduction group). The procedure has been improved by the Solomon technique by reducing twin anemia polycythemia sequence (3% Solomon vs. 16% standard laser) and recurrence of TTTS (1% Solomon vs. 7% standard laser) (Slaghekke et al. 2014).

### 60.4.2.2 Twin Reversed Arterial Perfusion (TRAP) Sequence

- ~1% of monochorionic twins.
- Characterized by an acardiac and/or anencephalic twin whose blood flow is provided by reversed perfusion through the normal twin's umbilical cord. Fetal demise occurs in approximately 60% of cases and is more likely if the anomalous twin is large, well-vascularized, or both.

Fetal surgery consists of ablation of the blood vessels that supply the acardiac twin, either via fetoscopy with monopolar or bipolarly diathermy, YAG laser, radio-frequency ablation, or microwave. Survival rates for the normal twin after ablation are >90%, higher than treatment with cord occlusion which are higher than survival rates from conservative management.

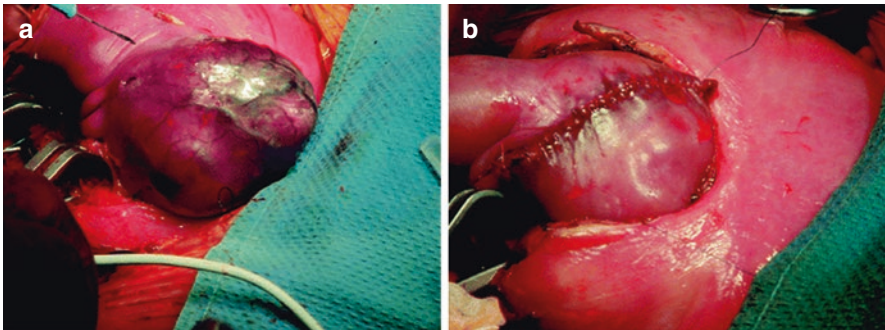
### 60.4.3 Fetal Mass Lesions with Hydrops

Large, vascularized mass lesions cause heart failure and hydrops either by impairing venous return or arteriovenous shunting.

#### Principle

Reversal of fetal cardiac failure and hydrops by fetal mass excision.

The vast majority of mass lesions are benign and often spontaneously regress; however, some become so large that they cause high-output cardiac failure. The most common are *congenital pulmonary adenomatoid malformation (CPAM)* and *sacroccoccygeal teratoma (SCT)*. Fetal surgery for these lesions involves resection via an open approach (Fig. 60.3). A recent review showed improvement in survival of hydropic fetuses with mass lesions from <5% without intervention to 50% with resection. For microcystic or solid CPAMs with hydrops fetalis, survival is >80% with maternal steroid treatment. Fetal surgical resection should only be considered with persistent hydrops fetalis after 2 or more courses of steroids.



**Fig. 60.3** Sacroccoccygeal teratoma (a) before and (b) after fetal resection

### 60.4.4 Early Pregnancy Renal Anhydramnios

Early pregnancy renal anhydramnios (EPRA) occurs when fetal urine fails to enter the amniotic sac whether due to an obstruction or lack of production. The minimized amniotic fluid levels lead to pulmonary hypoplasia causing EPRA to be universally fatal as the fetus cannot develop functional lungs.

### 60.4.5 Bladder Outlet Obstruction (BOO) and Fetal Renal Failure

#### Principle

Relief of urinary obstruction may reduce renal failure and limit pulmonary hypoplasia.

When renal function is absent, amnioinfusions have the potential to rescue neonatal lung function.

Bladder outlet obstruction affects ~1 in 1000 live-births. The causes include:

- Posterior urethral valves (most common)
- Prune belly syndrome
- Urethral atresia

Congenital urinary obstruction leads to oligohydramnios, renal failure, and pulmonary hypoplasia. Insertion of a double-J pigtail vesicoamniotic shunt can prevent further deterioration and enhance lung growth; however, the *Percutaneous Lower Urinary Tract Obstruction (PLUTO) trial* (Morris et al. 2013) was not able to detect a difference in survival when comparing vesicoamniotic shunts to conservative management. Despite poor recruitment and a low sample size, survival at 28 days was 50% after vesicoamniotic shunt treatment and 27% after conservative treatment. Only two children survived to 2 years of age, and both were treated with vesicoamniotic shunts. Some centers are now investigating the role of fetal cystoscopy to treat fetal bladder outlet obstruction (Ruano et al. 2015).

Fetuses with congenital bilateral renal agenesis or early renal failure are both conditions preventing the production of urine which leads to progressive oligohydramnios and eventually anhydramnios resulting in pulmonary hypoplasia. Pulmonary function in these pregnancies may be improved by an exogenous source of fluid.

Replacing fetal urine with normal saline may improve lung hypoplasia. However, success rates and longer-term outcomes for serial amnioinfusions to treat these diseases have not been fully and systematically explored.

The *Renal Anhydramnios Fetal Therapy (RAFT) trial* (O'Hare et al. 2019) is a current multicenter, prospective, non-randomized trial to assess the feasibility of serial amnioinfusions for maternal and fetal safety. Furthermore, survival to neonatal dialysis and possible biomarkers will be determined in addition to efficacy of amnioinfusions in relationship to morbidities from neonatal dialysis, future surgeries (e.g., urinary tract reconstruction), and renal transplant (Jelin et al. 2020).

### 60.4.6 Myelomeningocele (Spina Bifida)

Neural tube defects (e.g., myelomeningocele (MMC) or spina bifida) occurs in ~1 in 1000 live-births and is associated with debilitating neurologic injury (e.g., loss of hind limb function, bowel and bladder incontinence, hydrocephalus, and Arnold<sup>1</sup>-Chiari<sup>2</sup> malformation (condition where part of cerebellum herniates through foramen magnum causing hydrocephalus)).

#### Principle

In utero repair of MMC may preserve peripheral neurological function and prevent Arnold-Chiari malformation.

Successful prenatal MMC repair rectifies error in neural tube development and minimizes damage to neural structures by the amniotic fluid. In the *MOMS trial*, repair consisted of open fetal surgery for neural tissue separation, dural suturing, and connection of myofascial tissue (Adzick et al. 2011). Despite prematurity, neonates receiving MMC repair in utero were less likely to die or require a cerebrospinal fluid shunt in the first year of life (68% prenatal MMC repair vs. 98% postnatal MMC repair). Advantages of prenatal MMC repair continued in the longer term with higher functionality of the prenatal group than postnatal at 30 months and 5–10 years of age (Houtrow et al. 2020).

Fetoscopic techniques for MMC repair have also been developed and tested through a Phase I trial called the *CECAM trial* (Pedreira et al. 2016). This utilized a one layer technique consisting of a simple skin closure over a biocellulose patch. The technique was improved to a 3-layer closure wherein a collagen patch is placed, dura-fascia or myo-fascia flaps are sutured to cover the patch, and the skin closed. Further studies are required to compare outcomes for fetoscopic and open techniques for MMC repair (Belfort MA et al. 2019).

<sup>1</sup>Julius Arnold (1835–1915)—German pathologist, published his case in 1894.

<sup>2</sup>Hans Chiari (1851–1915)—Austrian pathologist, published a series of cases, and a hypothesis concerning hydrocephalus in 1891.



### 60.4.7 Aortic Valve Stenosis

Prenatally diagnosed critical aortic valve stenosis leads to ventricular overload, chronic myocardial wall ischemia, and eventually hypoplastic left heart syndrome (HLHS). Postnatal therapy involves staged surgical repairs, but mortality is up to 25% after the first operation and survivors face a lifetime of cardiac and neurologic dysfunction.

#### Principle

In utero repair of valve stenosis may preserve ventricular function.

Percutaneous and open fetal aortic valvuloplasty have successfully relieved left ventricular obstruction and minimized left heart damage. The largest series from the Children's Hospital Boston ( $n = 100$ ) reported a technical success rate of 77% (Freud et al. 2014). Of the surviving fetuses with successful interventions, 50% developed a functional left ventricle. At most recent follow-up, participant ages ranged from 2 months to 13 years wherein no cardiac deaths reported for participants with a functional left ventricle at birth. Despite the decrease in mortality, participants with a functional left ventricle experienced morbidities at similar rates to those with HLHS (e.g., interventional catheterizations and neurodevelopmental delay) (Laraja et al. 2013).

### 60.4.8 Amniotic Band Syndrome

Strands from the amniotic sac have the potential to separate from the sac and entangle portions of the fetal body. Severe malformations result from tight entanglements to the limbs and other parts of the body resulting in deformities or possible fetal death.

#### Principle

Removal of amniotic bands may prevent death or lessen deformity.

Fetoscopic techniques are used to release amniotic bands from their entanglement about the fetal structure (Derderian et al. 2014). Surgeons transect the bands mechanically or with a laser. Success rates have been cited >74% with reasonable functionality of affected structure postnatally; however, postnatal surgeries are often indicated (Iqbal et al. 2015).

### 60.4.9 Congenital High Airway Obstruction Syndrome

Congenital high airway obstruction syndrome (CHOS) is characterized by a stenosis or mass lesion that blocks the fetal airway. Fetuses with CHOS that survive until birth face certain death secondary to airway obstruction.

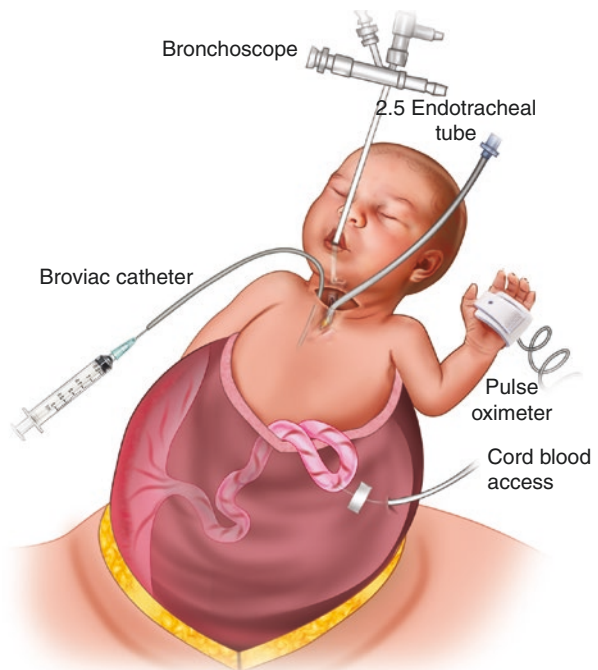
#### Principle

Correction of airway occlusion while still on placental support.

The *EXIT (ex utero intrapartum treatment) procedure* is a specialized mode of surgical delivery developed for fetuses with airway obstruction (Fig. 60.4). EXIT maintains the fetus on placental support while an airway is established by orotracheal intubation or tracheostomy. Once oxygenation of the fetus is achieved, the cord is clamped and cut, and the baby is delivered.

Experimental techniques such as fetoscopic laser laryngotomy are being attempted at multiple centers.

**Fig. 60.4** Schematic of an “EXIT” procedure



## 60.5 The Future of Fetal Surgery

For many fetuses with severe disease, fetal surgery offers the best and sometimes only therapy. The efficacy of intervention is still greatly limited by high rates of preterm labor and preterm birth, but as more is learned about the underlying mechanisms of labor, strategies are being developed to combat it. Minimally invasive techniques will continue to improve and replace open techniques. In the near term, stem cell transplantations are being performed in utero. Clinical trials are currently underway. In utero hematopoietic stem cell transplantation for  $\alpha$ -thalassemia major is currently recruiting patients at the University of California San Francisco. Another trial is the *Boost Brittle Bones Before Birth (BOOSTB4) trial*. BOOSTB4 is a European multisite Phase I/II trial for prenatal and/or postnatal allogenic expanded fetal mesenchymal stem cell transplantation for osteogenesis imperfecta. Future in utero interventions may also involve gene therapy via viral vectors or medication administration via microparticles for metabolic deficiencies, musculoskeletal anomalies, and neural defects with animal studies at Yale University and University College, London showing promise. The frontier of fetal therapy is with a nexus of multidisciplinary scientific and technological advancements; however, caution is warranted. It is uncertain how, or if, developments such as gene editing may impact fetal therapy in the distant future, but healthcare providers in the field are to remain cognizant of ethical considerations as steps forward are taken. Fetal therapy has evolved quickly since Dr. Harrison's first fetal surgery in 1981. Responsible and ethical research in the field will guarantee the next stage of fetal therapy to be as dramatic and promising.

---

### Further Reading

- Adzick NS, Thom EA, Spong CY, et al. A randomized trial of prenatal versus postnatal repair of myelomeningocele. *N Engl J Med*. 2011;364:993–1004.
- Belfort MA, Whitehead WE, Shamshirsaz AA, et al. Comparison of two fetoscopic open neural tube defect (ONTD) repair techniques: Single-layer vs three-layer closure. *Ultrasound Obstet Gynecol*. 2019; <https://doi.org/10.1002/uog.21915>.
- Derderian SC, Iqbal CW, Goldstein R, et al. Fetoscopic approach to amniotic band syndrome. *J Pediatr Surg*. 2014;49:359–62.
- Freud LR, McElhinney DB, Marshall AC, et al. Fetal aortic valvuloplasty for evolving hypoplastic left heart syndrome: postnatal outcomes of the first 100 patients. *Circulation*. 2014;130:638–45.
- Grethel EJ, Wagner AJ, Clifton MS, et al. Fetal intervention for mass lesions and hydrops improves outcome: a 15-year experience. *J Pediatr Surg*. 2007;42:117–23.
- Harrison MR. *The unborn patient: the art and science of fetal therapy*. 3rd ed. Philadelphia: W.B. Saunders; 2001. p. xv, 709 p., [6] p. of plates Google Scholar
- Harrison MR, Keller RL, Hawgood SB, et al. A randomized trial of fetal endoscopic tracheal occlusion for severe fetal congenital diaphragmatic hernia. *N Engl J Med*. 2003;349:1916–24.
- Houtrow AJ, Thom EA, Fletcher JM, et al. Prenatal repair of myelomeningocele and school-age functional outcomes. *Pediatrics*. 2020;145:e20191544.

- Iqbal CW, Derderian SC, Cheng Y, et al. Amniotic band syndrome: a single institutional experience. *Fet Diag Therap.* 2015;37:1–5.
- Jelin AC, Sagaser KG, Forster KR, Ibekwe T, et al. Etiology and management of early pregnancy renal anhydramnios: Is there a place for serial amnioinfusions? *Prenat Diagn.* 2020;40:528–37. <https://doi.org/10.1002/pd.5658>.
- Laraja K, Sadhwani A, Tworetzky W, et al. Neurodevelopmental outcome in children after fetal cardiac intervention for aortic stenosis with evolving hypoplastic left heart syndrome. *J Pediatr.* 2017;184:130–6.
- Lee H, Wagner AJ, Sy E, et al. Efficacy of radiofrequency ablation for twin-reversed arterial perfusion sequence. *Am J Obstet Gynecol.* 2007;196(459):e1–4.
- Loh KC, Jelin E, Hirose S, et al. Microcystic congenital pulmonary airway malformation with hydrops fetalis: steroids vs open fetal resection. *J Ped Surg.* 2012;47:36–9.
- Morris RK, Malin GL, Quinlan-Jones E, et al. Percutaneous vesicoamniotic shunting versus conservative management for fetal lower urinary tract obstruction (PLUTO): a randomised trial. *Lancet.* 2013;382:1496–506.
- Nolan HR, Gurria J, Peiro JL, et al. Congenital high airway obstruction syndrome (CHAOS): natural history, prenatal management strategies, and outcomes at a single comprehensive fetal center. *J Ped Surg.* 2019;54:1153–8.
- O’Hare EM, Jelin AC, Miller JL, et al. Amnioinfusions to treat early onset anhydramnios caused by renal anomalies: background and rationale for the renal anhydramnios fetal therapy Trial. *Fetal Diagn Ther.* 2019;45:365–72.
- Pedreira DAL, Zanon N, Nishikuni K, et al. Endoscopic surgery for the antenatal treatment of myelomeningocele: the CECAM trial. *Am J Obstet Gynecol.* 2016;214:111, e1–11.
- Ruano R, Sanases N, Sangi-Haghpeykar H, et al. Fetal intervention for severe lower urinary tract obstruction: a multicentre case-control study comparing fetal cystoscopy with vesicoamniotic shunting. *Ultrasound Obstet Gynecol.* 2015;45:452–8.
- Senat MV, Deprest J, Boulvain M, et al. Endoscopic laser surgery versus serial amnioreduction for severe twin-to-twin transfusion syndrome. *N Engl J Med.* 2004;351:136–44.
- Slaghekke F, Lopriore E, Lewi L, et al. Fetoscopic laser coagulation of the vascular equator versus selective coagulation for twin-to-twin transfusion syndrome: an open-label randomised controlled trial. *Lancet.* 2014;383:2144–51.
- Sugarman J, Anderson J, Baschat AA, et al. Ethical considerations concerning amnioinfusions for treating fetal bilateral renal agenesis. *Obstet Gynecol.* 2018;131:130–4.
- Tworetzky W, Wilkins-Haug L, Jennings RW, et al. Balloon dilation of severe aortic stenosis in the fetus: potential for prevention of hypoplastic left heart syndrome: candidate selection, technique, and results of successful intervention. *Circulation.* 2004;110:2125–31.



# Basic Pediatric Laparoscopy and Thoracoscopy

# 61

Steven S. Rothenberg

The safety and efficacy of minimally invasive surgery in infants and children have clearly been shown over the past 20 years. Appendectomy, cholecystectomy, fundoplication, and splenectomy can be considered the gold standard in this age group.

## 61.1 Introduction

The development of pediatric-specific instrumentation and advanced skills have allowed pediatric-specific procedures such as pyloromyotomy for pyloric stenosis, hernia repair for indirect hernias, colon pull-throughs for Hirschsprung's disease and imperforate anus, repair of intestinal atresias, and advanced thoracoscopic procedures in both neonates and children to become the norm in some centers.

## 61.2 General Principles

### 61.2.1 Positioning of the Patient and Port Placement

Ergonomics plays a strong role in dictating successful choices for positioning.

- Central (cross-table)
  - Infants (e.g., pyloromyotomy and pull-through). This gives the surgeon equal access to the head and foot of the patient while keeping them closer to the anesthesiologist during the case.

---

S. S. Rothenberg (✉)  
Rocky Mountain Hospital for Children, Denver, CO, USA

- Foot of table
  - For example, Nissen fundoplication. Surgeon stands at the patient's feet.
- Thoracoscopic procedures take advantage of lateral positioning to allow safe access to all structures within the thoracic space and use gravity to aid in retraction of the lung.

### 61.2.2 Pneumoperitoneum

- *Closed Veress<sup>1</sup> needle technique*—special spring-loaded needle.
- *Open Hasson<sup>2</sup> technique*—dissection through the fascia, visual identification of the cavity.

Initial concerns suggested the need for decreased insufflation pressures in infants and children, but subsequent physiologic data does not support this. There is an increase in end-tidal CO<sub>2</sub> with insufflation, but this can be remedied by increasing the minute ventilation. Hypotension and other physiologic effects have not been shown to be significant in most cases.

### 61.2.3 Pneumothorax

- CO<sub>2</sub> insufflation and valved trocars (pressures 4–8 mmHg).
- Single lung ventilation is by mainstem intubation of the contralateral bronchus.
- Double lumen endotracheal tube (adolescents).

The slight tension pneumothorax created by the CO<sub>2</sub> helps to provide complete collapse in most cases, creating an adequate working environment.

### 61.2.4 Instrumentation

#### Pediatric Specific (<10 kg)

- Shorter length shafts (18–20 cm)
- Smaller diameter (2.5–3 mm)

These instruments improve the ergonomics and allow the surgeon to perform fine dissection and suturing in a relatively confined space.

- Smaller scopes (3 and 4 mm) of shorter lengths (20 cm).

---

<sup>1</sup>Janos Veress (1903–1979)—Hungarian chest physician who used this needle for inducing pneumoperitoneum in the treatment of TB.

<sup>2</sup>Harrith M Hasson (1931–2012)—American gynecologist, working in Chicago, who first described this in 1971.

These may compromise light retrieval; therefore, a good light source and digital camera are imperative.

### 61.2.5 Standard Working Pressures

- *Children (12–15 mmHg). Flow rates of 3–5 L/min*
- *Infants (10–12 mmHg)*
  - In neonates, some insufflators are not sensitive enough to detect the rapid changes in pressure in their smaller peritoneal cavities, and this lack of sensitivity may result in over-insufflation.
- *Initial flow*
  - 0.5–1 L/min.

---

## 61.3 Pyloromyotomy for Pyloric Stenosis (See Chap. 16)

Laparoscopic pyloromyotomy was probably the first truly pediatric laparoscopic procedure. Many felt that a laparoscopic approach added little advantage over a standard RUQ or supra-umbilical incision, but the ease and quickness of the procedure along with the superior cosmetic result have made it one of the most commonly adopted MIS procedures.

1. Crossways placement on the table.
2. Umbilical incision, trocar, and a 3 or 4 mm 30° telescope lens.
3. RUQ and epigastrium stab wounds (R side of falciform ligament, at approximately the liver edge).
4. Grasp the duodenum using a 3-mm atraumatic grasper (Babcock or bowel clamp) through the RUQ incision.
5. Place retractable pyloromyotomy blade (*Karl Storz Endoskope*) guarded cautery blade through the epigastric incision.
6. Advance blade 2–3 mm past the shield and make longitudinal myotomy. The blade is then retracted back into the sheath and the blunt sheath is used to deepen and widen the myotomy.
7. The myotomy is then completed by either grabbing the upper muscle rim with the Babcock and detracting the lower muscle rim using the blunt sheath or by using a laparoscopic pyloromyotomy spreader.
8. The surgeon can visualize the muscle fibers splitting and can tell when the myotomy is complete by the bulging mucosa and the ability of the upper and lower muscle rims to slide tangentially to each other. If a mucosal perforation is noted, it should be suture closed and the pylorus rotated 90° and another myotomy made.

Postoperatively, feeds are started 1–2 h after surgery and volumes are rapidly increased. Most patients are discharged within 24 h.

## 61.4 Laparoscopic Fundoplication and Gastrostomy Button (See Chap. 49)

Laparoscopic fundoplications are now the gold standard in the pediatric population and recurrence rates at 20-year follow-up appear better than that achieved with traditional open surgery. There is also a striking decrease in morbidity, especially in terms of pulmonary complications and the incidence of postoperative bowel obstructions.

The most commonly performed procedure is the Nissen<sup>3</sup> fundoplication.

### 61.4.1 Five-Port Nissen Technique

Instrumentation and trocars are 5 or 3 mm in size depending on the size of the patient. Either a standard length 5 mm 30° telescope or a short wide-angle 4 mm 30° telescope is chosen based on patient size.

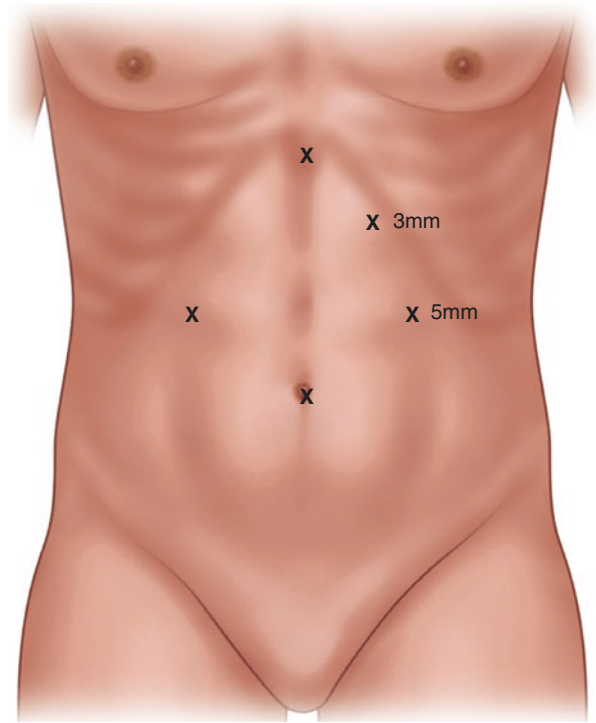
1. Ports
  - (a) Umbilicus—camera port
  - (b) The R and L mid-quadrants—working ports
  - (c) R mid or upper-quadrant—liver retractor
2. LUQ—stomach retractor and gastrostomy tube site (Fig. 61.1).
3. Retract the left lobe of the liver using a locking Babcock clamp, to expose the gastroesophageal junction.
  - (a) This is placed through the RUQ incision (just to the surgeon's left of the falciform ligament at the liver edge). The shaft of the clamp hooks the falciform helping to elevate the liver and the clamp is used to grasp the diaphragm above the esophageal hiatus, thus allowing the shaft of the instrument to act as a self-retaining retractor. In some cases with an extremely large liver, it is necessary to have the assistant hold this instrument so it can be moved frequently to provide the best exposure and avoid liver fatigue.
4. Divide the esophagogastric and phreno-esophageal ligaments and identify the R and L diaphragmatic crura.
5. Divide/coagulate short gastric vessels (using a 3-mm vessel sealer in patients <15 kg or one of the 5-mm sealing-dividing instruments in >15 kg).
6. Develop a retro-esophageal window—taking care not to injure the posterior vagus nerve.
7. Crural repair in all cases—using a 2-0 braided nonabsorbable suture.
8. Fundal wrap—formed around an intraesophageal stent (size dependent on the size of the patient).
  - (a) 1.5–3 cm in length and consist of 2–3 sutures going from stomach, to the anterior wall of the esophagus, to the retro-esophageal portion of the stomach.

---

<sup>3</sup>Rudolf Nissen (1896–1981)—German surgeon who also worked in Turkey and the USA, and ultimately in Basel, Switzerland.



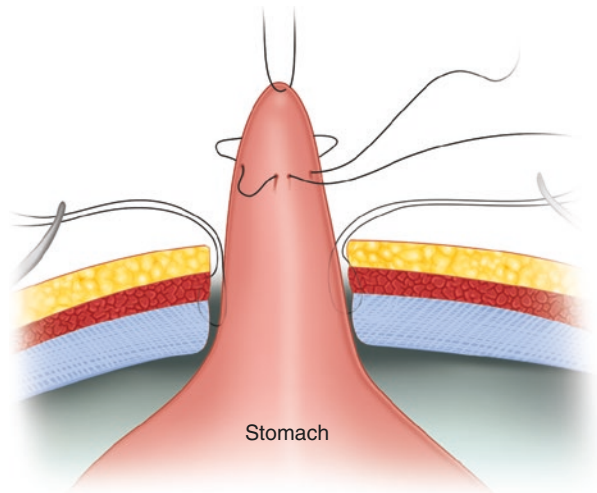
**Fig. 61.1** Trocar position for a laparoscopic Nissen fundoplication



- (b) The anterior portion of the wrap should lie at the 11 o'clock position to prevent tension or torsion of the esophagus, decreasing the incidence of dysphagia. The first stitch can also include the anterior diaphragmatic rim and some surgeons choose to place multiple collar stitches between the wrap and crus.
9. Gastrostomy button (optional—if the patient is a poor eater or has primary aspiration).
- (a) In infants and smaller children, this is most easily accomplished by bringing the stomach up through the LUQ trocar site. The button is secured with a purse-string suture and the stomach is tacked to the anterior abdominal fascia with two stay sutures, all placed through the trocar site (Fig. 61.2).
- (b) A Seldinger technique with a guidewire and dilators can also be used (alternative). This technique utilizes full-thickness sutures through the abdominal wall and the anterior gastric wall to temporarily secure the button.

If the patient undergoes a fundoplication alone, liquids are started immediately post-operatively and most are discharged on the first postoperative day. They are kept on a soft diet for approximately 1 week. In patients with gastrostomy buttons placed, feeds are started the next morning.

**Fig. 61.2** Siting a gastrostomy through working port



### 61.5 Malrotation and Ladd's<sup>4</sup> Procedure (See Chap. 19)

Malrotation can present as a partial proximal bowel obstruction, or in cases of volvulus, as a surgical emergency. Generally, the diagnosis of malrotation is made by upper GI contrast study, which shows an incomplete or abnormal C-loop. Once the diagnosis is made, the patient is explored. The duodenum is examined and an attempt is made to identify a normal ligament of Trietz.<sup>5</sup> If the ligament of Trietz is present but the cecum is not fixed, this is an incomplete rotation but not a malrotation, and no intervention is necessary.

If the diagnosis of malrotation is confirmed, the adhesions (Ladd's bands) overlying the malpositioned duodenum are divided. These are often draped over the duodenum extending to the right colon, causing external compression and partial obstruction. Once these bands are divided, the duodenum is mobilized and straightened so that it lies in the right gutter. The bowel is then run from proximal to distal, untwisting the bowel and dividing any congenital adhesions. During this process, the small bowel mesentery is widened. Once the colon is reached, it is positioned along the patient's left gutter and an appendectomy is performed. In infants, it is often easy to bring the appendix up through the umbilical incision and ligate and divide it extracorporeally.

More advanced laparoscopic procedures are beyond detailed description in this text. Procedures such as duodenal atresia repair, laparoscopic-assisted pull-through for Hirschsprung's, and laparoscopic repair of imperforate anus are all routinely performed at many institutions. Further descriptions of these procedures may be found in the sources listed at the end of this chapter.

<sup>4</sup>William Edwards Ladd (1880–1967)—American surgeon, widely regarded as the father of pediatric surgery in North America.

<sup>5</sup>Vaclav Wenzel Treitz (1819–1872)—Czech pathologist.

## 61.6 Thoracoscopic Procedures

### 61.6.1 Empyema

Previously, empyema has been treated with antibiotics, prolonged chest tube drainage, and, if this failed, open thoracotomy for debridement. The minimal morbidity associated with thoracoscopy makes it ideal for the early treatment of empyema in children resulting in much shorter hospitalizations and a quicker resolution of respiratory symptoms. However, at most institutions, the treatment of empyema is now done with lytic therapy with tPA (tissue plasminogen activator—Alteplase™) or urokinase and a VATS (Video-Assisted ThoracoScopy) decortication is only performed if this fails. A brief description is given below although the frequency of doing this procedure has dropped dramatically.

### 61.6.2 Technique

1. Single lung ventilation.
  - (a) Mainstem intubation of the contralateral bronchus (typically)—helps keep the lung collapsed during the procedure as the peel and effusion are removed. If not tolerated, then a standard tracheal intubation is acceptable.
2. Lateral decubitus position with the affected side up.
  - (a) Effective support (axillary roll and appropriate protective padding secured with tape or straps). In an older child, support can be provided by a beanbag. The upper arm is extended upward and outward and secured in position. If the patient does not tolerate this position, because of persistent desaturation, they may be placed more supine.
  - (b) As the surgeon will need to access the entire chest cavity, he/she may stand on either side of the patient. The surgical assistant is usually positioned on the opposite side of the table to hold the camera. Two monitors are used with one placed on each side of the patient at the level of the patient's chest near the shoulders to allow unobstructed views by the surgeon and assistant.
  - (c) A Veress needle is placed just anterior to the mid-axillary line at approximately the fourth or fifth interspace after infiltrating the site with local anesthetic and making a small transverse incision. If there is an identified site on ultrasound or CT with a big fluid pocket close to one of the proposed port sites, this should be chosen as the point of entry. Insufflation with low-flow CO<sub>2</sub> to a pressure of 4–5 mmHg may help collapse the lung and improve visualization as the fibrinous adhesions are taken down. A 5-mm trocar is then placed and the 30° scope is introduced. The endoscope may be used initially to take down adhesions and break up loculations and allow for the placement of the second trocar under thoracoscopic vision.

- (d) Second 5-mm port is placed posteriorly and inferiorly at approximately the sixth interspace along the posterior axillary line.
- (e) A suction-irrigator is introduced to aspirate the free pleural fluid and further break down loculations with blunt dissection. A sample of the fluid can be collected at this time. Grasping forceps or a bowel clamp can then be used to peel off and remove the fibrinous debris through the trocar. The scope and operating instrument can be interchanged from one port site to another to ensure that all of the pleural surfaces are reached.
- (f) Once the lung has been completely freed, the entire pleural fluid is drained, and most of the fibrinous peels are removed, the thoracic cavity is irrigated with warm normal saline that is subsequently aspirated out. The lung is allowed to expand fully with the help of positive pressure breaths from the anesthetist. Once full expansion is confirmed, the lower trocar is removed and a chest tube, appropriate to the child's size, is placed and positioned posteroinferiorly under thoracoscopic vision. The scope and remaining trocar are removed.
- (g) Port sites closed in two layers.

The chest tube is attached to a pleural drainage system (e.g., PleurEvac®—*Teleflex*) (initially at  $-10$  to  $-20$  cm H<sub>2</sub>O pressure).

Once drainage becomes minimal, there is no evidence of an air leak, and the child is improving; the chest tube can be removed, usually after a trial of underwater seal. The patient is usually discharged on antibiotics, after he/she has been afebrile for 48 h.

---

## 61.7 Esophageal Atresia Repair (See Chap. 14)

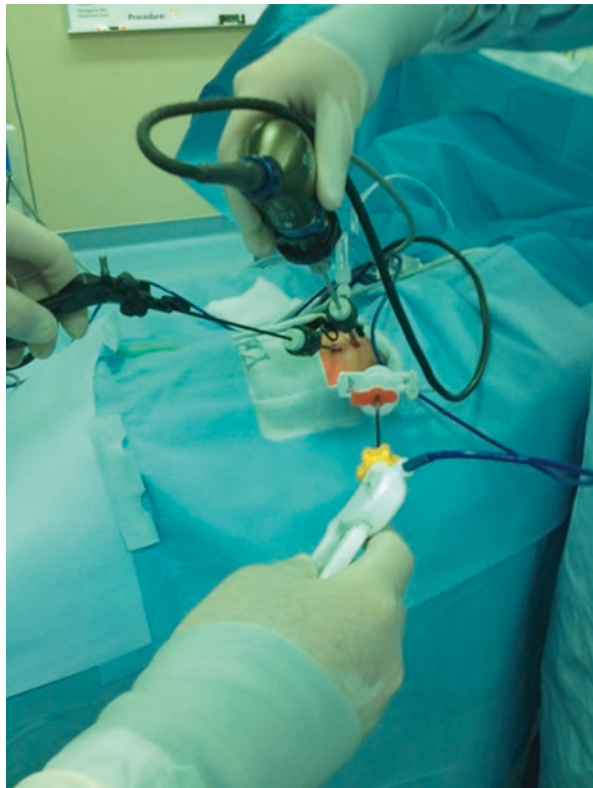In 2000, the first successful repair of an esophageal atresia (EA) with tracheoesophageal fistula (TEF) in a newborn using a completely thoracoscopic approach was performed, and the operation has now become the standard in many major pediatric centers across the world. The greatest advantage of this technique is the avoidance of the major morbidity associated with a formal thoracotomy in a neonate.

### 61.7.1 Technique

Endotracheal anesthesia with low-peak pressures is used until the fistula is ligated to prevent overdistension of the abdomen. Initially, attempts were made to obtain a left mainstem intubation; however, this can be difficult and time-consuming in a compromised newborn. We now perform the procedure with just a standard tracheal intubation, as excellent right lung collapse in newborns can be achieved with CO<sub>2</sub> insufflation alone. Wasting even minutes trying to place a bronchial blocker or other manipulations can compromise the eventual success of a thoracoscopic approach.

1. Modified prone position with the right side elevated approximately 30–45°. If there is a right-sided arch, then the approach is left sided.
  - (a) This positioning gives the surgeon access to the area between the anterior and posterior axillary line for trocar placement while allowing gravity to retract the lung away from the posterior mediastinum. This arrangement gives excellent exposure of the fistula and esophageal segments without the need for an extra trocar for a lung retractor.
2. The surgeon and the assistant stand at the patient's front and the monitor is placed at the patient's back. Because fine manipulation is necessary, the surgeon and the assistant should position themselves so that they are in the most ergonomic and comfortable position.
3. *Three-port technique*
  - (a) The initial camera port (3–5 mm) is placed in the fifth intercostal space just posterior to the tip of the scapula. A 4-mm 30° lens is used to allow the surgeon to “look down” on his instruments and avoid “dueling” (Fig. 61.3).
  - (b) Two instrument ports are placed. The first in the mid-axillary line 1–2 interspaces above the camera port. This port is 5 mm to allow for the clip applicator and suture unless the patient is under 2 kg, in which case the fistula is suture

**Fig. 61.3** Infant and trocar position for the repair of esophageal atresia



ligated. Lower port is 3 mm in size and is placed 1–2 inner spaces below and slightly posterior to the camera port. Ideally, these ports are placed so that the instrument tips will approximate a right angle ( $90^\circ$ ) at the level of the fistula. This positioning will facilitate suturing the anastomosis.

- (c) Once the chest has been insufflated and the lung collapsed, the surgeon must identify the fistula. In most cases, the fistula is attached to the membranous portion of the trachea just above the carina. This level is usually demarcated by the azygous vein.
- (d) Azygous vein mobilization using a curved dissector or 3 mm vessel sealer and sharp division is the safest way to manage the vein. Ties or clips are generally not necessary and could interfere with the dissection of the fistula. Some advocate preserving the azygous stating that it decreases the stricture and leak rate although there is little data to support this.
- (e) With the vein divided, the lower esophageal segment is identified and followed proximally to the fistula. Because of the magnification afforded by the thoracoscopic approach, it is easy to visualize exactly where the fistula enters the back wall of the trachea.
- (f) Clip the TEF using a 5-mm endoscopic clip. Care should be taken to avoid the vagus nerve. The fistula is divided with scissors. As the distal segment may retract making it difficult to visualize, it may be preferable to wait until the upper pouch is dissected out before completely dividing the fistula. Alternatively, the fistula can also be suture ligated. In general, we prefer a 4-0 PDS suture for this technique.
- (g) Attention is now turned to the thoracic inlet. The anesthesiologist places pressure on the nasogastric tube to help identify the upper pouch.
- (h) Identify the upper pouch by incising the pleura and mobilizing with blunt and sharp dissection. The plane between the esophagus and trachea can be seen well and the two should be separated by dissection with the 3-mm vessel sealer or with sharp dissection. Monopolar cautery should be avoided in this area to avoid injury to the membranous trachea and recurrent laryngeal nerve. Mobilization of the upper pouch is carried on up into the thoracic inlet as far as necessary to gain adequate length. Once adequate mobilization is achieved, the distal tip of the pouch is resected with a generous enough opening to prevent later stricture formation.
- (i) An anastomosis is performed using 4-0 or 5-0 monofilament absorbable suture on a small taper needle in an interrupted fashion.
  - (i) The back wall is placed first with the knots intraluminal.
  - (ii) Pass a nasogastric tube into the lower pouch and into the stomach.
  - (iii) The anterior wall is then completed with the NG tube acting as a stent to prevent the incorporation of the posterior wall and ensure patency of the anastomosis. Adequate bites should be placed to prevent the sutures from tearing out and, just as in the open procedure, it is important to get mucosa with all bites.

- (iv) On completion of the anastomosis, the NG is removed as a trans-anastomotic tube has been shown to be associated with a higher stricture rate. A chest tube can be left if desired but is also not necessary in most cases. The other ports are removed and the sites are closed with absorbable suture.

Generally, the patient is left NPO for 4–5 days at which time an esophagogram is obtained to check for any leak. If none are found, oral feeds are started and the chest tube is removed.

Thoroscopic procedures including mediastinal mass resections, lobectomies, wedge resections, and lung biopsies are all being performed successfully in the pediatric population. These procedures are described in greater detail in the sources listed in the suggested readings.

---

## Further Reading

- Avansino JR, Goldman B, Sawin RS, Flum DR. Primary operative versus non-operative therapy for pediatric empyema: a meta-analysis. *Pediatrics*. 2005;115:1652–9.
- Bax NM, Van der Zee DC. Laparoscopic treatment of intestinal malrotation in children. *Surg Endosc*. 1998;12:1314–6.
- Bax K, Georgeson KE, Rothenberg SS, Valla JS, Yeung CK, editors. *Endoscopic surgery in infants and children*. Berlin: Springer; 2008.
- Fraga JC, Rothenberg SS KE, Pierro A. Video-assisted thoracic surgery resection for pediatric mediastinal neurogenic tumors. *J Pediatr Surg*. 2012;47:1349–53.
- Georgeson KE, Jona JZ, Rothenberg SS, et al. Primary laparoscopic assisted endorectal colon pull-through for Hirschsprung’s disease—a new gold standard. *Ann Surg*. 1999;229:678–83.
- Georgeson KE, Inge TA, Albanese C. Laparoscopically assisted anorectal pull-through for high imperforate anus—a new technique. *J Pediatr Surg*. 2000;35:927–30.
- Holcomb GW, Rothenberg SS, editors. *Atlas of pediatric laparoscopy and thoracoscopy*. Amsterdam: Elsevier; 2020.
- Kay S, Yoder S, Rothenberg S (2009) Laparoscopic duodenoduodenostomy in the neonate. *J Pediatr Surg*. 2009;44:906–8.
- Levitt MA, Rothenberg SS, Tantoco JG, et al. Complication avoidance in miniature access pyloromyotomy. *Pediatr Endosc Innov Tech*. 2003;7:291–6.
- Rothenberg SS. Two decades experience with Laparoscopic Nissen Fundoplication in infants and children; A critical evaluation of indications, technique, and results. *J Laparoendosc Adv Surg Tech*. 2013;23:791–4.
- Rothenberg SS. Thoroscopic repair of esophageal atresia and tracheo-esophageal fistula in neonates: The current state of the art. *Pediatr Surg Int*. 2014;30:979–85.
- Rothenberg SS, Bealer J, Chang J. Primary laparoscopic gastrostomy button for feeding tubes. *Surg Endosc*. 1999;13:995–7.
- Rothenberg SS, Middlesworth W, Kadenne-Chiweshe A, Aspelund G, et al. Two decades of experience with thoroscopic lobectomy in infants and children: standardizing techniques for advanced thoroscopic surgery. *J Laparoendosc Adv Surg Tech*. 2015;25:423–8.
- Slater BJ, Rothenberg SS. The management of patent ductus arteriosus and vascular rings in infants and children. *J Laparoendosc Adv Surg Tech*. 2016;26:66–9.



Ramnik V. Patel, Joseph I. Curry, Chandrasen K. Sinha,  
and Mark Davenport

There is a fundamental conceptual division between *hemangiomas* and *vascular malformations*—the former being proliferating tumors and the latter developmental errors.

## 62.1 Pathology

### Infantile Hemangiomas

1. Mutation in a primitive stem cell is responsible for developing blood vessels.
2. Hemangioma is a model of pure, unopposed angiogenesis with a common expression of immunohistochemical markers including *glut-1*, *Fcy RII*, and *Lewis Y antigen*.
3. Possible derivation from or sharing a common precursor with placenta.
4. Angiogenic peptides.
  - (a) Proliferating phase—expression of vascular endothelial growth factor (VEGF), basic fibroblast growth factor (bFGF), and type IV collagenase.
  - (b) Involution phase—tissue inhibitor of metalloproteinases (TIMP-I) and mast cell-secreted modulators.

---

R. V. Patel (✉)

Memorial Sloan Kettering Cancer Center, New York, USA  
e-mail: [ramnik@doctors.org.uk](mailto:ramnik@doctors.org.uk)

J. I. Curry

Great Ormond Street Children Hospital, London, UK  
e-mail: [joecurry@doctors.org.uk](mailto:joecurry@doctors.org.uk)

C. K. Sinha

St George's Hospital, London, UK

M. Davenport

King's College Hospital, London, UK

© Springer Nature Switzerland AG 2022

C. K. Sinha, M. Davenport (eds.), *Handbook of Pediatric Surgery*,  
[https://doi.org/10.1007/978-3-030-84467-7\\_62](https://doi.org/10.1007/978-3-030-84467-7_62)



*Vascular malformations* are usually sporadic but can also be inherited in a family as an autosomal dominant trait. They are a manifestation of many different genetic syndromes that have a variety of inheritance patterns and chances for reoccurrence, depending on the specific syndrome.

## 62.2 Hemangioma Versus Vascular Malformation

Hemangiomas and vascular malformations may have nothing in common pathologically *except* a somewhat similar appearance. Vascular anomalies manifest with a very wide clinical spectrum of lesions ranging from small skin discoloration to very large life-threatening conditions.

Table 62.1 illustrates key clinical differences between these entities though in practice there can be difficulties in their separation (e.g., liver hemangiomas/vascular anomalies).

**Table 62.1** Biological classification

| Criteria            | Hemangioma   | Vascular malformations   |
|---------------------|--|--|
| Age, Sex            | Only occurs in infants, F: M: 5:1  | All ages, both sexes   |
| Incidence           | Most common benign tumor of infancy of proliferative endothelium with cellular hyperplasia | Localized defects of vascular morphogenesis of lymphatic, capillary, venous, arterial channels, or combined                            |
| Appearance          | Variety raised, flat, smooth, bosselated, superficial, deep-blue subcutaneous              | Thin and deep, diffuse, focal, or fruit-like appearance. Infiltrative and destructive  |
| Timing              | Not visible at birth, appear at 1–2 weeks  | Usually visible and present at birth   |
| Growth              | Rapid for 0–9 months, stop growing between 6 and 18 months, GLUT-1 +ve                     | Most grow slowly after birth or sudden onset and slow/intermittent growth  |
| Involution          | Essentially all, slow may take up to 10 years, often with a cosmetic deformity             | Essentially none, usually grow with an individual with growth spurts   |
| Involuted stage     | Permanent final residue  | Permanent malformations  |
| Locations           | 80% in Head and Neck, outside/inside body—e.g., brain, liver, intestine                    | Can be in the brain, liver, intestines, spine, stomach, or organs  |
| Complications       | Ulceration, infection, bleeding  | Bleeding   |
| Characteristics     | Stay same when sick, feels spongy, warm, compressible, rapid refill, pulsatile, bruit      | Lymphatic swell/shrink with respiratory illness. Venous fill when dependent, arterio-venous have a pulse when pressed. Transilluminate |
| Treatment           | Straight forward and conservative  | Complex, multidisciplinary modality  |
| Referral            | Problematic complicated ones   | Most cases need early referral   |
| Intervention timing | Early intervention is recommended but not always necessary                                 | Early intervention is recommended to minimize the extent of surgery  |

**Table 62.1** (continued)

| Criteria   | Hemangioma  | Vascular malformations   |
|--|---|--|
| Steroid therapy  | Systemic/intralesional lead to faster regression in 1/3, stabilization in 1/3, and no response in 1/3   | Responses, at best, are limited to occasional case reports                         |
| Propranolol  | Rapid involution 2–3 mg/kg in 2–3 divided doses per day   | No response, side effects of hypoglycemia, GORD, asthma, and bradycardia           |
| Angiogenesis inhibitor therapy (Alpha interferon, VCR) | It induces involution in almost all. Reserved for lesions that pose a threat to life, vital functions, or tissue due to its serious potential toxicity in infants | Essentially none   |
| Laser therapy  | Some respond to laser   | Some respond to laser  |
| Sclerotherapy  | Not indicated   | Intralesional for venous/lymphatic lesions-ethanol, OK432, Bleomycin, Tetracycline |
| Embolization   | In complicated large lesions, internal  | For arterial malformations   |
| Surgical therapy                                       | For residual lesion, complications  | Excision, contouring, or debulking   |
| Prognosis  | Generally good  | Variable depends on the type   |

## 62.3 Specific Examples (Table 62.2)

### 62.3.1 Kasabach-Merritt Syndrome<sup>1</sup>

Characterized by the combination of a rapidly growing vascular tumor, thrombocytopenia, microangiopathic hemolytic anemia and consumptive coagulopathy. The blood clotting disorder results from platelets and other clotting factors from the blood being “used up” within the tumor. Seen in extremities and some viscera (e.g., liver). There is a high mortality rate in untreated cases. Treatment may be a combination of surgical excision, interferon, systemic corticosteroids.

### 62.3.2 Klippel-Trenaunay Syndrome (KTS)<sup>2</sup>

Characterized by soft tissue hypertrophy and bony overgrowth of the extremity (usually single and lower limb) with PWS. Overgrowth is not present at birth and significant limb length discrepancy is possible later with prominent hypertrophy of

<sup>1</sup>Haig Kasabach (1898–1943) & Katherine Merritt (1886–1986)—American pediatricians described in 1940.

<sup>2</sup>Maurice Klippel (1858–1942), Paul Trénaunay (1875–?). Parisian physicians described case in 1900.

**Table 62.2** Summary of clinical features

| <b>Hemangiomas</b>  | <b>Vascular malformations</b>  |
|---|--|
| <ul style="list-style-type: none"> <li>• <b>Infantile hemangiomas</b></li> <li>• Congenital Hemangiomas               <ul style="list-style-type: none"> <li>– <i>Rapidly involuting CH-RICH</i></li> <li>– <i>Non-involuting CH-NICH</i></li> </ul> </li> <li>• Tumors producing KMP</li> <li>• Tufted angiomas               <ul style="list-style-type: none"> <li>– Kaposiform hemangioendothelioma</li> </ul> </li> <li>• Angiosarcoma</li> </ul>  | <ul style="list-style-type: none"> <li>• <i>High-Flow Lesions</i></li> <li><b>Arteriovenous malformations (AVM)</b></li> <li><b>Arteriovenous fistulas (AVF)</b></li> <li>• <i>Low-Flow Lesions</i></li> <li>Lymphatic malformations (LM)</li> <li>Capillary malformations (Port-wine stain)</li> <li>Venous malformations</li> <li>Combined malformations (LVM)</li> </ul>  |
| <b>Combined rare syndromes</b><br><i>Diffuse neonatal Hemangiomatosis</i><br>Multiple, small, dome-shaped, cutaneous lesions. May be associated with visceral lesions in liver, gastrointestinal tract, and CNS<br>High-output cardiac failure, hemorrhage, obstructive jaundice, and coagulopathy<br>Involution of cutaneous and visceral lesions by age 2 years<br><i>Kasabach-Merritt Syndrome</i> (see text)<br><i>PHACE(S) syndrome</i><br>Posterior fossa CNS malformations (Dandy-Walker), Hemangioma, Arterial anomalies, Cardiac anomalies, Eye anomalies, and (Sternal defects), lumbosacral lesions, spinal anomalies, genitourinary anomalies | <b>Combined rare syndromes</b><br><i>Klippel-Trenaunay Syndrome (KTS)</i> (see text)<br><i>Sturge-Weber syndrome (SWS)</i><br>Facial port-wine stain [V1 trigeminal sensory region must be involved]<br>CNS involvement—seizures, mental retardation, “railroad track” calcifications on cortex—ophthalmologic, ipsilateral choroidal angiomatosis<br>Glaucoma [can be seen with V2 lesions involving eyelid]<br><i>Parkes Weber Syndrome (PWS)</i> (see text)<br><i>Proteus Syndrome</i><br>PWS, partial gigantism, macrocephaly, epidermal nevi  |
| <b>Rare lesions</b><br><i>Sinus Pericranii</i><br><i>Glomovenous malformation</i><br><i>Banayan Riley Rubalcava Syndrome</i><br><i>CMTC</i> —Cutis marmorata telangiectatica congenita: rare disorder identified by marbled (cutis marmorata) patches of skin caused by widened (dilated) surface blood vessels (livedo reticularis telangiectases)<br><i>Multifocal Lymphangioendotheliomatosis with Thrombocytopenia</i><br><i>Hyperkeratotic cutaneous capillary-venous malformation</i>   | <i>Maffucci Syndrome</i> : Venous malformations, enchondromas on distal extremities<br><i>Blue-Rubber Bleb Nevus Syndrome</i> : Venous malformations of skin and GI tract—compressible, painful lesions—GI hemorrhage are a common cause of death<br><i>Gorham’s syndrome</i> : Venous and lymphatic malformations involving skin and skeleton—osteolytic bone disease<br><i>Bannayan-Zonana syndrome</i> : Subcutaneous/visceral venous malformation, lipomas, and macrocephaly<br><i>Cobb Syndrome</i> : Spinal cord vascular birthmarks or lesions—venous malformations of the spinal cord, truncal PWS<br><i>Wyburn-Mason syndrome</i> : Retinal and CNS AVMs, facial PWS<br><i>Riley-Smith syndrome</i> : Cutaneous venous malformation, macrocephaly |

the foot and toes. No CNS or visceral anomalies, Treatment: premature epiphyseal closure of longer leg, Surgical debulking not usually feasible.

### 62.3.3 Parkes Weber Syndrome (PWS)<sup>3</sup>

Similar to KTS except that an arteriovenous malformation (AVM) occurs in association with a cutaneous capillary malformation and skeletal or soft tissue hypertrophy.

### 62.3.4 Sturge-Weber Syndrome (SWS)<sup>4</sup>

Facial port-wine stain in the region of the trigeminal cranial nerve. V1 lesions—may cause seizures, mental retardation. Look for “railroad track” calcifications and eye lesions (ipsilateral choroidal angiomatosis, glaucoma can be seen with V2 lesions involving eyelid).

---

## 62.4 Investigations

Most vascular birthmarks can be diagnosed clinically without imaging studies/biopsy.

- *Laboratory*—FBC, C-RP, coagulation parameters, genetic studies.
- *Imaging*
  - Ultrasonography and Doppler US examinations are the best initially.
- *MR scan*—usually needed in most symptomatic patients to confirm the suspected diagnosis and to evaluate the extent of the lesion (hemangioma, arteriovenous malformation or AVM, venous malformation, lymphatic malformation, cystic hygroma, etc.). In addition to making the diagnosis, MRI plays a major role in decision-making regarding how these lesions need to be treated surgery *versus* embolization/sclerotherapy.
- *Magnetic Resonance Angiography (MRA) and Magnetic Resonance Venography (MRV)* can supply additional information on vascularity.
- *CT scan and X-ray* (phleboliths, calcification) imaging have a limited role in vascular anomalies/birthmarks. On the other hand, new multi-detector CT scanners may be used.
- *CT angiography* in selected patients, particularly in patients with high flow vascular birthmarks (AVM, hemangioma, arteriovenous fistula).
- *Biopsy*: Rarely if malignancy cannot be excluded, e. g., infantile fibrosarcoma, teratoma, siloblastoma, and plexiform neurofibromatosis

---

<sup>3</sup>Frederick Parkes Weber (1863–1962). English physician, added to original description in 1907.

<sup>4</sup>William Allen Sturge (1850–1919). English physician.

## 62.5 Treatment

Treatment for hemangiomas depends upon their size, location, and severity.

- *Conservative treatment* is usually recommended for small, noninvasive hemangiomas, since they will become smaller (involute) on their own. However, hemangiomas that cause bleeding problems, feeding or breathing difficulties, growth disturbances, or impairment of vision may require multimodality treatment.

Options include the following:

- *Medical Treatment*
  - *Steroid therapy*: Topical, intralesional triamcinolone, or systemic oral steroids. For example, prednisolone 3, 2.5, 1.2, 0.6, 0.3 mg/kg from week 1–5 and maybe repeated up to 6–12 months. Rebound is well known.
  - *Propranolol*: 2–3 mg/kg 2–3 times a day but has side effects of hypoglycemia, sleepiness, GORD worsening, irritable airways and bradycardia need monitoring.
  - *Antiangiogenic drugs and immunomodulation* in selected cases.
- *Laser therapy*
  - *CT/Fluoroscopy guided*—different lasers can be used for treatment.
  - *Nd:YAG laser photocoagulation*—particularly effective because of its deep penetration into tissue.
- *Interventional radiology*—embolization of the blood vessels in internal lesions.
- *Surgical removal*—large and/or life-threatening lesions after evaluation by a multidisciplinary team of specialists.

Treatment for vascular malformations depends upon the type of malformation. Each type of malformation is treated differently; the importance of obtaining a correct diagnosis is extremely important and often difficult. Most often, a combination of these various treatments is used for effective management of the lesion.

- *Laser surgery*
  - Usually effective for capillary malformations or port wine stains, which tend to be flat, violet, or red patches on the face.
- *Sclerotherapy*
  - Venous malformations are usually treated by direct injection of a sclerosing medication, which causes clotting of the channels. Sclerosing agents may include: ethanol (alcohol), Sodium Tetradecyl Sulfate (STD—Sotradesol™), doxycycline, and OK 432.
- *Embolization*
  - Arterial malformations—blood flow into malformation is blocked by injecting material near the lesion. Embolization is the procedure in which abnormal vessels that are doing more harm than good are closed off with various

substances (e.g., alcohol, glue, and coil). Various materials may be used, depending on whether vessel occlusion is to be temporary or permanent, or whether large or small vessels are being treated.

- *Surgical removal of the lesion*
  - For cosmetic/functional or complications.

---

## 62.6 Complications

Several complications have been described including alarming hemangioma involving vital/important structures: eye, larynx, ear, and distal extremities. DIC and coagulopathy with platelet trapping can occur. Cosmetically sensitive regions are nose, lip, eye, and ear might need early intervention. Usual complications include bleeding, infection, ulceration, calcification (microthrombi), thrombosis with rapidly growing lesions, hypopigmentation, and the residual lesions. Each modality of treatment has its own complications as well.

---

## Further Reading

- Dasgupta R, Fishman SJ. ISSVA classification. *Semin Pediatr Surg.* 2014;23:158–61. <https://doi.org/10.1053/j.sempedsurg.2014.06.016>.
- Garzon MC, Weitz N, Powell J. Vascular anomalies: differential diagnosis and mimickers. *Semin Cutan Med Surg.* 2016;35:170–6. <https://doi.org/10.12788/j.sder.2016.052>.
- Gupta A, Verma A, Dhua A, Bhatnagar V. Vascular anomalies: a pediatric surgeon's perspective. *Indian J Pediatr.* 2017;84:612–7. <https://doi.org/10.1007/s12098-017-2355-8>.
- Mulliken JB, Fishman SJ, Burrows PE. Vascular anomalies. *Curr Probl Surg.* 2000;37:517–84.



Chandrasen K. Sinha, A. Saeed, and Mark Davenport

### 63.1 Tongue-Tie (Ankyloglossia)

This may be defined as a congenital anomaly in which a short lingual frenulum or a tight genioglossus muscle restricts tongue movement. It may interfere with breastfeeding and tooth development and (disputed) speech development.

- Male > female (2:1)
- Usually *sporadic*, but some genetic link has been mentioned in the literature (X-linked mutation of T box transcription factor TBX22) with or without the association of cleft lip/palate.
- *Posterior tongue-tie*
  - Thickened submucosal base of perhaps normal-looking frenulum from posterior to middle part of the tongue. In some cases, it can restrict the tongue movement.
- *Upper lip tie*
  - Rarely a cause of breastfeeding problems from ineffective latching due to inadequate eversion of the upper lip and release of these upper lip tie may be helpful in these cases.

---

C. K. Sinha  
St George's Hospital, London, UK

A. Saeed  
St George's University Hospital, London, UK  
e-mail: [atif.saeed1@nhs.net](mailto:atif.saeed1@nhs.net)

M. Davenport (✉)  
King's College Hospital, London, UK

### 63.1.1 Clinical Features

Tongue-tie is mostly asymptomatic but the best-defined consequence is difficulty with breastfeeding causing poor latch, insufficient and pronged feeding, and maternal nipple pain. It may lead to failure to thrive. Most infants with tongue-tie actually can breastfeed without difficulty.

Articulation problem of speech due to restricted tongue movement has been seen in some toddlers and young children. Speech sounds that may be affected include “t,” “d,” “z,” “s,” “th,” “n,” “l” (sibilants and lingual sounds). Involvement of a speech therapist is also important in the management process along with the release of tongue-tie. An actual delay in acquisition of speech is not caused by tongue-tie and other possible diagnoses should be sought.

Protrusion of the tongue causes its tip to become notched and not extend past the incisors or touch the roof of the mouth. In severe cases, the tongue is completely immobile and fixed.

Difficulty to maintain oral hygiene may cause periodontal disease due to lack of sweeping food debris from the teeth, and licking of lips.

Cosmetic and social problems like difficulty in kissing, playing a wind instrument, or licking an ice cream in public could be an embarrassing problem for these patients.

### 63.1.2 Management

The natural history of tongue-tie is unknown. Spontaneous elongation or natural release with time is postulated.

Assessment and management by breastfeeding counsellor/midwife are imperative before surgical referral. Frenotomy can be considered (without anesthetic) as curative by surgeon or the aforementioned. After infancy, it is judicious to wait for a reason (e.g., speech therapy defined problem) rather than preempt matters.

Division of frenulum is straightforward but should avoid the submandibular ducts on either side.

---

## 63.2 Umbilical Issues

*The umbilicus is the last link with fetal life and is the site of many peculiar embryonic vestiges.*

### 63.2.1 Embryology and Anatomy

Vascular connection to the placenta is maintained by a single large umbilical vein (to the porta hepatis) at 12 o'clock and two inferior umbilical arteries from the internal



iliac arteries at 5 and 7 o'clock. At birth, these structures close and obliterate but leave a potential space through the umbilical ring, which also has to close by a cicatrizing process. Failure to achieve this leads to the development of *umbilical herniation*.

Two further structures may lead to vestigial-related problems:

- *Vitello-intestinal duct*
  - Communication from the apex of the midgut to the yolk sac of embryonic life. It should vanish, but remnants may include a *Meckel's diverticulum*, a fibrous connection to the underside of umbilicus, or a completely patent duct.
- *Urachus*
  - Connection between the apex of bladder and allantois.<sup>1</sup>

### 63.2.2 Umbilical Hernia

- Prevalence is greatly increased in Afro-Caribbean ethnicity (particularly of West African origin) than those of Caucasian/Asian background.
- Low birth weight.
- M = F.
- Spontaneous closure is less likely if the defect is >1.5 cm.
- 13% (vs. 2%) at 1 year of age (USA study).

#### 63.2.2.1 Associations

- Congenital hypothyroidism (defective cicatrization)
  - May be associated with constipation
- ↑ Intra-abdominal fluid
  - For example, ascites and VP shunts
- Beckwith-Wiedemann syndrome, mucopolysaccharidoses
- Trisomy 21, Trisomy 18

#### 63.2.2.2 Clinical Features

These are mostly asymptomatic but in very rare cases it can cause feeding problems in young infants and seems to be related to the intestinal protrusion through the hernial ring.

Umbilical herniation is unique among hernias in that it may spontaneously reduce and close over time. There is a low risk (<3%) of irreducibility and intestinal obstruction. Incarceration if happens is more common in smaller defects.

#### 63.2.2.3 Management

As most hernias will close spontaneously, surgical closure should be considered in:

- Large defects (usually above 1.5 cm) at age 3–4 years.

---

<sup>1</sup>Allantois (Greek—sausage)—is a diverticulum of cloaca within connecting stalk to placenta—main function in reptiles and birds (both lay eggs) is as a repository of nitrogenous waste.

- No decrease in the size of the defect during a year of observation.
- Children who develop symptoms.

Large trunk-like hernias without any perceptible decrease in defect size are unlikely to close spontaneously and usually need operation.

#### 63.2.2.4 Surgery

Sub-umbilical skin crease incision:

- Reduce contents and then dissect around the whole circumference of the neck of sac.
- Separate overlying skin from sac and then excise this back to the fascial ring.
- Repair defect (usually transverse), typically with absorbable suture.
- Umbilicoplasty.
  - Mostly the skin can be tacked back to the repair and the cavity obliterated by pressure. Sometimes, so much skin has left that excision of a triangle and “swirling” the subsequent suture line is a better form of cosmesis.

### 63.2.3 Umbilical swellings

- *Umbilical granuloma*
  - Commonest umbilical swelling in neonates presenting as a pink, moist swelling, usually pedunculated in nature. The size varies from 0.3 to 1 cm. It can be treated with 75% silver nitrate application (once or twice weekly for few weeks).
  - Ligation of base with a suture until it falls off. Before ligation, the possibility of umbilical polyp should be ruled out.
- *Umbilical polyp*
  - Are usually larger and less common than umbilical granulomas. It presents as a relatively firmer swelling. It comprises intestinal epithelium or uroepithelium. The treatment is excision.
- *Urachal remnants*
  - Involution is the norm but may remain as a fibrous cord between the umbilicus and dome of the urinary bladder. A persistent urachus can be complete causing urinary discharge from the umbilicus or incomplete persistence can cause cystic swelling at the umbilicus, bladder, or in the mid-duct.

Symptoms may include umbilical swelling, discharge, abdomen pain, infection, or incidental diagnosis in a US scan. US scan is usually diagnostic, and also rules out any associated renal tract problem. Treatment should be surgical excision supplemented by diagnostic. If not removed (as in asymptomatic cases), parents should be made aware of the potential (albeit low) risk of malignancy in the future.

## 63.3 Rectal Prolapse

Of the falling down of the Fundament  
Ambroise Pare (1634)

May be defined as a protrusion of all or some of the rectal wall through the anus, though there are more complicated classifications that include internal or occult prolapse.

### Types

- Type 1: Incomplete/partial/mucosal prolapse
  - Radial mucosal folds
- Type 2: Full-thickness rectal prolapse/procidentia<sup>2</sup>
  - Circumferential concentric mucosal folds

### Epidemiology

- Common during infancy
- ↑ Incidence in tropical latitudes

### Associations

- Increased abdominal pressure and straining
  - Chronic constipation is the usual precipitating factor.
  - Protracted coughing, excessive vomiting, toilet training.
- Acute diarrheal illness
- Cystic fibrosis
  - ~3% of children with CF, and occasionally its presenting feature. Consider CF screening for recurrent prolapse with failure to thrive.
- Pelvic floor neuromuscular weakness
  - Spina bifida, sacral agenesis
- Malnutrition
- Ehlers–Danlos syndrome

### 63.3.1 Clinical Features

Usually nontender, red mucosal mass protruding from the anus, initially only on straining. It may become irreducible and present all the time.

---

<sup>2</sup>*Procidentia ani*—(Latin) *prōcidere*—to fall forward.

### 63.3.2 Differential

- Intussusception—much more severe symptoms,  $\pm$  intestinal obstruction. Finger or probe can freely be passed around all circumferences between anus and intussusceptum.
- Prolapsed rectal polyp.

### 63.3.3 Investigations

- Exclude underlying conditions, which may be overt (spina bifida) or covert (cystic fibrosis).
- If diarrhea—stool microscopy, culture and sensitivities, and screening for ova, cysts, and parasites.
- Lower GI endoscopy—to exclude rectal polyps. There is usually little evidence of anything abnormal in prolapse.

### 63.3.4 Management

- Manual reduction with adequate sedation. Firm compression to reduce edema, then reduction of innermost mucosal lead-point first. Application of sucrose/sugar in very large and edematous prolapse decrease swelling and thus helps in reduction.
- Thereafter, most would advocate a simple conservative policy of treating the underlying condition (e.g., constipation/diarrhea) and avoidance of straining. Most children (<4 years) recover spontaneously.

Intervention is more likely to be needed in older children and those with neuromuscular etiology.

### 63.3.5 Surgery

- *Sclerotherapy*
  - For example, oily (5%) phenol, hypertonic saline, dextrose (50%) solution. May need multiple injections. Avoid anterior needle placement (prostate or vagina at risk). Success rate up to 85%.
- *Thiersch<sup>3</sup> operation*
  - –Circumferential (typically absorbable) suture.
- *Rectopexy*: Although many of them are described, e.g., (laparoscopic suture rectopexy, posterior sagittal rectopexy, prosthetic/mesh fixation) these are rarely performed in children and are usually reserved for complicated or recurrent prolapse in elderly women.

---

<sup>3</sup>Karl Thiersch (1822–1895)—German surgeon who also pioneered use of split-skin grafts.

---

## Further Reading

- Chan WK, Kay SM, Laberge JM, et al. Injection sclerotherapy in the treatment of rectal prolapse in infants and children. *J Pediatr Surg.* 1998;33:255–8.
- Hintz GC, Zou VZ, Baird R. Sclerotherapy for rectal prolapse in children. A systematic review and meta-analysis. *J Pediatr Surg.* 2019;54:1083.
- O’Shea JE, Foster JP, O’Donnell CPF, et al. Frenotomy for tongue-tie in newborn infants. *Cochrane Database Syst Rev.* 2017;2017(3):CD011065.
- Pomeranz A. Anomalies, abnormalities, and care of the umbilicus. *Pediatr Clin N Am.* 2004;51:819–27.
- Rentea RM, St Peter SD. Pediatric Rectal Prolapse. *Clin Colon Rectal Surg.* 2018;31:108–16.



Ashish Desai

*Bariatric surgery is now an accepted treatment for selected morbidly obese adolescents with significant comorbidities.*

*Surgery is known to be the most effective treatment for weight loss.*

## 64.1 Definitions

For postpubertal children, BMI is an accepted mode of measurement. However, in younger children, the BMI centile is considered a better tool.

- **Body mass index (BMI) = weight (kg) ÷ height<sup>2</sup> (m) (kg/m<sup>2</sup>)**
- Overweight (children) = BMI ≥ 91st centile for age or ≥25 kg/m<sup>2</sup>
- Obesity (children) = BMI ≥ 98th centile BMI for age or ≥30 kg/m<sup>2</sup>
- Severe Obesity (children) = BMI > 99th centile = BMI Z-score of +3.5 and compares with adult BMI of 40 kg/m<sup>2</sup>.

## 64.2 Prevalence of Childhood/Adolescent Obesity

Table 64.1 illustrates the change in proportions from Reception to 11 years of age.

It is known to be more prevalent in families from lower socioeconomic status and certain ethnic backgrounds like Afro-Caribbean and Bangladeshi families.

---

A. Desai (✉)  
Royal London Hospital, London, UK  
e-mail: [ashishdesai@nhs.net](mailto:ashishdesai@nhs.net)

**Table 64.1** Prevalence of obesity in childhood

| England 2011   | Reception year (%) | Aged 11 years (%) |
|----------------|--------------------|-------------------|
| Overweight     | 13                 | 14                |
| Obese          | 9                  | 20                |
| Severely obese | 2.4                | 4                 |

### 64.3 Clinical Features

The main complaint is of uncontrolled weight gain despite multiple lifestyle changes. Comorbidities are common and include psychosocial dysfunction, hypertension, obstructive sleep apnea, type II diabetes, metabolic syndrome, non-alcoholic steatohepatitis, gastroesophageal reflux disease (GORD), and weight-related arthropathies.

Exacerbation of chronic illnesses like asthma is commonly seen. Pseudo-tumor cerebri.

All patients should have anthropometric measurements including BMI and waist circumference as baseline.

### 64.4 Surgery

#### 64.4.1 Preoperative Management

All patients need a thorough assessment by a specialist multidisciplinary team.

- General pediatrician with a special interest in obesity. Additional expertise in diabetes and endocrinology will help in managing common comorbidities.
- Dietitian.
- Psychologist/ Psychiatrist.
- Pediatric Surgeon with experience in bariatric surgery or bariatric surgeon with interest in pediatric patients.

The hospital should have appropriate access to suitable types of equipment including scales, theater tables, Zimmer frames, commodes, hoists, bed frames, pressure-relieving mattresses, and seating suitable for patients undergoing bariatric surgery.

Bariatric surgery is recommended as a treatment option for adolescents with obesity if all of the following criteria are fulfilled:

- BMI  $\geq 40$  kg/m<sup>2</sup> or BMI  $\geq 35$  kg/m<sup>2</sup> + significant comorbidity that could be improved if only they lost weight.
- All appropriate nonsurgical measures have been tried but have failed to achieve or maintain adequate, clinically beneficial weight loss for at least 6 months.
- A person has been receiving or will receive intensive management in a specialist obesity service.
- Fit for anesthesia and surgery.

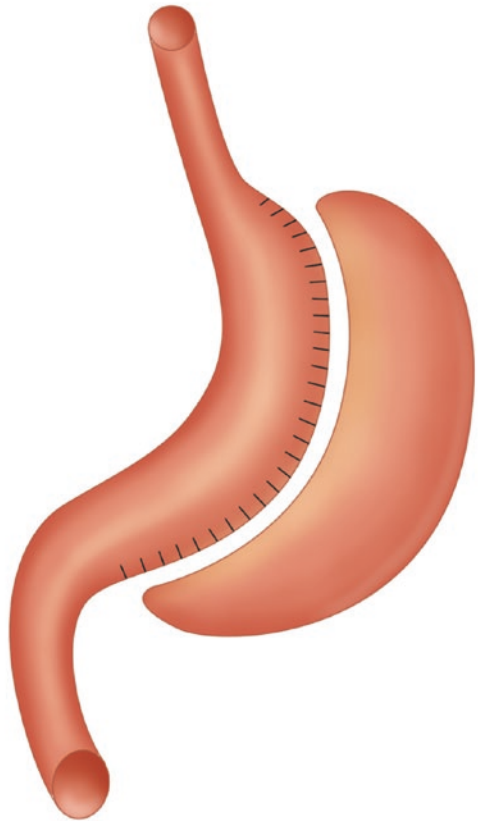
- Commits to the need for long-term follow-up.

### 64.4.2 Bariatric Operations

The commonest procedures are *Vertical Sleeve Gastrectomy (VSG)* and the *Roux-en-Y gastric bypass (RYGB)*. *Adjustable Gastric Banding (AGB)* was initially popular but is now offered by a few centers only. All procedures are performed laparoscopically.

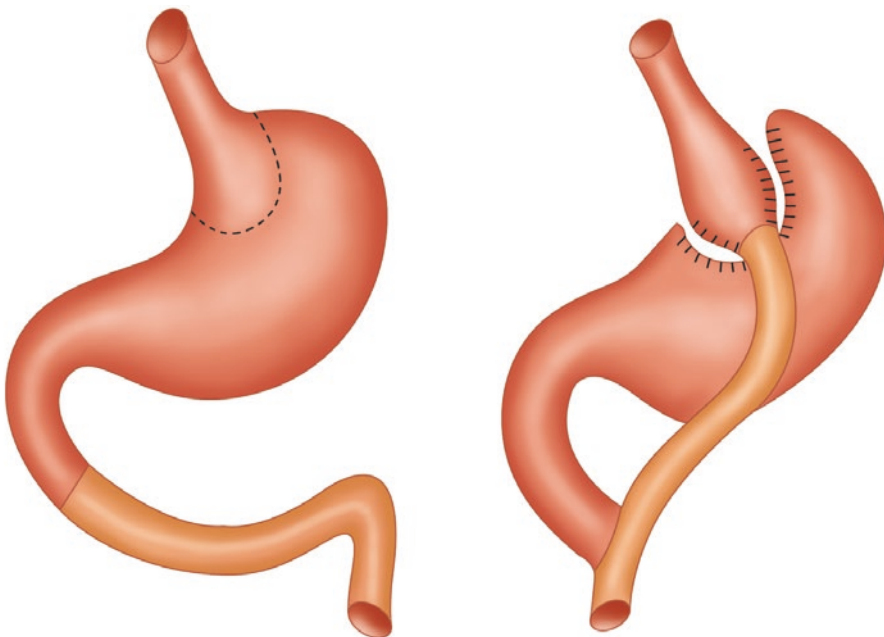
- *Vertical Sleeve Gastrectomy* (Fig. 64.1)
  - Stomach reduction is performed by creating a vertical tube from GOJ to pylorus along a lesser curve.
  - Almost 80% of the stomach is excised.

**Fig. 64.1** Sleeve gastrectomy

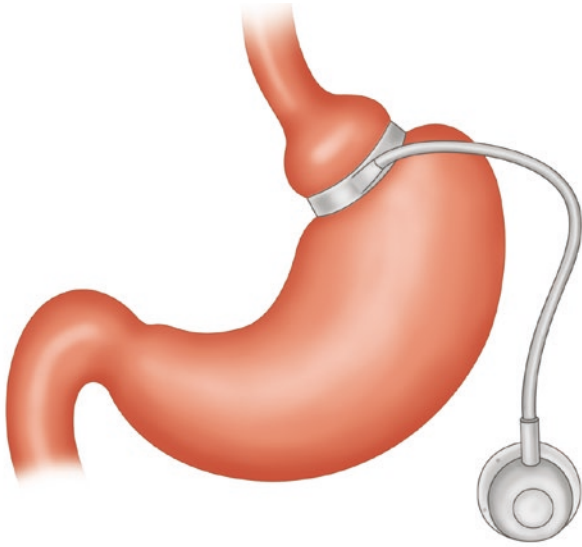



- It is now the commonest procedure performed in adolescents and adults.
  - Pros: Preservation of almost normal anatomy, no foreign body (Band).
  - Cons: Long suture line, weight loss, and comorbidity resolution are slightly less than RYGB and have the potential to cause GORD and Barrett’s esophagus.
- *Roux-en-Y gastric bypass (RYGB)* (Fig. 64.2)
  - “gold standard” procedure as it has the best available data in children.
  - It involves the creation of a small gastric pouch that is drained by a Roux-en-Y jejunal limb.
  - Very good weight loss and comorbidities resolution and it prevent GORD.
  - Surgery involves multiple anastomosis and has significantly increased chances of serious complications like internal hernia, Vit. B complex, and other micro-nutrient deficiency.
  - Known to cause dumping syndrome.
- *Adjusted gastric band (AGB)* (Fig. 64.3)
  - An adjustable band is placed around the stomach to create a small upper gastric pouch. A subcutaneous port allows adjustment of the band at subsequent clinic visits. It has the advantage of being a simple and easily reversible operation.
  - Known to have limited weight loss potential.
  - Known to cause frequent late complications like prolapse of the stomach through the band (15%) and erosion of the band into the stomach.



**Fig. 64.2** RYGBypass

**Fig. 64.3** Gastric band

---

## 64.5 Outcomes

- At 2 years
  - Excess weight loss after RYGB is around 70–75%
  - After LSG 50–60%
- Type 2 DM—remission in 95%
- Hypertension—remission in 75%
- Dyslipidemia—remission in 66%
- Significant improvement in quality of life in >95%

## Further Reading

Durkin N, Desai A. What is the evidence of paediatric/adolescent bariatric surgery? *Curr Obes Rep.* 2017;6:278–86.

Inge TH, Coley RY, Bazzano LA. Comparative effectiveness of bariatric procedures among adolescents: The PCORNET Bariatric Study. *Surg Obes Relat Dis.* 2018;14:1374–86.



# Airway Problems in Newborns and Children

# 65

Ana Bernic and Prince C. Modayil

## 65.1 Observations

- *Laryngomalacia*
  - Commonest cause of infant stridor. Only 5% enquire surgical intervention.
- *Vocal cord paralysis (VCP)*
  - Second most common cause of neonatal stridor. Fifty percent are bilateral, of which 50% are acquired and 50% require tracheostomy.
- *Subglottic stenosis*
  - Most common indication for neonatal tracheotomy
- *Laryngeal Clefts*
  - 0.3–0.5% of all congenital laryngeal anomalies
- *Subglottic hemangioma*
  - Represents 1.5% of all congenital laryngeal anomalies
- *Tracheomalacia*
  - Accounts for almost half of the congenital tracheal anomalies that present with stridor
- *Respiratory papillomatosis*
  - Most common laryngeal neoplasm in children. Diagnosis is most commonly made between the ages of 2 and 5 years.

## 65.2 Pathogenesis (Table 65.1)

There is a significant difference between infants, children, and adolescents due to anatomic differences of the airway that evolve with growth.

---

A. Bernic · P. C. Modayil (✉)

Department of Otorhinolaryngology, St George's University Hospital, London, UK

e-mail: [ana.bernic@nhs.net](mailto:ana.bernic@nhs.net)

**Table 65.1** Etiology of airway obstruction in infants and children

|                   | Congenital  | Infection   | Trauma   | Neoplasia   | Neurological  |
|-------------------|---|---|--|---|---|
| Supra-laryngeal   | Adenotonsillar hypertrophy,<br>Choanal atresia<br>Macroglossia<br>Retrognaethia<br>Ectopic thyroid<br>Craniofacial anomalies<br>Lymphatic malformations | Peritonsillar abscess<br>Retropharyngeal abscess        | Facial fractures<br>Foreign body   | Juvenile nasopharyngeal angiofibroma<br>Nasal tumors  | Cerebral palsy<br>Hydrocephalus<br>Myelomeningocele<br>Spina Bifida<br>Congenital Central Hypoventilation Syndrome (CCHS) |
| Laryngeal         | Laryngomalacia<br>Laryngeal web/Cyst<br>Laryngeal Cleft<br>Subglottic stenosis  | Epiglottitis (rare)<br>Laryngotracheobronchitis (croup) | Intubation trauma<br>External trauma<br>Foreign body<br>Burns (caustic and thermal)<br>Acquired<br>Subglottic stenosis | Respiratory papillomatosis<br>Subglottic haemangioma<br>Lymphatic malformations<br>Laryngeal sarcomas |   |
| Tracheo-bronchial | Tracheobronchomalacia<br>Vascular compression<br>Tracheoesophageal fistula  | Laryngotracheobronchitis<br>Bacterial tracheitis        | Foreign body   | External compression by thyroid/mediastinal tumors  |   |

- *Laryngomalacia*: immature, “floppy” laryngeal anatomy
- *Congenital laryngeal webs*: incomplete recanalization of the airway
- *Subglottic stenosis*—Prolonged/traumatic endotracheal intubation causes pressure necrosis of subglottic mucosa resulting in perichondritis-granulation-fibrosis.
- *Tracheomalacia*: low tone, reduced cartilaginous strength (intrinsic), external mass effect compression (vascular anomalies/mediastinal mass)
- *Choanal atresia*: persistence of the buco-nasal membrane or abnormal migration of neural crest cells
- *Laryngeal cleft*: due to the failed development of the tracheoesophageal septum
- *Tracheo-esophageal fistula*: failed re-cannulation or developmental failure (congenital), secondary to tracheostomy, long-term intubation, compression.
- *Subglottic hemangioma*: Vascular Endothelial Growth Factor (VEGF) appears to promote endothelial cell proliferation *in vitro*.
- *Obstructive sleep apnea*: upper airway obstruction due to adenotonsillar hypertrophy, pharyngeal hypotonia (Down’s syndrome, cerebral palsy) and obesity are the most common causes.
- *Respiratory papillomatosis*—Human Papillomavirus HPV 6 and 11 (more aggressive)

### 65.3 Clinical Features (Table 65.2)

This will depend on the severity and the level of the airway obstruction:

- *Bilateral Choanal atresia*:
  - Neonates are obligate nasal breathers during the first 6 weeks of life. This is associated with severe airway obstruction and cyanosis at birth. It will be impossible to pass nasal catheters.
- Nasopharyngeal obstruction will cause *stertor (snoring)*, often seen in obstructive sleep apnea.

#### 65.3.1 Stridor and Wheezing

There are three types of stridor:

**Table 65.2** Clinical presentation depending on the level of obstruction in the airway

| Level of the obstruction | Clinical presentation                                 |
|--------------------------|---|
| Nose and Nasopharynx     | Snoring/apnea   |
| Oropharynx               | Snoring, drooling                                     |
| Supraglottis             | Inspiratory stridor, feeding difficulties, aspiration |
| Glottis                  | Biphasic stridor, hoarseness, weak cry                |
| Subglottis               | Biphasic stridor, barking cough                       |
| Tracheobronchial         | Expiratory stridor, wheezing                          |

- Inspiratory (supraglottic obstruction)
- Biphasic (glottic/subglottic obstruction)
- Expiratory (Intrathoracic obstruction)

Wheezing or expiratory stridor often point to obstruction at the trachea-bronchial level.

- Increased work of breathing, feeding difficulties, failure to thrive are often observed in *laryngomalacia*. Twenty percent are associated with synchronous airway lesions.
- Cough, wheeze, and stridor are all possible symptoms of an inhaled foreign body (FB).
- *Unilateral VCP* usually presents as weak cry with aspiration. *Bilateral VCP* is diagnosed soon after birth, requires intubation and tracheostomy. These are mostly idiopathic but some are also associated with the Arnold–Chiari malformation.
- *Subglottic hemangioma*—stridor in first 6 months of life, 50% have associated cutaneous hemangiomas. There is usually spontaneous resolution over several years.
- *Subglottic stenosis*—Congenital cases present at birth with respiratory distress or later in life with recurrent croup. Failed trial of extubation would be the first indication in acquired cases.
- *Laryngeal papillomas*—Hoarseness, abnormal cry or both. Always perform flexible laryngoscopy in children with hoarse voice.
- *Vascular compression of the airway* varies from being asymptomatic to significant biphasic stridor, wheeze, and cyanotic episodes.
- *Laryngeal clefts* usually present with choking episodes, stridor, transient cyanosis, and recurrent chest infections.

---

## 65.4 Investigations

- Laboratory studies
  - Arterial blood gas, pulse oximetry
- Imaging
  - Lymphatic malformations (ultrasound scan)
  - Choanal atresia, vascular anomalies, FB (CT scan)
  - Arnold–Chiari malformation in bilateral VCP (MRI)
  - Laryngeal clefts (videofluoroscopy)
- Flexible nasolaryngoscopy
  - Laryngomalacia, papillomas, VCP
- Microlaryngobronchoscopy (MLB)
  - Subglottic stenosis, Laryngeal clefts, tracheobronchomalacia, FB etc.
- Pulmonary function testing
  - May help in showing site of airway obstruction and to rule out lower airway disorders
- Polysomnography

- Assessing severity of obstructive sleep apnea

## 65.5 Management

Management of airway disorders must be tailored depending on the underlying cause, level of the obstruction, and severity of the condition. Observation may be an adequate course of action in some children with mild problems (mild laryngomalacia). Nonetheless, medical treatment and surgery are necessary for most children with significant airway pathology. Dietary considerations are required in patients where an increased risk of aspiration exists (e.g., laryngomalacia, laryngeal cleft). In some cases, only minor modifications during feeding such as a change in position, pacing, thickened formula and similar, can be sufficient, while some children will need a nasogastric tube or percutaneous endoscopic gastrostomy.

Congenital airway disorders in the pediatric population require long term follow up due to the dynamic nature of pathology as the child develops.

### Management Options Depending on Underlying Pathology

- Choanal atresia (bilateral)
  - Intubation, surgical repair and endoscopic dilatation
- Obstructive sleep apnea (OSA)
  - Adenoidectomy, tonsillectomy, tracheostomy
- Laryngomalacia:
  - Observation, reflux management and surgery in 5% cases (supraglottoplasty)
- Vocal cord paralysis
  - Surgical is usually not required (unilateral).
  - Majority require tracheotomy and 58% will eventually recover (bilateral).
- Subglottic stenosis:
  - Endoscopic balloon dilatation, tracheotomy, laryngotracheal reconstruction
- Subglottic haemangioma
  - Long-term propranolol, tracheostomy, and open surgical excision
- Vascular compression
  - CPAP, temporary tracheostomy, aortopexy, division of vascular ring etc.
- Laryngeal cleft
  - Depending on the cleft type: endoscopic repair (Type 1, 2), open surgical repair, tracheostomy, gastrostomy

### 65.5.1 Surgery of the Pediatric Airway Disorders

- *Adenotonsillectomy*—For OSA
- *Supraglottoplasty*—Laryngomalacia
- *Endoscopic balloon dilatation*—Subglottic stenosis

- *Tracheostomy*
- *Laryngotracheal Reconstruction*—Subglottic stenosis
- *Repair of laryngeal cleft*

## 65.6 Outcomes

A multidisciplinary approach and specialized pediatric services are crucial.

Complications of pediatric airway surgery can be general or specific to the type of surgery performed. Bleeding, infection, surgical emphysema, damage to the surrounding structures, tracheostomy tube problems, respiratory arrest, pulmonary oedema, pneumothorax, swallowing issues, scarring, aspiration, recurrence, revision surgery, velopharyngeal insufficiency, and voice change have all been described.

---

## Further Reading

Mok Q. Airway problems in neonates—a review of the current investigation and management strategies. *Front Pediatr.* 2017;5 <https://doi.org/10.3389/fped.2017.00060>.

Pfleger A, Eber E. Management of acute severe upper airway obstruction in children. *Paediatr Respir Rev.* 2013;14:70–7.

Pfleger A, Eber E. Assessment and causes of stridor. *Paediatr Respir Rev.* 2016;18:64–72.

Rutter MJ. Evaluation and management of upper airway disorders in children. *Semin Pediatr Surg.* 2006;15:116–23.





Atif Saeed and Chandrasen K. Sinha

## Quality in Health Care

The surgeon, Ernest Codman, was first person to try and to describe this in 1917, describing the concept of continuous measurement and feedback as a fundamental principle in health care improvement.

## 66.1 Introduction

*Quality of care* is important not only to health care professionals but also to policymakers and service users. *Quality indicators* have been used in a variety of settings, facing different goals. Future demand for health services can be predicted through the monitoring of data on the utilization of services. Epidemiological data not only can help monitor health profiles and lifestyles but also can contribute to the delivery of better health outcomes and care for “at-risk” groups at community and household levels.

## 66.2 What Is Quality?

The concept of quality is mainly driven by the manufacturing industry, where it is relatively straight forward to define, high-quality products are those which are efficient with little or no failure. In the health care context, it is somewhat vague.

- The *Agency for Healthcare Research and Quality* describes it as:
  - “*doing the right thing, at the right time, in the right way, for the right person, and having the best possible results.*”

---

A. Saeed

Department of Paediatric Surgery, St Georges University Hospital, London, UK

C. K. Sinha (✉)

St George’s Hospital, London, UK

© Springer Nature Switzerland AG 2022

C. K. Sinha, M. Davenport (eds.), *Handbook of Pediatric Surgery*,  
[https://doi.org/10.1007/978-3-030-84467-7\\_66](https://doi.org/10.1007/978-3-030-84467-7_66)

- The *WHO* definition of quality of care is:
  - “*the extent to which health care services provided to individuals and patient populations improve desired health outcomes.*”

### 66.2.1 Institute of Medicine: USA

Quality in the context of health care is a multidimensional framework that captures six domains as described in its report of 2001 “*Crossing the Quality Chasm.*”

- Safety
  - Delivering health care that minimizes risks and harm to service users, avoiding preventable injuries and reducing medical errors.
- Patient centeredness
  - Providing care that takes into account the preferences and aspirations of individual service users and the culture of their community.
- Efficiency
  - Reducing delays in providing and receiving health care.
- Equity
  - Delivering health care that does not differ in quality according to personal characteristics such as gender, race, ethnicity, geographical location, or socio-economic status.
- Timeliness
  - Delivering health care in a manner that maximizes resource use and avoids waste.
- Effectiveness
  - Providing services based on scientific knowledge and evidence-based guidelines. Utilize the resources appropriately.

### 66.2.2 Care Quality Commission (CQC): UK

The CQC assesses the quality of care provided by various organizations and is more or less similar than above. There is an extra stress on leadership and teamwork. CQC assess the quality of care through the following criteria:

#### SCREW

- Safety
  - How safe are our services? What are the morbidities and mortalities? How that service is doing in terms of serious incidences?
- Caring
  - How caring and patient-centered are our services?
- Responsive
  - How responsive are we when something goes wrong? Do we deal with it efficiently, in a timely manner with the principle of equitability, i.e., everyone has equal opportunity?

- *Effective*
  - Is the provision of the services delivered in an effective manner and based on evidence?
- *Well-lead*
  - How well is an organization or a team led? If a leadership is lacking in the team, outcomes are not as per expectation.

---

## 66.3 How Can We Improve Quality?

Assessment and improvement of the quality of care are increasingly seen as an essential part of medical practice. Although quality may be improved without measuring it, for example, by the implementation of guidelines, measurement is important for the exact assessment and the continuous improvement of quality of care.

A combination of approaches is needed to ensure sustained improvements in health care quality. There are a number of external influences that need to be considered and used, where possible, to drive improvements in quality. These include professional requirements, centralized government initiatives, and economic drivers, e.g., *Commissioning Quality and Innovation (CQUIN) payment framework in the UK*. There is also a range of models and methods that individual organizations can put in place themselves.

Quality improvement draws on a wide variety of methodologies, approaches, and tools. However, many of these share some simple underlying principles, i.e., understanding the problem, with a particular emphasis on what the data tell you understanding the processes and systems within the organization particularly the patient pathway whether these can be simplified by analyzing the demand, capacity, and flow of the service choosing the tools to bring about change, including leadership and clinical engagement, skills development, staff, and patient participation evaluating and measuring the impact of a change.

Regardless of the approach to how the change is implemented—including factors such as leadership, clinical involvement, and resources are vital.

### 66.3.1 Quality Improvement Approaches

These approaches are mainly driven by the manufacturing industry and businesses but have been useful in health care as well. No one approach is better than the others, and some may be used simultaneously.

### 66.3.2 Business Process Reengineering

This approach revolves around how an organization's central processes are designed, the change is driven from the top. Organizations are restructured around key processes (defined as activities, or sets of activities) rather than specialist functions. In this way, organizations can identify waste and become more streamlined.

### 66.3.3 Experience-Based Co-design

In this approach, service is improved through patient and staff working in partnership. Data are gathered through feedback, in-depth interviews, observations, and group discussions and analyzed to identify the patients' experience.

### 66.3.4 Lean

The approach focuses on five principles: customer value, managing the value stream, regulating the flow of production (to avoid quiet patches and bottlenecks), reducing waste, and using "pull" mechanisms to support flow. Using "pull" means responding to actual demand, rather than allowing the organizational needs to determine production levels.

### 66.3.5 Model for Improvement (Including PDSA)

This is an approach to continuous improvement where changes are tested in small cycles that involves *Planning, Doing, Studying, Acting* (PDSA). These cycles are linked with three key questions.

- What are we trying to accomplish?
- How will we know that a change is an improvement?
- What changes can we make that will result in improvement?

### 66.3.6 Six Sigma

It focuses first on understanding how an organization's customers would define "defects" within its products or services. It then works to reduce factors that customers would define as being critical to quality, drawing on statistical methods.

### 66.3.7 Statistical Process Control

This approach examines the difference between natural variation (known as "*common cause variation*") and variation that can be controlled ("*special cause variation*"). Data are collected over time to show whether a process is within control limits in order to detect poor or deteriorating performance and target where improvements are needed.

---

### 66.3.8 Theory of Constraints

The theory of constraints came from a simple concept similar to the idea that a chain is only as strong as its weakest link. It recognizes that movement along a process, or chain of tasks, will only flow at the rate of the task that has the least capacity.

---

### 66.4 Who Provides the Standards for Quality of Care?

The benchmark of the quality of the care can be provided by an institution; national or international, by organization and relevant associations, e.g., in England, standard and indicator in health care settings are provided by *NICE (National Institute of Health and Care Excellence)*. The *Agency for Healthcare Research and Quality* provides this in the USA. However, other organizations, e.g., *British Association of paediatric surgeons (BAPS)*, *British Association of Paediatric Urologists (BAPU)*, *Royal Colleges (e.g., RCS, RCPCH)*, and *Get it Right First Time (GIRFT)* can provide guidance to establish benchmarks for quality of care in the context of pediatric surgery. These organizations develop specialty base guidelines and recommendations which can be used to establish standards, e.g.

The role of NICE is to:

- Identify areas for quality improvement
- Highlight emerging areas of practice
- Provide examples of current practice
- Support the quality standards

---

### 66.5 Quality of Care in Pediatric Surgery

There are only a few universally accepted quality metrics, and often policymakers and researchers are restricted to the use of indicators that are directly derivable from administrative data sources. They either reflect on a particular dimension of the quality of care framework or allow measurement of quality of care at a particular point in the patient pathway (e.g., quality at the initial hospital stay).

In many areas of health care, such as in pediatric surgery, evidence of good care is limited and often methodologically weak. Definite benchmarks for care in pediatric surgery are lacking. However, there is an increasing demand to achieve it. In these circumstances, indicators have to be developed using expert opinion. Group judgments are preferred to individual opinions, which can be facilitated by consensus. Characteristics of techniques to develop consensus include mailed questionnaires, elicitation of decisions, group feedback on choices, structured meetings, and aggregation, which all can be used in indicator development.

*Some examples:*

- In England, the *Children's Forum* in its 2013 report, published the standards for the provision of children's surgery. It ensures children can receive surgery in a safe, appropriate environment, which is as close to their home as possible. It recommends that local provider networks give ongoing support to surgeons, anesthetists, and the whole multidisciplinary team involved in delivering surgical care to children in local hospitals. It provides standards on Networks, Clinical Governance and Leadership, Delivery and Environment of Care, Education and Training, Outpatients service delivery, Day surgery, Emergency care, and Inpatient care.

Such support will enable this vital service to be delivered locally while establishing agreed policies and processes for transferring patients and their families when their needs cannot be met at the local level.

The *BAPS* and *BAPU* recommend many consensus guidelines.

**Example: BAPU—A Guideline for the Management of Primary Megaureter**  
Ureteric diameter >7 mm (abnormal).

Newborns with prenatally diagnosed hydroureteronephrosis should receive antibiotic prophylaxis and be investigated with an US scan and MCUG and then followed by a diuretic renogram once VUR and bladder outlet obstruction had been excluded.

Initial management of primary megaureters is conservative.

Indications for surgical intervention include symptoms such as febrile UTIs or pain, and in the asymptomatic patient, a differential renal function <40% is associated with massive or progressive hydronephrosis or a drop in differential function on serial renograms.

Ureteral reimplantation was recommended >1 year of age. Alternatives are the insertion of a temporary JJ stent or a refluxing reimplantation.

This guideline is widely followed by paediatric urologists in the UK and also in other parts of the world.

**WHO Surgical Safety Checklist**

Developed after extensive consultation, the guideline was to developed teamwork and communication. It decreases errors and adverse effects, ensures safety for the patients and has been shown to decrease morbidity and mortality.

## Further Reading

- Arca MJ, et al. Optimization of care for the pediatric surgical patient: why now? *Semin Pediatr Surg.* 2015;24:311–4.
- Cameron DB, Rangel SJ. Quality improvement in pediatric surgery. *Curr Opin Pediatr.* 2016;28:348–55. <https://doi.org/10.1097/MOP.0000000000000346>.
- Campbell SM, Roland MO, Buetow SA. Defining quality of care. *Soc Sci Med.* 2000;51:1611–25.
- Farrugia MK, et al. British Association of Paediatric Urologists consensus statement on the management of the primary obstructive megaureter. *J Pediatr Urol.* 2014;10(1):26–33. <https://doi.org/10.1016/j.jpuro.2013.09.018>.
- Heij HA. Noblesse oblige—the pediatric surgeon has the key to quality control and improvement. *J Pediatr Surg.* 2011;46:793–800.
- Robillard JM, Bourne SC, Tam MT, et al. Improving the paediatric surgery patient experience: an 8-year analysis of narrative quality data. *BMJ Open Q.* 2020;9:e000924. <https://doi.org/10.1136/bmjopen-2020-00092>.
- Standards for Children Surgery. Children surgical forum report 2013. Royal College of Surgeons
- WHO guidelines for safe surgery 2009, safe surgery saves lives. WHO/IER/PSP/2008. 08-1E.



Neel Mohan

## 67.1 Normal Variants in Early Years

Most of these are variations where limb function is unaffected so rather it is their altered appearance that causes anxiety.

- Syndactyly of lesser toes
  - This is an issue of appearance and perfect function of the foot is preserved.
- Curly lesser toes
  - As above, the function is usually normal.
- Flexible flat feet (common)
  - If the child can tiptoe well, this is termed as “flexible flat feet” as opposed to “rigid flat feet,” which can be pathological. A rigid flat foot may indicate underlying pathology such as tarsal coalition.
- Intoed gait
  - Either individually or as a combination of below should remodel with growth.
- Increased internal rotation of hips (common)
  - Caused by increased femoral anteversion (angle between the shaft and neck of the femur in the coronal plane). It is a prominent contributor to an intoed gait. May trip up when walking.
- Physiological *Genu Valgum* (knock knees) or *Genu Varum* (bowed legs)
  - Most obvious when the child starts walking and from about 2 years of age. Appearance usually improves from age of four.
- Congenital trigger thumb (IP joint fixed in flexion or snapping on extension)
- “Growing pain”
  - Not a pathology as such but an unexplained phenomenon that may occur between the ages of two to five or six.

---

N. Mohan (✉)  
St George's Hospital, London, UK  
e-mail: [neelmohan@doctors.org.uk](mailto:neelmohan@doctors.org.uk)



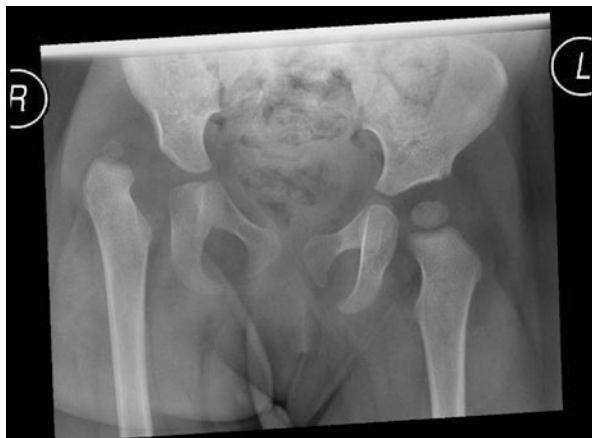- Child remains active during the day but complains of bilateral knee or leg pains in the late evening or at night.
- Stepladder pattern of some days of pain followed by many weeks of being asymptomatic. Although pain occurring at night is usually a worry, the bilateral nature of pain should reassure the clinician.

## 67.2 Congenital Orthopedic Conditions

### 67.2.1 Developmental Dysplasia of Hip (DDH) (Fig. 67.1)

- Known formerly as Congenital Dislocation of Hip (CDH).
  - Replaced because it implied only manifestation was a dislocated hip, i.e., one out of joint, whereas there is a *range of positions* the joint can assume before the two surfaces lose contact entirely. From a shallow acetabulum and mild instability at birth, through various degrees of subluxation to the dislocated femoral head.
- Subluxation leading to dislocation may be a gradual one over several weeks or months.
- Associated with
  - Females
  - Prematurity
  - Breech lie in utero and at birth
  - Family history of this condition
- Examination shows
  - *Barlow test*—provoking a located hip to ride out of joint.
  - *Ortolani test*—a gentle abduction maneuver of relocation of an already subluxed or dislocated hip.
  - Gently abduction with the knees flexed in the “frog” position (in a neonate the thighs almost touch the examining couch). This wide abduction should be

**Fig. 67.1** DDH. Dislocated right hip AP view. The joint surfaces are not in contact with each other



equal on both sides and any hint of a restricted abduction on one or both sides should alert the clinician.

- Radiology
  - During the first 6 months—acetabulum and femoral head are made of soft radiolucent cartilage and are difficult to accurately visualize on a plain X-ray.
  - Ultrasound examination of hips is more accurate and gentle provocation of the joint can detect dynamic instability unlike static investigation such as X-ray.
  - From the 7th month onward there is sufficient ossification and an X-ray has more value.
- Treatment
  - 0–6 months
    - Pavlik harness* for most apart from the irreducibly subluxed or dislocated hip with progress monitored by US.
  - >6 months
    - EUA and an arthrogram (injection of Iodine dye to coat the radio-opaque cartilage surfaces) with closed reduction and application of a spica cast.
    - If the dislocation is detected after the child attempts to walk, then an *open reduction of the hip* is performed after the age of one. This option is much less common than formerly because of the success of Pavlik Harness.

## 67.2.2 Congenital Talipes Equino-Varus (CTEV)

- Presents at birth or on antenatal scan.
- Unilateral or bilateral.
- *Serial plaster casts (after Ignacio Ponseti, Iowa, USA)*
  - Led by specialist physiotherapy teams

---

## 67.3 Acquired Orthopedic Conditions

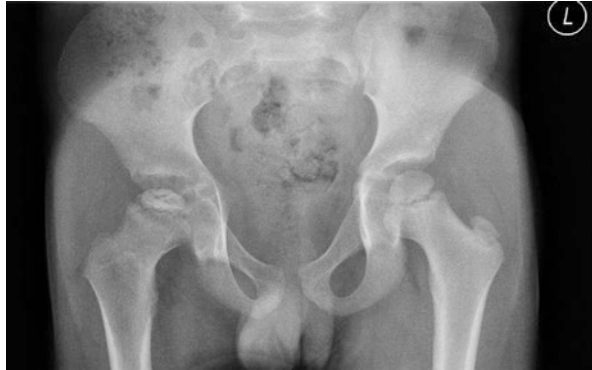### 67.3.1 Inflammation and Infection

A mild and temporary swelling of a joint with a subtle limp and normal markers of infection and inflammation is commonly due to a *transient synovitis* or an “*irritable*” joint frequently the hip or knee. Anti-inflammatory medication for a few days usually resolves the problem.

On occasion, a more sustained inflammation may present with a longer duration and more dramatically swollen joint or joints with raised blood markers of inflammation and this may point to *Juvenile Inflammatory Arthropathy (JIA)*. This is treated medically but sometimes aspiration of the joint and instillation of a steroid may be needed.

The important differential to be considered here is infection. This could be *Osteomyelitis* or *Septic Arthritis*. Child may appear unwell and there may be

**Fig. 67.2** Perthes disease right hip AP view. The avascular necrosis of the epiphysis of the femoral head and a collapse in its height can be seen



systemic signs of infection ( $\uparrow$  temperature and  $\uparrow$  CRP and WBC). Loss of function is more profound and all weight bearing is painful, and maybe not possible.

Plain X-ray in the early stages are not useful to differentiate between the two scenarios above and certainly if septic arthritis is being considered, this is a surgical emergency.

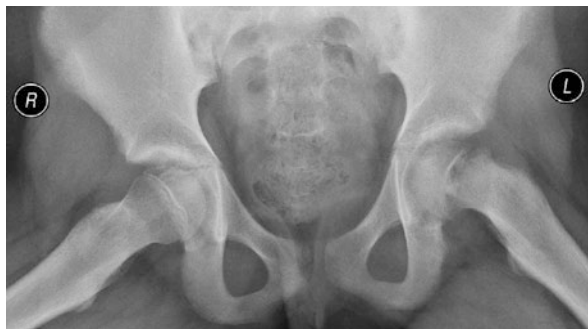### 67.3.2 Perthes Disease

- Hip disorder is usually seen between the ages of 3 and 8 years.
- Etiology is unknown, but considered to be a temporary avascularity of the femoral head that causes aseptic necrosis of its weight-bearing part, thereby changing its round shape and altering the dynamics of the joint.
- Presentation with an intermittent limp and restriction of hip range of motion (usually abduction and rotation).
- Plain AP X-ray is usually diagnostic (Fig. 67.2).

### 67.3.3 Slipped Upper Femoral Epiphysis (SUFE)

- The angulation is caused by the neck of the femur slipping anteriorly, leaving the epiphysis to appear to have slipped posteriorly on a Frog lateral view of both hips.
- Usually affects children from the ages of 9 years to the early teens.
- Slip can be classified as:
  - stable—child can bear weight on the affected side albeit with a limp
  - unstable—child cannot bear any weight on the affected side
- Plain X-ray should be diagnostic (Fig. 67.3).
  - Changes on an AP X-ray of “pelvis for hips” may be too subtle.
  - Angulation is caused by the posterior slip of the epiphysis of the femoral head on the neck of the femur (on a “Frog Lateral” view of both hips).
  - Ask for both hips to be included.

**Fig. 67.3** SUFE frog lateral view



- *Urgent surgical stabilization of the slip* is recommended as there is a risk to the precarious blood supply of the femoral head and may cause avascular necrosis of the epiphysis.
- A stable slip may be allowed to mobilize not bearing any weight on the affected side with crutches and rest at home pending admission to a hospital ward, but an unstable slip should be confined to bed or the trolley if in A and E and admitted to a ward straightaway.

#### 67.3.4 Anterior Knee Pain in Adolescents

The cause could be as simple as increased impact and contact sports becoming a regular daily fixture in the competitive adolescent or the occasional game an otherwise not very sporty child is compelled to take part in! If the tibial tuberosity is prominent and tender, a diagnosis of *Osgood Schlatter osteochondritis* is made and if the patella is at fault, a diagnosis of *Chondromalacia Patella* may be offered (more often in peri-pubertal girls).

Red flags may include reluctance to take part in sporting activity due to the pain, a pronounced limp, and pain waking the child at night requiring analgesics. Plain X-ray should be taken.

#### 67.3.5 Osteochondritis at Various Stages of Growth

There are a variety of bones that are affected by a type of inflammation during different stages of growth, with some being caused by varying degrees of avascularity. They all usually heal well with minimal long-term effects.

Basic pathology in all these conditions is osteochondritis and the pain associated is due to the inflammation caused by the temporary avascularity or more simply a traction phenomenon due to attached tendons. It is usually straightforward to diagnose on history and examination alone.

### 67.3.5.1 Kohler's Disease of the Navicular

- 3–7 years.
- Usually self-limiting presents with persistent pain and a limp.
- Plain X-ray—characteristic.
- Treated by a combination of NSAI and rest from impact activity, occasionally in some form of immobilization like a short fracture boot for a few days.

### 67.3.5.2 Sever's Disease of the Calcaneum

- Inflammation at the epiphysis of the calcaneum during impact activities.
- 8–11 years in girls and 9–12 years in boys.
- Pain lasts for several weeks or months and is usually managed by reducing impact activity, soft heel cushion inserts into shoes, occasional NSAI.

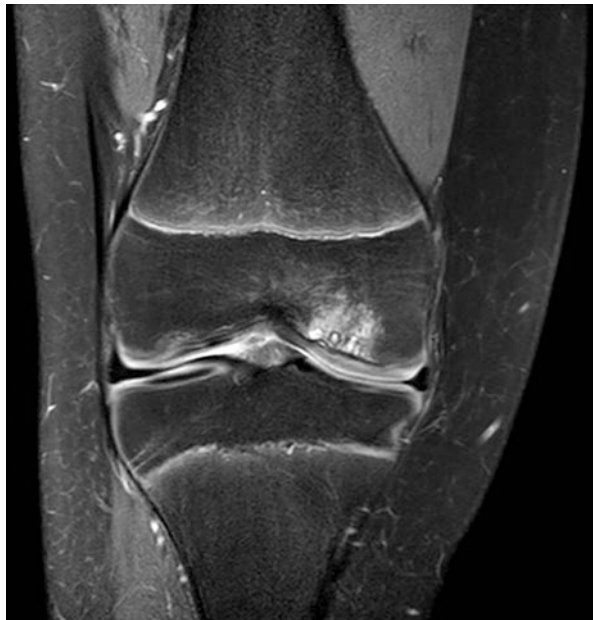### 67.3.5.3 Osgood-Schlatter's Disease of the Tibial Tuberosity

- Traction phenomenon causing inflammation rather than due to avascularity.
- 9–12 years in girls and 10–14 years in boys.

### 67.3.5.4 Osteochondritis Dissecans of the Knee

- Unusual location for an osteochondritis in that it occurs intra-articular, usually on or just below the joint surface of the medial femoral condyle (Fig. 67.4).
- Cause most likely to be avascular necrosis of a portion of the weight-bearing surface of the medial femoral condyle (i.e., a sort of “Perthes disease” of the medial femoral condyle).
- Its course could be benign, with mild symptoms usually on contact and high impact sport and it could resolve naturally.

**Fig. 67.4** Osteochondritis Dissecans of the distal femur. The lesion is sub-articulate with intact overlying cartilage



- Sometimes, like Perthes, if the original insult from the avascularity has been marked, there is a breakdown of the articular surface and subchondral inflammation with the formation of cysts, needing surgical intervention.

### 67.3.6 Neoplasm, Benign, and Malign

Benign bone lesions are common in orthopedic practice, and neoplastic lesions are uncommon. Interruption of the child's regular and favorite activity, pain at rest, and waking at night needing analgesics on a regular basis may be red flags of neoplasia.

Pathology can be straightforward like benign *Bone Cysts*, *Fibrous Dysplasia*, *Osteochondroma*, or serious and malignant like an *Osteosarcoma* or *Ewings Sarcoma*.

#### 67.3.6.1 Bone Cysts

These can be a variety of *simple bone cysts* that either resolve spontaneously or respond well to surgery, or *aneurysmal bone cysts* (ABC) that are more resistant to treatment and can recur.

A simple bone cyst is described as “unicameral” (UBC).<sup>1</sup> and is easy to diagnose on a plain radiograph. Frequently, the child presents with a pathological fracture through the weakened bone at the level of the cyst. A few flecks of cortical bone may be seen at the bottom of the cyst on the radiograph, known as the “*fallen leaf sign*.”

Multiple cyst cavities may look to have expanded the bone and maybe an aneurysmal bone cyst (ABC)—a blood-filled cavity that appears to grow. Difficult to heal, either by a natural occurrence of a pathological fracture or surgical intervention in which recurrence is common.

#### 67.3.6.2 Fibrous Dysplasia

- Congenital disorderly growth of bone tissue with replacement of normal organized bony tissue with poorly organized and structurally unsound weaker fibrous tissue and can take on a bizarre appearance, mimicking infection or neoplasm. Can be part of a complex disease involving not only bone but other tissues in multiple organs.
- Plain X-ray—areas of homogenous fibrous tissue can take on a “ground glass” appearance. However, the long duration of history and comparatively lesser symptoms should alert the clinician to consider this in the differential diagnosis. A useful adage to remember is that if the plain radiograph appearance of any lesion appears too bizarre to fit in with a description of any familiar pathology, fibrous dysplasia could be considered in the differential diagnosis.

#### 67.3.6.3 Osteochondroma

- Common benign outgrowth of bone that can arise as a solitary or multiple lesions in several bones and can be hereditary.

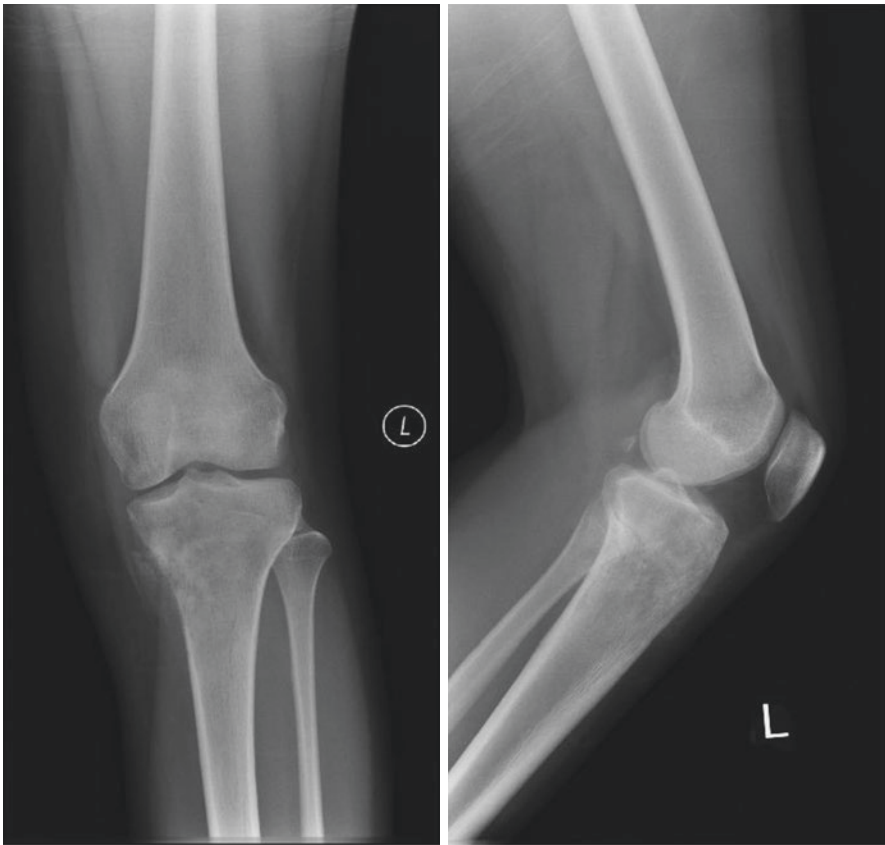
---

<sup>1</sup>Cameral—Latin camera—cavity or chamber.

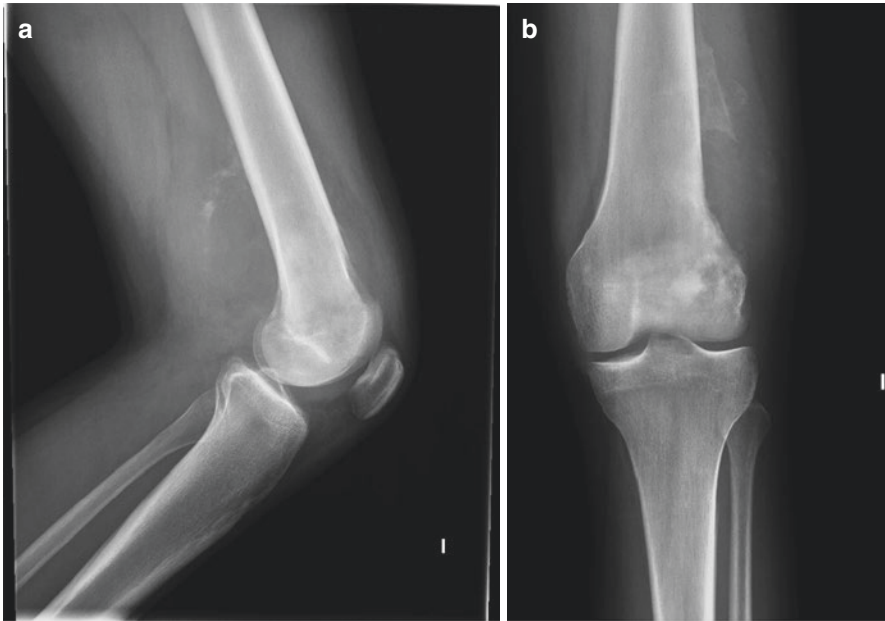
- Plain X-ray—usually diagnostic but occasionally an MRI scan may be needed.
- Morphology of the lesion could be pedunculated, which is more amenable to surgical excision or sessile that is usually left alone.

#### 67.3.6.4 Osteosarcoma

- Rare.
- Occurs in the 2nd and 3rd decades but with a preponderance in teenage years.
- Initial symptoms can be vague and general.
- Loss of function like inability to play sport, pain during usual day-to-day activities and at rest, and the frequent interruption of sleep at night requiring analgesics.
- Affects—metaphyses of long bones *around the knee in the distal femur and proximal tibia*, and thereafter in the *proximal humerus*.
- Plain X-ray shows a “permeative pattern” with no clear zone of transition from normal-to-abnormal bone (Fig. 67.5).



**Fig. 67.5** Osteosarcoma proximal tibia AP and Lateral. A typical permeative pattern is seen in the entire proximal tibia, with no clear zone of transition between normal and abnormal bone. The child was being treated with physiotherapy for presumed Osgood Schlatter’s disease



**Fig. 67.6** Osteosarcoma femur (**a** and **b**) showing characteristic features described

- Typical are a “*sunburst*” appearance due to increased bone activity and the laying down of spicules of new bone perpendicular to the axis of the shaft of the long bone, and the “*Codman triangle*” caused due to new periosteal bone growing in the acute angle between the diaphyseal shaft and the periosteum, which is rapidly stripped by neoplastic tissue growing from the metaphysis of a long bone (Fig. 67.6b).
- An “*onion peel*” appearance along the diaphysis of a long bone represents phases of increased neoplastic activity causing the stripping of the periosteum alternating with phases of decreased activity. Usually considered to be typical of the less common Ewing’s Sarcoma (Fig. 67.6a).

The teenager with an osteosarcoma of the distal femur (Fig. 67.6a, b) in the radiographs below had worsening symptoms for 6–7 months and was diagnosed as a sprain needing physiotherapy, despite having had pain at night requiring regular analgesics for several months before the diagnosis was made. The typical “*sunburst*” pattern and “*Codman triangle*” can be seen clearly in the lateral and AP plain radiographs.

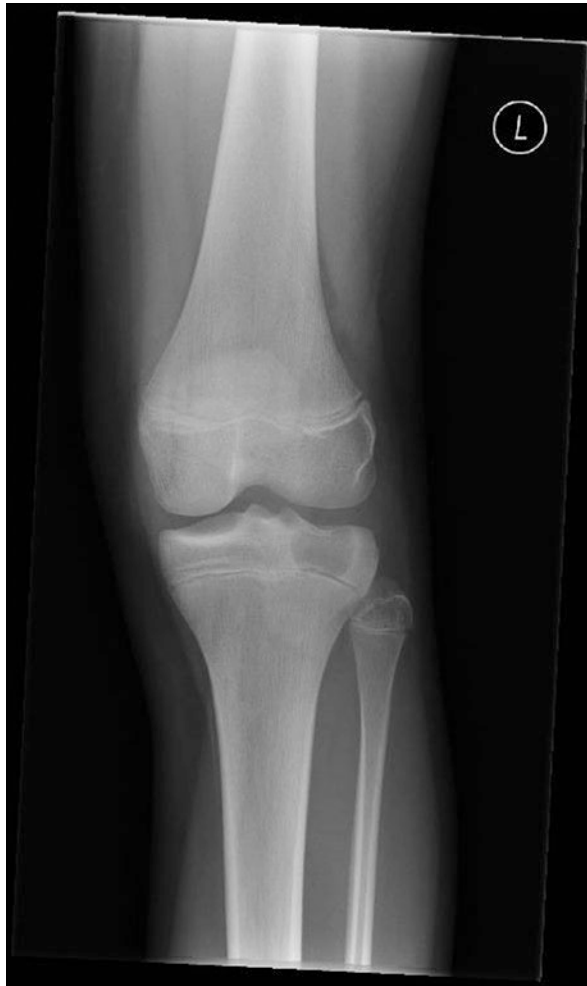### Chondroblastoma

Chondroblastoma is a rare type of benign lesion at the ends of long bones, close to the joint surface. Most often, they develop at the distal end of the femur or the



**Fig. 67.7**

Chondroblastoma knee AP view. A large benign lytic lesion can be seen on the lateral side of the epiphysis of the proximal tibia



proximal tibia (Fig. 67.7) and typically occur in children and young adults, being more common in males.

Although chondroblastomas are not malignant, they may continue to grow if left untreated. They can destroy surrounding bone or joint surface, making weight bearing and joint movement painful. Treatment almost always involves surgery to remove the tumor and insert a bone graft into the resulting defect to prevent damage to the joint surface.



Anja Matson, Chandrasen K. Sinha, and Munther Haddad

*The first reported pediatric case of robotic minimally invasive surgery was a Nissen fundoplication in 2000, performed on a 10-year-old girl in Germany.*

## 68.1 Introduction

Minimally invasive surgery (MIS), such as laparoscopic and endoscopic surgery, revolutionized practice in the 1980s by making it possible to operate through small incisions, which reduced patient recovery times and associated morbidity. In the last two decades, another field of MIS has flourished: robotic-assisted surgery.

Endoscopic and laparoscopic surgery can limit the surgeon's dexterity, degree of freedom of movement, and quality of visualization compared with the traditional "open" approach. Consequently, robotic platforms have been developed to overcome these limitations.

Following the approval of the first robotic surgical system, *the da Vinci™ system* (Intuitive Surgical Inc., Sunnyvale, CA) in 2000, robotic surgery has been used in a wide variety of surgical specialties for adults, for example in cardiac, thoracic, colorectal, head and neck, gynecology and urology surgery.

Robotic surgery within pediatrics presents some unique challenges, such as working within a small operative field with tools built for adults and costliness for hospitals, hence initial adoption of the technology has been slow.

---

A. Matson  
St George's University Hospital, London, UK  
e-mail: [m1500533@sgul.ac.uk](mailto:m1500533@sgul.ac.uk)

C. K. Sinha  
St George's Hospital, London, UK

M. Haddad (✉)  
Chelsea and Westminster Hospital, London, UK  
e-mail: [m.haddad@imperial.ac.uk](mailto:m.haddad@imperial.ac.uk)

© Springer Nature Switzerland AG 2022  
C. K. Sinha, M. Davenport (eds.), *Handbook of Pediatric Surgery*,  
[https://doi.org/10.1007/978-3-030-84467-7\\_68](https://doi.org/10.1007/978-3-030-84467-7_68)

The best example of success with robotic-assisted surgery within pediatrics has been in robotic-assisted *laparoscopic pyeloplasty (RALP)*. Some studies have shown reduced operating times and length of postoperative stay compared to other approaches.

---

## 68.2 The Da Vinci™ System and Other Robots

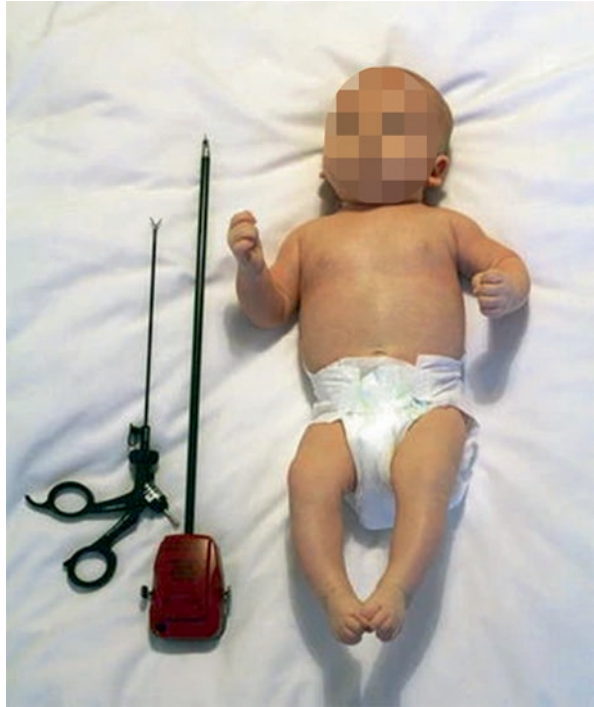- The da Vinci system is now in its 4th generation
- “Master–slave” system:
  - Lacks any autonomy
  - Function is dependent entirely on the operating surgeon.
- The system comprises three main components:
  - “Patient cart”—houses the instruments above the patient
  - “Vision cart”—processing and energy hub of the system
  - “Surgeon console”—surgeon control of the camera and instruments
- Camera
  - (Currently) 12 mm and 8 mm sizes
  - Articulated (termed EndoWrist) instruments
    - Available in 8 mm and 5 mm sizes. However, the articulation system of the 5 mm instruments requires a greater intra-corporeal working space than that of the 8 mm and so counter-intuitively the larger instruments are more appropriate for most pediatric procedures.
  - Conventional or smaller minimally invasive surgery in young children (Fig. 68.1)
    - 3 mm size conventional instruments are commonly used in the da Vinci Surgical System for children, but more precise smaller instruments with endoWrist (e.g., KidsArm) would be a vital addition in this field.
- Other Platforms
  - Following the 2003 merger with Computer Motion, Intuitive Surgical Inc. holds a monopoly in the market.
  - Alternative platforms are now at various stages of development and regulatory approval. There are competitors such as *Senhance™ Surgical Robotic System* by TransEnterix and *KidsArm™* (being developed by the Hospital for Sick Children in Southern Ontario), that are developing robotic technology designed specifically for minimally invasive pediatric surgery.

---

## 68.3 Advantages

- Similar to endoscopic/laparoscopic surgery
  - Faster recovery time, reduced levels of pain and blood loss, and improved cosmetic results
- The da Vinci system
  - High definition and high optical (10×) magnification stereoscopic (‘3D’) field of view.

**Fig. 68.1** Non-robotic 3 mm instrument and robotic 8 mm instrument and infant. Reprinted with permission from Cundy, T.P., Marcus, H.J., Hughes-Hallett, A. et al. Robotic surgery in children: adopt now, await, or dismiss? *Pediatr Surg Int* 31, 1119–1125 (2015). <https://doi.org/10.1007/s00383-015-3800-2>



- Remotely operated instruments that produce precise wrist-like articulation with 7 degrees of freedom of movement, which resembles the motions of performing open surgery much more closely than conventional endoscopic surgery does.
- Possible performance of more complex surgical cases
  - For example, Delicate reconstructive surgery and anastomoses, via a minimally invasive approach that traditionally was not achievable by conventional endoscopic techniques.
  - Depth perception allows a shorter learning curve for challenging intracorporeal work is reduced compared with that of conventional MIS.
  - Overall reported conversion-to-open-procedure rate is low, around 2.5%, which is comparable to conventional laparoscopic surgery.

## 68.4 Disadvantages

- Large financial burden of a robotic program in most healthcare economies given the initial cost of the robot in addition to ongoing costs of maintenance and supplies.
  - This cost is difficult to offset because of the invariably low volume of pediatric cases.

**Table 68.1** Advantages and disadvantages of robotic-assisted surgery

| Advantages   | Disadvantages   |
|--|---|
| Enhanced dexterity and mobility  | Platform designed for adult use   |
| Similar to the motions of performing “open” surgery, ↓learning curve for transitioning to robotic operating        | Too expensive<br>High initial cost in addition to ongoing costs of maintenance and supplies                                   |
| HD optics and high magnification (10×)   | Low-volume caseload   |
| Stereoscopic (“3D”) field of view allows for better depth perception   | Lack of strong empirical evidence for improved outcomes for the patient   |
| Micromovements and precise wrist-like articulation allows for reconstructive procedures (advanced suturing skills) | Not cost-effective for a restricted healthcare budget   |
| Tremor elimination   | Technology only accessible to a small number of tertiary institutions in the developed world                                  |
| Better ergonomics and comfort for the surgeon  | Unsustainable—models become outdated every 5–10 years and manufacturers threaten to stop maintenance support for older models |
| Reduced complication rates (in certain operations)   | Lacks the haptics (perception of touch) of open surgery   |

- Current systems are designed primarily for adult-sized abdomens.
  - Ports are required to be at least 6 cm apart (8–10 cm in older generations), which is not realistic in practice when operating in a space smaller than 40 mm<sup>3</sup>.
  - Physical constraints limit the use of the robot to mostly older or larger children with suitable abdominal or thoracic domains.
  - Because of the lack of comparative research in this field, there is little evidence to show that overall robotic-assisted surgery offers any additional benefits over the laparoscopic approach (Ref. Table 68.1).

## 68.5 Indications

### 68.5.1 Urological Surgery

- *Robotic-assisted laparoscopic pyeloplasty (RALP)*
- Best example of the technology’s capabilities in pediatric practice.
  - Using the conventional laparoscopic technique, the anastomosis during a pyeloplasty demands considerable technical skill and is associated with a significant learning curve.
  - Evidence suggests that because of the robotic assistance, RALP has significantly reduced operating time, length of postoperative stay and medication use, and improved scar cosmesis compared with the conventional approach.
- Urological surgery must often access deep structures of the pelvis in a narrow surgical field, which may be better suited to a robotic approach. Other urological procedures that have been successfully undertaken robotically include:
  - Robotic-assisted laparoscopic ureteric reimplantation (RALUR)

- Robotic-assisted Nephrectomy (RAN)/hemi-nephrectomy (RAHN)/laparoscopic nephroureterectomy (RALNU)
- Robotic-assisted pyelolithotomy
- Robotic-assisted uterocalicostomy and ureteroureterostomy
- Robotic-assisted augmentation cystoplasty
- Robotic-assisted creation of catheterizable conduits (appendicovesicostomy and antegrade continence enema)
- Robotic-assisted bladder neck reconstruction
- Robotic-assisted excision of bladder diverticulum, urachal cyst excision, excision of posterior urethral diverticulae, prostatic utricles, seminal vesicle cyst, and varicocele

### 68.5.2 General Surgery

- Fundoplication.
  - Little evidence for significant benefit over conventional laparoscopy
- Others include:
  - Robotic-assisted cholecystectomy and splenectomies
  - Robotic-assisted Heller’s myotomy
  - Robotic-assisted diaphragmatic hernia repair
  - Robotic-assisted duodeno-duodenostomy/duodenojejunostomy
  - Robotic-assisted pull-through
  - Robotic-assisted excision of choledochal malformation/cysts
  - Robotic-assisted ovarian cystectomy
  - Robotic-assisted salpingo-oophorectomy

### 68.5.3 Cardiothoracic Surgery

- Robotic-assisted thoracoscopic surgery (RATS) for a patent ductus arteriosus (PDA)
  - However, when compared with the conventional approach, video-assisted thoracoscopic surgery (VATS), the evidence shows no advantage of RATS over VATS.

### 68.5.4 Oncological Surgery

In adults, minimally invasive surgery is commonly used for oncological surgery, but with pediatric solid tumors, “open” surgery is the typical approach. There is a lack of comparative trials within oncology between MIS and robotic-assisted surgery in children. Nevertheless, the robotic platform has the potential to be useful for lymph node dissection because of enhanced optics and precision of movement.

- Most of the published studies are individual case reports, including:
  - Robotic-assisted excision of juvenile cystic adenomyoma
  - Robotic-assisted radical cystoprostatectomy
  - Robotic-assisted retroperitoneal lymph node dissection
  - Robotic-assisted partial adrenalectomy for pheochromocytoma

---

## 68.6 The Future

As the market grows, the emergence of strong competitors will likely drive down costs and spur further innovation. The current technology will likely be further developed to become more compatible with the constrained working space of neonatal abdomens and thoraxes. This would make a robotic approach possible for a wide variety of new procedures.

- Artificial intelligence and machine learning may make partially autonomous surgical robots a reality in the future, for example as previously mentioned KidsArm, being developed by the Hospital for Sick Children in Southern Ontario.
- Application of haptics to the robot console, which would provide the operator with proprioceptive feedback comparable to conventional open surgery, therefore reducing the learning curve associated with the transition to robotic operating.
- *Some of the newer devices are:*
  - *da Vinci SP* (single port) system.  
This system enables control for three fully-wristed, elbowed instruments, and the first fully-wristed da Vinci endoscope through a single 2.5 cm cannula.
  - *Autonomous Mini Robot (AMiRo)*  
This system is a modular and extensible mini robot platform. Currently, it is designed for scientific research and education. It offers remote controlling as well as an implementation of an artificial neural network running on the platform. Being the size of a tennis ball, this robot can be of great help for children in future.
  - *Microrobots*  
These robots exhibit special characteristics of size, function, and material choice. Recent evidence have encouraged fabrication techniques, locomotion at microscale environment, and targeted drug delivery. Due to their tiny size, they can travel through the body to perform tasks that no conventional robot could do. Microrobots can be made as small as bacteria. It can be injected via a small needle into the vitreous performing eye surgery using nanotechnology or can swim in small arteries, and detect diseases in humans.

– *Humanoid robot*

Designed to evolve among humans. These robots are safe and pleasant to interact. These robots are a promising platform to explore robotics surgeries, especially in children as they interact very well with children too.

---

## Further Reading

- Ballouhey Q, Clermidi P, Cros J, et al. Comparison of 8 and 5 mm robotic instruments in small cavities: 5 or 8 mm robotic instruments for small cavities? *Surg Endosc.* 2018;32:1027–34.
- Bruns N, Soldes O, Ponsky T. Robotic surgery may not “make the cut” in pediatrics. *Front Pediatr.* 2015;3:10.
- Cave J, Clarke S. Paediatric robotic surgery. *Ann R Coll Surg Engl.* 2018;100(Suppl 7):18–21.
- Cundy TP, Shetty K, Clark J, et al. The first decade of robotic surgery in children. *J Pediatr Surg.* 2013;48:858–65.
- Orvieto MA, Large M, Gundeti MS. Robotic paediatric urology. *BJU Int.* 2012;110(1):2–13.
- Sinha CK, Haddad M. Robot-assisted surgery in children: current status. *J Robot Surg.* 2008;1:243–6.





# Numerical References

# 69

Leena Sinha and Mark Davenport

## 69.1 Fluid Requirements (Table 69.1)

**Table 69.1** Fluid requirements

|                   | Day | ml/kg/day                         |
|-------------------|-----|-----------------------------------|
| Premature infant  | 1   | 60                                |
|                   | 2   | 70                                |
|                   | 3   | 90                                |
|                   | >3  | Up to 200                         |
| Term infant       | 1   | 60                                |
|                   | 2   | 80                                |
|                   | 3   | 100                               |
|                   | >3  | Up to 160                         |
| <b>Child</b>      |     |                                   |
| >4 weeks to 10 kg |     | 100                               |
| 10–20 kg          |     | 1000 ml + 50 ml/kg/day over 10 kg |
| >20 kg            |     | 1500 ml + 20 ml/kg/day over 20 kg |

L. Sinha  
Princess Alexandra Hospital, Harlow, Essex, UK

M. Davenport (✉)  
King's College Hospital, London, UK

## 69.2 Normal Heart Rate; Respiratory Rate; Blood Pressure (Table 69.2)

**Table 69.2** Normal measurements

| Age                  | Heart rate | Respiratory rate | Blood pressure   |
|----------------------|------------|------------------|------------------|
| <b>Neonate</b>       |            |                  |                  |
| 1–28 days            | 100–165    | >55              | 65/35 to 80/50   |
| <b>Infant</b>        |            |                  |                  |
| 1 month to 1 year    | 100–150    | 30–55            | 80/55 to 100/65  |
| <b>Child (years)</b> |            |                  |                  |
| 1–2                  | 70–110     | 20–30            | 90/55 to 105/70  |
| 3–5                  | 65–110     | 20–25            | 95/60 to 105/70  |
| 6–11                 | 60–95      | 14–22            | 100/65 to 115/75 |
| 12–15                | 55–85      | 12–18            | 110/70 to 120/80 |

## 69.3 Conversion Rates

Depending on origin and country, parents tend to talk in traditional units when discussing their offspring's measurements. Some conversion factors may be appropriate (Table 69.3).

**Table 69.3** Anglocentric (Imperial & USA) measurements

|                                   |   |
|-----------------------------------|---|
| <b>Weight</b>                     |   |
| 1 kg $\equiv$ 2.2 lb (pounds)     | 1 lb $\equiv$ 0.45 kg<br>14 lbs = 1 stone                               |
| 1 kg $\equiv$ 34 oz (ounces)      | 1 oz $\equiv$ 28 g  |
| 1 g $\equiv$ 0.035 oz             |   |
| <b>Length</b>                     |   |
| 1 m $\equiv$ 3.3 ft (feet)        | 1 yard $\equiv$ 0.91 m<br>1 ft $\equiv$ 0.30 m                          |
| 1 cm $\equiv$ 0.4 in (inch)       | 1 in $\equiv$ 2.5 cm  |
| <b>Liquid</b>                     |   |
| 1 l $\equiv$ 1.76 pt (pints) (UK) | 1 pt $\equiv$ 570 ml (UK)<br>1 pt (UK) = 20 fl oz                       |
| 1 l $\equiv$ 2.11 pt (US)         | 1 pt (US) = 16 fl oz<br>1 fl oz $\equiv$ 28 ml (UK) $\equiv$ 29 ml (US) |
| <b>Energy</b>                     |   |
| 1 kJ $\equiv$ 0.24 kcal           | 1 kcal $\equiv$ 4.2 kJ (Joules)   |
| <b>Pressure</b>                   |   |
| 1 kPa $\equiv$ 7.5 mmHg           | 1 mmHg $\equiv$ 133 Pa (Pascal)   |

## 69.4 Average and Normal (Table 69.4)

**Table 69.4** Height and weight

| Age                 | Weight (kg) | Height (cm) | Body surface area (m <sup>2</sup> ) |
|---------------------|-------------|-------------|-------------------------------------|
| Preterm (gestation) |             |             |                                     |
| 24 weeks            | 0.65        |             |                                     |
| 28                  | 1.1         |             |                                     |
| 32                  | 1.7         |             |                                     |
| 36                  | 2.6         |             |                                     |
| Term                |             |             |                                     |
| Neonate             | 3.5         | 50          | 0.23                                |
| 1 month             | 4.2         | 55          | 0.27                                |
| 3                   | 5.6         | 59          | 0.33                                |
| 6                   | 7.7         | 67          | 0.41                                |
| 1 year              | 10          | 76          | 0.49                                |
| 3                   | 15          | 94          | 0.65                                |
| 5                   | 18          | 108         | 0.74                                |
| 10                  | 30          | 132         | 1.1                                 |
| 14                  | 50          | 163         | 1.5                                 |
| Adult (male)        | 70          | 173         | 1.8                                 |
| Adult (female)      | 56          | 163         | 1.6                                 |

## 69.5 Normal Hematological Values (Table 69.5)

**Table 69.5** Hematology

|             | Age of life      |             |
|-------------|------------------|-------------|
| Hemoglobin  | 0–6 days         | 145–220 g/l |
|             | 7 days           | 140–186 g/l |
|             | 8 days–3 months  | 95–125 g/l  |
|             | 3 months–4 years | 110–140 g/l |
|             | 5–12 years       | 115–140 g/l |
| White cells | 0–6 days         | 10.2–26.0   |
|             | 7 days           | 5.0–21.0    |
|             | 8 days–6 months  | 6.0–15.0    |
|             | 7 months–5 years | 5.0–12.0    |
| Platelets   |                  | 150–450     |
| MCV         | 0–3 months       | 100–130 fl  |
|             | 3–4 months       | 85–100 fl   |
|             | 4 months–4 years | 70–86 fl    |
| Neutrophils | 0–3 days         | 5.0–13.0    |
|             | 4 days           | 1.5–10.0    |
|             | 5 days–6 years   | 1.5–8.0     |
|             | 7–11 years       | 2.0–6.0     |
| Lymphocytes | 0–2 days         | 2.0–4.5     |
|             | 3 days           | 3.0–9.0     |
|             | 4 days–12 months | 4.0–10.0    |
|             | 1–6 years        | 1.5–9.5     |

## 69.6 Calorie Requirements (Table 69.6)

**Table 69.6** Estimated calorie requirement per day by age, sex and physical activity (if they are sedentary they need roughly 20–25% less calorie)

| Age | Active male | Active female |
|-----|-------------|---------------|
| 2   | 1000        | 1000          |
| 3   | 1400        | 1400          |
| 4   | 1600        | 1400          |
| 5   | 1600        | 1600          |
| 6   | 1800        | 1600          |
| 7   | 1800        | 1800          |
| 8   | 2000        | 1800          |
| 9   | 2000        | 1800          |
| 10  | 2200        | 2000          |
| 11  | 2200        | 2000          |
| 12  | 2400        | 2200          |
| 13  | 2600        | 2200          |
| 14  | 2800        | 2400          |
| 15  | 3000        | 2400          |
| 16  | 3200        | 2400          |

## 69.7 Common Antibiotic Doses (Tables 69.7 and 69.8)

**Table 69.7** Oral antibiotic doses

| Antibiotic     | Oral (1 month–2 years) | Oral (2–6 years) | Oral (6–12 years) | Frequency |
|----------------|------------------------|------------------|-------------------|-----------|
| Penicillin G/V | 62.5 mg                | 125              | 250               | QDS       |
| Amoxicillin    | 0.25 ml/kg (125/31)    | 5 ml (125/31)    | 5 ml (125/31)     | TDS       |
| Flucloxacillin | 62.25 mg               | 125 mg           | 250               | QDS       |
| Cefuroxime     | 10 mg/kg               | 125 mg           | 250 mg            | TDS       |
| Metronidazole  | 125 mg                 | 250 mg           | 500 mg            | TDS       |
| Erythromycin   | 125 mg                 | 250 mg           | 500 mg            | QDS       |
| Vancomycin     | 5 mg/kg                | 5 mg/kg          | 62.5 mg           | TDS       |

**Table 69.8** Intravenous antibiotics

| Antibiotic                 | IV dose per kg                | Frequency        |
|----------------------------|-------------------------------|------------------|
| Ceftazidime                | 25 mg                         | TDS              |
| Ceftriaxone (IM/IV)        | 50 mg                         | OD               |
| Meropenem                  | 10 mg                         | TDS              |
| Gentamicin (levels needed) | 7 mg                          | OD               |
|                            | 2.5 mg                        | TDS              |
| Teicoplanin                | 10 mg (dose 1–3)<br>then 6 mg | BD<br>Once daily |



# Anatomical References

# 70

Ankit Sinha and Mark Davenport

---

## 70.1 Cranial Nerves

There are 12 cranial nerves which together convey specialized sensory input from the ears, tongue (taste), and nose (smell) together with skin sensation from the face, scalp, and neck; specialized motor control of the muscles of facial expression, some neck movements, and the delicate movements of the tongue, larynx, and muscles responsible for controlling swallowing; and finally parasympathetic control of the autonomic functions of the gastrointestinal tract and its offshoots (Table 70.1).

---

A. Sinha  
University College London, London, UK  
e-mail: [ankit.sinha.15@ucl.ac.uk](mailto:ankit.sinha.15@ucl.ac.uk)

M. Davenport (✉)  
King's College Hospital, London, UK

**Table 70.1** Cranial nerves

| Cranial nerve            | Role ( <i>S</i> Sensory;<br><i>M</i> Motor)                         | Course  | Notes   |
|--------------------------|---|---|---|
| I (Olfactory)            | S—smell   | Multiple through olfactory plate                      |   |
| II (Optic)               | S—vision  | Optic canal   | Part of central nervous system  |
| III (Oculomotor)         | M—all but two eye muscles   | Superior orbital fissure                              |   |
| IV (Trochlear)           | M—sup. oblique  | Superior orbital fissure                              | Smallest, longest, exits back of the brainstem                                      |
| V (Trigeminal)           | V1 S—ophthalmic   | V1 Sup. Orb. fissure                                  | M—mastication   |
|                          | V2 S—maxillary  | V2 F. rotundum  |   |
|                          | V3 S—mandibular   | V3 F. ovale   |   |
| VI (Abducens)            | M—abducens  | Superior orbital fissure                              |   |
| VII (Facial)             | M/S (taste)   | Internal acoustic canal→                              | M—facial expression, platysma, Stapedius<br><i>Secretory</i> —submandibular/lingual |
|                          | T—temporal<br>Z—zygomatic<br>B—buccal<br>M—mandibular<br>C—cervical | Facial canal (→chorda tympani) → Stylomastoid foramen |   |
| VIII (Vestibulocochlear) | S—hearing and balance   | Internal acoustic canal                               |   |
| IX (Glossopharyngeal)    | M/S—(taste)   | Jugular foramen                                       | M—stylopharyngeus, <i>secretory</i> —parotid  |
| X (Vagus)                | M/S   | Jugular foramen                                       | M—larynx, pharynx, GI tract   |
| XI (Accessory)           | M—neck  | Jugular foramen                                       | M—trapezius and sternomastoid   |
| XII (Hypoglossal)        | M—tongue  | Hypoglossal canal                                     |   |

### 70.2 Dermatomes and Myotomes

There is a fairly rigid demarcation of cranial and spinal nerve projection on the skin surface (dermatome). This is mirrored in the distribution of skeletal muscle control throughout the body (myotome) (Fig. 70.1).

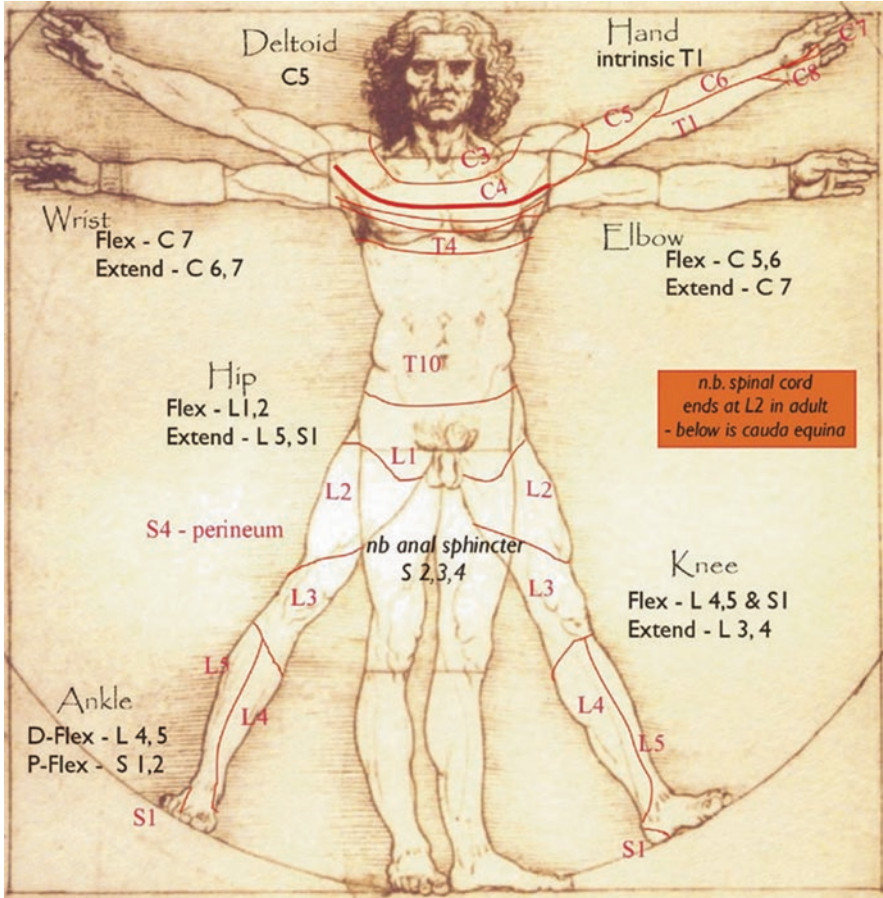


Fig. 70.1 Dermatomes and myotomes in Vitruvian Man (After Da Vinci)

### 70.3 Brachial Plexus

This is a nerve network receiving cutaneous sensory input from and controlling the muscles of the hand, forearm, arm, and shoulder from Cervical (C) 5 to Thoracic (T) 1. Each anterior nerve Root contributes to three Trunks which in turn refashion into the key median, ulnar, and radial nerves (Fig. 70.2).

#### Roots Trunks Division Cords Nerves

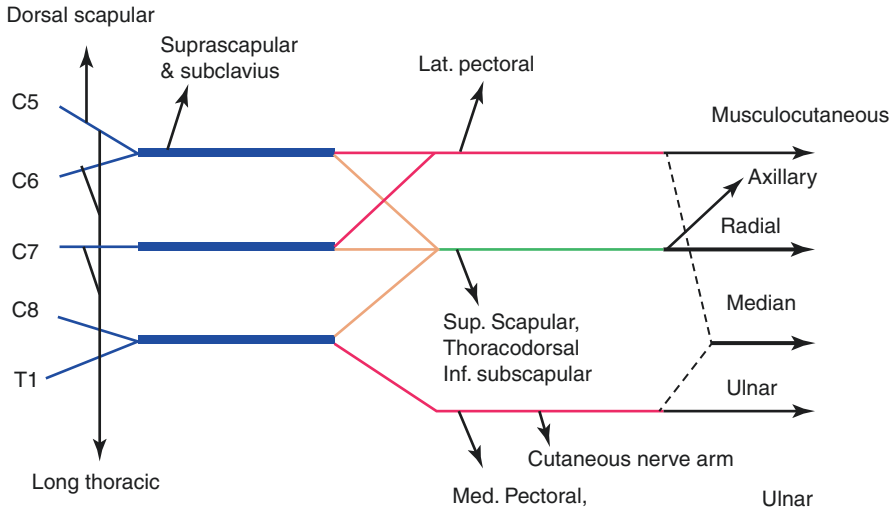


Fig. 70.2 Brachial plexus



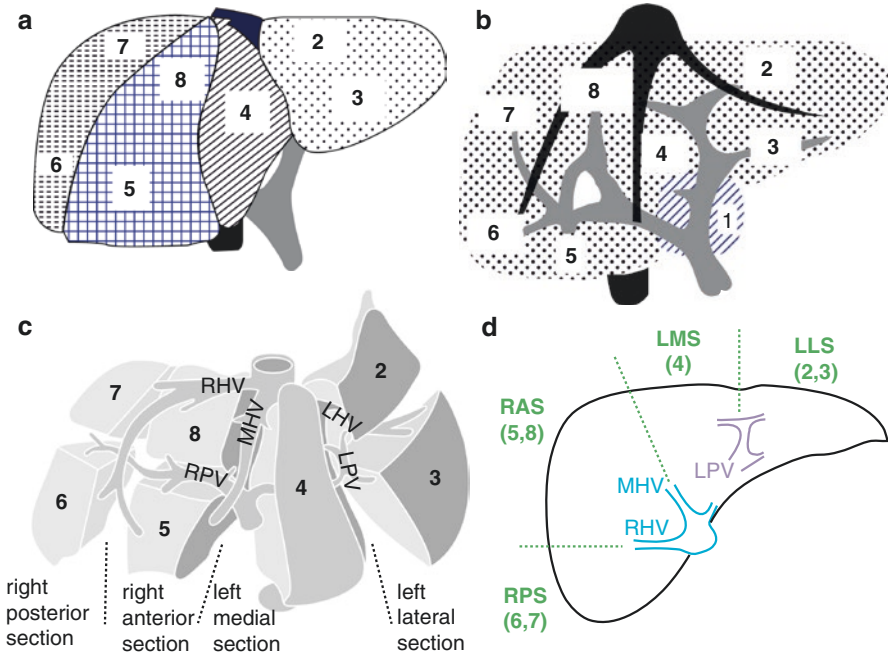
## 70.4 Segmental Liver Anatomy

The liver is the largest organ within the body. It has a dual blood supply (in-flow—portal vein 75%, hepatic artery 25%), which feeds a sinusoidal network with reformation as the hepatic veins and then drainage into the IVC.

There is a fundamental division into Right and Left along the “*Principle Plane*” of *Cantlie*,<sup>1</sup> each being supplied by right and left portal vein, respectively. The plane runs from gallbladder bed along the line of the middle hepatic vein toward its confluence with the left hepatic vein.

The “anatomical” lobes are a smaller left and larger right divided by a fissure from which the *falciform ligament* emerges to narrow onto the undersurface of the umbilicus. Its free edge carries the obliterated umbilical vein as the *ligamentum teres*.

There are *eight segments (of Couinaud)*<sup>2</sup> that are numbered in a clockwise manner I to IX. The *falciform ligament* separates segments II and III from IV. They are potentially independent units with a limited crossover (Fig. 70.3).



**Fig. 70.3** Liver anatomy. (a) segmental anatomy of liver (1-8). (b) coronal plane of liver showing distribution of segments 1-8. (c) 3D representation of liver showing distribution of segments 1-8 with 4 sections. (d) Four sections defined by right hepatic vein (RHV), middle hepatic vein (MHV) and left hepatic vein (LHV)

<sup>1</sup> Sir James Cantlie (1851–1926)—Scottish surgeon with close ties to Hong Kong where he founded the School of Medicine.

<sup>2</sup> Claude Couinaud (1922–2008)—French anatomist who developed this segmental concept in the 1950s.

- *Right*—V, VI, VII, VIII
- *Left*—II, III, IV (quadrate lobe)
- *Segment I—caudate lobe*. Surrounds the vena cava, and has separate venous drainage through 4–8 small direct veins.

## 70.5 The Lungs and Diaphragm

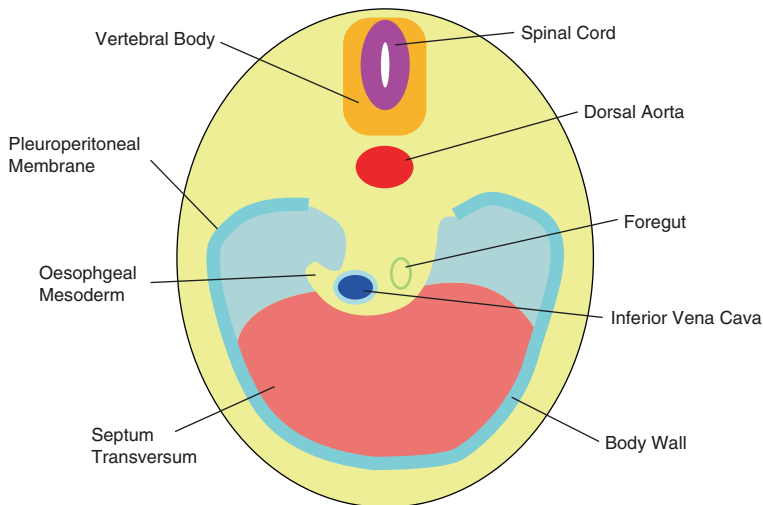
The respiratory tract can be anatomically divided into upper and lower parts. The upper tract consists of the nasopharynx and larynx, whereas the lower tract comprises the trachea, bronchi, and the lung parenchyma. The carina refers to the point of division of trachea into the bronchi with the right main bronchus being more vertical than the left, as well as being shorter and wider.

The right lung is divided into three lobes. The upper and middle lobes are divided by the horizontal fissure, and the middle and lower lobes are divided by the oblique fissure. The left lung is smaller and has an upper and lower lobe and a smaller analogous lobe restricted by the heart known as the lingular lobe. The hilum of the lung consists of the main bronchus, with the bronchopulmonary (hilar) lymph nodes inferior to it. The vessels consist of the pulmonary artery superiorly, with the pulmonary veins entering below it.

The lungs are surrounded by two layers of pleura. The visceral pleura adheres to the lung surface, and the parietal pleura lines the inner chest wall, outer mediastinum, and diaphragm.

The *diaphragm* is composed of the costal and crural domains. The costal diaphragm is a thin layer of muscle that extends from the ribs laterally and anteriorly to the central tendon at the apex of the domed diaphragm. The crural diaphragm is a thicker layer of muscle connecting the central tendon to the esophagus, aorta, and vertebrae posteriorly.

Figure 70.4 illustrates the developmental origins of the diaphragm and these are: the septum transversum, the pleuroperitoneal folds, and the somites of the esophageal mesoderm.



**Fig. 70.4** Embryology of diaphragm

## 70.6 Heart

Almost two-thirds of the sternocostal (anterior) surface of the heart is formed by the right ventricle. The left border is formed by the left ventricle and the auricle of the left atrium, and the right border is formed by the right atrium (which is related to the central tendon of the diaphragm at the level of T8).

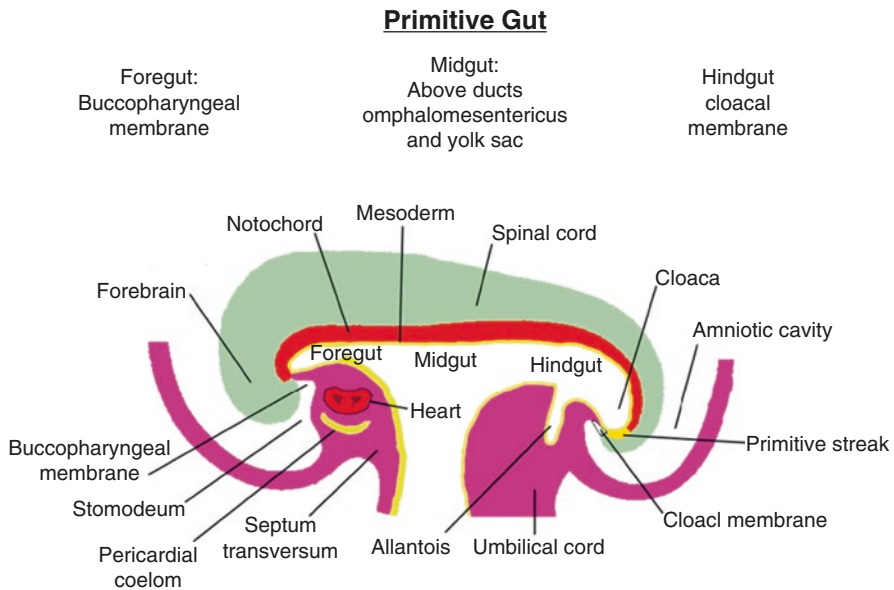
*Koch's triangle*<sup>3</sup> indicates the location of the atrioventricular node and is composed of the base of the septal leaflet of the tricuspid valve, the anterior side of the *tendon of Todaro*, and the medial margin of the coronary sinus ostium.

The conducting tissue of the heart is made up of a:

- Sinoatrial (SA) node
  - Blood supply—right coronary artery in 90% and left coronary artery in 10%.
- Atrioventricular (AV) node
  - Blood supply—right coronary artery in 60–70% of the population and left coronary artery in 30–40%.

## 70.7 Gastrointestinal Tract

The embryonic gastrointestinal tract can be divided into foregut, midgut, and hindgut, each with a blood supply derived from arteries from the front of the aorta—respectively the coeliac axis, superior mesenteric, and inferior mesenteric arteries (Fig. 70.5).



**Fig. 70.5** Cross-section of the embryo at day 18 (post-fertilization)

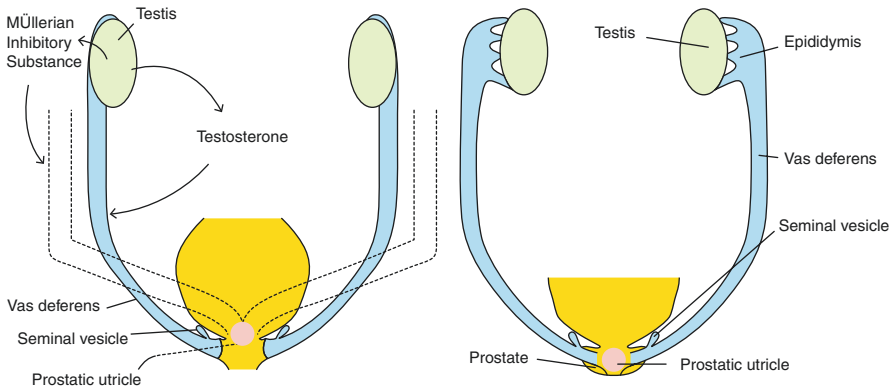
<sup>3</sup>Walter Karl Koch (1880–1962)—German cardiologist.

The foregut runs from the mouth through to the 2nd part of the duodenum, the midgut to a point about 2/3 along the future transverse colon and the hindgut to the upper anal canal.

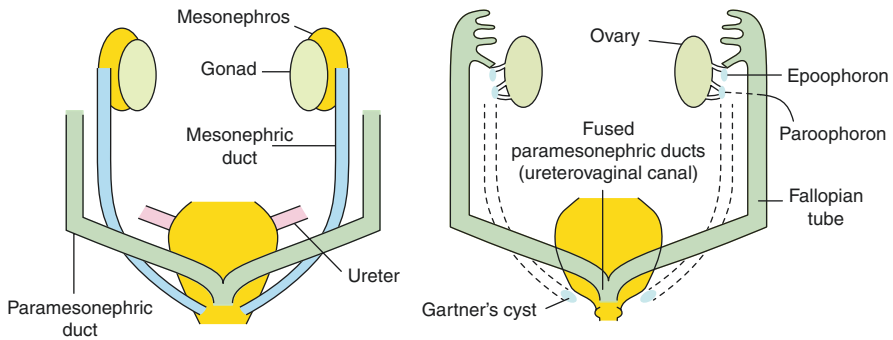
### 70.8 Genitourinary System

There are three distinct renal structures embryologically: the *pronephros* (cervical), *mesonephros* (thoracolumbar), and the *metanephros* (lumbar) derived from a bulge (*nephrogenic cord*) on the posterior abdominal wall, lateral to the attachment of the dorsal mesentery. Both the pronephros and mesonephros disappear though the mesonephric duct (or Wolffian duct) persists.

This Wolffian duct forms mainly the male genital tract, whereas the paramesonephric (or Mullerian) duct forms the female genital tract. The coelomic epithelium lining the medial nephrogenic cord forms the gonads (ovaries and testes). The cloaca is divided by the urorectal septum into the broad ventral Primitive urogenital sinus, and the narrow dorsal Primitive rectum (Figs. 70.6 and 70.7).



**Fig. 70.6** Development of male genitalia



**Fig. 70.7** Development of female genitalia

The *metanephros* (*permanent kidney*) develops from two sources. The lower part of the mesonephric duct forms the ureteric bud, which gives rise to the collecting part of the kidney: ureter, pelvis, calyces, and collecting tubules. The lower segments of the intermediate mesoderm comprise the metanephric cap, which forms the nephrons.

---

## 70.9 Inguinal Anatomy

The inguinal canal runs between the deep ring formed within transversus abdominis and the superficial triangular-shaped defect in the external oblique aponeurosis and is the pathway for the indirect inguinal hernia. The floor is formed by the in-turned aponeurosis as the inguinal ligament. Its roof is formed by arching fibers from the internal oblique and transversus abdominis muscles. Its anterior wall is formed by the external oblique aponeurosis and internal oblique muscle laterally with the posterior wall formed by the transversalis fascia and the conjoint tendon medially.

*Hasselbach's triangle* is the posterior wall: Bounded medially by the lateral margin of the rectus sheath; infero-laterally by the inguinal ligament; and laterally by the inferior epigastric artery. This is the site of a direct inguinal hernia.

---

## 70.10 Pharyngeal Arches

Pharyngeal (or branchial arches) are mesodermal thickenings in the cranial most part of the foregut appearing in the 4th week. There are six initially but the fifth arch disappears entirely. Each has its own nerve, artery, and cartilaginous core (Table 70.2).

**Table 70.2** Pharyngeal apparatus

| Name                  | Nerve                            | Artery  | Muscle  | Bone   | Other                               |
|-----------------------|----------------------------------|---|---|--|-------------------------------------|
| 1st (Mandibular arch) | Mandibular nerve, chorda tympani | Maxillary artery                              | Masseter, temporalis, mylohyoid, anterior digastric                     | Malleus, incus   |                                     |
| 2nd (Hyoid arch)      | VI (Facial)                      | Stapedial artery                              | Stapedius, stylohyoid, posterior digastric, platysma, facial, frontalis | Stapes, styloid process, part of hyoid, and lesser cornu |                                     |
| 3rd                   | IX (Glossopharyngeal)            | Internal carotid                              | Stylopharyngeus   | Greater cornu, and part of hyoid                         | Thymus(part), inferior parathyroids |
| 4th                   | X (superior laryngeal)           | Aortic arch (part)<br>Right subclavian (part) | Larynx and soft palate  |  | Superior parathyroids               |
| 6th                   | X (recurrent laryngeal)          | Pulmonary (part).                             |   |  |                                     |



Apurva More and Mark Davenport

## 71.1 Prenatal Development

- Total of 40 weeks (280 days) gestation and is conventionally measured from the first day of the last period—*so, fertilization should actually occur at +2 weeks.*

### Three Trimesters<sup>1</sup>

- 1st trimester
  - Weeks 1–13
- 2nd trimester
  - Weeks 14–27
- 3rd trimester
  - Weeks 28–40

### 71.1.1 “Egg” Phase: 1–4 Days

- Fertilization (*zygote*) leads to the *morula*,<sup>2</sup> and then the *blastocyst* (58 cells+) and finally implants into the wall of the uterus.

---

<sup>1</sup>Trimester (Latin)—3 months.

<sup>2</sup>Morula (Latin)—mulberry.

---

A. More  
Nottingham University Hospital, Nottingham, UK

M. Davenport (✉)  
King’s College Hospital, London, UK

### 71.1.2 Embryo Phase

Controversial definition of beginning but is said to end at the end of the 8th week.

- Gastrulation and formation of trilaminar disc (16 days)
- Yolk sac and amnion formation
- “Tube within a tube”
- Fusion of neural folds (22 days)
- Formation of urorectal septum, dorsal pancreatic bud, rupture of oropharyngeal membrane (26 days)
- Formation of primary intestinal loop (32 days)
- Ascent of the kidneys (37 days)
- Limb buds show distinct fingers (41 days)
- Closure of pericardio-pleural-peritoneal canals (51 days)
- SVC formed, patency of entire gastrointestinal tract (56 days)

### 71.1.3 Fetal Phase

- Extends from the 8th week until birth

---

## 71.2 Ultrasound Scans in Pregnancy

- *Viability scan*
  - 6–10 weeks
  - Carried out usually transvaginally. To determine number of fetuses and viability.
- *11–13 week scan*
  - Transabdominal. To determine accurate dating of pregnancy, assess the risks of chromosomal anomaly (nuchal translucency, etc.).
  - Some major anomalies visible.
- *Anomaly scan*
  - 18–22 weeks
  - Transabdominal. Assessment of facial appearance and determines whether thoracic and abdominal organ anomalies exist.
- *Cardiac scan*
  - 20 weeks onward
  - To assess the risk of cardiac anomalies
- *Well-being scan*
  - 32 weeks onward
  - To prepare for birth, and assess fetal growth and placental function



### 71.3 Developmental Milestones

Developmental delay occurs in up to 15% of children under 5 years of age, and about half with developmental problems are detected before they begin school. Developmental assessment may involve parent completed questionnaires, for example, the *Ages and Stages Questionnaire (ASQ 3™)* or practitioner completed assessment such as the *Denver Developmental Screening Test*. This was devised in 1969 and revised in 1992 (DENVER II) and breaks down development into four domains: Gross Motor; Fine Motor; Vision and Hearing; and Social skills.

#### Example Milestones

- 1–2 months
  - Smiles, responds to bell, lifts head, regards face
- 2–6 months
- Hand regard (i.e., follows hand with eyes)
  - Loses “grasp” reflex
  - Better head control
  - Objects taken to mouth
- 6 months
  - Gross
    - Rises, rolls over, sits with support, raises head, starts to crawl
  - Fine
    - Whole hand (“palmer”) grasp
  - Verbal
    - Babbles
  - Social
    - “Peek-a-boo”
- 12 months
  - Begins to walk, stands supported
  - “Pincer” grasp
  - Understands simple instructions, knows name
  - “Wants...,” plays ball, waves goodbye
- 18 months
  - Walks up stairs
  - Builds three cube tower, drinks from cup
  - Says 5–20 words, combines
  - Helps in house, uses spoon
- 2 years
  - Runs, kicks ball, jumps
  - Tower of eight cubes. Copies circle
  - Says up to 50 words. Two-word phrases. Intelligible
  - Scribbles, turns pages, puts on clothes

## Further Reading

Centre for Disease Control (USA). <https://www.cdc.gov/ncbddd/childdevelopment/screening.html>

# Index

## A

- Abdomen, acute
  - causes, 430
  - clinical features
    - acute appendicitis, 430–431
    - incarcerated inguinal hernia, 432
    - intussusception, 431–432
    - ovarian torsion, 432
  - definition, 429
  - schematic of, 429
- Abdominal pain, causes of
  - familial mediterranean fever, 439
  - Helicobacter pylori*, 435–436
  - lead poisoning (painter's colic), 438
  - porphyrias, 438
  - Yersinia infections, 436
- Abdominal trauma
  - blunt, nonoperative management, 102
  - clinical features, 100
  - epidemiology, 99
  - laparotomy for, 103
  - management, 100–102
  - mechanism of, 99–100
  - organs in
    - liver injury, 105–106
    - pancreatic injury, 107
    - renal injury, 107
    - splenic injury, 105
  - penetration of
    - laparotomy, 104
    - management of, 103–104
- Abdominal wall defects
  - exomphalos
    - appearance of, 144
    - clinical features, 174–175
    - embryology, 182
    - management, 176
  - gastroschisis
    - appearance of, 177
    - clinical features, 177
    - management, 178
- Acalculous cholecystitis, 224
- Acid–base
  - imbalance, 23
  - metabolic acidosis, 24
  - metabolic alkalosis, 24
- Adenocarcinoma, 258
- $\alpha$ -Feto protein ( $\alpha$ -FP), 392
- Airway problems
  - newborns and children
    - clinical features, 547–548
    - investigations, 548–549
    - management, 549–550
    - observations, 545
    - outcomes, 550
    - pathogenesis, 545–547
- Allergic reactions, 41
- Altman classification, sacrococcygeal teratomas, 395
- Anatomical reference
  - cranial nerves, 581, 582
  - dermatomes and myotomes, 581, 583
  - segmental liver anatomy, 582–583
- Anemia, 11
- Anion gap, 23
- Ankyloglossia. *See* Tongue tie
- Ann Arbor classification, Hodgkin's lymphoma, 399
- Annular pancreas, 228
- Anomaly scan, 592

- Anorectal malformations (ARMs)  
 anatomical classification of, 182  
 associated anomalies, 182  
 clinical features  
   female infant, algorithm for, 183–184  
   male infant, algorithm for, 183  
 colostomy, defunctioning, 186  
 embryology, 182  
 epidemiology, 181  
 management  
   posterior sagittal anorectoplasty (PSARP), 188–189  
   sacral ratio, 185
- Anorectal manometry (ARM), 473
- Antegrade continent enema (ACE), 474
- Anti-inflammatory cytokines, 28
- Aortic valve stenosis, 507
- Appendicitis  
 acute, 430–431  
 clinical features  
   imaging, 431  
   investigations, 431  
 epidemiology, 441  
 outcome, 445–446  
 pathology, 441–442  
 surgery  
   antibiotic regimen, 444  
   laparoscopic appendectomy, 445  
   open appendectomy, 445  
   timing, 444–445  
   trocar appendectomy, 446
- ARMs. *See* Anorectal malformations
- Ascending testes, 302
- Assisted ventilation, 84
- B**
- Bariatric surgery  
 clinical features, 540  
 outcomes, 543  
 prevalence of childhood/adolescent obesity, 539–540  
 surgery, 540–543
- Base excess/deficit, 23–24
- Benign liver tumors  
 clinical features, 387  
 focal nodular hyperplasia and hepatic adenomas, 388  
 hemangiomas, 386  
 management, 388  
 mesenchymal hamartomas, 388  
 pathology, 386–387
- Bilateral Wilms' tumor (stage V), 368
- Biliary atresia (BA)  
 classification, 216  
 clinical features, 216–217  
 complications, 218–219  
 embryology, 215–216  
 epidemiology, 215  
 investigations (*see* Jaundice)  
 outcome, 219  
 surgery, 217–218
- Biliary dyskinesia, 225
- Bilirubin metabolism, jaundice, 203–204
- Bisacodyl*<sup>TM</sup>, 472
- Bladder exstrophy. *See* Exstrophy–epispadias complex
- Bladder outlet obstruction, 288–289
- Blood transfusion (UK-specific)  
 ABO system, 39  
 cryoprecipitate, 41  
 fresh frozen plasma and platelets, 41  
 minor groups, 40  
 one unit–single donation, 40  
 Rhesus (D) system, 40  
 transfusion reactions, 41–42  
 transmissible hazards of, 42
- Blunt abdominal trauma, nonoperative management, 102
- Bone cysts, 565
- Branchial fistula/sinus/cyst, 490–492
- Bronchogenic cysts, 118–119
- Bronchopulmonary sequestration (BPS), 112–114
- C**
- Calories, catabolism, 17
- Cancer risk, ulcerative colitis (UC), 364
- Carbohydrate, PN constituents, 58–59
- Cardiac injury, 93–94
- Cardiac scan, 592
- Cardiogenic shock, 34
- Caroli's disease, 211
- Cat scratch disease, 494–495
- CBV. *See* Circulating blood volume (CBV)
- Cervical node infections, 493
- Chest syndrome, acute, 44
- Chest X-ray, diaphragmatic hernia, 123
- Children's oncology group (COG)  
 staging, 384
- Choledochal malformations  
 clinical features, 211–212  
 cystic malformation, surgery, 212–213  
 epidemiology, 209

Kings college hospital  
   classification, 209–211  
   outcome, 213  
   pathogenesis, 211  
 Cholestasis, 64  
 Chronic intestinal pseudo-obstruction  
   (CIP), 58  
 Circulating blood volume (CBV), 32  
 Cloacal exstrophy. *See* Exstrophy–  
   epispadias complex  
 Colloids vs. crystalloids, 35  
 Colon atresia, 149  
 Colorectal disease, 569  
 Congenital adrenal hyperplasia,  
   332, 335  
 Congenital cystic adenomatoid malformation  
   (CCAM), 114–117  
 Congenital diaphragmatic hernia  
   (CDH), 129–136  
 Congenital high airway obstruction syndrome  
   (CHAOS), 508  
 Congenital lobar emphysema (CLE), 118  
 Constipation  
   Botox injection, 475  
   clinical presentation, 471–472  
   investigations, 472–473  
   laxatives, 472  
   role of manual evacuation, 474  
   sigmoid colectomy, 475  
 Coombs' test, 42  
 Cord care, 9  
 Cranial nerves, 581, 582  
 Crohn's disease  
   clinical features  
     complications, 458  
     extra-intestinal features, 459  
     investigations, 458  
   etiology, 458  
   inflammatory bowel disease,  
     epidemiology of, 457  
   outcome, 463  
   pathology, 458  
   and ulcerative colitis, 457  
 Cryptorchidism  
   anatomy, 299  
   causes, 300  
   clinical features, 301  
   embryology, 300  
   management, 301–303  
   outcome, 303  
 Cystic fibrosis (CF), 165  
 Cystic malformation,  
   212–213  
 Cystoplasty complications, 321  
 Cytomegalovirus (CMV)  
   infection, 467

## D

Dehydration  
   infective causes, 19  
   management  
     rehydration solutions, 19  
     types of, 20  
     WHO classification of, 20  
   surgical causes, 20  
 Delayed extravascular hemolysis, 41  
 Dermatomes and myotomes, 581  
 Dermoid cysts, 498  
 Developmental lung anomalies  
   azygous lobe, 112  
   bronchogenic cysts  
     definition, 118  
     investigation, 119  
   bronchopulmonary anomalies, classifica-  
     tion of, 112  
   bronchopulmonary sequestration (BPS)  
     clinical features, 113  
     definition, 112  
     investigations, 113  
     types, 112–113  
   congenital cystic adenomatoid malforma-  
     tion (CCAM)  
     Adzick classification, 114  
     clinical features, 116  
     CT scan, 116  
     definition, 114  
     malignancy and, 117  
     Stocker classification, 117  
   congenital lobar emphysema (CLE)  
     clinical features, 118  
     definition, 118  
     surgery, 118  
   embryology, 111  
   management, 114  
   pulmonary agenesis and hypoplasia, 112  
 Diaphragmatic hernia  
   associations, 129–130  
   CDH, minimally invasive surgery of, 136  
   clinical features  
     antenatal, 131  
     chest X-ray, 132  
     postmortem picture of, 132  
     postnatal, 132–133  
   complications and outcome, 135  
   embryology, 130  
   epidemiology, 129  
   fetal surgery, 136  
   management  
     delivery suite, 133  
     in intensive care unit, 133–134  
     second-line therapy, 134  
   pulmonary hypoplasia, 131  
   surgery, 134–135

- Diaphragm injury, 95
- Disorder of sex development (DSD)
- clinical features, 331–334
  - embryology, 331
  - investigations, 334
  - long-term outcomes, 336
  - principles, 334–335
  - surgery, 334–335
- Distal intestinal obstruction syndrome (DIOS)
- clinical features, 170
  - definition, 170
  - management, 170
- Distributive shock, 31
- DSD. *See* Disorder of sex development
- Duodenal atresia (duodenoduodenostomy), 147–148
- Duplex anomalies, UPJ obstruction
- clinical features, 274
  - investigations, 274–275
  - pelvicaleceal systems, 273
  - treatment, 275
- E**
- EA. *See* Esophageal atresia
- EBV. *See* Epstein–Barr virus
- Ectopic ureter
- abnormalities, 275
  - clinical features, 276
  - surgery, 276
- Egg phase, prenatal development, 591
- Electrolytes
- calcium, 22
  - gastrointestinal secretions, 18
  - potassium, 21
  - requirements of, 18
- Embryonic prenatal development, 111
- Empyema, 517
- Endodermal sinus tumors (ESTs), 392
- Enuresis
- causes of, 338
  - clinical features, 338–339
  - management, 339–340
  - physiology, 338
- Epidermoid cysts, 498
- Epispadias. *See* Exstrophy–epispadias complex
- Epstein–Barr virus (EBV), 398
- Esophageal atresia (EA)
- anastomosis, 40
  - anatomical classification, 122
  - clinical features
    - postnatal, 123–124
    - prenatal, 123
  - embryology, 122
  - infant and trocar position for, 519
  - long-term outcome, 127
  - management, 123
  - prognostic classifications, 127
  - surgery
    - complications, 126
    - and distal TEF, 124
    - Foker procedure, 125
    - long-gap, 124–125
    - Replogle tube, 125
    - respiratory distress syndrome and TEF, 126
    - thorascopic repair, 126–127
- Ethibloc®, 498
- Exomphalos
- appearance of, 177
  - clinical features, 174–175
  - embryology, 173
  - management, 176
- Exstrophy–epispadias complex
- classic bladder exstrophy, 253
  - clinical features, 254–255
  - cloacal exstrophy, 253
  - complications, 257
  - embryology, 254
  - management
    - Kelly procedure, 256
    - Mitchell technique, 256
    - objectives of, 255
    - staged functional closure, 255–256
    - outcome, 257–258
    - primary epispadias, 258
- Extracorporeal membrane oxygenation (ECMO), 134
- Extragonadal GCT staging, 393
- Ex-utero intrapartum treatment (EXIT), 508
- F**
- Familial mediterranean fever, 439
- Fat, PN constituents, 58–60
- Febrile reaction, 41
- Feeding, 9
- Fetal circulation, 7
- Fetal surgery
- aortic valve stenosis, 507
  - assessment of
    - FETENDO approach, 501
    - open fetal surgery, 500
    - operating room setup for, 501
  - bladder outlet obstruction, 505–506
  - congenital diaphragmatic hernia (CDH), 502–503

- congenital high airway obstruction syndrome (CHAOS), 508
  - diseases, 499
  - efficacy of, 506
  - ethics, 500
  - mass lesions, hydrops, 504
  - myelomeningocele (spina bifida), 506
  - twin anomalies, 503–504
  - Fibrous dysplasia, 565
  - Fluid physiology. *See* Normal fluid physiology
  - Focal nodular hyperplasia and hepatic adenomas, 388
  - Fowler–Stephen’s principle, 302
- G**
- Gallbladder disease
    - acalculous cholecystitis, 224
    - biliary dyskinesia, 225
    - clinical features and investigations, 223
    - congenital anomalies of, 221
    - gallstone disease, 221–224
    - management, 224
    - surgery, 224
  - Gastro-esophageal reflux (GER)
    - associations and predispositions, 414–415
    - clinical features
      - airway problems, 415
      - investigations, 415–416
    - medical management, 417
    - outcome, 420
    - pathophysiology, 414
    - physiology, 413–414
    - surgery, 417–420
  - Gastrografin®, 166, 168
  - Gastrointestinal bleeding
    - causes of, 424
    - clinical features
      - high GI bleeding, 423–425
      - low GI bleeding, 425–427
    - investigations, 422
    - management of, 423–427
  - Gastrointestinal secretions, electrolyte content, 18
  - Gastroschisis
    - appearance of, 177
    - clinical features, 177
    - complications, 178–179
    - management, 178
    - outcome, 179
  - Gastrostomy button and laparoscopic fundoplication, 514–516
  - GER. *See* Gastro-esophageal reflux
  - Germ-cell tumors (GCTs). *See* Teratomas
  - Gestation age, definition, 9
  - Glasgow Coma Scale (GCS), 81
  - Graft *versus* host disease (GVHD), 485
  - Great vessel injury, 93
  - Groin hernia, 305–309.
    - See also* Inguinal hernias
- H**
- Head injury
    - in children, 79
    - classification and pathophysiology, 80–81
    - clinical assessment, 81–84
    - prevention of, 85
  - Helicobacter pylori*, 435–436
  - Hemangioendotheliomas, 386
  - Hemangiomas, 386
  - Hematology, surgeons. *See* Surgeons
    - hematology
  - Hemodynamically unstable vs. stable, 101
  - Hemolytic reaction, 41
  - Hemothorax, 92
  - Henderson equation, 23
  - Henderson-Hasselbalch equation, 23
  - Hepatoblastoma, 382
  - Hepatocellular carcinoma (HCC), 383
  - Hereditary multiple intestinal atresia (HMIA), 145
  - Hereditary pancreatitis, 230
  - Hernia. *See also* Inguinal hernias
    - umbilicus, 533–534
  - Hirschsprung’s disease (HD)
    - anatomy, 194–195
    - clinical features
      - contrast study, 197–198
      - differential diagnosis, 198
    - embryology, 194
    - epidemiology, 193–194
    - etiology, 195–196
    - genetics, 195
    - management, 198
    - outcome, 200
    - pathology, 196
    - segments in, 196
    - surgery
      - colostomy, 198–199
      - pull-through procedure, 199–200
  - Hodgkin’s lymphoma (HL)
    - childhood lymphomas, 397
    - clinical features and investigations, 398
    - etiology, 398
    - management, 399–400
    - outcome, 400
  - Hormonal therapy, 301–302

- Hormone manipulation, hypospadias, 264
- Hormone therapy, undescended testes, 301–302
- Human developmental milestones  
age and behavior, 593  
pregnancy, ultrasound scans, 592  
prenatal development, 591–592
- Hydrocele  
classification, 309  
clinical features, 310  
management, 310  
surgery, 309
- Hydrocephalus  
anatomy  
acquired, 353–354  
congenital, 353–354  
ventricular system, cast of, 353  
clinical features, 354–357  
imaging  
CT/MRI criteria for, 355  
radionuclide cisternography, 356  
management  
medical, 357  
shunt complications, 358–359  
surgery, 357–358  
outcome, 360  
physiology, 351–352
- Hypercalcemia, 22
- Hyperkalemia, 21
- Hypocalcemia, 22
- Hypokalemia, 21
- Hypospadias  
clinical features, 262–263  
embryology, 261–262  
long-term outcome, 266  
surgery  
postoperative phase, 266  
preoperative, 264  
principles, 263–264
- Hypovolemic shock, 33
- I**
- Infection, 561
- Inflammation, 561
- Inflammatory bowel disease, 457
- Inguinal hernias  
clinical features, 306–307  
embryology, 306  
incarcerated, 307  
management, 307–308  
outcome, 309
- Injury and sepsis, metabolic response  
age differences, 30
- ebb and flow, early period  
ADH release, 28  
adrenaline/noradrenaline release, 28  
glucocorticoids, 28  
renin–angiotensin–aldosterone release, 28  
late period, 28  
multiple organ dysfunction syndrome (MODS), 29–30  
systemic inflammatory response syndrome (SIRS), 29  
tissue response, 28
- Insensible fluid loss, 17
- International Neuroblastoma Staging System (INSS), 375, 376
- Intestinal atresia  
associations of, 144–145  
clinical features, 146–147  
embryology, 144  
epidemiology, 143  
outcome, 149  
pathology  
classification, 145  
hereditary multiple intestinal atresia (HMIA), 145  
surgery  
colon atresia, 149  
duodenal atresia (duodenoduodenostomy), 147–148  
jejuno-ileal atresia, 148–149
- Intestinal failure-associated liver disease (IFALD), 64
- Intussusception  
clinical features, 450  
epidemiology, 449  
laparoscopic reduction, 453–454  
management, 452  
pathogenesis, 449–450  
surgery, 452–453
- Islet cell hyperplasia, 407
- J**
- Jaundice, 11  
bilirubin metabolism, 203–204  
older child, surgical jaundice, 207  
preterm infants, 204–205  
surgical jaundice, infants  
duodenal aspiration, 206  
endoscopic retrograde cholangiopancreatography, 206  
investigations, 207  
laparoscopy and cholangiography, 207  
liver biopsy, 205–206



- magnetic resonance cholangiopancreatography, 206
  - percutaneous transhepatic cholangiogram, 206
  - radionuclear isotope, 206
  
- K**
- Kasabach–Merritt syndrome, 387
- Kasai portoenterostomy, 218
- Kawasaki's disease, 495–496
- Kelly procedure, 256
- Klippel–Trenaunay syndrome (KTS), 525–527
  
- L**
- LA. *See* Local anesthesia
- Ladd's procedure, malrotation, 155–156, 516
- Laparoscopic fundoplication and gastrostomy button, 514
- Lead poisoning (painter's colic), 438
- Leydig cells, 299
- Lipomeningocele, 345, 346
- Liver
  - anatomy, segmental, 352, 353
  - tumors
    - benign, 386–388
    - children's oncology group (COG), 384
    - clinical features, 383
    - hepatoblastoma, 387
    - hepatocellular carcinoma (HCC), 381, 382
    - management, 388
    - outcome and hepatic metastases, 386
    - pathology, malignant tumors, 381
    - PRETEXT classification, 384
    - surgery, 367–368
- Liver transplantation (LT)
  - child assessment, 244–245
  - family assessment, 244–245
  - indications and contraindications, 243–244
  - living-related donors
    - complications, 248–250
    - postoperative care, 248
    - retransplantation, 249
  - outcome, 250
  - surgery
    - donor operation, 245–247
    - recipient operation, 247–248
- Local anesthesia (LA), 48–51
- Lung anomalies. *See* Developmental lung anomalies
- Lymphadenitis, 493
- Lymphatic malformations, 497–498
  
- Lymphomas
  - Hodgkin's lymphoma, 397–400
  - non-Hodgkin's lymphoma, 400–402
  
- M**
- Malign, 564
- Malignant melanoma, 405–406
- Malrotation
  - associations of, 151–152
  - clinical features
    - contrast studies in, 155
    - investigations, 154–155
    - ultrasound and CT scan identification of, 154
  - embryology, 152, 153
  - Ladd's procedure, 155–156, 516
  - outcome and complications, 156–157
- Massive transfusion, 35–36
- MCUG. *See* Micturating cystourethrogram
- Meatoplasty and glanuloplasty, hypospadias, 264–265
- Meckel's diverticulum, 426
- Meconium ileus (MI)
  - abdominal pain, differential diagnosis of, 170
  - clinical features, 167–169
  - colon structures and pancreatic enzymes, 169
  - cystic fibrosis, 166
  - definition, 165
  - distal intestinal obstruction syndrome (DIOS)
    - clinical features, 170
    - definition, 170
    - management, 170
  - epidemiology, 166
  - management, 170
  - meconium plug syndrome (MPS), 169–170
  - outcome, 169
  - surgery, 168–169
- Megarectum (MR), 473
- Megaureter
  - classification, 277
  - clinical features, 278
  - management, 278
- Meningomyelocele, patulous anus, 345
- Meso-Rex shunt, 240
- Metabolic acidosis, 24
- Metabolic alkalosis, 24–25
- Metabolic response. *See* Injury and sepsis, metabolic response

- Methicillin-resistant staphylococcus aureus (MRSA), 53
- Micturating cystourethrogram (MCUG), 274
- Mitchell technique, 256
- MODS. *See* Multiple organ dysfunction syndrome
- Monro–Kellie Doctrine-volume, intracranial content, 84
- Movicol*<sup>TM</sup>, 472
- MRSA. *See* Methicillin-resistant staphylococcus aureus
- Multimodal analgesia, 48
- Multiple organ dysfunction syndrome (MODS), 29–30
- Myelomeningocele, 345, 506
- N**
- Necrotizing enterocolitis (NEC)
- clinical features
    - Bell's staging, 161
    - investigations, 161
  - epidemiology, 159
  - management, 161–162
  - outcomes, 163
  - pathogenesis, 160
  - prevention, 162
  - surgical options, 162
- Necrotizing fasciitis, 54
- Neoplasm, 564
- Nephroblastoma. *See* Wilms' tumor (WT)
- Neural tube defects (NTD), 343
- Neuroblastoma
- clinical features, 373
  - cytogenetics and prognostic factors, 373
  - fetal tumors, 378
  - management
    - high risk group, 377–378
    - intermediate risk group, 377
    - low risk group, 377
  - origin, sites of, 372
  - pathology, 372–373
  - Shimada system classification, 372
  - staging, complex and evolving infantile, 374–376
- Neurogenic bladder
- anatomy, 317, 318
  - classification, 317–318
  - clinical evaluation, 318–319
  - etiology, 317, 318
  - management, 319–322
  - urodynamics, 319
- Newborn care
- fetal circulation, 7
  - fluid management, 13
  - immediate management after birth, 8–9
  - neonatal infections, 12–13
  - neonatal nutrition, 13–14
  - problems of premature, 9–11
  - respiratory adaptation, 8
- Newborn physiology, 8
- Nissen fundoplication, 512, 514
- Non-Hodgkin's lymphoma, 400–402
- Nontuberculous mycobacterium (NTM), 494
- Normal fluid physiology, 15
- Numerical references
- blood pressure, 577–578
  - calorie requirements, 580
  - common antibiotic doses, 580
  - conversion rates, 578
  - fluid requirements, 577
  - normal heart rate, 577–578
  - normal hematological values, 579
  - respiratory rate, 577–578
- O**
- Orchidopexy, 302–303
- Organ injuries
- liver injury, 105–106
  - pancreatic injury, 107
  - renal injury, 107
  - splenic injury, 105
- Orthopedic/peripheral neurology, 348–349
- Osteochondroma, 565
- Osteosarcoma, 565–568
- Ovarian torsion, 432
- P**
- Pancreatic disease
- acute pancreatitis, 229–232
  - annular pancreas, 228
  - chronic pancreatitis, 232–233
  - pancreas divisum, 228–229
- Pancreatic tumors, 407
- Pancreatoblastoma, 407
- Parenchymal injury, 90–91
- Parenteral nutrition (PN)
- complications, 62–63
  - concomitant medications, 63
  - constituents, 58–60
  - indications, 57–58
  - initiation, 60
  - long term, 63–64
  - monitoring, 60
  - multidisciplinary team, 64

- Parenteral nutrition associated liver disease (PNALD), 64
- Pediatric laparoscopy and thoracoscopy  
 esophageal atresia repair, 518–521  
 five-port Nissen technique, 514–516  
 malrotation (Ladd's procedure), 516  
 principles  
   instrumentation, 512–513  
   patient and port placement positioning, 511–512  
   pneumoperitoneum, 512  
   pneumothorax, 512  
   pyloric stenosis, pyloromyotomy, 513  
   thoracoscopic procedures, 517–518
- Pediatric orthopedics  
 acquired orthopedic conditions, 561–568  
 congenital orthopedic conditions, 560–561  
 normal variants early years, 559–560
- Perianal disease, 462–463
- Persistent hyperinsulinemic hypoglycemia of infancy (PHHI), 233–234
- Perthes disease, 561–562
- PN. *See* Parenteral nutrition
- Pneumoperitoneum, 512
- Pneumothorax, 512
- PONV. *See* Postoperative nausea and vomiting (PONV)
- Porphyrias, 438–439
- Portal hypertension  
 anatomy, 237–238  
 causes of, 238–241
- Portosystemic shunt, 241
- Posterior urethral valves (PUV)  
 anatomy, 287  
 antenatal intervention, 296–297  
 classification, 287–288  
 clinical features, 289–290  
 epidemiology, 288  
 long-term management, 293–294  
 long-term outcomes, 295–296  
 management, 291–293  
 pathophysiology, 288–289
- Postoperative fluid regimens, 17–19
- Postoperative nausea and vomiting (PONV), 50
- Posttransplant lymphoproliferative disease (PTLD), 485
- Pouchitis, 469
- Primary brain injury, 80
- Pringle's maneuver, 106
- PTLD. *See* Posttransplant lymphoproliferative disease (PTLD)
- Pull-through procedure, Hirschsprung's disease (HD), 199–200
- Pulmonary hypoplasia, 131
- PUV. *See* Posterior urethral valves (PUV)
- Pyrexia, 51–52
- Q**
- Quality of care  
 assessment, 553  
 business process reengineering, 553  
 care quality commission, UK, 552–553  
 improvement, 553  
 institute of medicine, USA, 552  
 lean, 554  
 manufacturing industry, 551  
 PDSA, 554  
 pediatric surgery, 555–556  
 quality improvement approaches, 553  
 six sigma, 554  
 statistical process control, 554
- R**
- Radio-isotope renal studies, 327
- Rectal prolapse  
 clinical features, 535  
 differential, 536  
 epidemiology, 535  
 investigations, 536  
 management, 536  
 surgery, 536
- Renal transplantation, 295
- Respiratory adaptation, 8
- Respiratory distress syndrome (RDS), 10
- Rhabdomyosarcoma (RMS)  
 clinical features, 404  
 etiology, 403  
 investigations, 403–404  
 management, 404–405  
 outcome, 405  
 pathology and genetics, 403
- Rhesus (D) system, 40
- Robotic pediatric surgery  
 advantages, 570–571  
 disadvantages, 571–572  
 indications, 572–574  
 Vinci system, 570
- Rye classification, Hodgkin's lymphoma (HL), 398
- S**
- Sacrococcygeal teratomas (SCT), 394–396
- Saline vs. albumin fluid evaluation (SAFE) trial, 35

- SCD. *See* Sickle cell disease (SCD)
- Scrotum, acute, 311–313
- SCT. *See* Sacrococcygeal teratomas (SCT)
- Secondary brain injury, 80
- Senokor*<sup>TM</sup>, 472
- Sepsis, 485
- Sertoli cells, 299
- SFU. *See* Society of Fetal Urology (SFU)
- Shock
  - age differences, 33–34
  - classification, 31–32
  - clinical features, 32–33
  - degree
    - ATLS® classification, 32
    - circulating blood volume (CBV), 32
  - management
    - colloids vs. crystalloids, 35
    - massive transfusion, 35–36
    - principles, 34–35
- Shunt complications, 358–359
- Sickle cell disease (SCD), 43
- SIRS. *See* Systemic inflammatory response syndrome (SIRS)
- Slipped upper femoral epiphysis (SUFE), 562–563
- Small bowel transplantation
  - assessment, 478–480
  - history, 477
  - indications, 478
  - outcomes, 485
  - surgery
    - complications, 484–485
    - donor selection, 480
    - donor surgery, 480–482
    - postoperative care, 483–484
    - recipient surgery, 482–483
- Society of Fetal Urology (SFU), 271
- Sphincteric incompetence, 319
- Spina bifida. *See also* Myelomeningocele
  - demography, 343
  - embryology, 344–345
  - etiology, 343–344
  - long term issues, 348–349
  - management, 346–347
  - outcome, 349
  - spina bifida cystica, 345–346
  - spina bifida occulta, 345
  - surgery, 347–348
- Spinal cord compression, 378
- Spinal cord injury without radiographic abnormality (SCIWORA), 82
- Staphylococci spp., wound infection, 52
- Stephens classification, ureterocele, 279
- Sternomastoid tumor, 496
- St Jude (Murphy) system, 402
- Sturge–Weber syndrome (SWS), 527
- Superior mesenteric artery (SMA), 152
- Surgeons hematology
  - coagulation tests
    - acute chest syndrome, 44
    - coombs’ test, 42
    - hemophilia, 38–39
    - leucocytosis, 44
    - need for blood transfusion, 40–41
    - normal process of coagulation, 37–38
    - sickle cell disease, 43
    - transfusion reactions, 41–42
- Surgical issues
  - rectal prolapse, 535–536
  - tongue tie (ankyloglossia), 531–532
  - umbilical issues, 532–534
- Surgical jaundice
  - infants
    - duodenal aspiration, 206
    - endoscopic retrograde cholangiopancreatography, 206
    - liver biopsy, 205–206
    - magnetic resonance cholangiopancreatography, 206
    - percutaneous transhepatic cholangiogram, 206
    - radionuclear isotope, 206
  - older child
    - extramural, 207
    - intramural, 207
    - mural, 207
- Surgical neck pathology
  - branchial fistula/sinus/cyst
    - clinical features, 491
    - investigation, 491
    - surgery, 491–492
  - cat scratch disease, 494–495
  - cervical node infections
    - clinical features, 493
    - lymphadenitis, pathogens, 493
  - dermoid and epidermoid cysts, 498
  - embryology, 490
  - Kawasaki’s disease
    - clinical features, 495
    - investigation, 495
    - management, 496
  - lymphatic malformations
    - associations, 497
    - clinical features, 497
    - cystic hygroma, 497
    - investigation, 497
    - management, 497–498

- nontuberculous mycobacterium (NTM), 494
  - sternomastoid tumor
    - clinical features, 496
    - investigation, 496
    - management, 496
  - teratomas
    - embryology, 391–392
    - incidence, 391
    - management, 394
  - thyroid tumors, 407–409
  - Systemic inflammatory response syndrome (SIRS), 29
- T**
- Teratomas
    - embryology, 391–392
    - incidence, 391
    - management, 394
    - pathology and classification, 392
    - risk groups, 393–394
    - sacrococcygeal teratomas (SCT)
      - delivery, 395
      - surgery, 395–396
  - Testes
    - torsion of
      - classification, 311
      - clinical features, 311–312
      - demography, 311
      - investigations, 312
      - outcome, 313
      - perinatal testicular torsion, 313
      - surgery, 312
  - Testicular appendages, torsion of, 313–314
  - Thermoregulation, 9–11
  - Thoracic trauma
    - anatomy, 88
    - cardiac injury, 93–94
    - diaphragm injury, 95
    - esophageal rupture, 95–96
    - great vessel injury, 93
    - hemothorax, 92
    - mechanisms of, 87
    - parenchymal Injury, 90–91
    - pneumothorax, 91–92
    - principles of management, 88
    - rib cage injury, 88–90
    - tracheobronchial injury, 93
    - traumatic asphyxia, 96
  - Thoracoscopic procedures. *See* Pediatric laparoscopy and thoracoscopy
  - Thyroid tumors
    - clinical features, 408, 532
    - etiological factors, 407–408
    - investigation, 408
    - management, 532
    - surgery, 408–409
  - Tongue tie
    - clinical features, 532
    - management, 532
  - Trans-anal irrigation (TAI), 474
  - Transfusion reactions, 41–42
  - Trauma management, principles
    - important points about systemic injuries, 77–78
    - management plan, 70–76
    - supplemental data, 78
  - Tumor lysis syndrome, 503–504
  - Twin reversed arterial perfusion (TRAP)
    - sequence, 503–504
  - Twin-twin transfusion syndrome (TTTS), 503
- U**
- Ulcerative colitis (UC)
    - clinical features, 466
    - epidemiology, 466
    - investigations, 467
    - management, 467–470
  - Undervirilized male, 331
  - Ureter
    - anatomy, 269–270
    - clinical features, 271
    - duplex anomalies, 273–275
    - ectopic ureter, 275–276
    - embryology, 269–270
    - etiology, 271
    - investigations, 271–273
    - megaureter, 277–278
    - surgery, 276
    - ureteroceles
      - clinical features, 279–280
      - definition and types, 279
      - stephens classification, 279
  - Ureteropelvic junction (UPJ) obstruction, 270–273
  - Urinary tract infection (UTI)
    - clinical features, 324–325
    - imaging, 326–327
    - investigations, 325–326
    - microbiology, 324
    - outcome, 328
    - risk factors, 324
    - treatment, 327–328

**V**

Vertebral, anorectal, cardiac, tracheoesophageal, renal, limb anomalies  
(VACTERL), 121

Viability scan, 592

**W**

Wilms' tumor (WT)  
clinical features, 365–367  
clinical patterns, 364  
epidemiology, 364

genetics, 365

management, 367–369

pathology, 365

prognosis, 369

**X**

XY DSD. *See* Undervirilized male

**Y**

Yersinia infections, 459