



Introduction

The Discseel® Procedure treats chronic low back and cervical discogenic pain, with or without extremity radiculopathy. The procedure is defined as a sequence of two steps: a diagnostic, nonprovocation annulogram, followed by intra-annular injection of nonautologous fibrin into every morphologically abnormal disc (torn disc) and into needle puncture holes created by the preceding diagnostic annulogram. Needle puncture holes are so imperceptibly small that some may believe this step of sealing needle puncture holes unnecessary, but highly favorable outcomes result by following this strict, pragmatic protocol. Prior attempts to regenerate discs by utilizing stem cells (mesenchymal precursor cells), PRP (platelet-rich plasma), or any biologic fail to reliably provide relief [1–10]. A prospective investigation pending publication demonstrates safety and statistically significant improvement of all 15 outcomes measured in 373 subjects at 24 months following the Discseel® Procedure [11].

Logic dictates that the efficacy of other intradiscal biologic treatments is compromised if those biologics leak from intervertebral discs, and conversely, efficacy should improve if that biologic remains within the disc, which is, after all, the intended site of action. Logic also dictates that any biologic failing to target pathology within the disc provides little to no value. In vivo investigations demonstrate that biologics, whether viscous or nonviscous, leak from degenerated, torn,

or disrupted discs, even when encapsulated in hydrogels or other delivery systems. Annular tears obviously pose a problem and include all common disc pathologies. So any biologic not addressing tears serves little to no benefit. The need to seal tears easily explains the necessity of tissue adhesives such as fibrin. In a published in vivo investigation, all radiolabeled stem cells (MPCs) injected into intervertebral discs of rabbits leaked from those discs, negating any potential treatment efficacy [12]. More disconcerting, however, was the discovery that the radiolabeled cells, which leaked, migrated into adjacent bone and were found within new, exuberant osteophyte formations adjacent to the treated discs [13]. These osteophytes were readily evident through both radiographic and gross visual inspection. Seeing that stem cells were associated with new osteophyte (bone spur) formation changes everything. Because it is one thing to recognize that a specific stem cell treatment provides no patient benefit, yet it is an entirely different problem to recognize that injected stem cells meant to help may actually cause harm by noting new and potentially deleterious bone spurs in vertebral canals or foramen, which may already be compromised due to the nature of degenerated discs. The Discseel® Procedure does not cause injectate leakage because it utilizes FDA-approved fibrin, a soft, “disc-like consistency” bio-adhesive made of two components meeting and coming together within the disc’s annular layers. It is slightly stronger, yet equally soft, when compared with natural discs. Therefore, this biologic glue immediately seals, allowing no leakage. Even more important, fibrin instigates the new disc tissue growth [14, 15].

K. J. Pauza (✉)

Baylor Scott and White, Texas Spine and Joint Hospital,
Tyler, TX, USA

Regenerative Sports Care Institute, Senior Physician,
New York, NY, USA

M. Moradian

Interventional Physiatrist, iSCORE (Interventional Spine Care and
Orthopedic Regenerative Experts, PC), Arcadia, CA, USA

G. Lutz

Hospital for Special Surgery, Regenerative Sports Care Institute,
New York, NY, USA

Background

The Discseel Procedure uses an FDA-approved nonautologous fibrin as a tissue adhesive, which is FDA approved for multiple applications in the human body. Studies affirm fibrin’s properties as a sealant, adhesive, anti-inflammatory, and chemotactic regenerative agent [14–16].

The efficacy realized that treating spines obviously depends, in a large part, on establishing an accurate pretreatment diagnosis. Many studies affirm that the ability to identify symptom etiology is not reliable or consistent when using MRIs, CTs, myelograms, or other common spine imaging modalities [16–25].

Investigations associated with the Discseel® Procedure strongly suggest that diagnosis made by annulograms, in conjunction with patient history, symptoms, and other findings, results in greater efficacy than any treatments relying on other diagnostic means, including those other treatments relying on provocation discography. Prior to these investigations relying on annulograms, provocation discography was the gold standard and still may be optimal with those practitioners unskilled at performing nonprovocation annulograms, or without physicians available to perform nonprovocation annulograms. This is based on results realized when annulograms precede intra-annular fibrin injection.

Prior to the advent of the Discseel® Procedure, there were no treatments successfully treating annular tears. Knowing the annulus' morphology was not specifically necessary while employing those treatments injecting "something" into the nucleus pulposus. Injecting fibrin glue best addresses annular tears, and tears are best identified through annulograms because they evaluate every disc's annular morphology in the region of symptomology.

Discography & Annulograms

"Relatively-primitive" provocation discography tests were previously thought to improve diagnostic specificity when evaluating axial symptomology [25–67] in comparison to traditional imaging modalities, such as MRI or CT, and that is true, but now with the advent of annulograms, their sensitivity supersedes provocation discography. However, even though provocation discography was at one time considered the standard of care, it is important to note that no investigation directly correlates provocation discography results with a successful treatment outcome of any type. In comparison, the Discseel® Procedure directly associates positive annulograms with efficacy following intra-annular fibrin injection. Although discography was meant to establish symptom etiology, it lacks the ability to reliably evaluate annular tears residing within the outer portions of the 22–25 concentric layers of the discs' annular lamella [67].

Investigations by Caragee [49] suggested that provocation discography resulted in accelerated disc degeneration, disc herniation, loss of disc height, loss of MRI signal intensity, and the development of reactive end-plate changes when compared with matched controls. Those studies, however, are controversial and imply, but do not prove, a causal relationship

between discography and disc degeneration. A potential benefit of annulograms proceeding sealing discs with fibrin is that the relationship between discography and premature disc degeneration may be mitigated for two reasons: first, because discography's iatrogenic disc damage does not necessarily apply to "low-pressure, nonprovocation" annulograms, with their comparatively low pressures and volumes. Second, fibrin immediately seals all intra-annular punctures created by performing the annulogram during the Discseel® Procedure. Together, these seem to mitigate concerns raised by Caragee's investigations [49], unless and until proven otherwise.

Discseel® Procedure vs. Intranuclear Fibrin

Injecting any mass into the disc's center nucleus pulposus is counterintuitive if one's treatment goal is to contain the nucleus by strengthening the outer annulus fibrosus. Interestingly ironic is that the other intra-discal treatments rely on injecting a mass into the center nucleus pulposus. That potentially and seemingly damaging technique is purportedly performed to regenerate nucleus pulposus cells. However, injecting any fluid or other mass-occupying substance into discs' center nucleus pulposus gel displaces that gel outward. This denotes Archimedes' property of displacement in fluid dynamics, and therefore the Discseel® Procedure intentionally avoids injecting fibrin into discs' centers. More preferably, fibrin injected intra-annularly creates a barrier maintaining existing nucleus pulposus within the discs' centers where it is needed. Both in vitro [70] and in vivo [11] investigations support the clinical utility of intradiscal, and more specifically, intra-annular, fibrin [11]. A randomized, blinded investigation comparing intradiscal, nonautologous fibrin vs. normal saline control disc injections demonstrated that statistically significant mechanical repair occurred along with improvement of the disc's biochemical milieu following the intradiscal fibrin treatment [68]. Disc pH increased to normal, and inflammatory constituents disappeared following intra-discal injection of fibrin but not following intra-discal injection of normal saline.

Early investigations of intradiscal fibrin demonstrated its value even before current refinements were incorporated into the Discseel® Procedure [11, 69–72]. Refinements incorporated to make the Discseel® Procedure include the following:

- Testing every disc in the region of symptoms with an annulogram and not relying on provocation discography
- Treating all discs in the region of symptoms that possess annular tears based on the annulogram and sealing needle puncture holes of every disc tested [11, 69–74]

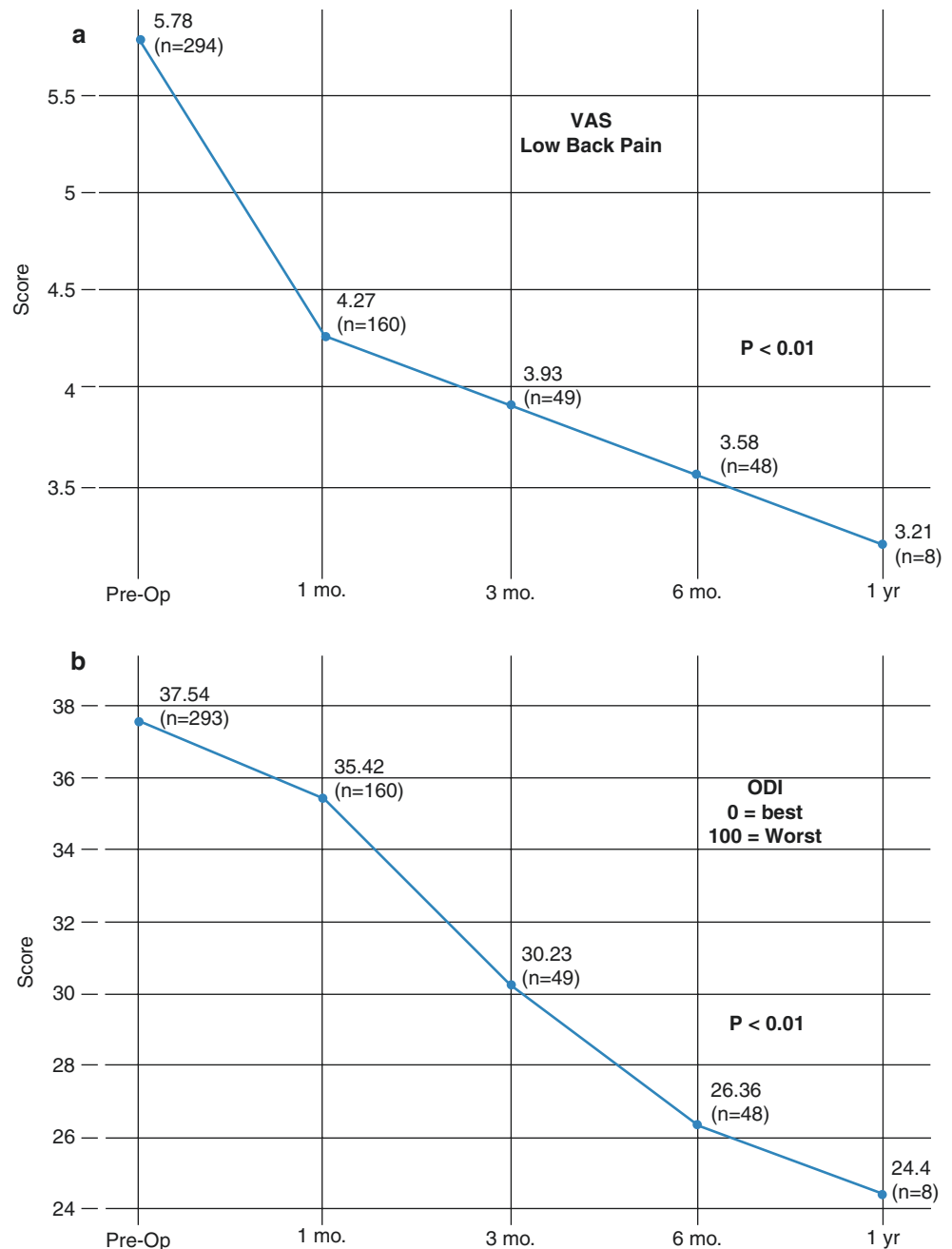
This Discseel® Procedure results in statistically significant improvement in treated patients’ pain, function, mental health, disability, and quality of life outcomes (Fig. 6.1) [11, 69–72]. Together, the combination of performing annulograms and injecting intra-annular fibrin at every location of disc annular tearing defines the Discseel® Procedure. Improved outcomes are realized with the aforementioned specific methodology [11].

Another benefit of annulograms over provocation discography is that they allow for the identification of otherwise radiographically imperceptible annular tears in otherwise seemingly normal discs, which might cause debilitating

symptoms. Detecting small peripheral annular tears may be necessary to adequately treat these tears. This process includes fastidiously performed annulograms done with contrast, allowing dynamic radiographic visualization of annular tears.

When annulograms are performed, contrast is visualized while flowing through annulus fibrosis defects (tears) while passing nociceptors, which may be sensitized by inflammatory constituents. This contrast flow mimics the flow of inflammatory mediators, or nucleus pulposus, which may often be “one in the same,” traveling through annular tears. The annulogram allows dynamic fluoroscopic visualization

Fig. 6.1 (a) Visual Analog Scores (VAS) from a prospective investigation following lumbar Discseel® Procedure performed in subjects with chronic low back pain with and without lower extremity symptoms. (b) Oswestry Disability Index (ODI) from a prospective investigation following lumbar Discseel® Procedure performed in subjects with chronic low back pain with and without lower extremity symptoms



of contrast flow within the 22–25 annular layers and outward onto tissue and structures adjacent to torn discs. Post-annulogram computed tomography (CT) is unnecessary to identify annular tears because static and dynamic plain film fluoroscopy obtained during annulograms provides adequate and precise tear identification.

Microanatomy and Biochemistry

The greatest concentration of nociceptors resides within the posterior aspect of the annulus fibrosus. The second greatest concentration exists in the posterolateral annulus fibrosus, and the lowest concentration of nociceptors exists within the anterior annulus fibrosus [73–80].

There is an innate region of weakness of the intervertebral disc at its posterolateral portion, which unfortunately corresponds with the region having greatest density of nociceptors. Therefore, disc pain is predictably common when one recognizes that the dense concentration of nociceptors resides in the region most commonly associated with annulus fibrosis tears or failure. These annular tears are important because they allow the extravasation of nucleus pulposus within the disc in the region with the greatest concentration of pain-transmitting nociceptors. Interestingly, the body reacts to this leaked nucleus pulposus as a foreign sustenance, responding with inflammation and the autoimmune response, causing pain. Resultant inflammatory cytokines play a role in mediating discogenic low back pain and lumbar radiculopathy. Histochemical studies in human and animal intervertebral discs show that the nucleus pulposus in contact with torn annulus fibrosus instigates the formation of inflammatory and autoimmune constituents that includes the formation of peptides such as calcitonin gene-related peptide (CGRP), vasoactive intestinal peptide (VIP), and substance P, which heightens the sensitivity of the local nociceptive nerve fibers [81–85].

Indications

Patient Selection

Patients should have experienced chronic low back pain for 6 months or more in duration, with or without lower extremity symptoms (either radicular or nonradicular, somatic referred leg symptoms). Studies currently pending publication also demonstrate high safety and efficacy of the Discseel® Procedure in treating chronic cervical pain, with and without extremity radiculopathy. Patient screening should consider limiting treatment of patients with abnormal psychosocial factors.

Annulograms, like any test, should only be performed when their results directly affect the direction of the treat-

ment algorithm. Annulograms, or the Discseel Procedure, may not typically be indicated for patients with acute or sub-acute LBP and/or leg pain because those symptoms will likely resolve spontaneously within six months. In comparison, those with chronic LBP are likely to experience pain persisting of at least five years duration following symptom onset. However, each situation deserves individual evaluation and consideration. Might an incapacitating acute injury merit treatment consideration, as routinely occurs with surgical discectomy?

In patients presenting with axial back pain with lumbar extension and relief with flexion, one should consider ruling out zygapophyseal joint etiology by performing diagnostic medial branch blocks or intra-articular zygapophyseal (Z-joint) injections with local anesthetic to determine whether the pain originates from the Z-joints. Extremity weakness including foot drop or reflex loss is not an exclusion criterion for the Discseel Procedure.

Blood thinners are relative contraindications, and patients should consult with the prescribing physician's office as well as the proceduralists prior to the procedure. Pre- and post-treatment blood coagulation lab values should be checked, and the risks and benefits discussed with each patient.

Prior Nonsurgical Treatment

The Discseel® Procedure pretreatment instructions do not require that patients undergo an epidural injection of corticosteroid because this injection is not site specific and will not corroborate the existence and exact location of a painful intervertebral disc and, although exceedingly low, the risks associated with epidural injections of corticosteroids are not zero [86].

Prior Spine Surgical Treatment

Prior spine surgery does not exclude patients, including laminectomy, laminotomy, discectomy, foraminotomy, anterior or poster interbody fusion with screws and rods, interspinous decompression devices, implanted spinal cord stimulators, or pumps. None excludes patients from undergoing the Discseel® Procedure. There are also some surgeries that increase stress and strain on the adjacent intervertebral discs, which may increase the need for the Discseel® Procedure [87–98].

Anatomic Exclusion Criteria

Exclusion criteria include severe vertebral canal or intervertebral foraminal stenosis, severe compression of the cauda equina or spinal cord at the level targeted for treatment, or

upper motor neuron signs, or cauda equina syndrome. These apply only to the location or level being treated. Displacement of the dura, spinal nerves, or spinal cord is not an exclusion criterion. Preferable, but not required, is nonoccupied vertebral canal space. A nonsequestered, extruded disc herniation causing moderate to severe stenosis is a relative contraindication, not an absolute contraindication. Motor weakness, including foot drop, is not a Discseel® Procedure absolute contraindication. At this juncture, no scientific basis exists to mandate that segmental instability be considered a contraindication. It is possible that instability may be caused by ligamentous laxity (anterior longitudinal ligament and posterior longitudinal ligament), which may improve with disc tissue growth following the Discseel® Procedure.

Patients with severe spinal stenosis may elect surgical decompression prior to undergoing the Discseel® Procedure. Because surgical discectomies cause iatrogenic annular disruption, a post-surgical Discseel® Procedure may be a treatment option to address discs that have had a portion of the annulus surgically removed during discectomy. The various discectomy techniques all increase annulus fibrosus disruption resulting in the potential for recurrent disc herniation or accelerated degeneration at the level of the discectomy [97, 98].

In addition to the indication for the performance of the Discseel® Procedure after discectomy, it may be performed after interbody fusion on the adjacent segments to treat the annular tearing caused increased aberrant forces known to increase the likelihood of adjacent segment accelerated degeneration [87–96]. Annular fibrin can also be injected into a disc that has been “fused” by a spanning pedicle screw and rod construct because the fused disc may still leak inflammatory mediators and produce pain. The intervertebral disc can be tested with an annulogram and treated with fibrin, if torn and considered possibly symptomatic, even following fusion.

Absolute Contraindications

- The patient is unable or unwilling to consent to the procedure.
- The patient has evidence of untreated localized infection at the procedural site.
- The patient is pregnant.

Relative Contraindications

- The patient has a known allergy to any of the substances used for the injections.
- There is the presence of an active bleeding diathesis.
- The patient is currently on anticoagulants.
- There is a known systemic infection present.

- The patient has undergone a dental procedure one week prior to treatment or six weeks following the procedure.

Equipment

The Discseel® Procedure is performed in a room suitable for fluoroscopically guided aseptic procedures. A sterile surgical suite is not necessary. The room must be equipped with fluoroscopy (C-arm or two-plane image intensifier) and an x-ray compatible table. The room should also be equipped with minimally invasive cardiopulmonary monitoring equipment including an ECG, pulse oximeter, and blood pressure cuff. Supplemental O₂ should also be available.

Sterile skin preparation may be an iodine-based solution (e.g., povidone-iodine), or an alcohol-based antiseptic (e.g., chlorhexidine gluconate 0.5% in 70% alcohol), or a combination of the two.

The placement of sterile drapes or sheets achieves a sterile field and an aseptic region for the injection site. A two-needle technique may be used to test and treat the discs but is not a necessary component of the procedure. The single needle technique employs an 18-gauge 150-mm (6.0 inch) curved tip Tuohy needle. A 90-mm (3.5 inch) small-gauge (23–27 gauge) needle is utilized for anesthetizing the skin. Sterile gloves and standard radiation protection are mandatory for the proceduralists, and a sterile gown and mask are optional, based on physician preference.

A 10–20-ml syringe can be used to inject contrast, or the contrast may be dispensed into smaller volume syringes for easier contrast injection and attached to minimal volume, short extension tubing for precise annulogram injection control.

Intravenous cannula access is recommended for administering sedation and emergent medication or fluids for cardiovascular emergencies.

Staff

At least one assistant in the procedure room prepares the contrast and heats and prepares the prothrombin and fibrinogen in the procedure room. Care should be taken to dispense each into its correctly labeled respective syringe.

A second assistant or radiologic technologist may operate the fluoroscope.

Pre-Procedure

History and Physical Examination

An appropriate pre-procedure history is obtained, and a physical examination is performed to establish the patient's

suitability for the diagnostic annulogram and Discseel® Procedure. The patients should avoid any dental procedures one week prior to their treatment and six weeks following their Discseel® Procedure.

Informed Consent

The patient should be informed of all aspects of the procedure, the risks and benefits of the procedure, and suitable alternative options. The patient also consents to understand the definition of off-label use of an FDA-approved medication. Off-label use of FDA-approved medications is commonplace and a well-accepted practice in the fields of medicine and surgery. For consideration, epidural injections of corticosteroids are an off-label use of corticosteroids because corticosteroids have never been specifically approved by the FDA for their epidural placement.

Premedication

The patient should be given standard NPO orders with the time specifications in accordance with the institution if IV sedation is offered.

Antibiotics Antibiotic prophylaxis against discitis, including cephazolin 1 g, clindamycin 900 mg, or ciprofloxacin 400 mg, may be administered intravenously within 15–60 minutes before the procedure, but this is not a mandate and was not performed in investigations referenced. This is also per consensus guidelines previously adopted by recognized spine procedural societies.

If the patient is allergic to penicillin, an alternative is clindamycin IV 600–900 mg [61].

Anesthetic and Sedation Local anesthetic (lidocaine 1.0–2.0%) is used for skin infiltration, and conscious sedation using the sedative medications of choice (i.e., midazolam/fentanyl/ketamine) may be used for patient comfort.

Allergy

If the patient has a known allergy to contrast medium, they may be pretreated with H1 and H2 blocking medications and corticosteroids prior to the procedure. Another option is to utilize gadolinium in those patients with a known contrast allergy.

A patient's ability to tolerate the anxiety associated with any invasive test, especially disc access procedures, is variable. Because of this, careful administration of sedatives and opioid medications is essential, allowing the patient to remain awake enough to convey sensations and locations of pain. This will allow for more accurate localization of the patient's pain generator and can help to avoid injury to the adjacent spinal nerves during the procedure. A full provocative discography procedure with a complete record of the patient's response is unnecessary.

Technique

Positioning The patient is positioned prone on a procedure table.

Sterility The skin of the lumbar region and upper gluteal region is prepared for an aseptic procedure as discussed above. The operator and any personnel within the vicinity of the patient and fibrin mixing station should wear clean attire (scrubs suits, for example). Surgical caps and masks are recommended, but not mandatory.

If the operator performs the sterile skin preparation, they should don fresh gloves after the skin has been prepared and prior to inserting any needles.

To help minimize the chance of bacterial contamination to the needle and/or the disc, the needle should not be unnecessarily exposed to the atmosphere. Upon being withdrawn from its scabbard, it should be inserted without significant delay. Although not scientifically validated, to further minimize the likelihood of disc contamination from skin bacterial flora, one may puncture the skin with a sterile, larger gauge needle (14–18 g) at the skin entry point and direct a smaller needle that will be used to puncture the disc through the outer needle [98].

Selecting Disc Levels to Test and Treat

If technically feasible, test every disc in the region of the patient's symptoms. Typically three to four intervertebral discs will be tested. Higher segmental levels should be tested if they correlate with recognized radicular or somatic pain patterns as expressed via the patient's history.

Target Identification

An anteroposterior (AP) image of the lumbar spine is obtained, and the target disc is identified.

The disc may be approached from either side, but it is recommended to optimize the ease of access by approaching the disc from the side that is less encumbered by osteophytes and less narrowed due to scoliosis or fusion hardware. If necessary, the needle may be rotated gently in alternating directions to penetrate bone overgrowth that is hindering disc access. Testing and treating incompletely fused discs is appropriate because annular disc tissue may be intact, even in segments with implanted cages.

Once the disc approach side has been selected, the fluoroscope is tilted caudal or cranial (tilted to the feet or head, respectively) so that the X-ray beam passes parallel to the

ring apophysis or the end plates of the vertebrae to maximize the radiographic height of the targeted disc.

The fluoroscope beam is rotated obliquely, allowing visualization of the target disc from the ipsilateral posterolateral oblique aspect. During traditional discography, the beam is rotated obliquely until the anterior aspect of the superior articular process (SAP) overlying the target disc lies parallel to the axial division of the anterior two-thirds and posterior one-third of the target disc. That view will allow the needle to be advanced parallel to the x-ray beam, directing the needle tip intentionally to the center of the nucleus pulposus as it passes across the anterior surface of the superior articular process. It is important to note that this discogram approach view differs from the Discseel® Procedure view described later insofar as the discogram view intentionally directs the needle tip trajectory to the center of the nucleus pulposus and the Discseel procedure view directs the needle to the posterior annulus. In comparison to a discogram, the Discseel™ Procedure's intent is to target the annulus fibrosus at its most posterior aspect of the intervertebral disc.

There are two differences in the Discseel® Procedure needle trajectory that allows for the needle tip to reach the posterior annulus fibrosis instead of the center nucleus pulposus.

One difference in the technique is to continue rotating the image intensifier to a more oblique position until the SAP is seen over the disc at the 1/3 posterior and 2/3 anterior junction (instead of at the 2/3 posterior and 1/3 anterior junction).

The second difference in technique is when the physician employs the common discogram imaging method previously described (SAP at the 1/3 posterior-2/3 anterior junction). Then, instead of marking and penetrating the skin at the typical location overlying the anterior portion of the SAP and inserting the needle directly along the pathway of the x-ray beam into the center of the nucleus pulposus, the physician marks and penetrates the skin over the radiographic anterior aspect of the disc. The needle then enters the skin at this slightly more anterior and lateral position and is directed posteromedially instead of parallel to the x-ray beam. Ideally, the needle will come in contact with the anterior portion of the SAP, so the appropriate needle tip depth can be determined without changing the position of the image intensifier. This will also ensure that the needle tip is in position to avoid injuring the descending spinal nerve that will be descending from the level above just anterior to the pathway of the needle. This needle trajectory will direct the needle tip to the desired target, the posterior aspect of the disc's annulus fibrosis.

Another precaution that can be taken to minimize the likelihood of the needle injuring a spinal nerve is to avoid injecting local anesthetic into the region of the disc or spinal

nerves until needle advancement and maneuvering is complete.

The target point for puncture of the annulus fibrosus lies at the superoinferior midline of the target disc, just lateral to the lateral margin of the superior articular process.

At the L5-S1 level, the iliac crest may overlie the disc target in the posterolateral oblique view. Care should be taken to obtain a view such that the target point lies between the superior articular process of S1 medially and the iliac crest laterally.

If the iliac crest continues to overlie the L5-S1 target, a skin puncture point could be placed over the location on the iliac crest closest to the target location. By the time the needle reaches the depth of the iliac crest, it may have traversed medially enough to bypass the bony crest itself. Alternatively, the needle entry point can be located over the point on the iliac crest closest to the target area, and the needle can be directed medially around the crest and back to the disc entry target.

In the posterolateral oblique view, a puncture point on the skin is selected, and a skin wheal is raised with local anesthesia (lidocaine 1% or 2%) using a 23–27-gauge skin needle.

Technique Needle Placement

New needles should be used for each disc injected to minimize infection likelihood. The skin overlying the target disc is marked and anesthetized with local anesthetic, but needle tract or disc region should not be anesthetized to avoid anesthetizing the descending spinal nerves. When performing the procedure, any new onset of leg pain reported by the patient should be noted to avoid injuring the descending ventral ramus with the needle or an errant injection. If the patient complains of paraesthesia or radicular pain, needle insertion should cease immediately and the needle is withdrawn slightly and redirected to avoid a nearby descending spinal nerve.

Additionally, because there are a limited number of nociceptors that exist along the needle trajectory from the skin to the disc, appropriate needle advancement should not cause undue patient discomfort. When the needle encounters the annulus, a firm and rubbery resistance is typically felt and the needle's progress is monitored by alternating between AP and lateral fluoroscopic projections.

When a single needle technique is used, a 22-gauge, 200-mm Tuohy needle is advanced carefully to the target within the annulus fibrosis at the posterior portion of the disc. Anteroposterior and lateral views confirm the correct needle tip position before a trace amount of nonionic radiopaque contrast is injected into the annulus fibrosis under dynamic fluoroscopic visualization (Fig. 6.2). Careful observation

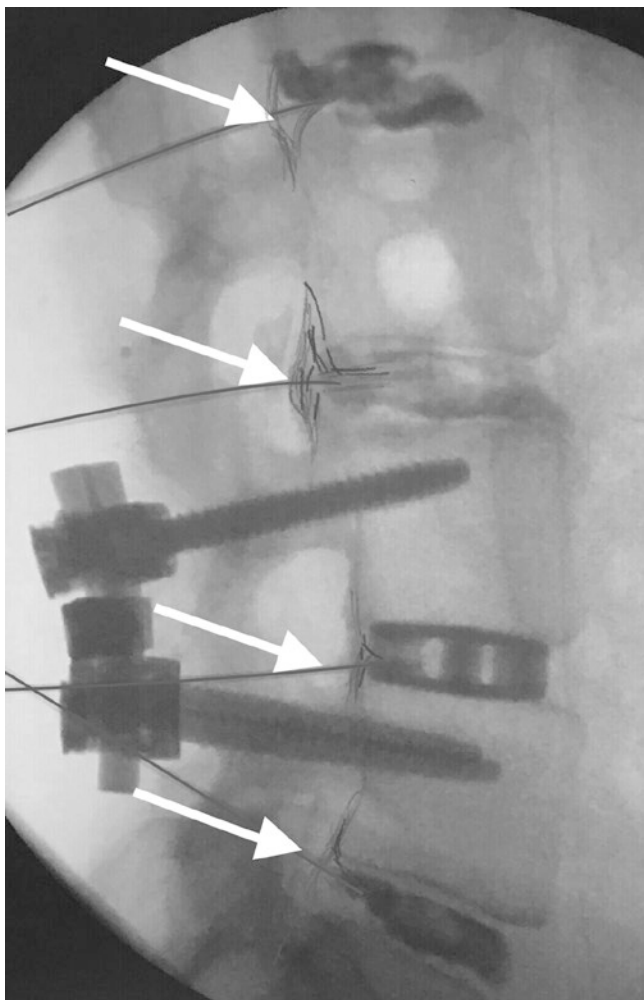


Fig. 6.2 Lateral fluoroscopic view showing the needles inserted into the lumbar intervertebral discs (white arrows) with contrast injected into the discs (white arrowheads)

allows visualization and documentation of contrast flow patterns within and outside the disc.

Following the annulogram, the connection tubing is disconnected and the apparatus combining the prothrombin and fibrinogen is connected to the needle hub. Using gentle pressure, the plunger is advanced. When injected, the prothrombin combines with the fibrinogen and aprotinin, producing fibrin as it is injected into the disc. Fibrin is slowly injected with gentle pressurization of the syringe. If resistance prevents the flow of fibrin, the needle's metal stylet is replaced to occupy the entire central portion of the needle. To assure that the stylet occupies the needle's entirety, rotate the stylet's notch until it rests entirely within the hub's groove. This assures that there is no fibrin or tissue obstruction or needle "kink" at the needle's most distal aspect that would impede flow. The physician cannot assume that the disc is entirely filled or sealed maximally due to the perception of complete resistance without first reinserting the stylet to

ensure that fibrin has not activated and obstructed the needle's lumen. Total fibrin volume injected per disc is highly variable and dependent on the disc's morphology but typically ranges from approximately 0.5 cc to 6.0 cc. Observation of the contrast departing the annular tears when injecting the fibrin indicates the presence of fibrin within those tears. Although the disc height often increases during fibrin injection, this is not necessarily the goal of the Discseel® Procedure. During a typical procedure in a patient with chronic low back pain, usually 3–4 discs are tested and treated.

Additionally, more cephalad discs may be tested and treated if the patient's symptoms and imaging studies indicate the need for this. If a morphologically normal disc is identified based on annulogram, the needle puncture site is sealed with fibrin to try to protect and preserve the integrity of that disc.

Post-Procedural Care

After needles are removed and the skin puncture points sterilely dressed, the patient is taken to recovery where cardiopulmonary monitoring is performed for approximately 30 min or longer if indicated. If the patient is stable at this point, they are discharged to a caregiver or a family member. Short-acting analgesics may be prescribed at this time. Patients are instructed not to drive on the day of their procedure and to expect increased discomfort for a few days to a few weeks. Intra-discal biologics that occupy the annular fissures instead of leaking can maintain the intervertebral disc height and can cause increased patient symptoms from the injected disc(s). These symptoms can be referred to as a full feeling, deep pressure, prolonged pain, or other post-procedure symptoms not commonly reported with other intradiscal procedures. Therefore prescriptions for pain medication to address this period of increased discomfort may be considered.

Conclusion

Being safe and efficacious, the Discseel® Procedure treats spine pathology with relative ease and high success. Because the Discseel® Procedure returns discs to their normal states, both mechanically and biochemically, it eliminates common and costly problems associated with all spine surgery, even minimally invasive spine surgery.

The Discseel® Procedure's ability to spare patients from needing additional spine surgery due to adjacent disc degeneration and "the domino effect" saves society pain, suffering, and billions of healthcare dollars.

The field of spine specialists is observing "decision-makers" evolve from old and contrarian spine treatments,

including spine surgery, to new treatments restoring spines to their pre-injury state, benefiting patients and the healthcare system.

References

- Richardson S, Kalamegam G, Pushparaj P, et al. Mesenchymal stem cells in regenerative medicine: focus on articular cartilage and intervertebral disc regeneration. *Methods*. 2015.
- Chen WH, Lo WC, Lee JJ, et al. Tissue-engineered intervertebral disc and chondrogenesis using human nucleus pulposus regulated through TGF-beta1 in platelet-rich plasma. *J Cell Physiol*. 2006;209(3):744–54.
- Gullung GB, Woodall JW, Tucci MA, et al. James J platelet-rich plasma effects on degenerative disc disease: analysis of histology and imaging in an animal model. *Evid Based Spine Care J*. 2011;2(4):13–8.
- Obata S, Akeda K, Imanishi T, et al. Effect of autologous platelet-rich plasma-releasate on intervertebral disc degeneration in the rabbit annular puncture model: a preclinical study. *Arthritis Res Ther*. 2012;14(6).
- Kim HJ, Yeom JS, Koh YG, et al. Anti-inflammatory effect of platelet-rich plasma on nucleus pulposus cells with response of TNF alpha and IL-1. *J Orthop Res*. 2014;32:551–6.
- Sawamura K, Ikeda T, Nagae M, et al. Characterization of in vivo effects of platelet-rich plasma and biodegradable gelatin hydrogel microspheres on degenerated intervertebral discs. *Tissue Eng Part A*. 2009;15:3719–27.
- Gullung G, Woodall J, Tucci M, et al. Platelet-rich plasma effects on degenerative disc disease: analysis of histology and imaging in an animal model. *Evid Based Spine Care J*. 2011;2:13–8.
- Tuakli-Wosornu YA, Terry A, Boachie-Adjei K, Harrison JR, et al. Lumbar intradiscal platelet-rich plasma (PRP) injections: a prospective randomized double-blind study. *PM and R*. 2016;8(1):1–10.
- Harrison JR, Herzog RJ, Lutz GE. Increased Nuclear T2 signal intensity following Intradiscal platelet rich plasma: a case report. Submitted to *PM&R*.
- Levi D, Horn S, Tyszkowski S, et al. Intradiscal platelet-rich plasma injection for chronic discogenic low back pain: preliminary results from a prospective trial. *Pain Med*. 2015;0:1–13.
- Amer. Acad. Ortho. Med. Annual Meeting. Evaluating the Safety and Efficacy of Fibrin to Treat Multi-level Chronic Discogenic Low Back Pain and associated Radiculopathy. 2020. Pending Publication, *Spine Jour*. 2021.
- Vadala G, Sowa G, Hubert M, et al. Mesenchymal stem cells injection in degenerated intervertebral disc: cell leakage may induce osteophyte formation. *J Tissue Eng Regen Med*. 2012;6(5):348–55.
- Li YY, Diao HJ, Chik TK, et al. Delivering mesenchymal stem cells in collagen microsphere carriers to rabbit degenerative disc: reduced risk of osteophyte formation. *Tissue Eng. Part A*. 2014;20(9–10).
- Ahmed TA, Dare EV, Hincke M. Fibrin: a versatile scaffold for tissue engineering applications. *Tissue Eng Part B Rev*. 2008;14(2):199.
- Colombini A, Ceriani C, Banfi G, et al. Fibrin in intervertebral disc tissue engineering. *Tissue Eng Part B Rev*. 2014;20(6):713–21.
- Schek RM, Michalek AJ, Iatridis JC. Genipin-crosslinked fibrin hydrogels as a potential adhesive to augment intervertebral disc annulus repair. *Eur Cell Mater*. 2011;5:275.
- Jansen M, Brant-Zawadzki M, Timo K, et al. Magnetic-resonance imaging of the spine in people without back pain. *N Engl J Med*. 1994;331:69–73.
- Grubb SA, Lipscomb HJ, Guilford WB. The relative value of lumbar roentgenograms, metrizamide myelography, and discography in the assessment of patients with chronic low-back-syndrome. *Spine*. 1987;12:282–6.
- Gaensler E. Nondegenerative diseases of the spine. In: Brant W, editor. *Fundamentals of diagnostic radiology*. Baltimore: Williams and Wilkins; 1999. p. 233–380.
- Jarvik JG, Deyo RA. Diagnostic evaluation of low Back pain with emphasis on imaging. *Ann Intern Med*. 2002;137:586–97.
- Yoshida H, Tamai K, et al. Diagnosis of symptomatic disc by magnetic resonance imaging: T2-weighted and gadolinium-DTPA-enhanced T1 weighted magnetic resonance imaging. *J Spinal Disord Tech*. 2002;15:193–8.
- Toyone T, Takahashi K, Kitahara H, et al. Vertebral bone-marrow changes in degenerative lumbar disc disease: an MRI study of 74 patients with low back pain. *J Bone Joint Surg Br*. 1994;76:757–64.
- Weishaupt D, Zanetti M, Hodler J, et al. Painful lumbar disk derangement: relevance of endplate abnormalities at MR imaging. *Radiology*. 2001;218:420–7.
- Sandhu HS, Sanchez-Caso LP, Parvataneni HK, et al. Association between findings of provocative discography and vertebral endplate signal changes as seen on MRI. *J Spinal Disord*. 2000;13:438–43.
- Braithwaite I, White J, Saifuddin A, et al. Vertebral end-plate (Modic) changes on lumbar spine MRI: correlation with pain reproduction at discography. *Eur Spine J*. 1998;7:363–8.
- Vanharanta H, Sachs BL, Spivey MA, et al. The relationship of pain provocation to lumbar disc deterioration as seen by CT/discography. *Spine*. 1987;12:295–8.
- Crock HV. Internal disc disruption: a challenge to disc prolapse. *Spine*. 1986;11:650–3.
- Moneta GB, Videman T, Kaivanto K, et al. Reported pain during lumbar discography as a function of annular ruptures and disc degeneration. A re-analysis of 833 Discograms. *Spine*. 1994;19(17):1968–74.
- Collis JS, Gardner WJ. Lumbar discography—an analysis of 1,000 cases. *J Neurosurg*. 1962;19:452–461.
- Erlacher PR. Nucleography. *J Bone Joint Surg*. 1952;34B:204–10.
- Hsien-Wen S, Yu-Min C, Hsing-T'Ang K, et al. Lumbar discography: an experimental and clinical study. *Chin Med J*. 1964;83:521–30.
- Nordlander S, Salen EF, Unander-Scharin L. Discography in low back pain and sciatica. *Acta Orthop Scandinav*. 1958;28:90–102.
- Walk L. Clinical significance of discography. *Acta Radiol*. 1956;46:36–7.
- Lindblom K. Diagnostic disc puncture of intervertebral disks in sciatica. *Acta Orthop Scandinav*. 1948;17:231–9.
- Lindblom K. Technique and results in myelography and disc puncture. *Acta Radiol*. 1950;34:321–30.
- Hirsch C. An attempt to diagnose the level of a disc lesion clinically by disc puncture. *Acta Orthop Scandinav*. 1949;18:132–40.
- Lindblom K. Technique and results of diagnostic disc puncture and injection (discography) in the lumbar region. *Acta Orthop Scandinav*. 1951;20:315–26.
- Lindblom K. Discography of dissecting transosseous ruptures of intervertebral discs in the lumbar region. *Acta Radiologica*. 1951. 36:13–16; Friedman J, Goldner MZ. Discography in evaluation of lumbar disc. *Radiology*. 1955;65:653–62.
- Feinberg SB. The place of discography in radiology in 2,320 cases. *AJR*. 1964;92:1275–81.
- Butt WP. Lumbar discography. *J Can Assoc Radiol*. 1963;14:172–81.
- Gardner WJ, Wise RE, Hughes CR, et al. X-ray visualization of the intervertebral disk with a consideration of the morbidity of disk puncture. *Arch Surg*. 1952;64:355–64; Braithwaite I, White J, Saifuddin A, et al. Vertebral end-plate (Modic) changes on lumbar spine MRI: correlation with pain reproduction at discography. *Eur Spine J*. 1998;7:363–8.

41. Keck C. Discography: technique and interpretation. *AMA Arch Surg.* 1960;80:580–6.
42. Wilson DH, MacCarty WC. Discography: its role in the diagnosis of lumbar disc protrusion. *J Neurosurg.*
43. Holt EP. The question of lumbar diskography. *J Bone Int Surg.* 1968;50A:720–5.
44. Pauza KJ, Howell S, Dreyfuss, et al. NASS OUTSTANDING PAPER. Prospective double blind, placebo controlled study evaluating the efficacy of intradiscal electrothermal therapy for the treatment of chronic discogenic low back pain. *Spine J.* 2004;4(1):27–35.
45. Bogduk N, editor. Practice Guidelines for spinal diagnostic and treatment procedures. *ISIS;* 2004.
46. Carragee EJ, Tanner CM, Yang B, et al. False-positive findings on lumbar discography. Reliability of subjective concordance assessment during provocative disc injection. *Spine.* 1999;24(23):2542–7.
47. Carragee EJ, Tanner CM, Khurana S, et al. The rates of false-positive lumbar discography in select patients without low back symptoms. *Spine.* 2000;25:1373–81.
48. Carragee EJ, Alamin TF, Miller J, et al. Provocative discography in volunteer subjects with mild persistent low back pain. *Spine J.* 2002;2:25–34.
49. Carragee EJ, Chen Y, Tanner CM, et al. Can discography cause long-term back symptoms in previously asymptomatic subjects? *Spine.* 2000;25:1803–8.
50. Carragee EJ, Chen Y, Tanner CM, et al. Provocative discography in patients after limited lumbar discectomy: a controlled, randomized study of pain response in symptomatic and asymptomatic subjects. *Spine.* 2000;25:3065–71.
51. Derby R, Kim BJ, Lee SH, et al. Comparison of discographic findings in asymptomatic subject discs and the negative discs of chronic LBP patients: can discography distinguish asymptomatic discs among morphologically abnormal discs? *Spine J.* 2005;5:389–94.
52. McCutcheon ME. CT scanning of lumbar discography: a useful diagnostic adjunct. *Spine.* 1986;11:257–9.
53. Sachs BL, Vanharanta H, Spivey MA, Guyer RD, Videman T, Rashbaum RF, Johnson RG, Hochschuler SH, Mooney V. Dallas discogram description: a new classification of CT/discography in lowback disorders. *Spine.* 1987;12:287–94.
54. Aprill C, Bogduk N. High intensity zone: a diagnostic sign of painful lumbar disc on magnetic resonance imaging. *Brit J Radiol.* 1992;65:361–9.
55. Vanharanta H, Sachs BL, Spivey MA, et al. The relationship of pain provocation to lumbar disc deterioration as seen by CT/discography. *Spine.* 1987;12:295298.
56. Moneta GB, Videman T, Kaivanto K, et al. Reported pain during lumbar discography as a function of annular ruptures and disc degeneration. A re-analysis of 833 discograms. *Spine.* 1994;17:1968–74.
57. Polk HC, Christmas AB. Prophylactic antibiotics in surgery and surgical wound infections. *Am Surg.* 2000;80:105–11.
58. International Spine Intervention Society (ISIS), Bogduk B. Proposed discography standards. *ISIS Newsletter, Vol. 2(1).* Daly City, California: International Spinal Injection Society; 1994. p. 10–3.
59. Bogduk N, Aprill C, Derby R. Discography. In: White AH, editor. *Spine care, Vol. 1.* St Louis: Mosby; 1995. p. 219–38.
60. Bogduk N, Chr PK. International spine intervention society practice guidelines for spinal diagnostic and treatment procedures. *Oxford Blackwell Science;* 2003.
61. Fraser RD, Osti AL, Vernon-Roberts B. Discitis after discography. *J Bone Joint Surg.* 1987;69B:26–35.
62. Alamin T. The functional anesthetic discogram: comparison of the results of a novel technique to that of provocative discography in a group of patients with chronic low back pain. *International Society for the Study of the Lumbar Spine. Abstracts.* June, 2006:52–53.
63. Ohtori S, Kinoshita T, Yamashita M, et al. Results of surgery for discogenic low back pain: a randomized study using discography versus discoblock for diagnosis. *Spine.* 2009;34(13):1345–8.
64. Ren J, Zhang Y, Chee, et al. Effects of local anesthetic and nonionic contrast agents on bovine intervertebral disc cells cultured in alginate. *Abstract. SAS.* 2010.
65. Derby R, Lee SH, Kim BJ, et al. Pressure-controlled lumbar discography volunteers without low back symptoms. *Pain Med.* 2005;6:213–21.
66. Derby R, Howard MW, Grant JM, et al. The ability of pressure-controlled discography to predict surgical outcomes. *Spine.* 1999;24:346–71.
67. DePalma M, Lee J, Peterson L, et al. Are outer annular fissures stimulated during discography the source of discogenic low-back pain? An analysis of analgesic discography data. *Pain Med.* 2009;10:3.
68. Buser Z, Kuelling F, Liu J, et al. Biological and biomechanical effects of fibrin injection into porcine intervertebral discs. *Spine.* 2011;36(18).
69. Yin W, Pauza K, Olan W, et al. Symptomatic lumbar internal disc disruption: results of a prospective multicenter pilot study with 24 month follow-up. *Pain Med.* 2014;15(1).
70. Pauza K, Yin W, Olan W, et al. Biostat Biologix intradiscal fibrin sealant used for the treatment of chronic low back pain caused by lumbar internal disc disruption: results of a 12 month, prospective multi-center pilot study. *Surgical Arthrodesis Society. Annual Meeting.* 2010.
71. Pauza K, Wright C, Fairbourn A. Treatment of annular tears and “leaky disc syndrome”. *Techn Reg Anesth Pain Manag.* (1–2): 45–9.
72. Pauza K. Intradiscal biologics. In: Gebhart GF, Schmidt RF, editors. *Encyclopedia of pain.* Philadelphia; 2013.
73. García-Cosamalón J, del Valle ME, Calavia MG, et al. Intervertebral disc, sensory nerves and neurotrophins: who is who in discogenic pain? *J Anat.* 2010;217(1):1–15.
74. Yoshizawa H, O’Brien JP, Thomas-Smith W, et al. The neuropathology of intervertebral discs removed for low-back pain. *J Pathol.* 1980;132:95–104.
75. Korkala O, Gronblad M, Liesi P, et al. Immunohistochemical demonstration of nociceptors in the ligamentous structures of the lumbar spine. *Spine.* 1985;10:156–7.
76. Bogduk N, Tynan W, Wilson S. The nerve supply to the human lumbar intervertebral discs. *J Anat.* 1981;132:39–56.
77. Bogduk N. The innervation of the lumbar spine. *Spine.* 1983;8:286–93.
78. Groen GJ, Baljet B, Drukker J. Nerves and nerve plexuses of the human vertebral column. *Am J Anat.* 1990;188:282–96.
79. Malinsky J. The ontogenetic development of nerve terminations in the intervertebral discs of man. *Acta Anat.* 1959;38:96–113.
80. Kontinen YT, Gronblad M, Antti-Poika I, et al. Neuroimmunohistochemical analysis of peridiscal nociceptive neural elements. *Spine.* 1990;15:383–6.
81. Peng B, Wu W, Li Z, Guo J, Wang X. Chemical radiculitis. *Pain.* 2007;127:11–6.
82. Olmarker K, Rydevik B, Nordborg C. Autologous nucleus pulposus induces neurophysiologic and histologic changes in porcine cauda equina nerve roots. *Spine.* 1993;18(11):1425–32.
83. Saal JS. The role of inflammation in lumbar pain. *Spine.* 1995;20(16):1821–7.
84. Bobechko W, Hirsch C. Autoimmune response to nucleus pulposus in rabbit. *J Bone Joint Surg.* 1965;47B:3; Marshall L, Trethewie E, Curtain C. Chemical radiculitis. A clinical, physiological, and immunological study. *Clin Ortho Relat Res.* 1977. 11.129.

85. Ohtori S, Inoue G, Ito T. Tumor necrosis factor-immunoreactive cells and PGP 9.5-immunoreactive nerve fibers in vertebral endplates of patients with discogenic low. *Spine*. 2000;25(13):1625–36.
86. Chou R, Hashimoto R, Friedly J, et al. Epidural corticosteroid injections for radiculopathy and spinal stenosis: A systematic review and meta-analysis. *Ann Intern Med*. 2015;163(5):373–81.
87. Ekman P, Möller H, Shalabi A, et al. A prospective randomised study on the long-term effect of lumbar fusion on adjacent disc degeneration. *Eur Spine J*. 2009;18(8):1175–86.
88. Harrop J, Youssef J, Maltenfort M, et al. Lumbar adjacent segment degeneration and disease after arthrodesis and total disc arthroplasty. *Spine*. 2008;33(15):1701–7.
89. Chen C, Cheng C, Liu C, et al. Stress analysis of the disc adjacent to interbody fusion in lumbar spine. *Med Eng Phys*. 2001;23(7):483–91.
90. Pezowicz C, Schechtman H, Robertson P, et al. Mechanisms of annular failure resulting from excessive intradiscal pressure: a microstructural-micromechanical investigation. *Spine*. 2006;31(25):2891–903.
91. Throckmorton T, Hilibrand A, Mencia G, et al. The impact of adjacent level disc degeneration on health status outcomes following lumbar fusion. *Spine*. 2003;28(22):2546–50.
92. Adams M, Freeman B, Morrison H, et al. Mechanical initiation of intervertebral disc degeneration. *Spine*. 2000;25(13):1625–36.
93. Zhang C, Berven S, Fortin M, et al. Adjacent segment degeneration versus disease after lumbar spine fusion for degenerative pathology: a systematic review with meta-analysis of the literature. *Clin Spine Surg*. 2016;29(1):21–9.
94. Lee C. Accelerated degeneration of the segment adjacent to the lumbar fusion. *Spine*. 1988;13(3):375–7.
95. Lee C. Accelerated degeneration of the segment adjacent to a lumbar fusion. *Spine*. 1988;3(13):375–7.
96. Sheng C, Cheng-Kung C-L, et al. Stress analysis of the disc adjacent to interbody fusion in lumbar spine. *Med Eng Phys*. 2001;23(7):483–91.
97. O’Connell G, Malhotra N, Vresilovic E, Elliott D. The effect of discectomy and the dependence on degeneration of human intervertebral disc strain in axial compression. *Spine*. 2011;72(2):181–204.
98. Schroeder J, Dettori J, Brodt E, et al. Disc degeneration after disc herniation: are we accelerating the process? *Evidence Based Spine Care J*. 2012;3(4):33–40.