Anorectal Crohn's Disease

47

Emily Steinhagen and Andrea Chao Bafford

Key Concepts

- Control sepsis: Infection must be addressed before starting immunosuppressive medications.
- Treat underlying luminal disease and control diarrhea, but avoid steroids for perianal Crohn's disease.
- Perineal care: Perineal hygiene should include gentle cleansing with sitz baths or showers and skin protection with barrier creams.
- Avoid surgery in patients who are asymptomatic or in the setting of active proctitis.
- In patients who are optimized, fistulas may be treated with long-term draining setons, advancement flaps, or LIFT.
- Skin tags or hemorrhoids should generally not be treated.
- Diversion may appropriate as component of the management of perianal Crohn's disease for some patients.

Introduction

Crohn's disease (CD) is a chronic, relapsing, inflammatory condition that can affect any part of the gastrointestinal tract, from mouth to anus. Perianal involvement was first described by Penner and Crohn in 1938 [1] and includes fistulizing (abscesses, fistulas) and non-fistulizing (hemorrhoids, skin tags, anal fissures/ulcers, anorectal stricture, malignancy) complications. Approximately 13–38% of CD patients have perianal involvement and more than 80% require surgery [2–5]. Perianal CD may cause a range of disabling symptoms, including pain, discharge, bleeding, and both sexual and defecatory dysfunction. The evaluation and treatment of patients with perianal CD requires a careful history and physical examination, endoscopic evaluation, occasional imaging, and often both medical and surgical intervention. Physicians should maintain close and candid relationships with patients and care approached in a multidisciplinary fashion. The overarching goal of treating patients with perianal CD is to provide symptom resolution while avoiding incontinence and proctectomy where possible.

General principles for management of patients with perianal CD:

- Control sepsis: Infection must be addressed before starting immunosuppressive medications.
- Treat underlying luminal disease.
- Control diarrhea.
- Perineal care: Perineal hygiene includes gentle cleansing with sitz baths or showers and skin protection with barrier creams.
- Avoid steroids: Steroids do not typically have a role in the treatment of perianal CD.
- Avoid surgery in patients who are asymptomatic.
- Avoid surgery in the setting of active proctitis when possible.

Fistulizing Complications

Epidemiology and Risk Factors

Perianal fistulas are a common feature of CD, accounting for 50–87% of perianal lesions [6]. In one population-based study, 20% of patients with CD had at least one anorectal fistula during a 25-year period [4]. Approximately 10% of CD patients present with perianal fistulas as their initial manifestation, most of whom go on to develop intestinal manifestations in the year following diagnosis [7–9]. Only about 5% of patients maintain disease isolated to the peri-

E. Steinhagen (✉)
University Hospitals Cleveland Medical Center, Case Western Reserve University School of Medicine, Department of Surgery, Cleveland, OH, USA
e-mail: Emily.Steinhagen@UHhospitals.org

A. C. Bafford
University of Maryland School of Medicine, Department of Surgery, Baltimore, MD, USA

© Springer Nature Switzerland AG 2022

S. R. Steele et al. (eds.), *The ASCRS Textbook of Colon and Rectal Surgery*, https://doi.org/10.1007/978-3-030-66049-9_47

anal region [10, 11]. The incidence of fistulizing perianal disease increases with greater disease duration and severity and more distal disease involvement [2–4, 10, 12]. Hellers reported the incidence of perianal fistulas to be 12% in patients with ileal disease, 15% in those with ileocolonic disease, 41% in patients with colonic disease sparing the rectum, and 92% in patients with colonic and rectal disease [2]. Tang found that patients with perineal fistulas had a more than threefold higher likelihood of having colonic rather than isolated ileal disease [13]. CD-related perianal fistulas frequently recur, with one prospective cohort study showing the risk of recurrent fistula activity being 48% at 1 year and 59% at 2 years [14].

Pathogenesis

Two leading mechanisms exist with regard to the pathogenesis of anorectal fistulas and abscesses: (1) Rectal inflammation causes ulcers and/or shallow fistulas, which then extend deeper with persistent exposure to feces and pressure caused by defecation [15]; and (2) infected anal glands penetrate the intersphincteric space and then progress to form fistulas or abscesses [16]. CD-related fistulas are thought to arise from the former, while the latter explains idiopathic fistulas.

Clinical Presentation and Classification

Patients with fistulizing perianal CD may present acutely with abscesses or chronically with draining fistulas. Abscesses typically cause acute onset pain, perianal swelling and tenderness, and fever. Additional signs of systemic sepsis may also occur. Fistulas without abscess typically cause chronic anorectal discomfort and mucoid, bloody, or feculent discharge from an external opening in the perianal skin, groin, or vagina or, in the case of urinary fistulization, may be associated with pneumaturia or fecaluria.

Abscess

Up to 62% of patients with perianal CD develop an anorectal abscess [17]. Abscesses occur in the perianal, ischiorectal, interspincteric, and supralevator spaces (Fig. 47.1). Ischiorectal abscesses are most common, accounting for 40% of CD-related perirectal abscesses [18]. Perianal and ischiorectal abscesses result in erythema, swelling, tenderness, induration (early), and fluctuance (late) on the affected side. Intersphincteric and supralevator abscesses may cause few overt clinical signs, and therefore imaging studies, such as CT [19], endorectal ultrasound [20], or MRI [21], are often needed for diagnosis.

Management

Prompt surgical drainage of perianal abscesses is required to control sepsis and limit damage to the sphincters and surrounding anorectal tissues [3, 22]. General anesthesia is typically advised except for the most superficial abscesses, which may be amenable to drainage under local anesthesia with incisions placed over areas of obvious fluctuance. Ischiorectal abscesses are best drained with incisions made close to the sphincter complex to result in shorter subsequent fistula tracts. Intersphincteric abscesses may be palpated via

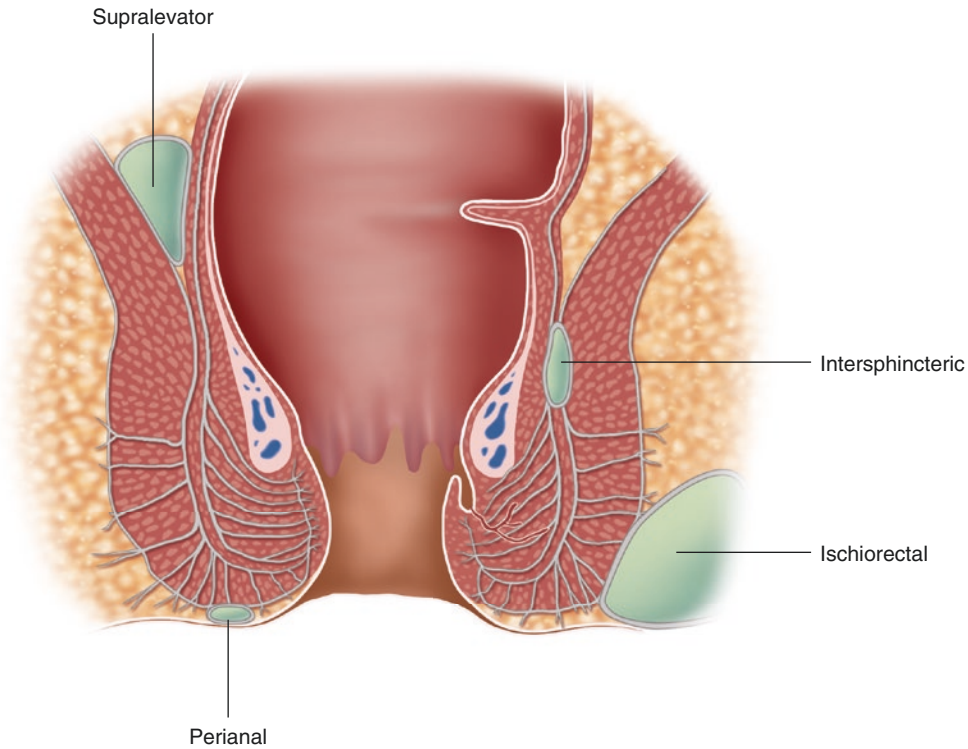

Fig. 47.1 Anorectal abscess locations

digital rectal examination as fluctuant masses within the anorectal wall. Drainage into the rectal lumen is accomplished via division of mucosa and internal sphincter muscle overlying the abscess. When fluctuance cannot be determined, needle aspiration may allow for localization of the abscess cavity. Larger abscesses are best treated with mushroom catheter drainage as wound healing is often poor in the face of acute inflammation and infection; wound packing can impede drainage and dressing changes are often poorly tolerated. For similar reasons, when an internal fistula opening is identified at the time of abscess drainage, seton drainage rather than fistulotomy should be performed even when fistulas are low-lying. The addition of aerobic and anaerobic culture and antibiotic treatment should be considered in immunosuppressed patients and those with significant cellulitis or systemic signs of sepsis.

Anorectal Fistula

A fistula is a chronic track of granulation tissue connecting two epithelial-lined surfaces. CD-related perianal fistulas can connect the anorectum with the perianal, buttock, perineal, thigh, or inguinal skin, the vagina, and the urinary tract. In 1976, Parks proposed an anatomical classification system for anal fistulas defined by their relationship to the external sphincter [16]. In order to also describe additional perianal manifestations of CD, the American Gastroenterological Association developed an empiric approach to fistula classification based on physical and endoscopic examinations [3]. Fistulas are classified as either "simple" or "complex." A simple fistula is low (superficial, low intersphincteric, low transsphincteric), has a single external opening, has no pain or fluctuance to suggest perianal abscess, is not a rectovaginal fistula, and is not associated with an anorectal stricture. A complex fistula is high (high intersphincteric, high transsphincteric, extrasphincteric, or suprasphincteric), may have multiple external openings, may be associated with the presence of pain or fluctuance suggestive of an abscess, may be associated with the presence of a rectovaginal fistula, may be associated with the presence of an anorectal stricture, and may be associated with the presence of active rectal disease at endoscopy.

Diagnosis

Precise determination of fistula anatomy is required for treatment of CD-related perianal fistulas. Fistula anatomy is typically determined using a multimodal approach combining physical examination, examination under anesthesia (EUA), and imaging techniques. On physical examination, external fistula openings may be visualized and underlying infection/inflammation determined by inspecting for erythema, purulence, and swelling, and palpating for induration, fluctuance, warmth, and tenderness. Occasionally, fistula tracks may be identified by palpating a firm "cord" of indurated tissue between the external fistula opening and the anus. Digital rectal examination may identify defects in the anorectal wall, fluctuance, an underlying stricture, or decreased sphincter tone. Anoscopy may identify internal fistula openings and underlying proctitis.

However, office examination, particularly DRE, and anoscopy are often limited by patient discomfort and are rarely therapeutic, making EUA favored in most situations. MRI and endorectal ultrasound (ERUS) have largely replaced CT and fistulography for imaging evaluation of perianal fistulas due to better accuracy. A triple blinded study comparing ERUS, MRI, and EUA showed excellent accuracy of all three modalities in determining fistula anatomy, rates being 91%, 87%, and 91%, respectively [23]. Combining any two modalities led to 100% accuracy. More recently, Sahni concluded that MRI exceeds EUA and ERUS in distinguishing complex from simple fistulas, based on a comprehensive review combining data from literature review, consensus guidelines, and consultations with experts [24]. The likelihood ratio for MRI confirming complex disease was found to be 22.7 compared to 2.1 and 6.2 for clinical examination and ERUS, respectively. Further, several societies, including the Shanghai Group and the European Society of Crohn's and Colitis (ECCO), also regard MRI as the gold standard imaging technique for perianal CD [25]. EUA without preceding imaging is likely adequate for patients with simple fistulas. For patients with complex fistulas, preoperative anatomic mapping via pelvic MRI should be considered prior to EUA.

Management

The first step in the management of patients with CD-related perianal fistulas is to eradicate infection. This is accomplished primarily with surgical drainage. Once sepsis is cleared, endoscopic evaluation is necessary to detect any luminal disease, in particular active proctitis also requiring treatment.

Medical Management

Antibiotics

Antibiotics are frequently used as the initial medical therapy for perianal CD in conjunction with treatment of underlying luminal disease; however the evidence for this is somewhat limited. Two randomized placebo-controlled trials (RCTs) have assessed antibiotic use combined with biologic therapy. Ciprofloxacin combined with infliximab had a higher response than infliximab alone (73% vs. 39%, $P = 0.12$) [26]. Given with adalimumab, ciprofloxacin also led to an improved 12-week clinical response (71% vs. 47%, $P = 0.047$) [27]. One small RCT comparing ciprofloxacin, metronidazole, and placebo was underpowered to detect any statistically significant effect [28].

In a prospective, open-label study, half of patients receiving either an 8-week regimen of ciprofloxacin (500–1000 mg/

day) or metronidazole (1000–1500 mg/day) in addition to azathioprine had significantly improved perianal disease scores (PDAI 8.4 ± 2.9 to 6 ± 4; $P < 0.0001$), with 25% achieving complete healing [29]. In a systemic review and meta-analysis including 3 trials of 123 patients with perianal CD fistula, treatment with either ciprofloxacin or metronidazole significantly reduced fistula drainage (RR = 0.8; 95% CI = 0.66–0.98), with a number needed to treat of 5 (95% CI = 3–20) [30]. In another meta-analysis, ciprofloxacin was effective in reducing perianal fistula drainage but not providing closure (RR, 1.64; 95% CI, 1.16–2.32; $P = 0.005$) [31]. However, recurrence following antibiotic discontinuation is common, and both side effects and potential for antibiotic resistance limit their use. Antibiotics should therefore be used primarily as a bridge to immunosuppressant therapy and not as sole therapy.

Thiopurines

Thiopurines are best used in combination with anti-TNF therapy or in patients who cannot tolerate anti-TNF therapy, rather than as first-line agents [32]. In a meta-analysis of RCTs comparing azathioprine (AZA) or 6-mercaptopurine (6-MP) to placebo, perianal fistula response, defined as complete healing or decreased discharge, was seen in 54% (22/49) of treated patients compared to 21% (6/29) in the placebo group (pooled OR 4.44, 95% CI 1.50–13.2) [33]. Lecomte found that 29% of patients with CD-related anal fistulas, fissures, and/or strictures responded to AZA or 6-MP; however, absence of fistula, age >40, and shorter disease duration predicted better response [34]. Due to delayed response times of 3 of more months, these immunomodulators should typically be initiated in conjunction with other medications and used to maintain rather than induce fistula closure [35].

Calcineurin Inhibitors

A small and short-term RCT by Sandborn showed that tacrolimus at 0.2 mg/kg/day was effective in improving fistula drainage (43% vs. 8%, $p < 0.05$), but not closure ($p = 0.86$) [36]. Cyclosporine has also been shown to have some efficacy in CD-related perianal fistulas in multiple non-controlled trials. In a retrospective study, intravenous cyclosporine followed by oral cyclosporine achieved symptomatic improvement in 80–85% of patients acutely and closure in 45% of patients chronically; however, recurrence occurred after discontinuation [37]. Present also reported high initial response (88%) and closure (44%) rates with parenteral and then oral cyclosporine with loss of response after treatment discontinuation [38]. These agents, however, have significant side effects including nephrotoxicity, and close drug monitoring is required. Their role appears to be limited to some patients with severe CD intolerant or unresponsive to multimodality therapy, including anti-TNF agents, in whom the options of fecal diversion or proctectomy are being considered as a last resort [3].

Biologics

Infliximab was the first anti-TNF agent to show efficacy in the treatment of CD-related perianal fistulas in two RCTs as well as in multiple non-controlled trials [39–43]. In an RCT, 85 patients with CD-related perianal fistulas were randomized to treatment with infliximab 5 or 10 mg/kg at 0, 2, and 6 weeks versus placebo [39]. Closure of at least 50% of fistulas was maintained for at least 4 weeks in 68% of patients treated with infliximab 5 mg/kg and 56% of patients treated with infliximab 10 mg/kg, compared with 26% of patients treated with placebo ($p = 0.002$ and $p = 0.02$, respectively). Closure of all fistulas was maintained for at least 4 weeks in 13% for placebo, 55% for infliximab 5 mg/kg, and 38% for infliximab 10 mg/kg ($p = 0.001$ and $p = 0.04$, respectively). The median time to response was 2 weeks and fistulas remained closed for approximately 3 months.

However, more patients treated with infliximab developed perianal abscesses than placebo-treated patients, thought possibly due to closure of the external fistula opening before the fistula tract itself. In the ACCENT II trial, 306 patients with fistulizing CD were treated with infliximab 5 mg/kg at weeks 0, 2, and 6. Patients who responded to therapy were then randomized into maintenance doses of placebo every 8 weeks beginning at week 14 or maintenance doses of infliximab 5 mg/kg every 8 weeks beginning at week 14 [40]. The median time to loss of response through week 54 was 14 weeks for patients in the placebo group and >40 weeks for patients treated with infliximab 5 mg/kg ($p < 0.001$). At week 54, 39% of patients in the infliximab maintenance group had complete closure of all draining fistulas compared to 19% of those in the placebo group ($p = 0.009$).

Adalimumab has also been shown to close CD-related fistulas in infliximab-naïve patients as well as those who previously failed infliximab treatment in two RCTs and multiple retrospective studies [44–49]. In the CHARM trial, 30% of patients with perianal fistulas treated with adalimumab for 26 weeks had fistula closure compared to 13% of patients treated with placebo ($p < 0.04$) [44]. Fistulas were closed in 33% of treated patients vs. 13% of controls at week 56 ($p < 0.02$). The efficacy of certolizumab in fistulizing perianal CD was evaluated within the PRECiSE trials [50, 51]. Fifteen of 28 (54%) of patients had fistula closure compared with 13/30 (43%) in the placebo group; this difference did not reach statistical significance ($p = 0.069$) [52].

Combining anti-TNF agents with additional therapies including thiopurines [53, 54], ciprofloxacin [26, 27], and exam under anesthesia [55] may further improve clinical response, remission durability, and patient tolerance. Feagan evaluated the efficacy of maintenance vedolizumab, an α4β7 integrin monoclonal antibody, in a subpopulation of patients

from the GEMINI 2 trial [56, 57]. Fistula closure was achieved in 28% of vedolizumab-treated patients versus 11% of control patients at 14 weeks. Vedolizumab-treated patients also had faster time to fistula closure and higher rates of fistula closure at week 52 (33% vs. 11%; HR 2.54; 95% CI, 0.54–11.96). Finally, in limited, small, retrospective studies, ustekinumab, an anti-IL12/23 IgG1 kappa human monoclonal antibody, has been shown to improve fistula symptoms and achieve closure in 61% and 31% of patients, respectively [58, 59].

Surgical Management

Fistula anatomy, underlying inflammation, and presence of complicating factors, such as proctitis and abscess, determine surgical options for CD-related perianal fistulas. In the setting of active proctitis or abscess, both fistulotomy and definite repair should be avoided due to risks of poor wound healing and failure. Unfortunately, complex fistulas are seen in 80% of CD patients, and these are associated with higher rates of recurrence and failure to heal [9, 60, 61]. As a result, patients with CD are more likely to have setons placed and less likely to undergo curative treatment for their anal fistulas [62].

Fistulotomy

Conventional fistulotomy by laying open the fistula tract and any side tracts can be safely performed in the absence of proctitis. This procedure is usually performed in the operating room under anesthesia in either prone or lithotomy position. A metal probe is passed from the external fistula to the internal fistula opening. Saline, diluted hydrogen peroxide, or diluted methylene blue injection may be used to help identify the internal fistula opening. The tissue overlying the probe is palpated and, if minimal or no sphincter muscle involvement is confirmed, divided with cautery. The wound is then gently debrided and may be marsupialized. In a study by Williams, 41 fistulotomies were performed in 33 patients with subcutaneous [17], intersphincteric [19], or low transsphincteric [5] fistulas with a 73% and 93% rate of wound healing at 3 and 6 months, respectively. Twelve percent of patients experienced minor degrees of incontinence [63]. Other retrospective studies have reported similar results [64–66]. A Crohn's Disease Activity Index (CDAI) of greater than 150 has been suggested as a contraindication to fistulotomy [67].

Draining Seton

Patients with complex perianal fistula without abscess typically require EUA with seton placement in conjunction with medical therapy. Loose, thin, silastic setons should be placed after identifying the fistula tracts as described above for fistulotomy. Draining setons maintain fistula tract patency, decrease inflammation around the tract, and often prevent the development of recurrent abscesses [62, 68]. Studies have demonstrated higher rates of fistula healing and longer duration of closure when draining setons are added to anti-TNF and other medical therapies [53, 69, 70]. A recent systematic review by de Groof included 10 non-controlled studies, with a total of 305 patients treated with setons and anti-TNF therapy. Complete fistula closure rate varied between 13.6% and 100% and recurrence ranged from 0% to 83% [71]. Setons may remain in place for months to years, or even permanently. After active proctitis is addressed medically, seton removal can occur in up to 98% of patients at a median of 33 weeks [53]. Timing of seton removal should be coordinated between the patient's colorectal surgeon and gastroenterologist, typically after anti-TNF induction is complete [68].

Endorectal Advancement Flap

Endorectal advancement flaps can be used in CD patients without active proctitis. The internal fistula opening is identified, and the crypt-bearing tissue as well as a rim of anoderm below is excised. The internal anal sphincter opening is then closed and a U-shaped flap of mucosa, submucosa, and internal anal sphincter advanced over this closure and sutured down without tension. Success rates of about 60–64% have been reported; however recurrence rates of 57% and incontinence rates of 9.4% were also found [72–74]. Joo showed that the presence of concomitant small bowel disease predicted poorer outcome [73]. Smoking has also been found to negatively impact results of flap repair [75]. In addition to proctitis, cavitating ulceration and anal stenosis are also considered relative contraindications to this technique [76]. The advancement rectal sleeve procedure involves circumferential excision, lifting the anal canal mucosa from the dentate line to the anorectal ring, mobilization of a full-thickness rectal flap, and anastomosis of the rectal sleeve to the dentate line; Marchesa described this as an alternative technique in patients with severe, complex fistulizing disease in whom proctectomy is being considered [77].

Ligation of the Internal Fistula Tract (LIFT)

The LIFT procedure involves ligating and transecting the fistula tract within the intersphincteric space. Two small retrospective studies examined the use of this technique in CD-related perianal fistulas. Gingold reported a 67% rate of clinical healing at 12 months in 15 patients, with no patient experiencing incontinence [78]. Kaminski reported healing in 6 of 8 (75%) patients at less than 1-year follow-up and 5 of 15 (33%) patients with more than 1-year follow-up [79]. In multifocal CD, success was higher in patients with small bowel disease ($p = 0.04$) compared with colonic disease ($p = 0.02$).

Fibrin Glue and Fistula Plugs

Fibrin glue treatment involves the injection of biodegradable glue into the fistula tract in order to stimulate fibroblasts to form a fibrin clot seal [80]. This technique has the advantage of maintaining the integrity of the anal sphincters, and therefore repeat injections can be performed. Highly variable success rate between 0% and 100% has been reported, and data in CD patients is limited to small case series with relatively short-term follow-up [80–82]. Anal fistula plugs are bioprosthetic grafts that provide a collagen scaffold over which a patient's endogenous cells populate. Similar to fibrin glue, published results vary widely with studies showing a 15–100% rate of healing [83–86]. In a systematic review, the success rate of the plug was 55% [85]. One multicenter RCT in 106 CD patients reported that fistula plug treatment had similar efficacy as seton removal alone [87].

Mesenchymal Stem Cell Therapy

Local injection of mesenchymal stem cells is a promising new therapy for nonhealing perianal fistulas. In a phase 3 trial of 212 CD patients with complex fistulas, higher rates of fistula closure were found for patients who received adipose-derived stem cell injection compared to placebo (56.3% vs. 38.6%, respectively; 95% CI 4.2–31.2, $p = 0.010$) [88]. Study patients also had significantly shorter time to clinical remission (6.7 vs. 14.6 weeks). Other trials have similarly shown this procedure is safe and efficacious in patients with CD [89–94].

In a recent systematic review and meta-analysis of 11 studies, Lightner reported improved healing with mesenchymal stem cells compared with placebo at primary end points of 6–24 weeks [OR = 3.06 (95% CI, 1.05–8.90); $p = 0.04$] and 24–52 weeks [OR = 2.37 (95% CI, 0.90–6.25); $p = 0.08$] [95]. Another meta-analysis showed higher healing and clinical response rates in patients with baseline CDAI >150 than those with baseline CDAI <50 (79.17 vs. 47.53, $P = 0.011$), higher healing rate and lower recurrence rate with a moderate dose of 2–4 × 107 cells/mL compared to other dosages, and lower recurrence with adipose-derived MSCs therapy compared to bone marrow-derived MSCs (RR 7.4 ± 4.28 vs. 13.39 ± 0.89) [96]. These studies, however, were limited by heterogeneous patient populations, variable medication dosing, non-standardized methods of drug delivery, and differing definitions of success. One study reported fistula relapse-free survival of 37% for 4 years after treatment and cumulative probabilities of surgery- and medical-free survival of 63% and 25% at 5 and 6 years, respectively; however, the majority of reports lack long-term follow-up [97].

Rectovaginal Fistula

The incidence of anovaginal or rectovaginal fistula (RVF) in women with CD is approximately 10%; the median age of onset is 34 years [4, 98]. They are caused by an inflammatory process in the anus or rectum that is severe enough to erode through the vaginal wall. The most frequent disease distribution associated with RVF is colonic rather than small bowel disease [99, 100]. While some RVFs cause minimal or no symptoms, many significantly impact quality of life. Patients may experience seepage or incontinence of gas or stool via the fistula, leading to vaginal and perineal irritation. Sexual dysfunction, including dyspareunia, and urinary tract infections may also be present.

Prior to considering repair of an RVF, control of perianal sepsis and optimization of medical management should be accomplished. Examination under anesthesia with drainage of any abscesses and placement of setons can often accomplish the former; close collaboration with a gastroenterologist is essential for the latter. It may be helpful to establish the extent of sphincter damage and whether it is intact either via MRI or ultrasound [101]. Options for repair include advancement flaps from the anal or vaginal side, interposition either with gracilis or Martius (bulbocavernosus) flaps, episioproctotomy, or abdominal approaches such as pull-through procedures. Other approaches that have been described include fibrin glue or stem cell injection, fistula plugs, mesh interposition, and other novel techniques. The data on outcomes following RVF repair tends to be small case series, including fewer than 20 patients. As such, predictors of successful healing are largely unknown.

One study of RVF repair with rectal advancement flap found a healing rate of 42% for initial repair in 12 patients; this rose to 83% after up to 3 attempts [102]. This technique is appropriate in women with an otherwise normal anal canal, as those with significant stricture or sphincter defect are less likely to heal. In cases of anal stenosis, a vaginal flap consisting of healthy, nondiseased tissue may be more appropriate [103]. Sphincter defects should be repaired simultaneously, when present.

The Martius flap utilizes a pedicle graft to interpose healthy tissue between the rectal and vaginal sides of the fistula. After perineal dissection separating the rectovaginal septum to above the fistula defect is completed, an incision is made over the labia majora and the bulbocavernosus muscle mobilized. A subcutaneous tunnel is then created to the mobilized rectovaginal septum and the anterior portion of the flap pulled through the tunnel and sutured to the posterior vaginal wall. Healing rates varying between 50% and 100%, with or without fecal diversion, have been reported [104, 105]. For gracilis flap repairs, the gracilis muscle is harvested from the thigh, preserving the neurovascular bundle. The flap is rotated into the rectovaginal space via a subcutaneous tunnel and secured in place. Series of RVF repair with gracilis flap formation report healing rates ranging from 33% to 80%; however none included more than 11 patients [106–109]. One study that assessed quality of life before and after gracilis flap repair found that while seven of eight women

were sexually active before surgery, only four remained active following repair [109].

There are two studies with just three and nine patients that described the use of biologic (porcine-derived) mesh for RVF; healing ranged from 50% to 78% [110, 111]. Plugs have a healing rate of 50% in CD patients based on limited studies [112]. In an RCT of stem cell injection, CD patients with RVF achieved a remission rate of 51% at 24 weeks compared to 35% in controls [113]. In studies that include more than one technique with the primary end point of overall fistula healing, success rates range from 50% to 80% at 5 years with a rate of proctectomy of about 20% [114, 115].

In general, starting with an advancement flap repair and proceeding to more complex procedures if there is failure often makes sense. In the setting of recurrent fistulas, diversion is more frequently considered. Stomas may also be used before repair to minimize symptoms and improve inflammation of the perineal tissues related to seepage and soilage. Up to 60% of CD patients with RVF require temporary fecal diversion, and up to half require a permanent stoma for their perianal disease [116].

Medical management plays an important role in healing of RVF. Immunomodulators improve healing rates, while smoking and steroid use decrease success [117, 118]. A study of RVF repair that included a number of different techniques in both CD and non-CD patients found that repair at a short interval from diagnosis, no previous repairs, major procedures, and fecal diversion were also prognostic of success [119].

Non-fistulizing Complications

Anal Fissures and Ulcers

In the setting of CD, the etiology of anal fissures may be similar to that in non-Crohn's patients – from repeated bowel movements traumatizing the anal canal – or as a sequelae of anal canal inflammation related to the disease itself. Idiopathic fissures are generally located in the anterior (10%) or posterior (90%) midline and are associated with sharp pain and bright red blood with bowel movements. These fissures are located between the anal verge and dentate line and are associated with a hypertonic internal anal sphincter. CD patients experience idiopathic fissures as well as atypical fissures, which are frequently multiple and located off midline [120]. Atypical fissures classically have a granulating base with overhanging edges and may extend beyond the verge onto the perianal skin (Fig. 47.2). Large cavitating ulcers with significant tissue loss may also be seen (Fig. 47.3).

Atypical fissures occur due to direct involvement of the perianal tissues with CD-related inflammation. They often cause pain, bleeding, and, occasionally, pruritus. Unlike idiopathic fissures, they are not associated with increased internal anal sphincter tone. Biopsies demonstrate non-necrotizing epithelioid cell granulomas in about three-quarters of cases [121]. When these lesions present in healthy patients not known to have CD, other ulcer-related anal diseases such as carcinoma, radiation-related changes, syphilis, herpes, AIDS, gonorrhea, chlamydia, tuberculosis, and leukemia must be ruled out [122].

If fissures appear to be idiopathic in nature, even in patients with CD, they should be treated with the same algorithm used in non-CD patients. When fissures are present in the context of numerous bowel movements, controlling stool frequency is an appropriate first goal. This is accomplished by treating the underlying luminal disease and may be aided by anti-diarrheal or bulking agents, such as psyllium-based fiber. Minimizing toilet time, gentle perianal skin care, and topical agents such as nitroglycerine, calcium channel block-

Fig. 47.2 Severe fissures and ulcers

Fig. 47.3 Cavitating ulcers

ers, and botulinum toxin injections may also be useful. Hot baths and perianal hygiene may relieve symptoms as well. While these measures are highly successful in non-CD patients, data regarding their use in CD patients is limited.

The safety and efficacy of lateral internal sphincterotomy (LIS) in patients with CD has been studied in a small series by Fleshner [120]. The authors concluded that if patients have a single, characteristic midline fissure associated with a hypertonic sphincter and a disease-free rectum, LIS is appropriate. Additionally, when medical management was compared to LIS combined with fissurectomy in 56 CD patients, there was 67% short-term healing in the surgical group compared to 50% in the medical group. In the subset of patients with luminal disease, the healing rate fell to 43%. In long-term follow-up, 60% of the surgical group healed compared with 49% of the medical group. Of the patients with non-healed fissures, one quarter eventually developed a fistula. However, in other series, nearly 60% of CD patients treated surgically for fissure (botulinum toxin +/− fissurectomy, or LIS) experienced complications, including poor wound healing, recurrence, and fistulas [123].

Fissures and ulcers associated with CD inflammation are challenging to treat. In the absence of sphincter hypertonicity, strategies that decrease tone should be avoided, both because they will not help and because they can threaten continence in patients who may already have impaired control and are prone to loose bowel movements. Topical metronidazole 10% has demonstrated improvement in pain, drainage, induration, and CDAI at 4 weeks [124]. Tacrolimus 0.1% has also been used successfully. Systemic treatments such as steroids, antibiotics, aminosalicylates, and immunomodulators have shown inconsistent results [125–129]. Other small studies have reported some success with thalidomide [130], cyclosporine [37], hyperbaric oxygen [131], and local infiltration of infliximab [132].

Systemic anti-TNF medications have become the gold standard for the treatment of perianal CD, including fissures and ulcers. One large retrospective study demonstrated a 43% rate of complete healing and symptom resolution with anti-TNF therapy; healing was maintained in 73% of responders at 175 weeks [53]. Local infliximab injection adds minimal benefit in patients already receiving systemic infliximab [132].

The presence of CD-related fissures and ulcers is not insignificant; the likelihood of anoproctectomy is approximately 80% in patients with cavitating ulcers [133].

Skin Tags

CD-related skin tags can be classified by their appearance [3]. Type 1 skin tags are edematous and hard and may be cyanotic and tender (Fig. 47.4). These typically arise as sequelae of fissures, ulcers, or hemorrhoids when there is lymphedema secondary to lymphatic obstruction. Type 2 skin tags are raised lesions with a range of shapes from broad to narrow and soft or firm; these painless tags are often referred to as "elephant ear tags" and generally occur in multiplicity (Fig. 47.4b). The cumulative 10-year incidence of skin tags among CD patients is about 19% [134]. Skin tags may be asymptomatic or cause discomfort, pruritus related to difficulty with hygiene, or poor cosmesis. Additionally, symptomatic skin tags may signify active intraluminal disease [135].

Patients with symptomatic skin tags and active proctitis should have treatment directed at controlling inflammation. This has the dual purpose of improving bowel movements and decreasing inflammation of the tags themselves. Sitz baths, moistened wipes for hygiene, and careful cleansing also help reduce the symptoms of irritated skin tags.

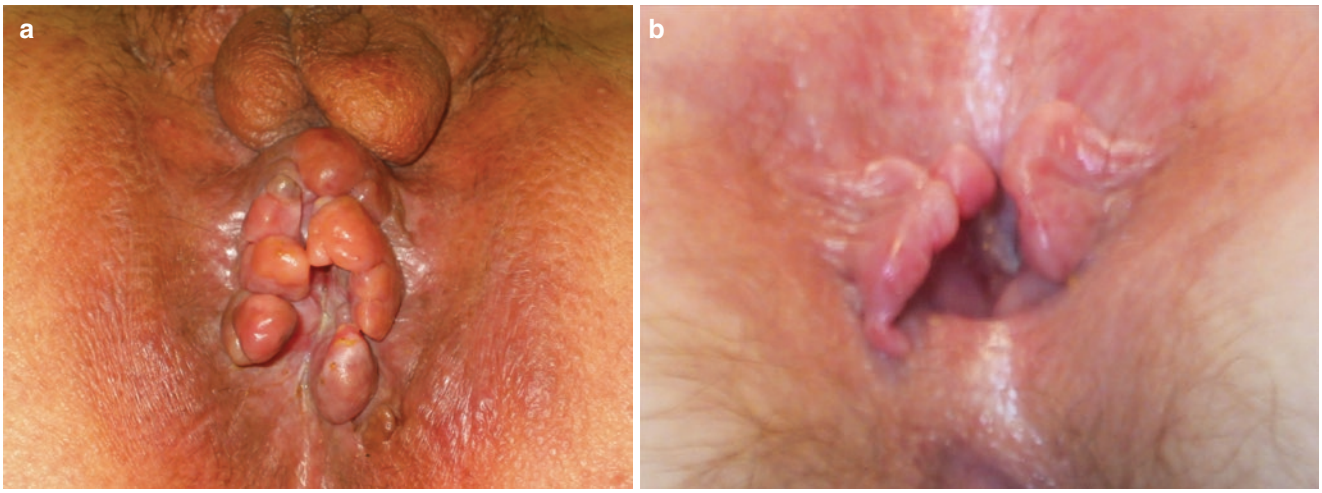

Fig. 47.4 (**a**, **b**) Type 1 and Type 2 skin tags

For patients in remission complaining of hygiene issues and impaired quality of life due to large or multiple skin tags, excision can be considered, particularly when tags are narrow-based and resulting defects will be small. However, it is difficult to truly quantify the risk in this situation, and a good understanding of the potential complications is critical.

Hemorrhoids

Hemorrhoidal disease is uncommon in the setting of CD; in a cohort of 50,000 hemorrhoid patients, only 20 had CD [136]. In studies specifically of IBD patients, 3–20% are reported to have hemorrhoids [137].

Studies show poor outcomes following hemorrhoid surgery in patients with CD; however the quality of this data is limited. Multiple early reports describe high rates of proctectomy following hemorrhoid surgery [137]. However, these studies likely demonstrate an association between hemorrhoids and skin tags with severe distal disease, rather than implicate that complications of hemorrhoid surgery lead to proctectomy. In other words, proctectomy is a reflection of the natural progression of severe disease rather than the hemorrhoid excision itself. Despite the dictum to avoid hemorrhoid surgery in CD patients, some authors have suggested that carefully selected patients may have acceptable outcomes [138]. While historically, poor wound healing has limited the application of hemorrhoid surgery to CD patients [137], a more recent study showed that of 36 patients who underwent excisional hemorrhoidectomy, only 4 had complications of nonhealing wound, anal stenosis, abscess/fistula, and recurrent bleeding. Three patients (8%) required fecal diversion for their perianal disease at a median follow-up of 31 months [139].

In patients with CD, addressing hemorrhoids surgically may be reasonable in those with luminal remission without the need for corticosteroids and a CDAI <150 [123]. However, conservative management is generally preferred.

Anal Stricture

Anal or rectal strictures typically arise as a consequence of prolonged transmural inflammation. They occur in 17% of patients with perianal CD and rarely occur without concurrent perianal disease [133]. While some patients are asymptomatic, most report symptoms of hematochezia, constipation, pain, or incontinence [140]. Digital rectal exam or proctoscopy easily establishes the diagnosis. Asymptomatic strictures do not require any specific treatment, although underlying proctitis or other perianal manifestations should be treated. When strictures obstruct defecation, dilation can be performed either manually or with balloon or Hegar dilators. Repeat dilations are frequently needed as strictures tend to recur. However, this should not be regarded as treatment failure so long as the patient experiences symptomatic relief between dilations. Rectal advancement has also been described for anal stricture with some success [141]. Nevertheless, about half of patients with an anorectal stricture eventually undergo proctectomy [140, 142].

Fig. 47.5 Squamous cell carcinoma in multiple fistula tracts

Anal Cancer

The risk of both adenocarcinoma and squamous cell carcinoma is increased in patients with long-standing perianal CD [143, 144]. These occur in the anal canal itself or within chronic fistula tracts (Fig. 47.5). Diagnosis is made by biopsy. Cancers are often discovered late and require a high index of suspicion [145]. A long-standing previously asymptomatic fistula that acutely causes symptoms is suspicious for malignant degeneration as is a newly inflamed chronic fissure. The treatment of anal cancer in patients with perianal CD mirrors that for sporadic cancer.

Diversion and Proctectomy for Perianal Crohn's Disease

Severe perianal CD may require temporary or permanent fecal diversion (Fig. 47.6). This occurs at a rate of 10–20% [22]. Risk is increased with active rectal disease and anal stricture [146]. Patients with active colonic CD and an anal stricture are also at increased risk of permanent diversion as well as proctectomy.

Fig. 47.6 Severe perianal CD requiring diversion

The risk of perineal wound complications following primary closure is up to 36% in patients with CD [147, 148]. Risk is higher with active inflammation and in patients with extensive perianal disease causing a "watering-can" perineum. Even after prolonged healing, some patients will have chronic perineal sinuses [149].

Depending on the presence of active inflammation, a staged approach to complete proctectomy may be most appropriate. During the first stage, the rectum is transected at the level of the levator muscles, and a permanent stoma is created. Once the patient has recovered, the perianal disease is often substantially improved allowing for a limited perineal anoproctectomy with decreased risk of wound complications [150]. An intersphincteric dissection sparing the external sphincter muscle should be utilized when feasible to minimize the risk and size of the perineal wound. Primary closure is associated with poor healing in up to one-third of patients [151]. Nonhealing wounds lead to significant morbidity and may necessitate skin grafting or myocutaneous flap reconstruction.

Conclusions

Perianal CD is a source of significant morbidity for those affected by it. Early treatment of perianal sepsis is essential. Straightforward problems, such as skin tags, hemorrhoids, and simple fistulas, can often be managed similarly to their non-CD forms. Combined medical and surgical therapy and close collaboration between surgeons and gastroenterologists are essential for optimal outcomes, particularly in more complex cases. The goals of treatment should be elimination of infection, adequate symptomatic control, preservation of continence and function, and maximizing quality of life.

References

1. Penner A, Crohn BB. Perianal fistulae as a complication of regional ileitis. Ann Surg. 1938;108(5):867–73.
2. Hellers G, Bergstrand O, Ewerth S, Holmström B. Occurrence and outcome after primary treatment of anal fistulae in Crohn's disease. Gut. 1980;21:525–7.
3. Sandborn WJ, Fazio VW, Feagan BG, Hanauer SB, American Gastroenterological Association Clinical Practice Committee. AGA technical review on perianal Crohn's disease. Gastroenterology. 2003;125(5):1508–30.
4. Schwartz DA, Loftus EV Jr, Tremaine WJ, et al. The natural history of fistulizing Crohn's disease in Olmsted County, Minnesota. Gastroenterology. 2002;122(4):875–80.
5. Lapidus A, Bernell O, Hellers G, Lofberg R. Clinical course of colorectal Crohn's disease: a 35-year follow-up study of 507 patients. Gastroenterology. 1998;114(6):1151–60.
6. Geltzeiler CB, Wieghard N, Tsikitis VL. Recent developments in the surgical management of perianal fistula for Crohn's disease. Ann Gastroenterol. 2014;27(4):320–30.
7. Kotze PG, Shen B, Lightner A, et al. Modern management of perianal fistulas in Crohn's disease: future directions. Gut. 2018;67(6):1181–94.
8. Williams DR, Coller JA, Corman ML, Nugent FW, Veidenheimer MC. Anal complications in Crohn's disease. Dis Colon Rectum. 1981;24(1):22–4.
9. Molendijk I, Nuij VJ, van der Meulen-de Jong AE, van der Woude CJ. Disappointing durable remission rates in complex Crohn's disease fistula. Inflamm Bowel Dis. 2014;20(11):2022–8.
10. Farmer RG, Hawk WA, Turnbull RB Jr. Clinical patterns in Crohn's disease (a statistical study of 615 cases). Gastroenterology. 1975;68(4 Pt 1):627–35.
11. Lockhart-Mummery HE. Symposium. Crohn's disease: anal lesions. Dis Colon Rectum. 1975;18(3):200–2.
12. Cosnes J, Cattan S, Blain A, et al. Long-term evolution of disease behavior of Crohn's disease. Inflamm Bowel Dis. 2002;8(4):244–50.
13. Tang LY, Rawsthorne P, Bernstein CN. Are perineal and luminal fistulas associated in Crohn's disease? A population-based study. Clin Gastroenterol Hepatol. 2006;4(9):1130–4.
14. Makowiec F, Jehle EC, Starlinger M. Clinical course of perianal fistulas in Crohn's disease. Gut. 1995;37(5):696–701.
15. Hughes LE. Surgical pathology and management of anorectal Crohn's disease. J R Soc Med. 1978;71(9):644–51.
16. Parks AG. Pathogenesis and treatment of fistula-in-ano. Br Med J. 1961;1(5224):463–9.
17. Wolff BG, Culp CE, Beart RW, Ilstrup DM, Ready RL. Anorectal Crohn's disease. A long-term perspective. Dis Colon Rectum. 1985;28(10):709–11.
18. Solomon MJ. Fistulae and abscesses in symptomatic perianal Crohn's disease. Int J Color Dis. 1996;11(5):222–6.
19. Khati NJ, Sondel Lewis N, et al. CT of acute perianal abscesses and infected fistulae: a pictorial essay. Emerg Radiol. 2015;22(3):329–35. https://doi.org/10.1007/s10140-014-1284-3.
20. Visscher AP, Felt-Bersma RJ. Endoanal ultrasound in perianal fistulae and abscesses. Ultrasound Q. 2015;31(2):130–7. https://doi.org/10.1097/RUQ.0000000000000124.
21. O'Malley RB, Al-Hawary MM, Kaza RK, Wasnik AP, Liu PS, Hussain HK. Rectal imaging: part 2, Perianal fistula evaluation on pelvic MRI--what the radiologist needs to know. AJR Am J Roentgenol. 2012;199(1):W43–53. https://doi.org/10.2214/AJR.11.8361.
22. Singh B, McC Mortensen NJ, Jewell DP, George B. Perianal Crohn's disease. Br J Surg. 2004;91(7):801–14.

23. Schwartz DA, Wiersema MJ, Dudiak KM. A comparison of endoscopic ultrasound, magnetic resonance imaging, and exam under anesthesia for evaluation of Crohn's perianal fistulas. Gastroenterology. 2001;121(5):1064–72.
24. Sahni V, Ahmad R. Which method is best for imaging of perianal fistula? Abdom Imaging. 2008;33(1):26–30. https://doi.org/10.1007/s00261-007-9309-y.
25. Gallego JC, Echarri A. Role of magnetic resonance imaging in the management of perianal Crohn's disease. Insights Imaging. 2018;9(1):47–58. https://doi.org/10.1007/s13244-017-0579-9.
26. West RL, van der Woude CJ, Hansen BE, et al. Clinical and endosonographic effect of ciprofloxacin on the treatment of perianal fistulae in Crohn's disease with infliximab: a double-blind placebo-controlled study. Aliment Pharmacol Ther. 2004;20(11–12):1329–36.
27. Dewint P, Hansen BE, Verhey E, et al. Adalimumab combined with ciprofloxacin is superior to adalimumab monotherapy in perianal fistula closure in Crohn's disease: a randomised, double-blind, placebo controlled trial (ADAFI). Gut. 2014;63(2):292–9.
28. Thia KT, Mahadevan U, Feagan BG, et al. Ciprofloxacin or metronidazole for the treatment of perianal fistulas in patients with Crohn's disease: a randomized, double-blind, placebo-controlled pilot study. Inflamm Bowel Dis. 2009;15(1):17–24.
29. Dejaco C, Harrer M, Waldhoer T, et al. Antibiotics and azathioprine for the treatment of perianal fistulas in Crohn's disease. Aliment Pharmacol Ther. 2003;18(11–12):1113–20.
30. Khan KJ, Ullman TA, Ford AC, et al. Antibiotic therapy in inflammatory bowel disease: a systematic review and meta-analysis. Am J Gastroenterol. 2011;106(4):661–73.
31. Su JW, Ma JJ, Zhang HJ. Use of antibiotics in patients with Crohn's disease: a systematic review and meta-analysis. J Dig Dis. 2015;16(2):58–66.
32. Steinhart AH, Panaccione R, Targownik L, et al. Clinical practice guideline for the medical management of perianal fistulizing Crohn's disease: the Toronto consensus. Inflamm Bowel Dis. 2019;25(1):1–13.
33. Pearson DC, May GR, Fick GH, Sutherland LR. Azathioprine and 6-mercaptopurine in Crohn disease. A meta-analysis. Ann Intern Med. 1995;123(2):132–42.
34. Lecomte T, Contou JF, Beaugerie L, et al. Predictive factors of response of perianal Crohn's disease to azathioprine or 6-mercaptopurine. Dis Colon Rectum. 2003;46(11):1469–75.
35. Present DH, Korelitz BI, Wisch N, Glass JL, Sachar DB, Pasternack BS. Treatment of Crohn's disease with 6-mercaptopurine. A long-term, randomized, double-blind study. N Engl J Med. 1980;302(18):981–7.
36. Sandborn WJ, Present DH, Isaacs KL, et al. Tacrolimus for the treatment of fistulas in patients with Crohn's disease: a randomized, placebo-controlled trial. Gastroenterology. 2003;125(2):380–8.
37. Cat H, Sophani I, Lemann M, Modiglani R, Solue JC. Cyclosporin treatment of anal and perianal lesions associated with Crohn's disease. Turk J Gastroenterol. 2003;14(2):121–7.
38. Present DH, Lichtiger S. Efficacy of cyclosporine in treatment of fistula of Crohn's disease. Dig Dis Sci. 1994;39(2):374–80.
39. Present DH, Rutgeerts P, Targan S, et al. Infliximab for the treatment of fistulas in patients with Crohn's disease. N Engl J Med. 1999;340(18):1398–405.
40. Sands BE, Anderson FH, Bernstein CN, et al. Infliximab maintenance therapy for fistulizing Crohn's disease. N Engl J Med. 2004;350(9):876–85.
41. Ricart E, Panaccione R, Loftus EV, Tremaine WJ, Sandborn WJ. Infliximab for Crohn's disease in clinical practice at the Mayo Clinic (the first 100 patients). Am J Gastroenterol. 2001;96(3):722–9.
42. Cohen RD, Tsang JF, Hanauer SB. Infliximab in Crohn's disease (first anniversary clinical experience). Am J Gastroenterol. 2000;95(12):3469–77.
43. Farrell RJ, Shah SA, Lodhavia PJ, et al. Clinical experience with infliximab therapy in 100 patients with Crohn's disease. Am J Gastroenterol. 2000;95(12):3490–7.
44. Colombel JF, Sandborn WJ, Rutgeerts P, et al. Adalimumab for maintenance of clinical response and remission in patients with Crohn's disease: the CHARM trial. Gastroenterology. 2007;132(1):52–65.
45. Lichtiger S, Binion DG, Wolf DC, et al. The CHOICE trial: adalimumab demonstrates safety, fistula healing, improved quality of life and increased work productivity in patients with Crohn's disease who failed prior infliximab therapy. Aliment Pharmacol Ther. 2010;32(1):1228–39.
46. Castaño-Milla C, Chaparro M, Saro C, et al. Effectiveness of adalimumab in perianal fistulas in Crohn's disease patients naive to anti-TNF therapy. J Clin Gastroenterol. 2015;49(1):34–40.
47. Fortea-Ormaechea JI, González-Lama Y, Casis B, et al. Adalimumab is effective in long-term real life clinical practice in both luminal and perianal Crohn's disease. The Madrid experience. Gastroenterol Hepatol. 2011;34(7):443–8.
48. Kotze PG, Spinelli A. Adalimumab for perianal fistulizing Crohn's disease: real-world data adds important information for clinical practice. J Clin Gastroenterol. 2015;49(2):174–5.
49. Echarri A, Castro J, Barreiro M, Carpio D, Pereira S, Lorenzo A. Evaluation of adalimumab therapy in multidisciplinary strategy for perianal Crohn's disease patients with infliximab failure. J Crohns Colitis. 2010;4(6):654–60.
50. Schreiber S, Khaliq-Kareemi M, Lawrance IC, et al.; PRECISE 2 Study Investigators. Maintenance therapy with certolizumab pegol for Crohn's disease. N Engl J Med. 2007;357(3):239–50.
51. Sandborn WJ, Feagan BG, Stoinov S, et al. Certolizumab pegol for the treatment of Crohn's disease. N Engl J Med. 2007;357(3):228–38.
52. Schreiber S, Lawrance IC, Thomsen O, Hanauer SB, Bloomfield R, Sandborn WJ. Randomised clinical trial: certolizumab pegol for fistulas in Crohn's disease - subgroup results from a placebo-controlled study. Aliment Pharmacol Ther. 2011;33(2):185–93.
53. Bouguen G, Siproudhis L, Gizard E, et al. Long-term outcome of perianal fistulizing Crohn's disease treated with infliximab. Clin Gastroenterol Hepatol. 2013;11(8):975–8. e1–e4.
54. Ochsenkuhn T, Goke B, Sackmann M. Combining infliximab with 6-mercaptopurine/azathioprine for fistula therapy in Crohn's disease. Am J Gastroenterol. 2002;97(8):2022–5.
55. Regueiro M, Mardini H. Treatment of perianal fistulizing Crohn's disease with infliximab alone or as an adjunct for exam under anesthesia with seton placement. Inflamm Bowel Dis. 2003;9(2):98–103.
56. Feagan B, Schwartz D, Danese S, et al. Efficacy of Vedolizumab in fistulising Crohn's disease: exploratory analysis of data from GEMINI 2. J Crohns Colitis. 2018;12(5):621–6.
57. Sandborn WJ, Feagan BG, Rutgeerts P, et al.; GEMINI 2 Study Group. Vedolizumab as induction and maintenance therapy for Crohn's disease. N Engl J Med. 2013;369(8):711–21.
58. Ma C, Fedorak RN, Kaplan GG, et al. Clinical, endoscopic and radiographic outcomes with ustekinumab in medically-refractory Crohn's disease: real world experience from a multicentre cohort. Aliment Pharmacol Ther. 2017;45(9):1232–43.
59. Khorrami S, Ginard D, Marín-Jiménez I, et al. Ustekinumab for the treatment of refractory Crohn's disease: the Spanish experience in a large multicentre open-label cohort. Inflamm Bowel Dis. 2016;22(7):1662–9.
60. Pittet V, Juillerat P, Michetti P, et al. Appropriateness of therapy for fistulizing Crohn's disease: findings from a national

inflammatory bowel disease cohort. Aliment Pharmacol Ther. 2010;32(8):1007–16.
61. Loffler T, Welsch T, Muhl S, Hinz U, Schmidt J, Kienle P. Long-term success rate after surgical treatment of anorectal and rectovaginal fistulas in Crohn's disease. Int J Color Dis. 2009;24(5):521–6.
62. Gecse KB, Bemelman W, Kamm MA, et al.; World Gastroenterology Organization International Organisation for Inflammatory Bowel Diseases IOIBD European Society of Coloproctology and Robarts Clinical Trials. A global consensus on the classification, diagnosis and multidisciplinary treatment of perianal fistulising Crohn's disease. Gut. 2014;63(9):1381–92.
63. Williams JG, Rothenberger DA, Nemer FD, Goldberg SM. Fistula-in-ano in Crohn's disease. Results of aggressive surgical treatment. Dis Colon Rectum. 1991;34(5):378–84.
64. Sangwan YP, Schoetz DJ Jr, Murray JJ, Roberts PL, Coller JA. Perianal Crohn's disease. Results of local surgical treatment. Dis Colon Rectum. 1996;39(5):529–35.
65. Levien DH, Surrell J, Mazier WP. Surgical treatment of anorectal fistula in patients with Crohn's disease. Surg Gynecol Obstet. 1989;169(2):133–6.
66. Morrison JG, Gathright JB Jr, Ray JE, Ferrari BT, Hicks TC, Timmcke AE. Surgical management of anorectal fistulae in Crohn's disease. Dis Colon Rectum. 1989;32(6):492–6.
67. Lozynskyy YS. Treatment algorithms in the case of perianal complications of Crohn's disease. Dig Dis. 2009;27(4):565–70.
68. Hyder SA, Travis SP, Jewell DP, McC Mortensen NJ, George BD. Fistulating anal Crohn's disease: results of combined surgical and infliximab treatment. Dis Colon Rectum. 2006;49(12):1837–41.
69. Regueiro M, Mardini H. Treatment of perianal fistulizing Crohn's disease with infliximab alone or as an adjunct to exam under anesthesia with seton placement. Inflamm Bowel Dis. 2003;9(2):98–103.
70. Topstad DR, Panaccione R, Heine JA, Johnson DR, MacLean AR, Buie WD. Combined seton placement, infliximab infusion, and maintenance immunosuppressives improve healing rate in fistulizing anorectal Crohn's disease: a single center experience. Dis Colon Rectum. 2003;46(5):577–83.
71. de Groof EJ, Sahami S, Lucas C, Ponsioen CY, Bemelman WA, Buskens CJ. Treatment of perianal fistula in Crohn's disease: a systematic review and meta-analysis comparing seton drainage and anti-tumour necrosis factor treatment. Color Dis. 2016;18(7):667–75.
72. Mizrahi N, Wexner SD, Zmora O, et al. Endorectal advancement flap: are there predictors of failure? Dis Colon Rectum. 2002;45(12):1616–21.
73. Joo JS, Weiss EG, Nogueras JJ, Wexner SD. Endorectal advancement flap in perianal Crohn's disease. Am Surg. 1998;64(2):147–50.
74. Soltani A, Kaiser AM. Endorectal advancement flap for cryptoglandular or Crohn's fistula-in-ano. Dis Colon Rectum. 2010;53(4):486–95.
75. Zimmerman DD, Delemarre JB, Gosselink MP, Hop WC, Briel JW, Schouten WR. Smoking affects the outcome of transanal mucosal advancement flap repair of trans-sphincteric fistulas. Br J Surg. 2003;90(3):351–4.
76. Sordo-Mejia R, Gaertner WB. Multidisciplinary and evidence-based management of fistulizing perianal Crohn's disease. World J Gastrointest Pathophysiol. 2014;5(3):239–51.
77. Marchesa P, Hull TL, Fazio VW. Advancement sleeve flaps for treatment of severe perianal Crohn's disease. Br J Surg. 1998;85(12):1695–8.
78. Gingold DS, Murrell ZA, Fleshner PR. A prospective evaluation of the ligation of the intersphincteric tract procedure for complex anal fistula in patients with Crohn disease. Ann Surg. 2013;260(6):1057–61.
79. Kamiński JP, Zaghiyan K, Fleshner P. Increasing experience of LIFT procedure for patients with Crohn's disease: what have we learned? Color Dis. 2017;19(8):750–5.
80. Grimaud J, Munoz-Bongrand N, Siproudhis L, et al. Fibrin glue is effective healing perianal fistulas in patients with Crohn's disease. Gastroenterology. 2010;138(7):2275–81.
81. Cirocchi R, Farinella E, La Mura F, et al. Fibrin glue in the treatment of anal fistula: a systematic review. Ann Surg Innov Res. 2009;3:12.
82. Zmora O, Mizrahi N, Rotholtz N, et al. Fibrin glue sealing in the treatment of perianal fistulas. Dis Colon Rectum. 2003;46(5):584–9.
83. Ky AJ, Sylla P, Steinhagen R, Steinhagen E, Khaitov S, Ly EK. Collagen fistula plug for the treatment of anal fistulas. Dis Colon Rectum. 2008;51(6):838–43.
84. Taxonera C, Schwartz DA, García-Olmo D. Emerging treatments for complex perianal fistula in Crohn's disease. World J Gastroenterol. 2009;15(34):4263–72.
85. O'Riordan JM, Datta I, Johnston C, Baxter NN. A systematic review of the anal fistula plug for patients with Crohn's and non- Crohn's related fistula-in-ano. Dis Colon Rectum. 2012;55(3):351–8.
86. O'Connor L, Champagne B, Ferguson M, Orangio G, Schertzer M, Armstrong D. Efficacy of anal fistula plug in closure of Crohn's anorectal fistulae. Dis Colon Rectum. 2006;49(10):1569–73.
87. Senéjoux A, Siproudhis L, Abramowitz L, et al. Fistula plug in fistulising ano-perineal Crohn's disease: a randomised controlled trial. J Crohns Colitis. 2016;10(2):141–8.
88. Panés J, García-Olmo D, Van Assche G, et al.; ADMIRE CD Study Group Collaborators. Expanded allogeneic adipose-derived mesenchymal stem cells (Cx601) for complex perianal fistulas in Crohn's disease: a phase 3 randomised, double-blind controlled trial. Lancet. 2016;388(10051):1281–90.
89. Lee WY, Park KJ, Cho YB, et al. Autologous adipose tissue-derived stem cells treatment demonstrated favorable and sustainable therapeutic effect for Crohn's fistula. Stem Cells. 2013;31(11):2575–81.
90. Ciccocioppo R, Bernardo ME, Sgarella A, et al. Autologous bone marrow-derived mesenchymal stromal cells in the treatment of fistulising Crohn's disease. Gut. 2011;60(6):788–98.
91. de la Portilla F, Alba F, García-Olmo D, Herrerías JM, González FX, Galindo A. Expanded allogeneic adipose-derived stem cells (eASCs) for the treatment of complex perianal fistula in Crohn's disease: results from a multicenter phase I/IIa clinical trial. Int J Color Dis. 2013;28(3):313–23.
92. Molendijk I, Bonsing BA, Roelofs H, et al. Allogeneic bone marrow–derived mesenchymal stromal cells promote healing of refractory perianal fistulas in patients with Crohn's disease. Gastroenterology. 2015;149(4):918–27.e6.
93. García-Olmo D, García-Arranz M, Herreros D, Pascual I, Peiro C, Rodríguez-Montes JA. A phase I clinical trial of the treatment of Crohn's fistula by adipose mesenchymal stem cell transplantation. Dis Colon Rectum. 2005;48(7):1416–23.
94. Cho YB, Lee WY, Park KJ, Kim M, Yoo HW, Yu CS. Autologous adipose tissue-derived stem cells for the treatment of Crohn's fistula: a phase I clinical study. Cell Transplant. 2013;22(2):279–85.
95. Lightner AL, Wang Z, Zubair AC, Dozois EJ. "A systematic review and meta-analysis of mesenchymal stem cell injections for the treatment of perianal crohn's disease: progress made and future directions. Dis Colon Rectum. 2018;61(5):629–40. https://doi.org/10.1097/DCR.0000000000001093.
96. Cao Y, Ding Z, Han C, Shi H, Cui L, Lin R. Efficacy of mesenchymal stromal cells for fistula treatment of Crohn's disease: a systematic review and meta-analysis. Dig Dis Sci. 2017;62(4):851–60.
97. Ciccocioppo R, Gallia A, Sgarella A, Kruzliak P, Gobbi PG, Corazza GR. Long-term follow-up of Crohn disease fistulas after

local injections of bone marrow–derived mesenchymal stem cells. Mayo Clin Proc. 2015;90(6):747–55.
98. Radcliffe AG, Ritchie JK, Hawley PR, Lennard-Jones JE, Northover JMA. Anovaginal and rectovaginal fistulas in Crohn's disease. Dis Colon Rectum. 1988;31:94. https://doi.org/10.1007/BF02562636.
99. Ritchie JK, Lennard Jones JE. Crohn's disease of the distal large bowel. Scand J Gastroenterol. 1976;11:433.
100. Van Patter WN, Bargen JA, Dockerty MB, Feldman WH, Mayo CW, Waugh JM. Regional enteritis. Gastroenterology. 1954;26:347. https://doi.org/10.1016/S0016-5085(54)80024-2.
101. Deleon MF, Hull TL. Treatment strategies in Crohn's-associated rectovaginal fistula. Clin Colon Rectal Surg. 2019;32:261. https://doi.org/10.1055/s-0039-1683908.
102. Jarrar A, Church J. Advancement flap repair: a good option for complex anorectal fistulas. Dis Colon Rectum. 2011;54:1537. https://doi.org/10.1097/DCR.0b013e31822d7ddd.
103. Sher ME, Bauer JJ, Gelernt I. Surgical repair of rectovaginal fistulas in patients with Crohn's disease: transvaginal approach. Dis Colon Rectum. 1991;34(8):641–8. http://www.ncbi.nlm.nih.gov/pubmed/1855419.
104. Songne K, Scotté M, Lubrano J, et al. Treatment of anovaginal or rectovaginal fistulas with modified Martius graft. Color Dis. 2007;9:653. https://doi.org/10.1111/j.1463-1318.2007.01232.x.
105. Pitel S, Lefevre JH, Parc Y, Chafai N, Shields C, Tiret E. Martius advancement flap for low rectovaginal fistula: short- and long-term results. Color Dis. 2011;13:e112. https://doi.org/10.1111/j.1463-1318.2011.02544.x.
106. Wexner SD, Ruiz DE, Genua J, Nogueras JJ, Weiss EG, Zmora O. Gracilis muscle interposition for the treatment of recto-urethral, rectovaginal, and pouch-vaginal fistulas: results in 53 patients. Ann Surg. 2008;248:39. https://doi.org/10.1097/SLA.0b013e31817d077d.
107. Fürst A, Schmidbauer C, Swol-Ben J, Iesalnieks I, Schwandner O, Agha A. Gracilis transposition for repair of recurrent anovaginal and rectovaginal fistulas in Crohn's disease. Int J Color Dis. 2008;23:349. https://doi.org/10.1007/s00384-007-0413-9.
108. Ulrich D, Roos J, Jakse G, Pallua N. Gracilis muscle interposition for the treatment of recto-urethral and rectovaginal fistulas: a retrospective analysis of 35 cases. J Plast Reconstr Aesthet Surg. 2009;62:352. https://doi.org/10.1016/j.bjps.2008.11.067.
109. Lefèvre JH, Bretagnol F, Maggiori L, Alves A, Ferron M, Panis Y. Operative results and quality of life after gracilis muscle transposition for recurrent rectovaginal fistula. Dis Colon Rectum. 2009;52:1290. https://doi.org/10.1007/DCR.0b013e3181a74700.
110. Schwandner O, Fuerst A, Kunstreich K, Scherer R. Innovative technique for the closure of rectovaginal fistula using SurgisisTM mesh. Tech Coloproctol. 2009;13:135. https://doi.org/10.1007/s10151-009-0470-x.
111. Mege D, Frasson M, Maggiori L, Panis Y. Is biological mesh interposition a valid option for complex or recurrent rectovaginal fistula? Color Dis. 2016;18(2):O61–5. https://doi.org/10.1111/codi.13242.
112. Gajsek U, McArthur DR, Sagar PM. Long-term efficacy of the button fistula plug in the treatment of ileal pouch-vaginal and Crohn's-related rectovaginal fistulas. Dis Colon Rectum. 2011;54:999. https://doi.org/10.1097/DCR.0b013e31821df266.
113. Panés J, García-Olmo D, Van Assche G, et al. Long-term efficacy and safety of stem cell therapy (Cx601) for complex perianal fistulas in patients with Crohn's disease. Gastroenterology. 2018;154:1334. https://doi.org/10.1053/j.gastro.2017.12.020.
114. Löffler T, Welsch T, Mühl S, Hinz U, Schmidt J, Kienle P. Long-term success rate after surgical treatment of anorectal and rectovaginal fistulas in Crohn's disease. Int J Color Dis. 2009;24:521. https://doi.org/10.1007/s00384-009-0638-x.
115. O'Leary DP, Milroy CE, Durdey P. Definitive repair of anovaginal fistula in Crohn's disease. Ann R Coll Surg Engl. 1998;80(4):250–2.
116. Mueller MH, Geis M, Glatzle J, et al. Risk of fecal diversion in complicated perianal Crohn's disease. J Gastrointest Surg. 2007;11:529. https://doi.org/10.1007/s11605-006-0029-3.
117. El-Gazzaz G, Hull T, Mignanelli E, Hammel J, Gurland B, Zutshi M. Analysis of function and predictors of failure in women undergoing repair of Crohn's related rectovaginal fistula. J Gastrointest Surg. 2010;14(5):824–9. https://doi.org/10.1007/s11605-010-1167-1.
118. Penninckx F, Moneghini D, D'Hoore A, Wyndaele J, Coremans G, Rutgeerts P. Success and failure after repair of rectovaginal fistula in Crohn's disease: analysis of prognostic factors. Color Dis. 2001;3:406. https://doi.org/10.1046/j.1463-1318.2001.00274.x.
119. Corte H, Maggiori L, Treton X, Lefevre JH, Ferron M, Panis Y. Rectovaginal fistula: what is the optimal strategy?: an analysis of 79 patients undergoing 286 procedures. Ann Surg. 2015;262:855. https://doi.org/10.1097/SLA.0000000000001461.
120. Fleshner PR, Schoetz DJ Jr, Roberts PL, Murray JJ, Coller JA, Veidenheimer MC. Anal fissure in Crohn's disease: a plea for aggressive management. Dis Colon Rectum. 1995;38(11):1137–43. http://www.ncbi.nlm.nih.gov/pubmed/7587755.
121. Figg RE, Church JM. Perineal Crohn's disease: an indicator of poor prognosis and potential proctectomy. Dis Colon Rectum. 2009;52:646. https://doi.org/10.1007/DCR.0b013e3181a0a5bf.
122. Pfenninger JL, Zainea GG. Common anorectal conditions. Obstet Gynecol. 2001;98:1130. https://doi.org/10.1016/S0029-7844(01)01687-8.
123. D'Ugo S, Franceschilli L, Cadeddu F, et al. Medical and surgical treatment of haemorrhoids and anal fissure in Crohn's disease: a critical appraisal. BMC Gastroenterol. 2013;13 https://doi.org/10.1186/1471-230X-13-47.
124. Stringer EE, Nicholson TJ, Armstrong D. Efficacy of topical metronidazole (10 percent) in the treatment of anorectal Crohn's disease. Dis Colon Rectum. 2005;48:970. https://doi.org/10.1007/s10350-004-0873-8.
125. Hart AL, Plamondon S, Kamm MA. Topical tacrolimus in the treatment of perianal Crohn's disease: exploratory randomized controlled trial. Inflamm Bowel Dis. 2007;13:245. https://doi.org/10.1002/ibd.20073.
126. Sweeney JL, Ritchie JK, Nicholls RJ. Anal fissure in Crohn's disease. Br J Surg. 1988;75:56. https://doi.org/10.1002/bjs.1800750120.
127. Buchmann P, Michael Keighley SR, Robert Allan EN, Henry Thompson E, John Alexander-Williams E. Natural history of perianal Crohn's disease ten year follow-up: a plea for conservatism. https://ac.els-cdn.com/0002961080900483/1-s2.0-0002961080900483-main.pdf?_tid=8326e71b-f774-40bd-9b4f-05bd7da49ac5&acdnat=1530544446_63b178098fc8836b3e4565a596c4256d. Accessed 2 July 2018.
128. Kruis W, Katalinic A, Klugmann T, et al. Predictive factors for an uncomplicated long-term course of Crohn's disease: a retrospective analysis. J Crohn's Colitis. 2013; https://doi.org/10.1016/j.crohns.2012.10.012.
129. Siproudhis L, Mortaji A, Mary JY, Juguet F, Bretagne JF, Gosselin M. Anal lesions: any significant prognosis in Crohn's disease? Eur J Gastroenterol Hepatol. 1997;9:239. https://doi.org/10.1097/00042737-199703000-00004.
130. Plamondon S, Ng SC, Kamm MA. Thalidomide in luminal and fistulizing Crohn's disease resistant to standard therapies. Aliment Pharmacol Ther. 2007;25:557. https://doi.org/10.1111/j.1365-2036.2006.03239.x.
131. Colombel JF, Mathieu D, Bouault JM, et al. Hyperbaric oxygenation in severe perineal Crohn's disease. Dis Colon Rectum. 1995;38:609. https://doi.org/10.1007/BF02054120.

132. Poggioli G, Laureti S, Pierangeli F, et al. Local injection of infliximab for the treatment of perianal Crohn's disease. Dis Colon Rectum. 2005;48(4):768–74. https://doi.org/10.1007/s10350-004-0832-4.
133. Keighley MRB, Allan RN. Current status and influence of operation on perianal Crohn's disease. Int J Color Dis. 1986;1(2):104–7. https://doi.org/10.1007/BF01648416.
134. Peyrin-Biroulet L, Loftus EV, Tremaine WJ, Harmsen WS, Zinsmeister AR, Sandborn WJ. Perianal Crohn's disease findings other than fistulas in a population-based cohort. Inflamm Bowel Dis. 2012;18:43. https://doi.org/10.1002/ibd.21674.
135. Alexander-Williams J, Buchmann P. Perianal Crohn's disease. World J Surg. 1980;4(2):203–8. http://www.ncbi.nlm.nih.gov/pubmed/7405258. Accessed 2 July 2018.
136. Jeffery PJ, Ritchie J, Parks AG. Treatment of haemorrhoids in patients with inflammatory bowel disease. Lancet. 1977;309(8021):1084–5. https://doi.org/10.1016/S0140-6736(77)92337-6.
137. Cracco N, Zinicola R. Is haemorrhoidectomy in inflammatory bowel disease harmful? An old dogma re-examined. Color Dis. 2014;16:516. https://doi.org/10.1111/codi.12555.
138. Wolkomir AF, Luchtefeld MA. Surgery for symptomatic hemorrhoids and anal fissures in Crohn's disease. Dis Colon Rectum. 1993;36(6):545–7. http://www.ncbi.nlm.nih.gov/pubmed/8500370. Accessed 2 July 2018.
139. Lightner AL, Kearney D, Giugliano D, et al. Excisional hemorrhoidectomy: safe in patients with Crohn's disease? Inflamm Bowel Dis. 2019;26:1390. https://doi.org/10.1093/ibd/izz255.
140. Linares L, Moreira LF, Andrews H, Allan RN, Alexander-Williams J, Keighley MR. Natural history and treatment of anorectal strictures complicating Crohn's disease. Br J Surg. 1988;75(7):653–5. http://www.ncbi.nlm.nih.gov/pubmed/3416120. Accessed 5 Jan 2017.
141. Simmang CL, Lacey SW, Huber PJ. Rectal sleeve advancement: repair of rectovaginal fistula associated with anorectal stricture in Crohn's disease. Dis Colon Rectum. 1998;41:787. https://doi.org/10.1007/BF02236270.
142. Bauer JJ, Gelernt IM, Salk BA, Kreel I. Proctectomy for inflammatory bowel disease. Am J Surg. 1986;151:157. https://doi.org/10.1016/0002-9610(86)90026-7.
143. Slesser AAP, Bhangu A, Bower M, Goldin R, Tekkis PP. A systematic review of anal squamous cell carcinoma in inflammatory bowel disease. Surg Oncol. 2013;22:230. https://doi.org/10.1016/j.suronc.2013.08.002.
144. Shwaartz C, Munger JA, Deliz JR, et al. Fistula-associated anorectal cancer in the setting of Crohn's disease. Dis Colon Rectum. 2016;59(12):1168–73. https://doi.org/10.1097/DCR.0000000000000700.
145. Vermeire S, Van Assche G, Rutgeerts P. Perianal Crohn's disease: classification and clinical evaluation. Dig Liver Dis. 2007;39:959. https://doi.org/10.1016/j.dld.2007.07.153.
146. Galandiuk S, Kimberling J, Al-Mishlab TG, Stromberg AJ. Perianal Crohn disease: predictors of need for permanent diversion. Ann Surg. 2005;241(5):796–801; discussion 801–2. https://doi.org/10.1097/01.sla.0000161030.25860.c1.
147. Corman ML, Veidenheimer MC, Coller JA, Ross VH. Perineal wound healing after proctectomy for inflammatory bowel disease. Dis Colon Rectum. 1978;21:155. https://doi.org/10.1007/BF02586557.
148. Baudot P, Keighley MRB, Alexander-Williams J. Perineal wound healing after proctectomy for carcinoma and inflammatory disease. Br J Surg. 1980;67:275. https://doi.org/10.1002/bjs.1800670415.
149. Yamamoto T, Bain LM, Allan RN, Keighley MRB. Persistent perineal sinus after proctocolectomy for Crohn's disease. Dis Colon Rectum. 1999;42:96. https://doi.org/10.1007/BF02235190.
150. Sher ME, Bauer JJ, Gorphine S, Gelernt I. Low Hartmann's procedure for severe anorectal Crohn's disease. Dis Colon Rectum. 1992;35:975. https://doi.org/10.1007/BF02253501.
151. Yamamoto T, Allan RN, Keighley MRB. Audit of single-stage proctocolectomy for Crohn's disease: postoperative complications and recurrence. Dis Colon Rectum. 2000;43:249. https://doi.org/10.1007/BF02236990.