13 Laparoscopic Subtotal Cholecystectomy and Other Laparoscopic Techniques

Elena Schembari, Maurizio Mannino, Adriana Toro, Piero Marco Fisichella, and Isidoro Di Carlo

13.1 Introduction

When laparoscopic cholecystectomy (LC) is difficult due to a severe inflammation degree that makes the Calot's triangle dissection challenging, conversion to open surgery was suggested in the past. Nowadays, thanks to the increasing surgeons' laparoscopic experience, several tricks have been described to have a better visualization of the operative field in order to finalize the total cholecystectomy by laparoscopy. Moreover, when a "critical view of safety" (CVS) is not possible, other laparoscopic techniques have been advised to manage the difficult cases that can be treated by subtotal cholecystectomy or other techniques that do not resect the gallbladder in its entirety but leave a part of the gallbladder wall in place. This chapter will explore all these possible solutions and suggest that a change in surgical laparoscopic strategy can give better results than the open conversion.

13.2 Tricks

Many tricks have been reported in literature to make a cholecystectomy easier. Santos et al. [1] described the trocars' position in obese patients. The camera trocar should not be inserted at the umbilicus but 15 cm below the xiphoid process. The reason is that in these patients the umbilicus is located lower in the abdomen, and consequently the placement of the camera trocar in this site would make more distant and difficult the visualization of the gallbladder. Even previous median laparotomies are contraindications for umbilical access; in these cases, the first trocar should be placed in the upper left or right quadrant in order to remove adhesions in the umbilical region and allowing a safe insertion of the camera trocar.

Moreover, in obese patients with a substantial amount of intra-abdominal fat and the omentum covering the gallbladder, the traditional reverse Trendelenburg position slightly turned on the left side could not be enough to achieve a good visualization of the gallbladder and an instrument should be used to take them away from the surgical field.

In addition, the use of a further 5 mm trocar should be considered as a valid option for facilitating the surgeon's performance as for bulky left lobe of the liver that can be found not only in obese patients but also in normal weight subjects.

E. Schembari
Barts Health NHS Trust, London, UK

M. Mannino · I. Di Carlo (✉)
Department of Surgical Sciences and Advanced Technologies "GF Ingrassia", University of Catania, Cannizzaro Hospital, Catania, Italy
e-mail: idicarlo@unict.it

A. Toro
Department of General Surgery, E. Muscatello Hospital, Augusta (SR), Italy

P. M. Fisichella
Feinberg School of Medicine, Northwestern University, Evanston, IL, USA

© Springer Nature Switzerland AG 2021
I. Di Carlo (ed.), *Difficult Acute Cholecystitis*, https://doi.org/10.1007/978-3-030-62102-5_13

A 30° or 45° laparoscope should be preferred to a 0° one because this facilitates the vision during the lateral and medial dissections.

Decompression of gallbladder by needle aspiration is advised when its distension is too exaggerated and interferes with the field of view [2].

During the dissection, the intensity of diathermy should be regulated according to the size of the patient and the surgeon's skills. High levels of energy can not only damage closer organs such as duodenum and stomach during adhesiolysis but also burn the liver with possible postoperative bile leakages. Undoubtedly, modern energy devices (Harmonic, Thunderbeat) facilitate the hemostasis in patients with acute cholecystitis or cirrhosis, even if there are some risks of serious injuries due to the thermal spread [1]. Persistent mild bleedings should be managed by compression, while uncontrolled clipping and electrocautery should be avoided [2].

Another fundamental step during the dissection is the correct exposure of the Calot's triangle. An adequate retraction of the infundibulum towards the lateral and caudal parts of the patient allows the opening of the triangle. Without this maneuver, the cystic duct would lay parallel to the common bile duct and distinguishing these two structures could be challenging, with an obvious increased risk of damaging the common bile duct. The assistant could make this phase easier, facilitating the visualization of the infundibulum by pulling up and to the right patient's shoulder the fundus of the gallbladder. Moreover, thanks to this maneuver, the incision of the medial peritoneal attachment of the gallbladder can be safely performed. This in conjunction with the lateral attachment incision will result in a further opening of the Calot's triangle and give access to gallbladder's wall through the inflammatory capsule [1].

When the cystic artery is short or enters high into the gallbladder, it hinders a reliable achievement of CVS. In such occasions, it has been advised to cut it. The aim of this procedure is to allow clear visualization of the cystic duct which will be the only tubular structure in the Calot's triangle. However, before performing this division, the surgeon must be sure that the identified structure is the cystic artery. This represents a crucial step because, basing this assessment just on the presence of pulsation or its size, the cystic artery could be confused with the right hepatic artery or with the cystic duct. In order to avoid this unpleasant and dangerous misidentification, removing all the tissue (such as fat) which surrounds the cystic artery is fundamental, and this vascular structure should be followed from its origin to its entrance into the gallbladder [3].

However, surgical decision-making remains the most fundamental element in the management of difficult cholecystectomy [4]. Unclear anatomy, bleedings, bile leakage, and the use of several clips are all factors that should encourage the young surgeon to ask for some help. Converting to open cholecystectomy can be useful to get out of Dodge, but it is not always the best solution to make a cholecystectomy easier. In fact, having the opinion of a colleague with good expertise in laparoscopic surgery can be more effective rather than converting to open surgery. Moreover, there are other strategies that can be used to overcome these difficult situations because the safety of patients has to ever guide the surgeon's behavior.

13.3 Alternative Strategies

The surgeon should always bear in mind that cholecystectomy is usually performed for benign disease [4]. Dangerous maneuvers, which can lead to serious injuries and sometimes life-threating situations, should not be carried out especially because there are other solutions that are safe and effective. So, the decision of changing the surgical strategy should be made before doing vascular or biliary injuries.

The CVS is not the only technique to isolate the cystic duct, but the infundibular technique could be also adopted (Fig. 13.1). According to this method, the dissection of the cystic duct is made on the front and back of the Calot's triangle once the cystic duct is found, and it is traced on to the union with the gallbladder. A typical flare or funnel shape is evident when the cystic duct joins the gallbladder. However, this technique seems to

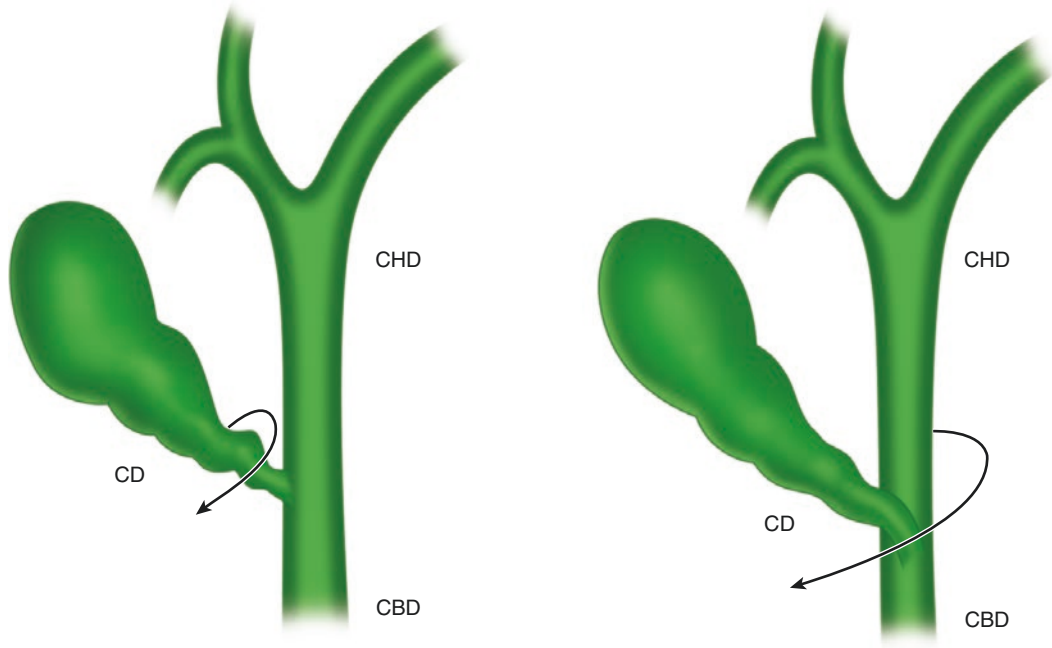

Fig. 13.1 The infundibular technique of laparoscopic cholecystectomy. Left: typical anatomy, where the dissection is made around the cystic duct (CD), which can be easily distinguished and is far away from the common hepatic duct (CHD) and the common bile duct (CBD). Right: due to the inflammatory process, the CHD could be adherent to the CD and misidentified as this. So, the circular dissection is more likely to be wrongly made around the block CBD–CD rather than just around the CD, causing biliary injuries

create a flaw in the visualization of the cystic duct. In fact, it has been demonstrated that, in case of severe inflammation, it is hidden, and the risk of misidentifying the common bile duct as the cystic duct and biliary injury is high. In these situations, the dissection around the left and the right sides of the common bile duct instead of anteriorly and posteriorly to the Calot's triangle can be done but very cautiously and only in expert hands. As a result, this technique is unreliable, even if it is performed by expert surgeons, and should be avoided [5].

In 1994, LC from "fundus downward" or "fundus first" was proposed by Kato et al. [6]. When the exposure of the cystic duct was difficult, the gallbladder dissection should start from the fundus and the cystic duct should be clipped and cut at the end of the procedure. This technique was slightly modified by Uyama et al. [7], who lifted the liver bed up to the diaphragm by a suture, obtaining a good view of the operative field. However, because of the contraction of the Calot's triangle occurring during an inflammatory process, the lower end of the gallbladder becomes closer to the common hepatic duct, the right hepatic artery, and the right or main portal veins. So, gallbladder and common hepatic duct can be perceived by the surgeon as one structure, the route of the dissection will be wrong, and, at the end of the procedure, the common hepatic duct will be divided [8].

The impossibility of obtaining a CVS is a clear signal that a bailout procedure should be considered [2]. Thanks to a subtotal cholecystectomy (SC), it is possible to treat the disease at once, avoiding a second operation. Indeed, subtotal cholecystectomy in the case of portal hypertension or cholecystitis is a well-known technique [9]. Generally speaking, "subtotal" means almost complete removal of an organ, while "partial" refers to the removal of a portion of an organ. These two terms have been used in literature to describe the same extension of an incomplete gallbladder resection. However, Strasberg [10]

suggested that the term "subtotal" was more accurate to describe this type of surgical procedure and avoid confusion. The term "fundectomy" should be adopted referring to the removal of the top part of the gallbladder. As a result, the word "partial" should not be used anymore. Furthermore, the terms "reconstituting" and "fenestrating" refer to the presence or absence of a gallbladder remnant that in the majority of cases concerns the posterior wall. The remaining portion of the gallbladder wall can be left open or closed, when it is sutured this has to be done as close as possible to the cystic duct. Otherwise the residual sutured stump, called "remnant," will result in a new and smaller gallbladder.

Overall, some differences come to light when the articles about subtotal cholecystectomy are examined. In fact, the authors of the published articles have controversial opinions about how to perform some steps of this procedure.

One of the most critical steps of the subtotal cholecystectomy is the handling of the cystic duct. Some authors prefer to isolate and close the cystic duct with surgical clips, suture ligation, Endoloop (Ethicon), purse-string suture, or intracorporeal sutures for closure [11, 12].

Palanivelu et al. [13] introduced the concept of tailored subtotal cholecystectomy by laparoscopy. In fact, they classified laparoscopic subtotal cholecystectomy (LSC) in three types which were performed according to the risk of damaging liver bed or hilum. So, in type I, they suggested to not remove the posterior wall of the gallbladder when its dissection from the liver bed was difficult for an increased risk of bleeding. The remnant mucosa could be removed (mucosectomy) or electrofulgurated. Type II should be performed when recognizing the hilar structures was complicate, the entire gallbladder was removed, and the infundibulum was cut close to the cystic duct and sutured with a continuous suture of polyglactin 3–0. Finally, when high-risk hilum and gallbladder bed coexisted, a combination of LSC I and II should be performed and this was called LSC III.

When LSC is performed, there are two possible options to manage the remnant gallbladder stump. The first option is to close it, reconstituting the gallbladder as in open surgery described by Strasberg. Several methods can be used to do it like an absorbable suture [14], a purse-string suture [11], endoloop [15], or an EndoGIA stapler [12]. All these techniques have to be used carefully, and they can be applied only when a safe distance between the cystic duct and the common bile ducts exists. Otherwise, the risk is to have the traction and consequently involvement of the CBD and all related immediate or late complications. This closure can be performed also when the posterior wall of the gallbladder is not excised [10]; in this case, it is completely cauterized with the only exception of the part that will be sutured. The second option is to leave it open (fenestrating LSC), closing the cystic duct [16, 17] or leaving it open. Drains are usually placed [18, 19].

Recently, the association of "fundus first" LC and subtotal cholecystectomy has been proposed [20, 21]. According to Harilingam et al. [20], the procedure starts with the opening of the fundus to drain its content (pus, bile, stones). After dividing the gallbladder into two halves, the posterior wall is used to make traction and pulling up the liver and the anterior wall is transected at the level of Hartmann's pouch. Then, the posterior wall is divided from the liver bed, but, when this dissection is difficult, it is cauterized. The cystic duct or the small gallbladder remnant is closed with an intracorporeal stitch or endoloop. The rationale of this technique is that viewing the gallbladder from the inside could make the dissection safe, reducing the risk of biliary and vascular injuries. Moreover, an intraoperative cholangiography could be performed. Nasr et al. [21] proposed the traditional fundus first technique, but they ended the dissection at the so-called "Critical Point of Surgical Control" (CPSC) of the gallbladder. The CPSC is the junction between the gallbladder neck and the cystic duct where the cystic artery comes into the gallbladder. When they arrived at CPSC, an endoloop was applied to control the hilum of the gallbladder. However, due to the small number of patients involved in these studies [20, 21], it is not possible to conclude if these techniques have better outcomes than the others [2].

13.4 Outcomes

Overall, postoperative bile leakage was more frequent after laparoscopic subtotal cholecystectomy compared with open conversion, while rates of retained stones, subhepatic collections, wound infections, reoperations and mortality were all lower [22]. Moreover, the incidence of postoperative complications after subtotal cholecystectomy (SC) is similar to that after a total cholecystectomy (TC) and, taking into account that SC is usually performed in difficult cases, this means that SC is a safe and simple method to manage complex situations. It is important to highlight the lower rate of common bile duct injury after SC rather than TC, which is one of the most important reasons why the SC is performed because it avoids hazardous maneuvers in the Calot's triangle [22]. In fact, vascular injuries can cause acute liver failure, while biliary obstruction dues to the wrong closure of the CBD could lead to secondary biliary cirrhosis and chronic liver failure. In both cases, liver transplantation is the only treatment [23, 24].

The most common complication of LSC is bile leak, which varies from 10.6% [25] to 18% [22]. This incidence is higher after laparoscopy maybe because the cystic duct (CD) can be closed with a tighter knot during an open procedure. The increased rate of bilomas and bile leaks after SC can be consequent to the inflammation because, when the inflammatory process is resolved, the edema disappears and the sutures used to close CD or Hartmann's pouch can become looser [22]. Bile leaks are more common when CD or Hartmann's pouch is left open rather than when they are closed [22, 25]. Leaving drainages in place is useful to monitor the evolution of the leakage also because the majority of bile fistulas can resolve spontaneously [22]. Otherwise, percutaneous drainage or ERCP can be used to address the problem [25].

The fundus-down technique is associated with a high incidence of vasculo-biliary injury, especially in difficult cases like severe inflammation with the fusion of the structures because it is easier to misidentify the correct plane [26]. For this reason, performing the dissection close to the gallbladder has been advised [2].

The incidence of recurrent or residual gallstones after intentional incomplete cholecystectomy has been estimated between 0.0% and 16% [18, 27]. During SC, stones placed in the gallbladder stump or cystic duct could not be identified, this could explain the increased incidence of retained stones after SC than TC. The difference in the rate of this complication is not statistically significant between cystic duct/gallbladder stump open and close, even if this appears to be slightly higher when cystic duct/gallbladder stump is left open [22]. In long-term follow-up, recurrent symptomatic stones can form in the gallbladder remnant in only 5% of patients, giving symptoms of cholecystolithiasis [2, 10, 25]. There is no evidence that increasing the number of LSC and reducing laparotomic conversions causes a rise in the rate of residual or recurrent gallstones. The size of the remnant could influence the probability of stone formation. Gallstones relapse is more possible if a "fundectomy" is done instead of a true subtotal cholecystectomy [28]. According to the intraoperative findings that some symptomatic gallbladder remnants had an internal diameter of only about 1 cm, the section during an SLC should be performed very close to the cystic duct [10, 29]. Gallstones recurrence is a complication that a surgeon should consider in patients with symptoms related to biliary colic after an SC. Diagnosis of stone recurrence in a gallbladder remnant is quite complex, and it arises mainly from ultrasonography (US), computed tomography (CT), magnetic resonance cholangiopancreatography (MRCP), endoscopic retrograde cholangiopancreatography (ERCP) (which is also useful to treat residual gallstones of the common bile duct), and endoscopic ultrasonography (EUS). The surgical treatment represents the best option. The laparoscopic approach should be performed by expert surgeons because of the scar around the Calot's triangle following the previous operation [27, 28].

One of the disadvantages of LSC is that in the case of cancer that has not diagnosed preoperatively, there is the risk of tumor dissemination in

the abdominal cavity and remnant tumors. A tumor should be excluded before surgery [30], even if the unexpected rate of gallbladder cancer has been reported to be very low, around 0.2–0.8% [31].

13.5 Conclusions

Severe inflammation could make LC difficult with an increased risk of vasculo-biliary injuries. A bailout procedure should be adopted when a CVS cannot be achieved because of severe fibrosis which hides the structures of the Calot's triangle. To avoid these damages, several rescue procedures have been proposed over time but only a few have been recommended. The first one is the laparoscopic subtotal cholecystectomy. This is superior to open conversion and TC in terms of postoperative complications and biliary injuries. So, SLC is a procedure that should be definitively considered in difficult situations. Conversely, there is no clear evidence about the safety of the fundus first technique even when it is combined with SLC. The open conversion is a controversial issue because the decision to convert into open depends on the surgeon's experience [2]. Most surgeons trained in the past 20 years have little experience in open cholecystectomy [8], so open conversion does not make surgery easier. Otherwise, open conversion does not exclude the opportunity to perform an SC when the intraoperative findings discourage a TC [2].

References

1. Santos BF, Brunt LM, Pucci MJ. The difficult gallbladder: a safe approach to a dangerous problem. J Laparoendosc Adv Surg Tech. 2017;27:571–8.
2. Wakabayashi G, Iwashita Y, Hibi T, et al. Tokyo Guidelines 2018: surgical management of acute cholecystitis: safe steps in laparoscopic cholecystectomy for acute cholecystitis (with videos). J Hepatobiliary Pancreat Sci. 2018;25:73–86.
3. Mascagni P, Spota A, Felli E, et al. Conclusive identification and division of the cystic artery: a forgotten trick to optimize exposure of the critical view of safety in laparoscopic cholecystectomy. J Am Coll Surg. 2019;229:e5–7.
4. Pucci MJ, Brunt LM, Deziel DJ. Safety first, total cholecystectomy second. J Am Coll Surg. 2016;223:543–4.
5. Strasberg SM, Eagon CJ, Drebin JA. The "hidden cystic duct" syndrome and the infundibular technique of laparoscopic cholecystectomy - the danger of the false infundibulum. J Am Coll Surg. 2000;191:661–7.
6. Kato K, Matsuda M, Onodera K, et al. Laparoscopic cholecystectomy from fundus downward. Surg Laparosc Endosc. 1994;4:373–4.
7. Uyama I, Iida S, Ogiwara H, et al. Laparoscopic retrograde cholecystectomy (from fundus downward) facilitated by lifting the liver bed up to the diaphragm for inflammatory gallbladder. Surg Laparosc Endosc. 1995;5:431–6.
8. Strasberg SM. Error traps and vasculo-biliary injury in laparoscopic and open cholecystectomy. J Hepatobiliary Pancreat Surg. 2008;15:284–92.
9. Bornman PC, Terblanche J. Sub-total cholecystectomy: for the difficult gall bladder in portal hypertension and cholecystitis. Surgery. 1985;98:1–6.
10. Strasberg SM, Pucci MJ, Brunt LM, Deziel DJ. Subtotal cholecystectomy–"Fenestrating" vs "Reconstituting" subtypes and the prevention of bile duct injury: definition of the optimal procedure in difficult operative conditions. J Am Coll Surg. 2016;222:89–96.
11. Michalowski K, Bornman PC, Krige JEJ. Laparoscopic subtotal cholecystectomy in patients with complicated acute cholecystitis or fibrosis. Br J Surg. 1998;85:904–6.
12. Chowbey PK, Sharma A, Khullar R, et al. Laparoscopic subtotal cholecystectomy: a review of 56 procedures. J Laparoendosc Adv Surg Tech A. 2000;10:31–4.
13. Palanivelu C, Rajan PS, Jani K, et al. Laparoscopic cholecystectomy in cirrhotic patients: the role of subtotal cholecystectomy and its variants. J Am Coll Surg. 2006;203:145–51.
14. Nakajima J, Sasaki A, Obuchi T, et al. Laparoscopic subtotal cholecystectomy for severe cholecystitis. Surg Today. 2009;39:870–5.
15. Singhal T, Balakrishnan S, Hussain A, et al. Laparoscopic subtotal cholecystectomy: initial experience with laparoscopic management of difficult cholecystitis. Surgeon. 2009;7:263–8.
16. Bickel A, Shtamler B. Laparoscopic subtotal cholecystectomy. J Laparoendosc Surg. 1993;3:365–7.
17. Hubert C, Annet L, van Beers BE, Gigot JF. The "inside approach of the gallbladder" is an alternative to the classic Calot's triangle dissection for a safe operation in severe cholecystitis. Surg Endosc. 2010;24:2626–32.
18. Beldi G, Glättli A. Laparoscopic subtotal cholecystectomy for severe cholecystitis. Surg Endosc. 2003;17:1437–9.

19. Sinha I, Smith ML, Safranek P. Laparoscopic subtotal cholecystectomy without cystic duct ligation. Br J Surg. 2007;94:1527–9.
20. Harilingam MR, Shrestha AK, Basu S. Laparoscopic modified subtotal cholecystectomy for difficult gall bladders: a single-centre experience. J Minim Access Surg. 2016;12:325–9.
21. Nasr MM. An innovative emergency laparoscopic cholecystectomy technique; early results towards complication free surgery. J Gastrointest Surg. 2017;21:302–11.
22. Elshaer M, Gravante G, Thomas K, et al. Subtotal cholecystectomy for "difficult gallbladders": systematic review and metaanalysis. JAMA Surg. 2015;150:159e168.
23. Parrilla P, Robles R, Varo E, et al. Liver transplantation for bile duct injury after open and laparoscopic cholecystectomy. Br J Surg. 2014;101:63–8.
24. Silva Filho JFRE, Coelho GR, Leite Filho JAD, et al. Liver transplantation for bile duct inijury after cholecystectomy. Arq Gastroenterol. 2019;56:300–3.
25. Henneman D, Da Costa DW, Vrouenraets BC, et al. Laparoscopic partial cholecystectomy for the difficult gallbladder: a systematic review. Surg Endosc. 2013;27:351–8.
26. Strasberg SM, Gouma DJ. "Extreme" vasculobiliary injuries: association with fundus-down cholecystectomy in severely inflamed gallbladders. HPB. 2012;14:1–8.
27. Chowbey PK, Bandyopadhyay SK, Sharma A, et al. Laparoscopic reintervention for residual gallstone disease. Surg Laparosc Endosc Percutan Tech. 2003;13:31–5.
28. Pernice LM, Andreoli F. Laparoscopic treatment of stone recurrence in a gallbladder remnant: report of an additional case and literature review. J Gastrointest Surg. 2009;13:2084–91.
29. Di Carlo I, Pulvirenti E, Toro A, Corsale G. Modified subtotal cholecystectomy: results of a laparotomy procedure during thelaparoscopic era. World J Surg. 2009;33:520e525.
30. Kuwabara J, Watanabe Y, Kameoka K, et al. Usefulness of laparoscopic subtotal cholecystectomy with operative cholangiography for severe cholecystitis. Surg Today. 2014;44:462–5.
31. Ouchi K, Mikuni J, Kakugawa Y, et al. Laparoscopic cholecystectomy for gallbladder carcinoma: results of a Japanese survey of 498 patients. J Hepatobiliary Pancreat Surg. 2002;9:256–60.