



# Blepharoplasty

# 70

Maryam Abdulraheem, Rani Hammoud,  
Shanmugam Ganesan, and Alwyn D'Souza

## 70.1 Introduction

Blepharoplasty is one of the most common surgical procedures performed for both functional improvements in the aging patient as well as aesthetic rejuvenation of the periocular region and midface [1]. It is a surgical procedure in which the eyelid skin, orbicularis oculi muscle, and orbital fat are excised or sculpted to rejuvenate the aesthetic look of the patient along with the correction of any functional abnormality [2]. Usually, the upper eyelid blepharoplasty is performed for both aesthetic and functional indications, while the lower eyelid blepharoplasty is commonly performed for esthetic reasons [3, 4].

## 70.2 Eyelid Anatomy

The eyelid is a bilamellar structure comprising an anterior lamella and a posterior lamella separated by the orbital septum (Figs. 70.1 and 70.2).

### 70.2.1 The Anterior Lamella

The eyelid has two lamellas, an outer and an inner lamella separated by the orbital septum, which is also known as the palpebral pigment. It is a dense fibrous membrane extending from the periosteum of the orbital rim to the tarsus, and in the upper eyelid, it fuses with the levator aponeurosis. The orbital septum is considered a barrier to both neoplastic and inflammatory invasion.

The outer lamella consists of two parts, the skin measuring around 0.3 mm and the oculi muscle, which is supplied by the facial nerve, and it furtherly subdivided into three parts.

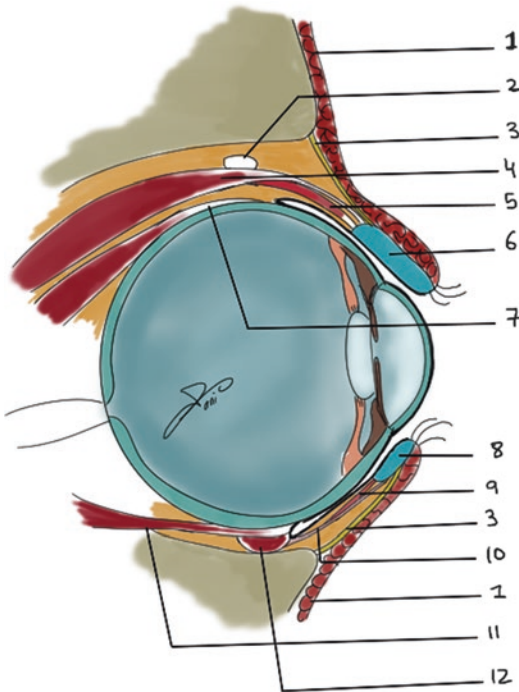
The outermost is the pretarsal fibers found over the tarsal plate responsible for the involuntary blink and the mechanism of lacrimal pumping. The second part is the preseptal fibers that overlie the orbital septum; these fibers assist with blinking. The orbital fibers overlying the orbital rims are responsible for the voluntary and forceful eyelid closure.

The tarsal plate is a dense connective tissue found at the margin of the eyelids approximately 1–2 mm in thickness attached medially to the anterior lacrimal crest by the medial canthal tendon and to the orbital tubercle of the zygomatic bone by the lateral canthal tendon.

The superior tarsus is around 12–15 mm in vertical height and serves as an attachment for the Muller's muscle and the levator aponeurosis superiorly. On the other hand, the inferior tarsus

M. Abdulraheem (✉) · R. Hammoud · S. Ganesan  
ENT Department, Hamad Medical Corporation,  
Doha, Qatar  
e-mail: [mabdulraheem1@hamad.qa](mailto:mabdulraheem1@hamad.qa); [Rhammoud3@hamad.qa](mailto:Rhammoud3@hamad.qa); [Sganesan@hamad.qa](mailto:Sganesan@hamad.qa)

A. D'Souza  
University Hospital Lewisham, London, UK



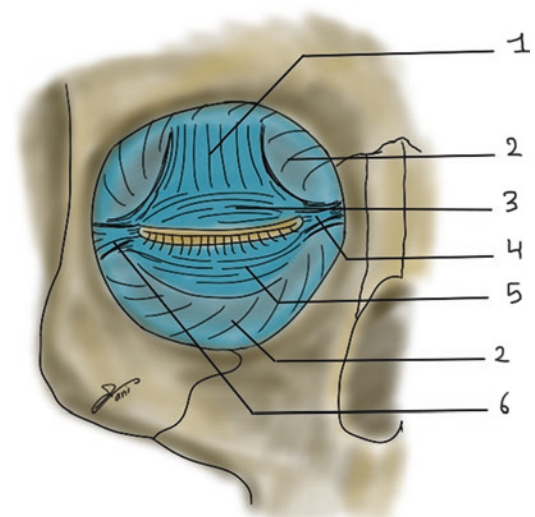
1. orbicularis oris muscle
2. Whitnall's ligament
3. Orbital septum
4. Levator palpebrae superioris muscle
5. Muller's muscle (superior tarsal muscle)
6. Superior tarsus
7. Superior rectus muscle
8. Inferior tarsus
9. Inferior tarsus muscle
10. Capsulopalpebral fascia
11. Inferior rectus muscle
12. Inferior oblique muscle

**Fig. 70.1** Sagittal view. (1) Orbicularis oris muscle. (2) Whitnall's ligament. (3) Orbital septum. (4) Levator palpebrae superioris muscle. (5) Muller's muscle (superior tarsal muscle). (6) Superior tarsus. (7) Superior rectus muscle. (8) Inferior tarsus. (9) Inferior tarsus muscle. (10) Capsulopalpebral fascia. (11) Inferior rectus muscle. (12) Inferior oblique muscle

is smaller and has a vertical height of 4–10 mm and is usually continuous with the capsulopalpebral fascia inferiorly.

### 70.2.2 The Eyelid Retractors

The upper lid has two retractors, the Muller's muscle which arises from the inferior part of the levator muscle fibers and inserts into the superior part of the superior tarsus and is innervated by the



1. Tendon of the levator palpebrae superioris muscle
2. Orbital septum
3. Superior tarsus
4. Medial canthal ligament
5. Inferior tarsus
6. Lateral canthal ligament

**Fig. 70.2** Frontal view. (1) Tendon of the levator palpebrae superioris muscle. (2) Orbital septum. (3) Superior tarsus. (4) Medial canthal ligament. (5) Inferior tarsus. (6) Lateral canthal ligament

sympathetic nervous system, and the levator palpebrae superioris that arises from the sphenoid wing and extends to the superior edge of the superior tarsus. The levator is supplied by the superior division of the oculomotor nerve.

The Whitnall's ligament is a dense fibrous connective tissue that serves as a fulcrum that redirects the vector of pull from horizontal to vertical for the lid retraction.

The lower lid has one main retractor, the capsulopalpebral fascia, a dense fibroelastic tissue found anterior to the Lockwood ligament, and joins the inferior tarsus.

### 70.2.3 The Layers Found at the Upper Eyelid Crease

1. Skin
2. Orbicularis muscle
3. Orbital septum

4. Orbital fat
5. Levator aponeurosis
6. Muller's muscle
7. Tarsal portion

---

### 70.3 Indication

Indications for blepharoplasty include dermatochalasis, which is an acquired draping of excess skin over lids, and blepharochalasis which is characterized by recurrent attacks of lid edema resulting in swelling and edema of the lids, progressive tissue breakdown, prolapse of the orbital fat, and drooping of the lid. Other indications also include pseudoherniation, where orbital fat protrudes through a lax orbital septum behind orbicularis muscle resulting in baggy lids, orbicularis hypertrophy which also results in bagginess, and blepharoptosis in which droopy eyelid caused by levator muscle malfunction [5].

---

### 70.4 Preoperative Evaluation [6]

#### 70.4.1 History

Proper selection of patients is crucial to achieve the most satisfying results in blepharoplasty and avoid unhappy patients. It is also essential to discuss the patient's goals and expectations as unrealistic expectations will lead to an unhappy patient. Limitations, the normal healing process, and complications of the surgery should be clearly explained during the preoperative evaluation. When taking history, it is essential to inquire about history of systemic diseases, such as Graves' disease, Sjogren's syndrome, rosacea, myasthenia gravis, and diabetes. Previous eye surgery, especially a history of laser in situ keratomileusis (LASIK) or previous cosmetic surgery, should also be included while taking history. It is also important to query patients preoperatively regarding bleeding disorders, the use of medications that may increase their risk of bleeding (e.g., aspirin, warfarin), and factors associated with poor wound healing, such as smoking and steroid use [1].

### 70.4.2 Physical Examination


Before surgery, an examination of the forehead, brows, and eyelids should be performed, as abnormalities or asymmetries in these structures may require repair at the same time as blepharoplasty to ensure a satisfactory result. Brow position must be assessed in all patients. Patients with significant brow ptosis, as well as dermatochalasis, should be considered for combined correction of the brow ptosis along with blepharoplasty. Eyelids should be evaluated preoperatively for pre-existing ptosis, asymmetrical lid creases, as well as any scarring that may be indicative of previous surgery or trauma. It is also essential to look for exophthalmos, lid retraction, inferior scleral show, lid laxity, entropion, and ectropion. Evaluation should also include palpebral fissure, marginal reflex distance, amount of lagophthalmos, and lid crease height. Corrected visual acuity, extraocular motility evaluation, and Schirmer's test can be helpful before blepharoplasty. Lastly, clinical photos should be obtained in order to document the patient's preoperative appearance, as well as for postoperative comparison [1, 7].

---

### 70.5 Surgical Technique [8, 9]

#### 70.5.1 Upper Eyelid Blepharoplasty

Address the upper lid after the brow and before the lower lid. Mark the estimated upper lid skin to be excised. With the patient in an upright position, pinch the excess skin with forceps. To prevent webbed scar formation, avoid extending the incision beyond the medial canthus. Intraoperatively the lid should leave 1–2 mm lagophthalmos. Address lateral hooding by extending the incision lateral to the orbital rim. For better definition, a strip of orbicularis oculi may be removed with the heavy lid. The orbital septum is opened to access the pseudoherniated fat, which is clamped and excised. Lacrimal gland ptosis may be treated by plication to the periosteum.



**Fig. 70.3** Upper and lower blepharoplasty

### 70.5.2 Lower Eyelid Blepharoplasty

The two main approaches are subciliary and transconjunctival. Subciliary approach is most common, and it allows easier modification of skin and muscle. The transconjunctival approach avoids lid retraction and has no visible scar. It may be used effectively in patients with excessive fat herniation with little skin redundancy. Depending on the underlying anatomy and the desired result, the skin, muscle, and pseudohermiated fat are excised in a customized fashion. Inferior orbital fat can be repositioned inferiorly with the SOOF by opening the orbital septum for subtle changes (Fig. 70.3).

## 70.6 Complications

The complication of blepharoplasty include ptosis, lagophthalmos, and upper eyelid overcorrection, ectropion and lower eyelid correction,

asymmetries, dry eye syndrome, chemosis, hematomas, diplopia, infection, and wound dehiscence [1, 7]. True ptosis secondary to blepharoplasty is usually temporary and is usually caused by eyelid edema, hematoma, or supratarsal fixation sutures in the perioperative period. It usually resolves during the first several postoperative weeks. Permanent post-blepharoplasty ptosis is usually caused by direct trauma to the levator muscle. When persistent ptosis occurs, it is advised to wait at least 3 months before surgical correction, as it often improves spontaneously. Lagophthalmos is common in the first postoperative week and is most often self-limited. It is managed with aggressive ocular lubrication, with both artificial tears during the day and lubricating ointment at bedtime. Persistent lagophthalmos is usually due to excessive skin resection or traction on the orbital septum. When the surgical site has completely healed, and conservative measures have failed, only then should surgical reconstruction be considered. Ectropion and lower lid malposition is the most common complication of transcutaneous lower lid blepharoplasty; it is usually due to either middle lamellar contracture, excess skin removal or both. Dry eye syndrome is very common in the early postoperative period and is usually managed with ocular surface lubrication with artificial tears during the day time and lubricating ointment at bedtime. Preserving orbicularis oculi and its innervation, avoiding inadvertent resection of the lacrimal gland, especially in patients who may have prolapse of their lacrimal gland, can minimize the risk of persistent dry eye syndrome. Superficial hematomas occur more commonly after lower eyelids blepharoplasty. These are most commonly preseptal and have no impact on visual function. They usually resolve without intervention in several weeks. Orbital or retrobulbar hemorrhages are rare; however, it can lead to significant visual loss if untreated. The following measures should be taken to minimizing the risk of a retrobulbar hemorrhage; the patient is in a relaxed condition with well-controlled blood pressure, meticulous surgical technique with cauterization of any bleeding vessels and avoidance of excess traction on orbital fat, and adequate postoperative pain and nausea control to avoid blood pressure spikes and episodes of emesis.

Symptoms will include significant pain and pressure, double vision, blurred vision, nausea, and vomiting. On examination, patients often have significant eyelid and subconjunctival ecchymosis with a firm periocular area, chemosis, restricted extraocular motility, decreased vision, and an afferent papillary defect. When suspected, prompt surgical intervention is indicated as permanent visual loss can occur in as little as 90 min. Diplopia following blepharoplasty usually results from muscle injury by aggressive dissection or use of thermocautery. Knowledge of the periocular anatomy and careful dissection in the areas of extraocular muscles can minimize the risk of postoperative diplopia. Due to the rich vascular supply of the periorbital soft tissue, infection following blepharoplasty is rare. Infection is most commonly caused by *Staphylococcus* and *β*-hemolytic streptococcus and is usually preseptal. Symptoms include swelling, warmth, and erythema along the surgical incision. It can be safely treated with broad-spectrum oral antibiotics. Orbital cellulitis following blepharoplasty is significantly less common than preseptal cellulitis. Symptoms include pain and swelling of the eyelid and may be associated with proptosis, ptosis, restricted eye movement, pupillary defects, impaired color vision, and decreased visual acuity. Orbital cellulitis is a medical emergency as it can progress rapidly, and without proper management can lead to optic nerve compression, blindness, meningitis, panophthalmitis, and brain abscess. Treatment includes appropriate intravenous broad-spectrum antibiotics [1].

#### Take Home Messages

- Patient selection and thorough preoperative assessment, including clear discussion regarding complications and outcomes, will enhance both patient and surgeon satisfaction.

- While serious blepharoplasty complications are rare, the surgeon needs to be aware of the possible complications and have a thorough understanding of the management of these complications if they do arise.
- Although hemorrhages following blepharoplasty are usually preseptal and resolve without intervention, however, the surgeon should always be mindful of the possibility of retrobulbar hemorrhage and intervene quickly if a retrobulbar hemorrhage is suspected.

#### References

1. Sniegowski M, Davies B, Hink E, Durairaj VD. Complications following blepharoplasty. *Expert Rev Ophthalmol*. 2014;9(4):341–9.
2. Bhattacharjee K, Misra DK, Deori N. Updates on upper eyelid blepharoplasty. *Indian J Ophthalmol*. 2017;65:551–8.
3. McCord CD. Upper blepharoplasty and eyebrow surgery. In: Chen WP, editor. *Oculoplastic surgery*. New York: Thieme; 2001. p. 125–45.
4. Rees TD. Blepharoplasty. In: Rees TD, Wood Smith D, editors. *Cosmetic facial surgery*. Philadelphia, PA: Saunders; 1973. p. 44–133.
5. Raza P, Justin SG. *Otolaryngology head and neck surgery clinical reference guide*. 4th ed. California: Plural Publishing; 2014. p. 487–93.
6. Golan S, Goldberg RA. Time course analysis of upper blepharoplasty complications. *Dermatol Surg*. 2017;43(2):307–9. <https://doi.org/10.1097/DSS.0000000000000919>.
7. Oestreicher J, Mehta S. Complications of blepharoplasty: prevention and management. *Plast Surg Int*. 2012;2012:252368. <https://doi.org/10.1155/2012/252368>.
8. Charles HT. Blepharoplasty. In: Mark AC, Derek TF, editors. *Grabb and Smith's plastic surgery*. 6th ed. Philadelphia: Lippincott Williams & Wilkins; 2007. p. 486–97.
9. Jeffery EJ. Eyelid reconstruction. In: Jason EL, Smita RR, Jeffery EJ, editors. *Essentials of plastic surgery*. 2nd ed. Florida: CRC Press; 2014. p. 392–402.