Redo Fundoplication

10

Luigi Bonavina, Emanuele Asti, and Daniele Bernardi

The definition of surgical success and failure of fundoplication for gastroesophageal reflux disease with or without hiatus hernia vary considerably in the literature. Inappropriate patient selection and choice of the operative procedure, as well as technical errors occurring during the course of the operation, may account for failure of the primary repair. Eventually, 3–6% of patients complaining of severe symptoms and/or mechanical wrap complications require revisional surgery [1–3].

Laparoscopic Nissen fundoplication has been for several decades the gold standard surgical procedure for GERD. It is a safe, effective, and durable anti-reflux procedure when performed in specialized centers. A multicenter European trial comparing medical therapy with fundoplication performed by expert surgeons has shown that 92% of medical patients and 85% of surgical patients remained in remission at 5 years of follow-up [4]. Despite a remarkably low morbidity and mortality rates, the operation is still underused due to the perception of long-term side effects and fear of failure [5]. Also, wide variability in clinical outcomes related to interindividual surgical expertise and/or non-standardized technical modifications have restricted the adoption of laparoscopic fundoplication mainly to patients with severe long-lasting disease and large hiatal hernia [6]. A negative trend in the utilization of laparoscopic surgical fundoplication has been reported in the United States over the past decade [7, 8], and many surgeons have moved away from the Nissen in favor of the Toupet partial fundoplication. More recently, the laparoscopic LINX procedure has emerged as a possible alternative to fundoplication in selected patients [9, 10].

Results of remedial operations for persistent or recurrent symptoms following anti-reflux surgery are generally less satisfactory compared to the primary

L. Bonavina (✉) · E. Asti · D. Bernardi
Division of General and Foregut Surgery, IRCCS Policlinico San Donato, University of Milan, Milan, Italy
e-mail: luigi.bonavina@unimi.it; emanuele.asti@grupposandonato.it; daniele.bernardi@grupposandonato.it

© Springer Nature Switzerland AG 2021

S. F. Schoppmann, M. Riegler (eds.), *Multidisciplinary Management of Gastroesophageal Reflux Disease*, https://doi.org/10.1007/978-3-030-53751-7_10

procedure, especially after multiple failed surgical attempts [11–13]. This is related to the difficulties in recognizing the pattern of failure and to the inherent technical difficulties due to adhesions and gross anatomical distortion from the previous operation. When the cause of failure has been properly identified and addressed by an appropriate surgical technique, the majority of patients can benefit from a reoperation [14, 15].

10.1 Prevention of Fundoplication Failures

There are four categories of errors that can cause immediate, early, or late failure of the anti-reflux repair. Awareness of such potential mistakes can reduce the complication rate and the need for reoperation.

Wrong patient selection. Most surgical failures can be prevented if patients are properly selected and procedures are properly performed. It is important to make sure that preoperative symptoms are clearly related to gastroesophageal reflux and not to achalasia, gallstones, irritable esophagus, myocardial ischemia, etc. The accuracy of endoscopy is quite limited in this setting and, therefore, especially in the absence of typical symptoms, the preoperative work-up should always include esophageal manometry and ambulatory esophageal pH monitoring.

Wrong choice of operative procedure. The pattern of esophageal motility should be carefully investigated and a potentially obstructive Nissen fundoplication be avoided when the patient complains of dysphagia and/or there is evidence of an esophageal body motility disorder or a high outflow resistance at the gastroesophageal junction. In such circumstances, a Toupet fundoplication is expected to cause less obstruction and is better tolerated, especially by female patients [16].

Wrong surgical technique. Failure to adequately mobilize the distal esophagus and fundus to recognize a true shortened esophagus, to properly repair the hiatus, and to properly construct the fundoplication may be the reason for recurrence. Esophageal shortening may result in misidentification of the gastroesophageal junction and placement of the fundoplication around the proximal stomach rather than at the gastroesophageal junction. Although this is often called a "slipped Nissen," it should be considered a misplaced rather than a slipped wrap. Recognition of the fat pad around the angle of His and liberal use of intraoperative endoscopy can help to identify the true gastroesophageal junction. Intraoperative confirmation of a true short esophagus should alert the surgeon to perform a Collis lengthening procedure instead of a standard fundoplication. Disruption of the fundoplication is another common reason of technical failure of the primary repair and may be due to excessive radial tension especially when the short gastric vessels have not been divided and only the anterior fundic wall has been used. In fact, the laparoscopic Nissen-Rossetti fundoplication has been associated to a higher failure rate, especially during the learning curve phase [17]. Herniation of the wrap in the mediastinum with an intact fundoplication occurs as a result of excessive longitudinal tension or inadequate closure of the hiatus. Other causes of failed anti-reflux surgery include a too long and/or tight fundoplication and a twisted fundoplication that can cause severe postoperative dysphagia, which is usually refractory to dilatation.

Wrong postoperative management. Immediate surgical failures are commonly the result of uncontrolled postoperative nausea and vomiting causing abrupt rises in intra-abdominal pressure and subsequent mediastinal migration of the wrap. Early failures can occur also as a result of sentinel events such as heavy lifting, abdominal straining, or trauma. Control of early retching and vomiting is critical after anti-reflux surgery. It has been found that about one-third of patients with early retching developed mediastinal herniation of the wrap requiring revisional surgery [18]. Avoiding the use of nasogastric tubes and opioids, and routine application of a pharmacologic protocol including dexamethasone and metoclopramide, can reduce the incidence of this complication.

10.2 Assessment of Failed Anti-Reflux Surgery

Exhaustive evaluation of recurrent or persistent symptoms and correlation of symptoms with the presurgical status and current anatomic and pathophysiological abnormalities are the crucial steps before considering a reoperation. The most common postoperative complaints are dysphagia, heartburn, and abdominal discomfort related to meals. It is important to remind that all these symptoms may be present during a normal postoperative course, especially in the first 3 months after surgery. Most symptomatic failures, such as the slipped Nissen with "hourglass" stomach, are usually observed in the first 2 years after the initial procedure and half of them will undergo reoperation within 5 years [19]. Late mediastinal migration of the wrap is frequently observed in patients operated for large type III hiatal hernia, but it may not require correction if the hernia is small and asymptomatic [20, 21].

Anatomical assessment is based on endoscopy, barium swallow study, and CT scan to evaluate the presence of strictures, paraesophageal hernia, and the anatomical status of the previous fundoplication [22]. Functional assessment includes esophageal manometry and ambulatory esophageal pH-impedance monitoring to evaluate the presence of a motility disorder or persistent gastroesophageal reflux, respectively. High-resolution manometry allows to identify abnormalities not seen on conventional perfused manometry, such as the double-hump configuration of the high-pressure zone that indicates spatial separation and implies sphincter failure [23, 24].

Indications to reoperation should be based on the patient's physiological state, the severity of symptoms, and the response to conservative therapy. In most patients with refractory reflux or dysphagia combined with mechanical outflow resistance, a reoperation is mandatory due to the risk of respiratory complications and even pulmonary fibrosis secondary to aspiration [25].

10.3 Remedial Surgery

The revisional procedure should be tailored to the individual patient by considering a number of factors: reasons for failure of the first operation, esophageal length, peristaltic reserve, presence of Barrett's esophagus, and concomitant gastric

pathology. In most patients, laparoscopic fundoplication revision is feasible, although the procedure is generally expected to be long and tedious due to the adhesions of a previous laparotomy and the difficulties that may be encountered in the takedown of the fundoplication. Esophageal resection should only be considered in patients with multiple previous repairs, extensive fibrosis with stricture refractory to multiple endoscopic dilatations, and evidence of dysplasia on Barrett's esophagus [26].

In patients with a slipped/misplaced Nissen and/or chest herniation of the wrap attention should be directed first to assess the tissue quality of the crura and to consider the opportunity of mesh reinforcement [20, 21] and/or crural relaxing incisions [27]. Some individuals may require an esophageal lengthening procedure combined with re-fundoplication if the esophagus is found to be truly short. Complete takedown of the old repair is a mandatory step. A stapled wedge resection of the gastric fundus provides a safe esophageal elongation and is easier to perform and to teach compared to the Steichen "buttonhole" technique, requiring both circular and linear stapling, and to the trans-thoracic gastroplasty [28, 29]. In patients with excessive longitudinal tension, truncal vagotomy has been proposed as a safe alternative to the Collis gastroplasty [30].

In patients with impaired esophageal motility (>30% synchronous esophageal waves or mean amplitude less than 30 mmHg, or criteria of ineffective esophageal motility at high-resolution manometry), a partial 270° Toupet rather than a 360° Nissen fundoplication may be an option. An esophageal myotomy combined with a Dor fundoplication is usually performed in patients with previously misdiagnosed achalasia [31, 32].

In some patients, a re-fundoplication cannot be performed because the fundus is inadequate. An alternative surgical strategy, especially after multiple previously failed surgical attempts, consists of vagotomy, antrectomy, and Roux-en-Y reconstruction to effectively reduce both acid and alkaline components of the refluxate [33]. Laparoscopic gastric bypass is an alternative option that can be considered in obese patients [34]. Pyloroplasty, or even a total gastrectomy in extreme cases, may be indicated in patients who present with severe gastroparesis possibly related to inadvertent vagotomy at the time of the index operation [35].

10.4 Techniques of Laparoscopic Revisional Surgery

Historically, reoperations for failed anti-reflux procedures were performed through an open trans-abdominal or trans-thoracic technique. Today, more redo operations are performed laparoscopically. All redo procedures should be considered complex and should be scheduled as the first case of the day. On-table endoscopy is routinely performed after induction of anesthesia, and the scope is left in the esophagus for intraoperative evaluation. Adhesiolysis between the stomach and the liver and around the hiatus should be very careful to avoid visceral perforations and injury to the vagal trunks. Full mobilization of the fundoplication is

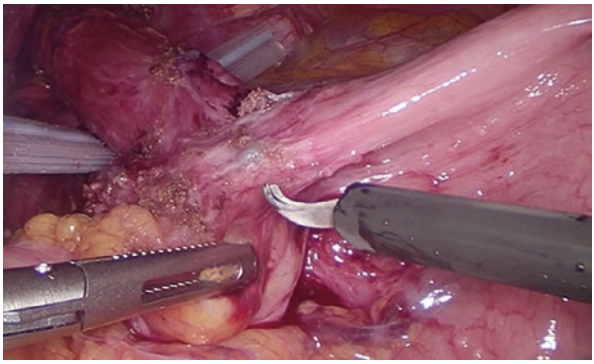

Fig. 10.1 Take down of a misplaced Nissen fundoplication with complete separation of the two valves from the gastric body

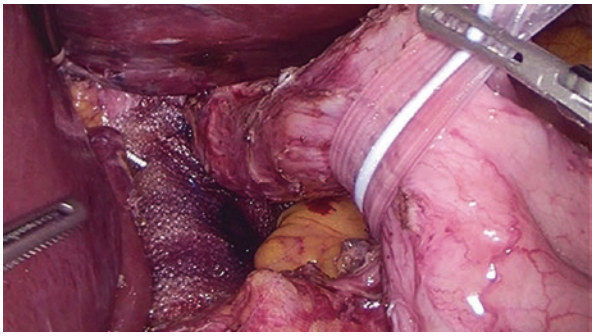

Fig. 10.2 After completing the posterior hiatoplasty with interrupted nonabsorbable stitches, a synthetic absorbable mesh (PHASYX®) is placed over the crura repair

performed by removing the crural sutures and by taking down residual short gastric vessels. A linear stapler can help dividing the two halves of the wrap. The fat pad should be routinely excised to identify the true gastroesophageal junction and a 3-cm tension-free intra-abdominal esophageal segment should be obtained. (Fig. 10.1). Care should be taken to minimize tension on the crura repair by clearing the entire surface of the right crus and decrease the insufflation pressure to less than 10 mmHg to facilitate approximation of the crura. The hiatus is repaired with interrupted nonabsorbable stitches and placement of a composite or synthetic absorbable mesh should be considered (Fig. 10.2). A total or partial fundoplication is then performed (Fig. 10.3).

If a short esophagus is suspected, a modified Collis wedge gastroplasty procedure can be performed. Once the gastric fundus has been completely freed from posterior and lateral adhesions, a bougie is inserted in the esophagus under direct laparoscopic visualization and placed across the gastroesophageal junction along the lesser curve. The fundus is retracted inferiorly to the patient's left side, and sequential fires of a linear stapler are directed toward the bougie to a point 3 cm below the gastroesophageal junction. The gastroplasty is then completed by resecting the wedge of fundus with the stapler applied parallel to the bougie toward the angle of His. A fundoplication around the neo-esophagus concludes the procedure (Fig. 10.4).

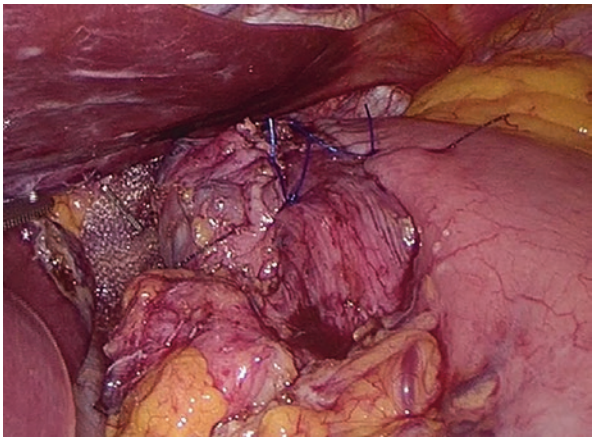

Fig. 10.3 Completed Toupet fundoplication

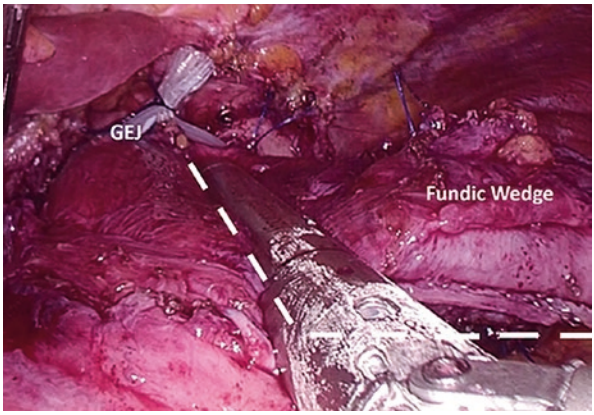

Fig. 10.4 Wedge Collis gastroplasty. A linear stapler is applied across the upper fundus toward the lesser curve; the gastroplasty is completed by applying the stapler parallel to the lesser curve toward the angle of His

10.5 Outcome of Laparoscopic Revisional Surgery

A systematic review and meta-analysis of laparoscopic revisional anti-reflux surgery, including 19 case series and one case-control study, reported on 922 patients operated operated between 1990 and 2010 [36]. The mean surgical duration was 166 min and the conversion rate to open revision 7%. The most common indication to reoperation was reflux (61%) followed by dysphagia (31%), gas bloat syndrome (4%), regurgitation or vomit (3%), and chest pain (2%). The most common anatomic problem found at reoperation was mediastinal migration of the wrap. Nissen fundoplication was performed in 70% of patients. The overall complication rate was 14% (0–44%). A satisfactory to excellent result was reported in 84% of patients, while 5% of patients required further surgery.

10.6 Fundoplication After Removal of Linx Device

An analysis of the safety profile of the first 1000 worldwide implants of the magnetic sphincter augmentation device (LINX procedure) in 82 hospitals showed 1.3% hospital readmission rate, 5.6% need of postoperative endoscopic dilations, and 3.4% reoperation rate [37]. A more recent study reported the technique and the long-term results of one-stage laparoscopic removal and fundoplication [38]. Once the scar tissue at the gastroesophageal junction corresponding to the site of the LINX implant is identified, a monopolar electrocautery hook is used to cut the scar tissue and to expose a pair of anterior titanium beads. The independent titanium wire connecting the beads is cut with ultrasonic scissors, and one bead is grasped with an Endo Clinch and retracted upward. This allows step-by-step cutting of the thin fibrous capsule overlying each bead and pulling out of the device. The total bead count in the explanted device is confirmed and the device removed through a 10 mm port. Intraoperative endoscopic assistance helps to check the integrity of the esophageal mucosa during and after removal, and/or to assist during retrieval of the beads migrated into the esophageal lumen. A concurrent anti-reflux repair (partial or total fundoplication) can then be performed. Out of 164 patients implanted with a LINX device, 11 (6.7%) were explanted at a later date. The main presenting symptom requiring device removal was recurrence of heartburn or regurgitation in 46%, dysphagia in 37%, and chest pain in 18%. In two patients (1.2%) full thickness erosion of the esophageal wall with partial endoluminal penetration of the device occurred. Device removal was most commonly combined with partial fundoplication. There were no conversions to laparotomy; the postoperative course was uneventful in all patients and the GERD-HRQL score returned to normal limits at 12–58 months after surgery.

10.7 Conclusions

Revisional surgery after fundoplication is complex, requires good surgeon's judgment and expertise, but is generally feasible laparoscopically. Accurate preoperative and intraoperative assessment is necessary to identify the cause of the failure and to tailor the procedure to the individual patient. With the rising epidemic of gastroesophageal reflux disease, reoperative hiatus surgery remains a challenge whose complexity and volume is expected to remain stable or to increase in the future.

References

1. DeMeester TR, Bonavina L, Albertucci M. Nissen fundoplication for gastroesophageal reflux disease. Evaluation of primary repair in 100 consecutive patients. Ann Surg. 1986;204:9–20.
2. Carlson MA, Frantzides CT. Complications and results of primary minimally invasive antireflux procedures: a review of 10,735 reported cases. J Am Coll Surg. 2001;193:428–39.
3. Van Beek DB, Auyang ED, Soper NJ. A comprehensive review of laparoscopic redo fundoplication. Surg Endosc. 2011;25:706–12.

4. Galmiche JP, Hatlebakk J, Attwood S, et al. Laparoscopic antireflux surgery vs esomeprazole treatment for chronic GERD: the LOTUS randomized clinical trial. JAMA. 2011;18(305):1969–77.
5. Niebisch S, Fleming FJ, Galey KM, et al. Perioperative risk of laparoscopic fundoplication: safer than previously reported—analysis of the American College of Surgeons National Surgical Quality Improvement Program 2005 to 2009. J Am Coll Surg. 2012;215:61–9.
6. Richter JE, Dempsey DT. Laparoscopic antireflux surgery: key to success in the community setting. Am J Gastroenterol. 2008;103:289–91.
7. Finks JF, Wei Y, Birkmeyer JD. The rise and fall of antireflux surgery in the United States. Surg Endosc. 2006;20:1698–701.
8. Khan F, Maradey-Romero C, Ganocy S, Frazier R, Fass R. Utilisation of surgical fundoplication for patients with gastro-oesophageal reflux disease in the USA has declined rapidly between 2009 and 2013. Aliment Pharmacol Ther. 2016;43:1124–31.
9. Bonavina L, DeMeester TR, Fockens P, et al. Laparoscopic sphincter augmentation device eliminates reflux symptoms and normalizes esophageal acid exposure. Ann Surg. 2010;252:857–62.
10. Bonavina L, Attwood S. Laparoscopic alternatives to fundoplication for gastroesophageal reflux: the role of magnetic augmentation and electrical stimulation of the lower esophageal sphincter. Dis Esophagus. 2016;29(8):996–1001.
11. Gadenstatter M, Hagen JA, DeMeester TR, et al. Esophagectomy for unsuccessful antireflux operations. J Thorac Cardiovasc Surg. 1998;115:296–300.
12. Bonavina L, Chella B, Segalin A, Incarbone R, Peracchia A. Surgical therapy in patients with failed antireflux repairs. Hepatogastroenterology. 1998;45:1344–7.
13. Madenci AL, Reames BN, Chang AC, et al. Factors associated with rapid progression to esophagectomy for benign disease. J Am Coll Surg. 2013;217:889–95.
14. Smith CD, McClusky DA, Rajad MA, Lederman AB, Hunter JG. When fundoplication fails: redo? Ann Surg. 2005;241:861–9.
15. Khajanchee YS, O'Rourke R, Cassera MA, et al. Laparoscopic reintervention for failed antireflux surgery: subjective and objective outcomes in 176 consecutive patients. Arch Surg. 2007;142:785–91.
16. Chen Z, Thompson SK, Jamieson GG, Devitt PG, Watson DI. Effect of sex on symptoms associated with gastroesophageal reflux. Arch Surg. 2011;146:1164–9.
17. Dallemagne B, Weerts JM, Jehaes C, Markiewicz S. Causes of failures of laparoscopic antireflux operations. Surg Endosc. 1996;10:305–10.
18. Soper NJ, Dunnegan D. Anatomic fundoplication failure after laparoscopic antireflux surgery. Ann Surg. 1999;229:669–76.
19. Stirling MC, Orringer MB. Surgical treatment after the failed antireflux operation. J Thorac Cardiovasc Surg. 1986;92:667–72.
20. Asti E, Lovece A, Bonavina L, et al. Laparoscopic management of large hiatus hernia: five-year cohort study and comparison of mesh-augmented versus standard crura repair. Surg Endosc. 2016;30:5404–9.
21. Asti E, Sironi A, Bonitta G, Lovece A, Milito P, Bonavina L. Crura augmentation with Bio-A® mesh for laparoscopic repair of hiatal hernia: single-institution experience with 100 consecutive patients. Hernia. 2017;21:623–8. [Epub ahead of print].
22. Jobe BA, Kahrilas PJ, Vernon AH, et al. Endoscopic appraisal of the gastroesophageal valve after antireflux surgery. Am J Gastroenterol. 2004;99:233–43.
23. Tatum RP, Soares RV, Figueredo E, Oelschlager BK, Pellegrini CA. High-resolution manometry in evaluation of factors responsible for fundoplication failure. J Am Coll Surg. 2010;210:611–7.
24. Hoshino M, Srinivasan A, Mittal SK. High-resolution manometry patterns of lower esophageal sphincter complex in symptomatic post-fundoplication patients. J Gastrointest Surg. 2012;16:705–14.
25. Allaix ME, Fisichella PM, Noth I, Mendez BM, Patti MG. The pulmonary side of reflux disease: from heartburn to lung fibrosis. J Gastrointest Surg. 2013;17:1526–35.

26. Little AG, Ferguson MK, Skinner DB. Reoperation for failed antireflux operation. J Thorac Cardiovasc Surg. 1986;91:511–7.
27. Alicuben ET, Worrell SG, DeMeester SR. Impact of crural relaxing incisions, Collis gastroplasty, and non-cross-linked human dermal mesh crural reinforcement on early hiatal hernia recurrence rates. J Am Coll Surg. 2014;219:988–92.
28. Terry ML, Vernon A, Hunter JG. Stapled-wedge Collis gastroplasty for the shortened esophagus. Am J Surg. 2004;188:195–9.
29. Horvath KD, Swanstrom LL, Jobe BA. The short esophagus: pathophysiology, incidence, presentation, and treatment in the era of laparoscopic antireflux surgery. Ann Surg. 2000;232:630–40.
30. Oelschlager BK, Yamamoto K, Woltman T, Pellegrini C. Vagotomy during hiatal hernia repair: a benign esophageal lengthening procedure. J Gastrointest Surg. 2008;12:1155–62.
31. Bonavina L, Bona D, Saino G, Clemente C. Pseudoachalasia occurring after laparoscopic Nissen fundoplication and crural mesh repair. Langenbecks Arch Surg. 2007;392:653–6.
32. Indolfi C, Bonavina L, Kavitt RT, Konda VJ, Asti E, Patti MG. Importance of esophageal manometry and pH monitoring in the evaluation of patients with refractory gastroesophageal reflux disease: a multicenter study. J Laparoendosc Adv Surg Tech A. 2016;26:548–50.
33. Fékété F, Pateron D. What is the place of antrectomy with Roux-en-Y in the treatment of reflux disease? Experience with 83 total duodenal diversions. World J Surg. 1992;16:349–54.
34. Makris KI, Panwar A, Willer BL, et al. The role of short-limb Roux-en-Y reconstruction for failed antireflux surgery: a single-center 5-years experience. Surg Endosc. 2012;26:1279–86.
35. Van Rijin S, Roebroek YGM, Conchillo JM, Bouvy ND, Masclee AAM. Effect of vagus nerve injury on the outcome of antireflux surgery: an extensive literature review. Dig Surg. 2016;33:230–9.
36. Symons NRA, Purkayastha S, Dillemans B, et al. Laparoscopic revision of failed antireflux surgery: a systematic review. Am J Surg. 2011;202:336–43.
37. Lipham JC, Taiganides PA, Louie BE, Ganz RA, DeMeester TR. Safety analysis of first 1000 patients treated with magnetic sphincter augmentation for gastroesophageal reflux disease. Dis Esophagus. 2015;28:305–11.
38. Asti E, Siboni S, Lazzari V, et al. Removal of the magnetic sphincter device. Surgical technique and results of a single-center cohort study. Ann Surg. 2017;265:941–5.