



Volumetric Ultrasound and Related Dental Applications

12

Oliver D. Kripfgans and Hsun-Liang (Albert) Chan

12.1 Review of 3D Ultrasound Technology

Three-dimensional ultrasonic imaging is well established and many manufacturers are offering 3D and 4D imaging on their platforms (see Table 12.1). The latter is live 3D imaging and allows the visualization of 3D structures in real-time or in gated mode, such as cardiac gating, which is beneficial for cardiovascular applications. Computed tomography (CT), cone-beam CT (CBCT), and MRI (magnetic resonance imaging) are natural 3D imaging modalities. They are accepted as diagnostic tools and operate with a standardized patient orientation for each procedure. Ultrasound differs not only in its physical principle of imaging, i.e. mechanical versus atomic/electronic, but also from a procedural concept. Ultrasound has a very narrow field of view and is always directed to the immediate location of the body part of interest. Images are taken in real-time and the probe is positioned under this real-time guidance by the sonographer or other healthcare personnel. CT, CBCT, and MRI on the other hand use a few scout scans and then obtain a 3D volume for post-scan slicing of the image volume. In addition, CT, CBCT, and MRI slice thicknesses can be selected such that an almost isotropic voxel resolution results, which then lends itself for 3D reslicing after the scan. Ultrasound on the other hand has poor out of plane beam resolution such that the lateral–elevational slice plane has a poor resolution in comparison to the axial–lateral plane. This is especially true for 1D (transducer) arrays. There are predominantly two methods for

O. D. Kripfgans (✉)

Department of Radiology, Medical School, University of Michigan, Ann Arbor, MI, USA

e-mail: greentom@umich.edu

H.-L. (Albert) Chan

Department of Periodontics and Oral Medicine, School of Dentistry, University of Michigan, Ann Arbor, MI, USA

e-mail: hlchan@umich.edu

Table 12.1 Review of commercial clinical ultrasound scanners with 3D capabilities

Company	3D methods	Probes	Applications
Alpinion	Mechanical	SVC1-6H VE3-10H	Abdomen, OB/GYN, emergency medicine (EM) OB/GYN, urology web reference (http://www.alpinion.com/web/download/low/E-CUBE15%20Platinum%20OBGYN%20Catalog.pdf , 2020)
BK	2× 2D static	8824 I12C5b	Intraoperative biplane, intraoperative Intraoperative biplane, intraoperative, musculoskeletal, peripheral vascular web reference (https://www.bkmedical.com/transducers/?product=flex-focus)
Biosound Esaote	Not specified	BC441 and SB2C41	Abdominal, OB/GYN, contrast agents procedures, 3D biopsy variable-band bi-scan volumetric convex array web reference (https://www.esaote.com/en-US/ultrasound/probes/ , 2020)
Butterfly Network	2D array (CMUT)	No 3D modes	General imaging, only 2D however web reference (https://www.butterflynetwork.com/iq , 2020)
Canon	Mechanical 2D array 2D array	4D 9CV2 i6SVX2 i7SVX2	Wideband, OB, radiology Abdominal, OB examinations, real-time 3D biopsy guidance, 4D SMI and CEUS, TEE 3D cardiac (pediatric heart) web reference (https://us.medical.canon/products/ultrasound/aplio-i-series/technology/#i6SVX2)
Chison	Mechanical	V4C40L	Volume scans web reference (http://www.chison.com/Images/UpFile/2019826103753611.pdf , 2020)
Edan	Mechanical	C5-2MD	OB, abdomen, gynecology web reference (http://www.edan.com/html/EN/products/ultrasound/CDUltrasonnd/201601/292173.html , 2020)
GE	Mechanical Mechanical Mechanical Mechanical	RNA5-9-D H48651MY RSP6-16-D H48651MR RIC6-12D H48651NA RAB4-8-D H48651MP	Abdomen, small parts, cardiology, obstetrics, pediatrics Small parts, breast, peripheral vascular, pediatrics, musculoskeletal Obstetrics, gynecology, urology Abdomen, obstetrics, gynecology, pediatric, urology
	2D matrix array 2D matrix array	RM14L H48681AR RM6C H48671ZG	Small parts, breast, peripheral vascular, pediatrics, musculoskeletal Abdomen, obstetrics, gynecology, pediatrics, urology

(continued)

Table 12.1 (continued)

Company	3D methods	Probes	Applications
	Mechanical	Invenia ABUS 2.0	Breast web reference (https://www.gehealthcare.co.uk/-/media/c34db4de9e774c5e99f41f42b6251f18.pdf?la=en-gb&rev=b2bb13b216064d199fe454e8d8dbe48a&hash=2FC3A215E7BD7476DC20946ECF8723AD , 2020) web reference (https://www.gehealthcare.com/products/ultrasound/abus-breast-imaging/invenia-abus , 2020)
Hitachi Aloka	Mechanical	VC41V Not named	3D/4D endocavity, endocavity volume Biplane imaging, 3D live imaging, 3D and 4D cardiac evaluation and analysis web reference (http://www.hitachi-aloka.com/products/lisendo-880/cardiovascular , 2020)
Konica Minolta	–	No 3D transducers	web reference (https://www.konicaminolta.com/medicalusa/product/sonimage-hs1/ , 2020)
Mindray	Mechanical	DE10-3U D8-4U	OB/GYN, urology, volume CEUS Adult abdomen, OB/GYN, volume CEUS web reference (https://www2.mindraynorthamerica.com/Resona7-transducer-family-pdf , 2020)
Philips	Mechanical	V6-2	General purpose abdominal, obstetrical, and gynecological volumetric applications. Supports interventional applications
	Mechanical	3D9-3v	Endovaginal obstetrics and gynecology
	Mechanical	VL13-5	High resolution superficial applications including small parts, breast, and vascular imaging
	2D matrix array	V9-2	OB/GYN
	2D matrix array	X6-1	Abdominal, obstetrics, fetal, gynecology, vascular
	2D matrix array	XL14-3	Vascular, MSK
	2D matrix array	X7-2t	Adult TEE applications web reference (https://www.usa.philips.com/healthcare/solutions/ultrasound/ultrasound-transducer , 2020) web reference (https://www.usa.philips.com/healthcare/product/HC989605409251/xl14-3-xmatrix-transducer/specifications)
Samsung	Mechanical	CV1-8AD	Abdomen, obstetrics, gynecology
	Mechanical	VE4-8	Abdomen, obstetrics, gynecology
	Mechanical	V5-9	Abdomen, obstetrics, gynecology
	Mechanical	3D4-9	Abdomen, obstetrics, gynecology

(continued)

Table 12.1 (continued)

Company	3D methods	Probes	Applications
	Mechanical	LV3-14A	Musculoskeletal, small parts, vascular web reference (https://www.samsunghealthcare.com/en/products/UltrasoundSystem/RS85/Radiology/transducers)
Siemens Acuson	Mechanical	EV9F3 EV9F4	Early OB, OB/GYN
	2D matrix array	4Z1c	Transthoracic adult echo, volume stress echo, contrast agent studies
	2D matrix array	Z6Ms	Transesophageal echo
	Mechanical	S2000 ABVS	Breast web reference (https://static.healthcare.siemens.com/siemens_hwem-hwem_sxxa_websites-context-root/wcm/idc/groups/public/@global/@imaging/@ultrasound/documents/download/mdaz/mzc1/~edisp/acuson_x700_womens_imaging_transducer_flyer-01433431.pdf)
SIUI	Mechanical Mechanical	Not named IBUS BE3	Real-time and static stereoscopic fetal imaging Breast web reference (http://www.siuui.com/ax0/a/caichao/20190419/277.html)
Sono Scape	Mechanical	Not named	Volumetric abdominal probe web reference (http://www.sonoscape.com/html/2018/exceed_0921/86.html)
Sonosite	–	No 3D transducers	web reference (https://www.sonosite.com/products/transducers , 2020)
Super Sonic Imagine	Mechanical	SLV16-5 12-3	Breast, general OB-GYN, genitourinary, general web reference (https://www.supersonicimagine.com/Aixplorer-R/TRANSDUCERS , 2020)
Terason	–	No 3D transducers	web reference (https://www.terason.com/usmart-3300/ , 2020)
Visual Sonics	Mechanical	No specific transducer	MS and MX series transducers web reference (https://www.visualsonics.com/ , 2020)
Whale Imaging	–	No 3D transducers	web reference (https://whaleimaging.com/products/p-series-benefits/probes/ , 2020)

Given are the company name, the method of 3D provided in their product description, the associated probe label as well as clinical target applications. Reviewed from companies' official websites on August 20th, 2019. Dashes ("–") indicate information missing from the websites. Highlighted companies offer products with 2D matrix arrays. Note: The 3D methods are listed as "Mechanical" if not stated by the manufacturer as 2D matrix array




Fig. 12.1 Example of a mechanically steered commercial transducer (RSP6-12) from GE Healthcare. **(a)** Axial–lateral view of the interior body of the transducer. The main probe cable enters the housing from the top and passes the motor and gearbox to then enter a bag filled with oil in which it is connected to the transducer elements. Oil is used to couple the transducer array to the scanning window, seen on the bottom of both panels. An axial–elevational view of the same transducer is shown on the right side in panel **(b)** [1]

3D ultrasonic imaging. The first one is based on mechanically moving a 2D imaging transducer (1D array) in the elevational direction to form a 3D image. Some systems might support this motion to be free-hand. However, most systems provide modified 1D transducers, for 2D imaging, that employ a motorized mechanical sweep of the transducer in the elevational direction to obtain a lateral, axial, elevational image volume. Figures 12.1 and 12.2 provide examples of these two methods. Mechanically sweeping a transducer in the elevational direction is a direct extension of the axial–lateral scan plane. It comes in several implementations:

- Angular sweep of (curvi-)linear array transducer for abdominal and vascular applications, for example (see vendors listed in Table 12.1).
- Angular sweep of phased array transducer for cardiac or neonatal applications, for example (see vendors listed in Table 12.1).
- Linear sweep of linear array transducer for breast applications, for example (see GE, Siemens, and SIUI in Table 12.1).

Angular sweep transducers can achieve a very large field of view (e.g. $>140^\circ$ elevationally for neonatal applications) and currently form the majority of 3D imaging ultrasound transducers. However, they suffer from a decrease in elevational resolution as axial distance increases. The angular beam density is constant, but the linear spacing increases by $d \times \sin(\alpha)$ for d being the axial distance from

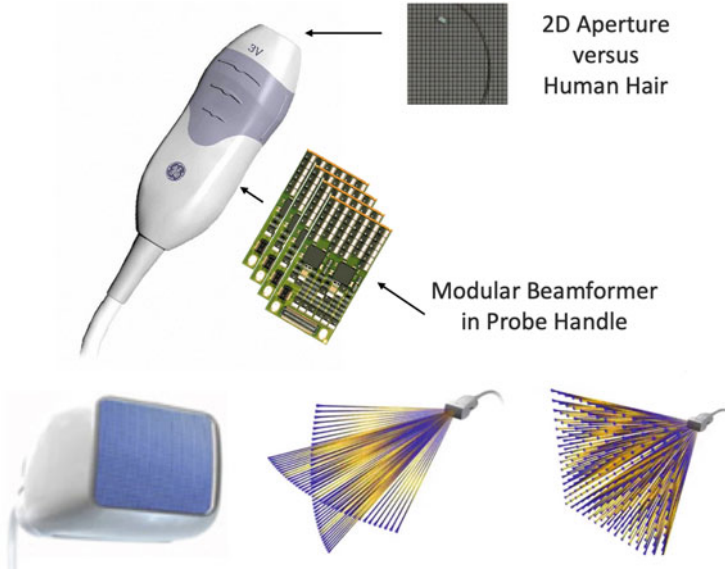


Fig. 12.2 Example illustrations of 2D array matrix transducers. Top: 3V from GE Healthcare (adapted from [1]), bottom: xMatrix (X6-1, X5-1, or XL14-3) from Philips Healthcare web reference (<https://www.usa.philips.com/healthcare/resources/feature-detail/xmatrix>). A 2D aperture allows the system to produce an ultrasound beam that is electronically focused in the lateral and in the elevational directions as well as steerable in both of these directions. Thus 2D matrix array transducer can produce 3D image volumes without the need for mechanically moving the transducer. Left: Illustration of transducer housing. Middle: Schematic of beams fanning a 3D volume. Right: Schematic of beams fanning 2 orthogonal image planes in 3D, predominantly one in the axial–lateral slice and the other in the axial–elevational slice

the elevational pivot point and α being the angular step size. The left and middle panels of Fig. 12.3 illustrate this change in resolution. Curvilinear and phased array transducers also suffer from a loss of lateral image resolution for increasing distance for the same reason, which is an immediate trade-off to an increase in the field of view. While linear sweeping transducers (right panel of Fig. 12.3) form a smaller field of view, they yield constant image resolution, independent of image depth. Associated applications are those that require a great level of spatial detail even at depth, such as breast ultrasound.

Ideally a two-dimensional transducer aperture would be employed to obtain 3D ultrasound images. These are called matrix arrays and are able to rapidly steer the acoustic beam in the lateral and elevational directions using electronic phasing in the same fashion as one-dimensional transducers can steer the beam in the lateral direction for phased arrays or virtual phased arrays. However, matrix arrays are technologically difficult as they require an equal number of acoustic transmit–receive elements in the lateral and elevational directions. Without these, the resulting field of view is significantly limited. Matrix arrays started within the field of cardiology, where real-time volumetric images are crucial to depict the

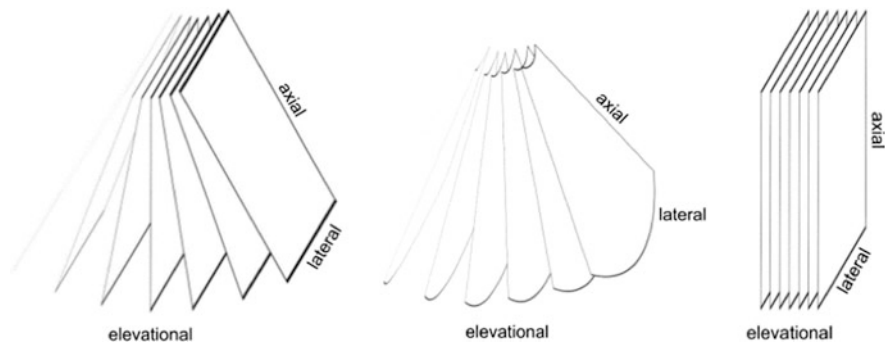


Fig. 12.3 Example illustrations of elevational transducer plane steering of a mechanically swept array transducer. Left: Angular steering of a linear array transducer. Middle: Angular steering of a phased array transducer. Right: Linear sweep of a linear array transducer

function of heart valves and other cardiac structures. Even though early transducers already had thousands of transmit–receive elements (1000–2000), the resulting images had poor spatial resolution due to the inherent low frequency of cardiac imaging, the required high temporal resolution of cardiac imaging, and small apertures. Phased arrays typically possess 96 or more transmit–receive elements, all of which are used for beamforming. Linear arrays, while being composed of 128 or more elements, usually use variable sized subapertures for constant f-number beamforming. However, linear arrays can only steer up to approximately 20° . Thus, a matrix phased array should ideally be composed of at least $962 = 9216$ transmit–receive elements. It is obvious that managing to integrate drive circuits for almost 10,000 elements below a surface of approximately 3 by 3 cm is challenging. One has to keep in mind the required dynamic range of nominally at least 120 dB of a state-of-the-art clinical ultrasound scanner, which corresponds to transmitting electric pulses between 10 and 100 V, and being sensitive to receive signals of the order of 10–100 μV for up to 6 MHz for pediatric cardiac applications. A 2019 online assessment of commercially available matrix arrays yields a matrix array with as many as 65,000 elements at up to 14 MHz operating frequency. This number of elements corresponds to a true 128×128 aperture with equal lateral and elevational resolution. Specifically a lateral resolution of $\Delta x = \lambda \times f\#$, where λ is the wavelength in tissue, i.e. 1.54 mm for 1 MHz operating frequency and 0.11 mm for 14 MHz operating frequency. Typical f-numbers, i.e. $f\#$, for linear array imaging are of the order of 3–5. Thus the lateral and elevational resolution of a 2D matrix array is of the order of 330–550 μm , which compares favorably to 200–500 μm spatial resolution of cone-beam CT. The axial resolution at 14 MHz operating frequency is with 165 μm (assuming a 1.5-cycle transmit–receive pulse) even higher.

12.2 Geometry Considerations

A large variety of clinical 3D ultrasound transducers exist. Most of them are based on mechanically swept arrays and thus have large housings to cover the array, motor, gearbox, and cabling (see Fig. 12.1). The smallest devices using mechanically swept arrays are those for endocavitary use, due to the spatial constraints of the particular clinical application. However, they are small only in two dimensions, namely in the lateral and elevational directions (typically less than 2 cm). The axial dimension of this class of 3D transducers is on the order of 20–30 cm. Overall, none of these devices lend themselves for dental imaging except for the buccal side of the frontal incisors or canines. And even those will be difficult to image given the physical dimensions of mechanically swept arrays. Matrix arrays offer smaller geometries due to the replacement of mechanical components (motor, gearbox, etc.) with electronic components (larger aperture, local beamforming circuits). Despite these reductions in the spatial requirements, matrix arrays are still too large for routine dental applications. While this is true in general, there is one exception. Transesophageal echo, abbreviated as TEE, also requires small form factors. Currently at least one commercially available TEE device exists that allows for 3D imaging and is based on matrix arrays. The Philips X7-2t is composed of 2500 elements and operates at 2–7 MHz. Its aperture is the size of a US quarter coin, i.e. 24 mm, and it is oriented sideways, i.e. the aperture is perpendicular to the transducer cable. This geometry would allow the user to place the transducer deep inside the oral cavity and image gum tissue and jaw bone, root, and crown surfaces. However, the lower operating frequencies also lower the achievable spatial resolution, which in this case at most 660–1100 μm laterally and 330 μm axially. Several key factors have to be addressed to obtain a clinically relevant 3D imaging transducer. Namely physical size, spatial resolution, and form factor. Physical size is constrained by the need to reach deep into the oral cavity to image 2nd molars from the buccal and the lingual side. For such applications, a device of the order of the toothbrush would be ideal. Second, spatial resolution; CBCT is currently providing a detailed resolution of approximately 200–500 μm , which is realistically achievable, even for matrix array transducers. The last key factor, i.e. form factor, relates to the orientation of the aperture with respect to the transducer housing and the cable. The above comparison to a toothbrush also holds for this key factor. As the bristles of the brush are oriented perpendicular to the handle, the transducer aperture needs to also be oriented perpendicular to the transducer cable.

12.3 Volume Imaging Considerations

Ultrasonic imaging is a real-time scanning modality with immediate feedback to the user, similar to fluoroscopy. However, this is potentially misleading as only 2D images are obtained. Mechanically swept array transducers typically take several seconds to sweep a volume and thus lose the real-time character of

ultrasonic scanning. While it is possible to achieve real-time volume scanning even on mechanically sweeping transducers, it is only possible when reducing scan line density in the lateral and elevational directions, which significantly reduces the resulting image quality, which might be suitable for some applications. The underlying reason for slow ultrasonic scanning is the slow speed of sound, which is nominally 1540 m/s compared to the speed of light which is 3×10^8 m/s. Taking the example of a mechanically swept linear array with nominally 100 lateral scan lines, 100 elevational frames, and a scan depth of 4 cm, one computes $100 \times 100 \times 40 \text{ mm} \times 2/1.54 \text{ mm}/\mu\text{s}$, i.e. 519 ms to obtain one image volume. While this time might seem fast, i.e. 2 Hz volume rate due to 519 ms per volume, it would present itself for a user monitoring the image(s) as laggy. Typical real-time 2D images are at least 10 Hz, more likely 20 Hz, keeping in mind that the human eye can detect changes up to 70 Hz. Real-time visualization of 3D image volumes is difficult. Only 3D surfaces or 2D cross-sections can be visualized. Thus either the former or the latter would be shown to a user. In cardiology and obstetrics segmentation can be used to obtain 3D surfaces. Either the low echogenicity of the blood (cardiac imaging) or of the amniotic fluid (OB imaging) is used to perform real-time segmentation and visualize a 3D surface. Figure 12.4 illustrates both of these cases. The left panel shows a cardiac 4D image with removal (segmentation) of image voxels of small acoustic backscatter, i.e. voxels with little intensity. In particular, the right side of the left panel shows the 3D surface visualization and the left side shows two cross-sectional images (2D grayscale, i.e. B-mode). This allows the user to maneuver the ultrasound transducer in the right position with respect to the desired anatomical view. By means of the cross-sectional image the user can also see the underlying tissues. The right panel of Fig. 12.4 shows a 3D obstetrics imaging example, a yawning fetus. Segmentation was done here also by removing low intensity voxels. All diagnostic ultrasound imaging procedures are based on 2D images. Three-dimensional visualization for ultrasound is diagnostically not required. However, retrospective visualization beyond a given 2D image plane might be helpful. Yet, the real-time character of ultrasound creates the certain difference between CT and MRI imaging procedures, where retrospective visualization is the standard method as real-time images are (a) not available, (b) scanning does not rely on acoustic windows, i.e. there is unblocked view from any direction, (c) the image resolution can be close to isotropic, which allows for retrospective visualization in oblique planes. In contrast to that, ultrasound benefits from real-time placement of the transducer to ensure adequate acoustic access (acoustic window) and to align the desired anatomical structures in the axial–lateral scan plane, where the resolution is the highest.

12.4 Dental Applications of Volumetric Imaging

Dental imaging spans across several modalities and levels of dimensions, including but not limited to one-dimensional pocket-depth assessment, two-dimensional plain-film, panoramic or optical, three-dimensional cone-beam CT (CBCT). Soft-

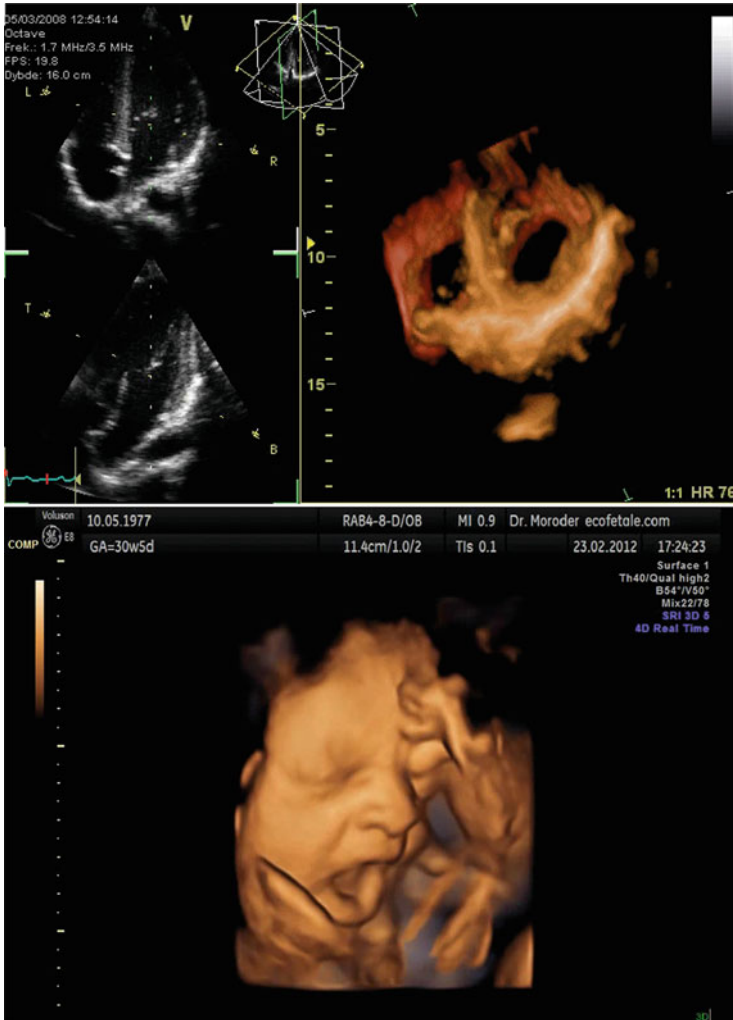


Fig. 12.4 Examples of 3D surface visualization based on tissue segmentation between high intensity tissue and low intensity fluids, such as blood in cardiac imaging (top) or amniotic fluid on obstetric imaging (bottom). Source: <https://upload.wikimedia.org/wikipedia/commons/6/61/Apikal4D.gif> (2020) Kjetil Lenes [CC BY-SA 3.0] (<https://creativecommons.org/licenses/by-sa/3.0>). Source: This Photo was taken by Wolfgang Moroder (web page: https://commons.wikimedia.org/wiki/File:Fetal_yawning_4D_ultrasound_ecografia_4D_Dr._Wolfgang_Moroder.theora.ogv, 2020)

tissue imaging is currently limited to low contrast X-ray methods, namely CBCT and superficial optical imaging including visual assessment of the care provider. Ultrasound naturally provides cross-sectional images of high soft-tissue contrast and thus extends the currently available diagnostic information. Volumetric ultrasonic

scanning would allow the clinician to coregister images between, for example, CBCT and ultrasound. Contrary to that the position and orientation of single images without the possibility of coregistration might leave spatial uncertainties. The significance of these uncertainties depends on the individual patient imaging cases.

Three-dimensional ultrasonic imaging in dentistry can yield anatomically referenced information. Figure 12.5 shows the example of a 3D ultrasound scanned implant. A coronal section is shown in the left panel, as the interior of 3D solid tissue cannot be visualized except by means of cut-sections. The section was placed in the anterior–posterior direction such that both adjacent teeth and the central implant crown are demarcated. In this view the facial bone level can be seen relative to the spatial position of the adjacent teeth and the implant crown. The absolute value and any subsequent change in the bone level can thus be quantified. The middle panel illustrates the anterior–posterior position of the coronal plane as a vertical yellow line. Analogous, the cross-sectional plane position is also shown in the coronal plane as a vertical yellow line. Bone width and level relative to the implant can be quantified in this cross-sectional view and the absolute position of the view is determined by the coronal slice. The 3D volume data can also be superimposed with CBCT data as available to further its diagnostic value. The right panel shows the corresponding photographic view of the same anatomical location with a virtual view of the placed implant. The red and yellow lines indicate the relative positions between the ultrasonic and optical images.

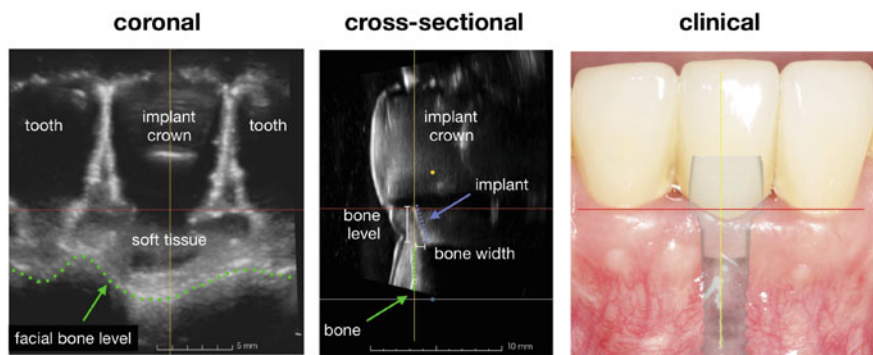


Fig. 12.5 Example of an ultrasonic 3D implant scan. The yellow vertical and red horizontal lines correspond to each other in all three panels. Left: Coronal cut-plane at an anterior–posterior position where the implant crown and adjacent teeth are fully demarcated. The resulting facial bone level is labeled by the green dotted line. Middle: Midfacial, cross-sectional, view of the implant. Here bone level and width can be directly measured. The red and yellow slice plane markers define the absolute position of the 2D cut-sections within the complete 3D image data. The latter can also be directly compared to CBCT. Right: Optical visualization of the same anatomical location with an overlaid virtual illustration of the implant. Source: HUM00140205

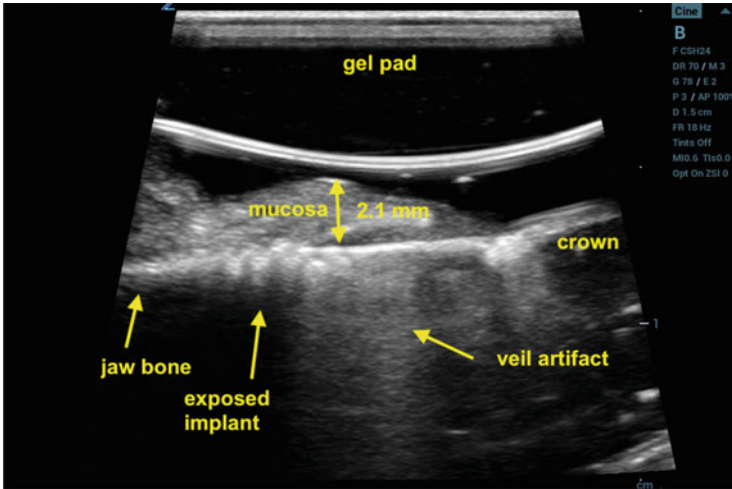


Fig. 12.6 Example of tissue recession after implant placement. The ultrasonic image shows a maximum mucosal thickness of 2.1 mm. Source: HUM00140205

12.4.1 Tissue Recession

Tissue thickness can be assessed with CBCT, though the soft-tissue contrast is low. It can also be assessed by poking with a needle into the soft tissue and reading the depth at which the needle comes to a rest when it impacts the underlying bone or implant. Ultrasound on the other side can visualize the soft tissue in section as shown in Fig. 12.6. Absolute tissue thickness can be immediately assessed using caliper tools on the ultrasound scanner. In this example the mucosa is 2.1 mm thick. A much thicker mucosal tissue can be seen in Fig. 12.7 (6 mm). Repeated thickness measurements can be performed without penetrating the soft tissue mechanically or accumulating radiation dose (CBCT).

12.4.2 Bone Recession

Jaw bone recession is usually diagnosed by means of CBCT if the bone is visually covered by soft tissue. For cases where CBCT is impaired, i.e. those that include nearby implants, bone recession may go undiagnosed or not be reliable. Ultrasound penetrates any overlying soft tissue and can directly visualize the jaw bone surface as well as the implant if it is not fully covered by hard tissue. Figure 12.7 gives an example for this case. The implant threads are seen as the periodic structure in the ultrasound image. In addition, the implant also creates an image artifact, here a veil artifact, i.e. an internal reverberation of the incident sound field inside the metallic implant. Also seen is a horizontal reverberation artifact of the gel coupling pad. Two-dimensional ultrasonic imaging may be lacking an absolute spatial reference.

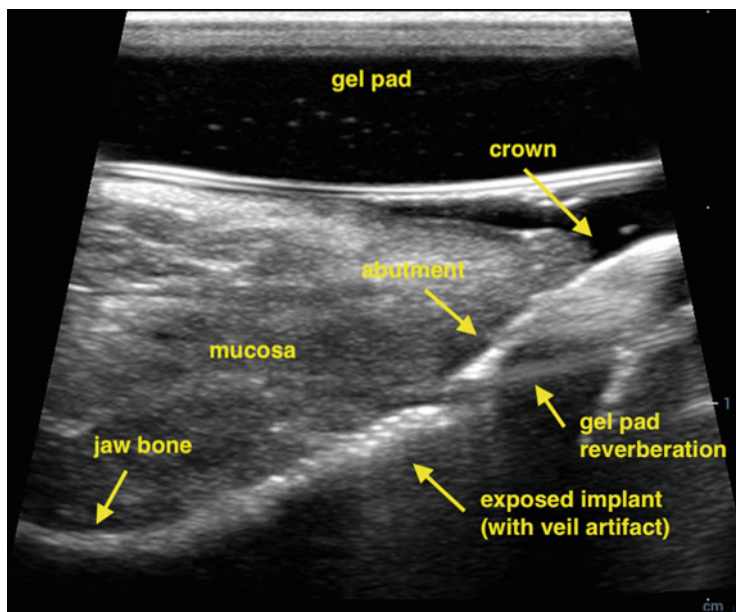


Fig. 12.7 Example of bone recession after implant placement. Current dental imaging based on CBCT cannot yield diagnostic information due to scattering artifacts of CBCT surrounding the implant. This reduces spatial resolution and contrast to a degree that implant delineation versus the jaw bone is not warranted. Source: HUM00140205

Similar to 2D X-ray, there is only one frame within which spatial coordinates can be compared to each other. In other words, directly measuring bone recession from a 2D ultrasound image may be impossible since the absolute location of the image is not known a priori. CBCT encompasses the entire oral anatomy and thus allows for referencing relative to other spatial structures. However, experience and confidence need to be established to understand if referencing a crown, for example, is clinically sufficient for observing spatial bone changes and to what degree they can be quantified.

Reference

1. Prager RW, et al. Three-dimensional ultrasound imaging. *Proc Inst Mech Eng H* 2010;224(2):193–223. ISSN:0954-4119 (Print); 0954-4119 (Linking). <https://doi.org/10.1243/09544119JEIM586>. <https://www.ncbi.nlm.nih.gov/pubmed/20349815>.