

# Chapter 7

## Putting It All Together: What to Keep and What to Refer?



Richard M. Schwend

*“Back pain in a nutshell- what is the child’s growth (age and maturity) and what is the underlying diagnosis?”*

*Richard Schwend*

*“Young children are all about activity, teenagers about appearance, adults about comfort.”*

*Colin Mosely*

### Practice Gap

Twenty to thirty percent of office visits may be for musculoskeletal-related disorders, but only about 2% of time in pediatric residency training is spent on musculoskeletal medicine [1]. Many pediatricians in training and practice describe a deficiency in knowledge, competency, confidence, and performance in the evaluation of a child with a musculoskeletal condition.

### Change of Practice

Perform a focused history and physical examination on all children with back pain, and when appropriate, obtain plain radiographs and laboratory tests. Make an accurate diagnosis, appropriate treatment, or timely referral.

---

**Electronic Supplementary Material** The online version of this chapter ([https://doi.org/10.1007/978-3-030-50758-9\\_7](https://doi.org/10.1007/978-3-030-50758-9_7)) contains supplementary material, which is available to authorized users.

---

R. M. Schwend (✉)  
Department of Orthopaedic Surgery, Children’s Mercy Hospital, Kansas City, MO, USA  
e-mail: [rmschwend@cmh.edu](mailto:rmschwend@cmh.edu)

### Learning Objectives

- Perform a focused, practical back examination including a neurological exam.
- Understand ten history and ten physical red flags associated with back pain. These will be emphasized in the case studies in Chaps. 8–32.
- Understand when to treat and follow a patient yourself and when to refer.

## Epidemiology

Back pain is very common in children and even more common in adults. Although at any given time fewer than 10% of children have back pain, approximately a third of adolescents presenting to a pediatric sports practice report having had back pain in the past year [2]. As with pain in general, back pain is a nonspecific complaint that is more prevalent in older children, females, those with a greater BMI, backpack wearers, and those who participate in sports [2]. Many cases of back pain should be considered as a normal life experience, and for some children, no treatment is needed. Surgery is rarely indicated, so it should be unusual to refer a child with “back pain” and no underlying diagnosis to a surgeon. Despite this, nonspecific back pain is a very common reason for a referral to an orthopedic surgeon from a pediatrician office [3].

The actual prevalence of an underlying diagnosis depends on the population and referral pattern. In a subspecialty pediatric spine practice, a cause for the back pain was found in 85% of cases [4]. However, more recent studies from emergency room and office settings reported the reverse to be the case. Brooks et al., in a review of pediatric emergency department cases, found a non-pathologic diagnosis in 77% of back pain visits. Brooks reported that the pain was due to mechanical back pain or muscle strain in most cases [5]. Only 2.3% of visits had an underlying pathologic diagnosis, with plain radiographs rather than MRI, CT, or laboratory studies helping to make the diagnosis. Another emergency room study about back pain found the following diagnoses: direct trauma (25%), muscle strain (24%), sickle cell crisis (13%), idiopathic (13%), urinary tract infection (5%), and viral (4%) [6]. Feldman et al. in Toronto evaluated a wide age range of children with disabling back pain presenting to a pediatric orthopedic office using SPECT scan [7]. The study population included young children (range 2.7–17 years old) and children having severe pain. In 78% of cases, there was no obvious etiology. Spondylolysis was found in 7%, tumor in 4.6%, and “other” in 10% (infection, Scheuermann kyphosis, herniated disc, kidney disease, facet arthritis, disc disease, congenital anomalies, and tethered spinal cord) [7]. Miller likewise reported that 78% of children 10–19 years of age presenting with back pain had mechanical low back pain [8].

## Risk Factors

Some risk factors may be preventable: high BMI, smoking, sport specialization with overuse, excessive muscle tightness, working excessive hours, and backpack use [9]. Backpacks may cause short-term pain. More pain occurs if the backpack is of a large weight or if not worn properly. One author reports that backpacks can cause an acute loss of disc height on MRI [10]. Sports specialization in soccer, basketball and lacrosse, baseball, tennis, and football can lead to back pain and spondylolysis even in the fittest of athletes [11].

## Natural History

A history of back pain in childhood is the best predictor of back pain as an adult [12]. A large Danish twin study confirmed this association of low back pain in childhood and adolescence and low back pain in adults [13]. While one-half of adolescents entering adulthood continue to have a low prevalence of back pain, up to 10–33% will have either an increase or persistently high prevalence of low back pain as adults [14, 15]. Feldman et al. found that for children with disabling pain, 71% continued to have pain years later [7].

## Difference Between a Younger and Older Child

Postnatal growth is greatest during infancy. Young children are very active, and some have pain by the end of the day. The pain can be nonspecific (growing pains) and poorly localized. Very young children with significant back pain may present with abdominal pain, pelvic pain, or reluctance to walk. As the child becomes older, pain localization becomes easier, but the common locations of pain can change. For example, in a cross-sectional study of children in Denmark, thoracic back pain was most common in childhood; lumbar and thoracic pain was equally common in adolescents. Neck pain or pain in more than one location was unusual [16].

## General Principles of Back Pain in Children

- Back pain is a symptom not a diagnosis, so always seek the underlying diagnosis.
- Under age 10 years, think of inflammation and the pitfall diagnoses to avoid missing tumors and infections. Inflammation = stiffness. This inflammation can show up as night pain, limp, or refusal to walk.

- For the child older than age 10 years, think of mechanical etiology, spondylolysis, spondylolisthesis, or Scheuermann kyphosis, but don't forget the pitfall diagnoses.
- Some conditions are seen in all ages: infection, injury, osteochondromas, osteoid osteoma, and mechanical back pain.
- Pitfall diagnoses don't always present with significant back pain.
- Always examine the patient distally for signs of neurological dysfunction. Inquire about bowel or bladder dysfunction. Also ask about limb pain, spasticity, weakness, numbness or other symptoms, and difficulty walking or running.
- Always examine the feet when evaluating the spine, and examine the spine when evaluating the feet.
- Scoliosis may or may not have associated back pain. It is helpful to classify scoliosis into four different types: idiopathic, congenital, syndromic, and neuromuscular. This helps with determining associated workup needed, natural history, treatment, and appropriate referral.



### Ten History Red Flags

- Children under age 10 years
- Loss of function related to the pain
- Recurring or worsening pain
- Early morning stiffness
- Night pain
- Localized pain
- A child that stops walking or playing
- Fever or weight loss
- Postural change
- Limp or altered gait

## Physical Examination

William Osler taught the four key components of the physical examination: inspection, palpation, auscultation, and contemplation. Inspection starts when you first meet the child and family. Inspect the child's appearance and behavior. Palpation can start with a handshake, if appropriate, and later during the actual hands on physical examination. In a patient with back pain, auscultation occurs with careful listening to the child's story. General recommendations are as follows: The child needs to have shorts on and shoes and socks off. Pay attention to overall features such as height, weight, BMI, and rate of growth since previous visits. Look at the child's appearance and comfort. Does she look ill? Check nutrition. Check developmental stages, Tanner stage, and other measures of maturity. Menses typically occurs after the growth spurt. Growth spurt is typically during Tanner stage 2 or 3. Inspect with your mind wide open. Look for syndromic or associated conditions. Check posture, balance, motion, strength, and reflexes including the abdominal reflex (Video 7.1). Evaluate trunk core muscle strength by asking the patient to do things such as get off

the floor (Gower sign), squat, perform push-ups and sit-ups, and walk and run down the hall. Examine the child supine and prone. Always examine the bare feet. A screening spine examination can be completed in under 2 minutes (Video 7.2). Finally, the most important phase of the examination is contemplation. Pause and reflect about the findings and what might be the underlying cause.

### Ten Red Flags of Physical Examination

- Child impossible to examine due to pain
- Poor nutrition
- Fever and tachycardia
- Deformity of the spine—scoliosis, kyphosis, and lordosis
- Lymphadenopathy or other masses
- Back tenderness
- Stiffness
- Limp, reluctance to walk, or altered gait
- Any neurological deficit
- Bowel or bladder dysfunction

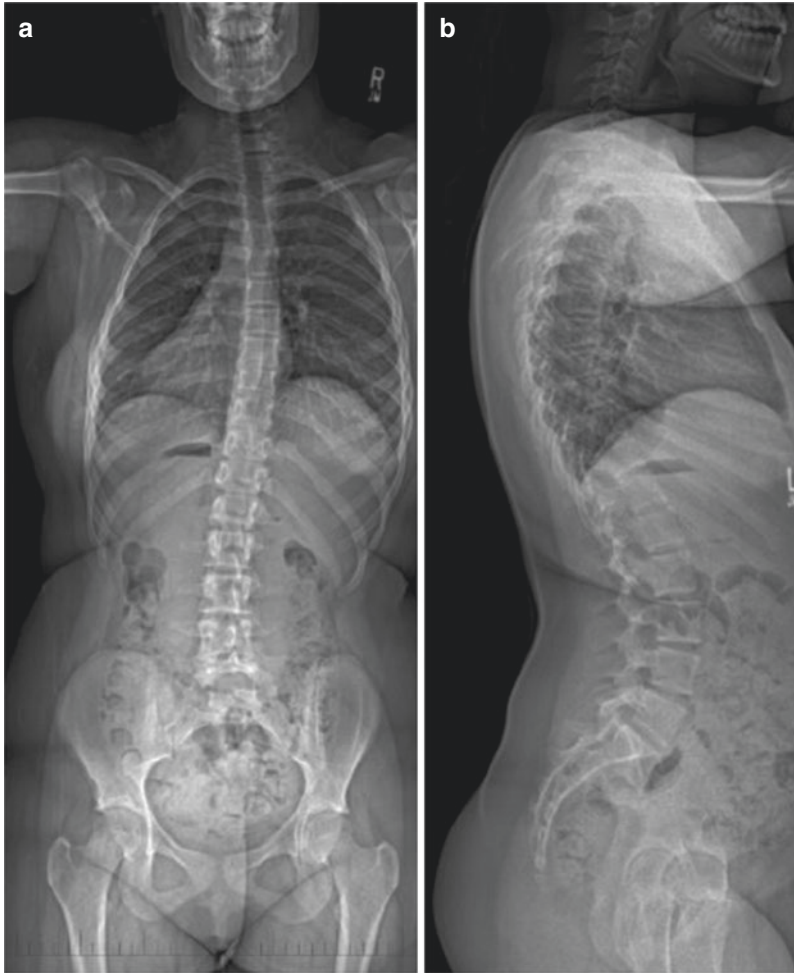
### Pitfalls to Avoid

- An overly aggressive workup of nonspecific back pain. A laboratory and radiographic workup may not reveal the underlying cause, sometimes because there is no underlying disease.
- Going straight to MRI or CT scan.
- Although rare, be aware of the disasters to avoid such as tumor or infection.
- Examining the patient only one time—If unsure, see the patient again.
- Referral to the orthopedic surgeon for back pain without doing a workup.
- If still unsure after a workup, obtain a consult, or discuss the case over the phone with your orthopedic colleague.
- Think outside the spine box.

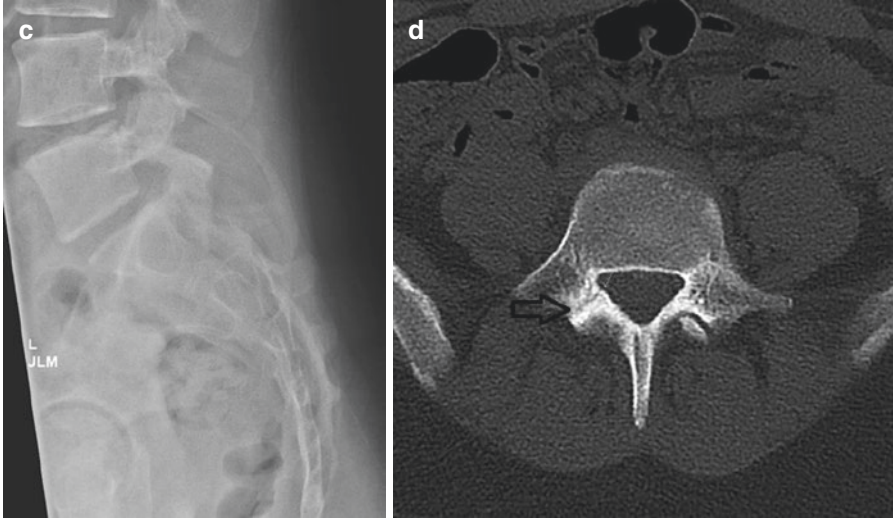
## Referring Patients

### What to Keep

- Nonspecific back pain or no specific diagnosis in a child >10 years old with a normal exam and workup
- Postural kyphosis
- Spondylolysis or grade 1 spondylolisthesis responsive to rest and therapy (Fig. 7.1)
- Mild adolescent scoliosis (AIS) measuring <20 degrees on x-ray
- Apical trunk rotation (ATR) on the scoliometer <7 degrees



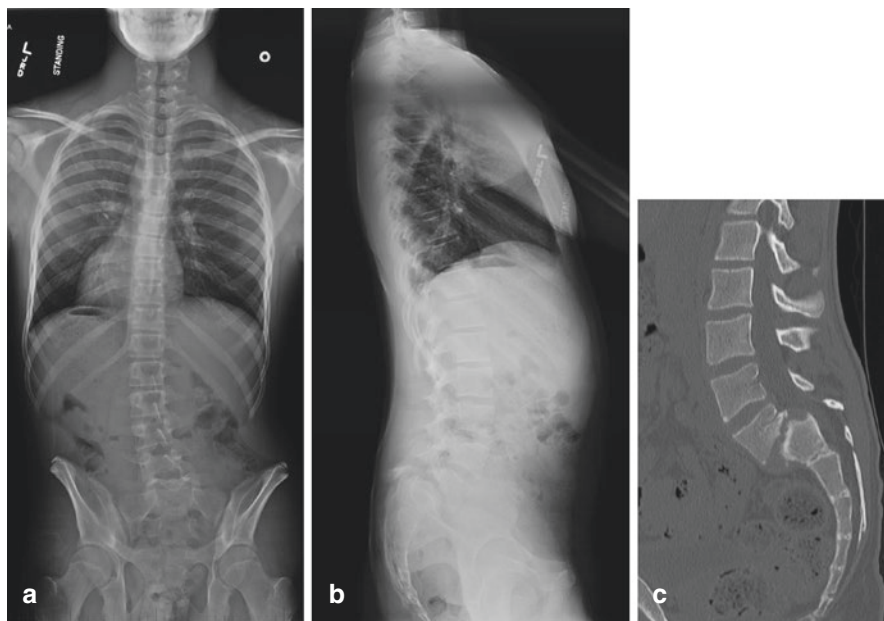
**Fig. 7.1** A 12-year-old girl had a 3-month history of low back pain after starting volleyball. Pain was worse by end of the day and after practice or games. It was relieved by a 2-week period of rest. There was no radiation of the pain to the lower extremities or weakness. She had not started menses. Examination showed that she was overweight with a BMI of 26. She stood with mild trunk shift to the right, had a flexible spine, but noticed low back pain with hyperextension. Her core muscles were weak. Screening 2 minute spine exam was otherwise normal. **(a)** Posteroanterior (PA) radiograph shows mild trunk shift to the right with minimal scoliosis. **(b)** Lateral radiograph was normal. **(c)** Lateral radiograph focused at L5/S1 showed no evidence of spondylolysis or spondylolisthesis. The posterior elements of L5 appear normal. Clinically, she was felt to have spondylolisthesis. Core strengthening, nutrition counselling, and taking a break from volleyball were recommended by her pediatrician which helped initially. **(d)** Six weeks later, she was back competing in volleyball and the pain recurred. CT scan was performed, which showed a unilateral pars defect (open black arrow) on the axial image. The spondylolysis defect had minimal gap and appeared to be attempting to heal. Her symptoms eventually resolved by waiting out the volleyball season. She never needed a brace or surgery. This case is an example of a child with spondylolysis who was successfully treated without referral to the orthopedic service



**Fig. 7.1** (continued)

### What to Refer

- In general, it is best to have a presumptive diagnosis for the back pain to better understand the condition and natural history and to whom the referral should go.
- Unexplained back pain in a young child <10 years old, especially if <5 years old.
- Scheuermann kyphosis in a growing child.
- Spondylolisthesis grade 0/1 not responsive to conservative treatment (Fig. 7.1).
- Grade 2 or greater spondylolisthesis (Fig. 7.2).
- AIS >20 degrees in a growing child.
- Apical trunk rotation (ATR) on the scoliometer >7 degrees.
- Underlying diagnosis of syndromic, congenital, or neuromuscular scoliosis or structural kyphosis.
- Neurological findings such as weakness, numbness, bowel or bladder involvement, clonus, and spasticity.
- Red flags of history or physical examination.
- If you are not sure if a patient should be referred, call your orthopedic colleague on the phone directly.



**Fig. 7.2** A 14-year-old boy had a 3-year history of mild back pain. Over the past several months, the pain has increased in intensity and began to radiate down his right lower extremity to the foot. He also began walking with legs that were “stiff” and he had difficulty running fast. Parents noticed that his posture looked “odd.” He was not an athlete. Physical examination showed him to have scoliosis, a posterior pelvic tilt, stiffness on forward bend, hamstring tightness, mild weakness of right ankle dorsiflexion, and short stride when walking. **(a)** Standing PA radiograph showed a long left apex scoliosis. This has an atypical appearance, which is frequently seen in painful spondylolisthesis. **(b)** Standing lateral radiograph shows a vertical sacrum, rounding of the dome of the sacrum, trapezoidal-shaped L5, and greater than 50% forward slip of L5 on S1 (grade 3). These features are typical for high-grade (>50% slip) dysplastic (abnormal-shaped bones) spondylolisthesis. **(c)** CT scan confirmed the high-grade forward slip of L5 on S1 as well as the dysplastic bony features of the L5/S1 articulation. Red flags include the back stiffness, gait abnormality, radiation of pain to the foot, weakness of dorsiflexion on examination, and the high-grade and dysplastic nature of the slip. Once a spondylolisthesis has slipped more than 50%, it frequently needs surgical treatment. Referral to orthopedic spine surgeon is indicated

## Treatment

Treatment depends on the underlying diagnosis and anticipated natural history. Fortunately, most children with back pain have a self-limited condition related to sports activity, overuse, or deconditioning. The pain requires either no treatment or modification of risk factors such as weight management, rest, core strengthening, proper backpack wear, and modifying work schedules. Having the symptom of back pain is an opportunity for the physician to review lifestyle habits with the adolescent including sleep hygiene, nutrition, physical activity, stress, work, screen time, and posture. When a specific diagnosis is made, treatment can be prescribed or a referral to the appropriate specialist performed.



## Summary

Back pain is very common in children and even more common in adults. Back pain is a symptom, not a diagnosis, so seek a deeper understanding of the condition. Always evaluate the child's development and growth. Be very concerned about a young child with a stiff spine, night pain, or abnormal neurological findings. Seek the underlying diagnosis in evaluating back pain or scoliosis. For the child under age 10 years, consider inflammation and the common pitfalls to avoid—especially tumors and infections. Stiffness can be a sign of inflammation. This inflammation can show up as night pain, limp, or refusal to walk. For the child older than age 10 years, think of mechanical origins, spondylolysis, spondylolisthesis, or Scheuermann kyphosis, but don't forget the possible pitfalls. After a thorough evaluation, there may be no specific diagnosis, and you then need to reassure the family and provide comfort.

## References

1. Murphy RF, LaPorte DM, Wadey VM, American Academy of Orthopaedic Surgeons Orthopaedic Education Study Group. Musculoskeletal education in medical school: deficits in knowledge and strategies for improvement. *J Bone Joint Surg Am*. 2014;96(23):2009–14.
2. Peter Fabricant. The epidemiology of Back pain in children and adolescents: a cross-sectional study of 3,669 American youth. Paper presented at: American Academy of Orthopaedic Surgeons. 2019 March 13; Las Vegas.
3. Schwend RM, Geiger J. Outpatient pediatric orthopedics: common and important conditions. *Pediatr Clin N Am*. 1998;45(4):943–71.
4. Hensinger RN. Acute back pain in children. *Instr Course Lect*. 1995;44:111–26.
5. Brooks TM, Friedman LM, Silvis RM. Back pain in a pediatric emergency department: etiology and evaluation. *Pediatr Emerg Care*. 2018;34(1):e1–6.
6. Selbst SM, Lavelle JM, Soyupack SK, Markowitz RI. Back pain in children who present to the emergency department. *Clin Pediatr*. 1999;38(7):401–6.
7. Feldman DS, Hedden DM, Wright JG. The use of bone scan to investigate back pain in children and adolescents. *J Pediatr Orthop*. 2000;20(6):790–5.
8. Miller R, Beck NA, Sampson NR, Zhu X, Flynne JM, Drummond D. Imaging modalities for low back pain in children: a review of spondylolysis and undiagnosed mechanical back pain. *J Pediatr Orthop*. 2013;33(3):282–8.
9. Korovessis P, Koureas G, Papazisis Z. Correlation between backpack weight and way of carrying. *J Spinal Disord Tech*. 2004;17(1):33–40.
10. Talbot NR, Bhattacharya A, Davis KG, Shukla R, Levin L. School backpacks: it's more than just a weight problem. *Work*. 2009;34(4):481–94.
11. Ladenhauf HN, Fabricant PD, Grossman E, Widmann R, Green DW. Athletic participation in children with symptomatic spondylolysis in the New York area. *Med Sci Sports Exerc*. 2013;45(10):1971–4.
12. Jones GT, MacFarlane GJ. Epidemiology of low back pain in children and adolescents. *Arch Dis Child*. 2005;90(3):321–6.
13. Hestbaek L, Leboeuf-Yde C, Kyvik KO, Manniche C. The course of low back pain from adolescence to adulthood: eight-year follow-up of 9600 twins. *Spine*. 2006;31(4):468–72.
14. Junge T, Wedderkopp N, Boyle E, Kjaer P. The natural course of low back pain from childhood to young adulthood- a systematic review. *Chiropr Man Therap*. 2019;27:10.

15. Coenen P, Smith A, Paananen M, O'Sullivan P, Beales D, Straker L. Trajectories of low back pain from adolescence to young adulthood. *Arthritis Care Res (Hoboken)*. 2017;69(3):403–12.
16. Wedderkopp N, Leboeuf-Yde C, Anderson LB, Froberg K, Hansen HS. Back pain reporting pattern in a Danish population-based sample of children and adolescents. *Spine*. 2001;26(17):1879–83.

## ***Resources***

Good site for 5 simple steps to a pain free back. <https://www.health.harvard.edu/pain/5-steps-to-a-pain-free-back> . Accessed May 7, 2019.