45 Upper Eyelid Blepharoplasty

Hadi Ghadimi and Bahram Eshraghi

45.1 Introduction

The eyes have a central role in facial beauty as they are usually the first part of the face noticed during social encounters. Certain characteristics of periocular tissues like the unusually thin skin of the eyelids make this region particularly susceptible to the aging process. Depending on different involutional changes of periocular area, various rejuvenation methods have been introduced to address the unsightly effects of aging. These range from neuromodulation by botulinum toxin to counter the dynamic wrinkles to fat or filler injection to compensate for the lost volume of certain areas of periorbital region. Upper blepharoplasty is among the most commonly performed aesthetic procedures and, when properly planned and performed in the ideal candidate, can bear satisfactory outcome for the patient and the surgeon (Fig. 45.1). By fixing several aging changes in the periocular area, upper blepharoplasty and its adjunctive procedures can restore a youthful view to the eyelids and contribute to the facial rejuvenation attempts.

45.2 Anatomical Considerations

Although a thorough discussion of periorbital anatomy is beyond the scope of this chapter, certain key points should be emphasized.

The average height of normal palpebral fissure (the vertical distance between upper and lower lid margins) is 9–10 mm. [1] Based on the location of pupillary light reflex, the vertical palpebral fissure is divided into an upper portion (margin-reflex distance 1, between pupillary light reflex and upper lid margin) and a lower portion (margin-reflex distance 2, between pupillary light reflex and lower lid margin). Normally, the upper lid margin covers the superior 1–2 mm of cornea [1], therefore the normal MRD-1 is at least 3 mm. Measurements less than this indicate upper lid ptosis which is a common finding among blepharoplasty candidates and should be sought for and properly documented and managed. Any scleral show in the upper part of palpebral fissure indicates upper lid retraction and should alert the physician to the probability of presence of thyroid eye diseases.

Upper eyelid crease in the Caucasian individuals is normally located 8–10 mm above the lid margin in women, compared to 6–8 mm for men [2]. The location of lid crease is defined by adhesion of fibers from levator palpebrae superioris aponeurosis that attach to the skin of upper lid usually near the upper margin of tarsal plate. While the lid crease may be absent in certain patients with congenital ptosis, it is often displaced superiorly in patients with involutional ptosis because of disinsertion of levator aponeurosis from its original insertion site on the anterior surface of superior portion of tarsal plate. In patients with oriental ethnicity, the lid crease is located much closer to the lid margin, with only a minimal tarsal plate show superiorly. This is due to the variation they have in the attachment of levator aponeurosis, which inserts on the lower half of anterior surface of tarsal plate, creating a lower lid crease and allowing preaponeurotic fat to descend as low as anterior surface of tarsal plate [3]. In older patients with dermatochalasia, the excess overhanging skin of upper lid bends over the eyelid crease and covers the tarsal plate and may even descend lower than eyelid margin to mimic eyelid ptosis (termed pseudotosis). In fact, the reason for many aesthetic blepharoplasty candidates is the hidden tarsal plate show by redundant, lax upper lid skin that prevents them from properly using upper lid makeup. In cases of severe dermatochalasia, the overhanging skin may cover the visual axis and limit the superior visual field and account for the functional blepharoplasty procedure.

Normally, the youthful female eyebrow is located well above the orbital rim while the males have eyebrows located at the level of superior bony orbital rim. From the aestheticians' point of view, it is expected that the palpebral fissure

H. Ghadimi · B. Eshraghi (✉)
Eye Research Center, Feiz Eye Hospital, Isfahan University of Medical Sciences, Isfahan, Iran

© Springer Nature Switzerland AG 2021

S. O. Keyhan et al. (eds.), *Integrated Procedures in Facial Cosmetic Surgery*, https://doi.org/10.1007/978-3-030-46993-1_45

Fig. 45.1 Outcome of upper blepharoplasty (**a**) with internal browpexy (**b**) in a female and a male patient, respectively

height and the distance between upper lid margin and eyebrow would be in the golden ratio. [4] Careful attention to the position of eyebrows is critical in assessment of blepharoplasty candidates as eyebrow ptosis is commonly found among the aging population and its presence dramatically changes the operative planning. Minimal eyebrow asymmetry between the two sides is commonly observed among normal population, but the surgeon should consider the possibility of compensation of mild upper lid ptosis by frontalis muscle overaction on the side of ptotic eyelid and higher eyebrow. The eyebrow skin is considerably thicker than the eyelid skin and preservation of enough skin of both tissues is essential in achieving optimal outcome from blepharoplasty.

The eyelid structure is classically divided into three lamella for better presentation of the anatomical details. The skin and orbicularis oculi muscle form the anterior lamella; the orbital septum and levator aponeurosis contribute to the middle lamella and the tarsal plate, conjunctiva and Muller's muscle make the posterior lamella. The eyelid skin is the thinnest skin in the body with thickness of 0.3 mm in some areas [5] and essentially no subcutaneous fat and dermal appendages like hair follicles or sweat glands. The eyelid skin can be distinguished from thicker eyebrow skin which is lighter in color compared to the more darkly pigmented skin of the eyelids. In dermatochalasia, only eyelid skin excess is present, so eyebrow skin which is essentially part of forehead skin should not be resected instead of dermatochalasis.

Orbicularis oculi muscle is a fine muscle with circular fibers surrounding the eyelids and serves the crucial function of blinking and eye closure. Damage to orbicularis oculi (e.g., excessive resection of the muscle during surgery) impairs blinking and aggravates dry eye, which is extremely disturbing for the patient. What tissue lies just beneath orbicularis oculi depends on the level of dissection. In normal Caucasian patients, below the eyelid crease, only tarsal plate and conjunctiva lie posterior to the orbicularis. Where the dissection is performed higher than this, first the orbital septum exists beneath the orbicularis. However, just above superior tarsal margin, the orbital septum is combined with levator aponeurosis to form the conjoint tendon. Posterior to this layer is Muller's muscle and finally conjunctiva. If dissection is performed a few millimeters higher than superior tarsal margin, the orbital septum is found to be separated from levator aponeuosis/muscle by pre-aponeurotic fat pad. This is essentially the central fat pad of the upper lid. In patients with severe periorbital fat atrophy (like those with deep superior sulci), this fat has regressed backward into the orbit and can only be noticed by meticulous search after retropulsion on the globe to bring the fat forward. Inadvertent injury to levator aponeurosis during surgery can result in ptosis. Involutional ptosis patients often have dehiscence of insertion of levator aponeurosis and the edge of levator may be found a few millimeters higher than the superior tarsal margin. Apart from the central fat pad, upper lid has another fat pad, namely medial fat pad [6]. The medial fat pad is located in close proximity to the trochlea of superior oblique muscle. Again, extreme caution should be applied in the dissection of this area, as injury to trochlea or superior oblique muscle can cause disturbing diplopia. The medial fat pad has more fibrous tissue and looks whiter and firmer com-

pared to the middle fat pad. There is essentially no lateral fat pad in upper lid, unlike the lower lid. The lateral compartment of upper orbit is occupied by the lacrimal gland, which should be carefully distinguished from the fat pads, as inadvertent injury or resection of this gland can compromise tear production and cause dry eye. Occasionally, a lateral extension of the middle fat pad is spread to the lateral orbital area and rarely a separate third, lateral fat pad can be observed.

The orbital septum extends from periosteum at the orbital rim and is a fibrous tissue which separates anterior lamella from the posterior lamella of the eyelids. Inferiorly, it fuses with levator aponeurosis to attach on the anterior surface of superior tarsal plate. To access the fat pads, levator muscle, and lacrimal gland, the orbital septum should be opened. The septum should not be sutured or lid retraction and adhesions ensue. Whenever the orbital septum is not opened, a probable hematoma remains limited to anterior lamella and does not endanger vision. However, if septum is opened, uncontrolled bleeding can extend to posterior orbital space and potentially compromise circulation of deep orbital tissues including the optic nerve, with the possibility of blindness.

Muller's muscle is a delicate, highly vascular muscle originating from underneath the levator palpebral superioris. Located posterior to levator aponeurosis, it inserts on superior border of tarsal margin and has a small role in elevation of upper lid. Posterior to Muller's muscle, conjunctiva forms the last layer of eyelid tissue.

45.3 Aging Changes in the Periocular Area

Several changes gradually occur during the aging process in almost all parts of the orbit and eyelids. One of the most pronounced changes is excess skin of upper lid, referred to as dermatochalasia. This must be differentiated from blepharochalasia which is essentially of inflammatory origin and occurs in younger individuals who suffer from repeated bouts of inflammatory episodes in the periocular area, ultimately resulting in excess and thinned eyelid skin and several other changes. Aging patients usually seek to remove the excess skin on their upper lids, but the physician should distinguish whether the excess skin is due to dermatochalasia or brow ptosis. Often, both processes contribute to these changes and each should be separately addressed. Apparently, brow ptosis should be corrected with lifting procedures (see Chap. 49), while dermatochalasis is treated with blepharoplasty. Alternatively, brow position can be secured during blepharoplasty with adjunctive internal or external browpexy procedures. Often patients need both brow lifting and blepharoplasty to fix the aging changes in both the eyebrows and eyelid skin.

Other common involutional changes include pseudoherniation of orbital fat pads (particularly the medial fat pad), atrophy of orbital and sub-brow fat, prolapse of lacrimal gland out of its bony fossa, vertical glabellar furrows due to overaction of corrugator and procerus muscles, and true ptosis of upper lid due to weakness and/or dehiscence of attachments of levator palpebrae superioris. [7] To achieve optimal outcome, all changes should be considered and corrected as much as possible. Therefore, it is obviously evident that pure skin resection blepharoplasty is not an adequate treatment for the majority of people who seek upper blepharoplasty, despite the widespread belief among some surgeons who underestimate the adjunctive procedures as additional, unnecessary steps in the operation.

45.4 Preoperative Assessment

The physician should carefully evaluate the patient who intends to perform blepharoplasty. The evaluation begins with general assessment of psychological and physical health. Obviously, patients with unrealistic expectations from surgery should be excluded. There are several red flags including severe obsession or body dysmorphic disorder, addiction to cosmetic procedures, demanding a substantially different appearance like that of a celebrity, criticizing other surgeons and complimenting you, and so on. [8] Novice surgeons had better start their experience with older easy-going patients with more severe aging changes who essentially demand a functional blepharoplasty.

General health of the patient should be noticed and special attention should be paid to the conditions that may interfere with optimal surgery or postoperative wound healing. Examples include systemic hypertension, diabetes, cardiac and pulmonary disorders, and thyroid or renal dysfunction. Review of the drugs the patient uses is of utmost importance as many prescribed or over-the-counter drugs may affect perfect hemostasis. These include (but are not limited to) aspirin, heparin, warfarin, clopidogrel, nonsteroidal anti-inflammatory drugs (NSAIDs), vitamin E, fish oil and omega-3, ginkgo, and ginseng. Proper counseling should be provided regarding the use or discontinuation of medications in the perioperative period. As blepharoplasty is an elective cosmetic procedure, with some rare, potentially grave consequences like blindness due to orbital hemorrhage, such medications must be stopped in appropriate time before surgery or the operation should be delayed or canceled.

Ocular examination is required to assess and document visual acuity, ocular motions, Bell's reflex, tear production (Schirmer's test), and comorbidities like proptosis or true eyelid ptosis. Patients with recent history of corneal refractive surgery (like LASIK) are at increased risk of dry eye symptoms following blepharoplasty. [9] It is recommended to wait for at least 6 months before upper blepharoplasty in patients who have undergone corneal refractive surgery. Fullness in the lateral orbital area may be simply due to accumulation of

excess skin (temporal hooding) due to dermatochalasis and brow ptosis or may indicate lacrimal gland ptosis. Lacrimal gland supporting structures are weakened during aging process and the prolapsed gland may be noted as superotemporal puffiness which may be noted by the patient or the physician, preoperatively or on the operating table. Patients with sleep apnea are particularly prone to this condition. [10] Attention to the brow position is of utmost importance and the significance of correction of brow ptosis (by lifting procedures or browpexy) cannot be overemphasized. Any asymmetry should be documented and the patient should be notified in the preoperative visit, or significant dissatisfaction will result after the surgery, because the patient who may have noticed the asymmetry just after the surgery may blame the surgeon for causing the problems.

Proper photographic documentation is essential for all patients who undergo blepharoplasty and other cosmetic procedures. For preparation of standard photographs, certain points should be considered which are beyond the scope of this chapter. Most importantly, frontal and profile photos of high quality in neutral facial position (without smiling and brow elevation) should be taken in well-lit room with plain background. The postoperative photos should be taken in similar light, background, and position to be comparable to the preoperative records.

After explaining to the patient about the procedure, the probable average outcome, postoperative course and precautions, and review of possible rare and common complications, an informed consent should be obtained. Patients should be clearly instructed about what aging changes could be fixed by the procedure and what cannot be achieved by blepharoplasty. Sometimes, a second operation may be required, either to correct associated involutional changes that were not addressed during blepharoplasty (like eyelid or brow ptosis) or to resect more redundant tissue which may have been undercorrected in the prior surgery.

45.5 The Procedure

Upper blepharoplasty operation begins with marking the incisions. This is followed by local anesthesia, incision, resection of skin and fat, adjunctive procedures based on patient's needs and is terminated by wound closure. Each step is discussed in the section below.

45.5.1 Marking the Incision Site

Marking is believed by most authors to be the most important step in upper blepharoplasty surgery. Before marking, any make up should be cleaned and the area can be wiped with alcohol pads to degrease the skin in order to make marking more accurate. A fine-tip permanent marker should be used to minimize fading the marks and maximize the precision of incisions which are supposed to be based on the marks. Some surgeons mark the area before prep and drape (P&D), but we recommend marking after P&D. The reason for suggestion of marking before P&D is to allow adequate time for onset of effect of vasoconstrictor injected during local anesthesia while waiting for the area to be prep and draped. Otherwise, the surgeon who marks after P&D should wait about 10 min for epinephrine injected with local anesthetic to show enough vasoconstrictor effect. However, the possibility of deletion of marking during P&D is a concern in the former approach. If the marks are accidentally deleted during P&D and after local anesthetic injection, the operation has to be canceled as it is impossible to repeat accurate marking at this step. While some surgeons have suggested marking the patient in sitting position to avoid changes in the location of eyebrows by gravitational forces on the scalp skin in supine position, we prefer to mark in supine position, as we have found it to bear similar results in our experience, yet provide more comfort for the patient and the surgeon.

The marking is usually in the shape of lazy S [11] and consists of a lower and an upper border. The lower border defines the position of lid crease and tarsal plate show postoperatively, so it is of crucial importance to be properly located. Most surgeons agree that the patient's own lid crease is the best place for the lower marking. However, there are a few exceptions, like those who have involutional ptosis with a higher than normal lid crease. Additionally, patients of Asian ethnicity may not have a well-defined crease or may desire a higher lid crease to enhance their tarsal plate show. Generally, the ideal location of the center of lower border of marking should be placed 8–10 mm from lid margin in women and 6–8 mm in men. Whatever distance used for marking of one side should be precisely repeated on the other side to avoid creating asymmetric lid creases. The distance of the marking to lid margin decreases in medial and lateral ends and is on average 2–3 mm lower compared to the center of the marking. The medial end of the marking should not be medial to upper punctum (except for correction of Asian lid crease). Laterally, the lower line is continued by an almost 45° angle upward toward the upper border of marking. [11] If this angle is smaller, the incision will be longer but smoother and if it is larger, the incision will more likely be directed toward the eyebrow and "dog ear" formation is more likely during suturing the incision.

The upper marking is usually determined by skin pinch test. A non-toothed forceps is used to grasp the excess skin supposed to be surgically removed and the marker is used to mark just above this point. It is generally believed that

at least 20–25 mm of skin is required to be present between lower border of eyebrow and upper lid margin to allow proper night-time lid closure. Otherwise, patients will have difficulty closing their eyes during sleep and dry eye and its sequela may complicate the postoperative course. In order to preserve 20 mm of skin, the distance between upper marking and lower border of eyebrow must add up to the remaining skin of lid crease. For example, if lower marking (on lid crease) is located 8 mm above lid margin, the upper marking should be 12 mm below the eyebrow. The authors recommend to check marking by both methods (pinch test and caliper measurement of remaining skin). In our practice, the patients are asked to open their eyes after marking and we check to make sure the upper marking is visible and is not covered by the folded excess skin. Novice surgeons should be on the side of undercorrection of dermatochalasia, as it is always possible to remove more redundant skin later, while adding proper skin if over-resection had been performed is a cumbersome process. Younger patients are particularly more prone to lagophthalmos if overcorrected because of their thicker skin and minimal brow ptosis.

The medial marking should not be extended to the nasal skin, or skin webbing will ensue which is extremely difficult to correct. To avoid such complications, the mark should not be more medial than superior punctum. If excessive skin on medial side is present, the surgeon can remove a Burrow's triangle at the time of wound closure to address the skin redundancy (Fig. 45.2). Laterally, the marking is extended to include the lateral hooding, and may occasionally extend beyond the lateral orbital rim. In addition, for better symmetry of lateral incision, we measure the lateral end of marking from lateral canthus on both sides and adjust the marks if necessary.

Fig. 45.2 Excision of Burrow's triangle (arrow) to remove excess skin medially and prevent dog ear formation while suturing

45.5.2 Local Anesthesia

Most surgeons use a combination of 2% lidocaine with or without 5% bupivacaine and 1:100,000 epinephrine to achieve the desired anesthesia and hemostatic effect. For better patient experience and having less pain, usually systemic analgesics are used, mostly in the form of intravenous sedation and less frequently as oral premedication by diazepam, for instance. Fine 27-gauge needle is used for injection of local anesthetic solution and the injection should be in the subcutaneous plane. The physician should carefully look for and avoid visible subcutaneous vessels to prevent hematoma formation during injection. First, a few points are injected to provide skin anesthesia, then higher volume of anesthetic is used for hydro-dissection of skin from orbicularis oculi. Local anesthetics often need to be repeated during the procedure, especially for adjunctive procedures like fat excision, browpexy, and lacrimal gland fixation, as the orbital septum prevents spread of superficially injected local anesthetic to the deeper structures like orbital fat pads or lacrimal glands.

45.5.3 Skin Incision

The incision classically includes either eyelid skin only (skin flap), or skin and orbicularis oculi (skin-muscle flap). We, like most other authors, prefer the former and avoid extensive muscle resection. Various methods are used for skin incision, including scalpel blade, radiofrequency units, and laser devices. While the latter instruments allow better hemostasis, it is argued that cold blade incisions have better healing and result in more aesthetically acceptable wound edges and scars. Each surgeon selects a method based on personal experience and availability of instruments, and most authors believe the differences in the final outcome are negligible, regardless of the method of incision. Proper traction should be maintained on the eyelid skin during incision and the lower border is usually incised first, followed by the upper border.

45.5.4 Resection of Tissues

The skin should be dissected from the underlying orbicularis before resection (Fig. 45.3). The dissection can be performed by Westcott scissors or fine-tip monopolar cautery units like Colorado Microdissection needle (Stryker, Kalamazoo, MI), which is a useful instrument for dissection of fine eyelid tissues while providing hemostasis simultaneously. After removal of excess skin marked between the upper and lower border incisions, the surgeon should decide whether to open

Fig. 45.3 Skin resection in upper blepharoplasty

Fig. 45.4 Excision of orbital fat in upper blepharoplasty (**a**). The fat can be grasped with hemostat for cauterization of the base of the fat pad after resection of excess fat (**b**)

the orbital septum to remove fat and find access to deeper structures needing adjunctive procedures. Occasionally, the patient might need no more than pure skin resection blepharoplasty, when the surgeon can directly proceed to wound closure.

Resection of orbicularis oculi is debated among surgeons, [12] but most agree that the muscle should be preserved because no excess muscle is produced during the aging phenomenon. As this muscle serves the crucial role of lid closure, its aggressive resection affects blinking and may cause lagophthalmos which aggravate dry eye symptoms. However, the proponents of muscle resection adjust it in cases with overly hypertrophic orbicularis oculi when the patient has crowding of orbital tissue and needs more sculpting to achieve aesthetically acceptable eyelid appearance. Our preference is partial excision of orbicularis oculi (superior preseptal portion and occasionally a small strip of orbital portion) in patients with puffy eyelids. Depending on puffiness, we decide to whether remove it on the entire length of incision or just resect its lateral portion. Without orbicularis myectomy, the intact muscle may roll on itself when the edges of skin incisions are sutured, hence increasing eyelid puffiness. We have found partial preseptal orbicularis resection to result in no lagophthalmos, while producing better cosmetic outcomes in our patients. In any case, the muscle resection must be conservative and confined to the preseptal portion of the muscle. Pretarsal orbicularis oculi should be kept intact to preserve blinking and lid closure. As this muscle is richly vascularized, meticulous hemostasis is required after its incision or excision.

Bulging orbital fat pads could be partially resected. However, the surgeon should avoid over-resection of fat to prevent creation of a skeletonized orbital appearance, which is more senescent than youthful. Usually, the medial orbital fat pad is the only fat needing resection. Opening of medial part of orbital septum allows access to this fat pad. Retropulsion on globe can bring the fat pads forward to assist in better identification and dissection of the fat. Blunt dissection around the fat is performed to free it from surrounding tissues like trochlea of superior oblique. The use of cotton tip applicators, curved hemostat, and fine skin hooks for better exposure and blunt, atraumatic dissection is recommended.

As the orbital septum prevents subcutaneously injected anesthetics to reach the fat pads, they should be injected with lidocaine when exposed through opening of orbital septum. Fat manipulation would otherwise be painful and intolerable. To avoid over-resection of fat and skletonization of orbit, only the fat prolapsed anterior to orbital rim with gentle pressure on the globe should be excised. Traction on fat pads should be avoided, as it may rupture deeply located vessels in orbit and the ensuing hemorrhage would be difficult to control, while potentially blinding. The fat could be grasped with hemostat, the excess fat resected (Fig. 45.4) and the base cauterized to achieve optimal hemostasis. However, some surgeons advise against holding the fat with hemostat, as the traction can be transferred deeply into the orbital com-

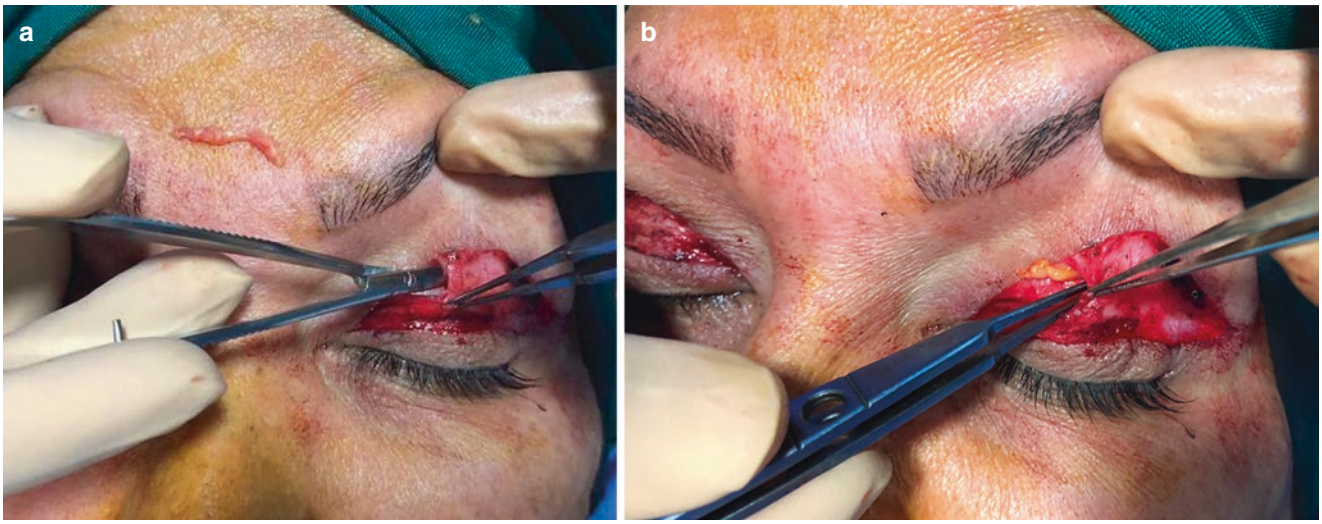

Fig. 45.5 A sub-orbicularis tunnel (arrow) is made by dissection under orbicularis oculi (**a**) for placement of the excess fat removed from medial fat pad (asterisk) in cases where volumization of hollow superior sulcus is necessary (**b**)

ponents of the fat and can cause pain or bleeding. Instead, fat can be resected with monopolar cautery in a graded fashion. Some surgeons recommend transposition of medial fat pad over the central upper lid sulcus to both address the bulging medial fat and the A-frame deformity due to senile atrophy of the middle fat pad. [13] In this method, the excess medial fat is dissected but not excised and essentially serves as a flap for covering the hollow sulcus. Alternatively, the excised medial fat can be used like a free graft. It is left beneath a tunnel under orbicularis oculi to achieve fullness in cases with hollow and deep sulcus (Fig. 45.5).

The middle orbital fat pad is rarely required to be resected. If overly prominent, it could be sculpted by application of thermal cautery over the exposed fat or even over the intact orbital septum. Alternatively, in occasional cases with severe eyelid puffiness, the middle fat pad may bulge spontaneously after orbital septum is opened. In such instances, we remove only the bulging middle fat without pressure on the globe to avoid overcorrection.

Bulging tissue in the lateral orbit should be assumed to be lacrimal gland and should never be resected. A prolapsed lacrimal gland can be fixed with non-absorbable sutures to the periosteum of lacrimal fossa in superolateral orbit (Fig. 45.6). It has been shown to be a necessary adjunctive procedure in about 10% of patients who undergo cosmetic blepharoplasty. [14]

45.5.5 Adjunctive Procedures

Apart from dacryoadenopexy (fixation of prolapsed lacrimal gland) explained above, several other adjunctive procedures can be performed at the time of upper blepharoplasty to enhance the cosmetic outcome.

Correction of brow ptosis can ideally be performed through endoscopic forehead lift [15] (see Chap. 49), especially in cases with severe brow ptosis. Occasionally, the crowding of periocular tissues and hooding which has caused the patient's complaints are completely addressed with forehead lift, without the need to upper blepharoplasty (Fig. 45.7). However, most patients need both procedures, which can be performed in one session in experienced hands. As the forehead lift greatly affects the amount of skin which could be excised by blepharoplasty, the marking and planning needs sufficient experience to avoid overcorrection. Novice surgeons are advised to perform blepharoplasty a few weeks after forehead lift to allow better judgment of amount of skin which could be safely excised.

For milder cases of brow ptosis, oculoplastic surgeons usually perform internal browpexy, [16] using non-absorbable monofilament sutures (e.g., Prolene) to fix the sub-brow tissue to the periosteum of frontal bone, approximately 12–15 mm above the superior orbital rim (Fig. 45.8). However, the extent of dissection is relatively larger; we usually release orbicularis retaining ligament attachments on lateral sides to allow en-bloc dissection of ROOF and overlying tissues from periosteum of frontal bone up to 25 mm from the orbital rim. Alternative dissection planes have been used, like dissection superficial to ROOF. The effect of internal browpexy can be enhanced using Endotine Transbleph (Coapt systems, Palo Alto, CA), a bio-absorbable implant for adjustable anchoring of soft tissues, [17] now commonly used in a variety of plastic surgical procedures. In this approach, dissection is required to be further extended superiorly and medially, near the supraorbital nerve.

External browpexy [18] is less commonly performed and most candidates are elderly men with thick brow hairs which can camouflage the cutaneous scar. In this adjunctive proce-

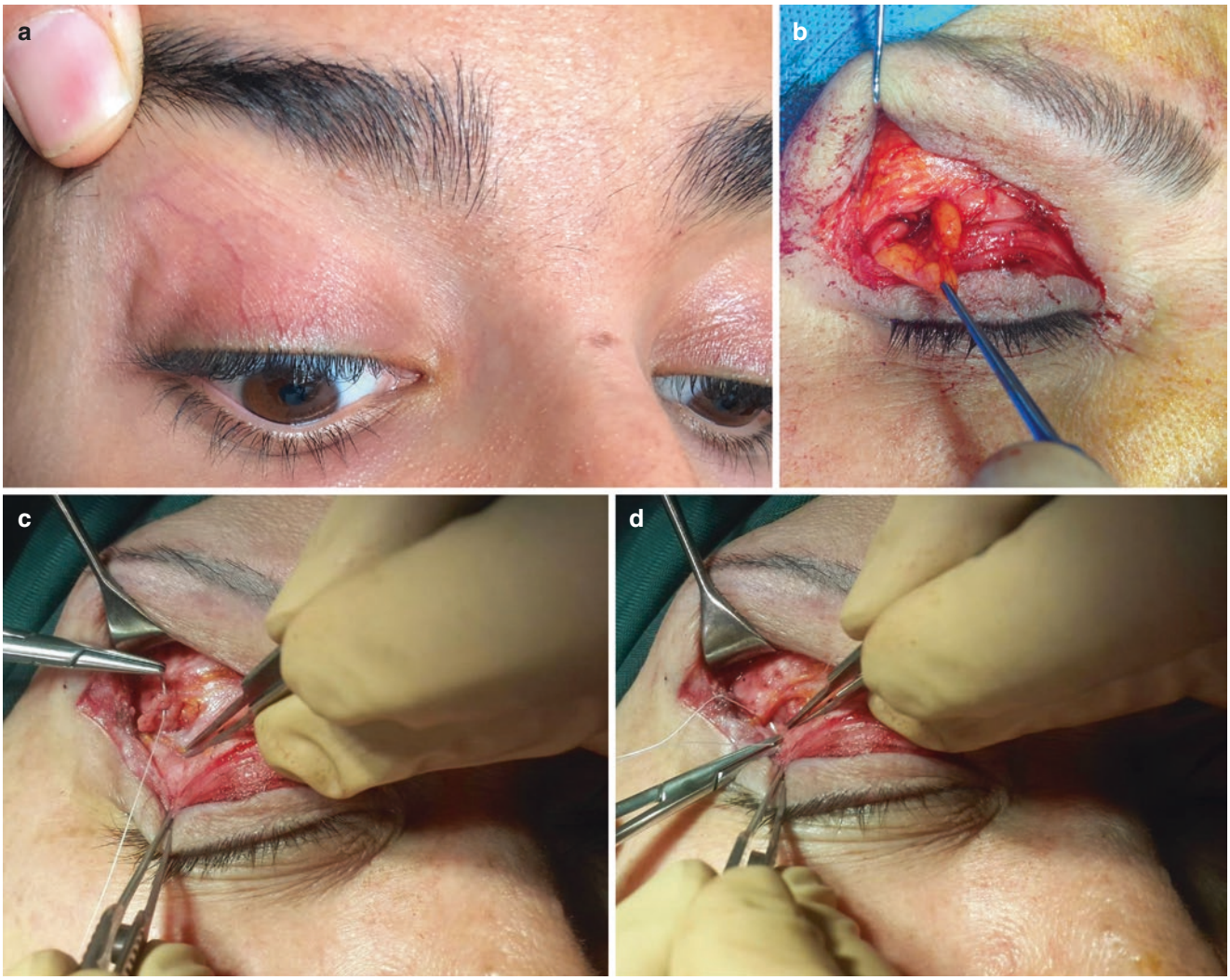

Fig. 45.6 Lacrimal gland prolapse in a young patient (**a**). Intraoperative view of the prolapsed lacrimal gland below lateral orbital roof (long arrow), located adjacent to medial orbital fat pad (**b**). Mersilene suture is passed through the prolapsed lacrimal gland (**c**) to fix it to the periosteum of superior orbital rim (**d**)

dure, an 8-mm incision is made just above the temporal part of eyebrows and the sub-brow tissue is fixed to the underlying periosteum on a higher point with 4–0 Prolene, and the wound is repaired with 5–0 nylon or Prolene running horizontal mattress sutures to create wound eversion. This procedure can lead to 2 mm brow elevation without creating a feminized appearance in men. Alternatively, some surgeons resect a crescent-shaped flap of skin and subcutaneous tissue just above the temporal eyebrow and suture the edges of the incision without fixation to deeper tissues (temporal browplasty).

Some patients may have deep superior sulcus or sub-brow fat atrophy which can be corrected by superior orbital or sub-brow fat injection, respectively. [19] Others may have hypertrophy or descent of retro-orbicularis oculi fat (ROOF), which can be partially excised and sculpted [20] (Fig. 45.9). Particularly in patients with puffy eyelids, the ROOF may extend below the orbital rim and even lie over orbital septum. In such cases, resection of part of ROOF which is located lower than orbital rim is recommended.

Variable degrees of upper lid ptosis are common among older age blepharoplasty candidates. [21] Failure to diagnose preexisting ptosis can lead to patients' complaints postoperatively. Ptosis repair can be obtained via posterior approach conjunctivo-Muller resection in milder cases or anterior approach levator advancement, tucking, or resection. While the former approach has its proponents, we prefer the anterior approach levator surgery to directly address the underlying pathology which most often lies in the levator muscle or aponeurosis, without damaging the conjunctiva and its goblet cells.

There is controversy regarding the order of the two procedures; some surgeons first correct lid ptosis and then perform blepharoplasty after a few weeks. Others might do both pro-

cedures in one session. We suggest simultaneous surgery to be exclusively performed by highly experienced surgeons. Generally, it is prudent to instruct patients with coexisting ptosis and dermatochalasis to be prepared for two sessions of surgery, the first for ptosis correction and the second for blepharoplasty and probably adjustment of ptosis repair if under or overcorrection has been performed in the first session. The main reason is possibility of over or undercorrection of ptosis requiring revision surgery and if the patient had been scheduled for only one operation session (including blepharoplasty and ptosis correction), dissatisfaction will ensue in case ptosis revision surgery is needed. Another reason is possibility of contralateral ptosis following unilateral ptosis correction which is due to Hering's law of equal innervation and is observed in up to 17% of patients after unilateral ptosis surgery. [22] If patients have already been scheduled for only one operation session, they will not be happy to undergo another procedure and may attribute contralateral ptosis to the primary surgery, while the real reason is unmasking of preexisting ptosis when less neural impulse is sent to levator muscles of both sides after correction of ptosis on one side (Hering's law). However, if the physician has previously explained the need for two surgical sessions, correction of contralateral ptosis can be achieved in the second operation without causing patient discomfort.

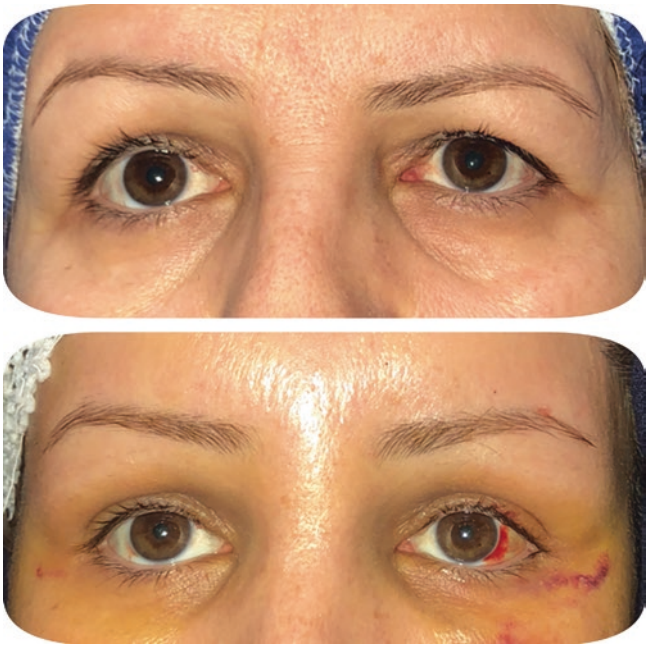

Fig. 45.7 Differentiation of brow ptosis from dermatochalasis is essential, as some patients only require brow lifting for improvement of droopy eyelid tissues. The picture shows patient's appearance before and 5 days after endoscopic forehead lift which successfully corrected her lateral hooding, more pronounced on the left side

Another adjunctive procedure which can be performed during upper blepharoplasty is weakening of glabellar muscles (corrugator supercilii) [23]. This procedure is routinely a part of endoscopic forehead lift, but proper dissection of sub-brow tissue through blepharoplasty incision can also provide enough visualization of superomedial orbital structures. Careful dissection and meticulous hemostasis is mandatory because this area contains numerous blood vessels and nerves like supra-orbital and supra-trochlear neurovascular complexes. The glabellar muscles, which normally act as brow depressors, are located deep to the orbicularis oculi and can be partially resected to correct vertical glabellar furrows made during frowning. These procedures should better be performed only by surgeons who have enough mastery of anatomy of this area. Less experienced surgeons can use neuromodulatory adjunctives like botulinum toxin injection for correction of glabellar wrinkles.

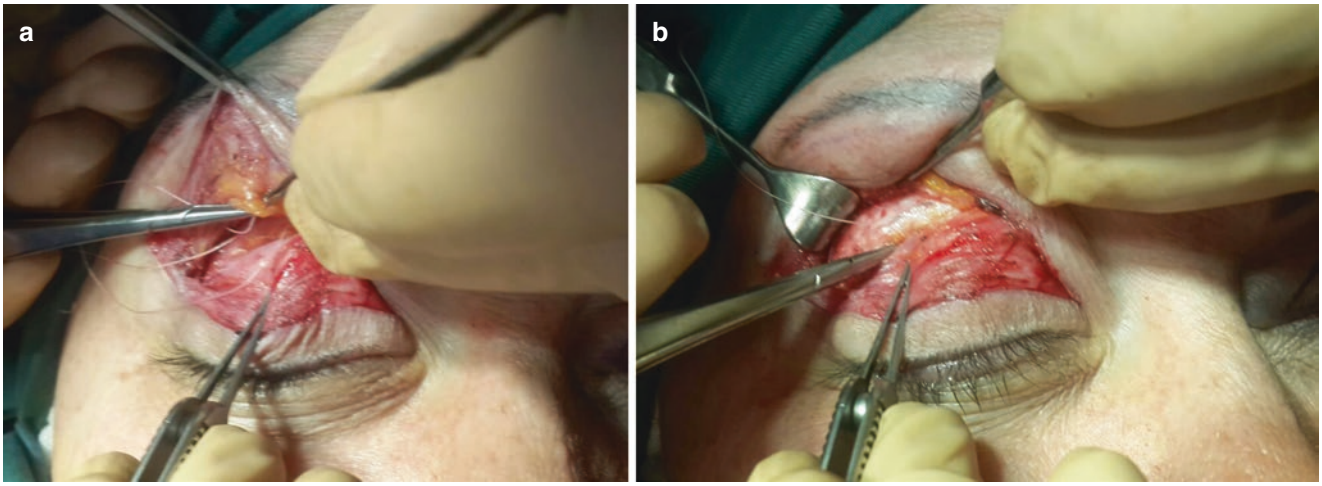

Fig. 45.8 Internal browpexy with mattress suture engaging retro-orbicularis oculi fat (**a**) below the eyebrow and fixing it to the periosteum of frontal bone at the desired location to achieve optimal brow elevation (**b**)

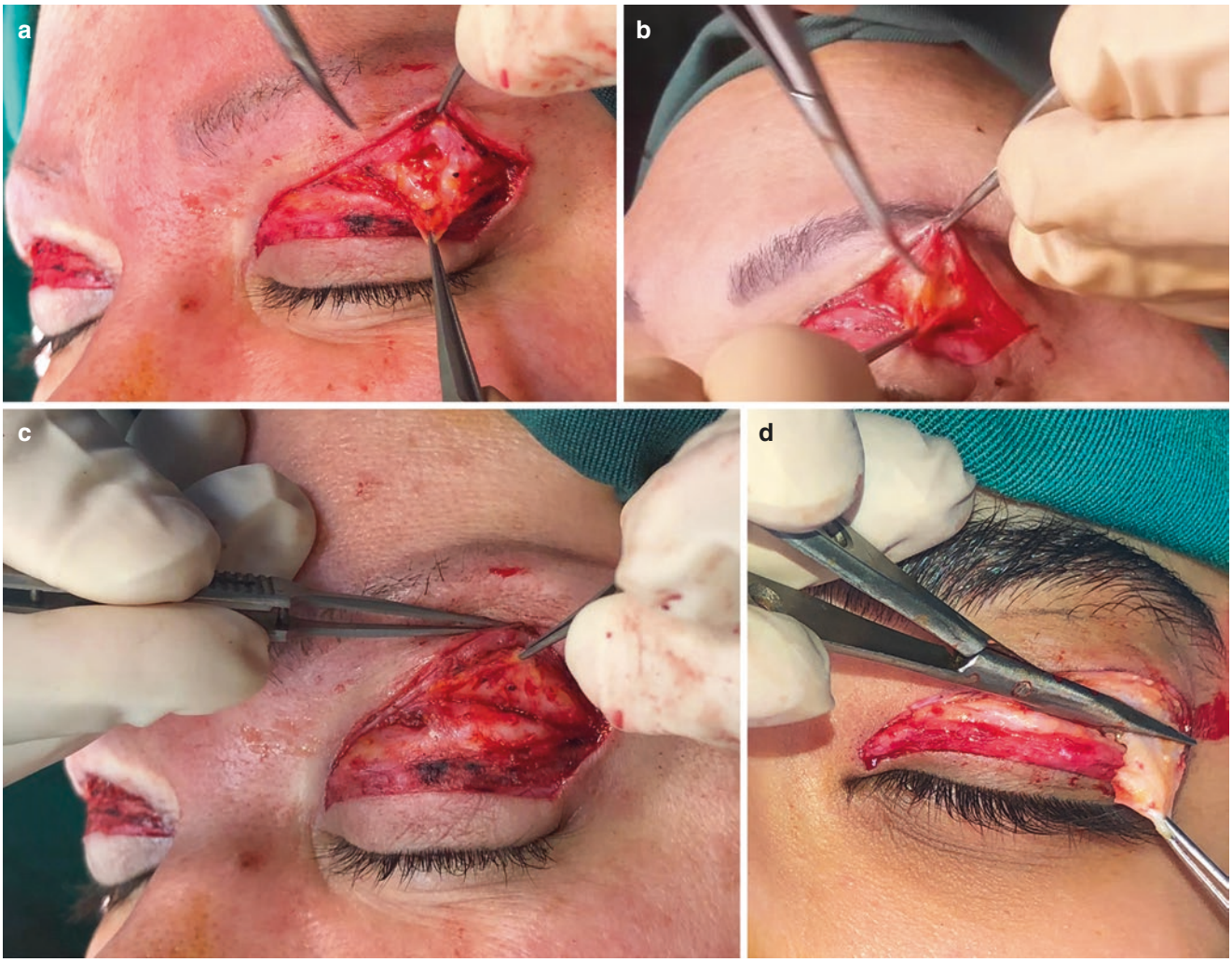

Fig. 45.9 Retro-orbicularis oculi fat (**a**) is dissected from other layers (**b**), and shown as a distinct layer (arrow) of thick fatty tissue in some patients (**c**), which may be partially removed (**d**)

45.5.6 Wound Closure

Several methods are commonly used by surgeons for suturing the blepharoplasty incisions. If the tissues are properly apposed, the ultimate result will not be significantly different, regardless of suture material and suturing techniques. Most surgeons use either fast-absorbing chromic gut sutures or non-absorbable synthetic monofilament material like Prolene or nylon. We prefer 6–0 Prolene sutures which are believed to result in minimum suture-related complications like suture milia. The surgeon can use simple separate sutures, but most physicians find it more time-consuming. Instead, running sutures are more commonly used for wound closure. Alternatively, running subcuticular sutures can be used. A few points of incision lines need to be securely closed with separate sutures, particularly the lateral third [24] of the wound which has the greatest tension and the highest probability of wound dehiscence. Sutures need to engage only the skin, and minimal orbicularis oculi engagement is acceptable. Following suturing, Steri-Strip adhesives can be used to dress the wound.

45.6 Postoperative Care

Cold compress should be initiated as soon as possible in the recovery area. This is recommended for the first 48 hours after surgery to minimize postoperative bruising and hematoma formation. Thereafter, warm compress is recommended.

Lubricating eye drops and topical antibiotic ointments are usually prescribed during the first postoperative weeks. Patients should return 6–7 days after surgery for suture removal. Danger signs should be clearly reminded to the patients, including eyelid swelling, hematoma, blurring of vision, unexpected eyelid pain and proptosis or limitation of

eye movements. If any of these complaints are reported during the postoperative course, the patient should be urgently evaluated for retro-bulbar hemorrhage.

The patients can return to their daily routines after the first week. Strenuous exercise could be re-instated after 3 weeks. Make up can be used after the first week.

45.7 Complications

Upper blepharoplasty is commonly performed with minor complications and, if planned and undertaken carefully, yields satisfaction for the patient and the surgeon. Nevertheless, some complications are possible like any other procedure.

Blindness due to orbital (retrobulbar) hemorrhage is the most dreadful complication. It is extremely rare, but possible, following upper blepharoplasty. Most cases of orbital hemorrhage and blindness have been reported following lower rather than upper blepharoplasty. Patients who have disorders in blood coagulation are prone to this complication. These patients should be identified in the preoperative assessment and proper preventive measures must be ensured before and during surgery. Patients who use any medications affecting hemostasis should be instructed to stop those drugs in appropriate time before surgery. If the drugs could not be stopped due to medical conditions (for example, atrial fibrillation with cardiac intramural clot), the patient should refrain from cosmetic surgery. Preoperative screening laboratory tests for assessment of coagulation and hemostasis is necessary. Meticulous intraoperative hemostasis is mandatory. Careful dissection and gentle handling of orbital fat is necessary to avoid deep orbital vessels from bleeding. Fat resection should always be followed by cauterization of the base of the remaining fat. Cold compress should be initiated as soon as possible after wound closure. Patients should avoid strenuous physical activity during early postoperative period. If retrobulbar hemorrhage occurs, the patient will begin to feel severe retro-orbital pain which is unusual for the blepharoplasty cases. Depending on the source of bleeding which can be arterial or venous, blood accumulates with different rates in the confined space of orbital cavity and compresses circulation of orbital contents, globe, and optic nerve. Left untreated, this can result in proptosis, limitation of ocular movements, and blindness. It is a true emergency and the first step is opening the sutures, followed by lateral canthotomy and cantholysis to allow blood egress from the confined orbital space. The surgical site could be explored to identify the bleeding vessel and apply coagulation and cauterization. Rarely, classic bony decompression of orbit is required to fasten blood drainage from the orbit. The wound and canthotomy site should be closed later.

Injury to different periocular structures is possible if the surgeon is not familiar with anatomical details, uses nonstandard techniques, or has poor visualization due to bleeding in the surgical field. Inadvertent trauma to trochlea, levator aponeurosis, or lacrimal gland can lead to diplopia, ptosis, and dry eye, respectively. While postoperative ptosis caused by traumatic manipulation during surgery is usually permanent, sometimes transient and reversible ptosis occurs which will resolve spontaneously.

Overcorrection of dermatochalasia leaves essentially so little skin on the eyelids that eye closure is impossible. This is a troublesome complication for the patient who will experience dry eye symptoms and for the surgeon who has to add skin graft to eyelids to allow proper eye closure. Milder cases can be managed with botulinum toxin injection of lower parts of frontalis muscle to induce brow ptosis to facilitate eye closure. However, the cosmetic outcome will be negatively affected. So, the surgeons should err on the side of undercorrection instead. Undercorrection of dermatochalasia or fat prolapse needs nothing more than an additional surgery and is far less of a problem compared to overcorrection. Overcorrection of fat prolapse by too much fat resection can cause skeletonized orbital appearance (A-frame deformity) which results in more aged appearance. Filler or fat injection should be used for correction of these cases.

Scar on the surgical site is often unnoticeable a few months after surgery due to the unique characteristics of eyelid tissue like thin skin and rich vascularization. However, if the scar extends laterally out of the orbital rim, it would be noticed, especially in men who cannot easily use make up to cover the scars. So, it is recommended to terminate the incision just at the level of lateral orbital rim. Medially, skin webbing can occur if the incision extends beyond superior punctum to the upper nasal skin (Fig. 45.10). The surgeon should resist the temptation for overcorrection of excess skin in the superomedial area, especially in patients with bulging orbital fat pads. The reason is the dead space that will be created after resection of orbital fat which causes the scar tissue to form adhesions from deeper planes to the skin tissue and result in depressed scar. For correction of redundant superomedial skin, resection of a Burrow's triangle or lazy S incisions are recommended. Another possible complication is asymmetry of incisions which is due to inaccurate marking.

Wound dehiscence is a rarely encountered complication (2%) and is often seen in the lateral portion of the incision, the site with maximum tension, especially in younger patients with relatively thicker skin. This usually presents after the first week (days 6–15) [25] and depressed scar will perma-

Fig. 45.10 Medial skin web formation following upper blepharoplasty

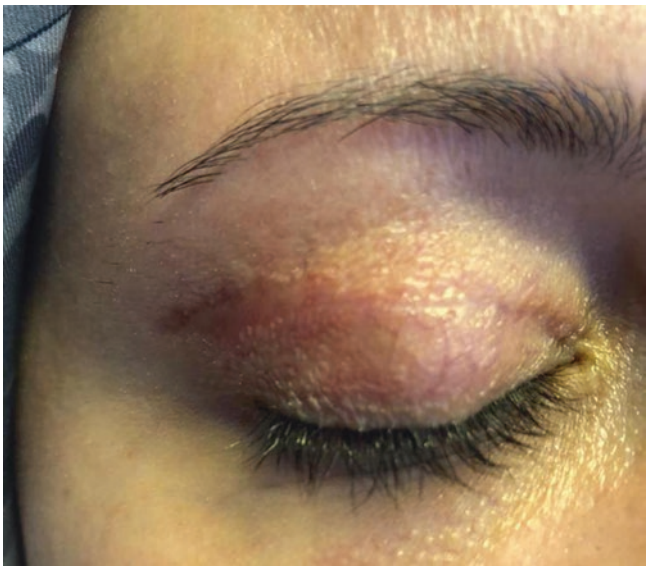

Fig. 45.11 Lateral wound dehiscence (arrow) appears as depressed scar

nently be visible on the site of dehiscence (Fig. 45.11). Up to three buried subcutaneous 6–0 Vicryl sutures on orbicularis oculi in the lateral part of incision have been successfully used to decrease the possibility of this complication. [26]

Milia are small epidermal inclusion cysts which may be formed on the site of suturing needle entry into the skin. Prolene sutures in subcuticular fashion are believed to be rarely associated with this complication. [27] If the patient is severely bothered by the appearance, these could be marsupialized by fine 27-gauge needles after application of local anesthetic creams.

References

1. Codner MA, McCord CD. Eyelid and periorbital surgery. 2nd ed. New York: Thieme; 2016.
2. Kikkawa DO, Lemke BN. Orbital and eyelid anatomy. In: Dortzbach RK, editor. Ophthalmic plastic surgery: prevention and Management of Complications. New York: Raven Press; 1994.
3. Doxanas MT, Anderson RL. Oriental eyelids: an anatomic study. Arch Ophthalmol. 1984;102:1232–5.
4. Fedok FG, Carniol PJ. Minimally invasive and office-based procedures in facial plastic surgery. New York: Thieme; 2014.
5. Barker DE. Skin thickness in the human. Plast Reconstr Surg. 1951;7:115–6.
6. Kashkouli MB, Abdolalizadeh P, Abolfathzadeh N, Sianati H, Sharepour M, Hadi Y. Periorbital facial rejuvenation; applied anatomy and pre-operative assessment. J Curr Ophthalmol. 2017;29:154–68.
7. Branham G, Holds JB. Brow/upper lid anatomy, aging and aesthetic analysis. Facial Plast Surg Clin North Am. 2015;23:117–27.
8. Niamtu J. Cosmetic facial surgery. 2nd ed. Edinburgh: Elsevier; 2018.
9. Burroughs JR, Anderson RL, Patrinely JR, Weinberg DA, McCann JD, McMullan TF. Preoperative assessment of the eye and periocular region. Semin Plast Surg. 2007;21:5–17.
10. Mojon DS, Goldblum D, Fleischhauer J, Chiou AG, Frueh BE, Hess CW, et al. Eyelid, conjunctival, and corneal findings in sleep apnea syndrome. Ophthalmology. 1999;106:1182–5.
11. Hartstein ME, Holds JB, Massry G. Pearls and pitfalls in cosmetic oculoplastic surgery. New York: Springer; 2015.
12. Hoorntje LE, Lei BV, Stollenwerck GA, Kon M. Resecting orbicularis oculi muscle in upper eyelid blepharoplasty-a review of the literature. J Plast Reconstr Aesthet Surg. 2010;63:787–92.
13. Massry GG. Nasal fat preservation in upper eyelid blepharoplasty. Ophthalmic Plast Reconstr Surg. 2011;27:352–5.
14. Eshraghi B, Ghadimi H. Lacrimal gland prolapse in upper blepharoplasty. Orbit. 2020;39:165–70.
15. Angelos PC, Stallworth CL, Wang TD. Forehead lifting: state of the art. Facial Plast Surg. 2011;27:50–7.
16. Baker MS, Shams PN, Allen RC. The quantitated internal suture browpexy: comparison of two brow-lifting techniques in patients undergoing upper blepharoplasty. Ophthalmic Plast Reconstr Surg. 2016;32:204–6.
17. Langsdon PR, Williams GB, Rajan R, Metzinger SE. Transblepharoplasty brow suspension with a biodegradable fixation device. Aesthet Surg J. 2010;30:802–9.
18. Massry GG. The external browpexy. Ophthal Plast Reconstr Surg. 2011;28:90–5.
19. Tzikas TL. Fat grafting volume restoration to the brow and temporal regions. Facial Plast Surg. 2018;34:164–72.
20. May JW Jr, Fearon J, Zingarelli P. Retro-orbicularis oculus fat (ROOF) resection in aesthetic blepharoplasty: a 6-year study in 63 patients. Plast Reconstr Surg. 1990;86:682–9.
21. Martin JJ Jr. Ptosis repair in aesthetic blepharoplasty. Clin Plast Surg. 2013;40:201–12.
22. Erb MH, Kersten RC, Yip CC, Hudak D, Kulwin DR, McCulley TJ. Effect of unilateral blepharoptosis repair on contralateral eyelid position. Ophthalmic Plast Reconstr Surg. 2004;20:418–22.
23. Guyuron B, Michelow BJ, Thomas T. Corrugator supercilii muscle resection through blepharoplasty incision. Plast Reconstr Surg. 1995;95:691–6.
24. Hahn S, Holds JB, Couch SM. Upper lid blepharoplasty. Facial Plast Surg Clin North Am. 2016;24:119–27.

25. Spiliotis J, Tsiveriotis K, Datsis AD, Vaxevanidou A, Zacharis G, Giafis K, et al. Wound dehiscence: is still a problem in the 21th century: a retrospective study. World J Emerg Surg. 2009;4:12.
26. Kashkouli MB, Jamshidian-Tehrani M, Sharzad S, Sanjari MS. Upper blepharoplasty and lateral wound dehiscence. Middle East Afr J Ophthalmol. 2015;22:452–6.
27. Joshi AS, Janjanin S, Tanna N, Geist C, Lindsey WH. Does suture material and technique really matter? Lessons learned from 800 consecutive blepharoplasties. Laryngoscope. 2007;117:981–4.