Management of Diaphragmatic Injuries

Patrizio Petrone, D'Andrea K. Joseph, Collin E. M. Brathwaite, L. D. Britt, and Juan A. Asensio

Key Points

- The diaphragm is the principal muscle of inspiration. The function of each hemidiaphragm revolves around the dynamic generation of a tidal volume.
- The left diaphragm is affected in 75% of the cases as opposed to 25% on the right side, while bilateral TDI occur only in 2% of the patients.
- Clinical presentation may range from hemodynamic stability with few or no physical findings to severe hemodynamic compromise and/or presentation *in extremis* of patients with massive destruction of the thoracoabdominal region.
- Minimally invasive techniques such as laparoscopy and thoracoscopy are now part of the trauma surgeon's diagnostic armamentarium for both diagnosis and repair of TDI.
- Mortality from TDI is generally due to the associated injuries.

Introduction

The anatomo-physiologic structure and function of the diaphragm is responsible for the higher incidence of left-sided TDI. A congenital weakness along the embryonic fusion of the costal and lumbar portions of the diaphragm predisposes the left hemi-diaphragm to a greater incidence of injury from blunt trauma. In contrast, the presence of the liver along with its attachments underneath the right hemi-diaphragm accounts for the lower incidence of trans-diaphragmatic herniation following small defects from either penetrating or blunt trauma. In general, because of the significantly greater force required to cause right sided TDI, patients with injury to the right hemi-diaphragm have a higher pre-hospital mortality when compared to patients with left diaphragmatic injuries from associated severe hepatic and vascular injuries. The diagnosis of TDI requires a multimodality

P. Petrone (✉) · D. K. Joseph · C. E. M. Brathwaite
NYU Langone Health-NYU Winthrop Hospital, NYU Long Island School of Medicine, 222 Station Plaza N., Suite 300, Mineola, NY, USA
e-mail: patrizio.petrone@nyulangone.org; patrizio.petrone@gmail.com

L. D. Britt
Eastern Virginia Medical School, Norfolk, VA, USA

J. A. Asensio
Division of Trauma Surgery & Surgical Critical Care, Creighton University School of Medicine, Creighton University Medical Center, Omaha, NE, USA

© Springer Nature Switzerland AG 2020

C. E. Nistor et al. (eds.), *Thoracic Surgery*, https://doi.org/10.1007/978-3-030-40679-0_63

diagnostic approach. In fact, no single diagnostic study has been shown to be sufficiently sensitive and/or specific enough to accurately diagnose the presence of blunt or penetrating diaphragmatic injury. Minimally invasive procedures such as diagnostic laparoscopy and thoracoscopy are more commonly used to diagnose TDI in asymptomatic patients with penetrating trauma to the thoraco-abdominal region. The operative management of TDI depends on the clinical presentation of the patient and on the timeliness of the diagnosis. Patients with acute TDI typically undergo immediate open or laparoscopic operative management depending on the presence or absence of associated injuries. The objective of this chapter is to provide a concise approach to the diagnosis, surgical management, and treatment of diaphragmatic injury.

Physiology of the Diaphragm

The diaphragm is the principal muscle of inspiration. When the muscle is at rest, it presents a domed surface that is concave towards the abdomen. When the muscular fibers contract, they become less arched or nearly straight, causing the central tendon to descend. As a result, the level of the chest wall is lowered and the vertical diameter of the chest is proportionally increased. During this descent, the different parts of the tendon move unequally. The left leaflet descends to a greater extent than the right leaflet, primarily due to the liver, and the central leaflet descends the least because of its connection to the pericardium. In descending, the diaphragm compresses the abdominal viscera and causes an outward projection of the abdominal wall. However, because the central tendon becomes a fixed point, this enables the circumferential muscular fibers to contract and elevate the lower ribs thus expanding the lower part of the thoracic cavity. When at the end of inspiration the diaphragm relaxes, the thoracic wall return to its natural position as a consequence of its elastic recoil and of the elasticity and weight of the displaced viscera [1, 2].

In all acts in which expulsion of body fluids and/or solid materials, such as before vomiting, defecation, urination, and delivery of a fetus from a gravid uterus, and before sneezing, coughing, laughing, and crying, the diaphragm is called into action to give an additional power to the expulsive effort [1].

The height of the diaphragm varies during respiration as the muscle is carried upward and downward from the average level. Its height also varies according to the distention of the abdominal hollow viscera and the size of the liver. After a forced expiration, the right arch is on the level of the fourth costal cartilage; at the side, with the fifth, sixth, and seventh ribs; and behind, with the eight rib, the left arch being usually one to two ribs' breadth below the level of the right one. In a forced inspiration, it descends between one to two inches [1].

Pathophysiology of Diaphragmatic Injury

The function of each hemi-diaphragm revolves around the dynamic generation of a tidal volume. The generation of a normal tidal volume produces a 3–5 cm bidirectional trajectory of the diaphragm, with inferior displacement during inhalation and superior displacement during exhalation. During exhalation, the right hemi-diaphragm rises anteriorly to the level of the fourth intercostal space whereas the left hemi-diaphragm rises to the fifth intercostal space. Posteriorly, both hemi-diaphragm ascend to the eighth intercostal space. Constant diaphragmatic motion tends to preserve the negativity of the intrathoracic pressure, and during inhalation increases to its maximum.

As the main respiratory muscle of the body, the diaphragm has both inspiratory and expiratory functions. Changes in lung volume have a direct effect on diaphragmatic muscle fibers and their function. It is known that the transdiaphragmatic pressure from stimulation of the phrenic nerve decreases almost linearly with lung volume. This implies that the force-generating capacity of the diaphragm is reduced.

A close relationship also exists between the diaphragm and the musculature of the abdominal wall. These muscles also have both inspiratory and expiratory function. The abdominal wall muscles will contract during expiration, forcing the diaphragm cephalad into the thoracic cavity. Physiologic factors such as sudden and abrupt increases in the pleuroperitoneal pressure gradient have been identified as a pathogenetic mechanism of diaphragmatic injury. Marchand [3] demonstrated that there is a normal pattern of fluctuation in the intraperitoneal pressure during quiet respiration, which ranges from +2 cm to +10 cm of H_2O, while the corresponding intrapleural pressure fluctuates from −5 to −10 cm H_2O. With the body in the supine position, the pleuroperitoneal gradient fluctuates from +7 to +20 cm H_2O. With maximal inspiration, this gradient may exceed +100 cm of H_2O. Sudden increases in intra-abdominal pressure of +150 to 200 cm of H_2O are associated with the acute transfer of large amount of kinetic energy to the domes of the diaphragm, which in turn may cause diaphragmatic disruption.

If a violation of the anatomic integrity of the diaphragm occurs via laceration, perforation, or rupture, the pleuroperitoneal gradient will favor transdiaphragmatic migration and therefore herniation of intra-abdominal viscera [4]. Diaphragmatic disruption is associated with immediate hemodynamic and respiratory derangements. Transdiaphragmatic migration of herniating intra-abdominal viscera can restrict ventricular filling decreasing ventricular end-diastolic volumes, thereby reducing cardiac output. The displaced intra-abdominal viscera that migrate into the ipsilateral chest cavity can also compromise ventilation and may eventually compromise ventilation in the contralateral lung as the mediastinal shift increases.

Incidence and Injury Location

Diaphragmatic injuries occur infrequently in patients with both blunt and penetrating trauma. In a large review of the literature [5] that included 53,031 patients, a total of 592 patients were identified to have suffered with TDI, accounting for an overall incidence of 3% of all abdominal injuries. The mechanism of injury (MOI) of TDI depends on the reporting trauma center. Penetrating injuries predominate as the MOI in the inner-city and urban trauma centers, while blunt trauma is a much more common MOI of TDI in sub-urban and rural settings [6, 7]. The more widespread use of computed tomography particularly for the evaluation of blunt trauma patients has been associated with an overall relative increase in the incidence and detection of blunt traumatic diaphragm injuries [8].

Particularly in the setting of blunt trauma, left-sided hemi-diaphragmatic injuries are considerably more common than right-sided injuries. The incidence of left diaphragmatic was reported to be 75% as opposed to 25% right TDI, while bilateral diaphragm injuries were uncommon occurring only in 2% of the patients with TDI [9–11]. To elucidate the cause of the left-sided prevalence of diaphragmatic rupture, an study was performed in which 10 diaphragms were harvested from cadavers within the first 24 hours of death. Both the right and left hemi-diaphragm were mounted separately in a pressure chamber, and pressures were progressively increased until rupture of the hemi-diaphragm occurred. Although appeared that the right hemi-diaphragm required consistently higher pressures to rupture, the data did not reach statistical significance. Blunt left-sided injuries are usually located at the postero-lateral aspect of the hemi-diaphragm between the spleen and the abdominal aorta, and extend medially in a radial orientation towards the central tendon. Left-sided defects may present with herniation of the stomach, small bowel, colon, spleen, liver or omentum into the thoracic cavity.

Patients with right-sided hemidiaphragm rupture have higher pre-hospital mortality resulting from the greater impacting force required to produce a right-sided TDI, with such greater force typically associated with significant vascular tears in the inferior vena cava or hepatic veins. The apparent low incidence of right-sided TDI has been attributed to the cushioning effect of

the liver and to the greater force required to rupture the right hemi-diaphragm. It has been postulated that diaphragmatic injuries result from the transmission of force through the abdominal viscera to the diaphragm, resulting in rupture. This would explain the common involvement of the left hemi-diaphragm, which is unprotected as compared to the right. The energy from the force applied to the abdomen or flank should be distributed equally in all directions throughout the abdominal visceral contents.

Mechanisms of Injury

Penetrating injuries occur due to gunshot wounds, stab wounds, and shotgun wounds, whereas blunt injuries result from motor vehicle collisions, falls from heights or direct impacts to the thoracoabdominal area from vehicles (as is in the case of pedestrians being struck by vehicles). Blunt force trauma to the thoracoabdominal region or a history of crush injury should also alert the trauma surgeon to the possibility of an underlying diaphragmatic injury. A recent review of the National Trauma Data Bank (NTDB) revealed that patients with blunt traumatic diaphragmatic injuries are older and have a higher injury severity score (ISS) [12].

Associated Injuries

The diaphragm, because of its anatomic and its dynamic function, is rarely injured in isolation; in fact, the presence of associated injuries is the rule rather than the exception. The pattern of associated injuries generally depends on the mechanism of diaphragmatic injury (i.e., blunt versus penetrating, crush versus fall, etc.). Blunt trauma generally produces a significant number of extra-abdominal and/or extrathoracic injuries. The presence of diaphragmatic injury in the setting of blunt trauma should alert the physician to the high probability of associated solid organ and pelvic injury.

Clinical Presentation

In patients involved in MVC, information about the velocity of impact, the severity of vehicular damage, where the patient was found within the vehicle, and the direction of impact are all important in assessing the severity of the injury. Additionally, the presence or absence of passenger-compartment intrusion, the use and type of safety restraints, deformity of the steering wheel, and the duration and type of extrication required to retrieve the victim are also useful in understanding the impact to the patient and can help the treating physician assess possible associated injuries.

Falls from great heights, direct impacts on the thoracoabdominal area from vehicles, or a history of crush injury should also alert the trauma surgeon to the possibility of an underlying diaphragmatic injury. In general, the severity of other associated injuries may distract the attention of the trauma surgeon and compromise the ability to identify the presence of diaphragmatic injuries.

While blunt trauma generally produces no external signs that are pathognomonic for TDI, penetrating trauma in the thoracoabdominal area immediately alerts the trauma surgeon to the possibility of diaphragmatic injury. The thoracoabdominal region consists of the lower chest and upper abdomen. It is divided into the following: the anterior thoracoabdominal zone, defined as the area between the nipples superiorly and the costal margin inferiorly; the lateral component, defined superiorly by a line drawn from the anterior axillary line at the level of the nipples posteriorly to the tip of the scapula and inferiorly to the costal margin; and the posterior thoracoabdominal area, defined anteriorly by a line at the level of the tips of the scapula and inferiorly by a line beginning at the posterior axillary line at the level of the inferior most ribs. In general, the incidence of diaphragmatic injury is approximatively the same for penetrating injuries to the three thoracoabdominal areas [13].

Presentation may range from hemodynamic stability with few or no physical findings to

severe hemodynamic compromise and/or presentation *in extremis* of patients with massive destruction of the thoracoabdominal region from close-range shotgun injuries (less than 3 yards or 2.7 meters). In the majority of patients, there are no signs or symptoms directly attributable to the diaphragmatic defect. Symptoms and signs attributable to TDI include shoulder and/or epigastric pain, respiratory distress, and the presence of obvious bowel sounds in the involved hemithorax.

Diagnosis and Imaging Studies

The diagnosis of a diaphragmatic injury presents a challenge to the trauma surgeon, as evidenced by the large number of investigative procedures employed to arrive to the diagnosis. Injuries to the diaphragm may be identified non-invasively with radiological studies and/or invasively with interventional diagnostic procedures. The initial test of choice is a chest X-ray, which can be diagnostic when hollow abdominal viscera or a nasogastric tube is/are detected in the hemithorax. The treating physician must be aware that on the initial films, diaphragmatic rupture may present as atelectasis, hemothorax, pneumothorax, gastric dilatation, pulmonary contusion, intra-abdominal fluid, traumatic pneumatocele or congenital eventration.

Occasionally, in acute ruptures of the left hemidiaphragm, the nasogastric or orogastric tube placed during the resuscitative phase can be found coiled in the left hemithoracic cavity (Fig. 1). Other findings occasionally

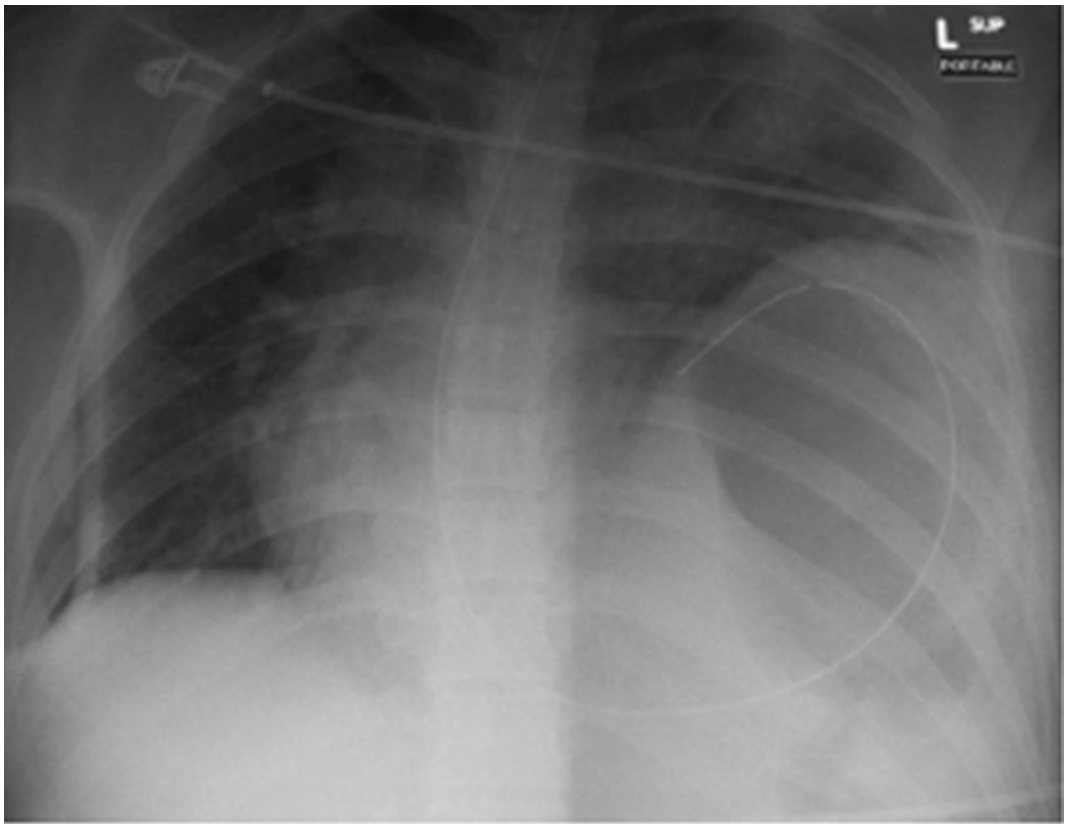

Fig. 1 A coiled nasogastric tube within the left hemithoracic cavity is pathognomonic for a rupture of the left hemidiaphragm (with permission from Dr. Petrone's personal archives)

identified radiographically are curvilinear shadows and air-fluid levels consistent with hollow viscera, such as colon or small bowel in the intra-thoracic space. These findings are pathognomonic for rupture of the diaphragm.

Computed tomography (CT) has become readily available in the assessment of the acutely injured patient. Currently, reconstructed images are routinely obtained in patients with chest radiographic findings suspicious of TDI, namely an abnormally elevated hemi-diaphragm. The use of multi-detector computed tomography (MDCT) with coronal and sagittal multiplanar reformation (MPR) has improved the accuracy of CT for the diagnosis of TDI.

Minimally invasive techniques such as laparoscopy and thoracoscopy are also part of the trauma surgeon's diagnostic armamentarium. Laparoscopy has been shown to be extremely useful to detect diaphragmatic injury in patients who have no other indications for laparotomy. Hemodynamically stable patients without abdominal symptoms with left thoracoabdominal penetrating trauma should undergo diagnostic laparoscopy for the diagnosis and repair of diaphragmatic injury from penetrating trauma [14, 15].

Although thoracoscopy is used s less frequently than laparoscopy, it has been shown to have a high sensitivity and specificity with an accuracy rate of 98–100% for the diagnosis of diaphragmatic injury in stable patients. Its main disadvantages include the amount of time it takes to place the patient in a thoracotomy position, it does not always allow repair of the diaphragm, and it always requires chest tube insertion even if negative. In addition, in the acute setting and with concerns for intra-abdominal injury, thoracoscopy is limited. These seem to be the reported reasons why thoracoscopy is used less frequently than laparoscopy. It is our opinion that the choice of laparoscopy or thoracoscopy for the diagnosis and treatment of diaphragmatic injury in the setting of penetrating trauma to the thoracoabdominal region depends on the familiarity and comfort level of the individual trauma surgeon with each modality [14, 16].

Surgical Management of Diaphragmatic Injuries

In patients suspected of having TDI, special attention must be paid to avoiding low placement of thoracostomy tubes, particularly if the CXR is suggestive of the presence of herniated viscera into the chest.

The majority of TDIs can be approached through a standard laparotomy. Full visualization of the diaphragm is required; exposure of the right hemi-diaphragm requires transection of the falciform ligament, whereas visualization of the left hemi-diaphragm requires gentle downward retraction of the spleen and greater curvature of the stomach, along with the central tendon of the diaphragm and the esophageal hiatus [17].

All herniated viscera must be reduced, with relocation to the original abdominal positions. After careful reduction and relocation of all herniated viscera, debridement should be undertaken of any devitalized diaphragmatic tissue. The defect is repaired with non-absorbable suture and an ipsilateral tube thoracostomy is usually performed under direct visualization. Diaphragmatic lacerations smaller than 5 cm should be repaired with non-absorbable suture, in vertical mattress fashion placed at approximately 1 cm from the edges, everting the diaphragmatic muscle toward the abdomen. In the cases of lacerations larger than 5 cm, we favor repair with a running interlocking suture with a non-absorbable suture, such as polypropylene. A diaphragmatic injury identified during

Table 1 American Association for the Surgery of Trauma-Organ Injury Scale (AAST-OIS) for Diaphragmatic Injuries [18]

Grade	Injury description
I	Contusion
II	Laceration ≤2 cm
III	Laceration 2–10 cm
IV	Laceration >10 cm with tissue loss ≤25 cm^2
V	Laceration with tissue loss >25 cm^2

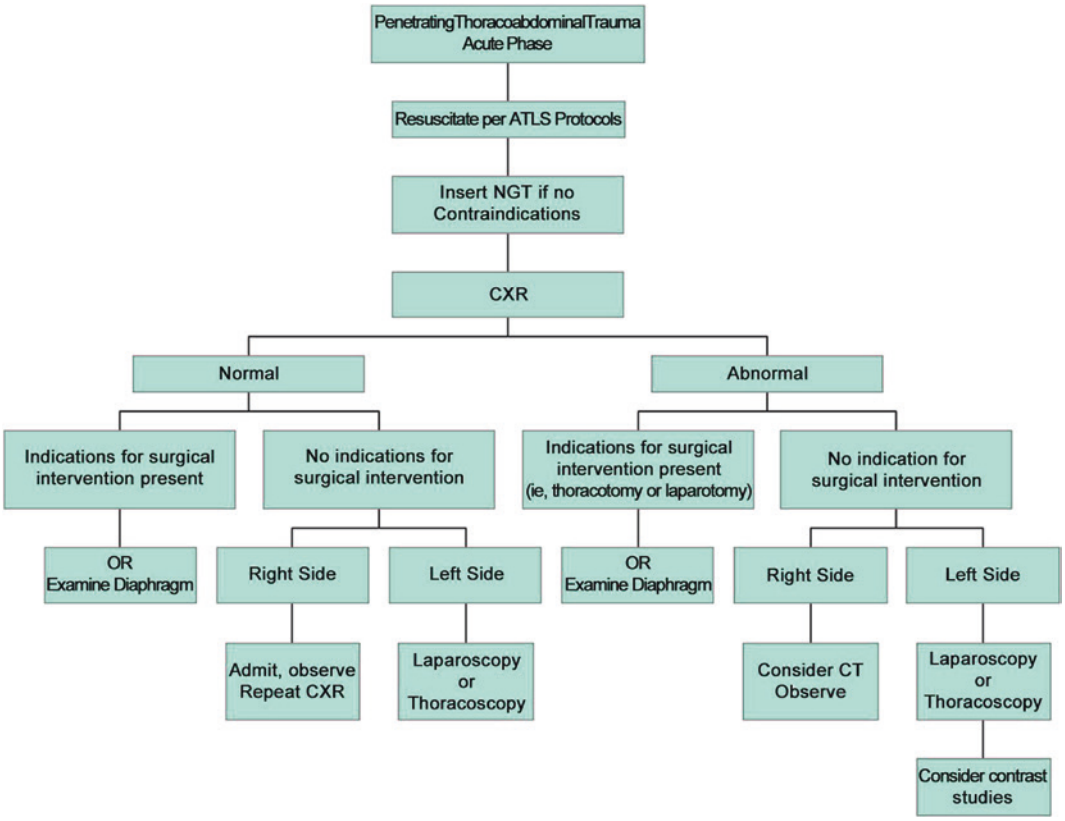

Fig. 2 Algorithm for penetrating thoracoabdominal trauma. ATLS, Advanced Trauma Life Support; CT, computed tomography; CXR, chest radiograph; OR, operating room; NGT, nasogastric tube (adapted and reproduced with permission from Asensio, Petrone and Demetriades [5])

laparoscopy or thoracoscopy may be repaired The anesthesiologist produces a forceful insufflation of the lung and the catheter is removed while simultaneously placing the final stitch in the diaphragm, The integrity of the diaphragmatic repair should be confirmed by having the anesthesiologist inflate the lung with large tidal volumes (15 ml/kg) followed by a Valsalva maneuver while the upper abdominal compartments are flooded with sterile saline [5].

Diaphragmatic lacerations smaller than 5 cm should be repaired with non-absorbable material, in vertical mattress fashion placed at approximately 1 cm from the edges, everting the diaphragmatic muscle. In the cases of lacerations larger than 5 cm we favor repair with a running interlocking suture with a non-absorbable suture, such as Prolene. A diaphragmatic injury identified during laparoscopy or thoracoscopy may be repaired laparoscopically or thoracoscopically as well.

Patients with TDIs associated with massive contamination of the pleural space from enteric content should undergo anterolateral thoracotomy followed by copious lavage to evacuate the contaminating material and placement of a 28 F right angle and 36 F straight chest tubes to drain the chest cavity and allow resorption of the pneumothorax, respectively. Penetration of the pericardial cavity with contamination requires lavage, keeping the pericardium open and placement of a pericardial drain.

While repair of acute TDIs can be accomplished through a thoracotomy, we believe that the trans-abdominal approach offers advantages over the thoracotomy approach with respect to

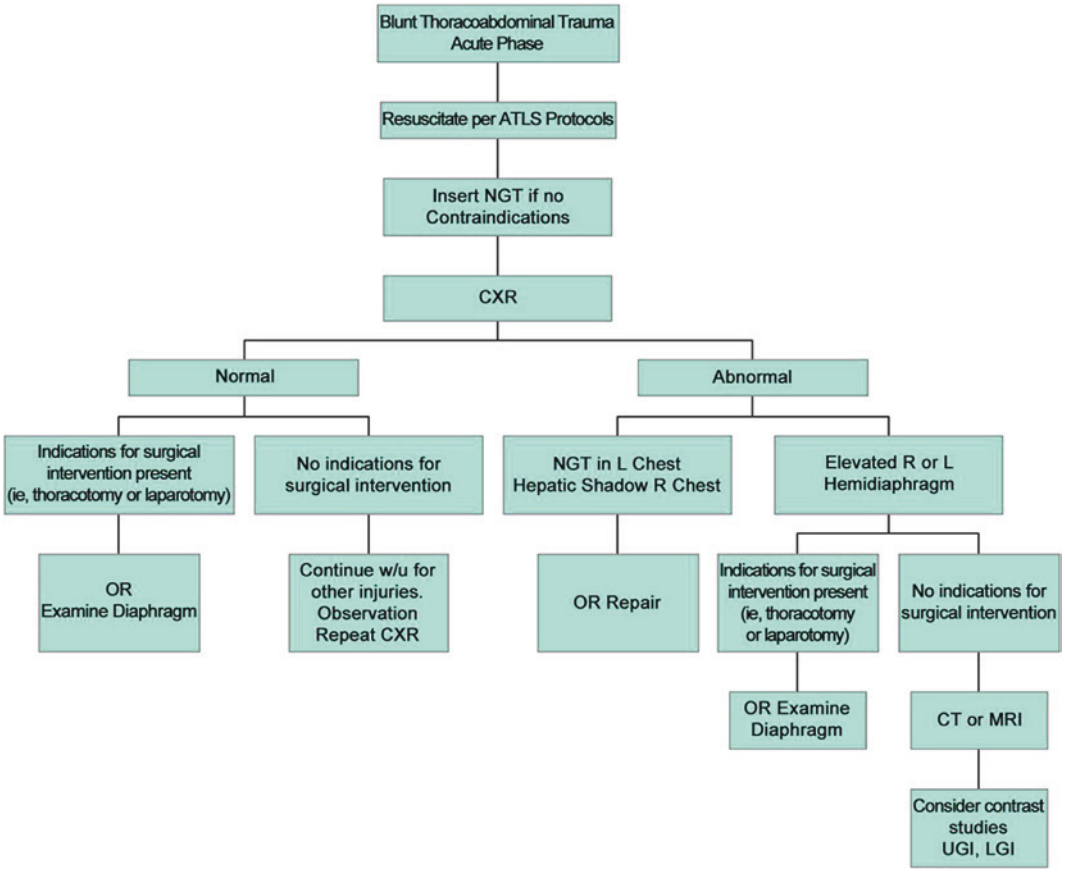

Fig. 3 Algorithm for blunt thoracoabdominal trauma. ATLS, Advanced Trauma Life Support; CT, computed tomography; CXR, chest radiograph; LGT, lower gastrointestinal; MRI, magnetic resonance imaging; NGT, nasogastric tube; OR, operating room; UGT, upper gastrointestinal (adapted and reproduced with permission from Asensio, Petrone and Demetriades [5])

the ease of reduction of herniated intra-abdominal viscera and with respect to the avoidance of missed intra-abdominal injuries.

Massive destruction of the diaphragm and chest wall can be caused from close-range (less than 3 yards) shotgun wounds. Patients who survive these devastating injuries present the operating surgeon with technical challenges that require complex reconstruction of the diaphragm and chest wall sometimes with staged procedures. Immediate reconstruction of the chest wall in patients with limited injury to the diaphragm that allows its use as a rotation flap can be accomplished by detaching the affected hemi-diaphragm from its anterior, lateral, and posterior attachments and by translocating it to a position above the chest wall defect. Following the repositioning of the diaphragm, by suturing it to the muscles at a higher level of intercostal space, the newly created abdominal wall defect can be repaired with a latissimus myo-cutaneous flap. Prosthetic non-absorbable mesh material can also be used to reconstruct the diaphragm, but its use is contra-indicated in the presence of contamination in either or both cavities, because of the associated risks of infection.

The authors recommend using the American Association for the Surgery of Trauma Organ Injury Scale (AAST-OIS) to grade

TDIs (Table 1) [18], as it has value as both a descriptive and research tool. Shown in Figs. 2 and 3 are the management algorithms for both penetrating and blunt thoracoabdominal trauma.

Morbidity and Mortality

The morbidity associated with traumatic diaphragmatic injuries can be subdivided into the morbidity attributable to the injury itself and the morbidity resulting from the surgical procedure required to repair the injury. The surgical morbidity includes suture-line dehiscence, and hemidiaphragmatic paralysis secondary to iatrogenic phrenic nerve injuries. The morbidity directly attributable to the injury itself includes respiratory insufficiency, and the development of empyema and sub-phrenic abscess. The morbidity associated with the missed diagnosis of TDIs includes respiratory compromise, most often secondary to atelectasis of the ipsilateral lung, pneumonia, bowel obstruction, strangulation and occasionally, perforation of herniated intra-abdominal viscera.

Mortality from diaphragmatic injuries is generally due to the associated injuries, and it can be as high as 51% in patients with four or more associated injuries and shock lasting longer than 30 minutes. The mortality rates are higher in series reporting TDIs from blunt diaphragmatic injuries reporting mortality rates of 27% and higher, as opposed to series of patients with TDIs from penetrating trauma, that report an average mortality of only 5%.

Self-study

1. Which diaphragmatic leaflet/s is/are most frequent affected?
   a. Right side
   b. Left side
   c. Bilateral
2. Which statement is true?
   a. There are not physical findings most of the time.
   b. MRI is the imaging study of choice to arrive to the diagnosis.
   c. Mortality from diaphragmatic injuries is generally due to the associated injuries.

Correct answers
Question 1: Answer b.
Question 2: Answer c.

References

1. Gray H. Muscles and fasciae of the thorax. In: Pick TP, Howden R, editors. Gray's anatomy. New York, NY: Bounty Books; 1977. p. 350–6.
2. Bryant LR, Morgan CV Jr. Chest wall, pleura, lung, and mediastinum. In: Schwartz SI, editor. Principles of surgery. 4th ed. New York, NY: McGraw-Hill; 1984, p. 602–732.
3. Marchand P. A study of the forces productive of gastroesophageal regurgitation and herniation through the diaphragmatic hiatus. Thorax. 1957;12(3):189–202.
4. Hood RM. Traumatic diaphragmatic hernia. Ann Thorac Surg. 1971;12(3):311–24.
5. Asensio JA, Petrone P, Demetriades D. Injury to the diaphragm. In: Moore EE, Feliciano DV, Mattox KL, editors. Trauma. 5th ed. New York, NY: McGraw-Hill; 2004, p. 613–35.
6. Calhoon JH, Grover FL, Trinkle JK. Chest trauma. Approach and management. Clin Chest Med. 1992;13(1):55–67.
7. Søreide K, Krüger AJ, Vårdal AL, Ellinqsen CL, Søreide E, Lossius HM. Epidemiology and contemporary patterns of trauma deaths: changing place, similar place, older face. World J Surg. 2007;31(11):2092–103.
8. Ties JS, Peschman JR, Moreno A, Mathiason MA, Kallies KJ, Martin RF, Brasel KJ, Cogbill TH. Evolution in the management of traumatic diaphragmatic injuries: a multicenter review. J Trauma Acute Care Surg. 2014;76(4):1024–8.
9. Holm A, Bessey PQ, Aldrete JS. Diaphragmatic rupture due to blunt trauma: morbidity and mortality in 42 cases. South Med J. 1988;81(8):956–62.
10. Voeller GR, Reisser JR, Fabian TC, Kudsk K, Mangiante EC. Blunt diaphragm injuries. A five-year experience. Am Surg. 1990;56(1):28–31.
11. Smithers BM, O'Loughlin BO, Strong RW. Diagnosis of ruptured diaphragm following blunt trauma: results from 85 cases. Aust N Z J Surg. 1991;61(10):737–41.
12. Fair KA, Gordon NT, Barbosa RR, Rowell SE, Watters JM, Schreiber MA. Traumatic diaphragmatic injury in the American College of Surgeons National Trauma Data Bank: a new examination of a rare diagnosis. Am J Surg. 2015;209(5):864–9.
13. Murray JA, Demetriades D, Asensio JA, Cornwell EE 3rd, Velmahos GC, Belzberg H, Berne TV.

Occult injuries to the diaphragm: prospective evaluation of laparoscopy in penetrating injuries to the lower left chest. J Am Coll Surg. 1998;187(6):626–30.
14. Petrone P, Asensio JA. Thoracoabdominal penetrating injuries. In: Juambeltz C, Machado F, Trostchansky J, editors. Trauma. The disease of the new millennium. Montevideo, Uruguay: Arena Editorial; 2005, p. 475–80.
15. Asensio JA, Petrone P. Diaphragmatic injury. In: Cameron JL, editor. Current surgical therapy. Elsevier Mosby Co: Philadelphia, PA; 2004. p. 946–55.
16. Petrone P, Asensio JA, Marini CP. Diaphragmatic injuries and post-traumatic diaphragmatic hernias. Curr Probl Surg. 2017;54(1):11–32.
17. Petrone P, Leppäniemi A, Inaba K, Søreide K, Asensio JA. Diaphragmatic injuries: challenges in the diagnosis and management. Trauma. 2007;9(4):227–36.
18. Moore EE, Malangoni MA, Cogbill T, Shackford SR, Champion HR, Jurkovich GJ, McAninch JW, Trafton PG. Organ injury scaling. IV: thoracic vascular, lung, cardiac, and diaphragm. J Trauma. 1994;36(3):299–300.
19. Scharff JR, Naunheim KS. Traumatic diaphragmatic injuries. Thorac Surg Clin. 2007;17(1):81–5.