

# Chapter 19

## IOL Implantation in the Absence of Capsular Support



### Secondary IOL After Initial Aphakia: Ciliary Sulcus Fixation and IOL Placement in Absence of Capsular Support

Jan Tjeerd de Faber and Martha Tjon-Fo-Sang

The use of an intraocular lens (IOL) in pediatric cataract surgery became common practice in the 1990s. Refined surgical techniques, technology, and IOL material advancements together decreased complication rates making IOL placement a more viable option. However, in very young children, primary implantation of an IOL remains controversial because of the ongoing growth of the eye, increased rate of complications, adverse events, and additional associated surgeries [1, 2]. Thus, the clinical decision is often made to keep the eye aphakic after lensectomy and to correct the aphakia with either contact lenses or spectacles. Secondary implantation can then ideally be considered after the age of 2 or at any moment when contact lens intolerance occurs. In patients with adequate capsular support, the IOL may be placed in the bag or the sulcus, in front of the remnants of the anterior and posterior capsule. In cases of trauma or inadequate capsular or zonular support (e.g., Marfan's syndrome), IOL implantation outside the bag may be necessary.

#### Artisan® Iris-Fixated Anterior Chamber IOL

When there is inadequate capsular support for an IOL, options include the use of the Artisan® (Ophtec, Groningen, the Netherlands) iris-fixated IOL in the anterior chamber (AC) [3] and scleral-sutured or scleral-glued posterior chamber IOLs. The Artisan® iris-fixated IOL was first designed by Jan Worst in 1979 based on a

---

J. T. de Faber (✉) · M. Tjon-Fo-Sang

The Rotterdam Eye hospital, Department of Pediatric ophthalmology and Strabismus, Rotterdam, The Netherlands

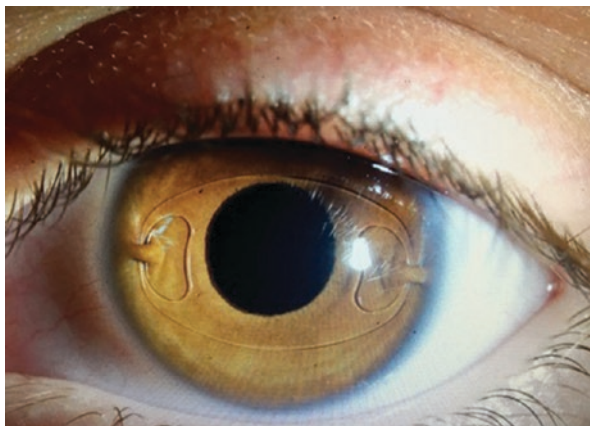e-mail: [j.defaber@oogziekenhuis.nl](mailto:j.defaber@oogziekenhuis.nl); [M.tjon@oogziekenhuis.nl](mailto:M.tjon@oogziekenhuis.nl)

© Springer Nature Switzerland AG 2020

C. L. Kraus (ed.), *Pediatric Cataract Surgery and IOL Implantation*,  
[https://doi.org/10.1007/978-3-030-38938-3\\_19](https://doi.org/10.1007/978-3-030-38938-3_19)

193

**Fig. 19.1** Artisan Aphakic IOL with good centration and adequate enclavation of nasal and temporal peripheral iris 12 years after implantation

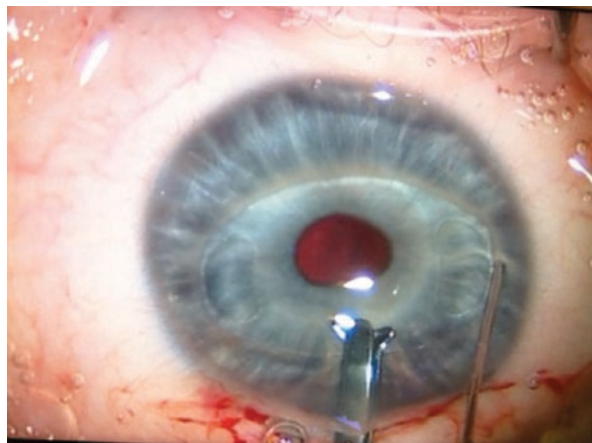


concept that the peripheral iris stroma is almost immobile and therefore could serve as a fixing point in the eye. The haptics of the Artisan® IOL are shaped like a ring with an incision site. The lens is enclavated by passing the iris through this break in the haptics. Attached to the peripheral iris, the lens is far away from the angle of the anterior chamber and the corneal endothelium, reducing problems associated with the chamber angle and limiting contact with endothelial cells. A major advantage of the Artisan® IOL over a scleral-sutured or scleral-glued PC IOL is that it can be easily and safely explanted or exchanged should there be a large myopic shift due to excessive axial elongation (Fig. 19.1).

Before implanting an Artisan® IOL, the surgeon should take a moment and anticipate the enclavation sites of the haptics. This assists the surgeon in selecting the site of the paracenteses, which in these cases are made obliquely to allow access to the peripheral iris. A 5.6 mm main incision is created, which most often is created superiorly and tunneled as the IOL is rigid and unable to be folded to allow passage through a smaller incision. The IOL is inserted through the main incision and while one hand stabilizes the IOL over the center of the pupil, the other uses enclavation forceps or needle to pass the midperipheral iris tissue through the slit of the haptics, making sure that an adequate amount of iris tissue is enclavated (Fig. 19.2).

It is the authors' preference to fixate the lens on the anterior surface of the iris because this enables easier monitoring of the IOL's stability and fixation during slit lamp examination. Additionally, if the IOL was to dislocate it is easier to locate and retrieve in the anterior chamber than in the vitreous. Some surgeons prefer to fixate the Artisan® on the posterior surface of the iris arguing that the IOL is then physically farther from the cornea, creating less stress on the corneal endothelium. If fixating on the anterior surface of the iris, the convex side of the lens must face up and the haptics angulate posteriorly to prevent pseudophakic glaucoma. When using it on the posterior surface of the iris, the convex side should be facing the vitreous (Fig. 19.3). This is only feasible when a full vitrectomy has been performed, because a posterior fixation will interfere with the vitreous base and the peripheral retina risking retinal tears or detachments.

**Fig. 19.2** While one hand holds the Artisan over the central pupil, the other hand enclavates iris tissue between the haptics. One should select the desired spot on the iris before starting the enclavation movement



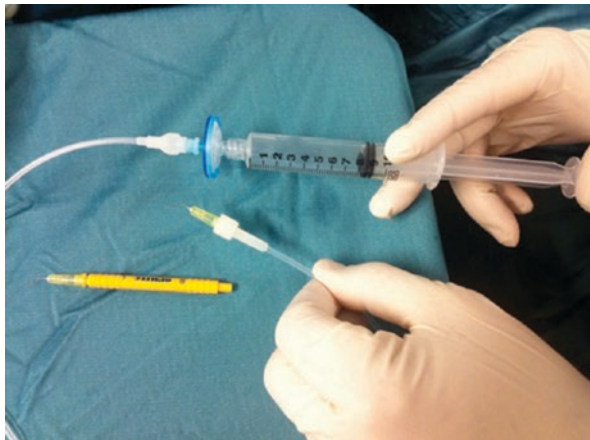**Fig. 19.3** In posterior iris fixation, concave angulation facilitates enclavation of posterior iris tissue



In extremely difficult cases where the iris tissue is stiff and so flat that grasping it for enclavation presents a significant challenge, the manufacturer designed the VacuFix enclavation system. This consists of two handles, which are connected to the phaco-machine, and when the VacuFix contacts the iris, the suction allows for an easier grasp of iris tissue and lift of the fold of iris through the slot of the haptic. When the VacuFix system is not available the enclavation needle attached to a 1 or 3 cc syringe with extension tubing (Fig. 19.4) can be employed. During enclavation, an assistant is instructed to pull back on the plunger of the syringe, creating a vacuum, enabling the surgeon to aspirate strands of iris tissue to facilitate enclavation.

For all cases where an iris claw lens is used, an iridotomy or iridectomy is essential in order to prevent pseudophakic pupillary block glaucoma, especially in eyes that have only had a core vitrectomy. Iridotomies can be performed during surgery or with a neodymium-yttrium-aluminum-garnet (Nd:YAG) laser prior to surgery.

**Fig. 19.4** Connecting the enclavation needle with an extension tube to a syringe will add a suction function to the needle to facilitate enclavation



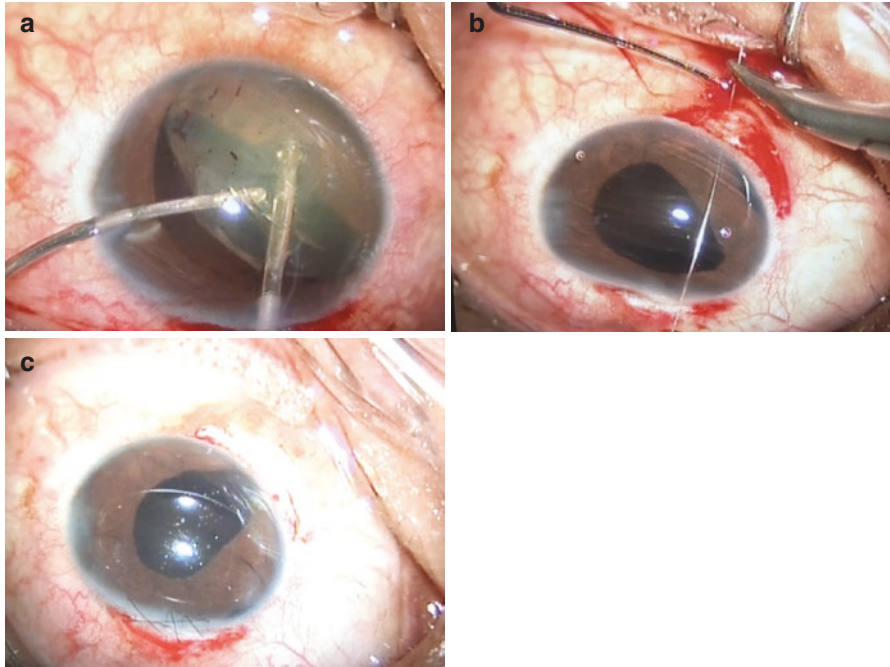
## Case 1

A 12-year-old male presented 1 week following a trauma in the left eye related to a firework injury. Presenting visual acuity (VA) was 20/800 in the affected eye and 20/20 in the unaffected. A red reflex was visualized, but view to the fundus was difficult; B-scan showed an attached retina with some blood in the vitreous cavity. IOP was around 20 mmHg. Due to the blast the entire lens had luxated into the anterior chamber. Additionally, the iris showed iridodialysis over 3'clock hours (Fig. 19.5). There were no corneal lacerations or scleral breaks due to trauma. Medical history of the child was unremarkable.

In this case, initial management consisted of aspiration of the lens followed by an anterior vitrectomy. Subsequently, the pupil was contracted with an intracameral miotic agent and the AC again deepened with a cohesive viscoelastic device. The ruptured iris was reattached with two Prolene 10.0 sutures to the iris root in the angle of the anterior chamber. Despite iris trauma, an Artisan® lens was able to be enclavated horizontally.

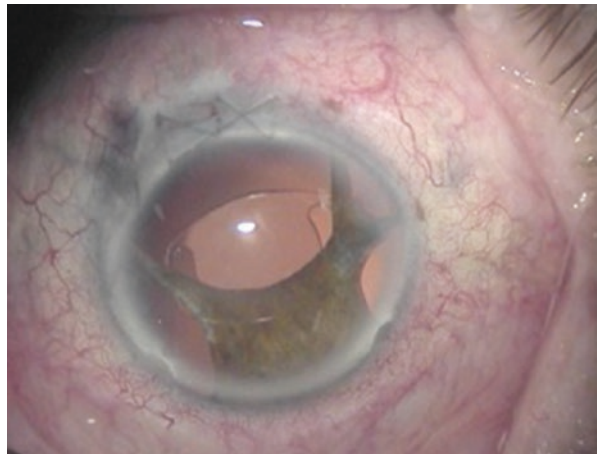
Following the procedure, the child did well with a postoperative month one VA of 20/200 due to a macular scar caused by a choroidal rupture. No further complications or surgeries were required.

**Comment** The Artisan® IOL can be successfully implanted in cases with limited available iris tissue, even after trauma. The Artisan® needs very little support as long as there is a large enough iris bite through the fibrous strands of the iris and the iris is not tremulous. After a trauma the iris can be damaged or a traumatic mydriasis can make enclavation challenging but not impossible as seen in Fig. 19.6. It is also possible to enclavate the lens during primary lensectomy, allowing immediate best possible refractive correction and potential acuity.



**Fig. 19.5** The crystalline lens is luxated into the anterior chamber following blast injury with fireworks. It is aspirated (a). Iris dialysis of 3'clock hours is repaired using 2 10-0 Prolene sutures to the iris root (b). An iris claw lens is enclavated to the remaining iris and the wound closed with running 10-0 nylon (c)

**Fig. 19.6** Traumatic cataract and mydriasis after firework injury follow-up picture after 8 years, note how little enclavation room there is used to bridge the traumatic wide pupil



## Artisan® IOL in Cases of Subluxated Lenses Due to Marfan's Disease

In pediatric cases with lens subluxation the decision for surgery is weighed against the risk of amblyopia. When the lenticular astigmatism can no longer be corrected by spectacles and the VA regresses despite occlusion therapy, the risk of amblyopia is high and surgery may be recommended. At this stage, patients are most often older than two and IOL implantation can be pursued instead of the use of aphakic contact lenses postoperatively.

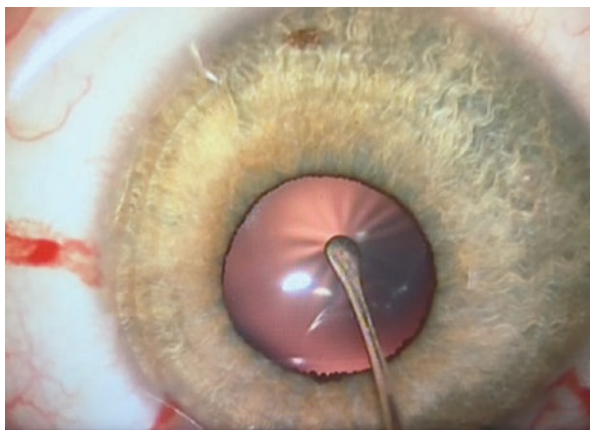
During surgery, the amount of zonular support can be assessed by using a blunt instrument, such as a sweep, to press down on the anterior capsule. When there is lack of zonular support despite the use of a viscoelastic device, radial folds will appear on the anterior capsule. This is pathognomonic for weak zonular fibers (Fig. 19.7).

Opening the anterior capsule is more difficult due to the loose zonular fibers. Inserting an iris or capsular retractor in the rhexis helps to pull the lens toward the loose zonular fibers, stabilizing the lens and facilitating a properly sized capsulorhexis so the lens material can safely be aspirated (Fig. 19.8).

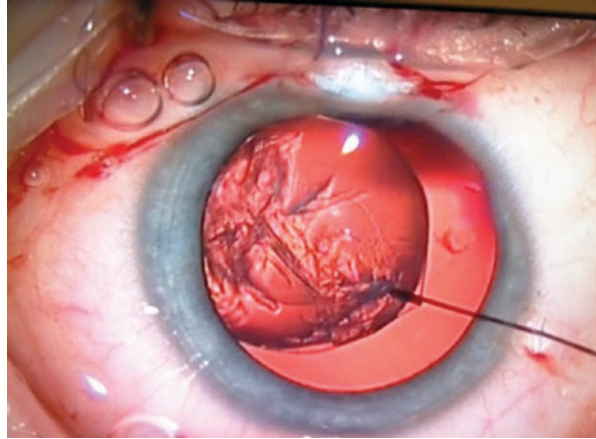
Once the bag is empty it can be carefully removed using smooth forceps ensuring the breakage of the intact zonular fibers without rupturing the capsule or disrupting the anterior hyaloid membrane. In the event of vitreous loss, an anterior vitrectomy should be performed; however, in our series we were able to spare the anterior hyaloid membrane in 72% of the cases, precluding the need for an anterior vitrectomy (Fig. 19.9).

Next, the pupil is contracted with a miotic agent (e.g., pilocarpine or Miochol) and an Artisan® IOL can be inserted through the main wound and placed horizontally on the iris.

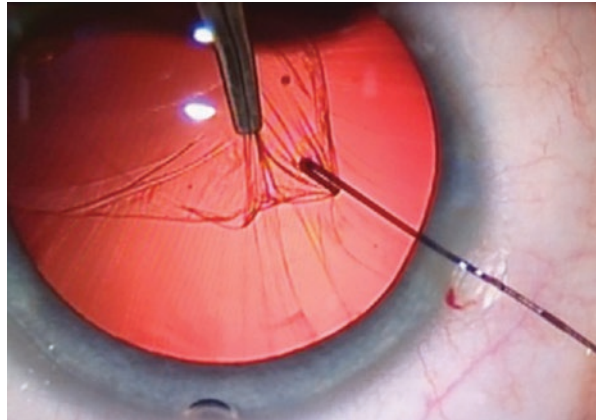
**Fig. 19.7** Pushing with a blunt instrument on the anterior capsule shows radial folds indicating weak zonular fibers in a 3-year-old child with lens subluxation due to Marfan's disease



**Fig. 19.8** An iris hook is used to pull the rhexis more to the center of the pupil. This facilitates the aspiration of lens cortex behind the iris



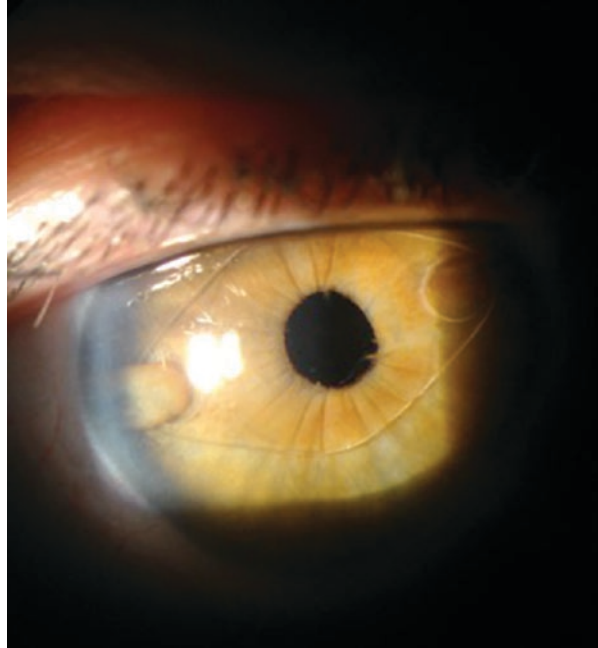
**Fig. 19.9** With a forceps the rhexis of the bag is gently pulled to the wound giving the remaining zonular fibers time to break without rupturing the hyaloid membrane. The intact bag is pulled out of the eye through the main wound



## Long-Term Results

There are numerous studies on the long-term effect of the Artisan® Aphakia IOL on the endothelial cell density (ECD) in children. In a retrospective study, it was found that the mean endothelial cell counts after 10 years of follow-up was comparable to mean normal ECD in a same age group of children reported in literature [4]. Our own patient population who have received Artisan® IOLs more than 25 years ago maintain excellent ECD counts and are now requesting the same procedure for their own children with Marfan's disease (Fig. 19.10).

**Fig. 19.10** 25 years after implantation of first type of Artisan Aphakic IOL



## Complications of Artisan IOL

Complications of the Artisan® aphakia IOL include those that occur in the immediate perioperative period, as well as longer postoperative period. Decentration can occur early or late following surgery. Careful enclavation is the key to prevent decentration of the IOL. Haptics may dislocate with blunt trauma and require urgent re-enclavation. Fortunately in approximately 95% of the cases only one haptic is involved and the patient almost universally notices an immediate drop in VA as well as discomfort when the cornea is intermittently touched by the loose haptic.

Hypemias occur intraoperatively or in the immediate postoperative period from both manual separation of adhesions before implantation or inadvertent tearing of the iris. Pigmentary dispersion can result from multiple attempts to grasp the iris. If the iridotomy or iridectomy is inadequate, pupillary block leads to acute glaucoma. If this occurs, additional peripheral iridectomies with a YAG laser should be attempted. When dealing with a shallow anterior chamber, an optimal location to place the iridectomy would be just between the claw and the optic where the iris is stretched and not in contact with corneal endothelium.



## Angle Supported Anterior Chamber IOLs (ACIOL)

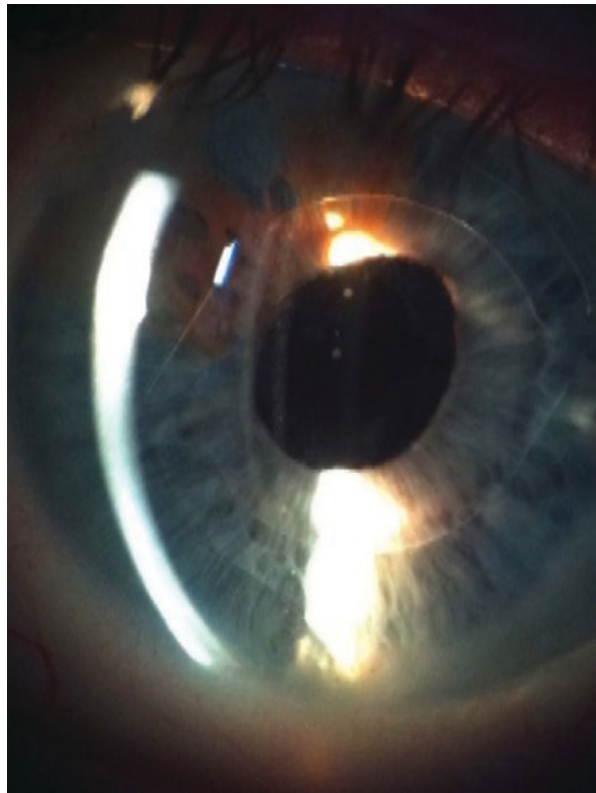
The placement of ACIOL haptics in the angle of the anterior chamber (Fig. 19.11) creates a risk of trabecular meshwork damage, angle fibrosis, and even peripheral anterior synechiae formation [5]. This creates an obstruction to aqueous outflow, whereby IOP can increase resulting in secondary glaucoma. Therefore, it is the authors' recommendation that angle-supported anterior chamber lenses not be used as a secondary implant in children.

### *Posterior Chamber Intraocular Lenses*

#### **Iris-Sutured Lenses**

Several surgeons have described techniques to suture posterior chamber IOLs to the iris. However, one of the reported complications is chafing of the iris. Placing sutures within iris tissue holding an IOL can trigger chronic inflammation because

**Fig. 19.11** Anterior chamber angle-supported IOL, note slightly distorted pupil and loss of iris pigment



of the mobility of iris tissue. The location and the tightness of the sutures are two important considerations that can increase the likelihood of chafing. The central iris is the most mobile – the more central the suture placement, the more inflammation is to be expected. It can also create an irregular pupil with peaking at the sites of suturing. Excessively tight sutures or excessively large bites of iris can cause peaking of the pupil or bunching of the iris, resulting in increased contact of iris and IOL and, thus, increased chafing.

### **Scleral-Sutured Lenses**

Scleral-sutured PC IOLs are also an option to correct aphakia in cases with absent capsular support. However, IOL tilt or displacement into the anterior vitreous has been reported as a result of suture loosening or breakage. In the past, polypropylene sutures have been used, but these are prone to biodegradation after 7–10 years [6, 7]. Gore-Tex sutures seem to have a longer lifetime and are therefore now widely used [8].

### **Fibrin-Glued PC IOL**

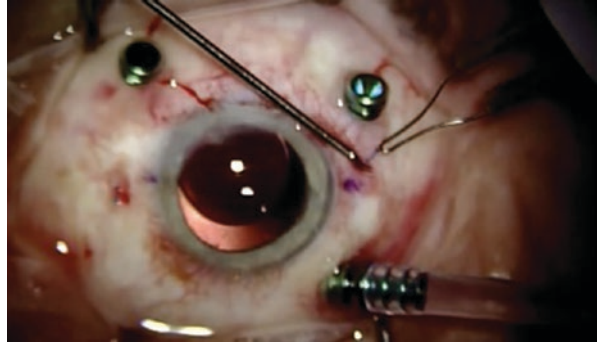
This is a technique using fibrin glue to embed the flexible prolene haptics of a multipiece IOL under two scleral flaps. After the scleral flaps have been made, the haptics of the PC IOL are externalized and attached to the scleral bed with glue. Then, the flap and the conjunctiva are also closed with fibrin glue. Adopters of this technique argue that the fibrin glue provides good flap closure and IOL centration and stability without suture-related complications [9]. We have no experience with this technique in children.

### **Flanged Intrasceral PC IOL Fixation**

In 2017 Yamane [10] described fixation of a PC IOL by making a flange at the end of the haptic. After two scleral tunnels have been made, the prolene haptics of a multipiece IOL are externalized and cauterized to make a flange of the haptics (Fig. 19.12). The flanges of the haptics are subsequently pushed back where they become embedded in the scleral tunnel due to their increased thickness. This allows fixation and centration of the PC IOL without the use of glue or sutures. This procedure can only be performed in an eye that has undergone vitrectomy combined with preventive laser coagulation of the peripheral retina.

Implanting an IOL has become the standard of care in many cases of pediatric cataract surgery. Although there have been many technical advancements since Sir Harold Ridley first implanted his lens, we still prefer to place the lens as he did, in

**Fig. 19.12** The tunneled prolene haptic is heated at the end. This will create a flange which will hold the IOL at the entrance of the tunnels on opposing sides of the eye



the capsular bag. Unfortunately, it is not always possible to follow this approach due to either preexisting conditions or surgical difficulties. Many procedures have been described to allow IOL implantation in an eye without capsular support. Each of these techniques differs with regard to technical difficulty, potential postoperative problems, and long-term complications. Improvements to implant design and material development have made anterior chamber lenses a more attractive and feasible alternative.

## References

1. Por YM, Lavin MJ. Techniques of intraocular lens suspension in the absence of capsular/zonular support. *Surv Ophthalmol.* 2005;50:429–62.
2. Wilson ME, et al. In-the-bag secondary intraocular lens implantation in children. *J AAPOS.* 1997;3:350–5.
3. Pol van der BEA, Worst JGF. Iris-claw intraocular lenses in children. *Doc Ophthalmol.* 1996;22:29–35.
4. Sminia ML, et al. Long term follow up of corneal endothelium after aphakic iris fixated IOL implantation for bilateral cataract in children. *J Cataract Refract Surg.* 2011;37: 866–72.
5. Ellerton, et al. Secondary implantation of open-loop, flexible anterior chamber intraocular lenses. *J Cataract Refract Surg.* 1996;22:951–4.
6. Solomon, et al. Incidence and management of complications of transsclerally sutured posterior chamber lenses. *J Cataract Refract Surg.* 1993;19:488–93.
7. Buckley EG. Scleral fixated (sutured) posterior chamber lens implantation in children. *J AAPOS.* 1999;3:289–94.
8. Khan MA, Gupta OP, Smith RG, et al. Scleral fixation of intraocular lenses using Gore-Tex suture: clinical outcomes and safety profile. *Br J Ophthalmol.* 1996;100:638–43.
9. Agrawal DA, Kumar S, Jacob C, Baid A, Agrawal S. Fibrin glue-assisted sutureless posterior chamber intraocular lens implantation in eyes with deficient posterior capsules. *J Cataract Refract Surg.* 2008;34:1433–8.
10. Yamane S, Sato S, Maruyama-Inoue M, Kadosono K. Flanged intrascleral intraocular lens fixation with double-needle technique. *Ophthalmology.* 2017;124(8): 1136–42.

***Recommended Books***

Budo CJR. The Artisan lens. *Highlights Ophthalmol Int.* 2004;1:0–183.

Wilson ME, Trivedi RH, Pandey SK. *Pediatric cataract surgery.* Philadelphia: Lippincott Williams and Wilkins; 2005.

Lloyd IC, Lambert SR, editors. *Congenital cataract.* Cham: Springer International Publishing; 2016.