



# General Principles of Talus Fractures

# 3

David Hubbard and James Richman

## Anatomy

The talus is divided into three parts, the head, neck, and body, and two processes, lateral and posterior. It has five articular surfaces, all of which have a weight-bearing function. The surfaces of the talus are illustrated in Fig. 3.1. Two-thirds of the talus is covered with articular cartilage, and no tendons insert or originate on it [2].

The head of the talus articulates with the navicular. The body includes the dome of the talus, which articulates with the ankle joint above. The inferior surface of the talar body is concave in the long axis and articulates with the posterior facet of the calcaneus. The neck of the talus does not articulate with the ankle or calcaneus, and it does not have articular cartilage. It sits atop the sinus tarsi laterally and the sustentaculum tali medially [1].

The talar neck is angled at a mean of 24 degrees plantaromedial with respect to the talar

dome [2]. It is the weakest portion of the talus because it has both the smallest cross-sectional area and the most porosity due to its extensive vascular ingrowth. The medial border of the talar neck directly aligns with the medial border of the talar body, whereas the lateral cortex of the talar neck is concave and flares as one moves posterior to the lateral process. The talocalcaneal ligament, one of the main stabilizers of the subtalar joint, attaches on the inferior talar neck.

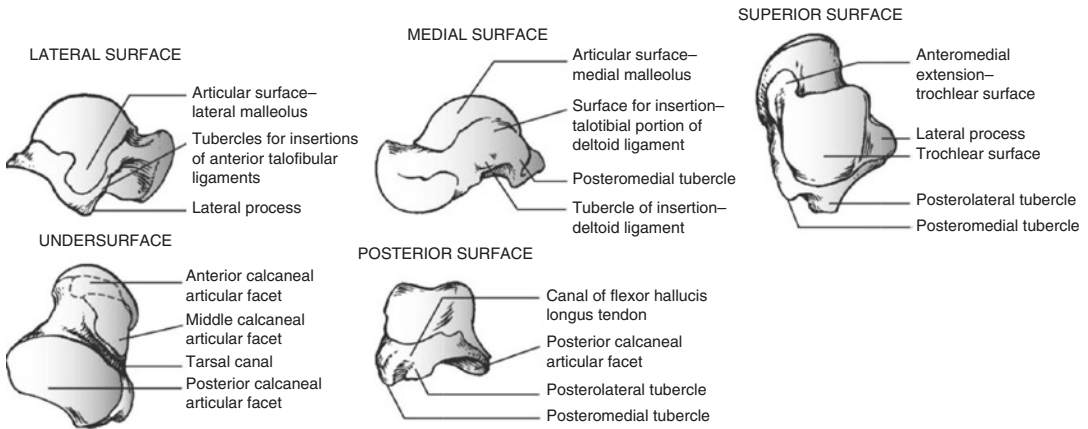
The talar body's superior surface is completely covered with articular cartilage. The talar body's shape is that of a large trapezoidal dome. The transverse diameter is greater anteriorly than posteriorly, meaning maximal congruence of the ankle joint occurs when the talus is dorsiflexed. The medial surface of the talar body articulates with the medial malleolus. The posterior inferior portion of this surface has a large oval area for insertion of the deep deltoid ligament.

The lateral surface of the talar body articulates with the distal fibula. The most lateral portion of this surface is the lateral process of the talus. The lateral process is the lower margin of the talar articular surface with the fibula. It also articulates with the anterolateral corner of the posterior facet of the calcaneus. Because of this boney architecture as well as its ligamentous attachments for the anterior and posterior talofibular ligaments, it is important in the stability of the ankle mortise and subtalar joint.

---

D. Hubbard  
Orthopaedic Trauma Service, J.W. Ruby Memorial  
Hospital, West Virginia University,  
Morgantown, WV, USA  
e-mail: [dhubbard@hsc.wvu.edu](mailto:dhubbard@hsc.wvu.edu)

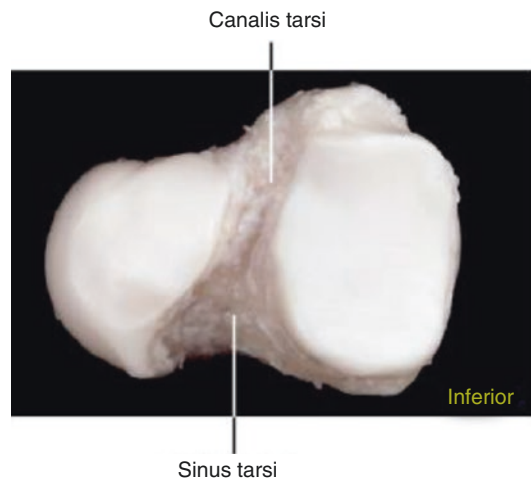
J. Richman (✉)  
MultiCare Orthopedics & Sports Medicine,  
Tacoma, WA, USA  
e-mail: [jhrichman@multicare.org](mailto:jhrichman@multicare.org)



**Fig. 3.1** Overview of the bony surfaces of the talus [1]

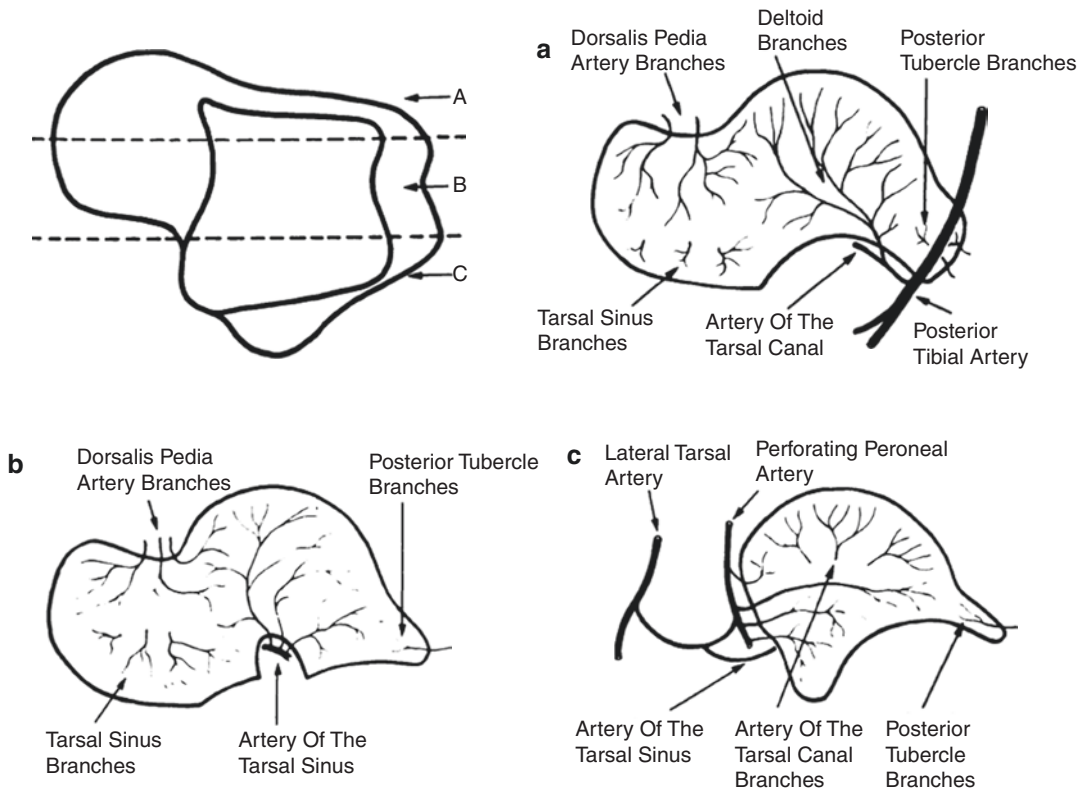
The posterior process of the talar body includes posterolateral and posteromedial tubercles that flank the sulcus for the flexor hallucis longus tendon. The posterolateral tubercle is larger and has an articular segment with the posterior facet of the calcaneus. The tubercle may either be oversized or appear as an accessory bone known as an os trigonum in up to 50% of the population. An os trigonum may be present unilaterally or bilaterally and may be fused to the talus or calcaneus [3]. The posteromedial tubercle also varies in size and is important for attachment of the talotibial component of the deltoid ligament.

The talar head is a convex round surface. It is rotated an average of 45 degrees laterally relative to the axis of the talar neck [4]. It too is covered by articular cartilage. The plantar spring ligament passes inferiorly to the talar head connecting the calcaneus to the navicular. The talar head forms its main articulation with the navicular in an area called the acetabulum pedis. Detailed by Sarrafian, it is composed of the anterior and middle calcaneal sections of the talus and linked to the navicular via the inferior and superomedial calcaneonavicular ligaments. The calcaneonavicular segment of the bifurcate ligament becomes the lateral hinge. The medial side is supported by the spring ligament and posterior tibial tendon.



**Fig. 3.2** Sulcus tali [5]

On the undersurface of the talus between the posterior and anterior/middle facets runs a deep groove called the sulcus tali (Fig. 3.2) It runs 40 degrees from anterolateral to posteromedial [2]. The sulcus is broader laterally and is thus referred to as the sinus tarsi, whereas medially it is more narrow and referred to as the tarsal canal. This sulcus gives rise to the strong talocalcaneal interosseous ligament as well as arteries of the tarsal canal and sinus tarsi, which provide the blood supply for two-thirds of the talar body.



**Fig. 3.3** The blood supply of the talus based on anatomic location [6]. (a) The dorsal view of the blood supply to the medial one third of the talus. (b) The dorsal view of the

blood supply to the middle one third of the talus. (c) The dorsal view of the blood supply to the lateral one third of the talus

## Blood Supply

The blood supply to the talus is diffuse and arises from branches of the posterior tibial artery, the dorsalis pedis artery, and the peroneal artery (Fig. 3.3). The artery of the tarsal canal arises from the posterior tibial artery about 1 cm proximal to the origin of the medial and lateral plantar arteries. It passes between the sheaths of the flexor digitorum longus and flexor hallucis longus tendons to enter the tarsal canal. In the canal, the artery is dorsal. Branches into the body are given off in the canal with the largest branch entering the middle of the body. The artery of the tarsal canal anastomoses with the artery of the tarsal sinus in the tarsal canal. The deltoid branch of the artery of the tarsal canal arises about 5 mm from its origin. The deltoid branch runs between

the talotibial and talocalcaneal parts of the deltoid ligament. It supplies the medial surface of the body and anastomoses with anterior tibial artery branches over the neck and talus [7].

The artery of the tarsal sinus generally originates from an anastomotic loop between the lateral tarsal branch of the dorsalis pedis artery and the perforating peroneal artery. It gives off a few branches to the talar head and then enters the tarsal canal. In the tarsal canal, it gives off branches to the talar body before anastomosing with the artery of the tarsal canal [8].

The peroneal artery gives off small branches that join the calcaneal branches of the posterior tibial artery to form a plexus over the posterior process of the talus. Of note, in some patients, the artery of the tarsal sinus is a branch of the peroneal artery rather than the dorsalis pedis artery.

The head of the talus is supplied directly from branches of the dorsalis pedis artery on its dorsal medial portion and from the artery of the tarsal sinus on its plantar lateral portion. The most important blood supply to the body of the talus comes from the anastomotic artery between the artery of the tarsal canal and the artery of the tarsal sinus. This artery gives about five main branches into the body that supply almost all of the middle and lateral thirds of the talar body. The blood supply to the medial third of the body come from the deltoid branches, which enter the body on its medial periosteal surface.

### Injury Mechanism

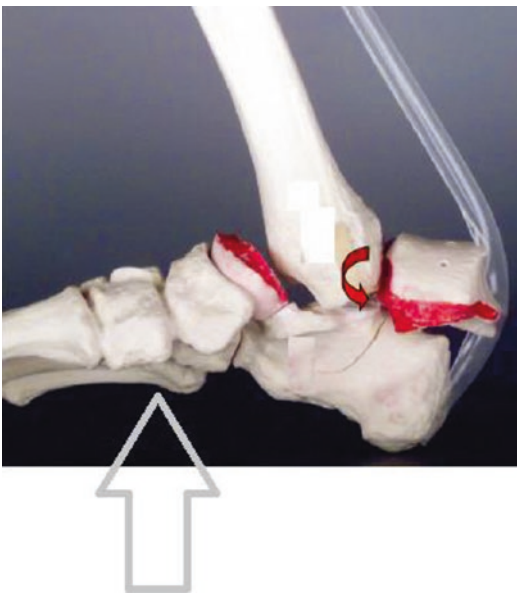
Talar neck fractures are high-energy injuries that result from a dorsally directed force applied to the plantar surface of the foot distal to the talus (Fig. 3.4). The ankle is generally in neutral position. If the dorsally directed force is strong enough, it can disrupt the posterior and interosseous talocalcaneal ligaments and cause the calcaneus to dislocate anteriorly either lat-

erally or medially. The talar head would be displaced dorsally with respect to the neck. Further dorsal force can lead to complete disruption of the posterior ankle capsule, resulting in the talar body extruding posterior medial between the Achilles tendon and the medial malleolus. The medial neurovascular bundle is infrequently injured as it is shielded by the flexor hallucis muscle belly [9]. Forced supination of the foot is another less frequent mechanism for talar neck fractures and is more often associated with combined talar neck/medial malleolus fractures [10]. The medial malleolus fracture is usually vertical, indicating a compression force is imparted onto the medial side of the talus. Accordingly, talar neck fractures from supination have comminution dorsomedially. Supination is thought to be caused by a contracted Achilles tendon, which imparts a supination stress on the foot and leads to compression on the medial side [11].

Talar body fractures are intra-articular injuries involving both the ankle and subtalar joints. The injury generally results from high-energy axial compression. They may also occur due to the shear mechanism described above for talar neck fractures (Fig. 3.4). The dorsally directed plantar force distal to the talus may lead to a more posterior fracture that involves the talar body rather than the neck [9].

Talar head fractures occur via other compression or shear forces. Compression injuries are the results of the talar head experiencing an axial load against a plantarflexed foot. This force causes the navicular to compress against the talar head and usually results in a medial-sided crush injury to the talar head [12]. In the other injury pattern, forced inversion of the midfoot causes the navicular to shear off a portion of the medial talar head, which generates two distinct fracture fragments [4].

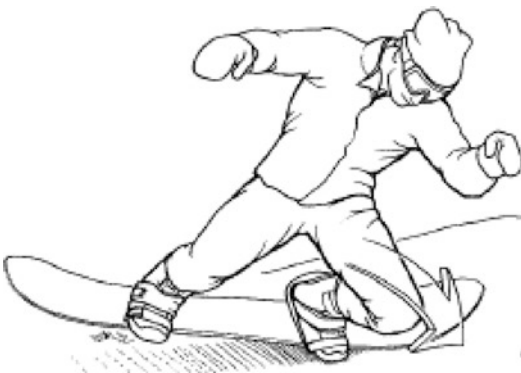The lateral tubercle of the posterior process may fracture by a direct mechanism from forced plantarflexion of the foot that causes compression of the posterior tibial plafond against the posterolateral process. This mechanism may result in fracture of the posterior process, separation of the fibrous attachment of the os trigonum



**Fig. 3.4** Mechanism of injury for talar neck and body fractures. The talar body extrudes posteromedially

from the talus, or fracture of the os trigonum. This first mechanism is most common and has been associated with soccer players and ballet dancers [13]. The other mechanism involves forced dorsiflexion on the ankle, which results in a tension-sided failure as the posterior talofibular ligament avulses off the posterolateral tubercle [14]. The medial tubercle of the posterior process is very rarely injured. The mechanism of injury involves avulsion of the posterior talotibial ligament when the ankle is dorsiflexed and pronated. Patients generally will have a tender firm mass behind the medial malleolus with an absence of the normal contour of the posteromedial ankle [15].

Finally, lateral process fractures are most commonly associated with snowboarding injuries. The injury mechanism is an axial load to a dorsiflexed ankle combined with forced external rotation or eversion of the hindfoot (Fig. 3.5) [17]. The foot is positioned in dorsiflexion during snowboarding with associated knee flexion, which further augments the degree of dorsiflexion achieved. During a fall forward, the leg positioned in front rotates toward the front of the board, which imparts an external rotation force or eversion force onto the ankle. Due to the relative frequency of this fracture among this sports group, lateral process fractures are generally termed “snowboarder’s fracture” [18].

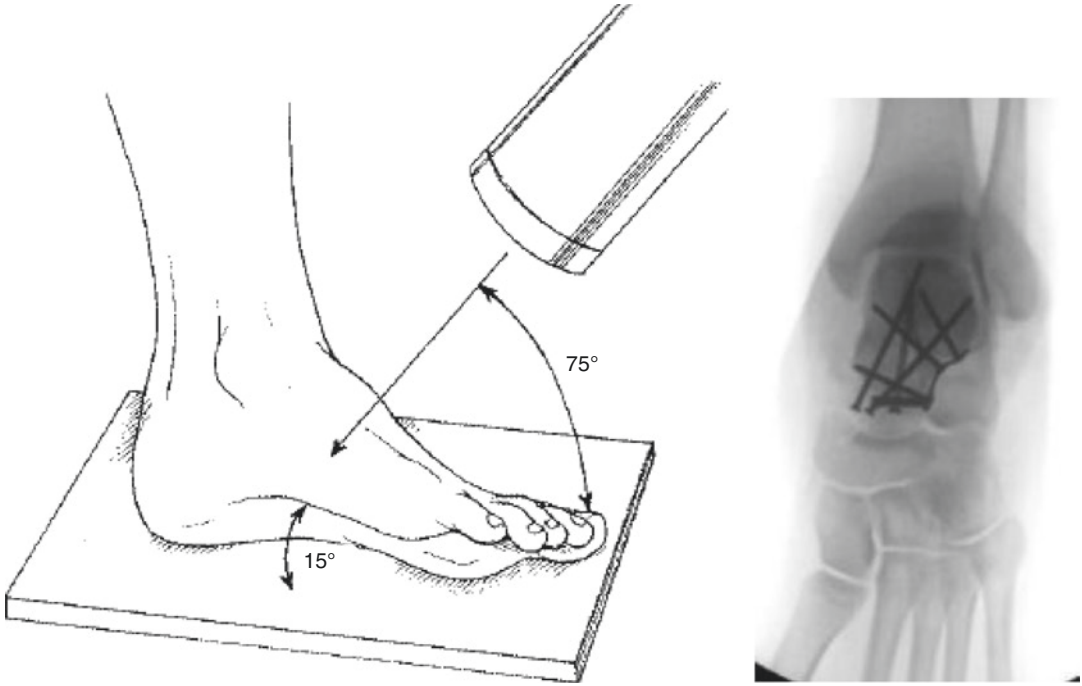


**Fig. 3.5** The typical mechanism for lateral process fractures in snowboarders is shown here. An external rotation or eversion force is placed on the dorsiflexed ankle, which results in a lateral process fracture of the talus [16]

## Imaging

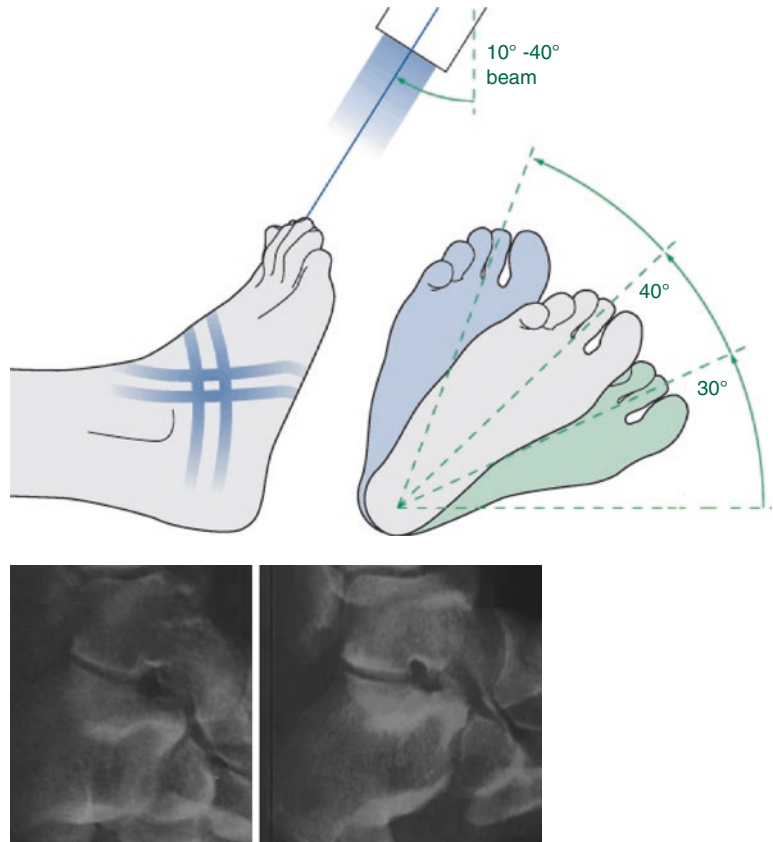
Initial radiographic evaluation should begin with AP, lateral, and oblique radiographs of the foot and ankle. The oblique (mortise) view of the ankle will demonstrate the position of the talus beneath the tibial plafond. The lateral ankle radiograph is the best standard view to assess fractures of the talus. This view is best to assess dorsal-plantar displacement of a talus fracture as well. However, coronal displacement (varus-valgus) is difficult to ascertain from an AP view. Therefore, the Canale view is recommended as an additional view to discover talus fractures and understand coronal displacement, especially in talar neck fractures [19]. This view is taken with the x-ray beam directed cephalad and pointing 75 degrees with respect to the horizontal. The foot is held in maximal plantar flexion and 15 degrees of pronation (Fig. 3.6). For posterior process fractures, a lateral radiograph is best. It may be difficult to distinguish a posterior process fracture from an os trigonum; clues of a fracture on lateral radiograph include roughened and irregular surfaces of the two bone surfaces. Furthermore, fractures tend to be larger and extend into the talar body [20]. Lateral process fractures are best seen on the AP and lateral ankle radiographs. A Brodén view may also be helpful to show a lateral process fracture as well as to evaluate the subtalar joint for any irregularity or impaction fractures of the undersurface of the talus. Brodén views are taken with the x-ray beam aimed cephalad 10–40 degrees with respect to the vertical with the foot in neutral position and internally rotated at varying degrees from 20 to 60 degrees with respect to the vertical (Fig. 3.7) [22].

CT is helpful to diagnose nondisplaced talus fractures as well as to delineate the fracture pattern and degree of displacement. Multiplanar 1–2-mm cuts are especially helpful in identifying posterior process, lateral process, and avulsion fractures [23]. For process fractures in particular, a CT will help define the size of the fragment, the degree of displacement, the presence of comminution, and the involvement of the subtalar joint.



**Fig. 3.6** Canale view [19]

**Fig. 3.7** Brodén views [21]





## References

- Sanders R, et al. Fractures and fracture-dislocations of the talus. Mann's surgery of the foot and ankle. 9th ed. Philadelphia: Elsevier; 2014.
- Sarrafian S. Anatomy of the foot and ankle. Philadelphia: Lippincott; 1983.
- Grogan DP, Walling AK, Ogden JA. Anatomy of the os trigonum. *J Pediatr Orthop*. 1990;10:618–22.
- Sangeorzan BJ, editor. Traumatized foot. Rosemont: Am Acad Orthop Surg; 2001.
- Rammelt S, Zwipp H. Talar neck and body fractures. *Injury*. 2009;40:120–35.
- Mulfinger GL, Trueta J. The blood supply of the talus. *J Bone Joint Surg*. 1970;52B:160–7.
- Haliburton RA, Sullivan CR, Kelly PJ, Peterson LF. The extra-osseous and intra-osseous blood supply of the talus. *J Bone Joint Surg Am*. 1958;40-A:1115–20.
- Schwarzenbach B, Dora C, Lang A, Kissling RO. Blood vessels of the sinus tarsi and the sinus tarsi syndrome. *Clin Anat*. 1997;10:173–82.
- Daniels TR, Smith JW. Talar neck fractures. *Foot Ankle*. 1993;14:225–34.
- Sneppen O, Buhl O. Fracture of the talus. A study of its genesis and morphology based upon cases with associated ankle fracture. *Acta Orthop Scand*. 1974;45:307–20.
- Penny JN, Davis LA. Fractures and fracture-dislocations of the neck of the talus. *J Trauma*. 1980;20:1029–37.
- Coltart WD. Aviator's astralagus. *JBJS Br*. 1952;34(4):545–66.
- Hamilton WG. Stenosing tenosynovitis of the flexor hallucis longus tendon and posterior impingement upon the os trigonum in ballet dancers. *Foot Ankle*. 1982;3:74–80.
- Yan YY, Mehta KV, Tan TJ. Fracture of the os trigonum: a report of two cases and review of the literature. *Foot Ankle Surg*. 2016;22(4):21–4.
- Cedell CA. Rupture of the posterior talotibial ligament with the avulsion of a bone fragment from the talus. *Acta Orthop Scand*. 1974;45:454–61.
- Funk J, Srinivasan S, Crandall J. Snowboarder's talus fractures experimentally produced by eversion and dorsiflexion. *Am J Sports Med*. 2003;31(6):921–8.
- Boon AJ, Smith J, Zobitz ME, Amrami KM. Snowboarder's talus fracture. Mechanism of injury. *Am J Sports Med*. 2001;29:333–8.
- Kirkpatrick DP, Hunter RE, Janes PC, et al. The snowboarder's foot and ankle. *Am J Sports Med*. 1998;26:271–7.
- Canale ST, Kelly FB Jr. Fractures of the neck of the talus: long-term evaluation of seventy-one cases. *J Bone Joint Surg Am*. 1978;60:143–56.
- Paulos LE, Johnson CL, Noyes FR. Posterior compartment fractures of the ankle. A commonly missed athletic injury. *Am J Sports Med*. 1983;11:439–43.
- Schatzker J, Buckley R, Sands A. Calcaneus-simple undisplaced body fractures. AO Foundation. [www.AOsurgery.org](http://www.AOsurgery.org). 2010.
- Gregory P, DiPasquale T, Herscovici D, Sanders R. Ipsilateral fractures of the talus and calcaneus. *Foot Ankle Int*. 1996;17:701–5.
- Ebraheim NA, Skie MC, Podeszwa DA, Jackson WT. Evaluation of process fractures of the talus using computed tomography. *J Orthop Trauma*. 1994;8:332–7.