

Diffuse Alveolar Hemorrhage

33

Hem Desai, Joshua Smith, and Mark Daren Williams

Case Presentation

A 43-year-old Hispanic male originally from Honduras presented to the emergency room with cough producing yellow sputum for 1 month, with recent change to blood tinged over the previous days. His past medical history was pertinent for hypertension and end stage renal disease requiring thrice weekly hemodialysis. He had missed dialysis for the previous week prior to presentation due to bad weather. He also reported fever, chills, and sore throat with the onset of hemoptysis. Of note, the patient had presented to another local hospital 2 months prior with similar symptoms of hemoptysis. He was evaluated by gastroenterology and otolaryngology and an endoscopy and laryngoscopy were performed. There were no obvious signs of bleeding but endoscopy did note blood emanating from the larynx. At presentation, his physical exam was notable for bilateral inspiratory rales with normal vital signs including oxygen saturation of 98% on room air.

He was initially diagnosed with end-stage renal failure 18 months prior following a motor vehicle accident. The patient was uninjured but was noted to have a serum creatinine of 21 mg/dL. A renal ultrasound showed renal parenchymal disease attributed to long-standing hypertension. He was started on hemodialysis. The patient had lived in the United States for the previous 10 years with no recent travel or sick contacts. He denied any use of tobacco, alcohol, or illicit drug use. He previously worked as a roofer, but was currently unemployed due to his dialysis dependence.

At the time of presentation, his laboratory data was notable for anemia with hemoglobin of 5.9 g/dL, Potassium 6.6 mmol/L, BNP 2092 pg/mL and serum creatinine 23 mg/dL. A chest X-ray showed multifocal bilateral alveolar opacities (Figs. 33.1 and 33.2). The patient was initially treated

with hemodialysis, broad spectrum antibiotics, and placed in respiratory isolation for evaluation of tuberculosis. The patient reported that his hemoptysis improved significantly following serial sessions of dialysis, yet chest imaging remained unchanged. Sputum culture, respiratory viral antigen panel, and AFB smears were negative. A bronchoscopy was performed 4 days after admission and revealed a progressively bloody bronchoalveolar lavage (Fig. 33.3) consistent with a diagnosis of diffuse alveolar hemorrhage. Serologic analysis confirmed the diagnosis.

Question

What is the diagnosis?

Answer Capillaritis with diffuse alveolar hemorrhage.

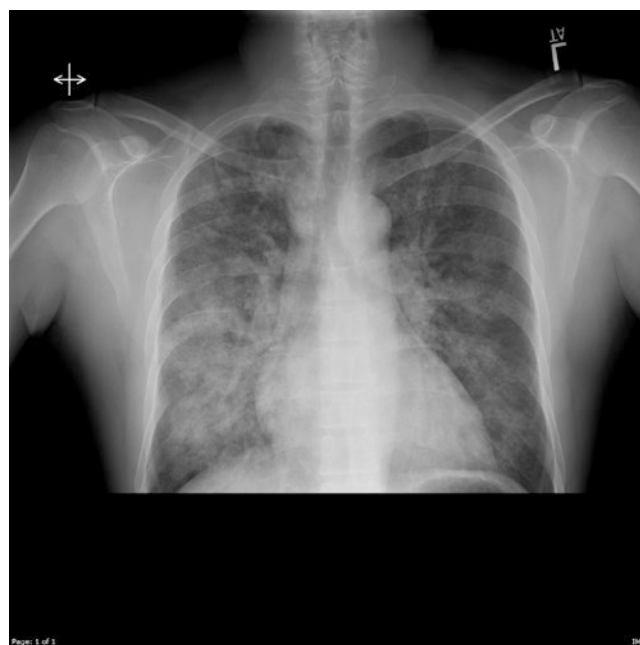

Fig. 33.1 Chest X-ray at initial presentation showing multifocal bilateral alveolar opacities

H. Desai · J. Smith · M. D. Williams (✉)
 Division of Pulmonary/Critical Care Medicine, Indiana University
 School of Medicine, Indianapolis, IN, USA
 e-mail: hemdesai@iu.edu; jrsmith@medicine.wisc.edu

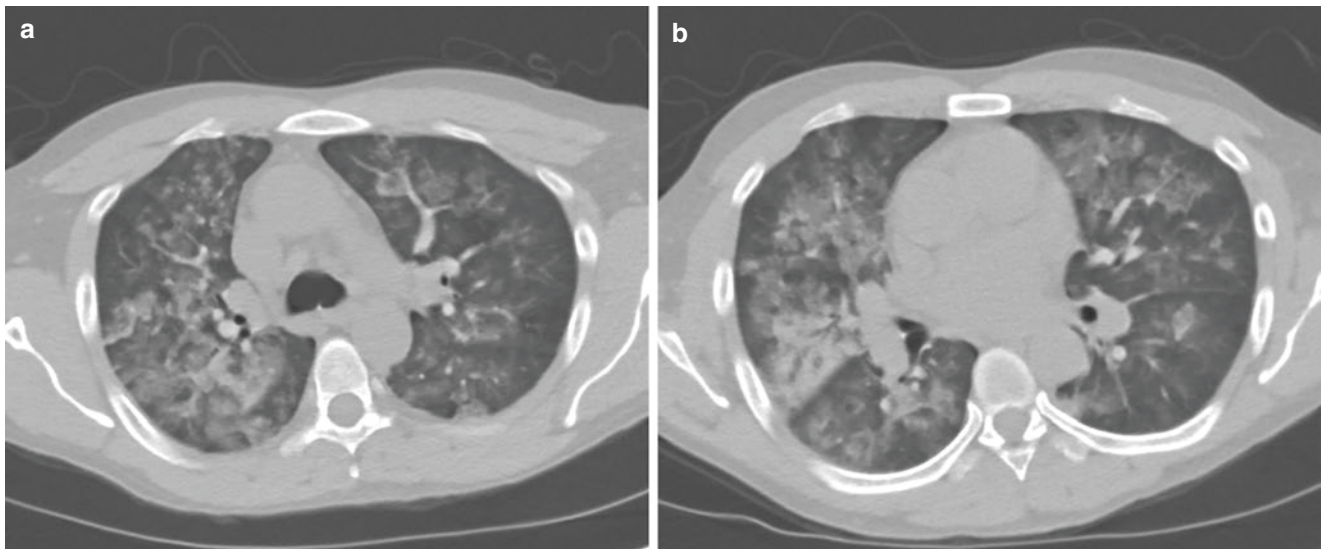


Fig. 33.2 (a, b) Chest CT images performed after hemodialysis showing diffuse bilateral alveolar opacities




Fig. 33.3 Sequential bronchoalveolar lavages starting left to right showing progressively bloody return

This patient presented with hemoptysis confirmed to be diffuse alveolar hemorrhage and chronic renal failure. The initial suspected etiology was volume overload due to missed dialysis sessions due to the elevated BNP level. The patient was treated conservatively with dialysis and while his reported hemoptysis improved, his chest X-ray showed persistent alveolar infiltrates. The serologic analysis that confirmed the diagnosis included Antinuclear Antibody of 1:360, P-ANCA positivity, and antibody to Myeloperoxidase of greater than 8.0 units. The constellation of diffuse alveolar hemorrhage, renal involvement, and p-ANCA/MPO positivity confirmed a diagnosis of Microscopic Polyangiitis. Imaging of the sinuses showed no signs of inflammation of

the upper respiratory tract. The patient was treated with prednisone and cyclophosphamide pulse dosing for six doses. He had one subsequent episode of hemoptysis requiring hospitalization 1 month after initial presentation. In general, he responded well to treatment and was weaned from corticosteroids over the next 3 months after completion of cyclophosphamide with improvement on chest imaging (Fig. 33.4).

Principles of Management

Differential Diagnosis

The differential diagnosis for diffuse alveolar hemorrhage can be quite extensive ranging from autoimmune to coagulopathy to medications. Three characteristic patterns have been identified: Capillaritis, ‘Bland’ pulmonary hemorrhage, and alveolar bleeding due to another process [1, 2]. Capillaritis is the most common cause of DAH and is typically a result of antibody-mediated cell damage. Autoimmune conditions associated with DAH include antineutrophil cytoplasmic antibody (ANCA) associated vasculitides, Goodpasture Syndrome, Systemic Lupus Erythematosus (Table 33.1). Initial evaluation of a patient with hemoptysis and suspected diffuse alveolar hemorrhage typically includes fiberoptic bronchoscopy to identify a source of bleeding, identification of potential infectious etiologies, and serologic workup for autoimmune conditions. DAH should be distinguished from other causes of pulmonary hemorrhage caused by localized pulmonary abnormalities and the bronchial circulation.

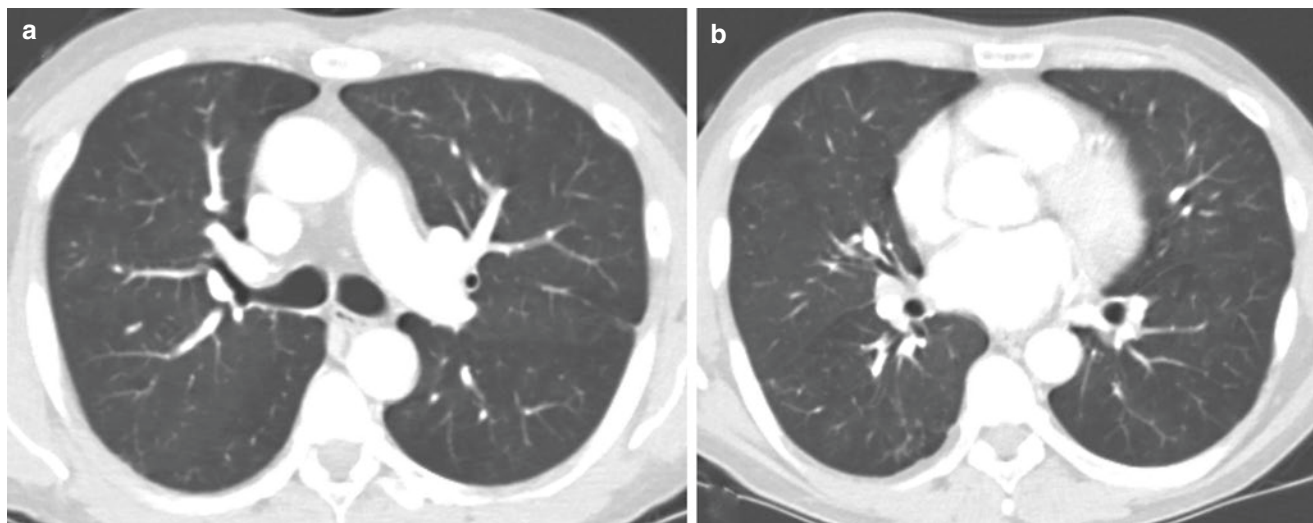


Fig. 33.4 (a, b) Chest CT images performed after 1 year of immunosuppressive treatment showing resolution of alveolar opacities

Table 33.1 Causes of diffuse alveolar hemorrhage

<i>Capillaritis</i>
Granulomatosis with polyangiitis (GPA)
Churg-Strauss syndrome
Microscopic polyangiitis (MPA)
Isolated pauci-immune pulmonary capillaritis
Idiopathic pauci-immune glomerulonephritis
Primary immune complex-mediated vasculitis
Goodpasture's syndrome
Henoch-Schonlein purpura
Systemic lupus erythematosus
Rheumatoid arthritis
Antiphospholipid antibody syndrome
Mixed connective tissue disease
Polymyositis/dermatomyositis
Essential cryoglobulinemia
Behcet's disease
Acute lung transplantation rejection
<i>Bland pulmonary hemorrhage</i>
Idiopathic pulmonary hemosiderosis
Coagulopathy: Anticoagulants, anti-platelet, thrombolytics, DIC
Mitral stenosis, pulmonary veno-occlusive disease
Infection: Human immunodeficiency virus infection, infective endocarditis
Toxin or inhalation injury: Isocyanates, crack cocaine, retinoic acid
Drug-associated disease: Propylthiouracil, diphenylhydantoin, amiodarone, mitomycin,
D-penicillamine, sirolimus, methotrexate, haloperidol, nitrofurantoin, gold,
All-trans-retinoic acid (ATRA), bleomycin, montelukast, zafirlukast, infliximab
<i>Alveolar bleeding due to another condition</i>
Diffuse alveolar damage
Pulmonary embolism
Sarcoidosis
High-altitude pulmonary edema, barotrauma

Infection: Invasive aspergillosis, cytomegalovirus infection, legionellosis, herpes simplex virus infection, Mycoplasma, hantavirus infection, leptospirosis, other bacterial pneumonias
Malignant conditions
Lymphangioleiomyomatosis
Tuberous sclerosis
Pulmonary capillary hemangiomatosis
Lymphangiography

Classification

Microscopic Polyangiitis (MPA) is a member of the group of ANCA-associated vasculitides. This group also includes granulomatosis with polyangiitis (GPA) and eosinophilic granulomatosis with polyangiitis (EGPA or Churg-Strauss Syndrome). These diseases are characterized by pauci-immune necrotizing inflammation of small vessels [3]. MPA has previously been described as a subgroup of Polyarteritis Nodosa (small vessel form) and is distinguished from GPA by the absence of granuloma formation. MPA is most commonly associated with rapidly progressive glomerulonephritis, although alveolar hemorrhage has been reported in up to 12–29% of cases [4].

Diagnosis

The diagnosis of ANCA-associated vasculitides is usually based upon findings of pulmonary and/or renal abnormalities with small-vessel necrotizing inflammation with the presence of auto-antibodies directed against neutrophilic anti-

gens. Previously, ANCA directed antibodies were classified as cytoplasmic-pattern and perinuclear-pattern, c-ANCA and p-ANCA, respectively. The two ANCA antigens commonly identified are proteinase 3 (PR3) and myeloperoxidase (MPO). MPO is more commonly associated with microscopic polyangiitis with a sensitivity of 50–70%, although PR3 has been identified in cases of MPA with a sensitivity of 26% [5–7]. Specificity of the combination of P-ANCA and MPO for ANCA-associated vasculitides is significantly greater at 99.8% [8]. In a review of patients with MPA and alveolar hemorrhage, 14 out of 27 patients revealed p-ANCA positivity while 11 out of 27 patients were c-ANCA positive [4]. Among those with p-ANCA antibodies, 12 out of 12 patients were positive for MPO specific antibodies. The requirement of biopsy for the diagnosis of ANCA associated vasculitides remains controversial. In the correct clinical setting with rapidly progressive glomerulonephritis, radiographic abnormalities, and serologic confirmation of antibody, the diagnosis of ANCA-associated vasculitis can be determined. Given the relapsing nature of disease and requirements for prolonged immunosuppression, it is suggested that confirmation of diagnosis by histopathology be determined whenever possible.

Treatment

Treatment of diffuse alveolar hemorrhage can be categorized as follows—management of the underlying cause such as vasculitis, management of the pulmonary hemorrhage, and treatment of the hypoxia. Historically, initial management of ANCA-associated vasculitides has centered on immunosuppression with corticosteroids and cyclophosphamide. The goal of treatment is induction of remission and maintenance of disease suppression. Therapy is typically tailored to severity of disease, notably mild vs. moderate to severe. These determinations are based upon organ-threatening or life-threatening manifestations. Pulmonary involvement, and specifically alveolar hemorrhage, is considered moderate to severe disease. Plasmapheresis has been shown to be beneficial in patients with diffuse alveolar hemorrhage and ANCA-associated vasculitis [9].

In many cases the pulmonary hemorrhage may be exacerbated by coagulopathy. Aggressive treatment with platelets for thrombocytopenia or fresh frozen plasma may be needed for control of the alveolar hemorrhage. There may be a component of pulmonary congestion due to left heart pathology. Increasing positive end-expiratory pressure can improve pulmonary congestion by decreasing afterload and preload thus helping with alveolar hemorrhage. Also, as a patient with DAH becomes hypoxemic, increasing peep may recruit more alveoli and improve oxygenation.

Evidence Contour

Supportive Care for Treatment of Hypoxia

Ventilation in the prone position has been mostly studied in patients with acute respiratory distress syndrome (ARDS), but may be useful to treat hypoxia due to pulmonary hemorrhage. In addition to facilitate recruitment and improved v/q mismatch prone position can improve drainage of the bloody secretions [10].

ECMO can also be used as a rescue therapy for DAH patients with severe hypoxemia and $\text{PaO}_2/\text{FiO}_2$ of <100 mmHg despite optimal ventilator settings [11]. There is concern that the ECMO circuit will need systemic anticoagulation to prevent thrombus formation. There have been cases of performing ECMO without systemic anticoagulation in patients with DAH without major complications. Another option is to use local citrate anticoagulation for the ECMO circuit. Reduced levels of anticoagulation represents another possibility although the optimal level of anticoagulation is unknown [12, 13].

Rituximab

Recently, there have been alternative treatment options identified in the treatment of ANCA-associated vasculitides. Cyclophosphamide carries several adverse reactions including cytopenias, infertility, bladder injury, and risk of malignancy. It has been identified that B lymphocytes play an integral role in the pathogenicity of auto-immunity [14]. Rituximab, an anti-CD20 monoclonal antibody, has been successfully used to reduce B-lymphocyte populations. Since 2010, there has been growing evidence that Rituximab can be used as an alternative to cyclophosphamide in the treatment of ANCA-associated vasculitides. When compared with cyclophosphamide, Rituximab was found to be non-inferior at induction of remission and maintenance of remission [15, 16]. In fact, Rituximab was found to be more effective for inducing remission of relapsing disease (67% vs. 42) [15]. Rituximab has been found to be superior to azathioprine in disease remission over 2 years [17]. Thus, rituximab has been shown to be a viable option for treatment of ANCA-associated vasculitides. While the patient in the case report was treated with cyclophosphamide, the use of rituximab could have been entertained.

Recombinant Factor VII

Refractory diffuse alveolar hemorrhage can present a therapeutic dilemma. Systemic recombinant Factor VII has been successfully used in a case of massive hemoptysis due to

community acquired pneumonia [18]. Case reports and observational studies have shown a beneficial effect of intrapulmonary administration of activated recombinant factor VII in cases of refractory diffuse alveolar hemorrhage [19–21]. Primarily, this practice has been shown to be beneficial in cases of DAH in allogeneic hematopoietic stem cell transplant recipients. Limited case reports, however, have reported successful cessation of bleeding in cases of ANCA-associated vasculitis [19, 21]. At this time, use of recombinant Factor VII is considered “off-label” but further study is warranted for general use in cases of diffuse alveolar hemorrhage refractory to standard therapy.

Tranexamic acid (TXA)

TXA has antifibrinolytic activity by binding to plasminogen which is the precursor to plasmin. The rationale for its use in DAH is that it can enhance the activity of depleted anti-fibrinolytic factors in ongoing bleeding sites along the bronchial tree [22]. Case series have reported that 500 mg/5 mL through a nebulizer may be an effective dose to halt pulmonary hemorrhage. Although further research is needed, TXA can be a rescue therapy if a patient continues to bleed despite maximal therapy.

References

- Ioachimescu OC, Stoller JK. Diffuse alveolar hemorrhage: diagnosing it and finding the cause. *Cleve Clin J Med*. 2008;75(4):258–80.
- Park MS. Diffuse alveolar hemorrhage. *Tuberc Respir Dis*. 2013;74(4):151–62.
- Jennette JC, Falk RJ, Bacon PA, Basu N, Cid MC, Ferrario F, et al. 2012 revised International Chapel Hill Consensus Conference Nomenclature of Vasculitides. *Arthritis Rheum*. 2013;65(1):1–11.
- Lauque D, Cadranet J, Lazor R, Pourrat J, Ronco P, Guillevin L, et al. Microscopic polyangiitis with alveolar hemorrhage. A study of 29 cases and review of the literature. *Groupe d'Etudes et de Recherche sur les Maladies "Orphelines" Pulmonaires (GERM"O" P)*. *Medicine*. 2000;79(4):222–33.
- Kallenberg CG. Pathogenesis of ANCA-associated vasculitides. *Ann Rheum Dis*. 2011;70(Suppl 1):i59–63.
- Frankel SK, Schwarz MI. The pulmonary vasculitides. *Am J Respir Crit Care Med*. 2012;186(3):216–24.
- Brown KK. Pulmonary vasculitis. *Proc Am Thorac Soc*. 2006;3(1):48–57.
- Choi HK, Liu S, Merkel PA, Colditz GA, Niles JL. Diagnostic performance of antineutrophil cytoplasmic antibody tests for idiopathic vasculitides: metaanalysis with a focus on antimyeloperoxidase antibodies. *J Rheumatol*. 2001;28(7):1584–90.
- Klemmer PJ, Chalermkulrat W, Reif MS, Hogan SL, Henke DC, Falk RJ. Plasmapheresis therapy for diffuse alveolar hemorrhage in patients with small-vessel vasculitis. *Am J Kidney Dis*. 2003;42(6):1149–53.
- Hayes-Bradley C. Hypoxia from vasculitic pulmonary haemorrhage improved by prone position ventilation. *Br J Anaesth*. 2004;92(5):754–7.
- Claudio CP, Charbonney E, Durand M, Kolan C, Laskine M. Extracorporeal membrane oxygenation in diffuse alveolar hemorrhage secondary to systemic lupus erythematosus. *J Clin Med Res*. 2014;6(2):145.
- Darryl A, Angerstrand CL, Bisotti M, et al. Extracorporeal membrane oxygenation in the management of diffuse alveolar hemorrhage. *ASAIO J*. 2015;61(2):216–8.
- Delvino P, Monti S, Balduzzi S, et al. The role of extra-corporeal membrane oxygenation (ECMO) in the treatment of diffuse alveolar haemorrhage secondary to ANCA-associated vasculitis: report of two cases and review of the literature. *Rheumatol Int*. 2019;39(2):367–75.
- Martin F, Chan AC. Pathogenic roles of B cells in human autoimmunity; insights from the clinic. *Immunity*. 2004;20(5):517–27.
- Stone JH, Merkel PA, Spiera R, Seo P, Langford CA, Hoffman GS, et al. Rituximab versus cyclophosphamide for ANCA-associated vasculitis. *N Engl J Med*. 2010;363(3):221–32.
- Specks U, Merkel PA, Seo P, Spiera R, Langford CA, Hoffman GS, et al. Efficacy of remission-induction regimens for ANCA-associated vasculitis. *N Engl J Med*. 2013;369(5):417–27.
- Guillevin L, Pagnoux C, Karras A, Khouatra C, Aumaitre O, Cohen P, et al. Rituximab versus azathioprine for maintenance in ANCA-associated vasculitis. *N Engl J Med*. 2014;371(19):1771–80.
- Macdonald JA, Fraser JF, Foot CL, Tran K. Successful use of recombinant factor VII in massive hemoptysis due to community-acquired pneumonia. *Chest J*. 2006;130(2):577–9.
- Heslet L, Nielsen JD, Levi M, Sengeløv H, Johansson PI. Successful pulmonary administration of activated recombinant factor VII in diffuse alveolar hemorrhage. *Crit Care*. 2006;10(6):R177.
- Heslet L, Nielsen JD, Nepper-Christensen S. Local pulmonary administration of factor VIIa (rFVIIa) in diffuse alveolar hemorrhage (DAH)—a review of a new treatment paradigm. *Biologics*. 2012;6:37.
- Dabar G, Harmouche C, Jammal M. Efficacy of recombinant activated factor VII in diffuse alveolar haemorrhage. *Rev Mal Respir*. 2011;28(1):106–11.
- Solomonov A, Fruchter O, Zuckerman T, Brenner B, Yigla M. Pulmonary hemorrhage: a novel mode of therapy. *Respir Med*. 2009;103(8):1196–200.