

Current Clinical Neurology

*Series Editor: Daniel Tarsy*

Syed A. Rizvi

Jonathan F. Cahill

Patricia K. Coyle *Editors*

# Clinical Neuroimmunology

Multiple Sclerosis and Related Disorders

*Second Edition*

 Humana Press

---

# Current Clinical Neurology

## Series Editor

Daniel Tarsy  
Beth Israel Deaconness Medical Center  
Department of Neurology  
Boston, MA  
USA

Current Clinical Neurology offers a wide range of practical resources for clinical neurologists. Providing evidence-based titles covering the full range of neurologic disorders commonly presented in the clinical setting, the Current Clinical Neurology series covers such topics as multiple sclerosis, Parkinson's Disease and nonmotor dysfunction, seizures, Alzheimer's Disease, vascular dementia, sleep disorders, and many others. Series editor Daniel Tarsy, MD, is professor of neurology, Vice Chairman of the Department of Neurology, and Chief of the Movement Disorders division at Beth Israel Deaconess Hospital, Boston, Massachusetts.

More information about this series at <http://www.springer.com/series/7630>

---

Syed A. Rizvi • Jonathan F. Cahill  
Patricia K. Coyle  
Editors

# Clinical Neuroimmunology

Multiple Sclerosis and Related  
Disorders

Second Edition

 Humana Press

*Editors*

Syed A. Rizvi, MD, EMHL  
Rhode Island Hospital and Alpert  
Medical School of Brown University  
Brown Neurology  
Providence, RI  
USA

Jonathan F. Cahill, MD  
Rhode Island Hospital and Alpert  
Medical School of Brown University  
Brown Neurology  
Providence, RI  
USA

Patricia K. Coyle, MD  
Department of Neurology  
MS Comprehensive Care Center  
Stony Brook University Medical Center  
Stony Brook, NY  
USA

ISSN 1559-0585

ISSN 2524-4043 (electronic)

Current Clinical Neurology

ISBN 978-3-030-24435-4

ISBN 978-3-030-24436-1 (eBook)

<https://doi.org/10.1007/978-3-030-24436-1>

© Springer Nature Switzerland AG 2020

This work is subject to copyright. All rights are reserved by the Publisher, whether the whole or part of the material is concerned, specifically the rights of translation, reprinting, reuse of illustrations, recitation, broadcasting, reproduction on microfilms or in any other physical way, and transmission or information storage and retrieval, electronic adaptation, computer software, or by similar or dissimilar methodology now known or hereafter developed.

The use of general descriptive names, registered names, trademarks, service marks, etc. in this publication does not imply, even in the absence of a specific statement, that such names are exempt from the relevant protective laws and regulations and therefore free for general use.

The publisher, the authors, and the editors are safe to assume that the advice and information in this book are believed to be true and accurate at the date of publication. Neither the publisher nor the authors or the editors give a warranty, express or implied, with respect to the material contained herein or for any errors or omissions that may have been made. The publisher remains neutral with regard to jurisdictional claims in published maps and institutional affiliations.

This Humana imprint is published by the registered company Springer Nature Switzerland AG  
The registered company address is: Gewerbestrasse 11, 6330 Cham, Switzerland

---

## Preface

Immune activation of the central or peripheral nervous system (CNS or PNS) has been shown to play a key role in the pathogenesis of many neurological disorders. Basic concepts in clinical neuroimmunology have changed significantly during the last 10 years and are constantly evolving. New data has driven treatment concepts for a large number of autoimmune diseases, none more so than multiple sclerosis. As this area of research has become increasingly active and productive, the need for a comprehensive up-to-date second edition of this handbook has become apparent.

*Clinical Neuroimmunology: Multiple Sclerosis and Related Disorders (Second Edition)* has been written with the clinician in mind and targets residents, fellows, internists, nurse practitioners, as well as general neurologists. The aim of this book is to make recent developments in neuroimmunology accessible to the clinicians who feel daunted by such advances and requires a clear explanation of the scientific and clinical issues. The chapters have been written by experts in their field and been extensively revised and updated. Two new chapters have been added. *Part I* provides a logical and straightforward overview of neuroimmunology. *Part II* consists of eight chapters focused on multiple sclerosis and includes a chapter on clinical decision-making and a chapter on vitamin D in MS. *Part III* has four chapters and focuses on other CNS inflammatory disorders including neuromyelitis optica, ADEM, vasculitis, autoimmune encephalopathies, and immunological aspects of cancer. *Part IV* includes two chapters that describe autoimmune disorders of the PNS. *Part V*, the final part, includes a single chapter that focuses on neurologic manifestation of systemic rheumatologic diseases such as systemic lupus erythematosus (SLE), neuro-sarcoidosis, and Behcet's. We hope health professionals who are interested in neuroimmunological disorders will find this book useful.

Finally, we would like to thank our contributing authors for their hard work and guidance.

Providence, RI, USA  
Providence, RI, USA  
Stony Brook, NY, USA

Syed A. Rizvi, MD  
Jonathan F. Cahill, MD  
Patricia K. Coyle, MD

---

## Series Editor's Introduction

The role of the immune system in the pathophysiology of central and peripheral nervous system disorders continues to be a topic of great interest among clinicians and researchers in the field. As stated by Drs. Rizvi, Cahill, and Coyle, the editors of *Clinical Immunology, Second Edition*, basic concepts in this field have changed significantly due to a constant evolution of knowledge since the publication of the first edition of this book in 2011. This comprehensive and up-to-date second edition of this useful handbook is therefore a welcome addition to the field.

*Clinical Immunology, Second Edition*, continues to be written primarily for clinicians in the field and targets general neurologists, internists, fellows, residents, and nurse practitioners. Although clinically oriented, the chapters all include updated authoritative information on new understandings of the basic mechanisms of the disorders being discussed. Section 1 begins with two useful chapters which provide an excellent introduction and overview of clinical neuroimmunology and the principles of immunotherapy. Section 2 covers multiple sclerosis and includes new chapters on clinical decision-making in the management of multiple sclerosis and the role of vitamin D in this disease. Section 3 covers other central nervous system inflammatory disorders, such as neuromyelitis optica, acute disseminated encephalomyelitis, and CNS vasculitis, and a new chapter on paraneoplastic disorders. Section 4 covers immunologic disorders of muscle and peripheral nerve, and Section 5 provides a new chapter concerning the neurologic manifestations of systemic rheumatologic disorders. The readers of this volume will discover that the quantity of new knowledge accumulated in the past 10 years is worthy of this new and highly comprehensive summary of the field.

Daniel Tarsy, MD  
Professor in Neurology, Harvard Medical School  
Beth Israel Deaconess Medical Center  
Boston, MA, USA

---

# Contents

## Part I Introduction

- 1 Introduction to Neuroimmunology** ..... 3  
Patricia K. Coyle
- 2 Principles of Immunotherapy** ..... 17  
Jennifer Joscelyn, Javier Ochoa-Repáraz, and Lloyd Kasper

## Part II Multiple Sclerosis

- 3 Immunopathogenesis** ..... 45  
Patricia K. Coyle
- 4 Epidemiology and Genetics** ..... 71  
Tina Roostaei and Philip L. De Jager
- 5 Clinical Features, Symptom Management, and Diagnosis** ..... 89  
Jacqueline F. Rosenthal, James M. Stankiewicz,  
and Guy J. Buckle
- 6 Magnetic Resonance Imaging and Analysis in  
Multiple Sclerosis** ..... 109  
Dejan Jakimovski, Deepa P. Ramasamy, and Robert Zivadinov
- 7 Disease-Modifying Agents** ..... 137  
Syed A. Rizvi
- 8 Clinical Decision-Making in the Management of  
Multiple Sclerosis** ..... 159  
Syed A. Rizvi, Joshua A. Stone, Saima T. Chaudhry,  
Nichola Haddad, Brian Wong, and Jennifer O. Grimes
- 9 Multiple Sclerosis in Children** ..... 179  
Charles D. Tyshkov, Leigh Elkins Charvet,  
and Lauren B. Krupp
- 10 Vitamin D and Multiple Sclerosis** ..... 197  
Michael J. Bradshaw, Michael F. Holick,  
and James M. Stankiewicz



### Part III Other CNS inflammatory Disorders

- 11 Acute Disseminated Encephalomyelitis** ..... 215  
Patricia K. Coyle
- 12 Neuromyelitis Optica Spectrum Disorders** ..... 227  
Jonathan F. Cahill
- 13 Paraneoplastic and Other Autoimmune Disorders** ..... 235  
Alexander Mohler, Mayra Montalvo, and Julie Roth
- 14 Adult and Childhood Vasculitis of the Nervous System** ..... 257  
David S. Younger

### Part IV Peripheral Nervous System Disorders

- 15 Immunologic Disorders of Neuromuscular Junction and Muscle** ..... 285  
James M. Gilchrist and John E. Donahue
- 16 Autoimmune Neuropathies** ..... 299  
Jacques Reynolds and George Sachs

### Part V Systemic Disorders

- 17 Neurologic Manifestations of Systemic Rheumatologic Diseases** ..... 321  
Michael J. Bradshaw, Shamik Bhattacharyya,  
Nagagopal Venna, and Jonathan F. Cahill
- Index** ..... 343

---

## Contributors

**Shamik Bhattacharyya, MD, MS** Department of Neurology, Brigham and Women's Hospital, Boston, MA, USA

**Michael J. Bradshaw, MD** Department of Neurology, Chicago Medical School, Rosalind Franklin University of Medicine and Science, Billings Clinic, Billings, MT, USA

**Guy J. Buckle, MD, MPH** Shepherd Center, Multiple Sclerosis Institute, Atlanta, GA, USA

**Jonathan F. Cahill, MD** Rhode Island Hospital and Alpert Medical School of Brown University, Brown Neurology, Providence, RI, USA

**Leigh Elkins Charvet, PhD** Department of Neurology, Multiple Sclerosis Comprehensive Care Center, NYU Langone Health, New York, NY, USA

**Saima T. Chaudhry, MD** MS Fellow, Brown Neurology, Providence, RI, USA

**Patricia K. Coyle, MD** Department of Neurology, MS Comprehensive Care Center, Stony Brook University Medical Center, Stony Brook, NY, USA

**Philip L. De Jager, MD, PhD** Department of Neurology, New York – Presbyterian Hospital, New York, NY, USA

**John E. Donahue, MD** Department of Neuropathology, Rhode Island Hospital, Providence, RI, USA

**James M. Gilchrist, MD** Department of Neurology, Southern Illinois University School of Medicine, Springfield, IL, USA

**Jennifer O. Grimes, MA, MD Candidate** Alpert Warren Medical School of Brown University, Providence, RI, USA

**Nichola Haddad, BA** Alpert Warren Medical School of Brown University, Providence, RI, USA

**Michael F. Holick, PhD, MD** Department of Medicine, Boston University Medical Center, Boston, MA, USA

**Dejan Jakimovski, MD** Department of Neurology, Buffalo General Hospital, University of Buffalo, Buffalo, NY, USA

**Jennifer Joscelyn, MS, OT** Thought Leader Liaison, Hooksett, NH, USA

**Lloyd Kasper, MD** Department of Microbiology/Immunology, Dartmouth College, Hanover, NH, USA  
Symbiotix Biotherapies, Boston, MA, USA

**Lauren B. Krupp, MD** Department of Neurology, Multiple Sclerosis Comprehensive Care Center, NYU Langone Health, New York, NY, USA

**Alexander Mohler, MD** Alpert Medical School of Brown University, Providence, RI, USA

Department of Neurology, Rhode Island Hospital, Providence, RI, USA

**Mayra Montalvo, MD** Department of Neurology, Rhode Island Hospital, Providence, RI, USA

**Javier Ochoa-Repáraz, PhD** Eastern Washington University, Cheney, WA, USA

**Deepa P. Ramasamy, MD** Department of Neurology, Buffalo General Hospital, University of Buffalo, Buffalo, NY, USA

**Jacques Reynolds, MS/DO** Department of Neurology, Midcoast Hospital, Brunswick, ME, USA

**Syed A. Rizvi, MD, EMHL** Rhode Island Hospital and Alpert Medical School of Brown University, Brown Neurology, Providence, RI, USA

**Tina Roostaei, MD, MPH** Department of Neurology, Center for Translational and Computational Neuroimmunology, Columbia University Medical Center, New York, NY, USA

**Jacqueline F. Rosenthal, MD** Shepherd Center, Multiple Sclerosis Institute, Atlanta, GA, USA

**Julie Roth, MD** Alpert Medical School of Brown University, Providence, RI, USA

Department of Neurology, Rhode Island Hospital, Providence, RI, USA

**George Sachs, MD, PhD** Department of Neurology, Warren Alpert Medical School of Brown University, Rhode Island Hospital, Providence, RI, USA

**James M. Stankiewicz, MD** Partners Multiple Sclerosis Center, Harvard Medical School, Boston, MA, USA

**Joshua A. Stone, MD** MS Fellow, Brown Neurology, Providence, RI, USA

**Charles D. Tyshkov, MD** Department of Pediatrics/Child Neurology, New York Presbyterian Weill Cornell Medical Center/Brooklyn Methodist Hospital, New York, NY, USA

**Nagagopal Venna, MD, MRCP(I), MRCP (UK)** Neuro-Infectious Diseases, Harvard Medical School, Boston, MA, USA

---

Division of Neuroimmunology, Department of Neurology, Massachusetts General Hospital, Boston, MA, USA

**Brian Wong, MD** Department of Neurology, Hartford Healthcare, University of Connecticut School of Medicine, Southington, CT, USA

**David S. Younger, MD, MPH, MS** Department of Neurology, White Plains Hospital, New York, NY, USA

**Robert Zivadinov, MD, PhD** Department of Neurology, Buffalo General Hospital, University of Buffalo, Buffalo, NY, USA

---

## **Part 1**

# **Introduction**

# Introduction to Neuroimmunology

# 1

Patricia K. Coyle

## Introduction

The nervous system can be considered the single most important body organ. It encompasses both the central nervous system (CNS) (brain, spinal cord, and optic nerve) and the peripheral nervous system (PNS) (peripheral nerves, neuromuscular junction, skeletal muscle). The autonomic nervous system can be considered a functional subdivision, with both CNS and PNS components.

Historically, the CNS has been described as a sequestered compartment protected from the systemic immune system. However, more recent studies not only support clear communication links between the CNS and specific extraneural systems, but the existence of a brain innate immune system (Table 1.1) [1, 2]. The CNS is more accurately characterized as an immunologically privileged site [3].

Neuroimmunology is the neuroscience specialty that focuses on interactions between the nervous system and immune system. It includes both basic science fields and clinical disciplines which deal with a special set of CNS and PNS disorders (Table 1.2) [4–6]. These disorders result from immune-mediated damage and require diagnostic and therapeutic approaches

that recognize and address this fact. Some are truly autoimmune, with a recognized pathogenic neural autoantigen target, while others are not. Most will be covered in subsequent chapters.

Sometimes unusual diseases are characterized as neuroimmune based on their pathology and/or therapeutic response. Chronic lymphocytic inflammation with pontine perivascular enhancement responsive to steroids (CLIPPERS) is a recently described rare disorder that predominantly targets brainstem, cerebellum, and spinal cord. The MRI pattern is suggestive, with punctate (<3 mm) homogeneously enhancing pontine and cerebellar nodules [7]. Neuropathology shows dense perivascular and parenchymal lymphocyte infiltration (particularly CD4+ T cells, with some B cells and plasma cells) without loss of myelin. CSF changes are nonspecific, but proteomic studies support roles for complement activation, IgG deposition, and altered extracellular matrix [8]. Patients show a marked corticosteroid response.

**Table 1.1** CNS and immune system connections

<i>CNS innate immune system</i>
Glial cells and neurons (in certain circumstances) secrete immune factors (chemokines, cytokines)
<i>CNS meningeal lymphatic system</i>
Found in mice, primates, humans
<i>CNS undergoes constant immune surveillance within the meningeal spaces</i>
<i>Paravascular glymphatic system</i>
<i>CNS-gut-microbiome axis</i>
Microbiota impacts CNS, immune system

P. K. Coyle (✉)  
 Department of Neurology, MS Comprehensive Care  
 Center, Stony Brook University Medical Center,  
 Stony Brook, NY, USA  
 e-mail: [patricia.coyle@stonybrookmedicine.edu](mailto:patricia.coyle@stonybrookmedicine.edu)

**Table 1.2** Neuroimmune disorders

<i>CNS</i>
Acute disseminated encephalomyelitis (ADEM)/postinfectious encephalomyelitis
Autoimmune encephalitis/cerebellitis
Multiple sclerosis
Neuromyelitis optica spectrum disorder
Acute transverse myelitis
Optic neuritis
MOG-associated syndromes
Tropical spastic paraparesis—HTLV1-associated myelopathy
Rasmussen encephalitis
Stiff person syndrome
Poststreptococcal movement disorders
Pediatric autoimmune neuropsychiatric disorders (PANDAS)
Hashimoto's and other misc. autoimmune encephalopathy/encephalitis
Paraneoplastic syndromes (can involve PNS)
CNS vasculitis
CLIPPERS
Susac syndrome
<i>PNS</i>
Peripheral nerve
Guillain-Barre syndrome
Chronic relapsing/inflammatory demyelinating polyneuropathy
Multifocal motor neuropathy
Other immune polyneuropathies (anti-MAG, anti-sulfatide, GALOP, POEMS, etc.)
<i>Neuromuscular junction</i>
Myasthenia gravis
Lambert-Eaton myasthenic syndrome
Arthrogryposis multiplex congenital
<i>Muscle</i>
Polymyositis
Dermatomyositis
Inclusion body myositis (degenerative plus inflammation components)

Rasmussen's encephalitis is another rare disorder characterized by unilateral hemispherical inflammation, with refractory seizures and progressive neurologic deterioration [9]. Average age at onset is 6 years. Rasmussen's encephalitis appears to involve a cytotoxic CD8+ T cell response that may be enhanced by autoantibodies. There is marked microglial and astrocyte activation, and adjacent brain injury may be mediated by T cell-microglia interactions. The only cure for the refractory seizures involves removal of the hemisphere.

Susac syndrome is a presumed immune-mediated disorder that involves a retino-cochlea-

cerebral microangiopathy. There are occlusions of precapillary arterioles in the brain, retina, and cochlea [10]. Patients develop subacute encephalopathy with headache with or without focal deficits, branch retinal artery occlusions with or without visual issues, and sensorineural hearing loss. Only 13% of patients show the complete clinical triad at onset however [11]. Brain MRI shows multifocal round hyperintense T2 and FLAIR lesions with invariable central corpus callosum involvement and characteristic retinal fluorescein angiography abnormalities (occlusions and segmental vessel wall staining) [11]. Treatments have included a variety of immunosuppressive approaches (corticosteroids, cyclophosphamide, anti-CD20 monoclonal antibody, intravenous immune globulin, azathioprine, mycophenolate) [10].

Recently autoimmune encephalitis/cerebellitis (also referred to as antibody-mediated encephalitis) has emerged as an ever-increasing group of disorders with prominent neuropsychiatric symptoms and antibodies against neuronal cell surface proteins, ion channels, or receptors [12].

Finally, there are several disorders of unclear etiology where a neuroimmune basis has been suggested but not proven. They include postural orthostatic tachycardia syndrome [13, 14], fibromyalgia with central sensitization syndrome and associated small fiber neuropathy, and chronic fatigue syndrome/systemic exertion intolerance disease [15]. Further studies are needed before they can be considered to be neuroimmune. The rest of this chapter will describe various CNS aspects, components, and cell populations as a foundation to better understand neuroimmunology.

---

## Unique Anatomy

CNS anatomy is unique. Because the CNS is encased by bone, with a relatively inelastic dura lining, small volume changes can result in injury. The brain and spinal cord are encased in the bony protective skull and vertebral column, as well as a three parts membranous covering (pia, arachnoid, dura). The pia and arachnoid membranes form the subarachnoid space, which is filled with cerebrospinal fluid (CSF). In essence, the brain

and spinal cord float in a water bath, since CSF is 99% water [16, 17]. It acts as a buoyancy fluid. CSF is an active product of the secretory epithelium of the choroid plexus, but up to 40% is formed by extracellular fluid from the CNS parenchyma. This extracellular fluid is added to CSF at virtually all points along the neuraxis. CSF circulates from within the ventricles (where the choroid plexi are situated) into the subarachnoid space, flowing down the spinal axis and back up, to be resorbed into the venous blood system via the arachnoid villi. These arachnoid villi are outpouchings of the arachnoid membrane that extend into the venous sinuses of the cerebral hemispheres. CSF is made continually, at approximately 20 cc/h. The total volume (125–150 cc in a typical adult) is completely turned over 4–1/2 times every 24 h.

Since the ependymal cells which line the ventricles lack tight junctions, there is essentially free communication between CNS white matter extracellular fluid and ventricular CSF. CNS gray matter fluid at the brain surface also communicates with CSF via the Virchow-Robin spaces, specialized perivascular spaces associated with penetrating arteries that are continuous with the subarachnoid space.

CSF leukocyte count in normal controls ranges up to 5 WBCs/mm<sup>3</sup>. WBCs are largely (80%) CD4+ memory T cells [18]. About 5% are monocytes, while <1% are B cells. CSF T cells express CD27 and CD45 RO, markers of central memory T cells. Very late antigen-4 (VLA-4) expression is also increased compared to peripheral T cells. CSF T cells show higher expression of CXC chemokine receptor 3, compared to other chemokines. CSF memory T cells can encounter potential antigen-presenting cells (APCs) at several sites, including the ependyma, Virchow-Robin spaces, and choroid plexus.

---

## Blood-Brain Barriers

The blood-brain barrier (BBB) can be demonstrated by inhibition of entry of intravenous dyes into the CNS [19, 20]. It is formed by specialized features unique to CNS blood vessels. CNS capillaries not only lack fenestrae, but they have

interendothelial cell tight junctions which prevent cell migration. They have a continuous basal lamina. They also do not pinocytose effectively and only have a few pinocytic vesicles. The BBB is not absolute. It is relative or even selective, limiting entry of large hydrophilic proteins, but allowing entry of smaller lipophilic compounds and small gaseous molecules [21]. The endothelial basement membrane and perivascular glia limitans do not seem to play a role in the BBB.

Although the choroid plexus capillaries are fenestrated, with 80 nm openings [3], the choroid plexus epithelium has tight junctions. This is the anatomic basis for the blood-CSF barrier. There are specific CNS regions which do not have a barrier. The circumventricular organs (area postrema, organum vasculosum of the lamina terminalis, median eminence, subfornical organ) lack tight junctions between capillary endothelial cells. At these sites molecules can diffuse very easily into the CNS. The nasal barrier is another leaky site, where there is continuing turnover of olfactory receptor neuron axons which pass through the subarachnoid CSF to terminate on olfactory bulb mitral cells [22].

The BBB and blood-CSF barrier, along with the CSF circulation, provide bidirectional control of flow. Damaging CNS factors can be removed via efflux transporters into the blood, while influx transporters can promote nutrients into the CNS. The PNS has a similar blood-nerve barrier in peripheral nerve, but this is absent in spinal roots and at the dorsal root ganglia.

---

## CNS Lymphatics

A meningeal lymphatic system has been discovered in mice, nonhuman primates, and humans [23, 24]. This system carries macromolecules (fluids and immune cells) from the CNS CSF and interstitial fluids and connects to deep cervical lymph nodes [25]. The lymphatics are found along large blood vessels and cranial nerves in the dura mater [24]. Meningeal lymphatic disruption in young mice leads to impaired brain CSF perfusion and learning and memory deficits [25].

There are several other CSF draining pathways. The subarachnoid space surrounding the



olfactory bulb crosses the cribriform plate at the base of the ethmoid bone, into nasal submucosal lymphatics [26]. In animals, CSF drains from the subarachnoid space along cranial and spinal nerve roots, and to a lesser extent the dura mater, to cervical and lumbar lymph nodes [26]. This route is also present in humans [27]. CSF moves directly into venous circulation through the arachnoid villi granulations in the walls of the venous sinuses. CNS soluble antigens within the CSF can access lymphoid tissue via both cervical lymphatics and venous drainage [3].

---

## CNS Immunity

The CNS is composed of neurons, glia, blood vessels, and meninges. Neurons contain dendritic, somatic, axonal, and synaptic regions. Glia consists of neuroectodermal cells (astrocytes, oligodendrocytes, ependymal cells) as well as bone marrow-derived cells (microglia).

The CNS has a resident immune system. Both microglia and astrocytes play key roles in CNS innate immune responses. They are complemented by infiltrating monocytes and dendritic cells from the blood that accumulate at non-parenchymal CNS sites [28]. Innate immune responses can be neuroprotective or neurotoxic.

In contrast, acquired immune responses are more difficult to initiate within the CNS. Activated T cells (regardless of antigen specificity) penetrate into the CNS as a normal phenomenon, but then rapidly exit. CD4+ and CD8+ T cells penetrate by different mechanisms [29]. Usually T cells accumulate in the perivascular Virchow-Robin spaces and subarachnoid spaces. These T cells cause problems only if they recognize specific antigens in the context of major histocompatibility complex (MHC). CD4+ T cells recognize antigen in the context of MHC Class II, while CD8+ T cells recognize antigen in the context of MHC Class I. Normally the CNS has low level of MHC expression. Since microglia and astrocytes are nonprofessional APCs, they express low levels of MHC and costimulatory molecules. They are more likely to induce T cell allergy rather than activate naïve T cells [28].

Dendritic cells are recognized as the most potent professional APCs. There are no resident dendritic cells within the CNS, although recent reports describe a resident population in mouse brain [30, 31]. Dendritic cells can infiltrate into CSF, choroid plexus, meninges, perivascular spaces, and CNS parenchyma as part of a neuro-inflammatory response [32]. Along with macrophages, they probably reactivate T cells which enter the CNS [29]. Diverse chronic inflammatory processes can result in peripheral dendritic cells entering the brain [33]. Dendritic cells can be derived from monocytes or lymphoid precursors. Both myeloid and lymphoid dendritic cells are capable of entering the CNS under inflammatory conditions.

The CNS immune/inflammatory response differs from that in other organ systems. CNS neurons are largely postmitotic and nonregenerating. Neuronal necrosis induced by neurotoxin injection does not elicit a typical inflammatory response. Virus inoculated into the parenchyma is cleared slowly and inefficiently [34]. Yet neuroinflammation is how the CNS responds to altered homeostasis [35]. It involves resident glia, infiltrating immune cells, cytokines and cytokine signaling, and the BBB.

There are three distinct routes of entry for white blood cells (WBCs) into the CNS [3, 36]. The first pathway involves cells moving from blood vessels into the stroma of the choroid plexus and then crossing the blood-CSF barrier into CSF. This appears to be the most likely site for physiologic entry of leukocytes into CSF. A second route of cell entry is also across the blood-CSF barrier, into the subarachnoid space, involving postcapillary venules at the pia into the subarachnoid space and the Virchow-Robin perivascular spaces. The endothelial cells express adhesion molecules, which promote T cell adherence, allowing direct exchange between circulating leukocytes and perivascular cells [37, 38]. The third route involves activated T cells moving from blood to the parenchymal perivascular space, across the BBB [29].

Leukocyte transmigration into tissue, including the CNS, involves a coordinated stepwise process [39]. There is initial contact, then tether-

ing/rolling (involving selectins and glycoprotein ligands), activation (involving chemokines and G protein-coupled receptors), adhesion (involving integrins and adhesion molecules), and diapedesis with migration to vascular junctions, penetration into the subendothelial compartment, and breach of the vascular basement membrane into tissue [39]. T cell migration into the CNS under inflammatory conditions involves  $\alpha$  (alpha) 4 $\beta$  (beta) 1 integrin expressed on T cells, interacting with vascular cell adhesion molecule 1 on activated endothelial cells. Expression of chemokines and chemokine receptors also plays a role in T cell trafficking. The rate-limiting step in transmigration is crossing the basement membrane laminins. T cells migrate across laminin 411 but not laminin 511. Laminin  $\alpha$  (alpha) 4 (a component of laminin 411) preferentially involves CD4+ T cell migration, but not CD8+ T cell macrophages or dendritic cells.

It has been suggested that WBC extravasation into the spinal cord may differ somewhat from that into the brain, but very little work has been done in this area [40].

CNS immune surveillance may occur primarily within the subarachnoid space [29]. This is thought to be the initial site of T cell infiltration, where cells can be reactivated by MHC Class II APCs, with T cell proliferation and formation of large cellular aggregates. There can be a rapid T cell response within the subarachnoid space to antigen challenge. This reactivation of T cells promotes further inflammation and cell entry into the perivascular space and then the brain parenchyma.

---

## Major Histocompatibility Molecule Expression

In the CNS resting state, there is absent or minimal expression of MHC Class I and II molecules [41, 42]. MHC expression is generally limited to low-level expression on microglia and endothelial cells, but can be induced in a variety of CNS components [43]. Interferon gamma (IFN $\gamma$ ) induces MHC expression on neurons [28]. Astrocytes can also express MHC.

## CNS Cell Components

### Microglia

Microglia make up the primary CNS resident immune cell [44]. They are the main APCs in the CNS, responsible for innate immune surveillance [45, 46]. Microglia are derived from erythro-myeloid progenitors in the yolk sac before embryonic day 1 [47]. They continuously proliferate throughout the lifetime of the individual. Microglia make up about 10–15% of all glial cells [48]. They are usually in a resting state. Microglial activation and proliferation is increased when there is any sort of CNS injury including neurodegeneration. These glia are present throughout the CNS but enriched in certain areas, with more microglia in gray matter than white matter [49]. Mature cells express macrophage-specific markers including toll-like receptors (TLRs), CD11b integrin, and the F4/80 glycoprotein, but show lower expression of CD45. Based on morphology, microglia are classified as resting ramified, activated, or amoeboid phagocytic cells [44]. Amoeboid phagocytic microglia predominate in the perinatal brain, but become ramified resting microglia during postnatal development. They can be activated by injury, infection, or neurodegenerative processes [46]. Microglia are constantly active, surveying the brain and interacting with synapses. They help to prune redundant synapses and actively participate in synaptic remodeling along with astrocytes [35].

In macrophage biology, responses are classified as M1 (upregulation of proinflammatory mediators and production of reactive oxygen species) and M2a (anti-inflammatory activity) and M2c (deactivation/wound healing activity) [50]. It remains controversial whether microglia can truly be classified as M1/M2.

Microglial function is driven by CNS microenvironment changes. Microglia monitor their microenvironment and conduct routine surveillance of the CNS via pinocytosis and neuronal interaction [48, 51]. They respond to a complex mix of excitatory and inhibitory input, including cell-cell contact and soluble factor exposures.

Activation by inflammatory or injury factors provokes a preprogrammed response designed to both kill and promote recovery and repair. Classical activation, alternative activation, and acquired deactivation are all going on, but may differ within regional areas. As examples, substance P neurotransmitter causes activation, while neuronal activity inhibits MHC class II expression to IFN $\gamma$ . A neuronal surface molecule (CD200) appears to be an important regulator of microglial function. Soluble factors such as granulocyte-macrophage colony-stimulating factor (GM-CSF) and macrophage-CSF (MO-CSF) affect microglia function and development.

Resting ramified microglia are activated by detecting lipopolysaccharides, amyloid beta, thrombin, IFN $\gamma$ , and other proinflammatory cytokines [52]. Microglia express TLR. They can initiate innate immune responses by producing cytokines such as interleukin-1 (IL-1), IL-6, and tumor necrosis factor  $\alpha$  (TNF $\alpha$ ); chemokines such as monocyte chemoattractant protein-1 (MCP-1), macrophage inflammatory protein-1, and RANTES; and nitric oxide (NO) (Table 1.3). The net result is local cell production of more proinflammatory cytokines and chemokines, and upregulation of immunomodulatory surface markers, with injury to the BBB and subsequent entry of soluble factors and systemic immune cells. Microglial activation precedes this systemic cell entry. CNS injury results in phagocytic and cytotoxic activities of microglia. Complement and Fc gamma receptors are upregulated, leading to enhanced phagocytic ability. Cytotoxic superoxide radicals and NO are released into the microenvironment.

Resting microglia are very poor APCs. However, activation causes marked expression of

MHC and costimulatory molecules [53, 54]. The activation state involves morphological changes as well as gene expression changes, migratory and proliferative responses, and phagocytic behavior. Activated microglia will express CD40, CD80, CD86, and MHC class II molecules. Subsequent interaction with T cells leads to microglial release of nitric synthase. IFN $\gamma$  promotes MHC class II as well as adhesion and costimulatory molecule expression.

Microglia have an important role in the development and plasticity of synapses [55]. In essence they shape normal CNS circuitry and modify circuits during inflammation. Microglia also play an important role in regulation. Microglia express Fas ligand, which can bind to Fas receptor on T cells, leading to activation-induced T cell apoptosis. Cytotoxic microglial products, such as NO, can lead to death of immune cells (Table 1.3). Thus, activation of microglia can be self-limited, as it leads ultimately to removal of effector immune cells.

Microglia dynamically modulate neurons and astrocytes, share receptors, and produce factors that activate these surrounding cells. Microglia modulate glutamate levels and can protect or injure neurons [56]. They are a central immune system player in the CNS and interact with and regulate astrocytes. Disease-associated microglia have been identified in areas of neurodegeneration; they appear to be generated through the detection of neurodegeneration-associated molecular pattern, using Trem2 signaling pathways [57].

## Astrocytes

Astrocytes are the most common glial cell in the CNS and make up 20–40% of the total number of CNS cells. They play multiple roles, including neural circuit formation with trophic as well as structural support to neurons, promoting formation of synapse as well as their pruning (Table 1.4) Astrocytes maintain microenvironment homeostasis and contribute to recovery after CNS injury [58, 59]. They produce antioxidants (glutathione), recycle neurotransmitters (glutamate,

**Table 1.3** Activated microglia products

Chemokines
Complement proteins
Cytokines
Neurotrophic factors
Prostaglandins
Proteinases
Reactive oxygen species/reactive nitrogen species (nitric oxide, peroxynitrite, superoxide)

**Table 1.4** Role of astrocytes

Neuronal support
Microenvironmental ion, pH homeostasis
Glycogen storage
Clearance of toxic waste products
Neural circuit formation and support
Synapse formation
Synapse pruning
<i>Synaptic transmission modulation</i>
Glutamate uptake
Release of neuromodulatory factors
Astrocyte neuron gap junction
Neuron and glial survival
Production of neurotrophins: brain-derived neurotrophic factor (BDNF), neurotrophin-3 (NT-3), at baseline; BDNF, nerve growth factor (NGF) on injury
Astrocyte-mediated growth factor production
Maintenance of blood-brain barrier
Astrocyte end feet surround CNS capillaries and perivascular macrophages
Astrocyte products can increase or tighten permeability
Immune function
Contribute to both innate and acquired immunity

GABA), and maintain the BBB. The astrocyte foot process helps to form the BBB and glymphatic system [60].

There is regional variation in astrocyte to neuron ratio, with higher ratios in areas that are dense with dendrite and axons [59]. Overall astrocyte to neuron ratio is controversial, ranging from four to five times more astrocytes, down to a one to one ratio [61].

Astrocyte morphology can differ. Protoplasmic astrocytes are found in gray matter, where their processes envelope synapses [61]. They show numerous ramified branches contacting neurons and blood vessels [21]. Fibrous astrocytes are found in white matter, where their processes contact nodes of Ranvier [59]. They show longer, thinner processes.

All astrocytes express intermediate filament glial fibrillary acidic protein (GFAP). Activation results in upregulation of GFAP as part of gliosis. Astrocytes are dynamic and plastic. A host of CNS insults (trauma, stroke, infection, neurodegenerative disease) can trigger astrocytes moving from the resting to reactive state. Two distinct types of reactive astrocytes are described, A1 and

A2 [58]. A1 astrocytes are induced by classically activated neuroinflammatory microglia, via release of IL1 $\alpha$ , TNF, and C1q. A1 astrocytes upregulate destructive complement cascade genes and induce rapid death of neurons and oligodendrocytes. In contrast A2 astrocytes upregulate neurotrophic factors and can be considered neuroprotective. It has been postulated that A1 astrocytes contribute to the death of neurons and oligodendrocytes in neurodegenerative diseases.

It is also known that astrocytes can process glucose to lactate. They may provide lactate as an energy source to neurons during periods of increased demand [62].

Astrocytes play an important role in regulating CNS inflammation and cell trafficking. In vitro, they can produce proinflammatory cytokines and chemokines, and reactive oxygen species (ROS) to enhance inflammation, as well as regulatory cytokines and ROS scavengers to limit inflammation [63]. Astrocytes have important interactions with blood vessels. Reactive astrocytes can act as perivascular barriers to restrict leukocyte entry during pathologic states.

With regard to the role of the astrocyte as an immune cell, they appear to function in both innate and acquired immunity, both in the normal and inflamed CNS. Astrocytes have dual actions, both beneficial and injurious. Astrocytes can express a variety of pattern recognition receptors, including TLRs, dsRNA-dependent protein kinase, complement receptors, mannose receptors, and scavenger receptors. Astrocytes also show APC-like function in vitro. They can be induced to express MHC class I and II molecules, to upregulate costimulatory molecules CD80 and CD86, to activate CD4+ and CD8+ T cells, and to present antigen to CD4+ T cells [4, 21]. During inflammation astrocytes release a variety of cytokines (IL-1, IL-6, and IL-10; TNF $\alpha$ ; transforming growth factor  $\beta$  (TGF $\beta$ )) that influence T cell responses. Astrocytes can contribute to lymphocyte penetration into the CNS in three ways: by a BBB effect, by expression of adhesion molecules such as ICAM-1 and VCAM-1, and by release of chemokines such as CCL5, CCL2, CXCL8, and CXCL10. Therefore astrocytes can participate in amplifying CNS inflammatory responses, but

also appear to suppress T cell activation by upregulating cytotoxic T lymphocyte antigen (CTLA)-4 on activated T cells [21]. Astrocytes can also induce regulatory T cells exhibiting suppressor activity. Activated astrocytes release IL-17 to suppress Th17 cells.

Astrocytes both impede and promote CNS repair mechanisms. By forming a glial scar there is an additional physical barrier producing multiple biochemical changes, including expression of molecules on the astrocyte surface that can block axon regeneration as well as oligodendrocyte precursor cells. By production of certain chemokines, cytokines, and matrix metalloproteinases, as well as their tissue inhibitors, repair is promoted.

## Oligodendrocytes

Oligodendrocytes are the myelin-making glial cells of the CNS. Oligodendrocytes form a myelin sheath around multiple axons to electrically insulate them. This results in sodium channel clustering at the nodes of Ranvier, to allow saltatory conduction. Normal axonal transport and neuronal viability seems to require proper myelination, which also boosts axon diameter. Oligodendrocytes provide trophic support to neurons via neurotrophic factors such as glial derived (GDNF), brain derived (BDNF), and insulin-like 1 (IGF-1) growth factors [64].

At peak myelination, an oligodendrocyte supports a membrane weight 100 times its cell body [65]. Oligodendrocytes do not just myelinate, but facilitate transfer of metabolites to neurons and support axonal health.

Oligodendrocyte precursor cells (OPCs) with high mitochondrial demands are highly susceptible to metabolic stress injury. They are glucose dependent. Oligodendrocytes also show extremely high metabolic rates and consume large quantities of oxygen and adenosine triphosphate (ATP), leading to high levels of intracellular hydrogen peroxide and ROS [66, 67]. The numerous myelin synthesis enzymes, which require iron as a cofactor, results in OPCs containing the highest intracellular iron

stores in the brain [64]. This can result in free radical formation and lipid peroxidation. Oligodendrocytes also have only low concentrations of the anti-oxidative enzyme glutathione. The capacity of the oligodendrocyte's endoplasmic reticulum to produce and fold proteins is susceptible to minimum changes causing marked disturbances. All of this makes oligodendrocytes particularly vulnerable to oxidative damage and mitochondrial injury and more vulnerable to bystander damage than neurons or astrocytes.

Oligodendrocytes are vulnerable to excitotoxic cell damage; they express glutamate  $\alpha$ -amino-3-hydroxy-5-methyl-4-isoxazolepropionic acid (AMPA), kainate, and *N*-methyl-D-aspartate (NMDA) receptors and the ATP receptor P2x7. Proinflammatory cytokines such as TNF $\alpha$  induce oligodendrocyte apoptosis by binding to the p55 TNF receptor [67]. Although IFN $\gamma$  has no negative effect on mature oligodendrocytes, it is highly toxic for proliferating OPCs and mildly toxic for immature oligodendrocytes. A variety of proinflammatory cytokines can induce mitochondrial injury, indirectly damaging the more vulnerable oligodendrocyte population. Autoantibodies which bind to surface myelin or oligodendrocyte epitopes can lead to damage via complement activation or Fc receptor recognition on activated neurophages.

Oligodendrocytes do not express MHC antigens, but in vitro exposure to IFN $\gamma$  results in MHC class I induction.

## Neurons

Although neurons have been said not to express MHC, recent work indicates they most likely do express MHC class I that can be up- or down-regulated by various factors [68]. In vitro exposure to IFN $\gamma$  induces MHC class I expression on human axons [69]. This would make them vulnerable to attack by CD8+ T cells. Natural killer (NK) cells can also lead to neuronal destruction. MHC class II was also noted on discrete subsets of human neural stem cells during development, independent of inflammatory stimuli [70].

Neurons can regulate T cell activities either directly or indirectly, using a variety of contact-dependent and contact-independent mechanisms. They release soluble factors (neurotransmitters, neuropeptide, neurotrophins, cytokines, soluble Fas ligand, soluble ICAM-5) that can reduce microglial and T cell activation. This downregulation occurs predominantly within the perivascular and subarachnoid spaces [28]. Neurons can also interact directly with microglia and T cells via contact-dependent mechanisms involving neuronal glycoproteins such as CD22, CD47, CD200, neural cell adhesion molecule, and semaphorins [28].

## Endothelial Cells

CNS endothelial cells express MHC class I but not class II antigen. Brain capillary endothelium contain enzymes not otherwise found in the CNS (alkaline phosphatase and  $\gamma$ -glutamyl transpeptidase). They have much fewer cytoplasmic vesicles than non-CNS endothelium, which will contribute to lower penetration into the CNS. Pericytes (of mesodermal origin) are found along the length of the cerebral capillaries and partially surround the endothelium and contribute to the basal lamina [19, 71]. They play a critical role in BBB maturation and maintenance [72]. (C, E). Astrocytes have integrins on their end feet that bind to laminin in the basal membrane to provide an additional seal to the BBB. There is actually a dual basement membrane surrounding the endothelium, a three-dimensional mesh as thick as 200 nm, consisting of proteins including integrins, dystroglycans, collagens, and laminins. Disruption of extracellular matrix increases BBB permeability [73].

---

## Other Immunologic Factors

### Cytokines

Immune system cells produce cytokines that can have important effects on the nervous system. Cytokines such as IL-1, IL-6, and TNF cross the

BBB around the hypothalamus, due to fenestration as well as active transport mechanisms. They have direct impact on the hypothalamic neurons which regulate temperature, appetite, and sleep [5].

### Matrix Metalloproteinases (MMPs)

MMPs are a family of calcium-dependent zinc-containing endopeptidases that degrade extracellular matrix to increase capillary permeability and permit cell penetration. They also proteolytically process many signaling molecules [74]. They are involved in post-injury remodeling, axonal growth, neurogenesis, angiogenesis, myelinogenesis, CNS barrier disruption, demyelination, and a variety of immune factor actions [75]. They can be divided into four groups of enzymes: collagenases, stromelysins, gelatinases, and membrane-type metalloproteinases [56]. They are activated by cleavage, plasmin, or reactive oxygen radicals. MMP-2 (gelatinase A) is normally present in brain tissue and CSF. MMP-9 (gelatinase B), MMP-3, and MMP-12 are induced during an inflammatory response involving immediate early genes (c-FOS, c-JUNE) and cytokines such as TNF $\alpha$  (alpha) and IL-1B. Astrocytes stain for MMP-2. MMP-9 appears in endothelial cells and neutrophils during CNS injury. MMP-3 has been detected in microglia and neurons during ischemia, while MMP-12 is expressed by activated microglia and macrophages.

### Toll-Like Receptors (TLRs)

TLRs are part of the innate immune system. They are pathogen recognition receptors, type I transmembrane glycoprotein receptors with a highly variable extracellular region, and a highly conserved intracellular tail, localized to the cell surface or within endosomes [76]. They protect the host against pathogens. Many different TLRs are expressed by microglia [77]. They trigger a standardized cytokine and chemokine response, regardless of the inciting antigen, that can be

beneficial or harmful. Activation of astrocytes, oligodendrocytes, and neurons can also result in TLR expression. These TLRs play various roles which are cell specific and include cell migration and differentiation, limiting inflammation, and mounting repair processes.

## Nervous Immune and Endocrine System Network

There is a strong reciprocal relationship between the nervous, immune, and endocrine systems. These three systems participate in an extensive tri-directional network that involves both cell to cell contact and soluble factors (cytokines/chemokines, growth factors, hormones, neurotransmitters/neuropeptides). Sharing regulatory molecules allows coordinated responses to homeostasis disturbance produced by inflammation, infection, or stress [78]. These three body organ systems are anatomically and functionally connected. Neuroimmune activation and neuroinflammation play an important role even in diseases not considered to be classically neuroimmune, such as stroke, Alzheimer disease, and Parkinson disease.

Neurotransmitters help regulate the host response to injury and infection. Immune cells express neurotransmitter receptors. Catecholamines can affect antigen presentation by dendritic cells, enhance antibody responses, and suppress cellular immune responses, clonal lymphocyte expansion, and cell migration and trafficking [79]. Net effects reflect whether  $\alpha$  (alpha) or  $\beta$  (beta) adrenergic receptors are activated.

The brain helps control immune activation. The cholinergic vagus nerve excites sympathetic neurons that innervate the spleen and synapse directly on immune cells [80]. Immune cells express receptors for pituitary hormones (prolactin, human growth hormone, thyroid-stimulating hormone, insulin-like growth factor 1) as well as neurotransmitters (acetylcholine, glutamate, norepinephrine, endorphins). In turn, MHC Class I molecules modulate neural synapse formation during brain development and can regulate these

synapses as well in the mature brain [81]. Cytokines such as TNF regulate the AMPA class of glutamatergic receptors.

The brain and immune system communicate via the hypothalamic-pituitary-adrenal gland (HPA) axis and the sympathetic nervous system. The HPA axis maintains homeostasis by regulating the neuroendocrine, sympathetic nervous system, and immune system. Abnormalities in HPA axis have been implicated in autoimmune-/immune-mediated disorders [82]. It is an important feedback loop and a major component of how the nervous and endocrine systems communicate. The paraventricular nucleus of the hypothalamus secretes two peptides, vasopressin and corticotropin-releasing hormone (CRH). They in turn act on the anterior lobe of the pituitary gland to secrete adrenocorticotrophic hormone (ACTH). In turn, ACTH acts on the adrenal gland cortex to produce glucocorticoid hormones (chiefly cortisol), which in a negative feedback loop suppress CRH and ACTH release. CRH synthesis is influenced by stress cortisol blood levels and the diurnal sleep-wake cycle. Cortisol normally rises 30–45 min after awakening in the morning, and in the late afternoon, and is lowest in the middle of the night.

Psychoneuroimmunology is a reflection of the organ system links outlined above. It studies the interactions between psychological processes, such as stress and anxiety, and the nervous and immune systems. Traumatic life events, personality traits, coping mechanisms, and strong emotions can impact on nervous and immune function. For example, cell-mediated immunity can be impaired in individuals who lose a loved one. Stress can make individuals more vulnerable to infections. Psychoneuroimmunology evaluates models such as sickness behavior, neuropsychiatric disorders, and the effects of stress on the nervous system.

---

## Summary

The immune system plays a pivotal role in neuroimmune disorders. In addition, it is increasingly recognized to be a factor in most major

neurologic diseases. It also determines how the body responds behaviorally to external factors. Practicing neurologists who are familiar with basic neuroimmunology concepts will have a better understanding of current and future advances in understanding and treating nervous system disorders.

## References

1. Gruol D. Advances in neuroimmunology. *Brain Sci.* 2017;7(10) <https://doi.org/10.3390/brainsci7100124>.
2. Martin CR, Osadchiy V, Kalani A, et al. The brain-gut-microbiome axis. *Cell Mol Gastroenterol Hepatol.* 2018;6:133–48.
3. Ransohoff RM, Kivisakk P, Kidd G. Three or more routes for leukocyte migration into the central nervous system. *Nat Rev Immunol.* 2003;3:569–81.
4. Pender MP. An introduction to neuroimmunology. In: Pender MP, McCombe PA, editors. *Autoimmune neurological disease.* Cambridge: Cambridge University Press; 1995. p. 14–25.
5. Bhat R, Steinman L. Innate and adaptive autoimmunity directed to the central nervous system. *Neuron.* 2009;64:123–32.
6. Diamond B, Huerta PT, Mina-Osorio P, et al. Losing your nerves? Maybe it's the antibodies. *Nat Rev Immunol.* 2009;9:449–56.
7. Tobin WO, Guo Y, Krecke KN, et al. Diagnostic criteria for chronic lymphocytic inflammation with pontine perivascular enhancement responsive to steroids (CLIPPERS). *Brain.* 2017;140:2415–25.
8. Blaabjerg M, Hemdrup AL, Drisci L, et al. Omics-based approach reveals complement-mediated inflammation in chronic lymphocytic inflammation with pontine perivascular enhancement responsive to steroids (CLIPPERS). *Front Immunol.* 2018;9:741.
9. Varadkar S, Bien CG, Kruse CA, et al. Rasmussen's encephalitis: clinical features, pathobiology, and treatment advances. *Lancet Neurol.* 2014;13:195–2015.
10. van der Kooij SM, van Buchem MA, Overbeek OM, et al. Susac syndrome: a report of four cases and a review of the literature. *Neth J Med.* 2015;73(1):10–6.
11. Kleffner I, Dörr J, Ringelstein M, et al. Diagnostic criteria for Susac syndrome. *J Neurol Neurosurg Psychiatry.* 2016;87:1287–95.
12. Dalmau J, Graus F. Antibody-mediated encephalitis. *N Engl J Med.* 2018;378(9):840–51.
13. Vernino S, Stiles LE. Autoimmunity in postural orthostatic tachycardia syndrome: current understanding. *Auton Neurosci.* 2018; <https://doi.org/10.1016/j.autneu.2018.04.005>.
14. Doherty TA, White AA. Postural orthostatic tachycardia syndrome and the potential role of mast cell activation. *Auton Neurosci.* 2018; <https://doi.org/10.1016/j.autneu.2018.05.001>.
15. Blomberg J, Gottfries CG, Elfaitouri A, et al. Infection elicited autoimmunity and myalgic encephalomyelitis/chronic fatigue syndrome: an explanatory model. *Front Immunol.* 2018;9:229.
16. Regeniter A, Kuhle J, Mehling M, et al. A modern approach to CSF analysis: pathophysiology, clinical application, proof of concept and laboratory reporting. *Clin Neurol Neurosurg.* 2009;111:313–8.
17. Maurer MH. Proteomics of brain extracellular fluid (ECF) and cerebrospinal fluid (CSF). *Mass Spec Rev.* 2010;29:17–28.
18. Svenningsson A, et al. Adhesion molecule expression on cerebrospinal fluid T lymphocytes: evidence for common recruitment mechanisms in multiple sclerosis, aseptic meningitis, and normal controls. *Ann Neurol.* 1993;34:155–61.
19. Engehardt B, Sorokin L. The blood-brain and the blood-cerebrospinal fluid barriers: function and dysfunction. *Semin Immunopathol.* 2009;31:497–511.
20. Palmer AM. The role of the blood-CNS barrier in CNS disorders and their treatment. *Neurobiol Dis.* 2010;37:3–12.
21. Nair A, Frederick TJ, Miller SD. Astrocytes in multiple sclerosis: a product of their environment. *Cell Mol Life Sci.* 2008;65:2702–20.
22. Dhuria SV, Hanson LR, Frey WH II. Intranasal delivery to the central nervous system: mechanisms and experimental considerations. *J Pharm Sci.* 2010;99:1654–73.
23. Louveau A, Smirnov I, Keyes TJ, et al. Structural and functional features of central nervous system lymphatics. *Nature.* 2015;523(7560):337–41.
24. Goodman JR, Adham ZA, Woltjer RL, et al. Characterization of dural sinus-associated lymphatic vasculature in human Alzheimer's dementia subjects. *Brain Behav Immun.* 2018; <https://doi.org/10.1016/j.bbi.2018.07.020>.
25. Da Mesquita S, Louveau A, Vaccari A, et al. Functional aspects of meningeal lymphatics in ageing and Alzheimer's disease. *Nature.* 2018;560(7717):185–91.
26. Weller RO, Kida S, Zhang ET. Pathways of fluid drainage from the brain: morphological aspects and immunological significance in rat and man. *Brain Pathol.* 1992;2:277–84.
27. Johnston M, Zakharov A, Papaiconomou G, et al. Evidence of connections between cerebrospinal fluid and nasal lymphatic vessels in humans, non-human primates and other mammalian species. *Cerebrospinal Fluid Res.* 2004;1:2–15.
28. Tian L, Rauvala H, Gahmberg CG. Neuronal regulation of immune responses in the central nervous system. *Trends Immunol.* 2009;30:91–9.
29. Goverman J. Autoimmune T cell responses in the central nervous system. *Nat Rev Immunol.* 2009;9:393–407.
30. Bulloch K, Miller MM, Gal-Toth J, et al. CD11c/EYFP transgene illuminated a discrete network of dendritic cells within the embryonic, neonatal, adult, and injured mouse brain. *J Comp Neurol.* 2008;508:687–710.



31. Felger JC, Abe T, Kaunzner UW, et al. Brain dendritic cells in ischemic stroke: Time course, activation state, and origin. *Brain Behav Immun*. 2010;24(5):724–37.
32. Hatterer E, Touret M, Belin MF, et al. Cerebrospinal fluid dendritic cells infiltrate the brain parenchyma and target the cervical lymph nodes under neuroinflammatory conditions. *PLoS One*. 2008;3:1–15.
33. Gottfried-Blackmore A, Kaunzner UW, Idoyaga J, et al. Acute in vivo exposure to interferon- $\gamma$  enables resident brain dendritic cells to become effective antigen presenting cells. *Proc Natl Acad Sci U S A*. <https://doi.org/10.1073/PNAS.0911509106>.
34. Stevenson PG, Austyn JM, Hawke S. Uncoupling of virus-induced inflammation and anti-viral immunity in the brain parenchyma. *J Gen Virol*. 2002;83:1735–43.
35. Ransohoff RM, Schafer D, Vincent A, et al. Neuroinflammation: ways in which the immune system affects the brain. *Neurotherapeutics*. 2015;12(4):896–909.
36. Kivisakk P, Mahad DJ, Callahan MK, et al. Human cerebrospinal fluid central memory CD4+ T cells: evidence by trafficking through choroid plexus and meninges via P-selectin. *Proc Natl Acad Sci U S A*. 2003;100:8389–94.
37. Lassman H, Schmied M, Vass K, et al. Bone marrow derived elements and resident microglia in brain inflammation. *Glia*. 1993;7:19–24.
38. Hickey WF. Leukocyte traffic in the central nervous system: the participants and their roles. *Semin Immunol*. 1999;11:125–37.
39. Lee BPL, Imhof BA. Lymphocyte transmigration in the brain: a new way of thinking. *Nat Immunol*. 2008;9:117–8.
40. Vajkoczy P, Laschinger M, Engelhardt B.  $\alpha$ 4-integrin-VCAM-1 binding mediates G protein-independent capture of encephalitogenic T cell blasts to CNS white matter microvessels. *J Clin Invest*. 2001;108:557–65.
41. Yang I, Kremen TJ, Giovannone AJ, et al. Modulation of major histocompatibility complex class I molecules and major histocompatibility complex-bound immunogenic peptides induced by interferon-alpha and interferon-gamma treatment of human glioblastoma multiforme. *J Neurosurg*. 2004;100:310–9.
42. Stoll M, Capper D, Dietz K, et al. Differential microglial regulation in the human spinal cord under normal and pathological conditions. *Neuropathol Appl Neurobiol*. 2006;32:650–61.
43. Cebrián C, Loike JD, Sulzer D. Neuronal MHC-I expression and its implications in synaptic function, axonal regeneration and Parkinson's and other brain diseases. *Front Neuroanat*. 2014;8:114.
44. Ling EA, Wong WC. The origin and nature of ramified and amoeboid microglia: a historical review and current concepts. *Glia*. 1993;7:9–18.
45. van Rossum D, Hanisch UK. Microglia. *Metab Brain Dis*. 2004;19:393–411.
46. Block ML, Hong JS. Microglia and inflammation-mediated neurodegeneration: multiple triggers with a common mechanism. *Prog Neurobiol*. 2005;76:77–98.
47. Schetters STT, Gomez-Nicola D, Garcia-Vallejo JJ, et al. Neuroinflammation: microglia and T cells ready to tango. *Front Immunol*. 2018;8:1905.
48. Barres BA. The mystery and magic of glia: a perspective on their roles in health and disease. *Neuron*. 2008;60:430–40.
49. Rivest S. Regulation of innate immune responses in the brain. *Nat Rev Immunol*. 2009;9:429–39.
50. Biber K, Owens T, Boddeke E. What is microglia neurotoxicity (not)? *Glia*. 2014;62:841–54.
51. Nimmerjahn A, Kirchhoff F, Helmchen F. Resting microglial cells are highly dynamic surveillants of brain parenchyma in vivo. *Science*. 2005;308:1314–8.
52. Bsibi M, Ravid R, Gveric D, et al. Broad expression of Toll-like receptors in the human central nervous system. *J Neuropathol Exp Neurol*. 2002;61:1013–21.
53. De Simone R, Giampaolo A, Giometto B, et al. The costimulatory molecule B7 is expressed on human microglia in culture and in multiple sclerosis acute lesions. *J Neuropathol Exp Neurol*. 1995;54:175–87.
54. Kreutzberg GW. Microglia: a sensor for pathological events in the CNS. *Trends Neurosci*. 1996;19:312–8.
55. Wu Y, Dissing-Olesen L, MacVicar BA, et al. Microglia: dynamic mediators and synapse development and plasticity. *Trends Immunol*. 2015;36(10):605–13.
56. Wang J, Tsirka SE. Contribution of extracellular proteolysis and microglia to intracerebral hemorrhage. *Neurocrit Care*. 2005;3:77–85.
57. Deczkowska A, Keren-Shaul H, Weiner A, et al. Disease-associated microglia: a universal immune sensor of neurodegeneration. *Cell*. 2018;173(5):1073–81.
58. Liddelow SA, Guttenplan KA, Clarke LE, et al. Neurotoxic reactive astrocytes are induced by activated microglia. *Nature*. 2017;541(7638):481–7.
59. Khakh BS, Sofroniew MV. Diversity of astrocyte functions and phenotypes in neural circuits. *Nat Neurosci*. 2015;18(7):942–52.
60. Snyder JM. Nervous system. In: *Comparative anatomy and histology: a mouse, rat, and human atlas*. 2nd ed. Seattle: Elsevier; 2018.
61. Sofroniew MV, Vinters HV. Astrocytes: biology and pathology. *Acta Neuropathol*. 2010;119:7–35.
62. Jha MK, Morrison BM. Glia-neuron energy metabolism in health and diseases: new insights into the role of nervous system metabolic transporters. *Exp Neurol*. 2018;309:23–31.
63. Voskuhl RR, Peterson RS, Song B, et al. Reactive astrocytes form scar-like perivascular barriers to leukocytes during adaptive immune inflammation of the CNS. *J Neurosci*. 2009;37:11511–22.
64. Bradl M, Lassmann H. Oligodendrocytes: biology and pathology. *Acta Neuropathol*. 2010;119:37–53.
65. Rosko L, Smith VN, Yamazaki R, et al. Oligodendrocyte bioenergetics in health and disease. *Neuroscientist*. 2018; <https://doi.org/10.1177/1073858418793077>.
66. McTigue DM, Tripathi RB. The life, death, and replacement of oligodendrocytes in the adult CNS. *J Neurochem*. 2008;107:1–19.

67. Jurewicz A, Matysiak M, Tybor K, et al. Tumour necrosis factor-induced death of adult human oligodendrocytes is mediated by apoptosis inducing factor. *Brain*. 2005;128:2675–88.
68. Shatz CJ. MHC class I: an unexpected role in neuronal plasticity. *Neuron*. 2009;64:40–5.
69. Clarkson BDS, Patel MS, LaFrance-Corey RG, et al. Retrograde toll like re-gamma signaling induces major histocompatibility class I expression in human-induced pluripotent stem cell-derived neurons. *Ann Clin Transl Neurol*. 2018;5(2):172–85.
70. Vagaska B, New SEP, Alvarez-Gonzalez C, et al. MHC-class-II are expressed in a subpopulation of human neural stem cells in vitro in an IFN $\gamma$ -independent fashion and during development. *Sci Rep*. 2016;6:24251.
71. Krueger M, Bechmann I. CNS pericytes: concepts, misconceptions, and a way out. *Glia*. 2010;58:1–10.
72. Yamazaki T, Mukouyama YS. Tissue specific origin, development, and pathological perspectives of pericytes. *Front Cardiovasc Med*. 2018;5:78.
73. Abbott NJ, Patagbendige AAK, Dolman DEM, et al. Structure and function of the blood-brain-barrier. *Neurobiol Dis*. 2010;37:13–25.
74. Andries L, Van Hove I, Moons L, et al. Matrix metalloproteinases during axonal regeneration, a multifactorial role from start to finish. *Mol Neurobiol*. 2017;54:2114–25.
75. Brkic M, Balusu S, Libert C, et al. Friends of foes: matrix metalloproteinases and their multifaceted roles in neurodegenerative diseases. *Mediat Inflamm*. 2015;2015:620581.
76. Fukata M, Vamadevan AS, Abreu MT. Toll-like receptors (TLRs) and Nod-like receptors (NLRs) in inflammatory disorders. *Semin Immunol*. 2009;21:242–53.
77. Van Noort JM, Bsibsi M. Toll-like receptors in the CNS: implications for neurodegeneration and repair. *Prog Brain Res*. 2009;175:139–48.
78. Chesnokova V, Melmed S. Minireview: neuro-immuno-endocrine modulation of the hypothalamic-pituitary-adrenal (HPA) axis by gp130 signaling molecules. *Endocrinology*. 2002;14:1571–4.
79. Tracey KJ. Reflex control of immunity. *Nat Rev Immunol*. 2009;9:418–28.
80. Pavlov VA, et al. Brain acetylcholinesterase activity controls systemic cytokine levels through the cholinergic anti-inflammatory pathway. *Brain Behav Immun*. 2009;23:41–5.
81. Goddard CA, Butts DA, Shatz CJ. Regulation of CNS synapses by neuronal MHC class I. *Proc Natl Acad Sci U S A*. 2007;104:6828–33.
82. Morale C, Brouwer J, Testa N, et al. Stress, glucocorticoids and the susceptibility to develop autoimmune disorders of the central nervous system. *Neurol Sci*. 2001;2:159–62.



# Principles of Immunotherapy

# 2

Jennifer Joscelyn, Javier Ochoa-Repáraz,  
and Lloyd Kasper

## Introduction

Immunotherapeutic intervention varies from immunomodulation, which adjusts the immune system back toward a state of homeostasis, to immunosuppression, which ablates specific compartments or pathways involved in the pathologic process. These approaches carry both benefit and risk. This chapter will discuss current and future principles of immunotherapeutic approaches.

## Autoimmunity

Autoimmune disease results from failure of tolerance, the ability to discriminate between self and nonself. The immune system may then attack the individual's own cells and tissues. An inflammatory state may arise due to excessive

activation of effector cells (resulting in a pro-inflammatory state) or insufficient regulatory cells leading to a loss of immune tolerance [1]. Several mechanisms work together to prevent autoimmunity. These mechanisms include central and peripheral tolerance, including T cell depletion, clonal anergy, and immune suppression provided by an important subpopulation of T regulatory (Treg) cells. These cells may carry either a CD4+ or CD8+ phenotype and include CD25+FoxP3+Tregs. Immunologic tolerance is controlled by this population of T cells [2]. Restoration of tolerance may be critical to the effective resolution of autoimmune disease processes (Fig. 2.1).

In addition to the loss of immune homeostatic balance in those with autoimmune conditions, genetic predisposition provides a further complex association. Multiple gene loci, most importantly the MHC/HLA haplotypes, are fundamental for the presentation of peptide antigens to T cells. Environmental variables such as geography, exposure, commensal microbiota, and infection also play a key role. Infections may activate self-reactive lymphocytes and lead to the development of autoimmune diseases in predisposed individuals.

Many autoimmune diseases follow a relapsing-remitting course, with periods of exacerbation followed by stability. This may relate to infection-triggered immune changes. The initiating response amplifies rapidly via activation of the

---

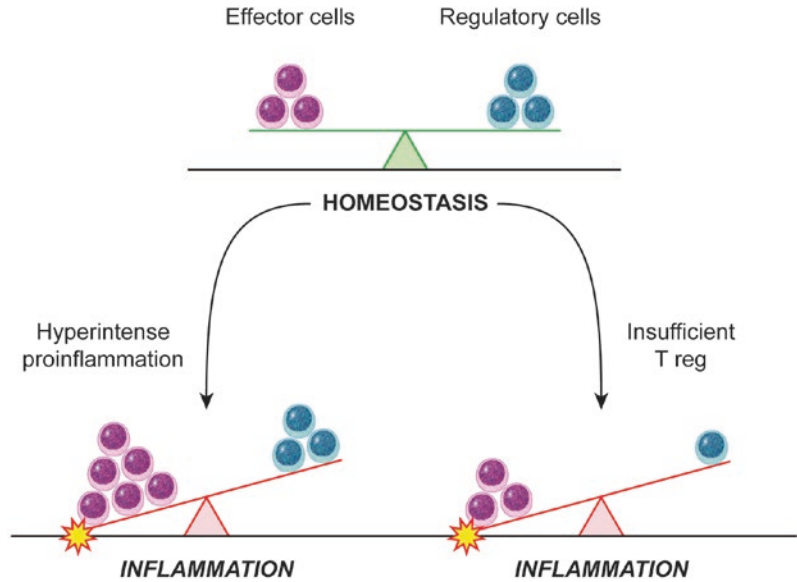
J. Joscelyn  
Thought Leader Liaison, Hooksett, NH, USA  
e-mail: [jjoscelyn@comcast.net](mailto:jjoscelyn@comcast.net)

J. Ochoa-Repáraz (✉)  
Eastern Washington University, Cheney, WA, USA  
e-mail: [jochoareparaz@ewu.edu](mailto:jochoareparaz@ewu.edu)

L. Kasper  
Department of Microbiology/Immunology,  
Dartmouth College, Hanover, NH, USA

Symbiotix Biotherapies, Boston, MA, USA

**Fig. 2.1** Homeostatic balance of immune system. (Reprinted with permission from William Scavone)



©2009 William Scavone

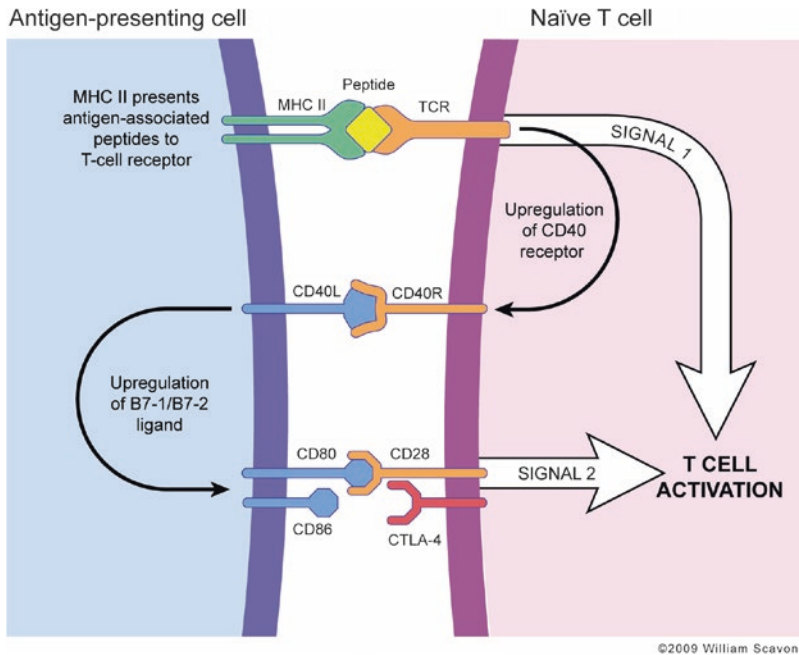
innate immune system but is soon followed by a more target-specific response via the adaptive immune system. This includes antigen-specific T cells and antibody-producing B cells. Cytotoxic T cells and antibodies lead to efficient destruction of the invading microbe by eliciting specific inflammatory molecules, such as the interleukins that further activate the immune system and destroy the target in a variety of ways (including direct cell to target contact and oxidative molecules such as nitric oxide). Once the invading organism is eliminated the reduction in the immune response is rapid, limiting the damage to host tissue. Memory cells persist and provide the basis for secondary antigen-specific response. In autoimmune disorders, the tissue damage and immunological response does not completely subside, although clinical remissions are commonplace [3].

Clinical autoimmunity arises as a result of an altered balance between autoreactive effector cells and regulatory [1, 4]. The goal of treating autoimmune disease is to re-establish immune homeostasis and restore the balance between effector and regulatory T lymphocytes. Current immunotherapies are primarily used to intervene early and reduce epitope spread, induce and support the “quiescent” stage, and prevent future exacerbations.

The immune system may often seem overwhelming and too complex for the non-immunologist to fully understand, but there are recognized patterns to make organizing the information and concepts easier. The immune system is always trying to maintain balance, so for each action, there is an equal and opposite reaction. Cell lineage and generative lymphoid organs form a second pattern (Fig. 2.2).

## T Cells

In T cell-mediated autoimmunity one of the most important players is the CD4+ T cell. Emerging from the thymus, naïve CD4+ cells differentiate into subtypes based on the cytokines they encounter in the periphery and/or within the CNS. Each CD4+ T cell subtype exhibits unique functions largely based on the cytokines they produce [5]. CD4+ T cells are both effector and regulatory. Effector CD4+ T cells can be categorized as either Th1 or Th2 T cells by their cytokine production. The signature cytokine for Th1 cells is interferon (IFN)- $\gamma$  and for Th2 cells is IL-4 (Fig. 2.3). Upon encounter with antigen/MHC complexes, naïve T cells become activated



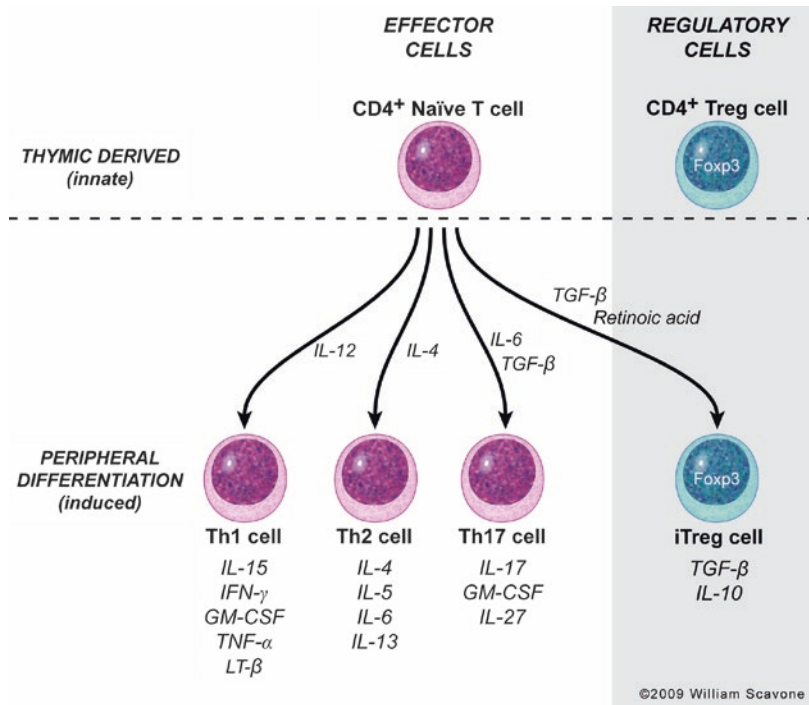
**Fig. 2.2** Adaptive immune activation. Co-stimulation and T cell activation: full activation of T cells in the periphery is dependent on the recognition of co-stimulation factors on antigen-presenting cells (APCs) and completion of the two-signal activation. The first signal is comprised of antigen recognition: the APC presents MHC-associated antigenic peptides to the T cell receptor (TCR) on the naïve T cell. Chemokines are released from the APC that react with the G-protein-coupled receptor (GPCR) on the T cell, increasing the affinity and avidity of the T cell/APC adhesion. Once the first signal is complete another set of molecules participate in increasing co-

stimulatory signaling and secreting polarizing cytokines; for example, CD40 receptor is upregulated on the APC and engages with the constitutively expressed CD40 ligand on the T cell. The second signal is comprised of an upregulation of B7-1/B7-2 (CD80/CD86) ligand on the APC, following antigen recognition, that binds to the CD28 receptor on the T cell. Once the second signal is complete, the T cell is activated leading to clonal expansion and differentiation into effector functions. It is important to note that without the completion of the second signal the T cells become functionally inactive, anergic. (Reprinted with permission from William Scavone)

and can polarize into either a Th1 or Th2 cell. The process is influenced by a variety of factors, the most important of which is the cytokine milieu. The principal cytokines produced by antigen-presenting cells (APCs) for influencing Th1 cell polarization is IL-12, and for the TH2 it is IL-4 (Fig. 2.3). Once polarized, on the single-cell level the CD4+ Th1 and Th2 cells are committed and cannot revert back to a naïve phenotype or convert to the other lineage. Using the early definition of T cell functions, IFN- $\gamma$  facilitates macrophage activation and IL-4 facilitates the production of certain immunoglobulin subtypes. However, the lines between Th1 and Th2 functions have become blurred. IFN- $\gamma$  is also required for the production of certain immunoglobulin (Ig) subtypes, and IL-4 can also be

involved in macrophage activation [5]. The Igs induced by IL-4 serve specific functions, separating the activity of the two T cells. IL-4 is required for the production of IgG1 and IgE. IgE sensitizes mast cells, a consequence of which can be allergic reactions; IgG1 is involved in opsonization of pathogens. The IFN- $\gamma$ -induced or classically activated macrophages produce nitric oxide (NO), which is pro-inflammatory and drives chronic inflammation and tissue injury. Other cytokines produced by Th2 cells that influence the immune response include IL-5, IL-6, and IL-13 (Fig. 2.3). Th1 T cells also produce IL-2, IL-15, granulocyte macrophage colony-stimulating factor (GM-CSF), tumor necrosis factor (TNF)- $\alpha$ , and other cytokines (Fig. 2.3). Like CD8+ T cells, Th1 cells also have the capac-

**Fig. 2.3** Naive CD4+ lineage. Naive CD4+ cells emerge from the thymus and further differentiate into subtypes based on the cytokine microenvironment. Each subtype of CD4 T cell exhibits unique functions largely based on the cytokines that they produce. Treg cells are both thymic derived and induced in the periphery (iTreg). (Reprinted with permission from William Scavone)



ity to induce cytotoxicity of target cells by several different mechanisms. The immune response can be shaped by controlling the phenotype of the responding CD4 T cell [5].

Treg cells are essential in the everyday control of immune responses and maintaining peripheral tolerance [6, 7]. Two populations of  $T_{reg}$  control inflammation: natural (constitutive) Treg cells and induced Treg cells (iTreg) (Fig. 2.3). Natural  $T_{reg}$  cells are a population of CD4+ lymphocytes residing in the thymus that express the interleukin (IL)-2 receptor CD25 and the transcription repression factor FoxP3. These cells constitute 5–12% of the entire CD4+ cell population and represent a very small proportion of the circulating WBC population. Specific populations of natural  $T_{reg}$  cells are generated principally by interaction with immature APCs in the periphery. They recognize major histocompatibility complex (MHC) molecules in association with autoantigens with high specificity. These natural  $T_{reg}$  cells are normally anergic but can be activated by exposure to antigens or to high concentrations of IL-2 released from activated TH1 cells. Induced  $T_{reg}$  cells are derived from either

naïve CD8+ or CD4+ precursor cells in the thymus in response to the local antigen or cytokine environment. Three subpopulations of iTreg cells can be distinguished on the basis of surface markers: CD8+  $T_{reg}$  cells, TH3 cells, and TR1 cells. The latter two are derived from CD4+ precursors. In autoimmune disease, autoantigens can stimulate the differentiation of these iTreg cells. iTreg cells release cytokines such as IL-10 and TGF- $\beta$  (Fig. 2.3) that suppress the activity of effector T cells as well as of APCs. Effector cells and APCs may be inhibited by direct contact with natural and induced  $T_{reg}$  cells and involve interactions of cell surface proteins. This helps prevent the development of hypersensitivity reactions of allergies, autoimmune disease, and promotes long-term graft tolerance. On the other hand, there may also be detrimental effects of inhibition of immune function by  $T_{reg}$  cells; it attenuates immunity to pathogens and reduces both immunological surveillance and prevention of tumorigenesis.

The best-studied  $T_{reg}$  cell to date is the Foxp3+ CD4+ T cell, a key regulatory molecule in the development and function of  $T_{reg}$  cells. FoxP3 is a

transcriptional repression factor of the Forkhead/winged box family. It is expressed by all functional  $T_{reg}$  cells except the TR1 class. Mutations in FoxP3 impair the development of  $T_{reg}$  cells in the thymus and are associated with inherited autoimmune diseases, such as Scurfy in the mouse and IPEX (an X-linked fatal autoimmune disorder) in humans [8, 9]. Seminal experiments have demonstrated that depletion of CD4+CD25+ suppressor cells results in the onset of systemic autoimmune disease in mice [10]. The defining influence of these cells in the control of autoimmunity was demonstrated in an experimental murine model. Foxp3 expressing cells were specifically depleted in adult mice, resulting in the development of rapidly fatal autoimmunity that involved a variety of host tissue beyond the lymphatic system [2]. Although the exact mechanisms by which  $T_{reg}$  cells regulate and suppress immune responses are not always clear, one method is through the production of the anti-inflammatory cytokine IL-10 [11]. IL-10 controls inflammation by regulating the expression of cytokines and molecules involved in antigen presentation.  $T_{reg}$  cells mediate peripheral tolerance by suppressing proliferation and cytokine production of autoreactive effector T cells that cause tissue damage and inflammation [12]. CD4 T cell population heterogeneity is essential for a properly functioning inflammatory response, and their differential production of cytokines is one method by which they exert their unique functions. As noted above,  $iT_{reg}$  can be derived from naïve CD8+ cells as well as CD4+ cells. The possibility that CD8+ T cells may also possess regulatory functions has received less attention, despite earlier studies [13]. CD8+ T cells can suppress the response of activated CD4+ cells. FoxP3 Treg cells inhibit the proliferation and cytokine production by both Th1 and Th2 cells and may suppress B cells [14].

---

## NK Cells

Natural killer (NK) cells are a subset of bone marrow-derived lymphocytes, distinct from B and T cells, that function in innate response to

kill microbe-infected cells and to activate phagocytes by secreting IFN- $\gamma$ ; they enhance the adaptive response against infectious agents [15]. NK cells do not express clonally distributed antigen receptors such as Ig or TCRs. Their activation is regulated by a combination of stimulatory and inhibitory cell surface receptors. The inhibitory cell surface receptors are responsible for recognizing self-MHC molecules [15]. The ability of NK cells to protect against infections is enhanced by IL-12 produced by macrophages, as well as antibody-mediated targeting. NK cells and other leukocytes may bind to antibody-coated cells and destroy them by opsonization. NK cells express an Fc receptor, Fc $\gamma$ RIII (CD16), that binds to IgG antibody arrays attached to a cell [15]. As a result, NK cells are activated and kill the opsonized target, via antibody-dependent cellular cytotoxicity (ADCC). Although NK cell-mediated ADCC is not as important as phagocytosis of microbes in defense against most bacterial and viral infections [15], in autoimmunity the connection between infections and initiation/amplification of the aberrant immune response is key. NK cells play opposing roles in autoimmunity, as they function as both regulators and inducers of autoimmune diseases, dependent on the cytokine milieu and cell-cell interactions. NK cells comprise about 10% of the lymphocytes in the blood and peripheral organs.

IL-15 appears to play pivotal roles in the differentiation of NK cells from their progenitors and their survival and activation. CD56bright NK cells are an important NK cell subset that exerts immunoregulatory effects [16]. In vivo, blockade of the human IL-2R by a monoclonal antibody (daclizumab) has been used for immunosuppression in transplantation, to treat leukemia and autoimmune diseases. In one study, in uveitis patients, administration of a humanized IL-2R blocking mAb induced a 4- to 20-fold expansion of CD56bright regulatory NK cells. The induced CD56bright regulatory NK cells from patients exhibited similar phenotype to naturally occurring CD56bright cells. Patients with active uveitis had a significantly lower level of CD56bright NK cells compared with normal donors. In addition, the induced CD56bright cells, but not CD56dim

cells, could secrete large amounts of immunosuppressive cytokine IL-10. This suggests that the induction of the CD56bright cells might lead to the remission of active uveitis [17]. This observation may have implications for IL-2R blockade therapy and for the potential role of CD56bright regulatory NK cells in autoimmune diseases. By blocking the IL-2R $\alpha$  chain the mAb can limit T cell expansion and direct the co-stimulated cell toward NK production (CD56bright) through the heterodimer IL2R $\beta$ , inducing IL-15. Antibodies to IL-2R $\alpha$  do not inhibit the action of IL-15 [18]. The IL-15 receptor includes IL-2/15R and  $\gamma$ c subunits, which are shared with IL-2 and an IL-15-specific receptor subunit, IL-15R [18]. The induced expansion of NK cells produced similar phenotype and function as naturally occurring NK cells and correlated highly to the reduction of inflammatory activity in human and animal studies.

---

## NKT Cells

Natural killer T (NKT) cells share characteristics of both T and NK cells and play a regulatory role in autoimmunity. NKT cells are thymically derived innate lymphocytes that express the TCR and receptors of the NK lineage, NK1.1. The TCR on the majority of the NKT cells expresses an invariant Va-Ja combination that translates into Va14 Ja281 (also called Ja18) in the mouse and Va24 JaQ in humans [19]. NKT cells recognize glycolipids, such as  $\alpha$ -galactosylceramide ( $\alpha$ -GalCer), presented by the CD1d molecule on APCs [20, 21]. Unlike the classical MHC molecule that presents protein to lymphocytes, the CD1d molecule presents glycolipids to the TCR on the NKT cell [22]. Because of TCR chain characteristics on classical NKT cells, they are also called invariant (i)NKT cells [19]. Invariant NKT cells (iNKTs) are regulatory T lymphocytes that are CD1d reactive with an invariant TCR $\alpha$  chain, V $\alpha$ 24-J $\alpha$ QV $\beta$ 11 [21]. The regulatory function of iNKT cells is related to their rapid and diverse secretion of cytokines like IFN- $\gamma$ , IL-4, IL-5, and IL-10 upon TCR stimulation. iNKTs play a dual role in the

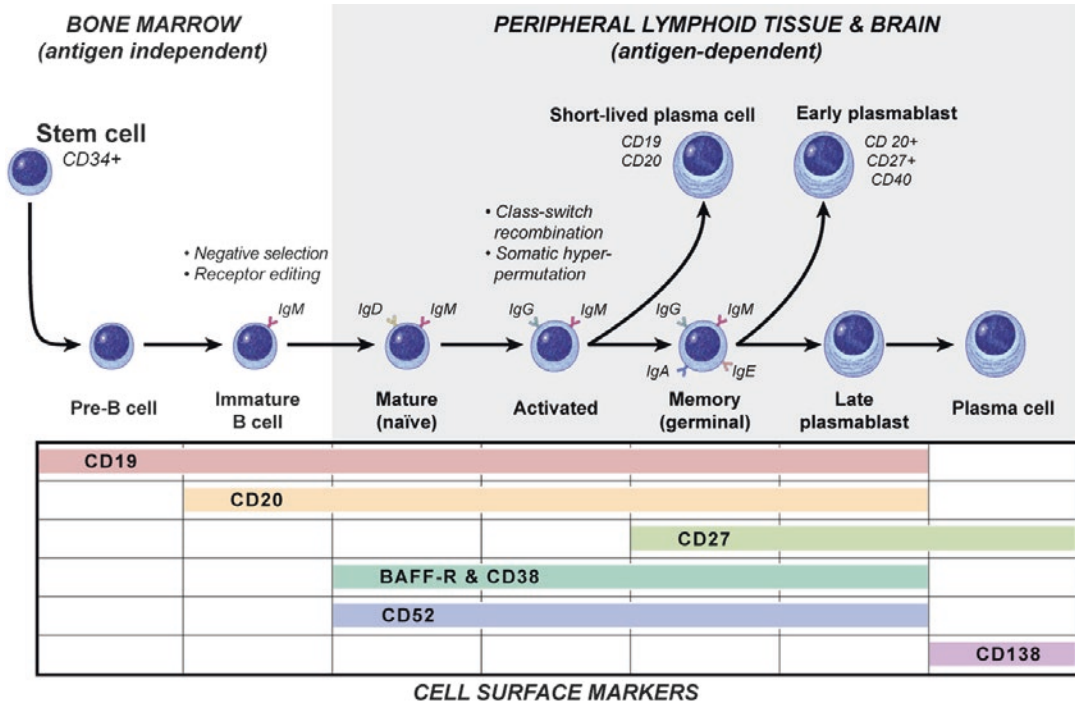
modulation of T cell-mediated immunity. They provide frontline defense against parasites, bacteria, and viruses and induce tolerance for the prevention of autoimmune diseases (similar to that of classical T<sub>regs</sub>). Balancing the two functions of adjuvant and regulation is related to the microenvironment, either to build an effective inflammatory immune response (upregulation of IL-12/IL-23 by APC or effector cells) or prevent autoimmunity with regulation/counter-regulation (upregulation of CD1d or IL-10 by APCs or effector cells). In EAE, it was noted that the lipid structure of the CD1 ligands influences the duration of interaction between APCs and iNKT cells and thus the cytokine secretion by the activated iNKT cell. A shortened glycolipid and TCR contact time produced TH2 cytokine profile, while a longer glycolipid and TCR contact time resulted in a pronounced TH1 cytokine profile of iNKT cells [19]. Concerted interactions between iNKT cells and CD1d+ cells, DCs, macrophages, and B cells are involved in rendering autoreactive T cells unresponsive [19]. A primary goal in the treatment of autoimmune disorders is to find a therapeutic regime that inhibits reactive T cells while improving regulatory cell function. iNKT cells represent an important cellular bridge between the innate and adaptive arms of the immune system.

---

## B Cells

The role of B cells in normal immunity is well understood. The role of B cells is less clear in autoimmune diseases and historically associated with antibody production, the antibody-dependent role. Lymphocytes are the main immune cells. As discussed earlier, T lymphocytes dictate cell-mediated immunity. B lymphocytes are responsible for humoral immunity, the host defense mediated by secreted antibodies that protect against extracellular microbes and their toxins [15]. Humoral immunity is important to prevent infection. Generation of the mature B cell pool involves stepwise development of hematopoietic stem cells into pro-B cells, which mature into pre-B cells and then





©2009 William Scavone

**Fig. 2.4** B cell maturation and humoral immune response. The maturation of B lymphocytes proceeds through sequential steps. Many of which occur within the bone marrow. There are receptor editing and negative selection prior to maturation. Once mature, the naive IgM+IgD+ B cell is able to recognize antigen and undergo activation upon engagement with T lymphocytes and

stimuli within the microenvironment. The activated, antigen-specific, effector cells can undergo class switching and affinity maturation, improving the capacity to identify and bind to an identified antigen. The expression of cell surface receptors is important to the understanding of B cell therapeutic targets for autoimmunity. (Reprinted with permission from William Scavone)

immature B cells [15, 23] (Fig. 2.4). Immature B cells are then exported to the periphery as transitional B cells, which undergo further selection and development. When mature IgM+IgD+ B cells encounter T cell-dependent antigen (Ag), they differentiate into high-affinity effector cells, namely, memory B cells and immunoglobulin (Ig)-secreting cells (plasma cells) within the secondary lymphoid tissue of germinal centers [15, 23] (Fig. 2.4). Mature B cells are responsible for the generation of humoral immunity and long-lived serological memory. The coordinated differentiation of B cells at these different stages of development and maturation is influenced by multiple factors, such as stromal cells and cytokines provided within the bone marrow environment, Ag exposure, and interactions between B cells, Ig-specific T cells, and dendritic cells (DC)

in the periphery [15, 24, 25]. Accumulating evidence strongly supports an increased involvement of B cells in autoimmune neurological diseases, with noted antibody-dependent and antibody-independent roles.

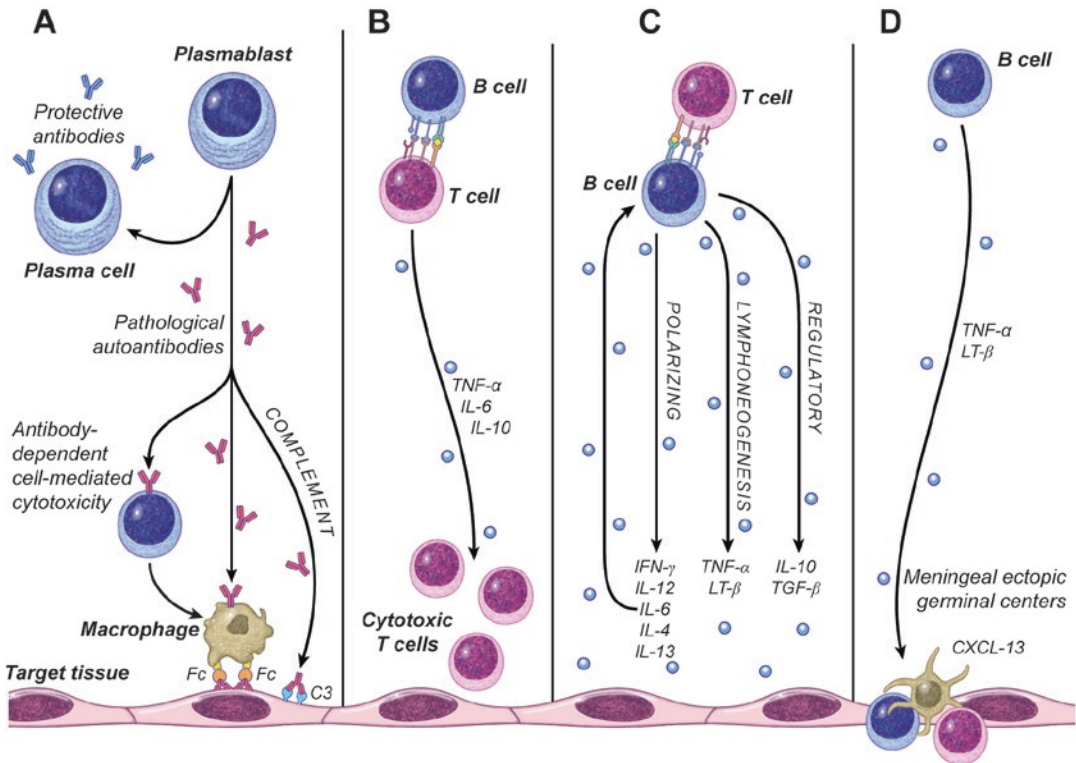
B cell development is complex and a multiple-step process. Differentiation of mature B cells into effector cells must be strictly regulated to ensure sufficient specific humoral immunity while simultaneously avoiding the production of autoantibodies. Receptor-ligand pairs of the tumor necrosis factor receptor (TNF-R/TNF) superfamily play critical roles in humoral immunity by regulating activated B cell responses [26]. Two members of the TNF family, B cell activating factor (BAFF) and a proliferation-inducing ligand (APRIL), have been identified in recent years as crucial factors for B cell survival,

differentiation, germinal center formation, and antibody production [27]. BAFF binds three receptors, which all belong to the TNF-R superfamily—BAFF receptor (BAFF-R) [28], transmembrane activator and calcium modulator and cyclophilin ligand interactor (TACI), and B cell maturation antigen (BCMA) [29, 30]; the latter two receptors also bind APRIL [27]. BAFF is predominately produced by myeloid cells such as macrophages, monocytes, dendritic cells, and astrocytes [31, 32] and neutrophils [33]. However, production can be further induced by cytokines (INF- $\gamma$  and IL-10) [32, 34]. Pathogen-associated molecular pattern (PAMP) molecules and toll-like receptors (TLR) can also induce production of BAFF in B cells, in response to microbial components such as peptidoglycan, CpG dsDNA, and lipopolysaccharide (LPS) when they are within contact [35, 36]. BAFF is required for late B cell development and maintenance of B cell homeostasis. Normal human B cells first express BAFF receptors at the transitional stage of development and remain capable of receiving BAFF-dependent signals at least until they terminally differentiate into plasma cells (PC) (Fig. 2.4). Dysregulation of BAFF has been observed in patients with many systemic autoimmune diseases. The serum levels of BAFF are notably increased in these patients and correlated with the severity of their symptoms [37–41]. It is speculated that BAFF protects self-reactive B cells from deletion by modifying the expression of pro- and anti-apoptotic molecules; it reduces the pro-apoptotic molecules while increasing the anti-apoptotic molecules [24, 26] and impairs B cell self-tolerance. Normally, BAFF provides survival signals for B cells involved in immune defenses against infection. Elevated BAFF levels are involved in the survival of self-reactive B cells and autoimmune diseases. BAFF does not affect the central self-tolerance of B cells during their early development in bone marrow, but influences the peripheral self-tolerance of B cells, especially in later transitional stages of B cell development (Fig. 2.4) [26, 42]. The relationship between BAFF and toll-like receptor (TLR) signaling is strong in mouse models of autoimmunity [36]

and therefore another potential area of therapeutic opportunity, as TLR signaling is also implicated in the pathogenesis of human autoimmune diseases [26]. Antagonists of BAFF are promising therapeutic agents to treat autoimmune diseases [26, 27].

Many organ-specific autoimmune diseases in humans are believed to be caused by T cells. Antibodies that cause disease are most often autoantibodies against self-antigens and less commonly are specific for foreign antigens. Autoantibodies may bind to self-antigens in tissues or they may form immune complexes with circulating self-antigens [15], such as in myasthenia gravis (MG). The contribution of activated B cells has traditionally been viewed as a secondary consequence of the breakdown of T cell tolerance. In certain neurological diseases, including myasthenia gravis and specific neuropathies, autoantibodies are pathogenic and exert a direct effect on self-antigens either by functioning as neutralizing antibodies or by activating and fixing complement on the targeted tissues (Fig. 2.5a) [27]. Normally the complement system helps eliminate microbes during innate and adaptive immune responses. Opsonization is probably the most important function of complement activation. However, during the membrane attack small peptide fragments are produced by proteolysis. These fragments are chemotactic for neutrophils and stimulate the release of inflammatory mediators from various leukocytes. Neutrophils also act on endothelium to enhance the movement of leukocytes and plasma proteins into affected tissues to eliminate microbes. In normal individuals, B cells are tightly controlled and prevented from making autoantibodies, perhaps via their interaction with  $T_{\text{regs}}$ . In autoimmune disorders, this process of activating and fixing complement by autoantibodies leads to activation of ADCC (Fig. 2.5a) [27]. In ADCC, NK cells and other leukocytes may bind to antibody-coated cells and destroy them.

Another mechanism of B cell involvement in autoimmune disorders involves the presentation of antigenic peptides, with clonal expansion of either autoreactive or regulatory T cells (Fig. 2.5b) [27, 43–45]. Divergence of T cell phe-



©2009 William Scavone

**Fig. 2.5** B cell functions in autoimmunity. (a) Antibody-producing cells—plasma cells (b). Antigen-presenting cells (autoreactive T cells with a specific antigen; regulatory with low levels of nonspecific antigen) (c). Cytokine-producing cells; regulatory (B cell activation with isolated CD40 stimulation), polarizing (B cell activation with dual

stimulation of BCR and CD40), lymphoneogenesis (memory B cells primarily produce pro-inflammatory cytokines, TNF $\alpha$ /LT following dual stimulation of BCR and CD40) (d). Development of tertiary/ectopic germinal centers. (Reprinted with permission from William Scavone)

notypes and functions relates once again to the environment and specificity of antigens. B cells present specific antigens to cognate CD4<sup>+</sup> T cells with extremely high efficiency to drive autoreactivity, so that they obtain help from CD4<sup>+</sup> T cells for the production of high-affinity antibodies. Nonspecific antigens derived from low levels of endogenous proteins are also presented by B cells, but the outcome of presentation of nonspecific antigens is T cell tolerance [43]. B cells are 100–1000 times more potent in antigen presentation than other postulated APCs, including dendritic cells [27, 46, 47]. B lymphocytes that bind protein antigens by their specific antigen receptors endocytose these antigens, process them in endosomal vesicles, and display MHC II-associated peptides for recognition. They are

also effective at presenting low concentrations of antigen. The membrane Ig of the B cell is a high-affinity receptor that specifically binds a particular antigen, even when the extracellular concentration of the antigen is very low [15]. Affinity maturation is in response to an antigen and increases with prolonged or repeated exposure. In addition to presenting antigen via MHCII, B cells also express co-stimulatory factors (such as B7) that activate, via two-signal co-stimulation, the autoreactive T lymphocyte. This, in turn, activates T cells by expressing CD40 ligand and secreting cytokines. This promotes clonal expansion, proliferation, and differentiation. As this co-activation between B cell (APC) and T cell occurs, heavy chain class switching and affinity maturation are also stimulated, demonstrating

further that B cells play an important role in magnifying and sustaining the T cell response. Although the antigens are unknown, modulating/suppressing B cells and the ensuing co-stimulation of T cells may contribute to the treatment effects noted with early treatment of many neurological autoimmune disorders.

Cytokine-producing B cells influence the initiation of immune responses and regulate T cell responses. As noted in Fig. 2.5c, another antibody-independent function of B cells is the production of a diverse array of cytokines, including regulatory (IL-10, TGF $\beta$ ), polarizing (IL-4, IL-13, IFN- $\gamma$ , IL-12), and lymphoid tissue-organizing cytokines (TNF $\alpha$ , LT $\beta$ ) [47, 48]. B cell-derived cytokines are produced and dictated by the balance of stimulatory signals via the B cell receptor (BCR) and CD40 [49]. CD40 is constitutively expressed on all B cells [50] and therefore B cells are capable of activation via BCR/CD40 ligation or singularly with CD40L via local immune responsive T cells [49]. Cytokines produced by B cells, including IL-6, play important roles in regulating autoimmune responses. IL-6 produced by activated (BCR/CD40 stimulated) B cells functions in an auto-crine fashion. It induces differentiation of IL-6 receptor (IL-6R) expressing B cells into antibody-secreting plasma cells and enhances the long-term survival of the IL-6R+ plasma cells [47]. In normal B cells the IL-6/IL-6R autocrine loop is tightly regulated. Dysregulation of B cell-derived IL-6 has been suggested to contribute to the formation of autoantibodies and development and magnification of autoimmune disorders [47, 49]. IL-10 is a suppressive cytokine produced by normal B cells and B cells associated with autoimmune disorders. IL-10-producing B cells, in EAE, have the ability to downregulate the ongoing type 1 autoimmune response [51, 52] and suppress the expansion of autoimmune type 1 cells [53]. Duddy and colleagues demonstrated that naïve (CD19+CD27 $-$ ) and memory (CD19+CD27+) human B cells express distinct profiles of effector cytokines and reconfirmed earlier findings of context-dependent cytokine production of IL-10 and TNF $\alpha$ /LT [2]. Regulatory B cells control active CNS demyelination in a

murine EAE model [54]. Naïve B cells (CD19+CD27 $-$ ) almost exclusively produce IL-10, specifically after B cell activation with isolated CD40 stimulation *ex vivo* [2, 49]. As a well-established regulatory cytokine that suppresses APC and T cell activation, B cell IL-10 likely decreases inappropriate immune responses by limiting undesirable polyclonal expansion and inducing apoptosis [49]. Memory B cells (CD19+CD27+) primarily produce pro-inflammatory cytokines, TNF $\alpha$ /LT following dual stimulation of BCR and CD40 [2, 49]. It is important to remember the homeostatic function of the immune system; IL-10-producing B cells may ameliorate T cell-mediated autoimmune disease, while activated B cells are proficient producers of inflammatory cytokines, such as lymphotoxin (LT) and TNF $\alpha$  (Fig. 2.5d). Current and future therapeutics are focused on selective B cell depletion (anti-CD20 mAb) and chemoablative techniques (anti-CD52 mAb, autologous stem cell therapy) [2].

Lymphotoxins and TNF $\alpha$  produced by B cells are responsible for organizing secondary and tertiary/ectopic lymphoid structures (Fig. 2.5d) [27] in autoimmune disorders. Ectopic lymphoid structures could represent a critical step in sustaining humoral autoimmunity and disease exacerbation in neurological autoimmune disorders [55]. In a healthy immune response, peripheral lymphoid organs are organized to concentrate antigen, APCs, and lymphocytes in a way that optimizes interactions among the cells and produces an appropriate adaptive response. An example of this organization would be in lymph nodes (LNs), specialized organs for trapping antigen from local tissue supplied by lymphatic vessels. LNs can be divided into three regions: cortex, paracortex, and medulla [15]. Naïve mature B cells are drawn into developing LNs by expression of the chemokine CXCL13. These B cells are then organized into follicles containing follicular dendritic cells (FDCs), located in the cortex of LNs, surrounded by T lymphocytes within the paracortex containing dendritic cells (DCs). The organization of the T and B cells adjacent to one another enables the two cells to migrate toward each other and interact to help B

cells differentiate into antibody-producing cells. Normally affinity maturation occurs in the germinal centers of lymphoid follicles, as a result of somatic hypermutation of the Ig genes [15]. In autoimmune disorders, LT produced by B cells facilitates the development of tertiary structures, referred to as lymphoid neogenesis, occurring in the intermeningeal spaces of patients with MS, in the thymus of myasthenia gravis patients, and in the target organs associated with RA, Sjogren's, and thyroiditis [15, 47]. Ectopic germinal centers of the thymus have also been found to develop preferentially in patients with early onset myasthenia gravis (EOMG) [56, 57]. In other autoimmune diseases, it has been demonstrated that ectopic follicles are found in tissues with the highest degree of inflammation, indicating that formation of ectopic lymphoid tissue requires a strong immune activation via autoimmune dysregulation and/or infectious stimulus (viral/bacterial) that results in a persistent inflammatory microenvironment [58, 59]. Formation of ectopic lymphoid tissue is viewed as part of an adaptive response against infection. It may also have the potential to support autoimmunity through expansion and activation of autoreactive B and T lymphocytes and further destruction of tissue [68]. Therapeutic targets (possibly B cell depletion, chemokine antagonists, or LT $\beta$ R-Ig) should be focused on prevention or eradication of such tertiary lymphoid structures nested within the CNS and other target organs of autoimmunity.

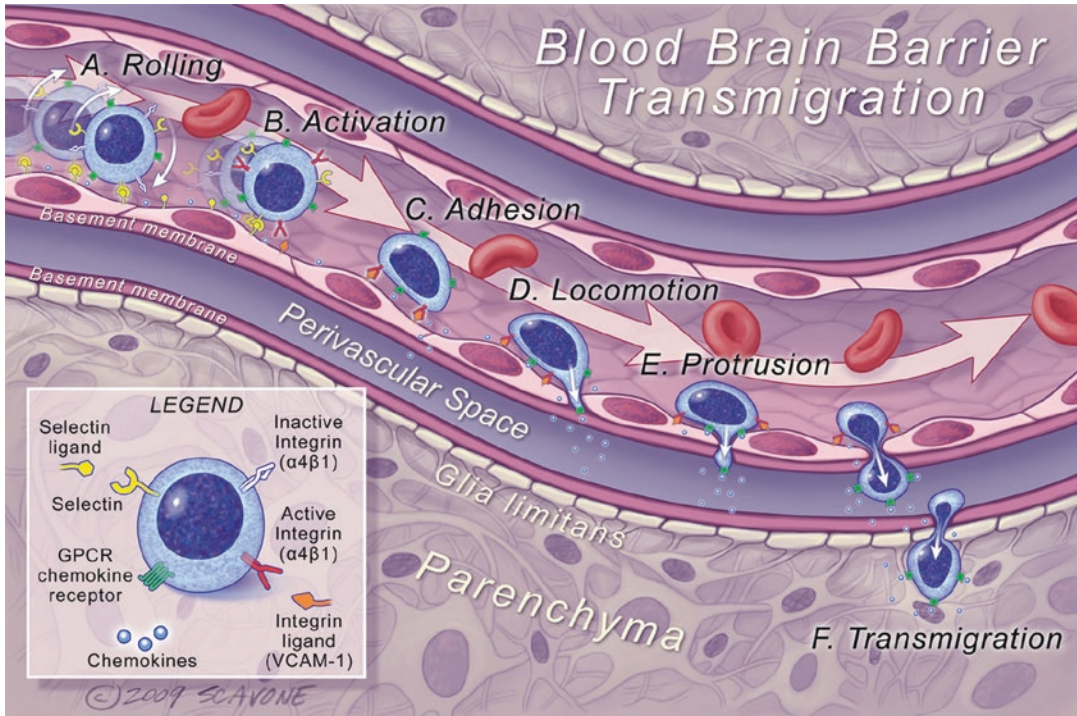
---

## Trafficking Molecules

The central nervous system (CNS) is characterized by an immune-specialized environment as a result of limited lymphatic drainage, resident DCs, and MHC expression [15, 60]. Under normal conditions, the CNS strictly controls immunosurveillance, localized to the perivascular and subarachnoid spaces, as it is crucial for host defense [60]. Often the blood-brain barrier (BBB) is the only site of leukocyte transmigration. There are three potential sites for leukocytes to enter into the CNS: the BBB, the blood-CSF barrier (BCSFB), and the blood-spinal cord barrier

(BSpCB) [60, 61]. The remaining discussion will focus on the BBB, which should be thought to include both capillary and postcapillary venules (they show equal restriction of molecules, with no differential characteristics) [60]. Slight differences between BBB meningeal and parenchymal microvessels have been identified. The meningeal microvessels lack astrocytic ensheathment [62], while the parenchymal microvessels lack P-selectin [63]. The choroid plexus epithelium establishes the brain-CSF barrier (BCSFB). Data suggests that lymphocytes enter the CSF across the BCSFB during normal immunosurveillance to monitor the subarachnoid space. They retain the capacity to initiate a local immune reaction if needed or return to secondary lymphoid organs, via CCR7 and L-selectin [63]. Ventricular and lumbar CSF from healthy patients is uniformly composed of CD4+ central memory T cells [64]. What guides autoreactive leukocytes (lymphocytes, macrophages, monocytes, eosinophils, neutrophils) into the CNS in neuroimmune inflammation disorders is still unclear. Whether antigen presentation takes place in the cervical or lumbar lymph nodes, as both are specific lymphatic drainage sites for CNS solutes (molecular mimicry) and antigens (neuro-specific antigens) [65], is not yet clarified. There are chemokine gradients between brain parenchyma and circulation that could be initiated by a viral or bacterial infection that would then trigger TLRs in innate immune cells of the brain (microglia and astrocytes) [66]. Could prolonged inflammation and/or specific BBB transmigration thru postcapillary venules give way to ectopic germinal center formation and amplification of the disease process? Understanding the mechanisms of leukocyte trafficking into the brain might provide insight into how to modulate pathologic immune responses with specific therapeutic targets.

Leukocyte transmigration is governed by chemoattractant cytokines, chemokines, and adhesion molecules and is a multistep well-orchestrated response to injury and inflammation (Fig. 2.6). It requires specific adhesion molecules (AMs), selectins, to make transient contact with the endothelium cells. Autoreactive leukocytes loosely tether and roll along the endothelial cells



**Fig. 2.6** Blood-brain barrier transmigration. Multistep recruitment of leukocytes across the blood and CSF barriers in the inflamed brain. **(a)** Rolling: Autoreactive leukocytes loosely tether and roll along the endothelial cells due to the binding of selectins and associated ligands. The shear forces of the blood flow continue the autoreactive leukocyte in a rolling motion while sensing activating factors. **(b)** Activation: Once the rolling leukocyte slows in velocity, it reacts to chemokines on the endothelial surface via G-protein-coupled receptor, resulting in activation and conformational changes of integrins on the leukocyte surface. **(c)** Adhesion: Activation leads to an increased affinity and avidity for endothelial ligands and arrest of the leukocyte rolling motion. Only activated leukocytes are

able to mediate firm adhesion. **(d)** Locomotion: Arrested leukocytes move across the endothelial surface until the tight junctions of the endothelium, interendothelial junctions, are identified. **(e)** Protrusion: Activated leukocytes extend protrusions through the tight junctions sensing chemokines that serve as guides. **(f)** Transmigration: Diapedesis of leukocytes through the endothelial barrier between the endothelial basement membrane and the basement membrane of the glia limitans within the perivascular space. Matrix metalloproteinases (MMPs) facilitate the leukocytes migrating both basement membranes and the glia limitans, providing entry into the parenchyma. (Reprinted with permission from William Scavone)

due to the low-affinity binding of selectins and associated ligands (Fig. 2.6a) [60, 61]. There are three types of selectins: L-selectin is expressed on most circulating leukocytes, while P- and E-selectin expressions are inducible on endothelial cells involved in acute and chronic inflammatory processes. The shear forces of the blood flow continue the autoreactive leukocyte in a rolling motion, while it senses activating factors on the endothelial surface [60, 61]. Luminal chemokines are immobilized on endothelial surfaces to trigger activation of integrins from circulating leukocytes (Fig. 2.6a) [61].

Once the rolling leukocyte slows in velocity, it reacts to chemokines on the endothelial surface via G-protein-coupled receptor, resulting in activation and conformational changes of integrins on the leukocyte surface (Fig. 2.6b). Integrins are a large family of  $\alpha\beta$  heterodimeric transmembrane proteins that provide a physical linkage, mediating cell-cell and cell-extracellular matrix interactions, and help to regulate cell behavior through discrete regulatory cues [15]. Upregulated integrins on the autoaggressive leukocytes include P-selectin glycoprotein ligand-1 (PSGP-1) and very late antigen-4 (VLA-4)/ $\alpha 4$  integrin

( $\alpha4\beta7$ ). G-protein-dependent activation leads to secure lymphocyte fixation, due to increased affinity and avidity of integrins for endothelial ligands vascular cell adhesion molecule-1 (VCAM-1) and intracellular adhesion molecule-1 (ICAM-1) (Fig. 2.6c). Newly identified adhesion molecules, junctional adhesion molecule-A (JAM-A) and platelet-endothelial cell adhesion molecule-1 (PECAM-1), are involved in the permeability and transmigration of the BBB [60]. They may be future therapeutic targets.

Only activated leukocytes mediate firm adhesion and arrest of rolling. They then travel across endothelial surfaces until they identify interendothelial tight junctions (Fig. 2.6d) [67]. Activated leukocytes extend protrusions through the tight junctions in response to chemokines (Fig. 2.6e) [61]. Chemokines are a large family of low-molecular-weight chemotactic cytokines that direct cells to specific sites of inflammation or injury and play an important role in leukocyte homing [68]. Chemokines secreted by lymph node cells attract B cells to germinal centers, DCs and T cells to T cell areas. The chemokine family is comprised of approximately 50 molecules and 20 receptors [68, 69]. The chemokine ligand superfamily is divided into subgroups, the largest being CC chemokines (28 members), CXC chemokines (16 members), and CX3C chemokines (1 member) [68, 70]. Subgroup members are functionally related and signal to corresponding families of chemokine G-protein-coupled receptors (GPCRs). Most of the receptors bind several different chemokines, and many chemokines bind different receptors. Chemokine receptors are localized to various cell types, direct adaptive immune responses, and contribute to the pathogenesis of many diseases. In the CNS, specific chemokine receptors have been detected on microglia, astrocytes, oligodendrocytes, neurons, and brain microvasculature [68]. Chemokines are implicated in many autoimmune disorders as they regulate a multitude of effector cells by governing their departure from the bloodstream into tissues, their migration through lesions, and their effector functions. Assigning roles to individual receptors is critical to the identification of relevant therapeutic targets.

Transmigration (diapedesis) occurs as leukocytes extravagate thru the endothelial barrier, between the endothelial basement membrane and the basement membrane of the glia limitans within the perivascular space (Fig. 2.6f). Activated cells (including monocytes, macrophages, T lymphocytes, neutrophils, endothelial cells, microglia, astrocytes, oligodendrocytes) secrete matrix metalloproteinases (MMPs). MMPs are enzymes that digest various collagen components of the extracellular matrix and basement membrane [71]. Tissue inhibitor of metalloproteinases (TIMP) controls the activity of MMPs. MMPs in coordination with TIMP facilitate the final step of leukocytes migrating the basement membrane and glia limitans, providing entry into the parenchyma [61]. There are many immunological targets to halt leukocyte trafficking into the parenchyma including, but not limited to, G-protein-coupled receptor, adhesion molecules, chemokines, and MMP/TIMP.

---

## S1P1

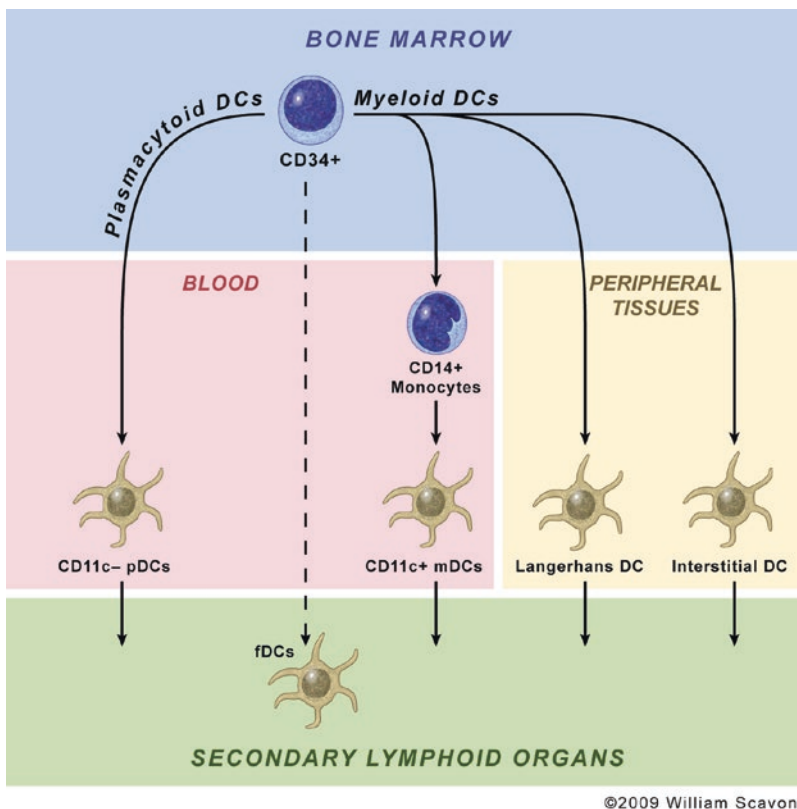
A newer therapeutic paradigm to affect leukocyte transmigration involves blocking leukocyte lymphoid and thymic egress, thru sphingosine 1-phosphate (S1P). S1P is an important signaling molecule produced inside cells by sphingosine kinase-driven phosphorylation [72]. Once the S1P cells are transported and externalized into blood and interstitial fluids, they actively engage with associated G-PCRs, regulated by cellular activation, on a multitude of cells. Both sphingolipid metabolites, S1P and ceramide, have been identified as critical regulators of cell survival and death [73]. S1P is associated with decreased apoptosis, while ceramide conversely is associated with pro-apoptosis. Not only do these two sphingolipid metabolites exert opposing roles, but they are also interconvertible. This suggests the dynamic ratio between S1P and ceramide is responsible for cell fate [74], and ultimately health or disease, in a wide distribution of systems. S1P receptors 1–5 are ubiquitously expressed, but show differential cell association and physiological action [72]. In the context of neurological autoimmunity, S1P1 normally trans-

duces S1P effects on lymph node (LN) egress and tissue migration of naive lymphocytes, S1P4 has been detected primarily in the immune compartments and leukocytes [75], and it has been postulated that S1P4 may participate in cytokine production by T lymphocytes [76]; S1P5 is expressed primarily in the CNS white matter tracts, specifically in the oligodendrocytes [77]. S1P1 receptor regulates the mobilization of NKT cells to inflammation within the periphery [78]. S1P1 agonist prevents lymphocyte egress from secondary lymphoid tissues, resulting in a reduction of peripheral lymphocytes and therefore limiting potential recirculation into the CNS. Small molecules pro-ligand (agonists) and modulators for sphingosine

1-phosphate receptor (S1P), S1P receptor agonists and modulators, are approved or being developed for the treatment of MS. The T11FNb protein, CD69, also impairs the function of S1P1 in a similar function [79]. S1P is a clear therapeutic target for many serious medical conditions such as cancer, inflammation, and immune-mediated disorders such as MS.

## Dendritic Cells

DCs are bone marrow-derived cells (HPCs) (Fig. 2.7), found in epithelia and most organs, morphologically characterized by thin membra-



**Fig. 2.7** Dendritic cell lineage and subtypes. Two main pathways of dendritic cells (DCs) originate from bone marrow hematopoietic progenitor cells (HPCs), into myeloid DC (mDCs) and plasmacytoid DC (pDCs). Resident DC is mature and found in the secondary lymphoid tissues. Follicular DC (fDC) is unique and found within the germinal centers of lymph nodes with the primary role of presenting antigen to B cells, not T cells.

pDC exists in the blood/circulatory compartment. mDCs exist in the peripheral tissues, blood, and secondary lymphoid compartments. Within the peripheral tissues, there are two additional subtypes: interstitial DC (intDC), located within the dermis and responsible for humoral immunity, and Langerhans DC (LC), located within the epidermis and responsible for cell-mediated immunity. (Reprinted with permission from William Scavone)

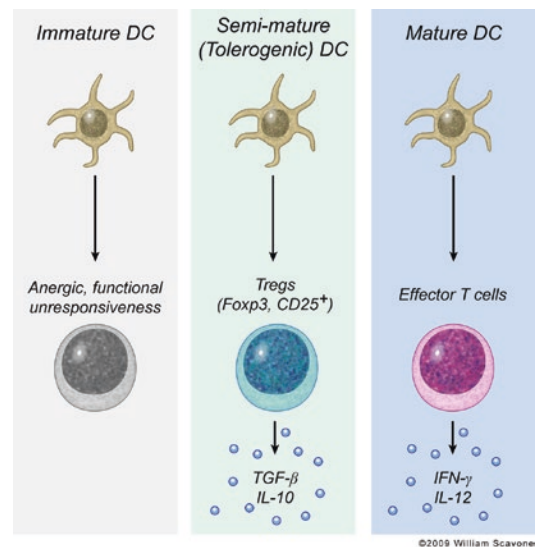


nous projections, dendrites. DCs are specialized to capture and process antigens, to present their peptides to lymphocyte. They are found in all peripheral tissues, blood/circulatory system, and lymphoid organs [4, 80]. DCs play a pivotal role in orchestrating the immune response. The activation status and cytokine secretion profile of DCs control both activation and tolerization of immune responses against self and nonself antigens. They function as “professional” APCs for naïve T lymphocytes and are important for the initiation of the adaptive immune response to protein antigens [15]. Integral to specific autoimmune diseases is an imbalance in the production of a particular cytokine (i.e., rheumatoid arthritis, TNF $\alpha$ ; systemic lupus erythematosus (SLE), T1IFN; MS, IL-12/23, IL-17) that are dependent upon DC interactions. In MS, it is well known that the cytokine profiles of CD4+ T lymphocytes are dictated by the ability of APCs (such as DCs) to secrete either IL-12/IL-23, for a Th1 response, or the combination of TGF $\beta$  and IL-6, for a Th17 response. In addition, DCs secreting IL-10 have been shown to induce IL-10-producing Tregs [81, 82]. The immune system is a dynamic system of cytokine vectors. Equilibrium maintains health and protective immunity, while a predominant skewing leads to autoimmunity and immunopathology. DC maturation and subsets play a critical role in stimulating immune responses as well as maintaining tolerance. This understanding has led to the potential of DCs as a distinct therapeutic target for various inflammatory and autoimmune diseases [4].

## Dendritic Cell Subtype and Maturation

The maturation and subtypes of DCs are presumably a response to the encountered pathogen and the cytokine milieu, either in the peripheral lymph nodes via the lymph or in the spleen via the circulatory system. Nonactivated immature DCs are thought to continuously present self-antigens to autoreactive T cells in the absence of co-stimulation. This induces anergy or deletion of potentially harmful T cells (Fig. 2.8) [83]. If a microbe breaches the epithelium to enter connective tissue

and parenchymal organs, it can be captured by an immature DC that reside in these tissues and be transported to the peripheral lymph nodes for antigen presentation to T lymphocytes. Recent studies indicate that soluble antigens directly diffuse into draining LNs via lymphatics and conduits, thereby reaching the resident DCs [84]. Despite their proficiency as APCs, during this process of migration into the lymph nodes, the activated DCs can undergo semi-maturation into tolerogenic DCs. Semi-mature DCs, in a steady-state, have demonstrated tolerogenic functions by skewing TH1/TH2 balance as well as generating and interacting with regulatory T lymphocytes (CD4+CD25+FOXP3), to suppress autoimmunity (Fig. 2.8) [85]. DCs become activated following the capture of antigens, triggering of toll-like receptors (TLRs) and the innate pro-inflammatory cytokine production. Activated DCs lose adhesiveness for epithelial tissue, but express surface



**Fig. 2.8** DC maturation. DCs are referred to as immature prior to binding and endocytosing antigen, as they are inactive and inefficient at stimulating T lymphocytes. Semi-mature DCs have demonstrated tolerogenic functions by skewing TH1/TH2 balance (producing IL-10 and TGF $\beta$ ) as well as generating and interacting with regulatory T lymphocytes (CD4+CD25+FOXP3), to suppress autoimmunity. Mature DCs are immunogenic once antigens are encountered, endocytosed, and presented to T lymphocytes in an inflammatory microenvironment, resulting in effector functions (production of IFN- $\gamma$  and IL-2). (Reprinted with permission from William Scavone)

receptors for homing chemokines that direct the DCs into the lymph and peripheral lymph nodes. Antigen presentation of both MHC I and II, as well as expression of co-stimulatory molecules (CD80/CD86), and pro-inflammatory cytokines efficiently activate T lymphocyte effector functions and cytokine production of TNF $\alpha$  and IL-2 (Fig. 2.8) [86]. Traditionally, DCs have been referred to as mobile sentinels due to their capacity to capture antigen, migrate to LNs, and present to and activate lymphocytes. However, recent research has uncovered that DCs have the ability to minimize autoimmunity. Once these processes are better understood, they may be used to induce tolerance in autoimmune diseases.

---

## Cytokines

Cytokines represent critical mediators of the autoimmune process. They are generally small molecular weight soluble proteins that are secreted and responsible for communication between leukocytes and between leukocytes and other cells. They bind to their cognate receptors to induce a signaling cascade [5]. Cytokines function in both an autocrine and paracrine manner to induce a number of cellular responses. There are currently 35 interleukins (ILs) that have been cloned and characterized, tumor necrosis factor (TNF), chemokines, interferon- $\gamma$  (IFN- $\gamma$ ), and type I interferons  $\alpha/\beta$  (T1IFNs). Many of the cytokines were found to be members of a family based on sequence similarity, sharing of subunits, sharing of receptors, or having cognate receptors that share subunits. For example, IL-2 is an important T cell cytokine produced at high levels by naive CD4 T cells following antigen recognition. It serves as a growth and survival factor for T cells. IL-2 binds to its receptor, called the IL-2 receptor (IL-2R), which can consist of up to three chains:  $\alpha$ ,  $\beta$ , and c. The combination of receptor components determines the affinity of IL-2 to its receptor. On naive T cells, the  $\alpha$ -chain, also known as CD25, is rapidly upregulated following antigen recognition and in combination with the  $\beta$  and c chains forms a high-affinity

receptor. The c chain, also called the IL-2R common c chain, is also a component of the IL-4, IL-7, and IL-15 receptors [5]. Monoclonal antibodies to cytokine receptors are being developed in order to suppress cytokine binding and proliferation of the cytokine production, leading to specific autoimmunity (i.e., daclizumab, anti-CD25 (IL-2R)). There are a number of cytokine families that influence T cell biology and could be targeted in autoimmune disorders.

Endogenous T1IFN is a naturally occurring regulatory cytokine that is ubiquitously expressed except on red blood cells. Interferon (IFN) is pivotal for bridging the innate and adaptive immune response, as it is produced in response to viral stimuli by innate cells (T1IFN and IFN- $\gamma$ ) as well as T lymphocytes (IFN- $\gamma$ ) [15]. The key cell type that produces T1IFN is plasmacytoid dendritic cells (pDCs) [82]. pDCs are induced by toll-like receptors (TLR) on APCs. The pleiotropic effects of IFN include potent antiviral activity, antiproliferation, and immunomodulatory activities on the immune system [87]. T1IFN can stimulate the transcription of many genes primarily through the Janus kinase (JAK)-STAT pathway. In addition to gene induction, T1IFN can also inhibit the transcription of selected genes, although less is known about the mechanisms underlying IFN- $\beta$ -mediated negative gene regulation [88]. Cells targeted by T1IFNs include, but are not limited to, DCs, lymphocytes, macrophages, astrocytes, and neurons. Type I IFNs are differentially involved with a number of autoimmune disorders [87] and therefore intriguing therapeutic targets.

---

## Stem Cells

Stem cells have varying potential as therapeutic targets for neurologic autoimmune disorders. While highly controversial, embryonic stem cells are considered truly pluripotent and most versatile for regenerative medicine; adult stem cells also hold therapeutic potential. They are multipotent and far less controversial. Stem cells have

common attributes that enable their self-renewal, survival, and maintenance of genomic integrity [89]. All tissues appear to have stem cells, and within each tissue type stem cells are located in a specialized vascular microenvironment called a “niche.” Critical to the maintenance of the stem cell niche are microenvironmental cues and cell-cell interactions (cell adhesion molecules and integrins) that balance stem cell quiescence with proliferation, specification, and differentiation of progenitor cells [89, 90]. The microenvironment, a common theme in the homeostasis of immunity and health, plays a key role in the therapeutic potential of adult stem cells, whether endogenous or exogenous/transplanted.

Adult bone marrow contains at least three stem cell populations: hematopoietic stem cells (HSCs), mesenchymal stem/stromal cells (MSCs), and endothelial progenitor cells (EPCs) [89]. HSCs are rare among bone marrow cells, with a frequency of perhaps 1 in 10,000 or more [89]. Identification of HSCs is based upon the cell surface marker CD34+. Transdifferentiation/cell fusion [91, 92] is but one of many potentially therapeutic properties of adult stem cells and possibly one of the most important [93, 94]. Other potential mechanisms include but are not limited to dedifferentiation, transdetermination, true pluripotent stem cell behavior, and production of trophic factors [91]. The rationale behind autologous hematopoietic stem cell transplantation (HSCT) for MS, for example, is to induce new and self-tolerant lymphocytes (resetting the immune system) following chemotherapy-induced elimination of self-reactive lymphocytes [95]. Similar to malignancy response to HSCT, autoimmune diseases that respond to immunosuppressive therapy tend to respond to immunosuppressive conditioning followed by autologous HSCT rescue. Relapsing-remitting MS is an example of an inflammatory, immune responsive disease where an autologous HSCT study showed positive results in the form of 100% progression-free survival after a mean follow-up of 3 years (as defined by “no deterioration in their Expanded Disability Status Scale”) [95]. In contrast, traditional immune

nonresponsive diseases such as primary progressive MS and late secondary progressive MS show little to no improvement following autologous HSCT [96]. Current research is ongoing to review the risk-benefit of autologous HSCT as well as the optimal conditioning regime (complete/partial/non-myeloablation) prior to autologous HSCT [95–98].

MSCs have been studied in animal models and, following acute neurologic injury, migrate to the damaged brain [99]. MSCs can proliferate extensively *in vitro* and differentiate under appropriate conditions into bone, cartilage, and other mesenchymal tissues, as well as multiple other cells including neuroectodermal cells [99–101]. These results, albeit in animal models, suggest that human MSCs could provide an ideal cell source for repair of injured organs including the CNS. Studies with human MSCs have identified comprehensive immunomodulating properties [93]. Modulation of host immune responses due to low immunogenic properties [102, 103] and the ability to secrete neurotrophins provides a microenvironment that induces neuronal cell survival and regeneration. Transplantation of MSCs, similar to HSCT, provide the most benefit in acute neurological injury and/or early inflammatory stages of disease. MSCs are rare and decline with age, so that alternative sources of MSCs may be integral for allogeneic therapeutic application in the future, particularly MSCs isolated from human umbilical cord blood [104].

CNS stem cells have tri-lineage potential, capable of generating neurons, oligodendrocytes, and astrocytes. During CNS development the neuroepithelial cells in the embryonic ventricular layer generate most of the neurons and glia (astrocytes and oligodendrocytes). A consensus view is that astrocytes are the main stem cell population, with small numbers of neural stem cells (NSCs) in other regions [89]. The niche for these NSCs has been identified as the subventricular zone (SVZ) lining the lateral ventricles and the subgranular zone (SGZ) of the dentate gyrus of the hippocampus [105]. The neural stem cell niches define zones where stem

cells are retained after embryonic development for the production of new cells of the nervous system. This continual supply of new neurons and glia then provides the postnatal and adult brain with an added capacity for cellular plasticity, neurogenesis, and gliogenesis that is restricted to the SVZ and SGZ within the brain [90]. In EAE, prolonged inflammation extensively alters the proliferative and migration of endogenous NSCs *in vivo* [106]. In animal models research has demonstrated that transplanted NSCs migrate specifically to the injured CNS under the guidance of immune responsive cells, potentially directing targeted migration of stem cells toward the sites of inflammation/disease [107, 108]. Therapeutics aimed at facilitating endogenous or exogenous reparative processes will need to realize the timing of therapeutic potential, as it relates to stage and duration of disease process.

Remyelination represents one of the most compelling examples of adult multipotent progenitor cells contributing to the endogenous regeneration of the injured CNS [109]. This process has been noted to occur in the clinical disease MS [110], and the experimental disease EAE, revealing the impressive ability of the adult CNS to repair itself. The inconsistency of remyelination in MS, with loss of axonal integrity, makes enhancement of remyelination an important therapeutic objective. There is tremendous research in this area, looking to expand upon ways in which to improve specification, differentiation, translocation/mobilization, and function of endogenous NSCs and/or transplanted adult stem cells. The goal is to repair the degenerated or injured neuronal pathways [111, 112]. Autologous stem cell transplantation (HSC, MSC, NSC) may provide greater potential than just cell replacement. The concept of “therapeutic plasticity” refers to the capacity of stem cells to produce neuroprotection and immunomodulation in response to specific microenvironmental needs of different pathological conditions [108]. Pharmacological and cell-based restorative immunotherapies will need to demonstrate remodeling and enhancement of neurological function while providing an acceptable risk-benefit ratio.

## The Gut Microbiome in Multiple Sclerosis

Among the environmental factors that have been associated with elevated risk for multiple sclerosis, the gut microbiome is perhaps the most significant. Although our understanding of the microbial world has been traditionally driven by the study of pathogenic microbes, most are non-pathogenic. We are surrounded and colonized by a complex community of microbes that include bacteria, archaea, viruses, fungi, and other microscopic eukaryotic cells. Collectively, the community of microbes found at a given system is named the microbiota, while the interactive combination of microbiota with the host is termed microbiome. Despite the direct and indirect negative impact of pathogenic microbes in health, we now understand that most microbes are symbionts with the host. While receiving nutrients and a physically defined space to survive, microbes reciprocally provide metabolic benefits to the host. New molecular, genetic, and animal experimental tools provide a novel framework for the study of the interactions between the microbiome and the host, and the complex multifactorial interactions are now beginning to be understood. The most studied microbiome is the gut microbiome of both mice and humans. Genetic, physical, and chemical factors shape the composition of the gut microbiome in healthy individuals, and as evidenced by the most recent findings, disease and disease-modifying therapies also affect such composition. In this section, we will highlight the most salient findings that suggest an interaction between the gut microbiome and animal models of multiple sclerosis and between the gut microbiome and the human disease.

## The Anatomy of the Gut Epithelium in the Context of Disease

Because of the elevated amounts of microbes and microbial antigens present, the mucosa-associated to the gastrointestinal (GI) tract contains 80% of the host immune cells comprising the largest concentration of immune cells in the

body [113]. Despite its function absorbing nutrients and reabsorbing water sequentially, the gut epithelium establishes an effective barrier against microbes serving as a physical and chemical separation between the lumen of the gut and the internal tissues, by the effects of the mucus produced by goblet cells and antimicrobial peptides produced by Paneth cells residing within the crypts of the small and large intestine (although much reduced in numbers in the large intestine).

As mentioned before because of the elevated numbers of microbes and derived antigens and metabolites, the immune system is explicitly present in the gut, forming the gut-associated lymphoid tissues (GALT). The proposed function for the GALT is the constant surveillance for pathogens and the maintenance of immune tolerance to beneficial members of the microbiome. As a combined secondary lymphoid tissues associated with the gut mucosa, the GALT is composed of diffuse lymphoid follicles, more organized Peyer's patches, and lymphatics that drain into structurally defined mesenteric lymph nodes (MLN) through afferent lymphatic vessels. Antigen-presenting cells that sample the gut as well as soluble antigens traffic through the MLN on a CCL21- and CCR7-dependent mechanism where they encounter naïve T cells that entered the lymph nodes through the high endothelial venules from circulation. Within the lymph nodes T cell activation, clonal expansion, and differentiation occur. Differentiation into specialized effectors is necessary for generating specific responses against microbes. Peripheral tolerance also occurs within the GALT, by the direct effects of regulatory T cells (Tregs) or by anergy.

### The GALT as a Regulator of Immune Function

T helper (Th) cells such as Th1, Th2, and Th17 help mobilizing and recruit innate immune cells against microbes. However, in the gut, there is a very pressing need of activating active and passive mechanisms of peripheral tolerance in order to control inflammatory responses against non-pathogenic and potentially beneficial microbes.

Immune cells will render nonresponsive in the absence of appropriate co-stimulation or be controlled by Tregs. Some gut symbionts, such as *Bacteroides fragilis*, promote immunotolerance by directing the production of interleukin-10 (IL-10)-producing Tregs in the GALT through the recognition of dendritic cells of polysaccharide A (PSA) [114] described later in further detail. Anergy is another mechanism of peripheral tolerance characterized by the lack of an immunological response to antigen. Although the mechanism remains to be elucidated, gut symbionts could promote incomplete activation of T cells with no co-stimulatory signal that would result in nonresponsive T cells [115].

Due to the importance of the gut microbiome shaping immune responses, many labs across the world have focused their efforts on understanding the association between the microbiome and diseases, with particular emphasis on autoimmune diseases hypothesized to be linked to immune functional deficiencies. Furthermore, the gut microbiome composition is affected by factors including host genetics, geographical location, diet, lifestyle choices, prescribed pharmaceuticals, mode of delivery during birth, antibiotic exposure, and others that have been previously proposed to impact the risk for diseases. Specifically, the concept of dysbiosis proposes that factors that unbalance the composition of the gut microbiome result in changes in immune function that can lead to disease. The paradigm that an unbalanced gut microbiome could shift a homeostatic immune system toward a pro-inflammatory state could exacerbate functional dysfunction associated with the peripheral tolerance in MS patients. Furthermore, the disruption of the integrity of the intestinal barrier promotes endotoxin and bacterial translocation that exacerbates systemic inflammation [116], which in turn could impact significantly CNS immunity and the integrity of the blood-brain barrier [117].

In MS, Tregs are defective in their ability to control the proliferation of pro-inflammatory, autoreactive, T cells [118, 119]. Since demyelination could be potentiated by the effects of Th17 cells by the secretion of pro-inflammatory media-

tors that recruit pathogenic cells, and both Treg and Th17 cell balances are impacted by the composition of the gut microbiome, recent efforts have put special emphasis on dysbiosis in the context of MS.

## The Gut Microbiome of Multiple Sclerosis Patients

The first studies designed to evaluate the potential association between the gut microbiome and CNS inflammatory demyelination that characterizes MS used the murine experimental autoimmune encephalomyelitis (EAE); most used animal model to study MS. First, we reported a number of years ago that the oral administration of a mixture of broad-spectrum antibiotics reduced the severity of EAE in mice, by reshaping the balance between pro-inflammatory and Tregs [120] and by impacting the function of gut-derived natural killer T (NKT) cells [121]. Antibiotics have also been shown to impact the severity of other models of autoimmunity such as experimental autoimmune uveitis [122]. In this later study, the treatment with antibiotics significantly increased the expression of Tregs and reduced IL-17-producing Th17 cells [122], similar to the studies performed in EAE mice [120].

The impact of the gut microbiome regulating the severity of EAE was later confirmed in studies using germ-free (GF) mice, wherein mice that are born and raised under strict sterile conditions are unable to mount an inflammatory CNS demyelinating condition. It was previously shown that GF mice show reduced frequencies of gut-derived Th17 cells [123] that impacts their susceptibility to a variety of experimental autoimmune diseases such as diabetes [124], inflammatory bowel disease (IBD) [125], RA [126], and EAE [127, 128] when compared with conventional housed animals. In EAE and some other experimental conditions, GF mice exposed to the monocolonization with segmented filamentous bacterium (SFB), a known inducer of Th17 cells in the GALT, restored susceptibility to disease, consistent with what has been observed in conventionally housed mice [126, 128].

In MS patients, significant modifications of specific microbial taxa have been observed [129–131]. Although overall the broad composition of the microbiome remains unaffected in MS patients when compared to healthy individuals, a more profound view of a multitude of microbial taxonomical units shows patterns associated with specific changes that could lead to dysbiosis. Moreover, recent evidence suggests a functional impact of the gut microbiome those with MS. Two recent works demonstrate that the fecal transplantation of dysbiotic MS gut microbiome into GF mice restores the susceptibility of these mice to EAE [132, 133].

Causality as to whether the microbiome changes are responsible for the disease state or conversely the consequence of disease remains to be elucidated [134]. Effects of immunomodulatory therapeutics that target immune cells associated with the immunopathology of MS on the gut microbiome have been demonstrated. Furthermore, EAE studies in nonobese diabetic mice have shown that active induction of disease promotes significant changes on the microbiome that are most apparent at early stages of the disease [135]. Remarkably, the early treatment of EAE mice with antibiotics reduced the severity of the disease while later treatments did not affect the progression of disease.

The increase in the understanding of the interactions between the microbiome and disease offers alternative venues for the development of newer therapeutics. While microbes of the oral microbiome such as *Porphyromonas gingivalis* exacerbates EAE [136, 137], other components of the microbiome or even microbial products show promising immunomodulatory effects that result in reduced severity in experimental models of disease. *Bifidobacterium animalis* reduces rat-induced EAE [138] and *Lactobacillus* spp. are protective against EAE in mice in a mechanism dependent on the induction of IL-10-producing Tregs [139]. A similar mechanism of action has been proposed for the protective effects of *Prevotella histicola*, a common member of the human gut microbiome that reduces Th1 and Th17 cell function by promoting tolerance [140]. Another member of the human gut microbiome,

*Bacteroides fragilis*, expresses eight capsular polysaccharides, one of which, the zwitterion polysaccharide A (PSA), promotes protection against different autoimmune experimental models by IL-10-producing CD4+ T cells (both Foxp3 positive and negative) [141]. PSA is considered a symbiotic factor since its production facilitates the survival of the microbe in the gut and also promotes the induction of population regulatory CD4+ T cells, including Tregs [141, 142], Foxp3-negative CD4+ T cells [143], and CD39+ T cells that may or may not express Foxp3 [144, 145] that suppress the pro-inflammatory cell populations. In the context of EAE PSA is protective [142, 144, 145]. Furthermore, PSA is capable of promoting a regulatory phenotype in human peripheral blood mononuclear cells (PBMCs) isolated from both healthy individuals [146] and MS patients [147]. The regulatory function of the human regulatory T cells promoted by PSA is associated with an enhanced IL-10 production that has been shown to suppress TNF- $\alpha$  production by monocytes stimulated with LPS in vitro [146]. The later studies demonstrate that gut microbiome-derived symbiont factors promote immunomodulatory responses in EAE mice and in samples isolated from MS patients, opening new possibilities in the search for novel therapeutics. Thus, the gut microbiome represents a unique and truly novel “treasure trove” of potential metabolites and antigens that may serve as a profound basis for future therapeutic intervention in a wide range of human disease including autoimmunity and multiple sclerosis.

---

## Conclusion

Bench and clinical research focused on autoimmunity have provided abundant details related to the pathogenesis of many neurological diseases and a greater understanding of the current and novel treatment approaches to regulate the immune system. Much remains in question. The immune microenvironment drives cellular response. In order to re-establish immune homeostasis and regain tolerance, it will require the con-

certed action of multiple cell types. If any one of the cell types is missing, peripheral tolerance will be avoided. The possibility of a single therapeutic agent, directed at a single target, resolving the complex interactions in disease pathogenesis may not be attainable. It may take multiple targets, treated simultaneously or serially, in order to restore the homeostatic balance needed for disease resolution. Restoration of the dysfunctional immune response will in all likelihood require careful dissection and manipulation rather than a sweeping ablative therapy that could be harmful. More bench and clinical research is needed to study other therapeutic targets such as allogeneic HSCT, antimetabolites, toll-like receptors, statins, vitamins D and A (retinoic acid), commensal bacteria, continued genomic evaluation, and individualized treatments regimes.

---

## References

1. Kasper L, Haque A, Haque SDA. Regulatory mechanisms of the immune system in multiple sclerosis. T regulatory cells: turned on to turn off. *J Neurol.* 2007;254(Suppl 1):110–4.
2. Duddy M, et al. Distinct effector cytokine profiles of memory and naive human B cell subsets and implication in multiple sclerosis. *J Immunol.* 2007;178(10):6092–9.
3. Richman DP, Agius MA. Treatment principles in the management of autoimmune myasthenia gravis. *Ann N Y Acad Sci.* 2003;998:457–72.
4. Blanco P, et al. Dendritic cells and cytokines in human inflammatory and autoimmune diseases. *Cytokine Growth Factor Rev.* 2008;19(1):41–52.
5. Dittel BN. CD4 T cells: balancing the coming and going of autoimmune-mediated inflammation in the CNS. *Brain Behav Immun.* 2008;22(4):421–30.
6. Costantino CM, Baecher-Allan C, Hafler DA. Multiple sclerosis and regulatory T cells. *J Clin Immunol.* 2008;28(6):697–706.
7. Kasper G, et al. Matrix metalloprotease activity is an essential link between mechanical stimulus and mesenchymal stem cell behavior. *Stem Cells.* 2007;25(8):1985–94.
8. Chang X, et al. Foxp3 controls autoreactive T cell activation through transcriptional regulation of early growth response genes and E3 ubiquitin ligase genes, independently of thymic selection. *Clin Immunol.* 2006;121(3):274–85.
9. Chang X, et al. The Scurfy mutation of FoxP3 in the thymus stroma leads to defective thymopoiesis. *J Exp Med.* 2005;202(8):1141–51.

10. Sakaguchi S. Regulatory T cells: key controllers of immunologic self-tolerance. *Cell*. 2000;101(5):455–8.
11. Taylor A, et al. Mechanisms of immune suppression by interleukin-10 and transforming growth factor-beta: the role of T regulatory cells. *Immunology*. 2006;117(4):433–42.
12. Miyara M, Sakaguchi SD-M. Natural regulatory T cells: mechanisms of suppression. *Trends Mol Med*. 2007;13(3):108–16.
13. Reder AT, et al. Low T8 antigen density on lymphocytes in active multiple sclerosis. *Ann Neurol*. 1984;16(2):242–9.
14. Sakaguchi S, Wing K, Miyara MD-N. Regulatory T cells – a brief history and perspective. *Eur J Immunol*. 2007;37(Suppl 1):S116–23.
15. Abbas AK, Lichtman A. Cellular and molecular immunology. 2nd ed. Philadelphia: Saunders Elsevier; 2006. p. 324.
16. Zhang C, Zhang J, et al. The regulatory effect of natural killer cells: do “NK-reg cells” exist? *Cell Mol Immunol*. 2006;3(4):241–54.
17. Li Z, Lim WK, et al. Cutting edge: in vivo blockade of human IL-2 receptor induces expansion of CD56(bright) regulatory NK cells in patients with active uveitis. *J Immunol*. 2005;174(9):5187–91.
18. Waldmann TA, Tagaya Y. The multifaceted regulation of interleukin-15 expression and the role of this cytokine in NK cell differentiation and host response to intracellular pathogens. *Annu Rev Immunol*. 1999;17:19–49.
19. Nowak M, Stein-Streilein J. Invariant NKT cells and tolerance. *Int Rev Immunol*. 2007;26(1–2):95–119.
20. Bendelac A, Savage PB, Teyton L. The biology of NKT cells. *Annu Rev Immunol*. 2007;25:297–336.
21. Yamaura A, et al. Human invariant Valpha24+ natural killer T cells acquire regulatory functions by interacting with IL-10-treated dendritic cells. *Blood*. 2008;111(8):4254–63.
22. Godfrey DI, McCluskey J, Rossjohn J. CD1d antigen presentation: treats for NKT cells. *Nat Immunol*. 2005;6(8):754–6.
23. Burrows PD, Cooper MD. B-cell development in man. *Curr Opin Immunol*. 1993;5(2):201–6.
24. Tangye SG, et al. BAFF, APRIL and human B cell disorders. *Semin Immunol*. 2006;18(5):305–17.
25. Uckun FM. Regulation of human B-cell ontogeny. *Blood*. 1990;76(10):1908–23.
26. Sun J, Lin Z, et al. BAFF-targeting therapy, a promising strategy for treating autoimmune diseases. *Eur J Pharmacol*. 2008;597(1–3):1–5.
27. Dalakas MC. B cells as therapeutic targets in autoimmune neurological disorders. *Nat Clin Pract Neurol*. 2008;4(10):557–67.
28. Schneider P, et al. BAFF, a novel ligand of the tumor necrosis factor family, stimulates B cell growth. *J Exp Med*. 1999;189(11):1747–56.
29. Gross JA, et al. TACI and BCMA are receptors for a TNF homologue implicated in B-cell autoimmune disease. *Nature*. 2000;404(6781):995–9.
30. Thompson JS, et al. BAFF-R, a newly identified TNF receptor that specifically interacts with BAFF. *Science*. 2001;293(5537):2108–11.
31. Krumbholz M, et al. BAFF is produced by astrocytes and up-regulated in multiple sclerosis lesions and primary central nervous system lymphoma. *J Exp Med*. 2005;201(2):195–200.
32. Nardelli B, et al. Synthesis and release of B-lymphocyte stimulator from myeloid cells. *Blood*. 2001;97(1):198–204.
33. Ng LG, et al. B cell-activating factor belonging to the TNF family (BAFF)-R is the principal BAFF receptor facilitating BAFF costimulation of circulating T and B cells. *J Immunol*. 2004;173(2):807–17.
34. Craxton A, et al. Macrophage- and dendritic cell-dependent regulation of human B-cell proliferation requires the TNF family ligand BAFF. *Blood*. 2003;101(11):4464–71.
35. Katsenelson N, et al. Synthetic CpG oligodeoxynucleotides augment BAFF- and APRIL-mediated immunoglobulin secretion. *Eur J Immunol*. 2007;37(7):1785–95.
36. Meyer-Bahlburg A, Rawlings DG. B cell autonomous TLR signaling and autoimmunity. *Autoimmun Rev*. 2008;7(4):313–6.
37. Cheema GS, et al. Elevated serum B lymphocyte stimulator levels in patients with systemic immune-based rheumatic diseases. *Arthritis Rheum*. 2001;44(6):1313–9.
38. Groom J, et al. Association of BAFF/BLyS overexpression and altered B cell differentiation with Sjogren’s syndrome. *J Clin Invest*. 2002;109(1):59–68.
39. Krumbholz M, et al. Interferon-beta increases BAFF levels in multiple sclerosis: implications for B cell autoimmunity. *Brain*. 2008;131(Pt 6):1455–63.
40. Hamzaoui K, et al. Serum BAFF levels and skin mRNA expression in patients with Behcet’s disease. *Clin Exp Rheumatol*. 2008;26(4 Suppl 50):S64–71.
41. Thangarajh M, et al. Expression of B-cell-activating factor of the TNF family (BAFF) and its receptors in multiple sclerosis. *J Neuroimmunol*. 2004;152(1–2):183–90.
42. Thien M, et al. Excess BAFF rescues self-reactive B cells from peripheral deletion and allows them to enter forbidden follicular and marginal zone niches. *Immunity*. 2004;20(6):785–98.
43. Chen X, Jensen PE. The role of B lymphocytes as antigen-presenting cells. *Arch Immunol Ther Exp (Warsz)*. 2008;56(2):77–83.
44. Hawker K. B-cell-targeted treatment for multiple sclerosis: mechanism of action and clinical data. *Curr Opin Neurol*. 2008;21(Suppl 1):S19–25.
45. Chan OT, et al. A novel mouse with B cells but lacking serum antibody reveals an antibody-independent role for B cells in murine lupus. *J Exp Med*. 1999;189(10):1639–48.
46. Lanzavecchia A. Receptor-mediated antigen uptake and its effect on antigen presentation to class II-restricted T lymphocytes. *Annu Rev Immunol*. 1990;8:773–93.



47. Lund FE, et al. Regulatory roles for cytokine-producing B cells in infection and autoimmune disease. *Curr Dir Autoimmun.* 2005;8:25–54.
48. Pistoia V. Production of cytokines by human B cells in health and disease. *Immunol Today.* 1997;18(7):343–50.
49. Duddy ME, Alter A and bar-or a distinct profiles of human B cell effector cytokines: a role in immune regulation? *J Immunol.* 2004;172(6):3422–7.
50. Banchereau J, et al. The CD40 antigen and its ligand. *Annu Rev Immunol.* 1994;12:881–922.
51. Fillatreau S, et al. B cells regulate autoimmunity by provision of IL-10. *Nat Immunol.* 2002;3(10):944–50.
52. Mizoguchi A, et al. Chronic intestinal inflammatory condition generates IL-10-producing regulatory B cell subset characterized by CD1d upregulation. *Immunity.* 2002;16(2):219–30.
53. Mauri C, et al. Prevention of arthritis by interleukin 10-producing B cells. *J Exp Med.* 2003;197(4):489–501.
54. Matsushita T, et al. Regulatory B cells inhibit EAE initiation in mice while other B cells promote disease progression. *J Clin Invest.* 2008;118(10):3420–30.
55. Serafini B, et al. Detection of ectopic B-cell follicles with germinal centers in the meninges of patients with secondary progressive multiple sclerosis. *Brain Pathol.* 2004;14(2):164–74.
56. Sims GP, et al. Somatic hypermutation and selection of B cells in thymic germinal centers responding to acetylcholine receptor in myasthenia gravis. *J Immunol.* 2001;167(4):1935–44.
57. Roxanis I, et al. Thymic myoid cells and germinal center formation in myasthenia gravis; possible roles in pathogenesis. *J Neuroimmunol.* 2002;125(1–2):185–97.
58. Aloisi F, et al. Lymphoid chemokines in chronic neuroinflammation. *J Neuroimmunol.* 2008;198(1–2):106–12.
59. Magliozzi R, et al. Meningeal B-cell follicles in secondary progressive multiple sclerosis associate with early onset of disease and severe cortical pathology. *Brain.* 2007;130(Pt 4):1089–104.
60. Engelhardt B, Ransohoff RM. The ins and outs of T-lymphocyte trafficking to the CNS: anatomical sites and molecular mechanisms. *Trends Immunol.* 2005;26(9):485–95.
61. Man S, Ubogu EE, Ransohoff RM. Inflammatory cell migration into the central nervous system: a few new twists on an old tale. *Brain Pathol.* 2007;17(2):243–50.
62. Allt G, Lawrenson JG. Is the pial microvessel a good model for blood-brain barrier studies? *Brain Res Brain Res Rev.* 1997;24(1):67–76.
63. Kivisakk P, et al. Human cerebrospinal fluid central memory CD4+ T cells: evidence for trafficking through choroid plexus and meninges via P-selectin. *Proc Natl Acad Sci U S A.* 2003;100(14):8389–94.
64. Provencio JJ, et al. Comparison of ventricular and lumbar cerebrospinal fluid T cells in non-inflammatory neurological disorder (NIND) patients. *J Neuroimmunol.* 2005;163(1–2):179–84.
65. Weller RO, et al. Lymphatic drainage of the brain and the pathophysiology of neurological disease. *Acta Neuropathol.* 2009;117(1):1–14.
66. Konat GW, Borysiewicz E, Fil D, James I. Peripheral challenge with double-stranded RNA elicits global up-regulation of cytokine gene expression in the brain. *J Neurosci Res.* 2009;87(6):1381–8.
67. Schenkel AR, Mamdouh Z. Locomotion of monocytes on endothelium is a critical step during extravasation. *Nat Immunol.* 2004;5(4):393–400.
68. Charo IF, Ransohoff RM. The many roles of chemokines and chemokine receptors in inflammation. *N Engl J Med.* 2006;354(6):610–21.
69. Cardona AE, et al. Chemokines in and out of the central nervous system: much more than chemotaxis and inflammation. *J Leukoc Biol.* 2008;84(3):587–94.
70. Bazan JF, et al. A new class of membrane-bound chemokine with a CX3C motif. *Nature.* 1997;385(6617):640–4.
71. Avolio C, et al. Serum MMP-9/TIMP-1 and MMP-2/TIMP-2 ratios in multiple sclerosis: relationships with different magnetic resonance imaging measures of disease activity during IFN-beta-1a treatment. *Mult Scler.* 2005;11(4):441–6.
72. Takabe K, et al. “Inside-out” signaling of sphingosine-1-phosphate: therapeutic targets. *Pharmacol Rev.* 2008;60(2):181–95.
73. Spiegel S, Milstien S. Sphingosine-1-phosphate: an enigmatic signalling lipid. *Nat Rev Mol Cell Biol.* 2003;4(5):397–407.
74. Cuvillier O, et al. Suppression of ceramide-mediated programmed cell death by sphingosine-1-phosphate. *Nature.* 1996;381(6585):800–3.
75. Graler MH, et al. The sphingosine 1-phosphate receptor S1P4 regulates cell shape and motility via coupling to Gi and G12/13. *J Cell Biochem.* 2003;89(3):507–19.
76. Wang W, Huang MC, Goetzl EJ. Type 1 sphingosine 1-phosphate G protein-coupled receptor (S1P1) mediation of enhanced IL-4 generation by CD4 T cells from S1P1 transgenic mice. *J Immunol.* 2007;178(8):4885–90.
77. Terai K, et al. Edg-8 receptors are preferentially expressed in oligodendrocyte lineage cells of the rat CNS. *Neuroscience.* 2003;116(4):1053–62.
78. Allende ML, et al. S1P1 receptor expression regulates emergence of NKT cells in peripheral tissues. *FASEB J.* 2008;22(1):307–15.
79. Shioh LR, et al. CD69 acts downstream of interferon-alpha/beta to inhibit S1P1 and lymphocyte egress from lymphoid organs. *Nature.* 2006;440(7083):540–4.
80. Lande R, et al. Plasmacytoid dendritic cells in multiple sclerosis: intracerebral recruitment and impaired maturation in response to interferon-beta. *J Neuropathol Exp Neurol.* 2008;67(5):388–401.
81. Wakkach A, et al. Characterization of dendritic cells that induce tolerance and T regulatory 1 cell differentiation in vivo. *Immunity.* 2003;18(5):605–17.

82. Ito T, et al. Plasmacytoid dendritic cells prime IL-10-producing T regulatory cells by inducible costimulator ligand. *J Exp Med.* 2007;204(1):105–15.
83. Meriggioli MN, et al. Strategies for treating autoimmunity: novel insights from experimental myasthenia gravis. *Ann NY Acad Sci.* 2008;1132:276–82.
84. Itano AA, et al. Distinct dendritic cell populations sequentially present antigen to CD4 T cells and stimulate different aspects of cell-mediated immunity. *Immunity.* 2003;19(1):47–57.
85. Tarbell KV, Yamazaki S. The interactions of dendritic cells with antigen-specific, regulatory T cells that suppress autoimmunity. *Semin Immunol.* 2006;18(2):93–102.
86. Groux H, Fournier N. Role of dendritic cells in the generation of regulatory T cells. *Semin Immunol.* 2004;16(2):99–106.
87. Javed A, Reder AT. Therapeutic role of beta-interferons in multiple sclerosis. *Pharmacol Ther.* 2006;110(1):35–56.
88. Zhao W, et al. Stat2-dependent regulation of MHC class II expression. *J Immunol.* 2007;179(1):463–71.
89. Alison MR, Islam S. Attributes of adult stem cells. *J Pathol.* 2009;217(2):144–60.
90. Conover JC, Notti RQ. The neural stem cell niche. *Cell Tissue Res.* 2008;331(1):211–24.
91. Rice CM, Scolding NJ. Adult stem cells—reprogramming neurological repair? *Lancet.* 2004;364(9429):193–9.
92. Singec I, Snyder EY. Inflammation as a matchmaker: revisiting cell fusion. *Nat Cell Biol.* 2008;10(5):503–5.
93. Whone AL, Scolding NJ. Mesenchymal stem cells and neurodegenerative disease. *Clin Pharmacol Ther.* 2009;85(1):19–20.
94. Korblyng M, Estrov Z, Champlin R. Adult stem cells and tissue repair. *Bone Marrow Transplant.* 2003;32(Suppl 1):S23–4.
95. Burt RK, et al. Autologous non-myeloablative haemopoietic stem cell transplantation in relapsing-remitting multiple sclerosis: a phase I/II study. *Lancet Neurol.* 2009;8(3):244–53.
96. Burt RK, et al. Hematopoietic stem cell transplantation for progressive multiple sclerosis: failure of a total body irradiation-based conditioning regimen to prevent disease progression in patients with high disability scores. *Blood.* 2003;102(7):2373–8.
97. Burt RK, et al. The promise of hematopoietic stem cell transplantation for autoimmune diseases. *Bone Marrow Transplant.* 2003;31(7):521–4.
98. Freedman MS, Atkins HL. Suppressing immunity in advancing MS: too much too late, or too late for much? *Neurology.* 2004;62(2):168–9.
99. Li Y, et al. Human marrow stromal cell therapy for stroke in rat: neurotrophins and functional recovery. *Neurology.* 2002;59(4):514–23.
100. Pittenger MF, et al. Multilineage potential of adult human mesenchymal stem cells. *Science.* 1999;284(5411):143–7.
101. Zappia E, et al. Mesenchymal stem cells ameliorate experimental autoimmune encephalomyelitis inducing T-cell anergy. *Blood.* 2005;106(5):1755–61.
102. Larghero J, Vija L, Lecourt S, Michel L, Verrecchia F, Farge D. Mesenchymal stem cells and immunomodulation: toward new immunosuppressive strategies for the treatment of autoimmune diseases? *Rev Med Interne.* 2009;30(3):287–99.
103. Bai L, Lennon DP, Eaton V, Maier K, Caplan AI, Miller SD, Miller RH. Human bone marrow-derived mesenchymal stem cells induce Th2-polarized immune response and promote endogenous repair in animal models of multiple sclerosis. *Glia.* 2009;57(11):1192–203.
104. Wang M, et al. The immunomodulatory activity of human umbilical cord blood-derived mesenchymal stem cells in vitro. *Immunology.* 2009;126(2):220–32.
105. Yadirgi G, Marino S. Adult neural stem cells and their role in brain pathology. *J Pathol.* 2009;217(2):242–53.
106. Pluchino S, et al. Persistent inflammation alters the function of the endogenous brain stem cell compartment. *Brain.* 2008;131(Pt 10):2564–78.
107. Ben-Hur T, et al. Transplanted multipotential neural precursor cells migrate into the inflamed white matter in response to experimental autoimmune encephalomyelitis. *Glia.* 2003;41(1):73–80.
108. Pluchino S, Martino G. The therapeutic plasticity of neural stem/precursor cells in multiple sclerosis. *J Neurol Sci.* 2008;265(1–2):105–10.
109. Patrikios P, et al. Remyelination is extensive in a subset of multiple sclerosis patients. *Brain.* 2006;129(Pt 12):3165–72.
110. Patani R, et al. Remyelination can be extensive in multiple sclerosis despite a long disease course. *Neuropathol Appl Neurobiol.* 2007;33(3):277–87.
111. Franklin RJ, Kottler MR. The biology of CNS remyelination: the key to therapeutic advances. *J Neurol.* 2008;255(Suppl 1):19–25.
112. Kuhlmann T, et al. Differentiation block of oligodendroglial progenitor cells as a cause for remyelination failure in chronic multiple sclerosis. *Brain.* 2008;131(Pt 7):1749–58.
113. Joscelyn J, Kasper LH. Digesting the emerging role for the gut microbiome in central nervous system demyelination. *Mult Scler J.* 2014;20(12):1553–9.
114. Round JL, Mazmanian SK. Inducible Foxp3+ regulatory T-cell development by a commensal bacterium of the intestinal microbiota. *Proc Natl Acad Sci U S A.* 2010;107(27):12204–9.
115. Domingues-Villar M, Gautron AS, de Marcken M, Keller MJ, Hafler DA. TLR7 induces anergy in human CD4+ T cells. *Nat Immunol.* 2014;16(1):118–28.
116. Bates JM, Akerlund J, Mittege E, Guillmin K. Intestinal alkaline phosphatase detoxifies lipopolysaccharide and prevents inflammation in zebrafish in response to the gut microbiota. *Cell Host Microbe.* 2007;2(6):371–82.

117. Mirza A, Mao-Draayer Y. The gut microbiome and microbial translocation in multiple sclerosis. *Clin Immunol.* 2017;183:213–24.
118. Venken K, et al. Natural naïve CD4+CD25+CD127high regulatory T cell (Treg) development and function are disturbed in multiple sclerosis patients: recovery of memory Treg homeostasis during disease progression. *J Immunol.* 2008;180:6411–20.
119. Venken K, et al. Compromised CD4+CD25high regulatory T-cell function in patients with relapse-remitting multiple sclerosis is correlated with reduced frequency of FOXP3 positive cells and reduced FOXP3 expression at the single-cell level. *Immunology.* 2008;123:79–89.
120. Ochoa-Repáraz J, Mielcarz DW, Ditrío LE, Burroughs AR, Foureau DM, Haque-Begum S, Kasper LH. Role of gut commensal microflora in the development of experimental autoimmune encephalomyelitis. *J Immunol.* 2009;183(10):6041–50.
121. Yokote H, Miyake S, Croxford JL, Oki S, Mizusawa H, Yamamura T. NKT cell-dependent amelioration of a mouse model of multiple sclerosis by altering gut flora. *Am J Pathol.* 2008;173(6):1714–23.
122. Nakamura YK, Metea C, Karstens L, Asquith M, Gruner H, Moscibrocki C, Lee I, Brislaw CJ, Jansson JK, Rosenbaum JT, Lin P. Gut microbial alterations associated with protection from autoimmune uveitis. *Invest Ophthalmol Vis Sci.* 2016;57:3747–58.
123. Round JL, Mazmanian SK. The gut microbiota shapes intestinal immune responses during health and disease. *Nat Rev Immunol.* 2009;9:313–23.
124. Bäckhed F, Manchester JK, Semenkovich CF, Gordon JI. Mechanisms underlying the resistance to diet-induced obesity in germ-free mice. *Proc Natl Acad Sci.* 2007;104(3):979–84.
125. Sellon RK, Tonkonogy S, Schultz M, Dieleman LA, Grenther W, Balish E, Rennick DM, Sartor RB. Resident enteric bacteria are necessary for development of spontaneous colitis and immune system activation in interleukin-10-deficient mice. *Infect Immun.* 1998;66(11):5224–31.
126. Wu H-J, Ivanov II, Darce J, Hattori K, Shima T, Umesaki Y, Littman DR, Benoist C, Mathis D. Gut-residing segmented filamentous bacteria drive autoimmune arthritis via T helper 17 cells. *Immunity.* 2016;32(6):1–13.
127. Berer K, Mues M, Koutoulos M, Rasbi ZA, Boziki M, Johner C, Wekerle H, Krishnamoorthy G. Commensal microbiota and myelin autoantigen cooperate to trigger autoimmune demyelination. *Nature.* 2011;479(7374):538–41.
128. Lee YK, Menezes JS, Umesaki Y, Mazmanian SK. Proinflammatory T-cell responses to gut microbiota promote experimental autoimmune encephalomyelitis. *Proc Natl Acad Sci.* 2011;108(Suppl 1):4615–22.
129. Miyake S, et al. Dysbiosis in the gut microbiota of patients with multiple sclerosis, with a striking depletion of species belonging to clostridia XIVa and IV clusters. *PLoS One.* 2015;10:e0137429.
130. Chen J, Chia N, Kalari KR, Yao JZ, Novotna M, Paz Soldan MM, Luckey DH, Marietta EV, Jeraldo PR, Chen X, Weinschenker BG, Rodriguez M, Kantarci OH, Nelson H, Murray JA, Mangalam AK. Multiple sclerosis patients have a distinct gut microbiota compared to healthy controls. *Sci Rep.* 2016;6:28484.
131. Jangi S, Gandhi R, Cox LM, Li N, von Glehn F, Yan R, Patel B, Mazzola MA, Liu S, Glanz BL, Cook S, Tankou S, Stuart F, Melo K, Nejad P, Smith K, Topçuoğlu BD, Holden J, Kivisäkk P, Chitnis T, De Jager PL, Quintana FJ, Gerber GK, Bry L, Weiner HL. Alterations of the human gut microbiome in multiple sclerosis. *Nat Commun.* 2016;7:12015.
132. Berer K, Gerdes LA, Cekanaviciute E, Jia X, Xiao L, Xia Z, Liu C, Klotz L, Stauffer U, Baranzini SE, Kümpfel T, Hohlfeld R, Krishnamoorthy G, Wekerle H. Gut microbiota from multiple sclerosis patients enables spontaneous autoimmune encephalomyelitis in mice. *PNAS.* 2017;114(40):10719–24.
133. Cekanaviciute E, Yoo BB, Runia TF, Debelius JW, Singh S, Nelson CA, Kanner R, Bencosme Y, Lee YK, Hauser SL, Crabtree-Hartman E, Sand IK, Gacias M, Zhu Y, Casaccia P, Cree BA, Knight R, Mazmanian SK, Baranzini SE. Gut bacteria from multiple sclerosis patients modulate human T cells and exacerbates symptoms in mouse models. *PNAS.* 2017;114(40):10713–8.
134. Ochoa-Repáraz J, Magori K, Kasper LH. The chicken or the egg dilemma: intestinal dysbiosis in multiple sclerosis. *Ann Transl Med.* 2017;5(6):145.
135. Colpitts SL, Kasper EJ, Keever A, Liljenberg C, Kirby T, Magori K, Kasper LH, Ochoa-Repáraz J. A bidirectional association between the gut microbiota and CNS disease in a biphasic murine model of multiple sclerosis. *Gut Microbes.* 2017;8:561–73.
136. Shapira L, Ayalon S, Brenner T. Effects of *Porphyromonas gingivalis* on the central nervous system: activation of glial cells and exacerbation of experimental autoimmune encephalomyelitis. *J Periodontol.* 2002;73(5):511–6.
137. Nichols FC, Housley WJ, O'Connor CA, Manning T, Wu S, Clark RB. Unique lipids from a common human bacterium represent a new class of Toll-like receptor 2 ligands capable of enhancing autoimmunity. *Am J Pathol.* 2009;175(6):2430–8.
138. Ezendam J, de Klerk A, Gremmer ER, van Loveren H. Effects of bifidobacterium *animalis* administered during lactation on allergic and autoimmune responses in rodents. *Clin Exp Immunol.* 2008;154(3):424–31.
139. Lavasani S, Dzhambazov B, Nouri M, Fâk F, Buske S, Molin G, Thorlacius H, Alenfall J, Jeppsson B, Weström B. A novel probiotic mixture exerts a therapeutic effect on experimental autoimmune encephalomyelitis mediated by IL-10 producing regulatory T cells. *PLoS One.* 2010;5(2):e9009–11.

140. Mangalam A, Shahi SK, Luckey D, Karau M, Marietta E, Luo N, Choung RS, Ju J, Sompallae R, Gibson-Corley K, Patel R, Rodriguez M, David C, Taneja V, Murray J. Human gut-derived commensal bacteria suppress CNS inflammatory and demyelinating disease. *Cell Rep.* 2017;20(6):1269–77.
141. Mazmanian SK, Liu CH, Tzianabos AO, Kasper DL. An immunomodulatory molecule of symbiotic bacteria directs maturation of the host immune system. *Cell.* 2005;122(1):107–18.
142. Ochoa-Repáraz J, Mielcarz DW, Wang Y, Begum-Haque S, Dasgupta S, Kasper DL, Kasper LH. A polysaccharide from the human commensal *Bacteroides fragilis* protects against CNS demyelinating disease. *Mucosal Immunol.* 2010;3(5):487–95.
143. Johnson JL, Jones MB, Cobb BA. Bacterial capsular polysaccharide prevents the onset of asthma through T-cell activation. *Glycobiology.* 2015;25:368–75.
144. Wang Y, Telesford KM, Ochoa-Reparaz J, Haque-Begum S, Christy M, Kasper EJ, Wang L, Wu Y, Robson SC, Kasper DL, Kasper LH. An intestinal commensal symbiosis factor controls neuroinflammation via TLR2-mediated CD39 signalling. *Nat Commun.* 2014;5:4432.
145. Wang Y, Begum-Haque S, Telesford KM, Ochoa-Reparaz J, Christy M, Kasper EJ, Kasper DL, Robson SC, Kasper LH. A commensal bacterial product elicits and modulates migratory capacity of CD39(+) CD4 T regulatory subsets in the suppression of neuroinflammation. *Gut Microbes.* 2014;5(4):552–61.
146. Telesford KM, Yan W, Ochoa-Reparaz J, Pant A, Kircher C, Christy MA, Begum-Haque S, Kasper DL, Kasper LH. A commensal symbiotic factor derived from *Bacteroides fragilis* promotes human CD39(+)Foxp3(+) T cells and Treg function. *Gut Microbes.* 2015;6(4):234–42.
147. Burgess JN, Pant AB, Kasper LH, Colpitts Brass S. CD4+ T cells from multiple sclerosis patients respond to a commensal-derived antigen. *Ann Clin Transl Neurol.* 2017;4(11):825–9.

---

**Part II**

**Multiple Sclerosis**

# Immunopathogenesis

# 3

Patricia K. Coyle

## Introduction

Although the precise etiology of multiple sclerosis (MS) remains unknown, three factors are involved (Table 3.1). The first is genetic vulnerability. Over 230 risk/susceptibility genes, along with occasional protection and disease severity genes, are being identified at an increasing pace. They are typically linked to immune/inflammatory rather than central nervous system (CNS) factors. Linked genes are not universal and can vary based on patient racial, ethnic, and geographic background. The second factor involves environmental exposures, which probably occur at critical time points especially earlier in life. These include vitamin D deficiency, Epstein-Barr virus (EBV) infection, adolescent obesity, smoking, and ultraviolet light exposure. The final factor is the host immune system, which damages the CNS. MS is clearly an immune-mediated disease. It appears to be heterogeneous, however, with different pathways leading to disease expression [1]. Studies focused on pathology and immunology allow important insights into MS pathogenesis and pathophysiology. This chapter will begin with a review of the neuropathology of MS and then cover current concepts on major immunologic disease factors

**Table 3.1** Proposed etiologic factors in MS

Gene associations
30–50% of MS risk is genetic
20% of risk from gene associations (>230) from GWAS; largely increase susceptibility, especially HLA-DRB1*1501
Some decrease susceptibility/protect
Rare reports of genes influencing disease severity
5% of risk from low-frequency variants (NLRP8, PRKRA, HDAC7, PRF1)
Environmental factors/lifestyle
Vitamin D deficiency
Epstein-Barr virus (EBV) infection (infectious mononucleosis; high antibody levels to EBV nuclear antigen)
Tobacco exposure
Ultraviolet radiation exposure
Gut microbiota
Adolescent obesity
Organic solvents
Shift work
Immune system factors
Acquired and innate immunity is involved
CNS inflammation (both focal and diffuse), including leptomeningeal inflammation
Changes in CNS components (BBB, glial cells, neurons, axoglial unit, ion channels, synapses)

involved. Distinctions between relapsing and progressive MS will be highlighted.

## Pathology

Since there is no true animal model for MS, neuropathologic studies are uniquely informative. Unfortunately biopsy and autopsy materials are

P. K. Coyle (✉)  
 Department of Neurology, MS Comprehensive Care  
 Center, Stony Brook University Medical Center,  
 Stony Brook, NY, USA  
 e-mail: [patricia.coyle@stonybrookmedicine.edu](mailto:patricia.coyle@stonybrookmedicine.edu)

**Table 3.2** Pathologic changes in MS

Increased water content (edema), BBB injury
Endothelial cell injury
Inflammation (lymphocytes, monocytes/macrophages, dendritic cells)
Demyelination
Axonal injury and loss
Oligodendrocyte injury and loss
Neuronal injury and loss
Dendrites, synapses affected
Microglial activation
Astrocytosis
Remyelination
Focal macroscopic plaques (typically centered around venules) in white matter and gray matter (cortex and deep nuclei)
Widespread microscopic injury

limited and subject to the criticism that they may not be representative of MS in general. Nevertheless, such studies have provided novel insights.

Abnormal pathology in MS is confined to the CNS. There are two major pathological processes. The first is focal inflammation leading to formation of macroscopic plaques, visualized initially as contrast-positive lesions on neuroimaging. This reflects major focal breach of the blood-brain barrier (BBB) and is a hallmark of relapsing MS. The second pathologic process is neurodegeneration, with microscopic injury to axons, neurons, synapses, and dendrites and subsequent tissue volume loss. This is believed to be the neuropathologic substrate of progressive MS [2]. These two key pathologic processes, resulting in macroscopic and microscopic lesions, involve a spectrum of changes that can vary over time, as well as between patients (Table 3.2). Studies indicate progression is age dependent, which might support neurodegeneration as a truly independent process from focal inflammation [3]. In this setting, transition to progressive MS might reflect critical loss of CNS reserve.

### Macroscopic Injury

Multifocal lesions referred to as plaques occur in waves and can occur throughout the course of

MS, but especially in the early years. They result from focal inflammation. About 80–85% of MS plaques are centered around small veins. They show sharp margins. Plaque pathology involves edema and inflammation early, variable degrees of myelin loss and axonal injury/loss, oligodendrocyte and neuronal loss including via programmed cell death (apoptosis), myelin pallor or vacuolization, normal or aberrant remyelination, microglial activation, and reactive astrocytosis. Programmed necrosis (necroptosis) has been suggested as a neuronal cell death mechanism in MS via microglial activation [4, 5]. Early on there is infiltration of cells with marked BBB breakdown, identified by contrast enhancement on magnetic resonance imaging (MRI). This breakdown likely reflects direct effects of proinflammatory cytokines and chemokines, as well as indirect WBC-related injury [6]. This is followed by a local immune cascade, with proinflammatory cytokine and chemokine release, local cell activation, and injury to myelin, underlying axons, and oligodendrocytes. There is disruption of blood vessel walls, with deposition of perivascular serum albumin, fibrinogen, and immunoglobulins [7]. The edema and influx of serum components lead to nerve conduction block at nodes of Ranvier [8]. Over time inflammatory cells clear, leaving a permanent area of damage surrounded by an astrocytic scar. These macroscopic lesions are visualized on MRI as hyperintense foci on T2/fluid-attenuated inversion recovery (FLAIR) sequences. When there is marked tissue matrix damage, they will also appear as chronic hypointense black holes on T1 sequences.

Plaques form in preferential areas, including corpus callosum, periventricular white matter, optic nerves, cortical gray matter, juxtacortical white matter, brain stem/cerebellum, and spinal cord. They always seem to be close to blood or cerebrospinal fluid (CSF), raising the issue of diffusible humoral factors playing a role in their occurrence. White matter plaques are typically most apparent, but gray matter plaques and gray matter demyelination can be extensive. Neocortical lesions have been divided into leukocortical (Type I), intracortical (Type II), or subpial (Type III). Most cortical lesions are subpial

[7]. Macroscopic injury, along with the microscopic damage discussed below, leads over time to discernable atrophy of the brain and spinal cord. The corpus callosum thins, and the lateral ventricles expand. In 5–10% of patients, there is severe hydrocephalus ex vacuo [7].

### Microscopic Injury

MS CNS shows diffuse global injury. Much of the normal-appearing CNS, in between the macroscopic plaques, is microscopically abnormal [9]. Changes include BBB disturbances, low-grade (CD8+ T cell) inflammation, gliosis, microglial activation, axonal injury, and damage to the nerve fiber layer of the retina [10]. This has been documented using imaging techniques such as magnetization transfer imaging, diffusion tensor imaging, magnetic resonance spectroscopy, and optical coherence tomography and confirmed with careful pathologic studies. Inflammatory cuffs are often seen in normal-appearing white matter. There is variable axonal injury, characterized by axonal spheroids and terminal swellings. Cellular and molecular changes point toward axonal transport disturbances, hypoxic injury, and loss of neurites and synapses [7]. Progressive MS patients in particular show both perivascular and parenchymal inflammatory infiltrates (see “Progressive MS” section). This microscopic injury is independent of macroscopic pathology.

### Plaque Pathology

Formation of the MS lesion goes through stages with distinct differences. In an autopsy study of very early MS, the pathologic changes that preceded myelin phagocytosis involved marked loss of oligodendrocytes, often by apoptosis; marked microglial activation; myelin pallor without myelin loss; and virtually no systemic inflammatory cells [11]. The authors suggested these very early prephagocytic lesions, characterized by oligodendrocyte loss and microglial activation, preceded systemic inflammation. They interpreted

this as most consistent with a primary in situ disturbance at the level of the oligodendrocyte and/or microglial cell, provoking a secondary systemic inflammatory response. This supports an “inside-out” hypothesis for MS and has important implications for the role of the systemic immune system in MS, which will be discussed later. More recent reports suggest abnormalities in astrocyte foot processes may also be a very early lesion feature [12].

The next stage in very early lesions is detection of macrophages ingesting myelin. Myelin phagocytosis represents an innate response of macrophages, and is not a CD4+ T cell-mediated process [13]. Normal tissue surrounding these active lesions shows microglial activation, except in very acute cases (when the duration is in days). Normal-appearing white matter also shows IgG-positive reactive astrocytes and occasional IgG-positive oligodendrocytes and axons. Very early lesions show CD 209+ dendritic cells in perivascular spaces within and surrounding new lesions, consistent with their being a major antigen-presenting cell (APC) in MS. Proliferating monocytes are present in the Virchow-Robin spaces and adjacent tissues in very early lesions.

CD4+ and CD8+ T cells are seen in perivascular spaces of parenchyma of recently demyelinated tissue, along with B cells and plasma cells and occasional regenerating oligodendrocytes. This has been interpreted as the start of an adaptive/acquired immune response, as opposed to the innate response of the very early lesion.

The tissue bordering active expanding lesions shows early loss of oligodendrocytes accompanied by activated microglia, with little inflammatory infiltrate. There is subsequent accumulation of activated T cells, B cells, and IgG-positive plasma cells, with some oligodendrocyte regeneration.

Early active lesions are marked by heavy infiltration of macrophages that phagocytize myelin fragments. Active plaques are defined by the presence of partially demyelinated axons with myelin-filled macrophages [14]. Male and female MS patients show no inflammation differences in T cells, CD8+ T cells, and macrophages in early MS lesions [15].



The dominant cell in active plaques is the myelin-laden macrophage, which originates from microglia with participation of systemic infiltrating monocytes. They outnumber lymphocytes ten to one. With regard to T cells, clonally expanded CD8+ T cells markedly outnumber CD4+ T cells. B cells and plasma cells are limited. Immunoglobulin and complement products are found on the degenerating myelin sheaths, with variable loss of oligodendrocytes. This inflammatory infiltrate leads to upregulation of proinflammatory cytokines, such as interleukin-1 (IL-1) and IL-2, tumor necrosis factor (TNF), and interferon  $\gamma$  (IFN $\gamma$ ), and activation of endothelial cells, which will express stress proteins, MHC class II and adhesion molecules, and other factors.

Late chronic disease plaques show little inflammation and highly reactive microglia at their rim and can have some macrophages containing myelin debris [7]. Burnt-out chronic inactive plaques are marked by demyelination with little to no inflammation and are surrounded by an astrocytic scar.

## Autopsy Specimens

A 2009 study evaluated 67 MS autopsy brains compared to 28 control brains [16]. The MS cohort involved acute MS leading to death within 12 months ( $N=9$ ); relapsing MS ( $N=5$ ); secondary progressive MS (SPMS) ( $N=35$ ); primary progressive MS (PPMS) ( $N=13$ ); asymptomatic MS ( $N=4$ ); and benign relapsing MS ( $N=1$ ). A total of 1148 lesions were evaluated: 378 were active, 222 were slowly expanding (an inactive center, surrounded by a rim of activated microglia and some macrophages at the lesion margin), and 548 were inactive (a sharp lesion border without macrophages and no microglial activation). Detailed quantitative analysis was performed on a subset of 228 lesions (85 active, 50 slowly expanding, 93 inactive). In addition 139 normal-appearing white matter regions, 121 meninges, and 120 control areas were also analyzed from the MS brains.

Several important observations were made. The most marked inflammation was found in acute and relapsing MS brains. T cells were most marked in active lesions (which were most common in the acute and relapsing MS brains), followed by slowly expanding lesions (which were only found in progressive MS). Inactive lesions and normal-appearing white matter showed low T cell numbers. T cells were virtually absent from cortex, but markedly present in meninges. Most of the lesional T cells were CD8+ as opposed to CD4+ cells. B cells showed a similar distribution pattern but were tenfold fewer than T cells. They were predominantly found in perivascular cuffs or meninges; very few were within parenchyma. Cortical lesions have shown limited inflammation at postmortem. They are often associated with leptomeningeal inflammation. They show loss of neurites, decreased synapses, and decreased neurons [7]. Macrophages (HLA-D+) were present in all active lesions, microglia were prominent in slowly expanding lesions, and a ramified microglia-like cell was present in inactive lesions. Plasma cells were mainly found in perivascular and meningeal connective tissue rather than lesions, parenchyma, cortex, or normal-appearing white matter. They were most common in progressive MS. Lymph node-like follicle structures were found only in 22% of the active progressive MS brains.

Acute axonal injury was most marked in active plaques, followed by slowly expanding lesions, inactive plaques, normal-appearing white matter, and cortex. Normal-appearing white matter from progressive MS showed greater axonal injury. Acute axonal injury correlated with inflammation in all MS subtypes, including progressive MS.

An intriguing observation was that in older MS brains (average age was 76 years), inflammation and axonal injury declined to levels consistent with age-matched controls. All lesions seemed inactive, suggesting that perhaps the MS disease process burns out with age. However this concept has not been verified, and ongoing MS damage may be quite marked in elderly individuals. In these brains, there was active remyelination with evidence of shadow plaques.

It could be speculated that clearance of activated microglia permitted resumption of remyelination. These patients could show concomitant vascular and Alzheimer pathology however.

The authors concluded that progressive MS was associated with inflammation, but did not show the degree of endothelial leakiness found in relapsing MS. There was differential cell distribution. T cells were seen in large perivascular cuffs, as well as in brain parenchyma. In contrast, B cells and especially plasma cells accumulated in connective tissue spaces (perivascular spaces and meninges). Plasma cells accumulated later than T and B cells, but persisted long after T and B cells had cleared.

The pathologic data supported a role for multiple cells (CD8+ T cells, B cells, plasma cells, macrophages, monocytes, microglia) in MS, in addition to CD4+ T cells.

In another study of 16 MS brains and 8 controls, focused on the cerebellar dentate nucleus, reduced numbers and density of synapses were found [17]. There was evidence for both a gliamediated and direct neuronal damage process. In a third study of eight MS brains and eight controls, widespread primary dendrite spine loss was found in MS cortex [18].

### Myelocortical MS

A recent study reported on 100 consecutive MS autopsies over a 14-year period [19]. Twelve showed a unique neuropathologic picture. There was no evidence for cerebral white matter myelin loss, despite very abnormal brain MRIs. Cerebral axons were diffusely swollen, with intact myelin. There were activated microglia, astrocytosis, and serum proteins observed in the cerebral regions. The authors referred to this newly recognized disease subtype as myelocortical MS. There was the expected myelin loss in the subpial cortex and spinal cord. Compared to non-myelocortical MS, this subtype had the most profound loss of cortical neurons. Cortical neuron loss did not correlate with cortical demyelination, suggesting independent injury to myelin and neurons. Myelocortical MS patients

had secondary progressive (SP) MS (67%), primary progressive (PP) MS (16.5%), and relapsing MS (16.5%).

### Progressive MS

The neuropathology of progressive MS differs from relapsing MS. Progressive MS is believed to represent neurodegeneration, injury to axons, neurons, and synapses. Although both progressive and relapsing MS contain focal inflammatory demyelinating lesions, with variable axonal injury and loss, progressive MS as noted above has been associated with a compartmentalized low-grade diffuse inflammatory process behind a relative intact BBB, with slow expansion of white matter lesions, marked activated microglia, and extensive cortical demyelination. Most focal white matter lesions in progressive MS show slow expansion at the lesion edge or are inactive [20]. The slowly expanding lesions show no oligodendrocyte precursors, and no active remyelination. They appear to reflect mitochondrial injury and implicate an energy disturbance. The diffuse inflammation in progressive MS does not express apoptosis or proliferative markers. It is associated with marked neurodegeneration, with extensive axonal injury and microscopic changes. Such a process could be driven by local antigen exposure or local cytokine production within the CNS microenvironment. There is diffuse injury to normal-appearing brain, along with marked gray matter demyelination within cerebral and cerebellar cortex. Fast axonal transport disturbances, resulting in neurodegeneration, correlate with inflammatory changes in T cells, B cells, and macrophages. Inflammatory lymphocytes predominate in perivascular cuffs. These T cells, B cells, and plasma cells are found largely in the meninges. Despite significant inflammation, progressive MS patients show little to no contrast-enhancing lesion activity. This has been interpreted as progressive MS showing inflammation trapped behind a closed or repaired BBB.

In a recent study of the brain and spinal cord of 34 SPMS patients and 13 PPMS patients, the SPMS patients showed larger brain plaques and

greater demyelination and plaque inflammation, while PPMS showed greater remyelination with more remyelinated shadow plaques [21]. Incomplete remyelination in the spinal cord, but not in brain, correlated with greater disability.

Blood vessels in progressive patients may show thick perivascular infiltrates without leakiness [20]. Progressive patients can also show ectopic lymphoid follicle-like structures, resembling secondary lymphoid tissue, in connective tissue compartments of the CNS. In a subset of SPMS, these lymphoid follicles form within meninges where there is underlying inflammation and demyelination. They also form adjacent to large active subpial cortical lesions. The severity of meningeal inflammation and lymphoid follicles was said to correlate with extent of cortical lesion activity. However, in another study, cortical demyelination did not correlate with meningeal inflammation [22]. The chronically inflamed brain in progressive MS could create a local microenvironment favoring retention of inflammatory cells. In short, the neuropathology supports distinct mechanisms involved in progressive vs. relapsing MS [23].

In a recent study from the Netherlands Brain Bank, progressive MS patients with a mean disease duration of 28.6 years showed marked inflammation: 57% of all lesions were active, and 78% were mixed active/inactive [24]. Progressive MS (vs. relapsing MS) showed higher lesion load ( $p = 0.001$ ) and fewer remyelinated lesions ( $p = 0.03$ ). They also showed higher proportion of mixed active/inactive lesions ( $p = 0.006$ ).

### Lesion Heterogeneity

The MS Lesion Project originally proposed four patterns of acute MS plaques: demyelination with abundant macrophages, with or without immunoglobulin and complement deposition; oligodendrocyte apoptosis, with distal dying-back oligodendrogliopathy, and rare primary oligodendrocyte injury [25, 26]. It was suggested that those with immunoglobulin and complement

responded to plasma exchange [27]. To date these patterns have not been confirmed definitively, and have not proven clinically useful.

### Remyelination

Remyelination occurs in about 70–75% of MS plaques and is associated with oligodendrocyte progenitor cell (OPC) recruitment. Chronic remyelinated lesions are referred to as shadow plaques. This myelin is thinner than normal [7]. Vessels often show wall dissection and fibrosis and enlarged perivascular spaces (pseudo-channels). In the other 25–30% of lesions, remyelination is absent, and oligodendrocyte numbers are limited, suggesting a failure to recruit OPCs [28]. Within a given macroscopic plaque, deeper sections can show signs of repair (remyelination, oligodendrocyte regeneration) even though the edges show continued destructive activity [29]. An important goal of current research efforts involves ways to enhance remyelination.

### Axon Pathology

Acute axon injury including transection occurs in early MS, within both active and chronic plaques, as well as normal-appearing brain tissue and periplaque white matter [30–33]. Axon pathology correlates with degree of inflammation. Inflammatory intermediates reduce energy metabolism in demyelinated axons, perhaps by direct mitochondrial effects or by interfering with blood flow resulting in ischemia [8].

More specifically, CD8+ T cell inflammation has been associated with axonal injury [34]. Although there is a symbiotic relationship between myelin and axon, axon changes can occur independent of demyelination [34]. This is emphasized in the myelocortical MS previously discussed. In a study of MS spinal cord tissue, diffuse axonal loss correlated with density of both activated microglia and meningeal T cells [35]. In another recent study of brain tissue from

19 children with early MS, early axonal injury was much more extensive than in 12 adult MS samples [36].

With axon injury, there are sodium influx, activation of calcium-dependent proteases, upregulation of voltage-gated calcium channels, and destruction of the axon cytoskeleton. Small axons (<2.5  $\mu\text{m}$  cross-sectional area) are preferentially lost within MS spinal cord and optic nerve [37, 38].

### Cortical/Gray Matter Pathology

Although MS has been described as a demyelinating white matter disease, pathologic studies document marked gray matter involvement in deep nuclei as well as cortex. Thalamic neuronal loss in MS is estimated at 30–35% [39]. As mentioned earlier, three types of cortical lesions are described. Type I lesions span the cortex and white matter, Type II are completely intracortical, and Type III extend from the pial surface into the cortex, generally to cortical layer 3 or 4, and cover several gyri [40]. Although not visualized on conventional MRI, cortical lesions are common in MS. They are hypocellular compared to white matter plaques, and may not be associated with breakdown of the BBB. Although there are few inflammatory cells and no perivascular cuffs, activated microglia are plentiful. These lesions show loss of axons and neurons. As noted previously, progressive MS patients show more cortical pathology than relapsing patients.

### Unusual MS Variants

Tumefactive MS refers to patients who present with an unusually large brain plaque, generally singular, with surrounding edema and mass effect. The lesion mimics a brain tumor or abscess and may lead to urgent biopsy. In rare cases this is the presentation of MS. It can also occur in well-established MS and has been seen in fingolimod- and natalizumab-treated patients [41, 42]. Neuroradiologic features involve size typically

>2 cm and mass effect, with edema and/or ring enhancement [43]. The pathology shows active inflammation with myelin loss, reactive gliosis, myelin-laden macrophages, and relative axonal sparing. Prognosis does not differ from classic relapsing MS.

Marburg variant MS refers to a clinically malignant and fulminant disease expression, where patients go on to profound disability or even death within months to a year or 2. Lesion pathology is more destructive [10]. There are many, often large, macroscopic lesions which may become confluent. Active lesions show massive macrophage infiltration, marked myelin loss, severe axon loss, and tissue necrosis. There may be deposition of immunoglobulin and complement activation in some cases. It has been suggested that Marburg variant is associated with increased (>80%) citrullinated myelin basic protein (MBP), a more immature and unstable form of this core CNS myelin component [44, 45].

Balo concentric sclerosis is an unusual demyelinating variant reported as more frequent in the Philippines and Asia. Cognitive features may be prominent. There is often a severe stroke-like onset [46]. The striking pathology involves alternating rings of intact myelin, separated by demyelinated regions. Oligodendrocyte apoptosis along with selective loss of myelin-associated glycoprotein (MAG) has been noted in the demyelinated regions. The demyelinating pattern has been described as similar to what hypoxic injury might produce, with local expression of iNOS and upregulated expression of tissue-preconditioning proteins at the lesion edge [10, 47, 48]. These lesions show defects in mitochondrial respiratory chain proteins [49]. Aquaporin 4 loss without complement or immunoglobulin deposition was extensive in both demyelinated and myelinated regions in four cases of Balo disease [50].

Myelinoclastic diffuse sclerosis (Schilder disease) is a very rare predominantly pediatric disorder, characterized by one or two large (3  $\times$  2 cm) cerebral inflammatory demyelinating lesions [51]. This disorder is typically monophasic and steroid responsive [52]. It behaves like a postinfectious encephalitis [53].

Progressive solitary sclerosis was first described in 1990. It refers to an isolated/single CNS demyelinating lesion which produces progressive motor impairment. In the largest series reported to date ( $N = 30$ ) [54], lesion location was most commonly the cervical spinal cord (60%), followed by cervicomedullary junction/brain stem (20%), thoracic spinal cord (13.3%), and cerebral white matter (6.7%). Patients presented with hemiparesis/monoparesis (80%), quadriplegia (16.7%), or paraparesis (13.3%). The course is typically a slow worsening, but rare presentations are acute to subacute. Median age has been 48.5 (23–71) years, 50% are female, and 50% show CSF abnormalities consistent with MS. Thirteen percent report a first degree relative with MS. Limited studies confirm demyelination, and in rare cases, there is late MRI dissemination. This has been proposed to be a forme fruste of PPMS [55].

---

## Summary

Pathologic studies in MS reinforce several key features. They include the inevitable presence of abnormal inflammation, both focal and diffuse; macroscopic and microscopic pathology; extensive gray matter involvement; neurodegeneration in addition to myelin and oligodendrocyte injury; and distinctive features for relapsing vs. progressive MS. More work is needed to clarify the role of recently described myelocortical MS and whether early in situ pathology triggers systemic inflammatory cell infiltration in a subset of MS or is a more general phenomenon.

---

## Immunology

Traditional MS immunopathogenesis concepts focused on systemic autoreactive CD4+ T cells, sensitized to one or more CNS myelin components, along with proinflammatory cytokine production and a preferential T helper (Th)1 response. This was based on a key animal model discussed below. However, the immunology of MS is now appreciated to be much more com-

plex, with bidirectional interactions between systemic components and resident CNS cells [6]. Mucosal immunity (in particular the gut microbiota) may play a crucial role. In fact it is not even clear that MS is a true autoimmune disorder, since no critical autoantigen target (including any myelin component) has ever been identified. It is more accurate to describe MS as an immune-mediated disorder, with multiple immune system components and factors mediating the key pathologic changes of MS. Changes in systemic immune factors (increase in innate immunity, including myeloid dendritic cells) may contribute to development of SPMS, along with in situ CNS inflammation trapped behind a closed BBB [20, 56, 57]. This CNS-compartmentalized inflammation likely contributes to CNS injury but is poorly targeted by current therapies.

## Animal Models

There is no true animal model for MS, but immune-mediated and toxin- and virus-induced models have been studied. The major one is experimental allergic/autoimmune encephalomyelitis (EAE). It is produced in susceptible animal strains by immunizing with CNS whole myelin or myelin components such as myelin oligodendrocyte glycoprotein (MOG), myelin basic protein (MBP), and proteolipid protein. The immunization procedure requires potent adjuvants. Depending on the strain and immunization protocols, clinical expression can involve monophasic, relapsing, or progressive disease. In EAE both cellular (CD4+, CD8+ T cell) and humoral immune responses play a role. The most common model involves CD4+ Th1 cells initiating delayed-type hypersensitivity responses to myelin antigens. Pathogenic CD4+ T cells adoptively transfer EAE, with the brunt of pathology seen in the spinal cord. Myelin-specific CD8+ T cells as well as Th17 cells can also induce EAE [58]. Recent studies suggest three forms of EAE, which can be driven by adoptive transfer of CD4+ Th1, Th17, or Th2/Th9 cells [59, 60]. In the EAE model, inflammation first enters the subarachnoid space and then

the parenchyma. This may be similar to what happens in MS. Although MOG-induced EAE probably comes closest to looking like MS, no EAE model truly duplicates MS. EAE seems to be a truer model for acute disseminated encephalomyelitis (ADEM)/postinfectious encephalitis or encephalomyelitis, which has an immunopathology distinct from MS [61].

Toxin-induced demyelination models include direct injection of gliotoxins (such as ethidium bromide, lysolecithin) into white matter or systemically delivered toxins such as cuprizone [62].

The best infectious animal model for MS involves Theiler's murine encephalomyelitis virus (TMEV), a nonenveloped single-strand RNA picornavirus [58]. This causes an acute mild polio-encephalomyelitis in mice, followed by a chronic inflammatory demyelinating spinal cord infection, with virus detectable in glial cells and macrophages. The chronic infection results in an immune-mediated myelopathy with features reminiscent of MS. However, it is relatively easy to document the persistent infection, whereas this has not been shown in MS. Other infection models have included canine distemper virus and mouse hepatitis virus, but none truly recapitulate MS.

### MS Immunologic Scenarios

Distinct immunologic scenarios have been proposed for MS (Table 3.3). The most popular "outside-in" hypothesis involves proinflammatory CD4+ T cells, both Th1 and Th17, activated in the periphery by an unknown (likely antimicrobial) antigen. The triggering antigen presumably shares antigenic sequences with myelin or other CNS antigens. These proinflammatory cells attach to the CNS endothelium via adhesion molecules to cross the BBB. This is facilitated by release of proteolytic enzymes such as matrix metalloproteinases (MMPs). Once inside the CNS parenchyma, molecular mimicry results in cross-reactivity, and the misdirected immune attack results in pathologic lesions. Instead of quickly exiting, the infiltrating cells see this shared antigen and are further activated locally to cause injury. This results in further leukocyte

**Table 3.3** MS immunologic scenarios [6]

Environmental pathogen(s) or other factor leads to systemic immune response
This response cross-reacts with CNS/possibly myelin antigen
Sensitized systemic cells penetrate the CNS and result in primary tissue damage
Outside-in hypothesis
Intrinsic CNS abnormality (at level of oligodendrocyte, astrocyte, microglia, or neuron) leads to in situ disturbance
Secondary systemic immune cell penetration with secondary tissue damage
Inside-out hypothesis
Progressive vs. relapsing MS
Less focal inflammation; CNS-compartmentalized inflammation
CD8+ T cells, plasma cells; activated microglia, astrocyte inflammatory responses
Accentuated neuro-axonal degeneration (with oxidative stress, mitochondrial dysfunction, extracellular free iron accumulation, loss of myelin trophic support), altered glutamate, proinflammatory microenvironment

recruitment, inflammation, local cell activation, and damage to CNS tissue. There is evidence that immunity to myelin antigen targets can worsen MS. Altered peptide ligands (APL) are created as partial agonists or antagonists to the T cell receptor of autoreactive lymphocytes. In a phase II trial of an APL to MBP 83–99, a subset of patients had marked worsening on MRI with clinical relapse, coincident with a marked expansion of MBP reactive T cells [63].

The inside-out hypothesis is based on a primary in situ CNS abnormality which somehow provokes systemic immune cells to infiltrate, producing secondary inflammatory-mediated damage. This could reflect an abnormality of intrinsic CNS cells (oligodendrocytes, microglia, astrocytes, neurons) or their components (mitochondria, ion channels). The in situ disturbance could be a chronic CNS infection, metabolic, or vascular defect. In this scenario, MS could be a neurodegenerative disorder, with demyelination a secondary issue [64].

Finally, the immunology and damage mechanisms between progressive and relapsing MS may be distinct, with a much more important role for intrathecal mechanisms in progressive MS.

Since MS is most likely heterogeneous, it is quite possible that more than one scenario can result in MS. For example, could disease be driven by persistent CNS infection? It will be important to define distinct MS subsets.

---

## Immune System Cells

### T Cells

Although the human immune system does not have true distinct Th1 and Th2 cells, CD4+ Th1-like cells promote proinflammatory cytokines and enhance cellular immunity, while CD4+ Th2-like cells promote antagonistic regulatory cytokines and enhance humoral immunity. CD4+ T cells, depending on whether they are naïve or activated, can show abnormalities in number and/or function in MS patients vs. controls [65].

T regulatory (Treg) cells are immunosuppressive CD4+ T cells that express CD25 and Foxp3. They inhibit autoreactive effector cells [65]. CD4+ CD25+ Treg cells are implicated in development of autoimmune disorders. A number of studies have suggested that Treg number and function are abnormal in MS [66–68]. Transcription factor Foxp3 is the programmer for the suppressive function of Treg cells. Foxp3 mRNA and protein levels are reported as reduced in MS [69]. Recently CD8+ Treg cells were described and found to be decreased in blood and CSF of MS patients who were in an acute attack [70].

CD4+ Th17 cells are distinct from Th1, Th2, and Treg cells and have been associated with inflammation, autoimmunity, and response to extracellular pathogens [71]. Naïve T cells require exposure to transforming growth factor  $\beta$  (TGF $\beta$ ) and either IL-6 or IL-21 to become Th17 cells, along with exposure to IL-23 produced by macrophages and dendritic cells [72]. IL-23 is a main driver. Th17 cells produce IL-17, which promotes inflammatory responses [68]. IL-17 messenger RNA (mRNA) is elevated in MS patients. These cells also produce IL-21 and IL-22. Th17 cells excel at infiltrating tissues to cause severe inflammation. They express the che-

mokine receptor CCR6 on their surface [66]. Th17 cells are clearly implicated in MS [73–75].

CD8+ T cells function as cytotoxic/regulatory cells. They are activated in the periphery and then enter the CNS. They dramatically outnumber CD4+ T cells within MS lesions at all disease stages [70]. CD8+ T cells show the most profound and reproducible clonal and oligoclonal expansion [76], and memory CD8+ T cells are enriched in both blood and CSF of MS patients [77]. CD8+ T cells are associated with axonal injury in early MS [68]. They interact with autoreactive CD4+ T cells to suppress them. CD8+ T cells are also reduced during MS relapses [69].

A small subpopulation of T cells have a T cell receptor composed of  $\gamma/\delta$  polypeptides, as opposed to the usual  $\alpha/\beta$  polypeptides. They are mainly located in skin and mucosal tissues. These  $\gamma/\delta$  T cells are involved in both innate and adaptive immune responses and have been reported as clonally expanded in the CSF of early MS patients [78]. Another subset was associated with very aggressive MS [79]. They are increased in MS lesions and may be involved in oligodendrocyte lysis [80].  $\gamma/\delta$  T cells in the EAE model control inflammatory cell migration into the CNS, promote apoptosis of encephalitogenic T cells, and play a key role in recovery. Their potential role in MS remains to be determined. Terminally differentiated effector memory  $\gamma/\delta$  T cells were decreased in the periphery during relapse [81].

There is also a small subpopulation of CD20+ T cells. They make up 3–5% of T cells and are proinflammatory with a high proliferative capacity to CNS antigens. They were reported to be enriched in the blood and CSF of MS patients [82].

### B Cells

B cells play a major role in MS (Table 3.4). B cells and plasma cells are present in the brain and CSF of MS patients [83]. There are clonal expansion and somatic mutation of B cell receptor genes, consistent with an antigen-driven response [84, 85]. Healthy controls rarely show B cells in CSF. In contrast, MS patients show clonally

**Table 3.4** Role for B cells in MS

B cells and plasma cells are present in CNS tissue
Express hypermutated immunoglobulins (local CNS antigen-driven activation)
Positive response to B cell-depleting anti-CD20 monoclonal antibody
In relapsing MS
In PPMS
CSF oligoclonal bands and intrathecal immunoglobulin production as diagnostic signatures
Data suggests oligoclonal IgM/IgG; elevated IgG index indicates poorer prognosis
Lymphoid follicles in meninges of MS
EBV seropositivity required for development of MS (at least adult onset); EBV persistently infects B cells

expanded CSF memory B cells, centroblasts, and short-lived plasmablasts as the predominant antibody-secreting cell in CSF [86]. When meningeal lymphoid follicles with germinal centers are detected in SPMS patients, they are associated with younger age at MS onset, more severe disability, and more cortical demyelination [87]. Diffusion of antibodies or other soluble factors from the meningeal follicles to the cortex may be responsible for enhanced gray matter lesions. EBV causes persistent infection of B cells, and this results in immunologic changes that might promote development of MS.

Oligoclonal IgG in CSF is a hallmark diagnostic signature in MS. The specificity of these bands is not known, but they are not directed against myelin components and could represent a non-specific polyantigenic exposure response [88]. In a recent study, MS oligoclonal bands were at least partly directed against ubiquitous intracellular autoantigens released during tissue destruction [89]. Oligoclonal IgM (lipid specific) in particular has been suggested to be a poor prognosis marker [90]. Although initial reports suggested anti-myelin antibodies to MBP and MOG might indicate more severe disease, these findings have not been confirmed [91–93]. With a more accurate cell-based assay, anti-MOG IgG appears to be associated with unique non-MS disorders including seronegative NMO spectrum disorder, ADEM, chronic relapsing inflammatory optic neuropathy, and isolated cases of optic neuritis, transverse myelitis, and encephalitis [94].

Elevated IgG index, as a marker of intrathecal immunoglobulin production, is another less specific CSF diagnostic marker.

Perhaps the most impressive data supporting a role for B cells in MS is the success of anti-CD20 monoclonal antibody therapy in relapsing and PPMS [95, 96]. This anti-inflammatory response likely represents an effect on B cells as APCs and T cell regulators, since any effect on humoral antibody production is likely to be delayed for some years.

### Plasma Cells

Plasma cells, along with B cells, also show clonal expansion in MS CSF [97]. Plasma cells show a distinct pattern from T and B cells. They accumulate in connective tissue spaces in the meninges and perivascular space [16]. They accumulate in MS CNS tissue later but (unlike T and B cells) will persist. They do not show proliferative markers, suggesting they are long-lived cells [98]. They are most marked in progressive MS. Clonally expanded plasma cells are the presumptive source of CSF oligoclonal bands and intrathecal immunoglobulin production [99].

### Monocytes/Macrophages

The mononuclear phagocyte system consists of circulating blood monocytes, tissue macrophages, and dendritic cells [100]. Blood-borne monocytes/tissue macrophages are known to be the major cell type in the perivascular infiltrates in MS. Monocytes enhance T cell migration across the BBB and are the precursor for macrophages. There are three subsets (classic, nonclassical, intermediate) based on expression of CD14 and CD16. MS patients have been reported to show increased levels of nonclassical CD14+ CD16++ monocytes and decreased classic monocytes (CD14++, CD16–) [101]. Monocytes/macrophages along with microglia represent innate immunity. They play an important role in lesion pathogenesis and local tissue injury, in phagocytic removal of debris, as well as in repair processes [102].



Early peripheral blood monocyte count was reported to correlate with MS severity in a Japanese population [103].

## Dendritic Cells

Dendritic cells are professional APCs which initiate primary immune responses and develop and maintain immune tolerance [104]. They are the most potent APC. There are myeloid (CD11c+) and plasmacytoid (CD11c<sup>dim</sup> CD123) types [105]. They are typically elevated in the blood, CSF, and lesions of MS [105, 106]. MS dendritic cells secrete higher levels of proinflammatory cytokines (IL-6, TNF, IL-23) than healthy controls and show decreased expression of maturation markers [105]. There may be deficiencies in the maturation of dendritic cells in PPMS [106, 107].

Recent studies have explored how dendritic cells enter the CNS (BBB, choroid plexus, meninges) and traffic to draining lymph nodes [108]. Tolerogenic DCs have also been proposed as a therapy for MS [109].

## Natural Killer (NK) Cells

NK cells, part of innate immunity, are a subset of lymphocytes that are cytotoxic to virus-infected cells and tumor cells; they also secrete cytokines [110]. These distinct functions coincide with two subsets, CD56<sup>dim</sup> NK cells and CD56<sup>bright</sup> NK cells. NK cells are found in MS lesions. NK cell abnormalities are described in MS, including certain subpopulations being increased during periods where patients are not actively relapsing [111, 112]. Other subpopulations are reduced in untreated MS, as well as first-attack patients [110, 113]. A number of MS therapies (IFN $\beta$ , cyclophosphamide, natalizumab, dimethyl fumarate) increase NK cells [110, 114, 115].

Invariant NK-T cells share properties of NK cells and T cells. These cells are reported as decreased in MS, and cell lines isolated from MS patients show higher secretion of IL-4 [66, 110].

It is debated whether enhancing NK cells is beneficial or detrimental in MS [116–118]. Clearly further work is needed.

## Mast Cells

Mast cells are innate immune cells that are involved in allergic reactions. They contain granules and can release histamine and cytokines when activated [119]. Mast cells are found in the brain and meninges normally and are certainly present in MS brain. Elevated levels of CSF histamine and tryptase (a specific mast cell enzyme) have been reported in MS CSF [119–120]. Mast cells may play a role in MS meningeal inflammation and neuroinflammation [119, 121] and are the therapeutic target in the MS masitinib trial [122, 123].

---

## Immune System Factors

### Cytokines

Proinflammatory Th1 cytokines include IL-17, IL-22, IL-23, granulocyte-macrophage colony-stimulating factor (GM-CSF), TNF $\alpha$ , IL-1, IL-6, IL-8, IL-12, and IFN $\gamma$ . They are opposed by anti-inflammatory/regulatory Th2 cytokines such as IL-4 and IL-10 [124]. A number of reports find various proinflammatory cytokines elevated or upregulated in MS, while certain regulatory cytokines may be downregulated [124–130]. It has also been noted that there are gene pathways associated with MS that involve cytokine production, in addition to other mechanisms [124]. Several MS disease-modifying therapies are believed to work in part through a Th1 to Th2 shift. The proinflammatory IFN $\gamma$  cytokine has been reported to worsen MS [131], while IFN $\beta$  is used to treat MS. This cytokine picture is not straightforward. Blockade of another proinflammatory cytokine, TNF $\alpha$ , actually worsens MS [132, 133]. Progressive MS patients are reported to show greater IL-12 and IL-18 production by systemic immune cells [56, 134]. Targeted cytokine therapies continue to be therapeutic strategies.

## Chemokines

Chemokines are a family of small cytokines involved in chemo-attraction and cell migration. They are also involved in adhesion molecule expression, matrix metalloproteinase and cytokine secretion, T cell activation, and synaptic transmission [135]. They are part of a network which also involves chemokine receptors. Chemokines control the selective CNS recruitment of inflammatory cells in MS [136]. In particular CCL5, CCL2, CXCL10, and CXCL13 are implicated in MS. CCL5 (Rantes) is upregulated at the edge of MS plaques to attract monocytes [137]. CCL2 is expressed by local astrocytes to attract mononuclear cells [138]. MS CSF shows elevated levels of CXCL10 and CCL5, which draws activated T cells, and CXCL13, which draws B cells [135, 139]. CCL18 is reported to be elevated in the blood of MS patients, especially with progressive disease [140]. Chemokines are another potential therapeutic target in MS.

## Osteopontin

Osteopontin, early T lymphocyte activation-1, is a proinflammatory cytokine expressed by activated T cells, dendritic cells, and macrophages [59, 141]. It is a member of the small integrin binding-proteins, the SIBLING family [142]. It binds to  $\alpha 4\beta 1$  integrin and modulates Th1 and Th17 cytokines, and studies have reported elevated levels in the blood and CSF during relapses [143–145]. High expression of osteopontin has been found in MS brain lesions using cDNA microarray technology [146]. It has been proposed as a blood and CSF biomarker in MS [147].

## Adhesion Molecules

Cell adhesion molecules are located on the surface of cells and mediate binding to other cells or to extracellular matrix via an adhesion process. This is important to cell penetration into the CNS in MS. Adhesion molecules involve four

families (immunoglobulin superfamily, integrins, cadherins, selectins). The endothelial cells within MS lesions express elevated levels of intercellular adhesion molecule (ICAM)-1 and vascular cell adhesion molecule (VCAM)-1 [136]. Activated immune cells express selectins and integrins such as lymphocyte function-associated antigen (LFA)-1 and very late antigen (VLA)-4, which bind to their ligand adhesion molecules on the endothelium. Anti-adhesion molecule therapy (such as natalizumab, a monoclonal antibody directed against  $\alpha 4$  integrin, a component of VLA-4) has been used successfully to treat MS. In a recent study, another immunoglobulin superfamily member, neural cell adhesion molecule (NCAM or CD56), was shed from neural and glial cells [148]. Plasma levels of soluble NCAM correlated with soluble VCAM-1 levels in MS and health controls. In contrast, only MS showed correlated elevations in soluble ICAM-1 and VCAM-1. Levels of soluble NCAM ( $p = 0.05$ ) and VCAM-1 ( $p = 0.028$ ) were higher in progressive MS compared to healthy controls [148].

## Matrix Metalloproteinases

MMPs are part of a family of almost 40 endopeptidases, proteolytic enzymes that are involved in extracellular matrix and basement membrane degradation. These proteases include tissue inhibitors of matrix proteases (TIMPs), which downregulate MMPs. Activated immune cells secrete MMPs to help penetrate through the BBB basement membrane and extracellular matrix, to enter the CNS. Matrix proteinases may directly injure CNS cells, as well as activating membrane-bound proinflammatory cytokines, but may also promote CNS repair and regeneration. MMPs are implicated in BBB permeability and CNS inflammation in MS.

MMP-9 is elevated in the serum and CSF of MS, especially during relapses [149]. Elevated serum and CSF MMP-9 levels are reported to correlate with MS disease activity [150]. MMP-2 to TIMP-2 ratio is increased in the CSF and serum of relapsing MS, with evidence of

intrathecal MMP-2 production [151]. Serum MMP-2 and MMP-2/TIMP-1 ratio is said to be elevated in progressive MS [152]. In a recent study, MMP-9 gene expression and protein levels were significantly reduced at baseline in MS patients destined to develop progressive multifocal leukoencephalopathy on natalizumab, compared to healthy controls [153].

---

## CNS Cells and Components

### Microglia

Microglia are the resident CNS macrophages as well as immune cells. They act as APCs, produce cytokines, and are involved in phagocytosis. Along with astrocytes, they modulate CNS inflammation and neurodegeneration [154]. They show plasticity, with neuroinflammatory as well as neuroprotective properties shaped by their CNS microenvironment [155]. In fact, both microglia and macrophages are sometimes classified as M1 (proinflammatory) or M2 (anti-inflammatory), although this division has been challenged [156]. Activated microglia are noted in all MS patients but are especially associated with the progressive phenotypes. Clusters are also found in MS normal-appearing white matter [157].

Activated microglia and macrophages produce cytotoxic molecules including proinflammatory and cytotoxic cytokines, reactive oxygen and nitrogen intermediates, and proteolytic and lipolytic enzymes [102]. Microglia are likely to be an important component of the MS damage process and are particularly involved in axonal injury [158]. It has been suggested that T cells in MS tissue may drive continued activation of microglia [159]. Microglia also promote repair, since they can secrete neurotrophins such as brain-derived neurotrophic factor (BDNF), neurotrophin-3 (NT3), and insulin-like growth factor-1 (IGF-1), as well as regulatory cytokines [110]. In a recent study of autopsy brains, on average, 45% of the macrophage-like cells in active lesions were calculated to be derived from resident microglia [156]. Active lesion

microglia showed a proinflammatory phenotype, which changed in later stages to an intermediate phenotype.

### Oligodendrocytes and Myelination

Oligodendrocytes show variable degrees of loss in MS. They may be an early target and can die by apoptosis prior to formation of demyelinating plaques [160]. Oligodendrocytes are especially vulnerable to oxidative stress because of their high metabolic rate, high ATP usage to synthesize myelin, large intracellular iron content, high hydrogen peroxide level, high levels of polyunsaturated fatty acid within the myelin, and low levels of antioxidants [161]. It has been suggested that intrinsic apoptosis due to oxidative stress is an important cause for oligodendrocyte loss in MS. Fas/CD95 is expressed on oligodendrocytes in chronic MS lesions; FasL expressed on microglia and inflammatory lymphocytes are likely to play a role in intrinsic oligodendrocyte apoptosis [161, 162].

Remyelination involves generating new mature oligodendrocytes [163]. Oligodendrocytes can be replaced by OPCs, a population of adult CNS stem/precursor cells widely placed within the adult CNS. They are present in white and gray matter at a density similar to microglia. They appear to be the main source of remyelination in MS, as opposed to surviving adult oligodendrocytes. However, in two recent animal models, adult oligodendrocytes did participate in myelination [164]. There is also recent evidence for MS-specific oligodendrocyte lineage cells [165]. At least in animal models, adult neural stem cells (in the third ventricular subventricular zone and the dentate gyrus subgranular zone) contribute to oligodendroglial lineage [166]. Remyelination in MS is ultimately inadequate and fails. This is likely to represent in part non-disease-related factors (genetic and immune system background, sex, increasing age) as well as a failure of OPC differentiation and maturation [163, 167, 168].

Along with oligodendrocyte loss, MS involves extensive demyelination. Myelin is stripped and

**Table 3.5** Possible basis for myelin and oligodendrocyte injury in MS

Cell based
CD4+ T cells sensitized to myelin antigens
Antigen-specific cytotoxic CD8+ T cells
Astrocyte disturbance
Immune system factors
Proinflammatory cytokines
Antibody-mediated injury
Complement cascade components
Bystander demyelination following infectious superantigen cell activation
Macrophage-mediated injury
Hypoxic/ischemic stress
Reactive oxygen or nitrogen species; oxidative, endoplasmic reticulum stress
CNS tissue infection
Axonal dysregulation with 2° myelin loss
Glutamate excitotoxicity
Excitatory amino acid transporters
Proteolytic, lipolytic enzymes
Fas antigen-ligand interactions
Unstable myelin
Apoptosis (programmed cell death)

phagocytized by macrophages. The basis for myelin and oligodendrocyte injury is unknown and likely multifactorial (Table 3.5). There could even be intrinsic myelin instability.

MBP in MS shows a higher rate of citrullination/deimination (45%) compared to controls (15–20%) [160]. This is developmentally immature myelin, which is less compact and therefore destabilized. An unproven hypothesis is that unstable MBP is a primary factor leading to MS [45, 169, 170].

### Astrocytes

Astrocytes are the most abundant CNS cell and are involved in BBB function, glutamate metabolism, weak APC activity, extracellular potassium maintenance, and release of trophic factors for surrounding cells [171]. It is possible that MS could represent a primary disturbance of astrocytes, considering that another CNS inflammatory demyelinating disorder, neuromyelitis optica spectrum disorder, often targets an astrocyte water channel, aquaporin 4

(AQP4). MS patients show changes in sodium channels in reactive astrocytes. There is focal upregulation of the sodium channel Nav 1.5 within, as well as at the edge of, active and chronic MS lesions [172]. This upregulation is not seen in MS NAWM or control brain. It is also seen in astrocytes surrounding brain tumors and cerebrovascular accidents, suggesting it is a compensatory mechanism to CNS damage. Very active MS lesions show structural changes involving astrocytes [173]. Acute MS lesions were reported to show loss of astrocytes along with their food processes that accompanied demyelination [174]. Resolving lesions were repopulated with AQP4-negative stellate astrocytes, but astrocytes were mainly AQP4 positive in older lesions. Decreased levels of creatine kinase B, localized to astrocytes, was reported in the white matter of MS patients but not controls [175]. Activated astrocytes have been shown to promote B cell survival and activation, which may be particularly important in progressive MS [176]. It is clear that the role of astrocytes in MS is not just to form glial scars but to play a role in lesion formation, recruitment of lymphocytes, tissue damage, and tissue repair [177].

### Neurons/Axons

Neurons, along with dendrites, axons, and nodes of Ranvier, are damaged and lost in MS [39, 178]. This is not just sequelae of loss of trophic myelin, although demyelinated axons express increased sodium channels and deficits in ATP production, making them more vulnerable to physiologic stressors [179]. The increased expression of sodium channels on the demyelinated axon leads to excess sodium within the axons, requiring increased ATP to correct the sodium concentration. This increased energy demand, along with mitochondrial dysfunction, leads to axonal hypoxia [180]. This appreciation of ion channel changes has led to voltage-gated sodium channel blockade being proposed as a strategy to treat MS [181].

Acute axonal injury is prominent in active inflammatory plaques and correlates with inflammation (CD8+ T cells, macrophages, microglia) [16, 33]. Axonal injury does not require demyelination. Retinal nerve fiber layer, made up of unmyelinated axons, can be evaluated by optical coherence tomography and shows deficits in MS [182]. These include thinning of the retinal fiber layer and thinning of the ganglion cell-inner plexiform layer [183]. Within cortical lesions, neuronal loss is estimated to be at least 20% of the total cell population [184].

The mechanism of axon damage is believed to be multifactorial, mediated by inflammatory cells and soluble factors, loss of trophic support from myelin and glia, Wallerian degeneration, and antibodies. Autoantibodies directed against axo-glial gray matter antigens such as contactin 2, neurofilament light chain, and neurofascin are found in CSF and serum of MS patients [185]. Contactin 2 is a cell adhesion molecule expressed by neuronal subpopulations and juxtaparanodal axon/myelin [180, 186]. Neurofilaments are part of the axonal cytoskeleton. Elevated levels of the light and heavy subunits are reported in the CSF of progressive patients [187]. Neurofilament light protein is also elevated in CSF during acute relapses [188]. Increased CSF neurofilament levels may predict a worse prognosis [189]. Neurofascin is a cell adhesion molecule expressed by oligodendrocytes at the paranode [190, 191]. About 30% of MS patients show antibodies to neurofascin, an axonal component. This is much more common in progressive vs. relapsing MS and seems to enhance axonal injury.

In addition, the neuronal 14-3-3 proteins are reported as elevated in the CSF of patients with more severe disability and disease progression [192]. Abnormally phosphorylated tau, with formation of insoluble tau, has been correlated with transition to secondary progressive MS, implicating tau as a neuronal damage mechanism [2].

Neurofilament light protein (an axon/neuron injury marker) can be measured in blood. It is being proposed as a future prognostic and treatment response biomarker for MS [193].

## Blood-Brain Barrier and Vascular System

The BBB involves multiple players that form a neurovascular unit: endothelia, perivascular astrocytes, pericytes, myocytes, neurons, and extracellular matrix components [194]. These endothelial cells lack fenestrations and show reduced pinocytotic activity [195]. There are tight junctions and adherens junctions between cells. The BBB is disrupted in MS at two levels [196]. First, there is marked focal disruption characterized by contrast enhancement on neuroimaging, associated with early focal edema and inflammation, which results in macroscopic plaque formation. This is characteristic of relapsing MS but is also seen in progressive MS. Second, there is a much more subtle but diffuse BBB disturbance with abnormal permeability, tight junction disturbances, and changes in basement membrane and extracellular matrix [196–198]. This is present in normal-appearing brain tissue, and not just the lesion areas. The BBB is also immunologically activated in MS, with upregulation and expression of surface markers as well as secretion of immune factors [194]. Although BBB abnormalities have been thought to be a secondary phenomenon in MS, it is not ruled out that they could reflect a primary disturbance [195].

There are reports of early cerebral blood flow reductions and decreased cerebrovascular reactivity in MS [199]. Deposition of blood-derived fibrin has been proposed as an immunotherapeutic target in MS [200]. Down regulation of claudin-11 is reported at the BBB, blood-spinal cord barrier, and blood-arachnoid barrier in MS [201].

It has also been proposed that the pericyte might offer a new therapeutic target for MS [202].

## Excitotoxins

Glutamate is the major excitatory amino acid. Excess glutamate is capable of causing cell death. Glutamate-mediated excitotoxicity involves activation of ionotropic and metabotropic receptors, with calcium cytoplasmic

accumulation leading to cell death. Glutamate is elevated within MS lesions and normal-appearing white matter, as well as CSF. This could be from activated immune cells, astrocytes, or axons [8]. AMPA, NMDA, and kainate receptors are all upregulated. Glutamate transporter expression is also altered [203]. Genetic variation is reported to play a role in glutamate levels [204]. Astrocytes, oligodendrocytes, and myelin all express glutamate receptors. They are all potential targets for excitotoxic damage. Finally, glutamate directly activates T cells [205]. Abnormal CNS glutamate levels and signaling, as well as glutamate activation of T cells and glutamate release by T cells, may all contribute to MS pathophysiology [205].

### Nitric Oxide

Nitric oxide (NO) is a free radical implicated as a damage mechanism in MS. It impairs the BBB [206]. Elevated levels of NO will modify function of ion channels, transporters, and glycolytic enzymes, resulting in axonal damage. Both NO and its derivative, peroxynitrite, inhibit neuronal and glial mitochondria and the ability of the axon to generate ATP. NO impairs oligodendrocyte metabolism by damaging cell mitochondria [207]. A key enzyme involved in NO synthesis, NO synthase (iNOS), is upregulated in macrophages and reactive astrocytes in acute MS lesions [208]. NO activity in CSF rises during MS relapses [209–212]. It has been proposed that NO plays a key role in MS by stimulating local inflammation, disrupting the BBB, and increasing permeability, causing neuronal and DNA damage, disrupting axons and mitochondria, and inhibiting myelin formation genes [213].

### Mitochondria

Mitochondria produce ATP, control calcium homeostasis, and play a role in apoptosis. They contain nonnuclear DNA which encodes subunits of the mitochondrial respiratory chain complexes. Mitochondrial abnormalities reported in

MS include reduced respiratory chain complex activities, increase in neuron mitochondrial DNA copies, and evidence of oxidative damage to mitochondrial DNA [37, 49].

Mitochondria have been implicated in both conduction block and axonal injury, through calcium-mediated cytoskeletal changes as well as oxidative stress [37]. Mitochondrial abnormalities are believed to play a key role in neurodegeneration [214] and have been proposed as a therapeutic target in MS [215].

### Neurotrophic Factors

Neurotrophic factors encompass three families: nerve growth factor (NGF) family, glial cell line-derived neurotrophic factor (GDNF) family ligands, and neurotrophic cytokines [216]. They promote differentiation and survival of CNS cells and their components. They also increase antioxidant enzymes and inhibit free radical formation. They are secreted by activated immune cells and are the basis for the concept of neuroprotective autoimmunity. CNS inflammatory cells may help contain damage and boost repair and cell survival, by releasing these neurotrophic factors in MS brain and spinal cord [217–219]. Those that could have pertinence in MS include NGF, BDNF, NT-3 and NT-4, ciliary neurotrophic factor, and leukemia inhibitory factor [216].

---

### Other Factors

#### Vitamin D

Vitamin D deficiency is a risk factor for MS, at least among Caucasians. Vitamin D is obtained from synthesis in the skin (triggered by sunlight) and dietary intake. 25-Hydroxy vitamin D is the major circulating metabolite and is the one to measure in blood, while 1,25-dihydroxy vitamin D (calcitriol) is the biologically active metabolite. Biologic effects are mediated via the vitamin D receptor [220], a member of the steroid receptor superfamily. Vitamin D receptor is expressed by monocytes, APCs, and activated lymphocytes.

Vitamin D appears to shift immune responses to a more anti-inflammatory regulatory role and enhances Treg function. Various MS susceptibility genes are located within or near genes associated with vitamin D metabolism [221]. Higher levels may play a role in treating MS, but this is not yet clearly proven [222]. The role of vitamin D in MS is the subject of ongoing research.

### Exosomes and MicroRNAs

Exosomes are small (50 nm to 1  $\mu$ m) extracellular vesicles that provide cell-to-cell communication [223]. They are involved in immune regulation. These vesicles contain proteins, lipids, transcriptional factors, RNA, and DNA [224]. They contain microRNAs (miRNAs), a group of small single-stranded non-coding RNA molecules 21–23 nucleotides in length. They degrade mRNA or repress mRNA translation. They can impact the genetic program of their target cell and influence both innate and acquired immune responses.

Exosomes are increased in the serum and CSF of relapsing MS, particularly during an acute attack [224]. Serum exosomes contain myelin proteins in both MS and healthy controls; exosomes containing MOG correlated with disease activity [223]. Exosome release in MS appears to facilitate immune cell transportation across the BBB.

miRNAs are being studied in the circulation of MS patients, as well as within MS immune cells. This appears to be a promising area to shed further light on the immunology of MS [225–227].

### Gut Microbiota

There is a very important gut-brain axis, with bidirectional communication [228]. The gut microbiota influences systemic immunity and inflammation, including within the CNS [229]. There may be a gut microbiota that predisposes to MS, as well as a gut microbiota that can treat MS [230, 231]. This is discussed further in Chap. 5.

### Summary

CNS damage in MS is mediated by a number of immune and inflammatory factors beyond the CD4 Th1 cell. Key immune factors may differ based on subsets of MS patients and different stages of the disease. A better appreciation of this immune system complexity is guiding therapeutic developments.

Novel targets are being proposed (ion channels, mitochondria, NO, glutamate) that may lead to improved outcomes. Current personalized medicine emphasizes an individualized approach. Future precision medicine will use validated molecular markers to guide optimal diagnosis and management.

### References

1. Barnett MH, Parratt JDE, Pollard JD, et al. MS: is it one disease? *Int MS J.* 2009;16:57–65.
2. Anderson JM, Hampton DW, Patani R, et al. Abnormally phosphorylated tau is associated with neuronal and axonal loss in experimental autoimmune encephalomyelitis and multiple sclerosis. *Brain.* 2008;131:1736–48.
3. Koch M, Mostert J, Heersema D, et al. Progression in multiple sclerosis: further evidence of an age dependent process. *J Neurol Sci.* 2007;255:35–41.
4. Ofengeim D, Ito Y, Najafov A, et al. Activation of necroptosis in multiple sclerosis. *Cell Rep.* 2015;10(110):1836–49.
5. Dhib-Jalbut S, Kalvakolanu DV. Microglia and necroptosis: the culprits of neuronal cell death in multiple sclerosis. *Cytokine.* 2015;76(2):583–4.
6. Filippi M, Bar-Or A, Piehl F, et al. Multiple sclerosis. *Nat Rev Dis Primers.* 2018;4(1):43.
7. Matthews PM, Roncaroli F, Waldman A, et al. A practical review of the neuropathology and neuroimaging of multiple sclerosis. *Pract Neurol.* 2016;16:279–87.
8. Trapp BD, Nave K-A. Multiple sclerosis: an immune or neurodegenerative disorder? *Annu Rev Neurosci.* 2008;31:247–69.
9. Kutzelnigg A, Lucchinetti CF, Stadelmann C, et al. Cortical demyelination and diffuse white matter injury in multiple sclerosis. *Brain.* 2005;128(pt 11):2705–12.
10. Hu W, Lucchinetti CF. The pathological spectrum of CNS inflammatory demyelinating diseases. *Semin Immunopathol.* 2009;31:439–53.
11. Barnett MH, Prineas JW. Relapsing and remitting multiple sclerosis: pathology of the newly forming lesion. *Ann Neurol.* 2004;55:458–68.

12. Parratt JDE, Prineas JW. Neuromyelitis optica: a demyelinating disease characterized by acute destruction and regeneration of perivascular astrocytes. *Mult Scler*. 2010;16:1156–72.
13. Henderson APD, Barnett MH, Parratt JDE, et al. Multiple sclerosis. Distribution of inflammatory cells in newly forming lesions. *Ann Neurol*. 2009;66:739–53.
14. Prineas JW, McDonald WI, Franklin RJM. Demyelinating diseases. In: Graham DI, Cantos PL, editors. *Greenfield's neuropathology*. 7th ed. London: Arnold; 2002. p. 471–550.
15. Kuhlmann T, Goldschmidt T, Antel J, et al. Gender differences in the histopathology of MS? *J Neurol Sci*. 2009;286:86–91.
16. Frischer JM, Bramow S, Dal-Bianco A, et al. The relation between inflammation and neurodegeneration in multiple sclerosis brains. *Brain*. 2009;132:1175–89.
17. Albert M, Barrantes-Freer A, Lohrberg M, et al. Synaptic pathology in the cerebellar dentate nucleus in chronic multiple sclerosis. *Brain Pathol*. 2017;27:737–47.
18. Jürgens T, Jarafi M, Kreutzfeldt M, et al. Reconstruction of single cortical projection neurons reveals primary spine loss in multiple sclerosis. *Brain*. 2016;139:39–46.
19. Trapp BD, Vignos M, Dudman J, et al. Cortical neuronal densities and cerebral white matter demyelination in multiple sclerosis: a retrospective study. *Lancet Neurol*. 2018;17:870–4.
20. Bradl M, Lassmann H. Progressive multiple sclerosis. *Semin Immunopathol*. 2009;31:455–65.
21. Bramow S, Frischer JM, Lassmann H, et al. Demyelination versus remyelination in progressive multiple sclerosis. *Brain*. 2010;133:2983–98.
22. Kooi EJ, Geurts JIG, van Horssen J, et al. Meningeal inflammation is not associated with cortical demyelination in chronic multiple sclerosis. *J Neuropathol Exp Neurol*. 2009;68:1021–8.
23. Lassmann H, Bruck W, Lucchinetti CF. The immunopathology of multiple sclerosis: an overview. *Brain Pathol*. 2007;17:210–8.
24. Luchetti S, Fransen NL, van Eden CG, et al. Progressive multiple sclerosis patients show substantial lesion activity that correlates with clinical disease severity and sex: a retrospective autopsy cohort analysis. *Acta Neuropathol*. 2018;135:511–28.
25. Lucchinetti C, Bruck W, Parisi J, et al. Heterogeneity of multiple sclerosis lesions: implications for the pathogenesis of demyelination. *Ann Neurol*. 2000;47:707–17.
26. Reich DS, Lucchinetti CF, Calabresi PA. Multiple sclerosis. *N Engl J Med*. 2018;378(2):169–80.
27. Keegan M, König F, McClelland R, et al. Relation between humoral pathological changes in multiple sclerosis and response to therapeutic plasma exchange. *Lancet*. 2005;366:579–82.
28. Lucchinetti CF, Bruck W, Parisi J, et al. A quantitative analysis of oligodendrocytes in multiple sclerosis lesions: a study of 113 cases. *Brain*. 1999;122:2279–95.
29. Prineas JW, Barnard RO, Kwon EE, et al. Multiple sclerosis: remyelination of nascent lesions. *Ann Neurol*. 1993;33:137–51.
30. Ferguson B, Matyszak M, Esiri MM, et al. Axonal damage in acute multiple sclerosis lesions. *Brain*. 1997;120:393–9.
31. Trapp BD, Peterson J, Ransohoff RM, et al. Axonal transection in the lesions of multiple sclerosis. *N Engl J Med*. 1998;338:278–85.
32. Evangelou N, Esiri MM, Smith S, et al. Quantitative pathological evidence for axonal loss in normal appearing white matter in multiple sclerosis. *Ann Neurol*. 2000;47:391–5.
33. Kuhlmann T, Lingfeld G, Bitsch A, et al. Acute axonal damage in multiple sclerosis is most extensive in early disease stages and decreases over time. *Brain*. 2002;125:2202–12.
34. Bitsch A, Schuchart J, Bunkowski S, et al. Acute axonal injury in multiple sclerosis: correlation with demyelination and inflammation. *Brain*. 2000;123:1174–83.
35. Androdias G, Reynolds R, Chanal M, et al. Meningeal T cells associate with diffuse axonal loss in multiple sclerosis spinal cords. *Ann Neurol*. 2010;68:465–76.
36. Pfeifenbring S, Bunyan RF, Metz I, et al. Extensive acute axonal damage in pediatric multiple sclerosis lesions. *Ann Neurol*. 2015;77(4):655–67.
37. Mahad D, Lassmann H, Turnbull D. Mitochondria and disease progression in multiple sclerosis. *Neuropathol Appl Neurobiol*. 2008;34:577–89.
38. Lassmann H. Axonal and neuronal pathology in multiple sclerosis: what have we learn from animal models. *Exp Neurol*. 2010;225:2–8.
39. Cifelli A, Arridge M, Jezzard P, et al. Thalamic neurodegeneration in multiple sclerosis. *Ann Neurol*. 2002;52:650–3.
40. Bo L, Vedeler CA, Nyland HI, et al. Subpial demyelination in the cerebral cortex of multiple sclerosis patients. *J Neuropathol Exp Neurol*. 2003;62:723–32.
41. Moghadasi AN, Baghbanian SM. Tumefactive demyelinating lesions in a patient with multiple sclerosis receiving natalizumab. *Acta Neurol Belg*. 2018; <https://doi.org/10.1007/s13760-018-0948-2>.
42. Sanchez P, Meca-Lallana V, Vivancos J. Tumefactive multiple sclerosis lesions associated with fingolimod treatment: report of 5 cases. *Mult Scler Relat Disord*. 2018;25:95–8.
43. Lucchinetti CF, Gavrilova RH, Metz I, et al. Clinical and radiographic spectrum of pathologically confirmed tumefactive multiple sclerosis. *Brain*. 2008;131:1759–75.
44. Wood DD, Bilbao JM, O'Connors P, et al. Acute multiple sclerosis (Marburg type) is associated with developmentally immature myelin basic protein. *Ann Neurol*. 1996;40:18–24.



45. Harauz G, Musse AA. A tale of two citrullines—structural and functional aspects of myelin basic protein deamination in health and disease. *Neurochem Res.* 2007;32:137–58.
46. Behrens JR, Wanner J, Kuchling J, et al. 7 Tesla MRI of Balo's concentric sclerosis versus multiple sclerosis lesions. *Ann Clin Transl Neurol.* 2018;5(8):900–12.
47. Yao DL, Webster H, Hudson LD, et al. Concentric sclerosis (Balo): morphometric and in situ hybridization study of lesions in six patients. *Ann Neurol.* 1994;35:18–30.
48. Stadelmann C, Ludwin SK, Tabira T, et al. Hypoxic preconditioning explains concentric lesions in Balo's type of multiple sclerosis. *Brain.* 2005;128:979–87.
49. Mahad D, Ziabreva I, Lassmann H, et al. Mitochondrial defects in acute multiple sclerosis lesions. *Brain.* 2008;131:1722–35.
50. Matsuoka T, Suzuki SO, Iwaki T, et al. Aquaporin-4 astrocytopathy in Balo's disease. *Acta Neuropathol.* 2010;120:651–60.
51. Bacigaluppi S, Polonara G, Zavanone ML, et al. Schilder's disease: non-invasive diagnosis? *Neurol Sci.* 2009;30:421–30.
52. Dunn-Pirio A, Eckstein C. Recurrent schilder's disease. *Mult Scler Relat Disord.* 2018;26:8–10.
53. Genç HM, Kara B, Uyur Yalçın E, et al. Long-term clinical and radiologic follow-up of Schilder's disease. *Mult Scler Relat Disord.* 2017;13:47–51.
54. Keegan BM, Kaufmann TJ, Weinshenker BG, et al. Progressive solitary sclerosis: gradual motor impairment from a single CNS demyelinating lesion. *Neurology.* 2016;87:1713–9.
55. Lebrun C, Cohen M, Mondot L, et al. A case report of solitary sclerosis: this is really multiple sclerosis. *Neurol Ther.* 2017;6:259–63.
56. Vaknin-Dembinsky A, Weiner HL. Relationship of immunologic abnormalities and disease stage in multiple sclerosis: implications for therapy. *J Neurol Sci.* 2007;259:90–4.
57. Meinel E, Krumbholz M, Derfuss T, et al. Compartmentalization of inflammation in the CNS: a major mechanism driving progressive multiple sclerosis. *J Neurol Sci.* 2008;274:42–4.
58. Sato F, Tanaka H, Hasanovic F, et al. Theiler's virus infection: pathophysiology of demyelination and neurodegeneration. *Pathophysiology.* 2011;18(1):31–41. <https://doi.org/10.1016/j.pathophys.2010.04.011>.
59. Steinman L. Shifting therapeutic attention in MS to osteopontin, type 1 and type 2 IFN. *Eur J Immunol.* 2009;39:2358–60.
60. Jager A, Dardalhon V, Sobel RA, et al. Th1, Th17, and Th9 effector cells induce experimental autoimmune encephalomyelitis with different pathological phenotypes. *J Immunol.* 2009;183:7169–77.
61. Wingerchuk DM, Lucchinetti CF. Comparative immunopathogenesis of acute disseminated encephalomyelitis, neuromyelitis optica and multiple sclerosis. *Curr Opin Neurol.* 2007;20:343–50.
62. Bjelobaba I, Begovic-Kupresanin V, Pekovic S, et al. Animal models of multiple sclerosis: focus on experimental autoimmune encephalomyelitis. *J Neurosci Res.* 2018;96:1021–42.
63. Bielekova B, Goodwin B, Richert N, et al. Encephalitogenic potential of the myelin basic protein peptide in multiple sclerosis: results of a phase II clinical trial with an altered peptide ligand. *Nat Med.* 2000;6:1167–75.
64. Tsutsui S, Stys PK. Degeneration versus autoimmunity in multiple sclerosis. *Ann Neurol.* 2009;66:711–3.
65. Mikulkova Z, Praksova P, Stourac P, et al. Imbalance in T-cell and cytokine profiles in patients with relapsing-remitting multiple sclerosis. *J Neurol Sci.* 2011;300:135–41.
66. Batoulis H, Addicks K, Kuerten S. Emerging concepts in autoimmune encephalomyelitis beyond the CD4/Th1 paradigm. *Ann Anat.* 2010;192:179–93.
67. Vonken K, Hellings N, Hensen K, et al. Secondary progressive in contrast to relapsing-remitting multiple sclerosis patients show a normal CD4+CD25+ regulatory T-cell function and FoxP3 expression. *J Neurosci Res.* 2006;83:1432–46.
68. Bennett JL, Stuve O. Update on inflammation, neurodegeneration, and immunoregulation in multiple sclerosis: therapeutic implications. *Clin Neuropharmacol.* 2009;32:121–32.
69. Huan J, Cubertson N, Spencer L, et al. Decreased FOXP3 levels in multiple sclerosis patients. *J Neurosci Res.* 2005;81:45–52.
70. Correale J, Villa A. Role of CD8+ CD25+ Foxp3+ regulatory T cells in multiple sclerosis. *Ann Neurol.* 2010;67:625–38.
71. Harrington LE, Hatton RD, Mangan PR, et al. Interleukin 17-producing CD4+ effector T cells develop via a lineage distinct from the T helper type 1 and 2 lineages. *Nat Immunol.* 2005;6:1123–32.
72. Korn T. Pathophysiology of multiple sclerosis. *J Neurol.* 2008;255:2–6.
73. Lock C, Hermans G, Pedotti R, et al. Gene-microarray analysis of multiple sclerosis lesions yields new targets validated in autoimmune encephalomyelitis. *Nat Med.* 2002;8:500–8.
74. Tzartos JS, Friese MA, Craner MJ, et al. Interleukin-17 production in central nervous system-infiltrating T cells and glial cells is associated with active disease in multiple sclerosis. *Am J Pathol.* 2008;172:146–55.
75. Kebir H, Kreyenborg K, Ifergan I, et al. Human T(H)17 lymphocytes promote blood-brain barrier disruption and central nervous system inflammation. *Nat Med.* 2007;13:1173–5.
76. Babbe H, Roers A, Waisman A, et al. Clonal expansions of CD8(+) T cells dominate the T cell infiltrate in active multiple sclerosis lesions as shown by micromanipulation and single cell polymerase chain reaction. *J Exp Med.* 2000;192:393–404.

77. Jacobsen M, Cepok S, Quak E, et al. Oligoclonal expansion of memory CD8+ T cells in cerebrospinal fluid from multiple sclerosis patients. *Brain*. 2002;125:538–50.
78. Shimonkevitz R, Colburn C, Burnham JA, et al. Clonal expansions of activated gamma/delta T cells in recent-onset multiple sclerosis. *Proc Natl Acad Sci U S A*. 1993;90:923–7.
79. Chen Z, Freedman MS. Correlation of specialized CD16+ gammadelta cells with disease course and severity in multiple sclerosis. *J Neuroimmunol*. 2008;194:147–52.
80. Selmaj K, Brosnan CF, Raine CS. Colocalization of lymphocytes bearing gamma delta T-cell receptor and heat shock protein hsp65+ oligodendrocytes in multiple sclerosis. *Proc Natl Acad Sci*. 1991;88:6452–6.
81. Monteiro A, Cruto C, Rosado P, et al. Characterization of circulating gamma-delta T cells in relapsing vs. remission multiple sclerosis. *J Neuroimmunol*. 2018;318:65–71.
82. Von Essen MR, Ammitzboll C, Hansen RH, et al. Proinflammatory CD20+ T cells in the pathogenesis of multiple sclerosis. *Brain*. 2019;142:120–32.
83. Cepok S, Rosche B, Grummel V, et al. Short-lived plasma blasts are the main B cell effector subset during the course of multiple sclerosis. *Brain*. 2005;128:1667–76.
84. Harp C, Lee J, Lambracht-Washington D, et al. Cerebrospinal fluid B cells from multiple sclerosis patients are subject to normal germinal center selection. *J Neuroimmunol*. 2007;183:189–99.
85. Owens GP, Ritchie AM, Burgoon MP, et al. Single-cell repertoire analysis demonstrates that clonal expansion is a prominent feature of the B cell response in multiple sclerosis cerebrospinal fluid. *J Immunol*. 2008;171:2725–3.
86. Fraussen J, Vrolix K, Martinez-Martinez P, et al. B cell characterization and reactivity analysis in multiple sclerosis. *Autoimmun Rev*. 2009;8:654–8.
87. Magliozzi R, Howell O, Vora A, et al. Meningeal B-cell follicles in secondary progressive multiple sclerosis associate with early onset of disease and severe cortical pathology. *Brain*. 2007;130:1089–104.
88. Owens GP, Bennett JL, Lassmann H, et al. Antibodies produced by clonally expanded plasma cells in multiple sclerosis cerebrospinal fluid. *Ann Neurol*. 2009;65:639–49.
89. Brändle SM, Obermeier B, Senel M, et al. Distinct oligoclonal band antibodies in multiple sclerosis recognize ubiquitous self-proteins. *Proc Natl Acad Sci U S A*. 2016;113(28):7864–9.
90. Thangarajh M, Gomez-Rial J, Hedstrom AK, et al. Lipid-specific immunoglobulin M in CSF predicts adverse long-term outcome in multiple sclerosis. *Mult Scler*. 2008;14:1208–13.
91. Berger T, Rubner P, Schautzer F, et al. Antimyelin antibodies as a predictor of clinically definite multiple sclerosis after a first demyelinating event. *N Engl J Med*. 2003;349:139–45.
92. Kuhle J, Lindberg RL, Regeniter A, et al. Antimyelin antibodies in clinically isolated syndromes correlate with inflammation in MRI and CSF. *J Neurol*. 2007;254:160–8.
93. O'Connor KC, McLaughlin KA, De Jager PL, et al. Self-antigen tetramers discriminate between myelin autoantibodies to native or denatured protein. *Nat Med*. 2007;13:211–7.
94. Jarius S, Paul F, Aktas O, et al. MOG encephalomyelitis: international recommendations on diagnosis and antibody testing. *J Neuroinflamm*. 2018;15:134.
95. Hauser SI, Bar-Or A, Comi G, et al. Ocrelizumab versus interferon beta-1a in relapsing multiple sclerosis. *N Engl J Med*. 2017;376(3):221–34.
96. Montalban X, Hauser SL, Kappos L, et al. Ocrelizumab versus placebo in primary progressive multiple sclerosis. *N Engl J Med*. 2017;376(3):209–20.
97. Von Budingen HC, Harrer MD, Kuenzle S, et al. Clonally expanded plasma cells in the cerebrospinal fluid of MS patients produce myelin-specific antibodies. *Eur J Immunol*. 2008;38:2014–23.
98. Pollok K, Mothes R, Ulbricht C, et al. The chronically inflamed central nervous system provides niches for long-lived plasma cells. *Acta Neuropathol Commun*. 2017;5:88.
99. Von Budingen HC, Gulati M, Kuenzle S, et al. Clonally expanded plasma cells in the cerebrospinal fluid of patients with central nervous system autoimmune demyelination produce “oligoclonal bands”. *J Neuroimmunol*. 2010;218:134–9.
100. Ajami B, Steinman L. Nonclassical monocytes: are they the next therapeutic targets in multiple sclerosis? *Immunol Cell Biol*. 2018;96:125–7.
101. Gjelstrup MC, Stilund M, Petersen T, et al. Subsets of activated monocytes and markers of inflammation in incipient and progressed multiple sclerosis. *Immunol Cell Biol*. 2018;96(2):160–74.
102. Merson TD, Binder MD, Kilpatrick TJ. Role of cytokines as mediators and regulators of microglial activity in inflammatory demyelination of the CNS. *NeuroMolecular Med*. 2010;12:99–132.
103. Akaishi T, Takahashi T, Nakashima I. Peripheral blood monocyte count at onset may affect the prognosis in multiple sclerosis. *J Neuroimmunol*. 2018;319:37–40.
104. Kim SH, Jung HH, Lee CK. Generation, characteristics and clinical trials of ex vivo generated tolerogenic dendritic cells. *Yonsei Med J*. 2018;59(7):807–15.
105. Comabella M, Montalban X, Munz C, et al. Targeting dendritic cells to treat multiple sclerosis. *Nat Rev Neurol*. 2010;6:499–507.
106. Zozulya AL, Clarkson BD, Ortler S, et al. The role of dendritic cells in CNS autoimmunity. *J Mol Med*. 2010;88:535–44.
107. Schwab N, Zozulya AL, Kieseier BC, et al. An imbalance of two functionally and phenotypically different subsets of plasmacytoid dendritic

- cells characterizes the dysfunctional immune regulation in multiple sclerosis. *J Immunol.* 2010;184:5368–74.
108. De Laere M, Berneman ZN, Cools N. To the brain and back: migratory paths of dendritic cells in multiple sclerosis. *J Neuropathol Exp Neurol.* 2018;77(3):178–92.
  109. Florez-Grau G, Zubizarreta I, Cabezon R, et al. Tolerogenic dendritic cells as a promising antigen-specific therapy in the treatment of multiple sclerosis and neuromyelitis optica from preclinical to clinical trials. *Front Immunol.* 2018;9:1169.
  110. Gandhi R, Laroni A, Weiner HL. Role of the innate immune system in the pathogenesis of multiple sclerosis. *J Neuroimmunol.* 2010;221:7–14.
  111. O'Keefe J, Gately CM, Counihan T, et al. T-cells expressing natural killer (NK) receptors are altered in multiple sclerosis and responses to  $\alpha$ -galactosylceramide are impaired. *J Neurol Sci.* 2008;275:22–8.
  112. Sakuishi K, Miyake S, Yamamura T. Role of NK cells and invariant NKT cells in multiple sclerosis. *Results Probl Cell Differ.* 2010;51:127–47.
  113. De Jager PL, Rossin E, Pyne S, et al. Cytometric profiling in multiple sclerosis uncovers patient population structure and a reduction of CD8 low cells. *Brain.* 2008;131:1701–11.
  114. Putzki N, Baranwal MK, Tettenborn B, et al. Effects of natalizumab on circulating B cells, T regulatory cells and natural killer cells. *Eur Neurol.* 2010;63:311–7.
  115. Smith MD, Calabresi PA, Bhargava P. Dimethyl fumarate treatment alters NK cell function in multiple sclerosis. *Eur J Immunol.* 2018;48(2):380–3.
  116. Segal BM. Enhancing natural killer cells is beneficial in multiple sclerosis – commentary. *Mult Scler.* 2018; <https://doi.org/10.1177/1352458518809296>.
  117. Liu Q, Shi FD. Enhancing natural killer cells is beneficial in multiple sclerosis – no. *Mult Scler.* 2018; <https://doi.org/10.1177/1352458518799591>.
  118. Laroni A. Enhancing natural killer cells is beneficial in multiple sclerosis – yes. *Mult Scler.* 2018; <https://doi.org/10.1177/1352458518800776>.
  119. Hendriksen E, van Bergeijk D, Oosting RS, et al. Mast cells in neuroinflammation and brain disorders. *Neurosci Biobehav Rev.* 2017;79:119–33.
  120. Rozniecki JJ, Hauser SL, Stein M, et al. Elevated mast cell tryptase in cerebrospinal fluid of multiple sclerosis patients. *Ann Neurol.* 1995;37:63–6.
  121. Brown MA, Weinberg RB. Mast cells and innate lymphoid cells: underappreciated players in CNS autoimmune demyelinating disease. *Front Immunol.* 2017;9:514.
  122. Conti P, Kempuraj D. Important role of mast cells in multiple sclerosis. *Mult Scler Relat Disord.* 2016;5:77–80.
  123. Efficacy and safety of masitinib in the treatment of progressive multiple sclerosis. Retrieved from <https://clinicaltrials.gov/ct2/show/NCT01433497>. Accessed 10 Dec 2018.
  124. Wang K, Song F, Fernandez-Escobar A, et al. The properties of cytokines in multiple sclerosis: pros and cons. *Am J Med Sci.* 2018;356(6):552–60.
  125. Li YF, Zhang SX, Ma XW, et al. Levels of peripheral Th17 cells and serum Th17-related cytokines in patients with multiple sclerosis: a meta-analysis. *Mult Scler Relat Disord.* 2017;18:20–5.
  126. Bassi MS, Iezzi E, Landi D, et al. Delayed treatment of MS is associated with high CSF levels of IL-6 and IL-8 and worse future disease course. *J Neurol.* 2018;265:2540–7.
  127. Khaibullin T, Ivanova V, Martynova E, et al. Elevated levels of proinflammatory cytokines in cerebrospinal fluid of multiple sclerosis patients. *Front Immunol.* 2017;8:531.
  128. Kallaur AP, Oliveira SR, Colado Simão AN, et al. Cytokine profile in relapsing-remitting multiple sclerosis patients and the association between progression and activity of the disease. *Mol Med Rep.* 2013;7(3):1010–20.
  129. Rasouli J, Ciric B, Imitola J, et al. Expression of GM-CSF in T cells is increased in multiple sclerosis and suppressed by IFN $\beta$  therapy. *J Immunol.* 2015;194:5085–93.
  130. Trenova AG, Slavov GS. Cytokines in multiple sclerosis – possible targets for immune therapies. *J Neurol Exp Neurosci.* 2016;1(2):25–9.
  131. Panitch HS, Hirsch RL, Schindler J, et al. Treatment of multiple sclerosis with gamma interferon: exacerbations associated with activation of the immune system. *Neurology.* 1987;27:1097–102.
  132. Van Oosten BW, Barkhoff F, Truyen L, et al. Increased MRI activity and immune activation in two multiple sclerosis patients treated with the monoclonal anti-tumor necrosis factor antibody cA2. *Neurology.* 1996;47:1531–4.
  133. The Lenercept Multiple Sclerosis Study Group and the University of British Columbia MS/MRI Analysis Group. TNF neutralization in MS: results of a randomized, placebo-controlled multicenter study. *Neurology.* 1999;53:457–65.
  134. Balashov KE, Smith DR, Khoury SJ, et al. Increased interleukin 12 production in progressive multiple sclerosis: induction by activated CD4+ T cells via CD40 ligand. *Proc Natl Acad Sci.* 1997;94:599.
  135. Iwanowski P, Losy J, Kramer L, et al. CXCL10 and CXCL13 chemokines in patients with relapsing remitting and primary progressive multiple sclerosis. *J Neurol Sci.* 2017;380:22–6.
  136. Bar-Or A. The immunology of multiple sclerosis. *Semin Neurol.* 2008;28:29–45.
  137. Hvas J, McLean C, Justesen J, et al. Perivascular T cells express the pro-inflammatory chemokines. RANTES mRNA in multiple sclerosis lesions. *Scand J Immunol.* 1997;46:195–203.
  138. Van Der Voorn P, Tekstra J, Beeden RH, et al. Expression of MCP-1 by reactive astrocytes in demyelinating multiple sclerosis lesions. *Ann J Pathol.* 1999;154:45–51.

139. Szczucinski A, Losy J. CCL5, CXCL10 and CXCL11 chemokines in patients with active and stable relapsing-remitting multiple sclerosis. *Neuroimmunomodulation*. 2011;18:67–72.
140. Ziliotto N, Bernardi F, Jakimovski D, et al. Increased CCL18 plasma levels are associated with neurodegenerative MRI outcomes in multiple sclerosis. *Mult Scler Relat Disord*. 2018;25:37–42.
141. Morimoto J, Kon S, Matsui Y, et al. Osteopontin; as a target molecule for the treatment of inflammatory diseases. *Curr Drug Targets*. 2010;11:494–505.
142. Bhat R, Steinman L. Innate and adaptive autoimmunity directed to the central nervous system. *Neuron*. 2009;64:123–32.
143. Vogt MH, Lopatinskaya L, Smits M, et al. Elevated osteopontin levels in active-remitting multiple sclerosis. *Ann Neurol*. 2003;53:819–22.
144. Comabella M, et al. Plasma osteopontin levels in multiple sclerosis. *J Neuroimmunol*. 2005;158:231–9.
145. Chowdhury SA, Lin J, Sadiq SA. Specificity and correlation with disease activity of cerebrospinal fluid osteopontin levels in patients with multiple sclerosis. *Arch Neurol*. 2008;65:232–5.
146. Chabas D, Baranzini SE, Mitchell D, et al. The influence of the proinflammatory cytokine, osteopontin, on autoimmune demyelinating disease. *Science*. 2001;294:1731–5.
147. Agah E, Zardoui A, Saghazadeh A, et al. Osteopontin (OPN) as a CSF and blood biomarker for multiple sclerosis: a systematic review and met-analysis. *PLoS One*. 2018;13(1):e0190252.
148. Ziliotto N, Zivadinov R, Jakimovski D, et al. Plasma levels of soluble NCAM in multiple sclerosis. *J Neurol Sci*. 2019;396:36–41.
149. Leppert D, Ford J, Stabler G, et al. Matrix metalloproteinase-9 (gelatinase B) is selectively elevated in CSF during relapses and stable phases of multiple sclerosis. *Brain*. 1998;121:2327–34.
150. Fainardi E, Castellazzi M, Bellini T, et al. Cerebrospinal fluid and serum levels and intrathecal production of active matrix metalloproteinase-9 (MMP-9) as markers of disease activity in patients with multiple sclerosis. *Mult Scler*. 2006;12:294–301.
151. Fainardi E, Castellazzi M, Tamborino C, et al. Potential relevance of cerebrospinal fluid and serum levels and intrathecal synthesis of active matrix metalloproteinase-2 (MMP-2) as markers of disease remission in patients with multiple sclerosis. *Mult Scler*. 2009;15:547–54.
152. Benesova Y, Vasku A, Novotna H, et al. Matrix metalloproteinase-9 and matrix metalloproteinase-2 as biomarkers of various courses in multiple sclerosis. *Mult Scler*. 2009;15:316–22.
153. Fissolo N, Pignolet B, Matute-Blanch C, et al. Matrix metalloproteinase 9 is decreased in natalizumab-treated multiple sclerosis patients at risk for progressive multifocal leukoencephalopathy. *Ann Neurol*. 2017;82(2):186–95.
154. Rothhammer V, Borucki DM, Tjon EC, et al. Microglial control of astrocytes in response to microbial metabolites. *Nature*. 2018;557(7707):724–8.
155. Voet S, Prinz M, van Loo G. Microglia in central nervous system inflammation and multiple sclerosis pathology. *Trends Mol Med*. 2019; <https://doi.org/10.1016/j.molmed.2018.11.005>.
156. Zrzavy T, Hametner S, Simmer I, et al. Loss of ‘homeostatic’ microglia and patterns of their activation in active multiple sclerosis. *Brain*. 2017;140:1900–13.
157. Bogie JFJ, Stinissen P, Hendriks JJA. Macrophage subsets and microglia in multiple sclerosis. *Acta Neuropathol*. 2014;128:191–213.
158. Howell OW, Rundle JL, Garg A, et al. Activated microglia mediate axoglial disruption that contributes to axonal injury in multiple sclerosis. *J Neuropathol Exp Neurol*. 2010;69:1017–33.
159. Friese MA, Fugger L. T cells and microglia as drivers of multiple sclerosis pathology. *Brain*. 2007;130:2755–7.
160. Artemiadis AK, Anagnostouli MC. Apoptosis of oligodendrocytes and post-translational modifications of myelin basic protein in multiple sclerosis: possible role for the early stages of multiple sclerosis. *Eur Neurol*. 2010;63:65–72.
161. Jana A, Pahan K. Sphingolipids in multiple sclerosis. *Neuromol Med*. 2010;12(4):351–61.
162. D’Souza SD, Bonetti B, Balasingman B, et al. Multiple sclerosis Fas signaling on oligodendrocyte cell death. *J Exp Med*. 1996;184:2361–70.
163. Franklin RJM, Ffrench-Constant C. Remyelination in the CNS: from biology to therapy. *Nat Rev Neurosci*. 2008;9:839–55.
164. Duncan ID, Radcliff AB, Heidari M, et al. The adult oligodendrocyte can participate in remyelination. *Proc Natl Acad Sci U S A*. 2018; <https://doi.org/10.1073/pnas.1808064115>.
165. Falcão AM, van Bruggen D, Marques S, et al. Disease-specific oligodendrocyte lineage cells arise in multiple sclerosis. *Nat Med*. 2018;24:1837–44.
166. Kremer D, Akkermann R, Küry P, et al. Current advancements in promoting remyelination in multiple sclerosis. *Mult Scler*. 2018; <https://doi.org/10.1177/1352458518800827>.
167. Kuhlmann T, Miron V, Cuo Q, et al. Differentiation block of oligodendroglial progenitor cells as a cause for remyelination failure in chronic multiple sclerosis. *Brain*. 2008;131:1749–58.
168. Mi S, Miller RH, Tang W, et al. Promotion of central nervous system remyelination by induced differentiation of oligodendrocyte precursor cells. *Ann Neurol*. 2009;65:304–15.
169. Whitaker JN, Mitchell GW. A possible role for altered myelin basic protein in multiple sclerosis. *Ann Neurol*. 1996;40:3–4.
170. Moscarello MA, Mastronardi FG, Wood DD. The role of citrullinated proteins suggests a novel mechanism in the pathogenesis of multiple sclerosis. *Neurochem Res*. 2007;32:251–6.

171. Chastain EML, Duncan DS, Rodgers JM, et al. The role of antigen presenting cells in multiple sclerosis. *Biochim Biophys Acta*. 2010; <https://doi.org/10.1016/j.bbadis.2010.07.008>.
172. Black JA, Newcombe J, Waxman SG. Astrocytes within multiple sclerosis lesions upregulate sodium channel Nav1.5. *Brain*. 2010;133:835–46.
173. Sharma R, Fischer MT, Bauer J, et al. Inflammation induced by innate immunity in the central nervous system leads to primary astrocyte dysfunction followed by demyelination. *Acta Neuropathol*. 2010;120:223–36.
174. Prineas JW, Lee S. Multiple sclerosis: destruction and regeneration of astrocytes in acute lesions. *J Neuropathol Exp Neurol*. 2019; <https://doi.org/10.1093/jnen/nly121>.
175. Steen C, Wilczak N, Hoogduin JM, et al. Reduced creatine kinase B activity in multiple sclerosis normal appearing white matter. *PLoS One*. 2010;5:e10811.
176. Touil H, Kobert A, Lebeurrier N, et al. Human central nervous system astrocytes support survival and activation of B cells: implications for MS pathogenesis. *J Neuroinflamm*. 2018;15:114.
177. Ponath G, Park C, Pitt D. The role of astrocytes in multiple sclerosis. *Front Neurol*. 2018;9:217.
178. Pirko I, Lucchinetti CF, Sriram S, et al. Gray matter involvement in multiple sclerosis. *Neurology*. 2007;68:634–42.
179. Siffirin V, Vogt J, Radbruch H, et al. Multiple sclerosis – candidate mechanisms underlying CNS atrophy. *Trends Neurosci*. 2010;33:202–10.
180. Derfuss T, Linington C, Hohlfeld R. Axo-glia antigens as targets in multiple sclerosis: implications for axonal and grey matter injury. *J Mol Med*. 2010;88:753–61.
181. Mantegazza M, Curia G, Biagini G, et al. Voltage-gated sodium channels as therapeutic targets in epilepsy and other neurological disorders. *Lancet Neurol*. 2010;9:413–24.
182. Henderson APD, Trip SA, Schlottmann PG, et al. An investigation of the retinal nerve fibre layer in progressive multiple sclerosis using optical coherence tomography. *Brain*. 2008;131:277–87.
183. Srinivasan S, Efron N. Optical coherence tomography in the investigation of systemic neurologic disease. *Clin Exp Optom*. 2018; <https://doi.org/10.1111/cxo.12858>.
184. Vercellino M, Plano F, Votta B, et al. Grey matter pathology in multiple sclerosis. *J Neuropathol Exp Neurol*. 2005;64:1101–7.
185. Meinel E, Derfuss T, Krumbholz M, et al. Humoral autoimmunity in multiple sclerosis. *J Neurol Sci*. 2010;001:10.1016.
186. Derfuss T, Parikh K, Velhin S, et al. Contactin 2/ TAG-1-directed autoimmunity is identified in multiple sclerosis patients and mediates gray matter pathology in animals. *Proc Natl Acad Sci*. 2009;106:8302–7.
187. Semra YK, Seidi OA, Sharief MK. Heightened intrathecal release of axonal cytoskeletal proteins in multiple sclerosis is associated with progressive disease and clinical disability. *J Neuroimmunol*. 2002;122:132–9.
188. Malmestrom C, Haghghi S, Rosengren L. Neurofilament light protein and glial fibrillary acidic protein as biological markers in MS. *Neurology*. 2003;61:1720–5.
189. Lim ET, Sellebjerg F, Jensen CV, et al. Acute axonal damage predicts clinical outcome in patients with multiple sclerosis. *Mult Scler*. 2005;11:532–6.
190. Mathey EK, Derfuss T, Storch MK, et al. Neurofascin as a novel target for autoantibody-mediated axonal injury. *Exp Med*. 2007;204:2363–72.
191. Pomicter AD, Shroff SM, Fuss B, et al. Novel forms of neurofascin 155 in the central nervous system: alterations in paranodal disruption models and multiple sclerosis. *Brain*. 2010;133:389–405.
192. Colucci M, Roccatagliata L, Capello E, et al. The 14-3-3 protein in multiple sclerosis: a marker of disease severity. *Mult Scler*. 2004;10:477–81.
193. Disanto G, Barro C, Benkert P, et al. Serum neurofilament light: a biomarker of neuronal damage in multiple sclerosis. *Ann Neurol*. 2017;81(6):857–70.
194. Alvarez JI, Cayrol R, Prat A. Disruption of central nervous system barriers in multiple sclerosis. *Biochim Biophys Acta*. 2010;D01:10.1016.
195. Spencer JI, Bell JS, DeLuca GC. Vascular pathology in multiple sclerosis: reframing pathogenesis around the blood-brain barrier. *J Neurol Neurosurg Psychiatry*. 2018;89:42–52.
196. Bennett J, Basivireddy J, Kollar A, et al. Blood-brain barrier disruption and enhanced vascular permeability in the multiple sclerosis model EAE. *J Neuroimmunol*. 2010;229(1-2):180–91.
197. Hochmeister S, Grundtner R, Bauer J, et al. Dysferlin is a new marker for leaky brain blood vessels in multiple sclerosis. *J Neuropathol Exp Neurol*. 2006;65:855–65.
198. Padden M, Leech S, Craig B, et al. Differences in expression of junctional adhesion molecule-A and beta-catenin in multiple sclerosis brain tissue: increasing evidence for the role of tight junction pathology. *Acta Neuropathol*. 2007;113:177–86.
199. Sweeney MD, Kisler K, Montagne A, et al. The role of brain vasculature in neurodegenerative disorders. *Nat Neurosci*. 2018;21:1318–31.
200. Ryu JK, Rafalski VA, Meyer-Franke A, et al. Fibrin-targeting immunotherapy protects against neuroinflammation and neurodegeneration. *Nat Immunol*. 2018;19(11):1212–23.
201. Uchida Y, Sumiya T, Tachikawa M, et al. Involvement of claudin-11 in disruption of blood-brain, -spinal cord, and -arachnoid barriers in multiple sclerosis. *Mol Neurobiol*. 2018; <https://doi.org/10.1007/s12035-018-1207-5>.

202. Cheng J, Korte N, Nortley R, et al. Targeting pericytes for therapeutic approaches to neurological disorders. *Acta Neuropathol.* 2018;136:507–23.
203. Centonze D, Muzio L, Rossi S, et al. The link between inflammation, synaptic transmission and neurodegeneration in multiple sclerosis. *Cell Death Differ.* 2010;17:1083–91.
204. Baranzini SE, Srinivasan R, Khankhanian P, et al. Genetic variation influences glutamate concentrations in brains of patients with multiple sclerosis. *Brain.* 2010;133:2603–11.
205. Levite M. Glutamate, T cells and multiple sclerosis. *J Neural Transm (Vienna).* 2017;124(7):775–98.
206. Thiel VE, Audus KL. Nitric oxide and blood-brain barrier integrity. *Antioxid Redox Signal.* 2001;3:273–8.
207. Lan M, Tang X, Zhang J, et al. Insights in pathogenesis of multiple sclerosis: nitric oxide may induce mitochondrial dysfunction of oligodendrocytes. *Rev Neurosci.* 2018;29(1):39–53.
208. Oleszak EL, Zaczynska E, Bhattacharjee M, et al. Inducible nitric oxide synthase and nitrotyrosine are found in monocytes/macrophages and/or astrocytes in acute, but not in chronic, multiple sclerosis. *Clin Diagn Lab Immunol.* 1998;5:438–45.
209. Giovannoni G. Cerebrospinal fluid and serum nitric oxide metabolites in patients with multiple sclerosis. *Mult Scler.* 1998;4:27–30.
210. Brundin L, Morcos E, Olsson T, et al. Increased intrathecal nitric oxide formation in multiple sclerosis: cerebrospinal fluid nitrite as activity marker. *Eur J Neurol.* 1999;6:585–90.
211. Calabrese V, Scapagnini G, Ravagna A, et al. Nitric oxide synthase is present in the cerebrospinal fluid of patients with active multiple sclerosis and is associated with increases in cerebrospinal fluid protein nitrotyrosine and S-nitrosothiols and with changes in glutathione levels. *J Neurosci Res.* 2002;70:580–7.
212. Rejdak K, Eikelenboom MJ, Petzold A, et al. CSF nitric oxide metabolites are associated with activity and progression of multiple sclerosis. *Neurology.* 2004;63:1439–45.
213. Tang X, Lan M, Zhang M, et al. Effect of nitric oxide to axonal degeneration in multiple sclerosis via downregulating monocarboxylate transporter 1 in oligodendrocytes. *Nitric Oxide.* 2017;67:75–80.
214. Kozin MS, Kulakova OG, Favorova OO. Involvement of mitochondria in neurodegeneration in multiple sclerosis. *Biochemistry (Mosc).* 2018;83(7):813–30.
215. Lassmann H. Pathophysiology of inflammation and tissue injury in multiple sclerosis: what are the targets for therapy. *J Neurol Sci.* 2010;D01:10.1016.
216. Razavi S, Nazem G, Mardani M, et al. Neurotrophic factors and their effects in the treatment of multiple sclerosis. *Adv Biomed Res.* 2015;4:53.
217. Linker R, Gold R, Luhder F. Function of neurotrophic factors beyond the nervous system: inflammation and autoimmune demyelination. *Crit Rev Immunol.* 2009;29:43–68.
218. De Santi L, Annunziata P, Setta E, et al. Brain-derived neurotrophic factor and TrkB receptor in experimental autoimmune encephalomyelitis and multiple sclerosis. *J Neurol Sci.* 2009;287:17–26.
219. Urshansky N, Mausner-Fainberg K, Auriel E, et al. Dysregulated neurotrophin mRNA production by immune cells of patients with relapsing remitting multiple sclerosis. *J Neurol Sci.* 2010;295:31–7.
220. Smolders J, Damoiseaux J, Menheere P, et al. Vitamin D as an immune modulator in multiple sclerosis, a review. *J Neuroimmunol.* 2008;194:7–17.
221. Lu M, Taylor B, Körner H. Genomic effects of the vitamin D receptor: potentially the link between vitamin D, immune cells, and multiple sclerosis. *Front Immunol.* 2018;9:477.
222. McLaughlin L, Clarke L, Khalilidehkordi E, et al. Vitamin D for the treatment of multiple sclerosis: a meta-analysis. *J Neurol.* 2018;265:2893–905.
223. Galazka G, Mycko MP, Selmaj I, et al. Multiple sclerosis: serum-derived exosomes express myelin proteins. *Mult Scler.* 2018;24(4):449–58.
224. Selmaj I, Mycko MP, Raine CS, et al. The role of exosomes in CNS inflammation and their involvement in multiple sclerosis. *J Neuroimmunol.* 2017;306:1–10.
225. Vistbakka J, Elovaara I, Lehtimäki T, et al. Circulating microRNAs as biomarkers in progressive multiple sclerosis. *Mult Scler.* 2017;23(3):403–12.
226. Liu C, Yang H, Shi W, et al. MicroRNA-mediated regulation of T helper type 17/regulatory T-cell balance in autoimmune disease. *Immunology.* 2018;155(4):427–34.
227. Nuzziello N, Vilaro L, Pelucchi P, et al. Investigating the role of microRNA and transcription factor co-regulatory networks in multiple sclerosis pathogenesis. *Int J Mol Sci.* 2018;19(11):3652.
228. Camara-Lemarrroy CR, Metz LM, Wee YV. Focus on the gut-brain axis: multiple sclerosis, the intestinal barrier and the microbiome. *World J Gastroenterol.* 2018;24(37):4217–23.
229. Rojas OL, Pröbstel AK, Porfilio EA, et al. Recirculating intestinal IgA-producing cells regulate neuroinflammation via IL-10. *Cell.* 2019;176:1–15.
230. Forbes JD, Chen C, Knox NC, et al. A comparative study of the gut microbiota in immune-mediated inflammatory diseases—does a common dysbiosis exist? *Microbiome.* 2018;6:221.
231. Kirby TO, Ochoa-Reparaz J. The gut microbiome in multiple sclerosis: a potential therapeutic avenue. *Med Sci (Basel).* 2018;6(3) <https://doi.org/10.3390/medsci6030069>.



Tina Roostaei and Philip L. De Jager

## Distribution of MS in Human Populations

MS affects approximately 500,000 people in the United States and 2.5 million people throughout the world [1, 2]. Most MS patients develop the disease between 20 and 40 years of age, with a preponderance of women being affected. While the overall prevalence rate is generally cited as approximately 1 in 1000 for populations of European ancestry, the lifetime risk in certain populations is as high as 1 in 200 for women and slightly less for men. Indeed, MS is between 1.5 and 3 times more prevalent in women, and this skewed gender distribution has been rising over time [3]. Much less is known about the prevalence of MS in non-European populations and admixed populations such as African-Americans. The available evidence suggests that prevalence is reduced, particularly in populations of African and East Asian ancestry [1]. However, some recent studies in the United States have shown an increase in incidence in African-American popu-

lation comparable to that of people from European ancestry [4].

Overall, MS prevalence demonstrates a latitude gradient, with an increased prevalence in northern latitudes of Europe and North America and in southern regions of Australia and New Zealand. This difference in geographical distribution was noted early in the study of MS and is unlikely to be explained by issues such as access to medical care and lack of familiarity with a diagnosis of MS in areas of low prevalence. However, there are notable exceptions to this general statement, with Sardinians having substantially higher rates of MS than other Italians and Parsis being more commonly affected than other ethnic groups in South Asia [5]. These observations suggest that the variable frequency of genetic susceptibility factors across human populations is likely to explain at least some of the geographical distribution of the disease.

There are a few observations that cannot be attributed to genetic factors. People who migrate to areas of greater MS prevalence tend to adopt the risk of their new homeland if they migrate in childhood, whereas those who migrate in later years retain the risk of their place of origin. Nor can genetics explain the differences in risk among those of common ancestry who migrate to areas of different MS prevalence [6]. It has also been argued that the recent decline in the latitude gradient and the relative increase in MS prevalence for Caucasian women in the United States and

---

T. Roostaei

Department of Neurology, Center for Translational and Computational Neuroimmunology, Columbia University Medical Center, New York, NY, USA  
e-mail: [tr2525@cumc.columbia.edu](mailto:tr2525@cumc.columbia.edu)

P. L. De Jager (✉)

Department of Neurology, New York – Presbyterian Hospital, New York, NY, USA  
e-mail: [pld2115@cumc.columbia.edu](mailto:pld2115@cumc.columbia.edu)

Canada must indicate exogenous factors, since genetic change does not occur over such a short period of time [7–9].

The much-quoted observation of change in risk depending on age at migration has been called into question. The cutoff for many years was assumed to be 15 years of age, but a study with a homogeneous Australian population demonstrated that when 15 years was used as the point of stratification, age of migration had no effect on MS susceptibility, suggesting that risk from migration must span a wider age range [10]. Overall, it is clear that neither genetic nor environmental risk factors are sufficient to independently explain the distribution of MS in different human populations; there is an active interplay between these two sets of risk factors.

---

### Sunlight, Vitamin D, and MS

The search for environmental agents tied to latitude that might directly affect risk of MS has been difficult. Norman and colleagues studied a US veteran population and reported that air pollution index, concentrations of minerals in groundwater, temperature measures, measures of annual rainfall and average humidity, and amount of annual solar radiation, when analyzed by multiple regression, did not influence MS risk independently from latitude [11]. That study notwithstanding, much of the research for a latitude correlate has centered on the amount and duration of sunlight [12]. Studies measuring MS mortality as a function of occupational exposure to sunlight [13], skin cancer rates as a proxy for the amount of sun exposure [14], as well as self-reported [15, 16] and objectively measured (actinic damage) [17] sun exposure have all showed a protective role for sunlight in MS. However, it should be noted that this evidence, while intriguing, might be misleading. The occupational exposure, skin cancer, and skin damage studies that appear to show a relationship between less sunlight and MS risk may in fact reflect “reverse causation”—an epiphenomenon in which MS patients may preferentially avoid the sun as heat can exacerbate their symptoms,

rather than sun exposure protecting against MS. Furthermore, case-control surveys can be confounded by recall bias; for example, it is possible that being aware of the posited relationship between sunlight and MS would affect the reporting of exposure in MS patients. Nonetheless, increased sunlight exposure remains an attractive hypothesis that could contribute to the latitude gradient.

Exceptions to the latitude rule provide an important insight as to how sunlight might be acting to promote MS susceptibility. The first anomaly is the high prevalence of MS at low altitudes and the low MS rates at high altitudes in Switzerland [18]. The second is the high prevalence of MS inland and the lower MS prevalence along the coast in Norway [19, 20]. Both of these phenomena can be convincingly explained by examining the role of vitamin D in this pathway. UV light is stronger at higher altitudes, encouraging endogenous production of vitamin D<sub>3</sub>, and coastal residents eat more vitamin D-rich fish oils than do inland residents in Norway. Experimental data also support the role of vitamin D by showing that 1,25-dihydroxyvitamin D given exogenously prevents experimental autoimmune encephalomyelitis (EAE), the mouse model of MS [21, 22], while in vitamin D-deficient mice, the onset of EAE is accelerated [23]. Nevertheless, it seems that the dissection of the effects of sunlight exposure and vitamin D requires further investigation, as some evidence suggests that both may have independent effects on the risk of MS [17, 24].

Case-control studies have shown lower dietary vitamin D intake [25] and serum concentrations of 25-hydroxyvitamin D<sub>3</sub> [25(OH)D] [26], an objective measure of vitamin D status, in MS patients in comparison to matched controls. However, these studies are also subject to the potential problem of reverse causation and, in the case of dietary intake studies, further subject to recall bias. Somewhat stronger evidence for a causal role for vitamin D in susceptibility to MS comes from studies that provided unbiased information on vitamin D status of participants prior to the onset of MS. A longitudinal prospective study performed using dietary vitamin D intake



data from the Nurses' Health Study (NHS) and NHS II found that higher total vitamin D intake (including intake from vitamin D supplements) was associated with lower risk of developing MS in later life [27]. Two nested case-control studies performed on blood samples collected from active-duty US military personnel [28] and population-based biobanks from the northern half of Sweden [29] further demonstrated that serum 25(OH)D levels were lower in individuals who later developed MS in comparison to matched healthy controls years before clinical onset of MS symptoms. However, as MS has an insidious onset, the temporal and hence causal relation between lower 25(OH)D levels and MS onset still requires further investigation to determine the exact window where this risk factor exerts its effect: a number of studies have found associations between lower vitamin D intake around adolescence [30] and even neonatal 25(OH)D status [31] with higher risk of MS.

Mendelian randomization studies, on the other hand, can address the causality of the relationship between vitamin D and MS risk from a different perspective, by assessing whether genes that are associated with lower serum 25(OH)D levels also contribute to higher risk of developing MS. The assumption for these studies is that the genetic variants associated with different traits are inherited randomly, and therefore, these studies can represent a randomized trial that minimizes the effects of confounding and reverse causation. Two recent such studies have demonstrated that individuals with polygenic scores associated with higher 25(OH)D levels are at lower risk of MS [32, 33]. However, residual pleiotropy (i.e., the possibility that the genetic variants influence both 25(OH)D levels and MS risk) cannot be ruled out.

In addition to the risk of MS, studies have found associations between vitamin D and MS disease activity, in terms of relapses, new lesions, and also conversion from clinically isolated syndrome to MS [34–36]. Although the association with relapse rate and disability was not replicated in more recent and larger longitudinal studies [37, 38] and clinical trials of vitamin D supplementation [39, 40], evidence suggests that the

association of vitamin D with lower increase in brain new and active lesions remains significant consistent with the previous studies [37, 39].

---

## Infectious Agents and MS

Given the geographical distribution of MS, the change in risk among migrants of different age, and the possible occurrence of MS epidemics [6, 41], the hypothesis that MS results from exposure to an infectious agent was proposed early and has been repeatedly explored. Certainly, the idea that a virus could infect many people but only cause pathological manifestations in a few was already evident from poliomyelitis and provided a possible model for MS. This model of a viral cause was conceptually supported by observations that several viruses were associated with demyelinating encephalomyelitis both in human patients and in experimental animals and that high concentrations of IgG (oligoclonal bands) are found in many patients with MS [42].

Two competing hypotheses have aimed to explain the relationship of microbes to MS. The prevalence hypothesis argues that MS comes about as a result of a pathogen that is more common in areas of high MS prevalence. Alternatively, the hygiene hypothesis states that a heavy burden of microbial or parasitic infections creates a persistent effect on the immune system early in childhood, conferring protection against MS (and other autoimmune diseases). The effect on the immune system may include a shift from pro-inflammatory helper T cell (Th17) profile to a Th2 profile, such as that is seen following helminthic infections and is associated with diminished inflammation in MS [43]. The hygiene hypothesis has generally been favored over the prevalence hypothesis in MS because it is better able to account for the latitude gradient, recent increases in prevalence (improved hygiene), and changing risk among migrants [3].

Over the years, various pathogens—such as human herpesvirus 6 (HHV6), *Chlamydia pneumoniae*, and endogenous retroviruses—have been investigated for possible connection to MS, but none have been definitively linked with the

disease [44]. The pathogen with the most robust evidence to support it is the Epstein-Barr virus (EBV) [45], the virus associated with infectious mononucleosis (IM), lymphoma, and nasopharyngeal carcinoma. The vast majority of adults have been infected with EBV. Interestingly, both IM and MS occur in adolescents and young adults and specifically target populations where EBV infection is known to occur at a later age (i.e., those with higher socioeconomic status and more education). IM also follows a similar latitude gradient to MS [46]. Thus, late infection with EBV, marked by the appearance of IM, is associated with MS risk; conversely, early acquisition of EBV is seen in various parts of the world, such as Asia, where MS prevalence is low. Seropositivity to EBV nuclear antigen 1 (EBNA-1) and history of IM are among the most replicated environmental associations found in relation to MS [45]. A number of studies have also investigated the temporality of this association and have found associations with EBV seroconversion [47] and elevated levels of anti-EBNA-1 antibodies many years prior to clinical manifestations of MS [48].

At this point, epidemiological and serological studies suggest a role for EBV in MS susceptibility, but how can the hygiene hypothesis and a putative role for EBV be reconciled? The hygiene hypothesis argues that a large burden of microbes in early childhood shifts the immunological profile toward protection from MS. EBV alone is unlikely to be sufficient to explain such a shift. However, it is known that children who are seronegative for EBV (presumably members of the high hygiene group) have a very low risk of MS as long as they are EBV-negative [49]. On the other hand, individuals who are infected and develop IM have a relative risk of MS of 2.3 compared with those who never developed IM [50, 51]. The “EBV variant” of the hygiene hypothesis argues that good hygiene is detrimental from the MS perspective only insofar as it causes one to be infected with EBV later in life and hence have a higher chance of developing MS [49].

Molecular evidence for the role of EBV in MS has extended these epidemiologic observations. A genome-wide association study of the anti-

EBNA-1 IgG titers has shown that polygenic risk for this antibody is correlated with the genetic risk for MS [52]. EBNA-1 and EBNA-2 are among EBV nuclear proteins expressed in latently infected B lymphocytes. Interestingly, a recent study has demonstrated significant overlap between EBNA-2 DNA-binding sites and more than 40 MS-associated genetic loci in B lymphocyte cell lines [53], suggesting a biological basis for the association.

A group of researchers have reported the presence of lymphoid infiltrates within the meninges and also cortical lesions of MS patients [54, 55]. These structures were noted to contain many B cells and plasma cells with evidence of EBV infection. Although the replication of these results has been challenging [56], if replicated, this will offer a concrete link between EBV and MS-related neuropathology. The importance of B cell dysregulation in MS has been suggested by the successful trials of rituximab and more recently ocrelizumab (anti-CD20 monoclonal antibodies) in patients with relapsing-remitting disease [57, 58]. So, evaluating EBV further in this context is critical. In vitro studies have suggested that, because of amino acid sequence homologies between EBV proteins and myelin basic protein, immune responses directed against EBV antigen could cross-react with self-antigen. In a genetically susceptible host under the right circumstances, the threshold of such autoreactive reactions may be lower. For example, immune response to EBV may be modulated by vitamin D, and suboptimal levels could lead to the activation of autoreactive T cells [59]. Thus, while definitive evidence for a role of EBV or another microbial trigger of MS remains elusive, it is likely that one or more different infectious agents may play a role in the initiation of the inflammatory process in MS.

---

## Smoking and MS

Several studies suggest that cigarette smoking is a risk factor for multiple sclerosis. Meta-analyses performed on the association between smoking and susceptibility to MS have relatively large

sample sizes, and it does not appear that there is large heterogeneity among the included studies [45, 60]. While there is some concern in these retrospective analyses that self-reported smoking status may not be very reliable, it has been shown that MS survey participants do reliably report their smoking status [61]. Moreover, these results are replicated in longitudinal studies, which, though varying in their definitions of smoking, have shown a 1.5-fold increase in the relative risk of MS for smokers when they are compared to individuals who had never smoked [62]. Studies have also demonstrated a dose-related increase in MS risk for smoking, with the highest risk in heavy smokers and people with higher cumulative doses of smoking [62, 63]. There is also an interaction observed with sex, with a higher increase in risk of MS with smoking in males in comparison to females, which may explain the recent trends in increasing MS female-to-male ratio, as there has been a decrease in smoking behavior in males over time [3, 63].

Several hypotheses have been proposed to explain the effect of smoking on MS risk. A systemic effect of smoking on the immune system is supported by the fact that smoking increases risk not only for MS but also for other autoimmune diseases [64]. Lung irritation and increase in respiratory infections, vascular effects, neurotoxic effects, and effects on central nervous system signaling pathways are among other suggested mechanisms [3]. Interestingly, a negative interaction has been observed between smoking and IM, so that there is no increased risk associated with smoking in people who have a history of IM suggesting some shared biological pathways between the two [65]. On the other hand, the common use of smokeless oral tobacco (snuff) in Sweden has allowed for dissociating the effect of smoking from that of oral tobacco, demonstrating that unlike smoking, snuff is associated with decreased risk of MS [63].

Smoking is also linked to transition to secondary progressive disease in MS [66], and it has been noted that smoking may promote acute exacerbations of MS [67]. Furthermore, it is suggested that smoking is also a risk factor for early conversion to MS after an initial demyelinating

event [68]. However, these results were not replicated in recent studies including a prospective longitudinal study of ~500 participants enrolled with clinically isolated syndrome [69].

---

## Early-Life Obesity and MS

Obesity has emerged as a potential risk factor for MS in the past decade in large case-control [70, 71] and prospective [72, 73] studies. These epidemiological studies suggest that obesity around adolescence, rather than high body mass index (BMI) at later ages, is associated with ~2-fold increase in risk of MS. This effect is further shown to remain significant independent of the effects of other major genetic and environmental risk factors of MS including history of IM and smoking [74]. Results from two Mendelian randomization studies further support a causal association between obesity and MS by demonstrating that the genetic risk score for higher BMI is associated with increased risk of MS [75, 76]. This is further supported by evidence of significant genetic correlation between MS, BMI, and childhood obesity [77]. Similar to the other environmental risk factors, mechanisms underlying the association between obesity and MS are not yet clear. Low-grade systemic inflammation and an increase in pro-inflammatory processes along with decreased circulating 25(OH)D levels are thought to contribute to the effect of obesity on risk of MS [78].

---

## Neuro-endocrine and Other Factors

There is some evidence for the role of hormones in MS risk, although, admittedly, it is not as robust as the data supporting the susceptibility factors discussed above. Given (1) the increased ratio of females to males affected with MS, (2) symptom onset in young adulthood, (3) higher risk of MS with younger age at menarche [79, 80], and (4) the fact that women with MS appear to suffer somewhat fewer relapses in the second and third trimesters of pregnancy followed by an increase in rate of

relapse in the first trimester postpartum [81], sex hormones have been investigated for a possible role as modulators of MS risk. Progesterone appears to cause a switch from a Th1 to a Th2 immune response, while testosterone exerts anti-inflammatory and immunosuppressive effects in mouse models of autoimmunity [82]. The protection during pregnancy and the increased risk postpartum could be mediated by hormonal fluctuations of progesterone, estrogen, or other factors affected by pregnancy: for example, progesterone levels increase during gestation, reaching their peak during the third trimester, at which point evidence of protection from MS is the strongest, and then plummet in the puerperium [83]. Further, it has been proposed that estradiol, the form of estrogen common in nonpregnant women, is deleterious with regard to MS but that estriol, the predominant estrogen in pregnant women, is protective [84]. Two recent clinical trials have suggested beneficial effects for estriol and oral contraceptives on relapse rate and active lesions in MRI, respectively [85, 86]. However, epidemiological investigations of oral contraception use [87], parity, and age at first birth suggest that these factors are not robustly associated with the risk of the disease, and their effects on disease activity or progression are short-lived [62].

Other factors such as dietary intake of salt and fatty acids, alcohol and coffee consumption, physical exercise, and exposure to other viruses and chemicals and more recently the microbiota are also being investigated as factors affecting the risk of MS [78, 88], which, if solidified, can have important implications for the prevention of the disease. However, the causality and extent of these associations yet remain to be elucidated. On the other hand, based on the prevalence and effect size of the established environmental risk factors—i.e., smoking, low vitamin D levels, obesity, and IM—it is estimated that there may be up to a 60% reduction in MS at the population level, if these risk factors are prevented [3]. Such an estimate is likely to be high, but it illustrates the point that modifying environmental risk factors could have an important effect in reducing the incidence of MS.

## Genetic Susceptibility in MS

Risk of MS is higher among biological relatives of MS patients and increases with the degree of relatedness [89]. Heritability of MS risk (amount of variation in developing MS that is due to genetic causes) is estimated to be between 35% and 75% [90]. While monozygotic twins have a concordance rate of 20–30%, the risk of the disease reduces to ~5% in dizygotic twins, 3% in siblings, and 2% in parents and children, which is still 10- to 20-fold higher than the age-adjusted risk in general population (0.1–0.2%) [91]. Although familial recurrence is seen in MS, no simple Mendelian form of MS has been described to date, and unlike certain diseases, such as cystic fibrosis and sickle cell anemia, in which mutations in a single gene are wholly responsible for pathogenesis, MS is a genetically complex trait. That is to say, many different genetic loci with incomplete penetrance contribute to an individual's risk of developing MS. The evidence indicates that each of these genes only exert a modest influence on susceptibility. The most recent studies of the International Multiple Sclerosis Genetics Consortium (IMSGC) [92, 93] on 115,635 individuals of European ancestry expanded our understanding of the major histocompatibility complex (MHC), a region of the genome that contains at least 31 different susceptibility factors, including the *HLA-DRB1\*1501* allele that has a unique role in MS given its high frequency in the population and its nearly three-fold increase in risk of the disease. Outside of the MHC, these studies have extended evidence of association to >200 common genetic variants with smaller effect sizes (i.e.,  $1.05 < OR < 1.5$ ) [92, 94] on risk of the disease. Although the current data supports the common disease-common variant model, the possibility of the existence of rare variants with larger effect sizes cannot be ruled out at this time. However, nonsignificant results from linkage studies for regions outside the MHC suggest that even if such rare variants exist, their effect size would be limited (i.e.,  $OR < 6$ ) or that few affected families share the same affected gene [94, 95]. In this section, we will discuss in more detail what we have learned

to date about the genetics of MS. However, we note that our knowledge is mainly based on studies on people with European ancestry, as studies on other populations have been limited.

### The Major Histocompatibility Complex (MHC)

Human leukocyte antigen (HLA) genes, located within the MHC on chromosome 6p21, were first found to be associated with MS in 1972 [96, 97]. Numerous linkage and association studies have since made this the most replicated finding in MS genetics [98]. Although the association between this region and MS has been known for decades now, the characterization and identification of relevant variants within the region has been difficult, as the MHC is a locus with high gene density and extended linkage disequilibrium (LD, the co-occurrence of alleles at two or more loci more frequently than would be expected by chance), and the genes within the MHC are highly polymorphic. However, advances in genotyping technology and statistical methodologies have led to the creation of reference panels followed by imputation algorithms specific to the MHC that have enabled well-powered efforts to resolve independent effects within this region. The strongest effect in the MHC is the *HLA-DRB1\*15:01* allele. The allele is frequent in populations of European ancestry (minor allele frequency = 13%) [99]. The individuals who carry an *HLA-DRB1\*15:01* allele are at ~3 times higher risk of developing MS than the people who don't have it [92].

Although it has been demonstrated that some of the observed associations between MS risk and other MHC class II alleles such as *HLA-DQB1\*06:02* and *HLA-DQA1\*01:02* can be explained by their linkage disequilibrium with *HLA-DRB1\*15:01*, evidence has also emerged demonstrating multiple independent associations with MS susceptibility with a number of other alleles within this dense region [92, 100, 101]. Stepwise conditional analysis performed in the most recent IMSSC meta-analysis study confirmed previous findings and extended the evi-

dence to 31 statistically independent effects within the MHC consisting of a combination of HLA alleles, amino acid changes and single nucleotide polymorphisms (SNPs), some of which are protective: seven independent effects in the *HLA-DRB1* locus, nine independent effects in other MHC class II alleles (*HLA-DPB1*, *DPB2*, *DQA1*, and *DQB1*), seven effects in MHC class I (*HLA-A* and *B*), and eight effects in non-classical HLA and non-HLA genes [92]. Part of the association between *HLA-DR* alleles and MS risk is explained by changes in amino acids that reside in the peptide-binding groove of these proteins, thus suggesting that these genetic variants exert their effect through changes in the binding of peptides and recognition of antigens [101].

In addition to the independent main effects observed in the MHC, interaction effects have also been reported between MHC class II alleles [92, 99, 102]. However, the current data suggests that there is no strong evidence for the modulation of the effect of HLA alleles by non-MHC polymorphisms from across the genome, nor is there a polygenic epistasis effect [99, 100]. The interaction effects between HLA alleles require both further biological and statistical explorations. These may also suggest a haplotypic or diplotypic nature for the association between the MHC and MS susceptibility [102].

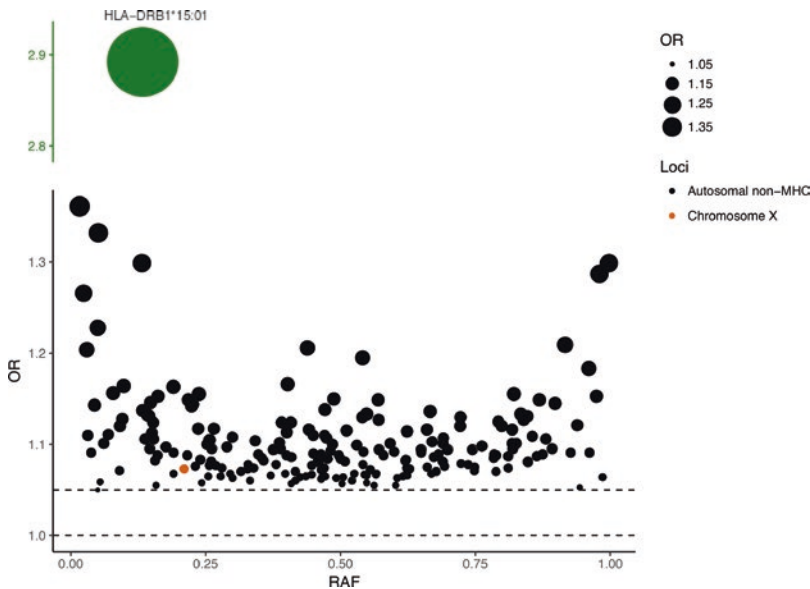
### Association-Based Mapping and Non-MHC Risk Alleles

The search for susceptibility loci in MS initially relied on linkage studies of families with multiple cases of MS, with limited success. This was consistent with theoretical discussions that highlighted the lack of statistical power of the linkage approach in discovering genetic variants of modest effect. Instead, an association-based approach such as a simple case-control design was put forward as the preferred method for gene discovery [103]. This realization led to the formation of the IMSSC, since an association study design requires very large sample sizes and dense genotyping to be successful. This, coupled with concurrent development of

resources such as HapMap, a catalog of common genetic variation, technological advances including novel high-throughput genotyping platforms, and more powerful statistical methodologies, led to the first genome-wide association study (GWAS) of MS in 2007 [104]. This study was performed on data from ~1000 trios and a replication cohort of ~5500 participants and, for the first time, resulted in the identification of a region outside of the MHC as being significantly associated with MS after accounting for genome-wide testing (threshold of significance is a  $P$ -value  $< 5 \times 10^{-8}$ ) [104]. The top hit after the *HLA-DRB1* locus was a single nucleotide polymorphism (SNP), rs12722489, located in an intronic region of the gene *IL2RA*. The *IL2RA* gene product, interleukin-2 receptor alpha chain (also called CD25), is expressed on the surface of activated T cells and B cells, and daclizumab, a humanized monoclonal antibody directed against this protein, was used for the treatment of MS [105] before recently being withdrawn from the market due to its side effects. The soluble form of *IL2RA* is increased in the serum of

MS patients, and its levels are associated with the risk genotype in healthy individuals and MS patients [106].

Following the first GWAS, a series of genome-wide association and meta-analysis studies have been performed with a growing number of sample sizes over the past decade [92, 100, 107, 108]. The subsequent studies have also taken advantage of improved reference panels, imputation methods, and specialized genotyping kits such as ImmunoChip and MS chip designed for the purpose of replication and fine-mapping of the previously associated loci [92, 108–110]. The most recent GWAS of IMISGC is performed on data from ~8,000,000 SNPs with minor allele frequency  $>1\%$  on a total of 115,635 participants [92]. This study has extended the number of genome-wide significant independent association effects outside the MHC to 201 loci and has for the first time identified a non-autosomal effect on the X chromosome. With the currently available sample sizes, we have been able to identify effects with odds ratio as low as 1.05 (Fig. 4.1).



**Fig. 4.1** Odds ratio (OR) for the non-MHC genome-wide significant alleles associated with susceptibility to MS (including the recently identified X chromosome association locus) from the most recent IMISGC studies on European populations [92, 93]. The effect size for the strongest association from the MHC locus (*HLA-*

*DRB1\*15:01*) is shown separately in green for comparison. The dashed lines represent  $OR = 1$  and  $1.05$ . Each circle represents one susceptibility variant, and its size is proportional to the effect size of that variant. *RAF* risk allele frequency

## “Missing Heritability”

It is estimated that the currently identified common variants explain ~40% of MS heritability: the MHC region explains 20%, and the other 20% is explained by the non-MHC genome-wide significant effects [92]. Part of the remaining heritability may be attributable to common, low-frequency, and rare variants that remain to be discovered, and some of these will be identified using larger sample sizes, studies on non-European populations, and utilization of whole-exome and whole-genome sequencing instead of genotyping arrays. For example, another recent IMSCG study which investigated the association of low-frequency and rare variants in the coding regions of the genome with MS using exome chip genotyping arrays [93] identified five additional effects with minor allele frequencies between 0.2% and 5.6% not previously tagged with common SNPs in the previous studies. It is also probable that part of the unexplained heritability can be attributed to “phantom” heritability, which results from the presence of gene-gene and gene-environment interactions among the currently identified risk factors. Although two-by-two interactions within the MHC locus have been investigated previously [99, 100, 111], more complex patterns of epistasis and the interactions between loci outside the MHC are understudied. Much larger studies will be needed to evaluate this question in a statistically powerful manner.

---

## Functional Implications of the MS-Associated Loci

Information on the functional consequences of MS susceptibility variants can guide our understanding of the etiology and pathology of the disease. However, the majority of the MS-associated loci are in intronic or intergenic regions or in regions containing several genes [92]. With advances in sequencing technologies and statistical methodologies, efforts have begun to map the relation of genetic variation to the transcriptomes and epigenomes of human cells and tissues [112–114]. These atlases can be used to elucidate the

regulatory and functional effects of genetic variation associated with disease and can help to prioritize genes, cell types, and tissues involved in disease processes for further studies.

Enrichment analyses performed to date on the MS GWAS results have found that MS-associated loci are overrepresented in promoters, enhancers, and accessible chromatin regions from not only T cells but also B cells, natural killer cells, and dendritic cells [92, 115]. Evidence also suggests enrichment for microglia, but not astrocytes and neurons [92, 115]. Although these results provide interesting evidence for the role of different cell types involved in both adaptive and innate immunities in MS, they should not be interpreted as if they rule out the role of neurons and the brain tissue, as a number of the genetic loci can still exert their effects through regulatory changes in these cell types, either as molecular changes specific to these cells or through pathways shared between them and immune cells.

In addition to prioritizing cell types and tissues, some functional studies have been successful in prioritizing genes and validating the mechanisms through which some of the MS-associated loci exert their effects: it has been shown that the MS-associated loci found in close proximity of *IL2RA*, *IL7R*, and *TNFRSF1A* genes affect the alternative splicing of these receptors [106, 116, 117]. Another example is the genetic variation in the *TYK2* locus that results in decreased activity of the tyrosine kinase 2 enzyme which is in turn associated with a shift favoring the secretion of Th2 cytokines [118]. Future studies are yet to resolve the full picture of the effects of each MS-associated locus on the molecular machinery and function of cells in a cell type- and status-specific manner.

---

## Genetic Associations with Other Autoimmune and Neurodegenerative Disorders

Multiple reports suggest that MS patients and their families tend to be affected by other autoimmune diseases more frequently than the general population [31, 119]. Shared heritability analyses

also support significant genetic correlation between MS and a number of autoimmune diseases, such as inflammatory bowel disease, primary biliary cirrhosis, systemic lupus erythematosus, and rheumatoid arthritis [77]. On the other hand, associations with neurologic and psychiatric disorders including amyotrophic lateral sclerosis, Alzheimer's disease, and Parkinson's disease have been nonsignificant [120, 121].

In the hopes of providing insights into common disease pathways, efforts have been made to identify susceptibility alleles shared among different autoimmune disorders [122]. As in MS, the MHC contains the major susceptibility alleles for other autoimmune disorders such as Type 1 diabetes (T1DM), rheumatoid arthritis (RA), and autoimmune thyroid disease (AITD). In addition, a large number of autosomal non-MHC loci are associated with more than one autoimmune disease [100, 108, 123]. For example, the SNP rs6897932 (*IL7R*), found to be associated with MS, is also related to T1DM [124]; and the Ser307 allele of the *CD226* gene, whose product is a transmembrane protein involved in adhesion and co-stimulation of T cells, predisposes to MS, T1DM, and primary sclerosing cholangitis [125, 126].

Although the colocalization evidence at a number of loci, such as the *TYK2* locus, support the existence of a single causal variant that is associated with the risk for MS, T1DM, RA, and celiac disease [122], more detailed analyses of some of the other autoimmune disease-associated loci suggest more complex patterns of shared and discrete associations. For example, the *HLA-DRB1\*15:01-HLA-DQB1\*06:02* haplotype likely confers risk for narcolepsy through *HLA-DQ6*-mediated autoimmunity, rather than *HLA-DRB1\*15:01*, the top susceptibility locus for MS. On the other hand, the latter haplotype is protective against T1DM, autoimmune polyglandular syndrome, and immunoglobulin A (IgA) deficiency [127]. The *IL2RA* locus consists of multiple independent risk and susceptibility effects for MS and T1DM [122, 128]. Another example is a single causal variant on chromosome 6q25 containing the *TAGAP* gene that is

associated with both celiac disease and MS. However, the risk allele for MS is the protective allele for celiac [108, 122]. These suggest that the genetic associations between different autoimmune diseases are complex and require further investigation.

---

## Influence of Genetics on Clinical Features and Endophenotypes

Evidence from concordance studies in families with two or more MS patients suggest that genetic factors may affect some clinical features of the disease such as age at onset and clinical course but not disease severity [129, 130]. Multiple studies have investigated the association between MS susceptibility loci and clinical features of the disease. The *HLA-DRB1\*1501* haplotype has been shown to be associated with an earlier age of onset, with heterozygotes presenting approximately 1 year earlier [99, 100], while another haplotype (the *HLA-DQA1\*01:01* haplotype) has been associated with an increased onset age [99]. However, it seems that there is no association between the HLA region and clinical measures of disease course and severity [99, 100]. Studies that have investigated the association between non-MHC autosomal MS-associated loci with disease severity, either with individual SNPs or aggregate measures of risk in the form of polygenic scores, have also mainly had nonsignificant results [110, 131, 132]. Some candidate gene studies have suggested a number of genetic associations with disease course or severity, but the majority of these studies have small sample sizes, and the results need further replication in larger and independent samples [133]. Genome-wide association studies performed to date on disease severity have reported no genome-wide significant results, which supports the lack of association observed with the MS susceptibility loci [134–137]. Interestingly, the enriched pathways, if replicated, seem to point to distinct biological processes being involved in progression vs. susceptibility to the disease [134, 135, 137].

Moderate sample size, disease heterogeneity, shortcomings of commonly used clinical



measures such as Multiple Sclerosis Severity Scale (MSSS), and cross-sectional study design are among the reasons for the absence of replicated genome-wide significant associations with disease severity to date. Larger studies that utilize longitudinal clinical data, such as one that is currently being performed by the IMSSGC, may shed light on the genetic mechanisms underlying heterogeneity in disease severity and progression. Another approach is to use disease endophenotypes that are representative of different mechanisms involved in the pathobiology of the disease as outcomes for the genome-wide association studies. Such studies have proven to be more successful, and a number of haplotypes, including *HLA-DRB1\*15:01*, are demonstrated to affect measures such as the presence or absence of oligoclonal bands and cerebrospinal fluid IgG index levels in MS patients [138]. Similarly, the *HLA B\*44* haplotype which is protective in terms of MS susceptibility is also associated with larger brain volume and reduced brain lesions among MS patients [139]. Other small studies have also reported results relating to brain lesion distribution [140], cortical thickness [141], and brain glutamate concentration [142]. As our understanding of disease pathology and our methods for measuring different mechanisms involved in disease severity (e.g., measures derived from positron emission tomography, diffusion- and susceptibility-weighted MRI, and optical coherence tomography) improve, these measures can also be used as endophenotypes in larger and independent studies of the genetic architecture of disease heterogeneity and progression.

Genetic studies can also be used to find biomarkers for treatment response or side effects which help us in moving toward the goal of providing more personalized medical care for MS patients. While a growing number of candidate gene and genome-wide association pharmacogenetics studies are being performed on response to treatment to the majority of disease-modifying therapies [143], the results of the first studies have generally not been reliably replicated. One exception is a study of interferon- $\beta$  response that returned a genome-wide result which was replicated [144]; this variant was found near the

*SLC9A9* gene which is differentially expressed in the presence of interferon- $\beta$ . However, a replication limited to individuals that are negative for neutralizing antibodies failed to replicate this result, illustrating the need for much larger studies with consistent subject selection criteria to return definitive results. In contrast to response to treatment, for which definition may vary widely depending on the study, the genetic studies on the development of neutralizing antibody to interferon- $\beta$  converge on the effect of MHC class II alleles [145, 146].

---

### Integrating Environmental and Genetic Risk Factors

As a complex trait, MS susceptibility and progression are thought to be affected by a combination of environmental and genetic factors in each individual. It is also likely that these factors modify the effect of each other, so that individuals with different genetic susceptibility to MS may respond differently to environmental exposures or certain environmental factors are dependent on a particular genetic architecture. Given that *HLA-DRB1* is a co-receptor for EBV entry and that the *HLA-DRB1\*1501* allele may be able to present EBV antigen that may mimic self-antigen, assessing the interaction of these two strong risk factors has been of great interest. The results demonstrate a synergistic effect between infectious mononucleosis and *HLA-DRB1\*1501* [147–149]. Studies performed on the interaction between smoking and *HLA-DRB1\*1501* show a similar effect [150]. Moreover, smoking was shown to interact with a variant in a non-HLA gene, *NAT1*, which is an *N*-acetyltransferase involved in drug metabolism, affecting risk of MS: susceptibility to MS was increased in smokers in comparison to nonsmokers only in people who carried the polymorphism [151]. These observations suggest that diagnostic modeling may become practical as we further uncover the interrelations between genetic and environmental factors. Furthermore, these can help identify mechanisms underlying resilience to the effects of certain risk factors.

The information on the genetic and environmental risk factors of MS have also been used to calculate personalized aggregate risk scores for each individual in order to investigate the correlations between these scores and different outcomes related to the disease. Although these aggregate scores do not have high sensitivity and specificity in distinguishing MS from healthy controls [152], they may be useful in stratifying at-risk asymptomatic individuals or people with subclinical signs and symptoms for more detailed follow-up or even early intervention. By concentrating the resources on the study of first-degree relatives of MS patients, who are at about 30 times higher risk of developing MS than the general population, more detailed prospective longitudinal studies can be performed in order to identify the timing and the sequence of events in the process of developing MS and to find the mechanisms and phenotypes that are related or not related to the genetic and environmental risk factors [153]. For example, one such study has suggested that asymptomatic first-degree relatives who have a higher aggregate genetic and environmental risk score are more likely to have subclinical MS manifestations, including poorer vibration sensation and a number of MRI findings such as perivenous T2-weighted hyperintense lesions and focal leptomeningeal enhancement [154].

## Conclusion

As we have seen, a variety of environmental and genetic factors have been implicated in the onset of MS. Sunlight exposure and vitamin D intake, infection with EBV, smoking, and other environmental risk factors have substantial epidemiological evidence supporting their role as MS risk factors. On the other hand, genetic association studies have shown that polymorphisms in the MHC and many non-MHC loci predispose individuals to develop MS. Fine-mapping of MS patients will be required to determine which specific variant is causal in each locus, and we will need to follow with studies on the functional consequences of those variants. The abil-

ity of genome-wide scans to detect modest genetic associations has been a great boon for MS research, highlighting susceptibility pathways that need to be pursued further. The next step would be to attack critical questions such as whether there are genetically distinct subgroups of patients within which particular alleles have a much greater effect or whether particular molecular pathways are preferentially targeted in each subgroup of patients. The answers to these and many other questions will guide us in our dissection of disease pathways, in drug development, and in the design of more personalized clinical algorithms for diagnosis and possibly prognosis.

## References

1. Thompson AJ, Baranzini SE, Geurts J, Hemmer B, Ciccarelli O. Multiple sclerosis. *Lancet*. 2018;391(10130):1622–36.
2. Dilokthornsakul P, Valuck RJ, Nair KV, Corboy JR, Allen RR, Campbell JD. Multiple sclerosis prevalence in the United States commercially insured population. *Neurol Am Acad Neurol*. 2016;86(11):1014–21.
3. Ascherio A, Munger KL. Epidemiology of multiple sclerosis: from risk factors to prevention—an update. *Semin Neurol*. 2016;36(2):103–14.
4. Wallin MT, Culpepper WJ, Coffman P, Pulaski S, Maloni H, Mahan CM, et al. The Gulf War era multiple sclerosis cohort: age and incidence rates by race, sex and service. *Brain*. 2012;135(6):1778–85.
5. Rosati G. The prevalence of multiple sclerosis in the world: an update. *Neurol Sci*. 2001;22(2):117–39.
6. Gale CR, Martyn CN. Migrant studies in multiple sclerosis. *Prog Neurobiol*. 1995;47(4–5):425–48.
7. Hernán MA, Olek MJ, Ascherio A. Geographic variation of MS incidence in two prospective studies of US women. *Neurology*. 1999;53(8):1711–8.
8. Orton S-M, Herrera BM, Yee IM, Valdar W, Ramagopalan SV, Sadovnick AD, et al. Sex ratio of multiple sclerosis in Canada: a longitudinal study. *Lancet Neurol*. 2006;5(11):932–6.
9. Wallin MT, Page WF, Kurtzke JF. Multiple sclerosis in US veterans of the Vietnam era and later military service: race, sex, and geography. *Ann Neurol*. 2004;55(1):65–71.
10. Hammond SR, English DR, McLeod JG. The age-range of risk of developing multiple sclerosis: evidence from a migrant population in Australia. *Brain*. 2000;123(Pt 5):968–74.
11. Norman JE, Kurtzke JF, Beebe GW. Epidemiology of multiple sclerosis in U.S. veterans: 2. Latitude,

- climate and the risk of multiple sclerosis. *J Chronic Dis.* 1983;36(8):551–9.
12. Ascherio A, Munger K. Epidemiology of multiple sclerosis: from risk factors to prevention. *Semin Neurol.* 2008;28(1):017–28.
  13. Freedman DM, Dosemeci M, Alavanja MC. Mortality from multiple sclerosis and exposure to residential and occupational solar radiation: a case-control study based on death certificates. *Occup Environ Med.* 2000;57(6):418–21.
  14. Goldacre MJ, Seagroatt V, Yeates D, Acheson ED. Skin cancer in people with multiple sclerosis: a record linkage study. *J Epidemiol Community Health.* 2004;58(2):142–4.
  15. Bjørnevik K, Riise T, Casetta I, Drulovic J, Granieri E, Holmøy T, et al. Sun exposure and multiple sclerosis risk in Norway and Italy: the EnvIMS study. *Mult Scler J.* 2014;20(8):1042–9.
  16. van der Mei IAF, Ponsonby A-L, Dwyer T, Blizzard L, Simmons R, Taylor BV, et al. Past exposure to sun, skin phenotype, and risk of multiple sclerosis: case-control study. *BMJ.* 2003;327(7410):316.
  17. Lucas RM, Ponsonby A-L, Dear K, Valery PC, Pender MP, Taylor BV, et al. Sun exposure and vitamin D are independent risk factors for CNS demyelination. *Neurology.* 2011;76(6):540–8.
  18. Kurtzke JF. On the fine structure of the distribution of multiple sclerosis. *Acta Neurol Scand.* 1967;43(3):257–82.
  19. Swank RL, Lerstad O, Strøm A, Backer J. Multiple sclerosis in rural Norway its geographic and occupational incidence in relation to nutrition. *N Engl J Med.* 1952;246(19):722–8.
  20. Westlund K. Distribution and mortality time trend of multiple sclerosis and some other diseases in Norway. *Acta Neurol Scand.* 1970;46(4):455–83.
  21. Pedersen LB, Nashold FE, Spach KM, Hayes CE. 1,25-Dihydroxyvitamin D3 reverses experimental autoimmune encephalomyelitis by inhibiting chemokine synthesis and monocyte trafficking. *J Neurosci Res.* 2007;85(11):2480–90.
  22. Lemire JM, Archer DC. 1,25-dihydroxyvitamin D3 prevents the in vivo induction of murine experimental autoimmune encephalomyelitis. *J Clin Invest.* 1991;87(3):1103–7.
  23. Cantorna MT, Hayes CE, DeLuca HF. 1,25-Dihydroxyvitamin D3 reversibly blocks the progression of relapsing encephalomyelitis, a model of multiple sclerosis. *Proc Natl Acad Sci U S A.* 1996;93(15):7861–4.
  24. Bäärnhielm M, Hedström AK, Kockum I, Sundqvist E, Gustafsson SA, Hillert J, et al. Sunlight is associated with decreased multiple sclerosis risk: no interaction with human leukocyte antigen-DRB1\*15. *Eur J Neurol.* 2012;19(7):955–62.
  25. Bäärnhielm M, Olsson T, Alfredsson L. Fatty fish intake is associated with decreased occurrence of multiple sclerosis. *Mult Scler J.* 2014;20(6):726–32.
  26. Duan S, Lv Z, Fan X, Wang L, Han F, Wang H, et al. Vitamin D status and the risk of multiple sclerosis: a systematic review and meta-analysis. *Neurosci Lett.* 2014;570:108–13.
  27. Munger KL, Zhang SM, O'Reilly E, Hernán MA, Olek MJ, Willett WC, et al. Vitamin D intake and incidence of multiple sclerosis. *Neurology.* 2004;62(1):60–5.
  28. Munger KL, Levin LI, Hollis BW, Howard NS, Ascherio A. Serum 25-hydroxyvitamin D levels and risk of multiple sclerosis. *JAMA.* 2006;296(23):2832.
  29. Salzer J, Hallmans G, Nystrom M, Stenlund H, Wadell G, Sundstrom P. Vitamin D as a protective factor in multiple sclerosis. *Neurology.* 2012;79(21):2140–5.
  30. Cortese M, Riise T, Bjørnevik K, Holmøy T, Kampman MT, Magalhaes S, et al. Timing of use of cod liver oil, a vitamin D source, and multiple sclerosis risk: the EnvIMS study. *Mult Scler J.* 2015;21(14):1856–64.
  31. Nielsen N, Frisch M, Rostgaard K, Wohlfahrt J, Hjalgrim H, Koch-Henriksen N, et al. Autoimmune diseases in patients with multiple sclerosis and their first-degree relatives: a nationwide cohort study in Denmark. *Mult Scler J.* 2008;14(6):823–9.
  32. Mokry LE, Ross S, Ahmad OS, Forgetta V, Smith GD, Leong A, et al. Vitamin D and risk of multiple sclerosis: a Mendelian randomization study. *PLOS Med.* 2015;12(8):e1001866.
  33. Rhead B, Bäärnhielm M, Gianfrancesco M, Mok A, Shao X, Quach H, et al. Mendelian randomization shows a causal effect of low vitamin D on multiple sclerosis risk. *Neurol Genet.* 2016;2(5):e97.
  34. Ascherio A, Munger KL, White R, Köchert K, Simon KC, Polman CH, et al. Vitamin D as an early predictor of multiple sclerosis activity and progression. *JAMA Neurol.* 2014;71(3):306.
  35. Runia TF, Hop WCJ, de Rijke YB, Buljevac D, Hintzen RQ. Lower serum vitamin D levels are associated with a higher relapse risk in multiple sclerosis. *Neurology.* 2012;79(3):261–6.
  36. Kuhle J, Disanto G, Dobson R, Adutori R, Bianchi L, Topping J, et al. Conversion from clinically isolated syndrome to multiple sclerosis: a large multi-centre study. *Mult Scler J.* 2015;21(8):1013–24.
  37. Fitzgerald KC, Munger KL, Köchert K, Arnason BGW, Comi G, Cook S, et al. Association of vitamin D levels with multiple sclerosis activity and progression in patients receiving interferon beta-1b. *JAMA Neurol.* 2015;72(12):1458.
  38. Muris A-H, Smolders J, Rolf L, Klinkenberg LJJ, van der Linden N, Meex S, et al. Vitamin D status does not affect disability progression of patients with multiple sclerosis over three year follow-up. *PLoS One.* 2016;11(6):e0156122.
  39. Smolders J, Hupperts R, Vieth R, Holmøy T, Marhardt K, Schlupe M, Killestein J, Barkhof F, Grimaldi LME, Beelke M. High dose cholecalciferol (vitamin D3) oil as add-on therapy in subjects with relapsing-remitting multiple sclerosis receiving subcutaneous interferon b-1a. *ECTRIMS Online Library Hu M.* 2016;166:147013.

40. Hempel S, Graham GD, Fu N, Estrada E, Chen AY, Miake-Lye I, et al. A systematic review of the effects of modifiable risk factor interventions on the progression of multiple sclerosis. *Mult Scler J*. 2017;23(4):513–24.
41. Kurtzke JF, Hyllested K. Multiple sclerosis in the faroe islands: I. Clinical and epidemiological features. *Ann Neurol*. 1979;5(1):6–21.
42. Gildden DH. Infectious causes of multiple sclerosis. *Lancet Neurol*. 2005;4(3):195–202.
43. Compston A, Coles A. Multiple sclerosis. *Lancet*. 2008;372(9648):1502–17.
44. Giovannoni G, Cutter GR, Lunemann J, Martin R, Münz C, Sriram S, et al. Infectious causes of multiple sclerosis. *Lancet Neurol*. 2006;5(10):887–94.
45. Belbasis L, Bellou V, Evangelou E, Ioannidis JPA, Tzoulaki I. Environmental risk factors and multiple sclerosis: an umbrella review of systematic reviews and meta-analyses. *Lancet Neurol*. 2015;14(3):263–73.
46. Warner HB, Carp RI. Multiple sclerosis and Epstein-Barr virus. *Lancet*. 1981;2(8258):1290.
47. Levin LI, Munger KL, O'Reilly EJ, Falk KI, Ascherio A. Primary infection with the Epstein-Barr virus and risk of multiple sclerosis. *Ann Neurol*. 2010;67(6):824–30.
48. Levin LI, Munger KL, Rubertone MV, Peck CA, Lennette ET, Spiegelman D, et al. Temporal relationship between elevation of Epstein-Barr virus antibody titers and initial onset of neurological symptoms in multiple sclerosis. *JAMA*. 2005;293(20):2496–500.
49. Ascherio A, Munger KL. Environmental risk factors for multiple sclerosis. Part I: the role of infection. *Ann Neurol*. 2007;61(4):288–99.
50. Nielsen TR, Rostgaard K, Nielsen NM, Koch-Henriksen N, Haahr S, Sørensen PS, et al. Multiple sclerosis after infectious mononucleosis. *Arch Neurol*. 2007;64(1):72.
51. Thacker EL, Mirzaei F, Ascherio A. Infectious mononucleosis and risk for multiple sclerosis: a meta-analysis. *Ann Neurol*. 2006;59(3):499–503.
52. Zhou Y, Zhu G, Charlesworth JC, Simpson S, Rubicz R, Göring HH, et al. Genetic loci for Epstein-Barr virus nuclear antigen-1 are associated with risk of multiple sclerosis. *Mult Scler J*. 2016;22(13):1655–64.
53. Harley JB, Chen X, Pujato M, Miller D, Maddox A, Forney C, et al. Transcription factors operate across disease loci, with EBNA2 implicated in autoimmunity. *Nat Genet*. 2018;50:699–707.
54. Serafini B, Rosicarelli B, Franciotta D, Magliozzi R, Reynolds R, Cinque P, et al. Dysregulated Epstein-Barr virus infection in the multiple sclerosis brain. *J Exp Med*. 2007;204(12):2899–912.
55. Magliozzi R, Serafini B, Rosicarelli B, Chiappetta G, Veroni C, Reynolds R, et al. B-cell enrichment and Epstein-Barr virus infection in inflammatory cortical lesions in secondary progressive multiple sclerosis. *J Neuropathol Exp Neurol*. 2013;72(1):29–41.
56. Lassmann H, Niedobitek G, Aloisi F, Middelborg JM, NeuroproMiSe EBV Working Group. Epstein-Barr virus in the multiple sclerosis brain: a controversial issue—report on a focused workshop held in the Centre for Brain Research of the Medical University of Vienna, Austria. *Brain*. 2011;134(Pt 9):2772–86.
57. Hauser SL, Waubant E, Arnold DL, Vollmer T, Antel J, Fox RJ, et al. B-Cell Depletion with Rituximab in Relapsing-Remitting Multiple Sclerosis. *N Engl J Med*. 2008;358(7):676–88.
58. Kappos L, Li D, Calabresi PA, O'Connor P, Bar-Or A, Barkhof F, et al. Ocrelizumab in relapsing-remitting multiple sclerosis: a phase 2, randomised, placebo-controlled, multicentre trial. *Lancet*. 2011;378(9805):1779–87.
59. Holmøy T. Vitamin D status modulates the immune response to Epstein Barr virus: synergistic effect of risk factors in multiple sclerosis. *Med Hypotheses*. 2008;70(1):66–9.
60. Handel AE, Williamson AJ, Disanto G, Dobson R, Giovannoni G, Ramagopalan SV. Smoking and multiple sclerosis: an updated meta-analysis. *PLoS One*. 2011;6(1):e16149.
61. Marrie RA, Cutter G, Tyry T, Campagnolo D, Vollmer T. Smoking status over two years in patients with multiple sclerosis. *Neuroepidemiology*. 2009;32(1):72–9.
62. Ascherio A, Munger KL. Environmental risk factors for multiple sclerosis. Part II: noninfectious factors. *Ann Neurol*. 2007;61(6):504–13.
63. Hedstrom AK, Baarnhielm M, Olsson T, Alfredsson L. Tobacco smoking, but not Swedish snuff use, increases the risk of multiple sclerosis. *Neurology*. 2009;73(9):696–701.
64. Costenbader KH, Karlson EW. Cigarette smoking and autoimmune disease: what can we learn from epidemiology? *Lupus*. 2006;15(11):737–45.
65. Bjørnevik K, Riise E, Bostrom I, Casetta I, Cortese M, Granieri E, et al. Negative interaction between smoking and EBV in the risk of multiple sclerosis: the EnvIMS study. *Mult Scler J*. 2017;23(7):1018–24.
66. Hernán MA, Jick SS, Logroscino G, Olek MJ, Ascherio A, Jick H. Cigarette smoking and the progression of multiple sclerosis. *Brain*. 2005;128(Pt 6):1461–5.
67. Courville CB, Maschmeyer JE, Delay CP. Effects of smoking on the acute exacerbations of multiple sclerosis. *Bull Los Angel Neuro Soc*. 1964;29:1–6.
68. Di Pauli F, Reindl M, Ehling R, Schautzer F, Gneiss C, Lutterotti A, et al. Smoking is a risk factor for early conversion to clinically definite multiple sclerosis. *Mult Scler*. 2008;14(8):1026–30.
69. Munger KL, Fitzgerald KC, Freedman MS, Hartung H-P, Miller DH, Montalbán X, et al. No association of multiple sclerosis activity and progression with EBV or tobacco use in BENEFIT. *Neurology*. 2015;85(19):1694–701.

70. Hedström AK, Olsson T, Alfredsson L. High body mass index before age 20 is associated with increased risk for multiple sclerosis in both men and women. *Mult Scler J*. 2012;18(9):1334–6.
71. Wesnes K, Riise T, Casetta I, Drulovic J, Granieri E, Holmøy T, et al. Body size and the risk of multiple sclerosis in Norway and Italy: the EnvIMS study. *Mult Scler J*. 2015;21(4):388–95.
72. Munger KL, Chitnis T, Ascherio A. Body size and risk of MS in two cohorts of US women. *Neurology*. 2009;73(19):1543–50.
73. Munger KL, Bentzen J, Laursen B, Stenager E, Koch-Henriksen N, Sørensen TI, et al. Childhood body mass index and multiple sclerosis risk: a long-term cohort study. *Mult Scler J*. 2013;19(10):1323–9.
74. Gianfrancesco MA, Acuna B, Shen L, Briggs FBS, Quach H, Bellesis KH, et al. Obesity during childhood and adolescence increases susceptibility to multiple sclerosis after accounting for established genetic and environmental risk factors. *Obes Res Clin Pract*. 2014;8(5):e435–47.
75. Mokry LE, Ross S, Timpson NJ, Sawcer S, Davey Smith G, Richards JB. Obesity and multiple sclerosis: a mendelian randomization study. *PLOS Med*. 2016;13(6):e1002053.
76. Gianfrancesco MA, Glymour MM, Walter S, Rhead B, Shao X, Shen L, et al. Causal effect of genetic variants associated with body mass index on multiple sclerosis susceptibility. *Am J Epidemiol*. 2017;185(3):162–71.
77. Zheng J, Erzurumluoglu AM, Elsworth BL, Kemp JP, Howe L, Haycock PC, et al. LD Hub: a centralized database and web interface to perform LD score regression that maximizes the potential of summary level GWAS data for SNP heritability and genetic correlation analysis. *Bioinformatics*. 2017;33(2):272–9.
78. Olsson T, Barcellos LF, Alfredsson L. Interactions between genetic, lifestyle and environmental risk factors for multiple sclerosis. *Nat Rev Neurol*. 2017;13(1):25–36.
79. Ramagopalan SV, Valdar W, Criscuoli M, DeLuca GC, Dyment DA, Orton S-M, et al. Age of puberty and the risk of multiple sclerosis: a population based study. *Eur J Neurol*. 2009;16(3):342–7.
80. Nielsen NM, Harpsøe M, Simonsen J, Stenager E, Magyari M, Koch-Henriksen N, et al. Age at menarche and risk of multiple sclerosis: a prospective cohort study based on the Danish National Birth Cohort. *Am J Epidemiol*. 2017;185(8):712–9.
81. Confavreux C, Hutchinson M, Hours MM, Cortinouis-Tourniaire P, Moreau T. Rate of pregnancy-related relapse in multiple sclerosis. *N Engl J Med*. 1998;339(5):285–91.
82. Whitacre CC, Reingold SC, O’Looney PA. A gender gap in autoimmunity. *Science*. 1999;283(5406):1277–8.
83. Whitacre CC. Sex differences in autoimmune disease. *Nat Immunol*. 2001;2(9):777–80.
84. Tanzer J. Estrogen effect in multiple sclerosis more nuanced than described. *Ann Neurol*. 2008;63(2):263; Author reply 263.
85. Pozzilli C, De Giglio L, Barletta VT, Marinelli F, Angelis F, De Gallo V, et al. Oral contraceptives combined with interferon  $\beta$  in multiple sclerosis. *Neurol Neuroimmunol Neuroinflamm*. 2015;2(4):e120.
86. Voskuhl RR, Wang H, Wu TCJ, Sicotte NL, Nakamura K, Kurth F, et al. Estriol combined with glatiramer acetate for women with relapsing-remitting multiple sclerosis: a randomised, placebo-controlled, phase 2 trial. *Lancet Neurol*. 2016;15(1):35–46.
87. Alonso A, Clark CJ. Oral contraceptives and the risk of multiple sclerosis: a review of the epidemiologic evidence. *J Neurol Sci*. 2009;286(1–2):73–5.
88. Cortese M, Riise T, Bjørnevik K, Myhr K-M, Multiple Sclerosis Conscript Service Database Study Group. Body size and physical exercise, and the risk of multiple sclerosis. *Mult Scler J*. 2018;24(3):270–8.
89. Compston A, Coles A. Multiple sclerosis. *Lancet*. 2002;359(9313):1221–31.
90. Westerlind H, Ramanujam R, Uvehag D, Kuja-Halkola R, Boman M, Bottai M, et al. Modest familial risks for multiple sclerosis: a registry-based study of the population of Sweden. *Brain*. 2014;137(3):770–8.
91. O’Gorman C, Lin R, Stankovich J, Broadley SA. Modelling genetic susceptibility to multiple sclerosis with family data. *Neuroepidemiology*. 2013;40(1):1–12.
92. IMISGC, Patsopoulos N, Baranzini SE, Santaniello A, Shoostari P, Cotsapas C, et al. The multiple sclerosis genomic map: role of peripheral immune cells and resident microglia in susceptibility. *bioRxiv*. 2017:143933. <https://doi.org/10.1101/143933>.
93. IMISGC, Mitrovic M, Patsopoulos N, Beecham A, Dankowski T, Goris A, et al. Low frequency and rare coding variation contributes to multiple sclerosis risk. *Cell*. 2018;175(6):1679–1687.e7.
94. Sawcer S, Franklin RJM, Ban M. Multiple sclerosis genetics. *Lancet Neurol*. 2014;13(7):700–9.
95. Sawcer S, Ban M, Maranian M, Yeo TW, Compston A, Kirby A, et al. A high-density screen for linkage in multiple sclerosis. *Am J Hum Genet*. 2005;77(3):454–67.
96. Bertrams J, Kuwert E. HL-A antigen frequencies in multiple sclerosis. *Eur Neurol*. 1972;7(1–2):74–8.
97. Naito S, Namerow N, Mickey MR, Terasaki PI. Multiple sclerosis: association with HL-A3. *Tissue Antigens*. 1972;2(1):1–4.
98. Hollenbach JA, Oksenberg JR. The immunogenetics of multiple sclerosis: a comprehensive review. *J Autoimmun*. 2015;64:13–25.
99. Moutsianas L, Jostins L, Beecham AH, Dilthey AT, Xifara DK, Ban M, et al. Class II HLA interactions modulate genetic risk for multiple sclerosis. *Nat Genet*. 2015;47(10):1107–13.

100. International Multiple Sclerosis Genetics Consortium S, Wellcome Trust Case Control Consortium 2 G, Sawcer S, Hellenthal G, Pirinen M, Spencer CCA, et al. Genetic risk and a primary role for cell-mediated immune mechanisms in multiple sclerosis. *Nature*. 2011;476(7359):214–9.
101. Patsopoulos NA, Barcellos LF, Hintzen RQ, Schaefer C, van Duijn CM, Noble JA, et al. Fine-mapping the genetic association of the major histocompatibility complex in multiple sclerosis: HLA and non-HLA effects. *PLoS Genet*. 2013;9(11):e1003926.
102. Lincoln MR, Ramagopalan SV, Chao MJ, Herrera BM, Deluca GC, Orton S-M, et al. Epistasis among HLA-DRB1, HLA-DQA1, and HLA-DQB1 loci determines multiple sclerosis susceptibility. *Proc Natl Acad Sci U S A*. 2009;106(18):7542–7.
103. Risch N, Merikangas K. The future of genetic studies of complex human diseases. *Science*. 1996;273(5281):1516–7.
104. International Multiple Sclerosis Genetics Consortium, Hafler DA, Compston A, Sawcer S, Lander ES, Daly MJ, et al. Risk alleles for multiple sclerosis identified by a genomewide study. *N Engl J Med*. 2007;357(9):851–62.
105. Bielekova B, Richert N, Howard T, Blevins G, Markovic-Plese S, McCartin J, et al. Humanized anti-CD25 (daclizumab) inhibits disease activity in multiple sclerosis patients failing to respond to interferon. *Proc Natl Acad Sci*. 2004;101(23):8705–8.
106. Maier LM, Anderson DE, Severson CA, Baecher-Allan C, Healy B, Liu DV, et al. Soluble IL-2RA levels in multiple sclerosis subjects and the effect of soluble IL-2RA on immune responses. *J Immunol*. 2009;182(3):1541–7.
107. De Jager PL, Jia X, Wang J, de Bakker PIW, Ottoboni L, Aggarwal NT, et al. Meta-analysis of genome scans and replication identify CD6, IRF8 and TNFRSF1A as new multiple sclerosis susceptibility loci. *Nat Genet*. 2009;41(7):776–82.
108. Patsopoulos NA, de Bakker PIW, Steering Committees of Studies Evaluating IFN $\beta$ -1b and a CCR1-Antagonist, ANZgene Consortium, GeneMSA, International Multiple Sclerosis Genetics Consortium, et al. Genome-wide meta-analysis identifies novel multiple sclerosis susceptibility loci. *Ann Neurol*. 2011;70(6):897–912.
109. Cortes A, Brown MA. Promise and pitfalls of the Immunochip. *Arthritis Res Ther*. 2011;13(1):101.
110. Beecham AH, Patsopoulos NA, Xifara DK, Davis MF, Kempainen A, Cotsapas C, et al. Analysis of immune-related loci identifies 48 new susceptibility variants for multiple sclerosis. *Nat Genet*. 2013;45(11):1353–60.
111. Galarza-Muñoz G, Briggs FBS, Evsyukova I, Schott-Lerner G, Kennedy EM, Nyanhete T, et al. Human epistatic interaction controls IL7R splicing and increases multiple sclerosis risk. *Cell*. 2017;169(1):72–84.e13.
112. ENCODE Project Consortium. An integrated encyclopedia of DNA elements in the human genome. *Nature*. 2012;489(7414):57–74.
113. GTEx Consortium KG, Deluca DS, Segre AV, Sullivan TJ, Young TR, Gelfand ET, et al. Human genomics. The Genotype-Tissue Expression (GTEx) pilot analysis: multitissue gene regulation in humans. *Science*. 2015;348(6235):648–60.
114. Roadmap Epigenomics Consortium A, Kundaje A, Meuleman W, Ernst J, Bilenky M, Yen A, et al. Integrative analysis of 111 reference human epigenomes. *Nature*. 2015;518(7539):317–30.
115. Maurano MT, Humbert R, Rynes E, Thurman RE, Haugen E, Wang H, et al. Systematic localization of common disease-associated variation in regulatory DNA. *Science*. 2012;337(6099):1190–5.
116. Gregory SG, Schmidt S, Seth P, Oksenberg JR, Hart J, Prokop A, et al. Interleukin 7 receptor  $\alpha$  chain (IL7R) shows allelic and functional association with multiple sclerosis. *Nat Genet*. 2007;39(9):1083–91.
117. Gregory AP, Dendrou CA, Attfield KE, Haghikia A, Xifara DK, Butter F, et al. TNF receptor 1 genetic risk mirrors outcome of anti-TNF therapy in multiple sclerosis. *Nature*. 2012;488(7412):508–11.
118. Couturier N, Bucciarelli F, Nurtdinov RN, Debouverie M, Lebrun-Frenay C, Defer G, et al. Tyrosine kinase 2 variant influences T lymphocyte polarization and multiple sclerosis susceptibility. *Brain*. 2011;134(Pt 3):693–703.
119. Broadley SA, Deans J, Sawcer SJ, Clayton D, Compston DA. Autoimmune disease in first-degree relatives of patients with multiple sclerosis. A UK survey. *Brain*. 2000;123(Pt 6):1102–11.
120. Anttila V, Bulik-Sullivan B, Finucane H, Walters R, Bras J, Duncan L, et al. Analysis of shared heritability in common disorders of the brain. *Science*. 2018;360(6395):pii: eaap8757.
121. Goris A, van Setten J, Diekstra F, Ripke S, Patsopoulos NA, Sawcer SJ, et al. No evidence for shared genetic basis of common variants in multiple sclerosis and amyotrophic lateral sclerosis. *Hum Mol Genet*. 2014;23(7):1916–22.
122. Fortune MD, Guo H, Burren O, Schofield E, Walker NM, Ban M, et al. Statistical colocalization of genetic risk variants for related autoimmune diseases in the context of common controls. *Nat Genet*. 2015;47(7):839–46.
123. Cotsapas C, Voight BF, Rossin E, Lage K, Neale BM, Wallace C, et al. Pervasive sharing of genetic effects in autoimmune disease. *PLoS Genet*. 2011;7(8):e1002254.
124. Todd JA, Walker NM, Cooper JD, Smyth DJ, Downes K, Plagnol V, et al. Robust associations of four new chromosome regions from genome-wide analyses of type 1 diabetes. *Nat Genet*. 2007;39(7):857–64.
125. Hafler JP, Maier LM, Cooper JD, Plagnol V, Hinks A, Simmonds MJ, et al. CD226 Gly307Ser association with multiple autoimmune diseases. *Genes Immun*. 2009;10(1):5–10.
126. Ji S-G, Juran BD, Mucha S, Folseraas T, Jostins L, Melum E, et al. Genome-wide association study of primary sclerosing cholangitis identifies new risk loci and quantifies the genetic relationship with inflammatory bowel disease. *Nat Genet*. 2017;49(2):269–73.

127. Dendrou CA, Petersen J, Rossjohn J, Fugger L. HLA variation and disease. *Nat Rev Immunol.* 2018;18(5):325–39.
128. Maier LM, Lowe CE, Cooper J, Downes K, Anderson DE, Severson C, et al. IL2RA genetic heterogeneity in multiple sclerosis and type 1 diabetes susceptibility and soluble interleukin-2 receptor production. *PLoS Genet.* 2009;5(1):e1000322.
129. Hensiek AE, Seaman SR, Barcellos LF, Oturai A, Eraksoi M, Cocco E, et al. Familial effects on the clinical course of multiple sclerosis. *Neurology.* 2007;68(5):376–83.
130. Oturai AB, Ryder LP, Fredrikson S, Myhr K-M, Celius EG, Harbo HF, et al. Concordance for disease course and age of onset in Scandinavian multiple sclerosis coaffected sib pairs. *Mult Scler.* 2004;10(1):5–8.
131. George MF, Briggs FBS, Shao X, Gianfrancesco MA, Kockum I, Harbo HF, et al. Multiple sclerosis risk loci and disease severity in 7,125 individuals from 10 studies. *Neurol Genet.* 2016;2(4):e87.
132. Jensen CJ, Stankovich J, Van der Walt A, Bahlo M, Taylor BV, van der Mei IAF, et al. Multiple sclerosis susceptibility-associated SNPs do not influence disease severity measures in a cohort of Australian MS patients. *PLoS One.* 2010;5(4):e10003.
133. Jokubaitis VG, Butzkueven H. A genetic basis for multiple sclerosis severity: red herring or real? *Mol Cell Probes.* 2016;30(6):357–65.
134. Baranzini SE, Wang J, Gibson RA, Galwey N, Naegelin Y, Barkhof F, et al. Genome-wide association analysis of susceptibility and clinical phenotype in multiple sclerosis. *Hum Mol Genet.* 2009;18(4):767–78.
135. International Multiple Sclerosis Genetics Consortium. Genome-wide association study of severity in multiple sclerosis. *Genes Immun.* 2011;12(8):615–25.
136. Brynedal B, Wojcik J, Esposito F, Debailleul V, Yaouanq J, Martinelli-Boneschi F, et al. MGAT5 alters the severity of multiple sclerosis. *J Neuroimmunol.* 2010;220(1–2):120–4.
137. Giacalone G, Clarelli F, Osiceanu A, Guaschino C, Brambilla P, Sorosina M, et al. Analysis of genes, pathways and networks involved in disease severity and age at onset in primary-progressive multiple sclerosis. *Mult Scler J.* 2015;21(11):1431–42.
138. Goris A, Pauwels I, Gustavsen MW, van Son B, Hilven K, Bos SD, et al. Genetic variants are major determinants of CSF antibody levels in multiple sclerosis. *Brain.* 2015;138(3):632–43.
139. Healy BC, Liguori M, Tran D, Chitnis T, Glanz B, Wolfish C, et al. HLA B\*44: protective effects in MS susceptibility and MRI outcome measures. *Neurology.* 2010;75(7):634–40.
140. Gourraud P-A, Sdika M, Khankhanian P, Henry RG, Beheshtian A, Matthews PM, et al. A genome-wide association study of brain lesion distribution in multiple sclerosis. *Brain.* 2013;136(4):1012–24.
141. Matsushita T, Madireddy L, Sprenger T, Khankhanian P, Magon S, Naegelin Y, et al. Genetic associations with brain cortical thickness in multiple sclerosis. *Genes Brain Behav.* 2015;14(2):217–27.
142. Baranzini SE, Srinivasan R, Khankhanian P, Okuda DT, Nelson SJ, Matthews PM, et al. Genetic variation influences glutamate concentrations in brains of patients with multiple sclerosis. *Brain.* 2010;133(9):2603–11.
143. Coyle PK. Pharmacogenetic Biomarkers to Predict Treatment Response in Multiple Sclerosis: Current and Future Perspectives. *Mult Scler Int.* 2017;2017:6198530.
144. Esposito F, Sorosina M, Ottoboni L, Lim ET, Replogle JM, Raj T, et al. A pharmacogenetic study implicates SLC9a9 in multiple sclerosis disease activity. *Ann Neurol.* 2015;78(1):115–27.
145. Buck D, Andlauer TF, Igl W, Wicklein E-M, Mühlau M, Weber F, et al. Effect of *HLA-DRB1* alleles and genetic variants on the development of neutralizing antibodies to interferon beta in the BEYOND and BENEFIT trials. *Mult Scler J.* 2019;25(4):565–73.
146. Weber F, Cepok S, Wolf C, Berthele A, Uhr M, Bettecken T, et al. Single-nucleotide polymorphisms in HLA- and non-HLA genes associated with the development of antibodies to interferon- $\beta$  therapy in multiple sclerosis patients. *Pharmacogenomics J.* 2012;12(3):238–45.
147. Nielsen T, Rostgaard K, Askling J, Steffensen R, Oturai A, Jersild C, et al. Effects of infectious mononucleosis and HLA-DRB1\*15 in multiple sclerosis. *Mult Scler J.* 2009;15(4):431–6.
148. Sundqvist E, Sundström P, Lindén M, Hedström AK, Aloisi F, Hillert J, et al. Epstein-Barr virus and multiple sclerosis: interaction with HLA. *Genes Immun.* 2012;13(1):14–20.
149. De Jager PL, Simon KC, Munger KL, Rioux JD, Hafler DA, Ascherio A. Integrating risk factors: HLA-DRB1\*1501 and Epstein-Barr virus in multiple sclerosis. *Neurology.* 2008;70(13, Part 2):1113–8.
150. Hedström AK, Katsoulis M, Hössjer O, Bomfim IL, Oturai A, Sondergaard HB, et al. The interaction between smoking and HLA genes in multiple sclerosis: replication and refinement. *Eur J Epidemiol.* 2017;32(10):909–19.
151. Briggs FBS, Acuna B, Shen L, Ramsay P, Quach H, Bernstein A, et al. Smoking and risk of multiple sclerosis. *Epidemiology.* 2014;25(4):605–14.
152. De Jager PL, Chibnik LB, Cui J, Reischl J, Lehr S, Simon KC, et al. Integration of genetic risk factors into a clinical algorithm for multiple sclerosis susceptibility: a weighted genetic risk score. *Lancet Neurol.* 2009;8(12):1111–9.
153. Xia Z, White CC, Owen EK, Von Korff A, Clarkson SR, McCabe CA, et al. Genes and environment in multiple sclerosis project: a platform to investigate multiple sclerosis risk. *Ann Neurol.* 2016;79(2):178–89.
154. Xia Z, Steele SU, Bakshi A, Clarkson SR, White CC, Schindler MK, et al. Assessment of early evidence of multiple sclerosis in a prospective study of asymptomatic high-risk family members. *JAMA Neurol.* 2017;74(3):293–300.



# Clinical Features, Symptom Management, and Diagnosis

# 5

Jacqueline F. Rosenthal, James M. Stankiewicz,  
and Guy J. Buckle

## Introduction

Given its potential for diffuse dissemination throughout virtually every portion of the central nervous system (optic nerves, brain, and spinal cord), it is perhaps not surprising that a broad array of symptoms may be reported by patients with Multiple Sclerosis (MS). Nonetheless, the majority of patients with MS will at some point present with a stereotyped constellation of symptoms and signs constituting a first clinical “attack” of demyelination, often referred to as a Clinically Isolated Syndrome (CIS). CIS typically comprises unilateral optic neuritis, partial transverse myelitis, or a brainstem-cerebellar syndrome (see below). The majority of patients presenting with CIS will also have characteristic lesions on brain MRI not accounting for their clinical presentation and indicative of prior asymptomatic episodes of inflammatory demyelination. These patients

should be managed based on their risk of having a second attack and thus converting to Relapsing-Remitting MS (RRMS), also termed Clinically Definite MS (CDMS). Longitudinal studies suggest the rate of conversion to CDMS is 60–80% when characteristic demyelinating lesions are present on the baseline brain MRI and approximately 20% when baseline brain MRI is normal [1]. These findings underscore the prognostic value of MRI early in the course of MS. Using modern imaging criteria, it is now also possible to make a diagnosis of MS prior to a second clinical attack by demonstrating the presence of coexisting active and inactive asymptomatic lesions (i.e., dissemination in space and time) on a MRI single MRI scan, and most disease modifying therapies (DMTs) are utilized in both RRMS and CIS with characteristic abnormal MRI findings. In this chapter, we will discuss the signs and symptoms experienced by MS patients as well as the diagnosis and differential diagnosis of MS.

---

J. F. Rosenthal  
Shepherd Center, Multiple Sclerosis Institute, Atlanta,  
GA, USA  
e-mail: [jacqueline.rosenthal@shepherd.org](mailto:jacqueline.rosenthal@shepherd.org)

J. M. Stankiewicz  
Partners Multiple Sclerosis Center, Harvard Medical  
School, Boston, MA, USA  
e-mail: [jstankiewicz@bwh.harvard.edu](mailto:jstankiewicz@bwh.harvard.edu)

G. J. Buckle (✉)  
Shepherd Center, Multiple Sclerosis Institute,  
Atlanta, GA, USA  
e-mail: [Guy.buckle@shepherd.org](mailto:Guy.buckle@shepherd.org)

## Signs and Symptoms

No single symptom or sign is pathognomonic for MS, although in younger age groups, the typical symptoms and signs of CIS should always prompt an investigation into demyelinating disease. These include: (1) optic neuritis, typically subacute monocular central visual loss with pain on eye movement, red desaturation, and relative afferent pupillary defect (RAPD); (2) partial transverse



myelitis, typically unilateral or bilateral subacute ascending sensory disturbances and paresthesias, often with L'hermitte phenomenon, and with posterior column sensory loss and varying degrees of paraparesis, hyperreflexia, and autonomic disturbances; or (3) brainstem-cerebellar syndromes, typically combinations of diplopia, dysarthria, weakness, and incoordination, often with unilateral or bilateral internuclear ophthalmoparesis (INO) and varying degrees of ataxic hemiparesis.

Conversely, some symptoms (e.g., fatigue, overactive bladder), while nonspecific, occur with such frequency in MS that their conspicuous absence may warn the practitioner that other diagnoses should at least be more carefully considered. There is as yet no specific biomarker for MS (MRI comes closest), and diagnosis is ultimately based on clinical presentation and elimination of other possible etiologies/explanations (MS mimickers). In practice however, MS is relatively common in the young adult population, alternative etiologies for the typical CIS presentations are comparatively rare, especially when they are accompanied by MRI findings typical for demyelination, and the majority of CIS cases will evolve into CDMS over time.

---

## Cranial Nerves

Though any cranial nerve can be involved in MS, certain characteristic syndromes are *so common in MS that they should always prompt a workup for demyelinating disease*.

## Optic Neuritis

Optic nerve involvement typically presents as a subacute but often rapidly progressive loss of visual acuity, as well as pain on eye movement and color (especially red) desaturation. Nadir is generally reached within hours or days, not minutes or weeks. Pain with eye movement occurred in 92% of patients in the optic neuritis treatment trial and is thought to result from stretching of the dural sheath around an inflamed optic nerve [2]. Acutely, fundoscopic examination is normal in

2/3 of cases. A relative afferent pupillary defect (RAPD) can often be detected in the acute or subacute setting with the (Marcus-Gunn) swinging flashlight test and is estimated to be present chronically in 50% of MS patients that have experienced an episode of optic neuritis [3]. Almost all patients in the ONTT had improvement in visual acuity in one month, and at 15-year follow-up 72% of patients had at least 20/20 vision in the affected eye, though even patients improving to 20/20 acuity noted blurred or "washed out" vision [4, 5]. Visual Evoked Potentials (VEPs) classically show an increased P100 latency in the affected eye with preserved waveform, though amplitude can be slightly diminished. Optical coherence tomography (OCT) is also often used to assess for evidence of RNFL thinning as a marker of prior optic neuritis; however, it can take up to 6 months for these abnormalities to become evident [6]. Central scotomata are common, and peripheral visual loss occurs far less frequently. Uhthoff's phenomenon classically denotes enlargement of a central scotoma or "blind spot" with exercise, although the term has been generalized to denote the return of nearly any prior MS symptom upon even a mild elevation of core body temperature.

## Eye Movement Abnormalities

Complex cerebral, cerebellar, and brainstem circuitry mediates coordination of eye movements through some of the most heavily myelinated and rapidly conducting tracts of the CNS. The most common finding in MS is breakdown of smooth pursuit movements, which is frequently found in the absence of any overt symptoms. This is believed to be due to damage to cerebellar and descending supranuclear fibers and may implicate a second site of involvement of the CNS in patients presenting with an attack not involving these connections clinically. Up-beating vertical nystagmus is uncommon but often attributable to a lesion of the rostral interstitial medial longitudinal fasciculus (riMLF). Down-beating vertical nystagmus classically localizes to the cervicomedullary junction and can be caused by MS, but it can also occur with a Chiari malformation or paraneoplastic cerebellar

degeneration, two conditions that may occasionally mimic MS. Internuclear ophthalmoplegia (INO) results from damage to the medial longitudinal fasciculus (MLF), located in the dorsal pons/midbrain, which leads to poor integration between the oculomotor and abducens cranial nerve nuclei and consequent failure of binocular fusion. This is classically manifested as diplopia, although blurring, jumping, or shadowing of images may be described. Though classically the affected side experiences an inability to adduct past the midline, with nystagmus in the contralateral abducting eye, in practice it is more common to observe slowed adduction rather than paralysis, and in its mildest form (*forme fruste*) only a subtle nystagmus of the abducting eye may be present. Convergence is preserved, indicating intact third nerve nuclei rostrally. In a survey of 100 patients, Muri and Meienberg [7] reported a unilateral INO in 20 patients, bilateral in 14. Bilateral INO is nearly pathognomonic for MS, and long-standing cases may develop “wall-eyed,” bilateral INO (WEBINO) secondary to complete failure of adduction and resulting bilateral exotropia. Complete gaze palsy on one side and an INO on gaze to the opposite side constitutes the “one-and-a-half” syndrome, resulting from a lesion that damages either the paramedian pontine reticular formation (PPRF) or abducens nucleus (or both), together with the MLF on the same side. Individual palsies of cranial nerves III, IV, and VI are relatively uncommon. Other rarer eye movement abnormalities have been described.

### Other Cranial Nerves

The olfactory nerve may be involved in up to 40% of patients [8] but is infrequently tested. Trigeminal involvement is common, and, when it occurs, generally involves the second and/or third divisions and is often painful, i.e., trigeminal neuralgia (TGN). When facial palsy occurs it is usually subtle; and upper versus lower motor neuron involvement can be difficult to distinguish at the bedside in the absence of other brainstem or cerebellar findings. A “lower motor neuron” CN VII palsy can occasionally be seen from a CNS lesion involving the nerve root exit zone,

although more commonly, frontalis and orbicularis oculi muscles are spared in MS. Often isolated cranial nerve palsies are not always reflected on MRI and may be more sensitively identified with electrophysiological testing [9] although in practice this is rarely done, and clinical examination remains the most relevant and practical means of evaluation.

The vestibular-cochlear system is often involved in MS, and subtle forms of vertigo are frequent complaints. Patients often have concomitant spasticity and posterior column loss and frequently complain of difficulty with balance, station, and gait. They may describe a sensation of being suddenly “pushed” or “shoved,” as if by an unseen force, and have particular difficulty on descending stairs. Lesions of the brainstem and cerebellum can cause patients to become frankly vertiginous, even to the point of nausea and vomiting acutely, but benign positional vertigo can of course affect MS patients as well [10]. Though usually a low grade and frequently persistent symptom, vertigo can sometimes be intermittent and intense, simulating a labyrinthitis. Hearing loss can be an MS-related symptom, though it rarely occurs in isolation. Demyelinating lesions responsible for hearing loss are typically unilateral and also frequently cause vertigo and tinnitus on the affected side. Isolated retrocochlear hearing loss seen in an MS-like presentation with monocular visual loss and nonspecific T2 signal abnormalities on brain MRI should arouse suspicion for Susac syndrome. Spastic dysarthria occurs in patients with prominent motor involvement while “scanning speech” occurs classically with cerebellar dysfunction. Isolated tongue or palatal weakness is an uncommon manifestation, and severe difficulty swallowing is typically due to a failure of coordination of motor control and is generally seen as an end-stage complication in the otherwise severely disabled patient.

### Weakness, Hyperreflexia, Spasticity

Weakness is extremely common in MS and generally results from involvement of the spinal cord or brainstem, although capsular and even hemispheric syndromes occur on occasion, especially with “tumefactive” presentations. Weakness and

spasticity often increase over time, especially in progressive forms of MS, and tend to parallel the degree of spinal cord involvement. Isolated limb weakness is comparatively rare but can occur in presentations of primary progressive MS. Atrophy can occur as a result of deconditioning, but is not a common finding in early MS. Fasciculations in the setting of progressive motor weakness should of course always prompt a workup for motor neuron disease.

Brisk reflexes alone are not clearly pathologic and can be seen in young adults and anxious patients. Clinical experience suggests that evidence of reflex spread, sustained clonus, or upgoing toes relates better to evidence of CNS damage. The degree of hyperreflexia seen in MS is often severe and frequently parallels that seen in other forms of spinal cord injury. Absence of lower extremity reflexes in the setting of upgoing toes, progressive weakness, sensory loss and other signs of myelopathy should prompt consideration of subacute combined degeneration of the spinal cord from vitamin B12 deficiency, hereditary ataxias, and a variety of other conditions that may mimic progressive forms of MS (see Table 5.4).

Symptomatic spasticity was reported in 53% of the patients registered in the North American Research Committee on MS [11]. Patients frequently complain of pain, stiffness, and incoordination in the lower extremities on first rising in the morning or after prolonged periods of inactivity, such as long car rides or airplane flights. Symptoms of spasticity improve with stretching, exercise, or ambulation, in contrast to weakness, which typically worsens with prolonged ambulation, although frequently the two occur together as a consequence of spinal cord involvement. Clinically, spasticity tends to increase in cold weather or environments, whereas weakness in MS tends to increase with any factor that raises body temperature, and this distinction may be helpful in directing symptom management. Spasticity can impair gait and lead to increased disability early on, while treatment of spasticity may unmask muscle weakness in more disabled patients, because involuntary spastic muscle contraction of the quadriceps can compensate for decreased strength in the lower extremities and is

often relied upon for short-distance ambulation and transfers, especially in secondary progressive patients. Spasticity is the functional consequence of damage to the corticospinal, vestibulospinal, or reticulospinal tracts and frequently coexists with autonomic dysfunction of the bladder. Bladder and bowel abnormalities, such as urinary tract infections and constipation, can increase weakness and/or spasticity, even in the absence of detectable fever, by poorly understood mechanisms. Medication options for treatment of spasticity include “muscle relaxants” such as baclofen and tizanidine, which have comparable efficacy, but differ in their side-effect profiles. Baclofen stimulates gamma-aminobutyric acid (GABA) receptors and can cause lightheadedness, dry mouth, and drowsiness. Abrupt withdrawal of baclofen at high doses can precipitate seizures. Tizanidine is an adrenergic receptor agonist. It tends to be more sedating than Baclofen and can also precipitate hypotension, dry mouth, constipation, and asthenia. Benzodiazepines such as diazepam and clonazepam work well for spasticity but are sedating and have potential for dependence and withdrawal phenomena. Dantrolene sodium can be used in refractory cases but can cause acute liver toxicity, and liver function needs to be followed closely on this agent. Injectable botulinum toxin also can help treat MS-related spasticity, especially in small muscles of the upper extremity. Larger doses required for the quadriceps and other large lower extremity muscles frequently lead to neutralizing antibody formation. Intrathecal baclofen (ITB) pump implantation, once considered a “last resort” for wheelchair-bound patients with painful lower extremity spasticity, is now relatively commonplace and is increasingly initiated in ambulatory patients with moderate to severe painful lower extremity spasticity that are unable to tolerate the side effects of the oral medications.

### **Incoordination and Tremor**

Approximately 45% of MS patients complain of tremor [11, 12], and in some cases this may be the most disabling feature of their disease. The upper extremity is most frequently involved with postural and intention (“target-seeking”) tremors

being most common [13]. Resting tremor is comparatively rare, although titubation and truncal instability are relatively common in severely disabled patients. Speech can be ataxic with dysarthria and/or a scanning quality. Many MS patients with advanced disease walk with a wide-based gait, and often there is an ataxic component to their disability in combination with spasticity and posterior column sensory loss. Imbalance with feet together and eyes open suggests potential cerebellar involvement, in contrast to Romberg's test, which classically invokes posterior column sensory loss. MS-related tremor can be notoriously difficult to treat. Small controlled trials suggest that some therapeutic benefit might be achieved with propranolol, ethanol, isoniazid, carbamazepine, ondansetron, or dolasetron [13]. Mirtazapine, primidone, diazepam, and clonazepam are sometimes helpful but are all sedating. Severe cases are sometimes treated by implantation of a deep brain stimulator into the ventral intermediate nucleus of the thalamus; however, convincing evidence of a sustained benefit is lacking and the level of improvement is variable [14].

### Sensory Loss

Patients with MS frequently have involvement of the posterior columns, and sensory complaints are common. Impairment of vibratory sensation, often with preservation of pain and temperature sensation, in the lower extremities is especially common, even in the absence of sensory complaints or other motor or sensory findings, and should always be tested in cases of suspected MS. Proprioceptive loss occurs later and is generally seen with concomitant weakness. Spinothalamic tract involvement is less common, and pain and temperature loss may be relative rather than absolute, so that patients report a dulling of pinprick rather than an absence. Patients with acute spinal cord attacks can exhibit a clear sensory level to pain and temperature, though the posterior columns are typically also involved, and a true Brown-Sequard syndrome is rare. Paresthesias are common in MS and often persist after relapses with sensory disturbance. A concomitant neuropathy or radiculopathy can make

the examination more challenging, although preservation or exaggeration of ankle jerks and positive Babinski responses in the setting of decreased distal sensation to all modalities may be the telltale sign of combined central and peripheral nerve dysfunction.

### Ambulatory Difficulties

Gait abnormalities and slowed walking are common in MS. Multiple factors can impinge on an MS patient's ability to walk, including cerebellar or vestibular dysfunction, weakness, spasticity, and sensory loss. Walking time also tends to slow as the disease progresses. Dalfampridine has been approved by the FDA based on trials documenting improvement in walking in about a third of patients [15, 16]. It is a sustained-release preparation of 4-amino-pyridine (4-AP), available for decades as a compounded medication, which blocks potassium channels, serving to speed conduction along damaged demyelinated axons. It is suggested that through its mechanism of action dalfampridine may have other beneficial effects in MS, to include improvements in arm function, fatigue, mood, and quality of life [17, 18]. Compounded 4AP was associated with increased risk of seizure, though in trials seizure was no more frequently reported in the dalfampridine group than placebo. It is important, however, to highlight that patients with prior seizures were excluded from the trials, and a preexisting seizure disorder is considered a contraindication to its use. Side-effect profile otherwise was benign.

---

## Subjective or "Invisible" Symptoms of MS

### Fatigue

Point estimates indicate that fatigue is present in over 75% of MS patients [19] and is commonly present even in those with low T2 lesion load on brain MRI and little motor impairment or other disability. Many patients will complain of episodes of severe fatigue unrelated to effort. Though many affected patients typically awake reasonably well rested, they describe, "hitting a

wall” in the early afternoon, suggesting an effect related to MS itself rather than poor quality of sleep. Primary MS fatigue is also typically exacerbated in heat. Fatigue is frequently seen in otherwise normal-appearing, nondisabled patients with MS, but the possibility of secondary etiologies such as depression, metabolic abnormalities (e.g., anemia or hypothyroidism), sleep apnea, or medication-related side effects should also be considered in patients with this frequent complaint. The underlying explanation for MS-related fatigue has yet to be determined.

Pharmacologic intervention for fatigue includes amantadine, modafinil or armodafinil, and amphetamines. Extensive clinical experience confirms that modafinil is effective, well tolerated, nonhabit-forming, and works well in most patients, although placebo-controlled trials differ in terms of efficacy results [20, 21]. Support for the use of amantadine is largely anecdotal, although it is generally safe and may provide benefit in some patients for largely unknown reasons. Amphetamines are effective but are generally considered a last resort secondary to their potential for long-term dependence, addiction, and withdrawal.

## Depression

Lifetime prevalence rates of depression in MS range from 25% to 50% [22]. A study comparing patients with MS to patients who had similar levels of disability resulting from peripheral nervous system disorders found that depression was more common in the MS group, suggesting that depression in MS is likely related to the direct pathophysiologic effects of the disease on the brain [23]. Compared with nondepressed MS patients, patients with major depression had a greater T2-weighted lesion volume and less gray matter volume [24]. Interferon treatment in the past has been implicated as having the potential to exacerbate underlying depression; however, more recent studies suggest it is unlikely to increase risk of depression [25–27].

Standard antidepressant medications are generally effective in MS, although use of selective serotonin reuptake inhibitors (SSRIs) may be

limited by sexual side effects, especially in patients with spinal cord involvement. Tricyclic antidepressants can be limited by anti-cholinergic side effects at high doses, although low doses at bedtime often help with chronic pain, overactive bladder, and sleep disturbances in addition to mood. Many practitioners prefer atypical agents such as bupropion as first line, because of its relative lack of sedative and sexual side effects, although increased seizure risk should be kept in mind, especially in patients on interferons, which may also reduce seizure threshold.

## Cognitive Dysfunction

The prevalence of cognitive impairment ranges from 43% to 70% in individuals with MS [28]. Information processing speed, working memory, and episodic memory are most commonly affected [29, 30]. Language abilities are sometimes affected in terms of word-finding difficulties, but aphasia, apraxia, visuospatial deficits, and other cortical syndromes are relatively rare. Studies have demonstrated that patients early in the disease course, who may not manifest significant physical disability, still exhibit cognitive impairment [31]. Patients with cognitive difficulty can have social functional impairment and are more likely to be disabled or unemployed [32]. Fatigue and depression are common intercurrent morbidities in MS, and, although quality of life frequently suffers, overt dementia is rare [33]. Patients with greater MRI disease burden tend to have more cognitive impairment, as do patients with brain volume loss, especially gray matter atrophy [34, 35]. It remains unclear if reducing relapse rates and MRI lesion accumulation has a definite effect on progression of cognitive dysfunction. Cholinesterase inhibitors (i.e., donepezil, rivastigmine) have been studied with no consistent benefit shown in MS patients [36, 37].

## Pain

Though a survey found that the percentage of MS patients reporting pain (80%) was not substan-

tively different than a normal population (75%), MS patients experience pain of greater intensity, more frequently require medication for pain relief, and suffer greater impairment of quality of life from pain [38]. Several pain syndromes are highly suggestive of demyelinating disease, especially in younger age groups and when accompanied by focal neurologic signs and symptoms. Perhaps the most common pain phenomenon in MS is Lhermitte's sign, a sudden, brief and reproducible sensation of tingling, vibration or electrical shock-like sensations that spread down the spine, into the extremities, or throughout the body on flexion of the neck, generally indicative of posterior column involvement in the cervical spine. Two prospective studies estimate prevalence of Lhermitte's sign at nearly 40% patients [39, 40], while estimates of incidence range are lower (9–13%) [39, 41]. Although a strong association between Lhermitte's sign and intramedullary cervical spinal cord abnormalities on MRI has been demonstrated [42], it is not specific to demyelinating disease, and other conditions such as subacute combined degeneration of the cord, neck trauma, radiation myelitis, or herniated cervical disc can cause it. Another common pain syndrome seen in MS is trigeminal neuralgia (TGN). It typically manifests as a unilateral intermittent lancinating pain in the second or third division of the trigeminal nerve felt in the cheek, teeth, or gums. Pain can be quite severe and is frequently precipitated by "triggers" such as brushing the teeth or hot or cold beverages. TGN in MS is treated similarly to that in the general population. First-line agents include anticonvulsants such as carbamazepine and oxcarbazepine. Surgical therapies are reserved for refractory cases and may include microvascular decompression or ablative procedures.

"Tonic spasms" can also occur with MS and are typified by sudden brief (generally less than 1 min) involuntary contractions of an extremity, which may be mistaken for simple partial or partial-onset seizures, except that they are usually painful and do not result in loss of consciousness. They can be frequent throughout the day and disabling, although they generally respond to carbamazepine or benzodiazepines. They are most

often associated with spinal cord lesions, often near a root exit zone, and are thought to be caused by ephaptic transmission of nerve impulses.

## **Bladder, Bowel, and Sexual Dysfunction**

A study by Marrie et al. of nearly 10,000 MS patients found that 80% of patients reported either bowel or bladder symptoms [43]. Urinary tract infections were reported in 64% of patients within 6 months of survey, which was roughly six times higher than observed in the general female population. Symptoms reported as "greatly bothersome" included urinary frequency (16.5%), urgency (17.0%), urge incontinence (8.4%), difficulty with bladder emptying (12.5%), and nocturia (20.9%). Patients were at greater risk for urologic dysfunction if they were female, had a longer disease duration, or higher degree of disability. Clinically, it is commonly observed that patients with lower extremity weakness and spasticity are more likely to have autonomic nervous system involvement as well. Nocturia can be a significant cause of sleep disturbance and can result in falls. The pons contains a micturation center that coordinates urethral sphincter relaxation and bladder detrusor contraction via a complex network of sympathetic and parasympathetic fibers arising from multiple levels throughout the thoracic and lumbar spinal cord. An MRI study showed that detrusor hyporeflexia occurred more frequently with pontine involvement and detrusor-sphincter dyssynergia (a lack of coordination between bladder and external urethral sphincter) more commonly with spinal cord lesions [44]. Patients with detrusor hyperactivity often respond well to anticholinergics such as oxybutynin and tolterodine. Detrusor-sphincter dyssynergia may respond to a combination of anticholinergics and adrenergic antagonists or may require self-catheterization. Urinary retention frequently does not respond to pharmacologic treatment and requires self-catheterization, though adrenergic antagonists (i.e., tamsulosin, terazosin, doxazosin) can be trialed. Intra-detrusor botulinum neurotoxin injections have been shown to decrease incontinence, urinary urgency, and noc-

turia and to improve quality of life [45]. Urologic referral should be initiated for recurrent UTIs, uncontrolled incontinence, or persistent urinary retention with elevated post-void residuals.

Constipation and fecal incontinence are the two most common complaints involving bowel dysfunction. In a patient population with urologic issues and clinical evidence of spinal cord disease, only 25% of patients reported normal bowel function; 36% of patients had constipation, and 30% reported one episode of fecal incontinence in the past 3 months [46]. Similar numbers were reported in an earlier study by Hinds et al. in an unselected MS population [47]. The underlying causes of MS related bowel dysfunction are unclear. Bowel issues are important to address because they can cause embarrassment, pre-dispose to infection, and worsen spasticity. Anticholinergics taken for bladder dysfunction and muscle relaxants such as baclofen can worsen constipation. Copious fluid intake, fiber, and docusate may help keep bowels regular. If these are ineffective laxatives can be considered. In severely disabled and immobile patients with MS, abdominal pain resulting from abnormal colonic motility can occur, and manual disimpaction may be necessary.

Sexual dysfunction is common in MS. A survey of 56 Norwegian MS patients 2–5 years after diagnosis found that 50% of males and 14% of females were not satisfied with their sexual functioning [48]. Men most often complained of difficulty achieving or maintaining an erection, while women most often complained of difficulty having an orgasm. It is always important to review all patient medications when addressing sexual dysfunction, because some medications frequently used in MS, such as SSRIs, can cause impairment in sexual functioning. Mixed results have been achieved with sildenafil citrate in both men and women in clinical trials, although in practice erectile dysfunction often responds to this or similar agents [49–51].

## Seizures

Seizure prevalence is increased slightly in MS (approx 2%) relative to the general population

(0.5–1%) [52]. Two-thirds of seizures in MS are generalized. Simple partial seizures are more common than partial complex seizures, the reverse of what is expected in the general population. To date, no studies evaluating specific anti-epileptic medication efficacy in MS have been performed, although in practice seizure disorders in MS generally respond to conventional anticonvulsants and are rarely intractable. Cortical and juxtacortical lesions are increasingly recognized in MS and are not always well visualized on conventional MRI sequences. New-onset partial and/or secondarily generalized seizures may occasionally herald a new cortical/juxtacortical enhancing brain lesion, which may respond to steroid treatment acutely. Interferons have the potential to lower seizure threshold and should be used cautiously in patients with a preexisting seizure disorder, though in practice this is not necessarily an absolute contraindication.

## Sleep Difficulties

A higher prevalence of sleep disturbance is observed in MS patients than in the general population, with insomnia affecting nearly 50% of patients [53]. Common causes for insomnia in MS include bladder dysfunction (e.g., nocturia), pain, and mood-related disorders. Restless legs syndrome (RLS) is one of the more common sleep disorders encountered in MS, and there is a fourfold increased risk among MS patients (prevalence of 19% vs. 4% for controls) [54]. Risk factors for development of RLS include older age, longer disease duration, and increased disability [55].

## Other Symptoms

Patients may suffer from other paroxysmal symptoms such as intermittent dysarthria, ataxia, tonic spasms, itching, transient akinesia, and radicular thoracic sensations of pain or tightness (so-called MS hug), or other radicular type pain in an extremity. Some of these symptoms are covered in the section on pain. Anticonvulsants such as

carbamazepine and gabapentin often are helpful to decrease the frequency and severity of these spells.

---

## Diagnosis of Multiple Sclerosis

The majority of MS cases can be diagnosed by clinical or clinical and imaging parameters alone, provided these are properly applied and that other causes of CNS inflammatory white matter disease (so-called MS mimickers) are ruled out, usually by history, appropriate blood tests, and occasionally by CSF analysis. A CSF analysis that is positive for markers of abnormal intrathecal immunoglobulin synthesis (increased IgG index, synthesis rate, and/or oligoclonal bands) is highly useful in differentiating unusual presentations of MS with uncharacteristic features on MRI from MS mimics, as well as in primary progressive MS, where imaging may be negative, especially early in the disease course. Frequently however, the CSF can be negative for these markers, especially early in the disease course, and provides no supportive evidence in either direction. Visual evoked potential (VEP) recordings or optical coherence tomography (OCT) are usually unnecessary in the setting of acute optic neuritis but can be useful in documenting a prior episode of retrobulbar neuritis.

---

## Diagnostic Criteria

Initial criteria used to diagnose Multiple Sclerosis (MS) were based on clinical features alone and required demonstration of CNS lesions disseminated in space and time by objective abnormalities on the neurological examination, as well as the elimination of alternative diagnoses that might present with a similar clinical picture, ultimately rendering MS a diagnosis of exclusion. In 1983, the “Poser Criteria” [56] were proposed, which used paraclinical findings (neuroimaging, evoked potentials, and spinal fluid analysis) to supplement clinical evidence for the diagnosis in situations where strict clinical criteria were not met. An international panel chaired by W. Ian

McDonald met in July 2000 to review preexisting criteria for the diagnosis of MS and to incorporate modern imaging techniques into a diagnostic scheme that would allow the clinician to satisfy a requirement for dissemination of lesions in time and/or space without having to wait for a second clinical manifestation of disease, as had previously been the norm [57]. The resulting “McDonald Criteria” may appear cumbersome at first, but, if properly applied, show a sensitivity of 83%, specificity of 83%, negative predictive value of 89%, and accuracy of 83% for clinically definite MS at 3 years in patients initially presenting with a clinically isolated syndrome (CIS) suggestive of demyelinating disease [58]. These criteria have since been revised several times, most recently in 2017, in order to allow for both earlier and more accurate diagnosis of clinically definite MS (CDMS) after either a monosymptomatic presentation or a progressive course from the outset (primary progressive MS) [59–61]. Nearly all subsequent clinical trials in RRMS have relied on the McDonald criteria for inclusion. Since initiation of treatment at the time of CIS in patients with abnormal MRI findings has been shown to delay the onset of a second clinical attack, i.e., clinically definite MS (CDMS), most MS specialists now advocate early treatment, at the time of CIS, if the baseline MRI shows characteristic lesions indicative of prior asymptomatic demyelination. Earlier recognition allows for treatment to at least be considered after a first clinical episode and to tailor the follow-up approach with the patient. It should also be reemphasized that the McDonald criteria do not absolutely require an MRI in order to diagnose MS; however, it is recommended that brain MRI be obtained in all patients being considered for a diagnosis of MS [61]. In contradistinction, the criteria also do not provide for a diagnosis of MS based on imaging alone. At least one attack with objective clinical evidence of a CNS lesion on examination (CIS) is required before paraclinical data (chiefly MRI) come into play. Furthermore, it cannot be overemphasized that there must be no better explanation for any clinical or paraclinical abnormalities in order for the diagnosis to be secure, i.e., “MS mimickers” must be ruled out.



To simplify the McDonald criteria (Table 5.1), we can apply them to five common clinical scenarios:

1. *Two clinical attacks and two objective lesions on examination:* Here, no further paraclinical testing is technically needed, and a diagnosis of relapsing-remitting MS (RRMS) can be made anywhere in the world without the benefit of MRI or other paraclinical testing, provided other diagnostic possibilities have been ruled out, i.e., there is “no better explanation” for the findings.
2. *Two clinical attacks, one objective lesion on examination, and reasonable historical evidence of a prior attack involving a different neuroanatomical area:* Here, a history of a prior attack with symptoms and evolution typical for an inflammatory demyelinating event will count toward dissemination in time. No further paraclinical testing is technically needed, and a diagnosis of relapsing-remitting MS (RRMS) can be made.
3. *Two clinical attacks, one objective lesion on examination:* The diagnosis can be made either by waiting for an additional attack, or MRI evidence of dissemination in space can be demonstrated by documenting two or more characteristic demyelinating lesions on MRI (criteria summarized in Table 5.2).
4. *One clinical attack and two or more objective lesions on examination:* In this case, the criterion for dissemination in space was fulfilled by the neurological exam. The criterion for dissemination in time can be demonstrated by either waiting for a second attack, or by the demonstration of a new lesion on a follow-up MRI, or by the presence of CSF-specific oligoclonal bands (other CSF findings atypical for MS must be absent).
5. *One clinical attack and one objective lesion on examination:* The monosymptomatic presentation or so-called clinically isolated syndrome (CIS) generally comprises optic neuritis, partial transverse myelitis, and brainstem-cerebellar syndromes, although a capsular or large hemispheric lesion may occasionally present in this fashion. Here the

criterion for dissemination in space can again be satisfied by a second clinical attack (in a different anatomical location) or by fulfilling MRI criteria (Table 5.2). The criterion for dissemination in time is then satisfied either by a second clinical attack, or by documenting additional new lesions on a follow-up MRI, or by CSF-specific oligoclonal bands.

6. *Insidious neurological progression from the outset or primary progressive MS (PPMS):* Here it is difficult to prove dissemination in time or space and the MRI may not show characteristic demyelinating lesions, especially early in the disease course, so in order to diagnose PPMS, alternative criteria must be met (Table 5.1).

In each case, if the criteria indicated are fulfilled, the diagnosis is multiple sclerosis; if the criteria are not completely met, the diagnosis is “possible MS”; if the criteria are fully explored and not met, the diagnosis is “not MS.”

A common obfuscation in the application of the McDonald criteria seems to arise from the dual meaning of the word “lesion.” In the context of the initial clinical presentation (Table 5.1, left panel), “lesion” refers to a demonstrable clinical abnormality of the CNS on neurological examination and not to an area of signal abnormality on MRI. “Lesion” in the context of MRI criteria is also commonly used to define an area of signal abnormality seen on MRI (Table 5.1, right panel and Table 5.2). In our experience the most common difficulty, however, arises from the failure to differentiate MRI lesions that are typical for MS from those that are “nonspecific” and are frequently noted as incidental findings on routine imaging of patients with headache, vertigo, and a variety of other common conditions. The McDonald criteria address to some extent the issues of lesion number (>2 total) and location (infratentorial, cortical or juxtacortical, periventricular, spinal cord) in satisfying a requirement for dissemination in space. Other MRI features commonly seen in MS, though not specifically addressed in the criteria, include relatively sharp lesion borders, extensive involvement of the corpus callosum, periventricular lesions that are lin-

**Table 5.1** 2017 McDonald diagnostic criteria

Clinical presentation	Additional data needed for MS diagnosis
Two or more attacks; objective clinical evidence of two or more lesions	None <sup>a</sup>
Two or more attacks; objective clinical evidence of 1 lesion; historical evidence of a previous attack involving a lesion in a distinct anatomical location <sup>b</sup>	None <sup>a</sup>
Two or more attacks; objective clinical evidence of 1 lesion	Dissemination in space, demonstrated by an additional clinical attack or by MRI <sup>c</sup>
One attack; objective clinical evidence of 2 or more lesions	Dissemination in time, demonstrated by an additional clinical attack or by MRI <sup>d</sup> or demonstration of CSF-specific oligoclonal bands <sup>e</sup>
One attack; objective clinical evidence of one lesion	Dissemination in space, demonstrated by an additional clinical attack or MRI <sup>c</sup> AND Dissemination in time, demonstrated by an additional clinical attack or MRI <sup>d</sup> or demonstration of CSF-specific oligoclonal bands <sup>e</sup>
Progression from onset (primary progressive MS)	1 year of disability progression (retrospectively or prospectively determined) independent of clinical relapse PLUS two of the following: One or more T2-hyperintense lesions characteristic of MS in one or more of the following brain regions: periventricular, cortical or juxtacortical, or infratentorial Two or more T2-hyperintense lesions in the spinal cord Presence of CSF-specific oligoclonal bands

From Thompson et al. [61]

If the 2017 McDonald Criteria are fulfilled and there is no better explanation for the clinical presentation, the diagnosis is multiple sclerosis. If multiple sclerosis is suspected by virtue of a clinically isolated syndrome, the 2017 McDonald Criteria are not completely met, the diagnosis is possible multiple sclerosis. If another diagnosis arises during the evaluation that better explains the clinical presentation, the diagnosis is not multiple sclerosis

<sup>a</sup>No additional tests are required to demonstrate dissemination in space and time. However, unless MRI is not possible, brain MRI should be obtained in all patients in whom the diagnosis of multiple sclerosis is being considered. In addition, spinal cord MRI or CSF examination should be considered in patients with insufficient clinical and MRI evidence supporting multiple sclerosis, with a presentation other than a typical clinically isolated syndrome, or with atypical features. If imaging or other tests (e.g., CSF) are undertaken and are negative, caution needs to be taken before making a diagnosis of multiple sclerosis, and alternative diagnoses should be considered

<sup>b</sup>Clinical diagnosis based on objective clinical findings for two attacks is most secure. Reasonable historical evidence for one past attack, in the absence of documented objective neurological findings, can include historical events with symptoms and evolution characteristic for a previous inflammatory demyelinating attack; at least one attack, however, must be supported by objective findings. In the absence of residual objective evidence, caution is needed

<sup>c</sup>MRI criteria for dissemination in space are described in Table 5.2

<sup>d</sup>The MRI criteria for dissemination in time are described in Table 5.2

<sup>e</sup>The presence of CSF-specific oligoclonal bands does not demonstrate dissemination in time per se but can substitute for the requirement for demonstration of this measure

ear to ovoid and perpendicularly oriented to the ventricles (“Dawson fingers”), open ring enhancement, and well-circumscribed cord lesions usually less than two vertebral levels in length and less than ½ cord diameter. As for the issue of follow-up of CIS with a normal initial brain MRI, this is not specifically addressed in the criteria. There are also no specific recommendations for the increasingly common scenario of

the asymptomatic patient, with no prior history of a demyelinating episode, who has incidental MRI findings characteristic of prior areas of demyelination on a scan that was done for other reasons (e.g., headache, vertigo, trauma), or so-called Radiographically Isolated Syndrome (RIS), although this is an area of intensive research. Currently, in order for a diagnosis of MS to be made, there must be clinical manifestations [61].

**Table 5.2** 2017 McDonald criteria for dissemination in space and time

DIS	DIT
<p>≥1 T2-hyperintense lesions that are characteristic of multiple sclerosis in at least two of four areas of the CNS:</p> <ul style="list-style-type: none"> <li>Periventricular<sup>a</sup></li> <li>Cortical or juxtacortical</li> <li>Infratentorial</li> <li>Spinal cord</li> </ul>	<p>Simultaneous presence of gadolinium-enhancing and non-enhancing lesions at any time</p> <p>OR</p> <p>New T2-hyperintense or gadolinium-enhancing lesion on follow-up MRI with reference to a baseline scan, irrespective of the timing of the baseline MRI</p>

From Thompson et al. [61]

<sup>a</sup>For some patients—e.g., individuals older than 50 years or those with vascular risk factors—it might be prudent for the clinician to seek a higher number of periventricular lesions

## Differential Diagnosis

A key element in the diagnosis of MS is the exclusion of other possible disease entities. Distinguishing an MS presentation from that of another neurologic disease can at times be challenging, due to lack of homogeneity in clinical presentation and absence of a definitive paraclinical confirmatory test. Overlap between MS and other diseases that may have similar presentations and can also be difficult to diagnose further compounds the problem. For this reason, an awareness of neurologic diseases that are MS “look-alikes” or “mimics” is important and consideration for an alternate diagnosis is often based on presenting symptoms, clinical course (e.g., relapsing–remitting vs. progressive), and/or MRI findings. With regard to other autoimmune etiologies (e.g., ADEM, NMOSD), these are covered in greater detail elsewhere in this book and so this chapter will be limited to more general comments.

Optic neuritis, transverse myelitis, and brainstem/cerebellar syndromes represent some of the more common initial MS presentations and so having a more in-depth differential diagnosis for each of these is often important (Table 5.3).

**Optic Neuritis** There is a wide differential diagnosis for optic neuropathy to include infectious, autoimmune, compressive (e.g., primary tumors, aneurysm, thyroid ophthalmopathy), ischemic,

inherited (e.g., Leber’s hereditary optic neuropathy), and toxic/metabolic etiologies (e.g., B12 deficiency). Aside from multiple sclerosis, other diseases that can result in steroid-responsive optic neuropathies include sarcoidosis, neuromyelitis optica spectrum disorder, systemic lupus erythematosus, Behcet disease, and chronic relapsing inflammatory optic neuropathy (CRION). Brain MRI can be useful in helping to narrow the differential, for example, brainstem involvement is present in 51% [65] of those with Behcet disease and MRI leptomeningeal enhancement +/- parenchymal inflammation can be seen in 36% of those with neurosarcoidosis [66]. Other useful diagnostic studies to consider in the workup of neurosarcoidosis may include CSF/serum ACE level; chest X-ray or CT; whole body PET or Gallium scan; lymph node, lacrimal, or salivary gland biopsy; and occasionally brain biopsy. Infectious etiologies (e.g., syphilis, tuberculosis, Lyme disease, viral) are typically associated with severe optic disc edema and further supported by appropriate serum and CSF studies. Ischemic optic neuropathies (e.g., giant cell arteritis, AION, PION) tend to occur in older individuals and are of relatively abrupt onset. Optic neuropathy that is progressive (>2 weeks), persistent with complete loss of vision, of bilateral simultaneous onset, and/or associated with neuroretinitis or uveitis is atypical and should prompt consideration of an alternate diagnosis [62, 66].

**Brainstem/Cerebellar Syndrome** As stated previously in this chapter, brainstem/cerebellar syndromes presenting with cranial nerve deficits can often occur in multiple sclerosis; however, certain symptom presentations should raise suspicion for alternate etiologies. Progressive cerebellar symptoms can be seen in spinocerebellar ataxia or paraneoplastic syndromes. Persistent enhancement can be seen in neurosarcoidosis, Behcet disease, malignancy, histiocytosis, infection, or CLIPPERS [63]. Fever or meningismus would suggest infection. Sudden onset symptoms and/or signs following a vascular territory suggest ischemia. Alternatively, slowly progressive and/or fluctuating symptoms would be atypical in relapsing–remitting multiple sclerosis.

**Table 5.3** Differential diagnosis of common MS presentations

	Optic neuritis [62]	Brainstem syndrome [63]	Spinal cord syndrome [64]
Compressive	Primary tumors Metastasis Tuberculomas Thyroid ophthalmopathy Arterial aneurysms Sinus mucoceles	Malignancy Lymphoma Glioma	Intervertebral disc Tumor
Inflammatory	Sarcoidosis SLE CRION Behcet disease NMOSD ADEM Neuroretinitis	Sarcoidosis NMOSD Behcet disease Histiocytosis CLIPPERS SLE	NMOSD Sarcoidosis SLE Sjogren syndrome
Infectious	Syphilis TB Lyme disease Viral	Syphilis Listeria Lyme Whipple disease TB Viral	Syphilis Lyme TB Viral-HIV, HTLV
Vascular	AION PION GCA Diabetic papillopathy	Infarct Cavernous angioma Vasculitis	Ischemia AVM dural fistula
Toxic/metabolic	Vitamin B12 deficiency Tobacco-alcohol amblyopia Methanol intoxication Ehthambultol toxicity	Central pontine myelinolysis	B12 deficiency Copper deficiency NO toxicity
Genetic	LHON		
Other		Myasthenia Gravis	Non-cord mimics GBS Myasthenia Gravis

*ADEM* acute disseminated encephalomyelitis, *AION* anterior ischemic optic neuropathy, *AVM* arteriovenous malformation, *CLIPPERS* chronic lymphocytic inflammation with pontine perivascular enhancement responsive to steroids, *CRION* chronic relapsing inflammatory optic neuropathy, *HIV* human immunodeficiency virus, *HTLV* human T-lymphotropic virus, *GBS* Guillain-Barre syndrome, *GCS* giant cell arteritis, *LHON* Leber's hereditary optic neuropathy, *NMOSD* neuromyelitis optica spectrum disorder, *NO* nitrous oxide, *PION* posterior ischemic optic neuropathy, *SLE* systemic lupus erythematosus, *TB* tuberculosis

**Spinal Cord Syndrome** As with optic neuropathy and brainstem syndromes, spinal cord syndromes can also occur in the setting of compressive, vascular, inflammatory, infectious, and toxic/metabolic etiologies. Atypical for spinal cord syndromes in MS would be hyperacute onset, longitudinally extensive myelitis, complete (vs. partial) transverse myelitis, areflexia, radicular pain, sharp sensory level, or the presence of systemic symptoms (e.g., fever) [64].

As alluded to earlier, different MS subtypes overlap with alternate potential differential diagnoses, and so a crucial point of distinction in evaluating a patient may be whether they are presenting

with a relapsing vs. a progressive course. For example, because amyotrophic lateral sclerosis (ALS) is a progressive disease of motor neurons, it would be difficult to confuse with CIS or relapsing forms of MS. On the other hand, primary progressive MS and ALS could be, and often are, more readily confused. Symptoms and signs attributable to relapsing MS are often also seen in other autoimmune/inflammatory, vasculitic, infectious, metabolic, and paraneoplastic presentations, while infectious, metabolic, and structural entities most commonly overlap with a more progressive MS phenotype. Table 5.4 lists diseases more commonly mistaken for MS based on clinical course with some basic differential diagnosis points.

**Table 5.4** Diseases that mimic relapsing presentations of MS

Disease	Symptoms/exam	Paraclinical
<i>Diseases that may mimic relapsing presentations of MS</i>		
Neurosarcoidosis	Cranial neuropathy (80%), headaches (27%), visual failure (27%), ataxia (20%), vomiting (23%), seizures (17%) Note: 10% no evidence of systemic sarcoidosis [66]	serum ACE+ (29%) [67] CSF OCB+ (27%) CSF ACE (55–94%) MRI leptomeningeal enhancement (36%) [68] Abnormal CXR and chest CT (68%) [69] Gallium scanning + (67%)
Neuromyelitis optic spectrum disorder (NMOSD)	Optic neuritis, transverse myelitis, areas postrema syndrome, acute brainstem syndrome, symptomatic narcolepsy, and/or symptomatic cerebral syndrome [70]	NMO IgG Brain MRI normal or nonspecific white matter lesions Myelitis usually $\geq 3$ segments
Behcet disease	Brainstem involvement (51%) [65], arthritis (30–50%), thrombophlebitis (25%), oral ulcerations (97–99%), genital ulcerations (85%), uveitis (50%) Note: Rare without evidence of ulcerations [71]	CSF OCB not typically seen CSF pleocytosis (approx. 50%) MRI abnormal about 2/3 patients with CNS involvement, no specific feature
Systemic lupus erythematosus (SLE)	Neuropsychiatric (60%) Malar rash, photosensitivity, arthritis Visual loss frequently severe and painless if occurs	Serum ANA + (59%) Double-stranded DNA + (28%) Antiphospholipid antibody (33%) [72] CSF OCB (approx. 50%) MRI can look MS like or stroke-like
Antiphospholipid antibody syndrome	Hx of thrombosis, miscarriages, livedo reticularis, thrombocytopenia, transverse myelitis [73]	Antiphospholipid antibodies frequently + in active disease MRI spinal cord involvement usually $>2$ vertebral levels, typically thoracic
Sjogren syndrome	Peripheral nervous system involvement (62%), multiple mononeuropathies (9%), seizures (9%), cranial nerves (20%) Sicca sx (53%), spinal cord (35%) [74]	CSF OCB (30%) VEP abnl (61%) Anti-Ro/anti-la + (21%) ANA + (54%) MRI WM lesions (70%)
Lyme disease	Aseptic meningitis, radicular pain, cranial neuropathy (VII), arthralgia, rash, tick bite	CSF OCB, pleocytosis frequently present MRI WM lesion common Lyme testing very sensitive [75]
Vasculitis	Peripheral neuropathies, mono-neuritis-multiplex, oculomotor palsies, seizures, encephalopathy Fatigue, fever, night sweats, headaches, oligoarthropathy	CSF leukocytosis MRI stroke, hemorrhage, or meningeal enhancement, or multiple punctuate enhancing lesions Gold standard for dx: brain biopsy [76]
Cerebral autosomal dominant arteriopathy with subcortical infarcts and leukoencephalopathy (CADASIL)	Headache, stroke-like episodes Family history of stroke common	CSF OCB rarely present MRI diffuse extensive WM changes with anterior temporal and external capsule involvement (Table 5.5) NOTCH 3 gene +
Leber hereditary optic neuropathy (LHON)	Consider with recurrent optic neuritis Vision loss most commonly painless, progressive and binocular Affects men only	Point mutation in mitochondrial DNA
<i>Diseases that may mimic progressive presentations of MS</i>		
Vitamin B12 deficiency	Peripheral neuropathy, myelopathy Cognitive impairment (25%) Bilateral + Babinski, ankle jerks lost [77]	Macrocytic anemia B12 or methylmalonic acid low
Copper deficiency	Gait difficulty, myelopathy, lower extremity paresthesias, bilateral + Babinski, ankle jerks lost	Anemia frequent, Ceruloplasmin or copper levels low MRI can show brain or spinal cord involvement

**Table 5.4** (continued)

Disease	Symptoms/exam	Paraclinical
Paraneoplastic syndromes	Gait unsteadiness, dysarthria, diplopia, dysphagia, weight loss, pruritis, fevers	CSF lymphocytic pleocytosis, elevated protein, OCB MRI can show late cerebellar atrophy Anti-Yo, anti-HU, anti-Tr most frequently associated [78]
HTLV-1 myelopathy/tropical spastic paraparesis	Chronically progressive myelopathy	CSF OCB typically present MRI spinal cord lesions, brain can have white matter lesions Thoracic cord atrophy common HTLV-1 antibodies found in both serum and CSF
Whipple disease	Cognitive changes Supranuclear gaze palsies Neuro. symptoms rare before systemic (arthralgia, weight loss, diarrhea, fever) Oculomasticatory myorhythmia (20%) [79]	OCB can be present MRI can look MS-like PCR + T. whippleii
Spinocerebellar ataxias (SCA)	Primarily disequilibrium, incoordination	CSF OCB likely negative MRI atrophy of cerebellum, brainstem but T2/FLAIR changes unlikely Genetic testing available
Friedrich ataxia	Ataxia, weakness later, skeletal abnormalities, diabetes common, diminished reflexes, toes up-going [80]	CSF OCB can be present MRI at time gray and white matter involvement Genetic testing available (trinucleotide repeat)
Amyotrophic lateral sclerosis (ALS)	No sensory involvement Upper and lower motor neuron Fasciculations Bulbar symptoms	EMG/NCS confirmatory in advanced disease
Primary lateral sclerosis (PLS)	Similar to ALS, no lower motor neuron involvement	EMG/NCS confirmatory in advanced disease
celiac sprue	Progressive spinal and cerebellar decline Myoclonus, peripheral neuropathy, encephalopathy and seizures can occur	MRI can look MS-like [81] Antigliadin antibodies nonspecific, duodenal biopsy recommended
Leukodystrophies	In adults can look like progressive myelopathy Adrenoleukodystrophy (ALD): Addisonian features, bronzing of skin, abdominal pain, family history. Metachromatic leukodystrophy (MLD): progressive myelopathy	OCB absent ALD-serum very long chain fatty acids MLD-serum arylsulfatase A deficiency MRI ALD: WM involvement can occur [82] MRI MLD: WM involvement, sparing of “U” fibers [83]

ACE angiotensin converting enzyme, ANA antinuclear antibodies, CSF cerebrospinal fluid, CXR chest X-ray, dx diagnosis, EMG/NCS electromyogram/nerve conduction study, Hx history, OCB oligoclonal bands, PCR polymerase chain reaction, sx symptoms, VEP visual evoked potentials, WM white matter

Table 5.5 lists diseases that may mimic MRI findings in MS. When reviewing MRIs, special attention should be paid to the morphology, distribution and location of lesions, involvement of the corpus callosum (common in MS), and the presence of contrast-enhancement. Red flags would include the presence of acute ischemic

DWI/ADC changes, hemorrhage, persistent enhancement, or pronounced leptomeningeal enhancement. Still, it can be difficult to differentiate MS from non-MS patients based on MRI alone, and so imaging should be interpreted along with history, examination, and other paraclinical data, as previously discussed.

**Table 5.5** Diseases that may mimic MRI findings in MS<sup>a</sup>

Diagnosis	MRI findings
Small vessel disease (SVD)	Subcortical and periventricular lesions can be multifocal and punctate, or symmetric and confluent Central pons (vs. surface of the pons more common in MS) No contrast-enhancement (except in subacute infarction) T2 hyperintense rims around the ventricles Basal ganglia can be involved (this is rare in MS) U fibers, temporal lobes, and corpus callosum typically spared (vs. common/often in MS) No spinal cord involvement
Cerebrovascular autosomal dominant arteriopathy with subcortical infarcts and leukoencephalopathy (CADASIL)	Anterior temporal lobe, external and external capsule involvement Lacunar infarcts Hemorrhages/microhemorrhages Sparing of the corpus callosum and infratentorial regions
Susac syndrome	Periventricular white matter lesions arranged in “spoke wheel” appearance with defects in the central portion of the corpus callosum (vs. the underside in MS). +/- DWI changes during acute phase +/- Leptomeningeal enhancement
Acute demyelinating encephalomyelitis (ADEM)	Infrequent corpus callosum or periventricular white matter lesions Cortical and deep gray matter typically affected Symmetrical distribution Ill-defined margins Variable size of lesions, but usually at least one large (1–2 cm) Cord lesions are usually located in the thoracic regions Dissemination in time is atypical (note—recurrent or multiphasic ADEM can rarely occur)
Neuromyelitis optica spectrum disorder (NMOSD)	Normal white matter or nonspecific white matter changes LETM and affects the majority of the cross section of the spinal cord
Vasculitis/inflammatory Primary CNS vasculitis SLE Sjogren Sarcoidosis Neuro-Behcet CLIPPERS Wegener’s granulomatosis Crohn’s disease Celiac disease	Cortical or lacunar infarcts Lesions crossing gray-white matter boundaries and/or vascular territories May have enhancing areas of the parenchyma, leptomeningeal enhancement (esp. neurosarcoid), microhemorrhages, spinal cord involvement, and/or sinus venous thrombosis Brainstem and basal ganglia involvement sensitive/specific for neuro-Behcet disease T2 lesions within the pons, brainstem, cerebellum, and spinal cord involvement in CLIPPERS Calcifications in the occipital lobes on CT in celiac disease
Progressive multifocal leukoencephalopathy (PML)	Progressively enlarging and progressively confluent lesions with infrequent mass effect and infrequent enhancement <sup>b</sup> No spinal cord involvement
Lyme disease (with nervous system involvement)	No specific lesion pattern Lesions will enhance in the acute phase +/- leptomeninges enhancement +/- cranial nerve or spinal nerve root enhancement
Central pontine myelinolysis (CPM)	Central pons +/- deep gray matter and cerebral white matter Usually no contrast enhancement
Posterior reversible encephalopathy syndrome (PRES)	Areas of vasogenic edema largely in the parieto-occipital regions and to a lesser extent in the frontal, inferior temporal and cerebellar regions
Mitochondrial disorders (e.g., Kearns-Sayre syndrome, MELAS, Leigh’s syndrome)	Diffuse lactate increase on brain MRS Gray matter structures often involved (e.g., basal ganglia, brainstem nuclei, and cortex)

**Table 5.5** (continued)

Diagnosis	MRI findings
Adult-onset Leukodystrophies (e.g., metachromatic leukodystrophy, Krabbe's disease, Fabry disease, adrenomyeloneuropathy)	White matter lesions tend to be bilateral and symmetric U fibers typically spared
Neoplasm	Persistent enhancement Complete ring enhancement

*CLIPPERS* chronic lymphocytic inflammation with pontine perivascular enhancement responsive to steroids, *LETM* longitudinally extensive transverse myelitis, *MELAS* mitochondrial encephalomyopathy lactic acidosis and stroke-like episodes, *SLE* systemic lupus erythematosus

<sup>a</sup>Adapted from [84]

<sup>b</sup>Natalizumab-related PML will frequently show some degree of enhancement (compared to HIV patients with PML)

## Conclusion

MS can present with a wide variety of symptoms and signs, and there remains no substitute for clinical judgment. One must remain alert to alternate possible diagnoses, both at the initial visit and in follow-up. MRI is a remarkably sensitive paraclinical test that can be repeatedly used to demonstrate both the acute and chronic changes in CNS signal characteristics that are typically seen in MS. As such, it is used increasingly as both a diagnostic tool to establish dissemination in time and space, a prognostic tool at the time of CIS, and as a tool to monitor disease activity and the effectiveness of treatments. Ultimately, conventional (proton) MRI is not specific to any disease process and can be misleading if not interpreted in the proper clinical context. The typical “laundry list” differential generated by the radiologist in response to common nonspecific T2 signal changes in the white matter is daily proof of this and is almost never helpful. For this reason, it is the obligation of the diagnosing and treating neurologist to consider all clinical data and personally review the MRI scans. Neither do conventional measures of disease burden or activity, such as T2 lesion number or volume, or Gadolinium enhancement correlate particularly well with symptoms or disability on cross-sectional studies, much less at the office visit. One should not be drawn into the type of simple structure/function explanation that characterizes other CNS lesions. Surprising numbers of MS lesions may be found in supposedly “eloquent” areas of the CNS, including the brainstem

and spinal cord, without any corresponding symptoms or signs on examination. When determining diagnosis and management, one must incorporate the MRI into an overall picture of the patient that also includes clinical measures of disease activity, such as relapse rate, disability progression, and cognitive and psychosocial parameters.

## References

1. Miller DH, Chard DT, Ciccarelli O. Clinically isolated syndromes. *Lancet Neurol*. 2012;11:157–69.
2. Beck RW, Cleary PA, Anderson MM Jr, et al. A randomized, controlled trial of corticosteroids in the treatment of acute optic neuritis. *N Engl J Med*. 2012;326:581–8.
3. Honan WP, Heron JR, Foster DH, Edgar GK, Scase MO, Collins MF. Visual loss in multiple sclerosis and its relation to previous optic neuritis, disease duration and clinical classification. *Brain*. 1990;113:975–87.
4. Optic Neuritis Study Group. Visual function 15 years after optic neuritis: a final follow-up report from the Optic Neuritis Treatment Trial. *Ophthalmology*. 2008;115:1079–82.
5. Cole SR, Beck RW, Moke PS, Gal RL, Long DT. The National Eye Institute Visual Function Questionnaire: experience of the ONTT. *Optic Neuritis Treatment Trial*. *Invest Ophthalmol Vis Sci*. 2000;41:1017–21.
6. Costello F, Hodge W, Pan YI, et al. Tracking retinal nerve fiber layer loss after optic neuritis: a prospective study using optical coherence tomography. *Mult Scler J*. 2008;14:893–905.
7. Müri RM, Meienberg O. The clinical spectrum of internuclear ophthalmoplegia in multiple sclerosis. *Arch Neurol*. 1985;42:851–5.
8. Rolet A, Magnin E, Millot JL, et al. Olfactory dysfunction in multiple sclerosis: evidence of a decrease in different aspects of olfactory function. *Eur Neurol*. 2013;69:166–70.



9. Thömke F, Lensch E, Ringel K, Hopf HC. Isolated cranial nerve palsies in multiple sclerosis. *J Neurol Neurosurg Psychiatry*. 1997;63:682–5.
10. Frohman EM, Zhang H, Dewey RB, Hawker KS, Racke MK, Frohman TC. Vertigo in MS: utility of positional and particle repositioning maneuvers. *Neurology*. 2000;55:1566–9.
11. Rizzo MA, Hadjimichael OC, Preiningerova J, et al. Prevalence and treatment of spasticity reported by multiple sclerosis patients. *Mult Scler J*. 2004;10:589–95.
12. Rinker JR, Salter AR, Walker H, et al. Prevalence and characteristics of tremor in the NARCOMS multiple sclerosis registry: a cross-sectional survey. *BMJ Open*. 2015;5:e006714.
13. Koch M, Mostert J, Heersema D, De Keyser J. Tremor in multiple sclerosis. *J Neurol*. 2007;254:133–45.
14. Torres CV, Moro E, Lopez-Rios AL, et al. Deep brain stimulation of the ventral intermediate nucleus of the thalamus for tremor in patients with multiple sclerosis. *Neurosurgery*. 2010;67:646–51.
15. Goodman AD, Brown TR, Krupp LB, et al. Fampridine MS-F203 Investigators. Sustained-release oral fampridine in multiple sclerosis: a randomised, double-blind, controlled trial. *Lancet*. 2009;373:732–8.
16. Goodman AD, Brown TR, Cohen JA, et al. Fampridine MS-F202 Study Group. Dose comparison trial of sustained-release fampridine in multiple sclerosis. *Neurology*. 2008;71:1134–41.
17. Allart E, Benoit A, Blanchard-Dauphin A, et al. Sustained-released fampridine in multiple sclerosis: effects on gait parameters, arm function, fatigue, and quality of life. *J Neurol*. 2015;262:1936–45.
18. Pavsic K, Pelicon K, Ledinek AH, et al. Short-term impact of fampridine on motor and cognitive functions, mood and quality of life among multiple sclerosis patients. *Clin Neurol Neurosurg*. 2015;139:35–40.
19. Iriarte J, Subirá ML, Castro P. Modalities of fatigue in multiple sclerosis: correlation with clinical and biological factors. *Mult Scler*. 2000;6:124–30.
20. Rammohan KW, Rosenberg JH, Lynn DJ, Blumenfeld AM, Pollak CP, Nagaraja HN. Efficacy and safety of modafinil (provigil) for the treatment of fatigue in multiple sclerosis: a two centre phase 2 study. *J Neurol Neurosurg Psychiatry*. 2002;72:179–83.
21. Stankoff B, Waubant E, Confavreux C, et al. Modafinil for fatigue in MS: a randomized placebo-controlled double-blind study. *Neurology*. 2005;64:1139–43.
22. Minden SL, Schiffer RB. Affective disorders in multiple sclerosis. Review and recommendations for clinical research. *Arch Neurol*. 1990;47:98–104.
23. Schiffer RB, Babigian HM. Behavioral disorders in multiple sclerosis, temporal lobe epilepsy, and amyotrophic lateral sclerosis. An epidemiologic study. *Arch Neurol*. 1984;41:1067–9.
24. Feinstein A, Roy P, Lobaugh N, Feinstein K, O'Connor P, Black S. Structural brain abnormalities in multiple sclerosis patients with major depression. *Neurology*. 2004;62:586–90.
25. Feinstein A. Multiple sclerosis, disease modifying treatments and depression: a critical methodological review. *Mult Scler*. 2000;6:343–8.
26. Patten SB, Fridhandler S, Beck CA, Metz LM. Depressive symptoms in a treated multiple sclerosis cohort. *Mult Scler*. 2003;9:616–20.
27. Schippling S, O'Connor P, Knappertz V, et al. Incidence and course of depression in multiple sclerosis in the multinational BEYOND trial. *J Neurol*. 2016;263:1418–26.
28. Chiaravalloti ND, DeLuca J. Cognitive impairment in multiple sclerosis. *Lancet Neurol*. 2008;7:1139–51.
29. Rao SM, Leo GJ, Bernardin L, Unverzagt F. Cognitive dysfunction in multiple sclerosis. I. Frequency, patterns, and prediction. *Neurology*. 1991;41:685–91.
30. Benedict RH, Cookfair D, Gavett R, et al. Validity of the minimal assessment of cognitive function in multiple sclerosis (MACFIMS). *J Int Neuropsychol Soc*. 2006;12:549–58.
31. Glanz BI, Holland CM, Gauthier SA, et al. Cognitive dysfunction in patients with clinically isolated syndromes or newly diagnosed multiple sclerosis. *Mult Scler*. 2007;13:1004–10.
32. Rao SM, Leo GJ, Ellington L, Nauertz T, Bernardin L, Unverzagt F. Cognitive dysfunction in multiple sclerosis. II. Impact on employment and social functioning. *Neurology*. 1991;41:692–6.
33. Benito-León J, Morales JM, Rivera-Navarro J. Health-related quality of life and its relationship to cognitive and emotional functioning in multiple sclerosis patients. *Eur J Neurol*. 2002;9:497–502.
34. Rovaris M, Comi G, Filippi M. MRI markers of destructive pathology in multiple sclerosis-related cognitive dysfunction. *J Neurol Sci*. 2006;245:111–6.
35. Pirko I, Lucchinetti CF, Sriram S, Bakshi R. Gray matter involvement in multiple sclerosis. *Neurology*. 2007;68:634–42.
36. Shaygannejad V, Janghorbani M, Ashtari F, et al. Effects of rivastigmine on memory and cognition in multiple sclerosis. *Can J Neurol Sci*. 2008;35:476–81.
37. Krupp LB, Christodoulou C, Melville P, et al. Multicenter randomized clinical trial of donepezil for memory impairment in multiple sclerosis. *Neurology*. 2011;76:1500–7.
38. Svendsen KB, Jensen TS, Overvad K, Hansen HJ, Koch-Henriksen N, Bach FW. Pain in patients with multiple sclerosis: a population-based study. *Arch Neurol*. 2003;60:1089–94.
39. Al-Araji AH, Oger J. Reappraisal of Lhermitte's sign in multiple sclerosis. *Mult Scler*. 2005;11:398–402.
40. Kanchandani R, Howe JG. Lhermitte's sign in multiple sclerosis: a clinical survey and review of the literature. *J Neurol Neurosurg Psychiatry*. 1982;45:308–12.
41. Solaro C, Bricchetto G, Amato MP, et al. The prevalence of pain in multiple sclerosis: a multicenter cross-sectional study. *Neurology*. 2004;63:919–21.
42. Gutrecht JA, Zamani AA, Slagado ED. Anatomic-radiologic basis of Lhermitte's sign in multiple sclerosis. *Arch Neurol*. 1993;50:849–51.

43. Marrie RA, Cutter G, Tyry T, Vollmer T, Campagnolo D. Disparities in the management of multiple sclerosis-related bladder symptoms. *Neurology*. 2007;68:1971–8.
44. Araki I, Matsui M, Ozawa K, Takeda M, Kuno S. Relationship of bladder dysfunction to lesion site in multiple sclerosis. *J Urol*. 2003;169:1384–7.
45. Kalsi V, Gonzales G, Popat R, et al. Botulinum injections for the treatment of bladder symptoms of multiple sclerosis. *Ann Neurol*. 2007;62:452–7.
46. Chia YW, Fowler CJ, Kamm MA, Henry MM, Lemieux MC, Swash M. Prevalence of bowel dysfunction in patients with multiple sclerosis and bladder dysfunction. *J Neurol*. 1995;242:105–8.
47. Hinds JP, Eidelman BH, Wald A. Prevalence of bowel dysfunction in multiple sclerosis. A population survey. *Gastroenterology*. 1990;98:1538–42.
48. Nortvedt MW, Riise T, Frugård J, et al. Prevalence of bladder, bowel and sexual problems among multiple sclerosis patients two to five years after diagnosis. *Mult Scler*. 2007;13:106–1012.
49. Safarinejad MR. Evaluation of the safety and efficacy of sildenafil citrate for erectile dysfunction in men with multiple sclerosis: a double-blind, placebo controlled, randomized study. *J Urol*. 2009;181:252–8.
50. Fowler CJ, Miller JR, Sharief MK, Hussain IF, Stecher VJ, Sweeney M. A double blind, randomised study of sildenafil citrate for erectile dysfunction in men with multiple sclerosis. *J Neurol Neurosurg Psychiatry*. 2005;76:700–5.
51. Dasgupta R, Wiseman OJ, Kanabar G, Fowler CJ, Mikol DD. Efficacy of sildenafil in the treatment of female sexual dysfunction due to multiple sclerosis. *J Urol*. 2004;171:1189–93.
52. Koch M, Uyttenboogaart M, Polman S, De Keyser J. Seizures in multiple sclerosis. *Epilepsia*. 2008;49:948–53.
53. Stanton BR, Barnes F, Silber E. Sleep and fatigue in multiple sclerosis. *Mult Scler J*. 2006;12:481–6.
54. Schürks M, Bussfeld P. Multiple sclerosis and restless legs syndrome: a systematic review and meta-analysis. *Eur J Neurol*. 2013;20:605–15.
55. Italian REMS Study Group. Multicenter case-control study on restless legs syndrome in multiple sclerosis: the REMS study. *Sleep*. 2008;31:944–52.
56. Poser CM, Paty DW, Scheinberg L, et al. New diagnostic criteria for multiple sclerosis: guidelines for research protocols. *Ann Neurol*. 1983;13:227–30.
57. McDonald WI, Compston A, Edan G, et al. Recommended diagnostic criteria for multiple sclerosis: guidelines from the International Panel on the Diagnosis of Multiple Sclerosis. *Ann Neurol*. 2001;50:121–7.
58. Dalton CM, Brex PA, Miszkiel KA, et al. Application of the new McDonald criteria to patients with clinically isolated syndrome suggestive of multiple sclerosis. *Ann Neurol*. 2002;52:47–53.
59. Polman CH, Reingold SC, Edan G, et al. Diagnostic criteria for multiple sclerosis: 2005 revisions to the “McDonald Criteria”. *Ann Neurol*. 2005;58:840–6.
60. Polman CH, Reingold SC, Banwell B, et al. Diagnostic criteria for multiple sclerosis: 2010 revisions to the McDonald criteria. *Ann Neurol*. 2011;69(2):292–302.
61. Thompson AJ, Banwell BL, Barkhof F, et al. Diagnosis of multiple sclerosis: 2017 revisions of the McDonald criteria. *Lancet Neurol*. 2018;17(2):162–73.
62. Hickman SJ, Dalton CM, Miller DH, et al. Management of acute optic neuritis. *Lancet*. 2002;360:1953–62.
63. Sand IK, Lublin FD. Diagnosis and differential diagnosis of multiple sclerosis. *Continuum (Minneapolis Minn)*. 2013;19:922–43.
64. Miller DH, Weinschenker BG, Filippi M, et al. Differential diagnosis of suspected multiple sclerosis: a consensus approach. *Mult Scler*. 2008;14:1157–74.
65. Akman-Demir G, Serdaroglu P, Taşçı B. Clinical patterns of neurological involvement in Behçet’s disease: evaluation of 200 patients. The Neuro-Behçet Study Group. *Brain*. 1999;122:2171–82.
66. Joseph FG, Scolding NJ. Neurosarcoidosis: a study of 30 new cases. *J Neurol Neurosurg Psychiatry*. 2009;80:297–304.
67. Marangoni S, Argentiero V, Tavolato B. Neurosarcoidosis. Clinical description of 7 cases with a proposal for a new diagnostic strategy. *J Neurol*. 2006;253:488–95.
68. Pickuth D, Heywang-Köbrunner SH. Neurosarcoidosis: evaluation with MRI. *J Neuroradiol*. 2000;27:185–8.
69. Pawate S, Moses H, Sriram S. Presentations and outcomes of neurosarcoidosis: a study of 54 cases. *QJM*. 2009;102:449–60.
70. Wingerchuk DM, Banwell B, Bennett JL, et al. International consensus diagnostic criteria for neuromyelitis optica spectrum disorders. *Neurology*. 2015;85:177–89.
71. Al-Araji A, Kidd DP. Neuro-Behçet’s disease: epidemiology, clinical characteristics, and management. *Lancet Neurol*. 2009;8:192–204.
72. Roussel V, Yi F, Jauberteau MO, Couderq C, et al. Prevalence and clinical significance of anti-phospholipid antibodies in multiple sclerosis: a study of 89 patients. *J Autoimmun*. 2000;14:259–65.
73. Kovacs B, Lafferty TL, Brent LH, DeHoratius RJ. Transverse myelopathy in systemic lupus erythematosus: an analysis of 14 cases and review of the literature. *Ann Rheum Dis*. 2000;59:120–4.
74. Delalande S, de Seze J, Fauchais AL, et al. Neurologic manifestations in primary Sjögren syndrome: a study of 82 patients. *Medicine (Baltimore)*. 2004;83:280–91.
75. Steere AC, McHugh G, Damle N, Sikand VK. Prospective study of serologic tests for Lyme disease. *Clin Infect Dis*. 2008;47:188–95.
76. Stone JH, Pomper MG, Roubenoff R, Miller TJ, Hellmann DB. Sensitivities of noninvasive tests for central nervous system vasculitis: a comparison of lumbar puncture, computed tomography,

- and magnetic resonance imaging. *J Rheumatol.* 1994;21:1277–82.
77. Shorvon SD, Carney MW, Chanarin I, Reynolds EH. The neuropsychiatry of megaloblastic anaemia. *Br Med J.* 1980;281:1036–8.
  78. Dalmau J, Rosenfeld MR. Paraneoplastic syndromes of the CNS. *Lancet Neurol.* 2008;7:327–40.
  79. Louis ED, Lynch T, Kaufmann P, Fahn S, Odel J. Diagnostic guidelines in central nervous system Whipple's disease. *Ann Neurol.* 1996;40:561–8.
  80. Harding AE, Sweeney MG, Miller DH, et al. Occurrence of a multiple sclerosis-like illness in women who have a Leber's hereditary optic neuropathy mitochondrial DNA mutation. *Brain.* 1992;115:979–89.
  81. Ghezzi A, Filippi M, Falini A, Zaffaroni M. Cerebral involvement in celiac disease: a serial MRI study in a patient with brainstem and cerebellar symptoms. *Neurology.* 1997;49:1447–50.
  82. Eichler F, Mahmood A, Loes D, et al. Magnetic resonance imaging detection of lesion progression in adult patients with X-linked adrenoleukodystrophy. *Arch Neurol.* 2007;64:659–64.
  83. Rauschka H, Colsch B, Baumann N, et al. Late-onset metachromatic leukodystrophy: genotype strongly influences phenotype. *Neurology.* 2006;67:859–86.
  84. Aliaga ES, Barkhof FR. MRI mimics of multiple sclerosis. *Handb Clin Neurol.* 2014;122:291–316.



# Magnetic Resonance Imaging and Analysis in Multiple Sclerosis

# 6

Dejan Jakimovski, Deepa P. Ramasamy,  
and Robert Zivadinov

## Introduction

Multiple sclerosis (MS) is regarded as a chronic autoimmune demyelinating disease of the central nervous system (CNS), affecting more than two million people worldwide [1]. The multifocal demyelinated plaques seen on magnetic resonance imaging (MRI) appear throughout the CNS and are characterized with areas of focal inflammation, edema, glial reaction, and scarring. In the early stages of the disease, the acute appearance of the focal lesions is commonly accompanied with episodes of intermittent and accumulating neurological dysfunction [2]. Although MS still remains incurable, the early use of more than dozen available disease-modifying therapies allows fewer acute neurological episodes, lowers the MRI-detected pathological changes, and delays the accumulation of long-term physical disability [3].

Even though the conventional MRI is 5–10 times more sensitive than clinical examination in assessment of the MS disease activity, the technique has a number of drawbacks that limit the reliability as an overall surrogate marker for detecting clinical progression [4]. The unsuccessful efforts to link the MRI-derived markers and the clinical disability scores have resulted in

the coinage “clinical-radiologic” paradox [5]. Although the current gap between the clinical-radiologic paradox has been substantially reduced over the last decade, the overall MRI correlations still remain modest at best [6]. Therefore, this review will outline the major strengths and limitations of the conventional and nonconventional MRI techniques in their attempt to detect the inflammatory and neurodegenerative aspects of MS.

## Conventional MRI in Multiple Sclerosis

### MS Lesion Detection

Currently, there is no consensus on the precise and specific definition for the white matter (WM) hyperintensities (hereafter referred only as lesions) that are commonly seen in MS patients. Although variable, the MS lesions are usually ovoid or round in shape and are centered on small penetrating vessels. Their occurrence in the periventricular WM, juxtacortical, and infratentorial region is a relatively specific sign for MS. When imaged on sagittal MRI views, the ovoid lesions of the corpus callosum have typical radiographic appearance termed “Dawson fingers.” The characteristic decay of the nuclear spin is called transverse relaxation (T2) and it describes the time it takes for the signal to decrease to the 63% of its original value [7]. Among many variations

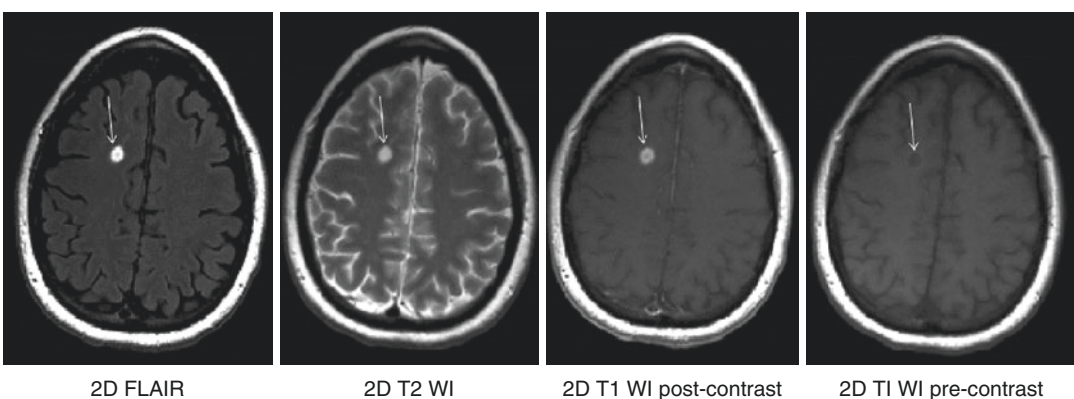
D. Jakimovski · D. P. Ramasamy · R. Zivadinov (✉)  
Department of Neurology, Buffalo General Hospital,  
University of Buffalo, Buffalo, NY, USA  
e-mail: [djakimovski@bnac.net](mailto:djakimovski@bnac.net);  
[dramasamy@bnac.net](mailto:dramasamy@bnac.net); [rzivadinov@bnac.net](mailto:rzivadinov@bnac.net)

between sequences that are able to detect the T2 changes, the most often recommended are: conventional echo, fast spin-echo (FSE), turbo spin-echo (TSE), and fluid-attenuated inversion recovery (FLAIR) [8]. T2-weighted imaging (WI) allows highly specific detection of the disease activity and the lesion appearance over time; however, it has intrinsic limitation in the ability to distinguish between the differential substrates of the T2-WI hyperintensities (inflammation, edema, demyelination, and axonal loss). Compared to higher sensitivity of the FLAIR sequence in detecting subcortical and discrete cerebral lesions, the FSE proton-density (PD) imaging allows better and more accurate detection of focal lesions within the infratentorial compartment [9]. Based on their appearance under different MR sequences, the majority of MS lesions are classified into three main groups: T2 hyperintense, chronic T1 hypointense (also known as “black holes”), and gadolinium (Gd) enhancing lesions on post-contrast T1-WI (Fig. 6.1).

Apart from the symptomatic lesion, clinically isolated syndrome (CIS) patients tend to exhibit multiple asymptomatic brain lesions even before their first onset clinical presentation (radiologically isolated syndrome, RIS). The number of T2 hyperintense lesions is directly associated with

the percentage and the time of reaching clinically definite MS diagnosis (81% of patients with  $\geq 10$  lesions when compared to only 9% in patients with an absence of T2 lesion, hazard ratio (HR) of 19.7) [10]. Similarly, the baseline T2 characteristics have the highest predictive value for detecting patients that will reach an Expanded Disability Status Score (EDSS) of 3.0 (22% of patients with  $\geq 10$  lesions when compared to only 4% in patients with absence of T2 lesion, HR of 4.4) [10]. The role of MRI-derived inflammatory biomarkers as high-impact prognostic factor have been also carefully studied and demonstrated within the initial large interventional MS trials [11]. Greater baseline MRI lesion volume and greater increase of lesion volume over time are moderately associated with clinical disability after 20 years [12]. Within this long-term follow-up, the rate of the lesion volume accumulation is substantially higher in patients that develop secondary progressive MS (SPMS) than in patients who maintain their relapsing–remitting MS (RRMS) status (2.89 cm<sup>3</sup>/year vs. 0.80 cm<sup>3</sup>/year) and this difference is already evident within 5 years of disease presentation [12].

The lack of specificity and the moderate correlations with the clinical disability call for improvement of the quality of T2-WI sequences



**Fig. 6.1** T1-weighted imaging, T2-weighted imaging, FLAIR, and gadolinium enhanced T1-weighted imaging. Conventional magnetic resonance imaging in multiple sclerosis patient including: (a) 2D fluid-attenuated inversion recovery (FLAIR) sequence, (b) T2-weighted image (WI) sequence, (c) T1-WI post-contrast sequence, and (d)

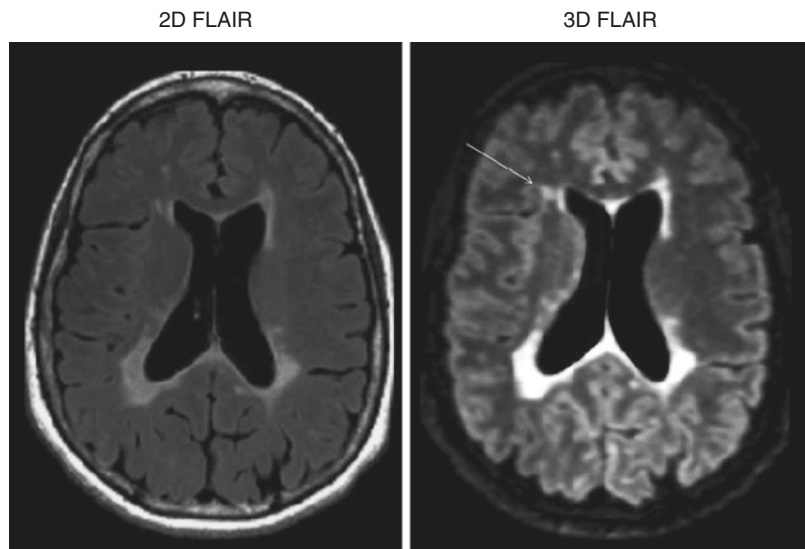
T1-WI pre-contrast sequence. The contrast enhancing lesion (white arrow) seen on the T1-WI post-contrast correlates with histopathological findings of blood-brain-barrier (BBB) breakdown and acute inflammation. Note the initial hypointensity of the acute MS lesion on the pre-contrast 2D T1-WI image

and use of additional quantitative approaches that will better characterize the lesions. The use of thinner 2D FLAIR slices (1.5 mm) can increase the sensitivity for detection of cortical and juxtacortical lesions in MS patients [13]. Lesion detection can be also substantially increased with the application of 3D MRI techniques, which provide equal spatial resolution along all three different axes. 3D FLAIR imaging uses inversion recovery preparation with variable flip angles that establishes pseudo-steady-states/relaxation contra-balancing, and allows nonblurred images despite the long echo trains. Although initially 3D FLAIR showed significant increase in the ability to detect MS lesions, the sequence required long, clinically unfeasible scanning times [14]. The 1.7 times increase in number of lesions detected by the single-slab 3D FLAIR when compared to the conventional 2D FLAIR may be also attributed to the significantly higher contrast-to-noise ratio (Fig. 6.2) [15]. However, recent optimization of the sequence parameters retained the increase in detection of both supra- and infratentorial lesions within acceptable reduction of the scanning time [16]. Despite the fact that many groups have tried to develop an automated and unsupervised method for MS lesion segmentation, thus far, these techniques are not readily available for wide clinical use [17].

The seminal paper by Trapp et al. demonstrated that the active inflammation during the demyelinating process causes a large number of axonal transections [18]. As a consequence of this acute focal axonal transection, the signal intensity within 80% of the active lesions shows initial T1-WI hypointensity [19]. As the inflammation subsides, 40% of the T1-WI hypointensities undergo process of remyelination, tissue repair, and return to their isotense signal characteristic [19]. However, the remaining percentage of acute black holes continues to degrade and develop into persistent black holes. The assessment of the persistent black holes was considered as the first measurable biomarker of the neurodegenerative process in MS [20]. Moreover, the presence and the extent of black holes have been repeatedly shown as one of the best predictive factors for disability in long-term follow-up studies [21, 22].

Gd enhancement is a transient phenomenon of the MS lesion that correlates with histopathological findings of blood-brain-barrier (BBB) breakdown and acute inflammation. When compared to T2-derived lesions, the Gd enhancing lesions are typically easier to identify and are less dependent on technical factors like acquisition parameters and intra- and interobserver variability. Due to the short interval of Gd persistence (3–6 weeks), the enhancing lesions may

**Fig. 6.2** Lesion detection comparison between 2D FLAIR and 3D FLAIR sequences. In addition to the improved lesion to noise contrast ratio, the 3D FLAIR image provides better delineation of white versus gray matter and allows detection of cortical lesions (white arrow)

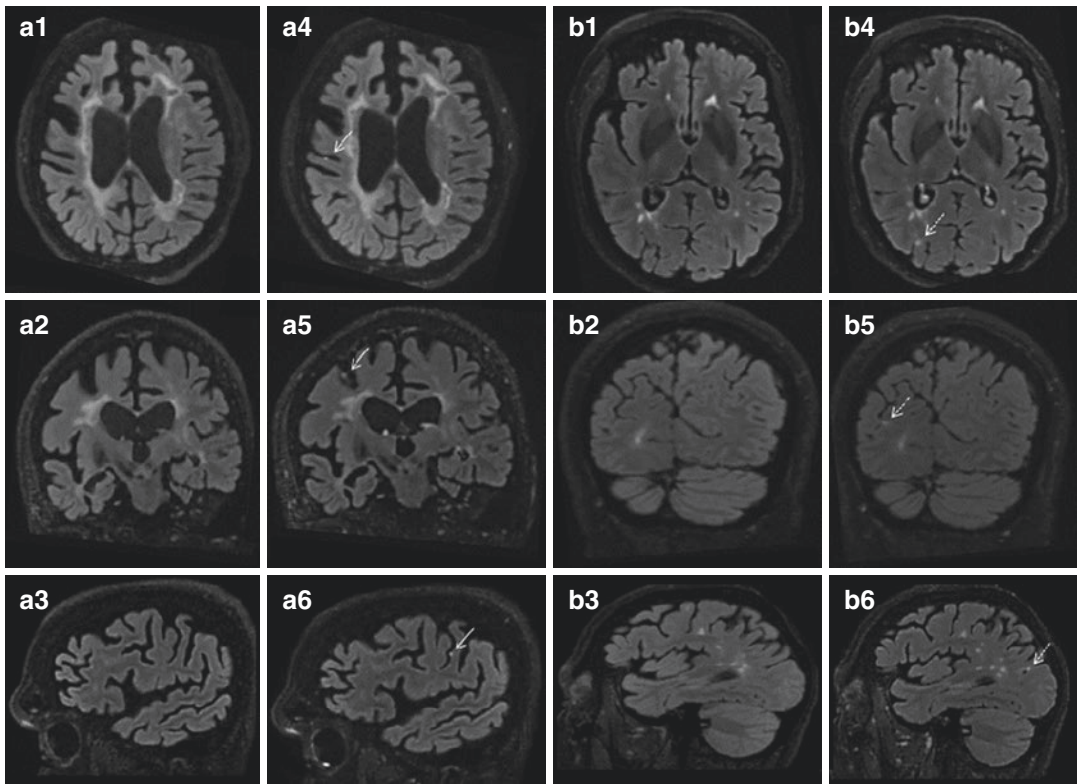


remain undetected by the regular 3–6 month re-scan periods. Therefore, Gd enhancing lesions are not sufficiently sensitive as singular measures of disease activity and treatment evaluation. In response to this limitation, in order to detect patients with suboptimal treatment response, several proposed scoring methods or criteria combine the clinical and MRI-derived measures [23]. In particular, the purposed scoring systems like the Rao scale, the modified Rao scale, and the European Medicines Agency (EMA) criteria showed variable sensitivity and specificity in detecting patients that will exhibit increased relapse rate or/and disability progression (ranging between 24% and 71% sensitivity and 71–97% specificity) [23]. A recent composite that included both absence of clinical and radiographic activity was initially termed “disease activity free status” (DAFS) and later renamed as “no evidence of disease activity” (NEDA). Although it has been shown that achieving and sustaining long-term NEDA status is especially difficult, NEDA has the potential to become a key therapeutic target goal in the future [24].

Both acute enhancing and chronic non-enhancing MS lesions show time-dependent increase in contrast enhancement [25]. The greater contrast enhancement seen in scans acquired after longer delay from the Gd administration suggests persistence of BBB leak [25]. Furthermore, several studies have shown that application of Gd would intensify the T1 effect on the FLAIR images and improve the detection of extra-axial pathology and meningeal enhancement [26]. Therefore, a combination of delayed post-contrast imaging and use of 3D FLAIR sequence allowed illustration of leptomeningeal contrast enhancement (LM CE) adjacent to the cortex of MS patients [27]. The aforementioned LM CE has been documented by several research groups and has been associated with patient age, disease severity, and the clinical type of MS [28]. A postmortem 7 T and histopathological examination of the structures that present as LM CE on MRI demonstrated that the aggregates of T- and B-cells are organized within a tertiary follicle-like structure [27]. The surrounding cortex of the sulcus that hosts the tertiary follicle-like structure

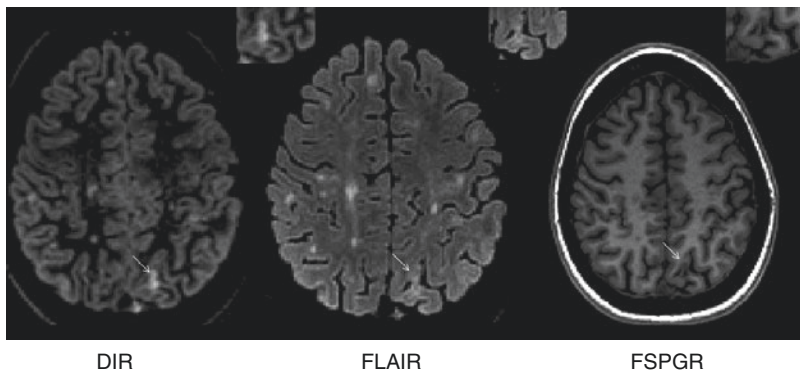
also shows extensive cortical demyelination [27]. Furthermore, the presence of LM CE was associated with lower global gray matter (GM) and cortical volume [29]. A similar 7 T MRI examination additionally showed that only a specific pattern of spread/fill foci are associated with the reduced cortical GM volumes, whereas the nodular foci may represent a normal variant [30]. Figure 6.3 exhibits the utility of post-contrast FLAIR in detecting the LMCE and demonstrates the differences between nodular versus spread/plate-type of LMCE. The proximity of the aforementioned tertiary follicle-like structures may potentially link the meningeal inflammation with the type III subpial cortical lesions. With the introduction of the new B-cell depleting therapies for MS, better understanding and reliable detection of the LM CE could potentially become a useful biomarker in assessing their therapeutic efficacy [31].

In contrast to the 3D FLAIR, the three-dimensional double inversion recovery (3D DIR) uses additional radiofrequency (RF) pulse that results in suppression of both the WM and the cerebrospinal fluid (CSF) [7]. The additional inversion pulse used in DIR imaging proves to decrease the signal-to-noise ratio and make the images appear noisier; however, it provides excellent contrast-to-noise ratio between the lesion and the parenchyma and may be an excellent tool for detecting cortical lesions (Fig. 6.4). The cortical lesions can be detected throughout all MS phenotypes and are mainly grouped as leukocortical or type I (lesions that extend through both GM and WM), intracortical or type II (lesions exclusively within the GM), and subpial or type III (lesions abutting the pia and extending into the cortex) [32]. Furthermore, DIR has been used for imaging of the optic nerve, the infratentorial segment, and the spinal cord. The DIR showed improved sensitivity at detecting lesions with a 7% gain with respect to FLAIR and 15% gain with respect to T2-WI [33]. The increase was even larger in respect to the infratentorial lesions with 56% increase when compared to FLAIR and 44% increase when compared to T2-WI [33]. In longitudinal examinations, DIR subtraction maps improved the detection of new and enlarged lesions both in terms of accuracy



**Fig. 6.3** Leptomeningeal enhancement in multiple sclerosis patients. The use of pre-contrast (a1–3 and b1–3) and post-contrast (a4–6 and b4–6) 3D fluid-attenuated inversion recovery (FLAIR) sequences in detection of leptomeningeal contrast enhancement (LMCE). Sixty-three-year-old secondary progressive multiple sclerosis patients

presenting with nodular LMCE enhancement (white arrow) demonstrated in all plane post-contrast 3D FLAIR images. Fifty-seven-year-old relapsing–remitting multiple sclerosis patients presenting with “spread/plate”-like LMCE (dotted white arrow)



**Fig. 6.4** Cortical lesion imaging using double inversion recovery (DIR) sequence. Double inversion recovery (DIR) sequence uses two separate radiofrequency pulses that suppress both the white matter and the cerebrospinal fluid signal. The sequence allows better detection of cortical lesions (white arrow) when compared to conventional sequences. (a) Double inversion recovery (DIR) sequence, (b) fluid-attenuated inversion recovery (FLAIR) sequence, and (c) fast spoiled gradient echo (FSPGR) sequence

cal lesions (white arrow) when compared to conventional sequences. (a) Double inversion recovery (DIR) sequence, (b) fluid-attenuated inversion recovery (FLAIR) sequence, and (c) fast spoiled gradient echo (FSPGR) sequence



and the time needed for the scan read [34]. The reported 1.7 times more detected active lesions using DIR subtraction was mainly driven by the strength of the DIR sequence in detecting cortical lesions [34]. The same group also demonstrated that post-contrast DIR imaging can detect significantly more (16%) contrast-enhancing lesion when compared to the traditional post-contrast T1-WI [35]. Despite the comparative improvement to the conventional FLAIR imaging, the 3D DIR technique is still not able to detect up to 80% of the cortical lesions seen under microscope [36]. The latest consensus recommendations for cortical lesion scoring using the DIR sequence included that (1) the GM lesions should be clearly hyperintense on DIR and (2) should cover at least three pixels based on minimal in-plane resolution of 1.0 mm<sup>2</sup> [37]. This recommendation also takes into account the relatively noisier 1.5 T DIR images when compared to 3 T. Due to the high association of cortical lesion load with physical and cognitive progression, the ability to successfully image the cortical pathology may help in early identification of patients with the most severe prognosis [38].

The latest guidelines published by the European Magnetic Resonance Imaging in MS (MAGNIMS) network recommended a standardized protocol for baseline and follow-up MRI examinations for patients with suspected or clinically definite MS [39]. The baseline examination included mandatory use of axial proton-density (PD) and/or T2-FLAIR/T2-WI, sagittal 2D or 3D FLAIR, and a 2D or 3D contrast-enhanced T1-WI. Additional (optional) sequences included unenhanced 2D or high-resolution 3D T1-WI, 2D and/or 3D DIR sequence, and an axial diffusion-weighted imaging (DWI) sequence. Similarly, the follow-up MRI examinations should include at least the mandatory PD or T2-FLAIR and the 2D or 3D contrast-enhanced T1-WI, with optional addition of the high-resolution 3D T1-WI, 2D/3D DIR, and axial DWI. Unfortunately, the minimum recommended milieu of sequences is not able to provide reliable prognostic information for establishing disease progression. The addition of repeat scans within the first few months of treatment initiation can considerably predict the

treatment response [23]. Additionally, the use of automated subtraction techniques (follow-up vs. baseline subtraction) can improve the accuracy and sensitivity of detecting new and/or enlarging T2 lesions [23]. As discussed later in this review, the current data still does not support the use of automated brain volume nor spinal cord measures in predicting the individual treatment response rate [23].

## MRI Contrast Agents and Contrast Deposition

The fundamental capability of contrast agents to efficiently lower the relaxation times of T1 and/or T2 allows generation of better MRI-derived signal and better detection of lesions. The addition of paramagnetic ions like gadolinium (Gd<sup>3+</sup>), iron (Fe<sup>2+,3+</sup>), and manganese (Mn<sup>2+</sup>) act as individual microscopic magnets that cause faster neighboring proton relaxation back to their equilibrium state. In comparison to Gd, the iron-based agents have stronger ability to affect the relaxation times and they are mostly used as dark MRI contrast (T2\* imaging). These iron oxide particles vary in size, from ultrasmall superparamagnetic particles of iron oxide (USPIOs, 5–50 nm) to superparamagnetic iron oxide particles (SPIOs, 50–150 nm) and micron-sized iron oxide particles (MPIOs, ≈1 μm) [40].

A major benefit in utilization of USPIOs in imaging of the inflammatory diseases like MS is their ability to be captured by the circulating monocytes/macrophages and travel to the site of inflammation. Thus, USPIO contrast agents are able to provide higher cell specificity and better understanding of the CNS inflammation. Additionally, potential coupling of MPIOs with anti-adhesion antibodies can provide direct imaging of endothelial surface markers (E-selectin and P-selectin) that control immune cell trafficking [41, 42]. The discrepancies of contrast enhancement seen while imaging with both USPIOs and Gd-based agents have suggested an active monocyte infiltration through the preserved integrity of the BBB [43]. However, the appearance of USPIO within an hour of its administration points to a

second, cell-independent transport indicates leaky BBB [44]. On that note, USPIO-related abnormalities can be already seen at day 10 after EAE disease induction, a period which does not include macrophage infiltration [44]. The later process of passive USPIO diffusion is cleared through neighboring cervical lymph nodes and does not produce significant contrast changes after 24 h of administration [44]. Therefore, knowledge about the USPIO kinetics is crucial in determining the temporal and mechanistic characteristic of USPIO imaging.

Due to the ionic radius of 0.99 Å, Gd in its stable oxidation state ( $Gd^{3+}$ ) can easily compete for the binding sites of  $Ca^{2+}$  and produce relative biological toxicity. Prior to its use in humans, the Gd requires a process of chelation that will prevent free  $Gd^{3+}$  circulation [45]. Generally, the current Gd-based MRI contrast agents (GBCAs) are divided into four types: macrocyclic or linear and they can be additionally separated as ionic (charged) or non-ionic. The particular chemical structure produces inherent differences in the kinetic stability [46]. In presence of endogenous cations like  $Cu^{2+}$  or  $Zn^{2+}$ , the linear agents can exhibit poorer kinetic stability and dissociate [46].

A potential association of MRI-detected brain abnormalities and previous exposure to linear chelate GBCAs has been initially published in 2014 [47]. It showed a positive correlation between high signal intensity of the dentate nucleus and history of multiple GBCA administrations [47]. These preliminary results were later confirmed with GBCA accumulation studies in patients with MS, brain metastasis, and in pediatric population [48]. A preclinical study investigated the amount of Gd deposition in rat brains after 20 consecutive injections of linear GBCA, macrocyclic GBCA, or placebo [49]. The results corroborated that linear GBCA leads to progressive increase in MRI signal intensity ratio [49]. Additionally, postmortem autopsy demonstrated higher amount of linear GBCA deposition when compared to rats exposed to the macrocyclic GBCA or placebo [49]. A similar study examined multiple formulations of GBCAs and showed that all three linear GBCAs tested had signifi-

cantly higher brain deposition than placebo or the macrocyclic GBCAs [50].

Until recently, the only other known adverse effect related to Gd administration was a rare nephrologic condition called nephrogenic systemic fibrosis. Due to the aforementioned reports of Gd deposition in the brain, the FDA issued warning, which suggests avoiding linear GBCAs administration if not necessary. The highest retention was seen among the linear gadodiamide (Omniscan<sup>®</sup>) and gadoversetamide (OptiMARK<sup>®</sup>), followed by gadopentetate dimeglumine (Magnevist<sup>®</sup>), gadobenate dimeglumine (MultiHance<sup>®</sup>), and gadoxetate disodium (Eovist<sup>®</sup>), and the lowest retention with the use of the macrocyclic gadoterate meglumine (Dotarem<sup>®</sup>), gadoteridol (ProHance<sup>®</sup>), and gadobutrol (Gadavist<sup>®</sup>). Additionally, the EMA suspended the use of the aforementioned Omniscan<sup>®</sup>, Magnevist<sup>®</sup>, OptiMARK<sup>®</sup>, and restricted the use of MultiHance<sup>®</sup> only for liver scans. In conclusion, convincing evidences demonstrate active deposition of Gd in the deep brain nuclei, particularly after repeated linear GBCAs exposure. The biological and clinical effect of this brain deposition still remains undetermined in patients with MS and other diseases [51].

### **2017 Revision of McDonald Criteria for Multiple Sclerosis Diagnosis**

Due to the rapid growth of the medical imaging field, periodical revision of the diagnosis guidelines would provide continuous improvement in the sensitivity and specificity of the criteria [52–54]. The new 2017 revision of the MS McDonald criteria has focused on clarifying and simplifying the constituents of the previous versions, changes that will ultimately allow lower frequency of MS misdiagnosis [54]. The previous 2010 revision of the McDonald criteria required that dissemination in space (DIS) should be demonstrated by  $\geq 1$  T2 lesion in at least two of four areas of the CNS (periventricular, juxtacortical, infratentorial, and spinal cord). On the other hand, for the demonstration of dissemination in time (DIT), it required: (1) a new T2 and/or Gd enhancing lesion on follow-up MRI or (2) simultaneous

presence of asymptomatic Gd enhancing and non-enhancing lesions at any time [53].

The first step into improving the CIS/MS classification was the inclusion of the CSF-derived oligoclonal bands (OCB) as acceptable substitute for the DIT requirement. The change was prompted by multiple recent studies showing that presence of CSF OCB is an independent predictor of consecutive second attack [10, 55]. In a large multicenter study, the presence of OCB was associated with increased conversion to MS (hazard ratio of 2.18) [56]. Furthermore, a meta-analysis showed that the presence of OCB in the CSF of CIS patients resulted in increased chance (odds ratio of 9.9) of conversion to MS [57].

As a second amendment, the new criteria remove the discrimination between symptomatic and asymptomatic T2 lesions in the determination of DIS or DIT [58, 59]. The previous distinction was done with an idea to exclude the symptomatic lesion from the required two out of four MS characteristic region involvement (periventricular, juxtacortical, infratentorial, and spinal cord) and prevent double counting. As an example, a patient presenting with an acute partial transverse myelitis would require only one or more T2-hyperintense lesions in the remaining three regions (paraventricular, juxtacortical, or infratentorial) in order to fulfill the new 2017-revised McDonald criteria. Although still debated, lesions in the optic nerve are considered as exception from this rule and still remain insufficient in documenting DIS or DIT [60, 61].

Lastly, the new 2017 McDonald criteria recommend the inclusion of cortical lesions as equal constituents for fulfilling the DIS requirement. The ability to routinely and reliably detect cortical lesions requires additional MRI sequences that were previously described in this review. The expert panel of the revised 2017 criteria has recognized the potential imaging artifacts and the current limitations of DIR imaging [62, 63].

The future alliterations of the MS diagnosis guidelines should focus on defining entities like RIS, solitary sclerosis, *possible multiple sclerosis*, pediatric multiple sclerosis, anti-MOG pathology, and the diagnosis of MS in more diverse populations [64–66]. Future standardiza-

tion of the nonconventional techniques like multi-echo MRI imaging, GM imaging, optical coherent tomography (OCT), evoked potentials, and laboratory tests may increase the accuracy of the diagnosis.

## Spinal Cord Imaging

Due to the inclusion of the spinal cord region as part of the four areas included in the McDonald criteria, spinal lesions can be used to demonstrate DIS. Therefore, spinal cord imaging is an essential diagnostic tool that should be obtained in patients with spinal cord symptomatology and patients in whom brain scans do not solemnly fulfill the McDonald criteria for MS diagnosis [67]. The spinal cord MRI abnormalities are not exclusively seen in MS and should be differentiated from diseases like neuromyelitis optica spectrum disorder (NMOSD), myelin oligodendrocyte glycoprotein myelopathy (anti-MOG disease), and idiopathic transverse myelitis (ITM) [68]. Regardless of the OCB and brain MRI findings, the spinal cord lesions independently contribute to two- to threefold increase in risk for reaching an MS diagnosis [69]. Indeed, even in patients with non-spinal CIS presentation, the detected spinal cord MRI abnormalities are able to explain a larger amount of follow-up disability progression when compared to the brain MRI measures [70]. Both the accumulation of asymptomatic spinal cord lesions and the progression of spinal cord atrophy in CIS patients contribute up to 50% of the MS-related disability accumulation over mid-term follow-up period [70].

Most spinal cord scans were traditionally acquired with the use of sagittal dual echo (PD and T2) sequence. Together with the increasing clinical 3 T availability, multiple combination of sequences have been purposed to increase the lesion detection and regional cord volume detection. For example, sequences like short tau inversion recovery (STIR) and phase-sensitive inversion recovery (PSIR) use fat suppression and allow better spinal cord lesion assessment and WM versus GM separation [71]. Multiple findings demonstrate that the preferential loss of

spinal cord GM is associated with more severe EDSS score and walking disability, whereas spinal cord WM did not [71, 72]. Manual and automated models of spinal cord volume segmentation have been additionally proposed [73].

The relationship between spinal cord pathology and the disability progression has been especially emphasized within SPMS and primary progressive (PP) MS patients [74]. In a large single-center retrospective study, all SPMS patients and almost all PPMS had spinal cord lesions at their C2–C3 level [74]. Additionally, PPMS patients had significantly more spinal cord atrophy when compared to SPMS and healthy controls [74]. The overall sample size calculations for the use of spinal cord cross-sectional area measurement in PPMS patients resulted only in 57 subjects per arm needed, whereas for SPMS it required at least 546 subjects per arm [74]. Therefore, future PPMS and neuroprotective MS trials should consider spinal cord imaging as part of their outcome measures.

The use of nonconventional spinal cord MRI studies are still in their very early stages and have relatively limited clinical applicability [75]. DTI of the spinal cord (FA metric) is the only nonconventional technique that provides moderate evidence of association with impairment in a number of neurological diseases [75]. The larger magnetic field inhomogeneity and the intensified intrinsic motion caused by the cardiac and respiratory cycles remain as major limiting factors in the acquisition of high-quality spinal cord data [70].

---

## Ultra-High-Field MRI Imaging in MS

The advantages and limitations of ultra-high-field imaging can be essentially explained by the increase of the main magnetic field ( $B_0$ ). The larger initial amount of spins that are transversely aligned with the magnet will produce larger net magnetization. However, the larger strength will also introduce a larger  $B_0$  inhomogeneity that can cause artifacts and signal loss. When compared to 1.5 T and 3 T MRI imaging, the 7 T scanners allow five- to tenfold increase of the signal-to-

noise ratio. Additional benefits of ultra-high-field MRI imaging are: improved contrast derived from the magnetic susceptibility variations, greater chemical shift dispersion, and faster echo planar imaging. The 7 T MRI scanners have been extensively used in understanding the prelesional WM changes, evolution of the cortex changes, detection of GM lesions, and understanding the process of neurodegeneration [76]. The increased number of WM lesions detected with the ultra-high-field MRI systems suggests that the current imaging protocols are not fully capturing the MS pathology [77]. Additionally, the higher imaging resolution provides improvement in the differential diagnosis of WM abnormalities and in their differentiation from other mimicking demyelinating lesions [78–80]. Several studies have shown that 7 T imaging allows more than double increase in the detection rate of cortical lesions in MS [62, 81, 82]. However, when compared to histopathological analysis, up to 40% of the subpial (type III) cortical lesions are still missed even at 7 T MRI [62]. Similarly, a study using 7 T, T2\* MRI sequence produced surface-based analysis that showed in vivo characterization of the degree of cortical pathology at different depths of the cortex [83]. The gradient in the intracortical pathology across different disease stages demonstrates that the pathology is driven from the pial surface itself [83]. As of October 12th, 2017, the FDA approved human clinical use of the first 7 T MRI device (Magnetom Terra®, Siemens), which allows for 0.2 mm in-plane resolution, voxel size of 0.14 cm<sup>3</sup>, and submillimeter fMRI BOLD signal specifications.

---

## Nonconventional Imaging

### Brain Atrophy

The physical and cognitive decline seen in the later stages of the disease are not represented by the sparse MRI-detected inflammatory lesions. The purposed two-stage process might potentially explain the failure of the current anti-inflammatory therapeutics in their ability to

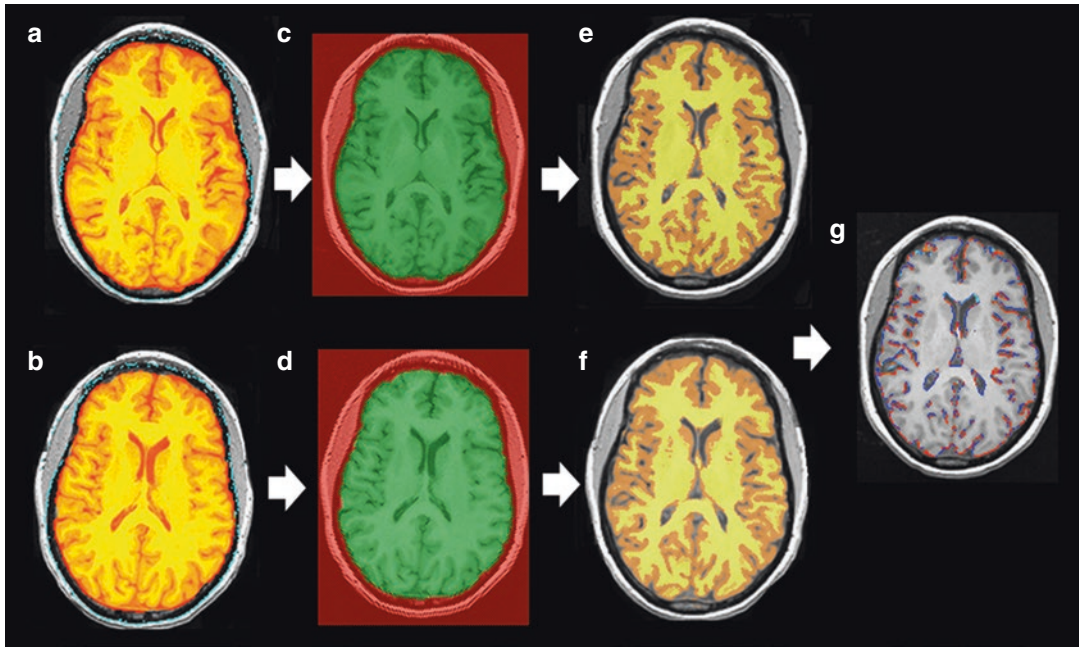
control the secondary inflammation-independent disability progression [84]. The underlying brain atrophy seen throughout all stages of MS can be generally explained by three main subsequent pathological processes: tissue loss within the lesions themselves (T1-hypointensities), Wallerian degeneration affecting the length of the transected axons, and independent neurodegenerative changes within the NAWM and NAGM [18]. As the axons do lose their myelin sheath, a compensatory upregulation of sodium channel expression sustains the signal transduction [85]. Intensified sodium channel usage requires greater amount of ATP that eventually gets depleted and induces mitochondrial dysfunction [85]. The mitochondrial dysfunction further causes global neuronal energy deficit and cascades to toxic accumulation of  $\text{Ca}^{2+}$ , which finally leads to neuronal death [85]. Potential inhibition of the specific  $\text{Na}_v1.6$  channels might prevent the “inside-out” pathophysiology of the MS neurodegeneration [86]. The robustness of the ongoing axonal loss has been documented with histological analysis of the cerebrospinal tract [87]. After a lifetime of MS (an average of 30 years of disease duration), the corticospinal tract loses approximately 60% of the total axonal pool [87]. Similarly, the normal-appearing white matter (NAWM) demonstrates substantial loss (50%) of both axon density and volume [88].

On the other hand, the GM atrophy is primarily affected by neurodegeneration, a co-occurring process that is not associated with presence of GM lesions, the overall myelin density, or the survival of the oligodendrocytes [89]. The first systematic histopathological and MRI investigation showed that the cortical volume in long-lasting MS patients is largely and independently explained by neuronal density, neuronal size, and axonal density [90]. After a mean disease duration of 27 years, MS patients have almost 40% less total number of neocortical neurons and almost 30% reduction in neuronal density when compared to controls [91]. This neuronal loss was seen in all lobes investigated with the exception of the primary occipital (visual) cortex. The association between the overall neuronal loss and the MRI-derived cortical volume demonstrates

that in vivo MRI studies can provide robust prediction of cortical pathology [91].

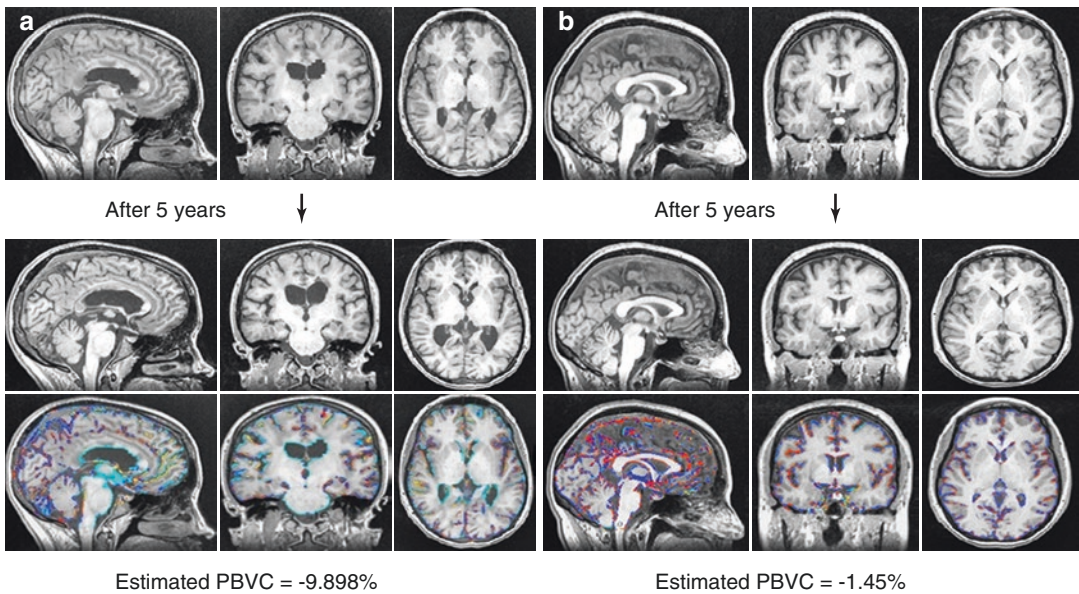
A serial yearly MRI scans acquired over a decade showed that ventricular CSF space and the whole brain atrophy in early MS patients can predict the development of disability progression over 10 years later (after 1 and 2 years, respectively) [92]. Similarly, a large multicenter study showed that a combination of central atrophy rate and the lesion volume change over the first 2 years was able to predict the disability over 10 years (74.3% of explained variance in clinical outcome) [93]. The atrophy of the deep gray matter (especially the thalamus) has been repeatedly shown as an effective MRI measure that is able to predict future conversion of CIS patients to clinically defined MS or predict patients with future disability progression [94, 95]. There is an increasing amount of evidence that the GM and deep GM atrophy occurs more rapidly through all stages of the disease when compared to the WM and may present as a meaningful indicator of neurodegeneration [96, 97]. The ability to detect an early brain atrophy rate that will subsequently predict the long-term disability outcomes allows better therapy monitoring (Figs. 6.5 and 6.6) [98].

A meta-analysis from all published RRMS clinical trials showed close relationship between the treatment effect on brain atrophy and on disability progression [99]. The treatment effect demonstrated an independent effect on active MRI lesions, an independent effect on the brain atrophy, and a synergistic effect of both MRI outcomes combined [99]. Based on several long-term follow-up studies, cutoff values of pathological yearly brain atrophy have been proposed [100–102]. A combined analysis of multiple observational and interventional MS trials that included more than 11,000 MRI scans demonstrated that  $-0.57\%$  annualized percentage change of corpus callosum volume had 90% specificity and 48% sensitivity in distinguishing between healthy controls and RRMS patients [101]. A small single-center study showed that an annual whole brain atrophy rate greater than 0.5% has 95% specificity or greater than 0.4% has 80% specificity in discriminating patients with MS from healthy controls [100]. Based on



**Fig. 6.5** Brain atrophy analysis using SIENA algorithm. SIENA algorithm for estimating the longitudinal total brain volume change between two input images taken from the same subject, at different timepoints. The upper row of images belongs to the initial MRI timepoint and the lower row of images belongs to the follow-up MRI

timepoint. (a, b) Represent the extracted brain images, (c, d) demonstrate the standard space masking within a common field of view, while (e, f) show the tissue segmentation that detects the brain/non-brain boundaries. In panel g, the final brain edge movement image shows atrophy (blue) or “growth” (orange)



**Fig. 6.6** Brain atrophy differences between age- and sex-matched relapsing–remitting multiple sclerosis patients assessed with SIENA algorithm over a 5-year follow-up period. *PBVC* percentage brain volume change. The relapsing–remitting multiple sclerosis (RRMS) patient in panel

(a) demonstrates a high rate of 5-year longitudinal atrophy rate (estimated  $PBVC = -9.898\%$  or  $1.98\%$  annualized), whereas the age- and sex-matched RRMS patient in panel (b) demonstrates comparatively lower brain atrophy rate (estimated  $PBVC = -1.45\%$  or  $0.29\%$  annualized)

the corresponding 0.4% of annual whole brain atrophy, similar sensitivity and specificity analysis determined the lateral ventricular volume cut-off at annual rate of 3.5% [102]. With a proposed individual expected brain volume calculation, the FREEDOMS I/FREEDOMS II trial patients were classified as low baseline volume (1 standard deviation below the expected), medium baseline brain volume (within 1 standard deviation of the expected), and high brain volume (1 standard deviation above the expected) [103]. Additional factors that were accounted into the model included the baseline age, sex, the disease duration, T2 lesion load and their baseline disability [103]. The aforementioned attempt of individual brain volume classification was able to differentiate patients with high risk of future disability worsening (low vs. high BV with hazard ratio of 1.73) [103]. Before undertaking the task of individual volumetric comparisons, it is critical to understand the processes of biological aging and the ability to separate the “normal aging atrophy” with “disease-specific atrophy” [104]. A step toward determining ideal regions that undergo disease-specific atrophy would ultimately lead to the ability of measuring the therapeutic interventions that would target the brain atrophy. Furthermore, the creation of a large population-wide volumetric database that archives the MRI scans and provides MS-specific atrophy rates across the lifespan of the patients may further overcome the current limitations of atrophy use [105]. Furthermore, the measurement of brain atrophy has special interest in the management of the questionably distinct and small cohort of patients (10%) termed as PPMS, which demonstrates continuous disability worsening despite the absence of clearly recognizable clinical relapses and active inflammatory MRI biomarkers [106].

The use and reliability of brain atrophy measurements in MS patients have substantially improved in the last two decades. Fully automated software like NeuroQuant<sup>®</sup>, MSmetrix<sup>™</sup>, and NeuroSTREAM<sup>®</sup> have been developed for computing cross-sectional and/or longitudinal changes of the whole brain volume, separate tissue-compartment volumes (GM and WM),

and lateral ventricular CSF volumes, respectively [107]. Based on the characteristics of the MRI sequences that are currently acquired throughout the United States (99.3% availability of T2-FLAIR vs. only 39.7% of 3D T1-WI), developing a feasible surrogate T2-FLAIR-derived atrophy calculation may additionally assist in future implementation of atrophy outcomes [108]. Although brain atrophy now is regularly used as a secondary endpoint in all recent and upcoming MS clinical trials, the utility and interpretation of individual brain volume changes within the clinical routine remain undetermined [109].

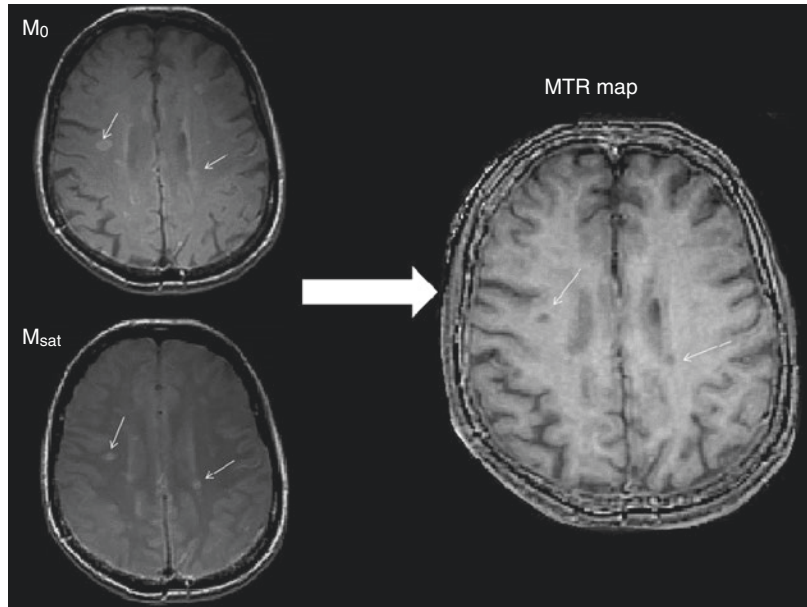
### Magnetization Transfer Imaging (MTI)

Magnetization transfer imaging (MTI) uses the different  $T_2$  relaxation properties of water molecules that are found in a free state ( $>10$  ms) or as bound to complex macromolecules ( $<200$   $\mu$ s). Application of an off-resonance RF pulse that will selectively pre-saturate only the immobile water protons causes exchange (transfer) of longitudinal magnetization between the rigid macromolecules and the free water protons. This magnetization transfer results in partial saturation of the free water molecules as well (it decreases the signal) and creates tissue contrast. The magnetization transfer ratio (MTR) can be quantified by acquiring and subtracting two sets of acquisitions, image with the off-resonance pulse ( $M_{\text{sat}}$ ) and conventional image ( $M_0$ ) (Fig. 6.7):

$$\text{MTR} = \frac{M_0 - M_{\text{sat}}}{M_{\text{sat}}}$$

Decrease in MTR has been associated with loss of myelin, axonal damage, and active cell infiltration, whereas the increase of MTR has been hypothesized as marker of possible remyelination and lesion resolution [110, 111]. The use of this technique in understanding the MS pathology has been further standardized and implemented in several pivotal MS trials. In the DEFINE trial, a double-blind, placebo-controlled

**Fig. 6.7** Magnetization transfer imaging (MTI) in multiple sclerosis. The magnetization transfer ratio (MTR) obtained by subtracting two sets of acquisitions: image with the off-resonance pulse ( $M_{\text{sat}}$ ) and conventional image ( $M_0$ ). The decrease in MTR as represented by hypointense signal areas in the MTR map (white arrows) is associated with loss of myelin, axonal damage, and active cell infiltration



study that randomized patients to dimethyl fumarate and placebo, the active treatment showed significant normal-appearing brain tissue (NABT) reduction when compared to placebo [112]. The similar utility of longitudinal MTR imaging was seen in BECOME [113] and ADVANCE trials [114], demonstrating the MTR responsiveness in clinical intervention settings. The use of MTR imaging in future remyelination trials is also planned.

Average NABT MTR changes have shown good specificity and positive predictive value in predicting individual disability progression over the 4.5-year follow-up period [115]. Similarly, a combination of percentage change of lesion MTR and GM MTR values are able to discriminate 66% of the MS patients with risk of long-term disability progression [116]. These MTR changes are present even at the earliest stages of MS and are not correlated to the inflammatory burden of the patient, alluding to independent pathophysiology [117]. Independently of the lesion load, a similar study also showed that the periventricular MTR changes in CIS patients are associated with later definitive MS diagnosis and subsequent disability accumulation [118].

Consecutive MTR scans have demonstrated that progressive local decrease in MTR values in

the NAWM precedes the development of enhancing lesions [119]. These changes appear 3 months before the Gd enhancement and may be attributed to perivascular inflammation, edema, astrocytic proliferation, and sequential demyelination [120]. At the time of enhancement the lesion shows major decrease of MTR that partially recovers over the following 4 months [121]. The heterogeneity is demonstrated where some lesions show partial recovery of the mean MTR, some show stable low levels of MTR, and others further continue to decline [121]. In situ, post-mortem MTR imaging of seven MS brains showed that normalized MTR of the cortex was significantly lower in presence of cortical lesions when compared to myelinated cortex [122]. The imaging was performed on 3 T clinically available MTR sequences and may be of additional benefit in the detection of cortical lesions [122].

Overall, the MTI can be used as proxy measurement of the absolute myelin content and provides additional information on the overall pathophysiology of the processes seen in NABT and in MS lesion evolution. The availability of MTI in most of the modern MRI scanners allows obtainable and achievable MTI imaging in large clinical remyelination trials [123]. Myelin water imaging (MWI), quantitative magnetization



transfer (QMT), multi-echo  $T_2$  mapping, and steady-state multicomponent relaxometry (mcDESPOT) are newer techniques that may further provide understanding of the myelin pathology observed in MS.

## Multi-echo Imaging

Magnetic susceptibility is the physical quantity that measures the extent to which a material is magnetized when placed in an extrinsic magnetic field. This is an intrinsic property of all biological tissues and the brain susceptibility is mainly driven by four molecules: water, iron, myelin, and calcium [124]. The magnetic susceptibility causes local field perturbation that creates various distortions of the MRI images. Although these image distortions were initially considered as unwanted, a number of sequences take advantage of them as a useful image contrast [125]. In contrast to the nuclear magnetization of the MRI signal, magnetic susceptibility originates from the orbital electrons [126]. Multi-echo spoiled-gradient-recalled-echo (SPGR or GRE) sequence is the most common method of capturing the effect of the aforementioned magnetic susceptibility. The exponential decay ( $T_2^*$  decay) measures the offset of the local Larmor frequency and captures the local field perturbations. Therefore, different biological tissues would have different  $T_2^*$  values that allow early and quantitative diagnosis of diseases.

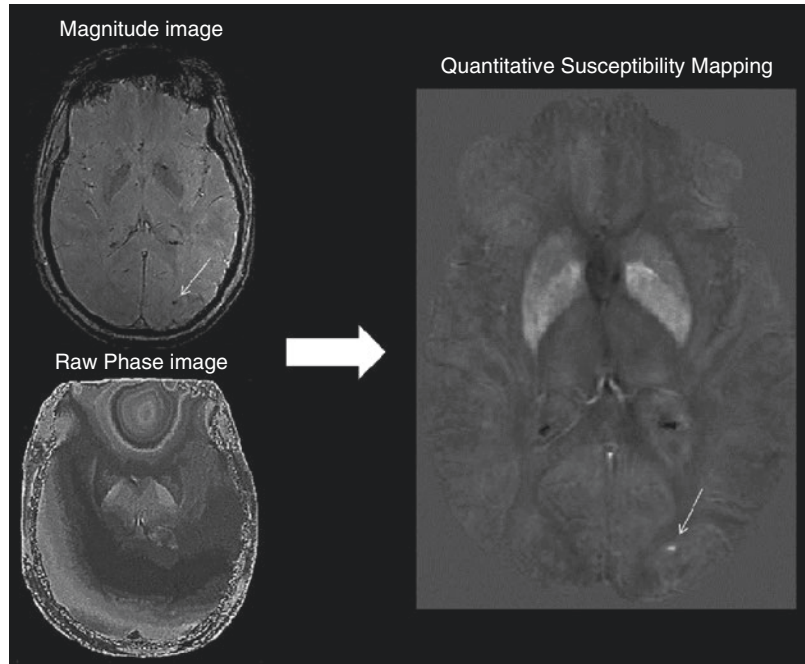
The simple MRI signal is an oscillating sinusoidal wave that has fundamental properties of frequency, amplitude, and phase. The susceptibility-weighted imaging (SWI) uses a combination of magnitude and phase in order to enhance the  $T_2^*$  contrast derived from the magnetic field perturbations. The sensitivity of the conventional sequences to detect MS lesions is high; however, the lack of specificity can be potentially overcome by SWI. The initial use of MR venography showed that 94 out of 95 lesions seen in MS patients have a vein running centrally through them, demonstrating the perivenular distribution of the pathology [127]. The North American Imaging in Multiple Sclerosis

(NAIMS) Cooperative later has recognized the utility of the “central vein sign” (CVS) as proposed MRI biomarker to increase the accuracy of the MS diagnosis [80]. Although the CVS can be seen among  $T_2$  hyperintensities originating from other inflammatory and non-inflammatory pathology, a threshold of 50% perivenular lesions allows MS discrimination with diagnostic accuracy of 100% [128]. Similar phase abnormalities are able to distinguish WM signal abnormalities in CIS patients and tend to be more predictive of conversion to definite MS than the conventional  $T_2$  lesions [129]. Outside of lesion discrimination, the SWI technique can be used in determining cerebral microbleeds [130] and abnormal phase tissue in the subcortical gray matter [131].

The field variations based on the biological magnetic susceptibility can be quantitatively assessed by quantitative susceptibility mapping (QSM) or susceptibility tensor imaging (STI) (Fig. 6.8). The potential use of QSM in MS imaging can be essential in understanding the substantial and long-lasting microglial inflammation that is actively occurring behind an intact BBB [132]. As such, changes in iron accumulation within the macrophages and microglia may provide additional information of the lesion evolution [133]. During active Gd enhancement, the susceptibility is initially isointense. As soon as the enhancement diminishes, the susceptibility drastically increases and remains constant until completely returning to the original isointense levels (formation of chronic silent lesions after several years) [134]. Similar use of QSM would allow detecting chronically active versus chronically inactive lesions. Lesions rich with iron-laden microglia express proinflammatory cytokines that promote slow smothering tissue damage around the rim of the lesion [135].

Several cross-sectional and longitudinal MS studies showed heterogeneity in the iron trajectories of the deep GM. Accumulating evidence is demonstrating that certain structures like the caudate are progressively accumulating more iron, whereas the thalamus, pulvinar, and the left lateral nuclear region decrease their iron content [136]. The susceptibility reduction seen in the thalamus and the pulvinar is also associated with

**Fig. 6.8** Multi-echo phase imaging and quantitative susceptibility mapping (QSM) processing. Quantitative susceptibility mapping provides sensitive tool for assessing the amount of iron and calcium within the tissues. After a series of processing steps, the final image is derived from a magnitude and raw phase image. The white arrow points to a microbleed



longer disease duration [137]. The thalamic reduction of susceptibility may potentially suggest an active process of iron depletion within the oligodendrocytes [137].

Future QSM studies have the potential to understand the role of global iron trafficking in terms of lesion evolution and neurodegeneration. Additional  $T_2^*$ -weighted methods that use the contrast from the magnetic field perturbations are myelin water imaging (MWI), STI, arterial spin labeling (ASL), and functional magnetic resonance imaging (fMRI).

### Diffusion-Weighted Imaging (DWI) and Diffusion Tensor Imaging (DTI)

The diffusion measurement captures the random thermal (Brownian) motion of water molecules constrained by the surrounding anatomy. Therefore, diffusion-weighted imaging (DWI) provides information dominated mainly by static neuroanatomy and less influenced by the physiology of the system [138]. Diffusion of the water in a circular fashion (spreading toward all sides) is called *isotropic* diffusion, whereas water that diffuses along one specific axis is called *anisotropic*

diffusion [139]. Diffusion tensor imaging (DTI) uses multiple DWI images acquired with different diffusion gradients that can be fitted into one diffusion tensor model and provides numerical quantification of mean diffusivity (MD), radial diffusivity (RD), axial diffusivity (AD), and fractional anisotropy (FA). Since water can easily diffuse along the length of the axonal bundles and between the myelin sheaths, the anisotropic properties allow estimation of axonal integrity and organization.

This technique has allowed systematic mapping of the macroscopic human brain circuits within projects like the Human Connectome Project (HCP), The BRAIN initiative, the Human Brain Project, and has a significant utility in understanding the MS pathology [140]. As mentioned previously, the disease hallmarks of axonal demyelination and neurodegeneration alter the geometry of the brain tissue and allow increase in isotropic diffusion. Preclinical models that are specific to demyelination and remyelination processes (cuprizone-induced mice models) demonstrated that the loss of myelin is a sufficient and independent driver of the RD change [141]. Although RD has been proposed as *in vivo* marker for demyelination, a multicompo-

ment analysis of additional DTI scalar maps substantially increases the accuracy in prediction of the lesion microstructure [142]. Similar to the previous MTI and QSM studies, DWI imaging can also detect local NAWM changes that occur 6 weeks before the enhancement appearance [143]. These DTI-derived changes continue to increase even after the enhancement subsides. Eventually, nine weeks after the enhancement, these lesions reach similar values to the ones of chronic MS lesion [143]. In comparison to WM lesions that are characterized with reduced FA, several studies have shown that the cortical lesions differ and demonstrate increase in their FA [144]. Compared to healthy controls, the increase in FA was also noted within the lesion-free GM [144]. This FA change in the GM can also help in explaining the long-term clinical outcomes in PPMS, a disease subtype that is still not fully characterized [145]. The contrasting results may be explained by the lower level of inflammation and the considerable increase in microglial proliferation seen in cortical lesions.

The DTI alterations are not only present in areas of current and/or future inflammatory involvement, but they are also widespread within the NABT and subcortical deep gray matter [146]. The DTI technique allows insight of the cerebral microscopic changes and provides deeper understanding of the structural changes that are otherwise not seen by conventional imaging [147]. For example, even when the volumetric changes are accounted for, the MD of the thalamus provides additional 7–13% of explained variance seen in the MS-associated cognitive decline [148]. Similarly, MS patients with slowing of their information processing speed showed reduction of FA within the corpus callosum, a region that is not primarily affected by T2-weighted lesions [149]. Since the corpus callosum is a vital structure for bi-hemispheric communication, any disruption of the callosal microstructural integrity may play an important role in the cognitive performance.

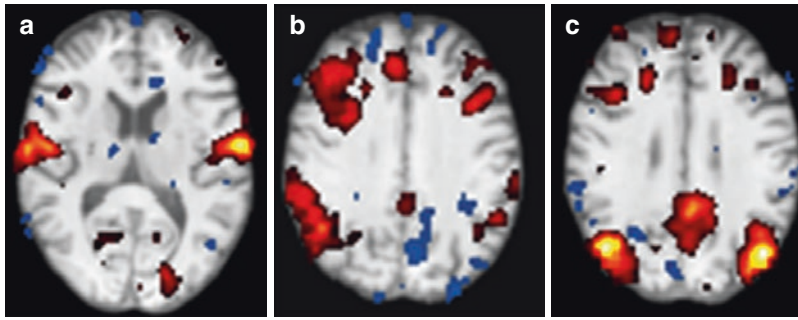
Future methods that should improve the *in vivo* evaluation of the structural integrity include tract-based spatial statistics (TBBS), diffusion kurtosis imaging (DKI), and neurite ori-

entation dispersion and density imaging (NODDI). Diffusion-weighted imaging can advance the understanding of the structural changes that contribute toward cognition, fatigue, brain reserve, and plasticity. Longitudinal studies have showed DTI applicability in examining the temporal evolution of the structural integrity changes [150]. Although the use of pre-standardized protocols improves the feasibility of longitudinal assessments, there are still considerable differences attributed to the acquisition centers [151]. Before implementation of diffusion-based imaging into clinical trials, additional standardization is needed.

### Functional Magnetic Resonance Imaging (fMRI)

The complex interplay between acute and chronic structural damage and the dynamic ability of the brain to adapt and recover is highlighting MS as ideal model for studying brain reserve and plasticity [152]. In general terms, processes in the brain activity changes are divided into adaptive (brain activity that will result in lowering the symptomatology) and maladaptive (brain activity that potentiates and worsens the existing symptomatology). This ability of structural, functional, and connection-wise reorganization can be measured and quantified using various MRI techniques. One accepted method of studying the change in activity is fMRI (Fig. 6.9). fMRI is an indirect measure of neuronal activity by measuring the amount of increased recruitment of oxygenated blood within the local cerebral blood flow. The hemodynamic response increases the delivery of oxygen-rich blood and displaces the deoxygenated one. Since deoxygenated hemoglobin has more magnetic properties (paramagnetic) when compared to the oxygenated hemoglobin, it produces changes in the magnetic field ( $T2^*$ ) and creates MRI signal called blood-oxygen-level-dependent (BOLD) contrast.

Task-based fMRI (tb-fMRI) is used to identify brain regions that are activated during performing a specific task. Most motor tb-fMRI studies involve a task of finger tapping, whereas N-back



**Fig. 6.9** Functional magnetic resonance imaging (fMRI) analysis. Independent component analysis of a single subjects resting-state fMRI time series reflects known func-

tional networks. Panel (a) demonstrate's the sensory-motor network, (b) demonstrates the frontoparietal network, and (c) demonstrates default mode network

tasks are used to study brain regions activated during cognitive/memory performance. A classic example of an adaptive process that involves an active cortical area reorganization is the activation of contralateral motor area during an MS relapse [153]. Since the new lesion would interfere with pathways that were previously in use, the movement of the affected extremity results in activation of both the contralateral and in relative activation increase of the ipsilateral motor cortex [153]. Additionally, patients with established RRMS phenotype and no disability have increased supplementary motor area activation when compared to CIS patients [154]. This supplementary motor area activation might be due to additional recruitment of preexisting motor pathways and reflects the increased efforts in order to perform the same motor task [154]. More comprehensive reviews on the changes in connectivity associated with motor performance have been published [155].

In comparison to the traditional tb-fMRI, capturing the spontaneous BOLD signal alterations in absence of a stimulus or a task is called resting-state fMRI (rs-fMRI). The large rs-fMRI data can be analyzed by two main models: functional segregation and functional integration [156]. The former allows determination of brain regions according to their specific function. Among commonly used methods for functional segregation analysis are the regional homogeneity (ReHo) and amplitude of low frequency fluctuations (ALFF). The increasing recognition of the brain as complex integrated network rather than

isolated activating regions has decreased the use of the functional segregation methods as preferred rs-fMRI analysis. On the other hand, the functional integration analysis allows measurement of the BOLD synchrony between two different brain regions. This synchrony does not imply structural connection of the regions (DTI-derived information) but the synchronic connectivity can be a result through an indirect link or mediating regions. Methods for functional integration analysis include independent component analysis (ICA) [157], ROI-based functional connectivity analysis [158], and graph analysis [159]. The default mode network (DMN) has been the most commonly studied network in the rs-fMRI analysis. This network is highly active during rest and decreases in activity over a broad range of goal-orientated cognitive tasks and is therefore named "task-negative" network [160]. The lack of DMN reduction during task performance results in decrease in attention and lower cognitive performance in healthy individuals [161]. The activity of DMN has been also negatively correlated with other task-based networks like the attention network [162].

In the early stages of MS, the diverging role of anatomical and functional connectivity measurements has been shown [163]. As the anatomical connectivity declines (a lesion causing disconnection between regions), the functional connectivity shows concurrent and compensatory increase in activity. However, in the later stages of the disease, the ability to activate larger brain regions gets depleted and an overall

decrease in activity is noted [164]. This decrease also has been associated with the T2 lesions load and correlated with disability [164]. Similarly, during the execution of the N-back task, the fMRI analysis demonstrated that cognitively impaired MS patients have decreased activity in the frontal regions and increased activity of the DMN network [165]. The aforementioned graph theory allows formation of networks that are defined by multiple nodes that are functionally connected. Parameters like modularity, centrality, clustering coefficient, and node degree describe this “small-world” network as organization that attempts to deliver information by spending the lowest energy in the most effective way possible [166]. This method was applied on 246 MS patients and 55 matched healthy controls and showed that MS patients had loss of network hubs, right lateralization of the basal ganglia, and formation of new hubs in the temporal lobe and cerebellum [167]. The impaired network was not able to exchange information efficiently and the analysis was able to discriminate the cognitively impaired patients [167].

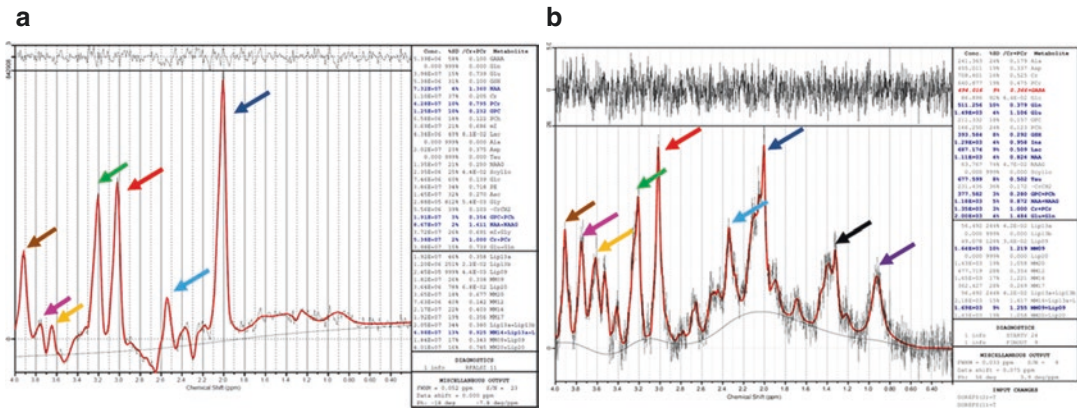
The previous analysis of functional connectivity solemnly depends on correlation between two remote brain regions and does not provide dynamic information. On the other hand, effective connectivity allows making inferences on the effect that one neuronal system exerts over another region, both on a synaptic or population based level [168]. Since there is no single method that defines the brain connectivity on its own, use of multiple complementary analyses may yield more complete connectivity characterization. The use of fMRI would substantially help in understanding the physiological background of cognitive decline, fatigue, and brain plasticity seen in MS patients [169].

## Magnetic Resonance Spectroscopy (MRS)

<sup>1</sup>H-Magnetic Resonance Spectroscopy (<sup>1</sup>H-MRS) allows imaging and quantifying the number of hydrogen protons that are positioned within different shielding environments. Since the number

of hydrogen protons situated within the molecules of water and fat is several thousand times higher than the amount of hydrogen protons within other molecules, an active water suppression is essential in visualizing the lower spectral peaks. This is usually performed with narrow bandwidth frequency-selective pulse (Chemical Shift Selective or CHESS), which is applied exactly at the Larmor frequency of the water. Recording of the free induction decay allows peaks to be plotted on a line that usually starts with 0 ppm molecule (tetra-methyl silane) at the left and until the suppressed water peak at 4.7 ppm at the right of the spectrum (Fig. 6.10). Since the ability to separate the peaks (spectral dispersion) is directly proportional to  $B_0$ , ultra-high-field MRS imaging enables enhanced capability of metabolite detection.

N-acetylaspartate (NAA), *myo*-inositol (mI), choline (Cho), creatine (Cr), glutamate (Glu), gamma-aminobutyric acid (GABA), and lactate (Lac) are several brain metabolites that are of particular interest in MS pathology [170]. After glutamate, NAA is the second most prevalent brain metabolite and colocalizes in the neuronal bodies, proximal dendrites, and axons [171]. Therefore, quantification of the NAA peak would generally provide valuable information about the neuronal integrity and neurodegeneration. Recent studies also showed high levels of NAA within the myelin itself [172]. The concentrations of NAA in the myelin of the WM tracts were comparable, or higher, to the cytosol of the central axon [172]. On the contrary, mI is a metabolite not seen in neurons but appears to be specific to the glia cells [173]. Due to its sugar-like properties, mI functions as the brain osmolyte, thus controlling the cell volume and fluid distribution. Additionally, mI is an essential precursor for the phospholipid molecules that are found in phospholipid cell membranes and myelin sheaths. Cho reflects the overall cell-membrane turnover, and elevated concentrations are seen in active processes of demyelination, remyelination, gliosis, and inflammation [174]. Lactate metabolite is an end product of the less efficient anaerobic glycolysis. As this metabolite is usually not present in a healthy brain tissue, it might define areas of



**Fig. 6.10** Magnetic resonance spectroscopy (MRS) frequency spectrum from human and mouse thalamus imaged on 3 T Toshiba MRI and on 9.4 T Bruker MRI scanners, respectively. Panel (a) demonstrates magnetic resonance spectroscopy (MRS) output from healthy human thalamus imaged with point resolved spectroscopy (PRESS) sequence on a 3 T Canon Medical MRI. Similarly, the panel (b) demonstrates the same PRESS sequence utilized for imaging of mouse thalamus on a 9.4 T Bruker MRI scanner. The major MRS metabolite peaks are shown

in increasing particles per million (from right to left) and labeled with different arrows: dark blue—*N*-acetyl aspartate, cyan—glutamate, glutamine, and GABA, red and pink—creatine and phosphocreatine, green—choline, yellow—*myo*-inositol and brown—glucose. The higher magnetic field ( $B_0$ ) of 9.4 T scanner allows better separation of the aforementioned metabolic peaks and isolation of additional peaks like lipids (magenta) and lactate (black). All peaks and their absolute quantification are shown in the corresponding MRS output

mitochondrial dysfunction and/or increased energy consumption [175]. Finally, Cr levels have been associated with the extent of gliosis.

As the pathology of the MS brain is not strictly confined to the T2-hyperintense lesions, the MRS imaging (similarly to the MTI) has also focused on two separate regions: lesions and the NABT.

The use of  $^1\text{H}$ -MRS in lesion analysis is heavily limited by the spatial resolution of the technique. Due to the large size of the MRS voxel, partial volumes from the NAWM and CSF space will contaminate the lesional output. Therefore, most of early MS spectroscopy analyses were confined to lesions larger than  $1\text{ cm}^3$ , despite the fact that these lesions are not characteristic of the disease itself. Several studies have examined the metabolic changes through the evolution of the lesions [176–178]. The concentrations of mI, Cr, and Cho in the pre-lesional tissue were not different when compared to chronic lesions, whereas the levels of NAA were higher [176]. This finding demonstrates that the processes responsible for lesion formation can be detected even before the actual lesion formation [176]. The additional drop of the NAA levels coincides with the appearance of the acute lesion on conventional

T2-WI. In months following the lesion appearance, the maintenance of low NAA levels was associated with persistence of the T2-hyperintensity, whereas NAA recovery was correlated with concurrent resolution of the lesion [176].

The decrease in NAA/Cr ratio is among the most reproducible changes within the NABT of MS patients [179, 180]. The changes within the NABT are seen both in relation to the vicinity of coexisting MS lesions, implying axonal transection, and in their complete absence [18, 181]. In testimony of the aforementioned diffuse brain pathology, a PPMS study demonstrated substantial decrease of the NAA/Cr ratio within the NABT and showed no differences when compared to the NAA levels measured at T2 lesions [182]. Similarly, a direct quantitative metabolite comparison showed no difference between the chronic T2 lesions and the NAWM [183]. The elevated markers of glial proliferation but normal levels of axonal injury during clinical remission are suggestive of ongoing diffuse inflammation that precedes the structural damage and brain atrophy [184]. A longitudinal  $^1\text{H}$ -MRS study showed that the

higher baseline ratio of mI:NAA measured in the NAWM can be considered as predictive of future brain atrophy [185]. This biomarker was also able to predict future changes in the EDSS, MS Functional Composite (MSFC), and in prediction of 12-month sustained EDSS progression [185]. The combined examination of several metabolites better portrays the complex pathophysiology of neuronal loss, gliosis, and inflammation. Future advances into the field of MRS imaging should include use of high field MRI strengths, diffusion-weighted spectroscopy (DW-MRS), improvement in the absolute quantification of the metabolites, and use of other MRS atomic nuclei like phosphorus ( $^{31}\text{P}$ ), carbon ( $^{13}\text{C}$ ), and fluorine ( $^{19}\text{F}$ ).

Additionally by using  $^1\text{H}$ -Nuclear Magnetic Resonance ( $^1\text{H}$ -NMR) spectroscopy, collected blood or CSF samples from MS patients can be ex vivo analyzed. For example, blood-derived samples showed metabolic differences within the tryptophan and energy metabolism [186]. The aforementioned pathways have been previously associated with MS pathology [187].

### Quantitative and Synthetic MRI (qMRI/syMRI)

Quantitative MRI (qMRI) uses the principal physical properties that create the MRI image: longitudinal relaxation rate ( $R_1$ ), transverse relaxation rate ( $R_2$ ), and the proton density (PD). Biological processes like inflammation, axonal injury, and gliosis will directly influence the relaxation properties of the tissue and cause absolute changes in  $R_1$ ,  $R_2$ , and PD values. Absolute quantification of the relaxation times will allow direct comparison of a single patient to a referenced and matched healthy group. As an additional benefit, the large sample size of acquired quantitative maps can be used for creating common brain templates and allow automated brain region segmentation. The qMRI method has been shown to outperform the conventional MRI imaging in detection of both WM and cortical lesions [188]. Similarly, qMRI measurements of the NABT show strong correlations

with measures of clinical disability and may further allow in vivo analysis of the MS pathophysiology [189].

Although the principles of absolute measurement of T1 and T2 relaxation times were initially described 60 years ago, the long scanning time and the high background noise has limited its clinical use [190]. Recent development of fast quantitative protocols like “quantification of relaxation times and proton density by multiecho acquisition of a saturation-recovery using turbo spin-echo readout (QRAPMASTER)” allows automated lesion segmentation, brain volume quantification, and mapping of the myelin based on the quantitative analysis [191]. Synthesis of the scans (syMRI) are based on the absolute quantitative values and allow complete head coverage within scan time of 6 min [192]. This short scanning time of syMRI produces good quality images that can be of great benefit to the pediatric population and the critically ill patients [192]. Additionally, the syMRI uses the acquired inverse relaxation time values ( $R_1$ ,  $R_2$ , and PD) to create virtual signal intensities in any combination of an echo and repetition time. Since most clinical radiologist have limited experience in reading quantitative maps, the syMRI also allows creation of T1-WI, T2-WI, and PD-WI that resemble the conventionally weighted contrast images. Currently, the synthetic MRI protocols are in the process of regulatory approval in several countries and will be integrated into the platforms provided by GE, Philips, and Siemens.

---

### Conclusion

MRI remains the most sensitive diagnostic and prognostic biomarker for MS patients. The current conventional MRI techniques have been additionally optimized for better detection of active and chronic lesions. However, the recent findings of widespread activity within the NABT have limited their use in fully apprehending the pathophysiology of MS. The nonconventional MRI techniques, new cell-specific contrast agents, synthetic MRI, and ultra-high-field scanners are among many MRI advancements that are

able to provide better understanding of the underlying disease pathology. Use of nonconventional techniques in the development of new clinical trials would additionally help to identify patients that would most benefit from the examined medication. Similarly, implementation of modalities that provide microstructural and myelin information can help with the discovery of future protective and remyelination medications. Before clinical implementation of these modalities, further standardization is still warranted.

**Acknowledgments** We are grateful to Dr. Ferdinand Schweser (University at Buffalo, BNAC) and Tom Fuchs (University at Buffalo, BNAC) for providing the magnetic resonance spectroscopy (MRS) and functional magnetic resonance imaging (fMRI) figures, respectively.

## References

1. Reich DS, Lucchinetti CF, Calabresi PA. Multiple sclerosis. *N Engl J Med*. 2018;378(2):169–80.
2. Brownlee WJ, Hardy TA, Fazekas F, Miller DH. Diagnosis of multiple sclerosis: progress and challenges. *Lancet*. 2017;389(10076):1336–46.
3. Cree B, Gourraud PA, Oksenberg JR, Bevan C, Crabtree-Hartman E, Gelfand JM, et al. Long-term evolution of multiple sclerosis disability in the treatment era. *Ann Neurol*. 2016;80(4):499–510.
4. Zivadinov R, Leist TP. Clinical-magnetic resonance imaging correlations in multiple sclerosis. *J Neuroimaging*. 2005;15(4 Suppl):10S–21S.
5. Barkhof F. The clinico-radiological paradox in multiple sclerosis revisited. *Curr Opin Neurol*. 2002;15(3):239–45.
6. Healy BC, Buckle GJ, Ali EN, Egorova S, Khalid F, Tauhid S, et al. Characterizing clinical and MRI dissociation in patients with multiple sclerosis. *J Neuroimaging*. 2017;27(5):481–5.
7. Poloni G, Minagar A, Haacke EM, Zivadinov R. Recent developments in imaging of multiple sclerosis. *Neurologist*. 2011;17(4):185–204.
8. Zivadinov R, Bakshi R. Role of MRI in multiple sclerosis I: inflammation and lesions. *Front Biosci*. 2004;9:665–83.
9. Gawne-Cain ML, O’Riordan JI, Thompson AJ, Moseley IF, Miller DH. Multiple sclerosis lesion detection in the brain: a comparison of fast fluid-attenuated inversion recovery and conventional T2-weighted dual spin echo. *Neurology*. 1997;49(2):364–70.
10. Tintore M, Rovira A, Rio J, Otero-Romero S, Arrambide G, Tur C, et al. Defining high, medium and low impact prognostic factors for developing multiple sclerosis. *Brain*. 2015;138(Pt 7):1863–74.
11. Jakimovski D, Kolb C, Ramanathan M, Zivadinov R, Weinstock-Guttman B. Interferon beta for multiple sclerosis. *Cold Spring Harb Perspect Med*. 2018;8(11):pii:a032003.
12. Fisniku LK, Brex PA, Altmann DR, Miszkiel KA, Benton CE, Lanyon R, et al. Disability and T2 MRI lesions: a 20-year follow-up of patients with relapse onset of multiple sclerosis. *Brain*. 2008;131(Pt 3):808–17.
13. Dolezal O, Dwyer MG, Horakova D, Havrdova E, Minagar A, Balachandran S, et al. Detection of cortical lesions is dependent on choice of slice thickness in patients with multiple sclerosis. *Int Rev Neurobiol*. 2007;79:475–89.
14. Tubridy N, Barker GJ, Macmanus DG, Moseley IF, Miller DH. Three-dimensional fast fluid attenuated inversion recovery (3D fast FLAIR): a new MRI sequence which increases the detectable cerebral lesion load in multiple sclerosis. *Br J Radiol*. 1998;71(848):840–5.
15. Bink A, Schmitt M, Gaa J, Mugler JP 3rd, Lanfermann H, Zanella FE. Detection of lesions in multiple sclerosis by 2D FLAIR and single-slab 3D FLAIR sequences at 3.0 T: initial results. *Eur Radiol*. 2006;16(5):1104–10.
16. Polak P, Magnano C, Zivadinov R, Poloni G. 3D FLAIRE: 3D fluid attenuated inversion recovery for enhanced detection of lesions in multiple sclerosis. *Magn Reson Med*. 2012;68(3):874–81.
17. Garcia-Lorenzo D, Francis S, Narayanan S, Arnold DL, Collins DL. Review of automatic segmentation methods of multiple sclerosis white matter lesions on conventional magnetic resonance imaging. *Med Image Anal*. 2013;17(1):1–18.
18. Trapp BD, Peterson J, Ransohoff RM, Rudick R, Mork S, Bo L. Axonal transection in the lesions of multiple sclerosis. *N Engl J Med*. 1998;338(5):278–85.
19. van Waesberghe JH, van Walderveen MA, Castelijns JA, Scheltens P, Lycklama a Nijeholt GJ, Polman CH, et al. Patterns of lesion development in multiple sclerosis: longitudinal observations with T1-weighted spin-echo and magnetization transfer MR. *AJNR Am J Neuroradiol*. 1998;19(4):675–83.
20. Bagnato F, Jeffries N, Richert ND, Stone RD, Ohayon JM, McFarland HF, et al. Evolution of T1 black holes in patients with multiple sclerosis imaged monthly for 4 years. *Brain*. 2003;126(Pt 8):1782–9.
21. Giorgio A, Stromillo ML, Bartolozzi ML, Rossi F, Battaglini M, De Leucio A, et al. Relevance of hypointense brain MRI lesions for long-term worsening of clinical disability in relapsing multiple sclerosis. *Mult Scler*. 2014;20(2):214–9.
22. Minneboo A, Uitdehaag BM, Jongen P, Vrenken H, Knol D, van Walderveen MA, et al. Association between MRI parameters and the MS severity scale: a 12 year follow-up study. *Mult Scler*. 2009;15(5):632–7.
23. Wattjes MP, Rovira A, Miller D, Yousry TA, Sormani MP, de Stefano MP, et al. Evidence-based guide-



- lines: MAGNIMS consensus guidelines on the use of MRI in multiple sclerosis—establishing disease prognosis and monitoring patients. *Nat Rev Neurol*. 2015;11(10):597–606.
24. Rotstein DL, Healy BC, Malik MT, Chitnis T, Weiner HL. Evaluation of no evidence of disease activity in a 7-year longitudinal multiple sclerosis cohort. *JAMA Neurol*. 2015;72(2):152–8.
  25. Silver NC, Tofts PS, Symms MR, Barker GJ, Thompson AJ, Miller DH. Quantitative contrast-enhanced magnetic resonance imaging to evaluate blood-brain barrier integrity in multiple sclerosis: a preliminary study. *Mult Scler*. 2001;7(2):75–82.
  26. Mathews VP, Caldemeyer KS, Lowe MJ, Greenspan SL, Weber DM, Ulmer JL. Brain: gadolinium-enhanced fast fluid-attenuated inversion-recovery MR imaging. *Radiology*. 1999;211(1):257–63.
  27. Absinta M, Vuolo L, Rao A, Nair G, Sati P, Cortese IC, et al. Gadolinium-based MRI characterization of leptomeningeal inflammation in multiple sclerosis. *Neurology*. 2015;85(1):18–28.
  28. Zurawski J, Lassmann H, Bakshi R. Use of magnetic resonance imaging to visualize leptomeningeal inflammation in patients with multiple sclerosis: a review. *JAMA Neurol*. 2016;74(1):100–9.
  29. Zivadinov R, Ramasamy DP, Vaneckova M, Gandhi S, Chandra A, Hagemeyer J, et al. Leptomeningeal contrast enhancement is associated with progression of cortical atrophy in MS: a retrospective, pilot, observational longitudinal study. *Mult Scler*. 2017;23(10):1336–45.
  30. Harrison DM, Wang KY, Fiol J, Naunton K, Royal W 3rd, Hua J, et al. Leptomeningeal enhancement at 7T in multiple sclerosis: frequency, morphology, and relationship to cortical volume. *J Neuroimaging*. 2017;27(5):461–8.
  31. Jakimovski D, Weinstock-Guttman B, Ramanathan M, Kolb C, Hojnacki D, Minagar A, et al. Ocrelizumab: a B-cell depleting therapy for multiple sclerosis. *Expert Opin Biol Ther*. 2017;17(9):1163–72.
  32. Zivadinov R, Pirko I. Advances in understanding gray matter pathology in multiple sclerosis: are we ready to redefine disease pathogenesis? *BMC Neurol*. 2012;12:9.
  33. Wattjes MP, Lutterbey GG, Gieseke J, Träber F, Klotz L, Schmidt S, et al. Double inversion recovery brain imaging at 3T: diagnostic value in the detection of multiple sclerosis lesions. *AJNR Am J Neuroradiol*. 2007;28(1):54–9.
  34. Eichinger P, Kirschke JS, Hoshi MM, Zimmer C, Muhlau M, Riederer I. Pre- and postcontrast 3D double inversion recovery sequence in multiple sclerosis: a simple and effective MR imaging protocol. *AJNR Am J Neuroradiol*. 2017;38(10):1941–5.
  35. Eichinger P, Wiestler H, Zhang H, Biberacher V, Kirschke JS, Zimmer C, et al. A novel imaging technique for better detecting new lesions in multiple sclerosis. *J Neurol*. 2017;38(10):1941–5.
  36. Seewann A, Kooi EJ, Roosendaal SD, Pouwels PJ, Wattjes MP, van der Valk P, et al. Postmortem verification of MS cortical lesion detection with 3D DIR. *Neurology*. 2012;78(5):302–8.
  37. Geurts JJ, Roosendaal SD, Calabrese M, Ciccarelli O, Agosta F, Chard DT, et al. Consensus recommendations for MS cortical lesion scoring using double inversion recovery MRI. *Neurology*. 2011;76(5):418–24.
  38. Calabrese M, Poretto V, Favaretto A, Alessio S, Bernardi V, Romualdi C, et al. Cortical lesion load associates with progression of disability in multiple sclerosis. *Brain*. 2012;135(Pt 10):2952–61.
  39. Rovira A, Wattjes MP, Tintore M, Tur C, Yousry TA, Sormani MP, et al. Evidence-based guidelines: MAGNIMS consensus guidelines on the use of MRI in multiple sclerosis-clinical implementation in the diagnostic process. *Nat Rev Neurol*. 2015;11(8):471–82.
  40. Korchinski DJ, Taha M, Yang R, Nathoo N, Dunn JF. Iron oxide as an MRI contrast agent for cell tracking. *Magn Reson Insights*. 2015;8(Suppl 1):15–29.
  41. McAteer MA, Sibson NR, von zur Muhlen C, Schneider JE, Lowe AS, Warrick N, et al. In vivo magnetic resonance imaging of acute brain inflammation using microparticles of iron oxide. *Nat Med*. 2007;13:1253.
  42. van Kasteren SI, Campbell SJ, Serres S, Anthony DC, Sibson NR, Davis BG. Glyconanoparticles allow pre-symptomatic in vivo imaging of brain disease. *Proc Natl Acad Sci U S A*. 2009;106(1):18–23.
  43. Vellinga MM, Oude Engberink RD, Seewann A, Pouwels PJ, Wattjes MP, van der Pol SM, et al. Pluriformity of inflammation in multiple sclerosis shown by ultra-small iron oxide particle enhancement. *Brain*. 2008;131(Pt 3):800–7.
  44. Oude Engberink RD, Blezer EL, Dijkstra CD, van der Pol SM, van der Toorn A, de Vries HE. Dynamics and fate of USPIO in the central nervous system in experimental autoimmune encephalomyelitis. *NMR Biomed*. 2010;23(9):1087–96.
  45. Ramalho J, Ramalho M, Jay M, Burke LM, Semelka RC. Gadolinium toxicity and treatment. *Magn Reson Imaging*. 2016;34(10):1394–8.
  46. Hao D, Ai T, Goerner F, Hu X, Runge VM, Tweedle M. MRI contrast agents: basic chemistry and safety. *J Magn Reson Imaging*. 2012;36(5):1060–71.
  47. Kanda T, Ishii K, Kawaguchi H, Kitajima K, Takenaka D. High signal intensity in the dentate nucleus and globus pallidus on unenhanced T1-weighted MR images: relationship with increasing cumulative dose of a gadolinium-based contrast material. *Radiology*. 2014;270(3):834–41.
  48. McDonald JS, McDonald RJ, Jentoft ME, Paolini MA, Murray DL, Kallmes DF, et al. Intracranial gadolinium deposition following gadodiamide-enhanced magnetic resonance imaging in pediatric patients: a case-control study. *JAMA Pediatr*. 2017;171(7):705–7.
  49. Robert P, Lehericy S, Grand S, Violas X, Fretellier N, Idee JM, et al. T1-weighted hypersignal in the

- deep cerebellar nuclei after repeated administrations of gadolinium-based contrast agents in healthy rats: difference between linear and macrocyclic agents. *Investig Radiol.* 2015;50(8):473–80.
50. Robert P, Violas X, Grand S, Lehericy S, Idee JM, Ballet S, et al. Linear gadolinium-based contrast agents are associated with brain gadolinium retention in healthy rats. *Investig Radiol.* 2016;51(2):73–82.
  51. Gulani V, Calamante F, Shellock FG, Kanal E, Reeder SB, International Society for Magnetic Resonance in M. Gadolinium deposition in the brain: summary of evidence and recommendations. *Lancet Neurol.* 2017;16(7):564–70.
  52. Polman CH, Reingold SC, Edan G, Filippi M, Hartung HP, Kappos L, et al. Diagnostic criteria for multiple sclerosis: 2005 revisions to the “McDonald Criteria”. *Ann Neurol.* 2005;58(6):840–6.
  53. Polman CH, Reingold SC, Banwell B, Clanet M, Cohen JA, Filippi M, et al. Diagnostic criteria for multiple sclerosis: 2010 revisions to the McDonald criteria. *Ann Neurol.* 2011;69(2):292–302.
  54. Thompson AJ, Banwell BL, Barkhof F, Carroll WM, Coetzee T, Comi G, et al. Diagnosis of multiple sclerosis: 2017 revisions of the McDonald criteria. *Lancet Neurol.* 2018;17(2):162–73.
  55. Huss AM, Halbgebauer S, Ockl P, Trebst C, Spreer A, Borisow N, et al. Importance of cerebrospinal fluid analysis in the era of McDonald 2010 criteria: a German-Austrian retrospective multicenter study in patients with a clinically isolated syndrome. *J Neurol.* 2016;263(12):2499–504.
  56. Kuhle J, Disanto G, Dobson R, Adiatori R, Bianchi L, Topping J, et al. Conversion from clinically isolated syndrome to multiple sclerosis: a large multi-centre study. *Mult Scler.* 2015;21(8):1013–24.
  57. Dobson R, Ramagopalan S, Davis A, Giovannoni G. Cerebrospinal fluid oligoclonal bands in multiple sclerosis and clinically isolated syndromes: a meta-analysis of prevalence, prognosis and effect of latitude. *J Neurol Neurosurg Psychiatry.* 2013;84(8):909–14.
  58. Filippi M, Preziosa P, Meani A, Ciccarelli O, Mesaros S, Rovira A, et al. Prediction of a multiple sclerosis diagnosis in patients with clinically isolated syndrome using the 2016 MAGNIMS and 2010 McDonald criteria: a retrospective study. *Lancet Neurol.* 2018;17(2):133–42.
  59. Brownlee WJ, Swanton JK, Miszkiel KA, Miller DH, Ciccarelli O. Should the symptomatic region be included in dissemination in space in MRI criteria for MS? *Neurology.* 2016;87(7):680–3.
  60. Filippi M, Rocca MA, Ciccarelli O, De Stefano N, Evangelou N, Kappos L, et al. MRI criteria for the diagnosis of multiple sclerosis: MAGNIMS consensus guidelines. *Lancet Neurol.* 2016;15(3):292–303.
  61. Galetta SL, Balcer LJ. The optic nerve should be included as one of the typical CNS regions for establishing dissemination in space when diagnosing MS – YES. *Mult Scler.* 2018;24(2):121–2.
  62. Kilsdonk ID, Jonkman LE, Klaver R, van Veluw SJ, Zwanenburg JJ, Kuijjer JP, et al. Increased cortical grey matter lesion detection in multiple sclerosis with 7 T MRI: a post-mortem verification study. *Brain.* 2016;139(Pt 5):1472–81.
  63. Maranzano J, Rudko DA, Arnold DL, Narayanan S. Manual segmentation of MS cortical lesions using MRI: a comparison of 3 MRI reading protocols. *AJNR Am J Neuroradiol.* 2016;37(9):1623–8.
  64. Gabelic T, Ramasamy DP, Weinstock-Guttman B, Hagemeyer J, Kennedy C, Melia R, et al. Prevalence of radiologically isolated syndrome and white matter signal abnormalities in healthy relatives of patients with multiple sclerosis. *AJNR Am J Neuroradiol.* 2014;35(1):106–12.
  65. Keegan BM, Kaufmann TJ, Weinschenker BG, Kantarci OH, Schmalstieg WF, Paz Soldan MM, et al. Progressive solitary sclerosis: gradual motor impairment from a single CNS demyelinating lesion. *Neurology.* 2016;87(16):1713–9.
  66. Spadaro M, Gerdes LA, Krumbholz M, Ertl-Wagner B, Thaler FS, Schuh E, et al. Autoantibodies to MOG in a distinct subgroup of adult multiple sclerosis. *Neurol Neuroimmunol Neuroinflamm.* 2016;3(5):e257.
  67. Kearney H, Miller DH, Ciccarelli O. Spinal cord MRI in multiple sclerosis—diagnostic, prognostic and clinical value. *Nat Rev Neurol.* 2015;11(6):327–38.
  68. Zalewski NL, Flanagan EP, Keegan BM. Evaluation of idiopathic transverse myelitis revealing specific myelopathy diagnoses. *Neurology.* 2018;90(2):e96–e102.
  69. Arrambide G, Rovira A, Sastre-Garriga J, Tur C, Castillo J, Rio J, et al. Spinal cord lesions: a modest contributor to diagnosis in clinically isolated syndromes but a relevant prognostic factor. *Mult Scler.* 2018;24(3):301–12.
  70. Brownlee WJ, Altmann DR, Alves Da Mota P, Swanton JK, Miszkiel KA, Wheeler-Kingshott CG, et al. Association of asymptomatic spinal cord lesions and atrophy with disability 5 years after a clinically isolated syndrome. *Mult Scler.* 2017;23(5):665–74.
  71. Schlaeger R, Papinutto N, Panara V, Bevan C, Lobach IV, Bucci M, et al. Spinal cord gray matter atrophy correlates with multiple sclerosis disability. *Ann Neurol.* 2014;76(4):568–80.
  72. Schlaeger R, Papinutto N, Zhu AH, Lobach IV, Bevan CJ, Bucci M, et al. Association between thoracic spinal cord gray matter atrophy and disability in multiple sclerosis. *JAMA Neurol.* 2015;72(8):897–904.
  73. Zivadinov R, Banas AC, Yella V, Abdelrahman N, Weinstock-Guttman B, Dwyer MG. Comparison of three different methods for measurement of cervical cord atrophy in multiple sclerosis. *AJNR Am J Neuroradiol.* 2008;29(2):319–25.
  74. Cawley N, Tur C, Prados F, Plantone D, Kearney H, Abdel-Aziz K, et al. Spinal cord atrophy as a primary

- outcome measure in phase II trials of progressive multiple sclerosis. *Mult Scler*. 2018;24(7):932–41.
75. Martin AR, Aleksanderek I, Cohen-Adad J, Tarmohamed Z, Tetreault L, Smith N, et al. Translating state-of-the-art spinal cord MRI techniques to clinical use: a systematic review of clinical studies utilizing DTI, MT, MWF, MRS, and fMRI. *Neuroimage Clin*. 2016;10:192–238.
  76. Filippi M, Evangelou N, Kangarlu A, Inglese M, Mainero C, Horsfield MA, et al. Ultra-high-field MR imaging in multiple sclerosis. *J Neurol Neurosurg Psychiatry*. 2014;85(1):60–6.
  77. Mistry N, Tallantyre EC, Dixon JE, Galazis N, Jaspan T, Morgan PS, et al. Focal multiple sclerosis lesions abound in ‘normal appearing white matter’. *Mult Scler*. 2011;17(11):1313–23.
  78. Tallantyre EC, Dixon JE, Donaldson I, Owens T, Morgan PS, Morris PG, et al. Ultra-high-field imaging distinguishes MS lesions from asymptomatic white matter lesions. *Neurology*. 2011;76(6):534–9.
  79. Gaitan MI, Sati P, Inati SJ, Reich DS. Initial investigation of the blood-brain barrier in MS lesions at 7 tesla. *Mult Scler*. 2013;19(8):1068–73.
  80. Sati P, Oh J, Constable RT, Evangelou N, Guttmann CR, Henry RG, et al. The central vein sign and its clinical evaluation for the diagnosis of multiple sclerosis: a consensus statement from the North American Imaging in Multiple Sclerosis Cooperative. *Nat Rev Neurol*. 2016;12(12):714–22.
  81. Pitt D, Boster A, Pei W, Wohleb E, Jasne A, Zachariah CR, et al. Imaging cortical lesions in multiple sclerosis with ultra-high-field magnetic resonance imaging. *Arch Neurol*. 2010;67(7):812–8.
  82. Schmierer K, Parkes HG, So PW, An SF, Brandner S, Ordidge RJ, et al. High field (9.4 Tesla) magnetic resonance imaging of cortical grey matter lesions in multiple sclerosis. *Brain*. 2010;133(Pt 3):858–67.
  83. Mainero C, Louapre C, Govindarajan ST, Gianni C, Nielsen AS, Cohen-Adad J, et al. A gradient in cortical pathology in multiple sclerosis by in vivo quantitative 7 T imaging. *Brain*. 2015;138(Pt 4):932–45.
  84. Scalfari A, Neuhaus A, Degenhardt A, Rice GP, Muraro PA, Daumer M, et al. The natural history of multiple sclerosis: a geographically based study 10: relapses and long-term disability. *Brain*. 2010;133(Pt 7):1914–29.
  85. Trapp BD, Stys PK. Virtual hypoxia and chronic necrosis of demyelinated axons in multiple sclerosis. *Lancet Neurol*. 2009;8(3):280–91.
  86. Raftopoulos R, Hickman SJ, Toosy A, Sharrack B, Mallik S, Paling D, et al. Phenytoin for neuroprotection in patients with acute optic neuritis: a randomised, placebo-controlled, phase 2 trial. *Lancet Neurol*. 2016;15(3):259–69.
  87. Petrova N, Carassiti D, Altmann DR, Baker D, Schmierer K. Axonal loss in the multiple sclerosis spinal cord revisited. *Brain Pathol*. 2018;28(3):334–48.
  88. Evangelou N, Esiri MM, Smith S, Palace J, Matthews PM. Quantitative pathological evidence for axonal loss in normal appearing white matter in multiple sclerosis. *Ann Neurol*. 2000;47(3):391–5.
  89. Wegner C, Esiri MM, Chance SA, Palace J, Matthews PM. Neocortical neuronal, synaptic, and glial loss in multiple sclerosis. *Neurology*. 2006;67(6):960–7.
  90. Popescu V, Klaver R, Voorn P, Galis-de Graaf Y, Knol DL, Twisk JW, et al. What drives MRI-measured cortical atrophy in multiple sclerosis? *Mult Scler*. 2015;21(10):1280–90.
  91. Carassiti D, Altmann DR, Petrova N, Pakkenberg B, Scaravilli F, Schmierer K. Neuronal loss, demyelination and volume change in the multiple sclerosis neocortex. *Neuropathol Appl Neurobiol*. 2018;44(4):377–90.
  92. Zivadinov R, Uher T, Hagemeyer J, Vaneckova M, Ramasamy DP, Tyblova M, et al. A serial 10-year follow-up study of brain atrophy and disability progression in RRMS patients. *Mult Scler*. 2016;22(13):1709–18.
  93. Popescu V, Agosta F, Hulst HE, Sluimer IC, Knol DL, Sormani MP, et al. Brain atrophy and lesion load predict long term disability in multiple sclerosis. *J Neurol Neurosurg Psychiatry*. 2013;84(10):1082–91.
  94. Zivadinov R, Havrdova E, Bergsland N, Tyblova M, Hagemeyer J, Seidl Z, et al. Thalamic atrophy is associated with development of clinically definite multiple sclerosis. *Radiology*. 2013;268(3):831–41.
  95. Eshaghi A, Prados F, Brownlee W, Altmann DR, Tur C, Cardoso MJ, et al. Deep grey matter volume loss drives disability worsening in multiple sclerosis. *Ann Neurol*. 2018;83(2):210–22.
  96. Filippi M, Preziosa P, Copetti M, Riccitelli G, Horsfield MA, Martinelli V, et al. Gray matter damage predicts the accumulation of disability 13 years later in MS. *Neurology*. 2013;81(20):1759–67.
  97. Bergsland N, Horakova D, Dwyer MG, Uher T, Vaneckova M, Tyblova M, et al. Gray matter atrophy patterns in multiple sclerosis: a 10-year source-based morphometry study. *Neuroimage Clin*. 2018;17:444–51.
  98. Zivadinov R, Dwyer MG, Bergsland N. Brain atrophy measurements should be used to guide therapy monitoring in MS – YES. *Mult Scler*. 2016;22(12):1522–4.
  99. Sormani MP, Arnold DL, De Stefano N. Treatment effect on brain atrophy correlates with treatment effect on disability in multiple sclerosis. *Ann Neurol*. 2014;75(1):43–9.
  100. De Stefano N, Stromillo ML, Giorgio A, Bartolozzi ML, Battaglini M, Baldini M, et al. Establishing pathological cut-offs of brain atrophy rates in multiple sclerosis. *J Neurol Neurosurg Psychiatry*. 2016;87(1):93–9.
  101. Uher T, Vaneckova M, Krasensky J, Sobisek L, Tyblova M, Volna J, et al. Pathological cut-offs of global and regional brain volume loss in multiple sclerosis. *Mult Scler*. 2019;25(4):541–53.

102. Dwyer MG, Hagemeyer J, Bergsland N, Horakova D, Korn JR, Khan N, et al. Establishing pathological cut-offs for lateral ventricular volume expansion rates. *Neuroimage Clin.* 2018;18:494–501.
103. Sormani MP, Kappos L, Radue EW, Cohen J, Barkhof F, Sprenger T, et al. Defining brain volume cutoffs to identify clinically relevant atrophy in RRMS. *Mult Scler.* 2018;23(5):656–64.
104. Azevedo CJ, Jaberzadeh A, Pelletier D. New concepts related to disease appreciation in multiple sclerosis. *Neurol Clin.* 2018;36(1):119–33.
105. Ghione E, Dwyer M, Bergsland N, Hagemeyer J, Jakimovski D, Paunkoski I, et al. Normative reference database for lateral ventricular volume change in multiple sclerosis patients. *Neurology.* 2017;88(16 Suppl):P4.380.
106. Lublin FD, Reingold SC, Cohen JA, Cutter GR, Sorensen PS, Thompson AJ, et al. Defining the clinical course of multiple sclerosis: the 2013 revisions. *Neurology.* 2014;83(3):278–86.
107. Dwyer MG, Silva D, Bergsland N, Horakova D, Ramasamy D, Durfee J, et al. Neurological software tool for reliable atrophy measurement (NeuroSTREAM) of the lateral ventricles on clinical-quality T2-FLAIR MRI scans in multiple sclerosis. *Neuroimage Clin.* 2017;15:769–79.
108. Zivadinov R, Bergsland N, Korn JR, Dwyer MG, Khan N, Medin J, et al. Feasibility of brain atrophy measurement in clinical routine without prior standardization of the MRI protocol: results from MS-MRIUS, a longitudinal observational, multicenter real-world outcome study in patients with relapsing-remitting MS. *AJNR Am J Neuroradiol.* 2018;39(2):289–95.
109. Zivadinov R, Jakimovski D, Gandhi S, Ahmed R, Dwyer MG, Horakova D, et al. Clinical relevance of brain atrophy assessment in multiple sclerosis. Implications for its use in a clinical routine. *Expert Rev Neurother.* 2016;16(7):777–93.
110. Gareau PJ, Rutt BK, Karlik SJ, Mitchell JR. Magnetization transfer and multicomponent T2 relaxation measurements with histopathologic correlation in an experimental model of MS. *J Magn Reson Imaging.* 2000;11(6):586–95.
111. Schmierer K, Scaravilli F, Altmann DR, Barker GJ, Miller DH. Magnetization transfer ratio and myelin in postmortem multiple sclerosis brain. *Ann Neurol.* 2004;56(3):407–15.
112. Arnold DL, Gold R, Kappos L, Bar-Or A, Giovannoni G, Selmaj K, et al. Magnetization transfer ratio in the delayed-release dimethyl fumarate DEFINE study. *J Neurol.* 2014;261(12):2429–37.
113. Brown RA, Narayanan S, Stikov N, Cook S, Cadavid D, Wolansky L, et al. MTR recovery in brain lesions in the BECOME study of glatiramer acetate vs interferon beta-1b. *Neurology.* 2016;87(9):905–11.
114. Arnold DL, Calabresi PA, Kieseier BC, Liu S, You X, Fiore D, et al. Peginterferon beta-1a improves MRI measures and increases the proportion of patients with no evidence of disease activity in relapsing-remitting multiple sclerosis: 2-year results from the ADVANCE randomized controlled trial. *BMC Neurol.* 2017;17(1):29.
115. Rovaris M, Agosta F, Sormani MP, Inglese M, Martinelli V, Comi G, et al. Conventional and magnetization transfer MRI predictors of clinical multiple sclerosis evolution: a medium-term follow-up study. *Brain.* 2003;126(Pt 10):2323–32.
116. Agosta F, Rovaris M, Pagani E, Sormani MP, Comi G, Filippi M. Magnetization transfer MRI metrics predict the accumulation of disability 8 years later in patients with multiple sclerosis. *Brain.* 2006;129(Pt 10):2620–7.
117. Fernando KT, Tozer DJ, Miszkil KA, Gordon RM, Swanton JK, Dalton CM, et al. Magnetization transfer histograms in clinically isolated syndromes suggestive of multiple sclerosis. *Brain.* 2005;128(Pt 12):2911–25.
118. Brown JW, Pardini M, Brownlee WJ, Fernando K, Samson RS, Prados Carrasco F, et al. An abnormal periventricular magnetization transfer ratio gradient occurs early in multiple sclerosis. *Brain.* 2017;140(2):387–98.
119. Goodkin DE, Rooney WD, Sloan R, Bacchetti P, Gee L, Vermathen M, et al. A serial study of new MS lesions and the white matter from which they arise. *Neurology.* 1998;51(6):1689–97.
120. Filippi M, Rocca MA, Martino G, Horsfield MA, Comi G. Magnetization transfer changes in the normal appearing white matter precede the appearance of enhancing lesions in patients with multiple sclerosis. *Ann Neurol.* 1998;43(6):809–14.
121. Chen JT, Collins DL, Atkins HL, Freedman MS, Arnold DL, Canadian MSBMTSG. Magnetization transfer ratio evolution with demyelination and remyelination in multiple sclerosis lesions. *Ann Neurol.* 2008;63(2):254–62.
122. Chen JT, Easley K, Schneider C, Nakamura K, Kidd GJ, Chang A, et al. Clinically feasible MTR is sensitive to cortical demyelination in MS. *Neurology.* 2013;80(3):246–52.
123. Altmann DR, Button T, Schmierer K, Hunter K, Tozer DJ, Wheeler-Kingshott CA, et al. Sample sizes for lesion magnetisation transfer ratio outcomes in remyelination trials for multiple sclerosis. *Mult Scler Relat Disord.* 2014;3(2):237–43.
124. Schweser F, Deistung A, Reichenbach JR. Foundations of MRI phase imaging and processing for quantitative susceptibility mapping (QSM). *Z Med Phys.* 2016;26(1):6–34.
125. Haacke EM, Xu Y, Cheng YC, Reichenbach JR. Susceptibility weighted imaging (SWI). *Magn Reson Med.* 2004;52(3):612–8.
126. Reichenbach JR, Schweser F, Serres B, Deistung A. Quantitative susceptibility mapping: concepts and applications. *Clin Neuroradiol.* 2015;25(Suppl 2):225–30.

127. Tan IL, van Schijndel RA, Pouwels PJ, van Walderveen MA, Reichenbach JR, Manoliu RA, et al. MR venography of multiple sclerosis. *AJNR Am J Neuroradiol.* 2000;21(6):1039–42.
128. Maggi P, Absinta M, Grammatico M, Vuolo L, Emmi G, Carlucci G, et al. The central vein sign differentiates MS from CNS inflammatory vasculopathies. *Ann Neurol.* 2018;83(2):283–94.
129. Hagemeyer J, Heininen-Brown M, Gabelic T, Guttuso T Jr, Silvestri N, Lichter D, et al. Phase white matter signal abnormalities in patients with clinically isolated syndrome and other neurologic disorders. *AJNR Am J Neuroradiol.* 2014;35(10):1916–23.
130. Zivadinov R, Ramasamy DP, Benedict RR, Polak P, Hagemeyer J, Magnano C, et al. Cerebral microbleeds in multiple sclerosis evaluated on susceptibility-weighted images and quantitative susceptibility maps: a case-control study. *Radiology.* 2016;281(3):884–95.
131. Zivadinov R, Heininen-Brown M, Schirda CV, Poloni GU, Bergsland N, Magnano CR, et al. Abnormal subcortical deep-gray matter susceptibility-weighted imaging filtered phase measurements in patients with multiple sclerosis: a case-control study. *NeuroImage.* 2012;59(1):331–9.
132. Wang Y, Spincemaille P, Liu Z, Dimov A, Deh K, Li J, et al. Clinical quantitative susceptibility mapping (QSM): biometal imaging and its emerging roles in patient care. *J Magn Reson Imaging.* 2017;46(4):951–71.
133. Chen W, Gauthier SA, Gupta A, Comunale J, Liu T, Wang S, et al. Quantitative susceptibility mapping of multiple sclerosis lesions at various ages. *Radiology.* 2014;271(1):183–92.
134. Zhang Y, Gauthier SA, Gupta A, Comunale J, Chia-Yi Chiang G, Zhou D, et al. Longitudinal change in magnetic susceptibility of new enhanced multiple sclerosis (MS) lesions measured on serial quantitative susceptibility mapping (QSM). *J Magn Reson Imaging.* 2016;44(2):426–32.
135. Bagnato F, Hametner S, Yao B, van Gelderen P, Merkle H, Cantor FK, et al. Tracking iron in multiple sclerosis: a combined imaging and histopathological study at 7 Tesla. *Brain.* 2011;134(Pt 12):3602–15.
136. Hagemeyer J, Zivadinov R, Dwyer MG, Polak P, Bergsland N, Weinstock-Guttman B, et al. Changes of deep gray matter magnetic susceptibility over 2 years in multiple sclerosis and healthy control brain. *NeuroImage Clin.* 2018;18:1007–16.
137. Schweser F, Raffaini Duarte Martins AL, Hagemeyer J, Lin F, Hanspach J, Weinstock-Guttman B, et al. Mapping of thalamic magnetic susceptibility in multiple sclerosis indicates decreasing iron with disease duration: a proposed mechanistic relationship between inflammation and oligodendrocyte vitality. *Neuroimage.* 2018;167:438–52.
138. Mori S, Zhang J. Principles of diffusion tensor imaging and its applications to basic neuroscience research. *Neuron.* 2006;51(5):527–39.
139. Beaulieu C. The basis of anisotropic water diffusion in the nervous system – a technical review. *NMR Biomed.* 2002;15(7–8):435–55.
140. Van Essen DC, Smith SM, Barch DM, Behrens TE, Yacoub E, Ugurbil K, et al. The WU-Minn Human Connectome Project: an overview. *NeuroImage.* 2013;80:62–79.
141. Song SK, Yoshino J, Le TQ, Lin SJ, Sun SW, Cross AH, et al. Demyelination increases radial diffusivity in corpus callosum of mouse brain. *NeuroImage.* 2005;26(1):132–40.
142. Boretius S, Escher A, Dallenga T, Wrzosek C, Tammer R, Bruck W, et al. Assessment of lesion pathology in a new animal model of MS by multiparametric MRI and DTI. *NeuroImage.* 2012;59(3):2678–88.
143. Rocca MA, Cercignani M, Iannucci G, Comi G, Filippi M. Weekly diffusion-weighted imaging of normal-appearing white matter in MS. *Neurology.* 2000;55(6):882–4.
144. Calabrese M, Rinaldi F, Seppi D, Favaretto A, Squarcina L, Mattisi I, et al. Cortical diffusion-tensor imaging abnormalities in multiple sclerosis: a 3-year longitudinal study. *Radiology.* 2011;261(3):891–8.
145. Rocca MA, Sormani MP, Rovaris M, Caputo D, Ghezzi A, Montanari E, et al. Long-term disability progression in primary progressive multiple sclerosis: a 15-year study. *Brain.* 2017;140(11):2814–9.
146. Cappellani R, Bergsland N, Weinstock-Guttman B, Kennedy C, Carl E, Ramasamy DP, et al. Diffusion tensor MRI alterations of subcortical deep gray matter in clinically isolated syndrome. *J Neurol Sci.* 2014;338(1–2):128–34.
147. Raz E, Cercignani M, Sbardella E, Totaro P, Pozzilli C, Bozzali M, et al. Clinically isolated syndrome suggestive of multiple sclerosis: voxelwise regional investigation of white and gray matter. *Radiology.* 2010;254(1):227–34.
148. Benedict RH, Hulst HE, Bergsland N, Schoonheim MM, Dwyer MG, Weinstock-Guttman B, et al. Clinical significance of atrophy and white matter mean diffusivity within the thalamus of multiple sclerosis patients. *Mult Scler.* 2013;19(11):1478–84.
149. Roosendaal SD, Geurts JJ, Vrenken H, Hulst HE, Cover KS, Castelljns JA, et al. Regional DTI differences in multiple sclerosis patients. *NeuroImage.* 2009;44(4):1397–403.
150. Preziosa P, Rocca MA, Pagani E, Stromillo ML, Enzinger C, Gallo A, et al. Structural MRI correlates of cognitive impairment in patients with multiple sclerosis: a multicenter study. *Hum Brain Mapp.* 2016;37(4):1627–44.
151. Pagani E, Hirsch JG, Pouwels PJ, Horsfield MA, Perego E, Gass A, et al. Intercenter differences in diffusion tensor MRI acquisition. *J Magn Reson Imaging.* 2010;31(6):1458–68.
152. Filippi M, Preziosa P, Rocca MA. Brain mapping in multiple sclerosis: lessons learned about the human brain. *NeuroImage.* 2019;190:32–45.
153. Reddy H, Narayanan S, Matthews PM, Hoge RD, Pike GB, Duquette P, et al. Relating axonal

- injury to functional recovery in MS. *Neurology*. 2000;54(1):236–9.
154. Rocca MA, Colombo B, Falini A, Ghezzi A, Martinelli V, Scotti G, et al. Cortical adaptation in patients with MS: a cross-sectional functional MRI study of disease phenotypes. *Lancet Neurol*. 2005;4(10):618–26.
  155. Peterson DS, Fling BW. How changes in brain activity and connectivity are associated with motor performance in people with MS. *Neuroimage Clin*. 2018;17:153–62.
  156. Lv H, Wang Z, Tong E, Williams LM, Zaharchuk G, Zeineh M, et al. Resting-state functional MRI: everything that nonexperts have always wanted to know. *AJNR Am J Neuroradiol*. 2018;39(8):1390–9.
  157. Kiviniemi V, Kantola JH, Jauhainen J, Hyvarinen A, Tervonen O. Independent component analysis of nondeterministic fMRI signal sources. *NeuroImage*. 2003;19(2 Pt 1):253–60.
  158. Tomasi D, Volkow ND. Functional connectivity density mapping. *Proc Natl Acad Sci U S A*. 2010;107(21):9885–90.
  159. Bullmore E, Sporns O. Complex brain networks: graph theoretical analysis of structural and functional systems. *Nat Rev Neurosci*. 2009;10(3):186–98.
  160. Greicius MD, Krasnow B, Reiss AL, Menon V. Functional connectivity in the resting brain: a network analysis of the default mode hypothesis. *Proc Natl Acad Sci U S A*. 2003;100(1):253–8.
  161. Sambataro F, Murty VP, Callicott JH, Tan HY, Das S, Weinberger DR, et al. Age-related alterations in default mode network: impact on working memory performance. *Neurobiol Aging*. 2010;31(5):839–52.
  162. Broyd SJ, Demanuele C, Debener S, Helps SK, James CJ, Sonuga-Barke EJ. Default-mode brain dysfunction in mental disorders: a systematic review. *Neurosci Biobehav Rev*. 2009;33(3):279–96.
  163. Hawellek DJ, Hipp JF, Lewis CM, Corbetta M, Engel AK. Increased functional connectivity indicates the severity of cognitive impairment in multiple sclerosis. *Proc Natl Acad Sci U S A*. 2011;108(47):19066–71.
  164. Rocca MA, Valsasina P, Leavitt VM, Rodegher M, Radaelli M, Riccitelli GC, et al. Functional network connectivity abnormalities in multiple sclerosis: correlations with disability and cognitive impairment. *Mult Scler*. 2018;24(4):459–71.
  165. Rocca MA, Valsasina P, Hulst HE, Abdel-Aziz K, Enzinger C, Gallo A, et al. Functional correlates of cognitive dysfunction in multiple sclerosis: a multicenter fMRI study. *Hum Brain Mapp*. 2014;35(12):5799–814.
  166. Liao X, Vasilakos AV, He Y. Small-world human brain networks: perspectives and challenges. *Neurosci Biobehav Rev*. 2017;77:286–300.
  167. Rocca MA, Valsasina P, Meani A, Falini A, Comi G, Filippi M. Impaired functional integration in multiple sclerosis: a graph theory study. *Brain Struct Funct*. 2016;221(1):115–31.
  168. Friston KJ. Functional and effective connectivity: a review. *Brain Connect*. 2011;1(1):13–36.
  169. Rocca MA, Amato MP, De Stefano N, Enzinger C, Geurts JJ, Penner IK, et al. Clinical and imaging assessment of cognitive dysfunction in multiple sclerosis. *Lancet Neurol*. 2015;14(3):302–17.
  170. Govindaraju V, Young K, Maudsley AA. Proton NMR chemical shifts and coupling constants for brain metabolites. *NMR Biomed*. 2000;13(3):129–53.
  171. Simmons ML, Frondoza CG, Coyle JT. Immunocytochemical localization of N-acetyl-aspartate with monoclonal antibodies. *Neuroscience*. 1991;45(1):37–45.
  172. Nordengen K, Heuser C, Rinholm JE, Matalon R, Gundersen V. Localisation of N-acetylaspartate in oligodendrocytes/myelin. *Brain Struct Funct*. 2015;220(2):899–917.
  173. Brand A, Richter-Landsberg C, Leibfritz D. Multinuclear NMR studies on the energy metabolism of glial and neuronal cells. *Dev Neurosci*. 1993;15(3–5):289–98.
  174. Sajja BR, Wolinsky JS, Narayana PA. Proton magnetic resonance spectroscopy in multiple sclerosis. *Neuroimaging Clin N Am*. 2009;19(1):45–58.
  175. Lin DD, Crawford TO, Barker PB. Proton MR spectroscopy in the diagnostic evaluation of suspected mitochondrial disease. *AJNR Am J Neuroradiol*. 2003;24(1):33–41.
  176. Kirov II, Liu S, Tal A, Wu WE, Davitz MS, Babb JS, et al. Proton MR spectroscopy of lesion evolution in multiple sclerosis: steady-state metabolism and its relationship to conventional imaging. *Hum Brain Mapp*. 2017;38(8):4047–63.
  177. Narayana PA, Doyle TJ, Lai D, Wolinsky JS. Serial proton magnetic resonance spectroscopic imaging, contrast-enhanced magnetic resonance imaging, and quantitative lesion volumetry in multiple sclerosis. *Ann Neurol*. 1998;43(1):56–71.
  178. Davie CA, Hawkins CP, Barker GJ, Brennan A, Tofts PS, Miller DH, et al. Serial proton magnetic resonance spectroscopy in acute multiple sclerosis lesions. *Brain*. 1994;117(Pt 1):49–58.
  179. De Stefano N, Filippi M, Miller D, Pouwels PJ, Rovira A, Gass A, et al. Guidelines for using proton MR spectroscopy in multicenter clinical MS studies. *Neurology*. 2007;69(20):1942–52.
  180. Ge Y, Gonen O, Inglese M, Babb JS, Markowitz CE, Grossman RI. Neuronal cell injury precedes brain atrophy in multiple sclerosis. *Neurology*. 2004;62(4):624–7.
  181. De Stefano N, Narayanan S, Francis SJ, Smith S, Mortilla M, Tartaglia MC, et al. Diffuse axonal and tissue injury in patients with multiple sclerosis with low cerebral lesion load and no disability. *Arch Neurol*. 2002;59(10):1565–71.
  182. Narayana PA, Wolinsky JS, Rao SB, He R, Mehta M, Group PRTM. Multicentre proton magnetic resonance

- spectroscopy imaging of primary progressive multiple sclerosis. *Mult Scler*. 2004;10(Suppl 1):S73–8.
183. Fleischer V, Kolb R, Groppa S, Zipp F, Klose U, Groger A. Metabolic patterns in chronic multiple sclerosis lesions and normal-appearing white matter: intraindividual comparison by using 2D MR spectroscopic imaging. *Radiology*. 2016;281(2):536–43.
  184. Kirov II, Patil V, Babb JS, Rusinek H, Herbert J, Gonen O. MR spectroscopy indicates diffuse multiple sclerosis activity during remission. *J Neurol Neurosurg Psychiatry*. 2009;80(12):1330–6.
  185. Lufriu S, Kornak J, Ratiney H, Oh J, Brenneman D, Cree BA, et al. Magnetic resonance spectroscopy markers of disease progression in multiple sclerosis. *JAMA Neurol*. 2014;71(7):840–7.
  186. Cocco E, Murgia F, Loreface L, Barberini L, Poddighe S, Frau J, et al. (1)H-NMR analysis provides a metabolomic profile of patients with multiple sclerosis. *Neurol Neuroimmunol Neuroinflamm*. 2016;3(1):e185.
  187. Lim CK, Bilgin A, Lovejoy DB, Tan V, Bustamante S, Taylor BV, et al. Kynurenine pathway metabolomics predicts and provides mechanistic insight into multiple sclerosis progression. *Sci Rep*. 2017;7:41473.
  188. Hagiwara A, Hori M, Yokoyama K, Takemura MY, Andica C, Tabata T, et al. Synthetic MRI in the detection of multiple sclerosis plaques. *AJNR Am J Neuroradiol*. 2017;38(2):257–63.
  189. West J, Aalto A, Tisell A, Leinhard OD, Landtblom AM, Smedby O, et al. Normal appearing and diffusely abnormal white matter in patients with multiple sclerosis assessed with quantitative MR. *PLoS One*. 2014;9(4):e95161.
  190. Hagiwara A, Warntjes M, Hori M, Andica C, Nakazawa M, Kumamaru KK, et al. SyMRI of the brain: rapid quantification of relaxation rates and proton density, with synthetic MRI, automatic brain segmentation, and myelin measurement. *Investig Radiol*. 2017;52(10):647–57.
  191. Warntjes JB, Leinhard OD, West J, Lundberg P. Rapid magnetic resonance quantification on the brain: optimization for clinical usage. *Magn Reson Med*. 2008;60(2):320–9.
  192. Krauss W, Gunnarsson M, Andersson T, Thunberg P. Accuracy and reproducibility of a quantitative magnetic resonance imaging method for concurrent measurements of tissue relaxation times and proton density. *Magn Reson Imaging*. 2015;33(5):584–91.



Syed A. Rizvi

## Introduction

Treatment strategies for multiple sclerosis over the last two decades have undergone a profound change. Several agents are now available, all targeting the inflammatory aspects of the disease. All disease-modifying agents (DMA) are effective in reducing relapses as well as MRI activity. The evidence for a beneficial effect (short and long term) on disability and brain atrophy is increasing. The treatment effect appears to be greater when these agents are used early in the disease course. This chapter will review currently used agents (both FDA approved and off label) and discuss several promising agents in various phases of development.

## Interferons

Interferons (IFN) act through cell receptors producing a variety of immunological and antiviral effects. Although the exact mechanism of action in multiple sclerosis is unknown, an anti-inflammatory effect may be the result of inhibition of interferon gamma, inhibition of T-cell activation, production of anti-inflammatory cytokines, reduced T-cell migration, decreased blood–brain

barrier permeability, or possibly other unknown mechanisms [1–3].

*IFN β (beta)-1b subcutaneous (S/Q)* every other day (Betaseron/Betaferon) was the first disease-modifying agent approved for the treatment of relapsing–remitting multiple sclerosis (RRMS). In the pivotal trial of *IFN β (beta)-1b* involving 372 RRMS patients, two different doses were compared to placebo [4]. Both doses were found to be significantly better than placebo with about one-third greater reduction in relapse rate (8 MIU vs. placebo  $p = 0.0001$ , 1.6 MIU vs. placebo  $p = 0.0101$ , 8 MIU vs. 1.6 MIU  $p = 0.0086$ ). *IFN β (beta)-1b* had a profound beneficial effect on MRI parameters [5, 6].

The pivotal trial for *IFN β (beta)-1a intramuscular (I/M)* once weekly (Avonex) involved 301 RRMS patients and also showed a relapse rate reduction of about one-third and a positive effect on MRI parameters [7–9]. Additionally, there was a significant beneficial effect on time to sustained disability, which was the primary endpoint. Further analysis of the study also revealed a beneficial effect on the rate of brain atrophy in the second year of treatment [10].

The definitive trial for *IFN β (beta)-1a subcutaneous (S/C)* three times weekly (Rebif) compared two different doses (6 and 12 MIU) to placebo in 560 RRMS patients. In the 2-year controlled phase, both doses had a significant effect on relapse rate reduction (about one-third) (6 MIU = 1.82, 12 MIU = 1.73, placebo = 2.56),

S. A. Rizvi (✉)  
Rhode Island Hospital and Alpert Medical School  
of Brown University, Brown Neurology, Providence,  
RI, USA  
e-mail: [srizvi@lifespan.org](mailto:srizvi@lifespan.org)



disability measures, and MRI parameters [11, 12]. After 2 years, the placebo group was re-randomized to receive either the low-dose or the high-dose IFN  $\beta$  (beta)-1a. After 4 years, a dose–response relationship was observed for some measures, but not others [13]. The higher-dose group continued to do better for up to 8 years when compared to the original placebo group [14]. A pegylated form of IFN  $\beta$  (beta)-1a (S/C) every 14 days (Plegridy) was approved after the ADVANCE study reported better MRI, relapse, and disability outcomes when tested against placebo [15, 16].

Interferons are generally well tolerated and have a proven long-term safety record. Side effects are more frequent with the high-dose, high-frequency formulations and may include injection site reactions, flu-like symptoms, elevated liver enzymes, lymphopenia, and depression [17]. The efficacy of interferons can be compromised by the development of neutralizing antibodies, which are more common with the high-frequency formulations [18]. The exact relationship of development of neutralizing antibodies to loss of efficacy is unclear.

---

## Glatiramer Acetate

Glatiramer acetate (GA) (Copaxone) is a synthetic molecule compound consisting of four amino acids (L-alanine, L-glutamic acid, L-tyrosine, L-lysine). Although the precise mechanism of action of GA is unknown, there is some evidence that GA might compete with myelin basic protein for antigen binding that can result in phenotypic shift of Th1 cells to Th2 cells. These cells then cross the blood–brain barrier and release anti-inflammatory cytokines and possibly neuroprotective factors [1, 19].

The pivotal trial of GA involving 251 RRMS patients showed a significant effect on relapse reduction (about one-third) compared to placebo [20, 21]. MRI parameters were not assessed in the pivotal study, but a follow-up imaging study demonstrated a significant reduction in MRI lesions when compared to placebo [22]. The MRI effects of GA are less pronounced compared to interferons, and this may be secondary to its lack

of direct effect on the blood–brain barrier. GA appears to have an excellent long-term safety and is often used in patients with mild disease. GA is available in two different formulations (40 mg three times a week and 20 mg daily) as well as several different generic options.

---

## Natalizumab

Natalizumab (Tysabri) was the first humanized monoclonal antibody to be approved for treatment of relapsing–remitting multiple sclerosis and has been shown to be effective both in the early relapsing–remitting population and patients worsening on first-line therapy [23, 24].

Natalizumab binds to alpha 4-antegrin, thus inhibiting adhesion of leukocytes to vascular cell adhesion molecule (VCAM) receptor, preventing leukocyte migration into the CNS and subsequent inflammatory events [25]. Treatment with natalizumab results in a significant reduction of CD4/CD8 cells in the CNS and reversal of CD4/CD8 ratio similar to what is seen in AIDS patients. This can persist up to 6 months after discontinuation of natalizumab [26].

The efficacy of natalizumab has been evaluated in two large double-blinded placebo-controlled randomized studies: the AFFIRM (Natalizumab Safety And Efficacy In Relapsing–Remitting Multiple Sclerosis) and SENTINEL (Safety and Efficacy of Natalizumab in Combination with IFN  $\beta$  (beta)-1a in patients with Relapsing–Remitting Multiple Sclerosis) [27]. The primary endpoint in both these studies was the rate of relapse at 1 year and cumulative probability of disability progression sustained for 12 weeks at 2 years. In the AFFIRM trial, 942 patients (natalizumab = 627, placebo = 315) were enrolled, and natalizumab monotherapy reduced the risk of disability progression sustained for 12 and 24 weeks over 2 years by 42% and 54%, respectively, compared to placebo. Natalizumab reduced the analyzed relapse rate by 68% compared to placebo at 1 year, and the reduction was maintained for greater than 2 years. In the SENTINEL study, natalizumab in combination with IFN  $\beta$  (beta)-1a reduced the risk of disability

progression sustained for 12 weeks over 2 years by 24% compared to IFN  $\beta$  (beta)-1a alone. No significant difference was noted at 24 weeks. There was a 54% relative reduction in analyzed relapse rate at 1 year and 55% at 2 years when natalizumab was added to patients on IFN  $\beta$  (beta)-1a [28]. In both studies, natalizumab had a profound effect on MRI measures but was unable to show a beneficial effect on rate of brain atrophy at 2 years, although a positive effect was noted in both trials in the second year of treatment [29]. Natalizumab was found to be even more effective in a subgroup of patients with highly active disease, both in the AFFIRM and the SENTINEL trials [30]. In about 6% of patients, persistent neutralizing antibodies developed resulting in loss of efficacy [31].

Natalizumab was found ineffective in the treatment of acute relapses [32]. When tested in combination with glatiramer acetate, it was found to be safe and well tolerated during 6 months of therapy, and interestingly the incidence of persistent anti-natalizumab antibodies was higher (13%) [33]. In a small study in children, natalizumab was noted to be well tolerated and resulted in strong suppression of disease activity [34].

Several studies have documented an increase in disease activity after discontinuation of natalizumab treatment, especially in patients who were resistant to other treatments prior to starting therapy with natalizumab [35–37]. Minimizing the transition gap (not more than 3 months) and using an effective agent may minimize the risk of severe rebound [38]. PML should be carefully excluded in this setting, since several cases of PML have been documented soon after transitioning to other agents.

### **Natalizumab and PML**

Natalizumab has been associated with >750 cases of PML in 177,000 patients exposed to the drug with almost a 20% mortality rate. The risk of developing PML is higher in patients who are positive for JCV antibody (high titers associated with highest risk), with duration of exposure >24 months and prior exposure to

immunosuppressive agents. PML is extremely rare in treated patients who remain JCV negative (five cases) [39].

Natalizumab may cause PML by reactivation of latent JC virus found in greater than 80% of individuals [40, 41]. Although the exact mechanism is unknown, evidence points to impairment of immune surveillance. PML usually occurs in immunocompromised individuals such as patients infected with HIV and patients treated with aggressive immunosuppressive agents and some monoclonal antibodies including rituximab [42–44]. Although PML in general carries a grave prognosis, most of the data comes from the HIV literature. Early recognition and discontinuation of natalizumab resulting in accelerated removal of natalizumab from the circulation may lead to a better outcome [45].

---

### **B-Cell-Depleting Therapies (Rituximab and Ocrelizumab)**

Rituximab is a chimeric monoclonal antibody targeting CD20-positive B lymphocytes [46, 47], resulting in rapid and sustained depletion of B cells (6–9 months). Rituximab is currently approved in the treatment of non-Hodgkin's lymphoma (NHL) [48], refractory rheumatoid arthritis [49], and diffuse B-cell lymphoma but has been used extensively for the treatment of MS (off-label). Several case reports and smaller open-label studies have found rituximab to be beneficial in the treatment of a range of autoimmune neurological disorders including neuromyelitis optica (NMO), where it is now considered standard of care [50]. Treatment of RMS patients with rituximab results in selective depletion of CD20-positive B cells resulting in significant reduction of gadolinium-enhancing lesions (91%) and clinical relapses (44%), as demonstrated in a phase II trial with 104 patients with relapsing multiple sclerosis treated with rituximab compared to placebo [51]. Even though the existence of a humoral component in MS has been implicated for decades, the results of this trial provided solid evidence regarding the role of B cells in the immunopathology of multiple scler-

rosis [52, 53]. Rituximab may be useful in patients with aggressive RRMS who have failed to respond to other conventional therapies [54] and offers superior efficacy when compared to other commonly used agents in newly diagnosed RRMS patients [55].

Ocrelizumab a humanized (90–95%) has a similar mode of action as rituximab but is expected to produce less side effects. Ocrelizumab was recently approved (March 2017) for the treatment of RMS and PPMS. In two identical RRMS trials (OPERA I and OPERA II), patients on ocrelizumab had 46% reduction in annualized relapse rate and significant reduction in MRI lesions and disability progression when compared to interferon beta-1a [56]. As of July 2019, approximately 100,000 patients have been infused with ocrelizumab. It appears to be well tolerated with no serious unexpected adverse events.

Both rituximab and ocrelizumab were tested in the PPMS population, and while rituximab failed to meet its primary endpoint of confirmed disability progression, ocrelizumab became the first disease-modifying agent approved for PPMS by reducing the relative risk of disability progression by 25% when compared to placebo [57].

In general, B-cell-depleting therapies when used as a monotherapy in patients with MS appear to be relatively safe [58]. As with several other monoclonal antibodies, both rituximab and ocrelizumab have been associated with serious infusion reactions. Treatment with rituximab has been associated with serious infections, including PML in patients with other autoimmune and neoplastic disease [59]. No cases of PML have been reported in MS patients treated with B-cell-depleting therapies. There appears to be an increased risk of herpes reactivation and a possible increased risk of breast cancer (ocrelizumab). The safety of long-term repeated fixed dose use of B-cell-depleting therapies is unknown. Individualized dosing based on CD19 counts is a possibility but would need to be confirmed in a clinical trial [60, 61].

B-cell-depleting therapies offer an effective and completely different approach for treatment of MS. These monoclonal antibodies have sev-

eral advantages including superior efficacy, acceptable risk profile, infrequent dosing (1–2 infusions every 6 months), and a documented effect on patients with progressive disease.

---

## Alemtuzumab

Alemtuzumab, a humanized MCA-targeting CD52 (expressed on circulating T and B cells), is approved for relapsing forms of MS. It has a unique dosing schedule given as two annual courses (initial 5 days of IV infusion followed by 3 days at the end of 1 year). In phase III trials alemtuzumab was compared to SC IFN beta-1a in naïve MS patients (CARE-MS-I) and patients who had inadequate response to prior treatment (CARE-MS II). In both clinical trials, alemtuzumab reduced relapses by approximately 50% when compared to IFN beta-1a [62, 63]. Long-term follow-up data reveals excellent retention rates (CARE-MS I 86%, CARE-MS II 79%) and sustained long-term efficacy with the majority of patients treated with alemtuzumab not requiring any further treatment for up to 6 years (CARE-MS I 64%, CARE-MS II 55%) [64, 65]. The effect on disability was significant in CARE-MS-II but did not reach significance in CARE-MS I. Alemtuzumab had a beneficial impact on all MRI measures and significantly reduced brain volume loss when compared to IFN beta-1a. The proportion of patient achieving no evidence of disease activity (NEDA) was consistent throughout the extension period of up to 6 years (CARE-MS I 57% at 6 years, CARE-MS II 60% at 6 years). The proportion of patients treated with alemtuzumab who had 6-month clinical definite improvement (CDI) was 34–43%. Very low number of patients in the CARE-MS trials converted to SPMS over the 6-year follow-up period (CARE-MS I 1.1%, CARE-MS II 3.7%). MSBase, an international registry conversion rates for a similar period was about 18% [66].

Treatment-related risk included infusion reactions which were common and in some cases severe as well as several documented cases of pneumonitis. Several infections related to an

immunocompromised state have been documented including herpetic (10%), nocardia, and several cases of *listeria monocytogenes*. Alemtuzumab has also been associated with secondary autoimmune diseases including autoimmune thyroid disease (42% at 6 years), immune thrombocytopenic purpura (ITP) (2.3%), and several cases of autoimmune nephropathy. Most patients with adverse events were easily managed with either observation or first-line interventions [67]. Several recent cases of cervical arterial dissection as well as ischemic and hemorrhagic strokes have also been reported.

Alemtuzumab is highly efficacious but because of its risk profile, it is generally used in patients who have failed to respond to other agents. The clinical development program for alemtuzumab includes several steps to mitigate risk and facilitate early detection of any side effects. Alemtuzumab (as well as mitoxantrone and cladribine) can be used as an induction agent early in the treatment of RRMS with potentially long-term benefits.

---

## Daclizumab

Daclizumab was the first FDA-approved humanized monoclonal antibody for clinical use, initially for prevention of renal transplant rejection and eventually for relapsing–remitting MS. It is a humanized IgG1 monoclonal antibody that binds to CD25, the alpha subunit of the high-affinity IL-2 receptor, resulting in upregulation of immunoregulatory CD56 NK cells, inhibition of IL-2 trans-presentation on dendritic cells, and down-regulation of effector and lymphoid inducer T cells [68]. Notably, the FDA-approved formulation of subcutaneous daclizumab beta differs from the original humanized form of daclizumab in terms of the extent of glycosylation, and this may have as yet unknown implications for mechanistic differences [69].

After several smaller studies reported a beneficial effect of IV daclizumab on MS patients, three major clinical trials have evaluated subcutaneous daclizumab in combination with IFN beta-1a or as monotherapy [70–72]. The CHOICE study was a phase II trial involving 230 patients with RRMS

or SPMS who were given daclizumab plus IFN or IFN and placebo and used imaging as the primary endpoint. Add-on daclizumab treatment reduced the number of GAD-enhancing lesions compared to IFN beta alone, but it did not significantly reduce the adjusted annualized relapse rate [73]. The SELECT trial was a phase II study with 621 RRMS patients randomized to either daclizumab monotherapy or placebo. Compared with placebo, there was a 54% reduction in annualized relapse rate with daclizumab 150 mg and a 50% reduction with daclizumab 300 mg [74]. Two extension studies (SELECTION and SELECTED) importantly showed no rebound effect during a washout period and made further observations on safety up to 6.5 years of treatment [75, 76]. Lastly, the DECIDE trial was a phase III study involving 1841 RRMS patients comparing daclizumab 150 mg directly to IFN. There was a 45% relative risk reduction in terms of annualized relapse rate for patients receiving daclizumab compared to IFN [77].

The most common adverse events include nasopharyngitis, upper respiratory infection, and headache. Serious adverse events include liver function testing abnormalities, cutaneous reactions, infections, and autoimmune phenomena. In a pooled analysis of the major clinical trials including a total of 2236 patients, 16% of patients experienced a severe adverse event other than MS relapse. Most adverse events were mild or moderate in severity; 13% of patients had to discontinue daclizumab due to an adverse event other than MS relapse [78].

Unfortunately, due to several serious adverse events, daclizumab was withdrawn from the market in March 2018.

---

## Fingolimod

Fingolimod (Gilenya) was the first oral disease-modifying therapy for the treatment of RRMS. It is a sphingosine-1-phosphate receptor modulator which binds to four out of five S1P receptors on lymphocytes resulting in receptor internalization [79]. These receptors deliver a recognition signal for lymphocytes to egress the thymus and

secondary lymphoid tissue. Lymphocytes, including Th17 central memory T cells, are retained in the lymphoid tissue and prevented from reaching sites of inflammation [80]. Fingolimod can enter the CNS and may have a beneficial neuroprotective effect on glial cells [81]. A small study described strong expression of S1P receptor 1 and 3 in reactive astrocytes in active and chronic inactive MS lesions [82].

A 6-month phase II study showed that once daily oral treatment with Fingolimod (1.25 or 5 mg) had a significant benefit on inflammatory measures of disease activity (MRI and relapse rate), and the effect seems to persist for at least 24 months [83]. In the TRANSFORMS study, patients treated with FTY720 had a 52% greater reduction of RR compared to IFN beta-1a (I/M) [84]. Side effects of FTY720 include two deaths from disseminated herpes, several skin malignancies, macular edema, initial dose bradycardia, decrease in FEV, elevated liver enzymes, and a single case each of posterior reversible encephalopathy syndrome (PRES) and focal encephalitis. In the FREEDOMS trial, which involved >1200 patients, FTY720 reduced the relapse rate by 54% in the 0.5 mg group and 60% in the 1.25 mg group compared to placebo ( $p = <0.001$ ) [85]. There were positive effects on MRI, including reduction in rate of brain atrophy and a 30% reduction in disability progression. There were no unexpected adverse events, and patients on the lower dose had very few side effects.

Treatment with fingolimod has been associated with serious infections including rare cases of PML [86], fungal meningitis [87], and herpetic encephalitis [84]. Several cases of severe disease exacerbations have been reported in patients treated with fingolimod soon after discontinuing treatment [88–90].

---

## Dimethyl Fumarate

Dimethyl fumarate (DMF) (Tecfidera) is an unsaturated carboxylic acid ester that was initially used to treat inflammatory skin diseases such as psoriasis [91]. DMF is rapidly hydrolyzed in the small intestine to its active metabo-

lite, monomethyl fumarate (MMF) [92, 93]. This molecule is then absorbed into systemic circulation where it is thought to increase expression of anti-inflammatory cytokines while inhibiting the expression of pro-inflammatory cytokines. DMF and its primary metabolite, MMF, have also been implicated in modulating cellular response to oxidative stress by activating the Nrf2 (nuclear-related erythroid-2 related factor 2) pathway, which leads to enhanced expression of antioxidant proteins leading to neuronal cell protection [94, 95]. Two randomized, double-blind, placebo-controlled phase III trials have shown that orally administered dimethyl fumarate reduces the annual relapse rate and number of new lesions on MRI in patients with relapsing–remitting multiple sclerosis. The DEFINE study was a 2-year clinical trial involving a total of 1237 patients that were randomly assigned to receive placebo or dimethyl fumarate at a dose of 240 mg either three times daily or two times daily. This study showed that both oral DMF dosages (240 mg twice daily or 240 mg three times daily) significantly reduced the annualized relapse rate (53% and 48% reduction respectively), the rate of disability progression, and the number of brain lesions on MRI when compared with placebo in patients with relapsing–remitting multiple sclerosis [96]. The CONFIRM study was another phase III trial where a total of 1417 patients were randomly assigned to receive one of the following: dimethyl 240 mg three times daily, dimethyl fumarate two times daily, glatiramer acetate 20 mg daily, or placebo. All therapies were found to significantly reduce relapse rates (DMF 3/day 51%, DMF 2/day 48%, GA 29%) and decrease the number of new lesions on neuroimaging when compared to placebo in patients with relapsing–remitting multiple sclerosis. There was no significant beneficial effect on disability [97].

The most common side effects noted with use of dimethyl fumarate have been flushing and gastrointestinal complaints such as diarrhea, nausea, and abdominal pain. These adverse events decrease after the first month of therapy [98]. Treatment with DMF has been associated with rare cases of PML [99].

## Teriflunomide

Teriflunomide is a once daily oral immunomodulating agent which selectively and reversibly inhibits dihydroorotate dehydrogenase (DHODH) resulting in inhibition of circulating activated T and B lymphocytes. It reduces pro-inflammatory unique CD4+ T-cell clones seen in MS patients [100]. Immune responses are preserved during treatment with teriflunomide [101]. It is an active metabolite of leflunomide which has been used for many years for the treatment of rheumatoid and psoriatic arthritis. In two phase III trials (TEMSO, TOWER), patients on the higher dose of teriflunomide (14 mg) had approximately one-third reduction in relapses and a beneficial effect on MRI-related measures and disability progression when compared to placebo [102, 103]. In the TEMSO trial, treatment with teriflunomide significantly reduced brain volume loss when compared to placebo over a 2-year period [104]. In the TOPIC study in patients with clinically isolated syndrome, teriflunomide reduced the risk of second relapse by 43% [105]. In the TENERE study, there was no difference in efficacy when teriflunomide was compared to IFN beta-1a (Rebif), although less patients on teriflunomide dropped out of the study [106]. Long-term extension data provides evidence in support of sustained beneficial effects of teriflunomide for treatment of relapsing MS [107].

Teriflunomide is well tolerated with very few serious side effects across several clinical trials.

Adverse events reported include abnormal liver function tests, transient hair thinning, diarrhea, and upper respiratory infections. Rare cases of tuberculosis reactivation have been reported [108]. Teriflunomide should be used with caution in female patients of child bearing age, although there have not been any confirmed cases of teratogenicity [109]. Treatment with cholestyramine or activated charcoal can rapidly reduce teriflunomide concentrations in case of pregnancy or other serious adverse events [110].

## Mitoxantrone

Mitoxantrone binds to DNA and inhibits topoisomerase II. It has an effect on B- and T-cell function and decreases secretion of TH1 cytokines [111]. After several small trials with encouraging results, a phase III trial using two different doses (12 and 5 mg/m<sup>2</sup>) was completed [112]. The higher dose had significantly more effect on a combined primary endpoint consisting of five clinical measures. The result led to the approval of mitoxantrone as a first chemotherapy drug for treatment of worsening MS. Mitoxantrone has also been used as induction treatment and in combination with other immunomodulating agents [113, 114]. The results have been encouraging, and in some cases, long-lasting effects were seen. Unfortunately, the use of mitoxantrone is very limited because of dose-related cardiotoxicity and several reports of therapy-related leukemia [115–117] (Table 7.1).

**Table 7.1** Treatment of MS

Radiologically isolated syndrome (RIS)	Observation with periodic exams and MRI Consider treatment in patients with persistent increase in lesion load	
CIS and RRMS	<i>Mild</i>	<i>Moderate/severe</i>
	GA	Natalizumab (JCV–)
	IFN	Ocrelizumab
	Teriflunomide	Fingolimod or Siponimod
	DMF	Alemtuzumab (induction)
Worsening RRMS and SPMS with relapses	Natalizumab (JCV–)	
	Ocrelizumab	
	Fingolimod or Siponimod	
	Alemtuzumab or Cladribine	
SPMS without relapses	Consider discontinuing DMA for stable patients >65 years old	
PPMS	Ocrelizumab	

## Treatment of Radiologically Isolated Syndrome (RIS)

Several recent studies have raised awareness of patients with incidentally discovered MRI lesions suggestive of multiple sclerosis, the so-called radiologically isolated syndrome (RIS). These studies have documented a conversion rate to CIS of about one-third within a 5-year period. Many more patients (59%) continue to have radiological progression [118, 119]. Furthermore, the risk of an alternate diagnosis with characteristic MRI finding suggestive of MS seems to be extremely low. Patients with evidence of ongoing disease activity may be candidates for treatment [120].

---

## Treatment of Clinically Isolated Syndrome (CIS) and Newly Diagnosed Mild RRMS

Several natural history and long-term longitudinal studies have provided useful information regarding progress in individual patients with multiple sclerosis. An increased rate of relapses in the first few years, poor recovery from relapses, high lesion burden on MRI, spinal cord lesions, and African-American race are all associated with a relatively poor long-term outcome. On the other hand, lack of poor prognostic indicators may not necessarily point toward a benign outcome. Benign MS is mostly a relapsing disease either mild RRMS or CIS without further episodes [121]. Rare cases of benign PPMS have also been documented [122]. Patient with an EDSS <2 after 10 years from diagnosis may have a higher chance (70–80%) of having a benign course, although these patients represent <20% of RRMS patients [123, 124]. Histopathological and advanced imaging studies have revealed that significant axonal loss occurs early in the course of MS, and this loss of axons may be the principal determinant of fixed permanent disability [125–127]. Long-term MRI studies (10–20-year follow-up) have suggested that the lesion load on the initial MRI

may be a prognostic indicator for long-term disability [128].

There is overwhelming evidence suggesting a better response to disease-modifying treatments when used early in the disease course. Several studies have looked into the effect of these agents when initiated at the time of first clinical event (clinically isolated syndrome or CIS). These trials have demonstrated a beneficial effect on disease activity with a reduction in relapse rates and new MRI lesions in the critical first 2 years after the initial event. Other controlled trials have compared early versus late treatment and have demonstrated a beneficial effect of starting treatment early. It appears that in the early phases of multiple sclerosis there may be a window of opportunity to target the inflammatory component of the disease. However, it is unclear if the benefit persists as the disease progresses.

In the BENEFIT study (Betaseron in Newly Emerging Multiple Sclerosis for Initial Treatment), 468 patients with a first clinical event were randomized to receive IFN  $\beta$  (beta)-1b versus placebo [129, 130]. After 2 years, the treated group did much better with only 26% of treated patients converting to clinically definite multiple sclerosis (CDMS) versus 44% in the placebo group ( $p < 0.0001$ ). The patients in the placebo group who converted to CDMS were offered open-label IFN  $\beta$  (beta)-1b and were followed for an additional 3 years. After 11 years, early treatment with IFN  $\beta$  (beta)-1b reduced the risk of CDMS by 33%, although there was no significant difference between the groups on MRI and EDSS [131]. In the CHAMPS study (Controlled High-Risk Subjects Avonex Multiple Sclerosis Prevention Study trial), 383 patients with an initial mono-focal demyelinating event were randomized to receive IFN  $\beta$  (beta)-1a (I/M once weekly) or placebo [132]. The trial was stopped early after an interim analysis suggested a positive outcome. Thirty-five percent of the treated group converted to CDMS versus 50% in the placebo group ( $p = 0.002$ ). The benefit of early treatment was shown to persist for at least 5 years on relapses and MRI measures, but not on disability [133]. In the ETOMS (Early Treatment of

Multiple Sclerosis) trial, patients ( $N = 309$ ) treated with a low-dose IFN  $\beta$  (beta)-1a, 22  $\mu\text{m}$  once weekly S/C, were also less likely to have subsequent attacks compared to placebo (34% vs. 45%) [134]. The PRECISE study randomized mono-focal CIS patients to GA or placebo similar to the interferon CIS studies. Patients treated with GA had a reduced risk of developing CDMS (25% vs. 43%) [135]. In the TOPIC trial, patients on teriflunomide had a 43% reduction versus placebo in conversion to definite MS [105]. MS diagnostic criteria have evolved significantly over the last decade resulting in earlier diagnosis of definite MS and a shrinking CIS patient population.

### Treatment of Aggressive Onset and Worsening RRMS

CIS and newly diagnosed RRMS patients with positive prognostic indicators including severe or multiple relapses, high lesion burden, spinal cord lesions, and African Americans should be considered for a more aggressive approach with higher efficacy agents [136, 137]. One-third of patients do not achieve an optimal response to an initial disease-modifying agent, and the percentage of patients failing may increase with time [138]. The outcome with recently approved higher efficacy agents may be better. In the absence of a validated clinical or laboratory surrogate marker of a suboptimal response most specialists would consider an increase in relapse rate (compared to baseline), and the presence of new MRI activity as a sign of worsening disease. An aggressive treatment approach could also be considered to achieve a disease-activity-free status in multiple sclerosis using “no evidence of disease activity” (NEDA). More specifically, NEDA-3 has been defined as (1) absence of relapses, (2) absence of focal MRI activity, and (3) absence of confirmed disability progression. NEDA-4 not only includes the criteria included in NEDA-3 but also requires an annualized rate of brain volume loss of less than 0.4% [139, 140]. Since brain volume loss has been shown to

correlate with disability progression and cognitive decline, this definition may more accurately reflect a complete absence of disease activity. However, NEDA criteria do not fully capture disability related to MS such as cognition, pain, and fatigue, and the evidence for an association between NEDA and lack of future disease progression is lacking, although some short-term studies have suggested positive outcomes in patients who achieve NEDA status [141–143]. It is difficult to sustain long-term NEDA status. In the CLIMB cohort of 2200 patients, only 7.9% maintained NEDA status after 7 years; however, NEDA status at 2 years had a positive predictive value of no progression of 78.3% at 7 years [144] (Table 7.2).

Possible options in managing patients with worsening disease include switching to alternate first-line or second-line agents and possibly enrolling in a clinical trial with an experimental agent. A more aggressive and increasingly acceptable approach is to minimize the risk of early progression by using high-efficacy agents as first-line or very early in the disease course. Several high-efficacy agents including natalizumab (JCV negative), ocrelizumab, and fingolimod offer acceptable efficacy/risk profiles and can be considered as first-line agents.

**Table 7.2** NEDA rates in clinical trials of at least 2-year duration

	Trial	NEDA-3 [reference]
IFN- $\beta$ 1a S/C three times a week	CARE-MS and OPERA	14–29% [56, 62, 63]
Teriflunomide (14 mg)	TEMPO	23% [145]
Dimethyl Fumarate	DEFINE CONFIRM	28% [145] 18%
Fingolimod	FREEDOMS	31% [140]
Plegridy	ADVANCE (1 year)	34% [146]
Natalizumab	AFFIRM	37% [147]
Alemtuzumab	CARE-MS I CARE-MS II	39% [62] 32% [63]
Cladribine	CLARITY	44% [148]
Ocrelizumab	OPERA I and II	48% [56]
Autologous stem cell transplant	Observational studies	78–83% [149]



## Treatment of Progressive MS

Almost 80% of patients RRMS eventually develop progressive disease after an initial inflammatory relapsing–remitting MS phase. These patients may continue to experience relapses and develop new MRI lesions in the earlier phases of SPMS. Several trials have suggested a modest benefit of using disease-modifying agents in this subgroup of patients with SPMS. The only disease agent approved for SPMS is mitoxantrone, although it is rarely used due to serious toxicity. Two large trials with IFN  $\beta$  (beta)-1b (European and North American Trials) produced mixed results [150, 151]. Unfortunately, there is no evidence that SPMS without relapses may benefit from any of the currently FDA-approved disease-modifying agents including natalizumab and fingolimod; both were highly effective treatment for RRMS and were found to be ineffective in the SPMS population [152, 153].

Results from EXPAND (phase III) trial for BAF321 suggest a beneficial effect in SPMS patients. BAF321 reduced confirmed disability progression at 6 months by 26% when compared to placebo [154]. Encouraging phase II results include a reduction in brain atrophy with simvastatin and reduction in disability with high-dose biotin [155, 156]. Larger confirmatory trials are being planned.

Finally, the ORATORIO trial provided a major breakthrough in PPMS patients. Ocrelizumab, a CD20 monoclonal antibody, became the first drug to show significant efficacy (and approved by FDA) in the PPMS population by reducing the risk of progression of clinical disability by 24% compared to placebo [57].

---

## Comparative Trials

Several trials have compared the efficacy of disease-modifying agents in a controlled setting sometimes with surprising results.

Several trials (INCOMIN, EVIDENCE, and BEYOND) comparing different formulations of interferons demonstrated lower relapse rate and MRI lesions with high-dose, high-frequency

compared to low-dose, low-frequency interferon [157–159]. Other trials (BEYOND, BECOME, and REGARD) compared efficacy of high-dose, high-frequency interferons and GA and found no difference in relapse rates or time of onset of clinical activity [160, 161]. In the TRANSFORMS study, fingolimod was more effective than low-dose, low-frequency interferon [84]. In the CONFIRM trial, reduction in annualized relapse rates when compared to placebo was proportionally higher for dimethyl fumarate when compared to GA [97]. Both alemtuzumab and ocrelizumab were tested against IFN beta-1a S/C three times a week and reduced the annualized relapse rate by approximately 50% versus the active comparator [56, 62].

---

## Other Agents Used in the Treatment of RRMS

*Cyclophosphamide* is an alkylating agent that binds to DNA and suppresses both B and T cells. It is commonly used as an antineoplastic agent and is also used to treat several immune-mediated disorders [162]. Two large trials in patients with progressive disease (the Northeast Cooperative Multiple Sclerosis Treatment Group and Canadian Cooperative Multiple Sclerosis Group) provided conflicting results. The Northeast trial suggested some benefit in young patients with maintenance dosing, while the Canadian study failed to show any benefit of using cyclophosphamide [163, 164]. Several recent small studies have reported a beneficial effect on a subgroup of patients who are young and have aggressive disease [165, 166]. It carries a significant risk of serious side effects such as hemorrhagic cystitis, bladder cancer, and azoospermia and should only be used in patients with fairly aggressive disease unresponsive to other agents [167, 168].

*Azathioprine* is an oral immunosuppressive agent used to treat several immune-based disorders, including myasthenia gravis and rheumatoid arthritis. Clinical trials testing azathioprine in MS have been relatively small and lacked standardized MRI measures. A meta-analysis involving 793 patients suggested a slight benefit

at 2 years of treatment, but the authors concluded that this probably did not outweigh the potential risks for long-term serious side effects [169].

*Mycophenolate mofetil* (Cellcept) is an immunosuppressive agent. It is increasingly being used in preventing organ transplant rejection and has been found to be beneficial in Crohn's disease [170, 171]. It also promotes recovery in experimental allergic encephalomyelitis (EAE) [172]. A phase II trial in a small number of patients resulted in disease stabilization when mycophenolate was used in combination with IFB  $\beta$  (beta)-1a [173].

*Intravenous immune globulin (IVIG)* may work by neutralizing circulating antibodies against myelin antigens, downregulating antibody production, or interfering with complement or macrophage-mediated damage. It has also been shown to produce re-myelination in animal models [174, 175]. A meta-analysis of four double-blinded studies reported a beneficial effect on annual relapse rate as well as change in EDSS scores [176]. Several other trials failed to show a beneficial effect [177, 178]. IVIG was also found to be useful in reducing relapses in the postpartum period and patients with acute relapses who are intolerant to steroids [179]. One small study noted a benefit in patients with a first demyelinating event [180].

*Plasmapheresis* may work by removing circulating autoantibodies and may be useful in patients with severe relapses unresponsive to steroids [181–184].

---

## Disease-Modifying Agents Currently in Development

### Cladribine

Cladribine is an oral deoxyadenosine analog pro-drug which causes moderate reduction in T and B cells with minimal effects on innate immune cells [185]. It has a unique dosing regimen with a total of 8–10 days of oral dosing with long-lasting effects. Cladribine (parenteral) is used as treatment for hairy cell leukemia and has been studied in other autoimmune conditions including MS. Earlier studies in MS patients using paren-

teral cladribine resulted in positive outcomes in MRI and clinical measures, but the outcomes were difficult to interpret. Two doses of oral cladribine were compared against placebo in a pivotal phase III trial [186]. The annualized relapse rate was significantly reduced in both cladribine tablet groups with relative reduction rates of 57.6% and 54.5% compared to placebo. Both disability and MRI measures (including brain atrophy) were significantly better in the cladribine-treated patients [187]. Long-term follow-up studies have suggested a sustained benefit after the first 2 years of treatment [188]. In the ORACLE study, two different doses of cladribine were tested against placebo in the CIS population. Patients who were on cladribine (both doses) had a significant delay in time to conversion to CDMS (62%, 67%) [189]. Although the study was terminated early because of a negative regulatory decision in relation to CLARITY data, the investigators did not feel it affected the outcome. Cladribine was well tolerated in most patients. Lymphopenia was an expected side effect. CD19 cells had a more robust reduction compared to T lymphocytes but returned to normal range within 48 weeks after dosing without any signs of significant overshoot. Infections were similar across groups except herpes zoster which was more common in treated patients [190]. Although there was a concern about increased risk of malignancy in the CLARITY study, an independent meta-analysis found that the cancer rates were not increased versus treatment group in other studies [191]. The European Medicine Agency (EMA) approved cladribine for highly active RRMS patients in 2017.

*Cladribine (Mavenclad) was approved by the FDA (March 2019) for the treatment of relapsing–remitting and active secondary process MS. Treatment risk (box warning) includes malignancy and fetal harm.*

### Ozanimod

Ozanimod is another selective sphingosine-1-phosphate receptor modulator (receptor types 1 and 5), currently in development for MS and

inflammatory bowel disease [192]. Two different doses of ozanimod were found to be superior to placebo and IFN beta-1a for relapse rate and MRI measures (including brain atrophy), but no significant differences were noted for disability outcomes [193]. Ozanimod has a favorable cardiac safety profile [194].

### Siponimod

Siponimod (BAF312) is a selective sphingosine-1-phosphate receptor modulator (receptor types 1 and 5) [195]. In the EXPAND trial, siponimod reduced the risk of disability progression in SPMS patients [154, 196]. Unlike other SPMS trials with positive results (IFN beta-1b and mitoxantrone), the EXPAND trial design allowed enrollment of patients widely representative of the SPMS population with minimal evidence of inflammatory activity. Early evidence suggests a possible neuroprotective effect [197, 198].

*Siponimod (Mayzent) was approved by the FDA (March 2019) for the treatment of relapsing forms of MS, including clinically isolated syndrome, RRMS, and active SPMS.*

### Ofatumumab

Ofatumumab is a fully humanized anti-CD20 monoclonal antibody currently being investigated in RRMS [199]. Two different phase II trials (IV and S/C) have demonstrated positive results with an excellent safety profile [200, 201]. Phase III trial comparing ofatumumab (S/C) to teriflunomide are currently ongoing [202].

### Ponesimod

Ponesimod is a highly selective, rapidly reversible and selective sphingosine receptor modulator. After successful phase II program, an ongoing phase III trial is comparing ponesimod with teriflunomide. The efficacy and side-effect profile of ponesimod appears to be comparable to fingolimod with the added advantage of having an optimized up-titrated regimen and a short

half-life resulting in less risk of adverse events [203, 204].

---

## Stem Cell Transplantation

Stem cell transplantation requires a collection of hematopoietic stem cells from the peripheral circulation followed by ablation of the immune system with chemotherapy agents with reinfusion of stem cells in the hope that the reconstituted immune system would be more tolerant to self-antigens. This idea is supported by several case reports of individual MS patients treated for malignancy and EAE animal models [205].

Several studies have looked at the effects of autologous hematopoietic stem cell transplantation and found encouraging results with prolonged periods of disease stabilization in patients with aggressive disease [149, 206–214]. Patients with aggressive RRMS, time of diagnosis <10 years, and minimal exposure to prior immunosuppressive agents have the best treatment response with minimal risk. A recent meta-analysis of 15 studies (mostly open label) revealed a significant benefit with >80% not progressing over a period of 2 years. The benefit was significantly greater in patients with RRMS. In five studies that reported NEDA at 5 years, NEDA was 67%. The overall transplant-related mortality was 2.1% in the study but significantly lower (0.3%) in patients enrolled in the last 10 years [215]. However, stem cell transplantation is a difficult process and carries a significant risk and should only be considered in patients with aggressive disease not responsive to other conventional agents. Data from future controlled trials may help us understand and better define the risk and benefits of this aggressive but promising approach for treating MS.

---

## Neuroprotection

A variety of agents thought to be neuroprotective have been tested in MS and have either been inconclusive or failed to show any beneficial effect; several others are in early phases of development [216, 217]. The lack of a clear sur-

rogate marker of demyelination and neuroprotection is a significant handicap in the development of neuroprotective agents. In the absence of any promising regenerative treatments, the best approach may be to prevent chronic inflammation and secondary neurodegeneration using effective disease-modifying agents as early as possible in the disease process.

## Conclusion

Over the last two decades, multiple disease-modifying agents have been approved for the treatment of relapsing forms of multiple sclerosis. The more recently approved agents appear to be increasingly more effective and target different proposed mechanisms of MS pathophysiology. These include several monoclonal antibodies and oral agents with novel mechanism of action. Several other options offer some hope in progressive patients as well. Early treatment with highly effective agents increases the probability of achieving long-term disease-free remission. Unfortunately, a more aggressive approach may be associated with an increased risk of serious adverse events, and only long-term data from controlled large-scale clinical trials will determine the extent of therapeutic efficacy and safety of these emerging therapies.

## References

1. Yong VW. Differential mechanisms of action of interferon-beta and glatiramer acetate in MS. *Neurology*. 2002;59:802–8.
2. Yong VW, Chabot S, Stuve O, Williams G. Interferon beta in the treatment of multiple sclerosis: mechanisms of action. *Neurology*. 1998;51:682–9.
3. Kieseier BC, Seifert T, Giovannoni G, Hartung HP. Matrix metalloproteinases in inflammatory demyelination: targets for treatment. *Neurology*. 1999;53:20–5.
4. The IFNB Multiple Sclerosis Study Group. Interferon beta-1b is effective in relapsing-remitting multiple sclerosis. I. Clinical results of a multi-center, randomized, double-blind, placebo-controlled trial. *Neurology*. 1993;43:655–61.
5. Paty DW, Li DK, UBC MS/MRI Study Group and the IFNB Multiple Sclerosis Study Group. Interferon beta-1b is effective in relapsing-remitting multiple sclerosis. II. MRI analysis results of a multicenter, randomized, double-blind, placebo-controlled trial. *Neurology*. 1993;43:662–7.
6. The IFNB Multiple Sclerosis Study Group and the University of British Columbia MS/MRI Analysis Group. Interferon beta-1b in the treatment of multiple sclerosis: final outcome of the randomized controlled trial. *Neurology*. 1995;45:1277–85.
7. Jacobs LD, Cookfair DL, Rudick RA, Herndon RM, Richert JR, Slazar AM, et al. Intramuscular interferon beta-1a for disease progression in relapsing multiple sclerosis. *Ann Neurol*. 1996;39:285–94.
8. Rudick RA, Goodkin DE, Jacobs LD, Cookfair DL, Herndon RM, Richert JR, Salazar AM, Fischer JS, Granger CV, Simon JH, Alam JJ, Simonian NA, Campion MK, Bartoszak DM, Bourdette DN, Braiman J, Brownschidle CM, Coats ME, Cohan SL, Dougherty DS, Kinkel RP, Mass MK, Munschauer FE, Priore RL, Whitham RH, et al. Impact of interferon beta-1a on neurologic disability in relapsing multiple sclerosis. The Multiple Sclerosis Collaborative Research Group. *Neurology*. 1997;49(2):358–63.
9. Simon JH, Jacobs LD, Campion M, Wende K, Simonian N, Cookfair DL, Rudick RA, Herndon RM, Richert JR, Salazar AM, Alam JJ, Fischer JS, Goodkin DE, Granger CV, Lajaunie M, Martens-Davidson AL, Meyer M, Sheeder J, Choi K, Scherzinger AL, Bartoszak DM, Bourdette DN, Braiman J, Brownschidle CM, Whitham RH, et al. Magnetic resonance studies of intramuscular interferon beta-1a for relapsing multiple sclerosis. The Multiple Sclerosis Collaborative Research Group. *Ann Neurol*. 1998;43:79–87.
10. Rudick RA, Fisher E, Lee JC, et al. Use of the brain parenchymal fraction to measure whole brain atrophy in relapsing-remitting MS. Multiple Sclerosis Collaborative Research Group. *Neurology*. 1999;53:1698–704.
11. PRISMS Study Group Randomized double-blind placebo-controlled study of interferon beta-1a in relapsing remitting multiple sclerosis. *Lancet*. 1998;352:1498–504.
12. Li DK, Paty DW. Magnetic resonance imaging results of the PRISMS trial: a randomized, double-blind, placebo-controlled study of interferonbeta1a in relapsing-remitting multiple sclerosis. Prevention of Relapses and Disability by Interferon-beta1a Subcutaneously in Multiple Sclerosis. *Ann Neurol*. 1999;46:197–206.
13. PRISMS Study Group. PRISMS-4: long-term efficacy of interferon beta-1a in relapsing MS. *Neurology*. 2001;56:1628–36.
14. Kappos L, Traboulsee A, Constantinescu C, et al. Long-term subcutaneous interferon beta-1a therapy in patients with relapsing-remitting MS. *Neurology*. 2006;67:944–53.
15. Calabresi PA, Kieseier BC, Arnold DL, ADVANCE Study Investigators et al. Pegylated interferon  $\beta$ -1a for relapsing-remitting multiple sclerosis (ADVANCE): a randomised, phase 3, double-blind study. *Lancet Neurol*. 2014;13:657–65.

16. Newsome SD, Kieseier BC, Liu S, You X, Kinter E, Hung S, Sperling B. Peginterferon beta-1a reduces disability worsening in relapsing-remitting multiple sclerosis: 2-year results from ADVANCE. *Ther Adv Neurol Disord.* 2017;10(1):41–50.
17. Walther EU, Hohlfeld R. Multiple sclerosis: side effects of interferon therapy and their management. *Neurology.* 1999;53:1622–7.
18. Goodin DS, Frohman EM, Hurwitz B, et al. Neutralizing antibodies to interferon beta: assessment of their clinical and radiographic impact: an evidence report: report of the Therapeutics and Technology Assessment Subcommittee of the American Academy of Neurology. *Neurology.* 2007;68:977–84.
19. Farina C, Weber MS, Meinl E, Wekerle H, Hohlfeld R. Glatiramer acetate in multiple sclerosis: update on potential mechanisms of action. *Lancet Neurol.* 2005;4:567–75.
20. Johnson KP, Brooks BR, Cohen JA, Ford CC, Goldstein J, Lisak RP, et al. Copolymer 1 reduces relapse rate and improves disability in relapsing-remitting multiple sclerosis: results of a phase III multicenter, double-blind placebo-controlled trial. *Neurology.* 1995;45:1268–76.
21. Johnson KP, Brooks BR, Cohen JA, Ford CC, Goldstein J, Lisak RP, Myers LW, Panitch HS, Rose JW, Schiffer RB, Vollmer T, Weiner LP, Wolinsky JS. Extended use of glatiramer acetate (copaxone) is well tolerated and maintains its clinical effect on multiple sclerosis relapse rate and degree of disability. Copolymer 1 Multiple Sclerosis Study Group. *Neurology.* 1998;50:701–8.
22. Comi G, Filippi M, Wolinsky JS. European/Canadian multicenter, double-blind, randomized, placebo-controlled study of the effects of glatiramer acetate on magnetic resonance imaging-measured disease activity and burden in patients with relapsing multiple sclerosis. European/Canadian Glatiramer Acetate Study Group. *Ann Neurol.* 2001;49:290–7.
23. Goodin DS, Cohen BA, O'Connor P, Kappos L, Stevens JC. Assessment: the use of natalizumab (Tysabri) for the treatment of multiple sclerosis (an evidence-based review): report of the Therapeutics and Technology Assessment Subcommittee of the American Academy of Neurology. *Neurology.* 2008;71:766–73.
24. Putzki N, Kollia K, Woods S, Igwe E, Diener HC, Limmroth V. Natalizumab is effective as second line therapy in the treatment of relapsing remitting MS. *Eur J Neurol.* 2009;16:424–6.
25. Engelhardt B, Kappos L. Natalizumab: targeting alpha4-integrins in multiple sclerosis. *Neurodegener Dis.* 2008;5:16–22.
26. Stive O, Cravens PD, Frohman EM, Phillips JT, Remington GM, von Geldern G, Cepok S, Singh MP, Cohen Tervaert JW, De Baets M, MacManus D, Miller DH, Radü EW, Cameron EM, Monson NL, Zhang S, Kim R, Hemmer B, Racke MK. Immunologic, clinical, and radiologic status 14 months after cessation of natalizumab therapy. *Neurology.* 2009;72:396–401.
27. Polman CH, O'Connor PW, Havrdova E, et al. AFFIRM Investigators. A randomized, placebo-controlled trial of natalizumab for relapsing multiple sclerosis. *N Engl J Med.* 2006;354:899–910.
28. Rudick RA, Stuart WH, Calabresi PA, SENTINEL Investigators, et al. Natalizumab plus interferon beta-1a for relapsing multiple sclerosis. *N Engl J Med.* 2006;354:911–23.
29. Miller DH, Soon D, Fernando KT, MacManus DG, Barker GJ, Yousry TA, Fisher E, O'Connor PW, Phillips JT, Polman CH, Kappos L, Hutchinson M, Havrdova E, Lublin FD, Giovannoni G, Wajgt A, Rudick R, Lynn F, Panzara MA, Sandrock AW, For the AFFIRM Investigators. MRI outcomes in a placebo-controlled trial of natalizumab in relapsing MS. *Neurology.* 2007;68:1390–401.
30. Hutchinson M, Kappos L, Calabresi PA, Confavreux C, Giovannoni G, Galetta SL, Havrdova E, Lublin FD, Miller DH, O'Connor PW, Phillips JT, Polman CH, Radue EW, Rudick RA, Stuart WH, Wajgt A, Weinstock-Guttman B, Wynn DR, Lynn F, Panzara MA, For the AFFIRM and SENTINEL Investigators. The efficacy of natalizumab in patients with relapsing multiple sclerosis: subgroup analyses of AFFIRM and SENTINEL. *J Neurol.* 2009;256(3):405–15.
31. Calabresi PA, Giovannoni G, Confavreux C, Galetta SL, Havrdova E, Hutchinson M, Kappos L, Miller DH, O'Connor PW, Phillips JT, Polman CH, Radue E-W, Rudick RA, Stuart WH, Lublin FD, Wajgt A, Weinstock-Guttman B, Wynn DR, Lynn F, Panzara MA, For the AFFIRM and SENTINEL Investigators. The incidence and significance of anti-natalizumab antibodies: results from AFFIRM and SENTINEL. *Neurology.* 2007;69:1391–403.
32. O'Connor PW, Goodman A, Willmer-Hulme AJ, Libonati MA, Metz L, Murray RS, Sheremata WA, Vollmer TL, Stone LA, The Natalizumab Multiple Sclerosis Trial Group. Randomized multicenter trial of natalizumab in acute MS relapses: clinical and MRI effects. *Neurology.* 2004;62:2038–43.
33. Goodman AD, Rossman H, Bar-Or A, Miller A, Miller DH, Schmierer K, Lublin F, Khan O, Bormann NM, Yang M, Panzara MA, Sandrock AW, For the GLANCE Investigators. Results of a phase 2, randomized, double-blind, placebo-controlled study. *Neurology.* 2009;72:806–12.
34. Ghezzi A, Pozzilli C, Grimaldi LM, Brescia Morra V, Bortolon F, Capra R, Filippi M, Moidola L, Rocca MA, Rottoli M, Sarchielli P, Zaffaroni M, Comi G. Safety and efficacy of natalizumab in children with multiple sclerosis. *Neurology.* 2010;75(10):912–7.
35. Vellinga MM, Castelijns JA, Barkhof F, Uitdehaag BM, Polman CH. Postwithdrawal rebound increase in T2 lesional activity in natalizumab-treated MS patients. *Neurology.* 2008;70:1150–1.
36. Miravalle A, Jensen R, Kinkel RP. Immune reconstitution inflammatory syndrome in patients with

- multiple sclerosis following cessation of natalizumab therapy. *Arch Neurol.* 2011;68(2):186–91.
37. West TW, Cree BA. Natalizumab dosage suspension: are we helping or hurting? *Ann Neurol.* 2010;68(3):395–9.
  38. Clerico M, Artusi CA, Di Liberto A, Rolla S, Bardina V, Barbero P, et al. Natalizumab in multiple sclerosis: long-term management. *Int J Mol Sci.* 2017;18(5):940.
  39. Reuwer AQ, Heron M, van der Dussen D, Schneider-Hohendorf T, Murk JL. The clinical utility of JC virus antibody index measurements in the context of progressive multifocal leukoencephalopathy. *Acta Neurol Scand.* 2017;136(Suppl. 201):37–44.
  40. Kleinschmidt-DeMasters BK, Tyler KL. Progressive multifocal leukoencephalopathy complicating treatment with natalizumab and interferon beta-1a for multiple sclerosis. *N Engl J Med.* 2005;353:369–74.
  41. Langer-Gould A, Atlas SW, Green AJ, Bollen AW, Pelletier D. Progressive multifocal leukoencephalopathy in a patient treated with natalizumab. *N Engl J Med.* 2005;353:375–81.
  42. Yousry TA, Major EO, Ryschkewitsch C, et al. Evaluation of patients treated with natalizumab for progressive multifocal leukoencephalopathy. *N Engl J Med.* 2006;354:924–33.
  43. Khalili K, White MK, Lublin F, Ferrante P, Berger JR. Reactivation of JC virus and development of PML in patients with multiple sclerosis. *Neurology.* 2007;68:985–90.
  44. Carson KR, Focosi D, Major EO, Petrini M, Richey EA, West DP, Bennett CL. Monoclonal antibody-associated progressive multifocal leukoencephalopathy in patients treated with rituximab, natalizumab, and efalizumab: a review from the Research on Adverse Drug Events and Reports (RADAR) Project. *Lancet Oncol.* 2009;10(8):816–24.
  45. Williamson EML, Berger JR. Diagnosis and treatment of progressive multifocal leukoencephalopathy associated with multiple sclerosis therapies. *Neurotherapeutics.* 2017;14(4):961–73.
  46. Bielekova B, Becker BL. Monoclonal antibodies in MS: mechanisms of action. *Neurology.* 2010;74(Suppl 1):S31–40.
  47. Liossis SN, Sfrikakis PP. Rituximab-induced B cell depletion in autoimmune diseases: potential effects on T cells. *Clin Immunol.* 2008;127:280–5.
  48. Fanale MA, Younes A. Monoclonal antibodies in the treatment of non-Hodgkin's lymphoma. *Drugs.* 2007;67:333–50.
  49. Schuna AA. Rituximab for the treatment of rheumatoid arthritis. *Pharmacotherapy.* 2007;27:1702–10.
  50. Cree BA, et al. An open label study of the effects of rituximab in neuromyelitis optica. *Neurology.* 2005;64:1270–2.
  51. Hauser SL, et al. B-cell depletion with rituximab in relapsing-remitting multiple sclerosis. *N Engl J Med.* 2008;358:676–88.
  52. Cepok S, et al. Short-lived plasma blasts are the main B cell effector subset during the course of multiple sclerosis. *Brain.* 2005;128:1667–76.
  53. Qin Y, et al. Intrathecal B-cell clonal expansion, an early sign of humoral immunity, in the cerebrospinal fluid of patients with clinically isolated syndrome suggestive of multiple sclerosis. *Lab Invest.* 2003;83:1081–8.
  54. Stuve O, et al. Clinical stabilization and effective B-lymphocyte depletion in the cerebrospinal fluid and peripheral blood of a patient with fulminant relapsing-remitting multiple sclerosis. *Arch Neurol.* 2005;62:1620–3.
  55. Granqvist M, Boremalm M, Poorghobad A, Svenningsson A, Salzer J, Frisell T, Piehl F. Comparative effectiveness of rituximab and other initial treatment choices for multiple sclerosis. *JAMA Neurol.* 2018; <https://doi.org/10.1001/jamaneurol.2017.4011>.
  56. Hauser SL, Bar-Or A, Comi G, Giovannoni G, Hartung HP, Hemmer B, Lublin F, Montalban X, Rammohan KW, Selmaj K, Traboulsee A, Wolinsky JS, Arnold DL, Klingenschmitt G, Masterman D, Fontoura P, Belachew S, Chin P, Mairon N, Garren H, Kappos L, OPERA I, Clinical Investigators OPERA II. Ocrelizumab versus interferon Beta-1a in relapsing multiple sclerosis. *N Engl J Med.* 2017;376:221–34.
  57. Montalban X, Hauser SL, Kappos L, Arnold DL, Bar-Or A, Comi G, de Seze J, Giovannoni G, Hartung HP, Hemmer B, Lublin F, Rammohan KW, Selmaj K, Traboulsee A, Sauter A, Masterman D, Fontoura P, Belachew S, Garren H, Mairon N, Chin P, Wolinsky JS, ORATORIO Clinical Investigators. Ocrelizumab versus placebo in primary progressive multiple sclerosis. *N Engl J Med.* 2017;376:209–20.
  58. Salzer J, Svenningsson R, Alping P, Novakova L, Björck A, Fink K, Islam-Jakobsson P, Malmeström C, Axelsson M, Vågberg M, Sundström P, Lycke J, Piehl F, Svenningsson A. Rituximab in multiple sclerosis. *Neurology.* 2016;87(20):2074–81.
  59. Carson KR, Evens AM, Richey EA, Habermann TM, Focosi D, Seymour JF, et al. Progressive multifocal leukoencephalopathy after rituximab therapy in HIV-negative patients: a report of 57 cases from the Research on Adverse Drug Events and Reports project. *Blood.* 2009;113(20):4834–40.
  60. Avasarala J. Anti-CD20 cell therapies in multiple sclerosis—a fixed dosing schedule for ocrelizumab is overkill. *Drug Target Insights.* 2017;11:1177392817737515.
  61. Greenberg BM, Graves D, Remington G, et al. Rituximab dosing and monitoring strategies in neuromyelitis optica patients: creating strategies for therapeutic success. *Mult Scler J.* 2012;18:1022–6.
  62. Cohen JA, Coles AJ, Arnold DL, et al. Alemtuzumab versus interferon beta 1a as treatment for patients with relapsing-remitting multiple sclerosis: a randomised controlled phase 3 trial. *Lancet.* 2012;380:1819–28.

63. Coles AJ, Twyman CL, Arnold DL, et al. Alemtuzumab for patients with relapsing multiple sclerosis after disease-modifying therapy: a randomised controlled phase 3 trial. *Lancet*. 2012;380:1829–39.
64. Coles AJ, Boyko AN, Cohen JA, et al. Alemtuzumab provides durable improvements in clinical outcomes in treatment-naïve patients with active relapsing-remitting multiple sclerosis over 6 years in the absence of continuous treatment (CARE-MS I). *Mult Scler*. 2016;22:P213.
65. Fox EJ, Alroughani R, Brassat D, et al. Efficacy of alemtuzumab is durable over 6 years in patients with active relapsing-remitting multiple sclerosis and an inadequate response to prior therapy in the absence of continuous treatment (CARE-MS II). *Mult Scler*. 2016;22:P1150.
66. Horakova D, Boster A, Ziemssen T, et al. Patients who received alemtuzumab in CARE-MS I or II show a low rate of conversion from relapsing-remitting MS to secondary progressive MS through 6 years. *Neurology*. 2017;88(Suppl. 16):P4.407.
67. Dayan C, Cuker A, LaGanke C, et al. Autoimmunity in patients treated with alemtuzumab for relapsing-remitting multiple sclerosis: 6-year follow-up of the CARE-MS Studies. *Mult Scler*. 2016;22:Presentation 168.
68. Baldassari LE, Rose JW. Daclizumab: development, clinical trials, and practical aspects of use in multiple sclerosis. *Neurotherapeutics*. 2017;14:842–58.
69. Sheridan JP, Robinson RR, Rose JW. Daclizumab, an IL-2 modulating antibody for treatment of multiple sclerosis. *Expert Rev Clin Pharmacol*. 2014;7(1):9–19.
70. Bielekova B, Howard T, Packer AN, et al. Effect of anti-CD25 antibody daclizumab in the inhibition of inflammation and stabilization of disease progression in multiple sclerosis. *Arch Neurol*. 2009;66(4):483–9.
71. Rose JW, Watt HE, White AT, Carlson NG. Treatment of multiple sclerosis with an anti-interleukin-2 receptor monoclonal antibody. *Ann Neurol*. 2004;56(6):864–7.
72. Rose JW, Burns JB, Bjorklund J, Klein J, Watt HE, Carlson NG. Daclizumab phase II trial in relapsing and remitting multiple sclerosis: MRI and clinical results. *Neurology*. 2007;69(8):785–9.
73. Wynn D, Kaufman M, Montalban X, et al. Daclizumab in active relapsing multiple sclerosis (CHOICE study): a phase 2, randomized, double-blind, placebo-controlled, add-on trial with interferon beta. *Lancet Neurol*. 2010;9(4):381–90.
74. Gold R, Giovannoni G, Selmaj K, et al. Daclizumab high-yield process in relapsing-remitting multiple sclerosis (SELECT): a randomized, double-blind, placebo-controlled trial. *Lancet*. 2013;381(9884):2167–75.
75. Giovannoni G, Gold R, Selmaj K, et al. Daclizumab high-yield process in relapsing-remitting multiple sclerosis (SELECTION): a multicenter, randomized, double-blind extension trial. *Lancet Neurol*. 2014;13(5):472–81.
76. Gold R, Radue EW, Giovannoni G, et al. Safety and efficacy of daclizumab in relapsing-remitting multiple sclerosis: 3-year results from the SELECTED open-label extension study. *BMC Neurol*. 2016;16:117.
77. Kappos L, Wiendl H, Selmaj K, et al. Daclizumab HYP versus interferon beta-1a in relapsing multiple sclerosis. *N Engl J Med*. 2015;373(15):1418–28.
78. Giovannoni G, Kappos L, Gold R, et al. Safety and tolerability profile of daclizumab in patients with relapsing-remitting multiple sclerosis: an integrated analysis of clinical studies. *Mult Scler Relat Disord*. 2016;9:36–46.
79. Brinkmann V, Davis MD, Heise CE, et al. The immune modulator FTY720 targets sphingosine 1-phosphate receptors. *J Biol Chem*. 2002;277:21453–7.
80. Mehling M, Lindberg R, Raulf F, Kuhle J, Hess C, Kappos L, Brinkmann V. Th17 central memory T cells are reduced by FTY720 in patients with multiple sclerosis. *Neurology*. 2010;75(5):403–10.
81. Sensken SC, Bode C, Gräler MH. Accumulation of fingolimod (FTY720) in lymphoid tissues contributes to prolonged efficacy. *Pharmacol Exp Ther*. 2009;328(3):963–9.
82. Van Doorn R, Van Horssen J, Verzijl D, Witte M, Ronken E, Van Het Hof B, Lakeman K, Dijkstra CD, Van Der Valk P, Reijerkerk A, Alewijnse AE, Peters SL, De Vries HE. Sphingosine 1-phosphate receptor 1 and 3 are upregulated in multiple sclerosis lesions. *Glia*. 2010;58(12):1465–76.
83. O'Connor P, Comi G, Montalban X, Antel J, Radue EW, de Vera A, Pohlmann H, Kappos L, FTY720 D2201 Study Group. Oral fingolimod (FTY720) in multiple sclerosis: two-year results of a phase II extension study. *Neurology*. 2009;72(1):73–9.
84. Cohen JA, Barkhof F, Comi G, et al. Oral fingolimod or intramuscular interferon for relapsing multiple sclerosis. *N Engl J Med*. 2010;362:402–15.
85. Kappos L, Radue EW, O'Connor P, et al. A placebo-controlled trial of oral fingolimod in relapsing multiple sclerosis. *N Engl J Med*. 2010;362:387–401.
86. Berger JR. Classifying PML risk with disease modifying therapies. *Mult Scler Relat Disord*. 2017;12:59–63.
87. Achtnichts L, Obreja O, Conen A, Fux CA, Nedeltchev K. Cryptococcal Meningoencephalitis in a patient with multiple sclerosis treated with fingolimod. *JAMA Neurol*. 2015;72(10):1203–5.
88. Castrop F, Kowarik MC, Albrecht H, et al. Severe multiple sclerosis relapse under fingolimod therapy: incident or coincidence? *Neurology*. 2012;78:928–30.
89. Kinney MO, McDonnell G. Re-tumefactive multiple sclerosis lesions under fingolimod treatment. *Neurology*. 2013;81:403.
90. Hellmann MA, Lev N, Lotan I, et al. Tumefactive demyelination and a malignant course in an MS

- patient during and following fingolimod therapy. *J Neurol Sci.* 2014;344:193–7.
91. Mrowietz U, Asadullah K. Dimethyl fumarate for psoriasis: more than a dietary curiosity. *Trends Mol Med.* 2005;11:43–8.
  92. Werdenberg D, Joshi R, Wolfram S, Merkle HP, Langguth P. Presystemic metabolism and intestinal absorption of antipsoriatic fumaric acid esters. *Biopharm Drug Dispos.* 2003;24:259–73.
  93. Nibbering PH, Thio B, Zomerdijk TP, Bezemer AC, Beijersbergen RL, Van FR. Effects of monomethyl-fumarate on human granulocytes. *J Invest Dermatol.* 1993;101:37–42.
  94. Nguyen T, Nioi P, Pickett CB. The Nrf2-antioxidant response element signaling pathway and its activation by oxidative stress. *J Biol Chem.* 2009;284(20):13291–5.
  95. Linker RA, Lee DH, Ryan S, et al. Fumaric acid esters exert neuroprotective effects in neuroinflammation via activation of the Nrf2 antioxidant pathway. *Brain.* 2011;134(Pt 3):678–92.
  96. Gold R, Kappos L, Arnold DL, Bar-Or A, Giovannoni G, Selmaj K, et al. Placebo-controlled phase 3 study of oral BG-12 for relapsing multiple sclerosis. *N Engl J Med.* 2012;367(12):1098–107.
  97. Fox RJ, Miller DH, Phillips JT, Hutchinson M, Havrdova E, Kita M, et al. Placebo-controlled phase 3 study of oral BG-12 or glatiramer in multiple sclerosis. *N Engl J Med.* 2012;367(12):1087–97.
  98. Linker RA, Gold R. Dimethyl fumarate for treatment of multiple sclerosis: mechanism of action, effectiveness, and side effects. *Curr Neurol Neurosci Rep.* 2013;13:394–8.
  99. Baharnoori M, Lyons J, Dastagir A, Koralknik I, Stankiewicz JM. Nonfatal PML in a patient with multiple sclerosis treated with dimethyl fumarate. *Neurol Neuroimmunol Neuroinflamm.* 2016;3(5):e274.
  100. Bar-Or A, Pachner A, Menguy-Vacheron F, et al. Teriflunomide and its mechanism of action in multiple sclerosis. *Drugs.* 2014;74:659–74.
  101. Bar-Or A, Freedman MS, Kremenchutzky M, et al. Teriflunomide effect on immune response to influenza vaccine in patients with multiple sclerosis. *Neurology.* 2013;81:552–8.
  102. O'Connor P, Wolinsky JS, Confavreux C, et al. Randomized trial of oral teriflunomide for relapsing multiple sclerosis. *N Engl J Med.* 2011;365:1293–303.
  103. Confavreux C, O'Connor P, Comi G, et al. Oral teriflunomide for patients with relapsing multiple sclerosis (TOWER): a randomised, double-blind, placebo-controlled, phase 3 trial. *Lancet Neurol.* 2014;13:247–56.
  104. Radue EW, Sprenger T, Gaetano L, et al. Teriflunomide slows BVL in relapsing MS: a reanalysis of the TEMSO MRI data set using SIENA. *Neurol Neuroimmunol Neuroinflamm.* 2017;4:e390.
  105. Miller AE, Wolinsky JS, Kappos L, et al. Oral teriflunomide for patients with a first clinical episode suggestive of multiple sclerosis (TOPIC): a randomised, double-blind, placebo-controlled, phase 3 trial. *Lancet Neurol.* 2014;13:977–86.
  106. Vermersch P, Czlonkowska A, Grimaldi LM, et al. Teriflunomide versus subcutaneous interferon beta-1a in patients with relapsing multiple sclerosis: a randomised, controlled phase 3 trial. *Mult Scler.* 2014;20:705–16.
  107. O'Connor P, Comi G, Freedman MS, et al. Long-term safety and efficacy of teriflunomide: nine-year follow-up of the randomized TEMSO study. *Neurology.* 2016;86:920–30.
  108. Comi G, Freedman MS, Kappos L, et al. Pooled safety and tolerability data from four placebo-controlled teriflunomide studies and extensions. *Mult Scler Relat Disord.* 2016;5:97–104.
  109. Kieseier BC, Benamor M. Pregnancy outcomes following maternal and paternal exposure to teriflunomide during treatment for relapsing-remitting multiple sclerosis. *Neurol Ther.* 2014;3:133–8.
  110. Genzyme Corporation. A Sanofi Company. AUBAGIO prescribing information. Cambridge: AUBAGIO Prescribing information; 2016.
  111. Neuhaus O, Wiendl H, Kieseier BC, Archelos JJ, Hemmer B, Stuve O, Hartung HP. Multiple sclerosis: mitoxantrone promotes differential effects on immunocompetent cells in vitro. *J Neuroimmunol.* 2005;168:128–37.
  112. Hartung HP, Gonsette R, Konig N, Kwiecinski H, Guseo A, Morrissey SP, Krapf H, Zwingers T. Mitoxantrone in Multiple Sclerosis Study Group (MIMS). Mitoxantrone in progressive multiple sclerosis: a placebo-controlled, double blind, randomized multicentre trial. *Lancet.* 2002;360:2018–25.
  113. Vollmer T, Panitch H, Bar-Or A, Dunn J, Freedman M, Gazda S, Campagnolo D, Deutsch F, Arnold D. Glatiramer acetate after induction therapy with mitoxantrone in relapsing multiple sclerosis. *Mult Scler.* 2008;14:663–70.
  114. Edan G, Comi G, Lebrun D, Brassat C, Lubetzki C, Stankoff B, Tourbah A, Pelletier J, Debouverie M, Confavreux C, Blanc S, Rouillet E, Tranchant C, Hauteceur P, Mackowiak A, Magy L, Rumbach L, Gout O, Aufavre D, Clavelou P, Moreau T, Maucardi GL, Zaffaroni M, Amato MP, Trojano M, Durelli L, Veillard D, Le Page E, Filippi M, Morrissey SP. The French-Italian mitoxantrone-interferon-beta trial: a 3-year randomized study. *Mult Scler.* 2007;13(Suppl 2):S22–3.
  115. Goffette S, van Pesch V, Vanoverschelde JL, Morandini E, Sindic CJ. Severe delayed heart failure in three multiple sclerosis patients previously treated with mitoxantrone. *J Neurol.* 2005;252:1217–22.
  116. Rizvi SA, Zwibel H, Fox EJ, Zwibel H, Edward J. Mitoxantrone for multiple sclerosis in clinical practice. *Neurology.* 2004;63:S25–7.



117. Ellis R, Boggild M. Therapy-related acute leukaemia with Mitoxantrone: what is the risk and can we minimise it? *Mult Scler*. 2009;15(4):505–8.
118. Okuda DT, Mowry EM, Beheshtian A, Waubant E, Baranzini SE, Goodin DS, Hauser SL, Pelletier D. Incidental MRI anomalies suggestive of multiple sclerosis: the radiologically isolated syndrome. *Neurology*. 2009;72(9):800–5. Erratum in *Neurology*. 2009;72(14):1284.
119. Okuda DT, Siva A, Kantarci O, Inglese M, Katz I, Tutuncu M, et al. Radiologically isolated syndrome: 5-year risk for an initial clinical event. *PLoS One*. 2014;9(3):e90509.
120. Tornatore C, Phillips JT, Khan O, Miller AE, Hughes M. Consensus opinion of US neurologists on practice patterns in RIS, CIS, and RRMS: evolution of treatment practices. *Neurol Clin Pract*. 2016;6(4):329–38.
121. Pittock SJ, McClelland RL, Mayr WT. Clinical implications of benign multiple sclerosis: a 20-year population-based follow-up study. *Ann Neurol*. 2004;56(2):303–6.
122. Koch M, Kingwell E, Rieckmann P. The natural history of primary progressive multiple sclerosis. *Neurology*. 2009;73(23):1996–2002.
123. Pittock SJ, McClelland RL, Mayr WT, Jorgensen NW, Weinschenker BG, Noseworthy J, Rodriguez M. Clinical implications of benign multiple sclerosis: a 20-year population-based follow-up study. *Ann Neurol*. 2004;56:303–6.
124. Sartori A, Abdoli M, Freedman MS. Can we predict benign MS: results of a twenty year old follow up study. *J Neurol*. 2017;264:1068.
125. Trapp BD, Peterson J, Ransohoff RM, Rudick R, Mork S, Bo L. Axonal transection in the lesions of multiple sclerosis. *N Engl J Med*. 1998;338:278–85.
126. Trapp BD, Ransohoff R, Rudick R. Axonal pathology in multiple sclerosis: relationship to neurologic disability. *Curr Opin Neurol*. 1999;12:295–302.
127. De Stefano N, Narayanan S, Francis GS, et al. Evidence of axonal damage in the early stages of multiple sclerosis and its relevance to disability. *Arch Neurol*. 2001;58:65–70.
128. Fisniku LK, Brex PA, Altmann DR, Miszkiel KA, Benton CE, Lanyon R, Thompson AJ, Miller DH. Disability and T2 MRI lesions: a 20-year follow-up of patients with relapse onset of multiple sclerosis. *Brain*. 2008;31:808–17.
129. Kappos L, Polman CH, Freedman MS, Edan G, Hartung HP, Miller DH, Montalban X, Barkhof F, Bauer L, Jakobs P, Pohl C, Sandbrink R. Treatment with interferon beta-1b delays conversion to clinically definite and McDonald MS in patients with clinically isolated syndromes. *Neurology*. 2006;67:1242–9.
130. Kappos L, Freedman MS, Polman CH, Edan G, Hartung HP, Miller DH, Montalban X, Barkhof F, Radu EW, Bauer L, Dahms S, Lanius V, Pohl C, Sandbrink R, BENEFIT Study Group. Effect of early versus delayed interferon beta-1b treatment on disability after a first clinical event suggestive of multiple sclerosis: a 3-year follow-up analysis of the BENEFIT study. *Lancet*. 2007;370:389–97.
131. Kappos L, Freedman MS, Polman CH, Edan G, Hartung HP, Miller DH, Montalban X, Barkhof F, Radu EW, Metz C, Bauer L, Lanius V, Sandbrink R, Pohl C, For the BENEFIT Study Group. Long-term effect of early treatment with interferon beta-1b after a first clinical event suggestive of multiple sclerosis: 5-year active treatment extension of the phase 3 BENEFIT trial. *Lancet Neurol*. 2009;8:987–97.
132. Jacobs LD, Beck RW, Simon JH, Kinkel RP, Brownschidle CM, Murray TJ, Simonian NA, Slator PJ, Sandrock AW. Intramuscular interferon beta-1a therapy initiated during a first demyelinating event in multiple sclerosis. CHAMPS Study Group. *N Engl J Med*. 2000;343:898–904.
133. Kinkel RP, Kollman C, O'Connor P, Murray TJ, Simon J, Arnold D, Bakshi R, Weinstock-Gutman B, Brod S, Cooper J, Duquette P, Eggenberger E, Felton W, Fox R, Freedman M, Galetta S, Goodman A, Guarnaccia J, Hashimoto S, Horowitz S, Javerbaum J, Kasper L, Kaufman M, Kerson L, Mass M, Rammohan K, Reiss M, Rolak L, Rose J, Scott T, Selhorst J, Shin R, Smith C, Stuart W, Thurston S, Wall M, CHAMPIONS Study Group. IM interferon beta-1a delays definite multiple sclerosis 5 years after a first demyelinating event. *Neurology*. 2006;66:678–84.
134. Comi G, Filippi M, Barkhof F, Durelli L, Edan G, Fernandez O, Hartung H, Seeltrayers P, Sorensen PS, Rovaris M, Martinelli V, Hommes OR. Effect of early interferon treatment on conversion to definite multiple sclerosis: a randomised study. *Lancet*. 2001;357:1576–82.
135. Comi G, Martinelli V, Rodegher M, Moiola L, Bajenaru O, Carra A, Elovaara I, Fazekas F, Hartung HP, Hillert J, King J, Komoly S, Lubetzki C, Montalban X, Myhr KM, Ravnborg M, Rieckmann P, Wynn D, Young C, Filippi M. Effect of glatiramer acetate on conversion to clinically definite multiple sclerosis in patients with clinically isolated syndrome (PreCISE study): a randomised, double-blind, placebo-controlled trial. *Lancet*. 2009;374:1503–11.
136. Rush CA, MacLean HJ, Freedman MS. Aggressive multiple sclerosis: proposed definition and treatment algorithm. *Nat Rev Neurol*. 2015;11(7):379–89.
137. Confavreux C, Vukusic S, Adeleine P. Early clinical predictors and progression of irreversible disability in multiple sclerosis: an amnesic process. *Brain*. 2003;126(Pt 4):770–82.
138. Gauthier SA, Glanz BJ, Mandel M, et al. Incidence and factors associated with treatment failure in the CLIMB multiple sclerosis cohort study. *J Neurol Sci*. 2009;284(1–2):116–9.
139. Stangel M, Penner IK, Kallmann BA, et al. Towards the implementation of “no evidence of disease activity” in multiple sclerosis treatment: the multiple sclerosis decision model. *Ther Adv Neurol Disord*. 2015;8:3–13.

140. Kappos L, De Stefano N, Freedman MS, et al. Inclusion of brain volume loss in a revised measure of “no evidence of disease activity” (NEDA-4) in relapsing-remitting multiple sclerosis. *Mult Scler*. 2016;22(10):1297–305.
141. Damasceno A, Damasceno BP, Cendes F. No evidence of disease activity in multiple sclerosis: implications on cognition and brain atrophy. *Mult Scler*. 2016;22:64–72.
142. Nygaard GO, Celius EG, de Rodez Benavent SA, et al. A longitudinal study of disability, cognition and gray matter atrophy in early multiple sclerosis patients according to evidence of disease activity. *PLoS One*. 2015;10(8):e0135974. <https://doi.org/10.1371/journal.pone.0135974>.
143. Pisa M, Guerrieri S, Di Maggio G, Medaglini S, Moiola L, Martinelli V, Comi G, Leocani L. No evidence of disease activity is associated with reduced rate of axonal retinal atrophy in MS. *Neurology*. 2017;89(24):2469–75.
144. Rotstein DL, Healy BC, Malik MT, et al. Evaluation of no evidence of disease activity in a 7-year longitudinal multiple sclerosis cohort. *JAMA Neurol*. 2015;72:152–8.
145. Nixon R, Bergvall N, Tomic D, Sfikas N, Cutter G, Giovannoni G. No evidence of disease activity: indirect comparisons of oral therapies for the treatment of relapsing-remitting multiple sclerosis. *Adv Ther*. 2014;31:1134–54.
146. Arnold DL, Calabresi PA, Kieseier BC, et al. Effect of peginterferon beta-1a on MRI measures and achieving no evidence of disease activity: results from a randomized controlled trial in relapsing-remitting multiple sclerosis. *BMC Neurol*. 2014;14:240–51.
147. Havrdova E, Galetta S, Hutchinson M, et al. Effect of natalizumab on clinical and radiological disease activity in multiple sclerosis: a retrospective analysis of the natalizumab safety and efficacy in relapsing-remitting multiple sclerosis (AFFIRM) study. *Lancet Neurol*. 2009;8:254–60.
148. Giovannoni G, Cook S, Rammohan K, et al. Sustained disease-activity-free status in patients with relapsing-remitting multiple sclerosis treated with cladribine tablets in the CLARITY study: a post-hoc and subgroup analysis. *Lancet Neurol*. 2011;10(4):329–37.
149. Burt RK, Balabanov R, Han X, et al. Association of nonmyeloablative hematopoietic stem cell transplantation with neurological disability in patients with relapsing-remitting multiple sclerosis. *JAMA*. 2015;313(3):275–84.
150. European Study Group on Interferon Beta-1b in Secondary Progressive MS. Placebo-controlled multicentre randomised trial of interferon beta-1b in treatment of secondary progressive multiple sclerosis. *Lancet*. 1998;352:1491–7.
151. Panitch H, Miller A, Paty D, Weinshenker B, North American Study Group on Interferon beta-1b in Secondary Progressive MS. Interferon beta-1b in secondary progressive MS: results from a 3-year controlled study. *Neurology*. 2004;63:1788–95.
152. Steiner D, Arnold DL, Freedman MS, et al. Natalizumab versus placebo in patients with secondary progressive multiple sclerosis (SPMS): results from ASCEND, a multicenter, double-blind, placebo-controlled, randomized phase 3 clinical trial. *Neurology*. 2016;87:e22.
153. Lublin FD, Miller D, Freedman M, et al. Oral fingolimod versus placebo in patients with primary progressive multiple sclerosis (PPMS): results of the INFORMS phase III trial. The 67th annual meeting of the American Academy of Neurology, Washington, DC, 18–25 Apr 2015.
154. Kappos L, Achiron A, et al. Siponimod versus placebo in secondary progressive multiple sclerosis (EXPAND): a double-blind, randomised, phase 3 study. *Lancet*. 2018;391(10127):1263–73.
155. Chataway J, Schuerer N, Alsanousi A. Effect of high-dose simvastatin on brain atrophy and disability in secondary progressive multiple sclerosis (MS-STAT): a randomised, placebo-controlled, phase 2 trial. *Lancet*. 2014;383:2213–21.
156. Tourbah A, Lebrun-Frenay C, Edan G, Clanet M, Papeix C, Vukusic S, et al. MD1003 (high-dose biotin) for the treatment of progressive multiple sclerosis: a randomised, double-blind, placebo-controlled study. *Mult Scler*. 2016;22(13):1719–31. <https://doi.org/10.1177/1352458516667568>.
157. Durelli L, Verdun E, Barbero P, et al. Every-other-day interferon beta-1b versus once-weekly interferon beta-1a for multiple sclerosis: results of a 2-year prospective randomised multicentre study (INCOMIN). *Lancet*. 2002;359:1453–60.
158. Panitch H, Goodin DS, Francis G, et al. Randomized, comparative study of interferon beta-1a treatment regimens in MS: the EVIDENCE Trial. *Neurology*. 2002;59:1496–506.
159. O’Connor P, Filippi M, Arnason B, Comi G, Cook S, Goodin D, Hartung HP, Jeffery D, Kappos L, Boateng F, Filippov V, Groth M, Knappertz V, Kraus C, Sandbrink R, Pohl C, Bogumil T, For the BEYOND Study Group. 250 µg or 500 µg interferon beta-1b versus 20 mg glatiramer acetate in relapsing-remitting multiple sclerosis: a prospective, randomised, multicentre study. *Lancet Neurol*. 2009;10:889–97.
160. Cadavid D, Wolansky LJ, Skurnick J, et al. Efficacy of treatment of MS with IFNβ-1b or glatiramer acetate by monthly brain MRI in the BECOME study. *Neurology*. 2009;72(23):1976–83.
161. Mikol DD, Barkhof F, Chang P, On behalf of the REGARD Study Group, et al. Comparison of subcutaneous interferon beta-1a with glatiramer acetate in patients with relapsing multiple sclerosis (the Rebif vs Glatiramer Acetate in Relapsing MS Disease [REGARD] study): a multicentre, randomised, parallel, open-label trial. *Lancet Neurol*. 2008;7:903–14.
162. Kovarsky J. Clinical pharmacology and toxicology of cyclophosphamide: emphasis on use in rheumatic diseases. *Semin Arthritis Rheum*. 1983;12:359–72.

163. Weiner HL, Mackin GA, Orav EJ, et al. Intermittent cyclophosphamide pulse therapy in progressive multiple sclerosis: final report of the Northeast Cooperative Multiple Sclerosis Treatment Group. *Neurology*. 1993;43:910–8.
164. The Canadian Cooperative Multiple Sclerosis Study Group. The Canadian cooperative trial of cyclophosphamide and plasma exchange in progressive multiple sclerosis. *Lancet*. 1991;337:441–6.
165. Weinstock-Guttman B. Treatment of fulminant multiple sclerosis with intravenous cyclophosphamide. *Neurologist*. 1997;3:178–85.
166. Khan OA, Zvartau-Hind M, Caon C, et al. Effect of monthly intravenous cyclophosphamide in rapidly deteriorating multiple sclerosis patients resistant to conventional therapy. *Mult Scler*. 2001;7:185–8.
167. Stillwell TJ, Benson RC Jr. Cyclophosphamide-induced hemorrhagic cystitis. A review of 100 patients. *Cancer*. 1988;61:451–7.
168. De Ridder D, van Poppel H, Demonty L, et al. Bladder cancer in patients with multiple sclerosis treated with cyclophosphamide. *J Urol*. 1998;159:1881–4.
169. Casetta I, Iuliano G, Filippini G. Azathioprine for multiple sclerosis. *Cochrane Database Syst Rev*. 2007;4:CD003982. Review.
170. Becker BN. Mycophenolate mofetil. *Transplant Proc*. 1999;31:2777–277.
171. Tan T, Lawrance IC. Use of mycophenolate mofetil in inflammatory bowel disease. *World J Gastroenterol*. 2009;15(13):1594–9.
172. Tran GT, Carter N, Hodgkinson SJ. Mycophenolate mofetil treatment accelerates recovery from experimental allergic encephalomyelitis. *Int Immunopharmacol*. 2001;1(9–10):1709–23.
173. Vermersch P, Waucquier N, Michelin E, Bourteel H, Stojkovic T, Ferriby D, de Seze J, G-SEP. Combination of IFN beta-1a (Avonex) and mycophenolate mofetil (Cellcept) in multiple sclerosis. *Eur J Neurol*. 2007;14(1):85–9.
174. Hartung H-P. Advances in the understanding of the mechanism of action of IVIg. *J Neurol*. 2008;255(Suppl 3):3–6.
175. Trebst C, Stangel M. Promotion of remyelination by immunoglobulins: implications for the treatment of multiple sclerosis. *Curr Pharm Des*. 2006;12(2):241–9.
176. Sørensen P, Fazekas F, Lee M. Intravenous immunoglobulin G for the treatment of relapsing-remitting multiple sclerosis: a meta-analysis. *Eur J Neurol*. 2002;9(6):557–63.
177. Fazekas F, Lublin FD, Li D, et al. Intravenous immunoglobulin in relapsing-remitting multiple sclerosis: a dose-finding trial. *Neurology*. 2008;71:265–71.
178. Hommes O, Soerensen P, Fazekas F, et al. Intravenous immunoglobulin in secondary progressive multiple sclerosis: randomised, placebo-controlled trial. *Lancet*. 2004;364:1149–56.
179. Haas J. High dose IVIG in the postpartum period for prevention of exacerbations in MS. *Mult Scler*. 2000;6(Suppl 2):S18–20; discussion S33.
180. Achiron A, Kishner I, Sarova-Pinhas I, et al. Intravenous immunoglobulin treatment following the first demyelinating event suggestive of multiple sclerosis: a randomized, double-blind, placebo-controlled trial. *Arch Neurol*. 2004;61:1515–20.
181. Lehmann HC, Hartung HP, Hetzel GR, Stuve O, Kieseier BC. Plasma exchange in neuroimmunological disorders: Part 1: rationale and treatment of inflammatory central nervous system disorders. *Arch Neurol*. 2006;63:930–5.
182. Weinshenker BG. Therapeutic plasma exchange for acute inflammatory demyelinating syndromes of the central nervous system. *J Clin Apher*. 1999;14:144–8.
183. Llufriu S, Castillo J, Blanco Y, Ramió-Torrentà L, Río J, Vallès M, Lozano M, Castellà MD, Calabria J, Horga A, Graus F, Montalban X, Saiz A. Plasma exchange for acute attacks of CNS demyelination: predictors of improvement at 6 months. *Neurology*. 2009;73:949–53.
184. Schilling S, Linker RA, König FB, Koziólek M, Bahr M, Müller GA, Paulus W, Gartner J, Bruck W, Chan A, Gold R. Plasma exchange therapy for steroid-unresponsive multiple sclerosis relapses: clinical experience with 16 patients. *Nervenarzt*. 2006;77:430–8.
185. Beutler E. Cladribine (2-chlorodeoxyadenosine). *Lancet*. 1992;340(8825):952–6.
186. Giovannoni G, Comi G, Cook S, et al. A placebo-controlled trial of oral cladribine for relapsing multiple sclerosis. *N Engl J Med*. 2010;362:416–26.
187. Comi G, Cook SD, Giovannoni G, et al. MRI outcomes with cladribine tablets for multiple sclerosis in the CLARITY study. *J Neurol*. 2013;260:1136–46.
188. Comi G, Cook S, Rammohan K, et al. Long-term effects of cladribine tablets on MRI activity outcomes in patients with relapsing-remitting multiple sclerosis: the CLARITY Extension study. *Ther Adv Neurol Disord*. 2018;11:1756285617753365. <https://doi.org/10.1177/1756285617753365>.
189. Freedman MS, Leist TP, Comi G, et al. The efficacy of cladribine tablets in CIS patients retrospectively assigned the diagnosis of MS using modern criteria: results from the ORACLE-MS study. *Mult Scler J Exp Transl Clin*. 2017;3(4):2055217317732802.
190. Giovannoni G, Soelberg Sorensen P, Cook S, et al. Safety and efficacy of cladribine tablets in patients with relapsing-remitting multiple sclerosis: results from the randomized extension trial of the CLARITY study. *Mult Scler*. 2018;24(12):1594–604.
191. Pakpoor J, Disanto G, Altmann DR, et al. No evidence for higher risk of cancer in patients with multiple sclerosis taking cladribine. *Neurol Neuroimmunol Neuroinflamm*. 2015;2(6):e158.
192. Scott FL, Clemons B, Brooks J, et al. Ozanimod (RPC1063) is a potent sphingosine-1-phosphate receptor-1 (S1P1) and receptor-5 (S1P5) agonist with autoimmune disease-modifying activity. *Br J Pharmacol*. 2016;173(11):1778–92.
193. Cohen JA, Arnold DL, Comi G, et al. Safety and efficacy of the selective sphingosine 1-phosphate receptor modulator ozanimod in relapsing multiple sclerosis (RADIANCE): a randomised, placebo-controlled, phase 2 trial. *Lancet Neurol*. 2016;15(4):373–81.

194. Tran JQ, Hartung JP, Olson AD, et al. Cardiac safety of ozanimod, a novel sphingosine-1-phosphate receptor modulator: results of a thorough QT/QTc study. *Clin Pharmacol Drug Dev.* 2018;7(3):263–76.
195. Pan S, Gray NS, Gao W, et al. Discovery of BAF312 (siponimod), a potent and selective S1P receptor modulator. *ACS Med Chem Lett.* 2013;4(3):333–7.
196. Gajofatto A. Spotlight on siponimod and its potential in the treatment of secondary progressive multiple sclerosis: the evidence to date. *Drug Des Devel Ther.* 2017;11:3153–7. <https://doi.org/10.2147/DDDT.S122249>.
197. O'Sullivan C, Schubart A, Mir AK, Dev KK. The dual S1PR1/S1PR5 drug BAF312 (Siponimod) attenuates demyelination in organotypic slice cultures. *J Neuroinflammation.* 2016;13:31.
198. Gentile A, Musella A, Bullitta S, et al. Siponimod (BAF312) prevents synaptic neurodegeneration in experimental multiple sclerosis. *J Neuroinflammation.* 2016;13(1):207.
199. O'Brien S, et al. Ofatumumab: a new CD20 monoclonal antibody therapy for B-cell chronic lymphocytic leukemia. *Clin Lymphoma Myeloma Leuk.* 2010;10(5):361–8.
200. Sorensen PS, Lisby S, Grove R, Derosier F, Shackelford S, Havrdova E, Drulovic J, Filippi M. Safety and efficacy of ofatumumab in relapsing-remitting multiple sclerosis. *Neurology.* 2014;82(7):573–81.
201. Bar-Or A, Grove RA, Austin DJ, Tolson JM, Van Meter SA, Lewis EW, Derosier FJ, Lopez MC, Kavanagh ST, Miller AE, Sorensen PS. Subcutaneous ofatumumab in patients with relapsing-remitting multiple sclerosis. *Neurology.* 2018;90(20):e1805–14.
202. National Library of Medicine (US). Efficacy and safety of ofatumumab compared to teriflunomide in patients with relapsing multiple sclerosis. Bethesda, MD: National Library of Medicine (US); 2000.
203. Olsson T, Boster A, Fernandez O, Freedman M, Pozzilli C, Bach D, et al. Oral ponemod in relapsing-remitting multiple sclerosis: a randomised phase II trial. *J Neurol Neurosurg Psychiatry.* 2014;85:1198–208.
204. Pozzilli C, Fernandez O, Olsson T, Freedman MS, Melanson M, Boster A, et al. Maintenance of efficacy, safety and tolerability of ponemod in patients with relapsing remitting multiple sclerosis: phase II extension study. Poster presentation atECTRIMS (2013) European Committee for Treatment & Research in Multiple Sclerosis, 29th Congress, Copenhagen, Denmark, 2–5 Oct 2013.
205. van Gelder M, van Bekkum DW. Effective treatment of relapsing experimental autoimmune encephalomyelitis with pseudoautologous bone marrow transplantation. *Bone Marrow Transplant.* 1996;18(6):1029–34.
206. Fassas A, Anagnostopoulos A, Kazis A, Kapinas K, Sakellari I, Kimiskidis V, et al. Peripheral blood stem cell transplantation in the treatment of progressive multiple sclerosis: first results of a pilot study. *Bone Marrow Transplant.* 1997;20(8):631–8.
207. Atkins HL, Bowman M, Allan D, Anstee G, Arnold DL, Bar-Or A, et al. Immunoablation and autologous haemopoietic stem-cell transplantation for aggressive multiple sclerosis: a multicentre single-group phase 2 trial. *Lancet.* 2016;388(10044):576–85. [https://doi.org/10.1016/S0140-6736\(16\)30169-6](https://doi.org/10.1016/S0140-6736(16)30169-6).
208. Burman J, Iacobaeus E, Svenningsson A, Lycke J, Gunnarsson M, Nilsson P, et al. Autologous haematopoietic stem cell transplantation for aggressive multiple sclerosis: the Swedish experience. *J Neurol Neurosurg Psychiatry.* 2014;85(10):1116–21.
209. Chen B, Zhou M, Ouyang J, Zhou R, Xu J, Zhang Q, et al. Long-term efficacy of autologous haematopoietic stem cell transplantation in multiple sclerosis at a single institution in China. *Neurol Sci.* 2012;33(4):881–6. <https://doi.org/10.1007/s10072-011-0859-y>.
210. Curro' D, Vuolo L, Gualandi F, Bacigalupo A, Roccatagliata L, Capello E, et al. Low intensity lympho-ablative regimen followed by autologous hematopoietic stem cell transplantation in severe forms of multiple sclerosis: a MRI-based clinical study. *Mult Scler.* 2015;21(11):1423–30. [10.1177/1352458514564484](https://doi.org/10.1177/1352458514564484).
211. Mancardi GL, Sormani MP, Di Gioia M, Vuolo L, Gualandi F, Amato MP, et al. Autologous haematopoietic stem cell transplantation with an intermediate intensity conditioning regimen in multiple sclerosis: the Italian multi-centre experience. *Mult Scler.* 2012;18(6):835–42. [10.1177/1352458511429320](https://doi.org/10.1177/1352458511429320).
212. Muraro PA, Pasquini M, Atkins HL, Bowen JD, Farge D, Fassas A, et al. Long-term outcomes after autologous hematopoietic stem cell transplantation for multiple sclerosis. *JAMA Neurol.* 2017;74(4):459–69. <https://doi.org/10.1001/jamaneurol.2016.5867>.
213. Nash RA, Hutton GJ, Racke MK, Popat U, Devine SM, Griffith LM, et al. High-dose immunosuppressive therapy and autologous hematopoietic cell transplantation for relapsing-remitting multiple sclerosis (HALT-MS): a 3-year interim report. *JAMA Neurol.* 2015;72(2):159–69. <https://doi.org/10.1001/jamaneurol.2014.3780>.
214. Shevchenko JL, Kuznetsov AN, Ionova TI, Melnichenko VY, Fedorenko DA, Kurbatova KA, et al. Long-term outcomes of autologous hematopoietic stem cell transplantation with reduced-intensity conditioning in multiple sclerosis: physician's and patient's perspectives. *Ann Hematol.* 2015;94(7):1149–57. [10.1185/09639659.2015.1149570](https://doi.org/10.1185/09639659.2015.1149570).
215. Sormani MP, Muraro PA, Schiavetti I, Signori A, Laroni A, Saccardi R, Mancardi GL. Autologous hematopoietic stem cell transplantation in multiple sclerosis. *Neurology.* 2017;88(22):2115–22.
216. Eisen A, Greenberg BM, Bowen JD, Arnold DL, Caggiano AO. A double-blind, placebo-controlled, single ascending-dose study of remyelinating antibody rHIgM22 in people with multiple sclerosis. *Mult Scler J Exp Transl Clin.* 2017;3(4):2055217317743097.
217. Ruggieri S, Tortorella C, Gasperini C. Anti lingo 1 (opicinumab) a new monoclonal antibody tested in relapsing remitting multiple sclerosis. *Expert Rev Neurother.* 2017;17(11):1081–9.



# Clinical Decision-Making in the Management of Multiple Sclerosis

# 8

Syed A. Rizvi, Joshua A. Stone, Saima T. Chaudhry,  
Nichola Haddad, Brian Wong,  
and Jennifer O. Grimes

## Escalation Versus Early Aggressive (or Induction) Treatment in the Management of Relapsing MS (RMS)

Early in the disease course, multiple sclerosis is characterized by periods of inflammation associated with demyelination and axonal injury. However, in the later phase of the disease, inflammation becomes less prominent, and neurodegeneration arises as the defining feature of the illness. While progressive MS is primarily managed symptomatically, the early inflammatory

phase in relapsing MS represents a critical period where the benefits of disease-modifying therapy (DMT) can be best realized. Several studies [1–7] have shown that early treatment with disease-modifying therapy results in better long-term outcomes in comparison with delayed treatment and consequently therapeutic strategies have evolved.

The two general approaches employed in selecting a disease-modifying therapy can be described as either an “escalation” strategy or an early aggressive strategy. An escalation approach entails the initial use of a first-line agent, generally glatiramer acetate (GA) or interferon  $\beta$ , and transitioning to a second-line agent in the event of disease progression or clinical relapses while on therapy [8]. This is a reasonable strategy, as a patient may be well controlled on an agent with a long safety profile history. However, this approach does not take into consideration how early or late a patient is in their disease course or the degree of initial clinical or radiographic activity. Alternatively, an early aggressive strategy utilizes initial treatment with a medication considered more potent than first-line therapies, such as fingolimod, natalizumab, or ocrelizumab, or the use of an “induction” agent. Induction therapies provide a sustained alteration of the immune system and ideally are able to provide a prolonged period free from disease activity. Three of the disease-modifying therapies are considered induction agents: mitoxantrone,

S. A. Rizvi (✉)

Rhode Island Hospital and Alpert Medical School  
of Brown University, Brown Neurology,  
Providence, RI, USA  
e-mail: [srizvi@lifespan.org](mailto:srizvi@lifespan.org)

J. A. Stone · S. T. Chaudhry  
MS Fellow, Brown Neurology, Providence, RI, USA

N. Haddad · J. O. Grimes  
Alpert Warren Medical School of Brown University,  
Providence, RI, USA  
e-mail: [nichola\\_haddad@brown.edu](mailto:nichola_haddad@brown.edu);  
[jennifer\\_grimes@brown.edu](mailto:jennifer_grimes@brown.edu)

B. Wong  
Department of Neurology, Hartford Healthcare,  
University of Connecticut School of Medicine,  
Southington, CT, USA  
e-mail: [brian.wong2@hhchealth.org](mailto:brian.wong2@hhchealth.org)

alemtuzumab, and cladribine [9]. Stem cell transplant therapies also fall in the category of induction therapy.

In general, the newer therapies have been shown to decrease clinical relapse rates to a greater degree than the older therapies, and many of the newer therapies decrease the rate of disability progression in MS [10]. However, stronger medications also come with an increase in risk of serious adverse events. Progressive multifocal leukoencephalopathy with the use of natalizumab and the precipitation of other autoimmune conditions with alemtuzumab, for instance, are concerning for adverse outcomes related to the use of these agents. Due to variations in presentation and the fact that some patients will present with aggressive disease which cannot be adequately managed by first-line therapies, individualizing the treatment regimen for the individual is paramount. Disease severity must be considered when selecting a medication. Use of a potent agent as an initial therapy is becoming more common in an effort to minimize disability, particularly in patients with risk factors for an aggressive course [9, 11–14].

An aggressive treatment approach is often considered in an attempt to achieve a disease-activity-free status in multiple sclerosis. Criteria for such a status have been debated; however, the term “no evidence of disease activity” (NEDA) is the currently agreed upon model [15]. More specifically, NEDA-3 has been defined as (1) the absence of relapses—a new, or worsening of a previously stable, neurological abnormality, present for at least 24 h and occurring in the absence of fever or infection; (2) the absence of focal MRI activity, new or enlarged T2 lesions and/or gadolinium-enhancing lesions; and (3) the absence of confirmed disability progression (CDP)—an increase in Expanded Disability Status Scale (EDSS) score of 1.5 points from a baseline of 0, of 1.0 point from a baseline score of at least 1.0, or of 0.5 points from a baseline score of greater than 5.0 and confirmed after 3 or 6 months. While NEDA-3 captures inflammatory disease activity well, it may not fully account for the neurodegenerative component of MS. Thus, another

more stringent definition, NEDA-4, incorporates the criteria included in NEDA-3, as well as an annualized rate of brain volume loss of less than 0.4% [16]. Since brain volume loss has been shown to correlate with disability progression and cognitive decline, this definition may more accurately reflect a complete cessation of disease activity. It should be noted, however, that NEDA criteria do not account for disability attributed to cognitive measures, visual function, fatigue, or pain [17, 18].

Sustained disease control with an induction agent has been demonstrated in several studies. Mitoxantrone, an intercalating agent which crosslinks DNA strands, has proven efficacious in the treatment of acute myeloid leukemia, breast cancer, liver carcinoma, and non-Hodgkin’s lymphoma. For MS, it is administered intravenously every 3 months but is limited by a cumulative maximum dose. A 5-year observational trial of patients who received mitoxantrone therapy for MS showed that 32% of patient remained relapse-free after 5 years and 60% of patients did not have worsening of their EDSS score [19]. However, it should be noted that the adverse outcomes of decreased left ventricular cardiac ejection fraction and leukemia often limit mitoxantrone use [20]. Alemtuzumab, a humanized anti-CD52 monoclonal antibody which binds to the CD52 receptor on B and T lymphocytes causing a long-lasting depletion of lymphocytes, has similarly exhibited positive outcomes. The CARE-MS I study demonstrated that as an initial therapy, alemtuzumab was superior to interferon beta 1a in achieving an endpoint equivalent to NEDA-3—referred to as “freedom from disease activity”—with 39% (139/360) of patients in the alemtuzumab arm achieving this outcome at 24 months, in comparison with 27% of patients in the interferon beta 1a group [21]. In the CARE-MS II trial, alemtuzumab was utilized as a second-line therapy, and 32% (127/396) of these patients achieved freedom from disease activity at 24 months, compared to 14% of patients in the interferon beta 1a group [22]. Cladribine data thus far is encouraging with an extension study demonstrating that after 4 years after initiating treatment, 75% of patients

remained relapse-free and 72.4% of patients were free from disability progression [23].

While modern DMTs have demonstrated improved efficacy in minimizing disease progression in relapsing-remitting MS (RRMS), autologous hematopoietic stem cell transplantation (AHST) for the treatment of MS has also shown encouraging results. AHST for MS patients, which can be considered the ultimate in induction therapies, began in 1995, and by 2008, approximately 400 cases had been performed worldwide [24]. Although protocols from early transplantations varied greatly, even initial data showed slowing of disease progression in the majority of patients following treatment. Unfortunately, transplant-related mortality in early trials was reported as high as 7.3%. This was particularly concerning due to the fact that MS patients tend to be young and otherwise unburdened by other diseases. Newer trials have fortunately shown positive outcomes with far less morbidity and mortality. A retrospective review analyzing results from 281 patients who had received AHST via various protocols between 1995 and 2006 and had a median follow-up of 6.6 years found that 46% of transplant patients did not progress in their EDSS after 5 years [25]. Younger age, relapsing type of MS, fewer prior immunotherapies, and lower baseline EDSS score were all associated with improved outcomes. Furthermore, 100-day mortality following AHST was 1.3% for transplants performed from 2001 to 2007.

Additional studies have further supported a freedom from disease progression over the long term. A 2009 study with 21 patients who were treated with AHST at Northwestern University found that 62% of patients had no disease progression as measured by EDSS, no clinical relapses, and no new MRI lesions at 3-year mean follow-up [26]. A 2015 Northwestern University study of 145 patients, primarily with RRMS, treated with AHST found that 52% (14/27) of patients showed improvements in EDSS of at least 1.0 point at the 5-year follow-up point [27]. The HALT-MS trial studying AHST in 24 patients with RRMS reported that 78% of patients achieved an endpoint comparable with NEDA—

termed “event-free survival”—after 3 years and 69.2% of patients achieved this endpoint after 5 years [28]. Lastly, a trial with 24 patients with aggressive disease as predicted by a dataset from London, Ontario, Canada, showed that 69.6% of patients were free from clinical relapse, new or Gd-enhancing lesions on MRI, and progression of EDSS at 3 years following AHST [29]. Overall AHST has demonstrated NEDA status rates of 78–83% at 2 years and 60–68% after 5 years [30].

---

### Can Disease-Modifying Treatment Be Discontinued in Non-active RRMS/SPMS Patients?

Among the reasons for discontinuing disease-modifying therapy (DMT) in multiple sclerosis (MS) patients, stopping in those who are deemed to have stable disease is perhaps the most controversial. The concept of “no evidence of disease activity” (NEDA) has made this topic even more relevant in recent years. This, combined with the extreme costs and potential complications of DMTs, means that stopping treatment if it is safe and reasonable to do so may be in our patients’ best interests. Expert opinion [31–33] has long dominated this area, but evidence is slowly starting to emerge to provide clinicians with some guidance in select patient groups. That being said, a prospective, randomized study of DMT discontinuation has yet to be completed, though one is currently in process (DISCO-MS, NCT03073603).

While starting DMT early in young, nondisabled patients is widely advocated in order to achieve the best long-term outcomes, it is unclear whether older, more disabled patients with inactive or secondary progressive MS derive any benefit [34, 35]. The concept of immune senescence may explain why disease activity seems to decline with age [36] and why DMT may become unnecessary at a certain point. Cerebrospinal fluid (CSF) biomarkers of inflammation and axonal injury have been shown to decline with age, particularly with MS patients over age 54 [37]. Accordingly, age has been shown to be the most

significant predictor of gadolinium (Gd) enhancement on MRI in natural history studies, with the probability of enhancement decreasing by 36% for each additional decade. The frequency of enhancement was 12% in the group aged 50 and older compared to 55% in the 20–30-year-old group. As expected, relapse rate similarly peaked in the 20s and 30s and declined by approximately 34% per decade. Patients aged 55 and older who had been deemed to have secondary progressive disease for 5 or more years had only a 5% probability of relapse [38]. The unique pathologic basis underlying progressive disease, with chronic activation of macrophages and microglia, could potentially help explain the lower likelihood of relapses in this group [39]. Patients who are newly diagnosed with MS at an older age suggest that there is more to this story [40], but these data seem to support that older, inactive patients and patients with progressive disease may be less likely to relapse while off DMT.

Several recent observational studies have evaluated outcomes for patients who have discontinued DMT, mostly involving injectable medications. In one US center, 77 patients with secondary progressive MS who had no evidence of disease activity for at least 2 years had an 11.7% rate of new lesions or relapses after stopping DMT. These patients had a median age of 61 and range of 2–20 years of disease inactivity prior to discontinuation [41]. A French study on 100 patients with secondary progressive MS for at least 2 years who stopped DMT showed that 33% had a relapse or new enhancing lesion at 3 years, but only five of those patients had relapses that resulted in sustained increases on the Expanded Disability Status Scale (EDSS) at 6 months. Factors significantly associated with relapses following discontinuation included enhancing lesions within 3 years of stopping and EDSS less than 6 prior to stopping. Notably, changes in T2 lesion load were not considered in this study. Whether new, non-enhancing T2 lesions have implications for disability progression in secondary progressive MS remains unclear [42].

A larger analysis of 485 patients across 28 sites used data from MSBase, an international

prospective Internet-based registry. These patients stopped injectable DMTs after having no relapses for at least 5 years. They had been treated continuously for at least 3 years prior to discontinuation and were followed for at least 3 years after stopping DMT. The relapse risk was 36.4% after stopping DMT, and 33.5% of patients who stopped DMT had confirmed disability progression. Only 10.8% of patients experienced both relapse and confirmed disability progression. Younger age and lower baseline disability were significant predictors of relapse risk. Survival time to confirmed disability progression was shorter among patients who stopped DMT, with patients who had a stable EDSS for 5 years prior to discontinuation contributing significantly to this observation. Notably, the MSBase registry did not include the reasons for discontinuing treatment for the majority of patients who were included in this study. Of those for whom it was listed, reasons were multifactorial including perceived disease progression, intolerance, and adverse events [43].

An Austrian study of 221 patients with relapsing–remitting MS (RRMS) who discontinued DMT identified possible criteria for selecting patients who may be more likely to remain relapse-free after doing so. These patients were treated continuously for at least 12 months prior to discontinuation and did so for a variety of reasons including adverse events or patient preference. Only 27% of the cohort discontinued DMT due to stable disease. Relapses occurred in 44% of patients during a mean of 3.8 years of follow-up. Age over 45 years and the absence of clinical relapses or enhancing lesions for at least 4 years prior to discontinuation were felt to predict freedom from relapses after stopping DMT with a hazard ratio of only 0.06. Disability progression occurred in 20.8% of patients and was associated with higher EDSS, age over 45 years, and longer disease duration at the time of discontinuation [44].

As attempts are made to identify groups of MS patients who may not be benefitting from DMT, particularly with prospective, randomized-controlled trials, clinicians will hopefully be able to



make evidence-based decisions with their patients to stop treatment. Such data will be particularly important for patients who are on medications such as natalizumab and fingolimod which are associated with a risk of disease “rebound” on cessation [45, 46]. The newer drugs ocrelizumab and siponimod which have been shown to slow disability progression even in the absence of objective evidence for inflammatory activity raise additional questions about the perceived lack of benefit of DMT in certain populations [47, 48]. Whichever group of patients may seem suited for a trial of discontinuation, what is clear is the need for close clinical and radiological monitoring after stopping.

---

### Rebound Disease Activity in Patients Discontinuing Disease-Modifying Drugs

Though many effective treatments are now available to inhibit multiple sclerosis disease progression, reports have emerged concerning for exaggerated disease activity upon cessation of treatment with these agents. Some patients treated with fingolimod or natalizumab, which target trafficking of lymphocytes from lymphoid tissues and across the blood–brain barrier, respectively, have demonstrated “rebound” or disease activity that exceeded pretreatment rates based upon both clinical assessment and contrast-enhanced MRI analysis [49]. As studies continued to profile risks of discontinuation of fingolimod and natalizumab, new cases began to emerge that also identified increased activity in multiple sclerosis patients who discontinued treatment with dimethyl fumarate and teriflunomide [50–52]. The potential for severe exacerbation upon drug withdrawal is particularly concerning for patients who must stop treatment or change to a different medication due to inadequate response to therapy, JC virus positivity, or desire for pregnancy.

The nature of this rebound disease upon medication discontinuation is not well characterized. Some discordance in the literature reflects disagreement in definition of “rebound” versus “reactivation” or inevitable progression

of an unpredictable disease. Some have suggested that those with severe reactivation compared to pretreatment status might simply be demonstrating a variant of natural disease progression that is independent of medication use [53], but comparison of large populations of patients who were on different doses of fingolimod versus placebo demonstrated that disease activity exceeded predicted disease progression [54]. Additionally, the time of increased disease activity seems to correlate with expected withdrawal from the discontinued medications. A large cohort study demonstrated significant relapse rate of disease between 2 and 8 months after cessation of natalizumab therapy with 10% of patients suffering rebound, corresponding with the 3-month decrease in concentrations of natalizumab and changes in the immune system that have been documented up to 6 months after cessation of treatment [55, 56]. Studies exploring rates of rebound with fingolimod washout are largely similar but vary from 5% to 10% [46, 50, 53, 57]. Research continues to debate whether the rebound phenomenon is of the same etiology across patient populations, John Cunningham virus (JCV) and Epstein–Barr virus (EBV) status, medication used, and other yet uncharacterized variables that could affect patient outcome.

Controversy similarly surrounds whether rebound activity is related to immune reconstitution inflammatory syndrome, or IRIS. While IRIS previously described an immune response to infectious agents, it was proposed as the culprit for rebound activity upon cessation of immunomodulatory therapies as a result of an *endogenous* antigenic cause of new activity. Characterizing “rebound” activity versus IRIS sparked a debate within the community: Was rebound an exaggerated immune response after ending therapy or was an independent mechanism to explain the increase in disease activity in excess of pretreatment levels [49, 50]? What were these endogenous antigens? According to the field hypothesis, an unidentified compound or molecule in tissue, possibly of viral origin, triggers focal inflammation [1]. Some authors favor an exogenous cause, having isolated EBV-

infected cells and T cell binding in white matter lesions in a fatal case of rebound after cessation of natalizumab [58, 59]. Others refuted the connection to IRIS and a viral antigenic etiology through description of a severe, fatal disease they characterized in a postmortem study as inconsistent with IRIS or PML. The lesional damage was extensive yet characteristic of active demyelinating MS progression. Additionally, CCR5 inhibitors have shown efficacy in treating PML/IRIS, but researchers detected low levels of expression in sampled brain tissue, suggesting that such treatment would have been ineffective in their rebound case [60].

Other hypotheses regarding disease mechanism and etiology are more specific to the distinct treatments. Long-term natalizumab therapy may change the dynamics of cell adhesion molecules in leukocytes [61], and changes in cell adhesion molecule expression might also explain the cases of rebound disease upon cessation of dimethyl fumarate [62], though these may be through different mechanisms. Individual patient variables may also affect outcomes. A case report describing an affected patient's neutralizing antibodies against natalizumab suggested that acceleration of T cells into CSF caused disease exacerbation beyond the patient's baseline. They also noted that natalizumab promotes immune activation by giving a costimulatory signal to T cells, causing a pro-inflammatory state so its withdrawal (and thus prevention of effector cell migration into CSF) results in an increase of disease activity above pretreatment baseline [63]. Immune cell populations also undergo changes with treatment that may contribute to rebound phenomena. Research has shown an increased peripheral Th17 cell population and IL-17 levels after use of natalizumab, while disease reactivation was associated with a drop in Th17 and decrease in serum IL-17, suggesting reentry into CSF that was confirmed in a postmortem pathologic study [60, 64]. Others note the contributions of a reduction of regulatory T cells and upregulation of effector T cells [65].

Rebound activity after cessation of fingolimod may be due to a completely different immune

dysregulatory effect. A predisposition for severe exacerbations may arise from compensatory overexpression of sphingosine-1-phosphate receptors involved in lymphocyte trafficking due to chronic receptor blockade by fingolimod [66]. These rebounds can be particularly severe, producing tumefactive demyelinating lesions (i.e., lesions that are larger than 2 cm, with edema or mass effect) [67] even during active fingolimod treatment [65]. A postmortem case report following a fatal discontinuation of fingolimod describes astrocytic gliosis within the tumefactive lesions with intense sphingosine-1-phosphate receptor 1 expression. Of note, researchers also found astrocytic gliosis within white matter regions that appeared grossly normal [68].

Due to the lack of clarity and seeming disparity in etiologies of rebound cases, clinicians should be cautious when selecting patients who are appropriate candidates for immunomodulatory therapies. Patients with disease rebound tend to have more pretreatment disease activity, as indicated by higher Expanded Disability Status Scale (EDSS) scores, higher annualized relapse rate, and mean enhancing lesions before treatment, demonstrating a correlation between prior disease activity and likelihood of rebound activity [55, 56]. These patients should be monitored with extra caution when discontinuing a medication regimen, especially with fingolimod or natalizumab. Prevention and treatment of rebound are not yet optimized, but current studies considering specific medication withdrawal and JCV status recommend that alternative therapy should be started as 2–4 weeks after cessation of fingolimod and within 4 months after ending natalizumab to align timing of treatment with washout [49]. This can be challenging if patients end treatment with these regimens due to JCV positivity: alemtuzumab, cladribine, and mitoxantrone may cause long-term lymphocyte depletion, thus hindering CD8-dependent T-cell defense against JCV. B-cell therapies, rituximab and ocrelizumab, may provide immunity against JCV escape variants, so transitioning or discontinuing therapies safely with these options is a unique challenge [49].

Additionally, prevention of rebound has proven difficult at best. After stopping fingoli-

mod therapy, patients have rebounded even with treatment with rituximab or two courses of steroids [46]. A case study of a patient's transition from fingolimod to alemtuzumab with methylprednisolone after a 5-week fingolimod washout still resulted in unexpected high activity as T cells displayed an activated HLA phenotype. However, this immune response may be connected with fingolimod insufficiency in this patient [69]. Similar difficulties have been documented in transitioning to other therapies from natalizumab. A patient who discontinued natalizumab and started daclizumab suffered rebound on his new therapy, but he responded well to methylprednisolone and alemtuzumab [70]. In JCV-positive patients who must switch from natalizumab to alemtuzumab or other induction therapies, some recommend bridging with fingolimod, citing its efficacy in controlling disease after stopping natalizumab [71], though others have found relapse during use of fingolimod in patients transitioning from natalizumab [72]. One study did not find any significant reduction in disease activity with preventative methylprednisolone treatment, and glatiramer acetate, fingolimod, nor interferon beta offered appropriate protection against resumption of disease activity [55]. However, while some cases of rebound respond poorly to steroids, rebound upon discontinuation of teriflunomide responded well in a patient to two courses of IV steroids and 60 mg oral prednisone daily for 2 weeks followed by rituximab [52]. Research suggests that dimethyl fumarate might be effective if started after a short (1 month) washout of natalizumab [73], but a case report has also demonstrated inefficacy of dimethyl fumarate in controlling rebound activity after natalizumab cessation when used after a cyclophosphamide bridge [74]. Other work suggests that a short course of treatment with 60 mg cladribine effectively suppresses inflammatory activity and allows partial recovery in a patient with progressive multiple sclerosis with rebound disease from fingolimod with no short-term safety issues or adverse events [75]. Further work is necessary to explicate the relationships among patient factors, rebound etiology, medication effects, immunologic characteristics, and risk

profiles with different bridging regimens to clarify which patients would benefit most from specific transition protocols and who would be less likely to respond to certain treatments.

---

### Extended/Reduced Dosing of DMD

Several of the disease-modifying agents have been associated with serious side effects related to sustained immunosuppression including but not limited to PML. One possible approach to mitigate the risk is to reduce the overall dose of the agents by extending dosing intervals. Although definite data is lacking, several small studies provide some supportive evidence for this approach.

A subset of patients on fingolimod have a higher risk of developing severe lymphopenia, infections, and liver function abnormalities. Reducing the frequency of dosing (alternate day) may improve laboratory abnormalities although there may be a higher risk of breakthrough disease activity [76–78]. Several observational studies have evaluated the risk of breakthrough disease in patients treated with natalizumab who were dosed less frequently (up to 8-week intervals) and found no significant increase in disease activity [79–82]. More recently, a statistical analysis of the large TOUCH registry (US REMS program) revealed a significant reduction of risk of developing PML in JCV-positive patients who are treated with extended dosing compared to standard dosing [83]. Less frequent dosing prior to discontinuation has also been shown to reduce the risk of developing rebound disease activity after natalizumab discontinuation [84]. Infrequent dosing for B-cell-targeted therapies is even less well studied. Both rituximab and ocrelizumab are dosed at fixed 6-month intervals. While this dose effectively maintains B-cell depletion in the majority of patients, the minimum dose required to achieve complete and persistent B-cell depletion is unclear. One small study showed 97% depletion of B cells in patients who were treated with 1 mg/m<sup>2</sup> (a fraction of the standard dose) although cells recovered to 60% of baseline within 4 weeks [85]. Similarly, several small

studies have suggested increasing the intervals between treatments (up to 9 months) or reducing the dosage (50%) of rituximab in RRMS patients maintains B-cell depletion and efficacy [85–87]. Some suggest flexible dosing based on CD19/20 counts [88].

Less frequent dosing seems to be a reasonable option in patients who are at risk of or are experiencing significant side effects on DMDs.

---

## Management of PML in MS Patients and Subsequent Disease-Modifying Treatment

Among the most feared complications of disease-modifying therapy (DMT) in multiple sclerosis (MS) patients is progressive multifocal leukoencephalopathy (PML), a rare but severely disabling disease of the central nervous system caused by the John Cunningham virus (JCV) [89]. Patients treated with natalizumab, one of the most effective treatment options for MS, are the third largest population at risk of developing PML after patients with HIV and hematologic malignancies [90]. Besides natalizumab, PML has also been reported to occur in a few cases of patients treated with dimethyl fumarate and fingolimod [91, 92]. However, natalizumab has the most well-established association with PML as an adverse effect among the immunomodulatory therapies, with over 800 cases reported since 2005 [93]. The incidence of PML associated with natalizumab ranges from 0.1% for patients without additional risk factors to 1.3% among patients who are JCV antibody-positive, have a history of prior immunosuppressive therapy, and have received more than 4 years of treatment [94, 95]. With significant disability being incurred by two-thirds of the approximately 80% of patients who survive natalizumab-associated PML, early diagnosis and institution of appropriate treatment are of paramount importance [93, 96].

Although JCV is widespread throughout the world, with most individuals infected by age 30–40 likely via a urine or fecal–oral route, pathological transformation occurs only in immunosuppressed individuals by poorly understood

mechanisms [90, 97]. Replication of the transformed JCV then leads to axonal demyelination via lysis of infected oligodendrocytes. Large plaques are thereby formed in the subcortical white matter, often involving U fibers. The multifocal destruction leads to the variable symptomatology, ranging from hemiparesis to visual deficits depending on the areas involved. Neuroimaging and PCR detection of JCV DNA from CSF combined with the clinical picture make diagnosis possible without the need for biopsy [97].

Patients receiving natalizumab are risk stratified for PML at regular intervals using quantitative JCV antibody testing. The cutoff values for a positive test and when to halt further treatment evolve over time based on available evidence. Several studies have documented a very low risk of PML in patients who remain JCV negative [98]. There are several potential limitations to this method of PML risk stratification, including variability in testing methodologies and the possible effect of natalizumab on JCV indices. It also does not take into account other PML risk factors, such as prior immune suppression and duration of treatment with natalizumab [98]. While it is currently unclear whether JCV antibody testing has resulted in significantly earlier detection of PML, such is the goal of risk stratification methods and will hopefully be the case as they are further refined. Given the small number of PML cases associated with fingolimod and dimethyl fumarate, monitoring parameters for the purposes of PML risk stratification have not yet been established, though a possible association with lymphopenia has been observed [89, 99].

Currently, there is no treatment for PML. The general approach once PML has been diagnosed, regardless of etiology, consists of immune reconstitution in order to support the body's natural response to JCV [89, 97]. In natalizumab-associated PML, this was historically achieved by plasma exchange (PLEX) with the aim of removing the drug as quickly as possible. As the half-life of natalizumab is  $\sim 11 \pm 4$  days, it would take 2–3.5 months to naturally clear 95% of the drug. Modeling based on a study of PLEX in

patients treated with natalizumab suggested that five sessions would reduce serum natalizumab concentrations to  $<1 \mu\text{g/mL}$  in  $>95\%$  of patients [95, 100]. Whether this approach is superior to simple drug cessation remains uncertain. Recent retrospective analyses have failed to support the use of PLEX for improving clinical outcome and survival [101, 102]. It is noteworthy that biological effects of natalizumab may persist for 6 months or more despite drug cessation [95, 103]. Newer treatments, including antiviral agents, immune response modulators, and even immunization strategies, are currently being investigated and will hopefully result in some positive outcomes [90].

A common complication in the treatment of PML is PML-immune reconstitution inflammatory syndrome (PML-IRIS). The majority of natalizumab-treated patients with PML go on to develop PML-IRIS upon removal of the drug within days to weeks. In this entity, the demyelination induced by PML is paradoxically enhanced by a robust immune response with macrophages and CD4 and CD8 lymphocytes [97]. Radiologically, PML-IRIS is more likely than PML to cause edema or mass effect and to enhance with contrast, particularly at the borders of an established PML lesion [104]. Treatment usually consists of high doses of corticosteroids followed by a prolonged taper while being mindful of the potential for exacerbating any coexistent infection [97]. This approach has not been evaluated in any controlled trials [90].

For the 80% of patients who survive PML, a standardized approach to resuming treatment of their MS does not exist. Not only are there concerns about which agent to choose, but there are also questions regarding how long to delay treatment following PML. A recent retrospective study evaluated outcomes in 23 patients treated with various DMTs following PML. Though only three patients had been treated with each, both dimethyl fumarate and fingolimod were used without any clinical or radiological worsening of PML. Of note, the mean duration of treatment with both drugs was shorter than the mean time to PML associated with these drugs in the cases described thus far.

The mean delay in switching ranged from 2.9 months with IFN- $\beta$  1B to 11.6 months with dimethyl fumarate. The length of delay should likely differ depending on the pre-natalizumab severity of disease activity [105].

While there is a need for prospective controlled trials on many fronts to inform PML diagnosis, treatment, and resumption of MS DMT for PML survivors, the small population for recruitment and the lack of an adequate PML animal model are major limitations [97]. What is perhaps most clear at present for the successful treatment of PML is the need for early detection and subsequently providing the immune system the ability to fight JCV, just not too well.

---

## Management of Issues Related to Pregnancy in MS

### Normal Pregnancy and Reproduction in Multiple Sclerosis

Multiple sclerosis (MS) is nearly three times more common in women than in men where onset typically occurs during childbearing years (20 and 40 years of age), a time when many individuals consider starting a family [106–108]. Many patients may wonder how MS will affect their ability to reproduce; thus, providers should thoroughly discuss pregnancy and its implications with patients and tailor specific disease management to the individual.

In starting this conversation, women should be reassured that the diagnosis of multiple sclerosis does not affect fertility. Studies have shown that MS females have normal fertility rates with no increase in spontaneous abortions or fetal abnormalities [107].

Although the etiology of MS still remains unclear, it is thought to involve the interaction between multiple genes and environmental factors [108, 109]. According to certain studies, the lifetime risk of developing MS in the normal population is about 100–300 cases per 100,000 [110, 111]. Individuals with first-degree relatives with MS have a 2–4% chance for developing the disease, although this is much higher (up to 20%)

in children that are born to two MS parent [110, 112]. MS patients should be reassured that their own diagnosis, however, does not increase their child's risk of developing the disease. Per expert opinion, MS patients carry a 96% chance of having a completely normal child [106, 110].

Prior to the 1960s, it was believed that pregnancy worsened the clinical progression of multiple sclerosis, and these patients were highly discouraged from becoming pregnant [109]. Instead, research in the modern era has shown that pregnancy is actually protective due to increased levels of immunosuppression and a state of immune tolerance [109]. Several retrospective and prospective studies show that pregnancy is associated with decreased MS relapses, particularly in the second and third trimesters. This was first demonstrated in 1998 through the *Pregnancy in Multiple Sclerosis* (PRIMS) study. In this trial, 254 pregnant MS patients were prospectively followed and were found to have a 70% reduction in annualized relapse rates during their third trimester of pregnancy compared to their prepregnancy year [106, 108, 109, 113]. Reduced relapse rate during pregnancy is thought to be due to estriol and progesterone, two female sex hormones which are found in higher concentrations in late pregnancy. These hormones are thought to increase anti-inflammatory cytokines and reduce pro-inflammatory cytokines [107–109]. After delivery, there is a sudden decline in these hormones which most likely accounts for the increased relapse rates observed in the 3- to 6-month postpartum period [107, 109]. Although MS relapse rates increase temporarily postpartum, the *PRIMS* study further showed there was no change in the overall course of the disease during the 3-year follow-up period. Thus, pregnancy, delivery, and postpartum relapse rates appear to have no effect on long-term MS disease progression or disability [108, 114].

Another common question asked by patients is whether babies born to MS mothers will have long-term health consequences compared to the normal population. Between 1967 and 2002, a study was conducted comparing birth outcomes in women with MS to those without by using the

Norwegian Medical Birth Registry [108, 110, 115]. Other than finding that MS mothers had higher rates of small-for-gestational age babies, this study showed there was no difference in Apgar scores, rates of birth defects, or neonatal mortality [108]. From this research, the general consensus is that babies born to MS mothers have no greater long-term health consequences compared to the normal population [106, 108, 110, 114, 115].

### Testing and Treatment of Acute Relapse During Pregnancy

When concern for acute MS exacerbation arises in pregnancy, providers must suggest appropriate testing which poses minimal to no harm on the developing fetus. In the past, use of MRI was avoided during the first trimester due to concern over the negative health ramifications on the growing baby. Instead, newer research has shown that *non-contrast* MRI poses no increased risk to the developing neonate and is considered safe throughout all stages of pregnancy. Use of gadolinium contrast, however, is strongly discouraged throughout pregnancy (in any trimester) due to an assortment of negative effects on the fetus including inflammatory/skin disorders, rheumatologic conditions, and neonatal death. Evoked potentials and lumbar puncture are other tests that can be pursued and considered safe throughout pregnancy [107].

MS relapses that occur during pregnancy can be effectively treated with intravenous (IV) methylprednisolone but should be reserved for severe exacerbations and are safest when used only in the second and third trimesters [114]. IV steroid use should be avoided in the first trimester of pregnancy as studies have shown an increased risk for craniofacial abnormalities, such as cleft palate [107, 108, 114, 116]. Instead, relapses occurring in the first trimester of pregnancy can be effectively treated with intravenous immunoglobulin (IVIG) as there are no effects on the developing fetus and very low rate of maternal side effects [107, 110, 111]. Testing and treatment of acute MS exacerbations during pregnancy

should be carefully discussed with the patient and tailored to each individual.

### **Risks of Disease-Modifying Therapy During Conception, Pregnancy, and Lactation**

Risk of disease-modifying therapy (DMT) should be thoroughly discussed with MS patients who are trying to conceive or discover they are pregnant. Available data regarding these risks are mainly based on incidental exposure to the drug or animal research. Each DMT has varying effects on the growing fetus and differ in length of time they should be discontinued prior to attempts at conception [107]. There is general agreement from the FDA and National MS Society that most DMTs should not be used in MS patients who are pregnant or breastfeeding and should be discontinued at least 3 months prior to conception [108, 110].

IFN- $\beta$ s, the oldest class of injectable DMT, are contraindicated in pregnancy and should be discontinued at least 3 months prior to conception [114]. Various animal studies show increased rates of miscarriage and spontaneous abortion with supra-therapeutic dosages (as high as 40 times the human therapeutic dose), leading to its category C rating by the FDA [114]. Certain reports show higher incidence of low birth weight and premature births in women incidentally exposed to these agents prior to conception or within the first trimester of pregnancy [110, 114, 117]. However, other studies do not confirm these findings such as the German Multiple Sclerosis and Pregnancy Registry, Betaseron Pregnancy Registry, or Avonex Pregnancy Exposure Registry [107, 114]. As a result, some providers still choose to continue interferon therapy up until conception, while others stop these agents at least 3 months prior [110]. The exact decision regarding discontinuation of therapy should be made between the provider and the patient and can be based largely on the severity of the patient's disease [108, 110].

Glatiramer acetate (GA) is the only MS disease-modifying agent labelled category B. It

does not cross the placenta and is shown to be safe during both pregnancy and lactation [106–108, 114]. In animal studies and human case reports, exposure to this agent during conception and throughout pregnancy has shown no teratogenic effects to the growing fetus, including no association with congenital abnormalities, low birth weight, premature birth, or spontaneous abortion [107, 108, 114]. Being a large amino acid polymer, GA is unable to be absorbed through the neonatal gastrointestinal tract and is thus safe during lactation and breastfeeding [114].

Fingolimod is rated category C by the FDA due to strong evidence showing increased teratogenicity (cardiovascular malformations) and spontaneous abortions during pregnancy [106, 107, 110, 114]. This agent has the ability to cross the placenta and should be discontinued at least 3 months prior to conception [114]. Fingolimod takes at least 2 months to be completely eliminated from the body after drug discontinuation [108, 110]. MS patients wanting to become pregnant should be counseled on the importance of drug discontinuation prior to conception and informed of its negative effects on a growing fetus. In over 50 human exposure cases, this agent was associated with high rates of cardiovascular fetal malformations at birth including Tetralogy of Fallot, persistent truncus arteriosus, ventricular septal defects, and even fetal death [114, 118]. When used during conception and pregnancy, fingolimod likely precipitates cardiovascular malformations due to its action on specific sphingosine-1-phosphate receptors, which are involved in fetal angiogenesis [110]. As this drug is also secreted in breast milk, breastfeeding while using fingolimod is strongly contraindicated [114].

Dimethyl fumarate has been labeled category C by the FDA due to animal studies showing increased embryonic lethality at supra-therapeutic dosages (two times higher than the approved human dose) [114]. Limited data exists on the effects of this drug when taken during or after conception. However, no adverse effects were found in a case series of 45 women who were incidentally exposed to this therapy during the

first trimester of pregnancy [114, 119]. Despite this, based mainly on animal studies, consensus recommendations are to stop this DMT 3 months prior to conception. Due to its short half-life, at least 1 month is indicated prior to discontinuation. As effects on the growing neonate remain unclear, women are further advised to avoid breastfeeding while on this medication [114].

Teriflunomide is contraindicated during conception, pregnancy, and lactation. Due to its mechanism of action (inhibition of pyrimidine synthesis), this drug has increased teratogenicity during embryogenesis and is labeled category X by the FDA [107, 110, 114]. In animal studies, teriflunomide was able to cross the placenta and caused multiple fetal abnormalities (craniofacial, axial, and appendicular skeletal malformations) at doses lower than those used for MS therapy [114, 120]. However, human exposure studies have not shown serious malformations or increased rate of spontaneous abortions compared to the general population [107, 110]. Despite this, caution when using teriflunomide is still advised. A pregnancy test should be administered prior to initiation of this agent in female MS patients, and it should not be used in patients with unreliable methods of contraception [107, 114]. Moreover, small amounts of this drug are found in male semen, although it is not known to damage human sperm or affect male fertility [110, 114]. Because of its long half-life, teriflunomide may stay in a patient's body between 8 months and 2 years after drug cessation. Because of this, discontinuation of the drug is advised at least 2 years prior to conception and pregnancy in both male and female patients [110, 114]. In cases of unplanned pregnancy or conception desired within 1 year of DMT, the rate of drug elimination from the body can be increased with use of cholestyramine or activated charcoal [107, 110, 114]. Teriflunomide has also been detected in rat milk and is thus contraindicated during breastfeeding [110, 114].

Alemtuzumab is an anti-CD52 humanized monoclonal antibody labeled category C by the FDA. In animal studies, early use of alemtuzumab during conception and pregnancy leads to increased rates of fetal loss and decreased lym-

phocytes in offspring upon birth [121]. In a case series involving over 130 pregnant women (where conception occurred at least 4 months after last alemtuzumab infusion), there was no evidence of increased spontaneous abortions or birth defects [114, 120]. Since this drug has been found in milk of lactating mice, breastfeeding is strongly contraindicated [114].

Natalizumab is considered category C by the FDA, and consensus recommendations include discontinuation of this DMT 3 months prior to conception and during breastfeeding [107, 110, 114]. In animal studies, supra-therapeutic doses were shown to decrease fertility and reduce neonatal survival [114]. In humans, the *Tysabri Pregnancy Exposure Registry*, which enrolled 369 MS patients exposed to the drug, showed minimal increase in spontaneous abortions and fetal malformations when compared to the general population. However, transient hematologic abnormalities were observed in patients with severe MS who were on this medication during the second and third trimesters of pregnancy [107, 110, 114]. This DMT has been found in breast milk and should be avoided during breastfeeding [110, 114].

Rituximab (an anti-CD20 chimeric monoclonal antibody) and ocrelizumab (the humanized version of rituximab) are labeled category C by the FDA [114]. Animal studies demonstrate that rituximab crosses the placenta but show no increased risk of spontaneous abortions or teratogenicity. However, transient B-cell depletion was observed in newborns when mothers were exposed to the drug during the second or third pregnancy trimesters [114, 122]. Ocrelizumab is a relatively newer agent with limited information available regarding its effect on the developing fetus and on the neonate while breastfeeding. Due to its unknown effects, patients are currently advised to discontinue treatment 6 months prior to conception and to avoid use while breastfeeding [114].

All chemotherapeutic agents are contraindicated in pregnancy and lactation and should be discontinued at least 3 months prior to conception. Mitoxantrone and azathioprine are placed in FDA category D where azathioprine has been associ-



ated with increased risk of intrauterine growth retardation [108, 110]. Methotrexate (FDA category X) is known to be teratogenic and carries a high risk of spontaneous abortion [108, 110].

Overall, choosing when to discontinue disease-modifying agents prior to conception can be a difficult decision for many patients with MS due to the risk of relapse that may occur if therapy is held for a prolonged period [114]. For MS patients hoping to become pregnant, a visit should be scheduled at least 6 months to 1 year prior to conception to discuss the various risks and benefits of DMT [107]. The risk of relapse due to DMT discontinuation can often be offset by the reduced rate of relapse during pregnancy [107]. Regardless of the DMT, advice must be tailored to each individualized patient.

## Managing Postpartum Relapse

Although MS relapse rates are known to decrease during pregnancy, numerous studies have shown higher rates of relapse in the 3 months postpartum [109, 110]. Acute disease exacerbation during this period has the potential to worsen postpartum depression or can interfere with the developing bond between both mother and child [110]. Three variables correlate with increased postpartum relapse: increased relapse rate in the year prior to pregnancy, increased relapse rate during pregnancy, and a higher Expanded Disability Status Scale score at pregnancy onset [109, 114]. In turn, women on DMT prior to or during conception and throughout pregnancy have shown lower relapse rates than those not on therapy [109]. Acute exacerbation in the postpartum period can effectively be treated with intravenous methylprednisolone [110, 123]. This is considered safe when breastfeeding as only small concentrations pass into milk from mother to child [123]. Based on retrospective studies, intravenous immunoglobulin can also be administered postpartum with no adverse effects and the ability to reduce relapse rates by about 50% [110, 124].

Limited evidence and no clear consensus exist on how to prevent postpartum relapse [109, 110].

After delivery, many practitioners decide to resume DMT; however, the optimal time to restart these agents remains unclear [109]. As discussed earlier, many maintenance therapies are contraindicated during breastfeeding. Although it is generally recommended to resume DMT in patients with highly active disease prepregnancy, there is evidence that exclusive breastfeeding reduces MS relapse [108, 125, 126]. A prospective study showed fivefold relapse rate reduction in patients who exclusively breastfed in the 2-month postpartum period [108, 110, 126]. However, earlier studies suggested no effect on postpartum relapse rates during lactation. Although this is still an area of controversy, the decision regarding breastfeeding versus reinstitution of DMT should be tailored to the individual and thoroughly discussed between patient and provider [108, 110].

---

## Use of Medical Marijuana in Multiple Sclerosis Patients

Although cannabis has been used medicinally for thousands of years, evidence of its role in the treatment of multiple medical and psychiatric disorders has only recently begun to accumulate. Over the last several decades, many randomized clinical trials (RCTs) have attempted to test the effectiveness of cannabinoid-based medications in treating neuropathic pain, cancer pain, inflammation, spinal cord injury, spasticity in multiple sclerosis (MS), and other conditions [127]. Notably, most of these novel medications still lack government approval, which limits their clinical usage. Nonetheless, there is both anecdotal and scientific evidence that cannabis extract or cannabinoid-based medication may be beneficial in managing symptoms such as spasticity, chronic pain, and bladder function and may improve overall quality of life [128].

In the United States, about 20% of MS patients either inhale or ingest cannabis, while an estimated 1–4% of MS patients in the United Kingdom and 14–16% of patients in Canada use cannabinoid-based medications [129, 130]. Cannabinoids come in multiple formulations aside from inhaled marijuana. Cannabis extract,

dronabinol (Marinol), and nabilone (Cesamet) are orally administered, while nabiximols (Sativex) is administered through an oromucosal spray [131]. More than 60 cannabinoids have been identified from the *Cannabis sativa* flowering plant, with delta-9-tetrahydrocannabinol (THC) and cannabidiol (CBD) being the major compounds [132]. The effects of cannabinoids are mediated through G protein-coupled receptors, specifically CB1 and CB2. Receptor activation inhibits adenylate cyclase, which converts cAMP to ATP and inhibits the release of neurotransmitters such as acetylcholine, dopamine, and glutamate [131]. The highest density of CB1 receptors is found in the cerebral cortex, cerebellum, basal ganglia, and hippocampus, while CB2 receptors are found not only predominantly in lymph tissue but also in the periaqueductal gray and other brain regions [131, 133, 134]. Cannabinoids also have indirect effects on opiate, serotonin, NMDA, and gamma-aminobutyric acid, which help explain the various physiologic responses seen with cannabis use [131].

THC is a partial CB1 receptor agonist shown to induce psychotic activity, analgesia, muscle relaxation, and hunger [135]. CBD, on the other hand, is a CB1/CB2 receptor antagonist with antipsychotic activity and has been shown to have anxiolytic, antioxidant, neuroprotective, and anticonvulsant effects [135]. Genetic knockout mice studies have demonstrated the neuroprotective effects of cannabinoids [136]. In relation to MS in particular, knockout models have shown that cannabinoids may improve inflammation, increase re-myelination of axons, and decrease apoptosis of oligodendrocytes [136].

The evidence around using cannabinoids as a therapeutic treatment for symptoms of MS is limited. However, a systemic review conducted by Nielsen et al. in February 2018 synthesizing the findings from high-quality 11 systemic reviews and 32 studies examining the efficacy and safety of cannabinoid use in MS found evidence that cannabinoids have modest efficacy in treating spasticity and chronic pain [137]. A meta-analysis of moderate-certainty evidence conducted by da Rovare et al. in 2017 including 16 placebo-

controlled RCTs (2597 patients) found that cannabinoid use in MS patients is associated with non-statistically significant improvements in spasticity, cognitive function, and pain [128]. A systemic review and meta-analysis of the benefits and adverse events of cannabinoids for medical use conducted by Whiting et al. in 2015 including 79 RCTs (6462 patients) found that cannabinoid use in MS patients was correlated with non-statistically significant improvements in spasticity and chronic neuropathic pain [138]. Lastly, a systemic review of the safety and efficacy of cannabinoids in the treatment of MS and other neurological disorders conducted by Koppel et al. in 2014 found that cannabis extract is effective and nabiximols and THC are probably effective in reducing patient-centered measures of spasticity, central pain, and painful spasms [131].

Although spasticity affects the majority of MS patients at some point in their disease course, conventional antispastic agents are often not efficacious or have intolerable side effects. Currently, Sativex, which contains CBD and THC in a 1:1 ratio, is the only commercially available formulation of cannabinoids available to MS patients who have spasticity refractory to first-line antispastic therapies. A literature review by Giacoppo et al. found that Sativex is effective in treating spasticity and also improves quality of life. In addition, it has a low incidence of adverse effects. Additionally, a double-blind, placebo-controlled RCT conducted by Markovà et al. in 2018 found that using Sativex as an add-on therapy improved spasticity significantly more than adjusting conventional antispastic agents in resistant MS spasticity ( $p < 0.01$ ) [138, 139].

Notably, research has consistently demonstrated that when compared to treatment with placebo or usual care, cannabinoids are associated with a significantly greater number of adverse effects such as headaches, dry mouth, dizziness, nausea, and somnolence [128, 138]. In addition, preliminary research with fMRI suggests that smoked cannabis may compromise information processing speed and memory, but in the absence of a high-quality clinical trial, the effects of cannabinoids on cognition are unknown [130]. Importantly, the side effects associated with can-

nabinoid use are considerably more tolerable than the side effects of conventional antispastic therapies such as baclofen, benzodiazepines, gabapentin, and tizanidine [128].

In summary, there is limited data on topics surrounding cannabis use in patients with MS despite the high prevalence of cannabinoid-related medications in the MS population across the globe. There is both anecdotal and scientific evidence that cannabis extracts may be effective in providing symptom relief for MS patients; however, more evidence in the form of large-scale RCTs is needed to better understand the effectiveness of cannabinoids in treating patient outcomes such as spasticity, pain, cognition, and bladder function. The classification of marijuana as a Schedule I drug in the United States makes research into its effects on MS and other neurological conditions more complicated, although more and more states are legalizing medical use of marijuana. Ultimately, it is up to individual physicians to weigh the constellation of evidence related to cannabinoid use and determine, for themselves, the role cannabis may play in patient care within the MS population.

## References

1. Comi G, Martinelli V, Rodegher M, Moiola L, Leocani L, Bajenaru O, et al. Effects of early treatment with glatiramer acetate in patients with clinically isolated syndrome. *Mult Scler*. 2013;19(8):1074–83.
2. Kappos L, Freedman MS, Polman CH, Edan G, Hartung HP, Miller DH, et al. Long-term effect of early treatment with interferon beta-1b after a first clinical event suggestive of multiple sclerosis: 5-year active treatment extension of the phase 3 BENEFIT trial. *Lancet Neurol*. 2009;8(11):987–97.
3. Kappos L, Edan G, Freedman MS, Montalban X, Hartung HP, Hemmer B, et al. The 11-year long-term follow-up study from the randomized BENEFIT CIS trial. *Neurology*. 2016;87(10):978–87.
4. Kavaliunas A, Manouchehrinia A, Stawiarz L, Ramanujam R, Agholme J, Hedstrom AK, et al. Importance of early treatment initiation in the clinical course of multiple sclerosis. *Mult Scler*. 2017;23(9):1233–40.
5. Kinkel RP, Dontchev M, Kollman C, Skaramagas TT, O'Connor PW, Simon JH, et al. Association between immediate initiation of intramuscular interferon beta-1a at the time of a clinically isolated syndrome and long-term outcomes: a 10-year follow-up of the controlled high-risk avonex multiple sclerosis prevention study in ongoing neurological surveillance. *Arch Neurol*. 2012;69(2):183–90.
6. Miller AE, Wolinsky JS, Kappos L, Comi G, Freedman MS, Olsson TP, et al. Oral teriflunomide for patients with a first clinical episode suggestive of multiple sclerosis (TOPIC): a randomised, double-blind, placebo-controlled, phase 3 trial. *Lancet Neurol*. 2014;13(10):977–86.
7. Romeo MAL, Martinelli V, Dalla Costa G, Colombo B, De Feo D, Esposito F, et al. Assessing the role of innovative therapeutic paradigm on multiple sclerosis treatment response. *Acta Neurol Scand*. 2018;138(5):447–53.
8. Freedman MS. Induction vs. escalation of therapy for relapsing multiple sclerosis: the evidence. *Neurol Sci*. 2008;29(Suppl 2):S250–2.
9. Le Page E, Edan G. Induction or escalation therapy for patients with multiple sclerosis? *Rev Neurol*. 2018;174(6):449–57.
10. Merkel B, Butzkueven H, Traboulsee AL, Havrdova E, Kalincik T. Timing of high-efficacy therapy in relapsing-remitting multiple sclerosis: a systematic review. *Autoimmun Rev*. 2017;16(6):658–65.
11. Giovannoni G, Turner B, Gnanapavan S, Offiah C, Schmierer K, Marta M. Is it time to target no evident disease activity (NEDA) in multiple sclerosis? *Mult Scler Relat Disord*. 2015;4(4):329–33.
12. Ingwersen J, Aktas O, Hartung HP. Advances in and algorithms for the treatment of relapsing-remitting multiple sclerosis. *Neurotherapeutics*. 2016;13(1):47–57.
13. Edan G, Le Page E. Induction therapy for patients with multiple sclerosis: why? When? How? *CNS Drugs*. 2013;27(6):403–9.
14. Gajofatto A, Benedetti MD. Treatment strategies for multiple sclerosis: when to start, when to change, when to stop? *World J Clin Cases*. 2015;3(7):545–55.
15. Bevan CJ, Cree BA. Disease activity free status: a new end point for a new era in multiple sclerosis clinical research? *JAMA Neurol*. 2014;71(3):269–70.
16. Kappos L, De Stefano N, Freedman MS, Cree BA, Radue EW, Sprenger T, et al. Inclusion of brain volume loss in a revised measure of 'no evidence of disease activity' (NEDA-4) in relapsing-remitting multiple sclerosis. *Mult Scler*. 2016;22(10):1297–305.
17. Matta AP, Nascimento OJ, Ferreira AC, Magalhaes TN, Benevides TP, Kirmse A, et al. No evidence of disease activity in multiple sclerosis patients. *Expert Rev Neurother*. 2016;16(11):1279–84.
18. Freedman MS. Are we in need of NEDA? *Mult Scler*. 2016;22(1):5–6.
19. Le Page E, Leray E, Taurin G, Coustans M, Chaperon J, Morrissey SP, et al. Mitoxantrone as induction treatment in aggressive relapsing remitting multiple sclerosis: treatment response factors in a 5 year follow-up observational study of 100 consecutive patients. *J Neurol Neurosurg Psychiatry*. 2008;79(1):52–6.

20. Le Page E, Leray E, Edan G, French Mitoxantrone Safety Group. Long-term safety profile of mitoxantrone in a french cohort of 802 multiple sclerosis patients: a 5-year prospective study. *Mult Scler*. 2011;17(7):867–75.
21. Cohen JA, Coles AJ, Arnold DL, Confavreux C, Fox EJ, Hartung HP, et al. Alemtuzumab versus interferon beta 1a as first-line treatment for patients with relapsing-remitting multiple sclerosis: a randomised controlled phase 3 trial. *Lancet*. 2012;380(9856):1819–28. [https://doi.org/10.1016/S0140-6736\(12\)61769-3](https://doi.org/10.1016/S0140-6736(12)61769-3).
22. Coles AJ, Twyman CL, Arnold DL, Cohen JA, Confavreux C, Fox EJ, et al. Alemtuzumab for patients with relapsing multiple sclerosis after disease-modifying therapy: a randomised controlled phase 3 trial. *Lancet*. 2012;380(9856):1829–39. [https://doi.org/10.1016/S0140-6736\(12\)61768-1](https://doi.org/10.1016/S0140-6736(12)61768-1).
23. Giovannoni G, Soelberg Sorensen P, Cook S, Rammohan K, Rieckmann P, Comi G, et al. Safety and efficacy of cladribine tablets in patients with relapsing-remitting multiple sclerosis: results from the randomized extension trial of the CLARITY study. *Mult Scler*. 2018;24(12):1594–604.
24. Mancardi G, Saccardi R. Autologous haematopoietic stem-cell transplantation in multiple sclerosis. *Lancet Neurol*. 2008;7(7):626–36.
25. Muraro PA, Pasquini M, Atkins HL, Bowen JD, Farge D, Fassas A, et al. Long-term outcomes after autologous hematopoietic stem cell transplantation for multiple sclerosis. *JAMA Neurol*. 2017;74(4):459–69.
26. Burt RK, Loh Y, Cohen B, Stefoski D, Balabanov R, Katsamakidis G, et al. Autologous non-myeloablative haemopoietic stem cell transplantation in relapsing-remitting multiple sclerosis: a phase I/II study. *Lancet Neurol*. 2009;8(3):244–53.
27. Burt RK, Balabanov R, Han X, Sharrack B, Morgan A, Quigley K, et al. Association of nonmyeloablative hematopoietic stem cell transplantation with neurological disability in patients with relapsing-remitting multiple sclerosis. *JAMA*. 2015;313(3):275–84.
28. Nash RA, Hutton GJ, Racke MK, Popat U, Devine SM, Steinmiller KC, et al. High-dose immunosuppressive therapy and autologous HCT for relapsing-remitting MS. *Neurology*. 2017;88(9):842–52.
29. Atkins HL, Bowman M, Allan D, Anstee G, Arnold DL, Bar-Or A, et al. Immunoablation and autologous haemopoietic stem-cell transplantation for aggressive multiple sclerosis: a multicentre single-group phase 2 trial. *Lancet*. 2016;388(10044):576–85.
30. Sormani MP, Muraro PA, Saccardi R, Mancardi G. NEDA status in highly active MS can be more easily obtained with autologous hematopoietic stem cell transplantation than other drugs. *Mult Scler*. 2017;23(2):201–4.
31. Freedman MS. Is there a safe time to discontinue therapy in MS? *Nat Rev Neurol*. 2017;13:10–1.
32. Kister I. Disease-modifying therapies can be safely discontinued in an individual with stable relapsing-remitting MS – YES. *Mult Scler J*. 2017;23(9):1188–090.
33. Tobin WO, Weinschenker BG. Disease-modifying therapies can be safely discontinued in an individual with stable relapsing-remitting MS – NO. *Mult Scler J*. 2017;23(9):1190–2.
34. European Study Group on interferon beta-1b in secondary progressive MS. Placebo-controlled multicentre randomised trial of interferon beta-1b in treatment of secondary progressive multiple sclerosis. *Lancet*. 1998;352(9139):1491–7.
35. Ontaneda D, Thompson AJ, Fox RJ, et al. Progressive multiple sclerosis: prospects for disease therapy, repair, and restoration of function. *Lancet*. 2017;389(10076):1357–66.
36. Tremlett H, Zhao Y, Joseph J, et al. Relapses in multiple sclerosis are age- and time-dependent. *J Neurol Neurosurg Psychiatry*. 2008;79(12):1368–74.
37. Khademi M, Dring AM, Gilthorpe JD, et al. Intense inflammation and nerve damage in early multiple sclerosis subsides at older age: a reflection by cerebrospinal fluid biomarkers. *PLoS One*. 2013;8(5):e63172.
38. Tortorella C, Bellacosa A, Paolicelli D, et al. Age-related gadolinium-enhancement of MRI brain lesions in multiple sclerosis. *J Neurol Sci*. 2005;239(1):95–9.
39. Bar-Or A. The immunology of multiple sclerosis. *Semin Neurol*. 2008;28:29–45.
40. Tobin W, Weinschenker BG. Stopping immunomodulatory medications in MS: frequency, reasons, and consequences. *Mult Scler Relat Disord*. 2015;4:437–43.
41. Birnbaum G. Stopping disease modifying-therapy in nonrelapsing multiple sclerosis: experience from a clinical practice. *Int J MS Care*. 2017;9(1):11–4.
42. Bonenfant J, Bajoux E, Deburghgrave V, et al. Can we stop immunomodulatory treatments in secondary progressive multiple sclerosis? *Eur J Neurol*. 2017;24(2):237–44.
43. Kister I, Spelman T, Alroughani R, et al. Discontinuing disease-modifying therapy in MS after a prolonged relapse-free period: a propensity score-matched study. *J Neurol Neurosurg Psychiatry*. 2016;87(10):1133–7.
44. Bsteh G, Feige J, Ehling R, et al. Discontinuation of disease-modifying therapies in multiple sclerosis – clinical outcome and prognostic factors. *Mult Scler*. 2017;23(9):1241–8.
45. Vellinga MM, Castelijns JA, Barkhof F, et al. Postwithdrawal rebound increase in T2 lesional activity in natalizumab-treated MS patients. *Neurology*. 2008;70(132):1150–1.
46. Hatcher SE, Waubant E, Nourbakhsh B, et al. Rebound syndrome in patients with multiple sclerosis after cessation of fingolimod treatment. *JAMA Neurol*. 2016;73(7):790–4.
47. Montalban X, Hauser SL, Kappos L, et al. Ocrelizumab versus placebo in primary progressive multiple sclerosis. *N Engl J Med*. 2017;376:209–20.
48. Kappos L. Efficacy and safety of siponimod in secondary progressive multiple sclerosis: results of the placebo-controlled, double-blind, phase III EXPAND study. *Neurology*. 2017;88:CT.002.
49. Giovannoni G, Hawkes C, Waubant E, Lublin F. The ‘field hypothesis’: rebound activity after stopping

- disease-modifying therapies. *Mult Scler Relat Disord*. 2017;15:A1.
50. Beran RG, Hegazi Y, Schwartz RS, Cordato DJ. Rebound exacerbation multiple sclerosis following cessation of oral treatment. *Mult Scler Relat Disord*. 2013;2(3):252–5.
51. Harmel P, Schlunk F, Harms L. Fulminant rebound of relapsing-remitting multiple sclerosis after discontinuation of dimethyl fumarate: a case report. *Mult Scler*. 2018;24(8):1131–3.
52. Yamout BI, Said M, Hannoun S, Zeineddine M, Massouh J, Khoury SJ. Rebound syndrome after teriflunomide cessation in a patient with multiple sclerosis. *J Neurol Sci*. 2017;380:79–81.
53. Frau J, Sormani MP, Signori A, et al. Clinical activity after fingolimod cessation: disease reactivation or rebound? *Eur J Neurol*. 2018;25(10):1270–5.
54. Vermersch P, Radue EW, Putzki N, Ritter S, Merschhemke M, Freedman MS. A comparison of multiple sclerosis disease activity after discontinuation of fingolimod and placebo. *Mult Scler J Exp Transl Clin*. 2017;3:2055217317730096–3. <https://www.ncbi.nlm.nih.gov/pmc/articles/PMC5624444>. Accessed 16 Sep 2018.
55. Sangalli F, Moiola L, Ferrè L, et al. Long-term management of natalizumab discontinuation in a large monocentric cohort of multiple sclerosis patients. *Mult Scler Relat Disord*. 2014;3(4):520–6.
56. Gueguen A, Roux P, Deschamps R, et al. Abnormal inflammatory activity returns after natalizumab cessation in multiple sclerosis. *J Neurol Neurosurg Psychiatry*. 2014;85(9):1038–40.
57. Gündüz T, Kürtüncü M, Eraksoy M. Severe rebound after withdrawal of fingolimod treatment in patients with multiple sclerosis. *Mult Scler Relat Disord*. 2017;11:1–3.
58. Serafini B, Zandee S, Rosicarelli B, et al. Epstein-Barr virus-associated immune reconstitution inflammatory syndrome as possible cause of fulminant multiple sclerosis relapse after natalizumab interruption. *J Neuroimmunol*. 2018;319:9–12.
59. Serafini B, Scorsi E, Rosicarelli B, Rigau V, Thouvenot E, Aloisi F. Massive intracerebral Epstein-Barr virus reactivation in lethal multiple sclerosis relapse after natalizumab withdrawal. *J Neuroimmunol*. 2017;307:14–7.
60. Laroche C, Metz I, Lécuyer MA, et al. Immunological and pathological characterization of fatal rebound MS activity following natalizumab withdrawal. *Mult Scler*. 2017;23(1):72–81.
61. Cobo-Calvo Á, Figueras A, Bau L, et al. Leukocyte adhesion molecule dynamics after natalizumab withdrawal in multiple sclerosis. *Clin Immunol*. 2016;171:18–24.
62. Giacomini PS. Rebound disease in multiple sclerosis. *Mult Scler*. 2018;24(8):1137–8.
63. Mulero P, Neri MJ, Rodriguez M, Arenillas JF, Téllez N. Immune reconstitution inflammatory syndrome and natalizumab—is it possible before removing the drug? *Mult Scler Relat Disord*. 2014;3(5):659–61.
64. Haas J, Schneider K, Schwarz A, et al. Th17 cells: a prognostic marker for MS rebound after natalizumab cessation? *Mult Scler*. 2017;23(1):114–8.
65. Sánchez P, Meca-Lallana V, Vivancos J. Tumefactive multiple sclerosis lesions associated with fingolimod treatment: report of 5 cases. *Mult Scler Relat Disord*. 2018;25:95–8.
66. Voskuhl R. Rebound relapses after ceasing another disease-modifying treatment in patients with multiple sclerosis: are there lessons to be learned? *JAMA Neurol*. 2016;73(7):775–6.
67. Sato K, Niino M, Kawashima A, Yamada M, Miyazaki Y, Fukazawa T. Disease exacerbation after the cessation of fingolimod treatment in Japanese patients with multiple sclerosis. *Intern Med*. 2018;57(18):2647–55.
68. Giordana MT, Cavalla P, Uccelli A, et al. Overexpression of sphingosine-1-phosphate receptors on reactive astrocytes drives neuropathology of multiple sclerosis rebound after fingolimod discontinuation. *Mult Scler*. 2018;24(8):1133–7.
69. Bernard-Valnet R, Pignolet B, Biotti D, et al. Unexpected high multiple sclerosis activity after switching from fingolimod to alemtuzumab. *Mult Scler Relat Disord*. 2018;25:216–8.
70. Uphaus T, Oberwittler C, Groppa S, Zipp F, Bittner S. Disease reactivation after switching from natalizumab to daclizumab. *J Neurol*. 2017;264(12):2491–4.
71. Giovannoni G, Marta M, Davis A, Turner B, Gnanapavan S, Schmierer K. Switching patients at high risk of PML from natalizumab to another disease-modifying therapy. *Pract Neurol*. 2016;16(5):389–93.
72. Lo Re M, Capobianco M, Ragonese P, et al. Natalizumab discontinuation and treatment strategies in patients with multiple sclerosis (MS): a retrospective study from two Italian MS Centers. *Neurol Ther*. 2015;4(2):147–57.
73. Calabrese M, Pitteri M, Farina G, et al. Dimethyl fumarate: a possible exit strategy from natalizumab treatment in patients with multiple sclerosis at risk for severe adverse events. *J Neurol Neurosurg Psychiatry*. 2017;88(12):1073–8.
74. Patti F, Leone C, Zappia M. Clinical and radiologic rebound after discontinuation of natalizumab therapy in a highly active multiple sclerosis patient was not halted by dimethyl-fumarate: a case report. *BMC Neurol*. 2015;15:252.
75. Alvarez-Gonzalez C, Adams A, Mathews J, et al. Cladribine to treat disease exacerbation after fingolimod discontinuation in progressive multiple sclerosis. *Ann Clin Transl Neurol*. 2017;4(7):506–11.
76. Longbrake EE, Kantor D, Pawate S, et al. Effectiveness of alternative dose fingolimod for multiple sclerosis. *Neurol Clin Pract*. 2018;8(2):102–7.
77. Tanak M, Park K, Tanaka K. Reduced fingolimod dosage treatment for patients with multiple sclerosis and lymphopenia or neutropenia. *Mult Scler*. 2013;19:1244–5.
78. Yamout BI. Safety and efficacy of reduced fingolimod dosage treatment. *J Neuroimmunol*. 2015;285:13–5.

79. Zhovtis RL, Frohman TC, Foley J, et al. Extended interval dosing of natalizumab in multiple sclerosis. *J Neurol Neurosurg Psychiatry*. 2016;87:885–9.
80. Bomprezzi R, Pawate S. Extended interval dosing of natalizumab: a two-center, 7-year experience. *Ther Adv Neurol Disord*. 2014;7(5):227–31.
81. Chan C, Siu R, Mellsop N, et al. Extended interval dosing of natalizumab in MS; a New Zealand experience. *Neurology*. 2018;90(15):6.351.
82. Herbert J, Zhovtis L, Tornatore C, et al. Multicenter retrospective study of extended dosing of natalizumab in multiple sclerosis: a strategy for mitigating risk of progressive multifocal leukoencephalopathy while maintaining efficacy. *Neurology*. 2014;82(10):2.251.
83. Ryerson LZ, Foley J, Chang I, et al. Natalizumab extended interval dosing (EID) is associated with a significant reduction in progressive multifocal leukoencephalopathy (PML) risk compared with standard interval dosing (SID) in the Touch<sup>®</sup> prescribing program. *J Neurol Neurosurg Psychiatry*. 2018;89:A29.
84. Weinstock-Guttman B, Hagemeyer J, Kavak KS, et al. Randomised natalizumab discontinuation study: taper protocol may prevent disease reactivation. *J Neurol Neurosurg Psychiatry*. 2016;87(9):937–43.
85. Schoergenhofer C, Schwameis M, Firbas C, et al. Single, very low rituximab doses in healthy volunteers – a pilot and a randomized trial: implications for dosing and biosimilarity testing. *Sci Rep*. 2018;8:124.
86. Salzer J, Svenningsson R, Alping P, et al. Rituximab in multiple sclerosis: a retrospective observational study on safety and efficacy. *Neurology*. 2016;87(20):2074–81.
87. Memon AB, Javed A, Caon C, et al. Long-term safety of rituximab induced peripheral B-cell depletion in autoimmune neurological diseases. *PLoS ONE*. 2018;13(1):e0190425. <https://doi.org/10.1371/journal.pone.0190425>.
88. Avsarala J. Anti-CD20 cell therapies in multiple sclerosis – a fixed dosing schedule for ocrelizumab is overkill. *Drug Target Insights*. 2017;11:1177392817737515.
89. Anton R, Haas M, Arlett P, et al. Drug-induced progressive multifocal leukoencephalopathy: European regulators' perspective. *Clin Pharmacol Ther*. 2017;102(2):283–9.
90. Pavlovic D, Patera AC, Nyberg F, et al. Progressive multifocal leukoencephalopathy: current treatment options and future perspectives. *Ther Adv Neurol Disord*. 2015;8(6):255–73.
91. [fda.gov/Drugs/DrugSafety/ucm424625.htm](https://www.fda.gov/Drugs/DrugSafety/ucm424625.htm). First online: 25 Nov 2014, update 16 Jan 2016.
92. [fda.gov/Drugs/DrugSafety/ucm456919.htm](https://www.fda.gov/Drugs/DrugSafety/ucm456919.htm). First online: 4 Aug 2015, update 6 Mar 2018.
93. Biogen Idec. Tysabri (natalizumab) postmarketing safety update. TY-US-0113(11). 2016. <https://medinfo.biogen.com/secure/pmlresource>.
94. Biogen Inc. Tysabri prescribing information (revised 08/2017). Cambridge, MA: Biogen Inc; 2017.
95. Tyler KL, Vollmer TL. To PLEX or not to PLEX in natalizumab-associated PML. *Neurology*. 2017;88:1108–9.
96. Vermersch P, Kappos L, Gold R, et al. Clinical outcomes of natalizumab-associated progressive multifocal leukoencephalopathy. *Neurology*. 2011;76(20):1697–704.
97. Williamson EML, Berger JR. Diagnosis and treatment of progressive multifocal leukoencephalopathy associated with multiple sclerosis therapies. *Neurotherapeutics*. 2017;14:961–73.
98. Ho P, Koendgen H, Campbell N, et al. Risk of natalizumab-associated progressive multifocal leukoencephalopathy in patients with multiple sclerosis: a retrospective analysis of data from four clinical studies. *Lancet Neurol*. 2017;16:925–33.
99. Berger JR. Classifying PML risk with disease modifying therapies. *Mult Scler Relat Disord*. 2017;12:59–63.
100. Khatri BO, Man S, Giovannoni G, et al. Effect of plasma exchange in accelerating natalizumab clearance and restoring leukocyte function. *Neurology*. 2009;72(5):402–9.
101. Landi D, Rossi ND, Zagaglia S, et al. No evidence of beneficial effects of plasmapheresis in natalizumab-associated PML. *Neurology*. 2017;88(12):1144–52.
102. Scarpazza C, Prosperini L, Rossi ND, et al. To do or not to do? Plasma exchange and timing of steroid administration in progressive multifocal leukoencephalopathy. *Ann Neurol*. 2017;82:697–705.
103. Stuve O, Marta CM, Bat-Or A, et al. Altered CD4+/CD8+ T-cell ratios in cerebrospinal fluid of natalizumab-treated patients with multiple sclerosis. *Arch Neurol*. 2006;63(10):1383–7.
104. Wattjes MP, Wijburg MT, Vennegoor A, et al. MRI characteristics of early PML-IRIS after natalizumab treatment in patients with MS. *J Neurol Neurosurg Psychiatry*. 2016;87(8):879–84.
105. Maillart E, Vidal J, Brassat D, et al. Natalizumab-PML survivors with subsequent MS treatment. *Neurol Neuroimmunol Neuroinflamm*. 2017;4(3):e346.
106. Houtchens M. Multiple sclerosis and pregnancy. *Clin Obstet Gynecol*. 2013;56(2):342–9.
107. Voskuhl R, Momtazee C. Pregnancy: effect on multiple sclerosis, treatment considerations, and breastfeeding. *Neurotherapeutics*. 2017;14(4):974–84.
108. Brookings William LM. Management of multiple sclerosis during pregnancy. *Prog Neurol Psychiatry*. 2009;13(6):9–11.
109. Alroughani R, Alowayesh MS, Ahmed SF, Behbehani R, Al-Hashel J. Relapse occurrence in women with multiple sclerosis during pregnancy in the new treatment era. *Neurology*. 2018;90(10):e840–e6.
110. Siroos B, Harirchian MH. Multiple sclerosis and pregnancy; what a neurologist may be asked for? *Iran J Neurol*. 2014;13(2):57–63.

111. Daroff RB, Fenichel GM, Jankovic J, Mazziotta J. Bradley's neurology in clinical practice. 6th ed. Bridgewater: Elsevier Health Sciences; 2012. p. 1284–310.
112. Confavreux C, Hutchinson M, Hours MM, et al. Rate of pregnancy-related relapse in multiple sclerosis. *N Eng J Med*. 1998;339:285–91.
113. Houtchens MK, Kaplan TB. Reproductive issues in MS. *Semin Neurol*. 2017;37(6):632–42.
114. Dahl J, Myhr KM, Daltveit AK, et al. Pregnancy, delivery and birth outcome in women with multiple sclerosis. *Neurology*. 2005;65:1961–3.
115. Bateman AM, Goldish GD. Autonomic dysreflexia in multiple sclerosis. *J Spinal Cord Med*. 2002;25:40–2.
116. Lu E, Wang BW, Guimond C, Synnes A, Sadovnick D, Tremlett H. Disease-modifying drugs for multiple sclerosis in pregnancy: a systematic review. *Neurology*. 2012;79(11):1130–5.
117. Karlsson G, Francis G, Koren G, et al. Pregnancy outcomes in the clinical development program of fingolimod in multiple sclerosis. *Neurology*. 2014;82(08):674–80.
118. Gold R, Phillips JT, Havrdova E, et al. Delayed-release dimethyl fumarate and pregnancy: preclinical studies and pregnancy outcomes from clinical trials and postmarketing experience. *Neurol Ther*. 2015;4(02):93–104.
119. Houtchens MK, Sadovnick AD. Health issues in women with multiple sclerosis. Vienna: Springer; 2017.
120. Coyle PK. Management of women with multiple sclerosis through pregnancy and after childbirth. *Ther Adv Neurol Disorder*. 2016;9(03):198–210.
121. Chakravarty EF, Murray ER, Kelman A, Farmer P. Pregnancy outcomes after maternal exposure to rituximab. *Blood*. 2011;117(05):1499–506.
122. Greenberger PA. Pharmacokinetics of prednisolone transfer to breast milk. *Clin Pharmacol Ther*. 1993;53:324.
123. Achiron A, Kishner DM, et al. Effect of intravenous immunoglobulin treatment on pregnancy and postpartum related relapses in multiple sclerosis. *J Neurol*. 2004;251(9):1133–7.
124. Nelson LM, Franklin GM, Jones MC. Risk of multiple sclerosis exacerbation during pregnancy and breastfeeding. *JAMA*. 1988;259(23):3441–3.
125. Langer-Gould A, Huang SM, Gupta R, et al. Exclusive breastfeeding and the risk of postpartum relapses in women with multiple sclerosis. *Arch Neurol*. 2009;66(8):958–63.
126. Potter D. The propagation, characterisation and optimisation of cannabis sativa L as a phytopharmaceutical. *JP MIBiol CBiol FLS CMIOSH*.
127. Da Rovare VP, Magalhaes GPA, Jardini GDA, et al. Cannabinoids for spasticity due to multiple sclerosis or paraplegia: a systemic review and meta-analysis of randomized clinical trials. *Complement Ther Med*. 2017;34:170–85.
128. Clark AJ, Ware MA, Yaser E, et al. Patterns of cannabis use among patients with multiple sclerosis. *Neurology*. 2004;62(11):2098–100.
129. Feinstein A, Banwell E, Pavisian B. What to make of cannabis and cognition in MS: in search of clarity amidst the haze. *Mult Scler*. 2015;21(14):1755–60.
130. Koppel BS, Brust JCM, Fife T, et al. Systemic review: efficacy and safety of medical marijuana in selected neurologic disorders. *Neurology*. 2014;82:1556–63.
131. Zajicek JP, Apostu VI. Role of cannabinoids in multiple sclerosis. *CNS Drugs*. 2011;25(3):187–201.
132. Rocha FC, Dos Santos Junior JG, Stefano SC, et al. Systematic review of the literature on clinical and experimental trials on the antitumor effects of cannabinoids in gliomas. *J Neuro-Oncol*. 2014;116(1):11–24.
133. Glass M, Faull RL, Dragunow M. Cannabinoid receptors in the human brain: a detailed anatomical and quantitative autoradiographic study in the fetal, neonatal and adult human brain. *Neuroscience*. 1997;77(2):299–318.
134. Howlett AC, Barth F, Bonner TI, et al. International Union of Pharmacology, XXVII: classification of cannabinoid receptors. *Pharmacol Rev*. 2002;54:161–202.
135. Arévalo-Martin A, Vela JM, Molina-Holgado E, et al. Therapeutic action of cannabinoids in a murine model of multiple sclerosis. *J Neurosci*. 2003;23(7):2511–6.
136. Nielsen S, Germanos R, Weier M, et al. The use of cannabis and cannabinoids in treating symptoms of multiple sclerosis: a systemic review of reviews. *Curr Neurol Neurosci Rep*. 2018;18(2):8.
137. Whiting PF, Wolff RF, Deshpande S, et al. Cannabinoids for medical use: a systemic review and meta-analysis. *JAMA*. 2015;313:2456–73.
138. Giacoppo S, Bramanti P, Mazzone E. Sativex in the management of multiple sclerosis-related spasticity: an overview of the last decade of clinical evaluation. *Mult Scler Relat Disord*. 2017;17:22–31.
139. Marková J, Essner U, Akmaz B, et al. Sativex® as add-on therapy vs. further optimized first-line ANTispastics (SAVANT) in resistant multiple sclerosis spasticity: a double-blind, placebo-controlled randomised clinical trial. *Int J Neurosci*. 2018;24:1–26.



# Multiple Sclerosis in Children

# 9

Charles D. Tyshkov, Leigh Elkins Charvet,  
and Lauren B. Krupp

## Introduction

Though still under-recognized, pediatric multiple sclerosis (MS) has been the subject of considerable clinical research since its special diagnostic challenges were first described over a decade ago. The International Pediatric Multiple Sclerosis Study Group (IPMSSG), established in 2004, has continued to clarify the frequency and treatment patterns of MS in children worldwide. A defining feature of childhood MS and demyelinating disease, in general, is the narrow window between environmental and biologic triggers and clinical expression of disease. Specifically, the interaction between genetic predisposition and environmental factors remains a growing area of interest. While management is complicated by a lack of pediatric pharmaceutical controlled trials, immunomodulatory therapy in adults has been clinically applied to children successfully over the years. Recently there has been a major effort

in studying disease-modifying therapy (DMT) in children in part due to incentives provided to industry coming from regulatory authorities if companies submit a pediatric investigational plan. This review will summarize key features in the current evaluation and treatment of a now increasingly reported condition.

## Demographics Profile

An estimated 2.7–5.4% of all MS patients experience their first attack before 18 years of age [1–8]. The frequency of disease is much lower among young children (age 10 and younger)—estimated to be 0.2–0.7% of all MS cases [4, 5, 7, 9, 10]. Prospective studies have helped to confirm the reliability of previous retrospective reports, offering incidence rates as opposed to estimations of prevalence. One such study in Canada found initial demyelinating events (IDE) of childhood to occur at an incidence rate of 0.9/100,000 [11]. The frequency of pediatric-onset MS in the world population has been 0.2–0.8/100,000 compared to adult onset which has a global median estimated incidence of 2.5/100,000 [11–16]. One interesting epidemiological outlier has been the population of the island of Sardinia located off the Italian coast, reporting a pediatric incidence of 2.85/100,000, which would make it among the highest rates in the world [17].

---

C. D. Tyshkov  
Department of Pediatrics/Child Neurology, New York  
Presbyterian Weill Cornell Medical Center/Brooklyn  
Methodist Hospital, New York, NY, USA  
e-mail: [cdt9001@med.cornell.edu](mailto:cdt9001@med.cornell.edu)

L. E. Charvet · L. B. Krupp (✉)  
Department of Neurology, Multiple Sclerosis  
Comprehensive Care Center, NYU Langone Health,  
New York, NY, USA  
e-mail: [leigh.charvet@nyumc.org](mailto:leigh.charvet@nyumc.org);  
[lauren.krupp@nyumc.org](mailto:lauren.krupp@nyumc.org)



Presenting characteristics have been relatively consistent across numerous studies. The majority of those with pediatric MS are adolescents, and in a prospective US study of pediatric MS cases, 72% of children with MS developed symptoms at 12 years of age and older [18]. In general, female preponderance has been shown to increase with age, with the female to male ratio being almost equal at 0.8:1 before the age of 6 and then climbing steadily until adolescence with a ratio of 2:1 for an onset over 10 years of age [19]. This feature implies a hormonal influence on the risk of developing MS and continues to be an active area of research.

There is also increasing interest in the racial and ethnic diversity exhibited by younger MS patients. African Americans represent a higher proportion of pediatric-onset MS compared to the adult-onset population. Additionally, African American patients can have a more severe presentation and course compared to their Caucasian counterparts [7, 19]. A US multiethnic study found the incidence rate of pediatric MS to be 0.51/100,000. In this cohort, black children were more likely to experience a pediatric acquired demyelinating condition compared to white children [12]. Among those with pediatric MS evaluated across nine geographically diverse sites in the USA, a high proportion were found to have one or more foreign-born parents (39%) [18]. The clinical significance and explanation for these demographic differences need further exploration.

---

## Risks Factors for Developing MS and Pathogenesis

Certain biologic, genetic, and environmental risk factors have been identified for both the adult and pediatric onset of MS and should be considered when evaluating inflammatory demyelinating syndromes in general. One theory as to why MS affects so few children compared to their adult counterparts is that they might need to be exposed to a greater risk factor load, leading to earlier development of disease.

The primary genetic risk profile identified in both adults and children involves the human leukocyte antigen (HLA) system which relates to immune function in general. There is a genetic predilection for the HLA DRB1\*15 group of alleles in pediatric and adult patients with MS [20, 21]. Interestingly, HLA DRB1 risk positivity is less frequent in non-European populations, suggesting a greater role for environmental or epigenetic factors in those pediatric MS patients who relocate from low-incidence areas.

Regarding environmental risk in children, vitamin D stands out as likely playing a role both in disease prevention and further modification of disease course. Vitamin D concentrations are commonly lower than expected among young people with MS [22], and in one Canadian study, levels at the time of any acquired demyelinating syndrome (ADS) onset were inversely associated with the likelihood of developing MS [23]. Also of interest, among the several environmental risk factors identified, only vitamin D insufficiency has been shown to affect disease course. Among those with early pediatric-onset MS, increases in vitamin D level were associated with a 34% reduction in the risk of subsequent relapses [24]. Given the known association between vitamin D and relapse rate and the interaction of this relation with genetic background, it is possible that vitamin D supplementation may be more effective in preventing relapses in those with a positive HLA DRB1\*15 genotype [25, 26].

Risk factors such as geographic origin, smoking exposure, obesity, and prior Epstein-Barr virus (EBV) infection have been demonstrated in children as they have in adult populations. Interestingly, unlike adults with MS who are more likely to report European heritage, pediatric patients are more likely to report Caribbean, Asian, or Middle Eastern ancestry [27]. Moderate and extreme obesity has also been shown to specifically increase the risk of MS among adolescent girls [28]. Some gene variants associated with obesity interact with age which may explain why body mass index (BMI) plays a greater role in adolescent-onset vs. adult-onset MS [29].

The role of viral infections continues to be a difficult area of research, particularly regarding the complex gene-gene and gene-environment interactions known to exist. For example, in a case-control study involving 189 patients with early pediatric MS, remote EBV was associated with increased risk for MS, while on the other hand, cytomegalovirus (CMV) infection was associated with lower risk [30]. Paradoxically herpes simplex virus-1 (HSV-1) was associated with increased odds of MS but only when combined with negative HLA allelic risk and decreased odds when paired with positive HLA status [31].

There is an additive interaction between EBV and HLA positivity in adults in that genetically susceptible individuals with a history of EBV exposure were at a 7.0-fold increased risk for developing MS compared to non-EBV-exposed individuals of a similar genotype [32]. A similar interaction has been suggested in children in whom EBV humoral antibody response was greater in the setting of positive HLA status [31]. The combined effect of HLA risk and early EBV exposure does not necessarily confer greatest MS risk, with one study examining the “hygiene hypothesis” showing low infant EBV exposure (prior to age 6) and HLA positivity together actually increase risk of disease [33]. Additional gene-environment interactions need to be studied, to further shed light on the nature and benefits of early immune priming in the context of genetic susceptibility.

## Definitions

Various definitions for pediatric MS have been proposed to facilitate research and to facilitate clinical diagnosis. Careful consideration is needed in order to distinguish syndromes of acute disseminated encephalomyelitis (ADEM) from MS, and criteria have undergone revision from when first proposed in 2007 to more recent versions in 2013 and 2016 [34–36]. The main point is that a patient presenting with ADEM who has subsequent clinical and radiologic events can be reclassified as MS.

Adult diagnostic tools such as 2010 McDonald criteria, though applicable in children, need to be used cautiously in very young patients [37–42]. The revised 2012 International Pediatric MS Study Group (IPMSSG) definitions, largely based on the 2010 McDonald criteria, allow for earlier diagnosis in children (at the time of first clinical attack) when MRI features fulfill specific dissemination in space (DIS) and dissemination in time (DIT) criteria [40]. Revisions and special considerations were made in 2016 with respect to clinical situations not conforming to current definitions. A major consideration continues to be the subgroup of children younger than 12 years who present differently than those 12 and older in terms of both clinical and MRI features [38–41].

Whether the most recent revision of the McDonald criteria in 2017 can be applied to all children is controversial, although preliminary reviews seem positive for adolescents [43]. The latest criteria which allow the presence of cerebral spinal fluid (CSF) oligoclonal bands (OCBs) to substitute for DIT in clinically isolated individuals still need to be approached carefully in young children, given that OCBs are known to be present in a variety of childhood neurological disorders [44, 45].

---

## Risks for Developing MS After an Initial Demyelinating Event (IDE)

Determining whether a child with an IDE will go on to have recurrence can be very challenging. The clinician must consider whether a first-time episode of optic neuritis (ON) or ADEM represents a polyphasic disease process. Several studies from a variety of countries have addressed this issue and have suggested various features that may help in making the ultimate diagnosis of MS. Table 9.1 summarizes these features [46–48].

A prospective study of 296 pediatric IDE patients found that after a mean observation period of 2.9 years, 57% experienced two or more episodes of demyelination [48]. Factors associated with an increased risk for a second attack and an outcome of MS included age over

**Table 9.1** Features of a childhood initial demyelinating event associated with a subsequent MS diagnosis

Monofocal onset
Family history of CNS demyelination
Absence of preceding infection
Optic neuritis (ON)
Absence of encephalopathy
Absence of seizures
Absence of meningismus or fever
MRI suggestive of MS
Intrathecal oligoclonal bands
Elevated IgG index

10 years, family history of CNS demyelination, optic neuritis, lack of change in mental status, and lack of isolated myelitis [49, 50]. Children presenting with a clinically isolated syndrome (CIS) and abnormal MRI (more than one high T2 signal) are more likely to develop relapsing remitting disease than children presenting with ADEM [49]. A large 2017 prospective study of >700 children with CIS further confirmed many of these findings in addition to showing that female patients and those with multifocal disease onset were at increased risk for a second attack, independent of DMT exposure [51].

As shown in Table 9.1, additional features suggestive of future MS following an IDE include a monofocal rather than polyfocal onset, absence of seizures, and lack of meningismus. Children who go on to develop MS are more likely to have positive OCBs in the CSF and an elevated IgG index [46–48, 52].

Additional MRI features at the time of clinical presentation which are associated with pediatric MS include the following: two or more periventricular lesions, presence of black holes, lesions that are discrete rather than diffuse, and additional lesions that involve a juxtacortical, infratentorial, or spinal cord location [53, 54].

While, in general, a change in mental status goes along with a self-limiting event, this is not a universal finding. As noted in a study from the Netherlands, there was no significant difference in developing MS in children with ADEM-like presentations with or without encephalopathy [47]. While most patients with encephalopathy (a defining feature of ADEM) have self-limited disease, 5–29% of pediatric patients meeting 2007

IPMSSG criteria for ADEM will go on to have recurrent episodes of CNS dysfunction and be reclassified as MS [19, 47, 48, 50, 51, 55, 56].

Radiologically isolated syndrome (RIS) has also received increased attention with researchers looking at clinical and radiologic outcomes in children who are incidentally found to have neuroimaging findings suggestive of demyelinating disease. In one retrospective pediatric study, as was found among adults with RIS, the presence of CSF oligoclonal bands and spinal cord lesions on MRI was associated with increased risk for a first-time clinical event with a median time interval of 2 years following an RIS diagnosis [57].

As with adults, pediatric ON when associated with an abnormal brain MRI is associated with an increased likelihood of MS [58]. In a large sample of 357 children with isolated optic neuritis, an abnormal cranial MRI, presence of CSF oligoclonal bands, and age were independent predictors of ultimate MS diagnosis [59]. The MS-confirming attack can occur many years after the initial event and the risk of MS increases with time [47, 60]. There is conflicting data as to whether bilateral relative to unilateral ON increases the risk of MS [58, 61].

---

## Clinical Features

Children with MS can present with a variety of symptoms including ON, sensory deficits, weakness, gait disorders, and brainstem-related dysfunction. They are commonly polysymptomatic (50–70%), though a monosymptomatic (30–50%) presentation is not uncommon [5, 48, 62]. Of the children with a monosymptomatic presentation, 30% will have motor symptoms, 30% sensory symptoms, 25% brainstem symptoms, 10–22% present with ON, and 5–15% with ataxia [48, 63, 64]. Isolated transverse myelitis is seen in less than 10% [1, 2, 48]. Seizures are estimated to occur in 5% [65]. Following CIS, a second clinical event follows typically between 11 and 71 months later [6, 9, 53, 64, 65].

Optical coherence tomography (OCT) can be used to assess retinal changes in pediatric MS in that there is a significant decrease in mean retinal

nerve fiber layer (RNFL) thickness in those with a history of MS and ON compared to that of healthy controls. Whether or not mean thickness is also decreased in those children with MS and no history of ON remains a topic of debate. In general, OCT is thought to be a useful confirmatory test for clinical history of ON. Unlike visual evoked potentials (VEP), OCT may infrequently identify retinal abnormalities in pediatric-onset MS patients without history of clinical optic nerve involvement [66, 67].

Several clinical features differ among younger (usually 10 years and under) children relative to postpubertal or adolescent MS patients. Younger patients have more seizures, more frequent ON, more brainstem or cerebellar involvement, and less spinal cord presentations. Younger patients also have more confluent disease on MRI and lesions that tend to vanish more quickly [19, 46, 53, 68, 69]. Those under the age of 12 compared with those 12 years and older had a longer relapse-free interval and lower number of relapses in the first 2 years [9]. CSF in younger children is less often oligoclonal band positive, and less often shows an elevated IgG index, but has a higher proportion of neutrophils [18, 70].

A number of individuals with pediatric MS experience cognitive slowing, fatigue, and mood problems. The overall frequency of poor performance on cognitive tests in research studies has been between 29% and 41% depending on the patients evaluated and the nature of the neuropsychological test battery [71–73]. Useful screening measures include the Symbol Digit Modalities Test (SDMT), the Brief International Cognitive Assessment for MS (BICAMS) adapted for children and adolescents, and computer-administered batteries such as the Cogstate Brief Battery [74, 75]. The course of cognitive change is unclear with some suggesting worsening function over time and others finding either little change over short intervals or what is perhaps most likely failure to achieve age-expected gains [76–78].

Mood problems can be diverse and include anxiety, depressive symptoms, and other symptoms. In general, there appears to be a pattern for

elevated symptoms of psychological distress rather than one major psychiatric disorder [79]. However, depression and anxiety are the most frequent problems and appear to be more often found in those with cognitive impairment.

Fatigue and excessive sleepiness may also be challenging. Parents in one study were more concerned about fatigue than were the patients. Others have not found major differences from controls on fatigue measures [77, 80].

---

## Prognosis

Over time, children with MS if untreated continue to relapse and can accumulate increasing disability. Annual relapse rates vary from 0.5 to 2.8 depending on differences in study design (prospective vs. retrospective) and duration of follow-up [6, 7, 67, 81]. Overall, when compared with adults, children with MS have a higher rate of relapse within the first 2 years of disease but progress more gradually [5, 53, 64].

Overall, with increasing time, disability accumulates, and in one prospective study of 54 children, the mean EDSS was 3.8 after a period of 10 years. In several retrospective studies, the time to reach an EDSS of 6.0 from diagnosis varied from 19 to 29 years [9, 82]. Although time to conversion to secondary progressive disease is about two times longer in pediatric compared to adult MS, the median age at conversion is lower for those with pediatric onset suggesting the seriousness of early disease [5, 9].

Features associated with a more severe prognosis include female sex, less than 1-year time interval between the first and second attack, the absence of encephalopathy at disease onset, and secondary progressive disease. In a prospective study of 197 children with an IDE, severe disease outcome was noted in 73% when this was defined by the occurrence of a third clinical event or a persistent EDSS of four or more [53]. In other studies, the accumulation of disability within the first year of disease onset or a high frequency of relapses within the first 2 years of onset has been associated with higher EDSS scores [64].

## Differential Diagnosis

Since progressive MS is extremely rare in pediatric MS, any child with a history of progressive cognitive or motor decline should be evaluated for conditions other than MS. In contrast, a relapsing-remitting course with dissemination in time and space is an essential feature to the diagnosis of MS, as well as absence of non-neurological involvement or systemic disease. Numerous diseases may still mimic MS. Lesion pattern and distribution on MRI as well as clinical course and risk factors should be carefully considered to help exclude these diseases. NMO and MOG (myelin oligodendrocyte glycoprotein) antibody syndrome are two important mimicking entities which can be diagnosed through serological testing. Below is an overview of some of the more common disorders which need to be considered in the differential diagnosis of MS in children.

### Acute Disseminated Encephalomyelitis (ADEM)

The first demyelinating event of MS can be perhaps the most difficult diagnosis to differentiate from ADEM. The challenge is due to the general understanding that the younger the patient, the more likely they are to present with ADEM as their initial event [11, 83]. Similarly, the younger the patient, the more likely it is that ADEM will be the first manifestation of MS and likely other CNS demyelinating disorders as well.

As shown in Table 9.2, there are certain clinical CSF and radiological features more in favor of ADEM compared with MS. ADEM presents with multiple CNS lesions corresponding to neurological deficits, due to a post- or para-infectious demyelinating process [68]. CSF OCB are less common and certain MRI features help distinguish ADEM from MS. Unfortunately, there is no biomarker that can help to differentiate monophasic ADEM from monophasic CIS or MS.

The increasingly recognized condition of anti-MOG syndrome is interesting in the context of childhood ADEM in that a significant number of

**Table 9.2** Features more common in ADEM vs. MS

Clinical
Younger age group (<10 years)
Recent viral infection or vaccination
Encephalopathy/meningismus
Bulbar symptoms
Seizures
Single event which can fluctuate over 12 weeks
CSF
Pleocytosis/lymphocytosis
Elevated protein
Absent oligoclonal bands
MRI
Diffuse large bilateral lesions
White and gray matter involvement
More deep gray nuclear involvement
Normal-appearing white matter (NAWM) intact
Absent T1 black holes
Lesions typically resolve

cases that would have commonly been referred to as classic monophasic ADEM transiently test positive for MOG antibody [84–87]. The significance of this transient positivity is unknown, and furthermore the persistence of this antibody beyond the event (6 months or more) is not well understood, particularly in children who first present with ADEM.

Pathologically, ADEM represents a more localized pathological process with limited focal demyelination restricted to a perivenular location with macrophages and lymphocytes. In contrast, the multifocal demyelination in MS is more confluent and extensive with more macrophages [88]. Consistent with the pathology, on neuroimaging using magnetization transfer, the normal-appearing white matter (NAWM) appears intact in ADEM where it is not in MS [89].

The International Pediatric MS Consensus definitions provide provisional diagnostic criteria for MS, ADEM, and other acquired demyelinating disorders of the central nervous system (CNS) [90]. The criteria for ADEM require multifocality and encephalopathy; however, this definition is likely to be too restrictive as some multifocal non-encephalopathic patients have a self-limited disease course as would occur in ADEM [47]. ADEM often includes prominent involvement of both white and gray matter on brain MRI. Rarely, a second inflammatory event may rarely be seen

in ADEM variants such as recurrent ADEM or multiphasic ADEM. However, unlike an MS attack, encephalopathy is present, and the MRI shows characteristic features of ADEM as described below. The disease is subsequently self-limited without further events after the second episode [68, 80].

In a retrospective chart review study, comparing ADEM and MS, patients with ADEM were more likely to have nonspecific symptoms such as fever, headache, vomiting, meningismus, encephalopathy, and bulbar symptoms such as dysarthria and dysphagia [91]. A history of recent viral illness or vaccination usually is typically elicited in ADEM. Other important features include seizures, cranial neuropathies, and optic neuritis [46, 47, 92]. CSF studies tend to show a mild leukocytosis, elevated protein, and a lower frequency of OCB compared with MS. Finally, ADEM is much more likely in young children and much less frequent in those who are adolescents.

Typically, the MRI in ADEM demonstrates multifocal lesions with indistinct margins distributed throughout the cerebral gray and white matters. Additional MRI features favoring ADEM are the presence of diffuse bilateral lesions, lack of two or more periventricular lesions, and lack of black holes. Efforts have been made to more formally distinguish MS and ADEM radiologically [93].

Differentiating ADEM from MS is particularly challenging in youngsters less than 10 years of age. In this subgroup, even though the children are destined to have MS, sometimes their initial MRI picture closely resembles ADEM. Often time and subsequent changes on MRI or clinical course reveal the correct diagnosis [94]. In the absence of a specific biomarker for either ADEM or MS, assessment of the paraclinical data and clinical course remain the most critical tools for making the distinction.

### Neuromyelitis Optica (NMO)

Another inflammatory disorder of the CNS that can mimic MS is neuromyelitis optica (NMO), formerly referred to as Devic's disease. The crite-

ria for the diagnosis require optic neuritis and transverse myelitis and either a longitudinally extensive lesion on spinal cord MRI or a positive NMO-IgG antibody titer [80]. The presence of brain involvement is not uncommon in children and does not exclude the diagnosis [95]. This disorder is discussed in detail in a separate chapter.

### Myelin Oligodendrocyte Glycoprotein (MOG) Antibody Syndrome

Since at least 2003, MOG antibodies have been associated with a variety of demyelinating diseases [96]. Improvements in the assay, however, have led to greater specificity and sensitivity. In general, persistent MOG Ab positivity is more typical of a non-MS outcome in children [74–77]. Antibodies have been detected in 18–35% of children with a first-time episode of acute demyelinating disease [74, 75, 97]. The significance of its occasional presence in children presenting with ADEM is unclear since seropositivity is often transient [74–77]. In some studies, some pediatric patients with a diagnosis of MS have detectable antibodies [98].

In a comprehensive study of 327 MOG seropositive patients with symptom onset ranging from 1 to 81 years, a subgroup had longitudinal serologic studies and persistence of antibody was associated with recurrent disease. It is unclear how many young children with ADEM were represented within this subcohort; however, the authors conclude that it may be worth considering treatment in any patient with persistent antibody beyond 6 months given the likelihood of relapse suggested by this data. Subjects within the same cohort who seroconverted to negative antibody status interestingly did not go on to have relapses [99].

### Infection and Other Disorders

Fever and CSF leukocytosis are the hallmarks of encephalitic or meningoencephalitic infectious processes in patients with acute presentations.

CNS Lyme disease may manifest with multifocal white matter lesions and rarely a seemingly relapsing/remitting clinical course. Other infections to exclude would be HIV encephalomyelitis, HTLV-1, neurosyphilis, progressive multifocal leukoencephalopathy (PML), Whipple's disease, and subacute sclerosing panencephalitis.

### Vascular and Inflammatory Disorders

CNS vasculitis and other autoimmune disorders can be difficult to distinguish from MS. The presence of systemic signs, abnormal serology, or beading on cerebral angiogram can suggest the diagnosis, as can elevated C-reactive protein or erythrocyte sedimentation rate (ESR). Unfortunately, in cases of isolated CNS vasculitis, the differential diagnosis is more difficult as there may be no laboratory or systemic abnormalities. In these cases, brain biopsy might establish the correct diagnosis. Autoimmune disorders such as systemic lupus erythematosus (SLE), Behçet disease, neurosarcoidosis, Sjogren's disease, and isolated CNS vasculitis can also present a varied, multifocal neurological clinical picture during or at the onset of disease. Vascular diseases mimicking MS in younger individuals are fortunately rare and would include moyamoya disease and cerebral autosomal dominant arteriopathy with subcortical infarcts and leukoencephalopathy (CADASIL). Other inflammatory disorders to distinguish from MS include macrophage activation syndrome (MAS) and Langerhans cell histiocytosis. MAS may resemble MS but most often affects very young children (usually 2 years old) and tends to have systemic involvement. This disorder may be related to hemophagocytic lymphohistiocytosis and consanguinity is not uncommon in these cases.

### Neoplasms

Tumefactive presentation of MS on neuroimaging may mimic intracranial neoplasms, particularly CNS lymphoma [100, 101]. MRS studies

performed along with routine MRI might help in the differential diagnosis in these instances. A relentlessly progressive course distinguishes neoplasms from the recovery typical of an acute MS relapse.

### Leukodystrophies

The leukodystrophies are another diagnostic group to consider when evaluating pediatric MS patients. The hallmark clinical feature that distinguishes these patients is their progressive course. Leukodystrophies can be subdivided into myelination failure, delay, or breakdown, as well as those associated with malformations. Typical features are bilateral symmetric involvement of the white matter on MRI in a fairly homogenous manner. Adrenoleukodystrophy and adrenomyeloneuropathy tend to show preferential involvement of posterior head regions, namely, the peritrigonal white matter, splenium of the corpus callosum, posterior limb of the internal capsule, the crus cerebri, and the cerebellar white matter [90].

Macrocrania with white matter dystrophy suggests either Alexander disease or Canavan disease. Early involvement of cortical U-fibers, as well as focal cystic changes on MRI, is characteristic of Canavan disease, particularly in the Ashkenazi Jewish population. Alexander disease exhibits preference for frontal white matter, subependymal areas, and heads of the caudate nuclei, as well as widened lateral ventricles, sylvian fissures, and subarachnoid spaces. While the infantile onset of leukodystrophies is usually clearly differentiated from MS, those with a juvenile onset can overlap. For example, in juvenile cases of Alexander disease, the posterior fossa may be preferentially involved and the bilateral frontal white matter involvement less conspicuous. Persistent contrast enhancement can also occur [102]. A case of Pelizaeus-Merzbacher has been described which overlapped considerably with MS both on clinical and radiologic manifestations. The patient's relapsing neurological problems were steroid responsive, and the MRI showed features typical of MS. Further, the CSF

was positive for OCB. The marked nystagmus led to testing of the proteolipid 1 protein abnormality and the correct diagnosis [103]. In general, progressive cognitive decline (as was present in the Pelizaeus-Merzbacher case) is typical for the leukodystrophies but extremely rare in MS. The onset of a progressive course (such as primary progressive MS) represents only 1–3% of pediatric MS.

Degenerative and metabolic diseases can rarely mimic MS and include metachromatic leukodystrophy, Krabbe disease, Refsum disease, vanishing white matter disease, Wilson's disease, Fabry disease, vitamin B12 deficiency, folate deficiency, vitamin E deficiency, and celiac disease.

### Mitochondrial Disorders

Mitochondrial disorders can also present with a relapsing pattern of events, but the course is typically progressive over time. Basal ganglia and brainstem involvement on MRI are good clues for the diagnosis of a mitochondrial disorder, such as Leigh syndrome. Further red flags, such as visual loss, bilateral hearing deficit, short stature, ophthalmoplegia (Kearns-Sayre), cardiac involvement (Kearns-Sayre), stroke-like events (MELAS), or myoclonic epilepsy (MERRF), can help hone in on the specific cytopathy. Rarely, patients with mitochondrial disorders can be steroid responsive as was the case of an adolescent with a DARS2 mutation who had myelopathy. Such aspects can add further challenges to the diagnosis [104].

---

### Diagnostic Testing

A standard diagnostic evaluation beyond imaging and CSF should include CBC, ESR, and ANA, while extended testing might include Lyme antibody titers, MR angiography, MR spectroscopy, evoked potentials, CSF lactate/pyruvate, serum vitamin levels (B12, D, E, folate), anti-Ro, anti-La, serum angiotensin-converting enzyme, HIV, rapid plasma reagin,

HTLV-1, serum EBV and mycoplasma titers, and MOG and NMO antibodies.

Many diagnosticians opt for an extended evaluation, particularly for diseases that are easily tested or amenable to treatment. Further laboratory testing for specific disorders in the differential diagnosis is more thoroughly reviewed elsewhere [90, 105].

---

## Treatment

### Communicating the Diagnosis

Being told of the diagnosis of MS can be traumatic for the patient and family. Adjustment is made more difficult due to the rare nature of the condition and uncertain prognosis is uncertain. Several considerations should go into the process of conveying the diagnosis. It is important to emphasize to the family that they are not alone and that online social network groups, support groups, and literature specific to the topic of pediatric MS are available. The National Multiple Sclerosis Society has programs for the families of children or teens with MS, and teen adventure summer programs or camps have been established in North America (see [www.msbrain-center.com](http://www.msbrain-center.com)).

While conveying the diagnosis, the importance of treatment designed to modify the disease course can be emphasized. The rapid rate of progress in our understanding and in treatment options offers much hope than in earlier years.

### Management of Relapses

The usual treatment for an acute relapse is with doses of parenteral methylprednisolone ranging from 20 to 30 mg/kg/day. In most instances, the maximum dose is 1000 mg administered intravenously (IV) once daily in the morning for 3–5 days. An oral prednisone taper is optional. An alternative to IV corticosteroids is high-dose oral prednisone (same dose as IV therapy) which in adults may be as effective as IV treatment [106] and seems effective in managing acute



relapses [107]. High-dose oral prednisone (up to 1200 mg/day) has also been found to have good bioavailability compared with intravenous therapy [108]. However, high-dose prednisone has only been used in adults with MS and is untested in children or adolescents. Adverse effects of steroids such as insomnia, mood disturbance including psychosis, hyperglycemia, and hypertension need to be monitored. Prolonged steroid use can also possibly retard growth in youngsters. Despite its long-term risks, short courses of steroid therapy are reasonably safe and well tolerated by most children.

Plasmapheresis or plasma exchange (PLEX) and intravenous immunoglobulins (IVIG) are options when IV steroids fail to improve a severe relapse. The use of either modality historically has been based on its success in a limited number of cases of children or adults [109, 110]. PLEX is increasingly being considered for children with severe life-altering attacks such as seen in profound or persistent optic neuritis and attacks involving the brainstem or spinal cord. One case series of four children in France showed promising results for refractory optic neuritis with PLEX and a related therapy known as immune adsorption [111]. Also of growing interest is the use of PLEX in patients with lesion patterns and other biomarkers suggestive of highly active, antibody-mediated disease [112]. Treatment with plasmapheresis continues to be an important tool as it has been safely and successfully performed on children with other immune-mediated disorders [110]. IVIG treatment at a dose of 0.4 g/kg/day for 5 days and continued 1 day/month at 0.4 g/kg has been studied in only small samples of ADEM and its variants [113, 114]. Of note the usefulness of IVIG in MOG positive syndromes has also been raised [115].

### **Treatment with Disease-Modifying Therapy (DMT)**

Multiple studies have demonstrated that the use of adult medications in pediatric MS is well tolerated. To the extent that efficacy can be established in the absence of placebo-controlled trials, the

body of evidence supports treatment. In contrast, pediatric patients with an IDE and features highly suggestive of MS have not been studied with respect to treatment.

The adult literature has demonstrated that medications differ in efficacy and meta-analyses have been attempted to estimate the hierarchical relationship among various therapies [116]. The relationship between high-potency vs. low-potency agents informs the strategy of management undertaken by clinicians whether it be therapy by induction or escalation. There is insufficient evidence in both adult and pediatric literature to favor one method over the other.

Increasingly the observation that patients fall into high and low disease-related disability categories has prompted the implementation of an individualized approach to the selection of therapy. Choosing the best fitting medication at clinical onset is an evidence-based, personalized, and family-oriented event that should ideally be carried out by a multidisciplinary team at an MS Care Center.

### **Overview of DMT Options**

The bulk of studies demonstrating treatment efficacy is drawn from comparisons of pretreatment relapse frequency to that during treatment. However, a comparison of untreated to treated patients also favored treatment. In this study, 197 pediatric MS patients were followed after their MS-defining event for a mean of 5.5 years. A total of 24 began interferon therapy a mean of 3.6 months after their relapse, whereas 73 remained untreated. Those treated had a relative reduction in relapses over the subsequent first 2 years on therapy with a hazard ratio of 0.40,  $p < 0.01$ . However, over the 4 years of follow-up, the benefit was less apparent [117].

As of 2017, the first global randomized clinical trial in pediatric MS (known as the PARADIGMS study) was successfully completed [118]. Other ongoing trials of similar design include those for dimethyl fumarate and teriflunomide, oral therapies already approved for adult MS.

## Early DMTs

Presently, interferon- $\beta$  (IFN- $\beta$ ) and glatiramer acetate (GA) continue to be the standard first-line treatments for pediatric MS patients worldwide. This is supported by numerous historical observational studies and expert consensus guidelines. Pediatric data on the use of IFN- $\beta$  therapies have largely been limited to small cohort studies and isolated case reports. These studies have generally found a drop in relapse rate from pretreatment to during therapy, good tolerability, and improved relapse rate with treatment [119–122].

One of the largest studies to date looked at records from 307 patients who received at least one injection of subcutaneous IFN  $\beta$ -1a for demyelinating events when aged 18 or younger. Annualized relapse rates were 1.79 before treatment and 0.47 during treatment [123]. Similarly, the two well-known studies to date looking at the efficacy of GA were performed on a small number of patients. Clinical outcome was favorable in both studies with no major adverse events reported [124, 125].

## Later Treatments

A general conclusion has been that the initial first-line therapies, though effective in many patients, are unable to achieve expected results in a subgroup who have ongoing relapses or new lesions, thereby requiring escalation of therapy with more aggressive management [126]. Alternatively, some advocate initiating with more potent therapies for patients with baseline factors worrisome for poor outcomes.

---

## Infusion Medications

### Natalizumab (Tysabri)

Several initial small series of children treated with natalizumab have been reported [127, 128]. Patients were 12–13 years at the time of therapy and had failed first-line DMTs (interferons and glatiramer acetate). A dose of 5 mg/kg of body

weight was administered with decrease in disease activity and, in three patients in whom it was recorded, improved quality of life. All patients tolerated the treatment well, but none at the time of the report had been followed for more than 24 months. Subsequent larger series of pediatric MS patients treated with natalizumab [129] confirmed positive outcomes with over half achieving no evidence of disease activity. The potential development of progressive multifocal leukoencephalopathy (PML) remains a substantial concern in choosing this treatment option but can be mitigated by monitoring for John Cunningham virus or JCV seropositive status.

### Rituximab (Rituxan)

Rituximab is an anti-CD20 chimeric monoclonal antibody that has been shown to effectively suppress clinical and radiological disease activity in MS as well as other demyelinating and inflammatory conditions. Its common use in the oncologic community has also made it a medication of choice for some patients given its known side effect profile and administrative predictability. In one retrospective review of 144 children with various pediatric CNS inflammatory disorders, a definite, probable, or possible benefit was reported in 87% of patients [130]. Another report from Sweden found that none of the 14 pediatric MS patients treated with rituximab experienced relapses after a mean treatment duration of almost 2 years [131]. Rituximab has been available for several decades and has a favorable safety profile in the pediatric population with diverse medical conditions [130]. Other anti-CD20 monoclonal antibody therapies have either been approved for adults (e.g., ocrelizumab or Ocrevus) or are in trials and are likely to be tested among those with pediatric MS in the future.

### Fingolimod (Gilenya)

The first large randomized, placebo-controlled study comparing the use of fingolimod and INF B1a among those with pediatric MS (ages

10–17 years) was completed in 2017 [118]. Unsurprisingly the positive results confirmed previous reports and clinical experience which have shown efficacy over first-line treatments [132].

The PARADIGM study's aim was to investigate the efficacy and safety of fingolimod up to 0.5 mg daily vs. IFN  $\beta$ -1a IM 30  $\mu$ g in pediatric patients with relapsing MS. Fingolimod was found to significantly reduce annualized relapse rate (ARR) by 82% vs. IFN- $\beta$ -1a IM. Other favorable end points achieved included reduction of annualized MRI findings, reduction of annual rate of brain atrophy from baseline, reduction of confirmed disability progression over a 24-month period, and fewer adverse events in the fingolimod group [118].

## Oral Therapies

Pediatric MS clinical trials are currently underway for dimethyl fumarate (Tecfidera) and teriflunomide (Aubagio). Small open-label studies suggest similar efficacy and side effect profiles as with adults with MS.

---

## Breakthrough Disease

Unfortunately, many children treated with first-line DMTs experience breakthrough disease and need to be switched to either another first-line treatment or second-line therapies. In a preliminary study of 164 treated children, 25% had breakthrough disease with initial DMT. Of these, eight children were switched to chemotherapy, two went on natalizumab, and two were treated with pulse IVIG [133].

Cyclophosphamide appears effective in children who are refractory to first-line treatments. In a study of 17 pediatric-onset patients, annualized relapse rates decreased from 3.8 to 1.1 per year after 1 year of treatment. However, adverse events included bladder carcinoma in one patient and idiopathic thrombocytopenic purpura (ITP) in another [134]. The availability of a broader range of effective DMT makes the need for Cytoxan less common than in the past.

## Treatment Adherence

Compliance requires the family, patient, and physician to jointly acknowledge the disease and treatment. Poor adherence can result from poor family dynamics, limited education about the disease, and incomplete understanding of the purpose of therapy. Among older children, responsibility shifts from the parents toward the adolescent. However, teens for which there is parental involvement have better compliance [122]. Reasons for poor adherence among teens include anger, loss of control, or failure to recognize that the therapy is designed to alter the disease course rather than provide symptomatic relief. Interventions to increase adherence to DMT include open discussions with the patient and parents, review of the treatment options including side effect profiles, and balancing the teen's need for autonomy with parental preference.

---

## Symptom Management

There are no specific studies of symptomatic management in pediatric MS. Therefore, most of the treatment approaches are based on adult studies and anecdotal reports. Most of the common MS symptoms associated with adult MS also occur in children [135]. These include problems with fatigue, cognitive impairment, mood disturbance, paroxysmal spasms, bladder/bowel dysfunction, and fine motor impairments.

It is important to emphasize exercise, participation in school activities including sports, and avoiding homeschooling as the socialization aspects of attending school are critical to normal development. Routine age appropriate vaccination is recommended. The majority of youngsters with MS do well and cope positively with the diagnosis. However, for some families, the process is very traumatic and counseling and other outreach efforts are critical to the child's wellbeing.

---

## Psychosocial Factors

Children and teens diagnosed with MS face more than the symptoms and management of the illness. They are now living with a chronic illness

with an uncertain prognosis, including the potential for disability. These psychosocial factors can influence the trajectory of academic, occupational, and social attainment [136, 137]. Indicative of the chronic stress from the illness, pediatric patients report elevated psychological and behavioral problems, but this nature of this expression can vary across patients [138]. While about one third of patients may have cognitive involvement, it is typically mild and would not necessarily impair learning at these early stages [75]. However, school performance may decline, often as result of missed days due to symptoms and for medical appointments [139]. It is important to view the pediatric patient's functioning in the full context of any potential challenges from home and school as well as their illness.

Routine screening for mood disturbance is recommended in order to identify the need for intervention the earliest stage. Supportive counseling is recommended if there are any indications of distress, and there should be an emphasis and expectation for resuming and maintaining daily activities as much as possible. Informal or structured mentors can also be strategically utilized in order to reduce the isolation a child or teen patient may experience and provide examples of those successfully managing the illness into young adulthood. A social worker experienced with pediatric MS and/or living with chronic illnesses in childhood can be a strong asset to the treatment team.

---

## Supporting the Family

MS affects the entire family including parents, siblings, and grandparents. Support, education, and reassurance are needed. We believe that the diagnosis should be shared with both the parents and the patient regardless of the age. There are a variety of different support systems available to assist in breaking the diagnosis to the family. Educational materials available through the National Multiple Sclerosis Society (NMSS) include "Children get MS too: A Guide for Parents," "Children and Teens with MS: A Network for Families," and "Mighty Special Kids—An Activity Book for Children with MS."

More information, additional services, and online networking for parents and teens are available at the website of the NMSS which is [www.NationalMSSociety.org/pediatricms](http://www.NationalMSSociety.org/pediatricms) or by phone 1 866—KIDS WMS (866 543 7967). Additional information can also be found at [www.pediatric-mscenter.org](http://www.pediatric-mscenter.org).

---

## Conclusion

Pediatric MS is a chronic disorder whose risk following an initial clinical attack varies with the specific features. Clearly some patients whose presentation resembles ADEM will subsequently be reclassified as MS. The differential diagnosis and clinical features differ slightly from adults with the disease and are most distinctive in the youngest patients. The management includes educating and reassuring the family, using medications to modify the disease course, and addressing the daily symptoms and psychosocial consequences of the disease. Most children appear to do reasonably well and do not develop a progressive course until decades later [9]. However, ongoing support and assistance in transitioning to adulthood as the children become older are all critical aspects to the care of this MS subgroup.

---

## References

1. Duquette P, Murray TJ, Pleines J, et al. Multiple sclerosis in childhood: clinical profile in 125 patients. *J Pediatr*. 1987;111(3):359–63.
2. Sindern E, Haas J, Stark E, Wurster U. Early onset MS under the age of 16: clinical and paraclinical features. *Acta Neurol Scand*. 1992;86(3):280–4.
3. Ghezzi A, Deplano V, Faroni J, et al. Multiple sclerosis in childhood: clinical features of 149 cases. *Mult Scler*. 1997;3(1):43–6.
4. Ruggieri M, Polizzi A, Pavone L, Grimaldi LM. Multiple sclerosis in children under 6 years of age. *Neurology*. 1999;53(3):478–84.
5. Simone IL, Carrara D, Tortorella C, et al. Course and prognosis in early-onset MS: comparison with adult-onset forms. *Neurology*. 2002;59(12):1922–8.
6. Boiko A, Vorobeychik G, Paty D, Devonshire V, Sadovnick D. Early onset multiple sclerosis: a longitudinal study. *Neurology*. 2002;59:1006–10.
7. Chitnis T, Glanz B, Jaffin S, Healy B. Demographics of pediatric-onset multiple sclerosis in an MS

- center population from the Northeastern United States. *Mult Scler.* 2009;15(5):627–31.
8. Harding KE, Liang K, Cossburn MD, et al. Long-term outcome of paediatric-onset multiple sclerosis: a population-based study. *J Neurol Neurosurg Psychiatry.* 2013;84(2):141–7.
  9. Renoux C, Vukusic S, Mikaeloff Y, et al. Natural history of multiple sclerosis with childhood onset. *N Engl J Med.* 2007;356:2603–13.
  10. Compston A. *McAlpine's multiple sclerosis.* 3rd ed. London: Churchill Livingstone; 1998.
  11. Banwell B, Kennedy J, Sadovnick D, et al. Incidence of acquired demyelination of the CNS in Canadian children. *Neurology.* 2009;72:232–9.
  12. Langer-Gould A, Zhang JL, Chung J, et al. Incidence of acquired CNS demyelinating syndromes in a multiethnic cohort of children. *Neurology.* 2011;77(12):1143–8.
  13. Koch-Henriksen N, Sørensen P. The changing demographic pattern of multiple sclerosis epidemiology. *Lancet Neurol.* 2010;9(5):520–32.
  14. Reinhardt K, Weiss S, Rosenbauer J, et al. Multiple sclerosis in children and adolescents: incidence and clinical picture – new insights from the nationwide German surveillance (2009–2011). *Eur J Neurol.* 2014;21(4):654–9.
  15. Boesen MS, Magyar M, Koch-Henriksen N, Thygesen LC, Born AP, Uldall PV, Blinkenberg M. Pediatric-onset multiple sclerosis and other acquired demyelinating syndromes of the central nervous system in Denmark during 1977–2015: a nationwide population-based incidence study. *Mult Scler.* 2018;24(8):1077–86.
  16. World Health Organisation. Atlas: multiple sclerosis resources in the world 2008. Geneva, Switzerland: World Health Organisation; 2008.
  17. Dell'Avvento S, Sotgiu MA, Manca S, Sotgiu G, Sotgiu S. Epidemiology of multiple sclerosis in the pediatric population of Sardinia, Italy. *Eur J Pediatr.* 2016;175(1):19–29.
  18. Belman AL, Krupp LB, Olsen CS, et al. Characteristics of children and adolescents with multiple sclerosis. *Pediatrics.* 2016;138(1):e20160120.
  19. Banwell B, Ghezzi A, Bar-Or A, Mikaeloff Y, Tardieu M. Multiple sclerosis in children: clinical diagnosis, therapeutic strategies, and future directions. *Lancet Neurol.* 2007;6:887–902.
  20. Boiko AN, Gusev EI, Sudomoina MA, et al. Association and linkage of juvenile MS with HLA-DR2(15) in Russians. *Neurology.* 2002;58:658–60.
  21. Disanto G, Magalhaes S, Handel AE, et al. HLA-DRB1 confers increased risk of pediatric-onset MS in children with acquired demyelination. *Neurology.* 2011;76:781–6.
  22. Duan S, Lv Z, Fan X, et al. Vitamin D status and the risk of multiple sclerosis: a systematic review and meta-analysis. *Neurosci Lett.* 2014;570:108–13.
  23. Banwell B, Bar-Or A, Arnold DL, Sadovnick D, Narayanan S, et al. Clinical, environmental, and genetic determinants of multiple sclerosis in children with acute demyelination: a prospective national cohort study. *Lancet Neurol.* 2011;10:436–45.
  24. Mowry EM, Krupp L, Milazzo M, Chabas D, Strober J, et al. Lower vitamin D levels are associated with a higher risk of relapse in early pediatric-onset multiple sclerosis. *Ann Neurol.* 2010;67:618–24.
  25. Graves J, Barcellos LF, Shao X, Noble J, US Network of Pediatric MS Centers, et al. Genetic predictors of relapse rate in pediatric multiple sclerosis. *Mult Scler.* 2016;22(12):1528–35. Epub 2016 Jan 14.
  26. Chabas D, Sadovnick AD, Hintzen RQ. Genetics of pediatric multiple sclerosis. In: Chabas D, editor. *Demyelinating disorders of the central nervous system in childhood.* Cambridge: Cambridge University Press; 2011. p. 169–82.
  27. Kennedy J, O'Connor P, Sadovnick AD, Perara M, Yee I, Banwell B. Age at onset of multiple sclerosis may be influenced by place of residence during childhood rather than ancestry. *Neuroepidemiology.* 2006;26:162–7.
  28. Langer-Gould A, Brara SM, Beaber BE, Koebnick C. Childhood obesity and risk of pediatric multiple sclerosis and clinically isolated syndrome. *Neurology.* 2013;80(6):548–52.
  29. Gianfrancesco MA, Shao X, Rhead B, et al. Increased body mass index is causally associated with pediatric MS onset: a Mendelian randomization study. Presented at the AAN Annual Meeting, Vancouver, 15–21 Apr 2016.
  30. Waubant E, Mowry EM, Krupp L, et al. Common viruses associated with lower pediatric multiple sclerosis risk. *Neurology.* 2011;76:1989–95.
  31. Waubant E, Mowry EM, Krupp L, et al. Antibody response to common viruses and human leukocyte antigen-DRB1 in pediatric multiple sclerosis. *Mult Scler.* 2013;19:891–5.
  32. Nielsen TR, Rostgaard K, Askling J, Steffensen R, Oturai A, Jersild C, Koch-Henriksen N, Sørensen PS, Hjalgrim H. Effects of infectious mononucleosis and HLA-DRB1\*15 in multiple sclerosis. *Mult Scler.* 2009;15(4):431–6.
  33. Ponsonby A, van der Mei I, Dwyer T, et al. Exposure to infant siblings during early life and risk of multiple sclerosis. *JAMA.* 2005;293(4):463–9.
  34. Krupp L, Banwell B, Tenenbaum S, International Pediatric MS Study Group. Consensus definitions proposed for pediatric multiple sclerosis and related disorders. *Neurology.* 2007;68(16 Suppl 2):S3–S12.
  35. Krupp LB, Tardieu M, Amato MP, et al. International Pediatric Multiple Sclerosis Study Group criteria for pediatric multiple sclerosis and immune-mediated central nervous system demyelinating disorders: revisions to the 2007 definitions. *Mult Scler.* 2013;19:1261–7.
  36. Tardieu M, Banwell B, Wolinsky JS, Pohl D, Krupp LB. Consensus definitions for pediatric MS and other demyelinating disorders in childhood. *Neurology.* 2016;87:S8–S11.

37. Poman CH, Reingold SC, Banwell B, et al. Diagnostic criteria for multiple sclerosis: 2010 revisions to the McDonald criteria. *Ann Neurol*. 2011;69:292–302.
38. Sedani S, Lim MJ, Hemingway C, Wassmer E, Absoud M. Paediatric multiple sclerosis: examining utility of the McDonald 2010 criteria. *Mult Scler*. 2012;18:679–82.
39. Kornek B, Schmitl B, Vass K, et al. Evaluation of the 2010 McDonald multiple sclerosis criteria in children with a clinically isolated syndrome. *Mult Scler*. 2012;18:1768–74.
40. Sadaka Y, Verhey LH, Shroff MM, et al. 2010 McDonald criteria for diagnosing pediatric multiple sclerosis. *Ann Neurol*. 2012;72:211–23.
41. Hummel H-M, Brück W, Dreha-Kulaczewski S, Gärtner J, Wuerfel J. Pediatric onset multiple sclerosis: McDonald criteria 2010 and the contribution of spinal cord MRI. *Mult Scler*. 2013;19:1330–5.
42. Williams MT, Tapos DO, Juhasz C. Use of the 2010 McDonald criteria can facilitate early diagnosis of pediatric multiple sclerosis in a predominantly Black cohort. *Pediatr Neurol*. 2014;51:826–30.
43. Fadda G, Brown RA, Longoni G, et al. MRI and laboratory features and the performance of international criteria in the diagnosis of multiple sclerosis in children and adolescents: a prospective cohort study. *Lancet Child Adolesc Health*. 2018;2(3):191–204.
44. Thompson AJ, et al. Diagnosis of multiple sclerosis: 2017 revisions of the McDonald criteria. *Lancet Neurol*. 2018;17(2):162–73.
45. Fishman RA. *Cerebrospinal fluid in diseases of the nervous system*. 2nd ed. Philadelphia: Saunders; 1992.
46. Dale RC, de Sousa C, Chong WK, Cox TC, Harding B, Neville BG. Acute disseminated encephalomyelitis, multiphasic disseminated encephalomyelitis and multiple sclerosis in children. *Brain*. 2000;123(Pt 12):2407–22.
47. Neuteboom RF, Boon M, Catsman Berrevoets CE, et al. Prognostic factors after a first attack of inflammatory CNS demyelination in children. *Neurology*. 2008;71:967–73.
48. Mikaeloff Y, Suissa S, Vallee L, et al. First episode of acute CNS inflammatory demyelination in childhood: prognostic factors for multiple sclerosis and disability. *J Pediatr*. 2004;144:246–52.
49. Dale RC, Brilot F, Banwell B. Pediatric central nervous system inflammatory demyelination: acute disseminated encephalomyelitis, clinically isolated syndromes, neuromyelitis optica, and multiple sclerosis. *Curr Opin Neurol*. 2009;22:233–40.
50. Mikaeloff Y, Caridade G, Husson B, Suissa S, Tardieu M. Acute disseminated encephalomyelitis cohort study: prognostic factors for relapse. *Eur J Paediatr Neurol*. 2007;11:90–5.
51. Iaffaldano P, Simone M, Lucisano G, Italian iMed-Web Registry and the MSBase Registry, et al. Prognostic indicators in pediatric clinically isolated syndrome. *Ann Neurol*. 2017;81(5):729–39.
52. Dale RC, Pillai SC. Early relapse risk after a first CNS inflammatory demyelination episode: examining international consensus definitions. *Dev Med Child Neurol*. 2007;49:887–93.
53. Mikaeloff Y, Caridade G, Assi S, Suissa S, Tardieu M. Prognostic factors for early severity in a childhood multiple sclerosis cohort. *Pediatrics*. 2006;118:1133–9.
54. Mikaeloff Y, Adamsbaum C, Husson B, et al. MRI prognostic factors for relapse after acute CNS inflammatory demyelination in childhood. *Brain*. 2004;127:1942–7.
55. Verhey LH, Branson HM, Shroff MM. MRI parameters for prediction of multiple sclerosis diagnosis in children with acute CNS demyelination: a prospective national cohort study. *Lancet Neurol*. 2011;10:1065–73.
56. Atzori M, Battistella PA, Perini P. Clinical and diagnostic aspects of multiple sclerosis and acute monophasic encephalomyelitis in pediatric patients: a single centre prospective study. *Mult Scler*. 2009;15:363–70.
57. Makhani N, Lebrun C, Siva A, et al. The radiologically isolated syndrome in children: clinical and radiological outcomes. *Neurol Neuroimmunol Neuroinflamm*. 2018;4:e395.
58. Bonhomme GR, Waldman AT, Balcer LJ, et al. Pediatric optic neuritis: brain MRI abnormalities and risk of multiple sclerosis. *Neurology*. 2009;72:881–5.
59. Heussinger N, Kontopantelis E, Gburek-Augustat J, et al. Oligoclonal bands predict multiple sclerosis in children with optic neuritis. *Ann Neurol*. 2015;77:1076–82.
60. Lucchinetti CF, Kiers L, O’Duffy A, et al. Risk factors for developing multiple sclerosis after childhood optic neuritis. *Neurology*. 1997;49:1413–8.
61. Alper G, Wang L. Demyelinating optic neuritis in children. *J Child Neurol*. 2009;24:45–8.
62. Ozakbas S, Idiman E, Baklan B, Yulug B. Childhood and juvenile onset multiple sclerosis: clinical and paraclinical features. *Brain Dev*. 2003;25:233–6.
63. Ghezzi A, Pozzilli C, Liguori M, et al. Prospective study of multiple sclerosis with early onset. *Mult Scler*. 2002;8:115–8.
64. Gusev E, Boiko A, Bikova O, et al. The natural history of early onset multiple sclerosis: comparison of data from Moscow and Vancouver. *Clin Neurol Neurosurg*. 2002;104:203–7.
65. Selcen D, Anlar B, Renda Y. Multiple sclerosis in childhood: report of 16 cases. *Eur Neurol*. 1996;36:79–84.
66. Yeh EA, Weinstock-Guttman B, Lincoff N, Reynolds J, Weinstock A, Madurai N, Agarwal N, Buch P, Karpinski M, Ramanathan M. Retinal nerve fiber thickness in inflammatory demyelinating diseases of childhood onset. *Mult Scler*. 2009;15(7):802–10.
67. Waldman AT, Liu GT, Lavery AM, et al. Optical coherence tomography and visual evoked potentials in pediatric MS. *Neurol Neuroimmunol Neuroinflamm*. 2017;4(4):e356.

68. Tenenbaum S, Chamoles N, Fejerman N. Acute disseminated encephalomyelitis: a long-term follow-up study of 84 pediatric patients. *Neurology*. 2002;59:1224–31.
69. Chabas D, Castillo-Trivino T, Mowry EM, Strober JB, Glenn OA, Waubant E. Vanishing MS T2-bright lesions before puberty: a distinct MRI phenotype? *Neurology*. 2008;71:1090–3.
70. Chabas D, Ness J, Belman A, et al. Younger children with pediatric MS have a distinct CSF inflammatory profile at disease onset. *Neurology*. 2010;74(5):399–405.
71. Amato MP, Goretti B, Ghezzi A, et al. Cognitive and psychosocial features of childhood and juvenile MS. *Neurology*. 2008;70:1891–7.
72. Julian L, Serafin D, Charvet L, et al. Cognitive impairment occurs in children and adolescents with multiple sclerosis: results from a United States network. *J Child Neurol*. 2013;28:102–7.
73. Till C, Deotto A, Tipu V, et al. White matter integrity and math performance in pediatric multiple sclerosis: a diffusion tensor imaging study. *Neuroreport*. 2011;22:1005–9.
74. Charvet LE, Beekman R, Amadiume N, Belman AL, Krupp LB. The Symbol Digit Modalities Test is an effective cognitive screen in pediatric onset multiple sclerosis (MS). *J Neurol Sci*. 2014;341:79–84.
75. Charvet LE, Shaw M, Frontario A, Langdon D, Krupp LB. Cognitive impairment in pediatric-onset multiple sclerosis is detected by the Brief International Cognitive Assessment for Multiple Sclerosis and computerized cognitive testing. *Mult Scler*. 2018;24(4):512–9.
76. Amato MP, Goretti B, Ghezzi A, et al. Cognitive and psychosocial features in childhood and juvenile MS: two-year follow-up. *Neurology*. 2010;75:1134–40.
77. Till C, Racine N, Araujo D, et al. Changes in cognitive performance over a 1-year period in children and adolescents with multiple sclerosis. *Neuropsychology*. 2013;27:210–9.
78. Charvet LE, O'Donnell EH, Belman AL, et al. Longitudinal evaluation of cognitive functioning in pediatric multiple sclerosis: report from the US Pediatric Multiple Sclerosis Network. *Mult Scler*. 2014;20:1502–10.
79. Charvet L, Cersosimo B, Schwarz C, Belman A, Krupp LB. Behavioral symptoms in pediatric multiple sclerosis (MS): relation to fatigue and cognitive impairment. *J Child Neurol*. 2016;31(8):1062–7.
80. MacAllister WS, Christodoulou C, Troxell R, Milazzo M, Block P, Preston TE, Bender HA, Belman A, Krupp LB. Fatigue and quality of life in pediatric multiple sclerosis. *Mult Scler*. 2009;15(12):1502–8.
81. Ghezzi A, Amato MP, Capobianco M, et al. Disease-modifying drugs in childhood-juvenile multiple sclerosis: results of an Italian co-operative study. *Mult Scler*. 2005;11:420–4.
82. Deryck O, Ketelaer P, Dubois B. Clinical characteristics and long-term prognosis in early onset multiple sclerosis. *J Neurol*. 2006;252:720–3.
83. Absoud M, Lim MJ, Chong WK, et al. Paediatric acquired demyelinating syndromes: incidence, clinical and magnetic resonance imaging features. *Mult Scler*. 2013;19:76–86.
84. Hacohen Y, Absoud M, Deiva K, et al. Myelin oligodendrocyte glycoprotein antibodies predict a non-MS demyelination course in children. *Neurol Neuroimmunol Neuroinflamm*. 2015;2:e81.
85. Ketelslegers IA, VanPelt DE, Bryde S, et al. Anti-MOG antibodies plead against MS diagnosis in an acquired demyelinating syndromes cohort. *Mult Scler*. 2015;12:1513–20.
86. Reindl M, Rostasy K. MOG antibody-associated diseases. *Neurol Neuroimmunol Neuroinflamm*. 2015;2:e60.
87. Fernandez-Carbonell C, Vargas-Lowy D, Masallam A, et al. Clinical and MRI phenotype of children with MOG. *Mult Scler*. 2016;22:2174–84.
88. Wingerchuk DM, Lucchinetti CF. Comparative immunopathogenesis of acute disseminated encephalomyelitis, neuromyelitis optica, and multiple sclerosis. *Curr Opin Neurol*. 2007;20:343–50.
89. Filippi M, Rocca MA. MRI evidence for multiple sclerosis as a diffuse disease of the central nervous system. *J Neurol*. 2005;252 Suppl 5:v16–24.
90. Krupp LB, Banwell B, Tenenbaum S. Consensus definitions proposed for pediatric multiple sclerosis and related disorders. *Neurology*. 2007;68:S7–12.
91. Brass SD, Caramanos Z, Santos C, Dilenge ME, Lapierre Y, Rosenblatt B. Multiple sclerosis vs acute disseminated encephalomyelitis in childhood. *Pediatr Neurol*. 2003;29:227–31.
92. Tenenbaum S, Chitnis T, Ness J, Hahn JS, Group IPMS. Acute disseminated encephalomyelitis. *Neurology*. 2007;68:S23–36.
93. Callen DJ, Shroff MM, Branson HM, et al. Role of MRI in the differentiation of ADEM from MS in children. *Neurology*. 2009;72:968–73.
94. Hynson JL, Kornberg AJ, Coleman LT, Shield L, Harvey AS, Kean MJ. Clinical and neuroradiologic features of acute disseminated encephalomyelitis in children. *Neurology*. 2001;56:1308–12.
95. Banwell B, Tenenbaum S, Lennon VA, et al. Neuromyelitis optica-IgG in childhood inflammatory demyelinating CNS disorders. *Neurology*. 2008;70:344–52.
96. Berger T, Rubner P, Schautzer F, et al. Antimyelin antibodies as a predictor of clinically definite multiple sclerosis after a first demyelinating event. *N Engl J Med*. 2003;349:139–45.
97. Pröbstel AK, Dormair K, Bittner R, et al. Antibodies to MOG are transient in childhood ADEM. *Neurology*. 2011;77:580–8.
98. Fernandez-Carbonell C, Vargas-Lowy D, Musallam A, et al. Clinical and MRI phenotype of children with MOG antibodies. *Mult Scler*. 2016;22(2):174–84.
99. Jurynczyk M, Messina S, Woodhall MR, et al. Clinical presentation and prognosis in MOG-antibody disease: a UK study. *Brain*. 2017;140:3128–38.

100. Hahn CD, Shroff MM, Blaser SI, Banwell BL. MRI criteria for multiple sclerosis: evaluation in a pediatric cohort. *Neurology*. 2004;62:806–8.
101. Hahn JS, Pohl D, Rensel M, Rao S. Differential diagnosis and evaluation in pediatric multiple sclerosis. *Neurology*. 2007;68:S13–22.
102. Van der Knaap MS. *Magnetic resonance of myelination and myelin disorders*. 3rd ed. New York: Springer; 2005.
103. Gorman MP, Golomb MR, Walsh LE, et al. Steroid-responsive neurologic relapses in a child with a proteolipid protein-1 mutation. *Neurology*. 2007;68:1305–7.
104. Wolf NI, Toro C, Kister I, et al. DARS-associated leukoencephalopathy can mimic a steroid-responsive neuroinflammatory disorder. *Neurology*. 2015;84(3):226–30.
105. Chitnis T. Pediatric multiple sclerosis. *Neurologist*. 2006;12:299–310.
106. Barnes D, Hughes RA, Morris RW, et al. Randomised trial of oral and intravenous methylprednisolone in acute relapses of multiple sclerosis. *Lancet*. 1997;349:902–6.
107. Martinelli V, Pulizzi A, Annovazzi P, Rocca M, Rodegher M, et al. A short-term MRI study comparing high-dose oral versus intravenous methylprednisolone in MS relapse. *Neurology*. 2008;70:A83–4.
108. Morrow SA, Stoian CA, Dmitrovic J, Chan SC, Metz LM. The bioavailability of IV methylprednisolone and oral prednisone in multiple sclerosis. *Neurology*. 2004;63:1079–80.
109. Weinshenker BG, O'Brien PC, Petterson TM, Noseworthy JH. A randomized trial of plasma exchange in acute central nervous system inflammatory demyelinating disease. *Ann Neurol*. 1999;46:878–86.
110. Duzova A, Bakkaloglu A. Central nervous system involvement in pediatric rheumatic diseases: current concepts in treatment. *Curr Pharm Des*. 2008;14:1295–301.
111. Jacquet C, Garnier A, Cheuret E. Plasma exchange and immunoadsorption in pediatric inflammatory optic neuropathy resistant to corticosteroid therapy: four French cases. *Neuropediatrics*. 2016;47(3):175–8.
112. Jarius S, König FB, Metz I, et al. Pattern II and pattern III MS are entities distinct from pattern I MS: evidence from cerebrospinal fluid analysis. *J Neuroinflammation*. 2017;14:171.
113. Hahn JS, Siegler DJ, Enzmann D. Intravenous gammaglobulin therapy in recurrent acute disseminated encephalomyelitis. *Neurology*. 1996;46:1173–4.
114. Nishikawa M, Ichiyama T, Hayashi T, Ouchi K, Furukawa S. Intravenous immunoglobulin therapy in acute disseminated encephalomyelitis. *Pediatr Neurol*. 1999;21:583–6.
115. Wong YYM, Hacoen Y, Armangue T, Wassmer E, Verhelst H, Hemingway C, van Pelt ED, Catsman-Berreoets CE, Hintzen RQ, Deiva K, Lim MJ, Rostásy K, Neuteboom RF. Paediatric acute disseminated encephalomyelitis followed by optic neuritis: disease course, treatment response and outcome. *Eur J Neurol*. 2018;25(5):782–6.
116. Tramacere I, Del Giovane C, Filippini G. Association of immunotherapies with outcomes in relapsing-remitting multiple sclerosis. *JAMA*. 2016;315(4):409–10.
117. Mikaeloff Y, Caridade G, Tardieu M, Suissa S. Effectiveness of early beta interferon on the first attack after confirmed multiple sclerosis: a comparative cohort study. *Eur J Paediatr Neurol*. 2008;12:205–9.
118. Chitnis T, Arnold DL, Banwell B, Brück W, Ghezzi A, Giovannoni G, Greenberg B, Krupp L, Rostásy K, Tardieu M, Waubant E, Wolinsky JS, Bar-Or A, Stites T, Chen Y, Putzki N, Merschhemke M, Gärtner J for the PARADIGMS Study Group. Trial of Fingolimod versus Interferon Beta-1a in Pediatric Multiple Sclerosis. *N Engl J Med*. 2018;379:1017–27.
119. Ghezzi A, Amato MP, Capobianco M, et al. Treatment of early-onset multiple sclerosis with intramuscular interferon-beta-1a: long-term results. *Neurol Sci*. 2007;28:127–32.
120. Pakdaman H, Fallah A, Sahraian MA, Pakdaman R, Meysamie A. Treatment of early onset multiple sclerosis with suboptimal dose of interferon beta-1a. *Neuropediatrics*. 2006;37:257–60.
121. Waubant E, Hietpas J, Stewart T, et al. Interferon beta-1a in children with multiple sclerosis is well tolerated. *Neuropediatrics*. 2001;32:211–3.
122. Mikaeloff Y, Moreau T, Debouverie M, et al. Interferon-beta treatment in patients with childhood-onset multiple sclerosis. *J Pediatr*. 2001;139:443–6.
123. Tenenbaum SN, Banwell B, Pohl D, Krupp LB, Boyko A, Meinel M, Lehr L, Rocak S, Cantogno EV, Moraga MS, Ghezzi A, REPLAY Study Group. Subcutaneous interferon Beta-1a in pediatric multiple sclerosis: a retrospective study. *J Child Neurol*. 2013;28(7):849–56.
124. Ghezzi A, Amato MP, Annovazzi P, et al. Long-term results of immunomodulatory treatment in children and adolescents with multiple sclerosis: the Italian experience. *Neurol Sci*. 2009;30:193–9.
125. Kornek B, Bernert G, Balassy C, et al. Glatiramer acetate treatment in patients with childhood and juvenile onset multiple sclerosis. *Neuropediatrics*. 2003;34:120–6.
126. Yeh EA, Waubant E, Krupp LB, et al. Multiple sclerosis therapies in pediatric patients with refractory multiple sclerosis. *Arch Neurol*. 2011;68:437–44.
127. Borriello G, Prosperini L, Luchetti A, Pozzilli C. Natalizumab treatment in pediatric multiple sclerosis: a case report. *Eur J Paediatr Neurol*. 2009;13(1):67–71.
128. Huppke P, Stark W, Zurcher C, Huppke B, Bruck W, Gartner J. Natalizumab use in pediatric multiple sclerosis. *Arch Neurol*. 2008;65:1655–8.
129. Ghezzi A, Moilila L, Pozzilli C, et al. Natalizumab in the pediatric MS population: results of the Italian registry. *BMC Neurol*. 2015;15:174.



130. Dale RC, Brilot F, Duffy LV, et al. Utility and safety of rituximab in pediatric autoimmune and inflammatory CNS disease. *Neurology*. 2014;83:142–50.
131. Salzer J, Lycke J, Wickstrom R, Naver H, Piehl F, Svenningsson A. Rituximab in paediatric onset multiple sclerosis: a case series. *J Neurol*. 2015;263:322–6.
132. Fragoso YD, Alves-Leon SV, Barreira AA, et al. Fingolimod prescribed for the treatment of multiple sclerosis in patients younger than age 18 years. *Pediatr Neurol*. 2015;53:166–8.
133. Yeh EA, Waubant E, Krupp L, Ness J, Chitnis T, Kuntz N, Ramanathan M, Belman A, Chabas D, Gorman M, Rodriguez M, Rinker J, Weinstock-Guttman B. MS therapies in pediatric MS patients with refractory disease. *Arch Neurol*. 2011;68(4):437–44.
134. Makhani N, Gorman MP, Branson HM, Stazzone L, Banwell BL, Chitnis T. Cyclophosphamide therapy in pediatric multiple sclerosis. *Neurology*. 2009;72:2076–82.
135. Krupp LB, Rizvi SA. Symptomatic therapy for underrecognized manifestations of multiple sclerosis. *Neurology*. 2002;58:S32–9.
136. Goretti B, Ghezzi A, Portaccio E, Lori S, Zipoli V, Razzolini L, Moidola L, Falautano M, De Caro MF, Viterbo R, Patti F, Vecchio R, Pozzilli C, Bianchi V, Roscio M, Comi G, Trojano M, Amato MP, Study Group of the Italian Neurological Society. Psychosocial issue in children and adolescents with multiple sclerosis. *Neurol Sci*. 2010;31(4):467–70.
137. MacAllister WS, Boyd JR, Holland NJ, Milazzo MC, Krupp LB, International Pediatric MS Study Group. The psychosocial consequences of pediatric multiple sclerosis. *Neurology*. 2007;68(16 Suppl 2):S66–9. Review.
138. Charvet L, Cersosimo B, Schwarz C, Belman A, Krupp LB. Behavioral symptoms in pediatric multiple sclerosis: relation to fatigue and cognitive impairment. *J Child Neurol*. 2016;31(8):1062–7.
139. MacAllister WS, Christodoulou C, Milazzo M, Preston TE, Serafin D, Krupp LB, Harder L. Pediatric multiple sclerosis: what we know and where are we headed? *Child Neuropsychol*. 2013;19(1):1–22.



# Vitamin D and Multiple Sclerosis

# 10

Michael J. Bradshaw, Michael F. Holick,  
and James M. Stankiewicz

## Introduction

Multiple sclerosis (MS) is the most common demyelinating disease of the central nervous system and the most common cause of nontraumatic disability among young adults [1, 2]. The incidence and prevalence of MS are increasing, and the medical, social, and economic burden of the disease is significant [3]. While the precise etiology of MS remains to be completely elucidated, it appears to arise from a combination of genetic and environmental factors. Vitamin D, “the sunshine vitamin,” and sunlight have been implicated among several other environmental factors thought to contribute to an individual’s risk of developing MS, others including smoking, obesity, and Epstein-Barr virus infection. The interaction between vitamin D and MS has been the subject of significant investigative efforts, and much has been learned. This chapter will discuss the role of vitamin D in the pathophysiology of

MS and review the evidence related to clinical outcomes in patients with MS who have vitamin D deficiency.

## Background

### Source and Metabolism of Vitamin D

Vitamin D is technically a prohormone that is synthesized in the skin from 7-dehydrocholesterol as a result of exposure to solar ultraviolet-B radiation (UVB) or obtained through ingestion. UVB radiation photolysis of 7-dehydrocholesterol to pre-vitamin D<sub>3</sub> which is subsequently isomerized by a nonenzymatic membrane enhanced catalysis to vitamin D<sub>3</sub> [4]. Although sun exposure is capable of yielding substantial amounts of vitamin D, a number of individual factors (e.g., age, increased skin pigmentation, use of sunscreen, time spent indoors) and environmental factors (e.g., time of day, latitude, climate) limit sunlight as a source of vitamin D [5]. Dietary sources of vitamin D such as salmon, tuna, egg yolk, shiitake mushrooms, and other mushrooms exposed to sunlight for UVB radiation as well as fortified milk, orange juice, and some cereals can provide modest amounts (between 100 and 200 international units (IU) per day) of vitamin D in the form of vitamin D<sub>3</sub> (cholecalciferol, animal sources) or vitamin D<sub>2</sub> (ergocalciferol, yeast, mushrooms, and plant sources) [6–8] (Fig. 10.1).

M. J. Bradshaw (✉)

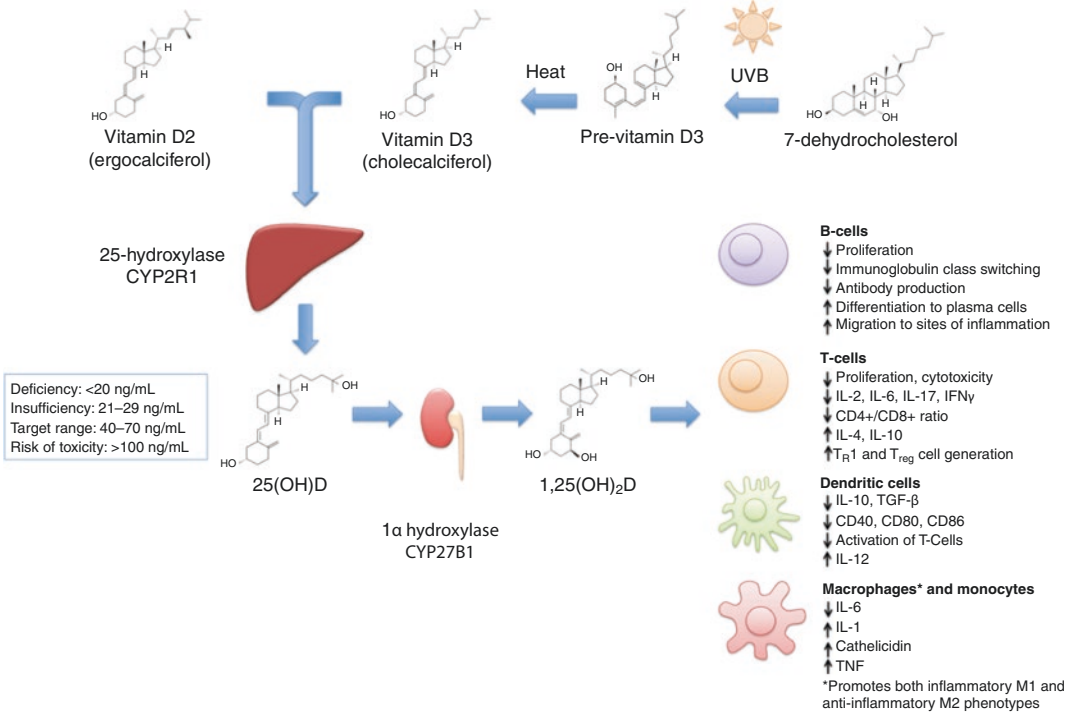
Department of Neurology, Chicago Medical School,  
Rosalind Franklin University of Medicine and  
Science, Billings Clinic, Billings, MT, USA

M. F. Holick

Department of Medicine, Boston University Medical  
Center, Boston, MA, USA  
e-mail: [MFHolick@BU.edu](mailto:MFHolick@BU.edu)

J. M. Stankiewicz

Partners Multiple Sclerosis Center, Harvard Medical  
School, Boston, MA, USA  
e-mail: [jstankiewicz@bwh.harvard.edu](mailto:jstankiewicz@bwh.harvard.edu)



**Fig. 10.1** Metabolism and immunomodulatory effects of vitamin D

Although vitamin D2 and vitamin D3 have no known intrinsic biological activity on calcium metabolism or on non-calcimimetic genomic activities, there is some evidence that vitamin D3 itself may play a fundamental role in stabilizing endothelial membranes reducing inflammatory activity. Vitamin D (D represents D2 or D3) is weakly bound to the vitamin D-binding protein and transported via the bloodstream to the liver for enzymatic conversion to 25-hydroxyvitamin D [25(OH)D]. This is subsequently hydroxylated to 1,25-dihydroxyvitamin D [1,25(OH)<sub>2</sub>D] in the kidneys for regulating calcium, phosphate, and bone metabolism [7, 8]. 1,25(OH)<sub>2</sub>D interacts with its nuclear vitamin D receptor (VDR) in the small intestine resulting in the enhancement of dietary calcium and phosphate absorption. In the bone, this hormone interacts with its receptor in osteoblasts resulting in the increased expression of receptor activator of NFκB (RANKL), which in turn interacts with monocytes to become mature osteoclasts. These cells are responsible

for removing calcium from the skeleton to help maintain calcium homeostasis.

There are a variety of tissues and cells that also have the capacity to convert 25(OH)D to 1,25(OH)<sub>2</sub>D including macrophages, monocytes, breast, colon, brain, and prostate among other tissues. It is believed that the local production of 1,25(OH)<sub>2</sub>D acts in an autocrine or paracrine fashion to regulate a wide variety of genes controlling DNA synthesis, apoptosis, and cellular maturation among many other activities. In addition to these genomic activities, locally produced 1,25(OH)<sub>2</sub>D initiates its own destruction by markedly enhancing the expression of the 25-hydroxyvitamin D-24-hydroxylase. This enzyme causes oxidation of the side chain producing a water-soluble inactive vitamin D metabolite calcitroic acid. When healthy adults ingested 2000 IUs/day of vitamin D for 12 weeks, 291 genes responsible for regulating more than 100 different metabolic processes were altered in their peripheral white blood cells [8]. These

non-calcemic genomic activities may be responsible for the importance of vitamin D in such diverse roles as cancer prevention [9], as well as immune [10], and cardiovascular disease [11].

### Immunomodulatory Effects of Vitamin D

The role of vitamin D in immune function has been the subject of extensive investigation since the discovery of VDRs in activated human T and B lymphocytes [12, 13]. VDRs have now been identified on virtually all immune cells, many of which are also capable of converting 25(OH)D into 1,25(OH)<sub>2</sub>D [12–17], allowing 1,25(OH)<sub>2</sub>D to modulate immune function at sites of inflammation [18]. Vitamin D modulates the response of both innate and adaptive immune cells [18]. Vitamin D does not appear to be immunosuppressive, but rather immunomodulatory, with pleiotropic effects on immune function. The immunomodulatory mechanisms of vitamin D have been recently reviewed extensively [18–20], so we will only discuss a few key findings pertinent to MS and experimental autoimmune encephalomyelitis (EAE).

Treatment with the active form of vitamin D, 1,25(OH)<sub>2</sub>D, promotes a tolerogenic state among dendritic cells, characterized by decreased production of inflammatory cytokines (e.g., interleukin-12 [IL-12]) and increased production of anti-inflammatory cytokines (e.g., IL-10, transforming growth factor-β) [21]. These tolerogenic dendritic cells are less capable of activating alloreactive T-cells and promote the differentiation of regulatory T-cells [21, 22]. The effects of 1,25(OH)<sub>2</sub>D on macrophages are more complex. Early in the course of an inflammatory stimulus, 1,25(OH)<sub>2</sub>D produced by macrophages promotes inflammatory and antimicrobial mechanisms essential for pathogen clearance [23, 24]. However, 1,25(OH)<sub>2</sub>D also attenuates toll-like receptor-mediated inflammation through enhancing negative feedback [25] which promotes decreased production of inflammatory cytokines such as IL-6 and TNF, increases production of IL-10, and impairs macrophage activation of

T-cells [18]. Thus while 1,25(OH)<sub>2</sub>D promotes the inflammatory M1 macrophage phenotype, it also abrogates inflammation through favoring the anti-inflammatory M2 macrophage phenotype.

Historically, vitamin D was thought to modulate adaptive immunity through its effects on innate immune function as outlined above. More recently, however, the role of vitamin D in directly modulating adaptive immunity has attracted interest and is beginning to be elucidated [20]. The effects of vitamin D on B-cells remain incompletely understood. 1,25(OH)<sub>2</sub>D reduces the proliferation of B-cells, inhibits immunoglobulin class switching, induces B-cell apoptosis, and decreases antibody production [20]. However, 1,25(OH)<sub>2</sub>D also stimulates terminally differentiating B-cell to become plasma cells and promotes B-cell migration to sites of inflammation [20].

T-cells are directly and indirectly affected by vitamin D, although the effects of 1,25(OH)<sub>2</sub>D differ between different T-cell subsets [26]. For example, 1,25(OH)<sub>2</sub>D inhibits the differentiation and activity of Th17 cells, and impairs the development of experimental autoimmune encephalomyelitis (EAE) by MOG-specific Th17 cells in a VDR-dependent fashion [27, 28]. 1,25(OH)<sub>2</sub>D reduces T-cell production of IL-2, IL-17, and IFNγ and abrogates the cytotoxic activities of CD4+ and CD8+ T-cells [29]. In vivo 1,25(OH)<sub>2</sub>D has been found to enhance the development of IL-10-producing T-cells, reduce the number of IL-6- and IL-17-secreting cells, and increase the number of CD4+CD25+ T-regulatory cells [30].

While 1,25(OH)<sub>2</sub>D is capable of preventing EAE in either male or female mice, even at high doses, vitamin D3 supplementation was only protective in female mice (in a 17-β-estradiol-dependent manner) [31, 32]. A sex-specific effect of vitamin D has not been observed in key epidemiological studies, however, as discussed below. In North America it is well documented that living below an approximate latitude equivalent to Atlanta, Georgia, for the first 10 years of life reduces risk of developing MS substantially, regardless of where the person locates after this time, suggesting that sun exposure possibly through the action of vitamin D has some benefit

[5]. UVB exposure also appears to inhibit the development of EAE [33], although it remains unclear whether vitamin D or other effects of UVB on immune function mediate this observation [34, 35]. In addition, neither UVB nor 25(OH)D appear capable of altering the course of EAE after the development of initial symptoms, while 1,25(OH)<sub>2</sub>D is capable of exerting immunomodulatory effects even after EAE onset [36].

One pilot study including 40 patients with MS randomized to 800 or 10,400 IU daily vitamin D<sub>3</sub> noted pleiotropic immunomodulatory effects of high-dose supplementation [37]. High-dose vitamin D<sub>3</sub> reduced the proportion of IL-17-producing CD4<sup>+</sup> T-cells, and reductions in IL-17 production correlated with increases in serum 25(OH)D levels. CD4<sup>+</sup>IL-17<sup>+</sup> T-cells (Th17) have been implicated in the immune pathogenesis of EAE and MS and IL-17 gene expression is increased in MS lesions [38]. The study also noted a reduction in the proportion of effector memory CD4<sup>+</sup> T-cells and an increase in central memory CD4<sup>+</sup> cells and naïve CD4<sup>+</sup> T-cells in the high-dose group. No differences were noted in the serum levels of 51 other cytokines evaluated in the study.

### Measuring Vitamin D Status

The renal production of 1,25(OH)<sub>2</sub>D is tightly regulated and has a relatively short half-life (4 h), while 25(OH)D has a longer half-life (20–60 days) [39, 40]. As an integrated measure of vitamin D produced by solar UVB exposure, dietary intake, and release from adipose tissues, serum levels of 25(OH)D are the best indicator of an individual's overall vitamin D status [41]. The 1,25(OH)<sub>2</sub>D levels in circulation are 1000 times lower than 25(OH)D levels, and they are often normal or elevated in patients with vitamin D deficiency because of the renal production of this hormone in response to increasing blood levels of parathyroid hormone. Thus the measurement of 1,25(OH)<sub>2</sub>D is of no value in determining a person's vitamin D status but is helpful in the differential diagnosis of acquired and inherited disorders in calcium, phosphate, and bone metab-

olism [7]. It should also be noted that extrarenal production is not tightly regulated. This is the reason why patients with granulomatous disorders developed hypercalciuria and hypercalcemia due to the unregulated production of 1,25(OH)<sub>2</sub>D by activated macrophages and its release into the circulation [7]. The 25(OH)D serum levels are reported in ng/mL or nmol/L with 1 ng/mL equal to 0.4006 nmol/L.

### Vitamin D Deficiency and Insufficiency

Nutritional rickets associated with vitamin D deficiency was widespread from the industrial age until the mid-twentieth century. Age of onset determines clinical manifestations but generally includes short stature, bone pain, bowing deformities of the legs and widening of the joints (epiphyseal plates), and severe proximal muscle weakness. In the 1920s, the value of cod liver oil, which contains adequate levels of vitamin D<sub>3</sub>, was recognized. At the same time, it was demonstrated that sun exposure could cure rickets, and initially the precursor of vitamin D<sub>2</sub> was added to milk and then exposed to ultraviolet radiation, which imparted antirachitic activity. In the 1930s when vitamin D was commercially produced, this process was eliminated and vitamin D<sub>2</sub> was added directly to the milk [5]. As a consequence, nutritional rickets was virtually eliminated in the United States by the 1940s. The importance of vitamin D in bone health and calcium homeostasis is now well-recognized and has been recently reviewed [42].

In 2011, the Institute of Medicine released guidelines for the general population which recommended a dietary vitamin D intake of 600 IU/day for those aged 1–70, and 800 IU/day for those >70 years old, corresponding to serum levels of 25(OH)D of 16 ng/mL [43]. The report did not recommend that all individuals attempt to achieve levels of 20 ng/mL or higher; rather it emphasized that most (97.5%) individuals' nutritional needs would be met at serum levels of 25(OH)D <20 ng/mL. However, the Endocrine Society whose guidelines were for the treatment

and prevention of vitamin D deficiency in children and adults defined deficiency as  $<20$  ng/mL, insufficiency as 21–29 ng/mL, and sufficiency as  $\geq 30$  ng/mL for maximum musculoskeletal health [44]. The definitions proposed by these two groups have been debated in the literature and will not be explored in detail herein [45–47].

---

## Vitamin D Status and Risk of Developing MS

Several key observations form the foundation for the hypothesis that hypovitaminosis D is an MS risk factor [48]. First, the prevalence of MS has been observed to increase with greater distance from the equator, which is strongly inversely correlated with duration and intensity of UVB exposure and 25(OH)D levels [5, 49–53]. Second, populations at high latitudes but with higher consumption of vitamin D-rich fatty fish have a lower than expected prevalence of MS [49, 52]. And third, the risk of MS appears to decrease with early migration from higher to lower latitudes [54, 55]. The final observation appears to have decreased in recent decades, possibly related to increasing tendency to avoid sun exposure and stay indoors for greater portions of the day even in warmer climates [56]. MS risk varies by latitude. Vitamin D status is inversely related to latitude [5], but other potentially involved factors also have a latitudinal gradient. For example, Epstein-Barr virus prevalence shows a direct latitude gradient, whereas parasite infections show an inverse relationship. How each of these factors contribute to overall risk of MS requires further characterization.

## Serum Levels of 25-Hydroxyvitamin D

If hypovitaminosis D has an effect on MS risk, we should observe MS incidence to increase with lower serum levels of 25(OH)D. Longitudinal studies examining 25(OH)D levels *before* the onset of MS are crucial because it is well established that serum 25(OH)D levels decrease after the onset of MS [57, 58]. Studies that only look at

vitamin D status after the development of MS leave open the potential for reverse causation as a confounder.

Although controversial [59], the risk of MS appears to be higher for individuals born in the spring (serum vitamin D status are lowest over the winter and early spring) than autumn, an observation that is most prominent in high-risk areas (higher latitude/less sunlight) and does not hold true in areas with higher sunlight exposure [60, 61]. Higher milk intake, dietary vitamin D consumption, and maternal predicted 25(OH)D were all associated with a decreased risk of MS in children of mothers from the Nurses Mother's Study, a prospective, longitudinal cohort study [62]. This suggests that maternal hypovitaminosis D during pregnancy may contribute to risk in the offspring. Further corroborating these results, a prospective, nested case-control study evaluated whether maternal serum 25(OH)D levels in early pregnancy are associated with MS risk in offspring [63]. The authors found that offspring of mothers with serum 25(OH)D  $<12$  ng/mL during early pregnancy had a nearly twofold increased risk of MS compared to offspring from mothers with normal 25(OH)D levels. Another study found that low concentrations of neonatal 25(OH)D were associated with an increased risk of MS, with the greatest risk in the lowest quintile ( $<8.3$  ng/mL) and lowest in the highest quintile ( $\geq 19.6$  ng/mL) suggesting a dose-response effect [64]. Taken together these studies suggest that low levels of vitamin D in utero and in neonates may increase the risk of MS.

Hypovitaminosis D also appears to increase risk of MS in adulthood. A prospective, nested case-control study of US military personnel found that high levels of serum vitamin D were associated with a decreased risk of MS [57]. A nested case-control study from another group including individuals in northern Sweden noted similar decreased risk of MS with higher vitamin D levels [65]. Munger and colleagues recently reported the results of a nested case-control study of 1092 women diagnosed with MS in the Finnish maternity cohort [66]. 25(OH)D was quantified in serum obtained prior to MS diagnosis, and subjects were matched with up to three controls

on date of birth and area of residence. Conditional logistic regression adjusted for year of sample collection, gravidity, and parity were used to estimate relative risks and 95% confidence intervals. They found that women with 25(OH)D levels <12 ng/mL had a 43% higher risk of MS compared to those with levels  $\geq 20$  ng/mL.

## Genetic Studies

Several recent studies have utilized Mendelian randomization to estimate the effect of vitamin D on the risk of MS. This is a method that uses measured variation in genes with known function to estimate the association of modifiable exposures in the risk of disease. Studies using this approach reduce the chance of reverse causation because inherited alleles are not affected by most confounding variables or disease status. In one study, genome-wide data of genetic variants shown to predict levels of serum 25(OH)D were applied to the International MS Genetics Consortium [67]. The authors found that alleles known to decrease levels of serum 25(OH)D predicted an increased susceptibility to MS. Another study found similar results in two separate populations, including white, non-Hispanic Americans and members of a Swedish population study [68]. A study of patients with pediatric-onset MS found independent effects of low vitamin D and high BMI [69]. These data further support the hypothesis that low levels of vitamin D exert independent causal effects on MS.

There are, however, a few studies with discrepant results worth considering. A population-based, multicenter, case-control study in Sweden investigated the link between vitamin D status at birth and the risk of MS using stored neonatal dried blood [70]. This study included 459 persons with MS and 663 controls and found no association between neonatal serum 25(OH)D quintiles and the risk of MS. Results were not appreciably different when adjusted for confounding factors such as month of birth, latitude of birth, breastfeeding or adult sun exposure, vitamin D intake, smoking, etc. The results of this study were viewed critically on several

grounds, including that blood samples were not well preserved with degradation of 25(OH)D noted in the study. Additionally, the range of 25(OH)D levels was narrow and mostly low (mean 11.9 ng/mL, median 10.3, interquartile range 6.8–15.4 ng/mL) [71].

---

## Vitamin D Status MS Disease Activity

Several studies have shown a correlation between relapse rates and vitamin D status. Although these are confounded by the possibility of reverse causation, they lend support to the possible role of vitamin D supplementation in MS. A retrospective study of pediatric patients with MS, after adjusting for several factors including age, race, ethnicity, disease duration, and treatment, found that every 10 ng/mL increase in 25(OH)D levels was associated with a 34% decrease in relapse rate [72]. Similar results were seen in adult-onset MS, where one study observed relapse rate to decrease by 27% for every doubling of 25(OH)D levels [73], and another noted that every increase in 25(OH)D by 4 ng/mL was associated with up to 12% reduction in relapse rate [74].

A 5-year longitudinal cohort study did not find a statistically significant correlation between vitamin D status and relapse rate in patients with relapsing-remitting multiple sclerosis (RRMS) or clinically isolated syndrome (CIS), but did observe a 15% lower risk of new T2 lesions and a 32% lower risk of new enhancing lesions on MRI for every 10 ng/mL increase in 25(OH)D [75]. A follow-up study found a tendency for an inverse relationship between average 25(OH)D levels and the composite endpoint of  $\geq 3$  new brain T2 lesions or  $\geq 1$  relapse within a year in patients with CIS [76]. A retrospective study of 100 patients with CIS from another group found that lower levels of serum 25(OH)D were associated with an increased risk of conversion to clinically definite MS, an association that was even stronger when controlling for additional risk factors for conversion [77]. Multiple studies have also correlated lower vitamin D status with greater

disability and disease severity, although reverse causation remains a concern in such studies.

Two MS treatment trials examined 25(OH)D levels and risk of MS progression. A possible advantage to these studies is that clinical outcomes such as relapses and MRI activity were more systematically ascertained than in observational cohorts. The BENEFIT (Betaferon/Betaseron in Newly Emerging Multiple Sclerosis For Initial Treatment) study was a randomized trial designed to evaluate the effect of early vs. delayed treatment with interferon beta-1b (IFNB-1b) in patients with CIS. As part of the study, serum 25(OH)D levels were tested at 0, 6, 12, and 24 months from randomization. Ascherio and colleagues analyzed the relationship between serum 25(OH)D levels and MS activity/progression using clinical and radiological data [78]. Low 25(OH)D levels were found to be a strong risk factor for long-term MS activity and progression with increased hazard of conversion to clinically definite MS (by radiologic or clinical criteria), higher rate of new lesion formation on MRI, higher rate of clinical relapses, and higher rate of brain atrophy on MRI with lower levels of 25(OH)D.

The BEYOND (Betaferon/Betaseron Efficacy Yielding Outcomes of a New Dose) study included measurements of 25(OH)D every 6 months, and a post hoc analysis of the data demonstrated that higher levels of 25(OH)D were associated with lower rates of MS activity on MRI; however, there was no significant association between serum 25(OH)D levels and rate of brain atrophy or clinical outcomes [79]. The association between 25(OH)D and MS activity was stronger in the early treatment (with IFNB-1b) group than in the delayed treatment group, suggesting that there may be an additive effect of IFNB-1b with vitamin D.

The aforementioned studies demonstrating that individuals with higher vitamin D levels experienced more MS disease control with IFNB-1b led to further exploration of possible immunomodulatory mechanisms [80]. Enhanced regulation of genes involved in immunomodulation was advanced as a possible explanation [81]. Lending support to this finding, an independent

team of investigators observed a greater production of vitamin D from sunlight in patients treated with IFNB [81]. In that study, every 10 ng/mL increase in 25(OH)D was associated with a 10% decrease in relapse rates, and interestingly IFNB was only protective against relapse in patients with higher levels of 25(OH)D. Patients with inadequate levels were at increased risk of relapse, despite IFNB treatment. However, another prospective cohort study of 88 patients with RRMS in Norway found that pre-IFN treatment, higher levels of 25(OH)D were associated with less radiologic disease activity, but this effect was no longer detected after IFNB treatment [82]. No associations were noted for relapses or EDSS progression.

The relationship between vitamin D status and other disease-modifying therapies was explored in the CLIMB (Comprehensive Longitudinal Investigation of Multiple Sclerosis at Brigham and Women's Hospital) study, a prospective cohort study that began enrolling patients in 2000 [83]. Rotstein and colleagues investigated the effect of vitamin D status on clinical and MRI outcomes in patients treated with IFN ( $n = 96$ ), glatiramer acetate (GA) ( $n = 151$ ), or fingolimod ( $n = 77$ ) [84]. Serum 25(OH)D levels were adjusted for season and patients were divided into subgroups based on 25(OH)D tertile. The primary endpoint was time to first inflammatory event, defined as either clinical relapse or gadolinium-enhancing lesion on MRI. The authors found that higher 25(OH)D levels were associated with longer time to the combined endpoint for patients on IFN or fingolimod, but not glatiramer. There was a significant association with gadolinium-enhancing lesions in both the IFN and GA groups, although the effect was greater for the IFN group, but no significant association with relapses was seen in either group. In the fingolimod group, there was a significant association for the combined endpoint and relapses, but not for gadolinium-enhancing lesions. These results suggest that patients with robust vitamin D status might experience a greater benefit from this with some disease-modifying therapies than others. It makes sense in theory that some medications may duplicate



many of vitamin D's effects and show less benefit when combined, while others might work primarily on separate pathways with an additive effect. Further research is necessary to better understand the interactions between MS drugs and vitamin D.

---

## Vitamin D Supplementation

### Vitamin D Supplementation as a Means to Preventing MS Development

Prospective non-randomized studies investigating whether vitamin D supplementation may lower the risk of developing MS are limited and have been conflicting. One study that included two large cohorts of women (the Nurses' Health Study with 92,253 women followed from 1980 to 2000 and Nurses' Health Study II with 95,310 women followed from 1991 to 2001) found a decreased pooled, age-adjusted relative risk of MS for subjects in the highest quintile of total vitamin D intake compared to the lowest quintile (RR = 0.67) [85]. The same study noted a reduced relative risk with vitamin D intake through supplements. Women who took  $\geq 400$  IU/day had a relative risk of 0.59 compared to those who did not take supplementation; however, no association was observed between MS incidence and vitamin D intake from food sources. Another study using the data from both the Nurses' Health Study and Nurses' Health Study II study examined the association of vitamin D intake specifically during adolescence with risk of MS and found no significant effect associated with vitamin D intake, including through supplementation [85, 86]. However, there was a non-statistically significant trend toward decreased risk of MS with supplementation  $\geq 400$  IU/day. Some have advocated for a more proactive approach consisting of vitamin D supplementation in hopes of preventing MS, at least for individuals at high risk including smokers, the obese, and those with a family history of MS [87].

### Vitamin D Supplementation as a Means to Decreasing MS Disease Severity

Studies investigating the role of vitamin D supplementation in MS are conflicting and no consensus has been reached regarding the use of vitamin D. A systematic review of randomized, controlled trials published in 2013 noted problems with small sample sizes (23–68 patients), heterogeneity in dosing, form of vitamin D (cholecalciferol vs. ergocalciferol), and outcome clinical measures [88]. Four of the five trials demonstrated no effect of vitamin D in MS, while one showed a reduction of the number of enhancing lesions only. The authors concluded that the evidence for vitamin D supplementation in MS is inconclusive and that larger studies are warranted [88]. A meta-analysis also from 2013 was only able to include 129 high-dose vitamin D-treated patients and 125 controls and found no correlation between high-dose vitamin D treatment and clinical relapses and similarly concluded that the existing studies were methodologically limited and further investigation was warranted in the form of larger, more prolonged studies [89]. Below we comment on some particular studies, attempting to offer some perspective about trials that have been conducted to date.

Two studies explored the effect of a 20,000 IU/week (equivalent = approximately 3000 IU daily) of vitamin D3 on clinical and MRI outcomes. A 1-year randomized controlled study including 66 patients with MS randomized patients to a weekly dose of 20,000 IU vitamin D3 or placebo. Eighty-four percent of patients in the treatment arm achieved levels of 25(OH)D  $> 34$  ng/mL and had fewer enhancing lesions on MRI. However the study was not powered to assess clinical outcomes. A 96-week trial originally designed to assess the effects of high-dose vitamin D3 supplementation on bone density in patients with MS found that a weekly dose of 20,000 IU of vitamin D3 was also not powered to assess clinical outcomes, but did not appear to affect the course of the disease [90].

One study randomized patients with clinically active RRMS to either a dose of 6000 or 1000 IU ergocalciferol daily in patients with clinically active RRMS [91]. The authors found no difference between groups in MRI-based outcome measures. A higher exit EDSS and a higher proportion of relapse were noted in the high-dose arm. A few methodologic limitations are worth mentioning, however. Only 23 patients were enrolled initially and 3 patients withdrew from the study. A patient in the high-dose group included in the analysis had 38 enhancing lesions at baseline, while all others had 2–5, and the low-dose group was on average 5–10 years younger than the high-dose group. Another study including 50 patients randomized to 8000 IU vitamin D3 or placebo daily found no effect on clinical or MRI metrics [92]. Mosayebi and colleagues randomized 62 patients to 300,000 IU (equivalent = 10,000 IU daily) once monthly to either vitamin D3 injection or placebo and no difference in clinical or radiological measures of disease activity, although lymphocyte proliferation rates were lower in the treatment arm [93].

The SOLAR study, another randomized, double-blind, placebo controlled phase 2 study including patients who were on subcutaneous IFNB-1a with 25(OH)D levels <60 ng/mL, did not find significant differences in clinical outcomes between groups, but was technically limited by poor recruitment [94, 95]. The study did note differences in MRI findings. The study included 229 patients who were randomized to treatment with 14,000 IU/day cholecalciferol or placebo. The primary endpoint was freedom from disease activity as measured by relapses, progression on EDSS, or new unique enhancing or T2 lesions. Only available in abstract format, the primary endpoint was changed due to delayed recruitment, allowing for reductions in study size and duration. Compared with placebo, vitamin D supplementation did not affect freedom from disease activity, but did reduce the number of new active lesions overall and new T1 hypointense lesions in patients aged 18–30 years. Another randomized, placebo-controlled phase 2 study included 129 patients with MS on IFNB-1a who

were randomized to either 100,000 IU vitamin D3 twice monthly (daily equivalent of 7143 IU) or placebo noted no effect on clinical parameters, but did observe a protective effect of vitamin D on MRI parameters. The authors found no statistically significant effect on clinical parameters in the intention-to-treat analysis, but the study may have been underpowered as a consequence of an unexpectedly low relapse rate among the control patients [96].

## Ongoing Studies

Three ongoing studies are registered with [www.clinicaltrials.gov](http://www.clinicaltrials.gov). The Efficacy of Vitamin D Supplementation in Multiple Sclerosis (EVIDIMS) study is a randomized, controlled, double-blind stratified phase 2 clinical trial of patients with CIS or MS on IFNB-1b in Germany [97]. Patients are randomized to high-dose (average 10,200 IU daily) or low-dose (average 200 IU daily) cholecalciferol for 18 months. The primary outcome measure is the number of new T2 lesions on brain MRI. Secondary endpoints include other MRI and OCT parameters, clinical metrics, and patient-reported outcomes such as quality of life and fatigue. Results are anticipated in 2018 or 2019.

Another ongoing study, the Vitamin D to Ameliorate Multiple Sclerosis (VIDAMS) study, is a randomized, controlled phase 3 study with a target recruitment of 172 patients with MS in the United States [98]. Patients will be randomized to high-dose (5000 IU daily) or low-dose (600 IU daily) vitamin D3 as add-on therapy to glatiramer acetate. The primary outcome is proportion of patients experiencing a relapse, and secondary outcomes include additional clinical and radiological metrics. The study will terminate in 2018. Finally, an actively recruiting, double-blind, randomized, controlled trial including 100 patients with MS will randomize patients to 1000 or 4000 IU vitamin D3 daily for 4 months. The primary outcome is the change in 25(OH)D levels, with goals including improving the understanding of immunomodulatory effects of vitamin D *in vivo*.

## Translating Data into Clinical Practice

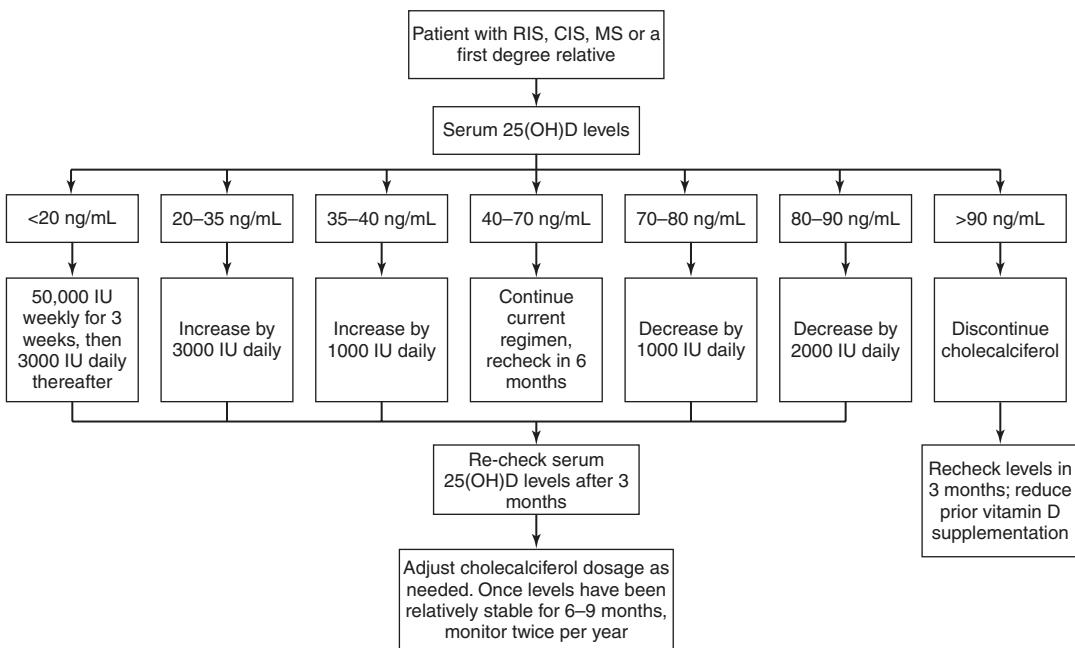
### Offering Vitamin D Supplementation to Patients

Although substantial evidence has demonstrated the safety and tolerability of even relatively high doses of vitamin D, the absence of definitive data from large randomized controlled trials has limited the application of vitamin D supplementation for patients with MS. Similarly, the role of vitamin D supplementation for the prevention of MS in the general public, as well as for higher-risk individuals, such as family members of persons with MS, remains incompletely defined.

It is unclear whether D2 or D3 might perform better as a supplement or if they are equivalent. In a meta-analysis of seven randomized trials evaluating serum 25(OH)D concentrations in patients requiring supplementation with D2 vs. D3, D3 increased serum 25(OH)D more efficiently than D2 [99]. This result should be interpreted cautiously given different dosing frequencies, doses, and time periods used in this

study. It is also unclear how this might apply to patients considered to be at a normal level who are supplemented to further increase their serum vitamin D 25OH [99].

Despite the limitations in our current understanding of whether vitamin D supplementation might alter MS disease course, we routinely evaluate the vitamin D status of patients with radiologically isolated syndrome (RIS), CIS, and MS and provide supplementation to target a level of 40–70 ng/mL with oral cholecalciferol, if necessary (Fig. 10.2). We choose 40 ng/mL as the lower bound based on an increased risk of disease development observed in the military nested case-control cohort [57] and worsening of MS observed in the post hoc analysis of the BENEFIT trial [78] in individuals with levels <40 ng/mL. We recheck serum levels 3–6 months after making any adjustments to supplementation, and once serum levels have been relatively stable on a consistent regimen, we check levels every 6–12 months for monitoring. Patients with a BMI >30 require 2–3 times more vitamin D to satisfy their requirements [100]. Similarly, those who are treated chronically with steroids or who have gut absorption prob-



**Fig. 10.2** Suggested daily vitamin D3 supplementation based on serum levels of 25(OH)D. *CIS* clinically isolated syndrome, *IU* international units, *MS* multiple sclerosis, *RIS* radiologically isolated syndrome

lems or are treated with antiepileptic medications such as phenytoin or phenobarbital may require higher supplemental doses [101].

### Offering Vitamin D to Those at Risk for MS

The evidence supporting a preventative effect of vitamin D is more compelling than the evidence suggesting a therapeutic effect. In addition to correcting low levels of 25(OH)D for patients with RIS, CIS, or MS, we generally recommend that first-degree relatives of persons with MS have their vitamin D status evaluated and corrected with oral supplementation if needed [87].

### Safety and Toxicity

When considering supplementation, an understanding of the safety profile of vitamin D and signs of intoxication are important. A double-blind, randomized pilot study demonstrated the safety and tolerability of high-dose vitamin D in MS patients over a 6-month study period [37]. The authors randomized 40 study participants to receive supplemental cholecalciferol at doses of 10,400 IU daily and 800 IU daily for 6 months. Adverse events were minor and did not differ between treatment groups. Three patients (one in the low-dose and two in the high-dose group) developed nausea that resolved after discontinuing supplementation. Baseline serum 25(OH)D levels did not differ between treatment groups, but increased to a greater extent in the high-dose than the low-dose group: the mean change from baseline was 34.9 ng/mL in the high-dose and 6.9 ng/mL in the low-dose group. One patient in the high-dose group was found to have a serum calcium level of 10.6 mg/dL (reference range 8.4–10.5 mg/dL; the participant's baseline level was 10.0 mg/dL) with a normal urine calcium. That participant completed the study, and at the 6-month follow-up, after stopping supplementation, the serum calcium level had normalized. Dosing frequency was reduced to every other day in one patient from each treatment group for elevated urine calcium/creatinine ratio.

An open-label, phase I/II dose-escalation trial of vitamin D found that high-dose vitamin D did not significantly increase serum calcium levels compared to patients not on high doses. Patients with MS were matched for demographics and disease characteristics and randomized to control or treatment with vitamin D [102]. Treatment arm patients were given escalating doses up to 40,000 IU daily. The study was not statistically precise enough nor designed to assess clinical outcomes, but did provide class II evidence that high-dose vitamin D given to patients with MS for 52 weeks does not significantly increase serum calcium levels compared to patients not on high-dose supplementation.

Toxicity from vitamin D is most often related to hypercalcemia, and associated serum 25(OH)D levels are typically well above 150 ng/mL in these patients [44]. Doses above 10,000 IU daily are generally required to achieve these levels [103]. A study in Canada reported that healthy adults taking as much as 20,000 IUs of vitamin D per day maintain blood levels of 25(OH)D in the range of 60–80 ng/mL without any evidence of toxicity [104]. The effects of long-term relatively high-dose vitamin D have not been well studied, however. A few reports suggest a correlation between serum levels of 25(OH)D >60 ng/mL and increased risks of any-cause mortality, pancreatic cancer, and vascular calcification, but one cannot assess cause and effect given the observational nature of these studies [105–107].

Vitamin D intoxication clinically manifests with confusion, polyuria, polydipsia, anorexia, emesis, and muscle weakness related to hypercalcemia. Hyperphosphatemia also occurs due to the suppression of PTH, and increased intestinal absorption of dietary phosphate and chronic vitamin D intoxication can cause nephrocalcinosis, vascular calcification, and bone demineralization. A recent systematic review and meta-analysis did not find an increased risk of cardiovascular events with vitamin D supplementation, and a Cochrane database review found a decreased risk of death in the elderly with vitamin D3 (but not vitamin D2 supplementation) [108, 109]. The level at which hypercalcemia occurs is undefined, but many experts define intoxication

as serum levels of 25(OH)D<sub>3</sub> ≥150 ng/mL [7, 44]. Our practice is to monitor serum 25(OH)D levels every 6 months while adjusting vitamin D3 supplementation and annually for patients with stable levels. Adjustments can be made based on the patient's serum 25(OH)D levels according to Fig. 10.2.

## Conclusion

Vitamin D has pleiotropic effects, some of which are beneficial to the immune system. It is our view that there is good evidence that in utero and beyond low vitamin D status predispose to the development of multiple sclerosis. It is also likely that MS patients with low 25(OH)D levels are at greater risk of MS disease activity. The data supporting the role vitamin D in the treatment of MS are not as compelling as those in the prevention of MS, but better prospective studies are needed. The trials to date are limited by methodological issues such as their small size and short duration, but the association between 25(OH)D levels and MS activity is stronger for MRI than for clinical outcomes. This may be related to higher sensitivity of MRI to disease activity than clinical metrics. In practice we recommend vitamin D supplementation to our MS patients and first-degree relatives employing the rationale that in our geographic area, oftentimes 25(OH)D levels are low and that it is unlikely to cause harm if moderate doses are used. Clinical trials are currently underway to more directly address the role of vitamin D supplementation in MS, yet further investigations are needed. As most studies have included primarily older Caucasians, it is important to evaluate the role of vitamin D in younger persons of non-Caucasian ethnicity.

## References

- Anderson DW, Ellenberg JH, Leventhal CM, Reingold SC, Rodriguez M, Silberberg DH. Revised estimate of the prevalence of multiple sclerosis in the United States. *Ann Neurol*. 1992;31(3):333–6.
- Pugliatti M, Rosati G, Carton H, Riise T, Drulovic J, Vecsei L, et al. The epidemiology of multiple sclerosis in Europe. *Eur J Neurol*. 2006;13(7):700–22.
- Koch-Henriksen N, Sorensen PS. The changing demographic pattern of multiple sclerosis epidemiology. *Lancet Neurol*. 2010;9(5):520–32.
- Holick MF. Vitamin D: a millennium perspective. *J Cell Biochem*. 2003;88(2):296–307.
- Wacker M, Holick MF. Sunlight and vitamin D: a global perspective for health. *Dermatoendocrinol*. 2013;5(1):51–108.
- Yetley EA. Assessing the vitamin D status of the US population. *Am J Clin Nutr*. 2008;88(2):558S–64S.
- Holick MF. Vitamin D deficiency. *N Engl J Med*. 2007;357(3):266–81.
- Hossein-nezhad A, Holick MF. Vitamin D for health: a global perspective. *Mayo Clin Proc*. 2013;88(7):720–55.
- Feldman D, Krishnan AV, Swami S, Giovannucci E, Feldman BJ. The role of vitamin D in reducing cancer risk and progression. *Nat Rev Cancer*. 2014;14(5):342–57.
- Kriegel MA, Manson JE, Costenbader KH. Does vitamin D affect risk of developing autoimmune disease?: a systematic review. *Semin Arthritis Rheum*. 2011;40(6):512–31.e8.
- Pilz S, Verheyen N, Grubler MR, Tomaschitz A, Marz W. Vitamin D and cardiovascular disease prevention. *Nat Rev Cardiol*. 2016;13(7):404–17.
- Provvedini DM, Tsoukas CD, Defetos LJ, Manolagas SC. 1,25-dihydroxyvitamin D3 receptors in human leukocytes. *Science*. 1983;221(4616):1181–3.
- Bhalla AK, Amento EP, Clemens TL, Holick MF, Krane SM. Specific high-affinity receptors for 1,25-dihydroxyvitamin D3 in human peripheral blood mononuclear cells: presence in monocytes and induction in T lymphocytes following activation. *J Clin Endocrinol Metab*. 1983;57(6):1308–10.
- Brennan A, Katz DR, Nunn JD, Barker S, Hewison M, Fraher LJ, et al. Dendritic cells from human tissues express receptors for the immunoregulatory vitamin D3 metabolite, dihydroxycholecalciferol. *Immunology*. 1987;61(4):457–61.
- Morgan JW, Kouttab N, Ford D, Maizel AL. Vitamin D-mediated gene regulation in phenotypically defined human B cell subpopulations. *Endocrinology*. 2000;141(9):3225–34.
- Chen L, Cencioni MT, Angelini DF, Borsellino G, Battistini L, Brosnan CF. Transcriptional profiling of gamma delta T cells identifies a role for vitamin D in the immunoregulation of the V gamma 9V delta 2 response to phosphate-containing ligands. *J Immunol*. 2005;174(10):6144–52.
- Jeffery LE, Qureshi OS, Gardner D, Hou TZ, Briggs Z, Soskic B, et al. Vitamin D antagonises the suppressive effect of inflammatory cytokines on CTLA-4 expression and regulatory function. *PLoS One*. 2015;10(7):e0131539.
- Dankers W, Colin EM, van Hamburg JP, Lubberts E. Vitamin D in autoimmunity: molecular mechanisms and therapeutic potential. *Front Immunol*. 2016;7:697.
- Rolf L, Muris AH, Hupperts R, Damoiseaux J. Illuminating vitamin D effects on B cells—

- the multiple sclerosis perspective. *Immunology*. 2016;147(3):275–84.
20. Peelen E, Knippenberg S, Muris AH, Thewissen M, Smolders J, Tervaert JW, et al. Effects of vitamin D on the peripheral adaptive immune system: a review. *Autoimmun Rev*. 2011;10(12):733–43.
  21. Penna G, Adorini L. 1,25-Dihydroxyvitamin D3 inhibits differentiation, maturation, activation, and survival of dendritic cells leading to impaired alloreactive T cell activation. *J Immunol*. 2000;164(5):2405–11.
  22. Unger WW, Laban S, Kleijwegt FS, van der Slik AR, Roep BO. Induction of Treg by monocyte-derived DC modulated by vitamin D3 or dexamethasone: differential role for PD-L1. *Eur J Immunol*. 2009;39(11):3147–59.
  23. Xu H, Soruri A, Gieseler RK, Peters JH. 1,25-Dihydroxyvitamin D3 exerts opposing effects to IL-4 on MHC class-II antigen expression, accessory activity, and phagocytosis of human monocytes. *Scand J Immunol*. 1993;38(6):535–40.
  24. Liu PT, Stenger S, Tang DH, Modlin RL. Cutting edge: vitamin D-mediated human antimicrobial activity against *Mycobacterium tuberculosis* is dependent on the induction of cathelicidin. *J Immunol*. 2007;179(4):2060–3.
  25. Chen Y, Liu W, Sun T, Huang Y, Wang Y, Deb DK, et al. 1,25-Dihydroxyvitamin D promotes negative feedback regulation of TLR signaling via targeting microRNA-155-SOCS1 in macrophages. *J Immunol*. 2013;190(7):3687–95.
  26. Palmer MT, Lee YK, Maynard CL, Oliver JR, Bikle DD, Jetten AM, et al. Lineage-specific effects of 1,25-dihydroxyvitamin D(3) on the development of effector CD4 T cells. *J Biol Chem*. 2011;286(2):997–1004.
  27. Joshi S, Pantalena LC, Liu XK, Gaffen SL, Liu H, Rohowsky-Kochan C, et al. 1,25-dihydroxyvitamin D(3) ameliorates Th17 autoimmunity via transcriptional modulation of interleukin-17A. *Mol Cell Biol*. 2011;31(17):3653–69.
  28. Meehan TF, DeLuca HF. The vitamin D receptor is necessary for 1alpha,25-dihydroxyvitamin D(3) to suppress experimental autoimmune encephalomyelitis in mice. *Arch Biochem Biophys*. 2002;408(2):200–4.
  29. Sintzel MB, Rametta M, Reder AT. Vitamin D and multiple sclerosis: a comprehensive review. *Neurol Ther*. 2018;7(1):59–85.
  30. Correale J, Ysraelit MC, Gaitan MI. Vitamin D-mediated immune regulation in multiple sclerosis. *J Neurol Sci*. 2011;311(1–2):23–31.
  31. Spach KM, Hayes CE. Vitamin D3 confers protection from autoimmune encephalomyelitis only in female mice. *J Immunol*. 2005;175(6):4119–26.
  32. Nashold FE, Spach KM, Spanier JA, Hayes CE. Estrogen controls vitamin D3-mediated resistance to experimental autoimmune encephalomyelitis by controlling vitamin D3 metabolism and receptor expression. *J Immunol*. 2009;183(6):3672–81.
  33. Hauser SL, Weiner HL, Che M, Shapiro ME, Gilles F, Letvin NL. Prevention of experimental allergic encephalomyelitis (EAE) in the SJL/J mouse by whole body ultraviolet irradiation. *J Immunol*. 1984;132(3):1276–81.
  34. Lucas RM, Ponsonby AL. Considering the potential benefits as well as adverse effects of sun exposure: can all the potential benefits be provided by oral vitamin D supplementation? *Prog Biophys Mol Biol*. 2006;92(1):140–9.
  35. Holick MF. Sunlight, ultraviolet radiation, vitamin D and skin cancer: how much sunlight do we need? *Adv Exp Med Biol*. 2014;810:1–16.
  36. Nataf S, Garcion E, Darcy F, Chabannes D, Muller JY, Brachet P. 1,25 Dihydroxyvitamin D3 exerts regional effects in the central nervous system during experimental allergic encephalomyelitis. *J Neuropathol Exp Neurol*. 1996;55(8):904–14.
  37. Sotirchos ES, Bhargava P, Eckstein C, Van Haren K, Baynes M, Ntranos A, et al. Safety and immunologic effects of high- vs low-dose cholecalciferol in multiple sclerosis. *Neurology*. 2016;86(4):382–90.
  38. Tzartos JS, Friese MA, Craner MJ, Palace J, Newcombe J, Esiri MM, et al. Interleukin-17 production in central nervous system-infiltrating T cells and glial cells is associated with active disease in multiple sclerosis. *Am J Pathol*. 2008;172(1):146–55.
  39. Armas LA, Hollis BW, Heaney RP. Vitamin D2 is much less effective than vitamin D3 in humans. *J Clin Endocrinol Metab*. 2004;89(11):5387–91.
  40. Trang HM, Cole DE, Rubin LA, Pierratos A, Siu S, Vieth R. Evidence that vitamin D3 increases serum 25-hydroxyvitamin D more efficiently than does vitamin D2. *Am J Clin Nutr*. 1998;68(4):854–8.
  41. Heaney RP. The vitamin D requirement in health and disease. *J Steroid Biochem Mol Biol*. 2005;97(1–2):13–9.
  42. Carpenter TO, Shaw NJ, Portale AA, Ward LM, Abrams SA, Pettifor JM. Rickets. *Nat Rev Dis Primers*. 2017;3:17101.
  43. Ross AC, Manson JE, Abrams SA, Aloia JF, Brannon PM, Clinton SK, et al. The 2011 report on dietary reference intakes for calcium and vitamin D from the Institute of Medicine: what clinicians need to know. *J Clin Endocrinol Metab*. 2011;96(1):53–8.
  44. Holick MF, Binkley NC, Bischoff-Ferrari HA, Gordon CM, Hanley DA, Heaney RP, et al. Evaluation, treatment, and prevention of vitamin D deficiency: an Endocrine Society clinical practice guideline. *J Clin Endocrinol Metab*. 2011;96(7):1911–30.
  45. Manson JE, Brannon PM, Rosen CJ, Taylor CL. Vitamin D deficiency – is there really a pandemic? *N Engl J Med*. 2016;375(19):1817–20.
  46. Holick MF. The vitamin D deficiency pandemic: approaches for diagnosis, treatment and prevention. *Rev Endocr Metab Disord*. 2017;18(2):153–65.
  47. Rosen CJ, Abrams SA, Aloia JF, Brannon PM, Clinton SK, Durazo-Arvizu RA, et al. IOM committee members respond to Endocrine Society vitamin D guideline. *J Clin Endocrinol Metab*. 2012;97(4):1146–52.

48. Pierrot-Deseilligny C, Souberbielle JC. Is hypovitaminosis D one of the environmental risk factors for multiple sclerosis? *Brain*. 2010;133(Pt 7):1869–88.
49. Swank RL, Lerstad O, Strom A, Backer J. Multiple sclerosis in rural Norway its geographic and occupational incidence in relation to nutrition. *N Engl J Med*. 1952;246(19):722–8.
50. van der Mei IA, Ponsonby AL, Blizzard L, Dwyer T. Regional variation in multiple sclerosis prevalence in Australia and its association with ambient ultraviolet radiation. *Neuroepidemiology*. 2001;20(3):168–74.
51. Vukusic S, Van Bockstael V, Gosselin S, Confavreux C. Regional variations in the prevalence of multiple sclerosis in French farmers. *J Neurol Neurosurg Psychiatry*. 2007;78(7):707–9.
52. Westlund K. Distribution and mortality time trend of multiple sclerosis and some other diseases in Norway. *Acta Neurol Scand*. 1970;46(4):455–83.
53. Orton SM, Wald L, Confavreux C, Vukusic S, Krohn JP, Ramagopalan SV, et al. Association of UV radiation with multiple sclerosis prevalence and sex ratio in France. *Neurology*. 2011;76(5):425–31.
54. Gale CR, Martyn CN. Migrant studies in multiple sclerosis. *Prog Neurobiol*. 1995;47(4–5):425–48.
55. Kurtzke JF, Beebe GW, Norman JE Jr. Epidemiology of multiple sclerosis in US veterans: III. Migration and the risk of MS. *Neurology*. 1985;35(5):672–8.
56. Ascherio A, Munger KL. Environmental risk factors for multiple sclerosis. Part II: Noninfectious factors. *Ann Neurol*. 2007;61(6):504–13.
57. Munger KL, Levin LI, Hollis BW, Howard NS, Ascherio A. Serum 25-hydroxyvitamin D levels and risk of multiple sclerosis. *JAMA*. 2006;296(23):2832–8.
58. van der Mei IA, Ponsonby AL, Dwyer T, Blizzard L, Taylor BV, Kilpatrick T, et al. Vitamin D levels in people with multiple sclerosis and community controls in Tasmania, Australia. *J Neurol*. 2007;254(5):581–90.
59. Fiddes B, Wason J, Kempainen A, Ban M, Compston A, Sawcer S. Confounding underlies the apparent month of birth effect in multiple sclerosis. *Ann Neurol*. 2013;73(6):714–20.
60. Grytten N, Torkildsen O, Aarseth JH, Benjaminsen E, Celius EG, Dahl OP, et al. Month of birth as a latitude-dependent risk factor for multiple sclerosis in Norway. *Mult Scler*. 2013;19(8):1028–34.
61. Torkildsen O, Grytten N, Aarseth J, Myhr KM, Kampman MT. Month of birth as a risk factor for multiple sclerosis: an update. *Acta Neurol Scand Suppl*. 2012;(195):58–62.
62. Mirzaei F, Michels KB, Munger K, O'Reilly E, Chitnis T, Forman MR, et al. Gestational vitamin D and the risk of multiple sclerosis in offspring. *Ann Neurol*. 2011;70(1):30–40.
63. Munger KL, Aivo J, Hongell K, Soilu-Hanninen M, Surcel HM, Ascherio A. Vitamin D status during pregnancy and risk of multiple sclerosis in offspring of women in the Finnish Maternity Cohort. *JAMA Neurol*. 2016;73(5):515–9.
64. Nielsen NM, Munger KL, Koch-Henriksen N, Hougaard DM, Magyari M, Jorgensen KT, et al. Neonatal vitamin D status and risk of multiple sclerosis: a population-based case-control study. *Neurology*. 2017;88(1):44–51.
65. Salzer J, Hallmans G, Nystrom M, Stenlund H, Wadell G, Sundstrom P. Vitamin D as a protective factor in multiple sclerosis. *Neurology*. 2012;79(21):2140–5.
66. Munger KL, Hongell K, Aivo J, Soilu-Hanninen M, Surcel HM, Ascherio A. 25-Hydroxyvitamin D deficiency and risk of MS among women in the Finnish Maternity Cohort. *Neurology*. 2017;89(15):1578–83.
67. Mokry LE, Ross S, Ahmad OS, Forgetta V, Smith GD, Goltzman D, et al. Vitamin D and risk of multiple sclerosis: a Mendelian Randomization Study. *PLoS Med*. 2015;12(8):e1001866.
68. Rhead B, Baarnhielm M, Gianfrancesco M, Mok A, Shao X, Quach H, et al. Mendelian randomization shows a causal effect of low vitamin D on multiple sclerosis risk. *Neurol Genet*. 2016;2(5):e97.
69. Gianfrancesco MA, Stridh P, Rhead B, Shao X, Xu E, Graves JS, et al. Evidence for a causal relationship between low vitamin D, high BMI, and pediatric-onset MS. *Neurology*. 2017;88(17):1623–9.
70. Ueda P, Rafatnia F, Baarnhielm M, Frobom R, Korzunowicz G, Lonnerbro R, et al. Neonatal vitamin D status and risk of multiple sclerosis. *Ann Neurol*. 2014;76(3):338–46.
71. Ascherio A, Munger KL. Not too late to take vitamin D supplements. *Ann Neurol*. 2014;76(3):321–2.
72. Mowry EM, Krupp LB, Milazzo M, Chabas D, Strober JB, Belman AL, et al. Vitamin D status is associated with relapse rate in pediatric-onset multiple sclerosis. *Ann Neurol*. 2010;67(5):618–24.
73. Runia TF, Hop WC, de Rijke YB, Buljevac D, Hintzen RQ. Lower serum vitamin D levels are associated with a higher relapse risk in multiple sclerosis. *Neurology*. 2012;79(3):261–6.
74. Simpson S Jr, Taylor B, Blizzard L, Ponsonby AL, Pittas F, Tremlett H, et al. Higher 25-hydroxyvitamin D is associated with lower relapse risk in multiple sclerosis. *Ann Neurol*. 2010;68(2):193–203.
75. Mowry EM, Waubant E, McCulloch CE, Okuda DT, Evangelista AA, Lincoln RR, et al. Vitamin D status predicts new brain magnetic resonance imaging activity in multiple sclerosis. *Ann Neurol*. 2012;72(2):234–40.
76. Mowry EM, Pelletier D, Gao Z, Howell MD, Zamvil SS, Waubant E. Vitamin D in clinically isolated syndrome: evidence for possible neuroprotection. *Eur J Neurol*. 2016;23(2):327–32.
77. Martinelli V, Dalla Costa G, Colombo B, Dalla Libera D, Rubinacci A, Filippi M, et al. Vitamin D levels and risk of multiple sclerosis in patients with clinically isolated syndromes. *Mult Scler*. 2014;20(2):147–55.

78. Ascherio A, Munger KL, White R, Kochert K, Simon KC, Polman CH, et al. Vitamin D as an early predictor of multiple sclerosis activity and progression. *JAMA Neurol.* 2014;71(3):306–14.
79. Fitzgerald KC, Munger KL, Kochert K, Arnason BG, Comi G, Cook S, et al. Association of vitamin D levels with multiple sclerosis activity and progression in patients receiving interferon beta-1b. *JAMA Neurol.* 2015;72(12):1458–65.
80. Munger KL, Kochert K, Simon KC, Kappos L, Polman CH, Freedman MS, et al. Molecular mechanism underlying the impact of vitamin D on disease activity of MS. *Ann Clin Transl Neurol.* 2014;1(8):605–17.
81. Stewart N, Simpson S Jr, van der Mei I, Ponsonby AL, Blizzard L, Dwyer T, et al. Interferon-beta and serum 25-hydroxyvitamin D interact to modulate relapse risk in MS. *Neurology.* 2012;79(3):254–60.
82. Loken-Amsrud KI, Holmoy T, Bakke SJ, Beiske AG, Bjerve KS, Bjornara BT, et al. Vitamin D and disease activity in multiple sclerosis before and during interferon-beta treatment. *Neurology.* 2012;79(3):267–73.
83. Gauthier SA, Glanz BI, Mandel M, Weiner HL. A model for the comprehensive investigation of a chronic autoimmune disease: the multiple sclerosis CLIMB study. *Autoimmun Rev.* 2006;5(8):532–6.
84. Rotstein DL, Healy BC, Malik MT, Carruthers RL, Musallam AJ, Kivisakk P, et al. Effect of vitamin D on MS activity by disease-modifying therapy class. *Neurol Neuroimmunol Neuroinflamm.* 2015;2(6):e167.
85. Munger KL, Zhang SM, O'Reilly E, Hernan MA, Olek MJ, Willett WC, et al. Vitamin D intake and incidence of multiple sclerosis. *Neurology.* 2004;62(1):60–5.
86. Munger KL, Chitnis T, Frazier AL, Giovannucci E, Spiegelman D, Ascherio A. Dietary intake of vitamin D during adolescence and risk of multiple sclerosis. *J Neurol.* 2011;258(3):479–85.
87. Marrie RA, Beck CA. Preventing multiple sclerosis: to (take) vitamin D or not to (take) vitamin D? *Neurology.* 2017;89(15):1538–9.
88. Pozuelo-Moyano B, Benito-Leon J, Mitchell AJ, Hernandez-Gallego J. A systematic review of randomized, double-blind, placebo-controlled trials examining the clinical efficacy of vitamin D in multiple sclerosis. *Neuroepidemiology.* 2013;40(3):147–53.
89. James E, Dobson R, Kuhle J, Baker D, Giovannoni G, Ramagopalan SV. The effect of vitamin D-related interventions on multiple sclerosis relapses: a meta-analysis. *Mult Scler.* 2013;19(12):1571–9.
90. Kampman MT, Steffensen LH, Mellgren SI, Jorgensen L. Effect of vitamin D3 supplementation on relapses, disease progression, and measures of function in persons with multiple sclerosis: exploratory outcomes from a double-blind randomised controlled trial. *Mult Scler.* 2012;18(8):1144–51.
91. Stein MS, Liu Y, Gray OM, Baker JE, Kolbe SC, Ditchfield MR, et al. A randomized trial of high-dose vitamin D2 in relapsing-remitting multiple sclerosis. *Neurology.* 2011;77(17):1611–8.
92. Shaygannejad V, Janghorbani M, Ashtari F, Dehghan H. Effects of adjunct low-dose vitamin D on relapsing-remitting multiple sclerosis progression: preliminary findings of a randomized placebo-controlled trial. *Mult Scler Int.* 2012;2012:452541.
93. Mosayebi G, Ghazavi A, Ghasami K, Jand Y, Kokhaei P. Therapeutic effect of vitamin D3 in multiple sclerosis patients. *Immunol Investig.* 2011;40(6):627–39.
94. Smolders J, Hupperts R, Barkhof F, Grimaldi LM, Holmoy T, Killestein J, et al. Efficacy of vitamin D3 as add-on therapy in patients with relapsing-remitting multiple sclerosis receiving subcutaneous interferon beta-1a: a Phase II, multicenter, double-blind, randomized, placebo-controlled trial. *J Neurol Sci.* 2011;311(1–2):44–9.
95. Hupperts R, Smolders J, Vieth R, Holmøy T, Marhardt K, Schlupe M, Killestein J, Barkhof F, Grimaldi LM, Beelke M. High dose cholecalciferol (vitamin D3) oil as add-on therapy in subjects with relapsing-remitting multiple sclerosis (RRMS) receiving subcutaneous interferon  $\beta$ -1a (scIFN $\beta$ -1a). *Neurology.* 2017;88(16 Suppl):S44.005.
96. Camu W, Pierrot-Deseilligny C, Hauteceur P, Besserve A, Deleglise A-SJ, Lehert P, Souberbielle J-C. Cholecalciferol supplementation in relapsing multiple sclerosis patients treated with subcutaneous interferon beta-1a: a randomized controlled trial. *Neurology.* 2017;88(16 Suppl):S44.004.
97. Dorr J, Ohlraun S, Skarabis H, Paul F. Efficacy of vitamin D supplementation in multiple sclerosis (EVIDIMS Trial): study protocol for a randomized controlled trial. *Trials.* 2012;13:15.
98. Bhargava P, Cassard S, Steele SU, Azevedo C, Pelletier D, Sugar EA, et al. The vitamin D to ameliorate multiple sclerosis (VIDAMS) trial: study design for a multicenter, randomized, double-blind controlled trial of vitamin D in multiple sclerosis. *Contemp Clin Trials.* 2014;39(2):288–93.
99. Tripkovic L, Lambert H, Hart K, Smith CP, Bucca G, Penson S, et al. Comparison of vitamin D2 and vitamin D3 supplementation in raising serum 25-hydroxyvitamin D status: a systematic review and meta-analysis. *Am J Clin Nutr.* 2012;95(6):1357–64.
100. Ekwaru JP, Zwicker JD, Holick MF, Giovannucci E, Veugelers PJ. The importance of body weight for the dose response relationship of oral vitamin D supplementation and serum 25-hydroxyvitamin D in healthy volunteers. *PLoS One.* 2014;9(11):e111265.
101. Rosen CJ. Clinical practice. Vitamin D insufficiency. *N Engl J Med.* 2011;364(3):248–54.
102. Burton JM, Kimball S, Vieth R, Bar-Or A, Dosch HM, Cheung R, et al. A phase I/II dose-escalation trial of vitamin D3 and calcium in multiple sclerosis. *Neurology.* 2010;74(23):1852–9.



103. Jones G. Pharmacokinetics of vitamin D toxicity. *Am J Clin Nutr.* 2008;88(2):582S–6S.
104. Pham TM, Ekwaru JP, Loehr SA, Veugelers PJ. The relationship of serum 25-hydroxyvitamin D and insulin resistance among nondiabetic Canadians: a longitudinal analysis of participants of a preventive health program. *PLoS One.* 2015;10(10):e0141081.
105. Wang TJ, Pencina MJ, Booth SL, Jacques PF, Ingelsson E, Lanier K, et al. Vitamin D deficiency and risk of cardiovascular disease. *Circulation.* 2008;117(4):503–11.
106. Stolzenberg-Solomon RZ, Jacobs EJ, Arslan AA, Qi D, Patel AV, Helzlsouer KJ, et al. Circulating 25-hydroxyvitamin D and risk of pancreatic cancer: Cohort Consortium Vitamin D Pooling Project of Rarer Cancers. *Am J Epidemiol.* 2010;172(1):81–93.
107. Melamed ML, Michos ED, Post W, Astor B. 25-Hydroxyvitamin D levels and the risk of mortality in the general population. *Arch Intern Med.* 2008;168(15):1629–37.
108. Ford JA, MacLennan GS, Avenell A, Bolland M, Grey A, Witham M, et al. Cardiovascular disease and vitamin D supplementation: trial analysis, systematic review, and meta-analysis. *Am J Clin Nutr.* 2014;100(3):746–55.
109. Bjelakovic G, Gluud LL, Nikolova D, Whitfield K, Wetterslev J, Simonetti RG, et al. Vitamin D supplementation for prevention of mortality in adults. *Cochrane Database Syst Rev.* 2014;(1):CD007470.

---

## Part III

# Other CNS inflammatory Disorders

# Acute Disseminated Encephalomyelitis

# 11

Patricia K. Coyle

## Introduction

Acute disseminated encephalomyelitis (ADEM), also called postinfectious encephalitis/encephalomyelitis, is an immune-mediated inflammatory and demyelinating syndrome of the central nervous system (CNS). It is typically multifocal but monophasic [1]. In most subjects ADEM follows within a few days to weeks of a triggering event, typically infection or more rarely vaccination (Table 11.1). The vaccine relationship has been questioned, and some studies report no association [2, 3]. A minority of patients have no identifiable prior event. A critical concept is that ADEM does not represent an ongoing CNS infection.

ADEM is predominantly a pediatric disorder. The average age at onset is 5–8 years [4–6]. ADEM is much less common in adults, where it can occur at any age but particularly affects young adults. It is rare in the very young (ages 2–3 years) and in the elderly. The incidence in children is reported to range from 0.1 to 0.64 cases per 100,000 population per year [4, 7–10]. Most series show a slight male predominance. ADEM is said to account for at least 8%, and perhaps as high as 20%, of acute encephalitis cases [11].

**Table 11.1** Triggering events for postinfectious encephalitis/encephalomyelitis

Exanthematous viral infections (more historical)
Measles (0.1%), varicella zoster virus, rubella, smallpox
Other viruses (HIV, HTLV-1, hepatitis, other herpes viruses, dengue, chikungunya, Zika, mumps, parechovirus)
Viral respiratory tract infection
Viral gastroenteritis
Nonspecific febrile illness
Bacterial infection
Group A beta hemolytic streptococci
<i>Borrelia burgdorferi</i>
Campylobacter, leptospira, chlamydia, legionella
Mycoplasma pneumonia
Protozoal infection
Malaria [109]
Rickettsial infection
<i>Rickettsia rickettsii</i>
Aseptic meningitis
Vaccination ( $\leq 1$ –5 cases per million)
Rabies, pertussis, diphtheria
Tetanus-polio, measles-mumps-rubella, influenza, smallpox, hepatitis B, Japanese B encephalitis, hog vaccine, yellow fever, papilloma virus, meningococcus
Animal/insect bites
Viper bite with antivenom therapy
Neoplastic process
Leukemia, non-Hodgkin's lymphoma
Organ transplant

P. K. Coyle (✉)  
 Department of Neurology, MS Comprehensive Care  
 Center, Stony Brook University Medical Center,  
 Stony Brook, NY, USA  
 e-mail: [patricia.coyle@stonybrookmedicine.edu](mailto:patricia.coyle@stonybrookmedicine.edu)

## Pathology

The pathologic hallmark of ADEM is widespread white and gray matter perivenous inflammation with demyelination [12]. The inflammatory infiltrate is made up of predominantly lymphocytes and monocytes/macrophages. Inflammation results in subsequent “sleeve-like” demyelination, with axons relatively spared [13]. In a recent pathology study, perivenous demyelination was associated with a distinct pattern of cortical microglial activation without myelin loss [12]. Perivenous lesions can coalesce to form larger demyelinated lesions. This neuropathology is quite distinct from multiple sclerosis (MS) or acute viral encephalitis. MS involves confluent demyelination [12]. Gross pathology can involve brain congestion and swelling, with engorged blood vessels within the white matter. Microscopically this is associated with hyperemia, endothelial swelling, vessel wall infiltration by inflammatory cells, and perivascular edema [14].

Acute hemorrhagic leukoencephalitis (AHLE), a hyperacute variant of ADEM discussed below, shows a somewhat different pathology, with prominent neutrophil infiltration, punctate petechial and ringlike hemorrhages, necrotizing vasculitis, and early perivascular astrocyte damage [4, 15].

## Clinical Features

At least 70% of patients report an antecedent prodromal event, with neurologic symptoms beginning 2–30 days later [11]. Most often this is infection, with less than 5% following vaccination [16]. Rabies vaccine, when it contained neural tissue components, was a clear risk [4]. Viral infection is the commonest trigger, but nonviral pathogens and rare noninfectious exposures are also reported [17, 18]. Classically exanthematous infections such as measles (0.1%) were a particular risk. The prototypic clinical picture of ADEM involves multifocal neurologic deficits superimposed on a diffuse encephalopathy (Table 11.2) [19]. There may be seizures. Altered conscious-

**Table 11.2** Clinical features of postinfectious encephalitis/encephalomyelitis

Encephalopathy (drowsiness/lethargy, stupor/coma)
Fever
Headache
Motor deficits
Ataxia
Sensory abnormalities
Seizures (focal or generalized)
Optic neuritis (unilateral or bilateral)
Bilateral may need to rule out neuromyelitis optica-Devic spectrum disorder
Transverse myelitis
Bladder, bowel disturbances
Language abnormalities
Cranial neuropathy/brainstem deficits
Visual field defects
Radicular, neuropathic features
Meningismus

ness is a key feature. Drowsiness, lethargy, stupor, or coma is much more suggestive for ADEM than is simple irritability or mood disturbance. Cognitive deficits are seen [20], and multifocal deficits can involve motor, sensory, visual, coordination, and gait disturbances. Ataxia and language disturbance may be more common in children than adults [19, 21]. Lower urinary tract dysfunction can be seen in 33% and may persist [22]. It is also common to have neurologic abnormalities outside the brain itself. The spinal cord is involved in up to 67% of cases, particularly in adults [11, 13]. Peripheral nervous system (PNS) involvement (polyradiculoneuropathy) occurs in 5–44% [11, 23], perhaps reflecting that ADEM is part of a much broader immune-mediated neurologic spectrum that includes Guillain-Barre syndrome. The clinical course is rapid, with maximal deficits within 2–5 days [4]. Unusual clinical manifestations include acute psychosis, cerebellar mutism, various movement disorders, and Klüver-Bucy syndrome [24–28]. ADEM can certainly present with a picture that suggests mass lesion with increased intracranial pressure. It has also developed following aseptic meningitis [29]. Sustained high fever and hyponatremia were noted in these meningitis patients.

Based on the most current diagnostic criteria (see below), clinical features may fluctuate. New features may appear over a 3-month period and

are still considered one episode. A small minority of ADEM patients (2–4%) will have a second attack [30]. In 80%, this second attack occurs within 2 years [30]. An early follow-up brain MRI (within 6 months), if it has new or persistent lesions, predicts multiphasic ADEM [31]. Brain MRI follow-up up to 2 years did not find silent MRI lesions in the monophasic group. Some pediatric ADEM patients will go on to develop MS, neuromyelitis optica spectrum disorder (NMOSD), or ADEM followed by optic neuritis (ADEM-ON) [4].

## Diagnosis

Diagnosis of ADEM depends on a consistent clinical and laboratory picture, with other possibilities ruled out. It is a diagnosis of exclusion [4]. Core laboratory tests involve blood work, neuroimaging, and cerebrospinal fluid (CSF) evaluation. The International Pediatric MS Study Group revised their formal consensus definition criteria for pediatric ADEM in 2012 (Table 11.3). They recognize the monophasic and multiphasic (second attack) variants. More than two attacks are now felt to reflect a chronic relapsing disorder, such as MS or NMOSD [30]. The revised diagnostic criteria propose that after pediatric ADEM, MS criteria would be met if a second

**Table 11.3** Revised pediatric postinfectious encephalitis/encephalomyelitis ADEM diagnostic criteria [30]

Monophasic ADEM
A first polyfocal clinical CNS event with presumed inflammatory cause
Encephalopathy that cannot be explained by fever
MRI typically shows diffuse, poorly demarcated, large, >1–2 cm lesions involving predominantly cerebral WM; T1-hypointense WM lesions are rare; deep GM lesions (e.g., thalamus or basal ganglia) can be present
No new symptoms, signs, or MRI findings after 3 months of the incident ADEM
Multiphasic ADEM
New event of ADEM 3 months or more after the initial event that can be associated with new or re-emergent prior clinical and MRI findings. Timing in relation to steroids is not pertinent

WM white matter, GM gray matter

clinical event occurred  $\geq 3$  months later, was non-encephalopathic, and was associated with new MRI lesions meeting dissemination in space criteria. The ADEM diagnostic criteria require polysymptomatic onset with encephalopathy. Many earlier studies did not use formal diagnostic standards, and entered patients with CNS inflammatory syndromes of unknown etiology, with or without encephalopathy. In such series up to 58% of what was considered ADEM did not have encephalopathy [32].

The diagnosis in adults is more problematic, since it is fairly easy to include multifocal clinically isolated syndrome (CIS) (representing the first attack of relapsing MS) in ADEM series, unless encephalopathy is required. Encephalopathy is virtually never seen in MS relapses. In one series of 60 patients over age 15, who presented with an acute demyelinating syndrome, ADEM was differentiated from MS by meeting at least two of three critical criteria: atypical clinical symptoms for MS, absent CSF oligoclonal bands, or gray matter involvement [33]. In another study of 40 adult ADEM cases, 35% were said to have developed MS [34]. However, encephalopathy was not required for the original ADEM diagnosis. A recent series reported on five elderly subjects (ages 57–85 years) with pathologically confirmed ADEM [35]. Their initial differential diagnosis was broad.

ADEM should be considered in anyone who presents with a suggestive neurologic syndrome. Recent illness or vaccination increases likelihood of this diagnosis, but is not required. The rare postvaccinal cases typically follow a primary rather than revaccination [13].

Neuroimaging is central for the diagnosis of ADEM. Although brain CT may show patchy areas of low attenuation in white matter, with focal or diffuse cortical enhancement, it is normal in about 70% of patients and is much less sensitive than magnetic resonance imaging (MRI) [36]. Brain MRI with and without contrast should be carried out in all patients, unless contraindicated. Normal brain MRI probably excludes a diagnosis of classic ADEM, although imaged lesions may be delayed for several weeks [37]. MRI typically shows multiple T2/

FLAIR hyperintense lesions involving white matter but also gray matter. ADEM lesions may (but do not have to) lack sharp borders. The classical imaging features for ADEM are symmetric bilateral lesions, relative periventricular sparing, and deep gray matter involvement. Deep gray matter (basal ganglia, thalamus) involvement is reported in 15–60% of adult cases [38]. Bilateral thalamic involvement is reported in 12% of pediatric cases [39]. In a recent study, MRI criteria were evaluated to differentiate ADEM from MS; the so-called Callen MS-ADEM criteria had the best sensitivity (75%) and specificity (91%) [40]. They involved meeting at least two of the following three criteria: absence of a diffuse bilateral lesion pattern, presence of black holes, and two or more periventricular lesions. Lesions affect subcortical white matter predominantly, although middle cerebellar peduncle and periventricular involvement can be seen [41]. Diffuse extensive supratentorial white matter involvement has also been seen [38]. Sometimes there can be a single tumefactive lesion, which can even be confined to the brainstem [10].

Contrast enhancement is not that helpful. Although very suggestive when it involves all lesions, there may be enhancement of only a subset of lesions, or none may enhance. There can be rare presentations with multiple ring enhancing lesions [42]. In pediatric ADEM, contrast enhancement of one or more lesions is noted in 14–30% [30].

Follow-up brain MRI 6 months after presentation should show partial or complete resolution of lesions, with no new lesions [13]. Spinal cord MRI may be abnormal as well. Cord lesions in ADEM are more likely to involve the thoracic region and may be diffuse and longitudinally extensive [43, 44].

There are limited reports using nonconventional MRI techniques. It would be helpful if a unique diagnostic imaging signature could be developed. Using diffusion MRI, apparent diffusion coefficient (ADC) was reported as decreased in early ADEM lesions and increased in later stages [41]. In another small series, diffusion tensor imaging signal was reported as abnormal

in ADEM vs. MS basal ganglia [45]. A recent series showed ADC values increased in 70% of 17 pediatric ADEM cases, consistent with vasogenic edema [46]. Using MR spectroscopy, acute and chronic phases of ADEM showed distinct patterns. Reduced *N*-acetylaspartate to creatine ratios were noted in supratentorial normal-appearing white matter, while choline to creatine ratios were increased acutely, but decreased back toward normal later. Myoinositol to creatine ratios were decreased acutely, but increased in the chronic phase, consistent with gliosis. Elevated lipids and lactate were noted in the acute phase for all subjects, but later normalized [47]. Elevated glutamine/glutamate was present in 67% acutely and then dropped. The authors suggested that the decrease in myoinositol during the acute phase might distinguish ADEM from MS [47]. Unlike MS, normal-appearing brain tissue did not show abnormal magnetization transfer imaging or diffusion tensor imaging values [48].

CSF is routinely examined as part of the diagnostic workup. It helps to exclude direct infection. CSF can be normal in up to 33% of cases [11]. Most often there is a low-grade mononuclear pleocytosis, with mildly elevated protein and normal glucose. Rarely neutrophils may predominate. All cultures and stains, and any PCR or antigen tests, should be negative. CSF pressure may be elevated. Positive oligoclonal bands or elevated intrathecal IgG production is reported in a minority of cases. ADEM can be associated with oligoclonal bands in both CSF and serum [11]. If positive, they are transient and not persistently abnormal. Myelin basic protein (MBP) is often elevated in CSF, as a nonspecific acute injury marker.

With regard to other laboratory testing, about 50% of patients show peripheral leukocytosis or elevated acute-phase reactants [21]. Myelin oligodendrocyte glycoprotein (MOG) IgG antibody should be obtained if possible (see below). Electroencephalogram (EEG) generally shows diffuse background slowing [19]. Brain biopsy is rarely necessary but may be indicated in confusing cases (particularly with continued deterioration).

**Table 11.4** Differential diagnosis of postinfectious encephalitis/encephalomyelitis

Acute infectious encephalitis/encephalomyelitis
Viruses (herpes viruses, West Nile virus)
Bacteria (legionnaires, listeria, tuberculosis)
Parasites (amebae)
Brain abscess
Systemic disorders
Autoimmune connective tissue disease
Hemophagocytic (cytokine storm) syndrome
Neurosarcoidosis
Vasculitis
Neoplastic and paraneoplastic disorders
Lymphoma, angioendotheliomatosis, gliomatosis cerebri
Multiple sclerosis
Tumefactive
Marburg variant
Toxic leukoencephalopathy
Inhaled heroin (“chasing the dragon”)
Carbon monoxide
Mitochondrial disorders
Metabolic disorders
Central and extrapontine myelinolysis
Marchiafava-Bignami disease
Wernicke-Korsakoff encephalopathy
Posterior reversible encephalopathy syndrome
X-linked Charcot-Marie-Tooth disease

## Differential Diagnosis

The differential diagnosis of ADEM involves principally other causes of encephalitis or encephalomyelitis, stupor, or brain MRI white matter lesions (Table 11.4) [1, 49–54]. The differential is influenced somewhat by age, since conditions such as mitochondrial disorders are more likely in the young, while toxic abuse is more likely in adults.

## Management

Symptomatic management involves general supportive measures, such as assuring airway and venous access, controlling fever, and treating electrolyte imbalance. Seriously ill patients or those who decompensate should be managed in an intensive care unit (ICU) setting, since increased intracranial pressure is a major concern

in severe cases. Appropriate measures are taken to prevent venous thrombosis, and any seizures are treated.

There are no randomized controlled trials for treatment of ADEM. Corticosteroids are standard therapy based on class III evidence [55]. The most typical dose is 1 g intravenous (IV) methylprednisolone for 3–7 days. Occasionally higher doses (up to 2 g) are used. Plasma exchange (typically seven exchanges) can be considered in steroid-unresponsive patients. The expected response rate is at least 44% [56]. Males, those with preserved reflexes, and those who receive early (within 21 days) plasma exchange appear to do better. In one study early treatment, and improvement at discharge, predicted good response 6 months post exchange [57]. Treatment with intravenous immune globulin (IVIG) can also be considered in steroid-resistant patients, typically 1–2 g/kg over 2–5 days [36, 58]. IVIG is preferred to plasma exchange for postvaccinal ADEM [13, 59]. PNS involvement, milder onset disability, and lower CSF albumin have predicted IVIG treatment response [11]. IV cyclophosphamide has also been used for patients who continue to deteriorate. Rarely aggressive surgical decompression or hypothermia may be needed to control brain swelling [60–62].

## Prognosis

With the exception of the AHLE hyperacute variant, ADEM overall has a good prognosis. Mortality rate is less than 5% in pediatric series, but has been reported as high as 8–25% in adults requiring ICU admission [38, 63]. Most patients make a good recovery from ADEM, though there may be permanent deficits in 10–30% including cognitive and psychosocial deficits [27, 28, 32, 34, 64]. In a pediatric series, initially severe course was associated with cognitive and visual spatial deficits years later [65]. In recent studies pediatric ADEM patients showed significantly reduced age-expected brain volume growth, and white matter development, compared to controls [66, 67]. Adults are reported to have a worse disease course and outcome than children [21].

In one small series of eight patients, brainstem involvement was associated with poorer outcome [68]. Peripheral nervous system involvement may also be associated with poorer recovery and higher risk of relapse [69]. Seizures and coma are also suggested to indicate worse prognosis [19, 27]. Other features associated with poorer outcome were older age onset, female gender, increased CSF protein, and spinal cord involvement [23]. In another very small series (two patients), decreased ADC in the internal capsule, consistent with cytotoxic edema, predicted poor motor outcome [70]. Patients with a relapsing attack are reported to have a good outcome in long-term (9–13 years) follow-up [71].

### ADEM Spectrum Overlap Disorders

ADEM can be considered part of a spectrum of CNS disorders (Table 11.5). As discussed previously, ADEM is typically monophasic but can involve a repeat episode in 2–4% of cases. A repeat episode must occur beyond 3 months. By convention, this is considered multiphasic ADEM.

MOG IgG antibody is reported in a subset of demyelinating CNS disorders. It is more common in pediatric cases and with optic neuritis (especially bilateral). It requires a cell-based assay for reliable detection of conformationally sensitive IgG. ELISA and immunoblot, used previously, provided unreliable results [72]. Anti-MOG IgG is rarely if ever detected in MS. However, it accounts for about 10% of seronegative NMOSD (negative for aquaporin 4 IgG antibodies). It is reported in subjects with optic neuritis, encephalitis with brain demyelinating lesions, and myelitis. Some have suggested the

eponym MOG-IgG-associated optic neuritis, encephalitis, and myelitis (MONEM) for this cohort [73]. The highest titers have been reported in ADEM but are generally transient and clear with recovery [72]. However persistent antibodies are also found in an unusual subset of ADEM that is followed by one or more attacks of optic neuritis (ADEM-ON).

In a Dutch study, this variant accounted for only 1.2% of pediatric acquired demyelinating disease [74]. Anti-MOG antibodies are said to predict a non-MS disease course [75]. ADEM-ON is typically anti-MOG IgG positive in blood. In an analysis of 17 pediatric patients, relapses involved a unilateral or bilateral optic neuritis (94.4%) or ADEM (5.6%) [76]. During a median follow-up of 5.3 years, half of relapses occurred at the time corticosteroids were being tapered (to <10 mg) or within 4 weeks of discontinuation. Residual deficits were found in 71%. Interattack intervals could exceed 5 years. There is a case report of good response to rituximab [77]; others report corticosteroid responsiveness [76]. The acute attack in MOG-related syndromes is treated with corticosteroids, plasma exchange, IVIG, or cyclophosphamide [73]. The optimal long-term therapeutic approach to MOG-related syndromes is unclear, but currently includes prolonged corticosteroids over months, pulse IVIG, anti-CD20 monoclonal antibody, or immunosuppression [73]. It is important to follow titers, since loss of antibodies may allow withdrawal of therapy.

AHLE (Hurst syndrome) is a very rare disorder. It is the hyperacute and most severe form of ADEM [78, 79]. AHLE typically follows non-specific respiratory tract infection. Clinical onset involves fever, confusion proceeding to stupor and coma, seizures, and focal neurologic deficits that mimic a rapidly expanding mass lesion within the brain. Mortality approaches 70% and occurs within days, with severe morbidity in survivors. MRI shows large hemispheric white matter lesions, with relative sparing of gray matter (although basal ganglia and thalamus may be involved, as can brainstem/cerebellum and spinal cord) [15]. There may be limited MRI enhancement despite

**Table 11.5** Postinfectious encephalitis/encephalomyelitis CNS spectrum overlap disorders

Multiphasic ADEM
ADEM followed by optic neuritis (ADEM-ON)
Acute hemorrhagic leukoencephalitis (AHLE)
Acute necrotizing encephalopathy
Bickerstaff brainstem encephalitis
Pediatric MS



**Table 11.6** Management of acute hemorrhagic leukoencephalitis

Admit to ICU
Ensure airway, breathing, oxygenation, IV access
Control fever, seizures
Monitor and control intracranial pressure (intracranial transducers, sedation, hypothermia, other measures)
Glucocorticoids; consider concomitant plasma exchange or IVIG
Surgical decompression to control swelling
Consider IV cyclophosphamide for ongoing process

ICU intensive care unit, IV intravenous, IVIG intravenous immune globulin

evidence of edema and hemorrhage. On diffusion MRI, both acute and subacute lesions showed increased ADC values [15]. CSF shows pleocytosis with RBCs. Neuropathology involves polymorphonuclear cell infiltration with fibrinoid necrosis of small blood vessels, perivascular exudates, microhemorrhages, and cerebral edema. Myelin loss occurs in the setting of relative preservation of axons. There are no formal guidelines on treatment, but one can formulate a reasonable approach based on small case series (Table 11.6). Therapy requires aggressive treatment of increased intracranial pressure and other complications [36]. Corticosteroids with plasma exchange, IVIG, and/or immunosuppressants (cyclophosphamide) may be tried, and surgical intervention and hypothermia may be needed for severe cases [60–62, 80–82]. Clinical improvement has been noted within 2 days of starting plasma exchange.

Acute necrotizing encephalopathy, formally characterized in 1995, is a rare disease which follows influenza, parainfluenza, human herpesvirus-6, measles, or mycoplasma infections [83, 84]. Young children under the age of 5 years, particularly from an Asian background (Japan and Taiwan), seem to be preferentially vulnerable [85]. The clinical syndrome is fulminant, with fever and altered mental status within 1–4 days of the viral febrile illness, progressing to coma within 24–72 h. Seizures (often refractory to treatment) are common, and mortality is 30–70%, typically due to cardiorespiratory issues [86]. Brain MRI shows multiple symmet-

ric lesions involving the thalami, brainstem tegmentum, cerebellum, periventricular white matter, and putamen [85]. The differential diagnosis includes Reye syndrome, Leigh's disease (subacute necrotizing encephalomyelopathy), Wernicke encephalopathy, Sandhoff disease, cerebrovascular event, or tumor [87]. CSF shows increased protein without pleocytosis and has been PCR positive for virus in only a minority of cases. Serum aminotransferases but not blood ammonia may be elevated. Postmortem studies show tissue necrosis, vascular changes with petechial hemorrhages, local vessel congestion, microthrombi, and vasogenic edema [86]. Some patients show high circulating levels of interleukin-6 and tumor necrosis factor [83]. Corticosteroids administered within 24 h of onset may be associated with better outcome, at least when brainstem is not involved [87]. An autosomal dominant disorder, involving recurrent bouts of acute necrotizing encephalopathy, has been associated with missense mutations in the Ran-binding protein 2 (RANBP2) gene on chromosome 2. This gene codes for a nuclear pore component [85, 88]. Acute necrotizing encephalopathy shows many similarities to AHLE. A recent case of AHLE in a 6-year-old girl with sickle cell disease was associated with a novel RANBP2 variant [89]. It is interesting to speculate whether acute necrotizing encephalopathy is an expression of AHLE in the very young.

Bickerstaff brainstem encephalitis is characterized by ophthalmoparesis, ataxia, and other CNS features including impaired consciousness. It appears to be part of a very broad neuro-immune spectrum which includes Guillain-Barré syndrome, especially the Miller Fisher variant [90, 91]. Reflexes in these brainstem encephalitis patients may be increased, normal, or even absent. Patients can show central motor and sensory abnormalities, and up to 66% have anti-GQ1b antibodies [92]. CSF shows cytoalbuminologic dissociation most often, but 32% do have a pleocytosis. Brain MRI is abnormal in up to 30%, with T2-hyperintense lesions most often within the brainstem [93]. Bickerstaff brainstem encephalitis is treated with either

IVIG or plasma exchange [94]. Outcome is generally good with spontaneous recovery, but several deaths have occurred [95].

MS is the major acquired CNS inflammatory demyelinating disease. It is certainly in the differential diagnosis for ADEM but can also be considered part of this immune-mediated spectrum. This is especially true for pediatric MS but also for adult-onset MS. Pediatric MS is discussed in a separate chapter. Compared to ADEM, pediatric MS is not monophasic. It has onset typically over age 10 years, shows female predominance, and has no triggering event. It is more likely to have a monosymptomatic vs. polysymptomatic onset and is much less likely to involve any encephalopathic features, bilateral optic neuritis, fever, headache, meningismus, or seizures [32, 96]. Family history of MS also favors MS over ADEM [32]. However up to 20% of pediatric MS patients experience ADEM as their initial event and then go on to clear-cut MS [97, 98]. These children tend to be under 10 years of age. Laboratory distinctions are helpful. In MS the CSF is more likely to show oligoclonal bands which persist, without increased protein or pleocytosis. Brain MRI is much more likely to show periventricular perpendicular and corpus callosum ovoid lesions with well-defined margins, without gray matter or brainstem/cerebellar macroscopic lesions [32, 96]. MS MRI lesions increase over time and do not resolve the way ADEM lesions do. MS spinal cord MRI lesions are virtually never longitudinally extensive (extending three or more vertebral segments) except in rare pediatric cases. MRI diffusion-weighted imaging shows MS vs. ADEM differences. ADC values within the corpus callosum were consistently elevated in MS compared to ADEM or neurosarcoidosis patients, consistent with nonrestricted water diffusion due to demyelination.

For adult-onset MS, multifocal CIS can be confused with ADEM, but a key feature is the lack of encephalopathy as a component of the CIS presentation.

## Etiology

ADEM is considered an immune-mediated CNS syndrome. It is believed that myelin components are generally the autoimmune targets. Several hypotheses have been proposed. The first is based on molecular mimicry. In this scenario an environmental pathogen or external vaccination contains antigenic epitopes that cross-react with myelin components and results in a misdirected systemic immune attack against the CNS. This would be akin to the major animal model for MS, experimental allergic/autoimmune encephalomyelitis, because it involves a systemic immune pathogenesis. This hypothesis is partially supported by early reports that rabies vaccines developed in CNS tissues had an excessive high rate of postinfectious sequelae.

A second hypothesis involves a transient infection of the CNS that results in blood-brain barrier damage, with release of sequestered myelin antigens to the systemic immune system. This is temporally linked to a secondary organ-specific immune attack against the CNS.

A third hypothesis requires a critically timed two-hit infection, with the second infection reactivating previously primed autoreactive lymphocytes.

In a limited number of cases, there is one final interesting observation: a mutation in the SCN1A sodium channel that has been associated with postvaccination ADEM [13, 99, 100].

T cells sensitized to MBP have been reported in ADEM. In an immunologic study of ADEM, most patients showed lymphocyte proliferation to MBP [101]. Some patients show antibodies to glycolipids such as galactocerebroside, as well as myelin proteins. IgG antibodies to MOG (but not to proteolipid protein or aquaporin 4) are present in most ADEM patients but are typically transient [102]. IgM antibodies to MOG were only found in 3 of 19 ADEM cases. In another series involving 19 children with ADEM vs. 25 with CIS, 28 other neurologic disease patients, and 30 healthy controls, IgM to EBV early antigen was present in 16% of ADEM cases only. Serum IgG to EBV was no different between ADEM and controls, but titers were higher in CIS patients. High IgG

titers to native MOG were found only in the ADEM and CIS cohorts and were unrelated to the EBV antibody response [103]. There has been a particular interest in anti-MOG antibodies because they demyelinate in vitro MOG. MOG is expressed on the outer lamella of the myelin sheath. Persistent MOG antibodies in ADEM mark a group at risk for subsequent optic neuritis (ADEM-ON).

Cytokines are implicated as well [104], and lesion formation is said to involve cytokines such as interleukin-2 (IL-2), interferon- $\gamma$ , and tumor necrosis factor [105]. In a study of chemokines and cytokines in ADEM, MS, and healthy control subjects, ADEM showed elevated CSF levels of chemokines involved in neutrophil and T helper 2 cell attraction [106]. There was no difference in serum cytokine/chemokine levels.

Human leukocyte antigen alleles have been studied a little bit in ADEM and in various populations have been similar (but not identical) to those associated with MS [107]. A recent child with biopsy-documented ADEM showed two heterozygous mutations of the polymerase gamma gene, consistent with mitochondrial disease [108]. The significance of this association in a single case is unclear.

## Summary

ADEM is an important neuroimmune syndrome that is part of a spectrum of CNS inflammatory demyelinating diseases. It is distinct from MS and carries overall a good prognosis with the exception of the hyperacute AHLE variant. The immunopathogenesis is not well understood, which limits development of preventive strategies and definitive therapies. A recent focus on IgG to MOG is helping to define useful ADEM subsets.

Diagnostic paradigms continue to be refined. Management involves appropriate supportive care and early institution of immunomodulatory therapies such as corticosteroids, plasma exchange, and IVIG. Aggressive management is always justified to control increased intracranial pressure, since such patients can ultimately do very well once this monophasic syndrome has ended.

## References

1. Young NP, Weinshenker BG, Lucchinetti CF. Acute disseminated encephalomyelitis: current understanding and controversies. *Semin Neurol*. 2008;28:84–94.
2. Baxter R, Lewis E, Goddard K, et al. Acute demyelinating events following vaccines: a case-centered analysis. *Clin Infect Dis*. 2016;63(11):1456–62.
3. Chen Y, Ma F, Xu Y, et al. Vaccines and the risk of acute disseminated encephalomyelitis. *Vaccine*. 2018;36(26):3733–9.
4. Pohl D, Alper G, Van Haren K, et al. Acute disseminated encephalomyelitis: updates on an inflammatory CNS syndrome. *Neurology*. 2016;87(9 Suppl 2):S38–45.
5. Mikaeloff Y, Suissa S, Vallee L, et al. First episode of acute CNS inflammatory demyelination in childhood: prognostic factors for multiple sclerosis and disability. *J Pediatr*. 2004;144:246–52.
6. Torisu H, Kira R, Ishizaki Y, et al. Clinical study of childhood acute disseminated encephalomyelitis, multiple sclerosis, and acute transverse myelitis in Fukuoka Prefecture, Japan. *Brain Dev*. 2010;32:454–62.
7. Leake JA, Albani S, Kao AS, et al. Acute disseminated encephalomyelitis in childhood: epidemiologic, clinical and laboratory features. *Pediatr Infect Dis J*. 2004;23:756–64.
8. Pohl D, Hennemuth I, von Kries R, et al. Paediatric multiple sclerosis and acute disseminated encephalomyelitis in Germany: results of a nationwide survey. *Eur J Pediatr*. 2007;166:405–12.
9. Banwell B, Kennedy J, Sadovnick D, et al. Incidence of acquired demyelination of the CNS in Canadian children. *Neurology*. 2009;20:232–9.
10. VanLandingham M, Hanigan W, Vedanarayanan V, et al. An uncommon illness with a rare presentation: neurosurgical management of ADEM with tumefactive demyelination in children. *Childs Nerv Syst*. 2010;26:655–61.
11. Sonnevile R, Klein IF, Wolff M. Update on investigation and management of postinfectious encephalitis. *Curr Opin Neurol*. 2010;23:300–4.
12. Young NP, Weinshenker BG, Parisi JE, et al. Perivenous demyelination: association with clinically defined acute disseminated encephalomyelitis and comparison with pathologically confirmed multiple sclerosis. *Brain*. 2010;133:333–48.
13. Huynh W, Cordato DJ, Kehdi E, et al. Post-vaccination encephalomyelitis: literature review and illustrative case. *J Clin Neurosci*. 2008;15:1315–22.
14. Garg RK. Acute disseminated encephalomyelitis. Review. *Postgrad Med J*. 2003;79:11–7.
15. Lee HY, Chang KH, Kim JH, et al. Serial MR imaging findings of acute hemorrhagic leukoencephalitis: a case report. *AJNR Am J Neuroradiol*. 2005;26:1996–9.

16. Bennetto L, Scolding N. Inflammatory/post-infectious encephalomyelitis. *J Neurol Neurosurg Psychiatry*. 2004;75:i22–8.
17. De Lau LM, Siepmann DA, Remmers MJ, et al. Acute disseminated encephalomyelitis following legionnaires disease. *Arch Neurol*. 2010;67:623–6.
18. Tripathy S, Routray PK, Mohapatra AK, et al. Acute demyelinating encephalomyelitis after anti-venous therapy in Russell's viper bite. *J Med Toxicol*. 2010;6:318–21.
19. Panicker JN, Nagaraja D, Kovoov JM, et al. Descriptive study of acute disseminated encephalomyelitis and evaluation of functional outcome predictors. *J Postgrad Med*. 2010;56:12–6.
20. Deery B, Anderson V, Jacobs R, et al. Childhood MS and ADEM: investigation and comparison of neurocognitive features in children. *Dev Neuropsychol*. 2010;35:508–21.
21. Ketelslegers IA, Visser IER, Neuteboom RF, et al. Disease course and outcome of acute disseminated encephalomyelitis is more severe in adults than in children. *Mult Scler*. 2011;17(4):441–8.
22. Panicker JN, Nagaraja D, Kovoov JME, et al. Lower urinary tract dysfunction in acute disseminated encephalomyelitis. *Mult Scler*. 2009;15:1118–22.
23. Marchioni E, Ravaglia S, Piccolo G, et al. Postinfectious inflammatory disorders: subgroups based on prospective follow-up. *Neurology*. 2005;65:1057–65.
24. Nasr JT, Andriola MR, Coyle PK. ADEM: literature review and case report of acute psychosis presentation. *Pediatr Neurol*. 2000;22:8–18.
25. Krishnakumar P, Jayakrishnan MP, Beegum MN, et al. Acute disseminated encephalomyelitis presenting as acute psychotic disorder. *Indian Pediatr*. 2008;45:999–1001.
26. Har-Gil M, Evrani M, Waternberg N. Torticollis as the only manifestation of acute disseminated encephalomyelitis. *J Child Neurol*. 2010;25:1415–8.
27. Jha S, Ansari MK. Partial Kluver-Bucy syndrome in a patient with acute disseminated encephalomyelitis. *J Clin Neurosci*. 2010;17:1436–8.
28. Parrish JB, Weinstock-Guttman B, Yeh EA. Cerebellar mutism in pediatric acute disseminated encephalomyelitis. *Pediatr Neurol*. 2010;42:259–66.
29. Fujiki F, Tsuboi Y, Hori T, et al. Aseptic meningitis as initial presentation of acute disseminated encephalomyelitis. *J Neurol Sci*. 2008;272:129–31.
30. Krupp LB, Tardieu M, Amato MP, et al. International Pediatric Multiple Sclerosis Study Group criteria for pediatric multiple sclerosis and immune-mediated central nervous system demyelinating disorders: revisions to the 2007 definitions. *Mult Scler*. 2013;19(10):1261–7.
31. Koelman DLH, Benkeser DC, Klein JP, et al. Acute disseminated encephalomyelitis: prognostic value of early follow-up brain MRI. *J Neurol*. 2017;264(8):1754–62.
32. Alper G, Heyman R, Wang L. Multiple sclerosis and acute disseminated encephalomyelitis diagnosed in children after long-term follow up: comparison of presenting features. *Dev Med Child Neurol*. 2009;51:480–6.
33. De Seze J, Debouverie M, Zephir H, et al. Acute fulminant demyelinating disease. A descriptive study of 60 patients. *Arch Neurol*. 2007;64:1426–32.
34. Schwarz S, Mohr A, Knauth M, et al. Acute disseminated encephalomyelitis: a follow-up study of 40 adult patients. *Neurology*. 2001;56:1313–8.
35. Kaunzner UW, Slamon E, Pentsova E, et al. An acute disseminated encephalomyelitis-like illness in the elderly: neuroimaging and neuropathology findings. *J Neuroimaging*. 2017;27(3):306–11.
36. Sonnevile R, Klein I, de Broucker T, et al. Post-infectious encephalitis in adults: diagnosis and management. *J Infect*. 2009;58:321–8.
37. Honkaniemi J, Dastidar P, Kahara U, et al. Delayed MR imaging changes in acute disseminated encephalomyelitis. *AJNR Am J Neuroradiol*. 2001;22:1117–24.
38. Sonnevile R, Demeret S, Klein I, et al. Acute disseminated encephalomyelitis in the intensive care unit: clinical features and outcome of 20 adults. *Intensive Care Med*. 2008;34:528–32.
39. Dardiotis E, Kountra P, Kapsalaki E, et al. Acute disseminated encephalomyelitis with bilateral thalamic necrosis. *J Child Neurol*. 2009;24:1001–4.
40. Ketelslegers IA, Neuteboom RF, Boon M, et al. A comparison of MRI criteria for diagnosing pediatric ADEM and MS. *Neurology*. 2010;74:1412–5.
41. Balasubramanya KS, Kovoov JME, Jayakumar PN, et al. Diffusion-weighted imaging and proton MR spectroscopy in the characterization of acute disseminated encephalomyelitis. *Neuroradiology*. 2007;49:177–83.
42. Kamel MH, Kelleher M, O'Riordan C, et al. CT and MRI ring sign may be due to demyelination: diagnostic pitfall. *Br J Neurosurg*. 2007;21:309–11.
43. Farber RS, DeVilliers L, Miller A, et al. Differentiating multiple sclerosis from other causes of demyelination using diffusion weighted imaging of the corpus callosum. *J Magn Reson Imaging*. 2009;30:732–6.
44. Yiu EM, Komberg AJ, Ryan MM, et al. Acute transverse myelitis and acute disseminated encephalomyelitis in childhood: spectrum or separate entities. *J Child Neurol*. 2009;24:287–96.
45. Holtmannspotter M, Inglese M, Rovaris M, et al. A diffusion tensor MRI study of basal ganglia from patients with ADEM. *J Neurol Sci*. 2003;206:27–30.
46. Zuccoli G, Panigrahy A, Sreedher G, et al. Vasogenic edema characterizes pediatric acute disseminated encephalomyelitis. *Neuroradiology*. 2014;56(8):679–84.
47. Ben Sira L, Miller E, Artzi M, et al. H-MRS for the diagnosis of acute disseminated encephalomyelitis: insight into the acute-disease stage. *Pediatr Radiol*. 2010;40:106–13.

48. Inglese M, Salvi F, Iannucci G, et al. Magnetization transfer and diffusion tensor MR imaging of acute disseminated encephalomyelitis. *AJNR Am J Neuroradiol.* 2002;23(2):267–72.
49. Borhani Haghighi A, Ashjazadeh N. Acute disseminated encephalomyelitis-like manifestations in a patient with neuro-Behcet disease. *Neurologist.* 2009;15:282–4.
50. Centers for Disease Control and Prevention. Balamuthia mandrillaris transmitted through organ transplantation. *MMWR Morb Mortal Wkly Rep.* 2010;59:1165–70.
51. Goraya J, Marks H, Khurana D, et al. Subacute sclerosing panencephalitis (SSPE) presenting as acute disseminated encephalomyelitis in a child. *J Child Neurol.* 2009;24:899–903.
52. Richard HT, Harrison JF, Abel TW, et al. Pediatric gliomatosis cerebri mimicking acute disseminated encephalomyelitis. *Pediatrics.* 2010;126:79–82.
53. Summerfield R, Al-Saleh A, Robbins SE. Small cell lung carcinoma presenting with acute disseminated encephalomyelitis. *Br J Radiol.* 2010;83:e54–7.
54. Zadro I, Brinar VV, Barun B, et al. Primary diffuse meningeal melanomatosis. *Neurologist.* 2010;16:117–9.
55. Tunkel AR, Glaser CA, Bloch KC, et al. The management of encephalitis: clinical practice guidelines by the Infectious Diseases Society of America. *Clin Infect Dis.* 2008;47:303–27.
56. Weinshenker BG, O'Brien PC, Petterson TM, et al. A randomized trial of plasma exchange in acute central nervous system inflammatory demyelinating disease. *Ann Neurol.* 1999;46:878–86.
57. Llufriu S, Castillo J, Blanco Y, et al. Plasma exchange for acute attacks of CNS demyelination: predictor of improvement at 6 months. *Neurology.* 2009;73:949–53.
58. Ravaglia S, Piccolo G, Ceroni M, et al. Severe steroid-resistant post-infectious encephalomyelitis general features and effects of IVIG. *J Neurol.* 2007;254:1518–23.
59. Van Dam CN, Syed S, Eron JJ, et al. Severe post-vaccinia encephalitis with acute disseminated encephalomyelitis: recovery with early intravenous immunoglobulin, high-dose steroids, and vaccinia immunoglobulin. *Clin Infect Dis.* 2009;48:47–9.
60. Takata T, Hirakawa M, Sakurai M, et al. Fulminant forms of acute disseminated encephalomyelitis: successful treatment with hypothermia. *J Neurol Sci.* 1999;165:94–7.
61. Payne ET, Rutka JT, Ho TK, et al. Treatment leading to dramatic recovery in acute hemorrhagic leukoencephalitis. *J Child Neurol.* 2007;22:109–13.
62. Ahmed AI, Eynon CA, Kinton L, et al. Decompressive craniectomy for acute disseminated encephalomyelitis. *Neurocrit Care.* 2010;13:393–5.
63. Absoud M, Parslow RC, Wassmer E, et al. Severe acute disseminated encephalomyelitis: a pediatric intensive care population-based study. *Mult Scler.* 2011;17(10):1258–61.
64. Beatty C, Bowler RA, Farooq O, et al. Long-term neurocognitive, psychosocial, and magnetic resonance imaging outcomes in pediatric-onset acute disseminated encephalomyelitis. *Pediatr Neurol.* 2016;57:64–73.
65. Rostasy K, Nagl A, Lutjen S, et al. Clinical outcome of children presenting with a severe manifestation of acute disseminated encephalomyelitis. *Neuropediatrics.* 2009;40:211–7.
66. Aubert-Broche B, Weier K, Longoni G, et al. Monophasic demyelination reduces brain growth in children. *Neurology.* 2017;88(18):1744–50.
67. Longoni G, Brown RA, MomayyezSiahkal P, et al. White matter changes in paediatric multiple sclerosis and monophasic demyelinating disorders. *Brain.* 2017;140:1300–15.
68. Donmez FY, Asian H, Coskun M. Evaluation of possible prognostic factors of fulminant acute disseminated encephalomyelitis (ADEM) on magnetic resonance imaging with fluid-attenuated inversion recovery (FLAIR) and diffusion-weighted imaging. *Acta Radiol.* 2009;50:334–9.
69. Marchioni E, Tavazzi E, Minoli L, et al. Acute disseminated encephalomyelitis. *Curr Infect Dis Rep.* 2008;10:307–14.
70. Kawashima S, Matsukawa N, Ueki Y, et al. Predicting the motor outcome of acute disseminated encephalomyelitis by apparent diffusion coefficient imaging: two case reports. *J Neurol Sci.* 2009;280:123–6.
71. Mar S, Lenox J, Benzinger T, et al. Long-term prognosis of pediatric patients with relapsing acute disseminated encephalomyelitis. *J Child Neurol.* 2010;25:681–8.
72. Weber MS, Derfuss T, Metz I, et al. Defining distinct features of anti-MOG antibody associated central nervous system demyelination. *Ther Adv Neurol Disord.* 2018;11:1–15.
73. dos Passos GR, Oliveira LM, da Costa BK, et al. MOG-IgG-associated optic neuritis, encephalitis, and myelitis: lessons learned from neuromyelitis optica spectrum disorder. *Front Neurol.* 2018;9:217.
74. Ketelslegers IA, Catsman-Berrevoets CE, Neuteboom RF, et al. Incidence of acquired demyelinating syndromes of the CNS in Dutch children: a nationwide study. *J Neurol.* 2012;259(9):1929–35. <https://doi.org/10.1007/s00415-012-6441-6>.
75. Di Pauli F, Reindl M, Berger T. New clinical implications of anti-myelin oligodendrocyte glycoprotein antibodies in children with CNS demyelinating diseases. *Mult Scler Relat Disord.* 2018;22:35–7.
76. Wong YYM, Hacoen Y, Armangue T, et al. Paediatric acute disseminated encephalomyelitis followed by optic neuritis: disease course, treatment response and outcome. *Eur J Neurol.* 2018;25(5):782–6.
77. Nagashima M, Osaka H, Ikeda T, et al. Rituximab was effective for acute disseminated encephalomyelitis followed by recurrent optic neuritis with anti-myelin oligodendrocyte glycoprotein antibodies. *Brain Dev.* 2018;40(7):607–11.

78. Hurst EW. Acute hemorrhagic leukoencephalitis: a previously undefined entity. *Med J Aust.* 1941;2:1–6.
79. Lann MA, Lovell MA, Kleinschmidt-DeMasters BK. Acute hemorrhagic leukoencephalitis: a critical entity for forensic pathologists to recognize. *Am J Forensic Med Pathol.* 2010;31:7–11.
80. Leake JA, Billman GF, Nespeca MP, et al. Pediatric acute hemorrhagic leukoencephalitis: report of a surviving patient and review. *Clin Infect Dis.* 2002;34:699–703.
81. Jasowiak JM. Treatment of hemorrhagic acute disseminated encephalomyelitis with cyclophosphamide. *Am J Health Syst Pharm.* 2016;73(4):202–5.
82. Ryan LJ, Bowman R, Zantek ND, et al. Use of therapeutic plasma exchange in the management of acute hemorrhagic leukoencephalitis: a case report and review of the literature. *Transfusion.* 2007;47:981–6.
83. Martin A, Reade EP. Acute necrotizing encephalopathy progressing to brain death in a pediatric patient with novel influenza A (H1N1) infection. *CID.* 2010;50:e50–2.
84. Wang GF, Li W, Li K. Acute encephalopathy and encephalitis caused by influenza virus infection. *Curr Opin Neurol.* 2010;23:305–11.
85. Gika AD, Rich P, Gupta S, et al. Recurrent acute necrotizing encephalopathy following influenza A in a genetically predisposed family. *Dev Med Child Neurol.* 2010;52:99–102.
86. Manara R, Franzoi M, Cogo P, et al. Acute necrotizing encephalopathy: combined therapy and favorable outcome in a new case. *Childs Nerv Syst.* 2006;22:1231–6.
87. Yadav S, Das CJ, Kumar V, et al. Acute necrotizing encephalopathy. *Indian J Pediatr.* 2010;77:307–9.
88. Neilson DE, Adams MD, Orr CMD, et al. Infection-triggered familial or recurrent cases of acute necrotizing encephalopathy caused by mutations in a component of the nuclear pore, RANBP2. *Am J Hum Genet.* 2009;84:44–51.
89. Alawadhi A, Saint-Martin C, Bhanji F, et al. Acute hemorrhagic encephalitis responding to combined decompressive craniectomy, intravenous immunoglobulin, and corticosteroid therapies: association with novel RANBP2 variant. *Front Neurol.* 2018;9:130.
90. Kimoto K, Koga M, Odaka M, et al. Relationship of bacterial strains to clinical syndromes of campylobacter-associated neuropathies. *Neurology.* 2006;28:1837–43.
91. Roos RP, Soliven B, Goldenberg F, et al. An elderly patient with Bickerstaff brainstem encephalitis and transient episodes of brainstem dysfunction. *Arch Neurol.* 2008;65:821–4.
92. Steer AC, Starr M, Kornberg AJ. Bickerstaff brainstem encephalitis associated with mycoplasma pneumoniae infection. *J Child Neurol.* 2006;21:533–4.
93. Odaka M, Yuki N, Yamada M, et al. Bickerstaff's brainstem encephalitis: clinical features of 62 cases and a subgroup associated with Guillain-Barre syndrome. *Brain.* 2003;126:2279–90.
94. Mori M, Kuwabara S. Fisher syndrome. *Curr Treat Options Neurol.* 2011;13:71–8.
95. Yuki N. Fisher syndrome and Bickerstaff brainstem encephalitis (Fisher-Bickerstaff syndrome). *J Neuroimmunol.* 2009;21:1–9.
96. Atzori M, Battistella PA, Perini P, et al. Clinical and diagnostic aspects of multiple sclerosis and acute monophasic encephalomyelitis in pediatric patients: a single centre prospective study. *Mult Scler.* 2009;15:363–70.
97. Banwell B, Krupp L, Kennedy L, et al. Clinical features and viral serologies in children with multiple sclerosis: a multinational observational study. *Lancet Neurol.* 2007;6:773–81.
98. Visudtibhan A, Tuntiyathorn L, Vaewpanich J, et al. Acute disseminated encephalomyelitis: a 10-year cohort study in Thai children. *Eur J Pediatr Neurol.* 2010;14:513–8.
99. Berkovic SF, Harkin L, McMahon JM, et al. De-novo mutations of the sodium channel gene SCN1a an alleged vaccine encephalopathy retrospective study. *Lancet Neurol.* 2006;5:488–92.
100. Sell E, Minassian BA. Demystifying vaccination-associated encephalopathy. *Lancet Neurol.* 2006;5:465–6.
101. Johnson RT, Griffin DE, Hirsch RL, et al. Measles encephalomyelitis – clinical and immunologic studies. *N Engl J Med.* 1984;310:137–41.
102. Brilot F, Dale RC, Selter RC, et al. Antibodies to native myelin oligodendrocyte glycoprotein in children with inflammatory demyelinating central nervous system disease. *Ann Neurol.* 2009;66:833–42.
103. Selter RC, Brilot F, Grummel V, et al. Antibody responses to EBV and native MOG in pediatric inflammatory demyelinating CNS diseases. *Neurology.* 2010;74:1711–5.
104. Kadhim H, De Prez C, Gazagnes MD, et al. In situ cytokine immune responses in acute disseminated encephalomyelitis: insights into pathophysiologic mechanisms. *Hum Pathol.* 2003;3:293–7.
105. Sabayan B, Zolghadrasli A. Vasculitis and rheumatologic diseases may play a role in the pathogenesis of acute disseminated encephalomyelitis (ADEM). *Med Hypotheses.* 2007;69:322–4.
106. Franciotta D, Zardini E, Ravaglia S, et al. Cytokines and chemokines in cerebrospinal fluid and serum of adult patients with acute disseminated encephalomyelitis. *J Neurol Sci.* 2006;247:202–7.
107. Alves-Leon SV, Veluttini-Pimentel ML, Gouveia ME, et al. Acute disseminated encephalomyelitis. *Arq Neuropsiquiatr.* 2009;67:643–51.
108. Harris MO, Walsh LE, Hattab EM, et al. Is it ADEM, POLG, or both? *Arch Neurol.* 2010;67:493–6.
109. Carreira J, Casella MI, Ascensão BB, et al. Acute disseminated encephalomyelitis, a rare post-malaria neurological complication: case report and review of the literature. *Travel Med Infect Dis.* 2019;28:81–5. <https://doi.org/10.1016/j.tmaid.2018.03.005>.



# Neuromyelitis Optica Spectrum Disorders

# 12

Jonathan F. Cahill

## Clinical Presentation

Optic neuritis (ON) and transverse myelitis (TM) have long been considered the core clinical characteristics of neuromyelitis optica spectrum disorder (NMOSD). The optic neuritis of NMOSD presents similarly to that of multiple sclerosis (MS) and other inflammatory ON with decreased visual acuity, loss of color vision, and pain with eye movement developing subacutely over hours to days. The episodes or attacks of optic neuritis are most commonly severe and of a relapsing and remitting course. Unilateral ON is most typical, although simultaneous bilateral ON is not uncommon [1, 2]. There is frequently incomplete recovery from attacks with a step-wise accrual of disability (loss of visual acuity and constriction of visual fields) over time. Similarly, the clinical presentation of TM with NMO is similar to that of MS, with paraparesis, bladder dysfunction, and a sensory level on the trunk being common symptoms. Lhermitte sign and tonic spasms, other symptoms of myelopathy, are also common. Compared to MS, severe symptoms and incomplete recovery are more common in NMOSD [3]. A third clinical presen-

tation in NMOSD, which is included as a core clinical characteristic in the 2015 NMOSD criteria [4], is that of the area postrema syndrome (APS). Lesions of the area postrema, the chemosensitive vomiting center of the brain in the dorsal medulla, can be caused by the extension of longitudinally extensive cervical cord lesions. APS is characterized by intractable hiccups, nausea, and vomiting [5].

About half of all patients with NMO have a relapse of symptoms within 1 year of diagnosis, and up to 90% have a clinical relapse within 3 years [6, 7]. Because residual symptoms after each attack are common and disability accrues with time, approximately half of all patients develop severe visual loss or inability to ambulate without assistance after 5 years [7, 8]. With the effect on neurological disability leading to other complications such as respiratory failure from high cervical lesions, the median survival for patients with NMO is less than 18 years [7, 9]. Factors associated with more severe disease and shorter survival include higher attack frequency during the first year of disease, incomplete recovery from the first attack, blindness at disease onset, and the presence of other autoimmune diseases [7, 9].

The main difference between typical MS and typical NMOSD is the lack of significant brain disease in NMOSD. The disease primarily affects the optic nerves and spinal cord, with relative sparing of the brain, although some specific brain

---

J. F. Cahill (✉)  
Rhode Island Hospital and Alpert Medical School  
of Brown University, Brown Neurology,  
Providence, RI, USA  
e-mail: [jonathan\\_cahill@brown.edu](mailto:jonathan_cahill@brown.edu)

areas are increasingly recognized as being affected in NMOSD. Another key clinical difference between NMOSD and MS is that NMOSD does not have a secondary progressive phase of illness [10]. NMOSD is a disease characterized almost exclusively by relapses, sometimes with incomplete recovery, which can be more severe than relapses of MS [1, 11, 12].

---

## Epidemiology

The median age of onset of symptoms in NMOSD is about 10 years later than in MS (39 years compared to 29 years) and the female-to-male ratio is significantly higher (range 3:1 to 9:1 in NMOSD) than in MS [11, 13, 14]. Other autoimmune diseases, especially systemic lupus erythematosus (SLE) and Sjogren syndrome (SS), have been associated with NMOSD and longitudinally extensive myelitis [15–18]. The serological markers of these systemic autoimmune disorders (antinuclear antibodies and Sjogren syndrome A antibodies) are also common in patients with NMOSD who do not have clinical manifestations of SLE or SS. In one study of 78 patients with NMOSD, 66.7% of them had aquaporin-4 antibodies, antinuclear antibodies were found in 43.8%, and Sjogren syndrome A antibodies in 15.7% [19]. Only five of the aquaporin-4 antibody-positive patients had coexisting clinical SLE, SS, or both.

---

## Pathology and Pathophysiology

The pathology of NMOSD is primarily demyelination. The degree of demyelination within lesions is frequently more extensive than in MS, and there is more commonly associated necrosis, cavitation, and acute axonal pathology (spheroids) [20, 21]. There is significant oligodendrocyte loss in both gray matter and white matter. In active lesions, there is perivascular inflammation with macrophages and T-cells, as well as neutrophils and eosinophils.

With the discovery of specific autoantibodies to the aquaporin-4 channel on astrocytes in

NMOSD [22], a biomarker for the disease was found. Aquaporin-4 is an astrocyte water channel found in the periventricular and periaqueductal brain and the gray matter of the spinal cord [23, 24]. The aquaporin-4 channel is one of a family of channels that allow for movement of water across cell membranes [25]. The channel is highly represented in the optic nerve, the spinal cord, and the area postrema. In NMOSD, specific autoantibodies to the aquaporin-4 channel have been shown to be pathogenic [26, 27]. Measurable aquaporin-4 immunoglobulin G antibodies (AQP4-IgG) can be found in 75–90% of patients with NMOSD, and when found, the AQP4-IgG is 91–100% specific for NMOSD [11].

---

## MOG Antibodies

In a subset of patients with a clinical presentation of NMOSD but without AQP-4-IgG, antibodies to the membrane-embedded myelin oligodendrocyte glycoprotein (MOG) have been found [28, 29]. MOG-IgG is also found in children with acute disseminated encephalomyelitis [30], but in those cases, the antibody seropositivity is not persistent and MOG-IgG cannot be detected after the monophasic illness. MOG-IgG is not found in patients with multiple sclerosis or AQP-4-IgG seropositive NMOSD [31]. The clinical presentation of MOG-IgG-positive NMOSD is like that of AQP-4-IgG-positive cases, with ON and TM as the most common presenting syndromes. Though the severity of symptoms is similar between the two, the degree of recovery from attacks of ON or TM in patients with MOG-IgG disease is generally greater than for those with AQP-4-IgG disease. Patients with MOG-IgG-positive disease are more likely to have simultaneous bilateral ON, rapidly sequential ON, or simultaneous ON and TM [32]. In one large cohort of 252 patients, 56% of MOG-IgG seropositive patients had a monophasic presentation [33]. Involvement of the cerebellum and brainstem is also more common in MOG-IgG-positive patients, and cases of seizures, encephalitis, and meningitis have been described [34–36]. Because of the greater degree of phenotypic variability in MOG-IgG-positive patients, some have



suggested it be considered a separate entity outside of NMOSD, and the terms MOG-IgG-associated optic neuritis, encephalitis, and myelitis (MONEM) have been suggested [37]. The natural history of MOG-IgG seropositive NMOSD is not fully understood, owing to the limited follow-up time and the low number of described cases. In clinical practice, most patients with MOG-IgG seropositive NMOSD are treated with long-term immunotherapy in a similar way to patients with AQP-4 IgG seropositive NMOSD [38].

---

## Imaging NMOSD

MRI is a valuable diagnostic tool for the diagnosis and monitoring of disease activity in NMOSD. Just as how the clinical presentation of NMOSD is similar but with notable specific differences from MS, the imaging abnormalities of the two diseases are distinct. A large majority of patients with NMOSD presenting with ON have gadolinium enhancement of the optic nerve visible on MRI [11]. Bilateral optic neuritis, chiasmatic involvement, and enhancement of more than half of the length of the optic nerve (longitudinally extensive optic neuritis—LEON) are features more typical of NMOSD than MS [4, 39].

At the time of diagnosis, brain MRI in NMOSD patients is normal in nearly 80%, and the remainder usually have nonspecific white matter T2 hyperintensities not meeting diagnostic criteria for MS [1]. Over time, the brain MRI in most patients with NMOSD demonstrates the accumulation of white matter T2 hyperintensities, but typically they remain nonspecific and not meeting MS criteria [1]. The brain MRI is useful in differentiating MS from NMOSD, but not in differentiating different antibody-mediated forms of NMOSD from one another [40]. At disease onset, several patterns of brain MRI lesions specific to NMOSD have been described, including lesions that are longitudinally extensive within the corticospinal tract, extensive hemispheric lesions, periependymal lesions surrounding the lateral ventricle, and cervicomedullary lesions [41]. With further follow-up imaging, a minority of patients (16%) ultimately develop

typical MS-like lesions which satisfy MS criteria [42, 43].

In NMOSD patients presenting with myelitis, a large majority (90%) have abnormal spinal cord MRI showing T2 hyperintensity most often in the central gray matter, which usually (88%) spans three or more vertebral body levels within the spinal cord [1]. Although longitudinally extensive transverse myelitis (LETM) is typical, lesions spanning less than three levels are also described [44]. Cord edema (50%) and gadolinium enhancement (64%) are common during the acute presentation, and over time, many patients develop cord atrophy [1].

---

## 2015 Criteria

Previous diagnostic criteria for NMOSD [1, 45] have defined NMOSD by the clinical presentation of ON and acute myelitis, with supportive evidence of AQP4-IgG seropositivity and MRI findings. Recognizing the role of AQP4-IgG in the pathogenesis of NMOSD, some have reported cases of AQP4-IgG seropositive patients not meeting previous NMOSD criteria [44, 46]. Many of these cases were first attacks or monophasic presentations of ON or acute myelitis. Some were cases of short-segment myelitis, hypothalamic, or brainstem syndromes.

With increasing recognition of several different CNS syndromes as within the spectrum of NMOSD, a consensus panel revised the diagnostic criteria in 2015 [4]. These criteria dichotomize NMOSD cases into those AQP4-IgG seropositive and those seronegative. Because of the specificity of the AQP4-IgG, the requirements for diagnosis of NMOSD are fewer in seropositive cases. Table 12.1 summarizes the 2015 NMOSD diagnostic criteria.

These criteria may facilitate earlier and more accurate diagnosis of NMOSD, often after only one clinical attack (in the AQP4-IgG-positive patients). The criteria may also prove helpful in diagnosing NMOSD in a subset of patients with atypical MS. As treatment for NMOSD with immunotherapy becomes more widespread, the importance of early and accurate diagnosis becomes clear.

**Table 12.1** 2015 NMO-spectrum disorders diagnostic criteria

AQP4-IgG seropositive	AQP4-IgG seronegative or unknown
At least one core clinical characteristic <sup>a</sup>	At least two core clinical characteristics <sup>a</sup> , occurring as a result of one or more clinical attacks, and meeting the following requirements: <ol style="list-style-type: none"> <li>1. One of the core clinical characteristics must be ON, myelitis with LETM, or APS</li> <li>2. Dissemination in space (two or more different core clinical characteristics)</li> <li>3. MRI findings consistent with NMOSD<sup>b</sup></li> </ol>

<sup>a</sup>*Core clinical characteristics:* (1) Optic neuritis (ON), (2) Acute myelitis, (3) Area postrema syndrome (APS), (4) Acute brainstem syndrome, (5) Symptomatic narcolepsy or acute diencephalic clinical syndrome with NMOSD-typical diencephalic MRI lesions<sup>b</sup>, (6) Symptomatic cerebral syndrome with NMOSD-typical brain MRI lesions<sup>b</sup>

<sup>b</sup>*MRI findings consistent with NMOSD:* (1) Brain MRI normal or only nonspecific white matter lesions, (2) Optic nerve MRI with T2-hyperintensity or gadolinium enhancement extending over half the optic nerve length (LEON) or involving optic chiasm, (3) Spinal cord MRI with lesion extension over three contiguous segments (LETM), or three contiguous segments of focal spinal cord atrophy in patients with history compatible with acute myelitis, (4) Area postrema syndrome requires associated dorsal medulla/area postrema lesions, (5) Acute brainstem syndrome requires associated periependymal brainstem lesions

## Immunotherapy for NMOSD

Like with MS, there are several goals of treatment for NMOSD. First, one should consider treating acute attacks of NMOSD with immunotherapy to reduce CNS damage and enhance repair. Second, long-term immunotherapy should be considered to reduce the frequency and severity of subsequent attacks in order to reduce disability in the long term. A third consideration, though not reviewed in detail here, is the use of pharmacological agents and other therapies to reduce chronic symptoms of NMOSD, much in the same way as MS.

The primary goals in treating acute attacks of NMOSD are to restore neurological function and to limit irreversible damage of the CNS. The mainstay of treatment for acute attacks of optic

neuritis and transverse myelitis, the two most common presenting symptoms of NMOSD, is high-dose corticosteroids [47]. A typical dose is 1000 mg of intravenous methylprednisolone daily for 3–5 days. Intravenous methylprednisolone has been the treatment of choice since the Optic Neuritis Treatment Trial demonstrated the superiority of intravenous steroids over low-dose oral steroids [48]; but several recent studies have shown high-dose bioequivalent oral steroids to be as effective as intravenous doses [49, 50]. Oral tapering doses of steroids following the high-dose course are optional, but have not been evaluated in a systematic way. An oral taper over 2–6 months may be considered in cases of limited recovery or instances when the long-term immunotherapy to be started has a delayed onset of action.

Because acute attacks of NMOSD can be severe and poorly responsive to corticosteroids, additional treatment options may be necessary. In cases of severe optic neuritis, severe transverse myelitis, and NMOSD attacks, plasmapheresis has been shown to be helpful in achieving better functional recovery [51–54]. The benefit of plasmapheresis is independent of AQP-4 IgG seropositivity in patients with NMOSD [55]. A typical regimen would be five to seven exchanges of 1–1.5 volumes of circulating plasma every other day [56]. Other acute immunotherapies such as intravenous immune globulin (IVIG) have not been shown to be effective in treating acute NMOSD attacks.

Because incomplete recovery from attacks is common, and the accrual of disability in NMOSD over time is largely dependent on the attack severity and frequency, long-term immunotherapy to reduce attacks is warranted in most patients. Unlike MS, NMOSD does not have a secondary progressive phase, and the therapeutic target in NMOSD is for reduced attack frequency only. Prior to 2019 no randomized controlled trials of preventative immunotherapy agents in NMOSD had been completed, though many different agents had shown benefit in small prospective and retrospective series, including oral corticosteroids, azathioprine, mycophenolate, methotrexate, mitoxantrone, and rituximab. Immunomodulating

agents used to treat MS, such as beta-interferon, natalizumab, and fingolimod, have largely been unsuccessful in NMOSD or shown to be harmful [57–59].

A small retrospective study showed long-term corticosteroid therapy in NMOSD to reduce relapse rates [60], but the side effects of long-term corticosteroid use limit its widespread adoption as first-line therapy. Several steroid-sparing agents have been investigated and used for NMOSD. Azathioprine, which inhibits de novo purine synthesis and prevents T-cell and B-cell proliferation, has been used to treat NMOSD for decades [61]. It has been shown to decrease annualized relapse rates in NMOSD patients when used alone or in conjunction with oral corticosteroids [62]. Because of the delayed onset of action of azathioprine, a typical approach is to treat with a target dose of 2–3 mg/kg/day in conjunction with oral prednisone, and to taper the prednisone over several months. Mycophenolate, an inhibitor of de novo guanosine synthesis, which prevents T-cell and B-cell proliferation, also has also been shown in a retrospective series to reduce relapse rates and reduce or stabilize disability in NMOSD [63]. Target doses for mycophenolate are 1000 mg twice daily. Like with azathioprine, there is a delayed onset of action with mycophenolate and a prolonged oral corticosteroid taper may be warranted. Long-term immunosuppression with azathioprine or mycophenolate has been associated with increased risk of infection, myelosuppression, and secondary malignancy. Small studies have shown benefits in NMOSD with the use of methotrexate [64] and mitoxantrone [65, 66], but the significant side effects of these drugs and the availability of other immunotherapeutic options have limited their use.

The understanding of the antibody-mediated pathogenesis of NMOSD has led to the use of rituximab, an anti-CD20 monoclonal antibody that depletes peripheral B-cell populations. Rituximab, dosed either as four weekly 375 mg/m<sup>2</sup> infusions or as 1000 mg biweekly infusions, reduces relapse rates in NMOSD [67, 68]. Disability scores in patients with NMOSD treated with rituximab also

either stabilize or decrease over the course of treatment, up to 2 years [69, 70]. A typical approach is to dose rituximab every 6 months, or alternatively to monitor circulating B-cells, and re-dose based on repopulation of CD19+ B-cells or CD27+ memory B-cells. Rituximab is generally well tolerated, with the most common side effect being allergy or infusion reaction, which can generally be avoided with pre-treatment with corticosteroids, diphenhydramine, and/or acetaminophen. Infections, including severe infections, are more common in patients treated with rituximab. And although cases of progressive multifocal leukoencephalopathy (PML) have been reported in patients being treated with rituximab for other autoimmune conditions (risk estimated 1:25,000) [56], to date, there have been no reports of PML in patients treated with rituximab monotherapy for NMOSD or MS.

In 2019, the results of clinical trials of three different monoclonal antibodies were presented, showing a reduction in relapse rates in NMOSD subjects. Eculizumab is a humanized monoclonal antibody which inhibits the terminal complement protein C5. As an add-on therapy to existing immunomodulating therapy, eculizumab reduced the likelihood of relapse in AQP4-IgG positive NMOSD subjects. Only 3% of subjects in the eculizumab group experienced an adjudicated relapse compared to 43% of placebo treated subjects [71]. Based on these results, eculizumab became the first drug approved by the US Food and Drug Administration for the treatment of AQP4-IgG positive NMOSD patients in June 2019. Inebilizumab, a monoclonal antibody targeting the B-cell marker CD19, reduced relapse rates by 73% in NMOSD subjects, the majority of whom were AQP4-IgG positive [72]. And satralizumab, an anti-IL-6 receptor monoclonal antibody, reduced relapse rates by 62% in a group of AQP4-IgG positive and negative subjects with NMOSD, although the treatment benefit was less evident in the antibody negative subjects [73]. The success of these three monoclonal antibodies in reducing relapse rates in NMOSD represents a breakthrough in the treatment of this disease and reinforces the importance of immunotherapy in NMOSD.

The optimal duration of immunotherapy treatment for NMOSD is not well studied. In part, this is because of the relatively recent recognition of the disease as a specific entity and the lack of a known cure. In this way, NMOSD is like MS, and most immunotherapy is continued for the long term depending on tolerability and the development of adverse effects. The decision to stop immunotherapy for NMOSD should be based on consideration of multiple factors including pre- and post-treatment relapse rates, relapse severity, disability, treatment tolerability, treatment duration, and other patient-specific factors (e.g., age, other comorbidities, considerations for potential pregnancy).

## Conclusion

Over the past two decades, neuromyelitis optica spectrum disorder has come to be understood as a unique disease entity distinct from multiple sclerosis. The unique pathology, pathophysiology, imaging, epidemiology, and responses to treatment set the disease apart. But NMOSD also has significant phenotypic heterogeneity, and new information, such as additional pathogenic autoantibodies, is coming to light each year.

## References

1. Wingerchuk DM, Hogancamp WF, O'Brien PC, Weinshenker BG. The clinical course of neuromyelitis optica (Devic's syndrome). *Neurology*. 1999;53:1107–14.
2. O'Riordan JI, Gallagher HL, Thompson AJ, et al. Clinical, CSF, and MRI findings in Devic's neuromyelitis optica. *J Neurol Neurosurg Psychiatry*. 1996;60:382–7.
3. Weinshenker BG. Neuromyelitis optica: what it is and what it might be. *Lancet*. 2003;361:889–90.
4. Wingerchuk DM, Banwell B, Bennett JL, International Panel for NMO Diagnosis, et al. International consensus diagnostic criteria for neuromyelitis optica spectrum disorders. *Neurology*. 2015;85(2):177–89.
5. Popescu BF, Lennon VA, Parisi JE, et al. Neuromyelitis optica unique area postrema lesions: nausea, vomiting, and pathogenic implications. *Neurology*. 2011;76(14):1229–37.
6. Kitley J, Leite MI, Nakashima I, et al. Prognostic factors and disease course in aquaporin-4 antibody-positive patients with neuromyelitis optica spectrum disorder from the United Kingdom and Japan. *Brain*. 2012;135:1834–49.
7. Wingerchuk DM, Weinshenker BG. Neuromyelitis optica: clinical predictors of a relapsing course and survival. *Neurology*. 2003;60:848–53.
8. Ghezzi A, Bergamaschi R, Martinelli V, et al. Clinical characteristics, course and prognosis of relapsing Devic's neuromyelitis optica. *J Neurol*. 2004;251:47–52.
9. Cabre P, González-Quevedo A, Bonnan M, et al. Relapsing neuromyelitis optica: long term history and clinical predictors of death. *J Neurol Neurosurg Psychiatry*. 2009;80(10):1162–4.
10. Wingerchuk DM, Pittock SJ, Lucchinetti CF, Lennon VA, Weinshenker BG. A secondary progressive clinical course is uncommon in neuromyelitis optica. *Neurology*. 2007;68:603–5.
11. Wingerchuk DM, Lennon VA, Lucchinetti CF, et al. The spectrum of neuromyelitis optica. *Lancet Neurol*. 2007;6:805.
12. de Seze J, Lebrun C, Stojkovic T, Ferriby D, Chatel M, Vermersch P. Is Devic's neuromyelitis optica a separate disease? A comparative study with multiple sclerosis. *Mult Scler*. 2003;9:521–5.
13. Asgari N, Lillevang ST, Skejoe HP, Falah M, Stenager E, Kyvik KO. A population-based study of neuromyelitis optica in Caucasians. *Neurology*. 2011;76:1589–95.
14. Cabrera-Gomez JA, Kurtzke JF, Gonzalez-Quevedo A, Lara-Rodriguez R. An epidemiological study of neuromyelitis optica in Cuba. *J Neurol*. 2009;256:35–44.
15. Giorgi D, Balacco Gabrieli C, Bonomo L. The association of optic neuropathy with transverse myelitis in systemic lupus erythematosus. *Rheumatology*. 1999;38:191–2.
16. Lehnhardt FG, Impekoven P, Rubbert A, et al. Recurrent longitudinal myelitis as primary manifestation of SLE. *Neurology*. 2004;63:1976.
17. Ferreira S, Marques P, Carneiro E, D'Cruz D, Gama G. Devic's syndrome in systemic lupus erythematosus and probable antiphospholipid syndrome. *Rheumatology*. 2005;44(5):693–5.
18. Chan AY, Liu DT. Devic's syndrome in systemic lupus erythematosus and probable antiphospholipid syndrome. *Rheumatology*. 2006;45:120–1.
19. Pittock SJ, Lennon VA, De Seze J, et al. Neuromyelitis optica spectrum disorders and non-organ-specific autoimmunity. *Arch Neurol*. 2008;65(1):78–83.
20. Lucchinetti CF, Mandler RN, McGavern D, et al. A role for humoral mechanisms in the pathogenesis of Devic's neuromyelitis optica. *Brain*. 2002;125:1450–61.
21. Mandler RN, Davis LE, Jeffery DR, Kornfeld M. Devic's neuromyelitis optica: a clinicopathological study of 8 patients. *Ann Neurol*. 1993;34:162–8.
22. Lennon VA, Wingerchuk DM, Kryzer TJ, et al. A serum autoantibody marker of neuromyelitis

- optica: distinction from multiple sclerosis. *Lancet*. 2004;364:2106.
23. Takahashi T, Fujihara K, Nakashima I, et al. Anti-aquaporin-4 antibody is involved in the pathogenesis of NMO: a study on antibody titre. *Brain*. 2007;130:1235.
  24. Lennon VA, Kryzer TJ, Pittock SJ, Verkman AS, Hinson SR. IgG marker of optic-spinal multiple sclerosis binds to the aquaporin-4 water channel. *J Exp Med*. 2005;202:473–7.
  25. Yukutake Y, Yasui M. Regulation of water permeability through aquaporin-4. *Neuroscience*. 2010;168(4):885–91.
  26. Hinson SR, Pittock SJ, et al. Pathogenic potential of IgG binding to water channel extracellular domain in neuromyelitis optica. *Neurology*. 2007;69(24):2221–31.
  27. Papadopoulos MC, Verkman AS. Aquaporin 4 and neuromyelitis optica. *Lancet Neurol*. 2012;11:535–44.
  28. Mader S, Gredler V, Schanda K, et al. Complement activating antibodies to myelin oligodendrocyte glycoprotein in neuromyelitis optica and related disorders. *J Neuroinflammation*. 2011;8:184.
  29. Kitley J, Woodhall M, Waters P, et al. Myelin-oligodendrocyte glycoprotein antibodies in adults with a neuromyelitis optica phenotype. *Neurology*. 2012;79(12):1273–7.
  30. Probstel AK, Dormmair K, Bittner R, et al. Antibodies to MOG are transient in childhood acute disseminated encephalomyelitis. *Neurology*. 2011;77(6):580–8.
  31. Kitley J, Waters P, Woodhall M, et al. Neuromyelitis optica spectrum disorders with aquaporin-4 and myelin-oligodendrocyte glycoprotein antibodies: a comparative study. *JAMA Neurol*. 2014;71(3):276–83.
  32. Jarius S, Ruprecht K, Kleiter I, in cooperation with the Neuromyelitis Optica Study Group (NEMOS), et al. MOG-IgG in NMO and related disorders: a multicenter study of 50 patients: Part 2: Epidemiology, clinical presentation, radiological and laboratory features, treatment responses, and long-term outcome. *J Neuroinflammation*. 2016;13(1):280.
  33. Jurynczyk M, Messina S, Woodhall MR, et al. Clinical presentation and prognosis in MOG-antibody disease: a UK study. *Brain*. 2017;140(12):3128–38.
  34. Fujimori J, Takai Y, Nakashima I, Sato DK, Takahashi T, Kaneko K, et al. Bilateral frontal cortex encephalitis and paraparesis in a patient with anti-MOG antibodies. *J Neurol Neurosurg Psychiatry*. 2017;88(6):534–6.
  35. Hamid SHM, Whittam D, Saviour M, Alorainy A, Mutch K, Linaker S, et al. Seizures and encephalitis in myelin oligodendrocyte glycoprotein IgG disease vs aquaporin 4 IgG disease. *JAMA Neurol*. 2018;75(1):65–71.
  36. Sarangi S, Wong B, Cahill J. Clinical episode of aseptic meningitis with leptomeningeal enhancement in patient with anti-MOG antibodies. Presented at the annual meeting of the American Academy of Neurology (AAN), Los Angeles, CA, April, 2018. P5.420; 2018.
  37. dos Passos GR, Oliveira LM, da Costa BK, et al. MOG-IgG-associated optic neuritis, encephalitis, and myelitis: lessons learned from neuromyelitis optica spectrum disorder. *Front Neurol*. 2018;9:217.
  38. Weber MS, Derfuss T, Bruck W. Anti-myelin oligodendrocyte glycoprotein antibody-associated central nervous system demyelination—a novel disease entity? *JAMA Neurol*. 2018;75(8):909–10.
  39. Mealy MA, Whetstone A, Orman G, Izbudak I, Calabresi PA, Levy M. Longitudinally extensive optic neuritis as an MRI biomarker distinguishes neuromyelitis optica from multiple sclerosis. *J Neurol Sci*. 2015;355(1–2):59–63.
  40. Jurynczyk M, Geraldes R, Probert F, et al. Distinct brain imaging characteristics of autoantibody-mediated CNS conditions and multiple sclerosis. *Brain*. 2017;140(3):617–27.
  41. Huh SY, Min JH, Kim W, Kim SH, Kim HJ, Kim BJ, Kim BJ, Lee KH. The usefulness of brain MRI at onset in the differentiation of multiple sclerosis and seropositive neuromyelitis optica spectrum disorders. *Mult Scler*. 2014;20(6):695–704.
  42. Pittock SJ, Lennon VA, Krecke K, Wingerchuk DM, Lucchinetti CF, Weinschenker BG. Brain abnormalities in neuromyelitis optica. *Arch Neurol*. 2006;63:390–6.
  43. Matthews L, Marasco R, Jenkinson M, et al. Distinction of seropositive NMO spectrum disorder and MS brain lesion distribution. *Neurology*. 2013;80:1330–7.
  44. Flanagan EP, Weinschenker BG, Krecke KN, et al. Short myelitis lesions in aquaporin-4-IgG-positive neuromyelitis optica spectrum disorders. *JAMA Neurol*. 2015;72:81–7.
  45. Wingerchuk DM, Lennon VA, Pittock SJ, Lucchinetti CF, Weinschenker BG. Revised diagnostic criteria for neuromyelitis optica. *Neurology*. 2006;66:1485–9.
  46. Sato DK, Nakashima I, Takahashi T, et al. Aquaporin-4 antibody-positive cases beyond current diagnostic criteria for NMO spectrum disorders. *Neurology*. 2013;80:2210–6.
  47. Wingerchuk DM, Weinschenker BG. Neuromyelitis optica. *Curr Treat Options Neurol*. 2008;10:55–66.
  48. Beck RW, Cleary PA, Anderson MM Jr, Keltner JL, Shults WT, Kaufman DI, Buckley EG, Corbett JJ, Kupersmith MJ, Miller NR, et al. A randomized, controlled trial of corticosteroids in the treatment of acute optic neuritis. The Optic Neuritis Study Group. *N Engl J Med*. 1992;326(9):581–8.
  49. Ramo-Tello C, Grau-Lopez L, Tintore M, et al. A randomized clinical trial of oral versus intravenous methylprednisolone for relapse of MS. *Mult Scler J*. 2014;20(6):717–25.
  50. Morrow SA, Fraser JA, Day C, et al. Effect of treating acute optic neuritis with bioequivalent oral vs intravenous corticosteroids. *JAMA Neurol*. 2018;75(6):690–6.
  51. Weinschenker BG, O'Brien PC, Petterson TM, Noseworthy JH, Lucchinetti CF, Dodick DW, et al. A randomized trial of plasma exchange in acute central nervous system inflammatory demyelinating disease. *Ann Neurol*. 1999;46(6):878–86.

52. Keegan M, Pineda AA, McClelland RL, Darby CH, Rodriguez M, Weinshenker BG. Plasma exchange for severe attacks of CNS demyelination: predictors of response. *Neurology*. 2002;58(1):143–6.
53. Ruprecht K, Klinker E, Dintelmann T, Reickmann P, Gold R. Plasma exchange for severe optic neuritis: treatment of 10 patients. *Neurology*. 2004;63(6):1081–3.
54. Watanabe S, Nakashima I, et al. Therapeutic efficacy of plasma exchange in NMO-IgG-positive patients with neuromyelitis optica. *Mult Scler*. 2007;13(1):128–32.
55. Bonnan M, Valentino R, et al. Plasma exchange in severe spinal attacks associated with neuromyelitis optica spectrum disorder. *Mult Scler*. 2009;15(4):487–92.
56. Kimbrough DJ, Fujihara K, Jacob A, et al. Treatment of neuromyelitis optica: review and recommendations. *Mult Scler Relat Disord*. 2012;1:180–7.
57. Papeix C, Vidal JS, de Seze J, et al. Immunosuppressive therapy is more effective than interferon in neuromyelitis optica. *Mult Scler*. 2007;13:256–9.
58. Min JH, Kim BJ, et al. Development of extensive brain lesions following fingolimod (FTY720) treatment in a patient with neuromyelitis optica spectrum disorder. *Mult Scler*. 2012;18(1):113–5.
59. Kleiter I, Hellwig K, et al. Failure of natalizumab to prevent relapses in neuromyelitis optica. *Arch Neurol*. 2012;69(2):239–45.
60. Watanabe S, Misu T, et al. Low-dose corticosteroids reduce relapses in neuromyelitis optica: a retrospective analysis. *Mult Scler*. 2007;13(8):968–74.
61. Mandler RN, Ahmed W, et al. Devic's neuromyelitis optica: a prospective study of seven patients treated with prednisone and azathioprine. *Neurology*. 1998;51(4):1219–20.
62. Costanzi C, Matiello M, et al. Azathioprine: tolerability, efficacy, and predictors of benefit in neuromyelitis optica. *Neurology*. 2011;77(7):659–66.
63. Jacob A, Matiello M, et al. Treatment of neuromyelitis optica with mycophenolate mofetil: retrospective analysis of 24 patients. *Arch Neurol*. 2009;66(9):1128–33.
64. Minagar A, Sheremata WA. Treatment of Devic's disease with methotrexate and prednisone. *Int J MS Care*. 2000;2(4):43–9.
65. Weinstock-Guttman B, Ramanathan M, et al. Study of mitoxantrone for the treatment of recurrent neuromyelitis optica (Devic disease). *Arch Neurol*. 2006;63(7):957–63.
66. Kim SH, Kim W, et al. Efficacy and safety of mitoxantrone in patients with highly relapsing neuromyelitis optica. *Arch Neurol*. 2011;68(4):473–9.
67. Cree BA, Lamb S, Morgan K, Chen A, Waubant E, Genain C. An open label study of the effects of rituximab in neuromyelitis optica. *Neurology*. 2005;64:1270–2.
68. Jacob A, Weinshenker BG, et al. Treatment of neuromyelitis optica with rituximab: retrospective analysis of 25 patients. *Arch Neurol*. 2008;65(11):1443–8.
69. Kim SH, Kim W, et al. Repeated treatment with rituximab based on the assessment of peripheral circulating memory B cells in patients with relapsing neuromyelitis optica over 2 years. *Arch Neurol*. 2011;68(11):1412–20.
70. Bedi GS, Brown AD, et al. Impact of rituximab on relapse rate and disability in neuromyelitis optica. *Mult Scler*. 2011;17(10):1225–30.
71. Pittock SJ, Berthele A, Fujihara K, Kim HJ, Levy M, Palace J, Nakashima I, Terzi M, Totolyan N, Viswanathan S, Wang K-C, Pace A, Fujita KP, Armstrong R, Wingerchuk DM. Eculizumab in aquaporin-4-positive neuromyelitis optica spectrum disorder. *N Engl J Med*. 2019. [Epub ahead of print].
72. Cree B, Bennett J, Kim HJ, et al. A double-masked, placebo-controlled study with open-label period to evaluate the efficacy and safety of inebilizumab in adult subjects with neuromyelitis optica spectrum disorders – top line efficacy and safety results. Philadelphia: Presented at the Annual Meeting of the American Academy of Neurology (AAN); 2019. Plen02.001.
73. Yamamura T, Kleiter I, Fujihara K, et al. Efficacy of satralizumab (SA237) in subgroups of patients in SAKuraSky: a phase III double-blind, placebo-controlled, add-on study in patients with neuromyelitis optica spectrum disorder (NMOSD). Philadelphia: Presented at the Annual Meeting of the American Academy of Neurology (AAN); 2019. S43.008.



# Paraneoplastic and Other Autoimmune Disorders

# 13

Alexander Mohler, Mayra Montalvo, and Julie Roth

## Abbreviations

ACTH	Adrenocorticotrophic hormone	CRMP5	Collapsin response-mediator protein-5
AEDs	Antiepileptic drugs	CSF	Cerebral spinal fluid
ALS	Amyotrophic lateral sclerosis	CT	Computer tomography
AMPA	$\alpha$ -Amino-3-hydroxy-5-methyl-4-isoxazolepropionic	DDPX	Dipeptidyl-peptidase-like protein-6
ANNA-1	Antineuronal nuclear antibody-1	EEG	Electroencephalogram
ANNA-2	Antineuronal nuclear antibody-2	EMG	Electromyogram
ANNA-3	Antineuronal nuclear antibody-3	ERG	Electroretinogram
BDUMP	Bilateral diffuse uveal melanocytic proliferation	FDG-PET	Fluorodeoxyglucose-positron emission tomography
BRAO	Branch retinal artery occlusion	FLAIR	Fluid-attenuated inversion recovery
CAR	Cancer-associated retinopathy	GABA	Gamma-aminobutyric acid
CASPR2	Contactin-associated protein-like 2	GABARAP	GABA receptor-associated protein
CD	Cluster of differentiation	GAD	Glutamic acid decarboxylase
CLIPPERS	Chronic lymphocytic inflammation with pontine perivascular enhancement responsive to steroids	HSE	Herpes simplex encephalitis
		IVIG	Intravenous immunoglobulin
		LEMS	Lambert Eaton Myasthenic Syndrome
		LGII	Leucine-rich, glioma-inactivated protein 1
		MAR	Melanoma-associated retinopathy
		MG	Myasthenia gravis
		MND	Motor neuron disease
		MRI	Magnetic resonance imaging
		mRS	Modified Rankin Scale
		NAP	Neuronal adaptin-like protein
		NCS	Nerve conduction studies
		NMDAR	<i>N</i> -Methyl <i>D</i> -Aspartate receptor
		NSCLC	Non-small-cell lung carcinoma
			opsoclonus myoclonus syndrome
		OMS	Opsoclonus myoclonus syndrome

A. Mohler (✉) · J. Roth  
Alpert Medical School of Brown University,  
Providence, RI, USA

Department of Neurology, Rhode Island Hospital,  
Providence, RI, USA  
e-mail: [AlexanderMo@baptisthealth.net](mailto:AlexanderMo@baptisthealth.net);  
[Julie\\_roth@brown.edu](mailto:Julie_roth@brown.edu)

M. Montalvo  
Department of Neurology, Rhode Island Hospital,  
Providence, RI, USA  
e-mail: [mayra.montalvoperero@lifespan.org](mailto:mayra.montalvoperero@lifespan.org)

PCA	Purkinje cell cytoplasmic antibody
PCD	Paraneoplastic cerebellar degeneration
PERM	Progressive encephalomyelitis with rigidity and myoclonus
PET/CT	Positron emission tomography/computed tomography
PND	Paraneoplastic neurologic disorder
PNMA	Paraneoplastic Ma antigens
POEMS	Polyneuropathy, organomegaly, endocrinopathy, monoclonal protein, skin changes
RNA	Ribonucleic acid
SCLC	Small-cell lung cancer
SPS	Stiff person syndrome
SREAT	Steroid responsive encephalopathy associated with autoimmune thyroiditis
SuS	Susac syndrome
VEGF	Vascular endothelial growth factor
VGCC	Voltage-gated calcium channel
VGKC	Voltage-gated potassium channel

---

## Introduction

The term paraneoplastic neurologic disorder (PND) can describe any condition or syndrome for which there is a causal relationship between a malignant process that is distal from the inciting tumor and a systemic illness or collection of symptoms. In other words, these disorders are associated with tumors but are not caused by direct tumor invasion of the target tissue. Technically, PNDs include systemic conditions like Trousseau's syndrome, a malignancy-associated disorder characterized by migratory superficial thrombosis and thrombophlebitis. However, more commonly when this term is used, it describes a neurologic condition associated with malignancy. The underlying mechanism of PND is thought to be an exaggerated immune response against a neuronal protein expressed by the tumor [1, 2].

It is of foremost importance to note that the initial evaluation of a suspected PND starts with a detailed neurologic history and examination to characterize the syndrome. Not uncommonly, neurological manifestations present before the tumor has manifested [2].

---

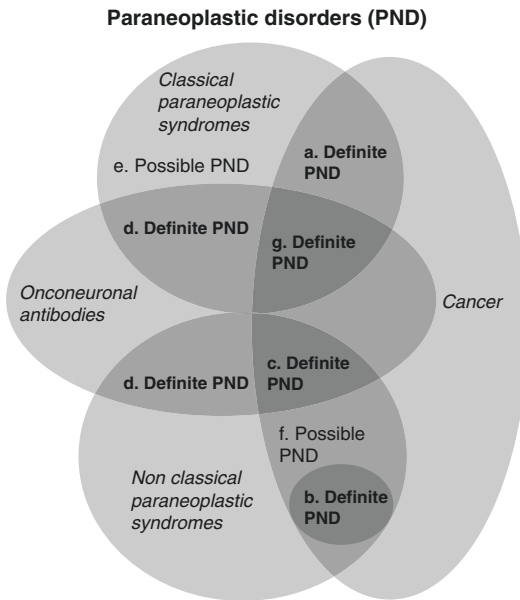
## Definition and Classifications

The list of paraneoplastic syndromes is rapidly growing as clinicians and scientists classify and associate antibodies with specific neurologic and non-neurologic symptoms and signs. The identification, classification, and treatment of paraneoplastic syndromes have become one of the most dynamic fields within neurology. Most neurologists who treat these conditions still divide them into two groups in an attempt to identify conditions that have stronger associations with malignancies, also known as "classical syndromes" prompting a more thorough evaluation for occult tumor, and those that have a more casual relationship with an underlying malignancy, also known as "nonclassical syndromes." These two groups can be further broken down based on location within the nervous system. Onconeural antibodies are directed against intracellular antigens.

Graus proposed diagnostic criteria that may help differentiate definite paraneoplastic disorders from possible paraneoplastic disorders [3] (see Fig. 13.1).

In addition to the distinction between classical and nonclassical paraneoplastic syndromes (Table 13.1), and possible versus definite paraneoplastic syndromes, a third method of classification of these syndromes exists that distinguishes clinical syndromes in relation to their antibodies. This system distinguishes syndromes with autoantibodies that are directed against intracellular proteins from those syndromes with autoantibodies opposed to proteins located on the cell surface (Tables 13.2 and 13.3). In general, this also separates non-paraneoplastic autoimmune encephalitis and other neurologic conditions from the classical paraneoplastic disorders. This antibody-based





**Fig. 13.1** Definite and possible paraneoplastic syndromes. (a) Classical syndrome and cancer that develops within 5 years of the diagnosis of the neurological disorder. (b) Nonclassical syndrome that resolves or improves after cancer treatment. (c) Nonclassical syndrome with onconeural antibodies and cancer that develops within 5 years of diagnosis of the neurological disorder. (d) Neurological syndrome (classical or not) with onconeural antibodies and no cancer. (e) Classical syndrome, no onconeural antibodies, no cancer but at high risk to have an underlying tumor. (f) Nonclassical syndrome, no onconeural antibodies (antibody and cancer present within 2 years of diagnosis). (g) A classical syndrome with onconeural antibodies and cancer

classification has important management and prognostic implications, as the response to immune therapy in patients with neuronal surface autoantibodies is far more favorable to immune therapy. This is not the case for paraneoplastic disorders caused by autoantibodies directed against intracellular proteins [1].

## Clinical Features of Classical Syndromes

To better understand the paraneoplastic disorders, we will describe briefly the classical syndromes and specific antibody-associated syndromes. The reader must keep in mind that one classic paraneoplastic syndrome may be

associated with multiple antibodies; for example, limbic encephalitis has been linked to 16 different antibodies (Tables 13.2 and 13.3) as of this publication. At the same time, one antibody can be associated with multiple paraneoplastic syndromes. The best example is the Anti-Hu antibody, which can present as a sensory neuronopathy, sensory-motor neuropathy, gastroparesis/autonomic involvement, limbic encephalitis, encephalomyelitis, and cerebellar degeneration (Table 13.2).

## CNS Classical Syndromes

### Paraneoplastic Limbic Encephalitis

Limbic encephalitis is the most common paraneoplastic syndrome. This classic syndrome may be paraneoplastic or idiopathic, depending on the type of associated antibodies. It presents as subacute psychiatric manifestations. Likely due to its temporal lobe and limbic structure involvement, this condition often presents with memory deficits, seizures, and behavioral abnormalities. Seizures that occur in limbic encephalitis may be difficult to control and often require multiple antiepileptic drugs (AEDs). Electroencephalograms (EEGs) in these patients can demonstrate diffuse or focal slowing and interictal discharges including sharp waves and spike waves.

Strict autoimmune encephalitis is more common than the classical paraneoplastic condition it resembles [4]. Although many of the antibodies that can cause these conditions can develop in association with an underlying malignancy, they can often be found in the absence of an associated cancer or mass lesion. These conditions may also occur in a wider range of patients including young adults and sometimes children. The antibodies associated with non-paraneoplastic autoimmune encephalitis tend to be cell surface antigens rather than intracellular antigens and thus may have a higher response rate to treatment than the classical PND counterparts. There are many different antibodies associated with limbic encephalitis, several of which will be discussed below.

**Table 13.1** Classical and nonclassical paraneoplastic syndromes classified by location

	Classical <sup>a</sup>	Nonclassical <sup>b</sup>
Supra-tentorial brain	Encephalomyelitis Limbic encephalitis	Demyelinating encephalopathy Chorea Parkinsonism
Brainstem and cerebellum	Cerebellar degeneration Opsoclonus/myoclonus	Brainstem encephalitis
Cranial nerves	Cancer-associated retinopathy Melanoma-associated retinopathy	Optic neuropathy Bilateral diffuse uveal melanocytic proliferation (BDUMP)
Spinal cord	Subacute motor neuropathy	Necrotizing myelopathy/neuromyelitis optica Inflammatory myelitis Motor neuron disease Stiff person syndrome
Dorsal root ganglia and peripheral nerves	Sensory neuropathy Chronic gastrointestinal pseudo-obstruction Polyneuropathy, organomegaly, endocrinopathy, monoclonal protein, skin changes (POEMS)	Autonomic neuropathy Acute sensorimotor neuropathy Polyradiculopathy Brachial neuropathy Chronic sensorimotor neuropathy Neuromyotonia
Neuromuscular junction and muscles	Lambert Eaton Myasthenic Syndrome Dermatomyositis	Myasthenia gravis Polymyositis Necrotizing myopathy Myotonia

<sup>a</sup>Strongly associated with malignancy even if antibodies are negative

<sup>b</sup>Not always associated with cancer

**Table 13.2** Antibodies against intracellular/cytoplasmic or nuclear antigens. Onconeurological antibodies

Antibody	Target	Symptoms and disorders	Associated malignancies
Anti-Hu/ANNA-1 [72]	Hu family of RNA-binding proteins HuA, HuB, HuC, HuD	Sensory neuropathy Cerebellar degeneration Limbic encephalitis Chronic gastrointestinal pseudoobstruction Lambert Eaton Myasthenic Syndrome (uncommon) Brainstem encephalitis Neuropathies Multifocal nervous system involvement	SCLC NSCLC Prostate Gastrointestinal Breast Bladder Pancreas Ovarian
Anti-Ri/ANNA-2	Ri family of RNA-binding proteins	Opsoclonus/myoclonus Lambert Eaton Myasthenic Syndrome (uncommon) Cerebellar ataxia Jaw dystonia Laryngospasm Cranial neuropathies Myelopathy	SCLC Breast NSCLC
ANNA-3 [110]	Unknown	Limbic encephalitis Cerebellar ataxia Sensorimotor neuropathy Myelopathy	SCLC
Anti-Yo (f-1)	Purkinje cells	Cerebellar degeneration	Gynecologic malignancy Endometrial, fallopian, ovarian Breast

**Table 13.2** (continued)

Antibody	Target	Symptoms and disorders	Associated malignancies
Anti-PCA-2	Purkinje cells	Cerebellar degeneration Limbic encephalitis Brainstem encephalitis	SCLC
Anti-Ma	PNMA1-6	Limbic encephalitis Brainstem encephalitis	Lung GI Breast Germ cell Lymphoma Salivary gland
Anti-Ma2	PNMA1-6	Limbic encephalitis Cranial neuropathies Brainstem encephalitis	Testicular germ cell Other testicular tumors Lung cancer
Anti-CRMP5 [111]	Collapsin response-mediator protein 5	Lambert Eaton Myasthenic Syndrome Limbic encephalitis Opsoclonus myoclonus Stiff person syndrome Optic neuropathy Movement disorders (chorea) Ataxia Myelopathy	SCLC Thymoma
Anti-GAD65	Purkinje cell cytoplasm	Stiff person syndrome Limbic encephalopathy Cerebellar degeneration Epilepsy Cerebellar ataxia Dyskinesia	Renal cell carcinoma Hodgkin disease SCLC GI malignancies
Anti-amphiphysin	Amphiphysin I (synaptic vessel recycling)	Stiff person syndrome Limbic encephalitis	SCLC Breast NSCLC
Zic-4 [112]	Granule cell neurons in cerebellum	Cerebellar degeneration	SCLC
Sox1 (anti-glial nuclear antibody) [113]	SRY-like HMG box proteins (nuclei of Bergmann)	Cerebellar degeneration Lambert Eaton Myasthenic Syndrome Limbic encephalitis Sensorimotor neuropathy	SCLC
Anti-Tr	Purkinje cell	Cerebellar degeneration	Hodgkin Lymphoma
Anti-protein kinase C gamma [114]	Purkinje cell	Cerebellar degeneration	NSCLC
Anti-ubiquitin conjugating enzyme UBE2E1 [115]		Encephalomyelitis	SCLC
Anti-NB (beta-NAP) [35]	Purkinje cell	Cerebellar degeneration	Unknown
Anti-Carp VIII [18]	Purkinje cell	Cerebellar degeneration	Melanoma NSCLC Colon

*ANNA* antineuronal nuclear antibody, *RNA* ribonucleic acid, *SCLC* small-cell lung carcinoma, *NSCLC* non-small-cell lung carcinoma, *PCA* Purkinje cell cytoplasmic antibody, *PNMA* paraneoplastic Ma antigens, *NAP* neuronal adaptin-like protein

**Table 13.3** Antibodies against neuronal surface antigens

Antibody	Target	Symptoms and disorder	Malignancies associated
Anti-NMDAR [13]	<i>N</i> -Methyl-D-aspartate receptor	Limbic encephalitis Encephalomyelitis Chorea/movement disorder Behavioral abnormalities	Ovarian teratoma Other ovarian pathology
LGI1 [19]	Leucine-rich, glioma-inactivated protein 1	Limbic encephalitis Morvan syndrome Faciobrachial dystonic seizures	
CASPR2 [61]	Contactin-associated protein-like 2	Limbic encephalitis Morvan syndrome	
AMPA [18]	$\alpha$ -Amino-3-hydroxy-5-methyl-4-isoxazolepropionic acid receptor	Limbic encephalitis Multifocal encephalomyelitis	Lung Thymoma Breast Ovarian
GABA-A-R [116]	GABA-A receptor-associated protein	Stiff person syndrome Limbic encephalitis	
GABA-B-R [117]	GABA-B receptor-associated protein	Limbic encephalitis	SCLC
mGluR5 [118]	Metabotropic glutamate receptors	Limbic encephalitis	Hodgkin lymphoma
mGluR1 [119]	Metabotropic glutamate receptors	Cerebellar degeneration	Hodgkin lymphoma
Homer 3 [18]	Post-synaptic scaffold protein	Cerebellar degeneration	SCLC
Dopamine D2 receptor	Dopamine D2 receptor	Encephalomyelitis	
Glycine receptor [55]	Glycine	Progressive encephalitis with rigidity and myoclonus	SCLC Breast cancer
DPPX [60]	Dipeptidyl-peptidase-like protein	Encephalopathy with muscle spasms, rigidity, myoclonus, hyperekplexia	B-cell neoplasms

### ***N*-Methyl D-Aspartate Receptor (NMDAR) Encephalitis**

For many years, the only paraneoplastic syndromes associated with antibodies against ion channels or receptors were Lambert Eaton Myasthenic Syndrome (LEMS) and myasthenia gravis (MG). Paraneoplastic encephalitis was believed only to affect cytoplasmic or nuclear proteins and was characterized by poor response to treatment. In 2007, antibodies to the NMDAR subunit were described in 12 women with a distinct syndrome of psychiatric illness, seizures, dysautonomia, and hypoventilation associated with teratomas that responded well to immunotherapy [5]. Anti-NMDAR autoimmune encephalitis results in cross-linking and internalization of target receptors in neurons, resulting in impaired neurotransmission [6]. This was the first type of autoimmune encephalitis characterized molecularly, and subsequently a multitude of antibodies

have been discovered [7]. Autoimmune encephalitis occurs at least ten times more common than all other synaptic antibody diseases combined [8], and is a more prevalent cause of encephalitis than any other single viral etiology [9]. These patients develop a predictable syndrome with progression of symptoms that resemble the clinical picture caused by noncompetitive agonists of NMDAR (such as phencyclidine or ketamine). The mild form of anti-NMDAR encephalitis can cause illusionary perceptions, ideas of reference, paranoia, and decreased executive function, which is characteristic of both disease onset, and months later, during recovery. More advanced disease can manifest as psychosis, agitation, stereotyped movements, repetitive motor behaviors, decreased responsiveness to pain, and memory disturbance. Very severe stages of anti-NMDAR encephalitis are characterized by dyskinesias, catatonia, autonomic dysfunction, hypoventila-

tion, and coma [10]. Triggers for the disease are tumors and viruses. In children, the clinical syndrome is different, characterized by behavioral changes and movement disorders (chorea, dyskinesia, or rigidity) rather than psychiatric manifestations. Seizures are common and can present at any stage of the disease [11].

Brain imaging typically shows contrast-enhancing lesions and fluid-attenuated inversion recovery (FLAIR) abnormalities in multiple regions but may have predominance in the hippocampus. Cerebral spinal fluid (CSF) may show lymphocytic pleocytosis and presence of oligoclonal bands [4]. EEGs can have a characteristic pattern called extreme delta brush [12].

Ovarian teratoma is concomitant in about 60% of cases in women aged 18 years or older [13]. NMDAR encephalitis has been reported in a variety of other tumors including teratomas outside the ovary, lymphomas, small-cell lung cancer (SCLC), and testicular germ cell tumors [14]. The frequency of an underlying teratoma is greater in females aged 12 years or older than in younger children and males (52% vs. 6%) [10]. Therefore, in females older than 12 years, the screening should be similar to that of paraneoplastic syndromes but screening of young children and males is unclear. Of note, approximately 20% of patients with herpes simplex encephalitis (HSE) develop antibodies against NMDAR [7].

In a large observational study, it was observed that immunotherapy and removal of any identified teratoma when applicable resulted in significant neurological recovery in about 81% of cases [12]. In this study, 91% of patients underwent first-line treatment with either high-dose steroids, intravenous immunoglobulin (IVIG), or plasma exchange alone or combined. Over 4 weeks, 53% of patients improved after first-line therapy and 97% of these patients had a good outcome of a modified Rankin Scale (mRS) 0–2 within 24 months. In the remainder of patients who continued to do poorly despite first-line therapy, 57% went on to receive second-line therapy which included rituximab, cyclophosphamide, or both. The patients receiving these interventions had better outcomes (in terms of mRS) than patients who received first-line treat-

ment again or no additional treatment, indicating that patients unresponsive to initial agents may respond to rituximab or cyclophosphamide [12]. Immune therapy is combined with removal of any potential tumor, which decreases the probability of a relapse [15]. The only known predictors of a good outcome are lower severity of symptoms (lack of intensive care unit requirement) and early initiation of tumor removal when indicated [10].

New animal models have shown that the antibodies involved in autoimmune encephalitis are directly pathogenic [16]. Furthermore, administration of ephrin-B2 ligand antagonizes the pathogenic effects of NMDAR antibodies on memory and synaptic plasticity, promising a novel targeted therapy for NMDAR autoimmune encephalitis [17]. The combination of yearly discovery of new antibodies causing autoimmune encephalitis, historical and present misdiagnosis of these cases as psychiatric illness, and exciting new prospects for treatment make this branch of neurology an active field of research.

### **Anti- $\alpha$ -Amino-3-Hydroxy-5-Methyl-4-Isoxazolepropionic (AMPA) Receptor Encephalitis**

Anti-AMPA receptor encephalitis occurs predominantly in women and in older populations as compared to NMDAR encephalitis. The median age for presentation is around 50–60 years [18]. The most common presentation is limbic encephalitis with seizures. Malignancy can be associated with this antibody in approximately 60% of cases, most commonly occurring in the lung, thymus, and breast [18].

### **LGI-1 (Leucine-Rich Glioma-Inactivated Protein 1) Encephalitis**

LGI-1 antibody syndrome bears special mention because of its unusual presentation and often robust response to treatment with immunotherapy. LGI-1 stands for leucine-rich, glioma-inactivated protein 1, and it is a surface protein that was formerly believed to be associated with the voltage-gated potassium channel. About 50% of patients with LGI-1 syndrome present with facio-brachial dystonic seizures. Patients with these clinical epi-

sodes demonstrate brief, sudden onset dystonic posturing of the hand and ipsilateral face, often between 10 and 50 times per day [19, 20]. The same patient can have episodes independently on the right and left sides, and while clinical activity is quite stereotyped, the EEG often demonstrates no electrographic correlate. As LGI-1 antibody syndrome develops, cognitive and behavioral changes ensue, with memory loss, hallucinations, emotional incontinence, as well as temporal lobe seizures and sleep disorders such as insomnia. Hyponatremia is present in many patients. One small case series notes 4 of 10 patients with mild hyponatremia and 1 patient with severe hyponatremia to 115 at initial presentation [21]. Magnetic resonance imaging (MRI) may reveal FLAIR T2 hyperintensities in the medial temporal lobes and hippocampus [21]. Patients with this disorder often respond successfully to some combination of IVIG, corticosteroids, and/or plasmapheresis, but relapses can occur and repeat treatments are often necessary. LGI-1 syndrome is most commonly autoimmune, but rarely is associated with malignancies [21]. LGI-1 antibody syndrome was formerly thought to be limbic encephalitis due to voltage-gated potassium channel (VGKC) antibodies; in recent years, overlap has been found with another clinical syndrome, Morvan's syndrome, which is discussed below [22].

### **Antibody-Negative Limbic Encephalitis**

There are cases of limbic encephalitis that do not have a known associated antibody that can be discovered. This is classified as antibody-negative limbic encephalitis. Graus et al. described 7% of 163 patients with a clinical and radiographic diagnosis of limbic encephalitis that do not have an identifiable causative antibody [23]. In almost half of these patients, a tumor was diagnosed at some point either prior to or subsequent to the diagnosis of limbic encephalitis. Despite the success in identifying new antibodies associated with autoimmune limbic encephalitis, there is still a subgroup of this condition where a causative antibody cannot be identified. In this small case series, a significant portion of patients responded to some immune suppression including steroids, IVIG, and rituximab [23].

### **Hashimoto's Encephalopathy**

LGI-1 antibody syndrome bears similarity in presentation to Hashimoto's encephalopathy, an autoimmune encephalopathy known for its exquisite response to corticosteroids—also termed “steroid responsive encephalopathy associated with autoimmune thyroiditis (SREAT).” Patients with Hashimoto's encephalopathy can present with either subacute or acute-onset (stroke-like) symptoms including cognitive impairment, transient aphasia, psychotic symptoms, as well as tremulousness, myoclonus, ataxia, sleep abnormalities, and extrapyramidal signs. The cause of this disorder is not known, but patients can have high titers of anti-thyroid antibodies, including anti-thyroglobulin and anti-thyroperoxidase (nonspecific and fairly common antibodies that are not thought to be causative). Patients with this disorder can (but need not) have CSF pleocytosis or elevated protein; EEG with generalized or focal slowing and triphasic or epileptiform features; and brain MRI with diffuse atrophy and white matter T2 hyperintensities and/or ischemia. The diagnosis is made clinically based on a response to corticosteroids [24]. Hashimoto's encephalopathy is not a classic paraneoplastic limbic encephalitis but should be in the differential diagnosis for any patient presenting with limbic encephalitis symptoms.

### **Paraneoplastic Encephalomyelitis**

This syndrome affects multiple regions of the central nervous system in addition to the limbic system. Often, there is cerebellar and brainstem involvement resulting in ataxia, vertigo, cranial nerve involvement, dysphagia, dysarthria, sleep disorders, and parkinsonism. It can also affect the spinal cord causing myelopathy. The most common malignancy associated is SCLC followed by testicular germ cell tumors [25]. The associated antibody is most commonly anti-Hu (associated with SCLC). This is followed by anti-Ma2 (associated with testicular germ cell tumors). Anti-collapsin response-mediator protein-5 (CRMP5), also known as CV2 antibodies, can also be associated with an encephalomyelitis but tends to involve additional symptoms including chorea and extrapyramidal symptoms as well as addi-

tional structures outside the brain and spinal cord including optic nerves and peripheral nerves [26]. There are a variety of other antibodies which can be associated with an encephalomyelitis including antibodies against amphiphysin, AMPA, gamma-aminobutyric acid (GABA), glutamic acid decarboxylase (GAD), and LGI-1. This condition, like most other paraneoplastic conditions, can occur in the absence of an identifiable antibody.

### **Paraneoplastic Cerebellar Degeneration**

Paraneoplastic cerebellar degeneration (PCD) is a collection of disorders grouped together by common symptomatology. It presents most commonly in a rather stereotyped fashion. Symptoms often start with some mild dizziness and vertigo but progress to a more fulminant cerebellar syndrome. Patients very quickly develop diplopia, difficulty swallowing (often requiring parenteral enteric g-tube placement), dysarthria, severe ataxia (often wheelchair bound), nystagmus, gaze apraxia, hypophonia, nausea/vomiting, and tremors. This disease most commonly progresses in a subacute fashion over a few weeks but can progress much more rapidly [27, 28]. Untreated, after several months, symptoms may eventually stabilize. Some patients can develop the cerebellar affective syndrome which is associated with negativism [2].

In the acute setting, in most cases, brain imaging is normal; however, in some rare instances, there can be evidence of cerebellar inflammation. If patients survive long enough, cerebellar atrophy is often seen [29, 30]. There are a multitude of autoantibodies seen associated with this condition; however, the most common association is with Anti-Yo antibodies which is commonly seen in breast and gynecologic malignancies. The target of Anti-Yo antibodies is the Purkinje cell itself and on histologic evaluation of cerebellum in patients with anti-Yo-associated PCD, a complete loss of the Purkinje cell layer is often seen [31]. Anti-Hu antibodies can also be associated with PCD; however, often there is other associated neurologic conditions related to this autoantibody. A third antibody, Anti-Tr, is seen in

association with Hodgkin disease [26]. Other antibodies associated with this syndrome include anti-GAD 65, anti-P/Q-type calcium channel antibody, and anti-mGluR1 antibody [32].

Due to its rapid, progressive nature, it is imperative to identify and treat this condition quickly. Often, symptoms of PCD are the presenting findings of a malignancy and many patients have limited-stage disease that would be amenable to anti-neoplastic therapies. This is particularly true with breast cancer patients [28]. However, this condition can progress to severe disability, but, in most cases, is not fatal.

### **Opsoclonus Myoclonus Syndrome**

Opsoclonus myoclonus syndrome (OMS) can occur in either a paraneoplastic or a non-paraneoplastic form. In the non-paraneoplastic setting, it is most often related to a viral infection or is idiopathic in nature. Paraneoplastic OMS in children is almost exclusively associated with neuroblastomas [33]. In adults, OMS has been reported to be associated with breast cancer and small cell lung cancer [34]. Symptoms usually start with gait difficulty and falls. Ophthalmologic evaluation identifies opsoclonus, involuntary movements of the eyes in all directions. In most cases, the opsoclonus is associated with myoclonus.

A multitude of antibodies have been associated with patients who have this illness including Hu, Ri, Ma2, amphiphysin, CRMP5, Zic2, Yo, voltage-gated calcium channel (VGCC), and mitochondrial [35]. In adults, it is most commonly associated with Anti-Ri, Anti-Hu, and NMDA antibodies [34]. Many adults with this condition, however, have a non-paraneoplastic form [36].

First-line treatment in children often includes adrenocorticotrophic hormone (ACTH) or high-dose steroids. Rituximab has also been found to be beneficial [37].

### **Cancer-Associated and Related Autoimmune Retinopathies and Optic Neuropathies**

There are a variety of retinopathies and optic neuropathies that are paraneoplastic in origin.

These disorders are quite uncommon and are caused by a variety of antibodies against retinal and optic nerve proteins. The typical presentation of these conditions is of subacute vision loss for which symptoms often predate the identification of a malignancy [38].

Anti-enolase antibodies are a more commonly associated antibody with CAR [39]. This antibody targets the alpha isoform of enolase which is present predominantly in retinal cells. There are several other less frequent antibodies which have been found to be pathologic in the development of cancer-associated antibody. These include glyceraldehyde-3-phosphate dehydrogenase antibodies, heat shock cognate protein 70 antibodies, Tubby-like protein antibodies, and anti-carbonic anhydrase II antibodies [40–43]. Electroretinogram (ERG) can be helpful in identifying these conditions. Abnormal ERGs which show a photoreceptor disorder should trigger a malignancy evaluation. This condition usually affects rods and cones together but can also affect them separately [44, 45]. ERGs can also be helpful in monitoring for progression of disease.

Melanoma-associated retinopathy (MAR) is an autoimmune retinopathy that is associated with melanoma. In this variant, it is much more common to present at the time of metastasis rather than at first diagnosis. Symptoms typically start with shimmering, flickering, and night blindness. Patients may also present with scotomas and may have significantly impaired visual acuity at the time of diagnosis. This condition is associated with a specific antibody: anti-bipolar cell antibodies. However, there are several other antibodies that may be associated with MAR. In addition, the ERG shows a characteristic pattern. This typically shows a reduction in the B wave amplitude and an abnormality in the “on” response to long flashes [44].

Paraneoplastic optic neuritis and neuropathies are extremely infrequent occurrences as either isolated conditions or in the setting of other more established disorders. Of the antibodies known to cause optic neuritis/neuropathy, anti-CRMP 5 (anti-CV2) is likely the most common. This antibody has been shown to cause both retinopathy

and neuropathy. SCLC is the most common malignant etiology, although there are case reports in multiple myeloma and thyroid cancer [46–49]. Aside from the treatment of the suspected causal tumor, systemic immunosuppression and intravitreal corticosteroids have shown to improve vision in some patients [50].

### **Stiff Person Syndrome (SPS) and Progressive Encephalomyelitis with Rigidity and Myoclonus (PERM)**

Stiff Person Syndrome (SPS) was first described in 1956 in a series of patients with progressive rigidity and painful spasms in axial and proximal muscles, and in particular, the paraspinal muscles [51]. Individuals with SPS typically present with progressive, regional, or generalized painful and rigid muscles; they are also prone to acute exacerbations of painful spasms, anxiety, and an exaggerated startle response. This startle response, as well as emotions like anxiety, anger, or fear, can in fact trigger painful spasms in the torso and limbs. These spasms can last hours or even days. During an exacerbation or with baseline muscle rigidity, the electromyography in SPS can detect hyperexcitable spinal motor neurons. Facial and jaw muscles are spared initially, although the face can be involved very late in the course of this disorder. The most common antibody associated with the condition is known as GAD65, which affects 60% of individuals with SPS [52]. GAD65 targets glutamic acid decarboxylase; the enzyme converts glutamate to GABA in the nervous system. Incidentally, this antibody is also frequently present in type I diabetics. In fact, 30% of patients with SPS also have insulin-dependent diabetes. Other diseases associated with GAD antibodies include autoimmune thyroiditis, cerebellar ataxia, and epilepsy. About 10–20% of individuals with SPS also have seizures [24].

SPS can be an autoimmune or paraneoplastic condition. Those with paraneoplastic SPS often have antibodies to amphiphysin; other autoantibodies implicated in the condition include gephyrin and GABA A receptor-associated protein (GABARAP) [53, 54].



A subpopulation of patients with SPS also have encephalomyelitis, which is considered a separate disorder known as progressive encephalomyelitis with rigidity and myoclonus (PERM), or “stiff person plus” disease [55]. This disorder is similar to SPS but more rapidly progressive (over weeks), and associated with other features including cognitive changes, seizures, diplopia, ophthalmoplegia, ptosis, dysphagia, ataxia, dysautonomia (including urinary and respiratory issues), hypersomnia, hyperhidrosis, myoclonus, itching, and panic attacks. PERM is associated with antibodies against glycine receptors (GlyR) present in serum and CSF [56, 57]. Both SPS and PERM have been described in patients with an underlying malignancy, without an underlying malignancy, and rarely following infection [58, 59].

Both paraneoplastic and autoimmune forms of SPS and PERM are typically treated with immune therapy, including but not limited to IVIG, plasmapheresis, corticosteroids, rituximab, and oral immunosuppressive medications. Symptoms can be managed with baclofen, benzodiazepines, and anticonvulsants [24].

PERM has also been associated with a novel antibody against dipeptidyl-peptidase-like protein-6 (DPP6 or DPPX). However, no malignancies have been associated with this antibody. DPPX is a regulatory subunit of the voltage-gated A-type Kv4.2 potassium channel complex expressed in neuronal dendrites and soma, which is critical for firing rates and back-propagations of action potentials into neuronal dendrites and cardiac rhythms. Since Kv4.2 channels are widespread in the nervous system, this manifests as a variety of symptoms besides PERM, which include encephalopathy involving cortex, cerebellum, and brainstem, weight loss, dysautonomia (temperature dysregulation, cardiac dysrhythmia), myelopathy, gastrointestinal dysmotility (diarrhea and gastroparesis), sleep disorders (insomnia, periodic limb movements, sleep apnea, hypersomnia), and psychiatric symptoms such as depression and psychosis [60].

### **Morvan’s Syndrome**

Morvan’s syndrome is a rare disease, more common in older males, that is characterized by

peripheral nerve hyperexcitability, autonomic instability, and neuropsychiatric manifestations [61]. Neurological symptoms and signs include insomnia, hallucinations, confusion, hyperhidrosis, pain, itching, muscle cramps, twitching (myokymia and/or myoclonus), and cerebellar features [62]. Morvan’s syndrome can be autoimmune or paraneoplastic, often associated with small-cell lung cancer and thymoma (20–50% of cases) [24, 62]. Morvan’s syndrome was formerly considered to be one of two paraneoplastic or autoimmune conditions associated with antibodies against voltage-gated potassium channels (VGKC antibodies), the other being a form of limbic encephalitis, with cognitive and behavioral changes and seizures [24, 63]. In fact, in recent years, two distinct antibodies have been identified with these two disorders: antibodies against contactin-associated protein-like 2 (CASPR2) are more frequently associated with the peripheral and autonomic hyperexcitability syndrome, while antibodies against (LGI-1) are more frequently associated with a type of limbic encephalitis, discussed elsewhere. However, substantial overlap can be found between these two antibodies and also with clinical syndromes [61]. In fact, among patients with CASPR2 antibodies, a limbic encephalitis presentation is in fact more common than Morvan’s syndrome [61]. Some patients with Morvan’s syndrome also co-express LGI-1 antibodies, and many co-express nonspecific antibodies to VGKC. However, there are many other patients with VGKC antibody positivity who have neither LGI-1 nor CASPR2 antibodies, and many more VGKC-positive patients are asymptomatic from a neurological standpoint, raising questions about the original designation of VGKC antibodies. LGI-1 and CASPR2 are both surface proteins, and treatment for associated clinical conditions can often include intravenous immunoglobulin, corticosteroids, and/or plasmapheresis. In patients with Morvan’s syndrome who have thymoma, thymectomy is indicated and can resolve the neurological condition [61].

## Peripheral Nervous System Classical Syndromes

### Lambert Eaton Myasthenic Syndrome

Lambert Eaton Myasthenic Syndrome (LEMS) is a paraneoplastic syndrome that is most commonly associated with anti-VGCC in patients with SCLC. LEMS has associated specific electromyogram (EMG) and nerve conduction studies (NCS) findings which can aid in the diagnosis. This condition is discussed in detail elsewhere in this text.

### Dermatomyositis

Dermatomyositis is an inflammatory myopathy that can present as a paraneoplastic syndrome in up to 15% of cases. It can be associated with a wide range of malignancies, particularly non-Hodgkin lymphoma, ovarian, and lung cancer [64]. Polymyositis and inclusion body myositis have low incidence of association with malignancies. This condition is discussed in detail elsewhere in this text.

### Subacute Sensory Neuronopathy

The subacute sensory neuronopathy syndrome is one of the earliest described paraneoplastic syndromes. It can either be seen in isolated form or in association with an encephalomyelitis. The onset of this condition is usually quite rapid and associated with loss of sensation and paresthesias. Symptoms with sensory neuronopathy can sometimes begin in regions along the trunk as opposed to starting in the extremities and this pattern may indicate a search for a paraneoplastic syndrome. Pain may or may not be a significant symptom seen in this condition [35].

On electrodiagnostic testing, findings indicated a non-length-dependent nerve pattern of injury and is typically found in a widespread pattern. Since this is a dorsal root ganglion disorder, motor action potentials are usually unaffected. However, occasional motor abnormalities can be seen as well, indicating more widespread involvement of the peripheral nerves.

Most commonly, this condition is associated with the anti-Hu antibody in patients with SCLC. Often patients may progress to develop limbic encephalitis or other clinical symptoms associated with anti-Hu antibodies. Aside from SCLC, this condition can be associated with other malignancies like breast cancer or non-small-cell lung cancer [35].

### Chronic Intestinal Pseudo-obstruction

This condition often presents with the symptoms of constipation and distension of the abdomen. It is caused by antibodies which react with the myenteric plexus and subsequent disruption of autonomic signaling to the gut. Most commonly, this occurs in relation to anti-Hu antibodies in association with SCLC [65]. Other antibodies may include anti-CRMP5 and a variety of voltage-gated channel antibodies.

### POEMS (Polyneuropathy, Organomegaly, Endocrinopathy, Monoclonal Protein, and Skin Changes)

POEMS syndrome is a condition most associated with patients who have monoclonal gammopathy or frank multiple myeloma. The underlying cause of this condition is unknown and, like most of the conditions on this list, it may not necessarily be caused directly by antibodies produced by the immune system but potentially by overproduction of chemokines [66].

The International Myeloma Working Group has come up with specific criteria for the diagnosis of this syndrome. Both polyneuropathy and monoclonal plasma cell proliferative disorder are mandatory criteria for diagnosis. In addition, one major criterion is required which includes osteosclerotic lesions, Castleman's disease, or elevated serum or plasma vascular endothelial growth factor (VEGF) levels. One minor criterion must also be met which includes organomegaly, volume overload, endocrinopathy, skin changes, papilledema, or thrombocytosis/polycythemia. The neuropathy is usually the dominant symptom seen in this condition. Nerve injury tends to be more length-dependent and tends to be motor predominant. However, they may start with sensory symptoms [67].

There is no specific treatment recommended for this condition. Lenolidamide- and bortezomib-based treatments are favored by hematologists for treatment of the underlying condition due to limited toxicity with these therapies. Other approaches include hematopoietic stem cell transplantation [68]. From a symptom standpoint, there may be some benefit in using some anti-VEGF-related therapies like bevacizumab, but this has not been thoroughly evaluated [69].

### **Other Nonclassical Neurologic Paraneoplastic Symptoms**

Outside of the classically defined paraneoplastic syndromes, there are a multitude of neurologic symptoms and syndromes which are thought to be paraneoplastic in origin. These can include simple neuropathies as well as paraneoplastic presentations of movement disorders like Parkinson disease and chorea, motor neuron diseases like amyotrophic lateral sclerosis (ALS), and myelopathies/myelitis.

Paraneoplastic movement disorders like chorea are some of the more common presentations of nonclassical autoimmune or paraneoplastic neurologic disorders. Choreiform movements can be found to be associated with multiple antibodies. Most commonly, this can involve anti-CRMP5 antibodies but can also occur with anti-Hu antibodies, GAD 65, CASPR2, and LGI1 antibodies. Paraneoplastic chorea is most often associated with SCLC, thymomas, non-Hodgkin lymphoma, and tonsillar squamous cell carcinoma. Non-paraneoplastic chorea can be associated with Lupus and antiphospholipid antibody syndrome [70, 71].

Isolated paraneoplastic myelopathies are uncommon; however, they may occur as part of a more extensive encephalomyelitis. There have been reports of transverse, necrotizing, and demyelinating myelitis. Anti-Hu antibodies are the most prevalent antibodies in paraneoplastic myelopathies [72]. Anti-CRMP5 antibodies have also been associated with necrotizing myelitis and bilateral optic neuritis in a neuromyelitis optica-like syndrome [73]. In many cases, paraneoplastic myelopathies present with

longitudinally extensive abnormalities on MRI [74].

Many of the motor neuron diseases (MND) such as ALS typically occur in the same age group as patients prone to developing malignancy which can make the overall cause difficult to ascertain. In fact, there are many studies which question if there is a link between motor neuron disease and malignancy [75]. There is no definitive way to determine if a motor neuron disease is paraneoplastic in nature; however, if there is measurable improvement after treating the tumor itself, this would go against the natural course of any of the traditional MNDs. There are several cases reported in the literature involving lung and renal cell, that demonstrate either symptomatic improvement or complete recovery [76]. Breast cancer also seems to have some association with a motor neuron disease, potentially the primary lateral sclerosis variant [77]. Antibodies discovered in patients with an identified malignancy concurrent with a motor neuron-like syndrome include Anti-Hu, CRMP5, Yo, Spectrin, and Ma2 [78]; the later presenting with a progressive muscular atrophy-like syndrome [79]. In summary, there may be some rare individual cases of paraneoplastic MND but the vast majority of cases do not have a paraneoplastic origin.

---

### **Classification Based on Antibodies**

In addition to classification of paraneoplastic disorders based on the disorder itself, these conditions can be classified based on the antibody causing the symptoms. Many paraneoplastic antibodies can present as several different disorders, both classical and nonclassical syndromes. The list of known antibodies identified seems to grow rapidly, not all of which are associated with malignancies. Antibodies can be grouped together into several larger categories including nuclear antibodies, cytoplasmic antibodies, and cell surface antibodies. Classifying these conditions based on the antibody itself may have some implications regarding treatment, since antibodies targeting cell surface antigens may have better

responses to immunosuppressants. Table 13.2 lists antibodies targeting antigens against intracellular, cytoplasmic, or nuclear antigens as well as known associated disorders and malignancies both common and uncommon that have been reported in these conditions. Table 13.3 lists cell surface antigens, their known symptoms, and associated malignancies.

### Checkpoint Inhibitors and Risk of Paraneoplastic Neurological Disorders

Checkpoint inhibitors are immunomodulatory antibodies that have dramatically improved the prognosis of advanced malignancies; however, it is further recognized that these treatments can be associated with neurological complications and the development of autoimmunity including conditions like cerebellar ataxia, autoimmune retinopathy, autoimmune endocrinopathies, acute inflammatory demyelinating polyradiculoneuropathy, autoimmune myopathy, and myasthenia gravis [80]. Furthermore, patients treated with checkpoint inhibitors can also develop autoimmune encephalitis associated with multiple known antibodies including CRMP5 [81], NMDAR autoimmune encephalitis [82], and anti-Hu antibodies [83, 84]. It is thought that these treatments may predispose patients to the development of paraneoplastic disorders in some instances.

---

### Diagnosis

Approaching the management of patients with suspected paraneoplastic disorders can also be a daunting task. The approach is different in patients who have a known malignancy compared to those without a known malignancy. Furthermore, patients with symptoms that fit within the classical paraneoplastic syndromes may alter the approach as well. By dividing patients with suspected PND into groups, the approach and the assessments necessary to manage these patients can be simplified.

In patients with no known cancer, an evaluation for evidence of a systemic malignancy should be performed after more common conditions are ruled out. Most often imaging of the nervous system is obtained to rule out structural or other causes of the presenting symptoms. Patients with classical paraneoplastic disorders, or in any patient who presents with unexplained subacute neurologic symptoms, warrant a systemic evaluation. Systemic imaging with a positron emission tomography/computed tomography or PET/CT or a CT of the chest, abdomen, and pelvis can identify asymptomatic malignancies. Of these modalities, a PET/CT scan could be of higher yield than a plain CT due to the often small nature of malignancies associated with PND. Other initial diagnostic testing depending on the clinical situation may include pelvic examination, mammogram, serum cancer markers, or a testicular ultrasound.

In patients with paraneoplastic encephalitis in many, but not all, cases, there are MRI findings that would be consistent with active inflammation. Mesiotemporal FLAIR hyperintensity  $\pm$  enhancement may be present. Reports of up to 2/3 of patients show evidence of T2 or FLAIR hyperintensities in patients with anti-Hu-associated encephalitis [85, 86]. Brain fluorodeoxyglucose-positron emission tomography (FDG-PET) imaging may be helpful in identifying increased metabolism in MRI-negative encephalitis [87].

The next step in evaluation would typically include basic CSF evaluation including cell counts, IgG synthesis, oligoclonal bands, cytologic evaluation, and a guided search for paraneoplastic autoantibodies in the serum and CSF [88]. In one large series of limbic encephalitis, only 60% of patients had detectable autoantibodies [86]. If there are positive autoantibodies associated with common PND, this should prompt frequent surveillance of these patients for the development of new malignancies.

In patients with a known malignancy, as with those without known malignancy, a thorough search for alternate diagnoses which could explain their symptoms should be performed.

This would be followed by an evaluation of serum and CSF with basic studies and a targeted search for paraneoplastic autoantibodies based on the presenting symptoms.

---

## Management

Due to the uncommon nature of PND and autoimmune encephalopathies, it is difficult to accrue evidence-based treatments for these conditions. Most data that have been gathered are in small case reports or case series. Despite the difficulty in collecting data regarding treatment of these uncommon conditions, there are some guidelines regarding management of PND that have been published [25].

The most effective method of treating these conditions is by initiating therapies directed toward the inciting tumor, which can include surgical resection, radiation, and chemotherapy. Resection is the most rapid way of removing the antigenic tissue, followed by radiation and then chemotherapy. If the source of the antigen is removed, it is possible to halt or slow progression of the condition. Immune modulatory therapies, including PD-1 inhibitors, could be used in certain scenarios but should be used cautiously as these medications tend to enhance the natural immune response to the tumor and thus theoretically may enhance the natural immune response to affected neural tissue as well [80, 89, 90].

Once a plan to address the primary malignancy is in place, treatments targeting the PND itself may be the next step. Frank immunosuppression or modulation of the immune system is generally thought to be the next step. These treatments generally start with high-dose methylprednisolone (1000 mg IV for 3–5 days). This can be used alone or in combination with other more acute therapies such as intravenous immunoglobulin or plasma exchange, particularly in more symptomatically severe or aggressive cases. Treatments such as these are usually initiated at initial diagnosis as more definitive, longer lasting treatments may take time to be arranged [91].

Cyclophosphamide is an immunosuppressant that can affect many facets of the immune system. There are several dosing regimens used in this setting, all of which are reported in small series. Dosing from a 1000 mg fixed dose to 750 mg/m<sup>2</sup> every 4 weeks split over 1–4 days per month has been used. This medication may be somewhat harsher than rituximab with regard to myelosuppression and systemic side effects. However, cyclophosphamide, a DNA alkylating agent, has a broader effect on the immune system than rituximab in that it can reduce proliferation of all cells within the immune system as opposed to rituximab which exerts its effects primarily on the B-cell population.

Rituximab, a CD20 monoclonal antibody, is primarily used in PND and other related disorders that are primarily antibody driven. In a single institutional study of patients with autoimmune limbic encephalopathy, the use of rituximab was found to be associated with more frequent functional improvement as compared to patients not treated with rituximab [92]. It has been shown to be beneficial in multiple paraneoplastic and other antibody-related conditions in small case reports including Morvan's syndrome, anti-NMDA receptor encephalitis, pediatric opsoclonus myoclonus syndrome, cancer-associated retinopathy, and paraneoplastic chronic intestinal pseudo-obstruction [93–95]. There are multiple regimens using rituximab, but most commonly, it is dosed at 375 mg/m<sup>2</sup> weekly over 4 weeks. There are even some regimens that rituximab is used in conjunction with cyclophosphamide [89, 96].

It is worth noting that the response to immune therapy in disorders mediated by antibodies targeting intracellular proteins may be less effective. These antibodies typically include most of the antibodies associated with the classical PNDs. Neurologic stability is often considered a favorable outcome in these conditions. Early diagnosis and immediate treatment may be key in preventing significant severe neurologic morbidity. On the contrary, synaptic and cell surface-mediated paraneoplastic syndromes have a better response to immune therapy. Many autoimmune encephalopathies

lities, like anti-NMDA receptor encephalitis, are included in this category, which highlights the significant functional improvements seen with aggressive treatment.

---

## Miscellaneous Neuroimmunologic Disorders

Outside of paraneoplastic and autoimmune neurologic disorders, there are several conditions or groups of conditions that affect the nervous system and have an inflammatory or immunologic component. These include conditions that may have a malignant component like several of the histiocytoses and conditions that are more strictly immunologic or inflammatory like Susac syndrome, or the chronic lymphocytic inflammation with pontine perivascular enhancement responsive to steroids syndrome (CLIPPERS). The rarity of many of these conditions limits the ability to better classify them and to develop appropriate therapies targeting them.

The histiocytoses make up a heterogeneous group of conditions that involve abnormalities in the macrophage system. These conditions are split into two categories: Langerhans cell histiocytosis (LCH) which is more common, and the non-Langerhans cell histiocytoses, which include conditions like Erdheim-Chester disease (ECD), Rosai-Dorfman-Destombes disease (RDD), and other xanthogranulomas. None of these conditions are restricted to the CNS and in fact, most cases have manifestation outside of the brain or spinal cord. LCH rarely involves the CNS with the exception of supraproptical and periventricular nuclei which leads to diabetes insipidus. Outside of hypothalamic-pituitary axis, when it does involve the nervous system, it is typically due to CNS extension from lesions within the calvarium [97]. With the discovery of clonal BRAF V600E mutations with relatively common frequency in patients with ECD, the pathogenesis of this condition is more consistent with a malignant process [98]. This condition tends to cause enhancing lesions often in deep structures including the brainstem. To date, no recurrent

mutation has been isolated in RDD and the most recent consensus guidelines favor an inflammatory origin for this condition [99].

---

## Susac Syndrome

Susac is a rare disorder defined by the classical triad of encephalopathy, branch retinal artery occlusion (BRAO), and sensorineural hearing loss [100], although the majority of patients do not present with the complete clinical triad. It is more common in females than males. The encephalopathy is most often accompanied by headache, likely due to damage of leptomeningeal vessels. BRAO can affect the periphery and be silent but they can also affect the larger branches resulting in symptoms. Hearing loss, caused by occlusion of cochlear and semicircular canals arterioles, can be severely disabling and can be accompanied by severe tinnitus [101].

The etiology of this disorder is unclear but it is thought to be a microvascular autoimmune endotheliopathy that affects the central nervous system, retina, and inner ear. Brain biopsies show microvascular endothelium and vessel wall structure damage resulting in microinfarctions. Also, there is evidence of T-cell inflammation involving small-medium-sized vessels [102]. Several diagnostic tools are used. MRI always shows involvement of the corpus callosum (usually the central portion) with microinfarcts that can appear as “snowball” lesions. Central callosal holes are pathognomonic of the disease. Fluorescein angiography should be used to evaluate BRAO even in asymptomatic patients, and is characterized by multifocal fluorescence due to leakage of fluorescein in the damaged vessel. Yellow emboli (Gass plaques) can also be observed and represent the focal disturbance of the endothelium. Audiometric testing usually reveals affection of the middle and lower frequencies first. CSF studies can show a lymphocytic pleocytosis with high protein. Angiography is without abnormality, as the vessels affected are too small to be detected [103]. Finally, antiendothelial antibodies can be of diagnostic significance [104].

The disease can relapse or remain continuously chronic. Encephalopathy and visual defects may remit but hearing loss is irreversible. It is important to diagnose this pathology early and treat aggressively to prevent relapses. Given the rarity of this disorder, there are no studies that show which are the best treatments. Immunotherapy is the mainstay of treatment and includes high-dose steroids, IVIG, cyclophosphamide, mycophenolate mofetil, infliximab, and rituximab [102, 103, 105].

### **Chronic Lymphocytic Inflammation with Pontine Perivascular Enhancement Responsive to Steroids Syndrome (CLIPPERS)**

CLIPPERS is another rare disease affecting predominantly perivascular spaces in the pons with variable involvement of adjacent structures and striking response to steroids [106]. The mean age of onset is 50 years and there is a male predominance of 3:1 [107]. The classic presentation includes development of subacute gait ataxia and diplopia, dysarthria, dizziness, nystagmus, tremor, spasticity, cognitive impairment, and facial paresthesias; however, there are no clinical symptoms that are specific to this condition [108]. Brain MRI is the preferred diagnostic modality and it shows FLAIR hyperintensities in the perivascular spaces and white matter regions as well as a characteristic pattern of punctate and curvilinear enhancement, “peppering” of the pons and adjacent regions including the medulla, brachium pontis, and midbrain. The lesions are smaller and less frequent farther away from the pons. Other described symptoms include supratentorial lesions in addition to the typical infratentorial lesions [109]. Typical CSF findings can show normal or mildly elevated protein and rarely a lymphocytic pleocytosis. Brain biopsies demonstrate lymphocytic infiltrates in the white matter with perivascular predominance and markedly CD3 positive T-lymphocytes, mild B-lymphocytes, and moderate macrophage infiltrates [108]. Response to steroids is characteristic of the disease and

often a helpful diagnostic tool. Steroid therapy is typically associated with improvement of symptoms and resolution of enhancing lesions [108], but patients often relapse when tapered off steroids. There are no guidelines for management due to the rarity of the disorder. Expert opinion suggests that response to treatment should be monitored periodically by clinical examination and serial brain MRI. Introduction of corticosteroid-sparing agents can be discussed in cases of relapse or due to steroid side effects. Agents to consider include methotrexate, cyclophosphamide, hydroxycloquine, and azathioprine [107].

### **References**

1. Lancaster E. Continuum: the paraneoplastic disorders. *Continuum (Minneapolis, Minn)*. 2015;21(20):452.
2. Graus F, Dalmau J. Paraneoplastic neurological syndromes. *Curr Opin Neurol*. 2012;25(6):795.
3. Graus F, Delattre J, Antoine J, Dalmau J, Giometto B, Grisold W, et al. Recommended diagnostic criteria for paraneoplastic neurological syndromes. *J Neurol Neurosurg Psychiatry*. 2004;75(8):1135–40.
4. Dalmau J, Rosenfeld MR. Autoimmune encephalitis update. *Neuro Oncol*. 2014;16(6):771–8.
5. Dalmau J, Tüzün E, Wu H, Masjuan J, Rossi JE, Voloschin A, et al. Paraneoplastic anti-N-methyl-D-aspartate receptor encephalitis associated with ovarian teratoma. *Ann Neurol*. 2007;61(1):25–36.
6. Moscato EH, Jain A, Peng X, Hughes EG, Dalmau J, Balice-Gordon RJ. Mechanisms underlying autoimmune synaptic encephalitis leading to disorders of memory, behavior and cognition: insights from molecular, cellular and synaptic studies. *Eur J Neurosci*. 2010;32(2):298–309.
7. Dalmau J. NMDA receptor encephalitis and other antibody-mediated disorders of the synapse: the 2016 Cotzias Lecture. *Neurology*. 2016;87(23):2471–82.
8. Lancaster E. Paraneoplastic disorders. *Continuum (Minneapolis, Minn)*. 2017;23(6, Neuro-oncology):1653–79.
9. Gable MS, Sheriff H, Dalmau J, Tilley DH, Glaser CA. The frequency of autoimmune N-methyl-D-aspartate receptor encephalitis surpasses that of individual viral etiologies in young individuals enrolled in the California Encephalitis Project. *Clin Infect Dis*. 2012;54(7):899–904.
10. Titulaer MJ, McCracken L, Gabilondo I, Armangué T, Glaser C, Iizuka T, et al. Treatment and prognostic factors for long-term outcome in patients with anti-NMDA receptor encephalitis: an observational cohort study. *Lancet Neurol*. 2013;12(2):157–65.

11. Davis R, Dalmau J. Autoimmunity, seizures, and status epilepticus. *Epilepsia*. 2013;54(s6):46–9.
12. Veciana M, Becerra J, Fossas P, Muriana D, Sansa G, Santamarina E, et al. EEG extreme delta brush: an ictal pattern in patients with anti-NMDA receptor encephalitis. *Epilepsy Behav*. 2015;49:280–5.
13. Dalmau J, Gleichman AJ, Hughes EG, Rossi JE, Peng X, Lai M, et al. Anti-NMDA-receptor encephalitis: case series and analysis of the effects of antibodies. *Lancet Neurol*. 2008;7(12):1091–8.
14. Dabner M, McCluggage WG, Bundell C, Carr A, Leung Y, Sharma R, et al. Ovarian teratoma associated with anti-N-methyl D-aspartate receptor encephalitis: a report of 5 cases documenting prominent intratumoral lymphoid infiltrates. *Int J Gynecol Pathol*. 2012;31(5):429–37.
15. Gabilondo I, Saiz A, Galan L, González V, Jdraque R, Sabater L, et al. Analysis of relapses in anti-NMDAR encephalitis. *Neurology*. 2011;77(10):996–9.
16. Planagumà J, Leypoldt F, Mannara F, Gutierrez-Cuesta J, Martín-García E, Aguilar E, et al. Human N-methyl D-aspartate receptor antibodies alter memory and behaviour in mice. *Brain*. 2014;138(1):94–109.
17. Planagumà J, Haselmann H, Mannara F, Petit-Pedrol M, Grünewald B, Aguilar E, et al. Ephrin-B2 prevents N-methyl-D-aspartate receptor antibody effects on memory and neuroplasticity. *Ann Neurol*. 2016;80(3):388–400.
18. Höftberger R, van Sonderen A, Leypoldt F, Houghton D, Geschwind M, Gelfand J, et al. Encephalitis and AMPA receptor antibodies: novel findings in a case series of 22 patients. *Neurology*. 2015;84(24):2403–12.
19. Irani SR, Michell AW, Lang B, Pettingill P, Waters P, Johnson MR, et al. Faciobrachial dystonic seizures precede Lgi1 antibody limbic encephalitis. *Ann Neurol*. 2011;69(5):892–900.
20. Wang M, Cao X, Liu Q, Ma W, Guo X, Liu X. Clinical features of limbic encephalitis with LGI1 antibody. *Neuropsychiatr Dis Treat*. 2017;13:1589.
21. Li Z, Cui T, Shi W, Wang Q. Clinical analysis of leucine-rich glioma inactivated-1 protein antibody associated with limbic encephalitis onset with seizures. *Medicine (Baltimore)*. 2016;95(28):e4244.
22. Flanagan EP, Kotsenas AL, Britton JW, McKeon A, Watson RE, Klein CJ, et al. Basal ganglia T1 hyperintensity in LGI1-autoantibody faciobrachial dystonic seizures. *Neurol Neuroimmunol Neuroinflamm*. 2015;2(6):e161.
23. Graus F, Escudero D, Oleaga L, Bruna J, Villarejo-Galende A, Ballabriga J, et al. Syndrome and outcome of antibody-negative limbic encephalitis. *Eur J Neurol*. 2018;25(8):1011–6.
24. Roth JL, Ott BR, Gaitanis JN, Blum AS. The neuroimmunology of cortical disease (dementia, epilepsy, and autoimmune encephalopathies). In: Rizvi SA, Coyle PK, editors. *Clinical neuroimmunology*. New York: Springer; 2011. p. 275–90.
25. Titulaer M, Sofieetti R, Dalmau J, Gilhus N, Giometto B, Graus F, et al. Screening for tumours in paraneoplastic syndromes: report of an EFNS task force. *Eur J Neurol*. 2011;18(1):19.
26. Honnorat J, Cartalat-Carel S, Ricard D, Camdessanche JP, Carpentier AF, Rogemond V, et al. Onco-neural antibodies and tumour type determine survival and neurological symptoms in paraneoplastic neurological syndromes with Hu or CV2/CRMP5 antibodies. *J Neurol Neurosurg Psychiatry*. 2009;80(4):412–6.
27. Rosenblum M, Posner J. Paraneoplastic cerebellar degeneration. IA clinical analysis of 55 anti-Yo antibody-positive patients. *Neurology*. 1992;42(10):1931.
28. Shams'ili S, Grefkens J, de Leeuw B, van den Bent M, Hooijkaas H, van der Holt B, et al. Paraneoplastic cerebellar degeneration associated with antineuronal antibodies: analysis of 50 patients. *Brain*. 2003;126(6):1409–18.
29. Rees J. Paraneoplastic cerebellar degeneration: new insights into imaging and immunology. *J Neurol Neurosurg Psychiatry*. 2006;77(4):427.
30. Gilmore CP, Elliott I, Auer D, Maddison P. Diffuse cerebellar MR imaging changes in anti-Yo positive paraneoplastic cerebellar degeneration. *J Neurol*. 2010;257(3):490–1.
31. Rojas I, Graus F, Keime-Guibert F, Rene R, Delattre J, Ramon J, et al. Long-term clinical outcome of paraneoplastic cerebellar degeneration and anti-Yo antibodies. *Neurology*. 2000;55(5):713–5.
32. Lancaster E, Dalmau J. Neuronal autoantigens—pathogenesis, associated disorders and antibody testing. *Nat Rev Neurol*. 2012;8(7):380.
33. Krug P, Schleiermacher G, Michon J, Valteau-Couanet D, Brisse H, Peuchmaur M, et al. Opsoclonus-myoclonus in children associated or not with neuroblastoma. *Eur J Paediatr Neurol*. 2010;14(5):400–9.
34. Klaas JP, Ahlskog JE, Pittock SJ, Matsumoto JY, Aksamit AJ, Bartleson J, et al. Adult-onset opsoclonus-myoclonus syndrome. *Arch Neurol*. 2012;69(12):1598–607.
35. Darnell R, Darnell RB, Posner JB. *Paraneoplastic syndromes*, vol. 79. New York: Oxford University Press; 2011.
36. Honnorat J. New findings in adult opsoclonus-myoclonus syndrome. *JAMA Neurol*. 2016;73(4):381–2.
37. Pranzatelli MR, Tate ED, Travelstead AL, Longee D. Immunologic and clinical responses to rituximab in a child with opsoclonus-myoclonus syndrome. *Pediatrics*. 2005;115(1):e115–9.
38. Grewal DS, Fishman GA, Jampol LM. Autoimmune retinopathy and antiretinal antibodies: a review. *Retina*. 2014;34(5):1023–41.
39. Magrys A, Anekonda T, Ren G, Adams G. The role of anti- $\alpha$ -enolase autoantibodies in pathogenicity of autoimmune-mediated retinopathy. *J Clin Immunol*. 2007;27(2):181–92.



40. Adamus G, Brown L, Schiffman J, Iannaccone A. Diversity in autoimmunity against retinal, neuronal, and axonal antigens in acquired neuro-retinopathy. *J Ophthalmic Inflamm Infect.* 2011;1(3):111–21.
41. Ohguro H, Ogawa K-I, Nakagawa T. Recoverin and Hsc 70 are found as autoantigens in patients with cancer-associated retinopathy. *Invest Ophthalmol Vis Sci.* 1999;40(1):82–9.
42. Kikuchi T, Arai J, Shibuki H, Kawashima H, Yoshimura N. Tubby-like protein 1 as an autoantigen in cancer-associated retinopathy. *J Neuroimmunol.* 2000;103(1):26–33.
43. Adamus G. Autoantibody targets and their cancer relationship in the pathogenicity of paraneoplastic retinopathy. *Autoimmun Rev.* 2009;8(5):410–4.
44. Dobson R, Lawden M. Melanoma associated retinopathy and how to understand the electroretinogram. *Pract Neurol.* 2011;11(4):234–9.
45. Kondo M, Sanuki R, Ueno S, Nishizawa Y, Hashimoto N, Ohguro H, et al. Identification of autoantibodies against TRPM1 in patients with paraneoplastic retinopathy associated with ON bipolar cell dysfunction. *PLoS One.* 2011;6(5):e19911.
46. Malik S, Furlan A, Sweeney P, Kosmorsky G, Wong M. Optic neuropathy: a rare paraneoplastic syndrome. *J Clin Neuroophthalmol.* 1992;12(3):137–41.
47. Chan JW. Paraneoplastic retinopathies and optic neuropathies. *Surv Ophthalmol.* 2003;48(1):12–38.
48. Lieberman F, Odel J, Hirsh J, Heinemann M, Michaeli J, Posner J. Bilateral optic neuropathy with IgGκ multiple myeloma improved after myeloablative chemotherapy. *Neurology.* 1999;52(2):414.
49. Kuroda Y, Miyahara M, Sakemi T, Matsui M, Ryu T, Yamaguchi M, et al. Autopsy report of acute necrotizing opticomyelopathy associated with thyroid cancer. *J Neurol Sci.* 1993;120(1):29–32.
50. Pulido J, Cross S, Lennon V, Swanson D, Muench M, Lachance D. Bilateral autoimmune optic neuritis and vitritis related to CRMP-5-IgG: intravitreal triamcinolone acetate therapy of four eyes. *Eye (Lond).* 2008;22(9):1191.
51. Moersch F. Progressive and fluctuating muscular rigidity and spasm (stiffman syndrome): report of a case and some observations in 13 other cases. *Proc Staff Meet Mayo Clin.* 1956;31(15):421–7.
52. Ciccotto G, Blaya M, Kelley RE. Stiff person syndrome. *Neurol Clin.* 2013;31(1):319–28.
53. Butler MH, Hayashi A, Ohkoshi N, Villmann C, Becker C-M, Feng G, et al. Autoimmunity to gephyrin in Stiff-Man syndrome. *Neuron.* 2000;26(2):307–12.
54. Raju R, Rakocevic G, Chen Z, Hoehn G, Semino-Mora C, Shi W, et al. Autoimmunity to GABA<sub>A</sub>-receptor-associated protein in stiff-person syndrome. *Brain.* 2006;129(12):3270–6.
55. Carvajal-Gonzalez A, Leite MI, Waters P, Woodhall M, Coutinho E, Balint B, et al. Glycine receptor antibodies in PERM and related syndromes: characteristics, clinical features and outcomes. *Brain.* 2014;137(8):2178–92.
56. Hutchinson M, Waters P, McHugh J, Gorman G, O’riordan S, Connolly S, et al. Progressive encephalomyelitis, rigidity, and myoclonus: a novel glycine receptor antibody. *Neurology.* 2008;71(16):1291–2.
57. Damásio J, Leite MI, Coutinho E, Waters P, Woodhall M, Santos MA, et al. Progressive encephalomyelitis with rigidity and myoclonus: the first pediatric case with glycine receptor antibodies. *JAMA Neurol.* 2013;70(4):498–501.
58. Hassin-Baer S, Kirson ED, Shulman L, Buchman AS, Bin H, Hindiyyeh M, et al. Stiff-person syndrome following West Nile fever. *Arch Neurol.* 2004;61(6):938–41.
59. Magira EE, Alexopoulos H, Charitatos E, Michas D, Dalakas MC. Progressive encephalomyelitis with rigidity and myoclonus (PERM): brucellosis as a possible triggering factor and long-term follow-up therapy with rituximab. *Ther Adv Neurol Disord.* 2016;9(1):69–73.
60. Tobin WO, Lennon VA, Komorowski L, Probst C, Clardy SL, Aksamit AJ, et al. DPPX potassium channel antibody frequency, clinical accompaniments, and outcomes in 20 patients. *Neurology.* 2014;83(20):1797–803.
61. van Sonderen A, Ariño H, Petit-Pedrol M, Leyboldt F, Körtvélyessy P, Wandinger K-P, et al. The clinical spectrum of Caspr2 antibody-associated disease. *Neurology.* 2016;87(5):521–8.
62. Abou-Zeid E, Boursoulian LJ, Metzger WS, Gundogdu B. Morvan syndrome: a case report and review of the literature. *J Clin Neuromuscul Dis.* 2012;13(4):214–27.
63. Barber P, Anderson N, Vincent A. Morvan’s syndrome associated with voltage-gated K channel antibodies. *Neurology.* 2000;54(3):771.
64. Chow W-H, Gridley G, Mellekjær L, McLaughlin JK, Olsen JH, Fraumeni JF. Cancer risk following polymyositis and dermatomyositis: a nationwide cohort study in Denmark. *Cancer Causes Control.* 1995;6(1):9–13.
65. Condom E, Vidal A, Rota R, Graus F, Dalmau J, Ferrer I. Paraneoplastic intestinal pseudo-obstruction associated with high titres of Hu autoantibodies. *Virchows Arch A Pathol Anat Histopathol.* 1993;423(6):507–11.
66. Dispenzieri A. POEMS syndrome. *Blood Rev.* 2007;21(6):285–99.
67. Rajkumar SV, Dimopoulos MA, Palumbo A, Blade J, Merlini G, Mateos M-V, et al. International Myeloma Working Group updated criteria for the diagnosis of multiple myeloma. *Lancet Oncol.* 2014;15(12):e538–48.
68. Dispenzieri A. POEMS syndrome: update on diagnosis, risk-stratification, and management. *Am J Hematol.* 2015;90(10):951–62.
69. Badros A, Porter N, Zimrin A. Bevacizumab therapy for POEMS syndrome. *Blood.* 2005;106(3):1135.

70. O'Toole O, Lennon VA, Ahlskog JE, Matsumoto JY, Pittock SJ, Bower J, et al. Autoimmune chorea in adults. *Neurology*. 2013;80(12):1133–44.
71. Honorat JA, McKeon A. Autoimmune movement disorders: a clinical and laboratory approach. *Curr Neurol Neurosci Rep*. 2017;17(1):4.
72. Graus F, Keime-Guibert F, Rene R, Benyahia B, Ribalta T, Ascaso C, et al. Anti-Hu-associated paraneoplastic encephalomyelitis: analysis of 200 patients. *Brain*. 2001;124(6):1138–48.
73. Ducray F, Roos-Weil R, Garcia PY, Slesari J, Heinzle O, Chatelain D, et al. Devic's syndrome-like phenotype associated with thymoma and anti-CV2/CRMP5 antibodies. *J Neurol Neurosurg Psychiatry*. 2007;78(3):325–7.
74. Flanagan EP, Keegan BM. Paraneoplastic myelopathy. *Neurol Clin*. 2013;31(1):307–18.
75. Fang F, Al-Chalabi A, Ronnevi L-O, Turner MR, Wirdefeldt K, Kamel F, et al. Amyotrophic lateral sclerosis and cancer: a register-based study in Sweden. *Amyotroph Lateral Scler Frontotemporal Degener*. 2013;14(5–6):362–8.
76. Mitchell D, Olczak S. Remission of a syndrome indistinguishable from motor neurone disease after resection of bronchial carcinoma. *Br Med J*. 1979;2(6183):176.
77. Freedman DM, Curtis RE, Daugherty SE, Goedert JJ, Kuncl RW, Tucker MA. The association between cancer and amyotrophic lateral sclerosis. *Cancer Causes Control*. 2013;24(1):55–60.
78. Khwaja S, Sripathi N, Ahmad B, Lennon VA. Paraneoplastic motor neuron disease with type 1 Purkinje cell antibodies. *Muscle Nerve*. 1998;21(7):943–5.
79. Waragai M, Chiba A, Uchibori A, Fukushima T, Anno M, Tanaka K. Anti-Ma2 associated paraneoplastic neurological syndrome presenting as encephalitis and progressive muscular atrophy. *J Neurol Neurosurg Psychiatry*. 2006;77(1):111–3.
80. Kao JC, Liao B, Markovic SN, Klein CJ, Naddaf E, Staff NP, et al. Neurological complications associated with anti-programmed death 1 (PD-1) antibodies. *JAMA Neurol*. 2017;74(10):1216–22.
81. Santomasso B, D'Angelo S. Anti-CRMP5-associated paraneoplastic neurologic syndrome developing in a patient with metastatic Merkel cell carcinoma during immune checkpoint inhibitor treatment (P5. 409). *Minneapolis: AAN Enterprises*; 2018.
82. Williams TJ, Benavides DR, Patrice K-A, Dalmau JO, De Ávila ALR, Le DT, et al. Association of autoimmune encephalitis with combined immune checkpoint inhibitor treatment for metastatic cancer. *JAMA Neurol*. 2016;73(8):928–33.
83. Hottinger AF, de Micheli R, Guido V, Karampera A, Hagmann P, Du Pasquier R. Natalizumab may control immune checkpoint inhibitor-induced limbic encephalitis. *Neurol Neuroimmunol Neuroinflamm*. 2018;5(2):e439.
84. Matsuoka H, Kimura H, Koba H, Tambo Y, Ohkura N, Hara J, et al. Nivolumab-induced limbic encephalitis with anti-Hu antibody in a patient with advanced pleomorphic carcinoma of the lung. *Clin Lung Cancer*. 2018;19(5):e597–9.
85. Li J, Lin W. Various clinical features of patients with anti-Hu associated paraneoplastic neurological syndromes: an observational study. *Medicine (Baltimore)*. 2018;97(18):e0649.
86. Gultekin SH, Rosenfeld MR, Voltz R, Eichen J, Posner JB, Dalmau J. Paraneoplastic limbic encephalitis: neurological symptoms, immunological findings and tumour association in 50 patients. *Brain*. 2000;123(7):1481–94.
87. Masangkay N, Basu S, Moghbel M, Kwee T, Alavi A. Brain 18F-FDG-PET characteristics in patients with paraneoplastic neurological syndrome and its correlation with clinical and MRI findings. *Nucl Med Commun*. 2014;35(10):1038–46.
88. Malter MP, Elger CE, Surges R. Diagnostic value of CSF findings in antibody-associated limbic and anti-NMDAR-encephalitis. *Seizure*. 2013;22(2):136–40.
89. Antoine J-C, Camdessanché J-P. Treatment options in paraneoplastic disorders of the peripheral nervous system. *Curr Treat Options Neurol*. 2013;15(2):210–23.
90. June CH, Warshauer JT, Bluestone JA. Is autoimmunity the Achilles' heel of cancer immunotherapy? *Nat Med*. 2017;23(5):540.
91. Rosenfeld MR, Dalmau J. Diagnosis and management of paraneoplastic neurologic disorders. *Curr Treat Options in Oncol*. 2013;14(4):528–38.
92. Lee W-J, Lee S-T, Byun J-I, Sunwoo J-S, Kim T-J, Lim J-A, et al. Rituximab treatment for autoimmune limbic encephalitis in an institutional cohort. *Neurology*. 2016;86(18):1683–91.
93. Badari A, Farolino D, Nasser E, Mehboob S, Crossland D. A novel approach to paraneoplastic intestinal pseudo-obstruction. *Support Care Cancer*. 2012;20(2):425–8.
94. Battaglia T, De Grandis E, Mirabelli-Badenier M, Boeri L, Morcaldi G, Barabino P, et al. Response to rituximab in 3 children with opsoclonus-myoclonus syndrome resistant to conventional treatments. *Eur J Paediatr Neurol*. 2012;16(2):192–5.
95. Or C, Collins DR, Merkur AB, Wang Y, Chan C-C, Forooghian F. Intravenous rituximab for the treatment of cancer-associated retinopathy. *Can J Ophthalmol*. 2013;48(2):e35–8.
96. Greenlee JE. Treatment of paraneoplastic neurologic disorders. *Curr Treat Options Neurol*. 2010;12(3):212–30.
97. Delprat C, Aricò M. Blood spotlight on Langerhans cell histiocytosis. *Blood*. 2014;124(6):867–72. <https://doi.org/10.1182/blood-2014-2002-556407>.
98. Diamond EL, Dagna L, Hyman DM, Cavalli G, Janku F, Estrada-Veras J, et al. Consensus guidelines for the diagnosis and clinical management of Erdheim-

- Chester disease. *Blood*. 2014;124(4):483–92. <https://doi.org/10.1182/blood-2014-2003-561381>.
99. Abła O, Jacobsen E, Picarsic J, Krenova Z, Jaffe R, Emile J-F, et al. Consensus recommendations for the diagnosis and clinical management of Rosai-Dorfman-Destombes disease. *Blood*. 2018;131(26):2877–90. <https://doi.org/10.1182/blood-2018-2003-839753>.
  100. Susac JO, Hardman JM, Selhorst JB. Microangiopathy of the brain and retina. *Neurology*. 1979;29(3):313.
  101. Lucchinetti CF, Popescu BF, Bunyan RF, Moll NM, Roemer SF, Lassmann H, et al. Inflammatory cortical demyelination in early multiple sclerosis. *N Engl J Med*. 2011;365(23):2188–97.
  102. Hardy TA, O'Brien B, Gerbis N, Barnett MH, Reddel SW, Brewer J, et al. Brain histopathology in three cases of Susac's syndrome: implications for lesion pathogenesis and treatment. *J Neurol Neurosurg Psychiatry*. 2015;86(5):582–4.
  103. Greco A, De Virgilio A, Gallo A, Fusconi M, Turchetta R, Tombolini M, et al. Susac's syndrome—pathogenesis, clinical variants and treatment approaches. *Autoimmun Rev*. 2014;13(8):814–21.
  104. Jarius S, Neumayer B, Wandinger K, Hartmann M, Wildemann B. Anti-endothelial serum antibodies in a patient with Susac's syndrome. *J Neurol Sci*. 2009;285(1–2):259–61.
  105. Mateen F, Zubkov A, Muralidharan R, Fugate J, Rodriguez F, Winters J, et al. Susac syndrome: clinical characteristics and treatment in 29 new cases. *Eur J Neurol*. 2012;19(6):800–11.
  106. Pittock SJ, Debruyne J, Krecke KN, Giannini C, Van Den Ameel J, De Herdt V, et al. Chronic lymphocytic inflammation with pontine perivascular enhancement responsive to steroids (CLIPPERS). *Brain*. 2010;133(9):2626–34.
  107. Taieb G, Allou T, Labauge P. Therapeutic approaches in CLIPPERS. *Curr Treat Options Neurol*. 2017;19(5):17.
  108. Tobin WO, Guo Y, Krecke KN, Parisi JE, Lucchinetti CF, Pittock SJ, et al. Diagnostic criteria for chronic lymphocytic inflammation with pontine perivascular enhancement responsive to steroids (CLIPPERS). *Brain*. 2017;140(9):2415–25.
  109. Gul M, Chaudhry AA, Chaudhry AA, Sheikh MA, Carsons S. Atypical presentation of CLIPPERS syndrome: a new entity in the differential diagnosis of central nervous system rheumatologic diseases. *J Clin Rheumatol*. 2015;21(3):144–8.
  110. Chan KH, Vernino S, Lennon VA. ANNA-3 anti-neuronal nuclear antibody: marker of lung cancer-related autoimmunity. *Ann Neurol*. 2001;50(3):301–11.
  111. Yu Z, Kryzer TJ, Griesmann GE, Kim KK, Benarroch EE, Lennon VA. CRMP-5 neuronal autoantibody: marker of lung cancer and thymoma-related autoimmunity. *Ann Neurol*. 2001;49(2):146–54.
  112. Höftberger R, Sabater L, Ortega A, Dalmau J, Graus F. Patient with homer-3 antibodies and cerebellitis. *JAMA Neurol*. 2013;70(4):506–9.
  113. Graus F, Vincent A, Pozo-Rosich P, Sabater L, Saiz A, Lang B, et al. Anti-glial nuclear antibody: marker of lung cancer-related paraneoplastic neurological syndromes. *J Neuroimmunol*. 2005;165(1):166–71.
  114. Sabater L, Bataller L, Carpentier AF, Aguirre-Cruz M, Saiz A, Benyahia B, et al. Protein kinase C $\gamma$  autoimmunity in paraneoplastic cerebellar degeneration and non-small-cell lung cancer. *J Neurol Neurosurg Psychiatry*. 2006;77(12):1359–62.
  115. Shams'ili S, de Leeuw B, Hulsenboom E, Jaarsma D, Smitt PS. A new paraneoplastic encephalomyelitis autoantibody reactive with the axon initial segment. *Neurosci Lett*. 2009;467(2):169–72.
  116. Petit-Pedrol M, Armangue T, Peng X, Bataller L, Cellucci T, Davis R, et al. Encephalitis with refractory seizures, status epilepticus, and antibodies to the GABAA receptor: a case series, characterisation of the antigen, and analysis of the effects of antibodies. *Lancet Neurol*. 2014;13(3):276–86.
  117. Boronat A, Sabater L, Saiz A, Dalmau J, Graus F. GABAB receptor antibodies in limbic encephalitis and anti-GAD-associated neurologic disorders. *Neurology*. 2011;76(9):795–800.
  118. Prüss H, Rothkirch M, Kopp U, Hamer HM, Hagg M, Sterzer P, et al. Limbic encephalitis with mGluR5 antibodies and immunotherapy-responsive prosopagnosia. *Neurology*. 2014;83(15):1384–6.
  119. Smitt PS, Kinoshita A, De Leeuw B, Moll W, Coesmans M, Jaarsma D, et al. Paraneoplastic cerebellar ataxia due to autoantibodies against a glutamate receptor. *N Engl J Med*. 2000;342(1):21–7.



# Adult and Childhood Vasculitis of the Nervous System

# 14

David S. Younger

## Introduction

Vasculitis results in a variety of clinical neurologic manifestations and neuropathologic changes in the central and peripheral nervous system (CNS and PNS). If unrecognized and therefore untreated, vasculitis leads to ischemia and injury of the involved tissues. Remarkable progress has been achieved in the pathogenesis, diagnosis, and treatment of vasculitis of the nervous system, making it an important topic for clinicians and researchers alike.

## Classification and Nosology

Vasculitis is defined as inflammation of blood vessel walls for at least some time during the course of the disease and affects arteries and veins of varying caliber. Two Chapel Hill Consensus Conferences (CHCC), one in 1994 [1], and the other in 2012 [2], provided consensus on nosology and definitions for the commonest forms of vasculitis. The revised CHCC nomenclature serves as a guide for the categorization of

diverse forms of vasculitis based upon the vessels involved, and provides a scheme for the neurologic aspects thereof (Table 14.1). Large vessel vasculitis (LVV) including giant cell arteritis (GCA) and Takayasu arteritis (TAK) affects the aorta, its major branches, and analogous veins. Medium vessel vasculitis (MVV) inclusive of polyarteritis nodosa (PAN) and Kawasaki disease (KD) involves main visceral arteries and veins and initial branches. The category of small vessel vasculitis (SVV) recognizes the involvement of intraparenchymal arteries, arterioles, capillaries, veins, and venules, with a disease mechanism related to antineutrophil cytoplasmic antibody (ANCA) and immune complexes. The category of ANCA-associated vasculitis (AAV) includes granulomatosis with polyangiitis (GPA) [Wegener granulomatosis (WG) type], eosinophilic granulomatosis with polyangiitis (EGPA) [Churg-Strauss syndrome (CSS)], and microscopic polyangiitis (MPA) (microscopic polyarteritis), while vasculitic disorders associated with immune complexes includes IgA vasculitis (IgAV) [Henoch-Schönlein purpura (HSP)], cryoglobulinemic vasculitis (CV), and hypocomplementemia urticarial vasculitis (HUV) associated with C1q antibodies. Vasculitis without a predominant vessel size and caliber, respectively from small to large, involving arteries, veins, and capillaries, comprises the category of variable vessel vasculitis (VVV), characteristic of Behçet disease (BD) and Cogan syndrome (CS). The

---

D. S. Younger (✉)  
Department of Neurology, White Plains Hospital,  
New York, NY, USA  
e-mail: [Youngd02@nyu.edu](mailto:Youngd02@nyu.edu);  
[David.Younger@nyumc.org](mailto:David.Younger@nyumc.org); [sahaana.sundar@nyu.edu](mailto:sahaana.sundar@nyu.edu)

**Table 14.1** Childhood and adult vasculitides with nervous system involvement

Large vessel vasculitis
Giant cell arteritis
Takayasu arteritis
Idiopathic aortitis (IgG4)
Medium vessel vasculitis
Polyarteritis nodosa
Kawasaki disease
Small vessel vasculitis
ANCA-associated vasculitis
Microscopic polyangiitis
Granulomatosis with polyangiitis (Wegener)
Eosinophilic granulomatosis with polyangiitis (Churg-Strauss)
Immune-complex vasculitis
Cryoglobulinemic vasculitis
IgA vasculitis (Henoch-Schönlein)
Hypocomplementemic urticarial vasculitis (IgA Vasculitis)
Variable vessel vasculitis
Behçet disease
Cogan syndrome
Primary CNS vasculitis
Vasculitis associated with collagen vascular disease
Systemic lupus erythematosus
Rheumatoid arthritis
Vasculitis due to substance abuse
Amphetamines
Cocaine
Opioids
Vasculitis and infection
Bacteria
Viruses
Neurosyphilis
Mycoses
Parasites
HIV/AIDS

category of vasculitis associated with systemic disease includes vasculitis associated with rheumatoid arthritis (RA) and systemic lupus erythematosus (SLE) and other connective tissue disorders, wherein the vasculitic process is secondary to or associated with the underlying systemic disorder. There is a category of vasculitis associated with a probable specific etiology, such as substance abuse and infection designated by the specific vasculitic disorder with a prefix to denote the causative agent. The category of single-organ vasculitis (SOV) involves arteries or veins of any size in a single organ without fea-

tures to indicate that it is a limited expression of a systemic vasculitis characterized by primary CNS vasculitis, nonsystemic peripheral nerve vasculitis (PNV), and isolated aortitis.

Recognizing that certain forms of vasculitis are more common in childhood and that some vasculitides display different disease courses compared to adult forms [3], the Pediatric Rheumatology European Society (PRES) and the European League against Rheumatism (EULAR) proposed specific classification criteria for the commonest childhood vasculitis syndrome [4] based upon vessel size, similar to the CHCC nomenclature [2]. In 2008, the EULAR, PRES, and the Pediatric Rheumatology International Trials Organization (PRINTO) reported their methodology and overall clinical, laboratory, and radiographic characteristics for several childhood systemic vasculitides [5] followed by a final validated classification [6].

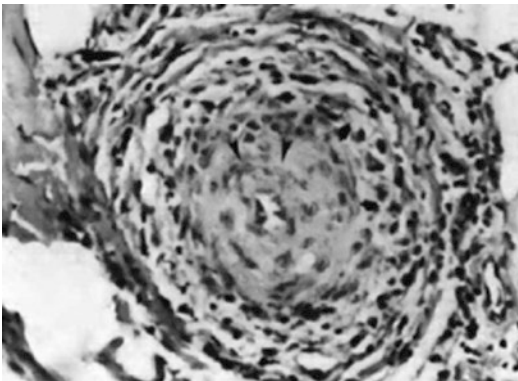
## A Century of Insights

*The early history of vasculitis is debatable, but one fact is clear, the earliest patients with vasculitis appeared to have had neurologic involvement.* According to Lamb [6], Kussmaul and Maier provided the first complete gross and microscopic description of a patient with leg pains, cramps, and tenderness so prominent that trichinosis was considered in an article entitled, “A hitherto undescribed peculiar disease of the arteries which is accompanied by Bright’s disease and a rapidly progressive general paralysis of the muscles.” At postmortem examination, there was widespread arteritis that resembled syphilitic periarteritis. The disorder was named periarteritis for the inflammation around blood vessels. In 1908, Langcope [7] described the first American patient with periarteritis, a 35-year-old man with constitutional symptoms and subacute leg pains. Postmortem examination showed widespread necrotizing arteritis and nodules along small and medium-sized vessels of the heart, liver, kidney, pancreas, testicles, brain, nerves and skeletal muscles, sparing the lungs and spleen. The histologic lesions consisted of mononuclear cell infiltration, necrosis of

internal and external elastic lamina of the media, fibrin deposition, aneurismal dilatation, perivascular inflammation of the adventitia, and intimal proliferation resulting in narrowing of arterial lumina. Kernohan and Woltman [8] summarized the clinical and neuropathologic aspects of adult PAN, and Kraulik and colleagues [9] reported the postmortem neurologic findings of fulminant childhood PAN (cPAN). The dominant neurologic picture of both adult and cPAN was a peripheral neuritis that occurred in one-half of patients early in the illness with a predilection for the legs. At postmortem examination, all had arteritic lesions along nutrient arteries of the peripheral nerves, and three-quarters had lesions in arteriae nervorum. The combination of acute and chronic lesions correlated with known exacerbations. Involvement of the CNS was estimated to occur in 8% of cases evident by clinically apparent brain infarcts resulting from occlusion of cerebral vessels, which was often insidious in its progression. In PAN, as in the other systemic necrotizing arteritis, the vasculitic lesion proceeded in a characteristic manner (Fig. 14.1) commencing with invasion of the intima, media, and adventitia by polymorphonuclear, plasma cells, eosinophils,

and lymphocytes, leading to swelling of the media, and fibrinoid necrosis that clusters around the vasa vasorum, with fragmentation of the internal elastic lamina. There was focal deposition of perivascular connective tissue, vascular necrosis, and denuding of the endothelium, followed by vascular thrombosis, ischemia, aneurysm formation, rupture, and hemorrhage. Healed lesions coexisted with active lesions. Harry Lee Parker conceptualized nerve and muscle biopsy in a discussion of the paper by Kernohan and Woltman [8] commenting, "It occurs to me that in any case in which polyarteritis nodosa may be suspected, it is advisable to take a biopsy from a peripheral nerve, muscle or artery." There are no published series confirming the correlation of the extent of systemic necrotizing arteritis that may be predicted by the singular finding of vasculitis in a cutaneous nerve biopsy specimen. Only one reported series [10] reported neither systemic nor isolated PNV was found at postmortem after diagnostic cutaneous nerve biopsy evidencing necrotizing vasculitis in life. A variant of PAN was recognized in very young children with mucocutaneous lymph node syndrome [11, 12]. Although early publications used the term infantile PAN [13, 14], KD is the preferred term to describe this childhood syndrome with worldwide occurrence, affecting children of all ages and races. Both PAN and KD are prototypical examples of MVV.

*Contemporaneously, SVV syndromes were recognized and differentiated from PAN.* First described by Wohlwill in 1923 [15], Davson and colleagues [16] and Wainwright and Davson [17] described MPA among 34 patients who differed from PAN due to selective involvement of small microscopic arteries, arterioles, capillaries, and venules including glomerular and pulmonary alveolar capillaries. Fever, arthralgia, purpura, hemoptysis, pulmonary hemorrhage, abdominal pain, and gastrointestinal bleeding likewise preceded the explosive phase of systemic necrotizing vasculitis that affected the kidney and lungs, with rapidly progressive glomerulonephritis and pulmonary capillaritis. Two of five deaths were attributed to CNS involvement by vasculitis during periods of disease respectively at 4 and 8 months; however,



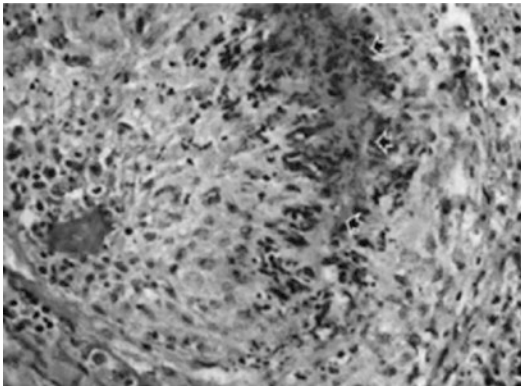
**Fig. 14.1** This small muscular artery from muscle is from a patient with polyarteritis nodosa. In the third, or proliferative, phase illustrated here, chronic inflammatory cells replace the neutrophils of the second phase; there is evidence of necrosis of the media, early intimal proliferation (arrowheads), and fibrosis. The lumen is almost completely occluded. Ultimately, in the healing phase, this process is replaced by dense, organized connective tissue (stain, hematoxylin and eosin; original magnification,  $\times 250$ )

that could not be confirmed since postmortem examinations were not performed. The disorder was later reclassified by the CHCC [1, 2] as a necrotizing SVV with little or no immune-complex deposition that primarily affected the kidney and lungs. Medium-sized arteries might be involved even though the disease was predominantly considered to affect small-sized arteries, arterioles, capillaries, and venules of the two organs most affected, with variable systemic necrotizing vasculitis.

The first patient with EGPA was probably Case 1 of Lamb [18] reported in 1914 under the heading of PAN. That patient, a 26-year-old man with 2 years of worsening asthma, developed fever, palpable purpura, nodular skin lesions, hemoptysis, vomiting, urinary difficulty, and granular urinary casts. He died 1 month later and postmortem examination showed necrotizing arteritis of small arteries, with dense collections of extravascular eosinophils and tissue eosinophilia in the heart, stomach, and kidney. Decades later, Churg and Strauss [19] described the clinical and postmortem findings of 13 patients with asthma, fever, and hypereosinophilia, accompanied by eosinophilic exudation, fibrinoid change, and granulomatous proliferation that constituted the so-called allergic granuloma, found within vessel walls and in extravascular connective tissue of major organ systems, leading to cardiac, pulmonary, gastrointestinal, skin, PNS, and CNS manifestations. In 1977, Chumbley and coworkers [20] described 30 asthmatic patients from the Mayo Clinic over the period 1950–1974, with necrotizing vasculitis of small arteries and veins with extravascular granulomas and infiltration of vessels and perivascular tissue with eosinophilia. The lungs, peripheral nerves, and skin were most frequently involved, and renal failure was encountered in only one patient. Corticosteroids seemed to confer long-term survival. In 1984, Lanham and colleagues [21] emphasized that the combination of necrotizing vasculitis, tissue infiltration by eosinophils and extravascular granulomas suggested by Churg and Strauss [19], occurred contemporaneously in only a minority of patients. Moreover, such histologic findings could be encountered in well as in other granulo-

matous, vasculitic, and eosinophilic disorders in the absence of clinical asthma, allergic rhinitis, sinusitis, pulmonary infiltrates, and cardiac involvement pathognomonic of EGPA. The authors described a phasic pattern of EGPA in which allergic disease preceded systemic vasculitis and eosinophilic tissue infiltrates might occur in the absence of peripheral blood eosinophilia. Pulmonary infiltrates, upper respiratory tract, and gastrointestinal disease often preceded the vasculitic component of the syndrome leading to cardiac, cutaneous, nervous system, renal, bone, and muscle involvement. In 1990, the American College of Rheumatology (ACR) [22] developed criteria for the classification of EGPA, that included ascertainment of four or more of the following: asthma, eosinophilia of >10%, mono-neuropathy or polyneuropathy, nonfixed pulmonary infiltrates on chest radiograph, paranasal sinus abnormality, and extravascular eosinophils on tissue biopsy that included an artery, arteriole, or venule. These criteria were inadequate in differentiating the various clinicopathologic expressions of SVV and a patient with asthma and paranasal sinusitis could fit the designation of EGPA. The 1994 CHCC [1] characterized EGPA as an eosinophil-rich and granulomatous inflammatory process that involved the respiratory tract, with necrotizing vasculitis that affected small to medium-sized vessels such as capillaries, venules, arterioles, and arteries, with associated asthma and eosinophilia.

In 1954, Godman and Churg [23] described the syndrome of GPA that included granuloma in the nasopharynx, sinuses, and lower respiratory tract with focal segmental glomerulonephritis and disseminated small vessel vasculitis (Fig. 14.2). Nervous system involvement in GPA was found in up to one-half of patients according to Drachman [24] who also described a patient with 1 month of headache that awakened him from sleep followed by rhinitis, nasal obstruction, epistaxis, mononeuropathy multiplex, confusion, and hypertension. Active arteritis and necrotizing granulomata were found in the brain, not in peripheral nerves. Two decades later, Fauci and colleagues [25] and Hoffman and colleagues [26] at the National Institutes of Health (NIH)



**Fig. 14.2** Wegener's granulomatosis. This small muscular artery is destroyed. A large confluent area of fibrinoid degradation (arrows) is surrounded by neutrophils, palisading histiocytes, lymphocytes, plasma cells, and some giant cells (stain, hematoxylin and eosin; original magnification,  $\times 250$ )

respectively reported a prospective series of 85 patients with GPA, and a retrospective assessment of 180 patients followed for 6 months to 24 years, describing nervous system involvement in up to 23% of patients. There was a preponderance of mononeuritis multiplex with CNS abnormalities in 8–10% of patients. CNS involvement included stroke, cranial nerve abnormalities, and diabetes insipidus. Fauci and colleagues [25] established the efficacy of cyclophosphamide and prednisone in achieving complete remissions in 93% of patients as well as the tendency of patients to relapse and accrue additive mortality from both disease and treatment; however, alternative immunosuppressant regimens were not equally effective [26]. In a landmark article, Godman and Churg [27] concluded that MPA, EGRA, and GPA were related to one another yet distinct from PAN. This astute conclusion was based mainly on pathologic features was later substantiated by their common association with ANCA, but not so for PAN [28].

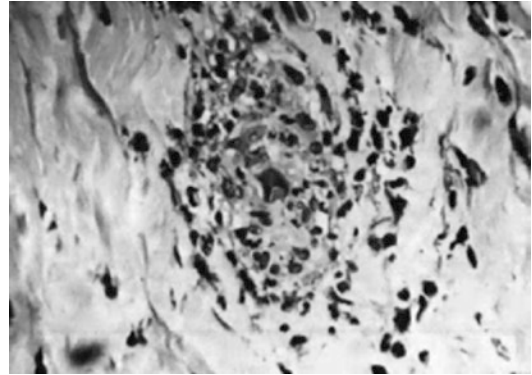
*There ensued a renaissance in the understanding of primary systemic vasculitis with convincing clinical evidence to support an important role for ANCA in the development of AAV.* Early observations of ANCA were provided by van der Woude and colleagues in 1985 [29], and Falk and Jennette [30] and Goldschmeding and colleagues [31] in

1988, followed by progress in the differentiation of these subtypes and understanding of the eponymous manifestations [32]. Proteinase 3 (PR3) is a serine protease found in the azurophilic granules of neutrophils and peroxidase-positive lysosomes of monocytes. Myeloperoxidase (MPO), which constitutes about 5% of the total protein content of the neutrophilic cell, is localized to the same cellular compartment as PR3. However, PR3 in contrast to MPO is also found on the plasma membrane of resting neutrophils and monocytes in many patients. Autoantibodies directed against PR3 and MPO are directed against multiple epitopes. Although sera from different patients may recognize different epitopes, all ANCA recognized restricted epitopes of PR3 involving its catalytic site [33]. An AAV classification appears to better recognize ANCA disease and predict prognosis than other any existing clinical classification systems [34]. However, as with other autoimmune disorders, the etiology and pathogenesis appeared multifactorial, involving the interplay of initiating and predisposing environment and genetic factors. Important contributing factors to the mediation of vascular and extravascular inflammation included a loss of regulatory T- and B-cell function, acute neutrophilic cell injury with release of ANCA-antigens, cytokine priming of neutrophilic cells, and subsequent complement activation by Fc and Fab2 engagement, and enhancement of complement-dependent cytotoxicity with release of ANCA-antigens into the microenvironment [35–37]. The ANCA lesion typical of GPA includes both vasculitic and granulomatous features in lung, with focal segmental glomerulonephritis typified pathologically by lysis of glomerular tufts, basement membrane disruption, accumulation of fibrinoid material, thrombosis of glomerular capillary loops, acute tubular necrosis, and cant deposition of immunoglobulin (Ig) and complement. There are genetic distinctions between MPO and GPA suggested by the strong association of PR3-ANCA disease with antigenic specificity of HLA-DP and the genes encoding  $\alpha 1$ -antitrypsin (*SERPINA1*) and PR3 (*PRTN3*), and HLA-DQ for MPO-ANCA [38]. An immunofluorescence technique (IFT) has been the standard method for routine determination of ANCA



in vasculitis using ethanol-fixed human neutrophils as substrate. Two main immunofluorescence patterns are distinguished, a cytoplasmic (c-ANCA) and perinuclear (p-ANCA). The 1999 “International consensus statement on testing and reporting ANCA” [39] required laboratories to screen for ANCA by IFT and to confirm the specificity of fluorescent sera by enzyme-linked immunoassay (ELISA) for PR3 and MPO-ANCA. However, conventional ELISA using PR3 immobilized to the surface of the ELISA plate shows great variation in performance and often lack sensitivity. Capture ELISA is superior in overall diagnostic performance to direct ELISA [40], but the capturing antibodies hiding relevant epitopes may reduce the sensitivity of capture ELISA. High sensitivity PR3 (hsPR3)-ANCA ELISA, which immobilizes PR3 via a bridging molecule to the plastic plate and preserves nearly all epitopes for the binding of ANCA, was superior to direct and capture techniques in GPA [41].

*Hypersensitivity vasculitis leading to cutaneous vasculitis was conceptualized as an immunologic response to antigenic material associated with clinically evident purpura, and small vessel inflammation affecting arterioles, capillaries, and postcapillary venules.* Between 1948 and 1952, Zeek [42, 43] separated the hypersensitivity vasculitides from allergic granulomatous angiitis, rheumatic arthritis, PAN, and GCA. Hemorrhage into the skin or palpable purpura was noted in virtually all patients resulting from extravasation of erythrocytes, pronounced endothelial swelling, polymorphonuclear, and later mononuclear cell infiltration, followed by fibrosis, necrosis, fibrinoid deposits, and visible polymorphonuclear debris termed leukocytoclasia (Fig. 14.3). Zeek [44] likened hypersensitivity vasculitis to the anaphylactoid Arthus reaction produced by the experimental injection of horse serum into rabbits [45]. Osler [46] first appreciated the relation of purpuric attacks to cerebral manifestations in the report of a patient with transient hemiparesis, and three others with potentially fatal cerebral hemorrhages. Gairdner [47] described HSP among 12 patients with anaphylactoid purpura including one child who developed rash, colic, melanotic



**Fig. 14.3** This arteriole from muscle is from a patient with leukocytoclastic vasculitis. The entire vessel and perivascular tissue is infiltrated with polymorphonuclear leukocytes and some chronic inflammatory cells with necrosis and nuclear debris. The vascular lumen is nearly obliterated (stain, hematoxylin and eosin; original magnification,  $\times 400$ )

stools, intussusception, and hematuria followed by a typical exanthema and convulsion. She died 3 months later and postmortem examination showed scattered cortical hemorrhages associated with cerebral necrotizing arteriolitis. Levitt and Burbank [48] described the clinicopathologic findings in two previously nonallergic patients with recurrent fatal attacks of HSP after injection of penicillin and ingestion of strawberries respectively that included glomerulonephritis alone or with systemic arteriolitis. The finding of IgA deposits in cutaneous blood vessel walls and in glomerular mesangial biopsies of patients with HSP and IgA nephropathy (IgAN) [49, 50] was circumstantially convincing enough to substitute the term IgAV for HSP.

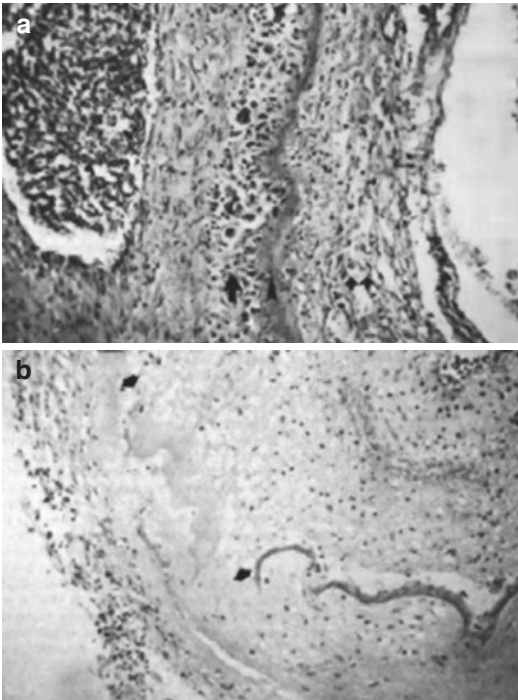
Wintrobe and Buell [51] described cryoglobulinemia in a patient with progressive frontal headache, facial pain, Raynaud symptoms, recurrent nosebleeds, exertional dyspnea, palpitation, and changes in the eye grounds due to central vein thromboses. Postmortem examination showed infiltrating myeloma of the humerus and lumbar vertebra and splenic enlargement. A unique plasma protein was detected that spontaneously precipitated with cold temperature and solubilized at high temperature differed from Bence-Jones proteinuria of other myeloma patients. Lerner and Watson [52] noted the

association with purpura, and later, Lerner and Watson [53] described its occurrence in 10% of pathological sera. Gorevic and colleagues [54] described mixed CV in forty patients, the clinical features of which included palpable purpura in all patients, polyarthralgia in three-quarters, and kidney involvement in slightly more than one-half, and deposits of IgG, IgM, and complement, or renal arteritis in a third of patients.

Recurrent attacks of erythematous, urticarial, and hemorrhagic skin lesions that last 24 h at a time, associated with recurrent attacks of fever, joint swelling, abdominal distress, and depressed serum complement indicative of HUV, were described by McDuffie and colleagues in 1973 [55]. Small amounts of cryoglobulin were present at one time or another in the serum of each patient. When tested by immunodiffusion against purified preparations of rheumatoid factor (RF) and human C1q, two patients consistently produced bands against the former, and two others reacted strongly with purified C1q. Skin biopsies showed leukocytoclasia characteristic of necrotizing vasculitis in one patient; anaphylactoid purpura in two others; and mild nonspecific perivascular infiltration in another. Immunofluorescence of skin specimens performed in three patients showed fixation of Ig in the patient with necrotizing vasculitis, while in two others with a pathologic picture of anaphylactoid purpura or nonspecific dermal infiltrate, and immunofluorescence was negative. Renal biopsy in two patients showed mild to moderate glomerulonephritis indistinguishable for those seen in other forms of chronic membranoproliferative glomerulonephritis. The differences from SLE included more urticarial and purpuric skin lesions, with relatively mild renal or absent and other visceral involvement in the patients with HUV, that was atypical for SLE. Moreover, serum speckled antinuclear and anti-DNA antibodies, and basement membrane Ig deposits were absent in those with HUV, also atypical for SLE. An etiopathogenesis related to chronic vascular inflammation resulting from deposits of immune complexes in small vessel walls seemed likely. Zeiss and colleagues [56] characterized C1q IgG precipitins from HUV sera that precipitated C1q in agarose gel among four additional patients. Wisnieski and

Naff [57] showed C1q-binding activity in IgG from HUV sera, which suggested a relation to LE, but that view was later amended.

*The historical account of the category of LVV spanned more than a century with notable advances in the past several years.* Hutchinson provided the first clinical description of temporal arteritis [58], followed by a pathologic description by Horton [59] more than 50 years after the description and designation of polymyalgia rheumatic (PMR) by Bruce [60] and Barber [61]. Temporal arteritis was named for the site of granulomatous giant cell inflammation and vessel involvement [62]. Those with biopsy-proven temporal arteritis and associated blindness due to vasculitic involvement of ophthalmic and posterior ciliary vessels were classified as cranial arteritis [63]. The occasional finding of giant cell lesions along the aorta, its branches, and in other medium- and large-sized arteries at autopsy in other patients warranted the additional diagnosis of generalized GCA [64]. The pathologic heterogeneity of temporal arteritis was further demonstrated by the finding of intracranial lesions in eight patients who also qualified for the diagnosis of granulomatous angiitis of the nervous system (GANS) [65–70]. PNS involvement in GCA was exceedingly uncommon [71]. The earliest lesions of GCA consisted of vacuolization of smooth muscle cells of the media, with enlargement of mitochondria, infiltration of lymphocytes, plasma cells, and histiocytes. With progression, there was extension of inflammation into the intima and adventitia leading to segmental fragmentation and necrosis of the elastic lamina, granuloma formation, and proliferation of connective tissue along the vessel wall. This eventuated in vascular thrombosis, intimal proliferation, and fibrosis (Fig. 14.4). One other LVV was described in the Japanese literature as unusual changes of the central vessels of the retina in the absence of peripheral arterial pulses in a woman [72]. This pulseless disease [73] and occlusive thromboangiopathy [74] or TAK disease [75], manifested constitutional complaints of malaise, fever, stiffness of the shoulders, nausea, vomiting, night sweats, anorexia, weight loss, and irregularity of menstrual periods weeks to months before the



**Fig. 14.4** Temporal arteritis. (a) In an early lesion of a large muscular artery, necrosis, inflammation, and giant cell formation (single arrow) can be seen immediately adjacent to the internal elastic lamina (arrowhead), which is undergoing degenerative changes, and there is some intimal proliferation (double arrows) (stain, hematoxylin and eosin; original magnification,  $\times 100$ ). (b) This more advanced lesion has complete segmental destruction of the internal elastic lamina and virtually the entire media (arrows). Marked intimal proliferation has nearly occluded the lumen, and few inflammatory cells remain (stain, hematoxylin and eosin; original magnification,  $\times 50$ )

local signs of vasculitis were recognized in up to two-thirds of patients. It is the commonest large vessel vasculitis among Asian women.

One other form of inflammatory aortic disease, aortitis, surfaced in the surgical literature with equally broad and far-reaching implications for concepts of autoimmunity. In 1972, Walker and colleagues [76] noted that 10% of 217 patients presenting with abdominal aneurysms at Manchester Royal Infirmary between 1958 and 1969 for resection showed excessive thickening of aneurysm walls and perianeurysmal adhesions at operation. Subsequent histologic examination of the walls of the aneurysms showed extensive active chronic inflammatory changes including plasma cell infiltration. The clinical features of

patients with inflammatory aneurysms differed from those with atherosclerotic disease due to generally younger age by a decade, lower incidence of rupture, lack of claudication of intermittent the limbs and presence of peripheral pulses, less likelihood of unusual presenting features, elevated ESR, and lack of calcification on preoperative abdominal radiographs. In 1985, Pennell and coworkers [77] reported inflammatory aortic or iliac aneurysms in 4.5% of 2816 patients undergoing repair for abdominal aortic aneurysm from 1955 to 1985. Ultrasound and CT imaging suggested the diagnosis respectively in 13.5% and 50% of patients, the former showing a sonolucent halo with clear definition of the aortic wall posterior to the thickened anterior and lateral aortic walls. In 2000, Rojo-Leyva and colleagues [78] noted idiopathic aortitis in 43% of 1204 aortic specimens gathered over a period of 20 years. In 96% of the patients with idiopathic aortitis, aneurysm formation and aortitis were present only in the thoracic aorta. In 2001, Hamano and colleagues [79] noted high concentrations of IgG4 associated with sclerosing pancreatitis characterized by obstructive jaundice, infrequent attacks of abdominal pain, irregular narrowing of the pancreatic duct, sonolucent swelling of the parenchyma, lymphoplasmacytic infiltration, fibrosis, and a favorable response to corticosteroid treatment. One year later, Hamano and coworkers [80] noted the association of sclerosing pancreatitis with raised concentrations of IgG4 among those with concomitant hydronephrosis that caused ureteral masses, later diagnosed as retroperitoneal fibrosis (RPF). Histologic examination of ureteral and pancreatic tissues revealed abundant tissue infiltration by IgG4-bearing plasma cells. In the same year, 2008, three important observations were in this area. First, Sakata and colleagues [81] concluded that inflammatory abdominal aortic aneurysm (IAAA) was related to IgG4 sclerosing disease. Second, Kasashima and colleagues [82] concluded that IAAA was an IgG-related disease (IgG4-RD) together with RPF. Third, Ito and colleagues [83] described a patient with IAAA, hydronephrosis caused by RPF, and high levels of IgG4 I in whom treatment with corticosteroids led to clinical improvement and reduction in

IgG4 levels. Histologic inspection of the aortic wall specimen showed lymphocytoplasmacytic infiltration. Immunohistochemical analysis of the tissue showed IgG4-positive plasma cells. The findings suggested that IAAA had an etiopathogenesis similar to autoimmune pancreatitis and that some cases of IAAA and RPF may be aortic and periaortic lesions of an IgG4-RD. One year later, in 2009, Khosroshahi and colleagues [84] described thoracic aortitis due to IgG4-RD with marked elevation of the serum IgG4 levels with progression to autoimmune pancreatitis, and Stone and coworkers [85] described IgG4-related thoracic aortitis with a media-predominant pattern of aortic wall infiltration and marked elevation of serum IgG4 levels, unequivocally linking IgG4-RD with thoracic lymphoplasmacytic aortitis.

*Two forms of VVV, BD and CD, were recognized with very different clinical presentations and systemic involvement.* Adamantiades [86] recognized the disorder of relapsing aphthous ulcers of the mouth, eye, and genitalia, and the clinicopathologic details of which were described in later detail by Behçet [87, 88] in two Turkish patients. Nervous system involvement of a 28-year-old Yemenite with relapsing oral, genital, and oral eruptions over 4 years, was accompanied by severe headache, memory loss, dizziness, lethargy, fatal seizures, and coma. Postmortem examination showed perivascular inflammatory cell infiltration of the meninges, brain, and central retinal artery and optic nerve with necrotic cerebral lesions. Encephalomyelopathy was detailed at postmortem examination in two Australian patients with BD [89] who presented with hemiparesis, while the other patient presented with pseudobulbar affect, vertical gaze palsy, nystagmus, and spastic paraplegias. Postmortem examination showed widespread lesions in cortical and brainstem white matter and hypothalamus, corresponding to small blood vessels including arterioles and veins that showed perivascular mononuclear cell infiltration. The first well-documented American patient with nervous system involvement of BD was described by Wolf and coworkers [90]. The patient was a 22-year-old woman with a 5-year history of recurrent oral and genital ulceration, and a 2-year

course of progressive visual loss, headache, hemiparesis, ataxia, tremor, dysarthria, cranial nerve palsy, cerebellar and corticospinal tract disease, and mental deterioration, which responded to prednisone therapy.

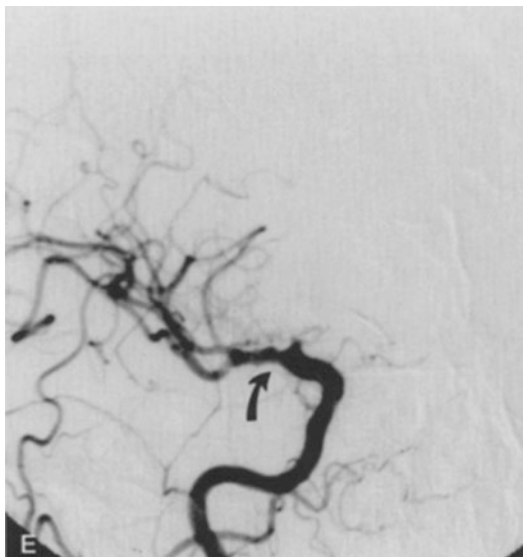
Mogan and Baumgartner [91] described a 26-year-old man with recurrent pain, spasm and redness of the left eye with photophobia, excessive tearing, and marked conjunctival injection, followed by severe attack of dizziness, tinnitus, vertigo, nausea, vomiting, ringing in the ears, profuse perspiration, and deafness. A diagnosis of recurrent interstitial keratitis and explosive Menière disease was made. In retrospect, he was probably the first reported patient with CS of nonsyphilitic interstitial keratitis (IK) [91]. Cogan [92] later described vestibuloauditory symptoms. Haynes and colleagues [93] set forth the diagnostic criteria for typical CS according to the definitions established by In a review of 30 patients seen at the National Eye Institute of the NIH by Cogan [92, 94, 95], symptoms of IK developed abruptly and gradually resolved, associated with photophobia, lacrimation, and eye pain which may be unilateral or bilateral. Such symptoms tended to recur periodically for years before becoming quiescent. Vestibuloauditory dysfunction was manifested by sudden onset of Menière-like attacks of nausea, vomiting, tinnitus, vertigo, and frequently progressive hearing loss that characteristically occurred before or after the onset of IK. However, within 1–6 months of the onset of eye symptoms, auditory symptoms progressed to deafness over a period of 1–3 months, certainly no longer than 2 years. Cody and Williams [96] provided a description of atypical CS if another significant inflammatory eye lesion in addition to, or instead of IK such as scleritis, episcleritis, retinal artery occlusion, choroiditis, retinal hemorrhage, papilledema, exophthalmos, or tendonitis. Haynes and colleagues [93] defined acute CS as the presence of acute eye disease within 2 weeks of hearing loss, while inactive CS was applied to patients without active eye disease or vestibuloauditory dysfunction of greater than 2 weeks prior to study. With less than 100 reported patients with this rare childhood and young adult disorder, the majority of reported patients with typical CS

appeared as single case reports or patient series [93, 97–100], often without pathologic confirmation [92, 94, 100, 101] or evidence of systemic vasculitis in a biopsy or at postmortem examination [95, 96, 102, 103]. In contrast to Mogan and Baumgartner [91] and Cogan [92, 94], headache and other CNS manifestations occurred. Norton and Cogan [95] described a patient with atypical acute CS in whom headache instead preceded detection of superior central retinal artery branch occlusion and orbital edema.

*The histopathologic appearance of vasculitis of the peripheral nerve is similar regardless of whether the process is primary or secondary to underlying systemic vasculitis.* Historically, detailed neurovascular anatomy historically arose from the careful dissection of amputated limbs following injection of India ink to opacify peripheral nerve vessels in World War II veterans [104, 105]. Such studies indicated that proximal stretches of each of the major nerves were supplied both by a single arterial vessel, such as in the axilla-to-elbow and knee-to-elbow segments located peripherally in the nerve trunk, and abundantly along their distal course by a succession of microvessel. Their repeated division and anastomosis outlined an unbroken vascular net that assured continuous vascular supply. As there was no evidence for the presence of watershed zones of poor vascular supply along major nerves of the arm or leg, ischemic paralysis of a limb should rarely if ever occur in the absence of widespread arteritis, abrupt occlusion of large named vessels, or focal nerve compression. A quarter-century later, Dyck and coworkers [106] ascribed ischemic centroparallel nerve fiber degeneration of named upper arm and thigh nerves in a patient with necrotizing angiopathic neuropathy to poor vascular perfusion along presumed watershed zones of the upper arm and thigh regions. However, the clinical details of the patient were not given, the centroparallel fiber loss was only pronounced in the legs, and extraneural blood vessels of the arms were not studied. Two decades later, Moore and Fauci [107] ascribed progressive weakness and sensory loss in the arms and subsequently in the legs distally from the knees in Patient 8 with extensive mononeuritis multiplex due to infarction of specific peripheral

nerves, culminating in ambulation with leg braces and good use of the hands. However, that patient was not studied pathologically. Vasculitis of the peripheral nerves leads to specific alterations in the arteriae nervorum with a caliber of 100  $\mu\text{m}$  located in the epineurial compartment, as well as in peripheral nerve fascicles ensheathed by perineurium and endoneurium. The key elements of pathologically definite nonsystemic vasculitic neuropathy, generally regarded as a form of SOV, are intramural inflammation accompanied by pathologic evidence of vascular wall damage without evidence of systemic involvement [108].

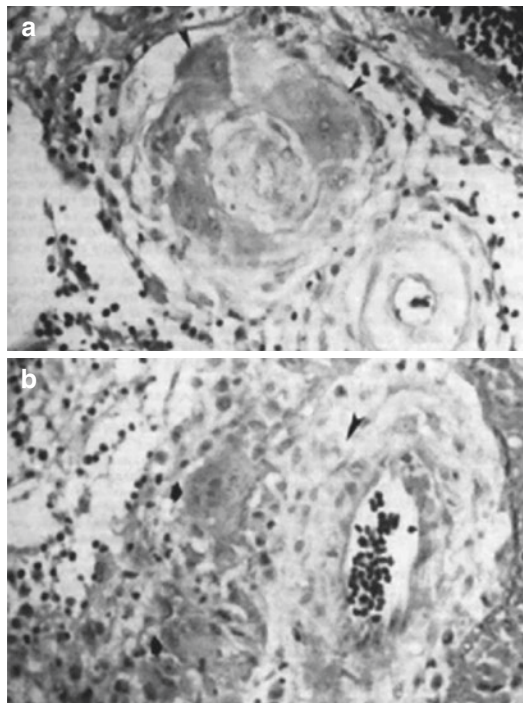
*Diverse syndromes of adult and childhood primary CNS vasculitis with very different clinical presentation, histopathology, and prognosis were described.* Primary CNS vasculitis was first described by Harbitz in 1922 [109] in one patient with worsening headaches, mental change, and ataxia culminating in stupor, spastic paraparesis, coma and death in 2 years. A second patient presented with hallucination and confusion progressing to gait difficulty, stupor, coma, and death in 9 months. At postmortem examination, both had granulomatous vasculitis of the meninges comprised of lymphocytes, multinucleate giant cells, and epithelioid cells with vessel necrosis and extension into the brain along involved veins and arteries of varying caliber. Over the ensuing quarter-century, additional patients were reported under the rubric of allergic angiitis and granulomatosis [110], giant cell arteritis [111], and sarcoidosis [112]. Cravioto and Fegin [113] delineated the clinicopathologic syndrome of noninfectious granulomatous angiitis, and for two more decades, rare affected patients were identified in life, but there was no effective treatment. Hinck and coworkers [114] in GCA and later by Cupps and Fauci [115] in other patients with first noted the identification of angiographic beading and a sausage-like appearance of cerebral vessels at sites of presumed arteritis (Fig. 14.5) so-called, isolated angiitis of the CNS (IACNS). The angiographic features of presumed vasculitis along with the judged efficacy of a combination immunosuppressive regimen of oral cyclophosphamide and alternate-day prednisone, including three patients with IACNS defined angiographically, and another with biopsy-



**Fig. 14.5** Radiographic features of cerebral vasculitis. Ectasia and beading in the M1 segment and lack of flow in the A1 segment of the right anterior cerebral artery (arrow)

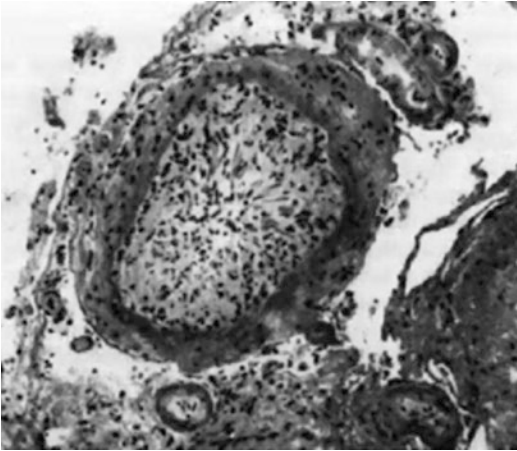
proven GANS of the filum terminale, led to prospective diagnostic and therapeutic recommendations [116]. At that time, investigators at the NIH regarded IACNS and GANS as equivalent entities with the former term emphasizing the restricted nature of the vasculitis and the latter the granulomatous histology. Giant cells and epithelioid cells, usually found at autopsy in GANS (Fig. 14.6), were an inconsistent finding in a meningeal and brain biopsy, and therefore considered unnecessary for antemortem diagnosis. In the same year of 1988, Calabrese and Mallek [117] proposed criteria for the diagnosis of PACNS, while Younger and colleagues [118] contemporaneously described the limits of granulomatous angiitis of the brain (GAB) and nervous system (GANS) [119]. The past quarter-century has witnessed an expansion in the present understanding of primary CNS vasculitis in children and adults.

*Vasculitis due to drug abuse captured the interest of successive generations of investigators.* The earliest reports of misuse of amphetamine sulfate occurred in 1937 when students used it to avoid sleep during examination periods [120]. This was followed by reports of death by those who ingested the drug repeatedly as a stim-



**Fig. 14.6** Central nervous system vasculitis. (a) The media and adventitia of this small leptomeningeal artery have been almost completely replaced by multinucleated giant cells (arrowheads). There is intimal proliferation with obliteration of the vascular lumen, and a dense, perivascular, mononuclear inflammatory infiltrate can be seen (stain, hematoxylin and eosin; original magnification,  $\times 250$ ). (b) A somewhat larger leptomeningeal vessel shows necrosis of the media and internal elastic lamina with multinucleated giant cell formation (arrows), intimal proliferation (arrowhead), and lymphocytic infiltration of the adventitia and neighboring meninges (stain, hematoxylin and eosin; original magnification,  $\times 250$ )

ulant for the same purpose [121], in a suicide attempt that resulted in a fatal intracerebral hemorrhage [122], or accidentally, when dexamphetamine and phenelzine were fatally ingested together decades later [123]. During the Second World War, amphetamine and methamphetamine were used clinically and illicitly, but their abuse soared in San Francisco after 1962 wherein it was illegally produced and distributed [124]. By 2009, the United Nations Office on Drugs and Crime estimated that 16–51 million persons between the age of 15 and 64 years consumed amphetamine drugs, with more than half using methamphetamine [125], exceeding the combined consumption of all other drugs of abuse



**Fig. 14.7** Cerebral vasculopathy in a case of intracerebral hemorrhage associated with the use of phenylpropanolamine as an aid to weight loss. The profound intimal hyperplasia all but obliterates the vascular lumen. Polymorphonuclear leukocytes are in all three vascular layers but particularly the intima. The media are remarkably well preserved compared with cases of polyarteritis nodosa and leukocytoclastic vasculitis (stain, hematoxylin and eosin; original magnification,  $\times 100$ )

except cannabis [126]. Such drug agents comprise a large spectrum of agents available in powder, capsule, tablet, and injectable fluid form that can be swallowed, snorted or taken intranasally, smoked or injected with highly variable purity and dosage equivalence. Histologically confirmed cerebral vasculitis (Fig. 14.7) due to amphetamine, methamphetamine, and related agents is exceedingly rare which is surprising given the number of substances that could cause this disorder if there was a true association.

*Perhaps, the most interesting recent development in vasculitides has been the recognition of rare encephalopathies and autoimmune encephalitides with a possible relation to CNS inflammation [127–129].* For almost half a century, neurologists have been pursuing the rare encephalopathy associated with Hashimoto thyroiditis with recent recognition of its association with autoimmune encephalitis and CNS vasculitis. In 1966, the British neurologist, Lord Brain and colleagues [130] described the entity of Hashimoto encephalopathy in a 40-year-old man with 12 ictal and stroke-like episodes of confusion and agitation 1 year after onset of treated hypothy-

roidism. The cerebral disorder remitted completely after 19 months commensurate with a decline in high serum thyroid-antibody levels. Treatment with prednisone and an anticoagulant for 3 months was ineffective. His neurologic symptoms remitted while he was taking only levothyroxine. The authors concluded that the likeliest explanation for this protracted and stuttering brain disorder was localized cerebral edema due to antibody-mediated autoimmunity. Jellinek and Ball [131] extended the results of Brain and colleagues [130], describing the original patient, who at age 62, died 12 years later of an unrelated cause. Postmortem examination showed virtually no remaining thyroid tissue and atheromatous cerebrovascular changes with splenic atrophy. The authors postulated that underlying autoimmunity was the cause of Hashimoto thyroiditis and encephalopathy, and splenic atrophy. In 2003, Rowland and colleagues [132] characterized the clinicopathologic findings of literature cases of Hashimoto encephalopathy beginning with the patient described by Lord Brain and coworkers [130] through 2002, and adding their own patient. The diagnosis of Hashimoto encephalopathy, as described by Rowland and coworkers [132] rested on the presence of thyroiditis with measurably high titers of thyroid peroxidase (TPO) or thyroglobulin (Tg) antibodies, clinical encephalopathy (clouding of consciousness with reduced wakefulness, attention, or cognitive function), and absence of cerebrospinal fluid (CSF) evidence of bacterial or viral infection. These criteria remain the standard for case selection; however, then as now, it is unknown whether antithyroid antibodies and concomitant thyroid dysfunction contribute to the pathogenesis of Hashimoto encephalopathy. Ochi and colleagues [133] provided a link between Hashimoto thyroiditis autoimmunity and the CNS. They developed a human brain proteome map using two-dimensional electrophoresis and applied it to the immunoscreening of brain proteins that reacted with serum antithyroid antibodies in Hashimoto's encephalopathy patients, identifying the novel antigen,  $\alpha$ -enolase, encoded on 1p36.23, as a candidate and marker for Hashimoto encephalopathy-related pathology

and corticosteroid sensitivity. Kishitani and coworkers [134] extended the findings of Ochi and colleagues [133] noting anti-NH<sub>2</sub>-terminal of  $\alpha$ -enolase antibodies in 24% of Hashimoto encephalopathy patient sera and limbic abnormalities on magnetic resonance imaging (MRI) demonstrating abnormal signal in unilateral or bilateral medial temporal lobes, and diffuse slow wave activity with epileptogenic discharges. These findings suggested that limbic encephalitis associated with anti-NH<sub>2</sub>-terminal of  $\alpha$ -enolase antibodies could be a possible manifestation of Hashimoto encephalopathy in some cases. Vasculitic pathogenesis also appeared to be likely in some cases of Hashimoto encephalopathy based upon the tendency for increased autoimmunity in Hashimoto thyroiditis. In addition, the available histopathology in Hashimoto encephalopathy also supports an inflammatory vasculopathy, so noted in one postmortem case that showed lymphocytic infiltration of brainstem veins [135]; and in brain biopsy tissue from another case, categorized as isolated angiitis due to lymphocytic infiltration of the walls of arterioles and veins [136]. Brain biopsy tissue of second living patient showed perivascular cuffs of lymphocytic cells [132]. It is noteworthy that patients with Hashimoto encephalopathy and circulating  $\alpha$ -enolase antibodies are at risk for heightened autoimmune activity, and a tendency for systemic and invasive autoimmune disorders including systemic vasculitis [137, 138]. Moreover, like Hashimoto encephalopathy, autoimmune encephalitis is a severe inflammatory disorder of the brain with diverse causes and a complex differential diagnosis including central nervous system vasculitis. Recent advances in the past decade have led to the identification of new syndromes and biologic markers of limbic encephalitis, the commonest presentation of autoimmune encephalitis. Autoimmune encephalitis is associated with serum and intrathecal antibodies to intracellular and surface neuronal antigens against constituents of the limbic system neuropil. This has led to a reconsideration of a number of neuropsychiatric and neurocognitive disorders as having shared mechanisms of origin. The successful use of serum and intrathecal anti-

bodies to diagnose affected patients, and their subsequent improvement with effective treatment has resulted in relatively few biopsy and post-mortem examinations. However, in those available, there are variable infiltrating inflammatory T cells with cytotoxic granules in close apposition to neurons, analogous to CNS vasculitis.

---

## Clinical Presentation and Laboratory Evaluation

The clinical presentation of a patient with vasculitis of the nervous system depends on three factors: distribution of the involved neural vessels, spectrum of extraneurologic organ involvement, and severity and rate of progression of the underlying vasculitic process. Patients with systemic vasculitis will have other involved tissues besides peripheral nerve, brain and spinal cord, including the skin, joints, kidneys, lungs, and gastrointestinal tract, although the dysfunction may be extremely mild or subclinical and detectable only after extensive laboratory evaluation. Constitutional symptoms such as fever, weight loss, anorexia, myalgia, arthralgia, and nonspecific fatigue and weakness occur in about 80% of patients, but careful general examination and laboratory investigation is mandatory to look for systemic abnormalities that may suggest a more generalized process. Two exceptions are patients with isolated PNV and primary CNS vasculitis in which systemic organ involvement by definition is lacking. Since the ischemic process in PNS vasculitis does not have a predilection for motor or sensory fibers, both modalities are nearly always affected. Most patients complain of deep aching discomfort in the affected limb that later evolves into burning dysesthetic pain. There may be restricted involvement such as unilateral foot drop or intrinsic hand muscle weakness due to single nerve involvement. However, multifocal nerve involvement is more typical at the outset, with up to one-half of patients presenting with mononeuropathy multiplex and a quarter to a third of patients demonstrating overlapping bilateral involvement resulting in distal symmetrical and asymmetrical polyneuropathy



due to extensive confluent ischemic involvement at many levels of multiple nerve trunks [139]. The clinical manifestations of primary CNS vasculitis range from minor to severe life-threatening signs of ischemia, although specific symptoms and signs depend upon the associated underlying mechanism. Affected adult and children present with headache, cognitive impairment, mood impairment, seizures, and focal deficits. It generally evolves in a stepwise or insidious fashion with progressive deficits culminating in quadriplegia, lethargy, coma, and death due to additional ischemic lesions.

The clinical manifestations of primary and secondary CNS vasculitis range from minor to severe life-threatening signs of ischemia, although specific symptoms and signs depend upon the associated underlying mechanism.

There is general agreement on four principles in the diagnosis of vasculitis, especially applicable to the nervous system:

First, vasculitis is a potentially serious disorder with a propensity for permanent disability owing to tissue ischemia and infarction; recognition of the neurologic manifestations is important in developing a differential etiologic diagnosis.

Second, undiagnosed and untreated, the outcome of vasculitis is potentially fatal.

Third, a favorable response to an empiric course of immunosuppressive and immunomodulating therapy should never be considered a substitute for the absolute proof of the diagnosis of vasculitis.

Fourth, histopathologic confirmation of vasculitis is essential for accurate diagnosis, such as by brain and meninges where there is CNS involvement, and analysis of nerve and muscle biopsy tissue when PNS involvement is postulated.

Serologically specific studies should be obtained in all patients guided by the clinical presentation and postulated etiologic diagnosis to avoid excessive cost and spurious results.

Electrodiagnostic studies are useful in the initial investigation of systemic vasculitis because they can identify areas of asymptomatic involvement and sites for muscle and nerve biopsy and distinguish the various neuropathic syndromes

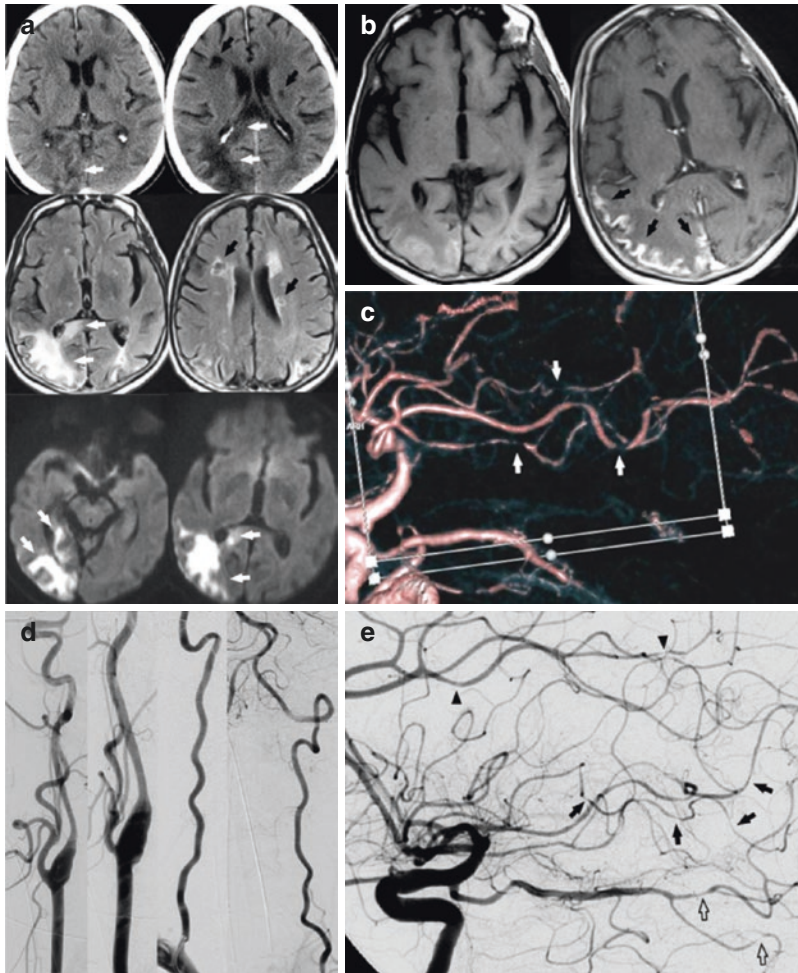
associated with peripheral nerve and muscle involvement. A wide sampling of nerves and muscles should be examined, both distal and proximal, using standard recording and needle electrodes for the performance of nerve conduction studies (NCS) and needle electromyography (EMG), at skin temperatures of 34 °C, with comparison to normative data. Most patients with peripheral nerve vasculitis show evidence of active axonopathy acutely in a mononeuritis multiplex pattern and over time in a distal symmetric or asymmetric pattern. Quantitative motor unit potential (MUP) analysis can delineate whether proximal wasting and weakness are caused by myopathic or neurogenic disease. In clinically suspected patients, open biopsy of a cutaneous sensory nerve is indispensable in the evaluation of primary and secondary PNV. Collectively, the observed primary pathologic process is generally an axonopathy with correlative findings on light microscopy employing cryostat- and paraffin-stained hematoxylin and eosin (H&E) sections, and later by plastic embedded, 1-mm, semithin sections, and teased nerve fiber studies. Such studies show Wallerian degeneration due to nerve ischemia and vasculitis supported by the presence of myelin ovoids, myelin debris, macrophage recruitment along the course of degenerated fibers, marked fascicular depletion of myelinated and unmyelinated nerve fibers, and endoneurial fibrosis. Immunocytochemical studies including lymphocyte cell marker analysis and complement immunofluorescence identify components of the cell-mediated and humoral immune system that may be present in active or chronic vasculitis.

Cerebrospinal fluid (CSF) analysis, electroencephalography (EEG), and CNS neuroimaging studies are integral to the diagnostic evaluation of most CNS disorders including vasculitis. Properly performed lumbar puncture carries minimal risk and provides potentially useful information regarding possible underlying vasculitis as suggested by pleocytosis in excess of 5 cells/mm<sup>3</sup>, protein elevation >100 mg/dL, and evidence of intrathecal synthesis of immunoglobulin (Ig) and oligoclonal bands. Molecular genetic, immunoassay, and

direct staining techniques to exclude spirochetal, fungal, mycobacterial and viral infections, as well as cytospin examination of CSF for possible malignant cells should be performed. There are no typical EEG findings in CNS vasculitis. Magnetic resonance imaging (MRI) is more sensitive than computed tomography (CT), but both methods lack specificity in histologically confirmed cases. The most common MRI findings are multiple bilateral cortical and deep white matter signal abnormalities and enhancement of the meninges after gadolinium. High-resolution 3-Tesla (3-T) MRI, MR angiography (MRA), and CT angiography (CTA) and functional imaging of the brain provide complementary information (Fig. 14.8). The former is useful in the evaluation of medium and large vessel disease, but can miss fine vessel contours better seen on cut-film or digital subtraction angiography (DSA). The abnormal diffuse and focal perfusion patterns seen on single photon emission-CT (SPECT) do not always correlate with neurologic symptoms or distinguish vasculitic from nonvasculitic vasculopathy. Some authorities have claimed that cerebral angiography showed diagnostic features, but that assertion was later modified. Beading of vessels is found in only about a third of patients with histologically proven CNS vasculitis, as well as in CNS infection, atherosclerosis, cerebral embolism, and vasospasm of diverse cause. Multiple microaneurysms, often seen on visceral angiography in systemic vasculitis, are distinctly rare in CNS vessels. The synergy of integrating functional imaging of  $^{18}\text{F}$ -deoxy-2-[fluorine-18]fluoro-D-glucose positron emission tomography with the anatomical nature of CT ( $^{18}\text{F}$ -FDG PET/CT) offers substantial benefits in the diagnostic work-up of patients with the clinical suspicion of LVV. One important feature of  $^{18}\text{F}$ -FDG PET imaging in this regard is its ability to reveal increased metabolism and functional vascular alterations that precede, or are concomitant with the morphologic changes of frank vasculitis.

Biopsy of the brain, spinal cord, and attached meningeal tissue are the gold standard for the diagnosis of CNS vasculitis, but false-negatives

occur because of focal lesions and sampling errors. Radiographic studies that guide the biopsy site toward the areas of abnormality appear to improve its sensitivity. The risk of serious morbidity related to biopsy is less than 2.0% at most centers, which is probably less than the cumulative risk of an empiric course of long-term immunosuppressive therapy. Experts in childhood and adult CNS vasculitis disagree in the correlation between brain and leptomeningeal biopsy and other clinical or laboratory predictors. Torres and colleagues [140] identified histopathologic evidence of CNS inflammation in 9/79 (11%) adults of mean age 55 year, with suspected primary angiitis of the CNS (PACNS). The authors noted perivascular inflammation instead of vessel wall inflammation in 18% of cases, and an alternative diagnosis in 30%, including cerebral amyloid angiopathy, encephalitis, demyelination, and lymphoma. They concluded that brain biopsy was an important diagnostic tool; however, further studies were needed to establish the clinical variables associated with a positive yield. Cellucci and colleagues [141] identified three different clinical groups in children whose mean age was 8.8 years with PCNSV, noting paresis and speech deficits as the commonest presenting features in the stroke phenotype; behavior changes, cognitive dysfunction, and seizures in the encephalopathy phenotype; and ataxia, vision abnormalities, and seizures in an encephalopathy/impaired vision phenotype. Altogether, 93% of the patients with the encephalopathy phenotype showed signs of vascular inflammation in CNS biopsy specimens, compared to none of those with the stroke phenotype. Salvarani and colleagues [142] studied adults of mean age 47 years, noting granulomatous, lymphocytic, and acute necrotizing patterns of inflammation in 29 of 47 (62%) patients who underwent CNS biopsy specimens with suspected primary CNS vasculitis (PCNSV), noting the absence of a clear clinical relation among the three histologists. However, the patients with a granulomatous pattern were most often older in age and presented with altered cognition. Notwithstanding, the CNS tissue examination would certainly be warranted if there were no other explanation for the



**Fig. 14.8** (a–e) Primary angiitis of the central nervous system. (a) Noncontrast CT (top) demonstrates multifocal regions of low attenuation. Those in the right frontal subcortical white matter and left basal ganglia (black arrows) are sharply defined without mass effect and likely reflect old infarctions. Both the cortex and underlying white matter of the right occipital lobe are involved, as is the right splenium of the corpus callosum (white arrows). In these locations, the margins are more ill-defined and there is subtle mass effect characterized by sulcal and ventricular effacement, suggesting acute ischemia in the right posterior cerebral artery territory. MRI FLAIR imaging (middle) demonstrates central low and peripheral high signal intensity within the frontal and periventricular white matter lesions (black arrows) consistent with chronic encephalomalacia from old infarctions. The FLAIR hyperintense signal within the right occipital lobe is more confluent and extends to the posterior temporal lobe and splenium, involving both cortex and white matter (white arrows) and better delineates the extent of the acute infarct. DWI (bot-

tom) demonstrates restricted diffusion consistent with acute ischemia. (b) T<sub>1</sub>-weighted imaging pre- and postgadolinium demonstrates extensive leptomeningeal enhancement along the cortical surface of the posterior temporal and occipital lobes. (c) CTA demonstrates multifocal vascular narrowing within several branches of the MCA (white arrows) with intervening regions of normal appearing vasculature. At the bottom of the image, there is vascular narrowing within the posterior cerebral artery. (d and e) Angiogram reveals completely normal extracranial vasculature. The anterior cerebral (black arrowheads), middle cerebral (black arrows) and posterior cerebral artery (black outlined arrows) demonstrate mild to severe short segment stenosis. *Abbreviations:* CT computed tomography, MRI magnetic resonance imaging, FLAIR fluid attenuation inversion recovery, CTA computed tomographic angiography, DWI diffusion-weighted imaging, MCA middle cerebral artery. (Reproduced from Ref. [164], with permission of the publisher)

progressive syndrome of fever, headache, encephalopathy, and focal cerebral signs, in association with CSF pleocytosis, and protein content elevation greater than 100 mg/dL [118].

## Treatment

Physicians treating vasculitides must choose the sequence and combination of available immunosuppressant and immunomodulating therapies to induce and sustain remission and treat relapses, recognizing the possible beneficial and adverse effects. Recommended treatment options for the different categories of vasculitis are summarized in Table 14.2.

The standard of care for the treatment of vasculitides, notably AAV, has been evolving in response to several factors [143]. One factor is the steady influx of multicenter, national, and international randomized clinical trials (RCT). A second factor has been large collaborative networks such as the French (FVSG), European (EUVAS), and Italian (IVSG) Vasculitis Study Groups, and the Vasculitis Clinical Research Consortium (VCRC) that share data. A third is the influence of gene-wide association studies (GWAS) that have elucidated risk gene loci, single nucleotide polymorphism (SNP) and human HLA in disease clusters and population cohorts [38]. Such inherited and environmental factors, gene-gene interactions, epigenetic factors, and other influences upon the immunopathogenesis of vasculitides have important theoretical importance for the performance of an RCT in vasculitides subtypes, as well as the relevance of screening studies and timing of therapy. The following section deals with the specific therapeutic agents employed in vasculitides.

The usefulness of corticosteroids in the treatment of systemic vasculitis has been appreciated for over 50 years; however, there has never been a randomized controlled trial conducted to support their use. The beneficial effects of corticosteroids are attributed to a multiplicity of effects on the cell and humoral immune system, including inhibition of activated T, and B cells, antigen-presenting cells (APC), and leukocytes at sites of

**Table 14.2** Recommendations for the treatment of vasculitides

<i>Large vessel vasculitis</i> GCA, TAK: CS, AZA, RTX, infliximab, anti-TNF- $\alpha$ , anti-IL-6, tocilizumab, and MM Adjunctive therapy: ASA and AC
<i>Medium vessel vasculitis</i> PAN, KD: CS and CYC; MM
<i>Small vessel vasculitis-AAV type</i> GPA, EGPA, MPA: Induction with CS + CYC; CS + RTX; or CS + MM and maintenance RTX, AZA, or MM
<i>Small vessel vasculitis-IC type</i> CV: MM; INF-alpha and PegINF-alpha plus ribavirin or RTX in HCV-associated MC IgAV: CS and/or MM; and supportive care Hypocomplementic-C1q: Antihistamines, IVIg, PE
<i>Variable vessel vasculitis</i> Cogan syndrome: CS BD: CS, MM; colchicine or anti-TNF $\alpha$
<i>Single-organ vasculitis—isolated aortitis, PACNS</i> Isolated aortitis: CS, AZA, MM, and MTX PACNS: Induction with CS, CS + CYC followed by maintenance with AZA, MTX or MM
<i>Vasculitis associated with systemic collagen vascular disease-SLE, RAV</i> SLE: CS, MM; and AC RAV: CS, RTX, infliximab, and AZA or MTX
<i>Vasculitis associated with illicit substance abuse</i> Avoid illicit substance
<i>Vasculitis associated with infection</i> Antimicrobial agents chosen specifically to treat a given etiologic organism

AC anticoagulation, ASA aspirin, AZA azathioprine, BD Behçet disease, CS corticosteroids, CV cryoglobulinemic vasculitis, CYC cyclophosphamide, EGPA eosinophilic granulomatosis with polyangiitis, GCA giant cell arteritis, GPA granulomatosis with polyangiitis, HCV hepatitis C virus, IC immune complex, IgAV IgA vasculitis, INF interferon, IL interleukin, IVIg intravenous immune globulin, KD Kawasaki disease, MC mixed cryoglobulinemia, MM mycophenolate mofetil, MPA microscopic polyangiitis, MTX methotrexate, PACNS primary angiitis of the central nervous system, PAN polyarteritis nodosa, PE plasma exchange, RAV rheumatoid arthritis vasculitis, RTX rituximab, SLE systemic lupus erythematosus, TAK Takayasu arteritis, TNF tumor necrosis factor

inflammation, interferon (IFN)- $\gamma$ , induced main histocompatibility class (MHC) class II expression, macrophage differentiation, pathogenic cytokine expression, complement interactions, and immunomodulation of cell adhesion molecules. Patients receiving long-term corticosteroid therapy for vasculitis should be monitored closely for hypertension, fluid retention, glucose

intolerance, cataracts, myopathy, avascular necrosis, infection, gastric and duodenal ulcers, and psychosis, and followed empirically for the need of short-acting insulin coverage as needed. The American College of Rheumatology (ACR) [144] addressed two serious complications of corticosteroid therapy, osteoporosis, and bone fracture. The guidelines, which assessed fracture risk by a Fracture Risk Assessment Tool (FRAX), categorized patients into low, medium, or high-risk categories depending on the estimated 10-year risk for major osteoporotic fracture. Patients at low risk should be offered bisphosphonate, whereas those at the highest risk of a major fracture should be treated with bisphosphonate therapy and teriparatide.

The effectiveness of a daily oral regimen of 2 mg/kg/day or oral cyclophosphamide with prednisone in GPA served as a template for the treatment of virtually all types of systemic vasculitis for decades [25], and together, they remained the standard treatment for inducing remission in virtually all forms of potentially fatal systemic vasculitis until 2010 when Stone [145], and Jones [146] and coinvestigators demonstrated the superiority and safety of rituximab. Although 75–90% of patients with GPA and other AAV achieve remission with oral or intravenous cyclophosphamide, few data are available on therapeutic strategies for patients with disease refractory to this first-line therapy. Its favorable effect on vasculitis derives from the preferential T-cell lysis resulting from the inhibition of hematopoietic precursors in the bone marrow, leaving stem cells unharmed. At high doses, this inhibition favors repopulation of the marrow and thus the cellular immune system. After an intravenous dose of cyclophosphamide, the nadir of peripheral leucopenia, which corresponded with peak marrow suppression, occurred in 7–18 days. Less than 20% of labeled cyclophosphamide is excreted unchanged in the urine. The toxic side effects include hemorrhagic cystitis, bladder cancer, bone marrow suppression, and the risk of fatal infection and gonadal toxicity. Bladder toxicity may be reduced by administration of the drug in a single daily oral morning dose followed by hydration; and administration of the drug intravenously as pulse ther-

apy, adjusting the dose to renal function. Intravenous cyclophosphamide, which can be administered as pulses therapy based on body surface area, is as effective as and less toxic than oral cyclophosphamide. Premature ovarian failure occurs in 30–50% of premenopausal women following cyclophosphamide therapy that is cumulative and more pronounced with increasing age at administration. Accordingly, women with GPA so treated with daily oral cyclophosphamide for up to 6 months had significant loss of ovarian reserve as measured by the anti-Müllerian hormone level [147]. The administration of gonadotropin-releasing hormone (GRH) analog 10 days prior to an intravenous bolus of cyclophosphamide appears to preserve fertility [148]. Cryopreservation techniques to preserve ovarian tissue and stimulate oocytes can be offered to childbearing women before treatment of cyclophosphamide [149].

Rituximab is a chimeric monoclonal anti-CD20 antibody that selectively depletes B cells, but not plasma cells. The rituximab versus cyclophosphamide in ANCA-associated vasculitis (RITUXVAS) [146] demonstrated nonsuperiority of rituximab to standard intravenous cyclophosphamide for severe AAV with highly sustained remission rates in both groups. Rituximab-based therapy was not associated with reductions in early adverse events. The rituximab in ANCA-associated vasculitis (RAVE) study [145] found that rituximab was not inferior to daily cyclophosphamide treatment for induction of remission in severe AAV and possibly superior in relapsing disease.

The bioavailable agents with activity against TNF- $\alpha$ , which include etanercept and infliximab have been well studied in AAV and other systemic vasculitides. In animal models, inhibition of TNF- $\alpha$  markedly decreases the development of bactericidal granulomas during Bacille de Calmette et Guérin (BCG) infection. Moreover, CD4+ T cells from patients with GPA are associated with HLA-DR+ CD4+ T cells that exhibit an unbalanced Th1-type cytokine pattern and elevated levels of TNF- $\alpha$  [150]. Serum levels of TNF- $\alpha$  receptor correlate with disease activity and TNF- $\alpha$ -positive cells infiltrate renal lesions

[151]. Treatment with the dimeric soluble TNF receptor etanercept was not effective for the maintenance of remission in patients with GPA and durable remissions were achieved in only a minority of patients, with a high rate of treatment-related complications including the development of solid cancers in six patients in the etanercept group as compared with none in the control group [152]. A pilot study of the anti-TNF- $\alpha$  antibody infliximab [153] were well tolerated during short-term follow-up and successfully induced prompt symptomatic responses in those with systemic vasculitis not responding to conventional treatments. Seven patients with GPA, two with RV, and one with CV of mean duration of 9, 21.5, and 17 years respectively, so treated had no major side effects.

Oral methotrexate at the dose of 20–25 mg/week with prednisolone was as effective as oral cyclophosphamide 2 mg/kg/day with prednisolone that was tapered and withdrawn over 12 months in the initial treatment of early nonsevere AAV [154]. However, the methotrexate regimen was less effective for induction of remission in those with extensive disease and pulmonary involvement, and associated with more relapses than with cyclophosphamide after the termination of treatment. The high relapse rates in both treatment groups supported the practice of continuing immunosuppressive treatment beyond 12 months. The adverse effects of methotrexate in that study [154] included infection, leukopenia, hypertension, liver dysfunction, nausea, and vomiting.

The purine analog azathioprine, which metabolizes to the cytotoxic derivative 6-mercaptopurine, exerts favorable action in vasculitis by the inhibition of T-cell activation and T-cell-dependent antibody-mediated responses. Azathioprine is generally considered a safe alternative although less effective agent to prednisone and cyclophosphamide in virtually all forms of vasculitis. However, there are three drawbacks to its use. First, idiosyncratic side effects, most often gastrointestinal and flu-like, occur in approximately 10% of patients and rarely necessitate permanent withdrawal of the medication. However, pancreatitis and gastritis severe enough to warrant hospitalization can occur. Second,

bone marrow suppression occurs in nearly all patients, usually manifested by mild pancytopenia. Third, there is typically a long delay in the onset of the therapeutic effect of 3 months or more. Taking all of these factors into account, most clinicians concur with the slow advancement of the dose over weeks, commencing with 50 mg/day and achieving maintenance levels of 2–3 mg/kg/day with careful monitoring of liver and marrow function.

Mycophenolate mofetil is an inhibitor of purine synthesis. It has been traditionally employed to prevent organ transplant rejection. Initial enthusiasm for mycophenolate in refractory autoimmune disorders was tempered by recognition of its predisposition to systemic tumor formation as a rare side effect as well as the inability to demonstrate superiority over corticosteroids and other immunosuppressants. Nevertheless, most experts agree that patients with systemic vasculitides who are poor candidates for corticosteroids, cyclophosphamide, and are intolerant of azathioprine may be given effective, safe, and long-term treatment with mycophenolate [155, 156]. While azathioprine and methotrexate appeared to be equally effective in maintaining remission in GPA [157], mycophenolate mofetil was less effective than azathioprine [158], it can be used as an alternative to cyclophosphamide, azathioprine and methotrexate in patients AAV with renal impairment where it carries less risk [159].

Infection is an important risk of immunosuppressant therapy; therefore, every effort should be made to exclude infection prior to initiation of such therapy including prophylaxis and vaccination when appropriate. Two-thirds of patients receiving immunosuppressive medications were asymptomatic at the time of HBV reactivation [160]. The latter is preventable with preemptive antiviral therapy in appropriately selected patients, particularly those with HBs and core antigenemia, or present HBV DNA. Patients with suspected TB exposure should be screened with a tuberculin skin test and interferon-gamma release assay (IGRA) prior to initiation of corticosteroids and immunosuppressive therapy [161]. Corticosteroids and cyclophosphamide with prolonged lymphopenia are known risk

factors for *Pneumocystis pneumonia*. Unlike HIV, there are no guidelines for prophylaxis in vasculitides although trimethoprim-sulfamethoxazole (TMP-SMZ) should be considered for all AAV patients receiving cyclophosphamide with dose adjustment for renal function. The Centers for Disease Control and Prevention (CDC) Vaccination should be considered for immunosuppressed patients with a minimum interval between vaccination and initiation of immunosuppressive therapy of 2 weeks. The live varicella, measles/mumps/rubella, yellow fever, typhoid fever, polio, and intranasal attenuated influenza, should be avoided in patients receiving greater than 20 mg/day of prednisone or other immunosuppressive medications. All patients should be offered inactive influenza vaccination annually. The pneumococcal polysaccharide vaccination should be administered to all eligible adults.

High dose IVIg therapy is the most widely employed immunomodulating agent for autoimmune neurologic disorders [162]. It is an alternative therapy for CNS and PNS vasculitis and diverse connective tissue disorders. Among 22 patients with relapsing AAV including 19 with GPA and 3 MPA, IVIg was administered at the dose of 0.5 g/kg/day for 4 days as additional therapy monthly for 6 months in conjunction with corticosteroids and immunosuppressants (21 patients) [163]. IVIg induced complete remissions of relapsed AAV in 13 of 22 patients at 9 months. The immunomodulating and anti-inflammatory actions of IVIg are provided by monthly doses of 2000 mg/kg/body weight given 400–500 mg/kg/day respectively over 4–5 days each month at a slow drip with acetaminophen and diphenhydramine pretreatment to prevent the commonest side effects including headache, fever, chills, rash, erythema, flushing, nausea, myalgia, arthralgia, abdominal cramps, and chest and back pain. True anaphylactic reactions to IVIg can occur in recipients with documented prior allergies to immune globulins or antibodies, especially IgA type. Transient reversible renal insufficiency occurs in individuals with preexisting renal disease. Susceptible individuals can be identified by less than normal expected 24-h

creatinine clearance rates for age and abnormal vascular perfusion on radionuclide scans. Aseptic meningitis rarely occurs several hours after treatment and resolves over several days with discontinuation of therapy.

## References

- Jennette JC, Falk RJ, Andrasay K, et al. Nomenclature of systemic vasculitides. Proposal of an international conference. *Arthritis Rheum.* 1994;37:187–92.
- Jennette JC, Falk RJ, Bacon PA, et al. 2012 Revised International Chapel Hill Consensus Conference nomenclature of vasculitides. *Arthritis Rheum.* 2013;65:1–11.
- Yildiz C, Ozen S. The specificities of pediatric vasculitis classification. *Presse Med.* 2013;42:546–50.
- Ozen S, Ruperto N, Dillon MJ, et al. EULAR/PRES endorsed consensus criteria for the classification of childhood vasculitides. *Ann Rheum Dis.* 2006;65:936–41.
- Ruperto N, Ozen S, Pistorio A, et al. EULAR/PINTO/PRES criteria for Henoch-Schönlein purpura, childhood polyarteritis nodosa, childhood Wegener granulomatosis and childhood Takayasu arteritis: Ankara 2008. Part I: Overall methodology and clinical characterization. *Ann Rheum Dis.* 2010;69:790–7.
- Ozen S, Pistorio A, Iusan SM, et al. EULAR/PRINTO/PRES criteria for Henoch-Schönlein purpura, childhood polyarteritis nodosa, childhood Wegener granulomatosis and childhood Takayasu arteritis. Ankara 2008. Part II: Final classification. *Ann Rheum Dis.* 2010;69:798–806.
- Longcope WT. Periarteritis nodosa with report of a case with autopsy. *Bull Auyer Clin Lab Pennsylvania Hosp.* 1908;1.
- Kernohan JW, Woltman HW. Periarteritis nodosa: a clinicopathologic study with special reference to the nervous system. *Arch Neurol.* 1938;39: 655–86.
- Krahulik L, Rosenthal M, Loughlin EH. Periarteritis nodosa (necrotizing panarteritis) in childhood with meningeal involvement. Report of a case with study of pathologic findings. *Am J Med Sci.* 1935;190:308–17.
- Younger DS. Diabetic neuropathy: a clinical and neuropathological study of 107 patients. *Neurol Res Int.* 2010;2010:140379.
- Kawasaki T. MLNS showing particular skin desquamation from the finger and toe in infants. *Allergy.* 1967;16:178–89.
- Tanaka N, Naoe S, Kawasaki T. Pathological study on autopsy cases of mucocutaneous lymph node syndrome. *J Jpn Red Cross Cent Hosp.* 1971;2:85–94.

13. Chamberlain JL, Perry LW. Infantile periarteritis nodosa with coronary and brachial aneurysms: a case diagnosed during life. *J Pediatr.* 1971;78:1039–40.
14. Landing BH, Larson EJ. Are infantile periarteritis nodosa with coronary artery involvement and fatal mucocutaneous lymph node syndrome the same? Comparison of 20 patients from North America with patients from Hawaii and Japan. *Pediatrics.* 1977;59:651–2.
15. Wohlwill F. Über die mur mikroskopisch erkenbare form der periarteritis nodosa. *Arch Pathol Anat.* 1923;246:377–411.
16. Davson J, Ball M, Platt R. The kidney in periarteritis nodosa. *QJM.* 1948;17:175–202.
17. Wainwright J, Davson J. The renal appearance in the microscopic form of periarteritis nodosa. *J Pathol Bacteriol.* 1950;62:189–96.
18. Lamb AR. Periarteritis nodosa—a clinical and pathological review of the disease with a report of two cases. *Arch Intern Med.* 1914;14:481–516.
19. Churg J, Strauss L. Allergic granulomatosis, allergic angiitis, and periarteritis nodosa. *Am J Pathol.* 1951;27:277–301.
20. Chumbley LC, Harrison EG, DeRemee RA. Allergic granulomatosis and angiitis (Churg-Strauss syndrome). Report and analysis of 30 cases. *Mayo Clin Proc.* 1977;52:477–84.
21. Lanham JG, Elkon KB, Pussey CD, et al. Systemic vasculitis with asthma and eosinophilia: a clinical approach to the Churg-Strauss syndrome. *Medicine.* 1984;63:65–81.
22. Masi AT, Hunder GG, Lie JT, et al. The American College of Rheumatology 1990 criteria for the classification of Churg-Strauss syndrome (allergic granulomatosis and angiitis). *Arthritis Rheum.* 1990;33:1094–100.
23. Godman GC, Churg J. Wegener's granulomatosis: pathology and review of the literature. *Arch Pathol.* 1954;58:533–53.
24. Drachman DA. Neurological complications of Wegener's granulomatosis. *Arch Neurol.* 1963;8:45–55.
25. Fauci AS, Haynes BF, Katz P, et al. Wegener's granulomatosis: prospective clinical and therapeutic experience with 85 patients over 21 years. *Ann Intern Med.* 1983;98:76–85.
26. Hoffman GS, Kerr GS, Leavitt RY, et al. Wegener granulomatosis: an analysis of 158 patients. *Ann Intern Med.* 1992;116:488–98.
27. Godman GC, Churg J. Wegener's granulomatosis: pathology and review of the literature. *Arch Pathol Lab Med.* 1954;58:533–53.
28. Guillemin L, Visser H, Noel LH, et al. Antineutrophil cytoplasm antibodies in systemic polyarteritis nodosa with and without hepatitis B virus infection and Churg-Strauss syndrome – 62 patients. *J Rheumatol.* 1993;20:1345–9.
29. van der Woude FJ, Rasmussen N, Lobatto S, et al. Autoantibodies against neutrophils and monocytes: tool for diagnosis and marker of disease activity in Wegener's granulomatosis. *Lancet.* 1985;1:425–9.
30. Falk RJ, Jennette JC. Anti-neutrophil cytoplasmic autoantibodies with specificity for myeloperoxidase in patients with systemic vasculitis and idiopathic necrotizing and crescentic glomerulonephritis. *N Engl J Med.* 1988;318:1651–7.
31. Goldschmeding R, Cohen Tervaert JW, van der Schoot CE, et al. Autoantibodies against myeloid lysosomal enzymes: a novel class of autoantibodies associated with vasculitic syndrome [Abstract]. *Kidney Int.* 1988;34:558–9.
32. Gadola SD, Gross WL. The renaissance of granulomatous inflammation in AAV. *Nat Rev Rheumatol.* 2012;8:74–6.
33. Griffith ME, Coulthart A, Pemberton S, et al. Antineutrophil cytoplasmic antibodies (ANCA) from patients with systemic vasculitis recognize restricted epitopes of proteinase-3 involving the catalytic site. *Clin Exp Immunol.* 2001;123:170–7.
34. Lionaki S, Blyth ER, Hogan SL, et al. Classification of anti-neutrophil cytoplasmic autoantibody vasculitides: the role of anti-neutrophil cytoplasmic autoantibody specificity for myeloperoxidase or proteinase 3 in disease recognition and prognosis. *Arthritis Rheum.* 2012;64:3452–62.
35. Savage CO, Gaskin G, Pusey CD, et al. Myeloperoxidase binds to vascular endothelial cells, is recognized by ANCA and can enhance complement dependent cytotoxicity. *Adv Exp Med Biol.* 1993;336:121–3.
36. Jennette JC, Falk RJ. Pathogenesis of ANCA-associated vasculitis: observations, theories, and speculations. *Presse Med.* 2013;42:493–8.
37. Free ME, Ciavatta DJ, Falk RJ. How antigens influence the disease: an immunologist point of view. *Presse Med.* 2013;42:577–9.
38. Lyons PA, Rayner TF, Trivedi S, et al. Genetically distinct subsets within ANCA-associated vasculitis. *N Engl J Med.* 2012;367:214–23.
39. Savige J, Gillis D, Benson E, et al. International consensus statement on testing and reporting of anti-neutrophil cytoplasmic antibodies (ANCA). *Am J Clin Pathol.* 1999;111:507–13.
40. Csernok E, Holle J, Hellmich B, et al. Evaluation of capture ELISA for detection of antineutrophil cytoplasmic antibodies against proteinase-3 in Wegener's granulomatosis: first results from a multicenter study. *Rheumatology.* 2004;43:174–80.
41. Hellmich B, Csernok E, Fredenhagen G, et al. A novel high sensitivity ELISA for detection of antineutrophil cytoplasm antibodies against proteinase-3. *Clin Exp Rheumatol.* 2007;25(Suppl 44):S1–5.
42. Zeek PM, Smith CC, Weeter JC. Studies on periarteritis nodosa. III. The differentiation between the vascular lesions of periarteritis nodosa and of hypersensitivity. *Am J Pathol.* 1948;24:889–917.
43. Zeek PM. Periarteritis nodosa—a critical review. *Am J Clin Pathol.* 1952;22:777–90.



44. Zeek PM. Periarteritis nodosa and other forms of necrotizing angiitis. *N Engl J Med.* 1953;248:764–72.
45. Arthus M, Breton M. Lésions cutanées produites par les injections de sérum de cheval chez le lapin anaphylactisé par et pour ce sérum. *Compt Rend Soc Biol.* 1903;55:1478–80.
46. Osler W. The visceral lesions of purpura and allied conditions. *BMJ.* 1914;1:517–25.
47. Gairdner D. The Schönlein-Henoch syndrome (anaphylactoid purpura). *QJM.* 1948;17:95–122.
48. Levitt LM, Burbank B. Glomerulonephritis as a complication of the Schonlein-Henoch syndrome. *N Engl J Med.* 1953;248:530–6.
49. Faille-Kuyber EH, Kater L, Kooiker CJ, et al. IgA-deposits in cutaneous blood-vessel walls and mesangium in Henoch-Schonlein syndrome. *Lancet.* 1973;1:892–3.
50. Conley ME, Cooper MD, Michael AF. Selective deposition of immunoglobulin A1 in immunoglobulin A nephropathy, anaphylactoid purpura nephritis, and systemic lupus erythematosus. *J Clin Invest.* 1980;66:1432–6.
51. Wintrobe MM, Buell MV. Hyperproteinemia associated with multiple myeloma. With report of a case in which an extraordinary hyperproteinemia was associated with thrombosis of the retinal veins and symptoms suggesting Raynauds disease. *Bull Johns Hopkins Hosp.* 1933;52:156–65.
52. Lerner AB, Watson CJ. Studies of cryoglobulins. I. Unusual purpura associated with the presence of a high concentration of cryoglobulin (cold precipitable serum globulin). *Am J Med Sci.* 1947;214:410–5.
53. Lerner AB, Watson CJ. Studies of cryoglobulins. II. The spontaneous precipitation of protein from serum at 5°C in various disease states. *Am J Med Sci.* 1947;214:416–21.
54. Gorevic PD, Kassab HJ, Levo Y, et al. Mixed cryoglobulinemia: clinical aspects and long-term follow-up of 40 patients. *Am J Med.* 1980;69:287–308.
55. McDuffie FC, Sams WM, Maldonado JE, et al. Hypocomplementemia with cutaneous vasculitis and arthritis. Possible immune complex syndrome. *Mayo Clin Proc.* 1973;48:340–8.
56. Zeiss CR, Burch FX, Marder RJ, et al. A hypocomplementemic vasculitic urticarial syndrome: report of four new cases and definition of the disease. *Am J Med.* 1980;68:867–75.
57. Wisniewski JJ, Naff GB. Serum IgG antibodies to C1q in hypocomplementemic urticarial vasculitis syndrome. *Arthritis Rheum.* 1989;32:1119–27.
58. Hutchinson J. On a peculiar form of thrombotic arteritis of the aged which is sometimes productive of gangrene. *Arch Surg.* 1890;1:323–9.
59. Horton BT, Magath BT, Brown GE. Arteritis of temporal vessels: report of 7 cases. *Mayo Clin Proc.* 1937;12:548–53.
60. Bruce GM. Senile rheumatic gout. *BMJ.* 1888;2:811–3.
61. Barber HS. Myalgic syndrome with constitutional effects: polymyalgia rheumatic. *Ann Rheum Dis.* 1957;16:230–7.
62. Jennings GH. Arteritis of the temporal vessels. *Lancet.* 1938;1:424–8.
63. Bruce GM. Temporal arteritis as a cause of blindness: review of the literature and report of a case. *Trans Am Ophthalmol Soc.* 1949;47:300–16.
64. Gilmour JR. Giant-cell chronic arteritis. *J Pathol Bacteriol.* 1941;53:263–77.
65. Jellinger K. Giant cell granulomatous angiitis of the central nervous system. *J Neurol.* 1977;215:175–90.
66. Kjeldsen M, Reske-Nielsen E. Pathological changes of the central nervous system in giant cell arteritis. *Acta Ophthalmol.* 1968;46:49–56.
67. McLean C, Gonzalez M, Dowling J. Systemic giant cell arteritis and cerebellar infarction. *Stroke.* 1993;24:899–902.
68. Morrison A, Abitol M. Granulomatous arteritis with myocardial infarction. *Ann Intern Med.* 1955;42:691–700.
69. Ritama V. Temporal arteritis. *Ann Med Intern Fenn.* 1951;40:63–87.
70. Save-Soderbergh J, Malmvall B, Anderson R, et al. Giant cell arteritis as a cause of death. *JAMA.* 1986;255:493–6.
71. Nesher G, Rosenberg P, Shorer Z, et al. Involvement of the peripheral nervous system in temporal arteritis-polymyalgia rheumatic. Report of 3 cases and review of the literature. *J Rheumatol.* 1987;14:358–60.
72. Takayasu M. Case with unusual changes of the central vessels in the retina [Japanese]. *Acta Soc Ophthalmol Jpn.* 1908;12:554–5.
73. Shimizu K, Sano K. Pulseless disease [Japanese]. *Clin Surg.* 1948;3:377–42.
74. Ishikawa K. Natural history and classification of occlusive thromboaropathy (Takayasu's disease). *Circulation.* 1978;57:27–35.
75. Nakao K, Ikeda M, Kimata S-I, et al. Takayasu's arteritis: clinical report of eighty-four cases and immunologic studies of seven cases. *Circulation.* 1967;35:1141–55.
76. Walker DI, Bloor K, Williams G, et al. Inflammatory aneurysms of the abdominal aorta. *Br J Surg.* 1972;59:609–14.
77. Pennell RC, Hollier LH, Lie JT, et al. Inflammatory abdominal aortic aneurysms: a thirty year review. *J Vasc Surg.* 1985;2:859–69.
78. Rojo-Leyva F, Ratliff NB, Cosgrove DM, et al. Study of 52 patients with idiopathic aortitis from a cohort of 1,204 surgical cases. *Arthritis Rheum.* 2000;43:901–7.
79. Hamano H, Kawa S, Horiuchi A, et al. High serum IgG4 concentrations in patients with sclerosing pancreatitis. *N Engl J Med.* 2001;344:732–8.
80. Hamano H, Kawa S, Ochi Y, et al. Hydronephrosis associated with retroperitoneal fibrosis and sclerosing pancreatitis. *Lancet.* 2002;359:1403–4.
81. Sakata N, Tashiro T, Uesugi N, et al. IgG4-positive plasma cells in inflammatory abdominal aortic aneurysm: the possibility of an aortic manifestation of IgG4-related sclerosing disease. *Am J Surg Pathol.* 2008;32:553–9.

82. Kasashima S, Zen Y, Kawashima A, et al. Inflammatory abdominal aortic aneurysm: close relationship to IgG4-related periaortitis. *Am J Surg Pathol.* 2008;32:197–204.
83. Ito H, Kalzaki Y, Noda Y, et al. IgG4-related inflammatory abdominal aortic aneurysm associated with autoimmune pancreatitis. *Pathol Int.* 2008;58:421–6.
84. Khosroshahi A, Stone JR, Pratt DS, et al. Painless jaundice with serial multiorgan dysfunction. *Lancet.* 2009;373:1494.
85. Stone JH, Khosroshahi A, Hilgenberg A, et al. IgG4-related systemic disease and lymphoplasmacytic aortitis. *Arthritis Rheum.* 2009;60:3139–45.
86. Adamantiades B. Sur un cas d'iritis a hypopion recidivant. *Ann Ocul (Paris).* 1931;168:271–8.
87. Behcet H. Ueber rezidivierende, aphthöse, durch ein virus verursachte Geschwüre am Mund, am Auge und an den Genitalien. *Dermat Wchnschr.* 1937;105:1152–7.
88. Behcet H, Matteson EL. On relapsing, aphthous ulcers of the mouth, eye and genitalia caused by a virus. 1937. *Clin Exp Rheumatol.* 2010;28(Suppl 60):S2–5.
89. McMenemey WH, Lawrence BJ. Encephalomyelopathy in Behcet's disease. Report of necropsy findings in two cases. *Lancet.* 1957;2:353–8.
90. Wolf SM, Schotland DL, Phillips LL. Involvement of nervous system in Behcet's syndrome. *Arch Neurol.* 1965;12:315–25.
91. Mogan RF, Baumgartner CJ. Meniere's disease complicated by recurrent interstitial keratitis: excellent results following cervical ganglionectomy. *West J Surg.* 1934;42:628.
92. Cogan DG. Syndrome of nonsyphilitic interstitial keratitis and vestibuloauditory symptoms. *Arch Ophthalmol.* 1945;33:144–9.
93. Haynes BF, Kaiser-Kupfer MI, Mason P, et al. Cogan's syndrome: studies in thirteen patients, long-term follow-up, and a review of the literature. *Medicine.* 1980;59:426–41.
94. Cogan DG. Nonsyphilitic interstitial keratitis with vestibuloauditory symptoms. Report of four additional cases. *Arch Ophthalmol.* 1949;42:42–9.
95. Norton EWD, Cogan DG. Syndrome of nonsyphilitic interstitial keratitis and vestibuloauditory symptoms. A long-term follow-up. *Arch Ophthalmol.* 1959;61:695–7.
96. Cody DTR, Williams HL. Cogan's syndrome. *Laryngoscope.* 1960;70:447–78.
97. Bicknell JM, Holland JV. Neurologic manifestations of Cogan syndrome. *Neurology.* 1976;28:278–28.
98. Gluth MB, Baratz KH, Matteson EL, et al. Cogan syndrome: a retrospective review of 60 patients throughout a half century. *Mayo Clin Proc.* 2006;81:483–8.
99. Cody DTR, Williams HL. Cogan's syndrome. *Mayo Clin Proc.* 1962;37:372–5.
100. Pagnini I, Zannin ME, Vittadello F, et al. Clinical features and outcome of Cogan syndrome. *J Pediatr.* 2012;160:303–7.
101. Vaiopoulos G, Sfrikakis PP, Skoumas B, et al. Lack of response to corticosteroids and pulse cyclophosphamide therapy in Cogan's syndrome. *Clin Rheumatol.* 1994;13:110–2.
102. Quinn FB Jr, Falls HF. Cogan's syndrome. Case report and a review of etiologic concepts. *Trans Am Acad Ophthalmol Otolaryngol.* 1958;62:716–21.
103. Albrite JP, Resnick DM. Cogan's syndrome. Case presentations. *Arch Otolaryngol.* 1961;74:501–6.
104. Sunderland S. Blood supply of the nerves of the upper limb in man. *Arch Neurol.* 1945;53:91–115.
105. Sunderland S. Blood supply of the sciatic nerve and its popliteal divisions in man. *Arch Neurol.* 1945;53:283–9.
106. Dyck PJ, Conn DL, Okazaki H. Necrotizing angio-pathic neuropathy. Three-dimensional morphology of fiber degeneration related to sites of occluded vessels. *Mayo Clin Proc.* 1972;47:461–75.
107. Moore PM, Fauci AS. Neurologic manifestations of systemic vasculitis. A retrospective and prospective study of the clinicopathologic features and responses to therapy in 25 patients. *Am J Med.* 1981;71:517–24.
108. Collins MP, Dyck PJ, Gronseth GS, et al. Peripheral Nerve Society Guideline on the classification, diagnosis, investigation, and immunosuppressive therapy of non-systemic vasculitis neuropathy: executive summary. *J Peripher Nerv Syst.* 2010;15:176–84.
109. Harbitz F. Unknown forms of arteritis with special reference to their relation to syphilitic arteritis and periarteritis nodosa. *Am J Med Sci.* 1922;163:250–72.
110. Neuman W, Wolf A. Noninfectious granulomatous angiitis involving the central nervous system. *Trans Am Neurol Assoc.* 1952;77:114–7.
111. McCormack H, Neuberger K. Giant cell arteritis involving small meningeal and intracerebral vessels. *J Neuropathol Exp Neurol.* 1958;17:471–8.
112. Meyer J, Foley J, Campagna-Pinto D. Granulomatous angiitis of the meninges in sarcoidosis. *Arch Neurol.* 1953;69:587–600.
113. Cravioto H, Fegin I. Noninfectious granulomatous angiitis with a predilection for the nervous system. *Neurology.* 1959;9:599–607.
114. Hinck V, Carter C, Rippey C. Giant cell (cranial) arteritis. A case with angiographic abnormalities. *AJR.* 1964;92:769–75.
115. Cupps T, Fauci A. Central nervous system vasculitis. *Major Probl Intern Med.* 1981;21:123–32.
116. Cupps TR, Moore PM, Fauci AS. Isolated angiitis of the central nervous system. Prospective diagnostic and therapeutic experience. *Am J Med.* 1983;74:97–105.
117. Calabrese HL, Mallek JA. Primary angiitis of the central nervous system: report of 8 new cases, review of the literature, and proposal for diagnostic criteria. *Medicine.* 1988;67:20–39.
118. Younger DS, Hays AP, Brust JCM, et al. Granulomatous angiitis of the brain. An inflammatory reaction of diverse etiology. *Arch Neurol.* 1988;45:514–8.

119. Younger DS, Calabrese LH, Hays AP. Granulomatous angiitis of the nervous system. *Neurol Clin.* 1997;15:821–34.
120. Editorial: Benzadrine sulfate “pep pills”. *JAMA.* 1937;108:1973–4.
121. Smith L. Collapse with death following the use of amphetamine sulfate. *JAMA.* 1939;113:10221023.
122. Gericke O. Suicide by ingestion of amphetamine sulfate. *JAMA.* 1945;128:1098–9.
123. Lloyd JT, Walker DR. Death after combined dexamphetamine and phenelzine. *BMJ.* 1965;2:168–9.
124. Anglin MD, Burke C, Perrochet B, et al. History of the methamphetamine problem. *J Psychoactive Drugs.* 2000;32:137–41.
125. United Nations Office on Drugs and Crime. UNODC 2009 world drug report. Vienne, Austria: United Nations; 2009.
126. United Nations Office on Drugs and Crime. World drug report 2000. New York: United Nations; 2000.
127. Younger DS. Autoimmune encephalitides. *World J Neurosci.* 2017;7:327–61.
128. Younger DS. Hashimoto’s thyroiditis and encephalopathy. *World J Neurosci.* 2017;7:307–26.
129. Younger DS. Hashimoto encephalopathy: encephalitis or vasculopathy? *World J Neurosci.* 2018;8:108–12.
130. Brain L, Jellinek EH, Ball K. Hashimoto’s disease and encephalopathy. *Lancet.* 1966;2:512–4.
131. Jellinek EH, Ball K. Hashimoto’s disease, encephalopathy, and splenic atrophy. *Lancet.* 1976;1:1248.
132. Chong JY, Rowland LP, Utiger RD. Hashimoto encephalopathy. Syndrome or myth? *Arch Neurol.* 2003;60:164–71.
133. Ochi H, Horiuchi I, Araki N, et al. Proteomic analysis of human brain identifies  $\alpha$ -enolase as a novel autoantigen in Hashimoto’s encephalopathy. *FEBS Lett.* 2002;528:197–202.
134. Kishitani T, Matsunaga A, Masamichi I, et al. Limbic encephalitis associated with anti-NH2-terminal of  $\alpha$ -enolase antibodies. A clinical subtype of Hashimoto encephalopathy. *Medicine.* 2017;96(10):e6181.
135. Nolte KW, Unbehau A, Sieker H, et al. Hashimoto encephalopathy: a brainstem encephalitis? *Neurology.* 2000;54:769–70.
136. Shibata N, Yamamoto Y, Sunami N, et al. Isolated angiitis of the CNS associated with Hashimoto’s disease. *Rinsho Shinkeigaku.* 1992;32:191–8.
137. Li M, Li J, Li Y, et al. Serum levels of anti- $\alpha$ -enolase activity in untreated systemic lupus erythematosus patients correlates with 24-hour protein and D-dimer. *Lupus.* 2017;27(1):139–42.
138. Pancholi V. Multifunctional alpha-enolase: its role in diseases. *Cell Mol Life Sci.* 2001;58:902–20.
139. Kissel JT, Slivka AP, Warmolts JR, Mendell JR. The clinical spectrum of necrotizing angiopathy of the peripheral nervous system. *Ann Neurol.* 1985;18:251–7.
140. Torres J, Loomis C, Cucchiara B, et al. Diagnostic yield and safety of brain biopsy for suspected primary central nervous system angiitis. *Stroke.* 2016;47:2127–9.
141. Cellucci T, Tyrrell PN, Twilt M, et al. Distinct phenotype clusters in childhood inflammatory brain diseases: implications for diagnostic evaluation. *Arthritis Rheum.* 2014;66:750–6.
142. Salvarani C, Brown RD, Calamia KT, et al. Primary central nervous system vasculitis: analysis of 101 patients. *Ann Neurol.* 2007;62:442–51.
143. Hoffman GS. Vasculitis treatment: is it time to change the standard of care for ANCA-associated vasculitis? *Presse Med.* 2013;42:643–50.
144. Grossman JM, Gordon R, Ranganath VK, et al. America College of Rheumatology 2010 recommendations for the prevention and treatment of glucocorticoid-induced osteoporosis. *Arthritis Care Res.* 2010;62:1515–26.
145. Stone JR, Merkel PA, Spiera R, et al. Rituximab versus cyclophosphamide for ANCA-associated vasculitis. *N Engl J Med.* 2010;363:221–32.
146. Jones RB, Tervaert JW, Hauser T, European Vasculitis Study Group, et al. Rituximab versus cyclophosphamide in ANCA-associated renal vasculitis. *N Engl J Med.* 2010;363:211–20.
147. Clowse ME, Copland SC, Hsieh TC, et al. Ovarian reserve is diminished by oral cyclophosphamide therapy for granulomatosis with polyangiitis (Wegener’s). *Arthritis Care Res.* 2011;63:1777–81.
148. Somers EC, Marder W, Christman GM, et al. Use of a gonadotropin-releasing hormone analog for protection against premature ovarian failure during cyclophosphamide therapy in woman with severe lupus. *Arthritis Rheum.* 2005;52:2761–7.
149. Henes JC, Henes M, von Wolff M, et al. Fertility preservation in women with vasculitis: experience from the FertiPROTEKT network. *Clin Exp Rheumatol.* 2012;30(Suppl. 70):S53–6.
150. Ludviksson BR, Sneller MC, Chua KS, et al. Active Wegener’s granulomatosis is associated with HLA-DR+ CD4+ T cells exhibiting an unbalanced Th1-type cytokine pattern: reversal with IL-10. *J Immunol.* 1998;160:3602–9.
151. Noronha IL, Kruger C, Andrassy K, et al. In situ production of TNF- $\alpha$ , IL-1 beta and IL-2R in ANCA-positive glomerulonephritis. *Kidney Int.* 1993;43:682–92.
152. Wegener’s Granulomatosis Etanercept Trial (WGET) Research Group. Etanercept plus standard therapy for Wegener’s granulomatosis. *N Engl J Med.* 2005;352:351–61.
153. Bartolucci P, Ramaoelina J, Cohen P, et al. Efficacy of the anti-TNF- $\alpha$  antibody infliximab against refractory systemic vasculitides: an open pilot study on 10 patients. *Rheumatology.* 2002;41:1126–32.
154. De Groot K, Rasmussen N, Bacon PA, European Vasculitis Study Group, et al. Randomized trial of cyclophosphamide versus methotrexate for induction of remission in early systemic antineutrophil cytoplasmic antibody-associated vasculitis. *Arthritis Rheum.* 2005;52:2461–9.

155. Alba MA, Flores-Suárez LF. Seven clinical conundrums in the treatment of ANCA-associated vasculitis. *Clin Exp Rheumatol*. 2013;31(Suppl 75):S74–83.
156. Chaigne B, Gatault P, Darrouzain F, et al. Mycophenolate mofetil in patients with antineutrophil cytoplasmic antibody-associated vasculitis: a prospective pharmacokinetics and clinical study. *Clin Exp Immunol*. 2014;176:172–9.
157. Jayne D, Rasmussen N, Andrassy K, European Vasculitis Study Group, et al. A randomized trial of maintenance therapy for vasculitis associated with antineutrophil cytoplasmic autoantibodies. *N Engl J Med*. 2003;349:36–44.
158. Hiemstra TF, Walsh M, Mahr A, European Vasculitis Study Group (EUVAS), et al. Mycophenolate mofetil vs azathioprine for remission maintenance in antineutrophil cytoplasmic antibody-associated vasculitis: a randomized controlled trial. *JAMA*. 2010;304:2381–8.
159. Jayne D. Treating vasculitis with conventional immunosuppressive agents. *Cleve Clin J Med*. 2012;79(Suppl 3):S46–9.
160. Droz N, Gilardin L, Cacoub P, et al. Kinetic profiles and management of hepatitis B virus reactivation in patients with immune-mediated inflammatory diseases. *Arthritis Care Res*. 2013;65:1504–14.
161. Matulis G, Juni P, Villager PM, et al. Detection of latent tuberculosis in immunosuppressed patients with autoimmune diseases: performance of a Mycobacterium tuberculosis antigen-specific interferon  $\gamma$  assay. *Ann Rheum Dis*. 2008;67:84–90.
162. Dalakas MC. Intravenous immunoglobulin in autoimmune neuromuscular diseases. *JAMA*. 2004;291:2367–75.
163. Martinez V, Cohen P, Pagnoux C, French Vasculitis Study Group, et al. Intravenous immunoglobulin for relapses of systemic vasculitides associated with antineutrophil cytoplasmic antibodies. *Arthritis Rheum*. 2008;58:308–17.
164. Davis A, Younger DS. Neuroimaging of the vasculitides. Chapter 2. In: *The vasculitides. Nervous system vasculitis and treatment*. New York: Nova Science Publishers; 2015. p. 19–47.

---

## Part IV

# Peripheral Nervous System Disorders



# Immunologic Disorders of Neuromuscular Junction and Muscle

# 15

James M. Gilchrist and John E. Donahue

## Introduction

A range of inherited and acquired processes can adversely affect the neuromuscular junction (NMJ) and muscle, many of which are not currently amenable to medical therapy, such as the muscular dystrophies. Autoimmune disorders of NMJ and muscle provide some of the limited number of peripheral neuromuscular diseases responsive to medical therapy and thus, are essential to recognize. Immune disorders account for the most common diseases of neuromuscular transmission and are very important to understand, not least because the autoimmune nature of disease provides opportunities for effective treatment. On the other hand, inflammatory disorders of muscle are a diverse group, some of which appear to have an immunologic basis, e.g., polymyositis and dermatomyositis, and possibly, inclusion body myositis.

---

J. M. Gilchrist (✉)  
Department of Neurology, Southern Illinois  
University School of Medicine, Springfield, IL, USA  
e-mail: [jgilchrist@siu.edu](mailto:jgilchrist@siu.edu)

J. E. Donahue  
Department of Neuropathology, Rhode Island  
Hospital, Providence, RI, USA  
e-mail: [Jdonahue3@lifespan.org](mailto:Jdonahue3@lifespan.org)

## Neuromuscular Junction Anatomy

The neuromuscular junction is a synapse which transmits signals between a motor nerve terminal and a muscle fiber, the pre- and post-synaptic areas, respectively. The motor axon terminal contains active zones of arranged P/Q-type voltage-gated calcium channels (VGCC). Acetylcholine (ACh)-filled synaptic vesicles collect at these active zones. The primary synaptic cleft, which divides the pre- and post-synaptic areas, is comprised of a basal lamina that contains acetylcholinesterase, which catabolizes acetylcholine as it diffuses across the primary synaptic cleft. The post-synaptic membrane is comprised of junctional folds containing nicotinic-acetylcholine receptors (AChR) with ligand-gated cation channels. At the base of the folds are voltage-gated sodium channels (VGSC). The adult AChR is a tetramer containing two  $\alpha$  subunits, and one each of  $\beta$ ,  $\delta$ , and  $\epsilon$  subunits. Fetal AChR contain a  $\gamma$  subunit in place of the  $\epsilon$  subunit. Each  $\alpha$  subunit contains a ligand site for ACh as well as a main immunogenic region (MIR). ACh must bind to both ligand sites to activate the receptor channel [1].

When an action potential reaches the motor nerve terminal, VGCC are activated allowing influx of calcium into the nerve terminal. The influx of calcium triggers exocytosis of the ACh-synaptic vesicles and ACh is released into the primary synaptic cleft. ACh passively diffuses

across the synaptic cleft to bind to post-synaptic AChR. Once activated, AChR undergo a conformational change allowing the influx of sodium and efflux of potassium, causing a small depolarization in the adjacent muscle membrane. A miniature endplate potential (MEPP) is the potential generated by the release of a single quantum of ACh. Since many synaptic vesicles are released, many MEPPs temporally and spatially summate to form an endplate potential (EPP). If this EPP is sufficient to depolarize the membrane to threshold, an action potential is generated and propagated by way of VGSC leading to muscle fiber contraction [1].

---

## Myasthenia Gravis

### Clinical Description

Myasthenia gravis (MG) was first described by Thomas Willis in 1672. It is characterized by fatigable weakness and prior to the discovery of anticholinesterase inhibitors and mechanical ventilation, it was a lethal disease. It is the most common disorder of neuromuscular transmission and the discovery of polyclonal autoantibodies directed against the post-synaptic neuromuscular junction in 1970 revolutionized the treatment and prognosis of MG. The most common presentation involves ocular, bulbar, and limb muscles. Fifty to sixty percent of patients present with ocular muscle weakness manifesting as ptosis and diplopia. An additional 30% will eventually develop ocular symptoms. Up to 90% of ocular myasthenic patients will eventually have generalized disease, causing bulbar, limb, and respiratory weakness [2]. Bulbar symptoms such as dysarthria and dysphagia can result in weight loss and aspiration pneumonia. Myasthenic crisis is the most severe manifestation when respiratory muscle weakness leads to respiratory failure.

Infants have a unique variety—neonatal myasthenia. Neonatal myasthenia occurs in progeny of myasthenic mothers within hours to days of birth. Arthrogryposis, generalized weakness, poor suck and swallow, and respiratory dysfunction can occur. Disease results from placentally transmit-

ted AChR autoantibodies and can be fatal if there is antenatal involvement. If not, symptoms generally fully resolve in a few weeks and the infants are not at further risk for myasthenia gravis.

### Diagnosis

The diagnosis is suggested by fatigable weakness of ocular, bulbar, or limb skeletal muscles. The clinical suspicion can be confirmed with autoantibody testing, short-acting anticholinesterase inhibitors such as edrophonium, and electrodiagnostic testing. Eighty percent of patients have antibodies against the acetylcholine receptor. These antibodies include binding, blocking, and modulating varieties, of which binding accounts for over 90% of acetylcholine receptor antibodies [1]. Seronegative myasthenia may be a manifestation of technical issues, antibodies with high affinity to their antigens, prolonged immunosuppression, or unknown autoantibodies. Cell-based assay for antibodies against clustered acetylcholine receptor antibodies is positive in nearly 40% of seronegative myasthenia gravis [3]. Up to a quarter of seronegative myasthenic patients have antibodies against muscle-specific kinase (MuSK) [1]. MuSK is a tyrosine kinase which regulates and maintains acetylcholine receptor clustering [4, 5]. These antibodies effectively disrupt clustering and function of the postsynaptic neuromuscular junction, without loss of acetylcholine receptors. Antibodies directed against other components of the neuromuscular junction have been discovered, including LRP-4, cortactin, and agrin, which account for a few percentage of patients though none are yet commercially available [6, 7]. Anti-striated muscle antibodies directed against thymic myoid cells are present in 27% of myasthenic patients and up to 90% of myasthenic patients with thymoma [8].

Edrophonium testing allows for transient improvement of symptoms in a clinically weak, easily tested muscle such as the deltoid or a ptotic eyelid. Such testing is 90–95% sensitive for generalized myasthenia and 80–90% sensitive and specific for ocular myasthenia. The Ice Cube test, in which an ice cube is placed on the muscle (this

only works with ptosis), can also be a useful bedside tool to diagnose myasthenia gravis [9]. Electrodiagnostic testing includes repetitive nerve stimulation and single-fiber electromyography (EMG). Repetitive nerve stimulation tests for compound motor action potential decrement from baseline and transient post-exercise facilitation. Single fiber EMG quantitatively assesses jitter, a manifestation of the variability in time it takes the EPP to reach threshold for action potential propagation at the neuromuscular junctions of individual muscle fibers. In myasthenia gravis, there is increased jitter with intermittent neuromuscular transmission blocking, clinically manifesting as weakness [1].

## Pathophysiology

Myasthenia gravis results from an antibody-mediated, T-cell-dependent autoimmune attack on the postsynaptic neuromuscular junction with associated damage to, and simplification of, the postsynaptic membrane and reduction in number of AChR. The autoimmune nature of MG is thought related to loss of tolerance to self-antigens originating from thymic T cells. Up to 70% of myasthenics have thymic hyperplasia and another 15% have thymomas [1]. The hyperplastic thymus has an increased number of myoid cells which produce AChR similar to endplate AChR. These myoid cells are in close proximity to MHC-II interdigitating cells, which function as antigen-presenting cells, and are thought to present AChR fragments to autoreactive T cells. These T cells then aid AChR B cells in producing autoantibodies through the production of cytokines. AChR-specific T cells are also found in patients without MG, implying loss of tolerance or inhibitory control is necessary to lead to myasthenia gravis [10].

Antibodies in MG are heterogeneous with differing mechanisms, epitope recognition, and isotypes. This polyclonal expansion may explain the lack of correlation at times between symptoms and antibody titers. Most AChR antibodies bind to the  $\alpha$  subunit, at the main immunogenic region (MIR). Antibodies may bind, block, or modulate

the AChR. Binding antibodies crosslink two AChR, causing internalization and degradation, a process which is accelerated if more than one antibody binds. In this latter case, the clustered AChR are destroyed as well as VGSC, thereby increasing the depolarization threshold needed for generation of action potentials [10]. Unlike antibodies directed against AChR in myasthenia gravis, antibodies against MuSk are IgG4, which does not fix complement [5].

Complement plays a major role in the destruction of the postsynaptic membrane in AChR ab+ myasthenia gravis. Lytic phase activation and membrane attack complex (MAC) deposition at the NMJ causes shedding of postsynaptic junctional folds and AChR. The combination of antibody degradation of AChR and MAC destruction of junctional folds limits the surface area and the number of AChR available at the postsynaptic NMJ [10].

## Treatment

Treatment can be symptomatic in purely ocular disease, using a longer acting form of acetylcholinesterase inhibitor such as pyridostigmine. Pyridostigmine is also efficacious in quickly but transiently treating fatigable weakness in generalized myasthenia. Pyridostigmine often has a paradoxical effect in MuSK+ myasthenia gravis, with no or adverse effect. Steroids are used as first-line immunomodulating therapy and can effectively induce clinical remission in up to 80% of patients, with sustained improvement beginning within 2 weeks. High-dose steroid induction can cause transient worsening of myasthenia and initiation requires inpatient hospitalization to monitor for respiratory failure. Second-line therapies include azathioprine, which inhibits T-cell proliferation, and mycophenolate mofetil, which inhibits an enzyme crucial in purine synthesis and critical for B- and T-cell production. Cyclosporine was proven effective by a prospective, double-blind, placebo-controlled trial but is usually limited to patients who fail steroids and azathioprine, due to kidney and liver toxicity, and hypertension. A



double-blind, controlled, randomized trial of methotrexate in myasthenia gravis failed to show improvement in the primary endpoint, decrease in prednisone dose, though did show trends toward improvement in several secondary measures [11]. A Cochrane review of immunosuppressants in MG found improvement with cyclophosphamide or with cyclosporine with or without corticosteroids in small randomized control trials. Other small randomized control trials showed no improvement with azathioprine, mycophenolate mofetil, or tacrolimus [12].

Intravenous immunoglobulin (IVIG) causes transient improvement in 70% of myasthenic patients within 5 days, and can last for 8–12 weeks. A Cochrane review showed benefit of IVIG over placebo, but no difference between IVIG and plasma exchange [13]. There was no difference between 1 and 2 g/kg of IVIG or between IVIG and oral methylprednisolone. Plasma exchange rapidly but temporarily reduces antibody titers and is a very important part of the treatment of myasthenic crisis [13]. It can also be useful in patients refractory to other treatments or in those needing immediate but transient improvement, such as prior to thymectomy. Thymectomy provides long-term benefit which may be delayed for 6–12 months and is usually done in patients between 18 and 55 with generalized disease. It is essential in the 15% of myasthenic patients with thymomas. The goal of thymectomy is improved symptoms, decreased medication requirement, and an increased rate of remission post thymectomy. What was missing to prove the value of thymectomy was a randomized trial. This was finally accomplished and conclusively showed not only improvement in the Quantitative Myasthenia Gravis score but also significant reduction in prednisone dose [14]. Rituximab, an anti-CD20+ monoclonal antibody, may be efficacious, particularly in MuSK ab+ myasthenia [15]. Eculizumab, an inhibitor of the C5 component of the complement cascade, therefore inhibiting the MAC, was approved in Europe and the USA for use in refractory seropositive generalized myasthenia gravis in late 2017 based on the results of the REGAIN trial [16].

## Lambert Eaton Myasthenic Syndrome

### Clinical Description

Lambert-Eaton myasthenic syndrome (LEMS) was initially described in 1953, as potentially the first paraneoplastic disease. LEMS presents insidiously with symmetric weakness and fatigue in a proximal to distal gradient. Muscle aches and paresthesias are often present. Reflexes are characteristically absent, but return transiently following voluntary muscle contraction [17]. Seventy-five percent of patients with LEMS have dysautonomia manifesting as dry mouth, dry eyes, impotence, constipation, difficulty with micturation, decreased sweating, and pupillary abnormalities [17]. Unlike myasthenia gravis, oculomotor abnormalities and respiratory crises are uncommon.

While 50% of LEMS patients are associated with paraneoplastic syndrome, three-quarters of the neoplasms are not diagnosed until 1–5 years following neurological presentation. Paraneoplastic LEMS is often associated with other paraneoplastic syndromes such as cerebellar degeneration, sensorimotor polyneuropathy, and encephalomyelitis, which helps to distinguish this from the autoantibody variety [17, 18].

One striking clinical feature pathognomonic to disorders of presynaptic neuromuscular junction transmission is facilitation. Muscles and reflexes that were weak return to nearly normal strength, transiently, after exercise.

### Diagnosis

Diagnosis is based on a high degree of clinical suspicion. Electrodiagnostic findings of reduced compound muscle action potentials (CMAP) with greater than 100% increment of CMAP amplitude following 10–30 s of exercise (post-exercise facilitation) are diagnostic of a pre-synaptic disorder. Similar post-exercise facilitation is seen following 20–50 Hz repetitive nerve stimulation, which is not recommended in the conscious patient due to its great discomfort. Slow repetitive nerve stimulation (2–5 Hz)

reveals >10% decrement pre-exercise with repair of decrement and increase in CMAP amplitude immediately following exercise and subsequent decrement after 2–3 min. Single-fiber EMG shows abnormal jitter with blocking, but jitter decreasing with an increase in firing rate. Electrodiagnostic testing cannot differentiate paraneoplastic from autoimmune LEMS [17].

Antibodies against P/Q-type voltage-gated calcium channels (VGCC) are found in up to 85% of LEMS patients. High-titers strongly support the diagnosis, whereas low titers can be seen in non-LEMS patients and absent titers do not rule out the diagnosis. Anti-Hu or other antinuclear neuronal antibodies are suggestive of paraneoplastic LEMS in association with small cell lung carcinoma [18].

Once the diagnosis is made, the search for neoplasm should focus on small cell lung carcinoma, the primary neoplasm implicated in paraneoplastic LEMS. Other neoplasms associated include T-cell leukemia, lymphoma, Castleman's syndrome, and reticulum-cell sarcoma [19].

## Pathophysiology

LEMS is caused by a polyclonal antibody attack directed against the P/Q VGCC located on the pre-synaptic membrane of the neuromuscular junction. VGCCs contain  $\alpha 1$ ,  $\beta$ , and  $\alpha 2/\delta$  subunits, with the  $\alpha 1$  subunit serving as the ligand-binding site as well as containing the calcium conductance channel. The autoimmune attack results in loss of calcium channels and disorganization of the active zones, where exocytosis of acetylcholine-containing synaptic vesicles occurs. There is reduction in acetylcholine release into the NMJ, resulting in fewer MEPPs at the post-synaptic terminal, resulting in a decreased EPP. If the EPP is below threshold for action potential generation, then neuromuscular transmission is unsuccessful and weakness occurs. Exercise serves to increase ingress of calcium, allowing for increased synaptic vesicle release, increased numbers of MEPPs and an EPP sufficient to reach threshold, thus explaining facilitation [17].

## Treatment

In paraneoplastic LEMS, treatment is directed at the primary neoplasm, removal of which often reduces symptoms or allows remission [17]. Symptomatic treatments include pyridostigmine, and 3,4-diaminopyridine (3,4 DAP). Pyridostigmine, an acetylcholinesterase inhibitor, inhibits the breakdown of acetylcholine, effectively enhancing the MEPP amplitudes allowing for increased EPP and successful neuromuscular transmission. Diaminopyridine inhibits voltage-gated potassium channels, which lengthens the action potential and prolongs calcium entry into the presynaptic terminal, thereby increasing acetylcholine release into the primary synaptic cleft. It has been the subject of two recent randomized, controlled trials, one testing the base version of DAP (DAPPER) and the other a more stable, salt form (Catalyst sponsored trial). Both showed significant efficacy [20, 21]. FDA approval is pending for both and the two forms have precipitated a discussion about pharmaceutical company pricing and unexpected consequences of the Orphan Drug program of the FDA [22].

Immunologic therapy is an important mainstay in patients not undergoing cancer treatment. Prednisone and azathioprine or their combination has been shown to be efficacious. Plasma exchange and IVIG are used as in myasthenia to remove autoantibodies or suppress their production. A Cochrane review of treatments in LEMS showed improvement in strength in two studies of 3,4-DAP with 38 total patients and one study of 9 patients using IVIg. Other LEMS treatments have not been studied in randomized, controlled trials [23].

---

## Polymyositis

### Clinical Description

Polymyositis (PM) presents insidiously in adults with progressive symmetric proximal weakness. Symptoms include difficulty climbing stairs, getting out of a chair, and combing hair. Up to 50% have myalgias and tenderness to palpation.

Atrophy occurs in severe weakness with associated reduced reflexes. Pharyngeal and neck extensor weakness may lead to dysphagia and head drop. In advanced cases, there may be involvement of respiratory muscles and distal hand muscles. Facial and extraocular muscles are typically spared. Other organ system involvement includes cardiac disease due to myocarditis and interstitial lung disease (ILD). Interstitial lung disease can be a result of methotrexate toxicity or in 10% of PM, seen in association with anti-Jo or ribonucleoprotein antibodies [24].

## Diagnosis

The diagnosis of PM is based on clinical suspicion, muscle enzyme testing, EMG, and muscle biopsy. Characteristically, creatine kinase can be up to 50 times the upper limit of normal. Evaluating for myositis-associated antibodies (MAA) or myositis-specific antibodies (MSA) is important for staging the disease and stratifying risk [24]. EMG findings include short-duration, low-amplitude polyphasic potentials with abnormal spontaneous activity which is characteristic of necrotic myopathies such as PM [24]. Muscle biopsy is the most specific diagnostic test, revealing endomysial inflammation with muscle fiber necrosis (Fig. 15.1). CD8+ T cells invading non-necrotic muscle fibers expressing MHC-1 antigens are characteristic [25]. Imaging is play-

ing an increasing role in diagnosis (see section “[Diagnosis](#)” of DM below).

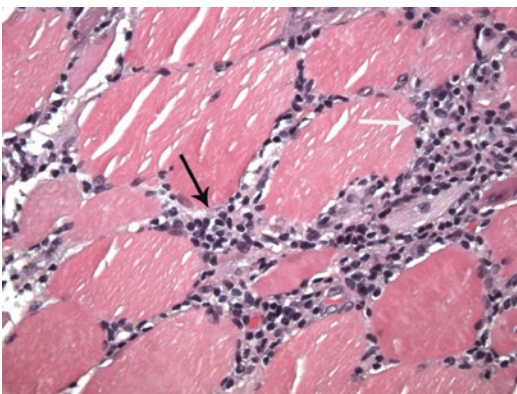
## Pathophysiology

PM is thought due to a T-cell-mediated attack on muscle fibers. Macrophages and cytotoxic CD8+ T cells surround and eventually invade non-necrotic muscle tissue, eventually leading to muscle fiber destruction. These cytotoxic T cells recognize an unknown antigenic target in association with MHC-1 antigens expressed by muscle fibers. T cells induce muscle fiber necrosis via perforin, a membrane lytic molecule [25, 26].

In up to 20% of inflammatory myopathies, there are autoantibodies against nuclear and cytoplasmic antigens (Table 15.1). Ribonucleoproteins are involved in translation and protein synthesis and are the target of several anti-cytoplasmic antibodies such as Jo-1 (the most common). These autoantibodies are not specific to PM as they can be seen in both dermatomyositis (DM) and inclusion body myositis (IBM), and occur in ILD in the absence of myositis [27, 28].

Anti-synthetase syndrome is the most common syndrome with myositis and autoantibodies. The typical presentation is ILD and myositis, often with Raynaud’s, fever, arthralgia, and thickened cracked fingers known as “mechanic’s hands,” often with a more acute, crescendo presentation. Anti-Jo-1, directed against histidyl-transfer RNA synthetase, comprises up to 75% of the anti-synthetase antibodies and accounts for 60–80% of MSA patients, with PL-7, PL-12, EJ, OJ, or KS found in the remainder. There is a threefold increase in mortality compared to PM, perhaps due to its association with ILD [27].

Overlap syndromes exist between connective tissue diseases and either PM or DM. Systemic lupus erythematosus has an associated myositis in 8% of patients. Of these patients, anti-nuclear antibodies directed against native DNA and anti-Sm are specific to SLE-myositis patients. Other antibodies include anti-SSA (Ro), anti-SS-B (La), and anti-U1 ribonuclear protein, but are not specific to SLE-myositis patients. Myositis is rarely associated with Sjogren’s syndrome with antibodies against the ribonucleoproteins SS-A



**Fig. 15.1** Polymyositis. Muscle fibers are surrounded by inflammatory cells, mainly lymphocytes (black arrow). At least one fiber in this figure is undergoing myophagocytosis (white arrow). H&E stain,  $\times 400$

**Table 15.1** Antibodies seen in inflammatory myopathies

Autoantibody	Antigen target	Clinical presentation
Anti-Jo 1	Histidyl t-RNA synthetase	Antisynthetase syndrome
Anti-PL-7	Threonyl-t-RNA synthetase	Polyarthritis
Anti-PL-12	Alanyl-t-RNA synthetase	
Anti-EJ	Glycyl-t-RNA synthetase	ILD
Anti-KS	Asparaginyt-t-RNA synthetase	“Mechanic” hands
Anti-OJ	Isoleucyl-t-RNA synthetase	Myositis
Anti-SRP	325-kDa ribonucleoprotein	Anti-SRP syndrome (muscle, cardiac involvement, steroid resistant)
Anti-Mi2	Transcription peptide complex	DM ± ILD
Anti-Scl-PM	Peptide complex	Scleroderma, myositis, scleroderma/PM or DM
Anti-Ku	Heterodimer associated with DNA-dependent protein kinase	Scleroderma/PM or DM overlap syndromes, SLE, scleroderma, MCTD, Sjogren’s, thyroiditis, pulmonary hypertension
Anti-PMS	DNA binding protein complex	PM and DM
Anti-56 kDa	Ribonucleoprotein	PM and DM of childhood onset

*ILD* inflammatory lung disease, *SRP* signal recognition protein, *DM* dermatomyositis, *PM* polymyositis, *SLE* systemic lupus erythematosus, *MCTD* mixed connective tissue disease

and SS-B. Up to 13% of rheumatoid arthritis is associated with myositis. Scleroderma has myositis as a feature in 5–17%. In North America, 25% of patients with scleroderma and myositis have anti-PM-Scl (anti-PM1) antibodies, while in Japan, anti-Ku antibodies are more common. Anti-U1 ribonuclear protein is seen in mixed connective tissue disease [24]. Anti-signal recognition particle antibodies were previously associated with PM, but recent studies have shown they are part of a distinctive syndrome consisting of a steroid-resistant necrotizing myopathy with little inflammation, and MAC deposition and capillary loss [29, 30] (see below).

PM can be seen during the course of other autoimmune diseases such as Crohn’s disease, vasculitis, sarcoidosis, celiac disease, primary biliary cirrhosis, Behcet’s disease, and Hashimoto’s disease, among others. Giant cell myositis is associated with thymomas and as such can also be seen in patients with myasthenia gravis.

## Treatment

Corticosteroids remain the mainstay of treatment for PM with more than 80% of patients responding to some degree. Noticeable clinical improvement occurs within 3–6 months. For patients who do not respond, or who relapse during prednisone therapy, second-line agents include azathioprine,

methotrexate, cyclophosphamide, rituximab, cyclosporine, mycophenolate mofetil, IVIG, and plasmapheresis. Methotrexate is a folate antagonist used in patients who respond poorly to steroids or azathioprine [24]. IVIG has been shown to provide significant improvement in muscle strength over 3 months [31]. Rituximab may be beneficial in refractory PM [32], particularly in patients with MSAs [24]. Relapses should be differentiated from steroid myopathy, which has normal CK levels, no abnormal spontaneous activity on needle EMG and type 2 fiber atrophy on muscle biopsy. The myositis, arthralgias, and systemic symptoms of anti-synthetase syndrome tend to respond to steroids, while the ILD can be steroid responsive, depending on subset. Undetectable anti-synthetase antibodies after treatment predict a favorable prognosis [27]. A Cochrane review of treatments for both PM and DM found equal efficacy with azathioprine, cyclosporine, and methotrexate, with the latter having a more favorable side effect profile [31].

## Dermatomyositis

### Clinical Description

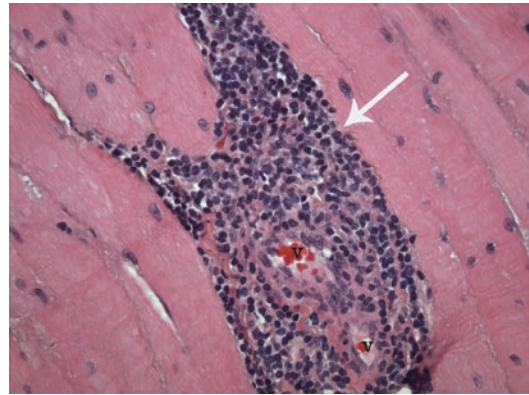
Dermatomyositis (DM) occurs in children and adults and is characterized by skin changes which accompany or may precede weakness.

An edematous bluish-purple discoloration of the upper eyelid, “heliotope rash”, flat erythematous rash of the face, chest and extensor surface dermatitis exacerbated by sun exposure, and Gottron’s rash, a erythematous, scaly, violaceous rash on the knuckles, are all characteristic. Nail changes with dilated capillary loops, thickened cuticles, and rough, cracked “mechanic hands” may occur. Subcutaneous calcifications occur more frequently in children and may cause ulcerations [24]. Weakness occurs subacutely with a proximal to distal gradient.

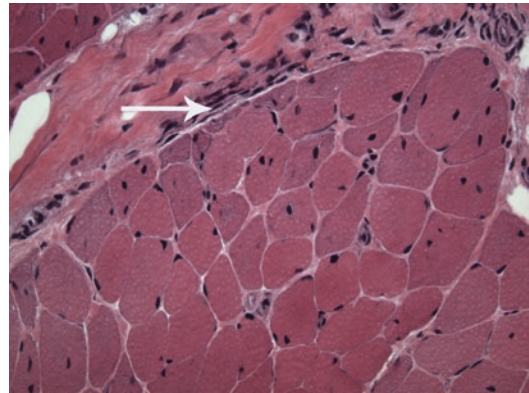
Cardiac manifestations include cardiomyopathy, conduction defects, and tachyarrhythmia similar to polymyositis. Pulmonary symptoms are related to interstitial lung disease, methotrexate toxicity, or thoracic muscle weakness. Gastrointestinal ulceration, joint contractures, and systemic symptoms occur. Rarely, renal failure and rhabdomyolysis may be seen in acute presentations. DM has an increased risk of malignancy which can precede the diagnosis, but usually occurs within 2 years of the myositis. Women over the age of 40 years appear to be at greatest risk of associated neoplasm. Commonly associated cancers include breast, lung, ovarian, and gastrointestinal [24]. Amyopathic dermatomyositis, i.e., dermatomyositis without muscle involvement, occurs in about 20% of patients [24].

## Diagnosis

Skin manifestations of dermatomyositis are pathognomonic. Clinical diagnosis can be confirmed with muscle enzyme testing, electrodiagnostic testing, and muscle biopsy. Creatine kinase often reflects disease severity and can be increased up to 50-fold. Testing for MAA/MSAs is important for staging the disease and stratifying risk [24]. Electromyography reveals myopathic features interspersed with rare neurogenic motor unit potentials and abnormal spontaneous activity. Perifascicular inflammation, endothelial hyperplasia, and capillary loss are characteristic muscle biopsy features (Figs. 15.2 and 15.3). Frequently, a high percentage of B cells and an



**Fig. 15.2** Dermatomyositis. Inflammatory cells, mainly lymphocytes (arrow) are seen completely surrounding and invading two small, interstitial blood vessels (V). H&E stain,  $\times 400$



**Fig. 15.3** Dermatomyositis. Unlike polymyositis, dermatomyositis is a vasculitis, which leads to ischemic damage along the periphery of the muscle fascicles, resulting in “perifascicular atrophy” (arrow). H&E stain,  $\times 400$

increased CD4+/CD8+ ratio may be found on immunohistochemistry of muscle [24]. Perifascicular atrophy (Fig. 15.3) results from watershed zone microinfarcts within muscle fascicles and is highly suggestive of DM. Magnetic resonance imaging is being used more often in both PM and DM, to detect affected muscles for biopsy, and to determine active inflammation (T2-weighted images) or atrophy (T1-weighted). Ultrasonography can distinguish between normal and pathologic muscle and is easier and less expensive than MRI, particularly for determining muscles best suited for biopsy [24].

## Pathophysiology

Dermatomyositis is most commonly thought to be caused by antibody-mediated damage of muscle capillaries with subsequent necrosis, capillary loss, and focal muscle ischemia. While the antigen is unknown, it is thought to be a component of the endothelium of endomysial vessels. Activation of complement C3 leads to the formation and deposition of C3bNEO and MAC deposition on endomysial capillaries. MAC deposition leads to endothelial damage and subsequent capillary necrosis [24]. The remaining capillaries dilate to compensate for the capillary loss, and perifascicular atrophy occurs as a result of hypoperfusion to this watershed area. Micro-infarcts occur as a result of necrosis of larger intramuscular vessels. Muscle fiber damage also occurs from the recruitment of macrophages and T cells by chemotactic factors as a result of complement activation.

## Treatment

The mainstay of treatment is corticosteroids in high doses. The mechanism of action is unclear but may involve inhibiting movement of lymphocytes to areas of muscle inflammation. Steroid-sparing medications include azathioprine, methotrexate, cyclosporine, and for refractory disease, IVIg and rituximab should be considered. A recent randomized trial in juvenile dermatomyositis compared prednisone to prednisone and methotrexate and to prednisone and cyclosporine. Both combinations were significantly more efficacious than prednisone alone, and the combination of prednisone and methotrexate had fewer side effects than with cyclosporine [33]. A Cochrane review of treatments showed benefit in DM with IVIg versus placebo in one small trial [31]. Rituximab given early or late was studied in a randomized, double-blind trial of refractory PM and DM. Steroids and other immunosuppressives were allowed at entry. There was no difference between the two rituximab regimens, and 83% of patients with refractory disease met the definition of improvement [32].

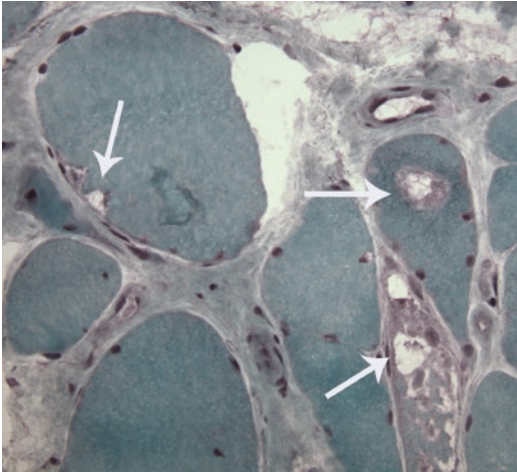
## Inclusion Body Myositis

### Clinical Description

Inclusion body myositis (IBM) is the most common primary muscle disorder in people older than 50 years. There is a male predominance and IBM is usually sporadic with rare autosomal recessive inheritance. The course is one of indolent progression of asymmetric weakness affecting the legs before the arms. Patients often present with falling and tripping from quadriceps and foot plantar flexor weakness. Finger flexor weakness contributes to difficulty with fine motor skills such as buttoning and opening jars. The combination of quadriceps and finger flexor weakness and atrophy is characteristic of IBM. Weak quadriceps muscles contribute to depressed patellar reflex. Other muscles commonly affected include biceps, triceps, iliopsoas, and tibialis anterior. Weakness is often asymmetric. Dysphagia is a presenting feature in 30–40%. Facial weakness can occur along with other cranial nerves but respiratory muscles are relatively spared [29, 34].

### Diagnosis

Diagnosis is based on clinical, laboratory, electrodiagnostic, and biopsy findings. Creatine kinase is often elevated two- to threefold but can be up tenfold or may be normal. Anti-cytosolic 5'-nucleosidase 1A (cN1A) autoantibodies have been reported to be specific for the diagnosis of IBM, though have also been reported in other autoimmune diseases [29]. Electrodiagnostic testing helps to exclude neurogenic conditions such as amyotrophic lateral sclerosis. Myopathic features are most commonly seen on needle electromyography though in 1/3 of patients neurogenic features may be interspersed with myopathic motor unit potentials. Spontaneous activity is seen due to myonecrosis but may be underwhelming. Muscle biopsy (Fig. 15.4) is the standard for diagnosis. Findings include rimmed vacuoles, endomysial inflammation, eosinophilic



**Fig. 15.4** Inclusion body myositis. Rimmed vacuoles (arrows) within muscle fibers are a prominent part of the pathology of inclusion body myositis. Modified Gomori trichrome stain,  $\times 400$

inclusions, swollen or vacuolated nuclei, and a combination of hypertrophic and atrophic fibers. Red ragged fibers may be seen due to abnormal mitochondria after nuclear damage. CD8+ T cells invading non-necrotic muscle fibers provide evidence for definite IBM. Electron microscopy reveals intranuclear and intracytoplasmic filamentous inclusions, approximately 10–18 nm in diameter.

### Pathophysiology

Muscle biopsy findings in IBM include significant endomysial inflammation similar to PM. Auto-aggressive CD8+ T cells comprise 70% of the endomysial inflammatory cells and preferentially invade non-necrotic muscle, implicating inflammatory cells in muscle fiber necrosis. MHC-I antigens have also been found surrounding these inflammatory cells, and the presence of cN1A antibodies implicates an autoimmune process [29]. Other pathologic features (rimmed vacuoles, abnormal protein aggregates, and the lack of response to immune therapies) suggest a degenerative process [29].

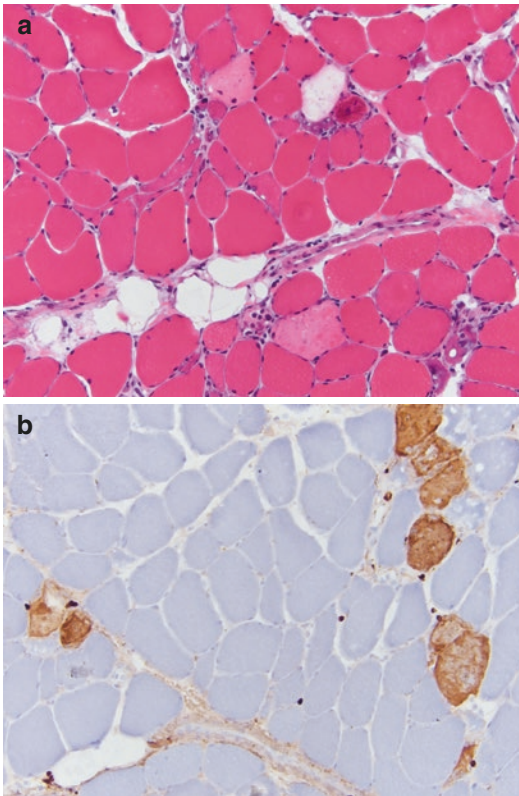
### Treatment

Treatment in IBM is largely supportive, as no effective pharmacologic treatment has been found [35]. Steroids, azathioprine, cyclophosphamide, methotrexate, beta interferon 1a, lymphoid irradiation, and IVIG have shown no benefit. Cricopharyngeal botulinum toxin may be beneficial in patients with severe dysphagia [36].

### Immune-Mediated Necrotizing Myopathy

Immune-mediated necrotizing myopathies are characterized by subacute weakness of limb muscles, elevated creatine kinase, myopathic EMG, and pathologic findings on muscle biopsy, including muscle fiber necrosis and very limited, if any, inflammatory infiltrates [29]. The autoimmune nature is bolstered by more recent delineation of an association with at least two particular myositis-specific antibodies, directed either at the signal recognition particle (SRP) or at 3-hydroxy-3-methylglutarylcoenzyme A reductase (HMGCR). The relative absence of inflammation and the presence of MSAs help differentiate these patients from those with other inflammatory myopathies (Fig. 15.5a). Patients can respond to immunosuppressive therapy, though usually requiring steroids and one or more additional immunotherapeutic agents (such as IVIG, MTX, AZA, rituximab) [29].

CD68+ iNOS+ macrophages and a Th-1 immune environment are involved in ongoing phagocytosis of necrotic muscle fibers and activation of the classical complement cascade occurs [30]. IgG1 isotype is seen amongst both anti-SRP and anti-HMGCR antibodies, which activates complement. C5b9 (Fig. 15.5b) and C1q, and both autoantibodies are deposited on the sarcolemmal membrane, indicating a direct role of the antibodies and that complement activation plays a pathogenic role [29, 30]. CK levels have been found to correlate with both the proportion of necrotic fibers as well as the titer of anti-SRP antibodies [30].



**Fig. 15.5** Immune-mediated necrotizing myopathy due to anti-SRP antibodies. (a) Myonecrosis affecting muscle fibers in the absence of significant inflammatory response. H&E,  $\times 20$ . (b) Multiple muscle fibers showing reactivity to C5b9,  $\times 20$

### Drug-Induced Inflammatory Myopathies

Immune checkpoint inhibitor (CI) therapy unleashes the body's immune system to attack cancer and has become an increasingly useful therapeutic strategy in more severe stages of cancer, with remarkable success. However, in allowing this avenue of attack on cancer, it opens the door to autoimmune attack upon other, healthy tissues such as neuromuscular junction and skeletal muscle. CI-induced disease is similar to non-CI disease in therapy but can differ in pathophysiology [37].

There are three targets of checkpoint inhibition with several target-specific monoclonal antibodies approved for use. Targets include cytoplasmic t-lymphocyte-associated antigen-4, targeted by ipilimumab; programmed cell death-1, targeted by pembrolizumab and by nivolumab; and programmed cell death ligand-1, targeted by avelumab, atezolizumab, and durvalumab [37]. Neurologic adverse events are rare, in the 1–3% range, with neuromuscular involvement accounting for a small portion of that. Myasthenia gravis, either as exacerbation of known disease or as de novo disease, is the most frequent neuromuscular adverse event. Patients can be AChR antibody positive or negative, but have not been MuSK antibody positive. Onset is usually within 3 months of onset of therapy, often within the first 6 weeks. Rhabdomyolysis, myositis, and myocarditis may also occur. Treatment requires high dose steroids and often, IVIG or plasmapheresis [37].

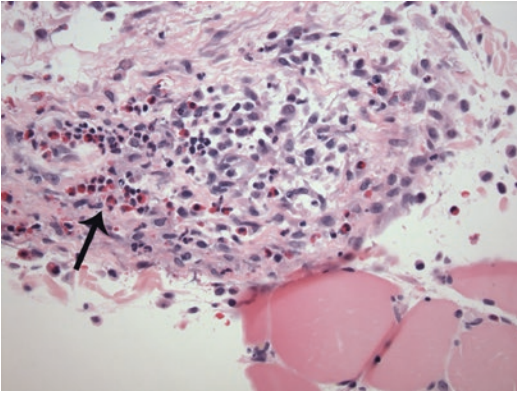
Myositis is less frequent, especially when encountered as the sole manifestation of autoimmunity. It can respond to steroids or steroid-sparing immunosuppressants [37].

### Other Myopathies

Eosinophilic myositis is a rare form of PM in which there is peripheral eosinophilia and eosinophilic infiltrates of the endomysium. The cytokine IL-5 is thought to activate eosinophils which invade muscle fibers (Fig. 15.6), degranulate and release cytotoxic materials. Eosinophilic myositis has occurred as a consequence of calpain-3 mutations, which often causes adult-onset limb girdle muscular dystrophy (LGMD type 2A), in children under 10 years with elevated creatinine kinase and peripheral eosinophilia [38, 39].

Several muscular dystrophies are associated with inflammation found on histochemical study of muscle. Laminin  $\alpha 2$  (merosin) deficiency can have an associated perimysial, endomysial, and perivascular B- and T-cell infiltration with myofiber necrosis [40]. Macrophages and lymphocytes

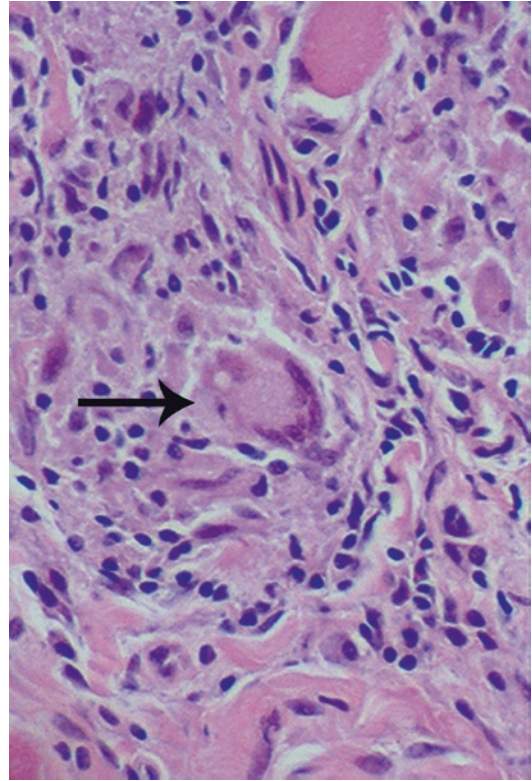




**Fig. 15.6** Eosinophilic myositis. A cluster of inflammatory cells with a prominent eosinophilic component (arrow) can be seen adjacent to a group of muscle fibers. The patient was thought to have Churg-Strauss syndrome. H&E stain,  $\times 400$

with MHC-I expression have been found in LGMD2L, Duchenne muscular dystrophy, and Becker muscular dystrophy, and inflammation has been found in up to 40% of dysferlinopathy (LGMD2B) biopsies [41]. Inflammatory cells are found in 40–80% of biopsies in facioscapulohumeral muscular dystrophy (FSHD) [42]. A compelling hypothesis is that sarcolemmal disruption due to genetically induced defects results in repeated cycles of muscle fiber degeneration and regeneration, thus triggering chronic inflammatory responses leading to functional muscle tissue being replaced by non-functional fibrotic tissue, perpetuating and exacerbating the underlying muscle disease. The benefit of steroids in Duchenne muscular dystrophy may arise from its anti-inflammatory effects. Chronic inflammation may result from calcium overflow-induced inflammation, reactive oxygen species, and/or activation of the NF- $\kappa$ B inflammatory pathway. There are several potential therapeutic targets which are under investigation [43].

While sarcoidosis may have a variety of neurologic presentations, 50–80% of patients with systemic sarcoid have muscle granulomas, over 90% of which are asymptomatic. Symptomatic sarcoid myositis presents with proximal weakness, myalgias, muscle tenderness, and weight loss. Chronic sarcoid myopathy presents as proximal muscle wasting of limb, trunk, and neck



**Fig. 15.7** Sarcoid myopathy. A multinucleated giant cell (arrow) is seen within a non-caseating granuloma. H&E stain,  $\times 400$

muscles. Non-caseating granulomas form in the muscle (Fig. 15.7) as a result of accumulation and aggregation of CD4+ helper T cells. The mainstay of treatment for systemic and symptomatic myopathic sarcoid is corticosteroids, though chronic sarcoid myopathy often responds poorly. Immunosuppressants such as methotrexate, azathioprine, cyclophosphamide, or irradiation are reserved for those patients who remain refractory or continue to progress despite treatment with corticosteroids [44].

---

## Conclusion

The discovery in 1970 of antibodies directed against the acetylcholine receptor in patients with myasthenia gravis finally provided a rationale for treatment directed at the underlying problem, and dramatically improved survival and quality of

life. The discovery a couple of decades later of autoantibodies in Lambert-Eaton myasthenic syndrome similarly provided treatment strategies beyond the merely symptomatic. Continued advances in immunologic knowledge have allowed for advances in diagnostic testing and new treatment options in the inflammatory diseases of muscle as well. Inclusion body myositis, however, remains stubbornly obdurate to our understanding and to effective treatment. Chronic inflammation as a factor in progressive weakness in muscular dystrophy offers opportunities for therapeutic advances. Further randomized, placebo-controlled trials are important to best determine the most effective treatments for these immune-mediated disorders.

## References

- Gilhus NE. Myasthenia gravis. *N Engl J Med*. 2016;375:2570–81.
- Grob D, Arsura EL, Brunner NG, Namba T. The course of myasthenia gravis and therapies affecting outcome. *Ann N Y Acad Sci*. 1987;505:472.
- Rodriguez Cruz PM, Al-Hajjar M, Huda S, et al. Clinical features and diagnostic usefulness of antibodies to clustered acetylcholine receptors in the diagnosis of seronegative myasthenia gravis. *JAMA Neurol*. 2015;72:642–9.
- Evoli A, Tonali PA, Padua L, et al. Clinical correlates with anti-MuSK antibodies in generalized seronegative myasthenia gravis. *Brain*. 2003;126:2304–11.
- Ghazanfari N, Trajanovska S, Morsch M, Liang SX, Reddel SW, Phillips WD. The mouse passive-transfer model of MuSK myasthenia gravis: disrupted MuSK signaling cause synapse failure. *Ann N Y Acad Sci*. 2018;1412:54–61.
- Zisimopoulou P, Evangelakou P, Tsartos J, et al. A comprehensive analysis of the epidemiology and clinical characteristics of anti-LRP4 in myasthenia gravis. *J Autoimmun*. 2014;52:139–45.
- Cortes-Vicente E, Gallardo E, Martinez MA, et al. Clinical characteristics of patients with double-seronegative myasthenia gravis and antibodies to cortactin. *JAMA Neurol*. 2016;73:1099–104.
- Limburg PC, The H, Hummel-Tappel E, Oosterhuis HJ. Anti-acetylcholine receptor antibodies in myasthenia gravis. Part I: Their relation to the clinical state and the effect of therapy. *J Neurol Sci*. 1983;58:357.
- Liu WW, Chen A. Diagnosing myasthenia gravis with an ice pack. *N Engl J Med*. 2016;375:19.
- Hohlfeld R, Wekerle H. The immunopathogenesis of myasthenia gravis. In: Engel AG, editor. *Myasthenia gravis and myasthenic disorders*. New York: Oxford University Press; 1999. p. 87–110.
- Pasnoor M, He J, Herbelin L, et al. A randomized controlled trial of methotrexate for patients with generalized myasthenia gravis. *Neurology*. 2016;87:57–64.
- Hart IK, Sathasivam S, Sharshar T. Immunosuppressive agents for myasthenia gravis. *Cochrane Database Syst Rev*. 2007;(4):CD005224.
- Gajdos P, Chevret S, Toyka K. Intravenous immunoglobulin for myasthenia gravis. *Cochrane Database Syst Rev*. 2012;(12):CD002277.
- Wolfe GI, Kaminski HJ, Aban IB, et al. Randomized trial of thymectomy in myasthenia gravis. *N Engl J Med*. 2016;375:511–22.
- Hehir MK, Hobson-Webb LD, Benatar M, et al. Rituximab as treatment for anti-MuSK myasthenia gravis. *Neurology*. 2017;89:1069–77.
- Howard JF Jr, Utsugisawa K, Benatar M, et al. Safety and efficacy of eculizumab in anti-acetylcholine receptor antibody-positive refractory generalized myasthenia gravis (REGAIN): a phase 3, randomized, double-blind, placebo-controlled, multicenter study. *Lancet Neurol*. 2017;16:976–86.
- Schoser B, Eymard B, Datt J, Mantegazza R. Lambert-Eaton myasthenia syndrome (LEMS): a rare autoimmune presynaptic disorder often associated with cancer. *J Neurol*. 2017;264:1854–63.
- Gozzard P, Woodhall M, Chapman C, et al. Paraneoplastic neurologic disorders in small cell lung carcinoma: a prospective study. *Neurology*. 2015;85:235–9.
- Newsome-Davis J, Lang B. The Lambert-Eaton myasthenic syndrome. In: Engel AG, editor. *Myasthenia gravis and myasthenic disorders*. New York: Oxford University Press; 1999. p. 205–28.
- Sanders DB, Juel VC, Harati Y, et al. 3,4-Diaminopyridine base effectively treats the weakness of Lambert-Eaton myasthenia. *Muscle Nerve*. 2018;57(4):561–8.
- Oh SJ, Shcherbakova N, Kostera-Pruszczyk A, et al. Amifampridine phosphate (Firdapse) is effective and safe in a phase 3 clinical trial in LEMS. *Muscle Nerve*. 2016;53:717–25.
- Burns RM, Smith GA, Allen JA, et al. Editorial by concerned physicians: Unintended effect of the orphan drug act on the potential cost of 3,4-diaminopyridine. *Muscle Nerve*. 2016;53:165–8.
- Maddison P, Newsome-Davis J. Treatment for Lambert-Eaton myasthenic syndrome. *Cochrane Database Syst Rev*. 2005;(2):CD003279.
- Findlay AR, Goyal NA, Mozaffar T. An overview of polymyositis and dermatomyositis. *Muscle Nerve*. 2015;51:638–56.
- Dalakas MC. Therapeutic targets in patients with inflammatory myopathies: present approaches and a look to the future. *Neuromuscul Disord*. 2006;16:223–36.
- Arahata K, Engel AG. Monoclonal antibody analysis of mononuclear cells in myopathies. I: Quantitation of subsets according to diagnosis and sites of accumulation and demonstration and counts of muscle fibers invaded by T cells. *Ann Neurol*. 1984;16:193–208.

27. Imbert-Massaeu A, Hamidou M, Agard C, Grolleau JY, Chérin P. Antisyntetase syndrome. *Joint Bone Spine*. 2003;70:161–8.
28. Sordet C, Goetz J, Sibilia J. Contribution of autoantibodies to the diagnosis and nosology of inflammatory muscle disease. *Joint Bone Spine*. 2006;73:646–54.
29. Milone M. Diagnosis and management of immune-mediated myopathies. *Mayo Clin Proc*. 2017;92:826–37.
30. Allenbach Y, Arouche-Depaperche L, Preusse C, et al. Necrosis in anti-SRP<sup>+</sup> and anti-MHGCR<sup>+</sup> myopathies. *Neurology*. 2018;90:e507–17.
31. Gordon PA, Winer JB, Hoogendijk JE, Choy EHS. Immunosuppressant and immunomodulatory treatment for dermatomyositis and polymyositis. *Cochrane Database Syst Rev*. 2012;(8):CD003643.
32. Oddis CV, Reed AM, Aggarwal R, et al. Rituximab in the treatment of refractory adult and juvenile dermatomyositis and adult polymyositis: a randomized, placebo-phase trial. *Arthritis Rheum*. 2013;65:314–24.
33. Ruperto N, Pistoria A, Oliveira S, et al. Prednisone versus prednisone plus cyclosporine versus prednisone plus methotrexate in new-onset juvenile dermatomyositis: a randomized trial. *Lancet*. 2016;387:671–8.
34. Lotz BP, Engel AG, Nishino H, Stevens JC, Litchy WJ. Inclusion body myositis: observations in 40 patients. *Brain*. 1989;112:727–47.
35. Benveniste O, Guiguet M, Freebody J, et al. Long-term observational study of sporadic inclusion body myositis. *Brain*. 2011;134:3176–84.
36. Liu LW, Tarnopolsky M, Armstrong D. Injection of botulinum toxin A to the upper esophageal sphincter for oropharyngeal dysphagia in two patients with inclusion body myositis. *Can J Gastroenterol*. 2004;18:397–9.
37. Kolb NA, Trevino CR, Waheed W, Sobhani F, Kandry KK, Thomas AA, Hehir M. Neuromuscular complications of immune checkpoint inhibitor therapy. *Muscle Nerve*. 2018; <https://doi.org/10.1002/mus.26070>.
38. Brown RH, Amato AA. Calpainopathy and eosinophilic myositis. *Ann Neurol*. 2006;59:875–7.
39. Krahn M, Lopez de Munain A, Streichenberger N, et al. CAPN3 mutations in patients with idiopathic eosinophilic myositis. *Ann Neurol*. 2006;59:905–11.
40. Pegoraro E, Mancias P, Swerdlow SH, et al. Congenital muscular dystrophy with primary laminin  $\alpha$ 2 (merosin) deficiency presenting as inflammatory myopathy. *Ann Neurol*. 1996;40:782–91.
41. Rosales XQ, Gastier-Foster JM, Lewis S, et al. Novel diagnostic features of dysferlinopathies. *Muscle Nerve*. 2010;42:14–21.
42. Arahata K, Ishihara T, Fukunaga H, et al. Inflammatory response in fascioscapulohumeral muscular dystrophy (FSHD): immunocytochemical and genetic analyses. *Muscle Nerve Suppl*. 1995;2:S56–66.
43. Miyatake S, Shimizu-Motohashi Y, Takeda S, Aoki Y. Anti-inflammatory drugs for Duchenne muscular dystrophy: focus on skeletal muscle-releasing factors. *Drug Des Dev Ther*. 2016;10:2745–58.
44. Maeshima S, Koike H, Noda S, et al. Clinicopathological features of sarcoidosis manifesting as generalized chronic myopathy. *J Neurol*. 2015;262:1035–45.



## Introduction

Autoimmune neuropathies comprise a diverse array of disorders. Their temporal evolution may be acute and self-limited, relapsing-remitting or chronically progressive. Deficits and symptoms may be distal or proximal, in a symmetric or multifocal pattern. Within each temporospatial profile, pathophysiology may reflect demyelination or axonal degeneration. Rather than attempt an exhaustive catalogue, this chapter will address major, common autoimmune neuropathies. Their clinical presentation, laboratory evaluation, pathogenesis, and therapeutic options will be reviewed.

## Guillain-Barré Syndrome

Historically, Guillain-Barré syndrome (GBS) represents the earliest description of an autoimmune neuropathy, though it was not recognized as such until nearly a century after Landry's initial case reports in 1859. The main contribution

of Guillain, Barre, and Strohl in 1916 was the identification of an associated elevation of protein in an acellular CSF [1]. This finding of albumino-cytologic dissociation served to distinguish GBS from the known infectious causes of ascending paralysis (i.e., polio and syphilis). Curiously, Guillain himself continued to favor an infectious etiology, rejecting proposals by Bannwarth and others that GBS was an allergic phenomenon [2]. The emergence of experimental allergic neuritis (EAN) as an animal model in the 1950s fostered acceptance of an immune-mediated pathogenesis for GBS [3, 4].

Pathologic and nerve conduction studies of GBS in Europe and North America revealed evidence of a primary demyelinating neuropathy similar to that found in the animal model of EAN [5]. As a result, the term acute inflammatory demyelinating polyneuropathy (AIDP) became synonymous with GBS. More recently, the study of GBS cases worldwide has emphasized its syndromic nature with different pathologic and physiologic processes leading to similar clinical presentations.

## Clinical Features

GBS is defined as an acute neuropathic weakness with strength decreasing to a nadir within 4 weeks along with loss of deep tendon reflexes. Its course is most often ascending, beginning in the lower extremities. Weakness of the limbs is nearly

---

J. Reynolds  
Department of Neurology, Midcoast Hospital,  
Brunswick, ME, USA

G. Sachs (✉)  
Department of Neurology, Warren Alpert Medical  
School of Brown University, Rhode Island Hospital,  
Providence, RI, USA  
e-mail: [gsachs@lifespan.org](mailto:gsachs@lifespan.org)

always symmetric or becomes so as it progresses. Initial weakness may involve proximal or distal muscles. Over half of GBS cases show facial or bulbar weakness. Respiratory muscle weakness is common with approximately one-quarter of patients requiring mechanical ventilation [6, 7].

Sensory symptoms often precede the onset of weakness. Over half of GBS cases begin with paresthesia in distal lower extremities; however, initial paresthesia may occur in any location. Sensory deficits tend to reflect preferential involvement of large caliber sensory axons and ataxia is common. The loss of tendon reflexes, even in relatively strong muscles, reflects conduction block or desynchronization in 1A afferents [6].

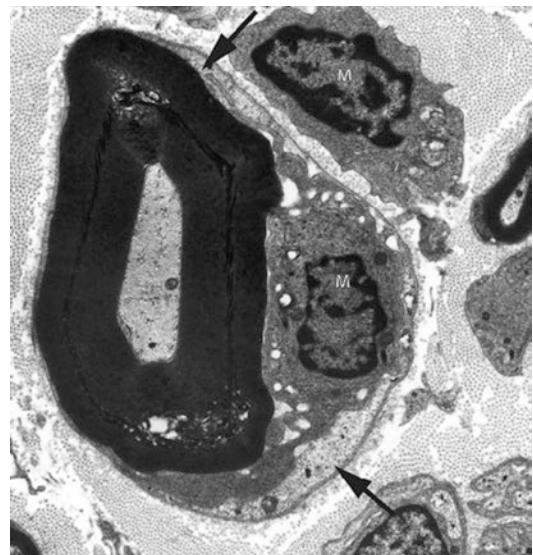
Autonomic dysfunction complicates nearly two-thirds of GBS cases. Alteration in blood pressure and cardiac arrhythmias predominate with hypertension and tachycardia being most common. Urinary incontinence occurs in roughly 25% of cases [6, 7].

## Laboratory Investigations

Approximately, 90% of GBS cases reveal elevated CSF protein without abnormal cell counts. Protein levels may not exceed normal range during the first week of symptoms, but usually peak by 2–3 weeks after onset. Thereafter, levels decline slowly for months. Cases with significant CSF pleocytosis (greater than five white blood cells) can occur in the setting of HIV, cytomegalovirus, Lyme disease, sarcoidosis, or carcinomatous or lymphomatous meningitis [8].

Electrodiagnostic studies typically reveal a picture of AIDP with evidence of a demyelinating polyneuropathy affecting motor more than sensory fibers [9, 10]. In some cases, particularly early in the course, distal conduction studies will be normal since demyelination may be largely proximal. Abnormalities may be limited to F waves, followed by patchy changes in distal latencies. As the disease progresses, the more classic features evolve, showing conduction block, temporal dispersion, and prolonged distal

and F-wave latencies. These classic findings may not be seen until several weeks into the illness. Various degrees of axonopathy may supervene reducing CMAP and SNAP potential amplitudes. This is accompanied by evidence of ongoing denervation on EMG. Low CMAP amplitudes with denervation provide the most reliable prognosis for slow recovery [11]. Sensory nerve conduction studies may show demyelinative slowing or less specific decrease in amplitude. One common feature of AIDP is preserved sural sensory conduction studies in the face of abnormal median and ulnar sensory studies [12]. This sural sparing may reflect the fact that this nerve is studied at a more proximal level than the nerves within the hand. Sural nerve biopsy is not routinely performed in cases with typical presentation especially if CSF findings or nerve conduction studies support the diagnosis. Pathologic studies of the AIDP form of GBS have shown changes similar to those found in experimental EAN [4]. There are areas of demyelination with variable lymphocytic infiltrates. Ultrastructural studies have revealed invasion of intact myelin lamellae by macrophages [13] (Fig. 16.1).

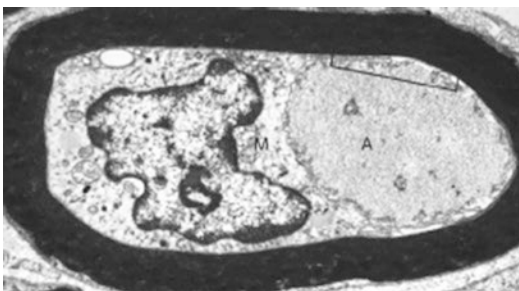

**Fig. 16.1** Electron micrograph from a case of AIDP demonstrating attack of myelin lamellae by macrophages (M). (Reprinted with permission from Hughes [148])

## GBS Variants

In the United States, Canada, and Europe, over 90% of GBS cases show AIDP as their underlying pathophysiology. The remaining minority of patients present as either acute primary axonopathies, the Miller Fisher variant or other regional variants. The existence of “axonal GBS” was long a matter of debate, until studies of GBS in China revealed that over 30% of cases could be classified as acute motor and sensory axonal neuropathy (AMSAN) or its pure motor counterpart acute motor axonal neuropathy (AMAN) [14]. These axonal subtypes show no evidence of demyelination on nerve conduction studies and typically present as quadriplegia with low amplitude or absent motor potentials and marked evidence of denervation on EMG. Pathologic studies confirm a primary axolemmal attack by macrophages [15]. An acute reversible pure motor syndrome marked by transient conduction block has been interpreted as a mild form of AMAN, where axolemmal attack may be limited to regions at nodes of Ranvier [16, 17] (Fig. 16.2).

The Miller Fisher variant of GBS presents with ophthalmoparesis, ataxia, and areflexia [18]. It accounts for approximately 5% of all GBS cases. Given its rarity and generally benign course, pathologic investigations have been lacking and the pathophysiology remains poorly elucidated. There is general agreement that cranial and sensory peripheral nerves are the primary targets of immune attack, though cases with accompanying limb weakness and CNS involvement have been



**Fig. 16.2** Electron micrograph from a case of AMAN demonstrating primary attack of a macrophage (M) on an axon (A) within an intact myelin sheath. (Reprinted with permission from Griffin et al. [149])

described. Nerve conduction studies typically reveal low amplitude or absent sensory nerve action potentials. These improve rapidly during clinical recovery, suggesting reversible demyelination or nodal conduction block as the underlying process [19, 20].

Other variants of GBS are even more rare and include pure sensory, pure autonomic presentations, as well as regional weakness (e.g., oropharyngeal variant). The underlying pathophysiology in some of these appears similar to that in AIDP. In other instances, distinct antibody profiles suggest different immune processes (see below).

## Immune Pathogenesis

The mechanisms of immune attack in GBS are complex, likely involving both cellular and humoral processes. Insights into cell-mediated hypersensitivity underlying AIDP have come from animal studies of EAN. Infiltrates of T-lymphocytes occur in areas of demyelination, in both AIDP and EAN [4]. Adoptive transfer studies in rats have demonstrated that injection of T cells sensitized to myelin proteins is sufficient to induce demyelination in peripheral nerve of naïve animals [21]. To what extent T-cell-mediated hypersensitivity accounts for AIDP is not clear. For AIDP, the triggering mechanism related to prior infection has not been delineated and antigenic protein targets in peripheral nerve myelin remain unspecified.

A clearer picture is emerging for antibody-mediated mechanisms in GBS variants (Table 16.1). Support for postinfectious molecular mimicry has advanced through investigations of anti-glycolipid antibodies in AMAN and Miller Fisher variants. Antibodies to gangliosides GM1, GM1b, or GD1a occur in approximately two-thirds of AMAN cases [22, 23]. These gangliosides localize to the axolemma and paranodal myelin of motor and sensory axons. Interestingly, antibodies to GD1a seem to bind selectively to motor axons, perhaps due to slight differences in GD1a fatty acid configuration in sensory axons [24]. About one-third of patients with AMAN

**Table 16.1** Antiganglioside antibodies associated with different subtypes of Guillain-Barré syndrome

GBS subtype	Antibodies
Acute inflammatory demyelinating polyradiculoneuropathy (AIDP)	Unknown
Acute motor and sensory axonal neuropathy (AMSAN)	GM1, GM1b, GD1a
Acute motor axonal neuropathy (AMAN)	GM1, GM1b, GD1a, GalNac-GD1a
Fisher syndrome	GQ1b, GD1b, GT1a
Oculopharyngeal variant	GT1a

Adapted from Ref. [22]

exhibit antibodies to a minor ganglioside (GalNac-GD1a), found only on motor axons [25].

Cases of Miller Fisher variant exhibit antibodies to another set of gangliosides. GQ1b ganglioside antibodies occur in over 85% of such cases, and interestingly, also occur in “overlap” cases of AIDP with ophthalmoparesis [22]. Though widely distributed in the PNS and optic nerves, the highest concentrations of GQ1b ganglioside occur at nodes of Ranvier and paranodal myelin in oculomotor cranial nerves [26]. A smaller percentage of Miller Fisher cases exhibit antibodies to GD1b and GT1a gangliosides. Antibodies to GD1b bind specifically to large neurons in dorsal root ganglia [24]. This suggests an underlying mechanism for the sensory ataxia and hyporeflexia. Along these lines, antibodies to GD1b also occur in cases of acute sensory neuronopathy [27]. GT1a antibodies may preferentially target cranial nerves as they occur in the oropharyngeal regional variant of GBS as well as in Miller Fisher cases [28].

Experimental studies in animals as well as findings from human trials of ganglioside therapy support a true pathogenic role for antiganglioside antibodies. Rabbits immunized with GM1 developed high titers of IgG antibodies and degeneration of ventral roots with pathologic findings similar to those in AMAN [29, 30]. Therapeutic trials of mixed ganglioside therapy for various neurologic disorders conducted in the 1990s resulted in a small number of acute neuropathies which closely resembled AMAN [31]. Melanoma patients receiving experimental monoclonal anti-ganglioside antibodies also developed an acute reversible neuropathy [32].

## ***Campylobacter* and Molecular Mimicry**

*Campylobacter* enteritis is the most common infection preceding GBS worldwide [33]. Although recognized as a prodrome for AIDP, *Campylobacter* infections are most closely associated with AMAN [34]. Studies of antiganglioside antibodies in AMAN and Miller Fisher variants have generated a coherent picture of molecular mimicry as a mechanism of postinfectious GBS. Lipooligosaccharides (LOSs) from certain strains of *Campylobacter* are structurally similar to various gangliosides. Such analogy was first documented between GM1 ganglioside and LOSs from *Campylobacter* infecting a patient with AMAN [35]. Later experimental studies in animals have supported a causal role of *Campylobacter* via molecular mimicry. Injection of appropriate bacterial LOSs into rabbits induced both GM1 antibodies and neuropathy resembling AMAN [30]. Strains of *Campylobacter* which precipitate the Miller Fisher variant exhibit LOSs structurally similar to GQ1b and GT1a gangliosides [36].

## **Treatment**

The most dramatic advances in the management of GBS have come with improvements in supportive ICU care. Vigilant monitoring and therapy for respiratory decompensation (including frequent measurements of forced vital capacity and maximal expiratory pressure), cardiac arrhythmia, blood pressure changes, and infections have had significant impact. These, along with preventative measures against deep vein thrombosis and pulmonary embolus have reduced overall mortality to 3–10% [37].

Beyond this, randomized placebo-controlled clinical trials have confirmed the benefit of immune-modulating therapies in GBS. The largest early trials of plasma exchange revealed significantly greater improvement in a disability scale at 4 weeks and faster recovery of ambulation [38, 39]. Subsequent studies documented that four exchange sessions (of 1.5 plasma

volumes each) accelerated recovery more than two sessions, but that recovery was no faster with six total sessions [40]. Data compiled from major plasma exchange trials indicates a higher rate of full recovery in strength compared with supportive treatment alone (relative rate of 1.24) [41].

Clinical trials have shown a comparable benefit from treatment with high-dose intravenous immune globulin (IVIG). Studies comparing IVIG to supportive treatment alone have been limited to small trials in children, and these indicated greater improvement in disability score and a higher rate of return to normal strength [42, 43]. Adult trials of IVIG have compared its effect to that of PE. The largest of these revealed equivalent improvement of a disability score at 4 weeks [44]. Smaller adult studies also failed to show significant differences between IVIG and PE in various outcome measures [45, 46]. A common dosing schedule for IVIG is 0.4 g/kg/day for 5 days, and it is not known whether this schedule is superior to administration of the same total dose over 2–3 days.

Overall, trials of corticosteroids have not shown significant benefit. Two trials of intravenous methylprednisolone produced no significant change in time to recovery or disability scores at 4 weeks to 6 months [47, 48]. Analysis of small trials using oral steroids indicated that they may have a negative effect at the 4-week mark [49, 50]. The combination of intravenous steroids and IVIG conferred no benefit over IVIG alone [51].

The choice between treatment with PE or IVIG usually depends on availability and side effect profile as their cost and efficacy are comparable. For these reasons, IVIG has become the preferred initial treatment. However, since trials of IVIG have entered patients only within 2 weeks of symptom onset, some guidelines endorse PE more strongly for treatment at 2–4 weeks [37]. There is limited evidence that ambulatory patients with milder disease may benefit from PE, while the effects of IVIG have not been tested in this group [40]. Data on axonal variants such as AMSAN and AMAN is insufficient to draw conclusions about the relative efficacy of IVIG and PE in these subgroups. A retrospective study has suggested that IVIG may provide more

benefit to GBS cases with GM1 antibodies [52], but this has not been rigorously proven and any practical utility would be limited by the time required for antibody testing in a clinical setting.

Both PE and IVIG treatment can be complicated by relapse within a few weeks of initial response [53]. In such cases, more sustained improvement usually follows a second course of the same treatment. Indications are less clear for patients that continue to deteriorate through their initial treatment. A large, controlled trial failed to show benefit from IVIG following a course of PE [44]. A very small observational study has suggested that patients continuing to worsen after initial IVIG treatment may benefit from a second course of IVIG [54]. Over time, the question of chronic inflammatory demyelinating polyradiculoneuropathy (CIDP) may arise in the setting of a protracted course. This is particularly so if progression occurs beyond 4 weeks or if symptoms occur 2 months after the onset of illness.

---

## CIDP

In its broadest definition, chronic inflammatory demyelinating polyradiculoneuropathy (CIDP) encompasses a wide variety of clinical presentations. Many chronic neuropathies involve some degree of immune-mediated demyelination. It is difficult to decide which of these should be included under the umbrella of CIDP. There is reasonable agreement concerning characteristics of “classic CIDP” but the classification of variant presentations continues to stir debate. From a practical standpoint, differential response to therapy should be a primary consideration in distinguishing various clinical entities.

## Clinical Features

Classic CIDP is often viewed as a chronic form of AIDP. As such, defining features include symmetric weakness of proximal and distal muscles, sensory disturbance involving large fiber modalities more than small, and generalized hyporeflexia. In contrast to AIDP, progression of



symptoms must extend beyond 8 weeks. Temporal evolution may be chronically progressive, stepwise progressive, or relapsing-remitting. There is a history of infection in the month preceding symptom onset in fewer than 20% of CIDP patients (as opposed to 70% of patients with AIDP) [55]. Involvement of cranial nerves occurs less frequently in CIDP than in AIDP (15% vs. 50%) [56]. Respiratory decompensation and dysautonomia are far less prevalent in CIDP. Urinary dysfunction and ventilatory failure complicate less than 25% and 10% of patients [57, 58].

Estimates of prevalence for classic CIDP have ranged from 1 to 4 cases per 100,000 in most populations [59–61]. This rate increases in patients with chronic viral infections of Hepatitis B and C as well as HIV.

Lymphoproliferative disorders including lymphomas are also associated with higher rates of CIDP as are lupus and other collagen vascular diseases. The prevalence of CIDP in diabetics exceeds general population rates and may be underestimated since neuropathies are less scrutinized within this group [62].

Monoclonal gammopathies are commonly associated with CIDP. Series collected within the last 25 years demonstrate paraproteinemia in 20–45% of patients with CIDP [63]. Clinical features and differential response to therapy distinguish the demyelinating neuropathies seen with a subset of paraproteinemic disorders (including POEMS syndrome and IgM gammopathies with anti-MAG antibodies) and these will be discussed separately below. Apart from these, CIDP associated with monoclonal gammopathies of undetermined significance (MGUS) is often viewed as similar to CIDP without paraproteinemia. However, the largest series comparing CIDP with and without MGUS noted that the MGUS cases were more indolent with less dramatic response to immunotherapy [64]. Some investigators have suggested that demyelinating neuropathies with IgM MGUS of any type are refractory to immunomodulating therapy [65, 66]. Other researchers have stressed that the high incidence of distally predominant weakness in IgM MGUS neuropathies accounts for this poor response. They advo-

cate classifying such cases as “Distal acquired demyelinating symmetric” (DADS) neuropathies, in contradistinction to CIDP [67].

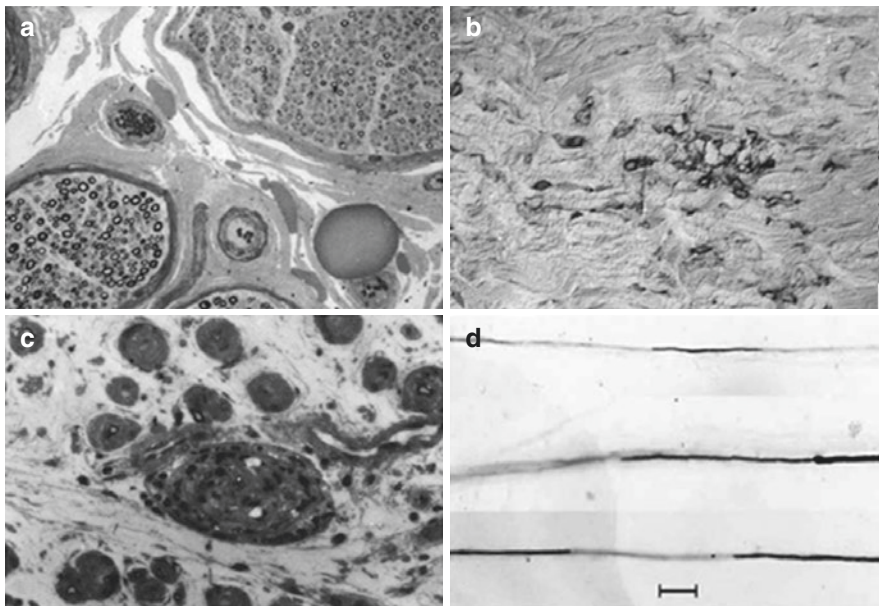
## Laboratory Studies

Most diagnostic criteria for CIDP require electrophysiologic findings of demyelination. Elevated CSF protein is generally considered supportive rather than requisite evidence, though over 90% of CIDP cases show levels exceeding 45 mg/dl [68]. CSF usually reveals fewer than 10 WBC. Cases of HIV-related CIDP often exhibit pleocytosis, but a WBC count exceeding 50 is extremely rare and excludes the diagnosis by some criteria [69]. Morphologic evaluation of autopsy material is limited and has shown abnormalities at the level of spinal roots and proximal nerve trunks. These include areas of segmental demyelination, remyelination, and onion-bulb formation. In addition, studies have found variable degrees of edema and inflammatory infiltrates within epineurium and endoneurium [70, 71]. Less specific findings of axonal degeneration along with clusters of regenerating axons have also been noted. In general, sural nerve biopsies are less helpful than electrodiagnostic studies and CSF analysis. Biopsies may appear relatively unremarkable or show axonal degeneration without the specific diagnostic findings seen at more proximal levels.

## Immune Pathogenesis

The immune mechanisms underlying CIDP are complex and only roughly delineated. As with AIDP, both cell-mediated and humorally mediated processes seem to contribute. There is evidence of T-cell activation and migration through the blood–nerve barrier. T cells infiltrating nerves are of CD4 and CD8 subgroups and may directly attack myelin in addition to activating macrophage attack and phagocytosis [72, 73].

Humoral immune processes have been implicated in CIDP by the observation of immunoglobulin and complement deposition on myelinated



**Fig. 16.3** CIDP. (a) Semi-thin section demonstrating loss of myelinated axons, more pronounced in the upper right fascicle. (b) Immunohistologic demonstration of lymphocytes within the endoneurium. (c) Higher power micrograph of a semi-thin section revealing endoneurial edema,

perivascular inflammation, and early onion bulbing around myelinated axons. (d) Teased fiber preparation demonstrating demyelinated segments of individual axons. ((a–c) Reprinted with permission from Rizzuto et al. [150]; (d) Reprinted with permission from Pytel et al. [151])

nerve fibers [74] as well as oligoclonal IgG bands in the CSF [75]. The therapeutic effect of plasma exchange in CIDP supports a humoral process. Further evidence derives from passive transfer experiments where serum or IgG from patients with CIDP cause nerve demyelination in rats [76]. Antibody responses to a number of targets in peripheral myelin have been identified including GM1 and other glycolipids [77, 78] as well as peripheral myelin protein 22 [79, 80].

Interestingly, more recent studies have proposed a novel concept of a “nodopathy,” whereby autoantibodies directed toward either the nodal or paranodal regions of a peripheral nerve may alter saltatory conduction and induce significant nerve dysfunction. The discovery of contactin-1 (CNTN1) and neurofascin-155 (NF155) antibodies have generated much interest in these areas of autoimmune attack. Other axo-glial autoimmune targets have been described, also located in these domains, and each region expresses a distinct set of proteins: Neurofascin 186, voltage-gated sodium channels, gliomedin, ankyrin G, and NRCAM are highly enriched at the node while

Caspr, contactin-1, and neurofascin 155 are enriched at the paranode. The paranodal antigens, in particular, CNTN1 and NF155, have been described in a small proportion of patients with CIDP wherein the presence of associated antibodies would predict a poor therapeutic response to IVIG therapy [81]. Despite these more recent findings, there is no predominant antigenic target yet identified to account for a major proportion of CIDP cases (Fig. 16.3).

## Treatment

Studies over the last 50 years have investigated the response of CIDP to immunomodulating therapy. The benefit of ACTH and oral steroids was initially recognized in the 1950s [82]. In 1982, Dyck et al. evaluated 35 patients in the only randomized, controlled trial of corticosteroids to date [83] and demonstrated a positive effect of prednisone on disability scores over 3 months. Progressive and relapsing cases showed similar improvement. Several observational

studies have also revealed benefit from corticosteroids. Overall, 60–75% of patients responded to treatment, though the first evidence of improvement occurred as late as 5 months in some cases [84].

Two randomized controlled trials of plasma exchange have demonstrated benefit in CIDP-related disability. The first compared 15 patients receiving six sessions of PE over 3 weeks with a parallel group receiving and sham exchange [85]. The second trial evaluated the effect of ten plasma exchange sessions over 4 weeks versus sham exchange in a crossover design [86]. Analysis of data combined from both trials revealed that approximately two-thirds of patients responded to active treatment. Responders improved rapidly, but the effect was short lived and rebound worsening occurred in some cases once treatment ceased. There was a moderate incidence of adverse events including myocarditis and stroke.

A greater number of rigorous studies have investigated the effects of IVIG in CIDP. At least seven randomized controlled trials have demonstrated benefit [87]. These have included various treatment schedules and most assessed change in disability within 1 month of treatment. The largest and most recent trial revealed sustained benefit from IVIG treatments (1 g/kg every 3 weeks) up to 24 weeks [88]. Studies comparing IVIG against corticosteroids [89] and plasma exchange [90] have demonstrated comparable benefits for these treatments.

With corticosteroids, PE and IVIG showing roughly equal efficacy, the choice of initial treatment for CIDP should weigh speed of response and side effect profile against convenience and cost. When available and affordable, IVIG is an option which acts rapidly with relatively few adverse effects. Risk of stroke and renal failure is generally low but may temper its use in patients with renal insufficiency and cerebrovascular disease. The main drawbacks to IVIG therapy are the cost and inconvenience of repeated treatments. Plasma exchange remains an alternative treatment for rapidly progressive CIDP but its invasive nature and lack of a home treatment option limit its suitability for long-term maintenance. Corticosteroid treatment is reasonable for debilitating but slowly progressive disease. Its

advantages include low initial cost, ease of administration and greater chance of inducing remission. Adverse effects accrue with longer steroid treatment and their associated long-term cost needs to be considered in comparing the economics of different therapies.

Approximately, two-thirds of the patients receiving any of the three major treatments will respond. Patients failing one of these treatments may show better response to either of the others [91]. For those refractory to all three, alternative immunosuppressants may prove beneficial. A number of series have demonstrated improvement with cyclophosphamide [92–96] or cyclosporine [97–101] and these are fairly frequently used in cases of debilitating refractory CIDP. However, there are no randomized controlled studies of these agents. A single controlled randomized trial evaluated azathioprine as add-on treatment to prednisone [102] but failed to show additional benefit. Since uncontrolled series have suggested a beneficial effect from azathioprine [68, 94], perhaps, its slow onset of action may help explain negative results in relatively short trials.

After an open label study of interferon beta [103] showed promise, it was evaluated as an IVIG sparing agent, but the study failed to show a benefit of adding interferon beta to IVIG. A slight benefit was noted in patients with severe disability and those requiring high doses of IVIG [104]. Recent data may suggest that rituximab is beneficial to the subset of treatment-resistant patients with antibodies against nodal and paranodal of proteins CNTN1 and NF155 [105]. Limited data suggests that alemtuzumab may also offer an alternative to traditional therapies for patients with refractory illness but further studies are needed and its use is experimental at this time [106]. There have been several trials of interferons (interferon-alfa 2a and interferon beta 1a) that did not demonstrate efficacy [107, 108]. A prospective placebo-controlled study of methotrexate failed to show significant benefit in allowing reduction in IVIG or corticosteroid dosing for CIDP patients [109]. Experimental treatments such as peripheral blood stem cell transplantation, have not demonstrated safety or efficacy to date [110]. There is little data regarding

nonpharmacologic interventions such as regular exercise but physical therapy referral should be considered for patients with CIDP for gait training and fall prevention when clinically indicated.

---

## CIDP Variants

### Multifocal Acquired Demyelinating Sensory and Motor Neuropathy (MADSAM)

This disorder, also known as Lewis-Sumner syndrome, is a demyelinating mononeuropathy multiplex marked by areas of persistent conduction block that affect both sensory and motor axons [111]. It presents with pain, paresthesia, and weakness in the distribution of individual nerves. Aside from this multifocality, it shares characteristics with classic CIDP. In addition to conduction block, electrodiagnostic studies reveal other demyelinating features including segmental slowing and temporal dispersion of potentials. Pathologic abnormalities resemble CIDP with inflammation and onion-bulb formation. Spinal fluid protein levels are frequently elevated. Most importantly, MADSAM and CIDP respond to the same range of immune therapies including corticosteroids, IVIG, and plasma exchange. There is general agreement that MADSAM represents a true variant form of CIDP, a fact underscored by the occasional evolution of multifocal cases into a more confluent picture of classic CIDP [112].

### Pure Sensory CIDP

Cases presenting the clinical picture of chronic pure sensory polyneuropathy may infrequently show electrophysiologic or pathologic evidence of a primary demyelinating process. Two small series have described cases with pathologic evidence of segmental demyelination on teased nerve preparations. However, one series revealed electrophysiologic evidence of demyelination in motor nerve fibers [113], where the other showed normal motor conduction or only axonopathic changes [114]. A third series demonstrated that CIDP cases with ini-

tial pure sensory presentations later developed motor deficits [115]. Taken together, these studies suggest that “sensory CIDP” may be part of a spectrum that includes more typical motor-predominant cases, rather than an entirely distinct entity. Though only limited data exist, sensory CIDP appears responsive to a similar range of immunomodulating treatment including corticosteroids, IVIG and plasma exchange.

### Distal Acquired Demyelinating Symmetric (DADS) Neuropathy

Some authors have drawn a distinction between chronic demyelinating neuropathies with limited, distal weakness and more classic CIDP. The former group which they refer to as DADS has a higher association with IgM monoclonal gammopathy. Patients with DADS and monoclonal gammopathy are predominantly male and older than CIDP patients on the average. They show significantly less response to immunomodulating therapy [67]. The features of DADS patients without gammopathy are less consistent.

### Multifocal Motor Neuropathy

This disorder presents as a chronic, motor-selective mononeuropathy multiplex. Although clinically it resembles motor neuron disease, its physiologic hallmark of motor conduction block has led many to classify it as a variant of CIDP [116]. Response to immunomodulating therapy has strengthened the association between MMN and CIDP. However, some investigators have emphasized the differences between these two disorders [117]. Conduction block in MMN may involve alterations in axolemmal properties rather than simple demyelination [118]. Moreover, the number of effective immunomodulating treatments is more limited for MMN than for CIDP.

### Clinical Features

MMN is an uncommon disorder with a prevalence of 1–2 cases per 100,000. It usually begins in young adulthood or middle age and affects men at least twice as often as women. Presenting as weakness

within the distribution of individual nerves, the lack of associated pain and sensory deficit differentiates MMN from other inflammatory mononeuropathies and nerve entrapments. Initially, weakened muscles may retain their bulk but atrophy supervenes with progressive axonal degeneration over time. Cramps and fasciculations are common symptoms. Upper motor neuron signs are not attributable to MMN and their presence would indicate an alternative or additional diagnosis.

The vast majority of patients with MMN suffer weakness in the distal upper extremities but foot drop is not uncommon. Involvement of cranial and phrenic nerves has been reported but is rare. Slowly progressive weakness is the most common course, though spontaneous improvement is occasionally seen. Acute presentations of multifocal motor neuropathies with rapid resolution have been described, but these may be more closely related to Guillain-Barré syndrome than MMN [16, 17].

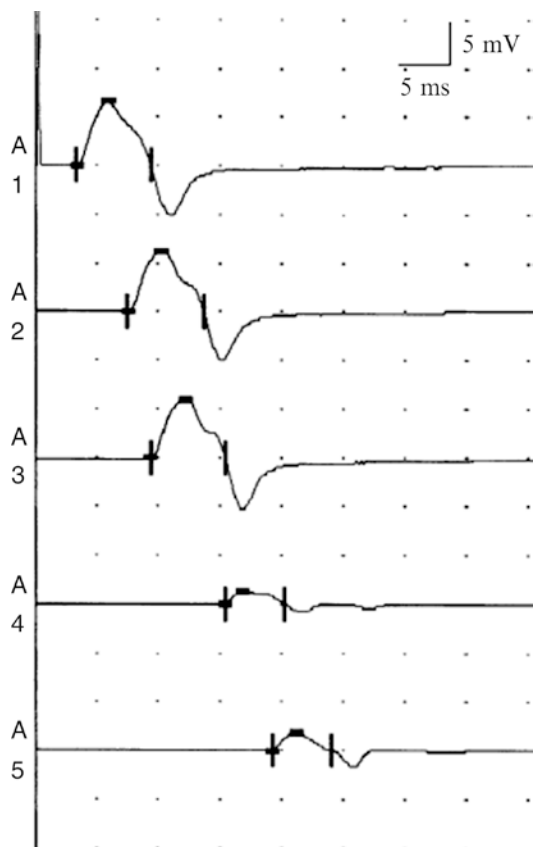
### Laboratory Studies

Motor conduction block is a defining characteristic of MMN. A particular feature of conduction block in MMN is its selectivity for motor axons with preserved conduction in sensory fibers through the same length of nerve. It is more commonly found in the forearm and calf than in more proximal segments of nerves or roots. This may, in part, reflect the technical difficulty of demonstrating conduction block at proximal levels, but the distribution of weak muscles is at least consistent with a distal predominance. In contrast to many cases of MADSAM or CIDP, sensory conduction studies and motor conduction outside the regions of block reveal only mild abnormalities. EMG of weakened muscles shows evidence of ongoing and chronic denervation, especially in cases of longstanding weakness.

IgM antibodies to gangliosides (mostly GM1 but also GD1a and GM2) can be detected in approximately half of the patients with MMN [119]. Estimates have ranged from 20% to 80% of MMN patients showing such antibodies with differences in assays likely accounting for much of this variation. Though GM1 antibodies are sometimes detected in disorders other than

MMN, reviews have indicated that their specificity is sufficiently high to confer clinical utility in supporting the diagnosis [120]. Other blood testing is usually unremarkable in MMN. CSF protein is normal in approximately half of cases with mild elevation in most of the other half.

Sural nerve biopsies have generally not shown dramatic or specific abnormalities. Mild demyelinating features have been noted on some electron microscopic studies [121]. Motor nerve fascicular biopsies at confirmed sites of conduction block have shown loss of large myelinated fibers without evidence of demyelination [122] (Fig. 16.4).



**Fig. 16.4** Conduction block in the ulnar nerve of a patient with MMN. Compound motor action potentials elicited from abductor digiti quinti by stimulation at the wrist (A1), below elbow (A2), above elbow (A3), axilla (A4), and Erb's point (A5). Reduction in amplitude by more than 50% demonstrates conduction block between the elbow and axilla. (Modified from Van Den Berg-Vos et al. [152])

## Immune Pathogenesis

Response to immunomodulating therapy and the frequent association of antiganglioside antibodies have fostered the notion that MMN is an autoimmune disorder. However, its pathogenesis remains largely unspecified. Disruption of paranodal myelin or axolemma mediated by GM1 antibodies is an attractive hypothesis, yet not all experimental studies have supported this [123]. GM1 ganglioside is enriched at paranodal myelin and particularly on motor axons. Intraneural injection of serum from MMN patients has induced conduction block both in vivo [124] and in vitro [125]. However, similar experiments using purified GM1 antibodies failed to show conduction block [126]. Whether this reflects an artifact of the purification process or indicates a role for other components of the transferred serum is not clear. Similar to CIDP, antibody reactivity to the nodal and paranodal proteins NF155 and CNTN1 have been previously suggested in MMN; however, a recently published study using confirmatory cell-based assay and indirect immunofluorescence determined that these antibodies were in fact absent in all MMN cases [81]. Although MMN is not typically recognized as a postinfectious disorder, a few case reports have described multifocal motor neuropathies with highly elevated levels of GM1 antibodies following *Campylobacter jejuni* enteritis [16, 17, 127]. These included acute, monophasic, and chronic relapsing presentations, raising the possibility that some cases of MMN may share the mechanism of molecular mimicry proposed for GBS following *Campylobacter* enteritis.

## Treatment

Although cyclophosphamide was the earliest recognized treatment of MMN [128], there is now general agreement that IVIG should be offered as initial therapy. At least four randomized controlled trials have demonstrated significant benefit with IVIG [129–132]. Overall, 75–80% of patients treated with IVIG showed improvement in strength, and this effect was often rapid. No serious adverse effects were reported in random-

ized trials, though minor symptoms such as headache, rash, and fever were encountered in over half the participants.

Corticosteroids and plasma exchange have consistently proven ineffective in patients with MMN. Furthermore, there are reports of worsening deficits following treatment with these agents [114]. This contrasts with the beneficial effect seen in many cases of classic CIDP or MADSAM and supports the concept of MMN as a distinct disorder.

Patients unresponsive to IVIG, or in whom its effect wanes with repeated treatments, may benefit from cytotoxic agents. A number of reports have shown improvement with cyclophosphamide [128, 133, 134], but it should be considered only for patients with significant deficit since it may cause serious adverse effects. Experience with azathioprine, rituximab, and beta-interferon has been much more limited. A randomized controlled trial of mycophenolate mofetil failed to show benefit in reducing the requirement for IVIG in 28 patients with MMN [135]. Given the long-term requirement for IVIG in most patients with MMN, continued efforts to identify more convenient and affordable treatments are warranted.

## Neuropathies Associated with Monoclonal Gammopathy

An estimated 10% of otherwise idiopathic polyneuropathies are associated with monoclonal gammopathy [136, 137]. This includes neuropathy complicating malignant plasma cell dyscrasias, and more commonly, neuropathy seen in conjunction with monoclonal gammopathies of undetermined significance (MGUS). Neuropathic symptoms often lead to the initial recognition of a gammopathy. Moreover, the existence of a neuropathy is of prognostic importance in MGUS as it confers a greater risk of eventual transformation to a malignant gammopathy. This section will describe the features of neuropathies associated with various malignant gammopathies and MGUS.

## Malignant Gammopathies

Waldenström's macroglobulinemia (WM), a lymphoplasmacytic lymphoma with monoclonal IgM, is often complicated by neuropathy. When prospectively studied, nearly half of patients with WM develop neuropathic symptoms or signs [138]. Sensory deficits predominate, involving both large and small fiber modalities. When weakness occurs, it is largely distal. Conduction studies show evidence of demyelination in a number of cases with prolonged distal latencies, slow conduction velocities but little conduction block. In approximately half of the demyelinating neuropathies, the IgM paraprotein reacts against MAG. These patients resemble MGUS patients with anti-MAG antibodies described below. Less frequently, patients with WM will suffer mononeuropathy multiplex due to amyloid deposition. Neuropathy will often improve with alkylating agents used to treat WM. Rituximab in combination with cyclophosphamide or fludarabine can also improve neuropathy. However, there are reports of dramatic worsening of neuropathy with rituximab in some cases [139, 140].

Although patients with multiple myeloma (MM) frequently show abnormalities on nerve conduction studies, only about 10% suffer significant neuropathic symptoms [141]. Typically, the neuropathy is distal, symmetric, and sensory-motor, with features of primary axonal degeneration. Pathologic studies reveal perineural deposition of IgG and IgM. Less frequently, the presentation is one of mononeuropathy multiplex due to infiltration of amyloid. Neuropathies associated with MM are generally refractory to treatment [128].

Osteosclerotic myeloma, as part of POEMS syndrome, occurs less frequently than MM but has a much higher rate of associated neuropathy [142]. The neuropathy commonly involves sensory loss in both small and large fiber modalities along with weakness. These symptoms begin distally but can advance to produce significant proximal weakness and loss of mobility. Nerve conduction studies show evidence of demyelination with prolonged distal latencies, slow con-

duction velocities, and temporal dispersion of motor potentials. Associated paraproteins are IgG or IgA with lambda light chains. Pathologic studies revealing endoneurial deposition of light chains argue that the paraproteins are pathogenic. Recent evidence has also implicated high-level production of VEGF and cytokines by the plasmacytomas [143]. The resultant proliferation of perineural vasculature and breakdown of the blood-nerve barrier lead to edema and demyelination. The marked increase in CSF protein seen in POEMS cases likely reflects these vascular changes. In cases with solitary or limited plasmacytomas, their irradiation or surgical excision can lead to resolution of the neuropathy along with skin and endocrinologic manifestations of POEMS syndrome.

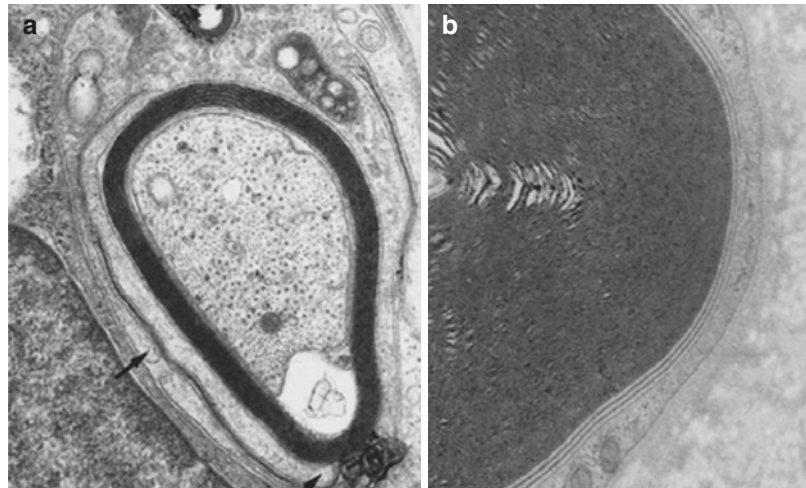
## Monoclonal Gammopathy of Undetermined Significance (MGUS)

Over two-thirds of monoclonal gammopathies fall into the category of MGUS. These are characterized by a low level of paraprotein (less than 3 g/dl) in serum, little or no urinary paraprotein and less than 5% plasma cells in the bone marrow. By definition, MGUS lacks features of malignant gammopathies such as anemia, renal failure, bone lesions, or amyloid deposition. The former designation of "benign monoclonal gammopathy" was abandoned as nearly one-quarter of cases ultimately undergo malignant transformation.

Although most cases of MGUS involve IgG paraproteins, 60% of cases with neuropathy show an IgM paraprotein compared to 30% with IgG and 10% with IgA [144, 145]. A variety of neuropathies occur with MGUS of each type, but cases of IgM MGUS are associated with the most distinct forms of neuropathy. In approximately, half of IgM MGUS-related neuropathies, antibodies react with myelin-associated glycoprotein (MAG) [146].

Anti-MAG neuropathy most commonly afflicts older men. Their clinical presentation is

**Fig. 16.5** (a) Electron micrographs demonstrating separation of outer myelin lamellae (arrow) in a case of IgM MGUS neuropathy. (b) A higher power electron micrograph showing similar separation of outer lamellae from another case of IgM MGUS neuropathy. (Reprinted with permission from Vital et al. [153])



marked by painless, gradual, distal loss of large fiber sensory modalities. This, along with distal weakness leads to a slowly progressive gait disorder. Nerve conduction studies reveal evidence of distal demyelination with disproportionate slowing of distal motor and sensory latencies. Nerve biopsies have shown separation of outer lamellae in myelin sheaths, a characteristic that anti-MAG cases may share with other IgM MGUS neuropathies (Fig. 16.5).

Neuropathy in many patients with IgM MGUS, but without specified autoantibodies, resembles the anti-MAG neuropathy described above. The category of distal acquired demyelinating sensorimotor (DADS) neuropathy is largely composed of IgM MGUS neuropathy. In general, their response to immunomodulating therapy is more modest than IgG and IgA MGUS neuropathies. Randomized controlled studies have shown short-term response to IVIG, but the overall benefit in these slowly progressive disorders is less clear. Small, uncontrolled series have reported benefit with fludarabine, cyclophosphamide, and rituximab. However, more systematic trials with long-term follow-up would be advisable for these potentially toxic treatments for a slowly progressive disorder.

Specific autoantibodies have not been identified for neuropathies in IgG and IgA MGUS. Therefore, a causal role for these paraproteins is less apparent. Associated neuropathies include

CIDP which does not differ significantly from classic CIDP and generally shows similar response to treatment.

### Vasculitic Neuropathy

Vasculitic neuropathy may arise in the context of systemic vasculitis or as a disorder limited to the peripheral nervous system (i.e., nonsystemic vasculitic neuropathy). Of the systemic vasculitides involving peripheral nerves, polyarteritis nodosa and rheumatoid vasculitis account for the majority of cases. Several other connective tissue disorders and infections comprise the remainder [147]. Clinical presentation, pathology, and electrophysiology are similar for neuropathies of systemic and nonsystemic vasculitis and have been discussed in detail in a separate chapter.

### Conclusion

Autoimmune neuropathies are defined largely by their clinical and electrodiagnostic features. GBS and CIDP are broad syndromic disorders, reflecting varied underlying pathophysiologic mechanisms. IVIG, corticosteroids, and plasmapheresis remain the principle treatments but identification of specific autoantibodies has begun to refine therapeutic approaches.



## References

- Guillain G, Barré JA, Strohl A. Sur un syndrome de radiculonévrite avec hyperalbuminose du liquide céphalo-rachidien sans réaction cellulaire. Remarques sur les caractères cliniques et graphiques des réflexes tendineux. *Bull Soc Méd Hôp Paris*. 1916;40:1462–70.
- Guillain G. Considerations sur le syndrome de Guillain-Barré. *Ann Med Interne*. 1953;54:81–149.
- Waksman BH, Adams RD. Allergic neuritis: experimental disease of rabbits induced by the injection of peripheral nervous tissue and adjuvants. *J Exp Med*. 1955;102:213–21.
- Asbury AK, Arnason BG, Adams RD. The inflammatory lesion in idiopathic polyneuritis. Its role in pathogenesis. *Medicine*. 1969;48:173–215.
- Haymaker W, Kernohan JW. The Landry Guillain Barre Syndrome: a clinicopathologic report of fifty fatal cases and a critique of the literature. *Medicine*. 1949;28:59–68.
- Ropper AH. The Guillain-Barre syndrome. *N Engl J Med*. 1992;326:1130.
- Gorson KC, Ropper AH. Guillain-Barre syndrome (acute inflammatory demyelinating polyneuropathy) and related disorders. In: Katirji B, Kaminski HJ, Preston DC, Ruff RL, Shapiro BE, editors. *Neuromuscular disorders in clinical practice*. Boston: Butterworth Heinemann; 2002. p. 544–66.
- Thaisetthawatkul P, Logigian EL. Peripheral nervous system manifestations of lyme borreliosis. *J Clin Neuromuscul Dis*. 2002;3(4):165–71.
- Albers JW, Donofrio PD, McGonagle TK. Sequential electrodiagnostic abnormalities in acute inflammatory demyelinating polyradiculoneuropathy. *Muscle Nerve*. 1985;6:504–9.
- Cornblath DR. Electrophysiology in Guillain-Barré syndrome. *Ann Neurol*. 1990;27(Suppl):S17–20.
- Cornblath MP, Mellits ED, Griffin JW, et al. Motor conduction studies in Guillain-Barre syndrome: description and prognostic value. *Ann Neurol*. 1988;23:354–9.
- Deepak G, Muraleedharan N, Baheti NN, Sarma SP, Abraham K. Electrodiagnostic and clinical aspects of Guillain-Barré syndrome: an analysis of 142 cases. *J Clin Neuromuscul Dis*. 2008;10(2):42–51.
- Prineas JW. Acute idiopathic polyneuritis. An electron microscope study. *Lab Invest*. 1972;26:133–47.
- McKhann GM, Cornblath DR, Griffin JW, et al. Acute motor axonal neuropathy: a frequent cause of acute flaccid paralysis in China. *Ann Neurol*. 1993;33(4):333–42.
- Hafer-Macko C, Hsieh ST, Li CY, et al. Acute motor axonal neuropathy: an antibody-mediated attack on axolemma. *Ann Neurol*. 1996;40:635–44.
- White JR, Sachs GM, Gilchrist J. Multifocal motor neuropathy with conduction block and *Campylobacter jejuni*. *Neurology*. 1996;46(2):562–3.
- Abruzzese M, Reni L, Schenone A, Mancardi GL, Primavera A. Multifocal motor neuropathy with conduction block after *Campylobacter jejuni* enteritis. *Neurology*. 1997;48:544.
- Fisher M. An unusual variant of acute immune polyneuritis (syndrome of ophthalmoplegia, ataxia, and areflexia). *N Engl J Med*. 1956;255:57–65.
- Guiloff RJ. Peripheral nerve conduction in Miller Fisher syndrome. *J Neurol Neurosurg Psychiatry*. 1977;40:801–7.
- Fross RD, Daube J. Neuropathy in the Miller-Fisher syndrome: clinical and electrophysiologic findings. *Neurology*. 1987;37:1493–8.
- Wietholder H, Hulser PJ, Meier DH, Wessel K. Electrophysiological follow up of experimental allergic neuritis mediated by permanent T cell lines in rats. *J Neurol Sci*. 1988;83:1–12.
- Hughes RA, Cornblath DR. Guillain Barre syndrome. *Lancet*. 2005;366:1653–66.
- Ogawara K, Kuwabara S, Mori M, et al. Axonal Guillain Barre syndrome: relation to antiganglioside antibodies and *Campylobacter jejuni* infection in Japan. *Ann Neurol*. 2000;48:624–31.
- Gong Y, Tagawa Y, Lunn MP, et al. Localization of major gangliosides in the PNS. *Brain*. 2002;125:2491–9.
- Yoshino H. Distribution of gangliosides in the nervous tissues recognized by axonal form of Guillain Barre syndrome. *Neuroimmunology*. 1997;5:174–82.
- Chiba A, Kusunoki S, Obata H, Machinami R, Kanazawa I. Ganglioside composition of the human cranial nerves, with special reference to pathophysiology of Miller Fisher syndrome. *Brain Res*. 1997;745:32–6.
- Notturmo F, Caporale CM, Uncini A. Acute sensory ataxic neuropathy with antibodies to GD1b and GQ1b gangliosides and prompt recovery. *Muscle Nerve*. 2008;37:265–8.
- Nagashima T, Koga M, Odaka M, Hirata K, Yuki N. Clinical correlates of serum anti-GT1a IgG antibodies. *J Neurol Sci*. 2004;219:139–45.
- Susuki K, Nishimoto Y, Yamada M, et al. Acute motor axonal neuropathy rabbit model: immune attack on nerve root axons. *Ann Neurol*. 2003;54:383–8.
- Yuki N, Yamada M, Koga M, et al. Animal model of axonal Guillain-Barré syndrome induced by sensitization with GM1 ganglioside. *Ann Neurol*. 2001;49:712–20.
- Illa I, Ortiz N, Gallard E, Juarez C, Grau JM, Dalakas MC. Acute axonal Guillain-Barré syndrome with IgG antibodies against motor axons following parenteral gangliosides. *Ann Neurol*. 1995;38:218–24.
- Saleh MN, Khazaeli MB, Wheeler RH, et al. Phase I trial of the murine monoclonal anti-GD2 antibody 14G2a in metastatic melanoma. *Cancer Res*. 1992;52:4342–7.
- Hughes RA, Hadden RD, Gregson NA, Smith KJ. Pathogenesis of Guillain Barre syndrome. *J Neuroimmunol*. 1999;100:74–97.

34. Kuwabara S, Ogawara K, Misawa S, et al. Does *Campylobacter jejuni* infection elicit “demyelinating” Guillain-Barré syndrome? *Neurology*. 2004;63:529–33.
35. Yuki N, Yoshino H, Sato S, et al. Acute axonal polyneuropathy associated with GM1 antibodies following *Campylobacter jejuni* enteritis. *Neurology*. 1990;40:1900–3.
36. Koga M, Gilbert M, Li J, et al. Antecedent infections in Fisher syndrome: a common pathogenesis of molecular mimicry. *Neurology*. 2005;64:1605–11.
37. Hughes RA, Wijdicks EF, Barohn R, Quality Standards Subcommittee of the American Academy of Neurology, et al. Practice parameter: immunotherapy for Guillain-Barré syndrome: report of the Quality Standards Subcommittee of the American Academy of Neurology. *Neurology*. 2003;61(6):736–40.
38. The Guillain-Barré Syndrome Study Group. Plasmapheresis and acute Guillain-Barré syndrome. *Neurology*. 1985;35:1096–104.
39. French Cooperative Group on Plasma Exchange in Guillain-Barré Syndrome. Plasma exchange in Guillain-Barré syndrome: one-year follow-up. *Ann Neurol*. 1992;32:94–7.
40. French Cooperative Group on Plasma Exchange in Guillain-Barré Syndrome. Appropriate number of plasma exchanges in Guillain-Barré syndrome. *Ann Neurol*. 1997;41:298–306.
41. Hughes R, Swan A, Raphael J, Annane D, Van Koningsveld R, Van Doorn P. Immunotherapy for Guillain-Barré syndrome: a systematic review. *Brain*. 2007;130:2245–57.
42. Gurses N, Uysal S, Cetinkaya F, Icslek I, Kalayci AG. Intravenous immunoglobulin treatment in children with Guillain-Barré syndrome. *Scand J Infect Dis*. 1995;27:241–3.
43. Korinthenberg R, Schessl J, Kirschner J, Mönning JS. Intravenous immunoglobulin in the treatment of childhood Guillain-Barré syndrome. *Pediatrics*. 2005;116:8–14.
44. Plasma Exchange/Sandoglobulin Guillain-Barré Syndrome Trial Group. Randomised trial of plasma exchange, intravenous immunoglobulin, and combined treatments in Guillain-Barré syndrome. *Lancet*. 1997;349:225–30.
45. Nomura T, Hamaguchi K, Hattori T, Satou T, Mannen T, et al. A randomized controlled trial comparing intravenous immunoglobulin and plasmapheresis in Guillain-Barré syndrome. *Neurol Ther*. 2000;18:69–81.
46. Diener HC, Haupt WF, Kloss TM, Rosenow F, Philipp T, Koeppon S, et al. A preliminary, randomized, multicenter study comparing intravenous immunoglobulin, plasma exchange, and immune adsorption in Guillain-Barré syndrome. *Eur Neurol*. 2001;46:107–9.
47. Guillain-Barré Syndrome Steroid Trial Group. Double-blind trial of intravenous methylprednisolone in Guillain-Barré syndrome. *Lancet*. 1993;341:586–90.
48. Garcia AC, Vidal BE, Rebolledo A, Texeira F, Ordaz FA, Futrán YJ. Treatment of the acute phase of Guillain-Barré-Strohl syndrome with megadosis of methylprednisolone. *Rev Invest Clín (Méx)*. 1985;37:119–24.
49. Shukla SK, Agarwal R, Gupta OP, Pande G, Mamta S. Double blind control trial of prednisolone in Guillain-Barré syndrome – a clinical study. *Clinician*. 1988;52:128–34.
50. Singh NK, Gupta A. Do corticosteroids influence the disease course or mortality in Guillain-Barré syndrome. *J Assoc Physicians India*. 1996;44:22–4.
51. Van Koningsveld R, Schmitz PIM, van der Meché FGA, Dutch GBS Study Group. Effect of methylprednisolone when added to standard treatment with intravenous immunoglobulin for Guillain-Barré syndrome: randomised trial. *Lancet*. 2004;363:192–6.
52. Kuwabara S, Masahiro M, Ogawara K, et al. Intravenous immunoglobulin therapy for Guillain-Barré syndrome with IgG anti-GM1 antibody. *Muscle Nerve*. 2001;24(1):54–8.
53. Ropper AH, Albers JW, Addison R. Limited relapse in Guillain-Barré syndrome after plasma exchange. *Arch Neurol*. 1988;45(3):314–5.
54. Farcas P, Avnun L, Frisher S, Herishanu YO, Wirguin I. Efficacy of repeated intravenous immunoglobulin in severe unresponsive Guillain-Barré syndrome. *Lancet*. 1997;350:1747.
55. Bouchard C, Lacroix C, Plante V, et al. Clinicopathologic findings and prognosis of chronic inflammatory demyelinating polyneuropathy. *Neurology*. 1999;52:498–503.
56. Rotta FT, Sussman AT, Bradley WG, Ram Ayyar D, Sharma KR, Shebert RT. The spectrum of chronic inflammatory demyelinating polyneuropathy. *J Neurol Sci*. 2000;173:129–39.
57. Sakakibara R, Hattori T, Kuwabara S, et al. Micturitional disturbance in patients with chronic inflammatory demyelinating polyneuropathy. *Neurology*. 1998;50:1179–85.
58. Gorson KC, Ropper AH. Chronic inflammatory demyelinating polyradiculoneuropathy (CIDP): a review of clinical syndromes and treatment approaches in clinical practice. *J Clin Neuromuscul Dis*. 2003;4(4):174–89.
59. Chio A, Cocito D, Bottacchi E, et al. Idiopathic chronic inflammatory demyelinating polyneuropathy: an epidemiological study in Italy. *J Neurol Neurosurg Psychiatry*. 2007;78:1349.
60. McCleod JG, Pollard JD, Macaskill P, Mohamed A, Spring P, Khurana V. Prevalence of chronic inflammatory demyelinating polyneuropathy in New South Wales, Australia. *Ann Neurol*. 1999;46:910–3.
61. Mygland A, Monstad P. Chronic polyneuropathies in Vest-Agder, Norway. *Eur J Neurol*. 2001;8:157–65.

62. Stewart JD, McKelvey R, Durcan L, et al. Chronic inflammatory demyelinating polyneuropathy (CIDP) in diabetics. *J Neurol Sci.* 1996;142:59–64.
63. Cocito D, Durelli L, Isoardo G. Different clinical, electrophysiological and immunological features of CIDP associated with paraproteinemia. *Acta Neurol Scand.* 2003;108:274–80.
64. Simmons Z, Albers JW, Bromberg MB, Feldman EL. Presentation and initial clinical course in patients with chronic inflammatory demyelinating polyradiculoneuropathy: comparison of patients without and with monoclonal gammopathy. *Neurology.* 1993;43:2202–9.
65. Dyck PJ, Dyck PJB. Atypical varieties of chronic demyelinating neuropathies. *Lancet.* 2000;355(9212):1293–4.
66. Dyck PJ, Low PA, Windebank AJ, et al. Plasma exchange in polyneuropathy associated with monoclonal gammopathy of undetermined significance. *N Engl J Med.* 1991;325(21):1482–6.
67. Katz JS, Saperstein DS, Gronseth G, Amato AA, Barohn RJ. Distal acquired demyelinating symmetric neuropathy. *Neurology.* 2000;54(3):615–20.
68. Barohn RJ, Kissel JT, Warmolts JR, Mendell JR. Chronic inflammatory demyelinating polyradiculoneuropathy. Clinical characteristics, course, and recommendations for diagnostic criteria. *Arch Neurol.* 1989;46(8):878–84.
69. Research criteria for diagnosis of chronic inflammatory demyelinating polyneuropathy (CIDP). Report from an Ad Hoc Subcommittee of the American Academy of Neurology AIDS Task Force. *Neurology.* 1991;41:617.
70. Dyck PJ, Prineas J, Pollard J. Chronic inflammatory demyelinating polyneuropathy. In: Dyck PJ, Thomas PK, Griffin JW, et al., editors. *Peripheral neuropathy.* Philadelphia: W.B. Saunders; 1993. p. 1498–517.
71. Krendel DA, Parks HP, Anthony DA, et al. Sural nerve biopsy in chronic inflammatory demyelinating polyradiculoneuropathy. *Muscle Nerve.* 1989;12:257–64.
72. Kieseier BC, Dalakas MC, Hartung HP. Immune mechanisms in chronic inflammatory demyelinating neuropathy. *Neurology.* 2002;59:S7.
73. Kiefer R, Kieseier BC, Stoll G, Hartung HP. The role of macrophages in immune-mediated damage to the peripheral nervous system. *Prog Neurobiol.* 2001;64:109–14.
74. Dalakas MC, Engel WK. Immunoglobulin and complement deposits in nerves of patients with chronic relapsing polyneuropathy. *Arch Neurol.* 1980;37:637.
75. Dalakas MC, Houff SA, Engel WK, et al. CSF “monoclonal” bands in chronic relapsing polyneuropathy. *Neurology.* 1980;30:86.
76. Yan WX, Taylor J, Andrias-Kauba S, Pollard JD. Passive transfer of demyelination by serum or IgG from chronic inflammatory demyelinating polyneuropathy patients. *Ann Neurol.* 2000;47:765–70.
77. Ilyas AA, Mithen FA, Dalakas MC, et al. Antibodies to acidic glycolipids in Guillain-Barre syndrome and chronic inflammatory demyelinating polyneuropathy. *J Neurol Sci.* 1992;107:111–9.
78. Melendez-Vasquez C, Redford J, Choudary PP, et al. Immunological investigation of chronic inflammatory demyelinating polyneuropathy. *J Neuroimmunol.* 1997;73:124–31.
79. Gabriel CM, Gregson NA, Hughes RA. Anti-PMP22 antibodies in patients with inflammatory neuropathy. *J Neuroimmunol.* 2000;104:139–45.
80. Ritz MF, Lechner-Scott J, Scott RJ, et al. Characterization of autoantibodies to peripheral myelin protein 22 in patients with hereditary and acquired neuropathies. *J Neuroimmunol.* 2000;104:155–61.
81. Mathey EK, Garg N, Park SB, Nguyen T, Baker S, Yuki N, Yiannikas C, Kiernan MC, et al. Autoantibody responses to nodal and paranodal antigens in chronic inflammatory neuropathies. *J Neuroimmunol.* 2017;309:41–6.
82. Austin JH. Recurrent polyneuropathies and their corticosteroid treatment. With five-year observations of a placebo controlled case treated with corticotrophin, cortisone and prednisone. *Brain.* 1958;81(2):157.
83. Dyck PJ, O’Brien PC, Oviatt KF, Dinapoli RP, Daube JR, Bartleson JD, et al. Prednisone improves chronic inflammatory polyradiculoneuropathy more than no treatment. *Ann Neurol.* 1982;11:136–41.
84. Mehndiratta MM, Hughes RA. Corticosteroids for chronic inflammatory demyelinating polyradiculoneuropathy. *Cochrane Database Syst Rev.* 2002;11:CD002062.
85. Dyck PJ, Daube J, O’Brien P, Pineda A, Low PA, Windebank AJ, et al. Plasma exchange in chronic inflammatory demyelinating polyradiculoneuropathy. *N Engl J Med.* 1986;314:461–5.
86. Hahn AF, Bolton CF, Pillay N, Chalk C, Benstead T, Bril V, et al. Plasma exchange in chronic inflammatory demyelinating polyradiculoneuropathy. A double blind, sham-controlled, crossover study. *Brain.* 1996;119(Pt 4):1055–66.
87. Eftimov F, Winer JB, Vermeulen M, de Haan R, van Schaik IN. Intravenous immunoglobulin for chronic inflammatory demyelinating polyradiculoneuropathy. *Cochrane Database Syst Rev.* 2009;(1):CD001797. <https://doi.org/10.1002/14651858.CD001797.pub2>
88. Hughes RA, Donofrio P, Bril V, et al. Intravenous immune globulin (10% caprylate-chromatography purified) for the treatment of chronic inflammatory demyelinating polyradiculoneuropathy (ICE study): a randomised placebo-controlled trial. *Lancet Neurol.* 2008;7(2):136–44.
89. Hughes R, Bensa S, Willison H, et al. Randomized controlled trial of intravenous immunoglobulin versus oral prednisolone in chronic inflammatory demyelinating polyradiculoneuropathy. *Ann Neurol.* 2001;50(2):195–201.
90. Dyck PJ, Litchy WJ, Kratz KM, Suarez GA, Low PA, Pineda AA, et al. A plasma exchange versus

- immune globulin infusion trial in chronic inflammatory demyelinating polyradiculoneuropathy. *Ann Neurol*. 1994;36(6):838–45.
91. Gorson KC, Allam G, Ropper AH. Chronic inflammatory demyelinating polyneuropathy: clinical features and response to treatment in 67 consecutive patients with and without a monoclonal gammopathy. *Neurology*. 1997;48:321.
92. Dalakas MC, Engel WK. Chronic relapsing (dysimmune) polyneuropathy: pathogenesis and treatment. *Ann Neurol*. 1981;9(Suppl):134–45.
93. Brannagan TH, Pradhan A, Heiman-Patterson T, Winkelman AC, Styler MJ, Topolsky DL, et al. High-dose cyclophosphamide without stem-cell rescue for refractory CIDP. *Neurology*. 2002;58(12):1856–8.
94. McCombe PA, Pollard JD, McLeod JG. Chronic inflammatory demyelinating polyradiculoneuropathy. A clinical and electrophysiological study of 92 cases. *Brain*. 1987;110(Pt 6):1617–30.
95. Gladstone DE, Prestrud AA, Brannagan TH III. High-dose cyclophosphamide results in long-term disease remission with restoration of a normal quality of life in patients with severe refractory chronic inflammatory demyelinating polyneuropathy. *J Peripher Nerv Syst*. 2005;10(1):11–6.
96. Good JL, Chehrena M, Mayer RF, Koski CL. Pulse cyclophosphamide therapy in chronic inflammatory demyelinating polyneuropathy. *Neurology*. 1998;51(6):1735–8.
97. Barnett MH, Pollard JD, Davies L, McLeod JG. Cyclosporin A in resistant chronic inflammatory demyelinating polyradiculoneuropathy. *Muscle Nerve*. 1998;21(4):454–60.
98. Hodgkinson SJ, Pollard JD, McLeod JG. Cyclosporin A in the treatment of chronic demyelinating polyradiculoneuropathy. *J Neurol Neurosurg Psychiatry*. 1990;53(4):327–30.
99. Mahattanakul W, Crawford TO, Griffin JW, Goldstein JM, Cornblath DR. Treatment of chronic inflammatory demyelinating polyneuropathy with cyclosporin-A. *J Neurol Neurosurg Psychiatry*. 1996;60(2):185–7.
100. Matsuda M, Hoshi K, Gono T, Morita H, Ikeda S. Cyclosporin A in treatment of refractory patients with chronic inflammatory demyelinating polyradiculoneuropathy. *J Neurol Sci*. 2004;224(1–2):29–35.
101. Odaka M, Tatsumoto M, Susuki K, Hirata K, Yuki N. Intractable chronic inflammatory demyelinating polyneuropathy treated successfully with cyclosporin. *J Neurol Neurosurg Psychiatry*. 2005;76(8):1115–20.
102. Dyck PJ, O'Brien P, Swanson C, Low P, Daube J. Combined azathioprine and prednisone in chronic inflammatory demyelinating polyneuropathy. *Neurology*. 1985;35(8):1173–6.
103. Vallat JM, Hahn AF, Léger JM, Cros DP, Magy L, Tabaraud F, et al. Interferon beta-1a as an investigational treatment for CIDP. *Neurology*. 2003;60(8 Suppl 3):23–8.
104. Hughes RAC, Gorson KC, Cros D, Griffin J, Pollard J, Vallat J-M, Maurer SL, Riester K, Davar G, Dawson K, Sandrock A, Avonex® CIDP Study Group. Intramuscular interferon beta-1a in chronic inflammatory demyelinating polyradiculoneuropathy. *Neurology*. 2010;74:651–7.
105. Querol L, Rojas-García R, Diaz-Manera J, Barcena J, Pardo J, Ortega-Moreno A, Sedano MJ, Illa I, et al. Rituximab in treatment-resistant CIDP with antibodies against paranodal proteins. *Neurol Neuroimmunol Neuroinflamm*. 2015;2(5):e149.
106. Marsh E, Hirst C, Llewelyn J, Cossburn M, et al. Alemtuzumab in the treatment of IVIG-dependent chronic inflammatory demyelinating polyneuropathy. *J Neurol*. 2010;257(6):913–9.
107. Gorson K, Ropper A, Clark B, et al. Treatment of chronic inflammatory demyelinating polyneuropathy with interferon-alpha 2a. *Neurology*. 1998;50(1):84–7.
108. Hadden R, Sharrack B, Bensa S, et al. Randomized trial of interferon beta-1a in chronic inflammatory demyelinating polyradiculoneuropathy. *Neurology*. 1999;53(1):57–61.
109. RMC Trial Group. Randomised controlled trial of methotrexate for chronic inflammatory demyelinating polyradiculoneuropathy (RMC Trial): a pilot, multicentre study. *Neurology*. 2009;8(2):158–64.
110. Mahdi-Rogers M, Kazmi M, Ferner R, et al. Autologous peripheral blood stem cell transplantation for chronic acquired demyelinating neuropathy. *J Peripher Nerv Syst*. 2009;14(2):118–24.
111. Lewis R, Sumner A, Brown MJ, Asbury AK. Chronic multifocal demyelinating neuropathy: a unique disorder with persistent conduction block. *Neurology*. 1982;32:958–62.
112. Viala K, Renie L, Maisonobe T, et al. Follow-up study and response to treatment in 23 patients with Lewis-Sumner syndrome. *Brain*. 2004;127:2010–7.
113. Oh SJ, Joy JJ, Kuruoglu R. “Chronic sensory demyelinating neuropathy”: chronic inflammatory demyelinating polyneuropathy presenting as a pure sensory neuropathy. *J Neurol Neurosurg Psychiatry*. 1992;55:677.
114. Chin RL, Latov N, Sander HW, et al. Sensory CIDP presenting as cryptogenic sensory polyneuropathy. *J Peripher Nerv Syst*. 2004;9:132–7.
115. Berger AR, Herskovitz S, Kaplan J. Late motor involvement in cases presenting as “chronic demyelinating polyneuropathy”. *Muscle Nerve*. 1995;18(4):440–4.
116. Parry GJ, Clarke S. Multifocal acquired demyelinating neuropathy masquerading as motor neuron disease. *Muscle Nerve*. 1988;11:103–7.
117. Lewis R. Conduction block neuropathies. *Curr Opin Neurol*. 2007;20(5):525–30.
118. Nobile-Orazio E. Multifocal motor neuropathy. *J Neuroimmunol*. 2001;115(1–2):4–18.
119. Kornberg AJ, Pestronk A. The clinical and diagnostic role of anti-GM1 antibody testing. *Muscle Nerve*. 1994;17:100–4.

120. Taylor BV, Gross LA, Windebank AJ. The sensitivity and specificity of anti-GM1 antibody testing. *Neurology*. 1996;47:951–5.
121. Corse AM, Chaudry W, Crawford TO, Cornblath DR, Kuncel RW, Griffin JW. Sural nerve pathology in multifocal motor neuropathy. *Ann Neurol*. 1996;39:319–25. Comment in: *Ann Neurol*. 1996;40:948–50.
122. Taylor BV, Dyck PJB, Engelstad J, Gruener G, Grant I, Dyck PJ. Multifocal motor neuropathy: pathologic alterations at the site of conduction block. *J Neuropathol Exp Neurol*. 2004;63:129–37.
123. Nobile-Orazio E, Cappellari A, Priori A. Multifocal motor neuropathy: current concepts and controversies. *Muscle Nerve*. 2005;31:663–80.
124. Santoro M, Uncini A, Corbo M, Staugaitis SM, Thomas FP, Hays AP, et al. Experimental conduction block induced by serum from a patient with anti-GM1 antibodies. *Ann Neurol*. 1992;31:385–90.
125. Arasaki K, Kusunoki S, Kudo N, Kanazawa I. Acute conduction block in vitro following exposure to anti-ganglioside sera. *Muscle Nerve*. 1993;16:587–93.
126. Harvey GK, Toyka KV, Zielasek J, Kiefer R, Simonis C, Hartung HP. Failure of anti-GM1 IgG or IgM to induce conduction block following intraneural transfer. *Muscle Nerve*. 1995;18:388–94.
127. Sugie K, Murataq K, Ikoma K, et al. A case of acute multifocal motor neuropathy with conduction block after *Campylobacter jejuni* enteritis. *Rinsho Shinkeigaku*. 1998;38:436.
128. Pestronk A, Cornblath DR, Ilyas A, Baba H, Quarles RH, Griffin JW, et al. A treatable multifocal motor neuropathy with antibodies to GM1 ganglioside. *Ann Neurol*. 1988;24:73–8.
129. Azulay JP, Blin O, Pouget J, Boucraut J, Billé-Turc F, Carles G, et al. Intravenous immunoglobulin treatment in patients with motor neuron syndromes associated with anti-GM1 antibodies: a double-blind, placebo-controlled study. *Neurology*. 1994;44(3 Pt 1):429–32.
130. Federico P, Zochodne DW, Hahn AF, Brown WF, Feasby TE. Multifocal motor neuropathy improved by IVIg: randomized, double-blind, placebo-controlled study. *Neurology*. 2000;55(9):1256–62.
131. Léger J-M, Chassande B, Musset L, Meininger V, Bouche P, Baumann N. Intravenous immunoglobulin therapy in multifocal motor neuropathy: a double-blind, placebo-controlled study. *Brain*. 2001;124(1):145–53.
132. Van den Berg LH, Kerkhoff H, Oey PL, Franssen H, Mollee I, Vermeulen M, et al. Treatment of multifocal motor neuropathy with high dose intravenous immunoglobulins: a double blind, placebo controlled study. *J Neurol Neurosurg Psychiatry*. 1995;59(3):248–52.
133. Pestronk A, Chaudry V, Feldman EL, Griffin JW, Cornblath DR, Denys EH, et al. Lower motor neuron syndromes defined by patterns of weakness, nerve conduction abnormalities, and high titers of anti-glycolipid antibodies. *Ann Neurol*. 1990;27(3):316–26.
134. Feldman EL, Bromberg MB, Albers JW, Pestronk A. Immunosuppressive treatment in multifocal motor neuropathy. *Ann Neurol*. 1991;30(3):397–401.
135. Piepers S, Van den Berg-Vos R, Van der Pol WL, Franssen H, Wokke J, Van den Berg L. Mycophenolate mofetil as adjunctive therapy for MMN patients: a randomized, controlled trial. *Brain*. 2007;130(Pt 8):2004–10.
136. Kelly JJ, Kyle RA, O'Brien PC, Dyck PJ. Prevalence of monoclonal protein in peripheral neuropathy. *Neurology*. 1981;31(11):1480–3.
137. Ropper AH, Gorson KC. Neuropathies associated with paraproteinemia. *N Engl J Med*. 1998;338(22):1601–7.
138. Levine T, Pestronk A, Florence J, et al. Peripheral neuropathies in Waldenström's macroglobulinaemia. *J Neurol Neurosurg Psychiatry*. 2006;77:224–8. This report describes the symptoms and signs of peripheral neuropathy in a cohort of patients with Waldenström's macroglobulinaemia.
139. Noronha V, Fynan TM, Duffy T. Flare in neuropathy following rituximab therapy in Waldenström's macroglobulinemia. *J Clin Oncol*. 2006;24(1):e3.
140. Mauermann ML, Ryan ML, Moon JS, Klein CJ. Case of mononeuropathy multiplex onset with rituximab therapy for Waldenström's macroglobulinemia. *J Neurol Sci*. 2007;260:240–3.
141. Kelly JJ Jr, Kyle RA, Miles JM, O'Brien PC, Dyck PJ. The spectrum of peripheral neuropathy in myeloma. *Neurology*. 1981;31:24–31.
142. Drieger H, Pruzanski W. Plasma cell neoplasia with peripheral polyneuropathy. *Medicine*. 1988;59:301–10.
143. Watanabe O, Maruyama I, Arimura K, et al. Overproduction of vascular endothelial growth factor/vascular permeability factor is causative in Crow-Fukase (POEMS) syndrome. *Muscle Nerve*. 1998;21:1390–7.
144. Gosselin S, Kyle RA, Dyck PJ. Neuropathy associated with monoclonal gammopathies of undetermined significance. *Ann Neurol*. 1991;30:54–61.
145. Yeung KB, Thomas PK, King RHM, et al. The clinical spectrum of peripheral neuropathies associated with benign monoclonal IgM, IgG and IgA paraproteinemia: comparative clinical, immunological and nerve biopsy findings. *J Neurol*. 1991;238:383–91.
146. Latov N, Hays AP, Sherman WH. Peripheral neuropathy and anti-MAG antibodies. *Crit Rev Neurobiol*. 1988;3:301–32.
147. Kissel JT, Collins MP. Peripheral nerve vasculitis. In: Younger DS, editor. *Motor disorders*. Philadelphia: Lippincott Williams and Wilkins; 1999. p. 243–56.
148. Hughes RAC. Guillain-Barré syndrome. Heidelberg: Springer-Verlag; 1998.
149. Griffin JW, Li CY, Macko C, et al. Early nodal changes in the acute motor axonal neuropathy pattern of the Guillain-Barré syndrome. *J Neurocytol*. 1996;25:33–51.
150. Rizzuto N, Morbin M, Cavallaro T, Ferrari S, Fallahi M, Galiazzo Rizzuto S. Focal lesions area feature of

- chronic inflammatory demyelinating polyneuropathy (CIDP). *Acta Neuropathol.* 1998;96:603–9.
151. Pytel P, Rezania K, Soliven B, Frank J, Wollmann R. Chronic inflammatory demyelinating polyradiculoneuropathy (CIDP) with hypertrophic spinal radiculopathy mimicking neurofibromatosis. *Acta Neuropathol.* 2003;105:185–8.
152. Van Den Berg-Vos RM, Van Den Berg LH, Visser J, de Visser M, Franssen H, Wokke JHJ. The spectrum of lower motor neuron disorders. *J Neurol.* 2003;250:1279–92.
153. Vital A, Lagueny A, Julien J, et al. Chronic inflammatory demyelinating polyneuropathy with dysglobulinemia: a peripheral nerve biopsy study in 18 cases. *Acta Neuropathol.* 2000;100:63–8.

---

## **Part V**

# **Systemic Disorders**



# Neurologic Manifestations of Systemic Rheumatologic Diseases

Michael J. Bradshaw, Shamik Bhattacharyya, Nagagopal Venna, and Jonathan F. Cahill

## Introduction

As neurologic manifestations of systemic autoimmune disease are increasingly recognized, the field of autoimmune neurology is rapidly expanding, creating the need for neurologists with specialized training in this field [1]. This chapter briefly reviews the neurologic manifestations, diagnostic approach, and treatment of the following systemic rheumatic diseases: sarcoidosis, IgG-4-related disease, Behçet syndrome, Sjögren syndrome, lupus, and rheumatoid arthritis. The

illustrative cases are not meant to be pathognomonic, but rather to highlight specific features of the diseases and their effects on the nervous system. As a group, the neurologic manifestations of these conditions include parenchymal brain and brainstem disease, myelopathy, radiculopathy, myopathy, and all forms of peripheral neuropathy. They can also present with secondary effects on neural structures from extra-axial or meningeal disease. With a brief consideration of several systemic autoimmune disorders with neurologic manifestations, this chapter should serve as a guide for the practicing clinician and springboard for the interested reader.

M. J. Bradshaw (✉)

Department of Neurology, Chicago Medical School, Rosalind Franklin University of Medicine and Science, Billings Clinic, Billings, MT, USA

S. Bhattacharyya

Department of Neurology, Brigham and Women's Hospital, Boston, MA, USA  
e-mail: [sbhattacharyya3@bwh.harvard.edu](mailto:sbhattacharyya3@bwh.harvard.edu)

N. Venna

Neuro-Infectious Diseases, Harvard Medical School, Boston, MA, USA

Division of Neuroimmunology, Department of Neurology, Massachusetts General Hospital, Boston, MA, USA

e-mail: [Nvenna1@partners.org](mailto:Nvenna1@partners.org)

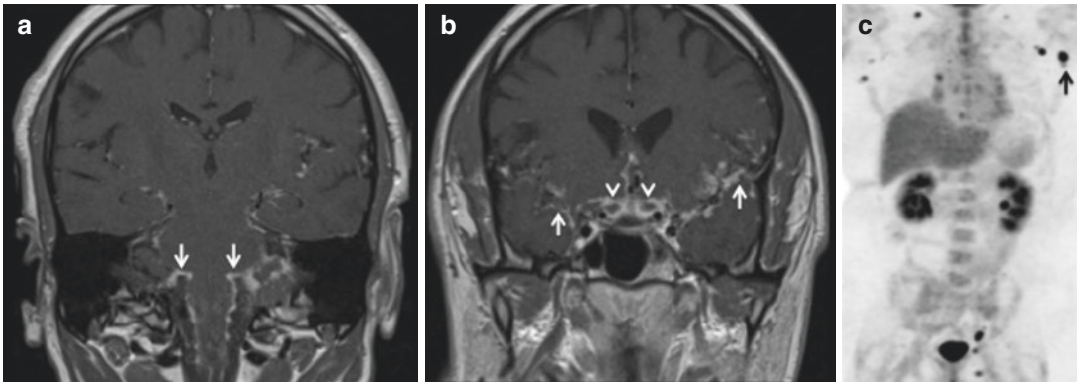
J. F. Cahill

Rhode Island Hospital and Alpert Medical School of Brown University, Brown Neurology, Providence, RI, USA  
e-mail: [jonathan\\_cahill@brown.edu](mailto:jonathan_cahill@brown.edu)

## Neurosarcoidosis (Fig. 17.1)

First described in 1877 by Hutchinson at King's College Hospital in London, sarcoidosis is an inflammatory disorder characterized by a heightened granulomatous immune response to unknown environmental antigen(s) that develops in genetically susceptible individuals [2]. Well-formed coalescent non- or minimally necrotizing epithelioid granulomas with scattered lymphocytes are the pathologic hallmarks of the disease [3]. Tumor necrosis factor (TNF) plays an important role in granuloma formation and maintenance and is avidly expressed on epithelioid and giant cells in sarcoid granulomas [4]. Sarcoidosis occurs worldwide in all races, with an incidence





**Fig. 17.1** (a, b) Coronal T1 MRI with gadolinium. (c) FDG-PET

in the United States of 3–10/100,000 Caucasians (highest in those of Scandinavian descent) and 35–80/100,000 African Americans [5]. Most patients are in their 30s–50s at the time of diagnosis [2]. While the lungs, skin, intrathoracic lymph nodes, and eyes are commonly affected sites, sarcoidosis can involve any organ system [6]. Neurosarcoidosis (NS) develops in ~5–10% of all patients with systemic sarcoidosis, but sub-clinical neurologic involvement is identified at autopsy in another 13–15% of cases [7]. Seventy-five percent of patients with known systemic sarcoidosis who develop NS do so within 2 years of systemic diagnosis [8]. Patients evaluated by neurologists often have no known evidence of systemic sarcoidosis at the time of presentation and sarcoidosis remains isolated to the nervous system in 10–20% of cases despite a thorough diagnostic evaluation [9–14].

## Clinical Manifestations

Despite its reputation as the “great mimicker,” NS has recognizable patterns like any other affliction. Both the central and/or peripheral nervous systems can be involved [15]. The most common clinical manifestations and their differential diagnosis are listed in Table 17.1 [13, 15–19].

Cranial neuropathies are among the most common manifestations of NS, with optic, facial, vestibulocochlear neuropathies commonly involved, although trigeminal neuropathy is also seen

relatively frequently. Most patients with NS and cranial neuropathy have additional neurologic dysfunction, and multiple cranial neuropathies with granulomatous meningitis (lymphocyte predominant) is a repeated and recognizable pattern. Recurrent cranial neuropathy is another clue to the diagnosis. The mechanism of cranial neuropathy is often related to leptomeningeal infiltration associated with epineural or perineural or inflammation. Less commonly, cranial neuropathy may develop consequent to compression by a dural-based granuloma [13]. Optic neuritis is generally subacute or chronic and bilateral in a slight majority of patients [10, 16]. Facial nerve palsy is common and is simultaneously or sequentially bilateral in approximately one-third of cases [13]. In contrast to optic neuritis associated with NS, facial nerve dysfunction is more likely to recover [20].

Meningeal sarcoidosis most often affects the base of the brain and basilar cisterns (Case 17.1). Cranial neuropathies (particularly the lower cranial nerves), meningismus, and headaches are common. MRI demonstrates leptomeningeal contrast enhancement and thickening that is typically nodular but can be smooth, diffuse, focal, or multifocal with a predilection for the base of the brain (basilar meningitis) [21]. Subacute communicating or non-communicating hydrocephalus may result from meningitis or from obstruction related to granulomatous mass lesions. Pachymeningeal lesions occasionally occur and typically appear as diffuse or discrete dural masses that homogeneously enhance with gadolinium [22].

**Table 17.1** Clinical manifestations and differential diagnosis of neurosarcoidosis

Clinical manifestation	Approximate frequency	Diagnostic considerations
Cranial neuropathy	50–75%	Multiple sclerosis (optic nerve/brainstem lesions), neuromyelitis optic spectrum disorders (optic nerve/brainstem lesions), Sjögren, lupus, Lyme, syphilis, HSV, VZV, glioma, meningioma, infiltrative neoplasm or histiocytosis
Optic nerve	7–35%	
Facial nerve	11–25%	
Vestibulocochlear nerve	3–17%	
Aseptic meningitis	10–20%	<i>Leptomeningitis</i> : Vogt-Koyanagi-Harada, Behçet's, brucellosis, Lyme, fungal or tubercular infection, infiltrative histiocytosis, leptomeningeal malignancy; <i>Pachymeningitis</i> : ANCA-associated vasculitis, IgG4-RD, meningioma, intracranial hypotension
Parenchymal disease	Up to 50%	Primary CNS lymphoma, infiltrative histiocytosis, infiltrative neoplasm, ANCA-associated vasculitis, Sjögren, lupus
Seizure	15%	
Mass lesions	5–10%	
Encephalopathy	5–10%	
Neuroendocrinopathy	2–8%	
Vascular disease	Rare	Atherosclerotic disease, embolism, vasculitis
Peripheral neuropathy	2–86%	Large fiber: AIDP/CIDP, ANCA-associated vasculitis, infectious neuropathy; Small fiber: DM, toxic neuropathy, celiac, Sjögren, rheumatoid arthritis, vasculitis, paraneoplastic neuropathy
Small fiber neuropathy		
Myelopathy	5–26%	Multiple sclerosis, neuromyelitis optic spectrum disorders, Sjögren, lupus, tuberculosis, VZV HTLV1, compressive myelopathy

**Case 17.1**

A 37-year-old man with no medical history developed mild cognitive dysfunction over a few weeks followed by a left peripheral abducens palsy. Brain MRI demonstrated leptomeningeal gadolinium enhancement on T1-post contrast images surrounding rostral cervical spinal cord and brainstem (**a**, arrows) that extended into the Sylvian fissures (**b**, arrows) and encasing the optic nerves (**b**, arrowheads). Combined PET/CT (**c**) demonstrated mild hilar and parabrachial lymphadenopathy (none larger than 1.5 cm) with FDG avid lymph nodes in the bilateral axillae. A left axillary FDG avid lymph node was biopsied (**c**, arrow) and was consistent with sarcoidosis. A diagnosis of probable NS was made and he was treated with oral prednisone, but was unable to taper below 10 mg daily without worsening of CNS sarcoidosis clinically and on MRI so methotrexate was added. One later, he again worsened clinically and radiologically and was treated with infliximab with complete clinical and radiological remission and has been stable on combination infliximab, low-dose methotrexate, and 5 mg prednisone every other day for 3 years.

Hypopituitarism related to granulomatous infiltration of the pituitary gland or hypophysis is not uncommon and manifests with diabetes insipidus, hypogonadotropic hypogonadism, hypothyroidism, and other neuroendocrine disruptions localizable to the pituitary gland/stalk [23]. Rarely disordered sleep, satiety, or thermoregulation may occur when granulomatous infiltration extends to the hypothalamus.

Intracranial granulomatous mass lesions occur in some 5–10% of patients [24]. These are typically isointense on T1-weighted images with variable gadolinium enhancement (6–37%) [18], and rarely contain areas of calcification, necrosis, or hemorrhage [22]. Associated leptomeningeal or pachymeningeal gadolinium enhancement is a clue to the diagnosis but biopsy is often necessary to exclude alternate etiologies.

Ischemic and hemorrhagic stroke are uncommon complications of NS that may affect the hemispheres, brainstem, or cerebellum. Although both the arterial and venous vessels can be affected by NS, small arterial perforators appear to be most commonly involved [19]. Cerebral vessel involvement is typically due to granulomatous perivascular infiltration rather than direct vessel wall inflammation. The propensity of sarcoid granulomas to spread along the perivascular spaces sometimes gives rise to a characteristic pattern of linear branching gadolinium

enhancement on MRI. Dural venous sinus thrombosis is exceptionally rare.

Subcortical encephalopathy including dementia can develop in patients with NS. Nonspecific periventricular white matter T2/FLAIR hyperintense lesions are seen in 30–46% of patients and can be small and focal or larger, more diffuse lesions that may mimic multiple sclerosis. Importantly, systemic sarcoidosis and multiple sclerosis can co-exist. When the clinical presentation and MRI are consistent with multiple sclerosis, the neurologic syndrome should not be assumed to be NS even in the presence of systemic sarcoidosis [25]. This is particularly important as TNF antagonists can worsen multiple sclerosis. Nonspecific T2 hyperintensities sometimes seen in patients with sarcoidosis or NS are not typically affected by treatment, nor do they correlate with clinical disability, making their relationship to NS uncertain [26]. In the absence of gadolinium enhancement, these are unlikely to reflect active NS and may be comorbid [18].

Depression is common (~60%) and other psychiatric illness such as psychosis and hallucinations occur in 20% of patients [27]. Psychiatric disease may arise as a consequence of living with a chronic illness, treatment toxicity or from parenchymal NS, in which case some patients may respond to glucocorticoids [27, 28].

Myelopathy was historically reported as a rare manifestation of NS, but contemporary studies have found spinal cord involvement in ~19–26% of patients [16, 29]. Myelopathy may result from intramedullary, intradural, or extradural sarcoidosis [30]. Most patients present with subacute proprioceptive disturbances, pain, hypoesthesia, motor deficits, or sexual/sphincter dysfunction [31]. The cervical and upper thoracic cords are the most often affected sites, but the conus medullaris and cauda equina may also be involved [32]. NS is an increasingly recognized cause of longitudinally extensive transverse myelitis (LETM) and intramedullary spinal NS can be associated with severe neurologic deficits [33]. MRI features, such as central canal and especially dorsal subpial or meningeal gadolinium enhancement suggest NS myelitis, which can be difficult to distinguish from other causes of LETM [34, 35]. Compressive myelopathy or radiculopathy from

granulomas can also occur as can a painful radiculitis with truncal radiculitis an uncommon but characteristic manifestation.

Peripheral neuropathy including sensorimotor, pure motor or sensory, Guillain-Barre-like syndromes, mononeuritis multiplex, and plexopathies with both large and small fiber involvement are relatively common in NS [36]. Small fiber neuropathy is likely an under-recognized manifestation of NS [37, 38]. Electromyography is typically normal with small fiber neuropathy, but skin biopsy and/or quantitative sudomotor axon reflex testing serve as objective measures of small fiber neuropathy. Three patterns of sarcoid myopathy were described in a 2018 series, including nodular (27%); smoldering (29%); acute, subacute, or progressive myopathic (35%); and combined myopathic and neurogenic pattern (10%) which imply different clinical courses (e.g., the nodular pattern was relapsing and remitting, while the myopathic pattern may have a progressive course) [39].

## Diagnostic Evaluation

The differential diagnosis of neurosarcoidosis is heavily influenced by the presenting syndrome (Table 17.1). Fundamentally, sarcoidosis is a pathological diagnosis and biopsy from the affected neurologic site or at least a systemic target should be pursued. The 1999 Zajicek criteria [10] are widely used, but updated diagnostic criteria were published in 2018 [40]. These include definite, probable, and possible NS and require a clinical syndrome suggesting NS, exclusion of other diseases and biopsy confirmation from a neurologic site (definite), or evidence of inflammation in the CNS, plus evidence of systemic sarcoidosis, ideally histologically proven (probable), or an appropriate clinical syndrome with exclusion of other diseases not meeting the aforementioned (possible).

The primary purpose of serum testing is to evaluate for other etiologies on the differential diagnosis (Table 17.1). Nonspecific markers of inflammation such as erythrocyte sedimentation rate and C-reactive protein may be elevated. Cerebrospinal fluid (CSF) is abnormal in many patients with CNS sarcoidosis, but no findings are sufficiently specific to establish the diagnosis.

Patients with isolated cranial neuropathy usually have normal CSF [17], in contrast to those with meningeal or parenchymal disease [16, 26]. Moderate pleocytosis (~100 nucleated cells/mL, usually lymphocyte predominant, although monocyte predominance may be seen) and elevated protein are typical, and hypoglycorrhachia (an important clue to the diagnosis), oligoclonal bands and/or an elevated IgG index may be seen [16, 26]. In one study CSF hypoglycorrhachia and elevated CSF ACE levels were uncommon, but exclusive to NS, and constitutional symptoms, CSF pleocytosis, and hilar adenopathy were significantly more common in NS compared to aquaporin 4+ neuromyelitis optica (NMO) or multiple sclerosis [35]. NS myelitis is more likely to be associated with elevated serum CRP and lactate dehydrogenase compared to NMO and multiple sclerosis [31]. CSF ACE levels are nonspecific and lack sufficient sensitivity for NS [41–44].

MRI with gadolinium is the preferred imaging modality for CNS sarcoidosis [45].

When an alternative diagnosis cannot be established by history, examination, neuroimaging, serum, or CSF studies, systemic imaging should be the next diagnostic step with a goal of identifying evidence of another etiology or locating a systemic target amenable to biopsy. Combined fluorodeoxyglucose positron emission tomography (PET)/CT imaging can identify biopsy targets when CT is unremarkable or equivocal and is an important consideration [46].

## Management

Barring strict contraindications, glucocorticoids are widely considered first-line therapy (Table 17.2) [8, 10, 11, 16, 18, 47]. Patients with aggressive disease at presentation may require

**Table 17.2** Medications commonly used in the treatment of neurosarcoidosis

Medication	Dose	Common adverse effects	Monitoring	Comments
<b>Glucocorticoids</b>				
Prednisone Methylprednisolone	0.25–1 mg/kg/day PO 1000 mg/ day × 3–5 days IV	Numerous including psychosis, osteoporosis, Cushing syndrome, hypertension, diabetes mellitus, gastric ulcers, glaucoma, cataracts	Blood pressure, blood glucose	Give with calcium, gastric protection and consider PCP prophylaxis for doses ≥20 mg/day prednisone for ≥3 months
<b>Immunosuppressant agent</b>				
Azathioprine	Up to 2 mg/kg PO daily	Anemia, neutropenia, hepatitis	CBC, LFTs	
Cyclophosphamide	50–200 mg/day PO 500 mg q 2–3 weeks IV	Cytopenias, hemorrhagic cystitis, infection, infertility, cardiac toxicity	CBC, LFTs, creatinine, UA	
Methotrexate	10–25 mg weekly PO or SQ	Cytopenias, hepatitis, pneumonitis, mucositis, teratogenicity, GI upset	CBC, LFTs,	Give with folic acid 1 mg PO daily
Mycophenolate mofetil	1–1.5 g PO BID	Anemia, GI upset, hepatitis, colitis	CBC, LFTs	
<b>Immunomodulators</b>				
Hydroxychloroquine	100–200 mg PO BID	Retinopathy, myopathy, cardiomyopathy, rash	Ophthalmologic examination	Side effects are rare, generally reserved for mild cases and in combination with glucocorticoids
Chloroquine	500–750 mg PO daily	Retinopathy, myopathy, cardiomyopathy, rash	Ophthalmologic examination	
<b>Tumor necrosis factor inhibitor</b>				
Infliximab	3–7 mg/kg IV at week 0, 2, 6 then 3–7 mg/kg IV q4–8 weeks	Infusion reaction, anti-drug antibodies, malignancy, demyelination, hepatitis, drug-induced lupus	CBC	Contraindicated in heart failure, test for TB and HBV before

pulse-dose glucocorticoids (1 g intravenous methylprednisolone daily for 3–5 days) followed by an oral prednisone taper over a few months. Oral prednisone at a dose of 1 mg/kg/day or less may be sufficient for patients with less severe presentations. Although many patients achieve remission with glucocorticoids, a significant proportion will be refractory to treatment or relapse when attempting to taper to safer/more tolerable doses. The long-term toxicities of glucocorticoids further complicate their use [48].

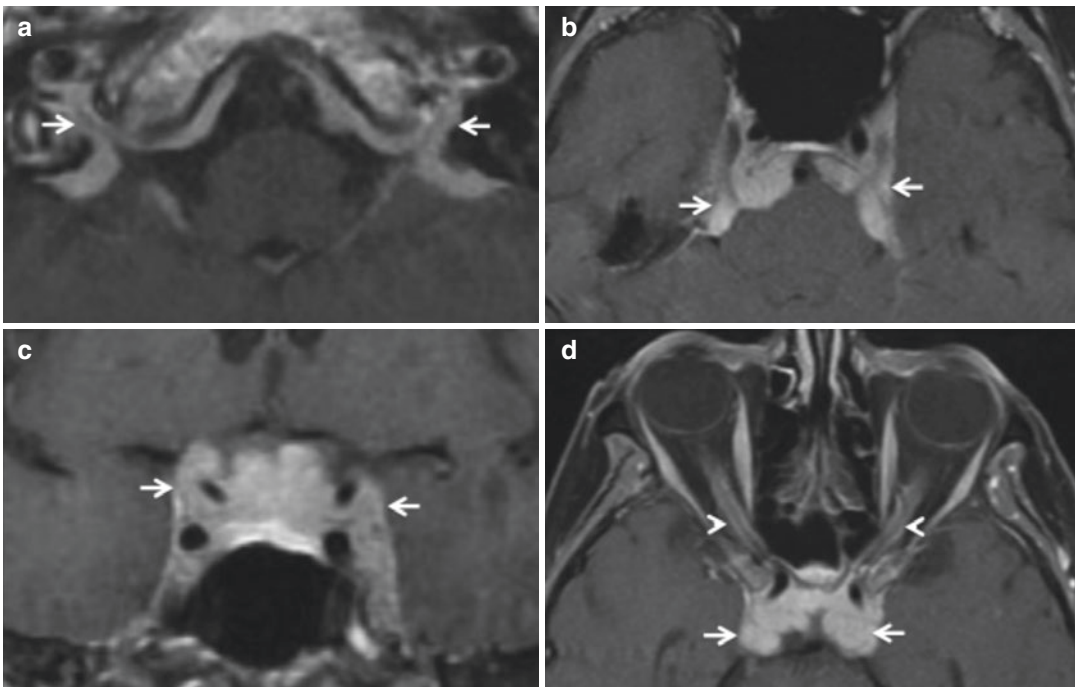
Retrospective evidence suggests that methotrexate may be more effective than mycophenolate [29, 49]. Accumulating evidence has provided support for the use of anti-TNF drugs such as infliximab for aggressive or refractory neurosarcoidosis, which is often combined with low-dose immunosuppression [14, 29, 50]. In the largest series to date, including 66 patients with aggressive and/or refractory CNS sarcoidosis, clinical improvement was observed in 77% of patients and favorable MRI response in 82% [14]. There are reports, however, of granulomatous reactions associated with TNF antagonists, particularly etanercept [51]. A clinical trial com-

paring infliximab to glucocorticoids is currently being planned.

Clinical history, examination, and MRI with gadolinium are essential for monitoring response to treatment. Rigorous phenotyping and follow-up remain critical, as is careful monitoring for infectious complications of treatment, including granulomatous infections (e.g., histoplasmosis) that can mimic worsening NS. Interdisciplinary coordination is extremely valuable in managing patients with NS, particularly when there is also systemic sarcoidosis.

### IgG-4-Related Disease (Fig. 17.2)

IgG4-related disease (IgG4-RD) is a multi-organ disorder characterized by a dense lymphoplasmacytic infiltrate (predominantly CD4+ T cells), storiform fibrosis, and obliterative phlebitis that can affect any organ [52]. The pathophysiology is thought to be an exaggerated immune response to as-yet-unidentified antigen(s) with critical interactions between CD4+ cytotoxic T cells, follicular helper T cells, and both B lymphocytes



**Fig. 17.2** (a–d) Axial T1 MRI with gadolinium. (c) Coronal T1 MRI with gadolinium

and plasmablasts. The IgG4 antibodies do not appear to be directly pathogenic. Great progress has been made toward understanding the clinical manifestations and pathophysiology in the last few years and like NS, recognizable clinical patterns have emerged [53].

## Clinical Manifestations

Most patients with IgG4-RD present in their sixth or seventh decade, and in contrast to most other immune-mediated diseases, IgG4-RD is more prevalent in men (3:1) unless the head/neck is involved. Two general patterns are seen: mass lesions that mimic malignancy and allergic/atopic presentations. Mikulicz' disease (dacryoadenitis and enlargement of both the parotid and submandibular glands) has a high positive predictive value for the diagnosis. Other common systemic manifestations include orbital disease (e.g., lacrimal gland enlargement), lymphadenopathy, pancreatitis, pulmonary nodules, ground-glass opacities and interstitial lung disease, and retroperitoneal fibrosis. Neurologic manifestations of IgG4-RD most often relate to infiltration the dura (pachymeninges), pituitary gland and/or stalk (IgG4-related hypophysitis), peripheral nerves and rarely brain parenchyma or lepto-meninges without pachymeningeal disease.

IgG4-RD is among the most common non-malignant causes of pachymeningitis, demonstrable on MRI as homogenous dural gadolinium enhancement and thickening that may be nodular in appearance. Clinical manifestations of pachymeningeal IgG4-RD depend upon the affected neuroanatomical structures and include headache, cranial neuropathy, and obstructive hydrocephalus [54] (Case 17.2). Symptoms of Tolosa-Hunt syndrome occur when the cavernous sinus is involved. Pachymeningeal thickening may be asymptomatic and discovered incidentally in a substantial number of cases. IgG4-related hypophysitis can produce neuroendocrine dysfunction related to the anterior or posterior pituitary, but most commonly causes pan-hypopituitarism. MRI demonstrates enlargement of the pituitary and/or thickened infundibulum that homogeneously enhance with gadolinium. Orbital

IgG4-RD may present to the neurologist given frequent involvement of branches of the trigeminal nerve, extraocular muscles as well as the optic, oculomotor, trochlear, and abducens nerves within the orbit [55]. Involvement of the infra-orbital nerve and enlargement of the neural foramen can be seen on imaging and are useful for distinguishing IgG4-RD orbital disease from other etiologies [56]. Peripheral nerves can be affected through compression related to nearby mass-like IgG4-RD or the epi/perineurium can be directly infiltrated. These produce predominantly axonal degeneration of both large and small fibers that may be accompanied by demyelinating features on electrophysiologic investigation [57].

### Case 17.2

A 69 -year-old woman developed left sided hearing loss and (a) MRI demonstrated nodular pachymeningeal gadolinium enhancement lining the internal auditory canals, prepontine, and perimesencephalic cisterns. Serum IgG was elevated (1620) with elevation of IgG1 (1100) and IgG4 (128) subtypes. CSF analysis revealed lymphocytic pleocytosis (72 nucleated cells; 97% lymphocytes), elevated protein 148, elevated CSF IgG (34.9) without oligoclonal bands. Infectious evaluation was negative and she was treated with glucocorticoids and methotrexate and remained clinically stable. Two years later, she developed worsening balance and bilateral optic neuropathy and MRI demonstrated worsened pachymeningitis affecting the basilar cisterns with (b) mass effect on the pons, (c) bilateral cavernous sinuses, pituitary, optic chiasm and (d) optic nerves, as well as stable encasement of the basilar artery and supraclinoid internal carotid arteries and developed hydrocephalus necessitating ventriculoperitoneal shunt. She was treated with rituximab and her vision improved to near baseline and she has been stable for 4 years on rituximab.

## Diagnostic Evaluation

The approach to the diagnosis is complex and integrates a range of clinical, radiological, laboratory, and pathological findings, none of which are pathognomonic. Diagnostic suspicion should be elevated when neurologic dysfunction is accompanied by unexplained enlargement or swelling of one or more organs [58]. Serum laboratory studies that provide a clue to the diagnosis include peripheral eosinophilia (present in 34%), hypergammaglobulinemia, elevated serum IgE levels (elevated in 58%), and hypocomplementemia (seen in 36%). A meta-analysis of >1200 patients with IgG4-RD and almost 5700 unaffected controls found that serum IgG4 concentrations >135 mg/dL have a sensitivity and specificity of 87% and 83%, respectively, making this a useful screening test if measured before steroid treatment (which lowers levels significantly) [59]. Untreated patients with systemic, but not CNS IgG4-RD have been shown to have markedly elevated blood plasmablast concentrations by flow cytometry, which is emerging as another important diagnostic study [60, 61]. CSF analysis is nonspecific but may demonstrate mild to moderate lymphocyte-predominant pleocytosis (1–100 cells/ $\mu$ L), normal to mildly increased protein (20–200 mg/dL), normal glucose, and possibly oligoclonal bands. MRI with gadolinium is the neuroimaging modality of choice for neurologic manifestations.

In order to definitively establish the diagnosis, tissue biopsy with the characteristic pathological findings is necessary [52]. This is also important for excluding alternative etiologies, as the aforementioned diagnostic studies are nonspecific and treatment varies significantly among the diagnostic considerations.

## Management

Glucocorticoids are considered first-line therapy for IgG4-RD [62]. A reasonable approach is oral prednisone with starting doses in the range of 0.6–1.0 mg/kg/day for a month followed by

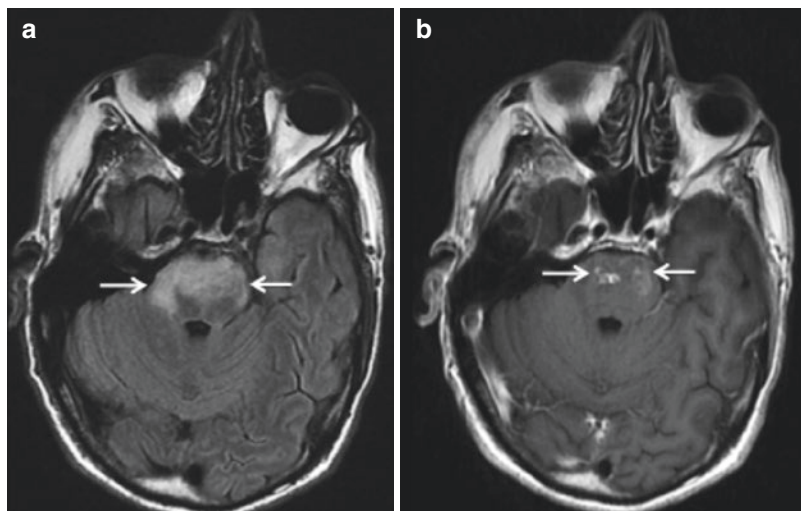
taper over 2–3 months to discontinuation while monitoring response. Steroid-sparing immunosuppressants such as azathioprine, mycophenolate mofetil, and methotrexate are also commonly used in IgG4-RD, but have not been studied prospectively. A retrospective study of 33 patients with IgG4-RD treated with rituximab observed a positive clinical response in 93.5% of patients, corroborating results seen in several previous studies [63]. An uncontrolled, open-label prospective pilot study of rituximab for IgG4-RD found treatment response in 97% and complete remission in 40% [64]. Eighty-seven percent were treated without glucocorticoids. Given these data, in addition to first-line glucocorticoids as above, we typically add rituximab (eg. two doses of 1 g separated by 2 weeks every 6 months), particularly if there is serious neurologic disease, multi-organ systemic IgG4-RD beyond the nervous system or serum IgG4 levels significantly above the upper limit of normal. Clinical history, examination, and serial MRI with gadolinium are useful metrics of response to therapy. Poor response to glucocorticoids should be considered a red flag for alternative diagnoses in patients without biopsy-confirmed IgG4-RD.

---

## Behçet Disease (Fig. 17.3)

Behçet disease (BD) was likely recognized by Hippocrates [65], but was named after Turkish dermatologist Hulusi Behçet who reported three patients with recurrent oral and genital ulceration and hypopyon-related uveitis in 1937 [66]. BD occurs most often in individuals with ancestry traceable to countries along the ancient Silk Route (highest prevalence is in Turkey, Iran and Japan). Although the precise etiology is unknown, epidemiologic data support a genetic predisposition to autoimmunity. There is debate about the roles innate and adaptive immunity play in the pathogenesis, but inflammatory cytokines including TNF are upregulated [67, 68]. Pathological investigations reveal arterial and venous perivascular infiltration by T cells, B cells, and neutrophils typically without fibrinoid

**Fig. 17.3** (a) Axial FLAIR MRI. (b) Axial T1 MRI with gadolinium



necrosis [69]. Onset is usually in the third or fourth decade of life with similar incidence in men and women, but young men tend to be most severely afflicted [70].

## Clinical Manifestations

BD is an inflammatory disorder characterized by recurrent mucocutaneous ulceration and systemic manifestations affecting the integumentary, musculoskeletal, vascular, gastrointestinal, and neurologic systems (Table 17.3) [71]. The typical course is characterized by intermittent exacerbations that tend to attenuate in intensity over time with an average disease course lasting 20 years before remitting [72].

Neurologic BD (NBD) occurs in roughly 10% of patients and is nearly three times more common in men than women [73]. In most cases, neurologic disease develops 3–6 years after systemic manifestations, but may be the initial manifestation. Neurologic exacerbations are typically subacute, often associated with systemic exacerbation including fever and mucocutaneous ulcerations [73]. NBD is divided into parenchymal and nonparenchymal disease, which may coexist in up to 20% of cases [74]. Parenchymal NBD manifests predominantly with encephalitis affecting the brainstem but can also involve the meninges, cranial nerves, thalamus, basal ganglia,

**Table 17.3** Clinical manifestations of Behçet disease

Clinical manifestation	Approximate frequency (%)
Neurologic	10
Ocular	
Uveitis	50
Mucocutaneous	
Oral ulcers	97–99
Genital ulcers	85
Pathergy reaction	60
Papulopustular lesions	85
Erythema nodosum	50
Musculoskeletal	
Arthritis	50
Vascular	
Thrombophlebitis	25
Deep venous thrombosis	10
Arterial occlusion/aneurysm	4
Gastrointestinal	1–30 (higher in Japan)

white matter, cerebral cortex, and uncommonly the spinal cord.

Brainstem dysfunction manifests as cranial neuropathies, pyramidal, and sensory deficits referable to the brainstem and cerebellar dysfunction depending on the affected neuroanatomic structures (Case 17.3). Optic neuritis and ischemic optic neuropathy are a rare manifestation (0.4%) and most cases of monocular vision loss are due to ocular involvement rather than optic neuritis. Extension of brainstem encephali-



tis to the thalamus and basal ganglia can produce deficits referable to these structures although movement disorders such as parkinsonism, chorea, and dystonia are rare despite frequent MRI abnormalities in the basal ganglia. Cortical disease can produce hemiparesis, hemisensory loss, seizures (2–5%), cognitive dysfunction and psychosis, and subcortical dementia has been reported. Clinical evidence of spinal cord dysfunction develops in approximately 10% of patients, but is seen on autopsy in another 20% and only rarely occurs in isolation.

Nonparenchymal NBD is less common than parenchymal NBD and most often manifests as cerebral venous sinus thrombosis (CVST) and occasionally arterial thrombosis. Onset is subacute to chronic in most, but may be acute (<48 h) in approximately 1/3 patients. CVST commonly presents with headache, papilledema, focal neurologic deficits, seizures, sixth nerve palsy, or altered mental status [75]. Inflammation and endothelial cell activation are implicated in the pathogenesis of CVST related to NBD. Arterial stenosis, aneurysm, or dissection are rarely reported. Peripheral nerve involvement manifesting as sensorimotor polyneuropathy, mononeuritis multiplex, autonomic neuropathy, or a Guillain-Barré-like syndrome uncommonly develop. Necrotizing myositis with pain, swelling, and myalgia is also rarely observed.

**Case 17.3**

A 54-year-old man developed recurrent painful oral and scrotal ulcers and a right knee effusion with high nucleated cell count but no bacteria or crystals identified. He later experienced episodes of confusion, followed by memory loss, which prevented him from working. He lost 60 lb over the course of a year. He deteriorated over 2 weeks, with progressive weakness of all extremities and ataxia. MRI brain demonstrated swelling and (a) T2 hyperintensity diffusely throughout the ventral pons with (b) areas of nodular intraparen-

chymal gadolinium enhancement. CRP was elevated to 25. CSF contained 31 nucleated cells (24% neutrophils), normal glucose, and elevated protein (135). He was treated with 5 days of IVMP and recovered.

**Table 17.4** Differential diagnosis of Neuro-Behçet disease

<i>Immune-mediated</i>	<i>Infectious</i>
Multiple sclerosis	<i>Listeria monocytogenes</i>
Neurosarcoidosis	Brucellosis
Primary CNS vasculitis	<i>Mycobacterium tuberculosis</i>
Secondary CNS vasculitis	<i>Tropheryma whipplei</i>
Vogt-Koyanagi-Harada syndrome	<i>Blastomyces dermatitidis</i>
Reiter syndrome	<i>Treponema pallidum</i>
Eales' disease	Herpes simplex viruses 1 and 2
Cogan's syndrome	Varicella zoster virus
Susac syndrome	JC virus (the cause of progressive multifocal leukoencephalopathy)
Neuro-Sweet syndrome	HIV
CLIPPERS	Enterovirus 71
	Flaviviruses
<i>Malignant</i>	<i>Other</i>
Primary CNS lymphoma	Stroke
Brainstem glioma	
Erdheim-Chester and other infiltrative histiocytoses	

**Diagnostic Evaluation**

The differential diagnosis of NBD includes primarily infectious, autoimmune, and malignant etiologies (Table 17.4) [76, 77]. No specific biomarkers exist to establish the diagnosis, which relies upon clinical criteria and exclusion of other conditions. Diagnostic criteria for BD were updated in 2014 [78], and NBD diagnostic criteria were proposed in the same year (Tables 17.5 and 17.6) [79].

Serum laboratory studies that are useful in addressing the differential diagnosis include

**Table 17.5** 2014 Diagnostic criteria for Behçet disease<sup>a</sup>

Ocular lesions	2
Genital aphthosis	2
Oral aphthosis	2
Skin lesions	1
Neurologic manifestations	1
Vascular manifestations	1
Positive pathergy test <sup>a</sup>	1 <sup>a</sup>

<sup>a</sup>Pathergy test is optional and the primary scoring system does not include pathergy testing. However, where pathergy testing is conducted, one extra point may be assigned for a positive result

**Table 17.6** 2014 Diagnostic criteria for neuro-Behçet disease<sup>a</sup>

<i>Definite NBD</i> meeting all of the following three criteria
1. Satisfy the ISG <sup>a</sup> criteria for BD
2. Neurologic syndrome (with objective neurologic signs) recognized to be caused by BD and supported by relevant and characteristic <sup>b</sup> abnormalities seen on either or both: (a) Neuroimaging (b) CSF
3. No better explanation for the neurologic findings
<i>Probable NBD</i> meeting one of the following two criteria in the absence of a better explanation for the neurologic findings:
1. Neurologic syndrome as in definite NBD, with systemic BD features but not satisfying the ISG criteria
2. A non-characteristic neurologic syndrome occurring in the context of ISG criteria-supported BD

<sup>a</sup>ISG international study group criteria 1990 or any other accepted current or future criteria

<sup>b</sup>Defined in Kalra et al. *J Neurol* (2014) 261:1662–1676

ESR/CRP (nonspecific but can provide evidence of systemic inflammation), ANA, SSA, and SSB. Human leukocyte antigen (HLA) typing can be useful as individuals with the HLA-B51 allele have a significantly increased risk of developing BD (odds ratio 5.78 depending on the ethnic group) [80]. However, while HLA-B51 is present in 60–70% of patients with Japanese or Turkish descent, this is only seen in 10–20% of those with European ancestry [73]. CSF is abnormal in 70–80% of patients with parenchymal NBD and typically reveals a modest neutrophilic, lymphocytic or mixed pleocytosis (0–400 nucleated cells/ $\mu$ L), elevated protein with normal glucose (hypoglycorrhachia suggests an alternative etiology such as fungal or

tuberculous meningitis or NS) and rarely oligoclonal bands [72, 81].

MRI with gadolinium is the preferred imaging modality for parenchymal NBD and lesions are hyperintense on T2-weighted images and isointense on T1-weighted images and often enhance with gadolinium during an acute relapse [82, 83]. In contrast to MS, the periventricular white matter is not preferentially affected in NBD, rather there is a predilection for the brainstem. Areas of microhemorrhage may be evident on susceptibility-weighted imaging [84]. When evaluating for the presence of CVST, MR venography, or CT venography are the preferred imaging modalities. PET and sequential positron emission tomography (SPECT) can reveal areas of decreased oxygen consumption and cerebral hypoperfusion and may be more sensitive than MRI for detecting brain lesions [85].

Biopsy of involved tissue is not routinely obtained in the evaluation of possible NBD, but may be needed in some cases to exclude malignancy. Pathological examination of parenchymal NBD reveals that NBD is not a true vasculitis, but rather an inflammatory perivasculitis with intense inflammatory infiltration by neutrophils, lymphocytes, macrophages, and rarely eosinophils with or without areas of necrosis [86].

## Management

There have been no randomized, controlled clinical trials for the treatment of NBD; therefore, treatment is based on expert recommendations [79]. Treatment of acute attacks consists of intravenous methylprednisolone 1 g daily for 5–10 days followed by oral prednisone starting at 0.5–1 mg/kg/day and a gradual taper by 0.5 mg/day/week over up to 6 months. Two-thirds of patients with brainstem encephalitis respond well to glucocorticoids, but the remaining third relapse or progress and should be treated early with a steroid-sparing agent [79]. Azathioprine is a commonly used agent with a predictable and mild side-effect profile, but mycophenolate mofetil, methotrexate, chlorambucil, and cyclophosphamide are other reasonable first-line options.

Poor prognostic indicators include brainstem/spinal cord presentation, frequent relapses, early disease progression, and high CSF pleocytosis. Severe or refractory NBD warrants IV glucocorticoids in combination with either TNF antagonism (e.g., infliximab 5 mg/kg at 0, 2, and 6 weeks then every 6 weeks) or cyclophosphamide (IV, 750 mg/m<sup>2</sup> given monthly up to 6 months) [87, 88]. Cyclosporine, while effective for treating ocular BD, should be avoided given a higher risk of NBD in treated patients.

Glucocorticoids are recommended for patients with CVST, and can be given with anticoagulation, which is standard for CVST of any etiology. Steroid-sparing immunosuppression should be given to patients with CVST, especially when there has been previous CVST, parenchymal NBD, or active systemic disease.

## Sjögren Syndrome

Sjögren syndrome (SS) is a chronic autoimmune disorder characterized by lymphocytic infiltration of exocrine glands (e.g., salivary and lacri-

mal) that manifests with xerostomia, xerophthalmia, and antibodies targeting the small ribonucleoprotein particles SSA and SSB, which are found in a high percentage of patients. SS was first comprehensively described in 1933 by Swedish ophthalmologist Henrik Sjögren, who noted its predilection for women (10:1) most of whom were perimenopausal [89]. SS may occur alone (primary SS) or accompanied by other autoimmune diseases such as rheumatoid arthritis, systemic lupus erythematosus, or systemic sclerosis.

## Clinical Manifestations and Diagnostic Evaluation

The diagnosis of SS is based on the criteria in Table 17.7 [90]. Patients with primary SS may develop a range of extra-glandular manifestations including skin, joint, muscle, pulmonary, and renal involvement. Neurologic symptoms develop in ~20% of patients with SS and may antedate xerostomia and xerophthalmia in many (25–92%) [91, 92]. In one series, more than half (57%) of

**Table 17.7** American-European Consensus Group Revised International Classification Criteria for Sjögren syndrome (quoted directly)

I. Ocular symptoms: a positive response to at least one of the following questions: <ol style="list-style-type: none"> <li>1. Have you had daily, persistent, troublesome dry eyes for more than 3 months?</li> <li>2. Do you have a recurrent sensation of sand or gravel in the eyes?</li> <li>3. Do you use tear substitutes more than three times a day?</li> </ol>
II. Oral symptoms: a positive response to at least one of the following questions: <ol style="list-style-type: none"> <li>1. Have you had a daily feeling of dry mouth for more than 3 months?</li> <li>2. Have you had recurrently or persistently swollen salivary glands as an adult?</li> <li>3. Do you frequently drink liquids to aid in swallowing dry food?</li> </ol>
III. Ocular signs—objective evidence of ocular involvement defined as a positive result for at least one of the following two tests: <ol style="list-style-type: none"> <li>1. Schirmer's test, performed without anesthesia (&lt;5 mm in 5 min)</li> <li>2. Rose Bengal score or other ocular dye score (&gt;4 according to van Bijsterveld's scoring system)</li> </ol>
IV. Histopathology: In minor salivary glands (obtained through normal-appearing mucosa) focal lymphocytic sialoadenitis, evaluated by an expert histopathologist, with a focus score >1, defined as a number of lymphocytic foci (which are adjacent to normal-appearing mucous acini and contain more than 50 lymphocytes) per 4 mm <sup>2</sup> of glandular tissue
V. Salivary gland involvement: objective evidence of salivary gland involvement defined by a positive result for at least one of the following diagnostic tests: <ol style="list-style-type: none"> <li>1. Unstimulated whole salivary flow (&lt;1.5 mL in 15 min)</li> <li>2. Parotid sialography showing the presence of diffuse sialectasias (punctate, cavitory or destructive pattern), without evidence of obstruction in the major ducts</li> <li>3. Salivary scintigraphy showing delayed uptake, reduced concentration and/or delayed excretion of tracer</li> </ol>
VI. Autoantibodies: presence in the serum of the following autoantibodies: <ol style="list-style-type: none"> <li>1. Antibodies to Ro(SSA) or La(SSB) antigens, or both</li> </ol>

patients had neurologic manifestations at presentation, half of whom had isolated neurologic manifestations (36% of total) [93]. Neurologic manifestations antedated the diagnosis of SS in 81%, and only 21% had antibodies to SSA/SSB. The most common neurologic manifestations include peripheral neuropathy and myelitis, but the range of neurologic manifestations is broad. Debilitating fatigue is a common neuropsychiatric manifestation, although like fatigue seen in multiple sclerosis, the precise etiology is unclear.

Neuropathy related to SS develops clinically in ~10–15% of cases, although more cases may be detected with nerve conduction studies. Patterns include sensory, sensorimotor, mononeuritis multiplex, cranial neuropathies (especially trigeminal neuralgia), radiculoneuropathy, and autonomic dysfunction [94]. Predominantly proximal symptoms consistent with small fiber neuropathy suggest SS. Small fiber neuropathy is usually chronic and characterized by lancinating or burning pain that may or may not be length dependent. Pure dorsal root ganglionitis affecting small fibers presents with painful asymmetric, patchy, non-length dependent dysesthesias. Nerve conduction studies are usually normal, but skin biopsy can demonstrate decreased nerve fiber density and axonal swelling. Mixed dorsal root ganglionitis (sometimes called ataxic neuropathy) presents with paresthesias, hyporeflexia, autonomic instability, and impaired proprioception with consequent sensory ataxia, pseudoathetosis, and Romberg sign [95]. Sensorimotor polyneuropathy manifests as paresthesias and distal, symmetric muscle weakness and hyporeflexia and nerve conduction studies typically demonstrate axonal polyneuropathy of sensory and motor fibers. Cryoglobulinemia may be identified on laboratory testing. Mononeuritis multiplex presents with subacute, painful neuropathy of named peripheral nerves and is generally vasculitic in etiology. Cranial neuropathies, most often trigeminal neuropathy, radiculoneuropathies, and isolated autonomic neuropathy also occur.

Although the lack of standardized diagnostic criteria makes estimation difficult, central

nervous system manifestations develop rarely (2%) in patients with SS and can involve the meninges, spinal cord, brainstem, basal ganglia, optic nerves, cerebellum, and cerebral hemispheres [94, 96]. When myelitis develops in SS, it often involves three or more levels of the spinal cord (LETM) on MRI and patient serum should be tested for the presence of aquaporin-4 IgG as contemporary studies suggest AQ P-4-positive NMO is often the underlying illness in these cases.

## Management

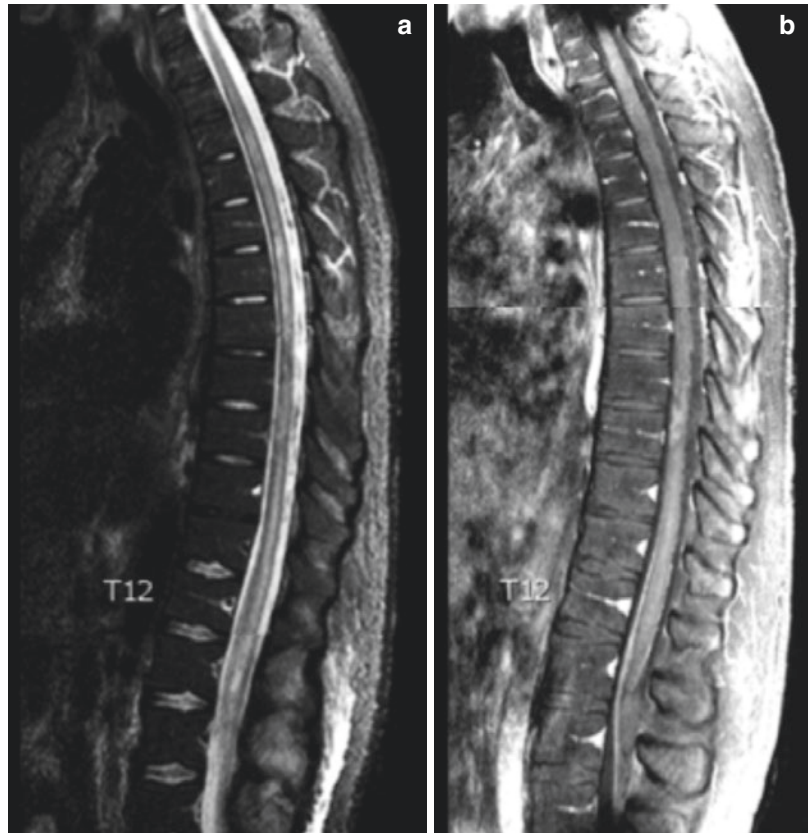
The treatment of neurologic manifestations of SS includes immunotherapy and symptom management. Intravenous corticosteroids are generally considered first-line for patients with acute CNS manifestations such as myelitis. For patients with severe disease or those who do not respond to treatment or relapse, steroid-sparing agents such as azathioprine, methotrexate, mycophenolate mofetil, rituximab, cyclophosphamide, or plasma exchange can be considered [97]. However, neuropathy in SS tends to be recalcitrant to treatment, therefore, symptom management including agents such as tricyclics, gabapentinoids, venlafaxine, duloxetine, or antiepileptics such as lamotrigine and topiramate should be considered. When there is LETM, the patient should be treated as though they have AQ P-4 positive NMOSD while the diagnostic evaluation is underway. This generally consists of high dose IV methylprednisolone, early plasma exchange and rituximab [98].

---

## Systemic Lupus Erythematosus (Fig. 17.4)

Systemic lupus erythematosus (SLE) is an inflammatory connective tissue disease with widely variable manifestations, both systemic and neurologic. Women are more frequently affected than men. Although the precise etiology is unclear, multiple mechanisms have been implicated, including hyperactivation of B and T lymphocytes with consequent overproduction

**Fig. 17.4** (a) Mid-sagittal STIR MRI. (b) Mid-sagittal T1 MRI with gadolinium



of autoantibodies, tissue deposition of immune complexes, apoptotic dysfunction with intracellular antigen exposure and high levels of inflammatory cytokines. Patients with SLE are known to produce a wide array of autoantibodies, most of which are not assessed in routine clinical practice [99]. Anti-double-stranded DNA (dsDNA) antibodies are the most common, a subset of which has been shown to cross-react with the *N*-methyl-D-aspartate receptor (NMDAR), termed dsDNA/NMDAR antibodies [100]. Neurologic involvement from SLE is a major source of mortality and morbidity and can be broadly divided into focal abnormalities and generalized neuropsychiatric disturbances. The underlying mechanisms of neurologic damage in SLE remain incompletely understood but evidence to date implicates disruption of the blood–brain barrier, endothelial cell autoreactive antibodies, complement deposition, inflammation mediated by cytokines

such as IL-1, IL-6 and TNF and vascular disease including accelerated atherogenesis and thrombosis [101, 102].

Diagnostic criteria for SLE were first proposed in 1971, and were most recently revised in 2012 [103]. This includes 11 clinical criteria and 6 immunologic criteria. Clinical features include acute and chronic skin findings, oral ulcers, alopecia, synovitis, serositis, proteinuria or red blood cell casts in the urine, hemolytic anemia, leukopenia, thrombocytopenia, and neurologic manifestations. The immunologic criteria include elevated antinuclear antibody (ANA), dsDNA, anti-Sm, antiphospholipid antibodies (aPL), low complement, and direct Coombs test in the absence of hemolytic anemia. Four criteria must be fulfilled, including at least one clinical and one immunologic, or biopsy-proven lupus nephritis found in the presence of ANA or dsDNA antibodies to establish the diagnosis. These criteria are cumulative and need not be present simultaneously.

**Table 17.8** Neurologic manifestations of systemic lupus erythematosus

Central nervous system
Stroke
Vasculopathy
Embolism (Libman Sacks)
Antiphospholipid antibodies
Vasculitis (rare)
Seizures
Migraine (association, likely not causation)
Demyelinating disease
Optic neuritis
Brain and brainstem encephalitis
Myelitis
Meningitis
Organic brain syndrome
Cognitive dysfunction
Dementia
Psychosis
Peripheral neuropathies

## Clinical Manifestations

Neurologic manifestations in SLE (termed neuropsychiatric SLE; NPSLE) (Table 17.8) were initially thought to be related to vasculitis; however, true vasculitis is extraordinarily rare in SLE [104]. Rather, many patients have a vasculopathy characterized by perivascular accumulation of mononuclear cells without actual vasculitis evinced by fibrinoid necrosis [105]. The incidence of ischemic stroke is increased in patients with SLE with 2–15% having a stroke in the course of their illness [106]. The risk is increased in the presence of aPL, high disease activity, and valvular disease (e.g., Libman-Sacks endocarditis). Cerebrovascular events account for 2–30% of mortality in SLE. Mechanisms of stroke include hypercoagulability, thromboembolism, accelerated atherosclerosis, and rarely vasculitis. Seizures affect some 8–18% of patients and can occur at any time in the course SLE, but most often develop early in the course [107]. Younger patients with high disease activity, episodes of psychosis, and previous stroke are at higher risk for seizures [108] and there appears to be an increased risk with anti-Smith and aPL.

Patients with true vasculitis present with fever, headache, and encephalopathy, and can rapidly progress to psychosis, seizures, and coma, which

may mimic NMDAR and other autoimmune encephalitides. Management of non-vasculitic stroke includes standard risk factor modification and treatment with statins, aspirin, or anticoagulation in the setting of hypercoagulable state. Immunosuppression should be considered for patients with evidence of vasculitis as the etiology of stroke.

Demyelinating syndrome is a rare (1–3%) but serious manifestation of SLE. When present, demyelinating disease is frequently the presenting manifestation of SLE (up to 40%) [109]. A recent meta-analysis identified five syndromes in SLE: AQP4+ NMO, NMOSD, demyelinating syndrome predominantly involving the brain, or the brainstem, and clinically isolated syndrome related to SLE without dissemination in time [109].

Myelitis is estimated to develop in 1–2% of patients [110]. Birnbaum et al. described two patterns of myelitis in NPSLE that appear to occur in equal proportion: predominantly gray matter myelitis typified by hyporeflexia and urinary retention and predominantly white matter myelitis with spasticity and hyperreflexia [111]. Patients with gray matter myelitis typically presented with a distinctive prodromal fever and urinary retention and were often initially misdiagnosed as having a urinary tract infection. These patients uniformly suffered a catastrophic, rapid progression to paralysis over less than 6 h, as in Case 17.4. Gray matter myelitis typically occurred in the setting of highly active SLE and was irreversible despite a monophasic course and aggressive immunosuppression. Those with white matter myelitis were more likely to meet NMOSD diagnostic criteria and to have aPL.

### Case 17.4

A 29-year-old man with SLE presented with fever, vomiting, and diarrhea. Complements were below baseline and dsDNA antibodies were elevated. His azathioprine was held given concern for infection. Over a period of 3.5 h, he developed back pain and rapidly progressive, flaccid paralysis to T10. MRI demonstrated extensive radiculomyelitis from the cauda equina to the

rostral medulla with hyperintensity on T2/STIR (**a**)\* and contrast enhancement throughout the nerve roots and thoracic and cervical cord (**b**)\* and he was transferred to neurology. He reported worsening weakness in the arms and dysphagia. LP revealed 2730 nucleated cells (99% neutrophils), glucose 15, protein 301, IgG index 0.92, and no oligoclonal bands. He was treated empirically with ceftriaxone, vancomycin, ampicillin, and acyclovir until infectious studies returned negative apart from norovirus in the stool (CSF PCR was negative). Aquaporin-4 IgG was negative on presentation and follow-up. Given concern for catastrophic lupus myelitis, he was simultaneously treated with IVMP 1 g daily  $\times$ 5 days (initiated within 10 h of myelitis onset), plasma exchange for five sessions, and 1 g IV cyclophosphamide. The weakness in his arms improved and his dysphagia resolved. Follow-up MRI (not shown) demonstrated significantly reduced enhancement but persistent T2 hyperintensity. He was given a prolonged steroid taper, but remained paralyzed below T10 in follow-up. \*Several images from the same study are overlaid in order to demonstrate the extent of the lesion.

## Diagnostic Evaluation

When NPSLE is suspected, the initial laboratory assessment should include complete blood count, comprehensive metabolic panel, ANA, anti-dsDNA, erythrocyte sedimentation rate, C-reactive protein, C3, C4, thyroid function studies, and urinalysis. More focused testing should be tailored to the presenting syndrome, for example, evidence of CNS pathology should be evaluated with contrasted MRI and CSF analysis while stroke-like presentations should include vascular imaging and aPL. When myelitis is the presenting syndrome, AQ P-4 IgG antibodies should be evaluated from serum.

Whenever there is a concern for lupus myelitis, the patient should undergo emergent MRI of the spi-

nal cord with and without contrast and CSF analysis. Infectious etiologies should be aggressively pursued and serum AQ P-4 antibodies should be evaluated [112]. CSF in patients with gray matter myelitis was statistically more inflamed (indistinguishable from bacterial meningitis), compared to those with white matter myelitis: median cell count was 385 vs. 10 cells/ $\mu$ L, with median neutrophilia of 71% vs. 15%, median protein of 254 vs. 57 mg/dL and median glucose of 33 vs. 54 mg/dL for patients with gray vs. white matter myelitis, respectively. MRI demonstrated LETM in most patients and cord swelling in 91.7% vs. 21.7% of patients with gray vs. white matter myelitis. However, contrast enhancement was seen only 25% (gray matter myelitis) vs. 42.9% (white matter myelitis) of patients. To explain the low rates of contrast enhancement and severe, irreparable damage seen in gray matter myelitis, the authors proposed a primarily inflammatory mechanism with early cord edema that produces ischemia and eventually infarction of the gray matter tracts with hypoperfusion leading to decrease efflux of gadolinium. Patients who develop myelitis should be treated aggressively, especially when febrile, including broad-spectrum antimicrobials under the supervision of infectious disease experts, possibly in combination with immunomodulatory therapy such as IVMP, plasma exchange, and/or cyclophosphamide.

## Management

There remains no cure for SLE and achieving durable, sustained remission is often challenging. It is important to consider carefully whether neurologic or psychiatric illness in any patient with SLE is caused by immune-mediated mechanisms or not. Mild to moderate neurologic manifestations attributed to immune-mediated mechanisms can reasonably be treated with glucocorticoids and steroid-sparing immunosuppressants such as azathioprine, mycophenolate mofetil, and methotrexate. For more severe disease such as lupus myelitis, high dose glucocorticoids, and immunosuppression should be initiated promptly. A systematic review of non-biologic immunosuppressive medications for NPSLE noted that cyclophosphamide may be useful for the treatment of NPSLE and

reduction of relapses [113–115]. Rituximab, plasma exchange, and IVIg may also be effective for NPSLE [116]. Antiepileptic drugs should be given to patients with seizures and anticoagulation for those with stroke and hypercoagulable state. Glucocorticoids, antidepressants, and atypical antipsychotics may be useful for cognitive and psychiatric illness, depending on the etiology.

---

## Rheumatoid Arthritis

Rheumatoid arthritis (RA) is a chronic systemic inflammatory disorder characterized by synovitis and erosive arthritis. The disease is more common in individuals of European descent and most often affects women. The etiology is unclear, but the disease develops in individuals with genetic susceptibility, environmental exposure (such as smoking), epigenetic modification, and post-translational modifications that ultimately lead to loss of tolerance and autoimmunity [117]. Synovitis is pathologically characterized by cellular hyperplasia (including pannus), increased synovial vascularity, and inflammatory infiltrates predominantly consisting of CD4+ T cells [117]. The 2010 American College of Rheumatology diagnostic criteria are commonly used for RA [118]. Typical findings include tender, swollen, symmetric polyarthritis of the hands with prolonged morning stiffness and joint erosion on X-ray imaging and abnormal laboratory test such as elevated ESR, CRP, rheumatoid factor (RF), and anticitrullinated peptide antibodies (ACPA; ~90–96% specific) [119, 120]. Extra-articular manifestations such as rheumatoid nodules, pulmonary involvement or vasculitis, and systemic comorbidities occur.

## Clinical Manifestations

The most common CNS pathology in RA is compressive myelopathy of the cervical spine, which presents with neck pain, headache, C2 radiculopathy, and signs of upper cervical myelopathy such as difficulty walking, sensory loss, hyperreflexia, and/or lower brainstem dysfunction.

Atlantoaxial subluxation, upward subluxation of the odontoid process against the medulla, or vertebral subluxation below C2 are described mechanisms. Plain X-rays may demonstrate pathology, but MRI is preferred. Meaningful spine disease from RA is rare in the absence of significant peripheral joint disease.

Neuropathy is clinically apparent in some 25% of patients, but nearly 60% have electrodiagnostic evidence of neuropathy, which is usually axonal (85%) [121]. Patterns include pure sensory, sensorimotor, entrapment neuropathies, and infrequently vasculitis manifesting as mononeuritis multiplex. Myopathy such as focal myositis (usually adjacent to actively involved joints), disseminated nodular myositis (non-necrotizing lymphocytic and plasma cell perivascular infiltrates), polymyositis (rare), and vasculitic/ischemic myopathy may be related to RA but steroid myopathy and disuse atrophy can also occur.

CNS vasculitis associated with RA typically affects small arteries that can include the meninges, gray or white matter and may present in isolation or with systemic vasculitis. Clinical manifestations are highly variable and include confusion, focal seizures, weakness, ataxia, cranial neuropathies, and changes in vision that typically progress subacutely.

## Diagnostic Evaluation

Inflammatory CNS manifestations are very rare in RA and include meningitis (headaches, cranial neuropathies), vasculitis (stroke or stroke-like episodes), and/or seizures. CSF in rheumatoid meningitis demonstrates mild pleocytosis (<100 cells/ $\mu$ L, mononuclear cell predominant) with normal to mildly elevated protein and normal or low glucose. Rarely, RF is present in the CSF, and is thought to be a specific marker of neurologic RA, but data are limited to case reports. MRI findings are nonspecific and include pachymeningeal and/or leptomenigeal thickening and enhancement that may appear nodular. Biopsy reveals mononuclear infiltration that may be rich in plasma cells and can include areas of necrosis and granulomata [122, 123]. When alternative



etiologies (see section “IgG-4-Related Disease,” above) have been appropriately excluded, treatment with intravenous glucocorticoids is reasonable and may be effective.

In CNS vasculitis associated with RA, systemic markers of inflammation may be present and CSF analysis may or may not reveal intrathecal inflammation. Brain MRI may demonstrate acute infarction, T2 hyperintensities in the cortex and/or subcortical or periventricular white matter. Conventional angiography is insensitive, given the small vessel nature of RA vasculitis. RA vasculitis is typically a late disease manifestation and histopathologically appears identical to polyarteritis nodosa with similar systemic signs/symptoms. Biopsy demonstrates intimal proliferation of fibrinoid necrosis, mononuclear cell cuffing and thickening of small arteries and veins [124]. Infectious vasculitis and meningoencephalitis must be excluded, even in the absence of fever as many patients are on immunosuppressive treatment [125]. Common causes of stroke should be evaluated and managed as appropriate.

## Management

The management of compressive myelopathy related to RA has been reviewed elsewhere [126]. When alternative etiologies for the inflammatory disease or vasculitis have been appropriately excluded, treatment with IV glucocorticoids may be effective. For vasculitis specifically, cyclophosphamide may be effective [127].

## Conclusion

The role of the neurologist in the management of patients with systemic autoimmune disease is increasing. There is a great need for neurologists with experience in autoimmune neurology as an integrated member of an interdisciplinary team including general internists, rheumatologists, pulmonologists, nephrologists, cardiologists, and infectious disease experts responsible for providing care to patients with systemic autoimmune

disease. Recognizing when a neurologic concern is related to immune-mediated or alternative mechanisms is a critical role for the neurologist as treatment decisions may be based on this assessment. Familiarity with the neurologic manifestations of systemic rheumatologic disease is therefore critical. The approach to treatment depends on the underlying mechanisms of disease, and decisions should be made in consultation with other experts assisting in the clinical care of an individual patient.

## References

1. Lopez-Chiriboga AS, Clardy SL. Emerging subspecialties in neurology: autoimmune neurology. *Neurology*. 2017;89(11):e129–e33.
2. Iannuzzi MC, Fontana JR. Sarcoidosis: clinical presentation, immunopathogenesis, and therapeutics. *JAMA*. 2011;305(4):391–9.
3. Rossi G, Cavazza A, Colby TV. Pathology of sarcoidosis. *Clin Rev Allergy Immunol*. 2015;49(1):36–44.
4. Horiuchi T, Mitoma H, Harashima S, Tsukamoto H, Shimoda T. Transmembrane TNF-alpha: structure, function and interaction with anti-TNF agents. *Rheumatology (Oxford)*. 2010;49(7):1215–28.
5. Ungprasert P, Carmona EM, Utz JP, Ryu JH, Crowson CS, Matteson EL. Epidemiology of sarcoidosis 1946–2013: a population-based study. *Mayo Clin Proc*. 2016;91(2):183–8.
6. Iannuzzi MC, Rybicki BA, Teirstein AS. Sarcoidosis. *N Engl J Med*. 2007;357(21):2153–65.
7. Iwai K, Tachibana T, Takemura T, Matsui Y, Kitaichi M, Kawabata Y. Pathological studies on sarcoidosis autopsy. I. Epidemiological features of 320 cases in Japan. *Acta Pathol Jpn*. 1993;43(7–8):372–6.
8. Krumholz A, Stern BJ. Neurologic manifestations of sarcoidosis. *Handb Clin Neurol*. 2014;119:305–33.
9. Oksanen V. Neurosarcoidosis: clinical presentations and course in 50 patients. *Acta Neurol Scand*. 1986;73(3):283–90.
10. Zajicek JP, Scolding NJ, Foster O, Rovaris M, Evanson J, Moseley IF, et al. Central nervous system sarcoidosis—diagnosis and management. *QJM*. 1999;92(2):103–17.
11. Scott TF, Yandora K, Valeri A, Chieffe C, Schramke C. Aggressive therapy for neurosarcoidosis: long-term follow-up of 48 treated patients. *Arch Neurol*. 2007;64(5):691–6.
12. Ferriby D, de Seze J, Stojkovic T, Hachulla E, Wallaert B, Destee A, et al. Long-term follow-up of neurosarcoidosis. *Neurology*. 2001;57(5):927–9.
13. Carlson ML, White JR Jr, Espahbodi M, Haynes DS, Driscoll CL, Aksamit AJ, et al. Cranial base manifes-

- tations of neurosarcoidosis: a review of 305 patients. *Otol Neurotol*. 2015;36(1):156–66.
14. Gelfand JM, Bradshaw MJ, Stern BJ, Clifford DB, Wang Y, Cho TA, et al. Infliximab for the treatment of CNS sarcoidosis: a multi-institutional series. *Neurology*. 2017;89(20):2092–100.
  15. Ungprasert P, Matteson EL. Neurosarcoidosis. *Rheum Dis Clin N Am*. 2017;43(4):593–606.
  16. Pawate S, Moses H, Sriram S. Presentations and outcomes of neurosarcoidosis: a study of 54 cases. *QJM*. 2009;102(7):449–60.
  17. Stern BJ, Krumholz A, Johns C, Scott P, Nissim J. Sarcoidosis and its neurological manifestations. *Arch Neurol*. 1985;42(9):909–17.
  18. Bagnato F, Stern BJ. Neurosarcoidosis: diagnosis, therapy and biomarkers. *Expert Rev Neurother*. 2015;15(5):533–48.
  19. Bathla G, Watal P, Gupta S, Nagpal P, Mohan S, Moritani T. Cerebrovascular manifestations of neurosarcoidosis: an underrecognized aspect of the imaging spectrum. *AJNR Am J Neuroradiol*. 2018;39(7):1194–200.
  20. Luke RA, Stern BJ, Krumholz A, Johns CJ. Neurosarcoidosis: the long-term clinical course. *Neurology*. 1987;37(3):461–3.
  21. Ginat DT, Dhillon G, Almast J. Magnetic resonance imaging of neurosarcoidosis. *J Clin Imaging Sci*. 2011;1:15.
  22. Lury KM, Smith JK, Matheus MG, Castillo M. Neurosarcoidosis—review of imaging findings. *Semin Roentgenol*. 2004;39(4):495–504.
  23. Murialdo G, Tamagno G. Endocrine aspects of neurosarcoidosis. *J Endocrinol Investig*. 2002;25(7):650–62.
  24. Nowak DA, Widenka DC. Neurosarcoidosis: a review of its intracranial manifestation. *J Neurol*. 2001;248(5):363–72.
  25. Tyshkov C, Pawate S, Bradshaw MJ, Kimbrough DJ, Chitnis T, Gelfand JM, Ryerson LZ, Kister I. Multiple sclerosis and sarcoidosis: A case for coexistence. *Neurol Clin Pract*. 2019;9(3):218–27. PMID:31341709.
  26. Terushkin V, Stern BJ, Judson MA, Hagiwara M, Pramanik B, Sanchez M, et al. Neurosarcoidosis: presentations and management. *Neurologist*. 2010;16(1):2–15.
  27. Spiegel DR, Morris K, Rayamajhi U. Neurosarcoidosis and the complexity in its differential diagnoses: a review. *Innov Clin Neurosci*. 2012;9(4):10–6.
  28. Hoitsma E, Faber CG, Drent M, Sharma OP. Neurosarcoidosis: a clinical dilemma. *Lancet Neurol*. 2004;3(7):397–407.
  29. Joubert B, Chapelon-Abrie C, Biard L, Saadoun D, Demeret S, Dormont D, et al. Association of prognostic factors and immunosuppressive treatment with long-term outcomes in neurosarcoidosis. *JAMA Neurol*. 2017;74(11):1336–44.
  30. Junger SS, Stern BJ, Levine SR, Sipos E, Marti-Masso JF. Intramedullary spinal sarcoidosis: clinical and magnetic resonance imaging characteristics. *Neurology*. 1993;43(2):333–7.
  31. Cohen-Aubart F, Galanaud D, Grabli D, Haroche J, Amoura Z, Chapelon-Abrie C, et al. Spinal cord sarcoidosis: clinical and laboratory profile and outcome of 31 patients in a case-control study. *Medicine (Baltimore)*. 2010;89(2):133–40.
  32. Smith JK, Matheus MG, Castillo M. Imaging manifestations of neurosarcoidosis. *AJR Am J Roentgenol*. 2004;182(2):289–95.
  33. Hashmi M, Kyritsis AP. Diagnosis and treatment of intramedullary spinal cord sarcoidosis. *J Neurol*. 1998;245(3):178–80.
  34. Zalewski NL, Krecke KN, Weinschenker BG, Aksamit AJ, Conway BL, McKeon A, et al. Central canal enhancement and the trident sign in spinal cord sarcoidosis. *Neurology*. 2016;87(7):743–4.
  35. Flanagan EP, Kaufmann TJ, Krecke KN, Aksamit AJ, Pittock SJ, Keegan BM, et al. Discriminating long myelitis of neuromyelitis optica from sarcoidosis. *Ann Neurol*. 2016;79(3):437–47.
  36. Zuniga G, Ropper AH, Frank J. Sarcoid peripheral neuropathy. *Neurology*. 1991;41(10):1558–61.
  37. Heij L, Dahan A, Hoitsma E. Sarcoidosis and pain caused by small-fiber neuropathy. *Pain Res Treat*. 2012;2012:256024.
  38. Tavee J, Culver D. Sarcoidosis and small-fiber neuropathy. *Curr Pain Headache Rep*. 2011;15(3):201–6.
  39. Aubart FC, Abbara S, Maisonobe T, Cottin V, Papo T, Haroche J, Mathian A, Pha M, Gilardin L, Hervier B, Soussan M, Morlat P, Nunes H, Benveniste O, Amoura Z, Valeyre D. Symptomatic muscular sarcoidosis. *Neurol Neuroimmunol Neuroinflamm*. 2018;5(3):e443.
  40. Stern BJ, Royal W III, Gelfand JM, Clifford DB, Tavee J, Pawate S, et al. Definition and consensus diagnostic criteria for neurosarcoidosis: from the Neurosarcoidosis Consortium Consensus Group. *JAMA Neurol*. 2018;75(12):1546–53.
  41. Dale JC, O'Brien JF. Determination of angiotensin-converting enzyme levels in cerebrospinal fluid is not a useful test for the diagnosis of neurosarcoidosis. *Mayo Clin Proc*. 1999;74(5):535.
  42. Tahmoush AJ, Amir MS, Connor WW, Farry JK, Didato S, Ulhoa-Cintra A, et al. CSF-ACE activity in probable CNS neurosarcoidosis. *Sarcoidosis Vasc Diffuse Lung Dis*. 2002;19(3):191–7.
  43. Bridel C, Courvoisier DS, Vuilleumier N, Lalive PH. Cerebrospinal fluid angiotensin-converting enzyme for diagnosis of neurosarcoidosis. *J Neuroimmunol*. 2015;285:1–3.
  44. Ungprasert P, Carmona EM, Crowson CS, Matteson EL. Diagnostic utility of angiotensin-converting enzyme in sarcoidosis: a population-based study. *Lung*. 2016;194(1):91–5.
  45. Bathla G, Singh AK, Policeni B, Agarwal A, Case B. Imaging of neurosarcoidosis: common, uncommon, and rare. *Clin Radiol*. 2016;71(1):96–106.
  46. Teirstein AS, Machac J, Almeida O, Lu P, Padilla ML, Iannuzzi MC. Results of 188 whole-body fluorodeoxyglucose positron emission tomogra-

- phy scans in 137 patients with sarcoidosis. *Chest*. 2007;132(6):1949–53.
47. Agbogu BN, Stern BJ, Sewell C, Yang G. Therapeutic considerations in patients with refractory neurosarcoidosis. *Arch Neurol*. 1995;52(9):875–9.
  48. Fritz D, van de Beek D, Brouwer MC. Clinical features, treatment and outcome in neurosarcoidosis: systematic review and meta-analysis. *BMC Neurol*. 2016;16(1):220.
  49. Bitoun S, Bouvry D, Borie R, Mahevas M, Sacre K, Haroche J, et al. Treatment of neurosarcoidosis: a comparative study of methotrexate and mycophenolate mofetil. *Neurology*. 2016;87(24):2517–21.
  50. Bradshaw MJ, Gelfand JM, Stern B, Clifford DB, Wang Y, Cho TA, Vu N, Sriram S, Moses H, Bagnato F, Koth LL, Hauser SL, Dierkhising J, Kaufmann JA, Ammah D, Yohannes TH, Hamblin MJ, Venna N, Green AJ, Pawate S. Infliximab for the treatment of neurosarcoidosis: a multi-institutional case series. *Neurology*. 2017;88(16):Supplement P1.335.
  51. Decock A, Van Assche G, Vermeire S, Wuyts W, Ferrante M. Sarcoidosis-like lesions: another paradoxical reaction to anti-TNF therapy? *J Crohns Colitis*. 2017;11(3):378–83.
  52. Deshpande V, Zen Y, Chan JK, Yi EE, Sato Y, Yoshino T, et al. Consensus statement on the pathology of IgG4-related disease. *Mod Pathol*. 2012;25(9):1181–92.
  53. AbdelRazek MA, Venna N, Stone JH. IgG4-related disease of the central and peripheral nervous systems. *Lancet Neurol*. 2018;17(2):183–92.
  54. Lu LX, Della-Torre E, Stone JH, Clark SW. IgG4-related hypertrophic pachymeningitis: clinical features, diagnostic criteria, and treatment. *JAMA Neurol*. 2014;71(6):785–93.
  55. Wu A, Andrew NH, McNab AA, Selva D. IgG4-related ophthalmic disease: pooling of published cases and literature review. *Curr Allergy Asthma Rep*. 2015;15(6):27.
  56. Soussan JB, Deschamps R, Sadik JC, Savatovsky J, Deschamps L, Puttermann M, et al. Infraorbital nerve involvement on magnetic resonance imaging in European patients with IgG4-related ophthalmic disease: a specific sign. *Eur Radiol*. 2017;27(4):1335–43.
  57. Ohyama K, Koike H, Takahashi M, Kawagashira Y, Iijima M, Watanabe H, et al. Immunoglobulin G4-related pathologic features in inflammatory neuropathies. *Neurology*. 2015;85(16):1400–7.
  58. Stone JH, Brito-Zeron P, Bosch X, Ramos-Casals M. Diagnostic approach to the complexity of IgG4-related disease. *Mayo Clin Proc*. 2015;90(7):927–39.
  59. Hao M, Liu M, Fan G, Yang X, Li J. Diagnostic value of serum IgG4 for IgG4-related disease: a PRISMA-compliant systematic review and meta-analysis. *Medicine (Baltimore)*. 2016;95(21):e3785.
  60. Mattoo H, Mahajan VS, Della-Torre E, Sekigami Y, Carruthers M, Wallace ZS, et al. De novo oligoclonal expansions of circulating plasmablasts in active and relapsing IgG4-related disease. *J Allergy Clin Immunol*. 2014;134(3):679–87.
  61. Wallace ZS, Mattoo H, Carruthers M, Mahajan VS, Della Torre E, Lee H, et al. Plasmablasts as a biomarker for IgG4-related disease, independent of serum IgG4 concentrations. *Ann Rheum Dis*. 2015;74(1):190–5.
  62. Khosroshahi A, Wallace ZS, Crowe JL, Akamizu T, Azumi A, Carruthers MN, et al. International consensus guidance statement on the management and treatment of IgG4-related disease. *Arthritis Rheumatol*. 2015;67(7):1688–99.
  63. Ebbo M, Grados A, Samson M, Groh M, Loundou A, Rigolet A, et al. Long-term efficacy and safety of rituximab in IgG4-related disease: data from a French nationwide study of thirty-three patients. *PLoS One*. 2017;12(9):e0183844.
  64. Carruthers MN, Topazian MD, Khosroshahi A, Witzig TE, Wallace ZS, Hart PA, et al. Rituximab for IgG4-related disease: a prospective, open-label trial. *Ann Rheum Dis*. 2015;74(6):1171–7.
  65. Feigenbaum A. Description of Behcet's syndrome in the Hippocratic third book of endemic diseases. *Br J Ophthalmol*. 1956;40(6):355–7.
  66. Behçet H. Über rezidivierende aphthöse durch ein virus verursachte geschwüre am mund, am auge und an den genitalien. *Dermatol Wochenschr*. 1937;105:1152–7.
  67. Gul A. Behcet's disease as an autoinflammatory disorder. *Curr Drug Targets Inflamm Allergy*. 2005;4(1):81–3.
  68. Zhang M, Xu WD, Wen PF, Liang Y, Liu J, Pan HF, et al. Polymorphisms in the tumor necrosis factor gene and susceptibility to Behcet's disease: an updated meta-analysis. *Mol Vis*. 2013;19:1913–24.
  69. Siva A, Saip S. The spectrum of nervous system involvement in Behcet's syndrome and its differential diagnosis. *J Neurol*. 2009;256(4):513–29.
  70. Yazici H, Tuzun Y, Pazarli H, Yurdakul S, Ozyazgan Y, Ozdogan H, et al. Influence of age of onset and patient's sex on the prevalence and severity of manifestations of Behcet's syndrome. *Ann Rheum Dis*. 1984;43(6):783–9.
  71. Yazici H, Fresko I, Yurdakul S. Behcet's syndrome: disease manifestations, management, and advances in treatment. *Nat Clin Pract Rheumatol*. 2007;3(3):148–55.
  72. Miller JJ, Venna N, Siva A. Neuro-Behcet disease and autoinflammatory disorders. *Semin Neurol*. 2014;34(4):437–43.
  73. Al-Araji A, Kidd DP. Neuro-Behcet's disease: epidemiology, clinical characteristics, and management. *Lancet Neurol*. 2009;8(2):192–204.
  74. Houman MH, Neffati H, Braham A, Harzallah O, Khanfir M, Miled M, et al. Behcet's disease in Tunisia. Demographic, clinical and genetic aspects in 260 patients. *Clin Exp Rheumatol*. 2007;25(4 Suppl 45):S58–64.
  75. Wechsler B, Vidailhet M, Piette JC, Bousser MG, Dell Isola B, Bletry O, et al. Cerebral venous thrombosis in Behcet's disease: clinical study and long-term follow-up of 25 cases. *Neurology*. 1992;42(3 Pt 1):614–8.

76. Bradshaw MJ, Pawate S, Bloch KC, Moots P, Reddy NM. Clinical reasoning: a 52-year-old man with diplopia and ataxia. *Neurology*. 2016;87(13):e140–3.
77. Jubelt B, Mihai C, Li TM, Veerapaneni P. Rhombencephalitis/brainstem encephalitis. *Curr Neurol Neurosci Rep*. 2011;11(6):543–52.
78. International Team for the Revision of the International Criteria for Behcet's Disease. The International Criteria for Behcet's Disease (ICBD): a collaborative study of 27 countries on the sensitivity and specificity of the new criteria. *J Eur Acad Dermatol Venereol*. 2014;28(3):338–47.
79. Kalra S, Silman A, Akman-Demir G, Bohlega S, Borhani-Haghighi A, Constantinescu CS, et al. Diagnosis and management of Neuro-Behcet's disease: international consensus recommendations. *J Neurol*. 2014;261(9):1662–76.
80. de Menthon M, Lavalley MP, Maldini C, Guillevin L, Mahr A. HLA-B51/B5 and the risk of Behcet's disease: a systematic review and meta-analysis of case-control genetic association studies. *Arthritis Rheum*. 2009;61(10):1287–96.
81. Saruhan-Direskeneli G, Yentur SP, Mutlu M, Shugaiv E, Yesilot N, Kurtuncu M, et al. Intrathecal oligoclonal IgG bands are infrequently found in neuro-Behcet's disease. *Clin Exp Rheumatol*. 2013;31(3 Suppl 77):25–7.
82. Scully SE, Stebner FC, Yoest SM. Magnetic resonance spectroscopic findings in neuro-Behcet disease. *Neurologist*. 2004;10(6):323–6.
83. Borhani Haghighi A, Sarhadi S, Farahangiz S. MRI findings of neuro-Behcet's disease. *Clin Rheumatol*. 2011;30(6):765–70.
84. Albayram S, Saip S, Hasiloglu ZI, Teke M, Ceyhan E, Tutuncu M, et al. Evaluation of parenchymal neuro-Behcet disease by using susceptibility-weighted imaging. *AJNR Am J Neuroradiol*. 2011;32(6):1050–5.
85. Kao CH, Lan JL, ChangLai SP, Chieng PU. Technetium-99m-HMPAO SPECT and MRI of brain in patients with neuro-Behcet's syndrome. *J Nucl Med*. 1998;39(10):1707–10.
86. Hirohata S. Histopathology of central nervous system lesions in Behcet's disease. *J Neurol Sci*. 2008;267:41–7.
87. Kikuchi H, Aramaki K, Hirohata S. Effect of infliximab in progressive neuro-Behcet's syndrome. *J Neurol Sci*. 2008;272(1–2):99–105.
88. Borhani Haghighi A, Safari A, Nazarinia MA, Habibagahi Z, Shenavandeh S. Infliximab for patients with neuro-Behcet's disease: case series and literature review. *Clin Rheumatol*. 2011;30(7):1007–12.
89. Sjögren H. Zur kenntnis der keratoconjunctivitis sicca (keratitis filiformis bei hypofunktion der tränen-drüsen). *Acta Ophthalmol*. 1933;11(Suppl 2):1–151.
90. Vitali C, Bombardieri S, Jonsson R, Moutsopoulos HM, Alexander EL, Carsons SE, et al. Classification criteria for Sjogren's syndrome: a revised version of the European criteria proposed by the American-European Consensus Group. *Ann Rheum Dis*. 2002;61(6):554–8.
91. Chai J, Logigian EL. Neurological manifestations of primary Sjogren's syndrome. *Curr Opin Neurol*. 2010;23(5):509–13.
92. Gono T, Kawaguchi Y, Katsumata Y, Takagi K, Tochimoto A, Baba S, et al. Clinical manifestations of neurological involvement in primary Sjogren's syndrome. *Clin Rheumatol*. 2011;30(4):485–90.
93. Delalande S, de Seze J, Fauchais AL, Hachulla E, Stojkovic T, Ferriby D, et al. Neurologic manifestations in primary Sjogren syndrome: a study of 82 patients. *Medicine (Baltimore)*. 2004;83(5):280–91.
94. Berkowitz AL, Samuels MA. The neurology of Sjogren's syndrome and the rheumatology of peripheral neuropathy and myelitis. *Pract Neurol*. 2014;14(1):14–22.
95. Mori K, Iijima M, Koike H, Hattori N, Tanaka F, Watanabe H, et al. The wide spectrum of clinical manifestations in Sjogren's syndrome-associated neuropathy. *Brain*. 2005;128(Pt 11):2518–34.
96. Margaretten M. Neurologic manifestations of primary Sjogren syndrome. *Rheum Dis Clin N Am*. 2017;43(4):519–29.
97. Ramos-Casals M, Garcia-Hernandez FJ, de Ramon E, Callejas JL, Martinez-Berriotoxa A, Pallares L, et al. Off-label use of rituximab in 196 patients with severe, refractory systemic autoimmune diseases. *Clin Exp Rheumatol*. 2010;28(4):468–76.
98. Bradshaw MJ, Kimbrough D. Neuromyelitis optica spectrum disorders. *Pract Neurol*. 2/2019. p. 76–89.
99. Yaniv G, Twig G, Shor DB, Furer A, Sherer Y, Mozes O, et al. A volcanic explosion of autoantibodies in systemic lupus erythematosus: a diversity of 180 different antibodies found in SLE patients. *Autoimmun Rev*. 2015;14(1):75–9.
100. Kowal C, Degiorgio LA, Lee JY, Edgar MA, Huerta PT, Volpe BT, et al. Human lupus autoantibodies against NMDA receptors mediate cognitive impairment. *Proc Natl Acad Sci U S A*. 2006;103(52):19854–9.
101. Stock AD, Wen J, Putterman C. Neuropsychiatric lupus, the blood brain barrier, and the TWEAK/Fn14 pathway. *Front Immunol*. 2013;4:484.
102. Muscal E, Brey RL. Neurologic manifestations of systemic lupus erythematosus in children and adults. *Neurol Clin*. 2010;28(1):61–73.
103. Petri M, Orbai AM, Alarcon GS, Gordon C, Merrill JT, Fortin PR, et al. Derivation and validation of the Systemic Lupus International Collaborating Clinics classification criteria for systemic lupus erythematosus. *Arthritis Rheum*. 2012;64(8):2677–86.
104. Johnson RT, Richardson EP. The neurological manifestations of systemic lupus erythematosus. *Medicine (Baltimore)*. 1968;47(4):337–69.
105. Ellison D, Gatter K, Heryet A, Esiri M. Intramural platelet deposition in cerebral vasculopathy of systemic lupus erythematosus. *J Clin Pathol*. 1993;46(1):37–40.
106. Timlin H, Petri M. Transient ischemic attack and stroke in systemic lupus erythematosus. *Lupus*. 2013;22(12):1251–8.

107. Jafri K, Patterson SL, Lanata C. Central nervous system manifestations of systemic lupus erythematosus. *Rheum Dis Clin N Am*. 2017;43(4):531–45.
108. Mikdashi J, Krumholz A, Handwerker B. Factors at diagnosis predict subsequent occurrence of seizures in systemic lupus erythematosus. *Neurology*. 2005;64(12):2102–7.
109. Piga M, Chessa E, Peltz MT, Floris A, Mathieu A, Cauli A. Demyelinating syndrome in SLE encompasses different subtypes: do we need new classification criteria? Pooled results from systematic literature review and monocentric cohort analysis. *Autoimmun Rev*. 2017;16(3):244–52.
110. Theodoridou A, Settas L. Demyelination in rheumatic diseases. *J Neurol Neurosurg Psychiatry*. 2006;77(3):290–5.
111. Birnbaum J, Petri M, Thompson R, Izbudak I, Kerr D. Distinct subtypes of myelitis in systemic lupus erythematosus. *Arthritis Rheum*. 2009;60(11):3378–87.
112. Majed M, Fryer JP, McKeon A, Lennon VA, Pittock SJ. Clinical utility of testing AQP4-IgG in CSF: guidance for physicians. *Neurol Neuroimmunol Neuroinflamm*. 2016;3(3):e231.
113. Pego-Reigosa JM, Cobo-Ibanez T, Calvo-Alen J, Loza-Santamaria E, Rahman A, Munoz-Fernandez S, et al. Efficacy and safety of nonbiologic immunosuppressants in the treatment of nonrenal systemic lupus erythematosus: a systematic review. *Arthritis Care Res (Hoboken)*. 2013;65(11):1775–85.
114. Barile-Fabris L, Ariza-Andraca R, Olguin-Ortega L, Jara LJ, Fraga-Mouret A, Miranda-Limon JM, et al. Controlled clinical trial of IV cyclophosphamide versus IV methylprednisolone in severe neurological manifestations in systemic lupus erythematosus. *Ann Rheum Dis*. 2005;64(4):620–5.
115. Greenberg BM, Thomas KP, Krishnan C, Kaplin AI, Calabresi PA, Kerr DA. Idiopathic transverse myelitis: corticosteroids, plasma exchange, or cyclophosphamide. *Neurology*. 2007;68(19):1614–7.
116. Tokunaga M, Saito K, Kawabata D, Imura Y, Fujii T, Nakayamada S, et al. Efficacy of rituximab (anti-CD20) for refractory systemic lupus erythematosus involving the central nervous system. *Ann Rheum Dis*. 2007;66(4):470–5.
117. Smolen JS, Aletaha D, McInnes IB. Rheumatoid arthritis. *Lancet*. 2016;388(10055):2023–38.
118. Aletaha D, Neogi T, Silman AJ, Funovits J, Felson DT, Bingham CO III, et al. 2010 Rheumatoid arthritis classification criteria: an American College of Rheumatology/European League Against Rheumatism collaborative initiative. *Arthritis Rheum*. 2010;62(9):2569–81.
119. Bhattacharyya S, Helfgott SM. Neurologic complications of systemic lupus erythematosus, Sjogren syndrome, and rheumatoid arthritis. *Semin Neurol*. 2014;34(4):425–36.
120. Dimberg EL. Rheumatology and neurology. *Continuum (Minneapolis)*. 2017;23(3, Neurology of Systemic Disease):691–721.
121. Agarwal V, Singh R, Wiclaf, Chauhan S, Tahlan A, Ahuja CK, et al. A clinical, electrophysiological, and pathological study of neuropathy in rheumatoid arthritis. *Clin Rheumatol*. 2008;27(7):841–4.
122. Yuh WT, Drew JM, Rizzo M, Ryals TJ, Sato Y, Bell WE. Evaluation of pachymeningitis by contrast-enhanced MR imaging in a patient with rheumatoid disease. *AJNR Am J Neuroradiol*. 1990;11(6):1247–8.
123. Bathon JM, Moreland LW, DiBartolomeo AG. Inflammatory central nervous system involvement in rheumatoid arthritis. *Semin Arthritis Rheum*. 1989;18(4):258–66.
124. Ramos M, Mandybur TI. Cerebral vasculitis in rheumatoid arthritis. *Arch Neurol*. 1975;32(4):271–5.
125. Bradshaw MJ, Cho TA, Chow FC. Central nervous system infections associated with immunosuppressive therapy for rheumatic disease. *Rheum Dis Clin N Am*. 2017;43(4):607–19.
126. DeQuattro K, Imboden JB. Neurologic manifestations of rheumatoid arthritis. *Rheum Dis Clin N Am*. 2017;43(4):561–71.
127. Ozkul A, Yilmaz A, Akyol A, Kiylioglu N. Cerebral vasculitis as a major manifestation of rheumatoid arthritis. *Acta Clin Belg*. 2015;70(5):359–63.

# Index

## A

- Abdominal aneurysms, 264
- Acetylcholine (ACh)-filled synaptic vesicles, 285
- Acquired demyelinating syndrome (ADS), 180
- Acute disseminated encephalomyelitis (ADEM), 181, 219
  - anti-MOG syndrome, 184
  - average age at onset, 215
  - clinical CSF and radiological features, 184, 185
  - clinical features, 216
  - cognitive deficits, 216
  - diagnosis
    - bilateral thalamic involvement, 218
    - classical imaging features, 218
    - CSF analysis, 218
    - diffuse extensive supratentorial white matter involvement, 218
    - electroencephalogram, 218
    - monophasic and multiphasic (second attack) variants, 217
    - multifocal clinically isolated syndrome, 217
    - neuroimaging, 217
    - nonconventional MRI techniques, 218
  - diagnostic criteria, 184
  - differential diagnosis, 219
  - etiology, 222, 223
  - incidence, 215
  - localized pathological process, 184
  - management, 219
  - MRI, 185
  - multifocal neurologic deficits, 216
  - pathology, 216
  - spectrum overlap disorders
    - acute necrotizing encephalopathy, 220, 221
    - ADEM-ON, 220
    - adult onset MS, 222
    - AHLE (Hurst syndrome), 220, 221
    - Bickerstaff brainstem encephalitis, 220, 221
    - multiphasic, 220
    - pediatric MS, 220, 222
  - triggering events, 215
- Acute hemorrhagic leukoencephalitis (AHLE), 216, 220, 221
- Acute inflammatory demyelinating polyneuropathy (AIDP), 299
- Acute motor and sensory axonal neuropathy (AMSAN), 301
- Acute necrotizing encephalopathy, 220, 221
- ADEM followed by optic neuritis (ADEM-ON), 220
- Adrenoleukodystrophy, 186
- Adrenomyeloneuropathy, 186
- Adult and childhood vasculitis
  - associated with diseases, 258
  - clinical presentation, 269, 270
  - collagen vascular disease, 258
  - eosinophilic granulomatosis with polyangiitis, 257, 260
  - history, 258
    - abdominal aneurysms, 264
    - adult PAN, 259
    - allergic granuloma, 260
    - amputated limbs, 266
    - anti-neutrophil cytoplasmic antibody (ANCA), 257, 261, 262
    - atypical acute CS, 266
    - autoimmune encephalitis, 269
    - central nervous system vasculitis, 267
    - cerebral vasculitis, 267, 268
    - cerebral vasculopathy, 268
    - chronic membranoproliferative glomerulonephritis, 263
    - cryoglobulinemia, 262
    - due to drug abuse, 267
    - excessive thickening of aneurysm walls and perianeurysmal adhesions, 264
    - extravascular granulomas, 260
    - fulminant childhood PAN, 259
    - GANS, 267
    - granulomatosis with polyangiitis, 260, 261
    - Hashimoto encephalopathy, 268, 269
    - hypersensitivity vasculitis, 262
    - IgG4-related thoracic aortitis, 265
    - inflammatory abdominal aortic aneurysm, 264
    - inflammatory aortic/iliac aneurysms, 264
    - ischemic centrop fascicular nerve fiber degeneration, 266
    - Kawasaki disease, 259
    - mucocutaneous lymph node syndrome, 259
    - necrotizing vasculitis, 260

- Adult and childhood vasculitis (*cont.*)
- non-infectious granulomatous angiitis, 266
  - nonsystemic vasculitic neuropathy, 266
  - periarthritis, 258
  - perivascular inflammatory cell infiltration, 265
  - polyarteritis nodosa, 259
  - primary CNS vasculitis, 266
  - recurrent oral and genital ulceration, 265
  - retroperitoneal fibrosis, 264
  - SVV syndromes, 259
  - systemic necrotizing arteritis, 259
  - temporal arteritis, 263, 264
  - tissue infiltration by eosinophils, 260
  - vestibuloauditory dysfunction, 265
- infection, 275
- laboratory evaluation
- biopsy, 271
  - cerebrospinal fluid analysis, 270
  - computed tomography, 271
  - CT angiography, 271
  - cut-film/digital subtraction angiography, 271
  - <sup>18</sup>2-deoxy-2-[fluorine-18]fluoro- D-glucose position emission tomography, 271
  - electrodiagnostic studies, 270
  - <sup>18</sup>F-FDG PET imaging, 271
  - functional imaging, 271
  - high-resolution 3-Tesla (3-T) MRI, 271
  - MR angiography, 271
  - MRI findings, 271
  - needle electromyography, 270
  - nerve conduction studies, 270
  - quantitative motor unit potential (MUP) analysis, 270
- large vessel vasculitis, 257, 258
- medium vessel vasculitis, 257, 258
- primary CNS vasculitis, 258
- revised CHCC nomenclature, 257, 258
- small vessel vasculitis, 257, 258
- substance abuse and infection, 258
- treatment
- corticosteroids, 273
  - etanercept and infliximab, 274, 275
  - high dose IVIg therapy, 276
  - immunosuppressant therapy, 275, 276
  - methotrexate, 275
  - mycophenolate mofetil, 275
  - oral cyclophosphamide with prednisone, 274
  - prednisolone, 275
  - purine analog azathioprine, 275
  - rituximab, 274
  - trimethoprim-sulfamethoxazole, 276
  - variable vessel vasculitis, 257, 258
- Albumino-cytologic dissociation, 299
- Alemtuzumab, 140, 141, 160, 165, 170
- Alexander disease, 186
- Allergic granuloma, 260
- Amputated limbs, 266
- Amyopathic dermatomyositis, 292
- ANCA-associated vasculitis (AAV), 257
- Anti MAG neuropathy, 310
- Anti-  $\alpha$ -amino-3-hydroxy-5-methyl-4-isoxazolepropionic (AMPA) receptor encephalitis, 241
- Antibody-negative limbic encephalitis, 242
- Anti-carbonic anhydrase II antibodies, 244
- Anti-collapsin response-mediator protein-5 (CRMP5), 242
- Anti-enolase antibodies, 244
- Anti-MOG syndrome, 184
- Anti-neutrophil cytoplasmic antibody (ANCA), 257, 261, 262
- Anti-synthetase syndrome, 290
- Anti-U1 ribonuclear protein, 291
- A proliferation-inducing ligand (APRIL), 23
- Aquaporin-4 immunoglobulin G antibodies (AQP4-IgG), 228
- Astrocytes, 8–10
- Atrophy, 290
- Atypical acute CS, 266
- Autoimmune disease
- antigen-specific response, 18
  - central and peripheral tolerance, 17
  - clinical autoimmunity, 18
  - co-stimulation and T-cell activation, 18, 19
  - environmental variables, 17
  - genetic predisposition, 17
  - immunologic tolerance, 17
  - immunotherapies, 18
  - infection-triggered immune changes, 17
  - restoration of tolerance, 17, 18
- Autoimmune disorders, 186
- Autoimmune encephalitis, 4, 237, 240, 269
- Autoimmune neuropathies
- associated with monoclonal gammopathy, 309
  - chronic inflammatory demyelinating polyradiculoneuropathy
    - chronic pure sensory polyneuropathy, 307
    - classic, 303
    - clinical features, 303, 304
    - distal acquired demyelinating symmetric neuropathy, 307
    - immune pathogenesis, 304, 305
    - laboratory studies, 304
    - multifocal acquired demyelinating sensory and motor neuropathy, 307
    - prevalence, 304
    - treatment, 305, 306
    - variants, 307–311
- Guillain-Barre syndrome
- albumino-cytologic dissociation, 299
  - antiganglioside antibodies with subtypes, 302
  - Campylobacter* enteritis, 302
  - complications, 300
  - definition, 299
  - electrodiagnostic studies, 300
  - experimental allergic neuritis, 299
  - immune pathogenesis, 301, 302
  - intact myelin lamellae, 300
  - lipooligosaccharides, 302
  - management, 302, 303
  - pathologic and nerve conduction studies, 299

- pathological studies, 300, 301
- sensory nerve conduction studies, 300
- sensory symptoms, 300
- variants, 301
- malignant gammopathies, 310
- monoclonal gammopathy of undetermined
  - significance, 310, 311
- multifocal motor neuropathy
  - clinical features, 307
  - conduction block, 308
  - immune pathogenesis, 309
  - laboratory studies, 308
  - treatment, 309
- vasculitic neuropathy, 311
- Autologous hematopoietic stem cell transplantation (AHSCT), 161
- Avonex Pregnancy Exposure Registry, 169
- Azathioprine, 146, 170

## B

- Balo concentric sclerosis, 51
- B cell activating factor (BAFF), 23, 24
- B-cell depleting therapies, 139, 140
- B cells
  - affinity maturation, 27
  - antibody-independent function, 26
  - in autoimmune disorders, 24
  - APRIL, 23
  - BAFF, 23, 24
  - B-cell derived cytokines, 26
  - CD40, 26
  - CNS demyelination control, 26
  - co-stimulatory factors, 25
  - cytokine-producing B cells, 26
  - development and maturation, 23
  - ectopic lymphoid structures, 26
  - hematopoietic stem cells development, 22, 23
  - high-affinity antibodies, 25
  - humoral immunity, 22, 23
  - IL-10, 26
  - IL-6/IL-6R autocrine loop, 26
  - inflammatory cytokines, 26
  - lymphotoxins, 26
  - memory B cells, 26
  - MHC II-associated peptides, 25
  - in MS, 54, 55
  - naïve (CD19+CD27-) and memory (CD19+CD27+)
    - human B cells, 26
  - naïve mature B cells, 26
  - opsonization, 24
  - organ-specific autoimmune diseases, 24
  - PAMPs, 24
  - TNF-R superfamily, 24
  - TNF $\alpha$ , 26
- Behçet disease (BD), 257
  - clinical manifestation, 329, 330
  - diagnostic criteria, 330, 331
  - differential diagnosis, 331
  - pathological investigations, 328

- prevalence, 328
- treatment, 331, 332
- Bence-Jones proteinuria, 262
- BENEFIT study, 144
- Benign monoclonal gammopathy, 310
- Betaferon Efficacy Yielding Outcomes of a New Dose (BEYOND) study, 203
- Betaseron Pregnancy Registry, 169
- Bickerstaff brainstem encephalitis, 220, 221
- Blood-CSF-barrier (BCSFB), 27
- Blood-spinal cord-barrier (BSpCB), 27
- Body mass index (BMI), 180
- Brain-CSF-barrier (BCSFB), 27
- Brainstem dysfunction, 329
- Brainstem-cerebellar syndromes, 90
- Brief International Cognitive Assessment (BICAMS), 183
- Brown-Sequard syndrome, 93

## C

- Campylobacter enteritis, 302
- Canavan disease, 186
- CCR5 inhibitors, 164
- Cell adhesion molecules, 57
- Cellcept, 147
- Central nervous system (CNS), 184
  - acquired immune responses, 6
  - anatomy, 4, 5
  - astrocytes, 8–10, 59
  - BBB, 60
  - blood brain barrier, 5
  - CSF draining pathways, 5
  - endothelial cells, 11
  - excitotoxins, 60, 61
  - exosomes, 62
  - histocompatibility molecule expression, 7
  - immune surveillance, 7
  - immune system connections, 3
  - immune/inflammatory response, 6
  - leukocyte transmigration, 6
  - lymphatic system, 5
  - microglia, 7, 8, 58
  - MiRNAs, 62
  - mitochondria, 61
  - neurons, 10, 11, 59, 60
  - neurotrophic factors, 61
  - nitric oxide, 61
  - oligodendrocytes, 10, 58, 59
  - primary angiitis, 272
  - resident immune system, 6
  - T cell migration, 7
  - Virchow-Robin perivascular spaces, 6
- Central nervous system vasculitis, 267
- Central scotomata, 90
- Cerebral spinal fluid (CSF) oligoclonal bands (OCBs), 181
- Cerebral vasculitis, 267, 268
- Cerebral vasculopathy, 268
- Cerebral venous sinus thrombosis (CVST), 330



- Cerebrospinal fluid (CSF) analysis, 270  
 CHAMPS study, 144  
 Checkpoint inhibitors, 248  
 Chemokine receptors, 29  
 Chemokines, 57  
 Chiari malformation, 90  
 Cholinesterase inhibitors, 94  
 Chronic inflammatory demyelinating polyradiculoneuropathy (CIDP)  
   chronic pure sensory polyneuropathy, 307  
   classic, 303  
   clinical features, 303, 304  
   distal acquired demyelinating symmetric neuropathy, 307  
   immune pathogenesis, 304, 305  
   laboratory studies, 304  
   multifocal acquired demyelinating sensory and motor neuropathy, 307  
   prevalence, 304  
   treatment, 305, 306  
   variants, 307–311  
 Chronic intestinal pseudoobstruction, 246  
 Chronic lymphocytic inflammation with pontine perivascular enhancement responsive to steroids (CLIPPERS), 3, 250, 251  
 Chronic membranoproliferative glomerulonephritis, 263  
 Chronic pure sensory polyneuropathy, 307  
 Chronic sarcoid myopathy, 296  
 Cladribine, 147  
 Classical syndrome  
   clinical features, 237  
   CNS  
   anti-AMPA receptor encephalitis, 241  
   antibody-negative limbic encephalitis, 242  
   Hashimoto's encephalopathy, 242  
   LGI-1 antibody syndrome, 241, 242  
   limbic encephalitis, 237  
   melanoma associated retinopathy, 244  
   Morvan's syndrome, 245  
   NMDAR, 240, 241  
   opsoclonus myoclonus syndrome, 243  
   paraneoplastic cerebellar degeneration, 243  
   paraneoplastic encephalomyelitis, 242  
   paraneoplastic optic neuritis and neuropathies, 244  
   progressive encephalomyelitis with rigidity and myoclonus, 245  
   Stiff Person syndrome, 244, 245  
   neuroimaging studies, 270  
   vs. nonclassical syndrome, 236, 238  
   PNS  
   chronic intestinal pseudoobstruction, 246  
   dermatomyositis, 246  
   nonclassical neurologic paraneoplastic symptoms, 247  
   POEMS syndrome, 246, 247  
   subacute sensory neuronopathy syndrome, 246  
   vasculitis, 337  
 Classical syndromes, 236  
 Clinically definite multiple sclerosis (CDMS), 89, 144, 145  
 Clinically isolated syndrome (CIS), 89, 90, 97, 98, 144–145, 202  
 Cogan syndrome (CS), 257  
 Cogstate Brief Battery, 183  
 Compound muscle action potentials (CMAP), 288  
 CONFIRM study, 142  
 CONFIRM trial, 146  
 Copaxone, *see* Glatiramer acetate  
 Corticosteroid therapy, 273, 274  
 Cranial neuropathy, 322  
 Cryoglobulinemic vasculitis (CV), 257  
 Cryoglobulinemia, 262  
 Cyclophosphamide, 146  
 Cytokines, 32, 56  
 Cytomegalovirus (CMV) infection, 181
- D**  
 Daclizumab, 141, 165  
 Dawson fingers, 99, 109  
 DEFINE study, 142  
 Demyelinating syndrome, 335  
 Dendritic cells (DC's)  
   activation status and cytokine secretion profile, 31  
   lineage and sub-types, 30  
   maturation and sub-types, 31, 32  
   proinflammatory cytokines, 56  
   tolerogenic DCs, 56  
<sup>182</sup>-deoxy-2-[fluorine-18]fluoro- D-glucose position emission tomography, 271  
 Depression, 324  
 Dermatomyositis (DM), 246  
   clinical description, 291, 292  
   diagnosis, 292  
   pathophysiology, 293  
   treatment, 293  
 Diapedesis, 29  
 Dimethyl fumarate (DMF), 142, 169  
 Disease modifying therapy (DMT), 161–163, 179  
   early, 189  
   global randomized clinical trial, 188  
   high-potency vs. low-potency agents, 188  
   late, 189  
 Dissemination in space (DIS) criteria, 181  
 Dissemination in time (DIT) criteria, 181  
 Distal acquired demyelinating symmetric (DADS), 304, 307  
 DMD, extended/reduced dosing, 165–166  
 Dotarem®, 115  
 Down-beating vertical nystagmus, 90  
 Drug-induced inflammatory myopathies, 295  
 Duchenne muscular dystrophy, 296
- E**  
 EBV nuclear antigen 1 (EBNA-1), 74  
 Ectopic lymphoid tissue, 27  
 Edrophonium testing, 286  
 Electrodiagnostic testing, 287  
 Electroencephalography (EEG), 270  
 Electroretinogram (ERG), 244  
 Encephalitic/meningo-encephalitic infectious processes, 185

Encephomyelopathy, 265  
 Endplate potential (EPP), 286  
 Eosinophilic granulomatosis with polyangiitis (EGPA), 257, 260  
 Eosinophilic myositis, 295, 296  
 Eosinophil-rich and granulomatous inflammatory process, 260  
 Eovist®, 115  
 Epstein-Barr virus (EBV), 74  
 Erdheim-Chester disease (ECD), 250  
 Escalation strategy, 159  
 European Medicines Agency (EMA) criteria, 112  
 Excitotoxins, 61  
 EXPAND (phase III) trial, 146  
 Expanded Disability Status Scale (EDSS), 110, 162, 164  
 Experimental allergic neuritis (EAN), 299  
 Experimental allergic/autoimmune encephalomyelitis (EAE), 52, 199  
 Extravascular granulomas, 260  
 Eye movement abnormalities, 90, 91

## F

Facial nerve palsy, 322  
<sup>18</sup>F-FDG PET imaging, 271  
 Fingolimod, 141, 142, 146, 164–165, 169  
 FoxP3, 20  
 Fracture Risk Assessment Tool (FRAX), 274

## G

Gadavist®, 115  
 Genome-wide association study (GWAS), 78  
 German Multiple Sclerosis and Pregnancy Registry, 169  
 Giant cell myositis, 291  
 Gilenya, *see* Fingolimod  
 Glatiramer acetate (GA), 138, 169  
 Glycerinaldehyde 3 phosphate dehydrogenase antibodies, 244  
 Gonadotropin-releasing hormone (GRH) analog, 274  
 Granulocyte macrophage colony stimulating factor (GM-CSF), 19  
 Granulomatosis with polyangiitis (GPA), 257, 260, 261  
 Granulomatous angiitis of the brain (GAB) and nervous system (GANS), 267  
 Granulomatous mass lesions, 323  
 Guillain-Barre syndrome (GBS)  
 albumino-cytologic dissociation, 299  
 antiganglioside antibodies with subtypes, 302  
*Campylobacter* enteritis, 302  
 complications, 300  
 definition, 299  
 electrodiagnostic studies, 300  
 experimental allergic neuritis, 299  
 immune pathogenesis, 301, 302  
 intact myelin lamellae, 300  
 lipooligosaccharides, 302  
 management, 302, 303  
 pathologic and nerve conduction studies, 299  
 pathologic studies, 301  
 pathological studies, 300

primary axolemmal attack, 301  
 sensory nerve conduction studies, 300  
 sensory symptoms, 300  
 variants, 301  
 Gut microbiome  
 anatomy, 34, 35  
 GALT, 35  
 genetic, physical and chemical factors, 34  
 molecular, genetic and animal experimental tools, 34  
 of multiple sclerosis patients, 36, 37  
 Gut microbiota, 62

## H

HALT-MS trial, 161  
 HapMap, 78  
 Hashimoto thyroiditis, 268  
 Hashimoto's encephalopathy, 242, 268, 269  
 Heat shock cognate protein 70 antibodies, 244  
 Herpes simplex virus-1 (HSV-1), 181  
 High dose IVIg therapy, 276  
 High sensitivity PR3 [hsPR3]-ANCA ELISA, 262  
<sup>1</sup>H-magnetic resonance spectroscopy (<sup>1</sup>H-MRS), 126, 127  
 Human Connectome Project (HCP), 123  
 Human leukocyte antigen (HLA) system, 180  
 Humoral immune processes, 304  
 Hygiene hypothesis, 181  
 Hypersensitivity vasculitis, 262  
 Hypocomplementemia urticarial vasculitis (HUV), 257  
 Hypopituitarism related to granulomatous infiltration, 323  
 Hypovitaminosis D, 201

## I

Idiopathic thrombocytopenic purpura (ITP), 190  
 IgA vasculitis (IgAV) (Henoch-Schönlein purpura [HSP]), 257  
 IgG4 associated with sclerosing pancreatitis, 264  
 IgG4-related disease (IgG4-RD)  
 clinical manifestations, 327–328  
 definition, 326  
 diagnosis, 328  
 management, 328  
 pathophysiology, 326  
 IgG4-related thoracic aortitis, 265  
 IL-15, 21  
 Immune checkpoint inhibitor (CI) therapy, 295  
 Immune-mediated necrotizing myopathy, 294, 295  
 Immunologic factors  
 cytokines, 11  
 MMPs, 11  
 nervous immune and endocrine system network, 12  
 toll-like receptors, 11–12  
 Immunologic therapy, 289  
 Immunomodulatory therapies, 163, 164, 166  
 Immunosuppressant therapy, 275, 276  
 Inclusion body myositis (IBM)  
 clinical description, 293  
 diagnosis, 293  
 pathophysiology, 294  
 treatment, 294

- Induction therapies, 159  
 Infiltrating myeloma, 262  
 Inflammatory abdominal aortic aneurysm (IAAA), 264  
 Inflammatory aortic/iliac aneurysms, 264  
 Inflammatory disorders, 186  
 Inflammatory myopathies, 290, 291  
 Initial demyelinating events (IDE), 179, 181  
 Interferons (IFN), 137, 138  
 International Multiple Sclerosis Genetics Consortium (IMSGC), 76  
 Internuclear ophthalmoplegia (INO), 91  
 Interstitial lung disease (ILD), 290  
 Intracellular adhesion molecule-1 (ICAM-1), 29  
 Intracranial neoplasms, 186  
 Intrathecal baclofen (ITB) pump implantation, 92  
 Intravenous immune globulin (IVIG), 147, 288  
 Invariant NKT cells (iNKT), 22  
 Ischemic and hemorrhagic stroke, 323  
 Ischemic centroposterior nerve fiber degeneration, 266  
 Ischemic stroke, 335  
 Isolated angitis of the CNS (IACNS), 266  
 Isolated paraneoplastic myelopathies, 247
- J**
- John Cunningham virus (JCV), 166  
 Junctional adhesion molecule-A (JAM-A), 29
- K**
- Kawasaki disease (KD), 257, 259
- L**
- L'Hermite phenomenon, 90  
 Lambert-eaton myasthenic syndrome (LEMS), 240, 246  
   clinical description, 288  
   diagnosis, 288  
   pathophysiology, 289  
   treatment, 289  
 Laminin  $\alpha 2$  (merosin) deficiency, 295  
 Langerhans cell histiocytosis (LCH), 186, 250  
 Large vessel vasculitis (LVV), 257, 258  
 Leucine-rich glioma inactivated protein 1 (LGI-1) encephalitis, 241, 242  
 Leukocyte transmigration, 27  
 Leukocytoclasia, 262  
 Leukocytoclastic vasculitis, 262  
 Leukodystrophies, 186  
 Lewis-Sumner syndrome, 307  
 Lhermitte's sign, 95  
 Limbic encephalitis, 237  
 Longitudinally extensive optic neuritis (LEON), 229  
 Long-term natalizumab therapy, 164  
 L-selectin, 28  
 Lymphoproliferative disorders, 304
- M**
- Macrocrania, 186  
 Macrophage activation syndrome (MAS), 186  
 Magnetization transfer imaging (MTI), 121  
 Magnevist®, 115  
 Main immunogenic region (MIR), 285, 287  
 Major histocompatibility complex (MHC), 77  
 Malignant gammopathies, 310  
 Marcus-Gunn swinging flashlight test, 90  
 Mast cells, 56  
 Matrix metalloproteinases (MMPs), 11, 57, 58  
 McDonald criteria, 97, 98, 115, 116  
 McDonald diagnostic criteria, 99  
 Medium vessel vasculitis (MVV), 257, 258  
 Melanoma associated retinopathy (MAR), 244  
 Meningeal sarcoidosis, 322  
 Methotrexate, 171  
 Microglia, 7, 8  
 Microscopic polyangiitis (MPA), 257  
 Miller Fisher variants, 301  
 Miniature endplate potential (MEPP), 286  
 Mitochondrial disorder, 187  
 Mitoxantrone, 143, 160, 170  
 Monoclonal gammopathies, 304  
 Monoclonal gammopathy of undetermined significance (MGUS), 310, 311  
 Mononuclear phagocyte system, 55  
 Morvan's syndrome, 245  
 Motor neuron diseases (MND), 247  
 Mucocutaneous lymph node syndrome, 259  
 Multifocal acquired demyelinating sensory and motor neuropathy (MADSAM), 307  
 Multifocal leukoencephalopathy, 160  
 Multifocal motor neuropathy (MMN)  
   clinical features, 307  
   conduction block, 308  
   immune pathogenesis, 309  
   laboratory studies, 308  
   treatment, 309  
 Multifocal nerve involvement, 269  
 MultiHance®, 115  
 Multiphasic acute disseminated encephalomyelitis, 220  
 Multiple myeloma (MM), 310  
 Multiple sclerosis (MS)  
   vs. ADEM  
   anti-MOG syndrome, 184  
   clinical CSF and radiological features, 184, 185  
   diagnostic criteria, 184  
   localized pathological process, 184  
   MRI, 185  
   ambulatory difficulties, 93  
   animal model, 52, 53  
   association-based approach, 77  
   autoimmune and neurodegenerative disorders, 79–80  
   autopsy specimens, 48, 49  
   axon pathology, 50, 51  
   bowel/bladder symptoms, 95, 96  
   brainstem/cerebellar syndrome, 100  
   brisk reflexes, 92  
   case-control studies, 72  
   case-control surveys, 72  
   childhood initial demyelinating event, 181, 182  
   cigarette smoking, 74, 75  
   clinical features, 182, 183  
   clinical progression, 168  
   cognitive impairment, 94

- cortical/gray matter pathology, 51
- definitions, 181
- degenerative and metabolic diseases, 187
- degree of hyperreflexia, 92
- demographics profile, 179
- depression, 94
- diagnostic evaluation, 97–99, 187
- dietary intake, 76
- differential diagnosis, 100, 101, 184
- disease modifying therapy, 169–171
- early-life obesity, 75
- environmental agents, 72
- environmental and genetic risk factors, 81, 82
- environmental exposures, 45
- environmental risk factors, 76
- epidemiological investigations, 76
- etiology, 45, 167
- family support, 191
- fatigue, 93, 94
- functional implications, 79
- genetic variants, 76
- genetic vulnerability, 45
- genome-wide association studies, 78, 80
- HapMap, 78
- heritability, 76, 79
- HLA B\*44* haplotype, 81
- HLA DRB1\*1501* allele, 76
- HLA-DRB1* locus, 78
- HLA-DRB1\*1501* haplotype, 80
- host immune system, 45
- in human populations, 71–72
- IL2RA* gene product, 78
- immunologic scenarios, 53, 54
- immunopathogenesis, 52
- infections, 186
- infectious agents, 73, 74, 185
- infusion medications
  - cyclophosphamide, 190
  - dimethyl fumarate (Tecfidera), 190
  - fingolimod, 189
  - natalizumab, 189, 190
  - rituximab, 189
  - teriflunomide (Aubagio), 190
- intrathecal baclofen pump implantation, 92
- lesion heterogeneity, 50
- leukodystrophies, 186
- longitudinal clinical data, 81
- macroscopic injury, 46, 47
- major histocompatibility complex, 77
- medical care, 81
- medical marijuana, 171–173
- Mendelian randomization studies, 73
- microscopic injury, 47
- mimic progressive presentations, 102
- mimic relapsing presentations, 102
- mitochondrial disorder, 187
- MOG antibody syndrome, 185
- mortality, 72
- MRI, 104–105
  - automated subtraction techniques, 114
  - clinical disability scores, 109
  - contrast agents, 114, 115
  - contrast-to-noise ratio, 111, 112
  - conventional FLAIR imaging, 114
  - disease activity free status, 112
  - 3D MRI techniques, 111
  - EDSS, 110
  - FLAIR images, 110–112
  - follow-up, 114
  - FSE proton-density imaging, 110
  - gadolinium enhanced T1-weighted imaging, 110
  - Gd administration, 115
  - Gd enhancement, 111, 112
  - inflammatory biomarkers, 110
  - leptomeningeal contrast enhancement, 112, 113
  - magnetic resonance spectroscopy frequency spectrum, 127
  - magnetization transfer imaging, 121
  - MAGNIMS network, 114
  - McDonald criteria, 115, 116
  - MRI-detected brain abnormalities, 115
  - no evidence of disease activity, 112
  - noisier 1.5T DIR images, 114
  - pathological changes, 109
  - post-contrast FLAIR, 112
  - Rao scale, 112
  - SIENA algorithm, 119
  - signal-to-noise ratio, 112
  - spinal cord imaging, 116, 117
  - 7T MRI examination, 112
  - T1-weighted imaging, 110, 111
  - T2 hyperintense lesions, 110
  - T2-weighted imaging, 110
  - three-dimensional double inversion recovery (3D DIR), 112–114
  - ultra-high-field imaging, 117
- muscle relaxants, 92
- myelocortical MS, 49
- neoplasms, 186
- neuromyelitis optica, 185
- non-conventional imaging
  - brain atrophy, 117, 118, 120
  - central vein sign, 122
  - diffusion tensor imaging, 123, 124
  - diffusion-weighted imaging, 123, 124
  - functional magnetic resonance imaging, 124–126
  - <sup>1</sup>H-magnetic resonance spectroscopy, 126, 127
  - magnetization transfer imaging, 120–122
  - multi-echo imaging, 122, 123
  - <sup>1</sup>H-nuclear magnetic resonance spectroscopy, 128
  - QRAPMASTER, 128
  - quantitative MRI, 128
  - quantitative susceptibility mapping, 122, 123
  - synthesis of the scans, 128
- non-MHC genome-wide significant alleles, 78
- Norwegian Medial Birth Registry, 168
- 25(OH)D levels, 73
- optic neuritis, 100
- pain, 94, 95
- paroxysmal symptoms, 96
- pathology, 46–48
- post-partum relapse management, 171
- prevalence, 71
- PRIMS study, 168

- Multiple sclerosis (MS) (*cont.*)
- progesterone, 76
  - prognosis, 183
  - progressive MS, 49, 50
  - psychosocial factors, 190–191
  - relapse testing and treatment, 168, 169
  - remyelination, 50
  - reverse causation, 72
  - risk factors, 180
  - Romberg's test, 93
  - seizures, 96
  - sensory loss, 93
  - SLC9A9* gene, 81
  - sleep disturbance, 96
  - spinal cord syndrome, 101, 103
  - sunlight exposure, 72
  - symptomatic management, 190
  - treatment
    - acute relapse, 187
    - adherence, 190
    - disease modifying therapy, 188, 189
    - high-dose prednisone, 188
    - intravenous immunoglobulins, 188
    - plasmapheresis/plasma exchange, 188
  - tremor, 92
  - unusual MS variants, 51, 52
  - vascular and inflammatory disorders, 186
  - vitamin D, 72, 73
    - BEYOND study, 203
    - CLIMB study, 203
    - clinically isolated syndrome, 202
    - deficiency, 61
    - genetic studies, 202
    - 25(OH)D levels, 201
    - prevalence, 201
    - relapsing remitting multiple sclerosis, 202
  - weakness and spasticity, 91, 92
- Muscle-specific kinase (MuSK), 286
- Myasthenia gravis (MG), 240
- clinical description, 286
  - diagnosis, 286
  - pathophysiology, 287
  - treatment, 287, 288
- Mycophenolate mofetil*, 147
- Myelin associated glycoprotein (MAG), 310
- Myelin oligodendrocyte glycoprotein (MOG), 228
- antibody syndrome, 185
  - IgG antibody, 218
- Myelin water imaging (MWI), 121
- Myelinoclastic diffuse sclerosis, 51
- Myelitis, 335
- Myelopathy, 324
- Myositis-associated antibodies (MAA), 290
- Myositis-specific antibodies (MSA), 290
- N**
- NAA/Cr ratio, 127
- Natalizumab, 138, 139, 164–167, 170
- Natalizumab therapy, 163
- Natural killer (NK) cells, 21, 22, 56
- Necrotizing vasculitis, 260, 263
- NEDA rates, 145
- Needle electromyography (EMG), 270
- Neonatal myasthenia, 286
- Nerve conduction studies (NCS), 270
- Nervous immune and endocrine system network, 12
- Neuro-Behçet disease (NBD)
- diagnostic criteria, 330, 331
  - differential diagnosis, 330
- Neuroimmune disorders, 3, 4
- Neurologic BD (NBD), 329
- Neurologic syndrome, 217
- Neuromuscular junction (NMJ)
- anatomy, 285
  - chronic sarcoid myopathy, 296
  - dermatomyositis
    - clinical description, 291, 292
    - diagnosis, 292
    - pathophysiology, 293
    - treatment, 293
  - drug-induced inflammatory myopathies, 295
  - Duchenne muscular dystrophy, 296
  - eosinophilic myositis, 295
  - immune-mediated necrotizing myopathies, 294
  - inclusion body myositis
    - clinical description, 293
    - diagnosis, 293
    - pathophysiology, 294
    - treatment, 294
  - inflammatory cells, 296
- Lambert-eaton myasthenic syndrome
- clinical description, 288
  - diagnosis, 288
  - pathophysiology, 289
  - treatment, 289
- muscular dystrophies, 295
- Myasthenia gravis
- clinical description, 286
  - diagnosis, 286
  - pathophysiology, 287
  - treatment, 287, 288
- polymyositis
- clinical description, 289
  - diagnosis, 290
  - pathophysiology, 290, 291
  - treatment, 291
- symptomatic sarcoid myositis, 296
- Neuromyelitis optica spectrum disorder (NMOSD), 185
- clinical presentation, 227
  - diagnostic criteria, 229, 230
  - epidemiology, 228
  - factors, 227
  - imaging, 229
  - immunotherapy treatment
    - acute attacks, 230
    - azathioprine, 231
    - immunomodulating agents, 230–231
    - intravenous methylprednisolone, 230
    - long term immunotherapy, 230
    - long-term corticosteroid therapy, 231
    - mycophenolate, 231
    - rituximab, 231

- MOG antibodies, 228
    - pathology, 228
    - pathophysiology, 228
    - vs. typical MS, 227
  - Neuroprotection, 148
  - Neurosarcoidosis
    - clinical description, 321
    - clinical manifestation, 322, 323
      - cranial neuropathies, 322
      - depression, 324
      - granulomatous mass lesions, 323
      - hypopituitarism related to granulomatous infiltration, 323
      - ischemic and hemorrhagic stroke, 323
      - meningeal sarcoidosis, 322
      - myelopathy, 324
      - peripheral neuropathy, 324
      - subcortical encephalopathy, 324
    - differential diagnosis, 324, 325
    - management, 325, 326
  - Neurotrophic factors, 61
  - NF- $\kappa$ B inflammatory pathway, 296
  - Nitric oxide (NO), 61
  - N-methyl D-aspartate receptor (NMDAR) encephalitis, 240, 241
  - No evidence of disease activity (NEDA), 160, 161
  - Non-calcemic genomic activities, 199
  - Nonclassical syndromes, 236
  - Non-infectious granulomatous angiitis, 266
  - Non-paraneoplastic autoimmune encephalitis, 237
  - Nonparenchymal NBD, 330
  - Nonsystemic vasculitic neuropathy, 266
  - Non-vasculitic stroke, 335
  - North American Imaging in Multiple Sclerosis (NAIMS) Cooperative, 122
  - Norwegian Medial Birth Registry, 168
- O**
- Ocrelizumab, 140, 163, 170
  - Ofatumumab, 148
  - Oligoclonal IgG, 55
  - Oligodendrocytes, 10, 58, 59
  - Onconeural antibodies, 238–239
  - Opsoclonus myoclonus syndrome (OMS), 243
  - Optic neuritis (ON), 89, 90, 181, 322
  - OptiMARK®, 115
  - ORATARIO trial, 146
  - Osteopontin, 57
  - Osteosclerotic myeloma, 310
  - Ovarian teratoma, 241
  - Overlap syndromes, 290
  - Ozanimod, 147–148
- P**
- Pachymeningeal lesions, 322
  - Paramedian pontine reticular formation (PPRF), 91
  - Paraneoplastic cerebellar degeneration (PCD), 243
  - Paraneoplastic encephalomyelitis, 242
  - Paraneoplastic movement disorders, 247
  - Paraneoplastic neurologic disorder (PND)
    - antibodies against intracellular/cytoplasmic or nuclear antigens, 238–239, 248
    - cell surface antigens, 240, 248
    - checkpoint inhibitors, 248
    - classical syndrome
      - anti-AMPA receptor encephalitis, 241
      - antibody-negative limbic encephalitis, 242
      - chronic intestinal pseudoobstruction, 246
      - clinical features, 237
      - dermatomyositis, 246
      - Hashimoto's encephalopathy, 242
      - LGI-1 antibody syndrome, 241, 242
      - limbic encephalitis, 237
      - melanoma associated retinopathy, 244
      - Morvan's syndrome, 245
      - NMDAR, 240, 241
      - vs. nonclassical syndrome, 236, 238, 247
      - opsoclonus myoclonus syndrome, 243
      - paraneoplastic cerebellar degeneration, 243
      - paraneoplastic encephalomyelitis, 242
      - paraneoplastic optic neuritis and neuropathies, 244
      - peripheral nervous system classical syndromes, 246–247
      - POEMS syndrome, 246, 247
      - progressive encephalomyelitis with rigidity and myoclonus, 245
      - Stiff Person syndrome, 244, 245
      - subacute sensory neuronopathy syndrome, 246
    - CLIPPERS, 250, 251
      - definition, 237
      - diagnosis, 248
      - management, 249
      - Susac syndrome, 250, 251
  - Partial transverse myelitis, 89–90
  - Pathogen associated molecular patterns (PAMPs), 24
  - Periarteritis, 258
  - Perifascicular atrophy, 292
  - Peripheral nervous system (PNS)
    - chronic intestinal pseudoobstruction, 246
    - dermatomyositis, 246
    - involvement, 216
    - nonclassical neurologic paraneoplastic symptoms, 247
    - POEMS syndrome, 246, 247
    - subacute sensory neuronopathy syndrome, 246
  - Peripheral neuropathy, 324
  - Perivascular inflammatory cell infiltration of the, 265
  - Plasma cells, 55
  - Plasmapheresis, 147
  - Platelet-endothelial cell adhesion molecule-1 (PECAM-1), 29
  - PML-immune reconstitution inflammatory syndrome (PML-IRIS), 167
  - POEMS syndrome, 310
  - Polyarteritis nodosa, 259
  - Polymyositis (PM)
    - clinical description, 289
    - diagnosis, 290
    - pathophysiology, 290, 291
    - treatment, 291

- Polyneuropathy, organomegaly, endocrinopathy, monoclonal protein and skin changes (POEMS), 246–247  
 Polyphasic disease process, 181  
 Ponesimod, 148  
 Poser criteria, 97  
 Post-infectious encephalitis/encephalomyelitis, *see* Acute disseminated encephalomyelitis  
 Postural orthostatic tachycardia syndrome, 4  
 P/Q-type voltage gated calcium channels (VGCC), 289  
 PRECISE study, 145  
 Pregnancy in multiple sclerosis (PRIMS) study, 168  
 Primary CNS vasculitis, 266  
 Progressive encephalomyelitis with rigidity and myoclonus (PERM), 245  
 Progressive multifocal leukoencephalopathy (PML), 166, 167, 231  
 Progressive solitary sclerosis, 52  
 ProHance®, 115  
 Psychoneuroimmunology, 12
- Q**
- Quantitative motor unit potential (MUP) analysis, 270
- R**
- Radiologically isolated syndrome (RIS), 99, 144, 182, 206  
 Rasmussen's encephalitis, 4  
 Rebound disease activity, 163–165  
 Receptor activator of NFκB (RANKL), 198  
 Recurrent oral and genital ulceration, 265  
 Relapsing remitting multiple sclerosis (RRMS), 89, 202  
   alemtuzumab, 141  
   azathioprine, 146  
   cyclophosphamide, 146  
   daclizumab, 141  
   fingolomod, 141  
   IFN β (beta)-1a intramuscular, 137  
   IFN β (beta)-1a subcutaneous, 137  
   intravenous immune globulin, 147  
   mycophenolate mofetil, 147  
   ocrelizumab, 140  
   plasmapheresis, 147  
   treatment, 137, 145  
 Relative afferent pupillary defect (RAPD), 90  
 Retino-cochlea-cerebral microangiopathy, 4  
 Retroperitoneal fibrosis (RPF), 264  
 Rheumatoid arthritis (RA), 258  
   clinical manifestation, 337  
   definition, 337  
   diagnostic evaluation, 337–338  
   etiology, 337  
   management, 338  
 Rituximab, 139, 140, 170  
 Romberg's test, 93
- Rosai-Dorfman-Destombes disease (RDD), 250  
 Rostral interstitial medial longitudinal fasciculus (riMLF), 90
- S**
- Sarcoid myopathy, 296, 324  
 Sarcoidosis, 321  
 Schilder disease, 51  
 Scleroderma, 291  
 SIENA algorithm, 119  
 Single-organ vasculitis (SOV), 258  
 Siponimod (BAF312), 148, 163  
 Sjögren syndrome (SS)  
   clinical manifestation, 333  
   definition, 332  
   diagnosis, 332, 333  
   treatment, 333  
 Small fiber neuropathy, 324  
 Small vessel vasculitis (SVV), 257, 258  
 Spastic dysarthria, 91  
 Sphingosine 1-phosphate (S1P), 29, 30  
 Standard anti-depressant medications, 94  
 Stem cell transplantation, 148  
 Stem cells, 32–34  
 Steroid responsive encephalopathy associated with autoimmune thyroiditis (SREAT), 242  
 Stiff Person syndrome (SPS), 244, 245  
 Subacute sensory neuronopathy syndrome, 246  
 Subcortical encephalopathy, 324  
 Susac syndrome, 4, 250, 251  
 Symbol digit modality test (SDMT), 183  
 Symptomatic sarcoid myositis, 296  
 Systemic lupus erythematosus (SLE), 258, 290  
   anti-double stranded DNA antibodies, 334  
   clinical manifestations, 335  
   diagnostic criteria, 334  
   diagnostic evaluation, 336  
   management, 336  
   mechanisms, 334  
   neurologic involvement, 334  
 Systemic necrotizing arteritis, 259  
 Systemic necrotizing vasculitis, 259  
 Systemic rheumatologic diseases  
   Behçet disease  
     clinical manifestation, 329, 330  
     diagnostic criteria, 330, 331  
     differential diagnosis, 331  
     pathological investigations, 328  
     prevalence, 328  
     treatment, 331, 332  
   IgG4-related disease  
     clinical manifestations, 327–328  
     definition, 326  
     diagnosis, 328  
     management, 328  
     pathophysiology, 326

neurosarcoidosis  
 clinical description, 321  
 clinical manifestation, 322–324  
 differential diagnosis, 324, 325  
 management, 325, 326

rheumatoid arthritis  
 clinical manifestation, 337  
 definition, 337  
 diagnostic evaluation, 337–338  
 etiology, 337  
 management, 338

Sjögren syndrome  
 clinical manifestation, 333  
 definition, 332  
 diagnosis, 332, 333  
 treatment, 333

systemic lupus erythematosus  
 anti-double stranded DNA antibodies, 334  
 clinical manifestations, 335  
 diagnostic criteria, 334  
 diagnostic evaluation, 336  
 management, 336  
 mechanisms, 334  
 neurologic involvement, 334

Systemic sarcoidosis, 322

Systemic vasculitis, 258, 273

## T

T-cell mediated autoimmunity, 18–21

T cells, 54

Tecfidera, *see* Dimethyl fumarate

Temporal arteritis, 263, 264

Teriflunomide, 143, 163, 165, 170

Theiler's Murine Encephalomyelitis virus (TMEV), 53

Toll-like receptors (TLRs), 11–12

Tolosa-Hunt syndrome, 327

Tonic spasms, 95

TOPIC trial, 145

TOUCH registry, 165

Toxin-induced demyelination models, 53

Trafficking molecules, 27–29

Treg cells, 20, 21

Trigeminal neuralgia (TGN), 91

Trimethoprim-sulfamethoxazole (TMP-SMZ), 276

*Tsyabri Pregnancy Exposure Registry*, 170

Tubby like protein antibodies, 244

Tumor necrosis factor (TNF), 321

Tysabri, *see* Natalixumab

## U

Uhthoff's phenomenon, 90

Up-beating vertical nystagmus, 90

UVB radiation photolysis 7-dehydrocholesterol, 197

## V

Variable vessel vasculitis (VvV), 257, 258

Vascular and inflammatory disorders, 186

Vascular cell adhesion molecule-1 (VCAM-1), 29

Vascular diseases, 186

Vasculitic neuropathy, 311

Vasculitis, 257

Vestibular-cochlear system, 91

Vestibuloauditory dysfunction, 265

Vitamin D  
 deficiency, 61, 62, 200  
 dietary sources, 197  
 immunomodulatory effects, 198–200  
 insufficiency, 201  
 measuring vitamin D status, 200  
 metabolism, 198  
 and multiple sclerosis  
 BEYOND study, 203  
 CLIMB study, 203  
 clinically isolated syndrome, 202  
 genetic studies, 202  
 25(OH)D levels, 201  
 prevalence, 201  
 relapsing remitting multiple sclerosis, 202  
 non-calcemic genomic activities, 199  
 stabilizing endothelial membranes reducing inflammatory activity, 198  
 supplementation  
 application, 206  
 to decreasing MS disease severity, 204–205  
 development risk, 204  
 limitations, 206  
 25(OH)D, 206  
 ongoing studies, 205  
 preventative effect, 207  
 safety profile, 207  
 toxicity, 207

Voltage-gated sodium channels (VGSC), 285

## W

Waldenstrom's macroglobulinemia (WM), 310

Wall-eyed bilateral INO (WEBINO), 91

Wegener's granulomatosis, 261

## X

X-linked fatal autoimmune disorder (IPEX), 21

## Y

Yellow emboli (Gass plaques), 250