



# Evaluation of Axillary Nodes

# 5

Mahmut Müslümanoğlu

## Introduction

Recent studies have demonstrated that the biological characteristics of tumors are more important in determining treatment plans and prognosis than other factors, such as tumor diameter and axillary involvement. Clinical staging is still used to determine the tumor load. Tumor diameter and axillary involvement were used for a long time, and it is difficult for clinicians to abandon these customs. Consequently, tumor diameter and axillary involvement are still considered important major prognostic factors for predicting survival and selecting adjuvant treatment. Although axillary evaluation (sentinel lymph node (SLN), axillary lymph node dissection (ALND)) does not have a profound effect on overall survival (OS), the removal of metastatic lymph nodes from the axilla may contribute to locoregional control and improve quality of life. In the past, axillary staging with ALND was used in clinically node-negative early-stage breast cancer patients; however, this method carries the risk of some arm and shoulder morbidity without any survival benefit. SLN biopsy (SLNB) is equivalent to ALND in clinically node-negative patients in terms of staging, accuracy, disease-free survival (DFS), and OS. Consequently, ALND is not currently advised for patients able to undergo SLNB. SLNB examines the first lymph nodes because the lymphatics of the breast drain to these lymph nodes, which therefore are the site most likely to be reached by tumor cells. If there is no cancer metastasis in the SLN, the other lymph nodes are considered clear (not containing cancer cells); thus, the ALND technique has been abandoned.

M. Müslümanoğlu (✉)  
Department of General Surgery, Istanbul Medical Faculty,  
Istanbul Medical School, Istanbul, Turkey

Surgery Department, Istanbul Medical Faculty, Istanbul, Turkey  
e-mail: [mahmutm@istanbul.edu.tr](mailto:mahmutm@istanbul.edu.tr)

## Lymphatic Drainage of the Breast

The lymphatics of the breast comprise interconnected superficial and deep lymphatic vessels. The sub-dermal plexus in the retro areolar space, which is called *Sappey's plexus*, drains the lymphatics of the areola and nipple. The lymphatics of the interlobular connective tissue of the breast and the lymphatics of the walls of the lactiferous channels also drain to this plexus. Efferent lymphatic channels leaving this plexus trace along the lateral border of the major pectoral muscle, penetrate the clavipectoral fascia, and enter the axilla. Axillary lymph nodes collect nearly 75% of the lymphatic drainage of the breast. The remaining lymphatics drain into the internal mammary (parasternal) lymph nodes (IMLNs) accompanying perforated branches of the internal mammary artery; this group generally receives drainage from the medial part of the breast.

## Sentinel Lymph Node Biopsy

Sentinel means “sentry,” and the SLN is the first lymph node at which cancer cells arrive via lymphatic channels starting from the primary tumor; multiple SLNs may exist. Because these lymph nodes are located on the lymphatic drainage course in breast cancer, they contain cancer cells when lymphatic metastasis has occurred. If metastasis is not detected in the pathological examination of the removed SLNs, the axilla is considered clear, and ALND is not performed.

Radioactive colloid and/or blue dye can be used to detect the SLN. Recently, iron oxide nanoparticles and indocyanine green have been developed for SLNB using the same technique. SLNs that are identified by scintigraphic imaging in the preoperative phase can be detected intraoperatively using a gamma probe and/or by injecting blue dye into the breast tissue; the dyed channel and lymph node can then be detected and removed surgically. There are different practices regarding the choice of agents used (blue dye, radioactive substance,

or both) and location of injection (periareolar, subareolar, peritumoral). Extra-axillary lymph node (internal mammary group) excision is advised if it is identified as the first draining site by lymphoscintigraphy.

### Indications for SLNB

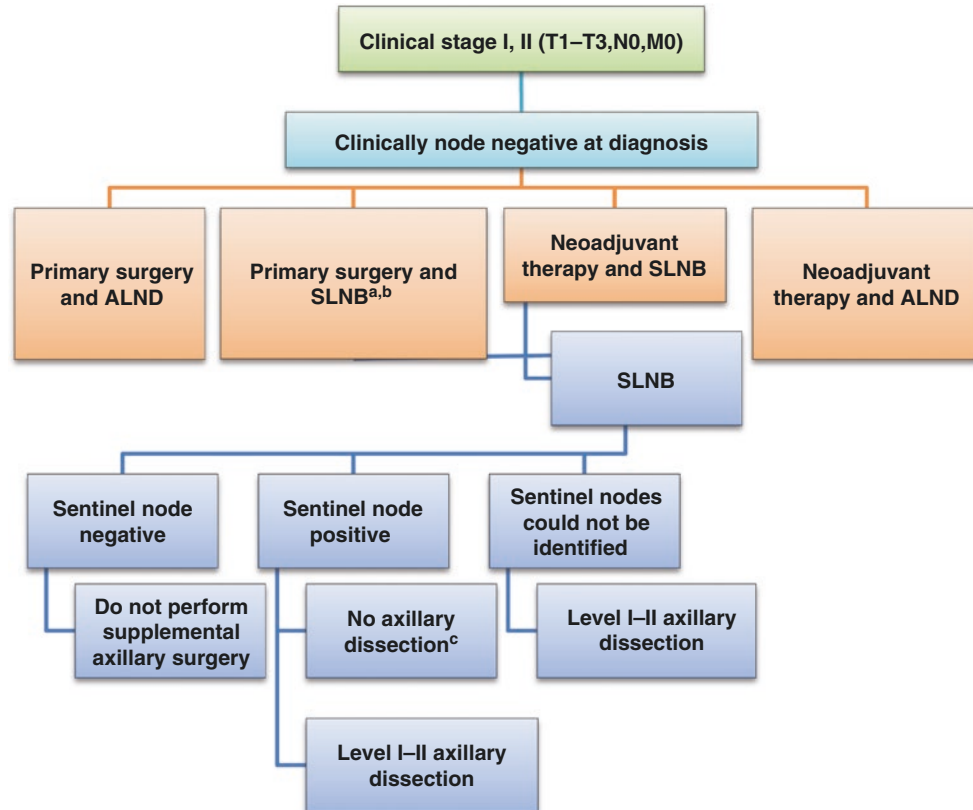
SLNB has been accepted as a standard treatment approach in all clinically node-negative (with physical examination and imaging techniques) early-stage (Fig. 5.1) breast cancer cases, regardless of tumor size (uni- or multiple) and location (central, inner, or outer part of the breast).

### Contraindications for SLNB

SLNB is contraindicated whenever a metastatic lymph node is clinically identified in the axilla. This increases the

false-negative rate. Diffuse blockage of lymphatic channels in locally advanced breast cancers (LABC) manifesting, as inflammatory breast cancer and dermal edema are also contraindications for SLNB.

Approximately 40% of node-positive patients can be detected with preoperative ultrasonography and needle biopsy [1]. Classically, ALND should be performed directly in this case, or neoadjuvant chemotherapy may be recommended. However, in the near future, axillary tumor load (one or multiple cortical asymmetries or cortical enlargement of the LNs versus multiple gross positive LNs) will become important for deciding further ALND. Whenever any suspicious lymph nodes (hard) (non-SLNs) are palpated in SLNB-negative patients, excision must be considered, especially for those patients in whom core biopsy of the primary tumor was not performed. Core biopsy can cause enlargement and stiffness in some of the axillary nodes, which may cause unnecessary LN excision together with SLNB. If metastasis is detected in SLNs or non-SLNs during



**Fig. 5.1** Axillary management of patients with clinical node-negative stage I–II. SLNB: sentinel lymph node biopsy, ALND: axillary lymph node dissection, BCS: breast-conserving surgery. <sup>a</sup>For BCS: In patients with macrometastases in 1–2 sentinel lymph nodes, complete axillary dissection can be safely omitted when “conservative resection with radiotherapy (RT)” is performed. <sup>b</sup>For mastectomy: In patients with macrometastases in 1–2 sentinel lymph nodes, complete axillary dissection must be performed when “no adjuvant RT is planned”; however, in patients for whom RT is planned, no consensus exists for

omitting axillary dissection. <sup>c</sup>In patients with T1 or T2 tumors with BCS and 1–2 positive SLNs, if there is no neoadjuvant chemotherapy and whole-breast irradiation is planned, axillary dissection is not needed. Axillary dissection is recommended for SLN-positive patients with triple-negative breast cancer. At least 2–3 SLNs should be assessed in patients receiving neoadjuvant treatment. Consider axillary dissection according to preoperative imaging results. (Neoadjuvant therapy mammography, ultrasonography and positron emission tomography (PET)/CT)

paraffin section examinations, ALND or radiation therapy is decided in a multidisciplinary meeting for each patient according to all factors affecting locoregional recurrence risks and the benefits of adjuvant therapies.

Allergic reactions are observed in approximately 1–3% of cases and can cause serious anaphylactic reactions [2]. Blue dye is not used during pregnancy due to its potentially fatal effects [3]. Some studies have indicated that radioactive substances in low doses can be safely used during pregnancy [4–6].

## SLNB in Specific Cases

### Ductal Carcinoma In Situ (DCIS)

Metastasis is observed in 1–2% of DCIS cases, suggesting that some DCIS cases can indeed be invasive and that failure to diagnose metastasis is due to a pathologic sampling error [7, 8]. Because invasive foci can be detected in paraffin sections and SLNB is not associated with extensive complications, SLNB should be performed in DCIS patients who have signs on palpation (tumor mass) or a large area of DCIS (calcified areas >2–3 cm) [3]. SLNB is also recommended for patients planning to undergo mastectomy [9].

### Multicentric and Multifocal Breast Cancer

In multifocal and multicentric breast cancer cases, SLNB can be safely performed. However, an increase in the false-negative rate has been reported in some studies. Performing the procedure using a radioactive substance may increase the accuracy of SLN [10–13].

### SLNB for Patients with Previous Axillary and Breast Surgery

Studies have demonstrated that SLNs can be detected if superficial and deep lymphatic channels are not disrupted via excisional biopsy (particularly together with a large skin incision at the upper lateral quadrant and if the deep pectoral fascia is not affected). However, in patients who have undergone breast-conserving surgery (BCS) and radiotherapy or have undergone ALND, lymphatic flow to the internal mammary glands and contralateral axilla is observed, and these areas are considered the second region for SLNs. The detection of axillary SLNs for the second time in patients who previously underwent SLNB is possible [14–17]. SLNB can be performed after aesthetic interventions and even mastectomy [18–20]. Using tandem methods (blue dye lymphoscintigraphy) during SLNB in patients with previous operations increases the success rate [14].

### Male Breast Cancer

Breast cancer in males is rare and constitutes 1% of all breast cancer cases. SLNB should be performed in clinically

node-negative male breast cancer to avoid unnecessary ALND. SLNB has the same identification and false-negative rates in males as in females [21–23].

### Elderly and Overweight Patients

Although studies report high success rates of SLN detection in elderly and overweight patients, we have observed that this patient group is more problematic in practice; it is particularly difficult to detect SLNs using blue dye alone. The utilization of lymphoscintigraphy along with blue dye in elderly and overweight patients increases the success rate.

### Axillary Staging in Patients Treated with Neoadjuvant Chemotherapy

The axilla is clinically negative in approximately 40–50% of patients who are planned to receive neoadjuvant chemotherapy. In cases with a positive axillary node, axillary downstaging occurs at a rate of 30–40% with treatment [24–26]. Research to identify an approach that avoids unnecessary ALND in these two patient groups is ongoing, and the method and timing of axillary staging remain controversial. In clinically axilla-negative cases, SLNB can be performed prior to neoadjuvant chemotherapy, and the need for ALND can be determined after treatment [24].

The opinion that alterations of the breast and lymphatic channels due to chemotherapeutic agents decrease the success rate of SLNB performed after chemotherapy and increase the false-negative rate has essentially been abandoned. In the NSABP-B27 trial, the SLN detection rate after neoadjuvant chemotherapy was 84.8%, and the false-negative rate was 10.6% [27]. Recent trials have shown that the use of radiocolloid alone or together with blue dye significantly enhances accuracy and that SLNB is possible after neoadjuvant chemotherapy [27–29]. ALND should be performed whenever the SLN cannot be detected.

## SLNB Technique

### Utilization of Radiocolloid and Lymphoscintigraphy

Lymphoscintigraphy is based on the detection of lymph nodes following drainage of the injected radiopharmaceutical agent to the regional lymph nodes via the lymphatic current. Regional lymphatic tracts are mapped using this method and whether an SLN is identified as axillary or extra-axillary using preoperative imaging techniques; during the operation, the SLN is detected by a gamma probe [30].

The most frequently used radiopharmaceuticals are <sup>99m</sup>Tc-sulfur colloid, <sup>99m</sup>Tc-nanocolloid, and <sup>99m</sup>Tc-antimony trisulfide colloid.

**Technique** During the operation, the tumor mass, including the primary site of injection, is excised first to perform the count correctly and minimize background activity. While the gamma probe is scanned over the skin of the axilla, the site producing the highest activity count is determined, and a small incision is made to enter the axilla. The gamma probe is inserted through the incision, and the lymph node yielding the highest activity count is excised together with its surrounding fat tissue by fine dissection. The activity count of the excised tissue is assessed in a separate location, and after confirming that it is the SLN, the axilla is reevaluated using the probe. If there are any remaining sites producing high activity counts, other SLNs are excised until the activity count is less than 10% of that of the initial node.

### Vital Stain

Blue dye injection is another method for visualizing the SLN. The vital stains used for this purpose include patent blue V, isosulfan blue (1% lymphazurin), and methylene blue. Isosulfan blue is the most frequently used agent; however, following injection, reactions ranging from a simple rash to serious anaphylaxis are observed with an incidence ratio of 1:1.1% [31, 32]. Methylene blue is a less expensive alternative that does not bind to plasma proteins and causes fewer anaphylactic reactions. However, methylene blue can cause skin necrosis when intradermally administered, and a dilution ratio of 1:2 is recommended [32]. Studies have yielded similar mapping results using both dyes.

**Technique** During the operation, approximately 2–5 ml of blue dye is injected by the subareolar routes, and the area is massaged toward the axilla for 2–5 min. Then, the axilla is entered using a 2–3-cm transverse incision just below the axillary hairline. After opening the clavipectoral fascia, the lateral thoracic vein, which extends toward the tail of the breast, is identified. The SLN is generally located where the intercostal nerve crosses this region (axilla, level 1). The blue-stained tract is identified via dissection. When traced either to the axilla or to the breast, a blue-stained lymph node or nodes can be observed. The blue-stained lymph node is removed together with the surrounding thin fat tissue. The results obtained with blue dye are similar to those obtained using radioactive substances [33].

### Combination of Vital Stains and Radioisotope Methods

Many studies have reported that blue staining and radiocolloid use are complementary methods that enable the detection of additional SLNs when used together. Moreover, the addition of blue dye to the radiocolloid prevents unnecessary dissections. The SLN detection rate is 95–98% using the radioisotope method [34] and is improved to 95–100% using the combined method. Both methods have high success rates

when performed alone, but combined methods should be used in select cases (elderly, overweight, patients who are undergoing SLNB for the second time). We use blue dye (isosulfan blue) in routine practice in our clinic. Lymphoscintigraphy has the advantage of showing extra-axillary drainage.

### Determining the Site of Injection

Studies suggest that SLN detection is more successful via the intradermal or subareolar/periareolar routes; however, most studies indicate that the location of injection does not have an effect on SLN detection [33–37]. Each clinic should perform the technique it finds successful. The radioisotope method [32] is improved to 95–100% using the combined method. Both methods have high success rates when performed alone, but combined methods should be used in select cases (elderly, overweight, patients who are undergoing SLNB for the second time). We use blue dye (isosulfan blue) in routine practice in our clinic. Lymphoscintigraphy has the advantage of showing extra-axillary drainage.

### Number of SLNs

Frequently, one SLN is removed from the axilla. The false-negative rate drops to 1% when three or more SLNs are removed. However, no benefit is observed when more than four to five SLNs are removed [38–40]. When more than one blue ganglion is detected, and if the lymph channel/channels can be identified and go to a single node, it is sufficient to remove the first 2–3 blue nodes. If channels cannot be identified and the first node is uncertain, it is better to remove all of the blue lymph nodes, which will decrease the false-negative rate.

### Behavior of Micrometastases

Detailed SLN examination (multiple sections with several ganglia) has enabled the detection of smaller metastases. Metastases smaller than 0.2 mm are defined as submicro-isolated tumor cells, metastases that are 0.2–2 mm in size are classified as micrometastases, and those >2 mm are macrometastases. When isolated tumor cells are detected, the axilla is considered negative. When micrometastasis is detected in SLNs, the rate of metastasis in non-SLNs is 10–40%. In macrometastasis, this rate is even higher. Patients with micrometastases in SLNs who did not undergo ALND in BCS and who received radiation therapy were investigated in a randomized trial in Z0011 [41]. This trial followed 446 patients who underwent SLNB and 445 patients who underwent SLNB + ALND. The proportion of patients who had three or more positive LNs was 5% in the SLNB group and 17.6% in the SLNB + ALND group ( $p < 0.001$ ). After an average follow-up of 9.3 years, the 10-year DFS was 80.2%

in the SLNB-alone group and 78.2% in the ALND group. The OS rate was 86.3% in the SLNB-alone group and 83.6% in the ALND group. At 5 years, one nodal recurrence was observed in the SLNB-alone group vs none in the ALND group. Ten-year regional recurrence did not differ significantly between the two groups [41]. According to this study, which was terminated due to difficulties in patient accrual and low recurrence rates, there was no benefit for the patients in the ALND group.

The detection of minimal disease (micrometastasis) in SLNs may be sufficient to initiate adjuvant therapy. In all valid protocols used today, these patients receive adjuvant therapy similar to that used in axilla+ disease (N1a). Therefore, treatment for these patients is not incomplete.

The only difficulty in treating micrometastatic disease is determining the irradiation area for axillary and peripheral lymphatics. The number of involved axillary lymph nodes is a critical component of this decision. Given the availability of effective adjuvant treatment options and the very low axillary recurrence rates (as in ALND), conservative decisions are now made on behalf of the patient when selecting a radiotherapy area; irradiating wide areas, as is done in Nx, appears to be overtreatment.

### Internal Mammary Lymph Node Biopsy (IMLNB)

A small percentage (10%) of lymphatics drain into the IMLNs, particularly in centrally and medially located tumors. IMLNB may alter the treatment plan in 0.1% of breast cancer patients and thus is regarded as unnecessary. However, according to the new staging system, only IMLN positivity is classified as N1c; therefore, IMLNB could change the stage for this group of patients. IMLN detection and sampling are necessary to make a decision regarding the adjuvant treatment policy in axilla-negative patients and to determine if IMLNs will be irradiated. For this reason, we recommend performing IMLNB when the axilla is negative in centrally or medially located tumors.

The only method demonstrating lymphatic drainage to this region is lymphoscintigraphy with the utilization of gamma probes. Usually, the second to third intercostal space is explored in selected axilla-negative cases.

### Locally Advanced Breast Cancer

In locally advanced breast cancer (LABC), the utilization of axilla-effective systemic treatment modalities (taxane, trastuzumab, etc.) in routine practice has led to increases in complete response rates (breast + axilla) from approximately 10% to 39–70%; for some specific patient groups (ER nega-

**Table 5.1** Nodal pCR after neoadjuvant therapy

	N	Nodal pCR <sup>a</sup>
ACOSOG Z1071 [24]	694	41%
FNAC [25]	145	35%
Mamtani [26]	195	49%

<sup>a</sup>Nodal pCR ranges from 21% in Er+/HER2– to 97% in ER–/HER2+ patients

tive, PR negative, HER2 positive), higher rates of complete response have been achieved. ALND following chemotherapy was the standard axillary approach for LABC, but SLNB is now recommended in patients with axilla positive prior to chemotherapy to obtain a complete clinical response after chemotherapy. According to the results of prospective randomized trials, if two to three lymph nodes are removed using both blue dye and lymphoscintigraphy, the false-negative rate is 14%, and the detection rate is 98% [24–26].

In cases with a positive axillary node, axillary downstaging occurs at a rate of 30–40% with treatment, and this rate is even higher in triple-negative and Her2-positive patients (Table 5.1) [24, 25, 26, 42]. The identification rate of SLNB may decrease in patients whose axilla become clinically negative after neoadjuvant therapy, and the false-negative rate may increase depending on case selection. The biology of the cancer is also an important factor predicting the response rate. In a prospective study, after neoadjuvant therapy ( $n = 195$ ), nodal pCR rates were overall 49%, “ER+/HER2–” 21%, “ER+/HER2+” 70%, “ER–/HER2+” 97%, and “ER–/HER2–” 47% [26]. The luminal A group has the lowest complete response rate. With neoadjuvant computed tomography (CT), axillary dissection can be avoided in up to 48% of patients [26]. ALND should be performed whenever the SLN cannot be detected (Figs. 5.1 and 5.2).

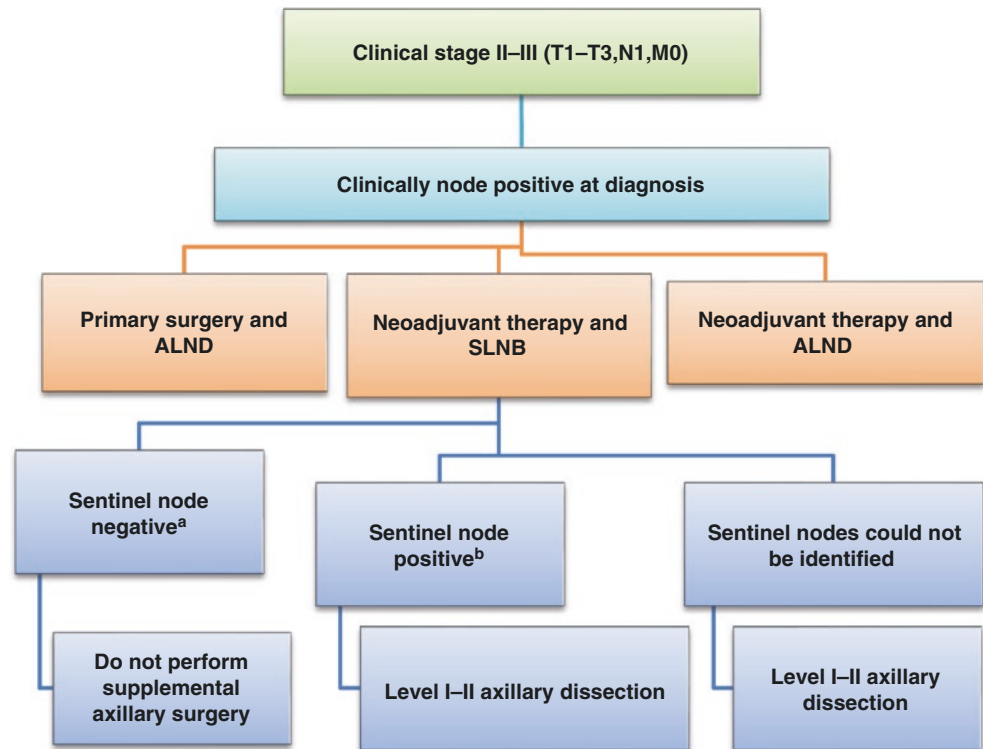
### Examination of the SLN

Paraffin blocks are prepared, and slices are obtained in numbers and thicknesses defined by the laboratory protocol; these sections are then evaluated using hematoxylin and eosin (H&E) and immunohistochemical staining methods. Intraoperative evaluation of the SLN in clinical axilla-negative patients lost its importance following the Z0011 trial based on the equivalent long-term results of ALND versus radiation therapy in axilla 1–2 micro-/macro-positive SLNs [41].

### False Negativity

False negativity is defined as the detection of negative SLNs when axillary metastasis is indeed present. SLNs should be detected in at least 85% of patients using the method of choice, and the false-negative rate should be less than 5% [10]. Use of the blue dye and radiocolloid techniques in

**Fig. 5.2** Axillary management of patients with clinical node-positive stage II or III invasive breast cancer. SLNB: sentinel lymph node biopsy; ALND: axillary lymph node dissection. <sup>a</sup>At least three SLNs should be assessed in patients receiving neoadjuvant treatment. In cases with triple-negative disease, consider ALND. <sup>b</sup>At least three SLNs should be assessed in patients receiving neoadjuvant treatment. After neoadjuvant therapy, if the SLN is positive (macrometastasis), level I–II ALND is recommended. In cases with micrometastases (non-triple-negative), consider ALND. In all cases with triple-negative tumors, ALND is recommended



combination is recommended for surgeons in training to allow them to become familiar with the anatomy and decrease false-negative results.

## Axillary Lymph Node Dissection

### Indications

ALND was once routinely practiced in breast cancer cases, but the indications for ALND have been revised as SLNB has become standard in early-stage (stage I, II) clinically N0 cases. Today, ALND is performed in clinical N+ early-stage breast cancer and N+ LABC post CT. General attitudes about early-stage N+ breast cancer have changed. Neoadjuvant CT is advised to achieve complete pathologic response to perform SLNB to preserve the axilla. ALND should also be performed when SLN cannot be detected.

### Anatomy of the Axilla

Lymph node groups are categorized into three levels according to their orientation to the minor pectoral muscle for the surgeon's convenience. *Level 1* contains the lateral border of the minor pectoral muscle. The central and interpectoral groups, which are located between the medial and lateral borders of the minor pectoral muscle, form *level 2*. The sub-

clavicular group, which is located medially or superiorly to the upper border of the minor pectoral muscle, is categorized as *level 3*.

### Axillary Structure

*The intercostal brachial and intercostal thoracic nerves* are sensory nerves; they innervate the skin at the medial part of the upper arm and the posterior part of the axilla. Injury will result in sensory loss at the corresponding skin area.

*The long thoracic nerve*, which innervates the serratus anterior muscle, originates from C5 to C7, extends inferiorly over the thoracic wall, and branches at the level of the fourth to fifth intercostal. Its injury causes a winged scapula defect.

*The thoracodorsal nerve*, which innervates the latissimus dorsi, originates from C6 to C8. Preservation of this nerve during dissection is important for subsequent reconstructive interventions.

*The Rotter ganglia* are in contact with the lateral pectoral pedicle, which is located posteriorly to the major pectoral muscle.

*The lateral pectoral nerve*, which is located in this pedicle, innervates the medial part of the major pectoral muscle. Its injury results in atrophy of the major pectoral muscle.

The medial pectoral is located anteriorly to the minor pectoral muscle at a distance of 1–2 cm, and the lateral nerve is located more laterally. It originates from the medial chord of the brachial plexus (C8–T1). Its injury results in the atrophy of both muscles.

Atrophy of the pectoral muscles does not cause problems at the early stage but results in cosmetic issues at the chest wall in the long term.

## ALND Technique

It is now known that extended lymphatic resection does not provide any benefit for patient survival. Therefore, in routine ALND, only level 1 and level 2 lymph nodes are removed. When lymph nodes are confirmed as positive by preoperative examinations or detected intraoperatively via palpation, level 3 lymph nodes are also included in the dissection. With efficient extraction, level 3 lymph nodes can be removed without sacrificing the minor pectoral muscle.

The incision should be made below the hairline to permit subsequent epilation and should not continue beyond the pectoral muscle anteriorly and the latissimus dorsi muscle posteriorly. Oblique transverse incisions, U-shaped incisions with the gap facing up, and reverse S incisions provide good exposure.

When started medially, the major pectoral muscle is elevated with a retractor. Anterior to the minor pectoral muscle below, the medial pectoral pedicle can be observed 1–2 cm medial of its border. This pedicle should be preserved to avoid atrophy of the major pectoral muscle.

The lateral border of the minor pectoral muscle is freed from the chest wall. This incision is extended upward until the axillary vein is exposed. In most cases, intercostal brachial nerves are sacrificed; however, with fine dissection at T2 and T3 above, the nerves can be separated from the axillary tissue and preserved.

Then, the long thoracic nerve is again identified over the serratus anterior muscle but located deeper (more posterior) than these sensory nerves. At the level of the third intercostal nerve below, it can be found by caressing the serratus anterior muscle with an index finger. It is located inside the fascia of the muscle and should always be preserved. After its exposure, the axillary tissue is dissected laterally from the chest wall. By retracting the major pectoral muscle, palpable lymph nodes are identified in the interpectoral region (Rotter ganglion). The few lymph nodes found here are removed without damaging the lateral pectoral pedicle, which extends anteriorly toward the major pectoral muscle.

There is no need to resect the minor pectoral muscle for a level 3 dissection. For a level 2 dissection, the surgeon should begin from the highest point posterior to the minor pectoral muscle. The surgeon should not extend the incision above the axillary vein; resection of the overlying fatty tissue increases the risk for lymphedema. Below the axillary vein, fatty tissue is skimmed off inferiorly from the chest wall. The dissection is continued inferiorly and later-

ally, and small branches emanating from the axillary vein are ligated. The lateral thoracic vein (thoracoepigastric vein), which originates from the direction of the axillary vein and enters the axillary tissue, is ligated. The thoracodorsal vein originates distally and posteriorly to the axillary vein and laterally to the lateral thoracic vein. The thoracodorsal nerve occasionally enters more medially, extends more deeply, and distally joins the thoracodorsal vessels. The thoracodorsal nerve can also be observed as a single pedicle adhered to the thoracodorsal vessels. However, it always enters the latissimus dorsi muscle from the medial side.

Fatty tissue between the long thoracic nerve and the thoracodorsal pedicle is skimmed off inferiorly from the axillary vein, and the subscapular muscle is exposed behind. Then, by placing an index finger on the long thoracic nerve, the nerve is traced until its entry site into the serratus anterior muscle (finger dissection). Laterally, the thoracodorsal pedicle is traced until its entry site into the latissimus dorsi muscle; the small venous branches are ligated, and the specimen is removed during this procedure.

While approaching the axilla laterally to medially, the latissimus dorsi muscle is traced upward from its border; at the site where it becomes tendinous, the axillary vein is exposed. Dissection should be continued below to where the latissimus dorsi muscle joins the serratus anterior muscle. Following removal of the tissue, a suction drain is placed in the axillary cavity near the incision.

## Complications of ALND

SLNB is now the method of choice to avoid short- and long-term morbidities caused by ALND. Unfortunately, ALND must still be performed in many cases.

### Neurovascular Injury

*The long thoracic nerve:* Injury of this nerve is caused by cutting, traction, or thermal damage; however, it is damaged in less than 1% of cases. Winged scapula defect caused by its injury results in cosmetic problems.

*The thoracodorsal nerve:* Because this does not cause a significant neurological deficit, this nerve can be excised to obtain a clean axilla if it is invaded by metastatic lymph nodes.

*The intercostal brachial nerve:* This nerve transverses the axilla and is generally cut during ALND, causing paresthesia at the medial half of the upper arm and adversely affecting quality of life in women.

Injury to *the medial pectoral nerve* does not cause short-term problems but results in cosmetic problems due to atrophy of the major pectoral muscle.

The brachial plexus is located superior to the axillary vein; thus, there is no risk of injury as long as one does not extend the dissection above the axillary vein.

### Seroma

Seroma forms in nearly all cases to some extent and is thus not considered a surgical complication. However, prolonged seroma increases the risk of infection and delays adjuvant treatment. A low-pressure suction drain is placed during the operation to inhibit seroma formation. Because prolonged seroma following removal of the drain is a source of infection, it should be emptied via percutaneous aspiration. One effective method is delaying exercise and complete shoulder movements until after the fifth day following the operation. However, some arm and shoulder exercises should be started in the early stage to prevent shoulder problems due to a limited range of movement.

### Chronic Pain and Limited Range of Movement

More than 50% of women experience neuropathic pain, which is sometimes severe and interferes with sleep. This pain increases with movement; is localized to the chest wall, axilla, arm, and shoulder regions; and can continue after the third month postoperatively. These pains are thought to be due to nerve injury and to the addition of radiotherapy and/or chemotherapy to treatment [43]. Patients who experience more pain with movement generally limit their shoulder movements, leading to frozen shoulder syndrome. Starting arm movements at the early period postoperatively with the aid of adequate analgesia prevents these complications.

### Lymphedema

Lymphatic fluid, which originates in small lymphatic channels, first drains into regional lymph nodes; it is then carried to the systemic circulation via efferent lymphatic channels and the main lymphatic duct. Any obstruction in these channels results in the development of lymphedema in the tissue that could not be drained. Irradiation of the peripheral lymphatics is another factor that increases lymphedema. Recurrent attacks of lymphangitis and cellulitis also increase the risk for lymphedema in the arm. Lymphedema of up to 1–2 cm is considered mild and is observed in 20–30% of patients with level 1–2 ALND. Larger swelling is considered a serious lymphedema and is observed in less than 5% of patients. The risk of lymphedema in patients with level 3 ALND is 30%, and therefore level 3 ALND is not performed without a valid reason. Mild lymphedema can be observed in 5% of patients following SLNB. The aims are to educate patients and prevent lymphedema before it develops. Patients who have undergone ALND should be advised not to strain the affected arm, not to suspend the arm while working, and to avoid procedures that could increase the risk of lymphangitis (skin injury due to manicure, etc.); patients are also recommended not to gain weight.

When lymphedema develops, its severity is first assessed as follows:

- Stage 0: There is only dullness in the arm.
- Stage 1: There is pitting edema (recoverable stage because there is no fibrosis).
- Stage 2: The arm is stretched, and there is fibrosis.
- Stage 3: Elephantiasis is present, with skin signs such as fibrosis, sclerosis, and keratosis.

### Treatment and Prevention

Regular trunk cleaning and massage, which is called manual lymphatic drainage, are applied to patients by trained physiotherapists, and bandaging is applied. If no response is obtained using these procedures and if fibrosis has begun in the arm, laser therapy (low-level laser therapy) can be attempted. Laser therapy resolves fibrotic scar tissue by acting on fibroblasts and stimulates lymphatic drainage. This method was demonstrated to have a lymphedema-reducing effect in 52% of cases [43, 44].

The detection and preservation of lymphatics of the arm in the axilla using the injection of blue dye into the upper arm is called reverse axillary mapping. Research on this subject is ongoing.

### Conclusion

SLNB is equivalent to ALND in clinically node-negative patients in terms of staging, accuracy, DFS, and OS. ALND has been considered mandatory in sentinel node-positive patients, but recent data with 10 years of follow-up have demonstrated that BCS and radiotherapy are equivalent to ALND of micro/macro-metastatic SLNs. This approach will reduce the morbidity of dissection without decreasing OS. SLNB is also beginning to be used in LABC patients treated with neoadjuvant chemotherapy. In these cases, axilla can be saved, as in early breast cancer. With neoadjuvant CT, axillary dissection can be avoided in up to half of patients. ALND should be performed whenever the SLN cannot be detected.

### References

1. Deurloo EE, Tanis PJ, Gilhuijs KG, Muller SH, Kröger R, Peterse JL, et al. Reduction in the number of sentinel lymph node procedures by preoperative ultrasonography of the axilla in breast cancer. *Eur J Cancer*. 2003;39:1068–73.
2. Raut CP, Hunt KK, Akins JS, Daley MD, Ross MI, Singletary SE, et al. Incidence of anaphylactoid reactions to isosulfan blue dye during breast carcinoma lymphatic mapping in patients treated with preoperative prophylaxis: results of a surgical prospective clinical practice protocol. *Cancer*. 2005;104:692–9.



3. Cheng G, Kurita S, Torigian DA, Alavi A. Current status of sentinel lymph node biopsy in patients with breast cancer. *Eur J Nucl Med Mol Imaging*. 2011;38(3):562–75.
4. Vogt H, Schmidt M, Bares R, Brenner W, Grünwald F, Kopp J, et al. Procedure guideline for sentinel node diagnosis. *Nuklear Med*. 2010;49:167–72.
5. Gentilini O, Cremonesi M, Toesca A, Colombo N, Peccatori F, Sironi R, et al. Sentinel lymph node biopsy in pregnant patients with breast cancer. *Eur J Nucl Med Mol Imaging*. 2010;37:78–83.
6. Spanheimer PM, Graham MM, Sugg SL, Scott-Conner CE, Weigel RJ. Measurement of uterine radiation exposure from lymphoscintigraphy indicates safety of sentinel lymph node biopsy during pregnancy. *Ann Surg Oncol*. 2009;16:1143–7.
7. Sakr R, Bezu C, Raouf I, Antoine M, Ettore F, Darcourt J, et al. The sentinel lymph node procedure for patients with preoperative diagnosis of ductal carcinoma in situ: risk factors for unsuspected invasive disease and for metastatic sentinel lymph nodes. *Int J Clin Pract*. 2008;62:1730–5.
8. Sakr R, Antoine M, Barranger E, Dubernard G, Salem C, Darai E, et al. Value of sentinel lymph node biopsy in breast ductal carcinoma in situ upstaged to invasive carcinoma. *Breast J*. 2008;14:55–60.
9. Ansari B, Ogston SA, Purdie CA, Adamson DJ, Brown DC, Thompson AM. Meta-analysis of sentinel node biopsy in ductal carcinoma in situ of the breast. *Br J Surg*. 2008;95:547–54.
10. Lyman GH, Somerfield MR, Bosserman LD, Perkins CL, Weaver DL, Giuliano AE. Sentinel lymph node biopsy for patients with early-stage breast cancer: American Society of clinical oncology clinical practice guideline update. *J Clin Oncol*. 2017;35(5):561–4.
11. Kumar R, Jana S, Heiba SI, Dakhel M, Axelrod D, Siegel B, et al. Retrospective analysis of sentinel node localization in multifocal, multicentric, palpable or nonpalpable breast cancer. *J Nucl Med*. 2003;44:7–10.
12. Knauer M, Konstantiniuk P, Haid A, Wenzl E, Riegler-Keilb M, Postlberger S, et al. Multicentric breast cancer: a new indication for sentinel node biopsy a multi-institutional validation study. *J Clin Oncol*. 2006;24:3374–80.
13. Goyal A, Newcombe RG, Mansel RE, Chetty U, Ell P, Fallowfield L, ALMANAC Trialists Group, et al. Sentinel lymph node biopsy in patients with multifocal breast cancer. *Eur J Surg Oncol*. 2004;30:475–9.
14. D'Eredita G, Giardina C, Ingravallo G, Rubini G, Lattanzio V, Berardi T. Sentinel lymph node biopsy in multiple breast cancer using subareolar injection of the tracer. *Breast*. 2007;16:316–22.
15. Port ER, Garcia-Etienne CA, Park J, Fey J, Borgen PI, Cody HS 3rd. Reoperative sentinel lymph node biopsy: a new frontier in the management of ipsilateral breast tumor recurrence. *Ann Surg Oncol*. 2007;14:2209–14.
16. Luini A, Galimberti V, Gatti G, Arnone P, Vento AR, Trifiro G, et al. The sentinel node biopsy after previous breast surgery: preliminary results on 543 patients treated at the European Institute of Oncology. *Breast Cancer Res Treat*. 2005;89:159–63.
17. Intra M, Trifiro G, Galimberti V, Gentilini O, Rotmensz N, Veronesi P. Second axillary sentinel node biopsy for ipsilateral breast tumor recurrence. *Br J Surg*. 2007;94:1216–9.
18. Koizumi M, Koyama M, Tada K, Nishimura S, Miyagi Y, Makita M, et al. The feasibility of sentinel node biopsy in the previously treated breast. *Eur J Surg Oncol*. 2008;34:365–8.
19. Rodriguez Fernandez J, Martella S, Trifiro G, Caliskan M, Chifu C, Brenelli F, et al. Sentinel node biopsy in patients with previous breast aesthetic surgery. *Ann Surg Oncol*. 2009;16:989–92.
20. Karam A, Stempel M, Cody HS 3rd, Port ER. Reoperative sentinel lymph node biopsy after previous mastectomy. *J Am Coll Surg*. 2008;207:543–8.
21. Boughey JC, Bedrosian I, Meric-Bernstam F, Ross MI, Kuerer HM, Akins JS, et al. Comparative analysis of sentinel lymph node operation in male and female breast cancer patients. *J Am Coll Surg*. 2006;203:475–80.
22. Gentilini O, Chagas E, Zurrada S, Intra M, De Cicco C, Gatti G, et al. Sentinel lymph node biopsy in male patients with early breast cancer. *Oncologist*. 2007;12:512–5.
23. Synn LW, Park J, Patil SM, Cody HS 3rd, Port ER. Sentinel lymph node biopsy is successful and accurate in male breast carcinoma. *J Am Coll Surg*. 2008;206:616–21.
24. Boughey JC, Suman VJ, Mittendorf EA, Ahrendt GM, Wilke LG, Taback B, et al. Sentinel lymph node surgery after neoadjuvant chemotherapy in patients with node-positive breast cancer: the ACOSOG Z1071 (Alliance) clinical trial. *JAMA*. 2013;310(14):1455–61.
25. Boileau JF, Poirier B, Basic M, Holloway MB, Gaboury L, Sideris L, et al. Sentinel node biopsy after neoadjuvant chemotherapy in biopsy proven node-positive breast cancer: the SN FNAC study. *JCO*. 2015;33(3):258–64.
26. Mantani A, Barrio AV, King TA, Zee KJV, Plitas G, Pilewskie M, et al. How often does neoadjuvant chemotherapy avoid axillary dissection in patients with histologically confirmed nodal metastases? Results of prospective study. *Ann Surg Oncol*. 2016;23(11):3467–74.
27. Mamounas EP, Brown A, Anderson S, Smith R, Julian T, Miller B, et al. Sentinel node biopsy after neoadjuvant chemotherapy in breast cancer: results from National Surgical Adjuvant Breast and Bowel Project Protocol B-27. *J Clin Oncol*. 2005;23:2694–702.
28. Xing Y, Foy M, Cox DD, Kuerer HM, Hunt KK, Cormier JN. Meta-analysis of sentinel lymph node biopsy after preoperative chemotherapy in patients with breast cancer. *Br J Surg*. 2006;93:539–46.
29. Kelly AM, Dwamena B, Cronin P, Carlos RC. Breast cancer sentinel node identification and classification after neoadjuvant chemotherapy-systematic review and meta-analysis. *Acad Radiol*. 2009;16:551–63.
30. Sherman AI, Ter-Pogossian M. Lymph-node concentration of radioactive colloidal gold following interstitial injection. *Cancer*. 1953;6:1238–40.
31. Albo D, Wayne JD, Hunt KK, Rahlfs TF, Singletary SE, Ames FC, et al. Anaphylactic reactions to isosulphane blue during sentinel lymph node biopsy for breast cancer. *Am J Surg*. 2001;182:393–8.
32. Stradling B, Aranha G, Gabram S. Adverse skin reactions after methylene blue injections for sentinel lymph node localization. *Am J Surg*. 2002;184:350–2.
33. Kargoaran H, Shah M, Li Y, Beckett L, Gandour-Edwards R, Schneider PD, et al. Concordance of peritumoral technetium 99m colloid and subareolar blue dye injection in Breast cancer sentinel lymph node biopsy. *J Surg Res*. 2007;143:126–9.
34. Rodier JF, Velten M, Wilt M, Martel P, Ferron G, Vaini-Elies V, et al. Prospective multicentric randomized study comparing periareolar and peritumoral injection of radiotracer and blue dye for the detection of sentinel lymph node in breast sparing procedures: Fransenode trial. *J Clin Oncol*. 2007;25:3664–9.
35. Derossis AM, Fey J, Yeung H, Yeh SD, Heerdt AS, Petrek J, et al. A trend analysis of the relative value of blue dye and isotope localization in 2,000 consecutive cases of sentinel node biopsy for breast cancer. *J Am Coll Surg*. 2001;193:473–8.
36. Bauer TW, Spitz FR, Callans LS, Alavi A, Mick R, Weinstein SP, et al. Subareolar and peritumoral injection identify similar sentinel nodes for breast cancer. *Ann Surg Oncol*. 2002;9:169–76.
37. Pelosi E, Baiocco C, Ala A, Gay E, Bello M, Varetto T, et al. Lymphatic mapping in early stage breast cancer: comparison between periareolar and subdermal injection. *Nucl Med Commun*. 2003;24:519–23.
38. Goyal A, Newcombe RG, Mansel RE, Axillary Lymphatic Mapping Against Nodal axillary Clearance (ALMANAC) Trialists Group. Clinical relevance of multiple sentinel nodes in patients with breast cancer. *Br J Surg*. 2005;92:438–42.

39. Goyal A, Newcombe RG, Chhabra A, Mansel RE, ALMANAC Trialists Group. Factors affecting failed localization and false-negative rates of sentinel node biopsy in breast cancer: results of the ALMANAC validation phase. *Breast Cancer Res Treat.* 2006;99:203–8.
40. Schrenk P, Rehberger W, Shamiyeh A, Wayand W. Sentinel node biopsy for breast cancer: does the number of sentinel nodes removed have an impact on the accuracy of finding a positive node? *J Surg Oncol.* 2002;803:130–6.
41. Giuliano AE, Ballman KV, McCall L, Beitsch PD, Brennan MB, Kelemen PR, et al. Effect of axillary dissection vs no axillary dissection on 10-year overall survival among women with invasive breast cancer and sentinel node metastasis: the ACOSOG Z0011 (Alliance) randomized clinical trial. *JAMA.* 2017;318:918–26.
42. Kuehn T, Bauerfeind I, Fehm T, Fleige B, Hausschild M, Helms G, et al. Sentinel- lymph-node biopsy in patients with breast cancer before and after neoadjuvant chemotherapy (SENTINA): a prospective, multicentre cohort study. *Lancet.* 2013;14:609–18.
43. Couceiro TC, Menezes TC, Valênça MM. Post mastectomy pain syndrome: the magnitude of the problem. *Rev Bras Anesthesiol.* 2009;59:358–65.
44. Dirican A, Andacoglu O, Johnson R, McGuire K, Mager L, Soran A. The short-term effects of low-level laser therapy in the management of breast-cancer-related lymphedema. *Support Care Cancer.* 2011;19:685–90.