

Chapter 2

Dermoscopy Basics



Sarah Kam and Neelam A. Vashi

Dermoscopy: The 2 Step Algorithm [1–3] (Fig. 2.1)

The first part of the 2-Step Algorithm (Fig. 2.1) involves determining if a cutaneous lesion is a pigmented lesion or not (Table 2.1). A pigmented lesion typically presents with one or more pigment pattern(s) as described in Tables 2.2 and 2.3. The only exception to this rule is if the lesion is unequivocally a dermatofibroma. If the lesion contains at least one pigment pattern, then proceed to Step 2 for melanocytic lesions. If the cutaneous lesion does not contain at least one pigment pattern, then proceed to Step 2 for non-melanocytic lesions.

S. Kam

Department of Dermatology, Boston University Medical Center,
Boston, MA, USA

e-mail: sarahkam@bu.edu

N. A. Vashi (✉)

Department of Dermatology, Boston University School of
Medicine and Boston Medical Center, Boston, MA, USA

US Department of Veterans Affairs, Boston Health Care System,
Boston, MA, USA

e-mail: nvashi@bu.edu

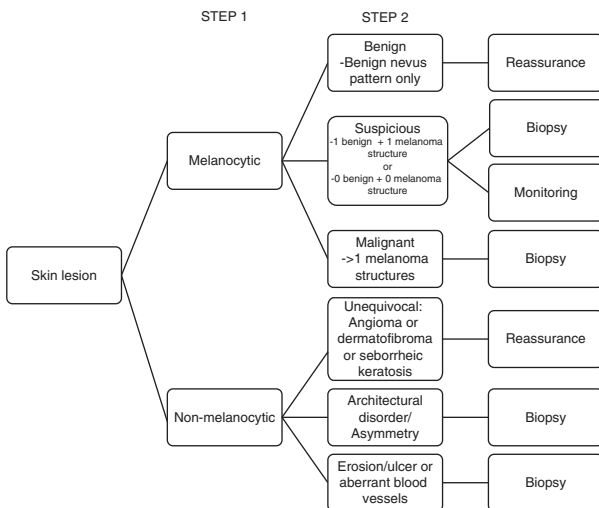









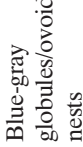








FIGURE 2.1 The 2-Step Algorithm

Step 1 (Table 2.1):

TABLE 2.1 Dermoscopic Findings of Common Cutaneous Lesions

Melanocytic lesions	Pigment network	Streaks	Aggregated globules	Uniform blue pigment	Pseudonetwork	Parallel pattern
						
Dermatofibroma	Delicate, peripheral pigment network with central scar-like structure and dimple sign 					
Basal cell carcinoma	Arborizing blood vessels  Leaf-like structures  Blue-gray globules/ovoid nests  Pearly areas/ulceration 					
Seborrheic keratosis	Milia-like cysts  Comedo-like openings  Crypts  Moth-eaten borders  Cerebriform pattern 					





Angioma or angiokeratoma	Red/blue/black lacunae					
Blood vessels in non-melanocytic tumors	Glomerular vessels at periphery: SCC		Crown vessels: Sebaceous hyperplasia/ Molluscum	“Pearls on a string” Clear cell acanthoma	Hairpin: Keratoacanthoma	
Blood vessels in melanocytic tumors	Intradermal nevus		Comma-shaped: Dotted	Linear	Hairpin	Polymorphous >2 types
Structureless	Structureless lesions are concerning for amelanotic melanoma					

TABLE 2.2 Dermoscopic Features of Benign Nevi






Pattern	Illustration
Reticular <ul style="list-style-type: none"> - Diffuse reticular - Patchy reticular - Peripheral reticular with central hypopigmentation - Peripheral reticular with central hyperpigmentation 	
Homogeneous	
Peripheral globules	
Starburst Globular 2 Components <ul style="list-style-type: none"> - Peripheral reticular + central globules - ½ reticular + ½ globules 	
Symmetrical multi-component	
Parallel furrow pattern in volar/acral skin	

TABLE 2.3 Dermoscopic features of melanoma










Features	Description	Image
Atypical pigment network and angulated lines	Significant variability in distribution and organization of pigment and lines	
Negative network	Serpiginous hypopigmented lines between hyperpigmented elongated lines	
Atypical dots or globules	Disorganized dots or globules of varying size, color, distribution	
Irregular streaks or pseudopods	Radiating linear pigment at periphery. Pseudopods are streaks with knobs at the end of the projections.	
Regression structures	Non-palpable depigmented areas	
Blue-white veil	Palpable area with blue-black area with overlying white ground-glass appearance	
Shiny white lines	Bright white lines in parallel or perpendicular orientation under polarized light	
Atypical blotch	Asymmetrical area of hyperpigmentation obscuring other structures	
Polymorphous vessels	2 or more type of blood vessels in disorganized distribution	

TABLE 2.4 Melanoma of special sites

Site	Description	Illustration
Face	<ul style="list-style-type: none"> - Blotches of pigment with obliteration of follicles - Concentric rings of pigment surrounding another circle - Gray circles in follicular openings - Incomplete circles in follicles - Angulated lines in adnexal openings 	
Mucosa	Structureless areas with blue/gray/white	
Volar/acral surfaces	Parallel ridge pattern: Thick lines of pigmentation on ridges	
Nail apparatus	Irregular pigmented bands with multiple colors, varying thickness and loss of parallelism	

References

1. Kittler H. The 2-step method and the recognition process in Dermoscopy. *JAMA Dermatol.* 2015;151(9):1037–8. <https://doi.org/10.1001/jamadermatol.2015.2000>.
2. Marghoob AA, Braun R. Proposal for a revised 2-step algorithm for the classification of lesions of the skin using dermoscopy. *Arch Dermatol.* 2010;146(4):426–8. <https://doi.org/10.1001/archdermatol.2010.41>.
3. Wolner ZJ, Yélamos O, Liopyris K, Rogers T, Marchetti MA, Marghoob AA. Enhancing skin cancer diagnosis with dermoscopy. *Dermatol Clin.* 2017;35(4):417–37. <https://doi.org/10.1016/j.det.2017.06.003>.