35 Hindfoot and Ankle Charcot Reconstruction

Roberto A. Brandão, Justin Daigre, and Christopher F. Hyer

35.1 Introduction

Charcot neuroarthropathy (CN) is a devastating illness. The destructive process leads to foot and ankle deformities possibly resulting in ulcerations, subsequent infections, and poor quality of life. The prevalence of CN is estimated at around 0.3% per thousand per year [1]. The incidence is probably higher than reported because of the increase in diabetes seen over the past few decades.

Quality of life is often poor for patients with CN of the foot/ankle. Successful nonoperative treatment has failed to improve quality of life measures in CN patients [2]. Recent studies have shown successful limb salvage and improvement in quality of life following Charcot reconstruction [3]. In light of the recent evidence, foot and ankle surgeons need to be prepared to treat CN patients with surgical reconstruction.

Wounds associated with CN of the foot/ankle have been shown to increase lower extremity amputations by a factor of 6 compared to patients without wounds. A 5-year mortality rate in diabetic patients after lower extremity amputation varies from around 39–68% [4]. As foot and ankle surgeons, preventing ulcerations and obtaining successful limb salvage are paramount in treating this difficult patient population.

CN of the hindfoot and ankle is particularly destructive and often leads to profound and severe instability which may be unbraceable (Fig. 35.1). Charcot of the ankle, especially in cases where the talus is essentially resorbed, can lead to below-knee amputation rates of 30–50% [5]. The treatment of hindfot and ankle CN is a challenging problem that can be associated with higher complication rates [6]. This rate may be higher in the unfortunate cases that have CN of both the ankle/hindfoot and midfoot. Additionally, patients who have CN collapse in the setting of deep infection or ulceration are at higher risk for amputation.

This chapter will review surgical techniques in patients with ankle and hindfoot CN deformities. Midfoot CN deformities are covered in Chap. 16.

35.2 Clinical Presentation

During the acute phase (Eichenholtz stage 0), patients present with a swollen, erythematous foot that is usually mistaken for infection or sometimes even gout. Pain may or may not be

R. A. Brandão (✉)
The Centers for Advanced Orthopaedics, Orthopaedic Associates of Central Maryland Division, Catonsville, MD, USA

J. Daigre
Decatur Morgan Hospital, Decatur Orthopaedic Clinic, Decatur, AL, USA

C. F. Hyer
Orthopedic Foot & Ankle Center, Worthington, OH, USA

© Springer Nature Switzerland AG 2019
C. F. Hyer et al. (eds.), *Essential Foot and Ankle Surgical Techniques*,
https://doi.org/10.1007/978-3-030-14778-5_35

Fig. 35.1 Clinical view profound unbraceable CN valgus ankle instability

Fig. 35.2 Clinical view profound unbraceable CN valgus ankle instability

present. Radiographs can be normal. As the process advances, subsequent bony fragmentation (Eichenholtz stage I) occurs leading to deformity. Patients tend to present with a clinically deformed hindfoot or ankle. Gross instability may be present depending on the amount of bony and soft tissue destruction. Pre-ulcerative lesions and frank ulcerations should be checked for and documented. Blood flow should be assessed using palpation of pedal pulses, Doppler, noninvasive arterial studies, or angiography.

Patients may present with gross hindfoot and ankle instability with or without crepitus of the affected joints. A valgus (Fig. 35.2) or varus (Fig. 35.3) ankle deformity can be present, with valgus a bit more commonly seen. Depending on the chronicity and bone remodeling, the deformity may present as rigid or profoundly unstable with dislocation of the ankle and/or hindfoot joints (Fig. 35.4). In cases of talar resorption, the foot will seemingly be hanging from the leg by the skin and soft tissue structures. In other cases, where bone remodeling or consolidation has occurred, the deformity may be rigid with significant bone hypertrophy. This nonreducible deformity is secondary to osseous impingement, or long-term adaptation of the deformity may be custom-braceable but likely will have "at-risk" areas of tissue. Pre-ulcerative lesions or frank ulcerations are common on the lateral or medial malleoli (particularly with ankle joint Charcot deformity), navicular tuberosity, or inferior to the cuboid, depending on level of deformity (Figs. 35.5 and 35.6). Ipsilateral edema secondary to the inflammatory nature of the disease process is often present with or without concomitant venous stasis disease. Morbid obesity is a common physical exam finding as well as loss of protective sensation and frank neuropathy. All aspects of motor, sensory, and autonomic neuropathic changes in the foot should be recognized and documented.

Fig. 35.3 Clinical view of unbraceable varus ankle from CN

Fig. 35.4 Lateral WB radiograph: Fragmentation and dislocation of the talus secondary to CN

Fig. 35.5 Clinical lateral ankle view: Pre-ulcerative lesion due to varus CN ankle instability

Fig. 35.6 Chronic hypertrophic lateral ankle ulcer with granulation tissue. Wound has had multiple I&Ds and wound grafts but remains secondary to instability

35.3 Nonoperative Treatment

Nonoperative treatment may be attempted in patients with mild to moderate deformities and acute Charcot with no deformity, patients without wounds or wounds that do not probe to bone, and patients with multiple comorbidities that greatly increase the risk of surgery. Management of ulcer-

Fig. 35.7 Example of patellar tendon weight-bearing custom brace

Fig. 35.8 Example of Arizona-type custom AFO

ations requires local debridement and off-loading usually in the form of total contact casting (TCC). After initial casting, most patients can be transitioned to either a CROW boot, double upright brace, patellar tendon weight-bearing brace (PTB), or diabetic shoe with accommodative inserts with possible Arizona or custom AFO bracing (Figs. 35.7, 35.8 and 35.9). Other off-loading options include complete nonweightbearing on the affected limb with the help of a wheelchair or knee scooter. This sequence of nonoperative treatment is to successfully move patients from Eichenholtz stages 0 and I to coalescence at stage II and finally reconstruction at stage II or III. A stable, shoe-able foot that is not at risk for ulceration is the goal of nonoperative treatment.

Fig. 35.9 Example of custom-fixed AFO with diabetic liner

35.4 Operative Treatment

Indications for surgical intervention in CN patients have expanded over the past decade. Failure of nonoperative treatment to improve

quality of life is one of the main reasons surgical intervention is more commonly performed. Surgery is often performed for patients with wounds that probe to the bone, acute Charcot that are not great candidates for casting, and moderate to severe deformities. Additionally, surgery is indicated in those with active infection, abscess and chronic pathology that has failed nonoperative treatment. Timing of surgical intervention is controversial. Some have recommended treating Eichenholtz stage 0 and I with nonoperative intervention before proceeding with surgery. That rule of thumb has been challenged, and some are treating more acute Charcot with surgical intervention. Currently the literature is not clear on timing to surgical intervention.

35.5 Preoperative Planning

35.5.1 Imaging

Radiographs of the foot and ankle, preferably weight-bearing radiographs, are essential in the monitoring and surgical planning of CN cases. Radiographs are used for preoperative planning, and the surgeon must be able to visualize the three-dimensional (3D) deformity from two-dimensional (2D) imaging (Figs. 35.10 and 35.11). Three-view standing radiographs of the foot and ankle should be obtained. A hindfoot alignment view can be helpful in assessing varus/valgus hindfoot deformities.

Fig. 35.11 AP WB radiograph: Partially consolidated ankle and hindfoot CN. Note vascular calcifications

Fig. 35.10 Lateral WB radiograph: Partially consolidated ankle and hindfoot CN

Advanced imaging is sometimes beneficial in treating Charcot deformities. CT is probably the most useful to evaluate bone loss, bone cysts, dislocations, subluxations, and erosive changes. Although not widely used, weight-bearing CT imaging can be very useful in visualizing the deformity in situ (Fig. 35.12).

MRI can be used to assess vascularity, fluid collections, bone marrow lesions, and edema as well as rule out abscess formation (Fig. 35.13). MRI is not great as a stand-alone test for diagnosing osteomyelitis as it is difficult to determine

Fig. 35.12 AP view CT scan noting CN fragmentation and dislocation at TN joint

Fig. 35.13 Lateral view MRI T2 image of CN foot with dorsal foot fluid collection and likely abscess

whether increased bone signal is from Charcot breakdown or osteomyelitis.

Tagged white blood cell scans and SPECT CT scans can be useful for diagnosing osteomyelitis. Bone biopsy is still the gold standard for suspected osteomyelitis.

35.5.2 Laboratory

Consideration should be given to optimizing laboratory levels preoperatively if possible. Preoperative laboratory testing is essential for assessing healing potential. Standard CBC, BMP, prealbumin, albumin, vitamin D levels, ESR, CRP, and A1C are obtained prior to surgery. Ideally surgical intervention should be undertaken once appropriate glucose control is met with some research suggesting an A1C of less than 7.5 and 8.0 [7, 8]. Tobacco use should be discontinued prior to any surgical intervention if possible. Many patients affected with hindfoot and ankle Charcot are not ideal surgical candidates, so expectations must be managed appropriately in regard to overall outcomes, need for revisional surgery, and the possible loss of limb.

Given the medically complex nature of this patient subset, it is important to engage the entire medical team including primary care; endocrinology; vascular, cardiac, and infectious disease; plastics; social care and home health; and orthotics/prosthetics in the management of these difficult cases. All aspects of this medical management, beyond the surgery itself, play pivotal roles in the overall success.

35.6 Operating Room Setup

1. The patient is positioned supine on the operating table. A thigh tourniquet is usually applied to the operative extremity to decrease blood loss. An ipsilateral hip bump is commonly used since many patients have externally rotated lower extremities.
2. OR positioners or blankets can be used to elevate the operative extremity above the contralateral leg. This will help with fluoroscopic imaging.
3. A mini or large C-arm can be used in hindfoot/ankle Charcot. Large C-arm imaging may be more useful in cases of external fixation or retrograde TTC nailing.
4. For mini-fluoroscopic imaging, it needs to come in from the ipsilateral side with the sur-

Fig. 35.14 Operative view of mini fluoroscopy positioning for retrograde nail placement

geon, and back table will be on the opposite side and at the end of the table. This will allow the surgeon to take the leg off the side of the bed to facilitate easier imaging (Fig. 35.14).

5. The leg is prepped above the knee with the surgeon's preference of antiseptic. For nonulcerated extremities, we commonly use a chlorhexidine scrub brush followed by chlorhexidine gluconate with isopropyl alcohol. For patients with ulcerations, we recommend povidone-iodine 7.5% scrub followed by povidone-iodine 10% solution.

35.6.1 Equipment

Since these cases are technically difficult and operative plans may change intraoperatively, the surgeon should confirm that all equipment that may be used is present for the case before the patient is taken to the operating room.

1. Most ankle cases will need a tibiotalocalcaneal (TTC) fusion system. An intramedullary device is most commonly used for ankle/hindfoot Charcot fixation, but there are plating options as well. Our preference is the retrograde TTC fusion nail to a 20 or 25 cm length.
2. Equipment for screw fixation should also be made avilable if the need for extending the fusion to the medial or lateral columns or adding supplemental fixation outside the TTC nail is preferable. Our preference is cannulated 6.5/7.0/8.0 titanium alloy screws outside the nail to fixate across the STJ and sometimes from calcaneus to tibia as well. Often the inferior screw in the nail that targets posterior to anterior in the calcaneus can be taken longer to cross the CC joint if needed.
3. External fixation equipment is also commonly used and should be available for all ankle/hindfoot Charcot cases. We prefer pre-built static frame constructs to fixate proximal in the tibia, above the nail and distally to anchor the foot. Antibiotic beads or cement should be available for all cases.
4. Large osteotomies and wedge resections may be needed in these cases. The use of electric sagittal saws as well as cordless drills/reamers will be required.
5. Biologic augments should be considered for these salvage cases and readily available if needed.

35.7 Approaches

35.7.1 General Rules

Dissection

- Avoid undermining and dissection planes on approach as this may violate the healthy vascularized subcutaneous layer. Attempt should be made to maintain a full-thickness envelope at all times.
- Be aware and reduce the use of extensive manual or self-retaining retractor on tenuous incisional areas including the anterior ankle and sinus tarsi incisions. Be aware of areas of prior ulcers and infections and avoid if possible.
- Limited periosteal dissection and devascularization of the soft tissue surrounding the talus given its inherent poor vascularity.

- Avoid thermal injury with the placement of wire and pin fixation (especially in external fixation applications).
- Be sure to decompress boney deformity and remove the exuberant fibrous and synovitic tissue that is common in Charcot. The foot must be destabilized, and reduction of the deformity is paramount.
- Take care to prepare all joints that are intended for fusion using standard joint prep techniques using combination of curettes, osteotomes, rongeurs, and solid drill bits. Prepare the joints for fusion by drilling the subchondral bone. Using an osteotome to fenestrate or "fish scale," the subchondral bone helps expose good bleeding bone that is optimal for fusion. Simply placing fixation across intact joints will often lead to late term complications of hardware failure and loss of deformity correction.
- These are long and complex cases. Have a solid surgical plan ahead of time, and be efficient with your tourniquet and surgical time. Frequently, the Ex Fix is applied with the incisions closed and the tourniquet deflated.

35.7.2 Lateral Approach

- The lateral curvilinear incision is the most common approach used. A lateral longitudinal incision is made along the distal aspect of the fibula using a 15 blade maintaining a full soft tissue envelope to the level of periosteum. A slight curve can be applied to the distal aspect of the incision over the sinus tarsi for access to the subtalar joint (Fig. 35.15). Dissection of the soft tissues of fibula can be accomplished with sharp dissection and a Cobb elevator circumferentially. Gelpi or Weitlaner retractors are placed deep for visualization.
- A fibular osteotomy is made with sagittal saw from proximal lateral to distal medial, approximately 5–6 cm above the distal tip of the fibula (Fig. 35.16). A Hohmann retractor is placed on the anterior and posterior aspect of the osteotomy to protect the soft tissues, blood supply, and the tibia from iatrogenic injury. The fibula is resected and removed from the soft tissues using a combination of an osteotome and sharp dissection (Fig. 35.17). This can then be morcelized as autograft if the bone is in good health and there isn't suspicion of chronic infection (Fig. 35.18). Once the fibula is resected, the ankle joint can be visualized with anterior and posterior capsular attachment released with Cobb elevator and use of laminar spreader (Fig. 35.19).
- Take the dissection distally to the subtalar joint staying just above the peroneal tendons. The subtalar joint should be mobilized as to allow full reduction and realignment of the hindfoot and ankle. The Cobb elevator can be

Fig. 35.15 Operative lateral view of lateral approach for ankle and STJ exposure

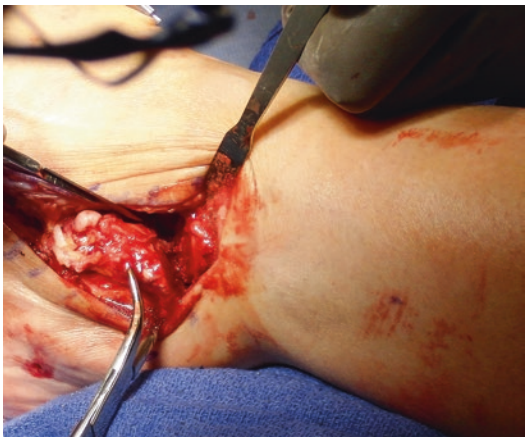

Fig. 35.16 Operative lateral view demonstrating fibular osteotomy

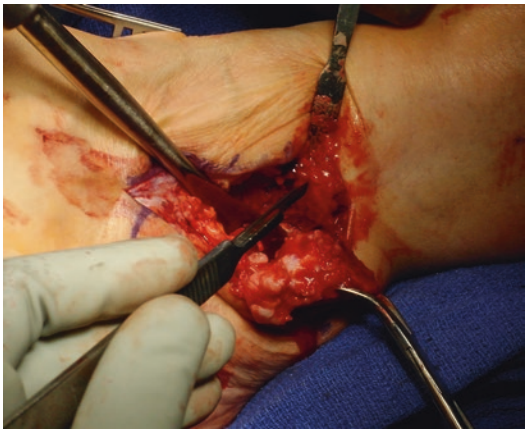

Fig. 35.17 Operative lateral view of excision of distal fibula and exposure of ankle joint

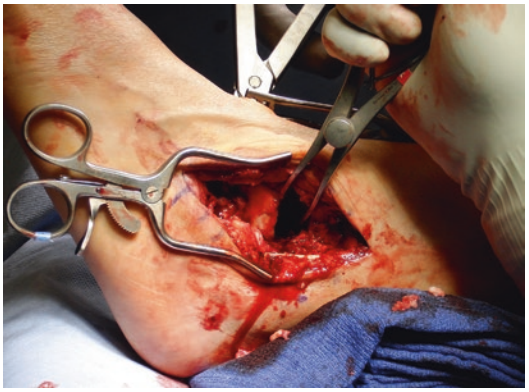

Fig. 35.19 Operative lateral view with fibula resected. Laminar spreader opening ankle joint for fusion preparation

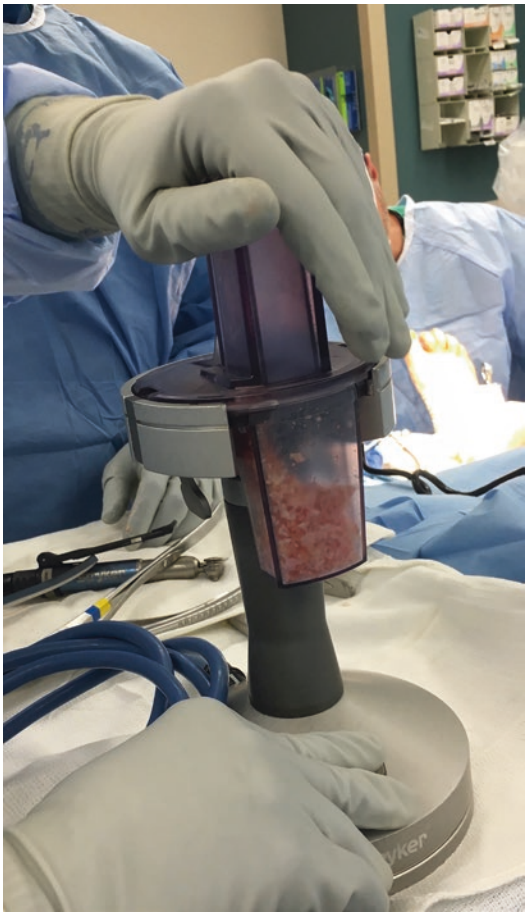

Fig. 35.18 Operative view of morcelization of fibular autograft using power reamer

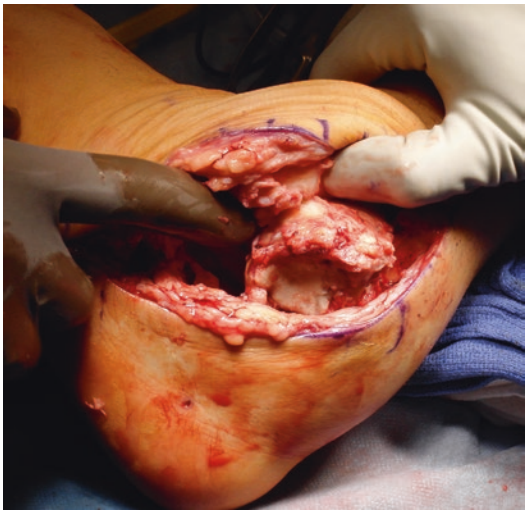

Fig. 35.20 Operative view of Charcot ankle deformity with fragmented and missing talus

helpful here. Often in the valgus hindfoot, significant fibrosis within the STJ will need to be removed as well. If the fibula wasn't resected, be sure to fully release the calcaneal-fibular ligament (CFL) as it is frequently scarred in and keeping the hindfoot in valgus.

- In some instances of significant Charcot of the ankle, the talus may be fragmented and nonviable, in which case either the entire talus is removed or the collapsed body is removed, while the viable head and neck of the talus is left intact (Fig. 35.20). In these

cases, preoperative planning to use either bulk femoral head allograft or titanium cage to replace the diseased talus must have been done and then performed. Another option in this type of case would be to perform a direct tibia calcaneal (TC) fusion.

Pearls

- The surgeon can access for the ankle and subtalar joint through one incision.
- Removal of the fibula allows soft tissue closure without tension.
- Lateral wounds can be resected entirely usually allowing for primary closure.
- Large dead spaces need to be avoided, or a negative pressure dressing or drain can be applied to reduce chance of hematomas or seromas.

35.7.3 Anterior Approach

- The anterior incision may be used in isolated if the STJ is already fused or as coupled approach with a standard sinus tarsi lateral approach for the STJ. A standard anterior incision is made at the level of the ankle using 15 blade maintaining a good soft tissue envelope. Care is taken to avoid the superficial peroneal nerve branches at the distal end of the incision as they cross lateral to medial. Take care to identify, elevate, and retract/protect the anterior neurovascular bundle.
- Sharp arthrotomy to bone is performed, and dissection of the soft tissues to the fibula and medial malleolus is accomplished with a Cobb elevator. The joint is mobilized as much as possible using an osteotome or Cobb elevator to break up adhesions to allow for deformity correction. Take care in varus deformity to release adhesions and fibrosis in the medial gutter and similarly in the lateral gutter in valgus deformity. Avoid excessive retraction superficially. Once deep dissection begins, a Gelpi retractor is placed for visualization (Fig. 35.21).

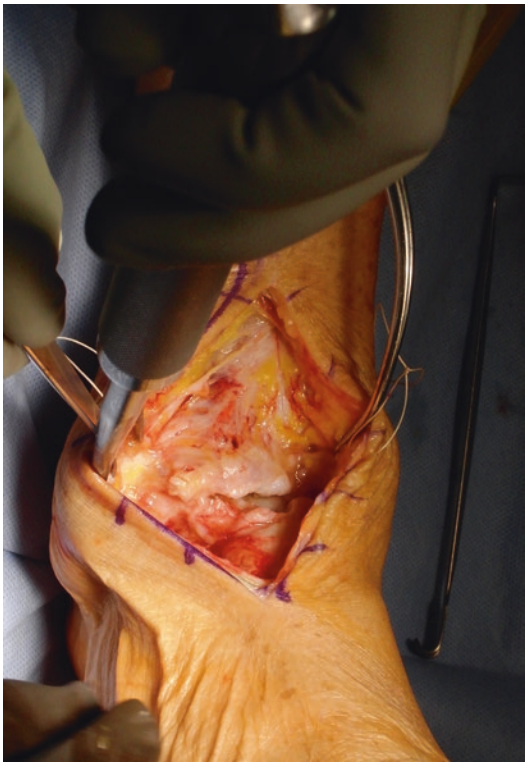

Fig. 35.21 Operative view of anterior ankle exposure

- Frequently, flat tabletop cuts of the distal tibia and talar dome are used. These cuts can be adjusted to resect intrinsic angular deformity if needed. Flat cut on the distal tibia is helpful to resect the posterior malleolar confines and allow the foot to be posteriorly translated on the tibia for optimal positioning. It is also recommended to adequately debride the medial ankle gutter, so the foot can be slightly medialized within the ankle mortise to aid in alignment of the tibia canal and the central body of the calcaneus, particularly if a retrograde TTC nail is to be used.

Pearls

- Well-known incision for foot and ankle surgeon with excellent visualization to correct varus and valgus deformities
- This incision may facilitate easier reduction of foot into optimal biomechanical position of slightly posteriorly translated in regard to the tibia

35.7.4 Posterior Ankle Approach

- The posterior approach is usually used if there soft tissue issues with the anterior or lateral ankle soft tissue envelopes. An incision is made at the posterior medial interval of the Achilles, just medial to the midline of the Achilles tendon with dissection through the skin and paratenon.
- Typically the Achilles is split in a frontal plane "Z" fashion and tagged for later repair (Fig. 35.22). The deep fascia is dissected until the FHL fascia and muscle are exposed and retracted medially. Care is taken to stay lateral to the FHL tendon since the neurovascular structures lie medial. Transverse veins can be present on the posterior joint capsule; electrocautery hemostasis is used if needed taking care to avoid indirect ligation or injury to the posterior neurovascular bundle.
- Sharp arthrotomy to both joints is undertaken and exposed (Fig. 35.23). This approach will allow good assessment of varus and valgus hindfoot deformities. It can be a bit challenging to fully access the anterior and middle facets of the STJ as well as the anterior recess of the ankle. Pin-based distractors or large laminar spreaders are often helpful to improve access and visualization (Fig. 35.24).
- This approach is useful if posterior TTC fusion plating is desired. This position/

Fig. 35.22 Operative view of posterior ankle approach with split "Z" trans-Achilles approach

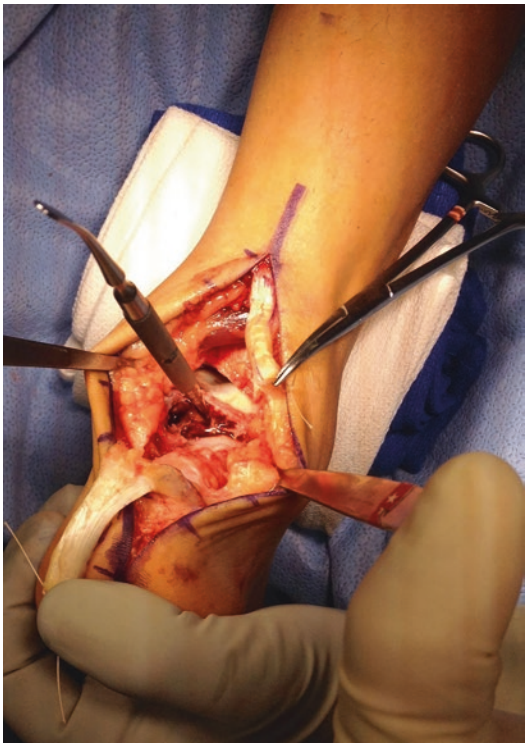

Fig. 35.23 Operative view of posterior ankle and STJ exposure. Freer elevator confirming location of posterior STJ. Cartilage of posterior ankle is visible superior to Freer

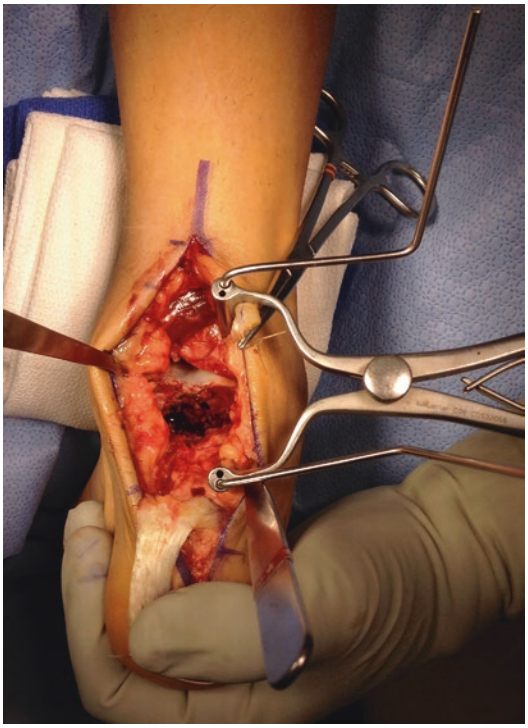

Fig. 35.24 Operative view of posterior ankle and STJ approach. Pin-based distractor in use to assist with joint prep access

approach is not ideal in cases of retrograde TTC nailing and/or circular external fixation which would likely necessitate redraping and repositioning patient to the supine position.

Pearls

- Good approach if lateral or anterior tissues are compromised from previous surgeries or poor soft tissue quality.
- Ankle and subtalar joints are accessed through one incision.
- Approach lends itself well to posterior TTC fusion plating.
- The flexor hallucis longus (FHL) can be your guide for the medial neurovascular structures as they will be medial and anterior on this approach. It may be a consistent landmark when approaching the joint via arthrotomy lateral to FHL.

35.7.5 Medial Ankle

- The medial approach is usually used in combination with the lateral approach. The medial approach is often needed if there is significant medial dislocation and varus contracture and if significant resection of hypertrophic medial bone is needed. A flattop medial to lateral tibial osteotomy or medially based wedge can be used through this incision to help correct significant boney valgus deformity.
- A curvilinear medial malleolar incision is made longitudinally, anterior to the posterior tibial (PT) tendon and posterior to the saphenous vein. This incision is paralleled to the saphenous vein and brought down to the medial gutter of the ankle. It can be used to debride the medial gutter to allow for talar reduction and for resection of the medial malleolus to gain access to the ankle joint. Hohmann retractors are used to retract the PT tendon posteriorly and protect the neurovascular bundle.
- If a medial to lateral tibial osteotomy or medial-based wedge resection is needed, 2.4 mm Steinman pins are driven from medial to lateral across the planned resection margins and confirmed under C-arm. These pins can serve as cut guides and offer added protection from the long sweep of the saw blade.

Pearls

- Approach is good for medially based ulcers that require removal of the medial malleolus.
- Useful adjunctive incision to the lateral approach to facilitate medial gutter preparation and reduction, as well as to allow medial wedge-based tibial osteotomy and resection.
- Care should be taken in cases of long-standing varus contracture as the soft tissues may also be contracted and have difficulty in closing. This is not the case in long-standing valgus deformities as the tissues will be lax after deformity correction.

35.7.6 Fixation Options

Surgical fixation of CN deformities of the hindfoot and ankle usually involves fusion of both the ankle and subtalar joints. Depending on the deformity, fixation may need to extend past the transverse tarsal joint and into the midfoot or across the CC joint in the lateral column.

Fusion of the STJ and/or TN joint may be coupled with TTC fusions for ankle/hindfoot CN but also may be done in conjunction with midfoot CN and medial column instability. In cases of coupling with midfoot CN, fixation of the STJ is usually done with 7.0 cannulated screws or beams and combined with medial and lateral column beam/bolt fixation with the ankle being spared. Thankfully it is rare to have cases requiring pantalar fusions of the ankle, STJ, CC, and TN joints in addition to medial and lateral column beaming. In those rare instances, strong consideration should be taken for a primary BKA with functional prosthesis as perhaps a better alternative.

As a general rule of thumb for fixation of CN, more fixation is better, and layering fixation in different planes also adds to overall construct strength.

Pearls

- Consider reduction and fusion of the subtalar joint on large deformities involving the talonavicular joint for additional stability and support.
- Considered "layered" fixation with multiple fixation devices in multiple planes for added strength.
- Since CN frequently will have delayed union or even non-union, selection of robust fixation is a must as well as fixation that can potentially dynamize over time. Beams/bolts and nails in many cases will perform better than plate/screw constructs for this reason.

Hindfoot and ankle CN deformity fixation is divided in two major categories: internal fixation and external fixation.

35.8 Internal Fixation (IF)

Retrograde intramedullary nailing, plate-screw fixation, and screw/beam fixation are options for treating hindfoot and ankle CN deformities. For TTC fusion, we prefer retrograde TTC nailing with supplemental screw fixation as well as combination circular ring fixation. For hindfoot Charcot without ankle involvement, the plate-screw and/or screw/beam fixation plus/minus external fixation is the usual choice.

35.8.1 Intramedullary Implants

Once all joint prep has been accomplished and any and all wedge resections performed, reduce the joint deformities, and temporarily pin the joints with smooth Kirschner wires (K-wires). Once optimal position is confirmed with fluoroscopic imaging, then fixation can be added.

For CN deformities that involve the ankle or the hindfoot, fixation begins first here and then works forward into the foot as neededWe favor the use of intramedullary nailing and beam/bolt to give a "rebar" effect and allow dynamization over time as bone quality and fusion potential are often poor. Intramedullary devices seem to be able to withstand cyclic loading better than plate and screw constructs and also more easily allow external fixation and other supplemental fixation devices around them (Fig. 35.25).

For beam/bolt fixation, there are solid and cannulated option and in different diameters depending on the applications. We prefer solid options for medial column beaming with larger diameters of 6.5 or 7.0. For mid-ray beaming down the second or third, a 5.0 solid beam works well here. STJ fusions usually have 2 × 6.5 or 7.0 cannulated screws, and the TTC nails vary from 10 to 13 mm diameters depending on manufacturer, but lengths over 20 cm are recommended for added mid-tibial fixation.

Fig. 35.25 Lateral radiograph of retrograde TTC fusion nail with proximal dynamic locking screw

35.8.2 Plate Constructs

Bridge plate constructs can be used to span bone grafts and other defects. There are now specifically designed titanium alloy plate systems with CN in mind with improved strength and yield characteristics compared to traditional trauma plates. Many of the plates have internal compression "ramps" to allow some compression along the construct to assist in fusion apposition.

Many specific plate options excision for CN include anterior, lateral, and posterior TTC fusion plates, medial column fusion, and utility fusion plates. Many of the Charcot plate systems also have more robust locking screw options to be used in these challenging cases. Sometimes plate constructs can be used "overtop" internal beam fixation as well for added stability.

35.9 External Fixation (Ex Fix)

External circular ring fixation can be a workhouse in CN surgery and is highly utilitarian. It can be customized for the specific indications and purposes such as infection and wound management and primary fixation of CN or as supplementary fixation of CN in addition to internal fixation. Ex Fix is the fixation of choice if an I&D, cement spacers, or other infection management options are needed. Internal fixation can be added at a later date if needed, or the Ex Fix may be used alone in these cases.

Dynamic corrective, "hinged" Ex Fix can be used to allow gradual correction of the CN deformity. This requires building hinges and "motors" into the construct in specific locations and to make adjustments at specific points and specific time schedule. This can be labor-intensive for both surgeon and patient alike, and there is concern with having wires pulling against Charcot skin as adjustment and movements are made.

It is our preference to utilize a static Ex Fix that is applied and left intact until removal at around 3 months postoperative (Fig. 35.26). This static Ex Fix is most often an augment to internal fixation as well. In cases of active or presumed

Fig. 35.26 Clinical AP view of static circular ring external fixator construct used for Charcot reconstruction

infection or significant soft tissue issues, the static frame is used alone but with a "bent-wire" technique to gain compression of the fusion sites.

35.9.1 Circular Frame

A pre-built construct is typically used. Several sizes are pre-built and sterilized and can be more efficiently applied in many cases. A standard two-ring tibial fixation is often used with extension to a foot plate or midfoot/forefoot rings via threaded rods.

Positioner blocks, stacks of towels, or scrubbed assistants are helpful to maintain the leg and foot in a centered position within the frame at all times until the wires and pins are set. We typically have closed all incisions and deflated the tourniquet during Ex Fix application.

We prefer fixation of the proximal tibial ring with two divergent smooth wires and one HA-coated half-pin in the center of the medial face. The midshaft tibial ring is also fixated with two wires and one half-pin but with care to place the half-pin off axis to the proximal one, usually on the tibial crest (Fig. 35.27).

Fig. 35.27 Clinical lateral view of static circular ring external fixator construct. Note foot and leg are centered in ring in all planes

Next, a medial to lateral calcaneal wire is placed to be later secured into the foot frame. Either divergent smooth wires, one from medial to lateral and another from lateral to medial, can be used to secure the calcaneus to the frame. Parallel opposing olive wires can also be used with one olive on the medial cortex and the other on the lateral cortex.

Fixation of the midfoot and forefoot can be done off the frame or guided by the frame. Crossed olive wires are preferred and can be "walked back" to allow compression through the tensioning of the wires.

In the forefoot, generally the first and second metatarsals are captured with one olive wire, and three to five are captured by another opposing wire. Some variability may be needed if internal fixation is present, and the wires may be redirected as necessary.

35.10 Technique Step by Step: Charcot Ankle/STJ TTC Nail

- If no active infection, plan for use of retrograde TTC nail, supplemental screw fixation outside the nail, and circular ring external fixation over top.
- Utilize the described lateral and medial approaches to the ankle and STJ. If the medial malleolus does not need to be resected and there isn't a need for a medially based closed wedge osteotomy of the distal tibia, the medial approach can be a simple medial arthrotomy of the ankle to allow thorough debridement of the medial ankle gutter.
- Confirm thorough joint preparation of the ankle and STJ with standard joint prep techniques. Reduce ankle and hindfoot deformities to neutral with the foot slightly posteriorly translated in the ankle as well as slightly medialized. Often there is gastroc-soleal equinus presence which may fight reduction. A percutaneous Hoke-type triple section TAL is then performed.
- If a talectomy is performed and a TC direct fusion is planned, a beveled cut off the anterior and posterior tibia should be considered

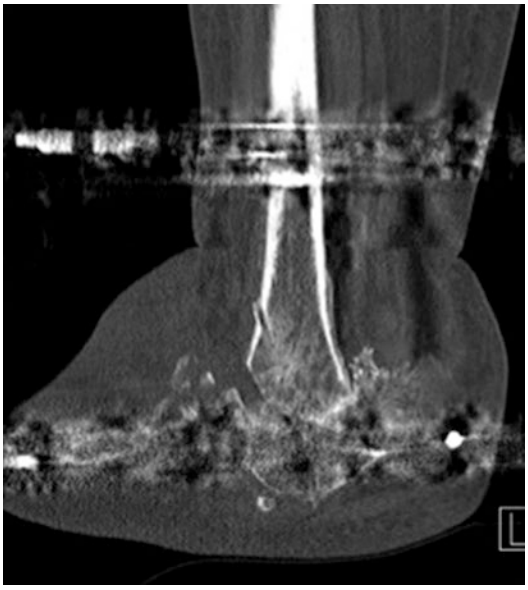

Fig. 35.28 Lateral CT scan showing anterior and posterior beveled cuts on the distal tibia when performing a tibio-calcaneal fusion. (Imaging provided by Hodges Davis, MD)

with the power sagittal saw to allow a better fit between the tibia and calcaneus. This technique has been described by Hodges Davis, MD (Fig. 35.28).

- If talectomy and femoral head allograft is planned, our preference is to use the cup and cone acetabular reamers to prepare the distal tibia, the calcaneal facets, and the opposing cortical surfaces of the femoral head allograft. The intent is not to totally decorticate the allograft but just those surfaces that will be pressed against the fusion surfaces of the calcaneus and tibia.
- Use entry wire from TTC nail system from inferior to superior across the STJ and ankle joints. It is helpful to have the leg and ankle on a bump of towels and have the heel float off the table. This allows the foot to posteriorly translate and keeps the table from pushing the heel forward (Fig. 35.29). On the lateral foot, this wire should enter in line with the lateral process of the talus, just at the junction of the sinus tarsi and posterior facet and parallel to the midline of the tibia (Fig. 35.30). From the plantar view, the entry point is slightly lateral to dead center in the heel.

Fig. 35.29 Operative view of insertion of entry wire for retrograde TTC nail. Note stabilization of corrected position by the assistant and use of bump behind the Achilles to "float" the heel off the table

Fig. 35.30 Intraoperative fluoroscopic lateral view demonstrating ideal guidewire placement bisecting the lateral talar process and colinear with the midline of the tibia

- It is also helpful to have an assistant view the trajectory of the wire placement from 90 degrees to the side to help with the alignment. If solo, drive the wire across both joints, and take the 90 degree view yourself to visualize. This limits a lot of back and forth with the C-arm and radiation exposure.
- Once position of the foot and wire seems appropriate, take multiple views with the

C-arm to confirm, including a calcaneal axial to make sure you're bisecting the calcaneus.

- At this point, incision is made on the plantar heel and blunt dissection down to the calcaneus along the entry wire. The soft tissue protection sleeve is then applied.
- The entry reamer is then used across the STJ and ankle joints per guidelines of the individual nail manufacturer. Take care to maintain reduction of the foot and placement of the femoral head (if needed). A supplemental 2.0 Steinman pin or two as temporary fixation can be useful.
- The entry wire is exchanged for a bead-tipped guidewire and inserted up to leg. C-arm views should be taken to confirm placement of the wire and continued good positioning of the ankle and hindfoot.
- Sequential reaming over the guidewire is then performed under standard technique. Care should be taken here to avoid thermal necrosis or iatrogenic injuries. Upsize reaming until chatter suggests good sizing (Fig. 35.31). A longer length nail of 20–25 cm is recommended. Longer IM nails in lengths of 28–30 cm are often available too and are only used in case external fixation is not planned.

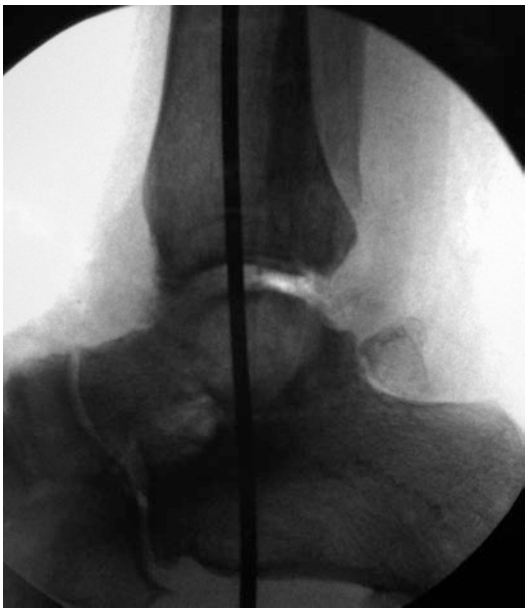

Fig. 35.31 Operative view of sequential reaming over guidewire in preparation for nail insertion. Note assistant maintaining correct alignment

- Prior to nail insertion, biologic adjunctives of choice are added to both joints and often in a periosteal sleeve around the anterior and posterior tibia.
- Careful insertion of the nail is performed and confirmed with C-arm. Check proximally for any stress risers, and confirm reduced position has been maintained.
- Transfixation screws through the nail are then applied per guidelines of the specific nail. We prefer dynamic screw fixation in the proximal nail when possible. We also prefer nail fixation that allows distal fixation that compresses within the nail and also has multi-planar screw fixation within the calcaneus for improved bone purchase.
- If fixation across the CC joint is also needed, most retrograde nails have a posterior- anterior screw in the calcaneus that can be taken long to cross the CC joint. In these cases, make sure to prepare the CC joint under standard technique and elevate the cuboid as it is frequently dropped as part of the rocker bottom foot. We find using a Cobb elevator underneath the cuboid to lift it as the screw inserted is a helpful pearl.
- Once the TTC nail is inserted and fixated, supplemental screw fixation is utilized to add additional stability across the STJ and sometime across the TTC segments. We prefer a cannulated 6.5/7.0/8.0 screw for this. This is usually done from a posterior-inferior to anterior-superior direction across the STJ and toward the anterior tibia. A cannulated guidewire is used and may need to be redirected a few times to miss the nail. It is felt that this supplemental screw fixation improved the STJ fusion rate and adds additional torsional stability (Fig. 35.32).
- Standard wound closures are performed. Incisional wound vac or JP drains can be used if needed.
- In most cases, a static external fixator is now applied overtop the TTC nail as described above. This is felt to give added stability to the overall construct, allows soft tissue wound care and incisions management to be performed, and avoids casting. This "belt and

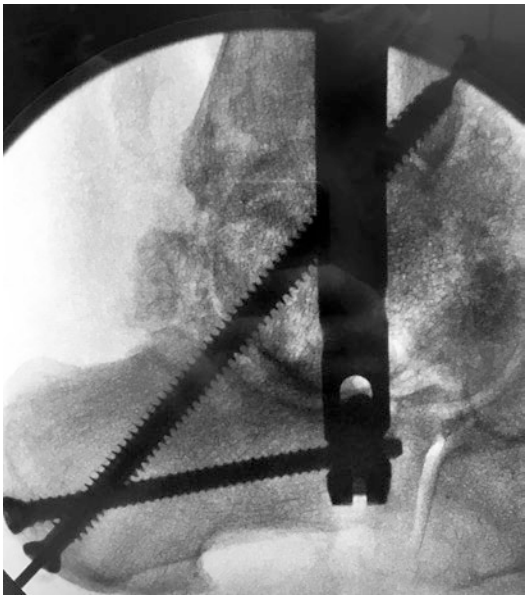

Fig. 35.32 Intraoperative fluoroscopic lateral view demonstrating "outside the nail" supplementary fixation using a fully threaded, cannulated 7.0 titanium screw crossing through a femoral head allograft

suspender" technique of using both internal and external fixation has worked well in our Charcot reconstruction cases.

35.11 Technique Step by Step: Charcot STJ/ TN fusion

- A STJ fusion for CN is never done in isolation but is coupled as part of the TTC fusion for ankle CN or as part of the midfoot/medial column fusions in midfoot/hindfoot CN.
- The STJ fusion provides added stability and overloading of the medial column and seems to stress shield the medial column reconstruction from failure and breakdown.
- STJ fusion as part of the TTC fusion has already been covered. If part of the medial column fusion, the STJ can be fused through the medial approach like one would with a medial double arthrodesis. This can be difficult if there is severe hindfoot valgus dislocation. A traditional lateral sinus tarsi approach can also be used. We prefer the medial approach when possible.
- A medial utility incision is created as part of the medial column fusion. This incision is placed at the inferior border of the posterior tibial tendon and the medial STJ and carried forward to the TN joint where it courses slightly more superiorly.
- Dissection is carried down to the PTT and this is followed to the TN joint. The TN joint is exposed and then mobilized with a Cobb elevator.
- A Gelpi or Weitlaner is used to elevate and retract the PTT. The floor of the flexor canal is incised and the FDL is identified. This is retracted inferiorly.
- The Cobb is placed in the TN joint and rounded into the plantar joint and back into the anterior and middle facet of the STJ. The Cobb and ½ inch curved osteotome are used to release any fibrosis as well as the interosseous ligament.
- The Cobb is used to open the joint and a laminar spreader is used for distraction. Standard joint prep principles are used for both the STJ and TN joints.
- At this point, full reduction of the hindfoot deformity should be possible. A TAL is performed when necessary. In some severe valgus cases, lengthening of the peroneal tendons may also be necessary. Additional biologics is usually added prior to fixation as well.
- Fixation of the STJ is performed first. Care is taken to insure the calcaneus is spun back under the talus and the talus and medial column are back in line. Temporary pin fixation can be used, and C-arm imaging is used to confirm position.
- Our preference is to use one or two cannulated 7.0 titanium alloy screws from inferior to superior across the STJ for fixation. Care is taken to keep the screws at the axial midline or slightly lateral in the talar body to allow clearance for medial column bolt fixation coming down the talar neck and into the medial midline of the talar body (Fig. 35.33).
- Once the STJ is stabilized, attention is directed to the TN joint. If the TN is to be fused with a TTC fusion behind it, two 5.0 cannulated

Fig. 35.33 Lateral radiograph demonstrating two fully threaded cannulated 7.0 screws used in Charcot STJ fusion coupled with medial column beaming with 6.5 solid bolt and central ray beaming with 5.0 solid bolt

screws as well as a locking plate or dynamic metal staple are used for fixation.

- In most TN Charcot fusions, this fusion is part of the larger medial column beams and external fixation construct. Care should be taken to reduce the TN joint in all planes but especially in the frontal plane. This is frequently mobilized and reduced at the same time with the CC joint to insure full resolution of forefoot or medial column varus and plantarflexed lateral column.
- Temporary pin fixation is used at both the TN and CC joint in preparation for definitive beam/bolt/screw fixation. Medial column beaming and reconstruction are covered in Chap. 16, Charcot Midfoot.

35.12 Adjunctive Procedures

35.12.1 I & D

- In cases of abscess and/or suspected osteomyelitis, I&D and appropriate infectious disease management are needed. Deep cultures should be taken to direct antibiotic therapy. Bone biopsy in cases of suspected OM is recommended. Circular external fixation placement is usually considered to provide soft tissue and limb stabilization during the process of infection clearance.
- Antibiotic beads and/or spacers are often utilized to increase antibiotic concentration in the area of concern and to fill dead space defects. These can be exchanged as needed and in some cases are left permanently.

35.12.2 Negative Pressure Wound Therapy

- Negative Pressure wound therarpy is often utilized to reduce bioburden, drainage collection and enhancement the wound bed environment. If this type of wound management is needed, this may be done in a staged fashion before definitive reconstruction is undertaken.
- In cases where severe bone deformity precludes wound healing secondary to pressure, an aggressive cheilectomy with I&D or osteotomy with circular Ex Fix may be done to decompress the tissue and improve chances of healing. The negative pressure device can be applied and managed around the external fixator.
- Incisional negative pressure devices can be used in case when the wounds or incisions are expected to have significant drainage.

35.12.3 Biologic Augments

- Addition of biologic agents such as PRP, BMA, stem cell allograft, BMPs, PDGF, and autograft are all on the table in Charcot limb salvage cases. There are pros and cons to each and left at discretion of the surgeon.
- Reaming and collection of tibial marrow contents can also be utilized in addition to morcelization of the distal fibula when available.

35.13 Postoperative Care

- Prolonged NWB is needed. Patients are instructed to remain NWB for 12 weeks. This is often a difficult issue in this patient subset. Care is taken to reaffirm this point at each office visit and its importance.
- Consider inpatient rehab admission if possible to assist in wound and pin care and to assist in remaining NWB.

- In home discharge situations, a home evaluation by an occupational therapist is recommended before surgery to help with placement of assistive devices and plans.
- In cases of external fixation, after 1 week patients are instructed to paint the pin and wire sites daily with Betadine. Normal showering and hygiene is permitted but no soaking is allowed.
- In cases of infections, PICC IV antibiotic management is done by infectious disease specialists. In non-infected cases, prophylactic oral antibiotics are used for 2 weeks or until all incisions or ulcerations are closed.

Intraoperative Pearls and Pitfalls

- Thorough preoperative workup of infection, comorbidity management and deformity planning are recommended.
- A staged approach including eradication of infection followed by definitive fixation should be considered.
- Careful consideration is given to fixation needs and use of biologic adjuvants to help assist in healing.
- Minimal soft tissue dissection when possible with full-thickness approaches.
- Consider the use of adjunctive procedures, and confirm deformity reduction prior to implantation of hardware.
- Internal and external fixation can be used concurrently. Consider layered fixation with more than you think you need and stability in multiple planes.

Potential complications

- Patient noncompliance
- Wound complications
- External fixation component irritation, infection, breakage, or failure
- Osteomyelitis
- Below-knee amputation: higher risk with ankle/hindfoot Charcot

35.14 Summary

Charcot neuroarthopathy of the ankle and/or hindfoot can produce profound instability and destruction of bone and soft tissue structures. Very often the limb is left with marginal functionality and is prone to breakdown, infections, and a high rate of amputation. Functional reconstruction and salvage takes a concerted effort by the surgeon, the patient, and the full team of medical specialists to achieve optimal results. Preoperative planning and technique is of the utmost importance if one is to achieve limb salvage. The goal remains to have a functional, braceable foot and ankle.

References

1. Fabrin J, Larsen K, Holstein PE. Long-term follow-up in diabetic Charcot feet with spontaneous onset. Diabetes Care. 2000;23(6):796–800.
2. Kroin E, Schiff A, Pinzur MS, Davis ES, Chaharbakhshi E, DiSilvio FA Jr. Functional impairment of patients undergoing surgical correction for Charcot foot arthropathy. Foot Ankle Int. 2017;38(7):705–9.
3. Pinzur MS, Schiff AP. Deformity and clinical outcomes following operative correction of Charcot foot: a new classification with implications for treatment. Foot Ankle Int. 2018;39(3):265–70.
4. Gök Ü, Selek Ö, Selek A, Güdük A, Güner MÇ. Survival evaluation of the patients with diabetic major lower-extremity amputations. Musculoskeletal Surg. 2016;100(2):145–8.
5. Pakarinen TK, Laine HJ, Mäenpää H, Mattila P, Lahtela J. Long-term outcome and quality of life in patients with Charcot foot. Foot Ankle Surg. 2009;15(4):187–91.
6. Wukich DK, Raspovic KM, Hobizal KB, Sadoskas D. Surgical management of Charcot neuroarthropathy of the ankle and hindfoot in patients with diabetes. Diabetes Metab Res Rev. 2016;32(S1):292–6.
7. Wukich DK, Crim BE, Frykberg RG, Rosario BL. Neuropathy and poorly controlled diabetes increase the rate of surgical site infection after foot and ankle surgery. J Bone Joint Surg Am. 2014;96(10):832.
8. Cancienne J, Cooper M, Werner B. The Association of Perioperative Glycemic Control with postoperative surgical site infection following elective foot surgery in patients with diabetes. Foot Ankle Orthop. 2017;21(2):2473011416S00005.