Chapter 11
Management of the "Failed" Cubital Tunnel Release

Rikesh A. Gandhi, Matthew Winterton, and Stephen Y. Liu

Introduction

Cubital tunnel surgery is considered a failure if patients have no improvement in symptoms or if symptoms recur. Reoperation rates after primary cubital tunnel release have been variable. It is estimated that up to 25% of patients treated for cubital tunnel syndrome will have persistent or recurrent symptoms [1]. Goldfarb and colleagues [2] reported a 7% failure rate after primary in situ decompression at 4-year follow-up, and failure rates of 8–10% have been reported for anterior submuscular transposition and partial medial epicondylectomy [3, 4]. The secondary surgery rate after a primary cubital tunnel surgery has been reported to be 5.7% overall, 2.5% for in situ release, and 11.1% for transposition [5]. Patients who are under 50 years old, have a history of elbow trauma, and underwent primary transposition are at

R. A. Gandhi · M. Winterton · S. Y. Liu (✉)
Department of Orthopaedic Surgery, University of Pennsylvania, Philadelphia, PA, USA
e-mail: rikesh.gandhi@uphs.upenn.edu; matthew.winterton@uphs.upenn.edu; stephen.liu@uphs.upenn.edu

© Springer Nature Switzerland AG 2019

J. R. Fowler (ed.), *Cubital Tunnel Syndrome*,
https://doi.org/10.1007/978-3-030-14171-4_11

increased risk of requiring revision surgery [5, 6]. Those with severe disease may experience less improvement secondary to chronic nerve changes [7, 8].

Causes of Failure

Failure of the index cubital tunnel surgery can be due to any combination of diagnostic, technical, or biologic factors. It may be the result of inadequate decompression, ulnar nerve subluxation, iatrogenic creation of a new site of compression, devascularization, perineural fibrosis or cicatrix formation, or intraoperative nerve injury [9]. Categorization of patients who have failed a primary cubital tunnel syndrome procedure into those with persistent, recurrent, or new and distinct symptoms may guide the appropriate treatment.

Patients with persistent symptoms experience either no relief or incomplete relief after a primary procedure may have residual sites of compression after index procedure, a new site of compression after transposition (Z-deformity), irreversible nerve pathology, or inaccurate diagnosis. The medial intermuscular septum and flexor-pronator aponeurosis were found to be the most common sites of residual compression at the time of revision surgery [10–12]. Less common sites of residual compression include anomalous muscles on the medial side of the elbow such as the anconeus epitrochlearis, fascial bands within the flexor carpi ulnaris, the flexor digitorum superficialis, and the medial head of the triceps [13]. Osteophytes, heterotopic ossification, and masses such as ganglion cysts in the cubital tunnel may also cause residual ulnar nerve compression. Ruling out conditions that mimic cubital tunnel syndrome and identifying associated pathology are particularly important. Conditions that that can mimic cubital tunnel syndrome include cervical radiculopathy, thoracic outlet syndrome, ulnar tunnel syndrome, brachial neuritis, systemic neuropathy (diabetes mellitus, chronic alcoholism with vitamin B12 deficiency), multiple sclerosis, and peripheral nerve tumors.

Recurrent symptoms are those that return after a period of symptomatic improvement and usually result from cicatrix formation and perineural fibrosis after surgery [14]. Perineural fibrosis is found to compress the ulnar nerve at an average of 2.2 sites during revision decompression [15]. Care must be taken to minimize soft tissue injury during the index procedure to minimize scar formation. The stability of the ulnar nerve, if not transposed during the index procedure, may also be the etiology of persistent or recurrent symptoms, although a meta-analysis of four randomized controlled trials showed no difference between in situ and anterior transpositions regardless of nerve stability [16, 17]. Stability is assessed intraoperatively after in situ decompression by evaluating the nerve for anterior translation during passive flexion of the elbow. The nerve is classified as stable (posterior to medial epicondyle), perched (rests on the medial epicondyle), or subluxated (remains anterior to medial epicondyle) [18]. Longitudinal tension may be present in cases of cubital tunnel syndrome that are not adequately addressed by in situ decompression alone [19].

New symptoms can result from direct damage to the ulnar nerve and the medial antebrachial cutaneous nerve (MABCN) or creation of an iatrogenic site of compression. We consider new symptoms complications rather than a "failed" release, although they are not mutually exclusive. Iatrogenic creation of a secondary compression point after transposition most commonly occurs at the medial intermuscular septum, the point of transposition, or the flexor-pronator aponeurosis. The MABCN is the terminal sensory branch of the medial cord of the brachial plexus, where it bifurcates into an anterior and posterior branch, and may be injured during exposure. The anatomy of the anterior branch of the MABCN is variable, and although it can typically be found 2–3 cm anterior the medial epicondyle, it can also be located proximal or distal to the medial epicondyle making it prone to injury [20]. MacKinnon found a neuroma of the MABCN in 73% of revision cases [13].

Evaluation of the Failed Cubital Tunnel Release

The evaluation begins by fully understanding the patient's symptoms prior to their index procedure. Postoperative complications, such as a hematoma or infection, should be noted. Changes in symptom frequency, severity, and character will offer critical information about whether the patient is experiencing persistent or recurrent symptoms. Other etiologies that present with similar symptoms, such as cervical spine pathology or thoracic outlet syndrome, should be ruled out.

The physical examination begins at the cervical spine to assess for evidence of radicular symptoms which can mimic or contribute to cubital tunnel syndrome causing a double crush injury. A positive Spurling's maneuver has a high specificity for cervical radiculopathy, and Lhermitte's sign may indicate cervical canal stenosis. The supraclavicular region is assessed to rule out a more proximal compression as seen in thoracic outlet syndrome. The Roos stress test or "elevated arm" test may reproduce symptoms that involve the entire extremity and helps identify a proximal site of compression. The Adson test with a marked decrease or disappearance of a radial pulse suggests a vascular thoracic outlet syndrome.

Elbow deformity, specifically cubitus valgus, and elbow range of motion should be noted. A small incision used to perform an anterior transposition could lead to a new site of compression. Patients with local hypersensitivity anterior to the incision and numbness posterior to the incision should raise concern for the presence of a MABCN neuroma. Palpation of the nerve should be performed along with Tinel's percussion test. A positive Tinel's sign remains useful in localizing potential sites of nerve compression. A distally traveling Tinel's at serial clinical visits may indicate nerve recovery. Assessment for traction neuropathy should be performed by asking the patient to flex and extend the elbow repeatedly (traction Tinel's sign) to see if symptoms worsen. The elbow flexion test with the elbow flexed and wrist extended may also point to a traction-related etiology for

ulnar neuropathy at the elbow. An enlarged medial head of the triceps can compress the nerve against the medial epicondyle with the elbow flexed. Radiographic imaging may demonstrate arthritic changes, orthopedic hardware, or malalignment of the elbow joint.

Atrophy of the first webspace, intrinsics, and hypothenar eminence along with weakened grip and pinch strength suggest chronic and severe ulnar neuropathy. Sensation is preserved over the dorsal ulnar hand in ulnar tunnel syndrome, as the dorsal cutaneous branch of the ulnar nerve bifurcates proximal to the site of compression. When asking the patient to composite a fist, there may be asynchronous movement as the interphalangeal joints flex before the MP joint due to intrinsic malfunction. The Wartenberg sign and Froment test indicate digital and thumb adductor weakness, respectively. Long-standing cases may demonstrate clawing of the fourth and fifth digit.

Prior operative reports should be obtained to understand the location of the ulnar nerve, although these may not always be accurate. Even in cases of failed in situ decompression, the nerve may not be located posterior to the medial epicondyle. Nerve conduction studies and electromyography (EMG) studies should be obtained and compared to preoperative electrodiagnostic studies, if available. Unchanged electrodiagnostic studies should be interpreted with caution, since even with complete surgical release and symptom improvement, the studies often show no improvement. If electrodiagnostic studies show worsening signs of ulnar neuropathy, then revision decompression is indicated, particularly if a new site of compression or ulnar nerve injury is suspected. In the event that electrodiagnostic studies localize findings to the cervical spine or Guyon's canal, consideration may be given to magnetic resonance imaging (MRI) of the affected area.

In certain circumstances, musculoskeletal ultrasound may be utilized to understand the dynamic changes of the ulnar nerve as the elbow moves from extension to flexion. Ultrasound can be useful to confirm nerve location, the presence of an ulnohumeral joint ganglion, changes in nerve

diameter, perineural scarring, and the presence of MABCN neuromas. 3-Tesla magnetic resonance neurography (MRN) has been shown to correctly localize the site of abnormality and may be useful for preoperative planning [21].

Indications for Revision Cubital Tunnel Release

There is currently no consensus on the ideal treatment for failed cubital tunnel release [22]. The literature demonstrates that outcomes for revision surgery are not as good as primary surgery, which makes it difficult to advise a patient if and when he or she requires revision cubital tunnel surgery. If there is certainty a complete release was performed, observation for up to 6 months is rational, especially if preoperative electrodiagnostic studies demonstrated severe nerve compression. Beware of the patient who experiences slight improvement, but plateaus, as this may be a result of irreversible nerve damage. If the patient reports no change in symptoms, but a nerve study shows improvement, then there is support to continue to observe the symptoms with the understanding that an incomplete release could theoretically improve electrodiagnostic findings. In patients where there is worsening sensory or motor deficits or electrodiagnostic findings, it is reasonable to pursue a repeat surgical management of their symptoms.

Treatment Options for Revision Cubital Tunnel Release

It is important to have a high level of certainty when deciding whether to observe or proceed with surgical intervention. Continued observation with persistent compression may lead to worsening and potentially irreversible nerve damage. Conversely, revision surgery is technically challenging and can lead to iatrogenic nerve injury to an otherwise recovering

nerve. Conservative therapy with night splinting and nerve-gliding exercises has not been evaluated in the revision setting. Such measures cause no harm and permit the patient to play an active role in their recovery.

The surgical options for revision cubital tunnel are varied with no clearly proven superior technique, similar to the situation for primary cubital tunnel surgery. The goals of revision surgery include removing any offending sites of external compression on the nerve, placing the nerve in a stable location without tension, and minimizing perineural scar formation.

The surgeon undertaking revision cubital tunnel syndrome should be familiar with the five potential sites of compression typically encountered during the primary procedure: the arcade of Struthers, medial intermuscular septum, medial epicondyle, Osborne's ligament, and flexor-pronator aponeurosis. It is of paramount importance to perform a thorough external neurolysis of the nerve, which requires finding the nerve outside the zone of the original surgery and dissecting toward the scar. In the event circumferential perineural scarring is encountered that is difficult to separate from the nerve, it is advisable to leave a cuff of scar to minimize iatrogenic injury.

Once the nerve has been completely freed, options include medial epicondylectomy, subcutaneous transposition, intramuscular transposition, submuscular transposition, and/or nerve wrapping. In the event that an obvious site of compression is found, some may not proceed with a transposition, although in our opinion any revision decompression should be performed with a transposition to release tension on the nerve and place it in a stable bed of vascularized tissue.

Anterior submuscular transposition remains the most commonly performed procedure for revision surgery [2, 12, 15, 23]. The flexor-pronator mass is completely released, and the ulnar nerve is transposed underneath the muscle belly before the overlying fascia is repaired. This places the nerve in a well-vascularized bed of tissue but at the cost of an extensive soft tissue dissection, increased scar formation, and potential external compression as the nerve is now located

beneath a contractile structure [22]. In cases of concomitant medial epicondylitis, additional consideration may be given to this technique as it can treat both pathologies simultaneously. This technique may provide additional protection to external compression when compared to subcutaneous transposition in thin patients.

Other options for revision cubital tunnel syndrome include simple external neurolysis [24], subcutaneous transposition [11], and intramuscular transposition [25]. Simple external neurolysis should be reserved for cases where recurrent symptoms arise following a period of symptom relief as the cause is more likely from perineural fibrosis and cicatrix formation rather than residual compression or traction on the nerve. External neurolysis alone has also been shown to have good outcomes for recurrent symptoms after failed anterior submuscular transposition [24].

Subcutaneous transposition has also shown promising results, independent of index procedure [11]. The nerve is moved between the flexor-pronator mass and the subcutaneous fat and tethered in place by multiple methods. This approach limits dissection through the muscle belly, through a relatively avascular plan, which may result in less scarring. Osterman described a technique where the subcutaneous fat is divided through its natural superficial and deep layers to form a long adipose sling that minimizes acute changes in sagittal positioning of the nerve. Intramuscular transposition involves step-cut lengthening of the flexor-pronator fascia and creating a tunnel within the muscular substance that stabilizes and protects the nerve along its anterior course, although this has not been evaluated in the revision setting.

The lack of evidence clearly favoring one treatment for revision cubital tunnel syndrome over others suggests that revision outcomes may have more to do with the quality of decompression and preventing scar formation around the nerve than where the nerve is ultimately placed. Various methods of nerve wrapping to minimize cicatrix formation have been described. Silicone elastomer bands [26], allograft biomatrix scaffolds [27], amniotic membrane wrapping [28], autologous vein wrapping [29], and porcine extracellular

matrix [30] have been proposed. Allograft sources obviate donor site morbidity. When placing a nerve wrap, it should not compress the nerve and be of adequate length to cover 1–2 cm proximal and distal to the area of concern.

Outcomes of Revision Cubital Tunnel Release

The available data on outcomes after revision cubital tunnel release is limited to level IV evidence with one retrospective case control [31]. There is very little consensus on the ideal revision procedure for cubital tunnel syndrome, which is demonstrated in the heterogeneity of data regarding failed primary surgery and the choice of revision procedure performed. In addition to this, outcome measures assessed are widely variable, limiting the ability to make direct comparisons between procedures.

Revision cubital tunnel release is generally a successful procedure with a majority of patients experiencing improvement in their preoperative symptoms but to a lesser degree than primary ulnar nerve decompression at the elbow. This may be attributed to the technical demands of revision surgery, the time elapsed after the index procedure, and nerve devascularization as a result of repeated insult to the nerve millieu [32]. More severe disease, as defined by McGowan grade 3, or evidence of denervation on EMG, limits the potential for spontaneous nerve recovery [12, 15]. Other factors associated with poor recovery include number of previous operations, age >50 years, and previous submuscular transposition [11, 15].

Overall, approximately 75% of patients will have symptomatic improvement, but few will have complete recovery. Submuscular transposition of the ulnar nerve is the most commonly performed procedure in the revision setting [10, 12, 14, 15, 31]. Following this procedure, satisfaction can be expected in 73–79% of cases, although only 20% of patients will be symptom-free based upon physician assessment and even fewer when reported by patients themselves [5]. Patient satisfaction appears to be greater than scoring reports may indicate [10] and greatly exceeds the proportion of patients

who have objective improvement in McGowan grading after surgery [31]. Improvement after previous submuscular transposition may be limited due to the extensive soft tissue dissection, postoperative immobilization, and more extensive postoperative perineural scarring.

In situ decompression is generally reserved for first-line surgical management of cubital tunnel syndrome; however, 89% of patients experienced good or fair results with normal or slightly diminished two-point discrimination and modest improvements in grip strength when performed for failed submuscular transposition [24]. The use of anterior subcutaneous transposition was evaluated independent of the index procedure, and it was found that patients consistently had relief of their paresthesias with 75% achieving good to excellent results, comparable to submuscular transposition [11].

Nerve wraps are gaining popularity, but the long-term results are lacking. Autologous vein wrapping after a minimum of two prior failed cubital tunnel surgeries demonstrated improvement in pain, grip strength, and two-point discrimination in all patients, although still diminished from accepted normal values. Increased velocity of motor and sensory nerve conduction may be seen on repeat electrodiagnostic studies, which is of variable clinical significance [29]. The main complication was swelling at the harvest site. In a similar cohort, the use of human amniotic membrane demonstrated promising short-term results with improvements in pain, QuickDASH, grip, and key pinch strength [28]. Similar results without graft-related morbidity can be expected using porcine extracellular matrix, with patients generally experiencing 50% of their overall improvement within the first 4 months postoperatively [30].

Treatment Algorithms for the "Failed" Cubital Tunnel Release

It is important to counsel patients that although they are likely to gain improvement in their symptoms and func-

tion, residual deficits are commonly experienced. Expectation management prior to surgery may help patients cope with the often protracted course of nerve recovery over the following months, even years. Understanding the common sites of compression, the etiology of failure in persistent and recurrent cubital tunnel syndrome, and basic fundamentals of treatment will help guide the decision-making process.

We believe that the external neurolysis is the most important portion of the procedure. The nerve is identified both proximally and distally to the previous surgical site and traced from known to unknown. The branches of the MABCN are identified, and if a neuroma is present, it is resected back to healthy nerve. The end is cauterized with bipolar electrocautery, and the nerve end is buried within the muscle that is outside of the area of scar. In cases where perineural scarring is densely adherent to the ulnar nerve, a small cuff of tissue is left attached to minimize iatrogenic injury. This is maximally invasive surgery and is performed in all revision cases.

In the case of persistent symptoms, we generally do not utilize nerve wraps although they are available, as the cause is most likely incomplete decompression or creation of a new site of compression in a transition zone. In the event of failed in situ decompression or medial epicondylectomy, we transpose the nerve subcutaneously, unless the patient is very thin, as this can be performed with less soft tissue dissection. If the previous procedure was a transposition, we move the nerve to a plane of tissue that is different from the index procedure if possible, which may not be available in multiply revised cases. The algorithm is depicted in Fig. 11.1.

When revising a cubital tunnel release for recurrent symptoms, we follow the same algorithm in patients with recurrent symptoms with the addition of an allograft nerve wrap made of porcine extracellular matrix (Fig. 11.2), as described by Papatheodorou [30]. The main difference is that we deflate the tourniquet before application of the allograft wrap, so swelling of the perineural vasculature does not lead to secondary compression.

Treatment Algorithms

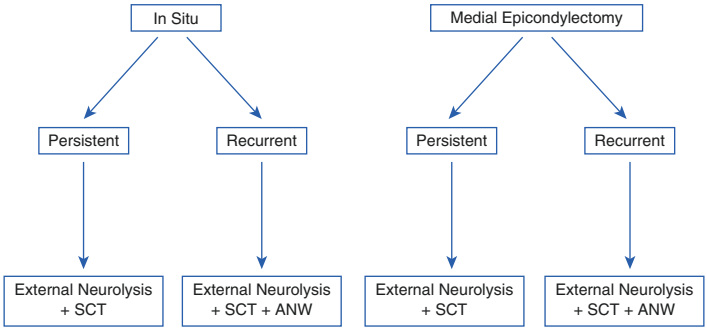

FIGURE 11.1 Revision cubital tunnel release algorithm for persistent and recurrent symptoms after in situ decompression or medial epicondylectomy. *SCT* subcutaneous transposition, *ANW* allograft nerve wrap

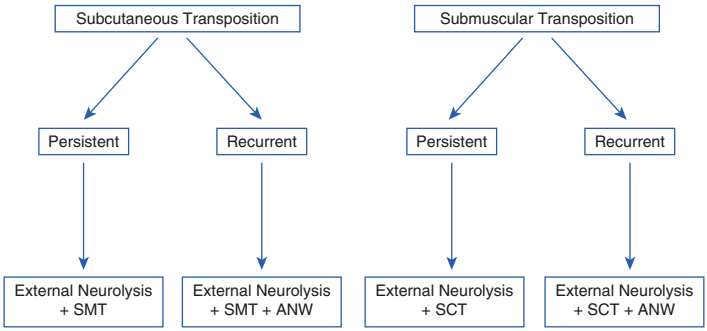

FIGURE 11.2 Revision cubital tunnel release algorithm for persistent and recurrent symptoms after subcutaneous or submuscular transposition. *SCT* subcutaneous transposition, *SMT* submuscular transposition, *ANW* allograft nerve wrap

References

1. Soltani AM, Allan BJ, Best MJ, Mir HS, Panthaki ZJ. Revision decompression and collagen nerve wrap for recurrent and persistent compression neuropathies of the upper extremity. Ann Plast Surg. 2014;72(5):572–8.

2. Goldfarb CA, Sutter MM, Martens EJ, Manske PR. Incidence of re-operation and subjective outcome following in situ decompression of the ulnar nerve at the cubital tunnel. J Hand Surg Eur Vol. 2009;34(3):379–83.
3. Dellon AL, Coert JH. Results of the musculofascial lengthening technique for submuscular transposition of the ulnar nerve at the elbow. J Bone Joint Surg Am. 2004;86-A(Suppl 1(Pt 2)):169–79.
4. Schnabl SM, Kisslinger F, Schramm A, et al. Subjective outcome, neurophysiological investigations, postoperative complications and recurrence rate of partial medial epicondylectomy in cubital tunnel syndrome. Arch Orthop Trauma Surg. 2011;131(8):1027–33.
5. Zhang D, Earp BE, Blazar P. Rates of complications and secondary surgeries after in situ cubital tunnel release compared with ulnar nerve transposition: a retrospective review. J Hand Surg Am. 2017;42(4):294.e291–5.
6. Gaspar MP, Kane PM, Putthiwara D, Jacoby SM, Osterman AL. Predicting revision following in situ ulnar nerve decompression for patients with idiopathic cubital tunnel syndrome. J Hand Surg Am. 2016;41(3):427–35.
7. Dellon AL. Review of treatment results for ulnar nerve entrapment at the elbow. J Hand Surg Am. 1989;14(4):688–700.
8. Mowlavi A, Andrews K, Lille S, Verhulst S, Zook EG, Milner S. The management of cubital tunnel syndrome: a meta-analysis of clinical studies. Plast Reconstr Surg. 2000;106(2):327–34.
9. Nellans K, Tang P. Evaluation and treatment of failed ulnar nerve release at the elbow. Orthop Clin North Am. 2012;43(4):487–94.
10. Vogel RB, Nossaman BC, Rayan GM. Revision anterior submuscular transposition of the ulnar nerve for failed subcutaneous transposition. Br J Plast Surg. 2004;57(4):311–6.
11. Caputo AE, Watson HK. Subcutaneous anterior transposition of the ulnar nerve for failed decompression of cubital tunnel syndrome. J Hand Surg Am. 2000;25(3):544–51.
12. Rogers MR, Bergfield TG, Aulicino PL. The failed ulnar nerve transposition. Etiology and treatment. Clin Orthop Relat Res. 1991;269:193–200.
13. Mackinnon SE, Novak CB. Operative findings in reoperation of patients with cubital tunnel syndrome. Hand. 2007;2(3):137–43.
14. Bartels RH, Grotenhuis JA. Anterior submuscular transposition of the ulnar nerve. For post-operative focal neuropathy at the elbow. J Bone Joint Surg Br. 2004;86(7):998–1001.

15. Gabel GT, Amadio PC. Reoperation for failed decompression of the ulnar nerve in the region of the elbow. J Bone Joint Surg Am. 1990;72(2):213–9.
16. Zlowodzki M, Chan S, Bhandari M, Kalliainen L, Schubert W. Anterior transposition compared with simple decompression for treatment of cubital tunnel syndrome. A meta-analysis of randomized, controlled trials. J Bone Joint Surg Am. 2007;89(12):2591–8.
17. Staples JR, Calfee R. Cubital tunnel syndrome: current concepts. J Am Acad Orthop Surg. 2017;25(10):e215–24.
18. Calfee RP, Manske PR, Gelberman RH, Van Steyn MO, Steffen J, Goldfarb CA. Clinical assessment of the ulnar nerve at the elbow: reliability of instability testing and the association of hypermobility with clinical symptoms. J Bone Joint Surg Am. 2010;92(17):2801–8.
19. Watanabe M, Yamaga M, Kato T, Ide J, Kitamura T, Takagi K. The implication of repeated versus continuous strain on nerve function in a rat forelimb model. J Hand Surg Am. 2001;26(4):663–9.
20. Benedikt S, Parvizi D, Feigl G, Koch H. Anatomy of the medial antebrachial cutaneous nerve and its significance in ulnar nerve surgery: an anatomical study. J Plast Reconstr Aesthet Surg. 2017;70(11):1582–8.
21. Chhabra A, Wadhwa V, Thakkar RS, Carrino JA, Dellon AL. Recurrent ulnar nerve entrapment at the elbow: correlation of surgical findings and 3-Tesla magnetic resonance neurography. Can J Plast Surg. 2013;21(3):186–9.
22. Tang P, Hoellwarth JS, Chauhan A. Recurrent cubital tunnel syndrome: a critical analysis review. JBJS Rev. 2016;4(3):e31–7.
23. Broudy AS, Leffert RD, Smith RJ. Technical problems with ulnar nerve transposition at the elbow: findings and results of reoperation. J Hand Surg Am. 1978;3(1):85–9.
24. Dagregorio G, Saint-Cast Y. Simple neurolysis for failed anterior submuscular transposition of the ulnar nerve at the elbow. Int Orthop. 2004;28(6):342–6.
25. Kleinman WB. Cubital tunnel syndrome: anterior transposition as a logical approach to complete nerve decompression. J Hand Surg Am. 1999;24(5):886–97.
26. Campbell JB, Post KD, Morantz RA. A technique for relief of motor and sensory deficits occurring after anterior ulnar transposition. Technical note. J Neurosurg. 1974;40(3):405–9.

27. Puckett BN, Gaston RG, Lourie GM. A novel technique for the treatment of recurrent cubital tunnel syndrome: ulnar nerve wrapping with a tissue engineered bioscaffold. J Hand Surg Eur Vol. 2011;36(2):130–4.
28. Gaspar MP, Abdelfattah HM, Welch IW, Vosbikian MM, Kane PM, Rekant MS. Recurrent cubital tunnel syndrome treated with revision neurolysis and amniotic membrane nerve wrapping. J Shoulder Elb Surg. 2016;25(12):2057–65.
29. Kokkalis ZT, Jain S, Sotereanos DG. Vein wrapping at cubital tunnel for ulnar nerve problems. J Shoulder Elb Surg. 2010;19(2 Suppl):91–7.
30. Papatheodorou LK, Williams BG, Sotereanos DG. Preliminary results of recurrent cubital tunnel syndrome treated with neurolysis and porcine extracellular matrix nerve wrap. J Hand Surg Am. 2015;40(5):987–92.
31. Aleem AW, Krogue JD, Calfee RP. Outcomes of revision surgery for cubital tunnel syndrome. J Hand Surg Am. 2014;39(11):2141–9.
32. Macadam SA, Gandhi R, Bezuhly M, Lefaivre KA. Simple decompression versus anterior subcutaneous and submuscular transposition of the ulnar nerve for cubital tunnel syndrome: a meta-analysis. J Hand Surg Am. 2008;33(8):1314.e1311–2.