

Chapter 1

Cholangiogram

Interpretation



Stephen Hasak and Daniel K. Mullady

Case Presentation

A 73-year-old female with no significant prior medical history presented with 7 days of progressive abdominal pain, dark urine, nausea, and jaundice. Initial laboratory evaluation revealed a total bilirubin of 9 mg/dl, alkaline phosphatase of 472 U/L, aspartate transaminase of 116 U/L, alanine transaminase of 224 U/L, and white blood cell count of 16.1 K/mm³. She underwent imaging with magnetic resonance imaging/magnetic resonance cholangiopancreatography (MRI/MRCP) which revealed a 1.5-cm hepatic hilar lesion consistent with at least Bismuth IIIa versus IV cholangiocarcinoma with right and left ductal dilation. The tumor appeared to abut the

S. Hasak · D. K. Mullady (✉)

Division of Gastroenterology, Washington University in St. Louis
School of Medicine, St. Louis, MO, USA

e-mail: mulladyd@wustl.edu

right hepatic artery, main portal vein, right portal vein, and takeoff of the left portal vein. She underwent ERCP at her local hospital with placement of a plastic biliary stent in the right intrahepatic duct. Brushings for cytology noted atypical glandular epithelial cells consistent with adenocarcinoma.

She was then transferred for surgical evaluation. Despite stent placement her bilirubin increased to 11.9 mg/dl. Her case was discussed in multidisciplinary hepatobiliary conference, and it was decided that extended right hepatectomy may be feasible. For hypertrophy of the left lobe, she was referred for repeat ERCP for removal of the right-sided stent and stenting of left-sided biliary tree, which was still significantly dilated.

Following removal of the previously placed right-sided stent, ERCP was performed with opacification of the main bile duct, hepatic duct bifurcation, right main hepatic duct, and right intrahepatic branches. The left ducts could not be opacified with gentle occlusion cholangiogram. After much effort, the left biliary tree was accessed with a 0.025" angled wire through a sphincterotome. The left main hepatic duct was shown to contain a single severe stenosis, and a 10 Fr by 10 cm biliary stent with a full external pigtail and a full internal pigtail was placed into the left hepatic duct (Figs. 1.1 and 1.2). She was discharged with follow-up plans to see medical oncology for neoadjuvant chemotherapy and IR-guided portal vein embolization.

The dilemma in this case is localizing pathology to the left or right biliary systems and ideally having multidisciplinary input prior to attempting biliary decompression. Identification of the appropriate sided intrahepatic duct was critical. The patient initially had stenting of the right side, which was the incorrect side of the liver to stent since the patient required a right hepatectomy. Additionally, this intervention did not lead to improvement of bilirubin and led to the need for repeat short-interval ERCP to stent the appropriate side of the liver.

Introduction

ERCP has been performed by gastroenterologists and surgeons for nearly 50 years. Since its inception to the

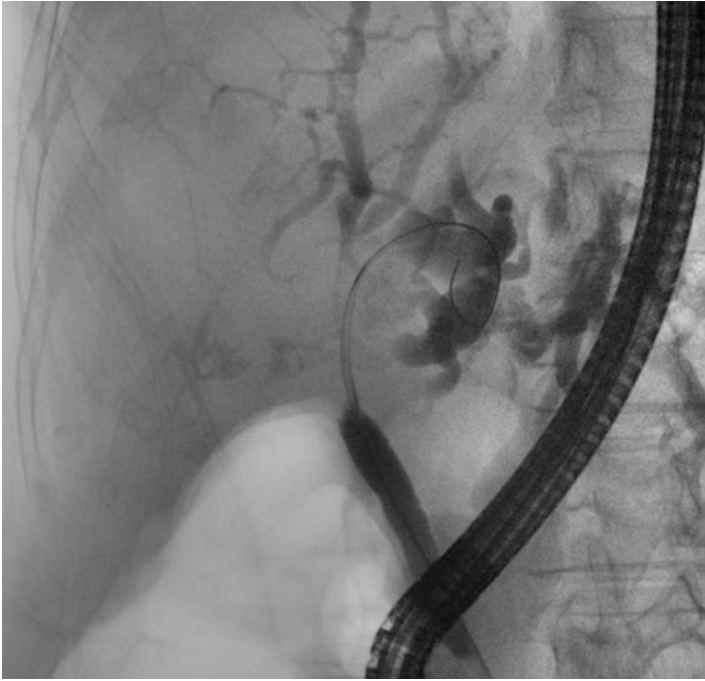

FIGURE 1.1 Opacification and wire access of the left biliary tree and extrahepatic bile duct with severe stricture of the common hepatic and left main ducts

present day, there has been a continuous shift in ERCP from an exclusively diagnostic test with the ability only to obtain fluoroscopic images of the pancreatic and biliary ducts to an almost therapeutic procedure with a wide variety of indications and therapeutic maneuvers. This shift has been due to two main factors: (1) improvements in cross-sectional imaging, particularly MRI/MRCP, and the emergence of endoscopic ultrasonography (EUS) which provide less invasive and more accurate images of the pancreatobiliary system and (2) improvements in through-the-scope technology which enable a wide variety of therapeutic maneuvers, many of which are discussed in other chapters in this book.

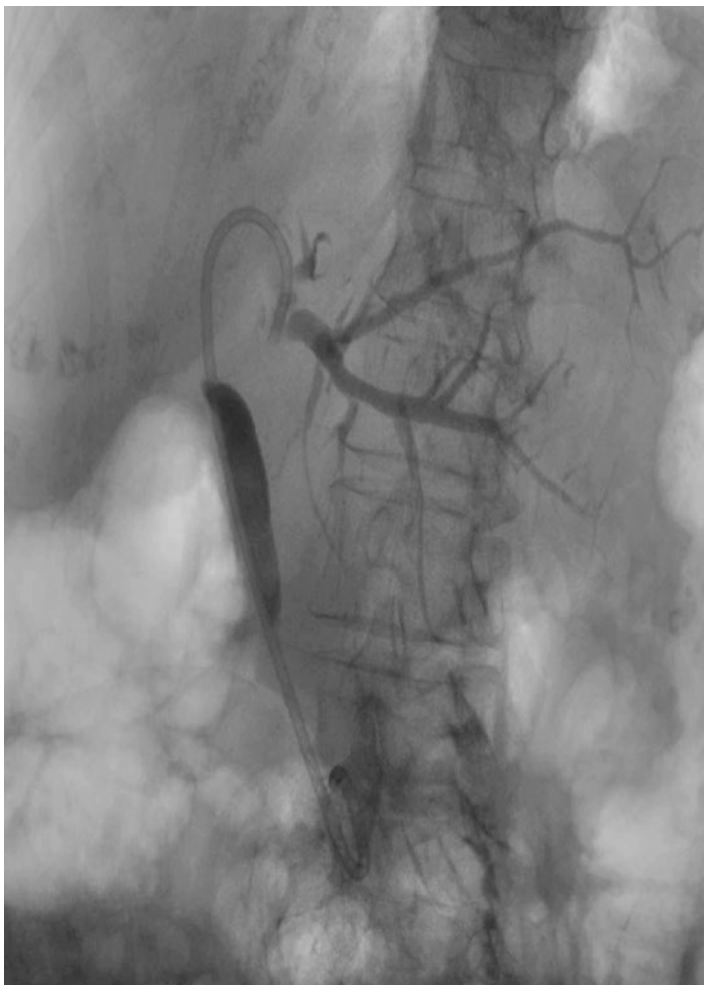

FIGURE 1.2 Cholangiogram showing double pigtail stent traversing the hilar stricture with proximal end in the left biliary tree

Obtaining good-quality cholangiography requires a thorough understanding of the biliary anatomy, knowing the limitations of cholangiography obtained endoscopically, and facility in use of fluoroscopy equipment to optimize imaging.

This is as imperative to procedural success as any other maneuver performed during ERCP [1,2].

The above cases highlight some of the difficulties in obtaining high-quality cholangiograms and interpreting them correctly. This chapter will focus on the difficulties in obtaining and interpreting cholangiograms as well as strategies to improve image quality and interpretation.

Diagnosis/Assessment

Data are lacking regarding optimal performance and interpretation of cholangiography obtained via ERCP. Additionally, there is inherent limitation of recreating three-dimensional anatomy with two-dimensional technology. This section will focus on preprocedural, intra-procedural, and post-procedural considerations and techniques to optimize cholangiography and the subsequent interpretation (Table 1.1).

A thorough understanding of normal biliary anatomy is essential for all providers performing ERCP. Biliary anatomy is complex and variable, and providers need to be well-versed in interpreting normal and variant anatomy. It is useful to have a readily available images of normal and variant anatomy in the ERCP suite [1]. Errors can occur when the endoscopist fails to identify anatomical variants or interprets the anatomy inaccurately. Additionally, endoscopists should be well-versed in understanding the cholangiographic correlates of segmental liver anatomy [2].

Normal Anatomy

In the majority of patients, the right main hepatic duct is formed by the confluence of the right posterior and the right anterior ducts (Figs. 1.3 and 1.4) [3–6]. The right posterior duct usually passes posteriorly to the anterior duct, joining it at the left medial side to form the right hepatic duct (Fig. 1.4) [5, 6]. Segmental bile ducts from liver segments II–IV unite to form the left hepatic duct (Fig. 1.3) [7].

TABLE 1.1 Key considerations for optimizing cholangiogram performance and interpretation

Time relative to procedure	Consideration/technique	Notes
Pre-procedure	Understanding normal anatomy and variants	Self-directed learning, training, experience
	Individual patient data review/clinical situation	Record/imaging review, discussion with referring provider, multidisciplinary conference, is there a need for further imaging prior to ERCP?
Intra-procedure	Room/suite setup	Staff training, digital imaging, fluoroscopy equipment (rotatable C-arm, portable C-arm, fixed C-arm, flat table with overhead carriage), anesthesia
	Patient positioning	Semi-prone (left ducts fill before right), supine (right ducts fill before left), Trendelenburg, right lateral, patient movement to visualize specific anatomy
	Fluoroscopy arm movement	Easier to perform than patient repositioning, but does not change the effect of gravity on contrast pooling
	Cholangiogram performance	Scout radiograph prior to contrast injection, image resolution of various equipment and contrast agents, balloon occlusion or injection force to identify underfilled ducts

TABLE 1.1 (continued)

Time relative to procedure	Consideration/ technique	Notes
	Contrast density	Standard— strictures and pancreatic duct anatomy; dilute— small stones in large ducts
Post-procedure	Documentation	Thorough documentation of findings and therapies/ interventions necessary for continued care, radiology interpretation
	Radiology interpretation	Routinely done but helpful in selective cases with subtle findings

Common Variants

Variant biliary anatomy usually relates to differences in confluence of the left main, right anterior, and right posterior ducts. A common variant of the major ducts is the failure of fusion of the anterior and posterior right segmental ducts resulting in an absence of the right main hepatic duct, which occurs in 11% of patients [4]. In these patients, the right anterior, right posterior, and left hepatic ducts form a confluence at the common hepatic duct, sometimes referred to as a “trifurcation” (Fig. 1.5) [7, 8]. In 16% of patients, the right posterior duct drains directly into the left hepatic duct proximally to the confluence (Fig. 1.6) [7, 8]. In 6% of patients, the RPD drains into the common hepatic duct (Fig. 1.7) [8]. The right and left ducts usually join just outside the porta hepatis, but the union can be much lower so that a common duct is not formed. In these cases, the cystic duct can insert into the right hepatic duct. An accessory right posterior hepatic duct may insert at the cystic duct or common hepatic duct [7]. There is variation in the formation of the left hepatic duct from segmental bile ducts, with three primary patterns of

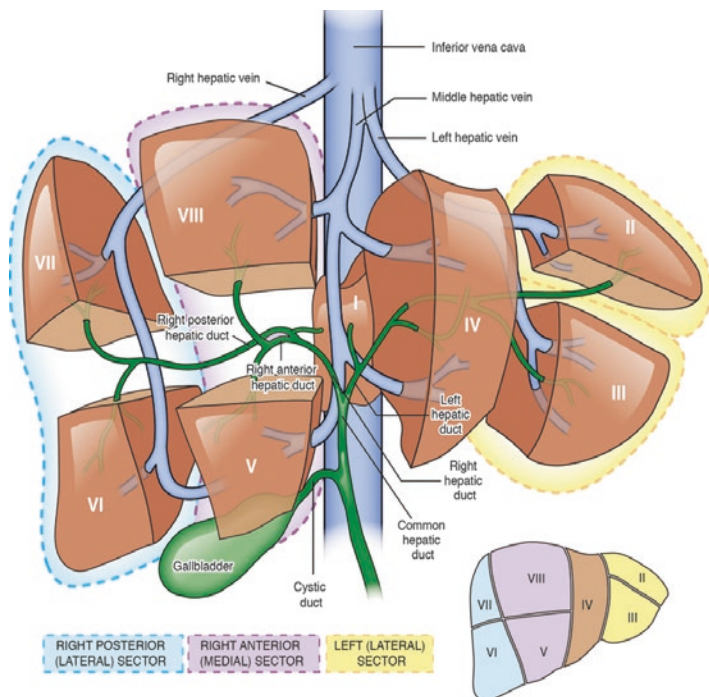


FIGURE 1.3 *Normal biliary anatomy and corresponding hepatic segments and sectors as they relate to ERCP and biliary drainage*

confluence [8]. Typically, the cystic duct joins the common bile duct about halfway from the hilum to the papilla, but the junction of the cystic duct is also variable [7]. This is important surgically because, if unrecognized during cholecystectomy, ligation of the cystic duct beyond the insertion of the cystic duct will result in bile duct injury. Failure to recognize variants can lead to difficult bile leaks following surgery and lead to delayed clinical improvement if not recognized during ERCP [9]. If there is a concern for a bile leak, initial imaging with MRCP may be useful to clarify anatomy because small, transected, and disconnected ducts will not opacify on ERCP [9]. If ERCP is performed prior to surgery, a good cholangiogram can highlight variant anatomy and help to minimize the risk of bile duct injury [10, 11].

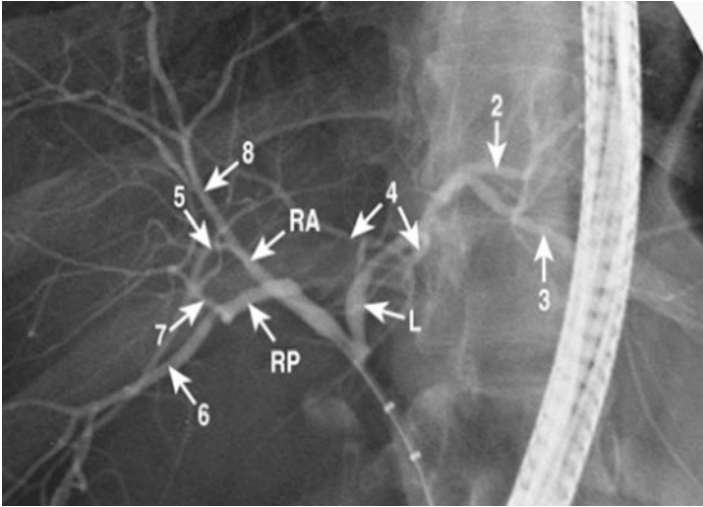


FIGURE 1.4 Normal duct anatomy—Type 1 right hepatic duct

Patient Anatomy/Review of Imaging/Records

In addition to understanding normal anatomy, understanding the individual patient's case prior to any procedure is important to maximize the chance of therapeutic success and minimize harm to the patient. In many cases, a complete understanding of a patient's biliary anatomy is not vital if an extrahepatic lesion such as a common bile duct stone or stricture can be identified and alleviated. However, in perihilar or intrahepatic disease processes, a better understanding on the individual patient's biliary ductal anatomy is vital. Such knowledge includes an understanding of any previous surgeries that could affect procedural approach and anatomy, such as bariatric surgery, liver transplantation, and prior liver resection, and review of any prior imaging. In cases where biliary anatomy is unclear, a pre-procedure MRCP may be helpful [1, 11–13].

An understanding of the expected goal(s) of the procedure is vital, and a thorough review of all imaging and clinical data should be performed prior to meeting the patient. If appropriate, an office visit should be scheduled to allow the

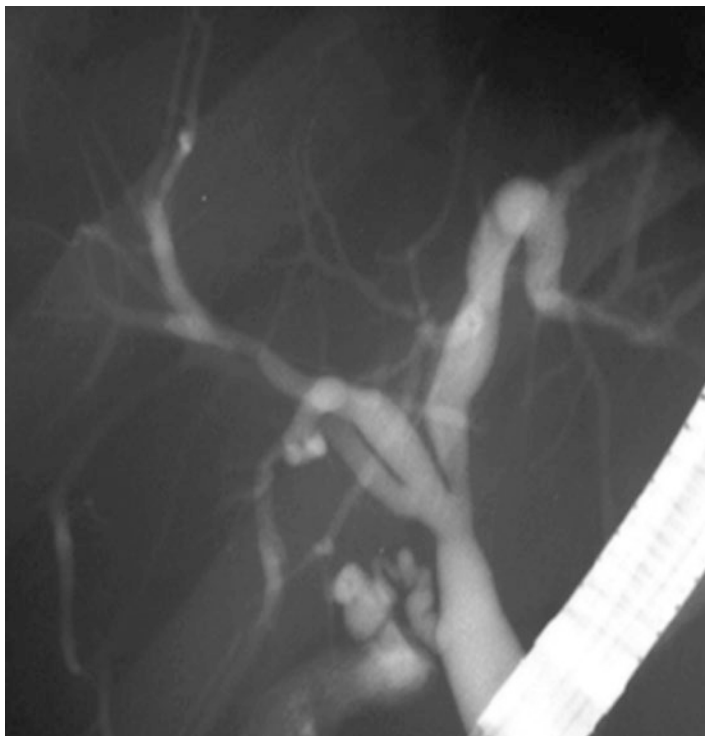

FIGURE 1.5 Trifurcation of the main biliary confluence—Type 2 right hepatic ducts

provider a more thorough review of the patient's imaging and other data and allow for a more in-depth discussion of risks, procedural goals, and alternatives.

Multidisciplinary Conference

Many centers have multidisciplinary conferences involving surgeons, diagnostic and interventional radiologists, endoscopists, and oncologists to discuss challenging cases, diagnostic dilemmas, or therapeutic options. This provides

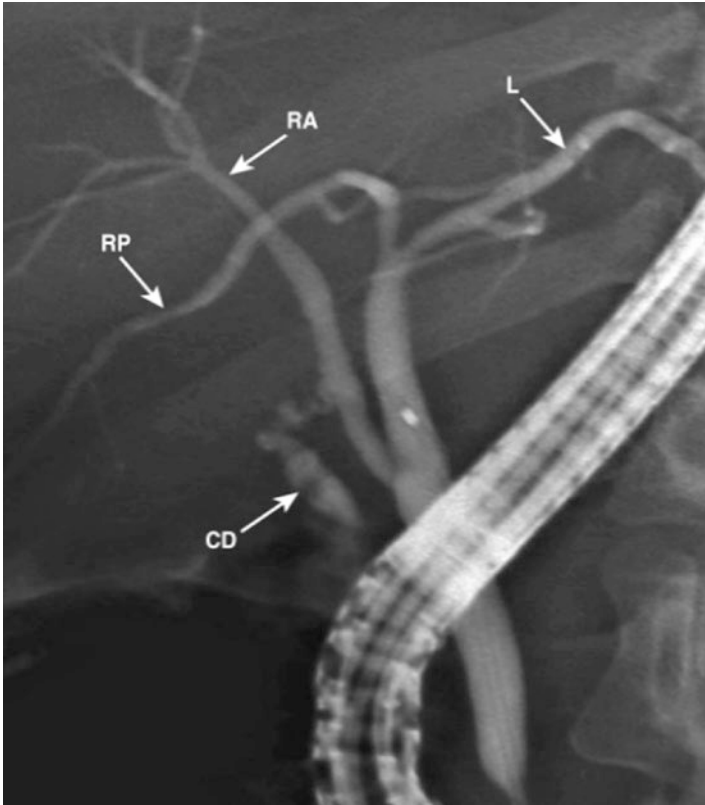


FIGURE 1.6 Right posterior duct draining into left hepatic proximal to the confluence—Type 3 hepatic duct

opportunities for better understanding of anatomy, treatment goals, and procedural limitations. Knowing the ultimate treatment plan, such as plans for subsequent surgery, is also necessary to ensure appropriate diagnostic images acquired for review, and appropriate therapy is performed. The benefits of collaboration have been borne out in multiple studies where a review of all data by providers from multiple specialties led to change in management in 25–30% of patients [14–16].

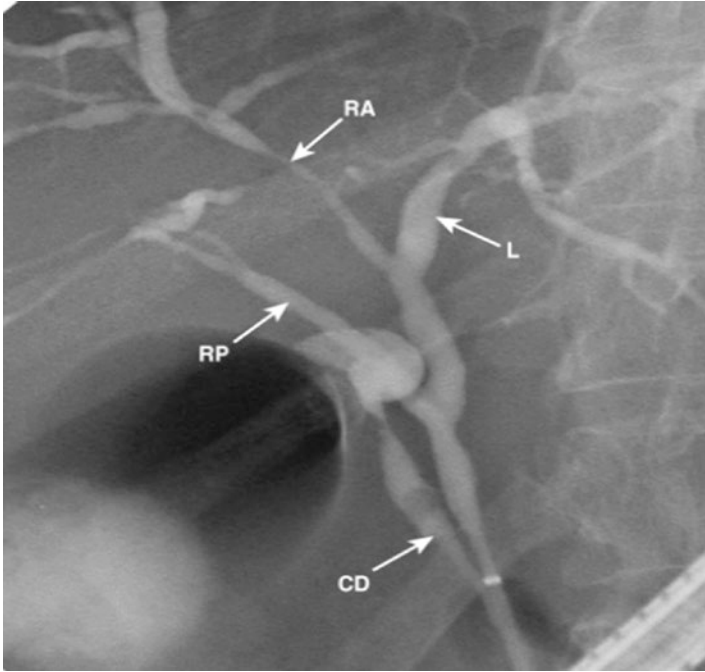


FIGURE 1.7 Right posterior duct drains into the common hepatic duct—Type 4 right hepatic ducts

Imaging Modalities

During pre-procedure planning, diagnostic ERCP has largely been replaced by CT and MRI/MRCP. These imaging modalities are widely available and noninvasive and provide highly accurate imaging of the biliary tree. CT and MRI have various protocols, which reconstruct anatomy in cross-sectional planes or other three-dimensional views, allowing users to visually grasp the complex anatomy of the bile ducts.

MRCP enables rapid, noninvasive evaluation of both the biliary tree and pancreatic duct without the use of intravenous contrast. MRCP provides better spatial and temporal resolution. CT, on the other hand, is more widely and rapidly available and more rapidly performed and may provide more

reliable information on the number and location of stones due to artifacts [5]. However, it exposes patients to radiation and is less sensitive in detecting smaller, distal stones or periampullary lesions and benign or malignant strictures.

Being able to accurately determine the location of a stricture in reference to the hepatic bifurcation can sometimes be made much easier during ERCP if imaged previously on MRCP. Accurate determination of biliary pathology by using MRCP before ERCP can also allow for appropriate procedural planning [17]. This can be especially important for selecting areas for contrast injection and drainage of hilar lesions so as to minimize the risk of post-ERCP cholangitis. In addition, using MRCP to guide biliary stent placement patients with inoperable hilar obstruction has been demonstrated to reduce the overall cost of treatment [18].

Training/Education

At this point, there are no objective standards for ensuring competency in radiologic interpretation of cholangiograms. However, in order to maximize success in performing ERCP, it is critical for trainees to gain a thorough anatomical understanding during fellowship. To date, the focus of training and competency assessment has been on technical aspects of ERCP, such as cannulation and therapeutic maneuvers [19]. Various studies have proposed minimal procedure numbers as thresholds to achieving competence, with a systematic review in 2015 suggesting 160–400 ERCPS for competence [20]. In reality, trainees learn and acquire ERCP skills at different rates [21]. A recent training assessment includes questions about evaluation of trainee cholangiogram performance and interpretation [19]. There are still limits to this assessment method because there are no standard methods of performing and viewing cholangiograms. Therefore, trainee learning is largely dependent on the individual trainer. Most agree that a fourth year of advanced endoscopy training is required to achieve proficiency and certification in pancreaticobiliary endoscopy due to the increased scope and complexity of

pancreaticobiliary endoscopy [20]. In this dedicated year of pancreaticobiliary, endoscopy trainees will get significant experience in cholangiogram interpretation through procedural volume, mentor-directed learning, and participation in multidisciplinary conferences to review pre-procedure imaging. However, future efforts should focus on developing standardized training in cholangiogram interpretation and competency assessment.

Intra-Procedural Considerations

There are a number of intra-procedural considerations and techniques to optimize performing and interpreting cholangiograms during ERCP.

Positioning

The patient's position should be agreed upon and understood by the anesthesia provider, the endoscopist, and the nurses and/or technical assistants. IV fluid lines, grounding wires, and ECG leads should be out of field of examination whenever possible. Historically, patients were placed prone, which created a favorable orientation for X-rays to pass through the patient between the fluoroscopy source and the detector. However, this is a difficult position for anesthesiologists to maintain a patent airway, so most often patients are placed in the semi-prone or modified prone position with the right chest elevated off the table using a shoulder roll or pillow [1, 2, 22]. The supine position is also used when performing ERCP but can be the most difficult position in which to access the descending duodenum, and secretions tend to pool over the ampulla. Additionally, the operator is usually required to stand facing away from the patient which can be a less than optimal ergonomic position. The supine position may be requested by the anesthesia provider for a morbidly obese patient because in the event of respiratory depression or a code [22]. Additionally, supine positioning provides better delineation of

the hilar biliary anatomy [23]. When ERCP is performed in the supine position, endotracheal intubation is mandatory to decrease the risk of aspiration [23]. Left lateral decubitus position is not ideal for ERCP due to the unusual projection of the radiologic image obtained during fluoroscopy. The directions taken by the opacified bile and pancreatic ducts are unfamiliar in the left lateral projection [2]. However, if a large, J-shaped stomach makes it difficult to access and intubate the pylorus with the duodenoscope, transiently repositioning the patient to the left lateral position will often facilitate passage of the scope into the second portion of the duodenum [2].

It is important that the endoscopist understands how the biliary anatomy will appear with the patient in different positions. Because contrast is denser than bile, it flows to dependent portions of ducts. The left and caudate lobes will be in the dependent position in the semi-prone position, as they are located anteriorly [24]. Therefore, the left lobe will fill earlier preferentially compared to the right side (Fig. 1.8a) [7, 25]. In this case, a greater injection force may be required to adequately fill the right ducts and should not be mistaken for underlying pathology. Complete visualization of the right side is important as the right side often has variant anatomy and to detect subtle findings, such as primary sclerosing cholangitis. Adequate filling is assured with visualization and delineation of the tertiary segments. Conversely, filling of the right system without opacification of the left may indicate pathology of the left biliary tree [26].

If visualization of the right intrahepatic system is not obtained with injection and still needed, a catheter can be passed over a wire directly into the intrahepatic system. Balloon occlusion of the common bile duct can be performed for more rapid and effective filling of the intrahepatic ducts [7]. Repositioning the patient in the supine or right lateral decubitus positions allows preferential right-sided filling and can be considered if right-sided visualization is still not obtained despite the above maneuvers but is less than practical to do [26]. Right-sided filling can also be accomplished by tilting the table to head down (Trendelenburg) and tilting the patient rightward.

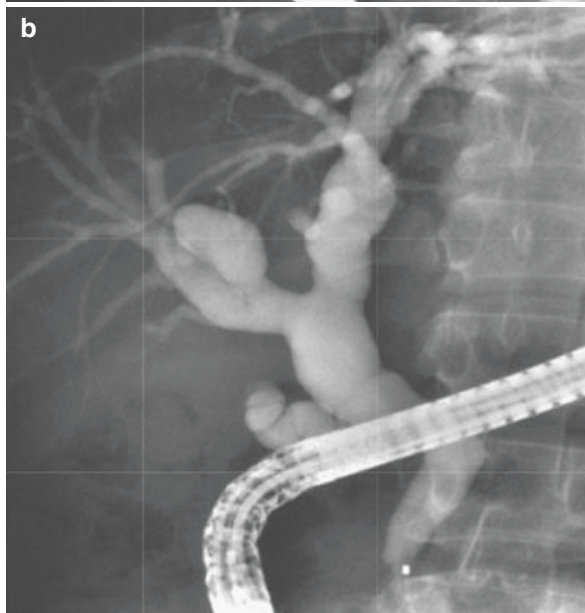
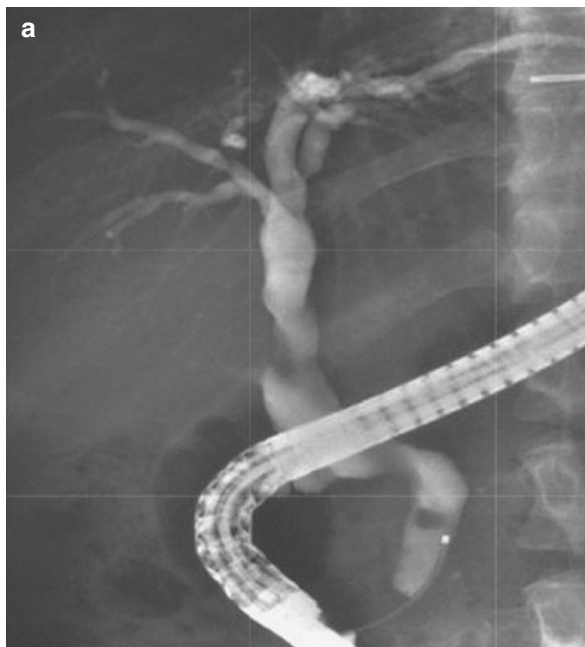
Other patient positioning can be considered in certain circumstances. Left lateral or fully prone positions will allow preferential filling of the left ductal systems. Trendelenburg positioning can aid in filling of the intrahepatic ducts bilaterally (Fig. 1.8b) [7]. In certain circumstances, lesions can be obscured by an oblique segment of the common hepatic duct, which forms a pronounced bend in some patients. The left oblique or left lateral position can allow better visualization. Likewise, rotation of the fluoroscopy C-arm can allow better evaluation of this segment [26].

There are a variety of lesions or artifacts that can be difficult to differentiate. The cystic duct can overlay the CBD. In this setting, rotation of the C-arm or patient is needed to separate superimposed ducts [2]. The pancreatic duct can overlay the CBD, which also requires changing angles to separate the ducts. In cases where stones mimic tumor, the endoscopist can change the angle of the C-arm or change the position of the patient [24]. Injection and withdrawal of contrast can help differentiate mobile stones from the tumor [1]. Occasionally, vascular impressions can mimic stones [27]. In such cases, it may be helpful to review pre-procedure imaging and compare with fluoroscopy.

Room Setup/Fluoroscopy Equipment

The planned setup of the endoscopic unit is also vital for performance of pancreaticobiliary endoscopy and optimizing imaging interpretation. Placement of fluoroscopy equipment and imaging monitors should be planned to make performance and viewing easy. All personnel should be trained in radiation safety and provided equipment to minimize exposure.

FIGURE 1.8 **(a)** Initial left lobe filling. This lobe fills preferentially because contrast medium is heavier than the bile and flows down into the dependent left lobe with the patient prone. This could be mistaken for complete biliary filling. **(b)** When the patient is tilted head down 20° and more volume is added, the right lobe can be viewed. Wire access and balloon occlusion of the right hepatic duct may facilitate right system cholangiogram as well



Exposure should be monitored and reported quarterly. A well-trained staff and dedicated anesthesia provider allow the endoscopist to focus on the procedure, including performance and interpretation of fluoroscopy.

Large centers typically perform ERCP in a dedicated fluoroscopy suite with digital imaging equipment. Optimal images are obtained with the aid of 180-degree rotatable C-arm, which provides for a wide variety of fluoroscopic projection angles. The ability to rotate the fluoroscopy is helpful in defining ductal strictures, separating ducts at the bifurcation, rotating the cystic duct off the bile duct, and assessing takeoff of ductal systems because pathology can be missed when performing a cholangiogram in only one body plane [7, 26]. It is important to remember that there is no standardized approach to viewing and delineating the ducts. In coronary angiography there are standardized views, such as right anterior oblique (RAO) and left anterior oblique (LAO) projections, in which there is an idea of how the coronary vessels should appear [28]. This standardization has not been created for ERCP. Therefore, it is important to understand the patient position and use the C-arm to adjust the projection and have an idea of where ducts should be. Easy manipulation of magnification and rapid image sequence acquisition are possible with the digital system. There are other fluoroscopy modalities used which have advantages and disadvantages. Portable C-arms are typically used when a case is performed outside of the fluoroscopy suite such as in the operating room or ICU. In these cases, the patients are typically too sick to travel to the fluoroscopy suite and have some other reasons why the procedure is performed in the nonstandard setting. Clearly, the benefit of the portable C-arm is that it can be moved and allows procedures to be performed on patients that need procedures but are otherwise too sick to travel away from critical care providers. These can also be used in setting where space is limited and allows rotation similar the rotatable C-arm. The image quality obtained from these is typically less than those obtained from fixed C-arm units [7]. Flat tables with fixed overhead carriages

are used in some settings, including radiology suites. When these are used, patients may need to be rotated to clarify findings and separate ducts. In some instances, this might involve rotating the patient into the supine position to better visualize the bifurcation. These provide high-quality images but expose the patient and ERCP team to higher radiation doses [7].

Cholangiograms

Scout radiographs should be taken before the injection of contrast to provide a baseline image and delineate any abnormalities that could interfere with interpretation after contrast is injected. Baseline findings that should be identified and documented before ERCP include pneumobilia, presence of surgical clips or contrast from recent CT scan, rib calcifications, and pancreatic calcifications, particularly in the area of the distal bile duct [1]. Scout radiographs are best taken centered over the intended area of interest. There is no standardized approach with some scout films taken before introducing the duodenoscope and some scout films obtained with the duodenoscope in position but before cannulation.

Sequence of films is also important with the number of films determined by the diagnostic concern. The sphincter of Oddi should be filmed when it is relaxed and contrast filled to avoid misdiagnosis of pseudo-obstruction. Early contrast films can demonstrate small stones that can be obscured by high-density contrast. Various contrast agents are available and can be diluted as needed. High-osmolality contrast media is the standard agent for ERCP due to its lower cost compared to low-osmolality contrast media [29]. Dilute contrast may help visualize small gallstones within large ducts, but strictures and pancreatic duct anatomy are better visualized with full-strength contrast [29]. The disadvantage of diluting contrast is the need for increased volume, poorer image quality, and the introduction of air during syringe changes [29]. Films in various positions help understand the influence of gravity and

contrast on the cholangiogram. Pathology in tortuous ducts may not be seen in one plane. Failure to recognize complete obstruction of left or right intrahepatic ducts is not uncommon. A sequence of films moving from prone to supine can separate the two lobes to avoid this error [25]. Likewise, early images of the bifurcation are also important, because extensive filling of dilated intrahepatics above a hilar lesion can then overlay and obscure the bifurcation [6].

Image resolution is also important for clear delineation of the biliary tree and is related to satisfactory opacification. Image density is related to concentration of contrast and peak kilovoltage (kVp). 85–95 kVp is average for average-sized patients [30]. Larger patients may require increased power (kilovolt-ampere (kVA)) [3]. Lower kVp increases exposure time with respiratory or cardiac motion affecting study quality [31].

The location of the duodenoscope can obscure pathology in some instances and can limit visualization of the entire distal common bile duct. To visualize this area, the duodenoscope should be advanced into the “long position,” so that the entire cholangiogram can be visualized and fluoroscopic images can be obtained [2]. If the distal segment cannot be completely evaluated with the duodenoscope in the long position, withdrawing the duodenoscope into the stomach after contrast can be performed. It is also important to move the scope, patient, or C-arm such that the duodenoscope is not overlying/obscuring visualization of the CBD [1].

Post-procedural Considerations

Diagnostic Radiology Interpretation

Initially, radiologists were an integral part in ERCP because it was unfamiliar for the endoscopist. ERCPs were largely diagnostic, so involving radiologists with knowledge of imaging interpretation and use of fluoroscopy equipment

made sense. At first, radiologists were even present, while ERCP was performed and provided real-time interpretation.

Radiologists are currently less involved due to decades of experience in performing and interpreting ERCP by endoscopists. Endoscopists have become quite comfortable interpreting fluoroscopic images with improvements in the quality of fluoroscopic imaging and with increased ERCP experience. Still, radiologists commonly provide post-procedure interpretation of static images provided by the endoscopists. However, their ability to reconstruct what was done during ERCP after the procedure is very limited, as they do not have access to the live, dynamic images. In fact, data suggests discrepancies between interpretations by endoscopists and radiologists are high. In one study, the radiology report did not report the findings of 50% of cases in which definite pathology was seen by the endoscopist [31]. Another study showed radiologist-endoscopist discordance rates in reading pancreatograms and cholangiograms of 38% and 47%, respectively [32].

In most settings where radiologic interpretation is routinely performed, it is important that the spot radiographs document in a stepwise manner the procedure being performed. If therapeutic procedures are performed, they should be clearly communicated to the radiologist interpreting the images. Good documentation of procedure processes, findings, and interventions is critical to optimizing radiologist interpretation.

Conclusion

An understanding of normal and common variant anatomy provides a foundation for accurate cholangiogram interpretation. Training in ERCP, typically during a fourth year of fellowship, allows sufficient time to gain a better grasp of biliary anatomy and how to optimize delineation of biliary anatomy via cholangiography in individual cases.

Cases should be approached systematically to optimize cholangiogram interpretation. Pre-procedure review of imaging, prior ERCP films, clinical symptoms, and goals of the procedure

provides a road map for accurate “live” cholangiogram interpretation and guide appropriate interventions. Questions about imaging and desired outcomes can be discussed with referring providers and in multidisciplinary conferences. These conferences also provide continuing education opportunities for physicians outside of fellowship.

Comfort with equipment and staff is vital for the success of ERCP. Knowledge of the pros and cons of different fluoroscopy equipment is important. Patient positioning can be guided by comorbidities and anesthesia preference but ultimately should be chosen to optimize cholangiography in each patient which may vary by location of pathology. The fluoroscopy unit/C-arm can be rotated, and patients can be tilted or moved during the procedure to uncover obscured or poorly visualized anatomy or lesions.

Case Outcomes

In this case, pre-procedure review of imaging, prior ERCP films, and clinical course was vital. The goals of the ERCP were discussed in multidisciplinary conference, and it was determined that drainage of the left system was needed to reduce risk of cholangitis and to induce hypertrophy of the planned remaining liver after right trisectionectomy. The right side was dilated and was planned to be removed. All attempts were made to minimize opacification because there was no plan to drain the right side. Initially, the left ducts could not be opacified initially, so position and technique changes led to visualization of a left main duct stenosis.

At follow-up 2 months later, her CT was unchanged, and bilirubin improved to 5.7 mg/dl. Repeat ERCP for stent exchange was performed over a guidewire due to the severity of the hilar stricture. A subsequent MRI showed no significant changes. Her bilirubin normalized over time, and she was started on neoadjuvant gemcitabine/cisplatin. Repeat ERCP for stent exchange was performed 2 months following the previous procedure. On cholangiogram, the left and right main

and left and right intrahepatic ducts were dilated. Balloon dilation of the hepatic duct bifurcation was performed (Fig. 1.9). Following this, a biliary stent was placed extending into the left biliary ducts, and one biliary stent was placed extending into the right anterior duct (Fig. 1.10). She tolerated four cycles of chemotherapy but then presented with malaise, fever, and leukocytosis, concerning for cholangitis. She was started on broad-spectrum antibiotics, and repeat ERCP was performed.

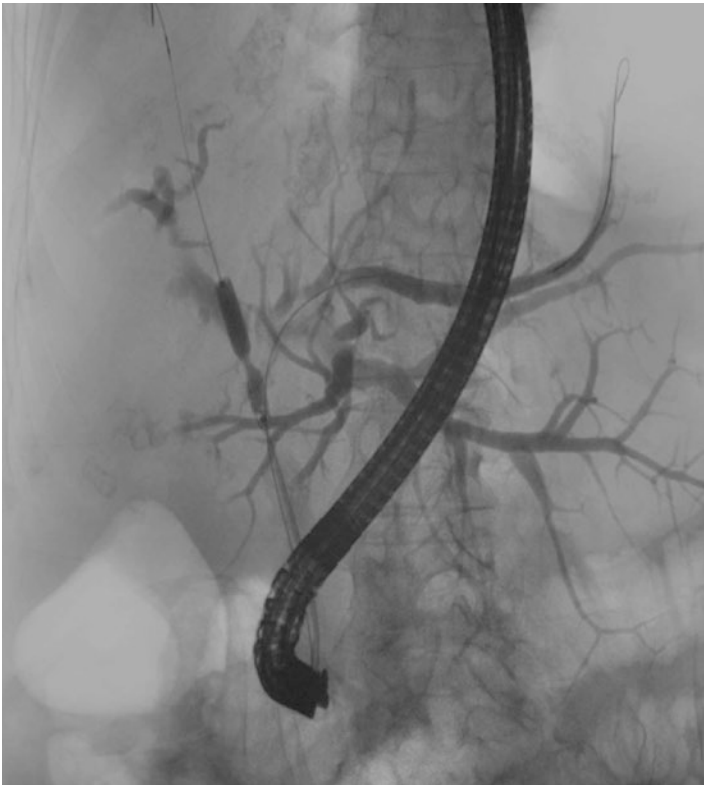

FIGURE 1.9 Follow-up ERCP for bilateral drainage after unilateral stenting of the left did not normalize bilirubin. The figure shows wire access to both left and right biliary trees with balloon dilation of a tight stricture of the right main duct

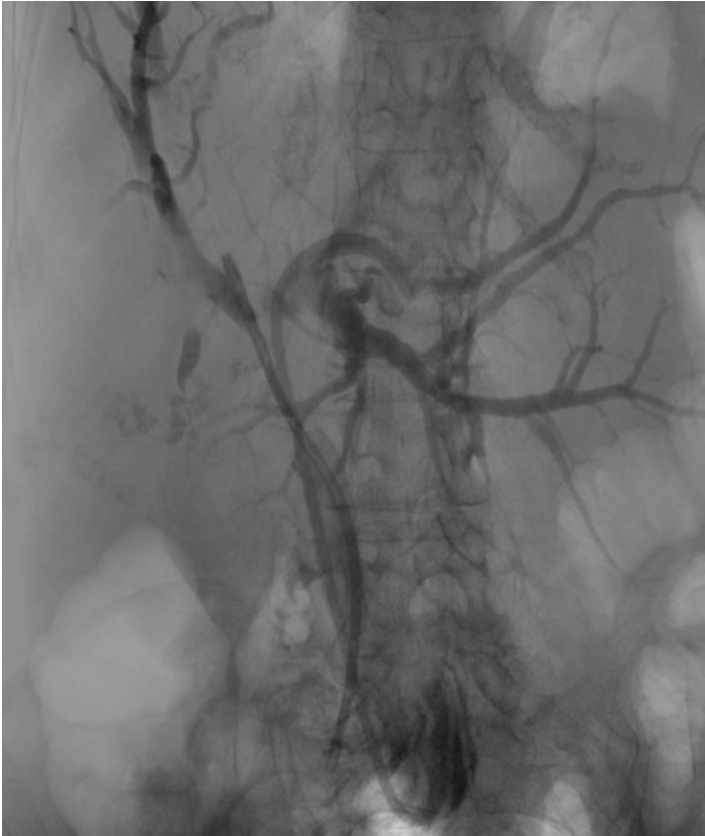


FIGURE 1.10 Cholangiogram showing stents within the right anterior and left biliary tree

The known hilar stenosis was dilated with a balloon to facilitate stent exchange. Contrast injection was limited due to concerns for cholangitis. The previously placed stents were exchanged. Her leukocytosis and jaundice improved. She subsequently underwent right portal vein embolization to induce hypertrophy of the left liver remnant in preparation for right hepatic trisectionectomy. Unfortunately, she developed disease progression with increase in the size of her known mass and new metastatic lesions in both hepatic lobes.

Pearls and Pitfalls

- It is critical for all practitioners performing ERCP to have a thorough understanding of the normal biliary anatomy and common hilar variants.
- Training in cholangiogram interpretation is largely dependent on the trainers, and competency develops at varying rates.
- While there is no standardized training program or means of assessment, skill in interpreting cholangiograms can be improved with dedicated training in interventional endoscopy, by discussing difficult cases with radiology and by attending multidisciplinary rounds with radiology and surgeons.
- For suspected hilar biliary obstruction, obtain good cross-sectional imaging, ideally with MRI/MRCP to provide a road map for subsequent ERCP.
- Prior to ERCP, obtain multidisciplinary input from surgeons and oncologists regarding tissue acquisition and surgical planning.
- When performing ERCP for perihilar obstruction, limit contrast injection to identification of stricture, and then gain wire access, with further injection performed proximal to the obstruction.
- Compare ERCP images with MRC images to optimize accuracy of determining laterality.
- Beware of misinterpreting right posterior ductal system for the left. This can be remedied by maximizing rotation of the C-arm and by comparing ERCP to MRCP images.
- A good understanding of how patients' position affects the appearance of anatomy on a cholangiogram can assist to clarify questions of specific anatomy. C-arm rotation is also critical for uncovering confusing anatomy.
- Understand how gravity will affect the course of injected contrast and how varying contrast densities can highlight different pathologies.

- Consult with radiologists in cases of complicated anatomy; good documentation will optimize their ability to assist in difficult cases and will provide a road map for repeat procedures.

References

1. Ballie J. ERCP from soup to nuts: evaluation, preparation, execution, and follow-up. ERCP and EUS: a case BAsed approach. New York: Springer Science; 2015. p. 57–76.
2. Baron TH, Kozarek RA, Carr-Locke DL. ERCP2. Philadelphia: Elsevier; 2013.
3. Zeman RK, Burrell MI. Biliary imaging techniques. In: Gallbladder and bile duct imaging: a clinical radiologic approach. New York: Churchill Livingstone; 1987. p. 47–104.
4. Sarawagi R, Sundar S, Raghuvanshi S, et al. Common and uncommon anatomical variants of intrahepatic bile ducts in magnetic resonance cholangiopancreatography and its clinical implication. *Pol J Radiol.* 2016;81:250–5.
5. Okada M, Fukada J, Toya K, et al. The value of drip infusion cholangiography using multidetector-row helical CT in patients with choledocholithiasis. *Eur Radiol.* 2005;15:2140–5.
6. Wang AY, Yachimski PS. Endoscopic management of pancreatobiliary neoplasms. *Gastroenterology.* 2018;154:1947–63.
7. Chandrasekhara V, Elmunzer BJ, Khashab M, Muthusamy VR. *Clinical gastrointestinal endoscopy.* Philadelphia: Elsevier Health Sciences; 2018.
8. Hyodo T, Kumano S, Okada M. CT and MR cholangiography: advantages and pitfalls in perioperative evaluation of biliary tree. *Br J Radiol.* 2012;85:887–96.
9. Kapoor V, Baron RL, Peterson M. Bile leaks after surgery. *Am J Roentgenol.* 2004;182:451–8.
10. Woods M, Traverso LW, Kozarek R, et al. Biliary tract complications of laparoscopic cholecystectomy are detected more frequently with routine intraoperative cholangiography. *Surg Endosc.* 1995;9:1076–80.
11. Costi R, Gnocchi A, Di Mario F, Sarli L. Diagnosis and management of choledocholithiasis in the golden age of

- imaging, endoscopy and laparoscopy. *World J Gastroenterol.* 2014;20:13382–401.
12. Hekimoglu K, Ustundag Y, Dusak A, et al. MRCP vs. ERCP in the evaluation of biliary pathologies: review of current literature. *J Dig Dis.* 2008;9:162–9.
 13. Soto J, Barish MA, Yucel E, et al. Magnetic resonance cholangiography: comparison with endoscopic retrograde cholangiopancreatography. *Gastroenterology.* 1996;110:589–97.
 14. Brauer DG, Strand MS, Sanford D, et al. Utility of a multidisciplinary tumor board in the management of pancreatic and upper gastrointestinal diseases: an observational study. *HPB (Oxford).* 2016;19:133–9.
 15. van Hagen P, Spaander MC, van der Gaast A, et al. Rotterdam Oesophageal Tumor Study Group. Impact of a multidisciplinary tumour board meeting for upper GI malignancies on clinical decision making: a prospective cohort study. *Int J Clin Oncol.* 2013;18:214–9.
 16. Boniface MM, Wani SB, Schefter TE, et al. Multidisciplinary management for esophageal and gastric cancer. *Cancer Manag Res.* 2016;8:39–44.
 17. Yeh T, Jan YY, Tseng J, et al. Malignant perihilar biliary obstruction: magnetic resonance cholangiopancreatographic findings. *Am J Gastroenterol.* 2000;95:432–40.
 18. Harewood GC, Baron TH. Cost analysis of magnetic resonance cholangiography in the management of inoperable hilar biliary obstruction. *Am J Gastroenterol.* 2012;97:1152–8.
 19. Wani S, Keswani R, Hall M, et al. A prospective multicenter study evaluating learning curves and competence in endoscopic ultrasound and endoscopic retrograde cholangiopancreatography among advanced endoscopy trainees: the rapid assessment of trainee endoscopy skills study. *Clin Gastroenterol Hepatol.* 2017;15:1758–67.
 20. Shahidi N, Ou G, Telford J, Enns R. When trainees reach competency in performing ERCP: a systematic review. *Gastrointest Endosc.* 2015;81:1337–42.
 21. Wani S, Hall M, Wang AY, et al. Variation in learning curves and competence for ERCP among advanced endoscopy trainees by using cumulative sum analysis. *Gastrointest Endosc.* 2016;83:711–9.
 22. Aman M, Sinha AC. Challenges of performing out of operating room anesthesia on the morbidly obese. In: *Out of the operating room anesthesia.* Cham: Springer; 2016. p. 369–85.

23. Dumonceau JM, Garcia-Fernandez FJ, Verdun F, et al. Radiation protection in digestive endoscopy: European Society of Digestive Endoscopy (ESGE) Guideline. *Endoscopy*. 2012;44:408–24.
24. Ansel H, Silvis SE, Rohrmann C. Text and atlas of endoscopic retrograde cholangiopancreatography. New York: Igaku-Shoin; 1995.
25. Gardner T, Baron TH. Optimizing cholangiography when performing endoscopic retrograde cholangiopancreatography. *Clin Gastroenterol Hepatol*. 2008;6:734–40.
26. Turner M, Cho SR, Messmer J. Pitfalls in cholangiographic interpretation. *Radiographics*. 1987;7:1067–105.
27. Benson E, Page RE. A practical reappraisal of the anatomy of the extrahepatic bile ducts and arteries. *Br J Surg*. 1976;63:853–60.
28. Aquilina O, Grech V, Felice H, et al. Normal adult coronary angiography. *Images Paediatr Cardiol*. 2006;8:1–17.
29. Mishkin D, Carpenter S, Croffie J, et al. ASGE technology status evaluation report: radiographic contrast media used in ERCP. *Gastrointest Endosc*. 2005;62:480–4.
30. El-Hennawy H, El-Kahlout EA, Bedar E, et al. Laparoscopic intraoperative cholangiography interpretation by surgeons versus radiologists, a comparative study review of 200 cholangiographies. *ISRN Minim Invasive Surg*. 2012;2012:1–5.
31. Khanna N, May G, Bass S, et al. Postprocedural interpretation of endoscopic retrograde cholangiopancreatography by radiology. *Can J Gastroenterol*. 2008;22:55–60.
32. Kucera S, Isenberg G, Chak A, et al. Postprocedure radiologist's interpretation of ERCP x-ray films: a prospective outcomes study. *Gastrointest Endosc*. 2007;66:79–83.