

Chapter 18

Emerging Technologies in Cartilage Restoration



Andrew J. Riff, Annabelle Davey, and Brian J. Cole

Injuries to articular cartilage are common and increasing in prevalence due to the rise in obesity and involvement in organized sports. However, due to limited vascularity and cellularity, articular cartilage possesses little capacity for spontaneous healing. If left untreated, articular cartilage injuries are one of the most common causes of permanent disability in athletes and may lead to widespread osteoarthritis. This increasing disease burden has prompted investigation into finding durable solutions to this challenging problem.

Over the last 25 years, surgical intervention for cartilage injury has increased dramatically, with the most broadly utilized techniques including marrow stimulation techniques (MST, including microfracture and subchondral drilling), autologous chondrocyte implantation (ACI), and osteochondral grafting (including osteochondral autograft transfer [OAT])

A. J. Riff (✉)

IU Health Physicians Orthopedics & Sports Medicine,
Indianapolis, IN, USA
e-mail: ariff@iuhealth.org

A. Davey

University of Vermont, College of Medicine, Burlington, VT, USA

B. J. Cole

Department of Orthopedic Surgery, Rush University Medical
Center, Chicago, IL, USA

and osteochondral allograft transplantation [OCA]). While each of these techniques has had a significant impact on the field of cartilage restoration, each has inherent drawbacks. Marrow stimulation is simple and inexpensive; however, it is limited by fibrocartilage repair tissue, poor durability, and poor results for larger lesions. ACI renders greater longevity and greater utility for larger lesions than microfracture; however, it is limited by its expense, two-stage nature, and the fact that it generates hyaline-like cartilage but not true hyaline cartilage. Osteochondral allografts offer immediate hyaline cartilage and the ability to restore subchondral bone; however, allografts are available in limited supply and have associated concerns regarding disease transmission and chondrocyte viability.

Due to the shortcomings of existing cartilage repair techniques, several new technologies have recently entered the global cartilage repair market. Many of these novel products are first introduced in Europe or Asia due to less strict regulatory standards than those required by the US Food and Drug Administration (FDA). A limited number of products are able to come to market quickly in the United States if they qualify as “minimally manipulated” or intended for “homologous use,” as such products do not require the FDA market approval pathway. Recently developed techniques that have garnered enthusiasm include augmented microfracture, matrix-assisted autologous chondrocyte implantation (MACI), minced cartilage products, off-the-shelf osteochondral implants, matrix plus stem cell products, and injectable agents. In this chapter, we will discuss new techniques being investigated abroad or recently introduced in the United States and the rationale behind each of these innovations and summarize available evidence for these new technologies.

Augmented Marrow Stimulation Techniques

Marrow stimulation techniques (MST), including microfracture and subchondral drilling, have long been the primary treatment for articular cartilage lesions due to the relative

ease and low cost. However, due to fibrocartilage repair tissue, MST has demonstrated inferior durability to more costly treatments [1]. In augmented MST, a matrix or scaffold is added to the defect following marrow stimulation to stabilize the mesenchymal clot and to improve mesenchymal stem cell (MSC) differentiation into more hyaline-like articular cartilage [2]. Augmented MST techniques include autologous matrix-induced chondrogenesis (AMIC), BST-CarGel, GelrinC, BioCartilage, and chondrotissue.

First described by Behrens and colleagues in 2010, AMIC was the first described augmented marrow stimulation technique. AMIC combines microfracture with the application of a porcine collagen I/III matrix (ChondroGide, Geistlich, Pharma AG) fixated with either autologous or allogeneic fibrin glue [3]. This technique can be employed either arthroscopically or following a mini-arthrotomy [4]. A retrospective case series of 21 patients with large chondral defects ($>2 \text{ cm}^2$) treated with AMIC reported MRI evidence of high-quality repair tissue in 67% of patients and 76% patient satisfaction [5]. These results are noteworthy because large lesions have demonstrated poor results with conventional MST [1]. A multicenter RCT compared AMIC with conventional microfracture in 47 patients with a mean defect size of $3.6 \pm 1.6 \text{ cm}^2$. Patients were randomized to receive either microfracture alone, glued AMIC, or sutured AMIC. All three groups showed significant improvements in Cincinnati and ICRS scores from preoperative to 2-year follow-up; however, patient-reported outcomes remained favorable between 2- and 5-year follow-up in both AMIC-treated groups, while the results of isolated microfracture declined between the 2- and 5-year time points. Moreover, MRI results indicated more complete defect fill in both AMIC groups than the isolated microfracture group [4].

BST-CarGel (Piramal Life Sciences, Laval, Quebec, Canada) is a bioscaffold containing liquid chitosan and autologous whole blood. Chitosan is an abundant glucosamine polysaccharide derived from the exoskeleton of crustaceans and is favored as a scaffold due to its biocompatibility,

biodegradability, and adhesive properties. BST-CarGel is typically applied to the microfracture site through a mini-arthrotomy after creating a “dry-field” by swabbing the lesion with gauze. In a multicenter randomized controlled trial, BST-CarGel was shown to have superior outcomes to microfracture at 1-year and at 5-year follow-up [6]. Eighty patients with symptomatic grade III or IV articular cartilage lesions were randomized to receive either conventional microfracture or microfracture augmented with BST-CarGel. Second-look arthroscopy was performed at a year postoperatively, and tissue biopsies were obtained. The BST-CarGel cohort demonstrated superior ICRS scores by surgeon visualization, superior histological parameters, and harbored repair tissue with improved collagen organization based on polarized light microscopy. At 5-year follow-up, the BST-CarGel group demonstrated superior fill by 3D quantitative MRI findings and reduced T2 relaxation times (suggesting more organized collagen).

GelrinC (Regentis Biomaterials, Or Akiva, Israel) is an investigational hydrogel composed of polyethylene glycol diacrylate (PEG-DA) and denatured fibrinogen. These two liquid materials are added to the defect following microfracture and are cross-linked in situ with UV light, forming a semisolid biodegradable scaffold for MSCs. In one study conducted in Austria reporting on the MRI outcomes of 21 patients undergoing microfracture augmented with GelrinC, the quality of the cartilage in the defect was found to be the same as healthy cartilage after 24 months in 81% of the patients as determined by global T2 index [7]. Additionally, average MOCART score increased at each follow-up time point from 6 months to 24 months, indicating that cartilage quality improved over the course of the postoperative time points [7]. While early results are promising, longer-term comparative literature is still necessary. A multicenter, open-label, phase I/II clinical trial is ongoing at institutions in Belgium, Germany, Israel, the Netherlands, and Poland (NCT00989794).

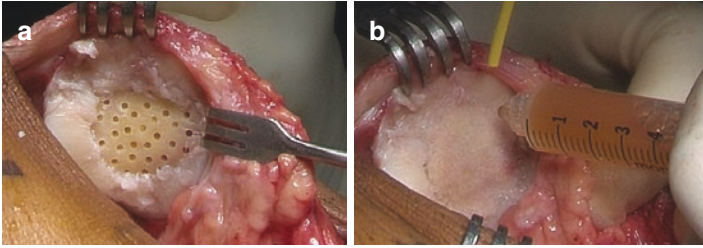


FIGURE 18.1 Central patellar chondral lesion measuring roughly 25 mm × 25 mm following lesion curettage and marrow stimulation (a) and application of BioCartilage and PRP (b)

BioCartilage (Arthrex, Inc., Naples, Florida) is a product made from dehydrated, micronized allogeneic cartilage that is designed to be implanted with platelet-rich plasma (PRP) (Fig. 18.1a, b). It contains components of hyaline cartilage extracellular matrix including type II collagen and proteoglycans that are thought to direct MSCs to produce higher-quality cartilage to fill the defect [2]. In a controlled laboratory study in an equine model, Fortier and colleagues demonstrated that microfracture augmented with BioCartilage and PRP was significantly better than microfracture alone in terms of ICRS histologic score and quantitative MRI T2 relaxation times at 13 months postoperatively [8]. There are currently no published clinical outcome studies in human subjects; however, Stannard and colleagues are currently conducting a single-center prospective cohort study comparing BioCartilage-augmented microfracture with microfracture in isolation (NCT02203071). BioCartilage is available for use in the United States.

Chondrotissue (BioTissue AG, Zurich, Switzerland) is a scaffold composed of polyglycolic acid (PGA) and hyaluronic acid (HA) immersed in PRP designed for application after marrow stimulation. In an ovine model, chondrotissue plus microfracture has been shown to improve the quality of repair tissue compared to isolated microfracture. Siclari and

colleagues published a series of 52 patients with focal chondral lesions in the knee treated with chondrotissue-enhanced subchondral drilling, noting significant improvements in KOOS scores and histology (from 4 s-look biopsies) consistent with hyaline-like to hyaline repair tissue with increased proteoglycan content and type II collagen [9]. Released in 2007, chondrotissue is CE marked for use in Europe, but not commercially available in the United States.

Matrix-Assisted Autologous Chondrocyte Implantation

Introduced in 1987 and first published in 1994, autologous chondrocyte implantation (ACI) represented the first cell-based surgical technique for cartilage restoration. First-generation ACI was limited by the need for periosteal flaps, graft hypertrophy, and formation of hyaline-like cartilage. Second- and third-generation ACI techniques make use of three-dimensional matrices that eliminate the need for periosteal flaps and offer the promise of generating more natural hyaline cartilage. Although just recently approved by the FDA for use in the United States in December 2016, matrix-assisted autologous chondrocyte implantation (MACI) has been performed extensively in Europe and Australia since 1999 [10, 11]. MACI products are made by application of cultured autologous chondrocytes to a substrate composed of a collagen hydrogel or membrane, a copolymer of polyglycolic or polylactic acid and polydioxanone, or HA. A multitude of MACI products have been investigated including Hyalograft C, cartilage regeneration system (CaReS), Novocart 3D, NeoCart, and Biocart, among others.

In use since 1999, Hyalograft C (Fidia Advanced Polymers, Abano Terme, Italy) was the first autologous tissue-engineered cartilage product to hit the market [11]. Hyalograft C is a MACI product utilizing a HYAFF-11 scaffold, a nonwoven, esterified derivative of hyaluronic acid designed to support *in vitro* growth of chondrocytes. Following cell harvest

performed in the same manner as conventional ACI, the biopsy specimen is sent to Fidia Advanced Biopolymers for in vitro cell culture. After 4 weeks of cell culture, the cell-seeded matrix can be implanted via a mini-arthrotomy and fixated around the periphery with fibrin glue. Initial studies revealed that Hyalograft C was safe, biocompatible, and avoided adverse events associated with the periosteal flap. Brix and colleagues published a case series of 53 subjects treated with Hyalograft C at an average 9-year follow-up [11]. The authors noted excellent patient-reported outcomes and survivability for simple cases (isolated defects $<4\text{cm}^2$ —failure rate of 4%) but poor results of salvage cases (early osteoarthritic changes or bipolar lesions—failure rate of 88%). Although Hyalograft C represented one of the most broadly used matrices on the market, it was removed from the European market in 2013 by the European Medical Association (EMA) due to concerns about manufacturing practices and low-quality comparative studies [12].

CaReS (Arthro Kinetics, Krems, Austria) is a MACI product based on type I collagen scaffold derived from rat tail tendons. Preparation of CaReS involves (1) isolation of chondrocytes from the biopsy specimen using collagenase, (2) suspension of isolated chondrocytes in type I collagen from rat tail tendons, (3) polymerization of the chondrocyte-collagen mixture in 37°C in a humidified atmosphere, and (4) culture in autologous serum for 10–13 days. To meet quality control standards, all specimens are required to display cell viability $>80\%$ and expression of type II collagen based on real-time PCR. CaReS implants can be manufactured to a custom height and area. Schneider and colleagues published a multicenter case series of 116 German patients treated with CaReS between 2003 and 2008 [13]. The authors noted significant improvement in all patient-reported outcomes and 80% patient satisfaction.

Novocart 3D (TeTeC, Reutlingen, Germany) is a bilayered type I collagen sponge containing chondroitin sulfate. After processing, harvested cells are seeded onto the scaffold and cultivated in homologous serum for 2 days, and the

graft is returned to the treating hospital. An Austrian study of Novocart 3D in 28 patients demonstrated that all patients had significant improvement in patient-reported outcomes and most cases revealed complete defect fill by MRI [14]. Somewhat concerning, Niethammer and colleagues noted MRI evidence of graft hypertrophy 25% of patients (11/44) treated with Novocart 3D, with particular abundance in those with history of acute trauma or OCD. It has been used commercially in Europe since 2003 and as part of a phase III trial in the United States since 2014 (NCT01957722).

NeoCart (Histogenics, Waltham, MA) combines a biodegradable bovine type I collagen patch with autogenous chondrocytes and bioreactor technology (Fig. 18.2a–d). Bioreactor treatment aims to optimize oxygen concentration, pressure, and perfusion and has been shown to improve integration of chondrocytes with a collagen matrix compared to untreated constructs in an *in vivo* porcine model [15, 16]. A phase II randomized clinical trial comparing NeoCart and microfracture in 30 patients with grade III lesions of the femoral condyle demonstrated that NeoCart was superior to microfracture with regard to percentage of patients improved and improvement in KOOS pain [17]. A phase III trial comparing NeoCart with microfracture is currently enrolling (NCT01066702).

BioCart II (Histogenics, Waltham, MA) is MACI product generated by culturing harvested chondrocytes with autologous serum and fibroblast growth factor 2v1 before they are seeded into a fibrin-hyaluronan matrix. Cells cultured in a medium containing an FGF variant have demonstrated a tenfold increase in cell proliferation compared to those cultured without the growth factor [18]. MRI evaluation of six knees between 15 and 27 months following treatment with BioCart II revealed that BioCart II rendered repair tissue similar to hyaline cartilage based on T2 relaxation times and dGEMRIC analysis [19]. A multicenter phase II trial comparing BioCart II to microfracture has been ongoing since 2008 but remains unpublished (NCT00729716).

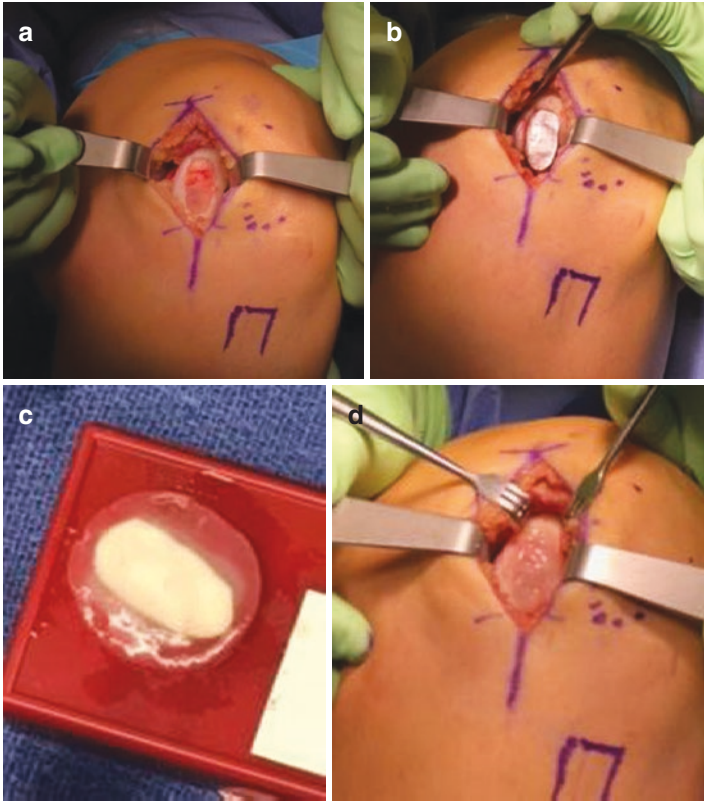


FIGURE 18.2 Large chondral lesion involving the medial femoral condyle measuring roughly 15 mm \times 30 mm following lesion curettage (a). Lesion templating with aluminum foil (b). NeoCart graft preparation on the back table (c). NeoCart graft placement (d)

A recent systematic review of MACI techniques revealed that MACI results in hyaline-like histology in 38–75% of cases and better histology and patient-reported outcomes than microfracture [12]. This review highlighted the poor quality of the available literature and the need for future studies comparing different matrices to help surgeons in selecting the optimal graft choice for their patients.

Matrix plus Mesenchymal Stem Cells

In pursuit of a single-stage alternative to ACI, multiple products have emerged that combine mesenchymal stem cells (MSCs) with three-dimensional scaffolds. Proponents of these techniques theorize that coupling MSCs with the appropriate matrix and growth factors may offer a reliable method of generating durable hyaline-like cartilage. MSCs augment the quality of repair tissue by increasing the aggrecan concentration and enhancing cartilage firmness [20]. Products are available in this category utilizing both autologous (Hyalofast) and allogeneic (Cartistem) MSCs.

Hyalofast (Anika Therapeutics, Bedford, Massachusetts, USA) is a product that combines the HYAFF11 scaffold (the same scaffold used in Hyalograft C) with MSCs derived from bone marrow aspirate concentrate (BMAC). BMAC contains adult MSCs, platelets, cytokines, and growth factors (including platelet-derived growth factor [PDGF], transforming growth factor beta [TGF β], and bone morphogenetic protein [BMP-2 and BMP-7]), which improve the healing milieu through their anabolic and anti-inflammatory properties [21–24]. MSCs constitute just 0.001% of nucleated cells in bone marrow aspirate; therefore, bone marrow aspirate is subjected to centrifugation to increase the MSC concentration. The Hyalofast technique involves templating the hyaluronan scaffold to the defect, soaking the scaffold with BMAC, and fixating it to surrounding cartilage with 6-0 PDS suture and/or fibrin glue. Gobbi and colleagues recently published a prospective matched cohort study comparing 25 patients treated with microfracture, and 27 patients were treated with Hyalofast [25]. At 2-year follow-up, a significantly greater proportion of the microfracture group had returned to pre-injury activity level, as determined by Tegner score. However, at 5-year follow-up, a significantly greater proportion of the HA-BMAC group had returned to the pre-injury activity level [25]. The same group published a Level 2 cohort study comparing results of Hyalofast in patients >45 years of age with those <45 years of age [26]. At 4-year

follow-up, both groups improved significantly in IKDC, KOOS, VAS, and Tenger scores, with no significant difference between the groups. As one would expect, patient-reported outcomes were superior in patients with lesion area $<8 \text{ cm}^2$ and in patients with a single lesion as opposed to multiple lesions [26]. Hyalofast is commercially available in most European countries and some Asian and South American countries but is not available in the United States.

Multiple other strategies combining autologous stem cells and matrices are in early phases of clinical testing. There is interest in the use of a collagen matrix seeded with bioactive factors and adipose-derived stem cells (ADSCs). While there are not yet any clinical results, Calabrese and colleagues have demonstrated that ADSCs are able to completely differentiate into mature chondrocytes when combined with a type I collagen scaffold and chondrogenic inducing factors in vitro [27]. Dragoo and colleagues are currently enrolling patients in a multicenter RCT comparing ADSCs plus collagen scaffold with microfracture for isolated chondral lesions of the knee (NCT02090140).

The use of allogeneic stem cells in conjunction with a three-dimensional scaffold is another option that is being explored to avoid donor site morbidity. Cartistem (Medipost Co., Ltd., Korea) is a product that utilizes a sodium hyaluronate scaffold seeded with culture-expanded human umbilical cord blood-derived mesenchymal stem cells (hUBC-MSCs). The only available literature on Cartistem is a phase I/II single-center clinical trial of seven patients treated with either low-dose or high-dose hUBC-MSCs conducted in Korea [28]. Six of the seven patients consented to undergo second-look arthroscopy at 12-week follow-up, at which point the treating physician observed maturing cartilage in all six knees. VAS and IKDC scores improved in all subjects from preoperative level to 3-month follow-up and remained relatively stable from 3 months to 7 years [28]. This study suggests that Cartistem is safe and effective, but it is limited by its small sample size. Cole and Gomoll are currently conducting a phase I/II clinical trial investigating the safety and efficacy

of Cartistem in 12 patients with full-thickness grade 3–4 articular cartilage defects of the knee which is expected to finish data collection in July of 2017 (NCT01733186).

Minced Cartilage Products

Minced cartilage repair is another treatment strategy that harnesses the theory of ACI in a single-stage alternative. This technique involves filling a chondral defect with a small amount of particulate hyaline cartilage secured with fibrin glue and often combined with a scaffold delivery system. Mincing cartilage into 1–2-mm³ fragments allows the chondrocytes to escape from the extracellular matrix and to produce hyaline-like cartilage that will integrate with the surrounding native tissue [29]. Minced cartilage products utilizing both autologous (Cartilage Autograft Implantation System [CAIS]) and allogeneic (DeNovo Natural Tissue) cartilage have been investigated.

Cartilage Autograft Implantation System (CAIS) (DePuy Mitek, Raynham, Massachusetts, USA) is a proprietary technique which involves harvesting autologous cells from the intercondylar notch or trochlear border, mincing cartilage into 1–2-mm³ fragments, securing minced fragments to a proprietary scaffold composed of polycaprolactone (35%) and PGA (65%) reinforced with PDO mesh, and fixating the implant to the defect using biodegradable anchors [30]. An initial randomized pilot study compared CAIS and microfracture in 29 patients with lesions involving the trochlea or femoral condyle [31]. At 24-month follow-up, both groups had a significant improvement in IKDC and KOOS scores from baseline, and the CAIS group had significantly higher scores than the microfracture group. Despite these promising results, the phase III multicenter randomized controlled trial (NCT00881023) was discontinued due to lack of enrollment and prohibitive expense [32].

DeNovo Natural Tissue (NT) (Zimmer Biomet, Warsaw, Indiana, USA) utilizes 1-mm³ pieces of allogeneic cartilage

from donors younger than 13 of age and secured with fibrin glue (Fig. 18.3a–d) [33]. The primary advantages of this technique relate to the fact that juvenile chondrocytes have a 100-fold increased ability to produce proteoglycans and that these cells do not stimulate an immunogenic response. The primary drawback of this technique is that DeNovo NT has a ~40-day shelf life and, as such, many surgeons will only perform this technique after performing a diagnostic arthroscopy making it a two-stage technique. While there are not yet any long-term outcome studies or Level I evidence, early clinical results are

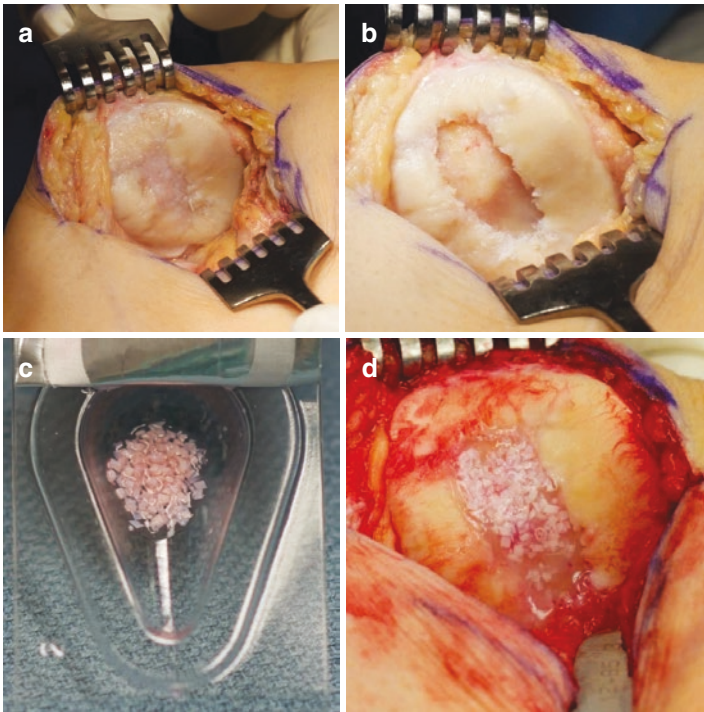


FIGURE 18.3 Central patellar lesion measuring 15 mm × 30 mm (a). Lesion following curettage to establish vertical walls (b). DeNovo NT graft in delivery packaging (c). Lesion following application of DeNovo NT with fibrin glue mixture (d)

extremely promising. In a case series of 25 patients with a mean femoral lesion size of $2.7 \pm 0.8 \text{ cm}^2$, IKDC and KOOS clinical outcome scores showed significant improvements compared to baseline at 24 months after surgery [34]. Additionally, quantitative MRI results with T2 mapping demonstrated that the repair cartilage was of a similar composition to native cartilage after 2 years. Histologic results from biopsies taken from eight patients indicated that there was excellent integration of the transplant tissue with the native cartilage, although the biopsies contained both hyaline and fibrocartilage [34]. Additionally, in a retrospective Level IV case series, 17 patients with patellar chondral lesions who were treated with DeNovo NT were reviewed. Follow-up at a mean 8.2 months revealed significant improvement in KOOS score [35]. This technique is rapidly gaining popularity, with approximately 8700 cases performed since 2007 [29].

CartiONE (Orteq Ltd., London, UK) is a novel technique that combines minced cartilage, BMAC, and a commercially available scaffold in a single-step cartilage repair technique. In a 1 h time span, non-articular hyaline cartilage is harvested from the periphery of the trochlea or the intercondylar notch and subjected to patented cell-isolation technology, co-cultured with BMAC, and added to a commercially available scaffold prior to implantation. The rationale behind this technique is based on literature suggesting that trophic factors from MSCs help to increase chondrocyte proliferation and matrix formation [36]. The INSTRUCT clinical trial evaluated PROs, histologic outcomes, and radiologic outcomes of 40 patients treated with CartiONE for symptomatic cartilage defects in the knee (NCT01041885). This trial reported significant improvements in KOOS, IKDC, and VAS; consistent defect filling by MRI; and evidence of hyaline cartilage in most patients.

Off-the-Shelf Osteochondral Implants

Fresh osteochondral allograft (OCA) transplantation has emerged as a valuable and successful treatment for chondral and osteochondral defects with graft survivorship approaching

90% at 10 years [37, 38]. Despite the success of this technique, OCA remains limited by graft availability and concerns regarding disease transmission. Additionally, due to graft expense, many surgeons perform diagnostic arthroscopy prior to OCA transplantation making this a two-stage technique. Due to these limitations, stand-alone proprietary osteochondral implants have been developed that are readily available with prolonged shelf lives. Three off-the-shelf osteochondral implants are presently available on the market including Chondrofix, Cartiform, and ProChondrix. Although they contain no osteocytes on chondrocytes, two novel scaffolds (Maioregen and Agili-C) are also discussed in this section as they are used in isolation for the treatment of osteochondral defects.

Made available in 2012, Chondrofix (Zimmer Inc., Warsaw, IN) represented the first off-the-shelf osteochondral allograft. Chondrofix is a decellularized osteochondral allograft which is available in four precut sizes and offers a 2-year shelf life. Unfortunately, a prospective series of 32 patients treated with Chondrofix demonstrated a 72% failure rate within 2 years of implantation [39]. Although the authors did not speculate in their abstract on the cause of the high failure rate, it is probable that the lack of viable chondrocytes played a role.

Cartiform (Arthrex Inc., Naples, FL) and ProChondrix (AlloSource, Centennial, CO) represent two recently released, commercially available osteochondral allograft disc implants that contain viable chondrocytes. Since these implants are considered “minimally manipulated,” they are available for use in the United States. Cartiform is a cryopreserved, viable osteochondral allograft (CVOCA) available in four sizes including 10 mm diameter, 20 mm diameter, 12x19mm, and 20x25mm. Cartiform contains full-thickness pores throughout its area that improve graft flexibility and allow the cryopreservation solution to penetrate the tissue to preserve cell viability throughout rather than just the surface of the graft. As a result, Cartiform possesses a 2-year shelf life when stored at -80°C . Additionally, Cartiform has a minimal bone component which further improves graft flexibility to match the topography of the underlying bone. Released in 2016,

ProChondrix is a fresh chondral allograft composed of viable chondrocytes, matrix, and growth factors. ProChondrix is stored at 4 °C with 87.5% viability at the expiration of its 35-day shelf life. The grafts are available in 11-mm, 13-mm, 15-mm, 17-mm, and 20-mm diameter discs. Cartiform and ProChondrix have both been used as isolated grafts and in conjunction with marrow stimulation, which affords both a reparative response and restorative approach from the allograft. There is not currently a consensus about the need for concomitant marrow stimulation. In vitro histological evaluation of Cartiform in a goat model revealed that the graft retains viable chondrocytes, chondrogenic growth factors, and ECM proteins within intact hyaline cartilage and that when used in conjunction with microfracture results in improved cartilage regrowth compared to microfracture alone [40]. Clinical results in humans are presently unavailable.

Maioregen (Finceramica Faenza SpA, Faenza, Italy) is a tri-layered biomimetic osteochondral scaffold first introduced for clinical use in 2011 in Europe. The acellular scaffold was designed for the treatment of osteochondral defects. The superficial layer consists of type I equine collagen, the intermediate layer of 60% equine collagen and 40% magnesium-enriched HA (Mg-HA), and the deep layer of 30% equine collagen and 70% Mg-HA. The scaffold has been shown to induce subchondral trabecular bone regeneration in an equine model [41]. Berruto and colleagues recently published on the use of Maioregen in 11 patients for the treatment of spontaneous osteonecrosis of the knee (SPONK) [42]. While 2 of 11 ultimately underwent total knee arthroplasty, the remaining 9 patients had favorable results with significant improvements in Lysholm, IKDC, and VAS scores. Maioregen is not currently available in the United States; however, a phase IV clinical trial is recently completed in Europe (NCT01282034).

Agili-C (CartiHeal, Israel) is a porous bioabsorbable biphasic scaffold derived from coral, to which HA is added. It contains (1) a bone phase composed of calcium carbonate in

an aragnite crystalline form and (2) a cartilage phase composed of modified aragonite and HA [43]. Aragonite possesses a nano-rough surface and porous architecture which permit cell adhesion and proliferation. Kon and colleagues reported complete histologic restoration of hyaline cartilage and subchondral bone in 6/7 goats 12 months following treatment with Agili-C for lesions measuring 6 mm in diameter and 10 mm in depth [44]. A multicenter European trial of 97 patients treated with tapered ($n = 21$) and cylindrical (76) implants revealed MRI findings 84% of patients with >75% defect fill and 90% with complete restoration of the cartilage interface [43]. Agili-C is not currently commercially available and is available only via a phase IV clinical trial in Europe (NCT02423629).

Injectable Agents

Traditional joint injections for osteoarthritis including corticosteroids or HA aim to decrease inflammation and improve symptoms without modifying the disease. Newer injectable agents including PRP, stem cells, and growth factors have recently become the focus of intensive study both to augment cartilage repair techniques and to delay progression of cartilage breakdown in osteoarthritis. The rationale behind these injections is to optimize the healing milieu within the joint by both increasing the concentration of favorable cytokines which increase glycosaminoglycan synthesis (IGF-1, FGF, and TGF-beta superfamily) and decreasing catabolic cytokines that contribute to osteoarthritis (IL-1, TNF, and IL-6, IL-7, and IL-8). Agents that have recently garnered attention include Orthokine/Regenokine, PRP, autologous and allogeneic MSCs, sprifermin (FGFR-18), and OP-1 (BMP7).

Much of the interest in injectable growth factors was sparked by reports of professional athletes traveling internationally for injections of Orthokine (Orthogen, Dusseldorf, Germany). Orthokine, now available in the United States as Regenokine, is autologous conditioned serum (ACS) which is

procured from autologous blood that is incubated with borosilicate glass spheres leading to increased levels of IL-1 receptor antagonist (IL-1ra) [45]. While there is little available literature on the use of Orthokine/Regenokine and nothing to suggest it is disease modifying, Baltzer and colleagues demonstrated that Orthokine/Regenokine rendered superior improvement in patient-reported outcomes (VAS, SF-8, and all WOMAC subscales) when compared to HA and saline in a randomized, controlled trial of 376 patients with knee osteoarthritis [46].

Platelet-rich plasma (PRP) is biologic therapeutic modality derived from centrifugation of autologous blood to attain a supraphysiologic concentration of platelet and plasma proteins that accelerate the repair process. Numerous growth factors in PRP stimulate cartilage matrix synthesis and counteract the effects of catabolic cytokines like IL-1 and TNF- α . A recent double-blind, randomized controlled trial demonstrated no difference between PRP and HA in WOMAC pain score; however, the authors did demonstrate a trend toward lower concentrations of IL-1 and TNF- α at 12 weeks following injection in the PRP group [47]. A recent systematic review of 29 studies evaluating results of PRP in the setting of osteoarthritis reported that 9 of 11 studies comparing PRP with HA revealed superior outcomes with PRP [48].

Bone marrow aspirate concentrate (BMAC) has been used as both a cell source for matrix plus MSC products and for symptomatic management of osteoarthritis. As discussed previously, BMAC contains adult bone marrow-derived MSCs (bmMSCs), platelets, cytokines, and growth factors—all of which harbor unique anti-inflammatory and immunomodulatory effects. Chahla and colleagues recently performed a systematic review of the use of BMAC for both repair of focal chondral defects and treatment of osteoarthritis [49]. Three studies demonstrated that BMAC is effective in treating osteoarthritis. The available literature demonstrated that BMAC rendered significant improvements in patient symptoms with more pronounced improvement in patients with

Kellgren and Lawrence grade II/III compared to grade IV disease; however, there is no available evidence to suggest that BMAC alters the natural history of osteoarthritis.

Lipogems (Lipogems International SpA, Milan, Italy) is a single-use system, available since 2013, designed for aspiration, processing, and transfer of adipose tissue for the harvest of adipose-derived MSCs (adMSCs). Evidence regarding Lipogems for the treatment of osteoarthritis is currently limited to case reports; however, significant improvements in pain, functional scores, and cartilage thickness have been reported in patients with osteoarthritis treated with Lipogems [50, 51]. Of note, *in vitro* comparison of chondrogenic potential of adMSCs and bmMSCs has demonstrated greater efficiency and quality of chondrogenesis with bmMSCs [52, 53].

Bone morphogenetic protein 7 (BMP7), marketed as osteogenic protein 1 (OP-1, Olympus Biotech, West Lebanon, NH), was the first isolated growth factor trialed for the treatment of osteoarthritis. OP-1 was shown to have reparative effects on cartilage including stimulating synthesis of proteoglycan, collagen, and HA and preventing catabolism by IL-1. While the phase I safety trial of OP1 demonstrated safety and subtle benefits relative to placebo [54], further trials were discontinued, and Olympus Biotech halted its effort to commercialize OP-1 in 2014.

Sprifermin (recombinant human fibroblast growth factor 18; rhFGF-18) binds to and activates fibroblast growth factor receptor 3 (FGFR-3) in cartilage to promote chondrogenesis and cartilage matrix production *in vivo*. Preclinical studies have demonstrated that sprifermin induces chondrocyte proliferation which results in increased extracellular matrix production [55]. However, a recent randomized, double-blind, placebo-controlled trial comparing sprifermin and placebo demonstrated no difference in cartilage thickness and inferior improvement in WOMAC pain scores in the sprifermin group compared to the control group [56]. A phase II multicenter, placebo-controlled clinical trial evaluating sprifermin in the setting of osteoarthritis is ongoing (NCT01919164).

Conclusion

A broad variety of new cartilage repair products have emerged over the last 20 years, designed to improve upon limitations of existing techniques. Most products combine a cell source with a matrix and/or growth factors to optimize the healing environment. Techniques that have generated excitement include augmented microfracture, matrix-assisted ACI, matrix plus stem cell productions, minced cartilage productions, off-the-shelf osteochondral implants, and injectable agents. While these products have demonstrated promising clinical and histologic results, many remain unavailable in the United States due to FDA restrictions. Additionally, while many of these techniques have compared favorably to conventional microfracture, there is very little literature comparing them to more sophisticated techniques (ACI or osteochondral grafting). Further results from ongoing clinical trials will be essential in changing the landscape of FDA-approved techniques and establishing the place for each of these techniques within the cartilage restoration algorithm.

References

1. Devitt BM, Bell SW, Webster KE, Feller JA. Surgical treatments of cartilage defects of the knee: systematic review of randomised controlled trials. *Knee*. 2017;24:508–17.
2. Cole BJ, Kercher JS, Strauss EJ, Barker JU. Augmentation strategies following the microfracture technique for repair of focal chondral defects. *Cartilage*. 2010;1:145–52.
3. Benthien JP, Behrens P. Autologous Matrix-Induced Chondrogenesis (AMIC). *Cartilage*. 2010;1:65–8.
4. Piontek T, Ciemniowska-Gorzela K, Szulc A. All-arthroscopic AMIC procedure for repair of cartilage defects of the knee. *Knee Surg*. 2012;20:922–5.
5. Schiavone Panni A, Del Regno C, Mazzitelli G. Good clinical results with autologous matrix-induced chondrogenesis (Amic) technique in large knee chondral defects. *Knee Surg*. 2017;26:1130–6.

6. Shive MS, Stanish WD, McCormack R, Forriol F, Mohtadi N, Pelet S, Desnoyers J, Méthot S, Vehik K, Restrepo A. BST-CarGel® treatment maintains cartilage repair superiority over microfracture at 5 years in a multicenter randomized controlled trial. *Cartilage*. 2015;6:62–72.
7. Trattnig S, Ohel K, Mlynarik V, Juras V, Zbyn S. Morphological and compositional monitoring of a new cell-free cartilage repair hydrogel technology—GelrinC by MR using semi-quantitative MOCART scoring and quantitative T2 index and new zonal T2 index calculation. *Osteoarthr Cartil*. 2015;23:2224–32.
8. Fortier LA, Chapman HS, Pownder SL, Roller BL, Cross JA, Cook JL, Cole BJ. BioCartilage improves cartilage repair compared with microfracture alone in an equine model of full-thickness cartilage loss. *Am J Sports Med*. 2016;44:2366–74.
9. Siclari A, Mascaro G, Gentili C, Kaps C, Cancedda R, Boux E. Cartilage repair in the knee with subchondral drilling augmented with a platelet-rich plasma-immersed polymer-based implant. *Knee Surg Sports Traumatol Arthrosc*. 2013;22:1225–34.
10. Bryan W. Approval letter for biologics license application for autologous cultured chondrocytes on porcine collagen membrane. U.S. Food & Drug Administration. December 13, 2016.
11. Brix MO, Stelzeneder D, Chiari C, Koller U, Nehrer S, Dorotka R, Windhager R, Domayer SE. Treatment of full-thickness chondral defects with hyalograft C in the knee: long-term results. *Am J Sports Med*. 2014;42:1426–32.
12. Wylie JD, Hartley MK, Kapron AL, Aoki SK, Maak TG. What is the effect of matrices on cartilage repair? A systematic review. *Clin Orthop Relat Res*. 2015;473:1673–82.
13. Schneider U, Rackwitz L, Andereya S, Siebenlist S, Fensky F, Reichert J, Löer I, Barthel T, Rudert M, Nöth U. A prospective multicenter study on the outcome of type I collagen hydrogel-based autologous chondrocyte implantation (CaReS) for the repair of articular cartilage defects in the knee. *Am J Sports Med*. 2011;39:2558–65.
14. Zak L, Albrecht C, Wondrasch B, Widhalm H, Vekszler G, Trattnig S, Marlovits S, Aldrian S. Results 2 years after matrix-associated autologous chondrocyte transplantation using the Novocart 3D scaffold. *Am J Sports Med*. 2014;42:1618–27.
15. Kusanagi A, Mascarenhas AC, Blahut EB, Johnson JM, Murata T, Mizuno S. Hydrostatic pressure with low oxygen stimulates extracellular matrix accumulation by human articular chon-

- drocytes in a 3-D collagen sponge. 51st Annual Meeting of the Orthopedic Research Society, Washington, DC, 384; 2005.
16. Kusanagi A, Mascarenhas AC, Blahut EB, Johnson JM. Hydrostatic pressure with low oxygen stimulates extracellular matrix accumulation by human articular chondrocytes in a 3-D collagen gel/sponge. *Transactions of the 51st Annual Orthopaedic Research Society*. 2005. p. 20–3
 17. Crawford DC, DeBerardino TM, Williams RJ III. NeoCart, an autologous cartilage tissue implant, compared with microfracture for treatment of distal femoral cartilage lesions. *J Bone Joint Surg Am*. 2012;94:979–89.
 18. Yayon A, Neria E, Blumenstein S, Stern B, Barkai H, Zak R, et al. BIO CART™II a novel implant for 3D reconstruction of articular cartilage. *J Bone Joint Surg Br Vol*. 2006;88-B(SUPP II):344.
 19. Domayer SE, Welsch GH, Nehrer S, Chiari C, Dorotka R, Szomolanyi P, Mamisch TC, Yayon A, Trattnig S. T2 mapping and dGEMRIC after autologous chondrocyte implantation with a fibrin-based scaffold in the knee: preliminary results. *Eur J Radiol*. 2010;73:636–42.
 20. Sampson S, Bemden AB-V, Aufiero D. Autologous bone marrow concentrate: review and application of a novel intra-articular orthobiologic for cartilage disease. *Phys Sportsmed*. 2013;41:7–18.
 21. Bain BJ. The bone marrow aspirate of healthy subjects. *Br J Haematol*. 1996;94:206–9.
 22. Cassano JM, Kennedy JG, Ross KA, Fraser EJ. Bone marrow concentrate and platelet-rich plasma differ in cell distribution and interleukin 1 receptor antagonist protein concentration. *Knee Surg*. 2016;26:333–42.
 23. Kim M, Kim J, Lim J, Kim Y, Han K. Use of an automated hematology analyzer and flow cytometry to assess bone marrow cellularity and differential cell count. *Ann Clin Lab Sci*. 2004;34:307–13.
 24. Yamamura R, Yamane T, Hino M, Ohta K, Shibata H, Tsuda I, Tatsumi N. Possible automatic cell classification of bone marrow aspirate using the CELL-DYN 4000 automatic blood cell analyzer. *J Clin Lab Anal*. 2002;16:86–90.
 25. Gobbi A, Whyte GP. One-stage cartilage repair using a hyaluronic acid-based scaffold with activated bone marrow-derived mesenchymal stem cells compared with microfracture. *Am J Sports Med*. 2016;44:2846–54.

26. Gobbi A, Scotti C, Karnatzikos G, Mudhigere A, Castro M, Peretti GM. One-step surgery with multipotent stem cells and Hyaluronan-based scaffold for the treatment of full-thickness chondral defects of the knee in patients older than 45 years. *Knee Surg Sports Traumatol Arthrosc.* 2017;25:2494–501.
27. Calabrese G et al. Combination of collagen-based scaffold and bioactive factors induces adipose-derived mesenchymal stem cells chondrogenic differentiation in vitro. *Front Physiol.* 2017. <https://doi.org/10.3389/fphys.2017.00050>.
28. Park YB, Ha CW, Lee CH, Yoon YC, Park YG. Cartilage regeneration in osteoarthritic patients by a composite of allogeneic umbilical cord blood-derived mesenchymal stem cells and hyaluronate hydrogel: results from a clinical trial for safety and proof-of-concept with 7 years of extended follow-up. *Stem Cells Transl Med.* 2017;6:613–21.
29. Yanke AB, Tilton AK, Wetters NG, Merkow DB, Cole BJ, DeNovo NT particulated juvenile cartilage implant. *Sports Med Arthrosc Rev.* 2015;23:125–9.
30. Cole BJ, Farr J, Winalski CS, Hosea T, Richmond J, Mandelbaum B, De Deyne PG. Outcomes after a single-stage procedure for cell-based cartilage repair: a prospective clinical safety trial with 2-year follow-up. *Am J Sports Med.* 2011;39:1170–9.
31. Cole BJ, Farr J, Winalski CS, Hosea T, Richmond J, Mandelbaum B, De Deyne PG. Outcomes after a single-stage procedure for cell-based cartilage repair. *Am J Sports Med.* 2011;39:1170–9.
32. Riboh JC, Cole BJ, Farr J. Particulated articular cartilage for symptomatic chondral defects of the knee. *Curr Rev Musculoskelet Med.* 2015;8:429–35.
33. Farr J, Yao JQ. Chondral defect repair with particulated juvenile cartilage allograft. *Cartilage.* 2011;2:346–53.
34. Farr J, Tabet SK, Margerrison E, Cole BJ. Clinical, radiographic, and histological outcomes after cartilage repair with particulated juvenile articular cartilage: a 2-year prospective study. *Am J Sports Med.* 2014;42:1417–25.
35. Buckwalter JA, Bowman GN. Clinical outcomes of patellar chondral lesions treated with juvenile particulated cartilage allografts. *Iowa Orthop J.* 2014;34:44–9.
36. Wu L, Leijten JCH, Georgi N, Post JN, van Blitterswijk CA, Karperien M. Trophic effects of mesenchymal stem cells increase chondrocyte proliferation and matrix formation. *Tissue Eng Part A.* 2011;17:1425–36.

37. Gracitelli GC, Meric G, Pulido PA, Gortz S, De Young AJ, Bugbee WD. Fresh osteochondral allograft transplantation for isolated patellar cartilage injury. *Am J Sports Med.* 2015;43:879–84.
38. Levy YD, Gortz S, Pulido PA, McCauley JC, Bugbee WD. Do fresh osteochondral allografts successfully treat femoral condyle lesions? *Clin Orthop Relat Res.* 2013;471:231–7.
39. Farr J, Gracitelli G, Gomoll AH. Decellularized osteochondral allograft for the treatment of cartilage lesions in the knee. *Orthop J Sports Med.* 2015;3(7).
40. Geraghty S, Kuang J-Q, Yoo D, LeRoux-Williams M, Vangsness CT, Danilkovitch A. A novel, cryopreserved, viable osteochondral allograft designed to augment marrow stimulation for articular cartilage repair. *J Orthop Surg Res.* 2015;10:66.
41. Kon E, Mutini A, Arcangeli E, Delcogliano M, Filardo G, Nicoli Aldini N, Pressato D, Quarto R, Zaffagnini S, Marcacci M. Novel nanostructured scaffold for osteochondral regeneration: pilot study in horses. *J Tissue Eng Regen Med.* 2010;4:300–8.
42. Berruto M, Ferrua P, Uboldi F, Pasqualotto S, Ferrara F, Carimati G, Usellini E, Delcogliano M. Can a biomimetic osteochondral scaffold be a reliable alternative to prosthetic surgery in treating late-stage SPONK? *Knee.* 2016;23:936–41.
43. Kon E, Robinson D, Verdonk P, Drobic M, et al. A novel aragonite-based scaffold for osteochondral regeneration: early experience on human implants and technical developments. *Injury.* 2016;47:S27–32.
44. Kon E, Filardo G, Shani J, Altschuler N, Levy A, Zaslav K, Eisman JE, Robinson D. Osteochondral regeneration with a novel aragonite-hyaluronate biphasic scaffold: up to 12-month follow-up study in a goat model. *J Orthop Surg Res.* 2015;10:81.
45. Fortier LA, Chapman HS, Pownder SL, Roller BL, Cross JA, Cook JL, Cole BJ. BioCartilage improves cartilage repair compared with microfracture alone in an equine model of full-thickness cartilage loss. *Curr Rev Musculoskelet Med.* 2015;44:2366–74.
46. Baltzer AW, Moser C, Jansen SA, Krauspe R. Autologous conditioned serum (Orthokine) is an effective treatment for knee osteoarthritis. *Osteoarthr Cartil.* 2009;17:152–60.
47. Cole BJ, Karas V, Hussey K, Pilz K, Fortier LA. Hyaluronic acid versus platelet-rich plasma. *Am J Sports Med.* 2017;45:339–46.
48. Laver L, Marom N, Dnyanesh L, Mei-Dan O, Espregueira-Mendes JO, Gobbi A. PRP for degenerative cartilage disease. *Cartilage.* 2016;8:194760351667070.

49. Chahla J, Dean CS, Moatshe G, Pascual-Garrido C, Serra Cruz R, LaPrade RF. Concentrated bone marrow aspirate for the treatment of chondral injuries and osteoarthritis of the knee. *Orthop J Sports Med.* 2016;4:232596711562548.
50. Striano RD, Battista V, Bilboo N. Non-responding knee pain with osteoarthritis, meniscus and ligament tears treated with ultrasound guided autologous, micro-fragmented and minimally manipulated adipose tissue. *Open J Regen Med.* 2017;6:17.
51. Franceschini M, Castellaneta C, Mineo G. Injection of autologous micro-fragmented adipose tissue for the treatment of post traumatic degenerative lesion of knee cartilage: a case report. *CellR4.* 2016;4:e1765.
52. Reich CM, Raabe O, Wenisch S, Bridger PS. Isolation, culture and chondrogenic differentiation of canine adipose tissue-and bone marrow-derived mesenchymal stem cells—a comparative study. *Vet Res Commun.* 2012;36:139–48.
53. Jakobsen RB, Shahdadfar A, Reinholt FP, Brinchmann JE. Chondrogenesis in a hyaluronic acid scaffold: comparison between chondrocytes and MSC from bone marrow and adipose tissue. *Knee Surg Sports Traumatol Arthrosc.* 2010;18:1407–16.
54. Hunter DJ, Pike MC, Jonas BL, Kissin E, Krop J, McAlindon T. Phase 1 safety and tolerability study of BMP-7 in symptomatic knee osteoarthritis. *BMC Musculoskelet Disord.* 2010;11:232.
55. Ellsworth JL, Berry J, Bukowski T, et al. Fibroblast growth factor-18 is a trophic factor for mature chondrocytes and their progenitors. *Osteoarthr Cartil.* 2002;10:308–20.
56. Lohmander LS, Hellot S, Dreher D, Krantz EFW, Kruger DS, Guermazi A, Eckstein F. Intraarticular sprifermin (recombinant human fibroblast growth factor 18) in knee osteoarthritis: a randomized, double-blind, placebo-controlled trial. *Arthritis Rheum.* 2014;66:1820–31.