

Stanley M. Goldberg and Patrick S. Tawadros

Introduction

Perianal sepsis is one of the most commonly observed anorectal lesions, leading to abscess formation and often fistula development. Despite its prevalence, it also remains one of the most challenging anorectal conditions to treat, often requiring multiple attempts and different management strategies. Fundamental to the adequate management of these conditions, however, is an understanding of anorectal anatomy and pathophysiology leading to abscess and fistula formation. Of interest, history is replete with ancient accounts of anorectal surgery, from ancient Egypt to Hippocrates, to John Ardene of England's "Treatise on Fistula, Hemorrhoids and Clyster" written in 1367. A turning point for anorectal surgery came in 1686 when the French King Louis XIV, who suffered from a fistula-in-ano, ordered his physician Philip to conduct clinical trials on the available methods of fistula treatment at that time. After 1 year of studies, the first "evidence-based" decision in anorectal surgery was made and the king submitted to a fistulotomy that ultimately cured him [1].

S.M. Goldberg, MD, FACS, HonFRACS (Aust), HonFRCS (Eng), HonAFC (Fr), HonFRCPS (Glasg), HonFRSM (Eng), HonFPCS (Phil), HonFRCS (Edin), Honoris Causa (Lleida), HonSAS (Spain), HonJSS (Japan) (✉) • P.S. Tawadros, MD, PhD, FRCSC
Division of Colon and Rectal Surgery,
Department of Surgery, University of Minnesota,
Minneapolis, MN, USA
e-mail: goldb003@umn.edu

Anatomy

A thorough discussion of anorectal sepsis cannot be accomplished without an understanding of the pertinent anatomy. While Chap. 2 was entirely dedicated to the anatomy of the anal canal, here we specifically review the pertinent aspects to the pathophysiology of anal sepsis.

Anal Canal

The anal canal is characterized at its mid-point by a transition from intestinal columnar epithelium proximally to squamous epithelium distally, also called anoderm (Fig. 17.1a). The transition is gradual over a distance of 6–12 mm in what is termed the transition zone [2]. Grossly, the change in colour from the red/purple proximal intestinal epithelium to the white distal squamous epithelium is undulated and referred to as the dentate line. As the anal canal is approximately 4 cm in length (variable depending on patient build), the dentate line is approximately 2 cm proximal to the anal verge.

The proximal aspect of the canal is defined by the anorectal ring, comprised of the proximal aspects of the internal and external sphincter muscles as well as the puborectalis muscle (Fig. 17.1b). This important ring forms the junction between the rectum and the anal canal and is critically important during the treatment of perianal sepsis as division of this ring would

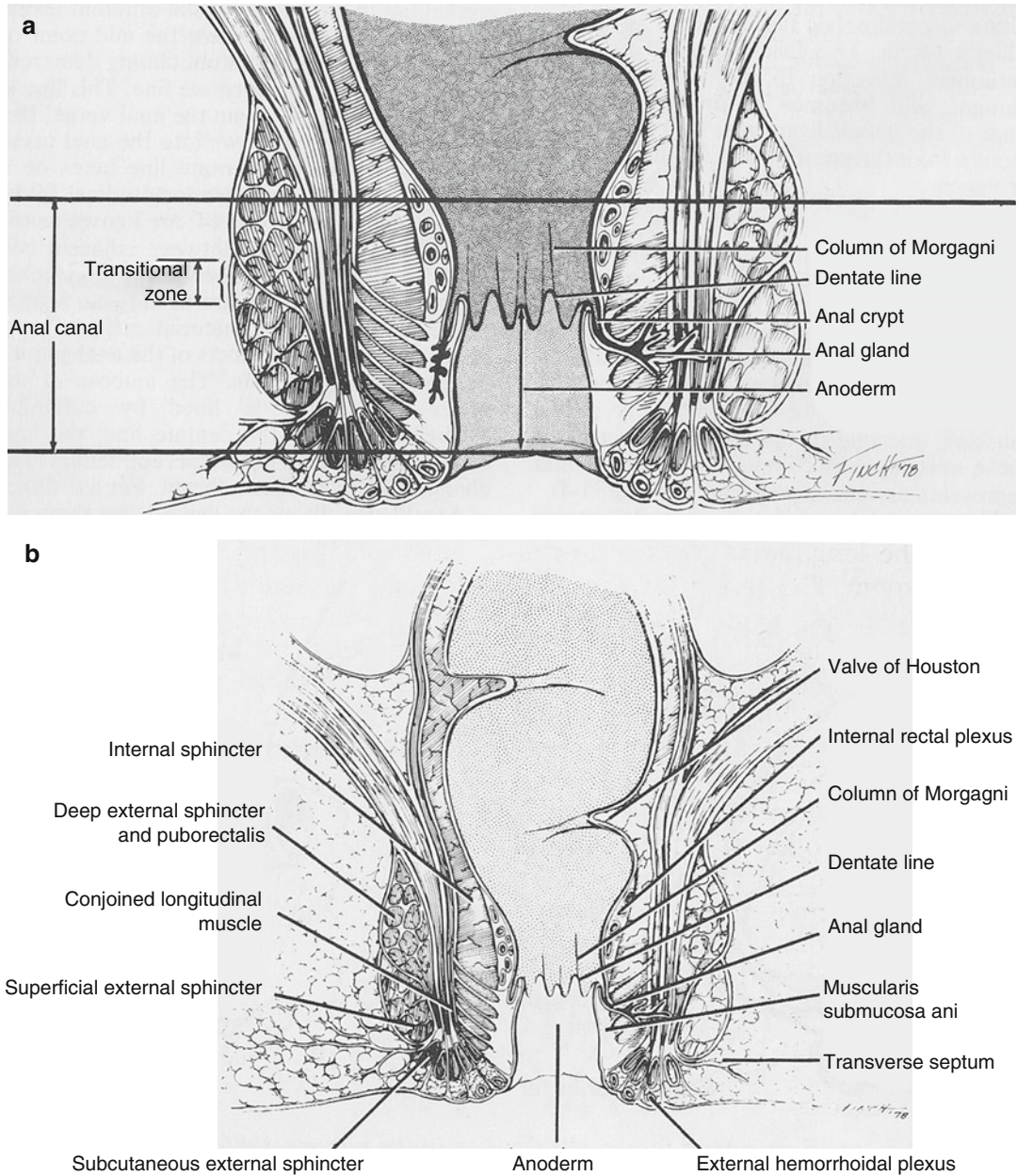


Fig. 17.1 (a) The anal canal [1]. (b) The anorectum [1]

inevitably affect continence. The distal aspect of the anal canal is the anal verge, defined as the area where anoderm becomes true skin characterized by pigmentation, hair, sweat glands and a ring of apocrine glands, which may contribute to the condition hidradenitis suppurativa.

Anal Glands

Because of the diminishing size calibre from rectum to anus, the undulated dentate line area of the anal canal is characterized by a pleated appearance, which is referred to as the columns of Morgagni. At the base of each column, at the

level of the dentate line, there is a small pocket or crypt. About half of these crypts communicate with the drainage ducts of anal glands that are located in the internal sphincter muscle area. These anal glands, which were first described by Hermann and Desfosses in 1844 [3], are located in the submucosal space, the internal sphincter muscle itself, and about half also communicate with the intersphincteric space, without involving the external sphincter muscle. Anal crypts are therefore of significant importance in the pathophysiology of anal sepsis as foreign material lodging itself in a crypt can obstruct the drainage path of anal glands and result in sepsis. The importance of this mechanism was first described by Parks in 1961 [4].

Perianal Spaces

The complex of muscles which surround and form the anal canal create a network of spaces that are of paramount importance in the management of perianal sepsis (Fig. 17.2a).

The *perianal space* is in the immediate area of the anal verge surrounding the anal canal. The lateral aspect is continuous with the subcutaneous fat of the buttocks, while medially, it extends into the anal canal to the dentate line. It includes the distal most aspect of the external sphincter muscle and communicates freely with the intersphincteric space. The space is itself divided by an array of radiating elastic septa that limit communication within the space and account for the severe pain produced by the accumulation of even a small amount of pus.

The *intersphincteric space* is the space between the internal and external sphincter muscles. Proximally it terminates in the rectal wall, while distally, it communicates with the perianal space. This is the space that is often first seeded by sepsis of cryptoglandular origin.

The *ischiorectal space or fossa* is delineated proximally by the levator ani muscle and extends distally to the skin of the perineum. Laterally, along the obturator foramen, it contains Alcock's canal which carries the internal pudendal vessels and nerve.

The *supralelevator spaces* are located proximal to the levator muscle on either side of the rectum. They extend proximally or superiorly to the peritoneal reflection and are limited laterally by the pelvic wall. Sepsis in this area may come from upward extension of perianal sepsis or downward extension of pelvic sepsis. Differentiating the source of sepsis in this space is important for deciding the appropriate route of drainage.

The *postanal space* is directly posterior to the anal canal and altogether distal to the levator ani muscle (Fig. 17.2b). It is divided into *deep and superficial postanal space* based on whether it is deep or superficial to the anococcygeal ligament. This space is of significant importance for understanding the pathophysiology of bilaterally communicating ischiorectal space sepsis, also known as a horseshoe abscess.

Pathophysiology

Anorectal sepsis is a common condition that can occur in healthy, normal individuals. Since anorectal abscesses often lead to fistulae formation, it is reasonable to consider both on the same pathological continuum.

Aetiology

There are several reasons that can account for the development of anal sepsis. Most commonly, the cause is of cryptoglandular origin, whereby anal crypts are obstructed and the drainage path of anal gland secretions is blocked. As a result, pus accumulates and builds in a retrograde fashion often seeding the intersphincteric space [5]. Other notable causes of perianal sepsis include perianal trauma and anal foreign bodies, which can cause abscess formation by the same mechanism as inspissated faecal material in anal crypts. Iatrogenic causes such as surgical wounds, haemorrhoid banding or injection have also been reported to occasionally cause perianal sepsis. More recently, two reviews have been published on stapled hemorrhoidectomy as another potential cause of severe perianal, pelvic and even

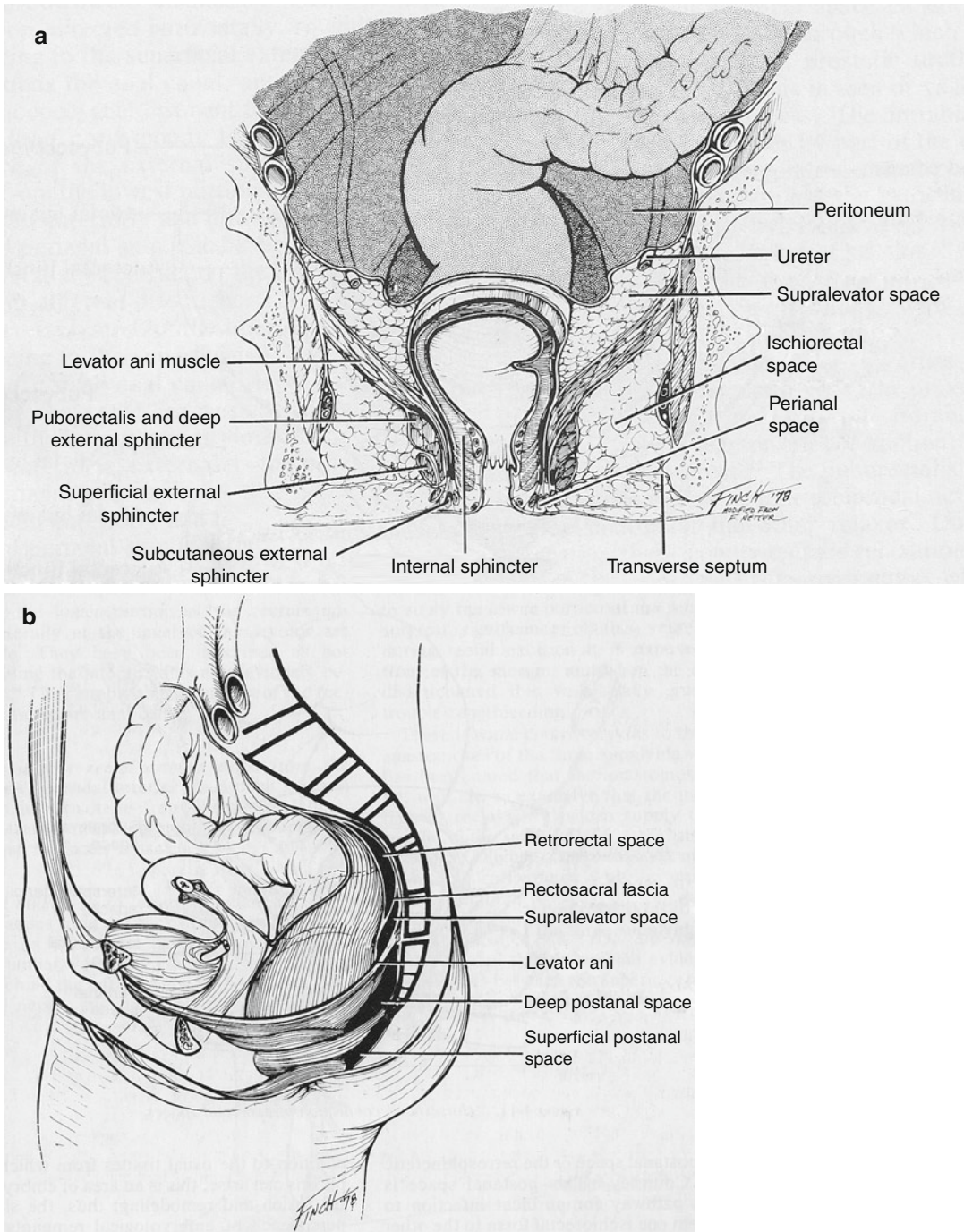


Fig. 17.2 (a) Perianal and perirectal spaces (frontal view) [1]. (b) Perianal and perirectal spaces (lateral view) [1]

intra-abdominal sepsis [6, 7]. Lastly, skin lesions such as hidradenitis suppurativa, localized pyoderma or infection of a sebaceous adenoma are also possible causes of perianal sepsis. Crohn's

disease, while not itself a cause, is a strongly predisposing factor in the development of perianal abscesses, usually via the cryptoglandular mechanism.

Table 17.1 Aetiology of anorectal fistulas

Nonspecific (90 %)	Cryptoglandular
Specific (10 %)	Crohn's disease
	Chronic ulcerative colitis
	Trauma
	Foreign body
	Carcinoma (anal Ca, rectal Ca)
	Leukaemia/lymphoma
	Radiation
	Tuberculosis
	Lymphogranuloma granulorum
	Actinomycosis
	Others

Anal fistulas are also predominantly of cryptoglandular origin and will develop in approximately one-third of patients who undergo drainage of an anorectal abscess. A recent retrospective cohort study of 148 patients with anorectal abscesses showed a 37 % overall rate of fistula formation over a mean follow-up period of 38 months and a twofold increased risk of fistula formation in patients under the age of 40 [8]. While about 90 % of fistulas have a cryptoglandular aetiology, not all fistulas come from antecedent abscesses, and not all abscesses lead to fistula formation. Indeed a previous history of abscess may not be elicited in one-third of patients with anal fistula [9]. The remaining 10 % of anal fistulas have the following specific aetiologies (Table 17.1): anorectal disease, inflammatory bowel disease, infection, malignancy and trauma. It is important to distinguish the aetiology of an anal fistula in order to provide adequate treatment. Indeed, perianal fistulizing disease may be the initial presentation in 10 % of Crohn's patients, preceding the diagnosis by several years, and remains the only manifestation of disease in about 5 % of patients [10].

Bacteriology

Many studies have been performed looking at the bacteriology of pus in anorectal sepsis. A mixed flora of anaerobes, gut-derived gram negative organisms and some aerobic Staphylococcal species are found. Interesting studies have been performed to look at whether the bacteriology profile

could be used to predict fistula formation. One conclusive such study was performed by Grace et al. in 1982 [11]. A prospective study of 165 patients presenting for incision and drainage of perianal abscess over 4 years had their pus sent for cultures. If a fistula was unapparent at the time of the first operation, another examination under anaesthesia was performed 10 days later for a second look, blinded to the culture results. The results were as follows: 54 % of the 114 patients who grew gut organisms were found to have a fistula, while none of the 34 patients who grew skin-derived organisms were found to have one. Other studies since then have confirmed this trend. The clinical implication from these studies is that all perianal abscesses should be cultured and only those that grow gut-derived organisms should be subjected to a second look for fistula formation if none was observed at the initial operation.

Spread of Infection

Perianal sepsis will spread using the path of least resistance. Commonly originating in the intersphincteric space, infection may spread distally into the perianal space, laterally through the external sphincter into the ischiorectal space or proximally along the intersphincteric space causing a supralelevator abscess (Fig. 17.3). Pus can then originate from any of these locations to form complicated tracts that may result in fistula formation. Fistula trajectory can be very difficult to predict in patients with Crohn's disease; however, the majority of ordinary fistulas follow Goodsall's rule whereby tracts with external openings around the anterior half of the anus tend to have straight trajectories toward the nearest crypt, while those with an external opening around the posterior half of the anus will typically have a curved trajectory toward a posterior midline crypt (Fig. 17.4).

Horseshoe Abscess

Perianal sepsis may also spread to affect the contralateral side. This circumferential extension of

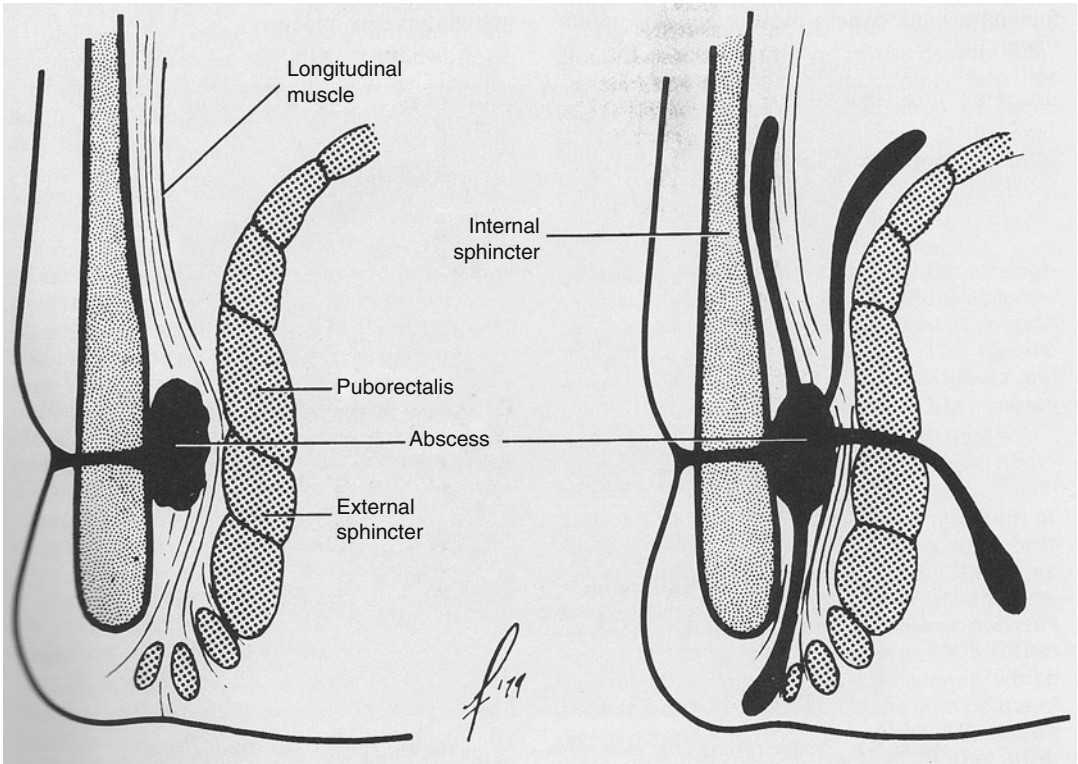


Fig. 17.3 Avenues of extension [1]

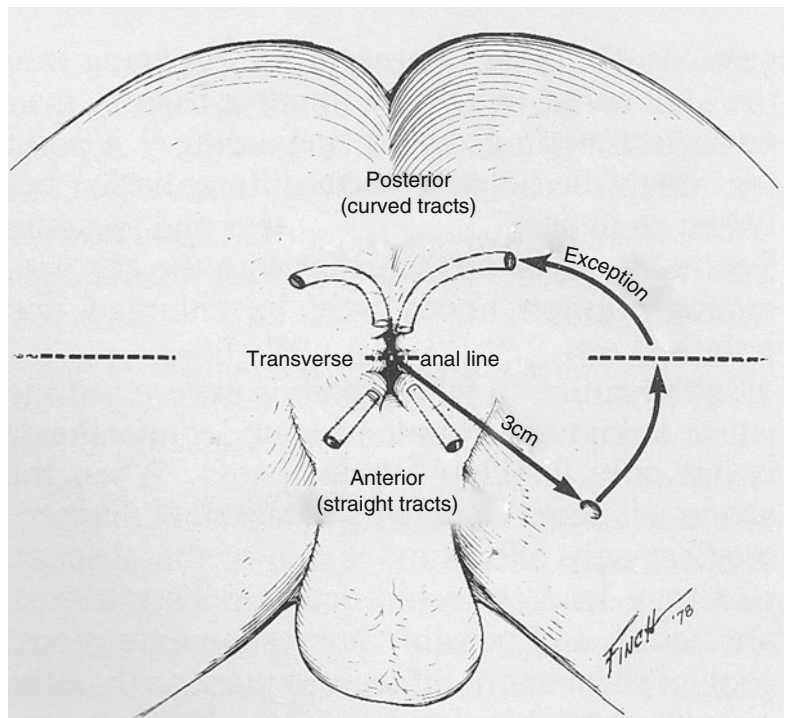
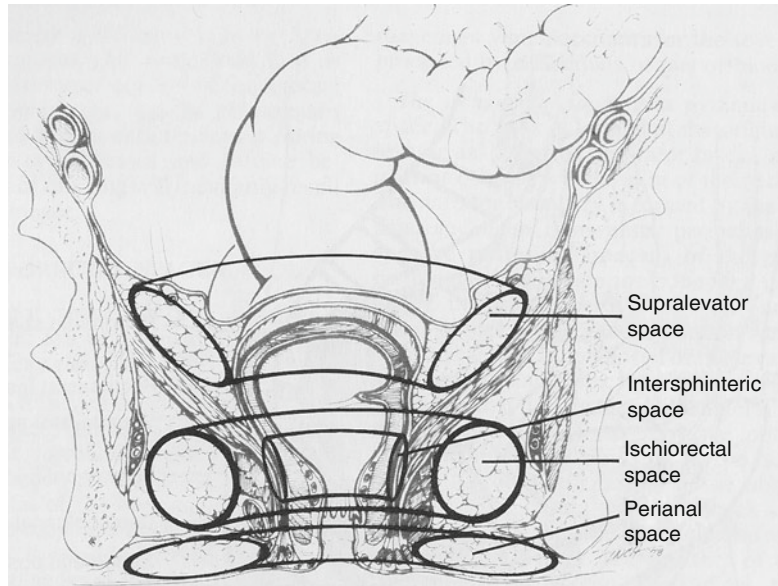


Fig. 17.4 Goodsall's rule [1]

Fig. 17.5 Horseshoe connections of anorectal spaces [1]



infection can occur at any level within the intersphincteric, ischioanal or supralelevator spaces, resulting in a so-called horseshoe abscess (Fig. 17.5). The ischioanal horseshoe abscess courses through the deep postanal space, while the supralelevator horseshoe wraps around the rectum in the retrorectal space.

Presentation

Clinical Presentation

Acute perianal sepsis typically presents with new onset of pain and swelling in the affected area. The pain is aggravated by movement and defecation and sometimes even coughing or sneezing. Systemically, the pain is often accompanied by general malaise and fever. A clinical history may also reveal an antecedent bout of diarrhoea.

In the scenario of an intersphincteric abscess, the pain can often persist undiagnosed. The pain is described as throbbing in character through day and night, and cause extreme pain on defecation to the point of causing secondary faecal impaction. Occasionally, minor anal bleeding and/or purulent discharge may be observed.

In the chronic scenario, the patient will often describe a history of pain followed by spontaneous purulent discharge and subsequent temporary relief. When drainage is incomplete, the abscess cavity may re-accumulate and the internal opening may bleed from chronic granulation tissue.

On examination, the cardinal signs of inflammation are typically present and include redness, swelling, warmth and tenderness. Pus may sometimes be seen or elicited at the internal opening. Perianal abscesses are often more readily visible than ischioanal ones, which can be deeper in the ischioanal fat and harder to palpate. Digital rectal examination is important when tolerated by the patient. A careful rectal exam can sometimes reveal an internal opening, and care should always be taken to also palpate the side opposite the swelling to gain information as to the possible presence of a bilateral process. Intersphincteric abscesses may be devoid of perianal signs but the patient will be exquisitely tender to digital rectal examination and the diagnosis must be differentiated from a fissure. One additional sign, other than a subtle mass-in-ano and/or pus extrusion, is that an abscess may be associated with inguinal lymphadenopathy whereas a fissure will not.

When the pain is severe but no abscess can be readily detected on physical examination, further

Table 17.2 Anorectal abscess classification

Perianal
Ischiorectal
Intersphincteric
Supralelevator

Table 17.3 Parks' classification of fistula-in-ano

Intersphincteric
Transsphincteric
Suprasphincteric
Extrasphincteric

investigations in the form of imaging or examination under anaesthesia are indicated to avoid abscess progression into deeper spaces and/or development of a horseshoe abscess.

Classifications

Anorectal abscesses are classified as listed in Table 17.2. This classification follows from the avenues of infection spread that were discussed in Fig. 17.3. In 1976, Parks and Gordon published the classification of fistula-in-ano listed in Table 17.3 [12].

Special Situation: Fournier's Gangrene

Fournier's gangrene is a rare but potentially devastating condition. It is a mixed microbial infection of aerobic and anaerobic flora, sometimes referred to as a synergistic necrotizing cellulitis, which can have its nidus in the genitourinary tract, gastrointestinal tract or perineal skin. Risk factors include immunocompromise, diabetes, alcohol abuse and paraplegia. The onset can seem like that of a perianal abscess, but the progression is much quicker and far out of keeping with that of a localized abscess. Pain is diffuse, scrotal involvement is common and systemic symptoms and signs can quickly evolve to septic shock and multi-organ failure. Imaging often reveals gas tracking along fascial planes. This diagnosis truly represents a surgical emergency. Management includes a

combination of systemic antibiotics and wide surgical debridement, often requiring a second look and sometimes even faecal diversion. The goal of surgical debridement is aggressive resection of skin and underlying tissue back to healthy bleeding tissue. Despite heightened alertness to this condition and expedited care, this condition carries a high mortality rate [13, 14].

Special Situation: The Immunocompromised Host

Anorectal sepsis in the immunocompromised host represents a special circumstance with uncommon presentation. The typical signs and symptoms are predictably less apparent and abscess progression can evolve more quickly. In a recent review of 83 immunocompromised patients with evidence of perianal sepsis, 28 % were HIV positive, 34 % were on steroids for IBD, 20 % had malignancies and 18 % had diabetes. The average age was 44, and 76 % were male. Most patients (40 %) had both an abscess and fistula at the time of presentation. The distribution of fistulas was similar to the general population, although the incidence of horseshoe abscess was higher at 14 %. Healing and complication rates were also comparable to those of the normal population, suggesting that perianal sepsis can be safely managed in immunocompromised patients, provided the diagnosis is made [15]. Patients with neutropenia will often fail to produce a pus-filled abscess and are therefore preferentially treated with antibiotics, unless there is a fluctuant mass mandating incision and drainage in addition to antibiotics [16].

References

1. Goldberg SM, Gordon PH, Nivatvongs S. Essentials of anorectal surgery. Philadelphia: J. B. Lippincott Company; 1980.
2. Morson B, Dawson I. Gastrointestinal pathology. Oxford: Blackwell Scientific Publications; 1972.
3. Hermann G, Desfosses L. Sur la muqueuse de la region cloacale du rectum. C R Seances Acad Sci. 1880;90:1301-4.

4. Parks AG. Pathogenesis and treatment of fistula-in-ano. *Br Med J*. 1961;1(5224):463–9.
5. Goligher JC, Ellis M, Pissidis AG. A critique of anal glandular infection in the aetiology and treatment of idiopathic anorectal abscesses and fistulas. *Br J Surg*. 1967;54(12):977–83.
6. Cirocco WC. Life threatening sepsis and mortality following stapled hemorrhoidopexy. *Surgery*. 2008; 143(6):824–9.
7. van Wensen RJ, van Leuken MH, Bosscha K. Pelvic sepsis after stapled hemorrhoidopexy. *World J Gastroenterol*. 2008;14(38):5924–6.
8. Hamadani A, Haigh PI, Liu IL, Abbas MA. Who is at risk for developing chronic anal fistula or recurrent anal sepsis after initial perianal abscess? *Dis Colon Rectum*. 2009;52(2):217–21.
9. Read DR, Abcarian H. A prospective survey of 474 patients with anorectal abscess. *Dis Colon Rectum*. 1979;22(8):566–8.
10. Ingle SB, Loftus Jr EV. The natural history of perianal Crohn's disease. *Dig Liver Dis*. 2007;39(10):963–9.
11. Grace RH, Harper IA, Thompson RG. Anorectal sepsis: microbiology in relation to fistula-in-ano. *Br J Surg*. 1982;69(7):401–3.
12. Parks AG, Gordon PH, Hardcastle JD. A classification of fistula-in-ano. *Br J Surg*. 1976;63(1):1–12.
13. Rotstein OD, Pruett TL, Simmons RL. Mechanisms of microbial synergy in polymicrobial surgical infections. *Rev Infect Dis*. 1985;7(2):151–70.
14. Thwaini A, Khan A, Malik A, et al. Fournier's gangrene and its emergency management. *Postgrad Med J*. 2006;82(970):516–9.
15. Munoz-Villasmil J, Sands L, Hellinger M. Management of perianal sepsis in immunosuppressed patients. *Am Surg*. 2001;67(5):484–6.
16. North Jr JH, Weber TK, Rodriguez-Bigas MA, Meropol NJ, Petrelli NJ. The management of infectious and noninfectious anorectal complications in patients with leukemia. *J Am Coll Surg*. 1996; 183(4):322–8.