

# 13

## Rectovaginal Fistulas

Rebecca G. Rogers and Dee E. Fenner

### 13.1 Introduction

There are few afflictions unattended with danger to life, which give rise to greater anxiety or produce more disagreeable results than cases of rectovaginal fistula.<sup>1</sup>

T.H. Tanner, 1855

Rectovaginal fistula is defined as a communication between the rectum and the vagina. Although relatively rare, the impact on quality of life of patients may be profound. Causes include traumatic, congenital, inflammatory, neoplastic and iatrogenic processes (see Table 13.1). While estimates vary, the most common cause of rectovaginal fistulas is thought to be secondary obstetrical complications, followed by inflammatory and neoplastic disorders.<sup>2-4</sup> Fistulas that occur as a result of congenital malformations are beyond the scope of discussion in this chapter. Only the presentation and repair of acquired fistulas with particular emphasis on fistulas that occur as a result of obstetrical trauma will be presented.

The majority of fistulas are not true rectovaginal fistulas but rather inflammatory tracts from the rectum and perineum that result from either infected anal glands or inflammatory bowel disease. Collectively, rectovaginal fistulas represent less than 5% of all fistulas.<sup>5-7</sup>

Inflammatory anorectal fistulas that tract into the vagina can become rectovaginal fistulas once the inflammation has resolved. Processes that cause these types of rectovaginal fistulas include inflammatory bowel disease, particularly Crohn's disease, as well as infections of the anorectal region.<sup>3</sup> Inflammatory fistulas can also occur as a result of a vaginal delivery. Typically, these fistu-

las are lined with inflammatory tissue, are painful on palpation and associated with a purulent discharge.<sup>7</sup> These inflammatory fistulas are collectively termed fistula-in-ano.

Of particular importance to the practising obstetrician and gynaecologist are rectovaginal fistulas that occur as a complication of either vaginal birth or gynaecologic surgeries. Whenever a postpartum or post-gynaecological surgery patient presents with complaints of faecal or flatal incontinence, rectovaginal fistula should be included in the differential diagnosis. Healed fistulas of obstetrical or gynaecologic origin are epithelial lined communications between the rectum and/or anus and the vaginal canal.

### 13.2 Historical Background

Obstetrical fistulas have plagued women for millennia, as proven by the discovery of a large fistula in a mummy of an ancient Egyptian woman. Avicenna, an Arabo-Persian physician, was the first to describe fistulas as a result of difficult labours.<sup>8</sup> The history of the surgical treatment of rectovaginal fistulas lies in the evolution of the treatment of vesicovaginal fistulas. The first attempts at surgical repairs of fistulas were of vesicovaginal fistulas and made by H. van Roonhuysen in 1676, who placed patients in lithotomy, exposed the fistula with a speculum and denuded the edges of the fistula before suturing it together.<sup>9</sup> The first cure of a rectovaginal fistula is credited to Barton in 1840 with the use of a seton.<sup>10</sup> In the late nineteenth century, a number of surgeons

**TABLE 13.1.** Aetiology of rectovaginal fistula.

Category	Condition	Mechanism	
Traumatic			
Obstetric	Prolonged second stage of labour	Pressure necrosis of rectovaginal septum	
	Midline episiotomy	Extension directed into rectum	
	Perineal lacerations		
Foreign body	Vaginal pessaries	Pressure necrosis	
	Violent coitus	Mechanical perforation	
	Sexual abuse	Mechanical perforation	
Iatrogenic	Hysterectomy	Injury to anterior rectal wall	
	Stapled colorectal anastomosis	Staple line includes vagina	
	Transanal excision of anterior rectal tumour	Deep margin of resection into vagina	
	Enemas	Mechanical perforation	
	Anorectal surgery such as incision and drainage of intramural abscesses	Mechanical perforation	
	Inflammatory	Crohn's disease	Transmural inflammation-perforation
		Pelvic radiation	Early-tumour necrosis
		Pelvic abscess	Late-transmural inflammation
	Neoplastic	Perirectal abscess	
		Rectal	Local tumour growth into neighbouring structure
Cervical			
Uterine			
Vaginal			
	Primary or recurrent tumours		

From: Stenchever and Benson.<sup>44</sup>

introduced innovations to the repair of vesicovaginal fistulas that were then popularised by James Marion Sims in a series of surgical experiments conducted from 1845 to 1849. Operating on three slave women over 6 years with more than 40 failed procedures, Sims managed surgically to close a vesicovaginal fistula. He attributed his success to the use of silver suture and the exposure of the operative site that he achieved with positioning the patient in the knee-chest position and the use of a speculum. Although he claimed credit for all of these innovations, others had utilised silver suture for the repair of fistulas prior to his publication.<sup>8</sup>

Rectovaginal fistulas, which occur less commonly than vesicovaginal fistulas, are also less commonly referred to in historical reports. The first treatise on the treatment of rectovaginal fistula was probably by a student and successor of Sims, Thomas Addis Emmet, who published a book *Vesico-vaginal fistula from parturition and other causes: with cases of recto-vaginal fistula* in 1868.<sup>11</sup> Emmet greatly expanded the work of his mentor and introduced many surgical innovations and principles of fistula repair that are still followed today. He insisted on preoperative preparation so that “not only the vaginal walls but also the hypertrophied and indurated edges of the fistula have attained a natural color and density” prior to taking the woman to surgery. The repairs were done without anaesthesia, in the left lateral position, and began with release of tension on the scarred edges of the fistula. Repairs often required staged procedures in order to close the fistula fully. Emmet advocated the use of scissors to achieve wide dissection of the tissues surrounding the fistula, and, for vesicovaginal fistulas, continual bladder drainage following the repair. These innovations were novel. Emmet was a meticulous surgeon and scientific investigator and probably is the true father of gynaecological reconstructive surgery.<sup>12</sup> Further advancements in the repair of rectovaginal fistulas in the late nineteenth century include the adaptation of Tait's technique of perineorrhaphy at the time of repair of the fistula. Until then, repairs of the fistulas were limited to splitting apart the perineum and allowing the perineum to heal by granulation, often with poor functional results.<sup>13</sup> These historical reports underline the basic tenets of the repair of rectovaginal fistulas today: tissue must be free from infection and induration, repairs need to be accomplished with wide dissection of the vaginal tissues so that sutures are not under tension, and attention needs to be paid to the perineum and sphincter complex to ensure that functional outcomes are optimal.

### 13.3 Incidence

Although the exact incidence of rectovaginal fistulas is unknown, the most common aetiology in the developed world is still thought to be obstetri-

cal, with approximately 0.1% of vaginal births resulting in a rectovaginal fistula.<sup>2,14</sup> The incidence of rectovaginal fistulas in the population of women who sustain a fourth degree laceration is higher and ranges from 0.4 to 3.0%. Infection of the perineal wound following delivery may contribute to the occurrence of a fistula in these cases.<sup>2,14–21</sup>

Fistulas secondary to obstructed labour are rare in the developed world but common worldwide. The exact prevalence of fistulas secondary to obstructed labour is unknown: in 1989, the World Health Organization estimated that more than 2 million girls and women around the world had either rectovaginal or vesicovaginal fistulas, estimates that probably underestimate the extent of the disease because they are based on women who present for care.<sup>22</sup> Isolated incidence rates for rectovaginal fistula do not exist; however, rates of vesicovaginal fistula in sub-Saharan Africa may reach up to 350 women per 100,000 live births.<sup>23</sup> These fistulas differ from direct obstetrical trauma associated with a severe perineal laceration at the time of delivery because they are accompanied by widespread tissue destruction and necrosis. While rectovaginal fistulas occur more rarely than vesicovaginal fistulas as a result of obstructed labour, approximately 17% of fistulas seen at a large fistula centre in Addis Addaba, Ethiopia were either isolated rectovaginal fistulas or combined rectovaginal and vesicovaginal fistulas.<sup>24</sup> Another series by Ayhan reported that 19% of 182 vesicovaginal fistula patients also had intestinal fistulas.<sup>25</sup> Double fistulas (rectovaginal and vesicovaginal) in this population are indicative of a poorer prognosis for surgical cure.

## 13.4 Classification

Various classification schemes have been proposed for rectovaginal fistulas. No standardised system has been adopted, which has limited the ability to compare results from surgical series or to define the incidence of disease. One system divides fistulas into “simple” and “complex”. Simple fistulas occur in the low or mid-vagina, are less than 2.5 cm in diameter, and are the result of trauma or infectious causes, while complex fistulas occur high in the vagina, are greater than 2.5 cm in diameter, and may occur from inflam-

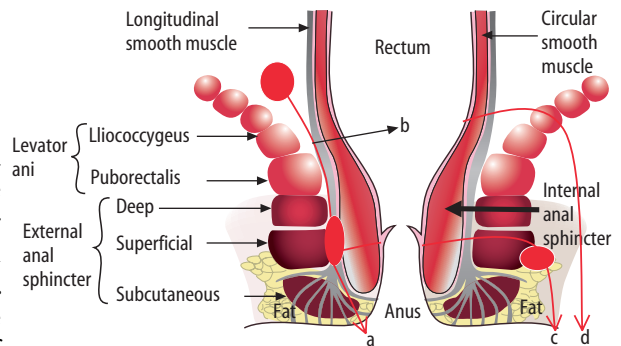
**TABLE 13.2.** Classification of rectovaginal fistulas.

Simple rectovaginal fistula	Complex rectovaginal fistula
Low or mid vagina ≤ 2.5 cm	High vagina >2.5 cm
Traumatic or infectious cause	Inflammatory bowel disease, irradiation, neoplastic causes, prolonged obstructed labour Failed prior repair

Modified from: Rothenberger and Goldberg.<sup>6</sup> Copyright 1983, with permission from Elsevier.

matory bowel disease, irradiation or other neoplastic causes.<sup>6</sup> Fistulas that have failed prior repair or result from prolonged obstructed labour should probably be added to the list of “complex fistulas” regardless of where the communication between rectum and vagina occurs<sup>12,24</sup> (Table 13.2). Other classification schemes divide fistulas by anatomic descriptions: high fistulas occur in the upper third of the vagina where the vagina is covered only by peritoneum, fistulas in the middle third of the vagina occur where there is only a thin septum between the vagina and rectum, and distal fistulas occur where the vagina and the anal canal are separated by the perineal body.<sup>26</sup>

Inflammatory fistulas are classified according to their relationship to the anal sphincter, dividing them into four main types: intersphincteric, trans-sphincteric, suprasphincteric and extrasphincteric<sup>27</sup> (Figure 13.1). This classification scheme helps to dictate the approach to surgical drainage of these inflammatory fistulas. Other classification schemes have included combinations of



**FIGURE 13.1.** Diagrammatic representation of types of fistula. **a** intersphincteric, **b** suprasphincteric **c** transsphincteric, **d** extrasphincteric. (Courtesy of A. Sultan and R. Thakar.)

the above as well as the addition of horseshoe fistulas.<sup>28</sup> Each of the above categories for inflammatory fistulas has multiple variations; fistulas of these types may be very extensive, involving the entire pelvis.

### 13.5 Pathophysiology

The pathophysiology of rectovaginal fistulas varies by aetiology including obstetrical and other traumatic causes, inflammatory bowel disease, infectious aetiologies and neoplastic processes.

#### 13.5.1 Obstetrical Fistulas

Obstetrical fistulas can occur as the result of direct trauma or as part of more global damage to the tissues of the pelvic floor. Obstetrical fistulas in the developed world are thought to occur through direct trauma to the rectovaginal septum and perineal body. Risk factors for third and fourth degree laceration of the anal sphincter are also thought to increase the risk for fistula formation and include episiotomy, operative vaginal delivery, as well as secondary infection of a repaired laceration.<sup>4,5</sup>

Failure to recognise injuries and inadequate repair have been implicated in the aetiology of rectovaginal fistulas.<sup>29</sup> Repair of obstetrical lacerations are often performed under suboptimal conditions with poor lighting, in an operative field contaminated by faecal material, and with lack of analgesia and surgical assistance. Identification and repair of severe lacerations is paramount to effective repair and may require moving a patient from the delivery room to the operating room to perform an examination under anaesthesia to determine the full extent of lacerations after a delivery. At the very least, a rectal examination with adequate lighting and analgesia is indicated, especially after an operative delivery, to detect lacerations to the rectovaginal septum. One study has determined that a second observer increased detection rates for severe lacerations by 15%, indicating that determining the extent of pelvic floor damage following delivery may be difficult under poor operative conditions with a single examiner.<sup>30</sup> Careful documentation of the extent

of the laceration, the repair performed, as well as the type of suture used should also be recorded. Repair of obstetrical lacerations is an operative procedure and should be documented in the medical chart as such.

Missed fourth degree lacerations with repair only of the perineum and not the sphincter or rectal mucosa may result in immediate postpartum incontinence or lead to infection followed by incontinence more remote from delivery. "Buttonhole" fistulas can also be missed at the time of delivery. These fistulas can occur above an intact perineum when a vaginal tear has extended into the rectum. Both missed fourth degree lacerations and buttonhole lacerations underline the importance of a careful rectal examination after delivery. These fistulas usually result in immediate incontinence postpartum. Any postpartum women with anal incontinence should be re-examined with adequate analgesia to ensure that a fistula is not present.

Fistulas can also occur after perineal repair of an obstetrical laceration that becomes infected or more rarely when a stitch from a repair transgresses the bowel lumen. These fistulas commonly present more remote from delivery after an infection of the wound and breakdown of the obstetrical repair. Debridement of the infected wound, removal of residual suture material and antibiotic therapy are essential prior to attempting repair of these fistulas. Although early repair of infected severe perineal lacerations has been described, repairs were only successful after daily extensive inpatient debridement of the perineal wound and antibiotic therapy until all signs of infection were resolved. More commonly, delaying repair until the inflammatory processes are completely resolved over a 2- to 3-month period is prudent.

Associated trauma to the anal sphincter complex is common in women with rectovaginal fistulas and should be evaluated by physical examination at the time of delivery as well as in the patient who presents remote from delivery with a rectovaginal fistula. Overt anal sphincter injury occurs in up to 6.4% of women after vaginal birth.<sup>32-35</sup> However, occult sphincter injuries are much more common and range in incidence from 6.8 to 44% of parous women. Sphincter disruption can probably be assumed to be even higher in women with rectovaginal fistulas.<sup>36,37</sup> The rate of

preoperative anal incontinence secondary to a disrupted sphincter has been reported as high as 48% in a series of 52 patients with rectovaginal fistulas.<sup>4,38</sup> Further evaluation of the anal sphincter complex including ultrasound, manometry and neurological studies has been recommended for the preoperative workup for any patient who presents with an obstetrically related fistula.<sup>4</sup>

Fistulas that occur as the result of obstructed labour form after “sloughing” of vaginal tissue that has become necrotic from pressure of the fetal head. Typically, the sloughing follows a week after the delivery of the fetus after a prolonged labour lasting more than 2 days. A fistula “field injury” including rectovaginal and/or vesicovaginal fistula, global pelvic floor dysfunction and foot drop has been described and is indicative of widespread pelvic tissue and neurological damage. Part of the “field injury” includes the massive social displacement of the fistula patient from their families and communities.<sup>24</sup>

### 13.5.2 Other Traumatic Causes

Other traumatic causes of fistula formation include a neglected foreign body such as a pessary that has been in place for many years without removal.<sup>39,40</sup> Erosion of vaginal pessaries into either the rectum or the bladder is extremely rare and is documented in the literature only in the form of case reports. Violent coitus or sexual abuse is similarly reported.<sup>41</sup>

Fistula formation after hysterectomy can occur after injury to the anterior rectal wall, and is also rare. One large series of 3,076 women who underwent vaginal hysterectomy had a reported incidence of rectal injuries of 0.5% and all of the injuries healed without the formation of a fistula.<sup>42</sup> Other authors have reported a similarly low incidence of 0.07% of rectal laceration as a complication of vaginal hysterectomy; all of the injuries were repaired primarily and none resulted in the formation of a fistula.<sup>43</sup> Stapled colorectal anastomosis, transanal excision of anterior rectal tumour with the deep margins of the resection into vagina, anorectal surgery such as incision and drainage of intramural abscesses and mechanical perforation have also been cited as rare causes of rectovaginal fistula formation.<sup>44</sup> The percentages of rectovagi-

nal fistulas resulting from “operative” or “iatrogenic” causes reported in case series of patients in the literature range from 2 to 24% and are largely dependent on the referral practice of the physician.<sup>45–50</sup>

### 13.5.3 Inflammatory Bowel Disease

Patients with Crohn’s disease have a reported lifetime risk of development of an anorectal or perineal fistula that ranges from 20 to 40%, with one series reporting a risk of development of a rectovaginal fistula in 9% of Crohn’s patients.<sup>51</sup> Rectovaginal fistulas may result from rupture of a cryptoglandular abscess or more commonly from deep ulcerations of the anterior rectal canal. Anorectal and presumably rectovaginal fistulas occur in women with colonic disease more commonly than in those with disease confined to the small intestine.<sup>28,51,52</sup>

### 13.5.4 Infectious Causes

Any infectious process contiguous with the rectovaginal septum can result in the formation of a fistula. The majority of these fistulas are thought to be the result of cryptoglandular infection; however, tuberculosis, lymphgranuloma venereum and schistosomiasis have all been reported to cause fistulas rarely. Diverticulosis is the most common cause of high rectovaginal fistulas, with women who have undergone a prior hysterectomy at higher risk.<sup>3–5</sup>

### 13.5.5 Neoplastic Causes

Fistulas can occur as a result of direct tumour extension into the rectum, or as the result of pelvic radiation, especially for endometrial and cervical cancers. The rates of rectovaginal fistula formation after irradiation for endometrial or cervical cancer range from 1 to 10%.<sup>4–6</sup> The development of these fistulas may occur as late as 2 years after therapy and is often preceded by the new onset of rectal bleeding. The evaluation of a fistula following treatment for neoplasm should include pathological evaluation of tissue to rule out tumour recurrence.

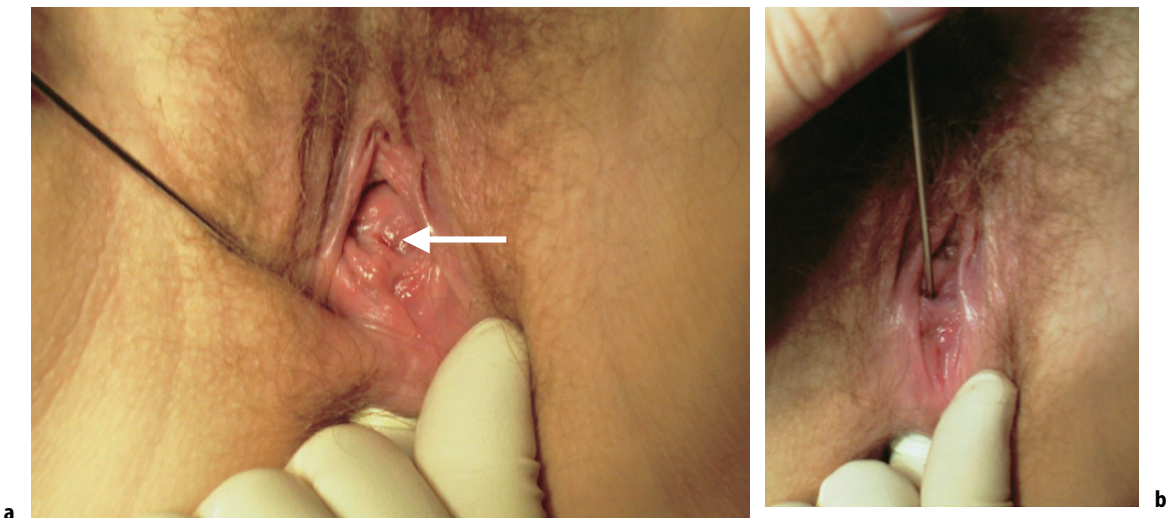
### 13.6 Diagnosis and Evaluation

Evaluation of a patient begins with a history and physical examination to determine the size, location and aetiology of the rectovaginal fistula. Women with very distal fistulas may be largely asymptomatic while women with fistulas that are large and involve the anal sphincter complex may have frank loss of stool. Women with small inflammatory fistulas may have only a purulent discharge and complain of pain without loss of bowel contents.

A thorough perineal examination, including observation of the anal opening as well as the perineal skin is warranted. Perianal dimpling and/or a “dovetail sign”, which consists of perianal folds posterior to the anal opening with smooth mucosa anteriorly, may indicate a disrupted anal sphincter as well as the presence of a fistula. Observation of the perineal skin for faecal material as well as noting loss of flatus during an examination warrants further inquiry and investigation on the part of the provider. Women with loss of faecal material have proven reluctant to seek help or acknowledge the condition. In a prospective cohort study of 94 women only a few of the 38% of women with symptoms of anal incontinence had sought evaluation due to embarrassment, socioeconomic reasons or lack of knowledge of where to obtain

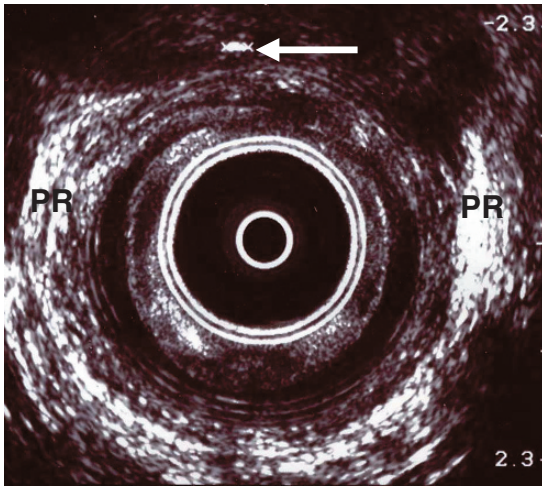
help.<sup>53</sup> An observant sensitive provider can enable a woman to seek care for this disabling condition.

Often the fistula can be visualised on rectovaginal examination, although this may be difficult with small fistula tracts (Figure 13.2). A rectal examination is also important to determine the integrity of the anal sphincters, the quality of the tissues surrounding the fistula, and to palpate for abscesses and other masses. The most likely location of the vaginal opening of the fistula is along a perineal or vaginal scar following episiotomy or laceration. On the rectal side, the most common location for the opening of the fistula is at the dentate line or superior edge of the external anal sphincter. Dimpling or retraction of the epithelium is often seen. Careful probing with a small lacrimal probe can help identify the opening (Figure 13.2). With a finger in the rectum, the probe can be passed through the fistula to the rectal side. Most patients tolerate this manipulation without pain unless there is active infection. If the fistula is not easily identified, placing methylene blue dyed lubricant in the rectum, massaging the rectovaginal septum and observing the posterior vaginal wall for extravasation can help to identify the fistula. Other techniques include the instillation of methylene blue stained fluid into the rectum via a large Foley catheter with a



**FIGURE 13.2.** **a** Small rectovaginal fistula opening on posterior vaginal wall (*arrow*). **b** The rectovaginal fistula track is demonstrated by inserting a lacrimal probe through the vaginal opening. (Courtesy of A. Sultan and R. Thakar.)





**FIGURE 13.3.** Endoanal ultrasound demonstrating the level of rectovaginal fistula track just above the level of the puborectalis (PR). (Courtesy of A. Sultan and R. Thakar.)

30-cc balloon that can be used to occlude the anal canal. The rectum can also be insufflated with air, while the vagina is filled with water or saline. Bubbling may indicate the site of the fistula. The use of barium enemas, contrast material placed vaginally, and hydrogen peroxide injected into the fistulous tract with an angiocath may help to define the exit or entrance to the tract.<sup>54</sup>

Endoanal ultrasound is indicated to identify concurrent sphincter laceration, and can also identify fistulous tracts (Figure 13.3).

In general, a mature epithelialised fistula that is not infected is not painful on digital examination. If the fistula cannot be identified or if it is too painful, an examination should be performed under anaesthesia. Office anoscopy or proctoscopy may also help to evaluate the surrounding tissues or to identify the fistula. In women where inflammatory bowel disease is suspected by history or physical examination, colonoscopy is warranted. Biopsy of the fistulous tract is indicated when neoplasia is suspected.

### 13.7 Repair Techniques

The approach to repair of rectovaginal fistulas should be dictated by the complexity of the fistula, its size and location as well as its cause.

For example, high fistulas are probably better addressed by abdominal procedures while distal fistulas are better addressed by transvaginal, transperineal or transrectal procedures. The tenets of repair of obstetrically related rectovaginal fistulas date back to the innovations and recommendations made nearly 135 years ago: repair without tension, an operative field free from infection or inflammation, wide mobilisation of the tissue surrounding the fistulous tract, excision of the tract if possible, and care to avoid strain on the repair in the immediate postoperative period. Most authors state that the fistula needs to be completely free from inflammation or induration, with waits as long as 3–6 months suggested before repair of obstetric fistulas be undertaken.<sup>53,54</sup>

However, a recent series of 1,716 obstetric vesicovaginal fistulas reported that patients were treated with early closure of their fistula even if all induration had not resolved by the time of surgery. Twelve per cent of these women also had rectovaginal fistulas. The primary closure rate for the fistulas was 92%, with low rates of postoperative infection, indicating that early closure may be possible after debridement of necrotic tissue.<sup>55</sup> If the local tissues have active infection and faecal contamination that does not respond to local measures, or the patient has a complex recurring fistula, a diverting colostomy is indicated until the tissue is suitable for repair.

Mechanical and antibiotic treatments, accompanied by a restricted diet for 1–3 days prior to surgery are often recommended, although no randomised data support these practices. A recent review of six randomised trials evaluating bowel surgery compared patients undergoing mechanical bowel preparation to those with no preparation and found no difference in wound infection rates (44/595 vs 35/609, OR 1.34, 95% CI 0.85–2.13) or other parameters measured, suggesting that these practices may need to be revisited.<sup>56</sup>

In general, distal rectovaginal fistulas are repaired transvaginally (as preferred by gynaecologists), transrectally (as preferred by colorectal surgeons) or transperineally. All three repair methods have similar reported success rates. Adherence to the basic tenets of fistula repair is probably more important than surgical approach to the success of the intervention.

Transvaginal repair methods include conversion of the fistula to a complete fourth degree laceration followed by excision of the fistulous tract and a layered closure. In the case of a fistula that is not accompanied by anal sphincter disruption, this entails damaging an intact sphincter. Given poor rates of success with sphincteroplasty at long-term follow-up,<sup>57-60</sup> this practice may not be in the patient's best interest. Other transvaginal repairs include inversion of the fistulous tract, followed by a layered closure. This method will spare an intact sphincter complex. The Latzko technique is a variation of this where the anterior and posterior walls of the vagina are joined to invert the fistula into the rectum. This closes off a portion of the upper vagina and is suitable for high fistulas.

Transvaginal repair of rectovaginal fistulas secondary to obstructed labour is influenced by the size of these fistulas (on average 2.3 by 2.5 cm) and the fact that the fistulas exist in a bed of severely damaged tissue. Excision of the fistulous tract may be impossible because of the size of the fistula and most authors introduce healthier tissue in the form of a Martius graft to ensure adequate blood supply to the area.

The transperineal approach starts with a curved incision on the perineum, through which the vagina and rectum are separated. The fistula is then divided and both the vaginal and rectal sides of the fistula are closed in layers in opposing directions so that the lines of the repair do not directly overlie one another.<sup>13</sup>

Transrectal repairs generally involve the development of rectal mucosal flaps, mobilised to cover the excised fistula tract. In these repairs, the rectal mucosa, submucosa with or without a portion of the rectovaginal septum and internal anal sphincter is mobilised. The fistula is excised and the flap is sutured over the previous site of the fistula. Proponents of this method of repair state that the high-pressure side of the fistula is in the rectum and that this approach focuses the repair on the rectal side. The vaginal side may be closed or left open to drain.

The best suture material for repair of fistulas has not been studied. Most series report the use of a delayed-absorbable suture, such as a 3-0 poly-sorb, or polyglycolic acid on all layers. Permanent suture is not used. The use of either a Martius fat

pad, or gracilis flap to bring well-vascularised tissue to the fistula site is widely recommended for the repair of complex fistulas.<sup>61,62</sup>

Abdominal approaches to high and complex fistulas secondary to radiation therapy, inflammatory bowel disease or multiple failed prior repairs include wide mobilisation of the rectovaginal septum, division of the fistula and layered closure with or without bowel resection. Usually omentum is introduced as a pedicled graft. Low anterior resections, colorectal anastomoses, and onlay patch anastomosis procedures have all been described. For women who have underlying disease not amenable to other surgical intervention, colostomy as a salvage operation may greatly improve quality of life.<sup>4,6,38</sup>

Postoperative management has not been studied extensively, but many surgeons recommend a restrictive diet including 3 days of clear liquids followed by a low-residue diet as well as the continuation of broad-spectrum antibiotics. A single randomised study of 54 patients undergoing other anorectal reconstructive surgery randomised patients to either a "regular" diet versus a "bowel confinement" regimen and found no benefit to dietary restriction.<sup>63</sup> Local care including sitz baths, followed by drying with a heat lamp or blow dryer is commonly recommended to keep the operative site clean and dry.<sup>54</sup>

### 13.8 Outcome of Surgery

Reports of success rates for rectovaginal fistula repair are largely limited to the success of closure of the fistula with little description of quality of life changes or functional outcomes. The literature is also limited by small retrospective series of patients with limited follow-up, inclusion of patients with different aetiologies for the fistula and lack of a standardised classification schema to make comparisons between reports. A thorough evaluation of the anal sphincter complex with associated sphincter repair may greatly influence surgical cure rates. If the fistula is closed, but the sphincter non-functional, the outcome may be less than desired for the patient. Reports of sexual function following fistula repair are limited to descriptions of the effect of a Martius graft on



function: Elkins reported on six patients with rectovaginal fistulas who were repaired with grafts, one of whom complained of mild dyspareunia.<sup>62</sup> Others have reported up to a 38% incidence of pain at the site of graft harvest in small series.<sup>64</sup>

Medical management of fistulising Crohn's disease includes anti-inflammatory medications, antibiotics, immunomodulators and anti-tumour necrosis factor-alpha therapies. Success of these interventions varies widely.<sup>28</sup> Inflammatory fistulas secondary to an acute infectious process or Crohn's disease are better addressed by either seton placement (loose nylon suture along fistula tract) or fistulotomy and drainage. For the treatment of simple perianal fistulas, reported rates of healing for these interventions range from 70 to 100%, with minor incontinence reported in 10% of individuals. Recurrence may occur up to 20% of the time.<sup>28</sup> For more complicated fistulas, or recurrent fistulas in the face of active rectal Crohn's disease with multiple tracts, surgery including seton placement, fistulotomy or advancement flaps shows improvement in symptoms in 25–100% of patients, with fistula recurrence rates up to 67%.<sup>28</sup>

Repair success rates of simple (less than 2.5 cm in size located in the distal rectovaginal septum) rectovaginal fistulas range from 40 to 86%.<sup>38</sup> In one summary of results from repair of simple rectovaginal fistula, recurrence rates ranged from 3% for perineoproctotomy to 12% for transanal advancement flaps. As the author pointed out, many series report operating on another surgeon's failures, which is not always figured into reports of primary closure rates.<sup>65</sup>

Cure rates for more complex obstetrically related rectovaginal fistulas secondary to obstructed labour are lower than reported rates for vesicovaginal fistulas: 78% for either combined vesicovaginal and rectovaginal fistula or isolated rectovaginal fistula, versus a widespread reported cure (or closure) rate of 90% for isolated vesicovaginal fistula.<sup>66</sup> Nearly all the literature describing the treatment of these complex fistulas is retrospective in nature and because of geographical barriers, most follow-up is limited to hospital discharge. All of these reports focus on the repair of vesicovaginal fistulas. Arrowsmith reported on 98 vesicovaginal fistula patients, of

whom nine had combined fistulas. However, he does not further describe the outcomes of this small cohort of combined rectovaginal fistulas.<sup>66</sup> Another series by Ayhan et al. reported that 19% of 182 patients had intestinal fistulas; the overall success rate for this series of patients was reported at 91%, with no further evaluation of the effect of rectovaginal fistula on surgical cure rates. Both surgical and obstetrical fistulas were represented in this cohort; however, the majority of the fistulas (76%) were obstetrical in origin.<sup>25</sup> A series by Kelly reports a similar cure rate of 85%, with approximately 20% of patients with either isolated or combined rectovaginal and vesicovaginal fistulas. Again the impact of rectovaginal fistulas on the cure rate was not analysed: however, even among this series of difficult fistulas, the author did classify rectovaginal fistulas as "complex".<sup>67</sup>

Elkins reported a series of fistula patients that he followed for 6 months. Women with combined vesicovaginal and rectovaginal fistulas had poorer outcomes than those with vesicovaginal fistulas alone, with success rates of the former with primary closure rates of 3/6 (50%) versus an overall primary closure rate of 78/82 (95%) for vesicovaginal fistulas. Despite repair, 46/78 (59%) women were found to have serious complications following successful closure of their fistula with continued complaints of either urinary or anal incontinence. In a review of fistula repair series in the same article for papers published between 1965 and 1993, primary closure rates for vesicovaginal fistula ranged from 58 to 95%.<sup>68</sup> A single series has examined the outcome of future pregnancies following vesicovaginal repair and concluded that women who were repaired had better obstetrical outcomes than those who were not repaired, and that prenatal planning resulted in more of the women undergoing the recommended caesarean delivery than those who were not scheduled for delivery.<sup>69</sup> Presumably, the same outcomes may be applicable to women who sustain rectovaginal fistulas, given that the overall reported prognosis for these fistulas is poorer than that for vesicovaginal fistulas. Unfortunately many women who sustain fistulas secondary to obstructed labour are infertile as part of the "field injury".

## 13.9 Conclusions

Rectovaginal fistulas are a devastating condition for patients and although rare in the developed world, they occur commonly worldwide. Repair of the fistula with restoration of continence can be challenging and requires a detailed knowledge of the continence mechanism. Evaluation and management include locating the fistula, assessing tissue quality and timing the repair. The integrity and function of the anal sphincters should be considered in planning the fistula repair. If the anal sphincters are involved in the fistula tract or the sphincters are not intact, surgery should address both the fistula and chronic sphincter laceration. Repair without tension, an operative field free from infection or inflammation, wide mobilisation of the tissue surrounding the fistulous tract, excision of the tract if possible, and care to avoid strain on the repair in the immediate postoperative period are rules for success. Repair or other treatment of these fistulas can restore patients to a healthy productive life.

## References

- Russell TR, Gallagher DM. Low rectovaginal fistulas. *Am J Surg* 1977;134:13–18.
- Venkatesh KS, Ramanujam PS, Larson DM, Haywood MA. Anorectal complications of vaginal delivery. *Dis Colon Rectum* 1989;32:1039–41.
- Saclaides TJ. *Surg Clin N Am* 2002;82:1261–72.
- Tsang CBS, Rothenberger DA. Rectovaginal fistulas. Therapeutic options. *Surg Clin N Am* 1997;77(1): 9–114.
- Stern HS, Dreznik Z. Rectovaginal fistula. *Adv Surg* 1987;21:245–62.
- Rothenberger DA, Goldberg SM. The management of rectovaginal fistulae. *Surg Clin N Am* 1983;63(1): 61–79.
- Howard D, Delancey JOL, Burney RE. Fistulo in ano after episiotomy. *Obstet Gynecol* 1999;93(5): 800–2.
- Rock JA. Historical development of pelvic surgery. In: Thompson J, Rock JA, eds. *Telinde's operative gynecology*. Philadelphia: JB Lippincott Co, 1992, pp 3–9.
- Thompson JD. Vesicovaginal fistulas. In: Thompson J, Rock JA, eds. *Telinde's operative gynecology*. Philadelphia: JB Lippincott Co, 1992, p 787.
- Barton JR. A rectovaginal fistula – cured. *Am J Med Sci* 1840;26:305–6.
- Emmet TA. Vesico-vaginal fistula from parturition and other causes: with cases of recto-vaginal fistula. New York: Samuel S and William Wood, 1868.
- Wall LL. Thomas Addis Emmet, the vesicovaginal fistula, and the origins of reconstructive gynecologic surgery. *Int Urogynecol J* 2002;13:145–55.
- Wiskind AK, Thompson JD. Transverse transperineal repair of rectovaginal fistulas in the lower vagina. *Am J Obstet Gynecol* 1992;107(3): 694–9.
- Goldaber KG, Wendel PJ, McIntire DD, Wendel GD. Postpartum perineal morbidity after fourth degree perineal repair. *Am J Obstet Gynecol* 1993; 168(2):489–93.
- Legino LJ, Woods MP, Rayburn WF, Mcgoogan LA. Third and fourth degree perineal tears. 50 years' experience at a university hospital. *J Reprod Med* 1988;33:423–6.
- Brantly JT, Burwell JC. A study of fourth degree perineal lacerations and their sequelae. *Am J Obstet Gynecol* 1960;80:711–14.
- O'Leary JL, O'Leary JA. The complete episiotomy: analysis of 1224 complete lacerations, sphincterotomies and episiotomies. *Obstet Gynecol* 1965;25:235–40.
- Mahomed K, Grant A, Ashurst H, James D. The Southmead perineal suture study. A randomised comparison of suture materials and suturing techniques for repair of perineal trauma. *Br J Obstet Gynaecol* 1989;96:1272–80.
- Kammerer-Doak DN, Wesol AB, Rogers RG, Dominguez CE, Dorin MH. A prospective cohort study of women after primary repair of obstetric anal sphincter laceration. *Am J Obstet Gynecol* 1999;181(6):1317–22.
- Sultan AH, Monga AK, Kumar D, Stanton SL. Primary repair of obstetric anal sphincter rupture using the overlap technique. *Br J Obstet Gynaecol* 1999;106:318–23.
- Homsy R, Daikoku NH, Littlejohn J, Wheelless CR. Episiotomy: risks of dehiscence and rectovaginal fistula. *Obstet Gynecol Surv* 1994;49:803–8.
- Murray C, Lopez A. Health dimensions of sex and reproduction. Geneva: WHO, 1998.
- Donnay F, Well L. Obstetric fistula: the international response. *Lancet* 2004;363:71–2.
- Arrowsmith S, Hamlin EC, Wall LL. Obstructed labor injury complex: obstetric fistula formation and the multifaceted morbidity of the maternal birth trauma in the developing world. *Obstet Gynecol Survey* 1996;51(9):568–74.
- Ayhan A, Tuncer ZS, Dogan L, Pekin S, Kisanisci HA. Results of treatment in 182 consecutive patients with genital fistulas. *Int J Gynecol Obstet* 1995;48: 43–7.

26. Rosenshein NB, Genadry RR, Woodruff JD. An anatomic classification of rectovaginal septal defects. *Am J Obstet Gynecol* 1980;137(4):439–42.
27. Parks AG, Gordon PH, Hardcastle JD. A classification of fistulo in ano. *Br J Surg* 1976;63:1–12.
28. Judge TA, Lichtenstein GR. Treatment of fistulizing Crohn's disease. *Gastroenterol Clin N Am* 2004;33: 421–54.
29. Thompson JD. Relaxed vaginal outlet, rectocele, faecal incontinence and rectovaginal fistula. In: Thompson J, Rock JA, eds. *Telinde's operative gynecology*. Philadelphia: JB Lippincott Co, 1992, pp 967–9.
30. Groom KM, Patterson-Brown S. Third degree tears: are they clinically underdiagnosed? *Gastroenterology International* 2000;13(2):76–8.
31. Hankins GDV, Jauth JC, Gilstrap LC. Early repair of episiotomy dehiscence. *Obstet Gynecol* 1990; 75(1):48–51.
32. Thacker SB, Banta HD. Benefits and risks of episiotomy: an interpretative review of the English language literature, 1860–1980. *Obstet Gynecol Surv* 1982;38:322–38.
33. Helwig JT, Thorp JM, Bowes WA. Does midline episiotomy increase the risk of third and fourth degree lacerations in operative vaginal deliveries? *Obstet Gynecol* 1993;82:276–9.
34. Combs CA, Robertson PA, Laros RK. Risk factors for third-degree and fourth-degree perineal lacerations in forceps and vacuum deliveries. *Am J Obstet Gynecol* 1990;163:100–4.
35. Zetterstrom J, Lopez A, Anzen B, Norman M, Holmstrom B, Mellgren A. Anal sphincter tears at vaginal delivery: risk factors and clinical outcome of primary repair. *Obstet Gynecol* 1999;94:21–8.
36. Sultan AH, Kamm MA, Hudson CN, Thomas JM, Bartram CI. Anal-sphincter disruption during vaginal delivery. *N Engl J Med* 1993;329:1905–11.
37. Varma A, Gunn J, Gardiner A, Lindow S, Duthie G. Obstetrical anal sphincter injury: prospective evaluation and incidence. *Dis Colon Rectum* 1999;42: 1537–43.
38. Tsang CBS, Madoff RD, Wong WD, Rothenberger DA, Finne CO, Singer D, Lowry AC. Anal sphincter integrity and function influences outcome in rectovaginal fistula repair. *Dis Colon Rectum* 1998;41(9): 1141–6.
39. Kankam OK, Geraghty R. An erosive pessary. *J R Soc Med* 2002;95:507.
40. Russell JK. The dangerous vaginal pessary. *BMJ* 1961;iii:1595–7.
41. Parra JM, Kellogg ND. A rectovaginal fistula in a sexually assaulted child. *Semin Perioper Nurs* 1995; 4(2):140–5.
42. Mathevet P, Valecia P, Cousin C, Mellier G, Dargent D. Operative injuries during vaginal hysterectomy. *Eur J Obstet Gynecol* 2001;97:71–5.
43. Hoffman MS, Lynch C, Lockhart J, Knapp R. Injury of the rectum during vaginal surgery. *Am J Obstet Gynecol* 1999;181:274–7.
44. Benson JT. *Atlas of Clinical Gynecology: Ilrogyne-cology and Reconstructive Pelvic Surgery*, Vol. 5, Philadelphia: Current Medicine, 2000.
45. Rothenberger DA, Christenson CE, Balcos EG, Schottler JL, Nemer FD, Nivatvongs S, Goldberg SM. Endorectal advancement flap for the treatment of simple rectovaginal fistula. *Dis Colon Rectum* 1982;25(4):297–300.
46. Given FT. Rectovaginal fistula: a review of 20 years' experience in a community hospital. *Am J Obstet Gynecol* 1970;108(1):41–6.
47. Jones IT, Fazio VW, Jagelman MS. The use of trans-anal rectal advancement flaps in the management of fistulas involving the anorectum. *Dis Colon Rectum* 1987;30(12):919–23.
48. Mazier WP, Senagore AJ, Schiesel EC. Operative repair of anovaginal and rectovaginal fistulas. *Dis Colon Rectum* 1995;38(1):4–6.
49. Kodner IJ, Mazor A, Shemesh EI, Fry RD, Fleshman JW, Birnbaum EH. Endorectal advancement flap repair of rectovaginal and other complicated anorectal fistulas. *Surgery* 1993;114(4):682–90.
50. Wise WE, Aguilar PS, Padmanabhan A, Meesig DM, Arnold MW, Stewart WRC. Surgical treatment of low rectovaginal fistulas. *Dis Colon Rectum* 1991;34(3):271–4.
51. Radcliffe A, Richie J, Hawley P, Lennard-Jones J, Northover J. Anovaginal and rectovaginal fistulas in Crohn's disease. *Dis Colon Rectum* 1988; 31:94–9.
52. Bandy LC, Addison A, Parker RT. Surgical management of rectovaginal fistulas in Crohn's disease. *Am J Obstet Gynecol* 1983;147(4):359–63.
53. Tetzschner T, Sorensen M, Lose G, Christiansen J. Anal and urinary incontinence in women with obstetric anal sphincter rupture. *Br J Obstet Gynaecol* 1996;103(10):1034–40.
54. Song AH, Advincola AP, Fenner DE. Common gastrointestinal problems in women and pregnancy. *Gastroenterology* 2004;6(3):755–73.
55. Waaldijk K. The immediate management of fresh obstetrical fistulas. *Am J Obstet Gynecol* 2004;191: 795–9.
56. Guenaga KF, Matos D, Castro AA, Atallah AN, Wille-Jorgensen P. Mechanical bowel preparation for elective colorectal surgery (Cochrane review). In: *The Cochrane Library*, Issue 2, 2004. Chichester, UK: John Wiley and Sons, Ltd.

57. Gutierrez AB, Madoff RD, Lowry AC, Parker SC, Buie WD, Baxter NN. Long-term results of anterior sphincteroplasty. *Dis Colon Rectum* 2004;47:727-32.
58. Malouf AJ, Norton CS, Engel AF, Nicholls RJ, Kamm MA. Long-term results of overlapping anterior anal-sphincter repair for obstetric trauma. *Lancet* 2000;355(9200):260-5.
59. Karoui S, Leroi AM, Koning E, Menard JF, Michot F, Denis P. Results of sphincteroplasty in 86 patients with anal incontinence. *Dis Colon Rectum* 2000;43(6):813-20.
60. Halverson AL, Hull TL. Long-term outcome of overlapping anal sphincter repair. *Dis Colon Rectum* 2002;45(3):345-8.
61. Wang YU, Hadley HR. The use of rotated vascularized pedicle flaps for complex transvaginal procedures. *Urology* 1993;149:590-2.
62. Elkins TE, DeLancey JO, McGuire EJ. The use of modified Martius graft as an adjunctive technique in vesicovaginal and rectovaginal fistula repair. *Obstet Gynecol* 1990;75(4):727-33.
63. Reissman P, Teoh TA, Cohen SM, Weiss EG, Nogueras JJ, Wexner SD. Is early oral feeding safe after elective colorectal surgery? A prospective randomised trial. *Ann Surg* 1995;222(1):73-7.
64. Tunuguntla HSGR, Gousse AE. Female sexual dysfunction following vaginal surgery: myth or reality? *Curr Urol Reports* 2004;5:403-11.
65. Watson SJ, Phillips RKS. Non-inflammatory rectovaginal fistula. *Br J Surg* 1995;82:1641-3.
66. Arrowsmith SD. Genitourinary reconstruction in obstetric fistulas. *J Urol* 1994;152:403-6.
67. Kelly J. Vesico-vaginal and recto-vaginal fistulae. *J Roy Soc Med* 1992;85:257-8.
68. Elkins TE. Surgery for the obstetric vesicovaginal fistula: a review of 100 operations in 82 patients. *Am J Obstet Gynecol* 1994;170(4):1108-18.
69. Emembolu J. The obstetric fistula: factors associated with improved pregnancy outcome after successful repair. *Int J Gynecol Obstet* 1992;39:205-12.