

12a

Surgical Management of Anal Incontinence Part A. Secondary Anal Sphincter Repair

Robin K. S. Phillips and Timothy J. Brown

12a.1 Introduction

As the prevalence of anal ultrasound examinations increases, so will the number of patients seen with a reported abnormality whose significance remains in doubt. Uncertainty regarding the meaning of abnormal studies in relation to long-term sequelae raises a few issues that could prove difficult: for example, the complexity of advising a woman how much improvement she can expect and how long that improvement will last. Furthermore, the actual operation of anal sphincter repair needs to be tailored to the severity of injury, whether it is simple with straightforward faecal incontinence, or a more complex case, either with an associated ano/rectovaginal fistula or with an accompanying evacuation disorder.

12a.2 Irritable Bowel Syndrome and Incontinence

Not all faecal incontinence is due to anal failure. A traveller who experiences severe gastroenteritis may be caught short; a sufferer with acute inflammatory bowel disease or even with cholera may lose bowel control; and a person with severe irritable bowel syndrome (IBS) may complain of faecal incontinence. A useful analogy to explain these situations is a hot plate on a hob; placed in the bare hands it will be dropped, yet there is nothing wrong with the strength of the grip. Similarly, in the above examples the stool can simply

be “too hot to handle”, leading to episodes of faecal incontinence.

Irritable bowel syndrome is extremely common, with a suggested prevalence of 9–12%;¹ postpartum women suffering with IBS demonstrate alteration of faecal continence.² It is also known that many women who have had a vaginal delivery, particularly an assisted delivery, have occult anal sphincter injuries.³ How does a surgeon know whether the faecal incontinence is a consequence of severe IBS or a result of the birth injury? If the former, surgery will have no role to play, but if the latter, an operation may need to be contemplated – but, given the IBS, it would be wise to advise the woman of an unpredictable result.

When there is anal failure there is graded incontinence, first gas, next liquid, and finally a formed or solid stool. But imagine having severe travellers' diarrhoea; there is no problem controlling flatus, it is the stool itself that causes urgency and incontinence. Likewise, with IBS, some patients actually experience great difficulty breaking wind, and yet have no control over a bowel motion itself. This means that an irritable rectum and anal failure can be distinguished from each other by analysing patient history: if there is graded incontinence, flatus > liquid stool > formed stool, it is highly likely to be a problem in the anal sphincter; but if there is continence to gas and only incontinence to stool, the problem is not likely to lie within the anal sphincter. Anorectal physiology testing can help minimally, with a reduced maximal tolerable volume to balloon distension being indicative of an irritable rectum.

12a.3 Extent of Anorectal Injury

Examine Figure 12a.1⁴ and imagine the rectovaginal septum being continuous with the anal sphincter complex in its inferior part. This figure depicts the usual mechanism of obstetric anal sphincter injury and the resulting scenarios that arise from it. Injury in the proximal part of the rectovaginal septum (Figure 12a.1A) can result in a rectocele; an anal sphincter injury (Figure 12a.1C) can result in faecal incontinence; Figure 12a.1B depicts injury throughout the rectovaginal septum/anal sphincter, leading potentially to combined faecal incontinence and a rectocele, possibly with an evacuation disorder. It is this last injury that may at its midpoint then necrose, resulting in one of the three types of postobstetric rectovaginal fistulas (see Chapter 13).

Preoperative investigations cannot easily discern the difference between these three types of injury, largely because current imaging does not depict the rectovaginal septum and therefore cannot show tears in it. It might be argued that a proctogram would show the rectocele bulge, but proctography falls short as it depends on anal sphincter function for contrast during bearing down at defaecation, which is not possible when

the anus is incontinent. Furthermore, up to 80% of normal women can be shown on proctography to have a rectocele.⁵ Therefore, what actually matters is the functionality, rather than the anatomy per se.

Again, the key is in the history. An incontinent woman with a simple anal sphincter injury (Figure 12a.1A) should have a low fibre diet and constipating agents such as loperamide, as this leads to a firmer stool that is easier for her weakened anus to grip. On the other hand, a woman with an injury throughout the entire length of the rectovaginal septum (Figure 12a.1B) avoids constipation. On closer questioning, the clinician will elicit that the woman prefers incontinence because of her inability to evacuate a firm stool.

This differentiation is infrequently made by colorectal surgeons, who generally are unaware of these differences, even though the injuries require different operations. In my practice, those patients with an associated rectovaginal septal injury along with an anal sphincter injury (Figure 12a.1B) undergo a more extended anal sphincter repair. The purpose of this operation is not only to perform an overlap of the anal sphincter itself, but also to enter the rectovaginal septum to the pouch of Douglas and perform a sutured repair of the rectovaginal septum with a non-absorbable material such as nylon.⁴ The intention is to perform a synchronous rectocele repair. Isolated injury to the anal sphincter (Figure 12a.1C) would involve only a standard anal sphincter repair.

This failure to identify the different groups means that some who should have had more complex surgery to repair the associated rectovaginal septal tear instead are left with an evacuation disorder for which biofeedback is recommended. The authors believe this to be an avoidable problem through more focused history-taking and by tailoring the repair to the predicted injury type.

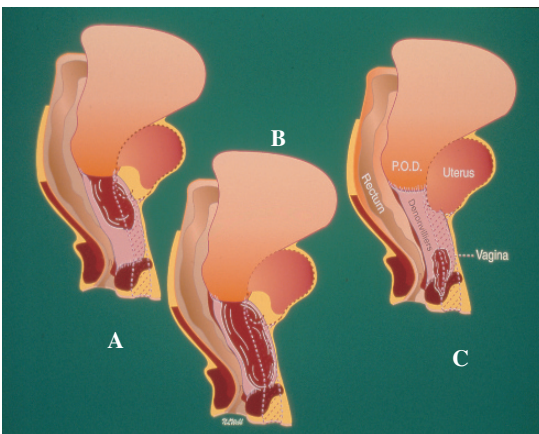


FIGURE 12a.1. The resultant injury to the rectovaginal septum may be in its upper part, resulting in a rectocele (A), in the lower part, resulting in incontinence (C), or throughout, resulting in both incontinence and an evacuation disorder (B). (Reprinted from Phillips,⁴ with permission from Elsevier.)

12a.4 Role of Neuropathy

Pudendal neuropathy is a useful concept but fraught with difficulty when it comes to evaluation. The gold-standard anorectal physiology test is the fibre density. This is rarely used now as it involves inserting needles into the anal sphincter,

which causes patient discomfort. Instead, the pudendal nerve terminal motor latency is used (as described in Chapter 9). The problem with this test is that it is not always reliable. An investigator is able to produce widely varying results on different occasions, just as several investigators can produce widely varying results on the same occasion. Because of these differences, doctors are able to continue testing until they receive a desired result.

What this means in practice is that pudendal neuropathy and the quality of the anal sphincter are largely clinical impressions rather than anorectal physiology issues. First, the pudendal nerve supplies more than just the anal sphincter. More global pelvic floor problems (for example associated urinary incontinence) suggest more than a simple tear in the anal sphincter. There may also be a mechanical problem in the anterior compartment caused through the same mechanisms that led to the anal sphincter tear, or it could be due to pudendal nerve injury.

Second, the pudendal nerve is a mixed motor and sensory nerve. A woman with associated vaginal numbness or who feels no need to defaecate until she has been faecally incontinent may well have nerve damage. Anorectal physiology testing that shows sensory change helps diagnosis, although anal canal scarring after a fourth degree tear may equally be responsible if the abnormality is observed when testing electrical sensation in the anal canal.

Third, anal sphincter quality may feel abnormal. Imagine an intact anal sphincter as the capital letter "O" and the divided anal sphincter as a "U". Feeling in the bend of the "U" should identify normal, vigorous muscle activity, but when examining a woman with damaged nerves, little or no activity may be felt.

It is hard to determine from the literature the impact of pudendal neuropathy on subsequent outcome of anal sphincter repair, probably because much of the literature depends on measured pudendal nerve terminal motor latency. There are articles that show that reduced pudendal nerve terminal motor latency is a poor prognostic indicator to outcome of external anal sphincter repair,^{6,7} and others even within the same institution that state it makes no difference to outcome.⁸

12a.5 The Extent of the Injury versus the Degree of the Symptoms

As a generality, surgeons are not able to repair a damaged and scarred internal anal sphincter. Although there are occasional reports of a separated plication or repair having been incorporated at the time of external anal sphincter repair,⁹ these have not been validated as having been successful by post-repair anal ultrasonography. As the internal anal sphincter largely controls resting anal pressure, an internal anal sphincter defect is going to be responsible for minor passive soiling. This would usually amount to flatus incontinence and anal "dribbling" of up to a teaspoonful of mucus/stool each day, depending on stool consistency.

There are scant data in the literature reporting on secondary repair of isolated internal sphincter defects. Leroi et al. reported on five patients who had overlapping repair performed on their internal sphincter.¹⁰ Of these five patients, there was a slight symptomatic improvement in two, but three felt that their symptoms had deteriorated. Objective measurement of outcome (endoanal ultrasound and manometry) was disappointing. Morgan et al. looked at 15 patients with internal sphincter incontinence.¹¹ Two of these patients underwent direct isolated repair of the internal sphincter. They reported no improvement in symptoms. Although in a methods paper reporting on anal ultrasound using endoscopic ultrasound, Meyenberger et al. remark that internal anal sphincter repair seems to have worked clinically in their hands, there was no post-repair anal ultrasound validation.¹²

12a.6 What Are the Best Results Achievable?

The result will depend on the extent of the anal sphincter injury itself (and in particular, whether the internal anal sphincter is divided), the quality of the anal muscle remote from the injury (pudendal neuropathy), the patient's natural bowel frequency (the anus needs to be of better quality in order to cope with two or three soft stools each day than it does to cope with two or three firm

motions each week), and the presence or absence of IBS.

Take as an example a woman who on an anal ultrasound shows a full-length defect involving both the internal anal sphincter and the external anal sphincter. There is perhaps an 80%¹³ chance that an anal sphincter repair will result in a complete circle of external anal sphincter around the anus afterwards. However, if the preoperative complaint is of flatus incontinence and mild mucus leakage, the clinician can reasonably deduce that as far as her symptoms are concerned, they are almost certainly arising as a consequence of the internal sphincter injury. Given that it is generally accepted that the internal anal sphincter is difficult if not impossible to repair, her best anticipated clinical result will be no better than her preoperative symptoms. At the same time she runs the general risks of surgery along with an approximately 20% chance of breakdown of the external anal sphincter component¹³ (the consequences of this are hard to predict – preoperatively they did not seem to be contributing to her symptoms of faecal incontinence, but the anal surgical disturbance along with a less than adequate repair runs some risk of causing actual deterioration in her continence). Such a woman should not be advised to have anal sphincter repair. It has been postulated that ageing/the menopause have an effect on anal sphincter musculature¹⁴ and, while it is true that as the woman ages and menopause approaches, so continence may decline, there is no evidence that a delayed anal sphincter repair is any the worse than one performed much earlier. A “wait-and-see” policy along with dietary advice, the use of loperamide, and perhaps biofeedback would seem wisest. For those postmenopausal women who have faecal incontinence, there is some early evidence that hormone replacement therapy may be helpful.¹⁴

There are women with a deficient perineum who have an injury to both the external anal sphincter and the internal anal sphincter, but whose level of incontinence is slight, as in the case above. Where reconstruction of the perineum is being performed on cosmetic/sexual grounds, rather than on the grounds of faecal incontinence, it does seem sensible to repair the anal sphincter at the same time – if only to give some added bulk to the perineum. However, the woman should

know that there would be at least a slight risk of continence deterioration were this to be done (offset by an anticipated prevention of continence deterioration at the time of the menopause).

As another example, a woman with an external anal sphincter defect but with an intact internal anal sphincter should anticipate achieving a perfect outcome from external anal sphincter reconstruction, within certain limitations:

1. There are always the risks of surgery. The wound could break down and there could be anaesthetic problems or other problems of a more general nature.

2. The operating surgeon must not damage the internal anal sphincter during the operation. Many surgeons perform a standardised repair of the anal sphincter, which involves dividing the entire, full-thickness length of the anal sphincter complex followed by overlapping repair. Such a technique, if employed in a case such as this, would be expected to result in an unrepaired internal anal sphincter with the consequence of flatus incontinence and mild passive soiling. It is not uncommon for a woman in this predicament to have complained of urge faecal incontinence preoperatively, but not to have had much in the way of flatus incontinence or minor soiling. This woman may perceive herself to have gained little from surgery and be quite unhappy with the result. The message is to image the sphincter complex preoperatively and if the internal anal sphincter is shown to be intact, it is imperative at surgery to ensure that only the external anal sphincter is mobilised and repaired.

3. Anal muscle quality must be good on clinical grounds (feeling in the “U” bend for vigorous muscle activity).

The most common injury is a combined injury to the external anal sphincter and the internal anal sphincter with flatus and faecal incontinence, with the associated social inconveniences.

In these circumstances, anal sphincter repair should produce an 80%¹³ chance of avoiding accidents in the street or at home, but should not be anticipated to result in perfect continence afterwards, for the reason that the internal anal sphincter is highly unlikely to be improved (Figure 12a.2). Women should also be counselled that, just as immediate repair of a third degree

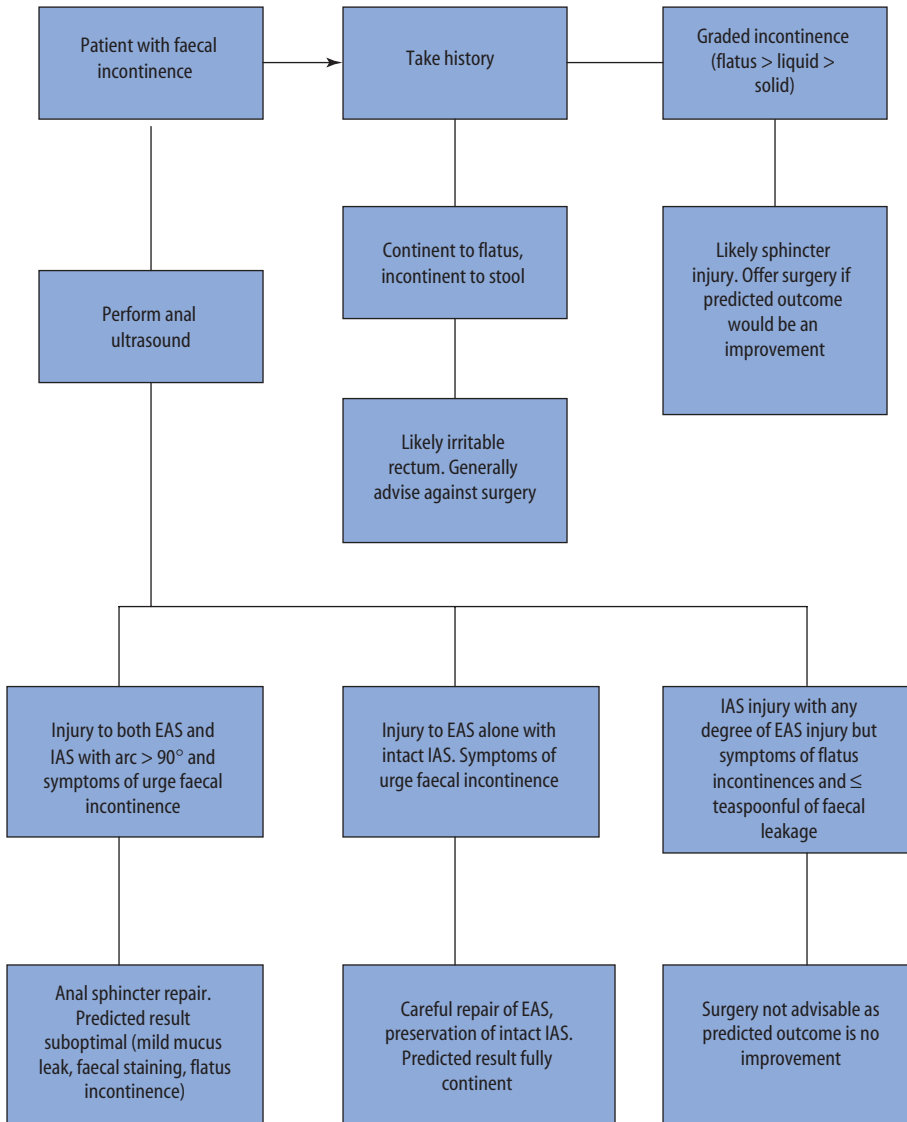


FIGURE 12a.2. Algorithm outlining selection criteria for sphincter repair. *EAS* external anal sphincter, *IAS* internal anal sphincter.

tear may deteriorate with time,¹⁵ so do delayed repairs.¹⁶

12a.7 When Is a Stoma Necessary?

Most surgeons now agree that for a straightforward anal sphincter injury, a colostomy is not required. But not all injuries are straightforward and many surgeons still consider using a stoma in the following circumstances:

1. When there is a cloacal injury. Some injuries are so extensive that the anterior half of the anus and the lower third of the vagina are one common cavity. The repair is precarious in the thin area of the distal remaining rectovaginal septum with a serious possibility of postoperative fistulation over the top of an otherwise successful sphincter reconstruction.

2. When there is an associated rectovaginal fistula. Fistulas to the vagina can be extremely hard to treat; the published overall results of about

80% success often overlook both the short-term failure in about half of the patients and the need for multiple reoperations before success is achieved.¹⁷ Whereas it is hard to accrue evidence that a colostomy will make a difference, most surgeons confronted by multiple failed attempts will finally resort to the use of a stoma as an adjunct to re-repair. Probably more importantly, given the high known rate of initial failure, many women find it easier to cope with failure if they feel they have already done everything possible.

3. In the presence of Crohn's disease or prior radiation therapy.

12a.8 When to Avoid Surgery

Women with gross pudendal neuropathy (that is to say, those who are numb perineally, or those who do not exhibit anal sphincter contraction in the bend of the "U" of the divided anal sphincter) are unlikely to benefit from anal sphincter repair. A wasted attempt may even compromise some of the other surgical options described in the next chapter.

12a.9 Anal Sphincter Surgery

12a.9.1 Historical Perspective

This has been extensively reviewed by Baig and Wexner.¹⁸ Sir Alan Parks was responsible for the current form of overlapping sphincter repair, initially employing stainless steel wire as the suture.¹⁹ Given the technical difficulties of operating with wire, many surgeons subsequently adopted nylon or prolene, later changing again to polydioxanone (PDS) or Vicryl to avoid the occasional stitch sinuses seen with the former. Slade modified Parks' overlapping repair²⁰ by leaving the scar tissue to aid the anchoring of sutures. Many early anal sphincter repairs were performed with a covering stoma, but when Thomson described a series of 31 patients undergoing sphincter repair and showed that success was independent of diversion of the faecal stream, most surgeons abandoned the use of a stoma as a routine.²¹

Comparison of the original method of end-to-end apposition with overlapping repair was subject to a recent, rather small randomised controlled trial in elective cases ($n = 23$)²² that reported no difference between the methods after only a fairly short follow-up.

12a.9.2 Operative Steps for Anal Sphincter Repair

Personal practice is to use full preoperative bowel preparation with sodium picosulphate and one dose of perioperative gentamicin (120 mg) and metronidazole (500 mg) intravenously. After catheterisation, positioning (lithotomy or prone jack-knife) is according to surgeon preference. A hemicircumferential incision along the line of anal sphincter pigmentation (which is the cutaneous sign of the boundary of the external anal sphincter) is made. Next, the incision is deepened into the ischioanal fat on either side and the vagina is separated from the anal scar tissue. If there is a history of an associated evacuation disorder, the operation will be extended to incorporate repair of the rectovaginal septum, instead of a more confined and simple sphincter repair. No attempt is made to separate external from internal sphincter unless the internal sphincter has not been damaged, in which case every attempt should be made to preserve it.

The midline anal scar tissue is then split down its entire length and the anal sphincter muscle is dissected off the underlying anal canal in one block making no attempt to separate the external and internal anal sphincter muscles from each other (Figure 12a.3).

The leading edge of one side of the divided scar tissue is sutured to the underside of the opposing edge, usually using a monofilament absorbable suture. This commences the overlap (Figure 12a.4).

Having tied these initial sutures, the other leading edge is sutured over the top of the first layer of sutures depicted in Figure 12a.4, thereby obscuring the first layer of sutures and completing the overlap (Figure 12a.5). Finally, a decision is made whether to close the wound primarily or leave the central part open to heal by secondary intention.

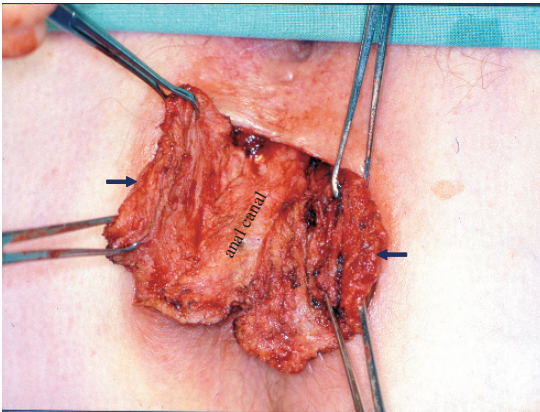


FIGURE 12a.3. The two divided ends of the anal sphincter muscle (arrows) are grasped, ready for overlapping repair.

Management of internal anal sphincter injury is more complicated. Overlapping repair and imbrication repair of isolated internal sphincter injuries is described but seems to be unsuccessful.¹¹ Other techniques designed to improve internal sphincter function have been employed with varying success (e.g. anoplasty, injection of bulking agents). Expert opinion among colorectal surgeons confronted by patients with internal sphincter injuries is that they cannot be repaired surgically.

Frequently at the end of the operation there is not enough available skin to perform a primary

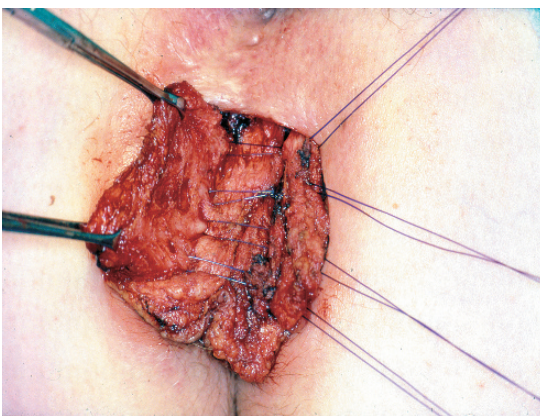


FIGURE 12a.4. The leading edge of the patient's left side of the anal sphincter (pictured to the right) is sutured to the deep surface of the opposing sphincter muscle usually using an absorbable suture.

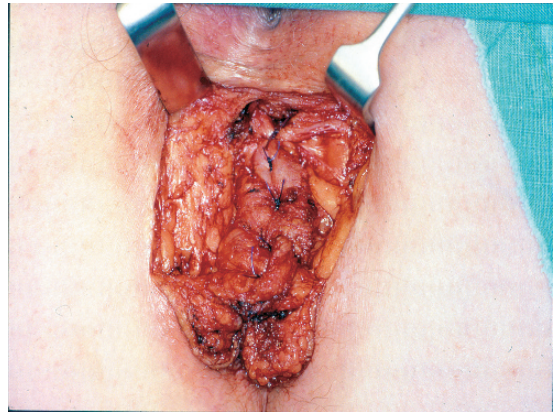


FIGURE 12a.5. Having tied the sutures depicted in Figure 12a.4, the overlap is completed, suturing the right hand side of muscle (depicted on the left of the image) over the first layer of sutures, thereby obscuring them from sight.

skin closure. Whereas there are various surgical flap techniques that can be employed to obtain primary skin cover, many surgeons only partially close the wound, leaving the centre open. After surgery, the patient can be allowed to eat and drink normally. A mild laxative is encouraged to prevent a faecal impaction, and the woman should be advised that this may initially falsely disappoint her as to the outcome of her surgery. There no longer seems to be a case for bowel confinement.²³ When comfortable and the bowels are working, the woman is allowed home, which is commonly within 5 days of surgery.

12a.9.3 Results of Surgery

As stated, it may be considered unproductive to examine in any detail the results in the literature, as there are so many confounding factors involved (but see Tables 12a.1 and 12a.2 as supplied by the editorial team). Not only do these include all those mentioned (sphincter quality, the state of the internal anal sphincter, whether or not there is an extended injury into the rectovaginal septum), but many reports also include patients with incontinence after fistula surgery, patients who are not immediately postpartum, and patients who have had surgery on multiple occasions unsuccessfully. There have been no publications that compare

TABLE 12a.1. Short-term (<5 years) outcomes after sphincteroplasty.

Author, year	N	Follow-up period Mean (range) months	Success (%)	Improved (%)
Fang et al. 1984 ²⁴	76	35 (2–62)	82	89
Browning and Motson 1984 ²⁵	83	39.2 (4–116)	78	91
Ctercteko et al. 1988 ²⁶	44	50	75	–
Laurberg et al. 1988 ⁶	19	18 (median; 9–36)	47	79
Yoshioka and Keighley 1989 ²⁷	27	48 (median; 16–108)	–	74.1
Wexner et al. 1991 ²⁸	16	10 (3–16)	76	87.5
Fleshman et al. 1991 ²⁹	55	0 (12–24)	72	87
Engel et al. 1994 ¹³	55	15 (6–36)	60.4	–
Engel et al. 1994 ³⁰	28	46 (median; 15–116)	75	–
Londono-Schimmer et al. 1994 ³¹	94	58.5 (median; 12–98)	50	75
Sitzler and Thomson 1996 ²¹	31	(1–36)	74	–
Oliveira et al. 1996 ³²	55	29 (3–61)	70.1	80
Nikiteas et al. 1996 ³³	42	38 (median; 12–66)	60	–
Gilliland et al. 1998 ⁷	100	24 (median; 2–96)	55	69

preoperative predictions of expected success to observed success. In general, most colorectal surgeons agree that:

1. A perfect result can be achieved only if the internal anal sphincter is initially intact and both anal sphincters are of good quality.
2. About 80% of patients receiving surgery for a combined injury to the internal and external anal sphincters will become continent to solid stool, but will still suffer from flatus incontinence and mild mucus leakage.

3. Those with a worse result should receive an anal ultrasound scan to determine whether or not the sphincter repair has achieved a complete ring of external anal sphincter. If it has not, repeat repair should be offered with an approximately equivalent chance of success.

4. Continence deteriorates with age. This deterioration happens not only to women who have had a secondary repair⁸ or to those who have had primary repair of a third degree tear,¹⁵ but to all women.

TABLE 12a.2. Long-term results following overlapping sphincteroplasty reported by continence type.

Author	Patients with follow-up/total (%)	Length follow-up Mean (range)	Outcomes
Malouf et al. 2000 ⁸	46/55 (84)	77 months (60–96)	0% continent 10% incontinent flatus only 79% soiling 21% incontinent solid stool 8/46 other surgery
Karoui et al. 2000 ³⁴	74/86 (86)	40 months	28% continent 23% incontinent flatus only 49% incontinent stool
Halverson et al. 2002 ³⁵	49/71 (69)	69 months (48–141)	14% continent 54% incontinent stool 7/49 other surgery
Gutierrez et al. 2004 ³⁶	135/191 (71)	10 years (7–16)	6% continent 16% incontinent flatus only 19% soiling 57% incontinent stool 5/135 other surgery

12a.10 Conclusion

Accurate patient selection is essential, along with a realistic explanation of the likely outcome. Outcome depends on the extent of the injury, the quality of the residual muscle and the presence or absence of IBS.³⁷ Repair of an isolated external sphincter injury seems to give the most successful surgical outcome, while a patient with an additional injury to the internal sphincter is unlikely to gain complete continence. An accurate history should be combined with up-to-date imaging.

References

- Guidelines for the management of irritable bowel syndrome. *Gut* 2000;47(Suppl II):1-19.
- Donnelly VS, O'Herlihy C, Campbell DM, O'Connell PR. Postpartum fecal incontinence is more common in women with irritable bowel syndrome. *Dis Colon Rectum* 1998;41(5):586-9.
- Sultan AH, Kamm MA, Hudson CN, Thomas JM, Bartram CI. Anal-sphincter disruption during vaginal delivery. *N Engl J Med* 1993;329(26):1956-7.
- Phillips RKS. Progress in the management of anal disorders. In: Taylor I, Johnson CD, eds. *Recent advances in surgery*, vol. 22. Edinburgh: Churchill Livingstone, 1999, pp 123-33.
- Shorvon PJ, McHugh S, Diamant NE, Somers S, Stevenson GW. Defaecography in normal volunteers: results and implications. *Gut* 1989;30:1737-49.
- Laurberg S, Swash M, Henry MM. Delayed external sphincter repair for obstetric tear. *Br J Surg* 1988;75:786-8.
- Gilliland R, Altomare DE, Moreira H Jr, Oliveira L, Gilliland JE, Wexner SD. Pudendal neuropathy is predictive of failure following anterior overlapping sphincteroplasty. *Dis Colon Rectum* 1998;41:1516-22.
- Malouf AJ, Norton CS, Engel AF, Nicholls RJ, Kamm MA. Long term results of overlapping anterior anal sphincter repair for obstetric trauma. *Lancet* 2000;355:260-5.
- Briel JW, de Boer LM, Hop WC, Schouten WR. Clinical outcome of anterior overlapping external anal sphincter repair with internal anal sphincter imbrication. *Dis Colon Rectum* 1998;41:209-14.
- Leroi AM, Kamm MA, Weber J, Denis P, Hawley PR. Internal anal sphincter repair. *Int J Colorectal Dis* 1997;12:243-5.
- Morgan R, Patel B, Beynon J, Carr ND. Surgical management of anorectal incontinence due to internal anal sphincter deficiency. *Br J Surg* 1997;84(2):226-30.
- Meyenberger C, Bertschinger P, Zala GF, Buchmann P. Anal sphincter defects in fecal incontinence: correlation between endosonography and surgery. *Endoscopy* 1996;28:217-24.
- Engel AF, Kamm MA, Sultan AH, Bartram CI, Nicholls RJ. Anterior anal sphincter repair in patients with obstetric trauma. *Br J Surg* 1994;81(8):1231-4.
- Donnelly V, O'Connell PR, O'Herlihy C. The influence of oestrogen replacement on faecal incontinence in postmenopausal women. *Br J Obstet Gynaecol* 1997;104(3):311-15.
- Tetzschner T, Sorensen M, Lose G, Christiansen J. Anal and urinary incontinence in women with obstetric anal sphincter rupture. *Br J Obstet Gynaecol* 1996;103(10):1034-40.
- Malouf AJ, Norton CS, Engel AF, Nicholls RJ, Kamm MA. Long-term results of overlapping anterior anal-sphincter repair for obstetric trauma. *Lancet* 2000;355(9200):260-5.
- Watson SJ, Phillips RKS. Non-inflammatory rectovaginal fistula. *Br J Surg* 1995;82:1641-3.
- Baig MK, Wexner SD. Factors predictive of outcome after surgery for faecal incontinence. *Br J Surg* 2000;87(10):1316-30.
- Parks AG, McPartlin JF. Late repair of injuries of the anal sphincter. *Proc R Soc Med* 1971;64(12):1187-9.
- Slade MS, Goldberg SM, Schottler JL, Balcos EG, Christenson CE. Sphincteroplasty for acquired anal incontinence. *Dis Colon Rectum* 1977;20(1):33-5.
- Sitzler PJ, Thomson JP. Overlap repair of damaged anal sphincter. A single surgeon's series. *Dis Colon Rectum* 1996;39(12):1356-60.
- Tjandra JJ, Han WR, Goh J, Carey M, Dwyer P. Direct repair vs. overlapping sphincter repair: a randomized, controlled trial. *Dis Colon Rectum* 2003;46(7):937-42.
- Nessim A, Wexner SD, Agachan F, Alabaz O, Weiss EG, Noguera JJ, Daniel N, Lee Billotti V. Is bowel confinement necessary after anorectal reconstructive surgery? A prospective, randomised, surgeon-blinded trial. *Dis Colon Rectum* 1999;42:16-23.
- Fang DT, Nivatvongs S, Vermeulen FD, Herman F, Goldberg SM, Rothenberger DA. Overlapping sphincteroplasty for acquired anal incontinence. *Dis Colon Rectum* 1984;27:720-2.
- Browning GG, Motson RW. Anal sphincter injury: management and results of Parks sphincter repair. *Anal Surg* 1984;58:703-10.

26. Ctercteko GC, Fazio VW, Jagelman DG, Lavery IC, Weakley FL, Melia M. Anal sphincter repair: a report of 60 cases and review of the literature. *Aust N Z J Surg* 1988;58:703–10.
27. Yoshioka K, Keighley MR. Sphincter repair for fecal incontinence. *Dis Colon Rectum* 1989;32:39–42.
28. Wexner SD, Marchetti F, Jagelman DG, Lavery IC, Weakley FL, Melia M. The role of sphincteroplasty for fecal incontinence reevaluated: a prospective physiologic and functional review. *Dis Colon Rectum* 1991;34:222–30.
29. Fleshman JW, Dreznik Z, Fry RD, Kodner IJ. Anal sphincter repair for obstetric injury: manometric evaluation of functional results. *Dis Colon Rectum* 1991;34:1061–7.
30. Engel AF, van Baal SJ, Brummelkamp WH. Late results of anterior sphincter placcation for traumatic faecal incontinence. *Eur J Surg* 1994;160:633–6.
31. Londono-Schimmer EE, Garcia-Duperly R, Nicholls RJ, Ritchie JK, Hawley PR, Thomson JP. Overlapping anal sphincter repair for faecal incontinence due to sphincter trauma: five year follow-up functional results. *Int J Colorectal Dis* 1994;9:110–13.
32. Oliveira L, Pfeifer J, Wexner SD. Physiological and clinical outcome of anterior sphincteroplasty. *Br J Surg* 1996;83:502–5.
33. Nikiteas N, Korsgen S, Kumar D, Keighley MR. Audit of sphincter repair: factors associated with poor outcome. *Dis Colon Rectum* 1996;39:1164–70.
34. Karoui S, Leroi AM, Koning E, Menard JF, Michot F, Denis P. Results of sphincteroplasty in 86 patients with anal incontinence. *Dis Colon Rectum* 2000;43(6):813–20.
35. Halverson AL, Hull TL. Long-term outcome of overlapping anal sphincter repair. *Dis Colon Rectum* 2002;45(3):345–8.
36. Gutierrez A, Madoff RD, Lowry AC, Parker SC, Buie WD, Baxter NN. Long-term results of anterior sphincteroplasty. *Dis Colon Rectum* 2004;47:727–32.
37. Vaizey CJ, Phillips RKS. A twisted tale. *Clinical Risk* 2005;11:53–6.