

F. Winston Gwathmey and J.W. Thomas Byrd

Introduction

The evolution of hip arthroscopy over the past quarter century is among the great advances in the treatment of hip injuries and conditions [1]. Improvements in techniques and instrumentation have helped overcome the anatomical obstacles inherent the tightly congruent femoroacetabular articulation and have established a wide array of interventions for a variety of hip pathology, both within the joint and in the adjacent extraarticular spaces [1–3]. Pathology that previously required extensive open surgery may now be effectively treated through a minimally invasive approach that spares exposure-related morbidity and accelerates recovery [4]. Hip arthroscopy has also elucidated previously misunderstood or unrecognized problems within the joint and has become the gold standard for the diagnosis of intraarticular hip pathology [3].

The ability to correlate arthroscopic findings with diagnostic imaging has greatly enhanced the overall understanding of hip anatomy and has improved the ability to diagnose pathology [5]. Magnetic resonance imaging (MRI) is the imaging modality of choice for the characterization of musculoskeletal anatomy around the hip and the diagnosis of injuries to soft tissue structures including muscle, tendons, ligaments, articular cartilage, and fibrocartilage. MR arthrography utilizes gadolinium injected into the joint to distend the joint capsule and better delineate intraarticular structures such as the labrum [6–9]. While arthrography improves the sensitivity and specificity of MR, important findings such as a joint effusion or subchondral edema may be obscured

by the high signal from the contrast [6]. Stronger magnets (1.5 and 3.0 Tesla) and surface coils have also improved the capabilities of MRI for evaluation of the hip [10].

The hip joint, however, presents diagnostic imaging challenges given its oblique orientation, spherical shape, and the anatomical variability among patients [9]. The close coaptation of the articular surfaces of the acetabulum and femoral head may obscure labral or cartilage pathology. Additionally, unlike the shoulder and knee in which decades of arthroscopic experience have allowed for systematic documentation and MR correlation of normal and variant anatomy as well as pathological entities, the comparatively shorter hip arthroscopy experience has not enabled an equivalent accumulation of information. The recent proliferation of hip arthroscopy, however, has propagated an expansion of the arthroscopic database of hip anatomy and pathology and has contributed to a concurrent evolution of hip imaging. This chapter will introduce hip arthroscopy and correlate arthroscopic anatomy with MR anatomy.

Hip Arthroscopy

Difficulty gaining operational access to the femoroacetabular articulation has historically restricted the ability to effectively apply arthroscopic techniques to the hip joint. The depth, orientation, and shape of the joint create additional instrumentation obstacles. Surgeons have developed strategies to overcome these obstacles and continue to expand the field of hip arthroscopy. Axial and lateral traction provided by a specialized operative table are used to pull the femoral head out of the acetabular socket, thus establishing a working space to diagnose and treat intraarticular pathology (Fig. 27.1). Alternating use of arthroscopes with 70 and 30° lenses is frequently necessary to adequately visualize and navigate the spaces within the hip joint. Cannulated systems permit safer and more efficient insertion of equipment, and specialized long and/or curved instruments allow intricate procedures to be carried out deep within the joint (Fig. 27.2).

F.W. Gwathmey, MD (✉)
Department of Orthopedic Surgery, University of Virginia
Health System, Charlottesville, VA, USA
e-mail: Fwg7d@hscmail.mcc.virginia.edu

J.W.T. Byrd, MD
Department of Orthopedics and Rehabilitation,
Vanderbilt University School of Medicine, Nashville, TN, USA
e-mail: byrd@nsmfoundation.org

Fig. 27.1 The patient is positioned on a specialized table that can apply traction to the leg to distract the femoral head from the acetabulum to facilitate intraarticular visualization and instrumentation. The table attachment also allows manipulation of the leg so that the hip can be rotated and flexed as needed. Fluoroscopy can be brought in between the legs or from the contralateral side of the table

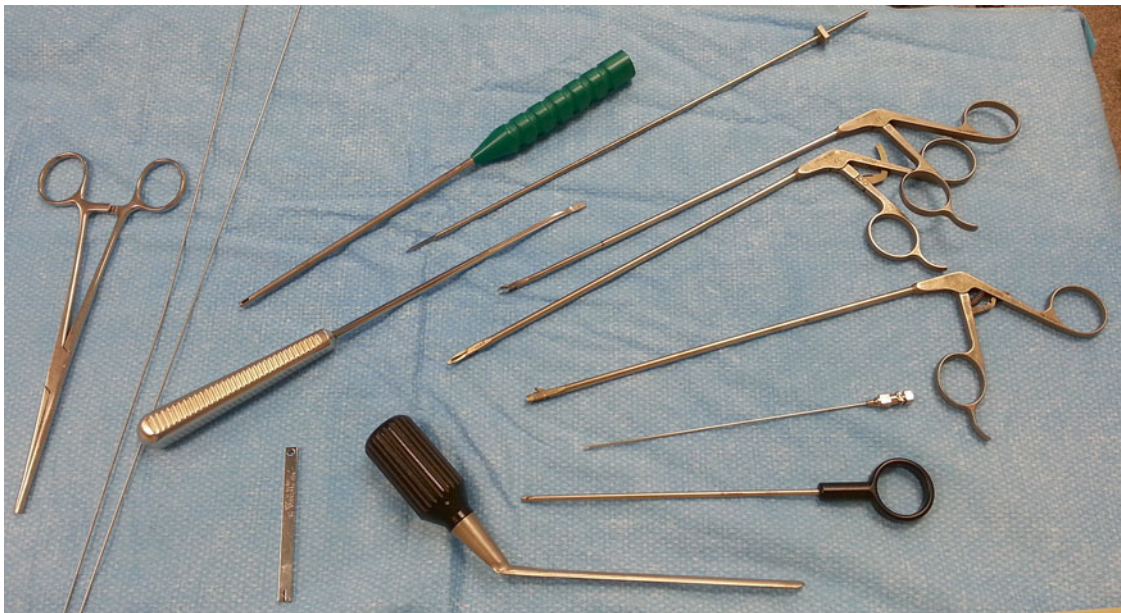
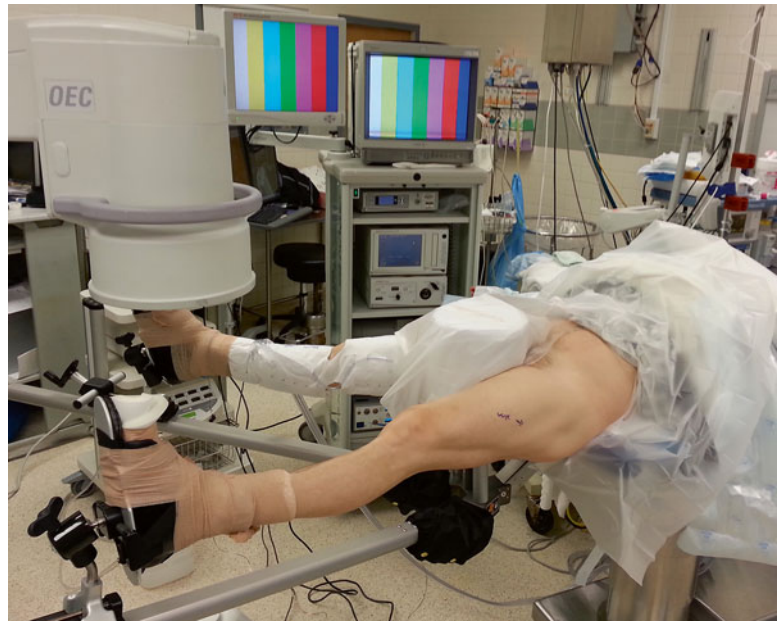


Fig. 27.2 Cannulated systems are commonly used for hip arthroscopy to safely establish portals and efficiently pass equipment into the joint. Hip arthroscopic instruments are longer than standard arthroscopic

instruments to permit intricate procedures to be performed deep within the body. Some surgeons use curved instruments to navigate the spherical and concave structures within the hip joint

Two distinct arthroscopic spaces are recognized within the hip joint, the central compartment between the femoral head and acetabulum and the peripheral compartment within the hip capsule but outside the femoroacetabular articulation (Fig. 27.3). In general, traction affords access to the central compartment, while the peripheral compartment is accessed out of traction and with some degree of hip flexion to relax the anterior capsule.

Depending on the planned procedure, two to five portals are used during hip arthroscopy. The neurovascular anatomy

surrounding the hip joint has been well studied and safe zones for portal placement have been described [11]. Standard portals include an anterolateral portal (just anterior to the tip of the greater trochanter), posterolateral portal (posterior to the tip of the greater trochanter), and an anterior portal (lateral and distal to the intersection of a line drawn transversely from the greater trochanter and a line drawn distally from the ASIS) [2] (Fig. 27.4). Modifications of these portals and additional portals have been introduced as techniques and instrumentation have evolved [12].

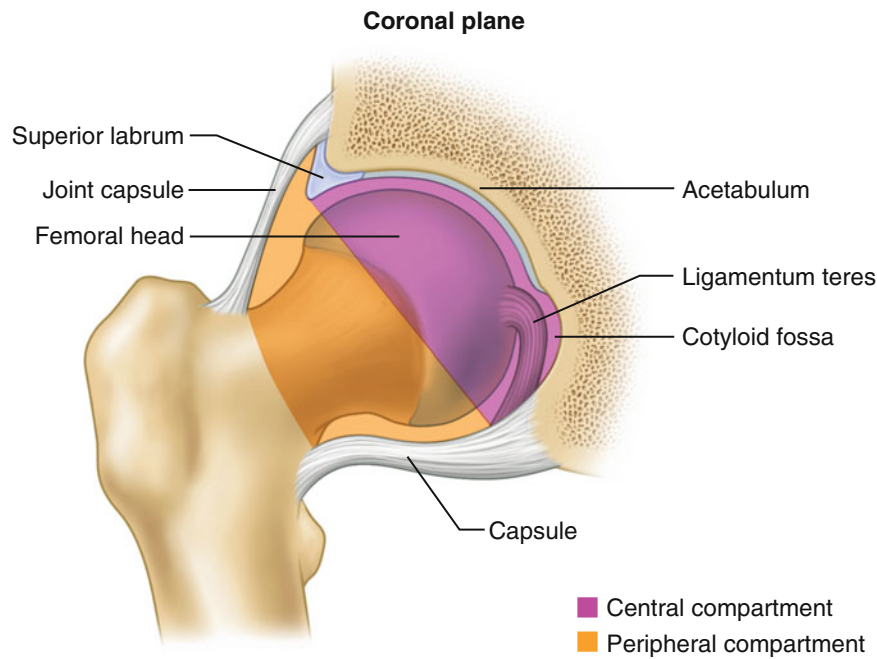


Fig. 27.3 During arthroscopy, two distinct compartments within the hip are recognized, the central and peripheral compartments. The central compartment comprises the space within joint encompassed by the acetabular labrum. Traction is required to pull the femoral head out of the acetabular fossa for access to the central compartment. Structures within the central compartment include the acetabular labrum, the artic-

ular cartilage surfaces of the femoral head and acetabulum, the cotyloid fossa, and the ligamentum teres. The peripheral compartment is accessed out of traction and with the hip in some flexion to relax the anterior capsule. Structures within the peripheral compartment include the femoral head/neck junction, femoral neck, medial and lateral synovial folds, zona orbicularis, and hip joint capsule

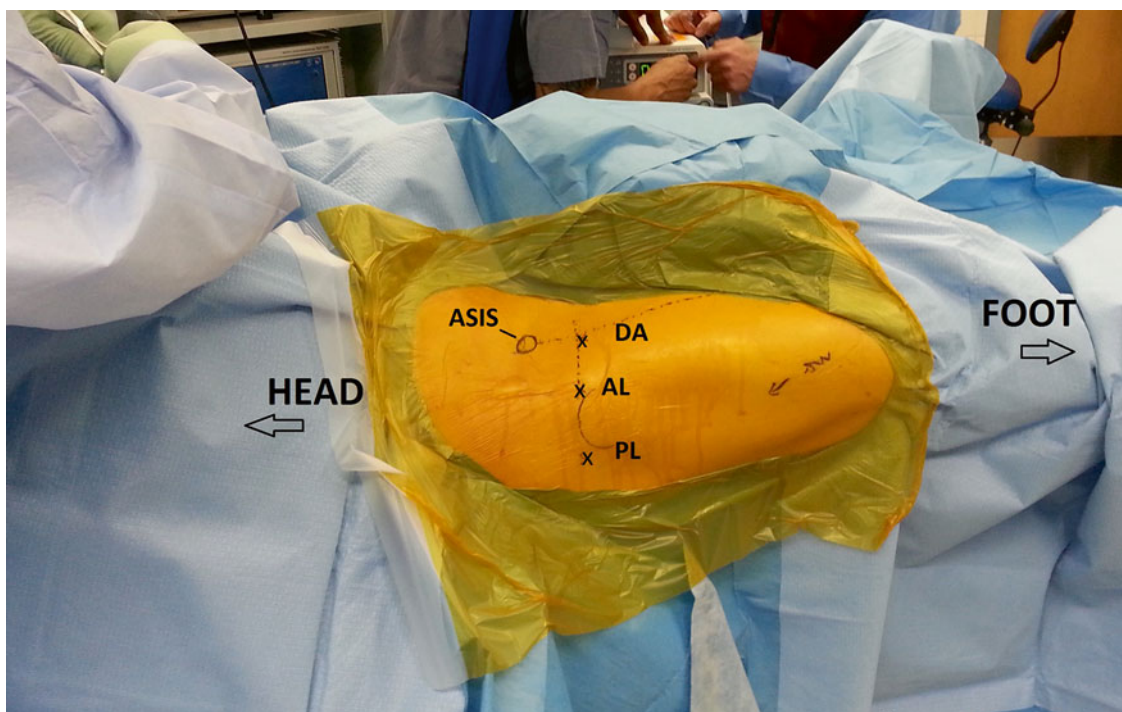


Fig. 27.4 Standard portals described for hip arthroscopy include the anterolateral (AL), anterior (DA), and posterolateral (PL) portals. Modifications of these portals and additional portals are commonly used depending on the procedure. The ASIS and greater trochanter are the key surface landmarks for portal placement. The anterolateral (AL)

and posterolateral (PL) portals are adjacent the anterior and posterior aspect of the greater trochanter. The direct anterior (DA) portal is positioned lateral and distal to the intersection between a line drawn distally from the ASIS and medially from the tip of the greater trochanter. Fluoroscopy may be used to verify position

Arthroscopic Anatomy

Central Compartment

Most hip arthroscopic procedures start with gaining access to the central compartment. Traction is applied to the leg to open the femoroacetabular articulation, and fluoroscopy is used to verify adequate distraction and guide the initial portal placement. The anterolateral portal is established under fluoroscopic guidance and the 70° scope is inserted into the joint. Through the anterolateral portal, a cursory initial inspection of the joint may be performed. An anterior portal for instrumentation may then be made under arthroscopic visualization.

Orientation within the joint may be confusing given the round concave configuration of the acetabulum and the spherical femoral head. A clockface applied to the acetabulum centered on the cotyloid fossa can be used for a systematic assessment of the joint and documentation of findings (Fig. 27.5). The clockface is positioned so that 6 o'clock marks the center of the transverse acetabular ligament and the apex of the cotyloid fossa is at the 12 o'clock position. On a right hip, the anterior joint is at the 3 o'clock position, while 9 o'clock references the posterior joint. On a left hip, some surgeons keep the clock facing forward and assign the 9 o'clock position to the anterior joint, while others invert the clockface to maintain consistency. An alternative geographic zone method has also been described [13].

Once the viewing and instrumentation portals have been established, the joint is inspected for pathology. With the arthroscope in the anterolateral portal, the structures of the

superior, anterior, and medial joint are examined. A probe inserted in the anterior portal is helpful to palpate and manipulate intraarticular structures (Fig. 27.6a–e). Most chondrolabral pathology tends to be anterior to the 12 o'clock position and this area should be emphasized in the diagnostic arthroscopy. Rotating the 70° scope in the anterolateral portal 180° brings the posterior labrum into view. A posterolateral portal may be established for access to the posterior joint. Visualization of far posterior and posteroinferior pathology may require placing the arthroscope into the posterolateral portal. The superolateral and lateral labrum and acetabulum are best visualized with the arthroscope in the anterior portal with the lens directed laterally (Fig. 27.7a–c). Use of cannulas in each portal that can accommodate the arthroscope aids efficient movement between portals. Capsulotomies of varying sizes and orientations also facilitate maneuverability within the joint.

Similar to the glenoid labrum in the shoulder, a variety of acetabular labral variants have been observed in the hip. Sublabral sulci or recesses may be present in up to 20% of patients and can be found at all anatomic positions around the acetabular labrum [14, 15]. On MRI, several features of a sublabral sulcus help differentiate it from a tear. A linear MR appearance and lack of secondary findings including cysts, chondral damage, or edema are suggestive of a normal anatomic variant [16]. The location on the acetabulum of the finding is also important. Sublabral sulci frequently occur posteriorly or inferomedially [14, 16] (Fig. 27.8a, b). Additionally, at the junction between the labrum and the transverse acetabular ligament, contrast may appear to penetrate the labrum. While labral variants

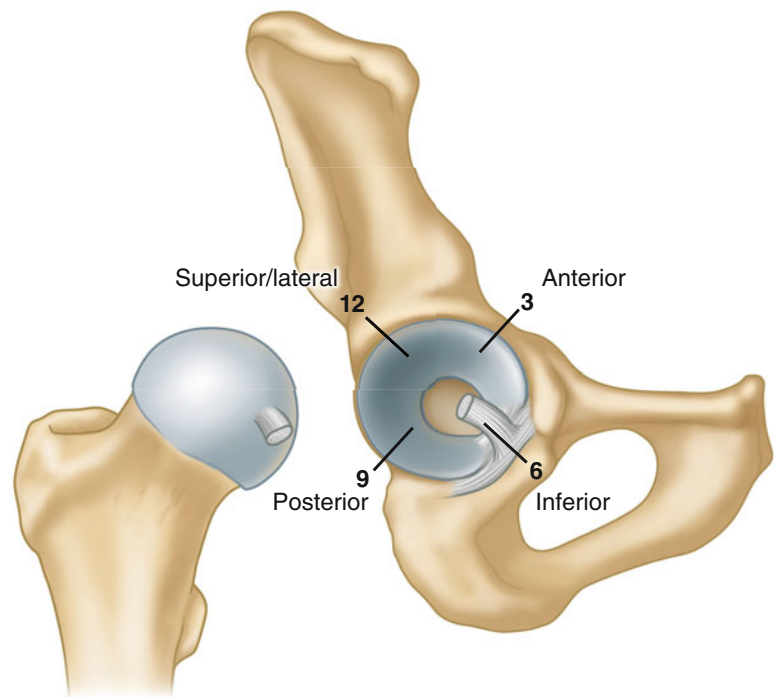


Fig. 27.5 For orientation and documentation, a clockface is often applied to the acetabular fossa. The 6 o'clock position is set at the transverse acetabular ligament with the 12 o'clock position directly opposite at the apex of the cotyloid fossa

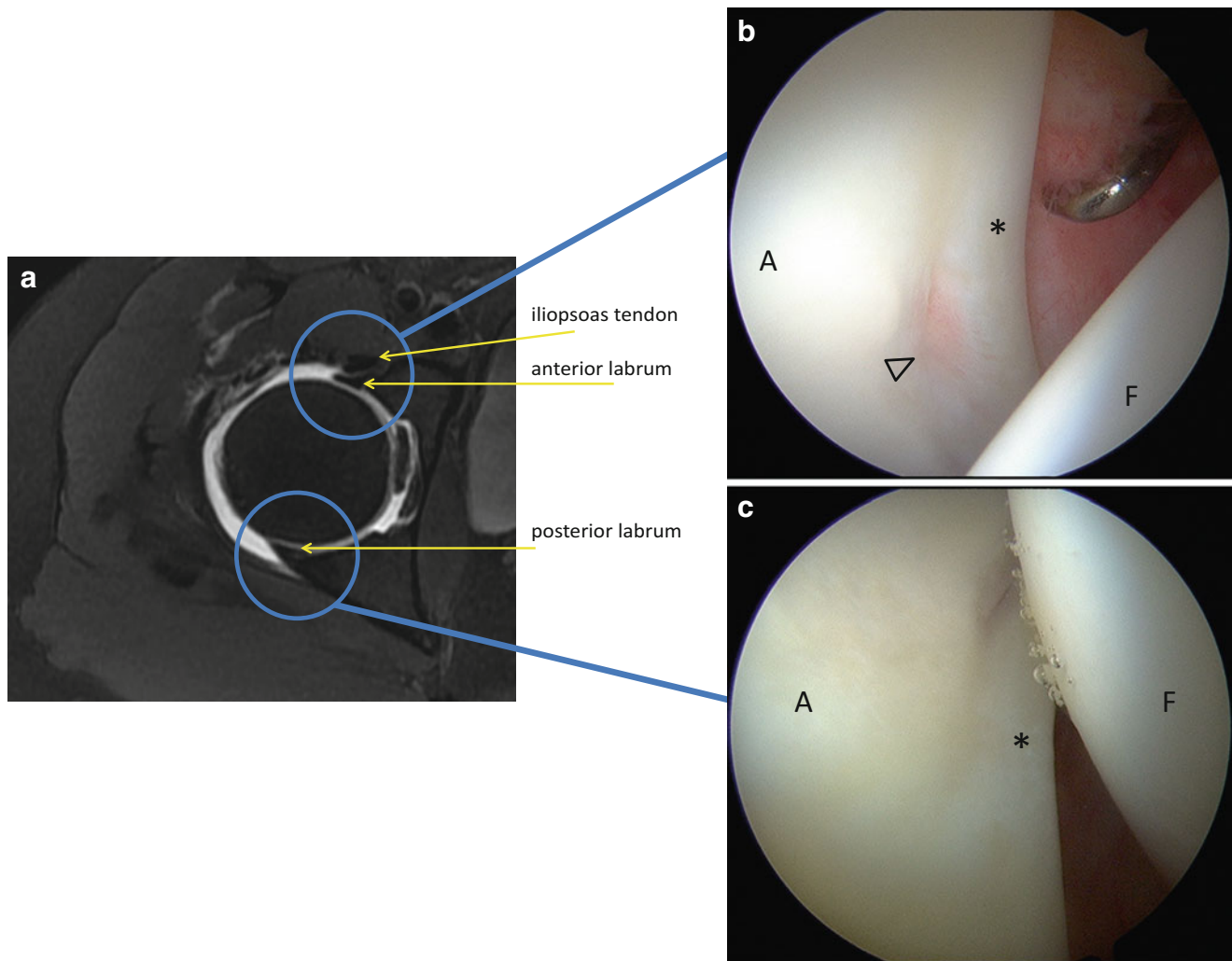


Fig. 27.6 (a) Axial T2 MR-arthrogram of the right hip. The outline of the anterior and posterior labrum may be seen on this sequence. The labrum conforms to the femoral head and the articular aspect blends into the articular cartilage. (b) Arthroscopic photograph of the anterior labrum (*asterisk*) at approximately the 3 o'clock position. The arthroscope is positioned in the anterolateral portal and the lens is directed anteriorly. The acetabulum (A) is on the *left* of the picture and the femoral head (F) is on the *right*. The probe is inserted through the anterior portal and is used to examine the structure of the anterior labrum and adjacent cartilage. A normal smooth transition is evident between the

labrum and articular cartilage. The recess in the acetabular rim here (*arrowhead*) corresponds to the approximate position of the iliopsoas tendon as it crosses the joint. (c) Arthroscopic photo of the posterior labrum (*asterisk*). The arthroscope is in the anterolateral portal and the lens is directed posteriorly. (d) Anatomical rendering of the anterior labrum viewed from the anterolateral portal with the 70° arthroscope. (e) Anatomical rendering of the posterior labrum viewed from the anterolateral portal by rotating the 70° arthroscope 180° and directing it posteriorly. Further visualization of the posteroinferior joint is afforded by moving the arthroscope to the posterolateral portal

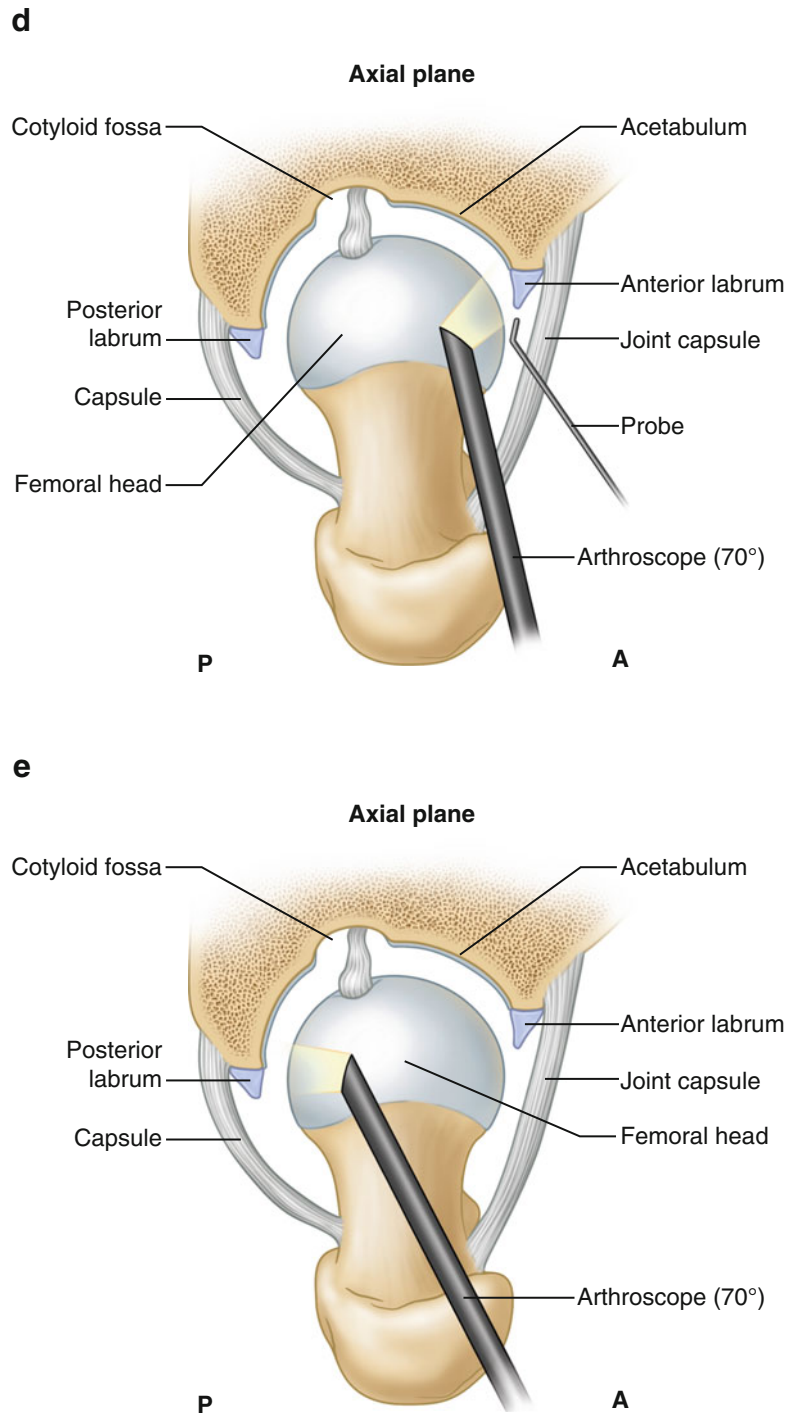


Fig. 27.6 (continued)

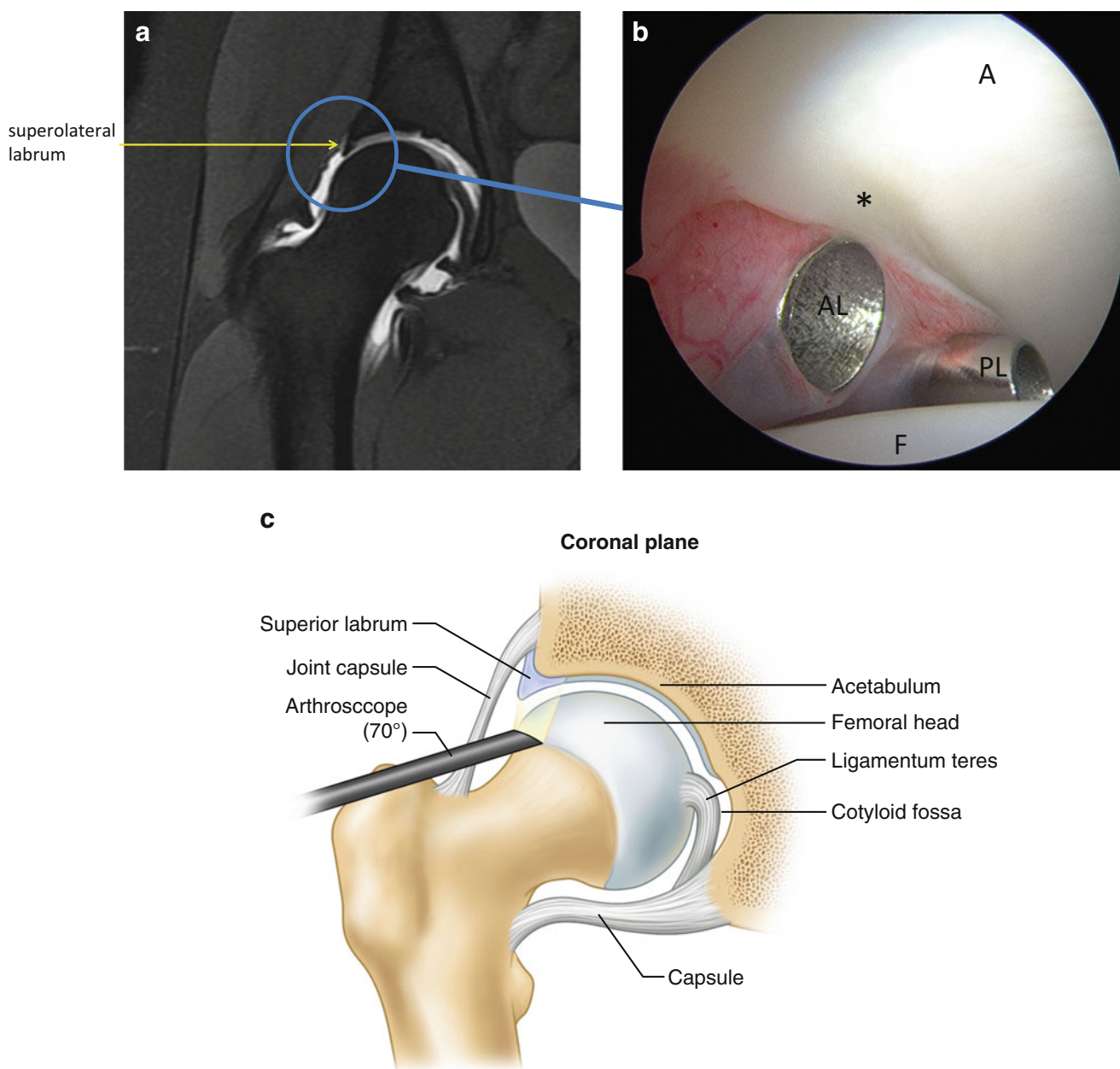


Fig. 27.7 (a) Coronal T2 MR-arthrogram of the right hip demonstrating the superolateral labrum (*arrow*). (b) Arthroscopic photograph of the lateral labrum. The arthroscope is in the anterior portal and the lens is directed laterally. The acetabulum (A) is at the *top right* of the picture

and the femoral head (F) is at the *bottom*. Metal cannulas are positioned in the anterolateral (AL) and posterolateral portals (PL). (c) Anatomical rendering showing that moving the 70° arthroscope into the anterior portal allows visualization of the superolateral labrum

may also occur anteriorly or superiorly, a higher index of suspicion for pathologic labral tear should be maintained in these locations. Underlying pincer morphology or acetabular dysplasia warrants consideration of true labral pathology [17].

The cotyloid fossa is situated at the most medial aspect of the acetabulum. This location cannot be accessed without traction and special care must be taken to avoid the femoral head as the arthroscope is moved into position. While the acetabular rim is best visualized by the 70° arthroscope, changing to a 30°

arthroscope improves visualization of the medial joint. The cotyloid fossa contains the ligamentum teres and the accompanying fat pad (Fig. 27.9a, b). The femoral head often presents a navigation obstacle and alternating among the portals may be necessary for complete inspection. Internal and external rotation of the hip may also be necessary for a thorough evaluation of the structures within the cotyloid fossa. Petechiae within the fat pad are often seen with the negative intraarticular pressure generated by the traction and should not be confused with a traumatic injury to the ligamentum teres (Fig. 27.9c).

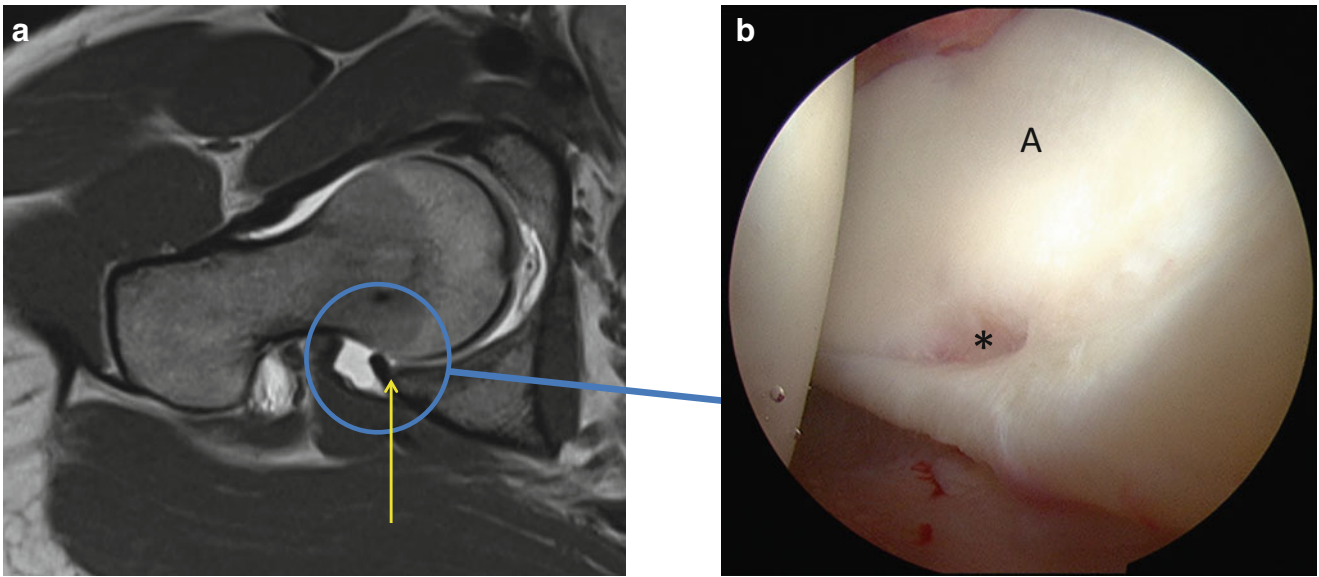


Fig. 27.8 (a) Coronal T1 MR-arthrogram of the right hip demonstrating a posterior labral recess (*arrow*). The contrast is visible penetrating the articular interface between the labrum and articular cartilage. The lack of signal within the substance of the labrum, the absence of secondary

findings, and the posterior location suggest that this finding is not pathological. (b) Arthroscopic photograph of the posterior labral recess. A cleft is visible between the labrum (*asterisk*) and acetabular cartilage (A). This is a common labral variant and does not represent a tear.

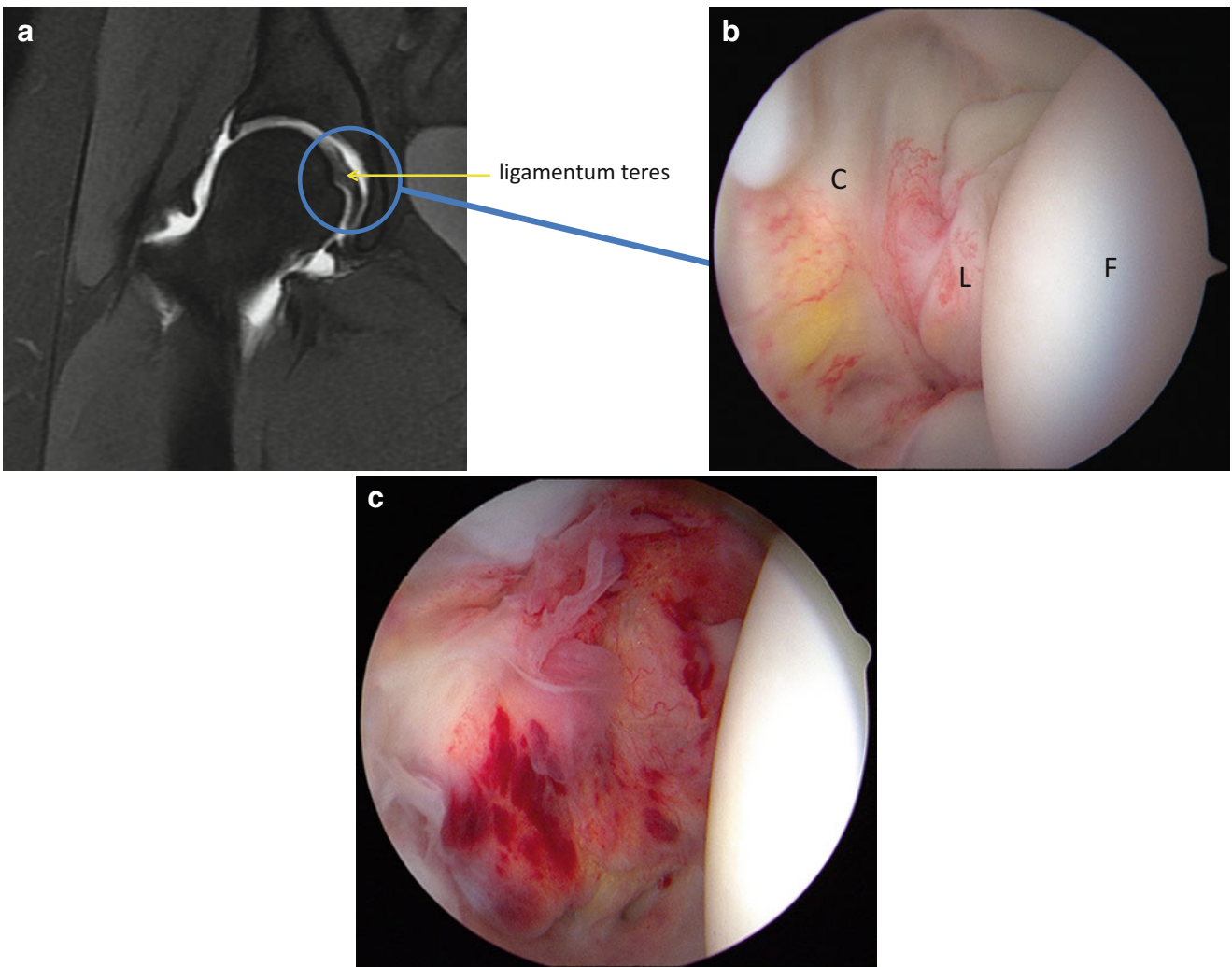


Fig. 27.9 (a) Coronal MR-arthrogram of the right hip demonstrating the acetabular fossa and ligamentum teres (*arrow*). (b) Arthroscopic photograph of the cotyloid fossa (C) and ligamentum teres (L) attaching to the femoral head (F). For adequate evaluation, an arthroscope with a

30° lens may be needed as well as visualization through multiple portals. (c) The negative intraarticular pressure created by applying traction to the hip may cause petechiae and localized hemorrhage within the fossa and synovium within the fossa

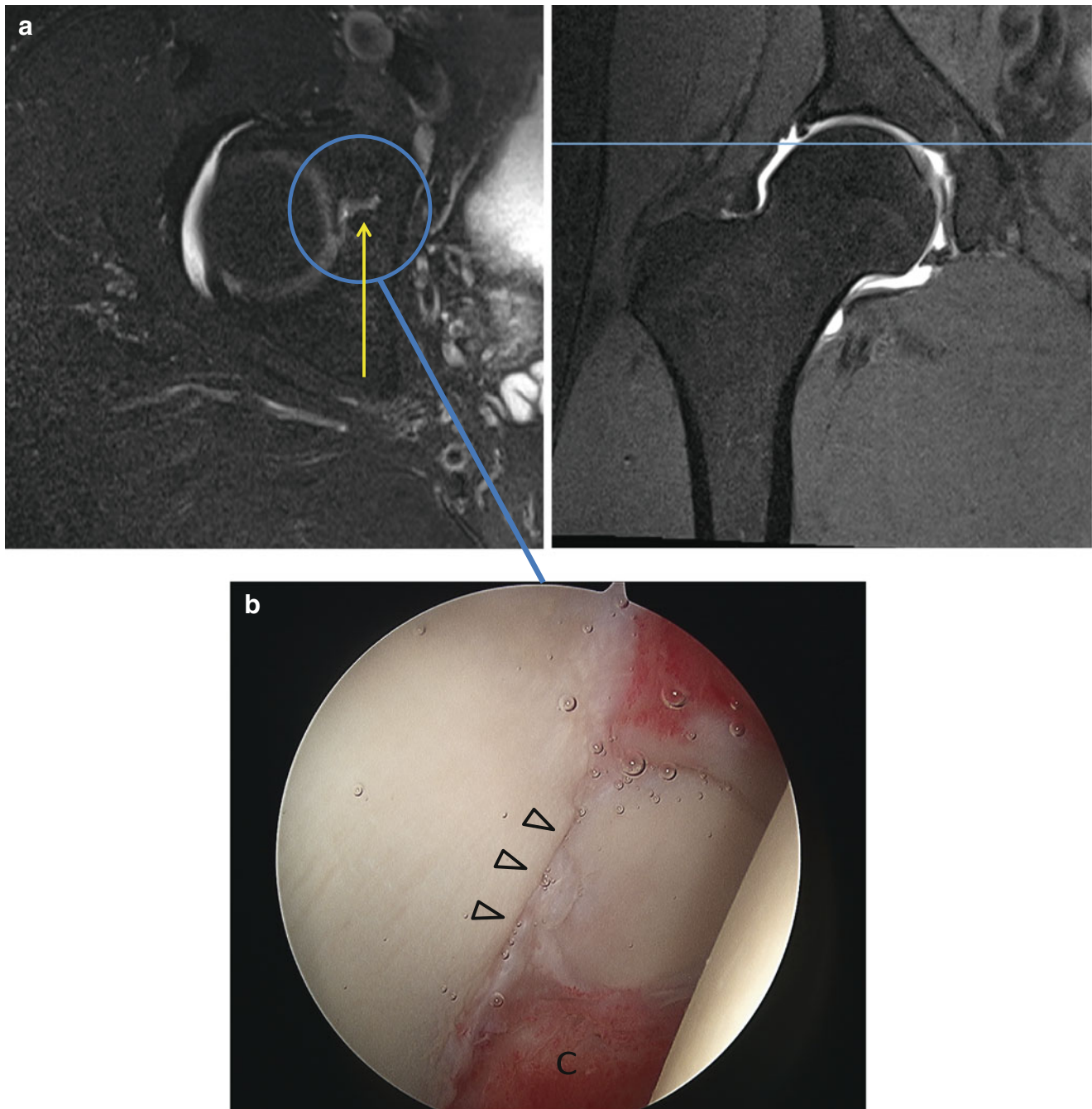


Fig. 27.10 (a) Linked axial and coronal T2 MR-arthrogram images of a physeal scar between the ilium and pubis (*arrow*). The scar is seen as a linear defect in the anteromedial aspect of the articular cartilage but

may not be readily apparent on imaging. (b) Arthroscopic appearance of the physeal scar (*arrowheads*) extending radially from the cotyloid fossa (C) to the medial acetabular rim

The adult acetabulum is made up of three bones, the pubis, ilium, and ischium, which normally fuse at the triradiate cartilage during adolescence. Persistence of a physeal scar anteriorly between the ilium and pubis or posteriorly between the ilium and ischium has been described [18]. These anatomical variants are difficult to identify on MR but may appear as a linear signal extending radially from the cotyloid fossa at the confluence between the two ossification centers (Fig. 27.10a, b).

Another developmental variant seen commonly in the central compartment during hip arthroscopy is a supraacetabular fossa [19]. Located in the acetabular roof at the apex of the cotyloid fossa, a supraacetabular fossa has been found in up to 10 % of normal adult hips and most likely represents a focal delay in skeletal maturation [20] (Fig. 27.11a, b). Sometimes mislabeled a focal cartilage defect or an osteochondritis dissecans lesion on MR, the supraacetabular fossa is found mostly

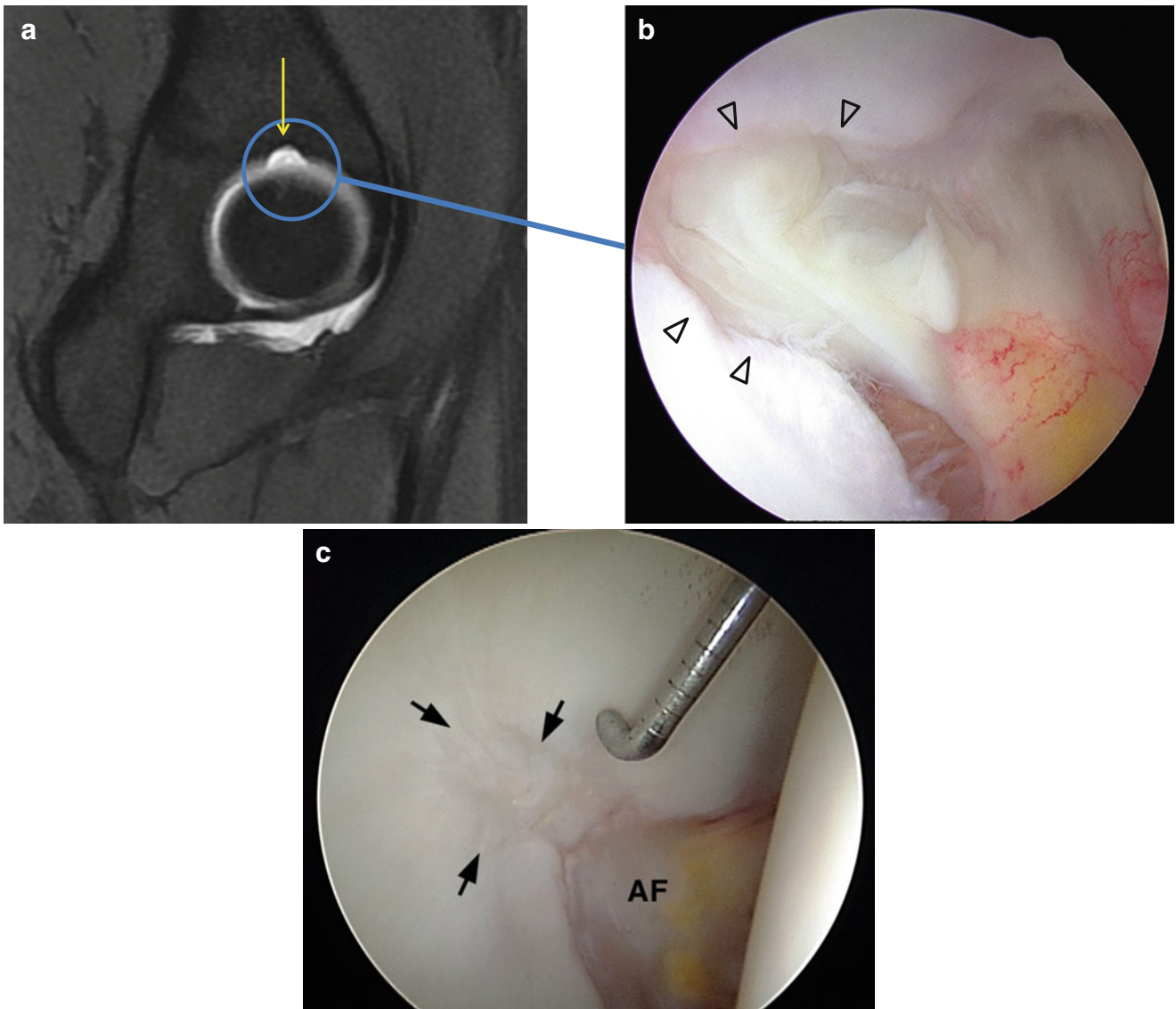
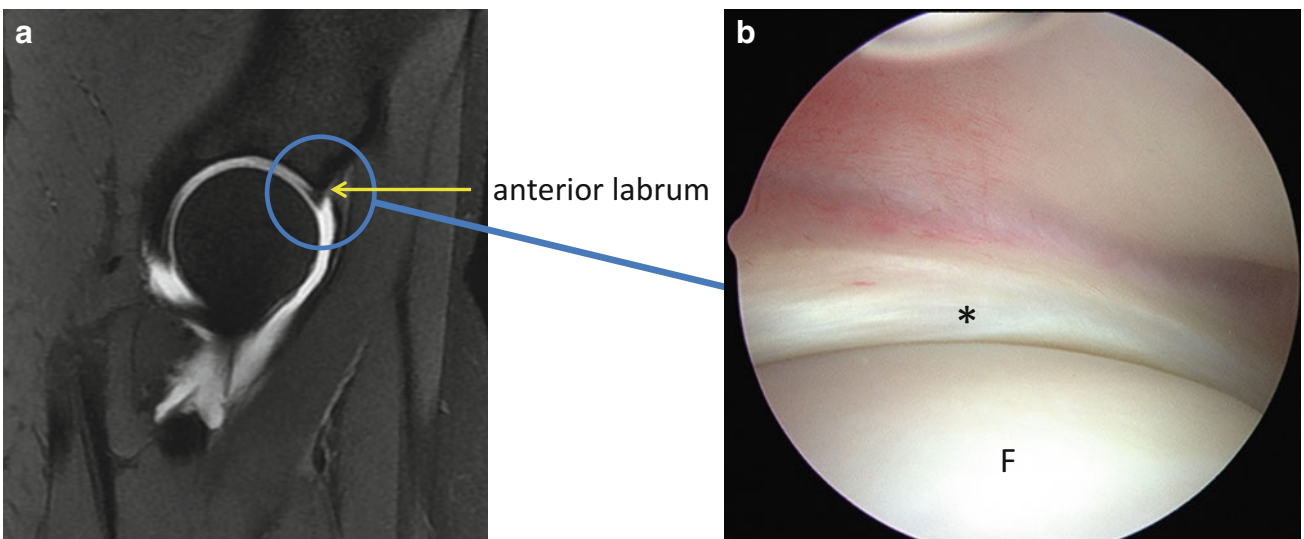


Fig. 27.11 (a) Sagittal T2 MR-arthrogram demonstrating a defect in the acetabular roof consistent with a supraacetabular fossa (*arrow*). (b) Arthroscopic appearance of the supraacetabular fossa (*arrowheads*) filled with fibrous tissue. (c) Arthroscopic appearance of the stellate crease (*arrowheads*) which appears to be a remnant of the filled in supraacetabular fossa (c: published with kind permission. Copyright © J.W. Thomas Byrd, MD)



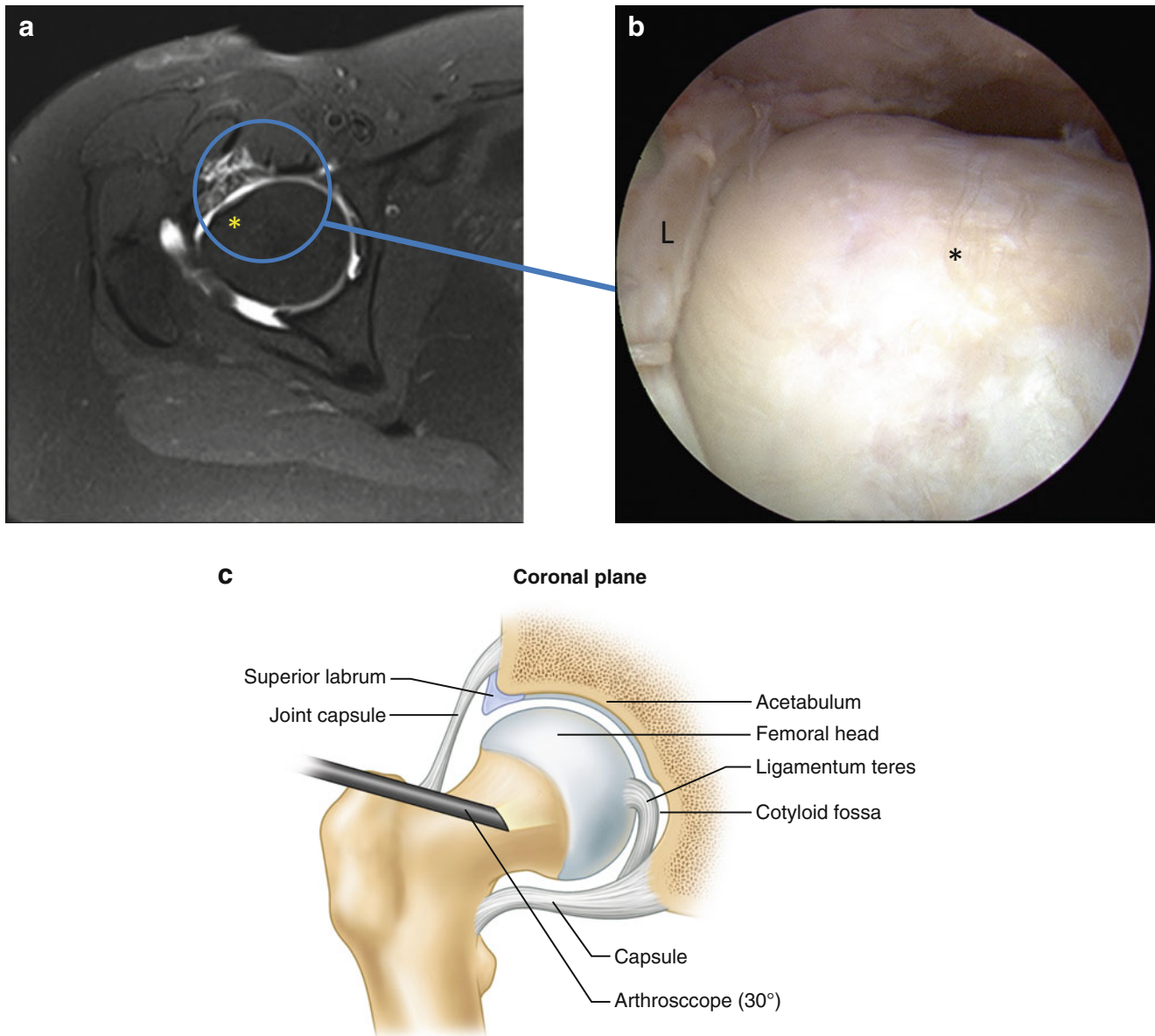
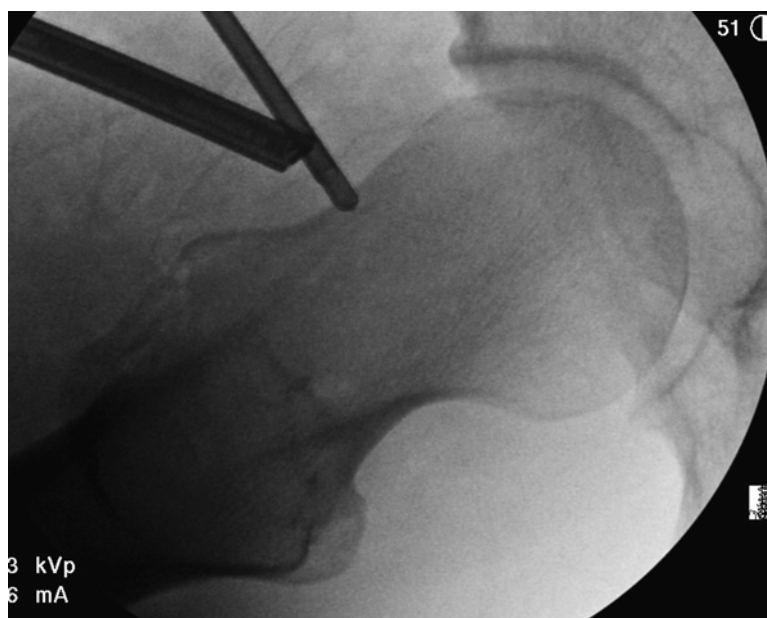

Fig. 27.13 (a) Axial T2 MR-arthrogram demonstrating the femoral head/neck junction (*asterisk*). Analysis of multiple cuts from cross-sectional imaging is essential to characterize the femoral head/neck junction to identify cam morphology. (b) Arthroscopic appearance of the femoral head/neck junction (*asterisk*). A capsulotomy connecting the anterior and anterolateral portals has been made and the hip is flexed to 35° to improve visualization of the entire anterior femoral neck. The repaired acetabular labrum (L) is on the left of the picture.

In general, the cam deformity of the femoral head/neck junction is adjacent the area of chondrolabral damage seen in the central compartment. Rotation of the hip aids in visualization of the medial and lateral aspects of the femoral neck. (c) Anatomical rendering showing that removing traction and flexing the hip to 40° permits access to the peripheral compartment and visualization of the femoral neck and head/neck junction. Switching to a 30° arthroscope may facilitate visualization within this space

Fig. 27.12 (a) Sagittal T2 MR-arthrogram demonstrating the relationship between the anterior labrum (*arrow*) and the femoral head. The labrum conforms circumferentially around the femoral head creating a seal that facilitates fluid joint motion, enhances joint stability through negative intra-articular pressure, and maintains lubrication of the articular surfaces. (b) Arthroscopic appearance of the labral seal (*asterisk*). Traction has been released to locate the femoral head (F) within the acetabular vault. The arthroscope is positioned within the peripheral compartment. Arthroscopic intervention in the joint must not compromise the labral seal so that the biomechanics of the labrum are maintained

Fig. 27.14 Intraoperative fluoroscopic image of a right hip during femoroplasty. Rotation of the hip under fluoroscopy helps to characterize deformities of the femoral head/neck junction and guides correction



in young adults and usually fills in over time. It has been proposed that the stellate crease represents a residual scar left after obliteration of the supraacetabular fossa [21–23] (Fig. 27.11c).

Peripheral Compartment

The peripheral compartment comprises the space within the joint capsule outside of the femoroacetabular articulation. Once traction is released and the femoral head returns to its position within the acetabular vault, the peripheral compartment is accessed by flexing the hip until the anterior capsule is sufficiently relaxed to permit navigation. While the previously made anterolateral or anterior portals generally allow access to peripheral compartment, adequate visualization and instrumentation are permitted by either expanding or extending the central compartment capsulotomy or by penetrating the anterolateral capsule distally from the central compartment capsulotomy. While some surgeons continue to use the 70° arthroscope in the peripheral compartment, the anatomy of the peripheral compartment is conducive to visualization with a 30° arthroscope.

The hip joint capsule has a proximal attachment circumferentially along the periphery of the acetabular rim and attaches distally at the intertrochanteric line anteriorly and on the femoral neck posteriorly. The femoroacetabular labral seal can be inspected proximally within the peripheral compartment (Fig. 27.12a, b). The labrum should fit snugly against the cartilage of the femoral head circumferentially around the joint and maintain contact throughout hip flexion and rotation. The quality of a pincer correction and labral refixation or repair may be assessed from this view.

An excessive or asymmetrical acetabuloplasty or femoroplasty may compromise the sealing function of the labrum.

The morphology of the femoral head/neck junction and femoral neck is evaluated in the peripheral compartment (Fig. 27.13a–c). While preoperative imaging is critical for demonstrating proximal femoral morphology, the pathological features of femoroacetabular impingement are best characterized during arthroscopy by the pattern of articular cartilage damage within the acetabular vault as well as the arthroscopic appearance of the femoral head/neck junction. Arthroscopic observation of the femoroacetabular articulation while the hip is taken through increasing flexion and internal and external rotation demonstrates the dynamic biomechanics underlying potential impingement. Intraoperative fluoroscopy helps to localize position on the femoral neck and helps define the femoroplasty (Fig. 27.14).

The medial and lateral arthroscopic borders of the peripheral compartment are the medial and lateral synovial folds, respectively. These folds contain the terminal retinacular branches of medial and lateral circumflex arteries and must be protected during arthroscopy of the peripheral compartment. Improved access to the medial and lateral gutters is afforded by external and internal rotation of the hip, respectively. The lateral epiphyseal vessels along the posterosuperior neck constitute the major blood supply to the femoral head [24–26]. These folds are frequently well demonstrated on MR arthrography as linear structures coursing parallel to the femoral neck (Fig. 27.15a–c). The zona orbicularis is a thickening of the joint capsule that runs circumferentially around the femoral neck resisting axial distraction of the joint [27]. This is seen arthroscopically running perpendicular to the retinacular vessels.

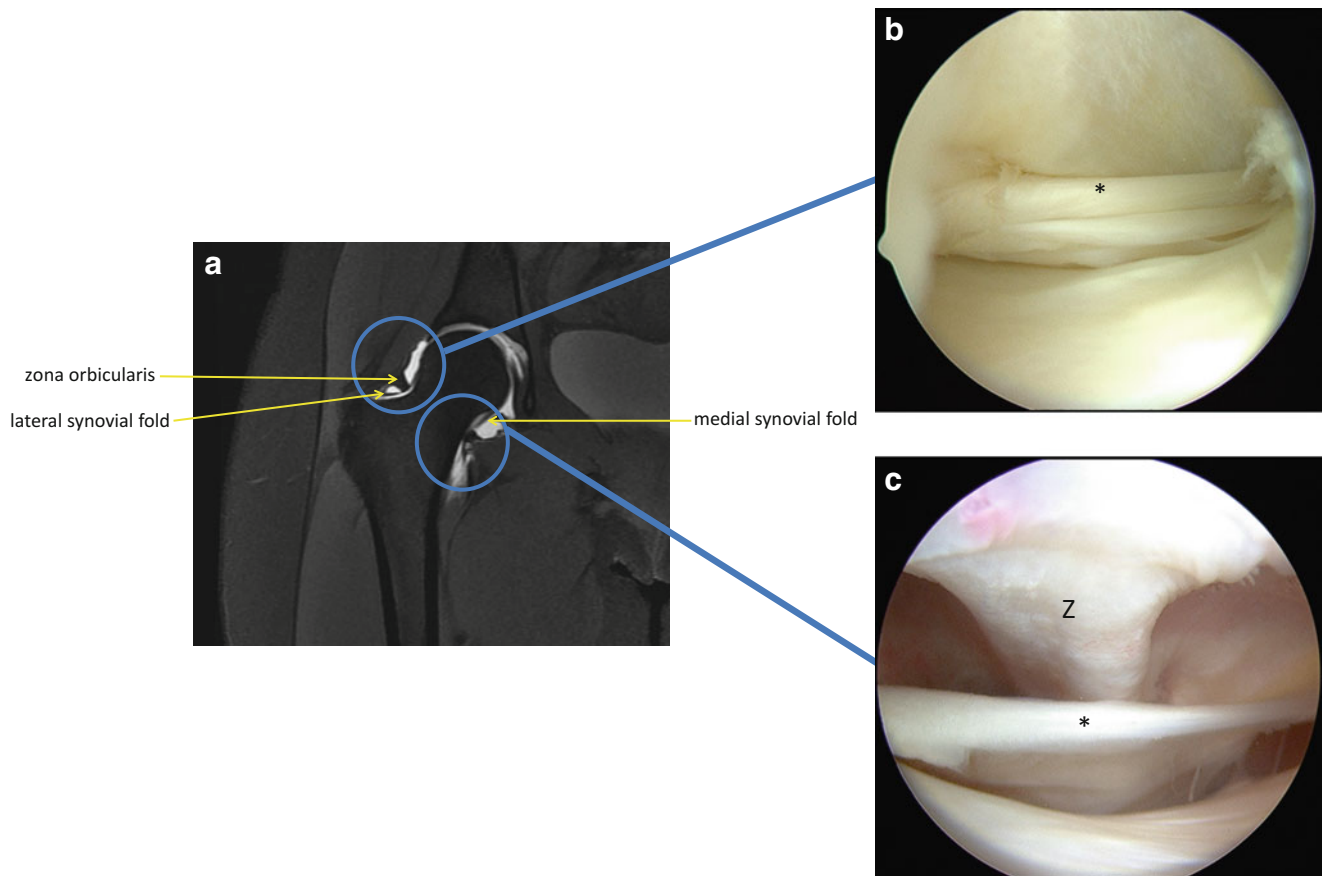


Fig. 27.15 (a) Coronal T2 MR-arthrogram of a right hip demonstrating the zona orbicularis and lateral and medial synovial folds. (b) The arthroscope is maneuvered into the lateral gutter of the peripheral compartment and the lens is directed posteromedially to visualize the lateral synovial fold (*asterisk*) and lateral retinacular vessels. These vessels

provide critical blood flow to the femoral head and must be protected during femoroplasty. (c) Arthroscopic appearance of the medial synovial fold (*asterisk*) passing under the zona orbicularis (Z). The arthroscope is maneuvered across the anterior femoral neck into the medial gutter to visualize this structure

The rectus femoris and iliopsoas tendons traverse the hip joint superficial to capsule. The origin of the rectus femoris consists of a direct head off of the anterior inferior iliac spine and an indirect head off of the posterolateral acetabular rim. The rectus femoris may be visualized from the central compartment in the extraarticular space through an extended anterior capsulotomy running perpendicular to the anterior acetabular rim (Fig. 27.16). The iliopsoas tendon may be seen as a linear indentation in the anteromedial capsule as it courses toward its insertion on the lesser trochanter of the femur (Fig. 27.17a, b). It may be exposed through an anteromedial capsulotomy from the central or peripheral compartment (Fig. 27.17c).

Conclusion

Treating a patient with a painful hip is challenging due to the complexities of the hip joint and the broad differential diagnosis of pathology in this region. Making an accurate diagno-

sis requires a systematic algorithm and incorporates elements of the history, examination, and preoperative imaging. MRI of the hip may be difficult to interpret given the anatomical complexity, variability, and orientation of the joint.

Hip arthroscopy has revolutionized the approach to the non-arthritic hip. The advancement of the technique is self-perpetuated as arthroscopy allows the development of innovative ways to treat hip pathology and continues to reveal newly understood hip pathology amenable to arthroscopic intervention. As our collective arthroscopic experience in the hip grows, our understanding of the complex anatomy and biomechanics of hip joint will also expand. Analysis of the variables inherent the morphology of the femoroacetabular articulation and systematic cataloguing of the anatomical variants and pathological entities of the hip joint will promote the continued evolution of hip arthroscopy. Correlation of arthroscopic findings to MR findings and collaboration with colleagues in musculoskeletal radiology will fuel a concomitant evolution of MR imaging of the hip joint. These

Fig.27.16 Arthroscopic appearance of the tendon of the rectus femoris during left hip arthroscopy. The arthroscope is positioned in the anterolateral portal with the lens directed anteriorly. A capsulotomy has been made that connects the anterolateral to the anterior portal. The tendon is visualized traveling perpendicular to the anterior labrum (L) and should be protected while extending the capsulotomy

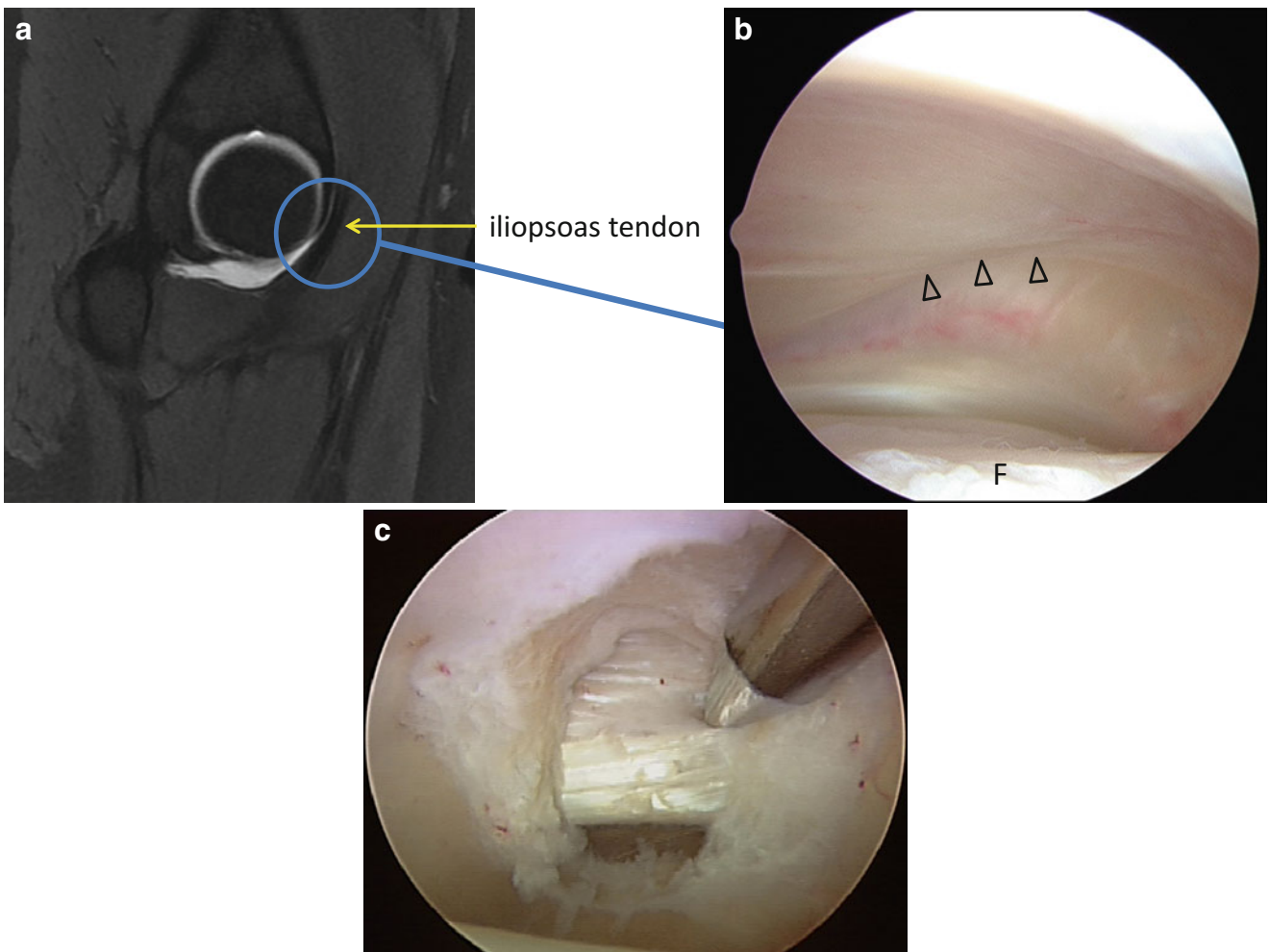
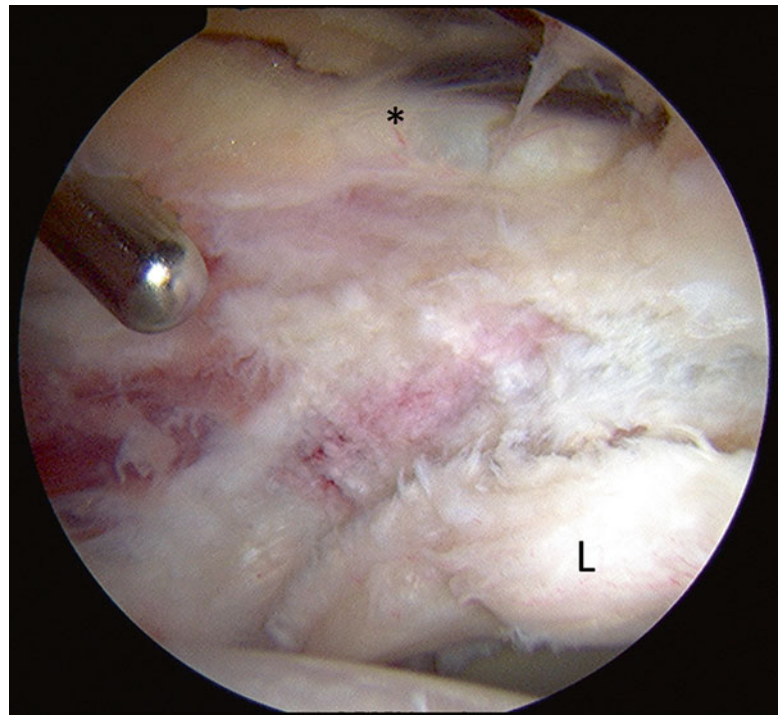


Fig.27.17 (a) Sagittal MR-arthrogram demonstrating the iliopsoas tendon (*arrow*) coursing just anterior to the anteromedial acetabulum. Note the intimate relationship between the anterior rim and the tendon. (b) Arthroscopic appearance of the indentation made in the capsule from the extraarticular iliopsoas tendon (*arrowheads*). The arthroscope is in the

peripheral compartment aimed anteriorly. The femoral neck (F) is at the *bottom* of the picture and the iliopsoas is seen coursing obliquely across the medial joint toward its insertion on the iliopsoas. (c) A small capsulotomy in the anteromedial capsule demonstrates the tendon of the iliopsoas (c: published with kind permission. Copyright © J.W. Thomas Byrd, MD)

advances promoted by hip arthroscopy will refine the diagnostic algorithm and improve our ability to deliver superior care to patients with hip problems.

References

1. McCarthy JC, Lee J-A. History of hip arthroscopy: challenges and opportunities. *Clin Sports Med.* 2011;30(2):217–24.
2. Byrd JWT. Hip arthroscopy. *J Am Acad Orthop Surg.* 2006;14(7):433–44.
3. Kelly BT, Williams RJ, Philippon MJ. Hip arthroscopy: current indications, treatment options, and management issues. *Am J Sports Med.* 2003;31(6):1020–37.
4. Matsuda DK, Carlisle JC, Arthurs SC, Wierks CH, Philippon MJ. Comparative systematic review of the open dislocation, mini-open, and arthroscopic surgeries for femoroacetabular impingement. *Arthroscopy.* 2011;27(2):252–69.
5. Keeney JA, Peelle MW, Jackson J, Rubin D, Maloney WJ, Clohisy JC. Magnetic resonance arthrography versus arthroscopy in the evaluation of articular hip pathology. *Clin Orthop Relat Res.* 2004;429:163–9.
6. Byrd JWT. Diagnostic accuracy of clinical assessment, magnetic resonance imaging, magnetic resonance arthrography, and intra-articular injection in hip arthroscopy patients. *Am J Sports Med.* 2004;32(7):1668–74.
7. Toomayan GA, Holman WR, Major NM, Kozlowicz SM, Vail TP. Sensitivity of MR arthrography in the evaluation of acetabular labral tears. *AJR Am J Roentgenol.* 2006;186(2):449–53.
8. Freedman BA, Potter BK, Dinauer PA, Giuliani JR, Kuklo TR, Murphy KP. Prognostic value of magnetic resonance arthrography for Czerny stage II and III acetabular labral tears. *Arthroscopy.* 2006;22(7):742–7.
9. Chang CY, Huang AJ. MR imaging of normal hip anatomy. *Magn Reson Imaging Clin N Am.* 2013;21(1):1–19.
10. Sundberg TP, Toomayan GA, Major NM. Evaluation of the acetabular labrum at 3.0-T MR imaging compared with 1.5-T MR arthrography: preliminary experience. *Radiology.* 2006;238(2):706–11.
11. Byrd JW, Pappas JN, Pedley MJ. Hip arthroscopy: an anatomic study of portal placement and relationship to the extra-articular structures. *Arthroscopy.* 1995;11(4):418–23.
12. Robertson WJ, Kelly BT. The safe zone for hip arthroscopy: a cadaveric assessment of central, peripheral, and lateral compartment portal placement. *Arthroscopy.* 2008;24(9):1019–26.
13. Ilizaliturri VM, Byrd JWT, Sampson TG, et al. A geographic zone method to describe intra-articular pathology in hip arthroscopy: cadaveric study and preliminary report. *Arthroscopy.* 2008;24(5):534–9.
14. Saddik D, Troupis J, Tirman P, O'Donnell J, Howells R. Prevalence and location of acetabular sublabral sulci at hip arthroscopy with retrospective MRI review. *AJR Am J Roentgenol.* 2006;187(5):W507–11.
15. Nguyen MS, Kheyfits V, Giordano BD, Dieudonne G, Monu JUV. Hip anatomic variants that may mimic abnormalities at MRI: labral variants. *AJR Am J Roentgenol.* 2013;201(3):W394–400.
16. Studler U, Kalberer F, Leunig M, et al. MR arthrography of the hip: differentiation between an anterior sublabral recess as a normal variant and a labral tear. *Radiology.* 2008;249(3):947–54.
17. Wenger DE, Kendell KR, Miner MR, Trousdale RT. Acetabular labral tears rarely occur in the absence of bony abnormalities. *Clin Orthop Relat Res.* 2004;426(426):145–50.
18. Paliobeis CP, Villar RN. Arthroscopic identification of iliopubic and ilioischial grooves in a single adult acetabulum. *BMJ Case Rep.* 2010;2010:1–3.
19. Byrd JWT. [Hip arthroscopy. Portal technique and arthroscopic anatomy]. *Orthopade.* 2006;35(1):41–2, 44–50, 52–3.
20. Dietrich TJ, Suter A, Pfirrmann CWA, Dora C, Fucntese SF, Zanetti M. Supraacetabular fossa (pseudodeflect of acetabular cartilage): frequency at MR arthrography and comparison of findings at MR arthrography and arthroscopy. *Radiology.* 2012;263(2):484–91.
21. Keene GS, Villar RN. Arthroscopic anatomy of the hip: an in vivo study. *Arthroscopy.* 1994;10(4):392–9.
22. Byrd JWT. Hip arthroscopy in athletes. In: Byrd JWT, editor. *Operative hip arthroscopy.* New York: Springer; 2012.
23. Byrd JWT. Supraacetabular fossa. *Radiology.* 2012;265(2):648. Author reply 648.
24. Gautier E, Ganz K, Krügel N, Gill T, Ganz R. Anatomy of the medial femoral circumflex artery and its surgical implications. *J Bone Joint Surg Br.* 2000;82(5):679–83.
25. Anderson K, Strickland SM, Warren R. Hip and groin injuries in athletes. *Am J Sports Med.* 2001;29(4):521–33.
26. Kalhor M, Beck M, Huff TW, Ganz R. Capsular and pericapsular contributions to acetabular and femoral head perfusion. *J Bone Joint Surg Am.* 2009;91(2):409–18.
27. Ito H, Song Y, Lindsey DP, Safran MR, Giori NJ. The proximal hip joint capsule and the zona orbicularis contribute to hip joint stability in distraction. *J Orthop Res.* 2009;27(8):989–95.