

ERRATUM TO

Chapter 6 Antithyroid Drug Therapy in Patients with Graves' Disease

Peter Laurberg and David S. Cooper

© Springer Science+Business Media New York 2015
R.S. Bahn (ed.), *Graves' Disease*, DOI 10.1007/978-1-4939-2534-6_6

DOI 10.1007/978-1-4939-2534-6_24

The image in Fig. 6.2 of chapter 6 has been captured incorrectly in page 73. The correct image for Fig. 6.2 is as follows:

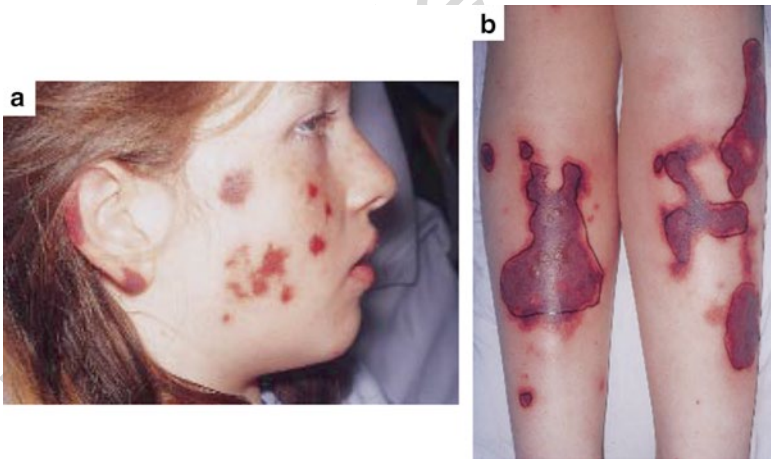


Fig. 6.2 (a) Multiple purpuric lesions on the face and ear. (b) Bilateral irregular purpuric areas on the lower legs. Lack of progression of the lesions beyond the demarcated borders illustrates their nonmigratory behavior. With permission: Chastain MA, Russo GG, Boh EE, Chastain JB, Falabella A, Millikan LE. Propylthiouracil hypersensitivity: report of two patients with vasculitis and review of the literature. *J Am Acad Dermatol.* 1999;41:757–64 [68]

The online version of the original chapter can be found at
http://dx.doi.org/10.1007/978-1-4939-2534-6_6